Get Full Access and More at ExpertConsult.com

Carranza's

Clinical Periodontology

Twelfth Edition

Newman
Takei
Klokkevold
Carranza

ELSEVIER

Carranza's

Clinical Periodontology

Carranza's

Clinical Periodontology

Twelfth Edition

MICHAEL G. NEWMAN, DDS, FACD
Professor Emeritus, Section of Periodontics
School of Dentistry
University of California
Los Angeles, California

HENRY H. TAKEI, DDS, MS, FACD
Distinguished Clinical Professor, Section of Periodontics
School of Dentistry
University of California
Los Angeles, California

PERRY R. KLOKKEVOLD, DDS, MS, FACD
Associate Professor, Section of Periodontics
Director, Postgraduate Periodontics Residency
School of Dentistry
University of California
Los Angeles, California

EDITOR EMERITUS
FERMIN A. CARRANZA, DR ODONT, FACD
Professor Emeritus, Section of Periodontics
School of Dentistry
University of California
Los Angeles, California

ELSEVIER

ELSEVIER
SAUNDERS

3251 Riverport Lane
St. Louis, Missouri 63043

CARRANZA'S CLINICAL PERIODONTOLOGY, 12TH EDITION ISBN: 978-0-323-18824-1

Copyright © 2015, 2012, 2006 by Saunders, an imprint of Elsevier Inc.

All rights reserved. No part of this publication may be reproduced or transmitted in any form or by any means, electronic or mechanical, including photocopying, recording, or any information storage and retrieval system, without permission in writing from the publisher. Details on how to seek permission, further information about the Publisher's permissions policies and our arrangements with organizations such as the Copyright Clearance Center and the Copyright Licensing Agency, can be found at our website: www.elsevier.com/permissions.

This book and the individual contributions contained in it are protected under copyright by the Publisher (other than as may be noted herein).

Notices

Knowledge and best practice in this field are constantly changing. As new research and experience broaden our understanding, changes in research methods, professional practices, or medical treatment may become necessary.

Practitioners and researchers must always rely on their own experience and knowledge in evaluating and using any information, methods, compounds, or experiments described herein. In using such information or methods they should be mindful of their own safety and the safety of others, including parties for whom they have a professional responsibility.

With respect to any drug or pharmaceutical products identified, readers are advised to check the most current information provided (i) on procedures featured or (ii) by the manufacturer of each product to be administered, to verify the recommended dose or formula, the method and duration of administration, and contraindications. It is the responsibility of practitioners, relying on their own experience and knowledge of their patients, to make diagnoses, to determine dosages and the best treatment for each individual patient, and to take all appropriate safety precautions.

To the fullest extent of the law, neither the Publisher nor the authors, contributors, or editors, assume any liability for any injury and/or damage to persons or property as a matter of products liability, negligence or otherwise, or from any use or operation of any methods, products, instructions, or ideas contained in the material herein.

International Standard Book Number: 978-0-323-18824-1

Executive Content Strategist: Kathy Falk
Senior Content Development Specialist: Brian Loehr
Publishing Services Manager: Julie Eddy
Senior Project Manager: Celeste Clingan
Senior Book Designer: Paula Catalano

Printed in Canada

Last digit is the print number: 9 8 7 6 5 4 3 2 1

ELSEVIER Book Aid International Working together to grow libraries in developing countries
www.elsevier.com • www.bookaid.org

EDITORS

ASSOCIATE AND SECTION EDITORS

Fermin A. Carranza, DR ODONT, FACD
Professor Emeritus, Section of Periodontics
School of Dentistry
University of California
Los Angeles, California

Jane L. Forrest, RDH, EdD
Professor of Clinical Dentistry
Section Chair, Behavioral Science and Practice Management
Director, National Center for Dental Hygiene Research and Practice
Herman Ostrow School of Dentistry of USC
University of Southern California
Los Angeles, California

Søren Jepsen, DDS, MD, MS, PhD
Professor and Chairman
Department of Periodontology
Operative and Preventive Dentistry
University of Bonn, Germany

Perry R. Klokkevold, DDS, MS, FACD
Associate Professor, Section of Periodontics
Director, Postgraduate Periodontics Residency
School of Dentistry
University of California
Los Angeles, California

Michael G. Newman, DDS, FACD
Professor Emeritus, Section of Periodontics
School of Dentistry
University of California
Los Angeles, California

Philip Preshaw, BDS, FDS RCSEd, FDS (Rest Dent) RCSEd, PhD
Professor of Periodontology
Institute of Cellular Medicine
School of Dental Sciences
Newcastle University
Newcastle upon Tyne, United Kingdom

Henry H. Takei, DDS, MS, FACD
Distinguished Clinical Professor, Section of Periodontics
School of Dentistry
University of California
Los Angeles, California

Wim Teughels, DDS, PhD
Associate Professor
Periodontology Unit
KU Leuven—Department of Oral Health Services
University Hospitals Leuven—Dentistry Department
Leuven, Belgium

ONLINE EDITOR

Nadeem Y. Karimbux, DMD, MMSc
Professor of Periodontology
Associate Dean for Dental Education
Tufts School of Dental Medicine
Boston, Massachusetts

CONTRIBUTORS

Elliot Abt, DDS, MS, MSc
Director
General Practice Residency Program
Advocate Illinois Masonic Medical Center
Chicago, Illinois

Alfredo Aguirre, DDS, MS
Director, Advanced Oral and Maxillofacial Pathology
Professor, Department of Oral Diagnostic Sciences
University at Buffalo, The State University of New York
Buffalo, New York

Edward P. Allen, DDS, PhD
Director
Center for Advanced Dental Education
Dallas, Texas

William F. Ammons, Jr., DDS, MSD[†]
Professor Emeritus
Department of Periodontics
University of Washington
School of Dentistry
Seattle, Washington

Maxwell H. Anderson, DDS, MS, MEd[†]
President and CEO, C3 Jian, Inc.
Inglewood, California

Akira Aoki, DDS, PhD
Instructor and Research Associate
Section of Periodontology
Department of Hard Tissue Engineering
Tokyo Medical and Dental University
Tokyo, Japan

Robert R. Azzi, DDS
Assistant Clinical Professor
Department of Periodontics
University of Paris VII—School of Dentistry
Paris, France

Janet G. Bauer, DDS, MSEd, MSPH, MBA
Professor
Restorative, Geriatric and Evidence-Based Dentistry
Center for Dental Research
School of Dentistry
Loma Linda University
Loma Linda, California

Mitchell J. Bloom, DMD
Clinical Associate Professor
Ashman Department of Periodontology & Implant Dentistry
New York University College of Dentistry
Private Practice
New York, New York

Charbel Bou Serhal, DDS, MSD, PhD
Consultant
Department of Periodontology
Catholic University of Leuven
Private Practice
Periodontology and Implantology
Leuven, Belgium

Jaime Bulkacz, Dr Odont, PhD
Lecturer, Section of Periodontics
School of Dentistry
University of California
Los Angeles, California

Bobby Butler, DDS
Private Practice
St. Petersburg, Florida
Affiliate Faculty Member
University of Washington
Seattle, Washington

Paulo M. Camargo, DDS, MS, MBA, FACD
Professor and Tarrson Family Endowed Chair of Periodontics
Division of Associated Clinical Specialties
Section of Periodontics
Associate Dean of Clinical Dental Sciences
School of Dentistry
University of California
Los Angeles, California

Fermin A. Carranza, Dr Odont, FACD
Professor Emeritus, Section of Periodontics
School of Dentistry
University of California
Los Angeles, California

Leandro Chambrone, DDS, MSc, PhD, Pos-Doc
Specialist in Periodontology
Specialist in Orthodontics & Dentofacial Orthopedics
Assistant Professor, Dental Research Division,
Department of Periodontology
Guarulhos University (UnG)
Guarulhos, SP, Brazil

[†]Deceased.

Ting-Ling Chang, DDS
Clinical Professor
Division of Advance Prosthodontics
School of Dentistry
University of California
Los Angeles, California

Sang-Choon Cho, DDS
Assistant Clinical Professor
Director, Implant Program for International Dentists
Ashman Department of Periodontology and Implant Dentistry
New York University College of Dentistry
New York, New York

Chih-Hung Chou, PhD
Center for Pharmacogenomics and Complex Disease Research
Department of Oral Biology, New Jersey Dental School
Department of Health Informatics,
School of Health Related Professions
University of Medicine and Dentistry of New Jersey
Newark, New Jersey

Evelyn Chung, DDS
Clinical Professor, Department of Advanced Prosthodontics
School of Dentistry
University of California
Los Angeles, California

Sebastian G. Ciancio, DDS
Distinguished Service Professor and Chair
Department of Periodontics and Endodontics
State University of New York–School of Dentistry
Buffalo, New York

David L. Cochran, DDS, PhD
Professor and Chair
Department of Periodontics
The University of Texas Health Science Center
San Antonio, Texas

Joseph P. Cooney, BDS, MS
Clinical Professor Emeritus
Restorative Dentistry
School of Dentistry
University of California
Los Angeles, California

James J. Crall, DDS, ScD
Professor
Pediatric Dentistry
School of Dentistry
University of California
Los Angeles, California

J. David Cross, DDS
Private Practice
Springfield, Illinois

Jesica Dadamio, Msc
Research Associate
Periodontology Unit
KU—Leuven
Department of Oral Health Sciences
Leuven, Belgium

Sophie De Geest
Post graduate student Periodontology
Department of Periodontology
Catholic University of Leuven
School of Dentistry
Oral Pathology and Maxillofacial Surgery
Leuven, Belgium

Raymond R. Derycke, DScD
Private Practice
Paris, France

Scott R. Diehl, PhD
Professor of Oral Biology
Rutgers School of Dental Medicine
Professor of Health Informatics
Rutgers School of Health Related Professions
Rutgers—The State University of New Jersey
New Brunswick, New Jersey

Jonathan Do, DDS
Lecturer, Section of Periodontics
School of Dentistry
University of California
Los Angeles, California

Henrik Dommisch, DDS, PhD
Associate Professor
Periodontology, Operative and Preventative Dentistry
University of Bonn
Bonn, Germany NRW
Associate Professor
Oral Health Sciences
University of Washington
Seattle, Washington

Donald F. Duperon, DDS, Msc
Professor Emeritus
Section of Pediatric Dentistry
School of Dentistry
University of California
Los Angeles, California

Daniel H. Etienne, DDS, MS
Department of Periodontology, Service of Odontology
Pitié-Salpêtrière Hospital
Denis Diderot University, UFR of Odontology
Paris, France

Robert C. Fazio, DMD
Associate Clinical Professor in Surgery
Yale Medical School
College of Medicine
New Haven, Connecticut
Private Practice
Norwalk, Connecticut

Richard D. Finkelman, DDS, PhD
Senior Medical Director
Oncology/New Opportunities
AstraZeneca LP
Wilmington, Delaware

Joseph P. Fiorellini, DMD, DMSc
Professor and Chair
Department of Periodontics
University of Pennsylvania School of Dental Medicine
Philadelphia, Pennsylvania

Jane L. Forrest, RDH, EdD
Professor of Clinical Dentistry
Section Chair, Behavioral Science and Practice Management
Director, National Center for Dental Hygiene Research and Practice
Herman Ostrow School of Dentistry of USC
University of Southern California
Los Angeles, California

Stuart J. Froum, DDS, PC
Diplomate of the American Board of Periodontology
Diplomate of the International Congress of Oral Implantology
Periodontics and Implant Dentistry
Clinical Professor and Director of Clinical Research
Department of Periodontology and Implant Dentistry
New York University College of Dentistry
New York, New York
Private Practice
New York, New York

Scott H. Froum, DDS
Clinical Assistant Professor
Ashman Department of Periodontology and Implant Dentistry
New York University, College of Dentistry
Private Practice
New York, New York

Christof Godts, Msc, PhD
Research Associate
Periodontology Unit
KU—Leuven
Department of Oral Health Sciences
Leuven, Belgium

Ying Gu, DDS, PhD
Associate Professor
Department of General Dentistry
Stony Brook University
School of Dental Medicine
Stony Brook, New York

Thomas J. Han, DDS, MS, FACD
Clinical Professor
Section of Periodontics
University of Southern California
School of Dentistry
Los Angeles, California

Gerald W. Harrington, DDS, MSD
Professor Emeritus and Chair
Department of Endodontics
University of Washington
School of Dentistry
Seattle, Washington

M. Cenk Haytac, PhD
Professor
Cukurova University
Faculty of Dentistry
Department of Periodontology
Adana, Turkey

James E. Hinrichs, DDS, MS
Professor and Director of Advanced Education Program in Periodontology
University of Minnesota
School of Dentistry
Minneapolis, Minnesota

Eva L. Hogan, MD, DDS, MS
Lecturer, Section of Periodontics
School of Dentistry
University of California
Los Angeles, California

Ching-Yu Huang, PhD
Senior Computer Scientist
Center for Pharmacogenomics and Complex Disease Research
Department of Oral Biology, New Jersey Dental School
University of Medicine and Dentistry of New Jersey
Newark, New Jersey

Philippe P. Hujoel, PhD, DDS, MSD, MS
Professor
Department of Oral Health Sciences
University of Washington
School of Dentistry
Seattle, Washington

Isao Ishikawa, DDS, PhD
Professor
Section of Periodontology
Department of Hard Tissue Engineering
Tokyo Medical and Dental University
Tokyo, Japan

Carol A. Jahn, RDH, MS
Senior Professional Relations Manager
Water Pik, Inc.
Warrenville, Illinois

Nick Jakubovics, BSc, PhD
Lecturer in Oral Biology
Newcastle University
School of Dental Sciences
Newcastle upon Tyne, United Kingdom

Søren Jepsen, DDS, MD, MS, PhD
Professor and Chairman
Department of Periodontology
Operative and Preventive Dentistry
University of Bonn, Germany

David L. Jolkovsky, DMD, MS
Private Practice
Davis, California
Lecturer, Section of Periodontics
School of Dentistry
Los Angeles, California

Brian P. Kamel, Esq
Managing Partner
Kamel and Maxwell, Attorneys at Law
Los Angeles, California

Mo K. Kang, DDS, PhD
Professor and Chairman
Jack A. Weichman Endowed Chair
Section of Endodontics
School of Dentistry
University of California
Los Angeles, California

Daniel W.K. Kao, DDS, MS, DMD
Instructor
Department of Periodontics
University of Pennsylvania School of Dental Medicine
Director, Predoctoral Periodontics
Philadelphia, Pennsylvania

Richard T. Kao, DDS, Phd
Private Practice
Cupertino, California
Clinical Professor
Division of Periodontology
University of California, San Francisco
Adjunct Clinical Professor
Department of Periodontology
University of Pacific
San Francisco, California

Moritz Kebschull, Dr Med Dent
Consultant
Department of Periodontology,
Operative and Preventive Dentistry
University of Bonn
Bonn, Germany

David M. Kim, DDS, DMSc
Assistant Professor, Oral Medicine, Infection, and Immunity
Director, Predoctoral Program in Periodontology
Harvard School of Dental Medicine
Boston, Massachusetts

Geon U. Kim, DDS, MS
Postgraduate Student in Implant Dentistry
Department of Periodontology and Implant Dentistry
New York University College of Dentistry
New York, New York
Research and Lecture Coordinator
Vizstara and Vizstara Professional
Englewood Cliffs, New Jersey

Keith L. Kirkwood, DDS, PhD
Professor and Chair, Department of Oral Health Sciences
Associate Dean for Research
Director, Center for Oral Health Research
James B. Edwards College of Dental Medicine
Professor of Microbiology and Immunology
Medical University of South Carolina College of Medicine
Charleston, South Carolina

Perry R. Klokkevold, DDS, MS, FACD
Associate Professor, Section of Periodontics
Director, Postgraduate Periodontics Residency
School of Dentistry
University of California
Los Angeles, California

Vincent G. Kokich, DDS, MSD[†]
Professor
Department of Orthodontics
University of Washington
School of Dentistry
Seattle, Washington

Olga Korczeniewska
Research Associate II
Rutgers School of Dental Medicine
Rutgers—The State University of New Jersey
Newark, New Jersey

Georgios Kotsakis
Resident in Periodontology
University of Minnesota
Minneapolis, Minnesota

Fengshen Kuo, MS
Senior Bioinformatics Scientist
Rutgers School of Dental Medicine
Rutgers—The State University of New Jersey
Newark, New Jersey

Isabelle Laleman
Post Graduate Student, Periodontology
Department of Periodontology
Catholic University of Leuven
School of Dentistry
Oral Pathology and Maxillofacial Surgery
Leuven, Belgium

Clarice S. Law, DMD, MS
Associate Clinical Professor
Sections of Pediatric Dentistry and Orthodontics
School of Dentistry
University of California
Los Angeles, California

Mark B. Lieberman, DDS
Clinical Lecturer, Section of Periodontics
School of Dentistry
University of California
Los Angeles, California

Sanjay M. Mallya, BDS, MDS, PhD
Assistant Professor
Director, Oral and Maxillofacial Radiology Program
Section of Oral and Maxiofacial Radiology
School of Dentistry
University of California
Los Angeles, California

[†]Deceased.

Angelo Mariotti, BS, DDS, PhD
Professor and Chair
Division of Periodontology
The Ohio State University
College of Dentistry
Columbus, Ohio

Michael J. McDevitt, DDS
Visiting Faculty
Advanced Education in Periodontics
College of Dental Medicine
Georgia Regents University
Augusta, Georgia
Visiting Faculty
LD Pankey Institute
Private Practice
Atlanta, Georgia

Adriana McGregor, DDS
Private Practice
Westlake Village, California

Brian L. Mealey, DDS, MS
Professor and Graduate Program Director
Department of Periodontics
The University of Texas Health Sciences Center at San Antonio
San Antonio, Texas

Philip R. Melnick, DMD
Lecturer, Section of Periodontics
School of Dentistry
University of California
Los Angeles, California

Robert L. Merin, DDS, MS
Private Practice
Woodland Hills, California

Greg W. Miller, DDS
Private Practice in General Dentistry
Deer Park, Washington

Syrene A. Miller, BA
Director
ebdLibrary
Deer Park, Washington

Ian Needleman, BDS, MSc, PhD, MRDRCS(Eng), FDSRCS(Eng), FFPH, FHEA
Professor of Restorative Dentistry and Evidence-Based Healthcare
Honorary Consultant and Specialist in Periodontology
Director, International Centre for Evidence-Based Oral Health (ICEBOH)
Unit of Periodontology
Division of Restorative Dental Sciences
UCL Eastman Dental Institute
London, England

Michael G. Newman, DDS, FACD
Professor Emeritus, Section of Periodontics
School of Dentistry
University of California
Los Angeles, California

Marc L. Nevins, DMD, MMSc
Assistant Clinical Professor
Division of Periodontology
Harvard School of Dental Medicine
Boston, Massachusetts

Russell J. Nisengard, DDS, PhD[†]
Distinguished Teaching Professor
Associate Dean for Advanced Education and Research
State University of New York
School of Dentistry
Buffalo, New York

Karen F. Novak, DDS, MS, PhD
Professor
Department of Periodontics
Center for Oral Health Research
University of Kentucky
Lexington, Kentucky

M. John Novak, BDS, LDS, PhD
Professor of Periodontics and Associate Director
Department of Periodontics
Center for Oral Health Research
University of Kentucky
Lexington, Kentucky

Joan Otomo-Corgel, DDS, MPH
Greater Los Angeles Veteran's Administration Healthcare System
Associate Clinical Professor, Section of Periodontics
School of Dentistry
University of California
Los Angeles, California

Onur Ozcelik, PhD
Associate Professor
Cukurova University
Faculty of Dentistry
Department of Periodontology
Adana, Turkey

Kwang-Bum Park, DDS, MS, PhD
Former Assistant Researcher in Periodontics
School of Dentistry
University of California
Los Angeles, California
Director,
MINEC Institute of Clinical Periodontics and Implantology
Lecturer in Oral Anatomy and Histology
Kyung-Pook National University
Taegu, Korea

Anna M. Pattison, RDH, MS
Associate Professor Emeritus
Division of Periodontics, Diagnostic Sciences and Dental Hygiene
Ostrow School of Dentistry
University of Southern California
Los Angeles, California

[†]Deceased.

Gordon L. Pattison, DDS
Private Practice
Los Angeles, California
Formerly, Instructor
Section of Periodontics
School of Dentistry
University of California
Los Angeles, California

Birgit Pelsmaekers, DDS
Private Practice
Leuven, Belgium

Dorothy A. Perry, RDH, PhD
Professor and Associate Dean for Education and Student Affairs
Department of Preventive and Restorative Dental Sciences
School of Dentistry
University of California
San Francisco, California

Flavia Q. Pirih, DDS, PhD
Diplomate, American Board of Periodontology
Assistant Professor, Section of Periodontics
School of Dentistry
University of California
Los Angeles, California

Alan M. Polson, DMD, MS
Professor of Periodontics and D. Walter Cohen Chair
Department of Periodontics
School of Dental Medicine at the University of Pennsylvania
Philadelphia, Pennsylvania

Philip Preshaw, BDS, FDS RCSEd, FDS (Rest Dent) RCSEd, PhD
Professor of Periodontology
Institute of Cellular Medicine and School of Dental Sciences
Newcastle University
Newcastle upon Tyne, United Kingdom

Marc Quirynen, DDS, PhD
Professor
Department of Periodontology
Catholic University of Leuven
School of Dentistry
Oral Pathology and Maxillofacial Surgery
Leuven, Belgium

Terry D. Rees, DDS, MSD
Professor
Department of Periodontics
Baylor College of Dentistry
Texas A&M University
Dallas, Texas

Mark A. Reynolds, DDS, PhD
Professor and Chair
Director, Postdoctoral Periodontics
Department of Periodontics
University of Maryland
School of Dentistry
Baltimore, Maryland

Carlos Rossa, Jr., DDS, MS, PhD
Associate Professor
Department of Diagnosis and Surgery
Faculdade de Odontologia de Araraquara
Universidade Estadual Paulista
UNESP
Araraquara, SP
Brazil

Maria Emanuel Ryan, DDS, PhD
Professor and Chair
Department of Oral Biology and Pathology
School of Dental Medicine
Medical Staff University Hospital
Stony Brook Medicine
Stony Brook University
Stony Brook, New York

E. Todd Scheyer, DDS, MS
Private Practice
Perio Health Professionals PLLC
Houston, Texas

Dennis A. Shanelec, DDS
Director
Microsurgery Training Institute
Santa Barbara, California

Kitetsu Shin, DDS, PhD
Professor
Division of Periodontology
Department of Oral Biology and Tissue Engineering
Meikai University
School of Dentistry
Sakado-shi, Saitama, Japan

Gerald Shklar, DDS, MS
Professor Emeritus
Charles A. Brackett Professor of Oral Pathology
Harvard University
School of Dental Medicine
Boston, Massachusetts

Daniela Rodrigues Silva, DDS, MS
Chair and Dr. Thomas K. Barber Endowed Chair
Director, Pediatric Dentistry Residency Program
Associate Clinical Professor
Section of Pediatric Dentistry
School of Dentistry
University of California
Los Angeles, California

Titus Schleyer, DMD, PhD, MBA
Clem McDonald Professor of Biomedical Informatics
Director, Center for Biomedical Informatics
Regenstrief Institute, Inc.
Professor of Medicine
Department of Medicine
Indiana University School of Medicine
Indianapolis, Indiana

Thomas N. Sims, DDS
Lecturer, Section of Periodontics
School of Dentistry
University of California
Los Angeles, California
Private Practice
Torrance and Santa Monica, California

Sue S. Spackman, DDS, FASGD
Associate Clinical Professor
Department of Oral Diagnosis, Radiology and Pathology
Department of Restorative Dentistry
School of Dentistry
Loma Linda University
Loma Linda, California

Frank M. Spear, DDS, MSD
Founder and Director
Spear Education
Seattle, Washington

Panagiota G. Stathopoulou, DDS, MS, PhD
Assistant Professor—Director, Predoctoral Periodontics
Department of Periodontics
School of Dental Medicine
University of Pennsylvania
Philadelphia, Pennsylvania

Corey Stein, MS
Dental Medicine Student
Western University of Health Sciences
College of Dental Medicine
Pomona, California

Henry H. Takei, DDS, MS, FACD
Distinguished Clinical Professor, Section of Periodontics
School of Dentistry
University of California
Los Angeles, California

Dennis P. Tarnow, DDS
Clinical Professor and Director of Implant Education
Columbia University College of Dental Medicine
New York, New York
Private Practice
New York, New York

John J. Taylor, PhD
Senior Lecturer in Molecular Immunology
Periodontal Immunobiology Research Group
Institute of Cellular Medicine and School of Dental Sciences
Newcastle University
Newcastle upon Tyne, United Kingdom

Sotirios Tetradis, DDS, PhD
Professor and Chair
Section of Oral and Maxillofacial Radiology
School of Dentistry
University of California
Los Angeles, California

Wim Teughels, DDS, PhD
Associate Professor
Periodontology Unit
KU Leuven—Department of Oral Health Services
University Hospitals Leuven—Dentistry Department
Leuven, Belgium

Vivek Thumbigere-Math, BDS, PhD
Research Fellow
National Institute of Health
Bethesda, Maryland

Thankam Thyvalikakath, DMD, MDS, PhD
Associate Professor and Director
Dental Informatics Core
Department of Restorative Dentistry
Indiana University School of Dentistry
Indianapolis, Indiana

Leonard S. Tibbetts, DDS, MSD
Private Practice
Arlington, Texas

Kenneth C. Trabert, DDS, MEd
Clinical Professor, Section of Endodontics
School of Dentistry
University of California
Los Angeles, California

Istvan A. Urban, DMD, MD, PhD
Assistant Professor
Graduate Implant Dentistry
Loma Linda University
Loma Linda, California
Private Practice
Budapest, Hungary

N. Buzin Uzel
Former Instructor
Department of Periodontics
University of Pennsylvania
Philadelphia, Pennsylvania

Sandra Van den Velde, MSc, PhD
Research Associate
Catholic University of Leuven
School of Dentistry
Oral Pathology and Maxillofacial Surgery
Leuven, Belgium

Betty Vandekerckhove, DDS, PhD
Instructor
Department of Periodontology
Catholic University of Leuven
School of Dentistry
Oral Pathology and Maxillofacial Surgery
Leuven, Belgium

Jose Luis Tapia Vasquez, DDS, MS
Assistant Professor
Department of Oral Diagnostic Sciences
School of Dental Medicine
University at Buffalo, The State University of New York
Buffalo, New York

Tomaso Vercellotti, DDS, MS
Honorary Professor and Faculty
University College of London
London, England
Private Practice
Genova, Italy

Keisuke Wada, DDS, PhD, DMSc, DMD
Associate Professor
Director of Implant Dentistry
Assistant Director of Postdoctoral Periodontics
Department of Periodontics
University of Pennsylvania
School of Dental Medicine
Philadelphia, Pennsylvania

Adrian Zacher, MBA
Founder and Director of Snorer.com
Co-founder, British Society of Dental Sleep Medicine

S. Jerome Zackin, DMD
Sarasota, Florida

ABOUT THE BOOK

Carranza's Clinical Periodontology, twelfth edition, is the definitive global reference text in periodontics. Edited by Drs. Michael G. Newman, Henry H. Takei, Perry R. Klokkevold, and editor emeritus Fermin A. Carranza, the twelfth edition provides highest quality information for students, residents, and practitioners.

The Editors welcome you to one of the most exciting and meaningful editions of *Clinical Periodontology* (CP12). The twelfth edition is truly transformational. It fully engages modern information technology while maintaining and refining its 50+ years of educational excellence. CP12 improves on the previous edition standard-bearer periodontal textbook by more accurately reflecting the essential core information of periodontology as well as the state-of-the-art methods in both the science and clinical knowledgebase. Contributors from more countries than ever before reflect a unifying view of the basic information related to the science and technology of modern periodontics.

The CP12 Expert Consult will be MUCH improved over the current online version in every aspect, including better speed, quality, functionality, access, and linking. There are more animations, videos, case reports, and one of the most comprehensive image libraries on periodontal pathology ever assembled.

The CP12 print book is a complete and thorough presentation of periodontology essentials while retaining the style and quality that makes *Carranza's Clinical Periodontology* the number one periodontal textbook in the world. Advances in printing and digital technology will make CP12 even more "readable" than the previous edition.

ABOUT THE AUTHORS

MICHAEL G. NEWMAN, DDS, FACD

Dr. Michael G. Newman graduated from the University of California, Los Angeles (UCLA) College of Letters and Sciences with a degree in psychology. He completed his dental training at the UCLA School of Dentistry in 1972. Dr. Newman received a Certificate in Periodontics and Oral Medicine at the Harvard School of Dental Medicine and a Certificate in Oral Microbiology from the Forsyth Dental Institute under the mentorship of Dr. Sigmund Socransky. He is a diplomate of the American Board of Periodontology and is Professor Emeritus of Periodontics at the UCLA School of Dentistry. Dr. Newman is a fellow and past President of the American Academy of Periodontology. In 1975, he won the Balint Orban Memorial Prize from the American Academy of Periodontology. He had been in private practice of periodontics for more than 25 years. In 2007, Dr. Newman received the Gold Medal, the highest honor bestowed by The American Academy of Periodontology.

Dr. Newman has published more than 260 abstracts, journal articles, and book chapters and has co-edited nine textbooks. He has served as an ad-hoc reviewer for the National Institute of Dental and Craniofacial Research, was a consultant to the Council on Scientific Affairs of the American Dental Association, and is a reviewer for numerous scientific and professional journals and governmental research organizations.

Professor Newman has lectured throughout the world on microbiology, antimicrobials, evidence-based methodology, risk factors, and diagnostic strategies for periodontal disease. He has a strong interest in applied science and transfer of new technology for practical use. Dr. Newman is a consultant to major dental and pharmaceutical companies throughout the world. He is the founding editor in chief of the *Journal of Evidence-Based Dental Practice (JEBDP), The JEBDP Annual Report Series*, and was the associate editor of the *International Journal of Oral and Maxillofacial Implants*.

HENRY H. TAKEI, DDS, MS, FACD

Dr. Henry H. Takei graduated in 1965 from the Marquette University School of Dentistry in Milwaukee, Wisconsin. He completed his Periodontics Certificate and Master of Science degree in 1967 at the Marquette University and the Veterans Administration Hospital in Wood, Wisconsin.

Dr. Takei is a Distinguished Clinical Professor of Periodontics at the UCLA School of Dentistry and a Consultant in Periodontics at the Veterans Administration Hospital in Los Angeles. He maintains a private practice limited to periodontics and implant surgery.

Dr. Takei has published numerous articles on periodontal surgery and has contributed chapters to five textbooks. He has been actively involved in continuing education and has lectured throughout the world on clinical periodontology and implant surgery.

Dr. Takei has been honored nationally and internationally with awards from numerous periodontal organizations, universities, and study clubs for his contributions to education.

He received the Distinguished Alumnus Award by Marquette University in 2001 and the Honorary Distinguished Alumnus Award by the University of California, Los Angeles in 1998. The American Academy of Periodontology has honored Dr. Takei with the prestigious Master Clinician Award in 2006.

PERRY R. KLOKKEVOLD, DDS, MS, FACD

Dr. Perry R. Klokkevold graduated from the University of California, San Francisco School of Dentistry in 1986. His postdoctoral clinical training includes a General Practice Residency in Hospital Dentistry completed in 1987, a Postgraduate Periodontal Residency completed in 1994, and a Surgical Implant Fellowship completed in 1995. All of his postgraduate training was completed at the UCLA School of Dentistry. He earned a Master of Science degree in Oral Biology at UCLA in 1995.

Dr. Klokkevold is a Diplomate of the American Board of Periodontology and a Fellow of the American College of Dentists. He is an Associate Professor in the Division of Associated Specialties, Section of Periodontics, at the UCLA School of Dentistry and Director of the UCLA Postgraduate Periodontics Residency program. Dr. Klokkevold served as Clinical Director and Director of the General Practice Residency program in Hospital Dentistry at UCLA School of Dentistry from 1987 to 1992. He has maintained a faculty practice limited to the specialty of periodontics and dental implant surgery at UCLA since 1995.

Dr. Klokkevold has published numerous articles for international journals and has written several book chapters on topics that include juvenile periodontitis, periodontal medicine, influence of systemic disease and risk factors on periodontitis, bone regeneration, and dental implants. He has served as a reviewer for several journals, including the *Journal of Periodontology* and the *International Journal of Oral and Maxillofacial Implants*. Dr. Klokkevold has lectured nationally and internationally on many periodontal and implant-related topics.

FERMIN A. CARRANZA, DR ODONT, FACD

Dr. Fermin A. Carranza graduated from the University of Buenos Aires School of Dentistry in Argentina in 1948 and completed his postdoctoral training in periodontics at Tufts University School of Dental Medicine in 1952 under the mentorship of Dr. Irving Glickman.

Dr. Carranza is Professor Emeritus of Periodontology at the UCLA School of Dentistry. He was head of the Department of Periodontics at the University of Buenos Aires from 1966 to 1974, and at UCLA from 1974 until his retirement in 1994.

Dr. Carranza has published more than 218 scientific papers and abstracts on basic and applied aspects of periodontics and 18 books, including the past five editions of Clinical Periodontology. He has received numerous awards and recognition for his work, including the IADR Science Award in Periodontal Disease and the Gies Award of the American Academy of Periodontology.

Dr. Carranza has lectured throughout the world on clinical periodontology, pathology, and therapy.

PREFACE

This twelfth edition is the most comprehensive textbook and information resource about periodontology available anywhere. Using Elsevier's advanced technology and high standards of quality, the international team of editors and contributors have developed the most comprehensive periodontal resource available.

Since publication of the first edition of this book 62 years ago, periodontology has made tremendous progress. Analysis of periodontal tissues and elucidation of the mechanisms and causes of disease have extended far beyond histology and physiology and into the realm of cellular and molecular biological understanding.

New therapeutic goals and clinical techniques, based on an improved understanding of disease, have facilitated better outcomes and brought us closer to achieving the ultimate goal of optimal periodontal health and function. Today, reconstruction and regeneration of lost periodontal structures, replacement of compromised teeth with implants, and creation of esthetic results are integral parts of clinical practice.

This book is written for all individuals, from students to educators, clinicians to researchers, and from specialists to generalists. It is our belief that identifying periodontal needs of the public is primarily the role of general dentists and dental hygienists. The responsibility to examine, diagnose, and either treat or refer all periodontal problems is unquestionable.

The multifaceted, complex task of producing the twelfth edition required the collaboration of numerous experts from various fields, and their contributions are invaluable. We know that this new edition will continue to be as useful to dentists, hygienists, periodontists, students, educators, and researchers as the previous editions have been and we know that it will contribute to continuous progress of our profession.

Michael G. Newman
Henry H. Takei
Perry R. Klokkevold
Fermin A. Carranza

ACKNOWLEDGMENTS

The originator of this book and author of its first four editions, published in 1953, 1958, 1964, and 1972, was Dr. Irving Glickman, Professor and Chairman of the Department of Periodontology at Tufts University School of Dental Medicine, in Boston, Massachusetts.

After Dr. Glickman's death in 1972 at age 58, responsibility for continuing this book moved to Dr. Fermin A. Carranza, once a student and collaborator of Dr. Glickman. At the time, Dr. Carranza was Professor and Chairman of periodontics at the School of Dentistry, University of California, Los Angeles (UCLA). The following four editions were published in 1979, 1984, 1990, and 1996 under the guidance of Dr. Carranza, who is now Professor Emeritus at UCLA.

In 2002, the task of maintaining the book's tradition of almost half a century changed hands once again. Dr. Michael G. Newman and Dr. Henry H. Takei joined Dr. Carranza to take major responsibility for the ninth edition. Subsequently, in 2006, Dr. Perry R. Klokkevold from UCLA joined them as a co-editor of the tenth edition.

Advances in basic science and clinical techniques have increased the knowledge base so dramatically that it is virtually impossible for a single individual to memorize and retain all of the information needed to practice excellently. It is also a certainty that the enormity of providing the information of a discipline must be borne by many experts willing to share their experience and knowledge.

The editors are indebted to everyone who has worked tirelessly to produce this milestone print and electronic edition of *Carranza's Clinical Periodontology*.

Many scientists and clinicians have shared their knowledge and expertise from previous editions of *Carranza's Clinical Periodontology*, but their names no longer appear as contributors to the present one. We express our deep gratitude to all of them for their many valuable concepts and ideas.

Our appreciation is given to Elsevier and particularly to Kathy Falk and Brian Loehr. Their expertise and detailed attention to every word and every concept contributed greatly to producing a quality book and a truly useful website.

We also would like to thank the following residents for their work on the website: Salem Alaqel, Mohammed N. Alasqah, Najla Al-Dabbagh, Shatha Alharthi, Sarah Almotlag, Raneem Alofi, Federico Ausenda, Seyed Hossein Bassir, Carlos Parra Carrasquer, Daniel Coleman, Irina F. Dragan, Waeil Elmisalati, Marcelo Freire, Sasan Ghaffarigarakani, Mindy Gil, Tae Kwon, Lorenzo Mordini, Zuhair S. Natto, Justin Raanan, Teresa Sun, Jeff Wang, Wichaya Wisitrasameewong, and Yau-hua Yu.

We express gratitude to our parents, colleagues, friends, and mentors who have always been so tolerant, encouraging, and understanding, and who guided our first steps in our profession and helped us develop our ideas in the field.

Dr. Newman: my family Susan, Andrea, Kara, Callahan and Natalie, Scott and Zoey; my parents Paul, Rose, John, and Inez. Sigmund S. Socransky, Fermin A. Carranza, Jr., and Henry H. Takei: My gratitude to my co-editors and contributors whose expertise and willingness to participate in this work have made this book an excellent educational standard.

Dr. Takei: My wife, June; my children Scott and Akemi; their spouses, Kozue and David; my grandchildren, Hana, Markus, Carter, and Arden. My graditude to my mentors Dr. Fermin A. Carranza, Jr., Dr. Donald Van Scotter, Dr. Delbert Nachazel, and Dr. John Pfeiffer. Thank you to my three co-editors and friends Michael G. Newman, Fermin A. Carranza, Jr., and Perry R. Klokkevold. Special gratitude to Laura Miyabe for her professional support. I would like to acknowledge and thank all of my periodontal postdoctoral students at UCLA for their help and support throughout the preparation of this classic textbook.

Dr. Klokkevold: my wife, Angie; my daughters Ashley and Brianna; my parents Carl and Loretta; my gratitude and appreciation for mentors Dr. Henry H. Takei, Dr. John Beumer III, Dr. Bradley G. Seto, Dr. Charles N. Bertolami, and Dr. Thomas Han. I thank all of the UCLA Postgraduate Periodontal Residents for the passion and inspiration they bring to me as an educator and clinician. Special thanks to my co-editors, Dr. Michael G. Newman, Dr. Henry H. Takei, and Dr. Fermin A. Carranza, Jr., for their friendship, support, and encouragement.

Dr. Carranza: my wife, Rita; my children Fermin, Patricia, and Laura; and my grandchildren, Irving Glickman, Fermin Carranza, Sr., and Romulo L. Cabrini. My gratitude also to my co-editors, who will continue the tradition of this book.

Michael G. Newman
Henry H. Takei
Perry R. Klokkevold
Fermin A. Carranza

Introduction: The Historical Background of Periodontology

Gerald Shklar and Fermin A. Carranza

CHAPTER OUTLINE

Early Civilizations
The Classical World
The Middle Ages
The Renaissance
The Eighteenth Century
The Nineteenth Century
The Twentieth Century
The History of This Book

Gingival and periodontal diseases have afflicted humans since the dawn of history. Studies in paleopathology have indicated that destructive periodontal disease, as evidenced by bone loss, affected early humans in such diverse cultures as ancient Egypt and early pre-Columbian America. The earliest historical records that involve medical topics reveal an awareness of periodontal disease and the need for treatment. Almost all early writings that have been preserved have sections or chapters dealing with oral diseases, and periodontal problems comprise a significant amount of space in these writings. Calculus and systemic disease were frequently postulated as causes of periodontal disorders.

However, methodic and carefully reasoned therapeutic discussions did not exist until the Arabic surgical treatises of the Middle Ages. Modern treatment, with illustrated text and sophisticated instrumentation, did not develop until the time of Pierre Fauchard during the eighteenth century.

Early Civilizations

Oral hygiene was practiced by the Sumerians, the Babylonians, and the Assyrians; this included gingival massage in combination with various herbal medications.[25,33]

Periodontal disease was the most common of all diseases found in the embalmed bodies of the ancient Egyptians.[7,44] The Ebers papyrus contains many references to gingival disease and offers a number of prescriptions for strengthening the teeth and gums.[14]

The medical works of ancient India and China devote significant space to oral and periodontal problems and oral hygiene,[47] and they describe gingival inflammations, periodontal abscesses, and gingival ulcerations.[12,21] The early Hebrews also recognized the importance of oral hygiene. Many pathologic conditions of the teeth and their surrounding structures are described in the Talmudic writings.

The Classical World

Among the ancient Greeks, Hippocrates of Cos (460 BC-377 BC), the father of modern medicine, discussed the function and eruption of the teeth and the etiology of periodontal disease. He believed that inflammation of the gums could be caused by accumulations of "pituita" or calculus, with gingival hemorrhage occurring in cases of persistent splenic maladies.[10,27]

Among the Romans, Aulus Cornelius Celsus (25 BC-50 AD) referred to diseases that affect the soft parts of the mouth and their treatment, including oral hygiene. Paul of Aegina (625 AD-690 AD) wrote that tartar deposits must be removed with either scrapers or a small file and that the teeth should be carefully cleaned after the last meal of the day.[41]

The Middle Ages

The decline and fall of the Roman Empire that plunged Europe into an age of darkness was accompanied by the rise of Islam and the golden age of Arabic science and medicine. The Arabic treatises derived their information from Greek medical treatises, but many refinements and novel approaches were added, particularly in surgical specialties.[45]

Albucasis (936-1013) was born and lived in Moorish Spain. His 30-volume medical encyclopedia, called *al-Tasrif,* was translated into Latin during the twelfth century, and it was the medical text used in European universities until the seventeenth century. The contributions of Albucasis to dentistry and periodontology were outstanding achievements.[1] He had a clear understanding of the major etiologic role of calculus deposits, and he described the techniques of scaling the teeth with the use of a set of instruments that he developed (Figure I-1), splinting loose teeth with gold wire, and filing gross occlusal abnormalities.

Avicenna (980-1037) was possibly the greatest of the Arabic physicians. His *Canon,* a comprehensive treatise on medicine, was in continuous use for almost 600 years. Avicenna used an extensive "materia medica" for oral and periodontal diseases and rarely resorted to surgery.[3]

The Renaissance

During the Renaissance—with the rebirth of classical scholarship, the development of scientific thought and medical knowledge, and the flowering of art, music, and literature—significant contributions were made to anatomy and surgery.

Albucasis' work was expanded during the fifteenth century by the Turkish author Serefeddin Sabuncuoglu (1385-1468), who included illustrations of the surgical removal of hypertrophic and swollen gingiva and lingual frenum (Figure I-2). Drug treatment should be initiated if there are swollen gums, mobile teeth, and pus

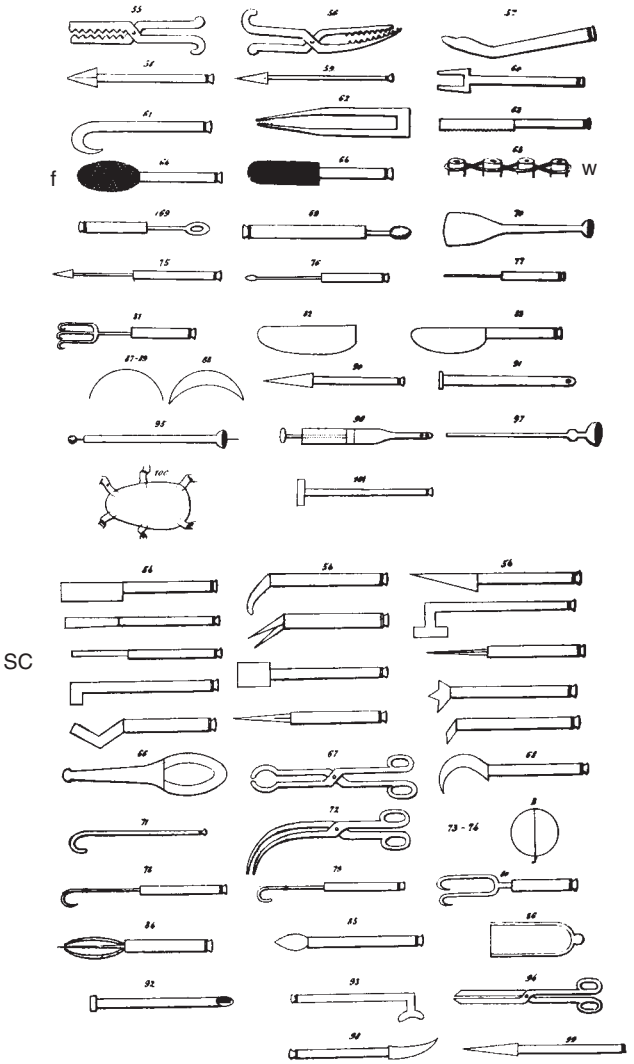

Figure I-1 Illustration of Albucasis' periodontal instruments, showing scalers *(sc),* files *(f),* and the wiring of loose teeth *(w).*

formation. If there is no response, surgical treatment should be performed. A tube is placed on the gums. A hot cautery is inserted into the cannula, and the gingival tissue is cauterized. If this is correctly applied, the adjacent teeth will be warm.

Paracelsus (1493-1541) developed an interesting and unusual theory of disease: the doctrine of calculus. Paracelsus recognized the extensive formation of tartar on the teeth and related this to toothache. He considered toothache to be comparable to the pain produced by calculus in other organs, such as the kidneys.[39]

Andreas Vesalius (1514-1564), who was born in Brussels, taught at the University of Padua and wrote a magnificent book about anatomy that included many excellent illustrations.[48] Bartholomeus Eustachius (1520-1574) of Rome was another outstanding anatomist who wrote a small book about dentistry, *Libellus de Dentibus* ("A Little Treatise on the Teeth"), which contained 30 chapters.[16] This was the first original book about the teeth, and it included a description of the periodontal tissues as well as information about the diseases of the mouth, their treatment modalities, and the rationale for treatment. For the treatment of periodontitis, Eustachius recommended both the scaling of calculus and the curettage of granulation tissue so that actual reattachment of the gingival and periodontal tissues could take place.

Figure I-2 Illustration by Serefeddin Sabuncuoglu showing gingival cauterization. *(From Abulcasis and redrawn by Professor Ilter Uzel, Turkey.)*

The Frenchman Ambroise Paré (1509-1590) was the outstanding surgeon of the Renaissance, and his contributions to dental surgery included gingivectomy for hyperplastic gingival tissues.[40] He also understood the etiologic significance of calculus and used a set of scalers to remove the hard deposits on the teeth.

The first book in the common language of German and specifically devoted to dental practice, which was entitled *Artzney Buchlein* or *Zene Artzney* ("Medicine of the Teeth"), was published in Leipzig in 1530.[2] It contains three chapters devoted to periodontal problems, including a crude concept of systemic and local factors in the etiology of periodontal disease. The presence of local infective agents or "worms" is also mentioned.

A variety of ointments, which are often astringent in nature, is suggested, and the binding of loose teeth to sound ones with silk or gold thread is recommended. Cauterizing the gingiva with a hot iron is mentioned.

The Italian physician, mathematician, and philosopher Girolamo Cardano (1501-1576) appears to have been the first to differentiate among the types of periodontal disease. In a publication dated 1562, he mentions one type of disease that occurs with advancing age and leads to progressive loosening and loss of teeth as well as a second very aggressive type that occurs in younger patients.[26] It was not until late in the twentieth century that this classification was rediscovered and became widely accepted.

Anton van Leeuwenhoek (1632-1723) of Delft, Holland, was a layman, but he had an inquisitive mind and a hobby of grinding lenses that allowed him to develop the microscope. He used it to discover microorganisms, cellular structure, blood cells, sperm, and various other microscopic structures, including the tubular structure of dentin.[9,13] Using material from his own mouth, Leeuwenhoek first described oral bacterial flora, and his drawings offered a reasonably good presentation of oral spirochetes and bacilli (Figure I-3). He even performed antiplaque experiments involving the use of strong vinegar in his own mouth and in vitro on bacteria in a dish.[13]



Figure I-3 Leeuwenhoek's drawing of oral spirochetes, bacilli, and other microorganisms.

LE CHIRURGIEN
DENTISTE,
OU
TRAITÉ DES DENTS,
OU L'ON ENSEIGNE LES MOYENS de les entretenir propres & sains, de les embellir, d'en réparer la perte & de remédier à leurs maladies, à celles des Gencives & aux accidens qui peuvent survenir aux autres parties voisines des Dents.
Avec des Observations & des Réflexions sur plusieurs cas singuliers.
Ouvrage enrichi de quarante-deux Planches en taille douce.
Par PIERRE FAUCHARD, Chirurgien Dentiste à Paris.
Deuxiéme Édition revûe, corrigée & considérablement augmentée.
TOME PREMIER.
A PARIS,
Chez PIERRE-JEAN MARIETTE, rué S. Jacques aux Colonnes d'Hercule.
Et chez l'Auteur, rué des grands Cordeliers.
M. DCC. XLVI.
Avec Approbations & Privilége du Roi.

Figure I-4 Frontispiece of Fauchard's book entitled *The Surgeon Dentist* (1746 edition).

The Eighteenth Century

Modern dentistry essentially developed in eighteenth century Europe, particularly France and England. Pierre Fauchard, who was born in Brittany in 1678, is rightly regarded as the father of the dental profession as we know it. His book, *The Surgeon Dentist,* which was published in 1728, covered all aspects of dental practice, including restorative dentistry, prosthodontics, oral surgery, periodontics, and orthodontics[17] (Figure I-4). Fauchard described in detail his periodontal instruments and the scaling technique for using them (Figure I-5).

John Hunter (1728-1793), who was the most distinguished anatomist, surgeon, and pathologist of eighteenth-century England, wrote an excellent treatise on dentistry entitled *The Natural History of the Human Teeth.*[30] He offered remarkably clear illustrations of the anatomy of the teeth and their supporting structures, and he described the features of periodontal diseases.

A contemporary of Hunter, Thomas Berdmore (1740-1785), was considered the outstanding dentist in England. In 1770, he published a book that had several chapters devoted to periodontal problems.[4]

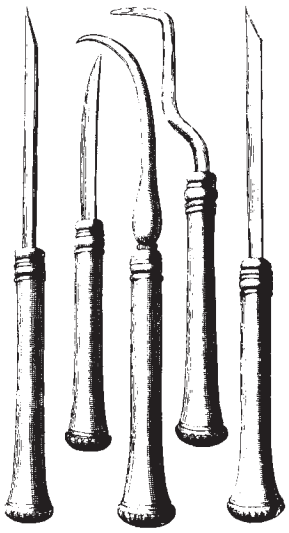

Figure I-5 The five types of instruments used by Fauchard for detaching tartar from the teeth: *1,* chisel; *2,* parrot beak; *3,* graver; *4,* convex blade; and *5,* Z-shaped hook.

The Nineteenth Century

Leonard Koecker (1785-1850) was a German-born dentist who practiced in Baltimore. In a paper in 1821, he mentioned the careful removal of tartar and the need for oral hygiene by the patient, recommending that it be performed in the morning and after every meal with the use of an astringent powder and a toothbrush, with care taken to place "the bristles … into the spaces of the teeth." Koecker was an early advocate of the "odontogenic focal infection" theory, and he recommended the extraction of all severely involved teeth and roots, including all unopposed molars, to prevent systemic infections.[35]

Levi Spear Parmly (1790-1859) was a New Orleans, Louisiana, dentist who is considered the father of oral hygiene and the inventor of dental floss.[11,18]

During the mid-nineteenth century, John W. Riggs (1811-1885) was the leading authority on periodontal disease and its treatment in the United States; in fact, at the time, periodontitis was known as "Riggs' disease" (Figure I-6). Riggs graduated from the Baltimore College of Dental Surgery in 1854 and practiced in Hartford, Connecticut, where he died on November 11, 1885. Riggs seems to have been the first individual to limit his practice to periodontics and therefore can be considered the first specialist in this field. Riggs' publications, however, are limited. In an 1876 paper, Riggs was a strong proponent of the so-called conservative approach to periodontal therapy; he developed the concept of oral prophylaxis and prevention, advocated for the cleanliness of the mouth, and opposed surgery, which at the time consisted of gingival resection.[43]

Riggs and his disciples had great influence on the dental profession. Among Riggs' followers were L. Taylor, D.D. Smith, R.B. Adair, and W.J. Younger. The instruments designed by Younger[57] and later modified by his student Robert Good were used widely until well beyond the middle of the twentieth century.

Several major developments in medical science occurred during the second half of the nineteenth century and started the era that can be called *modern medicine,* which includes dentistry.[9,36] The first was the discovery of anesthesia by Horace Wells (1813-1848) of Hartford, Connecticut, in 1845 and by William Morton (1819-1868) of Boston, Massachusetts, in 1846, who discovered the



Figure I-6 John W. Riggs (1811-1885). *(From Hoffman-Axthelm W:* History of dentistry, *Chicago, 1981, Quintessence.)*

general anesthetic effects of nitrous oxide and ether, respectively. *Local anesthesia* was developed by the Vienna ophthalmologist Carl Köller (1857-1944), who produced anesthesia of the eye with drops of cocaine. Procaine (Novocaine) was developed in 1905 by the Munich chemists Alfred Einhorn and Richard Willstädter. Later, with the addition of adrenaline, which was discovered separately in the United States by Jokichi Takamine and Thomas Bell Aldrich, local anesthesia was born.[29]

The second scientific breakthrough was made by the French chemist Louis Pasteur (1822-1895), who established the *germ theory of disease.* Subsequently, the German physician Robert Koch (1843-1910), in a series of brilliant investigations, discovered the microorganism that causes the cattle disease anthrax and the bacterial etiology of tuberculosis and cholera.

The concepts of Pasteur were transferred to clinical and surgical practice by Joseph Lister (1827-1912) of England, and thus the era of antisepsis—and later, asepsis—in surgery was born. Anesthesia and antisepsis made possible extraordinary advances in surgical techniques.

Pasteur, Koch, and their collaborators and followers—Elie Metchnikoff, Emile Roux, Paul Ehrlich, Emil von Behring, Shibasaburo Kitasato, and many others—discovered the bacterial etiologies of numerous diseases (e.g., pneumonia, puerperal fever, diphtheria, meningitis, plague, dysentery, syphilis) and gave birth to two sciences that became basic to periodontics: bacteriology and immunology.

A third scientific finding that changed the practice of dentistry in general and of periodontics in particular was the *discovery of radiographs* by the German physicist Wilhelm Röntgen (1845-1923; also written as *Roentgen*). Röntgen's discovery was made in 1895 at the University of Würzburg and was purely a basic science finding, but it was immediately taken up by physicians and dentists, and it proved to be a crucial development in periodontics and many other areas of medicine and dentistry.

Also during the late nineteenth century, studies by Rudolph Virchow (1821-1902), Julius Cohnhein (1839-1884), Elie Metchnikoff (1845-1916), and others had started to reveal the microscopic changes that occur during inflammation.[8,9] This resulted in an understanding of the pathogenesis of periodontal disease on the basis of histopathologic studies. The Russian N.N. Znamensky

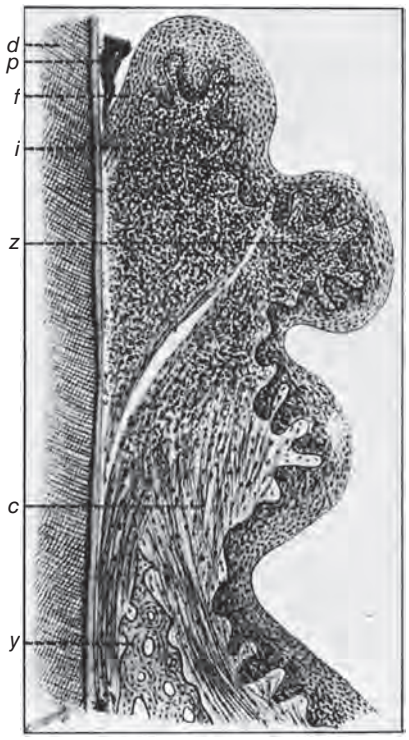

Figure I-7 Microscopic features of periodontal disease as presented by Znamensky.

described the complex interaction of local and systemic factors in the etiology of periodontal disease. His observations and concepts were summarized in 1902 in a classic paper in which he described the presence in inflamed gingivae of a cellular infiltrate that extends deeper as the disease progresses, thereby causing the bone resorption associated with multinucleated cells (osteoclasts) and Howship lacunae[58] (Figure I-7).

The first individual to identify bacteria as the cause of periodontal disease appears to have been the German dentist Adolph Witzel (1847-1906).[23,56] The first true oral microbiologist, however, was the American Willoughby D. Miller (1853-1907), whose professional activities took place in Berlin, where he embarked on a research career that introduced modern bacteriology principles to dentistry. Although his greatest accomplishments were in caries research, in his classic book, *The Microorganisms of the Human Mouth,* which was published in 1890, he described the features of periodontal disease and considered the role of predisposing factors, irritational factors, and bacteria in its etiology. He believed that the disease was not caused by a specific bacterium but by a complex array of various bacteria that are normally present in the oral cavity. This constitutes what was later known as the *nonspecific plaque hypothesis,* which went unchallenged for seven decades.[23,37]

Bacterial plaque was described by J. Leon Williams (1852-1932), an American dentist who practiced in London and who in 1897 described a gelatinous accumulation of bacteria adherent to the enamel surface in relation to caries.[55] In 1899, G.V. Black (1836-1915) coined the term *gelatinous microbic plaque.*[5]

Salomon Robicsek (1845-1928) was born in Hungary and practiced dentistry in Vienna. He developed a surgical technique that consisted of a scalloped, continuous gingivectomy excision that exposed the marginal bone for subsequent curettage and remodeling.[46]

The first description in 1901 of a possible role of trauma from occlusion and bruxism in periodontal disease is generally attributed

Figure I-8 Bernhard Gottlieb (1885-1950). *(From Gold SI:* J Clin Periodontol *12:171, 1985.)*

Figure I-9 Balint J. Orban (1899-1960). *(From* J Periodontol *31:266, 1960.)*

to the Austrian dentist Moritz Karolyi (1865-1945), who also recommended its correction by grinding occlusal surfaces and preparing bite plates.[34]

Necrotizing Ulcerative Gingivitis

Necrotizing ulcerative gingivitis had been recognized during the fourth century BC by Xenophon, who mentioned that Greek soldiers were affected with "sore mouth and foul-smelling breath." In 1778, Hunter described the clinical features of this disease and differentiated it from scurvy and chronic periodontitis.

Hyacinthe Jean Vincent (1862-1950),[23,49] a French physician working at the Pasteur Institute in Paris, and Hugo Carl Plaut (1858-1928)[42] in Germany described the spirillum and fusiform bacilli associated with what later became known as *Vincent's angina.* In 1904, Vincent described the presence of these organisms in ulceronecrotic gingivitis.[50]

The Twentieth Century

During the first third of the twentieth century, periodontics flourished in central Europe, with two major centers of excellence: Vienna and Berlin.[22]

Vienna

The Vienna school developed the basic histopathologic concepts on which modern periodontics was built. The major representative from this group was Bernhard Gottlieb (1885-1950), who published extensive microscopic studies of periodontal disease in human autopsy specimens (Figure I-8).[19] His major contributions appeared in the German literature during the 1920s, and they described the attachment of the gingival epithelium to the tooth, the histopathology of inflammatory and degenerative periodontal disease, the biology of the cementum, active and passive tooth eruption, and traumatic occlusion. A book published in 1938 by Gottlieb and Orban presented a complete review in English of the concepts developed by Gottlieb and his coworkers in Vienna.[24]

A younger contemporary of Gottlieb's in Vienna was Balint J. Orban (1899-1960) (Figure I-9), who carried out extensive histologic studies on periodontal tissues. These studies serve as the basis for much of current therapy. Other members of the Viennese school were Rudolph Kronfeld (1901-1940), Joseph P. Weinmann (1889-1960), and Harry Sicher (1889-1974). All of these scientists emigrated to the United States during the 1930s and contributed greatly to the progress of American dentistry.

Figure I-10 Oskar Weski (1879-1952). *(From Hoffman-Axthelm W:* History of dentistry, *Chicago, 1981, Quintessence.)*

Berlin

The Berlin group consisted mostly of clinical scientists who developed and refined the surgical approach to periodontal therapy. Prominent in this group were Oskar Weski (Figure I-10) and Robert Neumann (Figure I-11).

Weski (1879-1952) carried out pioneering studies that correlated radiographic and histopathologic changes in patients with periodontal disease.[53] He also conceptualized the periodontium as being formed by the cementum, gingiva, periodontal ligament, and bone, and he gave it the name *paradentium;* this was later changed for etymologic reasons to *parodontium,* which is a term that is still used in Europe.

Neumann (1882-1958), in a book published in 1912[38] (with new editions in 1915, 1920, and 1924), described the principles of

Figure I-11 Robert Neumann (1882-1958). *(Courtesy Dr. Steven I. Gold, New York.)*

periodontal flap surgery, including osseous recontouring as it is currently known[20] (Figure I-12). Other clinicians who described flap surgery at the beginning of the twentieth century were Leonard Widman of Sweden (1871-1956)[54] and A. Cieszynski of Poland. A bitter controversy developed among Widman, Cieszynski, and Neumann during the 1920s with regard to the priority of describing the periodontal flap.

The United States and Other Countries

In the United States, before World War II, important contributions to periodontal surgery were made by A. Zentler, J. Zemsky, G.V. Black, O. Kirkland, A.W. Ward, A.B. Crane, H. Kaplan, and others. In 1923, Ward introduced the surgical pack under the trade name Wondr-Pak.[51]

The nonsurgical approach was championed by Isadore Hirschfeld (1882-1965) of New York, who wrote classic papers about oral hygiene,[28] local factors, and other topics. In 1913, Alfred Fones (1869-1938) opened the first school for dental hygienists in Bridgeport, Connecticut.[9]

In other countries, H.K. Box (Canada); M. Roy and R. Vincent (France); R. Jaccard and A.-J. Held (Switzerland); F.A. Carranza, Sr, and R. Erausquin (Argentina); W.W. James, A. Counsell, and E.W. Fish (Great Britain); and A. Leng (Chile) are well known for their important contributions. Probably the most comprehensive book about periodontics published during the first half of the twentieth century was *El Paradencio, Su Patologia y Tratamiento,* which was written by the Uruguayan F.M. Pucci in 1939.

Focal Infection

The concept of systemic diseases originating in dental and oral infections had been mentioned in the Assyrian clay tablets (seventh century BC), by Hippocrates (460-370 BC), in the Babylonian Talmud (third century AD), and by Girolamo Cardano and the German Walter Hermann Ryff during the sixteenth century.[29,52] During the nineteenth century, Benjamin Rush (a famous physician and one of the signers of the American Declaration of Independence) in 1818 and Leonard Koecker in 1828 recognized the role of oral sepsis in rheumatic and other diseases. Later during the

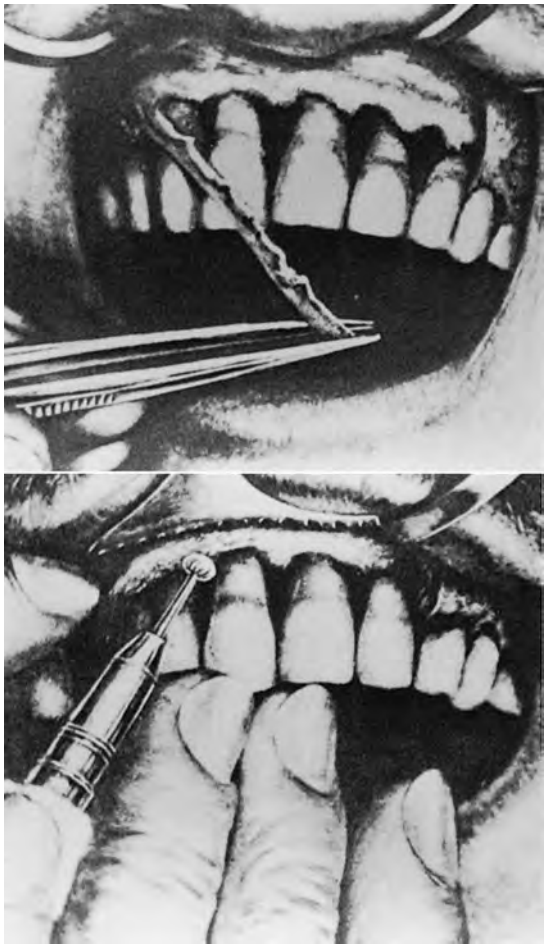

Figure I-12 Surgical procedure advocated by Robert Neumann during the early part of the twentieth century. *Top,* After raising a mucoperiosteal flap, its edge is trimmed with scissors to leave a scalloped outline. *Bottom,* Osseous recontouring with burs. *(From Gold SI:* J Periodontol *53:456, 1982.)*

nineteenth century, W.D. Miller also mentioned oral infections as the cause of many diseases.[37]

In a paper published in 1900[31] and a decade later in a lecture at McGill University in Montreal, Quebec, Canada,[32] William Hunter (1861-1937), a British physician, indicted dentistry as being the cause of oral sepsis, which in turn caused rheumatic and other chronic diseases. This idea was taken up by Billings, Rosenow, and many others, who advocated the extraction of all teeth with periodontal or periapical infections to prevent systemic diseases. This led to the wholesale extraction of teeth and the removal of the tonsils.

The focal infection theory fell into disrepute when it was found that extractions failed to eliminate or reduce the systemic diseases to which the infected teeth were supposed to be linked.[15] However, the concept was revisited during the 1990s, this time with a more solid research foundation.

Dental Implants

The replacement of human teeth with implants has been attempted for centuries. Skulls with metal or stone implants have been found in a Gallo-Roman necropolis in France and dated from the second century AD; they were also found in a mandible of Mayan origin dated about 600 AD.[9]

In 1806, the Italian M. Maggiolo attempted to place solid-gold roots in human jaws. Later during the nineteenth century, several

Figure I-13 Irving Glickman (1914-1972).

Figure I-14 Jens Waerhaug (1907-1980). *(From* J Clin Periodontol *7:534, 1980.)*

other investigators used porcelain and metallic implants. During the first half of the twentieth century, several attempts were made to use elaborate surgical techniques and complicated constructs of gold and other precious metals. Microscopic investigations were begun to address the tissue response to various metals.

In 1939, A.E. Strock of Harvard University started implanting cobalt–chromium (Vitallium) screws into tooth sockets. After World War II, numerous attempts were made with different materials and shapes of implants, including tantalum twisted spiral (Formiggini), Vitallium tree shaped (Lee), acrylic tooth root replica (Hodosh), Vitallium double helical spiral (Chércheve), tantalum tripodal pins (Scialom), tantalum vent-plant and titanium blade (Linkow), and vitreous carbon.[9]

During the 1950s, the Swedish orthopedic surgeon Per-Ingvar Bränemark developed a technique that involved the use of titanium screw-shaped intraosseous implants. This proved to be quite successful, and it was gradually adopted by the dental profession after the 1982 international conference in Toronto, Ontario, Canada. The success and predictability of Bränemark's technique are attributed to the achievement of direct contact between vital bone and the implant surface without intervening soft tissue; this phenomenon was later termed *osseointegration.*[6] Numerous variations of the Bränemark concept were presented by A. Kirsch, G.A. Niznick, A. Schroeder, and others, and they are widely used at present.

After World War II

The United States and Scandinavia took leading roles in basic and clinical periodontal research during and after the 1950s, with major advances made in the fields of experimental pathology, microbiology, immunology, and therapy.

In the United States, five individuals led the efforts to advance our understanding of disease processes and the technical approaches needed to address them: Irving Glickman (1914-1972) (Figure I-13), Henry M. Goldman (1911-1991), Balint J. Orban (1899-1960) (see Figure I-8), Sigurd P. Ramfjord (1911-1997), and Helmut A. Zander (1912-1991). In the clinical area, the influence of John Prichard (1907-1990) and Saul Schluger (1908-1990) led to new concepts and new directions in the pursuit of clinical success and excellence.

The leading figure of the Scandinavian group was Jens Waerhaug (1907-1980) (Figure I-14) of Oslo, Norway, whose dissertation entitled *The Gingival Pocket* (1952) and whose lifetime of research opened a new era in the understanding of the biology of the periodontium and the management of periodontal problems.

The next generations centered their attention more on the role of microorganisms and the host response, including its defensive and its destructive aspects. Their contributions, as well as those of their predecessors, are documented in this book.

Several workshops and international conferences have summarized existing knowledge regarding the biologic and clinical aspects of periodontology. Worthy of mention are those that were conducted in 1951, 1966, 1977, 1989, 1996, 1999, and 2008, which were cosponsored and published by the American Academy of Periodontology.

The American Academy of Periodontology, which was founded in 1914 by two female periodontists, Grace Rogers Spalding (1881-1953) and Gillette Hayden (1880-1929), has become the leader in organized periodontics. Its monthly scientific publication, *Journal of Periodontology,* presents all current advances in this discipline. In Europe, the periodontal societies have joined to form the European Federation of Periodontology, which meets regularly at the Europerio meeting. Their official publication is *Journal of Clinical Periodontology.* Other scientific periodontal journals in English include *Journal of Periodontal Research, Periodontology 2000,* and *International Journal of Periodontics and Restorative Dentistry.* With regard to journals in other languages, *Journal de Parodontologie* (France), *Periodoncia* (Spain), and *Journal of the Japanese Association of Periodontology* deserve mention.

Periodontal education in the United States also has grown during the second half of the twentieth century, and most dental schools have separate and independent units for teaching and research in this discipline. Periodontics was recognized as a specialty of dentistry by the American Dental Association in 1947. The first university-based programs for the training of specialists in periodontics were begun in several universities (e.g., Columbia, Michigan, Tufts) during the late 1940s; these 1-year programs expanded to 2-year programs about 10 years later. In 1995, the American Academy of Periodontology mandated that all postgraduate periodontal programs increase to a 3-year curriculum because of the increased knowledge in periodontics and the expansion of the scope of periodontics to include the placement of dental implants and the administration of conscious sedation. Currently

in the United States, more than 50 periodontal graduate programs are based in universities and hospitals.

The History of This Book

The originator of this book and the author of its first four editions, which were published in 1953, 1958, 1964, and 1972, was Dr. Irving Glickman (see Figure I-13), professor and chairman of the Department of Periodontology at Tufts University School of Dental Medicine in Boston, Massachusetts.

Dr. Glickman was an outstanding researcher, a superb educator, and a gifted speaker and writer whose concepts shaped periodontal thinking for many years. His style of writing, his ideas, and his philosophy of dental practice can still be found in many areas of this book.

After Dr. Glickman's death in 1972 at age 58, responsibility for continuing this book moved to Dr. Fermin A. Carranza, who had been a student and collaborator of Dr. Glickman. At the time, Dr. Carranza was professor and chairman of periodontics at the School of Dentistry of the University of California, Los Angeles. The following four editions were published in 1979, 1984, 1990, and 1996 under the guidance of Dr. Carranza, who is now professor emeritus at the University of California, Los Angeles.

In 2002, the task of maintaining the book's tradition of almost half a century changed hands once again. Drs. Michael G. Newman and Henry H. Takei joined Dr. Carranza to take major responsibility for the ninth edition. Starting with the tenth (2006) edition, they were joined by Dr. Perry Klokkevold.

References

References for this chapter are found on the companion website, www.expertconsult.com.

References

1. Albucasis: *La chirurgie*, Paris, 1861, Bailliére. (Translated by L LeClere).
2. *Artzney Buchlein*, Leipzig, 1530, Michael Blum. (English translation in *Dent Cosmos* 29:1, 1887).
3. Avicenna: *Liber Canonis*, Venice, 1507. (Reprinted, Hildesheim, 1964, Georg Olms.)
4. Berdmore T: *A treatise on the disorders and deformities of the teeth and gums*, London, 1786, B White.
5. Black GV: *Special dental pathology*, Chicago, 1915, Medico-Dental Publishers.
6. Bränemark PI, Hansson BO, Adell R, et al: Osseointegrated implants in the treatment of the edentulous jaw: experience from a 10-year period. *Scand J Plast Reconstr Surg Suppl* 16:1, 1977.
7. Breasted JH: *The Edwin Smith surgical papyrus*, Chicago, 1930, University of Chicago Press.
8. Carranza FA: *Héroes de la medicina*, Buenos Aires, 2008, EUDEBA.
9. Carranza FA, Shklar G: *The history of periodontology*, Chicago, 2003, Quintessence.
10. Castiglione A: *History of medicine*, ed 2, New York, 1941, Knopf.
11. Chernin D, Shklar G: Levi Spear Parmly: father of dental hygiene and children's dentistry in America. *J Hist Dent* 51:15, 2003.
12. Dabry P: *La medicine chez les Chinois*, Paris, 1863, Plon.
13. Dobell C: *Anton van Leeuwenhoek and his "little animals,"* New York, 1932, Harcourt. (Reprinted, New York, 1960, Dover Publications).
14. Ebbel B: *The papyrus Ebers*, Copenhagen, 1937, Levin and Munksgaard.
15. Editorial. *JAMA* 150:490, 1952.
16. Eustachius B: *A little treatise on the teeth*, 1999, Science History Publishers/USA. (Edited and introduced by DA Chernin and G Shklar; translated by JH Thomas.)
17. Fauchard P: *Le chirurgien dentiste, ou traite des dents*, Paris, 1728, J Maruiette. (Reprinted in facsimile, Paris, Prélat, 1961; English translation by L Lindsay, London, 1946, Butterworth & Co.)
18. Fischman SL: The history of oral hygiene: how far have we come in 6000 years. *Periodontol 2000* 15:7, 1997.
19. Fleischmann L, Gottlieb B: Beitrage zur histologie und pathogenese der alveolarpyorrhoe. *Z Stomatol* 2:44, 1920.
20. Gold SI: Robert Neumann: a pioneer in periodontal flap surgery. *J Periodontol* 53:456, 1982.
21. Gold SI: Periodontics: the past. Part I. Early sources. *J Clin Periodontol* 12:79, 1985.
22. Gold SI: Periodontics: the past. Part II. The development of modern periodontics. *J Clin Periodontol* 12:171, 1985.
23. Gold SI: Periodontics: the past. Part III. Microbiology. *J Clin Periodontol* 12:257, 1985.
24. Gottlieb B, Orban B: *Biology and pathology of the tooth and its supporting mechanism*, New York, 1938, Macmillan. (Translated and edited by M Diamond.)
25. Guerini V: *History of dentistry*, Philadelphia, 1909, Lea & Febiger.
26. Held A-J: *Periodontology—from its origins up to 1980: a survey*, Boston, 1989, Birkhauser.
27. *Hippocrates: Works*, London, 1923, Heinemann. (Edited and translated by WHS Jones and ET Withington, 1931.)
28. Hirschfeld I: *The toothbrush: its use and abuse*, New York, 1939, Dental Items of Interest Publishers.
29. Hoffman-Axthelm W: *History of dentistry*, Chicago, 1981, Quintessence.
30. Hunter J: *The natural history of the human teeth*, London, 1771, J Johnson. (Reprinted as Treatise in the natural history and diseases of the human teeth. In Bell T, editor: *Collected works,* London, 1835, Longman Rees.)
31. Hunter W: Oral sepsis as a cause of disease. *Br Med J* 1:215, 1900.
32. Hunter W: An address on the role of sepsis and antisepsis in medicine. *Lancet* 1:79, 1911.
33. Jastrow N: The medicine of the Babylonians and Assyrians. *Proc Soc Med London* 7:109, 1914.
34. Karolyi M: Beobachtungen ber pyorrhea alveolaris. *Vjschr Zahnheilk* 17:279, 1901.
35. Koecker A: An essay on the devastation of the gums and the alveolar processes. *Philadelphia J Med Phys Sci* 2:282, 1821.
36. Major RHL: *A history of medicine*, Springfield, IL, 1954, Charles C Thomas.
37. Miller WD: The human mouth as a focus of infection. *Dent Cosmos* 33:689, 1891.
38. Neumann R: *Die alveolarpyorrhoe und ihre behandlung*, Berlin, 1912, Meusser.
39. Paracelsus: *Sämtliche Werke (Collected works in modern German)*, vol 14, Munich, 1922, R Oldfenbourg. (Edited by K Sudhoff.)
40. Paré A: *Oeuvres completes*, Paris, 1840, Bailliére. (Edited by JF Malgaigne.)
41. *Paul of Aegina: The Seven Books*, London, 1844, Sydenham Society. (Translated by F Adams).
42. Plaut HC: Studien zur bakteriellen diagnostik der diphtherie und der anginen. *Dtsch Med Wochenschr* 20:920, 1894.
43. Riggs JW: Suppurative inflammation of the gums and absorption of the gums and alveolar process. *Pa J Dent Sci* 3:99, 1876. (Reprinted in *Arch Clin Oral Pathol* 2:423, 1938.)
44. Ruffer MA: *Studies in the paleopathology of Egypt*, Chicago, 1921, University of Chicago Press.
45. Shklar G: Stomatology and dentistry in the golden age of Arabian medicine. *Bull Hist Dent* 17:17, 1969.
46. Stern IB, Everett FG, Robicsek K: S. Robicsek: a pioneer in the surgical treatment of periodontal disease. *J Periodontol* 36:265, 1965.
47. *Susruta samhita*, Calcutta, 1907, KKL Bhishagratna.
48. Vesalius A: *De humanis corporis fabrica*, Basle, 1542. (Reproduced in facsimile, Brussels, 1966, Culture et Civilisation).
49. Vincent HJ: Sur l'etiologie et sur les lesions anatomopathologiques de la pourriture d'hospital. *Ann de l'Inst Pasteur* 10:448, 1896.
50. Vincent HJ: Recherche sur l'etiologie de la stomatitis ulceromembraneuse primitive. *Arch Int Laryngol* 17:355, 1904.
51. Ward AW: Inharmonius cusp relation as a factor in periodontoclasia. *J Am Dent Assoc* 10:471, 1923.
52. Weinberger BW: *An introduction to the history of dentistry*, St Louis, 1948, Mosby.
53. Weski O: Roentgenographische-anatomische studien auf dem gebiete der kieferpathologie. *Vjrsch Zahnh* 37:1, 1921.
54. Widman L: Surgical treatment of pyorrhea alveolaris. *J Periodontol* 42:571, 1971.
55. Williams JL: A contribution to the study of pathology of enamel. *Dent Cosmos* 39:169, 1897.
56. Witzel A: The treatment of pyorrhea alveolaris or infectious alveolitis. *Br J Dent Sci* 25(209):153, 1882.
57. Younger WJ: Pyorrhea alveolaris. *Schweiz Vierteljähresscrift Zahnheilk* 15:87, 1905.
58. Znamensky NN: Alveolar pyorrhoea: its pathological anatomy and its radical treatment. *J Br Dent Assoc* 23:585, 1902.

CHAPTER 1

Anatomy of the Periodontium

Joseph P. Fiorellini and Panagiota G. Stathopoulou

CHAPTER OUTLINE

Oral Mucosa
Gingiva
Periodontal Ligament
Cementum
Alveolar Process
Development of the Attachment Apparatus
External Forces and the Periodontium
Vascularization of the Supporting Structures

For online only content on the gingival epithelium, the alveolar process, and the attachment apparatus, please visit the companion website at www.expertconsult.com.

The normal periodontium provides the support necessary to maintain teeth in function. It consists of four principal components: gingiva, periodontal ligament, cementum, and alveolar bone. Each of these periodontal components is distinct in its location, tissue architecture, biochemical composition, and chemical composition, but all of these components function together as a single unit. Recent research has revealed that the extracellular matrix components of one periodontal compartment can influence the cellular activities of adjacent structures. Therefore, the pathologic changes that occur in one periodontal component may have significant ramifications for the maintenance, repair, or regeneration of other components of the periodontium.[18]

This chapter first discusses the structural components of the normal periodontium; it then describes their development, vascularization, innervation, and functions (video 1-1).

Oral Mucosa

The *oral mucosa* consists of the following three zones:

1. The gingiva and the covering of the hard palate, termed the *masticatory mucosa* (The *gingiva* is the part of the oral mucosa that covers the alveolar processes of the jaws and surrounds the necks of the teeth.)
2. The dorsum of the tongue, covered by *specialized mucosa*
3. The oral mucous membrane lining the remainder of the oral cavity

Gingiva

Clinical Features

In an adult, normal gingiva covers the alveolar bone and tooth root to a level just coronal to the cementoenamel junction. The gingiva is divided anatomically into *marginal, attached,* and *interdental areas.* Although each type of gingiva exhibits considerable variation in differentiation, histology, and thickness according to its functional demands, all types are specifically structured to function appropriately against mechanical and microbial damage.[7] In other words, the specific structure of different types of gingiva reflects each one's effectiveness as a barrier to the penetration by microbes and noxious agents into the deeper tissue.

Marginal Gingiva. The marginal or unattached gingiva is the terminal edge or border of the gingiva that surrounds the teeth in collarlike fashion (Figures 1-1 and 1-2).[6] In about 50% of cases, it is demarcated from the adjacent attached gingiva by a shallow linear depression called the *free gingival groove.*[6] The marginal gingiva is usually about 1 mm wide, and it forms the soft-tissue wall of the gingival sulcus. It may be separated from the tooth surface with a periodontal probe. The most apical point of the marginal gingival scallop is called the *gingival zenith.* Its apicocoronal and mesiodistal dimensions vary between 0.06 and 0.96 mm.[171]

Gingival Sulcus. The gingival sulcus is the shallow crevice or space around the tooth bounded by the surface of the tooth on one side and the epithelium lining the free margin of the gingiva on the other side. It is V-shaped, and it barely permits the entrance of a periodontal probe. The clinical determination of the depth of the gingival sulcus is an important diagnostic parameter. Under absolutely normal or ideal conditions, the depth of the gingival sulcus is 0 mm or close to 0 mm.[105] These strict conditions of normalcy can be produced experimentally only in germ-free animals or after intense and prolonged plaque control.[13,49]

In clinically healthy human gingiva, a sulcus of some depth can be found. The depth of this sulcus, as determined in histologic sections, has been reported as 1.8 mm, with variations from 0 to 6 mm[195]; other studies have reported 1.5 mm[289] and 0.69 mm.[93] The clinical evaluation used to determine the depth of the sulcus involves the introduction of a metallic instrument (i.e., the periodontal probe) and the estimation of the distance it penetrates (i.e., the probing depth). The histologic depth of a sulcus does not need to be exactly equal to the depth of penetration of the probe. The penetration of the probe depends on several factors, such as probe diameter, probing force, and level of inflammation.[91] Consequently,

Figure 1-1 Normal gingiva in a young adult. Note the demarcation (mucogingival line) *(arrows)* between the attached gingiva and the darker alveolar mucosa.

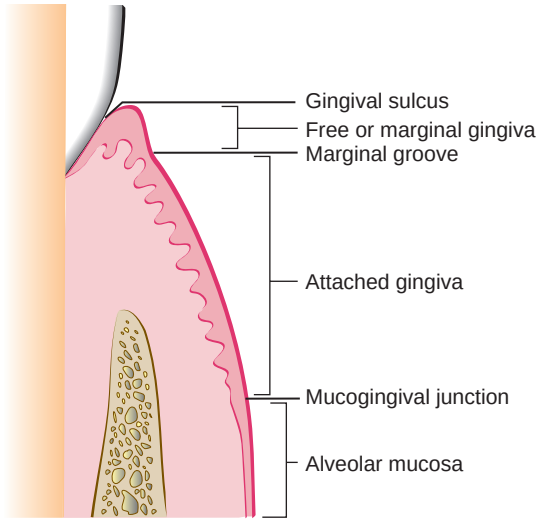

Figure 1-2 Diagram showing the anatomic landmarks of the gingiva.

the probing depth is not necessarily exactly equal to the histologic depth of the sulcus. The so-called probing depth of a clinically normal gingival sulcus in humans is 2 to 3 mm (see Chapter 30).

Attached Gingiva. The attached gingiva is continuous with the marginal gingiva. It is firm, resilient, and tightly bound to the underlying periosteum of alveolar bone. The facial aspect of the attached gingiva extends to the relatively loose and movable alveolar mucosa; it is demarcated by the *mucogingival junction* (see Figure 1-2).

The *width of the attached gingiva* is another important clinical parameter.[7] It is the distance between the mucogingival junction and the projection on the external surface of the bottom of the gingival sulcus or the periodontal pocket. It should not be confused with the *width of the keratinized gingiva,* although this also includes the marginal gingiva (see Figure 1-2).

The width of the attached gingiva on the facial aspect differs in different areas of the mouth.[40] It is generally greatest in the incisor region (i.e., 3.5 to 4.5 mm in the maxilla, 3.3 to 3.9 mm in the mandible) and narrower in the posterior segments (i.e., 1.9 mm in the maxillary first premolars and 1.8 mm in the mandibular first premolars)[6] (Figure 1-3).

Figure 1-3 Mean width of the attached gingiva in the human permanent dentition.

Because the mucogingival junction remains stationary throughout adult life,[4] changes in the width of the attached gingiva are caused by modifications in the position of its coronal portion. The width of the attached gingiva increases by the age of 4 years and in supraerupted teeth.[5] On the lingual aspect of the mandible, the attached gingiva terminates at the junction of the lingual alveolar mucosa, which is continuous with the mucous membrane that lines the floor of the mouth. The palatal surface of the attached gingiva in the maxilla blends imperceptibly with the equally firm and resilient palatal mucosa.

Interdental Gingiva. The interdental gingiva occupies the gingival embrasure, which is the interproximal space beneath the area of tooth contact. The interdental gingiva can be pyramidal, or it can have a "col" shape. In the former, the tip of one papilla is located immediately beneath the contact point; the latter presents a valleylike depression that connects a facial and lingual papilla and that conforms to the shape of the interproximal contact[62] (Figures 1-4 and 1-5). The shape of the gingiva in a given interdental space depends on the presence or absence of a contact point between the adjacent teeth, the distance between the contact point and the osseous crest,[260] and the presence or absence of some degree of recession. Figure 1-6 depicts the variations in normal interdental gingiva.

The facial and lingual surfaces are tapered toward the interproximal contact area, whereas the mesial and distal surfaces are slightly concave. The lateral borders and tips of the interdental papillae are formed by the marginal gingiva of the adjoining teeth. The intervening portion consists of attached gingiva (Figure 1-7). If a diastema is present, the gingiva is firmly bound over the interdental bone to form a smooth, rounded surface without interdental papillae (Figure 1-8).

Microscopic Features

Microscopic examination reveals that gingiva is composed of the overlying stratified squamous epithelium and the underlying central core of connective tissue. Although the epithelium is predominantly cellular in nature, the connective tissue is less cellular and composed primarily of collagen fibers and ground substance. These two tissues are considered separately.*

*A detailed description of gingival histology can be found in Schroeder HE: *The periodontium,* New York, 1986, Springer-Verlag; and in Biological structure of the normal and diseased periodontium, *Periodontol 2000* 13:1, 1997.

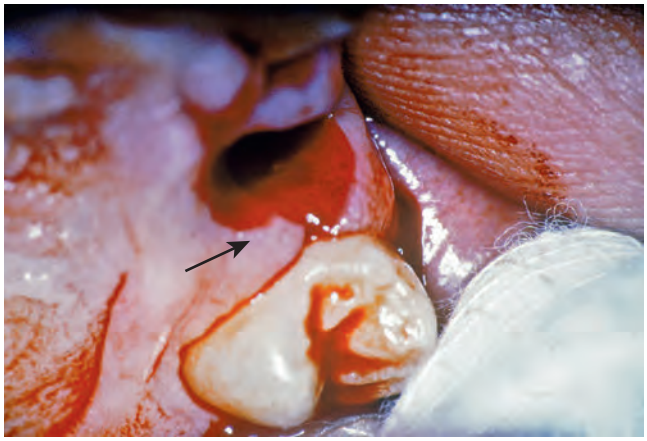

Figure 1-4 Site of extraction showing the facial and palatal interdental papillae and the intervening col *(arrow)*.

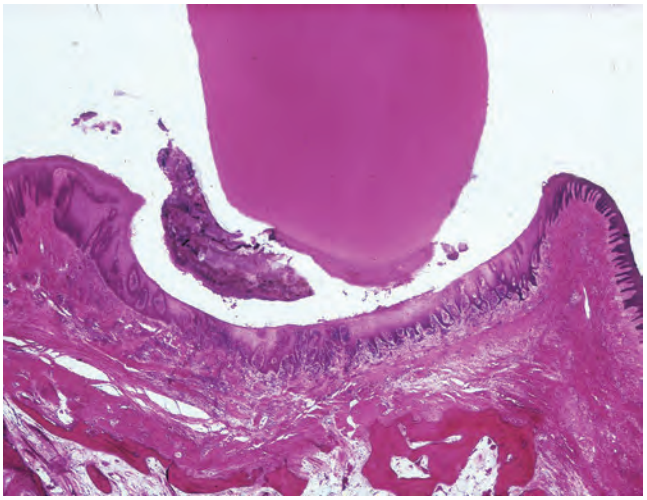

Figure 1-5 Faciolingual section of a monkey showing the col between the facial and lingual interdental papillae. The col is covered with nonkeratinized stratified squamous epithelium.

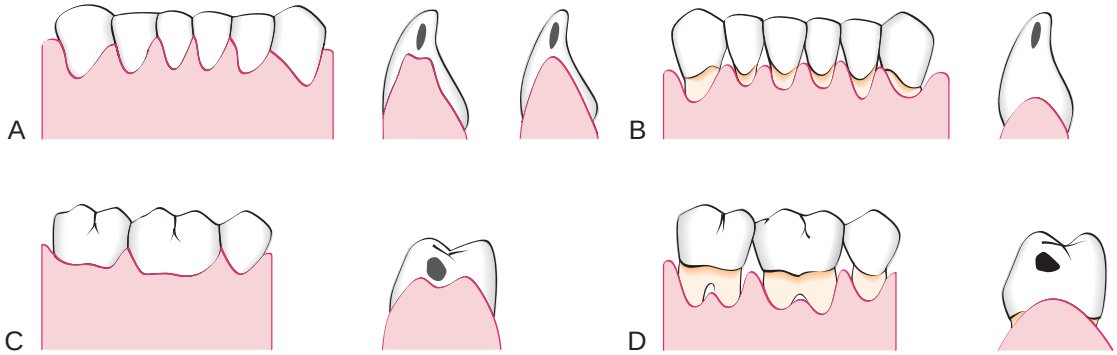

Figure 1-6 A diagram that compares anatomic variations of the interdental col in the normal gingiva *(left side)* and after gingival recession *(right side)*. **A** and **B,** Mandibular anterior segment, facial and buccolingual views, respectively. **C** and **D,** Mandibular posterior region, facial and buccolingual views, respectively. Tooth contact points are shown with black marks in the lower individual teeth.

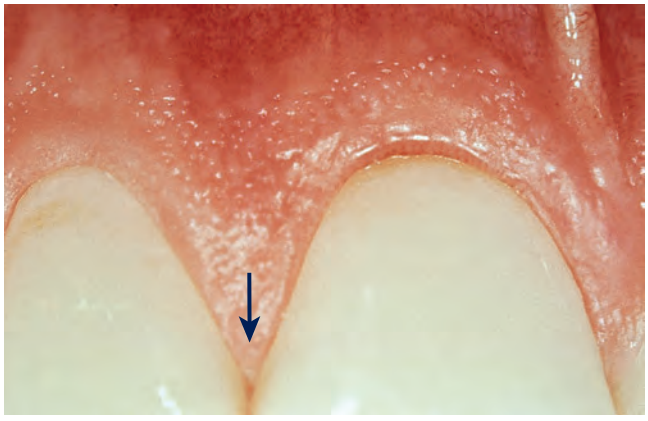

Figure 1-7 Interdental papillae *(arrow)* with a central portion formed by the attached gingiva. The shape of the papillae varies according to the dimension of the gingival embrasure. *(Courtesy Dr. Osvaldo Costa.)*

Figure 1-8 An absence of interdental papillae and col where the proximal tooth contact is missing. *(Courtesy Dr. Osvaldo Costa.)*

Gingival Epithelium

General Aspects of Gingival Epithelium Biology. Historically, the epithelial compartment was thought to provide only a physical barrier to infection and the underlying gingival attachment. However, we now believe that epithelial cells play an active role in innate host defense by responding to bacteria in an interactive manner,[67] which means that the epithelium participates actively in responding to infection, in signaling further host reactions, and in integrating innate and acquired immune responses. For example, epithelial cells may respond to bacteria by increased proliferation, the alteration of cell-signaling events, changes in differentiation and cell death, and, ultimately, the alteration of tissue homeostasis.[67] To understand this new perspective of the epithelial innate defense responses and the role of epithelium in gingival health and disease, it is important to understand its basic structure and function (Box 1-1).

Immunohistochemistry, gel electrophoresis, and immunoblot techniques have made the identification of the characteristic pattern of cytokeratins possible in each epithelial type. The keratin proteins are composed of different polypeptide subunits characterized by their isoelectric points and molecular weights. They are numbered in a sequence that is contrary to their molecular weight. In general, basal cells begin synthesizing lower-molecular-weight keratins (e.g., K19 [40 kD]), and they express other higher-molecular-weight keratins as they migrate to the surface. K1 keratin polypeptide (68 kD) is the main component of the stratum corneum.[60]

Other proteins unrelated to keratins are synthesized during the maturation process. The most extensively studied are *keratolinin* and *involucrin,* which are precursors of a chemically resistant structure (the envelope) located below the cell membrane, and *filaggrin,* which has precursors that are packed into the keratohyalin granules. At the sudden transition to the horny layer, the keratohyalin granules disappear and give rise to filaggrin, which forms the matrix of the most differentiated epithelial cell, the *corneocyte.*

Thus, in the fully differentiated state, the corneocytes are mainly formed by bundles of keratin tonofilaments embedded in an amorphous matrix of filaggrin and surrounded by a resistant envelope under the cell membrane. The immunohistochemical patterns of the different keratin types, envelope proteins, and filaggrin change under normal or pathologic stimuli, thereby modifying the keratinization process.[128-130]

Electron microscopy reveals that keratinocytes are interconnected by structures on the cell periphery called *desmosomes.*[154] These desmosomes have a typical structure that consists of two dense attachment plaques into which tonofibrils insert and an intermediate, electron-dense line in the extracellular compartment. Tonofilaments, which are the morphologic expression of the cytoskeleton of keratin proteins, radiate in brushlike fashion from the attachment plaques into the cytoplasm of the cells. The space between the cells shows cytoplasmic projections that resemble microvilli and that extend into the intercellular space and often interdigitate.

Less frequently observed forms of epithelial cell connections are tight junctions *(zonae occludens),* in which the membranes of the adjoining cells are thought to be fused.[268,287] Evidence suggests that these structures allow ions and small molecules to pass from one cell to another.

Cytoplasmic organelle concentration varies among different epithelial strata. Mitochondria are more numerous in deeper strata and decrease toward the surface of the cell.

Accordingly, the histochemical demonstration of succinic dehydrogenase, nicotinamide-adenine dinucleotide, cytochrome oxidase, and other mitochondrial enzymes reveals a more active tricarboxylic cycle in basal and parabasal cells, in which the proximity of the blood supply facilitates energy production through aerobic glycolysis.

Conversely, enzymes of the pentose shunt (an alternative pathway of glycolysis), such as glucose-6-phosphatase, increase their activity toward the surface. This pathway produces a larger amount of intermediate products for the production of ribonucleic acid (RNA), which in turn can be used for the synthesis of keratinization proteins. This histochemical pattern is in accordance with the increased volume and the amount of tonofilaments observed in cells reaching the surface; the intensity of the activity is proportional to the degree of differentiation.[72,82,127,202]

The uppermost cells of the stratum spinosum contain numerous dense granules called *keratinosomes* or *Odland bodies,* which are modified lysosomes. They contain a large amount of acid phosphatase, an enzyme involved in the destruction of organelle membranes, which occurs suddenly between the granulosum and corneum strata and during the intercellular cementation of cornified cells. Thus, acid phosphatase is another enzyme that is closely related to the degree of keratinization.[46,125,284] These contain tyrosinase, which hydroxylates tyrosine to dihydroxyphenylalanine (dopa), which in turn is progressively converted to melanin. Melanin granules are phagocytosed and contained within other cells of the epithelium and connective tissue called *melanophages* or *melanophores.*

The gingival epithelium consists of a continuous lining of stratified squamous epithelium. There are three different areas that can be defined from the morphologic and functional points of view: the oral or outer epithelium, the sulcular epithelium, and the junctional epithelium.

The principal cell type of the gingival epithelium—as well as of other stratified squamous epithelia—is the *keratinocyte.* Other cells found in the epithelium are the clear cells or nonkeratinocytes, which include the Langerhans cells, the Merkel cells, and the melanocytes.

The main function of the gingival epithelium is to protect the deep structures while allowing for a selective interchange with the oral environment. This is achieved via the proliferation and differentiation of the keratinocytes. The *proliferation* of keratinocytes takes place by mitosis in the basal layer and less frequently in the suprabasal layers, in which a small proportion of cells remain as a proliferative compartment while a larger number begin to migrate to the surface.

Differentiation involves the process of keratinization, which consists of progressions of biochemical and morphologic events that occur in the cell as they migrate from the basal layer (Figure 1-9). The main morphologic changes include the following: (1) the progressive flattening of the cell with an increasing prevalence of tonofilaments; (2) the couple of intercellular junctions with the production of keratohyalin granules; and (3) the disappearance of the nucleus. (See Schroeder[230] for further details.)

A complete keratinization process leads to the production of an *orthokeratinized* superficial horny layer similar to that of the skin, with no nuclei in the stratum corneum and a well-defined stratum granulosum (Figure 1-10). Only some areas of the outer gingival epithelium are orthokeratinized; the other gingival areas are covered by parakeratinized or nonkeratinized epithelium[45] and considered to be at intermediate stages of keratinization. These areas can progress to maturity or dedifferentiate under different physiologic or pathologic conditions.

In *parakeratinized epithelia,* the stratum corneum retains pyknotic nuclei, and the keratohyalin granules are dispersed rather than giving rise to a stratum granulosum. The *nonkeratinized epithelium* (although cytokeratins are the major component, as in all epithelia) has neither granulosum nor corneum strata, whereas superficial cells have viable nuclei.

Non-keratinocyte cells are present in gingival epithelium as in other malpighian epithelia. *Melanocytes* are dendritic cells located in the basal and spinous layers of the gingival epithelium. They synthesize melanin in organelles called *premelanosomes* or *melanosomes*[61,228,252] (Figure 1-11).

Langerhans cells are dendritic cells located among keratinocytes at all suprabasal levels (Figure 1-12). They belong to the mononuclear phagocyte system (reticuloendothelial system) as modified monocytes derived from the bone marrow. They contain

BOX 1-1 Functions and Features of Gingival Epithelium

Functions
Mechanical, chemical, water, and microbial barrier
Signaling functions

Architectural Integrity
Cell–cell attachments
Basal lamina
Keratin cytoskeleton

Major Cell Type
Keratinocyte

Other Cell Types
Langerhans cells
Melanocytes
Merkel cells

Constant Renewal
Replacement of damaged cells

Cell–Cell Attachments
Desmosomes
Adherens junctions
Tight junctions
Gap junctions

Cell–Basal Lamina
Synthesis of basal lamina components
Hemidesmosome

Modified from Dale BA: *Periodontol 2000* 30:71, 2002.

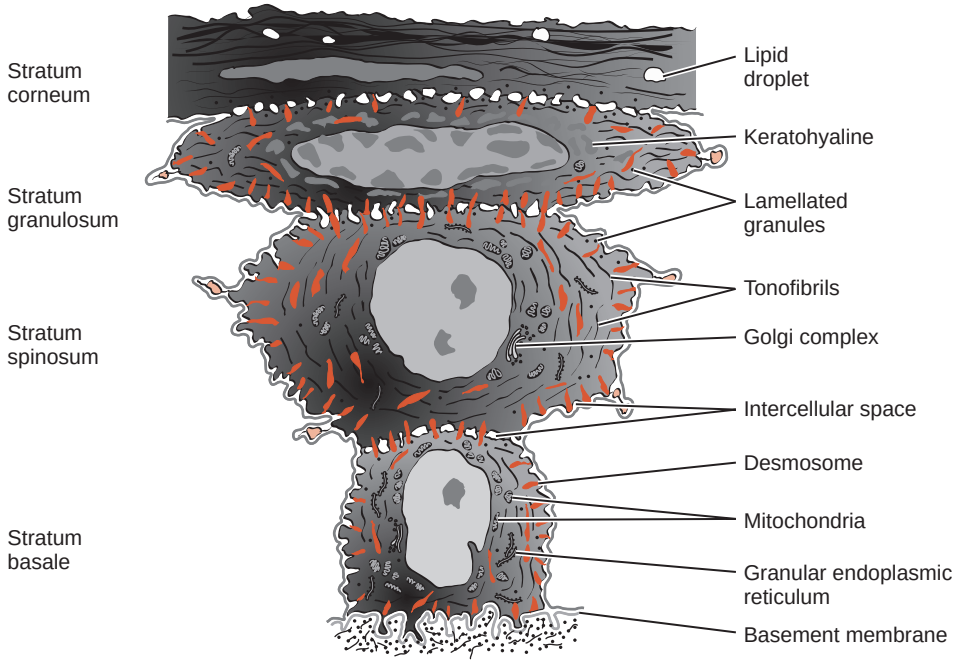

Figure 1-9 Diagram showing representative cells from the various layers of stratified squamous epithelium as seen by electron microscopy. *(Modified from Weinstock A: In Ham AW:* Histology, *ed 7, Philadelphia, 1974, Lippincott.)*



Figure 1-10 **A,** Scanning electron micrograph of keratinized gingiva showing the flattened keratinocytes and their boundaries on the surface of the gingiva (×1000). **B,** Scanning electron micrograph of the gingival margin at the edge of the gingival sulcus showing several keratinocytes about to be exfoliated (×3000). *(From Kaplan GB, Pameijer CH, Ruben MP:* J Periodontol *48:446, 1977.)*

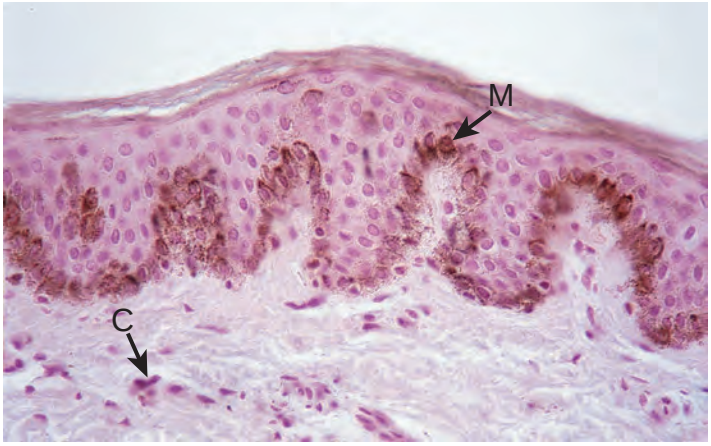

Figure 1-11 Pigmented gingiva of dog showing melanocytes *(M)* in the basal epithelial layer and melanophores *(C)* in the connective tissue (Glucksman technique).

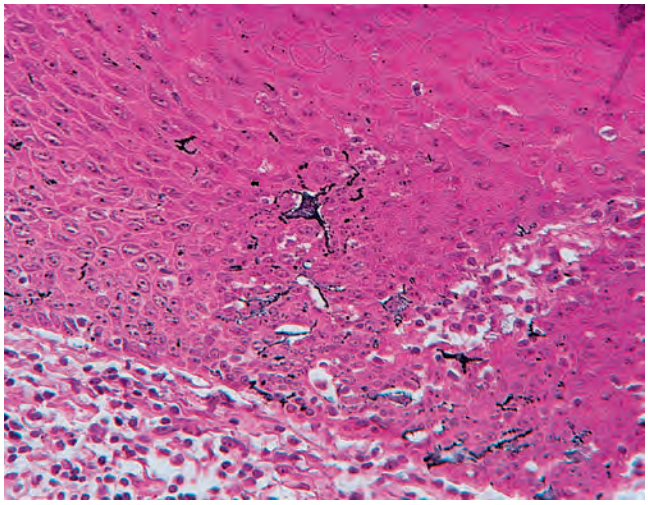

Figure 1-12 Human gingival epithelium, oral aspect. Immunoperoxidase technique showing Langerhans cells.

elongated granules, and they are considered macrophages with possible antigenic properties.[72] Langerhans cells have an important role in the immune reaction as antigen-presenting cells for lymphocytes. They contain g-specific granules (Birbeck granules), and they have marked adenosine triphosphatase activity. They are found in the oral epithelium of normal gingiva and in smaller amounts in the sulcular epithelium; they are probably absent from the junctional epithelium of normal gingiva.

Merkel cells are located in the deeper layers of the epithelium; they harbor nerve endings, and they are connected to adjacent cells by desmosomes. They have been identified as tactile perceptors.[188]

The epithelium is joined to the underlying connective tissue by a *basal lamina* 300 to 400 Å thick and lying approximately 400 Å beneath the epithelial basal layer.[147,235,254] The basal lamina consists of lamina lucida and lamina densa. Hemidesmosomes of the basal epithelial cells abut the lamina lucida, which is mainly composed of the glycoprotein laminin. The lamina densa is composed of type IV collagen.

The basal lamina, which is clearly distinguishable at the ultrastructural level, is connected to a reticular condensation of the underlying connective tissue fibrils (mainly collagen type IV) by the anchoring fibrils.[183,213,257] Anchoring fibrils have been measured at 750 nm in length from their epithelial end to their connective tissue end, where they appear to form loops around collagen fibers. The complex of basal lamina and fibrils is the periodic acid–Schiff–positive and argyrophilic line observed at the optical level [237,258] (Figure 1-13). The basal lamina is permeable to fluids, but it acts as a barrier to particulate matter.

Structural and Metabolic Characteristics of Different Areas of Gingival Epithelium. The epithelial component of the gingiva shows regional morphologic variations that reflect tissue adaptation to the tooth and alveolar bone.[231] These variations include the oral epithelium, the sulcular epithelium, and the junctional epithelium. Whereas the oral epithelium and the sulcular epithelium are largely protective in function, the junctional epithelium serves many more roles and is of considerable importance in the regulation of tissue health.[18] It is now recognized that epithelial cells are not "passive bystanders" in the gingival tissues; rather, they are metabolically active and capable of reacting to external stimuli by synthesizing a number of cytokines, adhesion molecules, growth factors, and enzymes.[18]

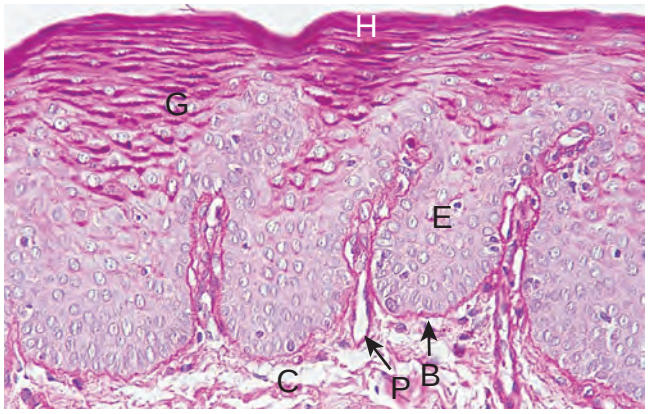

Figure 1-13 Normal human gingiva stained with the periodic acid–Schiff histochemical method. The basement membrane *(B)* is seen between the epithelium *(E)* and the underlying connective tissue *(C)*. In the epithelium, glycoprotein material occurs in cells and cell membranes of the superficial hornified *(H)* and underlying granular layers *(G)*. The connective tissue presents a diffuse, amorphous ground substance and collagen fibers. The blood vessel walls stand out clearly in the papillary projections of the connective tissue *(P)*.

The degree of gingival keratinization diminishes with age and the onset of menopause,[199] but it is not necessarily related to the different phases of the menstrual cycle.[131] Keratinization of the oral mucosa varies in different areas in the following order: palate (most keratinized), gingiva, ventral aspect of the tongue, and cheek (least keratinized).[181]

Oral (Outer) Epithelium. The oral or outer epithelium covers the crest and outer surface of the marginal gingiva and the surface of the attached gingiva. On average, the oral epithelium is 0.2 to 0.3 mm in thickness. It is keratinized or parakeratinized, or it may present various combinations of these conditions (Figure 1-14). The prevalent surface, however, is parakeratinized.[32,45,285] The oral epithelium is composed of four layers: stratum basale (basal layer), stratum spinosum (prickle cell layer), stratum granulosum (granular layer), and stratum corneum (cornified layer).

Sulcular Epithelium. The sulcular epithelium lines the gingival sulcus (Figure 1-15). It is a thin, nonkeratinized stratified squamous epithelium without rete pegs, and it extends from the coronal limit of the junctional epithelium to the crest of the gingival margin (Figure 1-16). It usually shows many cells with hydropic degeneration.[32]

Despite these morphologic and chemical characteristics, the sulcular epithelium has the potential to keratinize if it is reflected and exposed to the oral cavity[44,48] or if the bacterial flora of the sulcus is totally eliminated.[50] Conversely, the outer epithelium loses its keratinization when it is placed in contact with the tooth.[50] These findings suggest that the local irritation of the sulcus prevents sulcular keratinization.

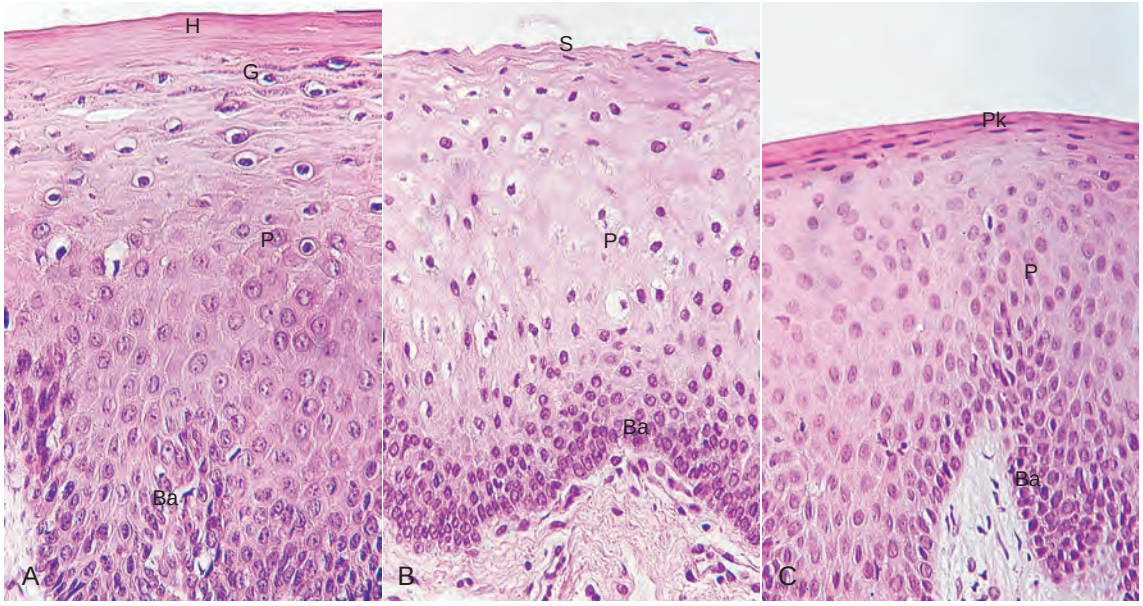

Figure 1-14 Variations in the gingival epithelium. **A,** Keratinized. **B,** Nonkeratinized. **C,** Parakeratinized. Horny layer *(H)*, granular layer *(G)*, prickle cell layer *(P)*, basal cell layer *(Ba)*, flattened surface cells *(S)*, and parakeratotic layer *(Pk)*.

Keratins K1, K2, and K10 through K12, which are specific to epidermal-type differentiation, are immunohistochemically expressed with high intensity in orthokeratinized areas and with less intensity in parakeratinized areas. K6 and K16, which are characteristic of highly proliferative epithelia, and K5 and K14, which are stratification-specific cytokeratins, also are present. Parakeratinized areas express K19, which is usually absent from orthokeratinized normal epithelia.[37,205]

In keeping with the complete or almost-complete maturation, histoenzyme reactions for acid phosphatase and pentose-shunt enzymes are very strong.[47,127]

Glycogen can accumulate intracellularly when it is not completely degraded by any of the glycolytic pathways. Thus, its concentration in normal gingiva is inversely related to the degree of keratinization[236,285] and inflammation.[71,273,276]

As with other nonkeratinized epithelia, the sulcular epithelium lacks granulosum and corneum strata and K1, K2, and K10 through K12 cytokeratins, but it contains K4 and K13, the so-called "esophageal-type cytokeratins." It also expresses K19, and it normally does not contain Merkel cells.

Histochemical studies of enzymes have consistently revealed a lower degree of activity in the sulcular than in the outer epithelium, particularly in the case of enzymes related to keratinization. Glucose-6-phosphate dehydrogenase expresses a faint and homogeneous reaction in all strata, unlike the increasing gradient toward the surface observed in cornified epithelia.[127] Acid phosphatase staining is negative,[46] although lysosomes have been described in exfoliated cells.[148]

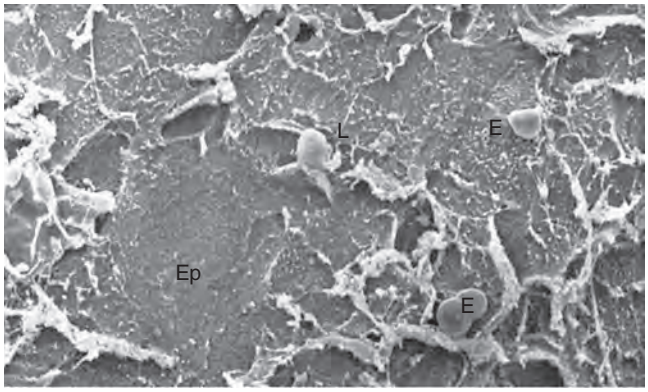

Figure 1-15 Scanning electron microscopic view of the epithelial surface facing the tooth in a normal human gingival sulcus. The epithelium *(Ep)* shows desquamating cells, some scattered erythrocytes *(E)*, and a few emerging leukocytes *(L)*. (×1000.)

Figure 1-16 Epon-embedded human biopsy specimen showing a relatively normal gingival sulcus. The soft-tissue wall of the gingival sulcus is made up of the oral sulcular epithelium *(ose)* and its underlying connective tissue *(ct)*, whereas the base of the gingival sulcus is formed by the sloughing surface of the junctional epithelium *(je)*. The enamel space is delineated by a dense cuticular structure *(dc)*. A relatively sharp line of demarcation exists between the junctional epithelium and the oral sulcular epithelium *(arrow)*, and several polymorphonuclear leukocytes *(pmn)* can be seen traversing the junctional epithelium. The sulcus contains red blood cells that resulted from the hemorrhage that occurred at the time of biopsy. (×391; inset ×55.) *(From Schluger S, Youdelis R, Page RC:* Periodontal disease, *Philadelphia, ed 2, 1990, Lea & Febiger.)*

The sulcular epithelium is extremely important; it may act as a semipermeable membrane through which injurious bacterial products pass into the gingiva and through which tissue fluid from the gingiva seeps into the sulcus.[267] Unlike the junctional epithelium, however, the sulcular epithelium is not heavily infiltrated by polymorphonuclear neutrophil leukocytes, and it appears to be less permeable.[18]

Junctional Epithelium. The junctional epithelium consists of a collarlike band of stratified squamous non-keratinizing epithelium. It is 3 to 4 layers thick in early life, but the number of layers increases with age to 10 or even 20 layers. In addition, the junctional epithelium tapers from its coronal end, which may be 10 to 29 cells wide to 1 or 2 cells wide at its apical termination, which is located at the cementoenamel junction in healthy tissue. These cells can be grouped in two strata: the basal layer that faces the connective tissue and the suprabasal layer that extends to the tooth surface. The length of the junctional epithelium ranges from 0.25 to 1.35 mm (Figure 1-17).

The junctional epithelium is formed by the confluence of the oral epithelium and the reduced enamel epithelium during tooth eruption However, the reduced enamel epithelium is not essential for its formation; in fact, the junctional epithelium is completely restored after pocket instrumentation or surgery, and it forms around an implant.[151]

The junctional epithelium is attached to the tooth surface (epithelial attachment) by means of an internal basal lamina. It is attached to the gingival connective tissue by an external basal lamina that has the same structure as other epithelial–connective tissue attachments elsewhere in the body.[155,161]

The internal basal lamina consists of a lamina densa (adjacent to the enamel) and a lamina lucida to which hemidesmosomes are attached. Hemidesmosomes have a decisive role in the firm attachment of the cells to the internal basal lamina on the tooth surface.

Recent data suggest that the hemidesmosomes may also act as specific sites of signal transduction and thus may participate in the regulation of gene expression, cell proliferation, and cell differentiation.[134] Organic strands from the enamel appear to extend into the lamina densa.[256] The junctional epithelium attaches to afibrillar cementum that is present on the crown (usually restricted to an area within 1 mm of the cementoenamel junction)[233] and root cementum in a similar manner.

Histochemical evidence for the presence of neutral polysaccharides in the zone of the epithelial attachment has been reported.[272] Data also have shown that the basal lamina of the junctional epithelium resembles that of endothelial and epithelial cells in its laminin content but differs in its internal basal lamina, which has no type IV collagen.[142,223] These findings indicate that the cells of the junctional epithelium are involved in the production of laminin and play a key role in the adhesion mechanism.

The attachment of the junctional epithelium to the tooth is reinforced by the gingival fibers, which brace the marginal gingiva against the tooth surface. For this reason, the junctional epithelium and the gingival fibers are considered together as a functional unit referred to as the *dentogingival unit.*[158]

In conclusion, it is usually accepted that the junctional epithelium exhibits several unique structural and functional features that contribute to preventing pathogenic bacterial flora from colonizing the subgingival tooth surface.[205] First, junctional epithelium is firmly attached to the tooth surface, thereby forming an epithelial barrier against plaque bacteria. Second, it allows access of gingival fluid, inflammatory cells, and components of the immunologic host defense to the gingival margin. Third, junctional epithelial cells exhibit rapid turnover, which contributes to the host–parasite equilibrium and the rapid repair of damaged tissue. Some investigators have also indicated that the cells of the junctional epithelium have an endocytic capacity equal to that of macrophages and neutrophils and that this activity may be protective in nature.[57]

Development of Gingival Sulcus. After enamel formation is complete, the enamel is covered with *reduced enamel epithelium*

Cell layers that are not juxtaposed to the tooth exhibit numerous free ribosomes, prominent membrane-bound structures (e.g., Golgi complexes), and cytoplasmic vacuoles that are presumably phagocytic. Lysosome-like bodies also are present, but the absence of keratinosomes (Odland bodies) and histochemically demonstrable acid phosphatase, which are correlated with the low degree of differentiation, may reflect a low-defense power against microbial plaque accumulation in the gingival sulcus. Similar morphologic findings have been described in the gingiva of germ-free rats. Polymorphonuclear neutrophil leukocytes are found routinely in the junctional epithelium of both conventional rats and germ-free rats.[296] Research has shown that, although numerous migrating polymorphonuclear neutrophil leukocytes are evident and present around healthy junctional epithelium, a considerable increase in polymorphonuclear neutrophil leukocyte numbers can be expected with the accumulation of dental plaque and gingival inflammation.[18]

The different keratin polypeptides of the junctional epithelium have a particular histochemical pattern. Junctional epithelium expresses K19, which is absent from keratinized epithelia, and the stratification-specific cytokeratins K5 and K14.[224] Morgan and colleagues[182] reported that reactions to demonstrate K4 or K13 reveal a sudden change between sulcular and junctional epithelia; the junctional area is the only stratified nonkeratinized epithelium in the oral cavity that does not synthesize these specific polypeptides. Another particular behavior of junctional epithelium is the lack of expression of K6 and K16, which is usually linked to highly proliferative epithelia, although the turnover of the cells is very high.

Similar to sulcular epithelium, junctional epithelium exhibits lower glycolytic enzyme activity than outer epithelium, and it also lacks acid phosphatase activity.[46,127]

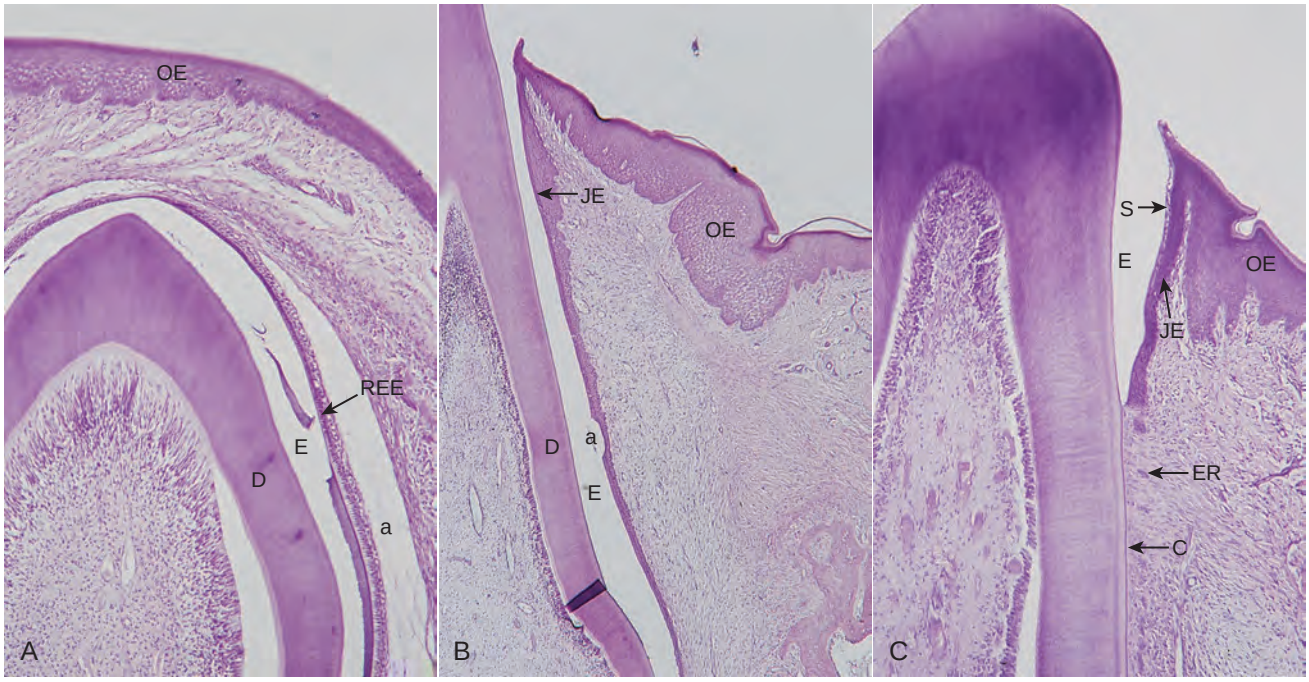

Figure 1-17 Eruption process in cat's tooth. **A,** Unerupted tooth. Dentin *(D)*, remnants of enamel matrix *(E)*, reduced enamel epithelium *(REE)*, oral epithelium *(OE)*, and artifact *(a)*. **B,** Erupting tooth forming junctional epithelium *(JE)*. **C,** Completely erupted tooth. Sulcus with epithelial debris *(S)*, cementum *(C)*, and epithelial rests *(ER)*.

(REE), which is attached to the tooth by a basal lamina and hemidesmosomes.[156,255] When the tooth penetrates the oral mucosa, the REE unites with the oral epithelium and transforms into the junctional epithelium. As the tooth erupts, this united epithelium condenses along the crown, and the ameloblasts, which form the inner layer of the REE (see Figure 1-17), gradually become squamous epithelial cells. The transformation of the REE into a junctional epithelium proceeds in an apical direction without interrupting the attachment to the tooth. According to Schroeder and Listgarten,[233] this process takes between 1 and 2 years.

The junctional epithelium is a continually self-renewing structure, with mitotic activity occurring in all cell layers.[156,255] The regenerating epithelial cells move toward the tooth surface and along it in a coronal direction to the gingival sulcus, where they are shed[22] (Figure 1-18). The migrating daughter cells provide a continuous attachment to the tooth surface. The strength of the epithelial attachment to the tooth has not been measured.

The gingival sulcus is formed when the tooth erupts into the oral cavity. At that time, the junctional epithelium and the REE form a broad band that is attached to the tooth surface from near the tip of the crown to the cementoenamel junction. The gingival sulcus is the shallow, V-shaped space or groove between the tooth and the gingiva that encircles the newly erupted tip of the crown. In the fully erupted tooth, only the junctional epithelium persists. *The sulcus consists of the shallow space that is coronal to the attachment of the junctional epithelium and bounded by the tooth on one side and the sulcular epithelium on the other. The coronal extent of the gingival sulcus is the gingival margin.*

Renewal of Gingival Epithelium. The oral epithelium undergoes continuous renewal. Its thickness is maintained by a balance between new cell formation in the basal and spinous layers and the

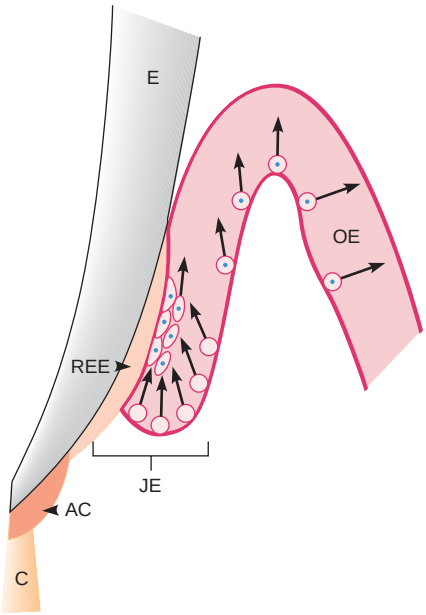

Figure 1-18 Junctional epithelium on an erupting tooth. The junctional epithelium *(JE)* is formed by the joining of the oral epithelium *(OE)* and the reduced enamel epithelium *(REE)*. Afibrillar cementum *(AC)* is sometimes formed on enamel after the degeneration of the REE. The arrows indicate the coronal movement of the regenerating epithelial cells, which multiply more rapidly in the JE than in the OE. *E,* Enamel; *C,* root cementum. A similar cell turnover pattern exists in the fully erupted tooth. *(Modified from Listgarten MA:* J Can Dent Assoc *36:70, 1970.)*

The mitotic rate in experimental animals varies among different areas of the oral epithelium in descending order: buccal mucosa, hard palate, sulcular epithelium, junctional epithelium, outer surface of the marginal gingiva, and attached gingiva.[9,112,160,274] The following have been reported as turnover times for different areas of the oral epithelium in experimental animals: palate, tongue, and cheek, 5 to 6 days; gingiva, 10 to 12 days, with the same or more time required with age; and junctional epithelium, 1 to 6 days.[22,249]

shedding of old cells at the surface. The mitotic activity exhibits a 24-hour periodicity, with the highest and lowest rates occurring in the morning and evening, respectively.[256] The mitotic rate is higher in nonkeratinized areas and increased in gingivitis, without significant gender differences. Opinions differ with regard to whether the mitotic rate is increased[160,161,179] or decreased[15] with age.

With regard to junctional epithelium, it was previously thought that only epithelial cells facing the external basal lamina were rapidly dividing. However, evidence indicates that a significant number of the cells (e.g., the basal cells along the connective tissue) are capable of synthesizing deoxyribonucleic acid (DNA), thereby demonstrating their mitotic activity.[221,222] The rapid shedding of cells effectively removes bacteria that adheres to the epithelial cells and therefore is an important part of the antimicrobial defense mechanisms at the dentogingival junction.[205]

Cuticular Structures on the Tooth. The term *cuticle* describes a thin acellular structure with a homogeneous matrix that is sometimes enclosed within clearly demarcated linear borders.

Listgarten[159] has classified cuticular structures into coatings of developmental origin and acquired coatings. *Acquired coatings* include those of exogenous origin such as saliva, bacteria, calculus, and surface stains (see Chapters 21 and 22). *Coatings of developmental origin* are those that are normally formed as part of tooth development. They include the REE, the coronal cementum, and the dental cuticle.

After enamel formation is completed, the ameloblastic epithelium is reduced to one or two layers of cells that remain attached to the enamel surface by hemidesmosomes and a basal lamina. This REE consists of postsecretory ameloblasts and cells from the stratum intermedium of the enamel organ. In some animal species, the REE disappears entirely and very rapidly, thereby placing the enamel surface in contact with the connective tissue. Connective tissue cells then deposit a thin layer of cementum known as *coronal cementum* on the enamel. In humans, thin patches of afibrillar cementum sometimes may be seen in the cervical half of the crown.

Electron microscopy has demonstrated a dental cuticle that consists of a layer of homogeneous organic material of variable thickness (approximately 0.25 µm) overlying the enamel surface. It is non-mineralized, and it is not always present. In some cases, near the cementoenamel junction, it is deposited over a layer of afibrillar cementum, which in turn overlies enamel. The cuticle may be present between the junctional epithelium and the tooth. Ultrastructural histochemical studies have shown that the dental cuticle is proteinaceous,[143] and it may be an accumulation of tissue fluid components.[87,232]

Gingival Fluid (Sulcular Fluid). The value of the gingival fluid is that it can be represented as either a transudate or an exudate. The gingival fluid contains a vast array of biochemical factors, thereby offering its potential use as a diagnostic or prognostic biomarker of the biologic state of the periodontium in health and disease[81] (see Chapter 6). It also contains components of connective tissue, epithelium, inflammatory cells, serum, and microbial flora that inhabit the gingival margin or the sulcus (pocket).[79]

In the healthy sulcus, the amount of gingival fluid is very small. During inflammation, however, the gingival fluid flow increases, and its composition starts to resemble that of an inflammatory exudate.[59] The main route of the gingival fluid diffusion is through the basement membrane, through the relatively wide intercellular spaces of the junctional epithelium, and then into the sulcus.[205] The gingival fluid is believed to do the following: (1) cleanse material from the sulcus; (2) contain plasma proteins that may improve adhesion of the epithelium to the tooth; (3) possess antimicrobial properties; and (4) exert antibody activity to defend the gingiva.

Gingival Connective Tissue. The major components of the gingival connective tissue are collagen fibers (about 60% by volume), fibroblasts (5%), vessels, nerves, and matrix (about 35%). The connective tissue of the gingiva is known as the *lamina propria,* and it consists of two layers: (1) a *papillary layer* subjacent to the epithelium that consists of papillary projections between the epithelial rete pegs; and (2) a *reticular layer* that is contiguous with the periosteum of the alveolar bone.

Connective tissue has a cellular compartment and an extracellular compartment composed of fibers and ground substance. Thus, the gingival connective tissue is largely a fibrous connective tissue that has elements that originate directly from the oral mucosal connective tissue as well as some fibers (dentogingival) that originate from the developing dental follicle.[18]

The *ground substance* fills the space between fibers and cells; it is amorphous, and it has a high water content. It is composed of proteoglycans (mainly hyaluronic acid and chondroitin sulfate) and glycoproteins (mainly fibronectin). Glycoproteins account for the faint periodic acid–Schiff–positive reaction of the ground substance.[82] Fibronectin binds fibroblasts to the fibers and many other components of the intercellular matrix, thereby helping to mediate cell adhesion and migration. Laminin, which is another glycoprotein found in the basal lamina, serves to attach it to epithelial cells.

The three types of connective tissue fibers are collagen, reticular, and elastic. Collagen type I forms the bulk of the lamina propria and provides the tensile strength to the gingival tissue. Type IV collagen (argyrophilic reticulum fiber) branches between the collagen type I bundles, and it is continuous with fibers of the basement membrane and the blood vessel walls.[161]

The elastic fiber system is composed of oxytalan, elaunin, and elastin fibers distributed among collagen fibers.[56] Therefore, densely packed collagen bundles that are anchored into the acellular extrinsic fiber cementum just below the terminal point of the junctional epithelium form the connective tissue attachment. The stability of this attachment is a key factor in the limitation of the migration of junctional epithelium.[57]

Gingival Fibers. The connective tissue of the marginal gingiva is densely collagenous, and it contains a prominent system of collagen fiber bundles called the *gingival fibers.* These fibers consist of type I collagen.[213] The gingival fibers have the following functions:

1. To brace the marginal gingiva firmly against the tooth
2. To provide the rigidity necessary to withstand the forces of mastication without being deflected away from the tooth surface
3. To unite the free marginal gingiva with the cementum of the root and the adjacent attached gingiva

The gingival fibers are arranged in three groups: gingivodental, circular, and transseptal.[146]

The *gingivodental fibers* are those on the facial, lingual, and interproximal surfaces. They are embedded in the cementum just beneath the epithelium at the base of the gingival sulcus. On the facial and lingual surfaces, they project from the cementum in a fanlike conformation toward the crest and outer surface of the marginal gingiva, where they terminate short of the epithelium (Figures 1-19 and 1-20). They also extend externally to the periosteum of the facial and lingual alveolar bones, terminating in the attached gingiva or blending with the periosteum of the bone. Interproximally, the gingivodental fibers extend toward the crest of the interdental gingiva.

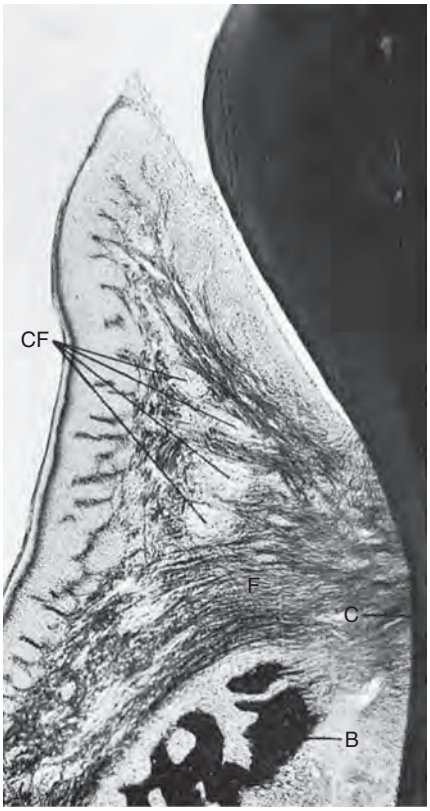

Figure 1-19 Faciolingual section of marginal gingiva showing gingival fibers *(F)* that extend from the cementum *(C)* to the crest of the gingiva, to the outer gingival surface, and external to the periosteum of the bone *(B)*. Circular fibers *(CF)* are shown in cross-section between the other groups. *(Courtesy Sol Bernick.)*

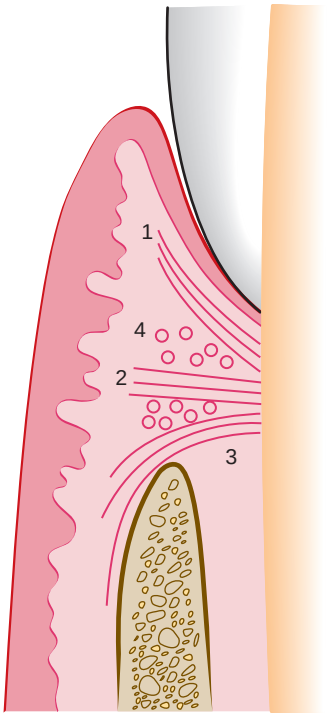

Figure 1-20 Diagram of the gingivodental fibers that extend from the cementum *(1)* to the crest of the gingiva, *(2)* to the outer surface, and *(3)* external to the periosteum of the labial plate. Circular fibers *(4)* are shown in cross-section.

The *circular fibers* course through the connective tissue of the marginal and interdental gingivae and encircle the tooth in ringlike fashion.

The *transseptal fibers,* which are located interproximally, form horizontal bundles that extend between the cementum of the approximating teeth into which they are embedded. They lie in the area between the epithelium at the base of the gingival sulcus and the crest of the interdental bone, and they are sometimes classified with the principal fibers of the periodontal ligament.

Page and colleagues[198] described a group of *semicircular fibers* that attach at the proximal surface of a tooth immediately below the cementoenamel junction, go around the facial or lingual marginal gingiva of the tooth, and attach on the other proximal surface of the same tooth; they also discussed a group of *transgingival fibers* that attach in the proximal surface of one tooth, traverse the interdental space diagonally, go around the facial or lingual surface of the adjacent tooth, again traverse the interdental space diagonally, and then attach in the proximal surface of the next tooth.

Tractional forces in the extracellular matrix produced by fibroblasts are believed to be the forces responsible for generating tension in the collagen. This keeps the teeth tightly bound to each other and to the alveolar bone.

Cellular Elements. The preponderant cellular element in the gingival connective tissue is the *fibroblast.* Numerous fibroblasts are found between the fiber bundles. Fibroblasts are of mesenchymal origin and play a major role in the development, maintenance, and repair of gingival connective tissue. As with connective tissue elsewhere in the body, fibroblasts synthesize collagen and elastic fibers as well as the glycoproteins and glycosaminoglycans of the amorphous intercellular substance. Fibroblasts also regulate collagen degradation through phagocytosis and the secretion of collagenases.

Fibroblast heterogeneity is now a well-established feature of fibroblasts in the periodontium.[226] Although the biologic and clinical significance of such heterogeneity is not yet clear, it seems that this is necessary for the normal functioning of tissues in health, disease, and repair.[18]

Mast cells, which are distributed throughout the body, are numerous in the connective tissue of the oral mucosa and the gingiva.[52,244,245,288] *Fixed macrophages* and *histiocytes* are present in the gingival connective tissue as components of the mononuclear phagocyte system (reticuloendothelial system) and are derived from blood monocytes. *Adipose cells* and *eosinophils,* although scarce, are also present in the lamina propria.

In clinically normal gingiva, small foci of plasma cells and lymphocytes are found in the connective tissue near the base of the sulcus (Figure 1-21). Neutrophils can be seen in relatively high numbers in both the gingival connective tissue and the sulcus. These inflammatory cells are usually present in small amounts in clinically normal gingiva.

Repair of Gingival Connective Tissue. Because of the high turnover rate, the connective tissue of the gingiva has remarkably good healing and regenerative capacity. Indeed, it may be one of the best healing tissues in the body, and it generally shows little evidence of scarring after surgical procedures. This is likely caused by the rapid reconstruction of the fibrous architecture of the tissues.[178] However, the reparative capacity of gingival connective tissue is not as great as that of the periodontal ligament or the epithelial tissue.

Blood Supply, Lymphatics, and Nerves. Microcirculatory tracts, blood vessels, and lymphatic vessels play an important role in the drainage of tissue fluid and in the spread of inflammation. In individuals with gingivitis and periodontitis, the

Speculations about whether small amounts of leukocytes should be considered a normal component of the gingiva or an incipient inflammatory infiltrate without clinical expression are of theoretic rather than practical importance. Lymphocytes are absent when gingival normalcy is judged by strict clinical criteria or under special experimental conditions,[13,192] but they are practically constant in healthy, normal gingiva, even before complete tooth eruption.[150,167,229]

Immunohistochemical studies involving monoclonal antibodies have identified the different lymphocyte subpopulations. The infiltrate in the area below the junctional epithelium of healthy gingiva in newly erupted teeth in children is mainly composed of T lymphocytes (helper, cytotoxic, suppressor, and natural killer)[12,98,242] and thus could be interpreted as a normal lymphoid tissue involved in the early defense recognition system. As time elapses, B lymphocytes and plasma cells appear in greater proportions to elaborate specific antibodies against already-recognized antigens that are always present in the sulcus of clinically normal gingiva.[234]

Blood vessels are easily evidenced in tissue sections by means of immunohistochemical reactions against proteins of endothelial cells (i.e., factor VIII and adhesion molecules). Before these techniques were developed, vascularization patterns of periodontal tissues had been described using histoenzymatic reactions for alkaline phosphatase and adenosine triphosphatase because of the great activity of these enzymes in endothelial cells.[54,297]

In experimental animals, perfusion with India ink also was used to study vascular distribution. The injection and subsequent demonstration of peroxidase allow for blood vessel identification and permeability studies.[239] The periodic acid–Schiff reaction also outlines vascular walls by revealing a positive line in the basal membrane.[237] Endothelial cells express 5-nucleotidase activity as well.[126] Scanning electron microscopy can be used after the injection of plastic into the vessels through the carotid artery, which is followed by the corrosion of the soft tissues.[84] In addition, laser Doppler flow measurement provides a noninvasive means for the observation of blood flow modifications related to disease.[8]

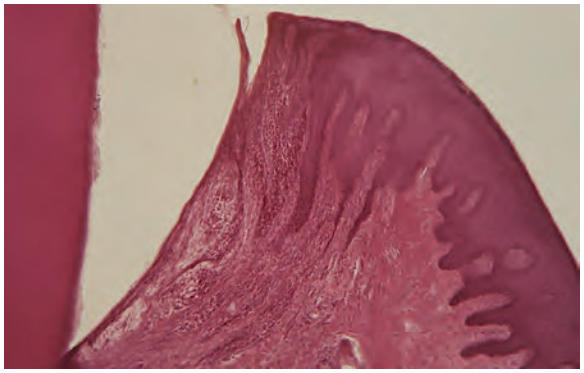

Figure 1-21 Section of clinically normal gingiva showing some degree of inflammation, which is almost always present near the base of the sulcus.

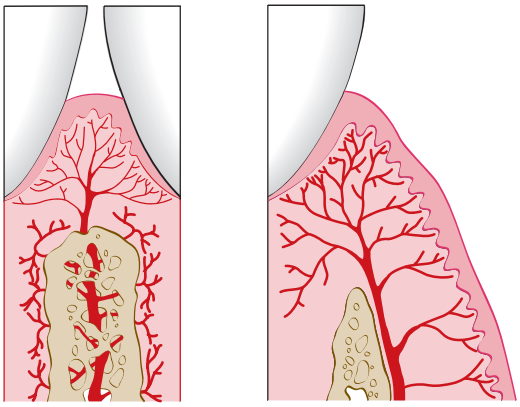

Figure 1-22 Diagram of an arteriole penetrating the interdental alveolar bone to supply the interdental tissues *(left)* and a supraperiosteal arteriole overlying the facial alveolar bone, sending branches to the surrounding tissue *(right)*.

Figure 1-23 Blood supply and peripheral circulation of the gingiva. Tissues perfused with India ink. Note the capillary plexus parallel to the sulcus *(S)* and the capillary loops in the outer papillary layer. Note also the supraperiosteal vessels external to the bone *(B)*, which supply the gingiva, and a periodontal ligament vessel anastomosing with the sulcus plexus. *(Courtesy Sol Bernick.)*

microcirculation and vascular formation change greatly in the vascular network directly under the gingival sulcular epithelium and the junctional epithelium.[170]

Three sources of blood supply to the gingiva are as follows (Figures 1-22 and 1-23):

1. *Supraperiosteal arterioles* along the facial and lingual surfaces of the alveolar bone from which capillaries extend along the sulcular epithelium and between the rete pegs of the external gingival surface[8,76,113]: Occasional branches of the arterioles pass through the alveolar bone to the periodontal ligament or run over the crest of the alveolar bone.
2. *Vessels of the periodontal ligament,* which extend into the gingiva and anastomose with capillaries in the sulcus area.
3. *Arterioles,* which emerge from the crest of the interdental septa[84] and extend parallel to the crest of the bone to anastomose with vessels of the periodontal ligament, with capillaries in the gingival crevicular areas and vessels that run over the alveolar crest.

Beneath the epithelium on the outer gingival surface, capillaries extend into the papillary connective tissue between the epithelial rete pegs in the form of terminal hairpin loops with efferent and afferent branches, spirals, and varices[54,113] (Figure 1-24; see Figure 1-23). The loops are sometimes linked by cross-communications,[86] and flattened capillaries serve as reserve vessels when the circulation is increased in response to irritation.[99]

Along the sulcular epithelium, capillaries are arranged in a flat, anastomosing plexus that extends parallel to the enamel from the base of the sulcus to the gingival margin.[54] In the col area, a mixed pattern of anastomosing capillaries and loops occurs.

As mentioned previously, anatomic and histologic changes have been shown to occur in the gingival microcirculation of individuals with gingivitis. Prospective studies of the gingival vasculature in animals have demonstrated that, in the absence of inflammation, the vascular network is arranged in a regular, repetitive, and layered pattern.[54,216] By contrast, the inflamed gingival vasculature exhibits an irregular vascular plexus pattern, with the microvessels exhibiting a looped, dilated, and convoluted appearance.[216]

The role of the lymphatic system in removing excess fluids, cellular and protein debris, microorganisms, and other elements is important for controlling diffusion and the resolution of inflammatory processes.[168] The *lymphatic drainage of the gingiva* brings in the lymphatics of the connective tissue papillae.[238] It progresses into the collecting network external to the periosteum of the alveolar process and then moves to the regional lymph nodes, particularly the submaxillary group. In addition, lymphatics just beneath the junctional epithelium extend into the periodontal ligament and accompany the blood vessels.

Neural elements are extensively distributed throughout the gingival tissues. Within the gingival connective tissues, most nerve fibers are myelinated and closely associated with the blood vessels.[162] *Gingival innervation* is derived from fibers that arise from nerves in the periodontal ligament and from the labial, buccal, and palatal nerves.[30] The following nerve structures are present in the connective tissue: a meshwork of terminal argyrophilic fibers, some of which extend into the epithelium; Meissner-type tactile corpuscles; Krause-type end bulbs, which are temperature receptors; and encapsulated spindles.[14]

Correlation of Clinical and Microscopic Features

An understanding of the normal clinical features of the gingiva requires the ability to interpret them in terms of the microscopic structures that they represent.

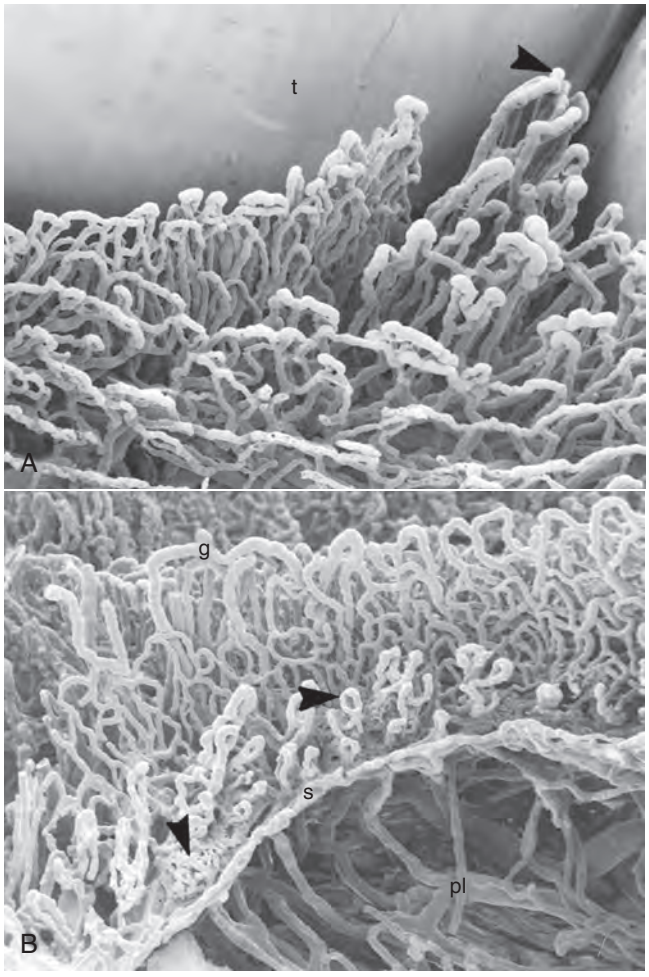

Figure 1-24 Scanning electron microscopic view of the gingival tissues of rat molar palatal gingiva after the vascular perfusion of plastic and the corrosion of soft tissue. **A,** Oral view of gingival capillaries: *t,* tooth; interdental papilla *(arrowhead)* (×180). **B,** View from the tooth side. Note the vessels of the plexus next to the sulcular and junctional epithelium. The arrowheads point to vessels in the sulcus area with mild inflammatory changes. *g,* Crest of the marginal gingiva; *s,* bottom of the gingival sulcus; *pl,* periodontal ligament vessels. (×150.) *(Courtesy NJ Selliseth and K Selvig, University of Bergen, Norway.)*

Color. The color of the attached and marginal gingiva is generally described as "coral pink"; it is produced by the vascular supply, the thickness and degree of keratinization of the epithelium, and the presence of pigment-containing cells. The color varies among different persons and appears to be correlated with the cutaneous pigmentation. It is lighter in blond individuals with fair complexions than in swarthy, dark-haired individuals (Figure 1-25).

The attached gingiva is demarcated from the adjacent alveolar mucosa on the buccal aspect by a clearly defined mucogingival line. The alveolar mucosa is red, smooth, and shiny rather than pink and stippled. A comparison of the microscopic structure of the attached gingiva with that of the alveolar mucosa provides an explanation for the difference in appearance. The epithelium of the alveolar mucosa is thinner and nonkeratinized, and it contains no rete pegs (Figure 1-26). The connective tissue of the alveolar mucosa is loosely arranged, and the blood vessels are more numerous.

Physiologic Pigmentation (Melanin). Melanin is a non–hemoglobin-derived brown pigment with the following characteristics:

- Melanin is responsible for the normal pigmentation of the skin, the gingiva, and the remainder of the oral mucous membrane.
- Melanin is present in all normal individuals (often not in sufficient quantities to be detected clinically), but it is absent or severely diminished in albinos.
- Melanin pigmentation in the oral cavity is prominent in black individuals (see Figure 1-25).
- Ascorbic acid directly downregulates melanin pigmentation in gingival tissues.[246]

According to Dummett,[73] the distribution of oral pigmentation in black individuals is as follows: gingiva, 60%; hard palate, 61%; mucous membrane, 22%; and tongue, 15%. Gingival pigmentation occurs as a diffuse, deep-purplish discoloration or as irregularly shaped brown and light-brown patches. It may appear in the gingiva as early as 3 hours after birth, and it is often the only evidence of pigmentation.[73]

Oral repigmentation refers to the clinical reappearance of melanin pigment after a period of clinical depigmentation of the oral mucosa as a result of chemical, thermal, surgical, pharmacologic, or idiopathic factors.[74] Information about the repigmentation of oral tissues after surgical procedures is extremely limited, and no definitive treatment is offered at this time.

Size. The size of the gingiva corresponds with the sum total of the bulk of cellular and intercellular elements and their vascular supply. Alteration in size is a common feature of gingival disease.

Contour. The contour or shape of the gingiva varies considerably and depends on the shape of the teeth and their alignment in the arch, the location and size of the area of proximal contact, and the dimensions of the facial and lingual gingival embrasures.

Figure 1-25 **A,** Clinically normal gingiva in a young adult. **B,** Heavily pigmented (melanotic) gingiva in a middle-aged adult. (*From Glickman I, Smulow JB:* Periodontal disease: clinical, radiographic, and histopathologic features, *Philadelphia, 1974, Saunders.)*

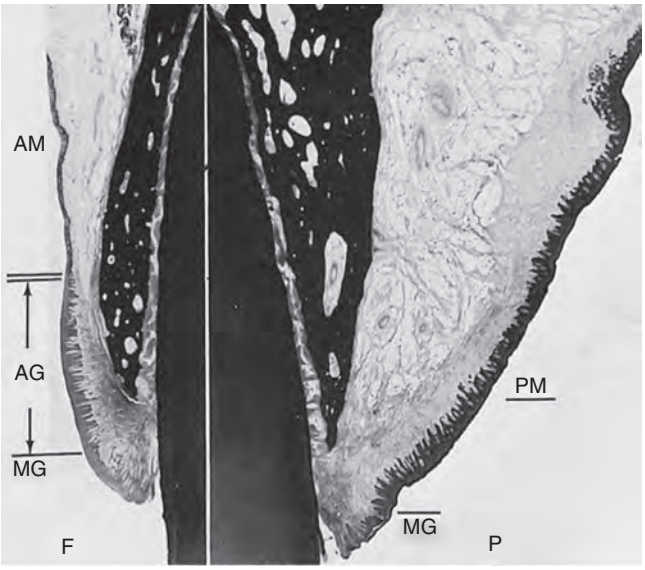

Figure 1-26 Oral mucosa, facial and palatal surfaces. The facial surface *(F)* shows the marginal gingiva *(MG)*, the attached gingiva *(AG)*, and the alveolar mucosa *(AM)*. The double line marks the mucogingival junction. Note the differences in the epithelium and the connective tissue in the attached gingiva and the alveolar mucosa. The palatal surface *(P)* shows the marginal gingiva *(MG)* and the thick, keratinized palatal mucosa *(PM)*.

Figure 1-27 A thickened, shelflike contour of gingiva on a tooth in lingual version aggravated by local irritation caused by plaque accumulation.

The marginal gingiva envelops the teeth in collarlike fashion and follows a scalloped outline on the facial and lingual surfaces. It forms a straight line along teeth with relatively flat surfaces. On teeth with pronounced mesiodistal convexity (e.g., maxillary canines) or teeth in labial version, the normal arcuate contour is accentuated, and the gingiva is located farther apically. On teeth in lingual version, the gingiva is horizontal and thickened (Figure 1-27). In addition, the gingival tissue biotype varies significantly. A thin and clear gingiva is found in one third of the population and primarily in females with slender teeth with a narrow zone of keratinized tissue, whereas a clear, thick gingiva with a broad zone of keratinized tissue is present in two thirds of the population and primarily in males.[70]

Shape. The shape of the interdental gingiva is governed by the contour of the proximal tooth surfaces and the location and shape of the gingival embrasures.

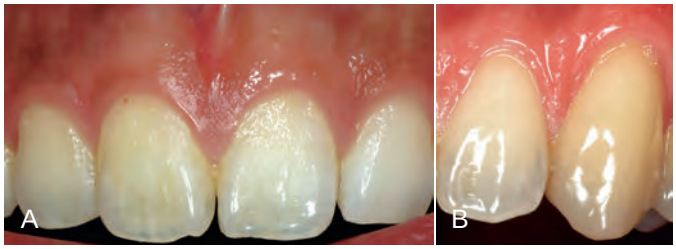

Figure 1-28 Shape of the interdental gingival papillae correlated with the shape of the teeth and the embrasures. **A,** Broad interdental papillae. **B,** Narrow interdental papillae.

When the proximal surfaces of the crowns are relatively flat faciolingually, the roots are close together, the interdental bone is thin mesiodistally, and the gingival embrasures and interdental gingiva are narrow mesiodistally. Conversely, with proximal surfaces that flare away from the area of contact, the mesiodistal diameter of the interdental gingiva is broad (Figure 1-28). The height of the interdental gingiva varies with the location of the proximal contact. Thus, in the anterior region of the dentition, the interdental papilla is pyramidal in form, whereas the papilla is more flattened in a buccolingual direction in the molar region.

Consistency. The gingiva is firm and resilient and, with the exception of the movable free margin, tightly bound to the underlying bone. The collagenous nature of the lamina propria and its contiguity with the mucoperiosteum of the alveolar bone determine the firmness of the attached gingiva. The gingival fibers contribute to the firmness of the gingival margin.

Surface Texture. The gingiva presents a textured surface similar to that of an orange peel and is referred to as *stippled* (see Figure 1-25). Stippling is best viewed by drying the gingiva. *The attached gingiva is stippled; the marginal gingiva is not.* The central portion of the interdental papillae is usually stippled, but the marginal borders are smooth. The pattern and extent of stippling vary among individuals and among different areas of the same mouth.[108,216] Stippling is less prominent on lingual than facial surfaces and may be absent in some persons.

Stippling varies with age. It is absent during infancy, it appears in some children at about 5 years of age, it increases until adulthood, and it frequently begins to disappear during old age.

Microscopically, stippling is produced by alternate rounded protuberances and depressions in the gingival surface. The papillary layer of the connective tissue projects into the elevations, and the elevated and depressed areas are covered by stratified squamous epithelium (Figure 1-29). The degree of keratinization and the prominence of stippling appear to be related.

Scanning electron microscopy has shown considerable variation in shape but a relatively constant depth of stippling. At low magnification, a rippled surface is seen, and this is interrupted by irregular depressions that are 50 µm in diameter. At higher magnification, cell micropits are seen.[61]

Stippling is a form of adaptive specialization or reinforcement for function. It is a feature of healthy gingiva, and the reduction or loss of stippling is a common sign of gingival disease. When the gingiva is restored to health after treatment, the stippled appearance returns.

The surface texture of the gingiva is also related to the presence and degree of epithelial keratinization. Keratinization is considered a protective adaptation to function. It increases when the gingiva is stimulated by toothbrushing. However, research on free gingival

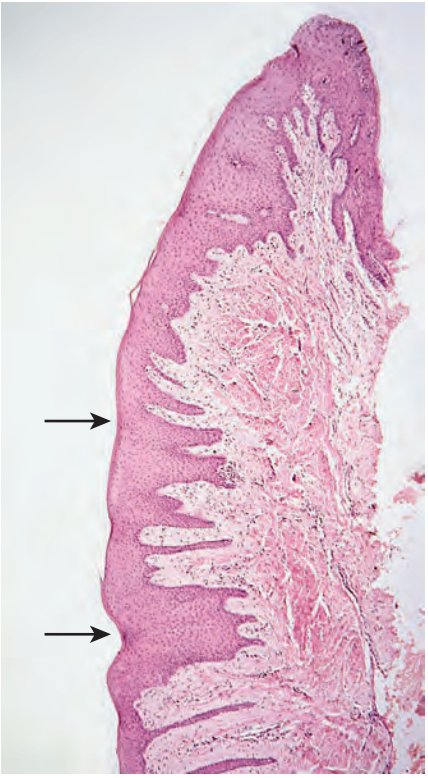

Figure 1-29 Gingival biopsy of the patient shown in Figure 2-7 demonstrating alternate elevations and depressions *(arrows)* in the attached gingiva that are responsible for the stippled appearance.

grafts (see Chapter 63) has shown that, when connective tissue is transplanted from a keratinized area to a nonkeratinized area, it becomes covered by a keratinized epithelium.[140] This finding suggests a connective-tissue–based genetic determination of the type of epithelial surface.

Position. The *position* of the gingiva is the level at which the gingival margin is attached to the tooth. When the tooth erupts into the oral cavity, the margin and sulcus are at the tip of the crown; as eruption progresses, they are seen closer to the root. During this eruption process, as described previously, the junctional epithelium, the oral epithelium, and the reduced enamel epithelium undergo extensive alterations and remodeling while maintaining the shallow physiologic depth of the sulcus. Without this remodeling of the epithelia, an abnormal anatomic relationship between the gingiva and the tooth would result.

Continuous Tooth Eruption. According to the concept of continuous eruption,[105] eruption does not cease when the teeth meet their functional antagonists; rather, it continues throughout life. Eruption consists of an active phase and a passive phase. *Active eruption* is the movement of the teeth in the direction of the occlusal plane, whereas *passive eruption* is the exposure of the teeth via apical migration of the gingiva.

This concept distinguishes between the anatomic crown (i.e., the portion of the tooth covered by enamel) and the anatomic root (i.e., the portion of the tooth covered by cementum) and between the clinical crown (i.e., the part of the tooth that has been denuded of its gingiva and projects into the oral cavity) and the clinical root (i.e., the portion of the tooth covered by periodontal tissues). When the teeth reach their functional antagonists, the gingival sulcus and the junctional epithelium are still on the enamel, and the clinical crown is approximately two thirds of the anatomic crown.

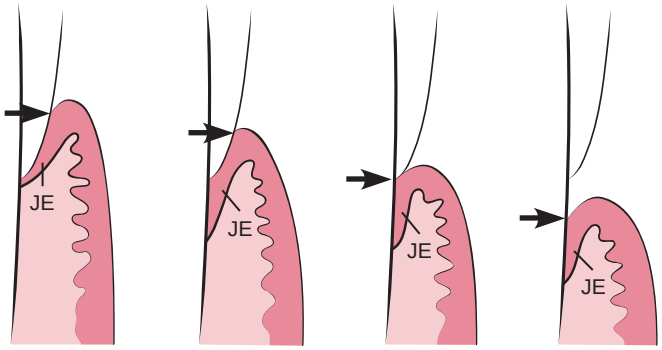

Figure 1-30 Diagrammatic representation of the four steps of passive eruption according to Gottlieb and Orban.[105] **1,** The base of the gingival sulcus *(arrow)* and the junctional epithelium *(JE)* are on the enamel. **2,** The base of the gingival sulcus *(arrow)* is on the enamel, and part of the junctional epithelium is on the root. **3,** The base of the gingival sulcus *(arrow)* is at the cementoenamel line, and the entire junctional epithelium is on the root. **4,** The base of the gingival sulcus *(arrow)* and the junctional epithelium are on the root.

Gottlieb and Orban[105] believed that active and passive eruption proceed together. Active eruption is coordinated with attrition; the teeth erupt to compensate for tooth substance that has been worn away by attrition. Attrition reduces the clinical crown and prevents it from becoming disproportionately long in relation to the clinical root, thus avoiding excessive leverage on the periodontal tissues. Ideally, the rate of active eruption keeps pace with tooth wear, thereby preserving the vertical dimension of the dentition.

As teeth erupt, cementum is deposited at the apices and furcations of the roots, and bone is formed along the fundus of the alveolus and at the crest of the alveolar bone. In this way, part of the tooth substance lost by attrition is replaced by the lengthening of the root, and the socket depth is maintained to support the root.

Although originally thought to be a normal physiologic process, passive eruption is now considered a pathologic process. Passive eruption is divided into the following four stages (Figure 1-30):

Stage 1: The teeth reach the line of occlusion. The junctional epithelium and the base of the gingival sulcus are on the enamel.

Stage 2: The junctional epithelium proliferates so that part is on the cementum and part is on the enamel. The base of the sulcus is still on the enamel.

Stage 3: The entire junctional epithelium is on the cementum, and the base of the sulcus is at the cementoenamel junction. As the junctional epithelium proliferates from the crown onto the root, it does not remain at the cementoenamel junction any longer than at any other area of the tooth.

Stage 4: The junctional epithelium has proliferated farther on the cementum. The base of the sulcus is on the cementum, a portion of which is exposed. Proliferation of the junctional epithelium onto the root is accompanied by degeneration of the gingival and periodontal ligament fibers and their detachment from the tooth. The cause of this degeneration is not understood. At present, it is believed to be the result of chronic inflammation and therefore a pathologic process.

As noted, apposition of bone accompanies active eruption. The distance between the apical end of the junctional epithelium and the crest of the alveolus remains constant throughout continuous tooth eruption (i.e., 1.07 mm).[93]

Exposure of the tooth via the apical migration of the gingiva is called *gingival recession* or *atrophy.* According to the concept of continuous eruption, the gingival sulcus may be located on the

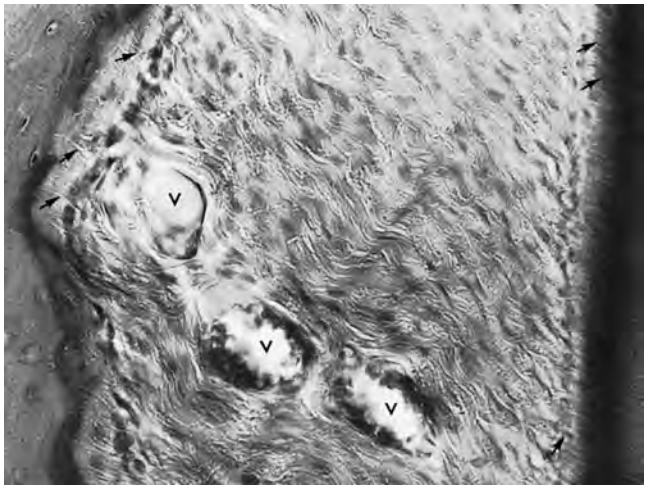

Figure 1-31 Principal fibers of the periodontal ligament follow a wavy course when sectioned longitudinally. The formative function of the periodontal ligament is illustrated by the newly formed osteoid and osteoblasts along a previously resorbed bone surface *(left)* and the cementoid and cementoblasts *(right)*. Note the fibers embedded in the forming calcified tissues *(arrows)*. *V,* Vascular channels.

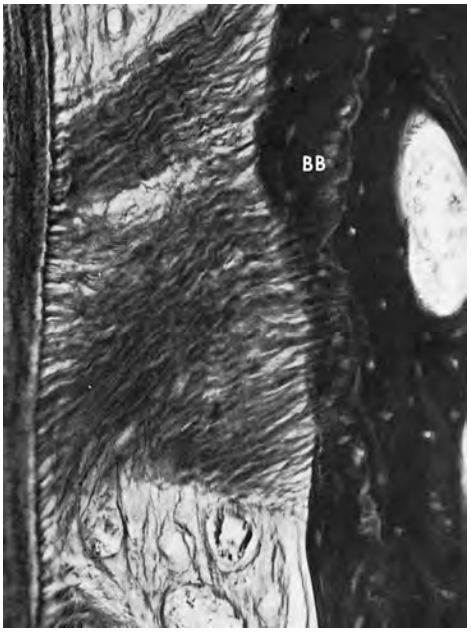

Figure 1-32 Collagen fibers embedded in the cementum *(left)* and the bone *(right)* (silver stain). Note the Sharpey fibers within the bundle bone *(BB)* overlying the lamellar bone.

crown, the cementoenamel junction, or the root, depending on the age of the patient and the stage of eruption. Therefore, some root exposure with age would be considered normal and referred to as *physiologic recession.* Again, this concept is not accepted at present. Excessive exposure is termed *pathologic recession* (see Chapter 13).

Periodontal Ligament

The periodontal ligament is composed of a complex vascular and highly cellular connective tissue that surrounds the tooth root and connects it to the inner wall of the alveolar bone.[175] It is continuous with the connective tissue of the gingiva, and it communicates with the marrow spaces through vascular channels in the bone. Although the average width of the periodontal ligament space is documented to be about 0.2 mm, considerable variation exists. The periodontal space is diminished around teeth that are not in function and in unerupted teeth, but it is increased in teeth that have been subjected to hyperfunction.

Periodontal Fibers

The most important elements of the periodontal ligament are the *principal fibers,* which are collagenous and arranged in bundles and which follow a wavy course when viewed in longitudinal section (Figure 1-31). The terminal portions of the principal fibers that are inserted into cementum and bone are termed *Sharpey fibers* (Figure 1-32). The principal fiber bundles consist of individual fibers that form a continuous anastomosing network between tooth and bone.[25,58] Once embedded in the wall of the alveolus or in the tooth, Sharpey fibers calcify to a significant degree. They are associated with abundant non-collagenous proteins that are typically found in bone, and they have also recently been identified in tooth cementum.[33,132,175] Notable among these proteins are osteopontin and bone sialoprotein. These proteins are thought to contribute to the regulation of mineralization and to tissue cohesion at sites of increased biomechanical strain.[175]

Collagen is a protein that is composed of different amino acids, the most important of which are glycine, proline, hydroxylysine, and hydroxyproline.[51] The amount of collagen in a tissue can be

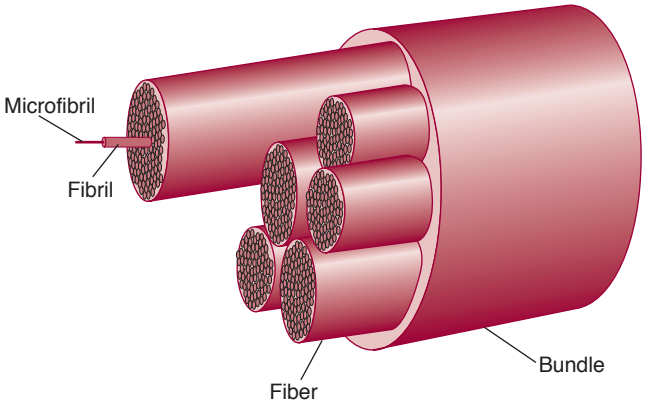

Figure 1-33 Collagen microfibrils, fibrils, fibers, and bundles.

determined by its hydroxyproline content. Collagen is responsible for the maintenance of the framework and the tone of tissue, and it exhibits a wide range of diversity.[80] There are at least 19 recognized collagen species encoded by at least 25 separate genes dispersed among 12 chromosomes.[80]

Collagen biosynthesis occurs inside the fibroblasts to form tropocollagen molecules. These aggregate into microfibrils that are packed together to form fibrils. Collagen fibrils have a transverse striation with a characteristic periodicity of 64 µm; this striation is caused by the overlapping arrangement of the tropocollagen molecules. In collagen types I and III, these fibrils associate to form fibers; in collagen type I, the fibers associate to form bundles (Figure 1-33).

Collagen is synthesized by fibroblasts, chondroblasts, osteoblasts, odontoblasts, and other cells. The several types of collagen are all distinguishable by their chemical composition, distribution, function, and morphology.[138] The principal fibers are composed mainly of collagen type I,[211] whereas reticular fibers are composed of collagen type III. Collagen type IV is found in the basal lamina.[212,214] The expression of type XII collagen during the tooth

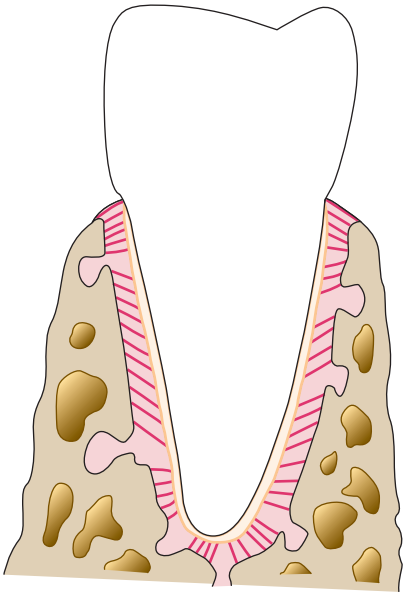

Figure 1-34 Diagram of the principal fiber groups.

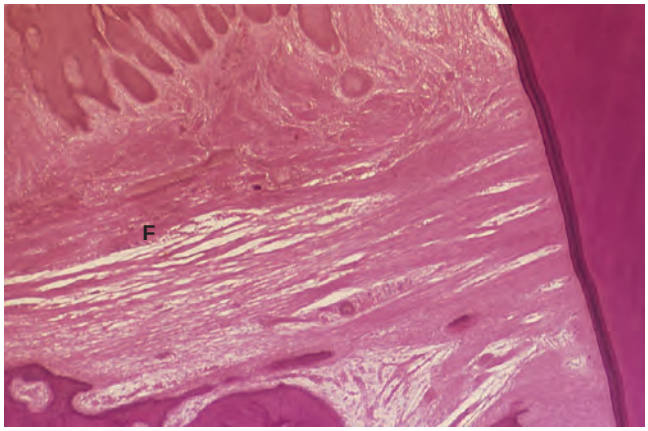

Figure 1-35 Transseptal fibers *(F)* at the crest of the interdental bone.

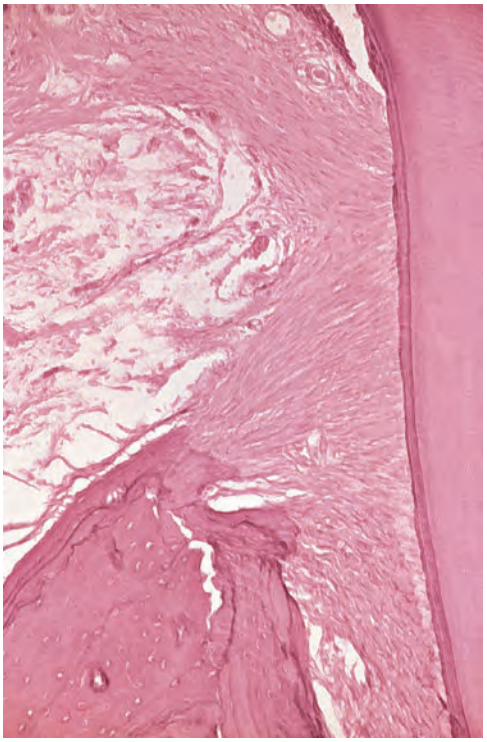

Figure 1-36 Rat molar section showing alveolar crest fibers radiating coronally.

development is timed with the alignment and organization of periodontal fibers and is limited in tooth development to cells within the periodontal ligament.[164] Type VI collagen has also been immunolocalized in the periodontal ligament and the gingiva.[83]

The molecular configuration of collagen fibers provides them with a tensile strength that is greater than that of steel. Consequently, collagen imparts a unique combination of flexibility and strength to the tissues.[138]

The principal fibers of the periodontal ligament are arranged in six groups that develop sequentially in the developing root: the transseptal, alveolar crest, horizontal, oblique, apical, and interradicular fibers (Figure 1-34).

Transseptal fibers extend interproximally over the alveolar bone crest and are embedded in the cementum of adjacent teeth (Figure 1-35). They are reconstructed even after destruction of the alveolar bone that results from periodontal disease. These fibers may be considered as belonging to the gingiva, because they do not have osseous attachment.

Alveolar crest fibers extend obliquely from the cementum just beneath the junctional epithelium to the alveolar crest (Figure 1-36). Fibers also run from the cementum over the alveolar crest and to the fibrous layer of the periosteum that covers the alveolar bone. The alveolar crest fibers prevent the extrusion of the tooth[53] and resist lateral tooth movements. The incision of these fibers during periodontal surgery does not increase tooth mobility unless significant attachment loss has occurred.[97]

Horizontal fibers extend at right angles to the long axis of the tooth from the cementum to the alveolar bone.

Oblique fibers, which comprise the largest group in the periodontal ligament, extend from the cementum in a coronal direction obliquely to the bone (see Figure 1-34). They bear the brunt of vertical masticatory stresses and transform such stresses into tension on the alveolar bone.

The *apical fibers* radiate in a rather irregular manner from the cementum to the bone at the apical region of the socket. They do not occur on incompletely formed roots.

The *interradicular fibers* fan out from the cementum to the tooth in the furcation areas of multi-rooted teeth.

Other well-formed fiber bundles interdigitate at right angles or splay around and between regularly arranged fiber bundles. Less regularly arranged collagen fibers are found in the interstitial connective tissue between the principal fiber groups; this tissue contains the blood vessels, lymphatics, and nerves.

Although the periodontal ligament does not contain mature elastin, two immature forms are found: oxytalan and elaunin. The so-called oxytalan fibers[89,103] run parallel to the root surface in a vertical direction and bend to attach to the cementum[89] in the cervical third of the root. They are thought to regulate vascular flow.[88] An elastic meshwork has been described in the periodontal ligament[133] as being composed of many elastin lamellae with peripheral oxytalan fibers and elaunin fibers. Oxytalan fibers have been shown to develop de novo in the regenerated periodontal ligament.[219]

The principal fibers are remodeled by the periodontal ligament cells to adapt to physiologic needs[265,295] and in response to different stimuli.[277] In addition to these fiber types, small collagen fibers

associated with the larger principal collagen fibers have been described. These fibers run in all directions and form a plexus called the *indifferent fiber plexus.*[243]

Cellular Elements

Four types of cells have been identified in the periodontal ligament: connective tissue cells, epithelial rest cells, immune system cells, and cells associated with neurovascular elements.[26,27]

Connective tissue cells include fibroblasts, cementoblasts, and osteoblasts. Fibroblasts are the most common cells in the periodontal ligament; they appear as ovoid or elongated cells oriented along the principal fibers, and they exhibit pseudopodia-like processes.[210] These cells synthesize collagen and possess the capacity to phagocytose "old" collagen fibers and degrade them[265] via enzyme hydrolysis. Thus, collagen turnover appears to be regulated by fibroblasts in a process of intracellular degradation of collagen that does not involve the action of collagenase.[24]

Phenotypically distinct and functionally different subpopulations of fibroblasts exist in the adult periodontal ligament. They appear to be identical at both the light and electron microscopic levels,[115] but they may have different functions, such as the secretion of different collagen types and the production of collagenase.

Osteoblasts, cementoblasts, osteoclasts, and odontoclasts are also seen in the cemental and osseous surfaces of the periodontal ligament.

The *epithelial rests of Malassez* form a latticework in the periodontal ligament and appear as either isolated clusters of cells or interlacing strands (Figure 1-37), depending on the plane in which the microscopic section is cut. Continuity with the junctional epithelium has been suggested in experimental animals.[106] The epithelial rests are considered remnants of the Hertwig root sheath, which disintegrates during root development (Figure 1-37, *A*).

Epithelial rests are distributed close to the cementum throughout the periodontal ligament of most teeth; they are most numerous in the apical area[207] and the cervical area.[279,280] They diminish in number with age[248] by degenerating and disappearing or by undergoing calcification to become cementicles. The cells are surrounded by a distinct basal lamina, they are interconnected by hemidesmosomes, and they contain tonofilaments.[24]

Although their functional properties are still considered to be unclear,[259] the epithelial rests are reported to contain keratinocyte growth factors, and they have been shown to be positive for tyrosine kinase A neurotrophin receptor.[92,281,291] In addition, epithelial rests proliferate when stimulated,[261,266,275] and they participate in the formation of periapical cysts and lateral root cysts.

The *defense cells* in the periodontal ligament include neutrophils, lymphocytes, macrophages, mast cells, and eosinophils. These cells, as well as those associated with neurovascular elements, are similar to the cells found in other connective tissues.

Ground Substance

The periodontal ligament also contains a large proportion of ground substance that fills the spaces between fibers and cells. This substance consists of two main components: *glycosaminoglycans,* such as hyaluronic acid and proteoglycans, and *glycoproteins,* such as fibronectin and laminin. It also has a high water content (i.e., 70%).

The cell surface proteoglycans participate in several biologic functions, including cell adhesion, cell–cell and cell–matrix interactions, binding to various growth factors as co-receptors, and cell repair.[292] For example, fibromodulin (a small proteoglycan rich in keratan sulfate and leucine) has recently been identified in bovine periodontal ligament.[283] The most comprehensive study of the proteoglycans in periodontal ligament was performed with the use of fibroblast cultures of human ligament.[149]

The periodontal ligament may also contain calcified masses called *cementicles,* which are adherent to or detached from the root surfaces (Figure 1-38).

Cementicles may develop from calcified epithelial rests; around small spicules of cementum or alveolar bone traumatically displaced into the periodontal ligament; from calcified Sharpey fibers; and from calcified, thrombosed vessels within the periodontal ligament.[180]

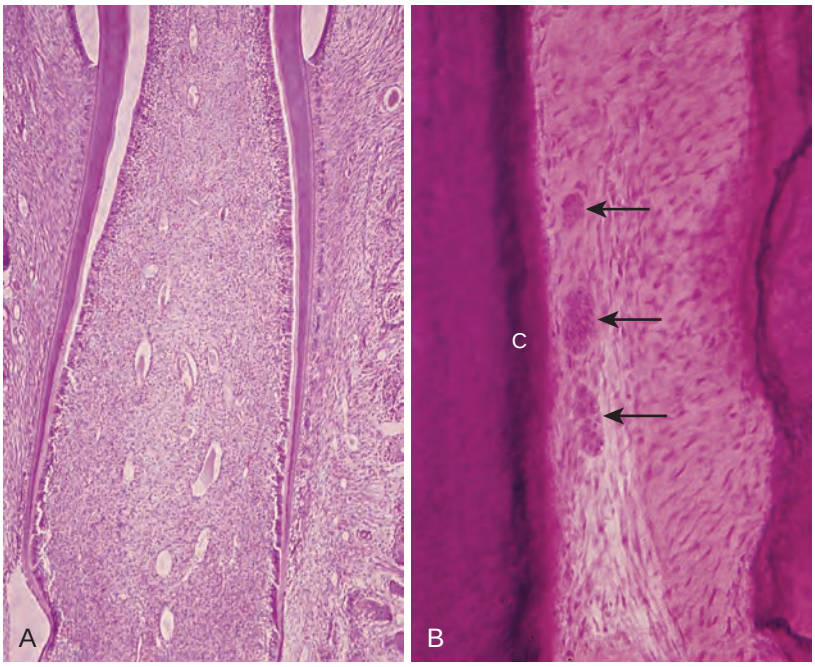

Figure 1-37 Epithelial rests of Malassez. **A,** Erupting tooth in a cat. Note the fragmentation of the Hertwig epithelial root sheath giving rise to epithelial rests located along and close to the root surface. **B,** Human periodontal ligament with rosette-shaped epithelial rests *(arrows)* lying close to the cementum *(C).*

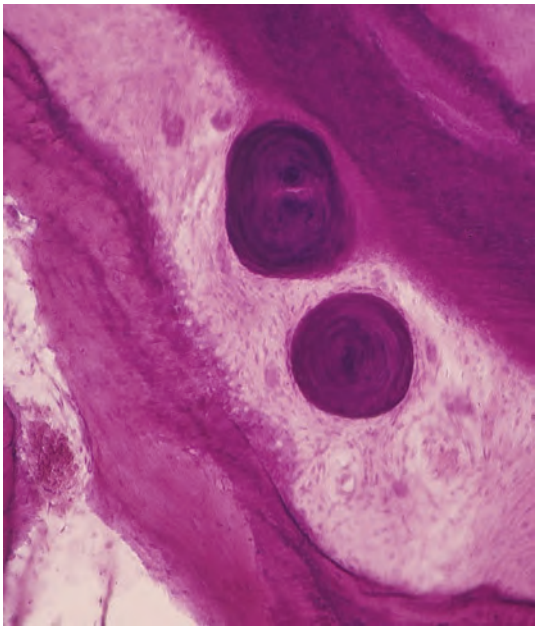

Figure 1-38 Cementicles in the periodontal ligament. One is lying free and the other is adherent to the tooth surface.

Functions of Periodontal Ligament

The functions of the periodontal ligament are categorized as physical, formative and remodeling, nutritional, and sensory.

Physical Functions. The physical functions of the periodontal ligament entail the following:

1. Provision of a soft-tissue "casing" to protect the vessels and nerves from injury by mechanical forces
2. Transmission of occlusal forces to the bone
3. Attachment of the teeth to the bone
4. Maintenance of the gingival tissues in their proper relationship to the teeth
5. Resistance to the impact of occlusal forces (i.e., shock absorption)

Resistance to Impact of Occlusal Forces (Shock Absorption). Two theories pertaining to the mechanism of tooth support have been considered: the tensional theory and the viscoelastic system theory.

The tensional theory of tooth support states that the principal fibers of the periodontal ligament are the major factor in supporting the tooth and transmitting forces to the bone. When a force is applied to the crown, the principal fibers first unfold and straighten, and they then transmit forces to the alveolar bone, thereby causing an elastic deformation of the bony socket. Finally, when the alveolar bone has reached its limit, the load is transmitted to the basal bone. Many investigators find this theory insufficient to explain available experimental evidence.

The viscoelastic system theory states that the displacement of the tooth is largely controlled by fluid movements, with fibers having only a secondary role.[31,43] When forces are transmitted to the tooth, the extracellular fluid passes from the periodontal ligament into the marrow spaces of the bone through the foramina in the cribriform plate. These perforations of the cribriform plate link the periodontal ligament with the cancellous portion of the alveolar bone; they are more abundant in the cervical third than in the middle and apical thirds (Figure 1-39).

After the depletion of tissue fluids, the fiber bundles absorb the slack and tighten. This leads to a blood vessel stenosis. Arterial back pressure causes ballooning of the vessels and passage of the blood ultrafiltrates into the tissues, thereby replenishing the tissue fluids.[31]

Figure 1-39 Foramina perforating the lamina dura of a dog jaw.

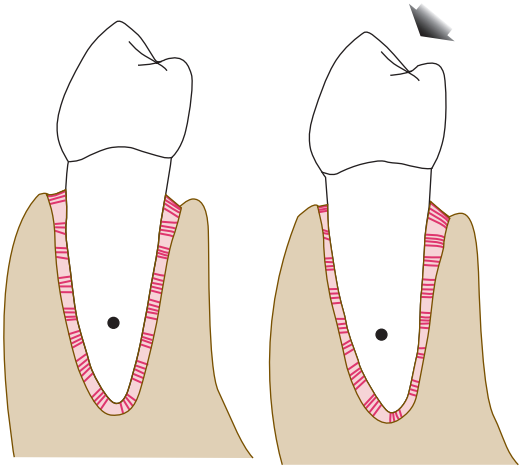

Figure 1-40 **Left,** Diagram of a mandibular premolar in a resting state. **Right,** When a force is exerted on the tooth—in this case, in faciolingual direction *(arrow)*—the tooth rotates around the fulcrum or axis of rotation *(black circle on root)*. The periodontal ligament is compressed in areas of pressure and distended in areas of tension.

Transmission of Occlusal Forces to Bone. The arrangement of the principal fibers is similar to that of a suspension bridge or a hammock. When an axial force is applied to a tooth, a tendency toward displacement of the root into the alveolus occurs. The oblique fibers alter their wavy, untensed pattern, assume their full length, and sustain the major part of the axial force. When a horizontal or tipping force is applied, two phases of tooth movement occur. The first is within the confines of the periodontal ligament, and the second produces a displacement of the facial and lingual bony plates.[69] The tooth rotates about an axis that may change as the force is increased.

The apical portion of the root moves in a direction that is opposite to the coronal portion. In areas of tension, the principal fiber bundles are taut rather than wavy. In areas of pressure, the fibers are compressed, the tooth is displaced, and a corresponding distortion of bone exists in the direction of root movement.[203]

In single-rooted teeth, the axis of rotation is located in the area between the apical third and the middle third of the root (Figure 1-40). The root apex[184] and the coronal half of the clinical root have

TABLE 1-1 Thickness of the Periodontal Ligaments of 172 Teeth from 15 Human Subjects

	Average of Alveolar Crest (mm)	Average of Midroot (mm)	Average of Apex (mm)	Average of Tooth (mm)
Ages 11 through 16 years 83 teeth from 4 jaws	0.23	0.17	0.24	0.21
Ages 32 through 50 years 36 teeth from 5 jaws	0.20	0.14	0.19	0.18
Ages 51 through 67 years 35 teeth from 5 jaws	0.17	0.12	0.16	0.15
Age 24 years (1 case) 18 teeth from 1 jaw	0.16	0.09	0.15	0.13

Modified from Coolidge ED: *J Am Dent Assoc* 24:1260, 1937.

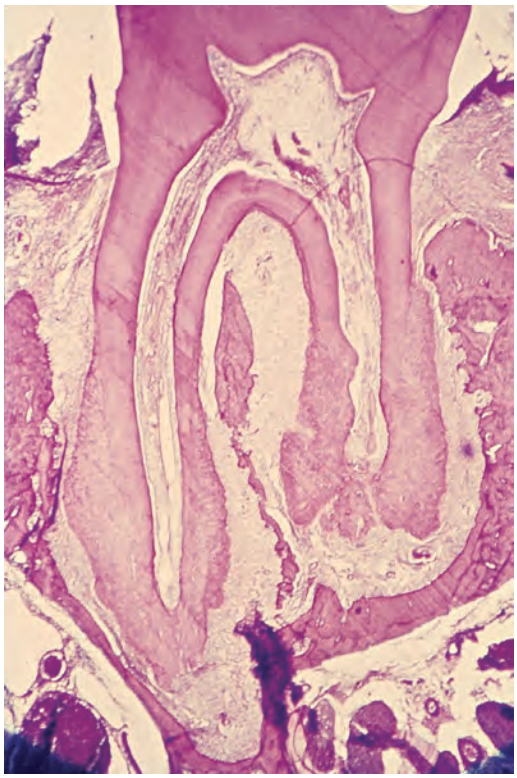

Figure 1-41 Microscopic view of a rat molar subjected to occluso-horizontal forces. Note the alternating widened and narrowed areas of the periodontal ligament as the tooth rotates around its axis of rotation. The axis of rotation is in the interradicular space.

been suggested as other locations of the axis of rotation. The periodontal ligament, which has an hourglass shape, is narrowest in the region of the axis of rotation[65,145] (Table 1-1). In multi-rooted teeth, the axis of rotation is located in the bone between the roots (Figure 1-41). In compliance with the physiologic mesial migration of the teeth, the periodontal ligament is thinner on the mesial root surface than on the distal surface.

Formative and Remodeling Function. Periodontal ligament and alveolar bone cells are exposed to physical forces in response to mastication, parafunction, speech, and orthodontic tooth movement.[173] Cells of the periodontal ligament participate in the formation and resorption of cementum and bone, which occur during physiologic tooth movement, during the accommodation of the periodontium to occlusal forces, and during the repair of injuries.

Variations in cellular enzyme activity are correlated with the remodeling process.[94-96] Although applied loads may induce vascular and inflammatory reactive changes in periodontal ligament cells, current evidence suggests that these cells have a mechanism to respond directly to mechanical forces via the activation of various mechanosensory signaling systems, including adenylate cyclase, stretch-activated ion channels, and via changes in cytoskeletal organization.[173]

Cartilage formation in the periodontal ligament, although unusual, may represent a metaplastic phenomenon in the repair of this ligament after injury.[20]

The periodontal ligament is constantly undergoing remodeling. Old cells and fibers are broken down and replaced by new ones, and mitotic activity can be observed in the fibroblasts and the endothelial cells.[185] Fibroblasts form the collagen fibers, and the residual mesenchymal cells develop into osteoblasts and cementoblasts. Therefore, the rate of formation and the differentiation of osteoblasts, cementoblasts, and fibroblasts affect the rate of formation of collagen, cementum, and bone.

Radioautographic studies with radioactive thymidine, proline, and glycine indicate a high turnover rate of collagen in the periodontal ligament. The rate of collagen synthesis is twice as fast as that in the gingiva and four times as fast as that in the skin, as established in the rat molar.[250] A rapid turnover of sulfated glycosaminoglycans in the cells and amorphous ground substance of the periodontal ligament also occurs.[21] It should be noted that most of these studies have been performed in rodents and that information about primates and humans is scarce.[232]

Nutritional and Sensory Functions. The periodontal ligament supplies nutrients to the cementum, bone, and gingiva by way of the blood vessels, and it also provides lymphatic drainage as discussed later in this chapter. In relation to other ligaments and tendons, the periodontal ligament is highly vascularized tissue; almost 10% of its volume in the rodent molar is blood vessels.[35,174] This relatively high blood vessel content may provide hydrodynamic damping to applied forces as well as high perfusion rates to the periodontal ligament.[173]

The periodontal ligament is abundantly supplied with sensory nerve fibers that are capable of transmitting tactile, pressure, and pain sensations via the trigeminal pathways.[14,30] Nerve bundles pass into the periodontal ligament from the periapical area and through channels from the alveolar bone that follow the course of the blood vessels. The bundles divide into single myelinated fibers, which

ultimately lose their myelin sheaths and end in one of four types of neural termination: (1) free endings, which have a treelike configuration and carry pain sensation; (2) Ruffini-like mechanoreceptors, which are located primarily in the apical area; (3) coiled Meissner corpuscles and mechanoreceptors, which are found mainly in the midroot region; and (4) spindlelike pressure and vibration endings, which are surrounded by a fibrous capsule and located mainly in the apex.[88,166]

Regulation of Periodontal Ligament Width. Some of the most interesting features of the periodontal ligament in animals are its adaptability to rapidly changing applied force and its capacity to maintain its width at constant dimensions throughout its lifetime.[174] These are important measures of periodontal ligament homeostasis that provide insight into the function of the biologic mechanisms that tightly regulate the metabolism and spatial locations of the cell populations involved in the formation of bone, cementum, and periodontal ligament fibers. In addition, the ability of periodontal ligament cells to synthesize and secrete a wide range of regulatory molecules is an essential component of tissue remodeling and periodontal ligament homeostasis.[173]

Cementum

Cementum is the calcified, avascular mesenchymal tissue that forms the outer covering of the anatomic root. The two main types of cementum are acellular *(primary)* and cellular *(secondary)* cementum.[104] Both consist of a calcified interfibrillar matrix and collagen fibrils.

The two main sources of collagen fibers in cementum are Sharpey fibers *(extrinsic)*, which are the embedded portion of the principal fibers of the periodontal ligament[214] and which are formed by the fibroblasts, and fibers that belong to the cementum matrix *(intrinsic)*, which are produced by the cementoblasts.[240] Cementoblasts also form the noncollagenous components of the interfibrillar ground substance, such as proteoglycans, glycoproteins, and phosphoproteins. Proteoglycans are most likely to play a role in regulating cell–cell and cell–matrix interactions, both during normal development and during the regeneration of the cementum.[17] In addition, immunohistochemical studies have shown that the distribution of proteoglycans is closely associated with the cementoblasts and the cementocytes.[1,2]

The major proportion of the organic matrix of cementum is composed of type I (90%) and type III (about 5%) collagens. Sharpey fibers, which constitute a considerable proportion of the bulk of cementum, are composed of mainly type I collagen.[206] Type III collagen appears to coat the type I collagen of the Sharpey fibers.[16]

Acellular cementum is the first cementum formed; it covers approximately the cervical third or half of the root, and it does not contain cells (Figure 1-42). This cementum is formed before the tooth reaches the occlusal plane, and its thickness ranges from 30 to 230 µm.[248] Sharpey fibers make up most of the structure of acellular cementum, which has a principal role in supporting the tooth. Most fibers are inserted at approximately right angles into the root surface and penetrate deep into the cementum, but others enter from several different directions. Their size, number, and distribution increase with function.[123] Sharpey fibers are completely calcified, with the mineral crystals oriented parallel to the fibrils as in dentin and bone, except in a 10- to 50-µm–wide zone near the cementodentinal junction, where they are only partially calcified. The peripheral portions of Sharpey fibers in actively mineralizing cementum tend to be more calcified than the interior regions, according to evidence obtained by scanning electron microscopy.[137]

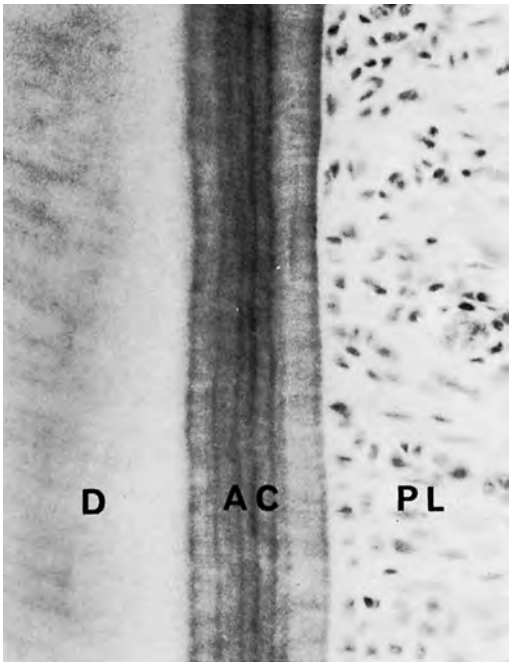

Figure 1-42 Acellular cementum *(AC)* showing incremental lines running parallel to the long axis of the tooth. These lines represent the appositional growth of cementum. Note the thin, light lines running into the cementum perpendicular to the surface; these represent the Sharpey fibers of the periodontal ligament *(PL)*. *D,* Dentin. (×300.)

Acellular cementum also contains intrinsic collagen fibrils that are calcified and irregularly arranged or parallel to the surface.[232]

Cellular cementum, which is formed after the tooth reaches the occlusal plane, is more irregular and contains cells (cementocytes) in individual spaces (lacunae) that communicate with each other through a system of anastomosing canaliculi (Figure 1-43). Cellular cementum is less calcified than the acellular type.[124] Sharpey fibers occupy a smaller portion of cellular cementum and are separated by other fibers that are arranged either parallel to the root surface or at random. Sharpey fibers may be completely or partially calcified, or they may have a central, uncalcified core surrounded by a calcified border.[135,240]

Both acellular cementum and cellular cementum are arranged in lamellae separated by incremental lines parallel to the long axis of the root (see Figures 1-42 and 1-43). These lines represent "rest periods" in cementum formation, and they are more mineralized than the adjacent cementum.[215] In addition, the loss of the cervical part of the reduced enamel epithelium at the time of tooth eruption may place portions of mature enamel in contact with the connective tissue, which then will deposit an acellular and afibrillar type of cementum over the enamel.[157]

On the basis of these findings, Schroeder[133,134] has classified cementum as follows:

- Acellular afibrillar cementum contains neither cells nor extrinsic or intrinsic collagen fibers, except for a mineralized ground substance. Acellular afibrillar cementum is a product of cementoblasts and found as coronal cementum in humans, with a thickness of 1 to 15 µm.
- Acellular extrinsic fiber cementum is composed almost entirely of densely packed bundles of Sharpey fibers and lacks cells. Acellular extrinsic fiber cementum is a product of fibroblasts and cementoblasts. It is found in the cervical third of roots in humans, but it may extend farther apically. Its thickness is between 30 and 230 µm.

It is well known that the protein extracts of mature cementum promote cell attachment and cell migration and stimulate the protein synthesis of gingival fibroblasts and periodontal ligament cells.[225] Studies of cementum have identified adhesion proteins with arginyl–glycyl–aspartic acid sequences: bone sialoprotein, osteopontin, and osteonectin.[39,175] Bone sialoprotein and osteopontin are expressed during early tooth root development by cells along the root surface, and they are thought to play a major role in the differentiation of the cementoblast progenitor cells to the cementoblasts.[109,225]

Some of the molecules unique to the cementum have been described. Recent work has investigated the role of *cementum attachment protein,* which is a collagenous cementum-derived protein. Cementum attachment protein has been shown to promote the adhesion and spreading of mesenchymal cell types, with osteoblasts and periodontal ligament fibroblasts showing better adhesion than gingival fibroblasts and keratinocytes.[220] In addition, Ikezawa and colleagues[122] described the characterization of *cementum-derived growth factor,* which is an insulin-like, growth factor-I–like molecule. Cementum-derived growth factor has been shown to enhance the proliferation of gingival fibroblasts and periodontal ligament cells.

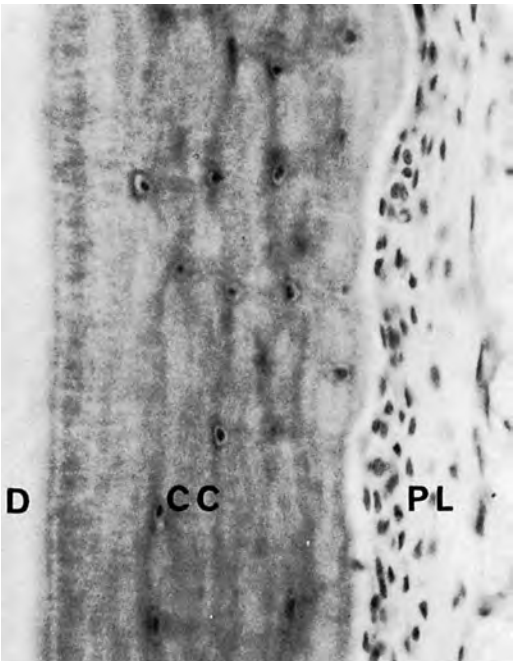

Figure 1-43 Cellular cementum *(CC)* showing cementocytes lying within the lacunae. Cellular cementum is thicker than acellular cementum (see Figure 2-45). The evidence of incremental lines also exists, but they are less distinct than in the acellular cementum. The cells adjacent to the surface of the cementum in the periodontal ligament *(PL)* space are cementoblasts. *D,* Dentin. (×300.)

- Cellular mixed stratified cementum is composed of extrinsic (Sharpey) and intrinsic fibers, and it may contain cells. Cellular mixed stratified cementum is a co-product of fibroblasts and cementoblasts. In humans, it appears primarily in the apical third of the roots and apices and in furcation areas. Its thickness ranges from 100 to 1000 µm.
- Cellular intrinsic fiber cementum contains cells but no extrinsic collagen fibers. Cellular intrinsic fiber cementum is formed by cementoblasts, and, in humans, it fills the resorption lacunae.

Intermediate cementum is a poorly defined zone near the cementodentinal junction of certain teeth that appears to contain cellular remnants of the Hertwig sheath embedded in calcified ground substance.[77,153]

Inorganic content of cementum (hydroxyapatite; Ca10[Po4] 6[OH]2) is 45% to 50%, which is less than that of bone (65%), enamel (97%), or dentin (70%).[299] Opinions differ with regard to whether the microhardness increases[189] or decreases with age,[282] and no relationship has been established between aging and the mineral content of cementum.

Permeability of Cementum

In very young animals, acellular cementum and cellular cementum are very permeable and permit the diffusion of dyes from the pulp and the external root surface. In cellular cementum, the canaliculi in some areas are contiguous with the dentinal tubuli. The permeability of cementum diminishes with age.[36]

Cementoenamel Junction

The cementum at and immediately subjacent to the *cementoenamel junction* is of particular clinical importance in root-scaling procedures. Three types of relationships involving the cementum may exist at the cementoenamel junction.[190] In about 60% to 65% of cases, cementum overlaps the enamel (Figure 1-44); in about 30%, an edge-to-edge butt joint exists; and in 5% to 10%, the cementum and enamel fail to meet. In the last case, gingival recession may result in accentuated sensitivity as a result of exposed dentin.

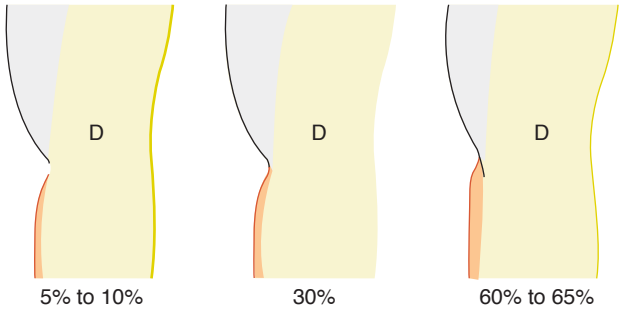

Figure 1-44 Normal variations in tooth morphology at the cementoenamel junction. **A,** Space between the enamel and the cementum with the dentin *(D)* exposed. **B,** End-to-end relationship of enamel and cementum. **C,** Cementum overlapping the enamel.

Cementodentinal Junction

The terminal apical area of the cementum where it joins the internal root canal dentin is known as the *cementodentinal junction.* When root canal treatment is performed, the obturating material should be at the cementodentinal junction. There appears to be no increase or decrease in the width of the cementodentinal junction with age; its width appears to remain relatively stable.[253] Scanning electron microscopy of the human teeth reveals that the cementodentinal junction is 2 to 3 µm wide. The fibril-poor layer contains a significant amount of proteoglycans, and fibrils intermingle between the cementum and the dentin.[293,294]

Thickness of Cementum

Cementum deposition is a continuous process that proceeds at varying rates throughout life. Cementum formation is most rapid in the apical regions, where it compensates for tooth eruption, which itself compensates for attrition.

The thickness of cementum on the coronal half of the root varies from 16 to 60 µm, which is about the thickness of a hair. It attains its greatest thickness (≤150 to 200 µm) in the apical third and in the furcation areas. It is thicker in distal surfaces than in mesial surfaces, probably because of functional stimulation from mesial drift over time.[68] Between the ages of 11 and 70 years, the average thickness of the cementum increases threefold, with the greatest increase seen in the apical region. Average thicknesses of 95 µm at the age of 20 years and of 215 µm at the age of 60 years have been reported.[298]

Abnormalities in the thickness of cementum may range from an absence or paucity of cellular cementum (i.e., cemental aplasia or hypoplasia) to an excessive deposition of cementum (i.e., cemental hyperplasia or hypercementosis).[152]

The term *hypercementosis* refers to a prominent thickening of the cementum. It is largely an age-related phenomenon, and it may be localized to one tooth or affect the entire dentition. As a result of considerable physiologic variation in the thickness of cementum among different teeth in the same person and also among different persons, distinguishing between hypercementosis and the physiologic thickening of cementum is sometimes difficult. Nevertheless, the excessive proliferation of cementum may occur with a broad spectrum of neoplastic and nonneoplastic conditions, including benign cementoblastoma, cementifying fibroma, periapical cemental dysplasia, florid cemento-osseous dysplasia, and other benign fibro-osseous lesions.[152]

Hypercementosis occurs as a generalized thickening of the cementum, with nodular enlargement of the apical third of the root. It also appears in the form of spikelike excrescences (i.e., cemental spikes) created by either the coalescence of cementicles that adhere to the root or the calcification of periodontal fibers at the sites of insertion into the cementum.[153]

Radiographically, the radiolucent shadow of the periodontal ligament and the radiopaque lamina dura are always seen on the outer border of an area of hypercementosis, enveloping it as it would in normal cementum.[152] On the other hand, from a diagnostic standpoint, periapical cemental dysplasia, condensing osteitis, and focal periapical osteopetrosis may be differentiated from hypercementosis, because all of these entities are located outside of the shadow of the periodontal ligament and the lamina dura.[290]

The cause of hypercementosis varies and is not completely understood. The spikelike type of hypercementosis generally results from excessive tension caused by orthodontic appliances or occlusal forces. The generalized type occurs in a variety of circumstances. In teeth without antagonists, hypercementosis is interpreted as an effort to keep pace with excessive tooth eruption. In teeth that are subject to low-grade periapical irritation that arises from pulp disease, it is considered compensation for the destroyed fibrous attachment to the tooth. The cementum is deposited adjacent to the inflamed periapical tissue. Hypercementosis of the entire dentition may occur in patients with Paget disease.[218] Other systemic disturbances that may lead to or may be associated with hypercementosis include acromegaly, arthritis, calcinosis, rheumatic fever, and thyroid goiter.[152]

Hypercementosis itself does not require treatment. It could pose a problem if an affected tooth requires extraction. In a multi-rooted tooth, sectioning of the tooth may be required before extraction.[19]

Cementum Resorption and Repair

Permanent teeth do not undergo physiologic resorption as primary teeth do. However, the cementum of erupted (as well as unerupted) teeth is subject to resorptive changes that may be of microscopic proportion or sufficiently extensive to present a radiographically detectable alteration in the root contour.

Microscopic cementum resorption is extremely common; in one study, it occurred in 236 of 261 teeth (90.5%).[118] The average number of resorption areas per tooth was 3.5. Of the 922 areas of resorption, 708 (76.8%) were located in the apical third of the root, 177 (19.2%) in the middle third, and 37 (4.0%) in the gingival third. Approximately 70% of all resorption areas were confined to the cementum without involving the dentin.

Cementum resorption may be caused by local or systemic factors, or it may occur without apparent etiology (i.e., idiopathic). Local conditions that cause cementum resorption include trauma from occlusion[194] (Figure 1-45); orthodontic movement[117,193,217]; pressure from malaligned erupting teeth, cysts, and tumors[144]; teeth without functional antagonists; embedded teeth; replanted and transplanted teeth[3,135]; periapical disease; and periodontal disease. Systemic conditions that are cited as predisposing an individual to or inducing cemental resorption include calcium deficiency,[136] hypothyroidism,[23] hereditary fibrous osteodystrophy,[269] and Paget disease.[218]

Cementum resorption appears microscopically as baylike concavities in the root surface. (Figure 1-46) Multinucleated giant cells and large mononuclear macrophages are generally found adjacent to cementum that is undergoing active resorption (Figure 1-47). Several sites of resorption may coalesce to form a large area of destruction. The resorptive process may extend into the underlying dentin and even into the pulp, but it is usually painless. Cementum resorption is not necessarily continuous and may alternate with periods of repair and the deposition of new cementum. The newly formed cementum is demarcated from the root by a deeply staining irregular line termed a *reversal line,* which delineates the border of the previous resorption. A recent study showed that the reversal lines of human teeth contain a few collagen fibrils and highly accumulated proteoglycans with mucopolysaccharides (glycosaminoglycans) and that fibril intermingling occurs only in some places between reparative cementum and resorbed dentin or cementum.[293,294] Embedded fibers of the periodontal ligament reestablish a functional relationship in the new cementum.

Cementum repair requires the presence of viable connective tissue. If epithelium proliferates into an area of resorption, repair will not take place. Cementum repair can occur in devitalized as well as vital teeth.

Histologic evidence demonstrates that cementum formation is critical for the appropriate maturation of the periodontium, both during development and during the regeneration of lost periodontal tissues.[225] In other words, a variety of macromolecules present in the extracellular matrix of the periodontium are likely to play a regulatory role in cementogenesis.[169]

The regeneration of cementum requires cementoblasts, but the origin of the cementoblasts and the molecular factors that regulate their recruitment and differentiation are not fully understood. However, recent research provides a better understanding; for example, the epithelial cell rests of Malassez are the only odontogenic epithelial cells that remain in the periodontium after the eruption of teeth, and they may have some function in cementum repair and regeneration under specific conditions.[114] The rests of Malassez may be related to cementum repair by activating their potential to secrete matrix proteins that have been expressed in tooth development, such as amelogenins, enamelins, and sheath proteins. Several growth factors have been shown to be effective in cementum regeneration, including members of the transforming growth factor superfamily (i.e., bone morphogenetic proteins), platelet-derived growth factor, insulin-like growth factor, and enamel matrix derivatives[139,225] (Figure 1-48).

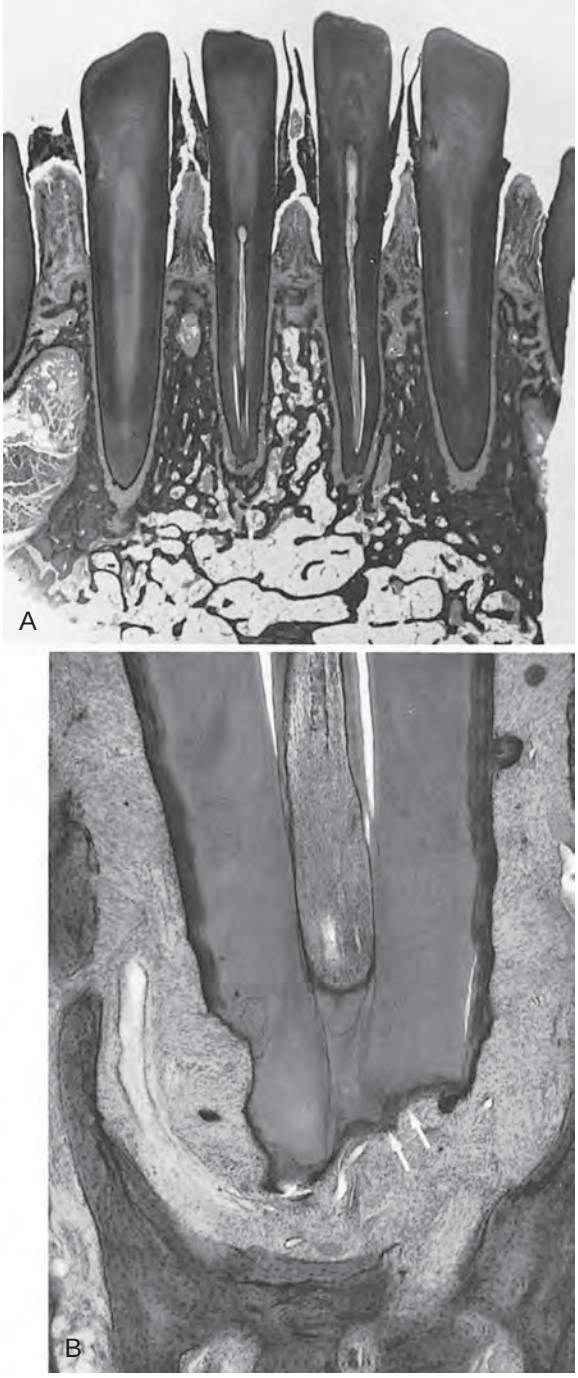

Figure 1-45 Cemental resorption associated with excessive occlusal forces. **A,** Low-power histologic section of the mandibular anterior teeth. **B,** High-power micrograph of the apex of the left central incisor shortened by the resorption of cementum and dentin. Note the partial repair of the eroded areas *(arrows)* and the cementicle at the upper right.

Ankylosis. Fusion of the cementum and the alveolar bone with obliteration of the periodontal ligament is termed *ankylosis*. Ankylosis occurs in teeth with cemental resorption, which suggests that it may represent a form of abnormal repair. Ankylosis may also develop after chronic periapical inflammation, tooth replantation, and occlusal trauma and around embedded teeth. This condition is relatively uncommon, and it occurs most frequently in the primary dentition.[176]

Exposure of Cementum to the Oral Environment

Cementum becomes exposed to the oral environment in cases of gingival recession and as a result of the loss of attachment in pocket formation. The cementum is sufficiently permeable to be penetrated in these cases by organic substances, inorganic ions, and bacteria. Bacterial invasion of the cementum occurs frequently in individuals with periodontal disease, and cementum caries can develop (see Chapter 13).

Alveolar Process

The alveolar process is the portion of the maxilla and mandible that forms and supports the tooth sockets (alveoli). It forms when the tooth erupts to provide the osseous attachment to the forming periodontal ligament; it disappears gradually after the tooth is lost.

Because the alveolar processes develop and undergo remodeling with tooth formation and eruption, they are tooth-dependent bony structures.[227] Therefore, the size, shape, location, and function of the teeth determine their morphology. Interestingly, although the growth and development of the bones of the jaw determine the position of the teeth, a certain degree of repositioning of the teeth can be accomplished through occlusal forces and in response to orthodontic procedures that rely on the adaptability of the alveolar bone and the associated periodontal tissues.[251]

The alveolar process consists of the following:

1. An external plate of cortical bone is formed by haversian bone and compacted bone lamellae.
2. The inner socket wall of thin, compact bone called the *alveolar bone proper* is seen as the lamina dura in radiographs. Histologically, it contains a series of openings (i.e., the *cribriform plate*) through which neurovascular bundles link the periodontal ligament with the central component of the alveolar bone: the cancellous bone.



Figure 1-46 Scanning electron micrograph of a root exposed by periodontal disease showing a large resorption bay *(R)*. Remnants of the periodontal ligament *(P)* and calculus *(C)* are visible. Cracking of the tooth surface occurs as a result of the preparation technique. (×160.) *(Courtesy Dr. John Sottosanti, La Jolla, CA.)*

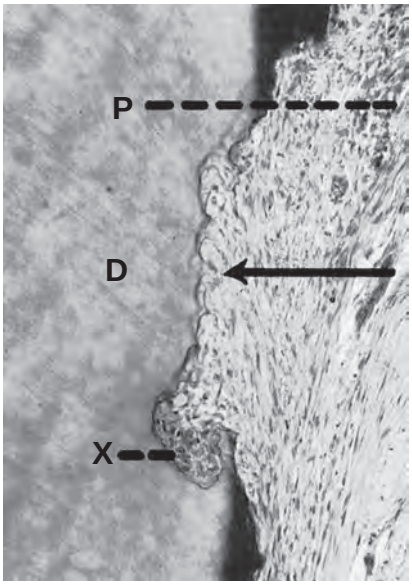

Figure 1-47 Resorption of cementum and dentin. A multinuclear osteoclast in seen *(X)*. The direction of resorption is indicated by the arrow. Note the scalloped resorption front in the dentin *(D)*. The cementum is the darkly stained band at the upper and lower right. *P,* Periodontal ligament.

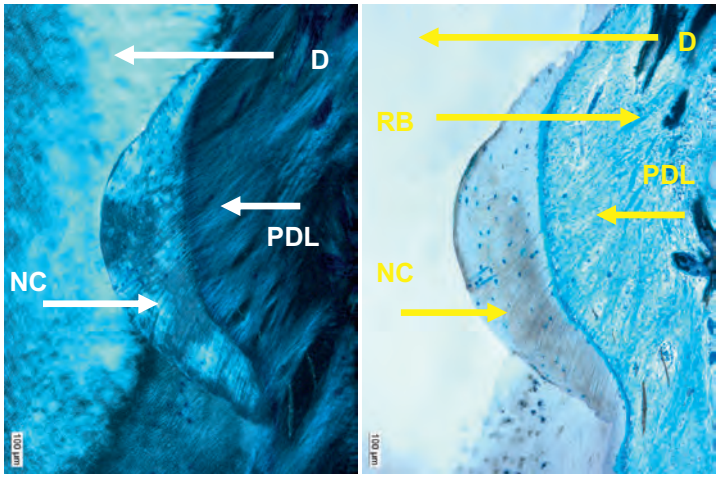

Figure 1-48 A clinical human histology shows that new cementum and new periodontal ligament fiber formed at a previous periodontal defect treated with recombinant human platelet-derived growth factor-BB with β-tricalcium phosphate. *(Courtesy Dr. Daniel WK Kao, Philadelphia, PA.)*

Ankylosis results in the resorption of the root and its gradual replacement by bone tissue. For this reason, reimplanted teeth that ankylose will lose their roots after 4 to 5 years and will be exfoliated. Clinically, ankylosed teeth lack the physiologic mobility of normal teeth, which is one diagnostic sign for ankylotic resorption. In addition, these teeth usually have a special metallic percussion sound; if the ankylotic process continues, they will be in infraocclusion.[90] However, the clinical diagnosis of ankylosis by mobility and percussion tests alone is only reliable when at least 20% of the root surface is affected.[10]

As the periodontal ligament is replaced with bone during ankylosis, proprioception is lost, because pressure receptors in the periodontal ligament are deleted or do not function correctly. Furthermore, the physiologic drifting and eruption of teeth can no longer occur, and thus the ability of the teeth and periodontium to adapt to altered force levels or directions of force is greatly reduced.[173] Radiographically, resorption lacunae are filled with bone, and the periodontal ligament space is missing.

Because no definitive causes can be found in ankylotic root resorption, no predictable treatment can be suggested. Treatment modalities range from a conservative approach, such as restorative intervention, to surgical the extraction of the affected tooth.[186]

When titanium implants are placed in the jaw, healing results in bone that is formed in direct apposition to the implant without intervening connective tissue. This may be interpreted as a form of ankylosis. Because resorption of the metallic implant cannot occur, the implant remains indefinitely "ankylosed" to the bone. In addition, a true periodontal pocket will not form; the apical proliferation of the epithelium along the root, which is a key element of pocket formation, is not possible because of the ankylosis.

The regulation of bone remodeling is a complex process that involves hormones and local factors acting in an autocrine and a paracrine manner on the generation and activity of differentiated bone cells.[251] Bone contains 99% of the body's calcium ions and therefore is the major source for calcium release when the calcium blood levels decrease; this is monitored by the parathyroid gland. A decrease in blood calcium is mediated by receptors on the chief cells of the parathyroid glands, which then release parathyroid hormone. Parathyroid hormone stimulates osteoblasts to release interleukin-1 and interleukin-6, which stimulate monocytes to migrate into the bone area. Leukemia-inhibiting factor, which is secreted by osteoblasts, coalesces monocytes into multinucleated osteoclasts, which then resorb bone, thereby releasing calcium ions from hydroxyapatite into the blood. This release normalizes the blood level of calcium. A feedback mechanism of normal blood levels of calcium turns off the secretion of parathyroid hormone. Meanwhile, osteoclasts have resorbed organic matrix along with hydroxyapatite. The breakdown of collagen from the organic matrix releases various osteogenic substrates, which are covalently bound to collagen. This in turn stimulates the differentiation of osteoblasts, which ultimately deposit bone. This interdependency of osteoblasts and osteoclasts in remodeling is called *coupling*.

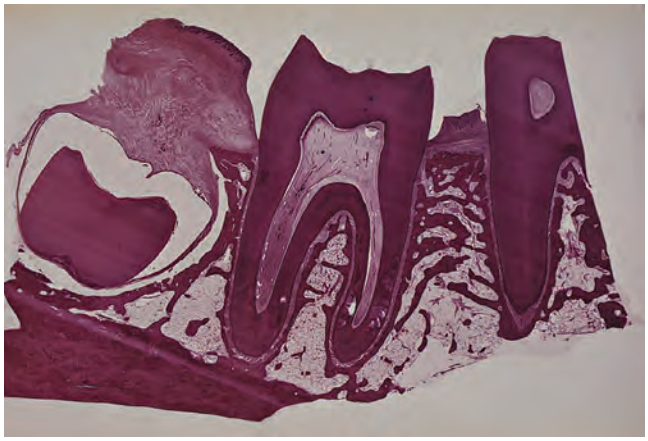

Figure 1-49 Mesiodistal section through the mandibular molars of a 17-year-old girl obtained at autopsy. Note the interdental bony septa between the first and second molars. The dense cortical bony plates represent the alveolar bone proper (i.e., the cribriform plates) and are supported by cancellous bony trabeculae. The third molar is still in the early stages of root formation and eruption.

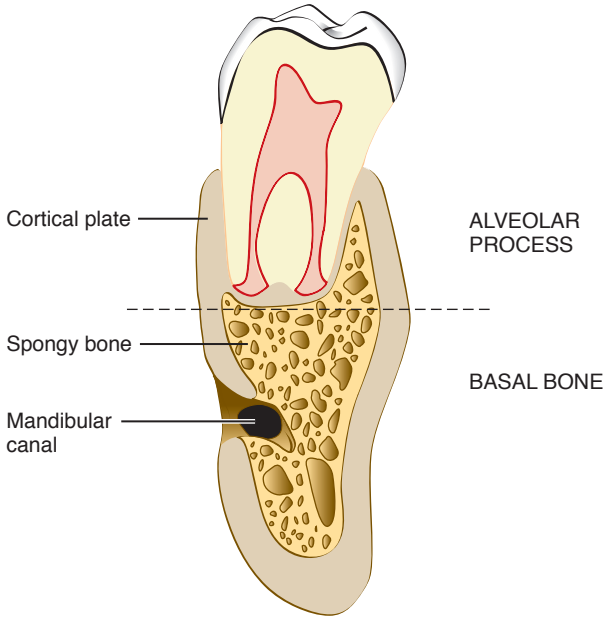

Figure 1-50 Section through a human jaw with a tooth in situ. The dotted line indicates the separation between the basal bone and the alveolar bone. *(Redrawn from Ten Cate AR:* Oral histology: development, structure, and function, *ed 4, St Louis, 1994, Mosby.)*

3. Cancellous trabeculae between these two compact layers act as supporting alveolar bone. The *interdental septum* consists of cancellous supporting bone enclosed within a compact border (Figure 1-49).

In addition, the bones of the jaw include the basal bone, which is the portion of the jaw located apically but unrelated to the teeth (Figure 1-50).

The alveolar process is divisible into separate areas on an anatomic basis, but it functions as a unit, with all parts interrelated in the support of the teeth. Figures 1-51 and 1-52 show the relative proportions of cancellous bone and compact bone that form the alveolar process. Most of the facial and lingual portions of the sockets are formed by compact bone alone; cancellous bone surrounds the lamina dura in apical, apicolingual, and interradicular areas.

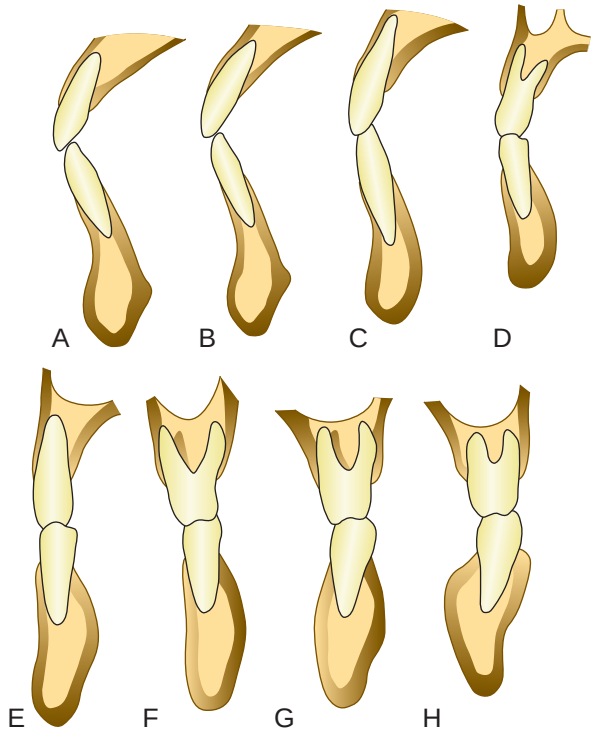

Figure 1-51 Relative proportions of cancellous bone and compact bone in a longitudinal faciolingual section of, **A,** mandibular molars; **B,** lateral incisors; **C,** canines; **D,** first premolars; **E,** second premolars; **F,** first molars; **G,** second molars; and **H,** third molars.

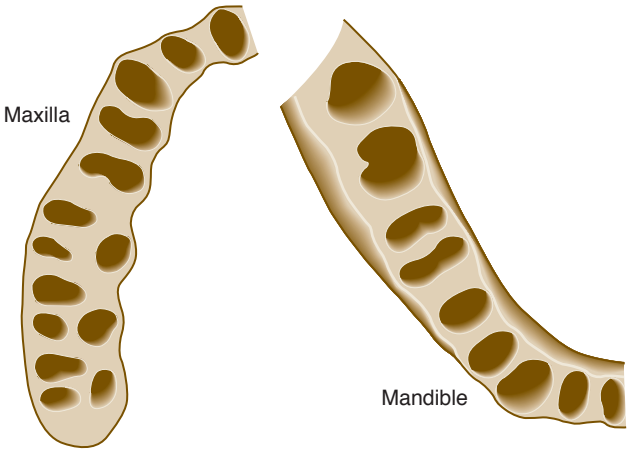

Figure 1-52 The shape of the roots and the surrounding bone distribution in a transverse section of maxilla and mandible at the midroot level.

Bone consists of two thirds inorganic matter and one third organic matrix. The inorganic matter is composed principally of the minerals calcium and phosphate, along with hydroxyl, carbonate, citrate, and trace amounts of other ions[101,102] such as sodium, magnesium, and fluorine. The mineral salts are in the form of hydroxyapatite crystals of ultramicroscopic size and constitute approximately two thirds of the bone structure.

The organic matrix[75] consists mainly of collagen type I (90%),[185] with small amounts of noncollagenous proteins such as osteocalcin, osteonectin, bone morphogenetic protein, phosphoproteins, and proteoglycans.[209] Osteopontin and bone sialoprotein are cell-adhesion proteins that appear to be important for the adhesion of both osteoclasts and osteoblasts.[163] In addition, paracrine factors,

including cytokines, chemokines, and growth factors, have been implicated in the local control of mesenchymal condensations that occur at the onset of organogenesis. These factors probably play a prominent role in the development of the alveolar processes.[251]

Although the alveolar bone tissue is constantly changing its internal organization, it retains approximately the same form from childhood through adult life. Bone deposition by osteoblasts is balanced by resorption by osteoclasts during tissue remodeling and renewal. It is well known that the number of osteoblasts decreases with aging; however, no remarkable change in the number of osteoclasts has ever been reported.[191]

Remodeling is the major pathway of bony changes in shape, resistance to forces, repair of wounds, and calcium and phosphate homeostasis in the body. Indeed, the coupling of bone resorption with bone formation constitutes one of the fundamental principles by which bone is necessarily remodeled throughout its life. Bone remodeling involves the coordination of activities of cells from two distinct lineages, the osteoblasts and the osteoclasts, which form and resorb the mineralized connective tissues of bone.[251]

The bone matrix that is laid down by osteoblasts is nonmineralized osteoid. While new osteoid is being deposited, the older osteoid located below the surface becomes mineralized as the mineralization front advances.

Bone resorption is a complex process that is morphologically related to the appearance of eroded bone surfaces (i.e., Howship lacunae) and large, multinucleated cells (osteoclasts) (Figure 1-53). Osteoclasts originate from hematopoietic tissue[55,110,197] and are formed by the fusion of mononuclear cells of asynchronous populations.[141,201,264] When osteoclasts are active rather than resting, they possess an elaborately developed ruffled border from which hydrolytic enzymes are thought to be secreted.[278] These enzymes digest the organic portion of bone. The activity of osteoclasts and the morphology of the ruffled border can be modified and regulated by hormones such as parathyroid hormone (indirectly) and calcitonin, which has receptors on the osteoclast membrane.

Another mechanism of bone resorption involves the creation of an acidic environment on the bone surface, thereby leading to the dissolution of the mineral component of bone. This event can be produced by different conditions, including a proton pump through the cell membrane of the osteoclast,[34] bone tumors, and local pressure[197] translated through the secretory activity of the osteoclast.

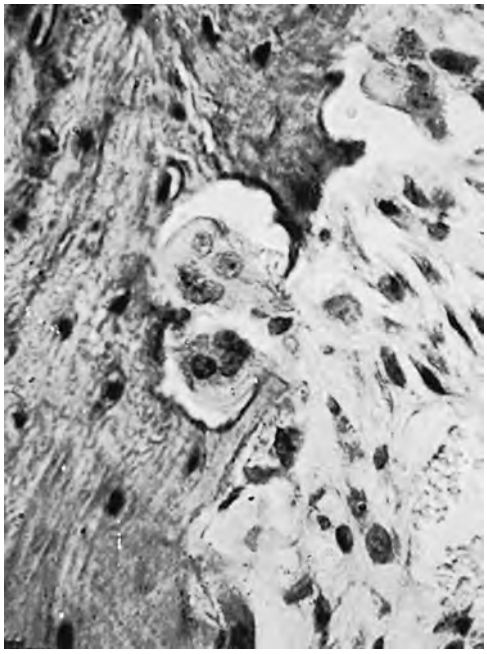

Figure 1-53 Rat alveolar bone. This histologic view show two multinucleated osteoclasts in the Howship lacuna.

Ten Cate[264] described the sequence of events in the resorptive process as follows:

1. Attachment of osteoclasts to the mineralized surface of bone
2. Creation of a sealed acidic environment through the action of the proton pump, which demineralizes bone and exposes the organic matrix
3. Degradation of the exposed organic matrix to its constituent amino acids via the action of released enzymes (e.g., acid phosphatase, cathepsin)
4. Sequestering of mineral ions and amino acids within the osteoclast

Notably, the cellular and molecular events involved in bone remodeling have a strong similarity to many aspects of inflammation and repair. The relationships among matrix molecules (e.g., osteopontin, bone sialoprotein, SPARC [secreted protein, acidic, rich in cysteine], osteocalcin), blood clotting, and wound healing are clearly evident.[251]

Cells and Intercellular Matrix

Osteoblasts, which are the cells that produce the organic matrix of bone, are differentiated from pluripotent follicle cells. Alveolar bone is formed during fetal growth by intramembranous ossification, and it consists of a calcified matrix with osteocytes enclosed within spaces called *lacunae.* The osteocytes extend processes into *canaliculi* that radiate from the lacunae. The canaliculi form an anastomosing system through the intercellular matrix of the bone, which brings oxygen and nutrients to the osteocytes through the blood and removes metabolic waste products. Blood vessels branch extensively and travel through the periosteum. The endosteum lies adjacent to the marrow vasculature. Bone growth occurs via the apposition of an organic matrix that is deposited by osteoblasts. Haversian systems (i.e., *osteons*) are the internal mechanisms that bring a vascular supply to bones that are too thick to be supplied only by surface vessels. These are found primarily in the outer cortical plates and the alveolar bone proper.

Socket Wall

The socket wall consists of dense, lamellated bone, some of which is arranged in haversian systems and bundle bone. *Bundle bone* is the term given to bone adjacent to the periodontal ligament that contains a great number of Sharpey fibers[286] (Figure 1-54). It is characterized by thin lamellae arranged in layers parallel to the root, with intervening appositional lines (Figure 1-55). Bundle bone is localized within the alveolar bone proper. Some Sharpey fibers are completely calcified, but most contain an uncalcified central core within a calcified outer layer.[240] Bundle bone is not unique to the jaws; it occurs throughout the skeletal system wherever ligaments and muscles are attached.

The cancellous portion of the alveolar bone consists of trabeculae that enclose irregularly shaped marrow spaces lined with a layer of thin, flattened endosteal cells. Wide variation occurs in the trabecular pattern of cancellous bone,[200] which is affected by occlusal forces. The matrix of the cancellous trabeculae consists of irregularly arranged lamellae separated by deeply staining incremental and resorption lines indicative of previous bone activity, with an occasional haversian system.

Cancellous bone is found predominantly in the interradicular and interdental spaces and in limited amounts facially or lingually,

except in the palate. In the adult human, more cancellous bone exists in the maxilla than in the mandible.

Bone Marrow

In the embryo and the newborn, the cavities of all bones are occupied by red hematopoietic marrow. The red marrow gradually undergoes a physiologic change to the fatty or yellow inactive type of marrow. In the adult, the marrow of the jaw is normally of the latter type, and red marrow is found only in the ribs, sternum, vertebrae, skull, and humerus. However, foci of the red bone marrow are occasionally seen in the jaws, often accompanied by the resorption of bony trabeculae.[41] Common locations are the maxillary tuberosity, the maxillary and mandibular molar and premolar areas, and the mandibular symphysis and ramus angle, which may be visible radiographically as zones of radiolucency.

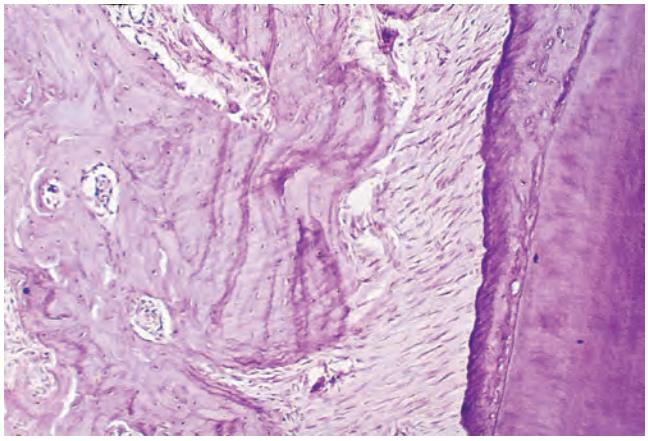

Figure 1-54 Deep penetration of Sharpey fibers into bundle bone of a rat molar.

Periosteum and Endosteum

Layers of differentiated osteogenic connective tissue cover all of the bone surfaces. The tissue that covers the outer surface of bone is termed *periosteum,* whereas the tissue that lines the internal bone cavities is called *endosteum.*

The periosteum consists of an *inner layer* composed of osteoblasts surrounded by osteoprogenitor cells, which have the potential to differentiate into osteoblasts, and an *outer layer* rich in blood vessels and nerves and composed of collagen fibers and fibroblasts. Bundles of periosteal collagen fibers penetrate the bone, thereby binding the periosteum to the bone. The endosteum is composed of a single layer of osteoblasts and sometimes a small amount of connective tissue. The inner layer is the osteogenic layer, and the outer layer is the fibrous layer.

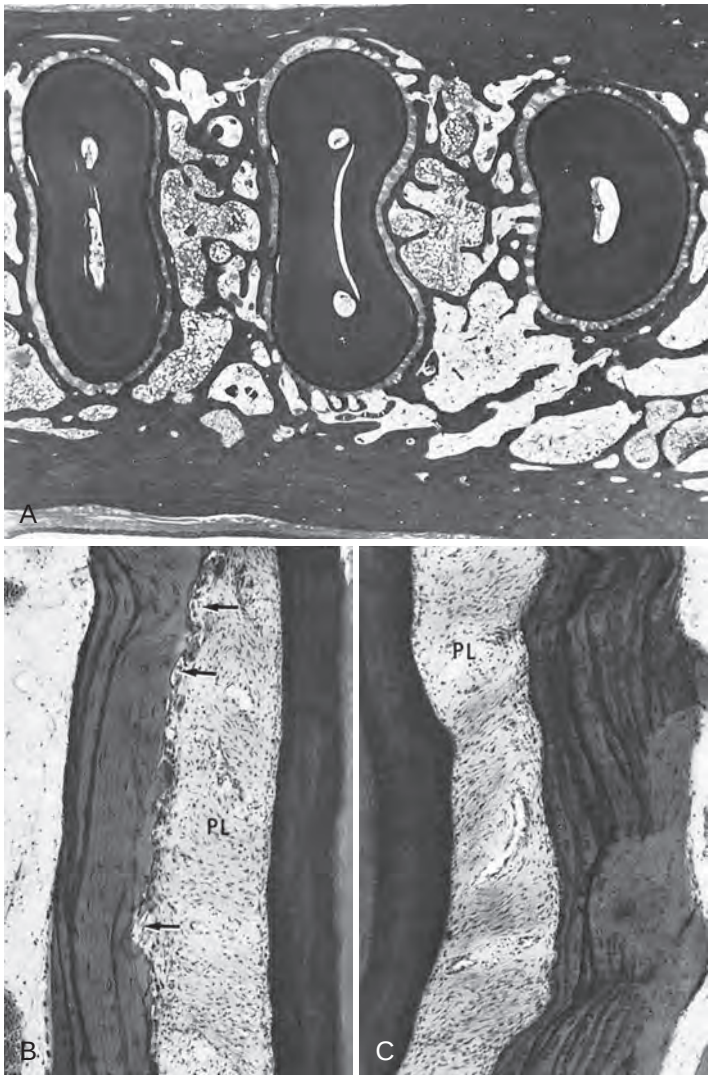

Figure 1-55 Bundle bone associated with the physiologic mesial migration of the teeth. **A,** Horizontal section through the molar roots during the process of mesial migration (*left,* mesial; *right,* distal). **B,** Mesial root surface showing osteoclasis of bone *(arrows).* **C,** Distal root surface showing bundle bone that has been partially replaced with dense bone on the marrow side. *PL,* Periodontal ligament.

Cellular events at the periosteum modulate bone size throughout an individual's life span, and a change in bone size is probably the result of the balance between periosteal osteoblastic and osteoclastic activities. Little is currently known about the control of periosteal osteoblastic activity or the clinical importance of variations in periosteal bone formation.[196] Moreover, the nature and impact of periosteal bone resorption are virtually unexplored.

Interdental Septum

The interdental septum consists of cancellous bone that is bordered by the socket wall cribriform plates (i.e., lamina dura or alveolar bone proper) of approximating teeth and the facial and lingual cortical plates (Figure 1-56). If the interdental space is narrow, the septum may consist of only the cribriform plate. In one study, for example, the space between the mandibular second premolars and first molars consisted of cribriform plate and cancellous bone in 85% of the cases and of only cribriform plate in the remaining 15%.[116] If the roots are too close together, an irregular "window" can appear in the bone between adjacent roots (Figure 1-57). Between maxillary molars, the septum consisted of cribriform plate and cancellous bone in 66.6% of cases; it was composed of only cribriform plate in 20.8%, and it had a fenestration in 12.5%.[116]

Determining root proximity radiographically is important (see Chapters 31 and 33). The mesiodistal angulation of the crest of the interdental septum usually parallels a line drawn between the cementoenamel junctions of the approximating teeth.[209] The distance between the crest of the alveolar bone and the cemento-enamel junction in young adults varies between 0.75 and 1.49 mm (average, 1.08 mm). This distance increases with age to an average of 2.81 mm.[93] However, this phenomenon may not be as much a function of age as of periodontal disease.

The mesiodistal and faciolingual dimensions and shape of the interdental septum are governed by the size and convexity of the crowns of the two approximating teeth as well as by the position of the teeth in the jaw and their degree of eruption.[209]

Osseous Topography

The bone contour normally conforms to the prominence of the roots, with intervening vertical depressions that taper toward the margin (Figure 1-58). Alveolar bone anatomy varies among patients and has important clinical implications. The height and thickness of the facial and lingual bony plates are affected by the alignment of the teeth, the angulation of the root to the bone, and occlusal forces.

On teeth in labial version, the margin of the labial bone is located farther apically than it is on teeth that are in proper alignment. The bone margin is thinned to a knife edge, and it presents an accentuated arc in the direction of the apex. On teeth in lingual version, the facial bony plate is thicker than normal. The margin is blunt, rounded, and horizontal rather than arcuate. The effect of the root-to-bone angulation on the height of alveolar bone is most noticeable on the palatal roots of the maxillary molars. The bone

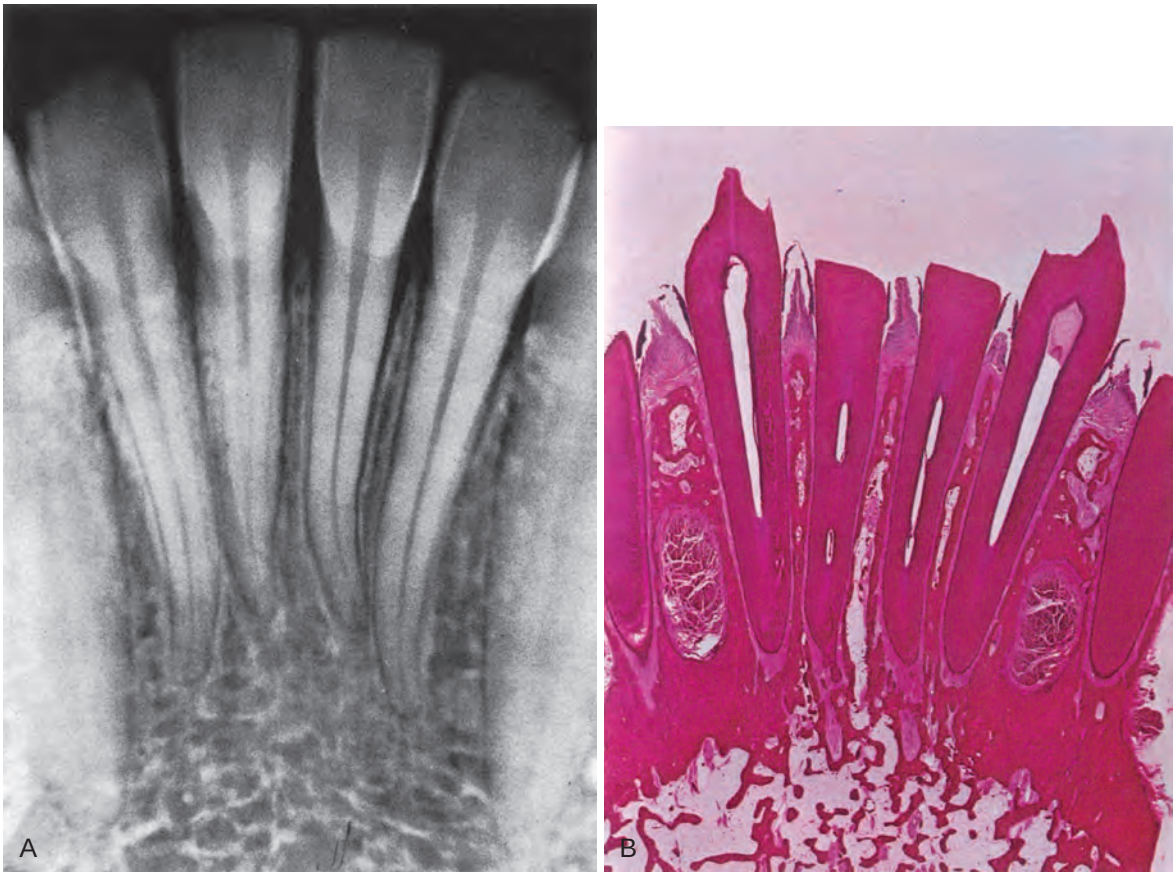

Figure 1-56 Interdental septa. **A,** Radiograph of the mandibular incisor area. Note the prominent lamina dura. **B,** Interdental septa between the mandibular anterior teeth shown in A. There is a slight reduction in bone height with widening of the periodontal ligament in the coronal areas. The central cancellous portion is bordered by the dense bony cribriform plates of the socket, which form the lamina dura around the teeth in the radiograph. Attachments for the mentalis muscle are seen between the canine and lateral incisors. *(From Glickman I, Smulow J:* Periodontal disease: clinical, radiographic, and histopathologic features, *Philadelphia, 1974, Saunders.)*

margin is located farther apically on the roots, and it forms relatively acute angles with the palatal bone.[120] The cervical portion of the alveolar plate is sometimes considerably thickened on the facial surface, apparently as reinforcement against occlusal forces (Figure 1-59).

Fenestration and Dehiscence

Isolated areas in which the root is denuded of bone and the root surface is covered only by periosteum and overlying gingiva are termed *fenestrations*. In these areas, the marginal bone is intact. When the denuded areas extend through the marginal bone, the defect is called a *dehiscence* (Figure 1-60).

Such defects occur on approximately 20% of the teeth; they occur more often on the facial bone than on the lingual bone, they are more common on anterior teeth than on posterior teeth, and they are frequently bilateral. Microscopic evidence of lacunar resorption may be present at the margins. The cause of these defects is not clear. Prominent root contours, malposition, and labial protrusion of the root in combination with a thin bony plate are predisposing factors.[78] Fenestration and dehiscence are important because they may complicate the outcome of periodontal surgery.

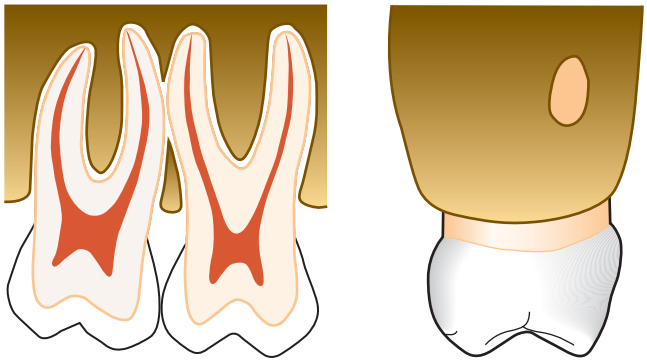

Figure 1-57 Boneless "window" between adjoining close roots of molars.

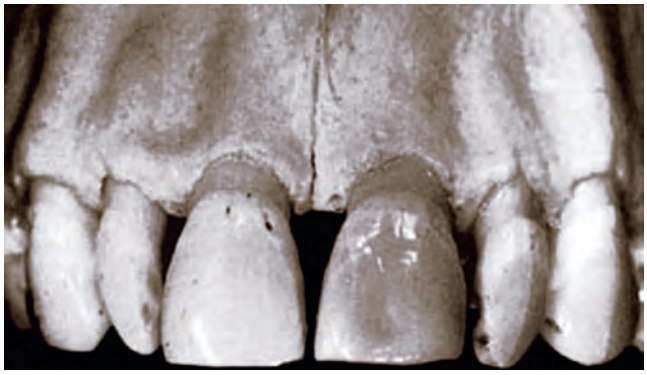

Figure 1-58 Normal that the bone contour conforms to the prominence of the roots.

Remodeling of Alveolar Bone

In contrast with its apparent rigidity, alveolar bone is the least stable of the periodontal tissues, because its structure is in a constant state of flux. A considerable amount of internal remodeling takes place by means of resorption and formation, and this is regulated by local and systemic influences. Local influences include functional requirements on the tooth and age-related changes in bone cells. Systemic influences are probably hormonal (e.g., parathyroid hormone, calcitonin, vitamin D_3).

The remodeling of the alveolar bone affects its height, contour, and density and is manifested in the following three areas: adjacent to the periodontal ligament, in relation to the periosteum of the facial and lingual plates, and along the endosteal surface of the marrow spaces.

Development of the Attachment Apparatus

After the crown has formed, the stratum intermedium and the stellate reticulum of the enamel organ disappear. The outer and inner epithelia of the enamel organ remain and form REE. The apical portion of this constitutes the Hertwig epithelial root sheath, which will continue to grow apically and which determines the shape of the root. Before the beginning of root formation, the root sheath bends horizontally at the future cementoenamel junction, thereby narrowing the cervical opening and forming the epithelial diaphragm. The epithelial diaphragm separates the dental follicle from the dental papilla.

After root dentin formation begins, the Hertwig root sheath breaks up and partially disappears; the remaining cells form the epithelial clusters or strands known as the *epithelial rests of Malassez* (see Figure 1-37, *A*). In multi-rooted teeth, the epithelial diaphragm grows in such a way that tonguelike extensions develop horizontally, thereby leaving spaces for each of the future roots to form.

The role of the Hertwig epithelial root sheath in root development, especially as it relates to the initiation of cementogenesis, has become a focus of research.[271] On the basis of various studies, it is now generally accepted that there is a transient period of the secretion of proteins (e.g., bone sialoprotein, osteopontin, amelin) by the cells of the Hertwig epithelial root sheath.[38,85] In addition, research shows that growth and differentiation factors may play

Figure 1-59 Variations in the cervical portion of the buccal alveolar plate. **A,** Shelflike conformation. **B,** Comparatively thin buccal plate.

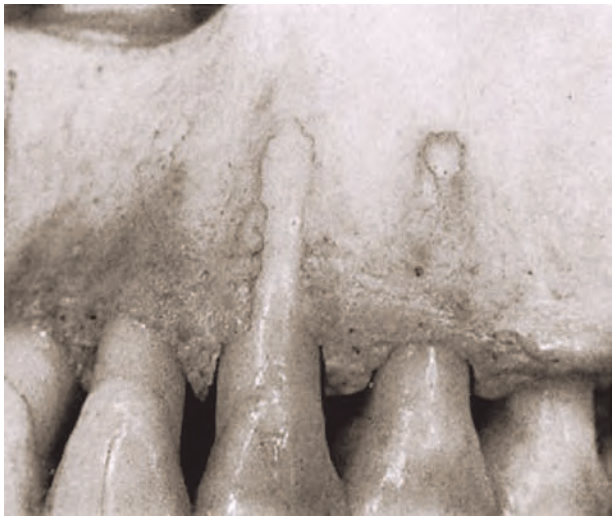

Figure 1-60 Dehiscence on the canine and fenestration of the first premolar.

roles in the development of the attachment apparatus of periodontal tissues. Pluripotent dental follicle cells have been shown to differentiate into osteoblasts, cementoblasts, and periodontal fibroblasts.[241]

Cementum

The rupture of the Hertwig root sheath allows the mesenchymal cells of the dental follicle to contact the dentin, where they start forming a continuous layer of cementoblasts. On the basis of immunochemical and ultrastructural studies, Thomas[270] and others[35,165] have speculated that cementoblasts can be of epithelial origin (i.e., the Hertwig root sheath), having undergone an epithelial mesenchymal transformation.

Cementum formation begins with the deposition of a meshwork of irregularly arranged collagen fibrils sparsely distributed in a ground substance or matrix called *precementum* or *cementoid.* This is followed by a phase of matrix maturation, which subsequently mineralizes to form cementum. Cementoblasts, which are initially separated from the cementum by uncalcified cementoid, sometimes become enclosed within the matrix and are trapped. After they are enclosed, they are referred to as *cementocytes,* and they will remain viable in a manner similar to that of osteocytes.

A layer of connective tissue known as the *dental sac* surrounds the enamel organ and includes the epithelial root sheath as it develops. The zone that is immediately in contact with the dental organ and continuous with the ectomesenchyme of the dental papilla is called the *dental follicle,*[262,263,266] and it consists of undifferentiated fibroblasts.

Periodontal Ligament

As the crown approaches the oral mucosa during tooth eruption, these fibroblasts become active and start producing collagen fibrils. They initially lack orientation, but they soon acquire an orientation that is oblique to the tooth. The first collagen bundles then appear in the region immediately apical to the cementoenamel junction and give rise to the gingivodental fiber groups. As tooth eruption progresses, additional oblique fibers appear and become attached to the newly formed cementum and bone. The transseptal and alveolar crest fibers develop when the tooth merges into the oral cavity. Alveolar bone deposition occurs simultaneously with periodontal ligament organization.[250]

The developing periodontal ligament and the mature periodontal ligament contain undifferentiated stem cells that retain the potential to differentiate into osteoblasts, cementoblasts, and fibroblasts.[172]

Alveolar Bone

Just before mineralization, osteoblasts start producing matrix vesicles. These vesicles contain enzymes (e.g., alkaline phosphatase) that help to jump start the nucleation of hydroxyapatite crystals. As these crystals grow and develop, they form coalescing bone nodules, which, with fast-growing nonoriented collagen fibers, are the substructure of woven bone and the first bone formed in the alveolus. Later, through bone deposition, remodeling, and the secretion of oriented collagen fibers in sheets, mature lamellar bone is formed.[28,29]

The hydroxyapatite crystals are generally aligned with their long axes parallel to the collagen fibers, and they appear to be deposited on and within the collagen fibers in mature lamellar bone. In this way, bone matrix is able to withstand the heavy mechanical stresses applied to it during function.

The alveolar bone develops around each tooth follicle during odontogenesis. When a deciduous tooth is shed, its alveolar bone is resorbed. The succedaneous permanent tooth moves into place and develops its own alveolar bone from its own dental follicle. As the tooth root forms and the surrounding tissues develop and mature, alveolar bone merges with the separately developing basal bone, and the two become one continuous structure. Although alveolar bone and basal bone have different intermediate origins, both are ultimately derived from neural crest ectomesenchyme.

Mandibular basal bone begins mineralization at the exit of the mental nerve from the mental foramen, whereas the maxillary basal bone begins at the exit of the infraorbital nerve from the infraorbital foramen.

Physiologic Migration of the Teeth

Tooth movement does not end when active eruption is completed and the tooth is in functional occlusion. With time and wear, the proximal contact areas of the teeth are flattened, and the teeth tend to move mesially. This is referred to as *physiologic mesial migration.* By the age of 40 years, this process results in a reduction of about 0.5 cm in the length of the dental arch from the midline to the third molars. Alveolar bone is reconstructed in compliance with the physiologic mesial migration of the teeth. Bone resorption is increased in areas of pressure along the mesial surfaces of the teeth, and new layers of bundle bone are formed in areas of tension on the distal surfaces (see Figure 1-55).

External Forces and the Periodontium

The periodontium exists for the purpose of supporting teeth during function, and it depends on the stimulation that it receives from function for the preservation of its structure. Therefore, a constant and sensitive balance is present between external forces and the periodontal structures.

Alveolar bone undergoes constant physiologic remodeling in response to external forces, particularly occlusal forces. Bone is removed from areas where it is no longer needed and added to areas where it is presently needed.

The socket wall reflects the responsiveness of alveolar bone to external forces. Osteoblasts and newly formed osteoid line the socket in areas of tension; osteoclasts and bone resorption occur in areas of pressure. Forces exerted on the tooth also influence the number, density, and alignment of cancellous trabeculae. The bony trabeculae are aligned in the path of the tensile and compressive

Studies of the squirrel monkey have shown that, during eruption, cemental Sharpey fibers appear first, followed by Sharpey fibers emerging from the bone.[107] Sharpey fibers are fewer in number and more widely spaced than those that emerge from the cementum. At a later stage, alveolar fibers extend into the middle zone to join the lengthening cemental fibers and to attain their classic orientation, thickness, and strength when occlusal function is established.

Early investigators suggested that the individual fibers, rather than being continuous, consisted of two separate parts spliced together midway between the cementum and the bone in a zone called the *intermediate plexus.* The plexus has been reported in the periodontal ligament of continuously growing incisors but not in the posterior teeth of rodents[119,177,300] or in actively erupting human and monkey teeth[107] and not after teeth reach occlusal contact. The rearrangement of the fiber ends in the plexus is supposed to accommodate tooth eruption without necessitating the embedding of new fibers into the tooth and the bone.[177] The existence of such a plexus, however, has not been confirmed by radioautographic data and other studies, and it is considered a microscopic artifact.[232]

Figure 1-61 Bony trabeculae realigned perpendicular to the mesial root of a tilted molar.

TABLE 1-2 Comparison of Periodontal Width of Functioning and Functionless Teeth in a 38-Year-Old Man

	AVERAGE WIDTH OF PERIODONTAL SPACE		
	Entrance of Alveolus (mm)	Middle of Alveolus (mm)	Fundus of Alveolus (mm)
Heavy Function: Left upper second bicuspid	0.35	0.28	0.30
Light Function: Left lower first bicuspid	0.14	0.10	0.12
Functionless: Left upper third molar	0.10	0.06	0.06

Modified from Kronfeld R: *J Am Dent Assoc* 18:1242, 1931.

stresses to provide maximal resistance to the occlusal force with a minimum of bone substance[100,247] (Figure 1-61). When forces are increased, the cancellous bony trabeculae increase in number and thickness, and bone may be added to the external surface of the labial and lingual plates.

A study has shown that the presence of antagonists of occlusal force and the severity of periodontal disease increase the extension of periodontal tissue resorption.[66]

The periodontal ligament also depends on the stimulation provided by function to preserve its structure. Within physiologic limits, the periodontal ligament can accommodate increased function with an increase in width (Table 1-2), a thickening of its fiber bundles, and an increase in the diameter and number of Sharpey fibers. Forces that exceed the adaptive capacity of the periodontium produce injury called *trauma from occlusion.* Because trauma from occlusion can only be confirmed histologically, the clinician is challenged to use clinical and radiographic surrogate indicators in an attempt to facilitate and assist with its diagnosis[111] (see Chapter 20).

When occlusal forces are reduced, the number and thickness of the trabeculae are reduced.[64] The periodontal ligament also atrophies and appears thinned; the fibers are reduced in number and density, disoriented,[11,208] and ultimately arranged parallel to the root

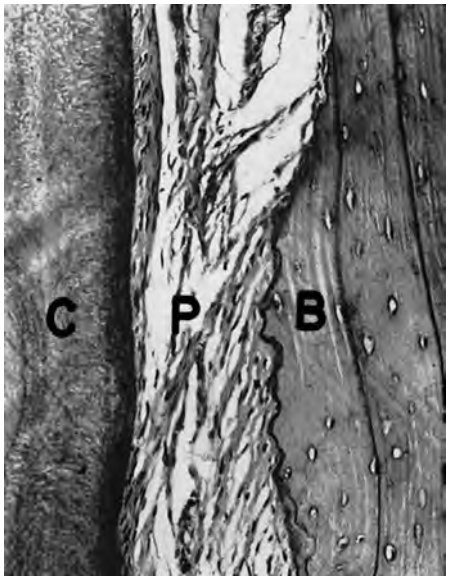

Figure 1-62 Atrophic periodontal ligament *(P)* of a tooth devoid of function. Note the scalloped edge of the alveolar bone *(B)*, which indicates that resorption has occurred. *C,* Cementum.

surface (Figure 1-62). This phenomenon is termed *disuse atrophy* or *afunctional atrophy.* With this condition, the cementum is either unaffected[64] or thickened, and the distance from the cemento-enamel junction to the alveolar crest is increased.[204]

Decreased occlusal function causes changes in the periodontal microvasculature, such as the occlusion of blood vessels and a decrease in the number of blood vessels.[121] For example, Murrell and colleagues[187] reported that the application and removal of orthodontic force produced significant changes in blood vessel number and density; however, no evidence-based explanation exists for why the force stimulated such changes in the number of blood vessels.

Orthodontic tooth movement is thought to result from site-specific bone remodeling in the absence of inflammation. It is well recognized that tensional forces will stimulate the formation and activity of osteoblastic cells, whereas compressive forces promote osteoclastic activity.[251]

Vascularization of the Supporting Structures

The blood supply to the supporting structures of the tooth is derived from the inferior and superior alveolar arteries to the mandible and maxilla, and it reaches the periodontal ligament from three sources: apical vessels, penetrating vessels from the alveolar bone, and anastomosing vessels from the gingiva.[63]

The branches of the apical vessels supply the apical region of the periodontal ligament before the vessels enter the dental pulp. The transalveolar vessels are branches of the intraseptal vessels that perforate the lamina dura and enter the ligament. The intraseptal vessels continue to vascularize the gingiva; these gingival vessels in turn anastomose with the periodontal ligament vessels of the cervical region.[84]

The vessels within the periodontal ligament are contained in the interstitial spaces of loose connective tissue between the principal fibers, and they are connected in a netlike plexus that runs longitudinally and closer to the bone than the cementum[54] (Figures 1-63 and 1-64). The blood supply increases from the incisors to the molars; it is greatest in the gingival third of single-rooted teeth, less in the apical third, and least in the middle; it is equal in the

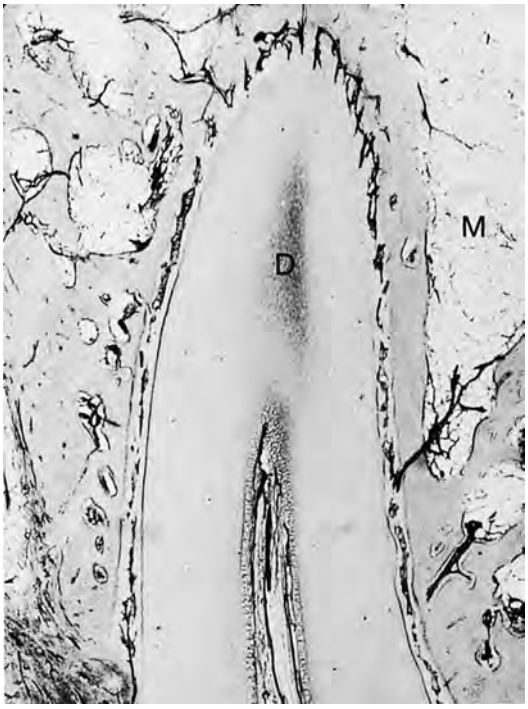

Figure 1-63 Vascular supply of a monkey periodontium perfused with India ink. Note the longitudinal vessels in the periodontal ligament and the alveolar arteries passing through channels between the bone marrow *(M)* and the periodontal ligament. *D,* Dentin. *(Courtesy Dr. Sol Bernick, Los Angeles.)*

Figure 1-64 Vascular supply to the periodontal ligament in a rat molar as viewed by scanning electron microscopy after perfusion with plastic and tissue corrosion. Middle and apical areas of the periodontal ligament are shown with longitudinal blood vessels from the apex *(below)* to the gingiva *(above)*, perforating vessels entering the bone *(b)*, and many transverse connections *(arrowheads)*. Apical vessels *(a)* form a cap that connects with the pulpal vessels. *(Courtesy NJ Selliseth and K Selvig, University of Bergen, Norway.)*

apical and middle thirds of multi-rooted teeth; it is slightly greater on the mesial and distal surfaces than on the facial and lingual surfaces; and it is greater on the mesial surfaces of the mandibular molars than on the distal surfaces.[33]

The vascular supply to the bone enters the interdental septa through nutrient canals together with veins, nerves, and lymphatics. Dental arterioles, which also branch off of the alveolar arteries, send tributaries through the periodontal ligament, and some small branches enter the marrow spaces of the bone through the perforations in the cribriform plate. Small vessels that emanate from the facial and lingual compact bone also enter the marrow and spongy bone.

The **venous drainage** of the periodontal ligament accompanies the arterial supply. Venules receive the blood through the abundant capillary network. In addition, arteriovenous anastomoses bypass the capillaries and are seen more frequently in apical and interradicular regions; their significance is unknown.

Lymphatics supplement the venous drainage system. Lymphatic channels that drain the region just beneath the junctional epithelium pass into the periodontal ligament and accompany the blood vessels into the periapical region.[42] From there, they pass through the alveolar bone to the inferior dental canal in the mandible or the infraorbital canal in the maxilla and then go on to the submaxillary lymph nodes.

Suggested Readings

Ainamo J, Löe H: Anatomical characteristics of gingiva: a clinical and microscopic study of the free and attached gingiva. *J Periodontol* 37:5, 1966.

Bernick S: Innervation of the teeth and periodontium. *Dent Clin North Am* 503, 1959.

Carranza FA, Carranza FA Jr: The management of the alveolar bone in the treatment of the periodontal pocket. *J Periodontol* 27:29, 1956.

Gottlieb B: Biology of the cementum. *J Periodontol* 13:13, 1942.

Grant D, Bernick S: Formation of the periodontal ligament. *J Periodontol* 43:17, 1972.

Listgarten MA: The ultrastructure of human gingival epithelium. *Am J Anat* 114:49, 1964.

Orban B: Tissue changes in traumatic occlusion. *J Am Dent Assoc* 15:2090, 1928.

Schroeder HE, Listgarten MA: The gingival tissues: the architecture of periodontal protection. *Periodontol 2000* 13:91, 1997.

Selvig KA: The fine structure of human cementum. *Acta Odontol Scand* 23:423, 1965.

Tarnow DP, Magner AW, Fletcher P: The effect of the distance from the contact point to the crest of bone on the presence or absence of the interproximal dental papilla. *J Periodontol* 63:995, 1992.

Ten Cate AR: The development of the periodontium. In Melcher AH, Bowen WH, editors: *Biology of the periodontium*, New York, 1969, Academic Press.

Turesky S, Glickman I, Litwin T: A histochemical evaluation of normal and inflamed human gingivae. *J Dent Res* 30:792, 1951.

Weinmann JP, Sicher H: *Bone and bones: fundamentals of bone biology*, ed 2, St Louis, 1955, Mosby.

Zander HA, Hurzeler B: Continuous cementum apposition. *J Dent Res* 37:1035, 1958.

References

References for this chapter are found on the companion website www.expertconsult.com.

References

1. Ababneh KT, Hall RC, Embery G: Immunolocalization of glycosaminoglycans in ageing, healthy and periodontally diseased human cementum. *Arch Oral Biol* 43:235, 1998.
2. Ababneh KT, Hall RC, Embery G: The proteoglycans of human cementum: immunohistochemical localization in healthy, periodontally involved and ageing teeth. *J Periodontal Res* 34:87, 1999.
3. Agnew RG, Fong CC: Histologic studies on experimental transplantation of teeth. *J Oral Surg* 9:18, 1956.
4. Ainamo A: Influence of age on the location of the maxillary mucogingival junction. *J Periodontal Res* 13:189, 1978.
5. Ainamo A, Ainamo J: The width of attached gingiva on supraerupted teeth. *J Periodontal Res* 13:194, 1978.
6. Ainamo J, Löe H: Anatomical characteristics of gingiva: a clinical and microscopic study of the free and attached gingiva. *J Periodontol* 37:5, 1966.
7. Ainamo J, Talari A: The increase with age of the width of attached gingiva. *J Periodontal Res* 11:182, 1976.
8. Ambrosini P, Cherene S, Miller N, et al: A laser Doppler study of gingiva blood flow variations following periosteal stimulation. *J Clin Periodontol* 29:103, 2002.
9. Anderson GS, Stern IB: The proliferation and migration of the attachment epithelium on the cemental surface of the rat incisor. *Periodontics* 4:15, 1966.
10. Andersson L, Blomlof L, Lindskog S, et al: Tooth ankylosis: clinical, radiographic and histological assessments. *Int J Oral Surg* 13:423, 1984.
11. Anneroth G, Ericsson SG: An experimental histological study of monkey teeth without antagonist. *Odontol Rev* 18:345, 1967.
12. Armitt KL: Identification of T cell subsets in gingivitis in children. *Periodontology* 7:3, 1986.
13. Attstrom R, Graf-de Beer M, Schroeder HE: Clinical and histologic characteristics of normal gingiva in dogs. *J Periodontal Res* 10:115, 1975.
14. Avery JK, Rapp R: Pain conduction in human dental tissues. *Dent Clin North Am* 489:July 1959.
15. Barakat NJ, Toto PD, Choukas NC: Aging and cell renewal of oral epithelium. *J Periodontol* 40:599, 1969.
16. Bartold PM: Turnover in periodontal connective tissues: dynamic homeostasis of cells, collagen and ground substances. *Oral Dis* 1:238, 1995.
17. Bartold PM, Narayanan AS: *Biology of the periodontal connective tissues*, Chicago, 1998, Quintessence.
18. Bartold PM, Walsh LJ, Narayanan AS: Molecular and cell biology of the gingiva. *Periodontol 2000* 24:28, 2000.
19. Basdra EK, Stellzig A, Komposch G: Generalized hypercementosis in a young female patient. *Oral Surg Oral Med Oral Pathol Oral Radiol Endod* 83:418, 1997.
20. Bauer WH: Effect of a faultily constructed partial denture on a tooth and its supporting tissue, with special reference to formation of fibrocartilage in the periodontal membrane as a result of disturbed healing caused by abnormal stresses. *Am J Orthod Oral Surg* 27:640, 1941.
21. Baumhammers A, Stallard RE: S35-sulfate utilization and turnover by connective tissues of the periodontium. *J Periodontal Res* 3:187, 1968.
22. Beagrie GS, Skougaard MR: Observations on the life cycle of the gingival epithelial cells of mice as revealed by autoradiography. *Acta Odontol Scand* 20:15, 1962.
23. Becks H: Root resorptions and their relation to pathologic bone formation. *Int J Orthod Oral Surg* 22:445, 1936.
24. Beertsen W, McCullough CAG, Sodek J: The periodontal ligament: a unique, multifunctional connective tissue. *Periodontol 2000* 13:20, 1997.
25. Berkovitz BK: The structure of the periodontal ligament: an update. *Eur J Orthod* 12:51, 1990.
26. Berkovitz BK, Shore RC: Cells of the periodontal ligament. In Berkovitz BK, Moxham BJ, Newman HE, editors: *The periodontal ligament in health and disease*, London, 1982, Pergamon.
27. Bernard GW, Ko JS: Osteoclast formation in vitro from bone marrow mononuclear cells in osteoclast-free bone. *Am J Anat* 161:415, 1981.
28. Bernard GW, Marvaso V: Matrix vesicles as an assay for primary tissue calcification in vivo and in vitro. In Ascenzi A, Bonucci B, DeBernard B, editors: *Matrix vesicles: Proceedings of the 3rd International Conference on Matrix Vesicles*, Milano, 1981, Wichtig.
29. Bernard GW, Pease DC: An electron microscopic study of initial intramembranous osteogenesis. *Am J Anat* 125:271, 1969.
30. Bernick S: Innervation of the teeth and periodontium. *Dent Clin North Am* 503:July 1959.
31. Bien SM: Hydrodynamic damping of tooth movement. *J Dent Res* 45:907, 1966.
32. Biolcati EL, Carranza FA, Jr, Cabrini RL: Variaciones y alteraciones de la queratinizacion en encias humanas clinicamente sanas. *Rev Asoc Odontol Argent* 41:446, 1953.
33. Birn H: The vascular supply of the periodontal membrane: an investigation of the number and size of perforations in the alveolar wall. *J Periodontal Res* 1:51, 1966.
34. Blair HC, Teitelbaum SL, Ghiselli R, et al: Osteoclastic bone resorption by a polarized vacuolar proton pump. *Science* 245:855, 1989.
35. Blaushild N, Michaeli Y, Steigman S: Histomorphometric study of the periodontal vasculature of the rat incisor. *J Dent Res* 71:1908, 1992.
36. Blayney JR, Wassermann F, Groetzinger G, et al: Further studies in mineral metabolism of human teeth by the use of radioactive phosphorus. *J Dent Res* 29:559, 1941.
37. Bosch FX, Ouhayoun JP, Bader BL, et al: Extensive changes in cytokeratin expression patterns in pathologically affected human gingiva. *Virchows Arch B Cell Pathol* 58:59, 1989.
38. Bosshardt DD, Nanci A: Immunolocalization of epithelial and mesenchymal matrix constituents in association with inner enamel epithelial cells. *J Histochem Cytochem* 46:135, 1998.
39. Bosshardt DD, Zalzal S, McKee MD, et al: Developmental appearance and distribution of bone sialoprotein and osteopontin in human and rat cementum. *Anat Rec* 250:13, 1998.
40. Bowers GM: A study of the width of the attached gingiva. *J Periodontol* 34:210, 1963.
41. Box HK: Bone resorption in red marrow hyperplasia in human jaws. *Can Dent Res Found Bull* 21:1936.
42. Box KF: Evidence of lymphatics in the periodontium. *J Can Dent Assoc* 15:8, 1949.
43. Boyle PE: Tooth suspension: a comparative study of the paradental tissues of man and of the guinea pig. *J Dent Res* 17:37, 1938.
44. Bral MM, Stahl SS: Keratinizing potential of human crevicular epithelium. *J Periodontol* 48:381, 1977.
45. Cabrini R, Cabrini RL, Carranza FA, Jr: Estudio histologico de la queratinizacion del epitelio gingival y de la adherencia epitelial. *Rev Asoc Odontol Argent* 41:212, 1953.
46. Cabrini RL, Carranza FA, Jr: Histochemical study on alkaline phosphatase in gingivae, varying the pH and the substrate. *J Dent Res* 30:28, 1951.
47. Cabrini RL, Carranza FA, Jr: Histochemistry of periodontal tissues: a review of the literature. *Int Dent J* 16:466, 1966.
48. Caffesse RG, Karring T, Nasjleti CE: Keratinizing potential of sulcular epithelium. *J Periodontol* 48:140, 1977.
49. Caffesse RG, Kornman KS, Nasjleti CE: The effect of intensive antibacterial therapy on the sulcular environment in monkeys. Part II. Inflammation, mitotic activity and keratinization of the sulcular epithelium. *J Periodontol* 5:155, 1980.
50. Caffesse RG, Nasjleti CE, Castelli WA: The role of sulcular environment in controlling epithelial keratinization. *J Periodontol* 50:1, 1979.
51. Carneiro J, Fava de Moraes F: Radioautographic visualization of collagen metabolism in the periodontal tissues of the mouse. *Arch Oral Biol* 10:833, 1955.
52. Carranza FA, Jr, Cabrini RL: Mast cells in human gingiva. *J Oral Surg* 8:1093, 1955.
53. Carranza FA, Carranza FA, Jr: The management of the alveolar bone in the treatment of the periodontal pocket. *J Periodontol* 27:29, 1956.

54. Carranza FA, Jr, Itoiz ME, Cabrini RL, et al: A study of periodontal vascularization in different laboratory animals. *J Periodontal Res* 1:120, 1966.
55. Chambers TJ: The cellular basis of bone resorption. *Clin Orthop Relat Res* Sep(151):283, 1980.
56. Chavier C: Elastic fibers of healthy human gingiva. *J Periodontol* 9:29, 1990.
57. Cho MI, Garant PR: Development and general structure of the periodontium. *Periodontol 2000* 24:9, 2000.
58. Ciancio SC, Neiders ME, Hazen SP: The principal fibers of the periodontal ligament. *Periodontics* 5:76, 1967.
59. Cimasoni G: Crevicular fluid updated. *Monogr Oral Sci* 12:1, 1983.
60. Clausen H, Moe D, Buschard K, et al: Keratin proteins in human oral mucosa. *J Oral Pathol* 15:36, 1986.
61. Cleaton-Jones P, Buskin SA, Volchansky A: Surface ultrastructure of human gingiva. *J Periodontal Res* 13:367, 1978.
62. Cohen B: Morphological factors in the pathogenesis of periodontal disease. *Br Dent J* 107:31, 1959.
63. Cohen L: Further studies into the vascular architecture of the mandible. *J Dent Res* 39:936, 1960.
64. Cohn SA: Disuse atrophy of the periodontium in mice. *Arch Oral Biol* 10:909, 1965.
65. Coolidge ED: The thickness of the human periodontal membrane. *J Am Dent Assoc* 24:1260, 1937.
66. Crespo Vázquez E, Crespo Abelleira A, Suárez Quintanilla JM, et al: Correlation between occlusal contact and root resorption in teeth with periodontal disease. *J Periodontal Res* 46:82, 2011.
67. Dale BA: Periodontal epithelium: a newly recognized role in health and disease. *Periodontol 2000* 30:70, 2002.
68. Dastmalchi R, Polson A, Bouwsma O, et al: Cementum thickness and mesial drift. *J Clin Periodontol* 17:709, 1990.
69. Davies WR, Picton DC: Dimensional changes in the periodontal membrane of monkeys' teeth with horizontal thrusts. *J Dent Res* 46:114, 1967.
70. De Rouck T, Eghbali R, Collys K, et al: The gingival biotype revisited: transparency of the periodontal probe through the gingival margin as a method to discriminate thin from thick gingiva. *J Clin Periodontol* 36:428, 2009.
71. Dewar MR: Observations on the composition and metabolism of normal and inflamed gingivae. *J Periodontol* 26:29, 1955.
72. DiFranco CF, Toto PD, Rowden G, et al: Identification of Langerhans cells in human gingival epithelium. *J Periodontol* 56:48, 1985.
73. Dummett CO: Physiologic pigmentation of the oral and cutaneous tissues in the Negro. *J Dent Res* 25:421, 1946.
74. Dummett CO, et al: Oral pigmentation: physiologic and pathologic. *NY State Dent J* 25:407, 1959.
75. Eastoe JE: The organic matrix of bone. In Bourne GH, editor: *The biochemistry and physiology of bone*, New York, 1956, Academic Press.
76. Egelberg J: The topography and permeability of blood vessels at the dento-gingival junction in dogs. *J Periodontal Res* 1:1, 1967.
77. El Mostehy MR, Stallard RE: Intermediate cementum. *J Periodontal Res* 3:24, 1968.
78. Elliot JR, Bowers GM: Alveolar dehiscence and fenestration. *Periodontics* 1:245, 1963.
79. Embery G, Waddington R: Gingival crevicular fluid: biomarkers of periodontal tissue activity. *Adv Dent Res* 8:329, 1994.
80. Embery G, Waddington RJ, Hall RC, et al: Connective tissue elements as diagnostic aids in periodontology. *Periodontol 2000* 24:193, 2000.
81. Embery G, Waddington RJ, Hall RC, et al: Connective tissue elements as diagnostic aids in periodontology. *Periodontol 2000* 24:193, 2000.
82. Engel MB: Water-soluble mucoproteins of the gingiva. *J Dent Res* 32:779, 1953.
83. Everts V, Niehof A, Jansen D, et al: Type VI collagen is associated with microfibrils and oxytalan fibers in the extracellular matrix of periodontium, mesenterium and periosteum. *J Periodontal Res* 33:118, 1998.
84. Folke LE, Stallard RE: Periodontal microcirculation as revealed by plastic microspheres. *J Periodontal Res* 2:53, 1967.
85. Fong CD, Slaby I, Hammarström L, et al: Amelin: an enamel-related protein, transcribed in the cells of epithelial root sheath. *J Bone Miner Res* 11:892, 1996.
86. Forsslund G: Structure and function of capillary system in the gingiva in man: development of stereophotogrammetric method and its application for study of the subepithelial blood vessels in vivo. *Acta Odontol Scand* 17:9, 1959.
87. Frank RM, Cimasoni G: On the ultrastructure of the normal human gingivo-dental junction. *Z Zellforsch Mikrosk Anat* 109:356, 1970.
88. Freeman E: The periodontium. In Ten Cate R, editor: *Oral histology*, ed 4, St Louis, 1994, Mosby.
89. Fullmer HM, Sheetz JH, Narkates AJ: Oxytalan connective tissue fibers: a review. *J Oral Pathol* 3:291, 1974.
90. Fuss Z, Tsesis I, Lin S: Root resorption: diagnosis, classification and treatment choices based on stimulation factors. *Dent Trauma* 19:175, 2003.
91. Garnick JJ, Keagle JG, Searle JR, et al: Gingival resistance to probing forces. II. The effect of inflammation and pressure on probe displacement in beagle dog gingivitis. *J Periodontol* 60:498, 1989.
92. Gao Z, Flaitz CM, Mackenzie IC: Expression of keratinocyte growth factor in periapical lesions. *J Dent Res* 75:1658, 1996.
93. Gargiulo AW, Wentz FM, Orban B: Dimensions and relations of the dentogingival junction in humans. *J Periodontol* 32:261, 1961.
94. Gibson WA, Fullmer HM: Histochemistry of the periodontal ligament. I. The dehydrogenases. *Periodontics* 4:63, 1966.
95. Gibson WA, Fullmer HM: Histochemistry of the periodontal ligament. 2. The phosphatases. *Periodontics* 5:226, 1967.
96. Gibson WA, Fullmer HM: Histochemistry of the periodontal ligament. 3. The esterases. *Periodontics* 6:71, 1968.
97. Gillespie BR, Chasens AI, Brownstein CN, et al: The relationship between the mobility of human teeth and their supracrestal fiber support. *J Periodontol* 50:120, 1979.
98. Gillett R, Cruchley A, Johnson NW: The nature of the inflammatory infiltrates in childhood gingivitis, juvenile periodontitis and adult periodontitis: immunohistochemical studies using monoclonal antibody to HLADr. *J Clin Periodontol* 13:281, 1986.
99. Glickman I, Johannessen LB: Biomicroscopic (slit-lamp) evaluation of the normal gingiva of the albino rat. *J Am Dent Assoc* 41:521, 1950.
100. Glickman I, Roeber FW, Brion M, et al: Photoelastic analysis of internal stresses in the periodontium created by occlusal forces. *J Periodontol* 41:30, 1970.
101. Glimcher MJ: The nature of the mineral component of bone and the mechanism of calcification. In Avioli LV, Krane SM, editors: *Metabolic bone disease and clinical related disorders*, Philadelphia, 1990, Saunders.
102. Glimcher MJ, Friberg UA, Levine PT: The identification and characterization of a calcified layer of coronal cementum in erupted bovine teeth. *J Ultrastruct Res* 10:76, 1964.
103. Goggins JF: The distribution of oxytalan connective tissue fibers in periodontal ligaments of deciduous teeth. *Periodontics* 4:182, 1966.
104. Gottlieb B: Biology of the cementum. *J Periodontol* 13:13, 1942.
105. Gottlieb B, Orban B: Active and passive continuous eruption of teeth. *J Dent Res* 13:214, 1933.
106. Grant D, Bernick S: A possible continuity between epithelial rests and epithelial attachment in miniature swine. *J Periodontol* 40:87, 1969.
107. Grant D, Bernick S: Formation of the periodontal ligament. *J Periodontol* 43:17, 1972.
108. Greene AH: A study of the characteristics of stippling and its relation to gingival health. *J Periodontol* 33:176, 1962.
109. Grzesik WJ, Narayanan AS: Cementum and periodontal wound healing and regeneration. *Crit Rev Oral Biol Med* 13:474, 2002.
110. Hagel-Bradway S, Dziak R: Regulation of bone cell metabolism. *J Oral Pathol Med* 18:344, 1989.
111. Hallmon WW, Harrel SK: Occlusal analysis, diagnosis and management in the practice of periodontics. *Periodontol 2000* 34:151, 2004.
112. Hansen ER: Mitotic activity of the gingival epithelium in colchicinized rats. *Odontol Tidskr* 74:229, 1966.

113. Hansson BO, Lindhe J, Branemark PI: Microvascular topography and function in clinically healthy and chronically inflamed dento-gingival tissues: a vital microscopic study in dogs. *Periodontics* 6:264, 1968.
114. Hasegawa N, Kawaguchi H, Ogawa T, et al: Immunohistochemical characteristics of epithelial cell rests of Malassez during cementum repair. *J Periodontal Res* 38:51, 2003.
115. Hassell TM, Stanek EJ 3rd: Evidence that healthy human gingiva contains functionally heterogenous fibroblast subpopulations. *Arch Oral Biol* 28:617, 1983.
116. Heins PJ, Wieder SM: A histologic study of the width and nature of inter-radicular spaces in human adult premolars and molars. *J Dent Res* 65:948, 1986.
117. Hemley S: The incidence of root resorption of vital permanent teeth. *J Dent Res* 20:133, 1941.
118. Henry JL, Weinmann JP: The pattern of resorption and repair of human cementum. *J Am Dent Assoc* 42:270, 1951.
119. Hindle MC: Quantitative differences in periodontal membrane fibers. *J Dent Res* 43:953, 1964.
120. Hirschfeld I: A study of skulls in the American Museum of Natural History in relation to periodontal disease. *J Dent Res* 5:241, 1923.
121. Howard PS, Kucich U, Taliwal R, et al: Mechanical forces alter extracellular matrix synthesis by human periodontal ligament fibroblasts. *J Periodontal Res* 33:500, 1998.
122. Ikezawa K, Hart CE, Williams DC, et al: Characterization of cementum derived growth factor as an insulin-like growth factor-I like molecule. *Connect Tissue Res* 36:309, 1997.
123. Inoue M, Akiyoshi M: Histological investigation on Sharpey's fibers in cementum of teeth in abnormal function. *J Dent Res* 41:503, 1962.
124. Ishikawa G, Yamamoto H, Ito K, et al: Microradiographic study of cementum and alveolar bone. *J Dent Res* 43:936, 1964.
125. Itoiz ME, Carranza FA, Jr, Cabrini RL: Histotopographic distribution of alkaline and acid phosphatase in periodontal tissues of laboratory animals. *J Periodontol* 35:470, 1964.
126. Itoiz ME, Carranza FA, Jr, Cabrini RL: Histotopographic study of esterase and 5-nucleotidase in periodontal tissues of laboratory animals. *J Periodontol* 38:130, 1967.
127. Itoiz ME, Carranza FA, Jr, Gimenez IB, et al: Microspectrophotometric analysis of succinic dehydrogenase and glucose-6-phosphate dehydrogenase in human oral epithelium. *J Periodontal Res* 7:14, 1972.
128. Itoiz ME, Conti CJ, Gimenez IB, et al: Immunodetection of involucrin in lesions of the oral mucosa. *J Oral Pathol* 15:205, 1986.
129. Itoiz ME, Conti CJ, Lanfranchi HE, et al: Immunohistochemical detection of filaggrin in preneoplastic and neoplastic lesions of the human oral mucosa. *Am J Pathol* 119:456, 1985.
130. Itoiz ME, Lanfranchi HE, Gimenez-Conti IB, et al: Immunohistochemical demonstration of keratins in oral mucosa lesions. *Acta Odontol Latinoam* 1:47, 1984.
131. Iusem R: A cytology study of the cornification of the oral mucosa in women: a preliminary report. *J Oral Surg* 3:1516, 1950.
132. Johnson RB: A new look at the mineralized and unmineralized components of intraosseous fibers of the interdental bone of the mouse. *Anat Rec* 206:1, 1983.
133. Johnson RB, Pylypas SP: A re-evaluation of the distribution of the elastic meshwork within the periodontal ligament of the mouse. *J Periodontal Res* 27:239, 1992.
134. Jones JC, Hopkinson SB, Goldfinger LE: Structure and assembly of hemidesmosomes. *Bioessays* 20:488, 1998.
135. Jones ML, Aldred MJ, Hardy P: Tooth resorption in the two-stage transplantation technique: a case report. *Br J Orthod* 10:157, 1983.
136. Jones MR, Simonton FV: Mineral metabolism in relation to alveolar atrophy in dogs. *J Am Dent Assoc* 15:881, 1928.
137. Jones SJ, Boyde A: A study of human root cementum surfaces as prepared for and examined in the scanning electron microscope. *Z Zellforsch Mikrosk Anat* 130:318, 1972.
138. Junqueira LC, Carneiro J, Kelley RO: *Basic histology*, ed 6, Norwalk, Conn, 1989, Appleton & Lange.
139. Kao D: *Correlating of clinical, radiographic and histological results in periodontal regeneration by using recombinant human platelet derived growth factor-BB* [dissertation], Philadelphia, 2008, University of Pennsylvania School of Dental Medicine.
140. Karring T, Lang NP, Löe H: The role of gingival connective tissue in determining epithelial differentiation. *J Periodontal Res* 10:1, 1975.
141. Ko JS, Bernard GW: Osteoclast formation in vitro from bone marrow mononuclear cells in osteoclast-free bone. *Am J Anat* 161:415, 1981.
142. Kobayashi K, Rose GG: Ultrastructural histochemistry of the dento-epithelial junction. II. Colloidal thorium and ruthenium red. *J Periodontal Res* 13:164, 1978.
143. Kobayashi K, Rose GG: Ultrastructural histochemistry of the dento-epithelial junction. III. Chloramine T–silver methenamine. *J Periodontal Res* 14:123, 1979.
144. Kronfeld R: Histologic study of the influence of function on the human periodontal membrane. *J Am Dent Assoc* 18:1242, 1931.
145. Kronfeld R: The biology of cementum. *J Am Dent Assoc* 25:1451, 1938.
146. Kronfeld R: *Histopathology of the teeth and their surrounding structures*, Philadelphia, 1939, Lea & Febiger.
147. Kurahashi Y, Takuma S: Electron microscopy of human gingival epithelium. *Bull Tokyo Dent Coll* 3:29, 1962.
148. Lange D, Camelleri GE: Cytochemical demonstration of lysosomes in exfoliated epithelial cells of the gingival cuff. *J Dent Res* 46:625, 1967.
149. Larjava H, Häkkinen L, Rahemtulla F: A biochemical analysis of human periodontal tissue proteoglycans. *Biochem J* 284:267, 1992.
150. Laurell L, Rylander H, Sundin Y: Histologic characteristics of clinically healthy gingiva in adolescents. *Scand J Dent Res* 95:456, 1987.
151. Lavelle CLB: Mucosal seal around endosseous dental implants. *J Oral Implantol* 9:357, 1981.
152. Leider AS, Garbarino VE: Generalized hypercementosis. *Oral Surg Oral Med Oral Pathol* 63:375, 1987.
153. Lester KS: The incorporation of epithelial cells by cementum. *J Ultrastruct Res* 27:63, 1969.
154. Listgarten MA: The ultrastructure of human gingival epithelium. *Am J Anat* 114:49, 1964.
155. Listgarten MA: Electron microscopic study of the gingivo-dental junction of man. *Am J Anat* 119:147, 1966.
156. Listgarten MA: Phase-contrast and electron microscopic study of the junction between reduced enamel epithelium and enamel in unerupted human teeth. *Arch Oral Biol* 11:999, 1966.
157. Listgarten MA: A light and electron microscopic study of coronal cementogenesis. *Arch Oral Biol* 13:93, 1968.
158. Listgarten MA: Changing concepts about the dento-gingival junction. *J Can Dent Assoc* 36:70, 1970.
159. Listgarten MA: Structure of surface coatings on teeth: a review. *J Periodontol* 47:139, 1976.
160. Löe H, Karring T: Mitotic activity and renewal time of the gingival epithelium of young and old rats. *J Periodontal Res* 4:18, 1969.
161. Löe H, Karring T: A quantitative analysis of the epithelium–connective tissue interface in relation to assessments of the mitotic index. *J Dent Res* 48:634, 1969.
162. Luthman J, Johansson O, Ahlström U, et al: Immunohistochemical studies of the neurochemical markers CGRP, enkephalin, galanin, gamma-MSH, NPY, PHI, proctolin, PTH, somatostatin, SP, VIP, tyrosine hydroxylase and neurofilament in nerves and cells of the human attached gingiva. *Arch Oral Biol* 33:149, 1988.
163. Mackie EJ: Osteoblasts: novel roles in orchestration of skeletal architecture. *Int J Biochem Cell Biol* 35:1301, 2003.
164. MacNeil RL, Berry JE, Strayhorn CL, et al: Expression of type I and XII collagen during development of the periodontal ligament in the mouse. *Arch Oral Biol* 43:779, 1998.
165. MacNeil RL, Thomas HF: Development of the murine periodontium. II. Role of the epithelial root sheath in formation of the periodontal attachment. *J Periodontol* 64:285, 1993.
166. Maeda T, Kannari K, Sato O, et al: Nerve terminals in human periodontal ligament as demonstrated by immunohistochemistry for neurofilament protein (NFP) and S-100 protein. *Arch Histol Cytol* 53:259, 1990.

167. Magnusson B: Mucosal changes in erupting molars in germ-free rats. *J Periodontal Res* 4:181, 1969.
168. Marchetti C, Poggi P: Lymphatic vessels in the oral cavity: different structures for the same function. *Microsc Res Tech* 56:42, 2002.
169. Matias MA, Li H, Young WG, et al: Immunohistochemical localization of fibromodulin in the periodontium during cementogenesis and root formation in the rat molar. *J Periodontal Res* 38:502, 2003.
170. Matsuo M, Takahashi K: Scanning electron microscopic observation of microvasculature in periodontium. *Microsc Res Tech* 56:3, 2002.
171. Mattos CM, Santana RB: A quantitative evaluation of the spatial maxillary anterior dentition. *J Periodontol* 79:1880, 2008.
172. McCulloch CA: Basic considerations in periodontal wound healing to achieve regeneration. *Periodontol 2000* 1:16, 1993.
173. McCulloch CA, Lekic P, McKee MD: Role of physical forces in regulating the form and function of the periodontal ligament. *Periodontol 2000* 24:56, 2000.
174. McCulloch CA, Melcher AH: Cell density and cell generation in the periodontal ligament of mice. *Am J Anat* 167:43, 1983.
175. McKee MD, Zalzal S, Nanci A: Extracellular matrix in tooth cementum and mantle dentin: localization of osteopontin and other noncollagenous proteins, plasma proteins, and glycoconjugates by electron microscopy. *Anat Rec* 245:293, 1996.
176. McNamara TG, O'Shea D, McNamara CM, et al: The management of traumatic ankylosis during orthodontics: a case report. *J Clin Pediatr Dent* 24:265, 2000.
177. Melcher AH: Remodeling of the periodontal ligament during eruption of the rat incisor. *Arch Oral Biol* 12:1649, 1967.
178. Melcher AH: On the repair potential of periodontal tissues. *J Periodontol* 47:256, 1976.
179. Meyer J, Marwah AS, Weinmann JP: Mitotic rate of gingival epithelium in two age groups. *J Invest Dermatol* 27:237, 1956.
180. Mikola OJ, Bauer WH: "Cementicles" and fragments of cementum in the periodontal membrane. *Oral Surg Oral Med Oral Pathol* 2:1063, 1949.
181. Miller SC, Soberman A, Stahl SS: A study of the cornification of the oral mucosa of young male adults. *J Dent Res* 30:4, 1951.
182. Morgan PR, Leigh IM, Purkis PE, et al: Site variation in keratin expression in human oral epithelia: an immunocytochemical study of individual keratins. *Epithelia* 1:31, 1987.
183. Moss ML: Phylogeny and comparative anatomy of oral ectodermal-ectomesenchymal inductive interactions. *J Dent Res* 48:732, 1969.
184. Mühlemann HR: The determination of tooth rotation centers. *Oral Surg* 7:392, 1954.
185. Mühlemann HR, Zander HA, Halberg F: Mitotic activity in the periodontal tissues of the rat molar. *J Dent Res* 33:459, 1954.
186. Mullally BH, Blakely D, Burden DJ: Ankylosis: an orthodontic problem with a restorative solution. *Br Dent J* 179:426, 1995.
187. Murrell EF, Yen EH, Johnson RB: Vascular changes in the periodontal ligament after removal of orthodontic forces. *Am J Orthod Dentofac Orthop* 110:280, 1996.
188. Ness KH, Morton TH, Dale BA: Identification of Merkel cells in oral epithelium using antikeratin and antineuroendocrine monoclonal antibodies. *J Dent Res* 66:1154, 1987.
189. Nihei I: A study on the hardness of human teeth. *J Osaka Univ Dent Soc* 4:1, 1959.
190. Noyes FB, Schour I, Noyes HJ: *A textbook of dental histology and embryology*, ed 5, Philadelphia, 1938, Lea & Febiger.
191. Ogasawara T, Yoshimine Y, Kiyoshima T, et al: In situ expression of RANKL, RANK, osteoprotegerin and cytokines in osteoclasts of rat periodontal tissue. *J Periodontal Res* 39:42, 2004.
192. Oliver RC, Holm-Pederen P, Löe H: The correlation between clinical scoring, exudate measurements and microscopic evaluation of inflammation in the gingiva. *J Periodontol* 40:201, 1969.
193. Oppenheim A: Human tissue response to orthodontic intervention of short and long duration. *Am J Orthodont Oral Surg* 28:263, 1942.
194. Orban B: Tissue changes in traumatic occlusion. *J Am Dent Assoc* 15:2090, 1928.
195. Orban B, Kohler J: Die physiologische zahn-fleischtasche, epithelansatz und epitheltiefenwucherung. *Z Stomatol* 22:353, 1924.
196. Orwoll ES: Toward an expanded understanding of the role of the periosteum in skeletal health. *J Bone Miner Res* 18:949, 2003.
197. Otero RL, Parodi RJ, Ubios AM, et al: Histologic and histometric study of bone resorption after tooth movement in rats. *J Periodontal Res* 8:327, 1973.
198. Page RC, Ammons WF, Schectman LR, et al: Collagen fibre bundles of the normal marginal gingiva in the marmoset. *Arch Oral Biol* 19:1039, 1972.
199. Papic M, Glickman I: Keratinization of the human gingiva in the menstrual cycle and menopause. *Oral Surg Oral Med Oral Pathol* 3:504, 1950.
200. Parfitt GJ: An investigation of the normal variations in alveolar bone trabeculation. *Oral Surg Oral Med Oral Pathol* 15:1453, 1962.
201. Parodi RJ, Ubios AM, Mayo J, et al: Total body irradiation effects on the bone resorption mechanism in rats subjected to orthodontic movement. *J Oral Pathol* 2:1, 1973.
202. Person P, Felton J, Fine A: Biochemical and histochemical studies of aerobic oxidative metabolism of oral tissues. 3. Specific metabolic activities of enzymatically separated gingival epithelium and connective tissue components. *J Dent Res* 44:91, 1965.
203. Picton DC, Davies WI: Dimensional changes in the periodontal membrane of monkeys (Macaca irus) due to horizontal thrusts applied to the teeth. *Arch Oral Biol* 12:1635, 1967.
204. Pihlstrom BL, Ramfjord SP: Periodontal effect of nonfunction in monkeys. *J Periodontol* 42:748, 1971.
205. Pöllänen MT, Salonen JI, Uitto VJ: Structure and function of the tooth-epithelial interface in health and disease. *Periodontol 2000* 31:12, 2003.
206. Rao LG, Wang HM, Kalliecharan R, et al: Specific immunohistochemical localization of type I collagen in porcine periodontal tissues using the peroxidase-labelled antibody technique. *Histochem J* 11:73, 1979.
207. Reeve CM, Wentz FM: The prevalence, morphology and distribution of epithelial rests in the human periodontal ligament. *Oral Surg Oral Med Oral Pathol* 15:785, 1962.
208. Rippin JW: Collagen turnover in the periodontal ligament under normal and altered functional forces. II. Adult rat molars. *J Periodontal Res* 13:149, 1978.
209. Ritchey B, Orban B: The crests of the interdental alveolar septa. *J Periodontol* 24:75, 1953.
210. Roberts WE, Chamberlain JG: Scanning electron microscopy of the cellular elements of rat periodontal ligament. *Arch Oral Biol* 23:587, 1978.
211. Romaniuk K: Some observations of the fine structure of human cementum. *J Dent Res* 46:152, 1967.
212. Romanos G, Schroter-Kermani C, Hinz N, et al: Immunohistochemical distribution of the collagen types IV, V and VI and glycoprotein laminin in the healthy rat, marmoset (Callithrix jacchus) and human gingivae. *Matrix* 11:125, 1991.
213. Romanos GE, Bernimoulin JP: Collagen as a basic element of the periodontium: immunohistochemical aspects in the human and animal. 1. Gingiva and alveolar bone. *Parodontologie* 4:363, 1990.
214. Romanos GE, Schroter-Kermani C, Bernimoulin J-P: Das kollagen als basis-element des parodonts: immunohistochemische aspekte bein menschen und bei tieren. *Parodontologie* 1:47, 1991.
215. Romanos GE, Schroter-Kermani C, Hinz N, et al: Immunohistochemical localization of collagenous components in healthy periodontal tissues of the rat and marmoset (Callithrix jacchus). I. Distribution of collagens type I and III. *J Periodontal Res* 27:101, 1992.
216. Rosenberg HM, Massler M: Gingival stippling in young adult males. *J Periodontol* 38:473, 1967.
217. Rudolph CE: An evaluation of root resorption occurring during orthodontic treatment. *J Dent Res* 19:367, 1940.
218. Rushton MA: The dental tissues in osteitis deformans. *Guy's Hosp Rep* 88:163, 1938.
219. Saffar JL, Lasfargues JJ, Cherruau M: Alveolar bone and the alveolar process: the socket that is never stable. *Periodontol 2000* 13:76, 1997.

220. Saito M, Narayana AS: Signaling reactions induced in human fibroblasts during adhesion to cementum-derived attachment protein. *J Bone Miner Res* 14:65, 1999.
221. Salonen JI: Proliferative potential of the attached cells of human junctional epithelium. *J Periodontal Res* 29:41, 1994.
222. Salonen JI, Pöllänen MT: Junctional epithelial cells directly attached to the tooth. *Acta Med Dent Helv* 2:137, 1997.
223. Sawada T, Yamamoto T, Yanagisawa T, et al: Electron-immunocytochemistry of laminin and type-IV collagen in the junctional epithelium of rat molar gingiva. *J Periodontal Res* 25:372, 1990.
224. Sawaf MH, Ouhayoun JP, Forest N: Cytokeratin profiles in oral epithelial: a review and a new classification. *J Biol Buccale* 19:187, 1991.
225. Saygin NE, Giannobile WV, Somerman MJ: Molecular and cell biology of cementum. *Periodontol 2000* 24:73, 2000.
226. Schor SL, Ellis I, Irwin CR, et al: Subpopulations of fetal-like gingival fibroblasts: characterisation and potential significance for wound healing and the progression of periodontal disease. *Oral Dis* 2:155, 1996.
227. Schroeder H: *Oral structural biology*, New York, 1991, Time Medical Publishers.
228. Schroeder HE: Melanin containing organelles in cells of the human gingiva. *J Periodontal Res* 4:1, 1969.
229. Schroeder HE: Transmigration and infiltration of leucocytes in human junctional epithelium. *Helv Odontol Acta* 17:6, 1973.
230. Schroeder HE: *Differentiation of human oral stratified epithelia*, New York, 1981, Karger.
231. Schroeder HE: Gingiva. In Oksche A, Vollrath L, editors: *The periodontium handbook of microscopic anatomy*, vol 5, Berlin, 1986, Springer-Verlag.
232. Schroeder HE: *The periodontium*, Berlin, 1986, Springer-Verlag.
233. Schroeder HE, Listgarten MA: Fine structure of the developing epithelial attachment of human teeth. *Monographs in developmental biology*, Basel, 1971, Karger.
234. Schroeder HE, Listgarten MA: The gingival tissues: the architecture of periodontal protection. *Periodontol 2000* 13:91, 1997.
235. Schroeder HE, Theilade J: Electron microscopy of normal human gingival epithelium. *J Periodontal Res* 1:95, 1966.
236. Schultz-Haudt SD, From S: Dynamics of periodontal tissues. I. The epithelium. *Odont T* 69:431, 1961.
237. Schultz-Haudt SD, Paus S, Assev S: Periodic acid–Schiff reactive components of human gingiva. *J Dent Res* 40:141, 1961.
238. Schweitzer G: Lymph vessels of the gingiva and teeth. *Arch Mik Anat Ent* 69:807, 1907.
239. Schwint AE, Itoiz ME, Cabrini RL: A quantitative histochemical technique for the study of vascularization in tissue sections using horseradish peroxidase. *Histochem J* 16:907, 1984.
240. Selvig KA: The fine structure of human cementum. *Acta Odontol Scand* 23:423, 1965.
241. Sena K, Morotome Y, Baba O, et al: Gene expression of growth differentiation factors in the developing periodontium of rat molars. *J Dent Res* 82:166, 2003.
242. Seymour GJ, Crouch MS, Powell RN, et al: The identification of lymphoid cell subpopulations in sections of human lymphoid tissue and gingivitis in children using monoclonal antibodies. *J Periodontal Res* 17:247, 1982.
243. Shackleford JM: The indifferent fiber plexus and its relationship to principal fibers of the periodontium. *Am J Anat* 131:427, 1971.
244. Shapiro S, Ulmansky M, Scheuer M: Mast cell population in gingiva affected by chronic destructive periodontal disease. *J Periodontol* 40:276, 1969.
245. Shelton LE, Hall WB: Human gingival mast cells. *J Periodontal Res* 3:214, 1968.
246. Shimada Y, Tai H, Tanaka A, et al: Effects of ascorbic acid on gingival melanin pigmentation in vitro and in vivo. *J Periodontol* 80:317, 2009.
247. Sicher H, DuBrul EL: *Oral anatomy*, ed 6, St Louis, 1975, Mosby.
248. Simpson HE: The degeneration of the rest of malassez with age as observed by the apoxestic technique. *J Periodontol* 36:288, 1965.
249. Skougaard MR, Beagrie GS: The renewal of gingival epithelium in marmosets (Callithrix jacchus) as determined through autoradiography with thymidine-H3. *Acta Ondontol Scand* 20:467, 1962.
250. Sodek J: A comparison of the rates of synthesis and turnover of collagen and non-collagen proteins in adult rat periodontal tissues and skin using a microassay. *Arch Oral Biol* 22:655, 1977.
251. Sodek J, McKee MD: Molecular and cellular biology of alveolar bone. *Periodontol 2000* 24:99, 2000.
252. Squier CA, Waterhouse JP: The ultrastructure of the melanocyte in human gingival epithelium. *J Dent Res* 46:113, 1967.
253. Stein TJ, Corcoran JF: Anatomy of the root apex and its histologic changes with age. *Oral Surg Oral Med Oral Pathol* 69:238, 1990.
254. Stern IB: Electron microscopic observations of oral epithelium. I. Basal cells and the basement membrane. *Periodontics* 3:224, 1965.
255. Stern IB: The fine structure of the ameloblast-enamel junction in rat incisors, epithelial attachment and cuticular membrane. Presented at 5th International Congress for Electron Microscopy, 1966, p 6.
256. Stern IB: Further electron microscopic observations of the epithelial attachment, International Association for Dental Research Abstracts, 45th general meeting, 1967, p 118.
257. Susi F: *Histochemical, autoradiographic and electron microscopic studies of keratinization in oral mucosa* [thesis], Bedford, MA, 1967, Tufts University.
258. Swift JA, Saxton CA: The ultrastructural location of the periodate-Schiff reactive basement membrane of the dermoepidermal junctions of human scalp and monkey gingiva. *J Ultrastruct Res* 17:23, 1967.
259. Tadokoro O, Maeda T, Heyeraas KJ, et al: Merkel-like cells in Malassez epithelium in the periodontal ligament of cats: an immunohistochemical, confocal-laser scanning and immuno electron-microscopic investigation. *J Periodontal Res* 37:456, 2002.
260. Tarnow DP, Magner AW, Fletcher P: The effect of the distance from the contact point to the crest of bone on the presence or absence of the interproximal dental papilla. *J Periodontol* 63:995, 1992.
261. Ten Cate AR: The histochemical demonstration of specific oxidative enzymes and glycogen in the epithelial cell rests of Malassez. *Arch Oral Biol* 10:207, 1965.
262. Ten Cate AR: The development of the periodontium. In Melcher AH, Bowen WH, editors: *Biology of the periodontium*, New York, 1969, Academic Press.
263. Ten Cate AR: Formation of supporting bone in association with periodontal ligament organization in the mouse. *Arch Oral Biol* 20:137, 1975.
264. Ten Cate AR: Hard tissue formation and destruction. In Ten Cate AR, editor: *Oral histology: development, structure, and function*, ed 4, St Louis, 1994, Mosby.
265. Ten Cate AR, Deporter DA: The degradative role of the fibroblast in the remodeling and turnover of collagen in soft connective tissue. *Anat Rec* 182:1, 1975.
266. Ten Cate AR, Mills C, Solomon G: The development of the periodontium: a transplantation and autoradiographic study. *Anat Rec* 170:365, 1971.
267. Thilander H: Permeability of the gingival pocket epithelium. *Int Dent J* 14:416, 1964.
268. Thilander H, Bloom GD: Cell contacts in oral epithelia. *J Periodontal Res* 3:96, 1968.
269. Thoma KH, Sosman MC, Bennett GA: An unusual case of hereditary fibrous osteodystrophy (fragilitas ossium) with replacement of dentine by osteocementum. *Am J Orthodont Oral Surg* 29:1, 1943.
270. Thomas HF: Root formation. *Int J Dev Biol* 39:231, 1995.
271. Thomas HF, Kollar EJ: Tissue interactions in normal murine root development. In Davidovitch Z, editor: *The biological mechanisms of tooth eruption and root resorption*, Birmingham, 1988, EBSCO Media.
272. Thonard JC, Scherp HW: Histochemical demonstration of acid mucopolysaccharides in human gingival epithelial intercellular spaces. *Arch Oral Biol* 7:125, 1962.
273. Trott JR: An investigation into the glycogen content of the gingivae. *Dent Pract* 7:234, 1957.

274. Trott JR, Gorenstein SL: Mitotic rates in the oral and gingival epithelium of the rat. *Arch Oral Biol* 8:425, 1963.
275. Trowbridge HO, Shibata F: Mitotic activity in epithelial rests of Malassez. *Periodontics* 5:109, 1967.
276. Turesky S, Glickman I, Litwin T: A histochemical evaluation of normal and inflamed human gingivae. *J Dent Res* 30:792, 1951.
277. Ubios AM, Cabrini RL: Tritiated thymidine uptake in periodontal tissue subject to orthodontic movement. *J Dent Res* 50:1160, 1971.
278. Vaes G: Cellular biology and biochemical mechanism of bone resorption: a review of recent developments on the formation, activation, and mode of action of osteoclasts. *Clin Orthop* 231:239, 1988.
279. Valderhaug JP, Nylen MU: Function of epithelial rests as suggested by their ultrastructure. *J Periodontal Res* 1:69, 1966.
280. Valderhaug JP, Zander H: Relationship of "epithelial rests of Malassez" to other periodontal structures. *Periodontics* 5:254, 1967.
281. Vandevska-Radunovic V, Kvinnsland IH, Kvinnsland S, et al: Immunocompetent cells in rat periodontal ligament and their recruitment incident to experimental orthodontic tooth movement. *Eur J Oral Sci* 105:36, 1997.
282. Warren EB, Hansen NM, Swartz ML, et al: Effects of periodontal disease and of calculus solvents on microhardness of cementum. *J Periodontol* 35:505, 1964.
283. Watanabe T, Kubota T: Characterization of fibromodulin isolated from bovine periodontal ligament. *J Periodontal Res* 33:1, 1998.
284. Waterhouse JP: The gingival part of the human periodontium, its ultrastructure and the distribution in it of acid phosphatase in relation to cell attachment and the lysosome concept. *Dent Pract Dent Rec* 15:409, 1965.
285. Weinmann JP, Meyer J: Types of keratinization in the human gingiva. *J Invest Dermatol* 32:87, 1959.
286. Weinmann JP, Sicher H: *Bone and bones: fundamentals of bone biology*, ed 2, St Louis, 1955, Mosby.
287. Weinstock A, Albright JT: Electron microscopic observations on specialized structures in the epithelium of the normal human palate. *J Dent Res* 45:79, 1966.
288. Weinstock A, Albright JT: The fine structure of mast cells in normal human gingiva. *J Ultrastruct Res* 17:245, 1967.
289. Weski O: Die chronische marginales enzundungen des alveolarfortsatzes mit besonderer berucksichtigung der alveolarpyorrhoe. *Vierteljahrschr Zahnheilk* 38:1, 1922.
290. Wood NK, Goaz PW: *Differential diagnosis of oral lesions*, ed 2, St Louis, 1984, Mosby.
291. Woodnutt DA, Wager-Miller J, O'Neill PC, et al: Neurotrophin receptors and nerve growth factor are differentially expressed in adjacent nonneuronal cells of normal and injured tooth pulp. *Cell Tissue Res* 299:225, 2000.
292. Worapamorn W, Li H, Pujic Z, et al: Expression and distribution of cell-surface proteoglycans in the normal Lewis rat molar periodontium. *J Periodontal Res* 35:214, 2000.
293. Yamamoto T, Domon T, Takahashi S, et al: The fibrillar structure of cement lines on resorbed root surfaces of human teeth. *J Periodontal Res* 35:208, 2000.
294. Yamamoto T, Domon T, Takahashi S, et al: The fibrous structure of the cemento-dentinal junction in human molars shown by scanning electron microscopy combined with NaOH-maceration. *J Periodontal Res* 35:59, 2000.
295. Yamamoto T, Wakita M: Bundle formation of principal fibers in rat molars. *J Periodontal Res* 27:20, 1992.
296. Yamasaki A, Nikai H, Niitani K, et al: Ultrastructure of the junctional epithelium of germ-free rat gingiva. *J Periodontol* 50:641, 1979.
297. Zander HA: The distribution of phosphatase in gingival tissue. *J Dent Res* 20:347, 1941.
298. Zander HA, Hurzeler B: Continuous cementum apposition. *J Dent Res* 37:1035, 1958.
299. Zipkin J: The inorganic composition of bones and teeth. In Schraer H, editor: *Biological calcification*, New York, 1970, Appleton-Century-Crofts.
300. Zwarych PD, Quigley MB: The international plexus of the periodontal ligament history and further observations. *J Dent Res* 44:383, 1965.

CHAPTER 2

Aging and the Periodontium

Ian Needleman

CHAPTER OUTLINE

Effects of Aging on the Periodontium
Effects of Aging on the Progression of Periodontal Diseases
Aging and the Response to Treatment of the Periodontium

Increased health awareness and improvements in preventive dentistry have led to decreasing tooth loss for all age groups. The effects of this shift in tooth retention need to be considered carefully. In particular, increased life expectancy and greater health expectations may lead to changes in demand from older individuals for periodontal treatment and potentially a substantial increase in supportive periodontal therapy. Therefore, an understanding of the impact of aging on the periodontium is critical. This chapter will first review the literature concerning the fundamental aspects of aging on the periodontal tissues; broader aspects of aging will then be examined and their possible effects on treatment outcomes discussed.

The evidence base is not without problems, many of which make it difficult to draw conclusions about the effects of aging. Some of these problems include inconsistency with regard to the definition of a true "older" group, the inadequate exclusion of adults with systemic diseases that can modify study findings, and attempts to extrapolate results from animal research. For the purposes of this chapter, the effects of aging will be limited to a narrow review of possible biologic and microbiologic changes. (For further reading about the effects of aging on the dental and periodontal patient, the reader should consult Lamster and Northridge's *Improving Oral Health for the Elderly. An Interdisciplinary Approach* [Springer, 2008, New York].) The reader should be fully aware that this excludes many important age-associated phenomena, including reductions in an individual's cognitive or motor function skills, which may have a direct impact on periodontal management. These will be discussed more fully in Chapter 39.

Since first writing this chapter 14 years ago, the volume of new research into aging and the periodontium has not increased substantially. Highly sensitive molecular and genomic techniques have been employed in related laboratory research, and these are starting to provide insight into age-associated effects. These approaches will likely be proven fruitful in the future. Despite the limited data directly related to the periodontium, much effort and many resources have been employed to research questions at least partially related to this topic. These include the effect of periodontal infection on general health (see Chapter 28) and the impact of osteoporosis on periodontal status (see Chapter 38).

Effects of Aging on the Periodontium

Gingival Epithelium

Thinning and decreased keratinization of the gingival epithelium have been reported with age.[46] The significance of these findings could mean an increase in epithelial permeability to bacterial antigens, a decreased resistance to functional trauma, or both. If so, such changes may influence long-term periodontal outcomes. However, other studies have found no age-related differences in the gingival epithelium of humans or dogs.[8,22] Other reported changes with aging include the flattening of rete pegs and altered cell density. Conflicting data regarding the surgical regeneration times for gingival epithelium have been ascribed to problems with research methodology.[51]

The effect of aging on the location of the junctional epithelium has been the subject of much speculation. Some reports show migration of the junctional epithelium from its position in healthy individuals (i.e., on the enamel) to a more apical position on the root surface with accompanying gingival recession.[8] However, in other animal studies, no apical migration has been noted.[25] With continuing gingival recession, the width of the attached gingiva would be expected to decrease with age, but the opposite appears to be true.[2,3] Alternatively, the migration of the junctional epithelium to the root surface could be caused by the tooth erupting through the gingiva in an attempt to maintain occlusal contact with its opposing tooth (i.e., passive eruption) as a result of tooth surface loss from attrition (Fig. 2-1). The consensus is that gingival recession is not an inevitable physiologic process of aging but rather that it can be explained by the cumulative effects of inflammation or trauma on the periodontium[6,8] (Fig. 2-2); this is discussed in more detail later in this chapter. Changes in the apoptotic gene expression of gingival tissue with age have recently been reported in nonhuman primates.[17] This finding requires further research to understand its potential impact on gingival homeostasis and the pathogenesis of periodontal diseases.

Gingival Connective Tissue

Increasing age results in coarser and denser gingival connective tissues.[54] Qualitative and quantitative changes to collagen have

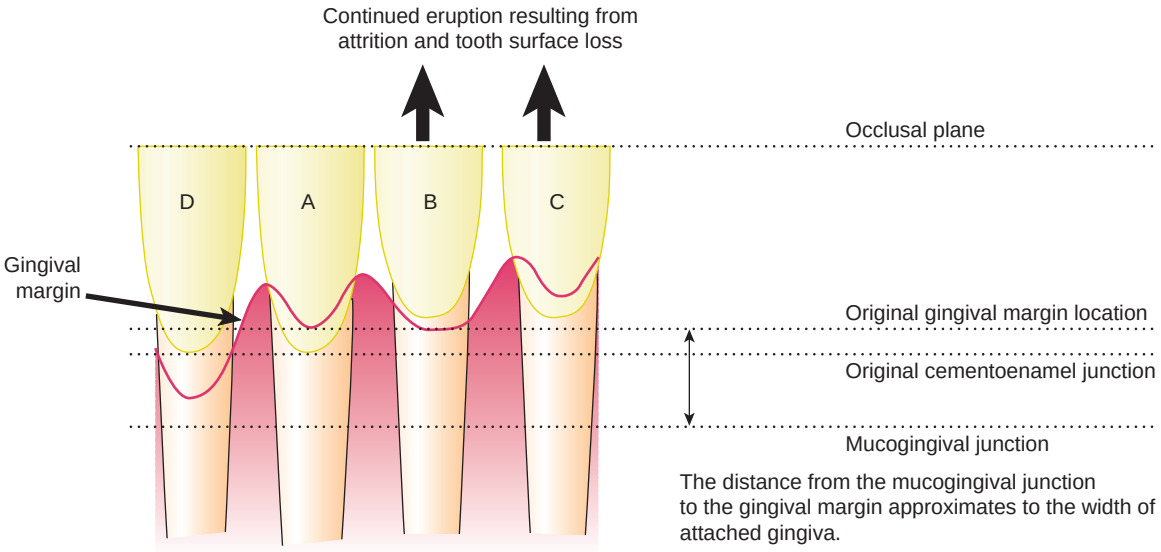

Figure 2-1 Diagram showing the relationship of the gingival margin with the crown and root surface. **A,** Normal relationship with the gingival margin 1 to 2 mm above the cementoenamel junction. **B,** Wear of the incisal edge and continued tooth eruption. The gingival margin remains in the same position as shown in **A.** Therefore, the root surface is exposed, and clinical recession is evident. The width of the attached gingiva has not changed. **C,** Wear of the incisal edge and continued tooth eruption. The gingival margin has moved with the tooth; therefore, the entire dentogingival complex has moved coronally, with a resulting increase in the width of the attached gingiva. **D,** No wear of incisal edge is evident. The gingiva has moved apically, and clinical recession is evident. The width of attached gingiva is reduced.

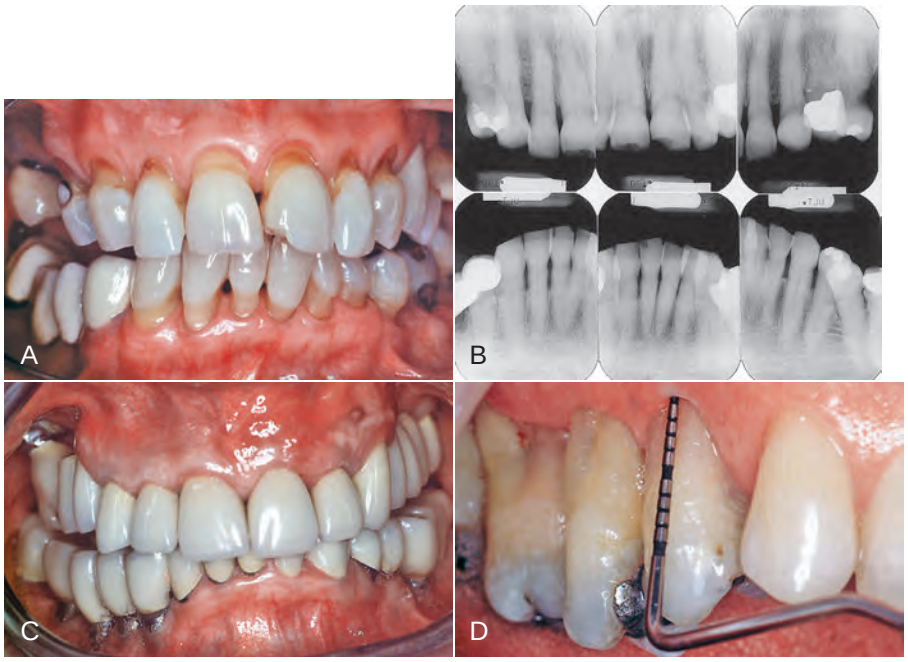

Figure 2-2 Three scenarios illustrating the variation of the position of the gingival margin with age. **A,** Overeruption with recession in an older individual (i.e., a 68-year-old woman) with generalized recession and a history of previously treated periodontitis. Note some overeruption of the lower anterior teeth and wear of teeth related to oral hygiene measures. **B,** Radiographs of the patient shown in **A. C,** Overeruption without recession in an older individual (i.e., a 72-year-old woman) with no periodontitis but marked lower incisor tooth wear and overeruption. Note how the gingival margin has migrated coronally with the erupting teeth. **D,** Extensive recession in a younger individual (i.e., a 32-year-old man) with marked recession and no history of periodontitis. The recession has resulted from a combination of anatomically thin tissues and toothbrush-related trauma.

been reported. These include an increased rate of conversion of soluble to insoluble collagen, increased mechanical strength, and increased denaturing temperature. These results indicate increased collagen stabilization caused by changes in the macromolecular conformation.[29] Not surprisingly, an increased collagen content has been found in the gingivae of older animals, despite a lower rate of collagen synthesis decreasing with age.[8,29,51]

Periodontal Ligament

Changes in the periodontal ligament that have been reported with aging include decreased numbers of fibroblasts and a more irregular structure, thus paralleling the changes seen in the gingival connective tissues.[8,29,51] Other findings include decreased organic matrix production, epithelial cell rests, and increased amounts of elastic fiber.[51] Conflicting results have been reported for changes in the width of the periodontal ligament in human and animal models. Although true variation may exist, this finding probably reflects the functional status of the teeth in the studies: the width of the space will decrease if the tooth is unopposed (i.e., hypofunction) or increase with excessive occlusal loading.[29,51] Both scenarios can be anticipated as a result of tooth loss in this population. These effects may also explain the variability in studies that have reported qualitative changes within the periodontal ligament.

Recognition that the periodontal ligament has an important role in alveolar bone metabolism has led to an increased interest in investigating this role in relation to the maintenance of periodontal health and the pathogenesis of periodontitis. One approach to investigating this role is to examine mediators of bone homeostasis, such as receptor activator of nuclear factor-κB ligand (RANKL) and osteoprotegerin (OPG). RANKL is widely recognized for its role in activating osteoclasts, whereas OPG antagonizes RANKL binding, thus helping to maintain balance. The interplay of cytokines—and, in particular, the interleukin family—has also been extensively researched in periodontal pathogenesis. Some of the interleukins are potent mediators of inflammation (e.g., IL-1), whereas others have been shown to down-regulate this process (e.g., IL-4, IL-10). Therefore, evaluating the balance between these homeostatic processes would seem to be of great merit when evaluating possible negative changes in the periodontium. Such a strategy appears to be predictive of hard-tissue destruction among individuals with rheumatoid arthritis.[16] Recent findings comparing periodontal ligament cells in older individuals (i.e., >60 years old) with those of younger individuals (i.e., 15 to 20 years old) have suggested greater gene expression for pro-inflammatory cytokines.[7] This has been reported more widely as an age-associated change, although it is unclear whether it is a cause or an effect.[38] However, in addition to increased IL-1 and IL-6 expression, OPG was also increased, which suggests that increased OPG may be a homeostatic response to the up-regulation of inflammation.[7] If this homeostatic mechanism was effective, it may explain why an increase in inflammation did not result in greater tissue damage with age. Periodontal ligament cell proliferation was decreased with age, thereby suggesting an impairment of repair potential, although such an impact does not appear to be manifested clinically.[53] Further research investigating periodontal ligament cells from individuals diagnosed with periodontitis will be important to understand the potentially important relationship between aging and periodontal ligament cells.

Cementum

Some consensus regarding the effect of aging on cementum exists. An increase in cemental width is a common finding; this increase may be 5 to 10 times with increasing age.[8] This finding is not surprising, because deposition continues after tooth eruption. The increase in width is greater apically and lingually.[51] Although cementum has limited capacity for remodeling, an accumulation of resorption bays explains the finding of increasing surface irregularity.[18]

Alveolar Bone

Reports of morphologic changes in alveolar bone mirror age-related changes in other bony sites. Specific to the periodontium are findings of a more irregular periodontal surface of bone and the less-regular insertion of collagen fibers.[51] Although age is a risk factor for the bone mass reductions in individuals with osteoporosis, it is not causative and therefore should be distinguished from physiologic aging processes.[21] Overriding the diverse observations of bony changes with age is the important finding that the healing rate of bone in extraction sockets appears to be unaffected by increasing age.[4] Indeed, the success of osseointegrated dental implants, which relies on intact bone healing responses, does not appear to be age related.[9] However, balancing this view is the recent observation that bone graft preparations (i.e., decalcified freeze-dried bone) from donors who were more than 50 years old possessed significantly less osteogenic potential than graft material from younger donors.[45] The possible significance of this phenomenon for normal healing responses needs to be investigated.

Bacterial Plaque

Dentogingival plaque accumulation has been suggested to increase with age.[20] This might be explained by the increase in hard-tissue surface area as a result of gingival recession and the surface characteristics of the exposed root surface as a substrate for plaque formation as compared with enamel. Other studies have shown no difference in plaque quantity with age. This contradiction might reflect the different age ranges of experimental groups as variable degrees of gingival recession and root surface exposure. For supragingival plaque, no real qualitative differences have been shown for plaque composition.[20] With regard to subgingival plaque, one study has shown subgingival flora to be similar to normal flora, whereas another study reported increased numbers of enteric rods and pseudomonads in older adults.[34,49] Mombelli suggests caution when interpreting this finding because of the increased oral carriage of these species among older adults.[32] It has been speculated that a shift occurs in the importance of certain periodontal pathogens with age, specifically including an increased role for *Porphyromonas gingivalis* and a decreased role for *Aggregatibacter actinomycetemcomitans*. However, differentiating true age effects from the changes in ecologic determinants for periodontal bacteria will be difficult. This topic was considered in more detail in a recent review.[32]

Another approach to investigating microbiology is to conduct intervention studies and to examine their impact on the microflora. Among individuals who were 60 to 75 years old, the prevalence of *P. gingivalis, Treponema forsythia, Treponema denticola, A. actinomycetemcomitans,* and *Prevotella intermedia* were high and were not clearly related to probing depth.[42] The finding of high levels of the organisms could have been related to the sample of individuals: the participants were mostly those with low incomes and with no recent dental care. Long-term use (i.e., 5 years) of a 0.12% chlorhexidine mouthrinse did not promote reductions in the proportions of the organisms in individuals experiencing alveolar bone loss as compared with the placebo mouthrinse, possibly as a result of the mouthrinse routine being less frequent than daily.[42]

Immune and Inflammatory Responses

Recent advances in the study of the effects of aging on the immune response (i.e., immunosenescence) have altered the understanding of this phenomenon. In particular, more recent studies have set tighter controls on excluding individuals with systemic conditions known to affect the immune response. As a result, age has been recognized as having much less effect on the alteration of the host response than previously thought.[23,30] Differences between younger and older individuals can be demonstrated for T and B cells, cytokines, and natural killer cells but not for polymorphonuclear cells and macrophage activity. McArthur concluded the following: "Measurement of indicators of immune and inflammatory competency suggested that, within the parameters tested, there was no evidence for age-related changes in host defenses correlating with periodontitis in an elderly (65 to 75 years) group of individuals, with and without disease."[30] Recent laboratory studies have shown age-related changes in the expression of pro-inflammatory mediators[12] and innate immunity[19] with the potential to alter the pathology of periodontal diseases or antimicrobial function. However, the relevance of these findings to the clinical situation has not been demonstrated. Age-related differences in the inflammatory response among individuals with gingivitis have been clearly demonstrated and are discussed later in this textbook.

In relation to systematic inflammatory responses, C-reactive protein (CRP) is an acute phase protein that is widely regarded as a marker of inflammatory burden and response to bacterial infection.[47] When investigating serum CRP levels among individuals who are 60 to 75 years old and comparing individuals with progressive periodontitis with those with stable disease, CRP levels were increased in those with progressive periodontitis and no other systemic conditions.[50] This may indicate that inflammatory burden can be investigated with the use of CRP, although there is growing evidence that CRP alone may not be as reliable a marker in older people.[43]

A further modulator of the immune and inflammatory responses is nutrition. Interest in this field is increasing rapidly as part of both medicine and periodontology.[11] Nutrition has been studied extensively in geriatric medicine as a result of the nutritional intake changes that occur with age. The impact of this as a potential risk factor for periodontal diseases and their progression is therefore of interest. Data have started to appear that suggest a negative association of serum folate with periodontitis. After controlling for major known confounders, lower serum folate levels in dentate adults who are more than 60 years old are associated with greater levels of periodontitis.[56] These cross-sectional data cannot demonstrate causality alone, but the recognized relationship between folate protection for chronic inflammatory diseases (e.g., cardiovascular disease[31]) offers biologic plausibility to a potential relationship that merits further investigation with prospective studies.

Although many contradictions exist, a survey of the literature demonstrates that some age-related changes are evident in the periodontium and the host response. Whether these changes are significant in the alteration of the progression of periodontal diseases or the response of an older adult to periodontal treatment will be examined next.

Effects of Aging on the Progression of Periodontal Diseases

In a classic experimental gingivitis study, subjects were rendered free of plaque and inflammation through frequent professional cleaning. After this was achieved, the subjects abstained from oral hygiene measures for periods of 3 weeks to allow gingivitis to develop.[28] In this experimental model, a comparison of developing gingivitis between younger and older individuals demonstrated a greater inflammatory response in older subjects, both in humans and in dogs.[8,13,14,20] In the older age group (i.e., 65 to 80 years), the findings included a greater amount of infiltrated connective tissue, increased gingival crevicular fluid flow, and an increased gingival index.[13,14] Other studies have not demonstrated differences between subjects; this may be related to smaller differences between the ages of the younger and older experimental groups.[55] Intriguingly, even at the baseline level of excellent gingival health before the commencement of plaque accumulation, differences may exist between groups, with older individuals demonstrating more inflammation.[13,14]

The phrase *getting long in the tooth* expresses a widespread belief that age is inevitably associated with an increased loss of connective tissue attachment. However, this observation may equally well reflect cumulative exposure to a number of potentially destructive processes. These exposures may include plaque-associated periodontitis, chronic mechanical trauma from toothbrushing, and iatrogenic damage from unfavorable restorative dentistry or repeated scaling and root planing. The effects of these exposures act in one direction only (i.e., an increased loss of attachment).[52]

In an attempt to differentiate the effects of age from these other processes, several studies have been designed to eliminate confounding issues and to address more clearly the question of age as a risk factor for periodontitis. A *risk factor* is defined as "any characteristic, behavior, or exposure with an association to a particular disease. The relationship is not necessarily causal in nature. … Some risk factors, if causal, can be modified to reduce one's risk of initiation or progression of disease, such as smoking or improved oral hygiene … while other factors cannot be modified, such as genetic factors."[15] The conclusions from these studies are strikingly consistent and show that the effect of age is either nonexistent or provides a small and clinically insignificant increased risk of loss of periodontal support.[10,27,35,39,40] Indeed, in comparison with the odds ratio of 20.52 for poor oral hygiene status and periodontitis, the odds ratio for age was only 1.24,[1] and smoking was much more influential than age.[35] Therefore, age has been suggested to be not a true risk factor but rather a background or associated factor for periodontitis.[39] In addition, the clarification of a genetic basis for susceptibility to severe forms of periodontitis underlines the overriding importance of plaque, smoking, and susceptibility in explaining most of the variations in periodontal disease severity among individuals.[24] Nevertheless, a longitudinal study of essentially untreated periodontitis in an elderly (≥70 years old) Japanese population indicated that 296 of 394 individuals (75%) had a least one site with 3 mm or more loss of attachment over a 2-year period.[36] Smoking and a baseline attachment level of 6 mm or more were significantly associated with disease progression.

Aging and the Response to Treatment of the Periodontium

The successful treatment of periodontitis requires both meticulous home plaque control by the patient and meticulous supragingival and subgingival debridement by the therapist.[33] Unfortunately, only a few studies have directly compared such an approach among patients of different age groups. The few studies that have done so clearly demonstrate that, despite the histologic changes in the periodontium with aging, no differences in response to nonsurgical or surgical treatment have been shown for periodontitis.[5,26,53] However, if plaque control is not ideal, the continued loss of attachment is inevitable. Furthermore, without effective periodontal therapy, the

progression of disease may be faster with increasing age.[41] Attempts to increase plaque control by chemical means have also been reported.[48]

A purely biologic or physiologic review indicates that aging has some impact on the structure and function of the periodontium as well as on the immune response and the nature of either supragingival or subgingival plaque. However, these changes have a negligible impact on an individual's responsiveness to treatment. Aging may affect other aspects of the management of periodontal health (e.g., the risk of root caries[44]; see Chapter 39), and the resulting difficulties should not be underestimated. Interestingly, a recent study has identified greater compliance with supportive maintenance among older individuals as compared with younger patients.[37]

Suggested Readings

Amler MH, Amler MH: Age factor in human alveolar bone repair. *J Oral Implantol* 19:138–142, 1993.

Benatti BB, Silvqrio KG, Casati MZ, et al: Inflammatory and bone-related genes are modulated by aging in human periodontal ligament cells. *Cytokine* 46:176–181, 2009.

Bryant SR, Zarb GA, Bryant SR, et al: Osseointegration of oral implants in older and younger adults. *Int J Oral Maxillofac Implants* 13:492–499, 1998.

Burt BA, Burt BA: Periodontitis and aging: reviewing recent evidence. *J Am Dent Assoc* 125:273–279, 1994.

Chung HY, Lee EK, Choi YJ, et al: Molecular inflammation as an underlying mechanism of the aging process and age-related diseases. *J Dent Res* 90:830–840, 2011.

Garcia RI, Nunn ME, Dietrich T: Risk calculation and periodontal outcomes. *Periodontol 2000* 50:65–77, 2009.

Hajishengallis G: Too old to fight? Aging and its toll on innate immunity. *Mol Oral Microbiol* 25:25–37, 2010.

Needleman I, Suvan J, Moles DR, et al: A systematic review of professional mechanical plaque removal for prevention of periodontal diseases. *J Clin Periodontol* 32(Suppl 6):229–282, 2005.

Newman MG, Grinenco V, Weiner M, et al: Predominant microbiota associated with periodontal health in the aged. *J Periodontol* 49:553–559, 1978.

Ostan R, Bucci L, Capri M, et al: Immunosenescence and immunogenetics of human longevity. *Neuroimmunomodulation* 15:224–240, 2008.

References

References for this chapter are found on the companion website www.expertconsult.com.

References

1. Abdellatif HM, Burt BA, Abdellatif HM, et al: An epidemiological investigation into the relative importance of age and oral hygiene status as determinants of periodontitis. *J Dent Res* 66:13–18, 1987.
2. Ainamo A, Ainamo J, Poikkeus R, et al: Continuous widening of the band of attached gingiva from 23 to 65 years of age. *J Periodontal Res* 16:595–599, 1981.
3. Ainamo J, Talari A, Ainamo J, et al: The increase with age of the width of attached gingiva. *J Periodontal Res* 11:182–188, 1976.
4. Amler MH, Amler MH: Age factor in human alveolar bone repair. *J Oral Implantol* 19:138–142, 1993.
5. Axelsson P, Lindhe J, Nystrom B, et al: On the prevention of caries and periodontal disease. Results of a 15-year longitudinal study in adults. *J Clin Periodontol* 18:182–189, 1991.
6. Baker DL, Seymour GJ, Baker DL, et al: The possible pathogenesis of gingival recession. A histological study of induced recession in the rat. *J Clin Periodontol* 3:208–219, 1976.
7. Benatti BB, Silvqrio KG, Casati MZ, et al: J. Inflammatory and bone-related genes are modulated by aging in human periodontal ligament cells. *Cytokine* 46:176–181, 2009.
8. Berglundh T, Lindhe J, Sterrett JD, et al: Clinical and structural characteristics of periodontal tissues in young and old dogs. *J Clin Periodontol* 18:616–623, 1991.
9. Bryant SR, Zarb GA, Bryant SR, et al: Osseointegration of oral implants in older and younger adults. *Int J Oral Maxillofac Implants* 13:492–499, 1998.
10. Burt BA, Burt BA: Periodontitis and aging: reviewing recent evidence. *J Am Dent Assoc* 125:273–279, 1994.
11. Chapple IL: Potential mechanisms underpinning the nutritional modulation of periodontal inflammation. *J Am Dent Assoc* 140:178–184, 2009.
12. Chung HY, Lee EK, Choi YJ, et al: Molecular inflammation as an underlying mechanism of the aging process and age-related diseases. *J Dent Res* 90:830–840, 2011.
13. Fransson C, Berglundh T, Lindhe J, et al: The effect of age on the development of gingivitis. Clinical, microbiological and histological findings. *J Clin Periodontol* 23:379–385, 1996.
14. Fransson C, Mooney J, Kinane DF, et al: Differences in the inflammatory response in young and old human subjects during the course of experimental gingivitis. *J Clin Periodontol* 26:453–460, 1999.
15. Garcia RI, Nunn ME, Dietrich T: Risk calculation and periodontal outcomes. *Periodontol 2000* 50:65–77, 2009.
16. Geusens PP, Landewe RB, Garnero P, et al: The ratio of circulating osteoprotegerin to RANKL in early rheumatoid arthritis predicts later joint destruction. *Arthritis Rheum* 54:1772–1777, 2006.
17. Gonzalez OA, Stromberg AJ, Huggins PM, et al: Apoptotic genes are differentially expressed in aged gingival tissue. *J Dent Res* 90:880–886, 2011.
18. Grant D, Bernick S, Grant D, et al: The periodontium of ageing humans. *J Periodontol* 43:660–667, 1972.
19. Hajishengallis G: Too old to fight? Aging and its toll on innate immunity. *Mol Oral Microbiol* 25:25–37, 2010.
20. Holm-Pedersen P, Agerbaek N, Theilade E, et al: Experimental gingivitis in young and elderly individuals. *J Clin Periodontol* 2:14–24, 1975.
21. Jeffcoat MK, Jeffcoat MK: Osteoporosis: a possible modifying factor in oral bone loss. *Ann Periodontol* 3:312–321, 1998.
22. Karring T, Loe H, Karring T, et al: A computerized method for quantitative estimation of the epithelium-connective tissue interface applied to the gingiva of various age groups. *Acta Odontol Scand* 31:241–248, 1973.
23. Kay MMB: Immunology and ageing. In Holm-Pedersen P, editor: *Textbook of geriatric dentistry*, ed 2, Copenhagen, Denmark, 1996, Blackwell-Wiley.
24. Kinane DF, Shiba H, Hart TC: The genetic basis of periodontitis. *Periodontol 2000* 39:91–117, 2005.
25. Lindhe J, Hamp SE, Loe H, et al: Plaque induced periodontal disease in beagle dogs. A 4-year clinical, roentgenographical and histometrical study. *J Periodontal Res* 10:243–255, 1975.
26. Lindhe J, Socransky S, Nyman S, et al: Effect of age on healing following periodontal therapy. *J Clin Periodontol* 12:774–787, 1985.
27. Locker D, Slade GD, Murray H, et al: Epidemiology of periodontal disease among older adults: a review. *Periodontol 2000* 16:16–33, 1998.
28. Loe H, Theilade E, Jensen SB: Experimental gingivitis in man. *J Periodontol* 36:177, 1965.
29. Mackenzie IC, Holm-Pedersen P, Karring T: Age changes in the oral mucous membranes and periodontium. In Holm-Pedersen P, editor: *Textbook of geriatric dentistry*, ed 2, Copenhagen, Denmark, 1996, Wiley-Blackwell.
30. McArthur WP: Effect of aging on immunocompetent and inflammatory cells. *Periodontol 2000* 16:53–79, 1998.
31. Mente A, de Koning L, Shannon HS, et al: A systematic review of the evidence supporting a causal link between dietary factors and coronary heart disease. *Arch Intern Med* 169:659–669, 2009.
32. Mombelli A: Aging and the periodontal and peri-implant microbiota. *Periodontol 2000* 16:44–52, 1998.
33. Needleman I, Suvan J, Moles DR, et al: A systematic review of professional mechanical plaque removal for prevention of periodontal diseases. *J Clin Periodontol* 32(Suppl 6):229–282, 2005.
34. Newman MG, Grinenco V, Weiner M, et al: Predominant microbiota associated with periodontal health in the aged. *J Periodontol* 49:553–559, 1978.
35. Norderyd O, Hugoson A, Grusovin G: Risk of severe periodontal disease in a Swedish adult population. A longitudinal study. *J Clin Periodontol* 26:608–615, 1999.
36. Ogawa H, Yoshihara A, Hirotomi T, et al: Risk factors for periodontal disease progression among elderly people. *J Clin Periodontol* 29:592–597, 2002.
37. Ojima M, Hanioka T, Shizukuishi S: Survival analysis for degree of compliance with supportive periodontal therapy. *J Clin Periodontol* 28:1091–1095, 2001.
38. Ostan R, Bucci L, Capri M, et al: Immunosenescence and immunogenetics of human longevity. *Neuroimmunomodulation* 15:224–240, 2008.
39. Page RC, Beck JD: Risk assessment for periodontal diseases. *Int Dent J* 47:61–87, 1997.
40. Papapanou PN, Lindhe J, Sterrett JD, et al: Considerations on the contribution of ageing to loss of periodontal tissue support. *J Clin Periodontol* 18:611–615, 1991.
41. Papapanou PN, Wennstrom JL, Grondahl K: A 10-year retrospective study of periodontal disease progression. *J Clin Periodontol* 16:403–411, 1989.
42. Persson GR, Yeates J, Persson RE, et al: The impact of a low-frequency chlorhexidine rinsing schedule on the subgingival microbiota (the TEETH clinical trial). *J Periodontol* 78:1751–1758, 2007.
43. Ramos AM, Pellanda LC, Gus I, et al: Inflammatory markers of cardiovascular disease in the elderly. *Arq Bras Cardiol* 92:221–234, 2009.
44. Reiker J, van der Velden U, Barendregt DS, et al: A cross-sectional study into the prevalence of root caries in periodontal maintenance patients. *J Clin Periodontol* 26:26–32, 1999.
45. Schwartz Z, Somers A, Mellonig JT, et al: Ability of commercial demineralized freeze-dried bone allograft to induce new bone formation is dependent on donor age but not gender. *J Periodontol* 69:470–478, 1998.
46. Shklar G: The effects of aging upon oral mucosa. *J Invest Dermatol* 47:115–120, 1966.
47. Simon L, Gauvin F, Amre DK, et al: Serum procalcitonin and C-reactive protein levels as markers of bacterial infection: a systematic review and meta-analysis. *Clin Infect Dis* 39:206–217, 2004.
48. Simons D, Brailsford S, Kidd EA, et al: The effect of chlorhexidine acetate/xylitol chewing gum on the plaque and gingival indices of elderly occupants in residential homes. *J Clin Periodontol* 28:1010–1015, 2001.
49. Slots J, Feik D, Rams TE: Age and sex relationships of superinfecting microorganisms in periodontitis patients. *Oral Microbiol Immunol* 5:305–308, 1990.

50. Swoboda JR, Kiyak HA, Darveau R, et al: Correlates of periodontal decline and biologic markers in older adults. *J Periodontol* 79:1920–1926, 2008.
51. Van der Velden U: Effect of age on the periodontium. *J Clin Periodontol* 11:281–294, 1984.
52. American Academy of Periodontology: *Epidemiology of periodontal disease—review of the literature*, Ann Arbor, MI, 1966, American Academy of Periodontology.
53. Wennstrom JL: Treatment of periodontal disease in older adults. *Periodontol 2000* 16:106–112, 1998.
54. Wentz FM, Maier AW, Orban B: Age changes and sex differences in the clinically 'normal' gingiva. *J Periodontol* 23:13, 1952.
55. Winkel EG, Abbas F, Van der Velden U, et al: Experimental gingivitis in relation to age in individuals not susceptible to periodontal destruction. *J Clin Periodontol* 14:499–507, 1987.
56. Yu YH, Kuo HK, Lai YL: The association between serum folate levels and periodontal disease in older adults: data from the National Health and Nutrition Examination Survey 2001/02. *J Am Geriatr Soc* 55:108–113, 2007.

CHAPTER 3

Classification of Diseases and Conditions Affecting the Periodontium

James E. Hinrichs and Georgios Kotsakis

CHAPTER OUTLINE

Gingival Diseases
Periodontitis
Necrotizing Periodontal Diseases
Abscesses of the Periodontium
Periodontitis Associated with Endodontic Lesions
Developmental or Acquired Deformities and Conditions

For an expanded discussion of periodontitis as a manifestation of systemic diseases, please visit the companion website at www.expertconsult.com. Some figures may be out of numeric order in this printed chapter.

Our understanding of the causes and pathogenesis of oral diseases and conditions is continually changing with increased scientific knowledge. In light of this, a classification can be most consistently defined by the differences in the clinical manifestations of diseases and conditions: they are clinically consistent and require little (if any) clarification by scientific laboratory testing. The classification presented in this chapter is based on the most recent internationally accepted consensus opinions of the diseases and conditions that affect the tissues of the periodontium; it was presented and discussed at the 1999 International Workshop for the Classification of the Periodontal Diseases organized by the American Academy of Periodontology (AAP).[5] Box 3-1 presents the overall classification system, and each disease or condition is discussed where clarification is needed. In each case, the reader is referred to pertinent reviews on the subject and specific chapters within this book that discuss the topics in more detail.

Gingival Diseases

Dental-Plaque–Induced Gingival Diseases

Gingivitis that is associated with dental plaque formation is the most common form of gingival disease (Figure 3-1). Box 3-2 outlines the classifications of gingival diseases. The epidemiology of gingival disease is reviewed in Chapter 4, and its causes are discussed in greater detail in Chapters 5 through 13 and elsewhere in this textbook.[15,23,26,39,40] Gingivitis has been previously characterized by the presence of clinical signs of inflammation that are confined to the gingiva and associated with teeth showing no attachment loss. Gingivitis has also been observed to affect the gingiva of periodontitis-affected teeth that have previously lost attachment but that have received periodontal therapy to stabilize any further attachment loss. In these treated cases, plaque-induced gingival inflammation may recur but without any evidence of further attachment loss.

From this evidence, it has been concluded that plaque-induced gingivitis may occur on a periodontium with no attachment loss or on a periodontium with previous attachment loss that is stable and not progressing. This implies that gingivitis may be the diagnosis for inflamed gingival tissues associated with a tooth with no previous attachment loss or with a tooth that has previously undergone attachment and bone loss (i.e., with reduced periodontal support) but that is not currently losing attachment or bone, even though gingival inflammation is present (Figure 3-2). For this diagnosis to be made, longitudinal records of periodontal status, including clinical attachment levels, should be available.

Gingivitis Associated with Dental Plaque Only. Plaque-induced gingival disease is the result of an interaction between the microorganisms found in the dental plaque biofilm and the tissues and inflammatory cells of the host. The plaque–host interaction can be altered by the effects of local factors, systemic factors, medications, and malnutrition, all of which can influence the severity and duration of the response. Local factors may contribute to gingivitis formation in addition to plaque-retentive calculus formation on crown and root surfaces (see Chapter 7). These factors are contributory because of their ability to retain plaque microorganisms and to inhibit the removal of those microorganisms via patient-initiated plaque-control techniques.

Gingival Diseases Modified by Systemic Factors. Systemic factors that contribute to gingivitis—such as the endocrine changes associated with puberty (Figure 3-3), the menstrual cycle, pregnancy (Figure 3-4, *A*), and diabetes—may be exacerbated as a result of alterations in the gingival inflammatory response to plaque.[23,25,39] This altered response appears to result from the effects of systemic conditions on the host's cellular and immunologic functions. These changes are most apparent during pregnancy, when the prevalence and severity of gingival inflammation

BOX 3-1 Classification of Periodontal Diseases and Conditions

Gingival Diseases
Plaque-induced gingival diseases*
Non–plaque-induced gingival lesions

Chronic Periodontitis†
Localized
Generalized

Aggressive Periodontitis
Localized
Generalized

Periodontitis as a Manifestation of Systemic Disease

Necrotizing Periodontal Diseases
Necrotizing ulcerative gingivitis
Necrotizing ulcerative periodontitis

Abscesses of the Periodontium
Gingival abscess
Periodontal abscess
Pericoronal abscess

Periodontitis Associated With Endodontic Lesions
Endodontic–periodontal lesion
Periodontal–endodontic lesion
Combined lesion

Developmental or Acquired Deformities and Conditions
Localized tooth-related factors that predispose an individual to plaque-induced gingival diseases or periodontitis
Mucogingival deformities and conditions around the teeth
Mucogingival deformities and conditions on edentulous ridges
Occlusal trauma

*These diseases may occur on a periodontium with no attachment loss or on a periodontium with attachment loss that is stable and not progressing.

†Chronic periodontitis can be further classified on the basis of its extent and severity. As a general guide, extent can be characterized as localized (<30% of sites involved) or generalized (>30% of sites involved). Severity can be characterized on the basis of the amount of clinical attachment loss (CAL) as follows: slight, 1 or 2 mm CAL; moderate, 3 or 4 mm CAL; and severe, ≥5 mm CAL.

Data from Armitage GC: *Ann Periodontol* 4:1, 1999.

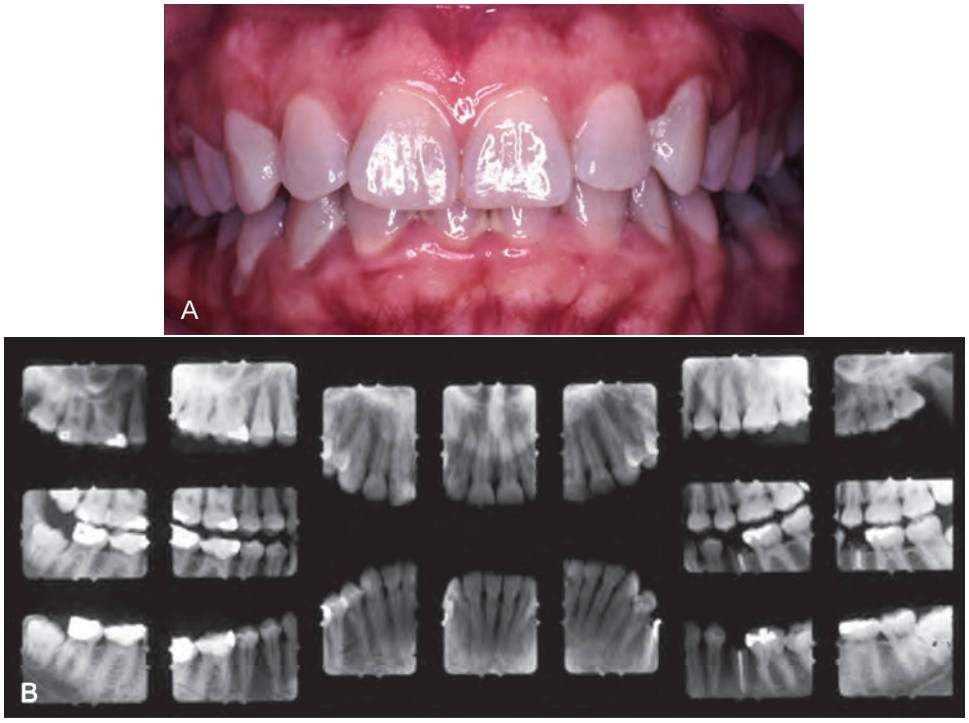

Figure 3-1 **A,** Plaque-related gingivitis and marginal and papillary inflammation, with 1- to 4-mm probing depths and generalized zero clinical attachment loss, except for the recession seen with tooth #28. **B,** Radiographic images of the patient.

may increase, even in the presence of low levels of plaque. Blood dyscrasias (e.g., leukemia) may alter immune function by disturbing the normal balance of the immunologically competent white blood cells that supply the periodontium. Gingival enlargement and bleeding are common findings that may be associated with the swollen, spongy gingival tissues caused by the excessive infiltration of blood cells (Figure 3-5).

Gingival Diseases Modified by Medications. Gingival diseases that are modified by medications are increasingly prevalent as a result of the increased use of drugs known to induce gingival enlargement. These include anticonvulsant drugs such as phenytoin, immunosuppressive drugs such as cyclosporine (Figure 3-6), and calcium channel blockers such as nifedipine (Figure 3-7), verapamil, diltiazem, and sodium valproate.[15,26,39]

BOX 3-2 Gingival Diseases

Dental-Plaque–Induced Gingival Diseases

These diseases may occur on a periodontium with no attachment loss or on a periodontium with attachment loss that is stable and not progressing.

I. Gingivitis associated with dental plaque only
   A. Without local contributing factors
   B. With local contributing factors (see Box 3-4)
II. Gingival diseases modified by systemic factors
   A. Associated with the endocrine system
      1. Puberty-associated gingivitis
      2. Menstrual-cycle–associated gingivitis
      3. Pregnancy-associated conditions
         a. Gingivitis
         b. Pyogenic granuloma
      4. Diabetes-mellitus–associated gingivitis
   B. Associated with blood dyscrasias
      1. Leukemia-associated gingivitis
      2. Other
III. Gingival diseases modified by medications
   A. Drug-influenced gingival diseases
      1. Drug-influenced gingival enlargements
      2. Drug-influenced gingivitis
         a. Oral-contraceptive–associated gingivitis
         b. Other
IV. Gingival diseases modified by malnutrition
   A. Ascorbic-acid–deficiency gingivitis
   B. Other

Non–Plaque-Induced Gingival Lesions

I. Gingival diseases of specific bacterial origin
   A. *Neisseria gonorrhoeae*
   B. *Treponema pallidum*
   C. *Streptococcus* species
   D. Other
II. Gingival diseases of viral origin
   A. Herpesvirus infections
      1. Primary herpetic gingivostomatitis
      2. Recurrent oral herpes
      3. Varicella zoster
   B. Other
III. Gingival diseases of fungal origin
   A. *Candida* species infections: generalized gingival candidiasis
   B. Linear gingival erythema
   C. Histoplasmosis
   D. Other
IV. Gingival lesions of genetic origin
   A. Hereditary gingival fibromatosis
   B. Other
V. Gingival manifestations of systemic conditions
   A. Mucocutaneous lesions
      1. Lichen planus
      2. Pemphigoid
      3. Pemphigus vulgaris
      4. Erythema multiforme
      5. Lupus erythematosus
      6. Drug-induced conditions
      7. Other
   B. Allergic reactions
      1. Dental restorative materials
         a. Mercury
         b. Nickel
         c. Acrylic
         d. Other
      2. Reactions attributable to the following:
         a. Toothpastes or dentifrices
         b. Mouth rinses or mouthwashes
         c. Chewing-gum additives
         d. Foods and additives
      3. Other
VI. Traumatic lesions (factitious, iatrogenic, or accidental)
   A. Chemical injury
   B. Physical injury
   C. Thermal injury
VII. Foreign-body reactions
VIII. Not otherwise specified

Data from Holmstrup P: *Ann Periodontol* 4:20, 1999; and Mariotti A: *Ann Periodontol* 4:7, 1999.

The development and severity of gingival enlargement in response to medications are patient specific and may be influenced by uncontrolled plaque accumulation as well as by elevated hormonal levels. The increased use of oral contraceptives by premenopausal women has been associated with a higher incidence of gingival inflammation and the development of gingival enlargement, which may be reversed by discontinuation of the oral contraceptive.

Gingival Diseases Modified by Malnutrition. Gingival diseases modified by malnutrition have received attention because of clinical descriptions of bright red, swollen, and bleeding gingiva associated with severe ascorbic acid (vitamin C) deficiency or scurvy.[26] Nutritional deficiencies are known to affect immune function, and they may alter the host's ability to protect himself or herself against some of the detrimental effects of cellular products such as oxygen radicals. Unfortunately, little scientific evidence is available to support a role for specific nutritional deficiencies in the development or severity of gingival inflammation or periodontitis in humans.

Non–Plaque-Induced Gingival Lesions

Oral manifestations of systemic conditions that produce lesions in the tissues of the periodontium are rare. These effects are observed more frequently among lower socioeconomic groups, in developing countries, and in immunocompromised individuals.[20] Benign mucous membrane pemphigoid is an example of a non–plaque-induced lesion without socioeconomic implications. Sloughing gingival tissues leave painful ulcerations of the gingiva (Figure 3-8, *A* and *B*). Autoimmune antibodies are targeted at the basement membrane and cleave it from the underlying connective tissue (Figure 3-8, *C* and *D*).

Gingival Diseases of Specific Bacterial Origin. Gingival diseases of specific bacterial origin are increasing in prevalence, especially as a result of sexually transmitted diseases such as gonorrhea *(Neisseria gonorrhoeae)* and, to a lesser degree, syphilis *(Treponema pallidum)*.[41,46] Oral lesions may be a result of systemic infection, or they may occur through direct infection. Streptococcal gingivitis or gingivostomatitis is a rare entity that may present as an acute condition with fever, malaise, and pain associated with acutely inflamed, diffuse, red, and swollen gingiva with increased bleeding and occasional gingival abscess formation. The gingival infections are usually preceded by tonsillitis, and they have been associated with group A β-hemolytic streptococcal infections.

Gingival Diseases of Viral Origin. Gingival diseases of viral origin may be caused by a variety of deoxyribonucleic acid and ribonucleic acid viruses, with the most common being the herpesviruses (Figure 3-9, *A* and *B*). Lesions are frequently related to the reactivation of latent viruses, especially as a result of reduced immune function. The oral manifestations of viral infection have been comprehensively reviewed.[20,45] Viral gingival diseases are treated with topical or systemic antiviral drugs (Figure 3-9, *C* and *D*).

Gingival Diseases of Fungal Origin. Gingival diseases of fungal origin are relatively uncommon in immunocompetent individuals, but they occur more frequently in immunocompromised individuals and in those with normal oral flora that has been disturbed by the long-term use of broad-spectrum antibiotics.[20,46,47] The most common oral fungal infection is candidiasis, which is caused by infection with *Candida albicans;* it can also be seen under prosthetic devices, in individuals using topical steroids, and in individuals with decreased salivary flow, increased salivary glucose, or decreased salivary pH. A generalized candidal infection may manifest as white patches on the gingiva, tongue, or oral mucous membrane that can be removed with gauze and that leave

Figure 3-2 The maxillary second molar exhibits mild inflammation at the mesial–palatal surface. However, the clinical attachment loss has been stable for 15 years after the placement of an apically positioned flap and periodontal maintenance. The diagnosis is a history of moderate periodontitis, but the case is in remission.

Figure 3-3 A 13-year-old girl with hormone-exaggerated marginal and papillary inflammation, with 1- to 4-mm probing depths yet minimal clinical attachment loss. **A,** Facial view. **B,** Lingual view.

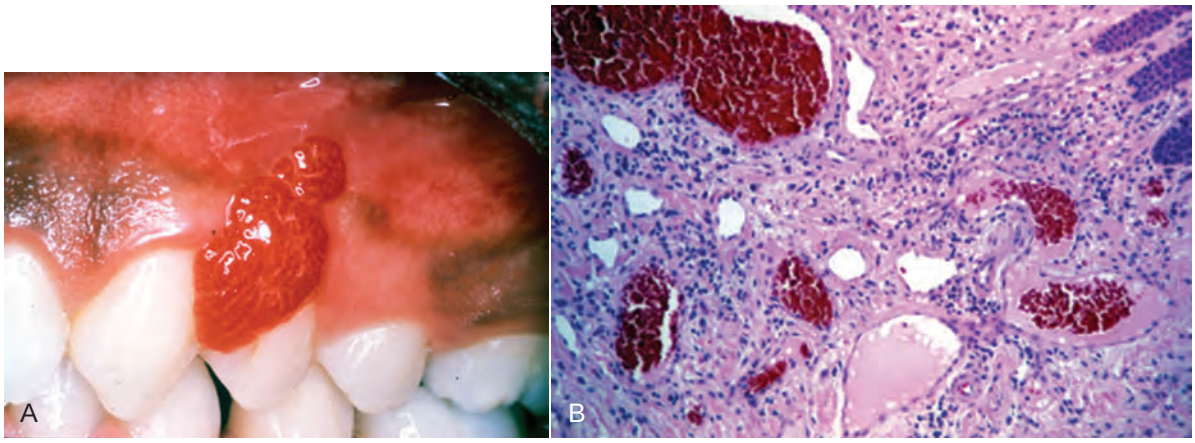

Figure 3-4 **A,** Clinical image of pyogenic granuloma in 27-year-old pregnant woman. **B,** A histologic image depicts dense inflammatory infiltrate and prominent vessels.

a red, bleeding surface. In individuals with human immunodeficiency virus (HIV), candidal infection may present as erythema of the attached gingiva; this has been referred to as *linear gingival erythema* or *HIV-associated gingivitis* (see Chapter 26).

The diagnosis of candidal infection can be made by culture, smear, or biopsy. Less common fungal infections have also been described.[46,47]

Figure 3-5 A 12-year-old girl with a primary medical diagnosis of leukemia who exhibits swollen and spongy gingiva.

Gingival Diseases of Genetic Origin. Gingival diseases of genetic origin may involve the tissues of the periodontium and have been described in detail.[2] One of the most clinically evident conditions is *hereditary gingival fibromatosis,* which exhibits autosomal-dominant or (rarely) autosomal-recessive modes of inheritance. The gingival enlargement may completely cover the teeth, delay eruption, and present as an isolated finding; alternatively, it may be associated with several more generalized syndromes.

Gingival Manifestations of Systemic Conditions. Gingival manifestations of systemic conditions may appear as desquamative lesions, ulcerations of the gingiva, or both.[20,38,46] Allergic reactions that manifest with gingival changes are uncommon but have been observed in association with several restorative materials (Figure 3-10, *A*), toothpastes, mouthwashes, chewing gums (Figure 3-11), and foods (see Box 3-2). The diagnosis of these conditions may prove difficult and may require an extensive history and the selective elimination of potential causes. Histologic traits of biopsies from gingival allergic reactions include a dense infiltrate of eosinophilic cells (Figure 3-10, *B* and *C*).

Traumatic Lesions. Traumatic lesions may be self-inflicted and *factitious* in origin, which means that they are produced by intentional or unintentional artificial means (Figure 3-12). Other

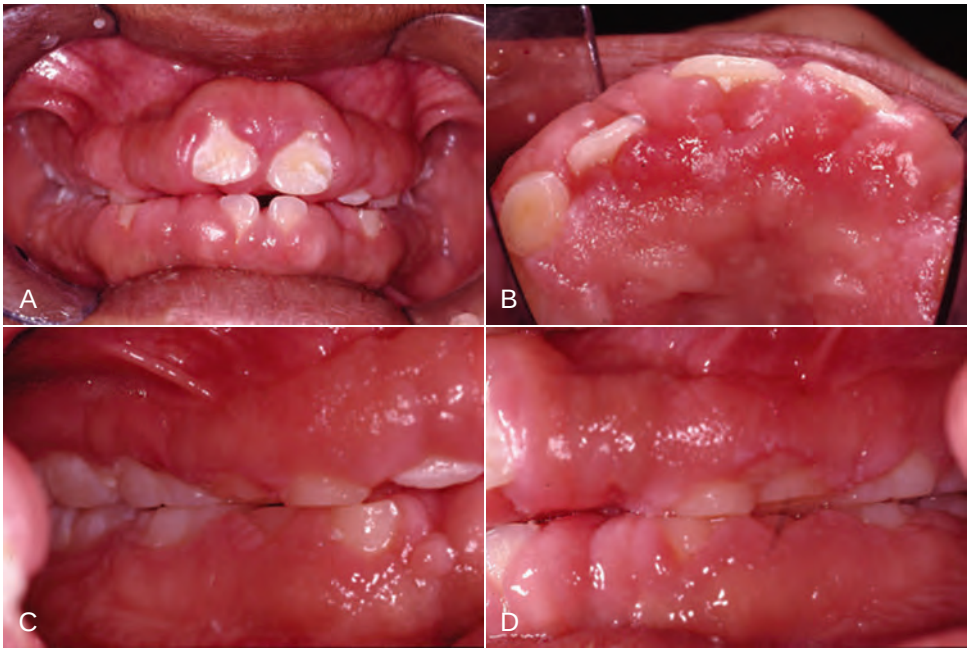

Figure 3-6 Clinical images of a 9-year-old boy with severe gingival overgrowth as a result of a heart transplant and cyclosporine therapy.

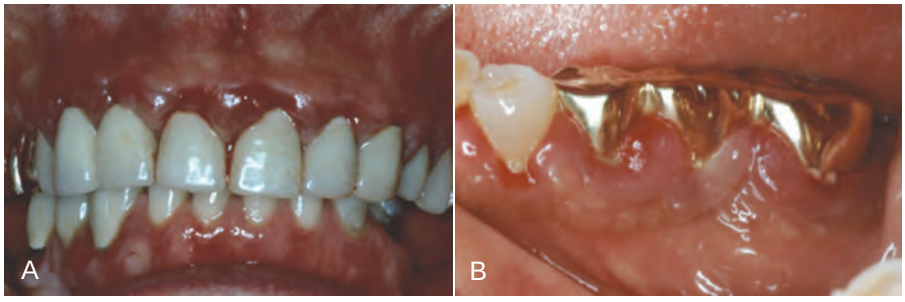

Figure 3-7 Clinical images of gingival overgrowth after the use a of calcium channel blocker to control hypertension.

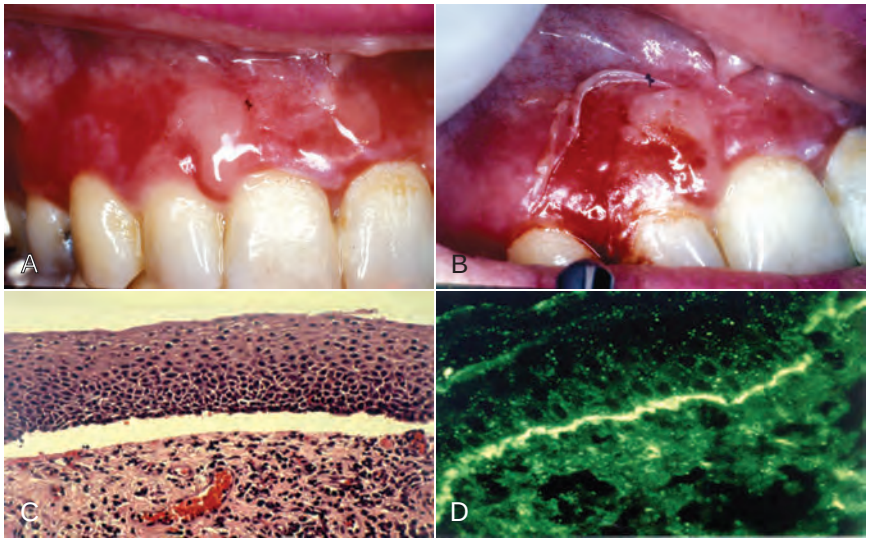

Figure 3-8 A 62-year-old woman with benign mucous membrane pemphigoid. **A** and **B,** Clinical images with sloughing of the epithelial surface. **C,** Hematoxylin-eosin stain depicting the separation of the epithelium from the connective tissue. **D,** Immunofluorescent-labeled antibodies in the basement membrane.

Figure 3-9 **A** and **B,** A 29-year-old man with primary herpetic infection and severe gingival inflammation. **C** and **D,** Six weeks after treatment with systemic acyclovir.

examples of traumatic lesions include toothbrush trauma that results in gingival ulceration, recession, or both. *Iatrogenic trauma* (i.e., induced by the dentist or health professional) to the gingiva can be caused by the induction of orthodontic cement or preventive or restorative materials (Figure 3-13, *A*). Peripheral ossifying fibroma may develop in response to the embedment of a foreign body (Figure 3-13, *B* and *C*). Alternatively, *accidental damage* to the gingiva may occur as a result of minor burns from hot foods and drinks.[20]

Foreign-Body Reactions. Foreign-body reactions lead to localized inflammatory conditions of the gingiva and are caused by the introduction of foreign material into the gingival connective tissues through breaks in the epithelium.[20] Common examples are the introduction of amalgam into the gingiva during the placement of a restoration, the extraction of a tooth, or an endodontic apicoectomy with retrofill leaving an amalgam tattoo (Figure 3-14, *A*), with resultant metal fragments observed during biopsies (Figure 3-14, *B*); abrasives may also be introduced during polishing procedures.

Periodontitis

Periodontitis is defined as "an inflammatory disease of the supporting tissues of the teeth caused by specific microorganisms or

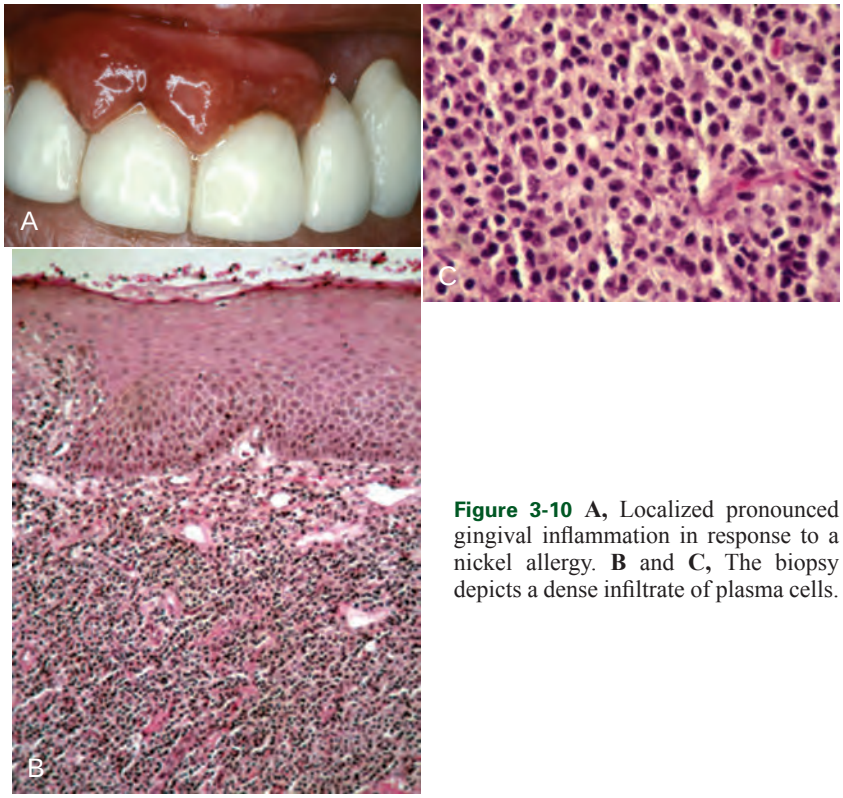

Figure 3-10 **A,** Localized pronounced gingival inflammation in response to a nickel allergy. **B** and **C,** The biopsy depicts a dense infiltrate of plasma cells.

Figure 3-11 A generalized severe allergic response of the gingiva in response to an additive in chewing gum.

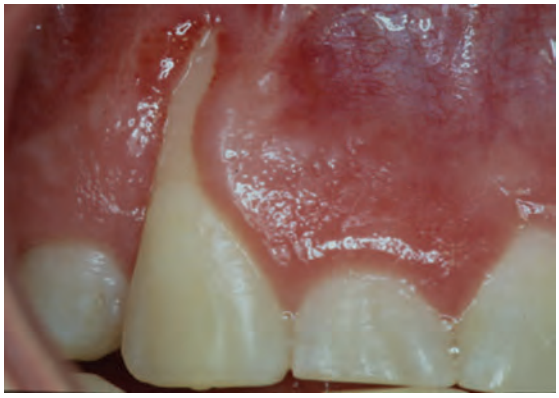

Figure 3-12 Self-inflicted gingival dehiscence induced via the patient's fingernail.

groups of specific microorganisms, resulting in progressive destruction of the periodontal ligament and alveolar bone with increased probing depth formation, recession, or both." The clinical feature that distinguishes periodontitis from gingivitis is the presence of clinically detectable attachment loss. This loss is often accompanied by periodontal pocket formation and changes in the density and height of the subjacent alveolar bone. In some cases, recession of the marginal gingiva may accompany attachment loss, thereby masking ongoing disease progression if only probing depth measurements are taken without measurements of clinical attachment levels. Clinical signs of inflammation—such as changes in color, contour, and consistency as well as bleeding with probing—may not always be positive indicators of ongoing attachment loss. However, the presence of continued bleeding with probing during sequential visits has proved to be a reliable indicator of the presence of inflammation and the potential for subsequent attachment loss at the bleeding site. The attachment loss associated with periodontitis has been shown to progress either continuously or in episodic bursts of disease activity.

Although many classifications of the different clinical manifestations of periodontitis have been presented over the past 20 years, consensus workshops in North America in 1989[8] and in Europe in 1993[6] identified that periodontitis may present in early-onset, adult-onset, and necrotizing forms (Table 3-1). In addition, the AAP consensus concluded that periodontitis may be associated with systemic conditions (e.g., diabetes, HIV) and that some forms of periodontitis may be refractory to conventional therapy. Early-onset disease was distinguished from adult-onset disease by the age of onset (35 years of age was set as an arbitrary separation of diseases), the rate of disease progression, and the presence of alterations in host defenses. The early-onset diseases were more aggressive, occurred in individuals younger than 35 years old, and were associated with defects in host defenses; alternatively, adult

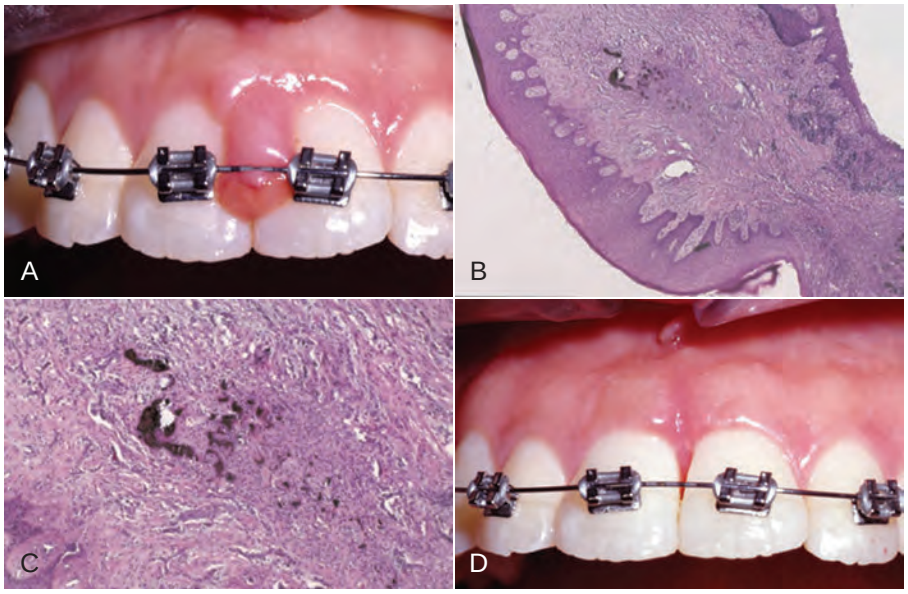

Figure 3-13 **A,** Proliferative gingival overgrowth as a result of the impaction of foreign body. **B,** Histology of peripheral ossifying fibroma. **C,** Higher magnification of the image shown in **B**. **D,** Four weeks after excisional biopsy.

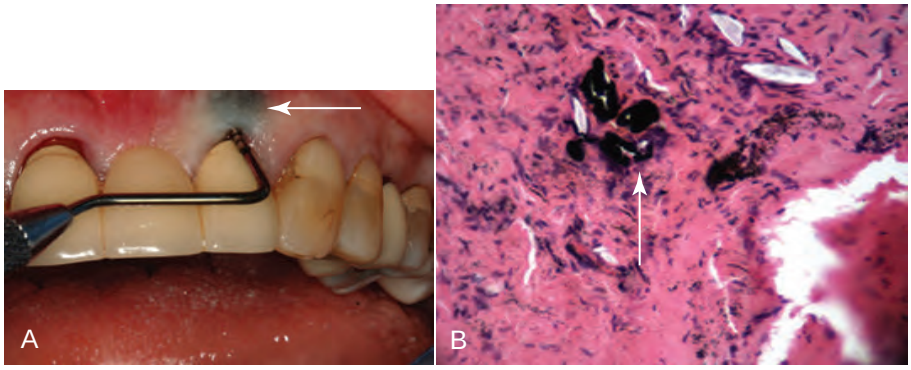

Figure 3-14 **A,** Gingival pigmentation associated with previous apicoectomy and amalgam retrofill. **B,** Biopsy depicting metal fragments.

forms of disease were slowly progressive, became clinically more evident during the fourth decade of life, and were not associated with defects in host defenses. In addition, early-onset periodontitis was subclassified into prepubertal, juvenile, and rapidly progressive forms with localized or generalized disease distributions.

Extensive clinical and basic scientific research involving these disease entities has been performed in many countries, and some disease characteristics that were outlined 10 years ago no longer stand up to rigid scientific scrutiny.[13,23,49] In particular, supporting evidence was lacking for the distinct classifications of adult periodontitis, refractory periodontitis, and the various different forms of early-onset periodontitis as outlined by the AAP Workshop for the International Classification of Periodontal Diseases in 1999[3] (see Table 3-1).

It has been observed that chronic periodontal destruction caused by the accumulation of local factors (e.g., plaque, calculus) can occur before the age of 35 years and that the aggressive disease seen in young patients may be independent of age and instead have a familial (genetic) association. With respect to refractory periodontitis, little evidence supports that this condition is indeed a distinct clinical entity; the causes of continued loss of clinical attachment and alveolar bone after periodontal therapy are currently poorly defined and apply to many disease entities. In addition, the clinical and causative manifestations of the different diseases outlined in North America in 1989 and in Europe in 1993 were not consistently observed in different countries around the world and did not always fit the models presented. As a result, the AAP held an International Workshop for the Classification of Periodontal Diseases in 1999 to further refine the classification system with the use of current clinical and scientific data.[5] The resulting classification of the different forms of periodontitis was simplified to describe three general clinical manifestations of periodontitis: chronic periodontitis, aggressive periodontitis, and periodontitis as a manifestation of systemic disease (see Table 3-1 and Box 3-3).

Chronic Periodontitis

Chronic periodontitis is the most common form of periodontitis[13]; Box 3-3 includes the characteristics of this form of periodontitis. Chronic periodontitis is most prevalent in adults, but it can also be observed in children; therefore, the age range of more than 35 years that had been previously designated for the classification of this

TABLE 3-1 Classification of the Various Forms of Periodontitis

Classification	Forms of Periodontitis	Disease Characteristics
American Academy of Periodontology World Workshop in Clinical Periodontics, 1989[5]	Adult periodontitis	Age of onset >35 years Slow rate of disease progression No defects in host defenses
	Early-onset periodontitis (may be prepubertal, juvenile, or rapidly progressive)	Age of onset <35 years Rapid rate of disease progression Defects in host defenses Associated with specific microflora
	Periodontitis associated with systemic disease	Systemic diseases that predispose to rapid rates of periodontitis Diseases: diabetes, Down syndrome, human immunodeficiency virus infection, Papillon–Lefèvre syndrome
	Necrotizing ulcerative periodontitis	Similar to acute necrotizing ulcerative gingivitis but with associated clinical attachment loss
	Refractory periodontitis	Recurrent periodontitis that does not respond to treatment
European Workshop in Periodontology, 1993[5]	Adult periodontitis	Age of onset: fourth decade of life Slow rate of disease progression No defects in host response
	Early-onset periodontitis	Age of onset <40 years Rapid rate of disease progression Defects in host defense
	Necrotizing periodontitis	Tissue necrosis with attachment and bone loss
American Academy of Periodontology International Workshop for Classification of Periodontal Diseases, 1999[4]	Chronic periodontitis; aggressive periodontitis; periodontitis as a manifestation of systemic disease	See Box 3-3

BOX 3-3 Periodontitis

The disease periodontitis can be subclassified into the following three major types on the basis of clinical, radiographic, historical, and laboratory characteristics.

Chronic Periodontitis

The following characteristics are common to patients with chronic periodontitis:

- Prevalent in adults but can occur in children
- Amount of destruction consistent with local factors
- Associated with a variable microbial pattern
- Subgingival calculus frequently found
- Slow to moderate rate of progression, with possible periods of rapid progression
- Possibly modified by or associated with the following:
  - Systemic diseases (e.g., diabetes mellitus, human immunodeficiency virus)
  - Local factors that predispose an individual to periodontitis
  - Environmental factors (e.g., cigarette smoking, emotional stress)

Chronic periodontitis may be further subclassified into localized and generalized forms and characterized as slight, moderate, or severe on the basis of the common features described previously and the following specific features:

- Localized form: <30% of sites involved
- Generalized form: >30% of sites involved
- Slight: 1 to 2 mm of clinical attachment loss
- Moderate: 3 to 4 mm of clinical attachment loss
- Severe: ≥5 mm of clinical attachment loss

Aggressive Periodontitis

The following characteristics are common to patients with aggressive periodontitis:

- Otherwise clinically healthy patient
- Rapid attachment loss and bone destruction
- Amount of microbial deposits inconsistent with disease severity
- Familial aggregation of diseased individuals

The following characteristics are common but not universal:

- Diseased sites infected with *Actinobacillus actinomycetemcomitans*
- Abnormalities in phagocyte function
- Hyperresponsive macrophages that produce increased levels of prostaglandin E_2 and interleukin-1β
- In some cases, self-arresting disease progression

Aggressive periodontitis may be further classified into localized and generalized forms on the basis of the common features described here and the following specific features:

Localized Form

- Circumpubertal onset of disease
- Localized first molar or incisor disease with proximal attachment loss on at least two permanent teeth, one of which is a first molar
- Robust serum antibody response to infecting agents

Continued

BOX 3-3 Periodontitis—cont'd

Generalized Form

- Usually (but not always) affects people who are <30 years old
- Generalized proximal attachment loss that affects at least three teeth other than the first molars and incisors
- Pronounced episodic nature of periodontal destruction
- Poor serum antibody response to infecting agents

Periodontitis as a Manifestation of Systemic Diseases

Periodontitis may be observed as a manifestation of the following systemic diseases:

1. Hematologic disorders
   a. Acquired neutropenia
   b. Leukemias
   c. Other
2. Genetic disorders
   a. Familial and cyclic neutropenia
   b. Down syndrome
   c. Leukocyte adhesion deficiency syndromes
   d. Papillon–Lefèvre syndrome
   e. Chédiak–Higashi syndrome
   f. Histiocytosis syndromes
   g. Glycogen storage disease
   h. Infantile genetic agranulocytosis
   i. Cohen syndrome
   j. Ehlers–Danlos syndrome (types IV and VIII, autosomal dominant)
   k. Hypophosphatasia
   l. Other
3. Not otherwise specified

Data from Flemmig TF: *Ann Periodontol* 4:32, 1999; Kinane DF: *Ann Periodontol* 4:54, 1999; and Tonetti MS, Mombelli A: *Ann Periodontol* 4:39, 1999.

BOX 3-4 Developmental or Acquired Deformities and Conditions

Localized Tooth-Related Factors That Modify or Predispose Individuals to Plaque-Induced Gingival Diseases or Periodontitis

1. Tooth anatomic factors
2. Dental restorations and appliances
3. Root fractures
4. Cervical root resorption and cemental tears

Mucogingival Deformities and Conditions Around the Teeth

1. Gingival or soft-tissue recession
   a. Facial or lingual surfaces
   b. Interproximal (papillary)
2. Lack of keratinized gingiva
3. Decreased vestibular depth
4. Aberrant frenum or muscle position
5. Gingival excess
   a. Pseudopocket
   b. Inconsistent gingival margin
   c. Excessive gingival display
   d. Gingival enlargement (see Box 3-2)
   e. Abnormal color

Mucogingival Deformities and Conditions of the Edentulous Edges

1. Vertical or horizontal ridge deficiency
2. Lack of gingiva or keratinized tissue
3. Gingival or soft-tissue enlargements
4. Aberrant frenum or muscle position
5. Decreased vestibular depth
6. Abnormal color

Occlusal Trauma

1. Primary occlusal trauma
2. Secondary occlusal trauma

Data from Blieden TM: *Ann Periodontol* 4:91, 1999; Halmon WW: *Ann Periodontol* 4:102, 1999; and Pini Prato GP: *Ann Periodontol* 4:98, 1999.

disease has been discarded. Chronic periodontitis is associated with the accumulation of plaque and calculus; it generally has a slow to moderate rate of disease progression, but periods of more rapid destruction may also be observed. Increases in the rate of disease progression may be caused by the impact of local, systemic, or environmental factors that may influence the normal host–bacteria interaction. Local factors may influence plaque accumulation (Box 3-4); systemic diseases (e.g., diabetes mellitus, HIV) may influence the host's defenses; and environmental factors (e.g., cigarette smoking, stress) may also influence the response of the host to plaque accumulation. Chronic periodontitis may occur as a localized disease in which less than 30% of evaluated sites demonstrate attachment and bone loss, or it may occur as a more generalized disease with which more than 30% of sites are affected. The disease may also be described by the severity of disease as either slight (1 to 2 mm of loss; Figure 3-15), moderate (3 to 4 mm of loss; Figure 3-16), or severe (≥5 of loss mm; Figure 3-17) on the basis of the amount of clinical attachment loss (see Box 3-3).

Aggressive Periodontitis

Aggressive periodontitis differs from the chronic form primarily by the rapid rate of disease progression seen in an otherwise healthy individual (Figures 3-18 and 3-19); the absence of large accumulations of plaque and calculus; and the presence of a family history of aggressive disease that is suggestive of a genetic trait[34,49] (see Box 3-3). This form of periodontitis was previously classified as early-onset periodontitis (see Table 3-1) and therefore still includes many of the characteristics previously identified with the localized and generalized forms of early-onset periodontitis. Although the clinical presentation of aggressive disease appears to be universal, the causative factors involved are not always consistent. Box 3-3 outlines additional clinical, microbiologic, and immunologic characteristics of aggressive disease that may be present. As was previously described for early-onset disease, aggressive forms of periodontitis usually affect young individuals during or shortly after puberty and may be observed during the second and third decades of life (i.e., 10 to 30 years of age). The disease may be localized

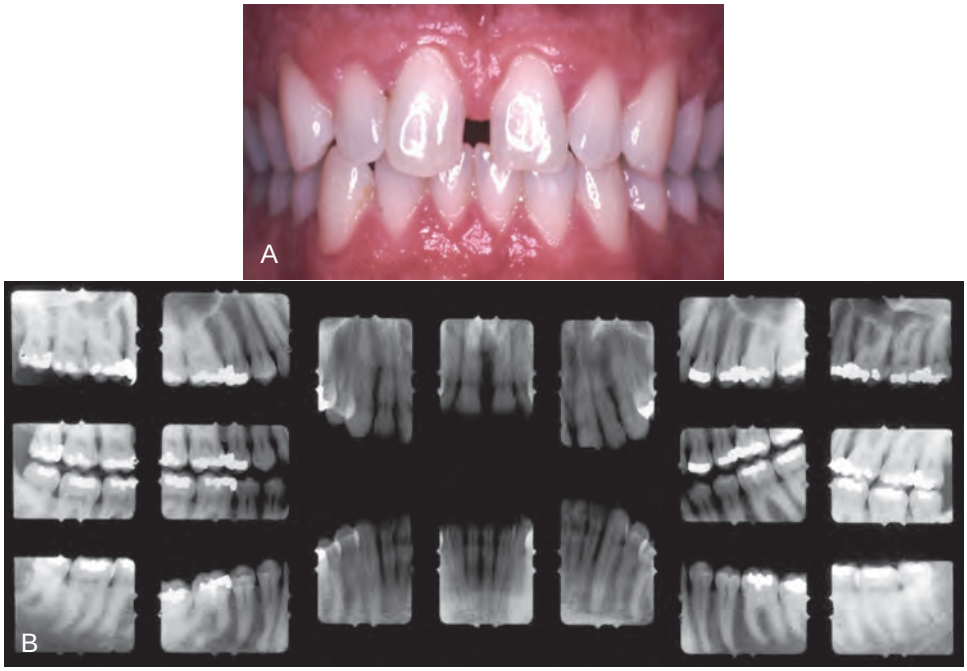

Figure 3-15 **A,** Clinical image of plaque-related slight early chronic periodontitis with 1 to 2 mm of clinical attachment loss in a 40-year-old woman. **B,** Radiographic images of the patient.

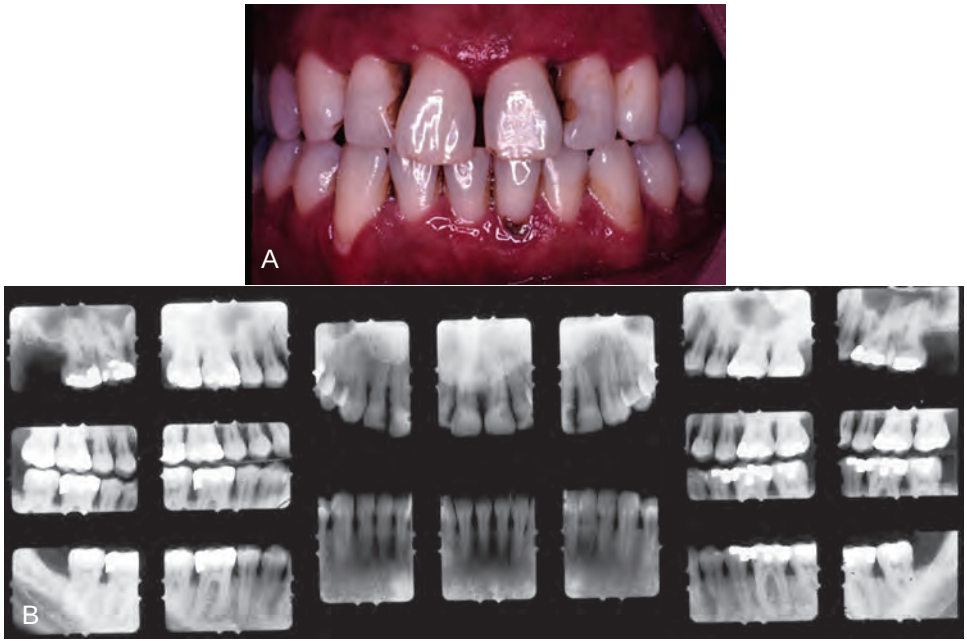

Figure 3-16 **A,** Clinical image of plaque-related moderate chronic periodontitis with 3 to 4 mm of clinical attachment loss in a 53-year-old man who smokes. **B,** Radiographic images of the patient.

as previously described for localized juvenile periodontitis or generalized as previously described for generalized juvenile periodontitis and rapidly progressive periodontitis (see Table 3-1). Box 3-3 provides the common features of the localized and generalized forms of aggressive periodontitis.

Periodontitis as a Manifestation of Systemic Disease

Several hematologic and genetic disorders have been associated with the development of periodontitis in affected individuals[22,23] (see Box 3-3). The majority of these observations of effects on the periodontium are the result of case reports, and few research studies have been performed to investigate the exact nature of the effect of the specific condition on the tissues of the periodontium. It is speculated that the major effect of these disorders is through alterations in host defense mechanisms that have been clearly described for disorders (e.g., neutropenia, leukocyte adhesion deficiencies) but that are less well understood for multifaceted syndromes. The clinical manifestation of many of these disorders appears at an early age and may be confused with aggressive forms

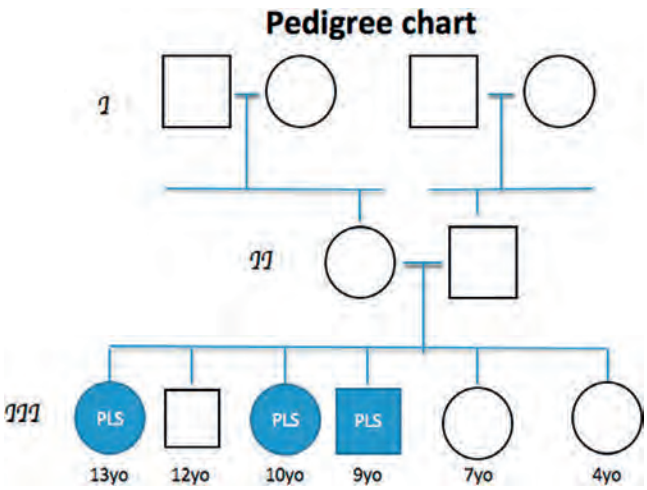

Figure 3-24 No history of consanguinity was reported in this case. However, approximately one third of diagnosed Papillon–Lèfevre syndrome cases descend from same ancestor. Offsprings III1, III3, and III4 display a Papillon–Lèfevre syndrome phenotype. All siblings should be thoroughly examined by a periodontist after a case of Papillon–Lèfevre syndrome has been diagnosed. *(Courtesy Dr. Georgios Kotsakis, Minneapolis, MN.)*

Individuals with PLS are often initially screened by a dermatologist or a pediatrician, and the phenotype of the syndrome may be mistaken for atopic dermatitis (eczema) or palmoplantar keratoderma.[35] A multidisciplinary treatment approach for these patients that includes referral to a periodontist cannot be overemphasized. After a diagnosis of PLS has been established, it is important to collect a complete family history and to construct a pedigree to help identify undiagnosed or misdiagnosed siblings (Figure 3-24). In 1979, Haneke proposed palmoplantar hyperkeratosis, the loss of primary and permanent teeth, and an autosomal-recessive pattern of inheritance as being essential criteria to verify a diagnosis of PLS.[16] Secondary manifestations of PLS may include ectopic intracranial calcifications and increased susceptibility to infections, including pyogenic liver abscesses that can be fatal.[9]

PLS clinically affects both the primary and permanent dentition. Signs of palmoplantar keratoderma usually appear simultaneously with the eruption of the first primary teeth (i.e., 5 to 6 months of age), but they may appear as early as the age of 1 month.[18] By the age of 4 to 5 years, the primary teeth have typically exfoliated or been extracted as a result of severe periodontal destruction. Subsequently, an edentulous phase occurs during which a reduction in the oral microbial load is noted and gingival health is restored. After the eruption of the permanent dentition, a similar cycle of severe periodontal inflammation is repeated that generally does not respond to conventional periodontal therapy.[11] An increase in tooth mobility and periodontal abscesses is frequently observed shortly after the eruption of the permanent teeth.

During recent years, the periodontal prognosis for patients with PLS has significantly improved in response to an increase in the prompt and accurate diagnosis of the syndrome, the better understanding of its pathogenesis, and more efficient professional supervision. There appears to be a consensus among clinicians that the successful treatment of periodontitis among individuals with PLS requires the eradication of Aa.[10,12,43] Treatment of the primary dentition includes frequent prophylaxis appointments to ensure that the patient maintains adequate masticatory function and nutrition during early childhood. To create a healthy environment for the permanent teeth to erupt into, it has been advocated that a course of antibiotics effective against Aa be systemically administered along with the extraction of all primary teeth 6 to 12 months before the eruption of the first permanent tooth. Patients with PLS who are exhibiting signs of aggressive periodontitis affecting their permanent dentition should have all teeth with a poor or hopeless prognosis extracted in conjunction with antibiotic treatment; scaling and root planning should also occur in addition to the use of chlorhexidine rinses and constant periodontal monitoring. The combination of amoxicillin and metronidazole has been shown to frequently eradicate Aa. However, culture and sensitivity testing of the subgingival plaque may enhance the selection of the most effective antibiotic regimen. De Vree and colleagues (2000) described two patients with PLS[10]: Aa was eradicated from one individual, who was able to retain most of his teeth over a 15-year period; the second individual's Aa was found to be resistant to the antibiotics combination, and he lost all of his teeth despite intensive treatment. The combination of trimethoprim and sulfamethoxazole (i.e., co-trimoxazole) has also been shown to be effective against Aa and to lead to a significant improvement in neutrophilic function against Aa.[24] A stringent periodontal maintenance schedule is of utmost importance to efficaciously monitor the patient's oral hygiene and to be able to intercede promptly if signs of inflammation reoccur.[32] Retinoids, which are synthetic analogs of vitamin A, have been shown to be a safe and effective treatment modality against PLS skin manifestations, and they may also be used as an adjunct for the treatment of periodontitis.[12,24]

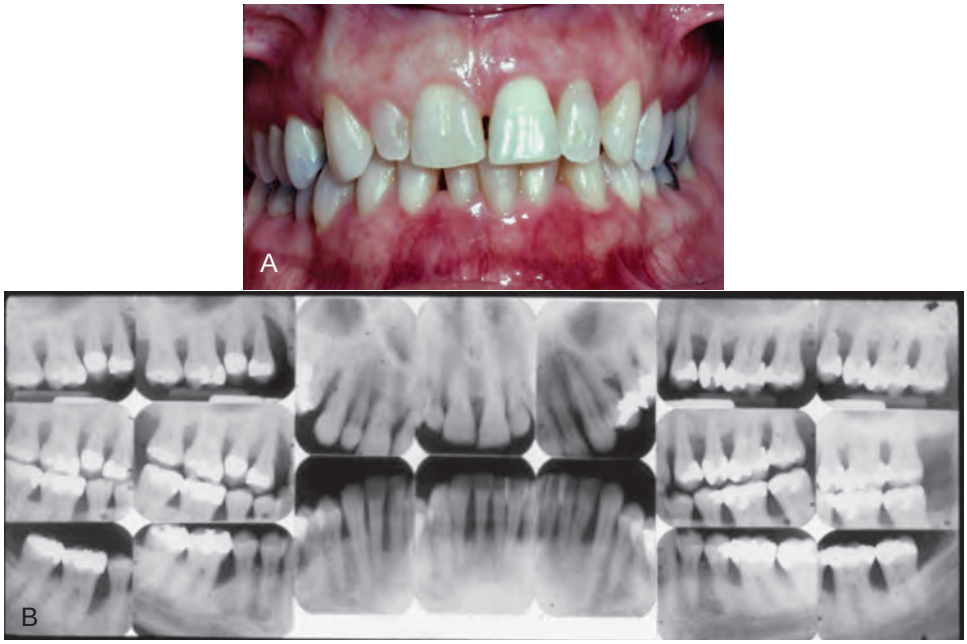

Figure 3-17 **A,** Clinical image of plaque-related severe advanced chronic periodontitis with >5 mm of clinical attachment loss in a 47-year-old woman. **B,** Radiographic images of the patient.

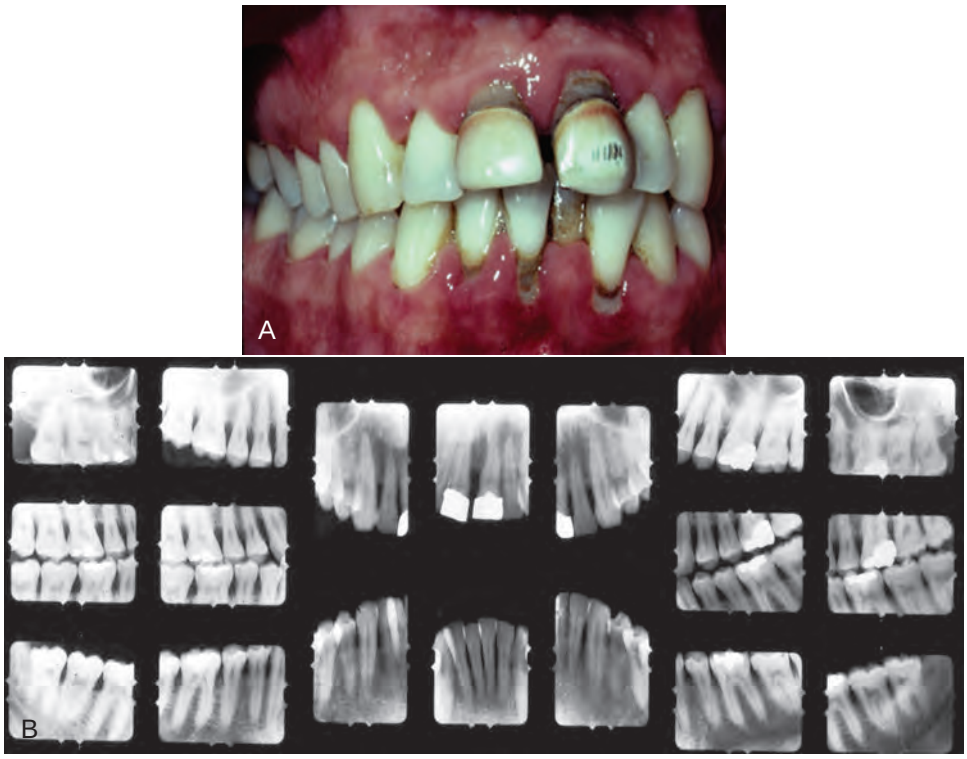

Figure 3-18 **A,** Clinical image of plaque-related aggressive moderate periodontitis with 1 to 7 mm of PD and 3 to 4 mm of clinical attachment loss in a 31-year-old man. **B,** Radiographic images of the patient.

of periodontitis with rapid attachment loss and the potential for early tooth loss. With the introduction of this form of periodontitis in this and previous classification systems (see Table 3-1), the potential exists for overlap and confusion between periodontitis as a manifestation of systemic disease and both the aggressive and the chronic form of disease when a systemic component is suspected. At present, *periodontitis as a manifestation of systemic disease* is the diagnosis to be used when the systemic condition is the major predisposing factor and when local factors (e.g., large quantities of plaque and calculus) are not clearly evident. In the case in which periodontal destruction is clearly the result of local factors but has been exacerbated by the onset of such conditions

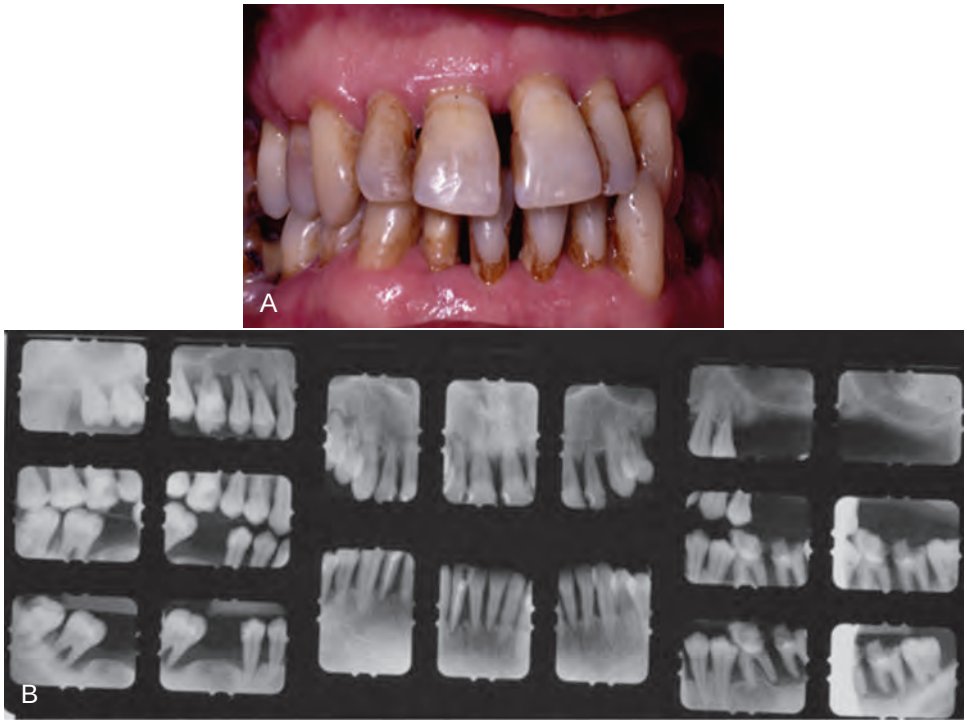

Figure 3-19 **A,** Clinical image of plaque-related aggressive severe periodontitis with 3 to 13 mm of PD and 7 to 15 mm of clinical attachment loss in a 32-year-old man. **B,** Radiographic images of the patient.

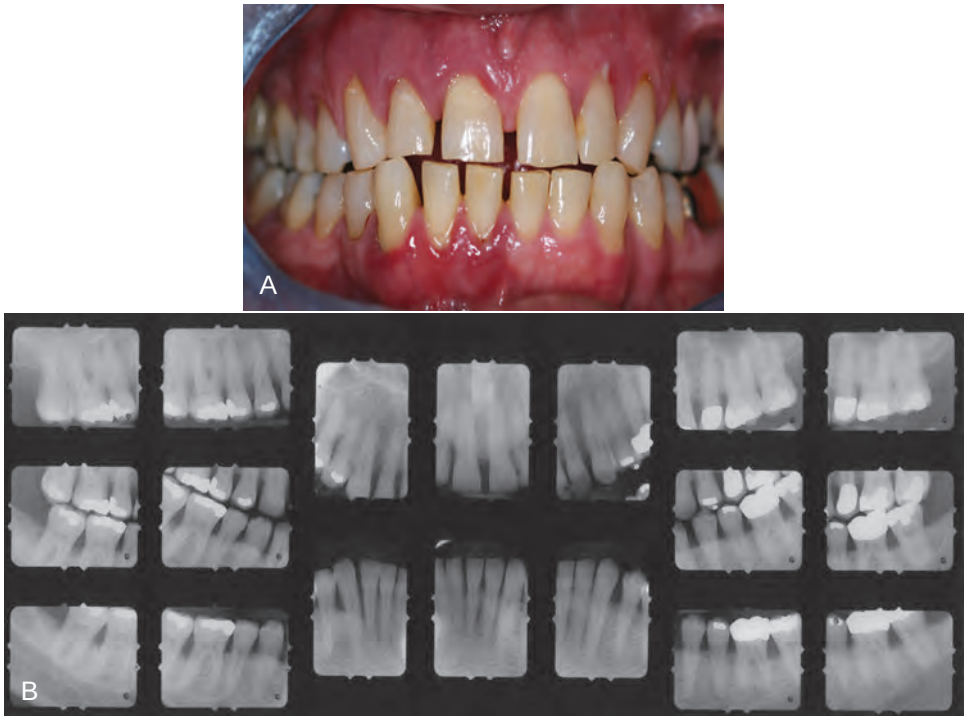

Figure 3-20 **A,** Clinical image of plaque-related severe aggressive periodontitis in a 53-year-old man who smokes and who has diabetes and a hemoglobin A_{1c} level of 10.7. **B,** Radiographic images of the patient.

as diabetes mellitus (Figures 3-20 and 3-21) or HIV infection, the diagnosis should be *chronic periodontitis modified by the systemic condition.*

Papillon–Lefèvre syndrome (PLS) is an autosomal-recessive disorder caused by mutations in the cathepsin C gene located on chromosome 11q14.[17] The clinical manifestations of the syndrome include severe aggressive periodontitis and diffuse keratoderma on the palms and on the soles, the knees, or both[16,18] (Figures 3-22 and 3-23). The consanguinity of the parents is a common finding in approximately one third of the cases.[31]

Impaired neutrophil function is considered to be the primary cause of PLS and to eventually result in the deregulation of the

Figure 3-21 Selective probing depths of the same 53-year-old diabetic patient shown in Figure 3-20 with severe aggressive periodontitis.

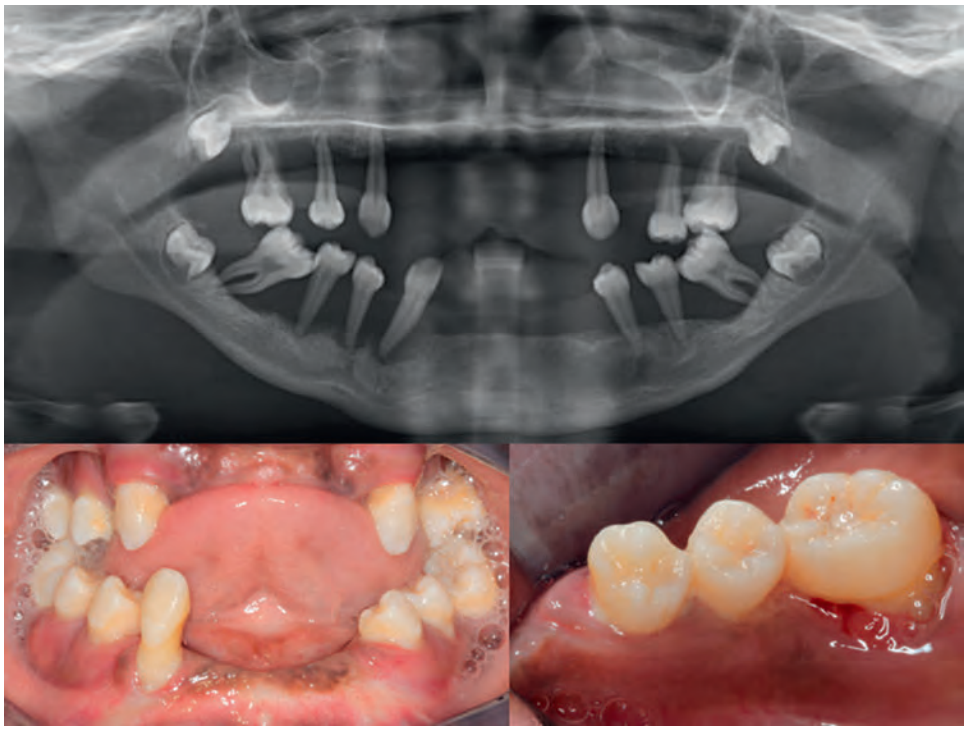

Figure 3-22 Panoramic radiograph and clinical photographs of a 13-year-old girl with Papillon–Lèfevre syndrome (PLS). *(Courtesy Dr. Georgios Kotsakis, Minneapolis, MN.)*

polymorphonuclear leukocyte response to microbial infection.[11] Although the subgingival microflora associated with PLS is diverse, opportunistic periodontal pathogens such as *Aggregatibacter actinomycetemcomitans* (Aa), *Porphyromonas gingivalis, Tannerella forsythia, Fusobacterium nucleatum,* and *Prevotella intermedia* are frequently identified among plaque samples from PLS patients.[1,50] Serum immunoglobulin G titers against Aa are typically elevated in individuals with PLS, thereby implicating Aa as a significant causative factor.[50]

Sarcoidosis is a chronic disease that is expressed as a cell-mediated, delayed-type hypersensitivity that primarily affects the lungs, lymph nodes, skin, eyes, liver, spleen, and small bones of the hands and feet.[36] Sarcoidosis rarely affects the oral cavity, with incidence of occurrence in descending order noted in the lymph nodes, lips, soft palate, buccal mucosa, gingiva, tongue, and bone.[36] Figure 3-25 depicts the pretreatment pattern of bone loss and recession associated with sarcoidosis, with pulmonary parenchymal fibrous infiltrate being noted in the lungs as depicted by a white lacy pattern on a chest radiograph (Figure 3-25, *C*). Histologic features of sarcoidosis include the presence of an intense chronic inflammatory infiltrate with focal areas of noncaseating granulomas and a positive Kveim test[4] (Figure 3-26, *C*). The

Figure 3-23 Patient with Papillon–Lèfevre syndrome exhibiting hyperkeratosis on the palms of the hands and the soles of the feet. *(Courtesy Dr. Georgios Kotsakis, Minneapolis, MN.)*

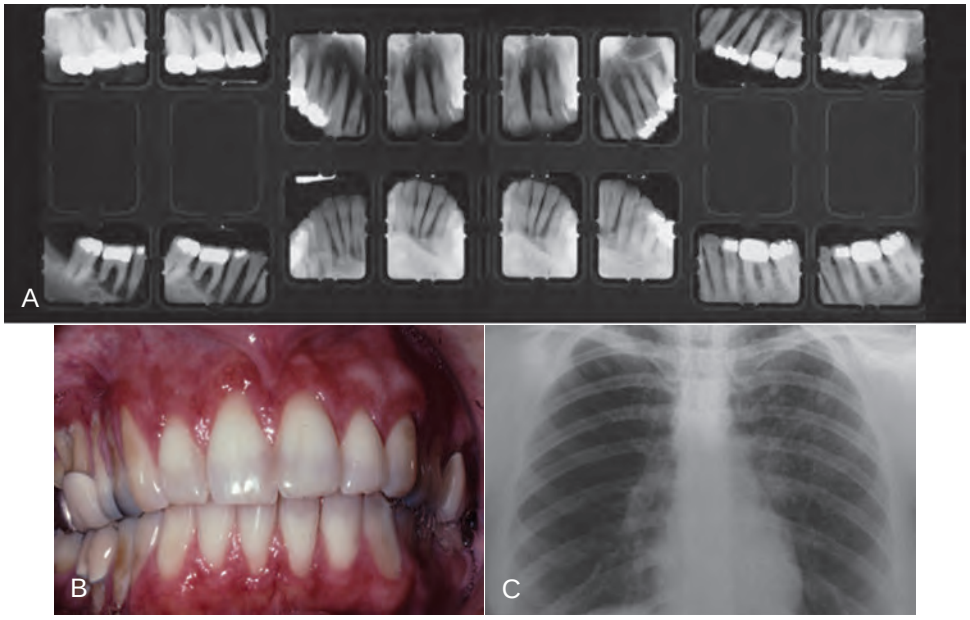

Figure 3-25 Sarcoidosis pretreatment. **A,** Intraoral radiographs depict more extensive bone loss than clinical attachment loss for the anterior teeth. **B,** Extensive recession plus clinical attachment loss. **C,** Pulmonary parenchymal fibrous infiltrate.

remineralization of alveolar bone is noted on radiographs obtained 1 year after the systemic administration of steroids (e.g., prednisone)[30] (Figure 3-26, *A*).

Bisphosphonate-Related Osteonecrosis of the Jaw

Bisphosphonates (BPs) are pyrophosphate analogs with a high affinity for hydroxyapatite crystals. They inhibit osteoclast-mediated bone resorption and play a key role in the management of osteolytic bone disorders, including osteoporosis, Paget disease, bone metastasis, and multiple myeloma.[Q44] However, their prolonged use is associated with bisphosphonate-related osteonecrosis of the jaw (BRONJ).[19]

The American Association of Oral and Maxillofacial Surgeons defines BRONJ as "exposed bone in the maxillofacial area occurring in the absence of head and neck irradiation and showing no evidence of healing for at least 8 weeks after identification in patients treated with BP therapy"[3] (Figure 3-27 and 3-28). To date, the true incidence, causes of, and risk factors for the development of BRONJ are largely unknown. An overwhelming proportion (i.e., 97%) of the reported cases are related to the high-dose intravenous BP given to patients with cancer, although a small fraction (i.e., 3%) has been reported in patients with osteoporosis and patients with Paget disease who are receiving oral BP.[19] The estimated incidence of BRONJ in patients with osteoporosis who are receiving oral BP is around 0.7 per 100,000 persons/years of exposure.[4]

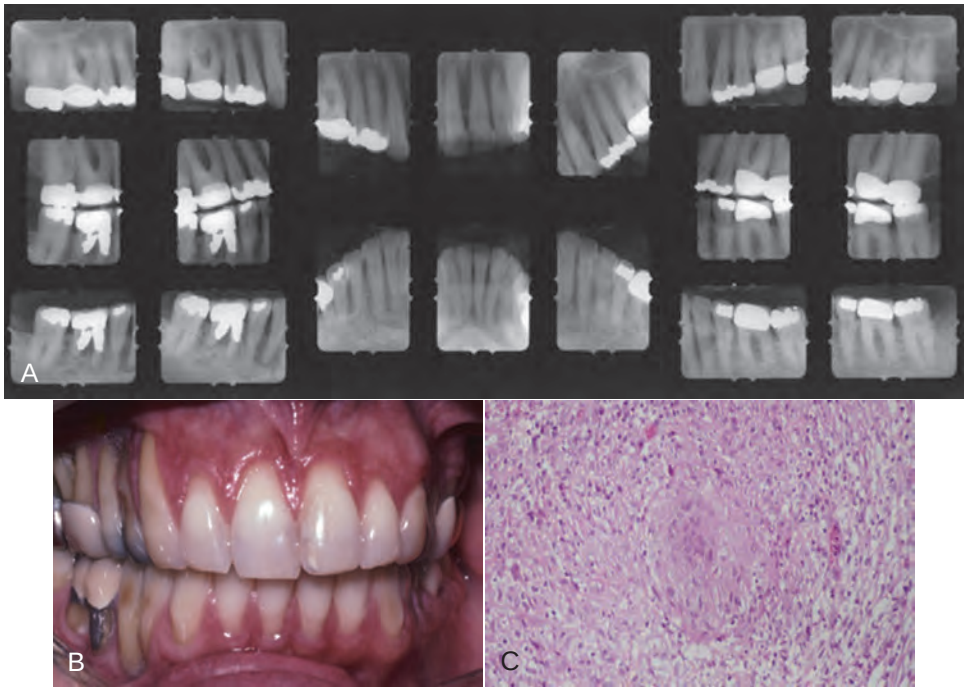

Figure 3-26 Sarcoidosis after treatment with prednisone. **A,** Intraoral radiographs depict the remineralization of bone. **B,** Reduction in gingival inflammation while extensive recession and clinical attachment loss persist. **C,** Pretreatment biopsy.

Figure 3-27 Exposed bone on the buccal lower premolar and molar in a patient with bisphosphonate-associated osteonecrosis of the jaw after extraction of the first molar. *(Courtesy Dr. Vivek Thumbigere Math, Minneapolis, MN.)*

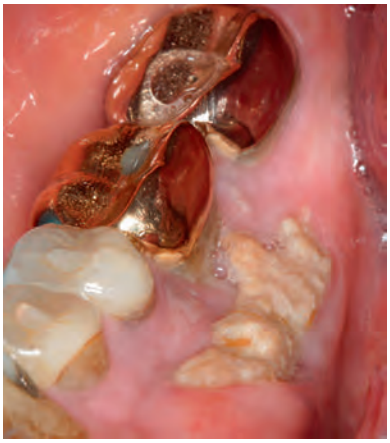

Figure 3-28 Patient with bisphosphonate-associated osteonecrosis of the jaw with exposed bone on the lingual aspect of the lower premolar and molar after root canal treatment. *(Courtesy Dr. Vivek Thumbigere Math, Minneapolis, MN.)*

The incidence of BRONJ among patients with cancer who are receiving intravenous BP ranges from 0.72% to 7.4%.[19]

BRONJ lesions may be asymptomatic, or they may present with pain, purulent discharge, swelling, tooth mobility, and paresthesia, thereby culminating in a reduced ability to eat and speak. BRONJ occurs most frequently in the mandible (65%), followed by the maxilla (26%) and both jaws (95%).[51] The frequency of BRONJ is higher in the posterior region of the jaw.[19] Among patients who develop BRONJ, approximately 60% of cases occur after an invasive dental procedure (e.g., tooth extraction), whereas 40% develop spontaneously.[48] Radiographic evaluation is usually inconclusive for early lesions; in advanced cases, a poorly defined moth-eaten radiolucency is noted with radiopaque sequestra.

Currently, there is no effective treatment for BRONJ, and the discontinuance of BP is not helpful, because these compounds tend to reside in the bone for very long periods of time.[25] Radical surgical intervention often exacerbates the condition, and the merit of hyperbaric oxygen treatment for the management BRONJ is not conclusive. Patients are typically treated via minimally invasive conservative debridement, antibiotics, and chlorhexidine mouth rinses to limit the extent of the damage and to facilitate wound healing.[48] The American Dental Association suggests that an oral health program that consists of sound hygiene practices and regular dental care is a valuable approach to lowering the risk of the development of BRONJ.[19] Practitioners are encouraged to use atraumatic surgical techniques and to minimize the extent of dentoalveolar manipulation. Communication with the patient's physician and proper risk assessment are fundamental to the successful management of patients who are receiving BP therapy.

Necrotizing Periodontal Diseases

The clinical characteristics of necrotizing periodontal diseases may include (but are not limited to) ulcerated and necrotic papillary and marginal gingiva covered by a yellowish-white or grayish slough or pseudomembrane, blunting and cratering of the papillae, bleeding on provocation or spontaneous bleeding, pain, and fetid breath.

These diseases may be accompanied by fever, malaise, and lymphadenopathy, although these characteristics are not consistent. Two forms of necrotizing periodontal disease have been described: *necrotizing ulcerative gingivitis (NUG)* (Figure 3-29) and *necrotizing ulcerative periodontitis (NUP)* (Figure 3-30). NUG has been previously classified as "gingival disease" or "gingivitis," because clinical attachment loss is not a consistent feature; NUP has been classified as a form of "periodontitis," because attachment loss is present. Recent reviews of the causative and clinical characteristics of NUG and NUP have suggested that the two diseases represent clinical manifestations of the same disease, except that distinct features of NUP are clinical attachment and bone loss. As a result, both NUG and NUP have been determined to comprise a separate group of diseases that have *tissue necrosis* as a primary clinical feature (see Box 3-1).

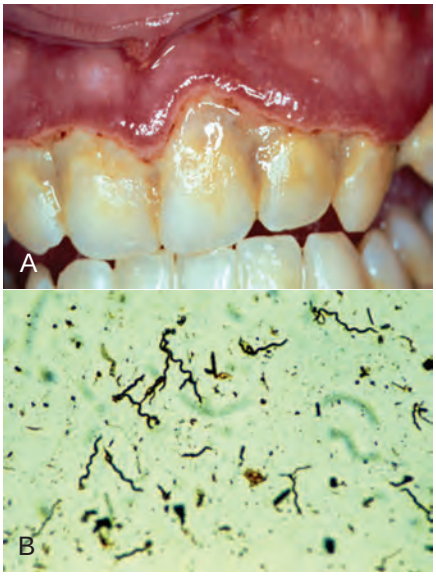

Figure 3-29 **A,** Ulcerative gingivitis illustrating the sloughing of the marginal gingiva. **B,** Phase-contrast microscopy reveals spirochetes in the subgingival plaque sample.

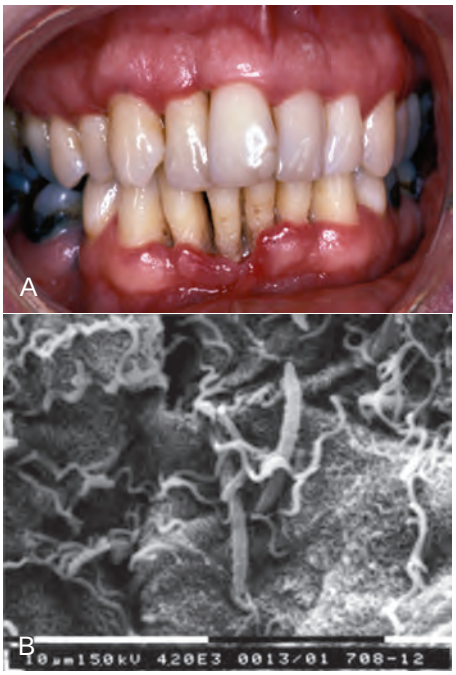

Figure 3-30 **A,** Necrotizing ulcerative periodontitis with severe clinical attachment loss in a 28-year-old man with human immunodeficiency virus. **B,** Spirochetes are noted on the surface of sloughed epithelial cells.

Necrotizing Ulcerative Gingivitis

The clinical and causative characteristics of NUG[42] are described in detail in Chapter 17. The defining characteristics of NUG are its bacterial cause, its necrotic lesion, and its predisposing factors, such as psychologic stress, smoking, and immunosuppression. In addition, malnutrition may be a contributing factor in developing countries. NUG is usually seen as an acute lesion that responds well to antimicrobial therapy in combination with professional plaque and calculus removal and improved oral hygiene.

Necrotizing Ulcerative Periodontitis

NUP differs from NUG in that the loss of clinical attachment and alveolar bone is a consistent feature.[33] All other characteristics appear to be the same between the two forms of necrotizing disease. The characteristics of NUP are described in detail in Chapter 24. NUP may be observed among patients with HIV infection; it manifests as local ulceration and the necrosis of gingival tissue with the exposure and rapid destruction of underlying bone, spontaneous bleeding, and severe pain. Patients with HIV and NUP are 20.8 times more likely to have CD4+ cell counts of less than 200 cells/mm^3 of peripheral blood as compared with patients with HIV without NUP, which suggests that immunosuppression is a major contributing factor. In addition, the predictive value of NUP for patients with HIV with CD4+ cell counts of less than 200 cells/mm^3 was 95.1%, and the cumulative probability of death within 24 months of a NUP diagnosis among individuals with HIV was 72.9%. In developing countries, NUP has also been associated with severe malnutrition, which may lead to immunosuppression in some patients.

Abscesses of the Periodontium

A periodontal abscess is a localized purulent infection of periodontal tissues, and it is classified by its tissue of origin.[28] The clinical, microbiologic, immunologic, and predisposing characteristics are discussed in Chapters 4 and 8.

Periodontitis Associated With Endodontic Lesions

The classification of lesions that affect the periodontium and the pulp is based on the sequence of the disease process.

Endodontic–Periodontal Lesions

In endodontic–periodontal lesions, pulpal necrosis precedes periodontal changes. A periapical lesion that originates with pulpal infection and necrosis may drain to the oral cavity through the periodontal ligament, thereby resulting in the destruction of the periodontal ligament and the adjacent alveolar bone. This may present clinically as a localized, deep, periodontal probing depth that extends to the apex of the tooth (Figure 3-31, *A*). A resultant extensive alveolar ridge defect (Figure 3-31, *B* and *C*) may necessitate reconstructive surgery (Figure 3-31, *D*) before the placement of implants and prostheses (Figure 3-32) to reestablish a functional and aesthetic outcome. Pulpal infection may also drain through accessory canals, especially in the area of the furcation, and this may lead to furcal involvement through the loss of clinical attachment and alveolar bone.

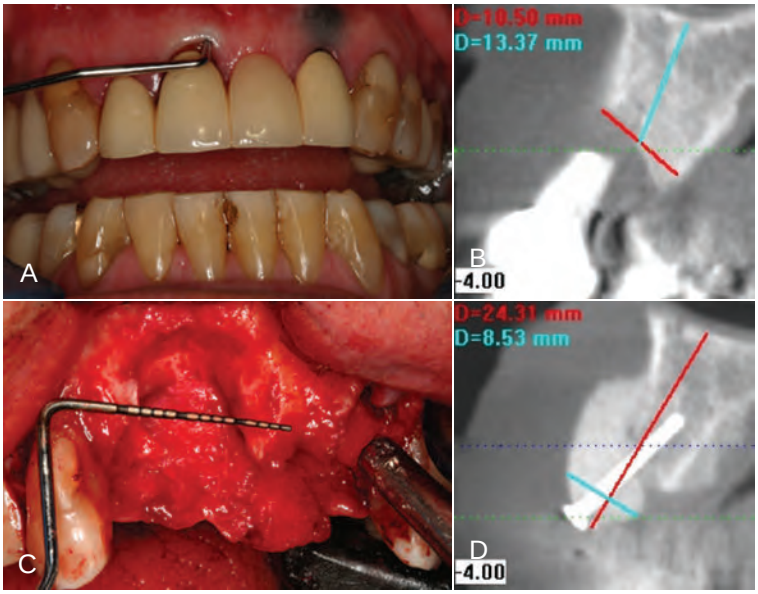

Figure 3-31 **A** and **C,** Clinical images of extensive loss of the alveolar ridge as a result of a periapical endodontic lesion. **B,** A computed tomography image that depicts alveolar bone loss. **D,** A computed tomography image of a ridge that was regenerated with the use of allogenic bone graft and a tenting screw and membrane.

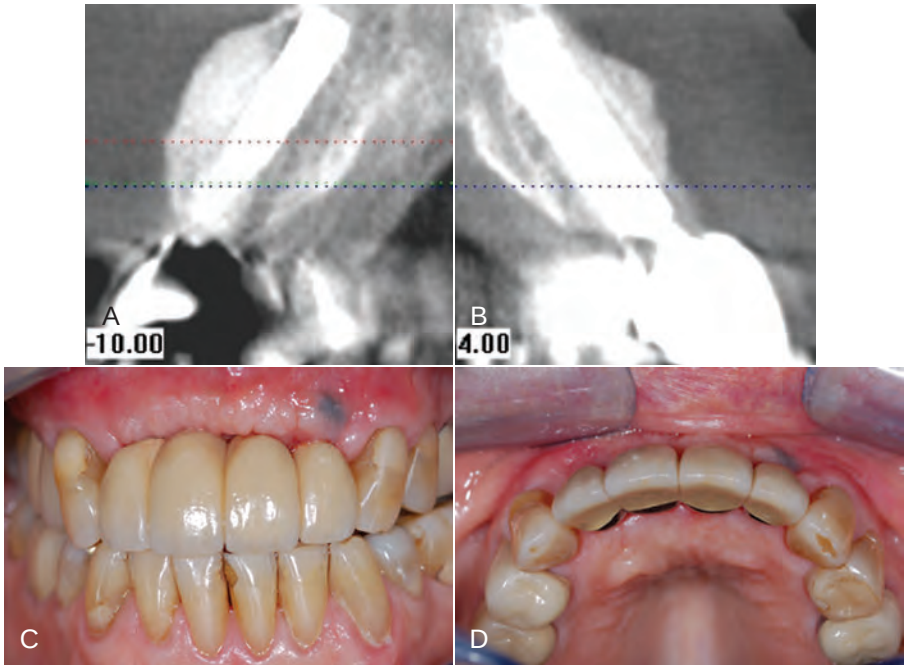

Figure 3-32 The same patient who was depicted in Figure 3-31. **A** and **B,** A computed tomography image of a regenerated ridge, with implants placed in areas #7, #9, and #10. **C** and **D,** Clinical image of the implant-supported bridge.

Periodontal–Endodontic Lesions

In periodontal–endodontic lesions, bacterial infection from a periodontal pocket associated with a loss of attachment and root exposure may spread through the accessory canals to the pulp, thereby resulting in pulpal necrosis. In the case of advanced periodontal disease, the infection may reach the pulp through the apical foramen. Scaling and root planing remove cementum and underlying dentin, which may lead to chronic pulpitis through the bacterial penetration of dentinal tubules. However, many teeth that have been affected by periodontitis that have been scaled and root planed show no evidence of pulpal involvement.

Combined Lesions

Combined lesions occur when pulpal necrosis and a periapical lesion occur on a tooth that is also periodontally involved. An angular intrabony defect that communicates with a periapical lesion of pulpal origin results in a combined periodontal–endodontic lesion.

In all cases of periodontitis associated with endodontic lesions, the endodontic infection should be controlled before the definitive management of the periodontal lesion is begun, especially when regenerative or bone-grafting techniques are planned.[29]

Developmental or Acquired Deformities and Conditions

Localized Tooth-Related Factors That Modify or Predispose Individuals to Plaque-Induced Gingival Diseases or Periodontitis

In general, these localized tooth-related factors contribute to the initiation and progression of periodontal disease through the enhancement of plaque accumulation or the prevention of effective plaque removal via normal oral hygiene measures.[7] These factors fall into the four subgroups outlined in Box 3-4.

Tooth Anatomic Factors. Tooth anatomic factors are associated with malformations of tooth development or tooth location. Anatomic factors (e.g., cervical enamel projections, enamel pearls) have been associated with clinical attachment loss, especially in furcation areas. Cervical enamel projections are found on 15% to 24% of mandibular molars and on 9% to 25% of maxillary molars, and strong associations have been observed with furcation involvement.[27] Palatogingival grooves, which are found primarily on maxillary incisors, are observed in 8.5% of individuals, and they are associated with increased plaque accumulation, clinical attachment, and bone loss. Proximal root grooves on incisors and maxillary premolars also predispose individuals to plaque accumulation, inflammation, and the loss of clinical attachment and bone.

Tooth location is considered important for the initiation and development of disease. Malaligned teeth predispose individuals to plaque accumulation with resultant inflammation in children, and they may predispose adults to clinical attachment loss, especially when they are associated with poor oral hygiene habits. In addition, open contacts have been associated with an increased loss of alveolar bone, most likely through food impaction.[21]

Dental Restorations and Appliances. Dental restorations or appliances are frequently associated with the development of gingival inflammation, especially when they are located subgingivally. This may apply to subgingivally placed onlays, crowns, fillings, and orthodontic bands. Restorations may impinge on the biologic width by being placed deep in the sulcus or within the junctional epithelium. This may promote inflammation and the loss of clinical attachment and bone, with apical migration of the junctional epithelium and the reestablishment of the attachment apparatus at a more apical level.

Root Fractures. Root fractures that are caused by traumatic forces or by restorative or endodontic procedures (Figure 3-33, *A* to *C*) may lead to periodontal involvement through the apical migration of plaque along the fracture when the fracture originates coronal to the clinical attachment and is exposed to the oral environment, with a resulting alveolar ridge defect (Figure 3-33, *D*).

Cervical Root Resorption and Cemental Tears. Cervical root resorption (as noted on the computed tomography scans shown in Figure 3-34, *A* and *B*) and cemental tears may lead to periodontal destruction when the lesion communicates with the oral cavity and allows bacteria to migrate subgingivally. Avulsed teeth that are reimplants frequently develop ankylosis and cervical resorption many years after reimplantation. The atraumatic removal of such ankylosed teeth and the reconstruction of resultant ridge defects with bone grafts, dental implants, and prostheses are viable solutions for such defects (Figure 3-35).

Mucogingival Deformities and Conditions Around the Teeth

Mucogingival deformity is a generic term used to describe the mucogingival junction and its relationship to the gingiva (Figure 3-36), the alveolar mucosa, and frenula muscle attachments. A *mucogingival deformity* is a significant departure from the normal shape of the gingiva and the alveolar mucosa, and it may involve the underlying alveolar bone. *Mucogingival surgery* corrects defects in the morphology, position, or amount of gingiva; it is described in detail in Chapter 62. The surgical correction of mucogingival deformities may be performed for aesthetic reasons, to enhance function, or to facilitate oral hygiene.[37]

Mucogingival Deformities and Conditions of the Edentulous Ridges

Mucogingival deformities, such as a lack of stable keratinized gingiva between the vestibular fornices and the floor of the mouth (Figure 3-37, *A*), may require soft-tissue grafting and vestibular deepening before prosthodontic reconstruction (Figure 3-37, *B*

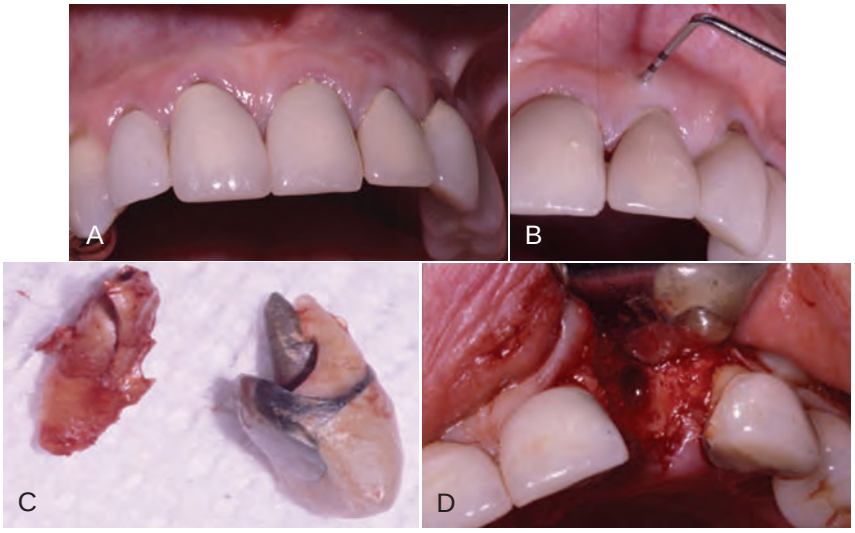

Figure 3-33 **A** and **B,** Clinical images of a fistula tract. **C,** Root fracture. **D,** Resultant alveolar ridge defect.

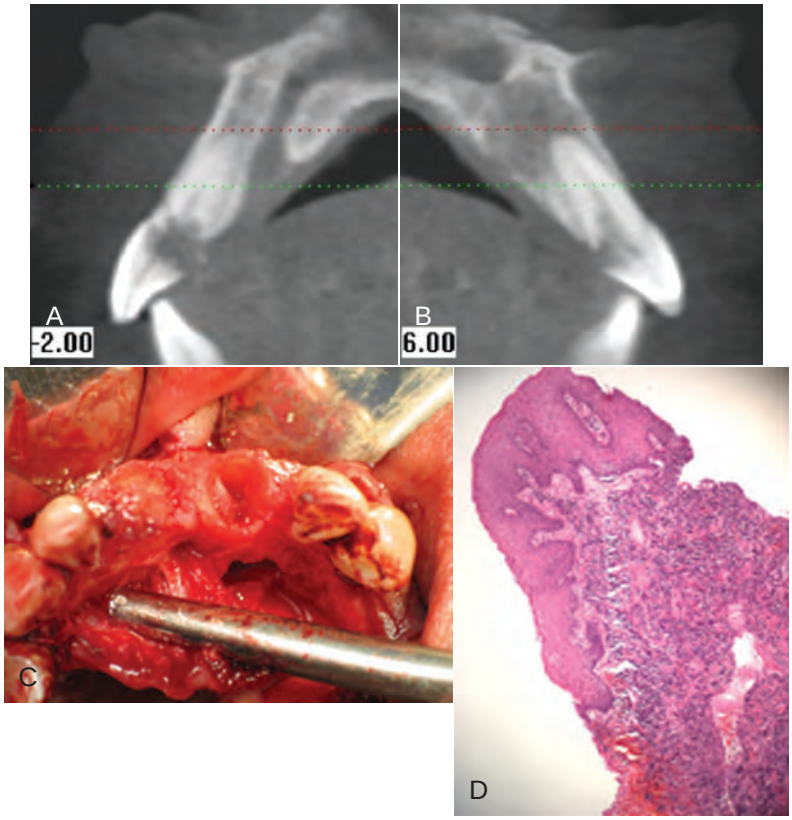

Figure 3-34 **A** and **B,** Computed tomography scanning reveals severe cervical root resorption of the maxillary central incisors and periapical abscess. **C,** Crowns fractured as a result of resorption. **D,** Biopsy of soft tissue from the resorption.

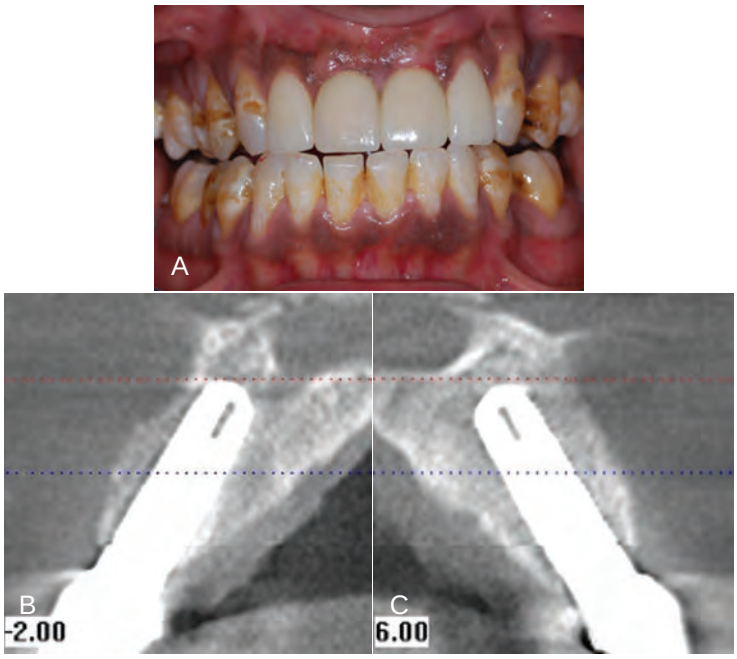

Figure 3-35 **A,** Posttreatment clinical image of the same patient depicted in Figure 3-34 with implant-supported crowns and veneers on the lateral surfaces. **B** and **C,** Computed tomography images of bone grafts and implants replacing central incisors that were lost as a result of severe cervical root resorption.

Figure 3-36 **A,** Mucogingival defect depicted by recession. **B,** Defects extend into the alveolar mucosa, which lacks keratinized gingiva.

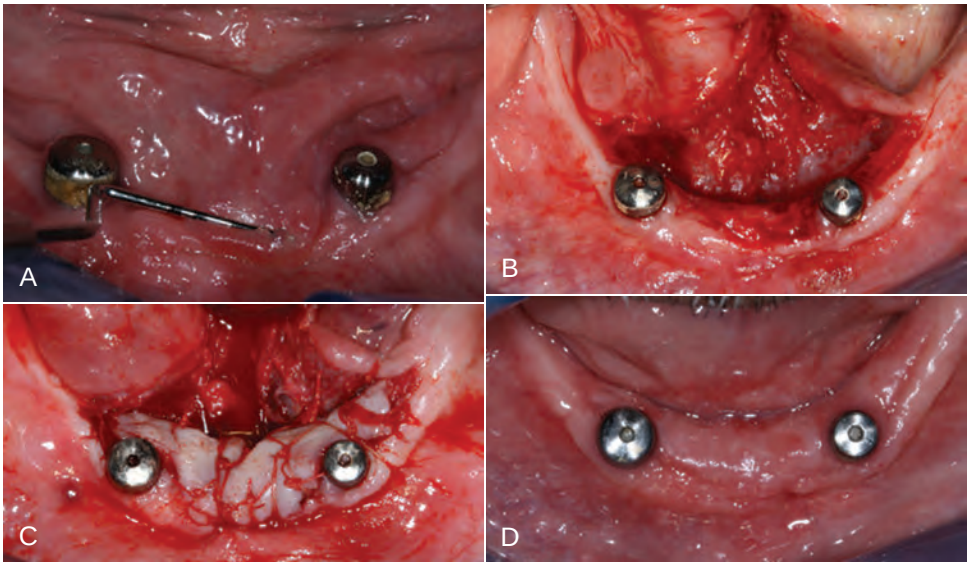

Figure 3-37 **A,** Mucogingival ridge defect from the floor of the mouth to the vestibular fornix. **B,** A partial-thickness flap with vestibular deepening. **C,** The placement of free gingival graft. **D,** The reestablishment of vestibular depth and keratinized attached gingiva.

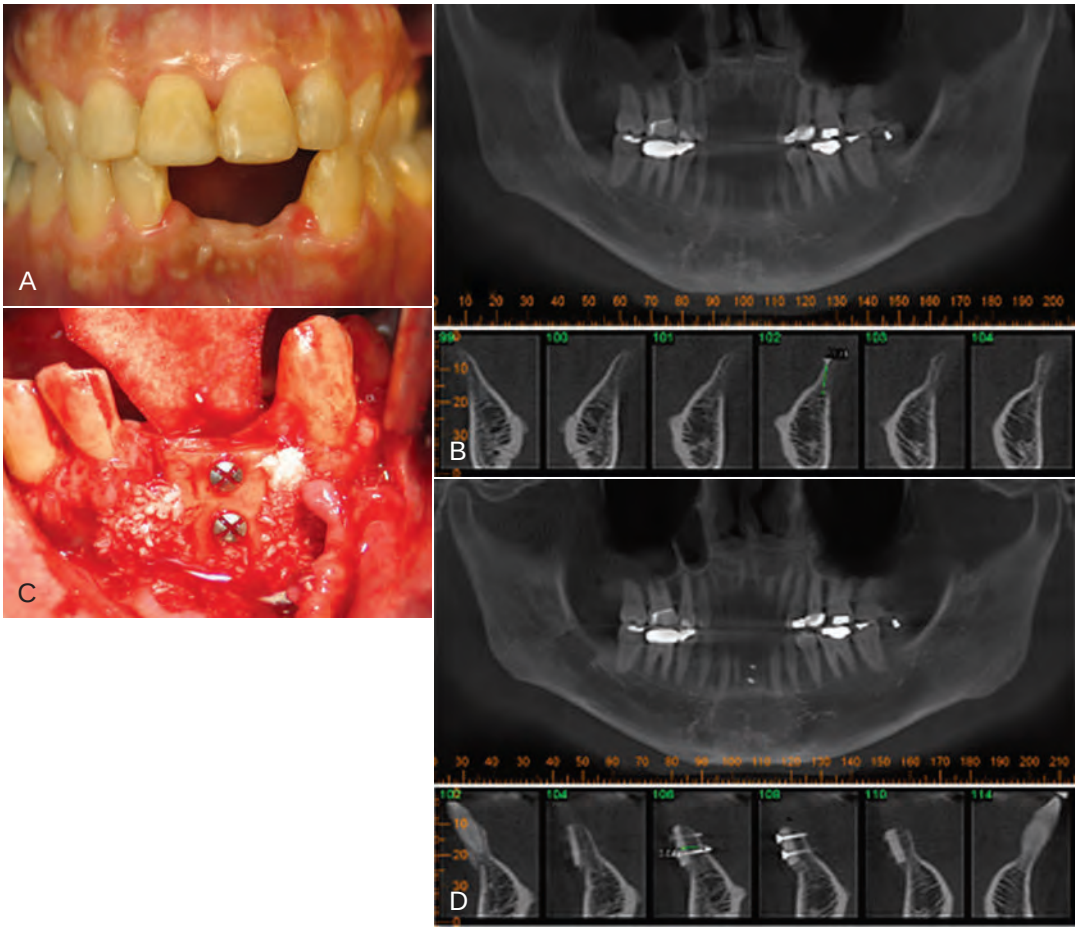

Figure 3-38 **A,** Clinical image of an edentulous ridge defect. **B,** Pretreatment computed tomography image of the defect. **C,** Ridge that was reconstructed ridge with the use of a ramus block graft. **D,** Computed tomography scan of the grafted site.

Figure 3-39 **A,** Clinical image of the ridge 6 months after grafting. **B,** Placement of implants in the areas of teeth #23 and #25. **C,** Porcelain-fused-to-metal crowns for the maxillary incisors and an implant-supported bridge from teeth #23 through #25.

through *D*). Alveolar bone defects in edentulous ridges (Figure 3-38, *A* and *B*) usually require corrective surgery (Figure 3-38, *C* and *D*) to restore form and function before the placement of implants and prostheses to replace missing teeth (Figure 3-39).[37]

Occlusal Trauma

The causes of trauma from occlusion and the effect of this trauma on the periodontium[14] are discussed in detail in Chapters 27 and 50.

Suggested Readings

American Association of Oral and Maxillofacial: Surgeons position paper on bisphosphonate-related osteonecrosis of the jaws. *J Oral Maxillofac Surg* 65:369–376, 2007.

Armitage GC: Development of a classification system for periodontal diseases and conditions. *Ann Periodontol* 4:1, 1999.

Attstrom R, Vander Velden U: Summary of session 1. In Lang N, Karring T, editors: *Proceedings of the 1st European workshop in periodontology*, Berlin, 1993, Quintessence.

Caton J: Periodontal diagnosis and diagnostic aids: consensus report. *Proceedings of the world workshop in clinical*, 1989, American Academy of Periodontology.

Hellstein JW, Adler RA, Edwards B, et al: Managing the care of patients receiving antiresorptive therapy for prevention and treatment of osteoporosis: executive summary of recommendations from the American Dental Association Council on Scientific Affairs. *J Am Dent Assoc* 142:1243–1251, 2011.

Kinane DF: Periodontitis modified by systemic factors. *Ann Periodontol* 4:54, 1999.

Mariotti A: Dental plaque-induced gingival diseases. *Ann Periodontol* 4:7, 1999.

Pini Prato GP: Mucogingival deformities. *Ann Periodontol* 4:98, 1999.

Tonetti MS, Mombelli A: Early-onset periodontitis. *Ann Periodontol* 4:39, 1999.

Woo SB, Hellstein JW, Kalmar JR: Narrative [corrected] review: bisphosphonates and osteonecrosis of the jaws. *Ann Intern Med* 144:753–761, 2006.

References

References for this chapter are found on the companion website www.expertconsult.com.

References

1. Albandar JM, Khattab R, Monem F, et al: The subgingival microbiota of Papillon-Lefèvre syndrome. *J Periodontol* 83:902–908, 2012.
2. Aldred MJ, Bartold PM: Genetic disorders of the gingivae and periodontium. *Periodontol 2000* 18:7, 1998.
3. American Association of Oral and Maxillofacial: Surgeons position paper on bisphosphonate-related osteonecrosis of the jaws. *J Oral Maxillofac Surg* 65:369–376, 2007.
4. Antunes KB, Miranda AM, Carvalho SR, et al: Sarcoidosis presenting as gingival erosion in a patient under long-term clinical control. *J Periodontol* 79:556–561, 2008.
5. Armitage GC: Development of a classification system for periodontal diseases and conditions. *Ann Periodontol* 4:1, 1999.
6. Attstrom R, Vander Velden U: Summary of session 1. In Lang N, Karring T, editors: *Proceedings of the 1st European workshop in periodontology*, Berlin, 1993, Quintessence.
7. Blieden TM: Tooth-related issues. *Ann Periodontol* 4:91, 1999.
8. Caton J: Periodontal diagnosis and diagnostic aids: consensus report. In *Proceedings of the wold workshop in clinical*, 1989, American Academy of Periodontology.
9. Dalgic B, Bukulmez A, Sari S: Pyogenic liver abscess and peritonitis due to Rhizopus oryzae in a child with Papillon–Lefevre syndrome. *Eur J Pediatr* 170:803–805, 2011.
10. De Vree H, Steenackers K, De Boever JA: Periodontal treatment of rapid progressive periodontitis in 2 siblings with Papillon-Lefèvre syndrome: 15-year follow-up. *J Clin Periodontol* 27:354–360, 2000.
11. Dhanrajani PJ: Papillon-Lefevre syndrome: clinical presentation and a brief review. *Oral Surg Oral Med Oral Pathol Oral Radiol Endod* 108:1–7, 2009.
12. Eickholz P, Kugel B, Pohl S, et al: Combined mechanical and antibiotic periodontal therapy in a case of Papillon-Lefèvre syndrome. *J Periodontol* 72:542–549, 2001.
13. Flemmig TF: Periodontitis. *Ann Periodontol* 4:32, 1999.
14. Hallmon WW: Occlusal trauma: effect and impact on the periodontium. *Ann Periodontol* 4:102, 1999.
15. Hallmon WW, Rossmann JA: The role of drugs in the pathogenesis of gingival overgrowth. *Periodontol 2000* 21:176, 1999.
16. Haneke E: The Papillon-Lefevre syndrome: keratosis palmoplantaris with periodontopathy. Report of a case and review of the literature. *Hum Genet* 51:1–35, 1979.
17. Hart TC, Hart PS, Bowden DW, et al: Mutations of the cathepsin C gene are responsible for Papillon-Lefèvre syndrome. *Med Genet* 36:881–887, 1999.
18. Hattab FN, Rawashdeh MA, Yassin OM, et al: Papillon-Lefevre syndrome: a review of the literature and report of 4 cases. *J Periodontol* 66:413–420, 1995.
19. Hellstein JW, Adler RA, Edwards B, et al: Managing the care of patients receiving antiresorptive therapy for prevention and treatment of osteoporosis: executive summary of recommendations from the American Dental Association Council on Scientific Affairs. *J Am Dent Assoc* 142:1243–1251, 2011.
20. Holmstrup P: Non–plaque-induced gingival lesions. *Ann Periodontol* 4:20, 1999.
21. Jernberg GR, Bakdash MB, Keenan KM: Relationship between proximal tooth open contacts and periodontal disease. *J Periodontol* 54:529–533, 1983.
22. Kinane DF: Blood and lymphoreticular disorders. *Periodontol 2000* 21:84, 1999.
23. Kinane DF: Periodontitis modified by systemic factors. *Ann Periodontol* 4:54, 1999.
24. Lee MR, Wong LC, Fischer GO: Papillon-Lefèvre syndrome treated with acitretin. *Australas J Dermatol* 46:199–201, 2005.
25. Lin JH: Bisphosphonates: A review of their pharmacokinetic properties. *Bone* 18:75–85, 1996.
26. Mariotti A: Dental plaque-induced gingival diseases. *Ann Periodontol* 4:7, 1999.
27. Masters D, Hoskins S: Projection of Cervical Enamel into Molar Furcations. *J Periodontol* 35:49–53, 1964.
28. Meng HX: Periodontal abscess. *Ann Periodontol* 4:79, 1999.
29. Meng HX: Periodontic-endodontic lesions. *Ann Periodontol* 4:84, 1999.
30. Moretti AJ, Fiocchi MF, Flaitz CM: Sarcoidosis affecting the periodontium: a long-term follow-up case. *J Periodontol* 78:2209–2215, 2007.
31. Muppa R, Prameela B, Duddu M, et al: Papillon-Lefevre syndrome: a combined approach from the dermatologist and dentist - a clinical presentation. *Indian J Dermatol* 56:740–743, 2011.
32. Nickles K, Schacher B, Schuster G, et al: Evaluation of two siblings with Papillon-Lefèvre syndrome 5 years after treatment of periodontitis in primary and mixed dentition. *J Periodontol* 82:1536–1547, 2011.
33. Novak MJ: Necrotizing ulcerative periodontitis. *Ann Periodontol* 4:74, 1999.
34. Novak MJ, Novak KF: Early-onset periodontitis. *Curr Opin Periodontol* 3:45, 1996.
35. Patel S, Davidson LE: Papillon-Lefevre syndrome: A report of two cases. *Int J Paediatr Dent* 14:288–294, 2004.
36. Pindborg JJ: *Atlas of diseases of the oral mucosa*, Copenhagen, Denmark, 1992, Munksgaard Publication, pp 156.
37. Pini Prato GP: Mucogingival deformities. *Ann Periodontol* 4:98, 1999.
38. Plemons JM, Gonzalez TS, Burkhart NW: Vesiculobullous diseases of the oral cavity. *Periodontol 2000* 21:158, 1999.
39. Porter SR: Gingival and periodontal aspects of diseases of the blood and blood-forming organs and malignancy. *Periodontol 2000* 18:102, 1998.
40. Rees TD: Drugs and oral disorders. *Periodontol 2000* 18:21, 1998.
41. Rivera Hidalgo F, Stanford TW: Oral mucosal lesions caused by infective microorganisms. I. Viruses and bacteria. *Periodontol 2000* 21:106, 1999.
42. Rowland RW: Necrotizing ulcerative gingivitis. *Ann Periodontol* 4:65, 1999.
43. Rüdiger S, Petersilka G, Flemmig TF: Combined systemic and local antimicrobial therapy of periodontal disease in Papillon-Lefèvre syndrome. A report of 4 cases. *J Clin Periodontol* 26:847–854, 1999.
44. Russell RG, Croucher PI, Rogers MJ: Bisphosphonates: pharmacology, mechanisms of action and clinical uses. *Osteoporos Int* (Suppl 2):S66–S80, 1999.
45. Scully C, Laskaris G: Mucocutaneous disorders. *Periodontol 2000* 18:81, 1998.
46. Scully C, Monteil R, Sposto MR: Infectious and tropical diseases affecting the human mouth. *Periodontol 2000* 18:47, 1998.
47. Stanford TW, Rivera-Hidalgo F: Oral mucosal lesions caused by infective microorganisms. II. Fungi and parasites. *Periodontol 2000* 21:125, 1999.
48. Thumbigere-Math V, Sabino MC, Gopalakrishnan R, et al: Bisphosphonate-Related Osteonecrosis of the Jaw: Clinical Features, Risk Factors, Management, and Treatment Outcomes of 26 Patients. *J Oral Maxillofac Surg* 67:1904–1913, 2009.
49. Tonetti MS, Mombelli A: Early-onset periodontitis. *Ann Periodontol* 4:39, 1999.
50. Wara-aswapati N, Lertsirivorakul J, Nagasawa T, et al: Papillon-Lefèvre syndrome: serum immunoglobulin G (IgG) subclass antibody response to periodontopathic bacteria. A case report. *J Periodontol* 72:1747–1754, 2001.
51. Woo SB, Hellstein JW, Kalmar JR: Narrative [corrected] review: bisphosphonates and osteonecrosis of the jaws. *Ann Intern Med* 144:753–761, 2006.

CHAPTER 4

Fundamentals in the Methods of Periodontal Disease Epidemiology

Philippe Hujoel

CHAPTER OUTLINE

The Need for Epidemiology
Epidemiologic Study Designs
Causes
Diagnosis

The Need For Epidemiology

"Periodontal [gum] diseases, including gingivitis and destructive periodontal disease, are serious infections."[1] This 2009 statement from a professional dental organization reflected the dominating belief of the last half century that periodontal conditions are caused by bacteria.[20] This bacterial dogma had several consequences. Clinical management and research became largely focused on vaccines, microbial diagnosis, antimicrobials, antibiotics, dental plaque, and immunology. Clinical diagnoses that did not fit the infection paradigm (e.g., periodontal atrophy) became eliminated from some periodontal disease classifications, and it was hypothesized that periodontal infections caused systemic diseases.

But are periodontal diseases really infectious diseases? A reliable answer to this question requires epidemiologic evidence. This chapter focuses on the role of epidemiology in the study of human diseases. *Case–control studies* and *cohort studies* are two epidemiologic study designs that identified common causes of chronic disease, such as smoking, ionizing radiation, hepatitis B, and high blood pressure. *Randomized controlled trials* are study designs that assessed the diagnosis, management, and prognosis of chronic diseases and which either confirmed or refuted the suspected causes of disease identified in case–control or cohort studies. Prostate surface antigen screening, polio vaccination, and hormone replacement therapy are examples of diagnoses and treatments for chronic diseases that were evaluated by means of randomized controlled trials.

Some of the essential characteristics of epidemiologic studies are that they are conducted in humans, that there is a control or a comparison group, and that clinically relevant endpoints are evaluated. Studies that are commonly cited in support of the periodontal infection hypothesis often lack these elements. For instance, is a "burst" of bone loss[23] subsequent to the injection of *Bacteroides gingivalis* in an animal model proof that "this microorganism [is] of great importance to the control of destructive periodontal disease"? In a modern evidence-based world, data from animal studies would be considered the lowest level of evidence to make the infection dogma a cornerstone of clinical thinking.

Epidemiologic studies, which are higher level than case–control studies and animal studies, have had a powerful impact on the incidence of some chronic diseases by reliably identifying the primary causes. Reliable evidence on what causes disease allows laboratory research to focus on sabotaging the causal pathways of disease, which can then lead to clinical trials. "Medical science continually passes the baton of discovery from [epidemiologic] observation to laboratory studies to human clinical trials."[45] For example, epidemiologic observations identified hepatitis B as the main cause of liver carcinoma, which is one of the most common cancers in the world.[4] Subsequently, the baton of discovery was passed to basic science, with which a recombinant engineered vaccine for hepatitis B was developed. Then, the baton of discovery was passed to clinical epidemiologists, who assessed the effectiveness of vaccinations and documented dramatic declines in mortality rates from liver cancer.[44] Similar success stories in the management of chronic diseases in which epidemiology played a critical role include coronary heart disease and blood pressure medication, dental caries and fluoride, and lung cancer and smoking intervention programs.

The emerging epidemiologic evidence regarding the cause of periodontal diseases suggests that factors such as cigarette smoking, sugar, cereals, and some of the consequences of conditions such as obesity and diabetes could be primary causes of periodontal disease and that their effect on the periodontium could be unrelated to infectious factors.[6,24,65] Organizations such as the World Health Organization suggest that periodontal disease prevention be made an integral part of programs that focus on tobacco control, diet, and physical activity.[57] Regardless of your current beliefs about the causes of periodontal disease, it may become important to become familiar with epidemiologic methodology to be able to judge this emerging evidence independently and critically.

Measuring the Occurrence of Conditions or Diseases

The fundamental tools of epidemiology are simple sums and divisions that reflect how many individuals or sites either have or develop a particular condition or disease.

The *prevalence* is the sum of all examined individuals or sites that exhibit the condition or disease of interest divided by the sum of the number of individuals or sites examined. The prevalence can range from 0% (no one has the condition or disease of interest) to 100% (everyone has the condition or disease of interest).

As an example of prevalence, the Centers for Disease Control and Prevention reported about the prevalence of individuals with at least one periodontal pocket depth of 4 mm or deeper. It was reported that, from 1988 to 1994, a little more than 1 in 5 Americans had such a condition, for a prevalence of a little more than 20%; from 1999 to 2004, only 1 in 10 Americans fell into this category,[16] for a prevalence of around 10%. These findings suggest a more than 50% decline in the prevalence of pocket depths greater than or equal to 4 mm for adults between the ages of 20 and 64 years, which occurred over approximately a decade. These epidemiologic data confirm another report of declining destructive periodontal prevalence in the United States.[8] Such information about prevalence measures of periodontal conditions may have implications for manpower needs in the United States and may provide clues with respect to the causative factors that drive such changes. Many countries do not have prevalence surveillance systems,[57] which makes it difficult to determine whether these trends observed in the United States are isolated events or part of a more general trend.

The *risk* is the probability than an individual or a site will develop a particular condition or disease during follow up. The risk for a condition or a disease, like prevalence, is a number that ranges between 0% and 100%. The simplest way to estimate risk is to have a fixed number of persons or sites at risk at some defining moment (i.e., time zero [t_0]). Individuals or sites within individuals are followed up over time after this defining moment. After a follow-up period (i.e., from t_0 to t_n), the risk can be calculated as the proportion of persons or sites in which the clinical outcome of interest develops during the follow-up period.

Because the risk is estimated as a proportion, it is without dimension, and it ranges between 0 and 1. When a risk is reported, it should be accompanied by a specific time period to which it is applied. A 5% risk for death may be considered small when it refers to a 20-year period but large when it refers to a 3-month period.

As an example, consider concerns about occupational human immunodeficiency virus (HIV) infection among dentists. It has been reported that the risk for developing an HIV infection within the year subsequent to an accidental needlestick with HIV-contaminated blood is 0.3%. Such a statistic has an intuitive appeal and can be related to patients or colleagues. A risk of 0.003 (0.3%) indicates that, for every 1000 individuals that have an accidental HIV-contaminated needlestick, 3 are expected to develop an HIV infection within a year of the event.

The *odds* for an event is the probability that an event happened divided by the probability that an event did not happen. Whereas probability is a value that has to range between 0 and 1, odds values range from 0 to infinity. If the probability for observing an event is small, then the odds and the probability are almost identical. For example, if the probability for a vertical root fracture after an endodontic procedure is 0.001, then the odds are 0.001/0.999 or 0.001001.

Odds are commonly reported in studies because they are often easier to estimate with statistical models than probabilities. For example, the odds for developing an HIV infection after to an accidental needlestick with HIV-contaminated blood is 0.003 (0.003/0.997).

Incidence rates are an alternative measure to describe disease occurrence. One example of an incidence rate is the speedometer in a car that displays at any given time the number of kilometers being traveled per hour. In clinical trials or epidemiology, the rate reflects the number of disease occurrences per person-time or site-time. The disease rate is a ratio in which the numerator is the number of subjects or sites diagnosed with the disease of interest and the denominator is the sum of the time at risk over all subjects or sites in the population.

Incidence rates—as opposed to the previously introduced measures of disease occurrence—imply an element of time. The denominator in the incidence rate has time as the dimension. Thus, the dimension of incidence rate is 1/time. This dimension is often referred to as "person-time" or "site-time" to distinguish the time summation from ordinary clock-time. The magnitude of the incidence rate can vary between 0 and infinity. When there are no new disease onsets during the study period, the incidence rate is 0. When every person observed dies instantaneously at the start of the study (and thus the sum of the time periods is 0), then the incidence rate is infinity.

An example of the application of rates is provided in Figure 4-1, in which the number of teeth lost per 1000 tooth-years is plotted as a function of the maximum probing depth at the start of follow up. The plot suggests a nonlinear relationship between maximum pocket depth and tooth loss, with a substantial increase in tooth loss rate for teeth that have periodontal pockets of 7 mm or deeper.

For the study of risk, the population studied is usually limited to those individuals at risk for the outcome of interest. Thus, if the outcome of interest is a disease, the following subjects are excluded from the cohort: persons who already have the disease, persons who have immunity to the disease, and persons who are biologically incapable of developing the disease.

Periodontal Conditions Typically Measured Clinically

A periodontal examination can measure various characteristics of the periodontium. Dental records of periodontal patients typically contain information about the teeth that are present, missing, or impacted as well as information about the periodontal status of those teeth that are measurable. Information such as clinical probing depth, bleeding on probing, gingival recession, mobility

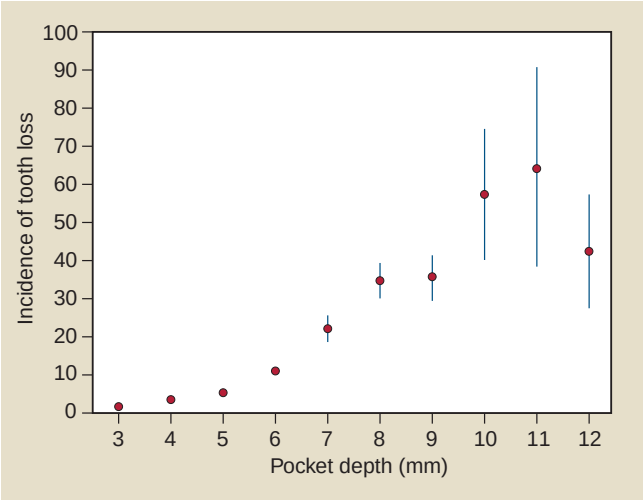

Figure 4-1 Rate of tooth loss per 1000 tooth-years as a function of maximum probing depth per tooth in a cohort of 1021 patients between the ages of 40 and 65 years under periodontal specialist care for destructive periodontal disease. *(Data from Hujoel PP, Cunha-Cruz J, Selipsky H, et al:* Periodontol 2000 *39:22-29, 2005.)*

of teeth, and the presence of furcation involvements can be charted. In addition, some clinicians may collect information about the presence of gingivitis by evaluating the color and form of the gingival tissues. These measures can be complemented with radiographic examinations that may provide information about marginal bone levels.

In research settings or in some selected private practices, additional periodontal measures may be collected, such as clinical attachment levels, microbiologic measures, gingival crevicular fluid volume, biomarkers in the crevicular fluid, and indices that measure the amount of gingival inflammation or dental plaque or debris accumulation.

Two common measures of gingival inflammation are the Gingival Index (GI) and bleeding on probing.[27] The GI was proposed in 1963 as a method for assessing the severity and quantity of gingival inflammation.[47,48] With this particular index, only gingival tissues are assessed. Each of the four gingival areas of the tooth (i.e., facial, mesial, distal, and lingual) are assessed for inflammation and rated as normal gingiva (a score of 0) to severely inflamed gingiva with a tendency to spontaneously bleed (a score of 3). Gingiva that is mildly inflamed but without bleeding on probing is given a score of 1, whereas moderately inflamed gingiva with bleeding is given a score of 2. The scores can be averaged for each patient to provide patient means. Alternatively, site-specific analyses can relate local and patient-specific factors to the GI that is measured at individual sites.[14]

Bleeding on probing is another measure of periodontal inflammation. The specific approach to obtain a bleeding measure can vary from one study to the next as well as from one clinician to another. For example, in the Third National Health and Nutrition Examination Survey (NHANES III),[54] bleeding measures were obtained as follows. First, the facial and mesiofacial sites of teeth in two randomly selected quadrants—one maxillary and one mandibular—were selected. A special probe known as the *National Institute of Dental Research probe* was used in these assessments. This color-coded probe is marked at 2, 4, 6, 8, 10, and 12 mm. To begin the assessment, the examiner dried a quadrant of teeth with air. Then, starting with the most posterior tooth in the quadrant (excluding the third molar), the examiner placed a periodontal probe 2 mm into the gingival sulcus at the facial site and carefully swept the probe from the mesiofacial to the mesial interproximal area. After probing the sites in the quadrant, the examiner assesses the presence or absence of bleeding at each probed site. The same procedure was repeated for the remaining quadrant.

Commonly used measures of periodontal tissue destruction include mean probing depth, mean attachment loss, and mean recession level.[35] The clinical protocols regarding how such mean values are collected and calculated can vary considerably. One example of how such values can be ascertained clinically is described in the National Institute of Dental and Craniofacial Research "periodontal destruction" examination.[54] This examination includes an assessment of periodontal attachment loss[61] as the distance in millimeters from the cementoenamel junction to the bottom of the gingival sulcus. This distance was measured at the facial and mesiofacial sites of teeth in a randomly selected maxillary and mandibular quadrant with the use of the indirect measurement method developed by Ramfjord.[61]

Translating Periodontal Conditions into Traditional Epidemiologic Measures of Disease Occurrence

The application of the traditional epidemiologic methods of risk, prevalence, and rate was challenging, because medical epidemiologists typically deal with patients. Dental epidemiologists deal with as many as 188 sites per patient. These periodontal sites within patients are correlated with many host-related factors. For example, gingival bleeding is suppressed in smokers.[7] Therefore, bleeding on probing in periodontal sites in smokers tends to be more alike than bleeding on probing in periodontal sites among nonsmokers. Sites within patients are not statistically independent. The statistical methodology that is used to deal with correlated observations can be complex, and, for most of the twentieth century, it was challenging to calculate the confidence intervals for site-specific risks or prevalence.[37] As a result, clinicians could not obtain reliable information about whether a periodontal site colonized with a particular microbiologic species was at an increased risk for periodontal attachment loss. These challenges may have hampered progress in the building of causal models of periodontal disease.

A common approach to dealing with this challenge of correlated observations was to summarize site-specific periodontal data at the patient level. These summaries could be calculated in a variety of ways. The information about the presence of bleeding in up to 188 periodontal sites in a patient could be summarized as the presence of at least 1 bleeding site, the presence of at least 5 bleeding sites, or a patient mean value.

The advent of modern statistical techniques to deal with the problem of correlated data made it possible to avoid summarizing site-specific information at a patient level.[14,15,31,36,37] These methods allow for the exploration of the role of patient- and site-specific factors in local site-specific events. For example, this can be used to determine whether the 3-mm loss of attachment at a site is related to site-specific factors (e.g., microflora present at that site), host factors (e.g., serum cotinine levels), or an interaction between a site-specific factor and a host factor.

True and Surrogate Measures of the Periodontal Condition

The epidemiologies of true and surrogate endpoints of periodontal disease do not necessarily coincide. *True endpoints* are tangible outcomes that directly measure how a patient feels, functions, or survives.[18] True endpoints include oral-health–related quality-of-life measurements[43,51,69] and self-reported problems, such as a positive answer to the following question: "When you brush or floss your teeth, do you notice bleeding that is both regular and that involves spitting blood-stained saliva?" *Surrogate endpoints* are intangible to the patient.[72] Surrogate endpoints in periodontal research include anatomic measures (e.g., probing depth), measures of inflammation (e.g., bleeding), microbiologic measures, and immunologic measures.[14] Surrogate endpoints are often objective, because they can be measured by the clinician (rather than relying on self-report by patients) or by laboratory methods.

Surrogate endpoints can be misleading when the goal is to provide reliable information about clinical decisions related to diagnosis, cause, treatment, or prognosis. An overview of situations in clinical research in which surrogate endpoints have led to misleading conclusions is provided in Table 82-1 on the Expert Consult website. One periodontal example is the use of systemic antibiotics that may have a beneficial impact on attachment gain[20] but a potential increased risk for tooth loss.[12]

Challenges of Obtaining Epidemiologic Measures of Periodontal Conditions and Diseases

Among the challenges that face the periodontal epidemiologist are the continuous changes in the type of surrogate data collected, the paucity of information about whether surrogate information

TABLE 4-1 Periodontal Status of the United States Population Among Adults Between the Ages of 20 and 64 Years

Status	1988 to 1994	1999 to 2004
Number of teeth present	24	25
Edentulism	6%	4%
Periodontal disease (i.e., one site with ≥3-mm attachment loss and ≥4-mm pocket depth)	15%	9%
Periodontal disease among the poor	28%	14%
Dental visits	66%	6%
Mean pocket depth	1.47 mm	1.02 mm
Mean loss of attachment	1.07 mm	0.72 mm
≥2-mm recession in at least one site	32%	21%
≥4-mm pocket depth in at least one site	23%	10%
≥4-mm attachment loss in at least one site	25%	17%

TABLE 4-2 Periodontal Status of the United States Population Among Seniors 65 Years Old and Older

Status	1988 to 1994	1999 to 2004
Number of teeth present	18	19
Edentulism	34%	27%
Periodontal disease (one site with ≥3-mm attachment loss and ≥4-mm pocket depth)	19.5%	10.5%
Periodontal disease among the poor	26.3%	16.6%
Dental visits	54%	55%
Mean pocket depth	1.47 mm	1.07 mm
Mean loss of attachment	2.04 mm	1.55 mm
≥2-mm recession in at least one site	73%	48%
≥4-mm pocket depth in at least one site	22%	12%
≥4-mm attachment loss in at least one site	59%	50%

provides reliable information regarding outcomes of tangible patient benefit (i.e., outcomes that the patient cares about), and the lack of diagnostic codes for the reasons for tooth loss.

The diversity of measures used to assess periodontal condition or disease is staggering. One survey of periodontal clinical trials conducted over a mere 4-year period indicated that a total of 153 distinct surrogate endpoints were defined and that more than 80% of these endpoints were used in fewer than 5 of the 82 trials.[27] Another survey similarly identified the diversity of methodologies and definitions as a challenging issue when systematically reviewing evidence.[66] This continuous creation of "new and improved" surrogate outcomes in periodontal research is likely an important driver of false-positive conclusions.[30]

The type of periodontal measures that are favored also depend on the era. Russell developed the Periodontal Index,[64] which scored the supporting tissues for each tooth in the mouth according to a progressive scale that gives little weight to gingival inflammation and relatively great weight to advanced periodontal disease. Although the Periodontal Index was used in the first NHANES, thereby gaining national prominence in the United States, it was never used again in any of the subsequent NHANES versions. Since then, most periodontal surveys in the United States have employed different examination protocols. Most recently, the survey methodology was changed yet again.[17] Studies of decreases in the use of scaling and root planing procedures in the state of Washington and at a national level,[9,62] long-term trends in decreasing edentulism, and decreasing periodontitis prevalence estimates in those national surveys with consistent methodology[16] suggest that periodontitis prevalence in the United States is dropping rapidly (Tables 4-1 and 4-2).

A second challenge when interpreting periodontal statistics is the common lack of information about measures that matter to patients, such as tooth loss or quality-of-life issues related to oral health. This situation creates challenges when interpreting evidence. It is similar to tracking prostate cancer by measuring inflammation or swelling of the prostate gland without knowing how this information relates to prostate cancer mortality. This challenge is further compounded by the absence of diagnostic codes for tooth loss, which has largely prevented the obtaining of reliable information about how many teeth are lost as a result of periodontal disease as opposed to dental caries.

Finally, the attempt to track a disease by only collecting a surrogate outcome measure such as probing depth from those teeth that are present leads to a type of bias that is typically referred to as *survival bias*. Most periodontal clinical trials performed during the twentieth century evaluated the effect of periodontal therapies on those teeth that survived the treatment. The more teeth that are lost, the more meaningless such data become. The imputation of data can provide an understanding of the extent to which such biases may alter the conclusions of studies.

In summary, the fundamental tool of periodontal epidemiology is a measure of the occurrence of periodontal conditions. These measures include epidemiologic statistics, such as prevalence, risk, and rate, and they focus on either patient-specific or site-specific markers, such as oral-health–related quality of life, tooth loss, anatomic measures, and measures of gingival inflammation. This wealth of possibilities when defining periodontal conditions in combination with statistical challenges when handling correlated data has made it difficult to answer even such a simple question as to whether a hidden periodontal disease epidemic occurred during the twentieth century.[32]

Epidemiologic Study Designs

The essence of epidemiology and clinical epidemiology is to relate measures of disease occurrence to suspected causes or interventions. Can the recent dramatic drop in destructive periodontal disease prevalence in the United States be attributed to a change in smoking prevalence? Can the presence of particular microbiologic species around a tooth be related to the risk of future tooth loss? Can the rate of tooth loss in a sample of elderly patients be related to the use of an antimicrobial rinse? With an evidence-based approach, these questions can be most reliably answered by three epidemiologic study designs. As mentioned earlier in this chapter and as briefly introduced in Chapter 2, these study designs (in order of decreasing reliability) are the randomized controlled trial, the cohort study, and the case–control study.

Randomized Controlled Trials

Randomized controlled trials in periodontics typically assign patients or some teeth within a patient randomly to a treatment. Patients are then monitored, and subsequent outcomes are assessed. Table 4-3 provides two examples of randomized controlled trials.

TABLE 4-3 Examples of Periodontal Randomized Controlled Trials

Periodontal Treatment	Outcome	Sample Size
Scaling and root planing for pregnant women[53]	Infants with low birth weights	823
Biphasic calcium phosphate ceramic[55]	Clinical attachment level	137

TABLE 4-4 Examples of Periodontal Cohort Studies

Periodontal Exposure	Outcome	Sample Size
Periodontal disease and tooth loss[39]	Coronary heart disease	51,529
Gingivitis[10]	Tooth loss	>500

The randomized controlled trial is the only study design that can provide a probabilistic basis for the making of a causal inference between an intervention and an outcome. Reliable inference regarding the causality of associations can be obtained if the delicate machinery of clinical trial design and analysis is strictly respected. For example, there needs to be a pretrial hypothesis that specifies the endpoint, the treatments to be compared, the patient population, and the degree of required precision. Other factors that are important for the obtaining of reliable answers include a secure randomization process, the masking of patients and clinicians, the presence of an independent data and safety monitoring board, and strict adherence to the pretrial hypothesis, which must include an intent-to-treat analysis. Such trials with exquisite attention to detail are referred to as *definitive trials,* and they are rare in any field, including periodontal research. Definitive trials are required to provide reliable answers about treatment efficacy. Most of the trials published in the literature are in the category of exploratory trials. These trials typically do not report a pretrial hypothesis, and they conclude that the intervention was successful when compared to the control.[28] Such conclusions are almost always false-positive conclusions.[30]

Cohort Studies

Cohort studies can also be referred to as *exposure-based study designs*. Subjects who are free of the disease of interest are classified with respect to an exposure (e.g., cigarette smoking, diabetes) and followed longitudinally for the assessment of periodontal outcomes. Table 4-4 provides two examples of cohort studies.

Cohorts can be defined by a geographic area, records, exposure status, or a combination of different criteria. In one study of the causal factors of edentulism, the population of interest was defined as the inhabitants of the town of Tecumseh, Michigan. Persons within this community were examined in 1959 as part of a community-wide health study. Twenty-eight years later, a subset of these patients was reexamined to study the risk factors for edentulism.[54] Some natural disease history studies of destructive periodontal disease have been conducted on the basis of geographic location. Examples include the Norwegian Longitudinal Study,[2] the Veterans Administration Longitudinal Study,[42] and the Sri Lanka study.[3] A cohort can be defined by records (e.g., schools, health insurance plans, unions, industries, professional organizations). Many cohort studies of periodontal disease outcomes are performed in patients who belong to a particular dental insurance company[13] or to a professional group.[39] Finally, cohorts can be defined on the basis of a specific exposure. For example, different levels of fluoride concentrations in the water supply have been used for the definition of cohorts.

TABLE 4-5 Examples of Periodontal Case–Control Studies

Case–Control Criteria	Investigated Risk Factors	Sample Size
Destructive periodontal disease[2]	Smoking	
Acute myocardial infarction[3]	Dental health	

Case–Control Studies

Case–control studies are typically referred to as *outcome-based study designs.* Persons with a condition or outcome of interest (i.e., cases) are compared with persons without a condition of interest (i.e., controls) with respect to the history of the suspected causal factors. Many people intuitively think along the lines of a case–control study when evaluating disease causes. For example, if an individual suffers from food poisoning after a party, he or she is likely to compare past food intake with those individuals who did *not* experience food poisoning. Similarly, if one is diagnosed with a serious illness, a common reaction is to ask, "Why me?" This is usually followed by a comparison of one's history of exposures with those of other individuals who did *not* develop the serious illness. The primary goal of a case–control study is to find out what *past* exposures or factors are different between patients with a disease versus those without the disease. Table 4-5 provides two examples of case–control studies.

The case–control study is a challenging type of study to conduct. Trying to minimize the role of bias in case–control studies requires careful planning, conduct, and analysis. Even when everything is done perfectly, one can come up with the wrong conclusions in case–control studies. A review of the quality of periodontal case–control studies suggested that they are frequently inadequately conducted and reported.[50]

Two important elements of the case–control study design are the definitions of the terms *case* and *control.* A *case* is a person in the population or study group who has been identified as having a particular disease, health disorder, or condition.[11] The case definition should be rigorous to minimize bias and misclassification; it can be based on symptoms, signs, or the results of diagnostic tests. For example, the case definition for a myocardial infarction in a case–control study of the relationship between dental health and acute myocardial infarction was as follows[3]:

1. Symptoms start within 36 hours before the admission
2. No prior myocardial infarction
3. Residing in Helsinki or an immediate neighborhood
4. Age <60 years for men and <65 years for women
5. Blood samples available at admission and at 4 weeks

In a case–control study, the *controls* should be at risk for developing the investigated disease and come from the same population that generated the cases. For example, if the investigated disease is root caries, the controls should be at risk for developing root caries (i.e., have exposed root surfaces) and originate from the same population that generated the cases that have root caries.

Causes

Human chronic diseases such as cancer, diabetes, and destructive periodontal disease have complex causes. The terms *necessary*

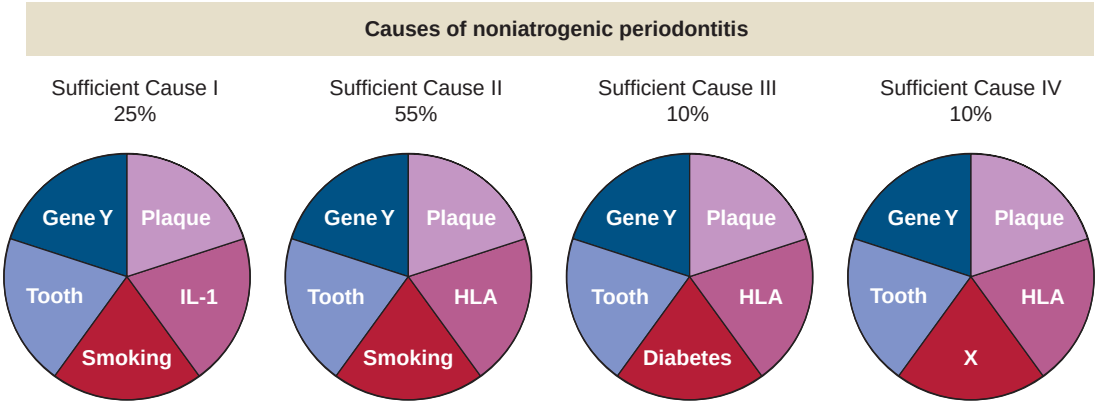

Figure 4-2 Causes of noniatrogenic periodontitis. *(Data from Rothman KJ:* Am J Epidemiol *141:90-95, 1995.)*

cause, component cause, and *sufficient cause* help to define the challenges of determining the cause of a disease and of verbalizing the complexity of chronic disease causes.[63]

The set of causes that initiate a chronic disease is referred to as a *sufficient cause.* Each sufficient cause consists of multiple component causes. Consider the hypothetical example in which four sufficient causes exist for noniatrogenic destructive periodontal disease (Figure 4-2). The first sufficient cause in this example includes the following component causes: smoking, delayed neutrophil apoptosis, an interleukin-1 gene defect, dental plaque, a tooth, and an unspecified gene defect. These different elements of a sufficient cause are referred to as *component causes.* All component causes of a sufficient cause need to be present for the disease process to be initiated. Multiple sufficient causes may be responsible for a given disease. For example, two sufficient causes exist for destructive periodontal diseases that do not include smoking.

A component cause, which is an element of all the sufficient causes for a given disease, is referred to as a *necessary cause.* For example, fermentable carbohydrates are a necessary cause for dental caries. However, there are very few examples of necessary causes: smoking is not a necessary cause of lung cancer or destructive periodontal disease, hepatitis B infection is not a necessary cause of liver cancer, and *Streptococcus viridans* is not a necessary cause of bacterial endocarditis. The search for necessary causes of disease is important, because the elimination of such causes could eradicate a disease.

The proportion of disease that results from different component causes does not add up to 100%. The component cause "smoking" is responsible for 80% of destructive periodontal disease cases; plaque is responsible for 100%, and diabetes is responsible for 10%.

The complex causal web that leads to the initiation and progression of chronic disease makes the reliable identification of causal components difficult. Over the last 50 years, epidemiology has succeeded in reliably identifying some of the causes of human chronic diseases. Now that those component causes responsible for a large proportion of cases for particular diseases (e.g., smoking for lung cancer) have been identified, the search for new causes is becoming significantly more challenging. For example, the hope existed that the Human Genome Project would lead to quick advances, but these hopes have not yet been fulfilled. Chronic diseases are typically caused not by one gene but rather by a set of many different genes, with each one responsible for only a small proportion of cases and acting in a variety of synergistic mechanisms for disease initiation.

Suspected Modifiable Causative Factors for Periodontal Disease

Tobacco Smoking. Tobacco smoking is recognized by several organizations as one of the primary drivers of periodontal disease epidemiology.[6] Many criteria for causality have been satisfied,[19] and smoking cessation has been shown to slow the progression of periodontal disease.[41,42,58] The strong impact of tobacco smoking on periodontal disease has the potential to induce spurious causal associations in other suspected risk factors for periodontal disease. For example, smoking is a risk factor for both type 2 diabetes[73] and periodontal disease, thereby making associations between type 2 diabetes and periodontal disease susceptible to biases. To obtain reliable inferences about causal factors other than smoking, studies of periodontal disease epidemiology may need to be restricted to those who have never smoked.

Nutrition. Several studies have demonstrated relationships between periodontal disease and a variety of medical conditions that center on carbohydrate metabolism, including intake of dietary carbohydrates, exercise, obesity, prediabetes, and diabetes. A systematic review of randomized controlled trials involving carbohydrates suggested that the increased intake of fermentable carbohydrates may cause an increase in gingivitis.[28] Two systematic reviews suggested that diabetes was a risk factor for destructive periodontal disease.[65,68]

Dental Plaque. Several systematic reviews have provided evidence that chemotherapeutic and mechanical plaque control will reduce gingival inflammation. Essential oils[5] and cetylpyridinium-chloride–containing mouth rinses[22] may reduce gingival inflammation. Interdental brushes may reduce dental plaque, bleeding, and probing pocket depth.[70] Power-driven toothbrushes may be more effective than manual toothbrushes for removing plaque and reducing inflammation.[67] Self-performed dental flossing may not be effective for reducing plaque and gingival inflammation.[5] Although these systematic reviews provide evidence about the role of dental plaque in gingival inflammation, such studies do not necessarily suggest that dental plaque is the primary cause of gingival inflammation.[25] Stomach acids may cause heartburn, and antacids may be effective at eliminating heartburn symptoms. However, this evidence does not make stomach acids a primary cause of heartburn. The primary cause of heartburn may, for instance, be a gluten allergy, and thus the cure of the heartburn requires the elimination of gluten from the diet. Antacids can be considered a palliative that is needed as long as the primary cause has not been identified.

There is no reliable randomized controlled trial evidence that oral hygiene has a beneficial impact on the prevention of periodontal destruction.[30,33]

The Cause of Periodontal Disease for the Patient Sitting in Your Chair

In clinical epidemiology, in a court of a law, and in modern-day clinical practice, uncertainty regarding the "cause" is an important consideration when discussing causality. The term *attributable risk percentage* is used to express the probability that a disease is caused by a suspected causative agent. For example, in a smoker with lung cancer, there may be a 20% probability that the lung cancer was caused by a factor other than smoking (e.g., radon). In an obese person with diabetes, there may be a 10% chance that obesity played no role in the onset of diabetes. For a worker with leukemia in the nuclear industry, there may be an 80% chance that the leukemia was not caused by the low-level protracted radiation exposures. One can almost never determine with certainty what caused a particular condition or disease to appear in a patient; all one can do is assign probabilities to the likelihood that a particular causal factor was responsible for the disease diagnosed in the patient. Destructive periodontal disease and periodontal inflammation are no exception to this general rule of uncertainty for determining a disease's cause. As a result, diagnostic names (e.g., plaque-induced gingival disease, non–plaque-induced inflammatory gingival lesions[46]) can be considered misnomers, because such names imply diagnostic certainty that lead to circular reasoning.[3] The principle of diagnostic uncertainty is also important when it comes to the diagnosis of periodontal conditions.

Diagnosis

Periodontal Conditions Versus Periodontal Diseases

Disease is defined as an attribute or a characteristic of a person, and *diagnosis* is the clinician's belief that the person has the attribute.[71] The World Health Organization defined disease as those adverse health consequences that include physical or psychological impairment, activity restrictions, and role limitations.[71] Certain periodontal conditions have been associated with such adverse consequences, and thus certain periodontal conditions qualify as diseases according to the World Health Organization definition. In one study, about 1 in 5 patients who presented to a periodontal specialist reported that their teeth, gums, or dentures had an impact fairly often or very often on either eating; relaxing; avoiding going out; or feeling self-conscious, pain, or discomfort. In this same study, 4 out of 10 patients rated their oral health as fair or poor.[12] Other studies have shown that gingival conditions (e.g., necrotizing ulcerative gingivitis, attachment loss in high school students) are similarly related to oral-health–related quality of life.[49]

An important thing to consider during periodontal diagnosis is to determine which periodontal conditions can be diagnosed as "diseased." Can a patient with a couple of sites with 1 or 2 mm of attachment loss be classified in this way? What about a patient with such subtle gingival inflammation that the majority of clinicians would not notice the inflammation and that even highly trained clinical examiners agree poorly about the presence of gingivitis? Disagreement regarding such questions is one of the reasons that the prevalence of gingivitis and destructive periodontal disease can range widely, depending on which reference levels are considered to be the cutoff for normal as compared with diseased.

Diagnostic Tests Available to Assess Periodontal Conditions

Diagnostic tests for periodontal disease can include anatomic measures of tissue destruction, such as probing pocket depth and clinical attachment loss; measures of gingival inflammation, such as redness, suppuration, bleeding, bleeding on probing, elevated gingival temperature, and gingival crevicular fluid markers; radiographic measures of bone destruction and tooth mobility; and microbiologic measures. These test results—in combination with factors such as age, dental history, and systemic conditions—can be translated into a distinct set of periodontal diagnoses.

Translating Periodontal Diagnostic Test Results into Periodontal Disease Diagnosis

Three different methods can be distinguished to translate clinical conditions into diseases: (1) normative or arbitrary values; (2) risk-based reference values; and (3) treatment-based reference values.[35]

Normative or Arbitrary Values to Diagnose Periodontal Disease. Diseases can be defined on the basis normative or arbitrary reference values. If the normal periodontium is assumed to have no pocket depths deeper than 3 mm, then one could define destructive periodontal disease as being present in a patient with any pocket equal to or deeper than 4 mm, or a patient with three pockets equal to or deeper than 5 mm could be classified as having destructive periodontal disease.

Alternatively, normative values could be based on parametric or nonparametric percentage cutoff values as derived from national surveys. For instance, the 97.5th percentile of the age-specific number of pockets deeper than 5 mm could be used to define destructive periodontal disease. On the basis of the NHANES III data, a 28-year-old individual with two pockets deeper than 5 mm could be diagnosed as having destructive periodontal disease, whereas five periodontal pockets deeper than 5 mm would be required in a 58-year-old individual.[34]

Diagnoses that are based on normative or arbitrary cutoffs result in normative or arbitrary disease prevalence levels, regardless of the distribution of underlying risk factors. Whether 5% or 95% of the population smoked two packs a day for 40 years, the prevalence of destructive periodontal disease would remain equal to the selected cutoff value. If all human chronic diseases were defined on the basis of an arbitrary 10th percentile cutoff value, the prevalence of all chronic disease would be equal to 5% (e.g., 5% of the population would have blood pressure that is too high, 5% would have a blood glucose level that is too high).

Risk-Based Reference Values to Diagnose Periodontal Disease. The diagnosis of disease can be set at the point on the diagnostic marker at which a steep increased risk for adverse health outcomes is present. The cutoff is still somewhat arbitrary, but it is connected to clinical realities in terms of the risk of adverse health outcomes. There is a tradeoff between the dangers of missed diagnoses when the cutoff is made too high (i.e., more specific) and the dangers of false-positive diagnoses when the cutoff is too low (i.e., more sensitive).

A risk-based diagnosis of destructive periodontal disease requires the conducting of longitudinal studies in which pocket depth at baseline is related to the risk of subsequent adverse outcomes (e.g., tooth loss). Figure 4-1 represents such a plot and suggests that a pocket depth of 6 mm could be a diagnostic marker for destructive periodontal disease, because a distinctive increased

risk for tooth loss is associated with pocket depth values of 6 mm or deeper.

The risk-based diagnosis of chronic diseases, much like the use of normative or arbitrary values, can do more harm than good. A diagnosis of obesity that is based on a body mass index of 28 may do more harm than good if weight loss treatments increase mortality risk.[40] A diagnosis of high blood pressure[60] or diabetes[52] may cause more harm than good if the prescribed treatment further increases the mortality risk. Similarly, a diagnosis of destructive periodontal disease that is based on the presence of periodontal pockets 6 mm or deeper may cause more harm than good if the suggested periodontal treatments increase periodontal morbidity.

Therapeutic Reference Values to Diagnose Periodontal Disease. A more attractive definition of disease is the therapeutic or treatment-based diagnosis. With this definition, a person is defined as diseased only if the diagnosis of disease leads to tangible benefits. Most commonly, it is best to avoid diagnosing disease unless it can be shown that the diagnosis and the subsequent treatment actually provide tangible patient outcomes. With such an approach to diagnoses, periodontal disease should only be diagnosed if it leads to less morbidity.

Periodontal Disease Diagnoses

The Medical Subject Heading (MeSH) term headings for periodontal disease, the classification systems for periodontal diseases developed by professional organizations, and a sampling of English-language periodontal textbooks indicate that periodontal disease diagnoses come and go at a fast rate. On PubMed, seven different entry terms are currently listed under the MeSH heading of *Periodontitis,* which reflects some of the distinct periodontal diagnoses that have been used in the literature since 1965. However, a recent conference consensus[38] concluded that five of those seven terms listed were obsolete. The American Academy of Periodontology reported 10 different classification systems in 20 years.[3] Periodontal textbooks have similarly reported different sets of periodontal diagnoses every decade.

Periodontal dystrophies provide one example on the apparent arbitrariness by which periodontal diagnoses come and go. Periodontal dystrophies were commonly reported from the eighteenth century until the 1960s. However, this diagnosis was subsequently decided to be obsolete,[59] because it did not appear to fit the infection paradigm. Periodontal textbooks no longer referred to the diagnosis of "periodontosis." Recently, however, an argument was made that this diagnosis should be resurrected.[56]

This example illustrates how profoundly the belief that periodontal disease is an infectious disease has influenced all aspects of clinical periodontics, including the system for classifying periodontal conditions. Periodontal diagnoses in some circles are based on the premise that periodontal diseases "follow an infection/host paradigm in which it is held that noxious materials from dental plaque bacteria induce an inflammatory response in the adjacent periodontal tissue. … Central to this paradigm is the notion that the destruction of periodontal tissues is accompanied by an inflammatory response."[2]

There are two reasons why the diagnostic classification of periodontal diseases should not be based on the infection paradigm or on any other assumed cause. First, high-level evidence from epidemiologic studies is required to determine that periodontal disease is indeed an infection. Such evidence remains largely missing.[26] Smoking and diabetes appear to be associated with destructive periodontal disease independent of microbial colonization. Second, for chronic diseases with multiple causes, it is not possible to determine the cause of the disease; therefore, it is of little clinical value to name the disease after a suspected cause. For example, periodontal disease in a diabetic patient cannot be referred to as "diabetic periodontitis." The clinician can only say that there is a certain probability that the periodontal disease in a diabetic patient is attributable to the diabetic condition.

From a clinical perspective, the ever-changing diagnostic classification systems that result from consensus conferences may be irrelevant, because no reliable evidence exists that the clinical use of such diagnostic systems improves patient outcomes. From a clinical perspective, the classification system developed by the American Dental Association and the American Academy of Periodontology may be all that is requires, because it provides information to the patient with respect to severity and prognosis, and it is free of assumptions when it comes to potential causative factors. The following four periodontal diagnoses can be recognized in the permanent dentition:

Case type I: Gingivitis
Case type II: Early periodontitis
Case type III: Moderate periodontitis
Case type IV: Advanced periodontitis

Such simple diagnostic systems of periodontal disease can have several advantages for patient care, because they provide useful information about both the severity of the disease and its prognosis.

Suggested Readings

Cunha-Cruz J, Hujoel PP, Kressin NR: Oral health-related quality of life of periodontal patients. *J Periodontal Res* 42:169–176, 2007.

DeRouen TA, Hujoel PP, Mancl LA: Statistical issues in periodontal research. *J Dent Res* 74:1731–1737, 1995.

DeRouen TA, Mancl L, Hujoel P: Measurement of associations in periodontal diseases using statistical methods for dependent data. *J Periodontal Res* 26:218–229, 1991.

Hujoel PP: Endpoints in periodontal trials: the need for an evidence-based research approach. *Periodontol 2000* 36:196–204, 2004.

Hujoel PP: Sample size, hypotheses and clinical significance: limiting false conclusions. In Giannobile WVG, Burt R, editors: *Clinical Research in Oral Health*, 2009.

International Workshop for a Classification of Periodontal Diseases and Conditions: Papers. Oak Brook, Illinois, October 30-November 2, 1999. *Ann Periodontol* 4:1–112, 1999.

Löe H: The Gingival Index, the Plaque Index and the Retention Index Systems. *J Periodontol* 38(Suppl):1967.

Löe H, Theilade E, Jensen SB: Experimental gingivitis in man. *J Periodontol* 36:177–187, 1965.

Ramfjord SP: Indices for prevalence and incidence of periodontal disease. *J Periodontol* 30:51–59, 1959.

References

References for this chapter are found on the companion website www.expertconsult.com.

References

1. The American Academy of Periodontology: *Causes of gum disease*, Chicago, 2009.
2. Armitage GC: Periodontal diagnoses and classification of periodontal diseases. *Periodontol 2000* 34:9–21, 2004.
3. Baelum V, Lopez R: Defining and classifying periodontitis: need for a paradigm shift? *Eur J Oral Sci* 111:2–6, 2003.
4. Beasley RP, Hwang LY, Lin CC, et al: Hepatocellular carcinoma and hepatitis B virus. A prospective study of 22 707 men in Taiwan. *Lancet* 2:1129–1133, 1981.
5. Berchier CE, Slot DE, Haps S, et al: The efficacy of dental floss in addition to a toothbrush on plaque and parameters of gingival inflammation: a systematic review. *Int J Dent Hyg* 6:265–279, 2008.
6. Bergstrom J: Tobacco smoking and chronic destructive periodontal disease. *Odontology* 92:1–8, 2004.
7. Bergstrom J, Bostrom L: Tobacco smoking and periodontal hemorrhagic responsiveness. *J Clin Periodontol* 28:680–685, 2001.
8. Borrell LN, Burt BA, Taylor GW: Prevalence and trends in periodontitis in the USA: the [corrected] NHANES, 1988 to 2000. *J Dent Res* 84:924–930, 2005.
9. Brown LJ, Johns BA, Wall TP: The economics of periodontal diseases. *Periodontol 2000* 29:223–234, 2002.
10. Burt BA, Ismail AI, Morrison EC, et al: Risk factors for tooth loss over a 28-year period. *J Dent Res* 69:1126–1130, 1990.
11. Chen C, Slots J: The current status and future prospects of altering the pathogenic microflora of periodontal disease. *Curr Opin Periodontol* 71–77, 1993.
12. Cunha-Cruz J, Hujoel PP, Kressin NR: Oral health-related quality of life of periodontal patients. *J Periodontal Res* 42:169–176, 2007.
13. Cunha-Cruz J, Hujoel PP, Maupome G, et al: Systemic antibiotics and tooth loss in periodontal disease. *J Dent Res* 87:871–876, 2008.
14. DeRouen TA, Hujoel PP, Mancl LA: Statistical issues in periodontal research. *J Dent Res* 74:1995, 1731–1737.
15. DeRouen TA, Mancl L, Hujoel P: Measurement of associations in periodontal diseases using statistical methods for dependent data. *J Periodontal Res* 26:218–229, 1991.
16. Dye BA, Tan S, Smith V, et al: Trends in oral health status: United States, 1988-1994 and 1999-2004. *Vital Health Stat* 11(248):1–92, 2007.
17. Eke PI, Dye BA, Wei L, CDC Periodontal Disease Surveillance workgroup, et al: James Beck (University of North Carolina, Chapel Hill, USA), Gordon Douglass (Past President, American Academy of Periodontology), Roy Page (University of Washington): Prevalence of periodontitis in adults in the United States: 2009 and 2010. *J Dent Res* 91(10):914–920, 2012.
18. Fleming TR, DeMets DL: Surrogate end points in clinical trials: are we being misled? *Ann Intern Med* 125:605–613, 1996.
19. Gelskey SC: Cigarette smoking and periodontitis: methodology to assess the strength of evidence in support of a causal association. *Community Dent Oral Epidemiol* 27:16–24, 1999.
20. Genco RJ, Goldman HM, Cohen DW: *Contemporary periodontics*, St Louis, 1990, Mosby.
21. Haffajee AD, Socransky SS, Gunsolley JC: Systemic anti-infective periodontal therapy. A systematic review. *Ann Periodontol* 8:115–181, 2003.
22. Haps S, Slot DE, Berchier CE, et al: The effect of cetylpyridinium chloride-containing mouth rinses as adjuncts to toothbrushing on plaque and parameters of gingival inflammation: a systematic review. *Int J Dent Hyg* 6:290–303, 2008.
23. Holt SC, Ebersole J, Felton J, et al: Implantation of *Bacteroides gingivalis* in nonhuman primates initiates progression of periodontitis. *Science* 239:55–57, 1988.
24. Hujoel P: Dietary carbohydrates and dental-systemic diseases. *J Dent Res* 88(6):490–502, 2009.
25. Hujoel P, Zina LG, Cunha-Cruz J, et al: Historical perspectives on theories of periodontal disease etiology. *Periodontol 2000* 58(1): 153–160, 2012.
26. Hujoel P, Zina L, Cunha-Cruz J, et al: Specific infections as the etiology of destructive periodontal disease: a systematic review. *Eur J Oral Sci* 121(1):2–6, 2013.
27. Hujoel PP: Definitive versus exploratory periodontal trials: a survey of published studies. *J Dent Res* 74:1453–1459, 1995.
28. Hujoel PP: Dietary carbohydrates and dental-systemic disease. *J Dent Res* 88:490–502, 2009.
29. Hujoel PP: Endpoints in periodontal trials: the need for an evidence-based research approach. *Periodontol 2000* 36:196–204, 2004.
30. Hujoel PP: Sample size, hypotheses and clinical significance: limiting false conclusions. In Giannobile WVG, Burt R, editors: *Clinical Research in Oral Health*, 2009.
31. Hujoel PP, Baab DA, DeRouen TA: Measures of treatment efficacy. *J Clin Periodontol* 20:601–605, 1993.
32. Hujoel PP, Bergström J, del Aguila MA, et al: A hidden periodontitis epidemic during the 20th century? *Community Dent Oral Epidemiol* 30:1–6, 2002.
33. Hujoel PP, Cunha-Cruz J, Loesche WJ, et al: Personal oral hygiene and chronic periodontitis: a systematic review. *Periodontol 2000* 37:29–34, 2005.
34. Hujoel PP, Cunha-Cruz J, Selipsky H, et al: Abnormal pocket depth and gingival recession as distinct phenotypes. *Periodontol 2000* 39:22–29, 2005.
35. Hujoel PP, DeRouen TA: A survey of endpoint characteristics in periodontal clinical trials published 1988-1992, and implications for future studies. *J Clin Periodontol* 22:397–407, 1995.
36. Hujoel PP, Loesche WJ, DeRouen TA: Assessment of relationships between site-specific variables. *J Periodontol* 61:368–372, 1990.
37. Hujoel PP, Weyant RJ, DeRouen TA: Measures of dental disease occurrence. *Community Dent Oral Epidemiol* 19:252–256, 1991.
38. International Workshop for a Classification of Periodontal Diseases and Conditions: Papers. Oak Brook, Illinois, October 30-November 2, 1999. *Ann Periodontol* 4:1–112, 1999.
39. Joshipura KJ, Rimm EB, Douglass CW, et al: Poor oral health and coronary heart disease. *J Dent Res* 75:1996, 1631–1636.
40. Kassirer JP, Angell M: Losing weight–an ill-fated New Year's resolution. *N Engl J Med* 338:52–54, 1998.
41. Krall EA, Dawson-Hughes B, Garvey AJ, et al: Smoking, smoking cessation, and tooth loss. *J Dent Res* 76:1653–1659, 1997.
42. Krall EA, Dietrich T, Nunn ME, et al: Risk of tooth loss after cigarette smoking cessation. *Prev Chronic Dis* 3:A115, 2006.
43. Leao A, Sheiham A: The development of a socio-dental measure of dental impacts on daily living. *Community Dent Health* 13:22–26, 1996.
44. Lee CL, Hsieh KS, Ko YC: Trends in the incidence of hepatocellular carcinoma in boys and girls in Taiwan after large-scale hepatitis B vaccination. *Cancer Epidemiol Biomarkers Prev* 12:57–59, 2003.
45. Levy D, Brink S: *A change of heart: how the Framingham heart study helped unravel the mysteries of cardiovascular disease*, New York, 2005, Knopf: Distributed by Random House.
46. Lindhe J, Karring T, Lang NP: *Clinical periodontology and implant dentistry*, Oxford, UK; Malden, MA, 2003, Blackwell.
47. Löe H: The Gingival Index, the Plaque Index and the Retention Index Systems. *J Periodontol* 38(Suppl):1967.
48. Löe H, Silness J: Periodontal disease in pregnancy. I. Prevalence and severity. *Acta Odontol Scand* 21:533–551, 1963.
49. Lopez R, Baelum V: Oral health impact of periodontal diseases in adolescents. *J Dent Res* 86:1105–1109, 2007.
50. Lopez R, Scheutz F, Errboe M, et al: Selection bias in case-control studies on periodontitis: a systematic review. *Eur J Oral Sci* 115:339–343, 2007.
51. McGrath C, Bedi R: An evaluation of a new measure of oral health related quality of life–OHQoL-UK(W). *Community Dent Health* 18:138–143, 2001.
52. Meinert CL, Knatterud GL, Prout TE, et al: A study of the effects of hypoglycemic agents on vascular complications in patients with adult-onset diabetes. II. Mortality results. *Diabetes* 19(Suppl):789–830, 1970.

53. Michalowicz BS, Hodges JS, DiAngelis AJ, et al: Treatment of periodontal disease and the risk of preterm birth. *N Engl J Med* 355:1885–1894, 2006.
54. National Health and Nutrition Examination Survey, III 1988-94 (NHANES III): U.S. Dept. of Health and Human Services, Centers for Disease Control and Prevention, National Center for Health Statistics, Hyattsville, MD, pp. 1 CD-ROM, 1996.
55. Nery EB, Lee KK, Czajkowski S, et al: A Veterans Administration Cooperative Study of biphasic calcium phosphate ceramic in periodontal osseous defects. *J Periodontol* 61:737–744, 1990.
56. Page RC, Sturdivant EC: Noninflammatory destructive periodontal disease (NDPD). *Periodontol 2000* 30:24–39, 2002.
57. Petersen PE, Ogawa H: Strengthening the prevention of periodontal disease: the WHO approach. *J Periodontol* 76:2187–2193, 2005.
58. Preshaw PM, Heasman L, Stacey F, et al: The effect of quitting smoking on chronic periodontitis. *J Clin Periodontol* 32:869–879, 2005.
59. Prichard JF: *The diagnosis and treatment of periodontal disease*, Philadelphia, 1979, Saunders.
60. Psaty BM, Heckbert SR, Koepsell TD, et al: The risk of myocardial infarction associated with antihypertensive drug therapies. *JAMA* 274:620–625, 1995.
61. Ramfjord SP: Indices for prevalence and incidence of periodontal disease. *J Periodontol* 30:51–59, 1959.
62. Robertson PB, del Aguila MA, Anderson MH: Trends in periodontal care. *Periodontol 2000* 30:104–110, 2002.
63. Rothman KJ: *Modern epidemiology*, ••, Little, Brown and Company.
64. Russell AL: A system of classification and scoring for prevalence surveys of periodontal disease. *J Dent Res* 35:350–359, 1956.
65. Ryan ME, Carnu O, Kamer A: The influence of diabetes on the periodontal tissues. *J Am Dent Assoc* 134(Spec No):34S–40S, 2003.
66. Savage A, Eaton KA, Moles DR, et al: A systematic review of definitions of periodontitis and methods that have been used to identify this disease. *J Clin Periodontol* 36:458–467, 2009.
67. Sicilia A, Arregui I, Gallego M, et al: A systematic review of powered vs manual toothbrushes in periodontal cause-related therapy. *J Clin Periodontol* 29(Suppl 3):39–54, discussion 90–91, 2002.
68. Skamagas M, Breen TL, LeRoith D: Update on diabetes mellitus: prevention, treatment, and association with oral diseases. *Oral Dis* 14:105–114, 2008.
69. Slade GD, Spencer AJ: Development and evaluation of the Oral Health Impact Profile. *Community Dent Health* 11:3–11, 1994.
70. Slot DE, Dorfer CE, Van der Weijden GA: The efficacy of interdental brushes on plaque and parameters of periodontal inflammation: a systematic review. *Int J Dent Hyg* 6:253–264, 2008.
71. Temple LK, McLeod RS, Gallinger S, et al: Essays on science and society. Defining disease in the genomics era. *Science* 293:807–808, 2001.
72. Temple RJ: A regulatory authority's opinion about surrogate endpoints. In Nimmo WS, Tucker GT, editors: *Clinical measurement in drug evaluation*, New York, 1995, Wiley.
73. Willi C, Bodenmann P, Ghali WA, et al: Active smoking and the risk of type 2 diabetes: a systematic review and meta-analysis. *JAMA* 298:2654–2664, 2007.

CHAPTER 5

Periodontal Pathogenesis

Philip M. Preshaw

CHAPTER OUTLINE

Histopathology of Periodontal Disease
Inflammatory Responses in the Periodontium
Linking Pathogenesis to Clinical Signs of Disease
Resolution of Inflammation
Immune Responses in Periodontal Pathogenesis
Concept of Host Susceptibility

Understanding periodontal pathogenesis is key to improving management strategies for this common, complex disease. The first challenge is to understand exactly what is meant by the term *pathogenesis.* According to *Merriam Webster's Collegiate Dictionary,* the word *pathogenesis* is defined as "the origination and development of a disease." Essentially, this refers to the step-by-step processes that lead to the development of a disease and that result in a series of changes in the structure and function of, in this case, the periodontium. In broad terms, the pathogenesis of a disease is the mechanism by which a causative factor or factors causes the disease. The word itself is derived from the Greek roots *pathos* (meaning "suffering") and *genesis* (meaning "generation or creation").

Our knowledge of periodontal pathogenesis has evolved over the years. It is important to be aware of this, because treatment philosophies have similarly changed in parallel with our improving understanding of the disease processes. For example, during the late 1800s, Willoughby D. Miller (an eminent dental researcher who established the important causal role of oral bacteria for dental caries) asserted that "during the last few years the conviction has grown continually stronger, among physicians as well as dentists, that the human mouth, as a gathering-place and incubator of diverse pathogenic germs, performs a significant role in the production of varied disorders of the body, and that if many diseases whose origin is enveloped in mystery could be traced to their source, they would be found to have originated in the oral cavity."[116] This marked the beginning of an era of dental treatment strategies that aimed to treat systemic diseases by eliminating the so-called "foci of infection" in the mouth. As a result, many patients underwent unnecessary dental clearances to manage their systemic diseases.

By the 1930s, such approaches were beginning to be questioned as evidenced by a clinical study of 200 patients with rheumatoid arthritis of whom 92 had their tonsils removed as treatment for the arthritis (even though only about 15% gave any history of tonsillitis or sore throat) and of whom 52 had some or all of their teeth removed.[28] Of the 92 who had their tonsils removed, there was no impact on the arthritis in 86 patients (although 2 got worse); of the 52 who had teeth removed, there was no benefit in 47 cases (and 3 reported a worsening of their arthritis after the extractions). The authors wrote that "focal infection is a splendid example of a plausible medical theory which is in danger of being converted by its too enthusiastic supporters into the status of an accepted fact."[28] The end of the focal infection era was signaled by an editorial in the *Journal of the American Medical Association* in 1952, which stated that "many patients with diseases presumably caused by foci of infection have not been relieved of their symptoms by removal of the foci, many patients with these same systemic diseases have no evident focus of infection, foci of infection are as common in apparently healthy persons as in those with disease."[165]

Advances in the management of periodontitis have been driven by improved knowledge of the epidemiology, causation, and pathogenesis of the disease.[195] During the 1970s, the role of plaque as the sole causative factor for periodontitis was unquestioned. In those days, nonsurgical treatment was in its infancy, and most treatment options involved surgery (e.g., gingivectomy for the treatment of shallower pockets, access flap surgery for the treatment of deeper sites). When looking back, it becomes clear that the treatment strategies used during a given time period are entirely dependent on the prevailing understanding of pathogenesis at that particular point in time. It is therefore very likely that the management options that we take for granted now will change again in the future. This is to be welcomed, because a progressive clinical discipline such as periodontology that is well founded in science and with patient benefit as its primary value should strive to improve therapeutic strategies in the light of continued discovery.

Periodontal disease results from a complex interplay between the subgingival biofilm and the host immune–inflammatory events that develop in the gingival and periodontal tissues in response to the challenge presented by the bacteria. It is generally accepted that gingivitis precedes periodontitis, but it is clear that not all cases of gingivitis progress to periodontitis. With gingivitis, the inflammatory lesion is confined to the gingiva; however, with periodontitis, the inflammatory processes extend to additionally affect the periodontal ligament and the alveolar bone. The net result of these inflammatory changes is the breakdown of the fibers of the periodontal ligament, resulting in clinical loss of attachment together with resorption of the alveolar bone.

During the 1970s and 1980s, bacterial plaque was generally considered to be preeminent as the cause of periodontitis. At that time, it was accepted that poor oral hygiene resulted in increased plaque accumulation, which in turn resulted in periodontal disease.

However, this model failed to take into account observations such as the fact that there are many individuals with poor oral hygiene who do not develop advanced periodontal disease and, conversely, that there are unfortunate individuals who, despite good oral hygiene and compliance with periodontal treatment protocols, continue to experience progressive periodontal breakdown and who would be considered to have aggressive periodontitis. These findings were confirmed by the work of Löe and colleagues, who studied Sri Lankan tea laborers who had no access to dental care and who could be divided into three main categories: (1) individuals (≈8% of the population studied) who had a rapid progression of periodontal disease; (2) those (≈81%) who had a moderate progression of such disease; and (3) those (≈11%) who demonstrated no progression of periodontal disease beyond gingivitis.[107] All patients in this population displayed abundant plaque and calculus deposits. The causative role of plaque bacteria is clear in that the bacteria initiate and perpetuate the inflammatory responses that develop in the gingival tissues. However, the major determinant of susceptibility to disease is the nature of the immune–inflammatory responses themselves. It is paradoxical that these defensive processes, which are protective by intent (i.e., to prevent the ingress of the bacteria and their products into the tissues), result in the majority of tissue damage that leads to the clinical manifestations of disease.

Periodontal disease is therefore a unique clinical entity. It is not an infection in the classic sense of the word. With most infections, a single infective organism causes the disease (e.g., human immunodeficiency virus/acquired immunodeficiency syndrome, syphilis, tuberculosis), and the identification of that organism provides the basis for the diagnosis. With periodontal disease, a large number of species are identifiable in the periodontal pocket, and many more are as yet unknown because they have not been cultured. It is impossible to conclude that a single species or even a group of species causes periodontal disease. Many of the species that are considered important in periodontal pathogenesis may simply reside in deep pockets because the pocket is a favorable environment in which they can survive (i.e., it is warm, moist, and anaerobic, with a ready supply of nutrients). Many of the unique features of periodontitis are derived from the anatomy of the periodontium, in which a hard, nonshedding surface (the tooth) is partly embedded within the body (within connective tissue), crosses an epithelial surface, and is partly exposed to the outside world (within the confines of the mouth). The bacteria that colonize this surface are effectively outside of the body (although they are in the subgingival crevice), yet the inflammatory response that develops is located within the body. These factors add complexity to our understanding of the role of the biofilm and the immune–inflammatory responses that are part of periodontal tissue breakdown.

Histopathology of Periodontal Disease

To better understand periodontal pathogenesis, it is important to have an appreciation of the histologic appearance of clinically healthy tissues as well as of inflamed gingival and periodontal tissues. It is important to note that, even in gingival tissues that clinically would be considered to be noninflamed and healthy, there is always evidence of inflammatory responses occurring if they are examined microscopically. This is normal given that there is a chronic low-grade challenge presented by the subgingival plaque bacteria. The low-grade inflammatory response that results is not detectable macroscopically at the clinical level, but it is an essential protective mechanism for combating the microbial challenge and for preventing bacteria and their products from infiltrating tissues and causing tissue damage. Our current understanding of susceptibility to periodontitis suggests that individuals who are more susceptible to the disease mount an excessive or dysregulated immune–inflammatory response for a given bacterial challenge, which leads to increased tissue breakdown as compared with those individuals who have a more normal inflammatory response.

Clinically Healthy Gingival Tissues

Clinically healthy gingival tissues (e.g., those observed in patients with excellent oral hygiene and no visible plaque deposits who typically have received regular and meticulous professional cleaning) are pink in appearance, not swollen, not inflamed, and firmly attached to the underlying tooth and bone, with minimal bleeding on probing. The dentogingival junction is a unique anatomic feature that functions to attach the gingiva to the tooth. It comprises an epithelial portion and a connective tissue portion, both of which are of fundamental importance for periodontal pathogenesis. The epithelial portion can be divided into three distinct epithelial structures: the gingival epithelium, the sulcular epithelium, and the junctional epithelium (Figure 5-1). These epithelial structures are in continuity with each other, but they have distinct structures and functions as indicated in Box 5-1.

The junctional epithelium is a particularly unique epithelial structure, because the surface cells are specialized for the purpose of attachment to the tooth.[11] Therefore, unlike other epithelial tissues elsewhere in the body, there is no opportunity for the sloughing of cells from the surface. Instead, cells at the basal layer

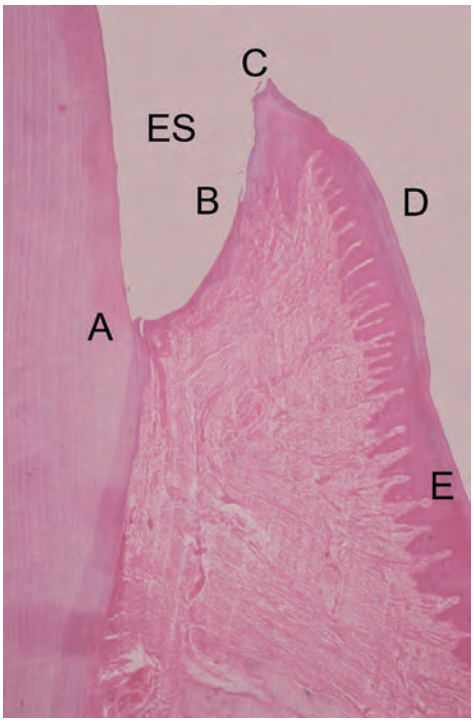

Figure 5-1 Histologic appearance of healthy gingiva. A photomicrograph of a demineralized tooth with the gingival tissues in situ (hematoxylin and eosin staining, low magnification). Amelocemental junction *(A)*. Enamel space *(ES)*. Gingival health is characterized by the organization of the epithelium into distinct zones; junctional epithelium *(A* and *B)*, sulcular epithelium *(B* and *C)*, free gingiva *(C* and *D)*, and attached gingiva *(D* and *E)*. The gingival connective tissue is composed of densely packed, organized, and interlacing collagen bundles. There are a few scattered inflammatory cells but no significant inflammatory cell infiltrate.

BOX 5-1 Characteristics of the Epithelial Component of the Dentogingival Unit

Gingival Epithelium
- Stratified squamous keratinized epithelium
- Continuous with the sulcular epithelium at the gingival crest/gingival margin
- Covers the gingiva and forms the clinically visible gingival tissues
- Covers both the free and attached gingival tissues

Sulcular Epithelium
- Stratified squamous epithelium
- Nonkeratinized
- Faces the tooth surface but is not attached to it
- Forms the soft-tissue lining of the gingival sulcus or the periodontal pocket

Junctional Epithelium
- Forms the epithelial attachment between the gingiva and the tooth
- Nonkeratinized
- Forms the floor of the sulcus/pocket
- Wraps around the tooth like a collar in health following the morphology of the cementoenamel junction
- Wider at the floor of the sulcus (i.e., 15 to 30 cells thick) and tapers apically to 3 to 4 cells thick
- Comprised of layers of flattened squamous cells oriented parallel to the tooth surface
- Surface cells attach to the tooth surface via hemidesmosomes
- Basal lamina differs from other basal laminae that oppose connective tissue in that type IV collagen is absent

continually divide and move to within two or three cell layers of the tooth surface and then migrate coronally and parallel to the tooth surface to eventually reach the floor of the sulcus and then be sloughed off into the gingival crevice. The extracellular spaces between the junctional epithelium are also greater than those seen with other epithelial tissues, with the intercellular spaces comprising approximately 18% of the volume of the epithelium. This is a result of a lower density of desmosomes in the junctional epithelium as compared with the gingival epithelium; the junctional epithelium is therefore intrinsically "leaky." This has great relevance for periodontal pathogenesis, because the widened intercellular spaces in the junctional epithelium permit the migration of neutrophils (polymorphonuclear leukocytes); they also allow macrophages from the gingival connective tissues to enter the sulcus to phagocytose bacteria, and the ingress of bacterial products and antigens occurs as well.

The connective tissue component of the dentogingival unit contains densely packed collagen fiber bundles (a mixture of type I and III collagen fibers) that are arranged in distinct patterns that maintain the functional integrity of the tissues and the tight adaptation of the soft tissues to the teeth. These include the following (see Chapter 1):
- Dentogingival fibers (extend from the cementum into the free and attached gingiva)
- Alveologingival fibers (extend from the alveolar crest into the free and attached gingiva)
- Circular fibers (wrap around the tooth, maintain the close adaptation of the free gingiva to the tooth, and interweave with other collagen fiber bundles)
- Dentoperiosteal fibers (run from the cementum over the alveolar crest and insert into the alveolar process)
- Transseptal fibers (run interdentally from the cementum just apical to the junctional epithelium and over the alveolar crest, where they insert into the cementum of the neighboring tooth).

It is important to note that, even in clinically healthy gingiva, the gingival connective tissue contains at least some inflammatory cells, particularly neutrophils. Neutrophils continually migrate through the connective tissues and pass through the junctional epithelium to enter the sulcus or pocket. These findings were reported in the classic investigations of the histology of periodontal disease reported by Page and Schroeder in 1976.[132] This low-grade inflammation occurs in response to the continued presence of bacteria and their products in the gingival crevice. There is a continuous exudate of fluid from the gingival tissues that enters the crevice and flows out as gingival crevicular fluid (GCF). In addition to the continuous migration of neutrophils through the gingival tissues, lymphocytes and macrophages also accumulate. The presence of leukocytes in the connective tissues results from the chemotactic stimulus created by the subgingival biofilm and bacterial products as well as from the chemoattractant factors produced by the host.

In clinically healthy tissues, this steady-state equilibrium between low-grade inflammation in the tissues and the continual presence of the subgingival microbiota may persist for many years or indeed for the lifetime of the individual. Overt clinical signs of gingivitis (i.e., redness, swelling, and bleeding on probing) do not develop because of several innate and structural defense mechanisms, including the following:
- The maintenance of an intact epithelial barrier (the junctional and sulcular epithelium)
- The outflow of GCF from the sulcus (dilution effect and flushing action)
- The sloughing of surface epithelial cells of the junctional and sulcular epithelium
- The presence of neutrophils and macrophages in the sulcus that phagocytose bacteria
- The presence of antibodies in the GCF (although it is not clear whether these are effective)

However, if plaque accumulation increases so that these defense mechanisms are overwhelmed, then inflammation and the classic clinical signs of gingivitis will develop. Although the development of gingivitis in response to the accumulation of plaque is fairly predictable, research has identified that a spectrum of responses may be observed, with some individuals developing marked gingival inflammation for a given plaque challenge and others developing minimal gingival inflammation.[183] These observations underscore the importance of variations in host responses between individuals in terms of gingival inflammatory responses. Furthermore, many individuals may never develop periodontitis, despite having widespread gingivitis. The host's immune–inflammatory response is fundamental for determining which individuals may progress to developing periodontitis, and it is likely that inflammatory responses are markedly different in those individuals who develop periodontitis as compared with those who never progress beyond gingivitis. The challenge that this presents clinically is that we do not yet know enough about susceptibility to periodontitis to identify these individuals before they actually develop signs of disease.

Histopathology of Gingivitis and Periodontitis

The development of gingivitis is very clearly observed from a clinical perspective. In addition, the changes that occur within the

tissues are very obvious when examined under a microscope. In broad terms, there is infiltration of the connective tissues by numerous defense cells, particularly neutrophils, macrophages, plasma cells, and lymphocytes. As a result of the accumulation of these defense cells and the extracellular release of their destructive enzymes, there is disruption of the normal anatomy of the connective tissues that results in collagen depletion and subsequent proliferation of the junctional epithelium. Vasodilation and increased vascular permeability lead to increased leakage of fluid out of the vessels and facilitate the passage of defense cells from the vasculature into the tissues, resulting in enlargement of the tissues, which appear erythematous and edematous (i.e., the clinical appearance of gingivitis). These changes are all reversible if the bacterial challenge is substantially reduced by improved oral hygiene.

The landmark studies of Page and Schroeder[132] described the histologic changes that occur in the gingival tissues as the *initial, early, established,* and *advanced* gingival lesions. In broad terms, the initial lesion corresponds with clinically healthy (but nonetheless slightly inflamed) tissues, the early lesion corresponds with the early stages of (clinically evident) gingivitis, the established lesion corresponds with chronic gingivitis, and the advanced lesion marks the transition to periodontitis, with attachment loss and bone resorption. It is important to note that these are *histologic descriptions only,* and they should not form part of a clinical diagnosis. It is not possible to make any statements about the histologic status of a patient's tissues, unless a biopsy is taken and the tissue examined microscopically. It is also important to note that these classic descriptions are primarily based on findings in experimental animals. The histologic stages of gingivitis are summarized in Box 5-2.

BOX 5-2 Key Features of the Histologic Stages of Gingivitis and Periodontitis

Initial Lesion (corresponds with clinically healthy gingival tissues)
- Slightly elevated vascular permeability and vasodilation
- Gingival crevicular fluid flows out of the sulcus
- Migration of leukocytes, primarily neutrophils, in relatively small numbers through the gingival connective tissue, across the junctional epithelium, and into the sulcus

Early Lesion (corresponds with early gingivitis that is evident clinically)
- Increased vascular permeability, vasodilation, and gingival crevicular fluid flow
- Large numbers of infiltrating leukocytes (mainly neutrophils and lymphocytes)
- Degeneration of fibroblasts
- Collagen destruction that results in collagen-depleted areas of the connective tissue
- Proliferation of the junctional and sulcular epithelium into collagen-depleted areas

Established Lesion (corresponds with established chronic gingivitis)
- Dense inflammatory cell infiltrate (i.e., plasma cells, lymphocytes, and neutrophils).
- Accumulation of inflammatory cells in the connective tissues
- Elevated release of matrix metalloproteinases and lysosomal contents from neutrophils
- Significant collagen depletion and proliferation of epithelium
- Formation of pocket epithelium that contains large numbers of neutrophils

Advanced Lesion (marks the transition from gingivitis to periodontitis)
- Predominance of neutrophils in the pocket epithelium and in the pocket
- Dense inflammatory cell infiltrate in the connective tissues (primarily plasma cells)
- Apical migration of junctional epithelium to preserve an intact epithelial barrier
- Continued collagen breakdown that results in large areas of collagen-depleted connective tissue
- Osteoclastic resorption of alveolar bone

Adapted from Page RC, Schroeder HE: *Lab Invest* 33:235-249, 1976; linked to the clinical stages of gingivitis and periodontitis.

The Initial Lesion. The initial lesion is typically said to develop within 2 to 4 days of the accumulation of plaque at a site that was otherwise free of plaque and at which there was no inflammation evident microscopically. However, this situation is probably never encountered in reality, and the gingival tissues always have characteristics of a low-grade chronic inflammatory response as a result of the continual presence of the subgingival biofilm. In other words, the initial lesion corresponds with the histologic picture that is evident in clinically healthy gingival tissues. This low-grade inflammation is characterized by dilation of the vascular network and increased vascular permeability, thus permitting the neutrophils and monocytes from the gingival vasculature to migrate through the connective tissues toward the source of the chemotactic stimulus: the bacterial products in the gingival sulcus. The upregulation of adhesion molecules such as intercellular adhesion molecule-1 (ICAM-1) and E-selectin in the gingival vasculature facilitates the migration of neutrophils from the capillaries into the connective tissues. The increased leakage of fluid from the vessels increases the hydrostatic pressure in the local microcirculation, and, as a result, GCF flow increases. Increased GCF flow has the effect of diluting bacterial products, and it also potentially has a flushing action to remove bacteria and their products from the crevice. However, given the nature of the bacterial biofilm, it is likely that only planktonic (free-floating) bacteria are removed in this way.

The Early Lesion. The early lesion develops after about 1 week of continued plaque accumulation and corresponds with the early clinical signs of gingivitis. The gingiva are erythematous in appearance as a result of the proliferation of capillaries, the opening up of microvascular beds, and continued vasodilation.[105] Increasing vascular permeability leads to increased GCF flow, and transmigrating neutrophils increase significantly in number. The predominant infiltrating cell types are neutrophils and lymphocytes (primarily thymic lymphocytes [T cells]),[136] and the neutrophils migrate through the tissues to the sulcus and phagocytose bacteria. Fibroblasts degenerate, primarily via apoptosis (programmed cell death), which increases the space available for infiltrating leukocytes. Collagen destruction occurs, which results in collagen depletion in the areas apical and lateral to the junctional and sulcular epithelium. The basal cells of these epithelial structures begin to proliferate to maintain an intact barrier against the bacteria and their products, and the epithelium can then be seen proliferating into the collagen-depleted areas of the connective tissues (Figure 5-2).[152] As a result of edema of the gingival tissues, the gingiva may appear slightly swollen, and, accordingly, the gingival sulcus becomes slightly deeper. The subgingival biofilm exploits this ecologic niche and proliferates apically (thereby rendering effective

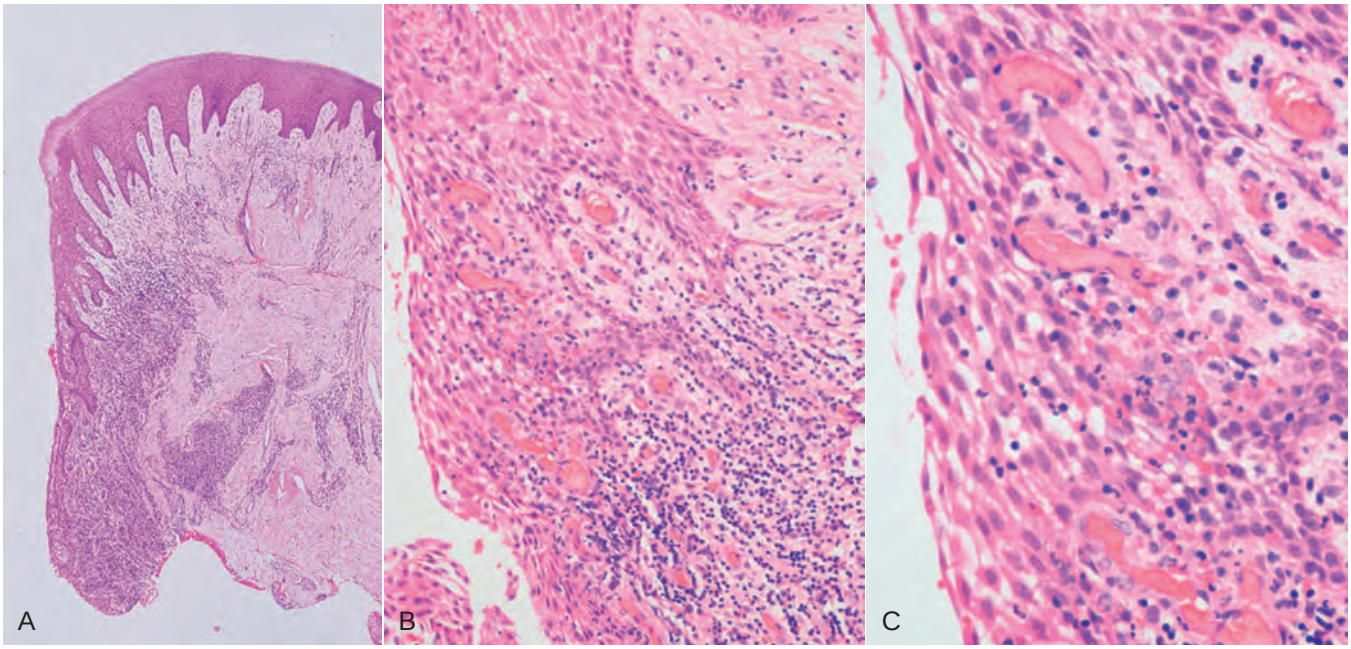

Figure 5-2 A series of photomicrographs illustrating the histologic appearance of gingivitis (hematoxylin and eosin staining). In all cases, the tooth is to the left side of the image. **A,** Low magnification of the gingiva demonstrates hyperplastic junctional and sulcular epithelium with a dense inflammatory cell infiltrate in the adjacent connective tissue. **B,** Medium magnification of the epithelial–connective tissue interface shows numerous intraepithelial inflammatory cells along with intercellular edema. The connective tissue contains dilated capillaries (hyperemia), and there is a dense inflammatory cell infiltrate. **C,** High magnification shows neutrophils and small lymphocytes transiting the sulcular epithelium.

plaque control more difficult). The early gingival lesion may persist indefinitely, or it may progress further.

The Established Lesion. The established lesion roughly corresponds with what clinicians would refer to as "chronic gingivitis." The progression from the early lesion to the established lesion depends on many factors, including the plaque challenge (the composition and quantity of the biofilm), host susceptibility factors, and risk factors (both local and systemic). In the initial work by Page and Schroeder, the established lesion was defined as being dominated by plasma cells.[132] In human studies, reports have suggested that plasma cells predominate in established gingivitis in older subjects,[51] whereas lymphocytes predominate in younger individuals, although the relevance of these findings is not clear.[23,51] What is clear from all of the studies is that there is a significant inflammatory cell infiltrate in established gingivitis that occupies a considerable volume of the inflamed connective tissues. Large numbers of infiltrating cells can be identified adjacent and lateral to the junctional and sulcular epithelium, around blood vessels, and between collagen fiber bundles.[22] Collagen depletion continues, with further proliferation of the epithelium into the connective tissue spaces. Neutrophils accumulate in the tissues and release their lysosomal contents extracellularly (in an attempt to kill bacteria that are not phagocytosed), thereby resulting in further tissue destruction. Neutrophils are also a major source of matrix metalloproteinase-8 (MMP-8; neutrophil collagenase) and MMP-9 (gelatinase B), and these enzymes are produced in large quantities in the inflamed gingival tissues as the neutrophils migrate through the densely packed collagen fiber bundles to enter the sulcus. The junctional and sulcular epithelium form a pocket epithelium that is not firmly attached to the tooth surface, that contains large numbers of neutrophils, and that is more permeable to the passage of substances into or out of the underlying connective tissue. The pocket epithelium may be ulcerated and less able to resist the passage of the periodontal probe, so bleeding on probing is a common feature of chronic gingivitis. It is important to remember that these inflammatory changes are still completely reversible if effective plaque control is reinstituted.

The Advanced Lesion. The advanced lesion marks the transition from gingivitis to periodontitis. This transition is determined by many factors, the relative importance of which is currently unknown but which includes the bacterial challenge (both the composition and the quantity of the biofilm), the host inflammatory response, and susceptibility factors, including environmental and genetic risk factors. Histologic examination reveals continued evidence of collagen destruction that extends into the periodontal ligament and the alveolar bone. Neutrophils predominate in the pocket epithelium and the periodontal pocket, and plasma cells dominate in the connective tissues. The junctional epithelium migrates apically along the root surface into the collagen-depleted areas to maintain an intact epithelial barrier. Osteoclastic bone resorption commences, and the bone retreats from the advancing inflammatory front as a defense mechanism to the prevent spread of bacteria into the bone (Figure 5-3). As the pocket deepens, plaque bacteria proliferate apically into a niche, which is very favorable for many of the species that are regarded as periodontal pathogens. The pocket presents a protected, warm, moist, and anaerobic environment with a ready nutrient supply, and, because the bacteria are effectively outside of the body (even though they are in the periodontal pocket), they are not significantly eliminated by the inflammatory response. Thus, a cycle develops in which chronic inflammation and associated tissue damage continue. The tissue damage is mainly caused by the inflammatory response, yet the

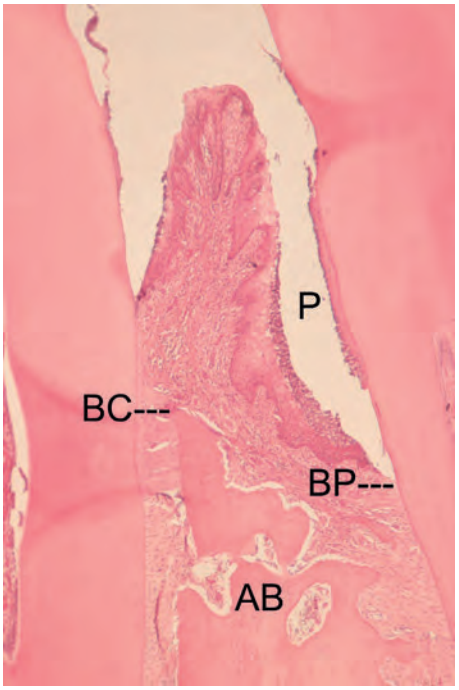

Figure 5-3 Histologic appearance of periodontitis. A photomicrograph of adjacent demineralized teeth with the interproximal gingiva and periodontium in situ (hematoxylin and eosin staining, low magnification). The root of the tooth on the right is coated with a layer of dental plaque/calculus, and there is attachment loss with the formation of a periodontal pocket *(P)*. The periodontium is densely inflamed, and there is alveolar bone *(AB)* loss that produces a triangular-shaped defect in addition to vertical bone loss. The base of the pocket *(BP)* is apical to the alveolar bone crest *(BC)*; this is called an *infrabony periodontal pocket. (From Soames JV, Southam JC:* Oral pathology, *ed 4, Oxford, UK, 2005, Oxford University Press.)*

initiating factor—the biofilm—is not eliminated. The destruction of collagen fibers in the periodontal ligament continues, bone resorption progresses, the junctional epithelium migrates apically to maintain an intact barrier, and as a result, the pocket deepens fractionally. This makes it even more difficult to remove the bacteria and to disrupt the biofilm through oral hygiene techniques, and thus the cycle is perpetuated.

Inflammatory Responses in the Periodontium

Now that the histopathology of gingivitis and periodontitis has been reviewed, it is important to consider some of the specific molecules that signal tissue damage as the inflammatory response develops. These can be broadly divided into two main groups: those derived from the subgingival microbiota (i.e., microbial virulence factors) and those derived from the host immune–inflammatory response. In terms of the relative importance of each, it is now clear that the great majority of the tissue breakdown results from the host's inflammatory processes. The bacteria are important because they initiate and perpetuate the inflammation, but they are only directly responsible for a relatively small proportion of the tissue damage that occurs.

Microbial Virulence Factors

The subgingival biofilm initiates and perpetuates inflammatory responses in the gingival and periodontal tissues. The subgingival bacteria also contribute directly to tissue damage by the release of noxious substances, but their primary importance in periodontal pathogenesis is that of activating immune–inflammatory responses that in turn result in tissue damage, which may well be beneficial to the bacteria located within the periodontal pocket by providing nutrient sources. Microbial virulence factors that are important in these processes are now discussed in turn.

Lipopolysaccharide. Lipopolysaccharides (LPSs) are large molecules composed of a lipid component (lipid A) and a polysaccharide component. They are found in the outer membrane of gram-negative bacteria, they act as endotoxins (LPSs are frequently referred to as *endotoxins*), and they elicit strong immune responses in animals. LPSs are highly conserved in gram-negative bacterial species, which reflects their importance in maintaining the structural integrity of the bacterial cells. Immune systems in animals have evolved to recognize LPS via Toll-like receptors (TLRs), a family of cell surface molecules that are highly conserved in animal species ranging from *Drosophila* (a genus of fruit flies) to humans, thereby reflecting their importance in innate immune responses. TLRs are also present in lower animals and are in fact more varied than in higher species.[26] TLRs are cell surface receptors that recognize *microbe-associated molecular patterns* (MAMPs), which are conserved molecular structures located on diverse pathogens. TLR-4 recognizes LPSs from gram-negative bacteria and functions as part of a complex of cell surface molecules, including CD14 and MD-2 (also known as *lymphocyte antigen 96*). The interaction of this CD14/TLR-4/MD-2 complex with LPSs triggers a series of intracellular events, the net result of which is the increased production of inflammatory mediators (most notably cytokines) and the differentiation of immune cells (e.g., dendritic cells) for the development of effective immune responses against the pathogens. It is particularly interesting to the periodontist that the pathogen *Porphyromonas gingivalis* has an atypical form of LPSs that are recognized by both TLR-2 and TLR-4.[38,45]

It is important to remember that a component of gram-positive cell walls, lipoteichoic acid, also stimulates immune responses, although less potently than LPSs. Lipoteichoic acid signals through TLR-2. Both LPSs and lipoteichoic acid are released from the bacteria present in the biofilm and stimulate inflammatory responses in the tissues, thereby resulting in increased vasodilation and vascular permeability, the recruitment of inflammatory cells by chemotaxis, and the release of proinflammatory mediators by the leukocytes that are recruited to the area. LPSs in particular are of key importance for initiating and sustaining inflammatory responses in the gingival and periodontal tissues.

Bacterial Enzymes and Noxious Products. Plaque bacteria produce a number of metabolic waste products that contribute directly to tissue damage. These include noxious agents such as ammonia (NH_3) and hydrogen sulfide (H_2S) as well as short-chain carboxylic acids such as butyric acid and propionic acid. These acids are detectable in GCF and found in increasing concentrations as the severity of periodontal disease increases. These substances have profound effects on host cells (e.g., butyric acid induces apoptosis in T cells, B cells, fibroblasts, and gingival epithelial cells).[95,96,166] The short-chain fatty acids may aid *P. gingivalis* infection through tissue destruction, and they may also create a nutrient supply for the organism by increasing bleeding into the periodontal pocket. The short-chain fatty acids also influence cytokine secretion by immune cells, and they may potentiate inflammatory responses after exposure to proinflammatory stimuli

such as LPS, interleukin-1β (IL-1β), and tumor necrosis factor alpha (TNF-α).[123]

Plaque bacteria produce proteases, which are capable of breaking down structural proteins of the periodontium such as collagen, elastin, and fibronectin. Bacteria produce these proteases to digest proteins and thereby provide peptides for bacterial nutrition. Bacterial proteases disrupt host responses, compromise tissue integrity, and facilitate the microbial invasion of the tissues. *P. gingivalis* produces two classes of cysteine proteases that have been implicated in periodontal pathogenesis. These are known as *gingipains,* and they include the lysine-specific gingipain Kgp and the arginine-specific gingipains RgpA and RgpB. The gingipains can modulate the immune system and disrupt immune–inflammatory responses, potentially leading to increased tissue breakdown.[138] Gingipains can reduce the concentrations of cytokines in cell culture systems,[7] and they digest and inactivate TNF-α.[25] The gingipains can also stimulate cytokine secretion via the activation of protease-activated receptors (PARs). For example, RgpB activates two different PARs (PAR-1 and PAR-2), thereby stimulating cytokine secretion,[108] and both Rgp and Kgp gingipains stimulate IL-6 and IL-8 secretion by monocytes via the activation of PAR-1, PAR-2 and PAR-3.[184]

Microbial Invasion. Microbial invasion of the periodontal tissues has long been a contentious topic. In histologic specimens, bacteria (including cocci, filaments, and rods) have been identified in the intercellular spaces of the epithelium.[50] Periodontal pathogens such as *P. gingivalis* and *Aggregatibacter actinomycetemcomitans* have been reported to invade the gingival tissues,[30,76,148] including the connective tissues.[147] *Fusobacterium nucleatum* can invade oral epithelial cells, and bacteria that routinely invade host cells may facilitate the entry of noninvasive bacteria by coaggregating with them (Figure 5-4).[47] It has also been shown that *A. actinomycetemcomitans* can invade epithelial cells and persist intracellularly.[49] The clinical relevance of these findings is unclear, however. Some investigators have suggested that tissue invasion by subgingival bacteria is an active process, whereas others have considered it to be an artifact or simply a passive translocation process.

The reports of bacteria present in the tissues have sometimes been used to justify the use of antibiotics for the treatment of periodontitis as a means of attempting to eliminate those organisms that are located in the tissues and that are therefore "protected" from mechanical disruption by root surface debridement. It has also been reported that bacteria in the tissues represent a "reservoir for reinfection" after nonsurgical management. However, until the clinical relevance of bacteria being present in the tissues is better defined, it is inappropriate to make clinical treatment decisions (e.g., whether to use adjunctive systemic antibiotics) on this premise alone.

Fimbriae. The fimbriae of certain bacterial species, particularly *P. gingivalis,* may also play a role in periodontal pathogenesis. *P. gingivalis* fimbriae stimulate immune responses, such as IL-6 secretion,[97,128] and the major fimbrial structural component of *P. gingivalis,* FimA, has been shown to stimulate nuclear factor (NF)-κβ and IL-8 in a gingival epithelial cell line via TLR-2.[5]. Monocytes are also stimulated by *P. gingivalis* FimA, secreting IL-6, IL-8, and TNF-α.[48] *P. gingivalis* fimbriae also interact with complement receptor-3 (CR-3) to activate intracellular signaling pathways that inhibit IL-12 production mediated by TLR-2 signalling.[66] This may be of clinical relevance, because IL-12 is important in the activation of natural killer (NK) cells and CD8+ cytotoxic T cells, which themselves may be important in killing *P. gingivalis*–infected host cells, such as epithelial cells. Indeed, the blockade of the CR-3 receptor promotes IL-12–mediated clearance of *P. gingivalis* and negates its virulence.[66] Bacterial fimbriae are therefore important for modifying and stimulating immune responses in the periodontium.

Bacterial Deoxyribonucleic Acid and Extracellular Deoxyribonucleic Acid. Bacterial deoxyribonucleic acid (DNA) stimulates immune cells via TLR-9, which recognizes hypomethylated CpG regions of the DNA.[93] CpG sites are regions of DNA at which a cytosine nucleotide is found next to a guanine nucleotide (separated by a phosphate molecule, which links the C and G nucleotides together, hence "CpG"). Extracellular DNA



Figure 5-4 Invasion of epithelial cells by *Fusobacterium nucleatum*. In both images, a single epithelial cell is shown being penetrated by invading *F. nucleatum* bacteria; three or four bacteria are evident in **A**, and one bacterium is evident in **B**. **A,** The ruffled surface of the epithelial cells (multiple small fingerlike projections that are much smaller than the *F. nucleatum* bacteria) is likely to be an artifact. **B,** *F. nucleatum* may facilitate the colonization of epithelial cells by bacteria that are unable to adhere or invade directly as evidenced by the single coccoid bacterium *(Streptococcus cristatus)* that has coaggregated with the *F. nucleatum* bacterium as it penetrates the epithelial cell. *(**A** and **B,** Courtesy Drs. A.E. Edwards (Imperial College, London), J.D. Rudney, and T.J. Grossman, Bath University, UK, and the University of Minnesota, US.)*

(eDNA) is likely to play a role in the development and structure of the biofilms formed by oral bacteria, and it has been identified as an important component of the matrix in a number of bacterial biofilms.[169,196] eDNA is derived from the chromosomal DNA of bacteria in biofilms, and the majority of eDNA is released after bacterial cell lysis.[2,178] However, there is also evidence that eDNA secretion may occur from bacterial cells by mechanisms that are independent of cell lysis.[68,142] The significance of this finding is not yet clear, but such "donated" DNA may be used by bacterial species as a means of increasing genetic diversity (if taken up by other bacteria), thereby contributing to antigenic variation and the spread of antibiotic resistance, and it may also modulate the host immune response. Thus eDNA may function as a source of genetic information for naturally transformable bacteria in the biofilm[191] or as a stimulus for host immunity. Little is known about the role of eDNA in oral biofilms, however. It has been demonstrated that DNA isolated from *P. gingivalis, A. actinomycetemcomitans,* and *Peptostreptococcus micros* stimulates macrophages and gingival fibroblasts to produce TNF-α and IL-6 in a dose-dependent manner; therefore, immune stimulation by bacterial DNA from subgingival species could contribute to periodontal pathogenesis.[124]

Host-Derived Inflammatory Mediators

The inflammatory and immune processes that develop in the periodontal tissues in response to the long-term presence of the subgingival biofilm are protective by intent but result in considerable tissue damage. This has sometimes been referred to as *bystander damage,* which denotes that the host response is mainly responsible for the tissue damage that occurs, thereby leading to the clinical signs and symptoms of periodontal disease. It is paradoxical that the host response causes most of the tissue damage, although this is by no means unique to periodontal disease. For example, the tissue damage that occurs in the joints in patients with rheumatoid arthritis results from prolonged and excessive inflammatory responses, and it is characterized by the increased production of many of the cytokines that are known to be important in periodontal pathogenesis. In the case of rheumatoid arthritis, the initiating factor is an autoimmune response to structural components of the joint; in periodontitis, the initiating factor is the subgingival biofilm. In both cases, however, the destructive inflammatory events are remarkably similar, although the pathogenesis varies as a result of the different anatomy.

Having understood that the majority of the tissue damage in periodontitis is derived from the excessive and dysregulated production of a variety of inflammatory mediators and destructive enzymes in response to the presence of the subgingival plaque bacteria, it is important to review the key types of mediators that orchestrate the host responses. These can be broadly divided into the cytokines, the prostanoids, and the matrix metalloproteinases (MMPs).

Cytokines. Cytokines play a fundamental role in inflammation, and they are key inflammatory mediators in periodontal disease.[140,161] They are soluble proteins, and they act as messengers to transmit signals from one cell to another. Cytokines bind to specific receptors on target cells, and they initiate intracellular signaling cascades that result in phenotypic changes in the cell via altered gene regulation.[17,176] Cytokines are effective in very low concentrations, they are produced transiently in the tissues, and they primarily act locally in the tissues in which they are produced. Cytokines are able to induce their own expression in either an autocrine or paracrine fashion, and they have pleiotropic effects (i.e., multiple biologic activities) on a large number of cell types. (Autocrine signaling means that the autocrine agent [in this case cytokines] binds to receptors on the cell that secreted the agent, whereas paracrine signaling affects other nearby cells.) Simply put, cytokines bind to cell surface receptors and trigger a sequence of intracellular events that lead ultimately to the production of protein by the target cell, which alters that cell's behavior and could result in, for example, the increased secretion of more cytokines in a positive feedback cycle that leads to inflammation.

Cytokines are produced by a large number of cell types, including infiltrating inflammatory cells (e.g., neutrophils, macrophages, lymphocytes) as well as resident cells in the periodontium (e.g., fibroblasts, epithelial cells).[172] Cytokines signal, broadcast, and amplify immune responses, and they are fundamentally important for regulating immune–inflammatory responses and for combating infections. However, they also have profound biologic effects that lead to tissue damage with chronic inflammation; the prolonged and excessive production of cytokines and other inflammatory mediators in the periodontium leads to the tissue damage that characterizes the clinical signs of the disease. For example, cytokines mediate connective tissue and alveolar bone destruction through the induction of fibroblasts and osteoclasts to produce proteolytic enzymes (i.e., MMPs) that break down structural components of these connective tissues.[12]

There is significant overlap and redundancy between the function of individual cytokines. Cytokines do not act in isolation; rather, they function in flexible and complex networks that involve both proinflammatory and anti-inflammatory effects and that bring together aspects of both innate and acquired immunity.[8] Cytokines play a key role at all stages of the immune response in periodontal disease.[140] Among the most studied (and probably the most important) cytokines in periodontal pathogenesis are the proinflammatory cytokines IL-1β and TNF-α. Both of these cytokines play a key role in the initiation, regulation, and perpetuation of innate immune responses in the periodontium, thereby resulting in vascular changes and the migration of effector cells such as neutrophils into the periodontium as part of a normal immune response to the presence of subgingival bacteria.[57]

Prostaglandins. The prostaglandins (PGs) are a group of lipid compounds derived from arachidonic acid, a polyunsaturated fatty acid found in the plasma membrane of most cells. Arachidonic acid is metabolized by cyclooxygenase-1 and -2 (COX-1 and COX-2) to generate a series of related compounds called the *prostanoids,* which includes the PGs, the thromboxanes, and the prostacyclins. PGs are important mediators of inflammation, particularly prostaglandin E_2 (PGE_2), which results in vasodilation and induces cytokine production by a variety of cell types. COX-2 is upregulated by IL-1β, TNF-α, and bacterial LPS, resulting in increased production of PGE_2 in inflamed tissues. PGE_2 is produced by various types of cells and most significantly in the periodontium by macrophages and fibroblasts. PGE_2 results in the induction of MMPs and osteoclastic bone resorption, and it has a major role in contributing to the tissue damage that characterizes periodontitis.

Matrix Metalloproteinases. MMPs are a family of proteolytic enzymes that degrade extracellular matrix molecules such as collagen, gelatin, and elastin. They are produced by a variety of cell types, including neutrophils, macrophages, fibroblasts, epithelial cells, osteoblasts, and osteoclasts. The names and functions of key MMPs are shown in Table 5-1. The nomenclature of MMPs has been based on the perception that each enzyme has its own specific substrate; for example, MMP-8 and MMP-1 are both collagenases (i.e., they break down collagen). However, it is now

TABLE 5-1 Classification of Matrix Metalloproteinases

Group	Enzyme	Name
Collagenases	MMP-1	Collagenase 1, fibroblast collagenase
	MMP-8	Collagenase 2, neutrophil collagenase
	MMP-13	Collagenase 3
Gelatinases	MMP-2	Gelatinase A
	MMP-9	Gelatinase B
Stromelysins	MMP-3	Stromelysin 1
	MMP-10	Stromelysin 2
	MMP-11	Stromelysin 3
Matrilysins	MMP-7	Matrilysin 1, pump-1
	MMP-26	Matrilysin 2
Membrane-type MMPs	MMP-14	MT1-MMP
	MMP-15	MT2-MMP
	MMP-16	MT3-MMP
	MMP-17	MT4-MMP
	MMP-24	MT5-MMP
	MMP-25	MT6-MMP
Others	MMP-12	Macrophage elastase
	MMP-19	—
	MMP-20	Enamelysin

MMPs, Matrix metalloproteinases; *MT,* membrane type.

(Adapted from Hannas AR, Pereira JC, Granjeiro JM, et al: *Acta Odontol Scand* 65:1-13, 2007).

appreciated that MMPs usually degrade multiple substrates, with significant substrate overlap between individual MMPs.[70] The substrate-based classification is still used, however, and MMPs can be divided into collagenases, gelatinases/type IV collagenases, stromelysins, matrilysins, membrane-type metalloproteinases, and others.

MMPs are secreted in a latent form (inactive) and are activated by the proteolytic cleavage of a portion of the latent enzyme. This is achieved by proteases, such as cathepsin G, produced by neutrophils. MMPs are inhibited by proteinase inhibitors, which have anti-inflammatory properties. Key inhibitors of MMPs found in the serum include the glycoprotein α_1-antitrypsin and α_2-macroglobulin, a large plasma protein produced by the liver that is capable of inactivating a wide variety of proteinases. Inhibitors of MMPs that are found in the tissues include the tissue inhibitors of metalloproteinases (TIMPs), which are produced by many cell types; the most important in periodontal disease is TIMP-1.[18] MMPs are also inhibited by the tetracycline class of antibiotics, which has led to the development of a subantimicrobial formulation of doxycycline as a licensed systemic adjunctive drug treatment for periodontitis that exploits the anti-MMP properties of this molecule (see Chapter 50).

Role of Specific Inflammatory Mediators in Periodontal Disease

Interleukin-1 Family Cytokines. The IL-1 family of cytokines comprises at least 11 members, including IL-1α, IL-1β, IL-1 receptor antagonist (IL-1Ra), IL-18, and IL-33.[140]

IL-1β plays a key role in inflammation and immunity; it is closely linked to the innate immune response, and it induces the synthesis and secretion of other mediators that contribute to inflammatory changes and tissue damage. For example, IL-1β stimulates the synthesis of PGE_2, platelet-activating factor, and nitrous oxide, thereby resulting in vascular changes associated with inflammation and increasing blood flow to the site of infection or tissue injury. IL-1β is mainly produced by monocytes, macrophages, and neutrophils and also by other cell types such as fibroblasts, keratinocytes, epithelial cells, B cells, and osteocytes.[40] IL-1β increases the expression of ICAM-1 on endothelial cells and stimulates the secretion of the chemokine CXCL8 (which is IL-8), thereby stimulating and facilitating the infiltration of neutrophils into the affected tissues. IL-1β also synergizes with other proinflammatory cytokines and PGE_2 to induce bone resorption. IL-1β has a role in adaptive immunity; it regulates the development of antigen-presenting cells (APCs) (e.g., dendritic cells), stimulates IL-6 secretion by macrophages (which in turn activates B cells), and has been shown to enhance the antigen-mediated stimulation of T cells.[13] GCF concentrations of IL-1β are increased at sites affected by gingivitis[73] and periodontitis,[99] and tissue levels of IL-1β correlate with clinical periodontal disease severity.[167] Studies in experimental animals have shown that IL-1β exacerbates inflammation and alveolar bone resorption.[88] It is clear from the multiplicity of studies that have investigated this cytokine that IL-1β plays a fundamental role in the pathogenesis of periodontal disease.[91]

IL-1α is primarily an intracellular protein that is not normally secreted and that therefore is not usually found in the extracellular environment or in the circulation.[43] Unlike IL-1β, biologically active IL-1α is constitutively expressed and likely mediates inflammation only when it is released from necrotic cells, thus acting as an "alarmin" to signal the immune system during cell and tissue damage.[16] The precise role of IL-1α in periodontal pathogenesis is not well defined, although studies have reported elevated IL-1α levels in GCF and gingival tissues in patients with periodontitis.[141] IL-1α is a potent bone-resorbing factor involved in the bone loss that is associated with inflammation.[174] It is possible that the measured level of IL-1α in gingival tissues represents intracellular IL-1α that has been released from damaged or necrotic cells. It is probable that IL-1α plays a role in periodontal pathogenesis, possibly as a signaling cytokine (signaling tissue damage) and contributing to bone resorptive activity.

IL-1Ra has structural homology to IL-1β, and it binds to the IL-1 receptor (IL-1R1). However, the binding of IL-1Ra does not result in signal transduction; therefore, IL-1Ra antagonizes the action of IL-1β.[42] IL-1Ra is important for the regulation of inflammatory responses, and it can be considered to be an anti-inflammatory cytokine. IL-1Ra levels have been reported to be elevated in the GCF and tissues of patients with periodontal disease, thereby suggesting that it has a role in immunoregulation in cases of periodontitis.[144]

IL-18 interacts with IL-1β and shares many of the pro-inflammatory effects of IL-1β.[140] It is mainly produced by stimulated monocytes and macrophages.[63] There is increasing evidence to suggest that IL-18 plays a significant role in inflammation and immunity. IL-18 results in pro-inflammatory responses, including the activation of neutrophils.[102] It is a chemoattractant for T cells,[89] and it interacts with IL-12 and IL-15 to induce interferon gamma (IFN-γ), thereby inducing T-helper (Th1) cells, which activate cell-mediated immunity.[199] Interestingly, in the absence of IL-12, IL-18 induces IL-4 and a Th2 response, which regulates humoral (antibody-mediated) immunity.[200] There is very limited direct evidence for a role of IL-18 in periodontal pathogenesis. Oral epithelial cells secrete IL-18 in response to stimulation with LPS,[145] and a correlation between GCF IL-18 levels and sulcus depth has been

reported.[82] IL-18 levels have been reported to be higher than those of IL-1β in patients with periodontitis, thereby suggesting that IL-18—along with IL-1β—is predominant in periodontitis lesions.[130] Because IL-18 has the ability to induce either Th1 or Th2 differentiation, it is likely to play an important role in periodontal disease pathogenesis.[131]

Other Interleukin-1 Family Cytokines. Six new members of the IL-1 family (IL-1F) of cytokines have been identified on the basis of their sequence homology, structure, gene location, and receptor binding.[4,10] Several of these cytokines were identified by different groups, who gave them a variety of names, and proposals were suggested for renaming all of the IL-1F cytokines in a more consistent manner, as indicated in Table 5-2. Our knowledge of the role of these cytokines in inflammation and immunity is very limited at present, and some of these cytokines may be evolutionarily redundant. IL-1F6, IL-1F8, and IL-1F9 are potential agonists (stimulating proinflammatory responses),[19,182] whereas IL-1F5 and IL-1F10 are potential antagonists.[19,33,103] IL-1F7 appears to have anti-inflammatory action.[44] It has five splice variants and one isoform, IL-1F7b, which is highly expressed by monocytes and upregulated by LPS.[24] An intracellular mode of action has been suggested for IL-1F7b; it translocates to the nucleus of macrophages, and it may act as a transcriptional modulator by reducing the production of LPS-stimulated proinflammatory cytokines, thus supporting an anti-inflammatory role for this cytokine.[163]

These novel IL-1F cytokines have limited tissue expression. For example, the agonists IL-1F6, IL-1F8, and IL-1F9 are mainly expressed in skin.[182] Therefore, although the primary cellular sources of IL-1β and IL-18 are hematopoietic cells (e.g., neutrophils, macrophages, monocytes, lymphocytes), IL-1F5 through IL-1F10 are mainly expressed outside of these lineages. At present, there are no data to support a role for IL-1F5 through IL-1F10 in periodontal pathogenesis. However, given that they are expressed mainly by epithelial cells, it will be interesting to learn whether they may play a role in inflammatory responses in the gingiva. This is relevant given the continual exposure of gingival epithelial cells to bacterial challenge, and these cytokines also have properties similar to the primary cytokines (e.g., IL-1β). For example, LPS results in the upregulation of IL-1F6, IL-1F8, and IL-1F9, and these cytokines also stimulate the secretion of IL-6 and IL-8.[182] *P. gingivalis* LPS upregulates IL-1F9 mRNA expression in monocytes, although it does not have an effect on IL-1F6, IL-1F7, IL-1F8, or IL-1F10.[10]

IL-33, which is also known as IL-1F11, is of particular interest because, uniquely among the IL-1 cytokines, it stimulates the production of Th2 cytokines (e.g., IL-5, IL-13), it activates Th2 cells, and it plays a role in mast cell development and function.[1,77,90,117,151] IL-33 is mainly found in nonimmune cells such as bronchial and arterial smooth muscle cells and epithelial cells from the bronchus.[151] It is constitutively expressed in the endothelial cells of small and large blood vessels, in the fibroblastic reticular cells of lymphoid tissues, and in epithelial cells.[27,118] Our knowledge of the expression of IL-33 in myeloid immune cells is very limited, and there are no data to support a role for IL-33 in periodontal pathogenesis. However, it has been reported that IL-33 activates Th2 cells[151] and that it is chemoattractant for these cells.[90] Given that Th2 cells are likely to play a role in the destructive phases of periodontal disease and that the balance of T-cell subsets is an important factor in determining disease progression,[58] IL-33 may yet prove to play a role in periodontal pathogenesis.

Tumor Necrosis Factor-α. TNF-α is a key inflammatory mediator in periodontal disease, and it shares many of the cellular actions of IL-1β.[64] It plays a fundamental role in immune responses, it increases neutrophil activity, and it mediates cell and tissue turnover by inducing MMP secretion. TNF-α stimulates the development of osteoclasts and limits tissue repair via the induction of apoptosis in fibroblasts. TNF-α is secreted by activated macrophages as well as by other cell types, particularly in response to bacterial LPS. The proinflammatory effects of TNF-α include the stimulation of endothelial cells to express selectins that facilitate leukocyte recruitment, the activation of macrophage IL-1β production, and the induction of PGE_2 by macrophages and gingival fibroblasts.[134] TNF-α—although it possesses similar activity to IL-1β—has a less potent effect on osteoclasts, and it is present at lower levels in inflamed gingival tissues than IL-1β.[168] GCF levels of TNF-α increase as gingival inflammation develops, and

TABLE 5-2 Nomenclature of Interleukin-1 Family Cytokines

Cytokine	Systematic Name	Function
IL-1α	IL-1F1	Intracellular protein, pro-inflammatory, contributes to bone resorption, functions as an intracellular transcriptional regulator
IL-1β	IL-1F2	Key role in inflammation and innate immunity, synergizes with other pro-inflammatory mediators, major role in adaptive immunity (i.e., regulation of T cells and myeloid cells), stimulates connective tissue breakdown and bone resorption
IL-1Ra	IL-1F3	Inhibits the action of IL-1α and IL-1β
IL-18	IL-1F4	Similar pro-inflammatory profile to IL-1β, activates neutrophils, synergizes with IL-12 to activate T-helper 1 cells
IL-1F5	IL-1F5	Anti-inflammatory effects via IL-4 induction, antagonizes IL-1F6 action
IL-1F6	IL-1F6	Pro-inflammatory but restricted expression (e.g., localized to skin)
IL-1F7	IL-1F7	Anti-inflammatory, acts as an intracellular regulator, reduces production of lipopolysaccharide-stimulated pro-inflammatory cytokines
IL-1F8	IL-1F8	Pro-inflammatory but restricted expression (e.g., localized to skin and synovial tissues)
IL-1F9	IL-1F9	Pro-inflammatory but restricted expression (e.g., localized to skin, placenta, and esophagus)
IL-1F10	IL-1F10	Putative antagonist with anti-inflammatory action.
IL-33	IL-1F11	Activation of T-helper 2 cells and mast cells, functions as an intracellular transcriptional regulator but restricted expression (e.g., endothelial cells, smooth muscle cells, and fibroblasts)

IL, Interleukin; *IL-1F,* interleukin-1 family.

higher levels are found in individuals with periodontitis.[64,73] The importance of TNF-α (and IL-1β) in periodontal pathogenesis is unquestioned, and it has particularly been highlighted by studies showing that the application of antagonists to IL-1β and TNF-α resulted in an 80% reduction in recruitment of inflammatory cells in proximity to the alveolar bone and a 60% reduction in bone loss.[6]

Interleukin-6 and Related Cytokines. The cytokines in this group—which include IL-6, IL-11, leukemia-inhibitory factor (LIF), and oncostatin M—share common signaling pathways via signal transducers glycoprotein (gp) 130.[74] IL-6 is the most extensively studied of this group, and it has pleiotropic proinflammatory properties.[87] IL-6 secretion is stimulated by cytokines such as IL-1β and TNF-α, and it is produced by a range of immune cells (e.g., T cells, B cells, macrophages, dendritic cells) as well as resident cells (e.g., keratinocytes, endothelial cells, fibroblasts).[188] IL-6 is also secreted by osteoblasts, and it stimulates bone resorption and the development of osteoclasts.[81,94] IL-6 is elevated in the cells, tissues, and GCF of patients with periodontal disease.[56,104] IL-6 may have an influence on monocyte differentiation into osteoclasts and a role in bone resorption in patients with periodontal disease.[129] IL-6 also has a key role in regulating the proliferation and differentiation of B cells and T cells, particularly the Th17 subset.[87] IL-6 therefore has an important role in periodontal pathogenesis, although it is less than that of IL-1β or TNF-α.

IL-6 also has many activities outside of the immune system, such as in the cardiovascular and nervous systems. It has an important role in hematopoiesis and in signaling the production of C-reactive protein in the liver. Furthermore, IL-6 stimulates T-cell differentiation and function, and it is important in the regulation of the balance of T-cell subsets, particularly the activation of Th17 cells (a subset of T cells that produce IL-17) and the balance with regulatory T cells (T_{reg} cells).[14]

Prostaglandin E_2. The cells primarily responsible for PGE_2 production in the periodontium are macrophages and fibroblasts. PGE_2 levels are increased in the tissues and the GCF at sites undergoing periodontal attachment loss. PGE_2 induces the secretion of MMPs as well as osteoclastic bone resorption, and it contributes significantly to the alveolar bone loss seen with periodontitis. PGE_2 release from monocytes from patients with severe or aggressive periodontitis is greater than that from monocytes from patients who are periodontally healthy.[55,126] A large body of evidence has demonstrated the importance of PGE_2 in periodontal pathogenesis, and, given that prostaglandins are inhibited by nonsteroidal anti-inflammatory drugs (NSAIDs), researchers have investigated the use of NSAIDs as potential host–response modulators in the management of periodontal disease.[193,194] However, daily administration for extended periods is necessary for the periodontal benefits to become apparent, and NSAIDs are associated with significant unwanted side effects, including gastrointestinal problems, hemorrhage (from impaired platelet aggregation resulting from inhibition of thromboxane formation), and renal and hepatic impairment. NSAIDs are therefore not indicated as adjunctive treatments for the management of periodontitis.

The prostaglandins, including PGE_2, are derived from the COX pathway of arachidonic acid metabolism. There are two main isoforms of the COX enzyme: COX-1 and COX-2. COX-1 is constitutively expressed and has antithrombogenic and cytoprotective functions. COX-2 is induced after stimulation with various cytokines, growth factors, and LPS. The inhibition of COX-1 by nonselective NSAIDs results in the majority of the unwanted effects associated with NSAID usage, such as gastrointestinal ulceration and impaired hemostasis. The induction of COX-2 results in the production of elevated quantities of prostaglandins (e.g., PGE_2); therefore, the inhibition of COX-2 by NSAIDs that selectively inhibit COX-2 results in a reduction of inflammation without the unwanted effects commonly seen after long-term NSAID use. Preliminary studies in animal models have shown that selective COX-2 inhibitors slowed alveolar bone loss,[15,78] and human studies confirmed that prostaglandin production in the periodontal tissues was modified.[189] However, in a dramatic and unfortunate development, the selective COX-2 inhibitors were later identified to be associated with significant and life-threatening adverse events, thereby resulting in several of these drugs being withdrawn from the market.[46] The selective COX-2 inhibitors therefore cannot be considered as adjunctive treatments for periodontal disease.

Matrix Metalloproteinases. MMPs are a family of zinc-dependent enzymes that are capable of degrading extracellular matrix molecules, including collagens.[18,146] MMPs play a key role in periodontal tissue destruction and are secreted by the majority of cell types in the periodontium, including fibroblasts, keratinocytes, endothelial cells, osteoclasts, neutrophils, and macrophages. In healthy tissues, MMPs are mainly produced by fibroblasts, which produce MMP-1 (also known as *collagenase-1*), and these have a role in the maintenance of the periodontal connective tissues. The transcription of genes coding for MMPs is upregulated by cytokines such as IL-1β and TNF-α.[109] MMP activity is regulated by specific endogenous TIMPs and serum glycoproteins such as α-macroglobulins, which form complexes with active MMPs and their latent precursors.[143] TIMPs are produced by fibroblasts, macrophages, keratinocytes, and endothelial cells; they are specific inhibitors that bind to MMPs in a 1 : 1 stoichiometry.[70] MMPs are also produced by some periodontal pathogens, such as *A. actinomycetemcomitans* and *P. gingivalis,* but the relative contribution of these bacterially derived MMPs to periodontal pathogenesis is small. The great majority of MMP activity in the periodontal tissues is derived from infiltrating inflammatory cells.

In healthy periodontal tissues, collagen homeostasis is a controlled process that is mediated extracellularly by MMP-1 (expressed by resident cells, primarily fibroblasts) and intracellularly by a variety of lysosomal-acid–dependent enzymes. In inflamed periodontal tissues, excessive quantities of MMPs are secreted by resident cells and by the large numbers of infiltrating inflammatory cells (particularly neutrophils) as they migrate through the tissues. As a result, the balance between MMPs and their inhibitors is disrupted, resulting in breakdown of the connective tissue matrix[18,177] and leading to the development of collagen-depleted areas within the connective tissues, as described previously. Neutrophils are key infiltrating cells in periodontitis that accumulate in large numbers in inflamed periodontal tissues (see Figure 5-2). Neutrophils have evolved to respond rapidly and aggressively to external stimuli, such as bacterial LPS, and they release large quantities of destructive enzymes very rapidly. The predominant MMPs in periodontitis, MMP-8 and MMP-9, are secreted by neutrophils,[62] and they are very effective at degrading type 1 collagen, which is the most abundant collagen type in the periodontal ligament.[111] MMP-8 and MMP-9 levels increase with increasing severity of periodontal disease and decrease after treatment.[61,62,85] The prolonged and excessive release of large quantities of MMPs in the periodontium leads to the significant breakdown of structural components of the connective tissues, thereby contributing to the clinical signs of disease.

TABLE 5-3 Biologic Activities of Selected Matrix Metalloproteinases Relevant to Periodontal Disease

MMP Type	Enzyme	Biologic Activity
Collagenases	All	Degrade interstitial collagens (types I, II, and III) Digest ECM and non-ECM molecules
	MMP-1	Keratinocyte migration and re-epithelialization Platelet aggregation
	MMP-13	Osteoclast activation
Gelatinases	All	Degrade denatured collagens and gelatin
	MMP-2	Differentiation of mesenchymal cells with inflammatory phenotype Epithelial cell migration Increased bioavailability of MMP-9
Stromelysins	All	Digest ECM molecules
	MMP-3	Activates pro-MMPs Disrupted cell aggregation Increased cell invasion
Matrilysins	MMP-7	Disrupted cell aggregation Increased cell invasion
Membrane-type MMPs	All	Digest ECM molecules Activate pro-MMP-2 (except MT4-MMP)
	MT1-MMP	Epithelial cell migration Degrade collagen types I, II and III

ECM, Extracellular matrix; *MMPs,* matrix metalloproteinases; *MT,* membrane type.

(Adapted from Hannas AR, Pereira JC, Granjeiro JM, et al: *Acta Odontol Scand* 65:1-13, 2007).

MMPs play a fundamental role in connective tissue homeostasis as well as disease pathogenesis, and they possess a wide range of biologic effects that are relevant in periodontitis (Table 5-3). MMPs are important in alveolar bone destruction. They are expressed by osteoclasts, which also express cathepsin K. Cathepsin K is a lysosomal cysteine protease that is mainly expressed in osteoclasts and that plays a key role in bone resorption and remodeling. This enzyme can catabolize collagen, gelatin, and elastin and can therefore contribute to the breakdown of bone and cartilage.

MMPs are critical for osteoclast access to the resorption site, particularly for MMP-9 and MMP-14. MMP-14 is located in the ruffled border of osteoclasts, and osteoblasts and osteocytes (but not osteoclasts) express MMP-13, which is present in resorption lacunae and which functions to remove collagen remnants left over by osteoclasts.[70] MMPs also contribute to osteoclast recruitment and activity by releasing cytokines and receptor activator of nuclear factor-κB ligand (RANKL; this is described in more detail later in this chapter). MMPs are also important in osteoblastic bone formation, including MMP-2, MMP-9, MMP-13, and MMP-14. MMP-14 also contributes to normal bone homeostasis, and MMP-14–activated transforming growth factor-β (TGF-β) inhibits osteoblast apoptosis.

Increased understanding of the importance of MMPs in periodontal pathogenesis has led to the development of systemic drug therapies to modulate the host inflammatory response by inhibiting MMP levels (see Chapter 50). Doxycycline has been used for this indication at subantimicrobial doses (i.e., 20 mg twice daily) that have no antibiotic effect but that do demonstrate an anticollagenase effect. Doxycycline, like all of the tetracyclines, possesses the ability to downregulate MMPs, and this was recognized as representing a novel treatment strategy for the management of periodontitis. The subantimicrobial formulation has been shown to inhibit collagenase activity in the gingival tissues and GCF of patients with chronic periodontitis,[61] and a large number of clinical trials have now confirmed the clinical effect of using this formulation of doxycycline as an adjunct to periodontal therapy.[139]

Chemokines. Chemokines are cytokine-like molecules that are characterized by their chemotactic activity. This activity gave rise to the term *chemokine* (i.e., they are chemotactic cytokines). Chemokines orchestrate leukocyte recruitment in physiologic and pathologic conditions,[20] so they are important for periodontal pathogenesis, which results in the chemotactic migration of neutrophils through the periodontal tissues toward the site of the bacterial challenge in the periodontal pocket.[164] Chemokines play a key role in neutrophil recruitment and the recruitment of other adaptive and innate immune cells to the site of immune and inflammatory responses. The chemokines are divided into two subfamilies according to structural similarity: the CC subfamily and the CXC subfamily.[162] The chemokine CXCL8, which is more familiarly known as IL-8, has been demonstrated to be localized in the gingival tissues in areas of plaque accumulation and in the presence of neutrophilic infiltration,[179] and it has also been found in GCF.[112] Interaction between bacteria and keratinocytes results in the upregulation of IL-8 and ICAM-1 expression in the gingival epithelium and the development of a chemotactic gradient of these molecules in the gingiva, which stimulates neutrophil migration into the tissues and the gingival sulcus.[180,181] Similar chemotactic gradients are also present in the gingiva of periodontally healthy individuals, which suggests a role for this process in the maintenance of periodontal health and which supports the findings of infiltrating neutrophils being present even in clinically healthy tissues.[181]

It is becoming clear that chemokines play an important role in leukocyte migration in periodontal disease. CCL2 and CCL5 (also known as *regulated on activation, normal T-cell expressed and secreted* [RANTES]) play a role in macrophage migration, and CCL3 (also known as *macrophage inflammatory protein-1α* [MIP-1α]) and CXCL10 play a role in T-cell migration in inflamed periodontal tissues.[164] Chemokines play important roles in immune responses, repair, and inflammation, and they regulate osteoclast activity by influencing myeloid cell differentiation into osteoclasts, which may be of particular importance in the context of periodontitis.

Anti-inflammatory Cytokines. The balance between pro-inflammatory and anti-inflammatory events is crucial for determining disease progression, and it is now clear that individual cytokines do not act in isolation but rather as part of complex networks of mediators that have different functional activities. Anti-inflammatory cytokines include IL-10, TGF-β, IL-1Ra, IL-1F5, and possibly IL-1F10.

The IL-10 family of cytokines has multiple pleiotropic effects and possesses immunosuppressive properties.[32,34] IL-10 is produced by T_{reg} cells, monocytes, and B cells, and it suppresses cytokine secretion by Th1 cells, Th2 cells, monocytes, and macrophages. The role of IL-10 in periodontal disease has been minimally studied, but animal models support that IL-10 downregulates

inflammatory responses. For example, IL-10 knockout mice are more susceptible to alveolar bone loss than wild-type mice.[149] IL-10 is also present in GCF and periodontal tissues.[79]

TGF-β is a growth factor that functions as a cytokine and has immunoregulatory roles, such as the regulation of T-cell subsets and the action of T_{reg} cells, and it also plays a role in repair and regeneration.[197] It has multifunctional roles in various cellular functions, including angiogenesis, the synthesis of the extracellular matrix, apoptosis, and the inhibition of cell growth. TGF-β levels are higher in the GCF and periodontal tissues of patients with periodontitis and gingivitis than those who are periodontally healthy.[69]

Linking Pathogenesis to Clinical Signs of Disease

Advanced forms of periodontal disease are characterized by the distressing symptoms of tooth mobility and tooth migration. These result from the loss of attachment between the tooth and its supporting tissues after the breakdown of the inserting fibers of the periodontal ligament and the resorption of alveolar bone. Having reviewed the histopathology and the inflammatory processes that develop in the periodontal tissues as a result of prolonged accumulation of dental plaque, it is now necessary to link these changes to the structural damage that occurs in the periodontium, thereby leading to the well-defined signs of disease.

It is important to note that even clinically healthy tissues demonstrate signs of inflammation when histologic sections are examined. For example, transmigrating neutrophils are evident in clinically healthy gingival tissues moving toward the sulcus for the purpose of eliminating bacteria. If the inflammation becomes more extensive, for example, because of an increase in the bacterial challenge, then vasodilation and increased vascular permeability lead to edema of the tissues as well as erythema, thereby causing gingival swelling, a slight deepening of the sulcus, and further compromising plaque removal. The increased infiltration of inflammatory cells (particularly neutrophils) and the breakdown of collagen result in the development of collagen-depleted areas below the epithelium; as a result, the epithelium proliferates to maintain tissue integrity.

The epithelium provides a physical barrier to impede the ingress of bacteria and their products; therefore, the disruption of the epithelial barrier can lead to further bacterial invasion and inflammation. Antimicrobial peptides, which are also called *defensins,* are expressed by epithelial cells, and gingival epithelial cells express two human β-defensins (hBD-1 and hBD-2). Furthermore, a cathelicidin class antimicrobial peptide, LL-37, which is found in the lysosomes of neutrophils, is also expressed in gingiva. These antimicrobial peptides are important for determining the outcomes of the host–pathogen interactions at the epithelial barrier.[192] The epithelium is therefore more than simply a passive barrier: it also has an active role in innate immunity.[37] Epithelial cells in the junctional and sulcular epithelium are in constant contact with bacterial products and respond to these by secreting chemokines (e.g., IL-8, CXCL8) to attract neutrophils, which migrate up the chemotactic gradient toward the pocket. Epithelial cells are therefore active in responding to infection and signaling further host responses.

If the bacterial challenge persists, the cellular and fluid infiltrate continues to develop, and neutrophils and other inflammatory cells soon occupy a significant volume of the inflamed gingival tissues. Neutrophils are key components of the innate immune system, and they play a fundamental role in maintaining periodontal health, despite the constant challenge presented by the plaque biofilm. Neutrophils are protective leukocytes that phagocytose and kill bacteria, and deficiencies in neutrophil functioning result in increased susceptibility to infections in general, as well as periodontal disease.[100] Neutrophils also release large quantities of destructive enzymes (e.g., MMPs) as they migrate through the tissues (particularly MMP-8 and MMP-9), which results in the breakdown of structural components of the periodontium and the development of collagen-depleted areas. Neutrophils also release their potent lysosomal enzymes, cytokines, and reactive oxygen species (ROS) extracellularly, thereby causing further tissue damage.[83] Neutrophil hyperactivity in periodontitis has also been suggested, which leads to the overproduction of damaging ROS and other mediators.[53] Patients with periodontitis have been reported to have neutrophils that demonstrate enhanced enzymatic activity and that produce increased levels of ROS.[113,114] However, it is not yet clear whether the enhanced responsiveness of neutrophils is the result of the innate properties of the neutrophils in certain individuals, of priming by cytokines or bacteria, or of a combination of these factors. It is certainly clear, however, that the extracellular release of lysosomal enzymes contributes to continued tissue damage and collagen depletion in the periodontal tissues. The degeneration of fibroblasts limits opportunities for repair, and the epithelium continues to proliferate apically, thus deepening the pocket further; the pocket is then rapidly colonized by the subgingival bacteria.

The very first steps in the development of the pocket result from a combination of factors, including the detachment of cells at the coronal aspect of the junctional epithelium, whereas those at the apical aspect migrate apically into the collagen-depleted areas; intraepithelial cleavage occurs within the junctional epithelium.[106,153,173] Epithelial tissues do not have their own blood supply and must rely on the diffusion of nutrients from the underlying connective tissues. Thus, as the epithelium proliferates and thickens, necrosis of epithelial cells that are more distant from the connective tissues can lead to intraepithelial clefts and splits, which also contribute to the early stages of pocket formation.

A cycle of chronic inflammation is therefore established in which the presence of subgingival bacteria drives inflammatory responses in the periodontal tissues; this is characterized by the infiltration by leukocytes, the release of inflammatory mediators and destructive enzymes, connective tissue breakdown, and the breakdown and proliferation of the epithelium in an apical direction. The junctional and pocket epithelium becomes thin and ulcerated and bleeds more readily, which results in more bleeding with probing. The bacteria in the pocket are never fully eliminated because they are effectively outside of the body, but their continued presence drives the destructive inflammatory response in the periodontal tissues. Attempts at effective oral hygiene are rendered more difficult by the deepening of the pocket, and the cycle continues.

Alveolar Bone Resorption

As the advancing inflammatory front approaches the alveolar bone, osteoclastic bone resorption commences.[31] This is a protective mechanism to prevent bacterial invasion of the bone, but it ultimately leads to tooth mobility and even tooth loss. The resorption of alveolar bone occurs simultaneously with the breakdown of the periodontal ligament in the inflamed periodontal tissues. There are two critical factors that determine whether bone loss occurs: (1) the concentration of inflammatory mediators in the gingival tissues must be sufficient to activate the pathways that lead to bone resorption; and (2) the inflammatory mediators must penetrate to within a critical distance of the alveolar bone.[64]

Histologic studies have confirmed that the bone resorbs so that there is always a width of noninfiltrated connective tissue of about 0.5 to 1.0 mm overlying the bone.[190] It has also been demonstrated that bone resorption ceases when there is at least a 2.5-mm distance between the site of bacteria in the pocket and the bone.[133] Osteoclasts are stimulated by pro-inflammatory cytokines and other mediators of inflammation to resorb the bone, and the alveolar bone "retreats" from the advancing inflammatory front. Osteoclasts are multinucleated cells that are formed from osteoclast progenitor cells and macrophages, and osteoclastic bone resorption is activated by a variety of mediators (e.g., IL-1β, TNF-α, IL-6, PGE_2).[121] Other mediators that also stimulate bone resorption include LIF, oncostatin M, bradykinin, thrombin, and various chemokines.[101]

Receptor Activator of Nuclear Factor-κβ Ligand and Osteoprotegerin

A key system for controlling bone turnover is the receptor activator of nuclear factor-βB (RANK)/RANK ligand (RANKL)/osteoprotegerin (OPG) system. RANK is a cell surface receptor expressed by osteoclast progenitor cells as well as by mature osteoclasts. RANKL is a ligand that binds to RANK and that is expressed by bone marrow stromal cells, osteoblasts, and fibroblasts. The binding of RANKL to RANK results in osteoclast differentiation and activation and thus bone resorption. Another ligand that binds to RANK is OPG, which is produced by bone marrow stromal cells, osteoblasts, and fibroblasts. Thus, RANKL and OPG are both cytokines that bind to RANK and that result in cellular responses. However, although RANKL promotes the activation and differentiation of osteoclasts, OPG has the opposite effect, instead inhibiting the differentiation of osteoclasts. The balance between OPG and RANKL activity can therefore drive bone resorption or bone formation.

IL-1β and TNF-α regulate the expression of RANKL and OPG, and T cells express RANKL, which binds directly to RANK on the surfaces of osteoclast progenitors and osteoclasts, thereby resulting in cell activation and differentiation to form mature osteoclasts. In individuals with periodontitis, elevated levels of proinflammatory cytokines (e.g., IL-1β, TNF-α) and increasing numbers of infiltrating T cells result in the activation of osteoclasts via RANK, which results in alveolar bone loss. It has been reported that levels of RANKL are higher and that levels of OPG are lower in sites with active periodontal breakdown as compared with sites with healthy gingiva.[35] In addition, GCF RANKL:OPG ratios are higher with periodontitis than in healthy tissue.[21] It is clear that alterations in the relative levels of these key regulators of osteoclasts play a key role in the bone loss that characterizes periodontal disease.

Resolution of Inflammation

Inflammation is an important defense mechanism to combat the threat of bacterial infection, but inflammation also results in tissue damage associated with the development and progression of most chronic diseases associated with aging, including periodontal disease.[185,187] It is becoming evident that the resolution of inflammation (i.e., "turning off" inflammation) is an active process that is regulated by specific mechanisms that restore homeostasis. It is possible that controlling or augmenting these mechanisms may lead to the development of new treatment strategies for managing chronic diseases such as periodontitis, and the mechanisms that regulate resolution of inflammation have begun to be identified.[84] The resolution of inflammation is an active process that results in a return to homeostasis, and it is mediated by specific molecules, including a class of endogenous, pro-resolving lipid mediators that includes the lipoxins, resolvins, and protectins.[157] These molecules are actively synthesized during the resolution phases of acute inflammation; they are anti-inflammatory, and they inhibit neutrophil infiltration. They are also chemoattractants, but they do not cause inflammation. For example, lipoxins stimulate infiltration by monocytes but without stimulating the release of inflammatory cytokines.

Lipoxins

The lipoxins include lipoxin A_4 (LXA_4) and lipoxin B_4 (LXB_4), and the appearance of these molecules signals the resolution of inflammation.[155] Lipoxins are lipoxygenase (LO)-derived eicosanoids that are generated from arachidonic acid. They are highly potent, they possess biologic activity at very low concentrations, and they inhibit neutrophil recruitment, chemotaxis, and adhesion.[171] Lipoxins also signal macrophages to phagocytose the remnants of apoptotic cells at sites of inflammation without generating an inflammatory response. Pro-inflammatory cytokines (e.g., IL-1β) released during acute inflammation can induce the expression of lipoxins, which promote the resolution of the inflammatory response.[115]

Resolvins and Protectins

Resolvins (i.e., resolution phase interaction products) are derived from the omega-3 fatty acids eicosapentaenoic acid and docosahexaenoic acid; they are classified as the E series resolvins (RvE) and the D series resolvins (RvD), respectively.[156] Resolvins inhibit neutrophil infiltration and transmigration as well as the production of pro-inflammatory mediators, and they have potent anti-inflammatory and immunoregulatory effects.[158] Resolvins are highly potent and have been shown to reduce neutrophil transmigration by around 50% at concentrations of as low as 10 nM.[170] Protectins are also derived from docosahexaenoic acid. They are produced by glial cells, and they reduce cytokine expression.[80] They also inhibit neutrophil infiltration, and they have been reported to reduce retinal injury[119] and stroke damage.[110]

Neutrophils play a key role in the initiation of acute inflammation in response to injury or infection. However, uncontrolled, excessive, or persistent inflammatory responses can lead to chronic disease. The release of pro-inflammatory mediators such as cytokines and prostanoids exacerbates the tissue damage. The release of endogenous pro-resolving molecules (e.g., lipoxins, resolvins, protectins) that "switch off" inflammation and act as "braking signals" for neutrophil activity indicates that the control of inflammation is an active process rather than simply being a passive dwindling of pro-inflammatory signals. These molecules could potentially offer benefit for the management of chronic diseases such as periodontitis. This concept has been tested in animal models of periodontitis.[186] In a rabbit model of *P. gingivalis* and ligature-induced experimental periodontitis, periodontal inflammation was clearly evident after 6 weeks; this was characterized by collagen breakdown and the resorption of alveolar bone. As the experiment progressed beyond 6 weeks, 4 μg/tooth of topical resolvin E1 (RvE1) was applied three times per week for an addition 6 weeks, whereas the control group continued to receive applications of topical *P. gingivalis.* In the control group, inflammation continued and led to further alveolar bone loss, with large increases in the numbers of osteoclasts and infiltrating neutrophils as well as significant collagen breakdown. However, in the animals that received the topical RvE1, the progression of periodontitis was prevented, the resolution of inflammation occurred, and the bone loss that had occurred during the first 6 weeks of the study was reversed, with evidence of bone gain in the RvE1-treated animals.[72]

These experiments suggest that the endogenous lipid mediators that resolve inflammation could offer potential for the development of new adjunctive treatments for the management of periodontitis.

Immune Responses in Periodontal Pathogenesis

The immune system is essential for the maintenance of periodontal health, and it is central to the host response to periodontal pathogens. However, if the immune response is dysregulated, inappropriate, persistent, or excessive in some way, then damaging chronic inflammatory responses such as those observed with periodontal disease can ensue. The immune response to plaque bacteria involves the integration at the molecular, cellular, and organ level of elements that are often categorized as being part of the innate immune system or the adaptive immune system. Furthermore, host responses in periodontal disease (and other major human diseases) were until recently represented as a linear progression from the host's recognition of microbial pathogens to innate immune responses dominated by the action of phagocytic neutrophils and culminating in the establishment of adaptive immune responses led by antigen-specific effector functions (e.g., cytotoxic T cells, antibodies). It is now widely appreciated that immune responses are complex biologic networks in which pathogen recognition, innate immunity, and adaptive immunity are integrated and mutually dependent.[52] This complex network is flexible and dynamic, with aspects of positive and negative regulation as well as feedback control; signals are amplified and broadcast, which leads to diverse effector functions. Furthermore, the immune system is integrated with other systems and processes, including the nervous system, hematopoiesis, and hemostasis as well as elements of tissue repair and regeneration.[122]

Observational studies of periodontal tissues and investigations of animal models and cell and tissue systems have allowed us to identify aspects of the immune response that are relevant to periodontal disease.[91,132] It is important to appreciate that immune responses, which underpin periodontal disease, have unique facets that must be considered before we can truly rationalize the detailed information that we have about individual immune cell functions and their responses to specific periodontal pathogens. Thus, we need to understand how the polymicrobial plaque biofilm (as opposed to individual species of periodontal pathogens) interacts with host immune defenses. We also need to appreciate specific immunologic properties that relate to the unique anatomy of the periodontium; to understand how immune responses contribute to the dynamic aspects of periodontal disease and its various clinical courses; and to gain a comprehension of how elements of host immunity contribute to tissue destruction, resolution, repair, and regeneration.

Innate Immunity

Defenses against infection include a wide range of mechanical, chemical, and microbiologic barriers that prevent pathogens from invading the cells and tissues of the body. Saliva, GCF, and the epithelial keratinocytes of the oral mucosa all protect the underlying tissues of the oral cavity and in particular the periodontium. The commensal microbiota (e.g., in dental plaque) may also be important for providing protection against infection by pathogenic microorganisms through effective competition for resources and ecologic niches and also by stimulating protective immune responses. The complex microanatomy of the periodontium, including the diversity of specialized epithelial tissues, presents many interesting challenges for the study of the immunopathogenesis of periodontal disease.

If bacterial products enter the tissues, then the cellular and molecular elements of the innate immune response are activated. The term *innate immunity* refers to the elements of the immune response that are determined by inherited factors (and therefore "innate"), that have limited specificity, and that are "fixed" in that they do not change or improve during an immune response or as a result of previous exposure to a pathogen. The recognition of pathogenic microorganisms and the recruitment of effector cells (e.g., neutrophils) and molecules (e.g., the complement system) are central to effective innate immunity. Innate immune responses are orchestrated by a broad range of cytokines, chemokines, and cell surface receptors, and the stimulation of innate immunity leads to a state of inflammation. If innate immune responses fail to eliminate infection (e.g., in the susceptible host), then the effector cells of adaptive immune response (lymphocytes) are activated. It is important to note that, whereas historically the adaptive immune system has been the focus of much research, more recently the innate immune system has enjoyed something of a renaissance fueled by an explosion in knowledge of pathogen-recognition systems (e.g., the TLRs). In particular, how the innate immune response signals adaptive immunity is the subject of intense research, not least in the discipline of periodontology. Thus, it is increasingly appreciated that the immune response functions as a network of interacting molecular and cellular elements in which innate immunity and adaptive (antigen-specific) immunity work together toward a common purpose. Aspects of innate immunity that are relevant to periodontal disease are now considered.

Saliva. Saliva that is secreted from the three major salivary glands (i.e., parotid, submandibular, and sublingual) as well as from the numerous minor salivary glands has an important role in the maintenance of oral and dental health. The action of shear forces associated with saliva flow is important for preventing the attachment of bacteria to the dentition and the oral mucosal surfaces. Human saliva also contains numerous molecular components that contribute to host defenses against bacterial colonization and periodontal disease (Table 5-4). These components include molecules that nonspecifically inhibit the formation of the plaque biofilm by inhibiting adherence to oral surfaces and promoting agglutination (e.g., mucins), those that inhibit specific virulence factors (e.g., histatins that neutralize LPS), and those that inhibit bacterial cell growth (e.g., lactoferrin) and that may induce cell death.[60,98] Saliva also contains specific immunoglobulin A (IgA) antibodies to periodontal pathogens that target specific antigens and that inhibit bacterial adherence. Patients with periodontal

TABLE 5-4 Constituents of Saliva That Contribute to Innate Immunity

Saliva Constituent	Host Defense Function
Antibodies (e.g., immunoglobulin A)	Inhibit bacterial adherence, promote agglutination
Histatins	Neutralize lipopolysaccharides, inhibit destructive enzymes
Cystatins	Inhibit bacterial growth
Lactoferrin	Inhibits bacterial growth
Lysozyme	Lyses bacterial cell walls
Mucins	Inhibits bacterial adherence, promotes agglutination
Peroxidase	Neutralizes bacterial hydrogen peroxide

disease have elevated levels of specific IgA as well as of IgG and IgM, which are antibodies to periodontal pathogens. However, tooth surfaces coated with a salivary pellicle can provide attachment opportunities for plaque bacteria; thus, *P. gingivalis* can attach to the salivary pellicle via fimbriae.

Epithelial Tissues. The epithelial tissues play a key role in host defense, because they are the main site of the initial interactions between plaque bacteria and the host, and they are also the site of the invasion of microbial pathogens. The keratinized epithelium of the sulcular and gingival epithelial tissues provides protection for the underlying periodontal tissue in addition to acting as a barrier against bacteria and their products.[11,154] By contrast, the unique microanatomic structure of the junctional epithelium has significant intercellular spaces; it is not keratinized, and it exhibits a higher cellular turnover rate. These properties render the junctional epithelium permeable, thereby allowing for the inward movement of microbes and their products and the outward movement of GCF and the cells and molecules of innate immunity. Furthermore, the spaces between the cells of the junctional epithelium widen with inflammation, which results in increased GCF flow.[154]

Some species of periodontal bacteria invade host epithelial tissues; at the molecular level, the processes of adhesion and invasion are coupled. Studies of the invasion of gingival epithelial cells by *P. gingivalis* have served as a paradigm for the study of this process; the infection of host cells by *P. gingivalis* involves the action of proteases and cell surface fimbriae.[3,97] Invasion by *P. gingivalis* is initiated through signaling via interaction of bacterial components with surface integrins PAR-1 and PAR-2 as well as TLRs.[67,97,198] This in turn activates intracellular signaling pathways (e.g., mitogen-activated protein kinase) and results in the reorganization of actin filaments and microtubules and a modulation of Ca^{2+} influx. It is thought that the inhibition of host cell apoptosis may facilitate the survival of intracellular bacteria and that bacteria inside of the cell are protected from the host immune response. The invasion of host cells could therefore be relevant to the spread and persistence of certain periodontal bacteria. In addition, in vivo analysis and the studies of a three-dimensional–engineered human oral mucosa model demonstrated that *P. gingivalis* can migrate through the basement membrane of epithelial layers and invade connective tissue.[3] Histologic analysis reveals that, in the presence of periodontitis, epithelial cells become more rounded and tend to detach from the underlying connective tissue.[154] Proteases break down cell-to-cell junctions in epithelial tissues by digesting transmembrane proteins and adhesion molecules (e.g., E-cadherin). Microanatomic changes associated with the onset of periodontitis, such as the widening of the spaces between the cells of the junctional epithelium and the development of the pocket epithelium, further facilitate bacterial invasion. Bacterial spread through the basement membrane and into the underlying connective tissues is facilitated by bacterial-derived proteases and host proteases derived from infiltrating neutrophils (e.g., MMPs).

At the cellular and molecular levels, most in vitro studies of epithelial cell responses to periodontal bacteria have been carried out in primary gingival epithelial cells or various immortalized cell lines derived from oral epithelial tissue; these studies have provided insight into host cell responses to periodontal bacteria.[3,67,69,198] Epithelial cells also constitutively express antimicrobial peptides (e.g., hBDs, LL-37), and the synthesis and secretion of these molecules is upregulated in response to periodontal bacteria. Neutrophils are also a source of antimicrobial peptides (i.e., α-defensins). Antimicrobial peptides are small, polycationic peptides that disrupt bacterial cell membranes and thereby directly kill bacteria with broad specificity.

The different categories of antimicrobial peptides are defined on the basis of structural homology. The α-defensins (e.g., human neutrophil peptides 1 through 4) are expressed by neutrophils and as such are commonly found in GCF. The hBDs (e.g., hBDs 1 through 3) are expressed in the gingival epithelial cells, the salivary glands, and the tongue as well as in immune cells (e.g., macrophages, dendritic cells); some hBDs are constitutively expressed, and others are only expressed in response to cytokines and bacterial products (e.g., gingipains of *P. gingivalis*).[3,37] A third class of antimicrobial peptides are the cathelicidins, of which LL-37 is the only known peptide in this category that is expressed in human cells. LL-37 is expressed in high levels in the junctional epithelium. However, like the hBDs, LL-37 has a widespread expression pattern in the mouth; it is found in the salivary glands, the tongue, and the leukocytes as well as in the connective tissue. Antimicrobial peptides have more recently assumed greater importance, because it has been recognized that they have a wider role in regulating innate and adaptive immune responses to infection.[41] Thus, these molecules have chemokine-like activity in that they stimulate the chemotaxis of a range of leukocytes involved in innate and acquired immunity. Antimicrobial peptides also stimulate mast cell degranulation and cytokine production, and they likely have a role in wound healing through their effect on keratinocyte differentiation. Furthermore, there is some interest in their possible role in therapy for oral inflammatory diseases.[41]

Epithelial cells that are directly stimulated with bacterial components and cytokines produce MMPs, which contribute to a loss of connective tissue. Epithelial cells also secrete a range of cytokines in response to periodontal bacteria (e.g., *P. gingivalis, A. actinomycetemcomitans, F. nucleatum, P. intermedia*), which signal immune responses. These include the pro-inflammatory cytokines IL-1β, TNF-α, and IL-6 as well as the chemokine IL-8 (CXCL8) and the monocyte chemoattractant protein-1 (MCP-1), which serve to signal neutrophil and monocyte migration from the vasculature into the periodontal tissue.

In some (but not all) experimental systems, *P. gingivalis* has been shown to inhibit IL-8; it has been suggested that this may result in a temporary local immune suppression in the periodontium and facilitate the accumulation and invasion of pathogenic periodontal bacteria and the initiation of periodontitis.[39,67] *P. gingivalis* is an example of one periodontal pathogen with a range of virulence factors that affect host immune defenses,[67,97] as indicated in Table 5-5.

TABLE 5-5 Virulence Factors of *Porphyromonas gingivalis* That Interact With the Immune System

Virulence Factor	Effect on Immune System
Proteases (gingipains)	Degradation of signalling molecules (CD14) and cytokines (e.g., interleukin-1β, interleukin-6)
Cell invasion capabilities	Inhibition of interleukin-8 secretion
Lipopolysaccharides	Antagonism of the stimulatory effects of lipopolysaccharides from other species; no upregulation of E-selectin
Fimbriae	Inhibition of interleukin-12 secretion in macrophages
Cell surface polysaccharides	Resistance to complement
Short-chain fatty acids	Induction of apoptosis in host cells

Gingival Crevicular Fluid. GCF originates from the postcapillary venules of the gingival plexus. It has a flushing action in the gingival crevice, but it also likely functions to bring the blood components (e.g., neutrophils, antibodies, complement components) of the host defenses into the sulcus.[65] The flow of GCF increases in inflammation, and neutrophils are an especially important component of GCF in periodontal health and disease.[91]

Pathogen Recognition and Activation of Cellular Innate Responses. If plaque bacteria and their products penetrate the periodontal tissues, specialized "sentinel cells" of the immune system recognize their presence and signal protective immune responses. These cells include macrophages and dendritic cells, which express a range of pattern recognition receptors (PRRs) that interact with specific molecular structures on microorganisms called MAMPs. The activation of PRRs activates innate immune responses to provide immediate protection, and adaptive immunity is also activated with the aim of establishing a sustained antigen-specific defense. Excessive and inappropriate or dysregulated immune responses lead to chronic inflammation and the concomitant tissue destruction associated with periodontal disease. A glossary of terms relevant to periodontal immunobiology is presented in Table 5-6.

The best studied of the signaling systems involved in the recognition of plaque bacteria is the interaction of bacterial LPS with TLRs: *P. gingivalis, A. actinomycetemcomitans,* and *F. nucleatum* all possess LPS molecules that interact with TLR-4 to activate myeloid immune cells. However, individual species of plaque bacteria have a wide variety of MAMPs, which may interact with PRRs. For example, *P. gingivalis* LPS signals via TLRs (predominantly TLR-2), and fimbriae, proteases, and DNA from *P. gingivalis* are all recognized by host cells through interaction with specific PRRs. A number of nonimmune cells in the periodontium (e.g., epithelial cells, fibroblasts) also express PRRs and may recognize and respond to MAMPs from plaque bacteria.

Although the signaling pathways activated by PRRs may be diverse, in general terms, they converge to elicit similar host cell responses in the form of the upregulation of cytokine secretion and, in the case of APCs such as dendritic cells, cell differentiation that leads to enhanced signaling of the adaptive immune response. Dendritic cells also have C-type lectin receptors (e.g., mannose receptor, langerin, DC-SIGN) that recognize glycans on pathogens. However, the role of these interactions in periodontal disease is not known.

The signaling of cytokine responses via PRRs influences innate immunity (e.g., neutrophil activity), adaptive immunity (e.g., T-cell effector phenotype), and the development of destructive inflammation (e.g., the activation of fibroblasts and osteoclasts). A number of cytokines are particularly important to innate immune signaling, and there is now good evidence that these have a role in immune responses in the periodontium. The archetypal pro-inflammatory cytokine is IL-1β, which exerts its action directly by activating other cells that express the IL-1R1 receptor (e.g., endothelial cells) or by stimulating the synthesis and secretion of other, secondary mediators such as PGE_2 and nitrous oxide. The effect of IL-1β is amplified via a synergistic action with other cytokines such as TNF-α. The upregulation of ICAM-1 and E-selectin on endothelial cells is central to the migration of neutrophils into the periodontium, and this is stimulated by IL-1β and TNF-α. IL-1β also stimulates the secretion of the chemokine IL-8, which stimulates neutrophil chemotaxis; this is described in more detail in the next section of this chapter. IL-1β and TNF-α also activate MMP secretion from fibroblasts and osteoclasts; this facilitates the movement of neutrophils through the connective tissues (and thus protective innate responses) but also contributes to the tissue destruction associated with periodontal disease, along with MMPs from neutrophils.

Other cytokines that are upregulated as a result of the activation of PRRs include IL-6, which influences the development of a number of immune cells (e.g., B cells, dendritic cells) and stimulates osteoclast differentiation and thus bone turnover. Other cytokines provide specific signals that contribute to the development of specific CD4+ T-helper cell subsets (e.g., IL-4, IL-12, IL-18; see the section of this chapter entitled "Adaptive Immunity"). In addition to cytokines that activate immune responses, other cytokines are upregulated that have a role in immune regulation by suppressing cytokine activity; these include IL-1Ra, IL-10, and TGF-β. Cytokines from T-cell subsets feedback to and modify innate immune responses; for example, IFN-γ from Th1 cells activates macrophages, IL-17 from Th17 cells synergizes with IL-1β and TNF-α to reinforce inflammatory reactions, and IL-10 and TGF-β suppress immune responses. The action of many cytokines produced in the periodontium is not limited to one aspect of the host immune response; in other words, cytokines are pleiotropic (i.e., they have multiple effects).

Neutrophil Function. Although macrophages have phagocytic capabilities, neutrophils are the "professional" phagocytes that are critical to the clearance of bacteria that invade host tissues. Neutrophils are present in clinically healthy gingival tissues, and they migrate through the intercellular spaces of the junctional epithelium into the sulcus.[90,154] This is part of a "low-grade defense" against plaque bacteria, and it is necessary to prevent inflammation and periodontal tissue damage.[154] The importance of neutrophils to the maintenance of periodontal health is demonstrated clinically by the observations of severe periodontitis in patients with neutrophil

TABLE 5-6 Glossary of Terms Relevant to Periodontal Immunobiology

Term	Definition
Cluster of differentiation (CD)	Molecules that define different immune cell lineages, functional phenotypes, and stages of development
CD4	Characteristic coreceptor molecule of T-helper cells
CD8	Characteristic coreceptor molecule of cytotoxic T-cells
CD14	Binds to LPS, facilitates interaction with TLRs, exists in soluble and membrane-bound forms
Cyclooxygenase-1 (COX-1) and cyclooxygenase-2 (COX-2)	Enzymes responsible for synthesis of inflammatory mediators (e.g., PGE_2) from arachidonic acid

TABLE 5-6 Glossary of Terms Relevant to Periodontal Immunobiology—cont'd

Term	Definition
Complement receptor-3 (CR-3)	Cellular receptor for complement that interacts with *Porphyromonas gingivalis* fimbriae to signal cytokines
CXCL and CCL	Two structurally distinct groups of chemokines, which are small proteins that activate and stimulate the movement of leukocytes
Dendritic cell-specific intercellular adhesion molecule (ICAM)-3–grabbing nonintegrins (DC-SIGN)	Cell surface molecule on dendritic cells that has a role in cell-to-cell interactions and antigen presentation
Extracellular DNA (eDNA)	Bacterial DNA found extracellularly within the plaque biofilm
Gingival crevicular fluid (GCF)	Serum exudate that flows from the gingival sulcus (particularly in individuals with periodontitis) and that contains molecular and cellular elements of the immune response
GroEl	Bacterial heat shock proteins that stimulate immune responses
Human β-defensins (hBD)	Antimicrobial peptides synthesized by epithelial cells that kill bacterial cells but that have other functions in immune responses
Intercellular adhesion molecule-1 (ICAM-1)	Expressed on endothelial molecules during inflammation; interacts with integrins on neutrophils to facilitate neutrophil movement
Interleukin (IL)	Generic term for cytokines produced by leukocytes that are grouped into families on the basis of structural and functional similarities (e.g., IL-1 family)
Lysine-specific gingipain A (KgpA)	Enzyme secreted by the periodontal pathogen *Porphyromonas gingivalis,* which is an important virulence factor
Leukemia-inhibitory factor (LIF)	Cytokine of the IL-6 family
Peptide cleavage product of human cathelicidin (LL-37)	An antimicrobial peptide widely expressed in tissues that kills bacterial cells and that has other functions in immune responses
Lipopolysaccharide (LPS)	A bacterial cell surface molecule that is characteristic of gram-negative bacteria and that stimulates innate cells via TLRs
Lipoteichoic acid (LTA)	Characteristic molecule of gram-positive bacterial cell walls that activates innate immune cells via TLRs
Lipoxin A_4 (LXA_4), lipoxin B_4 (LXB_4)	Arachidonic acid derivatives involved in the resolution of inflammation
Microbe-associated molecular pattern (MAMP)	Molecules associated with microorganisms that activate innate immunity through specific signalling pathways; MAMPs are sometimes also referred to as PAMPs (pathogen-associated molecular patterns); LPS is an example of a MAMP
MD-2	Part of the LPS receptor complex; binds to TLR as a prerequisite for binding LPS
Matrix metalloproteinases (MMPs)	Family of proteolytic enzymes that degrade extracellular matrix molecules
Natural killer (NK) cells	Large granular lymphocytes; distinct from T cells and B cells, which are important for innate immunity to intracellular pathogens
Nucleotide oligomerization domain receptors 1 (NOD 1) and 2 (NOD 2)	Intracellular PRRs that interact with intracellular bacteria and stimulate innate immunity
Osteoprotegerin (OPG)	Cytokine-like molecule that binds to RANK but that antagonizes the action of RANKL
Protease activated receptors 1 (PAR-1) and 2 (PAR-2)	Cellular receptors that, when activated by bacterial enzymes, can signal cytokine secretion
Prostaglandin E_2 (PGE_2)	Inflammatory mediator derived from arachidonic acid
Pattern-recognition receptors (PRRs)	Integrated membrane proteins and intracellular molecules of immune cells that interact with MAMPs and that signal innate immunity
Receptor activator of nuclear factor-κβ (RANK)	Osteoclast cell surface receptor important for bone regulation
Receptor activator of nuclear factor-κβ ligand (RANKL)	Cytokine-like molecule that is the ligand for RANK
Arginine-specific gingipains A (RgpA) and B (RgpB)	Enzymes secreted by the periodontal pathogen *Porphyromonas gingivalis* and that are important virulence factors
T-helper 1 subset (Th1 cells)	A subset of $CD4^+$ T cells that are characterized by their cytokine secretion profile and that activate cellular immunity
T-helper 2 subset (Th2 cells)	A subset of $CD4^+$ T cells that are characterized by their cytokine secretion profile and that activate humoral (antibody) immunity
T-helper 17 subset (Th17 cells)	A subset of $CD4^+$ T cells that are characterized by the secretion of IL-17 and that activate inflammatory responses (e.g., neutrophils)
Tissue inhibitors of matrix metalloproteinases (TIMPs)	Molecules concerned with the regulation of MMPs
Toll-like receptors (TLRs)	A class of PRRs that recognizes MAMPs (e.g., LPS) and that signals cytokine secretion in innate cells
Tumor necrosis factor-α (TNF-α)	Classic proinflammatory cytokine that activates innate immunity and shares many actions with IL-1β
Regulatory T-cell subset (T_{reg} cells)	A subset of $CD4^+$ T cells that are characterized by the secretion of TGF-α and IL-10 and that inhibit immune responses

defects[71] and the association of periodontitis with experimental immunosuppression in animal models.[91]

Small foci of other leukocytes (e.g., lymphocytes, plasma cells, macrophages) are also found in the healthy gingiva. A small proportion (1% to 2%) of the intercellular spaces in healthy junctional epithelium are occupied by neutrophils (and other leukocytes at various stages of differentiation), but this can increase to 30% with even modest inflammation. In the inflammatory state, there are changes to the local vasculature in the gingiva: high endothelial venules develop from the postcapillary venules of the gingival plexus, which facilitates leukocyte emigration and increases the flow of GCF into the pocket.[154]

Neutrophils migrate from the gingival plexus to the extravascular connective tissue and then into the junctional epithelium via the basement membrane. The presence of a layer of neutrophils in the junctional epithelium forms a host defense barrier between subgingival plaque and the gingival tissue. At the molecular level, the interaction of adhesion molecules (e.g., ICAM-1) on endothelial and epithelial cells with β2 integrins on neutrophils facilitates neutrophil migration. Indeed, there is evidence from immunohistochemistry for the existence of gradients of IL-8 (a "chemotactic gradient") as well as for gradients of ICAM-1, which direct the neutrophils from the vasculature into the tissues and toward the junctional epithelium.[181] The migration of neutrophils contributes to the disruption of the junctional epithelium via the degradation of the basement membrane through protease release and the action of ROS. The increased expression of IL-8 and adhesion molecules with inflammation may be the result of direct signaling by bacterial products or by signals from cytokines (e.g., IL-1β, TNF-α) upregulated by plaque bacteria. Acute phase proteins (e.g., α2-macroglobulin) are increased in periodontal tissues as a result of increased vascular leakage in the inflammatory state, thereby resulting in complement and plasmin activation, which also contributes to host defenses.

The neutrophils that infiltrate the periodontium express F_c receptors and complement receptors commensurate with their function during the phagocytosis of opsonized bacteria and bacterial antigens. Within the sulcus itself, 95% of the cells are neutrophils. Because neutrophils are present in both health and disease, the transmigration is thought to be a process distinct from that of GCF flow. The remaining 5% of cells are other leukocyte subtypes, possibly passively carried into the sulcus by the flow of GCF. The relative proportions of the different leukocytes are highly variable, which may reflect the fact that their presence is the result of a passive process or a reflection of the natural fluctuations of different cell types during an immune response. In addition, the distribution of leukocytes in periodontal tissues is not even; mononuclear cells predominate in the connective tissue, and neutrophils predominate in the sulcus. This may be the result of selective mechanisms mediated by specific chemokine responses and adhesion molecule interactions.

Adaptive Immunity

Adaptive immunity has evolved to provide a focused and intense defense against infections that overwhelm innate immune responses. Adaptive immunity is particularly important as ecologic, social, and demographic changes—which alter susceptibility to existing and emerging infective microorganisms—outpace the natural evolution of biologic systems. Furthermore, the development of effective vaccination is, along with the identification of antibiotics, perhaps one of the greatest triumphs of medical science; this success is based on knowledge of the elements and principles of adaptive immunity.

Adaptive immunity contrasts with innate immunity with regard to the dynamic of the underlying cellular and molecular responses: adaptive immunity is slower and reliant on complex interactions between APCs and T and B lymphocytes. A key element is the antigen specificity of the responses that facilitates the specific targeting of a diverse range of effector elements, including cytotoxic T cells and antibodies. Another facet is the ability of adaptive immune responses to improve during exposure to antigen and on subsequent infection events. Our current understanding suggests that the cellular and molecular elements of adaptive immunity are more diverse than those of innate immunity, and, although a role for many of these factors in periodontal disease has been identified, our knowledge is far from complete. The importance of adaptive immune responses in periodontal pathogenesis is endorsed by histologic studies of established lesions in periodontal disease.[91,132] The population of leukocytes in the periodontium in gingivitis (i.e., the early stages of responses to the plaque biofilm) and in stable periodontal lesions (i.e., those in which tissue destruction is apparently not progressing) is dominated by T cells, and these cells are clustered mainly around blood vessels. Cell surface marker studies suggest that these cells are activated but not proliferating.[59] In addition, there is a predominance of the helper T-cell subset (i.e., CD4-expressing T cells) over the cytotoxic T-cell subset (i.e., CD8-expressing T cells). These T cells are considered to be proactively maintaining tissue homeostasis in the face of the microbial challenge of the plaque biofilm.[59] By contrast, in active (progressing) periodontitis, B cells and plasma cells predominate and are associated with pocket formation and the progression of disease.

Antigen-Presenting Cells. A central element of the activation and function of T cells and B cells is the presentation of antigen by specialized APCs to T cells and the development of a specific cytokine milieu that influences the development of T cells with a particular effector function. APCs are sentinel cells in mucosal tissues such as the periodontium. These cells detect and take up microorganisms and their antigens, after which they may migrate to lymph nodes and interact with T cells to present antigen. The periodontium is often compared to other mucosal tissues and the skin in terms of its repertoire of immune cells, and it contains a number of "professional" APCs, including B cells, macrophages, and at least two types of dendritic cells (i.e., dermal dendritic cells and Langerhans cells).[36] These cells naturally express the major histocompatibility complex class II molecules necessary for antigen presentation to T-cell receptors, and they may take up specific antigens and transport them to local lymph nodes, thereby facilitating the activation of specific effector T cells and the generation of an antigen-specific immune response to periodontal pathogens. Although these cells have been identified in periodontal tissues, shown to stimulate antigen specific T-cell responses in experimental systems, and found to generally increase in the presence of periodontitis, their relative contribution to antigen presentation in vivo remains to be determined. The expression of major histocompatibility complex class II molecules may be induced in other cells that are present in the periodontium (e.g., fibroblasts, epithelial cells), which then also take up antigen and present antigen locally in the periodontium.

It is increasingly recognized that the engagement of PRRs (and in particular TLRs) by MAMPs from pathogenic microorganisms is not only central to signaling innate immunity in the form of cytokine upregulation; it is also a critical element of the activation of APCs and the elaboration of T-cell effector function. Thus, TLR activation increases the expression of costimulatory molecules on APCs, which are critical to the interaction of these cells with T

cells. In addition, TLR activation enhances antigen uptake and processing. Different APCs process and present antigens via different pathways and mechanisms, and this variation is one of the factors—along with the presence of specific combinations of cytokines—that influences the phenotype of T-cell effector function produced during specific immune responses.[59]

T Cells. There are a number of different subsets of thymic lymphocytes (i.e., T cells) that develop in the bone marrow and thymus and migrate to the peripheral tissues to participate in adaptive immune responses. The expression of the cell surface molecules (CD4 or CD8) or particular T-cell antigen receptors (αβ or γδ) broadly defines functional T-cell subsets that emerge from the thymus. The role of T-cells in periodontal disease has been established through immunohistologic studies of diseased tissues.[159] $CD4^+$ helper T cells are the predominant phenotype in the stable periodontal lesion, and it is thought that alterations in the balance of effector T-cell subsets within the $CD4^+$ population may lead to progression toward a destructive, B-cell–dominated lesion.[59] $CD4^+$ T-cell subsets are defined on the basis of their phenotypic characteristics and effector functions. The nature of the APCs, which present antigen to cognate T-cell receptors on T cells, and the presence of specific combinations of cytokines and chemokines influence the nature of the $CD4^+$ T-cell effector subset, which develops from naive T-cells (Figure 5-5). $CD4^+$ T-cell subsets are defined by the expression of specific transcription factors, and their functional characteristics are associated with their cytokine secretion profile.

The best-defined functional subsets of $CD4^+$ T cells are the Th1 and Th2 cells, and a dynamic interaction between Th1 and Th2 cells may provide, in part, an explanation for fluctuations in disease activity and the progression of periodontal disease (Box 5-3). Th1 cells secrete IFN-γ, which activates cell-mediated immunity (i.e., macrophages, NK cells, and $CD8^+$ cytotoxic T cells) against pathogenic microorganisms. The activation of macrophages promotes phagocytosis and killing of microbial pathogens, whereas NK cells and $CD8^+$ T cells are cytotoxic T cells that kill infected host cells. Conversely, Th2 cells regulate humoral (antibody-mediated) immunity and mast cell activity through the secretion of the cytokines IL-4, IL-5, and IL-13. Thus, the predominance of Th2 cells leads to a B-cell response. The B-cell response may be protective, for example, as a result of the production of specific antibodies that would serve to clear tissue infections through interaction with the complement system and by enhancing neutrophil phagocytosis. However, B cells are also a source of pro-inflammatory cytokines that contribute to tissue destruction.

T_{reg} cells have an immunosuppressive action that is mediated by the secretion of TGF-β and that is important to the prevention of autoimmune disease. These cells are increased in periodontitis lesions and may therefore have a role in disease pathogenesis.[120] A number of lines of evidence suggest that the pathogenesis of periodontal disease may involve some elements of autoimmunity.[59] For example, there is immunologic cross-reactivity between HSP60 expressed on human cells and the GroEL molecule of *P. gingivalis*, and specific serum antibodies and antigen-specific T cells to these molecules have been detected in periodontal disease. Similarly, autoantibodies and specific T cells against other host (i.e., self) molecules, such as type I collagen, have been identified in periodontal disease.

Th17 cells are another subset of T cells, and they have a pro-inflammatory action that is important in immune responses against extracellular infections mediated by the cytokine IL-17. Infections with a diverse range of pathogens have been shown to activate strong Th17 cell responses, and Th17 cells are thought to provide a substantial inflammatory response to clear microorganisms that Th1/Th2 cells have failed to eradicate. IL-17 has a number of activities in common with pro-inflammatory cytokines, such as IL-1β and TNF-α, and it has a synergistic activity with these cytokines, particularly TNF-α. IL-17 induces proinflammatory cytokine expression (including IL-1β and TNF-α) in macrophages, stimulates chemokine expression, and thereby activates neutrophil infiltration. There is increasing evidence for a role of IL-17 and Th17 cells in periodontal disease.[54] IL-17 has been detected in periodontal tissues at sites of advanced disease. IL-17 induces IL-6 and IL-8 secretion by gingival fibroblasts and also upregulates MMP-1 and MMP-3 in these cells. IL-17 also induces IL-1β and TNF-α secretion from macrophages and gingival epithelial cells. In a mouse model of periodontitis induced by *P. gingivalis,* IL-17 receptor deficiency (IL-17RA knockouts) resulted in increased susceptibility to alveolar bone loss, thereby suggesting a protective role of IL-17 in bone homeostasis, possibly via an effect on neutrophil function.

A number of other effector CD4+ T-cell subsets have been defined on the basis of their cytokine secretion profile: these include Th9 cells and Th22 cells. In addition, T-cell subsets have been defined on the basis of their specific anatomic location. For example, Th22 cells home to the skin in which they likely stimulate antimicrobial peptide production and the differentiation of keratinocytes. In addition, T follicular helper cells are located in germinal centers in lymph nodes in which they provide B-cell help and stimulate Ig class switching. The homing of particular T-cell subsets to specific anatomic locations is defined by the expression of specific chemokine receptors that confer responsiveness to specific chemotactic signals that are produced in those locations. However, thus far, the majority of the work on these novel T-cell subsets has been carried out in mouse models and in vitro systems; their relevance to human biology in vivo and in disease remains to be fully elucidated.

Cytokines produced by differentiated T-cell subsets feedback to stimulate differentiation and to sustain the activity of the cells from which they are derived (i.e., in a positive feedback loop). Simultaneously, they inhibit the development of other competing subsets. For example, IL-4 from Th2 cells inhibits the development of Th1 cells, and IFN-γ from Th1 cells inhibits Th2 cells.

It is increasingly appreciated that individual $CD4^+$ T-cell clones—after they have encountered antigen and differentiated in response under the influence of a specific cytokine environment (i.e., a milieu)—may not be terminally differentiated cells. Rather, there appears to be functional flexibility between T-cell subsets and in particular within the memory T-cell population (Figure 5-5). For example, Th17 and T_{reg} cells can interconvert, depending on the local concentrations of IL-6, IL-23, and TGF-β.[175] It is thought that the plethora of functional subsets of T cells, their anatomic location, and their ability to switch phenotype is a reflection of the requirement for effective responses against diverse pathogens. Other immune cells also have subsets that are defined by the expression of cell surface markers and diverse functional and anatomic locations (e.g., myeloid immune cells, NK cells), but these are less well defined than $CD4^+$ T-cell subsets.

The complexities of the interactions between cellular and molecular aspects of innate and adaptive immune functioning are presented in Figure 5-5. It is clear that multiple pro- and anti-inflammatory pathways, positive and negative feedback loops, and agonists and antagonists all play a role in determining the nature of the immune–inflammatory response to bacterial plaque and the degree of tissue damage that is experienced. Furthermore, the

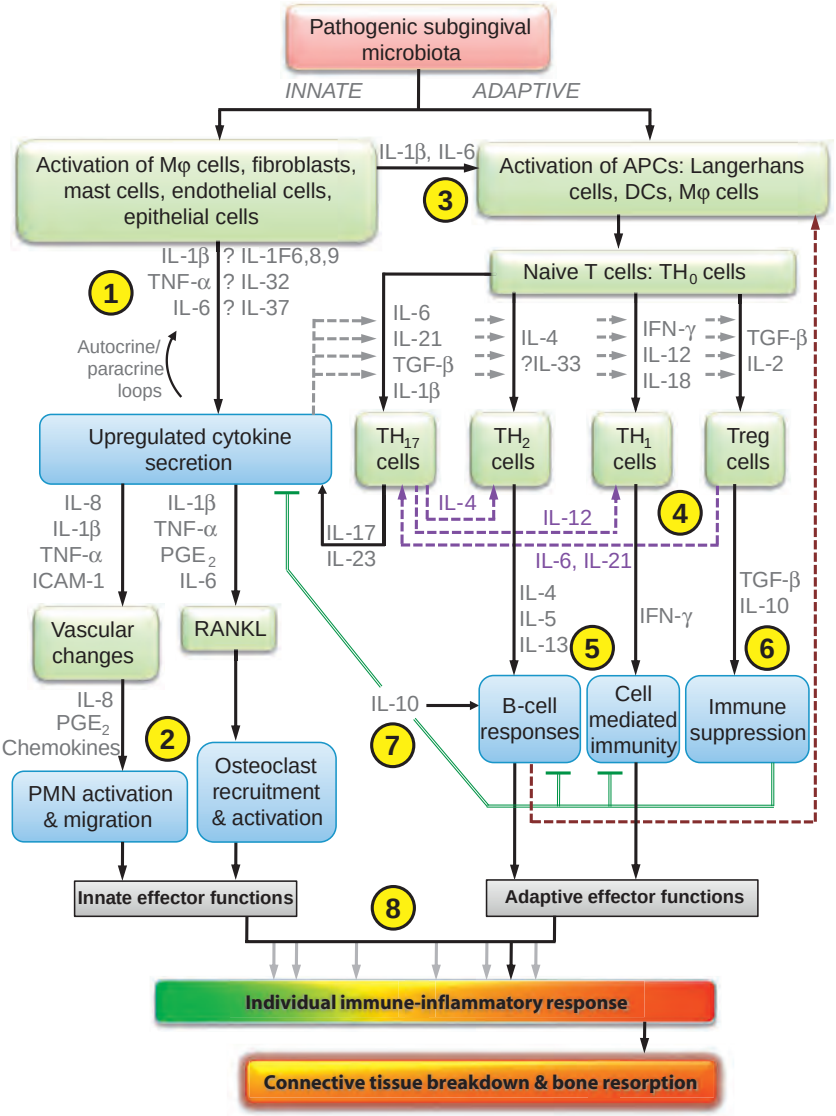

Figure 5-5 Cytokine networks in periodontal diseases. Schematic to illustrate the multiple interactions between cytokines and cellular functions in periodontal diseases. (1) Resident and infiltrating cells in the periodontium respond to MAMPs signalling via PRRs via the production of cytokines as an early step in innate immune responses. Cytokine upregulation is sustained by autocrine and paracrine feedback loops. (Note: Question marks [?] indicate more speculative suggestions about the role of specific cytokines in periodontal pathogenesis than are known at present.) (2) Upregulated cytokine activity leads to vascular changes, PMN activation and migration, and, ultimately, osteoclastogenesis and osteoclast activation. (3) Cytokines produced in innate responses contribute to the activation of APCs. These present specific antigens to naive CD41 T cells (Th_0 cells), which differentiate into CD41 effector T cells (e.g., Th_1, Th_2, Th_{17}, and T_{reg} cells) according to the local cytokine milieu (as indicated by the groups of four parallel horizontal grey dotted arrows). For example, Th0 cells differentiate into Th_{17} cells under the influence of IL-6, IL-21, TGF-β, and IL-1β. (APCs are also activated by B cells, which are themselves activated at a later stage in the cytokine network [indicated by the brown dotted arrow at the right edge of the figure]; this is an example of the complexities of sequential feedback loops that develop.) (4) Th_1 and Th_2 cells have a relatively stable phenotype, but other T-cell subsets can exhibit functional plasticity under the influence of different cytokine environments (indicated by purple dotted arrows). For example, Th_{17} cells can develop into Th_1 cells under the influence of IL-12 and into Th_2 cells under the influence of IL-4. (5) Different T-cell subsets are associated with various cytokine secretion profiles that regulate different aspects of immune responses and that contribute to upregulated cytokine activity. For example, Th_1 cells secrete IFN-γ (which activates cell-mediated immunity), and Th2 cells regulate antibody-mediated (humoral) immunity through the secretion of cytokines IL-4, IL-5, and IL-13. Cytokines produced by different T-cell subsets increase their further secretion in positive feedback loops and also inhibit the development of other T-cell subsets (e.g., IL-4 from Th_2 cells inhibits Th_1 development, and IFN-γ from Th_1 cells inhibits Th_2 T-cell subsets). (6) T_{reg} cells secrete TGF-β and IL-10, which have immune suppressive functions. For example, IL-10 suppresses Th_1 and Th_2 responses as well as Mφ and DC function, and it also downregulates cytokine production in various cells (i.e., Th_1 cells, Th_2 cells, PMNs, and NK cells). (Suppressive effects are indicated by flat-ended green lines.) (7) IL-10 functions as a regulatory mediator, but it can also exhibit other activities (e.g., the activation of B cells). The different aspects of IL-10 biology (i.e., immunosuppressive versus immunostimulatory) likely depend on the local cytokine environment. These dual roles of IL-10 are indicated by the green (inhibitory) line and the black (stimulatory) arrow. (8) The sum total of innate and adaptive effector functions results in an immune–inflammatory response, the precise nature of which will vary from person to person (as indicated by the multiple gray arrows, with some patients being more susceptible to disease than others) as well as over time within an individual. In this case, the black arrow indicates an individual who has a pro-inflammatory response that leads to connective tissue breakdown and bone resorption. *APC,* Antigen-presenting cell; *DC,* dendritic cell; *IFN-γ,* interferon-γ; *IL,* interleukin; *MAMP,* microbe-associated molecular pattern; *Mφ,* cell of monocyte/macrophage lineage; *NK,* natural killer; *PMN,* polymorphonuclear leucocyte; *PRR,* pattern-recognition receptor; *TGF-β,* transforming growth factor-β; *Th,* T-helper cell; T_{reg}, T regulatory cell. *(Reproduced with permission from Kinane DF, Preshaw PM, Loos BG.* J Clin Periodontol *38[Suppl 11]:44–48, 2011.)*

BOX 5-3 The T-Helper 1/T-Helper 2 Concept of Periodontal Disease Progression

A dynamic interaction between T-helper 1 (Th1) and T-helper 2 (Th2) cells represents a possible explanation for aspects of the fluctuations in disease activity and clinical progression seen with periodontal disease. It has been hypothesized that a strong innate response results in interleukin-12 synthesis (e.g., by tissue macrophages) that leads to a Th1 response that provides protective cell-mediated immunity that would be manifested as a "stable" periodontal lesion. Conversely, a poor innate response would lead to reduced interleukin-12, which would permit the development of Th2 responses and lead to the activation of B cells; this, in turn, would mediate a destructive lesion, possibly through enhanced B-cell–derived interleukin-1β.[59,160] However, definitive evidence of the existence of Th1 and Th2 cells and any association with different clinical presentations of periodontal disease has been difficult to obtain. It has been suggested that this is a result of variations among experimental studies, which have differed with respect to the material that has been used, the definitions of disease stages, the experimental designs, and analytic methods employed.[54,59,160] In addition, in general terms, the Th1/Th2 dichotomy does not explain all aspects of the regulation of adaptive immune responses. More recently, other T-cell subsets have been identified and defined. For example, regulatory T cells secrete interleukin-10 and transforming growth factor-β and thereby suppress immune responses. Th17 cells have a pro-inflammatory action via the secretion of interleukin-17, a cytokine that synergizes with interleukin-1β and tumor necrosis factor-α. Therefore, although it is widely accepted that Th1 and Th2 cells are likely to be important in the immunopathogenesis of periodontal disease, it is increasingly recognized that the Th1/Th2 model alone is probably inadequate to explain the role of T cells in this process.

nature of the inflammatory response varies between individuals; this could explain why certain people appear to be more susceptible to periodontitis than others.

Antibodies. Specific antibodies are produced in response to an increasing bacterial challenge in periodontal disease and are the endpoint of B-cell activation. Circulating antibodies may be more important than locally produced antibodies. Even so, these generally appear in a high titer but have low biologic activity, so there is some doubt as to their effectiveness. Commensurate with the appearance of antibodies against plaque bacterial antigens is the appearance of differentiated plasma cells that characterize the established lesion in periodontal disease. High levels of antibodies appear in GCF (in addition to those in the circulation), and these are produced locally by plasma cells in periodontal tissues.[9] Antibodies to periodontal pathogens are primarily IgG, with few IgM or IgA types produced.

Many species of oral bacteria elicit a polyclonal B-cell response (with the consequent production of specific antibodies against those bacteria). However, these responses augment responses against non-oral bacteria and may lead to the production of autoantibodies (e.g., antibodies against collagen and connective tissue proteins), which may contribute to tissue destruction in periodontal disease.[9,59] The incidence and levels of specific serum and GCF IgG antibodies are raised with chronic periodontitis, which suggests that local and peripheral generation of antibodies may be important in the immune response to periodontal pathogens. Antibodies (i.e., IgA) to periodontal pathogens are also found in saliva. Variations in the levels of specific antibodies to different species in different clinical presentations suggest differences in pathogenesis. For example, antibodies to *A. actinomycetemcomitans* of the IgG_2 subclass predominate in aggressive periodontitis.[150]

Other *P. gingivalis* molecules (i.e., fimbriae and hemagglutinin) also act as antigens. Specific antibodies are also generated by serotype-specific carbohydrate antigens (e.g., capsular polysaccharide of *P. gingivalis,* carbohydrate of *A. actinomycetemcomitans* LPS). The subclass distribution of antibodies is influenced by cytokines that are derived from monocytes.[150] For example, IgG_2 production is regulated by IL-1α, IL-1β, and PGE_2 from monocytes as well as by platelet-activating factor from neutrophils. PGE_2 and platelet-activating factor indirectly induce Th1 responses and therefore IFN-γ, which stimulates IgG_2 production. Individuals with aggressive periodontitis have monocytes that are hyperresponsive to LPS and that produce elevated quantities of PGE_2.[9] *A. actinomycetemcomitans* is commonly associated with aggressive periodontitis, which induces IL-12 production that regulates NK cells and Th1 cells. These cells are a source of IFN-γ, which in turn regulates IgG_2.

A number of studies have reported an effect of treatment on levels of specific antibodies to periodontal pathogens. For example, plaque removal reduces the titers of antibodies to *P. gingivalis* and *A. actinomycetemcomitans* in serum, GCF, and saliva.[9] Some studies have observed a transient increase in antibody titers after treatment, which may be due to the release of antigens into the tissue and circulation.

The significance of antibodies in periodontitis is not clear. It is not known if these antibodies have a protective function or whether they participate in disease pathogenesis. Although there is some evidence for a correlation between clinical parameters of disease and titers of specific antibodies to periodontal pathogens, other studies report an inverse correlation of antibody levels and avidity with periodontal destruction. In addition, specific antibodies to periodontal pathogens are found in healthy individuals as well as in those with periodontal disease.

Most research into the analysis of specific antibodies has focused on antibodies to *P. gingivalis*, and antigens derived from this organism have been investigated as potential vaccines for periodontal disease.[125,137] For example, a significant reduction in disease progression in nonhuman primate and rodent models was observed after immunization with heat-killed *P. gingivalis* or antigens from *P. gingivalis*. In addition, immunization with *P. gingivalis* proteases (i.e., gingipains) prevents colonization with *P. gingivalis* and reduces bone loss.[125]

Concept of Host Susceptibility

The immune and inflammatory processes that result from the challenge presented by the subgingival biofilm are complex and mediated by a large number of pro-inflammatory and anti-inflammatory cytokines and enzymes that function as a network of mediators with overlapping roles and activity (Figure 5-5). Immune responses to the bacterial challenge do not occur in isolation but rather take place in the context of other host and environmental factors that influence these responses and thereby determine the progression of disease. A number of risk factors increase susceptibility to periodontal disease, including smoking, diabetes, nutritional factors, and stress; these are considered in detail elsewhere in this book.

A feature of human development and evolution has been that quantitative and qualitative differences exist in immune responses between individuals.[75] Indeed, infectious agents (e.g., bacteria)

exert evolutionary selection pressures on the species that they infect. This may be relevant in periodontal disease, and a large number of studies have confirmed that immune cells from patients with periodontal disease secrete higher quantities of pro-inflammatory cytokines than those who are periodontally healthy.[176] Cytokine profiles are also different in those individuals with immune-mediated diseases as compared with healthy controls.

These observations have led to the development of the concept of the "hyperinflammatory trait" in which certain individuals possess a hyperinflammatory phenotype and that this accounts for their increased susceptibility to chronic inflammatory conditions such as periodontitis. Such a trait may also underpin shared susceptibility between conditions such as periodontitis and cardiovascular disease or diabetes. However, at present, it is not possible to identify with certainty those patients who may possess some form of hyperinflammatory trait. The concept of the periodontal hyper-responder (together with other risk factors) could explain increased susceptibility to periodontal disease.[29] The hyper-responder concept was originally proposed in the context of the responsiveness of monocytes to LPS challenge, which suggests that patients with disease possess an individual hyper-responsive monocytic trait that is characterized by elevated levels of inflammatory mediators released from monocytes in response to bacterial challenge.[126] It is likely that there are many reasons that contribute to disease variations among individuals, such as variations in immune responses, pathogenesis, and the plaque biofilm; this results in an uneven disease experience in the population.

Figure 5-6 is a schematic illustration of how increasing bacterial (i.e., LPS) challenge can result in differing levels of inflammatory response according to the response profile of an individual patient.[126] Most individuals would be considered normal, and, for a given bacterial challenge, they would produce a certain level of inflammatory mediators in the periodontal tissues. For those who are hyper-responders, the same bacterial challenge results in a greater inflammatory response, which over time would result in increased tissue breakdown, earlier presentation of the clinical signs of disease, and a clinical interpretation of having increased susceptibility to periodontitis. Those individuals who are hypo-responsive produce low levels of inflammatory mediators and are therefore somewhat resistant to the development of periodontitis, even though plaque may be present and they may have widespread gingivitis. The nature of the inflammatory response will be governed by genetic factors and environmental factors, and it may vary over time within the same individual (e.g., if environmental factors such as smoking status, stress, or systemic disease should change).

A similar dose–response curve can also be expressed in the context of stable or progressing disease, and, as shown in Figure 5-7, a certain level of bacterial challenge results in a moderate release of inflammatory cytokines, mediators, and enzymes. These mediators, together with the infiltrating defense cells, have a protective role to eliminate bacteria in the sulcus and do not trigger periodontal disease breakdown. Such a steady-state scenario may persist indefinitely. However, if something changes (e.g., the quantity or quality of the biofilm alters, the host defenses alter as a result of a change in an environmental exposure), then the secretion of cytokines, prostanoids, MMPs, and other mediators may increase in the tissues, thereby leading to the histopathologic changes described previously and a transition to periodontitis. Thus, there is a threshold between stable and active disease, and this will vary from person to person. The dose–response curve for any individual can shift to the left or the right according to environmental changes. A shift to the left would result in an increase in the quantities of inflammatory mediators produced for a given bacterial challenge

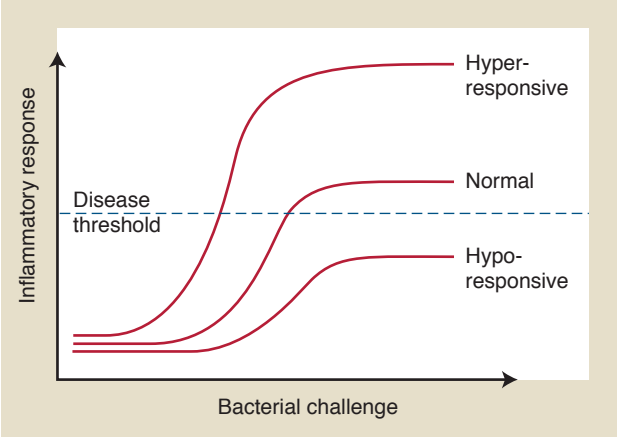

Figure 5-6 Inflammatory response characteristics in relation to bacterial challenge. A given bacterial challenge results in differing levels of inflammatory response according to the response profile of an individual. Most people are close to normal and produce a certain level of inflammatory mediators for a given challenge. Those who are hyper-responders generate an excessive inflammatory response for the same bacterial challenge and cross the threshold into active disease at an earlier stage. Those who are hypo-responsive produce lower levels of inflammatory mediators and, despite a significant bacterial challenge, may never develop periodontitis. *(Modified from Champagne CM, Buchanan W, Reddy MS, et al:* Periodontol 2000 *31:167–180, 2003.)*

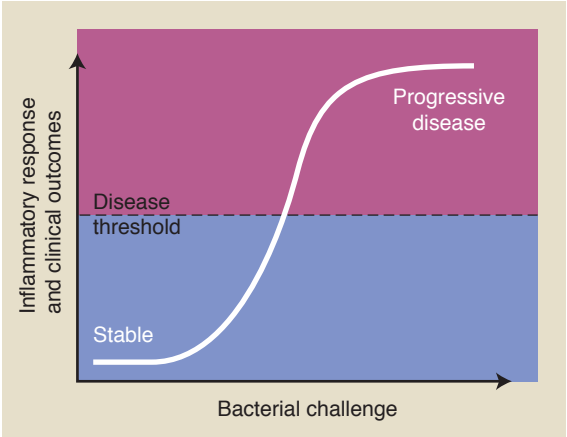

Figure 5-7 Inflammatory response characteristics in relation to an individual's threshold for periodontitis. A certain level of bacterial challenge results in a moderate inflammatory response, which is protective by intent and which may not be sufficient to transition to periodontal disease. This stable condition may persist for many years or even throughout the individual's lifetime. Changes in the bacterial burden (i.e., qualitative, quantitative, or both) or changes in the host response (e.g., as a result of a change in an environmental exposure) could result in an upregulated inflammatory response characterized by marked cellular infiltrate and the increased secretion of inflammatory mediators leading to tissue damage and a transition from the stable situation to periodontitis. The location of the threshold between stable and active disease varies from person to person. In addition, the dose–response curve for any individual can shift to the left or the right in accordance with environmental changes. A shift to the left would result in an increased inflammatory response to a given bacterial challenge and potentially an exacerbation of disease. A shift to the right would have the opposite effect. *(Modified from Champagne CM, Buchanan W, Reddy MS, et al:* Periodontol 2000 *31:167-180, 2003.)*

and potentially an exacerbation of disease; a shift to the right would have the opposite effect. In all cases, an increase in the LPS challenge would have the tendency to increase the production of inflammatory mediators, which may tip the site from a stable to a progressing periodontal lesion.

These are, of course, simplistic models to explain a highly complex phenomenon, and it is clear that cytokines and inflammatory mediators function in complicated networks (Figure 5-5).[86,140] Therefore, although increases and decreases in the absolute levels of cytokines have been reported in disease states, it is clear that the dysregulation of cytokine networks and other mediators is the key determinant of disease progression. Thus, the relative proportions of mediators within inflammatory networks are fundamental to determining disease progression, and changes in these proportions are driven by inflammatory challenges and the genetic and environmental factors that govern how the host responds to such challenges.[92,135] Schematic illustrations to explain the pathogenesis of periodontal disease, such as that presented in Figure 5-5, can be useful; however, given the complexity of the disease processes, they are inevitably simplistic. Earlier models were very simplistic indeed, being essentially linear and suggesting that periodontitis resulted directly from the microbial challenge.[92] This concept influenced periodontal treatment over the decades, resulting in treatment strategies that focused primarily on the biofilm. Increasing awareness of the importance of host factors in determining interindividual differences in disease progression has resulted in the realization that, although plaque bacteria initiate the inflammatory response, most of the tissue damage results from the host response, which is influenced by genetic factors as well as environmental and acquired risk factors. Risk factors such as smoking and genetic risk factors that are not yet clearly defined alter the progression of the immune–inflammatory response and shift the balance toward increased periodontal breakdown. This implies that the presence of plaque bacteria does not inevitably lead to tissue destruction, and this is supported by a large number of epidemiologic studies, which confirm that more advanced disease is usually confined to a minority of the population.[107]

Our improved understanding of the diseases processes in periodontitis has led to the development of a biologic systems model for representing periodontal pathogenesis. This involves bacterial components, environmental factors, specific inflammatory mechanisms, and host–genetic variations that are associated with disease.[92] A biologic systems approach provides a framework for viewing the contributions and relative importance of all of the components that contribute to the clinical presentation of disease. Thus, in the context of periodontal disease, such a system would include a person level, a genetic/epigenetic level, the biologic phenotype, and, ultimately, the clinical phenotype (Figure 5-8).[127] Such systems

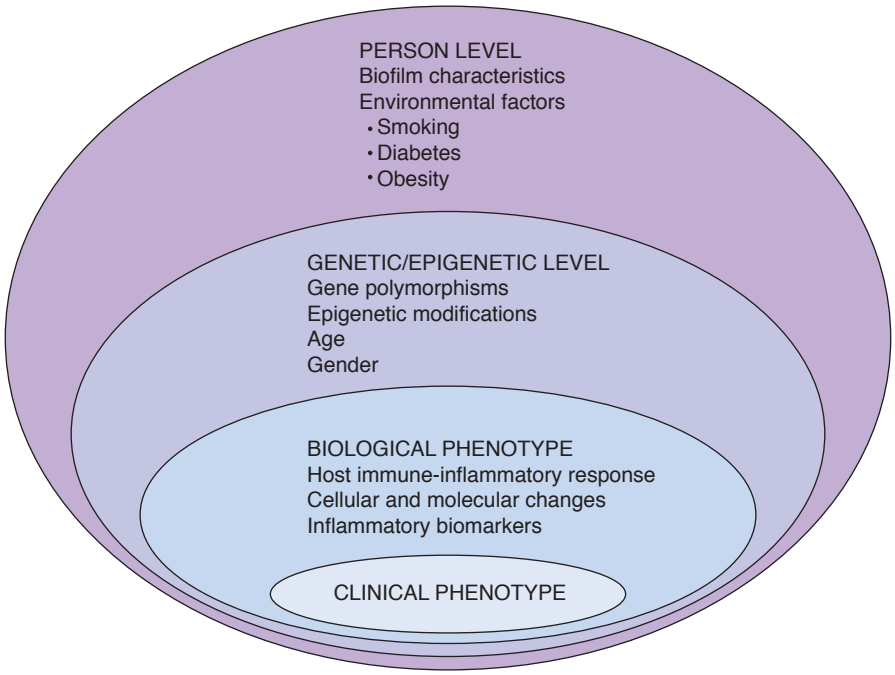

Figure 5-8 A biologic systems model of periodontitis. The outermost level of this model is the *Person Level,* which represents an individual's unique characteristics as they are related to periodontitis. These include the compositional characteristics of the subgingival biofilm as well as known risk factors and environmental exposures such as smoking and diabetes. The *Person Level* characteristics interact with the *Genetic/Epigenetic Level* characteristics, which include nonmodifiable factors such as age, gender, and genetic composition. Gene polymorphisms are known to be associated with periodontal disease, and epigenetics refers to changes in phenotype (i.e., clinical disease expression) caused by mechanisms other than changes in the underlying DNA sequence. Epigenetics can be defined as all of the meiotically and mitotically inherited changes in gene expression that are not encoded in the DNA sequence itself. Epigenetic modifications are important permissive and suppressive factors for controlling the expressed genome via gene transcription. Two major epigenetic mechanisms are the posttranslational modification of histone proteins in chromatin and the methylation of DNA. The *Genetic/Epigenetic Level* characteristics influence the *Biological Phenotype,* which is characterized by the specific immune–inflammatory responses (i.e., cellular and molecular events and the production of inflammatory mediators) that are associated with the *Clinical Phenotype* (i.e., the clinical presentation of the disease). This model reflects how different individuals with the same presentation (e.g., periodontitis) may have very different predisposing and risk factors. The model depicts the different biologic factors that underpin the development of periodontal disease in different individuals and that ultimately may be used to classify disease via the contribution provided to the clinical phenotype at each level. *(Data from Offenbacher S, Barros SP, Beck JD:* J Periodontol *79:1577-1584, 2008.)*

provide a more comprehensive view of the disease as a complex regulatory network in which aspects of the specific genetic factors, environmental exposures, and other modifying factors that an individual is exposed to determine the development of the disease state.

To summarize, it is clear that the subgingival bacteria initiate and perpetuate the immune–inflammatory responses in the periodontal tissues. These responses are characterized by classic signs of inflammation that are modified as a result of the unique anatomy of the periodontium and the dentogingival apparatus. The inflammatory events that develop in response to the bacterial challenge are protective by intent, but they result in the majority of tissue damage and breakdown that lead to the clinical signs of periodontitis. Individuals vary with regard to their susceptibility to periodontal disease and also in the threshold level at which a stable periodontal site progresses to an active site. Such variations are genetically determined, and they are influenced by environmental risk factors, some of which are modifiable and some of which are not. The challenge for the future is to identify at-risk individuals who possess the hyperinflammatory trait so that disease can be prevented by careful management strategies before tissue loss has occurred.

Suggested Readings

Champagne CM, Buchanan W, Reddy MS, et al: Potential for gingival crevice fluid measures as predictors of risk for periodontal diseases. *Periodontol 2000* 31:167–180, 2003.

Gaffen SL, Hajishengallis G: A new inflammatory cytokine on the block: re-thinking periodontal disease and the Th1/Th2 paradigm in the context of Th17 cells and IL-17. *J Dent Res* 87:817–828, 2008.

Gemmell E, Seymour GJ: Immunoregulatory control of Th1/Th2 cytokine profiles in periodontal disease. *Periodontol 2000* 35:21–41, 2005.

Gemmell E, Yamazaki K, Seymour GJ: The role of T cells in periodontal disease: homeostasis and autoimmunity. *Periodontol 2000* 43:14–40, 2007.

Handfield M, Baker HV, Lamont RJ: Beyond good and evil in the oral cavity: insights into host-microbe relationships derived from transcriptional profiling of gingival cells. *J Dent Res* 87:203–223, 2008.

Kinane DF, Preshaw PM, Loos BG: Host-response: understanding the cellular and molecular mechanisms of host-microbial interactions–consensus of the Seventh European Workshop on Periodontology. *J Clin Periodontol* 38(Suppl 11):44–48, 2011.

Kornman KS: Mapping the pathogenesis of periodontitis: a new look. *J Periodontol* 79:1560–1568, 2008.

Offenbacher S, Barros SP, Beck JD: Rethinking periodontal inflammation. *J Periodontol* 79:1577–1584, 2008.

Preshaw PM, Taylor JJ: How has research into cytokine interactions and their role in driving immune responses impacted our understanding of periodontitis? *J Clin Periodontol* 38(Suppl 11):60–84, 2011.

References

References for this chapter are found on the companion website www.expertconsult.com.

References

1. Allakhverdi Z, Smith DE, Comeau MR, et al: Cutting edge: the ST2 ligand IL-33 potently activates and drives maturation of human mast cells. *J Immunol* 179:2051–2054, 2007.
2. Allesen-Holm M, Barken KB, Yang L, et al: A characterization of DNA release in *Pseudomonas aeruginosa* cultures and biofilms. *Mol Microbiol* 59:1114–1128, 2006.
3. Andrian E, Grenier D, Rouabhia M: Porphyromonas gingivalis-epithelial cell interactions in periodontitis. *J Dent Res* 85:392–403, 2006.
4. Arend WP, Palmer G, Gabay C: IL-1, IL-18, and IL-33 families of cytokines. *Immunol Rev* 223:20–38, 2008.
5. Asai Y, Ohyama Y, Gen K, et al: Bacterial fimbriae and their peptides activate human gingival epithelial cells through Toll-like receptor 2. *Infect Immun* 69:7387–7395, 2001.
6. Assuma R, Oates T, Cochran D, et al: IL-1 and TNF antagonists inhibit the inflammatory response and bone loss in experimental periodontitis. *J Immunol* 160:403–409, 1998.
7. Baba A, Kadowaki T, Asao T, et al: Roles for Arg- and Lys-gingipains in the disruption of cytokine responses and loss of viability of human endothelial cells by *Porphyromonas gingivalis* infection. *Biol Chem* 383:1223–1230, 2002.
8. Banyer JL, Hamilton NH, Ramshaw IA, et al: Cytokines in innate and adaptive immunity. *Rev Immunogenet* 2:359–373, 2000.
9. Barbour SE, Tew JG, Schenkein HA: B-cell responses in periodontitis. In Henderson B, Curtis MA, Seymour R, et al, editors: *Periodontal medicine and systems biology*, Oxford, UK, 2009, Wiley-Blackwell, pp 339–356.
10. Barksby HE, Lea SR, Preshaw PM, et al: The expanding family of interleukin-1 cytokines and their role in destructive inflammatory disorders. *Clin Exp Immunol* 149:1–9, 2007.
11. Bartold PM, Walsh LJ, Narayanan AS: Molecular and cell biology of the gingiva. *Periodontol 2000* 24:28–55, 2000.
12. Bartold PM, Narayanan AS: Molecular and cell biology of healthy and diseased periodontal tissues. *Periodontol 2000* 40:29–49, 2006.
13. Ben-Sasson SZ, Hu-Li J, Quiel J, et al: IL-1 acts directly on CD4 T cells to enhance their antigen-driven expansion and differentiation. *Proc Natl Acad Sci USA* 106:7119–7124, 2009.
14. Bettelli E, Carrier Y, Gao W, et al: Reciprocal developmental pathways for the generation of pathogenic effector TH17 and regulatory T cells. *Nature* 441:235–238, 2006.
15. Bezerra MM, de Lima V, Alencar VB, et al: Selective cyclooxygenase-2 inhibition prevents alveolar bone loss in experimental periodontitis in rats. *J Periodontol* 71:1009–1014, 2000.
16. Bianchi ME: DAMPs, PAMPs and alarmins: all we need to know about danger. *J Leukoc Biol* 81:1–5, 2007.
17. Birkedal-Hansen H: Role of cytokines and inflammatory mediators in tissue destruction. *J Periodontal Res* 28:500–510, 1993.
18. Birkedal-Hansen H: Role of matrix metalloproteinases in human periodontal diseases. *J Periodontol* 64:474–484, 1993.
19. Blumberg H, Dinh H, Trueblood ES, et al: Opposing activities of two novel members of the IL-1 ligand family regulate skin inflammation. *J Exp Med* 204:2603–2614, 2007.
20. Bonecchi R, Galliera E, Borroni EM, et al: Chemokines and chemokine receptors: an overview. *Front Biosci* 14:540–551, 2009.
21. Bostanci N, Ilgenli T, Emingil G, et al: Gingival crevicular fluid levels of RANKL and OPG in periodontal diseases: implications of their relative ratio. *J Clin Periodontol* 34:370–376, 2007.
22. Brecx M: Histophysiology and histopathology of the gingiva. *J Western Soc Periodontol Periodontal Abstr* 39:33–38, 1991.
23. Brecx MC, Frohlicher I, Gehr P, et al: Stereological observations on long-term experimental gingivitis in man. *J Clin Periodontol* 15:621–627, 1988.
24. Bufler P, Azam T, Gamboni-Robertson F, et al: A complex of the IL-1 homologue IL-1F7b and IL-18-binding protein reduces IL-18 activity. *Proc Natl Acad Sci USA* 99:13723–13728, 2002.
25. Calkins CC, Platt K, Potempa J, et al: Inactivation of tumor necrosis factor-alpha by proteinases (gingipains) from the periodontal pathogen, *Porphyromonas gingivalis*. Implications of immune evasion. *J Biol Chem* 273:6611–6614, 1998.
26. Carpenter S, O'Neill LA: How important are Toll-like receptors for antimicrobial responses? *Cell Microbiol* 9:1891–1901, 2007.
27. Carriere V, Roussel L, Ortega N, et al: IL-33, the IL-1-like cytokine ligand for ST2 receptor, is a chromatin-associated nuclear factor in vivo. *Proc Natl Acad Sci USA* 104:282–287, 2007.
28. Cecil RL, Angevine DM: Clinical and experimental observations on focal infection, with an analysis of 200 cases of rheumatoid arthritis. *Ann Intern Med* 12:577–584, 1938.
29. Champagne CM, Buchanan W, Reddy MS, et al: Potential for gingival crevice fluid measures as predictors of risk for periodontal diseases. *Periodontol 2000* 31:167–180, 2003.
30. Christersson LA, Albini B, Zambon JJ, et al: Tissue localization of *Actinobacillus actinomycetemcomitans* in human periodontitis. I. Light, immunofluorescence and electron microscopic studies. *J Periodontol* 58:529–539, 1987.
31. Cochran DL: Inflammation and bone loss in periodontal disease. *J Periodontol* 79:1569–1576, 2008.
32. Commins S, Steinke JW, Borish L: The extended IL-10 superfamily: IL-10, IL-19, IL-20, IL-22, IL-24, IL-26, IL-28, and IL-29. *J Allergy Clin Immunol* 121:1108–1111, 2008.
33. Costelloe C, Watson M, Murphy A, et al: IL-1F5 mediates anti-inflammatory activity in the brain through induction of IL-4 following interaction with SIGIRR/TIR8. *J Neurochem* 105:1960–1969, 2008.
34. Couper KN, Blount DG, Riley EM: IL-10: the master regulator of immunity to infection. *J Immunol* 180:5771–5777, 2008.
35. Crotti T, Smith MD, Hirsch R, et al: Receptor activator NF kappaB ligand (RANKL) and osteoprotegerin (OPG) protein expression in periodontitis. *J Periodontal Res* 38:380–387, 2003.
36. Cutler CW, Jotwani R: Dendritic cells at the oral mucosal interface. *J Dent Res* 85:678–689, 2006.
37. Dale BA: Periodontal epithelium: a newly recognized role in health and disease. *Periodontol 2000* 30:70–78, 2002.
38. Darveau RP, Pham TT, Lemley K, et al: Porphyromonas gingivalis lipopolysaccharide contains multiple lipid A species that functionally interact with both toll-like receptors 2 and 4. *Infect Immun* 72:5041–5051, 2004.
39. Darveau RP: Innate immunity and homeostasis in the periodontium. In Henderson B, Curtis MA, Seymour R, et al, editors: *Periodontal medicine and systems biology*, Oxford, UK, 2009, Wiley-Blackwell, pp 263–277.
40. Delaleu N, Bickel M: Interleukin-1 beta and interleukin-18: regulation and activity in local inflammation. *Periodontol 2000* 35:42–52, 2004.
41. Devine D, Cosseau C: Antimicrobial host defence peptides in oral health and periodontitis. In Henderson B, Curtis MA, Seymour R, et al, editors: *Periodontal medicine and systems biology*, Oxford, UK, 2009, Wiley-Blackwell, pp 279–297.
42. Dinarello CA: Interleukin-1, interleukin-1 receptors and interleukin-1 receptor antagonist. *Int Rev Immunol* 16:457–499, 1998.
43. Dinarello CA: Immunological and inflammatory functions of the interleukin-1 family. *Annu Rev Immunol* 27:519–550, 2009.
44. Dinarello CA: Interleukin-1beta and the autoinflammatory diseases. *New Engl J Med* 360:2467–2470, 2009.
45. Dixon DR, Darveau RP: Lipopolysaccharide heterogeneity: innate host responses to bacterial modification of lipid A structure. *J Dent Res* 84:584–595, 2005.
46. Dogne JM, Hanson J, Supuran C, et al: Coxibs and cardiovascular side-effects: from light to shadow. *Curr Pharm Des* 12:971–975, 2006.
47. Edwards AM, Grossman TJ, Rudney JD: *Fusobacterium nucleatum* transports noninvasive *Streptococcus cristatus* into human epithelial cells. *Infect Immun* 74:654–662, 2006.
48. Eskan MA, Hajishengallis G, Kinane DF: Differential activation of human gingival epithelial cells and monocytes by *Porphyromonas gingivalis* fimbriae. *Infect Immun* 75:892–898, 2007.
49. Fives-Taylor P, Meyer D, Mintz K: Virulence factors of the periodontopathogen *Actinobacillus actinomycetemcomitans*. *J Periodontol* 67:291–297, 1996.

50. Frank RM: Bacterial penetration in the apical pocket wall of advanced human periodontitis. *J Periodontal Res* 15:563–573, 1980.
51. Fransson C, Berglundh T, Lindhe J: The effect of age on the development of gingivitis. Clinical, microbiological and histological findings. *J Clin Periodontol* 23:379–385, 1996.
52. Fraser ID, Germain RN: Navigating the network: signaling cross-talk in hematopoietic cells. *Nat Immunol* 10:327–331, 2009.
53. Fredriksson MI, Gustafsson AK, Bergström KG, et al: Constitutionally hyperreactive neutrophils in periodontitis. *J Periodontol* 74:219–224, 2003.
54. Gaffen SL, Hajishengallis G: A new inflammatory cytokine on the block: re-thinking periodontal disease and the Th1/Th2 paradigm in the context of Th17 cells and IL-17. *J Dent Res* 87:817–828, 2008.
55. Garrison SW, Nichols FC: LPS-elicited secretory responses in monocytes: altered release of PGE_2 in patients with but not IL-1 adult periodontitis. *J Periodontal Res* 24:88–95, 1989.
56. Gemmell E, Seymour GJ: Interleukin 1, interleukin 6 and transforming growth factor-beta production by human gingival mononuclear cells following stimulation with *Porphyromonas gingivalis* and *Fusobacterium nucleatum*. *J Periodontal Res* 28:122–129, 1993.
57. Gemmell E, Marshall RI, Seymour GJ: Cytokines and prostaglandins in immune homeostasis and tissue destruction in periodontal disease. *Periodontol 2000* 14:112–143, 1997.
58. Gemmell E, Seymour GJ: Immunoregulatory control of Th1/Th2 cytokine profiles in periodontal disease. *Periodontol 2000* 35:21–41, 2004.
59. Gemmell E, Yamazaki K, Seymour GJ: The role of T cells in periodontal disease: homeostasis and autoimmunity. *Periodontol 2000* 43:14–40, 2007.
60. Giannobile WV, Beikler T, Kinney JS, et al: Saliva as a diagnostic tool for periodontal disease: current state and future directions. *Periodontol 2000* 50:52–64, 2009.
61. Golub LM, Ciancio S, Ramamurthy NS, et al: Low-dose doxycycline therapy: effect on gingival and crevicular fluid collagenase activity in humans. *J Periodontal Res* 25:321–330, 1990.
62. Golub LM, Sorsa T, Lee HM, et al: Doxycycline inhibits neutrophil (PMN)-type matrix metalloproteinases in human adult periodontitis gingiva. *J Clin Periodontol* 22:100–109, 1995.
63. Gracie JA, Robertson SE, McInnes IB: Interleukin-18. *J Leukoc Biol* 73:213–224, 2003.
64. Graves DT, Cochran D: The contribution of interleukin-1 and tumor necrosis factor to periodontal tissue destruction. *J Periodontol* 74:391–401, 2003.
65. Griffiths GS: Formation, collection and significance of gingival crevice fluid. *Periodontol 2000* 31:32–42, 2003.
66. Hajishengallis G, Shakhatreh MA, Wang M, et al: Complement receptor 3 blockade promotes IL-12-mediated clearance of *Porphyromonas gingivalis* and negates its virulence *in vivo*. *J Immunol* 179:2359–2367, 2007.
67. Hajishengallis G: *Porphyromonas gingivalis*–host interactions: open war or intelligent guerilla tactics? *Microbes Infect* 11:637–645, 2009.
68. Hamilton HL, Domínguez NM, Schwartz KJ, et al: *Neisseria gonorrhoeae* secretes chromosomal DNA via a novel type IV secretion system. *Mol Microbiol* 55:1704–1721, 2005.
69. Handfield M, Baker HV, Lamont RJ: Beyond good and evil in the oral cavity: insights into host-microbe relationships derived from transcriptional profiling of gingival cells. *J Dent Res* 87:203–223, 2008.
70. Hannas AR, Pereira JC, Granjeiro JM, et al: The role of matrix metalloproteinases in the oral environment. *Acta Odontol Scand* 65:1–13, 2007.
71. Hart TC, Shapira L, van Dyke TE: Neutrophil defects as risk factors for periodontal diseases. *J Periodontol* 65:521–529, 1994.
72. Hasturk H, Kantarci A, Goguet-Surmenian E, et al: Resolvin E1 regulates inflammation at the cellular and tissue level and restores tissue homeostasis in vivo. *J Immunol* 179:7021–7029, 2007.
73. Heasman PA, Collins JG, Offenbacher S: Changes in crevicular, leukotriene B (fluid levels of interleukin-1_4), prostaglandin E_2, thromboxane B_2 in experimental and tumour necrosis factor gingivitis in humans. *J Periodontal Res* 28:241–247, 1993.
74. Heinrich PC, Behrmann I, Haan S, et al: Principles of interleukin (IL)-6-type cytokine signalling and its regulation. *Biochem J* 374:1–20, 2003.
75. Hill AV: Immunogenetics. Defence by diversity. *Nature* 398:668–669, 1999.
76. Hillmann G, Dogan S, Geurtsen W: Histopathological investigation of gingival tissue from patients with rapidly progressive periodontitis. *J Periodontol* 69:195–208, 1998.
77. Ho LH, Ohno T, Oboki K, et al: IL-33 induces IL-13 production by mouse mast cells independently of IgE-FcepsilonRI signals. *J Leukoc Biol* 82:1481–1490, 2007.
78. Holzhausen M, Rossa C, Jr, Marcantonio E, Jr, et al: Effect of selective cyclooxygenase-2 inhibition on the development of ligature-induced periodontitis in rats. *J Periodontol* 73:1030–1036, 2002.
79. Honda T, Domon H, Okui T, et al: Balance of inflammatory response in gingivitis and progressive periodontitis lesions. *Clin Exp Immunol* 144:35–40, 2006.
80. Hong S, Gronert K, Devchand PR, et al: Novel docosatrienes and 17S-resolvins generated from docosahexaenoic acid in murine brain, human blood, and glial cells. Autacoids in anti-inflammation. *J Biol Chem* 278:14677–14687, 2003.
81. Ishimi Y, Miyaura C, Jin CH, et al: IL-6 is produced by osteoblasts and induces bone resorption. *J Immunol* 145:3297–3303, 1990.
82. Johnson RB, Serio FG: Interleukin-18 concentrations and the pathogenesis of periodontal disease. *J Periodontol* 76:785–790, 2005.
83. Johnstone AM, Koh A, Goldberg MB, et al: A hyperactive neutrophil phenotype in patients with refractory periodontitis. *J Periodontol* 78:1788–1794, 2007.
84. Kantarci A, Hasturk H, Van Dyke TE: Host-mediated resolution of inflammation in periodontal diseases. *Periodontol 2000* 40:144–163, 2006.
85. Kinane DF, Darby IB, Said S, et al: Changes in gingival crevicular fluid matrix metalloproteinase-8 levels during periodontal treatment and maintenance. *J Periodontal Res* 38:400–404, 2003.
86. Kinane DF, Preshaw PM, Loos BG: Host-response: understanding the cellular and molecular mechanisms of host-microbial interactions–consensus of the Seventh European Workshop on Periodontology. *J Clin Periodontol* 38(Suppl 11):44–48, 2011.
87. Kishimoto T: Interleukin-6: from basic science to medicine—40 years in immunology. *Annu Rev Immunol* 23:1–21, 2005.
88. Koide M, Suda S, Saitoh S, et al: *In vivo* administration of IL-1 beta accelerates silk ligature-induced alveolar bone resorption in rats. *J Oral Pathol Med* 24:420–434, 1995.
89. Komai-Koma M, Gracie JA, Wei XQ, et al: Chemoattraction of human T cells by IL-18. *J Immunol* 170:1084–1090, 2003.
90. Komai-Koma M, Xu D, Li Y, et al: IL-33 is a chemoattractant for human Th2 cells. *Eur J Immunol* 37:2779–2786, 2007.
91. Kornman KS, Page RC, Tonetti MS: The host response to the microbial challenge in periodontitis: assembling the players. *Periodontol 2000* 14:33–53, 1997.
92. Kornman KS: Mapping the pathogenesis of periodontitis: a new look. *J Periodontol* 79:1560–1568, 2008.
93. Krieg AM: CpG motifs in bacterial DNA and their immune effects. *Annu Rev Immunol* 20:709–760, 2002.
94. Kurihara N, Bertolini D, Suda T, et al: IL-6 stimulates osteoclast-like multinucleated cell formation in long term human marrow cultures by inducing IL-1 release. *J Immunol* 144:4226–4230, 1990.
95. Kurita-Ochiai T, Amano S, Fukushima K, et al: Cellular events involved in butyric acid-induced T cell apoptosis. *J Immunol* 171:3576–3584, 2003.
96. Kurita-Ochiai T, Seto S, Suzuki N, et al: Butyric acid induces apoptosis in inflamed fibroblasts. *J Dent Res* 87:51–55, 2008.
97. Lamont RJ, Jenkinson HF: Life below the gum line: pathogenic mechanisms of *Porphyromonas gingivalis*. *Microbiol Mol Biol Rev* 62:1244–1263, 1998.
98. Lamont RJ, Jenkinson HF: Subgingival colonization by *Porphyromonas gingivalis*. *Oral Microbiol Immun* 15:341–349, 2000.

99. Lee HJ, Kang IK, Chung CP, et al: The subgingival microflora and gingival crevicular fluid cytokines in refractory periodontitis. *J Clin Periodontol* 22:885–890, 1995.
100. Lekstrom-Himes JA, Gallin JI: Immunodeficiency diseases caused by defects in phagocytes. *N Engl J Med* 343:1703–1714, 2000.
101. Lerner UH: Inflammation-induced bone remodeling in periodontal disease and the influence of post-menopausal osteoporosis. *J Dent Res* 85:596–607, 2006.
102. Leung BP, Culshaw S, Gracie JA, et al: A role for IL-18 in neutrophil activation. *J Immunol* 167:2879–2886, 2001.
103. Lin H, Ho AS, Haley-Vicente D, et al: Cloning and characterization of IL-1HY2, a novel interleukin-1 family member. *J Biol Chem* 276:20597–20602, 2001.
104. Lin SJ, Chen YL, Kuo MY, et al: Measurement of gp130 cytokines oncostatin M and IL-6 in gingival crevicular fluid of patients with chronic periodontitis. *Cytokine* 30:160–167, 2005.
105. Lindhe J, Rylander H: Experimental gingivitis in young dogs. *Scand J Dent Res* 83:314–326, 1975.
106. Listgarten MA: Pathogenesis of periodontitis. *J Clin Periodontol* 13:418–430, 1986.
107. Löe H, Anerud A, Boysen H, et al: Natural history of periodontal disease in man. Rapid, moderate and no loss of attachment in Sri Lankan labourers 14 to 46 years of age. *J Clin Periodontol* 13:431–440, 1986.
108. Lourbakos A, Potempa J, Travis J, et al: Arginine-specific protease from *Porphyromonas gingivalis* activates protease-activated receptors on human oral epithelial cells and induces interleukin-6 secretion. *Infect Immun* 69:5121–5130, 2001.
109. MacNaul KL, Chartrain N, Lark M, et al: Discoordinate expression of stromelysin, collagenase, and tissue inhibitor of metalloproteinases-1 in rheumatoid human synovial fibroblasts. Synergistic effects of interleukin-1 and tumor necrosis factor-alpha on stromelysin expression. *J Biol Chem* 265:17238–17245, 1990.
110. Marcheselli VL, Hong S, Lukiw WJ, et al: Novel docosanoids inhibit brain ischemia-reperfusion-mediated leukocyte infiltration and pro-inflammatory gene expression. *J Biol Chem* 278:43807–43817, 2003.
111. Mariotti A: The extracellular matrix of the periodontium: dynamic and interactive tissues. *Periodontol 2000* 3:39–63, 1993.
112. Mathur A, Michalowicz B, Castillo M, et al: Interleukin-1 alpha, interleukin-8 and interferon-alpha levels in gingival crevicular fluid. *J Periodontal Res* 31:489–495, 1996.
113. Matthews JB, Wright HJ, Roberts A, et al: Hyperactivity and reactivity of peripheral blood neutrophils in chronic periodontitis. *Clin Exp Immunol* 147:255–264, 2007.
114. Matthews JB, Wright HJ, Roberts A, et al: Neutrophil hyperresponsiveness in periodontitis. *J Dent Res* 86:718–722, 2007.
115. McMahon B, Godson C: Lipoxins: endogenous regulators of inflammation. *Am J Physiol Renal Physiol* 286:F189–F201, 2004.
116. Miller WD: The human mouth as a focus of infection. *Dental Cosmos* 33:689–713, 1891.
117. Moulin D, Donze O, Talabot-Ayer D, et al: Interleukin (IL)-33 induces the release of pro-inflammatory mediators by mast cells. *Cytokine* 40:216–225, 2007.
118. Moussion C, Ortega N, Girard JP: The IL-1-like cytokine IL-33 is constitutively expressed in the nucleus of endothelial cells and epithelial cells in vivo: a novel 'alarmin'? *PLoS ONE* 3:e3331, 2008.
119. Mukherjee PK, Marcheselli VL, Serhan CN, et al: Neuroprotectin D1: a docosahexaenoic acid-derived docosatriene protects human retinal pigment epithelial cells from oxidative stress. *Proc Natl Acad Sci USA* 101:8491–8496, 2004.
120. Nakajima T, Ueki-Maruyama K, Oda T, et al: Regulatory T-cells infiltrate periodontal disease tissues. *J Dent Res* 84:639–643, 2005.
121. Nanci A, Bosshardt DD: Structure of periodontal tissues in health and disease. *Periodontol 2000* 40:11–28, 2006.
122. Nathan C: Points of control in inflammation. *Nature* 420:846–852, 2002.
123. Niederman R, Zhang J, Kashket S: Short-chain carboxylic-acid-stimulated, PMN-mediated gingival inflammation. *Crit Rev Oral Biol Med* 8:269–290, 1997.
124. Nonnenmacher C, Dalpke A, Zimmermann S, et al: DNA from periodontopathogenic bacteria is immunostimulatory for mouse and human immune cells. *Infect Immun* 71:850–856, 2003.
125. O'Brien-Simpson NM, Veith PD, Dashper SG, et al: Antigens of bacteria associated with periodontitis. *Periodontol 2000* 35:101–134, 2004.
126. Offenbacher S, Salvi GE: Induction of prostaglandin release from macrophages by bacterial endotoxin. *Clin Infect Dis* 28:505–513, 1999.
127. Offenbacher S, Barros SP, Beck JD: Rethinking periodontal inflammation. *J Periodontol* 79:1577–1584, 2008.
128. Ogawa T, Uchida H: A peptide, ALTTE, within the fimbrial subunit protein from *Porphyromonas gingivalis*, induces production of interleukin 6, gene expression and protein phosphorylation in human peripheral blood mononuclear cells. *FEMS Immunol Med Microbiol* 11:197–205, 1995.
129. Okada H, Murakami S: Cytokine expression in periodontal health and disease. *Crit Rev Oral Biol Med* 9:248–266, 1998.
130. Orozco A, Gemmell E, Bickel M, et al: Interleukin-1 beta, interleukin-12 and interleukin-18 levels in gingival fluid and serum of patients with gingivitis and periodontitis. *Oral Microbiol Immun* 21:256–260, 2006.
131. Orozco A, Gemmell E, Bickel M, et al: Interleukin 18 and periodontal disease. *J Dent Res* 86:586–593, 2007.
132. Page RC, Schroeder HE: Pathogenesis of inflammatory periodontal disease. A summary of current work. *Lab Invest* 33:235–249, 1976.
133. Page RC, Schroeder HE: Current status of the host response in chronic marginal periodontitis. *J Periodontol* 52:477–491, 1981.
134. Page RC: The role of inflammatory mediators in the pathogenesis of periodontal disease. *J Periodontal Res* 26:230–242, 1991.
135. Page RC, Kornman KS: The pathogenesis of human periodontitis: an introduction. *Periodontol 2000* 14:9–11, 1997.
136. Payne WA, Page RC, Ogilvie AL, et al: Histopathologic features of the initial and early stages of experimental gingivitis in man. *J Periodontal Res* 10:51–64, 1975.
137. Persson GR: Immune responses and vaccination against periodontal infections. *J Clin Periodontol* 32(Suppl 6):39–53, 2005.
138. Potempa J, Pike RN: Corruption of innate immunity by bacterial proteases. *J Innate Immun* 1:70–87, 2009.
139. Preshaw PM: Host response modulation in periodontics. *Periodontol 2000* 48:92–110, 2008.
140. Preshaw PM, Taylor JJ: How has research into cytokine interactions and their role in driving immune responses impacted our understanding of periodontitis? *J Clin Periodontol* 38(Suppl 11):60–84, 2011.
141. Rasmussen L, Hanstrom L, Lerner UH: Characterization of bone resorbing activity in gingival crevicular fluid from patients with periodontitis. *J Clin Periodontol* 27:41–52, 2000.
142. Renelli M, Matias V, Lo RY, et al: DNA-containing membrane vesicles of *Pseudomonas aeruginosa* PAO1 and their genetic transformation potential. *Microbiology* 150:2161–2169, 2004.
143. Reynolds JJ, Meickle MC: Mechanisms of connective tissue matrix destruction in periodontitis. *Periodontol 2000* 14:144–157, 1997.
144. Roberts FA, Hockett RD, Jr, Bucy RP, et al: Quantitative assessment of inflammatory cytokine gene expression in chronic adult periodontitis. *Oral Microbiol Immunol* 12:336–344, 1997.
145. Rouabhia M, Ross G, Page N, et al: Interleukin-18 and gamma interferon production by oral epithelial cells in response to exposure to *Candida albicans* or lipopolysaccharide stimulation. *Infect Immun* 70:7073–7080, 2002.
146. Ryan ME, Ramamurthy NS, Golub LM: Matrix metalloproteinases and their inhibition in periodontal treatment. *Curr Opin Periodontol* 3:85–96, 1996.
147. Saglie FR, Newman MG, Carranza FA, Jr, et al: Bacterial invasion of gingiva in advanced periodontitis in humans. *J Periodontol* 53:217–222, 1982.
148. Saglie FR, Marfany A, Camargo P: Intragingival occurrence of *Actinobacillus actinomycetemcomitans* and *Bacteroides gingivalis* in active destructive periodontal lesions. *J Periodontol* 59:259–265, 1988.

149. Sasaki H, Okamatsu Y, Kawai T, et al: The interleukin-10 knockout mouse is highly susceptible to *Porphyromonas gingivalis*-induced alveolar bone loss. *J Periodontal Res* 39:432–441, 2004.
150. Schenkein HA, Barbour SE, Tew JG: Cytokines and inflammatory factors regulating immunoglobulin production in aggressive periodontitis. *Periodontol 2000* 45:113–127, 2007.
151. Schmitz J, Owyang A, Oldham E, et al: IL-33, an interleukin-1-like cytokine that signals via the IL-1 receptor-related protein ST2 and induces T helper type 2-associated cytokines. *Immunity* 23:479–490, 2005.
152. Schroeder HE: Quantitative parameters of early human gingival inflammation. *Arch Oral Biol* 15:383–400, 1970.
153. Schroeder HE, Munzel-Pedrazolli S, Page RC: Correlated morphometric and biochemical analysis of gingival tissue in early chronic gingivitis in man. *Arch Oral Biol* 18:899–923, 1973.
154. Schroeder HE, Listgarten MA: The gingival tissues: the architecture of periodontal protection. *Periodontol 2000* 13:91–120, 1997.
155. Serhan CN: Lipoxin biosynthesis and its impact in inflammatory and vascular events. *Biochim Biophys Acta* 1212:1–25, 1994.
156. Serhan CN, Hong S, Gronert K, et al: Resolvins: a family of bioactive products of omega-3 fatty acid transformation circuits initiated by aspirin treatment that counter proinflammation signals. *J Exp Med* 196:1025–1037, 2002.
157. Serhan CN: Resolution phase of inflammation: novel endogenous anti-inflammatory and proresolving lipid mediators and pathways. *Annu Rev Immunol* 25:101–137, 2007.
158. Serhan CN: Controlling the resolution of acute inflammation: a new genus of dual anti-inflammatory and proresolving mediators. *J Periodontol* 79:1520–1526, 2008.
159. Seymour GJ, Gemmell E, Reinhardt RA, et al: Immunopathogenesis of chronic inflammatory periodontal disease: cellular and molecular mechanisms. *J Periodontal Res* 28:478–486, 1993.
160. Seymour GJ, Gemmell E: Cytokines in periodontal disease: where to from here? *Acta Odontol Scand* 59:167–173, 2001.
161. Seymour GJ, Taylor JJ: Shouts and whispers: an introduction to immunoregulation in periodontal disease. *Periodontol 2000* 35:9–13, 2004.
162. Sharma M: Chemokines and their receptors: orchestrating a fine balance between health and disease. *Crit Rev Biotechnol* 30:1–22, 2010.
163. Sharma S, Kulk N, Nold MF, et al: The IL-1 family member 7b translocates to the nucleus and down-regulates proinflammatory cytokines. *J Immunol* 180:5477–5482, 2008.
164. Silva TA, Garlet GP, Fukada SY, et al: Chemokines in oral inflammatory diseases: apical periodontitis and periodontal disease. *J Dent Res* 86:306–319, 2007.
165. Smith A: Focal infection. *JAMA* 150:490–491, 1952.
166. Sorkin BC, Niederman R: Short chain carboxylic acids decrease human gingival keratinocyte proliferation and increase apoptosis and necrosis. *J Clin Periodontol* 25:311–315, 1998.
167. Stashenko P, Fujiyoshi P, Obernesser MS, et al: Levels of interleukin 1 beta in tissue from sites of active periodontal disease. *J Clin Periodontol* 18:548–554, 1991.
168. Stashenko P, Jandinski JJ, Fujiyoshi P, et al: Tissue levels of bone resorptive cytokines in periodontal disease. *J Periodontol* 62:504–509, 1991.
169. Steinberger RE, Holden PA: Extracellular DNA in single- and multiple-species unsaturated biofilms. *Appl Environ Microbiol* 71:5404–5410, 2005.
170. Sun YP, Oh SF, Uddin J, et al: Resolvin D1 and its aspirin-triggered 17R epimer. Stereochemical assignments, anti-inflammatory properties, and enzymatic inactivation. *J Biol Chem* 282:9323–9334, 2007.
171. Takano T, Clish CB, Gronert K, et al: Neutrophil-mediated changes in vascular permeability are inhibited by topical application of aspirin-triggered 15-epi-lipoxin A4 and novel lipoxin B4 stable analogues. *J Clin Invest* 101:819–826, 1998.
172. Takashiba S, Naruishi K, Murayama Y: Perspective of cytokine regulation for periodontal treatment: fibroblast biology. *J Periodontol* 74:103–110, 2003.
173. Takata T, Donath K: The mechanism of pocket formation. A light microscopic study on undecalcified human material. *J Periodontol* 59:215–221, 1988.
174. Tanabe N, Maeno M, Suzuki N, et al: IL-1 alpha stimulates the formation of osteoclast-like cells by increasing M-CSF and PGE2 production and decreasing OPG production by osteoblasts. *Life Sci* 77:615–626, 2005.
175. Tato CM, Cua DJ: Alternative lifestyles of T cells. *Nat Immunol* 9:1323–1325, 2008.
176. Taylor JJ, Preshaw PM, Donaldson PT: Cytokine gene polymorphism and immunoregulation in periodontal disease. *Periodontol 2000* 35:158–182, 2004.
177. Tervahartiala T, Pirila E, Ceponis A, et al: The in vivo expression of the collagenolytic matrix metalloproteinases (MMP-2, -8, -13, and -14) and matrilysin (MMP-7) in adult and localized juvenile periodontitis. *J Dent Res* 79:1969–1977, 2000.
178. Thomas VC, Hiromasa Y, Harms N, et al: A fratricidal mechanism is responsible for eDNA release and contributes to biofilm development of *Enterococcus faecalis*. *Mol Microbiol* 72:1022–1036, 2009.
179. Tonetti MS, Imboden MA, Gerber L, et al: Localized expression of mRNA for phagocyte-specific chemotactic cytokines in human periodontal infections. *Infect Immun* 62:4005–4014, 1994.
180. Tonetti MS: Molecular factors associated with compartmentalization of gingival immune responses and transepithelial neutrophil migration. *J Periodontal Res* 32:104–109, 1997.
181. Tonetti MS, Imboden MA, Lang NP: Neutrophil migration into the gingival sulcus is associated with transepithelial gradients of interleukin-8 and ICAM-1. *J Periodontol* 69:1139–1147, 1998.
182. Towne JE, Garka KE, Renshaw BR, et al: Interleukin (IL)-1F6, IL-1F8, and IL-1F9 signal through IL-1Rrp2 and IL-1RAcP to activate the pathway leading to NF-kappaB and MAPKs. *J Biol Chem* 279:13677–13688, 2004.
183. Trombelli L, Tatakis DN, Scapoli C, et al: Modulation of clinical expression of plaque-induced gingivitis. II. Identification of "high-responder" and "low-responder" subjects. *J Clin Periodontol* 31:239–252, 2004.
184. Uehara A, Imamura T, Potempa J, et al: Gingipains from *Porphyromonas gingivalis* synergistically induce the production of proinflammatory cytokines through protease-activated receptors with Toll-like receptor and NOD1/2 ligands in human monocytic cells. *Cell Microbiol* 10:1181–1189, 2008.
185. Van Dyke TE: Inflammation and periodontal diseases: a reappraisal. *J Periodontol* 79:1501–1502, 2008.
186. Van Dyke TE: The management of inflammation in periodontal disease. *J Periodontol* 79:1601–1608, 2008.
187. Van Dyke TE, Kornman KS: Inflammation and factors that may regulate inflammatory response. *J Periodontol* 79:1503–1507, 2008.
188. Van Snick J: Interleukin-6: an overview. *Annu Rev Immunol* 8:253–278, 1990.
189. Vardar S, Baylas H, Huseyinov A: Effects of selective cyclooxygenase-2 inhibition on gingival tissue levels of prostaglandin E_2 and prostaglandin F_2 and clinical parameters of chronic periodontitis. *J Periodontol* 74:57–63, 2003.
190. Waerhaug J: The angular bone defect and its relationship to trauma from occlusion and downgrowth of subgingival plaque. *J Clin Periodontol* 6:61–82, 1979.
191. Wang BY, Chi B, Kuramitsu HK: Genetic exchange between *Treponema denticola* and *Streptococcus gordonii* in biofilms. *Oral Microbiol Immun* 17:108–112, 2002.
192. Weinberg A, Krisanaprakornkit S, Dale BA: Epithelial antimicrobial peptides: review and significance for oral applications. *Crit Rev Oral Biol Med* 9:399–414, 1998.
193. Williams RC, Jeffcoat MK, Howell TH, et al: Ibuprofen: an inhibitor of alveolar bone resorption in beagles. *J Periodontal Res* 23:225–229, 1988.
194. Williams RC, Jeffcoat MK, Howell TH, et al: Three-year clinical trial of flurbiprofen treatment of human periodontitis: preliminary analysis. *J Dent Res* 67:370, 1988. Abstract 2062.

195. Williams RC: Understanding and managing periodontal diseases: a notable past, a promising future. *J Periodontol* 79:1552–1559, 2008.
196. Wu J, Xi C: Evaluation of different methods for extracellular DNA from the biofilm matrix. *Appl Environ Microbiol* 75:5390–5395, 2009.
197. Wynn TA: Cellular and molecular mechanisms of fibrosis. *J Pathol* 214:199–210, 2008.
198. Yilmaz O: The chronicles of *Porphyromonas gingivalis*: the microbium, the human oral epithelium and their interplay. *Microbiology* 154:2897–2903, 2008.
199. Yoshimoto T, Takeda K, Tanaka T, et al: IL-12 up-regulates IL-18 receptor expression on T cells, Th1 cells, and B cells: synergism with IL-18 for IFN-gamma production. *J Immunol* 161:3400–3407, 1998.
200. Yoshimoto T, Tsutsui H, Tominaga K, et al: IL-18, although antiallergic when administered with IL-12, stimulates IL-4 and histamine release by basophils. *Proc Natl Acad Sci USA* 96:13962–13966, 1999.

CHAPTER 6

Genetic Susceptibility to Periodontal Disease

Scott R. Diehl, Chih-Hung Chou, Fengshen Kuo, Ching-Yu Huang, and Olga A. Korczeniewska

CHAPTER OUTLINE

Genetic and Genomic Methods of the 21st Century
Inherited Variation and Risk of Periodontitis
Using Genetics for Personalized Treatment

Table 6-3, which is a comprehensive table about independent gene association reports for aggressive and chronic periodontitis, can be accessed on the companion website at www.expertconsult.com.

It is now widely accepted that differences among individuals who are at risk for the development of most diseases have a substantial inherited component. Factors in the environment (e.g., diet, smoking, preventive care, exposure to pathogens) interact with each person's genetic predisposition to determine his or her health outcomes. This complex combination of variables determines if and when a disease affects the person, how fast and how severely symptoms of the disease progress, and how the person responds to different treatments in terms of both side effects and the success of alternative therapies. Sometimes—and particularly with diseases such as cystic fibrosis and muscular dystrophy—the genetic component of risk predominates, and differences in environment play only a minor role. With other diseases, factors in the environment are most important, and variation inherited in the person's deoxyribonucleic acid (DNA) has only an infrequent or minor influence on disease susceptibility or progression. Examples of the latter include infectious diseases such as human immunodeficiency virus/acquired immunodeficiency syndrome (HIV/AIDS) as well as cancers such as mesothelioma, which is strongly associated with asbestos exposure. The majority of human diseases fall halfway between these two extremes, with genes and the environment both playing very important roles.

Most cases of periodontitis appear to fit this complex gene and environment model. With the exception of a handful of very rare syndromes caused by mutations of single genes, evidence indicates that inherited variation in DNA has a role roughly equal to that of the environment in determining who remains periodontally healthy versus who is affected by this disease. Beyond this broad generalization, however, and despite hundreds of studies of genetic polymorphisms reported to date, our understanding of which specific genes are important remains extremely limited. We know even less about the likely (though unproven) role that individual genetic differences may have in determining how patients respond to alternative periodontal treatments.

In this chapter, the challenges and barriers that have thus far limited progress in advancing our knowledge of the complex genetics of periodontitis will be reviewed. This requires a clear understanding of not only the architecture of the human genome and the complexity of genetic susceptibility but also of the critical roles that statistical power and sample size play in the process of discovery. These latter issues are important for all areas of research but especially for situations in which a large number of variables need to be evaluated. In genetic studies, more than 23,000 genes need to be considered as potential hypotheses or "candidates" for being disease risk factors. Depending on the gene's size and the frequency of genetic recombination in the gene's chromosomal region, scientists need to evaluate between a handful or up to several hundred inherited DNA variants in each gene as potential "biomarkers" of disease risk. Each one of these variants essentially amounts to a test of the hypothesis as to whether the variant is associated with disease risk. Furthermore, many complex diseases have been found to be very strongly associated with DNA variation in parts of the human genome where no genes are known to exist but where the genetic material may have important functional effects nonetheless. Therefore, to fully evaluate the entire human genome, the total number of hypotheses that need to be tested is truly enormous and involve roughly the equivalent of 1 million independent statistical tests. Only during the past few years have laboratory and computational tools been developed that make this scale of work technically possible, and thus far only one recent study has reported results of a whole genome analysis for periodontitis.

Opportunities for advanced study designs and next-generation genomic technologies to improve the understanding of the inherited basis of periodontitis make it likely (although by no means certain) that genetic variation will become an important variable to be routinely considered by practicing dentists within the next 5 to 10 years. If and when this occurs, dentists will need to learn how to access and interpret the massive amounts of information coded in the more than 3 billion bases of DNA in the human genome and to incorporate this into improved evidence-based practices for periodontal disease prevention, diagnosis, and treatment. Alternatively, new interdisciplinary teams will need to be established with dentists as key members working closely with experts in bioinformatics, genomics, and genetic counseling so that patients will be able to reap the potentially significant benefits of these scientific

advances. However the process evolves, it will surely lead to revolutionary changes in both dental education and dental practice in the not-so-distant future.[8,26]

Genetic and Genomic Methods of the 21st Century

Most health care professionals are aware of the many major advances in genetics accomplished during the past 20 years since the Human Genome Project officially began in 1990.[46] Headlines and announcements of "breakthroughs" have appeared regularly in print and television media. Too often, many of these stories seem to promise rapid and significant improvements in health care that are totally unrealistic.[11] More cautious assessments are usually not deemed as newsworthy by the media, and cautious understatement is not always in the interest of private companies and granting agencies involved in basic research and clinical trials. Consequently, the public has often received an overly optimistic picture of what the future of medical care based on genomic medicine really holds for them. Despite this all-too-common overstatement about rapid translation to clinical practice, advances in technical capabilities for genomic data acquisition and the accumulation of knowledge in the field of genetics have been truly enormous. The eventual impact of this explosion of biologic knowledge on all areas of human health, including those concerning the field of dentistry, is certain to be very substantial over the longer term.

Unfortunately, for reasons explored further in the next section, genomic advances have thus far contributed very little to advancing our understanding of the molecular–pathologic causes of periodontitis or pointed toward ways to improve treatment through "individualized" approaches that are based on a patient's inherited genetic variation. Only recently has the possibility of making major progress been realized on the basis of newly available genomic tools and approaches involving genome-wide association studies (GWAS; pronounced "gee-wahs") and "next-generation" DNA sequencing techniques. For these research strategies to be successful, however, they must be combined with further improvement in research definitions of periodontal disease and much larger sample sizes than have been used in most previous genetic studies of this condition. To help improve understanding, some of the commonly used terms in genetics are explained in Table 6-1.

Patterns in Populations and Pedigrees

With all of the attention focused on silicon arrays, laser scanners, and the other "glamorous" gadgets of advanced genomic technologies, it is important to consider how much needs to be learned about the genetic basis of a disease before stepping into a DNA laboratory. In fact, a strong foundation of knowledge about a disease's frequency in different populations and its occurrence among closely and distantly related family members (i.e., pedigrees) is absolutely essential. Without this foundation, endless gigabytes of DNA sequence data will not enable scientist–clinicians to develop a solid understanding of the causes of a disease. The human genome has not evolved in a test tube nor of inside a supercomputer; rather, it has existed for millennia in natural populations and been transmitted from generation to generation, from parents to children. Only by carefully studying the genetics of a disease in populations and pedigrees can we hope to begin to unearth the complex interactions between genes and the environment that underlie individual

TABLE 6-1 Glossary of Terms Relevant to the Genetics of Periodontal Disease

Allele	One of several possible alternative forms of a gene caused by small or large differences in the DNA sequence within or near the gene. These differences arise by mutation, and some may affect the function of the gene product (i.e., a protein) or its abundance in different kinds of cells.
Autosome	A chromosome that is not a sex chromosome.
Autosomal dominant	DNA variation in a gene located on an autosome that has a dominant effect over other forms of variation at this location within the gene. When the dominant DNA sequence is present in combination with some other sequence, the gene's function is entirely or nearly entirely determined by the dominant sequence, whereas the alternative sequence that occurs on the person's other chromosome is essentially silent.
Autosomal recessive	DNA variation in a gene located on an autosome that has an effect on the gene's function only when the person has inherited two copies: one from the mother and the other from the father. For example, if an individual has two copies of an abnormal gene that is autosomal recessive, they will be subject to the effects of that gene.
Chromosome	A nuclear structure that contains genetic information. Humans have 46 chromosomes that are arranged in 23 pairs. There are 22 pairs of autosomes and one pair of sex chromosomes (either XX or XY).
Concordance	The probability that a pair of individuals (e.g., twins) both have a certain characteristic (e.g., periodontal disease), given that one of the pair has the characteristic. Presented as a number from 0 to 1 or as a percentage.
Dizygotic twins	Twins that have resulted from the fertilization of two separate eggs. They are no more similar to each other (from a genetic perspective) than are nontwin siblings. Nonidentical twins.
Epigenetics	Term used to describe the changes in phenotype or gene expression that result from mechanisms other than changes in the underlying DNA sequences (i.e., changes in which the gene is expressed rather than a change in the DNA sequence itself). Nongenetic factors cause the organism's genes to be expressed differently.
Exon	Protein coding regions of DNA.
Frameshift mutation	A mutation that results from the insertion or deletion of one or more nucleotides into a gene, thereby causing the coding regions to be read in the wrong frame and usually causing the protein produced to be defective in function.
Gene	The basic unit of heredity that occupies a specific position (locus) on a chromosome and that has specific effect(s) on the phenotype of the organism. A piece of DNA that is transcribed into a molecule of RNA and then translated into a protein.
Gene expression	The process by which the information in a gene is used via transcription and translation, thereby leading to the production of protein. Differences in gene expression can affect the phenotype of the organism, including the risk of disease.
Genetic code	In RNA and DNA, the consecutive nucleotide triplets (codons) that specify the sequence of amino acids for protein synthesis (translation).

TABLE 6-1 Glossary of Terms Relevant to the Genetics of Periodontal Disease—cont'd

Genome	The entire hereditary information of an organism. This term refers to all of the genes and other nongene portions of DNA carried by an individual cell.
Genotype	The genetic makeup of an organism or cell as distinct from its expressed features or phenotype.
Haplotype	A contraction of the term *haploid genotype.* This word refers to a combination of alleles at multiple loci, which are usually transmitted together on the same region of a chromosome.
Heredity	The passing of traits to offspring from parents or ancestors. In biology, the study of heredity is referred to as *genetics.* As a result of heredity, variation among individuals allows species to evolve by natural selection in response to changes in their environment or by random change over long periods of time.
Homozygous	The presence of identical alleles at a specific position in a gene.
Heterozygous	The presence of two different alleles at a specific position in a gene.
Intron	A DNA region within a gene that is not translated into protein. These intervening (noncoding) portions of DNA or RNA are removed during RNA processing.
Isoform	Any of several different forms of the same protein. Isoforms may be produced from related genes, or they may arise from the same gene via alternative splicing. Many isoforms are caused by single nucleotide polymorphisms.
Ligand	A molecule that binds to another molecule (usually a cellular receptor molecule).
Linkage	A term used to describe the tendency for certain genes to be transmitted from parent to child together because they are located close to each other on the same chromosome.
Linkage disequilibrium	The occurrence of specific alleles at different locations in the DNA that are relatively close to each other (linked) more often than would be expected by chance alone (disequilibrium).
Locus	The physical location that a gene occupies within a chromosome. (Plural: loci.)
Monozygotic twins	Twins with identical genetic makeup (i.e., identical twins) as a result of the fertilization of a single egg that then splits into two embryos.
Mutation	Changes in the DNA sequence of the genome can result from errors that occur during DNA replication or meiosis and can be caused by radiation, viruses, and mutagenic chemicals. Most mutations have very little or no measurable effect on the gene's function; some are harmful, and a rare few may be advantageous.
Nucleotide	Molecules that, when linked together, make up the structural units of RNA and DNA. They are composed of a phosphate group; the bases adenine, cytosine, guanine, and thymine; and a pentose sugar. In RNA, the thymine base is replaced by uracil.
Penetrance	The proportion of individuals who have a particular allele/genotype who express an associated trait (phenotype). Genotypes with a high penetrance result in a larger number of individuals in the population with the associated phenotype as compared with genotypes with a low penetrance.
Phenotype	The observable characteristics displayed by an organism (e.g., morphology, development, gender, eye color, physiologic properties, behavior). Phenotype results from the expression of the organism's genes as well as from the influence of environmental factors and interactions between the two.
Polymorphism	Polymorphism exists when two or more different phenotypes exist within different individuals of the same population. In the context of genetics, it refers to a region of the genome that varies between individual members of the population in such proportions that the rarest of them cannot be maintained just by recurrent mutation. Polymorphism may be actively maintained in populations by natural selection and also by random drift.
Sequencing	Determining in the laboratory the linear arrangement of nucleotides (in RNA or DNA) or amino acids (in proteins).
Single nucleotide polymorphism (SNP)	A polymorphism in a gene caused by a change in a single nucleotide in the DNA sequence. A large number of protein isoforms result from SNPs. SNPs occur frequently; approximately every 100 to 1000 base pairs occur as a result of deletions, insertions, and substitutions. There are estimated to be more than 10 million SNPs in the human genome. Many SNPs that occur in genes have no effect on the encoded protein, but some SNPs do influence the function of the protein that the gene produces. An SNP initially arises as a very rare mutation, but it is considered to be an SNP if it occurs in at least 1% of the population.
Signal transduction	A cascade of intracellular events that occurs after the binding of an extracellular signal (e.g., a hormone, a cytokine) to a receptor on the cell surface. The intracellular cascade can result in changes in gene expression in the nucleus and hence an altered phenotype of the cell (e.g., as a result of different protein production).
Splicing	The removal of introns from transcribed RNA. The process of removal can vary, and some exons are skipped or excluded from splicing. This causes the production of "splice variants" or "alternatively spliced" protein isoforms, thereby resulting in the formation of different proteins from the same initial RNA.
Transcription	RNA synthesis. The process of creating an RNA copy of an equivalent section of DNA is the first step of gene expression, and it occurs in the nucleus. The RNA copy that is produced is called *messenger RNA* (mRNA).
Translation	The first stage of protein synthesis. mRNA produced during transcription is decoded to produce an amino acid chain that will later fold into an active protein. Translation occurs in the cytoplasm: ribosomes bind to the mRNA and then facilitate decoding via the binding of transfer RNAs (tRNAs) that have complementary anticodon sequences to those of mRNA. The tRNAs carry specific amino acids that are joined together to form a polypeptide as the mRNA passes through the ribosome.

DNA, Deoxyribonucleic acid; *RNA,* ribonucleic acid.

differences in disease susceptibility. This field of research is known as *genetic epidemiology.*

Genetic epidemiologists often first look at whether a disease occurs more often in some human populations than others. These comparisons can include both populations in different geographic areas as well as racial or ethnic groups living in the same region. Does the disease have more severe symptoms, more rapid rates of progression, or an earlier age of onset in some populations? Such findings suggest (but do not prove) that genetic differences that are important for the disease may exist among the populations.

Before the massive human migrations in recent centuries, most human populations existed in semi-isolation from other populations around the globe. As a consequence of natural selection (i.e., differential survival and reproduction), populations sometimes adapted genetically to their local environments. The most famous example of adaptation is the sickle cell hemoglobin variant that protects an individual against the infectious disease malaria. This variant is common among populations who live in areas where this mosquito-borne parasite has long been endemic, because it provides strong protection against the severe symptoms of this disease. The variant persists at high frequency in these populations, although persons who inherit two copies of the mutation (i.e., one from mother and one from father) are severely affected by the disease sickle cell anemia. A balance between the benefit of malaria resistance in persons who inherit only one copy of the variant versus the disadvantage of sickle cell disease keeps the variant at relatively high frequencies among populations where malaria is present. Another example of population differentiation by natural selection is the ability to digest the milk sugar lactose as an adult that evolved in Europeans in conjunction with the domestication of dairy cattle more than 8000 years ago. In addition to differentiation driven by natural selection, as is seen in these examples, a random process called *genetic drift* also causes populations with little or no migration between them to differentiate genetically over time. Thus, one cannot assume that every population difference observed has a functional biologic basis.

Regrettably, the comparison of periodontitis in different populations across the globe is extremely challenging because of the lack of calibrated examiners and standardized disease definitions.[6] One of the most dramatic population differences in which data quality is not an issue is the observation that both localized and generalized forms of early-onset aggressive periodontitis occur about 10 times more frequently among African Americans as compared with Caucasians.[33] Human racial and ethnic groups often differ dramatically with regard to the frequency of mutations at genes that have major effects on disease risk. For example, cystic fibrosis is caused exclusively by recessive mutations in the CFTR gene, and it varies in frequency from 1 in 3000 Caucasians to 1 in 15,000 African Americans in the United States, whereas only 1 in 350,000 Japanese individuals are affected.[49] It is possible that the tenfold higher prevalence of early-onset aggressive periodontitis in African Americans is caused by the elevated frequency of high-risk gene variants in this population. However, additional evidence is needed before such a conclusion can be drawn. Although comparative studies of different populations may provide clues as to possible genetic mechanisms underlying a disease, the environments of the populations may also be dissimilar in important ways. It is possible that variations in diet or in exposure to pathogenic oral bacteria or to some unknown and unmeasured environmental factors could entirely explain the observed differences in the frequency of aggressive periodontitis between population groups. Until solid data confirm a genetic basis for population differences, we need to wait before drawing firm conclusions.

The comparison of disease occurrence or severity in identical (monozygotic) versus nonidentical (dizygotic) twins is a very powerful method for distinguishing between effects caused by variation in genes versus factors in the environment. This requires us to make what is usually a reasonable assumption that the environments of pairs of identical twins are no more or less similar than the environments shared by pairs of nonidentical twins. If variation among individuals in disease susceptibility or severity is caused entirely by factors in the environment, then we expect pairs of identical twins to be no more similar to each other than pairs of nonidentical twins. All twins (whether identical or nonidentical) are expected to be more similar to their co-twins, on average, than to unrelated members of their local population because they were raised in the same family environment, with similar diets, microbial exposures, and so on. However, if genetic variation plays an important role in determining a certain trait, then genetically identical twin pairs will be more similar to each other than nonidentical twin pairs. This is because identical twins share 100% of the same genes, whereas nonidentical twin pairs share only 50% of their parents' genes on average. Genetic epidemiologists calculate a measure called *heritability* that is based on these correlations and that estimates the portion of all variation in the trait that is attributable to inherited genetic variation. Traits with variation that is determined entirely by differences in environmental exposures have heritabilities of 0.0, whereas traits with variation attributable solely to inherited genetic differences without any environmental influence have heritabilities of 1.0. Heritabilities are sometimes reported as a percentage that ranges from 0% to 100%.

Most human diseases and nondisease traits fall in the middle of this range, with heritability ranging between 0.25 and 0.75. For example, in one study, type II diabetes was estimated to have a heritability of 0.26, and abnormal glucose tolerance had a heritability of 0.61.[50] Note that, for it to be feasible to use the twin method with adequate statistical power, the disease has to be fairly common so that the researcher can recruit enough twin pairs in which at least one of the twins is affected by the disease. Not surprisingly, with regard to periodontal disease, only chronic periodontitis occurs frequently enough to have been studied using the twin design. Two twin studies of modest size (i.e., 110 and 117 pairs) have been reported, and these estimate the heritability of measures of chronic periodontitis to range between 40% and 80%, thereby clearly implicating genetic variation in disease risk.[43,44] Interestingly, a study of bacteria associated with periodontitis found no difference between identical versus nonidentical twins.[45] This suggests (at least for these twins, most of whom did not have severe periodontitis) that inherited variation in risk is not mediated by genes that influence the presence of specific bacteria in subgingival plaque.

Another method used by genetic epidemiologists to understand and distinguish different mechanisms of transmission of diseases through families is called *segregation analysis.* This is relatively straightforward for traits in which mutation in a single gene causes the disease to develop with nearly 100% certainty in carriers, whereas persons who do not inherit the mutation are at little or no risk. For example, carriers of a single copy of the Huntington disease gene mutation or carriers of two copies of a cystic fibrosis gene mutation always develop these diseases if they reach the ages at which symptoms of these conditions normally emerge. By tracking the transmission of these diseases in families, it is obvious, for example, that Huntington disease is a dominant single-gene disorder: it is transmitted with 50% probability to offspring of affected individuals and thus it is often found occurring across many generations of large pedigrees. By contrast, parents of children with

cystic fibrosis are very rarely affected themselves, and 25% of siblings are affected by cystic fibrosis when the disease is present in a nuclear family. This pattern of transmission is expected if a disease is recessive (i.e., it requires the inheritance of a mutated gene copy from both parents, who themselves have one normal and one mutated copy and so are not affected). For most common "complex" diseases, however, having a high-risk gene does not automatically lead to development of the disease; this phenomenon is called *reduced penetrance.* Furthermore, several genes or even dozens of different genes may influence disease susceptibility; this is known as *oligogenic inheritance* and *genetic heterogeneity.* Environmental exposures are also important modifiers of disease risk. Such highly complex combinations of multiple genetic and environmental risk factors make the challenge of deciphering genetic mechanisms by merely observing transmission patterns in families using the segregation analysis approach unfeasible. The limitations of this approach were humorously illustrated a number of years ago in an analysis that facetiously presented evidence of a recessive gene controlling the trait of attending medical school.[39] "Risk" for this outcome among first-degree relatives of a doctor was elevated 61 times above that of the general population. More recently, a robust quantitative analysis of the family histories of characters in the Harry Potter series suggested that a dominant gene controls the inheritance of magic abilities.[54] Because the etiology of periodontitis is likely to be highly complex, segregation analyses of this disease that have been reported in the literature should be viewed with considerable skepticism. Unfortunately, the simplifying assumptions required for this method make the results unreliable and potentially misleading. For highly complex diseases, such as most cases of periodontitis, assays at the DNA level need to be combined with careful evaluations of clinical measures among related individuals to derive robust conclusions about a disease's genetic architecture. Some of the key features of the different techniques for studying the genetics of periodontal disease are explained in Table 6-2.

Searching for Answers in the DNA

In theory, a *genetic marker* can be any type of biomolecule or assay that allows us to "read" inherited differences among individuals in their DNA sequences. Blood groups, protein isozymes, and human leukocyte antigens (HLAs) were among the first developed markers, but even simple traits that are controlled by single genes (e.g., eye color) can also serve this purpose. Genomic methods have made these methods obsolete, because researchers can now determine a person's inherited variation directly at the DNA level for a much lower cost and with greater speed and accuracy. So-called "next-generation" DNA sequencing methods are projected to enable researchers and clinicians to obtain nearly the entire 3 billion DNA base human genetic blueprint for less than $1000 a few years from now.[18,67] At present, most genetic studies use a combination of whole genome arrays that can evaluate up to 1 million variable DNA sites in a single assay in combination with lower-throughput methods that are used for the fine mapping of chromosome regions of special interest.[53] These regions are said to contain *candidate genes* of high priority for further investigation either because of the genes' known biologic functions or because results of previous genome-wide surveys indicate strong statistical chances that disease susceptibility genes are located in certain regions of one or more chromosomes. Types of variation include single nucleotide polymorphisms (SNPs; pronounced "snips") in which one DNA base is substituted for another; small insertions and deletions ("in/dels") of one or more DNA bases; and larger structural changes in the DNA, such as inversions (in which a piece of DNA of hundreds or thousands of bases in size is cut out and sewn back into the chromosome in the opposite orientation) and copy number changes (in which a given segment of DNA is either missing or occurs in more than the usual two copies inherited as one copy from each parent).

Equipped with these powerful tools for rapidly measuring DNA variation, the next question to address is what kinds of study designs are most powerful for identifying the dozen or more variants that influence the risk of disease from among the millions of DNA differences that exist between any two individuals in a typical population. One method that has been highly successful for finding molecular defects related to simple genetic diseases caused by the mutation of a single gene, such as cystic fibrosis and Huntington disease, is *linkage analysis.*[1,7] This gene-mapping strategy requires families with one or more members affected by the disease to be recruited and clinically and molecularly evaluated for a relatively small number of genetic markers. Depending on the type of marker used, as few as 500 markers or up to 10,000 markers distributed evenly across the genome are needed. Investigators usually try to recruit families with two or more close relatives, such as sibling pairs, who are affected by the disease as well as parents and other siblings who may be unaffected. With a *null hypothesis* that suggests that a region of the chromosome does *not* contain genetic variation that influences disease risk, siblings are expected to share identical genetic material inherited from their parents an average of 50% of the time. However, if the region of the chromosome being evaluated contains a gene that has a substantial effect on disease risk (e.g., increases the risk by tenfold or more), then pairs of siblings who are both affected by the disease will share the chromosome region that contains the disease gene substantially more often than 50% of the time, and the null hypothesis of 50% sharing will be statistically rejected if the study has an adequately large enough sample of such families. This simple example illustrates how linkage analysis is performed. In practice, both small and large extended families are studied; this will include the simultaneous evaluation of the sharing of genetic material among both affected and unaffected relatives. Sophisticated mathematical algorithms and computer programs are used to carry out the huge number of calculations required for data analyses.

After achieving many successes with the use of linkage analysis for "simple" diseases caused by the mutation of a single gene, this method was extended to complex diseases caused by combinations of multiple susceptibility genes and environmental risk factors. Unfortunately, these conditions proved to be beyond the reach of linkage analysis in most instances. Numerous studies conducted during the 1990s either failed to find any genes, or initially positive findings failed to replicate. Linkage studies of very large numbers of carefully diagnosed families for complex diseases (e.g., orofacial clefting, in which twin studies had firmly established heritability of 70%) identified at most a tiny fraction of this genetic variation. Mathematical analyses have subsequently shown that the linkage analysis gene-mapping strategy has extremely low statistical power for complex diseases in which each individual susceptibility gene has a relatively small effect on risk (e.g., twofold or less) and in which there is extensive heterogeneity among different families that have different combinations of susceptibility genes and environmental exposures.[56] Consequently, it is not surprising that linkage analysis has only been successfully applied to syndromic forms of periodontitis; this information is summarized later in this book.

Disappointment over this setback in human disease mapping caused by the initially unrecognized limitations of linkage analysis was short-lived. An alternative approach called *association*

TABLE 6-2 Techniques for Studying the Genetics of Periodontal Disease

Candidate gene approach	A gene-mapping approach that tests whether one allele of a gene occurs more often in patients with the disease than in subjects without the disease. These methods are also referred to as *association analyses,* and they aim to identify which genes are associated with the disease. Candidate genes are chosen on the basis of their known or presumed function (i.e., they have some plausible role in the disease process, such as producing a protein that is important in the disease pathogenesis). Conceptually this makes sense, but it requires some knowledge of the candidate gene to look for it!
Case–control studies	Studies in which the genetic makeup is compared between cases (who have the disease in question) and controls (who do not). The populations need to be carefully matched, otherwise apparent observed differences between cases and controls could arise because of ethnic or geographic variation, for example.
Twin studies	Comparisons of traits—including diseases in monozygotic, dizygotic, or usually both types of twins—aimed at determining whether variation in the trait among members of a population is caused by genetic variation in inherited DNA sequences, environmental exposures in the subjects' lives, or some combination of both of these processes. Twin studies often measure the *concordance rates* of twins with regard to a particular trait or disease of interest. Monozygotic (identical) twins are very nearly identical in their DNA, whereas dizygotic (nonidentical) twins share an average of half of their DNA as identical sequences inherited from their parents. If a disease has high heritability, identical twins will be more likely to either be both affected or both unaffected (concordant). However, this assumption is complicated in many diseases. A genetic mutation may not have complete *penetrance,* and environmental conditions may contribute to the development of the disease (e.g., one twin may smoke and the other may not). Furthermore, many diseases are polygenic (i.e., caused by alterations in multiple genes).
Familial aggregation and relative risk	Many diseases run in families, and the degree of clustering within the family can be estimated by comparing the number of disease cases in relatives of patients to the risk of disease in the general population. Difficulties with this approach relate to the fact that, in addition to having many genes in common, family members also share many aspects of a common environment (e.g., diet, nutrition, smoking, infectious organisms, shared socioeconomic factors).
Segregation analyses	Statistical analyses of the patterns of transmission of a disease in families in an attempt to determine the relative likelihood that the disease is caused by a single gene with dominant or recessive inheritance, by multiple genes, or entirely by variation in exposure to risk factors. The observed proportions of offspring who have the trait or disease being evaluated (i.e., the phenotype) are compared with the proportions expected to be found in the general population.
Linkage analysis	A technique used to map a gene responsible for a trait to a specific location on a chromosome. These studies are based on the fact that genes that are located close to each other on the chromosome tend to be inherited together as a unit. As such, these genes are said to be "linked." Because linkage analysis initially requires the use very expensive DNA markers, this was originally only considered justified after finding strong evidence of a genetic basis for a trait with the use of segregation analyses or family aggregation studies. One difficulty with linkage analyses is that many diseases are not caused by a single gene of "major" effect but rather by multiple genes of "minor" effect. In the latter situation, multiple genes each contribute a small amount to the phenotype, disease, or trait. The linkage study approach has little power for detection, whereas association analysis methods may still be quite powerful.
Genome-wide analyses	A genome-wide association study (GWAS) investigates genetic variation across the entire genome simultaneously, with the aim of identifying genetic associations related to a trait or disease of interest. The completion of the Human Genome Project in 2003 and the development of microarray technologies capable of assaying more than half a million single nucleotide polymorphisms have made GWASs possible. This method has the potential to identify the genetic contributions to common diseases. Because the entire genome is analyzed, an important advantage of this approach is that the technique permits the genetics of a disease to be investigated in a nonhypothesis-driven way. In other words, it is not necessary to correctly guess which candidate genes are most interesting to evaluate. A GWAS requires that well-characterized cases and controls be identified. A disadvantage of GWASs is that large clinical sample sizes are required to reduce the likelihood of differences between the cases and controls being observed simply by chance as a result of the hundreds of thousands of multiple statistical tests required to search the entire human genome.

analysis was also available, although this had been relegated to studies of HLA and a few other markers of special interest during the prime of linkage approaches.[1,7] Mathematical analyses indicated that, if we make some reasonable assumptions about the nature of genetic factors in human disease, this method could provide adequate statistical power for finding genes of small to modest effect on risk while requiring only moderately large sample sizes that would be feasible to recruit.[56] There was, however, one major catch: to search the entire genome using the GWAS method, the number of genetic markers needed was several orders of magnitude greater (i.e., 500,000 to 1 million assays needed per subject). Fortunately, advances in molecular assay technologies converged at this time period, and several methods of array-based genotyping provided such a capability at an acceptable cost.[53]

How association studies are used to find disease susceptibility genes is illustrated for the case–control design in Figure 6-1. Association analyses are sometimes referred to as *case–control studies,* although this is only one of several sampling methods that can be used (including studies of families). Genotype frequencies of an inherited DNA variant for a group of periodontitis cases are

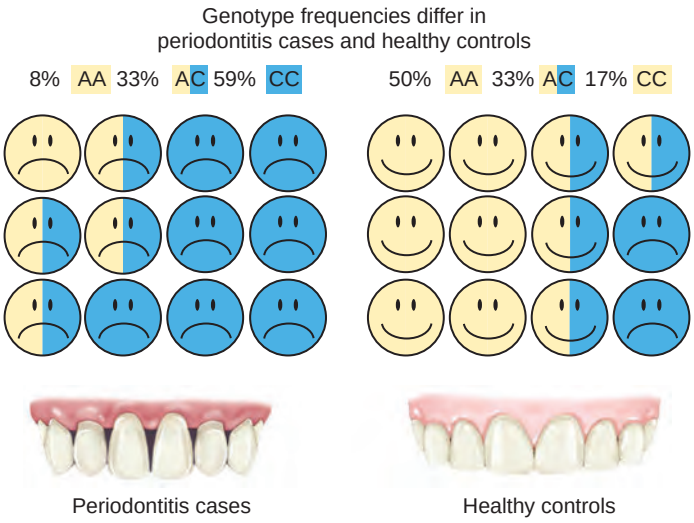

Figure 6-1 Case–control design for a genetic association study. Periodontitis cases shown on the left have frequencies for a hypothetical genetic marker of 8% AA, 33% AC, and 59% CC, which are substantially different from genotype frequencies found in healthy periodontal controls of 50% AA, 33% AC, and 17% CC. In this example, the CC genotype is associated with increased risk, because it occurs at much higher frequency in the disease cases; alternatively, the AA allele is protective, because this variant is much more common in the healthy controls.

statistically compared with the frequencies of the variant in a matched group of periodontally healthy control subjects. If the genotype frequencies differ so greatly that the results are very unlikely to occur by chance, then we conclude that the genotype that is more common in the cases as compared with the controls is "associated with" increased disease risk. In Figure 6-1, 59% of the cases have the CC genotype (having inherited a C allele from both of their parents), whereas only 17% of the healthy controls inherited the CC genotype. Therefore, this DNA variant could be used to predict periodontitis risk (but not until after the finding was validated in additional independent studies). Conversely, we can also say that the AA genotype is "protective" against disease because it occurs much more often in the healthy controls (50%) as compared with periodontitis cases (8%). Ideally, the cases and healthy controls are matched as closely as possible for race/ethnicity, smoking behavior, age, gender, and so on so that differences in genotype frequency are likely to be caused by real biologic effects on disease development or progression rather than as artifacts of some kind. For example, it is well known that races and ethnic groups sometimes differ dramatically with regard to genotype frequencies as a result of their historic isolation in different geographic regions. Consider, for example, a study that had mostly Swedish cases and mostly Italian controls. We know that there are thousands of DNA variants that differ substantially among these populations because of their geographic isolation throughout human history. Few if any of these variants have anything to do with differences in disease risk, but they could falsely appear to be associated because of the failure to carefully match ethnicity in cases and controls. In practice, this is usually not a problem, provided that investigators take reasonable precautions with regard to how cases and controls are selected. It is also now routine practice to use several statistical methods to check for mismatching and then adjust for this during data analysis if it occurs.

The good news is now clearly in: association studies have been a boon for the discovery of inherited genetic variation important for a wide range of complex diseases, including diabetes, cardiovascular disease, metabolic disorders, obesity, and mental illnesses. A recent review cites 24 genes identified with unquestionable statistical confidence for type 2 diabetes alone, and the list continues to grow.[64] Most of these genetic polymorphisms with elevated risk are very common in the population (i.e., from 5% up to >50%). Although each variant only increases risk slightly (i.e., twofold or less), because the risk alleles are so common, they can account for a nontrivial proportion of the occurrence of disease in the population; this is a measure that epidemiologists call *attributable risk.*

An especially attractive aspect of the GWAS approach is that, because the entire human genome is searched, we no longer have to depend on prior hypotheses about the disease's molecular pathology. In most GWAS studies, about half of the statistically definitive findings point to genes that experts in the field had no suspicion whatsoever were involved in the disease's etiology. This allows researchers to open up entirely new pathways for investigation that may lead to insights about the disease's biologic mechanism and suggest novel molecular strategies for pharmaceutical or other therapeutic interventions. In more than a few cases, robust GWAS findings implicate regions of the human genome in which no genes appear to be present, thereby highlighting the limitations of our current knowledge of basic genome functions.

Although great progress has been made toward understanding the etiology of many complex human diseases by using GWAS methods, the approach has nevertheless usually failed to account for most of the heritability known to exist for these conditions.[12,38] A recent study found that well-established nongenetic diabetes risk factors (e.g., gender, smoking, family history, body mass index, blood lipid and glucose levels) were better predictors of risk than a combination of the top 20 genetic markers for this disease.[65] To improve gene-based risk estimates, the missing heritability needs to be found. High hopes are now being placed on the emergence of next-generation DNA-sequencing tools. In theory, these may enable researchers to identify the less common (i.e., 1% to 5%) genetic variants that are predicted to have individual gene effects of greater magnitude on disease risk (i.e., greater than twofold but less than tenfold) that cannot readily be found with the use of either GWAS or linkage analysis methods.

Inherited Variation and Risk of Periodontitis

As a result of the appropriate focus on the role of bacterial infections in the disease pathogenesis of periodontitis, inherited human genetic variation is often referred to as *host defense* or, somewhat more broadly, *host response.* However, these terms cover only a small portion of the range of gene functions that may be important for periodontitis risk. Many additional biologic processes that are not directly related to defenses against or responses to infection by microbial pathogens are also likely to play important roles in determining an individual's susceptibility to this disease.

Periodontitis in Genetic Syndromes and Other Diseases

A number of extremely rare conditions consistently include periodontitis among the array of clinical manifestations that define a syndrome. Many genetic syndromes involve mutations of single genes or larger chromosomal regions. However, a number of syndromes, such as fetal alcohol syndrome, are purely environmental in origin. Some of the syndromes that include periodontitis are caused by mutations in specific genes. For example, mutations in

the cathepsin C gene have been shown to cause both Papillon–Lèfevre syndrome (Figure 6-2) and Haim–Munk syndrome as well as some forms of nonsyndromic prepubertal periodontitis, and they may also be associated with a risk of aggressive periodontitis.[48] Periodontitis frequently occurs with some subtypes of Ehlers–Danlos syndrome, Kindler syndrome, Down syndrome (trisomy 21), leukocyte adhesion deficiencies (Figure 6-3), hypophosphatasia, two types of neutropenia, and aplasia of the lacrimal and salivary glands. A large triracial extended family demonstrated evidence of a single gene that caused both early-onset aggressive periodontitis and dentinogenesis imperfecta. The gene has been mapped with the use of linkage to a chromosomal region that contains a dentin matrix protein gene.[37] Many of these conditions are so rare that few periodontists see even a single case during a lifetime of practice. However, dentists should be aware that these single-gene conditions exist; they need to be prepared to extend clinical evaluations to close relatives and to seek the assistance of or to refer to appropriately trained genetic counselors or specialists if a patient's medical history or the presentation of multiple symptoms raises the possibility that he or she may be affected. Clinicians can obtain updated information about these conditions by accessing the publicly available Online Mendelian Inheritance in Man database and typing in "periodontitis OR periodontal disease" as the query term.[2] Further research is necessary to determine whether

Figure 6-2 **A,** Oral, **B,** radiographic, and **C** and **D,** dermatologic findings of Papillon–Lefèvre syndrome. Advanced periodontal disease usually affects the primary and secondary dentition shortly after the teeth erupt, and many patients become edentulous while in their teens. Palmar–plantar keratodermas affect the palms of the hands and the plantar surfaces of the feet **(D)**, but they can also affect other sites, such as the elbow in this case **(C)**. *(Courtesy Dr. Robert J. Gorlin, Minneapolis.)*

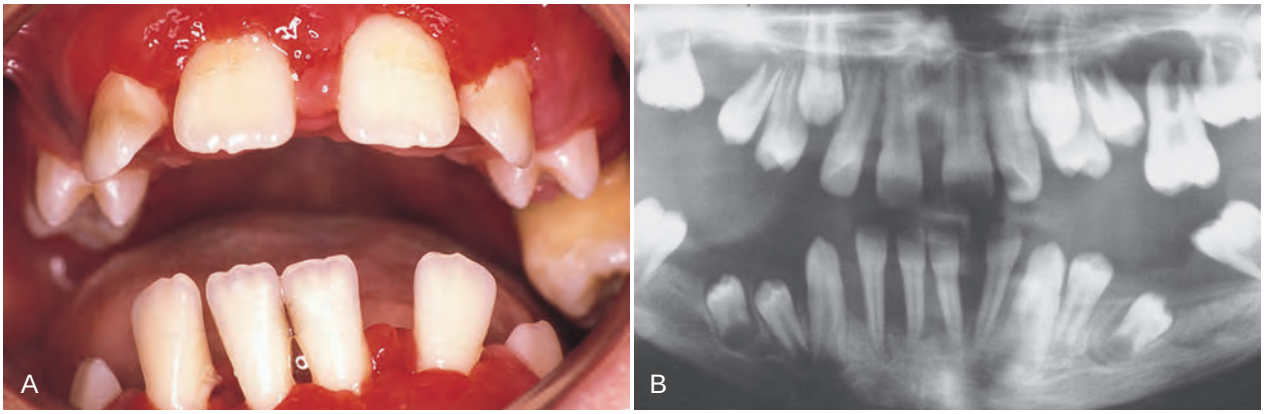

Figure 6-3 **A,** Oral and **B,** radiographic appearance of a patient with leukocyte adhesion deficiency. The child was deficient in CD18 (i.e., leukocyte adhesion deficiency type I), which results in absent or severely reduced levels of the β2 integrin molecule. The patient suffered from recurrent infections of the middle ear, the tongue, and the perirectal areas as well as of the periodontium. *(**B,** From Majorana A, Notarangelo LD, Savoldi E et al:* Oral Surg Oral Med Oral Pathol Oral Radiol Endod *87:691, 1999.)*

inherited variation in the genes that cause these rare syndromes may also influence the risk of nonsyndromic forms of aggressive or chronic periodontitis.

Nonsyndromic Aggressive and Chronic Periodontitis

In this section, evidence for the association of inherited genetic variation with aggressive and chronic periodontitis will be considered for cases that present without the co-occurrence of anomalies or disorders of other parts of the body or of the affected individual's behavior. Such cases are appropriately classified as *nonsyndromic periodontitis.* This terminology is similar to the way that other human diseases, such as orofacial clefting, have long been recognized as occurring in both syndromic and nonsyndromic forms. The elevated risk of periodontitis that is associated with metabolic conditions (e.g., diabetes, which is addressed elsewhere in this book) is more appropriately considered a comorbidity rather than being a cause for the designation of a syndrome.

> "A finding of no statistical significance in a well designed, conceptually sound, adequately powered study testing an important hypothesis is likely to provide more useful information than significance in a study that does not meet these criteria."[5]

As described previously, twin studies have shown that chronic periodontitis has very substantial heritability, and we know that aggressive periodontitis aggregates strongly in families. Because aggressive periodontitis occurs so rarely, it is not feasible to perform a twin study to confirm the heritability of this condition. Neither segregation analyses nor gene-mapping linkage studies are capable of providing reliable information about the genetic etiology of a highly complex disease such as periodontitis. However, large numbers of susceptibility genes have been identified for complex disorders, such as diabetes and cardiovascular disease, using association analysis. It seems reasonable to expect that similar successes could be achieved for periodontitis using this approach. In fact, during the past decade, several hundred papers have reported associations of nonsyndromic aggressive and chronic periodontitis with polymorphisms in a number of candidate genes. Certain classes of genes (e.g., cytokines) that have long been a focus of attention by immunologists and cell biologists studying pathogenic mechanisms associated with periodontitis have received the most attention. Early reports of relatively weak associations with variation in interleukin-1 (IL-1) genes led to a large number of attempts to replicate and extend these findings. Unfortunately, with very few exceptions, association studies of periodontitis have been very inadequately powered to detect genetic variation with modest effects on disease risk or progression (i.e., sample sizes that are much too small). In addition, inconsistency with regard to the methods used to classify subjects as periodontal cases versus controls or to quantitatively measure disease severity and extent greatly limit our ability to draw sound conclusions by comparing results reported in different studies.

The reason why association studies of periodontitis have largely failed will be challenging to fully address. The first issue is straightforward and simply a matter of numbers. It is noteworthy that the successes achieved for many complex diseases (e.g., diabetes) with the use of the GWAS mapping approach were based on sample sizes involving thousands of cases and controls, with multiple replications by *independent* teams of investigators. Statistical theory shows that, to detect genes of modest effect, these large

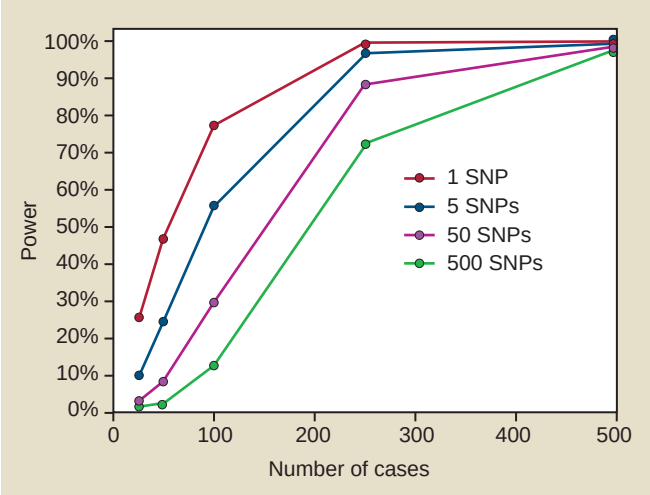

Figure 6-4 Statistical power estimates are shown for a situation in which we hypothesize that a dominantly transmitted disease susceptibility gene that increases risk by twofold and that has an allele frequency in the population of 25% is being mapped by a case–control association study. The lines illustrate the loss of statistical power caused by the requirement to adjust for multiple comparisons when a research study involves the evaluation of not just a single genetic marker but as many as 5, 50, or 500 independent genetic polymorphisms. Although only 100 cases (and 100 controls) may provide sufficient power if only a single marker is being tested, 250 cases and 250 controls are needed if 5 or 50 single nucleotide polymorphisms are assayed; a minimum of 500 cases and 500 controls are necessary if a study investigates 500 independent genetic markers.

sample sizes are absolutely essential. With the use of a statistical power calculator developed for case–control studies,[52] sample sizes required for 80% power are shown in Figure 6-4 for a study that involves only a single genetic marker as well as for studies that evaluate 5, 50, or 500 independent genetic markers in which the effects of multiple comparisons need to be accommodated. In this example, we assume that the risk gene acts in a dominant manner, with the high-risk allele occurring at a frequency of 25% in the population, and that this allele causes risk among carriers to increase by twofold (i.e., a greater effect on risk than observed for many susceptibility alleles found in GWAS studies of other complex diseases). Many periodontitis association studies reported in the literature involved multiple markers in each publication, and often the same research team reported positive findings for other genes in subsequent papers. Furthermore, because of the difficulties of publishing negative findings (i.e., when no association is found), many research teams working in this area may assay 50 or more genetic markers over the course of their work over several years. Results shown in Figure 6-4 demonstrate that, to obtain 80% power, a study of 50 markers would require more than 200 cases and 200 controls. Even if a research team assays only 5 SNPs, their study would still require 100 cases and 100 controls to achieve adequate power.

Our search of PubMed in early 2010 using the search term "(periodontal disease OR periodontitis) AND (SNP OR SNPs OR polymorphism OR polymorphisms OR linkage)" identified 311 periodontitis gene association tests with a *P* value of 0.05 or less for at least one statistical test reported. These results are summarized in Figure 6-5, in which the x-axis indicates the number of cases included in the study; the *P* value for the strongest finding is plotted on the y-axis. When more than one statistical test was

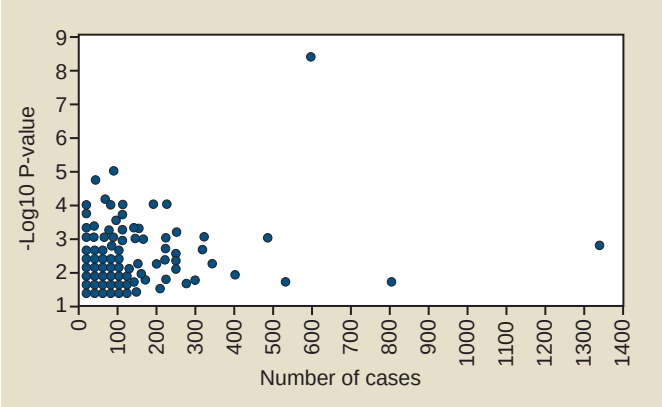

Figure 6-5 Number of cases and the *P* values reported for 307 gene association tests for aggressive or chronic periodontitis reported in the literature. Only findings with *P* values of 0.05 or less are included. When multiple tests were performed, the strongest association (i.e., the smallest *P* value) is the one used for this presentation.

reported, only the one with the smallest *P* value is shown in this figure. In some cases, this inflated the actual statistical significance, because investigators rarely adjust their findings for these multiple tests when the findings are reported in a publication. This analysis shows clearly that most association findings have been drastically underpowered if periodontitis is assumed to be a complex disease. The majority (66%) of these association reports for chronic and aggressive periodontitis are based on samples of 100 cases or less, and 41% are based on less than 60 cases. As shown in Figure 6-4, studies of such small sample size have little power to detect a susceptibility gene that increases risk by twofold. Given the added concern about publication bias (i.e., that positive findings are more likely to be accepted for publication), we can have little confidence that even the more statistically significant findings are valid and likely to be independently replicated if they are based on such very inadequate samples sizes. With only a few exceptions, which are noted later in this chapter, publications since 2010 have continued to involve small numbers of cases and to provide marginal statistical support for association.

Aside from important lessons about how *not* to carry out association studies of a complex disease, there are some tentative conclusions that can be drawn from the data available thus far. Detailed results of our review and manual curation of 298 publications reporting association findings for periodontitis are presented in Table 6-3, and key findings are condensed in Table 6-4.

This summary includes a total of 41 genes plus a combination of the IL-1A and IL-1B genes analyzed jointly. Only genes that had at least two findings classified as "weak" or one finding of association with a "moderate" or "strong" level of support are included in this summary. The technical criteria for these designations are based on a combination of each study's sample size (assuming larger studies are less likely to produce false positives) and the study's *P* value (statistical significance or type I error) as described in the Table 6-4 footnotes and in online supplementary documentation.

Genes in Table 6-4 have usually been evaluated in multiple independent studies for association with either aggressive or chronic periodontitis or both. Occasionally these subtypes of the disease have been pooled together, so it is not possible to determine from the publication whether the association involves primarily one subtype or both. With the exception of only the one GWAS study that has been published for this disease, all association tests reported to date involve the evaluation of candidate genes that were selected on the basis of known or postulated mechanisms of disease pathogenesis.

For example, when bacteria challenge gingival tissue, CD14 binds lipopolysaccharide, and TLR4 plays a key role in pathogen recognition and the activation of innate immunity.[31] Lactotransferrin (LTF) plays an antimicrobial role as the first line of host defense, and it can also neutralize endotoxin and inhibit the induction of nuclear factor-κβ (NF-κβ) in monocytes in response to lipopolysaccharides.[27,66] Myeloperoxidase (MPO) is an oxidative enzyme expressed in polymorphonuclear leukocytes. It is involved in the defense against periodontal bacteria and is also able to mediate inflammatory tissue destruction in periodontal disease.[40] Glutathione S-transferase mu 1 (GSTM1)[10] and *N*-acetyltransferase 2 (NAT2)[29] genes are responsible for the detoxification of a wide range of chemicals, including tobacco carcinogens. HLA complex genes[63] play a central role in the immune system by presenting extracellular peptides that are important for either self-recognition or initiating immune responses to foreign pathogens. The Fcγ receptor genes (FcγRS) encode receptors for the Fc portion of immunoglobulin G, and they are involved in the removal of antigen–antibody complexes from the circulation as well as other antibody-dependent responses.[35] Formyl peptide receptor (FPR1) is a G-protein–coupled receptor of phagocytic cells that interacts with bacterial peptides and that mediates chemotaxis, degranulation, and superoxide production involved in inflammation.[20] Cytokines such as the interleukins (IL-1, IL-2, IL-4, IL-6, IL-10), tumor necrosis factor (TNF), and lymphotoxin-alpha (LTA) play a number of important roles in the immunopathology of periodontal disease.[47] Prostaglandin-endoperoxide synthase (PTGS2), which is also known as *cyclooxygenase-2,* is the key enzyme in prostaglandin biosynthesis. It is regulated by specific stimulatory events, which suggests that it is responsible for the prostanoid biosynthesis involved in inflammation.[23] S100 calcium binding protein A8 (S100A8), which is the light subunit of calprotectin, is also associated with inflammatory diseases, including periodontitis.[32] Fibrinogen (FGB) is an acute-phase protein; FBG levels are elevated during inflammation, and the substance has been associated with cardiovascular disease risk.[57] Vitamin D receptor (VDR)[22] and estrogen receptor (ESR1)[68] are hormone receptors involved in skeletal muscle metabolism, including calcium absorption and bone loss. The matrix metalloproteinases (MMPs) are a group of endogenous proteinases that contribute to the degradation of extracellular and basement membrane components.[21] CDKN2B antisense RNA (CDKN2BAS) is a nonprotein coding gene of unknown function that has also been reported to be associated with coronary heart disease.[59] The one GWAS reported for periodontitis, which is described in detail later in this chapter, revealed a strong association of a glycosyltransferase gene (GLT6D1) with aggressive periodontitis,[61] but there is no clear functional relationship of this gene with periodontal disease pathogenesis.

With few exceptions, there are just as many or more reports in Table 6-4 in which no significant association was found for the gene as there were reports with positive findings. For example, HLA-B has nine negative reports and six weak positive findings. IL-1B has 45 negative reports, 20 weak associations, and 3 moderately supportive findings. The inconsistency among these findings requires a much deeper analysis to understand what may be going on. One possibility is that genetic variation at the candidate gene is *not* associated with periodontitis. When a large number of studies are performed using a multitude of alternative ways of classifying small numbers of cases versus controls, when multiple alternative statistical analyses are run for the same small data sets,

TABLE 6-3 Association Study

Gene Symbol	Disease Type	Cases	Total	Best *P* Value	Level of Support	Population	Study Design	Stratified or Covariate Adj	Gene Name	Gene Aliases	# SNPs Assayed	SNP Name	PubMed ID	Journal
ABCA1	CP	22	41	ns	None	Japanese	CC	N	ATP-binding cassette, sub-family A (ABC1), member 1	TGD; ABC1; CERP; ABC-1; HDLDT1; FLJ14958; MGC164864; MGC165011; ABCA1	3	Multiple SNPs	15490304	Suzuki A, Ji G, Numabe Y, Ishii K, Muramatsu M, Kamoi K. Large-scale investigation of genomic markers for severe periodontitis. Odontology. 2004 Sep;92(1):43-7.
ABCA4	CP	22	41	ns	None	Japanese	CC	N	ATP-binding cassette, sub-family A (ABC1), member 4	FFM; RMP; ABCR; RP19; STGD; ABC10; ARMD2; CORD3; STGD1; FLJ17534; DKFZp781N1972; ABCA4	2	Multiple SNPs	15490304	Suzuki A, Ji G, Numabe Y, Ishii K, Muramatsu M, Kamoi K. Large-scale investigation of genomic markers for severe periodontitis. Odontology. 2004 Sep;92(1):43-7.
ABCB11	CP	22	41	ns	None	Japanese	CC	N	ATP-binding cassette, sub-family B (MDR/TAP), member 11	BSEP; PGY4; SPGP; ABC16; BRIC2; PFIC2; PFIC-2; ABCB11	7	Multiple SNPs	15490304	Suzuki A, Ji G, Numabe Y, Ishii K, Muramatsu M, Kamoi K. Large-scale investigation of genomic markers for severe periodontitis. Odontology. 2004 Sep;92(1):43-7.
ABCC6	CP	22	41	ns	None	Japanese	CC	N	ATP-binding cassette, sub-family C (CFTR/MRP), member 6	ARA; PXE; MLP1; MRP6; PXE1; ABC34; MOATE; EST349056; ABCC6	9	Multiple SNPs	15490304	Suzuki A, Ji G, Numabe Y, Ishii K, Muramatsu M, Kamoi K. Large-scale investigation of genomic markers for severe periodontitis. Odontology. 2004 Sep;92(1):43-7.
ABCC8	CP	22	41	ns	None	Japanese	CC	N	ATP-binding cassette, sub-family C (CFTR/MRP), member 8	HI; SUR; HHF1; MRP8; PHHI; SUR1; ABC36; HRINS; TNDM2; ABCC8	8	Multiple SNPs	15490304	Suzuki A, Ji G, Numabe Y, Ishii K, Muramatsu M, Kamoi K. Large-scale investigation of genomic markers for severe periodontitis. Odontology. 2004 Sep;92(1):43-7.
ABP1	CP	22	41	ns	None	Japanese	CC	N	Amiloride binding protein 1 (amine oxidase (copper-containing))	ABP; AOC1; DAO; DAO1; KAO; ABP1	1	n/a	15490304	Suzuki A, Ji G, Numabe Y, Ishii K, Muramatsu M, Kamoi K. Large-scale investigation of genomic markers for severe periodontitis. Odontology. 2004 Sep;92(1):43-7.
ACACB	CP	22	41	ns	None	Japanese	CC	N	Acetyl-Coenzyme A (CoA) carboxylase beta	ACC2; ACCB; HACC275; ACACB	2	Multiple SNPs	15490304	Suzuki A, Ji G, Numabe Y, Ishii K, Muramatsu M, Kamoi K. Large-scale investigation of genomic markers for severe periodontitis. Odontology. 2004 Sep;92(1):43-7.

Continued

TABLE 6-3 Association Study—cont'd

Gene Symbol	Disease Type	Cases	Total	Best *P* Value	Level of Support	Population	Study Design	Stratified or Covariate Adj	Gene Name	Gene Aliases	# SNPs Assayed	SNP Name	PubMed ID	Journal
ACADL	CP	22	41	ns	None	Japanese	CC	N	Acyl-Coenzyme A dehydrogenase, long chain	LCAD; ACAD4; FLJ94052; ACADL	1	n/a	15490304	Suzuki A, Ji G, Numabe Y, Ishii K, Muramatsu M, Kamoi K. Large-scale investigation of genomic markers for severe periodontitis. Odontology. 2004 Sep;92(1):43-7.
ACAN	AgP+CP	251	376	ns	None	Japanese	CC	N	Aggrecan	AGC1; SEDK; AGCAN; CSPG1; MSK16; CSPGCP; ACAN	n/a	n/a	15081423	Suzuki A, Ji G, Numabe Y, Muramatsu M, Gomi K, Kanazashi M, Ogata Y, Shimizu E, Shibukawa Y, Ito A, Ito T, Sugaya A, Arai T, Yamada S, Deguchi S, Kamoi K. Single nucleotide polymorphisms associated with aggressive periodontitis and severe chronic periodontitis in Japanese. Biochem Biophys Res Commun. 2004 May 7;317(3):887-92.
ACE	AgP	103	203	ns	None	Turkish	CC	N	Angiotensin I converting enzyme (peptidyl-dipeptidase A) 1	DCP; ACE1; DCP1; CD143; MVCD3; MGC26566; ACE	1	I/D	19162259	Gürkan A, Emingil G, Saygan BH, Atilla G, Köse T, Baylas H, Berdeli A. Angiotensin-converting enzyme (ACE), angiotensinogen (AGT), and angiotensin II type 1 receptor (AT1R) gene polymorphisms in generalized aggressive periodontitis. Arch Oral Biol. 2009 Apr;54(4):337-44. Epub 2009 Jan 21.
ACE	CP	90	216	0.015	Weak	Turkish	CC	N	Angiotensin I converting enzyme (peptidyl-dipeptidase A) 1	DCP; ACE1; DCP1; CD143; MVCD3; MGC26566; ACE	1	I/D	19236533	Gürkan A, Emingil G, Saygan BH, Atilla G, Köse T, Baylas H, Berdeli A. Renin-angiotensin gene polymorphisms in relation to severe chronic periodontitis. J Clin Periodontol. 2009 Mar;36(3):204-11.
ACE	CP	22	41	ns	None	Japanese	CC	N	Angiotensin I converting enzyme (peptidyl-dipeptidase A) 1	DCP; ACE1; DCP1; CD143; MVCD3; MGC26566; ACE	5	Multiple SNPs	15490304	Suzuki A, Ji G, Numabe Y, Ishii K, Muramatsu M, Kamoi K. Large-scale investigation of genomic markers for severe periodontitis. Odontology. 2004 Sep;92(1):43-7.

ACE	CP	63	158	ns	None	Caucasian	CC	N	Angiotensin I converting enzyme (peptidyl-dipeptidase A) 1	DCP; ACE1; DCP1; CD143; MVCD3; MGC26566; ACE	1	Intron 16 I/D	11210078	Hollá LI, Fassmann A, Vasku A, Znojil V, Vanek J, Vácha J. Interactions of lymphotoxin alpha (TNF-beta), angiotensin-converting enzyme (ACE), and endothelin-1 (ET-1) gene polymorphisms in adult periodontitis. J Periodontol. 2001 Jan;72(1):85-9.
ACE.LTA	CP	63	158	0.0228	Weak	Caucasian	CC	N	n/a	n/a	2	Multiple Genes	11210078	Hollá LI, Fassmann A, Vasku A, Znojil V, Vanek J, Vácha J. Interactions of lymphotoxin alpha (TNF-beta), angiotensin-converting enzyme (ACE), and endothelin-1 (ET-1) gene polymorphisms in adult periodontitis. J Periodontol. 2001 Jan;72(1):85-9.
ACE2	CP	22	41	ns	None	Japanese	CC	N	Angiotensin I converting enzyme (peptidyl-dipeptidase A) 2	ACEH; DKFZp434A014; ACE2	3	Multiple SNPs	15490304	Suzuki A, Ji G, Numabe Y, Ishii K, Muramatsu M, Kamoi K. Large-scale investigation of genomic markers for severe periodontitis. Odontology. 2004 Sep;92(1):43-7.
ACSM3	CP	22	41	ns	None	Japanese	CC	N	Acyl-CoA synthetase medium-chain family member 3	SA; SAH; ACSM3	4	Multiple SNPs	15490304	Suzuki A, Ji G, Numabe Y, Ishii K, Muramatsu M, Kamoi K. Large-scale investigation of genomic markers for severe periodontitis. Odontology. 2004 Sep;92(1):43-7.
ADA	CP	22	41	ns	None	Japanese	CC	N	Adenosine deaminase	ADA	5	Multiple SNPs	15490304	Suzuki A, Ji G, Numabe Y, Ishii K, Muramatsu M, Kamoi K. Large-scale investigation of genomic markers for severe periodontitis. Odontology. 2004 Sep;92(1):43-7.
ADAMTS8	CP	22	41	ns	None	Japanese	CC	N	ADAM metallopeptidase with thrombospondin type 1 motif, 8	METH2; ADAM-TS8; FLJ41712; ADAMTS8	2	Multiple SNPs	15490304	Suzuki A, Ji G, Numabe Y, Ishii K, Muramatsu M, Kamoi K. Large-scale investigation of genomic markers for severe periodontitis. Odontology. 2004 Sep;92(1):43-7.
ADCY3	CP	22	41	ns	None	Japanese	CC	N	Adenylate cyclase 3	AC3; KIAA0511; ADCY3	3	Multiple SNPs	15490304	Suzuki A, Ji G, Numabe Y, Ishii K, Muramatsu M, Kamoi K. Large-scale investigation of genomic markers for severe periodontitis. Odontology. 2004 Sep;92(1):43-7.
ADCY6	CP	22	41	ns	None	Japanese	CC	N	Adenylate cyclase 6	AC6; KIAA0422; DKFZp779F075; ADCY6	1	n/a	15490304	Suzuki A, Ji G, Numabe Y, Ishii K, Muramatsu M, Kamoi K. Large-scale investigation of genomic markers for severe periodontitis. Odontology. 2004 Sep;92(1):43-7.

Continued

TABLE 6-3 Association Study—cont'd

Gene Symbol	Disease Type	Cases	Total	Best *P* Value	Level of Support	Population	Study Design	Stratified or Covariate Adj	Gene Name	Gene Aliases	# SNPs Assayed	SNP Name	PubMed ID	Journal
ADCY9	CP	22	41	ns	None	Japanese	CC	N	Adenylate cyclase 9	AC9; ADCY9	7	Multiple SNPs	15490304	Suzuki A, Ji G, Numabe Y, Ishii K, Muramatsu M, Kamoi K. Large-scale investigation of genomic markers for severe periodontitis. Odontology. 2004 Sep;92(1):43-7.
ADD1	CP	22	41	ns	None	Japanese	CC	N	Adducin 1 (alpha)	ADDA; MGC3339; MGC44427; ADD1	6	Multiple SNPs	15490304	Suzuki A, Ji G, Numabe Y, Ishii K, Muramatsu M, Kamoi K. Large-scale investigation of genomic markers for severe periodontitis. Odontology. 2004 Sep;92(1):43-7.
ADD2	CP	22	41	ns	None	Japanese	CC	N	Adducin 2 (beta)	ADDB; ADD2	6	Multiple SNPs	15490304	Suzuki A, Ji G, Numabe Y, Ishii K, Muramatsu M, Kamoi K. Large-scale investigation of genomic markers for severe periodontitis. Odontology. 2004 Sep;92(1):43-7.
ADH1C	CP	22	41	ns	None	Japanese	CC	N	Alcohol dehydrogenase 1C (class I), gamma polypeptide	ADH3; ADH1C	5	Multiple SNPs	15490304	Suzuki A, Ji G, Numabe Y, Ishii K, Muramatsu M, Kamoi K. Large-scale investigation of genomic markers for severe periodontitis. Odontology. 2004 Sep;92(1):43-7.
ADO22	CP	22	41	ns	None	Japanese	CC	N	n/a	n/a	1	n/a	15490304	Suzuki A, Ji G, Numabe Y, Ishii K, Muramatsu M, Kamoi K. Large-scale investigation of genomic markers for severe periodontitis. Odontology. 2004 Sep;92(1):43-7.
ADORA2A	CP	22	41	ns	None	Japanese	CC	N	Adenosine A2a receptor	RDC8; hA2aR; ADORA2; ADORA2A	3	Multiple SNPs	15490304	Suzuki A, Ji G, Numabe Y, Ishii K, Muramatsu M, Kamoi K. Large-scale investigation of genomic markers for severe periodontitis. Odontology. 2004 Sep;92(1):43-7.
AGER	CP	101	263	0.02	Weak	Caucasian	CC	N	Advanced glycosylation end product-specific receptor	RAGE; MGC22357; AGER	3	intron 7 (1704G/T)	11811511	Hollá LI, Kanková K, Fassmann A, Bucková D, Halabala T, Znojil V, Vanek J. Distribution of the receptor for advanced glycation end products gene polymorphisms in patients with chronic periodontitis: a preliminary study. J Periodontol. 2001 Dec;72(12):1742-6.

AGER	CP	22	41	ns	None	Japanese	CC	N	Advanced glycosylation end product-specific receptor	RAGE; MGC22357; AGER	2	Multiple SNPs	15490304	Suzuki A, Ji G, Numabe Y, Ishii K, Muramatsu M, Kamoi K. Large-scale investigation of genomic markers for severe periodontitis. Odontology. 2004 Sep;92(1):43-7.
AGT	AgP	103	203	0.004	Weak	Turkish	CC	N	Angiotensinogen (serpin peptidase inhibitor, clade A, member 8)	ANHU; FLJ92595; FLJ97926; SERPINA8; AGT	1	M235T	19162259	Gürkan A, Emingil G, Saygan BH, Atilla G, Köse T, Baylas H, Berdeli A. Angiotensin-converting enzyme (ACE), angiotensinogen (AGT), and angiotensin II type 1 receptor (AT1R) gene polymorphisms in generalized aggressive periodontitis. Arch Oral Biol. 2009 Apr;54(4):337-44. Epub 2009 Jan 21.
AGT	CP	90	216	ns	None	Turkish	CC	N	Angiotensinogen (serpin peptidase inhibitor, clade A, member 8)	ANHU; FLJ92595; FLJ97926; SERPINA8; AGT	1	M235T	19236533	Gürkan A, Emingil G, Saygan BH, Atilla G, Köse T, Baylas H, Berdeli A. Renin-angiotensin gene polymorphisms in relation to severe chronic periodontitis. J Clin Periodontol. 2009 Mar;36(3):204-11.
AGTR1	AgP	103	203	ns	None	Turkish	CC	N	Angiotensin II receptor, type 1	AT1; AG2S; AT1B; AT1R; AT2R1; HAT1R; AGTR1A; AGTR1B; AT2R1A; AT2R1B; AGTR1	1	A1166C	19162259	Gürkan A, Emingil G, Saygan BH, Atilla G, Köse T, Baylas H, Berdeli A. Angiotensin-converting enzyme (ACE), angiotensinogen (AGT), and angiotensin II type 1 receptor (AT1R) gene polymorphisms in generalized aggressive periodontitis. Arch Oral Biol. 2009 Apr;54(4):337-44. Epub 2009 Jan 21.
AGTR1	CP	90	216	0.03	Weak	Turkish	CC	N	Angiotensin II receptor, type 1	AT1; AG2S; AT1B; AT1R; AT2R1; HAT1R; AGTR1A; AGTR1B; AT2R1A; AT2R1B; AGTR1	1	A1166C	19236533	Gürkan A, Emingil G, Saygan BH, Atilla G, Köse T, Baylas H, Berdeli A. Renin-angiotensin gene polymorphisms in relation to severe chronic periodontitis. J Clin Periodontol. 2009 Mar;36(3):204-11.
AIRE	CP	22	41	ns	None	Japanese	CC	N	Autoimmune regulator	APS1; APSI; PGA1; AIRE1; APECED; AIRE	6	Multiple SNPs	15490304	Suzuki A, Ji G, Numabe Y, Ishii K, Muramatsu M, Kamoi K. Large-scale investigation of genomic markers for severe periodontitis. Odontology. 2004 Sep;92(1):43-7.

Continued

TABLE 6-3 Association Study—cont'd

Gene Symbol	Disease Type	Cases	Total	Best *P* Value	Level of Support	Population	Study Design	Stratified or Covariate Adj	Gene Name	Gene Aliases	# SNPs Assayed	SNP Name	PubMed ID	Journal
ALCAM	CP	22	41	ns	None	Japanese	CC	N	Activated leukocyte cell adhesion molecule	MEMD; CD166; FLJ38514; MGC71733; ALCAM	1	n/a	15490304	Suzuki A, Ji G, Numabe Y, Ishii K, Muramatsu M, Kamoi K. Large-scale investigation of genomic markers for severe periodontitis. Odontology. 2004 Sep;92(1):43-7.
ALDH2	CP	22	41	ns	None	Japanese	CC	N	Aldehyde dehydrogenase 2 family (mitochondriAl)	ALDM; ALDHI; ALDH-E2; MGC1806; ALDH2	3	Multiple SNPs	15490304	Suzuki A, Ji G, Numabe Y, Ishii K, Muramatsu M, Kamoi K. Large-scale investigation of genomic markers for severe periodontitis. Odontology. 2004 Sep;92(1):43-7.
ALDH3A1	CP	22	41	ns	None	Japanese	CC	N	Aldehyde dehydrogenase 3 family, member A1	ALDH3; ALDHIII; MGC10406; ALDH3A1	3	Multiple SNPs	15490304	Suzuki A, Ji G, Numabe Y, Ishii K, Muramatsu M, Kamoi K. Large-scale investigation of genomic markers for severe periodontitis. Odontology. 2004 Sep;92(1):43-7.
ALDH3A2	CP	22	41	ns	None	Japanese	CC	N	Aldehyde dehydrogenase 3 family, member A2	SLS; FALDH; ALDH10; FLJ20851; DKFZp686E23276; ALDH3A2	3	Multiple SNPs	15490304	Suzuki A, Ji G, Numabe Y, Ishii K, Muramatsu M, Kamoi K. Large-scale investigation of genomic markers for severe periodontitis. Odontology. 2004 Sep;92(1):43-7.
ALOX15	CP	22	41	ns	None	Japanese	CC	N	Arachidonate 15-lipoxygenase	15LOX-1; 15-LOX-1; ALOX15	1	n/a	15490304	Suzuki A, Ji G, Numabe Y, Ishii K, Muramatsu M, Kamoi K. Large-scale investigation of genomic markers for severe periodontitis. Odontology. 2004 Sep;92(1):43-7.
AMACR	CP	22	41	ns	None	Japanese	CC	N	Alpha-methylacyl-CoA racemase	RACE; CBAS4; AMACR	1	n/a	15490304	Suzuki A, Ji G, Numabe Y, Ishii K, Muramatsu M, Kamoi K. Large-scale investigation of genomic markers for severe periodontitis. Odontology. 2004 Sep;92(1):43-7.
AMPD1	CP	22	41	ns	None	Japanese	CC	N	Adenosine monophosphate deaminase 1 (isoform M)	MAD; MADA; AMPD1	3	Multiple SNPs	15490304	Suzuki A, Ji G, Numabe Y, Ishii K, Muramatsu M, Kamoi K. Large-scale investigation of genomic markers for severe periodontitis. Odontology. 2004 Sep;92(1):43-7.
APOA4	CP	22	41	ns	None	Japanese	CC	N	Apolipoprotein A-IV	MGC142154; MGC142156; APOA4	1	n/a	15490304	Suzuki A, Ji G, Numabe Y, Ishii K, Muramatsu M, Kamoi K. Large-scale investigation of genomic markers for severe periodontitis. Odontology. 2004 Sep;92(1):43-7.

APOH	CP	22	41	ns	None	Japanese	CC	N	Apolipoprotein H (beta-2-glycoprotein I)	BG; B2G1; APOH	1	n/a	15490304	Suzuki A, Ji G, Numabe Y, Ishii K, Muramatsu M, Kamoi K. Large-scale investigation of genomic markers for severe periodontitis. Odontology. 2004 Sep;92(1):43-7.
APOL1	CP	22	41	ns	None	Japanese	CC	N	Apolipoprotein L, 1	APOL; APO-L; APOL-I; APOL1	4	Multiple SNPs	15490304	Suzuki A, Ji G, Numabe Y, Ishii K, Muramatsu M, Kamoi K. Large-scale investigation of genomic markers for severe periodontitis. Odontology. 2004 Sep;92(1):43-7.
AQP8	CP	22	41	ns	None	Japanese	CC	N	Aquaporin 8	AQP8	1	n/a	15490304	Suzuki A, Ji G, Numabe Y, Ishii K, Muramatsu M, Kamoi K. Large-scale investigation of genomic markers for severe periodontitis. Odontology. 2004 Sep;92(1):43-7.
ART1	CP	22	41	ns	None	Japanese	CC	N	ADP-ribosyltransferase 1	RT6; ART2; CD296; MGC133217; ART1	1	n/a	15490304	Suzuki A, Ji G, Numabe Y, Ishii K, Muramatsu M, Kamoi K. Large-scale investigation of genomic markers for severe periodontitis. Odontology. 2004 Sep;92(1):43-7.
ASIP	CP	22	41	ns	None	Japanese	CC	N	Agouti signaling protein, nonagouti homolog (mouse)	ASP; AGSW; AGTI; AGTIL; SHEP9; MGC126092; MGC126093; ASIP	1	n/a	15490304	Suzuki A, Ji G, Numabe Y, Ishii K, Muramatsu M, Kamoi K. Large-scale investigation of genomic markers for severe periodontitis. Odontology. 2004 Sep;92(1):43-7.
B3GNT3	CP	22	41	ns	None	Japanese	CC	N	UDP-GlcNAc:betaGal beta-1,3-N-acetylglucosaminyltransferase 3	TMEM3; B3GN-T3; B3GNT-3; HP10328; B3GAL-T8; beta3Gn-T3; B3GNT3	1	n/a	15490304	Suzuki A, Ji G, Numabe Y, Ishii K, Muramatsu M, Kamoi K. Large-scale investigation of genomic markers for severe periodontitis. Odontology. 2004 Sep;92(1):43-7.
BAT1	CP&HIV	16	32	0.0002	Weak	Caucasian	CC	G	HLA-B associated transcript 1	UAP56; D6S81E; DDX39B; BAT1	1	HLA-B8	10551423	Price P, Calder DM, Witt CS, Allcock RJ, Christiansen FT, Davies GR, Cameron PU, Rogers M, Baluchova K, Moore CB, French MA. Periodontal attachment loss in HIV-infected patients is associated with the Major histocompatibility complex 8.1 haplotype (HLA-A1,B8,DR3). Tissue Antigens. 1999 Oct;54(4):391-9.
BDKRB1	CP	22	41	ns	None	Japanese	CC	N	Bradykinin receptor B1	B1R; BKR1; B1BKR; BKB1R; BRADYB1; BDKRB1	1	n/a	15490304	Suzuki A, Ji G, Numabe Y, Ishii K, Muramatsu M, Kamoi K. Large-scale investigation of genomic markers for severe periodontitis. Odontology. 2004 Sep;92(1):43-7.

Continued

TABLE 6-3 Association Study—cont'd

Gene Symbol	Disease Type	Cases	Total	Best *P* Value	Level of Support	Population	Study Design	Stratified or Covariate Adj	Gene Name	Gene Aliases	# SNPs Assayed	SNP Name	PubMed ID	Journal
BDKRB2	CP	22	41	ns	None	Japanese	CC	N	Bradykinin receptor B2	B2R; BK2; BK-2; BKR2; BRB2; DKFZp686O088; BDKRB2	1	n/a	15490304	Suzuki A, Ji G, Numabe Y, Ishii K, Muramatsu M, Kamoi K. Large-scale investigation of genomic markers for severe periodontitis. Odontology. 2004 Sep;92(1):43-7.
BMP2	AgP	98	186	ns	None	Japanese	CC	N	Bone morphogenetic protein 2	BMP2A; BMP2	1	rs1049007	16844084	Rabello D, Soedarsono N, Kamei H, Ishihara Y, Noguchi T, Fuma D, Suzuki M, Sakaki Y, Yamaguchi A, Kojima T. CSF1 gene associated with aggressive periodontitis in the Japanese population. Biochem Biophys Res Commun. 2006 Sep 1;347(3):791-6. Epub 2006 Jul 7.
BMP3	AgP	98	186	ns	None	Japanese	CC	N	Bone morphogenetic protein 3	BMP3A; BMP3	1	rs3733549	16844084	Rabello D, Soedarsono N, Kamei H, Ishihara Y, Noguchi T, Fuma D, Suzuki M, Sakaki Y, Yamaguchi A, Kojima T. CSF1 gene associated with aggressive periodontitis in the Japanese population. Biochem Biophys Res Commun. 2006 Sep 1;347(3):791-6. Epub 2006 Jul 7.
BMP4	AgP	98	186	ns	None	Japanese	CC	N	Bone morphogenetic protein 4	ZYME; BMP2B; OFC11; BMP2B1; MCOPS6; BMP4	1	rs2071047	16844084	Rabello D, Soedarsono N, Kamei H, Ishihara Y, Noguchi T, Fuma D, Suzuki M, Sakaki Y, Yamaguchi A, Kojima T. CSF1 gene associated with aggressive periodontitis in the Japanese population. Biochem Biophys Res Commun. 2006 Sep 1;347(3):791-6. Epub 2006 Jul 7.
BMP7	AgP	98	186	ns	None	Japanese	CC	N	Bone morphogenetic protein 7	OP-1; BMP7	6	Multiple SNPs	16844084	Rabello D, Soedarsono N, Kamei H, Ishihara Y, Noguchi T, Fuma D, Suzuki M, Sakaki Y, Yamaguchi A, Kojima T. CSF1 gene associated with aggressive periodontitis in the Japanese population. Biochem Biophys Res Commun. 2006 Sep 1;347(3):791-6. Epub 2006 Jul 7.

BMP8B	CP	22	41	ns	None	Japanese	CC	N	Bone morphogenetic protein 8b	OP2; BMP8; MGC131757; BMP8B	1	n/a	15490304	Suzuki A, Ji G, Numabe Y, Ishii K, Muramatsu M, Kamoi K. Large-scale investigation of genomic markers for severe periodontitis. Odontology. 2004 Sep;92(1):43-7.
BPI	CP	123	255	ns	None	German	CC	N	Bactericidal/permeability-increasing protein	BPI	1	Lys216Glu	16893388	Glas J, Török HP, Tonenchi L, Hamann S, Malachova O, Euba A, Folwaczny C, Folwaczny M. A645G (Lys216Glu) polymorphism of the bactericidal/permeability-increasing protein gene in periodontal disease. Int J Immunogenet. 2006 Aug;33(4):255-60.
C5	AgP+CP	229	436	0.001	Weak	Chinese	CC	AGS	Complement Component 5	CPAMD4; FLJ17816; FLJ17822; MGC142298; C5	4	Haplotype	19909405	Chai L, Song YQ, Zee KY, Leung WK. Single nucleotide polymorphisms of complement component 5 and periodontitis. J Periodontal Res. 2009 Nov 9.
C5	AgP+CP	229	436	0.007	Weak	Chinese	CC	AGS	Complement Component 5	CPAMD4; FLJ17816; FLJ17822; MGC142298; C5	11	rs17611	19909405	Chai L, Song YQ, Zee KY, Leung WK. Single nucleotide polymorphisms of complement component 5 and periodontitis. J Periodontal Res. 2009 Nov 9.
C9	CP	22	41	ns	None	Japanese	CC	N	Complement Component 9	C9	1	n/a	15490304	Suzuki A, Ji G, Numabe Y, Ishii K, Muramatsu M, Kamoi K. Large-scale investigation of genomic markers for severe periodontitis. Odontology. 2004 Sep;92(1):43-7.
CALCR	CP	22	41	0.0039	Weak	Japanese	CC	N	Calcitonin receptor	CRT; CTR; CTR1; CALCR	7	IMS-JST054515	15490304	Suzuki A, Ji G, Numabe Y, Ishii K, Muramatsu M, Kamoi K. Large-scale investigation of genomic markers for severe periodontitis. Odontology. 2004 Sep;92(1):43-7.
CASR	CP	22	41	ns	None	Japanese	CC	N	Calcium-sensing receptor	CAR; FHH; FIH; HHC; EIG8; HHC1; NSHPT; PCAR1; GPRC2A; MGC138441; CASR	1	n/a	15490304	Suzuki A, Ji G, Numabe Y, Ishii K, Muramatsu M, Kamoi K. Large-scale investigation of genomic markers for severe periodontitis. Odontology. 2004 Sep;92(1):43-7.
CAT	CP	22	41	ns	None	Japanese	CC	N	Catalase	MGC138422; MGC138424; CAT	5	Multiple SNPs	15490304	Suzuki A, Ji G, Numabe Y, Ishii K, Muramatsu M, Kamoi K. Large-scale investigation of genomic markers for severe periodontitis. Odontology. 2004 Sep;92(1):43-7.

Continued

TABLE 6-3 Association Study—cont'd

Gene Symbol	Disease Type	Cases	Total	Best *P* Value	Level of Support	Population	Study Design	Stratified or Covariate Adj	Gene Name	Gene Aliases	# SNPs Assayed	SNP Name	PubMed ID	Journal
CCK	CP	22	41	ns	None	Japanese	CC	N	Cholecystokinin	MGC117187; CCK	1	n/a	15490304	Suzuki A, Ji G, Numabe Y, Ishii K, Muramatsu M, Kamoi K. Large-scale investigation of genomic markers for severe periodontitis. Odontology. 2004 Sep;92(1):43-7.
CCKAR	CP	22	41	ns	None	Japanese	CC	N	Cholecystokinin A receptor	CCK-A; CCKRA; CCK1-R; CCKAR	2	Multiple SNPs	15490304	Suzuki A, Ji G, Numabe Y, Ishii K, Muramatsu M, Kamoi K. Large-scale investigation of genomic markers for severe periodontitis. Odontology. 2004 Sep;92(1):43-7.
CCL15	CP	22	41	ns	None	Japanese	CC	N	Chemokine (C-C motif) ligand 15	LKN1; NCC3; SY15; HCC-2; Lkn-1; MIP-5; NCC-3; SCYL3; MIP-1d; SCYA15; HMRP-2B; CCL15	1	n/a	15490304	Suzuki A, Ji G, Numabe Y, Ishii K, Muramatsu M, Kamoi K. Large-scale investigation of genomic markers for severe periodontitis. Odontology. 2004 Sep;92(1):43-7.
CCL25	CP	22	41	ns	None	Japanese	CC	N	Chemokine (C-C motif) ligand 25	TECK; Ckb15; SCYA25; MGC150327; CCL25	1	n/a	15490304	Suzuki A, Ji G, Numabe Y, Ishii K, Muramatsu M, Kamoi K. Large-scale investigation of genomic markers for severe periodontitis. Odontology. 2004 Sep;92(1):43-7.
CCL5	CP	106	175	ns	None	Caucasian	CC	S	Chemokine (C-C motif) ligand 5	SISd; SCYA5; RANTES; TCP228; D17S136E; MGC17164; CCL5	1	–471 A/G	17305874	Savarrio L, Donati M, Carr C, Kinane DF, Berglundh T. Interleukin-24, RANTES and CCR5 gene polymorphisms are not associated with chronic adult periodontitis. J Periodontal Res. 2007 Apr;42(2):152-8.
CCR2	CP	22	41	ns	None	Japanese	CC	N	Chemokine (C-C motif) receptor 2	CKR2; CCR2A; CCR2B; CD192; CKR2A; CKR2B; CMKBR2; MCP-1-R; CC-CKR-2; FLJ78302; MGC103828; MGC111760; MGC168006; CCR2	2	Multiple SNPs	15490304	Suzuki A, Ji G, Numabe Y, Ishii K, Muramatsu M, Kamoi K. Large-scale investigation of genomic markers for severe periodontitis. Odontology. 2004 Sep;92(1):43-7.
CCR5	CP	106	175	ns	None	Caucasian	CC	S	Chemokine (C-C motif) receptor 5	CKR5; CD195; CKR-5; CCCKR5; CMKBR5; IDDM22; CC-CKR-5; FLJ78003; CCR5	1	Delta32/wt	17305874	Savarrio L, Donati M, Carr C, Kinane DF, Berglundh T. Interleukin-24, RANTES and CCR5 gene polymorphisms are not associated with chronic adult periodontitis. J Periodontal Res. 2007 Apr;42(2):152-8.

CCR5	CP	137	219	ns	None	Caucasian	CC	GS	Chemokine (C-C motif) receptor 5	CKR5; CD195; CKR-5; CCCKR5; CMKBR5; IDDM22; CC-CKR-5; FLJ78003; CCR5	1	59653 C>T	16512757	Wohlfahrt JC, Wu T, Hodges JS, Hinrichs JE, Michalowicz BS. No association between selected candidate gene polymorphisms and severe chronic periodontitis. J Periodontol. 2006 Mar;77(3):426-36.
CCR5	CP	22	41	ns	None	Japanese	CC	N	Chemokine (C-C motif) receptor 5	CKR5; CD195; CKR-5; CCCKR5; CMKBR5; IDDM22; CC-CKR-5; FLJ78003; CCR5	1	n/a	15490304	Suzuki A, Ji G, Numabe Y, Ishii K, Muramatsu M, Kamoi K. Large-scale investigation of genomic markers for severe periodontitis. Odontology. 2004 Sep;92(1):43-7.
CCR5	CP	81	202	ns	None	Caucasian	CC	N	Chemokine (C-C motif) receptor 5	CKR5; CD195; CKR-5; CCCKR5; CMKBR5; IDDM22; CC-CKR-5; FLJ78003; CCR5	1	Delta32/wt	14697747	Folwaczny M, Glas J, Török HP, Fricke K, Folwaczny C. Prevalence of the chemokine receptor CCR5-Delta32 gene mutation in periodontal disease. Clin Immunol. 2003 Dec;109(3):325-9.
CD14	AgP	73	153	ns	None	German	CC	N	CD14 molecule	CD14	1	–159	19046305	Schulz S, Zissler N, Altermann W, Klapproth J, Zimmermann U, Gläser C, Schaller HG, Reichert S. Impact of genetic variants of CD14 and TLR4 on subgingival periodontopathogens. Int J Immunogenet. 2008 Dec;35(6):457-64.
CD14	AgP	73	200	ns	None	Caucasian	CC	N	CD14 molecule	CD14	2	Multiple SNPs	17309585	James JA, Poulton KV, Haworth SE, Payne D, McKay IJ, Clarke FM, Hughes FJ, Linden GJ. Polymorphisms of TLR4 but not CD14 are associated with a decreased risk of aggressive periodontitis. J Clin Periodontol. 2007 Feb;34(2):111-7.
CD14	AgP+CP	133	213	ns	None	German	CC	N	CD14 molecule	CD14	1	–159	19046305	Schulz S, Zissler N, Altermann W, Klapproth J, Zimmermann U, Gläser C, Schaller HG, Reichert S. Impact of genetic variants of CD14 and TLR4 on subgingival periodontopathogens. Int J Immunogenet. 2008 Dec;35(6):457-64.

Continued

TABLE 6-3 Association Study—cont'd

Gene Symbol	Disease Type	Cases	Total	Best *P* Value	Level of Support	Population	Study Design	Stratified or Covariate Adj	Gene Name	Gene Aliases	# SNPs Assayed	SNP Name	PubMed ID	Journal
CD14	AgP+CP	319	622	ns	None	Japanese	CC	AGS	CD14 molecule	CD14	1	–159	19892918	Kobayashi T, Nagata T, Murakami S, Takashiba S, Kurihara H, Izumi Y, Numabe Y, Watanabe H, Kataoka M, Nagai A, Hayashi J, Ohyama H, Okamatsu Y, Inagaki Y, Tai H, Yoshie H. Genetic risk factors for periodontitis in a Japanese population. J Dent Res. 2009 Dec;88(12): 1137-41.
CD14	CP	100	199	0.004	Weak	Caucasian	CC	AGPS	CD14 molecule	CD14	1	–260	16246938	Laine ML, Morré SA, Murillo LS, van Winkelhoff AJ, Peña AS. CD14 and TLR4 gene polymorphisms in adult periodontitis. J Dent Res. 2005 Nov;84(11):1042-6.
CD14	CP	98	134	0.006	Weak	Caucasian	CC	N	CD14 molecule	CD14	2	G-1359T	12414826	Holla LI, Buckova D, Fassmann A, Halabala T, Vasku A, Vacha J. Promoter polymorphisms in the CD14 receptor gene and their potential association with the severity of chronic periodontitis. J Med Genet. 2002 Nov;39(11):844-8.
CD14	CP	70	145	0.013	Weak	German	CC	G	CD14 molecule	CD14	1	–159	15491315	Folwaczny M, Glas J, Török HP, Fricke K, Folwaczny C. The CD14 -159C-to-T promoter polymorphism in periodontal disease. J Clin Periodontol. 2004 Nov;31(11):991-5.
CD14	CP	51	229	0.022	Weak	Caucasian	CC	GS	CD14 molecule	CD14	1	–260	17448042	Tervonen T, Raunio T, Knuuttila M, Karttunen R. Polymorphisms in the CD14 and IL-6 genes associated with periodontal disease. J Clin Periodontol. 2007 May;34(5):377-83.
CD14	CP	60	99	0.028	Weak	Caucasian	CC	N	CD14 molecule	CD14	1	–159	15842262	Donati M, Berglundh T, Hytönen AM, Hahn-Zoric M, Hanson LA, Padyukov L. Association of the -159 CD14 gene polymorphism and lack of association of the -308 TNFA and Q551R IL-4RA polymorphisms with severe chronic periodontitis in Swedish Caucasians. J Clin Periodontol. 2005 May;32(5):474-9.

CD14	CP	56	84	ns	None	Finnish	CC	N	CD14 molecule	CD14	1	–260	19500269	Raunio T, Knuuttila M, Karttunen R, Vainio O, Tervonen T. Serum sCD14, polymorphism of CD14(-260) and periodontal infection. Oral Dis. 2009 Jun 4. [Epub ahead of print]
CD14	CP	105	162	ns	None	Caucasian	CC	N	CD14 molecule	CD14	1	–260	19318422	Nicu EA, Laine ML, Morré SA, Van der Velden U, Loos BG. Soluble CD14 in periodontitis. Innate Immun. 2009 Apr;15(2):121-8.
CD14	CP	60	140	ns	None	German	CC	N	CD14 molecule	CD14	1	–159	19046305	Schulz S, Zissler N, Altermann W, Klapproth J, Zimmermann U, Gläser C, Schaller HG, Reichert S. Impact of genetic variants of CD14 and TLR4 on subgingival periodontopathogens. Int J Immunogenet. 2008 Dec;35(6):457-64.
CD14	CP	n/a	80	ns	None	Finnish	Quan	N	CD14 molecule	CD14	1	–260	19017034	Raunio T, Knuuttila M, Hiltunen L, Karttunen R, Vainio O, Tervonen T. IL-6(-174) genotype associated with the extent of periodontal disease in type 1 diabetic subjects. J Clin Periodontol. 2009 Jan;36(1):11-7. Epub 2008 Oct 31.
CD14	CP	95	189	ns	None	Caucasian	CC	N	CD14 molecule	CD14	2	Multiple SNPs	17309585	James JA, Poulton KV, Haworth SE, Payne D, McKay IJ, Clarke FM, Hughes FJ, Linden GJ. Polymorphisms of TLR4 but not CD14 are associated with a decreased risk of aggressive periodontitis. J Clin Periodontol. 2007 Feb;34(2):111-7.
CD14	CP	163	267	ns	None	Japanese	CC	N	CD14 molecule	CD14	1	–159	12885845	Yamazaki K, Ueki-Maruyama K, Oda T, Tabeta K, Shimada Y, Tai H, Nakajima T, Yoshie H, Herawati D, Seymour GJ. Single-nucleotide polymorphism in the CD14 promoter and periodontal disease expression in a Japanese population. J Dent Res. 2003 Aug;82(8):612-6.

Continued

TABLE 6-3 Association Study—cont'd

Gene Symbol	Disease Type	Cases	Total	Best *P* Value	Level of Support	Population	Study Design	Stratified or Covariate Adj	Gene Name	Gene Aliases	# SNPs Assayed	SNP Name	PubMed ID	Journal
CD14.IL6	CP	51	229	0.012	Weak	Caucasian	CC	GS	n/a	n/a	2	Multiple Genes	17448042	Tervonen T, Raunio T, Knuuttila M, Karttunen R. Polymorphisms in the CD14 and IL-6 genes associated with periodontal disease. J Clin Periodontol. 2007 May;34(5):377-83.
CD14.TLR4	CP	51	229	ns	None	Caucasian	CC	GS	n/a	n/a	2	Multiple Genes	17448042	Tervonen T, Raunio T, Knuuttila M, Karttunen R. Polymorphisms in the CD14 and IL-6 genes associated with periodontal disease. J Clin Periodontol. 2007 May;34(5):377-83.
CD2	CP	22	41	ns	None	Japanese	CC	N	CD2 molecule	T11; SRBC; FLJ46032; CD2	1	n/a	15490304	Suzuki A, Ji G, Numabe Y, Ishii K, Muramatsu M, Kamoi K. Large-scale investigation of genomic markers for severe periodontitis. Odontology. 2004 Sep;92(1):43-7.
CD36	AgP+CP	251	376	ns	None	Japanese	CC	N	CD36 molecule (thrombospondin receptor)	FAT; GP4; GP3B; GPIV; CHDS7; PASIV; SCARB3; CD36	n/a	n/a	15081423	Suzuki A, Ji G, Numabe Y, Muramatsu M, Gomi K, Kanazashi M, Ogata Y, Shimizu E, Shibukawa Y, Ito A, Ito T, Sugaya A, Arai T, Yamada S, Deguchi S, Kamoi K. Single nucleotide polymorphisms associated with aggressive periodontitis and severe chronic periodontitis in Japanese. Biochem Biophys Res Commun. 2004 May 7;317(3):887-92.
CD36	CP	22	41	ns	None	Japanese	CC	N	CD36 molecule (thrombospondin receptor)	FAT; GP4; GP3B; GPIV; CHDS7; PASIV; SCARB3; CD36	1	n/a	15490304	Suzuki A, Ji G, Numabe Y, Ishii K, Muramatsu M, Kamoi K. Large-scale investigation of genomic markers for severe periodontitis. Odontology. 2004 Sep;92(1):43-7.
CD4	CP	22	41	ns	None	Japanese	CC	N	CD4 molecule	CD4mut; CD4	1	n/a	15490304	Suzuki A, Ji G, Numabe Y, Ishii K, Muramatsu M, Kamoi K. Large-scale investigation of genomic markers for severe periodontitis. Odontology. 2004 Sep;92(1):43-7.

CD6	CP	22	41	ns	None	Japanese	CC	N	CD6 molecule	TP120; FLJ44171; CD6	4	Multiple SNPs	15490304	Suzuki A, Ji G, Numabe Y, Ishii K, Muramatsu M, Kamoi K. Large-scale investigation of genomic markers for severe periodontitis. Odontology. 2004 Sep;92(1):43-7.
CD81	CP	22	41	ns	None	Japanese	CC	N	CD81 molecule	S5.7; TAPA1; TSPAN28; CD81	3	Multiple SNPs	15490304	Suzuki A, Ji G, Numabe Y, Ishii K, Muramatsu M, Kamoi K. Large-scale investigation of genomic markers for severe periodontitis. Odontology. 2004 Sep;92(1):43-7.
CDKN2BAS	AgP	159	895	0.00069	Moderate	German	CC	DGS	CDKN2B antisense RNA (non-protein coding)	ANRIL; p15AS; NCRNA00089; RP11-145E5.4; CDKN2BAS	3	rs1333048	19214202	Schaefer AS, Richter GM, Groessner-Schreiber B, Noack B, Nothnagel M, El Mokhtari NE, Loos BG, Jepsen S, Schreiber S. Identification of a shared genetic susceptibility locus for coronary heart disease and periodontitis. PLoS Genet. 2009 Feb;5(2):e1000378. Epub 2009 Feb 13.
CDKN2BAS	AgP	146	514	0.0059	Weak	German	CC	DGS	CDKN2B antisense RNA (non-protein coding)	ANRIL; p15AS; NCRNA00089; RP11-145E5.4; CDKN2BAS	3	rs1333048	19214202	Schaefer AS, Richter GM, Groessner-Schreiber B, Noack B, Nothnagel M, El Mokhtari NE, Loos BG, Jepsen S, Schreiber S. Identification of a shared genetic susceptibility locus for coronary heart disease and periodontitis. PLoS Genet. 2009 Feb;5(2):e1000378. Epub 2009 Feb 13.
CHGB	CP	22	41	ns	None	Japanese	CC	N	Chromogranin B (secretogranin 1)	SCG1; CHGB	1	n/a	15490304	Suzuki A, Ji G, Numabe Y, Ishii K, Muramatsu M, Kamoi K. Large-scale investigation of genomic markers for severe periodontitis. Odontology. 2004 Sep;92(1):43-7.
CHI3L1	CP	22	41	ns	None	Japanese	CC	N	Chitinase 3-like 1 (cartilage glycoprotein-39)	GP39; ASRT7; YKL40; YYL-40; HC-gp39; HCGP-3P; FLJ38139; DKFZp686N19119; CHI3L1	1	n/a	15490304	Suzuki A, Ji G, Numabe Y, Ishii K, Muramatsu M, Kamoi K. Large-scale investigation of genomic markers for severe periodontitis. Odontology. 2004 Sep;92(1):43-7.

Continued

TABLE 6-3 Association Study—cont'd

Gene Symbol	Disease Type	Cases	Total	Best *P* Value	Level of Support	Population	Study Design	Stratified or Covariate Adj	Gene Name	Gene Aliases	# SNPs Assayed	SNP Name	PubMed ID	Journal
Chr19 Region	CP	300	600	0.019	Weak	Japanese	CC	N	n/a	n/a	13	rs11668269	19335087	Tabeta K, Shimada Y, Tai H, Ishihara Y, Noguchi T, Soga Y, Takashiba S, Suzuki G, Kobayashi T, Oka A, Kobayashi T, Yamazaki K, Inoko H, Yoshie H. Assessment of chromosome 19 for genetic association in severe chronic periodontitis. J Periodontol. 2009 Apr;80(4):663-71.
CKAP2L	AgP	415	1289	ns	None	Caucasian	CC	N	Cytoskeleton associated protein 2-like	FLJ40629; MGC39683; CKAP2L	2	Multiple SNPs	18723088	Fiebig A, Jepsen S, Loos BG, Scholz C, Schäfer C, Rühling A, Nothnagel M, Eickholz P, van der Velden U, Schenck K, Schreiber S, Grössner-Schreiber B. Polymorphisms in the interleukin-1 (IL1) gene cluster are not associated with aggressive periodontitis in a large Caucasian population. Genomics. 2008 Nov;92(5):309-15. Epub 2008 Sep 18.
CKAP2L	AgP	415	1289	ns	None	Caucasian	CC	N	Cytoskeleton associated protein 2-like	FLJ40629; MGC39683; CKAP2L	2	Haplotype	18723088	Fiebig A, Jepsen S, Loos BG, Scholz C, Schäfer C, Rühling A, Nothnagel M, Eickholz P, van der Velden U, Schenck K, Schreiber S, Grössner-Schreiber B. Polymorphisms in the interleukin-1 (IL1) gene cluster are not associated with aggressive periodontitis in a large Caucasian population. Genomics. 2008 Nov;92(5):309-15. Epub 2008 Sep 18.

COL12A1	AgP+CP	251	376	ns	None	Japanese	CC	N	Collagen, type XII, alpha 1	COL12A1L; BA209D8.1; DJ234P15.1; COL12A1	n/a	n/a	15081423	Suzuki A, Ji G, Numabe Y, Muramatsu M, Gomi K, Kanazashi M, Ogata Y, Shimizu E, Shibukawa Y, Ito A, Ito T, Sugaya A, Arai T, Yamada S, Deguchi S, Kamoi K. Single nucleotide polymorphisms associated with aggressive periodontitis and severe chronic periodontitis in Japanese. Biochem Biophys Res Commun. 2004 May 7;317(3):887-92.
COL15A1	AgP+CP	251	376	ns	None	Japanese	CC	N	Collagen, type XV, alpha 1	FLJ38566; COL15A1	n/a	n/a	15081423	Suzuki A, Ji G, Numabe Y, Muramatsu M, Gomi K, Kanazashi M, Ogata Y, Shimizu E, Shibukawa Y, Ito A, Ito T, Sugaya A, Arai T, Yamada S, Deguchi S, Kamoi K. Single nucleotide polymorphisms associated with aggressive periodontitis and severe chronic periodontitis in Japanese. Biochem Biophys Res Commun. 2004 May 7;317(3):887-92.
COL16A1	AgP+CP	251	376	ns	None	Japanese	CC	N	Collagen, type XVI, alpha 1	447AA; FP1572; COL16A1	n/a	n/a	15081423	Suzuki A, Ji G, Numabe Y, Muramatsu M, Gomi K, Kanazashi M, Ogata Y, Shimizu E, Shibukawa Y, Ito A, Ito T, Sugaya A, Arai T, Yamada S, Deguchi S, Kamoi K. Single nucleotide polymorphisms associated with aggressive periodontitis and severe chronic periodontitis in Japanese. Biochem Biophys Res Commun. 2004 May 7;317(3):887-92.

Continued

TABLE 6-3 Association Study—cont'd

Gene Symbol	Disease Type	Cases	Total	Best *P* Value	Level of Support	Population	Study Design	Stratified or Covariate Adj	Gene Name	Gene Aliases	# SNPs Assayed	SNP Name	PubMed ID	Journal
COL17A1	AgP+CP	251	376	0.008	Weak	Japanese	CC	N	Collagen, type XVII, alpha 1	BP180; BPAG2; LAD-1; FLJ60881; KIAA0204; BA16H23.2; COL17A1	n/a	Chr:10 C/T	15081423	Suzuki A, Ji G, Numabe Y, Muramatsu M, Gomi K, Kanazashi M, Ogata Y, Shimizu E, Shibukawa Y, Ito A, Ito T, Sugaya A, Arai T, Yamada S, Deguchi S, Kamoi K. Single nucleotide polymorphisms associated with aggressive periodontitis and severe chronic periodontitis in Japanese. Biochem Biophys Res Commun. 2004 May 7;317(3):887-92.
COL18A1	AgP+CP	251	376	ns	None	Japanese	CC	N	Collagen, type XVIII, alpha 1	KNO; KNO1; FLJ27325; FLJ34914; MGC74745; COL18A1	n/a	n/a	15081423	Suzuki A, Ji G, Numabe Y, Muramatsu M, Gomi K, Kanazashi M, Ogata Y, Shimizu E, Shibukawa Y, Ito A, Ito T, Sugaya A, Arai T, Yamada S, Deguchi S, Kamoi K. Single nucleotide polymorphisms associated with aggressive periodontitis and severe chronic periodontitis in Japanese. Biochem Biophys Res Commun. 2004 May 7;317(3):887-92.
COL19A1	AgP+CP	251	376	ns	None	Japanese	CC	N	Collagen, type XIX, alpha 1	COL9A1L; D6S228E; COL19A1	n/a	n/a	15081423	Suzuki A, Ji G, Numabe Y, Muramatsu M, Gomi K, Kanazashi M, Ogata Y, Shimizu E, Shibukawa Y, Ito A, Ito T, Sugaya A, Arai T, Yamada S, Deguchi S, Kamoi K. Single nucleotide polymorphisms associated with aggressive periodontitis and severe chronic periodontitis in Japanese. Biochem Biophys Res Commun. 2004 May 7;317(3):887-92.

COL1A1	AgP	46	136	ns	None	Greek	CC	N	Collagen, type I, alpha 1	OI4; COL1A1	1	Sp1	16911569	Sakellari D, Katsares V, Georgiadou M, Kouvatsi A, Arsenakis M, Konstantinidis A. No correlation of five gene polymorphisms with periodontal conditions in a Greek population. J Clin Periodontol. 2006 Nov;33(11):765-70. Epub 2006 Aug 14.
COL1A1	AgP+CP	251	376	0.003	Weak	Japanese	CC	N	Collagen, type I, alpha 1	OI4; COL1A1	n/a	Chr:17 A/C	15081423	Suzuki A, Ji G, Numabe Y, Muramatsu M, Gomi K, Kanazashi M, Ogata Y, Shimizu E, Shibukawa Y, Ito A, Ito T, Sugaya A, Arai T, Yamada S, Deguchi S, Kamoi K. Single nucleotide polymorphisms associated with aggressive periodontitis and severe chronic periodontitis in Japanese. Biochem Biophys Res Commun. 2004 May 7;317(3):887-92.
COL1A1	CP	56	146	ns	None	Greek	CC	N	Collagen, type I, alpha 1	OI4; COL1A1	1	Sp1	16911569	Sakellari D, Katsares V, Georgiadou M, Kouvatsi A, Arsenakis M, Konstantinidis A. No correlation of five gene polymorphisms with periodontal conditions in a Greek population. J Clin Periodontol. 2006 Nov;33(11):765-70. Epub 2006 Aug 14.
COL1A2	AgP+CP	251	376	ns	None	Japanese	CC	N	Collagen, type I, alpha 2	OI4; COL1A2	n/a	n/a	15081423	Suzuki A, Ji G, Numabe Y, Muramatsu M, Gomi K, Kanazashi M, Ogata Y, Shimizu E, Shibukawa Y, Ito A, Ito T, Sugaya A, Arai T, Yamada S, Deguchi S, Kamoi K. Single nucleotide polymorphisms associated with aggressive periodontitis and severe chronic periodontitis in Japanese. Biochem Biophys Res Commun. 2004 May 7;317(3):887-92.

Continued

TABLE 6-3 Association Study—cont'd

Gene Symbol	Disease Type	Cases	Total	Best *P* Value	Level of Support	Population	Study Design	Stratified or Covariate Adj	Gene Name	Gene Aliases	# SNPs Assayed	SNP Name	PubMed ID	Journal
COL2A1	AgP+CP	251	376	ns	None	Japanese	CC	N	Collagen, type II, alpha 1	AOM; ANFH; SEDC; COL11A3; MGC131516; COL2A1	n/a	n/a	15081423	Suzuki A, Ji G, Numabe Y, Muramatsu M, Gomi K, Kanazashi M, Ogata Y, Shimizu E, Shibukawa Y, Ito A, Ito T, Sugaya A, Arai T, Yamada S, Deguchi S, Kamoi K. Single nucleotide polymorphisms associated with aggressive periodontitis and severe chronic periodontitis in Japanese. Biochem Biophys Res Commun. 2004 May 7;317(3):887-92.
COL3A1	AgP+CP	251	376	ns	None	Japanese	CC	N	Collagen, type III, alpha 1	EDS4A; FLJ34534; COL3A1	n/a	n/a	15081423	Suzuki A, Ji G, Numabe Y, Muramatsu M, Gomi K, Kanazashi M, Ogata Y, Shimizu E, Shibukawa Y, Ito A, Ito T, Sugaya A, Arai T, Yamada S, Deguchi S, Kamoi K. Single nucleotide polymorphisms associated with aggressive periodontitis and severe chronic periodontitis in Japanese. Biochem Biophys Res Commun. 2004 May 7;317(3):887-92.
COL4A1	AgP+CP	251	376	0.003	Weak	Japanese	CC	N	Collagen, type IV, alpha 1	arresten; COL4A1	n/a	Chr:13 T/C	15081423	Suzuki A, Ji G, Numabe Y, Muramatsu M, Gomi K, Kanazashi M, Ogata Y, Shimizu E, Shibukawa Y, Ito A, Ito T, Sugaya A, Arai T, Yamada S, Deguchi S, Kamoi K. Single nucleotide polymorphisms associated with aggressive periodontitis and severe chronic periodontitis in Japanese. Biochem Biophys Res Commun. 2004 May 7;317(3):887-92.

COL4A3	AgP+CP	251	376	ns	None	Japanese	CC	N	Collagen, type IV, alpha 3 (Goodpasture antigen)	COL4A3	n/a	n/a	15081423	Suzuki A, Ji G, Numabe Y, Muramatsu M, Gomi K, Kanazashi M, Ogata Y, Shimizu E, Shibukawa Y, Ito A, Ito T, Sugaya A, Arai T, Yamada S, Deguchi S, Kamoi K. Single nucleotide polymorphisms associated with aggressive periodontitis and severe chronic periodontitis in Japanese. Biochem Biophys Res Commun. 2004 May 7;317(3):887-92.
COL4A4	AgP+CP	251	376	ns	None	Japanese	CC	N	Collagen, type IV, alpha 4	CA44; COL4A4	n/a	n/a	15081423	Suzuki A, Ji G, Numabe Y, Muramatsu M, Gomi K, Kanazashi M, Ogata Y, Shimizu E, Shibukawa Y, Ito A, Ito T, Sugaya A, Arai T, Yamada S, Deguchi S, Kamoi K. Single nucleotide polymorphisms associated with aggressive periodontitis and severe chronic periodontitis in Japanese. Biochem Biophys Res Commun. 2004 May 7;317(3):887-92.
COL5A3	AgP+CP	251	376	ns	None	Japanese	CC	N	Collagen, type V, alpha 3	COL5A3	n/a	n/a	15081423	Suzuki A, Ji G, Numabe Y, Muramatsu M, Gomi K, Kanazashi M, Ogata Y, Shimizu E, Shibukawa Y, Ito A, Ito T, Sugaya A, Arai T, Yamada S, Deguchi S, Kamoi K. Single nucleotide polymorphisms associated with aggressive periodontitis and severe chronic periodontitis in Japanese. Biochem Biophys Res Commun. 2004 May 7;317(3):887-92.

Continued

TABLE 6-3 Association Study—cont'd

Gene Symbol	Disease Type	Cases	Total	Best *P* Value	Level of Support	Population	Study Design	Stratified or Covariate Adj	Gene Name	Gene Aliases	# SNPs Assayed	SNP Name	PubMed ID	Journal
COL6A2	AgP+CP	251	376	ns	None	Japanese	CC	N	Collagen, type VI, alpha 2	PP3610; FLJ46862; DKFZp586E1322; COL6A2	n/a	n/a	15081423	Suzuki A, Ji G, Numabe Y, Muramatsu M, Gomi K, Kanazashi M, Ogata Y, Shimizu E, Shibukawa Y, Ito A, Ito T, Sugaya A, Arai T, Yamada S, Deguchi S, Kamoi K. Single nucleotide polymorphisms associated with aggressive periodontitis and severe chronic periodontitis in Japanese. Biochem Biophys Res Commun. 2004 May 7;317(3):887-92.
COL6A3	AgP+CP	251	376	ns	None	Japanese	CC	N	Collagen, type VI, alpha 3	FLJ34702; FLJ98399; DKFZp686N0262; DKFZp686D23123; DKFZp686K04147; COL6A3	n/a	n/a	15081423	Suzuki A, Ji G, Numabe Y, Muramatsu M, Gomi K, Kanazashi M, Ogata Y, Shimizu E, Shibukawa Y, Ito A, Ito T, Sugaya A, Arai T, Yamada S, Deguchi S, Kamoi K. Single nucleotide polymorphisms associated with aggressive periodontitis and severe chronic periodontitis in Japanese. Biochem Biophys Res Commun. 2004 May 7;317(3):887-92.
COL7A1	AgP+CP	251	376	ns	None	Japanese	CC	N	Collagen, type VII, alpha 1	EBD1; EBR1; EBDCT; COL7A1	n/a	n/a	15081423	Suzuki A, Ji G, Numabe Y, Muramatsu M, Gomi K, Kanazashi M, Ogata Y, Shimizu E, Shibukawa Y, Ito A, Ito T, Sugaya A, Arai T, Yamada S, Deguchi S, Kamoi K. Single nucleotide polymorphisms associated with aggressive periodontitis and severe chronic periodontitis in Japanese. Biochem Biophys Res Commun. 2004 May 7;317(3):887-92.

COL8A1	AgP+CP	251	376	ns	None	Japanese	CC	N	Collagen, type VIII, alpha 1	C3orf7; MGC9568; COL8A1	n/a	n/a	15081423	Suzuki A, Ji G, Numabe Y, Muramatsu M, Gomi K, Kanazashi M, Ogata Y, Shimizu E, Shibukawa Y, Ito A, Ito T, Sugaya A, Arai T, Yamada S, Deguchi S, Kamoi K. Single nucleotide polymorphisms associated with aggressive periodontitis and severe chronic periodontitis in Japanese. Biochem Biophys Res Commun. 2004 May 7;317(3):887-92.
COL9A1	AgP+CP	251	376	ns	None	Japanese	CC	N	Collagen, type IX, alpha 1	MED; EDM6; FLJ40263; DJ149L1.1.2; COL9A1	n/a	n/a	15081423	Suzuki A, Ji G, Numabe Y, Muramatsu M, Gomi K, Kanazashi M, Ogata Y, Shimizu E, Shibukawa Y, Ito A, Ito T, Sugaya A, Arai T, Yamada S, Deguchi S, Kamoi K. Single nucleotide polymorphisms associated with aggressive periodontitis and severe chronic periodontitis in Japanese. Biochem Biophys Res Commun. 2004 May 7;317(3):887-92.
COL9A2	AgP+CP	251	376	ns	None	Japanese	CC	N	Collagen, type IX, alpha 2	MED; EDM2; DJ39G22.4; COL9A2	n/a	n/a	15081423	Suzuki A, Ji G, Numabe Y, Muramatsu M, Gomi K, Kanazashi M, Ogata Y, Shimizu E, Shibukawa Y, Ito A, Ito T, Sugaya A, Arai T, Yamada S, Deguchi S, Kamoi K. Single nucleotide polymorphisms associated with aggressive periodontitis and severe chronic periodontitis in Japanese. Biochem Biophys Res Commun. 2004 May 7;317(3):887-92.

Continued

TABLE 6-3 Association Study—cont'd

Gene Symbol	Disease Type	Cases	Total	Best *P* Value	Level of Support	Population	Study Design	Stratified or Covariate Adj	Gene Name	Gene Aliases	# SNPs Assayed	SNP Name	PubMed ID	Journal
COLQ	AgP+CP	251	376	ns	None	Japanese	CC	N	Collagen-like tail subunit (single strand of homotrimer) of asymmetric acetylcholinesterase	EAD; FLJ55041; COLQ	n/a	n/a	15081423	Suzuki A, Ji G, Numabe Y, Muramatsu M, Gomi K, Kanazashi M, Ogata Y, Shimizu E, Shibukawa Y, Ito A, Ito T, Sugaya A, Arai T, Yamada S, Deguchi S, Kamoi K. Single nucleotide polymorphisms associated with aggressive periodontitis and severe chronic periodontitis in Japanese. Biochem Biophys Res Commun. 2004 May 7;317(3):887-92.
CSF1	AgP	98	186	0.024698	Weak	Japanese	CC	N	Colony stimulating factor 1 (macrophage)	MCSF; MGC31930; CSF1	5	G/T	16844084	Rabello D, Soedarsono N, Kamei H, Ishihara Y, Noguchi T, Fuma D, Suzuki M, Sakaki Y, Yamaguchi A, Kojima T. CSF1 gene associated with aggressive periodontitis in the Japanese population. Biochem Biophys Res Commun. 2006 Sep 1;347(3):791-6. Epub 2006 Jul 7.
CST1	CP	22	41	ns	None	Japanese	CC	N	Cystatin SN	CST1	1	n/a	15490304	Suzuki A, Ji G, Numabe Y, Ishii K, Muramatsu M, Kamoi K. Large-scale investigation of genomic markers for severe periodontitis. Odontology. 2004 Sep;92(1):43-7.
CST5	CP	22	41	ns	None	Japanese	CC	N	Cystatin D	MGC71922; CST5	5	Multiple SNPs	15490304	Suzuki A, Ji G, Numabe Y, Ishii K, Muramatsu M, Kamoi K. Large-scale investigation of genomic markers for severe periodontitis. Odontology. 2004 Sep;92(1):43-7.
CTF2	CP	22	41	ns	None	Japanese	CC	N	n/a	n/a	3	Multiple SNPs	15490304	Suzuki A, Ji G, Numabe Y, Ishii K, Muramatsu M, Kamoi K. Large-scale investigation of genomic markers for severe periodontitis. Odontology. 2004 Sep;92(1):43-7.

CTLA4	CP	137	219	ns	None	Caucasian	CC	GS	Cytotoxic T-lymphoCyte-associated protein 4	CD; GSE; ICOS; CD152; CTLA-4; IDDM12; CELIAC3; CTLA4	1	49 A>G	16512757	Wohlfahrt JC, Wu T, Hodges JS, Hinrichs JE, Michalowicz BS. No association between selected candidate gene polymorphisms and severe chronic periodontitis. J Periodontol. 2006 Mar;77(3):426-36.
CTSB	AgP+CP	251	376	ns	None	Japanese	CC	N	Cathepsin B	APPS; CPSB; CTSB	n/a	n/a	15081423	Suzuki A, Ji G, Numabe Y, Muramatsu M, Gomi K, Kanazashi M, Ogata Y, Shimizu E, Shibukawa Y, Ito A, Ito T, Sugaya A, Arai T, Yamada S, Deguchi S, Kamoi K. Single nucleotide polymorphisms associated with aggressive periodontitis and severe chronic periodontitis in Japanese. Biochem Biophys Res Commun. 2004 May 7;317(3):887-92.
CTSB	CP	22	41	ns	None	Japanese	CC	N	Cathepsin B	APPS; CPSB; CTSB	4	Multiple SNPs	15490304	Suzuki A, Ji G, Numabe Y, Ishii K, Muramatsu M, Kamoi K. Large-scale investigation of genomic markers for severe periodontitis. Odontology. 2004 Sep;92(1):43-7.
CTSC	AgP	110	188	0.034	Weak	German	CC	N	Cathepsin C	JP; HMS; JPD; PLS; CPPI; DPP1; DPPI; PALS; CTSC	5	p.I453V	18809751	Noack B, Görgens H, Hempel U, Fanghänel J, Hoffmann T, Ziegler A, Schackert HK. Cathepsin C gene variants in aggressive periodontitis. J Dent Res. 2008 Oct;87(10):958-63.
CTSC	PPP	3	7	ns	None	n/a	Fam	N	Cathepsin C	JP; HMS; JPD; PLS; CPPI; DPP1; DPPI; PALS; CTSC	3	Multiple SNPs	14974080	Hewitt C, McCormick D, Linden G, Turk D, Stern I, Wallace I, Southern L, Zhang L, Howard R, Bullon P, Wong M, Widmer R, Gaffar KA, Awawdeh L, Briggs J, Yaghmai R, Jabs EW, Hoeger P, Bleck O, Rüdiger SG, Petersilka G, Battino M, Brett P, Hattab F, Al-Hamed M, Sloan P, Toomes C, Dixon M, James J, Read AP, Thakker N. The role of cathepsin C in Papillon-Lefèvre syndrome, prepubertal periodontitis, and aggressive periodontitis. Hum Mutat. 2004 Mar;23(3):222-8.

Continued

TABLE 6-3 Association Study—cont'd

Gene Symbol	Disease Type	Cases	Total	Best *P* Value	Level of Support	Population	Study Design	Stratified or Covariate Adj	Gene Name	Gene Aliases	# SNPs Assayed	SNP Name	PubMed ID	Journal
CTSC	PPP	4	60	sig	Weak	Jordanian	Fam	N	Cathepsin C	JP; HMS; JPD; PLS; CPPI; DPP1; DPPI; PALS; CTSC	1	1040A->G	10662808	Hart TC, Hart PS, Michalec MD, Zhang Y, Marazita ML, Cooper M, Yassin OM, Nusier M, Walker S. Localisation of a gene for prepubertal periodontitis to chromosome 11q14 and identification of a cathepsin C gene mutation. J Med Genet. 2000 Feb;37(2):95-101.
CTSC	PPP	14	14	sig	Weak	Jordanian	Fam	N	Cathepsin C	JP; HMS; JPD; PLS; CPPI; DPP1; DPPI; PALS; CTSC	1	1040A-G	10662808	Hart TC, Hart PS, Michalec MD, Zhang Y, Marazita ML, Cooper M, Yassin OM, Nusier M, Walker S. Localisation of a gene for prepubertal periodontitis to chromosome 11q14 and identification of a cathepsin C gene mutation. J Med Genet. 2000 Feb;37(2):95-101.
CTSD	AgP+CP	251	376	0.0007	Moderate	Japanese	CC	N	Cathepsin D	CPSD; CLN10; MGC2311; CTSD	n/a	Chr:11 C/T	15081423	Suzuki A, Ji G, Numabe Y, Muramatsu M, Gomi K, Kanazashi M, Ogata Y, Shimizu E, Shibukawa Y, Ito A, Ito T, Sugaya A, Arai T, Yamada S, Deguchi S, Kamoi K. Single nucleotide polymorphisms associated with aggressive periodontitis and severe chronic periodontitis in Japanese. Biochem Biophys Res Commun. 2004 May 7;317(3):887-92.
CTSD	CP	22	41	ns	None	Japanese	CC	N	Cathepsin D	CPSD; CLN10; MGC2311; CTSD	3	Multiple SNPs	15490304	Suzuki A, Ji G, Numabe Y, Ishii K, Muramatsu M, Kamoi K. Large-scale investigation of genomic markers for severe periodontitis. Odontology. 2004 Sep;92(1):43-7.

CTSG	AgP+CP	251	376	ns	None	Japanese	CC	N	Cathepsin G	CG; MGC23078; CTSG	n/a	n/a	15081423	Suzuki A, Ji G, Numabe Y, Muramatsu M, Gomi K, Kanazashi M, Ogata Y, Shimizu E, Shibukawa Y, Ito A, Ito T, Sugaya A, Arai T, Yamada S, Deguchi S, Kamoi K. Single nucleotide polymorphisms associated with aggressive periodontitis and severe chronic periodontitis in Japanese. Biochem Biophys Res Commun. 2004 May 7;317(3):887-92.
CTSH	AgP+CP	251	376	ns	None	Japanese	CC	N	Cathepsin H	CPSB; ACC-4; ACC-5; MGC1519; minichain; DKFZp686B24257; CTSH	n/a	n/a	15081423	Suzuki A, Ji G, Numabe Y, Muramatsu M, Gomi K, Kanazashi M, Ogata Y, Shimizu E, Shibukawa Y, Ito A, Ito T, Sugaya A, Arai T, Yamada S, Deguchi S, Kamoi K. Single nucleotide polymorphisms associated with aggressive periodontitis and severe chronic periodontitis in Japanese. Biochem Biophys Res Commun. 2004 May 7;317(3):887-92.
CTSL1	AgP+CP	251	376	ns	None	Japanese	CC	N	Cathepsin L1	MEP; CATL; CTSL; FLJ31037; CTSL1	n/a	n/a	15081423	Suzuki A, Ji G, Numabe Y, Muramatsu M, Gomi K, Kanazashi M, Ogata Y, Shimizu E, Shibukawa Y, Ito A, Ito T, Sugaya A, Arai T, Yamada S, Deguchi S, Kamoi K. Single nucleotide polymorphisms associated with aggressive periodontitis and severe chronic periodontitis in Japanese. Biochem Biophys Res Commun. 2004 May 7;317(3):887-92.
CYBA	AgP	224	455	0.002	Weak	Mixed	CC	EGS	Cytochrome b-245, alpha polypeptide	p22-PHOX; CYBA	1	C242T	16899095	Nibali L, Parkar M, Brett P, Knight J, Tonetti MS, Griffiths GS. NADPH oxidase (CYBA) and FcgammaR polymorphisms as risk factors for aggressive periodontitis: a case-control association study. J Clin Periodontol. 2006 Aug;33(8):529-39.

Continued

TABLE 6-3 Association Study—cont'd

Gene Symbol	Disease Type	Cases	Total	Best *P* Value	Level of Support	Population	Study Design	Stratified or Covariate Adj	Gene Name	Gene Aliases	# SNPs Assayed	SNP Name	PubMed ID	Journal
CYBA	CP	22	41	ns	None	Japanese	CC	N	Cytochrome b-245, alpha polypeptide	p22-PHOX; CYBA	1	n/a	15490304	Suzuki A, Ji G, Numabe Y, Ishii K, Muramatsu M, Kamoi K. Large-scale investigation of genomic markers for severe periodontitis. Odontology. 2004 Sep;92(1):43-7.
CYBA. FCGR3B	AgP	224	455	0.001	Weak	Mixed	CC	EGS	n/a	n/a	2	Multiple Genes	16899095	Nibali L, Parkar M, Brett P, Knight J, Tonetti MS, Griffiths GS. NADPH oxidase (CYBA) and FcgammaR polymorphisms as risk factors for aggressive periodontitis: a case-control association study. J Clin Periodontol. 2006 Aug;33(8):529-39.
CYP1A1	CP	115	241	0.009	Weak	Korean	CC	S	Cytochrome P450, family 1, subfamily A, polypeptide 1	AHH; AHRR; CP11; CYP1; P1-450; P450-C; P450DX; CYP1A1	1	Msp1	15491310	Kim JS, Park JY, Chung WY, Choi MA, Cho KS, Park KK. Polymorphisms in genes coding for enzymes metabolizing smoking-derived substances and the risk of periodontitis. J Clin Periodontol. 2004 Nov;31(11):959-64.
CYP21A2	CP	22	41	ns	None	Japanese	CC	N	Cytochrome P450, family 21, subfamily A, polypeptide 2	CAH1; CPS1; CA21H; CYP21; CYP21B; P450c21B; MGC150536; MGC150537; CYP21A2	1	n/a	15490304	Suzuki A, Ji G, Numabe Y, Ishii K, Muramatsu M, Kamoi K. Large-scale investigation of genomic markers for severe periodontitis. Odontology. 2004 Sep;92(1):43-7.
CYP2E1	CP	115	241	0.05	Weak	Korean	CC	S	Cytochrome P450, family 2, subfamily E, polypeptide 1	CPE1; CYP2E; P450-J; P450C2E; CYP2E1	1	Pst1	15491310	Kim JS, Park JY, Chung WY, Choi MA, Cho KS, Park KK. Polymorphisms in genes coding for enzymes metabolizing smoking-derived substances and the risk of periodontitis. J Clin Periodontol. 2004 Nov;31(11):959-64.
CYP4B1	CP	22	41	ns	None	Japanese	CC	N	Cytochrome P450, family 4, subfamily B, polypeptide 1	CYPIVB1; P-450HP; CYP4B1	2	Multiple SNPs	15490304	Suzuki A, Ji G, Numabe Y, Ishii K, Muramatsu M, Kamoi K. Large-scale investigation of genomic markers for severe periodontitis. Odontology. 2004 Sep;92(1):43-7.

CYP4F2	CP	22	41	ns	None	Japanese	CC	N	Cytochrome P450, family 4, subfamily F, polypeptide 2	CPF2; CYP4F2	1	n/a	15490304	Suzuki A, Ji G, Numabe Y, Ishii K, Muramatsu M, Kamoi K. Large-scale investigation of genomic markers for severe periodontitis. Odontology. 2004 Sep;92(1):43-7.
DEFB1	AgP	532	2004	0.02	Weak	Caucasian	CC	SD	Defensin, beta 1	D1; HBD1; DEFB-1; DEFB101; MGC51822; DEFB1	12	Multiple SNPs	19829306	Schaefer AS, Richter GM, Nothnagel M, Laine ML, Rühling A, Schäfer C, Cordes N, Noack B, Folwaczny M, Glas J, Dörfer C, Dommisch H, Groessner-Schreiber B, Jepsen S, Loos BG, Schreiber S. A 3′ UTR transition within DEFB1 is associated with chronic and aggressive periodontitis. Genes Immun. 2009 Oct 15. [Epub ahead of print]
DEFB1	AgP	120	280	ns	None	Mixed	CC	N	Defensin, beta 1	D1; HBD1; DEFB-1; DEFB101; MGC51822; DEFB1	1	–44	15242954	Boniotto M, Hazbón MH, Jordan WJ, Lennon GP, Eskdale J, Alland D, Gallagher G. Novel hairpin-shaped primer assay to study the association of the -44 single-nucleotide polymorphism of the DEFB1 gene with early-onset periodontal disease. Clin Diagn Lab Immunol. 2004 Jul;11(4):766-9.
DEFB1	AgP+CP	1337	3128	0.002	Weak	Caucasian	CC	SD	Defensin, beta 1	D1; HBD1; DEFB-1; DEFB101; MGC51822; DEFB1	12	Multiple SNPs	19829306	Schaefer AS, Richter GM, Nothnagel M, Laine ML, Rühling A, Schäfer C, Cordes N, Noack B, Folwaczny M, Glas J, Dörfer C, Dommisch H, Groessner-Schreiber B, Jepsen S, Loos BG, Schreiber S. A 3′ UTR transition within DEFB1 is associated with chronic and aggressive periodontitis. Genes Immun. 2009 Oct 15. [Epub ahead of print]

Continued

TABLE 6-3 Association Study—cont'd

Gene Symbol	Disease Type	Cases	Total	Best *P* Value	Level of Support	Population	Study Design	Stratified or Covariate Adj	Gene Name	Gene Aliases	# SNPs Assayed	SNP Name	PubMed ID	Journal
DEFB1	CP	805	1124	0.02	Weak	Caucasian	CC	SD	Defensin, beta 1	D1; HBD1; DEFB-1; DEFB101; MGC51822; DEFB1	12	Multiple SNPs	19829306	Schaefer AS, Richter GM, Nothnagel M, Laine ML, Rühling A, Schäfer C, Cordes N, Noack B, Folwaczny M, Glas J, Dörfer C, Dommisch H, Groessner-Schreiber B, Jepsen S, Loos BG, Schreiber S. A 3′ UTR transition within DEFB1 is associated with chronic and aggressive periodontitis. Genes Immun. 2009 Oct 15. [Epub ahead of print]
DEFB1	CP	137	219	ns	None	Caucasian	CC	GS	Defensin, beta 1	D1; HBD1; DEFB-1; DEFB101; MGC51822; DEFB1	1	692 G>A	16512757	Wohlfahrt JC, Wu T, Hodges JS, Hinrichs JE, Michalowicz BS. No association between selected candidate gene polymorphisms and severe chronic periodontitis. J Periodontol. 2006 Mar;77(3):426-36.
DEFB1	CP	22	41	ns	None	Japanese	CC	N	Defensin, beta 1	D1; HBD1; DEFB-1; DEFB101; MGC51822; DEFB1	3	Multiple SNPs	15490304	Suzuki A, Ji G, Numabe Y, Ishii K, Muramatsu M, Kamoi K. Large-scale investigation of genomic markers for severe periodontitis. Odontology. 2004 Sep;92(1):43-7.
DPP4	CP	22	41	0.006	Weak	Japanese	CC	N	Dipeptidyl-peptidase 4	CD26; ADABP; ADCP2; DPPIV; TP103; DPP4	7	IMS-JST022880	15490304	Suzuki A, Ji G, Numabe Y, Ishii K, Muramatsu M, Kamoi K. Large-scale investigation of genomic markers for severe periodontitis. Odontology. 2004 Sep;92(1):43-7.
ECE1	CP	22	41	ns	None	Japanese	CC	N	Endothelin converting enzyme 1	ECE; ECE1	7	Multiple SNPs	15490304	Suzuki A, Ji G, Numabe Y, Ishii K, Muramatsu M, Kamoi K. Large-scale investigation of genomic markers for severe periodontitis. Odontology. 2004 Sep;92(1):43-7.
ECH1	CP	22	41	ns	None	Japanese	CC	N	Enoyl Coenzyme A hydratase 1, peroxisomal	HPXEL; ECH1	1	n/a	15490304	Suzuki A, Ji G, Numabe Y, Ishii K, Muramatsu M, Kamoi K. Large-scale investigation of genomic markers for severe periodontitis. Odontology. 2004 Sep;92(1):43-7.

EDN1	CP	22	41	ns	None	Japanese	CC	N	Endothelin 1	ET1; HDLCQ7; EDN1	4	Multiple SNPs	15490304	Suzuki A, Ji G, Numabe Y, Ishii K, Muramatsu M, Kamoi K. Large-scale investigation of genomic markers for severe periodontitis. Odontology. 2004 Sep;92(1):43-7.
EDN1	CP	63	158	ns	None	Caucasian	CC	N	Endothelin 1	ET1; HDLCQ7; EDN1	1	Intron4 TaqI	11210078	Hollá LI, Fassmann A, Vasku A, Znojil V, Vanek J, Vácha J. Interactions of lymphotoxin alpha (TNF-beta), angiotensin-converting enzyme (ACE), and endothelin-1 (ET-1) gene polymorphisms in adult periodontitis. J Periodontol. 2001 Jan;72(1):85-9.
EDN1.LTA	CP	63	158	0.0472	Weak	Caucasian	CC	N	n/a	n/a	2	Multiple Genes	11210078	Hollá LI, Fassmann A, Vasku A, Znojil V, Vanek J, Vácha J. Interactions of lymphotoxin alpha (TNF-beta), angiotensin-converting enzyme (ACE), and endothelin-1 (ET-1) gene polymorphisms in adult periodontitis. J Periodontol. 2001 Jan;72(1):85-9.
EDN3	CP	22	41	ns	None	Japanese	CC	N	Endothelin 3	ET3; MGC15067; MGC61498; EDN3	4	Multiple SNPs	15490304	Suzuki A, Ji G, Numabe Y, Ishii K, Muramatsu M, Kamoi K. Large-scale investigation of genomic markers for severe periodontitis. Odontology. 2004 Sep;92(1):43-7.
EGF	AgP+CP	251	376	0.004	Weak	Japanese	CC	N	Epidermal growth factor (beta-urogastrone)	URG; HOMG4; EGF	n/a	Chr:4 A/G	15081423	Suzuki A, Ji G, Numabe Y, Muramatsu M, Gomi K, Kanazashi M, Ogata Y, Shimizu E, Shibukawa Y, Ito A, Ito T, Sugaya A, Arai T, Yamada S, Deguchi S, Kamoi K. Single nucleotide polymorphisms associated with aggressive periodontitis and severe chronic periodontitis in Japanese. Biochem Biophys Res Commun. 2004 May 7;317(3):887-92.
EGF	CP	22	41	ns	None	Japanese	CC	N	Epidermal growth factor (beta-urogastrone)	URG; HOMG4; EGF	10	Multiple SNPs	15490304	Suzuki A, Ji G, Numabe Y, Ishii K, Muramatsu M, Kamoi K. Large-scale investigation of genomic markers for severe periodontitis. Odontology. 2004 Sep;92(1):43-7.

Continued

TABLE 6-3 Association Study—cont'd

Gene Symbol	Disease Type	Cases	Total	Best *P* Value	Level of Support	Population	Study Design	Stratified or Covariate Adj	Gene Name	Gene Aliases	# SNPs Assayed	SNP Name	PubMed ID	Journal
EGFR	AgP+CP	251	376	ns	None	Japanese	CC	N	Epidermal growth factor receptor (erythroblastic leukemia viral (v-erb-b) oncogene homolog, avian)	ERBB; HER1; mENA; ERBB1; PIG61; EGFR	n/a	n/a	15081423	Suzuki A, Ji G, Numabe Y, Muramatsu M, Gomi K, Kanazashi M, Ogata Y, Shimizu E, Shibukawa Y, Ito A, Ito T, Sugaya A, Arai T, Yamada S, Deguchi S, Kamoi K. Single nucleotide polymorphisms associated with aggressive periodontitis and severe chronic periodontitis in Japanese. Biochem Biophys Res Commun. 2004 May 7;317(3):887-92.
EIF2AK2	CP	22	41	ns	None	Japanese	CC	N	Eukaryotic translation initiation factor 2-alpha kinase 2	PKR; PRKR; EIF2AK1; MGC126524; EIF2AK2	2	Multiple SNPs	15490304	Suzuki A, Ji G, Numabe Y, Ishii K, Muramatsu M, Kamoi K. Large-scale investigation of genomic markers for severe periodontitis. Odontology. 2004 Sep;92(1):43-7.
ELN	AgP+CP	251	376	ns	None	Japanese	CC	N	Elastin	WS; WBS; SVAS; FLJ38671; FLJ43523; ELN	n/a	n/a	15081423	Suzuki A, Ji G, Numabe Y, Muramatsu M, Gomi K, Kanazashi M, Ogata Y, Shimizu E, Shibukawa Y, Ito A, Ito T, Sugaya A, Arai T, Yamada S, Deguchi S, Kamoi K. Single nucleotide polymorphisms associated with aggressive periodontitis and severe chronic periodontitis in Japanese. Biochem Biophys Res Commun. 2004 May 7;317(3):887-92.
EMR1	CP	22	41	ns	None	Japanese	CC	N	EGF-like module containing, mucin-like, hormone receptor-like 1	TM7LN3; EMR1	4	Multiple SNPs	15490304	Suzuki A, Ji G, Numabe Y, Ishii K, Muramatsu M, Kamoi K. Large-scale investigation of genomic markers for severe periodontitis. Odontology. 2004 Sep;92(1):43-7.

ENTPD6	AgP+CP	251	376	ns	None	Japanese	CC	N	Ectonucleoside triphosphate diphosphohydrolase 6 (putative function)	CD39L2; IL6ST2; IL-6SAG; FLJ36711; NTPDase-6; dJ738P15.3; DKFZp781G2277; DKFZp781K21102; ENTPD6	n/a	n/a	15081423	Suzuki A, Ji G, Numabe Y, Muramatsu M, Gomi K, Kanazashi M, Ogata Y, Shimizu E, Shibukawa Y, Ito A, Ito T, Sugaya A, Arai T, Yamada S, Deguchi S, Kamoi K. Single nucleotide polymorphisms associated with aggressive periodontitis and severe chronic periodontitis in Japanese. Biochem Biophys Res Commun. 2004 May 7;317(3):887-92.
EPHX1	CP	22	41	ns	None	Japanese	CC	N	Epoxide hydrolase 1, microsomal (xenobiotic)	MEH; EPHX; EPOX; EPHX1	2	Multiple SNPs	15490304	Suzuki A, Ji G, Numabe Y, Ishii K, Muramatsu M, Kamoi K. Large-scale investigation of genomic markers for severe periodontitis. Odontology. 2004 Sep;92(1):43-7.
EPYC	AgP+CP	251	376	ns	None	Japanese	CC	N	Epiphycan	PGLB; DSPG3; Pg-Lb; SLRR3B; EPYC	n/a	n/a	15081423	Suzuki A, Ji G, Numabe Y, Muramatsu M, Gomi K, Kanazashi M, Ogata Y, Shimizu E, Shibukawa Y, Ito A, Ito T, Sugaya A, Arai T, Yamada S, Deguchi S, Kamoi K. Single nucleotide polymorphisms associated with aggressive periodontitis and severe chronic periodontitis in Japanese. Biochem Biophys Res Commun. 2004 May 7;317(3):887-92.
ERAP1	CP	22	41	ns	None	Japanese	CC	N	Endoplasmic reticulum aminopeptidase 1	ALAP; A-LAP; ARTS1; ERAAP; APPILS; ARTS-1; ERAAP1; PILSAP; PILS-AP; KIAA0525; ERAP1	4	Multiple SNPs	15490304	Suzuki A, Ji G, Numabe Y, Ishii K, Muramatsu M, Kamoi K. Large-scale investigation of genomic markers for severe periodontitis. Odontology. 2004 Sep;92(1):43-7.
ESR1	AgP	90	181	ns	None	Chinese	CC	G	Estrogen receptor 1	ER; ESR; Era; ESRA; NR3A1; DKFZp686N23123; ESR1	2	Multiple SNPs	15324358	Zhang L, Meng H, Zhao H, Li Q, Xu L, Chen Z, Shi D, Feng X. Estrogen receptor-alpha gene polymorphisms in patients with periodontitis. J Periodontal Res. 2004 Oct;39(5):362-6.
ESR1	AgP	n/a	n/a	sig	Weak	Chinese	CC	N	Estrogen receptor 1	ER; ESR; Era; ESRA; NR3A1; DKFZp686N23123; ESR1	1	n/a	19031816	Wang HY, Pan YP. [Screening and analysis of multi-alleles in generalized aggressive periodontitis]. Zhonghua Kou Qiang Yi Xue Za Zhi. 2008 Jul;43(7):406-9. Chinese.

Continued

TABLE 6-3 Association Study—cont'd

Gene Symbol	Disease Type	Cases	Total	Best *P* Value	Level of Support	Population	Study Design	Stratified or Covariate Adj	Gene Name	Gene Aliases	# SNPs Assayed	SNP Name	PubMed ID	Journal
ESR1	CP	34	125	<0.01	Weak	Chinese	CC	G	Estrogen receptor 1	ER; ESR; Era; ESRA; NR3A1; DKFZp686N23123; ESR1	2	XbaI	15324358	Zhang L, Meng H, Zhao H, Li Q, Xu L, Chen Z, Shi D, Feng X. Estrogen receptor-alpha gene polymorphisms in patients with periodontitis. J Periodontal Res. 2004 Oct;39(5):362-6.
ESR1	CP	n/a	n/a	sig	Weak	Chinese	CC	N	Estrogen receptor 1	ER; ESR; Era; ESRA; NR3A1; DKFZp686N23123; ESR1	2	XbaI	18846948	Wang HY, Pan YP, Teng D, Zhao J, Lin L. [The relativity between chronic periodontitis and the genetic polymorphisms of vitamin D receptor and estrogen receptor]. Zhonghua Kou Qiang Yi Xue Za Zhi. 2008 Apr;43(4):236-9. Chinese.
ESR2	CP	22	41	ns	None	Japanese	CC	N	Estrogen receptor 2 (ER beta)	Erb; ESRB; ESTRB; NR3A2; ER-BETA; ESR-BETA; ESR2	5	Multiple SNPs	15490304	Suzuki A, Ji G, Numabe Y, Ishii K, Muramatsu M, Kamoi K. Large-scale investigation of genomic markers for severe periodontitis. Odontology. 2004 Sep;92(1):43-7.
ETFA	CP	22	41	ns	None	Japanese	CC	N	Electron-transfer-flavoprotein, alpha polypeptide	EMA; GA2; MADD; ETFA	1	n/a	15490304	Suzuki A, Ji G, Numabe Y, Ishii K, Muramatsu M, Kamoi K. Large-scale investigation of genomic markers for severe periodontitis. Odontology. 2004 Sep;92(1):43-7.
F5	CP	22	41	ns	None	Japanese	CC	N	Coagulation factor V (proaccelerin, labile factor)	FVL; PCCF; F5	6	Multiple SNPs	15490304	Suzuki A, Ji G, Numabe Y, Ishii K, Muramatsu M, Kamoi K. Large-scale investigation of genomic markers for severe periodontitis. Odontology. 2004 Sep;92(1):43-7.
FABP2	CP	22	41	ns	None	Japanese	CC	N	Fatty acid binding protein 2, intestinal	FABPI; I-FABP; MGC133132; FABP2	1	n/a	15490304	Suzuki A, Ji G, Numabe Y, Ishii K, Muramatsu M, Kamoi K. Large-scale investigation of genomic markers for severe periodontitis. Odontology. 2004 Sep;92(1):43-7.
FABP7	CP	22	41	ns	None	Japanese	CC	N	Fatty acid binding protein 7, brain	MRG; BLBP; FABPB; B-FABP; DKFZp547J2313; FABP7	1	n/a	15490304	Suzuki A, Ji G, Numabe Y, Ishii K, Muramatsu M, Kamoi K. Large-scale investigation of genomic markers for severe periodontitis. Odontology. 2004 Sep;92(1):43-7.

FAS	CP	22	41	ns	None	Japanese	CC	N	Fas (TNF receptor superfamily, member 6)	APT1; CD95; FAS1; APO-1; FASTM; ALPS1A; TNFRSF6; FAS	3	Multiple SNPs	15490304	Suzuki A, Ji G, Numabe Y, Ishii K, Muramatsu M, Kamoi K. Large-scale investigation of genomic markers for severe periodontitis. Odontology. 2004 Sep;92(1):43-7.
FASLG	CP	137	219	ns	None	Caucasian	CC	GS	Fas ligand (TNF superfamily, member 6)	FASL; CD178; CD95L; TNFSF6; APT1LG1; FASLG	1	–844 C>T	16512757	Wohlfahrt JC, Wu T, Hodges JS, Hinrichs JE, Michalowicz BS. No association between selected candidate gene polymorphisms and severe chronic periodontitis. J Periodontol. 2006 Mar;77(3):426-36.
FASLG	CP	22	41	ns	None	Japanese	CC	N	Fas ligand (TNF superfamily, member 6)	FASL; CD178; CD95L; TNFSF6; APT1LG1; FASLG	3	Multiple SNPs	15490304	Suzuki A, Ji G, Numabe Y, Ishii K, Muramatsu M, Kamoi K. Large-scale investigation of genomic markers for severe periodontitis. Odontology. 2004 Sep;92(1):43-7.
FBP1	CP	22	41	ns	None	Japanese	CC	N	Fructose-1,6-bisphosphatase 1	FBP; FBP1	1	n/a	15490304	Suzuki A, Ji G, Numabe Y, Ishii K, Muramatsu M, Kamoi K. Large-scale investigation of genomic markers for severe periodontitis. Odontology. 2004 Sep;92(1):43-7.
FCAR	AgP	46	126	0.014	Weak	Japanese	CC	N	Fc fragment of IgA, receptor for	CD89; FCAR	1	nt 324 A/G	15140034	Kaneko S, Kobayashi T, Yamamoto K, Jansen MD, van de Winkel JG, Yoshie H. A novel polymorphism of FcalphaRI (CD89) associated with aggressive periodontitis. Tissue Antigens. 2004 Jun;63(6):572-7.
FCAR	AgP	46	126	0.014	Weak	Japanese	CC	N	Fc fragment of IgA, receptor for	CD89; FCAR	1	nt 324 A/G	15140034	Kaneko S, Kobayashi T, Yamamoto K, Jansen MD, van de Winkel JG, Yoshie H. A novel polymorphism of FcalphaRI (CD89) associated with aggressive periodontitis. Tissue Antigens. 2004 Jun;63(6):572-7.
FCAR	AgP	224	455	ns	None	Mixed	CC	EGS	Fc fragment of IgA, receptor for	CD89; FCAR	1	324 A-G	16899095	Nibali L, Parkar M, Brett P, Knight J, Tonetti MS, Griffiths GS. NADPH oxidase (CYBA) and FcgammaR polymorphisms as risk factors for aggressive periodontitis: a case-control association study. J Clin Periodontol. 2006 Aug;33(8):529-39.

Continued

TABLE 6-3 Association Study—cont'd

Gene Symbol	Disease Type	Cases	Total	Best *P* Value	Level of Support	Population	Study Design	Stratified or Covariate Adj	Gene Name	Gene Aliases	# SNPs Assayed	SNP Name	PubMed ID	Journal
FCAR	AgP+CP	319	622	ns	None	Japanese	CC	AGS	Fc fragment of IgA, receptor for	CD89; FCAR	2	n/a	19892918	Kobayashi T, Nagata T, Murakami S, Takashiba S, Kurihara H, Izumi Y, Numabe Y, Watanabe H, Kataoka M, Nagai A, Hayashi J, Ohyama H, Okamatsu Y, Inagaki Y, Tai H, Yoshie H. Genetic risk factors for periodontitis in a Japanese population. J Dent Res. 2009 Dec;88(12): 1137-41.
FCAR	CP	113	221	ns	None	Japanese	CC	N	Fc fragment of IgA, receptor for	CD89; FCAR	2	Multiple SNPs	18321309	Komatsu Y, Galicia JC, Kobayashi T, Yamazaki K, Yoshie H. Association of interleukin-1 receptor antagonist +2018 gene polymorphism with Japanese chronic periodontitis patients using a novel genotyping method. Int J Immunogenet. 2008 Apr;35(2):165-70.
FCAR.TGFB1	CP	113	221	ns	None	Japanese	CC	N	n/a	n/a	3	Multiple Genes	18321309	Komatsu Y, Galicia JC, Kobayashi T, Yamazaki K, Yoshie H. Association of interleukin-1 receptor antagonist +2018 gene polymorphism with Japanese chronic periodontitis patients using a novel genotyping method. Int J Immunogenet. 2008 Apr;35(2):165-70.
FCGR2A	AgP	12	73	0.013	Weak	Caucasian	CC	S	Fc fragment of IgG, low affinity IIa, receptor (CD32)	CD32; FCG2; FcGR; CD32A; CDw32; FCGR2; IGFR2; FCGR2A1; MGC23887; MGC30032; FCGR2A	1	+131	12834496	Loos BG, Leppers-Van de Straat FG, Van de Winkel JG, Van der Velden U. Fcgamma receptor polymorphisms in relation to periodontitis. J Clin Periodontol. 2003 Jul;30(7):595-602.
FCGR2A	AgP	20	72	ns	None	Polish	CC	N	Fc fragment of IgG, low affinity IIa, receptor (CD32)	CD32; FCG2; FcGR; CD32A; CDw32; FCGR2; IGFR2; FCGR2A1; MGC23887; MGC30032; FCGR2A	1	CD32	19127818	Drozdzik A. [The effect of environmental and genetic factors in the pathogenesis of periodontitis]. Ann Acad Med Stetin. 2008;54(1):118-26. Polish.

FCGR2A	AgP	224	455	ns	None	Mixed	CC	EGS	Fc fragment of IgG, low affinity IIa, receptor (CD32)	CD32; FCG2; FcGR; CD32A; CDw32; FCGR2; IGFR2; FCGR2A1; MGC23887; MGC30032; FCGR2A	1	494 A/G	16899095	Nibali L, Parkar M, Brett P, Knight J, Tonetti MS, Griffiths GS. NADPH oxidase (CYBA) and FcgammaR polymorphisms as risk factors for aggressive periodontitis: a case-control association study. J Clin Periodontol. 2006 Aug;33(8):529-39.
FCGR2A	AgP	31	80	ns	None	Brazilian	CC	EG	Fc fragment of IgG, low affinity IIa, receptor (CD32)	CD32; FCG2; FcGR; CD32A; CDw32; FCGR2; IGFR2; FCGR2A1; MGC23887; MGC30032; FCGR2A	1	+131	16805673	de Souza RC, Colombo AP. Distribution of FcgammaRIIa and FcgammaRIIIb genotypes in patients with generalized aggressive periodontitis. J Periodontol. 2006 Jul;77(7):1120-8.
FCGR2A	AgP	32	104	ns	None	Japanese	CC	N	Fc fragment of IgG, low affinity IIa, receptor (CD32)	CD32; FCG2; FcGR; CD32A; CDw32; FCGR2; IGFR2; FCGR2A1; MGC23887; MGC30032; FCGR2A	1	n/a	14647193	Yasuda K, Sugita N, Kobayashi T, Yamamoto K, Yoshie H. FcgammaRIIB gene polymorphisms in Japanese periodontitis patients. Genes Immun. 2003 Dec;4(8):541-6.
FCGR2A	AgP	33	60	ns	None	Chinese	CC	N	Fc fragment of IgG, low affinity IIa, receptor (CD32)	CD32; FCG2; FcGR; CD32A; CDw32; FCGR2; IGFR2; FCGR2A1; MGC23887; MGC30032; FCGR2A	1	n/a	11776881	Fu Y, Cao C, Wang S. [Relevance of Fc gamma R polymorphism to the susceptibility of early-onset periodontitis]. Zhonghua Kou Qiang Yi Xue Za Zhi. 1999 Nov;34(6):364-6. Chinese.
FCGR2A	AgP	38	142	ns	None	Japanese	CC	N	Fc fragment of IgG, low affinity IIa, receptor (CD32)	CD32; FCG2; FcGR; CD32A; CDw32; FCGR2; IGFR2; FCGR2A1; MGC23887; MGC30032; FCGR2A	1	+131	11022771	Kobayashi T, Sugita N, van der Pol WL, Nunokawa Y, Westerdaal NA, Yamamoto K, van de Winkel JG, Yoshie H. The Fcgamma receptor genotype as a risk factor for generalized early-onset periodontitis in Japanese patients. J Periodontol. 2000 Sep;71(9):1425-32.
FCGR2A	AgP	48	115	ns	None	African American	CC	N	Fc fragment of IgG, low affinity IIa, receptor (CD32)	CD32; FCG2; FcGR; CD32A; CDw32; FCGR2; IGFR2; FCGR2A1; MGC23887; MGC30032; FCGR2A	n/a	131H/R	12027254	Fu Y, Korostoff JM, Fine DH, Wilson ME. Fc gamma receptor genes as risk markers for localized aggressive periodontitis in African-Americans. J Periodontol. 2002 May;73(5):517-23.

Continued

TABLE 6-3 Association Study—cont'd

Gene Symbol	Disease Type	Cases	Total	Best *P* Value	Level of Support	Population	Study Design	Stratified or Covariate Adj	Gene Name	Gene Aliases	# SNPs Assayed	SNP Name	PubMed ID	Journal
FCGR2A	AgP+CP	319	622	ns	None	Japanese	CC	AGS	Fc fragment of IgG, low affinity IIa, receptor (CD32)	CD32; FCG2; FcGR; CD32A; CDw32; FCGR2; IGFR2; FCGR2A1; MGC23887; MGC30032; FCGR2A	1	R131/H131	19892918	Kobayashi T, Nagata T, Murakami S, Takashiba S, Kurihara H, Izumi Y, Numabe Y, Watanabe H, Kataoka M, Nagai A, Hayashi J, Ohyama H, Okamatsu Y, Inagaki Y, Tai H, Yoshie H. Genetic risk factors for periodontitis in a Japanese population. J Dent Res. 2009 Dec;88(12): 1137-41.
FCGR2A	CP	213	422	0.03	Weak	Caucasian	CC	AGS	Fc fragment of IgG, low affinity IIa, receptor (CD32)	CD32; FCG2; FcGR; CD32A; CDw32; FCGR2; IGFR2; FCGR2A1; MGC23887; MGC30032; FCGR2A	1	+131	15152814	Yamamoto K, Kobayashi T, Grossi S, Ho AW, Genco RJ, Yoshie H, De Nardin E. Association of Fcgamma receptor IIa genotype with chronic periodontitis in Caucasians. J Periodontol. 2004 Apr;75(4):517-22.
FCGR2A	CP	166	246	<0.0125	Weak	Chinese	CC	N	Fc fragment of IgG, low affinity IIa, receptor (CD32)	CD32; FCG2; FcGR; CD32A; CDw32; FCGR2; IGFR2; FCGR2A1; MGC23887; MGC30032; FCGR2A	1	+131	15190804	Tang Y, Zhang JC, Zhang WH, Pang RY. [The association between Fc gamma receptor IIA gene polymorphism and susceptibility to chronic periodontitis in Chinese Han nationality]. Hua Xi Kou Qiang Yi Xue Za Zhi. 2004 Apr;22(2):158-61. Chinese.
FCGR2A	CP	132	205	<0.05	Weak	Caucasian	CC	N	Fc fragment of IgG, low affinity IIa, receptor (CD32)	CD32; FCG2; FcGR; CD32A; CDw32; FCGR2; IGFR2; FCGR2A1; MGC23887; MGC30032; FCGR2A	1	+131	16889631	Wolf DL, Neiderud AM, Hinckley K, Dahlén G, van de Winkel JG, Papapanou PN. Fcgamma receptor polymorphisms and periodontal status: a prospective follow-up study. J Clin Periodontol. 2006 Oct;33(10):691-8. Epub 2006 Aug 3.
FCGR2A	CP	32	84	ns	None	Polish	CC	N	Fc fragment of IgG, low affinity IIa, receptor (CD32)	CD32; FCG2; FcGR; CD32A; CDw32; FCGR2; IGFR2; FCGR2A1; MGC23887; MGC30032; FCGR2A	1	CD32	19127818	Drozdzik A. [The effect of environmental and genetic factors in the pathogenesis of periodontitis]. Ann Acad Med Stetin. 2008;54(1):118-26. Polish.

FCGR2A	CP	113	221	ns	None	Japanese	CC	N	Fc fragment of IgG, low affinity IIa, receptor (CD32)	CD32; FCG2; FcGR; CD32A; CDw32; FCGR2; IGFR2; FCGR2A1; MGC23887; MGC30032; FCGR2A	1	+131	18321309	Komatsu Y, Galicia JC, Kobayashi T, Yamazaki K, Yoshie H. Association of interleukin-1 receptor antagonist +2018 gene polymorphism with Japanese chronic periodontitis patients using a novel genotyping method. Int J Immunogenet. 2008 Apr;35(2):165-70.
FCGR2A	CP	100	200	ns	None	Japanese	CC	N	Fc fragment of IgG, low affinity IIa, receptor (CD32)	CD32; FCG2; FcGR; CD32A; CDw32; FCGR2; IGFR2; FCGR2A1; MGC23887; MGC30032; FCGR2A	1	nt 559 G/T	18052703	Kobayashi T, Ito S, Kuroda T, Yamamoto K, Sugita N, Narita I, Sumida T, Gejyo F, Yoshie H. The interleukin-1 and Fcgamma receptor gene polymorphisms in Japanese patients with rheumatoid arthritis and periodontitis. J Periodontol. 2007 Dec;78(12):2311-8.
FCGR2A	CP	50	124	ns	None	Taiwanese	CC	N	Fc fragment of IgG, low affinity IIa, receptor (CD32)	CD32; FCG2; FcGR; CD32A; CDw32; FCGR2; IGFR2; FCGR2A1; MGC23887; MGC30032; FCGR2A	1	+131	14761117	Chung HY, Lu HC, Chen WL, Lu CT, Yang YH, Tsai CC. Gm (23) allotypes and Fcgamma receptor genotypes as risk factors for various forms of periodontitis. J Clin Periodontol. 2003 Nov;30(11):954-60.
FCGR2A	CP	72	144	ns	None	Japanese	CC	N	Fc fragment of IgG, low affinity IIa, receptor (CD32)	CD32; FCG2; FcGR; CD32A; CDw32; FCGR2; IGFR2; FCGR2A1; MGC23887; MGC30032; FCGR2A	1	n/a	14647193	Yasuda K, Sugita N, Kobayashi T, Yamamoto K, Yoshie H. FcgammaRIIB gene polymorphisms in Japanese periodontitis patients. Genes Immun. 2003 Dec;4(8):541-6.
FCGR2A	CP	56	117	ns	None	Caucasian	CC	S	Fc fragment of IgG, low affinity IIa, receptor (CD32)	CD32; FCG2; FcGR; CD32A; CDw32; FCGR2; IGFR2; FCGR2A1; MGC23887; MGC30032; FCGR2A	1	+131	12834496	Loos BG, Leppers-Van de Straat FG, Van de Winkel JG, Van der Velden U. Fcgamma receptor polymorphisms in relation to periodontitis. J Clin Periodontol. 2003 Jul;30(7):595-602.
FCGR2A	CP	89	153	ns	None	Japanese	CC	S	Fc fragment of IgG, low affinity IIa, receptor (CD32)	CD32; FCG2; FcGR; CD32A; CDw32; FCGR2; IGFR2; FCGR2A1; MGC23887; MGC30032; FCGR2A	1	+131	11699473	Kobayashi T, Yamamoto K, Sugita N, van der Pol WL, Yasuda K, Kaneko S, van de Winkel JG, Yoshie H. The Fc gamma receptor genotype as a severity factor for chronic periodontitis in Japanese patients. J Periodontol. 2001 Oct;72(10):1324-31.

Continued

TABLE 6-3 Association Study—cont'd

Gene Symbol	Disease Type	Cases	Total	Best *P* Value	Level of Support	Population	Study Design	Stratified or Covariate Adj	Gene Name	Gene Aliases	# SNPs Assayed	SNP Name	PubMed ID	Journal
FCGR2A	CP	49	98	ns	None	German	CC	AS	Fc fragment of IgG, low affinity IIa, receptor (CD32)	CD32; FCG2; FcGR; CD32A; CDw32; FCGR2; IGFR2; FCGR2A1; MGC23887; MGC30032; FCGR2A	1	+131	11528518	Meisel P, Carlsson LE, Sawaf H, Fanghaenel J, Greinacher A, Kocher T. Polymorphisms of Fc gamma-receptors RIIa, RIIIa, and RIIIb in patients with adult periodontal diseases. Genes Immun. 2001 Aug;2(5):258-62.
FCGR2A	CP	83	187	ns	None	Japanese	CC	N	Fc fragment of IgG, low affinity IIa, receptor (CD32)	CD32; FCG2; FcGR; CD32A; CDw32; FCGR2; IGFR2; FCGR2A1; MGC23887; MGC30032; FCGR2A	1	+131	11022771	Kobayashi T, Sugita N, van der Pol WL, Nunokawa Y, Westerdaal NA, Yamamoto K, van de Winkel JG, Yoshie H. The Fcgamma receptor genotype as a risk factor for generalized early-onset periodontitis in Japanese patients. J Periodontol. 2000 Sep;71(9):1425-32.
FCGR2A	CP	100	205	ns	None	Japanese	CC	N	Fc fragment of IgG, low affinity IIa, receptor (CD32)	CD32; FCG2; FcGR; CD32A; CDw32; FCGR2; IGFR2; FCGR2A1; MGC23887; MGC30032; FCGR2A	1	+131	9284119	Kobayashi T, Westerdaal NA, Miyazaki A, van der Pol WL, Suzuki T, Yoshie H, van de Winkel JG, Hara K. Relevance of immunoglobulin G Fc receptor polymorphism to recurrence of adult periodontitis in Japanese patients. Infect Immun. 1997 Sep;65(9):3556-60.
FCGR2A	CP	86	113	ns	None	n/a	CC	S	Fc fragment of IgG, low affinity IIa, receptor (CD32)	CD32; FCG2; FcGR; CD32A; CDw32; FCGR2; IGFR2; FCGR2A1; MGC23887; MGC30032; FCGR2A	1	R131H	9667480	Colombo AP, Eftimiadi C, Haffajee AD, Cugini MA, Socransky SS. Serum IgG2 level, Gm(23) allotype and FcgammaRIIa and FcgammaRIIIb receptors in refractory periodontal disease. J Clin Periodontol. 1998 Jun;25(6):465-74.

FCGR2A	CP&RA	86	186	ns	None	Japanese	CC	N	Fc fragment of IgG, low affinity IIa, receptor (CD32)	CD32; FCG2; FcGR; CD32A; CDw32; FCGR2; IGFR2; FCGR2A1; MGC23887; MGC30032; FCGR2A	1	nt 559 G/T	18052703	Kobayashi T, Ito S, Kuroda T, Yamamoto K, Sugita N, Narita I, Sumida T, Gejyo F, Yoshie H. The interleukin-1 and Fcgamma receptor gene polymorphisms in Japanese patients with rheumatoid arthritis and periodontitis. J Periodontol. 2007 Dec;78(12):2311-8.
FCGR2A	CP&SLE	42	84	0.0013	Weak	Japanese	CC	N	Fc fragment of IgG, low affinity IIa, receptor (CD32)	CD32; FCG2; FcGR; CD32A; CDw32; FCGR2; IGFR2; FCGR2A1; MGC23887; MGC30032; FCGR2A	1	+131	12710759	Kobayashi T, Ito S, Yamamoto K, Hasegawa H, Sugita N, Kuroda T, Kaneko S, Narita I, Yasuda K, Nakano M, Gejyo F, Yoshie H. Risk of periodontitis in systemic lupus erythematosus is associated with Fcgamma receptor polymorphisms. J Periodontol. 2003 Mar;74(3):378-84.
FCGR2A	CP&SLE	42	60	0.011	Weak	Japanese	CC	N	Fc fragment of IgG, low affinity IIa, receptor (CD32)	CD32; FCG2; FcGR; CD32A; CDw32; FCGR2; IGFR2; FCGR2A1; MGC23887; MGC30032; FCGR2A	1	+131	12710759	Kobayashi T, Ito S, Yamamoto K, Hasegawa H, Sugita N, Kuroda T, Kaneko S, Narita I, Yasuda K, Nakano M, Gejyo F, Yoshie H. Risk of periodontitis in systemic lupus erythematosus is associated with Fcgamma receptor polymorphisms. J Periodontol. 2003 Mar;74(3):378-84.
FCGR2A. FCGR3A	CP	100	200	ns	None	Japanese	CC	N	n/a	n/a	2	Multiple Genes	18052703	Kobayashi T, Ito S, Kuroda T, Yamamoto K, Sugita N, Narita I, Sumida T, Gejyo F, Yoshie H. The interleukin-1 and Fcgamma receptor gene polymorphisms in Japanese patients with rheumatoid arthritis and periodontitis. J Periodontol. 2007 Dec;78(12):2311-8.
FCGR2A. FCGR3A	CP&RA	86	186	ns	None	Japanese	CC	N	n/a	n/a	2	Multiple Genes	18052703	Kobayashi T, Ito S, Kuroda T, Yamamoto K, Sugita N, Narita I, Sumida T, Gejyo F, Yoshie H. The interleukin-1 and Fcgamma receptor gene polymorphisms in Japanese patients with rheumatoid arthritis and periodontitis. J Periodontol. 2007 Dec;78(12):2311-8.

Continued

TABLE 6-3 Association Study—cont'd

Gene Symbol	Disease Type	Cases	Total	Best *P* Value	Level of Support	Population	Study Design	Stratified or Covariate Adj	Gene Name	Gene Aliases	# SNPs Assayed	SNP Name	PubMed ID	Journal
FCGR2A. FCGR3B	AgP	38	142	0.04	Weak	Japanese	CC	N	n/a	n/a	2	Multiple Genes	11022771	Kobayashi T, Sugita N, van der Pol WL, Nunokawa Y, Westerdaal NA, Yamamoto K, van de Winkel JG, Yoshie H. The Fcgamma receptor genotype as a risk factor for generalized early-onset periodontitis in Japanese patients. J Periodontol. 2000 Sep;71(9):1425-32.
FCGR2A. FCGR3B	AgP	31	80	<0.001	Weak	Brazilian	CC	EG	n/a	n/a	2	Multiple Genes	16805673	de Souza RC, Colombo AP. Distribution of FcgammaRIIa and FcgammaRIIIb genotypes in patients with generalized aggressive periodontitis. J Periodontol. 2006 Jul;77(7):1120-8.
FCGR2A. FCGR3B	CP	100	200	ns	None	Japanese	CC	N	n/a	n/a	2	Multiple Genes	18052703	Kobayashi T, Ito S, Kuroda T, Yamamoto K, Sugita N, Narita I, Sumida T, Gejyo F, Yoshie H. The interleukin-1 and Fcgamma receptor gene polymorphisms in Japanese patients with rheumatoid arthritis and periodontitis. J Periodontol. 2007 Dec;78(12):2311-8.
FCGR2A. FCGR3B	CP	83	187	ns	None	Japanese	CC	N	n/a	n/a	2	Multiple Genes	11022771	Kobayashi T, Sugita N, van der Pol WL, Nunokawa Y, Westerdaal NA, Yamamoto K, van de Winkel JG, Yoshie H. The Fcgamma receptor genotype as a risk factor for generalized early-onset periodontitis in Japanese patients. J Periodontol. 2000 Sep;71(9):1425-32.
FCGR2A. FCGR3B	CP&RA	86	186	ns	None	Japanese	CC	N	n/a	n/a	2	Multiple Genes	18052703	Kobayashi T, Ito S, Kuroda T, Yamamoto K, Sugita N, Narita I, Sumida T, Gejyo F, Yoshie H. The interleukin-1 and Fcgamma receptor gene polymorphisms in Japanese patients with rheumatoid arthritis and periodontitis. J Periodontol. 2007 Dec;78(12):2311-8.

FCGR2A. FCGR3B. FCGR2B	CP	113	221	ns	None	Japanese	CC	N	n/a	n/a	3	Multiple Genes	18321309	Komatsu Y, Galicia JC, Kobayashi T, Yamazaki K, Yoshie H. Association of interleukin-1 receptor antagonist +2018 gene polymorphism with Japanese chronic periodontitis patients using a novel genotyping method. Int J Immunogenet. 2008 Apr;35(2):165-70.
FCGR2B	AgP	32	104	0.002	Weak	Japanese	CC	N	Fc fragment of IgG, low affinity IIb, receptor (CD32)	CD32; FCG2; CD32B; FCGR2; IGFR2; FCGR2B	11	nt 695 (T-C)	14647193	Yasuda K, Sugita N, Kobayashi T, Yamamoto K, Yoshie H. FcgammaRIIB gene polymorphisms in Japanese periodontitis patients. Genes Immun. 2003 Dec;4(8):541-6.
FCGR2B	AgP	224	455	ns	None	Mixed	CC	EGS	Fc fragment of IgG, low affinity IIb, receptor (CD32)	CD32; FCG2; CD32B; FCGR2; IGFR2; FCGR2B	1	695 T-C	16899095	Nibali L, Parkar M, Brett P, Knight J, Tonetti MS, Griffiths GS. NADPH oxidase (CYBA) and FcgammaR polymorphisms as risk factors for aggressive periodontitis: a case-control association study. J Clin Periodontol. 2006 Aug;33(8):529-39.
FCGR2B	AgP+CP	319	622	ns	None	Japanese	CC	AGS	Fc fragment of IgG, low affinity IIb, receptor (CD32)	CD32; FCG2; CD32B; FCGR2; IGFR2; FCGR2B	2	n/a	19892918	Kobayashi T, Nagata T, Murakami S, Takashiba S, Kurihara H, Izumi Y, Numabe Y, Watanabe H, Kataoka M, Nagai A, Hayashi J, Ohyama H, Okamatsu Y, Inagaki Y, Tai H, Yoshie H. Genetic risk factors for periodontitis in a Japanese population. J Dent Res. 2009 Dec;88(12): 1137-41.
FCGR2B	CP	72	144	0.011	Weak	Japanese	CC	N	Fc fragment of IgG, low affinity IIb, receptor (CD32)	CD32; FCG2; CD32B; FCGR2; IGFR2; FCGR2B	11	nt 646 184 (A-G)	14647193	Yasuda K, Sugita N, Kobayashi T, Yamamoto K, Yoshie H. FcgammaRIIB gene polymorphisms in Japanese periodontitis patients. Genes Immun. 2003 Dec;4(8):541-6.
FCGR2B	CP	113	221	ns	None	Japanese	CC	N	Fc fragment of IgG, low affinity IIb, receptor (CD32)	CD32; FCG2; CD32B; FCGR2; IGFR2; FCGR2B	1	–232	18321309	Komatsu Y, Galicia JC, Kobayashi T, Yamazaki K, Yoshie H. Association of interleukin-1 receptor antagonist +2018 gene polymorphism with Japanese chronic periodontitis patients using a novel genotyping method. Int J Immunogenet. 2008 Apr;35(2):165-70.

Continued

TABLE 6-3 Association Study—cont'd

Gene Symbol	Disease Type	Cases	Total	Best *P* Value	Level of Support	Population	Study Design	Stratified or Covariate Adj	Gene Name	Gene Aliases	# SNPs Assayed	SNP Name	PubMed ID	Journal
FCGR3A	AgP	12	73	0.044	Weak	Caucasian	CC	S	Fc fragment of IgG, low affinity IIIa, receptor (CD16a)	CD16; FCG3; CD16A; FCGR3; IGFR3; FCR-10; FCRIII; FCGRIII; FCRIIIA; FCGR3A	1	–158V/F	12834496	Loos BG, Leppers-Van de Straat FG, Van de Winkel JG, Van der Velden U. Fcgamma receptor polymorphisms in relation to periodontitis. J Clin Periodontol. 2003 Jul;30(7):595-602.
FCGR3A	AgP	30	77	ns	None	Chinese	CC	N	Fc fragment of IgG, low affinity IIIa, receptor (CD16a)	CD16; FCG3; CD16A; FCGR3; IGFR3; FCR-10; FCRIII; FCGRIII; FCRIIIA; FCGR3A	1	–158V/F	19221562	An N, Ou-Yang XY, Cao CF, Ye J, Hui RT. [Association of Fc gamma receptors IIIA gene polymorphisms with the susceptibility to periodontitis in Chinese patients]. Beijing Da Xue Xue Bao. 2009 Feb 18;41(1):40-3. Chinese.
FCGR3A	AgP	9	41	ns	None	Japanese	CC	N	Fc fragment of IgG, low affinity IIIa, receptor (CD16a)	CD16; FCG3; CD16A; FCGR3; IGFR3; FCR-10; FCRIII; FCGRIII; FCRIIIA; FCGR3A	1	H/R131	19184295	Shimomura-Kuroki J, Yamashita K, Shimooka S. Tannerella forsythia and the HLA-DQB1 allele are associated with susceptibility to periodontal disease in Japanese adolescents. Odontology. 2009 Jan;97(1):32-7. Epub 2009 Jan 29.
FCGR3A	AgP	224	455	ns	None	Mixed	CC	EGS	Fc fragment of IgG, low affinity IIIa, receptor (CD16a)	CD16; FCG3; CD16A; FCGR3; IGFR3; FCR-10; FCRIII; FCGRIII; FCRIIIA; FCGR3A	1	559 G/T	16899095	Nibali L, Parkar M, Brett P, Knight J, Tonetti MS, Griffiths GS. NADPH oxidase (CYBA) and FcgammaR polymorphisms as risk factors for aggressive periodontitis: a case-control association study. J Clin Periodontol. 2006 Aug;33(8):529-39.
FCGR3A	AgP	32	104	ns	None	Japanese	CC	N	Fc fragment of IgG, low affinity IIIa, receptor (CD16a)	CD16; FCG3; CD16A; FCGR3; IGFR3; FCR-10; FCRIII; FCGRIII; FCRIIIA; FCGR3A	1	n/a	14647193	Yasuda K, Sugita N, Kobayashi T, Yamamoto K, Yoshie H. FcgammaRIIB gene polymorphisms in Japanese periodontitis patients. Genes Immun. 2003 Dec;4(8):541-6.

FCGR3A	AgP	38	142	ns	None	Japanese	CC	N	Fc fragment of IgG, low affinity IIIa, receptor (CD16a)	CD16; FCG3; CD16A; FCGR3; IGFR3; FCR-10; FCRIII; FCGRIII; FCRIIIA; FCGR3A	1	–158V/F	11022771	Kobayashi T, Sugita N, van der Pol WL, Nunokawa Y, Westerdaal NA, Yamamoto K, van de Winkel JG, Yoshie H. The Fcgamma receptor genotype as a risk factor for generalized early-onset periodontitis in Japanese patients. J Periodontol. 2000 Sep;71(9):1425-32.
FCGR3A	AgP	48	115	ns	None	African American	CC	N	Fc fragment of IgG, low affinity IIIa, receptor (CD16a)	CD16; FCG3; CD16A; FCGR3; IGFR3; FCR-10; FCRIII; FCGRIII; FCRIIIA; FCGR3A	n/a	158V/F	12027254	Fu Y, Korostoff JM, Fine DH, Wilson ME. Fc gamma receptor genes as risk markers for localized aggressive periodontitis in African-Americans. J Periodontol. 2002 May;73(5):517-23.
FCGR3A	AgP+CP	319	622	ns	None	Japanese	CC	AGS	Fc fragment of IgG, low affinity IIIa, receptor (CD16a)	CD16; FCG3; CD16A; FCGR3; IGFR3; FCR-10; FCRIII; FCGRIII; FCRIIIA; FCGR3A	1	559	19892918	Kobayashi T, Nagata T, Murakami S, Takashiba S, Kurihara H, Izumi Y, Numabe Y, Watanabe H, Kataoka M, Nagai A, Hayashi J, Ohyama H, Okamatsu Y, Inagaki Y, Tai H, Yoshie H. Genetic risk factors for periodontitis in a Japanese population. J Dent Res. 2009 Dec;88(12): 1137-41.
FCGR3A	CP	100	204	0.009	Weak	Japanese	CC	N	Fc fragment of IgG, low affinity IIIa, receptor (CD16a)	CD16; FCG3; CD16A; FCGR3; IGFR3; FCR-10; FCRIII; FCGRIII; FCRIIIA; FCGR3A	1	–158V/F	10444269	Sugita N, Yamamoto K, Kobayashi T, Van Der Pol W, Horigome T, Yoshie H, Van De Winkel JG, Hara K. Relevance of Fc gamma RIIIa-158V-F polymorphism to recurrence of adult periodontitis in Japanese patients. Clin Exp Immunol. 1999 Aug;117(2):350-4.
FCGR3A	CP	49	98	0.01	Weak	German	CC	AS	Fc fragment of IgG, low affinity IIIa, receptor (CD16a)	CD16; FCG3; CD16A; FCGR3; IGFR3; FCR-10; FCRIII; FCGRIII; FCRIIIA; FCGR3A	1	–158V/F	11528518	Meisel P, Carlsson LE, Sawaf H, Fanghaenel J, Greinacher A, Kocher T. Polymorphisms of Fc gamma-receptors RIIa, RIIIa, and RIIIb in patients with adult periodontal diseases. Genes Immun. 2001 Aug;2(5):258-62.

Continued

TABLE 6-3 Association Study—cont'd

Gene Symbol	Disease Type	Cases	Total	Best *P* Value	Level of Support	Population	Study Design	Stratified or Covariate Adj	Gene Name	Gene Aliases	# SNPs Assayed	SNP Name	PubMed ID	Journal
FCGR3A	CP	89	153	0.028	Weak	Japanese	CC	S	Fc fragment of IgG, low affinity IIIa, receptor (CD16a)	CD16; FCG3; CD16A; FCGR3; IGFR3; FCR-10; FCRIII; FCGRIII; FCRIIIA; FCGR3A	1	–158V/F	11699473	Kobayashi T, Yamamoto K, Sugita N, van der Pol WL, Yasuda K, Kaneko S, van de Winkel JG, Yoshie H. The Fc gamma receptor genotype as a severity factor for chronic periodontitis in Japanese patients. J Periodontol. 2001 Oct;72(10):1324-31.
FCGR3A	CP	131	178	ns	None	Chinese	CC	N	Fc fragment of IgG, low affinity IIIa, receptor (CD16a)	CD16; FCG3; CD16A; FCGR3; IGFR3; FCR-10; FCRIII; FCGRIII; FCRIIIA; FCGR3A	1	–158V/F	19221562	An N, Ou-Yang XY, Cao CF, Ye J, Hui RT. [Association of Fc gamma receptors IIIA gene polymorphisms with the susceptibility to periodontitis in Chinese patients]. Beijing Da Xue Xue Bao. 2009 Feb 18;41(1):40-3. Chinese.
FCGR3A	CP	100	200	ns	None	Japanese	CC	N	Fc fragment of IgG, low affinity IIIa, receptor (CD16a)	CD16; FCG3; CD16A; FCGR3; IGFR3; FCR-10; FCRIII; FCGRIII; FCRIIIA; FCGR3A	1	559 G/T	18052703	Kobayashi T, Ito S, Kuroda T, Yamamoto K, Sugita N, Narita I, Sumida T, Gejyo F, Yoshie H. The interleukin-1 and Fcgamma receptor gene polymorphisms in Japanese patients with rheumatoid arthritis and periodontitis. J Periodontol. 2007 Dec;78(12):2311-8.
FCGR3A	CP	72	144	ns	None	Japanese	CC	N	Fc fragment of IgG, low affinity IIIa, receptor (CD16a)	CD16; FCG3; CD16A; FCGR3; IGFR3; FCR-10; FCRIII; FCGRIII; FCRIIIA; FCGR3A	1	n/a	14647193	Yasuda K, Sugita N, Kobayashi T, Yamamoto K, Yoshie H. FcgammaRIIB gene polymorphisms in Japanese periodontitis patients. Genes Immun. 2003 Dec;4(8):541-6.
FCGR3A	CP	56	117	ns	None	Caucasian	CC	S	Fc fragment of IgG, low affinity IIIa, receptor (CD16a)	CD16; FCG3; CD16A; FCGR3; IGFR3; FCR-10; FCRIII; FCGRIII; FCRIIIA; FCGR3A	1	–158V/F	12834496	Loos BG, Leppers-Van de Straat FG, Van de Winkel JG, Van der Velden U. Fcgamma receptor polymorphisms in relation to periodontitis. J Clin Periodontol. 2003 Jul;30(7):595-602.

FCGR3A	CP	117	558	ns	None	German	CC	S	Fc fragment of IgG, low affinity IIIa, receptor (CD16a)	CD16; FCG3; CD16A; FCGR3; IGFR3; FCR-10; FCRIII; FCGRIII; FCRIIIA; FCGR3A	1	–158V/F	19570260	Meisel P, Heins G, Carlsson L, Giebel J, John U, Schwahn C, Kocher T. Impact of Genetic Polymorphisms on the Smoking-related Risk of Periodontal Disease: the Population-based Study SHIP. Tob Induc Dis. 2003 Sep 15;1(3):197.
FCGR3A	CP	83	187	ns	None	Japanese	CC	N	Fc fragment of IgG, low affinity IIIa, receptor (CD16a)	CD16; FCG3; CD16A; FCGR3; IGFR3; FCR-10; FCRIII; FCGRIII; FCRIIIA; FCGR3A	1	–158V/F	11022771	Kobayashi T, Sugita N, van der Pol WL, Nunokawa Y, Westerdaal NA, Yamamoto K, van de Winkel JG, Yoshie H. The Fcgamma receptor genotype as a risk factor for generalized early-onset periodontitis in Japanese patients. J Periodontol. 2000 Sep;71(9):1425-32.
FCGR3A	CP&RA	86	186	ns	None	Japanese	CC	N	Fc fragment of IgG, low affinity IIIa, receptor (CD16a)	CD16; FCG3; CD16A; FCGR3; IGFR3; FCR-10; FCRIII; FCGRIII; FCRIIIA; FCGR3A	1	559 G/T	18052703	Kobayashi T, Ito S, Kuroda T, Yamamoto K, Sugita N, Narita I, Sumida T, Gejyo F, Yoshie H. The interleukin-1 and Fcgamma receptor gene polymorphisms in Japanese patients with rheumatoid arthritis and periodontitis. J Periodontol. 2007 Dec;78(12):2311-8.
FCGR3A	CP&SLE	42	84	ns	None	Japanese	CC	N	Fc fragment of IgG, low affinity IIIa, receptor (CD16a)	CD16; FCG3; CD16A; FCGR3; IGFR3; FCR-10; FCRIII; FCGRIII; FCRIIIA; FCGR3A	1	–158V/F	12710759	Kobayashi T, Ito S, Yamamoto K, Hasegawa H, Sugita N, Kuroda T, Kaneko S, Narita I, Yasuda K, Nakano M, Gejyo F, Yoshie H. Risk of periodontitis in systemic lupus erythematosus is associated with Fcgamma receptor polymorphisms. J Periodontol. 2003 Mar;74(3):378-84.
FCGR3A	CP&SLE	42	60	ns	None	Japanese	CC	N	Fc fragment of IgG, low affinity IIIa, receptor (CD16a)	CD16; FCG3; CD16A; FCGR3; IGFR3; FCR-10; FCRIII; FCGRIII; FCRIIIA; FCGR3A	1	–158V/F	12710759	Kobayashi T, Ito S, Yamamoto K, Hasegawa H, Sugita N, Kuroda T, Kaneko S, Narita I, Yasuda K, Nakano M, Gejyo F, Yoshie H. Risk of periodontitis in systemic lupus erythematosus is associated with Fcgamma receptor polymorphisms. J Periodontol. 2003 Mar;74(3):378-84.

Continued

TABLE 6-3 Association Study—cont'd

Gene Symbol	Disease Type	Cases	Total	Best *P* Value	Level of Support	Population	Study Design	Stratified or Covariate Adj	Gene Name	Gene Aliases	# SNPs Assayed	SNP Name	PubMed ID	Journal
FCGR3A. FCGR3B	CP	89	153	0.0009	Moderate	Japanese	CC	S	n/a	n/a	2	Multiple Genes	11699473	Kobayashi T, Yamamoto K, Sugita N, van der Pol WL, Yasuda K, Kaneko S, van de Winkel JG, Yoshie H. The Fc gamma receptor genotype as a severity factor for chronic periodontitis in Japanese patients. J Periodontol. 2001 Oct;72(10):1324-31.
FCGR3A. FCGR3B	CP	100	200	ns	None	Japanese	CC	N	n/a	n/a	2	Multiple Genes	18052703	Kobayashi T, Ito S, Kuroda T, Yamamoto K, Sugita N, Narita I, Sumida T, Gejyo F, Yoshie H. The interleukin-1 and Fcgamma receptor gene polymorphisms in Japanese patients with rheumatoid arthritis and periodontitis. J Periodontol. 2007 Dec;78(12):2311-8.
FCGR3A. FCGR3B	CP&RA	86	186	ns	None	Japanese	CC	N	n/a	n/a	2	Multiple Genes	18052703	Kobayashi T, Ito S, Kuroda T, Yamamoto K, Sugita N, Narita I, Sumida T, Gejyo F, Yoshie H. The interleukin-1 and Fcgamma receptor gene polymorphisms in Japanese patients with rheumatoid arthritis and periodontitis. J Periodontol. 2007 Dec;78(12):2311-8.
FCGR3B	AgP	42	97	0.006	Weak	Japanese	CC	N	Fc fragment of IgG, low affinity IIIb, receptor (CD16b)	CD16; FCG3; CD16b; FCGR3; FCGR3B	1	NA1/NA2	11808760	Yoshihara A, Sugita N, Yamamoto K, Kobayashi T, Miyazaki H, Yoshi H. Analysis of vitamin D and Fcgamma receptor polymorphisms in Japanese patients with generalized early-onset periodontitis. J Dent Res. 2001 Dec;80(12):2051-4.
FCGR3B	AgP	32	104	0.016	Weak	Japanese	CC	N	Fc fragment of IgG, low affinity IIIb, receptor (CD16b)	CD16; FCG3; CD16b; FCGR3; FCGR3B	1	NA1/NA2	14647193	Yasuda K, Sugita N, Kobayashi T, Yamamoto K, Yoshie H. FcgammaRIIB gene polymorphisms in Japanese periodontitis patients. Genes Immun. 2003 Dec;4(8):541-6.

FCGR3B	AgP	224	455	0.019	Weak	Mixed	CC	EGS	Fc fragment of IgG, low affinity IIIb, receptor (CD16b)	CD16; FCG3; CD16b; FCGR3; FCGR3B	2	NA1/NA2	16899095	Nibali L, Parkar M, Brett P, Knight J, Tonetti MS, Griffiths GS. NADPH oxidase (CYBA) and FcgammaR polymorphisms as risk factors for aggressive periodontitis: a case-control association study. J Clin Periodontol. 2006 Aug;33(8):529-39.
FCGR3B	AgP	38	142	0.02	Weak	Japanese	CC	N	Fc fragment of IgG, low affinity IIIb, receptor (CD16b)	CD16; FCG3; CD16b; FCGR3; FCGR3B	1	NA1/NA2	11022771	Kobayashi T, Sugita N, van der Pol WL, Nunokawa Y, Westerdaal NA, Yamamoto K, van de Winkel JG, Yoshie H. The Fcgamma receptor genotype as a risk factor for generalized early-onset periodontitis in Japanese patients. J Periodontol. 2000 Sep;71(9):1425-32.
FCGR3B	AgP	48	115	0.024	Weak	African American	CC	N	Fc fragment of IgG, low affinity IIIb, receptor (CD16b)	CD16; FCG3; CD16b; FCGR3; FCGR3B	n/a	NA1/NA2	12027254	Fu Y, Korostoff JM, Fine DH, Wilson ME. Fc gamma receptor genes as risk markers for localized aggressive periodontitis in African-Americans. J Periodontol. 2002 May;73(5):517-23.
FCGR3B	AgP	31	80	<0.001	Weak	Brazilian	CC	EG	Fc fragment of IgG, low affinity IIIb, receptor (CD16b)	CD16; FCG3; CD16b; FCGR3; FCGR3B	1	NA1/NA2	16805673	de Souza RC, Colombo AP. Distribution of FcgammaRIIa and FcgammaRIIIb genotypes in patients with generalized aggressive periodontitis. J Periodontol. 2006 Jul;77(7):1120-8.
FCGR3B	AgP	21	47	<0.05	Weak	Chinese	CC	N	Fc fragment of IgG, low affinity IIIb, receptor (CD16b)	CD16; FCG3; CD16b; FCGR3; FCGR3B	1	NA1/NA2	12839649	Zhang HX, Xie H, Ren TG. [Relevance of FcgammaRIIIb genotype, IgG G2m(23) factor to the susceptibility of aggressive periodontitis]. Zhonghua Kou Qiang Yi Xue Za Zhi. 2003 Mar;38(2):129-31. Chinese.
FCGR3B	AgP	30	104	ns	None	Taiwanese	CC	N	Fc fragment of IgG, low affinity IIIb, receptor (CD16b)	CD16; FCG3; CD16b; FCGR3; FCGR3B	1	NA1/NA2	14761117	Chung HY, Lu HC, Chen WL, Lu CT, Yang YH, Tsai CC. Gm (23) allotypes and Fcgamma receptor genotypes as risk factors for various forms of periodontitis. J Clin Periodontol. 2003 Nov;30(11):954-60.

Continued

TABLE 6-3 Association Study—cont'd

Gene Symbol	Disease Type	Cases	Total	Best *P* Value	Level of Support	Population	Study Design	Stratified or Covariate Adj	Gene Name	Gene Aliases	# SNPs Assayed	SNP Name	PubMed ID	Journal
FCGR3B	AgP	12	73	ns	None	Caucasian	CC	S	Fc fragment of IgG, low affinity IIIb, receptor (CD16b)	CD16; FCG3; CD16b; FCGR3; FCGR3B	1	NA1/NA2	12834496	Loos BG, Leppers-Van de Straat FG, Van de Winkel JG, Van der Velden U. Fcgamma receptor polymorphisms in relation to periodontitis. J Clin Periodontol. 2003 Jul;30(7):595-602.
FCGR3B	AgP	33	60	sig	Weak	Chinese	CC	N	Fc fragment of IgG, low affinity IIIb, receptor (CD16b)	CD16; FCG3; CD16b; FCGR3; FCGR3B	1	NA1/NA2	11776881	Fu Y, Cao C, Wang S. [Relevance of Fc gamma R polymorphism to the susceptibility of early-onset periodontitis]. Zhonghua Kou Qiang Yi Xue Za Zhi. 1999 Nov;34(6):364-6. Chinese.
FCGR3B	AgP+CP	319	622	ns	None	Japanese	CC	AGS	Fc fragment of IgG, low affinity IIIb, receptor (CD16b)	CD16; FCG3; CD16b; FCGR3; FCGR3B	1	NA1/NA2	19892918	Kobayashi T, Nagata T, Murakami S, Takashiba S, Kurihara H, Izumi Y, Numabe Y, Watanabe H, Kataoka M, Nagai A, Hayashi J, Ohyama H, Okamatsu Y, Inagaki Y, Tai H, Yoshie H. Genetic risk factors for periodontitis in a Japanese population. J Dent Res. 2009 Dec;88(12): 1137-41.
FCGR3B	CP	100	205	0.0003	Moderate	Japanese	CC	N	Fc fragment of IgG, low affinity IIIb, receptor (CD16b)	CD16; FCG3; CD16b; FCGR3; FCGR3B	1	NA1/NA2	9284119	Kobayashi T, Westerdaal NA, Miyazaki A, van der Pol WL, Suzuki T, Yoshie H, van de Winkel JG, Hara K. Relevance of immunoglobulin G Fc receptor polymorphism to recurrence of adult periodontitis in Japanese patients. Infect Immun. 1997 Sep;65(9):3556-60.
FCGR3B	CP	83	187	0.009	Weak	Japanese	CC	N	Fc fragment of IgG, low affinity IIIb, receptor (CD16b)	CD16; FCG3; CD16b; FCGR3; FCGR3B	1	NA1/NA2	11022771	Kobayashi T, Sugita N, van der Pol WL, Nunokawa Y, Westerdaal NA, Yamamoto K, van de Winkel JG, Yoshie H. The Fcgamma receptor genotype as a risk factor for generalized early-onset periodontitis in Japanese patients. J Periodontol. 2000 Sep;71(9):1425-32.

FCGR3B	CP	73	119	0.03	Weak	Japanese	CC	N	Fc fragment of IgG, low affinity IIIb, receptor (CD16b)	CD16; FCG3; CD16b; FCGR3; FCGR3B	1	NA1/NA2	11379895	Sugita N, Kobayashi T, Ando Y, Yoshihara A, Yamamoto K, van de Winkel JG, Miyazaki H, Yoshie H. Increased frequency of FcgammaRIIIb-NA1 allele in periodontitis-resistant subjects in an elderly Japanese population. J Dent Res. 2001 Mar;80(3):914-8.
FCGR3B	CP	n/a	164	<0.001	Moderate	Japanese	Longitudinal	AS	Fc fragment of IgG, low affinity IIIb, receptor (CD16b)	CD16; FCG3; CD16b; FCGR3; FCGR3B	1	NA1/NA2	15974849	Yoshihara A, Sugita N, Yamamoto K, Kobayashi T, Hirotomi T, Ogawa H, Miyazaki H, Yoshie H. FcgammaRIIIb genotypes and smoking in periodontal disease progression among community-dwelling older adults in Japan. J Periodontol. 2005 Feb;76(2):250-5.
FCGR3B	CP	113	221	ns	None	Japanese	CC	N	Fc fragment of IgG, low affinity IIIb, receptor (CD16b)	CD16; FCG3; CD16b; FCGR3; FCGR3B	1	NA1/NA2	18321309	Komatsu Y, Galicia JC, Kobayashi T, Yamazaki K, Yoshie H. Association of interleukin-1 receptor antagonist +2018 gene polymorphism with Japanese chronic periodontitis patients using a novel genotyping method. Int J Immunogenet. 2008 Apr;35(2):165-70.
FCGR3B	CP	100	200	ns	None	Japanese	CC	N	Fc fragment of IgG, low affinity IIIb, receptor (CD16b)	CD16; FCG3; CD16b; FCGR3; FCGR3B	1	NA1/NA2	18052703	Kobayashi T, Ito S, Kuroda T, Yamamoto K, Sugita N, Narita I, Sumida T, Gejyo F, Yoshie H. The interleukin-1 and Fcgamma receptor gene polymorphisms in Japanese patients with rheumatoid arthritis and periodontitis. J Periodontol. 2007 Dec;78(12):2311-8.
FCGR3B	CP	132	205	ns	None	Caucasian	CC	N	Fc fragment of IgG, low affinity IIIb, receptor (CD16b)	CD16; FCG3; CD16b; FCGR3; FCGR3B	1	NA1/NA2	16889631	Wolf DL, Neiderud AM, Hinckley K, Dahlén G, van de Winkel JG, Papapanou PN. Fcgamma receptor polymorphisms and periodontal status: a prospective follow-up study. J Clin Periodontol. 2006 Oct;33(10):691-8. Epub 2006 Aug 3.

Continued

TABLE 6-3 Association Study—cont'd

Gene Symbol	Disease Type	Cases	Total	Best *P* Value	Level of Support	Population	Study Design	Stratified or Covariate Adj	Gene Name	Gene Aliases	# SNPs Assayed	SNP Name	PubMed ID	Journal
FCGR3B	CP	72	144	ns	None	Japanese	CC	N	Fc fragment of IgG, low affinity IIIb, receptor (CD16b)	CD16; FCG3; CD16b; FCGR3; FCGR3B	1	NA1/NA2	14647193	Yasuda K, Sugita N, Kobayashi T, Yamamoto K, Yoshie H. FcgammaRIIB gene polymorphisms in Japanese periodontitis patients. Genes Immun. 2003 Dec;4(8):541-6.
FCGR3B	CP	56	117	ns	None	Caucasian	CC	S	Fc fragment of IgG, low affinity IIIb, receptor (CD16b)	CD16; FCG3; CD16b; FCGR3; FCGR3B	1	NA1/NA2	12834496	Loos BG, Leppers-Van de Straat FG, Van de Winkel JG, Van der Velden U. Fcgamma receptor polymorphisms in relation to periodontitis. J Clin Periodontol. 2003 Jul;30(7):595-602.
FCGR3B	CP	117	558	ns	None	German	CC	S	Fc fragment of IgG, low affinity IIIb, receptor (CD16b)	CD16; FCG3; CD16b; FCGR3; FCGR3B	1	NA1/NA2	19570260	Meisel P, Heins G, Carlsson L, Giebel J, John U, Schwahn C, Kocher T. Impact of Genetic Polymorphisms on the Smoking-related Risk of Periodontal Disease: the Population-based Study SHIP. Tob Induc Dis. 2003 Sep 15;1(3):197.
FCGR3B	CP	52	107	ns	None	Japanese	CC	N	Fc fragment of IgG, low affinity IIIb, receptor (CD16b)	CD16; FCG3; CD16b; FCGR3; FCGR3B	1	NA1/NA2	11808760	Yoshihara A, Sugita N, Yamamoto K, Kobayashi T, Miyazaki H, Yoshi H. Analysis of vitamin D and Fcgamma receptor polymorphisms in Japanese patients with generalized early-onset periodontitis. J Dent Res. 2001 Dec;80(12):2051-4.
FCGR3B	CP	89	153	ns	None	Japanese	CC	S	Fc fragment of IgG, low affinity IIIb, receptor (CD16b)	CD16; FCG3; CD16b; FCGR3; FCGR3B	1	NA1/NA2	11699473	Kobayashi T, Yamamoto K, Sugita N, van der Pol WL, Yasuda K, Kaneko S, van de Winkel JG, Yoshie H. The Fc gamma receptor genotype as a severity factor for chronic periodontitis in Japanese patients. J Periodontol. 2001 Oct;72(10):1324-31.
FCGR3B	CP	49	98	ns	None	German	CC	AS	Fc fragment of IgG, low affinity IIIb, receptor (CD16b)	CD16; FCG3; CD16b; FCGR3; FCGR3B	1	NA1/NA2	11528518	Meisel P, Carlsson LE, Sawaf H, Fanghaenel J, Greinacher A, Kocher T. Polymorphisms of Fc gamma-receptors RIIa, RIIIa, and RIIIb in patients with adult periodontal diseases. Genes Immun. 2001 Aug;2(5):258-62.

FCGR3B	CP	86	113	ns	None	n/a	CC	S	Fc fragment of IgG, low affinity IIIb, receptor (CD16b)	CD16; FCG3; CD16b; FCGR3; FCGR3B	1	NA1/NA2	9667480	Colombo AP, Eftimiadi C, Haffajee AD, Cugini MA, Socransky SS. Serum IgG2 level, Gm(23) allotype and FcgammaRIIa and FcgammaRIIIb receptors in refractory periodontal disease. J Clin Periodontol. 1998 Jun;25(6):465-74.
FCGR3B	CP&RA	86	186	ns	None	Japanese	CC	N	Fc fragment of IgG, low affinity IIIb, receptor (CD16b)	CD16; FCG3; CD16b; FCGR3; FCGR3B	1	NA1/NA2	18052703	Kobayashi T, Ito S, Kuroda T, Yamamoto K, Sugita N, Narita I, Sumida T, Gejyo F, Yoshie H. The interleukin-1 and Fcgamma receptor gene polymorphisms in Japanese patients with rheumatoid arthritis and periodontitis. J Periodontol. 2007 Dec;78(12):2311-8.
FCGR3B	CP&SLE	42	84	ns	None	Japanese	CC	N	Fc fragment of IgG, low affinity IIIb, receptor (CD16b)	CD16; FCG3; CD16b; FCGR3; FCGR3B	1	NA1/NA2	12710759	Kobayashi T, Ito S, Yamamoto K, Hasegawa H, Sugita N, Kuroda T, Kaneko S, Narita I, Yasuda K, Nakano M, Gejyo F, Yoshie H. Risk of periodontitis in systemic lupus erythematosus is associated with Fcgamma receptor polymorphisms. J Periodontol. 2003 Mar;74(3):378-84.
FCGR3B	CP&SLE	42	60	ns	None	Japanese	CC	N	Fc fragment of IgG, low affinity IIIb, receptor (CD16b)	CD16; FCG3; CD16b; FCGR3; FCGR3B	1	NA1/NA2	12710759	Kobayashi T, Ito S, Yamamoto K, Hasegawa H, Sugita N, Kuroda T, Kaneko S, Narita I, Yasuda K, Nakano M, Gejyo F, Yoshie H. Risk of periodontitis in systemic lupus erythematosus is associated with Fcgamma receptor polymorphisms. J Periodontol. 2003 Mar;74(3):378-84.
FCN1	AgP+CP	251	376	ns	None	Japanese	CC	N	Ficolin (collagen/fibrinogen domain containing) 1	FCNM; FCN1	n/a	n/a	15081423	Suzuki A, Ji G, Numabe Y, Muramatsu M, Gomi K, Kanazashi M, Ogata Y, Shimizu E, Shibukawa Y, Ito A, Ito T, Sugaya A, Arai T, Yamada S, Deguchi S, Kamoi K. Single nucleotide polymorphisms associated with aggressive periodontitis and severe chronic periodontitis in Japanese. Biochem Biophys Res Commun. 2004 May 7;317(3):887-92.

Continued

TABLE 6-3 Association Study—cont'd

Gene Symbol	Disease Type	Cases	Total	Best *P* Value	Level of Support	Population	Study Design	Stratified or Covariate Adj	Gene Name	Gene Aliases	# SNPs Assayed	SNP Name	PubMed ID	Journal
FGA	CP	22	41	ns	None	Japanese	CC	N	Fibrinogen alpha chain	Fib2; MGC119422; MGC119423; MGC119425; FGA	1	n/a	15490304	Suzuki A, Ji G, Numabe Y, Ishii K, Muramatsu M, Kamoi K. Large-scale investigation of genomic markers for severe periodontitis. Odontology. 2004 Sep;92(1):43-7.
FGB	AgP+CP	319	622	ns	None	Japanese	CC	AGS	Fibrinogen beta chain	MGC104327; MGC120405; FGB	1	–455	19892918	Kobayashi T, Nagata T, Murakami S, Takashiba S, Kurihara H, Izumi Y, Numabe Y, Watanabe H, Kataoka M, Nagai A, Hayashi J, Ohyama H, Okamatsu Y, Inagaki Y, Tai H, Yoshie H. Genetic risk factors for periodontitis in a Japanese population. J Dent Res. 2009 Dec;88(12): 1137-41.
FGB	CP	n/a	121	0.008	Weak	Chinese	CC	N	Fibrinogen beta chain	MGC104327; MGC120405; FGB	1	–455 G/A	18683729	Ge S, Wu YF, Liu TJ, He QM, Zhao L, Meng S. [Correlation between levels of fibrinogen, beta455 g/A fibrinogen gene polymorphism and chronic periodontitis]. Zhonghua Kou Qiang Yi Xue Za Zhi. 2008 Feb;43(2):87-91. Chinese.
FGB	CP	79	154	0.01	Weak	Mixed	CC	N	Fibrinogen beta chain	MGC104327; MGC120405; FGB	1	HaeIII, -455	12710752	Sahingur SE, Sharma A, Genco RJ, De Nardin E. Association of increased levels of fibrinogen and the -455G/A fibrinogen gene polymorphism with chronic periodontitis. J Periodontol. 2003 Mar;74(3):329-37.
FGF1	AgP+CP	251	376	ns	None	Japanese	CC	N	Fibroblast growth factor 1 (acidic)	AFGF; ECGF; FGFA; ECGFA; ECGFB; HBGF1; GLIO703; ECGF-beta; FGF-alpha; FGF1	n/a	n/a	15081423	Suzuki A, Ji G, Numabe Y, Muramatsu M, Gomi K, Kanazashi M, Ogata Y, Shimizu E, Shibukawa Y, Ito A, Ito T, Sugaya A, Arai T, Yamada S, Deguchi S, Kamoi K. Single nucleotide polymorphisms associated with aggressive periodontitis and severe chronic periodontitis in Japanese. Biochem Biophys Res Commun. 2004 May 7;317(3):887-92.

FGF10	AgP+CP	251	376	ns	None	Japanese	CC	N	Fibroblast growth factor 10	FGF10	n/a	n/a	15081423	Suzuki A, Ji G, Numabe Y, Muramatsu M, Gomi K, Kanazashi M, Ogata Y, Shimizu E, Shibukawa Y, Ito A, Ito T, Sugaya A, Arai T, Yamada S, Deguchi S, Kamoi K. Single nucleotide polymorphisms associated with aggressive periodontitis and severe chronic periodontitis in Japanese. Biochem Biophys Res Commun. 2004 May 7;317(3):887-92.
FGF12	AgP+CP	251	376	ns	None	Japanese	CC	N	Fibroblast growth factor 12	FHF1; FGF12B; FGF12	n/a	n/a	15081423	Suzuki A, Ji G, Numabe Y, Muramatsu M, Gomi K, Kanazashi M, Ogata Y, Shimizu E, Shibukawa Y, Ito A, Ito T, Sugaya A, Arai T, Yamada S, Deguchi S, Kamoi K. Single nucleotide polymorphisms associated with aggressive periodontitis and severe chronic periodontitis in Japanese. Biochem Biophys Res Commun. 2004 May 7;317(3):887-92.
FGF12	AgP+CP	251	376	ns	None	Japanese	CC	N	Fibroblast growth factor 12	FHF1; FGF12B; FGF12	n/a	n/a	15081423	Suzuki A, Ji G, Numabe Y, Muramatsu M, Gomi K, Kanazashi M, Ogata Y, Shimizu E, Shibukawa Y, Ito A, Ito T, Sugaya A, Arai T, Yamada S, Deguchi S, Kamoi K. Single nucleotide polymorphisms associated with aggressive periodontitis and severe chronic periodontitis in Japanese. Biochem Biophys Res Commun. 2004 May 7;317(3):887-92.
FGF13	AgP+CP	251	376	ns	None	Japanese	CC	N	Fibroblast growth factor 13	FGF2; FHF2; FHF-2; FGF13	n/a	n/a	15081423	Suzuki A, Ji G, Numabe Y, Muramatsu M, Gomi K, Kanazashi M, Ogata Y, Shimizu E, Shibukawa Y, Ito A, Ito T, Sugaya A, Arai T, Yamada S, Deguchi S, Kamoi K. Single nucleotide polymorphisms associated with aggressive periodontitis and severe chronic periodontitis in Japanese. Biochem Biophys Res Commun. 2004 May 7;317(3):887-92.

Continued

TABLE 6-3 Association Study—cont'd

Gene Symbol	Disease Type	Cases	Total	Best *P* Value	Level of Support	Population	Study Design	Stratified or Covariate Adj	Gene Name	Gene Aliases	# SNPs Assayed	SNP Name	PubMed ID	Journal
FGF2	AgP+CP	251	376	ns	None	Japanese	CC	N	Fibroblast growth factor 2 (basic)	BFGF; FGFB; HBGF-2; FGF2	n/a	n/a	15081423	Suzuki A, Ji G, Numabe Y, Muramatsu M, Gomi K, Kanazashi M, Ogata Y, Shimizu E, Shibukawa Y, Ito A, Ito T, Sugaya A, Arai T, Yamada S, Deguchi S, Kamoi K. Single nucleotide polymorphisms associated with aggressive periodontitis and severe chronic periodontitis in Japanese. Biochem Biophys Res Commun. 2004 May 7;317(3):887-92.
FGF21	AgP+CP	251	376	ns	None	Japanese	CC	N	Fibroblast growth factor 21	FGF21	n/a	n/a	15081423	Suzuki A, Ji G, Numabe Y, Muramatsu M, Gomi K, Kanazashi M, Ogata Y, Shimizu E, Shibukawa Y, Ito A, Ito T, Sugaya A, Arai T, Yamada S, Deguchi S, Kamoi K. Single nucleotide polymorphisms associated with aggressive periodontitis and severe chronic periodontitis in Japanese. Biochem Biophys Res Commun. 2004 May 7;317(3):887-92.
FGF6	AgP+CP	251	376	ns	None	Japanese	CC	N	Fibroblast growth factor 6	HST2; HBGF-6; FGF6	n/a	n/a	15081423	Suzuki A, Ji G, Numabe Y, Muramatsu M, Gomi K, Kanazashi M, Ogata Y, Shimizu E, Shibukawa Y, Ito A, Ito T, Sugaya A, Arai T, Yamada S, Deguchi S, Kamoi K. Single nucleotide polymorphisms associated with aggressive periodontitis and severe chronic periodontitis in Japanese. Biochem Biophys Res Commun. 2004 May 7;317(3):887-92.

FGF9	AgP+CP	251	376	ns	None	Japanese	CC	N	Fibroblast growth factor 9 (glia-activating factor)	GAF; SYNS3; HBFG-9; MGC119914; MGC119915; FGF9	n/a	n/a	15081423	Suzuki A, Ji G, Numabe Y, Muramatsu M, Gomi K, Kanazashi M, Ogata Y, Shimizu E, Shibukawa Y, Ito A, Ito T, Sugaya A, Arai T, Yamada S, Deguchi S, Kamoi K. Single nucleotide polymorphisms associated with aggressive periodontitis and severe chronic periodontitis in Japanese. Biochem Biophys Res Commun. 2004 May 7;317(3):887-92.
FGFRL1	AgP+CP	251	376	ns	None	Japanese	CC	N	Fibroblast growth factor receptor-like 1	FHFR; FGFR5; FGFRL1	n/a	n/a	15081423	Suzuki A, Ji G, Numabe Y, Muramatsu M, Gomi K, Kanazashi M, Ogata Y, Shimizu E, Shibukawa Y, Ito A, Ito T, Sugaya A, Arai T, Yamada S, Deguchi S, Kamoi K. Single nucleotide polymorphisms associated with aggressive periodontitis and severe chronic periodontitis in Japanese. Biochem Biophys Res Commun. 2004 May 7;317(3):887-92.
FGL1	CP	22	41	ns	None	Japanese	CC	N	Fibrinogen-like 1	HFREP1; HP-041; LFIRE1; MGC12455; FGL1	2	Multiple SNPs	15490304	Suzuki A, Ji G, Numabe Y, Ishii K, Muramatsu M, Kamoi K. Large-scale investigation of genomic markers for severe periodontitis. Odontology. 2004 Sep;92(1):43-7.
FGL2	CP	22	41	0.007	Weak	Japanese	CC	N	Fibrinogen-like 2	T49; pT49; FGL2	1	IMS-JST003521	15490304	Suzuki A, Ji G, Numabe Y, Ishii K, Muramatsu M, Kamoi K. Large-scale investigation of genomic markers for severe periodontitis. Odontology. 2004 Sep;92(1):43-7.
FN1	AgP+CP	251	376	ns	None	Japanese	CC	N	Fibronectin 1	FN; CIG; FNZ; MSF; ED-B; FINC; GFND; LETS; GFND2; DKFZp686H0342; DKFZp686I1370; DKFZp686F10164; DKFZp686O13149; FN1	n/a	n/a	15081423	Suzuki A, Ji G, Numabe Y, Muramatsu M, Gomi K, Kanazashi M, Ogata Y, Shimizu E, Shibukawa Y, Ito A, Ito T, Sugaya A, Arai T, Yamada S, Deguchi S, Kamoi K. Single nucleotide polymorphisms associated with aggressive periodontitis and severe chronic periodontitis in Japanese. Biochem Biophys Res Commun. 2004 May 7;317(3):887-92.

Continued

TABLE 6-3 Association Study—cont'd

Gene Symbol	Disease Type	Cases	Total	Best *P* Value	Level of Support	Population	Study Design	Stratified or Covariate Adj	Gene Name	Gene Aliases	# SNPs Assayed	SNP Name	PubMed ID	Journal
FOXK2	AgP+CP	251	376	ns	None	Japanese	CC	N	Forkhead box K2	ILF; ILF1; ILF-1; FOXK2	n/a	n/a	15081423	Suzuki A, Ji G, Numabe Y, Muramatsu M, Gomi K, Kanazashi M, Ogata Y, Shimizu E, Shibukawa Y, Ito A, Ito T, Sugaya A, Arai T, Yamada S, Deguchi S, Kamoi K. Single nucleotide polymorphisms associated with aggressive periodontitis and severe chronic periodontitis in Japanese. Biochem Biophys Res Commun. 2004 May 7;317(3):887-92.
FPR1	AgP	49	422	0.00002	Moderate	Japanese	CC	N	Formyl peptide receptor 1	FPR; FMLP; FPR1	3	–12915C >T.301G >C.546C>A	17927965	Gunji T, Onouchi Y, Nagasawa T, Katagiri S, Watanabe H, Kobayashi H, Arakawa S, Noguchi K, Hata A, Izumi Y, Ishikawa I. Functional polymorphisms of the FPR1 gene and aggressive periodontitis in Japanese. Biochem Biophys Res Commun. 2007 Dec 7;364(1):7-13. Epub 2007 Oct 2.
FPR1	AgP	30	63	0.0005	Weak	African American	CC	N	Formyl peptide receptor 1	FPR; FMLP; FPR1	6	348T>C	19254133	Maney P, Emecen P, Mills JS, Walters JD. Neutrophil formylpeptide receptor single nucleotide polymorphism 348T>C in aggressive periodontitis. J Periodontol. 2009 Mar;80(3):492-8.
FPR1	AgP	30	50	0.0005	Weak	Mixed	CC	E	Formyl peptide receptor 1	FPR; FMLP; FPR1	3	Cys126Try or Phe110Ser	10534074	Gwinn MR, Sharma A, De Nardin E. Single nucleotide polymorphisms of the N-formyl peptide receptor in localized juvenile periodontitis. J Periodontol. 1999 Oct;70(10):1194-201.

FPR1	AgP	49	422	0.00098	Moderate	Japanese	CC	N	Formyl peptide receptor 1	FPR; FMLP; FPR1	30	–12915C>T	17927965	Gunji T, Onouchi Y, Nagasawa T, Katagiri S, Watanabe H, Kobayashi H, Arakawa S, Noguchi K, Hata A, Izumi Y, Ishikawa I. Functional polymorphisms of the FPR1 gene and aggressive periodontitis in Japanese. Biochem Biophys Res Commun. 2007 Dec 7;364(1):7-13. Epub 2007 Oct 2.
FPR1	AgP	111	226	0.0018	Weak	Mixed	CC	E	Formyl peptide receptor 1	FPR; FMLP; FPR1	6	N192K	12595898	Zhang Y, Syed R, Uygar C, Pallos D, Gorry MC, Firatli E, Cortelli JR, VanDyke TE, Hart PS, Feingold E, Hart TC. Evaluation of human leukocyte N-formylpeptide receptor (FPR1) SNPs in aggressive periodontitis patients. Genes Immun. 2003 Jan;4(1):22-9.
FPR1	AgP	30	63	0.0036	Weak	African American	CC	N	Formyl peptide receptor 1	FPR; FMLP; FPR1	4	Haplotype	19254133	Maney P, Emecen P, Mills JS, Walters JD. Neutrophil formylpeptide receptor single nucleotide polymorphism 348T>C in aggressive periodontitis. J Periodontol. 2009 Mar;80(3):492-8.
FPR1	AgP	37	75	0.017	Weak	African American	CC	N	Formyl peptide receptor 1	FPR; FMLP; FPR1	12	348T>C	19722801	Maney P, Walters JD. Formylpeptide Receptor Single Nucleotide Polymorphism 348T>C and Its Relationship to Polymorphonuclear Leukocyte Chemotaxis in Aggressive Periodontitis. J Periodontol. 2009 Sep;80(9):1498-505.
FPR1	AgP	37	75	ns	None	African American	CC	N	Formyl peptide receptor 1	FPR; FMLP; FPR1	4	Haplotype	19722801	Maney P, Walters JD. Formylpeptide Receptor Single Nucleotide Polymorphism 348T>C and Its Relationship to Polymorphonuclear Leukocyte Chemotaxis in Aggressive Periodontitis. J Periodontol. 2009 Sep;80(9):1498-505.
FPR1	AgP	75	138	ns	None	Turkish	CC	N	Formyl peptide receptor 1	FPR; FMLP; FPR1	6	Multiple SNPs	19254133	Maney P, Emecen P, Mills JS, Walters JD. Neutrophil formylpeptide receptor single nucleotide polymorphism 348T>C in aggressive periodontitis. J Periodontol. 2009 Mar;80(3):492-8.

Continued

TABLE 6-3 Association Study—cont'd

Gene Symbol	Disease Type	Cases	Total	Best *P* Value	Level of Support	Population	Study Design	Stratified or Covariate Adj	Gene Name	Gene Aliases	# SNPs Assayed	SNP Name	PubMed ID	Journal
FPR1	AgP	75	138	ns	None	Turkish	CC	N	Formyl peptide receptor 1	FPR; FMLP; FPR1	4	Haplotype	19254133	Maney P, Emecen P, Mills JS, Walters JD. Neutrophil formylpeptide receptor single nucleotide polymorphism 348T>C in aggressive periodontitis. J Periodontol. 2009 Mar;80(3):492-8.
FPR1	AgP	224	455	ns	None	Mixed	CC	EGS	Formyl peptide receptor 1	FPR; FMLP; FPR1	3	Multiple SNPs	16899095	Nibali L, Parkar M, Brett P, Knight J, Tonetti MS, Griffiths GS. NADPH oxidase (CYBA) and FcgammaR polymorphisms as risk factors for aggressive periodontitis: a case-control association study. J Clin Periodontol. 2006 Aug;33(8):529-39.
FPR1	AgP+CP	319	622	ns	None	Japanese	CC	AGS	Formyl peptide receptor 1	FPR; FMLP; FPR1	2	n/a	19892918	Kobayashi T, Nagata T, Murakami S, Takashiba S, Kurihara H, Izumi Y, Numabe Y, Watanabe H, Kataoka M, Nagai A, Hayashi J, Ohyama H, Okamatsu Y, Inagaki Y, Tai H, Yoshie H. Genetic risk factors for periodontitis in a Japanese population. J Dent Res. 2009 Dec;88(12): 1137-41.
FPR1	CP	22	41	ns	None	Japanese	CC	N	Formyl peptide receptor 1	FPR; FMLP; FPR1	2	Multiple SNPs	15490304	Suzuki A, Ji G, Numabe Y, Ishii K, Muramatsu M, Kamoi K. Large-scale investigation of genomic markers for severe periodontitis. Odontology. 2004 Sep;92(1):43-7.
GAL3ST1	CP	22	41	ns	None	Japanese	CC	N	Galactose-3-O-sulfotransferase 1	CST; GAL3ST1	1	n/a	15490304	Suzuki A, Ji G, Numabe Y, Ishii K, Muramatsu M, Kamoi K. Large-scale investigation of genomic markers for severe periodontitis. Odontology. 2004 Sep;92(1):43-7.
GBP2	CP	22	41	ns	None	Japanese	CC	N	Guanylate binding protein 2, interferon-inducible	GBP2	1	n/a	15490304	Suzuki A, Ji G, Numabe Y, Ishii K, Muramatsu M, Kamoi K. Large-scale investigation of genomic markers for severe periodontitis. Odontology. 2004 Sep;92(1):43-7.

GC	AgP+CP	146	228	ns	None	Mixed	Fam	N	Group-specific component (vitamin D binding protein)	DBP; VDBG; VDBP; DBP/GC; GC	1	n/a	8100208	Hart TC, Marazita ML, McCanna KM, Schenkein HA, Diehl SR. Reevaluation of the chromosome 4q candidate region for early onset periodontitis. Hum Genet. 1993 Jun;91(5):416-22.
GCK	CP	22	41	ns	None	Japanese	CC	N	Glucokinase (hexokinase 4)	GK; GLK; HK4; HHF3; HKIV; HXKP; MODY2; GCK	3	Multiple SNPs	15490304	Suzuki A, Ji G, Numabe Y, Ishii K, Muramatsu M, Kamoi K. Large-scale investigation of genomic markers for severe periodontitis. Odontology. 2004 Sep;92(1):43-7.
GHRHR	CP	22	41	ns	None	Japanese	CC	N	Growth hormone releasing hormone receptor	GRFR; GHRFR; IGHD1B; GHRHRpsv; GHRHR	2	Multiple SNPs	15490304	Suzuki A, Ji G, Numabe Y, Ishii K, Muramatsu M, Kamoi K. Large-scale investigation of genomic markers for severe periodontitis. Odontology. 2004 Sep;92(1):43-7.
GIP	CP	22	41	ns	None	Japanese	CC	N	Gastric inhibitory polypeptide	GIP	2	Multiple SNPs	15490304	Suzuki A, Ji G, Numabe Y, Ishii K, Muramatsu M, Kamoi K. Large-scale investigation of genomic markers for severe periodontitis. Odontology. 2004 Sep;92(1):43-7.
GIPR	CP	22	41	ns	None	Japanese	CC	N	Gastric inhibitory polypeptide receptor	MGC126722; GIPR	1	n/a	15490304	Suzuki A, Ji G, Numabe Y, Ishii K, Muramatsu M, Kamoi K. Large-scale investigation of genomic markers for severe periodontitis. Odontology. 2004 Sep;92(1):43-7.
GLP1R	CP	22	41	ns	None	Japanese	CC	N	GlucaGon-like peptide 1 receptor	MGC138331; GLP1R	2	Multiple SNPs	15490304	Suzuki A, Ji G, Numabe Y, Ishii K, Muramatsu M, Kamoi K. Large-scale investigation of genomic markers for severe periodontitis. Odontology. 2004 Sep;92(1):43-7.
GLP2R	CP	22	41	ns	None	Japanese	CC	N	Glucagon-like peptide 2 receptor	GLP2R	3	Multiple SNPs	15490304	Suzuki A, Ji G, Numabe Y, Ishii K, Muramatsu M, Kamoi K. Large-scale investigation of genomic markers for severe periodontitis. Odontology. 2004 Sep;92(1):43-7.
GLT6D1	AgP	447	1787	5.51E-09	Strong	Caucasian	CC	ADGS	Glycosyltransferase 6 domain containing 1	GT6M7; GLTDC1; GLT6D1	GWAS	rs1537415	19897590	Schaefer AS, Richter GM, Nothnagel M, Manke T, Dommisch H, Jacobs G, Arlt A, Rosenstiel P, Noack B, Groessner-Schreiber B, Jepsen S, Loos BG, Schreiber S. A genome-wide association study identifies GLT6D1 as a susceptibility locus for periodontitis. Hum Mol Genet. 2009 Dec 1.

Continued

TABLE 6-3 Association Study—cont'd

Gene Symbol	Disease Type	Cases	Total	Best *P* Value	Level of Support	Population	Study Design	Stratified or Covariate Adj	Gene Name	Gene Aliases	# SNPs Assayed	SNP Name	PubMed ID	Journal
GNB3	CP	22	41	ns	None	Japanese	CC	N	Guanine nucleotide binding protein (G protein), beta polypeptide 3	GNB3	2	Multiple SNPs	15490304	Suzuki A, Ji G, Numabe Y, Ishii K, Muramatsu M, Kamoi K. Large-scale investigation of genomic markers for severe periodontitis. Odontology. 2004 Sep;92(1):43-7.
GNRH1	CP	22	41	0.0008	Weak	Japanese	CC	N	Gonadotropin-releasing hormone 1 (luteinizing-releasing hormone)	GRH; GNRH; LHRH; LNRH; GNRH1	1	IMS-JST057216	15490304	Suzuki A, Ji G, Numabe Y, Ishii K, Muramatsu M, Kamoi K. Large-scale investigation of genomic markers for severe periodontitis. Odontology. 2004 Sep;92(1):43-7.
GPR39	CP	22	41	ns	None	Japanese	CC	N	G protein-coupled receptor 39	MGC149541; GPR39	1	n/a	15490304	Suzuki A, Ji G, Numabe Y, Ishii K, Muramatsu M, Kamoi K. Large-scale investigation of genomic markers for severe periodontitis. Odontology. 2004 Sep;92(1):43-7.
GPX3	CP	22	41	ns	None	Japanese	CC	N	Glutathione peroxidase 3 (plasma)	GPx-P; GSHPx-3; GSHPx-P; GPX3	1	n/a	15490304	Suzuki A, Ji G, Numabe Y, Ishii K, Muramatsu M, Kamoi K. Large-scale investigation of genomic markers for severe periodontitis. Odontology. 2004 Sep;92(1):43-7.
GPX5	CP	22	41	ns	None	Japanese	CC	N	Glutathione peroxidase 5 (epididymal androgen-related protein)	GPX5	1	n/a	15490304	Suzuki A, Ji G, Numabe Y, Ishii K, Muramatsu M, Kamoi K. Large-scale investigation of genomic markers for severe periodontitis. Odontology. 2004 Sep;92(1):43-7.
GRP	CP	22	41	ns	None	Japanese	CC	N	Gastrin-releasinG peptide	BN; GRP-10; proGRP; preproGRP; GRP	1	n/a	15490304	Suzuki A, Ji G, Numabe Y, Ishii K, Muramatsu M, Kamoi K. Large-scale investigation of genomic markers for severe periodontitis. Odontology. 2004 Sep;92(1):43-7.
GSTM1	AgP	14	75	0.002	Weak	Caucasian	CC	N	Glutathione S-transferase mu 1	MU; H-B; GST1; GTH4; GTM1; MU-1; GSTM1-1; MGC26563; GSTM1a-1a; GSTM1b-1b; GSTM1	1	n/a	17524385	Concolino P, Cecchetti F, D'Autilia C, Santonocito C, Di Stasio E, Zuppi C, Arcuri C, Deli G, Giardina B, Capoluongo E, Ameglio F. Association of periodontitis with GSTM1/GSTT1-null variants-a pilot study. Clin Biochem. 2007 Sep;40(13-14):939-45. Epub 2007 Apr 27.

GSTM1	AgP+CP	83	144	0.0007	Moderate	Caucasian	CC	N	Glutathione S-transferase mu 1	MU; H-B; GST1; GTH4; GTM1; MU-1; GSTM1-1; MGC26563; GSTM1a-1a; GSTM1b-1b; GSTM1	1	n/a	17524385	Concolino P, Cecchetti F, D'Autilia C, Santonocito C, Di Stasio E, Zuppi C, Arcuri C, Deli G, Giardina B, Capoluongo E, Ameglio F. Association of periodontitis with GSTM1/GSTT1-null variants-a pilot study. Clin Biochem. 2007 Sep;40(13-14):939-45. Epub 2007 Apr 27.
GSTM1	CP	69	130	0.001	Weak	Caucasian	CC	AGHS	Glutathione S-transferase mu 1	MU; H-B; GST1; GTH4; GTM1; MU-1; GSTM1-1; MGC26563; GSTM1a-1a; GSTM1b-1b; GSTM1	1	n/a	17524385	Concolino P, Cecchetti F, D'Autilia C, Santonocito C, Di Stasio E, Zuppi C, Arcuri C, Deli G, Giardina B, Capoluongo E, Ameglio F. Association of periodontitis with GSTM1/GSTT1-null variants-a pilot study. Clin Biochem. 2007 Sep;40(13-14):939-45. Epub 2007 Apr 27.
GSTM1	CP	115	241	0.05	Weak	Korean	CC	S	Glutathione S-transferase mu 1	MU; H-B; GST1; GTH4; GTM1; MU-1; GSTM1-1; MGC26563; GSTM1a-1a; GSTM1b-1b; GSTM1	1	n/a	15491310	Kim JS, Park JY, Chung WY, Choi MA, Cho KS, Park KK. Polymorphisms in genes coding for enzymes metabolizing smoking-derived substances and the risk of periodontitis. J Clin Periodontol. 2004 Nov;31(11):959-64.
GSTM1. GSTT1	AgP	14	75	<0.0001	Moderate	Caucasian	CC	N	n/a	n/a	2	Multiple Genes	17524385	Concolino P, Cecchetti F, D'Autilia C, Santonocito C, Di Stasio E, Zuppi C, Arcuri C, Deli G, Giardina B, Capoluongo E, Ameglio F. Association of periodontitis with GSTM1/GSTT1-null variants-a pilot study. Clin Biochem. 2007 Sep;40(13-14):939-45. Epub 2007 Apr 27.
GSTM1. GSTT1	AgP+CP	83	144	0.034	Weak	Caucasian	CC	AGHS	n/a	n/a	2	Multiple Genes	17524385	Concolino P, Cecchetti F, D'Autilia C, Santonocito C, Di Stasio E, Zuppi C, Arcuri C, Deli G, Giardina B, Capoluongo E, Ameglio F. Association of periodontitis with GSTM1/GSTT1-null variants-a pilot study. Clin Biochem. 2007 Sep;40(13-14):939-45. Epub 2007 Apr 27.

Continued

TABLE 6-3 Association Study—cont'd

Gene Symbol	Disease Type	Cases	Total	Best *P* Value	Level of Support	Population	Study Design	Stratified or Covariate Adj	Gene Name	Gene Aliases	# SNPs Assayed	SNP Name	PubMed ID	Journal
GSTT1	AgP	14	75	ns	None	Caucasian	CC	N	Glutathione S-transferase theta 1	GSTT1	1	n/a	17524385	Concolino P, Cecchetti F, D'Autilia C, Santonocito C, Di Stasio E, Zuppi C, Arcuri C, Deli G, Giardina B, Capoluongo E, Ameglio F. Association of periodontitis with GSTM1/GSTT1-null variants-a pilot study. Clin Biochem. 2007 Sep;40(13-14):939-45. Epub 2007 Apr 27.
GSTT1	AgP+CP	83	144	ns	None	Caucasian	CC	N	Glutathione S-transferase theta 1	GSTT1	1	n/a	17524385	Concolino P, Cecchetti F, D'Autilia C, Santonocito C, Di Stasio E, Zuppi C, Arcuri C, Deli G, Giardina B, Capoluongo E, Ameglio F. Association of periodontitis with GSTM1/GSTT1-null variants-a pilot study. Clin Biochem. 2007 Sep;40(13-14):939-45. Epub 2007 Apr 27.
GSTT1	CP	69	130	ns	None	Caucasian	CC	N	Glutathione S-transferase theta 1	GSTT1	1	n/a	17524385	Concolino P, Cecchetti F, D'Autilia C, Santonocito C, Di Stasio E, Zuppi C, Arcuri C, Deli G, Giardina B, Capoluongo E, Ameglio F. Association of periodontitis with GSTM1/GSTT1-null variants-a pilot study. Clin Biochem. 2007 Sep;40(13-14):939-45. Epub 2007 Apr 27.
GSTT2	CP	22	41	ns	None	Japanese	CC	N	Glutathione S-transferase theta 2	MGC182032; GSTT2	1	n/a	15490304	Suzuki A, Ji G, Numabe Y, Ishii K, Muramatsu M, Kamoi K. Large-scale investigation of genomic markers for severe periodontitis. Odontology. 2004 Sep;92(1):43-7.
GZMB	CP	22	41	ns	None	Japanese	CC	N	Granzyme B (granzyme 2, cytotoxic T-lymphocyte-associated serine esterase 1)	HLP; CCPI; CGL1; CSPB; SECT; CGL-1; CSP-B; CTLA1; CTSGL1; GZMB	2	Multiple SNPs	15490304	Suzuki A, Ji G, Numabe Y, Ishii K, Muramatsu M, Kamoi K. Large-scale investigation of genomic markers for severe periodontitis. Odontology. 2004 Sep;92(1):43-7.

HBEGF	AgP+CP	251	376	ns	None	Japanese	CC	N	Heparin-binding EGF-like growth factor	DTR; DTS; DTSF; HEGFL; HBEGF	n/a	n/a	15081423	Suzuki A, Ji G, Numabe Y, Muramatsu M, Gomi K, Kanazashi M, Ogata Y, Shimizu E, Shibukawa Y, Ito A, Ito T, Sugaya A, Arai T, Yamada S, Deguchi S, Kamoi K. Single nucleotide polymorphisms associated with aggressive periodontitis and severe chronic periodontitis in Japanese. Biochem Biophys Res Commun. 2004 May 7;317(3):887-92.
HFE	CP	22	41	ns	None	Japanese	CC	N	Hemochromatosis	HH; HFE1; HLA-H; MVCD7; MGC103790; dJ221C16.10.1; HFE	3	Multiple SNPs	15490304	Suzuki A, Ji G, Numabe Y, Ishii K, Muramatsu M, Kamoi K. Large-scale investigation of genomic markers for severe periodontitis. Odontology. 2004 Sep;92(1):43-7.
HGF	CP	22	41	ns	None	Japanese	CC	N	Hepatocyte growth factor (hepapoietin A; scatter factor)	SF; HGFB; HPTA; F-TCF; DFNB39; HGF	3	Multiple SNPs	15490304	Suzuki A, Ji G, Numabe Y, Ishii K, Muramatsu M, Kamoi K. Large-scale investigation of genomic markers for severe periodontitis. Odontology. 2004 Sep;92(1):43-7.
HLA-A	AgP	50	152	0.007	Weak	Caucasian	CC	N		HLAA; FLJ26655; HLA-A	n/a	A*30/31	12296785	Machulla HK, Stein J, Gautsch A, Langner J, Schaller HG, Reichert S. HLA-A, B, Cw, DRB1, DRB3/4/5, DQB1 in German patients suffering from rapidly progressive periodontitis (RPP) and adult periodontitis (AP). J Clin Periodontol. 2002 Jun;29(6):573-9.
HLA-A	AgP	50	152	0.007	Weak	Caucasian	CC	G	Major histocompatibility complex, class I, A	HLAA; FLJ26655; HLA-A	n/a	A*68/69	12485327	Reichert S, Stein J, Gautsch A, Schaller HG, Machulla HK. Gender differences in HLA phenotype frequencies found in German patients with generalized aggressive periodontitis and chronic periodontitis. Oral Microbiol Immunol. 2002 Dec;17(6): 360-8.
HLA-A	AgP	44	2085	0.018	Weak	Caucasian	CC	N	Major histocompatibility complex, class I, A	HLAA; FLJ26655; HLA-A	n/a	A24	3641478	Klouda PT, Porter SR, Scully C, Corbin SA, Bradley BA, Smith R, Davies RM. Association between HLA-A9 and rapidly progressive periodontitis. Tissue Antigens. 1986 Sep;28(3):146-9.

Continued

TABLE 6-3 Association Study—cont'd

Gene Symbol	Disease Type	Cases	Total	Best *P* Value	Level of Support	Population	Study Design	Stratified or Covariate Adj	Gene Name	Gene Aliases	# SNPs Assayed	SNP Name	PubMed ID	Journal
HLA-A	AgP	18	18	0.04	Weak	Black	CC	N	Major histocompatibility complex, class I, A	HLAA; FLJ26655; HLA-A	14	A33	3457042	Cogen RB, Roseman JM, Al-Joburi W, Louv WC, Acton RT, Barger BO, Go RC, Rasmussen RA. Host factors in juvenile periodontitis. J Dent Res. 1986 Mar;65(3):394-9.
HLA-A	AgP	50	152	0.04	Weak	Caucasian	CC	N	Major histocompatibility complex, class I, A	HLAA; FLJ26655; HLA-A	n/a	A*02, A*03	12941076	Stein J, Reichert S, Gautsch A, Machulla HK. Are there HLA combinations typical supporting for or making resistant against aggressive and/or chronic periodontitis? J Periodontal Res. 2003 Oct;38(5):508-17.
HLA-A	AgP	28	69	<0.003	Weak	Caucasian	CC	N	Major histocompatibility complex, class I, A	HLAA; FLJ26655; HLA-A	n/a	A2	1054359	Kaslick RS, West TL, Chasens AI, Terasaki PI, Lazzara R, Weinberg S. Association between HL-A2 antigen and various periodontal diseases in young adults. J Dent Res. 1975 Mar-Apr;54(2):424.
HLA-A	AgP	26	139	<0.005	Weak	non-Ashkenazi	CC	E	Major histocompatibility complex, class I, A	HLAA; FLJ26655; HLA-A	n/a	A9	15111626	Shapira L, Eizenberg S, Sela MN, Soskolne A, Brautbar H. HLA A9 and B15 are associated with the generalized form, but not the localized form, of early-onset periodontal diseases. J Periodontol. 1994 Mar;65(3):219-23.
HLA-A	AgP	49	89	<0.01	Weak	Caucasian	CC	N	Major histocompatibility complex, class I, A	HLAA; FLJ26655; HLA-A	n/a	A9	3163857	Amer A, Singh G, Darke C, Dolby AE. Association between HLA antigens and periodontal disease. Tissue Antigens. 1988 Feb;31(2):53-8.
HLA-A	AgP	26	139	<0.05	Weak	non-Ashkenazi	CC	E	Major histocompatibility complex, class I, A	HLAA; FLJ26655; HLA-A	n/a	B15	15111626	Shapira L, Eizenberg S, Sela MN, Soskolne A, Brautbar H. HLA A9 and B15 are associated with the generalized form, but not the localized form, of early-onset periodontal diseases. J Periodontol. 1994 Mar;65(3):219-23.
HLA-A	AgP	30	370	<0.05	Weak	Mixed	CC	E	Major histocompatibility complex, class I, A	HLAA; FLJ26655; HLA-A	n/a	Blank	6155463	Cullinan MP, Sachs J, Wolf E, Seymour GJ. The distribution of HLA-A and -B antigens in patients and their families with periodontosis. J Periodontal Res. 1980 Mar;15(2):177-84.

HLA-A	AgP	19	60	ns	None	Caucasian	CC	N	Major histocompatibility complex, class I, A	HLAA; FLJ26655; HLA-A	n/a	A2	50636	Terasaki PI, Kaslick RS, West TL, Chasens AI. Low HL-A2 frequency and periodontitis. Tissue Antigens. 1975 May;5(4):286-8.
HLA-A	AgP	19	60	ns	None	Caucasian	CC	N	Major histocompatibility complex, class I, A	HLAA; FLJ26655; HLA-A	n/a	A2	1054359	Kaslick RS, West TL, Chasens AI, Terasaki PI, Lazzara R, Weinberg S. Association between HL-A2 antigen and various periodontal diseases in young adults. J Dent Res. 1975 Mar-Apr;54(2):424.
HLA-A	AgP	10	130	ns	None	Mixed	CC	N	Major histocompatibility complex, class I, A	HLAA; FLJ26655; HLA-A	n/a	Multiple SNPs	3498813	Katz J, Goultschin J, Benoliel R, Brautbar C. Human leukocyte antigen (HLA) DR4. Positive association with rapidly progressing periodontitis. J Periodontol. 1987 Sep;58(9):607-10.
HLA-A	AgP	60	3791	sig	Weak	Turkish	CC	N	Major histocompatibility complex, class I, A	HLAA; FLJ26655; HLA-A	13	A9	8811476	Firatli E, Kantarci A, Cebeci I, Tanyeri H, Sönmez G, Carin M, Tuncer O. Association between HLA antigens and early onset periodontitis. J Clin Periodontol. 1996 Jun;23(6):563-6.
HLA-A	AgP	39	2006	sig	Weak	Danish	CC	N	Major histocompatibility complex, class I, A	HLAA; FLJ26655; HLA-A	n/a	A9, A28	272392	Reinholdt J, Bay I, Svejgaard A. Association between HLA-antigens and periodontal disease. J Dent Res. 1977 Oct;56(10):1261-3.
HLA-A	CP	102	204	0.032	Weak	Caucasian	CC	N	Major histocompatibility complex, class I, A	HLAA; FLJ26655; HLA-A	n/a	A*29	12296785	Machulla HK, Stein J, Gautsch A, Langner J, Schaller HG, Reichert S. HLA-A, B, Cw, DRB1, DRB3/4/5, DQB1 in German patients suffering from rapidly progressive periodontitis (RPP) and adult periodontitis (AP). J Clin Periodontol. 2002 Jun;29(6):573-9.
HLA-A	CP	102	204	0.032	Weak	Caucasian	CC	N	Major histocompatibility complex, class I, A	HLAA; FLJ26655; HLA-A	n/a	A*01, A*03	12941076	Stein J, Reichert S, Gautsch A, Machulla HK. Are there HLA combinations typical supporting for or making resistant against aggressive and/or chronic periodontitis? J Periodontal Res. 2003 Oct;38(5):508-17.

Continued

TABLE 6-3 Association Study—cont'd

Gene Symbol	Disease Type	Cases	Total	Best *P* Value	Level of Support	Population	Study Design	Stratified or Covariate Adj	Gene Name	Gene Aliases	# SNPs Assayed	SNP Name	PubMed ID	Journal
HLA-A	CP	102	204	0.04	Weak	Caucasian	CC	G	Major histocompatibility complex, class I, A	HLAA; FLJ26655; HLA-A	n/a	A*11	12485327	Reichert S, Stein J, Gautsch A, Schaller HG, Machulla HK. Gender differences in HLA phenotype frequencies found in German patients with generalized aggressive periodontitis and chronic periodontitis. Oral Microbiol Immunol. 2002 Dec;17(6): 360-8.
HLA-A	CP	40	120	ns	None	South Indian	CC	N	Major histocompatibility complex, class I, A	HLAA; FLJ26655; HLA-A	1	A9	17209778	Roshna T, Thomas R, Nandakumar K, Banerjee M. A case-control study on the association of human leukocyte antigen-A*9 and -B*15 alleles with generalized aggressive periodontitis in an Indian population. J Periodontol. 2006 Dec;77(12):1954-63.
HLA-A	CP	25	50	ns	None	Mixed	CC	E	Major histocompatibility complex, class I, A	HLAA; FLJ26655; HLA-A	n/a	A28	6584591	Goteiner D, Goldman MJ. Human lymphocyte antigen haplotype and resistance to periodontitis. J Periodontol. 1984 Mar;55(3):155-8.
HLA-A	CP	28	69	sig	Weak	Caucasian	CC	N	Major histocompatibility complex, class I, A	HLAA; FLJ26655; HLA-A	n/a	A2	50636	Terasaki PI, Kaslick RS, West TL, Chasens AI. Low HL-A2 frequency and periodontitis. Tissue Antigens. 1975 May;5(4):286-8.
HLA-A	CP	62	106	sig	Weak	French	CC	N	Major histocompatibility complex, class I, A	HLAA; FLJ26655; HLA-A	n/a	A9	3093668	Balndin-Texier A, Gueguin M, Fauchet R, Yardin M, Cathelineau G. [The HLA-A9 antigen and chronic periodontitis]. J Parodontol. 1986 Sep;5(3):221-7.
HLA-A. HLA-B	AgP	50	152	0.034	Weak	Caucasian	CC	N	n/a	n/a	n/a	Multiple Genes	12941076	Stein J, Reichert S, Gautsch A, Machulla HK. Are there HLA combinations typical supporting for or making resistant against aggressive and/or chronic periodontitis? J Periodontal Res. 2003 Oct;38(5):508-17.

HLA-A. HLA-B	CP	40	120	0.011	Weak	South Indian	CC	N	n/a	n/a	2	Multiple Genes	17209778	Roshna T, Thomas R, Nandakumar K, Banerjee M. A case-control study on the association of human leukocyte antigen-A*9 and -B*15 alleles with generalized aggressive periodontitis in an Indian population. J Periodontol. 2006 Dec;77(12):1954-63.
HLA-A. HLA-B	CP	102	204	0.03	Weak	Caucasian	CC	N	n/a	n/a	n/a	Multiple Genes	12941076	Stein J, Reichert S, Gautsch A, Machulla HK. Are there HLA combinations typical supporting for or making resistant against aggressive and/or chronic periodontitis? J Periodontal Res. 2003 Oct;38(5):508-17.
HLA-A.HLA-Cw	AgP	50	152	0.031	Weak	Caucasian	CC	N	n/a	n/a	n/a	Multiple Genes	12941076	Stein J, Reichert S, Gautsch A, Machulla HK. Are there HLA combinations typical supporting for or making resistant against aggressive and/or chronic periodontitis? J Periodontal Res. 2003 Oct;38(5):508-17.
HLA-B	AgP	30	370	<0.001	Weak	Mixed	CC	E	Major histocompatibility complex, class I, B	AS; HLAB; HLAC; SPDA1; HLA-B27; HLA-B73; MGC111087; HLA-B-7301; HLA-B	n/a	BW35	6155463	Cullinan MP, Sachs J, Wolf E, Seymour GJ. The distribution of HLA-A and -B antigens in patients and their families with periodontosis. J Periodontal Res. 1980 Mar;15(2):177-84.
HLA-B	AgP	18	18	ns	None	Black	CC	N	Major histocompatibility complex, class I, B	AS; HLAB; HLAC; SPDA1; HLA-B27; HLA-B73; MGC111087; HLA-B-7301; HLA-B	32	Multiple SNPs	3457042	Cogen RB, Roseman JM, Al-Joburi W, Louv WC, Acton RT, Barger BO, Go RC, Rasmussen RA. Host factors in juvenile periodontitis. J Dent Res. 1986 Mar;65(3):394-9.
HLA-B	AgP	60	3791	ns	None	Turkish	CC	N	Major histocompatibility complex, class I, B	AS; HLAB; HLAC; SPDA1; HLA-B27; HLA-B73; MGC111087; HLA-B-7301; HLA-B	18	Multiple SNPs	8811476	Firatli E, Kantarci A, Cebeci I, Tanyeri H, Sönmez G, Carin M, Tuncer O. Association between HLA antigens and early onset periodontitis. J Clin Periodontol. 1996 Jun;23(6):563-6.

Continued

TABLE 6-3 Association Study—cont'd

Gene Symbol	Disease Type	Cases	Total	Best *P* Value	Level of Support	Population	Study Design	Stratified or Covariate Adj	Gene Name	Gene Aliases	# SNPs Assayed	SNP Name	PubMed ID	Journal
HLA-B	AgP	50	152	ns	None	Caucasian	CC	N	Major histocompatibility complex, class I, B	AS; HLAB; HLAC; SPDA1; HLA-B27; HLA-B73; MGC111087; HLA-B-7301; HLA-B	n/a	n/a	12296785	Machulla HK, Stein J, Gautsch A, Langner J, Schaller HG, Reichert S. HLA-A, B, Cw, DRB1, DRB3/4/5, DQB1 in German patients suffering from rapidly progressive periodontitis (RPP) and adult periodontitis (AP). J Clin Periodontol. 2002 Jun;29(6):573-9.
HLA-B	AgP	50	152	ns	None	Caucasian	CC	G	Major histocompatibility complex, class I, B	AS; HLAB; HLAC; SPDA1; HLA-B27; HLA-B73; MGC111087; HLA-B-7301; HLA-B	n/a	n/a	12485327	Reichert S, Stein J, Gautsch A, Schaller HG, Machulla HK. Gender differences in HLA phenotype frequencies found in German patients with generalized aggressive periodontitis and chronic periodontitis. Oral Microbiol Immunol. 2002 Dec;17(6): 360-8.
HLA-B	AgP	50	152	ns	None	Caucasian	CC	N	Major histocompatibility complex, class I, B	AS; HLAB; HLAC; SPDA1; HLA-B27; HLA-B73; MGC111087; HLA-B-7301; HLA-B	n/a	n/a	12941076	Stein J, Reichert S, Gautsch A, Machulla HK. Are there HLA combinations typical supporting for or making resistant against aggressive and/or chronic periodontitis? J Periodontal Res. 2003 Oct;38(5):508-17.
HLA-B	AgP	49	89	ns	None	Caucasian	CC	N	Major histocompatibility complex, class I, B	AS; HLAB; HLAC; SPDA1; HLA-B27; HLA-B73; MGC111087; HLA-B-7301; HLA-B	n/a	n/a	3163857	Amer A, Singh G, Darke C, Dolby AE. Association between HLA antigens and periodontal disease. Tissue Antigens. 1988 Feb;31(2):53-8.
HLA-B	AgP	10	130	ns	None	Mixed	CC	N	Major histocompatibility complex, class I, B	AS; HLAB; HLAC; SPDA1; HLA-B27; HLA-B73; MGC111087; HLA-B-7301; HLA-B	n/a	Multiple SNPs	3498813	Katz J, Goultschin J, Benoliel R, Brautbar C. Human leukocyte antigen (HLA) DR4. Positive association with rapidly progressing periodontitis. J Periodontol. 1987 Sep;58(9):607-10.
HLA-B	AgP	44	2085	ns	None	Caucasian	CC	N	Major histocompatibility complex, class I, B	AS; HLAB; HLAC; SPDA1; HLA-B27; HLA-B73; MGC111087; HLA-B-7301; HLA-B	n/a	n/a	3641478	Klouda PT, Porter SR, Scully C, Corbin SA, Bradley BA, Smith R, Davies RM. Association between HLA-A9 and rapidly progressive periodontitis. Tissue Antigens. 1986 Sep;28(3):146-9.

HLA-B	AgP	39	2006	sig	Weak	Danish	CC	N	Major histocompatibility complex, class I, B	AS; HLAB; HLAC; SPDA1; HLA-B27; HLA-B73; MGC111087; HLA-B-7301; HLA-B	n/a	B15	272392	Reinholdt J, Bay I, Svejgaard A. Association between HLA-antigens and periodontal disease. J Dent Res. 1977 Oct;56(10):1261-3.
HLA-B	CP	40	120	0.0004	Weak	South Indian	CC	N	Major histocompatibility complex, class I, B	AS; HLAB; HLAC; SPDA1; HLA-B27; HLA-B73; MGC111087; HLA-B-7301; HLA-B	1	B15	17209778	Roshna T, Thomas R, Nandakumar K, Banerjee M. A case-control study on the association of human leukocyte antigen-A*9 and -B*15 alleles with generalized aggressive periodontitis in an Indian population. J Periodontol. 2006 Dec;77(12):1954-63.
HLA-B	CP	25	50	0.0059	Weak	Mixed	CC	E	Major histocompatibility complex, class I, B	AS; HLAB; HLAC; SPDA1; HLA-B27; HLA-B73; MGC111087; HLA-B-7301; HLA-B	n/a	B5	6584591	Goteiner D, Goldman MJ. Human lymphocyte antigen haplotype and resistance to periodontitis. J Periodontol. 1984 Mar;55(3):155-8.
HLA-B	CP	102	204	0.014	Weak	Caucasian	CC	N	Major histocompatibility complex, class I, B	AS; HLAB; HLAC; SPDA1; HLA-B27; HLA-B73; MGC111087; HLA-B-7301; HLA-B	n/a	B*14	12296785	Machulla HK, Stein J, Gautsch A, Langner J, Schaller HG, Reichert S. HLA-A, B, Cw, DRB1, DRB3/4/5, DQB1 in German patients suffering from rapidly progressive periodontitis (RPP) and adult periodontitis (AP). J Clin Periodontol. 2002 Jun;29(6):573-9.
HLA-B	CP	102	204	0.014	Weak	Caucasian	CC	G	Major histocompatibility complex, class I, B	AS; HLAB; HLAC; SPDA1; HLA-B27; HLA-B73; MGC111087; HLA-B-7301; HLA-B	n/a	B*14	12485327	Reichert S, Stein J, Gautsch A, Schaller HG, Machulla HK. Gender differences in HLA phenotype frequencies found in German patients with generalized aggressive periodontitis and chronic periodontitis. Oral Microbiol Immunol. 2002 Dec;17(6): 360-8.
HLA-B	CP	102	204	ns	None	Caucasian	CC	N	Major histocompatibility complex, class I, B	AS; HLAB; HLAC; SPDA1; HLA-B27; HLA-B73; MGC111087; HLA-B-7301; HLA-B	n/a	n/a	12941076	Stein J, Reichert S, Gautsch A, Machulla HK. Are there HLA combinations typical supporting for or making resistant against aggressive and/or chronic periodontitis? J Periodontal Res. 2003 Oct;38(5):508-17.

Continued

TABLE 6-3 Association Study—cont'd

Gene Symbol	Disease Type	Cases	Total	Best *P* Value	Level of Support	Population	Study Design	Stratified or Covariate Adj	Gene Name	Gene Aliases	# SNPs Assayed	SNP Name	PubMed ID	Journal
HLA-B.HLA-DQB1	CP	102	204	ns	None	Caucasian	CC	N	n/a	n/a	n/a	Multiple Genes	12941076	Stein J, Reichert S, Gautsch A, Machulla HK. Are there HLA combinations typical supporting for or making resistant against aggressive and/or chronic periodontitis? J Periodontal Res. 2003 Oct;38(5):508-17.
HLA-B.HLA-DQB1	CP	102	204	ns	None	Caucasian	CC	N	n/a	n/a	n/a	Multiple Genes	12941076	Stein J, Reichert S, Gautsch A, Machulla HK. Are there HLA combinations typical supporting for or making resistant against aggressive and/or chronic periodontitis? J Periodontal Res. 2003 Oct;38(5):508-17.
HLA-B.HLA-DRB1	CP	102	204	0.029	Weak	Caucasian	CC	N	n/a	n/a	n/a	Multiple Genes	12941076	Stein J, Reichert S, Gautsch A, Machulla HK. Are there HLA combinations typical supporting for or making resistant against aggressive and/or chronic periodontitis? J Periodontal Res. 2003 Oct;38(5):508-17.
HLA-C	AgP	18	18	ns	None	Black	CC	N	Major histocompatibility complex, class I, C	D6S204; FLJ27082; HLA-Cw; HLA-Cw12; HLA-JY3; HLC-C; PSORS1; HLA-C	4	Multiple SNPs	3457042	Cogen RB, Roseman JM, Al-Joburi W, Louv WC, Acton RT, Barger BO, Go RC, Rasmussen RA. Host factors in juvenile periodontitis. J Dent Res. 1986 Mar;65(3):394-9.
HLA-C	AgP	60	3791	ns	None	Turkish	CC	N	Major histocompatibility complex, class I, C	D6S204; FLJ27082; HLA-Cw; HLA-Cw12; HLA-JY3; HLC-C; PSORS1; HLA-C	4	Multiple SNPs	8811476	Firatli E, Kantarci A, Cebeci I, Tanyeri H, Sönmez G, Carin M, Tuncer O. Association between HLA antigens and early onset periodontitis. J Clin Periodontol. 1996 Jun;23(6):563-6.
HLA-C	AgP	50	152	ns	None	Caucasian	CC	N	Major histocompatibility complex, class I, C	D6S204; FLJ27082; HLA-Cw; HLA-Cw12; HLA-JY3; HLC-C; PSORS1; HLA-C	n/a	n/a	12296785	Machulla HK, Stein J, Gautsch A, Langner J, Schaller HG, Reichert S. HLA-A, B, Cw, DRB1, DRB3/4/5, DQB1 in German patients suffering from rapidly progressive periodontitis (RPP) and adult periodontitis (AP). J Clin Periodontol. 2002 Jun;29(6):573-9.

HLA-C	AgP	50	152	ns	None	Caucasian	CC	G	Major histocompatibility complex, class I, C	D6S204; FLJ27082; HLA-Cw; HLA-Cw12; HLA-JY3; HLC-C; PSORS1; HLA-C	n/a	n/a	12485327	Reichert S, Stein J, Gautsch A, Schaller HG, Machulla HK. Gender differences in HLA phenotype frequencies found in German patients with generalized aggressive periodontitis and chronic periodontitis. Oral Microbiol Immunol. 2002 Dec;17(6): 360-8.
HLA-C	AgP	50	152	ns	None	Caucasian	CC	N	Major histocompatibility complex, class I, C	D6S204; FLJ27082; HLA-Cw; HLA-Cw12; HLA-JY3; HLC-C; PSORS1; HLA-C	n/a	n/a	12941076	Stein J, Reichert S, Gautsch A, Machulla HK. Are there HLA combinations typical supporting for or making resistant against aggressive and/or chronic periodontitis? J Periodontal Res. 2003 Oct;38(5):508-17.
HLA-C	AgP	26	139	ns	None	non-Ashkenazi	CC	E	Major histocompatibility complex, class I, C	D6S204; FLJ27082; HLA-Cw; HLA-Cw12; HLA-JY3; HLC-C; PSORS1; HLA-C	n/a	n/a	15111626	Shapira L, Eizenberg S, Sela MN, Soskolne A, Brautbar H. HLA A9 and B15 are associated with the generalized form, but not the localized form, of early-onset periodontal diseases. J Periodontol. 1994 Mar;65(3):219-23.
HLA-C	AgP	10	130	ns	None	Mixed	CC	N	Major histocompatibility complex, class I, C	D6S204; FLJ27082; HLA-Cw; HLA-Cw12; HLA-JY3; HLC-C; PSORS1; HLA-C	n/a	Multiple SNPs	3498813	Katz J, Goultschin J, Benoliel R, Brautbar C. Human leukocyte antigen (HLA) DR4. Positive association with rapidly progressing periodontitis. J Periodontol. 1987 Sep;58(9):607-10.
HLA-C	AgP	44	2085	ns	None	Caucasian	CC	N	Major histocompatibility complex, class I, C	D6S204; FLJ27082; HLA-Cw; HLA-Cw12; HLA-JY3; HLC-C; PSORS1; HLA-C	n/a	n/a	3641478	Klouda PT, Porter SR, Scully C, Corbin SA, Bradley BA, Smith R, Davies RM. Association between HLA-A9 and rapidly progressive periodontitis. Tissue Antigens. 1986 Sep;28(3):146-9.
HLA-C	CP	102	204	0.014	Weak	Caucasian	CC	N	Major histocompatibility complex, class I, C	D6S204; FLJ27082; HLA-Cw; HLA-Cw12; HLA-JY3; HLC-C; PSORS1; HLA-C	n/a	Cw*08	12296785	Machulla HK, Stein J, Gautsch A, Langner J, Schaller HG, Reichert S. HLA-A, B, Cw, DRB1, DRB3/4/5, DQB1 in German patients suffering from rapidly progressive periodontitis (RPP) and adult periodontitis (AP). J Clin Periodontol. 2002 Jun;29(6):573-9.

Continued

TABLE 6-3 Association Study—cont'd

Gene Symbol	Disease Type	Cases	Total	Best *P* Value	Level of Support	Population	Study Design	Stratified or Covariate Adj	Gene Name	Gene Aliases	# SNPs Assayed	SNP Name	PubMed ID	Journal
HLA-C	CP	102	204	0.041	Weak	Caucasian	CC	G	Major histocompatibility complex, class I, C	D6S204; FLJ27082; HLA-Cw; HLA-Cw12; HLA-JY3; HLC-C; PSORS1; HLA-C	n/a	Cw*08	12485327	Reichert S, Stein J, Gautsch A, Schaller HG, Machulla HK. Gender differences in HLA phenotype frequencies found in German patients with generalized aggressive periodontitis and chronic periodontitis. Oral Microbiol Immunol. 2002 Dec;17(6): 360-8.
HLA-C	CP	102	204	ns	None	Caucasian	CC	N	Major histocompatibility complex, class I, C	D6S204; FLJ27082; HLA-Cw; HLA-Cw12; HLA-JY3; HLC-C; PSORS1; HLA-C	n/a	n/a	12941076	Stein J, Reichert S, Gautsch A, Machulla HK. Are there HLA combinations typical supporting for or making resistant against aggressive and/or chronic periodontitis? J Periodontal Res. 2003 Oct;38(5):508-17.
HLA-C. HLA-B	CP	102	204	0.014	Weak	Caucasian	CC	N	n/a	n/a	n/a	Multiple Genes	12941076	Stein J, Reichert S, Gautsch A, Machulla HK. Are there HLA combinations typical supporting for or making resistant against aggressive and/or chronic periodontitis? J Periodontal Res. 2003 Oct;38(5):508-17.
HLA-C.HLA-DQB1	CP	102	204	ns	None	Caucasian	CC	N	n/a	n/a	n/a	Multiple Genes	12941076	Stein J, Reichert S, Gautsch A, Machulla HK. Are there HLA combinations typical supporting for or making resistant against aggressive and/or chronic periodontitis? J Periodontal Res. 2003 Oct;38(5):508-17.
HLA-D	AgP	60	3791	sig	Weak	Turkish	CC	N	n/a	n/a	11	DR4	8811476	Firatli E, Kantarci A, Cebeci I, Tanyeri H, Sönmez G, Carin M, Tuncer O. Association between HLA antigens and early onset periodontitis. J Clin Periodontol. 1996 Jun;23(6):563-6.

HLA-DQ	AgP	50	152	0.019	Weak	Caucasian	CC	G	n/a	n/a	n/a	*05	12485327	Reichert S, Stein J, Gautsch A, Schaller HG, Machulla HK. Gender differences in HLA phenotype frequencies found in German patients with generalized aggressive periodontitis and chronic periodontitis. Oral Microbiol Immunol. 2002 Dec;17(6): 360-8.
HLA-DQ	AgP	26	139	ns	None	non-Ashkenazi	CC	E	n/a	n/a	n/a	n/a	15111626	Shapira L, Eizenberg S, Sela MN, Soskolne A, Brautbar H. HLA A9 and B15 are associated with the generalized form, but not the localized form, of early-onset periodontal diseases. J Periodontol. 1994 Mar;65(3):219-23.
HLA-DQ	CP	102	204	0.028	Weak	Caucasian	CC	G	n/a	n/a	n/a	DQB1*0303	12485327	Reichert S, Stein J, Gautsch A, Schaller HG, Machulla HK. Gender differences in HLA phenotype frequencies found in German patients with generalized aggressive periodontitis and chronic periodontitis. Oral Microbiol Immunol. 2002 Dec;17(6): 360-8.
HLA-DQ	CP	15	30	ns	None	Caucasian	CC	N	n/a	n/a	n/a	DQ1	8277407	Alley CS, Reinhardt RA, Maze CA, DuBois LM, Wahl TO, Duckworth WC, Dyer JK, Petro TM. HLA-D and T lymphocyte reactivity to specific periodontal pathogens in type 1 diabetic periodontitis. J Periodontol. 1993 Oct;64(10):974-9.
HLA-DQ	CP	15	30	ns	None	Caucasian	CC	N	n/a	n/a	n/a	DQ3	8277407	Alley CS, Reinhardt RA, Maze CA, DuBois LM, Wahl TO, Duckworth WC, Dyer JK, Petro TM. HLA-D and T lymphocyte reactivity to specific periodontal pathogens in type 1 diabetic periodontitis. J Periodontol. 1993 Oct;64(10):974-9.

Continued

TABLE 6-3 Association Study—cont'd

Gene Symbol	Disease Type	Cases	Total	Best *P* Value	Level of Support	Population	Study Design	Stratified or Covariate Adj	Gene Name	Gene Aliases	# SNPs Assayed	SNP Name	PubMed ID	Journal
HLA-DQ	CP&T1DM	15	30	0.008	Weak	Caucasian	CC	N	n/a	n/a	n/a	DQ1	8277407	Alley CS, Reinhardt RA, Maze CA, DuBois LM, Wahl TO, Duckworth WC, Dyer JK, Petro TM. HLA-D and T lymphocyte reactivity to specific periodontal pathogens in type 1 diabetic periodontitis. J Periodontol. 1993 Oct;64(10):974-9.
HLA-DQ	CP&T1DM	15	30	ns	None	Caucasian	CC	N	n/a	n/a	n/a	DQ3	8277407	Alley CS, Reinhardt RA, Maze CA, DuBois LM, Wahl TO, Duckworth WC, Dyer JK, Petro TM. HLA-D and T lymphocyte reactivity to specific periodontal pathogens in type 1 diabetic periodontitis. J Periodontol. 1993 Oct;64(10):974-9.
HLA-DQA1	AgP	68	104	0.021	Weak	Japanese	CC	N	Major histocompatibility complex, class II, DQ alpha 1	CD; GSE; DQ-A1; CELIAC1; HLA-DQA; FLJ27088; FLJ27328; MGC149527; HLA-DQA1	6	*03	11338294	Takahashi K, Ohyama H, Kitanaka M, Sawa T, Mineshiba J, Nishimura F, Arai H, Takashiba S, Murayama Y. Heterogeneity of host immunological risk factors in patients with aggressive periodontitis. J Periodontol. 2001 Apr;72(4):425-37.
HLA-DQA1	AgP	24	n/a	ns	None	Japanese	CC	N	Major histocompatibility complex, class II, DQ alpha 1	CD; GSE; DQ-A1; CELIAC1; HLA-DQA; FLJ27088; FLJ27328; MGC149527; HLA-DQA1	n/a	n/a	8884646	Ohyama H, Takashiba S, Oyaizu K, Nagai A, Naruse T, Inoko H, Kurihara H, Murayama Y. HLA Class II genotypes associated with early-onset periodontitis: DQB1 molecule primarily confers susceptibility to the disease. J Periodontol. 1996 Sep;67(9):888-94.
HLA-DQB1	AgP	50	152	0.016	Weak	Caucasian	CC	N	Major histocompatibility complex, class II, DQ beta 1	IDDM1; CELIAC1; HLA-DQB; HLA-DQB1	n/a	DQB1*02, DQB1*0301/4	12941076	Stein J, Reichert S, Gautsch A, Machulla HK. Are there HLA combinations typical supporting for or making resistant against aggressive and/or chronic periodontitis? J Periodontal Res. 2003 Oct;38(5):508-17.

HLA-DQB1	AgP	9	41	<0.001	Weak	Japanese	CC	N	Major histocompatibility complex, class II, DQ beta 1	IDDM1; CELIAC1; HLA-DQB; HLA-DQB1	1	BamHI	19184295	Shimomura-Kuroki J, Yamashita K, Shimooka S. Tannerella forsythia and the HLA-DQB1 allele are associated with susceptibility to periodontal disease in Japanese adolescents. Odontology. 2009 Jan;97(1):32-7. Epub 2009 Jan 29.
HLA-DQB1	AgP	100	200	ns	None	Caucasian	CC	N	Major histocompatibility complex, class II, DQ beta 1	IDDM1; CELIAC1; HLA-DQB; HLA-DQB1	1	BamHI	10488751	Hodge PJ, Riggio MP, Kinane DF. No association with HLA-DQB1 in European Caucasians with early-onset periodontitis. Tissue Antigens. 1999 Aug;54(2):205-7.
HLA-DQB1	AgP	55	100	ns	None	Japanese	CC	N	Major histocompatibility complex, class II, DQ beta 1	IDDM1; CELIAC1; HLA-DQB; HLA-DQB1	n/a	n/a	7913961	Takashiba S, Noji S, Nishimura F, Ohyama H, Kurihara H, Nomura Y, Taniguchi S, Murayama Y. Unique intronic variations of HLA-DQ beta gene in early-onset periodontitis. J Periodontol. 1994 May;65(5):379-86.
HLA-DQB1	AgP	50	152	ns	None	Caucasian	CC	N	Major histocompatibility complex, class II, DQ beta 1	IDDM1; CELIAC1; HLA-DQB; HLA-DQB1	n/a	n/a	12296785	Machulla HK, Stein J, Gautsch A, Langner J, Schaller HG, Reichert S. HLA-A, B, Cw, DRB1, DRB3/4/5, DQB1 in German patients suffering from rapidly progressive periodontitis (RPP) and adult periodontitis (AP). J Clin Periodontol. 2002 Jun;29(6):573-9.
HLA-DQB1	AgP	24	n/a	sig	Weak	Japanese	CC	N	Major histocompatibility complex, class II, DQ beta 1	IDDM1; CELIAC1; HLA-DQB; HLA-DQB1	n/a	n/a	8884646	Ohyama H, Takashiba S, Oyaizu K, Nagai A, Naruse T, Inoko H, Kurihara H, Murayama Y. HLA Class II genotypes associated with early-onset periodontitis: DQB1 molecule primarily confers susceptibility to the disease. J Periodontol. 1996 Sep;67(9):888-94.
HLA-DQB1	CP	102	204	ns	None	Caucasian	CC	N	Major histocompatibility complex, class II, DQ beta 1	IDDM1; CELIAC1; HLA-DQB; HLA-DQB1	n/a	n/a	12296785	Machulla HK, Stein J, Gautsch A, Langner J, Schaller HG, Reichert S. HLA-A, B, Cw, DRB1, DRB3/4/5, DQB1 in German patients suffering from rapidly progressive periodontitis (RPP) and adult periodontitis (AP). J Clin Periodontol. 2002 Jun;29(6):573-9.

Continued

TABLE 6-3 Association Study—cont'd

Gene Symbol	Disease Type	Cases	Total	Best *P* Value	Level of Support	Population	Study Design	Stratified or Covariate Adj	Gene Name	Gene Aliases	# SNPs Assayed	SNP Name	PubMed ID	Journal
HLA-DQB1	CP	102	204	ns	None	Caucasian	CC	N	Major histocompatibility complex, class II, DQ beta 1	IDDM1; CELIAC1; HLA-DQB; HLA-DQB1	n/a	n/a	12941076	Stein J, Reichert S, Gautsch A, Machulla HK. Are there HLA combinations typical supporting for or making resistant against aggressive and/or chronic periodontitis? J Periodontal Res. 2003 Oct;38(5):508-17.
HLA-DR	AgP	10	130	0.0254	Weak	Mixed	CC	N	n/a	n/a	n/a	DR4	3498813	Katz J, Goultschin J, Benoliel R, Brautbar C. Human leukocyte antigen (HLA) DR4. Positive association with rapidly progressing periodontitis. J Periodontol. 1987 Sep;58(9):607-10.
HLA-DR	AgP	50	152	0.026	Weak	Caucasian	CC	G	n/a	n/a	n/a	DRBblank	12485327	Reichert S, Stein J, Gautsch A, Schaller HG, Machulla HK. Gender differences in HLA phenotype frequencies found in German patients with generalized aggressive periodontitis and chronic periodontitis. Oral Microbiol Immunol. 2002 Dec;17(6): 360-8.
HLA-DR	AgP	18	18	ns	None	Black	CC	N	n/a	n/a	9	Multiple SNPs	3457042	Cogen RB, Roseman JM, Al-Joburi W, Louv WC, Acton RT, Barger BO, Go RC, Rasmussen RA. Host factors in juvenile periodontitis. J Dent Res. 1986 Mar;65(3):394-9.
HLA-DR	AgP	26	139	ns	None	non-Ashkenazi	CC	E	n/a	n/a	n/a	n/a	15111626	Shapira L, Eizenberg S, Sela MN, Soskolne A, Brautbar H. HLA A9 and B15 are associated with the generalized form, but not the localized form, of early-onset periodontal diseases. J Periodontol. 1994 Mar;65(3):219-23.
HLA-DR	AgP	44	2085	ns	None	Caucasian	CC	N	n/a	n/a	n/a	n/a	3641478	Klouda PT, Porter SR, Scully C, Corbin SA, Bradley BA, Smith R, Davies RM. Association between HLA-A9 and rapidly progressive periodontitis. Tissue Antigens. 1986 Sep;28(3):146-9.

HLA-DR	CP	15	30	0.002	Weak	Caucasian	CC	N	n/a	n/a	n/a	DR4	8277407	Alley CS, Reinhardt RA, Maze CA, DuBois LM, Wahl TO, Duckworth WC, Dyer JK, Petro TM. HLA-D and T lymphocyte reactivity to specific periodontal pathogens in type 1 diabetic periodontitis. J Periodontol. 1993 Oct;64(10):974-9.
HLA-DR	CP	102	204	ns	None	Caucasian	CC	G	n/a	n/a	n/a	n/a	12485327	Reichert S, Stein J, Gautsch A, Schaller HG, Machulla HK. Gender differences in HLA phenotype frequencies found in German patients with generalized aggressive periodontitis and chronic periodontitis. Oral Microbiol Immunol. 2002 Dec;17(6): 360-8.
HLA-DR	CP	15	30	ns	None	Caucasian	CC	N	n/a	n/a	n/a	DR6	8277407	Alley CS, Reinhardt RA, Maze CA, DuBois LM, Wahl TO, Duckworth WC, Dyer JK, Petro TM. HLA-D and T lymphocyte reactivity to specific periodontal pathogens in type 1 diabetic periodontitis. J Periodontol. 1993 Oct;64(10):974-9.
HLA-DR	CP	15	30	ns	None	Caucasian	CC	N	n/a	n/a	n/a	DR53	8277407	Alley CS, Reinhardt RA, Maze CA, DuBois LM, Wahl TO, Duckworth WC, Dyer JK, Petro TM. HLA-D and T lymphocyte reactivity to specific periodontal pathogens in type 1 diabetic periodontitis. J Periodontol. 1993 Oct;64(10):974-9.
HLA-DR	CP&T1DM	15	30	0.0002	Weak	Caucasian	CC	N	n/a	n/a	n/a	DR6	8277407	Alley CS, Reinhardt RA, Maze CA, DuBois LM, Wahl TO, Duckworth WC, Dyer JK, Petro TM. HLA-D and T lymphocyte reactivity to specific periodontal pathogens in type 1 diabetic periodontitis. J Periodontol. 1993 Oct;64(10):974-9.

Continued

TABLE 6-3 Association Study—cont'd

Gene Symbol	Disease Type	Cases	Total	Best *P* Value	Level of Support	Population	Study Design	Stratified or Covariate Adj	Gene Name	Gene Aliases	# SNPs Assayed	SNP Name	PubMed ID	Journal
HLA-DR	CP&T1DM	15	30	0.0005	Weak	Caucasian	CC	N	n/a	n/a	n/a	DR4	8277407	Alley CS, Reinhardt RA, Maze CA, DuBois LM, Wahl TO, Duckworth WC, Dyer JK, Petro TM. HLA-D and T lymphocyte reactivity to specific periodontal pathogens in type 1 diabetic periodontitis. J Periodontol. 1993 Oct;64(10):974-9.
HLA-DR	CP&T1DM	15	30	0.025	Weak	Caucasian	CC	N	n/a	n/a	n/a	DR53	8277407	Alley CS, Reinhardt RA, Maze CA, DuBois LM, Wahl TO, Duckworth WC, Dyer JK, Petro TM. HLA-D and T lymphocyte reactivity to specific periodontal pathogens in type 1 diabetic periodontitis. J Periodontol. 1993 Oct;64(10):974-9.
HLA-DRB1	AgP	50	152	0.046	Weak	Caucasian	CC	N	Major histocompatibility complex, class II, DR beta 1	SS1; DRB1; DRw10; HLA-DRB; FLJ75017; FLJ76359; HLA-DR1B; HLA-DRB1*; HLA-DRB1	n/a	DRB1*13	12296785	Machulla HK, Stein J, Gautsch A, Langner J, Schaller HG, Reichert S. HLA-A, B, Cw, DRB1, DRB3/4/5, DQB1 in German patients suffering from rapidly progressive periodontitis (RPP) and adult periodontitis (AP). J Clin Periodontol. 2002 Jun;29(6):573-9.
HLA-DRB1	AgP	24	n/a	ns	None	Japanese	CC	N	Major histocompatibility complex, class II, DR beta 1	SS1; DRB1; DRw10; HLA-DRB; FLJ75017; FLJ76359; HLA-DR1B; HLA-DRB1*; HLA-DRB1	n/a	n/a	8884646	Ohyama H, Takashiba S, Oyaizu K, Nagai A, Naruse T, Inoko H, Kurihara H, Murayama Y. HLA Class II genotypes associated with early-onset periodontitis: DQB1 molecule primarily confers susceptibility to the disease. J Periodontol. 1996 Sep;67(9):888-94.
HLA-DRB1	AgP	55	100	ns	None	Japanese	CC	N	Major histocompatibility complex, class II, DR beta 1	SS1; DRB1; DRw10; HLA-DRB; FLJ75017; FLJ76359; HLA-DR1B; HLA-DRB1*; HLA-DRB1	n/a	n/a	7913961	Takashiba S, Noji S, Nishimura F, Ohyama H, Kurihara H, Nomura Y, Taniguchi S, Murayama Y. Unique intronic variations of HLA-DQ beta gene in early-onset periodontitis. J Periodontol. 1994 May;65(5):379-86.

HLA-DRB1	AgP	50	152	ns	None	Caucasian	CC	N	Major histocompatibility complex, class II, DR beta 1	SS1; DRB1; DRw10; HLA-DRB; FLJ75017; FLJ76359; HLA-DR1B; HLA-DRB1*; HLA-DRB1	n/a	n/a	12941076	Stein J, Reichert S, Gautsch A, Machulla HK. Are there HLA combinations typical supporting for or making resistant against aggressive and/or chronic periodontitis? J Periodontal Res. 2003 Oct;38(5):508-17.
HLA-DRB1	AgP	n/a	n/a	sig	Weak	Chinese	CC	N	Major histocompatibility complex, class II, DR beta 1	SS1; DRB1; DRw10; HLA-DRB; FLJ75017; FLJ76359; HLA-DR1B; HLA-DRB1*; HLA-DRB1	1	* 1501	19031816	Wang HY, Pan YP. [Screening and analysis of multi-alleles in generalized aggressive periodontitis]. Zhonghua Kou Qiang Yi Xue Za Zhi. 2008 Jul;43(7):406-9. Chinese.
HLA-DRB1	CP	48	103	0.0058	Weak	Mixed	CC	N	Major histocompatibility complex, class II, DR beta 1	SS1; DRB1; DRw10; HLA-DRB; FLJ75017; FLJ76359; HLA-DR1B; HLA-DRB1*; HLA-DRB1	22	DRST2	10048640	Bonfil JJ, Dillier FL, Mercier P, Reviron D, Foti B, Sambuc R, Brodeur JM, Sedarat C. A "case control" study on the rôle of HLA DR4 in severe periodontitis and rapidly progressive periodontitis. Identification of types and subtypes using molecular biology (PCR.SSO). J Clin Periodontol. 1999 Feb;26(2):77-84.
HLA-DRB1	CP	134	215	<0.05	Weak	Chinese	CC	N	Major histocompatibility complex, class II, DR beta 1	SS1; DRB1; DRw10; HLA-DRB; FLJ75017; FLJ76359; HLA-DR1B; HLA-DRB1*; HLA-DRB1	1	* 1501	15269854	Zhang SJ, Yang AL, Zhang JC, Zhang YH, Tang Y. [Association of HLA-DRB1*1501 polymorphism with the susceptibility to severe chronic periodontitis in Chinese Han nationality]. Shanghai Kou Qiang Yi Xue. 2004 Jun;13(3):182-5. Chinese.
HLA-DRB1	CP	102	204	ns	None	Caucasian	CC	N	Major histocompatibility complex, class II, DR beta 1	SS1; DRB1; DRw10; HLA-DRB; FLJ75017; FLJ76359; HLA-DR1B; HLA-DRB1*; HLA-DRB1	n/a	n/a	12296785	Machulla HK, Stein J, Gautsch A, Langner J, Schaller HG, Reichert S. HLA-A, B, Cw, DRB1, DRB3/4/5, DQB1 in German patients suffering from rapidly progressive periodontitis (RPP) and adult periodontitis (AP). J Clin Periodontol. 2002 Jun;29(6):573-9.

Continued

TABLE 6-3 Association Study—cont'd

Gene Symbol	Disease Type	Cases	Total	Best *P* Value	Level of Support	Population	Study Design	Stratified or Covariate Adj	Gene Name	Gene Aliases	# SNPs Assayed	SNP Name	PubMed ID	Journal
HLA-DRB1	CP	102	204	ns	None	Caucasian	CC	N	Major histocompatibility complex, class II, DR beta 1	SS1; DRB1; DRw10; HLA-DRB; FLJ75017; FLJ76359; HLA-DR1B; HLA-DRB1*; HLA-DRB1	n/a	n/a	12941076	Stein J, Reichert S, Gautsch A, Machulla HK. Are there HLA combinations typical supporting for or making resistant against aggressive and/or chronic periodontitis? J Periodontal Res. 2003 Oct;38(5):508-17.
HLA-DRB1. HLA-DQB1	AgP	50	152	0.041	Weak	Caucasian	CC	N	n/a	n/a	n/a	Multiple Genes	12941076	Stein J, Reichert S, Gautsch A, Machulla HK. Are there HLA combinations typical supporting for or making resistant against aggressive and/or chronic periodontitis? J Periodontal Res. 2003 Oct;38(5):508-17.
HLA-DRB3/4/5	AgP	50	152	0.036	Weak	Caucasian	CC	N	n/a	n/a	n/a	DRBblank	12296785	Machulla HK, Stein J, Gautsch A, Langner J, Schaller HG, Reichert S. HLA-A, B, Cw, DRB1, DRB3/4/5, DQB1 in German patients suffering from rapidly progressive periodontitis (RPP) and adult periodontitis (AP). J Clin Periodontol. 2002 Jun;29(6):573-9.
HLA-DRB3/4/5	AgP	50	152	ns	None	Caucasian	CC	N	n/a	n/a	n/a	DRBblank	12941076	Stein J, Reichert S, Gautsch A, Machulla HK. Are there HLA combinations typical supporting for or making resistant against aggressive and/or chronic periodontitis? J Periodontal Res. 2003 Oct;38(5):508-17.
HLA-DRB3/4/5	CP	102	204	0.035	Weak	Caucasian	CC	N	n/a	n/a	n/a	DRBblank	12941076	Stein J, Reichert S, Gautsch A, Machulla HK. Are there HLA combinations typical supporting for or making resistant against aggressive and/or chronic periodontitis? J Periodontal Res. 2003 Oct;38(5):508-17.

HLA-DRB3/4/5	CP	102	204	ns	None	Caucasian	CC	N	n/a	n/a	n/a	DRBblank	12296785	Machulla HK, Stein J, Gautsch A, Langner J, Schaller HG, Reichert S. HLA-A, B, Cw, DRB1, DRB3/4/5, DQB1 in German patients suffering from rapidly progressive periodontitis (RPP) and adult periodontitis (AP). J Clin Periodontol. 2002 Jun;29(6):573-9.
HNF4A	CP	22	41	ns	None	Japanese	CC	N	Hepatocyte nuclear factor 4, alpha	TCF; HNF4; MODY; MODY1; NR2A1; TCF14; HNF4a7; HNF4a8; HNF4a9; NR2A21; FLJ39654; HNF4alpha; HNF4A	2	Multiple SNPs	15490304	Suzuki A, Ji G, Numabe Y, Ishii K, Muramatsu M, Kamoi K. Large-scale investigation of genomic markers for severe periodontitis. Odontology. 2004 Sep;92(1):43-7.
HPGD	AgP+CP	251	376	ns	None	Japanese	CC	N	Hydroxyprostaglandin deHydrogenase 15-(NAD)	PGDH; PGDH1; 15-PGDH; SDR36C1; HPGD	n/a	n/a	15081423	Suzuki A, Ji G, Numabe Y, Muramatsu M, Gomi K, Kanazashi M, Ogata Y, Shimizu E, Shibukawa Y, Ito A, Ito T, Sugaya A, Arai T, Yamada S, Deguchi S, Kamoi K. Single nucleotide polymorphisms associated with aggressive periodontitis and severe chronic periodontitis in Japanese. Biochem Biophys Res Commun. 2004 May 7;317(3):887-92.
HSPG2	AgP+CP	251	376	0.007	Weak	Japanese	CC	N	Heparan sulfate proteoglycan 2	PLC; SJA; SJS; SJS1; PRCAN; HSPG2	n/a	Chr:1 G/T	15081423	Suzuki A, Ji G, Numabe Y, Muramatsu M, Gomi K, Kanazashi M, Ogata Y, Shimizu E, Shibukawa Y, Ito A, Ito T, Sugaya A, Arai T, Yamada S, Deguchi S, Kamoi K. Single nucleotide polymorphisms associated with aggressive periodontitis and severe chronic periodontitis in Japanese. Biochem Biophys Res Commun. 2004 May 7;317(3):887-92.
HSPG2	CP	22	41	ns	None	Japanese	CC	N	Heparan sulfate proteoglycan 2	PLC; SJA; SJS; SJS1; PRCAN; HSPG2	1	n/a	15490304	Suzuki A, Ji G, Numabe Y, Ishii K, Muramatsu M, Kamoi K. Large-scale investigation of genomic markers for severe periodontitis. Odontology. 2004 Sep;92(1):43-7.

Continued

TABLE 6-3 Association Study—cont'd

Gene Symbol	Disease Type	Cases	Total	Best *P* Value	Level of Support	Population	Study Design	Stratified or Covariate Adj	Gene Name	Gene Aliases	# SNPs Assayed	SNP Name	PubMed ID	Journal
HTN3	CP	80	143	ns	None	Japanese	CC	N	Histatin 3	HIS2; HTN2; HTN5; HTN3	1	Codon23-HIS2	19753800	Fujigaki Y, Imamura Y, Oomori Y, Ouryouji K, Miyazawa H, Wang PL. Polymorphism of salivary histatin gene and periodontal disease in the Japanese population. J Int Acad Periodontol. 2009 Jul;11(3):220-5.
HTRA1	CP	22	41	ns	None	Japanese	CC	N	HtrA serine peptidase 1	L56; HtrA; ARMD7; ORF480; PRSS11; HTRA1	9	Multiple SNPs	15490304	Suzuki A, Ji G, Numabe Y, Ishii K, Muramatsu M, Kamoi K. Large-scale investigation of genomic markers for severe periodontitis. Odontology. 2004 Sep;92(1):43-7.
ICAM1	CP	137	219	ns	None	Caucasian	CC	GS	Intercellular adhesion molecule 1	BB2; CD54; P3.58; ICAM1	1	1548 A>G	16512757	Wohlfahrt JC, Wu T, Hodges JS, Hinrichs JE, Michalowicz BS. No association between selected candidate gene polymorphisms and severe chronic periodontitis. J Periodontol. 2006 Mar;77(3):426-36.
ICOS	CP	137	219	ns	None	Caucasian	CC	GS	Inducible T-cell co-stimulator	AILIM; CD278; MGC39850; ICOS	1	3990 G>T	16512757	Wohlfahrt JC, Wu T, Hodges JS, Hinrichs JE, Michalowicz BS. No association between selected candidate gene polymorphisms and severe chronic periodontitis. J Periodontol. 2006 Mar;77(3):426-36.
IFI27	CP	22	41	ns	None	Japanese	CC	N	Interferon, alpha-inducible protein 27	P27; ISG12; FAM14D; ISG12A; IFI27	2	Multiple SNPs	15490304	Suzuki A, Ji G, Numabe Y, Ishii K, Muramatsu M, Kamoi K. Large-scale investigation of genomic markers for severe periodontitis. Odontology. 2004 Sep;92(1):43-7.
IFI30	CP	22	41	ns	None	Japanese	CC	N	Interferon, gamma-inducible protein 30	GILT; IP30; IFI-30; MGC32056; IFI30	1	n/a	15490304	Suzuki A, Ji G, Numabe Y, Ishii K, Muramatsu M, Kamoi K. Large-scale investigation of genomic markers for severe periodontitis. Odontology. 2004 Sep;92(1):43-7.

IFNAR1	CP	22	41	ns	None	Japanese	CC	N	Interferon (alpha, beta and omega) receptor 1	AVP; IFRC; IFNAR; IFNBR; IFN-alpha-REC; IFNAR1	3	Multiple SNPs	15490304	Suzuki A, Ji G, Numabe Y, Ishii K, Muramatsu M, Kamoi K. Large-scale investigation of genomic markers for severe periodontitis. Odontology. 2004 Sep;92(1):43-7.
IFNAR2	CP	22	41	ns	None	Japanese	CC	N	Interferon (alpha, beta and omega) receptor 2	IFN-R; IFNABR; IFNARB; IFN-alpha-REC; IFNAR2	6	Multiple SNPs	15490304	Suzuki A, Ji G, Numabe Y, Ishii K, Muramatsu M, Kamoi K. Large-scale investigation of genomic markers for severe periodontitis. Odontology. 2004 Sep;92(1):43-7.
IFNG	AgP	72	146	ns	None	German	CC	N	Interferon, gamma	IFG; IFI; IFNG	1	874 T/A	18672993	Reichert S, Machulla HK, Klapproth J, Zimmermann U, Reichert Y, Gläser C, Schaller HG, Schulz S. Interferon-gamma and interleukin-12 gene polymorphisms and their relation to aggressive and chronic periodontitis and key periodontal pathogens. J Periodontol. 2008 Aug;79(8):1434-43.
IFNG	AgP	98	186	ns	None	Japanese	CC	N	Interferon, gamma	IFG; IFI; IFNG	1	rs2069718	16844084	Rabello D, Soedarsono N, Kamei H, Ishihara Y, Noguchi T, Fuma D, Suzuki M, Sakaki Y, Yamaguchi A, Kojima T. CSF1 gene associated with aggressive periodontitis in the Japanese population. Biochem Biophys Res Commun. 2006 Sep 1;347(3):791-6. Epub 2006 Jul 7.
IFNG	AgP+CP	53	109	ns	None	Iranian	CC	N	Interferon, gamma	IFG; IFI; IFNG	1	G5644A	18230112	Hooshmand B, Hajilooi M, Rafiei A, Mani-Kashani KH, Ghasemi R. Interleukin-4 (C-590T) and interferon-gamma (G5644A) gene polymorphisms in patients with periodontitis. J Periodontal Res. 2008 Feb;43(1):111-5.
IFNG	CP	52	126	ns	None	German	CC	N	Interferon, gamma	IFG; IFI; IFNG	1	874 T/A	18672993	Reichert S, Machulla HK, Klapproth J, Zimmermann U, Reichert Y, Gläser C, Schaller HG, Schulz S. Interferon-gamma and interleukin-12 gene polymorphisms and their relation to aggressive and chronic periodontitis and key periodontal pathogens. J Periodontol. 2008 Aug;79(8):1434-43.

Continued

TABLE 6-3 Association Study—cont'd

Gene Symbol	Disease Type	Cases	Total	Best *P* Value	Level of Support	Population	Study Design	Stratified or Covariate Adj	Gene Name	Gene Aliases	# SNPs Assayed	SNP Name	PubMed ID	Journal
IFNG	CP	122	236	ns	None	German	CC	N	Interferon, gamma	IFG; IFI; IFNG	1	874 T/A	17209781	Babel N, Cherepnev G, Babel D, Tropmann A, Hammer M, Volk HD, Reinke P. Analysis of tumor necrosis factor-alpha, transforming growth factor-beta, interleukin-10, IL-6, and interferon-gamma gene polymorphisms in patients with chronic periodontitis. J Periodontol. 2006 Dec;77(12):1978-83.
IFNGR1	AgP	98	186	ns	None	Japanese	CC	N	Interferon gamma receptor 1	CD119; IFNGR; FLJ45734; IFNGR1	1	rs3799488	16844084	Rabello D, Soedarsono N, Kamei H, Ishihara Y, Noguchi T, Fuma D, Suzuki M, Sakaki Y, Yamaguchi A, Kojima T. CSF1 gene associated with aggressive periodontitis in the Japanese population. Biochem Biophys Res Commun. 2006 Sep 1;347(3):791-6. Epub 2006 Jul 7.
IFNGR1	CP	62	118	0.014	Weak	Caucasian	CC	S	Interferon gamma receptor 1	CD119; IFNGR; FLJ45734; IFNGR1	1	(CA)n	14763782	Fraser DA, Loos BG, Boman U, van Winkelhoff AJ, van der Velden U, Schenck K, Dembic Z. Polymorphisms in an interferon-gamma receptor-1 gene marker and susceptibility to periodontitis. Acta Odontol Scand. 2003 Oct;61(5):297-302.
IGF1	AgP	98	186	ns	None	Japanese	CC	N	Insulin-like growth factor 1 (somatomedin C)	IGFI; IGF1A; IGF1	2	Multiple SNPs	16844084	Rabello D, Soedarsono N, Kamei H, Ishihara Y, Noguchi T, Fuma D, Suzuki M, Sakaki Y, Yamaguchi A, Kojima T. CSF1 gene associated with aggressive periodontitis in the Japanese population. Biochem Biophys Res Commun. 2006 Sep 1;347(3):791-6. Epub 2006 Jul 7.
IGF1	CP	22	41	ns	None	Japanese	CC	N	Insulin-like growth factor 1 (somatomedin C)	IGFI; IGF1A; IGF1	2	Multiple SNPs	15490304	Suzuki A, Ji G, Numabe Y, Ishii K, Muramatsu M, Kamoi K. Large-scale investigation of genomic markers for severe periodontitis. Odontology. 2004 Sep;92(1):43-7.

IGF2R	CP	22	41	ns	None	Japanese	CC	N	Insulin-like growth factor 2 receptor	MPR1; MPRI; CD222; CIMPR; M6P-R; IGF2R	7	Multiple SNPs	15490304	Suzuki A, Ji G, Numabe Y, Ishii K, Muramatsu M, Kamoi K. Large-scale investigation of genomic markers for severe periodontitis. Odontology. 2004 Sep;92(1):43-7.
IL10	AgP	64	132	0.023	Weak	German	CC	N	Interleukin 10	CSIF; TGIF; IL-10; IL10A; MGC126450; MGC126451; IL10	3	Haplotype	18230105	Reichert S, Machulla HK, Klapproth J, Zimmermann U, Reichert Y, Gläser CH, Schaller HG, Stein J, Schulz S. The interleukin-10 promoter haplotype ATA is a putative risk factor for aggressive periodontitis. J Periodontal Res. 2008 Feb;43(1):40-7.
IL10	AgP	65	191	0.0276	Weak	Taiwanese	CC	N	Interleukin 10	CSIF; TGIF; IL-10; IL10A; MGC126450; MGC126451; IL10	3	Haplotype	19210338	Hu KF, Huang KC, Ho YP, Lin YC, Ho KY, Wu YM, Yang YH, Tsai CC. Interleukin-10 (-592 C/A) and interleukin-12B (+16974 A/C) gene polymorphisms and the interleukin-10 ATA haplotype are associated with periodontitis in a Taiwanese population. J Periodontal Res. 2009 Jun;44(3):378-85. Epub 2009 Feb 6.
IL10	AgP	65	191	ns	None	Taiwanese	CC	N	Interleukin 10	CSIF; TGIF; IL-10; IL10A; MGC126450; MGC126451; IL10	3	–592	19210338	Hu KF, Huang KC, Ho YP, Lin YC, Ho KY, Wu YM, Yang YH, Tsai CC. Interleukin-10 (-592 C/A) and interleukin-12B (+16974 A/C) gene polymorphisms and the interleukin-10 ATA haplotype are associated with periodontitis in a Taiwanese population. J Periodontal Res. 2009 Jun;44(3):378-85. Epub 2009 Feb 6.
IL10	AgP	64	132	ns	None	German	CC	N	Interleukin 10	CSIF; TGIF; IL-10; IL10A; MGC126450; MGC126451; IL10	6	Multiple SNPs	18230105	Reichert S, Machulla HK, Klapproth J, Zimmermann U, Reichert Y, Gläser CH, Schaller HG, Stein J, Schulz S. The interleukin-10 promoter haplotype ATA is a putative risk factor for aggressive periodontitis. J Periodontal Res. 2008 Feb;43(1):40-7.

Continued

TABLE 6-3 Association Study—cont'd

Gene Symbol	Disease Type	Cases	Total	Best *P* Value	Level of Support	Population	Study Design	Stratified or Covariate Adj	Gene Name	Gene Aliases	# SNPs Assayed	SNP Name	PubMed ID	Journal
IL10	AgP	52	113	ns	None	Iranian	CC	N	Interleukin 10	CSIF; TGIF; IL-10; IL10A; MGC126450; MGC126451; IL10	1	–1082	17968299	Mellati E, Arab HR, Tavakkol-Afshari J, Ebadian AR, Radvar M. Analysis of -1082 IL-10 gene polymorphism in Iranian patients with generalized aggressive periodontitis. Med Sci Monit. 2007 Nov;13(11):CR510-514.
IL10	AgP	51	151	ns	None	Caucasian	CC	N	Interleukin 10	CSIF; TGIF; IL-10; IL10A; MGC126450; MGC126451; IL10	2	Multiple SNPs	16304445	Brett PM, Zygogianni P, Griffiths GS, Tomaz M, Parkar M, D'Aiuto F, Tonetti M. Functional gene polymorphisms in aggressive and chronic periodontitis. J Dent Res. 2005 Dec;84(12):1149-53.
IL10	AgP	18	39	ns	None	Caucasian	CC	N	Interleukin 10	CSIF; TGIF; IL-10; IL10A; MGC126450; MGC126451; IL10	2	Multiple SNPs	12423294	Gonzales JR, Michel J, Diete A, Herrmann JM, Bödeker RH, Meyle J. Analysis of genetic polymorphisms at the interleukin-10 loci in aggressive and chronic periodontitis. J Clin Periodontol. 2002 Sep;29(9):816-22.
IL10	AgP	18	70	ns	None	Japanese	CC	N	Interleukin 10	CSIF; TGIF; IL-10; IL10A; MGC126450; MGC126451; IL10	3	haplotype	11493351	Yamazaki K, Tabeta K, Nakajima T, Ohsawa Y, Ueki K, Itoh H, Yoshie H. Interleukin-10 gene promoter polymorphism in Japanese patients with adult and early-onset periodontitis. J Clin Periodontol. 2001 Sep;28(9):828-32.
IL10	AgP	72	145	ns	None	Caucasian	CC	N	Interleukin 10	CSIF; TGIF; IL-10; IL10A; MGC126450; MGC126451; IL10	1	(CA)n	11196688	Hennig BJ, Parkhill JM, Chapple IL, Heasman PA, Taylor JJ. Dinucleotide repeat polymorphism in the interleukin-10 gene promoter (IL-10.G) and genetic susceptibility to early-onset periodontal disease. Genes Immun. 2000 Aug;1(6):402-4.

IL10	AgP	77	102	ns	None	Caucasian	CC	N	Interleukin 10	CSIF; TGIF; IL-10; IL10A; MGC126450; MGC126451; IL10	2	Multiple SNPs	10685365	Kinane DF, Hodge P, Eskdale J, Ellis R, Gallagher G. Analysis of genetic polymorphisms at the interleukin-10 and tumour necrosis factor loci in early-onset periodontitis. J Periodontal Res. 1999 Oct;34(7):379-86.
IL10	AgP	55	98	ns	None	Brazilian	CC	S	Interleukin 10	CSIF; TGIF; IL-10; IL10A; MGC126450; MGC126451; IL10	1	–1082	19771178	Moreira PR, Costa JE, Gomez RS, Gollob KJ, Dutra WO. TNFA and IL10 Gene Polymorphisms are not Associated with Periodontitis in Brazilians. Open Dent J. 2009 Sep 7;3:184-90.
IL10	AgP+CP	118	186	ns	None	German	CC	N	Interleukin 10	CSIF; TGIF; IL-10; IL10A; MGC126450; MGC126451; IL10	6	Multiple SNPs	18230105	Reichert S, Machulla HK, Klapproth J, Zimmermann U, Reichert Y, Gläser CH, Schaller HG, Stein J, Schulz S. The interleukin-10 promoter haplotype ATA is a putative risk factor for aggressive periodontitis. J Periodontal Res. 2008 Feb;43(1):40-7.
IL10	AgP+CP	118	186	ns	None	German	CC	N	Interleukin 10	CSIF; TGIF; IL-10; IL10A; MGC126450; MGC126451; IL10	3	Haplotype	18230105	Reichert S, Machulla HK, Klapproth J, Zimmermann U, Reichert Y, Gläser CH, Schaller HG, Stein J, Schulz S. The interleukin-10 promoter haplotype ATA is a putative risk factor for aggressive periodontitis. J Periodontal Res. 2008 Feb;43(1):40-7.
IL10	AgP+CP	251	376	ns	None	Japanese	CC	N	Interleukin 10	CSIF; TGIF; IL-10; IL10A; MGC126450; MGC126451; IL10	n/a	n/a	15081423	Suzuki A, Ji G, Numabe Y, Muramatsu M, Gomi K, Kanazashi M, Ogata Y, Shimizu E, Shibukawa Y, Ito A, Ito T, Sugaya A, Arai T, Yamada S, Deguchi S, Kamoi K. Single nucleotide polymorphisms associated with aggressive periodontitis and severe chronic periodontitis in Japanese. Biochem Biophys Res Commun. 2004 May 7;317(3):887-92.

Continued

TABLE 6-3 Association Study—cont'd

Gene Symbol	Disease Type	Cases	Total	Best *P* Value	Level of Support	Population	Study Design	Stratified or Covariate Adj	Gene Name	Gene Aliases	# SNPs Assayed	SNP Name	PubMed ID	Journal
IL10	AgP+CP	319	622	ns	None	Japanese	CC	AGS	Interleukin 10	CSIF; TGIF; IL-10; IL10A; MGC126450; MGC126451; IL10	2	n/a	19892918	Kobayashi T, Nagata T, Murakami S, Takashiba S, Kurihara H, Izumi Y, Numabe Y, Watanabe H, Kataoka M, Nagai A, Hayashi J, Ohyama H, Okamatsu Y, Inagaki Y, Tai H, Yoshie H. Genetic risk factors for periodontitis in a Japanese population. J Dent Res. 2009 Dec;88(12): 1137-41.
IL10	CP	75	148	0.00007	Moderate	Turkish	CC	N	Interleukin 10	CSIF; TGIF; IL-10; IL10A; MGC126450; MGC126451; IL10	2	–597	17335372	Sumer AP, Kara N, Keles GC, Gunes S, Koprulu H, Bagci H. Association of interleukin-10 gene polymorphisms with severe generalized chronic periodontitis. J Periodontol. 2007 Mar;78(3):493-7.
IL10	CP	116	289	0.0006	Moderate	Brazilian	CC	N	Interleukin 10	CSIF; TGIF; IL-10; IL10A; MGC126450; MGC126451; IL10	1	–592	18725394	Claudino M, Trombone AP, Cardoso CR, Ferreira SB Jr, Martins W Jr, Assis GF, Santos CF, Trevilatto PC, Campanelli AP, Silva JS, Garlet GP. The broad effects of the functional IL-10 promoter-592 polymorphism: modulation of IL-10, TIMP-3, and OPG expression and their association with periodontal disease outcome. J Leukoc Biol. 2008 Dec;84(6):1565-73. Epub 2008 Aug 25.
IL10	CP	67	110	0.001	Weak	Brazilian	CC	G	Interleukin 10	CSIF; TGIF; IL-10; IL10A; MGC126450; MGC126451; IL10	3	Haplotype -592.-819.-1087	15142213	Scarel-Caminaga RM, Trevilatto PC, Souza AP, Brito RB, Camargo LE, Line SR. Interleukin 10 gene promoter polymorphisms are associated with chronic periodontitis. J Clin Periodontol. 2004 Jun;31(6):443-8.
IL10	CP	60	99	0.002	Weak	Caucasian	CC	S	Interleukin 10	CSIF; TGIF; IL-10; IL10A; MGC126450; MGC126451; IL10	1	–1087	12631183	Berglundh T, Donati M, Hahn-Zoric M, Hanson LA, Padyukov L. Association of the -1087 IL 10 gene polymorphism with severe chronic periodontitis in Swedish Caucasians. J Clin Periodontol. 2003 Mar;30(3):249-54.

IL10	CP	67	110	0.007	Weak	Brazilian	CC	G	Interleukin 10	CSIF; TGIF; IL-10; IL10A; MGC126450; MGC126451; IL10	3	–592	15142213	Scarel-Caminaga RM, Trevilatto PC, Souza AP, Brito RB, Camargo LE, Line SR. Interleukin 10 gene promoter polymorphisms are associated with chronic periodontitis. J Clin Periodontol. 2004 Jun;31(6):443-8.
IL10	CP	n/a	252	0.02	Weak	Caucasian	Longitudinal	AGS	Interleukin 10	CSIF; TGIF; IL-10; IL10A; MGC126450; MGC126451; IL10	2	Haplotype	18447856	Cullinan MP, Westerman B, Hamlet SM, Palmer JE, Faddy MJ, Seymour GJ, Middleton PG, Taylor JJ. Progression of periodontal disease and interleukin-10 gene polymorphism. J Periodontal Res. 2008 Jun;43(3):328-33.
IL10	CP	145	281	0.0248	Weak	Taiwanese	CC	N	Interleukin 10	CSIF; TGIF; IL-10; IL10A; MGC126450; MGC126451; IL10	3	Haplotype	19210338	Hu KF, Huang KC, Ho YP, Lin YC, Ho KY, Wu YM, Yang YH, Tsai CC. Interleukin-10 (-592 C/A) and interleukin-12B (+16974 A/C) gene polymorphisms and the interleukin-10 ATA haplotype are associated with periodontitis in a Taiwanese population. J Periodontal Res. 2009 Jun;44(3):378-85. Epub 2009 Feb 6.
IL10	CP	145	281	<0.05	Weak	Taiwanese	CC	N	Interleukin 10	CSIF; TGIF; IL-10; IL10A; MGC126450; MGC126451; IL10	3	–592	19210338	Hu KF, Huang KC, Ho YP, Lin YC, Ho KY, Wu YM, Yang YH, Tsai CC. Interleukin-10 (-592 C/A) and interleukin-12B (+16974 A/C) gene polymorphisms and the interleukin-10 ATA haplotype are associated with periodontitis in a Taiwanese population. J Periodontal Res. 2009 Jun;44(3):378-85. Epub 2009 Feb 6.
IL10	CP	117	225	ns	None	Japanese	CC	N	Interleukin 10	CSIF; TGIF; IL-10; IL10A; MGC126450; MGC126451; IL10	2	Multiple SNPs	19405833	Kobayashi T, Murasawa A, Ito S, Yamamoto K, Komatsu Y, Abe A, Sumida T, Yoshie H. Cytokine gene polymorphisms associated with rheumatoid arthritis and periodontitis in Japanese adults. J Periodontol. 2009 May;80(5):792-9.

Continued

TABLE 6-3 Association Study—cont'd

Gene Symbol	Disease Type	Cases	Total	Best *P* Value	Level of Support	Population	Study Design	Stratified or Covariate Adj	Gene Name	Gene Aliases	# SNPs Assayed	SNP Name	PubMed ID	Journal
IL10	CP	n/a	80	ns	None	Finnish	Quan	N	Interleukin 10	CSIF; TGIF; IL-10; IL10A; MGC126450; MGC126451; IL10	1	–1082	19017034	Raunio T, Knuuttila M, Hiltunen L, Karttunen R, Vainio O, Tervonen T. IL-6(-174) genotype associated with the extent of periodontal disease in type 1 diabetic subjects. J Clin Periodontol. 2009 Jan;36(1):11-7. Epub 2008 Oct 31.
IL10	CP	54	122	ns	None	German	CC	N	Interleukin 10	CSIF; TGIF; IL-10; IL10A; MGC126450; MGC126451; IL10	6	Multiple SNPs	18230105	Reichert S, Machulla HK, Klapproth J, Zimmermann U, Reichert Y, Gläser CH, Schaller HG, Stein J, Schulz S. The interleukin-10 promoter haplotype ATA is a putative risk factor for aggressive periodontitis. J Periodontal Res. 2008 Feb;43(1):40-7.
IL10	CP	54	122	ns	None	German	CC	N	Interleukin 10	CSIF; TGIF; IL-10; IL10A; MGC126450; MGC126451; IL10	3	Haplotype	18230105	Reichert S, Machulla HK, Klapproth J, Zimmermann U, Reichert Y, Gläser CH, Schaller HG, Stein J, Schulz S. The interleukin-10 promoter haplotype ATA is a putative risk factor for aggressive periodontitis. J Periodontal Res. 2008 Feb;43(1):40-7.
IL10	CP	51	229	ns	None	Caucasian	CC	GS	Interleukin 10	CSIF; TGIF; IL-10; IL10A; MGC126450; MGC126451; IL10	1	–1082	17448042	Tervonen T, Raunio T, Knuuttila M, Karttunen R. Polymorphisms in the CD14 and IL-6 genes associated with periodontal disease. J Clin Periodontol. 2007 May;34(5):377-83.
IL10	CP	122	236	ns	None	German	CC	N	Interleukin 10	CSIF; TGIF; IL-10; IL10A; MGC126450; MGC126451; IL10	1	–1082	17209781	Babel N, Cherepnev G, Babel D, Tropmann A, Hammer M, Volk HD, Reinke P. Analysis of tumor necrosis factor-alpha, transforming growth factor-beta, interleukin-10, IL-6, and interferon-gamma gene polymorphisms in patients with chronic periodontitis. J Periodontol. 2006 Dec;77(12):1978-83.

IL10	CP	57	157	ns	None	Caucasian	CC	N	Interleukin 10	CSIF; TGIF; IL-10; IL10A; MGC126450; MGC126451; IL10	2	Multiple SNPs	16304445	Brett PM, Zygogianni P, Griffiths GS, Tomaz M, Parkar M, D'Aiuto F, Tonetti M. Functional gene polymorphisms in aggressive and chronic periodontitis. J Dent Res. 2005 Dec;84(12):1149-53.
IL10	CP	23	44	ns	None	Caucasian	CC	N	Interleukin 10	CSIF; TGIF; IL-10; IL10A; MGC126450; MGC126451; IL10	2	Multiple SNPs	12423294	Gonzales JR, Michel J, Diete A, Herrmann JM, Bödeker RH, Meyle J. Analysis of genetic polymorphisms at the interleukin-10 loci in aggressive and chronic periodontitis. J Clin Periodontol. 2002 Sep;29(9):816-22.
IL10	CP	34	86	ns	None	Japanese	CC	N	Interleukin 10	CSIF; TGIF; IL-10; IL10A; MGC126450; MGC126451; IL10	3	haplotype	11493351	Yamazaki K, Tabeta K, Nakajima T, Ohsawa Y, Ueki K, Itoh H, Yoshie H. Interleukin-10 gene promoter polymorphism in Japanese patients with adult and early-onset periodontitis. J Clin Periodontol. 2001 Sep;28(9):828-32.
IL10	CP	67	110	ns	None	Brazilian	CC	S	Interleukin 10	CSIF; TGIF; IL-10; IL10A; MGC126450; MGC126451; IL10	1	–1082	19771178	Moreira PR, Costa JE, Gomez RS, Gollob KJ, Dutra WO. TNFA and IL10 Gene Polymorphisms are not Associated with Periodontitis in Brazilians. Open Dent J. 2009 Sep 7;3:184-90.
IL10	CP&RA	137	245	ns	None	Japanese	CC	N	Interleukin 10	CSIF; TGIF; IL-10; IL10A; MGC126450; MGC126451; IL10	2	Multiple SNPs	19405833	Kobayashi T, Murasawa A, Ito S, Yamamoto K, Komatsu Y, Abe A, Sumida T, Yoshie H. Cytokine gene polymorphisms associated with rheumatoid arthritis and periodontitis in Japanese adults. J Periodontol. 2009 May;80(5):792-9.
IL10.TNF	AgP	55	98	ns	None	Brazilian	CC	S	n/a	n/a	2	Multiple Genes	19771178	Moreira PR, Costa JE, Gomez RS, Gollob KJ, Dutra WO. TNFA and IL10 Gene Polymorphisms are not Associated with Periodontitis in Brazilians. Open Dent J. 2009 Sep 7;3:184-90.

Continued

TABLE 6-3 Association Study—cont'd

Gene Symbol	Disease Type	Cases	Total	Best *P* Value	Level of Support	Population	Study Design	Stratified or Covariate Adj	Gene Name	Gene Aliases	# SNPs Assayed	SNP Name	PubMed ID	Journal
IL10.TNF	CP	67	110	ns	None	Brazilian	CC	S	n/a	n/a	2	Multiple Genes	19771178	Moreira PR, Costa JE, Gomez RS, Gollob KJ, Dutra WO. TNFA and IL10 Gene Polymorphisms are not Associated with Periodontitis in Brazilians. Open Dent J. 2009 Sep 7;3:184-90.
IL10RA	AgP+CP	251	376	ns	None	Japanese	CC	N	Interleukin 10 receptor, alpha	IL10R; CDW210A; HIL-10R; IL-10R1; IL10RA	n/a	n/a	15081423	Suzuki A, Ji G, Numabe Y, Muramatsu M, Gomi K, Kanazashi M, Ogata Y, Shimizu E, Shibukawa Y, Ito A, Ito T, Sugaya A, Arai T, Yamada S, Deguchi S, Kamoi K. Single nucleotide polymorphisms associated with aggressive periodontitis and severe chronic periodontitis in Japanese. Biochem Biophys Res Commun. 2004 May 7;317(3):887-92.
IL10RB	AgP+CP	251	376	ns	None	Japanese	CC	N	Interleukin 10 receptor, beta	CRFB4; CRF2-4; D21S58; D21S66; CDW210B; IL-10R2; IL10RB	n/a	n/a	15081423	Suzuki A, Ji G, Numabe Y, Muramatsu M, Gomi K, Kanazashi M, Ogata Y, Shimizu E, Shibukawa Y, Ito A, Ito T, Sugaya A, Arai T, Yamada S, Deguchi S, Kamoi K. Single nucleotide polymorphisms associated with aggressive periodontitis and severe chronic periodontitis in Japanese. Biochem Biophys Res Commun. 2004 May 7;317(3):887-92.
IL12A	AgP	72	146	ns	None	German	CC	N	Interleukin 12A (natural killer cell stimulatory factor 1, cytotoxic lymphocyte maturation factor 1, p35)	P35; CLMF; NFSK; NKSF1; IL-12A; IL12A	1	1188 A/C	18672993	Reichert S, Machulla HK, Klapproth J, Zimmermann U, Reichert Y, Gläser C, Schaller HG, Schulz S. Interferon-gamma and interleukin-12 gene polymorphisms and their relation to aggressive and chronic periodontitis and key periodontal pathogens. J Periodontol. 2008 Aug;79(8):1434-43.

IL12A	CP	52	126	ns	None	German	CC	N	Interleukin 12A (natural killer cell stimulatory factor 1, cytotoxic lymphocyte maturation factor 1, p35)	P35; CLMF; NFSK; NKSF1; IL-12A; IL12A	1	1188 A/C	18672993	Reichert S, Machulla HK, Klapproth J, Zimmermann U, Reichert Y, Gläser C, Schaller HG, Schulz S. Interferon-gamma and interleukin-12 gene polymorphisms and their relation to aggressive and chronic periodontitis and key periodontal pathogens. J Periodontol. 2008 Aug;79(8):1434-43.
IL12B	AgP	65	191	ns	None	Taiwanese	CC	N	Interleukin 12B (natural killer cell stimulatory factor 2, cytotoxic lymphocyte maturation factor 2, p40)	CLMF; NKSF; CLMF2; NKSF2; IL-12B; IL12B	1	+16974	19210338	Hu KF, Huang KC, Ho YP, Lin YC, Ho KY, Wu YM, Yang YH, Tsai CC. Interleukin-10 (-592 C/A) and interleukin-12B (+16974 A/C) gene polymorphisms and the interleukin-10 ATA haplotype are associated with periodontitis in a Taiwanese population. J Periodontal Res. 2009 Jun;44(3):378-85. Epub 2009 Feb 6.
IL12B	CP	145	281	0.0187	Weak	Taiwanese	CC	N	Interleukin 12B (natural killer cell stimulatory factor 2, cytotoxic lymphocyte maturation factor 2, p40)	CLMF; NKSF; CLMF2; NKSF2; IL-12B; IL12B	1	+16974	19210338	Hu KF, Huang KC, Ho YP, Lin YC, Ho KY, Wu YM, Yang YH, Tsai CC. Interleukin-10 (-592 C/A) and interleukin-12B (+16974 A/C) gene polymorphisms and the interleukin-10 ATA haplotype are associated with periodontitis in a Taiwanese population. J Periodontal Res. 2009 Jun;44(3):378-85. Epub 2009 Feb 6.
IL12RB2	AgP	30	73	0.0075	Weak	Japanese	CC	N	Interleukin 12 receptor, beta 2	RP11-102M16.1; IL12RB2	4	–464	18353079	Takeuchi-Hatanaka K, Ohyama H, Nishimura F, Kato-Kogoe N, Soga Y, Matsushita S, Nakasho K, Yamanegi K, Yamada N, Terada N, Takashiba S. Polymorphisms in the 5′ flanking region of IL12RB2 are associated with susceptibility to periodontal diseases in the Japanese population. J Clin Periodontol. 2008 Apr;35(4):317-23.

Continued

TABLE 6-3 Association Study—cont'd

Gene Symbol	Disease Type	Cases	Total	Best *P* Value	Level of Support	Population	Study Design	Stratified or Covariate Adj	Gene Name	Gene Aliases	# SNPs Assayed	SNP Name	PubMed ID	Journal
IL12RB2	CP	80	123	ns	None	Japanese	CC	N	Interleukin 12 receptor, beta 2	RP11-102M16.1; IL12RB2	4	Multiple SNPs	18353079	Takeuchi-Hatanaka K, Ohyama H, Nishimura F, Kato-Kogoe N, Soga Y, Matsushita S, Nakasho K, Yamanegi K, Yamada N, Terada N, Takashiba S. Polymorphisms in the 5′ flanking region of IL12RB2 are associated with susceptibility to periodontal diseases in the Japanese population. J Clin Periodontol. 2008 Apr;35(4):317-23.
IL13	AgP	58	109	ns	None	German	CC	N	Interleukin 13	ALRH; BHR1; P600; IL-13; MGC116786; MGC116788; MGC116789; IL13	2	Multiple SNPs	17451413	Gonzales JR, Mann M, Stelzig J, Bödeker RH, Meyle J. Single-nucleotide polymorphisms in the IL-4 and IL-13 promoter region in aggressive periodontitis. J Clin Periodontol. 2007 Jun;34(6):473-9. Epub 2007 Apr 23.
IL15RA	CP	22	41	ns	None	Japanese	CC	N	Interleukin 15 receptor, alpha	MGC104179; IL15RA	1	n/a	15490304	Suzuki A, Ji G, Numabe Y, Ishii K, Muramatsu M, Kamoi K. Large-scale investigation of genomic markers for severe periodontitis. Odontology. 2004 Sep;92(1):43-7.
IL16	CP	123	245	ns	None	Caucasian	CC	N	Interleukin 16 (lymphocyte chemoattractant factor)	LCF; IL-16; prIL-16; FLJ16806; FLJ42735; FLJ44234; HsT19289; IL16	1	–295	16178875	Folwaczny M, Glas J, Török HP, Tonenchi L, Paschos E, Malachova O, Bauer B, Folwaczny C. Prevalence of the -295T-to-C promoter polymorphism of the interleukin (IL)-16 gene in periodontitis. Clin Exp Immunol. 2005 Oct;142(1):188-92.
IL18	AgP	111	191	ns	None	German	CC	N	Interleukin 18 (Interferon-gamma-inducing factor)	IGIF; IL-18; IL-1g; IL1F4; MGC12320; IL18	2	Multiple SNPs	18983635	Noack B, Görgens H, Lorenz K, Ziegler A, Hoffmann T, Schackert HK. TLR4 and IL-18 gene variants in aggressive periodontitis. J Clin Periodontol. 2008 Dec;35(12):1020-6. Epub 2008 Oct 28.

IL18	CP	123	244	ns	None	Caucasian	CC	N	Interleukin 18 (interferon-gamma-inducing factor)	IGIF; IL-18; IL-1g; IL1F4; MGC12320; IL18	6	Multiple SNPs	15842270	Folwaczny M, Glas J, Török HP, Tonenchi L, Paschos E, Bauer B, Limbersky O, Folwaczny C. Polymorphisms of the interleukin-18 gene in periodontitis patients. J Clin Periodontol. 2005 May;32(5):530-4.
IL18	CP	108	184	ns	None	Caucasian	CC	AGS	Interleukin 18 (interferon-gamma-inducing factor)	IGIF; IL-18; IL-1g; IL1F4; MGC12320; IL18	2	Multiple SNPs	19811440	Noack B, Görgens H, Lorenz K, Schackert HK, Hoffmann T. TLR4 and IL-18 gene variants in chronic periodontitis: impact on disease susceptibility and severity. Immunol Invest. 2009;38(3-4):297-310.
IL18R1	CP	22	41	ns	None	Japanese	CC	N	Interleukin 18 receptor 1	CD218a; IL18RA; IL1RRP; CDw218a; IL-1Rrp; IL18R1	4	Multiple SNPs	15490304	Suzuki A, Ji G, Numabe Y, Ishii K, Muramatsu M, Kamoi K. Large-scale investigation of genomic markers for severe periodontitis. Odontology. 2004 Sep;92(1):43-7.
IL1A	AgP	141	285	0.0065	Weak	Mixed	Fam	S	Interleukin 1, alpha	IL1; IL-1A; IL1F1; IL1-ALPHA; IL1A	1	–889	10328654	Diehl SR, Wang Y, Brooks CN, Burmeister JA, Califano JV, Wang S, Schenkein HA. Linkage disequilibrium of interleukin-1 genetic polymorphisms with early-onset periodontitis. J Periodontol. 1999 Apr;70(4):418-30.
IL1A	AgP	122	217	0.039	Weak	Chinese	CC	N	Interleukin 1, alpha	IL1; IL-1A; IL1F1; IL1-ALPHA; IL1A	1	+4845	16155691	Li QY, Zhao HS, Meng HX, Zhang L, Xu L, Chen ZB. [Interleukin-1 polymorphisms in patients with aggressive periodontitis]. Shanghai Kou Qiang Yi Xue. 2005 Aug;14(4):333-7. Chinese.
IL1A	AgP	122	217	0.039	Weak	Chinese	CC	AGS	Interleukin 1, alpha	IL1; IL-1A; IL1F1; IL1-ALPHA; IL1A	1	+4845	15732864	Li QY, Zhao HS, Meng HX, Zhang L, Xu L, Chen ZB, Shi D, Feng XH, Zhu XL. Association analysis between interleukin-1 family polymorphisms and generalized aggressive periodontitis in a Chinese population. J Periodontol. 2004 Dec;75(12):1627-35.

Continued

TABLE 6-3 Association Study—cont'd

Gene Symbol	Disease Type	Cases	Total	Best *P* Value	Level of Support	Population	Study Design	Stratified or Covariate Adj	Gene Name	Gene Aliases	# SNPs Assayed	SNP Name	PubMed ID	Journal
IL1A	AgP	31	62	<0.05	Weak	Turkish	CC	N	Interleukin 1, alpha	IL1; IL-1A; IL1F1; IL1-ALPHA; IL1A	1	+4845	18587204	Guzeldemir E, Gunhan M, Ozcelik O, Tastan H. Interleukin-1 and tumor necrosis factor-alpha gene polymorphisms in Turkish patients with localized aggressive periodontitis. J Oral Sci. 2008 Jun;50(2):151-9.
IL1A	AgP	9	41	ns	None	Japanese	CC	N	Interleukin 1, alpha	IL1; IL-1A; IL1F1; IL1-ALPHA; IL1A	2	Multiple SNPs	19184295	Shimomura-Kuroki J, Yamashita K, Shimooka S. Tannerella forsythia and the HLA-DQB1 allele are associated with susceptibility to periodontal disease in Japanese adolescents. Odontology. 2009 Jan;97(1):32-7. Epub 2009 Jan 29.
IL1A	AgP	415	1289	ns	None	Caucasian	CC	N	Interleukin 1, alpha	IL1; IL-1A; IL1F1; IL1-ALPHA; IL1A	5	Multiple SNPs	18723088	Fiebig A, Jepsen S, Loos BG, Scholz C, Schäfer C, Rühling A, Nothnagel M, Eickholz P, van der Velden U, Schenck K, Schreiber S, Grössner-Schreiber B. Polymorphisms in the interleukin-1 (IL1) gene cluster are not associated with aggressive periodontitis in a large Caucasian population. Genomics. 2008 Nov;92(5):309-15. Epub 2008 Sep 18.
IL1A	AgP	415	1289	ns	None	Caucasian	CC	N	Interleukin 1, alpha	IL1; IL-1A; IL1F1; IL1-ALPHA; IL1A	5	Haplotype	18723088	Fiebig A, Jepsen S, Loos BG, Scholz C, Schäfer C, Rühling A, Nothnagel M, Eickholz P, van der Velden U, Schenck K, Schreiber S, Grössner-Schreiber B. Polymorphisms in the interleukin-1 (IL1) gene cluster are not associated with aggressive periodontitis in a large Caucasian population. Genomics. 2008 Nov;92(5):309-15. Epub 2008 Sep 18.

IL1A	AgP	66	180	ns	None	Chinese	Fam	N	Interleukin 1, alpha	IL1; IL-1A; IL1F1; IL1-ALPHA; IL1A	1	+4845	18278133	Ren XY, Xu L, Meng HX. [Interleukin-1 family polymorphisms in aggressive periodontitis patients and their relatives]. Beijing Da Xue Xue Bao. 2008 Feb 18;40(1):28-33. Chinese.
IL1A	AgP	66	180	ns	None	Chinese	Fam	N	Interleukin 1, alpha	IL1; IL-1A; IL1F1; IL1-ALPHA; IL1A	1	+4845	18278133	Ren XY, Xu L, Meng HX. [Interleukin-1 family polymorphisms in aggressive periodontitis patients and their relatives]. Beijing Da Xue Xue Bao. 2008 Feb 18;40(1):28-33. Chinese.
IL1A	AgP	30	100	ns	None	Brazilian	CC	N	Interleukin 1, alpha	IL1; IL-1A; IL1F1; IL1-ALPHA; IL1A	1	–889	17823082	Maria de Freitas N, Imbronito AV, Neves AC, Nunes FD, Pustiglioni FE, Lotufo RF. Analysis of IL-1A(-889) and TNFA(-308) gene polymorphism in Brazilian patients with generalized aggressive periodontitis. Eur Cytokine Netw. 2007 Sep;18(3):142-7. Epub 2007 Sep 7.
IL1A	AgP	n/a	20	ns	None	Czech	Longitudinal	N	Interleukin 1, alpha	IL1; IL-1A; IL1F1; IL1-ALPHA; IL1A	1	n/a	17575917	Krátká Z, Bártová J, Krejsa O, Otcenásková M, Janatova T, Dusková J. Interleukin-1 gene polymorphisms as assessed in a 10-year study of patients with early-onset periodontitis. Folia Microbiol (Praha). 2007;52(2):183-8.
IL1A	AgP	45	70	ns	None	Caucasian	CC	N	Interleukin 1, alpha	IL1; IL-1A; IL1F1; IL1-ALPHA; IL1A	2	Multiple SNPs	17335371	Havemose-Poulsen A, Sørensen LK, Bendtzen K, Holmstrup P. Polymorphisms within the IL-1 gene cluster: effects on cytokine profiles in peripheral blood and whole blood cell cultures of patients with aggressive periodontitis, juvenile idiopathic arthritis, and rheumatoid arthritis. J Periodontol. 2007 Mar;78(3):475-92.
IL1A	AgP	55	96	ns	None	Brazilian	CC	S	Interleukin 1, alpha	IL1; IL-1A; IL1F1; IL1-ALPHA; IL1A	1	–889	17214636	Moreira PR, Costa JE, Gomez RS, Gollob KJ, Dutra WO. The IL1A (-889) gene polymorphism is associated with chronic periodontal disease in a sample of Brazilian individuals. J Periodontal Res. 2007 Feb;42(1):23-30.

Continued

TABLE 6-3 Association Study—cont'd

Gene Symbol	Disease Type	Cases	Total	Best *P* Value	Level of Support	Population	Study Design	Stratified or Covariate Adj	Gene Name	Gene Aliases	# SNPs Assayed	SNP Name	PubMed ID	Journal
IL1A	AgP	46	136	ns	None	Greek	CC	N	Interleukin 1, alpha	IL1; IL-1A; IL1F1; IL1-ALPHA; IL1A	1	+4845	16911569	Sakellari D, Katsares V, Georgiadou M, Kouvatsi A, Arsenakis M, Konstantinidis A. No correlation of five gene polymorphisms with periodontal conditions in a Greek population. J Clin Periodontol. 2006 Nov;33(11):765-70. Epub 2006 Aug 14.
IL1A	AgP	51	151	ns	None	Caucasian	CC	N	Interleukin 1, alpha	IL1; IL-1A; IL1F1; IL1-ALPHA; IL1A	1	–889	16304445	Brett PM, Zygogianni P, Griffiths GS, Tomaz M, Parkar M, D'Aiuto F, Tonetti M. Functional gene polymorphisms in aggressive and chronic periodontitis. J Dent Res. 2005 Dec;84(12):1149-53.
IL1A	AgP	36	111	ns	None	Chilean	CC	S	Interleukin 1, alpha	IL1; IL-1A; IL1F1; IL1-ALPHA; IL1A	1	+4845	15633328	Quappe L, Jara L, López NJ. Association of interleukin-1 polymorphisms with aggressive periodontitis. J Periodontol. 2004 Nov;75(11):1509-15.
IL1A	AgP	40	136	ns	None	Caucasian	CC	N	Interleukin 1, alpha	IL1; IL-1A; IL1F1; IL1-ALPHA; IL1A	1	+4845	15602586	Scapoli C, Trombelli L, Mamolini E, Collins A. Linkage disequilibrium analysis of case-control data: an application to generalized aggressive periodontitis. Genes Immun. 2005 Feb;6(1):44-52.
IL1A	AgP	44	91	ns	None	Mixed	CC	E	Interleukin 1, alpha	IL1; IL-1A; IL1F1; IL1-ALPHA; IL1A	1	+4845	12974682	Gonzales JR, Michel J, Rodríguez EL, Herrmann JM, Bödeker RH, Meyle J. Comparison of interleukin-1 genotypes in two populations with aggressive periodontitis. Eur J Oral Sci. 2003 Oct;111(5):395-9.

IL1A	AgP	47	144	ns	None	Japanese	CC	N	Interleukin 1, alpha	IL1; IL-1A; IL1F1; IL1-ALPHA; IL1A	1	+4845	12445219	Tai H, Endo M, Shimada Y, Gou E, Orima K, Kobayashi T, Yamazaki K, Yoshie H. Association of interleukin-1 receptor antagonist gene polymorphisms with early onset periodontitis in Japanese. J Clin Periodontol. 2002 Oct;29(10):882-8.
IL1A	AgP	14	14	ns	None	Brazilian	Fam	N	Interleukin 1, alpha	IL1; IL-1A; IL1F1; IL1-ALPHA; IL1A	1	–889	11940143	Trevilatto PC, Tramontina VA, Machado MA, Gonçalves RB, Sallum AW, Line SR. Clinical, genetic and microbiological findings in a Brazilian family with aggressive periodontitis. J Clin Periodontol. 2002 Mar;29(3):233-9.
IL1A	AgP	56	112	ns	None	Caucasian	CC	S	Interleukin 1, alpha	IL1; IL-1A; IL1F1; IL1-ALPHA; IL1A	1	–889	11350506	Hodge PJ, Riggio MP, Kinane DF. Failure to detect an association with IL1 genotypes in European Caucasians with generalised early onset periodontitis. J Clin Periodontol. 2001 May;28(5):430-6.
IL1A	AgP	37	141	ns	None	African American	CC	N	Interleukin 1, alpha	IL1; IL-1A; IL1F1; IL1-ALPHA; IL1A	1	–889	10872952	Walker SJ, Van Dyke TE, Rich S, Kornman KS, di Giovine FS, Hart TC. Genetic polymorphisms of the IL-1alpha and IL-1beta genes in African-American LJP patients and an African-American control population. J Periodontol. 2000 May;71(5):723-8.
IL1A	AgP	80	160	sig	Weak	Iranian	CC	N	Interleukin 1, alpha	IL1; IL-1A; IL1F1; IL1-ALPHA; IL1A	2	–889	19671938	Kiani Z, Tavakkol-Afshari J, Hojjat H, Arab HR, Radvar M, Sadeghizadeh M, Ebadian AR. Polymorphism of IL-1alpha(-889) Gene and Its Association with Aggressive Periodontitis. Iran J Allergy Asthma Immunol. 2009 Jun;8(2):95-8.

Continued

TABLE 6-3 Association Study—cont'd

Gene Symbol	Disease Type	Cases	Total	Best *P* Value	Level of Support	Population	Study Design	Stratified or Covariate Adj	Gene Name	Gene Aliases	# SNPs Assayed	SNP Name	PubMed ID	Journal
IL1A	AgP+CP	251	376	ns	None	Japanese	CC	N	Interleukin 1, alpha	IL1; IL-1A; IL1F1; IL1-ALPHA; IL1A	n/a	n/a	15081423	Suzuki A, Ji G, Numabe Y, Muramatsu M, Gomi K, Kanazashi M, Ogata Y, Shimizu E, Shibukawa Y, Ito A, Ito T, Sugaya A, Arai T, Yamada S, Deguchi S, Kamoi K. Single nucleotide polymorphisms associated with aggressive periodontitis and severe chronic periodontitis in Japanese. Biochem Biophys Res Commun. 2004 May 7;317(3):887-92.
IL1A	AgP+CP	319	622	ns	None	Japanese	CC	AGS	Interleukin 1, alpha	IL1; IL-1A; IL1F1; IL1-ALPHA; IL1A	1	4845	19892918	Kobayashi T, Nagata T, Murakami S, Takashiba S, Kurihara H, Izumi Y, Numabe Y, Watanabe H, Kataoka M, Nagai A, Hayashi J, Ohyama H, Okamatsu Y, Inagaki Y, Tai H, Yoshie H. Genetic risk factors for periodontitis in a Japanese population. J Dent Res. 2009 Dec;88(12): 1137-41.
IL1A	CP	67	108	0.006	Weak	Brazilian	CC	S	Interleukin 1, alpha	IL1; IL-1A; IL1F1; IL1-ALPHA; IL1A	1	–889	17214636	Moreira PR, Costa JE, Gomez RS, Gollob KJ, Dutra WO. The IL1A (-889) gene polymorphism is associated with chronic periodontal disease in a sample of Brazilian individuals. J Periodontal Res. 2007 Feb;42(1):23-30.
IL1A	CP	n/a	99	0.009	Weak	African	CC	N	Interleukin 1, alpha	IL1; IL-1A; IL1F1; IL1-ALPHA; IL1A	2	+4845	19708438	Saleh TA, Stephen L, Kotze M, Pretorius A. The composite interleukin-1 genotype in South Africa. SADJ. 2009 May;64(4):170-3.
IL1A	CP	83	110	0.045	Weak	Mixed	CC	ES	Interleukin 1, alpha	IL1; IL-1A; IL1F1; IL1-ALPHA; IL1A	1	–889	11145356	Shirodaria S, Smith J, McKay IJ, Kennett CN, Hughes FJ. Polymorphisms in the IL-1A gene are correlated with levels of interleukin-1alpha protein in gingival crevicular fluid of teeth with severe periodontal disease. J Dent Res. 2000 Nov;79(11):1864-9.

IL1A	CP	90	30	<0.0001	Weak	Maharashtrian	CC	N	Interleukin 1, alpha	IL1; IL-1A; IL1F1; IL1-ALPHA; IL1A	1	+4845	16945028	Agrawal AA, Kapley A, Yeltiwar RK, Purohit HJ. Assessment of single nucleotide polymorphism at IL-1A+4845 and IL-1B+3954 as genetic susceptibility test for chronic periodontitis in Maharashtrian ethnicity. J Periodontol. 2006 Sep;77(9):1515-21.
IL1A	CP	224	432	<0.0001	Moderate	Chilean	CC	SD	Interleukin 1, alpha	IL1; IL-1A; IL1F1; IL1-ALPHA; IL1A	1	–889	19792847	López NJ, Valenzuela CY, Jara L. Interleukin-1 gene cluster polymorphisms associated with periodontal disease in type 2 diabetes. J Periodontol. 2009 Oct;80(10):1590-8.
IL1A	CP	97	194	<0.001	Moderate	German	CC	N	Interleukin 1, alpha	IL1; IL-1A; IL1F1; IL1-ALPHA; IL1A	1	–889	17711477	Wagner J, Kaminski WE, Aslanidis C, Moder D, Hiller KA, Christgau M, Schmitz G, Schmalz G. Prevalence of OPG and IL-1 gene polymorphisms in chronic periodontitis. J Clin Periodontol. 2007 Oct;34(10):823-7. Epub 2007 Aug 17.
IL1A	CP	n/a	95	<0.001	Moderate	Japanese	Longitudinal	N	Interleukin 1, alpha	IL1; IL-1A; IL1F1; IL1-ALPHA; IL1A	1	+4845	17335373	Yoshie H, Tai H, Kobayashi T, Oda-Gou E, Nomura Y, Numabe Y, Ito K, Kurihara H, Kamoi K. Salivary enzyme levels after scaling and interleukin-1 genotypes in Japanese patients with chronic periodontitis. J Periodontol. 2007 Mar;78(3):498-503.
IL1A	CP	117	225	ns	None	Japanese	CC	N	Interleukin 1, alpha	IL1; IL-1A; IL1F1; IL1-ALPHA; IL1A	1	+4845	19405833	Kobayashi T, Murasawa A, Ito S, Yamamoto K, Komatsu Y, Abe A, Sumida T, Yoshie H. Cytokine gene polymorphisms associated with rheumatoid arthritis and periodontitis in Japanese adults. J Periodontol. 2009 May;80(5):792-9.

Continued

TABLE 6-3 Association Study—cont'd

Gene Symbol	Disease Type	Cases	Total	Best *P* Value	Level of Support	Population	Study Design	Stratified or Covariate Adj	Gene Name	Gene Aliases	# SNPs Assayed	SNP Name	PubMed ID	Journal
IL1A	CP	n/a	123	ns	None	Caucasian	Quan	N	Interleukin 1, alpha	IL1; IL-1A; IL1F1; IL1-ALPHA; IL1A	1	+4845	19053923	Geismar K, Enevold C, Sørensen LK, Gyntelberg F, Bendtzen K, Sigurd B, Holmstrup P. Involvement of interleukin-1 genotypes in the association of coronary heart disease with periodontitis. J Periodontol. 2008 Dec;79(12):2322-30.
IL1A	CP	n/a	80	ns	None	Finnish	Quan	N	Interleukin 1, alpha	IL1; IL-1A; IL1F1; IL1-ALPHA; IL1A	1	–889	19017034	Raunio T, Knuuttila M, Hiltunen L, Karttunen R, Vainio O, Tervonen T. IL-6(-174) genotype associated with the extent of periodontal disease in type 1 diabetic subjects. J Clin Periodontol. 2009 Jan;36(1):11-7. Epub 2008 Oct 31.
IL1A	CP	43	92	ns	None	Japanese	CC	N	Interleukin 1, alpha	IL1; IL-1A; IL1F1; IL1-ALPHA; IL1A	1	–889	18714935	Imamura Y, Fujigaki Y, Oomori Y, Kuno T, Ota N, Wang PL. Polymorphism of genes encoding toll-like receptors and inflammatory cytokines in periodontal disease in the Japanese population. J Int Acad Periodontol. 2008 Jul;10(3):95-102.
IL1A	CP	113	221	ns	None	Japanese	CC	N	Interleukin 1, alpha	IL1; IL-1A; IL1F1; IL1-ALPHA; IL1A	1	+4845	18321309	Komatsu Y, Galicia JC, Kobayashi T, Yamazaki K, Yoshie H. Association of interleukin-1 receptor antagonist +2018 gene polymorphism with Japanese chronic periodontitis patients using a novel genotyping method. Int J Immunogenet. 2008 Apr;35(2):165-70.
IL1A	CP	824	1297	ns	None	German	CC	N	Interleukin 1, alpha	IL1; IL-1A; IL1F1; IL1-ALPHA; IL1A	1	–889	18315433	Struch F, Dau M, Schwahn C, Biffar R, Kocher T, Meisel P. Interleukin-1 gene polymorphism, diabetes, and periodontitis: results from the Study of Health in Pomerania (SHIP). J Periodontol. 2008 Mar;79(3):501-7.

IL1A	CP	100	200	ns	None	Japanese	CC	N	Interleukin 1, alpha	IL1; IL-1A; IL1F1; IL1-ALPHA; IL1A	1	+4845	18052703	Kobayashi T, Ito S, Kuroda T, Yamamoto K, Sugita N, Narita I, Sumida T, Gejyo F, Yoshie H. The interleukin-1 and Fcgamma receptor gene polymorphisms in Japanese patients with rheumatoid arthritis and periodontitis. J Periodontol. 2007 Dec;78(12):2311-8.
IL1A	CP	51	229	ns	None	Caucasian	CC	GS	Interleukin 1, alpha	IL1; IL-1A; IL1F1; IL1-ALPHA; IL1A	1	–889	17448042	Tervonen T, Raunio T, Knuuttila M, Karttunen R. Polymorphisms in the CD14 and IL-6 genes associated with periodontal disease. J Clin Periodontol. 2007 May;34(5):377-83.
IL1A	CP	58	105	ns	None	Brazilian	CC	N	Interleukin 1, alpha	IL1; IL-1A; IL1F1; IL1-ALPHA; IL1A	1	+4845	16931944	Gonçalves Lde S, Ferreira SM, Souza CO, Colombo AP. IL-1 gene polymorphism and periodontal status of HIV Brazilians on highly active antiretroviral therapy. AIDS. 2006 Aug 22;20(13):1779-81.
IL1A	CP	56	146	ns	None	Greek	CC	N	Interleukin 1, alpha	IL1; IL-1A; IL1F1; IL1-ALPHA; IL1A	1	+4845	16911569	Sakellari D, Katsares V, Georgiadou M, Kouvatsi A, Arsenakis M, Konstantinidis A. No correlation of five gene polymorphisms with periodontal conditions in a Greek population. J Clin Periodontol. 2006 Nov;33(11):765-70. Epub 2006 Aug 14.
IL1A	CP	n/a	n/a	ns	None	n/a	CC	D	Interleukin 1, alpha	IL1; IL-1A; IL1F1; IL1-ALPHA; IL1A	1	n/a	16838563	Jansson H. Studies on periodontitis and analyses of individuals at risk for periodontal diseases. Swed Dent J Suppl. 2006;(180):5-49.
IL1A	CP	20	51	ns	None	Caucasian	CC	S	Interleukin 1, alpha	IL1; IL-1A; IL1F1; IL1-ALPHA; IL1A	1	+4845	16708852	Jansson H, Lyssenko V, Gustavsson A, Hamberg K, Söderfeldt B, Groop L, Bratthall G. Analysis of the interleukin-1 and interleukin-6 polymorphisms in patients with chronic periodontitis. A pilot study. Swed Dent J. 2006;30(1):17-23.

Continued

TABLE 6-3 Association Study—cont'd

Gene Symbol	Disease Type	Cases	Total	Best *P* Value	Level of Support	Population	Study Design	Stratified or Covariate Adj	Gene Name	Gene Aliases	# SNPs Assayed	SNP Name	PubMed ID	Journal
IL1A	CP	57	157	ns	None	Caucasian	CC	N	Interleukin 1, alpha	IL1; IL-1A; IL1F1; IL1-ALPHA; IL1A	1	–889	16304445	Brett PM, Zygogianni P, Griffiths GS, Tomaz M, Parkar M, D'Aiuto F, Tonetti M. Functional gene polymorphisms in aggressive and chronic periodontitis. J Dent Res. 2005 Dec;84(12):1149-53.
IL1A	CP	330	431	ns	None	Chilean	CC	N	Interleukin 1, alpha	IL1; IL-1A; IL1F1; IL1-ALPHA; IL1A	1	–889	15974847	López NJ, Jara L, Valenzuela CY. Association of interleukin-1 polymorphisms with periodontal disease. J Periodontol. 2005 Feb;76(2):234-43.
IL1A	CP	66	100	ns	None	Mixed	CC	DES	Interleukin 1, alpha	IL1; IL-1A; IL1F1; IL1-ALPHA; IL1A	1	+4845	14514232	Guzman S, Karima M, Wang HY, Van Dyke TE. Association between interleukin-1 genotype and periodontal disease in a diabetic population. J Periodontol. 2003 Aug;74(8):1183-90.
IL1A	CP	45	155	ns	None	Greek	CC	N	Interleukin 1, alpha	IL1; IL-1A; IL1F1; IL1-ALPHA; IL1A	1	+4845	12702109	Sakellari D, Koukoudetsos S, Arsenakis M, Konstantinidis A. Prevalence of IL-1A and IL-1B polymorphisms in a Greek population. J Clin Periodontol. 2003 Jan;30(1):35-41.
IL1A	CP	133	225	ns	None	Chinese	CC	N	Interleukin 1, alpha	IL1; IL-1A; IL1F1; IL1-ALPHA; IL1A	1	–889	12362317	Zhong L, Zhang Y, Zhang J, Yang A, Huang H. [The association of interleukin-1 gene polymorphisms with the susceptibility to chronic periodontitis in Uighur]. Zhonghua Yi Xue Yi Chuan Xue Za Zhi. 2002 Oct;19(5):405-8. Chinese.
IL1A	CP	77	154	ns	None	German	CC	S	Interleukin 1, alpha	IL1; IL-1A; IL1F1; IL1-ALPHA; IL1A	1	–889	11846196	Meisel P, Siegemund A, Dombrowa S, Sawaf H, Fanghaenel J, Kocher T. Smoking and polymorphisms of the interleukin-1 gene cluster (IL-1alpha, IL-1beta, and IL-1RN) in patients with periodontal disease. J Periodontol. 2002 Jan;73(1):27-32.

IL1A	CP	105	158	ns	None	Caucasian	CC	PS	Interleukin 1, alpha	IL1; IL-1A; IL1F1; IL1-ALPHA; IL1A	1	–889	11669477	Laine ML, Farré MA, González G, van Dijk LJ, Ham AJ, Winkel EG, Crusius JB, Vandenbroucke JP, van Winkelhoff AJ, Peña AS. Polymorphisms of the interleukin-1 gene family, oral microbial pathogens, and smoking in adult periodontitis. J Dent Res. 2001 Aug;80(8):1695-9.
IL1A	CP	32	64	ns	None	Caucasian	CC	N	Interleukin 1, alpha	IL1; IL-1A; IL1F1; IL1-ALPHA; IL1A	1	–889	9797049	Gore EA, Sanders JJ, Pandey JP, Palesch Y, Galbraith GM. Interleukin-1beta+3953 allele 2: association with disease status in adult periodontitis. J Clin Periodontol. 1998 Oct;25(10):781-5.
IL1A	CP	85	134	ns	None	Caucasian	CC	AS	Interleukin 1, alpha	IL1; IL-1A; IL1F1; IL1-ALPHA; IL1A	1	–889	9049801	Kornman KS, Crane A, Wang HY, di Giovine FS, Newman MG, Pirk FW, Wilson TG Jr, Higginbottom FL, Duff GW. The interleukin-1 genotype as a severity factor in adult periodontal disease. J Clin Periodontol. 1997 Jan;24(1):72-7.
IL1A	CP	20	30	ns	None	n/a	CC	N	Interleukin 1, alpha	IL1; IL-1A; IL1F1; IL1-ALPHA; IL1A	1	–889	12874528	Nastri L, Caruso F. [Association between interleukin-1 composite genotype and severe periodontitis: case-control study] Minerva Stomatol. 2003 Jun;52(6): 253-9.
IL1A	CP	182	271	sig	Weak	Chinese	CC	N	Interleukin 1, alpha	IL1; IL-1A; IL1F1; IL1-ALPHA; IL1A	1	–889	15562658	Huang HY, Zhang JC. [Investigation on the association of interleukin-1 genotype polymorphism with chronic periodontitis]. Hua Xi Kou Qiang Yi Xue Za Zhi. 2004 Oct;22(5):415-9. Chinese.
IL1A	CP&AMI	20	38	ns	None	German	CC	C	Interleukin 1, alpha	IL1; IL-1A; IL1F1; IL1-ALPHA; IL1A	1	–889	19563289	Stein JM, Smeets R, Reichert S, Chrobot J, Fickl S, Stanzel S, Kuch B. The role of the composite interleukin-1 genotype in the association between periodontitis and acute myocardial infarction. J Periodontol. 2009 Jul;80(7):1095-102.

Continued

TABLE 6-3 Association Study—cont'd

Gene Symbol	Disease Type	Cases	Total	Best *P* Value	Level of Support	Population	Study Design	Stratified or Covariate Adj	Gene Name	Gene Aliases	# SNPs Assayed	SNP Name	PubMed ID	Journal
IL1A	CP&CHD	n/a	96	0.027	Weak	Caucasian	Quan	N	Interleukin 1, alpha	IL1; IL-1A; IL1F1; IL1-ALPHA; IL1A	1	+4845	19053923	Geismar K, Enevold C, Sørensen LK, Gyntelberg F, Bendtzen K, Sigurd B, Holmstrup P. Involvement of interleukin-1 genotypes in the association of coronary heart disease with periodontitis. J Periodontol. 2008 Dec;79(12):2322-30.
IL1A	CP&HIV	16	32	ns	None	Caucasian	CC	G	Interleukin 1, alpha	IL1; IL-1A; IL1F1; IL1-ALPHA; IL1A	1	–889	10551423	Price P, Calder DM, Witt CS, Allcock RJ, Christiansen FT, Davies GR, Cameron PU, Rogers M, Baluchova K, Moore CB, French MA. Periodontal attachment loss in HIV-infected patients is associated with the Major histocompatibility complex 8.1 haplotype (HLA-A1,B8,DR3). Tissue Antigens. 1999 Oct;54(4):391-9.
IL1A	CP&RA	137	245	ns	None	Japanese	CC	N	Interleukin 1, alpha	IL1; IL-1A; IL1F1; IL1-ALPHA; IL1A	1	+4845	19405833	Kobayashi T, Murasawa A, Ito S, Yamamoto K, Komatsu Y, Abe A, Sumida T, Yoshie H. Cytokine gene polymorphisms associated with rheumatoid arthritis and periodontitis in Japanese adults. J Periodontol. 2009 May;80(5):792-9.
IL1A	CP&RA	86	186	ns	None	Japanese	CC	N	Interleukin 1, alpha	IL1; IL-1A; IL1F1; IL1-ALPHA; IL1A	1	+4845	18052703	Kobayashi T, Ito S, Kuroda T, Yamamoto K, Sugita N, Narita I, Sumida T, Gejyo F, Yoshie H. The interleukin-1 and Fcgamma receptor gene polymorphisms in Japanese patients with rheumatoid arthritis and periodontitis. J Periodontol. 2007 Dec;78(12):2311-8.
IL1A	CP&T2DM	69	542	0.012	Weak	German	CC	N	Interleukin 1, alpha	IL1; IL-1A; IL1F1; IL1-ALPHA; IL1A	1	–889	18315433	Struch F, Dau M, Schwahn C, Biffar R, Kocher T, Meisel P. Interleukin-1 gene polymorphism, diabetes, and periodontitis: results from the Study of Health in Pomerania (SHIP). J Periodontol. 2008 Mar;79(3):501-7.

IL1A	CP&T2DM	112	336	0.017	Weak	Chilean	CC	SD	Interleukin 1, alpha	IL1; IL-1A; IL1F1; IL1-ALPHA; IL1A	1	–889	19792847	López NJ, Valenzuela CY, Jara L. Interleukin-1 gene cluster polymorphisms associated with periodontal disease in type 2 diabetes. J Periodontol. 2009 Oct;80(10):1590-8.
IL1A.IL1B	AgP	36	111	ns	None	Chilean	CC	S	n/a	n/a	2	Multiple Genes	15633328	Quappe L, Jara L, López NJ. Association of interleukin-1 polymorphisms with aggressive periodontitis. J Periodontol. 2004 Nov;75(11):1509-15.
IL1A.IL1B	AgP	40	136	ns	None	Caucasian	CC	N	n/a	n/a	2	Multiple Genes	15602586	Scapoli C, Trombelli L, Mamolini E, Collins A. Linkage disequilibrium analysis of case-control data: an application to generalized aggressive periodontitis. Genes Immun. 2005 Feb;6(1):44-52.
IL1A.IL1B	AgP	37	141	ns	None	African American	CC	N	n/a	n/a	2	Multiple Genes	10872952	Walker SJ, Van Dyke TE, Rich S, Kornman KS, di Giovine FS, Hart TC. Genetic polymorphisms of the IL-1alpha and IL-1beta genes in African-American LJP patients and an African-American control population. J Periodontol. 2000 May;71(5):723-8.
IL1A.IL1B	AgP	n/a	20	sig	Weak	Czech	Longitudinal	N	n/a	n/a	2	Multiple Genes	17575917	Krátká Z, Bártová J, Krejsa O, Otcenásková M, Janatova T, Dusková J. Interleukin-1 gene polymorphisms as assessed in a 10-year study of patients with early-onset periodontitis. Folia Microbiol (Praha). 2007;52(2):183-8.
IL1A.IL1B	CP	n/a	323	0.0008	Moderate	Caucasian	Longitudinal	S	n/a	n/a	2	Multiple Genes	10863964	Lang NP, Tonetti MS, Suter J, Sorrell J, Duff GW, Kornman KS. Effect of interleukin-1 gene polymorphisms on gingival inflammation assessed by bleeding on probing in a periodontal maintenance population. J Periodontal Res. 2000 Apr;35(2):102-7.

Continued

TABLE 6-3 Association Study—cont'd

Gene Symbol	Disease Type	Cases	Total	Best *P* Value	Level of Support	Population	Study Design	Stratified or Covariate Adj	Gene Name	Gene Aliases	# SNPs Assayed	SNP Name	PubMed ID	Journal
IL1A.IL1B	CP	330	431	0.001	Moderate	Chilean	CC	N	n/a	n/a	1	Multiple Genes	15974847	López NJ, Jara L, Valenzuela CY. Association of interleukin-1 polymorphisms with periodontal disease. J Periodontol. 2005 Feb;76(2):234-43.
IL1A.IL1B	CP	224	432	0.002	Weak	Chilean	CC	SD	n/a	n/a	2	Multiple Genes	19792847	López NJ, Valenzuela CY, Jara L. Interleukin-1 gene cluster polymorphisms associated with periodontal disease in type 2 diabetes. J Periodontol. 2009 Oct;80(10):1590-8.
IL1A.IL1B	CP	403	414	0.013	Weak	Caucasian	CC	S	n/a	n/a	2	Multiple Genes	12598547	Meisel P, Siegemund A, Grimm R, Herrmann FH, John U, Schwahn C, Kocher T. The interleukin-1 polymorphism, smoking, and the risk of periodontal disease in the population-based SHIP study. J Dent Res. 2003 Mar;82(3):189-93.
IL1A.IL1B	CP	117	558	0.013	Weak	German	CC	S	n/a	n/a	2	Multiple Genes	19570260	Meisel P, Heins G, Carlsson L, Giebel J, John U, Schwahn C, Kocher T. Impact of Genetic Polymorphisms on the Smoking-related Risk of Periodontal Disease: the Population-based Study SHIP. Tob Induc Dis. 2003 Sep 15;1(3):197.
IL1A.IL1B	CP	77	154	0.022	Weak	German	CC	S	n/a	n/a	2	Multiple Genes	11846196	Meisel P, Siegemund A, Dombrowa S, Sawaf H, Fanghaenel J, Kocher T. Smoking and polymorphisms of the interleukin-1 gene cluster (IL-1alpha, IL-1beta, and IL-1RN) in patients with periodontal disease. J Periodontol. 2002 Jan;73(1):27-32.

IL1A.IL1B	CP	44	90	0.026	Weak	Mixed	CC	AES	n/a	n/a	2	Multiple Genes	10711605	McDevitt MJ, Wang HY, Knobelman C, Newman MG, di Giovine FS, Timms J, Duff GW, Kornman KS. Interleukin-1 genetic association with periodontitis in clinical practice. J Periodontol. 2000 Feb;71(2):156-63.
IL1A.IL1B	CP	90	30	<0.0001	Weak	Maharashtrian	CC	N	n/a	n/a	2	Multiple Genes	16945028	Agrawal AA, Kapley A, Yeltiwar RK, Purohit HJ. Assessment of single nucleotide polymorphism at IL-1A+4845 and IL-1B+3954 as genetic susceptibility test for chronic periodontitis in Maharashtrian ethnicity. J Periodontol. 2006 Sep;77(9):1515-21.
IL1A.IL1B	CP	490	1010	<0.001	Moderate	German	CC	S	n/a	n/a	2	Multiple Genes	15068111	Meisel P, Schwahn C, Gesch D, Bernhardt O, John U, Kocher T. Dose-effect relation of smoking and the interleukin-1 gene polymorphism in periodontal disease. J Periodontol. 2004 Feb;75(2):236-42.
IL1A.IL1B	CP	85	134	<0.002	Moderate	Caucasian	CC	AS	n/a	n/a	2	Multiple Genes	9049801	Kornman KS, Crane A, Wang HY, di Giovine FS, Newman MG, Pirk FW, Wilson TG Jr, Higginbottom FL, Duff GW. The interleukin-1 genotype as a severity factor in adult periodontal disease. J Clin Periodontol. 1997 Jan;24(1):72-7.
IL1A.IL1B	CP	61	861	<0.05	Weak	New Zealander	CC	AGS	n/a	n/a	2	Multiple Genes	11669478	Thomson WM, Edwards SJ, Dobson-Le DP, Tompkins GR, Poulton R, Knight DA, Braithwaite AW. IL-1 genotype and adult periodontitis among young New Zealanders. J Dent Res. 2001 Aug;80(8):1700-3.
IL1A.IL1B	CP	n/a	99	ns	None	African	CC	N	n/a	n/a	2	Multiple Genes	19708438	Saleh TA, Stephen L, Kotze M, Pretorius A. The composite interleukin-1 genotype in South Africa. SADJ. 2009 May;64(4):170-3.

Continued

TABLE 6-3 Association Study—cont'd

Gene Symbol	Disease Type	Cases	Total	Best *P* Value	Level of Support	Population	Study Design	Stratified or Covariate Adj	Gene Name	Gene Aliases	# SNPs Assayed	SNP Name	PubMed ID	Journal
IL1A.IL1B	CP	100	200	ns	None	Japanese	CC	N	n/a	n/a	2	Multiple Genes	18052703	Kobayashi T, Ito S, Kuroda T, Yamamoto K, Sugita N, Narita I, Sumida T, Gejyo F, Yoshie H. The interleukin-1 and Fcgamma receptor gene polymorphisms in Japanese patients with rheumatoid arthritis and periodontitis. J Periodontol. 2007 Dec;78(12):2311-8.
IL1A.IL1B	CP	58	105	ns	None	Brazilian	CC	N	n/a	n/a	2	Multiple Genes	16931944	Gonçalves Lde S, Ferreira SM, Souza CO, Colombo AP. IL-1 gene polymorphism and periodontal status of HIV Brazilians on highly active antiretroviral therapy. AIDS. 2006 Aug 22;20(13):1779-81.
IL1A.IL1B	CP	n/a	53	ns	None	Caucasian	Longitudinal	N	n/a	n/a	1	Multiple Genes	15898359	König J, Rühling A, Plagmann HC, Meisel P, Kocher T. Influence of interleukin (IL)-1 composite genotype on clinical variables in non-smoking, well-maintained compliant patients with chronic periodontitis. Swed Dent J. 2005;29(1):11-6.
IL1A.IL1B	CP	45	155	ns	None	Greek	CC	N	n/a	n/a	2	Multiple Genes	12702109	Sakellari D, Koukoudetsos S, Arsenakis M, Konstantinidis A. Prevalence of IL-1A and IL-1B polymorphisms in a Greek population. J Clin Periodontol. 2003 Jan;30(1):35-41.
IL1A.IL1B	CP	n/a	295	ns	None	Australian	Longitudinal	APS	n/a	n/a	2	Multiple Genes	11737511	Cullinan MP, Westerman B, Hamlet SM, Palmer JE, Faddy MJ, Lang NP, Seymour GJ. A longitudinal study of interleukin-1 gene polymorphisms and periodontal disease in a general adult population. J Clin Periodontol. 2001 Dec;28(12):1137-44.
IL1A.IL1B	CP	132	205	ns	None	Caucasian	CC	N	n/a	n/a	2	Multiple Genes	11350500	Papapanou PN, Neiderud AM, Sandros J, Dahlén G. Interleukin-1 gene polymorphism and periodontal status. A case-control study. J Clin Periodontol. 2001 May;28(5):389-96.

IL1A.IL1B	CP	n/a	33	ns	None	n/a	Longitudinal	N	n/a	n/a	2	Multiple Genes	10599909	Ehmke B, Kress W, Karch H, Grimm T, Klaiber B, Flemmig TF. Interleukin-1 haplotype and periodontal disease progression following therapy. J Clin Periodontol. 1999 Dec;26(12):810-3.
IL1A.IL1B	CP	29	46	ns	None	Brazilian	CC	N	n/a	n/a	2	Multiple Genes	20027454	Gonçalves Lde S, Ferreira SM, Souza CO, Colombo AP. Influence of IL-1 gene polymorphism on the periodontal microbiota of HIV-infected Brazilian individuals. Braz Oral Res. 2009 Oct-Dec;23(4):452-9.
IL1A.IL1B	CP	182	271	sig	Weak	Chinese	CC	N	n/a	n/a	2	Multiple Genes	15562658	Huang HY, Zhang JC. [Investigation on the association of interleukin-1 genotype polymorphism with chronic periodontitis]. Hua Xi Kou Qiang Yi Xue Za Zhi. 2004 Oct;22(5):415-9. Chinese.
IL1A.IL1B	CP&AMI	20	38	ns	None	German	CC	C	n/a	n/a	2	Multiple Genes	19563289	Stein JM, Smeets R, Reichert S, Chrobot J, Fickl S, Stanzel S, Kuch B. The role of the composite interleukin-1 genotype in the association between periodontitis and acute myocardial infarction. J Periodontol. 2009 Jul;80(7):1095-102.
IL1A.IL1B	CP&HIV	16	32	ns	None	Caucasian	CC	G	n/a	n/a	2	Multiple Genes	10551423	Price P, Calder DM, Witt CS, Allcock RJ, Christiansen FT, Davies GR, Cameron PU, Rogers M, Baluchova K, Moore CB, French MA. Periodontal attachment loss in HIV-infected patients is associated with the Major histocompatibility complex 8.1 haplotype (HLA-A1,B8,DR3). Tissue Antigens. 1999 Oct;54(4):391-9.
IL1A.IL1B	CP&HIV	29	59	ns	None	Brazilian	CC	N	n/a	n/a	2	Multiple Genes	20027454	Gonçalves Lde S, Ferreira SM, Souza CO, Colombo AP. Influence of IL-1 gene polymorphism on the periodontal microbiota of HIV-infected Brazilian individuals. Braz Oral Res. 2009 Oct-Dec;23(4):452-9.

Continued

TABLE 6-3 Association Study—cont'd

Gene Symbol	Disease Type	Cases	Total	Best *P* Value	Level of Support	Population	Study Design	Stratified or Covariate Adj	Gene Name	Gene Aliases	# SNPs Assayed	SNP Name	PubMed ID	Journal
IL1A.IL1B	CP&RA	86	186	0.00001	Moderate	Japanese	CC	N	n/a	n/a	2	Multiple Genes	18052703	Kobayashi T, Ito S, Kuroda T, Yamamoto K, Sugita N, Narita I, Sumida T, Gejyo F, Yoshie H. The interleukin-1 and Fcgamma receptor gene polymorphisms in Japanese patients with rheumatoid arthritis and periodontitis. J Periodontol. 2007 Dec;78(12):2311-8.
IL1A.IL1B	CP&T2DM	112	336	ns	None	Chilean	CC	SD	n/a	n/a	2	Multiple Genes	19792847	López NJ, Valenzuela CY, Jara L. Interleukin-1 gene cluster polymorphisms associated with periodontal disease in type 2 diabetes. J Periodontol. 2009 Oct;80(10):1590-8.
IL1A.IL1B. IL1RN	CP	105	158	0.0068	Weak	Caucasian	CC	PS	n/a	n/a	3	Multiple Genes	12212456	Laine ML, Farré MA, García-González MA, van Dijk LJ, Ham AJ, Winkel EG, Crusius JB, Vandenbroucke JP, van Winkelhoff AJ, Peña AS. [Risk factors in adult periodontitis: polymorphism in the interleukin-1 gene family]. Ned Tijdschr Tandheelkd. 2002 Aug;109(8):303-6. Dutch.
IL1A.IL1B. IL1RN	CP	105	158	0.0068	Weak	Caucasian	CC	PS	n/a	n/a	3	Multiple Genes	11669477	Laine ML, Farré MA, González G, van Dijk LJ, Ham AJ, Winkel EG, Crusius JB, Vandenbroucke JP, van Winkelhoff AJ, Peña AS. Polymorphisms of the interleukin-1 gene family, oral microbial pathogens, and smoking in adult periodontitis. J Dent Res. 2001 Aug;80(8):1695-9.
IL1A.IL1B. IL6	CP	20	51	ns	None	Caucasian	CC	S	n/a	n/a	3	Multiple Genes	16708852	Jansson H, Lyssenko V, Gustavsson A, Hamberg K, Söderfeldt B, Groop L, Bratthall G. Analysis of the interleukin-1 and interleukin-6 polymorphisms in patients with chronic periodontitis. A pilot study. Swed Dent J. 2006;30(1):17-23.

IL1A.IL1RN	CP	113	221	0.001	Moderate	Japanese	CC	N	n/a	n/a	2	Multiple Genes	18321309	Komatsu Y, Galicia JC, Kobayashi T, Yamazaki K, Yoshie H. Association of interleukin-1 receptor antagonist +2018 gene polymorphism with Japanese chronic periodontitis patients using a novel genotyping method. Int J Immunogenet. 2008 Apr;35(2):165-70.
IL1A.IL1RN	CP	77	154	0.005	Weak	German	CC	S	n/a	n/a	2	Multiple Genes	11846196	Meisel P, Siegemund A, Dombrowa S, Sawaf H, Fanghaenel J, Kocher T. Smoking and polymorphisms of the interleukin-1 gene cluster (IL-1alpha, IL-1beta, and IL-1RN) in patients with periodontal disease. J Periodontol. 2002 Jan;73(1):27-32.
IL1A.IL1RN	CP	100	200	ns	None	Japanese	CC	N	n/a	n/a	2	Multiple Genes	18052703	Kobayashi T, Ito S, Kuroda T, Yamamoto K, Sugita N, Narita I, Sumida T, Gejyo F, Yoshie H. The interleukin-1 and Fcgamma receptor gene polymorphisms in Japanese patients with rheumatoid arthritis and periodontitis. J Periodontol. 2007 Dec;78(12):2311-8.
IL1A.IL1RN	CP&RA	86	186	ns	None	Japanese	CC	N	n/a	n/a	2	Multiple Genes	18052703	Kobayashi T, Ito S, Kuroda T, Yamamoto K, Sugita N, Narita I, Sumida T, Gejyo F, Yoshie H. The interleukin-1 and Fcgamma receptor gene polymorphisms in Japanese patients with rheumatoid arthritis and periodontitis. J Periodontol. 2007 Dec;78(12):2311-8.
IL1B	AgP	141	285	0.0005	Moderate	Mixed	Fam	S	Interleukin 1, beta	IL-1; IL1F2; IL1-BETA; IL1B	1	+3953	10328654	Diehl SR, Wang Y, Brooks CN, Burmeister JA, Califano JV, Wang S, Schenkein HA. Linkage disequilibrium of interleukin-1 genetic polymorphisms with early-onset periodontitis. J Periodontol. 1999 Apr;70(4):418-30.

Continued

TABLE 6-3 Association Study—cont'd

Gene Symbol	Disease Type	Cases	Total	Best *P* Value	Level of Support	Population	Study Design	Stratified or Covariate Adj	Gene Name	Gene Aliases	# SNPs Assayed	SNP Name	PubMed ID	Journal
IL1B	AgP	66	180	0.002	Weak	Chinese	Fam	N	Interleukin 1, beta	IL-1; IL1F2; IL1-BETA; IL1B	1	–511	18278133	Ren XY, Xu L, Meng HX. [Interleukin-1 family polymorphisms in aggressive periodontitis patients and their relatives]. Beijing Da Xue Xue Bao. 2008 Feb 18;40(1):28-33. Chinese.
IL1B	AgP	122	217	0.006	Weak	Chinese	CC	AGS	Interleukin 1, beta	IL-1; IL1F2; IL1-BETA; IL1B	2	–511	15732864	Li QY, Zhao HS, Meng HX, Zhang L, Xu L, Chen ZB, Shi D, Feng XH, Zhu XL. Association analysis between interleukin-1 family polymorphisms and generalized aggressive periodontitis in a Chinese population. J Periodontol. 2004 Dec;75(12):1627-35.
IL1B	AgP	51	151	0.012	Weak	Caucasian	CC	N	Interleukin 1, beta	IL-1; IL1F2; IL1-BETA; IL1B	2	+3954	16304445	Brett PM, Zygogianni P, Griffiths GS, Tomaz M, Parkar M, D'Aiuto F, Tonetti M. Functional gene polymorphisms in aggressive and chronic periodontitis. J Dent Res. 2005 Dec;84(12):1149-53.
IL1B	AgP	70	142	0.025	Weak	Caucasian	CC	S	Interleukin 1, beta	IL-1; IL1F2; IL1-BETA; IL1B	1	+3953	10983602	Parkhill JM, Hennig BJ, Chapple IL, Heasman PA, Taylor JJ. Association of interleukin-1 gene polymorphisms with early-onset periodontitis. J Clin Periodontol. 2000 Sep;27(9):682-9.
IL1B	AgP	36	111	0.03	Weak	Chilean	CC	S	Interleukin 1, beta	IL-1; IL1F2; IL1-BETA; IL1B	1	+3954	15633328	Quappe L, Jara L, López NJ. Association of interleukin-1 polymorphisms with aggressive periodontitis. J Periodontol. 2004 Nov;75(11):1509-15.
IL1B	AgP	40	136	0.039	Weak	Caucasian	CC	N	Interleukin 1, beta	IL-1; IL1F2; IL1-BETA; IL1B	1	+3953	15602586	Scapoli C, Trombelli L, Mamolini E, Collins A. Linkage disequilibrium analysis of case-control data: an application to generalized aggressive periodontitis. Genes Immun. 2005 Feb;6(1):44-52.

IL1B	AgP	31	62	<0.001	Weak	Turkish	CC	N	Interleukin 1, beta	IL-1; IL1F2; IL1-BETA; IL1B	1	+3954	18587204	Guzeldemir E, Gunhan M, Ozcelik O, Tastan H. Interleukin-1 and tumor necrosis factor-alpha gene polymorphisms in Turkish patients with localized aggressive periodontitis. J Oral Sci. 2008 Jun;50(2):151-9.
IL1B	AgP	20	114	<0.05	Weak	Chinese	CC	N	Interleukin 1, beta	IL-1; IL1F2; IL1-BETA; IL1B	1	+3954	12593203	Duan H, Zhang J, Zhang Y. [The association between IL-1 gene polymorphisms and susceptibility to severe periodontitis]. Hua Xi Kou Qiang Yi Xue Za Zhi. 2002 Feb;20(1):48-51. Chinese.
IL1B	AgP	9	41	ns	None	Japanese	CC	N	Interleukin 1, beta	IL-1; IL1F2; IL1-BETA; IL1B	1	+3954	19184295	Shimomura-Kuroki J, Yamashita K, Shimooka S. Tannerella forsythia and the HLA-DQB1 allele are associated with susceptibility to periodontal disease in Japanese adolescents. Odontology. 2009 Jan;97(1):32-7. Epub 2009 Jan 29.
IL1B	AgP	20	72	ns	None	Polish	CC	N	Interleukin 1, beta	IL-1; IL1F2; IL1-BETA; IL1B	1	+3954	19127818	Drozdzik A. [The effect of environmental and genetic factors in the pathogenesis of periodontitis]. Ann Acad Med Stetin. 2008;54(1):118-26. Polish.
IL1B	AgP	415	1289	ns	None	Caucasian	CC	N	Interleukin 1, beta	IL-1; IL1F2; IL1-BETA; IL1B	2	Multiple SNPs	18723088	Fiebig A, Jepsen S, Loos BG, Scholz C, Schäfer C, Rühling A, Nothnagel M, Eickholz P, van der Velden U, Schenck K, Schreiber S, Grössner-Schreiber B. Polymorphisms in the interleukin-1 (IL1) gene cluster are not associated with aggressive periodontitis in a large Caucasian population. Genomics. 2008 Nov;92(5):309-15. Epub 2008 Sep 18.

Continued

TABLE 6-3 Association Study—cont'd

Gene Symbol	Disease Type	Cases	Total	Best *P* Value	Level of Support	Population	Study Design	Stratified or Covariate Adj	Gene Name	Gene Aliases	# SNPs Assayed	SNP Name	PubMed ID	Journal
IL1B	AgP	415	1289	ns	None	Caucasian	CC	N	Interleukin 1, beta	IL-1; IL1F2; IL1-BETA; IL1B	2	Haplotype	18723088	Fiebig A, Jepsen S, Loos BG, Scholz C, Schäfer C, Rühling A, Nothnagel M, Eickholz P, van der Velden U, Schenck K, Schreiber S, Grössner-Schreiber B. Polymorphisms in the interleukin-1 (IL1) gene cluster are not associated with aggressive periodontitis in a large Caucasian population. Genomics. 2008 Nov;92(5):309-15. Epub 2008 Sep 18.
IL1B	AgP	66	180	ns	None	Chinese	Fam	N	Interleukin 1, beta	IL-1; IL1F2; IL1-BETA; IL1B	1	–511	18278133	Ren XY, Xu L, Meng HX. [Interleukin-1 family polymorphisms in aggressive periodontitis patients and their relatives]. Beijing Da Xue Xue Bao. 2008 Feb 18;40(1):28-33. Chinese.
IL1B	AgP	n/a	20	ns	None	Czech	Longitudinal	N	Interleukin 1, beta	IL-1; IL1F2; IL1-BETA; IL1B	1	n/a	17575917	Krátká Z, Bártová J, Krejsa O, Otcenásková M, Janatova T, Dusková J. Interleukin-1 gene polymorphisms as assessed in a 10-year study of patients with early-onset periodontitis. Folia Microbiol (Praha). 2007;52(2):183-8.
IL1B	AgP	20	72	ns	None	Polish	CC	N	Interleukin 1, beta	IL-1; IL1F2; IL1-BETA; IL1B	1	+3954	17458053	Drozdzik A, Kurzawski M, Safronow K, Banach J. Polymorphism in interleukin-1beta gene and the risk of periodontitis in a Polish population. Adv Med Sci. 2006;51 Suppl 1:13-7.
IL1B	AgP	45	70	ns	None	Caucasian	CC	N	Interleukin 1, beta	IL-1; IL1F2; IL1-BETA; IL1B	2	Multiple SNPs	17335371	Havemose-Poulsen A, Sørensen LK, Bendtzen K, Holmstrup P. Polymorphisms within the IL-1 gene cluster: effects on cytokine profiles in peripheral blood and whole blood cell cultures of patients with aggressive periodontitis, juvenile idiopathic arthritis, and rheumatoid arthritis. J Periodontol. 2007 Mar;78(3):475-92.

IL1B	AgP	46	136	ns	None	Greek	CC	N	Interleukin 1, beta	IL-1; IL1F2; IL1-BETA; IL1B	1	+3954	16911569	Sakellari D, Katsares V, Georgiadou M, Kouvatsi A, Arsenakis M, Konstantinidis A. No correlation of five gene polymorphisms with periodontal conditions in a Greek population. J Clin Periodontol. 2006 Nov;33(11):765-70. Epub 2006 Aug 14.
IL1B	AgP	122	217	ns	None	Chinese	CC	N	Interleukin 1, beta	IL-1; IL1F2; IL1-BETA; IL1B	1	+3954	16155691	Li QY, Zhao HS, Meng HX, Zhang L, Xu L, Chen ZB. [Interleukin-1 polymorphisms in patients with aggressive periodontitis]. Shanghai Kou Qiang Yi Xue. 2005 Aug;14(4):333-7. Chinese.
IL1B	AgP	46	77	ns	None	Brazilian	CC	S	Interleukin 1, beta	IL-1; IL1F2; IL1-BETA; IL1B	1	+3954	15966908	Moreira PR, de Sá AR, Xavier GM, Costa JE, Gomez RS, Gollob KJ, Dutra WO. A functional interleukin-1 beta gene polymorphism is associated with chronic periodontitis in a sample of Brazilian individuals. J Periodontal Res. 2005 Aug;40(4):306-11.
IL1B	AgP	44	91	ns	None	Mixed	CC	E	Interleukin 1, beta	IL-1; IL1F2; IL1-BETA; IL1B	1	+3954	12974682	Gonzales JR, Michel J, Rodríguez EL, Herrmann JM, Bödeker RH, Meyle J. Comparison of interleukin-1 genotypes in two populations with aggressive periodontitis. Eur J Oral Sci. 2003 Oct;111(5):395-9.
IL1B	AgP	47	144	ns	None	Japanese	CC	N	Interleukin 1, beta	IL-1; IL1F2; IL1-BETA; IL1B	2	Multiple SNPs	12445219	Tai H, Endo M, Shimada Y, Gou E, Orima K, Kobayashi T, Yamazaki K, Yoshie H. Association of interleukin-1 receptor antagonist gene polymorphisms with early onset periodontitis in Japanese. J Clin Periodontol. 2002 Oct;29(10):882-8.
IL1B	AgP	14	14	ns	None	Brazilian	Fam	N	Interleukin 1, beta	IL-1; IL1F2; IL1-BETA; IL1B	2	Multiple SNPs	11940143	Trevilatto PC, Tramontina VA, Machado MA, Gonçalves RB, Sallum AW, Line SR. Clinical, genetic and microbiological findings in a Brazilian family with aggressive periodontitis. J Clin Periodontol. 2002 Mar;29(3):233-9.

Continued

TABLE 6-3 Association Study—cont'd

Gene Symbol	Disease Type	Cases	Total	Best *P* Value	Level of Support	Population	Study Design	Stratified or Covariate Adj	Gene Name	Gene Aliases	# SNPs Assayed	SNP Name	PubMed ID	Journal
IL1B	AgP	56	112	ns	None	Caucasian	CC	S	Interleukin 1, beta	IL-1; IL1F2; IL1-BETA; IL1B	1	+3953	11350506	Hodge PJ, Riggio MP, Kinane DF. Failure to detect an association with IL1 genotypes in European Caucasians with generalised early onset periodontitis. J Clin Periodontol. 2001 May;28(5):430-6.
IL1B	AgP	37	141	ns	None	African American	CC	N	Interleukin 1, beta	IL-1; IL1F2; IL1-BETA; IL1B	1	+3953	10872952	Walker SJ, Van Dyke TE, Rich S, Kornman KS, di Giovine FS, Hart TC. Genetic polymorphisms of the IL-1alpha and IL-1beta genes in African-American LJP patients and an African-American control population. J Periodontol. 2000 May;71(5):723-8.
IL1B	AgP	n/a	n/a	sig	Weak	Chinese	CC	N	Interleukin 1, beta	IL-1; IL1F2; IL1-BETA; IL1B	1	+3953	19031816	Wang HY, Pan YP. [Screening and analysis of multi-alleles in generalized aggressive periodontitis]. Zhonghua Kou Qiang Yi Xue Za Zhi. 2008 Jul;43(7):406-9. Chinese.
IL1B	AgP+CP	251	376	ns	None	Japanese	CC	N	Interleukin 1, beta	IL-1; IL1F2; IL1-BETA; IL1B	n/a	n/a	15081423	Suzuki A, Ji G, Numabe Y, Muramatsu M, Gomi K, Kanazashi M, Ogata Y, Shimizu E, Shibukawa Y, Ito A, Ito T, Sugaya A, Arai T, Yamada S, Deguchi S, Kamoi K. Single nucleotide polymorphisms associated with aggressive periodontitis and severe chronic periodontitis in Japanese. Biochem Biophys Res Commun. 2004 May 7;317(3):887-92.

IL1B	AgP+CP	319	622	ns	None	Japanese	CC	AGS	Interleukin 1, beta	IL-1; IL1F2; IL1-BETA; IL1B	2	–31	19892918	Kobayashi T, Nagata T, Murakami S, Takashiba S, Kurihara H, Izumi Y, Numabe Y, Watanabe H, Kataoka M, Nagai A, Hayashi J, Ohyama H, Okamatsu Y, Inagaki Y, Tai H, Yoshie H. Genetic risk factors for periodontitis in a Japanese population. J Dent Res. 2009 Dec;88(12): 1137-41.
IL1B	CP	330	431	0.001	Moderate	Chilean	CC	N	Interleukin 1, beta	IL-1; IL1F2; IL1-BETA; IL1B	1	+3954	15974847	López NJ, Jara L, Valenzuela CY. Association of interleukin-1 polymorphisms with periodontal disease. J Periodontol. 2005 Feb;76(2):234-43.
IL1B	CP	224	432	0.001	Weak	Chilean	CC	SD	Interleukin 1, beta	IL-1; IL1F2; IL1-BETA; IL1B	1	3954	19792847	López NJ, Valenzuela CY, Jara L. Interleukin-1 gene cluster polymorphisms associated with periodontal disease in type 2 diabetes. J Periodontol. 2009 Oct;80(10):1590-8.
IL1B	CP	224	432	0.006	Weak	Chilean	CC	SD	Interleukin 1, beta	IL-1; IL1F2; IL1-BETA; IL1B	1	–511	19792847	López NJ, Valenzuela CY, Jara L. Interleukin-1 gene cluster polymorphisms associated with periodontal disease in type 2 diabetes. J Periodontol. 2009 Oct;80(10):1590-8.
IL1B	CP	52	83	0.007	Weak	Brazilian	CC	S	Interleukin 1, beta	IL-1; IL1F2; IL1-BETA; IL1B	1	+3954	15966908	Moreira PR, de Sá AR, Xavier GM, Costa JE, Gomez RS, Gollob KJ, Dutra WO. A functional interleukin-1 beta gene polymorphism is associated with chronic periodontitis in a sample of Brazilian individuals. J Periodontal Res. 2005 Aug;40(4):306-11.
IL1B	CP	66	100	0.01	Weak	Mixed	CC	DES	Interleukin 1, beta	IL-1; IL1F2; IL1-BETA; IL1B	2	–511	14514232	Guzman S, Karima M, Wang HY, Van Dyke TE. Association between interleukin-1 genotype and periodontal disease in a diabetic population. J Periodontol. 2003 Aug;74(8):1183-90.

Continued

TABLE 6-3 Association Study—cont'd

Gene Symbol	Disease Type	Cases	Total	Best *P* Value	Level of Support	Population	Study Design	Stratified or Covariate Adj	Gene Name	Gene Aliases	# SNPs Assayed	SNP Name	PubMed ID	Journal
IL1B	CP	20	65	0.013	Weak	n/a	CC	N	Interleukin 1, beta	IL-1; IL1F2; IL1-BETA; IL1B	1	+3953	10589805	Galbraith GM, Hendley TM, Sanders JJ, Palesch Y, Pandey JP. Polymorphic cytokine genotypes as markers of disease severity in adult periodontitis. J Clin Periodontol. 1999 Nov;26(11):705-9.
IL1B	CP	32	64	0.043	Weak	Caucasian	CC	N	Interleukin 1, beta	IL-1; IL1F2; IL1-BETA; IL1B	2	+3953	9797049	Gore EA, Sanders JJ, Pandey JP, Palesch Y, Galbraith GM. Interleukin-1beta+3953 allele 2: association with disease status in adult periodontitis. J Clin Periodontol. 1998 Oct;25(10):781-5.
IL1B	CP	90	30	<0.0001	Weak	Maharashtrian	CC	N	Interleukin 1, beta	IL-1; IL1F2; IL1-BETA; IL1B	1	+3954	16945028	Agrawal AA, Kapley A, Yeltiwar RK, Purohit HJ. Assessment of single nucleotide polymorphism at IL-1A+4845 and IL-1B+3954 as genetic susceptibility test for chronic periodontitis in Maharashtrian ethnicity. J Periodontol. 2006 Sep;77(9):1515-21.
IL1B	CP	97	194	<0.001	Moderate	German	CC	N	Interleukin 1, beta	IL-1; IL1F2; IL1-BETA; IL1B	1	+3953	17711477	Wagner J, Kaminski WE, Aslanidis C, Moder D, Hiller KA, Christgau M, Schmitz G, Schmalz G. Prevalence of OPG and IL-1 gene polymorphisms in chronic periodontitis. J Clin Periodontol. 2007 Oct;34(10):823-7. Epub 2007 Aug 17.
IL1B	CP	n/a	n/a	<0.01	Weak	Chinese	CC	N	Interleukin 1, beta	IL-1; IL1F2; IL1-BETA; IL1B	1	+3954	14966591	Lin L, Pan YP, Yin LY. Study on the correlation of cytokine gene polymorphism with chronic periodontitis. Shanghai Kou Qiang Yi Xue. 2003 Dec;12(6):456-9.

IL1B	CP	30	124	<0.05	Weak	Chinese	CC	N	Interleukin 1, beta	IL-1; IL1F2; IL1-BETA; IL1B	1	+3954	12593203	Duan H, Zhang J, Zhang Y. [The association between IL-1 gene polymorphisms and susceptibility to severe periodontitis]. Hua Xi Kou Qiang Yi Xue Za Zhi. 2002 Feb;20(1):48-51. Chinese.
IL1B	CP	n/a	99	ns	None	African	CC	N	Interleukin 1, beta	IL-1; IL1F2; IL1-BETA; IL1B	2	Multiple SNPs	19708438	Saleh TA, Stephen L, Kotze M, Pretorius A. The composite interleukin-1 genotype in South Africa. SADJ. 2009 May;64(4):170-3.
IL1B	CP	117	225	ns	None	Japanese	CC	N	Interleukin 1, beta	IL-1; IL1F2; IL1-BETA; IL1B	2	Multiple SNPs	19405833	Kobayashi T, Murasawa A, Ito S, Yamamoto K, Komatsu Y, Abe A, Sumida T, Yoshie H. Cytokine gene polymorphisms associated with rheumatoid arthritis and periodontitis in Japanese adults. J Periodontol. 2009 May;80(5):792-9.
IL1B	CP	30	61	ns	None	Indian	CC	N	Interleukin 1, beta	IL-1; IL1F2; IL1-BETA; IL1B	1	+3954	19336858	Kaarthikeyan G, Jayakumar ND, Padmalatha O, Sheeja V, Sankari M, Anandan B. Analysis of the association between interleukin-1beta (+3954) gene polymorphism and chronic periodontitis in a sample of the south Indian population. Indian J Dent Res. 2009 Jan-Mar;20(1):37-40.
IL1B	CP	32	84	ns	None	Polish	CC	N	Interleukin 1, beta	IL-1; IL1F2; IL1-BETA; IL1B	1	+3954	19127818	Drozdzik A. [The effect of environmental and genetic factors in the pathogenesis of periodontitis]. Ann Acad Med Stetin. 2008;54(1):118-26. Polish.
IL1B	CP	n/a	123	ns	None	Caucasian	Quan	N	Interleukin 1, beta	IL-1; IL1F2; IL1-BETA; IL1B	2	Multiple SNPs	19053923	Geismar K, Enevold C, Sørensen LK, Gyntelberg F, Bendtzen K, Sigurd B, Holmstrup P. Involvement of interleukin-1 genotypes in the association of coronary heart disease with periodontitis. J Periodontol. 2008 Dec;79(12):2322-30.

Continued

TABLE 6-3 Association Study—cont'd

Gene Symbol	Disease Type	Cases	Total	Best *P* Value	Level of Support	Population	Study Design	Stratified or Covariate Adj	Gene Name	Gene Aliases	# SNPs Assayed	SNP Name	PubMed ID	Journal
IL1B	CP	n/a	80	ns	None	Finnish	Quan	N	Interleukin 1, beta	IL-1; IL1F2; IL1-BETA; IL1B	1	+3954	19017034	Raunio T, Knuuttila M, Hiltunen L, Karttunen R, Vainio O, Tervonen T. IL-6(-174) genotype associated with the extent of periodontal disease in type 1 diabetic subjects. J Clin Periodontol. 2009 Jan;36(1):11-7. Epub 2008 Oct 31.
IL1B	CP	43	92	ns	None	Japanese	CC	N	Interleukin 1, beta	IL-1; IL1F2; IL1-BETA; IL1B	1	+3953	18714935	Imamura Y, Fujigaki Y, Oomori Y, Kuno T, Ota N, Wang PL. Polymorphism of genes encoding toll-like receptors and inflammatory cytokines in periodontal disease in the Japanese population. J Int Acad Periodontol. 2008 Jul;10(3):95-102.
IL1B	CP	117	292	ns	None	Brazilian	CC	N	Interleukin 1, beta	IL-1; IL1F2; IL1-BETA; IL1B	1	+3954	18541658	Ferreira SB Jr, Trombone AP, Repeke CE, Cardoso CR, Martins W Jr, Santos CF, Trevilatto PC, Avila-Campos MJ, Campanelli AP, Silva JS, Garlet GP. An interleukin-1beta (IL-1beta) single-nucleotide polymorphism at position 3954 and red complex periodontopathogens independently and additively modulate the levels of IL-1beta in diseased periodontal tissues. Infect Immun. 2008 Aug;76(8):3725-34. Epub 2008 Jun 9.
IL1B	CP	113	221	ns	None	Japanese	CC	N	Interleukin 1, beta	IL-1; IL1F2; IL1-BETA; IL1B	1	–31	18321309	Komatsu Y, Galicia JC, Kobayashi T, Yamazaki K, Yoshie H. Association of interleukin-1 receptor antagonist +2018 gene polymorphism with Japanese chronic periodontitis patients using a novel genotyping method. Int J Immunogenet. 2008 Apr;35(2):165-70.

IL1B	CP	824	1297	ns	None	German	CC	N	Interleukin 1, beta	IL-1; IL1F2; IL1-BETA; IL1B	1	+3954	18315433	Struch F, Dau M, Schwahn C, Biffar R, Kocher T, Meisel P. Interleukin-1 gene polymorphism, diabetes, and periodontitis: results from the Study of Health in Pomerania (SHIP). J Periodontol. 2008 Mar;79(3):501-7.
IL1B	CP	100	200	ns	None	Japanese	CC	N	Interleukin 1, beta	IL-1; IL1F2; IL1-BETA; IL1B	1	+3954	18052703	Kobayashi T, Ito S, Kuroda T, Yamamoto K, Sugita N, Narita I, Sumida T, Gejyo F, Yoshie H. The interleukin-1 and Fcgamma receptor gene polymorphisms in Japanese patients with rheumatoid arthritis and periodontitis. J Periodontol. 2007 Dec;78(12):2311-8.
IL1B	CP	32	84	ns	None	Polish	CC	N	Interleukin 1, beta	IL-1; IL1F2; IL1-BETA; IL1B	1	+3954	17458053	Drozdzik A, Kurzawski M, Safronow K, Banach J. Polymorphism in interleukin-1beta gene and the risk of periodontitis in a Polish population. Adv Med Sci. 2006;51 Suppl 1:13-7.
IL1B	CP	51	229	ns	None	Caucasian	CC	GS	Interleukin 1, beta	IL-1; IL1F2; IL1-BETA; IL1B	1	+3954	17448042	Tervonen T, Raunio T, Knuuttila M, Karttunen R. Polymorphisms in the CD14 and IL-6 genes associated with periodontal disease. J Clin Periodontol. 2007 May;34(5):377-83.
IL1B	CP	n/a	100	ns	None	Chinese	Longitudinal	N	Interleukin 1, beta	IL-1; IL1F2; IL1-BETA; IL1B	1	–511	17334075	Wu XL, Huang P, Zhou XD. [Association of the progress of chronic periodontitis with interleukin-1B-511 genetic polymorphisms]. Hua Xi Kou Qiang Yi Xue Za Zhi. 2006 Dec;24(6):523-6. Chinese.
IL1B	CP	58	105	ns	None	Brazilian	CC	N	Interleukin 1, beta	IL-1; IL1F2; IL1-BETA; IL1B	1	+3954	16931944	Gonçalves Lde S, Ferreira SM, Souza CO, Colombo AP. IL-1 gene polymorphism and periodontal status of HIV Brazilians on highly active antiretroviral therapy. AIDS. 2006 Aug 22;20(13):1779-81.

Continued

TABLE 6-3 Association Study—cont'd

Gene Symbol	Disease Type	Cases	Total	Best *P* Value	Level of Support	Population	Study Design	Stratified or Covariate Adj	Gene Name	Gene Aliases	# SNPs Assayed	SNP Name	PubMed ID	Journal
IL1B	CP	56	146	ns	None	Greek	CC	N	Interleukin 1, beta	IL-1; IL1F2; IL1-BETA; IL1B	1	+3954	16911569	Sakellari D, Katsares V, Georgiadou M, Kouvatsi A, Arsenakis M, Konstantinidis A. No correlation of five gene polymorphisms with periodontal conditions in a Greek population. J Clin Periodontol. 2006 Nov;33(11):765-70. Epub 2006 Aug 14.
IL1B	CP	n/a	n/a	ns	None	n/a	CC	D	Interleukin 1, beta	IL-1; IL1F2; IL1-BETA; IL1B	1	n/a	16838563	Jansson H. Studies on periodontitis and analyses of individuals at risk for periodontal diseases. Swed Dent J Suppl. 2006;(180):5-49.
IL1B	CP	20	51	ns	None	Caucasian	CC	S	Interleukin 1, beta	IL-1; IL1F2; IL1-BETA; IL1B	1	+3954	16708852	Jansson H, Lyssenko V, Gustavsson A, Hamberg K, Söderfeldt B, Groop L, Bratthall G. Analysis of the interleukin-1 and interleukin-6 polymorphisms in patients with chronic periodontitis. A pilot study. Swed Dent J. 2006;30(1):17-23.
IL1B	CP	14	28	ns	None	Caucasian	CC	N	Interleukin 1, beta	IL-1; IL1F2; IL1-BETA; IL1B	1	+3953	16441737	Gustafsson A, Ito H, Asman B, Bergström K. Hyper-reactive mononuclear cells and neutrophils in chronic periodontitis. J Clin Periodontol. 2006 Feb;33(2):126-9.
IL1B	CP	57	157	ns	None	Caucasian	CC	N	Interleukin 1, beta	IL-1; IL1F2; IL1-BETA; IL1B	2	Multiple SNPs	16304445	Brett PM, Zygogianni P, Griffiths GS, Tomaz M, Parkar M, D'Aiuto F, Tonetti M. Functional gene polymorphisms in aggressive and chronic periodontitis. J Dent Res. 2005 Dec;84(12):1149-53.
IL1B	CP	48	130	ns	None	Caucasian	CC	G	Interleukin 1, beta	IL-1; IL1F2; IL1-BETA; IL1B	1	+3953	14723749	Moore S, Ide M, Randhawa M, Walker JJ, Reid JG, Simpson NA. An investigation into the association among preterm birth, cytokine gene polymorphisms and periodontal disease. BJOG. 2004 Feb;111(2):125-32.

IL1B	CP	64	128	ns	None	Japanese	CC	N	Interleukin 1, beta	IL-1; IL1F2; IL1-BETA; IL1B	3	Multiple SNPs	12795791	Soga Y, Nishimura F, Ohyama H, Maeda H, Takashiba S, Murayama Y. Tumor necrosis factor-alpha gene (TNF-alpha) -1031/-863, -857 single-nucleotide polymorphisms (SNPs) are associated with severe adult periodontitis in Japanese. J Clin Periodontol. 2003 Jun;30(6):524-31.
IL1B	CP	45	155	ns	None	Greek	CC	N	Interleukin 1, beta	IL-1; IL1F2; IL1-BETA; IL1B	1	+3954	12702109	Sakellari D, Koukoudetsos S, Arsenakis M, Konstantinidis A. Prevalence of IL-1A and IL-1B polymorphisms in a Greek population. J Clin Periodontol. 2003 Jan;30(1):35-41.
IL1B	CP	77	154	ns	None	German	CC	S	Interleukin 1, beta	IL-1; IL1F2; IL1-BETA; IL1B	1	+3954	11846196	Meisel P, Siegemund A, Dombrowa S, Sawaf H, Fanghaenel J, Kocher T. Smoking and polymorphisms of the interleukin-1 gene cluster (IL-1alpha, IL-1beta, and IL-1RN) in patients with periodontal disease. J Periodontol. 2002 Jan;73(1):27-32.
IL1B	CP	105	158	ns	None	Caucasian	CC	PS	Interleukin 1, beta	IL-1; IL1F2; IL1-BETA; IL1B	1	+3954	11669477	Laine ML, Farré MA, González G, van Dijk LJ, Ham AJ, Winkel EG, Crusius JB, Vandenbroucke JP, van Winkelhoff AJ, Peña AS. Polymorphisms of the interleukin-1 gene family, oral microbial pathogens, and smoking in adult periodontitis. J Dent Res. 2001 Aug;80(8):1695-9.
IL1B	CP	85	134	ns	None	Caucasian	CC	AS	Interleukin 1, beta	IL-1; IL1F2; IL1-BETA; IL1B	2	Multiple SNPs	9049801	Kornman KS, Crane A, Wang HY, di Giovine FS, Newman MG, Pirk FW, Wilson TG Jr, Higginbottom FL, Duff GW. The interleukin-1 genotype as a severity factor in adult periodontal disease. J Clin Periodontol. 1997 Jan;24(1):72-7.
IL1B	CP	20	30	ns	None	n/a	CC	N	Interleukin 1, beta	IL-1; IL1F2; IL1-BETA; IL1B	1	+3953	12874528	Nastri L, Caruso F. [Association between interleukin-1 composite genotype and severe periodontitis: case-control study] Minerva Stomatol. 2003 Jun;52(6): 253-9.

Continued

TABLE 6-3 Association Study—cont'd

Gene Symbol	Disease Type	Cases	Total	Best *P* Value	Level of Support	Population	Study Design	Stratified or Covariate Adj	Gene Name	Gene Aliases	# SNPs Assayed	SNP Name	PubMed ID	Journal
IL1B	CP	36	36	ns	None	Chinese	CC	N	Interleukin 1, beta	IL-1; IL1F2; IL1-BETA; IL1B	n/a	+3953	17348213	Tian YG, Pan YP, Lin L, Zhang DM, Zhao J. [The relationship of IL-1beta expressed in buccal cells and the polymorphisms of IL-1beta (+3953) with chronic periodontitis] Shanghai Kou Qiang Yi Xue. 2006 Oct;15(5):456-60.
IL1B	CP	182	271	sig	Weak	Chinese	CC	N	Interleukin 1, beta	IL-1; IL1F2; IL1-BETA; IL1B	2	–511,+3953	15562658	Huang HY, Zhang JC. [Investigation on the association of interleukin-1 genotype polymorphism with chronic periodontitis]. Hua Xi Kou Qiang Yi Xue Za Zhi. 2004 Oct;22(5):415-9. Chinese.
IL1B	CP	133	225	sig	Weak	Chinese	CC	N	Interleukin 1, beta	IL-1; IL1F2; IL1-BETA; IL1B	1	+3954	12362317	Zhong L, Zhang Y, Zhang J, Yang A, Huang H. [The association of interleukin-1 gene polymorphisms with the susceptibility to chronic periodontitis in Uighur]. Zhonghua Yi Xue Yi Chuan Xue Za Zhi. 2002 Oct;19(5):405-8. Chinese.
IL1B	CP&AMI	20	38	ns	None	German	CC	C	Interleukin 1, beta	IL-1; IL1F2; IL1-BETA; IL1B	1	+3954	19563289	Stein JM, Smeets R, Reichert S, Chrobot J, Fickl S, Stanzel S, Kuch B. The role of the composite interleukin-1 genotype in the association between periodontitis and acute myocardial infarction. J Periodontol. 2009 Jul;80(7):1095-102.
IL1B	CP&CHD	n/a	96	0.028	Weak	Caucasian	Quan	N	Interleukin 1, beta	IL-1; IL1F2; IL1-BETA; IL1B	2	–511	19053923	Geismar K, Enevold C, Sørensen LK, Gyntelberg F, Bendtzen K, Sigurd B, Holmstrup P. Involvement of interleukin-1 genotypes in the association of coronary heart disease with periodontitis. J Periodontol. 2008 Dec;79(12):2322-30.

IL1B	CP&HIV	16	32	ns	None	Caucasian	CC	G	Interleukin 1, beta	IL-1; IL1F2; IL1-BETA; IL1B	1	+3953	10551423	Price P, Calder DM, Witt CS, Allcock RJ, Christiansen FT, Davies GR, Cameron PU, Rogers M, Baluchova K, Moore CB, French MA. Periodontal attachment loss in HIV-infected patients is associated with the Major histocompatibility complex 8.1 haplotype (HLA-A1,B8,DR3). Tissue Antigens. 1999 Oct;54(4):391-9.
IL1B	CP&RA	137	245	0.008	Weak	Japanese	CC	AGS	Interleukin 1, beta	IL-1; IL1F2; IL1-BETA; IL1B	2	+3954	19405833	Kobayashi T, Murasawa A, Ito S, Yamamoto K, Komatsu Y, Abe A, Sumida T, Yoshie H. Cytokine gene polymorphisms associated with rheumatoid arthritis and periodontitis in Japanese adults. J Periodontol. 2009 May;80(5):792-9.
IL1B	CP&RA	86	186	0.03	Weak	Japanese	CC	N	Interleukin 1, beta	IL-1; IL1F2; IL1-BETA; IL1B	1	+3954	18052703	Kobayashi T, Ito S, Kuroda T, Yamamoto K, Sugita N, Narita I, Sumida T, Gejyo F, Yoshie H. The interleukin-1 and Fcgamma receptor gene polymorphisms in Japanese patients with rheumatoid arthritis and periodontitis. J Periodontol. 2007 Dec;78(12):2311-8.
IL1B	CP&T2DM	69	542	0.003	Weak	German	CC	N	Interleukin 1, beta	IL-1; IL1F2; IL1-BETA; IL1B	1	+3954	18315433	Struch F, Dau M, Schwahn C, Biffar R, Kocher T, Meisel P. Interleukin-1 gene polymorphism, diabetes, and periodontitis: results from the Study of Health in Pomerania (SHIP). J Periodontol. 2008 Mar;79(3):501-7.
IL1B	CP&T2DM	112	336	0.01	Weak	Chilean	CC	SD	Interleukin 1, beta	IL-1; IL1F2; IL1-BETA; IL1B	1	–511	19792847	López NJ, Valenzuela CY, Jara L. Interleukin-1 gene cluster polymorphisms associated with periodontal disease in type 2 diabetes. J Periodontol. 2009 Oct;80(10):1590-8.
IL1B	CP&T2DM	112	336	ns	None	Chilean	CC	SD	Interleukin 1, beta	IL-1; IL1F2; IL1-BETA; IL1B	1	3954	19792847	López NJ, Valenzuela CY, Jara L. Interleukin-1 gene cluster polymorphisms associated with periodontal disease in type 2 diabetes. J Periodontol. 2009 Oct;80(10):1590-8.

Continued

TABLE 6-3 Association Study—cont'd

Gene Symbol	Disease Type	Cases	Total	Best *P* Value	Level of Support	Population	Study Design	Stratified or Covariate Adj	Gene Name	Gene Aliases	# SNPs Assayed	SNP Name	PubMed ID	Journal
IL1B.IL1RN	AgP	70	142	0.01	Weak	Caucasian	CC	S	n/a	n/a	2	Multiple Genes	10983602	Parkhill JM, Hennig BJ, Chapple IL, Heasman PA, Taylor JJ. Association of interleukin-1 gene polymorphisms with early-onset periodontitis. J Clin Periodontol. 2000 Sep;27(9):682-9.
IL1B.IL1RN	CP	100	200	ns	None	Japanese	CC	N	n/a	n/a	2	Multiple Genes	18052703	Kobayashi T, Ito S, Kuroda T, Yamamoto K, Sugita N, Narita I, Sumida T, Gejyo F, Yoshie H. The interleukin-1 and Fcgamma receptor gene polymorphisms in Japanese patients with rheumatoid arthritis and periodontitis. J Periodontol. 2007 Dec;78(12):2311-8.
IL1B.IL1RN	CP	224	432	ns	None	Chilean	CC	SD	n/a	n/a	n/a	Multiple Genes	19792847	López NJ, Valenzuela CY, Jara L. Interleukin-1 gene cluster polymorphisms associated with periodontal disease in type 2 diabetes. J Periodontol. 2009 Oct;80(10):1590-8.
IL1B.IL1RN	CP&RA	86	186	ns	None	Japanese	CC	N	n/a	n/a	2	Multiple Genes	18052703	Kobayashi T, Ito S, Kuroda T, Yamamoto K, Sugita N, Narita I, Sumida T, Gejyo F, Yoshie H. The interleukin-1 and Fcgamma receptor gene polymorphisms in Japanese patients with rheumatoid arthritis and periodontitis. J Periodontol. 2007 Dec;78(12):2311-8.
IL1B.IL1RN	CP&T2DM	112	336	ns	None	Chilean	CC	SD	n/a	n/a	n/a	Multiple Genes	19792847	López NJ, Valenzuela CY, Jara L. Interleukin-1 gene cluster polymorphisms associated with periodontal disease in type 2 diabetes. J Periodontol. 2009 Oct;80(10):1590-8.

IL1F5	AgP	40	136	ns	None	Caucasian	CC	N	Interleukin 1 family, member 5 (delta)	FIL1; FIL1D; IL1L1; IL1HY1; IL1RP3; MGC29840; FIL1(DELTA); IL1F5	1	n/a	15602586	Scapoli C, Trombelli L, Mamolini E, Collins A. Linkage disequilibrium analysis of case-control data: an application to generalized aggressive periodontitis. Genes Immun. 2005 Feb;6(1):44-52.
IL1R1	AgP+CP	251	376	ns	None	Japanese	CC	N	Interleukin 1 receptor, type I	P80; IL1R; IL1RA; CD121A; D2S1473; IL-1R-alpha; IL1R1	n/a	n/a	15081423	Suzuki A, Ji G, Numabe Y, Muramatsu M, Gomi K, Kanazashi M, Ogata Y, Shimizu E, Shibukawa Y, Ito A, Ito T, Sugaya A, Arai T, Yamada S, Deguchi S, Kamoi K. Single nucleotide polymorphisms associated with aggressive periodontitis and severe chronic periodontitis in Japanese. Biochem Biophys Res Commun. 2004 May 7;317(3):887-92.
IL1R2	AgP+CP	251	376	ns	None	Japanese	CC	N	Interleukin 1 receptor, type II	IL1RB; CD121b; MGC47725; IL1R2	n/a	n/a	15081423	Suzuki A, Ji G, Numabe Y, Muramatsu M, Gomi K, Kanazashi M, Ogata Y, Shimizu E, Shibukawa Y, Ito A, Ito T, Sugaya A, Arai T, Yamada S, Deguchi S, Kamoi K. Single nucleotide polymorphisms associated with aggressive periodontitis and severe chronic periodontitis in Japanese. Biochem Biophys Res Commun. 2004 May 7;317(3):887-92.
IL1RL1	AgP+CP	251	376	ns	None	Japanese	CC	N	Interleukin 1 receptor-like 1	T1; ST2; DER4; ST2L; ST2V; FIT-1; MGC32623; IL1RL1	n/a	n/a	15081423	Suzuki A, Ji G, Numabe Y, Muramatsu M, Gomi K, Kanazashi M, Ogata Y, Shimizu E, Shibukawa Y, Ito A, Ito T, Sugaya A, Arai T, Yamada S, Deguchi S, Kamoi K. Single nucleotide polymorphisms associated with aggressive periodontitis and severe chronic periodontitis in Japanese. Biochem Biophys Res Commun. 2004 May 7;317(3):887-92.

Continued

TABLE 6-3 Association Study—cont'd

Gene Symbol	Disease Type	Cases	Total	Best *P* Value	Level of Support	Population	Study Design	Stratified or Covariate Adj	Gene Name	Gene Aliases	# SNPs Assayed	SNP Name	PubMed ID	Journal
IL1RN	AgP	47	144	0.005	Weak	Japanese	CC	N	Interleukin 1 receptor antagonist	DIRA; IRAP; IL1F3; IL1RA; MVCD4; IL-1ra3; ICIL-1RA; MGC10430; IL1RN	1	VNTR	12445219	Tai H, Endo M, Shimada Y, Gou E, Orima K, Kobayashi T, Yamazaki K, Yoshie H. Association of interleukin-1 receptor antagonist gene polymorphisms with early onset periodontitis in Japanese. J Clin Periodontol. 2002 Oct;29(10):882-8.
IL1RN	AgP	40	136	0.019	Weak	Caucasian	CC	N	Interleukin 1 receptor antagonist	DIRA; IRAP; IL1F3; IL1RA; MVCD4; IL-1ra3; ICIL-1RA; MGC10430; IL1RN	1	VNTR	15602586	Scapoli C, Trombelli L, Mamolini E, Collins A. Linkage disequilibrium analysis of case-control data: an application to generalized aggressive periodontitis. Genes Immun. 2005 Feb;6(1):44-52.
IL1RN	AgP	52	242	<0.001	Moderate	Turkish	CC	N	Interleukin 1 receptor antagonist	DIRA; IRAP; IL1F3; IL1RA; MVCD4; IL-1ra3; ICIL-1RA; MGC10430; IL1RN	1	VNTR	16423338	Berdeli A, Emingil G, Gürkan A, Atilla G, Köse T. Association of the IL-1RN2 allele with periodontal diseases. Clin Biochem. 2006 Apr;39(4):357-62. Epub 2006 Jan 19.
IL1RN	AgP	415	1289	ns	None	Caucasian	CC	N	Interleukin 1 receptor antagonist	DIRA; IRAP; IL1F3; IL1RA; MVCD4; IL-1ra3; ICIL-1RA; MGC10430; IL1RN	1	+2018	18723088	Fiebig A, Jepsen S, Loos BG, Scholz C, Schäfer C, Rühling A, Nothnagel M, Eickholz P, van der Velden U, Schenck K, Schreiber S, Grössner-Schreiber B. Polymorphisms in the interleukin-1 (IL1) gene cluster are not associated with aggressive periodontitis in a large Caucasian population. Genomics. 2008 Nov;92(5):309-15. Epub 2008 Sep 18.
IL1RN	AgP	66	180	ns	None	Chinese	Fam	N	Interleukin 1 receptor antagonist	DIRA; IRAP; IL1F3; IL1RA; MVCD4; IL-1ra3; ICIL-1RA; MGC10430; IL1RN	1	VNTR	18278133	Ren XY, Xu L, Meng HX. [Interleukin-1 family polymorphisms in aggressive periodontitis patients and their relatives]. Beijing Da Xue Xue Bao. 2008 Feb 18;40(1):28-33. Chinese.
IL1RN	AgP	66	180	ns	None	Chinese	Fam	N	Interleukin 1 receptor antagonist	DIRA; IRAP; IL1F3; IL1RA; MVCD4; IL-1ra3; ICIL-1RA; MGC10430; IL1RN	1	VNTR	18278133	Ren XY, Xu L, Meng HX. [Interleukin-1 family polymorphisms in aggressive periodontitis patients and their relatives]. Beijing Da Xue Xue Bao. 2008 Feb 18;40(1):28-33. Chinese.

IL1RN	AgP	45	70	ns	None	Caucasian	CC	N	Interleukin 1 receptor antagonist	DIRA; IRAP; IL1F3; IL1RA; MVCD4; IL-1ra3; ICIL-1RA; MGC10430; IL1RN	1	VNTR	17335371	Havemose-Poulsen A, Sørensen LK, Bendtzen K, Holmstrup P. Polymorphisms within the IL-1 gene cluster: effects on cytokine profiles in peripheral blood and whole blood cell cultures of patients with aggressive periodontitis, juvenile idiopathic arthritis, and rheumatoid arthritis. J Periodontol. 2007 Mar;78(3):475-92.
IL1RN	AgP	46	136	ns	None	Greek	CC	N	Interleukin 1 receptor antagonist	DIRA; IRAP; IL1F3; IL1RA; MVCD4; IL-1ra3; ICIL-1RA; MGC10430; IL1RN	1	VNTR	16911569	Sakellari D, Katsares V, Georgiadou M, Kouvatsi A, Arsenakis M, Konstantinidis A. No correlation of five gene polymorphisms with periodontal conditions in a Greek population. J Clin Periodontol. 2006 Nov;33(11):765-70. Epub 2006 Aug 14.
IL1RN	AgP	122	217	ns	None	Chinese	CC	N	Interleukin 1 receptor antagonist	DIRA; IRAP; IL1F3; IL1RA; MVCD4; IL-1ra3; ICIL-1RA; MGC10430; IL1RN	1	VNTR	16155691	Li QY, Zhao HS, Meng HX, Zhang L, Xu L, Chen ZB. [Interleukin-1 polymorphisms in patients with aggressive periodontitis]. Shanghai Kou Qiang Yi Xue. 2005 Aug;14(4):333-7. Chinese.
IL1RN	AgP	122	217	ns	None	Chinese	CC	AGS	Interleukin 1 receptor antagonist	DIRA; IRAP; IL1F3; IL1RA; MVCD4; IL-1ra3; ICIL-1RA; MGC10430; IL1RN	1	VNTR	15732864	Li QY, Zhao HS, Meng HX, Zhang L, Xu L, Chen ZB, Shi D, Feng XH, Zhu XL. Association analysis between interleukin-1 family polymorphisms and generalized aggressive periodontitis in a Chinese population. J Periodontol. 2004 Dec;75(12):1627-35.
IL1RN	AgP	20	114	ns	None	Chinese	CC	N	Interleukin 1 receptor antagonist	DIRA; IRAP; IL1F3; IL1RA; MVCD4; IL-1ra3; ICIL-1RA; MGC10430; IL1RN	1	VNTR intron2	12593203	Duan H, Zhang J, Zhang Y. [The association between IL-1 gene polymorphisms and susceptibility to severe periodontitis]. Hua Xi Kou Qiang Yi Xue Za Zhi. 2002 Feb;20(1):48-51. Chinese.

Continued

TABLE 6-3 Association Study—cont'd

Gene Symbol	Disease Type	Cases	Total	Best *P* Value	Level of Support	Population	Study Design	Stratified or Covariate Adj	Gene Name	Gene Aliases	# SNPs Assayed	SNP Name	PubMed ID	Journal
IL1RN	AgP	14	14	ns	None	Brazilian	Fam	N	Interleukin 1 receptor antagonist	DIRA; IRAP; IL1F3; IL1RA; MVCD4; IL-1ra3; ICIL-1RA; MGC10430; IL1RN	1	VNTR	11940143	Trevilatto PC, Tramontina VA, Machado MA, Gonçalves RB, Sallum AW, Line SR. Clinical, genetic and microbiological findings in a Brazilian family with aggressive periodontitis. J Clin Periodontol. 2002 Mar;29(3):233-9.
IL1RN	AgP	70	142	ns	None	Caucasian	CC	S	Interleukin 1 receptor antagonist	DIRA; IRAP; IL1F3; IL1RA; MVCD4; IL-1ra3; ICIL-1RA; MGC10430; IL1RN	1	VNTR	10983602	Parkhill JM, Hennig BJ, Chapple IL, Heasman PA, Taylor JJ. Association of interleukin-1 gene polymorphisms with early-onset periodontitis. J Clin Periodontol. 2000 Sep;27(9):682-9.
IL1RN	AgP+CP	251	376	ns	None	Japanese	CC	N	Interleukin 1 receptor antagonist	DIRA; IRAP; IL1F3; IL1RA; MVCD4; IL-1ra3; ICIL-1RA; MGC10430; IL1RN	n/a	n/a	15081423	Suzuki A, Ji G, Numabe Y, Muramatsu M, Gomi K, Kanazashi M, Ogata Y, Shimizu E, Shibukawa Y, Ito A, Ito T, Sugaya A, Arai T, Yamada S, Deguchi S, Kamoi K. Single nucleotide polymorphisms associated with aggressive periodontitis and severe chronic periodontitis in Japanese. Biochem Biophys Res Commun. 2004 May 7;317(3):887-92.
IL1RN	AgP+CP	319	622	ns	None	Japanese	CC	AGS	Interleukin 1 receptor antagonist	DIRA; IRAP; IL1F3; IL1RA; MVCD4; IL-1ra3; ICIL-1RA; MGC10430; IL1RN	1	+2018	19892918	Kobayashi T, Nagata T, Murakami S, Takashiba S, Kurihara H, Izumi Y, Numabe Y, Watanabe H, Kataoka M, Nagai A, Hayashi J, Ohyama H, Okamatsu Y, Inagaki Y, Tai H, Yoshie H. Genetic risk factors for periodontitis in a Japanese population. J Dent Res. 2009 Dec;88(12): 1137-41.
IL1RN	CP	113	221	0.021	Weak	Japanese	CC	N	Interleukin 1 receptor antagonist	DIRA; IRAP; IL1F3; IL1RA; MVCD4; IL-1ra3; ICIL-1RA; MGC10430; IL1RN	1	+2018	18321309	Komatsu Y, Galicia JC, Kobayashi T, Yamazaki K, Yoshie H. Association of interleukin-1 receptor antagonist +2018 gene polymorphism with Japanese chronic periodontitis patients using a novel genotyping method. Int J Immunogenet. 2008 Apr;35(2):165-70.

IL1RN	CP	51	241	<0.001	Moderate	Turkish	CC	N	Interleukin 1 receptor antagonist	DIRA; IRAP; IL1F3; IL1RA; MVCD4; IL-1ra3; ICIL-1RA; MGC10430; IL1RN	1	VNTR	16423338	Berdeli A, Emingil G, Gürkan A, Atilla G, Köse T. Association of the IL-1RN2 allele with periodontal diseases. Clin Biochem. 2006 Apr;39(4):357-62. Epub 2006 Jan 19.
IL1RN	CP	30	124	<0.05	Weak	Chinese	CC	N	Interleukin 1 receptor antagonist	DIRA; IRAP; IL1F3; IL1RA; MVCD4; IL-1ra3; ICIL-1RA; MGC10430; IL1RN	1	VNTR intron2	12593203	Duan H, Zhang J, Zhang Y. [The association between IL-1 gene polymorphisms and susceptibility to severe periodontitis]. Hua Xi Kou Qiang Yi Xue Za Zhi. 2002 Feb;20(1):48-51. Chinese.
IL1RN	CP	117	225	ns	None	Japanese	CC	N	Interleukin 1 receptor antagonist	DIRA; IRAP; IL1F3; IL1RA; MVCD4; IL-1ra3; ICIL-1RA; MGC10430; IL1RN	1	+2018	19405833	Kobayashi T, Murasawa A, Ito S, Yamamoto K, Komatsu Y, Abe A, Sumida T, Yoshie H. Cytokine gene polymorphisms associated with rheumatoid arthritis and periodontitis in Japanese adults. J Periodontol. 2009 May;80(5):792-9.
IL1RN	CP	n/a	123	ns	None	Caucasian	Quan	N	Interleukin 1 receptor antagonist	DIRA; IRAP; IL1F3; IL1RA; MVCD4; IL-1ra3; ICIL-1RA; MGC10430; IL1RN	1	VNTR	19053923	Geismar K, Enevold C, Sørensen LK, Gyntelberg F, Bendtzen K, Sigurd B, Holmstrup P. Involvement of interleukin-1 genotypes in the association of coronary heart disease with periodontitis. J Periodontol. 2008 Dec;79(12):2322-30.
IL1RN	CP	100	200	ns	None	Japanese	CC	N	Interleukin 1 receptor antagonist	DIRA; IRAP; IL1F3; IL1RA; MVCD4; IL-1ra3; ICIL-1RA; MGC10430; IL1RN	1	+2028	18052703	Kobayashi T, Ito S, Kuroda T, Yamamoto K, Sugita N, Narita I, Sumida T, Gejyo F, Yoshie H. The interleukin-1 and Fcgamma receptor gene polymorphisms in Japanese patients with rheumatoid arthritis and periodontitis. J Periodontol. 2007 Dec;78(12):2311-8.
IL1RN	CP	56	146	ns	None	Greek	CC	N	Interleukin 1 receptor antagonist	DIRA; IRAP; IL1F3; IL1RA; MVCD4; IL-1ra3; ICIL-1RA; MGC10430; IL1RN	1	VNTR	16911569	Sakellari D, Katsares V, Georgiadou M, Kouvatsi A, Arsenakis M, Konstantinidis A. No correlation of five gene polymorphisms with periodontal conditions in a Greek population. J Clin Periodontol. 2006 Nov;33(11):765-70. Epub 2006 Aug 14.

Continued

TABLE 6-3 Association Study—cont'd

Gene Symbol	Disease Type	Cases	Total	Best *P* Value	Level of Support	Population	Study Design	Stratified or Covariate Adj	Gene Name	Gene Aliases	# SNPs Assayed	SNP Name	PubMed ID	Journal
IL1RN	CP	66	100	ns	None	Mixed	CC	DES	Interleukin 1 receptor antagonist	DIRA; IRAP; IL1F3; IL1RA; MVCD4; IL-1ra3; ICIL-1RA; MGC10430; IL1RN	1	+2018	14514232	Guzman S, Karima M, Wang HY, Van Dyke TE. Association between interleukin-1 genotype and periodontal disease in a diabetic population. J Periodontol. 2003 Aug;74(8):1183-90.
IL1RN	CP	77	154	ns	None	German	CC	S	Interleukin 1 receptor antagonist	DIRA; IRAP; IL1F3; IL1RA; MVCD4; IL-1ra3; ICIL-1RA; MGC10430; IL1RN	1	VNTR	11846196	Meisel P, Siegemund A, Dombrowa S, Sawaf H, Fanghaenel J, Kocher T. Smoking and polymorphisms of the interleukin-1 gene cluster (IL-1alpha, IL-1beta, and IL-1RN) in patients with periodontal disease. J Periodontol. 2002 Jan;73(1):27-32.
IL1RN	CP	105	158	ns	None	Caucasian	CC	PS	Interleukin 1 receptor antagonist	DIRA; IRAP; IL1F3; IL1RA; MVCD4; IL-1ra3; ICIL-1RA; MGC10430; IL1RN	1	VNTR	11669477	Laine ML, Farré MA, González G, van Dijk LJ, Ham AJ, Winkel EG, Crusius JB, Vandenbroucke JP, van Winkelhoff AJ, Peña AS. Polymorphisms of the interleukin-1 gene family, oral microbial pathogens, and smoking in adult periodontitis. J Dent Res. 2001 Aug;80(8):1695-9.
IL1RN	CP	85	134	ns	None	Caucasian	CC	AS	Interleukin 1 receptor antagonist	DIRA; IRAP; IL1F3; IL1RA; MVCD4; IL-1ra3; ICIL-1RA; MGC10430; IL1RN	1	VNTR	9049801	Kornman KS, Crane A, Wang HY, di Giovine FS, Newman MG, Pirk FW, Wilson TG Jr, Higginbottom FL, Duff GW. The interleukin-1 genotype as a severity factor in adult periodontal disease. J Clin Periodontol. 1997 Jan;24(1):72-7.
IL1RN	CP	224	432	ns	None	Chilean	CC	SD	Interleukin 1 receptor antagonist	DIRA; IRAP; IL1F3; IL1RA; MVCD4; IL-1ra3; ICIL-1RA; MGC10430; IL1RN	n/a	VNTR	19792847	López NJ, Valenzuela CY, Jara L. Interleukin-1 gene cluster polymorphisms associated with periodontal disease in type 2 diabetes. J Periodontol. 2009 Oct;80(10):1590-8.

IL1RN	CP	133	225	Sig	Weak	Chinese	CC	N	Interleukin 1 receptor antagonist	DIRA; IRAP; IL1F3; IL1RA; MVCD4; IL-1ra3; ICIL-1RA; MGC10430; IL1RN	1	VNTR	14680589	Zhong LJ, Zhang YH, Zhang JC, Feng JH, Yang AL.[The association between interleukin-1 receptor antagonist genotype and chronic periodontitis of Uighur patients] Zhonghua Kou Qiang Yi Xue Za Zhi. 2003 Sep;38(5):370-3.
IL1RN	CP&CHD	n/a	96	ns	None	Caucasian	Quan	N	Interleukin 1 receptor antagonist	DIRA; IRAP; IL1F3; IL1RA; MVCD4; IL-1ra3; ICIL-1RA; MGC10430; IL1RN	1	VNTR	19053923	Geismar K, Enevold C, Sørensen LK, Gyntelberg F, Bendtzen K, Sigurd B, Holmstrup P. Involvement of interleukin-1 genotypes in the association of coronary heart disease with periodontitis. J Periodontol. 2008 Dec;79(12):2322-30.
IL1RN	CP&RA	137	245	ns	None	Japanese	CC	N	Interleukin 1 receptor antagonist	DIRA; IRAP; IL1F3; IL1RA; MVCD4; IL-1ra3; ICIL-1RA; MGC10430; IL1RN	1	+2018	19405833	Kobayashi T, Murasawa A, Ito S, Yamamoto K, Komatsu Y, Abe A, Sumida T, Yoshie H. Cytokine gene polymorphisms associated with rheumatoid arthritis and periodontitis in Japanese adults. J Periodontol. 2009 May;80(5):792-9.
IL1RN	CP&RA	86	186	ns	None	Japanese	CC	N	Interleukin 1 receptor antagonist	DIRA; IRAP; IL1F3; IL1RA; MVCD4; IL-1ra3; ICIL-1RA; MGC10430; IL1RN	1	+2028	18052703	Kobayashi T, Ito S, Kuroda T, Yamamoto K, Sugita N, Narita I, Sumida T, Gejyo F, Yoshie H. The interleukin-1 and Fcgamma receptor gene polymorphisms in Japanese patients with rheumatoid arthritis and periodontitis. J Periodontol. 2007 Dec;78(12):2311-8.
IL1RN	CP&T2DM	112	336	ns	None	Chilean	CC	SD	Interleukin 1 receptor antagonist	DIRA; IRAP; IL1F3; IL1RA; MVCD4; IL-1ra3; ICIL-1RA; MGC10430; IL1RN	n/a	VNTR	19792847	López NJ, Valenzuela CY, Jara L. Interleukin-1 gene cluster polymorphisms associated with periodontal disease in type 2 diabetes. J Periodontol. 2009 Oct;80(10):1590-8.

Continued

TABLE 6-3 Association Study—cont'd

Gene Symbol	Disease Type	Cases	Total	Best *P* Value	Level of Support	Population	Study Design	Stratified or Covariate Adj	Gene Name	Gene Aliases	# SNPs Assayed	SNP Name	PubMed ID	Journal
IL2	AgP	73	142	ns	None	German	CC	N	Interleukin 2	IL-2; TCGF; lymphokine; IL2	2	Multiple SNPs	19453859	Reichert S, Machulla HK, Klapproth J, Zimmermann U, Reichert Y, Gläser C, Schaller HG, Schulz S. Interleukin-2 -330 and 166 gene polymorphisms in relation to aggressive or chronic periodontitis and the presence of periodontopathic bacteria. J Periodontal Res. 2009 Oct;44(5):628-35. Epub 2009 May 18.
IL2	AgP	73	142	ns	None	German	CC	N	Interleukin 2	IL-2; TCGF; lymphokine; IL2	2	Haplotype	19453859	Reichert S, Machulla HK, Klapproth J, Zimmermann U, Reichert Y, Gläser C, Schaller HG, Schulz S. Interleukin-2 -330 and 166 gene polymorphisms in relation to aggressive or chronic periodontitis and the presence of periodontopathic bacteria. J Periodontal Res. 2009 Oct;44(5):628-35. Epub 2009 May 18.
IL2	AgP+CP	131	200	ns	None	German	CC	N	Interleukin 2	IL-2; TCGF; lymphokine; IL2	2	Multiple SNPs	19453859	Reichert S, Machulla HK, Klapproth J, Zimmermann U, Reichert Y, Gläser C, Schaller HG, Schulz S. Interleukin-2 -330 and 166 gene polymorphisms in relation to aggressive or chronic periodontitis and the presence of periodontopathic bacteria. J Periodontal Res. 2009 Oct;44(5):628-35. Epub 2009 May 18.
IL2	AgP+CP	131	200	ns	None	German	CC	N	Interleukin 2	IL-2; TCGF; lymphokine; IL2	2	Haplotype	19453859	Reichert S, Machulla HK, Klapproth J, Zimmermann U, Reichert Y, Gläser C, Schaller HG, Schulz S. Interleukin-2 -330 and 166 gene polymorphisms in relation to aggressive or chronic periodontitis and the presence of periodontopathic bacteria. J Periodontal Res. 2009 Oct;44(5):628-35. Epub 2009 May 18.

IL2	AgP+CP	251	376	ns	None	Japanese	CC	N	Interleukin 2	IL-2; TCGF; lymphokine; IL2	n/a	n/a	15081423	Suzuki A, Ji G, Numabe Y, Muramatsu M, Gomi K, Kanazashi M, Ogata Y, Shimizu E, Shibukawa Y, Ito A, Ito T, Sugaya A, Arai T, Yamada S, Deguchi S, Kamoi K. Single nucleotide polymorphisms associated with aggressive periodontitis and severe chronic periodontitis in Japanese. Biochem Biophys Res Commun. 2004 May 7;317(3):887-92.
IL2	AgP+CP	319	622	ns	None	Japanese	CC	AGS	Interleukin 2	IL-2; TCGF; lymphokine; IL2	1	–330	19892918	Kobayashi T, Nagata T, Murakami S, Takashiba S, Kurihara H, Izumi Y, Numabe Y, Watanabe H, Kataoka M, Nagai A, Hayashi J, Ohyama H, Okamatsu Y, Inagaki Y, Tai H, Yoshie H. Genetic risk factors for periodontitis in a Japanese population. J Dent Res. 2009 Dec;88(12): 1137-41.
IL2	CP	58	127	0.012	Weak	German	CC	N	Interleukin 2	IL-2; TCGF; lymphokine; IL2	2	–330	19453859	Reichert S, Machulla HK, Klapproth J, Zimmermann U, Reichert Y, Gläser C, Schaller HG, Schulz S. Interleukin-2 -330 and 166 gene polymorphisms in relation to aggressive or chronic periodontitis and the presence of periodontopathic bacteria. J Periodontal Res. 2009 Oct;44(5):628-35. Epub 2009 May 18.
IL2	CP	69	113	0.019	Weak	Brazilian	CC	N	Interleukin 2	IL-2; TCGF; lymphokine; IL2	1	–330	12354082	Scarel-Caminaga RM, Trevilatto PC, Souza AP, Brito RB, Line SR. Investigation of an IL-2 polymorphism in patients with different levels of chronic periodontitis. J Clin Periodontol. 2002 Jul;29(7):587-91.

Continued

TABLE 6-3 Association Study—cont'd

Gene Symbol	Disease Type	Cases	Total	Best *P* Value	Level of Support	Population	Study Design	Stratified or Covariate Adj	Gene Name	Gene Aliases	# SNPs Assayed	SNP Name	PubMed ID	Journal
IL2	CP	58	127	0.039	Weak	German	CC	N	Interleukin 2	IL-2; TCGF; lymphokine; IL2	1	Haplotype	19453859	Reichert S, Machulla HK, Klapproth J, Zimmermann U, Reichert Y, Gläser C, Schaller HG, Schulz S. Interleukin-2 -330 and 166 gene polymorphisms in relation to aggressive or chronic periodontitis and the presence of periodontopathic bacteria. J Periodontal Res. 2009 Oct;44(5):628-35. Epub 2009 May 18.
IL2	CP	117	225	ns	None	Japanese	CC	N	Interleukin 2	IL-2; TCGF; lymphokine; IL2	1	–330	19405833	Kobayashi T, Murasawa A, Ito S, Yamamoto K, Komatsu Y, Abe A, Sumida T, Yoshie H. Cytokine gene polymorphisms associated with rheumatoid arthritis and periodontitis in Japanese adults. J Periodontol. 2009 May;80(5):792-9.
IL2	CP&RA	137	245	ns	None	Japanese	CC	N	Interleukin 2	IL-2; TCGF; lymphokine; IL2	1	–330	19405833	Kobayashi T, Murasawa A, Ito S, Yamamoto K, Komatsu Y, Abe A, Sumida T, Yoshie H. Cytokine gene polymorphisms associated with rheumatoid arthritis and periodontitis in Japanese adults. J Periodontol. 2009 May;80(5):792-9.
IL24	CP	106	175	ns	None	Caucasian	CC	S	Interleukin 24	C49A; FISP; MDA7; ST16; IL-24; IL10B; Mob-5; mda-7; IL24	1	mda-7	17305874	Savarrio L, Donati M, Carr C, Kinane DF, Berglundh T. Interleukin-24, RANTES and CCR5 gene polymorphisms are not associated with chronic adult periodontitis. J Periodontal Res. 2007 Apr;42(2):152-8.
IL2RB	CP	22	41	ns	None	Japanese	CC	N	Interleukin 2 receptor, beta	CD122; P70-75; IL2RB	5	Multiple SNPs	15490304	Suzuki A, Ji G, Numabe Y, Ishii K, Muramatsu M, Kamoi K. Large-scale investigation of genomic markers for severe periodontitis. Odontology. 2004 Sep;92(1):43-7.

IL3	CP	22	41	ns	None	Japanese	CC	N	Interleukin 3 (colony-stimulating factor, multiple)	IL-3; MCGF; MGC79398; MGC79399; MULTI-CSF; IL3	2	Multiple SNPs	15490304	Suzuki A, Ji G, Numabe Y, Ishii K, Muramatsu M, Kamoi K. Large-scale investigation of genomic markers for severe periodontitis. Odontology. 2004 Sep;92(1):43-7.
IL4	AgP	58	109	0.02	Weak	German	CC	N	Interleukin 4	BSF1; IL-4; BCGF1; BCGF-1; MGC79402; IL4	2	–34 C>T	17451413	Gonzales JR, Mann M, Stelzig J, Bödeker RH, Meyle J. Single-nucleotide polymorphisms in the IL-4 and IL-13 promoter region in aggressive periodontitis. J Clin Periodontol. 2007 Jun;34(6):473-9. Epub 2007 Apr 23.
IL4	AgP	30	63	ns	None	Caucasian	CC	E	Interleukin 4	BSF1; IL-4; BCGF1; BCGF-1; MGC79402; IL4	2	Multiple SNPs	15086621	Gonzales JR, Kobayashi T, Michel J, Mann M, Yoshie H, Meyle J. Interleukin-4 gene polymorphisms in Japanese and Caucasian patients with aggressive periodontitis. J Clin Periodontol. 2004 May;31(5):384-9.
IL4	AgP	31	61	ns	None	Japanese	CC	E	Interleukin 4	BSF1; IL-4; BCGF1; BCGF-1; MGC79402; IL4	2	Multiple SNPs	15086621	Gonzales JR, Kobayashi T, Michel J, Mann M, Yoshie H, Meyle J. Interleukin-4 gene polymorphisms in Japanese and Caucasian patients with aggressive periodontitis. J Clin Periodontol. 2004 May;31(5):384-9.
IL4	AgP	18	42	sig	Weak	Caucasian	CC	N	Interleukin 4	BSF1; IL-4; BCGF1; BCGF-1; MGC79402; IL4	2	Promoter/Intron	11350513	Michel J, Gonzáles JR, Wunderlich D, Diete A, Herrmann JM, Meyle J. Interleukin-4 polymorphisms in early onset periodontitis. J Clin Periodontol. 2001 May;28(5):483-8.
IL4	AgP+CP	53	109	ns	None	Iranian	CC	N	Interleukin 4	BSF1; IL-4; BCGF1; BCGF-1; MGC79402; IL4	1	–590	18230112	Hooshmand B, Hajilooi M, Rafiei A, Mani-Kashani KH, Ghasemi R. Interleukin-4 (C-590T) and interferon-gamma (G5644A) gene polymorphisms in patients with periodontitis. J Periodontal Res. 2008 Feb;43(1):111-5.

Continued

TABLE 6-3 Association Study—cont'd

Gene Symbol	Disease Type	Cases	Total	Best *P* Value	Level of Support	Population	Study Design	Stratified or Covariate Adj	Gene Name	Gene Aliases	# SNPs Assayed	SNP Name	PubMed ID	Journal
IL4	AgP+CP	251	376	ns	None	Japanese	CC	N	Interleukin 4	BSF1; IL-4; BCGF1; BCGF-1; MGC79402; IL4	n/a	n/a	15081423	Suzuki A, Ji G, Numabe Y, Muramatsu M, Gomi K, Kanazashi M, Ogata Y, Shimizu E, Shibukawa Y, Ito A, Ito T, Sugaya A, Arai T, Yamada S, Deguchi S, Kamoi K. Single nucleotide polymorphisms associated with aggressive periodontitis and severe chronic periodontitis in Japanese. Biochem Biophys Res Commun. 2004 May 7;317(3):887-92.
IL4	AgP+CP	319	622	ns	None	Japanese	CC	AGS	Interleukin 4	BSF1; IL-4; BCGF1; BCGF-1; MGC79402; IL4	2	n/a	19892918	Kobayashi T, Nagata T, Murakami S, Takashiba S, Kurihara H, Izumi Y, Numabe Y, Watanabe H, Kataoka M, Nagai A, Hayashi J, Ohyama H, Okamatsu Y, Inagaki Y, Tai H, Yoshie H. Genetic risk factors for periodontitis in a Japanese population. J Dent Res. 2009 Dec;88(12): 1137-41.
IL4	CP	194	352	0.005	Weak	Czech	CC	N	Interleukin 4	BSF1; IL-4; BCGF1; BCGF-1; MGC79402; IL4	3	Haplotype	18834248	Holla LI, Fassmann A, Augustin P, Halabala T, Znojil V, Vanek J. The association of interleukin-4 haplotypes with chronic periodontitis in a Czech population. J Periodontol. 2008 Oct;79(10):1927-33.
IL4	CP	117	225	ns	None	Japanese	CC	N	Interleukin 4	BSF1; IL-4; BCGF1; BCGF-1; MGC79402; IL4	2	Multiple SNPs	19405833	Kobayashi T, Murasawa A, Ito S, Yamamoto K, Komatsu Y, Abe A, Sumida T, Yoshie H. Cytokine gene polymorphisms associated with rheumatoid arthritis and periodontitis in Japanese adults. J Periodontol. 2009 May;80(5):792-9.
IL4	CP	194	352	ns	None	Czech	CC	N	Interleukin 4	BSF1; IL-4; BCGF1; BCGF-1; MGC79402; IL4	3	Multiple SNPs	18834248	Holla LI, Fassmann A, Augustin P, Halabala T, Znojil V, Vanek J. The association of interleukin-4 haplotypes with chronic periodontitis in a Czech population. J Periodontol. 2008 Oct;79(10):1927-33.

IL4	CP	22	41	ns	None	Japanese	CC	N	Interleukin 4	BSF1; IL-4; BCGF1; BCGF-1; MGC79402; IL4	2	Multiple SNPs	15490304	Suzuki A, Ji G, Numabe Y, Ishii K, Muramatsu M, Kamoi K. Large-scale investigation of genomic markers for severe periodontitis. Odontology. 2004 Sep;92(1):43-7.
IL4	CP	30	60	ns	None	African American	CC	N	Interleukin 4	BSF1; IL-4; BCGF1; BCGF-1; MGC79402; IL4	2	Multiple SNPs	15001290	Pontes CC, Gonzales JR, Novaes AB Jr, Taba Júnior M, Grisi MF, Michel J, Meyle J, de Souza SL. 'Interleukin-4 gene polymorphism and its relation to periodontal disease in a Brazilian population of African heritage'. J Dent. 2004 Mar;32(3):241-6.
IL4	CP	32	182	ns	None	Korean	CC	N	Interleukin 4	BSF1; IL-4; BCGF1; BCGF-1; MGC79402; IL4	2	Multiple SNPs	12877559	Kang BY, Choi YK, Choi WH, Kim KT, Choi SS, Kim K, Ha NJ. Two polymorphisms of interleukin-4 gene in Korean adult periodontitis. Arch Pharm Res. 2003 Jun;26(6):482-6.
IL4	CP	69	113	ns	None	Brazilian	CC	N	Interleukin 4	BSF1; IL-4; BCGF1; BCGF-1; MGC79402; IL4	1	–590	12694433	Scarel-Caminaga RM, Trevilatto PC, Souza AP, Brito RB Jr, Line SR. Investigation of IL4 gene polymorphism in individuals with different levels of chronic periodontitis in a Brazilian population. J Clin Periodontol. 2003 Apr;30(4):341-5.
IL4	CP&CKD	75	148	ns	None	Turkish	CC	N	Interleukin 4	BSF1; IL-4; BCGF1; BCGF-1; MGC79402; IL4	2	Multiple SNPs	17851828	Kara N, Keles GC, Sumer P, Gunes SO, Bagci H, Koprulu H, Bek Y. Association of the polymorphisms in promoter and intron regions of the interleukin-4 gene with chronic periodontitis in a Turkish population. Acta Odontol Scand. 2007 Oct;65(5):292-7.
IL4	CP&RA	137	245	ns	None	Japanese	CC	N	Interleukin 4	BSF1; IL-4; BCGF1; BCGF-1; MGC79402; IL4	2	Multiple SNPs	19405833	Kobayashi T, Murasawa A, Ito S, Yamamoto K, Komatsu Y, Abe A, Sumida T, Yoshie H. Cytokine gene polymorphisms associated with rheumatoid arthritis and periodontitis in Japanese adults. J Periodontol. 2009 May;80(5):792-9.

Continued

TABLE 6-3 Association Study—cont'd

Gene Symbol	Disease Type	Cases	Total	Best *P* Value	Level of Support	Population	Study Design	Stratified or Covariate Adj	Gene Name	Gene Aliases	# SNPs Assayed	SNP Name	PubMed ID	Journal
IL4R	AgP+CP	251	376	ns	None	Japanese	CC	N	Interleukin 4 receptor	CD124; IL4RA; IL4R	n/a	n/a	15081423	Suzuki A, Ji G, Numabe Y, Muramatsu M, Gomi K, Kanazashi M, Ogata Y, Shimizu E, Shibukawa Y, Ito A, Ito T, Sugaya A, Arai T, Yamada S, Deguchi S, Kamoi K. Single nucleotide polymorphisms associated with aggressive periodontitis and severe chronic periodontitis in Japanese. Biochem Biophys Res Commun. 2004 May 7;317(3):887-92.
IL4R	CP	60	99	ns	None	Caucasian	CC	N	Interleukin 4 receptor	CD124; IL4RA; IL4R	1	Q551R	15842262	Donati M, Berglundh T, Hytönen AM, Hahn-Zoric M, Hanson LA, Padyukov L. Association of the -159 CD14 gene polymorphism and lack of association of the -308 TNFA and Q551R IL-4RA polymorphisms with severe chronic periodontitis in Swedish Caucasians. J Clin Periodontol. 2005 May;32(5):474-9.
IL4R	CP	22	41	ns	None	Japanese	CC	N	Interleukin 4 receptor	CD124; IL4RA; IL4R	3	Multiple SNPs	15490304	Suzuki A, Ji G, Numabe Y, Ishii K, Muramatsu M, Kamoi K. Large-scale investigation of genomic markers for severe periodontitis. Odontology. 2004 Sep;92(1):43-7.
IL6	AgP	24	168	0.001	Weak	Caucasian	CC	GES	Interleukin 6 (interferon, beta 2)	HGF; HSF; BSF2; IL-6; IFNB2; IL6	5	Haplotype	18269659	Nibali L, Griffiths GS, Donos N, Parkar M, D'Aiuto F, Tonetti MS, Brett PM. Association between interleukin-6 promoter haplotypes and aggressive periodontitis. J Clin Periodontol. 2008 Mar;35(3):193-8.
IL6	AgP	57	288	0.002	Weak	Mixed	CC	GES	Interleukin 6 (interferon, beta 2)	HGF; HSF; BSF2; IL-6; IFNB2; IL6	5	Haplotype	18269659	Nibali L, Griffiths GS, Donos N, Parkar M, D'Aiuto F, Tonetti MS, Brett PM. Association between interleukin-6 promoter haplotypes and aggressive periodontitis. J Clin Periodontol. 2008 Mar;35(3):193-8.

IL6	AgP	57	288	0.003	Weak	Mixed	CC	GES	Interleukin 6 (interferon, beta 2)	HGF; HSF; BSF2; IL-6; IFNB2; IL6	5	–1480	18269659	Nibali L, Griffiths GS, Donos N, Parkar M, D'Aiuto F, Tonetti MS, Brett PM. Association between interleukin-6 promoter haplotypes and aggressive periodontitis. J Clin Periodontol. 2008 Mar;35(3):193-8.
IL6	AgP	224	455	0.004	Moderate	Mixed	CC	GES	Interleukin 6 (interferon, beta 2)	HGF; HSF; BSF2; IL-6; IFNB2; IL6	5	Haplotype	18269659	Nibali L, Griffiths GS, Donos N, Parkar M, D'Aiuto F, Tonetti MS, Brett PM. Association between interleukin-6 promoter haplotypes and aggressive periodontitis. J Clin Periodontol. 2008 Mar;35(3):193-8.
IL6	AgP	224	455	0.006	Moderate	Mixed	CC	GES	Interleukin 6 (interferon, beta 2)	HGF; HSF; BSF2; IL-6; IFNB2; IL6	5	–1363	18269659	Nibali L, Griffiths GS, Donos N, Parkar M, D'Aiuto F, Tonetti MS, Brett PM. Association between interleukin-6 promoter haplotypes and aggressive periodontitis. J Clin Periodontol. 2008 Mar;35(3):193-8.
IL6	AgP	24	168	0.007	Weak	Caucasian	CC	AGS	Interleukin 6 (interferon, beta 2)	HGF; HSF; BSF2; IL-6; IFNB2; IL6	5	–1480	19084430	Nibali L, D'Aiuto F, Donos N, Griffiths GS, Parkar M, Tonetti MS, Humphries SE, Brett PM. Association between periodontitis and common variants in the promoter of the interleukin-6 gene. Cytokine. 2009 Jan;45(1):50-4. Epub 2008 Dec 11.
IL6	AgP	24	168	0.007	Weak	Caucasian	CC	GES	Interleukin 6 (interferon, beta 2)	HGF; HSF; BSF2; IL-6; IFNB2; IL6	5	–1480	18269659	Nibali L, Griffiths GS, Donos N, Parkar M, D'Aiuto F, Tonetti MS, Brett PM. Association between interleukin-6 promoter haplotypes and aggressive periodontitis. J Clin Periodontol. 2008 Mar;35(3):193-8.
IL6	AgP	24	168	0.01	Weak	Caucasian	CC	N	Interleukin 6 (interferon, beta 2)	HGF; HSF; BSF2; IL-6; IFNB2; IL6	5	Haplotype	19084430	Nibali L, D'Aiuto F, Donos N, Griffiths GS, Parkar M, Tonetti MS, Humphries SE, Brett PM. Association between periodontitis and common variants in the promoter of the interleukin-6 gene. Cytokine. 2009 Jan;45(1):50-4. Epub 2008 Dec 11.

Continued

TABLE 6-3 Association Study—cont'd

Gene Symbol	Disease Type	Cases	Total	Best *P* Value	Level of Support	Population	Study Design	Stratified or Covariate Adj	Gene Name	Gene Aliases	# SNPs Assayed	SNP Name	PubMed ID	Journal
IL6	AgP	112	256	0.013	Weak	Caucasian	CC	GES	Interleukin 6 (interferon, beta 2)	HGF; HSF; BSF2; IL-6; IFNB2; IL6	5	–1363	18269659	Nibali L, Griffiths GS, Donos N, Parkar M, D'Aiuto F, Tonetti MS, Brett PM. Association between interleukin-6 promoter haplotypes and aggressive periodontitis. J Clin Periodontol. 2008 Mar;35(3):193-8.
IL6	AgP	35	64	ns	None	Asian	CC	N	Interleukin 6 (interferon, beta 2)	HGF; HSF; BSF2; IL-6; IFNB2; IL6	5	Multiple SNPs	19084430	Nibali L, D'Aiuto F, Donos N, Griffiths GS, Parkar M, Tonetti MS, Humphries SE, Brett PM. Association between periodontitis and common variants in the promoter of the interleukin-6 gene. Cytokine. 2009 Jan;45(1):50-4. Epub 2008 Dec 11.
IL6	AgP	59	104	ns	None	Black	CC	N	Interleukin 6 (interferon, beta 2)	HGF; HSF; BSF2; IL-6; IFNB2; IL6	5	Multiple SNPs	19084430	Nibali L, D'Aiuto F, Donos N, Griffiths GS, Parkar M, Tonetti MS, Humphries SE, Brett PM. Association between periodontitis and common variants in the promoter of the interleukin-6 gene. Cytokine. 2009 Jan;45(1):50-4. Epub 2008 Dec 11.
IL6	AgP	88	232	ns	None	Caucasian	CC	N	Interleukin 6 (interferon, beta 2)	HGF; HSF; BSF2; IL-6; IFNB2; IL6	5	Multiple SNPs	19084430	Nibali L, D'Aiuto F, Donos N, Griffiths GS, Parkar M, Tonetti MS, Humphries SE, Brett PM. Association between periodontitis and common variants in the promoter of the interleukin-6 gene. Cytokine. 2009 Jan;45(1):50-4. Epub 2008 Dec 11.
IL6	AgP	59	104	ns	None	Black	CC	GES	Interleukin 6 (interferon, beta 2)	HGF; HSF; BSF2; IL-6; IFNB2; IL6	5	Multiple SNPs	18269659	Nibali L, Griffiths GS, Donos N, Parkar M, D'Aiuto F, Tonetti MS, Brett PM. Association between interleukin-6 promoter haplotypes and aggressive periodontitis. J Clin Periodontol. 2008 Mar;35(3):193-8.

IL6	AgP	33	78	ns	None	Black	CC	GES	Interleukin 6 (interferon, beta 2)	HGF; HSF; BSF2; IL-6; IFNB2; IL6	5	Multiple SNPs	18269659	Nibali L, Griffiths GS, Donos N, Parkar M, D'Aiuto F, Tonetti MS, Brett PM. Association between interleukin-6 promoter haplotypes and aggressive periodontitis. J Clin Periodontol. 2008 Mar;35(3):193-8.
IL6	AgP	88	232	ns	None	Caucasian	CC	N	Interleukin 6 (interferon, beta 2)	HGF; HSF; BSF2; IL-6; IFNB2; IL6	5	–1480	18269659	Nibali L, Griffiths GS, Donos N, Parkar M, D'Aiuto F, Tonetti MS, Brett PM. Association between interleukin-6 promoter haplotypes and aggressive periodontitis. J Clin Periodontol. 2008 Mar;35(3):193-8.
IL6	AgP	167	398	ns	None	Mixed	CC	N	Interleukin 6 (interferon, beta 2)	HGF; HSF; BSF2; IL-6; IFNB2; IL6	5	–1480	18269659	Nibali L, Griffiths GS, Donos N, Parkar M, D'Aiuto F, Tonetti MS, Brett PM. Association between interleukin-6 promoter haplotypes and aggressive periodontitis. J Clin Periodontol. 2008 Mar;35(3):193-8.
IL6	AgP	26	71	ns	None	Black	CC	N	Interleukin 6 (interferon, beta 2)	HGF; HSF; BSF2; IL-6; IFNB2; IL6	5	Multiple SNPs	18269659	Nibali L, Griffiths GS, Donos N, Parkar M, D'Aiuto F, Tonetti MS, Brett PM. Association between interleukin-6 promoter haplotypes and aggressive periodontitis. J Clin Periodontol. 2008 Mar;35(3):193-8.
IL6	AgP	88	232	ns	None	Caucasian	CC	N	Interleukin 6 (interferon, beta 2)	HGF; HSF; BSF2; IL-6; IFNB2; IL6	5	Haplotype	18269659	Nibali L, Griffiths GS, Donos N, Parkar M, D'Aiuto F, Tonetti MS, Brett PM. Association between interleukin-6 promoter haplotypes and aggressive periodontitis. J Clin Periodontol. 2008 Mar;35(3):193-8.
IL6	AgP	112	256	ns	None	Caucasian	CC	N	Interleukin 6 (interferon, beta 2)	HGF; HSF; BSF2; IL-6; IFNB2; IL6	5	Haplotype	18269659	Nibali L, Griffiths GS, Donos N, Parkar M, D'Aiuto F, Tonetti MS, Brett PM. Association between interleukin-6 promoter haplotypes and aggressive periodontitis. J Clin Periodontol. 2008 Mar;35(3):193-8.

Continued

TABLE 6-3 Association Study—cont'd

Gene Symbol	Disease Type	Cases	Total	Best *P* Value	Level of Support	Population	Study Design	Stratified or Covariate Adj	Gene Name	Gene Aliases	# SNPs Assayed	SNP Name	PubMed ID	Journal
IL6	AgP	167	398	ns	None	Mixed	CC	N	Interleukin 6 (interferon, beta 2)	HGF; HSF; BSF2; IL-6; IFNB2; IL6	5	Haplotype	18269659	Nibali L, Griffiths GS, Donos N, Parkar M, D'Aiuto F, Tonetti MS, Brett PM. Association between interleukin-6 promoter haplotypes and aggressive periodontitis. J Clin Periodontol. 2008 Mar;35(3):193-8.
IL6	AgP	51	151	ns	None	Caucasian	CC	N	Interleukin 6 (interferon, beta 2)	HGF; HSF; BSF2; IL-6; IFNB2; IL6	1	–174	16304445	Brett PM, Zygogianni P, Griffiths GS, Tomaz M, Parkar M, D'Aiuto F, Tonetti M. Functional gene polymorphisms in aggressive and chronic periodontitis. J Dent Res. 2005 Dec;84(12):1149-53.
IL6	AgP	17	34	sig	Weak	Caucasian	Fam	N	Interleukin 6 (interferon, beta 2)	HGF; HSF; BSF2; IL-6; IFNB2; IL6	3	–174	18752567	Nibali L, Donos N, Brett PM, Parkar M, Ellinas T, Llorente M, Griffiths GS. A familial analysis of aggressive periodontitis - clinical and genetic findings. J Periodontal Res. 2008 Dec;43(6):627-34. Epub 2008 Aug 22.
IL6	AgP+CP	251	376	ns	None	Japanese	CC	N	Interleukin 6 (interferon, beta 2)	HGF; HSF; BSF2; IL-6; IFNB2; IL6	n/a	n/a	15081423	Suzuki A, Ji G, Numabe Y, Muramatsu M, Gomi K, Kanazashi M, Ogata Y, Shimizu E, Shibukawa Y, Ito A, Ito T, Sugaya A, Arai T, Yamada S, Deguchi S, Kamoi K. Single nucleotide polymorphisms associated with aggressive periodontitis and severe chronic periodontitis in Japanese. Biochem Biophys Res Commun. 2004 May 7;317(3):887-92.
IL6	AgP+CP	319	622	ns	None	Japanese	CC	AGS	Interleukin 6 (interferon, beta 2)	HGF; HSF; BSF2; IL-6; IFNB2; IL6	2	n/a	19892918	Kobayashi T, Nagata T, Murakami S, Takashiba S, Kurihara H, Izumi Y, Numabe Y, Watanabe H, Kataoka M, Nagai A, Hayashi J, Ohyama H, Okamatsu Y, Inagaki Y, Tai H, Yoshie H. Genetic risk factors for periodontitis in a Japanese population. J Dent Res. 2009 Dec;88(12): 1137-41.

IL6	CP	34	84	0.001	Weak	Caucasian	CC	G	Interleukin 6 (interferon, beta 2)	HGF; HSF; BSF2; IL-6; IFNB2; IL6	1	–174	18181010	Dashash M, Nugent J, Baker P, Tansinda D, Blinkhorn F. Interleukin-6 -174 genotype, periodontal disease and adverse pregnancy outcomes: a pilot study. J Clin Immunol. 2008 May;28(3):237-43.
IL6	CP	148	255	0.001	Weak	Czech	CC	N	Interleukin 6 (interferon, beta 2)	HGF; HSF; BSF2; IL-6; IFNB2; IL6	3	–572	15025214	Holla LI, Fassmann A, Stejskalová A, Znojil V, Vanek J, Vacha J. Analysis of the interleukin-6 gene promoter polymorphisms in Czech patients with chronic periodontitis. J Periodontol. 2004 Jan;75(1):30-6.
IL6	CP	38	65	0.003	Weak	Brazilian	CC	G	Interleukin 6 (interferon, beta 2)	HGF; HSF; BSF2; IL-6; IFNB2; IL6	1	–174	19555357	Costa AM, Guimarães MC, de Souza ER, Nóbrega OT, Bezerra AC. Interleukin-6 (G-174C) and tumour necrosis factor-alpha (G-308A) gene polymorphisms in geriatric patients with chronic periodontitis. Gerodontology. 2009 Jun 25. [Epub ahead of print]
IL6	CP	48	84	0.0036	Weak	Caucasian	CC	N	Interleukin 6 (interferon, beta 2)	HGF; HSF; BSF2; IL-6; IFNB2; IL6	1	–174	12716337	Trevilatto PC, Scarel-Caminaga RM, de Brito RB Jr, de Souza AP, Line SR. Polymorphism at position -174 of IL-6 gene is associated with susceptibility to chronic periodontitis in a Caucasian Brazilian population. J Clin Periodontol. 2003 May;30(5):438-42.
IL6	CP	57	157	0.008	Weak	Caucasian	CC	N	Interleukin 6 (interferon, beta 2)	HGF; HSF; BSF2; IL-6; IFNB2; IL6	1	–174	16304445	Brett PM, Zygogianni P, Griffiths GS, Tomaz M, Parkar M, D'Aiuto F, Tonetti M. Functional gene polymorphisms in aggressive and chronic periodontitis. J Dent Res. 2005 Dec;84(12):1149-53.
IL6	CP	112	189	0.008	Weak	Japanese	CC	S	Interleukin 6 (interferon, beta 2)	HGF; HSF; BSF2; IL-6; IFNB2; IL6	5	–373	15663749	Komatsu Y, Tai H, Galicia JC, Shimada Y, Endo M, Akazawa K, Yamazaki K, Yoshie H. Interleukin-6 (IL-6)-373 A9T11 allele is associated with reduced susceptibility to chronic periodontitis in Japanese subjects and decreased serum IL-6 level. Tissue Antigens. 2005 Jan;65(1):110-4.

Continued

TABLE 6-3 Association Study—cont'd

Gene Symbol	Disease Type	Cases	Total	Best *P* Value	Level of Support	Population	Study Design	Stratified or Covariate Adj	Gene Name	Gene Aliases	# SNPs Assayed	SNP Name	PubMed ID	Journal
IL6	CP	n/a	80	0.009	Weak	Finnish	Quan	ADGLS	Interleukin 6 (interferon, beta 2)	HGF; HSF; BSF2; IL-6; IFNB2; IL6	1	–174	19017034	Raunio T, Knuuttila M, Hiltunen L, Karttunen R, Vainio O, Tervonen T. IL-6(-174) genotype associated with the extent of periodontal disease in type 1 diabetic subjects. J Clin Periodontol. 2009 Jan;36(1):11-7. Epub 2008 Oct 31.
IL6	CP	51	229	0.01	Weak	Caucasian	CC	GS	Interleukin 6 (interferon, beta 2)	HGF; HSF; BSF2; IL-6; IFNB2; IL6	1	–174	17448042	Tervonen T, Raunio T, Knuuttila M, Karttunen R. Polymorphisms in the CD14 and IL-6 genes associated with periodontal disease. J Clin Periodontol. 2007 May;34(5):377-83.
IL6	CP	122	236	0.0283	Weak	German	CC	N	Interleukin 6 (interferon, beta 2)	HGF; HSF; BSF2; IL-6; IFNB2; IL6	1	–174	17209781	Babel N, Cherepnev G, Babel D, Tropmann A, Hammer M, Volk HD, Reinke P. Analysis of tumor necrosis factor-alpha, transforming growth factor-beta, interleukin-10, IL-6, and interferon-gamma gene polymorphisms in patients with chronic periodontitis. J Periodontol. 2006 Dec;77(12):1978-83.
IL6	CP	11	24	0.035	Weak	Afro-Caribbean	CC	G	Interleukin 6 (interferon, beta 2)	HGF; HSF; BSF2; IL-6; IFNB2; IL6	1	–174	18181010	Dashash M, Nugent J, Baker P, Tansinda D, Blinkhorn F. Interleukin-6 -174 genotype, periodontal disease and adverse pregnancy outcomes: a pilot study. J Clin Immunol. 2008 May;28(3):237-43.
IL6	CP	155	209	0.036	Weak	Brazilian	CC	S	Interleukin 6 (interferon, beta 2)	HGF; HSF; BSF2; IL-6; IFNB2; IL6	1	–174	17286759	Moreira PR, Lima PM, Sathler KO, Imanishi SA, Costa JE, Gomes RS, Gollob KJ, Dutra WO. Interleukin-6 expression and gene polymorphism are associated with severity of periodontal disease in a sample of Brazilian individuals. Clin Exp Immunol. 2007 Apr;148(1):119-26.

IL6	CP	69	145	<0.001	Weak	Mixed	CC	G	Interleukin 6 (interferon, beta 2)	HGF; HSF; BSF2; IL-6; IFNB2; IL6	1	–174	18181010	Dashash M, Nugent J, Baker P, Tansinda D, Blinkhorn F. Interleukin-6 -174 genotype, periodontal disease and adverse pregnancy outcomes: a pilot study. J Clin Immunol. 2008 May;28(3):237-43.
IL6	CP	93	189	<0.05	Weak	Chinese	CC	N	Interleukin 6 (interferon, beta 2)	HGF; HSF; BSF2; IL-6; IFNB2; IL6	1	–572	19031817	Guan ZM, Liu JJ, Ma X, Wu DH, Yu J, Huang GQ. [Relationship between interleukin-6 gene-572C/G polymorphism and chronic periodontitis]. Zhonghua Kou Qiang Yi Xue Za Zhi. 2008 Jul;43(7):410-3. Chinese.
IL6	CP	159	294	ns	None	Chinese	CC	N	Interleukin 6 (interferon, beta 2)	HGF; HSF; BSF2; IL-6; IFNB2; IL6	3	Multiple SNPs	19549135	Xiao LM, Yan YX, Xie CJ, Fan WH, Xuan DY, Wang CX, Chen L, Sun SY, Xie BY, Zhang JC. Association among interleukin-6 gene polymorphism, diabetes and periodontitis in a Chinese population. Oral Dis. 2009 Jun 22. [Epub ahead of print]
IL6	CP	117	225	ns	None	Japanese	CC	N	Interleukin 6 (interferon, beta 2)	HGF; HSF; BSF2; IL-6; IFNB2; IL6	2	Multiple SNPs	19405833	Kobayashi T, Murasawa A, Ito S, Yamamoto K, Komatsu Y, Abe A, Sumida T, Yoshie H. Cytokine gene polymorphisms associated with rheumatoid arthritis and periodontitis in Japanese adults. J Periodontol. 2009 May;80(5):792-9.
IL6	CP	52	81	ns	None	Asian	CC	N	Interleukin 6 (interferon, beta 2)	HGF; HSF; BSF2; IL-6; IFNB2; IL6	5	Multiple SNPs	19084430	Nibali L, D'Aiuto F, Donos N, Griffiths GS, Parkar M, Tonetti MS, Humphries SE, Brett PM. Association between periodontitis and common variants in the promoter of the interleukin-6 gene. Cytokine. 2009 Jan;45(1):50-4. Epub 2008 Dec 11.
IL6	CP	33	78	ns	None	Black	CC	N	Interleukin 6 (interferon, beta 2)	HGF; HSF; BSF2; IL-6; IFNB2; IL6	5	Multiple SNPs	19084430	Nibali L, D'Aiuto F, Donos N, Griffiths GS, Parkar M, Tonetti MS, Humphries SE, Brett PM. Association between periodontitis and common variants in the promoter of the interleukin-6 gene. Cytokine. 2009 Jan;45(1):50-4. Epub 2008 Dec 11.

Continued

TABLE 6-3 Association Study—cont'd

Gene Symbol	Disease Type	Cases	Total	Best *P* Value	Level of Support	Population	Study Design	Stratified or Covariate Adj	Gene Name	Gene Aliases	# SNPs Assayed	SNP Name	PubMed ID	Journal
IL6	CP	206	350	ns	None	Caucasian	CC	N	Interleukin 6 (interferon, beta 2)	HGF; HSF; BSF2; IL-6; IFNB2; IL6	5	Multiple SNPs	19084430	Nibali L, D'Aiuto F, Donos N, Griffiths GS, Parkar M, Tonetti MS, Humphries SE, Brett PM. Association between periodontitis and common variants in the promoter of the interleukin-6 gene. Cytokine. 2009 Jan;45(1):50-4. Epub 2008 Dec 11.
IL6	CP	24	37	ns	None	Asian	CC	G	Interleukin 6 (interferon, beta 2)	HGF; HSF; BSF2; IL-6; IFNB2; IL6	1	–174	18181010	Dashash M, Nugent J, Baker P, Tansinda D, Blinkhorn F. Interleukin-6 -174 genotype, periodontal disease and adverse pregnancy outcomes: a pilot study. J Clin Immunol. 2008 May;28(3):237-43.
IL6	CP	n/a	n/a	ns	None	n/a	CC	D	Interleukin 6 (interferon, beta 2)	HGF; HSF; BSF2; IL-6; IFNB2; IL6	1	n/a	16838563	Jansson H. Studies on periodontitis and analyses of individuals at risk for periodontal diseases. Swed Dent J Suppl. 2006;(180):5-49.
IL6	CP	20	51	ns	None	Caucasian	CC	S	Interleukin 6 (interferon, beta 2)	HGF; HSF; BSF2; IL-6; IFNB2; IL6	1	–174	16708852	Jansson H, Lyssenko V, Gustavsson A, Hamberg K, Söderfeldt B, Groop L, Bratthall G. Analysis of the interleukin-1 and interleukin-6 polymorphisms in patients with chronic periodontitis. A pilot study. Swed Dent J. 2006;30(1):17-23.
IL6	CP	137	219	ns	None	Caucasian	CC	GS	Interleukin 6 (interferon, beta 2)	HGF; HSF; BSF2; IL-6; IFNB2; IL6	1	–174	16512757	Wohlfahrt JC, Wu T, Hodges JS, Hinrichs JE, Michalowicz BS. No association between selected candidate gene polymorphisms and severe chronic periodontitis. J Periodontol. 2006 Mar;77(3):426-36.
IL6	CP&RA	137	245	ns	None	Japanese	CC	N	Interleukin 6 (interferon, beta 2)	HGF; HSF; BSF2; IL-6; IFNB2; IL6	2	Multiple SNPs	19405833	Kobayashi T, Murasawa A, Ito S, Yamamoto K, Komatsu Y, Abe A, Sumida T, Yoshie H. Cytokine gene polymorphisms associated with rheumatoid arthritis and periodontitis in Japanese adults. J Periodontol. 2009 May;80(5):792-9.

IL6	CP&T2DM	110	245	0.002	Weak	Chinese	CC	N	Interleukin 6 (interferon, beta 2)	HGF; HSF; BSF2; IL-6; IFNB2; IL6	3	–572	19549135	Xiao LM, Yan YX, Xie CJ, Fan WH, Xuan DY, Wang CX, Chen L, Sun SY, Xie BY, Zhang JC. Association among interleukin-6 gene polymorphism, diabetes and periodontitis in a Chinese population. Oral Dis. 2009 Jun 22. [Epub ahead of print]
IL6R	AgP	43	183	0.04	Weak	Japanese	CC	N	Interleukin 6 receptor	CD126; IL6RA; IL-6R-1; MGC104991; IL-6R-alpha; IL6R	2	+48892 A/C	16899024	Galicia JC, Tai H, Komatsu Y, Shimada Y, Ikezawa I, Yoshie H. Interleukin-6 receptor gene polymorphisms and periodontitis in a non-smoking Japanese population. J Clin Periodontol. 2006 Oct;33(10):704-9. Epub 2006 Aug 7.
IL6R	AgP+CP	251	376	ns	None	Japanese	CC	N	Interleukin 6 receptor	CD126; IL6RA; IL-6R-1; MGC104991; IL-6R-alpha; IL6R	n/a	n/a	15081423	Suzuki A, Ji G, Numabe Y, Muramatsu M, Gomi K, Kanazashi M, Ogata Y, Shimizu E, Shibukawa Y, Ito A, Ito T, Sugaya A, Arai T, Yamada S, Deguchi S, Kamoi K. Single nucleotide polymorphisms associated with aggressive periodontitis and severe chronic periodontitis in Japanese. Biochem Biophys Res Commun. 2004 May 7;317(3):887-92.
IL6R	CP	169	239	0.02	Weak	Japanese	CC	N	Interleukin 6 receptor	CD126; IL6RA; IL-6R-1; MGC104991; IL-6R-alpha; IL6R	2	+48892 A/C	16899024	Galicia JC, Tai H, Komatsu Y, Shimada Y, Ikezawa I, Yoshie H. Interleukin-6 receptor gene polymorphisms and periodontitis in a non-smoking Japanese population. J Clin Periodontol. 2006 Oct;33(10):704-9. Epub 2006 Aug 7.
IL6ST	AgP+CP	251	376	0.009	Weak	Japanese	CC	N	Interleukin 6 signal transducer (gp130, oncostatin M receptor)	CD130; GP130; CDw130; IL6R-beta; GP130-RAPS; IL6ST	n/a	Chr:5 A/T	15081423	Suzuki A, Ji G, Numabe Y, Muramatsu M, Gomi K, Kanazashi M, Ogata Y, Shimizu E, Shibukawa Y, Ito A, Ito T, Sugaya A, Arai T, Yamada S, Deguchi S, Kamoi K. Single nucleotide polymorphisms associated with aggressive periodontitis and severe chronic periodontitis in Japanese. Biochem Biophys Res Commun. 2004 May 7;317(3):887-92.

Continued

TABLE 6-3 Association Study—cont'd

Gene Symbol	Disease Type	Cases	Total	Best *P* Value	Level of Support	Population	Study Design	Stratified or Covariate Adj	Gene Name	Gene Aliases	# SNPs Assayed	SNP Name	PubMed ID	Journal
IL8	CP	276	500	ns	None	Brazilian	CC	N	Interleukin 8	NAF; GCP1; LECT; LUCT; NAP1; CXCL8; GCP-1; LYNAP; MDNCF; MONAP; NAP-1; IL8	1	rs4073	19364277	Kim YJ, Viana AC, Curtis KM, Orrico SR, Cirelli JA, Scarel-Caminaga RM. Lack of association of a functional polymorphism in the interleukin 8 gene with susceptibility to periodontitis. DNA Cell Biol. 2009 Apr;28(4):185-90.
ILF2	AgP+CP	251	376	ns	None	Japanese	CC	N	Interleukin enhancer binding factor 2, 45kDa	NF45; MGC8391; PRO3063; ILF2	n/a	n/a	15081423	Suzuki A, Ji G, Numabe Y, Muramatsu M, Gomi K, Kanazashi M, Ogata Y, Shimizu E, Shibukawa Y, Ito A, Ito T, Sugaya A, Arai T, Yamada S, Deguchi S, Kamoi K. Single nucleotide polymorphisms associated with aggressive periodontitis and severe chronic periodontitis in Japanese. Biochem Biophys Res Commun. 2004 May 7;317(3):887-92.
IMPG1	AgP+CP	251	376	ns	None	Japanese	CC	N	Interphotoreceptor matrix proteoglycan 1	GP147; SPACR; IPM150; IMPG1	n/a	n/a	15081423	Suzuki A, Ji G, Numabe Y, Muramatsu M, Gomi K, Kanazashi M, Ogata Y, Shimizu E, Shibukawa Y, Ito A, Ito T, Sugaya A, Arai T, Yamada S, Deguchi S, Kamoi K. Single nucleotide polymorphisms associated with aggressive periodontitis and severe chronic periodontitis in Japanese. Biochem Biophys Res Commun. 2004 May 7;317(3):887-92.
INSR	CP	22	41	ns	None	Japanese	CC	N	Insulin receptor	HHF5; CD220; INSR	2	Multiple SNPs	15490304	Suzuki A, Ji G, Numabe Y, Ishii K, Muramatsu M, Kamoi K. Large-scale investigation of genomic markers for severe periodontitis. Odontology. 2004 Sep;92(1):43-7.

IRAK1	CP	22	41	ns	None	Japanese	CC	N	Interleukin-1 receptor-associated kinase 1	IRAK; pelle; IRAK1	3	Multiple SNPs	15490304	Suzuki A, Ji G, Numabe Y, Ishii K, Muramatsu M, Kamoi K. Large-scale investigation of genomic markers for severe periodontitis. Odontology. 2004 Sep;92(1):43-7.
IRF1	CP	22	41	ns	None	Japanese	CC	N	Interferon regulatory factor 1	MAR; IRF-1; IRF1	2	Multiple SNPs	15490304	Suzuki A, Ji G, Numabe Y, Ishii K, Muramatsu M, Kamoi K. Large-scale investigation of genomic markers for severe periodontitis. Odontology. 2004 Sep;92(1):43-7.
ITGB1	AgP+CP	251	376	ns	None	Japanese	CC	N	Integrln, beta 1 (fibronectln receptor, beta polypeptide, antigen CD29 Includes MDF2, MSK12)	CD29; FNRB; MDF2; VLAB; GPIIA; MSK12; VLA-BETA; ITGB1	n/a	n/a	15081423	Suzuki A, Ji G, Numabe Y, Muramatsu M, Gomi K, Kanazashi M, Ogata Y, Shimizu E, Shibukawa Y, Ito A, Ito T, Sugaya A, Arai T, Yamada S, Deguchi S, Kamoi K. Single nucleotide polymorphisms associated with aggressive periodontitis and severe chronic periodontitis in Japanese. Biochem Biophys Res Commun. 2004 May 7;317(3):887-92.
JAK1	CP	22	41	ns	None	Japanese	CC	N	Janus kinase 1	JTK3; JAK1A; JAK1B; JAK1	1	n/a	15490304	Suzuki A, Ji G, Numabe Y, Ishii K, Muramatsu M, Kamoi K. Large-scale investigation of genomic markers for severe periodontitis. Odontology. 2004 Sep;92(1):43-7.
KCNE1	CP	22	41	ns	None	Japanese	CC	N	Potassium voltage-gated channel, Isk-related family, member 1	ISK; JLNS; LQT5; MinK; JLNS2; LQT2/5; FLJ18426; FLJ38123; FLJ94103; MGC33114; KCNE1	1	n/a	15490304	Suzuki A, Ji G, Numabe Y, Ishii K, Muramatsu M, Kamoi K. Large-scale investigation of genomic markers for severe periodontitis. Odontology. 2004 Sep;92(1):43-7.
KCNM3L	CP	22	41	ns	None	Japanese	CC	N	n/a	n/a	1	n/a	15490304	Suzuki A, Ji G, Numabe Y, Ishii K, Muramatsu M, Kamoi K. Large-scale investigation of genomic markers for severe periodontitis. Odontology. 2004 Sep;92(1):43-7.
KL	CP	22	41	ns	None	Japanese	CC	N	Klotho	KL	4	Multiple SNPs	15490304	Suzuki A, Ji G, Numabe Y, Ishii K, Muramatsu M, Kamoi K. Large-scale investigation of genomic markers for severe periodontitis. Odontology. 2004 Sep;92(1):43-7.

Continued

TABLE 6-3 Association Study—cont'd

Gene Symbol	Disease Type	Cases	Total	Best *P* Value	Level of Support	Population	Study Design	Stratified or Covariate Adj	Gene Name	Gene Aliases	# SNPs Assayed	SNP Name	PubMed ID	Journal
KLK10	CP	22	41	ns	None	Japanese	CC	N	KalliKrein-related peptidase 10	NES1; PRSSL1; KLK10	2	Multiple SNPs	15490304	Suzuki A, Ji G, Numabe Y, Ishii K, Muramatsu M, Kamoi K. Large-scale investigation of genomic markers for severe periodontitis. Odontology. 2004 Sep;92(1):43-7.
KLK14	CP	22	41	ns	None	Japanese	CC	N	KalliKrein-related peptidase 14	KLK-L6; KLK14	1	n/a	15490304	Suzuki A, Ji G, Numabe Y, Ishii K, Muramatsu M, Kamoi K. Large-scale investigation of genomic markers for severe periodontitis. Odontology. 2004 Sep;92(1):43-7.
KLK2	CP	22	41	ns	None	Japanese	CC	N	KalliKrein-related peptidase 2	hK2; KLK2A2; MGC12201; KLK2	2	Multiple SNPs	15490304	Suzuki A, Ji G, Numabe Y, Ishii K, Muramatsu M, Kamoi K. Large-scale investigation of genomic markers for severe periodontitis. Odontology. 2004 Sep;92(1):43-7.
KLK3	CP	22	41	ns	None	Japanese	CC	N	KalliKrein-related peptidase 3	APS; PSA; hK3; KLK2A1; KLK3	1	n/a	15490304	Suzuki A, Ji G, Numabe Y, Ishii K, Muramatsu M, Kamoi K. Large-scale investigation of genomic markers for severe periodontitis. Odontology. 2004 Sep;92(1):43-7.
KLK4	CP	22	41	ns	None	Japanese	CC	N	KalliKrein-related peptidase 4	ARM1; EMSP; PSTS; AI2A1; EMSP1; KLK-L1; PRSS17; PROSTASE; MGC116827; MGC116828; KLK4	1	n/a	15490304	Suzuki A, Ji G, Numabe Y, Ishii K, Muramatsu M, Kamoi K. Large-scale investigation of genomic markers for severe periodontitis. Odontology. 2004 Sep;92(1):43-7.
KLK8	CP	22	41	ns	None	Japanese	CC	N	KalliKrein-related peptidase 8	NP; HNP; NRPN; PRSS19; TADG14; KLK8	1	n/a	15490304	Suzuki A, Ji G, Numabe Y, Ishii K, Muramatsu M, Kamoi K. Large-scale investigation of genomic markers for severe periodontitis. Odontology. 2004 Sep;92(1):43-7.

KRT18	AgP+CP	251	376	ns	None	Japanese	CC	N	Keratin 18	K18; CYK18; KRT18	n/a	n/a	15081423	Suzuki A, Ji G, Numabe Y, Muramatsu M, Gomi K, Kanazashi M, Ogata Y, Shimizu E, Shibukawa Y, Ito A, Ito T, Sugaya A, Arai T, Yamada S, Deguchi S, Kamoi K. Single nucleotide polymorphisms associated with aggressive periodontitis and severe chronic periodontitis in Japanese. Biochem Biophys Res Commun. 2004 May 7;317(3):887-92.
KRT23	AgP+CP	251	376	0.009	Weak	Japanese	CC	N	Keratin 23 (histone deacetylase inducible)	K23; CK23; HAIK1; MGC26158; DKFZp434G032; KRT23	n/a	Chr:17 T/C	15081423	Suzuki A, Ji G, Numabe Y, Muramatsu M, Gomi K, Kanazashi M, Ogata Y, Shimizu E, Shibukawa Y, Ito A, Ito T, Sugaya A, Arai T, Yamada S, Deguchi S, Kamoi K. Single nucleotide polymorphisms associated with aggressive periodontitis and severe chronic periodontitis in Japanese. Biochem Biophys Res Commun. 2004 May 7;317(3):887-92.
KRT2A	AgP+CP	251	376	ns	None	Japanese	CC	N	Keratin 2	KRTE; KRT2A; KRT2E; MGC116967; MGC116968; KRT2	n/a	n/a	15081423	Suzuki A, Ji G, Numabe Y, Muramatsu M, Gomi K, Kanazashi M, Ogata Y, Shimizu E, Shibukawa Y, Ito A, Ito T, Sugaya A, Arai T, Yamada S, Deguchi S, Kamoi K. Single nucleotide polymorphisms associated with aggressive periodontitis and severe chronic periodontitis in Japanese. Biochem Biophys Res Commun. 2004 May 7;317(3):887-92.
KRT32	AgP+CP	251	376	ns	None	Japanese	CC	N	Keratin 32	HA2; HKA2; hHa2; KRTHA2; KRT32	n/a	n/a	15081423	Suzuki A, Ji G, Numabe Y, Muramatsu M, Gomi K, Kanazashi M, Ogata Y, Shimizu E, Shibukawa Y, Ito A, Ito T, Sugaya A, Arai T, Yamada S, Deguchi S, Kamoi K. Single nucleotide polymorphisms associated with aggressive periodontitis and severe chronic periodontitis in Japanese. Biochem Biophys Res Commun. 2004 May 7;317(3):887-92.

Continued

TABLE 6-3 Association Study—cont'd

Gene Symbol	Disease Type	Cases	Total	Best *P* Value	Level of Support	Population	Study Design	Stratified or Covariate Adj	Gene Name	Gene Aliases	# SNPs Assayed	SNP Name	PubMed ID	Journal
KRT34	AgP+CP	251	376	ns	None	Japanese	CC	N	Keratin 34	HA4; Ha-4; hHa4; KRTHA4; KRT34	n/a	n/a	15081423	Suzuki A, Ji G, Numabe Y, Muramatsu M, Gomi K, Kanazashi M, Ogata Y, Shimizu E, Shibukawa Y, Ito A, Ito T, Sugaya A, Arai T, Yamada S, Deguchi S, Kamoi K. Single nucleotide polymorphisms associated with aggressive periodontitis and severe chronic periodontitis in Japanese. Biochem Biophys Res Commun. 2004 May 7;317(3):887-92.
KRT36	AgP+CP	251	376	ns	None	Japanese	CC	N	Keratin 36	HA6; hHa6; KRTHA6; KRT36	n/a	n/a	15081423	Suzuki A, Ji G, Numabe Y, Muramatsu M, Gomi K, Kanazashi M, Ogata Y, Shimizu E, Shibukawa Y, Ito A, Ito T, Sugaya A, Arai T, Yamada S, Deguchi S, Kamoi K. Single nucleotide polymorphisms associated with aggressive periodontitis and severe chronic periodontitis in Japanese. Biochem Biophys Res Commun. 2004 May 7;317(3):887-92.
KRT37	AgP+CP	251	376	ns	None	Japanese	CC	N	Keratin 37	HA7; hHa7; KRTHA7; KRT37	n/a	n/a	15081423	Suzuki A, Ji G, Numabe Y, Muramatsu M, Gomi K, Kanazashi M, Ogata Y, Shimizu E, Shibukawa Y, Ito A, Ito T, Sugaya A, Arai T, Yamada S, Deguchi S, Kamoi K. Single nucleotide polymorphisms associated with aggressive periodontitis and severe chronic periodontitis in Japanese. Biochem Biophys Res Commun. 2004 May 7;317(3):887-92.

KRT38	AgP+CP	251	376	ns	None	Japanese	CC	N	Keratin 38	HA8; hHa8; KRTHA8; KRT38	n/a	n/a	15081423	Suzuki A, Ji G, Numabe Y, Muramatsu M, Gomi K, Kanazashi M, Ogata Y, Shimizu E, Shibukawa Y, Ito A, Ito T, Sugaya A, Arai T, Yamada S, Deguchi S, Kamoi K. Single nucleotide polymorphisms associated with aggressive periodontitis and severe chronic periodontitis in Japanese. Biochem Biophys Res Commun. 2004 May 7;317(3):887-92.
KRT4	AgP+CP	251	376	ns	None	Japanese	CC	N	Keratin 4	K4; CK4; CYK4; FLJ31692; KRT4	n/a	n/a	15081423	Suzuki A, Ji G, Numabe Y, Muramatsu M, Gomi K, Kanazashi M, Ogata Y, Shimizu E, Shibukawa Y, Ito A, Ito T, Sugaya A, Arai T, Yamada S, Deguchi S, Kamoi K. Single nucleotide polymorphisms associated with aggressive periodontitis and severe chronic periodontitis in Japanese. Biochem Biophys Res Commun. 2004 May 7;317(3):887-92.
KRT84	AgP+CP	251	376	ns	None	Japanese	CC	N	Keratin 84	HB4; KRTHB4; KRT84	n/a	n/a	15081423	Suzuki A, Ji G, Numabe Y, Muramatsu M, Gomi K, Kanazashi M, Ogata Y, Shimizu E, Shibukawa Y, Ito A, Ito T, Sugaya A, Arai T, Yamada S, Deguchi S, Kamoi K. Single nucleotide polymorphisms associated with aggressive periodontitis and severe chronic periodontitis in Japanese. Biochem Biophys Res Commun. 2004 May 7;317(3):887-92.
KRT85	AgP+CP	251	376	ns	None	Japanese	CC	N	Keratin 85	HB5; Hb-5; hHb5; KRTHB5; KRT85	n/a	n/a	15081423	Suzuki A, Ji G, Numabe Y, Muramatsu M, Gomi K, Kanazashi M, Ogata Y, Shimizu E, Shibukawa Y, Ito A, Ito T, Sugaya A, Arai T, Yamada S, Deguchi S, Kamoi K. Single nucleotide polymorphisms associated with aggressive periodontitis and severe chronic periodontitis in Japanese. Biochem Biophys Res Commun. 2004 May 7;317(3):887-92.

Continued

TABLE 6-3 Association Study—cont'd

Gene Symbol	Disease Type	Cases	Total	Best *P* Value	Level of Support	Population	Study Design	Stratified or Covariate Adj	Gene Name	Gene Aliases	# SNPs Assayed	SNP Name	PubMed ID	Journal
LAMA2	AgP+CP	251	376	ns	None	Japanese	CC	N	Laminin, alpha 2	LAMM; LAMA2	n/a	n/a	15081423	Suzuki A, Ji G, Numabe Y, Muramatsu M, Gomi K, Kanazashi M, Ogata Y, Shimizu E, Shibukawa Y, Ito A, Ito T, Sugaya A, Arai T, Yamada S, Deguchi S, Kamoi K. Single nucleotide polymorphisms associated with aggressive periodontitis and severe chronic periodontitis in Japanese. Biochem Biophys Res Commun. 2004 May 7;317(3):887-92.
LAMA4	AgP+CP	251	376	ns	None	Japanese	CC	N	Laminin, alpha 4	LAMA3; LAMA4*-1; DKFZp686D23145; LAMA4	n/a	n/a	15081423	Suzuki A, Ji G, Numabe Y, Muramatsu M, Gomi K, Kanazashi M, Ogata Y, Shimizu E, Shibukawa Y, Ito A, Ito T, Sugaya A, Arai T, Yamada S, Deguchi S, Kamoi K. Single nucleotide polymorphisms associated with aggressive periodontitis and severe chronic periodontitis in Japanese. Biochem Biophys Res Commun. 2004 May 7;317(3):887-92.
LAMB1	AgP+CP	251	376	ns	None	Japanese	CC	N	Laminin, beta 1	CLM; MGC142015; LAMB1	n/a	n/a	15081423	Suzuki A, Ji G, Numabe Y, Muramatsu M, Gomi K, Kanazashi M, Ogata Y, Shimizu E, Shibukawa Y, Ito A, Ito T, Sugaya A, Arai T, Yamada S, Deguchi S, Kamoi K. Single nucleotide polymorphisms associated with aggressive periodontitis and severe chronic periodontitis in Japanese. Biochem Biophys Res Commun. 2004 May 7;317(3):887-92.

LAMB2	AgP+CP	251	376	ns	None	Japanese	CC	N	Laminin, beta 2 (Laminin S)	LAMS; LAMB2	n/a	n/a	15081423	Suzuki A, Ji G, Numabe Y, Muramatsu M, Gomi K, Kanazashi M, Ogata Y, Shimizu E, Shibukawa Y, Ito A, Ito T, Sugaya A, Arai T, Yamada S, Deguchi S, Kamoi K. Single nucleotide polymorphisms associated with aggressive periodontitis and severe chronic periodontitis in Japanese. Biochem Biophys Res Commun. 2004 May 7;317(3):887-92.
LAMB3	AgP+CP	251	376	ns	None	Japanese	CC	N	Laminin, beta 3	LAM5; LAMNB1; FLJ99565; BM600-125KDA; LAMB3	n/a	n/a	15081423	Suzuki A, Ji G, Numabe Y, Muramatsu M, Gomi K, Kanazashi M, Ogata Y, Shimizu E, Shibukawa Y, Ito A, Ito T, Sugaya A, Arai T, Yamada S, Deguchi S, Kamoi K. Single nucleotide polymorphisms associated with aggressive periodontitis and severe chronic periodontitis in Japanese. Biochem Biophys Res Commun. 2004 May 7;317(3):887-92.
LAMC1	AgP+CP	251	376	ns	None	Japanese	CC	N	Laminin, gamma 1 (formerLy LAMB2)	LAMB2; MGC87297; LAMC1	n/a	n/a	15081423	Suzuki A, Ji G, Numabe Y, Muramatsu M, Gomi K, Kanazashi M, Ogata Y, Shimizu E, Shibukawa Y, Ito A, Ito T, Sugaya A, Arai T, Yamada S, Deguchi S, Kamoi K. Single nucleotide polymorphisms associated with aggressive periodontitis and severe chronic periodontitis in Japanese. Biochem Biophys Res Commun. 2004 May 7;317(3):887-92.

Continued

TABLE 6-3 Association Study—cont'd

Gene Symbol	Disease Type	Cases	Total	Best *P* Value	Level of Support	Population	Study Design	Stratified or Covariate Adj	Gene Name	Gene Aliases	# SNPs Assayed	SNP Name	PubMed ID	Journal
LAMC2	AgP+CP	251	376	ns	None	Japanese	CC	N	Laminin, gamma 2	B2T; CSF; EBR2; BM600; EBR2A; LAMB2T; LAMNB2; MGC138491; MGC141938; LAMC2	n/a	n/a	15081423	Suzuki A, Ji G, Numabe Y, Muramatsu M, Gomi K, Kanazashi M, Ogata Y, Shimizu E, Shibukawa Y, Ito A, Ito T, Sugaya A, Arai T, Yamada S, Deguchi S, Kamoi K. Single nucleotide polymorphisms associated with aggressive periodontitis and severe chronic periodontitis in Japanese. Biochem Biophys Res Commun. 2004 May 7;317(3):887-92.
LAMC3	AgP+CP	251	376	ns	None	Japanese	CC	N	Laminin, gamma 3	DKFZp434E202; LAMC3	n/a	n/a	15081423	Suzuki A, Ji G, Numabe Y, Muramatsu M, Gomi K, Kanazashi M, Ogata Y, Shimizu E, Shibukawa Y, Ito A, Ito T, Sugaya A, Arai T, Yamada S, Deguchi S, Kamoi K. Single nucleotide polymorphisms associated with aggressive periodontitis and severe chronic periodontitis in Japanese. Biochem Biophys Res Commun. 2004 May 7;317(3):887-92.
LDLR	CP	22	41	ns	None	Japanese	CC	N	Low density Lipoprotein receptor	FH; FHC; LDLCQ2; LDLR	2	Multiple SNPs	15490304	Suzuki A, Ji G, Numabe Y, Ishii K, Muramatsu M, Kamoi K. Large-scale investigation of genomic markers for severe periodontitis. Odontology. 2004 Sep;92(1):43-7.
LEP	CP	22	41	ns	None	Japanese	CC	N	Leptin	OB; OBS; FLJ94114; LEP	2	Multiple SNPs	15490304	Suzuki A, Ji G, Numabe Y, Ishii K, Muramatsu M, Kamoi K. Large-scale investigation of genomic markers for severe periodontitis. Odontology. 2004 Sep;92(1):43-7.
LRP2	CP	22	41	ns	None	Japanese	CC	N	Low density Lipoprotein-related protein 2	DBS; gp330; LRP2	16	Multiple SNPs	15490304	Suzuki A, Ji G, Numabe Y, Ishii K, Muramatsu M, Kamoi K. Large-scale investigation of genomic markers for severe periodontitis. Odontology. 2004 Sep;92(1):43-7.

LRPAP1	CP	22	41	ns	None	Japanese	CC	N	Low density Lipoprotein receptor-related protein associated protein 1	RAP; MRAP; A2RAP; HBP44; A2MRAP; MGC138272; LRPAP1	3	Multiple SNPs	15490304	Suzuki A, Ji G, Numabe Y, Ishii K, Muramatsu M, Kamoi K. Large-scale investigation of genomic markers for severe periodontitis. Odontology. 2004 Sep;92(1):43-7.
LTA	CP	132	246	0.0094	Weak	Czech	CC	N	Lymphotoxin alpha (TNF superfamily, member 1)	LT; TNFB; TNFSF1; LTA	1	+252	12828656	Fassmann A, Holla LI, Buckova D, Vasku A, Znojil V, Vanek J. Polymorphisms in the +252(A/G) lymphotoxin-alpha and the -308(A/G) tumor necrosis factor-alpha genes and susceptibility to chronic periodontitis in a Czech population. J Periodontal Res. 2003 Aug;38(4):394-9.
LTA	CP	63	158	0.028	Weak	Caucasian	CC	N	Lymphotoxin alpha (TNF superfamily, member 1)	LT; TNFB; TNFSF1; LTA	1	Intron1 NcoI	11210078	Hollá LI, Fassmann A, Vasku A, Znojil V, Vanek J, Vácha J. Interactions of lymphotoxin alpha (TNF-beta), angiotensin-converting enzyme (ACE), and endothelin-1 (ET-1) gene polymorphisms in adult periodontitis. J Periodontol. 2001 Jan;72(1):85-9.
LTA	CP	22	41	ns	None	Japanese	CC	N	Lymphotoxin alpha (TNF superfamily, member 1)	LT; TNFB; TNFSF1; LTA	1	n/a	15490304	Suzuki A, Ji G, Numabe Y, Ishii K, Muramatsu M, Kamoi K. Large-scale investigation of genomic markers for severe periodontitis. Odontology. 2004 Sep;92(1):43-7.
LTA4H	CP	22	41	ns	None	Japanese	CC	N	Leukotriene A4 hydroLase	LTA4H	2	Multiple SNPs	15490304	Suzuki A, Ji G, Numabe Y, Ishii K, Muramatsu M, Kamoi K. Large-scale investigation of genomic markers for severe periodontitis. Odontology. 2004 Sep;92(1):43-7.
LTF	AgP	46	124	0.0007	Weak	Black	CC	N	Lactotransferrin	LF; HLF2; GIG12; LTF	1	+88 A/G Thr/Ala	16208406	Jordan WJ, Eskdale J, Lennon GP, Pestoff R, Wu L, Fine DH, Gallagher G. A non-conservative, coding single-nucleotide polymorphism in the N-terminal region of lactoferrin is associated with aggressive periodontitis in an African-American, but not a Caucasian population. Genes Immun. 2005 Oct;6(7):632-5.

Continued

TABLE 6-3 Association Study—cont'd

Gene Symbol	Disease Type	Cases	Total	Best *P* Value	Level of Support	Population	Study Design	Stratified or Covariate Adj	Gene Name	Gene Aliases	# SNPs Assayed	SNP Name	PubMed ID	Journal
LTF	AgP	65	153	0.0037	Weak	Taiwanese	CC	N	Lactotransferrin	LF; HLF2; GIG12; LTF	1	Lys/Arg	18973542	Wu YM, Juo SH, Ho YP, Ho KY, Yang YH, Tsai CC. Association between lactoferrin gene polymorphisms and aggressive periodontitis among Taiwanese patients. J Periodontal Res. 2009 Jun;44(3):418-24. Epub 2008 Oct 7.
LTF	AgP	9	26	<0.02	Weak	Mixed	CC	N	Lactotransferrin	LF; HLF2; GIG12; LTF	1	Lys/Arg	14573629	Velliyagounder K, Kaplan JB, Furgang D, Legarda D, Diamond G, Parkin RE, Fine DH. One of two human lactoferrin variants exhibits increased antibacterial and transcriptional activation activities and is associated with localized juvenile periodontitis. Infect Immun. 2003 Nov;71(11):6141-7.
LTF	AgP	77	131	ns	None	Caucasian	CC	N	Lactotransferrin	LF; HLF2; GIG12; LTF	1	+88 A/G Thr/Ala	16208406	Jordan WJ, Eskdale J, Lennon GP, Pestoff R, Wu L, Fine DH, Gallagher G. A non-conservative, coding single-nucleotide polymorphism in the N-terminal region of lactoferrin is associated with aggressive periodontitis in an African-American, but not a Caucasian population. Genes Immun. 2005 Oct;6(7):632-5.
LTF	CP	278	366	0.0212	Weak	Taiwanese	CC	N	Lactotransferrin	LF; HLF2; GIG12; LTF	1	Lys/Arg	18973542	Wu YM, Juo SH, Ho YP, Ho KY, Yang YH, Tsai CC. Association between lactoferrin gene polymorphisms and aggressive periodontitis among Taiwanese patients. J Periodontal Res. 2009 Jun;44(3):418-24. Epub 2008 Oct 7.
MBL2	CP	51	114	0.014	Weak	Japanese	CC	N	Mannose-binding lectin (protein C) 2, soluble (opsonic defect)	MBL; MBP; MBP1; COLEC1; HSMBPC; MGC116832; MGC116833; MBL2	1	Codon 54	19252378	Tsutsumi A, Kobayashi T, Ito S, Goto D, Matsumoto I, Yoshie H, Sumida T. Mannose binding lectin gene polymorphism and the severity of chronic periodontitis. Nihon Rinsho Meneki Gakkai Kaishi. 2009 Feb;32(1):48-52.

MBL2	CP	92	162	ns	None	Dutch	CC	N	Mannose-binding lectin (protein C) 2, soluble (opsonic defect)	MBL; MBP; MBP1; COLEC1; HSMBPC; MGC116832; MGC116833; MBL2	6	Multiple SNPs	18823346	Louropoulou A, van der Velden U, Schoenmaker T, Catsburg A, Savelkoul PH, Loos BG. Mannose-binding lectin gene polymorphisms in relation to periodontitis. J Clin Periodontol. 2008 Nov;35(11):923-30. Epub 2008 Sep 20.
MC5R	CP	22	41	ns	None	Japanese	CC	N	Melanocortin 5 receptor	MC5R	2	Multiple SNPs	15490304	Suzuki A, Ji G, Numabe Y, Ishii K, Muramatsu M, Kamoi K. Large-scale investigation of genomic markers for severe periodontitis. Odontology. 2004 Sep;92(1):43-7.
MET	CP	22	41	ns	None	Japanese	CC	N	Met proto-oncogene (hepatocyte growth factor receptor)	HGFR; AUTS9; RCCP2; c-Met; MET	10	Multiple SNPs	15490304	Suzuki A, Ji G, Numabe Y, Ishii K, Muramatsu M, Kamoi K. Large-scale investigation of genomic markers for severe periodontitis. Odontology. 2004 Sep;92(1):43-7.
MMP1	AgP	40	92	<0.001	Weak	Chinese	CC	N	Matrix metallopeptidase 1 (interstitial collagenase)	CLG; CLGN; MMP1	1	–1607 1G/2G	16302919	Cao Z, Li C, Jin L, Corbet EF. Association of matrix metalloproteinase-1 promoter polymorphism with generalized aggressive periodontitis in a Chinese population. J Periodontal Res. 2005 Dec;40(6):427-31.
MMP1	AgP	37	179	ns	None	Japanese	CC	N	Matrix metallopeptidase 1 (interstitial collagenase)	CLG; CLGN; MMP1	1	–1607,1G/2G	15312099	Itagaki M, Kubota T, Tai H, Shimada Y, Morozumi T, Yamazaki K. Matrix metalloproteinase-1 and -3 gene promoter polymorphisms in Japanese patients with periodontitis. J Clin Periodontol. 2004 Sep;31(9):764-9.
MMP1	AgP+CP	251	376	ns	None	Japanese	CC	N	Matrix metallopeptidase 1 (interstitial collagenase)	CLG; CLGN; MMP1	n/a	n/a	15081423	Suzuki A, Ji G, Numabe Y, Muramatsu M, Gomi K, Kanazashi M, Ogata Y, Shimizu E, Shibukawa Y, Ito A, Ito T, Sugaya A, Arai T, Yamada S, Deguchi S, Kamoi K. Single nucleotide polymorphisms associated with aggressive periodontitis and severe chronic periodontitis in Japanese. Biochem Biophys Res Commun. 2004 May 7;317(3):887-92.

Continued

TABLE 6-3 Association Study—cont'd

Gene Symbol	Disease Type	Cases	Total	Best *P* Value	Level of Support	Population	Study Design	Stratified or Covariate Adj	Gene Name	Gene Aliases	# SNPs Assayed	SNP Name	PubMed ID	Journal
MMP1	AgP+CP	319	622	ns	None	Japanese	CC	AGS	Matrix metallopeptidase 1 (interstitial collagenase)	CLG; CLGN; MMP1	1	–1607	19892918	Kobayashi T, Nagata T, Murakami S, Takashiba S, Kurihara H, Izumi Y, Numabe Y, Watanabe H, Kataoka M, Nagai A, Hayashi J, Ohyama H, Okamatsu Y, Inagaki Y, Tai H, Yoshie H. Genetic risk factors for periodontitis in a Japanese population. J Dent Res. 2009 Dec;88(12): 1137-41.
MMP1	CP	133	329	0.017	Weak	Caucasian	CC	S	Matrix metallopeptidase 1 (interstitial collagenase)	CLG; CLGN; MMP1	3	–422	15257748	Hollá LI, Jurajda M, Fassmann A, Dvorakova N, Znojil V, Vacha J. Genetic variations in the matrix metalloproteinase-1 promoter and risk of susceptibility and/or severity of chronic periodontitis in the Czech population. J Clin Periodontol. 2004 Aug;31(8):685-90.
MMP1	CP	50	87	0.0344	Weak	Brazilian	CC	N	Matrix metallopeptidase 1 (interstitial collagenase)	CLG; CLGN; MMP1	1	promoter	12622858	de Souza AP, Trevilatto PC, Scarel-Caminaga RM, Brito RB, Line SR. MMP-1 promoter polymorphism: association with chronic periodontitis severity in a Brazilian population. J Clin Periodontol. 2003 Feb;30(2):154-8.
MMP1	CP	60	110	<0.001	Weak	Chinese	CC	S	Matrix metallopeptidase 1 (interstitial collagenase)	CLG; CLGN; MMP1	1	–1607	16774538	Cao Z, Li C, Zhu G. MMP-1 promoter gene polymorphism and susceptibility to chronic periodontitis in a Chinese population. Tissue Antigens. 2006 Jul;68(1):38-43.
MMP1	CP	126	140	ns	None	Turkish	CC	S	Matrix metallopeptidase 1 (interstitial collagenase)	CLG; CLGN; MMP1	1	–1607	19040577	Ustun K, Alptekin NO, Hakki SS, Hakki EE. Investigation of matrix metalloproteinase-1–1607 1G/2G polymorphism in a Turkish population with periodontitis. J Clin Periodontol. 2008 Dec;35(12):1013-9.

MMP1	CP	102	199	ns	None	Turkish	CC	N	Matrix metallopeptidase 1 (interstitial collagenase)	CLG; CLGN; MMP1	2	–1607	18710412	Pirhan D, Atilla G, Emingil G, Sorsa T, Tervahartiala T, Berdeli A. Effect of MMP-1 promoter polymorphisms on GCF MMP-1 levels and outcome of periodontal therapy in patients with severe chronic periodontitis. J Clin Periodontol. 2008 Oct;35(10):862-70. Epub 2008 Aug 15.
MMP1	CP	114	223	ns	None	Brazilian	CC	N	Matrix metallopeptidase 1 (interstitial collagenase)	CLG; CLGN; MMP1	2	Multiple SNPs	16899023	Astolfi CM, Shinohara AL, da Silva RA, Santos MC, Line SR, de Souza AP. Genetic polymorphisms in the MMP-1 and MMP-3 gene may contribute to chronic periodontitis in a Brazilian population. J Clin Periodontol. 2006 Oct;33(10):699-703. Epub 2006 Aug 7.
MMP1	CP	205	347	ns	None	Japanese	CC	N	Matrix metallopeptidase 1 (interstitial collagenase)	CLG; CLGN; MMP1	1	–1607,1G/2G	15312099	Itagaki M, Kubota T, Tai H, Shimada Y, Morozumi T, Yamazaki K. Matrix metalloproteinase-1 and -3 gene promoter polymorphisms in Japanese patients with periodontitis. J Clin Periodontol. 2004 Sep;31(9):764-9.
MMP1. MMP3	CP	114	223	ns	None	Brazilian	CC	N	n/a	n/a	2	Multiple Genes	16899023	Astolfi CM, Shinohara AL, da Silva RA, Santos MC, Line SR, de Souza AP. Genetic polymorphisms in the MMP-1 and MMP-3 gene may contribute to chronic periodontitis in a Brazilian population. J Clin Periodontol. 2006 Oct;33(10):699-703. Epub 2006 Aug 7.
MMP10	AgP+CP	251	376	ns	None	Japanese	CC	N	Matrix metallopeptidase 10 (stromelysin 2)	SL-2; STMY2; MMP10	n/a	n/a	15081423	Suzuki A, Ji G, Numabe Y, Muramatsu M, Gomi K, Kanazashi M, Ogata Y, Shimizu E, Shibukawa Y, Ito A, Ito T, Sugaya A, Arai T, Yamada S, Deguchi S, Kamoi K. Single nucleotide polymorphisms associated with aggressive periodontitis and severe chronic periodontitis in Japanese. Biochem Biophys Res Commun. 2004 May 7;317(3):887-92.

Continued

TABLE 6-3 Association Study—cont'd

Gene Symbol	Disease Type	Cases	Total	Best *P* Value	Level of Support	Population	Study Design	Stratified or Covariate Adj	Gene Name	Gene Aliases	# SNPs Assayed	SNP Name	PubMed ID	Journal
MMP11	AgP+CP	251	376	ns	None	Japanese	CC	N	Matrix metallopeptidase 11 (stromelysin 3)	ST3; SL-3; STMY3; MMP11	n/a	n/a	15081423	Suzuki A, Ji G, Numabe Y, Muramatsu M, Gomi K, Kanazashi M, Ogata Y, Shimizu E, Shibukawa Y, Ito A, Ito T, Sugaya A, Arai T, Yamada S, Deguchi S, Kamoi K. Single nucleotide polymorphisms associated with aggressive periodontitis and severe chronic periodontitis in Japanese. Biochem Biophys Res Commun. 2004 May 7;317(3):887-92.
MMP12	AgP	92	249	ns	None	Turkish	CC	AGS	Matrix metallopeptidase 12 (macrophage elastase)	HME; MME; MGC138506; MMP12	1	–12357	18052707	Gürkan A, Emingil G, Saygan BH, Atilla G, Cinarcik S, Köse T, Berdeli A. Matrix metalloproteinase-2, -9, and -12 gene polymorphisms in generalized aggressive periodontitis. J Periodontol. 2007 Dec;78(12):2338-47.
MMP12	AgP+CP	251	376	ns	None	Japanese	CC	N	Matrix metallopeptidase 12 (macrophage elastase)	HME; MME; MGC138506; MMP12	n/a	n/a	15081423	Suzuki A, Ji G, Numabe Y, Muramatsu M, Gomi K, Kanazashi M, Ogata Y, Shimizu E, Shibukawa Y, Ito A, Ito T, Sugaya A, Arai T, Yamada S, Deguchi S, Kamoi K. Single nucleotide polymorphisms associated with aggressive periodontitis and severe chronic periodontitis in Japanese. Biochem Biophys Res Commun. 2004 May 7;317(3):887-92.
MMP12	CP	87	194	ns	None	Turkish	CC	AGS	Matrix metallopeptidase 12 (macrophage elastase)	HME; MME; MGC138506; MMP12	1	–12357	18155181	Gürkan A, Emingil G, Saygan BH, Atilla G, Cinarcik S, Köse T, Berdeli A. Gene polymorphisms of matrix metalloproteinase-2, -9 and -12 in periodontal health and severe chronic periodontitis. Arch Oral Biol. 2008 Apr;53(4):337-45. Epub 2007 Dec 21.

MMP13	CP	102	200	ns	None	Turkish	CC	N	Matrix metallopeptidase 13 (collagenase 3)	CLG3; MMP13	2	Multiple SNPs	19453573	Pirhan D, Atilla G, Emingil G, Tervahartiala T, Sorsa T, Berdeli A. MMP-13 promoter polymorphisms in patients with chronic periodontitis: effects on GCF MMP-13 levels and outcome of periodontal therapy. J Clin Periodontol. 2009 Jun;36(6):474-81. Epub 2009 Apr 22.
MMP14	AgP+CP	251	376	ns	None	Japanese	CC	N	Matrix metallopeptidase 14 (membrane-inserted)	MMP-X1; MTMMP1; MT1-MMP; MMP14	n/a	n/a	15081423	Suzuki A, Ji G, Numabe Y, Muramatsu M, Gomi K, Kanazashi M, Ogata Y, Shimizu E, Shibukawa Y, Ito A, Ito T, Sugaya A, Arai T, Yamada S, Deguchi S, Kamoi K. Single nucleotide polymorphisms associated with aggressive periodontitis and severe chronic periodontitis in Japanese. Biochem Biophys Res Commun. 2004 May 7;317(3):887-92.
MMP15	AgP+CP	251	376	ns	None	Japanese	CC	N	Matrix metallopeptidase 15 (membrane-inserted)	MTMMP2; SMCP-2; MT2-MMP; MMP15	n/a	n/a	15081423	Suzuki A, Ji G, Numabe Y, Muramatsu M, Gomi K, Kanazashi M, Ogata Y, Shimizu E, Shibukawa Y, Ito A, Ito T, Sugaya A, Arai T, Yamada S, Deguchi S, Kamoi K. Single nucleotide polymorphisms associated with aggressive periodontitis and severe chronic periodontitis in Japanese. Biochem Biophys Res Commun. 2004 May 7;317(3):887-92.
MMP19	AgP+CP	251	376	ns	None	Japanese	CC	N	Matrix metallopeptidase 19	MMP18; RASI-1; MMP19	n/a	n/a	15081423	Suzuki A, Ji G, Numabe Y, Muramatsu M, Gomi K, Kanazashi M, Ogata Y, Shimizu E, Shibukawa Y, Ito A, Ito T, Sugaya A, Arai T, Yamada S, Deguchi S, Kamoi K. Single nucleotide polymorphisms associated with aggressive periodontitis and severe chronic periodontitis in Japanese. Biochem Biophys Res Commun. 2004 May 7;317(3):887-92.

Continued

TABLE 6-3 Association Study—cont'd

Gene Symbol	Disease Type	Cases	Total	Best *P* Value	Level of Support	Population	Study Design	Stratified or Covariate Adj	Gene Name	Gene Aliases	# SNPs Assayed	SNP Name	PubMed ID	Journal
MMP2	AgP	92	249	ns	None	Turkish	CC	AGS	Matrix metallopeptidase 2 (gelatinase A, 72kDa gelatinase, 72kDa type IV collagenase)	CLG4; MONA; CLG4A; TBE-1; MMP-II; MMP2	1	–735	18052707	Gürkan A, Emingil G, Saygan BH, Atilla G, Cinarcik S, Köse T, Berdeli A. Matrix metalloproteinase-2, -9, and -12 gene polymorphisms in generalized aggressive periodontitis. J Periodontol. 2007 Dec;78(12):2338-47.
MMP2	AgP	79	207	ns	None	Chinese	CC	N	Matrix metallopeptidase 2 (gelatinase A, 72kDa gelatinase, 72kDa type IV collagenase)	CLG4; MONA; CLG4A; TBE-1; MMP-II; MMP2	1	–1306 C/T	17448043	Chen D, Wang Q, Ma ZW, Chen FM, Chen Y, Xie GY, Wang QT, Wu ZF. MMP-2, MMP-9 and TIMP-2 gene polymorphisms in Chinese patients with generalized aggressive periodontitis. J Clin Periodontol. 2007 May;34(5):384-9.
MMP2	AgP+CP	251	376	ns	None	Japanese	CC	N	Matrix metallopeptidase 2 (gelatinase A, 72kDa gelatinase, 72kDa type IV collagenase)	CLG4; MONA; CLG4A; TBE-1; MMP-II; MMP2	n/a	n/a	15081423	Suzuki A, Ji G, Numabe Y, Muramatsu M, Gomi K, Kanazashi M, Ogata Y, Shimizu E, Shibukawa Y, Ito A, Ito T, Sugaya A, Arai T, Yamada S, Deguchi S, Kamoi K. Single nucleotide polymorphisms associated with aggressive periodontitis and severe chronic periodontitis in Japanese. Biochem Biophys Res Commun. 2004 May 7;317(3):887-92.
MMP2	CP	149	276	0.036	Weak	Czech	CC	S	Matrix metallopeptidase 2 (gelatinase A, 72kDa gelatinase, 72kDa type IV collagenase)	CLG4; MONA; CLG4A; TBE-1; MMP-II; MMP2	4	–790	16018746	Holla LI, Fassmann A, Vasku A, Goldbergova M, Beranek M, Znojil V, Vanek J, Vacha J. Genetic variations in the human gelatinase A (matrix metalloproteinase-2) promoter are not associated with susceptibility to, and severity of, chronic periodontitis. J Periodontol. 2005 Jul;76(7):1056-60.

MMP2	CP	87	194	ns	None	Turkish	CC	AGS	Matrix metallopeptidase 2 (gelatinase A, 72kDa gelatinase, 72kDa type IV collagenase)	CLG4; MONA; CLG4A; TBE-1; MMP-II; MMP2	1	–735	18155181	Gürkan A, Emingil G, Saygan BH, Atilla G, Cinarcik S, Köse T, Berdeli A. Gene polymorphisms of matrix metalloproteinase-2, -9 and -12 in periodontal health and severe chronic periodontitis. Arch Oral Biol. 2008 Apr;53(4):337-45. Epub 2007 Dec 21.
MMP20	AgP+CP	251	376	ns	None	Japanese	CC	N	Matrix metallopeptidase 20	AI2A2; MMP-20; MMP20	n/a	n/a	15081423	Suzuki A, Ji G, Numabe Y, Muramatsu M, Gomi K, Kanazashi M, Ogata Y, Shimizu E, Shibukawa Y, Ito A, Ito T, Sugaya A, Arai T, Yamada S, Deguchi S, Kamoi K. Single nucleotide polymorphisms associated with aggressive periodontitis and severe chronic periodontitis in Japanese. Biochem Biophys Res Commun. 2004 May 7;317(3):887-92.
MMP24	AgP+CP	251	376	ns	None	Japanese	CC	N	Matrix metallopeptidase 24 (membrane-inserted)	MMP25; MT-MMP5; MT5-MMP; MMP24	n/a	n/a	15081423	Suzuki A, Ji G, Numabe Y, Muramatsu M, Gomi K, Kanazashi M, Ogata Y, Shimizu E, Shibukawa Y, Ito A, Ito T, Sugaya A, Arai T, Yamada S, Deguchi S, Kamoi K. Single nucleotide polymorphisms associated with aggressive periodontitis and severe chronic periodontitis in Japanese. Biochem Biophys Res Commun. 2004 May 7;317(3):887-92.
MMP25	AgP+CP	251	376	ns	None	Japanese	CC	N	Matrix metallopeptidase 25	MMP20; MMPL1; MMP20A; MT-MMP6; MT6-MMP; MMP25	n/a	n/a	15081423	Suzuki A, Ji G, Numabe Y, Muramatsu M, Gomi K, Kanazashi M, Ogata Y, Shimizu E, Shibukawa Y, Ito A, Ito T, Sugaya A, Arai T, Yamada S, Deguchi S, Kamoi K. Single nucleotide polymorphisms associated with aggressive periodontitis and severe chronic periodontitis in Japanese. Biochem Biophys Res Commun. 2004 May 7;317(3):887-92.

Continued

TABLE 6-3 Association Study—cont'd

Gene Symbol	Disease Type	Cases	Total	Best *P* Value	Level of Support	Population	Study Design	Stratified or Covariate Adj	Gene Name	Gene Aliases	# SNPs Assayed	SNP Name	PubMed ID	Journal
MMP25	AgP+CP	251	376	ns	None	Japanese	CC	N	Matrix metallopeptidase 25	MMP20; MMPL1; MMP20A; MT-MMP6; MT6-MMP; MMP25	n/a	n/a	15081423	Suzuki A, Ji G, Numabe Y, Muramatsu M, Gomi K, Kanazashi M, Ogata Y, Shimizu E, Shibukawa Y, Ito A, Ito T, Sugaya A, Arai T, Yamada S, Deguchi S, Kamoi K. Single nucleotide polymorphisms associated with aggressive periodontitis and severe chronic periodontitis in Japanese. Biochem Biophys Res Commun. 2004 May 7;317(3):887-92.
MMP3	AgP	37	179	ns	None	Japanese	CC	N	Matrix metallopeptidase 3 (stromelysin 1, progelatinase)	SL-1; STMY; STR1; CHDS6; MMP-3; STMY1; MGC126102; MGC126103; MGC126104; MMP3	1	–1171	15312099	Itagaki M, Kubota T, Tai H, Shimada Y, Morozumi T, Yamazaki K. Matrix metalloproteinase-1 and -3 gene promoter polymorphisms in Japanese patients with periodontitis. J Clin Periodontol. 2004 Sep;31(9):764-9.
MMP3	AgP+CP	251	376	ns	None	Japanese	CC	N	Matrix metallopeptidase 3 (stromelysin 1, progelatinase)	SL-1; STMY; STR1; CHDS6; MMP-3; STMY1; MGC126102; MGC126103; MGC126104; MMP3	n/a	n/a	15081423	Suzuki A, Ji G, Numabe Y, Muramatsu M, Gomi K, Kanazashi M, Ogata Y, Shimizu E, Shibukawa Y, Ito A, Ito T, Sugaya A, Arai T, Yamada S, Deguchi S, Kamoi K. Single nucleotide polymorphisms associated with aggressive periodontitis and severe chronic periodontitis in Japanese. Biochem Biophys Res Commun. 2004 May 7;317(3):887-92.
MMP3	AgP+CP	319	622	ns	None	Japanese	CC	AGS	Matrix metallopeptidase 3 (stromelysin 1, progelatinase)	SL-1; STMY; STR1; CHDS6; MMP-3; STMY1; MGC126102; MGC126103; MGC126104; MMP3	1	–1171	19892918	Kobayashi T, Nagata T, Murakami S, Takashiba S, Kurihara H, Izumi Y, Numabe Y, Watanabe H, Kataoka M, Nagai A, Hayashi J, Ohyama H, Okamatsu Y, Inagaki Y, Tai H, Yoshie H. Genetic risk factors for periodontitis in a Japanese population. J Dent Res. 2009 Dec;88(12): 1137-41.

MMP3	CP	114	223	0.008	Weak	Brazilian	CC	N	Matrix metallopeptidase 3 (stromelysin 1, progelatinase)	SL-1; STMY; STR1; CHDS6; MMP-3; STMY1; MGC126102; MGC126103; MGC126104; MMP3	1	–1612 5A/6A	16899023	Astolfi CM, Shinohara AL, da Silva RA, Santos MC, Line SR, de Souza AP. Genetic polymorphisms in the MMP-1 and MMP-3 gene may contribute to chronic periodontitis in a Brazilian population. J Clin Periodontol. 2006 Oct;33(10):699-703. Epub 2006 Aug 7.
MMP3	CP	114	223	0.008	Weak	Brazilian	CC	N	Matrix metallopeptidase 3 (stromelysin 1, progelatinase)	SL-1; STMY; STR1; CHDS6; MMP-3; STMY1; MGC126102; MGC126103; MGC126104; MMP3	1	–1612 5A/6A	16899023	Astolfi CM, Shinohara AL, da Silva RA, Santos MC, Line SR, de Souza AP. Genetic polymorphisms in the MMP-1 and MMP-3 gene may contribute to chronic periodontitis in a Brazilian population. J Clin Periodontol. 2006 Oct;33(10):699-703. Epub 2006 Aug 7.
MMP3	CP	205	347	ns	None	Japanese	CC	N	Matrix metallopeptidase 3 (stromelysin 1, progelatinase)	SL-1; STMY; STR1; CHDS6; MMP-3; STMY1; MGC126102; MGC126103; MGC126104; MMP3	1	–1171	15312099	Itagaki M, Kubota T, Tai H, Shimada Y, Morozumi T, Yamazaki K. Matrix metalloproteinase-1 and -3 gene promoter polymorphisms in Japanese patients with periodontitis. J Clin Periodontol. 2004 Sep;31(9):764-9.
MMP7	AgP+CP	251	376	ns	None	Japanese	CC	N	Matrix metallopeptidase 7 (Matrilysin, uterine)	MMP-7; MPSL1; PUMP-1; MMP7	n/a	n/a	15081423	Suzuki A, Ji G, Numabe Y, Muramatsu M, Gomi K, Kanazashi M, Ogata Y, Shimizu E, Shibukawa Y, Ito A, Ito T, Sugaya A, Arai T, Yamada S, Deguchi S, Kamoi K. Single nucleotide polymorphisms associated with aggressive periodontitis and severe chronic periodontitis in Japanese. Biochem Biophys Res Commun. 2004 May 7;317(3):887-92.

Continued

TABLE 6-3 Association Study—cont'd

Gene Symbol	Disease Type	Cases	Total	Best *P* Value	Level of Support	Population	Study Design	Stratified or Covariate Adj	Gene Name	Gene Aliases	# SNPs Assayed	SNP Name	PubMed ID	Journal
MMP8	AgP+CP	251	376	ns	None	Japanese	CC	N	Matrix metallopeptidase 8 (neutrophil collagenase)	HNC; CLG1; PMNL-CL; MMP8	n/a	n/a	15081423	Suzuki A, Ji G, Numabe Y, Muramatsu M, Gomi K, Kanazashi M, Ogata Y, Shimizu E, Shibukawa Y, Ito A, Ito T, Sugaya A, Arai T, Yamada S, Deguchi S, Kamoi K. Single nucleotide polymorphisms associated with aggressive periodontitis and severe chronic periodontitis in Japanese. Biochem Biophys Res Commun. 2004 May 7;317(3):887-92.
MMP9	AgP	92	249	0.04	Weak	Turkish	CC	AGS	Matrix metallopeptidase 9 (gelatinase B, 92kDa gelatinase, 92kDa type IV collagenase)	GELB; CLG4B; MMP-9; MMP9	1	–1562	18052707	Gürkan A, Emingil G, Saygan BH, Atilla G, Cinarcik S, Köse T, Berdeli A. Matrix metalloproteinase-2, -9, and -12 gene polymorphisms in generalized aggressive periodontitis. J Periodontol. 2007 Dec;78(12):2338-47.
MMP9	AgP	79	207	ns	None	Chinese	CC	N	Matrix metallopeptidase 9 (gelatinase B, 92kDa gelatinase, 92kDa type IV collagenase)	GELB; CLG4B; MMP-9; MMP9	1	–1562	17448043	Chen D, Wang Q, Ma ZW, Chen FM, Chen Y, Xie GY, Wang QT, Wu ZF. MMP-2, MMP-9 and TIMP-2 gene polymorphisms in Chinese patients with generalized aggressive periodontitis. J Clin Periodontol. 2007 May;34(5):384-9.
MMP9	AgP+CP	251	376	ns	None	Japanese	CC	N	Matrix metallopeptidase 9 (gelatinase B, 92kDa gelatinase, 92kDa type IV collagenase)	GELB; CLG4B; MMP-9; MMP9	n/a	n/a	15081423	Suzuki A, Ji G, Numabe Y, Muramatsu M, Gomi K, Kanazashi M, Ogata Y, Shimizu E, Shibukawa Y, Ito A, Ito T, Sugaya A, Arai T, Yamada S, Deguchi S, Kamoi K. Single nucleotide polymorphisms associated with aggressive periodontitis and severe chronic periodontitis in Japanese. Biochem Biophys Res Commun. 2004 May 7;317(3):887-92.

MMP9	CP	87	194	0.01	Weak	Turkish	CC	AGS	Matrix metallopeptidase 9 (gelatinase B, 92kDa gelatinase, 92kDa type IV collagenase)	GELB; CLG4B; MMP-9; MMP9	1	–1562	18155181	Gürkan A, Emingil G, Saygan BH, Atilla G, Cinarcik S, Köse T, Berdeli A. Gene polymorphisms of matrix metalloproteinase-2, -9 and -12 in periodontal health and severe chronic periodontitis. Arch Oral Biol. 2008 Apr;53(4):337-45. Epub 2007 Dec 21.
MMP9	CP	70	140	0.01	Weak	Turkish	CC	N	Matrix metallopeptidase 9 (gelatinase B, 92kDa gelatinase, 92kDa type IV collagenase)	GELB; CLG4B; MMP-9; MMP9	1	–1562	16945027	Keles GC, Gunes S, Sumer AP, Sumer M, Kara N, Bagci H, Koprulu H. Association of matrix metalloproteinase-9 promoter gene polymorphism with chronic periodontitis. J Periodontol. 2006 Sep;77(9):1510-4.
MMP9	CP	169	304	<0.01	Weak	Czech	CC	G	Matrix metallopeptidase 9 (gelatinase B, 92kDa gelatinase, 92kDa type IV collagenase)	GELB; CLG4B; MMP-9; MMP9	2	–1562	17076610	Holla LI, Fassmann A, Muzík J, Vanek J, Vasku A. Functional polymorphisms in the matrix metalloproteinase-9 gene in relation to severity of chronic periodontitis. J Periodontol. 2006 Nov;77(11):1850-5.
MMP9	CP	62	100	ns	None	Brazilian	CC	N	Matrix metallopeptidase 9 (gelatinase B, 92kDa gelatinase, 92kDa type IV collagenase)	GELB; CLG4B; MMP-9; MMP9	1	–1562	15691353	de Souza AP, Trevilatto PC, Scarel-Caminaga RM, de Brito RB Jr, Barros SP, Line SR. Analysis of the MMP-9 (C-1562 T) and TIMP-2 (G-418C) gene promoter polymorphisms in patients with chronic periodontitis. J Clin Periodontol. 2005 Feb;32(2):207-11.
MPO	CP	253	773	0.01	Weak	German	CC	AGS	Myeloperoxidase	MPO	1	–463	11960308	Meisel P, Krause T, Cascorbi I, Schroeder W, Herrmann F, John U, Kocher T. Gender and smoking-related risk reduction of periodontal disease with variant myeloperoxidase alleles. Genes Immun. 2002 Apr;3(2):102-6.
MPO	CP	117	558	0.05	Weak	German	CC	S	Myeloperoxidase	MPO	1	G-463A	19570260	Meisel P, Heins G, Carlsson L, Giebel J, John U, Schwahn C, Kocher T. Impact of Genetic Polymorphisms on the Smoking-related Risk of Periodontal Disease: the Population-based Study SHIP. Tob Induc Dis. 2003 Sep 15;1(3):197.

Continued

TABLE 6-3 Association Study—cont'd

Gene Symbol	Disease Type	Cases	Total	Best *P* Value	Level of Support	Population	Study Design	Stratified or Covariate Adj	Gene Name	Gene Aliases	# SNPs Assayed	SNP Name	PubMed ID	Journal
MTHFD1	CP	22	41	ns	None	Japanese	CC	N	Methylenetetrahydrofolate dehydrogenase (NADP+ dependent) 1, methenyltetrahydrofolate cyclohydrolase, formyltetrahydrofolate synthetase	MTHFC; MTHFD; MTHFD1	2	Multiple SNPs	15490304	Suzuki A, Ji G, Numabe Y, Ishii K, Muramatsu M, Kamoi K. Large-scale investigation of genomic markers for severe periodontitis. Odontology. 2004 Sep;92(1):43-7.
MTOR	CP	22	41	nst	None	Japanese	CC	N	Mechanistic target of rapamycin (serine/threonine kinase)	FRAP; FRAP1; FRAP2; RAFT1; RAPT1; FLJ44809; MTOR	6	Multiple SNPs	15490304	Suzuki A, Ji G, Numabe Y, Ishii K, Muramatsu M, Kamoi K. Large-scale investigation of genomic markers for severe periodontitis. Odontology. 2004 Sep;92(1):43-7.
MTRR	CP	22	41	ns	None	Japanese	CC	N	5-Methyltetrahydrofolate-homocysteine methyltransferase reductase	MSR; cblE; MGC129643; MTRR	2	Multiple SNPs	15490304	Suzuki A, Ji G, Numabe Y, Ishii K, Muramatsu M, Kamoi K. Large-scale investigation of genomic markers for severe periodontitis. Odontology. 2004 Sep;92(1):43-7.
MX1	CP	22	41	ns	None	Japanese	CC	N	Myxovirus (influenza virus) resistance 1, interferon-inducible protein p78 (mouse)	MX; MxA; IFI78; IFI-78K; MX1	5	Multiple SNPs	15490304	Suzuki A, Ji G, Numabe Y, Ishii K, Muramatsu M, Kamoi K. Large-scale investigation of genomic markers for severe periodontitis. Odontology. 2004 Sep;92(1):43-7.
NAT2	CP	75	149	0.003	Weak	Caucasian	CC	AS	*N*-Acetyltransferase 2 (arylamine N-acetyltransferase)	AAC2; PNAT; NAT2	6	Fast/Rapid	11005681	Meisel P, Timm R, Sawaf H, Fanghänel J, Siegmund W, Kocher T. Polymorphism of the N-acetyltransferase (NAT2), smoking and the potential risk of periodontal disease. Arch Toxicol. 2000 Aug;74(6):343-8.
NAT2	CP	117	558	0.05	Weak	German	CC	S	N-Acetyltransferase 2 (arylamine N-Acetyltransferase)	AAC2; PNAT; NAT2	1	T341C	19570260	Meisel P, Heins G, Carlsson L, Giebel J, John U, Schwahn C, Kocher T. Impact of Genetic Polymorphisms on the Smoking-related Risk of Periodontal Disease: the Population-based Study SHIP. Tob Induc Dis. 2003 Sep 15;1(3):197.

NAT2	CP	76	153	<0.001	Moderate	German	CC	AS	N-Acetyltransferase 2 (arylamine N-Acetyltransferase)	AAC2; PNAT; NAT2	6	NAT2*4	11846845	Kocher T, Sawaf H, Fanghänel J, Timm R, Meisel P. Association between bone loss in periodontal disease and polymorphism of N-acetyltransferase (NAT2). J Clin Periodontol. 2002 Jan;29(1):21-7.
NEBL	CP	22	41	ns	None	Japanese	CC	N	Nebulette	LNEBL; FLJ53769; bA56H7.1; MGC119746; MGC119747; NEBL	1	n/a	15490304	Suzuki A, Ji G, Numabe Y, Ishii K, Muramatsu M, Kamoi K. Large-scale investigation of genomic markers for severe periodontitis. Odontology. 2004 Sep;92(1):43-7.
NFATC2	AgP	98	186	ns	None	Japanese	CC	N	Nuclear factor of activated T-cells, cytoplasmic, calcineurin-dependent 2	NFAT1; NFATP; NFATC2	9	Multiple SNPs	16844084	Rabello D, Soedarsono N, Kamei H, Ishihara Y, Noguchi T, Fuma D, Suzuki M, Sakaki Y, Yamaguchi A, Kojima T. CSF1 gene associated with aggressive periodontitis in the Japanese population. Biochem Biophys Res Commun. 2006 Sep 1;347(3):791-6. Epub 2006 Jul 7.
NFKB1	CP	22	41	ns	None	Japanese	CC	N	Nuclear factor of kappa light polypeptide gene enhancer in B-cells 1	p50; KBF1; p105; EBP-1; MGC54151; NFKB-p50; NF-kappaB; NFKB-p105; NF-kappa-B; DKFZp686C01211; NFKB1	1	n/a	15490304	Suzuki A, Ji G, Numabe Y, Ishii K, Muramatsu M, Kamoi K. Large-scale investigation of genomic markers for severe periodontitis. Odontology. 2004 Sep;92(1):43-7.
NOD1	AgP	415	1289	ns	None	Caucasian	CC	GS	Nucleotide-binding oligomerization domain containing 1	CARD4; NLRC1; CLR7.1; NOD1	5	Multiple SNPs	19587002	Loos BG, Fiebig A, Nothnagel M, Jepsen S, Groessner-Schreiber B, Franke A, Jervøe-Storm PM, Schenck K, van der Velden U, Schreiber S. NOD1 gene polymorphisms in relation to aggressive periodontitis. Innate Immun. 2009 Aug;15(4):225-32. Epub 2009 Jul 8.
NOD1	AgP	415	1289	ns	None	Caucasian	CC	GS	Nucleotide-binding oligomerization domain containing 1	CARD4; NLRC1; CLR7.1; NOD1	5	Haplotype	19587002	Loos BG, Fiebig A, Nothnagel M, Jepsen S, Groessner-Schreiber B, Franke A, Jervøe-Storm PM, Schenck K, van der Velden U, Schreiber S. NOD1 gene polymorphisms in relation to aggressive periodontitis. Innate Immun. 2009 Aug;15(4):225-32. Epub 2009 Jul 8.

Continued

TABLE 6-3 Association Study—cont'd

Gene Symbol	Disease Type	Cases	Total	Best *P* Value	Level of Support	Population	Study Design	Stratified or Covariate Adj	Gene Name	Gene Aliases	# SNPs Assayed	SNP Name	PubMed ID	Journal
NOD2	CP	104	201	ns	None	Dutch	CC	PS	Nucleotide-binding oligomerization domain containing 2	CD; ACUG; BLAU; IBD1; NLRC2; NOD2B; CARD15; CLR16.3; PSORAS1; NOD2	2	Multiple SNPs	15367194	Laine ML, Murillo LS, Morré SA, Winkel EG, Peña AS, van Winkelhoff AJ. CARD15 gene mutations in periodontitis. J Clin Periodontol. 2004 Oct;31(10):890-3.
NOD2	CP	80	202	ns	None	Caucasian	CC	N	Nucleotide-binding oligomerization domain containing 2	CD; ACUG; BLAU; IBD1; NLRC2; NOD2B; CARD15; CLR16.3; PSORAS1; NOD2	1	3020insC	15279649	Folwaczny M, Glas J, Török HP, Mauermann D, Folwaczny C. The 3020insC mutation of the NOD2/CARD15 gene in patients with periodontal disease. Eur J Oral Sci. 2004 Aug;112(4):316-9.
NOS1	CP	22	41	ns	None	Japanese	CC	N	Nitric oxide synthase 1 (neuronal)	NOS; nNOS; IHPS1; NOS1	1	n/a	15490304	Suzuki A, Ji G, Numabe Y, Ishii K, Muramatsu M, Kamoi K. Large-scale investigation of genomic markers for severe periodontitis. Odontology. 2004 Sep;92(1):43-7.
NOS2	CP	22	41	ns	None	Japanese	CC	N	Nitric oxide synthase 2, inducible	NOS; INOS; NOS2A; HEP-NOS; NOS2	2	Multiple SNPs	15490304	Suzuki A, Ji G, Numabe Y, Ishii K, Muramatsu M, Kamoi K. Large-scale investigation of genomic markers for severe periodontitis. Odontology. 2004 Sep;92(1):43-7.
NOS3	AgP	48	221	0.015	Weak	Turkish	CC	N	Nitric oxide synthase 3 (endothelial cell)	eNOS; ECNOS; NOS3	1	Glu298Asp	16881803	Berdeli A, Gürkan A, Emingil G, Atilla G, Köse T. Endothelial nitric oxide synthase Glu298Asp gene polymorphism in periodontal diseases. J Periodontol. 2006 Aug;77(8):1348-54.
NOS3	CP	51	224	0.038	Weak	Turkish	CC	N	Nitric oxide synthase 3 (endothelial cell)	eNOS; ECNOS; NOS3	1	Glu298Asp	16881803	Berdeli A, Gürkan A, Emingil G, Atilla G, Köse T. Endothelial nitric oxide synthase Glu298Asp gene polymorphism in periodontal diseases. J Periodontol. 2006 Aug;77(8):1348-54.
NOTCH3	CP	22	41	ns	None	Japanese	CC	N	Notch homolog 3 (Drosophila)	CASIL; CADASIL; NOTCH3	1	n/a	15490304	Suzuki A, Ji G, Numabe Y, Ishii K, Muramatsu M, Kamoi K. Large-scale investigation of genomic markers for severe periodontitis. Odontology. 2004 Sep;92(1):43-7.

NOTCH4	CP	22	41	ns	None	Japanese	CC	N	Notch homolog 4 (Drosophila)	INT3; NOTCH3; FLJ16302; MGC74442; NOTCH4	2	Multiple SNPs	15490304	Suzuki A, Ji G, Numabe Y, Ishii K, Muramatsu M, Kamoi K. Large-scale investigation of genomic markers for severe periodontitis. Odontology. 2004 Sep;92(1):43-7.
NOX1	CP	22	41	ns	None	Japanese	CC	N	NADPH oxidase 1	MOX1; NOH1; NOH-1; GP91-2; NOX1	1	n/a	15490304	Suzuki A, Ji G, Numabe Y, Ishii K, Muramatsu M, Kamoi K. Large-scale investigation of genomic markers for severe periodontitis. Odontology. 2004 Sep;92(1):43-7.
NOX3	CP	22	41	ns	None	Japanese	CC	N	NADPH oxidase 3	GP91-3; NOX3	6	Multiple SNPs	15490304	Suzuki A, Ji G, Numabe Y, Ishii K, Muramatsu M, Kamoi K. Large-scale investigation of genomic markers for severe periodontitis. Odontology. 2004 Sep;92(1):43-7.
NPY	CP	22	41	ns	None	Japanese	CC	N	Neuropeptide Y	PYY4; NPY	1	n/a	15490304	Suzuki A, Ji G, Numabe Y, Ishii K, Muramatsu M, Kamoi K. Large-scale investigation of genomic markers for severe periodontitis. Odontology. 2004 Sep;92(1):43-7.
OAS3	CP	22	41	ns	None	Japanese	CC	N	2′-5′-Oligoadenylate synthetase 3, 100kDa	p100; MGC133260; OAS3	1	n/a	15490304	Suzuki A, Ji G, Numabe Y, Ishii K, Muramatsu M, Kamoi K. Large-scale investigation of genomic markers for severe periodontitis. Odontology. 2004 Sep;92(1):43-7.
OAT	CP	22	41	ns	None	Japanese	CC	N	Ornithine aminotransferase (gyrate atrophy)	HOGA; DKFZp781A11155; OAT	2	Multiple SNPs	15490304	Suzuki A, Ji G, Numabe Y, Ishii K, Muramatsu M, Kamoi K. Large-scale investigation of genomic markers for severe periodontitis. Odontology. 2004 Sep;92(1):43-7.
OPRM1	CP	22	41	ns	None	Japanese	CC	N	Opioid receptor, mu 1	MOR; LMOR; MOR1; OPRM; KIAA0403; OPRM1	1	n/a	15490304	Suzuki A, Ji G, Numabe Y, Ishii K, Muramatsu M, Kamoi K. Large-scale investigation of genomic markers for severe periodontitis. Odontology. 2004 Sep;92(1):43-7.
OSMR	CP	22	41	ns	None	Japanese	CC	N	Oncostatin M receptor	OSMRB; MGC75127; MGC150626; MGC150627; OSMR	1	n/a	15490304	Suzuki A, Ji G, Numabe Y, Ishii K, Muramatsu M, Kamoi K. Large-scale investigation of genomic markers for severe periodontitis. Odontology. 2004 Sep;92(1):43-7.

Continued

TABLE 6-3 Association Study—cont'd

Gene Symbol	Disease Type	Cases	Total	Best *P* Value	Level of Support	Population	Study Design	Stratified or Covariate Adj	Gene Name	Gene Aliases	# SNPs Assayed	SNP Name	PubMed ID	Journal
OTC	CP	22	41	ns	None	Japanese	CC	N	Ornithine carbamoyltransferase	OCTD; MGC129967; MGC129968; MGC138856; OTC	1	n/a	15490304	Suzuki A, Ji G, Numabe Y, Ishii K, Muramatsu M, Kamoi K. Large-scale investigation of genomic markers for severe periodontitis. Odontology. 2004 Sep;92(1):43-7.
P2RX7	CP	22	41	ns	None	Japanese	CC	N	Purinergic receptor P2X, ligand-gated ion channel, 7	P2X7; MGC20089; P2RX7	1	n/a	15490304	Suzuki A, Ji G, Numabe Y, Ishii K, Muramatsu M, Kamoi K. Large-scale investigation of genomic markers for severe periodontitis. Odontology. 2004 Sep;92(1):43-7.
P4HB	AgP+CP	251	376	ns	None	Japanese	CC	N	Prolyl 4-hydroxylase, beta polypeptide	DSI; GIT; PDI; PHDB; PDIA1; PO4DB; PO4HB; PROHB; ERBA2L; P4Hbeta; P4HB	n/a	n/a	15081423	Suzuki A, Ji G, Numabe Y, Muramatsu M, Gomi K, Kanazashi M, Ogata Y, Shimizu E, Shibukawa Y, Ito A, Ito T, Sugaya A, Arai T, Yamada S, Deguchi S, Kamoi K. Single nucleotide polymorphisms associated with aggressive periodontitis and severe chronic periodontitis in Japanese. Biochem Biophys Res Commun. 2004 May 7;317(3):887-92.
PCK1	CP	22	41	ns	None	Japanese	CC	N	Phosphoenolpyruvate carboxykinase 1 (soluble)	PEPCK1; PEPCKC; PEPCK-C; MGC22652; PCK1	4	Multiple SNPs	15490304	Suzuki A, Ji G, Numabe Y, Ishii K, Muramatsu M, Kamoi K. Large-scale investigation of genomic markers for severe periodontitis. Odontology. 2004 Sep;92(1):43-7.
PCK2	CP	22	41	ns	None	Japanese	CC	N	Phosphoenolpyruvate carboxykinase 2 (mitochondrial)	PEPCK; PEPCK2; PEPCK-M; PCK2	3	Multiple SNPs	15490304	Suzuki A, Ji G, Numabe Y, Ishii K, Muramatsu M, Kamoi K. Large-scale investigation of genomic markers for severe periodontitis. Odontology. 2004 Sep;92(1):43-7.
PCSK1	CP	22	41	ns	None	Japanese	CC	N	Proprotein convertase subtilisin/kexin type 1	PC1; PC3; NEC1; SPC3; BMIQ12; PCSK1	1	n/a	15490304	Suzuki A, Ji G, Numabe Y, Ishii K, Muramatsu M, Kamoi K. Large-scale investigation of genomic markers for severe periodontitis. Odontology. 2004 Sep;92(1):43-7.

PCSK2	CP	22	41	ns	None	Japanese	CC	N	Proprotein convertase subtilisin/ kexin type 2	PC2; NEC2; SPC2; PCSK2	13	Multiple SNPs	15490304	Suzuki A, Ji G, Numabe Y, Ishii K, Muramatsu M, Kamoi K. Large-scale investigation of genomic markers for severe periodontitis. Odontology. 2004 Sep;92(1):43-7.
PCSK6	CP	22	41	ns	None	Japanese	CC	N	Proprotein convertase subtilisin/ kexin type 6	SPC4; PACE4; PCSK6	1	n/a	15490304	Suzuki A, Ji G, Numabe Y, Ishii K, Muramatsu M, Kamoi K. Large-scale investigation of genomic markers for severe periodontitis. Odontology. 2004 Sep;92(1):43-7.
PFKL	CP	22	41	ns	None	Japanese	CC	N	Phosphofructokinase, liver	PFK-B; FLJ30173; FLJ40909; DKFZp686G1648; DKFZp686L2097; PFKL	3	Multiple SNPs	15490304	Suzuki A, Ji G, Numabe Y, Ishii K, Muramatsu M, Kamoi K. Large-scale investigation of genomic markers for severe periodontitis. Odontology. 2004 Sep;92(1):43-7.
PFLM	CP	22	41	ns	None	Japanese	CC	N	n/a	n/a	1	n/a	15490304	Suzuki A, Ji G, Numabe Y, Ishii K, Muramatsu M, Kamoi K. Large-scale investigation of genomic markers for severe periodontitis. Odontology. 2004 Sep;92(1):43-7.
PGAM1	CP	22	41	ns	None	Japanese	CC	N	Phosphoglycerate mutase 1 (brain)	PGAM-B; PGAMA; PGAM1	1	n/a	15490304	Suzuki A, Ji G, Numabe Y, Ishii K, Muramatsu M, Kamoi K. Large-scale investigation of genomic markers for severe periodontitis. Odontology. 2004 Sep;92(1):43-7.
PIK3R1	CP	22	41	0.0026	Weak	Japanese	CC	N	Phosphoinositide-3-kinase, regulatory subunit 1 (alpha)	p85; GRB1; p85-ALPHA; PIK3R1	3	IMS-JST013201	15490304	Suzuki A, Ji G, Numabe Y, Ishii K, Muramatsu M, Kamoi K. Large-scale investigation of genomic markers for severe periodontitis. Odontology. 2004 Sep;92(1):43-7.
PKD1	CP	22	41	ns	None	Japanese	CC	N	Polycystic kidney disease 1 (autosomal dominant)	PBP; Pc-1; PKD1	2	Multiple SNPs	15490304	Suzuki A, Ji G, Numabe Y, Ishii K, Muramatsu M, Kamoi K. Large-scale investigation of genomic markers for severe periodontitis. Odontology. 2004 Sep;92(1):43-7.
PLAGL1	CP	22	41	ns	None	Japanese	CC	N	Pleiomorphic adenoma gene-like 1	ZAC; LOT1; ZAC1; MGC126275; MGC126276; DKFZp781P1017; PLAGL1	5	Multiple SNPs	15490304	Suzuki A, Ji G, Numabe Y, Ishii K, Muramatsu M, Kamoi K. Large-scale investigation of genomic markers for severe periodontitis. Odontology. 2004 Sep;92(1):43-7.

Continued

TABLE 6-3 Association Study—cont'd

Gene Symbol	Disease Type	Cases	Total	Best *P* Value	Level of Support	Population	Study Design	Stratified or Covariate Adj	Gene Name	Gene Aliases	# SNPs Assayed	SNP Name	PubMed ID	Journal
PLAT	AgP	90	244	0.044	Weak	Turkish	CC	N	Plasminogen activator, tissue	TPA; T-PA; DKFZp686I03148; PLAT	1	Intron 8 I/D	17257155	Emingil G, Berdeli A, Gürkan A, Han Saygan B, Köse T, Atilla G. Gene polymorphisms of tissue plasminogen activator and plasminogen activator inhibitor-1 in Turkish patients with generalized aggressive periodontitis. J Clin Periodontol. 2007 Apr;34(4):278-84. Epub 2007 Jan 25.
PLAT	CP	84	189	ns	None	Turkish	CC	N	Plasminogen activator, tissue	TPA; T-PA; DKFZp686I03148; PLAT	1	Alu-repeat	17608581	Gürkan A, Emingil G, Saygan BH, Cinarcik S, Atilla G, Köse T, Berdeli A. Tissue plasminogen activator and plasminogen activator inhibitor-1 gene polymorphisms in patients with chronic periodontitis. J Periodontol. 2007 Jul;78(7):1256-63.
PLAT	CP	22	41	ns	None	Japanese	CC	N	Plasminogen activator, tissue	TPA; T-PA; DKFZp686I03148; PLAT	5	Multiple SNPs	15490304	Suzuki A, Ji G, Numabe Y, Ishii K, Muramatsu M, Kamoi K. Large-scale investigation of genomic markers for severe periodontitis. Odontology. 2004 Sep;92(1):43-7.
PLAU	CP	n/a	77	0.004	Weak	Mixed	Quan	DS	Plasminogen activator, urokinase	ATF, UPA, URK, u-PA	1	BamHI	17559626	DeCarlo AA, Grenett H, Park J, Balton W, Cohen J, Hardigan P. Association of gene polymorphisms for plasminogen activators with alveolar bone loss. J Periodontal Res. 2007 Aug;42(4):305-10.
PLCG1	CP	22	41	ns	None	Japanese	CC	N	Phospholipase C, gamma 1	PLC1; NCKAP3; PLC-II; PLC148; PLCgamma1; PLCG1	3	Multiple SNPs	15490304	Suzuki A, Ji G, Numabe Y, Ishii K, Muramatsu M, Kamoi K. Large-scale investigation of genomic markers for severe periodontitis. Odontology. 2004 Sep;92(1):43-7.
PLG	CP	22	41	ns	None	Japanese	CC	N	Plasminogen	DKFZp779M0222; PLG	2	Multiple SNPs	15490304	Suzuki A, Ji G, Numabe Y, Ishii K, Muramatsu M, Kamoi K. Large-scale investigation of genomic markers for severe periodontitis. Odontology. 2004 Sep;92(1):43-7.

PLOD1	AgP+CP	251	376	ns	None	Japanese	CC	N	Procollagen-lysine 1, 2-oxoglutarate 5-dioxygenase 1	LH; LH1; LLH; PLOD; FLJ42041; PLOD1	n/a	n/a	15081423	Suzuki A, Ji G, Numabe Y, Muramatsu M, Gomi K, Kanazashi M, Ogata Y, Shimizu E, Shibukawa Y, Ito A, Ito T, Sugaya A, Arai T, Yamada S, Deguchi S, Kamoi K. Single nucleotide polymorphisms associated with aggressive periodontitis and severe chronic periodontitis in Japanese. Biochem Biophys Res Commun. 2004 May 7;317(3):887-92.
PLOD2	AgP+CP	251	376	ns	None	Japanese	CC	N	Procollagen-lysine, 2-oxoglutarate 5-dioxygenase 2	LH2; TLH; PLOD2	n/a	n/a	15081423	Suzuki A, Ji G, Numabe Y, Muramatsu M, Gomi K, Kanazashi M, Ogata Y, Shimizu E, Shibukawa Y, Ito A, Ito T, Sugaya A, Arai T, Yamada S, Deguchi S, Kamoi K. Single nucleotide polymorphisms associated with aggressive periodontitis and severe chronic periodontitis in Japanese. Biochem Biophys Res Commun. 2004 May 7;317(3):887-92.
POMC	CP	22	41	ns	None	Japanese	CC	N	Proopiomelanocortin	LPH; MSH; NPP; POC; ACTH; CLIP; POMC	1	n/a	15490304	Suzuki A, Ji G, Numabe Y, Ishii K, Muramatsu M, Kamoi K. Large-scale investigation of genomic markers for severe periodontitis. Odontology. 2004 Sep;92(1):43-7.
PON1	CP	22	41	ns	None	Japanese	CC	N	Paraoxonase 1	ESA; PON; MVCD5; PON1	8	Multiple SNPs	15490304	Suzuki A, Ji G, Numabe Y, Ishii K, Muramatsu M, Kamoi K. Large-scale investigation of genomic markers for severe periodontitis. Odontology. 2004 Sep;92(1):43-7.
PON1	CP	n/a	104	sig	Weak	Turkish	Quan	N	Paraoxonase 1	ESA; PON; MVCD5; PON1	4	55	19003935	Unür M, Demirez E, Agaçhan B, Görmüs U, Ergen A, Dalan B, Isbir T. The relationship of oral disturbances of diabetes mellitus patients with paraoxonase gene polymorphisms. Cell Biochem Funct. 2008 Dec;26(8):870-3.
PON2	CP	22	41	ns	None	Japanese	CC	N	Paraoxonase 2	PON2	5	Multiple SNPs	15490304	Suzuki A, Ji G, Numabe Y, Ishii K, Muramatsu M, Kamoi K. Large-scale investigation of genomic markers for severe periodontitis. Odontology. 2004 Sep;92(1):43-7.

Continued

TABLE 6-3 Association Study—cont'd

Gene Symbol	Disease Type	Cases	Total	Best *P* Value	Level of Support	Population	Study Design	Stratified or Covariate Adj	Gene Name	Gene Aliases	# SNPs Assayed	SNP Name	PubMed ID	Journal
PON3	CP	22	41	ns	None	Japanese	CC	N	Paraoxonase 3	PON3	3	Multiple SNPs	15490304	Suzuki A, Ji G, Numabe Y, Ishii K, Muramatsu M, Kamoi K. Large-scale investigation of genomic markers for severe periodontitis. Odontology. 2004 Sep;92(1):43-7.
POSTN	AgP	98	186	ns	None	Japanese	CC	N	Periostin, osteoblast specific factor	PN; OSF2; OSF-2; PDLPOSTN; MGC119510; MGC119511; periostin; RP11-412K4.1; POSTN	1	rs2274082	16844084	Rabello D, Soedarsono N, Kamei H, Ishihara Y, Noguchi T, Fuma D, Suzuki M, Sakaki Y, Yamaguchi A, Kojima T. CSF1 gene associated with aggressive periodontitis in the Japanese population. Biochem Biophys Res Commun. 2006 Sep 1;347(3):791-6. Epub 2006 Jul 7.
PPARA	CP	22	41	ns	None	Japanese	CC	N	Peroxisome proliferator-activated receptor alpha	PPAR; NR1C1; hPPAR; MGC2237; MGC2452; PPARA	1	n/a	15490304	Suzuki A, Ji G, Numabe Y, Ishii K, Muramatsu M, Kamoi K. Large-scale investigation of genomic markers for severe periodontitis. Odontology. 2004 Sep;92(1):43-7.
PPARD	CP	22	41	ns	None	Japanese	CC	N	Peroxisome proliferator-activated receptor delta	FAAR; NUC1; NUCI; NR1C2; NUCII; PPARB; MGC3931; PPAR-beta; PPARD	5	Multiple SNPs	15490304	Suzuki A, Ji G, Numabe Y, Ishii K, Muramatsu M, Kamoi K. Large-scale investigation of genomic markers for severe periodontitis. Odontology. 2004 Sep;92(1):43-7.
PPARGC1A	CP	22	41	ns	None	Japanese	CC	N	Peroxisome proliferator-activated receptor gamma, coactivator 1 alpha	LEM6; PGC1; PGC1A; PGC-1v; PPARGC1; PGC-1(alpha); PPARGC1A	2	Multiple SNPs	15490304	Suzuki A, Ji G, Numabe Y, Ishii K, Muramatsu M, Kamoi K. Large-scale investigation of genomic markers for severe periodontitis. Odontology. 2004 Sep;92(1):43-7.
PRG4	AgP+CP	251	376	ns	None	Japanese	CC	N	Proteoglycan 4	MSF; SZP; CACP; HAPO; JCAP; FLJ32635; bG174L6.2; PRG4	n/a	n/a	15081423	Suzuki A, Ji G, Numabe Y, Muramatsu M, Gomi K, Kanazashi M, Ogata Y, Shimizu E, Shibukawa Y, Ito A, Ito T, Sugaya A, Arai T, Yamada S, Deguchi S, Kamoi K. Single nucleotide polymorphisms associated with aggressive periodontitis and severe chronic periodontitis in Japanese. Biochem Biophys Res Commun. 2004 May 7;317(3):887-92.

PRKCB	CP	22	41	ns	None	Japanese	CC	N	Protein kinase C, beta	PKCB; PRKCB1; PRKCB2; MGC41878; PKC-beta; PRKCB	8	Multiple SNPs	15490304	Suzuki A, Ji G, Numabe Y, Ishii K, Muramatsu M, Kamoi K. Large-scale investigation of genomic markers for severe periodontitis. Odontology. 2004 Sep;92(1):43-7.
PRL	CP	22	41	ns	None	Japanese	CC	N	Prolactin	PRL	3	Multiple SNPs	15490304	Suzuki A, Ji G, Numabe Y, Ishii K, Muramatsu M, Kamoi K. Large-scale investigation of genomic markers for severe periodontitis. Odontology. 2004 Sep;92(1):43-7.
PRODH	CP	22	41	ns	None	Japanese	CC	N	Proline dehydrogenase (oxidase) 1	POX; PIG6; SCZD4; HSPOX2; PRODH1; PRODH2; TP53I6; FLJ33744; MGC148078; MGC148079; PRODH	1	n/a	15490304	Suzuki A, Ji G, Numabe Y, Ishii K, Muramatsu M, Kamoi K. Large-scale investigation of genomic markers for severe periodontitis. Odontology. 2004 Sep;92(1):43-7.
PSD4	AgP	40	136	ns	None	Caucasian	CC	N	Pleckstrin and Sec7 domain containing 4	TIC; EFA6B; FLJ36237; FLJ37279; PSD4	1	n/a	15602586	Scapoli C, Trombelli L, Mamolini E, Collins A. Linkage disequilibrium analysis of case-control data: an application to generalized aggressive periodontitis. Genes Immun. 2005 Feb;6(1):44-52.
PSMB9	CP	22	41	ns	None	Japanese	CC	N	Proteasome (prosome, macropain) subunit, beta type, 9 (large multifunctional peptidase 2)	LMP2; PSMB6i; RING12; beta1i; MGC70470; PSMB9	1	n/a	15490304	Suzuki A, Ji G, Numabe Y, Ishii K, Muramatsu M, Kamoi K. Large-scale investigation of genomic markers for severe periodontitis. Odontology. 2004 Sep;92(1):43-7.
PSMD5	CP	22	41	ns	None	Japanese	CC	N	Proteasome (prosome, macropain) 26S subunit, non-ATPase, 5	S5B; KIAA0072; MGC23145; PSMD5	1	n/a	15490304	Suzuki A, Ji G, Numabe Y, Ishii K, Muramatsu M, Kamoi K. Large-scale investigation of genomic markers for severe periodontitis. Odontology. 2004 Sep;92(1):43-7.
PSMF1	CP	22	41	ns	None	Japanese	CC	N	Proteasome (prosome, macropain) inhibitor subunit 1 (PI31)	PI31; PSMF1	1	n/a	15490304	Suzuki A, Ji G, Numabe Y, Ishii K, Muramatsu M, Kamoi K. Large-scale investigation of genomic markers for severe periodontitis. Odontology. 2004 Sep;92(1):43-7.

Continued

TABLE 6-3 Association Study—cont'd

Gene Symbol	Disease Type	Cases	Total	Best *P* Value	Level of Support	Population	Study Design	Stratified or Covariate Adj	Gene Name	Gene Aliases	# SNPs Assayed	SNP Name	PubMed ID	Journal
PTGDS	AgP+CP	251	376	0.006	Weak	Japanese	CC	N	Prostaglandin D2 synthase 21kDa (brain)	PDS; PGD2; PGDS; LPGDS; PGDS2; L-PGDS; PTGDS	n/a	Chr:9 A/G	15081423	Suzuki A, Ji G, Numabe Y, Muramatsu M, Gomi K, Kanazashi M, Ogata Y, Shimizu E, Shibukawa Y, Ito A, Ito T, Sugaya A, Arai T, Yamada S, Deguchi S, Kamoi K. Single nucleotide polymorphisms associated with aggressive periodontitis and severe chronic periodontitis in Japanese. Biochem Biophys Res Commun. 2004 May 7;317(3):887-92.
PTGER1	AgP+CP	251	376	ns	None	Japanese	CC	N	Prostaglandin E receptor 1 (subtype EP1), 42kDa	EP1; PTGER1	n/a	n/a	15081423	Suzuki A, Ji G, Numabe Y, Muramatsu M, Gomi K, Kanazashi M, Ogata Y, Shimizu E, Shibukawa Y, Ito A, Ito T, Sugaya A, Arai T, Yamada S, Deguchi S, Kamoi K. Single nucleotide polymorphisms associated with aggressive periodontitis and severe chronic periodontitis in Japanese. Biochem Biophys Res Commun. 2004 May 7;317(3):887-92.
PTGER2	AgP+CP	251	376	ns	None	Japanese	CC	N	Prostaglandin E receptor 2 (subtype EP2), 53kDa	EP2; PTGER2	n/a	n/a	15081423	Suzuki A, Ji G, Numabe Y, Muramatsu M, Gomi K, Kanazashi M, Ogata Y, Shimizu E, Shibukawa Y, Ito A, Ito T, Sugaya A, Arai T, Yamada S, Deguchi S, Kamoi K. Single nucleotide polymorphisms associated with aggressive periodontitis and severe chronic periodontitis in Japanese. Biochem Biophys Res Commun. 2004 May 7;317(3):887-92.

PTGER3	AgP+CP	251	376	ns	None	Japanese	CC	N	Prostaglandin E receptor 3 (subtype EP3)	EP3; EP3e; EP3-I; EP3-II; EP3-IV; EP3-III; MGC27302; MGC141828; MGC141829; PTGER3	n/a	n/a	15081423	Suzuki A, Ji G, Numabe Y, Muramatsu M, Gomi K, Kanazashi M, Ogata Y, Shimizu E, Shibukawa Y, Ito A, Ito T, Sugaya A, Arai T, Yamada S, Deguchi S, Kamoi K. Single nucleotide polymorphisms associated with aggressive periodontitis and severe chronic periodontitis in Japanese. Biochem Biophys Res Commun. 2004 May 7;317(3):887-92.
PTGES	AgP+CP	251	376	ns	None	Japanese	CC	N	Prostaglandin E synthase	PGES; MPGES; PIG12; PP102; PP1294; MGST-IV; MGST1L1; TP53I12; mPGES-1; MGC10317; MGST1-L1; PTGES	n/a	n/a	15081423	Suzuki A, Ji G, Numabe Y, Muramatsu M, Gomi K, Kanazashi M, Ogata Y, Shimizu E, Shibukawa Y, Ito A, Ito T, Sugaya A, Arai T, Yamada S, Deguchi S, Kamoi K. Single nucleotide polymorphisms associated with aggressive periodontitis and severe chronic periodontitis in Japanese. Biochem Biophys Res Commun. 2004 May 7;317(3):887-92.
PTGFR	AgP+CP	251	376	ns	None	Japanese	CC	N	Prostaglandin F receptor (FP)	FP; MGC46203; MGC120498; PTGFR	n/a	n/a	15081423	Suzuki A, Ji G, Numabe Y, Muramatsu M, Gomi K, Kanazashi M, Ogata Y, Shimizu E, Shibukawa Y, Ito A, Ito T, Sugaya A, Arai T, Yamada S, Deguchi S, Kamoi K. Single nucleotide polymorphisms associated with aggressive periodontitis and severe chronic periodontitis in Japanese. Biochem Biophys Res Commun. 2004 May 7;317(3):887-92.
PTGIR	AgP+CP	251	376	ns	None	Japanese	CC	N	Prostaglandin I2 (Prostacyclin) receptor (IP)	IP; PRIPR; MGC102830; PTGIR	n/a	n/a	15081423	Suzuki A, Ji G, Numabe Y, Muramatsu M, Gomi K, Kanazashi M, Ogata Y, Shimizu E, Shibukawa Y, Ito A, Ito T, Sugaya A, Arai T, Yamada S, Deguchi S, Kamoi K. Single nucleotide polymorphisms associated with aggressive periodontitis and severe chronic periodontitis in Japanese. Biochem Biophys Res Commun. 2004 May 7;317(3):887-92.

Continued

TABLE 6-3 Association Study—cont'd

Gene Symbol	Disease Type	Cases	Total	Best *P* Value	Level of Support	Population	Study Design	Stratified or Covariate Adj	Gene Name	Gene Aliases	# SNPs Assayed	SNP Name	PubMed ID	Journal
PTGS2	AgP	85	238	<0.0001	Moderate	Taiwanese	CC	AGS	Prostaglandin-endoperoxide synthase 2 (Prostaglandin G/H synthase and cyclooxygenase)	COX2; COX-2; PHS-2; PGG/HS; PGHS-2; hCox-2; GRIPGHS; PTGS2	1	–765	18173398	Ho YP, Lin YC, Yang YH, Ho KY, Wu YM, Tsai CC. Cyclooxygenase-2 Gene-765 single nucleotide polymorphism as a protective factor against periodontitis in Taiwanese. J Clin Periodontol. 2008 Jan;35(1): 1-8.
PTGS2	CP	148	294	0.005	Weak	Chinese	CC	AGS	Prostaglandin-endoperoxide synthase 2 (Prostaglandin G/H synthase and cyclooxygenase)	COX2; COX-2; PHS-2; PGG/HS; PGHS-2; hCox-2; GRIPGHS; PTGS2	3	–1195GA	19236532	Xie CJ, Xiao LM, Fan WH, Xuan DY, Zhang JC. Common single nucleotide polymorphisms in cyclooxygenase-2 and risk of severe chronic periodontitis in a Chinese population. J Clin Periodontol. 2009 Mar;36(3):198-203.
PTGS2	CP	343	496	0.006	Weak	Taiwanese	CC	AGS	Prostaglandin-endoperoxide synthase 2 (Prostaglandin G/H synthase and cyclooxygenase)	COX2; COX-2; PHS-2; PGG/HS; PGHS-2; hCox-2; GRIPGHS; PTGS2	1	–765	18173398	Ho YP, Lin YC, Yang YH, Ho KY, Wu YM, Tsai CC. Cyclooxygenase-2 Gene-765 single nucleotide polymorphism as a protective factor against periodontitis in Taiwanese. J Clin Periodontol. 2008 Jan;35(1): 1-8.
PTGS2	CP	148	294	<0.001	Moderate	Chinese	CC	N	Prostaglandin-endoperoxide synthase 2 (Prostaglandin G/H synthase and cyclooxygenase)	COX2; COX-2; PHS-2; PGG/HS; PGHS-2; hCox-2; GRIPGHS; PTGS2	3	Haplotype	19236532	Xie CJ, Xiao LM, Fan WH, Xuan DY, Zhang JC. Common single nucleotide polymorphisms in cyclooxygenase-2 and risk of severe chronic periodontitis in a Chinese population. J Clin Periodontol. 2009 Mar;36(3):198-203.
PTH1R	CP	22	41	ns	None	Japanese	CC	N	Parathyroid hormone 1 receptor	PFE; PTHR; PTHR1; MGC138426; MGC138452; PTH1R	3	Multiple SNPs	15490304	Suzuki A, Ji G, Numabe Y, Ishii K, Muramatsu M, Kamoi K. Large-scale investigation of genomic markers for severe periodontitis. Odontology. 2004 Sep;92(1):43-7.
PTPRH	CP	22	41	ns	None	Japanese	CC	N	Protein tyrosine phosphatase, receptor type, H	SAP1; FLJ39938; MGC133058; MGC133059; PTPRH	4	Multiple SNPs	15490304	Suzuki A, Ji G, Numabe Y, Ishii K, Muramatsu M, Kamoi K. Large-scale investigation of genomic markers for severe periodontitis. Odontology. 2004 Sep;92(1):43-7.

RENBP	CP	22	41	ns	None	Japanese	CC	N	Renin binding protein	RBP; RNBP; RENBP	3	Multiple SNPs	15490304	Suzuki A, Ji G, Numabe Y, Ishii K, Muramatsu M, Kamoi K. Large-scale investigation of genomic markers for severe periodontitis. Odontology. 2004 Sep;92(1):43-7.
RPSA	AgP+CP	251	376	ns	None	Japanese	CC	N	Ribosomal protein SA	LRP; p40; 67LR; 37LRP; LAMBR; LAMR1; RPSA	n/a	n/a	15081423	Suzuki A, Ji G, Numabe Y, Muramatsu M, Gomi K, Kanazashi M, Ogata Y, Shimizu E, Shibukawa Y, Ito A, Ito T, Sugaya A, Arai T, Yamada S, Deguchi S, Kamoi K. Single nucleotide polymorphisms associated with aggressive periodontitis and severe chronic periodontitis in Japanese. Biochem Biophys Res Commun. 2004 May 7;317(3):887-92.
S100A8	AgP	70	321	0.009	Weak	Chinese	CC	G	S100 calcium binding protein A8	P8; MIF; NIF; CAGA; CFAG; CGLA; L1Ag; MRP8; CP-10; MA387; 60B8AG; S100A8	3	rs3806232	17069562	Li Q, Meng H, Zhang L, Xu L, Chen Z, Shi D, Feng X, Zhu X, Zhao H, Cao C. Correlation between single nucleotide polymorphisms in a calprotectin subunit gene and risk of periodontitis in a Chinese population. Ann Hum Genet. 2007 May;71(Pt 3):312-24. Epub 2006 Oct 27.
S100A8	AgP	30	108	0.039	Weak	Chinese	Fam	G	S100 calcium binding protein A8	P8; MIF; NIF; CAGA; CFAG; CGLA; L1Ag; MRP8; CP-10; MA387; 60B8AG; S100A8	2	rs3795391	19210342	Ren XY, Xu L, Meng HX, Zhao HS, Lu RF, Chen ZB, Feng XH, Shi D, Zhang L, Tian Y. Family-based association analysis of S100A8 genetic polymorphisms with aggressive periodontitis. J Periodontal Res. 2009 Apr;44(2):184-92. Epub 2009 Feb 6.
S100A8	AgP	30	58	ns	None	Chinese	CC	N	S100 calcium binding protein A8	P8; MIF; NIF; CAGA; CFAG; CGLA; L1Ag; MRP8; CP-10; MA387; 60B8AG; S100A8	1	n/a	15196380	Li QY, Zhao HS, Meng HX, Zhang L, Xu L, Chen ZB. [The relationship between a nucleotide substitution of S100A8 gene and aggressive periodontitis]. Zhonghua Kou Qiang Yi Xue Za Zhi. 2004 May;39(3):181-4. Chinese.

Continued

TABLE 6-3 Association Study—cont'd

Gene Symbol	Disease Type	Cases	Total	Best *P* Value	Level of Support	Population	Study Design	Stratified or Covariate Adj	Gene Name	Gene Aliases	# SNPs Assayed	SNP Name	PubMed ID	Journal
S100A8	CP	150	321	0.008	Weak	Chinese	CC	G	S100 calcium binding protein A8	P8; MIF; NIF; CAGA; CFAG; CGLA; L1Ag; MRP8; CP-10; MA387; 60B8AG; S100A8	3	rs3795391	17069562	Li Q, Meng H, Zhang L, Xu L, Chen Z, Shi D, Feng X, Zhu X, Zhao H, Cao C. Correlation between single nucleotide polymorphisms in a calprotectin subunit gene and risk of periodontitis in a Chinese population. Ann Hum Genet. 2007 May;71(Pt 3):312-24. Epub 2006 Oct 27.
SCARB1	AgP+CP	251	376	ns	None	Japanese	CC	N	Scavenger receptor class B, member 1	CLA1; SRB1; CLA-1; SR-BI; CD36L1; MGC138242; SCARB1	n/a	n/a	15081423	Suzuki A, Ji G, Numabe Y, Muramatsu M, Gomi K, Kanazashi M, Ogata Y, Shimizu E, Shibukawa Y, Ito A, Ito T, Sugaya A, Arai T, Yamada S, Deguchi S, Kamoi K. Single nucleotide polymorphisms associated with aggressive periodontitis and severe chronic periodontitis in Japanese. Biochem Biophys Res Commun. 2004 May 7;317(3):887-92.
SCARB2	AgP+CP	251	376	ns	None	Japanese	CC	N	Scavenger receptor class B, member 2	AMRF; CD36L2; HLGP85; LIMPII; SR-BII; SCARB2	n/a	n/a	15081423	Suzuki A, Ji G, Numabe Y, Muramatsu M, Gomi K, Kanazashi M, Ogata Y, Shimizu E, Shibukawa Y, Ito A, Ito T, Sugaya A, Arai T, Yamada S, Deguchi S, Kamoi K. Single nucleotide polymorphisms associated with aggressive periodontitis and severe chronic periodontitis in Japanese. Biochem Biophys Res Commun. 2004 May 7;317(3):887-92.
SCARB2	CP	22	41	ns	None	Japanese	CC	N	Scavenger receptor class B, member 2	AMRF; CD36L2; HLGP85; LIMPII; SR-BII; SCARB2	2	Multiple SNPs	15490304	Suzuki A, Ji G, Numabe Y, Ishii K, Muramatsu M, Kamoi K. Large-scale investigation of genomic markers for severe periodontitis. Odontology. 2004 Sep;92(1):43-7.

SELE	AgP+CP	88	227	<0.0001	Moderate	Iranian	CC	N	Selectin E	ELAM; ESEL; CD62E; ELAM1; LECAM2; SELE	1	Ser128Arg	18973547	Houshmand B, Rafiei A, Hajilooi M, Mani-Kashani K, Gholami L. E-selectin and L-selectin polymorphisms in patients with periodontitis. J Periodontal Res. 2009 Feb;44(1):88-93. Epub 2008 Oct 7.
SELE	CP	22	41	ns	None	Japanese	CC	N	Selectin E	ELAM; ESEL; CD62E; ELAM1; LECAM2; SELE	1	n/a	15490304	Suzuki A, Ji G, Numabe Y, Ishii K, Muramatsu M, Kamoi K. Large-scale investigation of genomic markers for severe periodontitis. Odontology. 2004 Sep;92(1):43-7.
SELL	AgP+CP	88	227	ns	None	Iranian	CC	N	Selectin L	Q1; LAM1; LNHR; LSEL; CD62L; LAM-1; LYAM1; Leu-8; PLNHR; hLHRc; LECAM1; Lyam-1; SELL	1	Phe206Leu	18973547	Houshmand B, Rafiei A, Hajilooi M, Mani-Kashani K, Gholami L. E-selectin and L-selectin polymorphisms in patients with periodontitis. J Periodontal Res. 2009 Feb;44(1):88-93. Epub 2008 Oct 7.
SERPINA1	CP	50	150	0.01	Weak	n/a	CC	N	Serpin peptidase inhibitor, clade A (alpha-1 antiproteinase, antitrypsin), member 1	PI; A1A; AAT; PI1; A1AT; MGC9222; PRO2275; MGC23330; SERPINA1	1	Pi	310876	Peterson RJ, Marsh CL. The relationship of alpha1-antitrypsin to inflammatory periodontal disease. J Periodontol. 1979 Jan;50(1):31-5.
SERPINA1	CP	31	31	ns	None	Mixed	CC	N	Serpin peptidase inhibitor, clade A (alpha-1 antiproteinase, antitrypsin), member 1	PI; A1A; AAT; PI1; A1AT; MGC9222; PRO2275; MGC23330; SERPINA1	3	Multiple SNPs	12492914	Scott DA, von Ahsen N, Palmer RM, Wilson RF. Analysis of two common alpha 1-antitrypsin deficiency alleles (PI*Z and PI*S) in subjects with periodontitis. J Clin Periodontol. 2002 Dec;29(12):1118-21.
SERPINB6	CP	22	41	ns	None	Japanese	CC	N	Serpin peptidase inhibitor, clade B (ovalbumin), member 6	CAP; PI6; PTI; SPI3; MSTP057; MGC111370; DKFZp686I04222; SERPINB6	1	n/a	15490304	Suzuki A, Ji G, Numabe Y, Ishii K, Muramatsu M, Kamoi K. Large-scale investigation of genomic markers for severe periodontitis. Odontology. 2004 Sep;92(1):43-7.
SERPINE1	AgP	90	244	ns	None	Turkish	CC	N	Serpin peptidase inhibitor, clade E (nexin, plasminogen activator inhibitor type 1), member 1	PAI; PAI1; PAI-1; PLANH1; SERPINE1	1	4G/5G	17257155	Emingil G, Berdeli A, Gürkan A, Han Saygan B, Köse T, Atilla G. Gene polymorphisms of tissue plasminogen activator and plasminogen activator inhibitor-1 in Turkish patients with generalized aggressive periodontitis. J Clin Periodontol. 2007 Apr;34(4):278-84. Epub 2007 Jan 25.

Continued

TABLE 6-3 Association Study—cont'd

Gene Symbol	Disease Type	Cases	Total	Best *P* Value	Level of Support	Population	Study Design	Stratified or Covariate Adj	Gene Name	Gene Aliases	# SNPs Assayed	SNP Name	PubMed ID	Journal
SERPINE1	CP	116	304	0.00021	Moderate	Czech	CC	S	Serpin peptidase inhibitor, clade E (nexin, plasminogen activator inhibitor type 1), member 1	PAI; PAI1; PAI-1; PLANH1; SERPINE1	1	4G/5G	12140748	Izakovicová Hollá L, Bucková D, Fassmann A, Benes P, Znojil V. Plasminogen-activator-inhibitor-1 promoter polymorphism as a risk factor for adult periodontitis in non-smokers. Genes Immun. 2002 Aug;3(5):292-4.
SERPINE1	CP	n/a	77	0.005	Weak	Mixed	Quan	DS	Serpin peptidase inhibitor, clade E (nexin, plasminogen activator inhibitor type 1), member 1	PAI; PAI1; PAI-1; PLANH1; SERPINE1	1	HindIII	17559626	DeCarlo AA, Grenett H, Park J, Balton W, Cohen J, Hardigan P. Association of gene polymorphisms for plasminogen activators with alveolar bone loss. J Periodontal Res. 2007 Aug;42(4):305-10.
SERPINE1	CP	84	189	0.025	Weak	Turkish	CC	S	Serpin peptidase inhibitor, clade E (nexin, plasminogen activator inhibitor type 1), member 1	PAI; PAI1; PAI-1; PLANH1; SERPINE1	1	4G/5G	17608581	Gürkan A, Emingil G, Saygan BH, Cinarcik S, Atilla G, Köse T, Berdeli A. Tissue plasminogen activator and plasminogen activator inhibitor-1 gene polymorphisms in patients with chronic periodontitis. J Periodontol. 2007 Jul;78(7):1256-63.
SERPINF2	CP	22	41	ns	None	Japanese	CC	N	Serpin peptidase inhibitor, clade F (alpha-2 antiplasmin, pigment epithelium-derived factor), member 2	AAP; API; PLI; A2AP; ALPHA-2-PI; SERPINF2	2	Multiple SNPs	15490304	Suzuki A, Ji G, Numabe Y, Ishii K, Muramatsu M, Kamoi K. Large-scale investigation of genomic markers for severe periodontitis. Odontology. 2004 Sep;92(1):43-7.
SFTPD	CP	105	227	ns	None	German	CC	N	Surfactant protein D	SP-D; PSP-D; SFTP4; COLEC7; SFTPD	3	Multiple SNPs	18498293	Glas J, Beynon V, Bachstein B, Steckenbiller J, Manolis V, Euba A, Müller-Myhsok B, Folwaczny M. Increased plasma concentration of surfactant protein D in chronic periodontitis independent of SFTPD genotype: potential role as a biomarker. Tissue Antigens. 2008 Jul;72(1):21-8. Epub 2008 May 20.
SIC1A3	CP	22	41	ns	None	Japanese	CC	N	n/a	n/a	2	Multiple SNPs	15490304	Suzuki A, Ji G, Numabe Y, Ishii K, Muramatsu M, Kamoi K. Large-scale investigation of genomic markers for severe periodontitis. Odontology. 2004 Sep;92(1):43-7.

SIGLEC5	CP	22	41	ns	None	Japanese	CC	N	Sialic acid binding Ig-like lectin 5	CD170; OBBP2; CD33L2; OB-BP2; SIGLEC-5; SIGLEC5	1	n/a	15490304	Suzuki A, Ji G, Numabe Y, Ishii K, Muramatsu M, Kamoi K. Large-scale investigation of genomic markers for severe periodontitis. Odontology. 2004 Sep;92(1):43-7.
SLC14A1	CP	22	41	ns	None	Japanese	CC	N	Solute carrier family 14 (urea transporter), member 1 (Kidd blood group)	JK; UT1; UTE; HUT11; RACH1; UT-B1; HsT1341; FLJ33745; FLJ41687; SLC14A1	1	n/a	15490304	Suzuki A, Ji G, Numabe Y, Ishii K, Muramatsu M, Kamoi K. Large-scale investigation of genomic markers for severe periodontitis. Odontology. 2004 Sep;92(1):43-7.
SLC15A1	CP	22	41	ns	None	Japanese	CC	N	Solute carrier family 15 (oligopeptide transporter), member 1	PEPT1; HPECT1; HPEPT1; SLC15A1	1	n/a	15490304	Suzuki A, Ji G, Numabe Y, Ishii K, Muramatsu M, Kamoi K. Large-scale investigation of genomic markers for severe periodontitis. Odontology. 2004 Sep;92(1):43-7.
SLC15A2	CP	22	41	ns	None	Japanese	CC	N	Solute carrier family 15 (H+/peptide transporter), member 2	PEPT2; FLJ33407; SLC15A2	1	n/a	15490304	Suzuki A, Ji G, Numabe Y, Ishii K, Muramatsu M, Kamoi K. Large-scale investigation of genomic markers for severe periodontitis. Odontology. 2004 Sep;92(1):43-7.
SLC16A8	CP	22	41	ns	None	Japanese	CC	N	Solute carrier family 16, member 8 (monocarboxylic acid transporter 3)	MCT3; REMP; SLC16A8	1	n/a	15490304	Suzuki A, Ji G, Numabe Y, Ishii K, Muramatsu M, Kamoi K. Large-scale investigation of genomic markers for severe periodontitis. Odontology. 2004 Sep;92(1):43-7.
SLC22A1	CP	22	41	ns	None	Japanese	CC	N	Solute carrier family 22 (organic cation transporter), member 1	OCT1; HOCT1; oct1_ cds; SLC22A1	1	n/a	15490304	Suzuki A, Ji G, Numabe Y, Ishii K, Muramatsu M, Kamoi K. Large-scale investigation of genomic markers for severe periodontitis. Odontology. 2004 Sep;92(1):43-7.
SLC22A14	CP	22	41	ns	None	Japanese	CC	N	Solute carrier family 22, member 14	OCTL2; OCTL4; ORCTL4; MGC163415; SLC22A14	4	Multiple SNPs	15490304	Suzuki A, Ji G, Numabe Y, Ishii K, Muramatsu M, Kamoi K. Large-scale investigation of genomic markers for severe periodontitis. Odontology. 2004 Sep;92(1):43-7.
SLC27A4	CP	22	41	ns	None	Japanese	CC	N	Solute carrier family 27 (fatty acid transporter), member 4	FATP4; ACSVL4; SLC27A4	1	n/a	15490304	Suzuki A, Ji G, Numabe Y, Ishii K, Muramatsu M, Kamoi K. Large-scale investigation of genomic markers for severe periodontitis. Odontology. 2004 Sep;92(1):43-7.

Continued

TABLE 6-3 Association Study—cont'd

Gene Symbol	Disease Type	Cases	Total	Best *P* Value	Level of Support	Population	Study Design	Stratified or Covariate Adj	Gene Name	Gene Aliases	# SNPs Assayed	SNP Name	PubMed ID	Journal
SLC2A1	CP	22	41	ns	None	Japanese	CC	N	Solute carrier family 2 (facilitated glucose transporter), member 1	PED; GLUT; DYT17; DYT18; GLUT1; MGC141895; MGC141896; SLC2A1	2	Multiple SNPs	15490304	Suzuki A, Ji G, Numabe Y, Ishii K, Muramatsu M, Kamoi K. Large-scale investigation of genomic markers for severe periodontitis. Odontology. 2004 Sep;92(1):43-7.
SLC2A2	CP	22	41	ns	None	Japanese	CC	N	Solute carrier family 2 (facilitated glucose transporter), member 2	GLUT2; SLC2A2	1	n/a	15490304	Suzuki A, Ji G, Numabe Y, Ishii K, Muramatsu M, Kamoi K. Large-scale investigation of genomic markers for severe periodontitis. Odontology. 2004 Sep;92(1):43-7.
SLC4A1	CP	22	41	ns	None	Japanese	CC	N	Solute carrier family 4, anion exchanger, member 1 (erythrocyte membrane protein band 3, Diego blood group)	DI; FR; SW; WD; WR; AE1; WD1; BND3; EPB3; CD233; EMPB3; RTA1A; MGC116750; MGC116753; MGC126619; MGC126623; SLC4A1	1	n/a	15490304	Suzuki A, Ji G, Numabe Y, Ishii K, Muramatsu M, Kamoi K. Large-scale investigation of genomic markers for severe periodontitis. Odontology. 2004 Sep;92(1):43-7.
SLC6A12	CP	22	41	ns	None	Japanese	CC	N	Solute carrier family 6 (neurotransmitter transporter, betaine/GABA), member 12	BGT1; BGT-1; FLJ38727; SLC6A12	1	n/a	15490304	Suzuki A, Ji G, Numabe Y, Ishii K, Muramatsu M, Kamoi K. Large-scale investigation of genomic markers for severe periodontitis. Odontology. 2004 Sep;92(1):43-7.
SLC6A4	AgP	61	132	<0.01	Weak	Brazilian	CC	N	Solute carrier family 6 (neurotransmitter transporter, serotonin), member 4	HTT; 5HTT; OCD1; SERT; 5-HTT; hSERT; 5-HTTLPR; SLC6A4	1	5-HTTLPR	18587210	Costa JE, Gomes CC, Cota LO, Pataro AL, Silva JF, Gomez RS, Costa FO. Polymorphism in the promoter region of the gene for 5-HTT in individuals with aggressive periodontitis. J Oral Sci. 2008 Jun;50(2):193-8.
SLC6A5	CP	22	41	ns	None	Japanese	CC	N	Solute carrier family 6 (neurotransmitter transporter, glycine), member 5	NET1; GLYT2; SLC6A5	1	n/a	15490304	Suzuki A, Ji G, Numabe Y, Ishii K, Muramatsu M, Kamoi K. Large-scale investigation of genomic markers for severe periodontitis. Odontology. 2004 Sep;92(1):43-7.
SLC7A4	CP	22	41	ns	None	Japanese	CC	N	Solute carrier family 7 (cationic amino acid transporter, y+ system), member 4	VH; CAT4; CAT-4; HCAT3; MGC129976; MGC129977; SLC7A4	2	Multiple SNPs	15490304	Suzuki A, Ji G, Numabe Y, Ishii K, Muramatsu M, Kamoi K. Large-scale investigation of genomic markers for severe periodontitis. Odontology. 2004 Sep;92(1):43-7.

SLC7A9	CP	22	41	ns	None	Japanese	CC	N	Solute carrier family 7 (cationic amino acid transporter, y+ system), member 9	BAT1; CSNU3; FLJ94301; SLC7A9	1	n/a	15490304	Suzuki A, Ji G, Numabe Y, Ishii K, Muramatsu M, Kamoi K. Large-scale investigation of genomic markers for severe periodontitis. Odontology. 2004 Sep;92(1):43-7.
SLC9A3	CP	22	41	ns	None	Japanese	CC	N	Solute carrier family 9 (sodium/ hydrogen exchanger), member 3	NHE3; MGC126718; MGC126720; SLC9A3	1	n/a	15490304	Suzuki A, Ji G, Numabe Y, Ishii K, Muramatsu M, Kamoi K. Large-scale investigation of genomic markers for severe periodontitis. Odontology. 2004 Sep;92(1):43-7.
SLCO2A1	AgP+CP	251	376	ns	None	Japanese	CC	N	Solute carrier organic anion transporter family, member 2A1	PGT; OATP2A1; SLC21A2; SLCO2A1	n/a	n/a	15081423	Suzuki A, Ji G, Numabe Y, Muramatsu M, Gomi K, Kanazashi M, Ogata Y, Shimizu E, Shibukawa Y, Ito A, Ito T, Sugaya A, Arai T, Yamada S, Deguchi S, Kamoi K. Single nucleotide polymorphisms associated with aggressive periodontitis and severe chronic periodontitis in Japanese. Biochem Biophys Res Commun. 2004 May 7;317(3):887-92.
SP110	CP	22	41	ns	None	Japanese	CC	N	SP110 nuclear body protein	IPR1; VODI; IFI41; IFI75; FLJ22835; SP110	1	n/a	15490304	Suzuki A, Ji G, Numabe Y, Ishii K, Muramatsu M, Kamoi K. Large-scale investigation of genomic markers for severe periodontitis. Odontology. 2004 Sep;92(1):43-7.
SPOCK1	AgP+CP	251	376	ns	None	Japanese	CC	N	Sparc/osteonectin, cwcv and kazal-like domains proteoglycan (testican) 1	TIC1; SPOCK; FLJ37170; TESTICAN; SPOCK1	n/a	n/a	15081423	Suzuki A, Ji G, Numabe Y, Muramatsu M, Gomi K, Kanazashi M, Ogata Y, Shimizu E, Shibukawa Y, Ito A, Ito T, Sugaya A, Arai T, Yamada S, Deguchi S, Kamoi K. Single nucleotide polymorphisms associated with aggressive periodontitis and severe chronic periodontitis in Japanese. Biochem Biophys Res Commun. 2004 May 7;317(3):887-92.
SPP1	CP	137	219	ns	None	Caucasian	CC	GS	Secreted phosphoprotein 1	OPN; BNSP; BSPI; ETA-1; MGC110940; SPP1	1	707 C>T	16512757	Wohlfahrt JC, Wu T, Hodges JS, Hinrichs JE, Michalowicz BS. No association between selected candidate gene polymorphisms and severe chronic periodontitis. J Periodontol. 2006 Mar;77(3):426-36.

Continued

TABLE 6-3 Association Study—cont'd

Gene Symbol	Disease Type	Cases	Total	Best *P* Value	Level of Support	Population	Study Design	Stratified or Covariate Adj	Gene Name	Gene Aliases	# SNPs Assayed	SNP Name	PubMed ID	Journal
SPTB	CP	22	41	ns	None	Japanese	CC	N	Spectrin, beta, erythrocytic	EL3; HS2; SPH2; HSpTB1; SPTB	1	n/a	15490304	Suzuki A, Ji G, Numabe Y, Ishii K, Muramatsu M, Kamoi K. Large-scale investigation of genomic markers for severe periodontitis. Odontology. 2004 Sep;92(1):43-7.
SREBF2	CP	22	41	ns	None	Japanese	CC	N	Sterol regulatory element binding transcription factor 2	SREBP2; bHLHd2; SREBF2	6	Multiple SNPs	15490304	Suzuki A, Ji G, Numabe Y, Ishii K, Muramatsu M, Kamoi K. Large-scale investigation of genomic markers for severe periodontitis. Odontology. 2004 Sep;92(1):43-7.
SSTR3	CP	22	41	ns	None	Japanese	CC	N	Somatostatin receptor 3	SSTR3	2	Multiple SNPs	15490304	Suzuki A, Ji G, Numabe Y, Ishii K, Muramatsu M, Kamoi K. Large-scale investigation of genomic markers for severe periodontitis. Odontology. 2004 Sep;92(1):43-7.
STC2	CP	22	41	ns	None	Japanese	CC	N	Stanniocalcin 2	STC-2; STCRP; STC2	1	n/a	15490304	Suzuki A, Ji G, Numabe Y, Ishii K, Muramatsu M, Kamoi K. Large-scale investigation of genomic markers for severe periodontitis. Odontology. 2004 Sep;92(1):43-7.
TAP1	CP	22	41	ns	None	Japanese	CC	N	Transporter 1, ATP-binding cassette, sub-family B (MDR/TAP)	APT1; PSF1; ABC17; ABCB2; RING4; TAP1N; D6S114E; FLJ26666; FLJ41500; TAP1*0102N; TAP1	4	Multiple SNPs	15490304	Suzuki A, Ji G, Numabe Y, Ishii K, Muramatsu M, Kamoi K. Large-scale investigation of genomic markers for severe periodontitis. Odontology. 2004 Sep;92(1):43-7.
TAP2	CP	22	41	ns	None	Japanese	CC	N	Transporter 2, ATP-binding cassette, sub-family B (MDR/TAP)	APT2; PSF2; ABC18; ABCB3; RING11; D6S217E; TAP2	3	Multiple SNPs	15490304	Suzuki A, Ji G, Numabe Y, Ishii K, Muramatsu M, Kamoi K. Large-scale investigation of genomic markers for severe periodontitis. Odontology. 2004 Sep;92(1):43-7.
TBXA2R	CP	22	41	ns	None	Japanese	CC	N	thromboxane A2 receptor	TXA2-R; TBXA2R	1	n/a	15490304	Suzuki A, Ji G, Numabe Y, Ishii K, Muramatsu M, Kamoi K. Large-scale investigation of genomic markers for severe periodontitis. Odontology. 2004 Sep;92(1):43-7.
TBXAS1	CP	22	41	ns	None	Japanese	CC	N	thromboxane A synthase 1 (platelet)	TS; TXS; CYP5; THAS; TXAS; CYP5A1; GHOSAL; TBXAS1	4	Multiple SNPs	15490304	Suzuki A, Ji G, Numabe Y, Ishii K, Muramatsu M, Kamoi K. Large-scale investigation of genomic markers for severe periodontitis. Odontology. 2004 Sep;92(1):43-7.

TCF1	CP	22	41	ns	None	Japanese	CC	N	n/a	n/a	2	Multiple SNPs	15490304	Suzuki A, Ji G, Numabe Y, Ishii K, Muramatsu M, Kamoi K. Large-scale investigation of genomic markers for severe periodontitis. Odontology. 2004 Sep;92(1):43-7.
TEP1	CP	22	41	ns	None	Japanese	CC	N	telomerase-associated protein 1	TLP1; TP1; TROVE1; VAULT2; p240; TEP1	6	Multiple SNPs	15490304	Suzuki A, Ji G, Numabe Y, Ishii K, Muramatsu M, Kamoi K. Large-scale investigation of genomic markers for severe periodontitis. Odontology. 2004 Sep;92(1):43-7.
TFP1	CP	22	41	ns	None	Japanese	CC	N	n/a	n/a	2	Multiple SNPs	15490304	Suzuki A, Ji G, Numabe Y, Ishii K, Muramatsu M, Kamoi K. Large-scale investigation of genomic markers for severe periodontitis. Odontology. 2004 Sep;92(1):43-7.
TFRC	CP	22	41	ns	None	Japanese	CC	N	Transferrin receptor (p90, CD71)	TFR; CD71; TFR1; TRFR; TFRC	3	Multiple SNPs	15490304	Suzuki A, Ji G, Numabe Y, Ishii K, Muramatsu M, Kamoi K. Large-scale investigation of genomic markers for severe periodontitis. Odontology. 2004 Sep;92(1):43-7.
TG	CP	22	41	ns	None	Japanese	CC	N	thyroglobulin	TGN; AITD3; TG	9	Multiple SNPs	15490304	Suzuki A, Ji G, Numabe Y, Ishii K, Muramatsu M, Kamoi K. Large-scale investigation of genomic markers for severe periodontitis. Odontology. 2004 Sep;92(1):43-7.
TGFA	AgP+CP	251	376	ns	None	Japanese	CC	N	Transforming growth factor, alpha	TFGA; TGFA	n/a	n/a	15081423	Suzuki A, Ji G, Numabe Y, Muramatsu M, Gomi K, Kanazashi M, Ogata Y, Shimizu E, Shibukawa Y, Ito A, Ito T, Sugaya A, Arai T, Yamada S, Deguchi S, Kamoi K. Single nucleotide polymorphisms associated with aggressive periodontitis and severe chronic periodontitis in Japanese. Biochem Biophys Res Commun. 2004 May 7;317(3):887-92.
TGFA	CP	22	41	ns	None	Japanese	CC	N	Transforming growth factor, alpha	TFGA; TGFA	1	n/a	15490304	Suzuki A, Ji G, Numabe Y, Ishii K, Muramatsu M, Kamoi K. Large-scale investigation of genomic markers for severe periodontitis. Odontology. 2004 Sep;92(1):43-7.

Continued

TABLE 6-3 Association Study—cont'd

Gene Symbol	Disease Type	Cases	Total	Best *P* Value	Level of Support	Population	Study Design	Stratified or Covariate Adj	Gene Name	Gene Aliases	# SNPs Assayed	SNP Name	PubMed ID	Journal
TGFB1	AgP	43	83	ns	None	Turkish	CC	N	Transforming growth factor, beta 1	CED; DPD1; TGFB; TGFbeta; TGFB1	3	Multiple SNPs	16824504	Atilla G, Emingil G, Köse T, Berdeli A. TGF-beta1 gene polymorphisms in periodontal diseases. Clin Biochem. 2006 Sep;39(9):929-34. Epub 2006 Jun 7.
TGFB1	AgP+CP	251	376	ns	None	Japanese	CC	N	Transforming growth factor, beta 1	CED; DPD1; TGFB; TGFbeta; TGFB1	n/a	n/a	15081423	Suzuki A, Ji G, Numabe Y, Muramatsu M, Gomi K, Kanazashi M, Ogata Y, Shimizu E, Shibukawa Y, Ito A, Ito T, Sugaya A, Arai T, Yamada S, Deguchi S, Kamoi K. Single nucleotide polymorphisms associated with aggressive periodontitis and severe chronic periodontitis in Japanese. Biochem Biophys Res Commun. 2004 May 7;317(3):887-92.
TGFB1	CP	50	87	0.0258	Weak	Caucasian	CC	N	Transforming growth factor, beta 1	CED; DPD1; TGFB; TGFbeta; TGFB1	1	–509	12795790	de Souza AP, Trevilatto PC, Scarel-Caminaga RM, de Brito RB, Line SR. Analysis of the TGF-beta1 promoter polymorphism (C-509T) in patients with chronic periodontitis. J Clin Periodontol. 2003 Jun;30(6):519-23.
TGFB1	CP	122	236	0.0421	Weak	German	CC	N	Transforming growth factor, beta 1	CED; DPD1; TGFB; TGFbeta; TGFB1	2	codon 25 (P25R)	17209781	Babel N, Cherepnev G, Babel D, Tropmann A, Hammer M, Volk HD, Reinke P. Analysis of tumor necrosis factor-alpha, transforming growth factor-beta, interleukin-10, IL-6, and interferon-gamma gene polymorphisms in patients with chronic periodontitis. J Periodontol. 2006 Dec;77(12):1978-83.
TGFB1	CP	51	91	0.047	Weak	Turkish	CC	N	Transforming growth factor, beta 1	CED; DPD1; TGFB; TGFbeta; TGFB1	3	+915G/C	16824504	Atilla G, Emingil G, Köse T, Berdeli A. TGF-beta1 gene polymorphisms in periodontal diseases. Clin Biochem. 2006 Sep;39(9):929-34. Epub 2006 Jun 7.

TGFB1	CP	117	225	ns	None	Japanese	CC	N	Transforming growth factor, beta 1	CED; DPD1; TGFB; TGFbeta; TGFB1	3	Multiple SNPs	19405833	Kobayashi T, Murasawa A, Ito S, Yamamoto K, Komatsu Y, Abe A, Sumida T, Yoshie H. Cytokine gene polymorphisms associated with rheumatoid arthritis and periodontitis in Japanese adults. J Periodontol. 2009 May;80(5):792-9.
TGFB1	CP	113	221	ns	None	Japanese	CC	N	Transforming growth factor, beta 1	CED; DPD1; TGFB; TGFbeta; TGFB1	1	–509	18321309	Komatsu Y, Galicia JC, Kobayashi T, Yamazaki K, Yoshie H. Association of interleukin-1 receptor antagonist +2018 gene polymorphism with Japanese chronic periodontitis patients using a novel genotyping method. Int J Immunogenet. 2008 Apr;35(2):165-70.
TGFB1	CP	22	41	ns	None	Japanese	CC	N	Transforming growth factor, beta 1	CED; DPD1; TGFB; TGFbeta; TGFB1	4	Multiple SNPs	15490304	Suzuki A, Ji G, Numabe Y, Ishii K, Muramatsu M, Kamoi K. Large-scale investigation of genomic markers for severe periodontitis. Odontology. 2004 Sep;92(1):43-7.
TGFB1	CP	90	198	ns	None	Czech	CC	S	Transforming growth factor, beta 1	CED; DPD1; TGFB; TGFbeta; TGFB1	6	Multiple SNPs	11966931	Holla LI, Fassmann A, Benes P, Halabala T, Znojil V. 5 polymorphisms in the transforming growth factor-beta 1 gene (TGF-beta 1) in adult periodontitis. J Clin Periodontol. 2002 Apr;29(4):336-41.
TGFB1	CP&RA	137	245	ns	None	Japanese	CC	N	Transforming growth factor, beta 1	CED; DPD1; TGFB; TGFbeta; TGFB1	3	Multiple SNPs	19405833	Kobayashi T, Murasawa A, Ito S, Yamamoto K, Komatsu Y, Abe A, Sumida T, Yoshie H. Cytokine gene polymorphisms associated with rheumatoid arthritis and periodontitis in Japanese adults. J Periodontol. 2009 May;80(5):792-9.

Continued

TABLE 6-3 Association Study—cont'd

Gene Symbol	Disease Type	Cases	Total	Best *P* Value	Level of Support	Population	Study Design	Stratified or Covariate Adj	Gene Name	Gene Aliases	# SNPs Assayed	SNP Name	PubMed ID	Journal
TGFB3	AgP+CP	251	376	ns	None	Japanese	CC	N	Transforming growth factor, beta 3	ARVD; FLJ16571; TGF-beta3; TGFB3	n/a	n/a	15081423	Suzuki A, Ji G, Numabe Y, Muramatsu M, Gomi K, Kanazashi M, Ogata Y, Shimizu E, Shibukawa Y, Ito A, Ito T, Sugaya A, Arai T, Yamada S, Deguchi S, Kamoi K. Single nucleotide polymorphisms associated with aggressive periodontitis and severe chronic periodontitis in Japanese. Biochem Biophys Res Commun. 2004 May 7;317(3):887-92.
TGFBI	AgP+CP	251	376	ns	None	Japanese	CC	N	Transforming growth factor, beta-induced, 68kDa	CSD; CDB1; CDG2; CSD1; CSD2; CSD3; EBMD; LCD1; BIGH3; CDGG1; TGFBI	n/a	n/a	15081423	Suzuki A, Ji G, Numabe Y, Muramatsu M, Gomi K, Kanazashi M, Ogata Y, Shimizu E, Shibukawa Y, Ito A, Ito T, Sugaya A, Arai T, Yamada S, Deguchi S, Kamoi K. Single nucleotide polymorphisms associated with aggressive periodontitis and severe chronic periodontitis in Japanese. Biochem Biophys Res Commun. 2004 May 7;317(3):887-92.
TGFBI	AgP+CP	319	622	ns	None	Japanese	CC	AGS	Transforming growth factor, beta-induced, 68kDa	BIGH3, CDB1, CDG2, CDGG1, CSD, CSD1, CSD2, CSD3, EBMD, LCD1	3	n/a	19892918	Kobayashi T, Nagata T, Murakami S, Takashiba S, Kurihara H, Izumi Y, Numabe Y, Watanabe H, Kataoka M, Nagai A, Hayashi J, Ohyama H, Okamatsu Y, Inagaki Y, Tai H, Yoshie H. Genetic risk factors for periodontitis in a Japanese population. J Dent Res. 2009 Dec;88(12): 1137-41.

TGFBR3	AgP+CP	251	376	ns	None	Japanese	CC	N	Transforming growth factor, beta receptor III	BGCAN; betaglycan; TGFBR3	n/a	n/a	15081423	Suzuki A, Ji G, Numabe Y, Muramatsu M, Gomi K, Kanazashi M, Ogata Y, Shimizu E, Shibukawa Y, Ito A, Ito T, Sugaya A, Arai T, Yamada S, Deguchi S, Kamoi K. Single nucleotide polymorphisms associated with aggressive periodontitis and severe chronic periodontitis in Japanese. Biochem Biophys Res Commun. 2004 May 7;317(3):887-92.
TGFBRAP1	CP	22	41	ns	None	Japanese	CC	N	Transforming growth factor, beta receptor associated protein 1	TRAP-1, TRAP1	1	n/a	15490304	Suzuki A, Ji G, Numabe Y, Ishii K, Muramatsu M, Kamoi K. Large-scale investigation of genomic markers for severe periodontitis. Odontology. 2004 Sep;92(1):43-7.
THBD	CP	22	41	ns	None	Japanese	CC	N	Thrombomodulin	TM; THRM; AHUS6; CD141; THBD	1	n/a	15490304	Suzuki A, Ji G, Numabe Y, Ishii K, Muramatsu M, Kamoi K. Large-scale investigation of genomic markers for severe periodontitis. Odontology. 2004 Sep;92(1):43-7.
TIMP1	AgP+CP	251	376	ns	None	Japanese	CC	N	TIMP metallopeptidase inhibitor 1	EPA; EPO; HCI; CLGI; TIMP; FLJ90373; TIMP1	n/a	n/a	15081423	Suzuki A, Ji G, Numabe Y, Muramatsu M, Gomi K, Kanazashi M, Ogata Y, Shimizu E, Shibukawa Y, Ito A, Ito T, Sugaya A, Arai T, Yamada S, Deguchi S, Kamoi K. Single nucleotide polymorphisms associated with aggressive periodontitis and severe chronic periodontitis in Japanese. Biochem Biophys Res Commun. 2004 May 7;317(3):887-92.
TIMP2	AgP	79	207	0.013	Weak	Chinese	CC	N	TIMP metallopeptidase inhibitor 2	CSC-21K; TIMP2	1	–418 G/C	17448043	Chen D, Wang Q, Ma ZW, Chen FM, Chen Y, Xie GY, Wang QT, Wu ZF. MMP-2, MMP-9 and TIMP-2 gene polymorphisms in Chinese patients with generalized aggressive periodontitis. J Clin Periodontol. 2007 May;34(5):384-9.

Continued

TABLE 6-3 Association Study—cont'd

Gene Symbol	Disease Type	Cases	Total	Best *P* Value	Level of Support	Population	Study Design	Stratified or Covariate Adj	Gene Name	Gene Aliases	# SNPs Assayed	SNP Name	PubMed ID	Journal
TIMP2	CP	62	100	ns	None	Brazilian	CC	N	TIMP metallopeptidase inhibitor 2	CSC-21K; TIMP2	1	G-418C	15691353	de Souza AP, Trevilatto PC, Scarel-Caminaga RM, de Brito RB Jr, Barros SP, Line SR. Analysis of the MMP-9 (C-1562 T) and TIMP-2 (G-418C) gene promoter polymorphisms in patients with chronic periodontitis. J Clin Periodontol. 2005 Feb;32(2):207-11.
TIMP3	AgP+CP	251	376	ns	None	Japanese	CC	N	TIMP metallopeptidase inhibitor 3	SFD; K222; K222TA2; HSMRK222; TIMP3	n/a	n/a	15081423	Suzuki A, Ji G, Numabe Y, Muramatsu M, Gomi K, Kanazashi M, Ogata Y, Shimizu E, Shibukawa Y, Ito A, Ito T, Sugaya A, Arai T, Yamada S, Deguchi S, Kamoi K. Single nucleotide polymorphisms associated with aggressive periodontitis and severe chronic periodontitis in Japanese. Biochem Biophys Res Commun. 2004 May 7;317(3):887-92.
TLR2	AgP	90	245	ns	None	Turkish	CC	N	Toll-like receptor 2	TIL4; CD282; TLR2	2	Multiple SNPs	18062119	Emingil G, Berdeli A, Baylas H, Saygan BH, Gürkan A, Köse T, Atilla G. Toll-like receptor 2 and 4 gene polymorphisms in generalized aggressive periodontitis. J Periodontol. 2007 Oct;78(10):1968-77.
TLR2	AgP	81	162	ns	None	German	CC	N	Toll-like receptor 2	TIL4; CD282; TLR2	1	Arg753Gln	15875057	Schröder NW, Meister D, Wolff V, Christan C, Kaner D, Haban V, Purucker P, Hermann C, Moter A, Göbel UB, Schumann RR. Chronic periodontal disease is associated with single-nucleotide polymorphisms of the human TLR-4 gene. Genes Immun. 2005 Aug;6(5):448-51.
TLR2	AgP+CP	90	190	ns	None	Chinese	CC	N	Toll-like receptor 2	TIL4; CD282; TLR2	2	Multiple SNPs	18618036	Zhu G, Li C, Cao Z, Corbet EF, Jin L. Toll-like receptors 2 and 4 gene polymorphisms in a Chinese population with periodontitis. Quintessence Int. 2008 Mar;39(3):217-26.

TLR2	AgP+CP	197	394	ns	None	German	CC	N	Toll-like receptor 2	TIL4; CD282; TLR2	1	Arg753Gln	15875057	Schröder NW, Meister D, Wolff V, Christan C, Kaner D, Haban V, Purucker P, Hermann C, Moter A, Göbel UB, Schumann RR. Chronic periodontal disease is associated with single-nucleotide polymorphisms of the human TLR-4 gene. Genes Immun. 2005 Aug;6(5):448-51.
TLR2	CP	43	92	ns	None	Japanese	CC	N	Toll-like receptor 2	TIL4; CD282; TLR2	1	Arg677Trp	18714935	Imamura Y, Fujigaki Y, Oomori Y, Kuno T, Ota N, Wang PL. Polymorphism of genes encoding toll-like receptors and inflammatory cytokines in periodontal disease in the Japanese population. J Int Acad Periodontol. 2008 Jul;10(3):95-102.
TLR2	CP	97	197	ns	None	Japanese	CC	N	Toll-like receptor 2	TIL4; CD282; TLR2	5	Multiple SNPs	17956467	Fukusaki T, Ohara N, Hara Y, Yoshimura A, Yoshiura K. Evidence for association between a Toll-like receptor 4 gene polymorphism and moderate/severe periodontitis in the Japanese population. J Periodontal Res. 2007 Dec;42(6):541-5.
TLR2	CP	83	189	ns	None	Turkish	CC	N	Toll-like receptor 2	TIL4; CD282; TLR2	2	Multiple SNPs	17555409	Berdeli A, Emingil G, Han Saygan B, Gürkan A, Atilla G, Köse T, Baylas H. TLR2 Arg753Gly, TLR4 Asp299Gly and Thr399Ile gene polymorphisms are not associated with chronic periodontitis in a Turkish population. J Clin Periodontol. 2007 Jul;34(7):551-7.
TLR2	CP	116	232	ns	None	German	CC	N	Toll-like receptor 2	TIL4; CD282; TLR2	1	Arg753Gln	15875057	Schröder NW, Meister D, Wolff V, Christan C, Kaner D, Haban V, Purucker P, Hermann C, Moter A, Göbel UB, Schumann RR. Chronic periodontal disease is associated with single-nucleotide polymorphisms of the human TLR-4 gene. Genes Immun. 2005 Aug;6(5):448-51.
TLR2	CP	122	244	ns	None	Caucasian	CC	N	Toll-like receptor 2	TIL4; CD282; TLR2	2	Multiple SNPs	14738464	Folwaczny M, Glas J, Török HP, Limbersky O, Folwaczny C. Toll-like receptor (TLR) 2 and 4 mutations in periodontal disease. Clin Exp Immunol. 2004 Feb;135(2):330-5.

Continued

TABLE 6-3 Association Study—cont'd

Gene Symbol	Disease Type	Cases	Total	Best *P* Value	Level of Support	Population	Study Design	Stratified or Covariate Adj	Gene Name	Gene Aliases	# SNPs Assayed	SNP Name	PubMed ID	Journal
TLR4	AgP	73	200	0.026	Weak	Caucasian	CC	N	Toll-like receptor 4	TOLL; CD284; hToll; ARMD10; TLR4	2	299	17309585	James JA, Poulton KV, Haworth SE, Payne D, McKay IJ, Clarke FM, Hughes FJ, Linden GJ. Polymorphisms of TLR4 but not CD14 are associated with a decreased risk of aggressive periodontitis. J Clin Periodontol. 2007 Feb;34(2):111-7.
TLR4	AgP	73	153	ns	None	German	CC	N	Toll-like receptor 4	TOLL; CD284; hToll; ARMD10; TLR4	2	Multiple SNPs	19046305	Schulz S, Zissler N, Altermann W, Klapproth J, Zimmermann U, Gläser C, Schaller HG, Reichert S. Impact of genetic variants of CD14 and TLR4 on subgingival periodontopathogens. Int J Immunogenet. 2008 Dec;35(6):457-64.
TLR4	AgP	111	191	ns	None	German	CC	N	Toll-like receptor 4	TOLL; CD284; hToll; ARMD10; TLR4	2	Multiple SNPs	18983635	Noack B, Görgens H, Lorenz K, Ziegler A, Hoffmann T, Schackert HK. TLR4 and IL-18 gene variants in aggressive periodontitis. J Clin Periodontol. 2008 Dec;35(12):1020-6. Epub 2008 Oct 28.
TLR4	AgP	90	245	ns	None	Turkish	CC	N	Toll-like receptor 4	TOLL; CD284; hToll; ARMD10; TLR4	2	Multiple SNPs	18062119	Emingil G, Berdeli A, Baylas H, Saygan BH, Gürkan A, Köse T, Atilla G. Toll-like receptor 2 and 4 gene polymorphisms in generalized aggressive periodontitis. J Periodontol. 2007 Oct;78(10):1968-77.
TLR4	AgP	51	151	ns	None	Caucasian	CC	N	Toll-like receptor 4	TOLL; CD284; hToll; ARMD10; TLR4	2	Multiple SNPs	16304445	Brett PM, Zygogianni P, Griffiths GS, Tomaz M, Parkar M, D'Aiuto F, Tonetti M. Functional gene polymorphisms in aggressive and chronic periodontitis. J Dent Res. 2005 Dec;84(12):1149-53.

TLR4	AgP	81	162	ns	None	German	CC	N	Toll-like receptor 4	TOLL; CD284; hToll; ARMD10; TLR4	2	Multiple SNPs	15875057	Schröder NW, Meister D, Wolff V, Christan C, Kaner D, Haban V, Purucker P, Hermann C, Moter A, Göbel UB, Schumann RR. Chronic periodontal disease is associated with single-nucleotide polymorphisms of the human TLR-4 gene. Genes Immun. 2005 Aug;6(5):448-51.
TLR4	AgP+CP	197	394	<0.0001	Moderate	German	CC	N	Toll-like receptor 4	TOLL; CD284; hToll; ARMD10; TLR4	2	Multiple SNPs	15875057	Schröder NW, Meister D, Wolff V, Christan C, Kaner D, Haban V, Purucker P, Hermann C, Moter A, Göbel UB, Schumann RR. Chronic periodontal disease is associated with single-nucleotide polymorphisms of the human TLR-4 gene. Genes Immun. 2005 Aug;6(5):448-51.
TLR4	AgP+CP	133	213	ns	None	German	CC	N	Toll-like receptor 4	TOLL; CD284; hToll; ARMD10; TLR4	2	Multiple SNPs	19046305	Schulz S, Zissler N, Altermann W, Klapproth J, Zimmermann U, Gläser C, Schaller HG, Reichert S. Impact of genetic variants of CD14 and TLR4 on subgingival periodontopathogens. Int J Immunogenet. 2008 Dec;35(6):457-64.
TLR4	AgP+CP	90	190	ns	None	Chinese	CC	N	Toll-like receptor 4	TOLL; CD284; hToll; ARMD10; TLR4	2	Multiple SNPs	18618036	Zhu G, Li C, Cao Z, Corbet EF, Jin L. Toll-like receptors 2 and 4 gene polymorphisms in a Chinese population with periodontitis. Quintessence Int. 2008 Mar;39(3):217-26.
TLR4	AgP+CP	319	622	ns	None	Japanese	CC	AGS	Toll-like receptor 4	TOLL; CD284; hToll; ARMD10; TLR4	2	Multiple SNPs	19892918	Kobayashi T, Nagata T, Murakami S, Takashiba S, Kurihara H, Izumi Y, Numabe Y, Watanabe H, Kataoka M, Nagai A, Hayashi J, Ohyama H, Okamatsu Y, Inagaki Y, Tai H, Yoshie H. Genetic risk factors for periodontitis in a Japanese population. J Dent Res. 2009 Dec;88(12): 1137-41.

Continued

TABLE 6-3 Association Study—cont'd

Gene Symbol	Disease Type	Cases	Total	Best *P* Value	Level of Support	Population	Study Design	Stratified or Covariate Adj	Gene Name	Gene Aliases	# SNPs Assayed	SNP Name	PubMed ID	Journal
TLR4	CP	116	232	0.0001	Moderate	German	CC	N	Toll-like receptor 4	TOLL; CD284; hToll; ARMD10; TLR4	2	Multiple SNPs	15875057	Schröder NW, Meister D, Wolff V, Christan C, Kaner D, Haban V, Purucker P, Hermann C, Moter A, Göbel UB, Schumann RR. Chronic periodontal disease is associated with single-nucleotide polymorphisms of the human TLR-4 gene. Genes Immun. 2005 Aug;6(5):448-51.
TLR4	CP	97	197	0.016	Weak	Japanese	CC	N	Toll-like receptor 4	TOLL; CD284; hToll; ARMD10; TLR4	4	+3725	17956467	Fukusaki T, Ohara N, Hara Y, Yoshimura A, Yoshiura K. Evidence for association between a Toll-like receptor 4 gene polymorphism and moderate/severe periodontitis in the Japanese population. J Periodontal Res. 2007 Dec;42(6):541-5.
TLR4	CP	60	140	ns	None	German	CC	N	Toll-like receptor 4	TOLL; CD284; hToll; ARMD10; TLR4	2	Multiple SNPs	19046305	Schulz S, Zissler N, Altermann W, Klapproth J, Zimmermann U, Gläser C, Schaller HG, Reichert S. Impact of genetic variants of CD14 and TLR4 on subgingival periodontopathogens. Int J Immunogenet. 2008 Dec;35(6):457-64.
TLR4	CP	n/a	80	ns	None	Finnish	Quan	N	Toll-like receptor 4	TOLL; CD284; hToll; ARMD10; TLR4	1	+896	19017034	Raunio T, Knuuttila M, Hiltunen L, Karttunen R, Vainio O, Tervonen T. IL-6(-174) genotype associated with the extent of periodontal disease in type 1 diabetic subjects. J Clin Periodontol. 2009 Jan;36(1):11-7. Epub 2008 Oct 31.
TLR4	CP	43	92	ns	None	Japanese	CC	N	Toll-like receptor 4	TOLL; CD284; hToll; ARMD10; TLR4	1	Asp299Gly	18714935	Imamura Y, Fujigaki Y, Oomori Y, Kuno T, Ota N, Wang PL. Polymorphism of genes encoding toll-like receptors and inflammatory cytokines in periodontal disease in the Japanese population. J Int Acad Periodontol. 2008 Jul;10(3):95-102.

TLR4	CP	171	389	ns	None	Czech	CC	N	Toll-like receptor 4	TOLL; CD284; hToll; ARMD10; TLR4	2	Multiple SNPs	17559631	Izakovicova Holla L, Buckova D, Fassmann A, Roubalikova L, Vanek J. Lack of association between chronic periodontitis and the Toll-like receptor 4 gene polymorphisms in a Czech population. J Periodontal Res. 2007 Aug;42(4):340-4.
TLR4	CP	83	189	ns	None	Turkish	CC	N	Toll-like receptor 4	TOLL; CD284; hToll; ARMD10; TLR4	2	Multiple SNPs	17555409	Berdeli A, Emingil G, Han Saygan B, Gürkan A, Atilla G, Köse T, Baylas H. TLR2 Arg753Gly, TLR4 Asp299Gly and Thr399Ile gene polymorphisms are not associated with chronic periodontitis in a Turkish population. J Clin Periodontol. 2007 Jul;34(7):551-7.
TLR4	CP	51	229	ns	None	Caucasian	CC	GS	Toll-like receptor 4	TOLL; CD284; hToll; ARMD10; TLR4	1	+896	17448042	Tervonen T, Raunio T, Knuuttila M, Karttunen R. Polymorphisms in the CD14 and IL-6 genes associated with periodontal disease. J Clin Periodontol. 2007 May;34(5):377-83.
TLR4	CP	95	189	ns	None	Caucasian	CC	N	Toll-like receptor 4	TOLL; CD284; hToll; ARMD10; TLR4	2	Multiple SNPs	17309585	James JA, Poulton KV, Haworth SE, Payne D, McKay IJ, Clarke FM, Hughes FJ, Linden GJ. Polymorphisms of TLR4 but not CD14 are associated with a decreased risk of aggressive periodontitis. J Clin Periodontol. 2007 Feb;34(2):111-7.
TLR4	CP	57	157	ns	None	Caucasian	CC	N	Toll-like receptor 4	TOLL; CD284; hToll; ARMD10; TLR4	2	Multiple SNPs	16304445	Brett PM, Zygogianni P, Griffiths GS, Tomaz M, Parkar M, D'Aiuto F, Tonetti M. Functional gene polymorphisms in aggressive and chronic periodontitis. J Dent Res. 2005 Dec;84(12):1149-53.
TLR4	CP	100	199	ns	None	Caucasian	CC	AGPS	Toll-like receptor 4	TOLL; CD284; hToll; ARMD10; TLR4	2	Multiple SNPs	16246938	Laine ML, Morré SA, Murillo LS, van Winkelhoff AJ, Peña AS. CD14 and TLR4 gene polymorphisms in adult periodontitis. J Dent Res. 2005 Nov;84(11):1042-6.

Continued

TABLE 6-3 Association Study—cont'd

Gene Symbol	Disease Type	Cases	Total	Best *P* Value	Level of Support	Population	Study Design	Stratified or Covariate Adj	Gene Name	Gene Aliases	# SNPs Assayed	SNP Name	PubMed ID	Journal
TLR4	CP	122	244	ns	None	Caucasian	CC	N	Toll-like receptor 4	TOLL; CD284; hToll; ARMD10; TLR4	2	Multiple SNPs	14738464	Folwaczny M, Glas J, Török HP, Limbersky O, Folwaczny C. Toll-like receptor (TLR) 2 and 4 mutations in periodontal disease. Clin Exp Immunol. 2004 Feb;135(2):330-5.
TLR4	CP	108	184	ns	None	Caucasian	CC	AGS	Toll-like receptor 4	TOLL; CD284; hToll; ARMD10; TLR4	2	Multiple SNPs	19811440	Noack B, Görgens H, Lorenz K, Schackert HK, Hoffmann T. TLR4 and IL-18 gene variants in chronic periodontitis: impact on disease susceptibility and severity. Immunol Invest. 2009;38(3-4):297-310.
TM7SF2	CP	22	41	ns	None	Japanese	CC	N	Transmembrane 7 superfamily member 2	ANG1; DHCR14A; TM7SF2	1	n/a	15490304	Suzuki A, Ji G, Numabe Y, Ishii K, Muramatsu M, Kamoi K. Large-scale investigation of genomic markers for severe periodontitis. Odontology. 2004 Sep;92(1):43-7.
TNF	AgP	38	89	ns	None	Brazilian	CC	N	Tumor necrosis factor (TNF superfamily, member 2)	DIF; TNFA; TNFSF2; TNF-alpha; TNF	1	–308	19148387	Menezes NG, Colombo AP. Lack of association between the TNF-alpha -308 (G/A) genetic polymorphism and periodontal disease in Brazilians. Braz Oral Res. 2008 Oct-Dec;22(4):322-7.
TNF	AgP	31	62	ns	None	Turkish	CC	N	Tumor necrosis factor (TNF superfamily, member 2)	DIF; TNFA; TNFSF2; TNF-alpha; TNF	1	–308	18587204	Guzeldemir E, Gunhan M, Ozcelik O, Tastan H. Interleukin-1 and tumor necrosis factor-alpha gene polymorphisms in Turkish patients with localized aggressive periodontitis. J Oral Sci. 2008 Jun;50(2):151-9.
TNF	AgP	30	100	ns	None	Brazilian	CC	N	Tumor necrosis factor (TNF superfamily, member 2)	DIF; TNFA; TNFSF2; TNF-alpha; TNF	1	–308	17823082	Maria de Freitas N, Imbronito AV, Neves AC, Nunes FD, Pustiglioni FE, Lotufo RF. Analysis of IL-1A(-889) and TNFA(-308) gene polymorphism in Brazilian patients with generalized aggressive periodontitis. Eur Cytokine Netw. 2007 Sep;18(3):142-7. Epub 2007 Sep 7.

TNF	AgP	64	142	ns	None	Chinese	CC	GS	Tumor necrosis factor (TNF superfamily, member 2)	DIF; TNFA; TNFSF2; TNF-alpha; TNF	1	–308	17686276	Zhu XL, Meng HX, Xu L, Zhang L, Chen ZB, Shi D. [Relationship between tumor necrosis factor A-308 gene polymorphism and aggressive periodontitis]. Zhonghua Kou Qiang Yi Xue Za Zhi. 2007 May;42(5):268-71. Chinese.
TNF	AgP	46	136	ns	None	Greek	CC	N	Tumor necrosis factor (TNF superfamily, member 2)	DIF; TNFA; TNFSF2; TNF-alpha; TNF	1	–308	16911569	Sakellari D, Katsares V, Georgiadou M, Kouvatsi A, Arsenakis M, Konstantinidis A. No correlation of five gene polymorphisms with periodontal conditions in a Greek population. J Clin Periodontol. 2006 Nov;33(11):765-70. Epub 2006 Aug 14.
TNF	AgP	51	151	ns	None	Caucasian	CC	N	Tumor necrosis factor (TNF superfamily, member 2)	DIF; TNFA; TNFSF2; TNF-alpha; TNF	1	–308	16304445	Brett PM, Zygogianni P, Griffiths GS, Tomaz M, Parkar M, D'Aiuto F, Tonetti M. Functional gene polymorphisms in aggressive and chronic periodontitis. J Dent Res. 2005 Dec;84(12):1149-53.
TNF	AgP	27	57	ns	None	Chilean	CC	D	Tumor necrosis factor (TNF superfamily, member 2)	DIF; TNFA; TNFSF2; TNF-alpha; TNF	1	–308	15627647	Pérez C, González FE, Pavez V, Araya AV, Aguirre A, Cruzat A, Contreras-Levicoy J, Dotte A, Aravena O, Salazar L, Catalán D, Cuenca J, Ferreira A, Schiattino I, Aguillón JC. The -308 polymorphism in the promoter region of the tumor necrosis factor-alpha (TNF-alpha) gene and ex vivo lipopolysaccharide-induced TNF-alpha expression in patients with aggressive periodontitis and/or type 1 diabetes mellitus. Eur Cytokine Netw. 2004 Oct-Dec;15(4):364-70.
TNF	AgP	14	14	ns	None	Brazilian	Fam	N	Tumor necrosis factor (TNF superfamily, member 2)	DIF; TNFA; TNFSF2; TNF-alpha; TNF	1	–308	11940143	Trevilatto PC, Tramontina VA, Machado MA, Gonçalves RB, Sallum AW, Line SR. Clinical, genetic and microbiological findings in a Brazilian family with aggressive periodontitis. J Clin Periodontol. 2002 Mar;29(3):233-9.

Continued

TABLE 6-3 Association Study—cont'd

Gene Symbol	Disease Type	Cases	Total	Best *P* Value	Level of Support	Population	Study Design	Stratified or Covariate Adj	Gene Name	Gene Aliases	# SNPs Assayed	SNP Name	PubMed ID	Journal
TNF	AgP	46	150	ns	None	Japanese	CC	N	Tumor necrosis factor (TNF superfamily, member 2)	DIF; TNFA; TNFSF2; TNF-alpha; TNF	5	Multiple SNPs	11759867	Endo M, Tai H, Tabeta K, Kobayashi T, Yamazaki K, Yoshie H. Analysis of single nucleotide polymorphisms in the 5'-flanking region of tumor necrosis factor-alpha gene in Japanese patients with early-onset periodontitis. J Periodontol. 2001 Nov;72(11):1554-9.
TNF	AgP	16	64	ns	None	Israeli	Fam	N	Tumor necrosis factor (TNF superfamily, member 2)	DIF; TNFA; TNFSF2; TNF-alpha; TNF	1	–308	11453117	Shapira L, Stabholz A, Rieckmann P, Kruse N. Genetic polymorphism of the tumor necrosis factor (TNF)-alpha promoter region in families with localized early-onset periodontitis. J Periodontal Res. 2001 Jun;36(3):183-6.
TNF	AgP	77	91	ns	None	Caucasian	CC	N	Tumor necrosis factor (TNF superfamily, member 2)	DIF; TNFA; TNFSF2; TNF-alpha; TNF	1	TNFa	10685365	Kinane DF, Hodge P, Eskdale J, Ellis R, Gallagher G. Analysis of genetic polymorphisms at the interleukin-10 and tumour necrosis factor loci in early-onset periodontitis. J Periodontal Res. 1999 Oct;34(7):379-86.
TNF	AgP	55	98	ns	None	Brazilian	CC	S	Tumor necrosis factor (TNF superfamily, member 2)	DIF; TNFA; TNFSF2; TNF-alpha; TNF	1	–308	19771178	Moreira PR, Costa JE, Gomez RS, Gollob KJ, Dutra WO. TNFA and IL10 Gene Polymorphisms are not Associated with Periodontitis in Brazilians. Open Dent J. 2009 Sep 7;3:184-90.
TNF	AgP	n/a	n/a	sig	Weak	Chinese	CC	N	Tumor necrosis factor (TNF superfamily, member 2)	DIF; TNFA; TNFSF2; TNF-alpha; TNF	1	–308	19031816	Wang HY, Pan YP. [Screening and analysis of multi-alleles in generalized aggressive periodontitis]. Zhonghua Kou Qiang Yi Xue Za Zhi. 2008 Jul;43(7):406-9. Chinese.

TNF	AgP&T1DM	27	57	ns	None	Chilean	CC	D	Tumor necrosis factor (TNF superfamily, member 2)	DIF; TNFA; TNFSF2; TNF-alpha; TNF	1	–308	15627647	Pérez C, González FE, Pavez V, Araya AV, Aguirre A, Cruzat A, Contreras-Levicoy J, Dotte A, Aravena O, Salazar L, Catalán D, Cuenca J, Ferreira A, Schiattino I, Aguillón JC. The -308 polymorphism in the promoter region of the tumor necrosis factor-alpha (TNF-alpha) gene and ex vivo lipopolysaccharide-induced TNF-alpha expression in patients with aggressive periodontitis and/or type 1 diabetes mellitus. Eur Cytokine Netw. 2004 Oct-Dec;15(4):364-70.
TNF	AgP+CP	123	175	ns	None	German	CC	N	Tumor necrosis factor (TNF superfamily, member 2)	DIF; TNFA; TNFSF2; TNF-alpha; TNF	2	Multiple SNPs	18363738	Schulz S, Machulla HK, Altermann W, Klapproth J, Zimmermann U, Gläser C, Kluttig A, Stein J, Schaller HG, Reichert S. Genetic markers of tumour necrosis factor alpha in aggressive and chronic periodontitis. J Clin Periodontol. 2008 Jun;35(6):493-500. Epub 2008 Mar 24.
TNF	AgP+CP	123	175	ns	None	German	CC	N	Tumor necrosis factor (TNF superfamily, member 2)	DIF; TNFA; TNFSF2; TNF-alpha; TNF	2	Haplotype	18363738	Schulz S, Machulla HK, Altermann W, Klapproth J, Zimmermann U, Gläser C, Kluttig A, Stein J, Schaller HG, Reichert S. Genetic markers of tumour necrosis factor alpha in aggressive and chronic periodontitis. J Clin Periodontol. 2008 Jun;35(6):493-500. Epub 2008 Mar 24.
TNF	AgP+CP	251	376	ns	None	Japanese	CC	N	Tumor necrosis factor (TNF superfamily, member 2)	DIF; TNFA; TNFSF2; TNF-alpha; TNF	n/a	n/a	15081423	Suzuki A, Ji G, Numabe Y, Muramatsu M, Gomi K, Kanazashi M, Ogata Y, Shimizu E, Shibukawa Y, Ito A, Ito T, Sugaya A, Arai T, Yamada S, Deguchi S, Kamoi K. Single nucleotide polymorphisms associated with aggressive periodontitis and severe chronic periodontitis in Japanese. Biochem Biophys Res Commun. 2004 May 7;317(3):887-92.

Continued

TABLE 6-3 Association Study—cont'd

Gene Symbol	Disease Type	Cases	Total	Best *P* Value	Level of Support	Population	Study Design	Stratified or Covariate Adj	Gene Name	Gene Aliases	# SNPs Assayed	SNP Name	PubMed ID	Journal
TNF	AgP+CP	319	622	ns	None	Japanese	CC	AGS	Tumor necrosis factor (TNF superfamily, member 2)	DIF; TNFA; TNFSF2; TNF-alpha; TNF	2	n/a	19892918	Kobayashi T, Nagata T, Murakami S, Takashiba S, Kurihara H, Izumi Y, Numabe Y, Watanabe H, Kataoka M, Nagai A, Hayashi J, Ohyama H, Okamatsu Y, Inagaki Y, Tai H, Yoshie H. Genetic risk factors for periodontitis in a Japanese population. J Dent Res. 2009 Dec;88(12): 1137-41.
TNF	CP	64	128	0.012	Weak	Japanese	CC	N	Tumor necrosis factor (TNF superfamily, member 2)	DIF; TNFA; TNFSF2; TNF-alpha; TNF	5	–1031, -863 or -857	12795791	Soga Y, Nishimura F, Ohyama H, Maeda H, Takashiba S, Murayama Y. Tumor necrosis factor-alpha gene (TNF-alpha) -1031/-863, -857 single-nucleotide polymorphisms (SNPs) are associated with severe adult periodontitis in Japanese. J Clin Periodontol. 2003 Jun;30(6):524-31.
TNF	CP	20	40	0.014	Weak	n/a	CC	N	Tumor necrosis factor (TNF superfamily, member 2)	DIF; TNFA; TNFSF2; TNF-alpha; TNF	1	–308	10589805	Galbraith GM, Hendley TM, Sanders JJ, Palesch Y, Pandey JP. Polymorphic cytokine genotypes as markers of disease severity in adult periodontitis. J Clin Periodontol. 1999 Nov;26(11):705-9.
TNF	CP	48	130	0.026	Weak	Caucasian	CC	G	Tumor necrosis factor (TNF superfamily, member 2)	DIF; TNFA; TNFSF2; TNF-alpha; TNF	1	–308	14723749	Moore S, Ide M, Randhawa M, Walker JJ, Reid JG, Simpson NA. An investigation into the association among preterm birth, cytokine gene polymorphisms and periodontal disease. BJOG. 2004 Feb;111(2):125-32.
TNF	CP	51	229	0.048	Weak	Caucasian	CC	GS	Tumor necrosis factor (TNF superfamily, member 2)	DIF; TNFA; TNFSF2; TNF-alpha; TNF	1	–308	17448042	Tervonen T, Raunio T, Knuuttila M, Karttunen R. Polymorphisms in the CD14 and IL-6 genes associated with periodontal disease. J Clin Periodontol. 2007 May;34(5):377-83.

TNF	CP	65	161	<0.001	Weak	Chinese	CC	N	Tumor necrosis factor (TNF superfamily, member 2)	DIF; TNFA; TNFSF2; TNF-alpha; TNF	1	–308	12475426	Qian W, Zhang J, Zhang Y. [The relationship between tumor necrosis factor A-308 gene polymorphism and susceptibility of severe periodontitis in adults]. Zhonghua Kou Qiang Yi Xue Za Zhi. 2002 Mar;37(2):126-8. Chinese.
TNF	CP	n/a	n/a	<0.01	Weak	Chinese	CC	N	Tumor necrosis factor (TNF superfamily, member 2)	DIF; TNFA; TNFSF2; TNF-alpha; TNF	1	–308	14966591	Lin L, Pan YP, Yin LY. Study on the correlation of cytokine gene polymorphism with chronic periodontitis. Shanghai Kou Qiang Yi Xue. 2003 Dec;12(6):456-9.
TNF	CP	38	65	ns	None	Brazilian	CC	G	Tumor necrosis factor (TNF superfamily, member 2)	DIF; TNFA; TNFSF2; TNF-alpha; TNF	1	–308	19555357	Costa AM, Guimarães MC, de Souza ER, Nóbrega OT, Bezerra AC. Interleukin-6 (G-174C) and tumour necrosis factor-alpha (G-308A) gene polymorphisms in geriatric patients with chronic periodontitis. Gerodontology. 2009 Jun 25. [Epub ahead of print]
TNF	CP	117	225	ns	None	Japanese	CC	N	Tumor necrosis factor (TNF superfamily, member 2)	DIF; TNFA; TNFSF2; TNF-alpha; TNF	2	Multiple SNPs	19405833	Kobayashi T, Murasawa A, Ito S, Yamamoto K, Komatsu Y, Abe A, Sumida T, Yoshie H. Cytokine gene polymorphisms associated with rheumatoid arthritis and periodontitis in Japanese adults. J Periodontol. 2009 May;80(5):792-9.
TNF	CP	74	125	ns	None	Brazilian	CC	N	Tumor necrosis factor (TNF superfamily, member 2)	DIF; TNFA; TNFSF2; TNF-alpha; TNF	1	–308	19148387	Menezes NG, Colombo AP. Lack of association between the TNF-alpha -308 (G/A) genetic polymorphism and periodontal disease in Brazilians. Braz Oral Res. 2008 Oct-Dec;22(4):322-7.

Continued

TABLE 6-3 Association Study—cont'd

Gene Symbol	Disease Type	Cases	Total	Best *P* Value	Level of Support	Population	Study Design	Stratified or Covariate Adj	Gene Name	Gene Aliases	# SNPs Assayed	SNP Name	PubMed ID	Journal
TNF	CP	127	304	ns	None	Brazilian	CC	N	Tumor necrosis factor (TNF superfamily, member 2)	DIF; TNFA; TNFSF2; TNF-alpha; TNF	1	–308	19076989	Trombone AP, Cardoso CR, Repeke CE, Ferreira SB Jr, Martins W Jr, Campanelli AP, Avila-Campos MJ, Trevilatto PC, Silva JS, Garlet GP. Tumor necrosis factor-alpha -308G/A single nucleotide polymorphism and red-complex periodontopathogens are independently associated with increased levels of tumor necrosis factor-alpha in diseased periodontal tissues. J Periodontal Res. 2009 Oct;44(5):598-608. Epub 2008 Dec 11.
TNF	CP	n/a	80	ns	None	Finnish	Quan	N	Tumor necrosis factor (TNF superfamily, member 2)	DIF; TNFA; TNFSF2; TNF-alpha; TNF	1	–308	19017034	Raunio T, Knuuttila M, Hiltunen L, Karttunen R, Vainio O, Tervonen T. IL-6(-174) genotype associated with the extent of periodontal disease in type 1 diabetic subjects. J Clin Periodontol. 2009 Jan;36(1):11-7. Epub 2008 Oct 31.
TNF	CP	122	236	ns	None	German	CC	N	Tumor necrosis factor (TNF superfamily, member 2)	DIF; TNFA; TNFSF2; TNF-alpha; TNF	1	–308	17209781	Babel N, Cherepnev G, Babel D, Tropmann A, Hammer M, Volk HD, Reinke P. Analysis of tumor necrosis factor-alpha, transforming growth factor-beta, interleukin-10, IL-6, and interferon-gamma gene polymorphisms in patients with chronic periodontitis. J Periodontol. 2006 Dec;77(12):1978-83.
TNF	CP	56	146	ns	None	Greek	CC	N	Tumor necrosis factor (TNF superfamily, member 2)	DIF; TNFA; TNFSF2; TNF-alpha; TNF	1	–308	16911569	Sakellari D, Katsares V, Georgiadou M, Kouvatsi A, Arsenakis M, Konstantinidis A. No correlation of five gene polymorphisms with periodontal conditions in a Greek population. J Clin Periodontol. 2006 Nov;33(11):765-70. Epub 2006 Aug 14.

TNF	CP	166	246	ns	None	Chinese	CC	N	Tumor necrosis factor (TNF superfamily, member 2)	DIF; TNFA; TNFSF2; TNF-alpha; TNF	1	–308	16400484	Pang RY, Chen KY, Zhang JC, Xu CR, Zhang X. [Association of TNFA-308 gene polymorphisms with susceptibility to chronic periodontitis in Chinese patients]. Shanghai Kou Qiang Yi Xue. 2005 Dec;14(6):586-9. Chinese.
TNF	CP	57	157	ns	None	Caucasian	CC	N	Tumor necrosis factor (TNF superfamily, member 2)	DIF; TNFA; TNFSF2; TNF-alpha; TNF	1	–308	16304445	Brett PM, Zygogianni P, Griffiths GS, Tomaz M, Parkar M, D'Aiuto F, Tonetti M. Functional gene polymorphisms in aggressive and chronic periodontitis. J Dent Res. 2005 Dec;84(12):1149-53.
TNF	CP	60	99	ns	None	Caucasian	CC	N	Tumor necrosis factor (TNF superfamily, member 2)	DIF; TNFA; TNFSF2; TNF-alpha; TNF	1	–308	15842262	Donati M, Berglundh T, Hytönen AM, Hahn-Zoric M, Hanson LA, Padyukov L. Association of the -159 CD14 gene polymorphism and lack of association of the -308 TNFA and Q551R IL-4RA polymorphisms with severe chronic periodontitis in Swedish Caucasians. J Clin Periodontol. 2005 May;32(5):474-9.
TNF	CP	81	161	ns	None	Caucasian	CC	N	Tumor necrosis factor (TNF superfamily, member 2)	DIF; TNFA; TNFSF2; TNF-alpha; TNF	1	–308	15142214	Folwaczny M, Glas J, Török HP, Mende M, Folwaczny C. Lack of association between the TNF alpha G -308 A promoter polymorphism and periodontal disease. J Clin Periodontol. 2004 Jun;31(6):449-53.
TNF	CP	132	246	ns	None	Czech	CC	N	Tumor necrosis factor (TNF superfamily, member 2)	DIF; TNFA; TNFSF2; TNF-alpha; TNF	1	–308	12828656	Fassmann A, Holla LI, Buckova D, Vasku A, Znojil V, Vanek J. Polymorphisms in the +252(A/G) lymphotoxin-alpha and the -308(A/G) tumor necrosis factor-alpha genes and susceptibility to chronic periodontitis in a Czech population. J Periodontal Res. 2003 Aug;38(4):394-9.

Continued

TABLE 6-3 Association Study—cont'd

Gene Symbol	Disease Type	Cases	Total	Best *P* Value	Level of Support	Population	Study Design	Stratified or Covariate Adj	Gene Name	Gene Aliases	# SNPs Assayed	SNP Name	PubMed ID	Journal
TNF	CP	90	354	ns	None	Mixed	CC	N	Tumor necrosis factor (TNF superfamily, member 2)	DIF; TNFA; TNFSF2; TNF-alpha; TNF	4	Multiple SNPs	11846846	Craandijk J, van Krugten MV, Verweij CL, van der Velden U, Loos BG. Tumor necrosis factor-alpha gene polymorphisms in relation to periodontitis. J Clin Periodontol. 2002 Jan;29(1):28-34.
TNF	CP	32	64	ns	None	Caucasian	CC	N	Tumor necrosis factor (TNF superfamily, member 2)	DIF; TNFA; TNFSF2; TNF-alpha; TNF	3	Multiple SNPs	9609372	Galbraith GM, Steed RB, Sanders JJ, Pandey JP. Tumor necrosis factor alpha production by oral leukocytes: influence of tumor necrosis factor genotype. J Periodontol. 1998 Apr;69(4):428-33.
TNF	CP	85	134	ns	None	Caucasian	CC	AS	Tumor necrosis factor (TNF superfamily, member 2)	DIF; TNFA; TNFSF2; TNF-alpha; TNF	1	–308	9049801	Kornman KS, Crane A, Wang HY, di Giovine FS, Newman MG, Pirk FW, Wilson TG Jr, Higginbottom FL, Duff GW. The interleukin-1 genotype as a severity factor in adult periodontal disease. J Clin Periodontol. 1997 Jan;24(1):72-7.
TNF	CP	67	110	ns	None	Brazilian	CC	S	Tumor necrosis factor (TNF superfamily, member 2)	DIF; TNFA; TNFSF2; TNF-alpha; TNF	1	–308	19771178	Moreira PR, Costa JE, Gomez RS, Gollob KJ, Dutra WO. TNFA and IL10 Gene Polymorphisms are not Associated with Periodontitis in Brazilians. Open Dent J. 2009 Sep 7;3:184-90.
TNF	CP&HIV	16	32	0.003	Weak	Caucasian	CC	G	Tumor necrosis factor (TNF superfamily, member 2)	DIF; TNFA; TNFSF2; TNF-alpha; TNF	1	–308	10551423	Price P, Calder DM, Witt CS, Allcock RJ, Christiansen FT, Davies GR, Cameron PU, Rogers M, Baluchova K, Moore CB, French MA. Periodontal attachment loss in HIV-infected patients is associated with the Major histocompatibility complex 8.1 haplotype (HLA-A1,B8,DR3). Tissue Antigens. 1999 Oct;54(4):391-9.

TNF	CP&RA	137	245	ns	None	Japanese	CC	N	Tumor necrosis factor (TNF superfamily, member 2)	DIF; TNFA; TNFSF2; TNF-alpha; TNF	2	Multiple SNPs	19405833	Kobayashi T, Murasawa A, Ito S, Yamamoto K, Komatsu Y, Abe A, Sumida T, Yoshie H. Cytokine gene polymorphisms associated with rheumatoid arthritis and periodontitis in Japanese adults. J Periodontol. 2009 May;80(5):792-9.
TNFRSF11A	AgP	99	188	ns	None	Japanese	CC	N	Tumor necrosis factor receptor superfamily, member 11a, NFKB activator	FEO; OFE; ODFR; OSTS; PDB2; RANK; CD265; OPTB7; TRANCER; LOH18CR1; TNFRSF11A	27	Multiple SNPs	16953816	Soedarsono N, Rabello D, Kamei H, Fuma D, Ishihara Y, Suzuki M, Noguchi T, Sakaki Y, Yamaguchi A, Kojima T. Evaluation of RANK/RANKL/OPG gene polymorphisms in aggressive periodontitis. J Periodontal Res. 2006 Oct;41(5):397-404.
TNFRSF11B	AgP	99	188	ns	None	Japanese	CC	N	Tumor necrosis factor receptor superfamily, member 11b	OPG; TR1; OCIF; MGC29565; TNFRSF11B	7	Multiple SNPs	16953816	Soedarsono N, Rabello D, Kamei H, Fuma D, Ishihara Y, Suzuki M, Noguchi T, Sakaki Y, Yamaguchi A, Kojima T. Evaluation of RANK/RANKL/OPG gene polymorphisms in aggressive periodontitis. J Periodontal Res. 2006 Oct;41(5):397-404.
TNFRSF11B	AgP+CP	49	98	0.028	Weak	Korean	CC	N	Tumor necrosis factor receptor superfamily, member 11b	OPG; TR1; OCIF; MGC29565; TNFRSF11B	8	T950	18938269	Park OJ, Shin SY, Choi Y, Kim MH, Chung CP, Ku Y, Kim KK. The association of osteoprotegerin gene polymorphisms with periodontitis. Oral Dis. 2008 Jul;14(5):440-4.
TNFRSF11B	CP	50	110	ns	None	Mixed	CC	N	Tumor necrosis factor receptor superfamily, member 11b	OPG; TR1; OCIF; MGC29565; TNFRSF11B	1	–223	18624938	Baioni CS, de Souza CM, Ribeiro Braosi AP, Luczyszyn SM, Dias da Silva MA, Ignácio SA, Naval Machado MA, Benato Martins WD, Riella MC, Pecoits-Filho R, Trevilatto PC. Analysis of the association of polymorphism in the osteoprotegerin gene with susceptibility to chronic kidney disease and periodontitis. J Periodontal Res. 2008 Oct;43(5):578-84. Epub 2008 Jul 4.

Continued

TABLE 6-3 Association Study—cont'd

Gene Symbol	Disease Type	Cases	Total	Best *P* Value	Level of Support	Population	Study Design	Stratified or Covariate Adj	Gene Name	Gene Aliases	# SNPs Assayed	SNP Name	PubMed ID	Journal
TNFRSF11B	CP	97	194	ns	None	German	CC	N	Tumor necrosis factor receptor superfamily, member 11b	OPG; TR1; OCIF; MGC29565; TNFRSF11B	2	Multiple SNPs	17711477	Wagner J, Kaminski WE, Aslanidis C, Moder D, Hiller KA, Christgau M, Schmitz G, Schmalz G. Prevalence of OPG and IL-1 gene polymorphisms in chronic periodontitis. J Clin Periodontol. 2007 Oct;34(10):823-7. Epub 2007 Aug 17.
TNFRSF11B	CP	137	219	ns	None	Caucasian	CC	GS	Tumor necrosis factor receptor superfamily, member 11b	OPG; TR1; OCIF; MGC29565; TNFRSF11B	1	245 T>G	16512757	Wohlfahrt JC, Wu T, Hodges JS, Hinrichs JE, Michalowicz BS. No association between selected candidate gene polymorphisms and severe chronic periodontitis. J Periodontol. 2006 Mar;77(3):426-36.
TNFRSF11B	CP&CKD	64	124	ns	None	Mixed	CC	N	Tumor necrosis factor receptor superfamily, member 11b	OPG; TR1; OCIF; MGC29565; TNFRSF11B	1	–223	18624938	Baioni CS, de Souza CM, Ribeiro Braosi AP, Luczyszyn SM, Dias da Silva MA, Ignácio SA, Naval Machado MA, Benato Martins WD, Riella MC, Pecoits-Filho R, Trevilatto PC. Analysis of the association of polymorphism in the osteoprotegerin gene with susceptibility to chronic kidney disease and periodontitis. J Periodontal Res. 2008 Oct;43(5):578-84. Epub 2008 Jul 4.
TNFRSF1A	AgP+CP	319	622	ns	None	Japanese	CC	AGS	Tumor necrosis factor receptor superfamily, member 1A	FPF; p55; p60; TBP1; TNF-R; TNFAR; TNFR1; p55-R; CD120a; TNFR55; TNFR60; TNF-R-I; TNF-R55; MGC19588; TNFRSF1A	1	–383	19892918	Kobayashi T, Nagata T, Murakami S, Takashiba S, Kurihara H, Izumi Y, Numabe Y, Watanabe H, Kataoka M, Nagai A, Hayashi J, Ohyama H, Okamatsu Y, Inagaki Y, Tai H, Yoshie H. Genetic risk factors for periodontitis in a Japanese population. J Dent Res. 2009 Dec;88(12): 1137-41.

TNFRSF1A	CP	22	41	ns	None	Japanese	CC	N	Tumor necrosis factor receptor superfamily, member 1A	FPF; p55; p60; TBP1; TNF-R; TNFAR; TNFR1; p55-R; CD120a; TNFR55; TNFR60; TNF-R-I; TNF-R55; MGC19588; TNFRSF1A	2	Multiple SNPs	15490304	Suzuki A, Ji G, Numabe Y, Ishii K, Muramatsu M, Kamoi K. Large-scale investigation of genomic markers for severe periodontitis. Odontology. 2004 Sep;92(1):43-7.
TNFRSF1B	AgP+CP	319	622	ns	None	Japanese	CC	AGS	Tumor necrosis factor receptor superfamily, member 1B	p75; TBPII; TNFBR; TNFR2; CD120b; TNFR1B; TNFR80; TNF-R75; p75TNFR; TNF-R-II; TNFRSF1B	2	n/a	19892918	Kobayashi T, Nagata T, Murakami S, Takashiba S, Kurihara H, Izumi Y, Numabe Y, Watanabe H, Kataoka M, Nagai A, Hayashi J, Ohyama H, Okamatsu Y, Inagaki Y, Tai H, Yoshie H. Genetic risk factors for periodontitis in a Japanese population. J Dent Res. 2009 Dec;88(12): 1137-41.
TNFRSF1B	CP	130	196	0.0075	Weak	Japanese	CC	N	Tumor necrosis factor receptor superfamily, member 1B	p75; TBPII; TNFBR; TNFR2; CD120b; TNFR1B; TNFR80; TNF-R75; p75TNFR; TNF-R-II; TNFRSF1B	1	+587	15142217	Shimada Y, Tai H, Endo M, Kobayashi T, Akazawa K, Yamazaki K. Association of tumor necrosis factor receptor type 2 +587 gene polymorphism with severe chronic periodontitis. J Clin Periodontol. 2004 Jun;31(6):463-9.
TNFSF11	AgP	99	188	ns	None	Japanese	CC	N	Tumor necrosis factor (ligand) superfamily, member 11	ODF; OPGL; sOdf; CD254; OPTB2; RANKL; TRANCE; hRANKL2; TNFSF11	7	Multiple SNPs	16953816	Soedarsono N, Rabello D, Kamei H, Fuma D, Ishihara Y, Suzuki M, Noguchi T, Sakaki Y, Yamaguchi A, Kojima T. Evaluation of RANK/RANKL/ OPG gene polymorphisms in aggressive periodontitis. J Periodontal Res. 2006 Oct;41(5):397-404.
TUB	CP	22	41	ns	None	Japanese	CC	N	Tubby homolog (mouse)	rd5; TUB	2	Multiple SNPs	15490304	Suzuki A, Ji G, Numabe Y, Ishii K, Muramatsu M, Kamoi K. Large-scale investigation of genomic markers for severe periodontitis. Odontology. 2004 Sep;92(1):43-7.
TULP	CP	22	41	ns	None	Japanese	CC	N	n/a	n/a	3	Multiple SNPs	15490304	Suzuki A, Ji G, Numabe Y, Ishii K, Muramatsu M, Kamoi K. Large-scale investigation of genomic markers for severe periodontitis. Odontology. 2004 Sep;92(1):43-7.

Continued

TABLE 6-3 Association Study—cont'd

Gene Symbol	Disease Type	Cases	Total	Best *P* Value	Level of Support	Population	Study Design	Stratified or Covariate Adj	Gene Name	Gene Aliases	# SNPs Assayed	SNP Name	PubMed ID	Journal
TXNL1	CP	22	41	ns	None	Japanese	CC	N	Thioredoxin-like 1	TxI; TXNL; TRP32; TXL-1; TXNL1	1	n/a	15490304	Suzuki A, Ji G, Numabe Y, Ishii K, Muramatsu M, Kamoi K. Large-scale investigation of genomic markers for severe periodontitis. Odontology. 2004 Sep;92(1):43-7.
UCP2	CP	22	41	ns	None	Japanese	CC	N	Uncoupling protein 2 (mitochondrial, proton carrier)	UCPH; BMIQ4; SLC25A8; UCP2	1	n/a	15490304	Suzuki A, Ji G, Numabe Y, Ishii K, Muramatsu M, Kamoi K. Large-scale investigation of genomic markers for severe periodontitis. Odontology. 2004 Sep;92(1):43-7.
UCP3	CP	22	41	ns	None	Japanese	CC	N	Uncoupling protein 3 (mitochondrial, proton carrier)	SLC25A9; UCP3	2	Multiple SNPs	15490304	Suzuki A, Ji G, Numabe Y, Ishii K, Muramatsu M, Kamoi K. Large-scale investigation of genomic markers for severe periodontitis. Odontology. 2004 Sep;92(1):43-7.
VDR	AgP	72	141	0.001	Weak	Caucasian	CC	N	Vitamin D (1,25- dihydroxyVitamin D3) receptor	NR1I1; VDR	1	TaqI in exon nine	10505806	Hennig BJ, Parkhill JM, Chapple IL, Heasman PA, Taylor JJ. Association of a vitamin D receptor gene polymorphism with localized early-onset periodontal diseases. J Periodontol. 1999 Sep;70(9):1032-8.
VDR	AgP	51	104	0.012	Weak	Chinese	CC	N	Vitamin D (1,25- dihydroxyVitamin D3) receptor	NR1I1; VDR	4	FokI	18205735	Li S, Yang MH, Zeng CA, Wu WL, Huang XF, Ji Y, Zeng JQ. Association of vitamin D receptor gene polymorphisms in Chinese patients with generalized aggressive periodontitis. J Periodontal Res. 2008 Jun;43(3):360-3. Epub 2008 Jan 17.
VDR	AgP	37	92	0.017	Weak	Chinese	CC	N	Vitamin D (1,25- dihydroxyVitamin D3) receptor	NR1I1; VDR	1	TaqI in exon nine	12836289	Tachi Y, Shimpuku H, Nosaka Y, Kawamura T, Shinohara M, Ueda M, Imai H, Ohura K, Sun J, Meng H, Cao C. Association of vitamin D receptor gene polymorphism with periodontal diseases in Japanese and Chinese. Nucleic Acids Res Suppl. 2001;(1):111-2.

VDR	AgP	37	76	0.017	Weak	Chinese	CC	N	Vitamin D (1,25- dihydroxyVitamin D3) receptor	NR1I1; VDR	1	TaqI	12200969	Sun JL, Meng HX, Cao CF, Tachi Y, Shinohara M, Ueda M, Imai H, Ohura K. Relationship between vitamin D receptor gene polymorphism and periodontitis. J Periodontal Res. 2002 Aug;37(4):263-7.
VDR	AgP	93	236	0.028	Weak	Korean	CC	N	Vitamin D (1,25- dihydroxyVitamin D3) receptor	NR1I1; VDR	3	27823C>T, FokI	16899094	Park KS, Nam JH, Choi J. The short vitamin D receptor is associated with increased risk for generalized aggressive periodontitis. J Clin Periodontol. 2006 Aug;33(8):524-8.
VDR	AgP	93	236	0.03	Weak	Korean	CC	N	Vitamin D (1,25- dihydroxyVitamin D3) receptor	NR1I1; VDR	3	C-G-T Haplotype	16899094	Park KS, Nam JH, Choi J. The short vitamin D receptor is associated with increased risk for generalized aggressive periodontitis. J Clin Periodontol. 2006 Aug;33(8):524-8.
VDR	AgP	51	151	ns	None	Caucasian	CC	N	Vitamin D (1,25- dihydroxyVitamin D3) receptor	NR1I1; VDR	1	–1056	16304445	Brett PM, Zygogianni P, Griffiths GS, Tomaz M, Parkar M, D'Aiuto F, Tonetti M. Functional gene polymorphisms in aggressive and chronic periodontitis. J Dent Res. 2005 Dec;84(12):1149-53.
VDR	AgP	42	97	ns	None	Japanese	CC	N	Vitamin D (1,25- dihydroxyVitamin D3) receptor	NR1I1; VDR	1	BsmI	11808760	Yoshihara A, Sugita N, Yamamoto K, Kobayashi T, Miyazaki H, Yoshi H. Analysis of vitamin D and Fcgamma receptor polymorphisms in Japanese patients with generalized early-onset periodontitis. J Dent Res. 2001 Dec;80(12):2051-4.
VDR	AgP	n/a	n/a	sig	Weak	Chinese	CC	N	Vitamin D (1,25- dihydroxyVitamin D3) receptor	NR1I1; VDR	1	n/a	19031816	Wang HY, Pan YP. [Screening and analysis of multi-alleles in generalized aggressive periodontitis]. Zhonghua Kou Qiang Yi Xue Za Zhi. 2008 Jul;43(7):406-9. Chinese.

Continued

TABLE 6-3 Association Study—cont'd

Gene Symbol	Disease Type	Cases	Total	Best *P* Value	Level of Support	Population	Study Design	Stratified or Covariate Adj	Gene Name	Gene Aliases	# SNPs Assayed	SNP Name	PubMed ID	Journal
VDR	AgP+CP	170	314	0.001	Moderate	Caucasian	CC	AG	Vitamin D (1,25- dihydroxyVitamin D3) receptor	NR1I1; VDR	1	–1056	18410395	Nibali L, Parkar M, D'Aiuto F, Suvan JE, Brett PM, Griffiths GS, Rosin M, Schwahn C, Tonetti MS. Vitamin D receptor polymorphism (-1056 Taq-I) interacts with smoking for the presence and progression of periodontitis. J Clin Periodontol. 2008 Jul;35(7):561-7. Epub 2008 Apr 10.
VDR	AgP+CP	319	622	0.002	Weak	Japanese	CC	AGS	Vitamin D (1,25- dihydroxyVitamin D3) receptor	NR1I1; VDR	1	+1056	19892918	Kobayashi T, Nagata T, Murakami S, Takashiba S, Kurihara H, Izumi Y, Numabe Y, Watanabe H, Kataoka M, Nagai A, Hayashi J, Ohyama H, Okamatsu Y, Inagaki Y, Tai H, Yoshie H. Genetic risk factors for periodontitis in a Japanese population. J Dent Res. 2009 Dec;88(12): 1137-41.
VDR	AgP+CP	65	110	ns	None	Black	CC	N	Vitamin D (1,25- dihydroxyVitamin D3) receptor	NR1I1; VDR	1	–1056	18410395	Nibali L, Parkar M, D'Aiuto F, Suvan JE, Brett PM, Griffiths GS, Rosin M, Schwahn C, Tonetti MS. Vitamin D receptor polymorphism (-1056 Taq-I) interacts with smoking for the presence and progression of periodontitis. J Clin Periodontol. 2008 Jul;35(7):561-7. Epub 2008 Apr 10.
VDR	AgP+CP	48	77	ns	None	Asian	CC	N	Vitamin D (1,25- dihydroxyVitamin D3) receptor	NR1I1; VDR	1	–1056	18410395	Nibali L, Parkar M, D'Aiuto F, Suvan JE, Brett PM, Griffiths GS, Rosin M, Schwahn C, Tonetti MS. Vitamin D receptor polymorphism (-1056 Taq-I) interacts with smoking for the presence and progression of periodontitis. J Clin Periodontol. 2008 Jul;35(7):561-7. Epub 2008 Apr 10.

VDR	AgP+CP	20	33	ns	None	Other	CC	N	Vitamin D (1,25- dihydroxyVitamin D3) receptor	NR1I1; VDR	1	–1056	18410395	Nibali L, Parkar M, D'Aiuto F, Suvan JE, Brett PM, Griffiths GS, Rosin M, Schwahn C, Tonetti MS. Vitamin D receptor polymorphism (-1056 Taq-I) interacts with smoking for the presence and progression of periodontitis. J Clin Periodontol. 2008 Jul;35(7):561-7. Epub 2008 Apr 10.
VDR	CP	n/a	125	0.004	Weak	Caucasian	Longitudinal	S	Vitamin D (1,25- dihydroxyVitamin D3) receptor	NR1I1; VDR	2	Apal	12666703	Inagaki K, Krall EA, Fleet JC, Garcia RI. Vitamin D receptor alleles, periodontal disease progression, and tooth loss in the VA dental longitudinal study. J Periodontol. 2003 Feb;74(2):161-7.
VDR	CP	17	97	0.01	Weak	Japanese	CC	ADGS	Vitamin D (1,25- dihydroxyVitamin D3) receptor	NR1I1; VDR	3	Apal.Bsml.FokI	17848979	Naito M, Miyaki K, Naito T, Zhang L, Hoshi K, Hara A, Masaki K, Tohyama S, Muramatsu M, Hamajima N, Nakayama T. Association between vitamin D receptor gene haplotypes and chronic periodontitis among Japanese men. Int J Med Sci. 2007 Aug 22;4(4):216-22.
VDR	CP	57	157	0.01	Weak	Caucasian	CC	N	Vitamin D (1,25- dihydroxyVitamin D3) receptor	NR1I1; VDR	1	–1056	16304445	Brett PM, Zygogianni P, Griffiths GS, Tomaz M, Parkar M, D'Aiuto F, Tonetti M. Functional gene polymorphisms in aggressive and chronic periodontitis. J Dent Res. 2005 Dec;84(12):1149-53.
VDR	CP	69	113	0.016	Weak	Brazilian	CC	N	Vitamin D (1,25- dihydroxyVitamin D3) receptor	NR1I1; VDR	1	TaqI	15455736	de Brito Júnior RB, Scarel-Caminaga RM, Trevilatto PC, de Souza AP, Barros SP. Polymorphisms in the vitamin D receptor gene are associated with periodontal disease. J Periodontol. 2004 Aug;75(8):1090-5.
VDR	CP	107	228	0.019	Weak	Chinese	CC	N	Vitamin D (1,25- dihydroxyVitamin D3) receptor	NR1I1; VDR	4	TaqI	19335080	Wang C, Zhao H, Xiao L, Xie C, Fan W, Sun S, Xie B, Zhang J. Association between vitamin D receptor gene polymorphisms and severe chronic periodontitis in a Chinese population. J Periodontol. 2009 Apr;80(4):603-8.

Continued

TABLE 6-3 Association Study—cont'd

Gene Symbol	Disease Type	Cases	Total	Best *P* Value	Level of Support	Population	Study Design	Stratified or Covariate Adj	Gene Name	Gene Aliases	# SNPs Assayed	SNP Name	PubMed ID	Journal
VDR	CP	30	60	0.023	Weak	Caucasian	CC	N	Vitamin D (1,25- dihydroxyVitamin D3) receptor	NR1I1; VDR	1	TaqI	19684957	Borges MA, de Figueiredo LC, de Brito RB Jr, Faveri M, Feres M. Microbiological composition associated with vitamin D receptor gene polymorphism in chronic periodontitis. Braz Oral Res. 2009 Apr-Jun;23(2):203-8.
VDR	CP	72	174	0.025	Weak	Turkish	CC	G	Vitamin D (1,25- dihydroxyVitamin D3) receptor	NR1I1; VDR	3	Haplotype	18316854	Gunes S, Sumer AP, Keles GC, Kara N, Koprulu H, Bagci H, Bek Y. Analysis of vitamin D receptor gene polymorphisms in patients with chronic periodontitis. Indian J Med Res. 2008 Jan;127(1):58-64.
VDR	CP	74	168	0.028	Weak	Japanese	CC	DS	Vitamin D (1,25- dihydroxyVitamin D3) receptor	NR1I1; VDR	2	TaqI in exon nine	14572874	Tachi Y, Shimpuku H, Nosaka Y, Kawamura T, Shinohara M, Ueda M, Imai H, Ohura K. Vitamin D receptor gene polymorphism is associated with chronic periodontitis. Life Sci. 2003 Nov 14;73(26):3313-21.
VDR	CP	72	166	0.041	Weak	Japanese	CC	N	Vitamin D (1,25- dihydroxyVitamin D3) receptor	NR1I1; VDR	1	TaqI in exon nine	12836289	Tachi Y, Shimpuku H, Nosaka Y, Kawamura T, Shinohara M, Ueda M, Imai H, Ohura K, Sun J, Meng H, Cao C. Association of vitamin D receptor gene polymorphism with periodontal diseases in Japanese and Chinese. Nucleic Acids Res Suppl. 2001;(1):111-2.
VDR	CP	69	113	<0.01	Weak	Brazilian	CC	N	Vitamin D (1,25- dihydroxyVitamin D3) receptor	NR1I1; VDR	2	TaqI/BsmI Haplotype	15455736	de Brito Júnior RB, Scarel-Caminaga RM, Trevilatto PC, de Souza AP, Barros SP. Polymorphisms in the vitamin D receptor gene are associated with periodontal disease. J Periodontol. 2004 Aug;75(8):1090-5.

VDR	CP	72	174	ns	None	Turkish	CC	N	Vitamin D (1,25- dihydroxyVitamin D3) receptor	NR1I1; VDR	3	Multiple SNPs	18316854	Gunes S, Sumer AP, Keles GC, Kara N, Koprulu H, Bagci H, Bek Y. Analysis of vitamin D receptor gene polymorphisms in patients with chronic periodontitis. Indian J Med Res. 2008 Jan;127(1):58-64.
VDR	CP	n/a	222	ns	None	Brazilian	CC	N	Vitamin D (1,25- dihydroxyVitamin D3) receptor	NR1I1; VDR	2	Multiple SNPs	17914260	de Souza CM, Braosi AP, Luczyszyn SM, Avila AR, de Brito RB Jr, Ignácio SA, Probst CM, Riella MC, Sotomaior VS, Mira MT, Pecoits-Filho R, Trevilatto PC. Association between vitamin D receptor gene polymorphisms and susceptibility to chronic kidney disease and periodontitis. Blood Purif. 2007;25(5-6):411-9. Epub 2007 Oct 3.
VDR	CP	17	97	ns	None	Japanese	CC	ADGS	Vitamin D (1,25- dihydroxyVitamin D3) receptor	NR1I1; VDR	3	Multiple SNPs	17848979	Naito M, Miyaki K, Naito T, Zhang L, Hoshi K, Hara A, Masaki K, Tohyama S, Muramatsu M, Hamajima N, Nakayama T. Association between vitamin D receptor gene haplotypes and chronic periodontitis among Japanese men. Int J Med Sci. 2007 Aug 22;4(4):216-22.
VDR	CP	22	41	ns	None	Japanese	CC	N	Vitamin D (1,25- dihydroxyVitamin D3) receptor	NR1I1; VDR	3	Multiple SNPs	15490304	Suzuki A, Ji G, Numabe Y, Ishii K, Muramatsu M, Kamoi K. Large-scale investigation of genomic markers for severe periodontitis. Odontology. 2004 Sep;92(1):43-7.
VDR	CP	69	113	ns	None	Brazilian	CC	N	Vitamin D (1,25- dihydroxyVitamin D3) receptor	NR1I1; VDR	1	Bsml	15455736	de Brito Júnior RB, Scarel-Caminaga RM, Trevilatto PC, de Souza AP, Barros SP. Polymorphisms in the vitamin D receptor gene are associated with periodontal disease. J Periodontol. 2004 Aug;75(8):1090-5.
VDR	CP	24	63	ns	None	Chinese	CC	N	Vitamin D (1,25- dihydroxyVitamin D3) receptor	NR1I1; VDR	1	Taql	12200969	Sun JL, Meng HX, Cao CF, Tachi Y, Shinohara M, Ueda M, Imai H, Ohura K. Relationship between vitamin D receptor gene polymorphism and periodontitis. J Periodontal Res. 2002 Aug;37(4):263-7.

Continued

TABLE 6-3 Association Study—cont'd

Gene Symbol	Disease Type	Cases	Total	Best *P* Value	Level of Support	Population	Study Design	Stratified or Covariate Adj	Gene Name	Gene Aliases	# SNPs Assayed	SNP Name	PubMed ID	Journal
VDR	CP	52	107	ns	None	Japanese	CC	N	Vitamin D (1,25- dihydroxyVitamin D3) receptor	NR1I1; VDR	1	Bsml	11808760	Yoshihara A, Sugita N, Yamamoto K, Kobayashi T, Miyazaki H, Yoshi H. Analysis of vitamin D and Fcgamma receptor polymorphisms in Japanese patients with generalized early-onset periodontitis. J Dent Res. 2001 Dec;80(12):2051-4.
VDR	CP	n/a	n/a	sig	Weak	Chinese	CC	N	Vitamin D (1,25- dihydroxyVitamin D3) receptor	NR1I1; VDR	3	Apal	18846948	Wang HY, Pan YP, Teng D, Zhao J, Lin L. [The relativity between chronic periodontitis and the genetic polymorphisms of vitamin D receptor and estrogen receptor]. Zhonghua Kou Qiang Yi Xue Za Zhi. 2008 Apr;43(4):236-9. Chinese.
VDR	CP	166	246	sig	Weak	Chinese	CC	N	Vitamin D (1,25- dihydroxyVitamin D3) receptor	NR1I1; VDR	3	Apal	15774153	Zhang JC, Geng HO, Ma WB, Huang P, Pang RY, Zhang YH. [Association of vitamin D receptor gene polymorphisms with the susceptibility to chronic periodontitis of Han nationality]. Zhonghua Kou Qiang Yi Xue Za Zhi. 2005 Jan;40(1):50-3. Chinese.
VDR. FCGR3B	AgP	42	97	0.011	Weak	Japanese	CC	N	n/a	n/a	2	Multiple Genes	11808760	Yoshihara A, Sugita N, Yamamoto K, Kobayashi T, Miyazaki H, Yoshi H. Analysis of vitamin D and Fcgamma receptor polymorphisms in Japanese patients with generalized early-onset periodontitis. J Dent Res. 2001 Dec;80(12):2051-4.
VDR. FCGR3B	CP	52	107	ns	None	Japanese	CC	N	n/a	n/a	2	Multiple Genes	11808760	Yoshihara A, Sugita N, Yamamoto K, Kobayashi T, Miyazaki H, Yoshi H. Analysis of vitamin D and Fcgamma receptor polymorphisms in Japanese patients with generalized early-onset periodontitis. J Dent Res. 2001 Dec;80(12):2051-4.

VEGFA	AgP	98	186	ns	None	Japanese	CC	N	Vascular endothelial growth factor A	VPF; VEGF; MVCD1; VEGF-A; MGC70609; VEGFA	15	Multiple SNPs	16844084	Rabello D, Soedarsono N, Kamei H, Ishihara Y, Noguchi T, Fuma D, Suzuki M, Sakaki Y, Yamaguchi A, Kojima T. CSF1 gene associated with aggressive periodontitis in the Japanese population. Biochem Biophys Res Commun. 2006 Sep 1;347(3):791-6. Epub 2006 Jul 7.
VEGFA	CP	22	41	ns	None	Japanese	CC	N	Vascular endothelial growth factor A	VPF; VEGF; MVCD1; VEGF-A; MGC70609; VEGFA	1	n/a	15490304	Suzuki A, Ji G, Numabe Y, Ishii K, Muramatsu M, Kamoi K. Large-scale investigation of genomic markers for severe periodontitis. Odontology. 2004 Sep;92(1):43-7.
VIPR1	CP	22	41	ns	None	Japanese	CC	N	Vasoactive intestinal peptide receptor 1	II; HVR1; RDC1; V1RG; VIPR; VIRG; VAPC1; VPAC1; VPCAP1R; FLJ41949; PACAP-R-2; VIPR1	4	Multiple SNPs	15490304	Suzuki A, Ji G, Numabe Y, Ishii K, Muramatsu M, Kamoi K. Large-scale investigation of genomic markers for severe periodontitis. Odontology. 2004 Sep;92(1):43-7.
VLDLR	CP	22	41	ns	None	Japanese	CC	N	Very low density lipoprotein receptor	CHRMQ1; VLDLRCH; FLJ35024; VLDLR	3	Multiple SNPs	15490304	Suzuki A, Ji G, Numabe Y, Ishii K, Muramatsu M, Kamoi K. Large-scale investigation of genomic markers for severe periodontitis. Odontology. 2004 Sep;92(1):43-7.
VWF	CP	22	41	ns	None	Japanese	CC	N	von Willebrand factor	VWD; F8VWF; VWF	3	Multiple SNPs	15490304	Suzuki A, Ji G, Numabe Y, Ishii K, Muramatsu M, Kamoi K. Large-scale investigation of genomic markers for severe periodontitis. Odontology. 2004 Sep;92(1):43-7.
YWHAH	CP	22	41	ns	None	Japanese	CC	N	Tyrosine 3-monooxygenase/ tryptophan 5-monooxygenase activation protein, eta polypeptide	YWHA1; YWHAH	4	Multiple SNPs	15490304	Suzuki A, Ji G, Numabe Y, Ishii K, Muramatsu M, Kamoi K. Large-scale investigation of genomic markers for severe periodontitis. Odontology. 2004 Sep;92(1):43-7.

Continued

TABLE 6-3 Association Study—cont'd

This table contains 15 columns, which are described in detail below. Each row represents the association test result from testing DNA polymorphisms of a gene against a specific disease definition among individuals from a specific population. Therefore, a study may have multiple rows in this table when it includes multiple disease definitions, multiple ethnic groups, and multiple candidate genes.

Header Description

A — Gene Symbol

National Center for Biotechnology Information (NCBI) official gene symbol (i.e., a clickable hyperlink to more information about the gene) or the study's reported gene symbol if the NCBI symbol is not available. When the genotype combinations of multiple genes are tested, the gene symbols are concatenated by a period (e.g., "IL1A.IL1B").

B — Disease Type

Types of periodontal disease being tested:

- AgP: Aggressive periodontitis
- AgP&T1DM: Aggressive periodontitis and type 1 diabetes mellitus
- AgP+CP: Test population includes aggressive periodontitis individual and chronic periodontal disease individual
- CP: Chronic periodontitis
- CP&AMI: Chronic periodontitis and acute myocardial infarction
- CP&CHD: Chronic periodontitis and coronary heart disease
- CP&CKD: Chronic periodontitis and chronic kidney disease
- CP&HIV: Chronic periodontitis and human immunodeficiency virus infection
- CP&RA: Chronic periodontitis and rheumatoid arthritis
- CP&SLE: Chronic periodontitis and systemic lupus erythematosus
- CP&T1DM: Chronic periodontitis and type 1 diabetes mellitus
- CP&T2DM: Chronic periodontitis and type 2 diabetes mellitus
- PPP: Prepubertal periodontitis

C — Cases

- Number of cases included in the tests

D — Total

- Total number of individuals included in the tests (cases and controls)

E — Best *P* Value

- The most significant reported *P* value; may also be reported as *sig* (significant but *P* value not available) or *ns* (not significant)

F — Level of Support

- Level of support of association according to the combination of study size and the reported best *P* value: *S,* strong; *M,* moderate; *W,* weak; and *None*

e sSple size (no. of cases)

***P* value**

<50	51–100	101–250	>250	
<0.05	W	W	W	W
<0.001	W	M	M	M
<0.0001	W	M	M	S

G — Population

- Reported ethnic group in the tests

H — Study Design

- *CC:* Case–control study; *Fam,* family study; *Longitudinal,* longitudinal study; *Quan:* quantitative measures study

I — Stratified or Covariate Adj

J — Gene Name

- NCBI official full name of gene; *n/a,* not available

K — Gene Aliases

- NCBI reported gene alias; *n/a,* not available

L	# SNPs Assayed • The number of molecular assays run for the gene *GWAS,* genome-wide association study; *n/a,* not available
M	SNP Name • SNP name reported in the study *Multiple Genes,* when combined genotype from different genes is tested; *Multiple SNPs,* when combined genotype from multiple SNPs of the gene is tested or none of SNPs tested are associated; *n/a,* not available
N	PubMed ID • PubMed ID of the study article, given as a clickable hyperlink to bring up the PubMed abstract page
O	Journal • Publication information from PubMed

1. Agrawal AA, Kapley A, Yeltiwar RK, et al: Assessment of single nucleotide polymorphism at IL-1A+4845 and IL-1B+3954 as genetic susceptibility test for chronic periodontitis in Maharashtrian ethnicity. *J Periodontol* 77(9):1515–1521, 2006.
2. Alley CS, Reinhardt RA, Maze CA: HLA-D and T lymphocyte reactivity to specific periodontal pathogens in type 1 diabetic periodontitis. *J Periodontol* 64(10):974–979, 1993.
3. Amer A, Singh G, Darke C, et al: Association between HLA antigens and periodontal disease. *Tissue Antigens* 31(2):53–58, 1988.
4. An N, Ou-Yang XY, Cao CF, et al: Association of Fc gamma receptors IIIA gene polymorphisms with the susceptibility to periodontitis in Chinese patients [article in Chinese]. *Beijing Da Xue Xue Bao* 41(1):40–43, 2009.
5. Astolfi CM, Shinohara AL, da Silva RA, et al: Genetic polymorphisms in the MMP-1 and MMP-3 gene may contribute to chronic periodontitis in a Brazilian population. *J Clin Periodontol* 33(10):699–703, 2006.
6. Atilla G, Emingil G, Kose T, et al: TGF-beta1 gene polymorphisms in periodontal diseases. *Clin Biochem* 39(9):929–934, 2006.
7. Babel N, Cherepnev G, Babel D: Analysis of tumor necrosis factor-alpha, transforming growth factor-beta, interleukin-10, IL-6, and interferon-gamma gene polymorphisms in patients with chronic periodontitis. *J Periodontol* 77(12):1978–1983, 2006.
8. Baioni CS, de Souza CM, Ribeiro Braosi AP: Analysis of the association of polymorphism in the osteoprotegerin gene with susceptibility to chronic kidney disease and periodontitis. *J Periodontal Res* 43(5):578–584, 2008.
9. Balndin-Texier A, Gueguin M, Fauchet R, et al: The HLA-A9 antigen and chronic periodontitis [article in French]. *J Parodontol* 5(3):221–227, 1986.
10. Berdeli A, Emingil G, Gurkan A, et al: Association of the IL-1RN2 allele with periodontal diseases. *Clin Biochem* 39(4):357–362, 2006.
11. Berdeli A, Emingil G, Han Saygan B: TLR2 Arg753Gly, TLR4 Asp299Gly and Thr399Ile gene polymorphisms are not associated with chronic periodontitis in a Turkish population. *J Clin Periodontol* 34(7):551–557, 2007.
12. Berdeli A, Gurkan A, Emingil G, et al: Endothelial nitric oxide synthase Glu298Asp gene polymorphism in periodontal diseases. *J Periodontol* 77(8):1348–1354, 2006.
13. Berglundh T, Donati M, Hahn-Zoric M, et al: Association of the -1087 IL 10 gene polymorphism with severe chronic periodontitis in Swedish Caucasians. *J Clin Periodontol* 30(3):249–254, 2003.
14. Bonfil JJ, Dillier FL, Mercier P: A "case control" study on the role of HLA DR4 in severe periodontitis and rapidly progressive periodontitis. Identification of types and subtypes using molecular biology (PCR.SSO). *J Clin Periodontol* 26(2):77–84, 1999.
15. Boniotto M, Hazbon MH, Jordan WJ: Novel hairpin-shaped primer assay to study the association of the -44 single-nucleotide polymorphism of the DEFB1 gene with early-onset periodontal disease. *Clin Diagn Lab Immunol* 11(4):766–769, 2004.
16. Borges MA, de Figueiredo LC, de Brito RB, Jr, et al: Microbiological composition associated with vitamin D receptor gene polymorphism in chronic periodontitis. *Braz Oral Res* 23(2):203–208, 2009.
17. Brett PM, Zygogianni P, Griffiths GS: Functional gene polymorphisms in aggressive and chronic periodontitis. *J Dent Res* 84(12):1149–1153, 2005.
18. Cao Z, Li C, Jin L, et al: Association of matrix metalloproteinase-1 promoter polymorphism with generalized aggressive periodontitis in a Chinese population. *J Periodontal Res* 40(6):427–431, 2005.
19. Cao Z, Li C, Zhu G: MMP-1 promoter gene polymorphism and susceptibility to chronic periodontitis in a Chinese population. *Tissue Antigens* 68(1):38–43, 2006.
20. Chai L, Song YQ, Zee KY, et al: Single nucleotide polymorphisms of complement component 5 and periodontitis. *J Periodontal Res* 45(3):301–308, 2010.
21. Chen D, Wang Q, Ma ZW: MMP-2, MMP-9 and TIMP-2 gene polymorphisms in Chinese patients with generalized aggressive periodontitis. *J Clin Periodontol* 34(5):384–389, 2007.
22. Chung HY, Lu HC, Chen WL, et al: Gm (23) allotypes and Fcgamma receptor genotypes as risk factors for various forms of periodontitis. *J Clin Periodontol* 30(11):954–960, 2003.
23. Claudino M, Trombone AP, Cardoso CR: The broad effects of the functional IL-10 promoter-592 polymorphism: modulation of IL-10, TIMP-3, and OPG expression and their association with periodontal disease outcome. *J Leukoc Biol* 84(6):1565–1573, 2008.
24. Cogen RB, Roseman JM, Al-Joburi W: Host factors in juvenile periodontitis. *J Dent Res* 65(3):394–399, 1986.
25. Colombo AP, Eftimiadi C, Haffajee AD, et al: Serum IgG2 level, Gm(23) allotype and FcgammaRIIa and FcgammaRIIIb receptors in refractory periodontal disease. *J Clin Periodontol* 25(6):465–474, 1998.
26. Concolino P, Cecchetti F, D'Autilia C: Association of periodontitis with GSTM1/GSTT1-null variants—a pilot study. *Clin Biochem* 40(13–14):939–945, 2007.
27. Costa AM, Guimaraes MC, de Souza ER, et al: Interleukin-6 (G-174C) and tumour necrosis factor-alpha (G-308A) gene polymorphisms in geriatric patients with chronic periodontitis. *Gerodontology* 27(1):70–75, 2010.
28. Costa JE, Gomes CC, Cota LO: Polymorphism in the promoter region of the gene for 5-HTT in individuals with aggressive periodontitis. *J Oral Sci* 50(2):193–198, 2008.
29. Craandijk J, van Krugten MV, Verweij CL, et al: Tumor necrosis factor-alpha gene polymorphisms in relation to periodontitis. *J Clin Periodontol* 29(1):28–34, 2002.
30. Cullinan MP, Sachs J, Wolf E, et al: The distribution of HLA-A and -B antigens in patients and their families with periodontosis. *J Periodontal Res* 15(2):177–184, 1980.
31. Cullinan MP, Westerman B, Hamlet SM: A longitudinal study of interleukin-1 gene polymorphisms and periodontal disease in a general adult population. *J Clin Periodontol* 28(12):1137–1144, 2001.
32. Cullinan MP, Westerman B, Hamlet SM: Progression of periodontal disease and interleukin-10 gene polymorphism. *J Periodontal Res* 43(3):328–333, 2008.
33. Dashash M, Nugent J, Baker P, et al: Interleukin-6 -174 genotype, periodontal disease and adverse pregnancy outcomes: a pilot study. *J Clin Immunol* 28(3):237–243, 2008.
34. de Brito Junior RB, Scarel-Caminaga RM, Trevilatto PC, et al: Polymorphisms in the vitamin D receptor gene are associated with periodontal disease. *J Periodontol* 75(8):1090–1095, 2004.

Continued

TABLE 6-3 Association Study—cont'd

35. de Souza AP, Trevilatto PC, Scarel-Caminaga RM, et al: MMP-1 promoter polymorphism: association with chronic periodontitis severity in a Brazilian population. *J Clin Periodontol* 30(2):154–158, 2003.
36. de Souza AP, Trevilatto PC, Scarel-Caminaga RM, et al: Analysis of the MMP-9 (C-1562 T) and TIMP-2 (G-418C) gene promoter polymorphisms in patients with chronic periodontitis. *J Clin Periodontol* 32(2):207–211, 2005.
37. de Souza AP, Trevilatto PC, Scarel-Caminaga RM, et al: Analysis of the TGF-beta1 promoter polymorphism (C-509T) in patients with chronic periodontitis. *J Clin Periodontol* 30(6):519–523, 2003.
38. de Souza CM, Braosi AP, Luczyszyn SM: Association between vitamin D receptor gene polymorphisms and susceptibility to chronic kidney disease and periodontitis. *Blood Purif* 25(5–6):411–419, 2007.
39. de Souza RC, Colombo AP: Distribution of FcgammaRIIa and FcgammaRIIIb genotypes in patients with generalized aggressive periodontitis. *J Periodontol* 77(7):1120–1128, 2006.
40. DeCarlo AA, Grenett H, Park J, et al: Association of gene polymorphisms for plasminogen activators with alveolar bone loss. *J Periodontal Res* 42(4):305–310, 2007.
41. Diehl SR, Wang Y, Brooks CN: Linkage disequilibrium of interleukin-1 genetic polymorphisms with early-onset periodontitis. *J Periodontol* 70(4):418–430, 1999.
42. Donati M, Berglundh T, Hytonen AM, et al: Association of the -159 CD14 gene polymorphism and lack of association of the -308 TNFA and Q551R IL-4RA polymorphisms with severe chronic periodontitis in Swedish Caucasians. *J Clin Periodontol* 32(5):474–479, 2005.
43. Drozdzik A: The effect of environmental and genetic factors in the pathogenesis of periodontitis [article in Polish]. *Ann Acad Med Stetin* 54(1):118–126, 2008.
44. Drozdzik A, Kurzawski M, Safronow K, et al: Polymorphism in interleukin-1beta gene and the risk of periodontitis in a Polish population. *Adv Med Sci* 51(Suppl 1):13–17, 2006.
45. Duan H, Zhang J, Zhang Y: The association between IL-1 gene polymorphisms and susceptibility to severe periodontitis [article in Chinese]. *Hua Xi Kou Qiang Yi Xue Za Zhi* 20(1):48–51, 2002.
46. Ehmke B, Kress W, Karch H, et al: Interleukin-1 haplotype and periodontal disease progression following therapy. *J Clin Periodontol* 26(12):810–813, 1999.
47. Emingil G, Berdeli A, Baylas H: Toll-like receptor 2 and 4 gene polymorphisms in generalized aggressive periodontitis. *J Periodontol* 78(10):1968–1977, 2007.
48. Emingil G, Berdeli A, Gurkan A, et al: Gene polymorphisms of tissue plasminogen activator and plasminogen activator inhibitor-1 in Turkish patients with generalized aggressive periodontitis. *J Clin Periodontol* 34(4):278–284, 2007.
49. Endo M, Tai H, Tabeta K, et al: Analysis of single nucleotide polymorphisms in the 5′-flanking region of tumor necrosis factor-alpha gene in Japanese patients with early-onset periodontitis. *J Periodontol* 72(11):1554–1559, 2001.
50. Fassmann A, Holla LI, Buckova D, et al: Polymorphisms in the +252(A/G) lymphotoxin-alpha and the –308(A/G) tumor necrosis factor-alpha genes and susceptibility to chronic periodontitis in a Czech population. *J Periodontal Res* 38(4):394–399, 2003.
51. Ferreira SB, Jr, Trombone AP, Repeke CE: An interleukin-1beta (IL-1beta) single-nucleotide polymorphism at position 3954 and red complex periodontopathogens independently and additively modulate the levels of IL-1beta in diseased periodontal tissues. *Infect Immun* 76(8):3725–3734, 2008.
52. Fiebig A, Jepsen S, Loos BG: Polymorphisms in the interleukin-1 (IL1) gene cluster are not associated with aggressive periodontitis in a large Caucasian population. *Genomics* 92(5):309–315, 2008.
53. Firatli E, Kantarci A, Cebeci I: Association between HLA antigens and early onset periodontitis. *J Clin Periodontol* 23(6):563–566, 1996.
54. Folwaczny M, Glas J, Torok HP, et al: Prevalence of the chemokine receptor CCR5-Delta32 gene mutation in periodontal disease. *Clin Immunol* 109(3):325–329, 2003.
55. Folwaczny M, Glas J, Torok HP, et al: The CD14 -159C-to-T promoter polymorphism in periodontal disease. *J Clin Periodontol* 31(11):991–995, 2004.
56. Folwaczny M, Glas J, Torok HP, et al: Toll-like receptor (TLR) 2 and 4 mutations in periodontal disease. *Clin Exp Immunol* 135(2):330–335, 2004.
57. Folwaczny M, Glas J, Torok HP, et al: The 3020insC mutation of the NOD2/CARD15 gene in patients with periodontal disease. *Eur J Oral Sci* 112(4):316–319, 2004.
58. Folwaczny M, Glas J, Torok HP, et al: Lack of association between the TNF alpha G -308 A promoter polymorphism and periodontal disease. *J Clin Periodontol* 31(6):449–453, 2004.
59. Folwaczny M, Glas J, Torok HP: Polymorphisms of the interleukin-18 gene in periodontitis patients. *J Clin Periodontol* 32(5):530–534, 2005.
60. Folwaczny M, Glas J, Torok HP: Prevalence of the -295 T-to-C promoter polymorphism of the interleukin (IL)-16 gene in periodontitis. *Clin Exp Immunol* 142(1):188–192, 2005.
61. Fraser DA, Loos BG, Boman U: Polymorphisms in an interferon-gamma receptor-1 gene marker and susceptibility to periodontitis. *Acta Odontol Scand* 61(5):297–302, 2003.
62. Fu Y, Cao C, Wang S: Relevance of Fc gamma R polymorphism to the susceptibility of early-onset periodontitis [article in Chinese]. *Zhonghua Kou Qiang Yi Xue Za Zhi* 34(6):364–366, 1999.
63. Fu Y, Korostoff JM, Fine DH, et al: Fc gamma receptor genes as risk markers for localized aggressive periodontitis in African-Americans. *J Periodontol* 73(5):517–523, 2002.
64. Fujigaki Y, Imamura Y, Oomori Y, et al: Polymorphism of salivary histatin gene and periodontal disease in the Japanese population. *J Int Acad Periodontol* 11(3):220–225, 2009.
65. Fukusaki T, Ohara N, Hara Y, et al: Evidence for association between a Toll-like receptor 4 gene polymorphism and moderate/severe periodontitis in the Japanese population. *J Periodontal Res* 42(6):541–545, 2007.
66. Galbraith GM, Hendley TM, Sanders JJ, et al: Polymorphic cytokine genotypes as markers of disease severity in adult periodontitis. *J Clin Periodontol* 26(11):705–709, 1999.
67. Galbraith GM, Steed RB, Sanders JJ, et al: Tumor necrosis factor alpha production by oral leukocytes: influence of tumor necrosis factor genotype. *J Periodontol* 69(4):428–433, 1998.
68. Galicia JC, Tai H, Komatsu Y, et al: Interleukin-6 receptor gene polymorphisms and periodontitis in a non-smoking Japanese population. *J Clin Periodontol* 33(10):704–709, 2006.
69. Ge S, Wu YF, Liu TJ, et al: Correlation between levels of fibrinogen, beta455 g/A fibrinogen gene polymorphism and chronic periodontitis [article in Chinese]. *Zhonghua Kou Qiang Yi Xue Za Zhi* 43(2):87–91, 2008.
70. Geismar K, Enevold C, Sorensen LK: Involvement of interleukin-1 genotypes in the association of coronary heart disease with periodontitis. *J Periodontol* 79(12):2322–2330, 2008.
71. Glas J, Beynon V, Bachstein B: Increased plasma concentration of surfactant protein D in chronic periodontitis independent of SFTPD genotype: potential role as a biomarker. *Tissue Antigens* 72(1):21–28, 2008.
72. Glas J, Torok HP, Tonenchi L: A645G (Lys216Glu) polymorphism of the bactericidal/permeability-increasing protein gene in periodontal disease. *Int J Immunogenet* 33(4):255–260, 2006.
73. Goncalves LS, Ferreira SM, Souza CO, et al: IL-1 gene polymorphism and periodontal status of HIV Brazilians on highly active antiretroviral therapy. *AIDS* 20(13):1779–1781, 2006.
74. Goncalves LS, Ferreira SM, Souza CO, et al: Influence of IL-1 gene polymorphism on the periodontal microbiota of HIV-infected Brazilian individuals. *Braz Oral Res* 23(4):452–459, 2009.
75. Gonzales JR, Kobayashi T, Michel J, et al: Interleukin-4 gene polymorphisms in Japanese and Caucasian patients with aggressive periodontitis. *J Clin Periodontol* 31(5):384–389, 2004.
76. Gonzales JR, Mann M, Stelzig J, et al: Single-nucleotide polymorphisms in the IL-4 and IL-13 promoter region in aggressive periodontitis. *J Clin Periodontol* 34(6):473–479, 2007.
77. Gonzales JR, Michel J, Diete A, et al: Analysis of genetic polymorphisms at the interleukin-10 loci in aggressive and chronic periodontitis. *J Clin Periodontol* 29(9):816–822, 2002.

78. Gonzales JR, Michel J, Rodriguez EL, et al: Comparison of interleukin-1 genotypes in two populations with aggressive periodontitis. *Eur J Oral Sci* 111(5):395–399, 2003.
79. Gore EA, Sanders JJ, Pandey JP, et al: Interleukin-1beta+3953 allele 2: association with disease status in adult periodontitis. *J Clin Periodontol* 25(10):781–785, 1998.
80. Goteiner D, Goldman MJ: Human lymphocyte antigen haplotype and resistance to periodontitis. *J Periodontol* 55(3):155–158, 1984.
81. Guan ZM, Liu JJ, Ma X, et al: Relationship between interleukin-6 gene-572C/G polymorphism and chronic periodontitis [article in Chinese]. *Zhonghua Kou Qiang Yi Xue Za Zhi* 43(7):410–413, 2008.
82. Gunes S, Sumer AP, Keles GC: Analysis of vitamin D receptor gene polymorphisms in patients with chronic periodontitis. *Indian J Med Res* 127(1):58–64, 2008.
83. Gunji T, Onouchi Y, Nagasawa T: Functional polymorphisms of the FPR1 gene and aggressive periodontitis in Japanese. *Biochem Biophys Res Commun* 364(1):7–13, 2007.
84. Gurkan A, Emingil G, Saygan BH: Matrix metalloproteinase-2, -9, and -12 gene polymorphisms in generalized aggressive periodontitis. *J Periodontol* 78(12):2338–2347, 2007.
85. Gurkan A, Emingil G, Saygan BH: Gene polymorphisms of matrix metalloproteinase-2, -9 and -12 in periodontal health and severe chronic periodontitis. *Arch Oral Biol* 53(4):337–345, 2008.
86. Gurkan A, Emingil G, Saygan BH: Angiotensin-converting enzyme (ACE), angiotensinogen (AGT), and angiotensin II type 1 receptor (AT1R) gene polymorphisms in generalized aggressive periodontitis. *Arch Oral Biol* 54(4):337–344, 2009.
87. Gurkan A, Emingil G, Saygan BH: Renin-angiotensin gene polymorphisms in relation to severe chronic periodontitis. *J Clin Periodontol* 36(3):204–211, 2009.
88. Gurkan A, Emingil G, Saygan BH: Tissue plasminogen activator and plasminogen activator inhibitor-1 gene polymorphisms in patients with chronic periodontitis. *J Periodontol* 78(7):1256–1263, 2007.
89. Gustafsson A, Ito H, Asman B, et al: Hyper-reactive mononuclear cells and neutrophils in chronic periodontitis. *J Clin Periodontol* 33(2):126–129, 2006.
90. Guzeldemir E, Gunhan M, Ozcelik O, et al: Interleukin-1 and tumor necrosis factor-alpha gene polymorphisms in Turkish patients with localized aggressive periodontitis. *J Oral Sci* 50(2):151–159, 2008.
91. Guzman S, Karima M, Wang HY, et al: Association between interleukin-1 genotype and periodontal disease in a diabetic population. *J Periodontol* 74(8):1183–1190, 2003.
92. Gwinn MR, Sharma A, De Nardin E: Single nucleotide polymorphisms of the N-formyl peptide receptor in localized juvenile periodontitis. *J Periodontol* 70(10):1194–1201, 1999.
93. Hart TC, Hart PS, Michalec MD: Localisation of a gene for prepubertal periodontitis to chromosome 11q14 and identification of a cathepsin C gene mutation. *J Med Genet* 37(2):95–101, 2000.
94. Hart TC, Marazita ML, McCanna KM, et al: Reevaluation of the chromosome 4q candidate region for early onset periodontitis. *Hum Genet* 91(5):416–422, 1993.
95. Havemose-Poulsen A, Sorensen LK, Bendtzen K, et al: Polymorphisms within the IL-1 gene cluster: effects on cytokine profiles in peripheral blood and whole blood cell cultures of patients with aggressive periodontitis, juvenile idiopathic arthritis, and rheumatoid arthritis. *J Periodontol* 78(3):475–492, 2007.
96. Hennig BJ, Parkhill JM, Chapple IL, et al: Association of a vitamin D receptor gene polymorphism with localized early-onset periodontal diseases. *J Periodontol* 70(9):1032–1038, 1999.
97. Hennig BJ, Parkhill JM, Chapple IL, et al: Dinucleotide repeat polymorphism in the interleukin-10 gene promoter (IL-10.G) and genetic susceptibility to early-onset periodontal disease. *Genes Immun* 1(6):402–404, 2000.
98. Hewitt C, McCormick D, Linden G: The role of cathepsin C in Papillon-Lefèvre syndrome, prepubertal periodontitis, and aggressive periodontitis. *Hum Mutat* 23(3):222–228, 2004.
99. Ho YP, Lin YC, Yang YH, et al: Cyclooxygenase-2 Gene-765 single nucleotide polymorphism as a protective factor against periodontitis in Taiwanese. *J Clin Periodontol* 35(1):1–8, 2008.
100. Hodge PJ, Riggio MP, Kinane DF: No association with HLA-DQB1 in European Caucasians with early-onset periodontitis. *Tissue Antigens* 54(2):205–207, 1999.
101. Hodge PJ, Riggio MP, Kinane DF: Failure to detect an association with IL1 genotypes in European Caucasians with generalised early onset periodontitis. *J Clin Periodontol* 28(5):430–436, 2001.
102. Holla LI, Buckova D, Fassmann A, et al: Promoter polymorphisms in the CD14 receptor gene and their potential association with the severity of chronic periodontitis. *J Med Genet* 39(11):844–848, 2002.
103. Holla LI, Fassmann A, Augustin P, et al: The association of interleukin-4 haplotypes with chronic periodontitis in a Czech population. *J Periodontol* 79(10):1927–1933, 2008.
104. Holla LI, Fassmann A, Benes P, et al: 5 polymorphisms in the transforming growth factor-beta 1 gene (TGF-beta 1) in adult periodontitis. *J Clin Periodontol* 29(4):336–341, 2002.
105. Holla LI, Fassmann A, Muzik J, et al: Functional polymorphisms in the matrix metalloproteinase-9 gene in relation to severity of chronic periodontitis. *J Periodontol* 77(11):1850–1855, 2006.
106. Holla LI, Fassmann A, Stejskalova A, et al: Analysis of the interleukin-6 gene promoter polymorphisms in Czech patients with chronic periodontitis. *J Periodontol* 75(1):30–36, 2004.
107. Holla LI, Fassmann A, Vasku A: Genetic variations in the human gelatinase A (matrix metalloproteinase-2) promoter are not associated with susceptibility to, and severity of, chronic periodontitis. *J Periodontol* 76(7):1056–1060, 2005.
108. Holla LI, Fassmann A, Vasku A, et al: Interactions of lymphotoxin alpha (TNF-beta), angiotensin-converting enzyme (ACE), and endothelin-1 (ET-1) gene polymorphisms in adult periodontitis. *J Periodontol* 72(1):85–89, 2001.
109. Holla LI, Jurajda M, Fassmann A, et al: Genetic variations in the matrix metalloproteinase-1 promoter and risk of susceptibility and/or severity of chronic periodontitis in the Czech population. *J Clin Periodontol* 31(8):685–690, 2004.
110. Holla LI, Kankova K, Fassmann A: Distribution of the receptor for advanced glycation end products gene polymorphisms in patients with chronic periodontitis: a preliminary study. *J Periodontol* 72(12):1742–1746, 2001.
111. Hooshmand B, Hajilooi M, Rafiei A, et al: Interleukin-4 (C-590T) and interferon-gamma (G5644A) gene polymorphisms in patients with periodontitis. *J Periodontal Res* 43(1):111–115, 2008.
112. Houshmand B, Rafiei A, Hajilooi M, et al: E-selectin and L-selectin polymorphisms in patients with periodontitis. *J Periodontal Res* 44(1):88–93, 2009.
113. Hu KF, Huang KC, Ho YP: Interleukin-10 (-592 C/A) and interleukin-12B (+16974 A/C) gene polymorphisms and the interleukin-10 ATA haplotype are associated with periodontitis in a Taiwanese population. *J Periodontal Res* 44(3):378–385, 2009.
114. Huang HY, Zhang JC: Investigation on the association of interleukin-1 genotype polymorphism with chronic periodontitis [article in Chinese]. *Hua Xi Kou Qiang Yi Xue Za Zhi* 22(5):415–419, 2004.
115. Imamura Y, Fujigaki Y, Oomori Y, et al: Polymorphism of genes encoding toll-like receptors and inflammatory cytokines in periodontal disease in the Japanese population. *J Int Acad Periodontol* 10(3):95–102, 2008.
116. Inagaki K, Krall EA, Fleet JC, et al: Vitamin D receptor alleles, periodontal disease progression, and tooth loss in the VA dental longitudinal study. *J Periodontol* 74(2):161–167, 2003.
117. Itagaki M, Kubota T, Tai H, et al: Matrix metalloproteinase-1 and -3 gene promoter polymorphisms in Japanese patients with periodontitis. *J Clin Periodontol* 31(9):764–769, 2004.
118. Izakovicova Holla L, Buckova D, Fassmann A, et al: Plasminogen-activator-inhibitor-1 promoter polymorphism as a risk factor for adult periodontitis in non-smokers. *Genes Immun* 3(5):292–294, 2002.
119. Izakovicova Holla L, Buckova D, Fassmann A, et al: Lack of association between chronic periodontitis and the Toll-like receptor 4 gene polymorphisms in a Czech population. *J Periodontal Res* 42(4):340–344, 2007.
120. James JA, Poulton KV, Haworth SE: Polymorphisms of TLR4 but not CD14 are associated with a decreased risk of aggressive periodontitis. *J Clin Periodontol* 34:111–117, 5:49, 2007.
121. Jansson H: Studies on periodontitis and analyses of individuals at risk for periodontal diseases. *Swed Dent J Suppl* 180, 2006.

Continued

TABLE 6-3 Association Study—cont'd

122. Jansson H, Lyssenko V, Gustavsson A: Analysis of the interleukin-1 and interleukin-6 polymorphisms in patients with chronic periodontitis. A pilot study. *Swed Dent J* 30(1):17–23, 2006.
123. Jordan WJ, Eskdale J, Lennon GP: A non-conservative, coding single-nucleotide polymorphism in the N-terminal region of lactoferrin is associated with aggressive periodontitis in an African-American, but not a Caucasian population. *Genes Immun* 6(7):632–635, 2005.
124. Kaarthikeyan G, Jayakumar ND, Padmalatha O, et al: Analysis of the association between interleukin-1beta (+3954) gene polymorphism and chronic periodontitis in a sample of the south Indian population. *Indian J Dent Res* 20(1):37–40, 2009.
125. Kaneko S, Kobayashi T, Yamamoto K, et al: A novel polymorphism of FcalphaRI (CD89) associated with aggressive periodontitis. *Tissue Antigens* 63(6):572–577, 2004.
126. Kang BY, Choi YK, Choi WH: Two polymorphisms of interleukin-4 gene in Korean adult periodontitis. *Arch Pharm Res* 26(6):482–486, 2003.
127. Kara N, Keles GC, Sumer P: Association of the polymorphisms in promoter and intron regions of the interleukin-4 gene with chronic periodontitis in a Turkish population. *Acta Odontol Scand* 65(5):292–297, 2007.
128. Kaslick RS, West TL, Chasens AI, et al: Association between HL-A2 antigen and various periodontal diseases in young adults. *J Dent Res* 54(424):2, 1975.
129. Katz J, Goultschin J, Benoliel R, et al: Human leukocyte antigen (HLA) DR4. Positive association with rapidly progressing periodontitis. *J Periodontol* 58(9):607–610, 1987.
130. Keles GC, Gunes S, Sumer AP: Association of matrix metalloproteinase-9 promoter gene polymorphism with chronic periodontitis. *J Periodontol* 77(9):1510–1514, 2006.
131. Kiani Z, Tavakkol-Afshari J, Hojjat H: Polymorphism of IL-1alpha(-889) gene and its association with aggressive periodontitis. *Iran J Allergy Asthma Immunol* 8(2):95–98, 2009.
132. Kim JS, Park JY, Chung WY, et al: Polymorphisms in genes coding for enzymes metabolizing smoking-derived substances and the risk of periodontitis. *J Clin Periodontol* 31(11):959–964, 2004.
133. Kim YJ, Viana AC, Curtis KM, et al: Lack of association of a functional polymorphism in the interleukin 8 gene with susceptibility to periodontitis. *DNA Cell Biol* 28(4):185–190, 2009.
134. Kinane DF, Hodge P, Eskdale J, et al: Analysis of genetic polymorphisms at the interleukin-10 and tumour necrosis factor loci in early-onset periodontitis. *J Periodontal Res* 34(7):379–386, 1999.
135. Klouda PT, Porter SR, Scully C: Association between HLA-A9 and rapidly progressive periodontitis. *Tissue Antigens* 28(3):146–149, 1986.
136. Kobayashi T, Ito S, Kuroda T: The interleukin-1 and Fcgamma receptor gene polymorphisms in Japanese patients with rheumatoid arthritis and periodontitis. *J Periodontol* 78(12):2311–2318, 2007.
137. Kobayashi T, Ito S, Yamamoto K: Risk of periodontitis in systemic lupus erythematosus is associated with Fcgamma receptor polymorphisms. *J Periodontol* 74(3):378–384, 2003.
138. Kobayashi T, Murasawa A, Ito S: Cytokine gene polymorphisms associated with rheumatoid arthritis and periodontitis in Japanese adults. *J Periodontol* 80(5):792–799, 2009.
139. Kobayashi T, Nagata T, Murakami S: Genetic risk factors for periodontitis in a Japanese population. *J Dent Res* 88(12):1137–1141, 2009.
140. Kobayashi T, Sugita N, van der Pol WL: The Fcgamma receptor genotype as a risk factor for generalized early-onset periodontitis in Japanese patients. *J Periodontol* 71(9):1425–1432, 2000.
141. Kobayashi T, Westerdaal NA, Miyazaki A: Relevance of immunoglobulin G Fc receptor polymorphism to recurrence of adult periodontitis in Japanese patients. *Infect Immun* 65(9):3556–3560, 1997.
142. Kobayashi T, Yamamoto K, Sugita N: The Fc gamma receptor genotype as a severity factor for chronic periodontitis in Japanese patients. *J Periodontol* 72(10):1324–1331, 2001.
143. Kocher T, Sawaf H, Fanghanel J, et al: Association between bone loss in periodontal disease and polymorphism of N-acetyltransferase (NAT2). *J Clin Periodontol* 29(1):21–27, 2002.
144. Komatsu Y, Galicia JC, Kobayashi T, et al: Association of interleukin-1 receptor antagonist +2018 gene polymorphism with Japanese chronic periodontitis patients using a novel genotyping method. *Int J Immunogenet* 35(2):165–170, 2008.
145. Komatsu Y, Tai H, Galicia JC: Interleukin-6 (IL-6)–373 A9T11 allele is associated with reduced susceptibility to chronic periodontitis in Japanese subjects and decreased serum IL-6 level. *Tissue Antigens* 65(1):110–114, 2005.
146. Konig J, Ruhling A, Plagmann HC, et al: Influence of interleukin (IL)-1 composite genotype on clinical variables in non-smoking, well-maintained compliant patients with chronic periodontitis. *Swed Dent J* 29(1):11–16, 2005.
147. Kornman KS, Crane A, Wang HY: The interleukin-1 genotype as a severity factor in adult periodontal disease. *J Clin Periodontol* 24(1):72–77, 1997.
148. Kratka Z, Bartova J, Krejsa O, et al: Interleukin-1 gene polymorphisms as assessed in a 10-year study of patients with early-onset periodontitis. *Folia Microbiol (Praha)* 52(2):183–188, 2007.
149. Laine ML, Farre MA, Garcia-Gonzalez MA: Risk factors in adult periodontitis: polymorphism in the interleukin-1 gene family [article in Dutch]. *Ned Tijdschr Tandheelkd* 109(8):303–306, 2002.
150. Laine ML, Farre MA, Gonzalez G: Polymorphisms of the interleukin-1 gene family, oral microbial pathogens, and smoking in adult periodontitis. *J Dent Res* 80(8):1695–1699, 2001.
151. Laine ML, Morre SA, Murillo LS, et al: CD14 and TLR4 gene polymorphisms in adult periodontitis. *J Dent Res* 84(11):1042–1046, 2005.
152. Laine ML, Murillo LS, Morre SA, et al: CARD15 gene mutations in periodontitis. *J Clin Periodontol* 31(10):890–893, 2004.
153. Lang NP, Tonetti MS, Suter J, et al: Effect of interleukin-1 gene polymorphisms on gingival inflammation assessed by bleeding on probing in a periodontal maintenance population. *J Periodontal Res* 35(2):102–107, 2000.
154. Li Q, Meng H, Zhang L: Correlation between single nucleotide polymorphisms in a calprotectin subunit gene and risk of periodontitis in a Chinese population. *Ann Hum Genet* 71(Pt 3):312–324, 2007.
155. Li QY, Zhao HS, Meng HX, et al: The relationship between a nucleotide substitution of S100A8 gene and aggressive periodontitis [article in Chinese]. *Zhonghua Kou Qiang Yi Xue Za Zhi* 39(3):181–184, 2004.
156. Li QY, Zhao HS, Meng HX, et al: Interleukin-1 polymorphisms in patients with aggressive periodontitis [article in Chinese]. *Shanghai Kou Qiang Yi Xue* 14(4):333–337, 2005.
157. Li QY, Zhao HS, Meng HX: Association analysis between interleukin-1 family polymorphisms and generalized aggressive periodontitis in a Chinese population. *J Periodontol* 75(12):1627–1635, 2004.
158. Li S, Yang MH, Zeng CA: Association of vitamin D receptor gene polymorphisms in Chinese patients with generalized aggressive periodontitis. *J Periodontal Res* 43(3):360–363, 2008.
159. Lin L, Pan YP, Yin LY: Study on the correlation of cytokine gene polymorphism with chronic periodontitis. *Shanghai Kou Qiang Yi Xue* 12(6):456–459, 2003.
160. Loos BG, Fiebig A, Nothnagel M: NOD1 gene polymorphisms in relation to aggressive periodontitis. *Innate Immun* 15(4):225–232, 2009.
161. Loos BG, Leppers-Van de Straat FG, Van de Winkel JG, et al: Fcgamma receptor polymorphisms in relation to periodontitis. *J Clin Periodontol* 30(7):595–602, 2003.
162. Lopez NJ, Jara L, Valenzuela CY: Association of interleukin-1 polymorphisms with periodontal disease. *J Periodontol* 76(2):234–243, 2005.
163. Lopez NJ, Valenzuela CY, Jara L: Interleukin-1 gene cluster polymorphisms associated with periodontal disease in type 2 diabetes. *J Periodontol* 80(10):1590–1598, 2009.
164. Louropoulou A, van der Velden U, Schoenmaker T, et al: Mannose-binding lectin gene polymorphisms in relation to periodontitis. *J Clin Periodontol* 35(11):923–930, 2008.

165. Machulla HK, Stein J, Gautsch A, et al: HLA-A, B, Cw, DRB1, DRB3/4/5, DQB1 in German patients suffering from rapidly progressive periodontitis (RPP) and adult periodontitis (AP). *J Clin Periodontol* 29(6):573–579, 2002.
166. Maney P, Emecen P, Mills JS, et al: Neutrophil formylpeptide receptor single nucleotide polymorphism 348T>C in aggressive periodontitis. *J Periodontol* 80(3):492–498, 2009.
167. Maney P, Walters JD: Formylpeptide receptor single nucleotide polymorphism 348T>C and its relationship to polymorphonuclear leukocyte chemotaxis in aggressive periodontitis. *J Periodontol* 80(9):1498–1505, 2009.
168. Maria de Freitas N, Imbronito AV, Neves AC, et al: Analysis of IL-1A(-889) and TNFA(-308) gene polymorphism in Brazilian patients with generalized aggressive periodontitis. *Eur Cytokine Netw* 18(3):142–147, 2007.
169. McDevitt MJ, Wang HY, Knobelman C: Interleukin-1 genetic association with periodontitis in clinical practice. *J Periodontol* 71(2):156–163, 2000.
170. Meisel P, Carlsson LE, Sawaf H, et al: Polymorphisms of Fc gamma-receptors RIIa, RIIIa, and RIIIb in patients with adult periodontal diseases. *Genes Immun* 2(5):258–262, 2001.
171. Meisel P, Heins G, Carlsson L: Impact of genetic polymorphisms on the smoking-related risk of periodontal disease: the population-based study SHIP. *Tob Induc Dis* 1(3):197, 2003.
172. Meisel P, Krause T, Cascorbi I: Gender and smoking-related risk reduction of periodontal disease with variant myeloperoxidase alleles. *Genes Immun* 3(2):102–106, 2002.
173. Meisel P, Schwahn C, Gesch D, et al: Dose-effect relation of smoking and the interleukin-1 gene polymorphism in periodontal disease. *J Periodontol* 75(2):236–242, 2004.
174. Meisel P, Siegemund A, Dombrowa S, et al: Smoking and polymorphisms of the interleukin-1 gene cluster (IL-1alpha, IL-1beta, and IL-1RN) in patients with periodontal disease. *J Periodontol* 73(1):27–32, 2002.
175. Meisel P, Siegemund A, Grimm R: The interleukin-1 polymorphism, smoking, and the risk of periodontal disease in the population-based SHIP study. *J Dent Res* 82(3):189–193, 2003.
176. Meisel P, Timm R, Sawaf H, et al: Polymorphism of the N-acetyltransferase (NAT2), smoking and the potential risk of periodontal disease. *Arch Toxicol* 74(6):343–348, 2000.
177. Mellati E, Arab HR, Tavakkol-Afshari J, et al: Analysis of -1082 IL-10 gene polymorphism in Iranian patients with generalized aggressive periodontitis. *Med Sci Monit* 13:514, CR510, 2007.
178. Menezes NG, Colombo AP: Lack of association between the TNF-alpha -308 (G/A) genetic polymorphism and periodontal disease in Brazilians. *Braz Oral Res* 22(4):322–327, 2008.
179. Michel J, Gonzales JR, Wunderlich D, et al: Interleukin-4 polymorphisms in early onset periodontitis. *J Clin Periodontol* 28(5):483–488, 2001.
180. Moore S, Ide M, Randhawa M, et al: An investigation into the association among preterm birth, cytokine gene polymorphisms and periodontal disease. *BJOG* 111(2):125–132, 2004.
181. Moreira PR, Costa JE, Gomez RS, et al: The IL1A (-889) gene polymorphism is associated with chronic periodontal disease in a sample of Brazilian individuals. *J Periodontal Res* 42(1):23–30, 2007.
182. Moreira PR, Costa JE, Gomez RS, et al: TNFA and IL10 gene polymorphisms are not associated with periodontitis in Brazilians. *Open Dent J* 3:184–190, 2009.
183. Moreira PR, de Sa AR, Xavier GM: A functional interleukin-1 beta gene polymorphism is associated with chronic periodontitis in a sample of Brazilian individuals. *J Periodontal Res* 40(4):306–311, 2005.
184. Moreira PR, Lima PM, Sathler KO: Interleukin-6 expression and gene polymorphism are associated with severity of periodontal disease in a sample of Brazilian individuals. *Clin Exp Immunol* 148(1):119–126, 2007.
185. Naito M, Miyaki K, Naito T: Association between vitamin D receptor gene haplotypes and chronic periodontitis among Japanese men. *Int J Med Sci* 4(4):216–222, 2007.
186. Nastri L, Caruso F: Association between interleukin-1 composite genotype and severe periodontitis: case-control study [article in Italian]. *Minerva Stomatol* 52(6):253–259, 2003.
187. Nibali L, D'Aiuto F, Donos N: Association between periodontitis and common variants in the promoter of the interleukin-6 gene. *Cytokine* 45(1):50–54, 2009.
188. Nibali L, Donos N, Brett PM: A familial analysis of aggressive periodontitis - clinical and genetic findings. *J Periodontal Res* 43(6):627–634, 2008.
189. Nibali L, Griffiths GS, Donos N: Association between interleukin-6 promoter haplotypes and aggressive periodontitis. *J Clin Periodontol* 35(3):193–198, 2008.
190. Nibali L, Parkar M, Brett P, et al: NADPH oxidase (CYBA) and FcgammaR polymorphisms as risk factors for aggressive periodontitis: a case-control association study. *J Clin Periodontol* 33(8):529–539, 2006.
191. Nibali L, Parkar M, D'Aiuto F: Vitamin D receptor polymorphism (-1056 Taq-I) interacts with smoking for the presence and progression of periodontitis. *J Clin Periodontol* 35(7):561–567, 2008.
192. Nicu EA, Laine ML, Morre SA, et al: Soluble CD14 in periodontitis. *Innate Immun* 15(2):121–128, 2009.
193. Noack B, Gorgens H, Hempel U: Cathepsin C gene variants in aggressive periodontitis. *J Dent Res* 87(10):958–963, 2008.
194. Noack B, Gorgens H, Hoffmann T: Novel mutations in the cathepsin C gene in patients with pre-pubertal aggressive periodontitis and Papillon-Lefevre syndrome. *J Dent Res* 83(5):368–370, 2004.
195. Noack B, Gorgens H, Lorenz K, et al: TLR4 and IL-18 gene variants in chronic periodontitis: impact on disease susceptibility and severity. *Immunol Invest* 38(3–4):297–310, 2009.
196. Noack B, Gorgens H, Lorenz K, et al: TLR4 and IL-18 gene variants in aggressive periodontitis. *J Clin Periodontol* 35(12):1020–1026, 2008.
197. Ohyama H, Takashiba S, Oyaizu K: HLA Class II genotypes associated with early-onset periodontitis: DQB1 molecule primarily confers susceptibility to the disease. *J Periodontol* 67(9):888–894, 1996.
198. Pang RY, Chen KY, Zhang JC, et al: Association of TNFA-308 gene polymorphisms with susceptibility to chronic periodontitis in Chinese patients [article in Chinese]. *Shanghai Kou Qiang Yi Xue* 14(6):586–589, 2005.
199. Papapanou PN, Neiderud AM, Sandros J, et al: Interleukin-1 gene polymorphism and periodontal status. A case-control study. *J Clin Periodontol* 28(5):389–396, 2001.
200. Park KS, Nam JH, Choi J: The short vitamin D receptor is associated with increased risk for generalized aggressive periodontitis. *J Clin Periodontol* 33(8):524–528, 2006.
201. Park OJ, Shin SY, Choi Y: The association of osteoprotegerin gene polymorphisms with periodontitis. *Oral Dis* 14(5):440–444, 2008.
202. Parkhill JM, Hennig BJ, Chapple IL, et al: Association of interleukin-1 gene polymorphisms with early-onset periodontitis. *J Clin Periodontol* 27(9):682–689, 2000.
203. Perez C, Gonzalez FE, Pavez V: The -308 polymorphism in the promoter region of the tumor necrosis factor-alpha (TNF-alpha) gene and ex vivo lipopolysaccharide-induced TNF-alpha expression in patients with aggressive periodontitis and/or type 1 diabetes mellitus. *Eur Cytokine Netw* 15(4):364–370, 2004.
204. Peterson RJ, Marsh CL: The relationship of alpha1-antitrypsin to inflammatory periodontal disease. *J Periodontol* 50(1):31–35, 1979.
205. Pirhan D, Atilla G, Emingil G, et al: Effect of MMP-1 promoter polymorphisms on GCF MMP-1 levels and outcome of periodontal therapy in patients with severe chronic periodontitis. *J Clin Periodontol* 35(10):862–870, 2008.
206. Pirhan D, Atilla G, Emingil G, et al: MMP-13 promoter polymorphisms in patients with chronic periodontitis: effects on GCF MMP-13 levels and outcome of periodontal therapy. *J Clin Periodontol* 36(6):474–481, 2009.
207. Pontes CC, Gonzales JR, Novaes AB, Jr: Interleukin-4 gene polymorphism and its relation to periodontal disease in a Brazilian population of African heritage. *J Dent* 32(3):241–246, 2004.
208. Price P, Calder DM, Witt CS: Periodontal attachment loss in HIV-infected patients is associated with the major histocompatibility complex 8.1 haplotype (HLA-A1,B8,DR3). *Tissue Antigens* 54(4):391–399, 1999.

Continued

TABLE 6-3 Association Study—cont'd

209. Qian W, Zhang J, Zhang Y: The relationship between tumor necrosis factor A-308 gene polymorphism and susceptibility of severe periodontitis in adults [article in Chinese]. *Zhonghua Kou Qiang Yi Xue Za Zhi* 37(2):126–128, 2002.
210. Quappe L, Jara L, Lopez NJ: Association of interleukin-1 polymorphisms with aggressive periodontitis. *J Periodontol* 75(11):1509–1515, 2004.
211. Rabello D, Soedarsono N, Kamei H: CSF1 gene associated with aggressive periodontitis in the Japanese population. *Biochem Biophys Res Commun* 347(3):791–796, 2006.
212. Raunio T, Knuuttila M, Hiltunen L, et al: IL-6(-174) genotype associated with the extent of periodontal disease in type 1 diabetic subjects. *J Clin Periodontol* 36(1):11–17, 2009.
213. Raunio T, Knuuttila M, Karttunen R, et al: Serum sCD14, polymorphism of CD14(-260) and periodontal infection. *Oral Dis* 15(7):484–489, 2009.
214. Reichert S, Machulla HK, Klapproth J: Interferon-gamma and interleukin-12 gene polymorphisms and their relation to aggressive and chronic periodontitis and key periodontal pathogens. *J Periodontol* 79(8):1434–1443, 2008.
215. Reichert S, Machulla HK, Klapproth J: Interleukin-2 -330 and 166 gene polymorphisms in relation to aggressive or chronic periodontitis and the presence of periodontopathic bacteria. *J Periodontal Res* 44(5):628–635, 2009.
216. Reichert S, Machulla HK, Klapproth J: The interleukin-10 promoter haplotype ATA is a putative risk factor for aggressive periodontitis. *J Periodontal Res* 43(1):40–47, 2008.
217. Reichert S, Stein J, Gautsch A, et al: Gender differences in HLA phenotype frequencies found in German patients with generalized aggressive periodontitis and chronic periodontitis. *Oral Microbiol Immunol* 17(6):360–368, 2002.
218. Reinholdt J, Bay I, Svejgaard A: Association between HLA-antigens and periodontal disease. *J Dent Res* 56(10):1261–1263, 1977.
219. Ren XY, Xu L, Meng HX: Interleukin-1 family polymorphisms in aggressive periodontitis patients and their relatives [article in Chinese]. *Beijing Da Xue Xue Bao* 40(1):28–33, 2008.
220. Ren XY, Xu L, Meng HX: Family-based association analysis of S100A8 genetic polymorphisms with aggressive periodontitis. *J Periodontal Res* 44(2):184–192, 2009.
221. Roshna T, Thomas R, Nandakumar K, et al: A case-control study on the association of human leukocyte antigen-A*9 and -B*15 alleles with generalized aggressive periodontitis in an Indian population. *J Periodontol* 77(12):1954–1963, 2006.
222. Sahingur SE, Sharma A, Genco RJ, et al: Association of increased levels of fibrinogen and the -455G/A fibrinogen gene polymorphism with chronic periodontitis. *J Periodontol* 74(3):329–337, 2003.
223. Sakellari D, Katsares V, Georgiadou M, et al: No correlation of five gene polymorphisms with periodontal conditions in a Greek population. *J Clin Periodontol* 33(11):765–770, 2006.
224. Sakellari D, Koukoudetsos S, Arsenakis M, et al: Prevalence of IL-1A and IL-1B polymorphisms in a Greek population. *J Clin Periodontol* 30(1):35–41, 2003.
225. Saleh TA, Stephen L, Kotze M, et al: The composite interleukin-1 genotype in South Africa. *SADJ* 64(4):170–173, 2009.
226. Savarrio L, Donati M, Carr C, et al: Interleukin-24, RANTES and CCR5 gene polymorphisms are not associated with chronic adult periodontitis. *J Periodontal Res* 42(2):152–158, 2007.
227. Scapoli C, Trombelli L, Mamolini E, et al: Linkage disequilibrium analysis of case-control data: an application to generalized aggressive periodontitis. *Genes Immun* 6(1):44–52, 2005.
228. Scarel-Caminaga RM, Trevilatto PC, Souza AP, et al: Interleukin 10 gene promoter polymorphisms are associated with chronic periodontitis. *J Clin Periodontol* 31(6):443–448, 2004.
229. Scarel-Caminaga RM, Trevilatto PC, Souza AP, et al: Investigation of an IL-2 polymorphism in patients with different levels of chronic periodontitis. *J Clin Periodontol* 29(7):587–591, 2002.
230. Scarel-Caminaga RM, Trevilatto PC, Souza AP, et al: Investigation of IL4 gene polymorphism in individuals with different levels of chronic periodontitis in a Brazilian population. *J Clin Periodontol* 30(4):341–345, 2003.
231. Schaefer AS, Richter GM, Groessner-Schreiber B: Identification of a shared genetic susceptibility locus for coronary heart disease and periodontitis. *PLoS Genet* 5:e1000378, 2009.
232. Schaefer AS, Richter GM, Nothnagel M, et al: A 3′ UTR transition within DEFB1 is associated with chronic and aggressive periodontitis. *Genes Immun* 11(1):45–54, 2009.
233. Schaefer AS, Richter GM, Nothnagel M, et al: A genome-wide association study identifies GLT6D1 as a susceptibility locus for periodontitis. *Hum Mol Genet* 19(3):553–562, 2010.
234. Schroder NW, Meister D, Wolff V: Chronic periodontal disease is associated with single-nucleotide polymorphisms of the human TLR-4 gene. *Genes Immun* 6(5):448–451, 2005.
235. Schulz S, Machulla HK, Altermann W: Genetic markers of tumour necrosis factor alpha in aggressive and chronic periodontitis. *J Clin Periodontol* 35(6):493–500, 2008.
236. Schulz S, Zissler N, Altermann W: Impact of genetic variants of CD14 and TLR4 on subgingival periodontopathogens. *Int J Immunogenet* 35(6):457–464, 2008.
237. Scott DA, von Ahsen N, Palmer RM, et al: Analysis of two common alpha 1-antitrypsin deficiency alleles (PI*Z and PI*S) in subjects with periodontitis. *J Clin Periodontol* 29(12):1118–1121, 2002.
238. Shapira L, Stabholz A, Rieckmann P, et al: Genetic polymorphism of the tumor necrosis factor (TNF)-alpha promoter region in families with localized early-onset periodontitis. *J Periodontal Res* 36(3):183–186, 2001.
239. Shimada Y, Tai H, Endo M, et al: Association of tumor necrosis factor receptor type 2 +587 gene polymorphism with severe chronic periodontitis. *J Clin Periodontol* 31(6):463–469, 2004.
240. Shimomura-Kuroki J, Yamashita K, Shimooka S: *Tannerella forsythia* and the HLA-DQB1 allele are associated with susceptibility to periodontal disease in Japanese adolescents. *Odontology* 97(1):32–37, 2009.
241. Shirodaria S, Smith J, McKay IJ, et al: Polymorphisms in the IL-1A gene are correlated with levels of interleukin-1alpha protein in gingival crevicular fluid of teeth with severe periodontal disease. *J Dent Res* 79(11):1864–1869, 2000.
242. Soedarsono N, Rabello D, Kamei H: Evaluation of RANK/RANKL/OPG gene polymorphisms in aggressive periodontitis. *J Periodontal Res* 41(5):397–404, 2006.
243. Soga Y, Nishimura F, Ohyama H, et al: Tumor necrosis factor-alpha gene (TNF-alpha) -1031/-863, -857 single-nucleotide polymorphisms (SNPs) are associated with severe adult periodontitis in Japanese. *J Clin Periodontol* 30(6):524–531, 2003.
244. Stein J, Reichert S, Gautsch A, et al: Are there HLA combinations typical supporting for or making resistant against aggressive and/or chronic periodontitis? *J Periodontal Res* 38(5):508–517, 2003.
245. Stein JM, Smeets R, Reichert S: The role of the composite interleukin-1 genotype in the association between periodontitis and acute myocardial infarction. *J Periodontol* 80(7):1095–1102, 2009.
246. Struch F, Dau M, Schwahn C, et al: Interleukin-1 gene polymorphism, diabetes, and periodontitis: results from the Study of Health in Pomerania (SHIP). *J Periodontol* 79(3):501–507, 2008.
247. Sugita N, Kobayashi T, Ando Y: Increased frequency of FcgammaRIIIb-NA1 allele in periodontitis-resistant subjects in an elderly Japanese population. *J Dent Res* 80(3):914–918, 2001.
248. Sugita N, Yamamoto K, Kobayashi T: Relevance of Fc gamma RIIIa-158V-F polymorphism to recurrence of adult periodontitis in Japanese patients. *Clin Exp Immunol* 117(2):350–354, 1999.
249. Sumer AP, Kara N, Keles GC, et al: Association of interleukin-10 gene polymorphisms with severe generalized chronic periodontitis. *J Periodontol* 78(3):493–497, 2007.
250. Sun JL, Meng HX, Cao CF: Relationship between vitamin D receptor gene polymorphism and periodontitis. *J Periodontal Res* 37(4):263–267, 2002.
251. Suzuki A, Ji G, Numabe Y, et al: Large-scale investigation of genomic markers for severe periodontitis. *Odontology* 92(1):43–47, 2004.

252. Suzuki A, Ji G, Numabe Y: Single nucleotide polymorphisms associated with aggressive periodontitis and severe chronic periodontitis in Japanese. *Biochem Biophys Res Commun* 317(3):887–892, 2004.
253. Tabeta K, Shimada Y, Tai H: Assessment of chromosome 19 for genetic association in severe chronic periodontitis. *J Periodontol* 80(4):663–671, 2009.
254. Tachi Y, Shimpuku H, Nosaka Y: Vitamin D receptor gene polymorphism is associated with chronic periodontitis. *Life Sci* 73(26):3313–3321, 2003.
255. Tachi Y, Shimpuku H, Nosaka Y: Association of vitamin D receptor gene polymorphism with periodontal diseases in Japanese and Chinese. *Nucleic Acids Res Suppl* 1:111–112, 2001.
256. Tai H, Endo M, Shimada Y: Association of interleukin-1 receptor antagonist gene polymorphisms with early onset periodontitis in Japanese. *J Clin Periodontol* 29(10):882–888, 2002.
257. Takahashi K, Ohyama H, Kitanaka M: Heterogeneity of host immunological risk factors in patients with aggressive periodontitis. *J Periodontol* 72(4):425–437, 2001.
258. Takashiba S, Noji S, Nishimura F: Unique intronic variations of HLA-DQ beta gene in early-onset periodontitis. *J Periodontol* 65(5):379–386, 1994.
259. Takeuchi-Hatanaka K, Ohyama H, Nishimura F: Polymorphisms in the 5′ flanking region of IL12RB2 are associated with susceptibility to periodontal diseases in the Japanese population. *J Clin Periodontol* 35(4):317–323, 2008.
260. Tang Y, Zhang JC, Zhang WH, et al: The association between Fc gamma receptor IIA gene polymorphism and susceptibility to chronic periodontitis in Chinese Han nationality [article in Chinese]. *Hua Xi Kou Qiang Yi Xue Za Zhi* 22(2):158–161, 2004.
261. Terasaki PI, Kaslick RS, West TL, et al: Low HL-A2 frequency and periodontitis. *Tissue Antigens* 5(4):286–288, 1975.
262. Tervonen T, Raunio T, Knuuttila M, et al: Polymorphisms in the CD14 and IL-6 genes associated with periodontal disease. *J Clin Periodontol* 34(5):377–383, 2007.
263. Thomson WM, Edwards SJ, Dobson-Le DP: IL-1 genotype and adult periodontitis among young New Zealanders. *J Dent Res* 80(8):1700–1703, 2001.
264. Tian YG, Pan YP, Lin L, et al: The relationship of IL-1beta expressed in buccal cells and the polymorphisms of IL-1beta (+3953) with chronic periodontitis [article in Chinese]. *Shanghai Kou Qiang Yi Xue* 15(5):456–460, 2006.
265. Trevilatto PC, Scarel-Caminaga RM, de Brito RB, Jr, et al: Polymorphism at position -174 of IL-6 gene is associated with susceptibility to chronic periodontitis in a Caucasian Brazilian population. *J Clin Periodontol* 30(5):438–442, 2003.
266. Trevilatto PC, Tramontina VA, Machado MA, et al: Clinical, genetic and microbiological findings in a Brazilian family with aggressive periodontitis. *J Clin Periodontol* 29(3):233–239, 2002.
267. Trombone AP, Cardoso CR, Repeke CE: Tumor necrosis factor-alpha -308G/A single nucleotide polymorphism and red-complex periodontopathogens are independently associated with increased levels of tumor necrosis factor-alpha in diseased periodontal tissues. *J Periodontal Res* 44(5):598–608, 2009.
268. Tsutsumi A, Kobayashi T, Ito S: Mannose binding lectin gene polymorphism and the severity of chronic periodontitis. *Nihon Rinsho Meneki Gakkai Kaishi* 32(1):48–52, 2009.
269. Unur M, Demirez E, Agachan B: The relationship of oral disturbances of diabetes mellitus patients with paraoxonase gene polymorphisms. *Cell Biochem Funct* 26(8):870–873, 2008.
270. Ustun K, Alptekin NO, Hakki SS, et al: Investigation of matrix metalloproteinase-1–1607 1G/2G polymorphism in a Turkish population with periodontitis. *J Clin Periodontol* 35(12):1013–1019, 2008.
271. Velliyagounder K, Kaplan JB, Furgang D: One of two human lactoferrin variants exhibits increased antibacterial and transcriptional activation activities and is associated with localized juvenile periodontitis. *Infect Immun* 71(11):6141–6147, 2003.
272. Wagner J, Kaminski WE, Aslanidis C: Prevalence of OPG and IL-1 gene polymorphisms in chronic periodontitis. *J Clin Periodontol* 34(10):823–827, 2007.
273. Walker SJ, Van Dyke TE, Rich S, et al: Genetic polymorphisms of the IL-1alpha and IL-1beta genes in African-American LJP patients and an African-American control population. *J Periodontol* 71(5):723–728, 2000.
274. Wang C, Zhao H, Xiao L: Association between vitamin D receptor gene polymorphisms and severe chronic periodontitis in a Chinese population. *J Periodontol* 80(4):603–608, 2009.
275. Wang HY, Pan YP: Screening and analysis of multi-alleles in generalized aggressive periodontitis [article in Chinese]. *Zhonghua Kou Qiang Yi Xue Za Zhi* 43(7):406–409, 2008.
276. Wang HY, Pan YP, Teng D, et al: The relativity between chronic periodontitis and the genetic polymorphisms of vitamin D receptor and estrogen receptor [article in Chinese]. *Zhonghua Kou Qiang Yi Xue Za Zhi* 43(4):236–239, 2008.
277. Wohlfahrt JC, Wu T, Hodges JS, et al: No association between selected candidate gene polymorphisms and severe chronic periodontitis. *J Periodontol* 77(3):426–436, 2006.
278. Wolf DL, Neiderud AM, Hinckley K, et al: Fcgamma receptor polymorphisms and periodontal status: a prospective follow-up study. *J Clin Periodontol* 33(10):691–698, 2006.
279. Wu XL, Huang P, Zhou XD: Association of the progress of chronic periodontitis with interleukin-1B-511 genetic polymorphisms [article in Chinese]. *Hua Xi Kou Qiang Yi Xue Za Zhi* 24(6):523–526, 2006.
280. Wu YM, Juo SH, Ho YP, et al: Association between lactoferrin gene polymorphisms and aggressive periodontitis among Taiwanese patients. *J Periodontal Res* 44(3):418–424, 2009.
281. Xiao LM, Yan YX, Xie CJ: Association among interleukin-6 gene polymorphism, diabetes and periodontitis in a Chinese population. *Oral Dis* 15(8):547–553, 2009.
282. Xie CJ, Xiao LM, Fan WH, et al: Common single nucleotide polymorphisms in cyclooxygenase-2 and risk of severe chronic periodontitis in a Chinese population. *J Clin Periodontol* 36(3):198–203, 2009.
283. Yamamoto K, Kobayashi T, Grossi S: Association of Fcgamma receptor IIa genotype with chronic periodontitis in Caucasians. *J Periodontol* 75(4):517–522, 2004.
284. Yamazaki K, Tabeta K, Nakajima T: Interleukin-10 gene promoter polymorphism in Japanese patients with adult and early-onset periodontitis. *J Clin Periodontol* 28(9):828–832, 2001.
285. Yamazaki K, Ueki-Maruyama K, Oda T: Single-nucleotide polymorphism in the CD14 promoter and periodontal disease expression in a Japanese population. *J Dent Res* 82(8):612–616, 2003.
286. Yasuda K, Sugita N, Kobayashi T, et al: FcgammaRIIB gene polymorphisms in Japanese periodontitis patients. *Genes Immun* 4(8):541–546, 2003.
287. Yoshie H, Tai H, Kobayashi T: Salivary enzyme levels after scaling and interleukin-1 genotypes in Japanese patients with chronic periodontitis. *J Periodontol* 78(3):498–503, 2007.
288. Yoshihara A, Sugita N, Yamamoto K: FcgammaRIIIb genotypes and smoking in periodontal disease progression among community-dwelling older adults in Japan. *J Periodontol* 76(2):250–255, 2005.
289. Yoshihara A, Sugita N, Yamamoto K, et al: Analysis of vitamin D and Fcgamma receptor polymorphisms in Japanese patients with generalized early-onset periodontitis. *J Dent Res* 80(12):2051–2054, 2001.
290. Zhang HX, Xie H, Ren TG: Relevance of FcgammaRIIIb genotype, IgG G2m(23) factor to the susceptibility of aggressive periodontitis [article in Chinese]. *Zhonghua Kou Qiang Yi Xue Za Zhi* 38(2):129–131, 2003.
291. Zhang JC, Geng HO, Ma WB, et al: Association of vitamin D receptor gene polymorphisms with the susceptibility to chronic periodontitis of Han nationality [article in Chinese]. *Zhonghua Kou Qiang Yi Xue Za Zhi* 40(1):50–53, 2005.
292. Zhang L, Meng H, Zhao H: Estrogen receptor-alpha gene polymorphisms in patients with periodontitis. *J Periodontal Res* 39(5):362–366, 2004.
293. Zhang SJ, Yang AL, Zhang JC, et al: Association of HLA-DRB1*1501 polymorphism with the susceptibility to severe chronic periodontitis in Chinese Han nationality [article in Chinese]. *Shanghai Kou Qiang Yi Xue* 13(3):182–185, 2004.
294. Zhang Y, Syed R, Uygar C: Evaluation of human leukocyte N-formylpeptide receptor (FPR1) SNPs in aggressive periodontitis patients. *Genes Immun* 4(1):22–29, 2003.
295. Zhong L, Zhang Y, Zhang J, et al: The association of interleukin-1 gene polymorphisms with the susceptibility to chronic periodontitis in Uighur [article in Chinese]. *Zhonghua Yi Xue Yi Chuan Xue Za Zhi* 19(5):405–408, 2002.
296. Zhong LJ, Zhang YH, Zhang JC, et al: The association between interleukin-1 receptor antagonist genotype and chronic periodontitis of Uighur patients [article in Chinese]. *Zhonghua Kou Qiang Yi Xue Za Zhi* 38(5):370–373, 2003.
297. Zhu G, Li C, Cao Z, et al: Toll-like receptors 2 and 4 gene polymorphisms in a Chinese population with periodontitis. *Quintessence Int* 39(3):217–226, 2008.
298. Zhu XL, Meng HX, Xu L, et al: Relationship between tumor necrosis factor A-308 gene polymorphism and aggressive periodontitis [article in Chinese]. *Zhonghua Kou Qiang Yi Xue Za Zhi* 42(5):268–271, 2007.

TABLE 6-4 Number of Independent Gene Association Reports for Aggressive Periodontitis and Chronic Periodontitis*

	AGGRESSIVE PERIODONTITIS				CHRONIC PERIODONTITIS		
Gene Symbol†	None‡	Weak	Moderate	Strong	None	Weak	Moderate
CD14	3				7	5	
CDKN2BAS		1	1				
ESR1	1	1				2	
FCGR2A	8	1			12	3	
FCGR2B	2	1			2	1	
FCGR3A	7	1			7	3	
FCGR3B	3	8			11	2	2
FGB	1				1	2	
FPR1	4	4	1		2		
GLT6D1				1			
GSTM1			1			2	
HLA-A	3	11			2	5	
HLA-B	8	2			1	4	
HLA-C	8				1	2	
HLA-DQ	1	1			1	1	
HLA-DQB1	3	3			2		
HLA-DR	3	2			2	1	
HLA-DRB1	3	2			2	2	
HLA-DRB3/4/5	1	1			1	1	
IL10	10	2			10	4	2
IL1A	17	5			23	5	3
IL1A.IL1B	3	1			9	8	4
IL1B	16	9	1		29	11	2
IL1RN	10	2	1		10	3	1
IL2	2				2	2	
IL4	2	2			7	1	
IL6	4	3	1		8	11	
IL6R		1				1	
LTA					1	2	
LTF	1	3				1	
MMP1	2	1			5	3	
MMP9	1	1			1	3	
MPO						2	
NAT2						2	1
NOS3		1				1	
PTGS2			1			2	1
S100A8	1	2				1	
SERPINE1	1					2	1
TGFB1	1				4	3	
TLR4	6	1			12	1	1
TNF	13	1			17	6	
VDR	3	6			7	12	

*Only genes with two or more reports of association are included.

†Full gene names and a summary of knowledge about the gene's function can be found by typing the gene symbol into the search box at http://www.ncbi.nlm.nih.gov/gene.

‡Strength of association is defined as follows: Weak (*P* value of <0.05 but ≥0.001; if <50 cases are in the study, then the finding is considered weak, regardless of the *P* value); Moderate (*P* value of <0.001 but ≥0.0001 or if <101 cases are in the study regardless of *P* value); Strong (*P* value <0.0001 and >250 cases in the study).

and when there may be a bias against the publication of negative results, then a substantial portion of studies should report positive findings, even if no real association exists. Then again, heterogeneity among studies may be real. The negative studies may differ in terms of the racial or ethnic composition of the subjects, and the findings may be valid for some human populations but not others. Different genetic polymorphisms in the candidate gene may be evaluated in the different studies, and only some of these may actually be associated with disease risk. Different clinical definitions or sources of information (e.g., clinical attachment loss versus bone loss measured from radiographs) may be used to define cases or various quantitative measures may be employed, and these sources of variation may also influence the outcome of association tests. With data limited to mostly small studies, it is not currently possible to definitively determine which of these potential explanations applies to most of the findings shown in Table 6-4.

Figure 6-5 shows that a handful of periodontitis association studies have been reported that approach the sample size needed for complex diseases with more than 400 cases.[16,34,41,42,59,60] This includes the GWAS in which more than 322,825 SNP genetic markers were evaluated for association with the risk of aggressive periodontitis.[61] In the GWAS, statistical testing was performed in sequence for three independent sets of samples with a total of 438 cases and 1320 controls. Interestingly, this relatively powerful analysis failed to yield significant support for "the usual suspect" candidate genes shown in Table 6-4, after adjusting for the large number of hypotheses tested in the analysis. Instead, several novel chromosomal regions and candidate genes were implicated, with among the strongest being a glycosyltransferase gene (GLT6D1), one of several glycosyltransferases in the human genome. This had an unadjusted *P* value of 0.000000006. However, the *P* value was reduced by three orders of magnitude to 0.000006 after accounting for the effects of gender, smoking, and diabetes. The adjusted *P* value indicates that we should expect to see a difference in genotype frequency of this magnitude by chance alone about 1 out of 166,666 times under the null hypothesis of no association with disease risk. This may seem to be very strong evidence for rejection of the null hypothesis, but this adjusted finding is actually only a marginal statistical significance in the context of a GWAS. In fact, this sometimes occurs by chance alone in the absence of a valid association, because this study involved testing more than 300,000 genetic markers. Because there is no obvious functional connection of this gene with what we currently know about the pathogenesis of periodontitis (the protein is thought to play a role in signaling in development), it may be tempting to further downplay the finding's significance. However, experience with GWAS studies of other complex diseases has shown that, quite often, valid gene associations are discovered in pathways that experts in the field did not previously realize were even related to the disease's biology. This makes such discoveries all the more valuable, assuming that they are definitively and independently replicated, because they offer the potential of revealing completely new avenues for further exploration at the cellular and molecular levels and because they potentially may also provide novel targets for therapeutic interventions.

During the 3 years since the report of a strong association of aggressive periodontitis with GLT6D1, it has been interesting that no replications of this finding have been reported. The first genome-wide study focused on chronic periodontitis has recently been reported, and this included 4504 European Americans, with 43% having moderate chronic periodontitis and 17% having severe chronic periodontitis.[15] No genome-wide significant associations were found in this large sample, with no support whatsoever for the much-studied periodontitis candidate genes IL1A, IL1B, IL1RN, IL4, IL6, IL10, CD14, FCGR2A, MMP1, TLR4, TNF, and VDR. However, intriguing suggestive evidence was found supporting the role of cellular immune response, nervous system and cytokine signaling pathways. By broadening the phenotype, a subset of these subjects were also analyzed using genome-wide SNP data for periodontal pathogen colonization, but again only statistically suggestive results were obtained with this smaller sample.[14] A large-scale replication analysis of 23 much-studied candidate genes in 600 aggressive periodontitis cases and 1448 control subjects of German ethnicity found support only for SNPs in IL10, but this association was not replicated in 1437 chronic periodontitis cases of German ethnicity.[58] It is clear from these findings that additional large-scale association studies, possibly involving family-based designs and searches for rare high-risk variants, will be necessary, as described later in this chapter.

Challenges and Opportunities for the Future

The classification of disease used for research studies is an especially difficult challenge to be faced if we are to benefit fully from the opportunities offered by the genomics revolution.[51] If we cannot agree which subjects in a study are affected by disease, by a particular subtype of disease, how severely they are affected, or how quantitative measures related to disease should be obtained and analyzed, then the chances of making progress will be very low, regardless of how advanced our molecular or bioinformatics technologies become. This problem is important for all kinds of research, not only genetics, and the issue of diagnosis is addressed elsewhere in this book. However, genetics may have a unique role to contribute toward solving this dilemma. This may best be illustrated by an example from the early 1980s, in which medical geneticists and oncologists could not agree about the classification of the disease neurofibromatosis (NF). "Splitters" argued for up to a dozen different etiologic subtypes, whereas "lumpers" suggested that there may be only a single disease with a lot of variation among individuals as a result of differences in environmental exposures and variation in "genetic background" (a term that encompasses the cumulative influence of all other genes distributed throughout the genome in addition to the "major gene"). It had been discovered in research conducted during earlier decades that NF was transmitted in families as a single dominant gene, but the question remained as to how many different genes were involved (locus heterogeneity). Furthermore, even if only one gene was involved, it was possible that different mutations caused unique patterns of signs and symptoms (allelic heterogeneity). The controversy was largely resolved by the discovery of the NF1[36] and NF2[62] genes. After these genes were identified, individual patients could be distinguished by DNA testing, and the diagnostic classification controversies were resolved. In hindsight, it became clear that the clustering of signs and symptoms fell into two major categories among different types of families and depended on which NF1 or NF2 mutation was involved and on what kind of gene mutation was involved. Although such gene-based clarity is unlikely for a complex multigenic condition such as periodontitis, the potential exists that subtypes of patients may eventually be classified more effectively by examining their DNA to see what kinds of susceptibility genes they inherited.

To move toward this desired outcome, however, we need to use the best strategies available today to classify research subjects into categories such as cases versus controls. Alternatively, we can attempt to use quantitative measures of bone loss or attachment loss to classify research subjects along a more continuous gradient that ranges from persons with extremely healthy periodontium with little or no signs of disease to those with tooth loss and very high measures of pocket depth and attachment loss in remaining teeth. Family studies have numerous advantages in genetics; for these designs, the use of a quantitative measures approach is especially attractive. When searching for gene associations in unrelated cases and controls, we can decide to select only subjects who are clearly affected as cases and compare them with control subjects who clearly are very periodontally healthy. When studying families, however, one has to assign a disease status to all of the family members to fully make use of all of the information in the biologic unit. We may initially recruit the family on the basis of an unambiguous case known as the *proband* (i.e., the subject who makes the family eligible for inclusion in the study), but the handling of parents, siblings, and other close relatives who may be neither clearly periodontally healthy nor clearly diseased is not easy to determine. For example, if we establish a threshold and require that

two or more teeth have a minimum of 4 mm of attachment loss for subjects to be classified as affected, then how we handle family members who are borderline becomes the challenge. For example, siblings of the proband may have several teeth with 3 mm of attachment loss in addition to one tooth with 6 mm of loss. Such subjects are close to but not quite over the threshold. They are neither clearly healthy nor clearly diseased, and this makes them very problematic for categorical data analyses that require them to be classified as cases versus controls.

One aspect of the diagnosis challenge that is especially poorly understood is how and why different teeth are affected by periodontitis. Dentists have long recognized that incisors and first molars are more likely to be affected during early-onset disease, but it is not straightforward to incorporate this information into threshold disease definitions. One way to begin to address the problem of variation among teeth is to apply multivariate methods, such as principal components analysis, as was done in a study of aggressive periodontitis.[13] This method maximizes the proportion of the total variation in attachment loss among all 28 teeth explained by a limited number of master variables called *principal components.* In this study, three principal components explained 77.8% of the total variance. The results are displayed in Figure 6-6, with color intensities being used to help visualize the patterns of correlation among different tooth types. Mixtures of red, green, and blue are "painted" onto the teeth, with each color's intensity adjusted according to the tooth's relative "weight" calculated for each of the principal components. This quantitative analysis shows how attachment loss is correlated among different kinds of teeth. First molar teeth are consistently painted a yellow color by their principal components scores; these teeth are very different from all of the other teeth with regard to their patterns of attachment loss. There is a gradual change in the patterns of attachment loss for the other teeth that extend out from the central incisors (magenta) to the lateral incisors (purple), the cuspids (blue), the premolars (blue green), and the second molars (green). In addition to generally exploring patterns of periodontal disease dispersed in the "geography" of the mouth, because these are studies conducted in families, we can also use genetic epidemiologic methods to validate and compare alternative measures of disease.

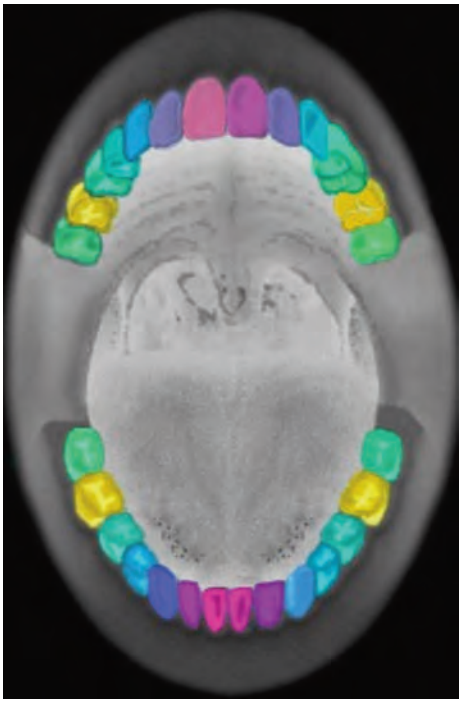

Figure 6-6 Illustration of the similarities and differences among different kinds of teeth with regard to the frequency and severity of attachment loss observed in early onset aggressive periodontitis patients and their unaffected family members with the use of the principal components analysis method.[13]

Specifically, we can calculate heritability for different quantitative variables (e.g., simple mean attachment loss averaged across all teeth or averaged for specific groups of teeth) as well as for more complex variables like these principal components. In the study of aggressive periodontitis illustrated in Figure 6-6, the principal component most heavily weighted on the first molars had a heritability of 30%, which was actually slightly higher than the 26% heritability estimated for a simple mean of attachment loss in the first molars. By using heritability and other genetic measures such as association with specific inherited polymorphisms, it may be possible to refine diagnostic and disease classification systems by aligning these according to subgroups of subjects that share homogeneous etiologies.

> Learning from the experience of other complex diseases, Sir Isaac Newton famously remarked in 1676: "What Descartes did was a good step. You have added much several ways … If I have seen a little further it is by standing on the shoulders of Giants."

Although there remains great enthusiasm for GWAS studies, as was noted previously, even the most successful GWAS results (e.g., those that have been obtained for type 2 diabetes) have failed to identify most of the genetic variation responsible for the disease. The discovery of more than 30 gene associations for type 2 diabetes accounts for a small fraction of the disease's heritability.[12] To track down the missing genetic variation, a great deal of attention is now turning toward whole genome DNA-sequencing methods that will be available at very low cost within 3 to 5 years. Sequencing methods also expand the ability to measure gene expression in various tissues. These data, in combination with the ever-increasing availability of proteomic assays, will challenge investigators with huge quantities of information. Aside from generating the many gigabytes of data involved in this technology, the greatest challenges of "systems biology" may lie in developing the bioinformatics tools needed to sift through and identify the key bits of information that are important for advancing our knowledge from among the vast rising sea of biologic data pouring out of our laboratories.[4]

Strategies for improving our understanding of the genetics of periodontitis as well as for increasing the possibilities for the translation of this knowledge to benefit patients in the clinic are being mapped out today by teams of geneticists, clinicians, and information scientists who are currently focused on major medical conditions. By continuing to learn from the experiences of these early genomic explorers, it is reasonable to hope that dental researchers will be able to avoid some of their mistakes and follow the quickest path to advances in knowledge about diseases of interest.

Using Genetics for Personalized Treatment

Pharmacogenomics and Individualized Dentistry

If individuals differ with regard to their susceptibility to disease and especially if underlying the superficial signs and symptoms of a disease there really are etiologically distinct subtypes of disease pathogenesis, then the traditional medical model of "one size fits

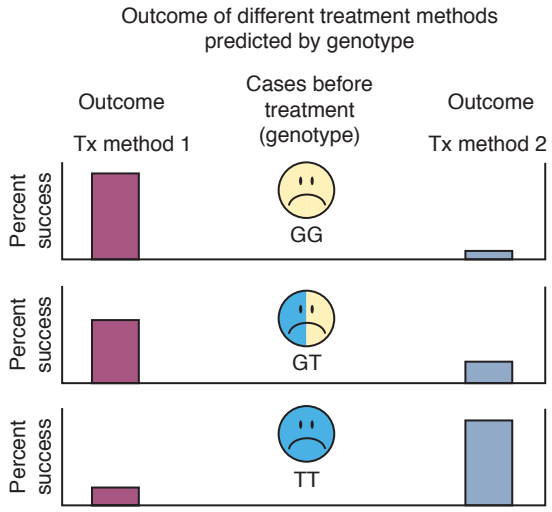

Figure 6-7 Inherited genetic variation determines treatment success. Individuals who inherited the GG or GT genotypes at a gene involved in a biologic pathway related to either the underlying disease susceptibility mechanisms or to the body's response to the therapy have very good chances for success with treatment method 1 *(Tx method 1)* but poor prognoses with treatment method 2 *(Tx method 2),* whereas individuals with the TT genotype respond positively to treatment method 2 only.

all" will not be optimal. As shown in Figure 6-7, cases of disease (as illustrated by circles with unhappy faces) may differ with regard to genotype for a gene that determines which treatment works best for each individual. Some cases inherited G alleles from both their mother and their father and thus have a GG genotype, whereas others have a GT or TT genotype. The gene may distinguish between different subtypes of disease etiology or pathogenesis, or it might code for an enzyme, transporter, or receptor important for the metabolism of a therapeutic drug and have nothing directly to do with disease susceptibility. In the example illustrated in this figure, treatment method 1 *(Tx method 1)* has a very high success rate when it is provided to subjects with the GG or GT genotypes, but it usually fails for cases with the TT genotype. TT genotypes experience much better outcomes when provided with treatment method 2 *(Tx method 2),* but this method often fails for subjects with the GG and GT genotypes. Sometimes concerns about severe side effects that limit the use of a therapy rather than differences in efficacy and risk of side effects can also be genetically determined. If clinicians are not aware of the relationships between these genotypes and treatment success or side effects, it would appear that neither treatment is consistently effective. Clinicians would be forced to use a trial-and-error approach, first trying one method and then switching to the other if the first method fails. At best, this causes unnecessary expense and does not provide an optimal quality of care. Furthermore—and especially for deadly diseases such as cancer—precious time may be lost in halting the advance of the disease; by the time the clinician discovers an individual's best treatment, it may be too late. This strategy of individualized medicine is already being practiced for an increasing number of diseases.[9,19]

In dentistry, a test based on genetic variations of the IL-1α and IL-1β cytokine and receptor antagonist genes to predict the progression and severity of periodontitis has been commercialized and is offered today, although it does not appear to be widely used. A number of reviews of the large number of studies of the IL-1 gene polymorphisms (see Table 6-3 [online] and Table 6-4) indicate that genetic variation at these loci may be associated with a modest effect on disease risk.[24,47] In 2007, Huynh-Ba and colleagues concluded that "there is insufficient evidence to establish if a positive IL-1 genotype status contributes to progression of periodontitis and/or treatment outcomes."[24] A similar lack of supporting evidence for the use of IL-1 genetic testing to predict implant success has also been reported.[3,25] A more recent meta-analysis of the available data suggested that these much-studied IL-1 polymorphisms have a small (odds ratio, ≈1.5) but significant effect on periodontitis risk, although only for chronic periodontitis in white populations.[28] However, it is essential to emphasize that, because heritability for chronic periodontitis is estimated to be 50%,[44] the small effect of the IL-1 polymorphisms makes up at most a very tiny fraction of the genetic component of risk for this disease (which remains missing, as discussed previously).

As the benefits of individualized or personalized treatments that are optimally matched to the genome of each patient have been demonstrated for cancer and increasing numbers of other human diseases, interest has grown in applying this approach to dentistry.[30,55] The first major study that attempted to develop guidelines for individualized treatment has recently been reported.[17] This study involved 5117 adults between the ages of 34 and 55 years with no prior diagnosis of early periodontitis who were followed retrospectively for 16 years. The aim was to evaluate whether only a subset of high-risk patients really benefits from two versus only one preventive visit per year to avert tooth loss. The risk factors that were tested were smoking, diabetes, and the IL-1 composite genotype. Although the study suggests that all three risk factors may predict which patients benefit from two preventive visits, the findings need to be independently replicated, ideally with the use of a prospective design, before this information is incorporated into clinical practice guidelines.

As genetic testing becomes widespread, especially if it is marketed through "direct-to-consumer" models, increasing responsibility will fall on dentists to fully understand and counsel their patients about the implications of test results for their treatment options and their risk of developing various dental diseases in the future. Tests for diseases of the oral cavity may likely combine inherited polymorphisms with oral microbial profiles, and they might also include assays of gene expression or proteomic data measured in saliva or other oral tissues. Few dentists practicing today have been educated to prepare themselves for these future challenges. This major shortfall of knowledge urgently needs to be addressed. This can be done by continually educating today's dental professionals about advances in knowledge of human genetics and the uses and potential misuses of genetic testing; by establishing multidisciplinary teams of health practitioners in which dentists work closely with genetics counselors and medical geneticists; or by combining these approaches.

Acknowledgments

We acknowledge the support provided by the National Institutes of Health's National Institute of Dental and Craniofacial Research grants 5R01DE016057 and 5R01DE018635 and the Foundation of the University of Medicine and Dentistry of New Jersey.

Suggested Readings

Collins A: Approaches to the identification of susceptibility genes. *Parasite Immunol* 31(5):225–233, 2009.

Collins FS: *The language of life: DNA and the revolution in personalized medicine*, New York, 2010, Harper.

Frazer KA, Murray SS, Schork NJ, et al: Human genetic variation and its contribution to complex traits. *Nat Rev Genet* 10(4):241–251, 2009.

Ginsburg GS, Willard HF: Genomic and personalized medicine: foundations and applications. *Transl Res* 154(6):277–287, 2009.
Kinane DF, Shiba H, Hart TC: The genetic basis of periodontitis. *Periodontol 2000* 39:91–117, 2005.
Nares S: The genetic relationship to periodontal disease. *Periodontol 2000* 32:36–49, 2003.
Takashiba S, Naruishi K: Gene polymorphisms in periodontal health and disease. *Periodontol 2000* 40:94–106, 2006.
Ragoussis J: Genotyping technologies for genetic research. *Annu Rev Genomics Hum Genet* 10:117–133, 2009.
Rodriguez-Murillo L, Greenberg DA: Genetic association analysis: a primer on how it works, its strengths and its weaknesses. *Int J Androl* 31(6):546–556, 2008.
Yoshie H, Kobayashi T, Tai H, et al: The role of genetic polymorphisms in periodontitis. *Periodontol 2000* 43:102–132, 2007.

References

References for this chapter are found on the companion website www.expertconsult.com.

References

1. Altshuler D, Daly MJ, Lander ES: Genetic mapping in human disease. *Science* 322:881, 2008.
2. Amberger J, Bocchini CA, Scott AF, et al: McKusick's Online Mendelian Inheritance in Man (OMIM). *Nucleic Acids Res* 37:D793, 2009.
3. Andreiotelli M, Koutayas SO, Madianos PN, et al: Relationship between interleukin-1 genotype and peri-implantitis: a literature review. *Quintessence Int* 39:289, 2008.
4. Auffray C, Chen Z, Hood L: Systems medicine: the future of medical genomics and healthcare. *Genome Med* 1:2, 2009.
5. Bernstein BA: An introduction to sample size and power. *J Dev Behav Pediatr* 29:516, 2008.
6. Borrell LN, Papapanou PN: Analytical epidemiology of periodontitis. *J Clin Periodontol* 32(Suppl 6):132, 2005.
7. Collins A: Approaches to the identification of susceptibility genes. *Parasite Immunol* 31:225, 2009.
8. Collins F, Tabak L: A call for increased education in genetics for dental health professionals. *J Dent Educ* 68:807, 2004.
9. Collins FS: *The language of life: DNA and the revolution in personalized medicine*, ed 1, New York, 2010, Harper.
10. Concolino P, Cecchetti F, D'Autilia C, et al: Association of periodontitis with GSTM1/GSTT1-null variants—a pilot study. *Clin Biochem* 40:939, 2007.
11. Condit CM: How geneticists can help reporters to get their story right. *Nat Rev Genet* 8:815, 2007.
12. Dickson SP, Wang K, Krantz L, et al: Rare variants create synthetic genome-wide associations. *PLoS Biol* 8:12, 2010.
13. Diehl SR, Wu T, Michalowicz BS, et al: Quantitative measures of aggressive periodontitis show substantial heritability and consistency with traditional diagnoses. *J Periodontol* 76:279, 2005.
14. Divaris K, Monda KL, North KE: Genome-wide association study of periodontal pathogen colonization. *J Dent Res* 91:21S, 2012.
15. Divaris K, Monda KL, North KE: Exploring the genetic basis of chronic periodontitis: a genome-wide association study. *Hum Mol Genet* 22:2312, 2013.
16. Fiebig A, Jepsen S, Loos BG, et al: Polymorphisms in the interleukin-1 (IL1) gene cluster are not associated with aggressive periodontitis in a large Caucasian population. *Genomics* 92:309, 2008.
17. Giannobile WV, Braun TM, Caplis AK: Patient stratification for preventive care in dentistry. *J Dent Res* 92:694, 2013.
18. Gilad Y, Pritchard JK, Thornton K: Characterizing natural variation using next-generation sequencing technologies. *Trends Genet* 25:463, 2009.
19. Ginsburg GS, Willard HF: Genomic and personalized medicine: foundations and applications. *Transl Res* 154:277, 2009.
20. Gunji T, Onouchi Y, Nagasawa T, et al: Functional polymorphisms of the FPR1 gene and aggressive periodontitis in Japanese. *Biochem Biophys Res Commun* 364:7, 2007.
21. Gurkan A, Emingil G, Saygan BH, et al: Gene polymorphisms of matrix metalloproteinase-2, -9 and -12 in periodontal health and severe chronic periodontitis. *Arch Oral Biol* 53:337, 2008.
22. Hennig BJ, Parkhill JM, Chapple IL, et al: Association of a vitamin D receptor gene polymorphism with localized early-onset periodontal diseases. *J Periodontol* 70:1032, 1999.
23. Ho YP, Lin YC, Yang YH, et al: Cyclooxygenase-2 gene-765 single nucleotide polymorphism as a protective factor against periodontitis in Taiwanese. *J Clin Periodontol* 35:1, 2008.
24. Huynh-Ba G, Lang NP, Tonetti MS, et al: The association of the composite IL-1 genotype with periodontitis progression and/or treatment outcomes: a systematic review. *J Clin Periodontol* 34:305, 2007.
25. Huynh-Ba G, Lang NP, Tonetti MS, et al: Association of the composite IL-1 genotype with peri-implantitis: a systematic review. *Clin Oral Implants Res* 19:1154, 2008.
26. Johnson L, Genco RJ, Damsky C, et al: Genetics and its implications for clinical dental practice and education: report of panel 3 of the Macy study. *J Dent Educ* 72:86, 2008.
27. Jordan WJ, Eskdale J, Lennon GP, et al: A non-conservative, coding single-nucleotide polymorphism in the N-terminal region of lactoferrin is associated with aggressive periodontitis in an African-American, but not a Caucasian population. *Genes Immun* 6:632, 2005.
28. Karimbux NY, Saraiya VM, Elangovan S: Interleukin-1 gene polymorphisms and chronic periodontitis in adult whites: a systematic review and meta-analysis. *J Periodontol* 83:1407, 2012.
29. Kocher T, Sawaf H, Fanghanel J, et al: Association between bone loss in periodontal disease and polymorphism of N-acetyltransferase (NAT2). *J Clin Periodontol* 29:21, 2002.
30. Kornman KS, Duff GW: Personalized medicine: will dentistry ride the wave or watch from the beach? *J Dent Res* 91:8S, 2012.
31. Laine ML, Morre SA, Murillo LS, et al: CD14 and TLR4 gene polymorphisms in adult periodontitis. *J Dent Res* 84:1042, 2005.
32. Li Q, Meng H, Zhang L, et al: Correlation between single nucleotide polymorphisms in a calprotectin subunit gene and risk of periodontitis in a Chinese population. *Ann Hum Genet* 71:312, 2007.
33. Loe H, Brown LJ: Early onset periodontitis in the United States of America. *J Periodontol* 62:608, 1991.
34. Loos BG, Fiebig A, Nothnagel M, et al: NOD1 gene polymorphisms in relation to aggressive periodontitis. *Innate Immun* 15:225, 2009.
35. Loos BG, Leppers-Van de Straat FG, Van de Winkel JG, et al: Fcgamma receptor polymorphisms in relation to periodontitis. *J Clin Periodontol* 30:595, 2003.
36. Lu-Emerson C, Plotkin SR: The neurofibromatoses. Part 1: NF1. *Rev Neurol Dis* 6:E47, 2009.
37. MacDougall M, Jeffords LG, Gu TT, et al: Genetic linkage of the dentinogenesis imperfecta type III locus to chromosome 4q. *J Dent Res* 78:1277, 1999.
38. Manolio TA, Collins FS, Cox NJ, et al: Finding the missing heritability of complex diseases. *Nature* 461:747, 2009.
39. McGuffin P, Huckle P: Simulation of Mendelism revisited: the recessive gene for attending medical school. *Am J Hum Genet* 46:994, 1990.
40. Meisel P, Krause T, Cascorbi I, et al: Gender and smoking-related risk reduction of periodontal disease with variant myeloperoxidase alleles. *Genes Immun* 3:102, 2002.
41. Meisel P, Schwahn C, Gesch D, et al: Dose-effect relation of smoking and the interleukin-1 gene polymorphism in periodontal disease. *J Periodontol* 75:236, 2004.
42. Meisel P, Siegemund A, Grimm R, et al: The interleukin-1 polymorphism, smoking, and the risk of periodontal disease in the population-based SHIP study. *J Dent Res* 82:189, 2003.
43. Michalowicz BS, Aeppli D, Virag JG, et al: Periodontal findings in adult twins. *J Periodontol* 62:293, 1991.
44. Michalowicz BS, Diehl SR, Gunsolley JC, et al: Evidence of a substantial genetic basis for risk of adult periodontitis. *J Periodontol* 71:1699, 2000.
45. Michalowicz BS, Wolff LF, Klump D, et al: Periodontal bacteria in adult twins. *J Periodontol* 70:263, 1999.
46. Nebert DW, Zhang G, Vesell ES: From human genetics and genomics to pharmacogenetics and pharmacogenomics: past lessons, future directions. *Drug Metab Rev* 40:187, 2008.
47. Nikolopoulos GK, Dimou NL, Hamodrakas SJ, et al: Cytokine gene polymorphisms in periodontal disease: a meta-analysis of 53 studies including 4178 cases and 4590 controls. *J Clin Periodontol* 35:754, 2008.
48. Noack B, Gorgens H, Hempel U, et al: Cathepsin C gene variants in aggressive periodontitis. *J Dent Res* 87:958, 2008.
49. O'Sullivan BP, Freedman SD: Cystic fibrosis. *Lancet* 373:1891, 2009.
50. Poulsen P, Kyvik KO, Vaag A, et al: Heritability of type II (non-insulin-dependent) diabetes mellitus and abnormal glucose tolerance—a population-based twin study. *Diabetologia* 42:139, 1999.
51. Preshaw PM: Definitions of periodontal disease in research. *J Clin Periodontol* 36:1, 2009.
52. Purcell S, Cherny SS, Sham PC: Genetic Power Calculator: design of linkage and association genetic mapping studies of complex traits. *Bioinformatics* 19:149, 2003.
53. Ragoussis J: Genotyping technologies for genetic research. *Annu Rev Genomics Hum Genet* 10:117, 2009.
54. Ramagopalan SV, Knight M, Ebers GC, et al: Origins of magic: review of genetic and epigenetic effects. *BMJ* 335:1299, 2007.

55. Razzouk S: Termatchi O: Host genome, epigenome and oral microbiome interactions: toward personalized periodontal therapy. *J Periodontol* 84:1266, 2013.
56. Risch N, Merikangas K: The future of genetic studies of complex human diseases. *Science* 273:1516, 1996.
57. Sahingur SE, Sharma A, Genco RJ, et al: Association of increased levels of fibrinogen and the -455G/A fibrinogen gene polymorphism with chronic periodontitis. *J Periodontol* 74:329, 2003.
58. Schaefer AS, Bochenek G, Manke T: Validation of reported genetic risk factors for periodontitis in a large-scale replication study. *J Clin Periodontol* 40:563, 2013.
59. Schaefer AS, Richter GM, Groessner-Schreiber B, et al: Identification of a shared genetic susceptibility locus for coronary heart disease and periodontitis. *PLoS Genet* 5:e1000378, 2009.
60. Schaefer AS, Richter GM, Nothnagel M, et al: A 3′ UTR transition within DEFB1 is associated with chronic and aggressive periodontitis. *Genes Immun* 11:45, 2010.
61. Schaefer AS, Richter GM, Nothnagel M, et al: A genome-wide association study identifies GLT6D1 as a susceptibility locus for periodontitis. *Hum Mol Genet* 19:553, 2010.
62. Selvanathan SK, Shenton A, Ferner R, et al: Further genotype–phenotype correlations in neurofibromatosis 2. *Clin Genet* 77:163, 2009.
63. Stein JM, Machulla HK, Smeets R, et al: Human leukocyte antigen polymorphism in chronic and aggressive periodontitis among Caucasians: a meta-analysis. *J Clin Periodontol* 35:183, 2008.
64. Stolerman ES, Florez JC: Genomics of type 2 diabetes mellitus: implications for the clinician. *Nat Rev Endocrinol* 5:429, 2009.
65. Talmud PJ, Hingorani AD, Cooper JA, et al: Utility of genetic and non-genetic risk factors in prediction of type 2 diabetes: Whitehall II prospective cohort study. *BMJ* 340:b4838, 2010.
66. Velliyagounder K, Kaplan JB, Furgang D, et al: One of two human lactoferrin variants exhibits increased antibacterial and transcriptional activation activities and is associated with localized juvenile periodontitis. *Infect Immun* 71:6141, 2003.
67. Voelkerding KV, Dames SA, Durtschi JD: Next-generation sequencing: from basic research to diagnostics. *Clin Chem* 55:641, 2009.
68. Zhang L, Meng H, Zhao H, et al: Estrogen receptor-alpha gene polymorphisms in patients with periodontitis. *J Periodontal Res* 39:362, 2004.

CHAPTER 7

The Role of Dental Calculus and Other Local Predisposing Factors

James E. Hinrichs and Vivek Thumbigere Math

CHAPTER OUTLINE

Calculus
Other Predisposing Factors

The primary cause of gingival inflammation is bacterial plaque. Other predisposing factors include calculus, faulty restorations, complications associated with orthodontic therapy, self-inflicted injuries, and the use of tobacco, in addition to several others. These will be discussed in turn.

Calculus

Calculus consists of mineralized bacterial plaque that forms on the surfaces of natural teeth and dental prostheses.

Supragingival and Subgingival Calculus

Supragingival calculus is located coronal to the gingival margin and therefore is visible in the oral cavity. It is usually white or whitish yellow in color; hard, with a claylike consistency; and easily detached from the tooth surface. After removal, it may rapidly recur, especially in the lingual area of the mandibular incisors. The color is influenced by contact with such substances as tobacco and food pigments. It may localize on a single tooth or group of teeth, or it may be generalized throughout the mouth.

The two most common locations for the development of supragingival calculus are the buccal surfaces of the maxillary molars (Figure 7-1) and the lingual surfaces of the mandibular anterior teeth (Figure 7-2).[34] Saliva from the parotid gland flows over the facial surfaces of the upper molars via the parotid duct, whereas the submandibular duct and the lingual duct empty onto the lingual surfaces of the lower incisors from the submaxillary and sublingual glands, respectively. In extreme cases, calculus may form a bridgelike structure over the interdental papilla of adjacent teeth or cover the occlusal surface of teeth that are lacking functional antagonists.

Subgingival calculus is located below the crest of the marginal gingiva and therefore is not visible on routine clinical examination. The location and extent of subgingival calculus may be evaluated by careful tactile perception with a delicate dental instrument such as an explorer. Clerehugh and colleagues[31] used a World Health Organization no. 621 probe to detect and score subgingival calculus. Subsequently, these teeth were extracted and visually scored for subgingival calculus. An agreement of 80% was found between these two scoring methods. Subgingival calculus is typically hard and dense; it frequently appears to be dark brown or greenish black in color (Figure 7-3), and it is firmly attached to the tooth surface. Supragingival calculus and subgingival calculus generally occur together, but one may be present without the other. Microscopic studies demonstrate that deposits of subgingival calculus usually extend nearly to the base of periodontal pockets in individuals with chronic periodontitis but do not reach the junctional epithelium.

When the gingival tissues recede, subgingival calculus becomes exposed and is therefore reclassified as supragingival (Figure 7-4, *A*). Thus, supragingival calculus can be composed of both supragingival calculus and previous subgingival calculus. A reduction in gingival inflammation and probing depths with a gain in clinical attachment can be observed after the removal of subgingival plaque and calculus (Figure 7-4, *B*; see Chapter 46).

Prevalence

Anerud and colleagues[4] observed the periodontal status of a group of Sri Lankan tea laborers and a group of Norwegian academicians for a 15-year period. The Norwegian population had ready access to preventive dental care throughout their lives, whereas the Sri Lankan tea laborers did not. The formation of supragingival calculus was observed early in life in the Sri Lankan individuals, probably shortly after the teeth erupted. The first areas to exhibit calculus deposits were the facial aspects of maxillary molars and the lingual surfaces of mandibular incisors. The deposition of supragingival calculus continued as individuals aged, and it reached a maximal calculus score when the affected individuals were around 25 to 30 years old. At this time, most of the teeth were covered by calculus, although the facial surfaces had less calculus than the lingual or palatal surfaces. Calculus accumulation appeared to be symmetric, and, by the age of 45 years, these individuals had only a few teeth (typically the premolars) without calculus. Subgingival calculus appeared first either independently or on the interproximal aspects of areas where supragingival calculus already existed.[4] By the age of 30 years, all surfaces of all teeth had subgingival calculus without any pattern of predilection.

The Norwegian academicians received oral hygiene instructions and frequent preventive dental care throughout their lives. The Norwegians exhibited a marked reduction in the accumulation of calculus as compared with the Sri Lankan group. However, despite the fact that 80% of teenagers formed supragingival

Figure 7-1 Supragingival calculus is depicted on the buccal surfaces of maxillary molars adjacent to the orifice for the parotid duct.

Figure 7-2 Extensive supragingival calculus is present on the lingual surfaces of the lower anterior teeth.

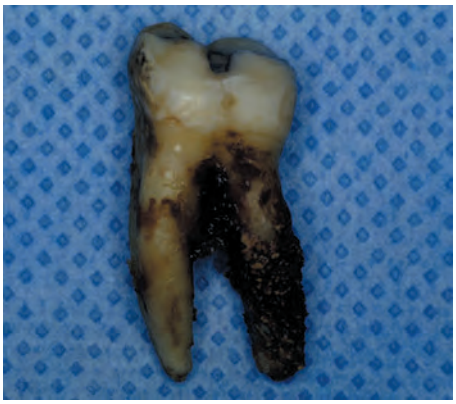

Figure 7-3 Dark pigmented deposits of subgingival calculus are shown on the distal root of an extracted lower molar.

calculus on the facial surfaces of the upper molars and the lingual surfaces of lower incisors, no additional calculus formation occurred on other teeth, and its presence did not increase with the individual's age.[4]

Both supragingival calculus and subgingival calculus may be seen on radiographs (see Chapter 32). Highly calcified interproximal calculus deposits are readily detectable as radiopaque projections that protrude into the interdental spaces (Figure 7-5). However, the sensitivity level of detecting calculus by radiographs is inconsistent.[24] The location of calculus does not indicate the bottom of the periodontal pocket, because the most apical plaque is not sufficiently calcified to be visible on radiographs.

Composition

Inorganic Content. Supragingival calculus consists of inorganic (70% to 90%[52]) and organic components. The major inorganic proportions of calculus have been reported as approximately 76% calcium phosphate, ($Ca_3[PO_4]_2$); 3% calcium carbonate ($CaCO_3$); and traces of magnesium phosphate ($Mg_3[PO_4]_2$) and other metals.[176] The percentage of inorganic constituents in calculus is similar to that of other calcified tissues of the body. The principal inorganic components have been reported as approximately 39% calcium, 19% phosphorus, 2% carbon dioxide, and 1% magnesium as well as trace amounts of sodium, zinc, strontium, bromine, copper, manganese, tungsten, gold, aluminum, silicon, iron, and fluorine.[113]

Figure 7-4 **A,** A 31-year-old white man with extensive supragingival and subgingival calculus deposits throughout his dentition is shown. **B,** One year after receiving thorough scaling and root planing to remove supragingival and subgingival calculus deposits, followed by restorative care. Note the substantial reduction in gingival inflammation.

At least two thirds of the inorganic component is crystalline in structure.[89] The four main crystal forms and their approximate percentages are as follows: hydroxyapatite, 58%; magnesium whitlockite, 21%; octacalcium phosphate, 12%; and brushite, 9%.

Two or more crystal forms are typically found in a sample of calculus. Hydroxyapatite and octacalcium phosphate are detected most frequently (i.e., in 97% to 100% of all supragingival calculus) and constitute the bulk of the specimen. Brushite is more common in the mandibular anterior region, and magnesium whitlockite is found in the posterior areas. The incidence of the four crystal forms varies with the age of the deposit.[16]

Organic Content. The organic component of calculus consists of a mixture of protein–polysaccharide complexes, desquamated epithelial cells, leukocytes, and various types of microorganisms.[99]

Between 1.9% and 9.1% of the organic component is carbohydrate, which consists of galactose, glucose, rhamnose, mannose, glucuronic acid, galactosamine, and sometimes arabinose, galacturonic acid, and glucosamine.[92,98,161] All of these organic

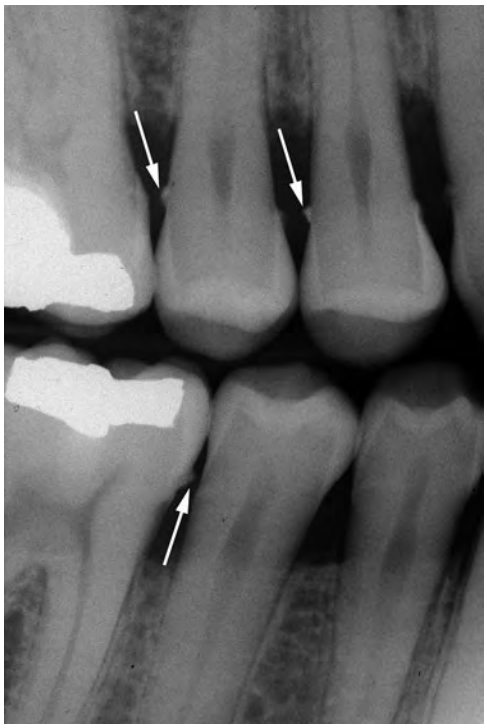

Figure 7-5 A bitewing radiograph illustrating subgingival calculus deposits that are depicted as interproximal spurs *(arrows)*.

components are present in salivary glycoprotein, with the exception of arabinose and rhamnose. Salivary proteins account for 5.9% to 8.2% of the organic component of calculus and include most amino acids. Lipids account for 0.2% of the organic content in the form of neutral fats, free fatty acids, cholesterol, cholesterol esters, and phospholipids.[93]

The composition of subgingival calculus is similar to that of supragingival calculus, with some differences. It has the same hydroxyapatite content, more magnesium whitlockite, and less brushite and octacalcium phosphate.[142,165] The ratio of calcium to phosphate is higher subgingivally, and the sodium content increases with the depth of periodontal pockets.[94] These altered compositions may be attributed to the origin of subgingival calculus being plasma, whereas supragingival calculus is partially composed of saliva constituents. Salivary proteins present in supragingival calculus are not found subgingivally.[11] Dental calculus, salivary duct calculus, and calcified dental tissues are similar in inorganic composition.

Attachment to the Tooth Surface

Differences in the manner in which calculus is attached to the tooth surface affect the relative ease or difficulty encountered during its removal. Four modes of attachment have been described.[85,145,152,181] Attachment by means of an organic pellicle on cementum is depicted in Figure 7-6, and attachment on enamel is shown in Figure 7-7. Mechanical locking into surface irregularities, such as caries lesions or resorption lacunae, is illustrated in Figure 7-8. The fourth mode of attachment consists of the close adaptation of the undersurface of calculus to depressions or gently sloping mounds of the unaltered cementum surface,[161] as shown in Figure 7-9, and the penetration of bacterial calculus into cementum, as shown in Figures 7-10 and 7-11.

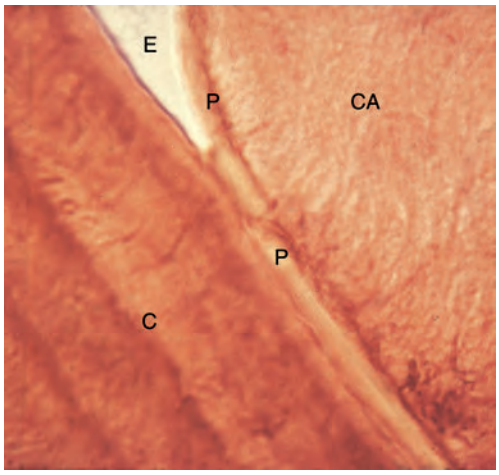

Figure 7-6 Calculus attached to the pellicle on the enamel surface and the cementum. An enamel void *(E)* has been created during the preparation of the specimen. *C,* Cementum; *CA,* calculus; *P,* pellicle.

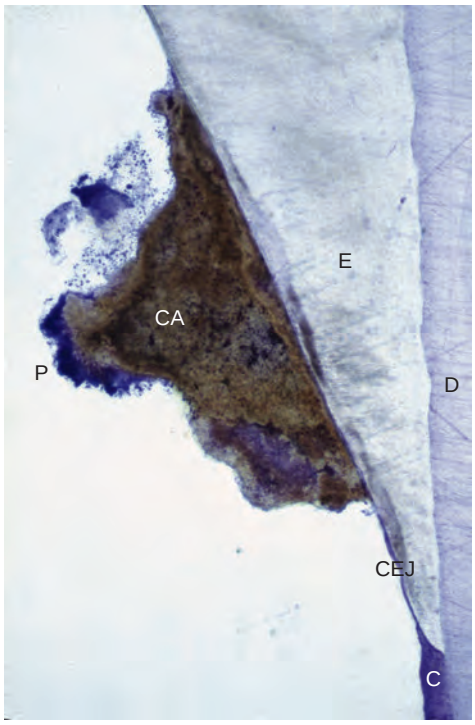

Figure 7-7 Non-decalcified specimen with calculus *(CA)* attached to enamel *(E)* surface just coronal to the cementoenamel junction *(CEJ)*. Note plaque *(P)* on the surface of the calculus; dentin *(D)* and cementum *(C)* are also identified. *(Courtesy Dr. Michael Rohrer, Minneapolis, MN.)*

Formation

Calculus is *mineralized dental plaque.* The soft plaque is hardened by the precipitation of mineral salts, which usually starts between the first and fourteenth days of plaque formation. Calcification has been reported to occur within as little as 4 to 8 hours.[166] Calcifying plaques may become 50% mineralized in 2 days and 60% to 90% mineralized in 12 days.[112,146,156] All plaque does not necessarily undergo calcification. Early plaque contains a small amount of inorganic material, which increases as the plaque develops into calculus. Plaque that does not develop into calculus reaches a

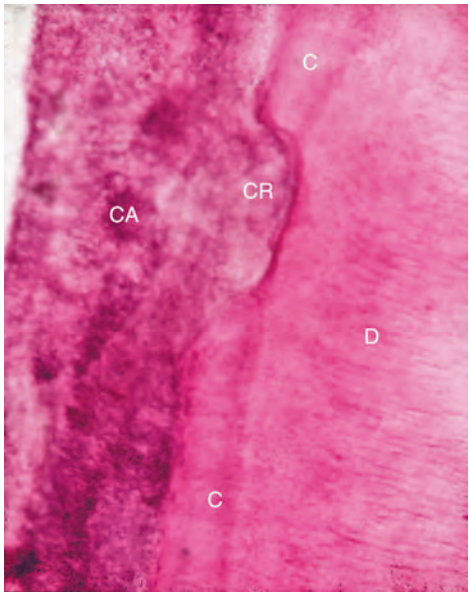

Figure 7-8 Calculus *(CA)* attached to a cemental resorption area *(CR)* with cementum *(C)* adjacent to dentin *(D)*.



Figure 7-9 Undersurface of subgingival calculus *(C)* previously attached to the cementum surface *(S)*. Note the impression of cementum mounds in the calculus *(arrows)*. *(Courtesy Dr. John Sottosanti, La Jolla, CA.)*

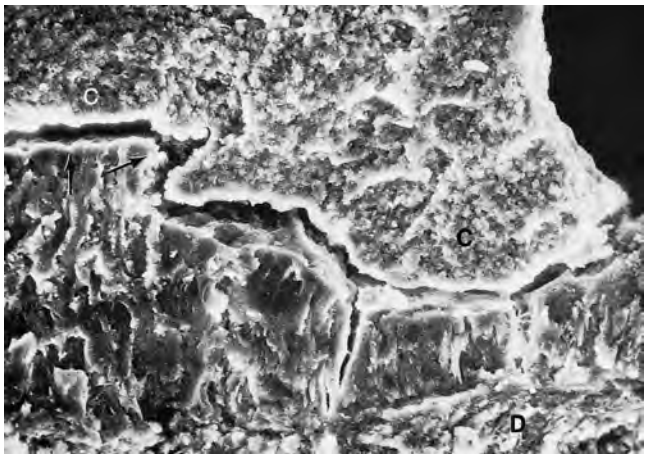

Figure 7-10 Subgingival calculus *(C)* embedded beneath the cementum surface *(arrows)* and penetrating to the dentin *(D)*, thereby making removal difficult. *(Courtesy Dr. John Sottosanti, La Jolla, CA.)*

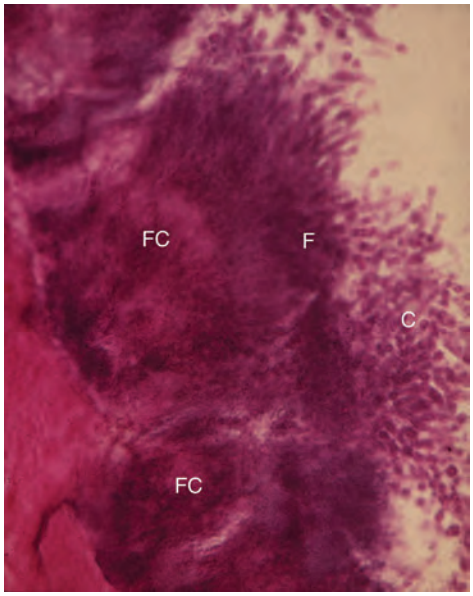

Figure 7-11 Plaque and calculus on the tooth surface. Note the spherical areas of focal calcification *(FC)* and the perpendicular alignment of the filamentous *(F)* organisms along the inner surface of plaque and cocci *(C)* on the outer surface.

plateau of maximal mineral content within 2 days.[147] Microorganisms are not always essential in calculus formation, because calculus occurs readily in germ-free rodents.[59]

Saliva is the source of mineralization for supragingival calculus, whereas the serum transudate called *gingival crevicular fluid* furnishes the minerals for subgingival calculus.[71,163] The calcium concentration/content in plaque is 2 to 20 times that found in saliva.[16] Early plaque of heavy calculus formers contains more calcium, three times more phosphorus, and less potassium than that of noncalculus formers, thereby suggesting that phosphorus may be more critical than calcium for plaque mineralization.[99] Calcification entails the binding of calcium ions to the carbohydrate–protein complexes of the organic matrix and the precipitation of crystalline calcium phosphate salts.[97] Crystals form initially in the intercellular matrix and on the bacterial surfaces and finally within the bacteria.[53,182]

The calcification of supragingival plaque and in the attached component of subgingival plaque begins along the inner surface adjacent to the tooth. Separate foci of calcification increase in size and coalesce to form solid masses of calculus (see Figure 7-11). Calcification may be accompanied by alterations in the bacterial content and staining qualities of the plaque. As calcification progresses, the number of filamentous bacteria increases, and the foci of calcification change from basophilic to eosinophilic. There is a reduction in the staining intensity of groups that exhibit a positive periodic acid–Schiff reaction.

Sulfhydryl and amino groups are also reduced and instead stain with toluidine blue, which is initially orthochromatic but which becomes metachromatic and disappears.[172] Calculus is formed in layers, which are often separated by a thin cuticle that becomes embedded in the calculus as calcification progresses.[101]

The initiation of calcification and the rate of calculus accumulation vary among individuals, among tooth variety in the same dentition, and at different times in the same person.[113,168] On the basis of these differences, persons may be classified as *heavy, moderate,* or *slight* calculus formers or as noncalculus formers. The

average daily increment in calculus formers is from 0.10% to 0.15% of dry weight calculus.[156,168] Calculus formation continues until it reaches a maximum, after which it may be reduced in amount. The time required to reach the maximal level has been reported to be between 10 weeks[32] and 6 months.[170]

The decline from maximal calculus accumulation, which is referred to as the *reversal phenomenon,* may be explained by the vulnerability of bulky calculus to mechanical wear from food and from the cheeks, lips, and tongue.

Theories Regarding the Mineralization of Calculus. The theoretical mechanisms by which plaque becomes mineralized can be stratified into two categories.[114]

1. Mineral precipitation results from a local rise in the degree of saturation of calcium and phosphate ions, which may be brought about in the following several ways:
   - *A rise in the pH of the saliva causes the precipitation of calcium phosphate salts by lowering the precipitation constant.* The pH may be elevated by the loss of carbon dioxide and the formation of ammonia by dental plaque bacteria or by protein degradation during stagnation.[15,66]
   - *Colloidal proteins in saliva bind calcium and phosphate ions and maintain a supersaturated solution with respect to calcium phosphate salts.* With the stagnation of saliva, colloids settle out, and the supersaturated state is no longer maintained, thereby leading to the precipitation of calcium phosphate salts.[130,149]
   - *Phosphatase liberated from dental plaque, desquamated epithelial cells, or bacteria precipitates calcium phosphate by hydrolyzing organic phosphates in saliva, thereby increasing the concentration of free phosphate ions.*[175] *Esterase* is another enzyme that is present in the cocci and filamentous organisms, leukocytes, macrophages, and desquamated epithelial cells of dental plaque.[9] Esterase may initiate calcification by hydrolyzing fatty esters into free fatty acids. The fatty acids form soaps with calcium and magnesium that are later converted into the less-soluble calcium phosphate salts.
2. Seeding agents induce small foci of calcification that enlarge and coalesce to form a calcified mass.[115] This concept has been referred to as the *epitactic concept* or, more appropriately, as *heterogeneous nucleation.* The seeding agents in calculus formation are not known, but it is suspected that the intercellular matrix of plaque plays an active role.[100,112,182] The carbohydrate–protein complexes may initiate calcification by removing calcium from the saliva (chelation) and binding with it to form nuclei that induce the subsequent deposition of minerals.[97,171]

Role of Microorganisms in the Mineralization of Calculus. Mineralization of plaque generally starts extracellularly around both gram-positive and gram-negative organisms, but it may also start intracellularly.[87] Filamentous organisms, diphtheroids, and *Bacterionema* and *Veillonella* species have the ability to form intracellular apatite crystals (see Figure 7-11). Mineralization spreads until the matrix and the bacteria are calcified.[53,183]

Bacterial plaque may actively participate in the mineralization of calculus by forming phosphatases, which changes the pH of the plaque and induces mineralization,[40,97] but the prevalent opinion is that these bacteria are only passively involved[53,137,175] and are simply calcified with other plaque components. The occurrence of calculus-like deposits in germ-free animals supports this opinion.[59] However, other experiments suggest that transmissible factors are involved in calculus formation and that penicillin in the diets of some of these animals reduces calculus formation.[10]

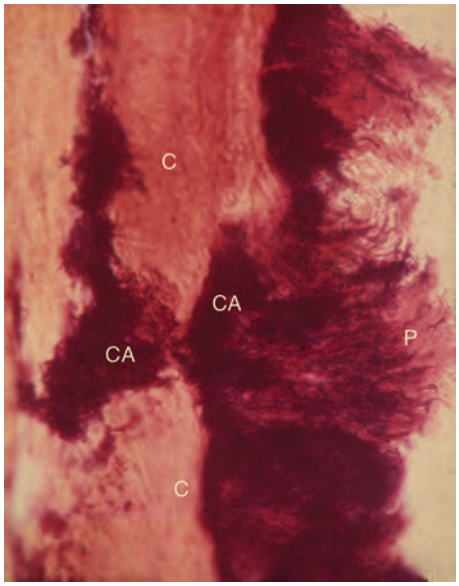

Figure 7-12 Calculus *(CA)* penetrates the tooth surface and is embedded within the cementum *(C).* Note the plaque *(P)* attached to the calculus.

Etiologic Significance

Distinguishing between the effects of calculus and plaque on the gingiva is difficult, because calculus is always covered with a nonmineralized layer of plaque.[147] A positive correlation between the presence of calculus and the prevalence of gingivitis exists,[132] but this correlation is not as great as that between plaque and gingivitis.[55] The initiation of periodontal disease in young people is closely related to plaque accumulation, whereas calculus accumulation is more prevalent in chronic periodontitis found in older adults.[55,90]

The incidence of calculus, gingivitis, and periodontal disease increases with age. It is extremely rare to find periodontal pockets in adults without at least some subgingival calculus being present, although the subgingival calculus may be of microscopic proportions.

Calculus does not contribute directly to gingival inflammation, but it provides a fixed nidus for the continued accumulation of plaque and its retention in close proximity to the gingiva (Figure 7-12). Subgingival calculus is likely to be the product rather than the cause of periodontal pockets. Plaque initiates gingival inflammation, which leads to pocket formation, and the pocket in turn provides a sheltered area for plaque and bacterial accumulation. The increased flow of gingival fluid associated with gingival inflammation provides the minerals that mineralize the continually accumulating plaque that results in the formation of subgingival calculus (Figure 7-13). Over a 6-year period, Albandar and colleagues observed 156 teenagers with aggressive periodontitis.[2] They noted that areas with detectable subgingival calculus at the initiation of the study were much more likely to experience a loss of periodontal attachment than sites that did not initially exhibit subgingival calculus.

Although the bacterial plaque that coats the teeth is the main etiologic factor in the development of periodontal disease, the removal of subgingival plaque and calculus constitute the cornerstone of periodontal therapy. Calculus plays an important role in maintaining and accentuating periodontal disease by keeping plaque in close contact with the gingival tissue and by creating

Figure 7-13 Scanning electron microscope view of an extracted human tooth showing a cross-section of subgingival calculus *(C)* separated *(arrows)* from the cemental surface during processing of the specimen. Note the bacteria *(B)* attached to the calculus and the cemental surfaces. *(Courtesy Dr. John Sottosanti, La Jolla, CA.)*

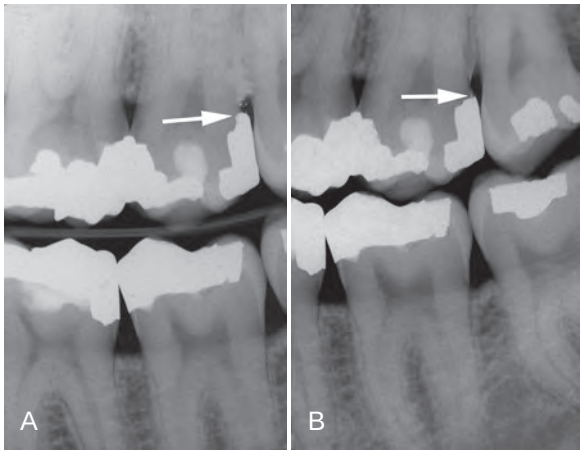

Figure 7-15 **A,** Radiograph of an amalgam overhang on the distal surface of the maxillary second molar that is a source of plaque retention and gingival irritation. **B,** Radiograph that depicts the removal of excessive amalgam.

Figure 7-14 Tobacco stains on the apical third of the clinical crown caused by cigarette smoking.

areas where plaque removal is impossible. Therefore, the clinician must not only possess the clinical skill to remove the plaque and calculus, but he or she must also be very conscientious about performing this task.

Materia Alba, Food Debris, and Dental Stains

Materia alba is an accumulation of microorganisms, desquamated epithelial cells, leukocytes, and a mixture of salivary proteins and lipids, with few or no food particles; it lacks the regular internal pattern observed in plaque.[148] It is a yellow or grayish-white, soft, sticky deposit, and it is somewhat less adherent than dental plaque. The irritating effect of materia alba on the gingiva is caused by bacteria and their products.

Most food debris is rapidly liquefied by bacterial enzymes and cleared from the oral cavity by salivary flow and the mechanical action of the tongue, cheeks, and lips. The rate of clearance from the oral cavity varies with the type of food and the individual. Aqueous solutions are typically cleared within 15 minutes, whereas sticky foods may adhere for more than 1 hour.[88,169] Dental plaque is not a derivative of food debris, and food debris is not an important cause of gingivitis.[39,75]

Pigmented deposits on the tooth surface are called *dental stains.* Stains are primarily an aesthetic problem and do not cause inflammation of the gingiva. The use of tobacco products (Figure 7-14), coffee, tea, certain mouthrinses, and pigments in foods can contribute to stain formation.[95,162]

Other Predisposing Factors

Iatrogenic Factors

Deficiencies in the quality of dental restorations or prostheses are contributing factors to gingival inflammation and periodontal destruction. Inadequate dental procedures that contribute to the deterioration of the periodontal tissues are referred to as *iatrogenic factors*. Iatrogenic endodontic complications that can adversely affect the periodontium include root perforations, vertical root fractures, and endodontic failures that may necessitate tooth extraction.[180,181]

Characteristics of dental restorations and removable partial dentures that are important to the maintenance of periodontal health include the location of the gingival margin for the restoration, the space between the margin of the restoration and the unprepared tooth, the contour of the restorations, the occlusion, the materials used in the restoration, the restorative procedure itself, and the design of the removable partial denture. These characteristics are described in this chapter as they relate to the etiology of periodontal disease. A more comprehensive review with special emphasis on the interrelationship between restorative procedures and the periodontal status is presented in Chapter 67.

Margins of Restorations. Overhanging margins of dental restorations contribute to the development of periodontal disease by (1) changing the ecologic balance of the gingival sulcus to an area that favors the growth of disease-associated organisms (predominantly gram-negative anaerobic species) at the expense of the health-associated organisms (predominantly gram-positive facultative species)[88] and (2) inhibiting the patient's access to remove accumulated plaque.

The frequency of overhanging margins on proximal restorations has varied in different studies from 16.5% to 75%.[18,51,70,121] A highly significant statistical relationship has been reported between marginal defects and reduced bone height.[18,60,70] The removal of overhangs allows for the more effective control of plaque, thereby resulting in a reduction of gingival inflammation and a small increase in radiographic alveolar bone support[54,63,159] (Figure 7-15).

The location of the gingival margin of a restoration is directly related to the health status of the adjacent periodontal tissues.[157] Numerous studies have shown a positive correlation between margins located apical to the marginal gingiva and the presence of gingival inflammation.[51,67,74,135,159] Subgingival margins are associated with large amounts of plaque, more severe gingivitis, and deeper pockets. Even high-quality restorations, if placed subgingivally, will increase plaque accumulation, gingival inflammation,[86,88,111,117,136,158] and the rate of gingival fluid flow.[12,56] Margins placed at the level of the gingival crest induce less severe inflammation, whereas supragingival margins are associated with a degree of periodontal health similar to that seen with nonrestored interproximal surfaces.[46,157]

Roughness in the subgingival area is considered to be a major contributing factor to plaque buildup and subsequent gingival inflammation.[157] The subgingival zone is composed of the margin of the restoration, the luting material, and the prepared and unprepared tooth surfaces. Sources of marginal roughness include grooves and scratches in the surface of acrylic resin, porcelain, or gold restorations (Figure 7-16); the separation of the restoration margin and the luting material from the cervical finish line, thereby exposing the rough surface of the prepared tooth (Figure 7-17); the dissolution and disintegration of the luting material between the preparation and the restoration, thereby leaving a space (Figure 7-18); and inadequate marginal fit of the restoration.[157] Subgingival margins typically have a gap of 20 to 40 µm between the margin of the restoration and the unprepared tooth.[155] Colonization of this gap by bacterial plaque undoubtedly contributes to the detrimental effect of margins placed in a subgingival environment.

Retained Cement/Periimplantitis. Periimplantitis is an inflammatory disease that affects the tissues around dental implants and that results in progressive bone loss (Figure 7-19, *A* and *B*).[91] The prevalence of periimplantitis among implant supported prosthesis/restoration ranges from 28% to 56%.[184] The early



Figure 7-16 **A,** Polished gold alloy crown demonstrating surface scratches. **B,** Gold alloy crown that had been in the patient's mouth for several years has scratches filled with deposits. *(From Silness J:* Dent Clin North Am *24:317, 1980.)*

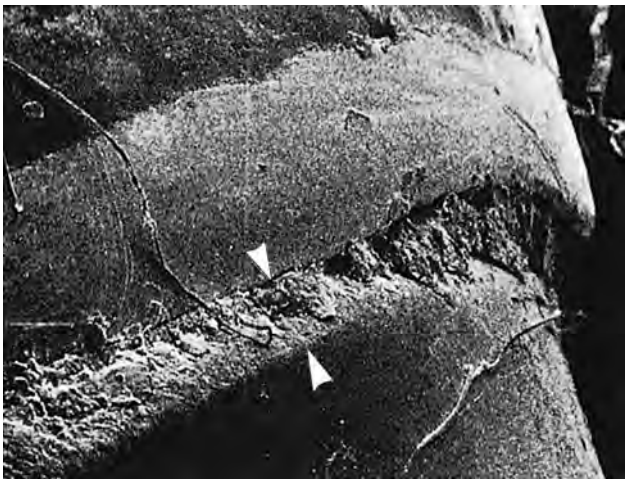

Figure 7-17 After cementation, luting material prevents the approximation of the crown margin and the finishing line, thereby leaving part of the prepared tooth uncovered *(area between arrowheads)*. *(From Silness J:* Dent Clin North Am *24:317, 1980.)*

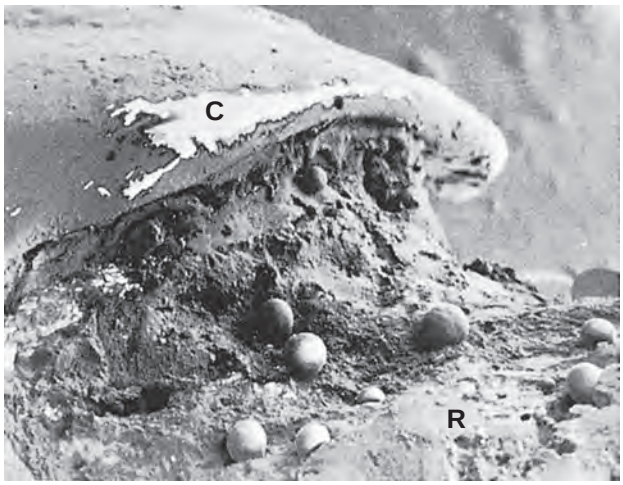

Figure 7-18 A void has developed after the dissolution and disintegration of the luting material. Spherical bodies are not identified. *C,* Crown; *R,* root. *(From Silness J:* Dent Clin North Am *24:317, 1980.)*

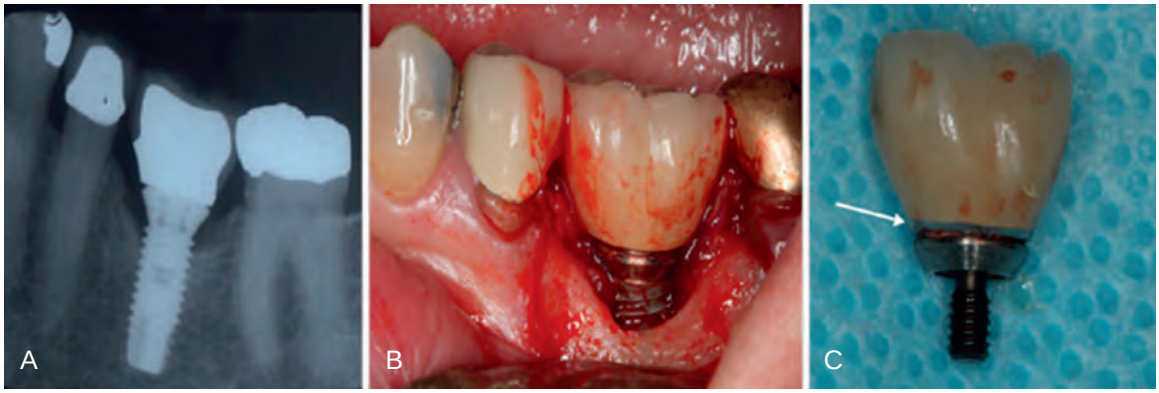

Figure 7-19 **A,** Radiograph of a moat like bony defect at a periimplantitis site associated with retained cement and a crown that is not fully seated. **B,** Moat like bony defect and retained excessive cement. **C,** The arrow points to visibly retained excessive cement between the crown margin and the abutment that prevents the full seating of the crown and leads to hyperocclusion. *(Courtesy Dr. Emilie Vachon, Minneapolis, MN.)*

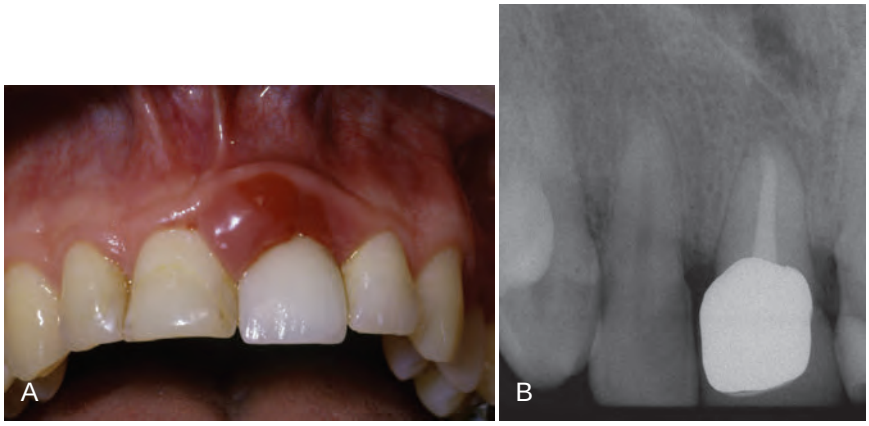

Figure 7-20 **A,** Inflamed marginal and papillary gingiva adjacent to an overcontoured porcelain-fused-to-metal crown on the maxillary left central. **B,** Radiograph of an ill-fitting porcelain-fused-to-metal crown.

diagnosis of this condition and its proper management are critical to the longevity of the implant and supported prosthesis.

Classic studies that explored the composition of the periimplant biofilm in disease have shown that periimplantitis is an infection that is dominated by gram-negative bacteria with many similarities to the microbiota that is responsible for the development of periodontal and periimplant diseases, including *Aggregatibacter actinomycetemcomitans, Porphyromonas gingivalis, Tannerella forsythia,* and *Fusobacterium* species. Recently, the application of new microbiologic approaches have allowed for a broader characterization of the periimplant microbiome, which has led to the identification of periimplant-specific microbial lineages such as *Streptococcus mutans* and *Butyrivibrio fibrisolvens*.[84,108,144]

A larger proportion of black-pigmented bacteria are found at periimplantitis sites in dentate patients as compared with edentulous patients. Presumably these periimplantitis infectious organisms arise from the sulcular microbiota of the natural dentition.[7] Consequently, it is critical that practitioners evaluate the patient's periodontal status and provide appropriate periodontal therapy in conjunction with implant rehabilitation.

Local factors such as retained residual cement or the inadequate seating of the implant abutment or prosthesis can lead to bone loss around an implant (Figure 7-19, *C*). Wilson recently conducted a retrospective study and found that 81% of the implants diagnosed with periimplantitis had residual cement associated with their cement-retained restorations.[178] The surgical removal of the residual cement resolved the infection and halted the periimplantitis in 74% of the implants.

The possible adverse effect of traumatic occlusion on implants has been correlated with early implant failures. However, the relationship between traumatic occlusion and periimplantitis is to date a controversial issue. In vivo experiments have shown that, in the absence of periimplant inflammation, the application of excessive occlusal stress leads to only minor alterations in the marginal bone level.[81] Alternatively, the application of excessive occlusal forces in the presence of plaque-induced inflammation can significantly increase the rate of bone loss around implant-supported restorations.[29]

Contours/Open Contacts. Overcontoured crowns and restorations tend to accumulate plaque and handicap oral hygiene measures in addition to possibly preventing the self-cleaning mechanisms of the adjacent cheek, lips, and tongue[6,82,110,179] (Figure 7-20). Restorations that fail to reestablish adequate interproximal embrasure spaces are associated with papillary inflammation. Undercontoured crowns that lack a protective height of contour do not retain as much plaque as overcontoured crowns and therefore may not be as detrimental during mastication as once thought.[179]

The contour of the occlusal surface as established by the marginal ridges and related developmental grooves normally serves to deflect food away from the interproximal spaces. The optimal cervico-occlusal location for a posterior contact is at the longest

mesiodistal diameter of the tooth, which is generally just apical to the crest of the marginal ridge. The integrity and location of the proximal contacts along with the contour of the marginal ridges and developmental grooves typically prevent interproximal food impaction. *Food impaction* is the forceful wedging of food into the periodontium by occlusal forces. As the teeth wear down, their originally convex proximal surfaces become flattened, and the wedging effect of the opposing cusp is exaggerated. Cusps that tend to forcibly wedge food into interproximal embrasures are known as *plunger cusps.* The interproximal plunger cusp effect may also be observed when missing teeth are not replaced and the relationship between the proximal contacts of adjacent teeth is altered. An intact proximal contact precludes the forceful wedging of food into the interproximal embrasure space, whereas a light or open contact is conducive to impaction.

The classic analysis of the factors that lead to food impaction was made by Hirschfeld,[65] who recognized the following factors: uneven occlusal wear, the opening of the contact point as a result of a loss of proximal support or from extrusion, congenital morphologic abnormalities, and improperly constructed restorations.

The presence of the previously mentioned abnormalities does not necessarily lead to food impaction and periodontal disease. A study of interproximal contacts and marginal ridge relationships[88] in three groups of periodontally healthy males revealed that 0.7% to 76% of the proximal contacts were defective and that 33.5% of adjacent marginal ridges were uneven.[120] However, greater probing depth and a loss of clinical attachment have been reported for sites that exhibited both an open contact and food impaction as compared with contralateral control sites without open contacts or food impaction.[72] Excessive anterior overbite is a common cause of food impaction on the lingual surfaces of the maxillary anterior teeth and the facial surfaces of the opposing mandibular teeth. These areas may be exemplified by attachment loss with gingival recession.

Materials. In general, restorative materials are not in themselves injurious to the periodontal tissues.[6,77] One exception to this may be self-curing acrylics[173] (Figure 7-21).

Plaque that forms at the margins of restorations is similar to that found on adjacent nonrestored tooth surfaces. The composition of plaque formed on all types of restorative materials is similar, with the exception of that formed on silicate.[115] Although surface textures of restorative materials differ with regard to their capacity to retain plaque,[177] all can be adequately cleaned if they are polished and accessible to methods of oral hygiene.[116,143] The undersurface of pontics in fixed bridges should barely touch the mucosa. Access for oral hygiene is inhibited with excessive pontic-to-tissue contact, thereby contributing to plaque accumulation that will cause gingival inflammation and possibly the formation of pseudopockets.[45,157]

Figure 7-21 Inflamed palatal gingiva associated with a maxillary provisional acrylic partial denture. Note the substantial difference in color of the inflamed gingiva adjacent to the premolars and the first molar as compared with the gingiva adjacent to the second molar.

Design of Removable Partial Dentures. Several investigations have shown that, after the insertion of partial dentures, mobility of the abutment teeth, gingival inflammation, and periodontal pocket formation all increase.[17,26,151] This is because partial dentures favor the accumulation of plaque, particularly if they cover the gingival tissue. Partial dentures that are worn during both night and day induce more plaque formation than those worn only during the daytime.[17] These observations emphasize the need for careful and personalized oral hygiene instruction to avoid the harmful effects of partial dentures on the remaining teeth and the periodontium.[12] The presence of removable partial dentures induces not only quantitative changes in dental plaque[49] but also qualitative changes, thereby promoting the emergence of spirochetal microorganisms.[50]

Restorative Dentistry Procedures. The use of rubber dam clamps, matrix bands, and burs in such a manner as to lacerate the gingiva results in varying degrees of mechanical trauma and inflammation. Although such transient injuries generally undergo repair, they are needless sources of discomfort to the patient. The forceful packing of a gingival retraction cord into the sulcus to prepare the subgingival margins of a tooth or for the purpose of obtaining an impression may mechanically injure the periodontium and leave behind impacted debris that are capable of causing a foreign body reaction.

Malocclusion

The irregular alignment of teeth as found in cases of malocclusion may make plaque control more difficult. Several authors have found a positive correlation between crowding and periodontal disease,[25,123,164] whereas other investigators did not find such a correlation.[48] Uneven marginal ridges of contiguous posterior teeth have been found to have a low correlation with pocket depth, loss of attachment, plaque, calculus, and gingival inflammation.[79] Roots of teeth that are prominent in the arch (Figures 7-22)—such as in a buccal or lingual version or that are associated with a high frenal attachment and small quantities of attached gingiva—frequently exhibit recession.[1,106]

The failure to replace missing posterior teeth may have adverse consequences on the periodontal support for the remaining teeth.[28] The following hypothetical scenario illustrates the possible ramifications of not replacing a missing posterior tooth. When the mandibular first molar is extracted, the initial change is a mesial drifting and tilting of the mandibular second and third molars with extrusion of the maxillary first molar. As the mandibular second molar tips mesially, its distal cusps extrude and act as plungers. The distal cusps of the mandibular second molar wedge between the maxillary first and second molars and open the contact by deflecting the maxillary second molar distally. Subsequently, food impaction may occur and be accompanied by gingival inflammation with the eventual loss of the interproximal bone between the maxillary first and second molars. This example does not occur in all cases in which mandibular first molars are not replaced. However, the drifting and tilting of the remaining teeth with an accompanying alteration of the proximal contacts is generally a consequence of not replacing posterior teeth that have been extracted.

Tongue thrusting exerts excessive lateral pressure on the anterior teeth, which may result in the spreading and tilting of the anterior teeth (Figure 7-23). Tongue thrusting is an important

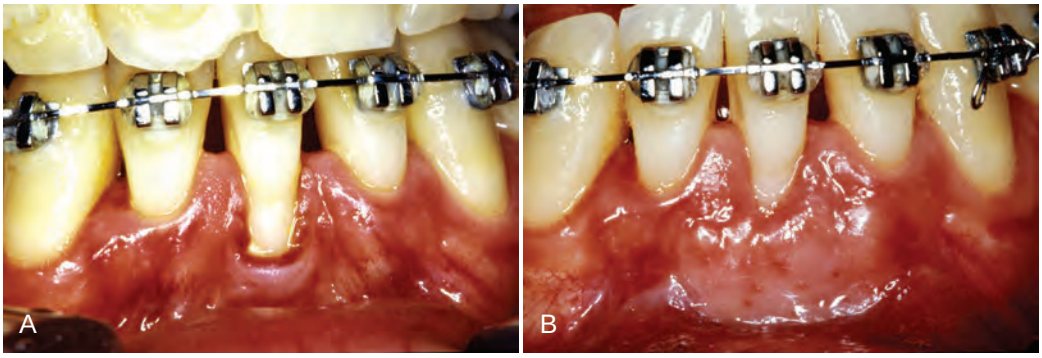

Figure 7-22 **A,** Lower incisor showing a prominent root with gingival recession and a lack of attached gingiva. **B,** Three months after the placement of a free gingival graft, which resulted in a gain in attached gingiva and a reduction in gingival recession.

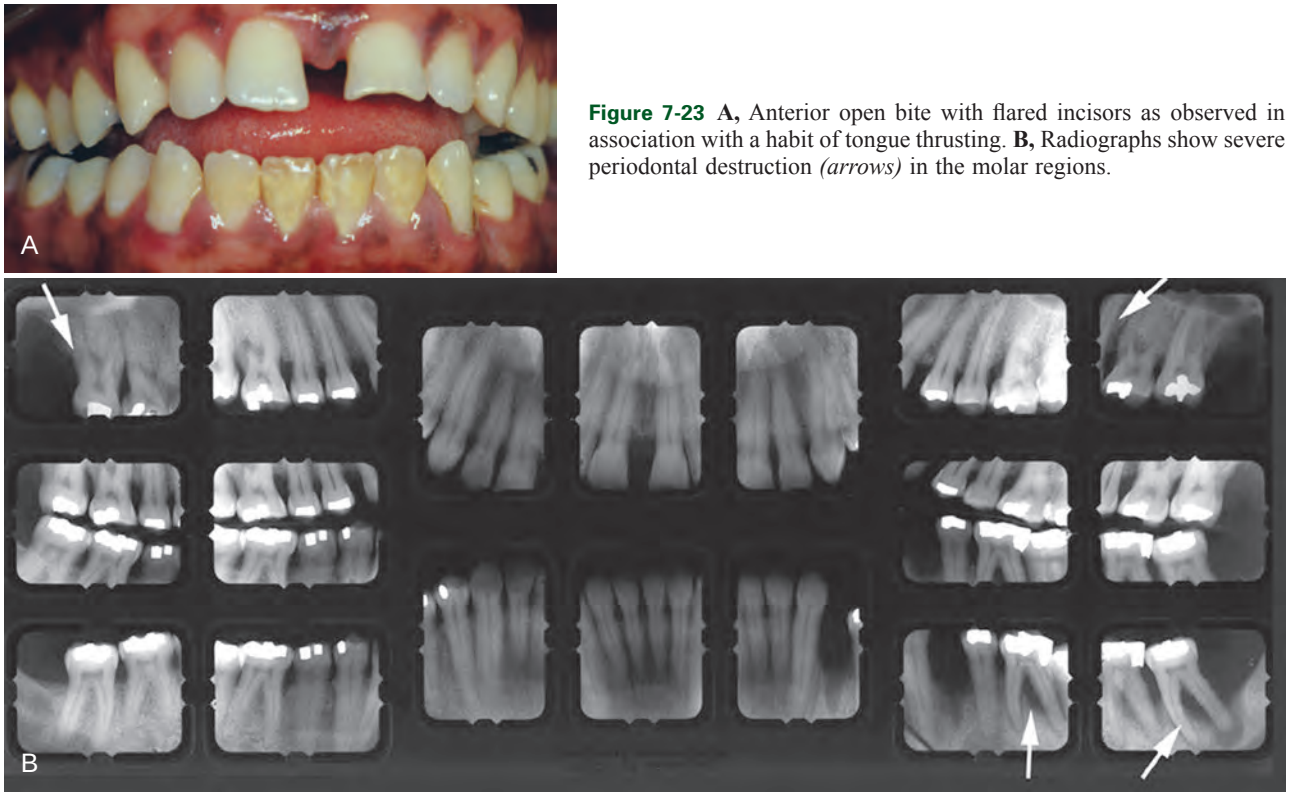

Figure 7-23 **A,** Anterior open bite with flared incisors as observed in association with a habit of tongue thrusting. **B,** Radiographs show severe periodontal destruction *(arrows)* in the molar regions.

contributing factor to tooth migration and the development of an anterior open bite.[27] Mouth breathing may be observed in association with a habit of tongue thrusting and an anterior open bite. Marginal and papillary gingivitis is frequently encountered in the maxillary anterior sextant in cases that involve an anterior open bite with mouth breathing. However, the role of mouth breathing as a local causative factor is unclear, because conflicting evidence has been reported.[3,68,69,164]

Restorations that do not conform to the occlusal pattern of the mouth result in occlusal disharmonies that may cause injury to the supporting periodontal tissues. More issues involving deeper initial probing depths, worse prognoses, and greater mobility have been observed for teeth with occlusal discrepancies as compared with teeth without initial occlusal discrepancies.[62,118] Histologic features of the periodontium for a tooth that has been subjected to traumatic occlusion include a widened subcrestal periodontal ligament space, a reduction in the collagen content of the oblique and horizontal fibers, an increase in vascularity and leukocyte infiltration, and an increase in the number of osteoclasts on bordering alveolar bone.[14] However, these observations are generally apical and separate from the bacteria-induced inflammation that occurs at the base of the sulcus. On the basis of current human trials, it is still impossible to definitively answer the question, "Does occlusal trauma modify the progression of periodontal attachment loss that is associated with periodontal inflammation?"[154] (See Chapter 50 for a more detailed explanation of periodontal trauma from occlusion and the periodontal response to external forces.)

Periodontal Complications Associated with Orthodontic Therapy

Orthodontic therapy may affect the periodontium by favoring plaque retention, by directly injuring the gingiva as a result of overextended bands, and by creating excessive forces, unfavorable forces, or both on the tooth and its supporting structures.

Plaque Retention and Composition. Orthodontic appliances tend to retain bacterial plaque and food debris, thereby resulting in gingivitis (Figure 7-24), and they are also capable of modifying the gingival ecosystem. An increase in *Prevotella melaninogenica, Prevotella intermedia,* and *Actinomyces odontolyticus* and a decrease in the proportion of facultative microorganisms was detected in the gingival sulcus after the placement of orthodontic bands.[37] More recently, *A. actinomycetemcomitans* was found in at least one site in 85% of children who were wearing orthodontic appliances.[122] By contrast, only 15% of unbanded control subjects were positive for *A. actinomycetemcomitans*.

Gingival Trauma and Alveolar Bone Height. Orthodontic treatment is often started soon after the eruption of the permanent teeth, when the junctional epithelium is still adherent to the enamel surface. Orthodontic bands should not be forcefully placed beyond the level of attachment, because this will detach the gingiva from the tooth and result in the apical proliferation of the junctional epithelium with an increased incidence of gingival recession.[124]

Figure 7-24 Gingival inflammation and enlargement associated with an orthodontic appliance and poor oral hygiene.

The mean alveolar bone loss per patient for adolescents who underwent 2 years of orthodontic care during a 5-year observation period ranged between 0.1 and 0.5 mm.[20] This small magnitude of alveolar bone loss was also noted in the control group and therefore considered to be of little clinical significance. However, the degree of bone loss during adult orthodontic care may be higher than that observed in adolescents,[96] especially if the periodontal condition is not treated before the initiation of orthodontic therapy. *Therefore, orthodontic treatment should not be commenced in the presence of uncontrolled periodontal disease.*

Tissue Response to Orthodontic Forces. Orthodontic tooth movement is possible because the periodontal tissues are responsive to externally applied forces.[134,150] Alveolar bone is remodeled by osteoclasts that induce bone resorption in areas of pressure and by osteoblasts that form bone in areas of tension. Although moderate orthodontic forces ordinarily result in bone remodeling and repair, excessive force may produce necrosis of the periodontal ligament and the adjacent alveolar bone.[127-129] Excessive orthodontic forces also increase the risk of apical root resorption.[22,23] The prevalence of severe root resorption (i.e., resorption of more than one third of the root length) during orthodontic therapy in adolescents has been reported at 3%.[73] The incidence of moderate to severe root resorption for incisors among adults who range in age from 20 to 45 years has been reported as 2% before treatment and 24.5% after treatment.[96] Risk factors associated with root resorption during orthodontic treatment include the duration of treatment, the magnitude of the force applied, the direction of the tooth movement, and the continuous versus intermittent application of forces[126] (Figure 7-25). *It is important to avoid excessive force and too-rapid tooth movement during orthodontic treatment*.

The use of elastics to close a diastema may result in severe attachment loss with possible tooth loss as the elastics migrate apically along the root (Figures 7-26). The surgical exposure of impacted teeth and orthodontic-assisted eruption has the potential

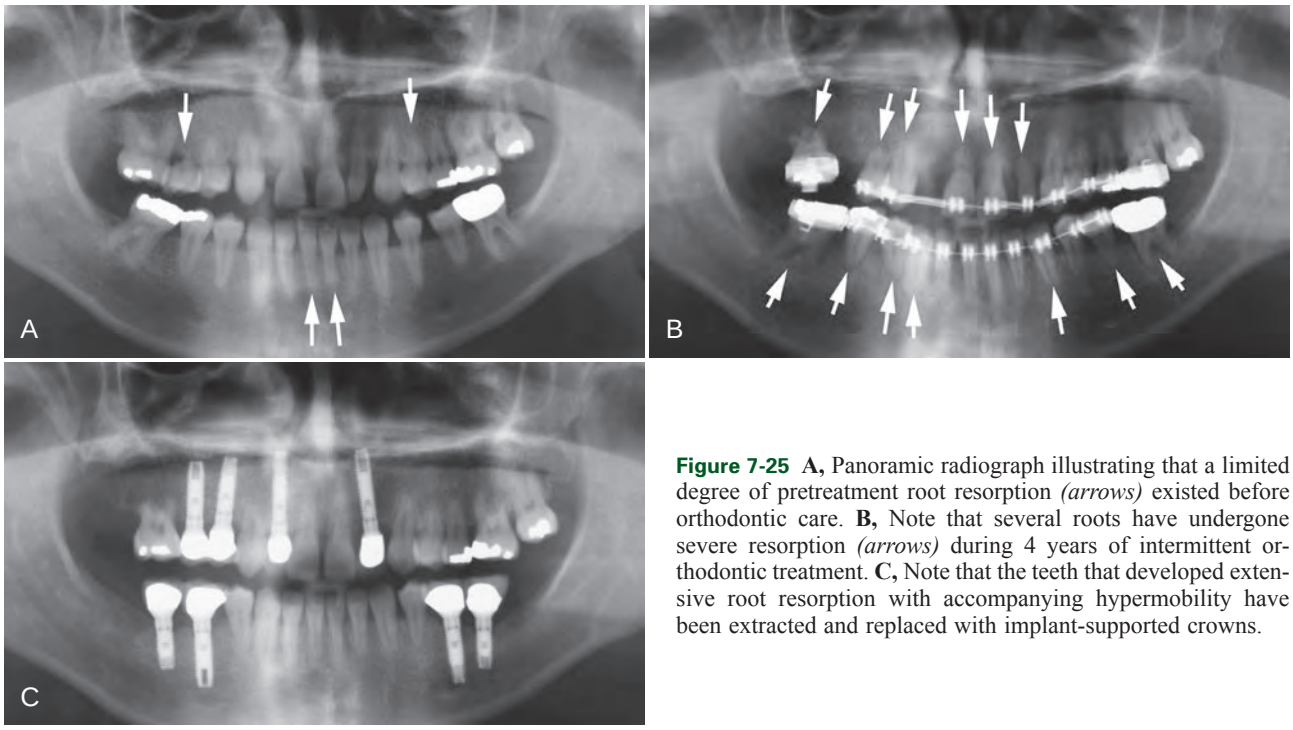

Figure 7-25 **A,** Panoramic radiograph illustrating that a limited degree of pretreatment root resorption *(arrows)* existed before orthodontic care. **B,** Note that several roots have undergone severe resorption *(arrows)* during 4 years of intermittent orthodontic treatment. **C,** Note that the teeth that developed extensive root resorption with accompanying hypermobility have been extracted and replaced with implant-supported crowns.

Figure 7-26 **A,** Maxillary central incisors for which an elastic ligature was used to close a midline diastema. Note the inflamed gingiva and the deep probing depths. **B:** Reflection of a full-thickness mucoperiosteal flap reveals elastic ligature and angular intrabony defects around the central incisors.

to compromise periodontal attachment on adjacent teeth (Figure 7-27). However, the majority of impacted teeth that are surgically exposed and aided in their eruption by orthodontic treatment subsequently exhibited more than 90% of their attachment as being intact.[64]

It has been reported that the dentoalveolar gingival fibers that are located within the marginal and attached gingiva are stretched when teeth are rotated during orthodontic therapy.[38] The surgical severing or removal of these gingival fibers in combination with a brief period of retention may reduce the incidence of relapse after orthodontic treatment that is intended to realign rotated teeth.[21,107]

Extraction of Impacted Third Molars

Numerous clinical studies have reported that the extraction of impacted third molars often results in the creation of vertical defects distal to the second molars.[8] This iatrogenic effect is unrelated to flap design,[30] and it appears to occur more often when third molars are extracted from individuals who are more than 25 years old.[8,83,104] Other factors that appear to play a role in the development of lesions on the distal surface of second molars—particularly in those who are more than 25 years old—include the presence of visible plaque, bleeding on probing, root resorption in the contact area between the second and third molars, the presence of a pathologically widened follicle, the inclination of the third molar, and the close proximity of the third molar to the second molar (Figure 7-28).[83] Other potential iatrogenic adverse consequences of the removal of the third molars include permanent paresthesia (i.e., numbness of the lip, tongue, and cheek), which occurs at a frequency of approximately 1 out of every 100,000 wisdom teeth removed in the United States.[47]

Habits and Self-Inflicted Injuries

Patients may not be aware of their self-inflicted injurious habits that may be important to the initiation and progression of their periodontal disease. Mechanical forms of trauma can stem from

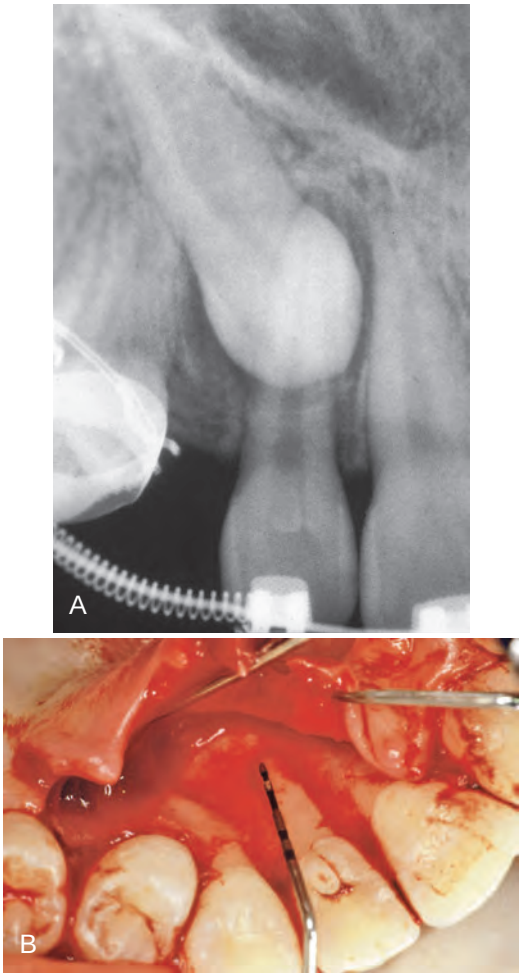

Figure 7-27 **A,** Radiograph of an impacted maxillary canine that required surgical exposure and orthodontic assistance to erupt. **B,** A palatal flap is reflected to reveal bony dehiscence on the maxillary lateral incisor after orthodontic therapy.

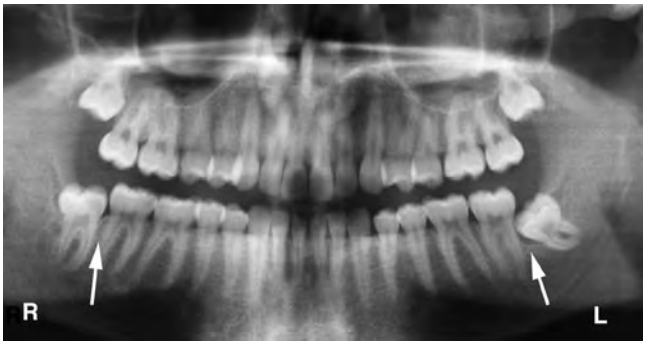

Figure 7-28 Panoramic radiograph illustrating a mesial impacted lower left third molar with a widened follicle and no apparent bone on the distal interproximal surface of the second molar. Alternatively, the lower right third molar is vertically impacted and exhibits interproximal bone distal to the second molar and mesial to the third molar.

the improper use of a toothbrush, the wedging of toothpicks between the teeth, the application of fingernail pressure against the gingiva, pizza burns, and other causes[19] (Figure 7-29). Sources of chemical irritation include the topical application of caustic medications such as aspirin or cocaine, allergic reactions to toothpaste

and chewing gum, the use of chewing tobacco, and concentrated mouthrinses.[153] Accidental and iatrogenic gingival injuries may be caused by a variety of chemical, physical, and thermal sources, yet they are generally self-limiting. Iatrogenic injuries are often acute, whereas factitious injuries tend to be more chronic in nature.[133]

Trauma Associated with Oral Jewelry. The use of piercing jewelry in the lip or tongue has become more common recently among teenagers and young adults (Figure 7-30, *A*). Whittle and Lamden[177] surveyed 62 dentists and found that 97% had seen patients with either lip- or tongue-piercing jewelry within the previous 12 months. The incidence of lingual recession with pocket formation (Figure 7-30, *B*) and radiographic evidence of bone loss (Figure 7-30, *C*) was 50% among subjects with a mean age of 22 years who wore lingual "barbells" for 2 or more years.[36] Chipped lower anterior teeth were noted in 47% of the patients who wore tongue-piercing jewelry for 4 years or more. Patients need to be informed of the risks of wearing oral jewelry and cautioned against such practices.

Figure 7-29 Gingival recession on a maxillary canine caused by self-inflicted trauma from the patient's fingernail.

Toothbrush Trauma. Abrasions of the gingiva as well as alterations in tooth structure may result from aggressive brushing in a horizontal or rotary fashion. The deleterious effect of excessively forceful brushing is accentuated when highly abrasive dentifrices are used. The gingival changes that are attributable to toothbrush trauma may be acute or chronic. The acute changes vary with regard to their appearance and duration, from scuffing of the epithelial surface to denudation of the underlying connective tissue with the formation of a painful gingival ulcer (Figure 7-31). Diffuse erythema and denudation of the attached gingiva throughout the mouth may be a striking result of overzealous brushing. Signs of acute gingival abrasion are frequently noted when the patient first uses a new brush. Puncture lesions may be produced when heavy pressure is applied to firm bristles that are aligned perpendicular to the surface of the gingiva. A forcibly embedded toothbrush bristle may be retained in the gingiva and cause an acute gingival abscess.

Chronic toothbrush trauma results in gingival recession with denudation of the root surface. Interproximal attachment loss is generally a consequence of bacteria-induced periodontitis, whereas buccal and lingual attachment loss is frequently the result of

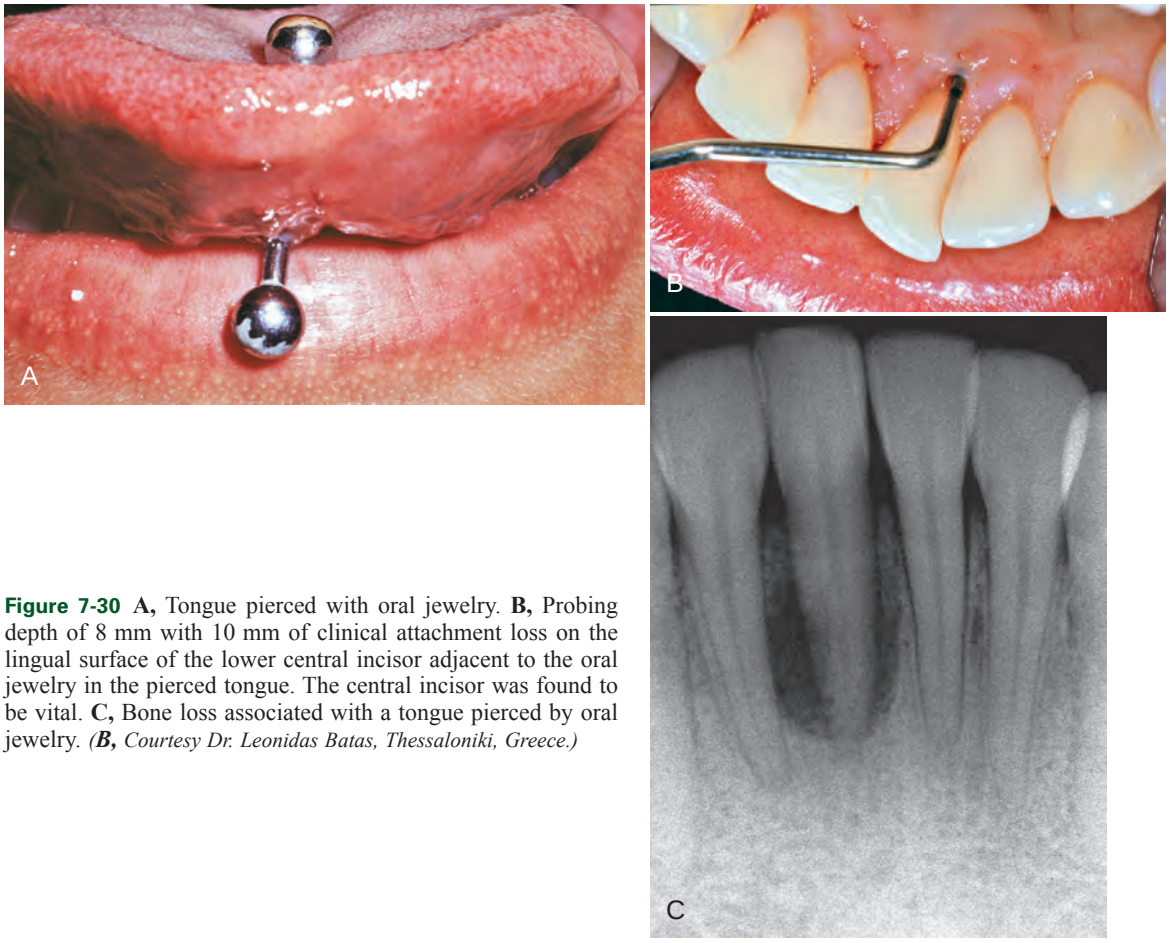

Figure 7-30 **A,** Tongue pierced with oral jewelry. **B,** Probing depth of 8 mm with 10 mm of clinical attachment loss on the lingual surface of the lower central incisor adjacent to the oral jewelry in the pierced tongue. The central incisor was found to be vital. **C,** Bone loss associated with a tongue pierced by oral jewelry. *(**B,** Courtesy Dr. Leonidas Batas, Thessaloniki, Greece.)*

Figure 7-31 The overzealous use of a toothbrush resulted in denudation of the gingival epithelial surface and exposure of the underlying connective tissue as a painful ulcer.

Figure 7-32 Chemical burn caused by aspirin; note the sloughing gingival tissue and the resultant recession.

toothbrush abrasion.[160] The improper use of dental floss may result in lacerations of the interdental papilla.

Chemical Irritation. Acute gingival inflammation may be caused by chemical irritation that results from either sensitivity or nonspecific tissue injury. In allergic inflammatory states, the gingival changes range from simple erythema to painful vesicle formation and ulceration. Severe reactions to ordinarily innocuous mouthwashes, dentifrices, and denture materials are often explainable on this basis.

Acute inflammation with ulceration may be produced by the nonspecific injurious effect of chemicals on the gingival tissues. The indiscriminate use of strong mouthwashes, the topical application of corrosive drugs such as aspirin (Figure 7-32) or cocaine, and accidental contact with drugs such as phenol or silver nitrate are common examples of chemicals that cause irritation of the gingiva. A histologic view of an aspirin-induced chemical burn shows vacuoles with serous exudates and an inflammatory infiltrate in the connective tissue (Figure 7-33).

Smokeless Tobacco

Snuff and chewing tobacco constitute the two main forms of smokeless tobacco. Snuff is a fine-cut form of tobacco that is available loosely packed or in small sachets. Chewing tobacco is a more coarse-cut tobacco that is available in the form of loose leaves, a solid block, a plug, or as a twist of dried leaves. Chewing tobacco is typically placed in the mandibular buccal vestibule for several

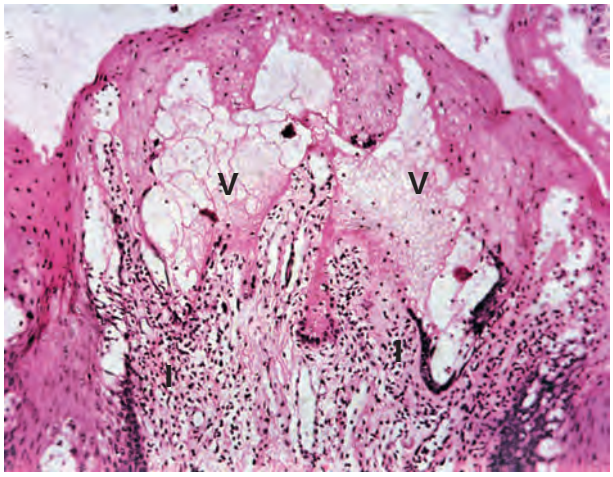

Figure 7-33 Biopsy of an aspirin-induced chemical burn. Note the intraepithelial vesicles *(V)* and inflammatory infiltrate *(I)* within the underlying connective tissue.

Figure 7-34 Oral leukoplakia in the vestibule associated with the use of smokeless tobacco.

hours, during which time saliva and dilute tobacco are periodically expectorated.[174] The nicotine uptake of smokeless tobacco is similar to that of smoking cigarettes in that the consumption of a 34-g container of smokeless tobacco is approximately equal to 1.5 packs of cigarettes.[57] Many professional baseball players use chewing tobacco. The perceived benefits of chewing tobacco are those derived from nicotine, including improved mental alertness, diminished reaction time, muscle relaxation, and reduced anxiety and appetite.[58,138] A 1990 survey of 1109 professional baseball players in the United States reported that 39% of the players used smokeless tobacco, with 46% of the users exhibiting leukoplakia within the gingiva or the mucosa (Figure 7-34).[42] Histologic features of oral leukoplakia associated with smokeless tobacco include (1) a chevronlike pattern of hyperkeratosis with focal areas of inflammation; and (2) hyperplasia in the basal cell layer (Figure 7-35). Increased incidences of gingival recession, cervical root abrasion, and root caries have been reported with smokeless tobacco (Figure 7-36).[119,139,140,167] The incidence of gingival recession among adolescents who use smokeless tobacco has been reported at 42% as compared with 17% among nonusers.[33,105,106,109] The Third National Health and Nutrition Examination Survey investigated the adverse effect of smokeless tobacco on the

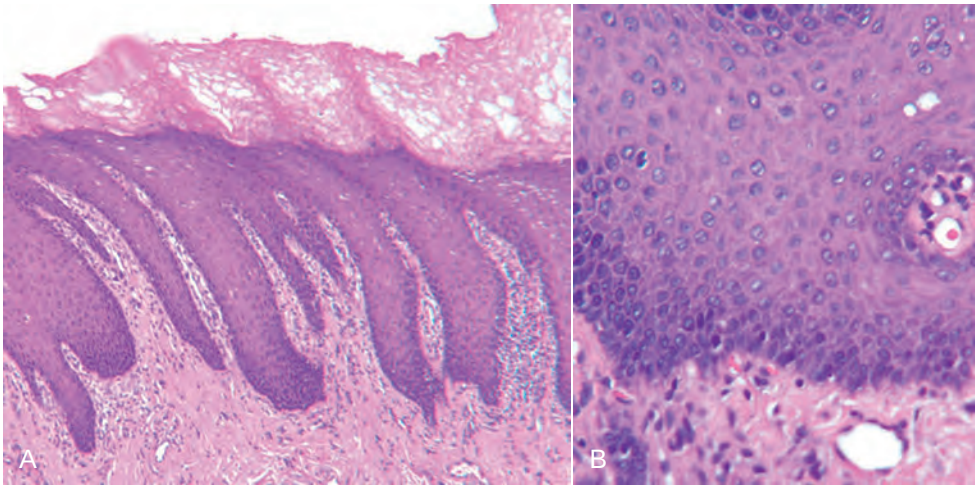

Figure 7-35 **A,** Histologic features of oral leukoplakia associated with smokeless tobacco. Note the chevronlike pattern of hyperkeratosis with focal areas of inflammation. **B,** Hyperplasia in the basal cell layer.

Figure 7-36 Oral leukoplakia, recession, and clinical attachment loss associated with the use of smokeless tobacco.

periodontium and found double the incidence of severe periodontitis (odds ratio, 2.1; 95% confidence interval, 1.2 to 3.7) among 12,932 adults who used smokeless tobacco but who never smoked cigarettes.[43] However, Bergstrom and colleagues found similar incidences of severe periodontitis among both smokeless tobacco users and nonusers.[13] It can be concluded that the use of smokeless tobacco is associated with at least localized gingival recession, clinical attachment loss, leukoplakia, and possibly enhanced susceptibility to severe periodontitis.

Radiation Therapy

Radiation therapy has cytotoxic effects on both normal cells and malignant cells. A typical total dose of radiation for head and neck tumors is in the range of 5000 to 8000 cGy (cGy = 1 rad) and equivalent to 50 to 80 Sieverts (Sv).[125] The total dose of radiation is generally given in partial incremental doses referred to as *fractionation.* Fractionation helps to minimize the adverse effects of radiation while maximizing the death rate for the tumor cells.[44] Fractionated doses are typically administered in the range of 100 to 1000 cGy or 1 to 10 Sv per week.

Radiation treatment induces an obliterative endarteritis that results in soft-tissue ischemia and fibrosis while irradiated bone becomes hypovascular and hypoxic.[102] Adverse effects of head and neck radiation therapy include dermatitis and mucositis of the irradiated area as well as muscle fibrosis and trismus, which may restrict access to the oral cavity.[141] The mucositis typically develops 5 to 7 days after radiation therapy is initiated. The severity of the mucositis can be reduced by asking the patient to avoid secondary sources of irritation (e.g., smoking, alcohol, spicy foods) to the mucous membrane. The use of a chlorhexidine digluconate mouthrinse may help to reduce the mucositis.[131] However, most chlorhexidine mouthrinses currently available in the United States have a high alcohol content that may act as an astringent, which dehydrates the mucosa and thus intensifies the pain. Saliva production is permanently impaired when salivary glands that are located within the portal of radiation receive 6000 cGy (60 Sv) or more.[103] Xerostomia results in greater plaque accumulation and a reduced buffering capacity of saliva. Effective oral hygiene, professional dental prophylaxis cleanings, fluoride applications, and frequent dental examinations are essential to control caries and periodontal disease. The use of customized trays appears to be a more effective method of fluoride application as compared with the toothbrush.[78]

Periodontal attachment loss and tooth loss have been reported to be greater among patients with cancer who were treated with high-dose unilateral radiation as compared with the nonradiated control side of the dentition.[41] Patients who are diagnosed with oral cancer and who require radiation therapy should ideally be assessed for dental needs (i.e., mucositis, xerostomia, faulty restorations, periapical lesion, coronal and cervical decay, and periodontal status) before the initiation of radiation treatment.[61] The treatment and prevention of trismus, oral fungal infections, odontogenic infections, osteoradionecrosis, decay, and periodontal disease are critical to minimize oral morbidity for these patients. Dental and periodontal infections have the potential to be severe risks for patients who have been treated with head and neck radiation. The risk of osteoradionecrosis for oncology patients can be minimized by evaluating their oral status, providing dental care, and allowing time for tissue repair before the commencement of radiotherapy.[80]

Oral conditions that increase the risk of osteoradionecrosis for patients about to undergo radiation therapy for oral malignancies include periodontal probing depths of more than 5 mm, dental plaque score of more than 40%, and alveolar bone loss of more than 60%.[76] Nonrestorable teeth and teeth with significant

periodontal problems should be extracted before radiation therapy to reduce the risk of postradiotherapy osteoradionecrosis.[80] (See Chapter 38 for more detail regarding the periodontal management of medically compromised patients.)

The risk of osteoradionecrosis must be evaluated before the performance of atraumatic extractions or limited periodontal surgical procedures in previously irradiated sites. Therefore, the dentist may choose to consult with the patient's oncologist before the initiation of therapy. A recent randomized multicenter clinical trial questioned the merit of using hyperbaric oxygen therapy to treat osteoradionecrosis because, at 1 year after treatment, only 19% of test subjects responded to hyperbaric oxygen therapy as compared with 32% of placebo subjects.[5] The administration of the combination of pentoxifylline with vitamin E as antioxidant therapy currently shows the greatest promise for the revascularization and treatment of osteoradionecrosis sites.[35]

Suggested Readings

Albandar J, Kingman A, Brown L, et al: Gingival inflammation and subgingival calculus as determinants of disease progression in early-onset periodontitis. *J Clin Periodontol* 25:231, 1998.

Anerud A, Löe H, Boysen H: The natural history and clinical course of calculus formation in man. *J Clin Periodontol* 18:160, 1991.

Jeffcoat M, Howell T: Alveolar bone destruction due to overhanging amalgam in periodontal disease. *J Periodontol* 51:599, 1980.

Kugelberg C: Third molar surgery. *Curr Opin Dent* 2:9, 1992.

Kumar PS, Mason MR, Brooker MR, et al: Pyrosequencing reveals unique microbial signatures associated with healthy and failing dental implants. *J Clin Periodontol* 39:425–433, 2012.

Lupi J, Handelman C, Sadowsky C: Prevalence and severity of apical root resorption and alveolar bone loss in orthodontically treated adults. *Am J Orthod Dentofacial Orthop* 109:28, 1996.

Sorensen J, Larsen I, Jorgensen K: Gingival and alveolar bone response to marginal fit of subgingival crown margins. *Scand J Dent Res* 94:109, 1986.

Wilson TG, Jr: The positive relationship between excess cement and peri-implant disease: a prospective clinical endoscopic study. *J Periodontol* 80:1388–1392, 2009.

Zander H: The attachment of calculus to root surfaces. *J Periodontol* 24:16, 1953.

References

References for this chapter are found on the companion website www.expertconsult.com.

References

1. Addy M, Dummer P, Hunter M, et al: A study of the association of fraenal attachment, lip coverage and vestibular depth with plaque and gingivitis. *J Periodontol* 58:752, 1987.
2. Albandar J, Kingman A, Brown L, et al: Gingival inflammation and subgingival calculus as determinants of disease progression in early-onset periodontitis. *J Clin Periodontol* 25:231, 1998.
3. Alexander A: Habitual mouth breathing and its effect on gingival health. *Parodontologie* 24:49, 1970.
4. Anerud A, Löe H, Boysen H: The natural history and clinical course of calculus formation in man. *J Clin Periodontol* 18:160, 1991.
5. Annane D, Depondt J, Aubert P, et al: Hyperbaric oxygen therapy for radionecrosis of the jaw: a randomized, placebo-controlled, double-blind trial from the ORN96 study group. *J Clin Oncol* 22:4893–4900, 2004.
6. App G: Effect of silicate, amalgam and cast gold on the gingiva. *J Prosthet Dent* 11:522, 1961.
7. Apse P, Ellen RP, Overall CM, et al: Microbiota and crevicular fluid collagenase activity in the osseointegrated dental implant sulcus: a comparison of sites in edentulous and partially edentulous patients. *J Periodontal Res* 24:96–105, 1989.
8. Ash M, Costich E, Hayward J: A study of periodontal hazards of third molars. *J Periodontol* 33:209, 1962.
9. Baer P, Burstone M: Esterase activity associated with formation of deposits on teeth. *Oral Surg* 12:1147, 1959.
10. Baer P, Keyes P, White C: Studies on experimental calculus formation in the rat. XII. On the transmissibility of factors affecting dental calculus. *J Periodontol* 39:86, 1968.
11. Baumhammers A, Stallard R: A method for the labeling of certain constituents in the organic matrix of dental calculus. *J Dent Res* 45:1568, 1966.
12. Bergman B, Hugoson A, Olsson C: Periodontal and prosthetic conditions in patients treated with removable partial dentures and artificial crowns. *Acta Odontol Scand* 29:621, 1971.
13. Bergstrom J, Keilani H, Lundholm C, et al: Smokeless tobacco (snuff) use and periodontal bone loss. *J Clin Periodontol* 33:549–554, 2006.
14. Biancu S, Ericsson I, Lindhe J: Periodontal ligament tissue reactions to trauma and gingival inflammation. An experimental study in beagle dogs. *J Clin Periodontol* 22:772, 1995.
15. Bibby B: The formation of salivary calculus. *Dent Cosmos* 77:668, 1935.
16. Birkeland J, Jorkjend L: The effect of chewing apples on dental plaque and food debris. *Community Dent Oral Epidemiol* 2:161, 1974.
17. Bissada N, Ibrahim S, Barsoum W: Gingival response to various types of removable partial dentures. *J Periodontol* 45:651, 1974.
18. Bjorn AL, Bjorn H, Grcovic B: Marginal fit of restorations and its relation to periodontal bone level. *Odontol Revy* 20:311, 1969.
19. Blanton P, Hurt W, Largent M: Oral factitious injuries. *J Periodontol* 48:33, 1977.
20. Bondemark L: Interdental bone changes after orthodontic treatment: a 5-year longitudinal study. *Am J Orthod Dentofacial Orthop* 114:25, 1998.
21. Brain W: The effect of surgical transsection of free gingival fibers on the regression of orthodontically rotated teeth in the dog. *Am J Orthod* 55:50, 1969.
22. Brezniak N, Wasserstein A: Root resorption after orthodontic treatment: Part 1. Literature review. *Am J Orthod Dentofacial Orthop* 103:62, 1993.
23. Brezniak N, Wasserstein A: Root resorption after orthodontic treatment: Part 2. Literature review. *Am J Orthod Dentofacial Orthop* 103:138, 1993.
24. Buchanan S, Jenderseck R, Granet M, et al: Radiographic detection of dental calculus. *J Periodontol* 58:747, 1987.
25. Buckley L: The relationship between malocclusion and periodontal disease. *J Periodontol* 43:415, 1972.
26. Carlsson G, Hedegard B, Koivumaa K: Studies in partial dental prosthesis. IV. Final results of a four-year longitudinal investigation of dentogingivally supported partial dentures. *Acta Odontol Scand* 23:443, 1965.
27. Carranza F, Sr, Carraro J: El empuje lingual como factor traumatizante en periodoncia. *Rev Asoc Odontol Argent* 47:105, 1959.
28. Chaikin B: Anterior periodontal destruction due to the loss of one or more unreplaced molars. *Dent Items Int* 61:17, 1939.
29. Chambrone L, Chambrone LA, Lima LA: Effects of occlusal overload on peri-implant tissue health: a systematic review of animal-model studies. *J Periodontol* 81:1367–1378, 2010.
30. Chin Quee T, Gosselin D, Millar E, et al: Surgical removal of the fully impacted mandibular third molar. The influence of flap design and alveolar bone height. *J Periodontol* 56:625, 1985.
31. Clerehugh V, Abdeia R, Hull P: The effect of subgingival calculus on the validity of clinical probing measurements. *J Dentistry* 24:329, 1996.
32. Conroy C, Sturzenberger O: The rate of calculus formation in adults. *J Periodontol* 39:142, 1968.
33. Creath C, Cutter G, Bradley D, et al: Oral leukoplakia and adolescent smokeless tobacco use. *Oral Surg Oral Med Oral Pathol* 72:35, 1991.
34. Dawes C: Recent research on calculus. *N Z Dent J* 94:60, 1998.
35. Delanian S, Lefaix JL: Current management for late normal tissue injury: radiation-induced fibrosis and necrosis. *Semin Radiat Oncol* 17:99–107, 2007.
36. De Moor RJ, De Witte AM, Delmé KI, et al: Dental and oral complications of lip and tongue piercings. *Br Dent J* 199:506–509, 2005.
37. Diamanti-Kipioti A, Gusberti F, Lang N: Clinical and microbiological effects of fixed orthodontic appliances. *J Clin Periodontol* 14:326, 1987.
38. Edwards J: A study of the periodontium during orthodontic rotation of teeth. *Am J Orthod* 54:441, 1968.
39. Egelberg J: Local effect of diet on plaque formation and development of gingivitis in dogs. III. Effect of frequency of meals and tube feeding. *Odontol Revy* 16:50, 1965.
40. Ennever J: Microbiologic mineralization: a calcifiable cell-free extract from a calcifiable microorganism. *J Dent Res* 41:1383, 1983.
41. Epstein J, Lunn R, Le N, et al: Periodontal attachment loss in patients after head and neck radiation therapy. *Oral Surg Oral Med Oral Pathol* 86:673, 1998.
42. Ernster VL, Grady DG, Greene JC, et al: Smokeless tobacco use and health effects among baseball players. *JAMA* 264:218–224, 1990.
43. Fisher MA, Taylor GW, Tilashalski KR: Smokeless tobacco and severe active periodontal disease, NHANES III. *J Dent Res* 84: 705–710, 2005.
44. Fletcher G: The role of irradiation in the management of squamous-cell carcinomas of the mouth and throat. *Head Neck Surg* 1:441, 1979.
45. Flemmig T, Sorensen J, Newman M, et al: Gingival enhancement in fixed prosthodontics. Part II. Microbiologic findings. *J Prosthet Dent* 65:365, 1991.
46. Flores-de-Jacoby L, Zafiropoulos G, Ciancio S: Effect of crown margin location on plaque and periodontal health. *Int J Periodontics Restorative Dent* 9:197, 1989.
47. Friedman JW: The prophylactic extraction of third molars: a public health hazard. *Am J Public Health* 97:1554–1559, 2007.
48. Geiger A, Wasserman B, Turgeon L: Relationship of occlusion and periodontal disease. VIII. Relationship of crowding and spacing to periodontal destruction and gingival inflammation. *J Periodontol* 45:43, 1974.
49. Ghamrawy E: Quantitative changes in dental plaque formation related to removable partial dentures. *J Oral Rehabil* 3:115, 1976.
50. Ghamrawy E: Qualitative changes in dental plaque formation related to removable partial dentures. *J Oral Rehabil* 6:183, 1979.
51. Gilmore N, Sheiham A: Overhanging dental restorations and periodontal disease. *J Periodontol* 42:8, 1971.
52. Glock G, Murray M: Chemical investigation of salivary calculus. *J Dent Res* 17:257, 1938.
53. Gonzales F, Sognnaes R: Electromicroscopy of dental calculus. *Science* 131:156, 1960.
54. Gorzo I, Newman H, Strahan J: Amalgam restoration, plaque removal and periodontal health. *J Clin Periodontol* 6:98, 1979.

55. Greene J: Oral hygiene and periodontal disease. *Am J Public Health* 53:913, 1963.
56. Grossi S, Genco R, Machtei E, et al: Assessment of risk for periodontal disease. II. Risk indicators for alveolar bone loss. *J Periodontol* 66:23, 1995.
57. Guggenheimer J: Implications of smokeless tobacco use in athletes. *Dent Clin North Am* 35:797–808, 1991.
58. Guggenheimer J: Tobacco and athletics. Update and current status. *Dent Clin North Am* 44:179–187, 2000.
59. Gustafsson B, Krasse B: Dental calculus in germ free rats. *Acta Odontol Scand* 20:135, 1962.
60. Hakkarainen K, Ainamo J: Influence of overhanging posterior tooth restorations of alveolar bone height in adults. *J Clin Periodontol* 7:114, 1980.
61. Hancock PJ, Epstein JB, Sadler GR: Oral and dental management related to radiation therapy for head and neck cancer. *J Can Dent Assoc* 69:585–590, 2003.
62. Harrel SK, Nunn ME: The effect of occlusal discrepancies on periodontitis. II. Relationship of occlusal treatment to the progression of periodontal disease. *J Periodontol* 72:495–505, 2001.
63. Highfield J, Powell R: Effects of removal of posterior overhanging metallic margins of restorations upon the periodontal tissues. *J Clin Periodontol* 5:169, 1978.
64. Hinrichs J, el-Deeb M, Waite D, et al: Periodontal evaluation of canines erupted through grafted alveolar cleft defects. *J Oral Maxillofac Surg* 42:717, 1984.
65. Hirschfeld I: Food impaction. *J Am Dent Assoc* 17:1504, 1930.
66. Hodge H, Leung S: Calculus formation. *J Periodontol* 21:211, 1950.
67. Huttner G: Follow-up study of crowns and abutments with regard to the crown edge and the marginal periodontium. *Dtsch Zahnarztl Z* 26:724, 1971.
68. Jacobson L: Mouth breathing and gingivitis. *J Periodont Res* 8:269, 1973.
69. Jacobson L, Linder-Aronson S: Crowding and gingivitis: a comparison between mouth breathers and non-mouth breathers. *Scand J Dent Res* 80:500, 1972.
70. Jeffcoat M, Howell T: Alveolar bone destruction due to overhanging amalgam in periodontal disease. *J Periodontol* 51:599, 1980.
71. Jenkins G: *The physiology of the mouth*, Oxford, 1966, Blackwell Scientific Publications.
72. Jernberg G, Bakdash B, Keenan K: Relationship between proximal tooth open contact and periodontal disease. *J Periodontol* 54:529, 1983.
73. Kaley J, Phillips C: Factors related to root resorption in edgewise practice. *Angle Orthod* 61:125, 1991.
74. Karlsen K: Gingival reactions to dental restorations. *Acta Odontol Scand* 28:895, 1970.
75. Kashket S, Zhang J, Niederman R: Gingival inflammation induced by food and short-chain carboxylic acids. *J Dent Res* 77:412, 1998.
76. Katsura K, Sasai K, Sato K, et al: Relationship between oral health status and development of osteoradionecrosis of the mandible: a retrospective longitudinal study. *Oral Surg Oral Med Oral Pathol Oral Radiol Endod* 105:731–738, 2008.
77. Kawakara H, Yamagani A, Nakamura M, Jr: Biological testing of dental materials by means of tissue culture. *Int Dent J* 18:443, 1968.
78. Keene H, Fleming T, Toth B: Cariogenic microflora in patients with Hodgkin's disease before and after mantle field radiotherapy. *Oral Surg Oral Med Oral Pathol* 78:577, 1994.
79. Kepic T, O'Leary T: Role of marginal ridge relationships as an etiologic factor in periodontal disease. *J Periodontol* 49:570, 1978.
80. Koga DH, Salvajoli JV, Alves FA: Dental extractions and radiotherapy in head and neck oncology: review of the literature. *Oral Dis* 14:40–44, 2008.
81. Koivumaa K, Wennstrom A: A histological investigation of the changes in gingival margins adjacent to gold crowns. *Odont T* 68:373, 1960.
82. Kozlovsky A, Tal H, Laufer BZ, et al: Impact of implant overloading on the peri-implant bone in inflamed and non-inflamed peri-implant mucosa. *Clin Oral Implants Res* 18:601–610, 2007.
83. Kugelberg C: Third molar surgery. *Curr Opin Dent* 2:9, 1992.
84. Kumar PS, Mason MR, Brooker MR, et al: Pyrosequencing reveals unique microbial signatures associated with healthy and failing dental implants. *J Clin Periodontol* 39:425–433, 2012.
85. Kopczyk L, Conroy M: The attachment of calculus to root planed surfaces. *Periodontics* 6:78, 1968.
86. Lang N, Kiel R, Anderhalden K: Clinical and microbiological effect of subgingival restorations with overhanging or clinically perfect margins. *J Clin Periodontol* 10:563, 1983.
87. Leach S, Saxton C: An electron microscopic study of the acquired pellicle and plaque formed on the enamel of human incisors. *Arch Oral Biol* 11:1081, 1966.
88. Leon A: Amalgam restorations and periodontal disease. *Br Dent J* 140:377, 1976.
89. Leung S, Jensen A: Factors controlling the deposition of calculus. *Int Dent J* 8:613, 1958.
90. Lilienthal B, Amerena V, Gregory G: An epidemiological study of chronic periodontal disease. *Arch Oral Biol* 10:553, 1965.
91. Lindhe J, Meyle J, Group D of European Workshop on Periodontology: Peri-implant diseases: Consensus Report of the Sixth European Workshop on Periodontology. *J Clin Periodontol* 35:282–285, 2008.
92. Little M, Bowman L, Casciani C, et al: The composition of dental calculus. III. Supragingival calculus. The amino acid and saccharide component. *Arch Oral Biol* 11:385, 1966.
93. Little M, Bowman L, Dirksen T: The lipids of supragingival calculus. *J Dent Res* 43:836, 1964.
94. Little M, Hazen S: Dental calculus composition. 2. Subgingival calculus: ash, calcium, phosphorus, and sodium. *J Dent Res* 43:645, 1964.
95. Löe H, Schiott C: The effect of mouth rinses and topical application of chlorhexidine on the development of dental plaque and gingivitis in man. *J Periodont Res* 5:79, 1970.
96. Lupi J, Handelman C, Sadowsky C: Prevalence and severity of apical root resorption and alveolar bone loss in orthodontically treated adults. *Am J Orthod Dentofacial Orthop* 109:28, 1996.
97. Mandel I: Calculus formation. The role of bacteria and mucoprotein. *Dent Clin North Am* 4:731, 1960.
98. Mandel I: Histochemical and biochemical aspects of calculus formation. *Periodontics* 1:43, 1963.
99. Mandel I: Biochemical aspects of calculus formation. *J Periodont Res* 4(Suppl):7, 1969.
100. Mandel I, Levy B, Wasserman B: Histochemistry of calculus formation. *J Periodontol* 28:132, 1957.
101. Manly R: A structureless recurrent deposit on teeth. *J Dent Res* 22:479, 1973.
102. Marciani R, Ownby H: Osteoradionecrosis of the jaw. *J Oral Maxillofac Surg* 44:218, 1986.
103. Markitziu A, Zafiropoulos G, Tsalkis L, et al: Gingival health and salivary function in head and neck-irradiated patients. A five year follow-up. *Oral Surg Oral Med Oral Pathol* 73:427, 1992.
104. Marmary Y, Brayer L, Tzukert A, et al: Alveolar bone repair following extraction of impacted mandibular third molars. *Oral Surg Oral Med Oral Pathol* 61:324, 1986.
105. Martin G, Brown J, Eifler C, et al: Oral leukoplakia status six weeks after cessation of smokeless tobacco use. *J Am Dent Assoc* 130:945, 1999.
106. Miller P: Root coverage with the free gingival graft. Factors associated with incomplete coverage. *J Periodontol* 58:674, 1987.
107. Moffett B: Remodeling changes of the facial sutures, periodontal and temporomandibular joints produced by orthodontic forces in Rhesus monkeys. *Bull Pac Coast Soc Orthod* 44:46, 1969.
108. Mombelli A, van Oosten MA, Schurch E, Jr, et al: The microbiota associated with successful or failing osseointegrated titanium implants. *Oral Microbiol Immunol* 2:145–151, 1987.
109. Monten U, Wennstrom JL, Ramberg P: Periodontal conditions in male adolescents using smokeless tobacco (moist snuff). *J Clin Periodontol* 33:863–868, 2006.
110. Morris M: Artificial crown contours and gingival health. *J Prosthet Dent* 12:1146, 1962.

111. Mueller H: The effect of artificial crown margins on the periodontal conditions in a group of periodontally supervised patients treated with fixed bridges. *J Clin Periodontol* 13:97, 1986.
112. Mühlemann H, Schroeder H: Dynamics of supragingival calculus formation. *Adv Oral Biol* 1:175, 1964.
113. Mühler J, Ennever J: Occurrence of calculus through several successive periods in a selected group of subjects. *J Periodontol* 33:22, 1962.
114. Mukherjee S: Formation and prevention of supragingival calculus. *J Periodont Res* 3(Suppl 2):1, 1968.
115. Neuman W, Neuman M: *The chemical dynamics of bone mineral*, Chicago, 1958, University of Chicago Press.
116. Norman R, Mehia R, Swartz M, et al: Effect of restorative materials on plaque composition. *J Dent Res* 51:1596, 1972.
117. Normann W, Regolati B, Renggli H: Gingival reaction to well-fitted subgingival proximal gold inlays. *J Clin Periodontol* 1:120, 1974.
118. Nunn ME, Harrel SK: The effect of occlusal discrepancies on periodontitis. I. Relationship of initial occlusal discrepancies to initial clinical parameters. *J Periodontol* 72:485–494, 2001.
119. Offenbacher S, Weathers DR: Effects of smokeless tobacco on the periodontal, mucosal and caries status of adolescent males. *J Oral Pathol* 14:169–181, 1985.
120. O'Leary T, Badell M, Bloomer R: Interproximal contact and marginal ridge relationships in periodontally healthy young males classified as to orthodontic status. *J Periodontol* 46:6, 1975.
121. Pack A, Coxhead L, McDonald B: The prevalence of overhanging margins in posterior amalgam restorations and periodontal consequences. *J Clin Periodontol* 17:145, 1990.
122. Paolantonio M, Girolamo G, Pedrazzoli V, et al: Occurrence of *Actinobacillus actinomycetemcomitans* in patients wearing orthodontic appliances. A cross-sectional study. *J Clin Periodontol* 23:112, 1996.
123. Paunio K: The role of malocclusion and crowding in the development of periodontal disease. *Int Dent J* 23:420, 1973.
124. Pearson L: Gingival height of lower central incisors, orthodontically treated and untreated. *Angle Orthod* 38:337, 1968.
125. Peterson D, D'Ambrosio J: Nonsurgical management of head and neck cancer patients. *Dent Clin North Am* 38:425, 1994.
126. Pizzo G, Licata ME, Guiglia R, et al: Root resorption and orthodontic treatment. Review of the literature. *Minerva Stomatol* 56:31–44, 2007.
127. Polson A, Reed BE: Long-term effect of orthodontic treatment on crestal alveolar bone levels. *J Periodontol* 55:28, 1984.
128. Polson A, Adams R, Zander H: Osseous repair in the presence of active tooth hypermobility. *J Clin Periodontol* 10:370, 1983.
129. Polson A: The relative importance of plaque and occlusion in periodontal disease. *J Clin Periodontol* 13:923, 1986.
130. Prinz H: The origin of salivary calculus. *Dent Cosmos* 63:231, 369, 503, 619, 1921.
131. Raether D, Walker P, Bostrum B, et al: Effectiveness of oral chlorhexidine for reducing stomatitis in a pediatric bone marrow transplant population. *Pediatr Dent* 11:37, 1989.
132. Ramfjord S: The periodontal status of boys 11 to 17 years old in Bombay, India. *J Periodontol* 32:237, 1961.
133. Rawal SY, Claman LJ, Kalmar JR, et al: Traumatic lesions of the gingiva: a case series. *J Periodontol* 75:762–769, 2004.
134. Reitan K: Tissue changes following experimental tooth movement as related to the time factor. *Dent Record* 73:559, 1953.
135. Renggli H: The influence of subgingival proximal filling borders on the degree of inflammation of the adjacent gingiva. A clinical study. *Schweiz Monatsschr Zahnheilkd* 84:181, 1974.
136. Renggli H, Regolati B: Gingival inflammation and plaque accumulation by well-adapted supragingival and subgingival proximal restorations. *Helv Odontol Acta* 16:99, 1972.
137. Rizzo A, Martin G, Scott D, et al: Mineralization of bacteria. *Science* 135:439, 1962.
138. Robertson PB, DeRouen TA, Ernster V, et al: Smokeless tobacco use: how it affects the performance of major league baseball players. *J Am Dent Assoc* 126:1115–1121, 1995.
139. Robertson PB, Walsh M, Greene J, et al: Periodontal effects associated with the use of smokeless tobacco. *J Periodontol* 61:438–443, 1990.
140. Robertson PB, Walsh MM, Greene JC: Oral effects of smokeless tobacco use by professional baseball players. *Adv Dent Res* 11: 307–312, 1997.
141. Rothwell B: Prevention and treatment of the orofacial complications of radiotherapy. *J Am Dent Assoc* 114:316, 1987.
142. Rowles S: The inorganic composition of dental calculus. In Blackwood HJ, editor: *Bone and tooth*, Oxford, 1964, Pergamon Press.
143. Sanchez-Sotres L, Van Huysen G, Gilmore H: A histologic study of gingival tissue response to amalgam, silicate and resin restorations. *J Periodontol* 42:8, 1969.
144. Sanz M, Newman MG, Nachnani S, et al: Characterization of the subgingival microbial flora around endosteal sapphire dental implants in partially edentulous patients. *Int J Oral Maxillofac Implants* 5:247–253, 1990.
145. Schoff F: Periodontia: an observation on the attachment of calculus. *Oral Surg* 8:154, 1955.
146. Schroeder H: Inorganic content and histology of early dental calculus in man. *Helv Odontol Acta* 7:17, 1963.
147. Schroeder H: Crystal morphology and gross structures of mineralizing plaque and of calculus. *Helv Odontol Acta* 9:73, 1965.
148. Schroeder H: *Formation and inhibition of dental calculus*, Berne, Germany, 1969, Hans Huber.
149. Schroeder H, Bambauer H: Stages of calcium phosphate crystallization during calculus formation. *Arch Oral Biol* 11:1, 1966.
150. Schwartz A: Tissue changes incidental to orthodontic tooth movement. *Ortho Oral Surg Rad Int J* 18:331, 1932.
151. Scoman S: Study of the relationship between periodontal disease and the wearing of partial dentures. *Aust Dent J* 8:206, 1963.
152. Selvig J: Attachment of plaque and calculus to tooth surfaces. *J Periodont Res* 5:8, 1970.
153. Serio F, Siegel M, Slade B: Plasma cell gingivitis of unusual origin. *J Periodontol* 62:390, 1991.
154. Serio F, Hawley C: Periodontal trauma and mobility. Diagnosis and treatment planning. *Dent Clin North Am* 43:37, 1999.
155. Setz J, Diehl J: Gingival reaction on crowns with cast and sintered metal margins: a progressive study. *J Prosthet Dent* 71:442, 1994.
156. Sharawy A, Sabharwal K, Socransky S, et al: A quantitative study of plaque and calculus formation in normal and periodontally involved mouths. *J Periodontol* 37:495, 1966.
157. Silness J: Fixed prosthodontics and periodontal health. *Dent Clin North Am* 24:317, 1980.
158. Sorensen J, Doherty F, Newman M, et al: Gingival enhancement in fixed prosthodontics. Part I. Clinical findings. *J Prosthet Dent* 65:100, 1991.
159. Sorensen J, Larsen I, Jorgensen K: Gingival and alveolar bone response to marginal fit of subgingival crown margins. *Scand J Dent Res* 94:109, 1986.
160. Spieler E: Preventing toothbrush abrasion and the efficacy of the Alert toothbrush. *Compend Contin Educ Dent* 17:478, 1996.
161. Standford J: Analysis of the organic portion of dental calculus. *J Dent Res* 45:128, 1966.
162. Stanton G: The relation of diet to salivary calculus formation. *J Periodontol* 40:167, 1969.
163. Stewart R, Ratcliff P: The source of components of subgingival plaque and calculus. *Periodont Abstr* 14:102, 1966.
164. Sutcliffe P: Chronic anterior gingivitis: an epidemiological study in school children. *Br Dent J* 125:47, 1968.
165. Theilade J, Schroeder H: Recent results in dental calculus research. *Int Dent J* 16:205, 1966.
166. Tibbetts L, Kashiwa H: A histochemical study of early plaque mineralization. Abstract No. 616. *J Dent Res* 19:202, 1970.
167. Tomar SL, Winn DM: Chewing tobacco use and dental caries among U.S. men. *J Am Dent Assoc* 130:1601–1610, 1999.
168. Turesky S, Renstrup G, Glickman I: Effects of changing the salivary environment on progress of calculus formation. *J Periodontol* 33:45, 1962.

169. Volker J, Pinkerton D: Acid production in saliva carbohydrates. *J Dent Res* 26:229, 1947.
170. Volpe A, Kupczak L, King W, et al: In vivo calculus assessment. Part IV. Parameters of human clinical studies. *J Periodontol* 40:76, 1969.
171. Von der Fehr F, Brudevold F: In vitro calculus formation. *J Dent Res* 39:1041, 1960.
172. Waerhaug J: The source of mineral salts in subgingival calculus. *J Dent Res* 34:563, 1955.
173. Waerhaug J, Zander H: Reaction of gingival tissue to self-curing acrylic restorations. *J Am Dent Assoc* 54:760, 1957.
174. Walsh PM, Epstein JB: The oral effects of smokeless tobacco. *J Can Dent Assoc* 66:22–25, 2000.
175. Wasserman B, Mandel J, Levy BM: In vitro calcification of calculus. *J Periodontol* 29:145, 1958.
176. White D: Dental calculus: recent insights into occurrence, formation, prevention, removal and oral health effects of supragingival and subgingival deposits. *Eur J Oral Sci* 105:508, 1997.
177. Whittle JG, Lamden KH: Lip and tongue piercing: experiences and views of general dental practitioners in South Lancashire. *Prim Dent Care* 11:92–96, 2004.
178. Wilson TG, Jr: The positive relationship between excess cement and peri-implant disease: a prospective clinical endoscopic study. *J Periodontol* 80:1388–1392, 2009.
179. Wise M, Dykema R: The plaque retaining capacity of four dental materials. *J Prosthet Dent* 33:178, 1975.
180. Yuodelis R, Weaver J, Sapkos S: Facial and lingual contours of artificial complete crowns and their effect on the periodontium. *J Prosthet Dent* 29:61, 1973.
181. Zadik Y, Sandler V, Bechor R, et al: Analysis of factors related to extraction of endodontically treated teeth. *Oral Surg Oral Med Oral Pathol Oral Radiol Endod* 106:31–35, 2008.
182. Zander H: The attachment of calculus to root surfaces. *J Periodontol* 24:16, 1953.
183. Zander H, Hazen S, Scott D: Mineralization of dental calculus. *Proc Soc Exp Biol Med* 103:257, 1960.
184. Zitzmann NU, Berglundh T: Definition and prevalence of peri-implantitis diseases. *J Clin Periodontol* 35:286–291, 2008.

CHAPTER 8

Biofilm and Periodontal Microbiology

Wim Teughels, Christof Godts, Marc Quirynen, and Nick Jakubovics

CHAPTER OUTLINE

The Oral Cavity From a Microbe's Perspective
Bacteria and Their Biofilm Mode of Living
Characteristics of Biofilm Bacteria (Life in "Slime City")
Bacterial Transmission and Translocation
Nonbacterial Inhabitants of the Oral Cavity
Microbiologic Specificity of Periodontal Diseases
The Transition From Health to Disease
Virulence Factors of Periodontopathogens
Future Advances in Periodontal Microbiology

For online only content on the criteria for the identification of periodontopathogens, video clips 8-1 through 8-4, as well as expanded discussions of the structure of a mature dental plaque biofilm, the initial adhesion/attachment of bacteria, colonization and plaque maturation, interactions between dental plaque bacteria, bacterial transmission and translocation, viruses, host susceptibility, adhesive surface proteins and fibrils, and tissue-destruction—promoting factors, please visit the companion website at www.expertconsult.com. Some figures may be out of numeric order in this printed chapter.

The human fetus inside the uterus is sterile, but, as soon as it passes through the birth canal, it acquires vaginal and fecal microorganisms.[79,107] Within 2 weeks, a nearly mature *microbiota* is established in the gut of the newborn baby. After weaning (>2 years), the entire human microbiota is formed and comprises a very complex collection of hundreds of different types of bacteria that totals approximately 10^{14} microbial cells.[249] From this moment on, our body contains *10 times more bacteria* than human cells. It has been estimated that, for a normal, healthy human being, the bacterial population comprises 2 kg of the total body weight. This is fascinating if one realizes that the average human brain weighs only about 1.4 kg.

The colonization of the oral cavity also starts close to the time of birth (Table 8-1). Within hours after birth, the sterile oral cavity will be colonized by low numbers of mainly facultative and aerobic bacteria.[369] At that time, the oral microbiota of newborns closely resembles the mother's vaginal microbiota or, for newborns delivered by cesarean section, the mother's skin microbiota.[79] From the second day, anaerobic bacteria can be detected in the infant's edentulous mouth.[92,319] The number of oral bacteria increases gradually as a result of exposure to external environmental microbial sources.[179,272,319] *Streptococcus salivarius* and *Streptococcus mitis* (Figure 8-1, *A*) have been identified as the first and most dominant oral microbes to colonize the oral cavity of newborn infants.[177,178,199] *Veillonella* spp. (Figure 8-1, *B*), *Neisseria* spp., *Actinomyces* spp. (Figure 8-1, *C* and *D*), and *Staphylococcus* spp. are also among the first colonizers of the oral cavity. After tooth eruption, a more complex oral microbiota is established. The species that colonize the teeth after eruption include *Streptococcus sanguinis* (Figure 8-1, *D*), *Lactobacillus* spp. (Figure 8-1, *E*), and *Streptococcus oralis*. Oral streptococci, including *S. oralis, Streptococcus anginosus,* mutans streptococci (*Streptococcus mutans* and *Streptococcus sobrinus*), and *Streptococcus gordonii* (Figure 8-1, *F*) are commonly reported to be present after the first year of life.[49,53,219,272] In addition, anaerobes, including *Fusobacterium* spp. (Figure 8-1, *G*) and *Prevotella* spp. (Figure 8-1, *H* and *I*), can also be detected in young children.[49,179] In later childhood, the bacterial diversity and numbers in the oral cavity increase as more teeth erupt and provide more areas for the adherence and retention of bacteria.[33] Because of the paucity of longitudinal studies, relatively little is known about the initial colonization of key microbes found in the oral cavity of children and adults.[199] It is estimated that *more than 500 different species* are capable of colonizing the adult mouth and that any individual typically harbors around 50 to 150 different species.[25,252,364] When one thinks about bacteria, one almost immediately associates them with different pathologies. However, most oral bacteria are harmless commensals under normal circumstances. This means that this microbiota lives in harmony with its host but that, under specific conditions (i.e., increased mass and/or pathogenicity, suppression of commensal or beneficial bacteria, and/or reduced host response), disease can occur. The importance of the commensal microbiota is clearly illustrated by the development of yeast infections when the normal oral microbiota is reduced, such as after a longer period of systemic antibiotic usage.[407] In addition, it has been shown that aggressive periodontitis is associated with a loss of colonization of *S. sanguinis*.[372] On the other hand, it was recently shown in mice that the commensal microbiota is required for *P. gingivalis*–induced bone loss.[2,72]

It is obvious that the periodontal microbiota is extremely complex. Because it affects the host, the oral environment, and periodontal treatment and because it is affected by the host, the oral environment, and periodontal treatment, a profound knowledge of periodontal microbiology is necessary.

TABLE 8-1 Colonization of the Oral Cavity

Type	MONTHS AFTER BIRTH												YEARS AFTER BIRTH					
	Birth	1	2	3	4	5	6	7	8	9	10	11	12	2	3	4	5	6	7
Gram-negative bacteria	*Veillonella* spp. *Prevotella melaninogenica* group																		
			Fusobacterium nucleatum *Porphyromonas catoniae* Nonpigmented *Prevotella* spp. *Leptotrichia* spp.																
	Haemophilus spp. *Neisseria* spp. Enteric or environmental gram-negative rods*																		
							Corroding rods *Capnocytophaga* spp.												
							Other *Fusobacteria*												
													Selenomonas spp. *Prevotella* spp. *(P. nigrescens, P. pallens)*						
																Aggregatibacter actinomycetemcomitans			
																	Porphyromonas gingivalis *Prevotella intermedia*		
Gram-positive bacteria	*Actinomyces* spp. *(A. odontolyticus)* *Streptococcus mitis* *Streptococcus salivarius* *Stomatococcus* spp. *Staphylococci**																		
							Streptococcus oralis Streptococcus sanguinis												
													Actinomyces naeslundii						
													Mutans streptococci						
													Streptococcus gordonii						
														Clostridium spp. *Peptostreptococcus* spp.					

Adapted from Kononen E: *Oral Dis* 5:278, 1999; and Kononen E: *Ann Med* 32:107, 2000.

Amenable periods for the establishment of the most frequent bacterial species or groups (prevalence, >25%) in infants' mouths. Anaerobic bacteria are indicated in green, and aerobic or facultative bacteria are indicated in orange.

*The prevalence of this bacteria decreases with age.



Figure 8-1 Various periodontal and cariogenic species grown on agar plates. **A**, *Streptococcus mitis* are gram-positive, fast-growing, facultatively anaerobic bacteria that are easy to culture on a blood-agar plate. A clear halo surrounding the colonies appears through hemolytic activity. **B,** *Veillonella parvula* are anaerobic gram-negative small cocci. They form small transparent colonies (<1.0 mm) after 48 hours of incubation. **C,** *Actinomyces viscosus* are microaerophilic to anaerobic gram-positive rods with possible branches (pseudomycelium). They form slimy white spherical colonies in 48 hours. **D,** The typical colony morphology of *Streptococcus sanguinis (right)* and *Actinomyces odontolyticus (left)*. **E,** *Lactobacillus* spp. will typically grow on Rogosa agar as a sesame seed. **F,** *Streptococcus gordonii* are facultative, anaerobic, gram-positive cocci. On a blood plate, colonies of 1 mm to 3 mm are formed within 48 hours. These bacteria are α-hemolytic, which results in the formation of a clear halo surrounding the colony. **G,** This selective agar plate, which contains crystal violet and erythromycin (i.e., a CVE-agar plate), will allow *Fusobacterium nucleatum* to grow as a round, flat rhizoid, opaque purple colony. **H,** A detailed picture of *Porphyromonas gingivalis* (green-brown colony) and *Prevotella intermedia* (black colony) on a classic nonspecific blood-agar plate. **I,** *Prevotella nigrescens* forms like *Prevotella intermedia*, a black pigmented colony on a blood agar plate. It is a strictly anaerobic bacterium with growth that is limited to an oxygen-free environment. **J,** A detailed picture of *Parvimonas micra* (small white colony) next to *Porphyromonas gingivalis* (green-brown colony) on a classic nonspecific blood-agar plate. **K,** A detailed picture of *Aggregatibacter actinomycetemcomitans* grown on a selective agar plate that contains tryptic soy, horse serum, bacitracin, and vancomycin (i.e., a TSBV-agar plate).



Figure 8-1, cont'd **L,** It is extremely difficult to culture *Treponema denticola* (spirochete) on an agar plate and therefore not possible to identify this bacteria with classic culture. A phase-contrast microscope, a dark-field microscope, or an electron microscope is often used to visualize this bacterium. Identification and quantification is only possible through DNA analysis. **M,** On a selective agar plate that contains trypticase yeast extract, cystine, sucrose, and bacitracin (i.e., a TYCSB agar plate), *Streptococcus mutans* will grow as a sugar cube. **N,** *Eubacterium nodatum* colony morphology strongly depends on its substrate. Its growth is very slow, and it is an obligate anaerobic gram-positive rod. **O,** *Tannerella forsythia* are fastidious bacteria that are therefore difficult to culture. This organism grows on a blood-agar plate as a smooth white colony with a faded edge. The bacteria are strictly anaerobic. **P,** The typical colony morphology of *Streptococcus sobrinus* on TYCSB agar (colony with a white halo). **Q,** Capnocytophaga are slowly growing bacteria that require an elevated CO_2 concentration for their growth. They are facultative anaerobic rods. **R,** *Campylobacter rectus* grows on a Hammond plate as small, smooth, opaque, round colonies with a black color. **S,** *Eikenella corrodens* has a variable colony morphology and shows different biochemical and serologic reactions. Because of the difficult determination with classic culture, identification and quantification through DNA techniques are very suitable for this organism. *E. corrodens* cells are facultative, anaerobic, gram-negative rods. *(**A, B, C, F, I, L, N, O, Q,** and **S** courtesy ADD Clinident, Malden, The Netherlands.)*

The Oral Cavity From a Microbe's Perspective

With the exception of those microorganisms that are present in feces and in secretory fluids, all bacteria maintain themselves within their host by adhering to a surface. This principle also applies to the oral cavity. From an ecologic viewpoint, the oral cavity, which communicates with the pharynx, should be considered as an "open growth system" with an uninterrupted ingestion and removal of microorganisms and their nutrients. A dynamic equilibrium exists between the adhesion forces of microorganisms and a variety of removal forces that originate from the following sources: (1) swallowing, mastication, or blowing the nose; (2) tongue and oral hygiene implements; (3) the wash-out effect of the salivary, nasal, and crevicular fluid outflow; and (4) the active motion of the cilia of the nasal and sinus walls. Most

organisms can only survive in the oropharynx when they adhere to either the soft tissues or the hard surfaces (i.e., teeth, restorative or prosthetic materials, and implants).

The ability of a bacterium to adhere to its host is crucial for the induction of infectious diseases, such as gingivitis or periodontitis.[310] Oral bacteria and especially pathogenic bacteria, such as *Porphyromonas gingivalis* (Figure 8-1, *H* and *J*) and *Aggregatibacter actinomycetemcomitans* (Figure 8-1, *K*), have a large battery of virulence factors, one of which is the ability to adhere to hard intraoral surfaces and/or to the oral mucosae (Figure 8-2).[56,58,105,358]

On the basis of physical and morphologic criteria, the oral cavity can be divided into *six major ecosystems* (also called *niches*), each with the following distinct ecologic determinants:

- The intraoral and supragingival hard surfaces (teeth, implants, restorations, and prostheses)
- Subgingival regions adjacent to a hard surface, including the periodontal/periimplant pocket (characterized by the presence of crevicular fluid, the root cementum or implant surface, and the pocket epithelium)
- The buccal palatal epithelium and the epithelium of the floor of the mouth
- The dorsum of the tongue
- The tonsils
- The saliva

In health, there is a core set of microorganisms that are almost universally present in these ecosystems. This core microbiome includes members of the phyla Firmicutes (*Streptococcus* spp., *Veillonella* spp., and *Granulicatella* spp.), Proteobacteria (*Neisseria* spp., *Campylobacter* spp., and *Haemophilus* spp.), Actinobacteria (*Corynebacterium* spp., *Rothia* spp., and *Actinomyces* spp.), Bacteroidetes (*Prevotella* spp., *Capnocytophaga* spp., and *Porphyromonas* spp.) and Fusobacteria (*Fusobacterium* spp.).[149,200,433]

Table 8-2 summarizes several publications that discuss the detection frequency of periodontopathogens in these different niches. Most species (with the exception of spirochetes) (Figure 8-1, *L*) are able to colonize all of them. Some periodontopathogens (e.g. *Fusobacterium nucleatum* [Figure 8-1, *G*], *Prevotella intermedia* [Figure 8-1, *H*]) are involved in the etiology of tonsillitis, and most periodontopathogens are able to colonize the maxillary sinus.[37,404]

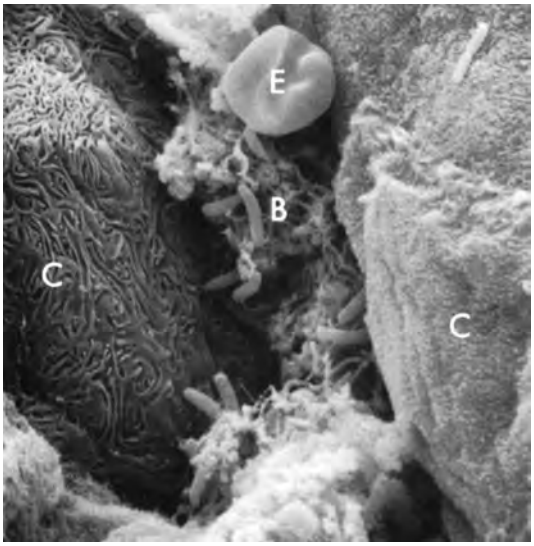

Figure 8-2 Scanning electron micrograph of epithelial intercellular spaces that contain bacterial plaque *(B)* enmeshed in a fibrinlike material. *C,* Epithelial cells; *E,* erythrocyte. The cells to the left show signs of necrosis. (×4000.)

The soft-tissue surfaces are actively involved in the process of bacterial adhesion and colonization.[146] They employ a variety of mechanisms to prevent the adhesion of pathogenic organisms, with shedding being one of the most important. The high turnover rate of the intraoral epithelial cells, especially of the gingiva, prevents the permanent accumulation of large masses of microorganisms on these surfaces. In essence, this is a natural cleansing mechanism. However, bacteria can also adhere to host cells and form a commensal relationship that is beneficial for both parties.

The host vaginal epithelial cells, for example, supply glucose for the colonized lactobacilli, which in turn produce acid. A lowering of the pH prevents the growth of many other species that have deleterious effects on the vaginal environment.[317] As such, these endogenous bacteria and their products can be considered necessary and beneficial components of a healthy body.

In periodontal pockets, studies have shown high numbers of bacteria attached to pocket epithelial cells in vivo. Areas of gingival inflammation are characterized by an increased number of adhering bacteria.[82,392] These adhering bacteria can also infiltrate the pocket wall in relatively large numbers and reach the underlying stroma (Figure 8-3).[99,232,327] In general, there is a positive correlation between the adhesion rate of pathogenic bacteria to different epithelia and the susceptibility of the affected patient to certain infections.[263]

Women prone to urinary tract infections, for example, harbor five times more bacteria per cell in adhesion assays of *Escherichia coli* to different epithelial cells of their urogenital tract (periurethral, vaginal, or uroepithelial cells). Similar observations have been made regarding the adhesion of *Streptococcus pneumoniae* to nasopharyngeal epithelial cells of children prone to recurrent otitis media infections as well as regarding the adhesion of *Haemophilus influenzae* to buccal cells of subjects prone to acute bronchitis.[69,381]

There are some indications that the same may be true for periodontal infections. Isogai and coworkers reported a significantly lower adherence rate of *P. gingivalis* and *P. intermedia* strains to gingival epithelial cells in rats that were resistant to gingivitis compared with susceptible rats.[155] An in vitro study of cultured human pocket epithelial cells (Figure 8-4) showed a similar tendency when patients who were resistant to periodontitis were compared with patients with severe periodontal breakdown.[299]

Bacteria also adhere to hard tissues. In the human body, teeth and nails are the only naturally occurring nonshedding surfaces. Artificial nonshedding surfaces of medical importance are prosthetic devices such as catheters, artificial joints, dental implants, and heart valves. From a microbiological viewpoint, teeth and implants are unique for two reasons: (1) they provide a hard, nonshedding surface that allows for the development of extensive structured bacterial deposits; and (2) they form a unique ectodermal interruption. There is a special seal of epithelium (junctional epithelium) and connective tissue between the external environment and the internal parts of the body. The accumulation and metabolism of bacteria on these hard surfaces is considered the primary cause of caries, gingivitis, periodontitis, periimplantitis, and, sometimes, bad breath.

In the periodontal pocket, different strategies contribute to bacterial survival, such as adhesion to the pocket epithelium and, when dentine is encountered, the colonization of the dentine tubules.[290] The crevicular fluid with its constant outflow does not

TABLE 8-2 Intraoral Habitats (Periodontal Pockets, Buccal Mucosa, Tongue, Saliva, Tonsils, and Supragingival Plaque) for Periodontopathogenic and Cariogenic Species

					DIFFERENT INTRAORAL NICHES					
Authors	**Infection**	**Age (n)**	**Species**	**No. of Positive Patients**	**Periodontal Pockets**	**Buccal Mucosa**	**Tongue**	**Saliva**	**Tonsils**	**Supragingival Plaque**
Asikainen et al, 1991	Periodontitis	Adult	*A.a.*	—	100%*	—	56%	72%	—	—
Petit et al, 1994	—	Child	*A.a.*	5	4†	3	1	3	2	—
		(45)	*P.g.*	1	0	1	0	1	1	—
			P.i.	34	23	18	25	31	22	—
			Spi	13	6	0	7	3	1	—
Petit et al, 1994	Periodontitis	Adult	*A.a.*	13	13†	11	11	11	5	—
		(24)	*P.g.*	18	18	14	7	10	11	—
			P.i.	24	24	22	23	23	23	—
			Spi	22	22	0	2	5	1	—
von Troil-Lindén et al, 1995	Periodontitis	Adult	*A.a.*	—	6‡	—	—	6	—	—
		(10)	*P.g.*	—	7	—	—	4	—	—
			P.i.	—	10	—	—	9	—	—
Danser et al, 1994	Perio/E	Adult	*A.a.*	2	2/—§	2/0	2/0	2/0	2/0	1/0
		(8)	*P.g.*	6	6/—	2/0	4/0	4/0	3/0	2/0
			P.i.	8	8/—	4/1	6/3	6/4	5/3	6/1
			Prev.	8	3/—	4/5	7/6	7/5	4/6	5/4
Danser et al, 1996	Perio/R	Adult	*A.a.*	11	9/4‖	10/9	—	5/2	—	2/0
		(15)	*P.g.*	10	6/5	9/7	—	4/1	—	6/0
			P.i.	15	11/1	15/15	—	14/13	—	11/1
Gibbons and van Houte, 1975	—¶	—¶	*S.m.*	—	?	<1‖	<1	<1	—	0 to 50
			L.		?	<0.1	< 0.1	<1	—	0 to 1

P.g., P. gingivalis; P.i., P. intermedia; A.a., A. actinomycetemcomitans; Spi, spirochetes; *Prev., Prevotella* spp. (e.g., *P. melaninogenica, P. denticola, P. loescheii, P. veroralis*); *S.m., S. mutans; L., Lactobacillus* spp.

*Percentage of "specific" positive sites in positive patients.

†Number of "specific" positive sites in positive patients.

‡Number of "specific" positive sites in patients with advanced periodontitis.

§Number of "specific" positive sites in positive patients before/after full mouth extraction *(E)* (e.g., 2 patients were positive for *A.a.* before extraction, and no patients were positive for *A.a.* after full mouth extraction).

‖ Number of "specific" positive sites in positive patients before/after periodontal therapy including surgery *(R)* (e.g., 9 patients were positive for *A.a.* before periodontal therapy as compared with only 4 patients after periodontal therapy).

¶Percentage of total flora cultivable in anaerobically incubated agar in nonspecific patients as estimated from several studies.

favor the maintenance of unattached bacteria in the periodontal pocket.

It has been suggested that teeth are the primary habitat for periodontopathogens, because soon after a full-mouth tooth extraction in patients with severe periodontitis, key pathogens such as *A. actinomycetemcomitans* and *P. gingivalis* disappeared from the oral cavity as determined by bacterial culturing techniques.[71] *Prevotella intermedia* and other black-pigmented *Prevotella* spp. did remain, but at lower detection frequencies and numbers (see Table 8-2).

The same applies to edentulous infants and wearers of full dentures in whom significant proportions of periodontopathogens have been recorded, with the exception of *A. actinomycetemcomitans* and *P. gingivalis*.[70,179] Therefore, teeth were considered as a "porte d'entrée" for periodontopathogens.

However, studies involving the use of molecular tools to detect and quantify oral bacteria seem to indicate that *A. actinomycetemcomitans* and *P. gingivalis* are not entirely eradicated after full-mouth extraction. They may remain colonizers of the oral cavity, but, when teeth are lost, their relative numbers decrease.[304]

Alternatively, cariogenic species were thought to be relatively restricted to solid surfaces (see Table 8-2). Therefore, *S. mutans* (Figure 8-1, *M*) was often considered an *obligate periphyte*.[380] In some studies, this species was only detected from the time that the deciduous teeth erupted in the oral cavity.[50] In a longitudinal observation of adults with severe dental caries, the cariogenic species fell below detection level after full-mouth extraction but reappeared a few days after denture insertion.[51] On the basis of these reports and on their own observations, Caufield and Gibbons concluded that most of the *S. mutans* cells in the saliva or on the tongue

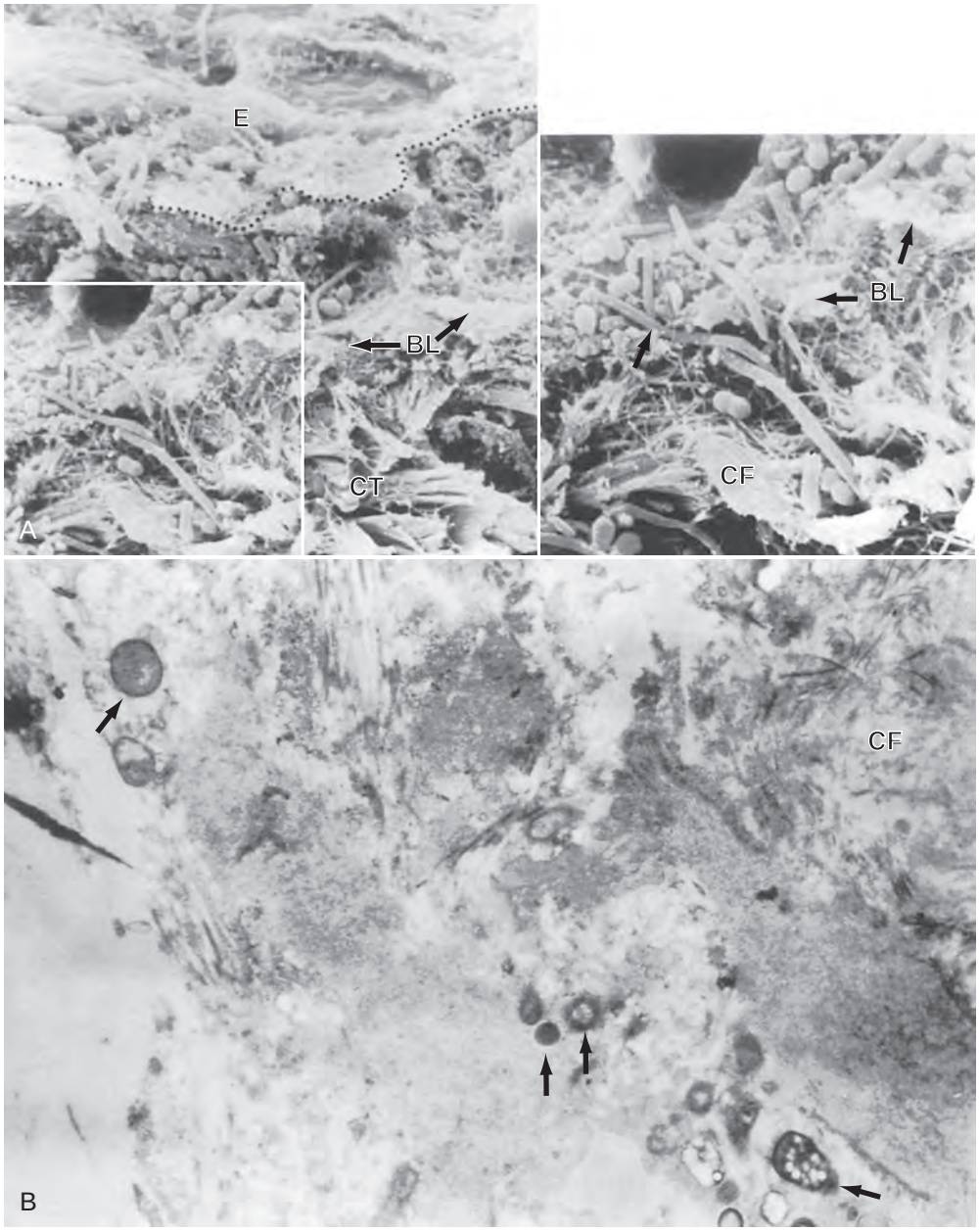

Figure 8-3 Bacterial penetration into the pocket wall with advanced periodontitis. **A,** The penetration through the pocket epithelium *(E)* and the basement lamina *(BL)* into the connective tissue *(CT) (arrows). CF,* Collagen fibers. **B,** Connective-tissue–associated bacteria in a patient with advanced periodontitis. *(**A** courtesy Dr. R. Saglie. **A** and **B** from Nissengard RJ, Newman MG:* Oral microbiology and immunology, *ed 2, Philadelphia, 1994, Saunders.)*

are derived from the biofilm present on the teeth and that the mucosae could not act as a reservoir for the infection of teeth by those organisms.[54] They suggested a "window of infectivity" for the acquisition of *S. mutans* at a mean age of 26 months (range, 9 to 44 months).[53] This observation has been supported by a few clinical studies, which showed that the initial colonization of *S. mutans* varied between 7 to 36 months, which is the time period that coincides with the eruption of the primary teeth.[7,49,101] On the other hand, longitudinal studies by Wan and coworkers[408,409] and Law and Seow[198] showed that *S. mutans* colonization increased with the age of children, without any discrete window of infectivity. There is now clinical evidence that *S. mutans* can be detected in the mouths of predentate children, before the eruption of the first tooth.[243,408,410]

Bacteria and Their Biofilm Mode of Living

To many people, the word *microbiologist* conjures images of someone in a laboratory coat swilling a flask of bacterial cells that are growing happily as pure cultures in nutrient-rich broth. In nature, bacteria rarely enjoy such an easy life. The major struggle faced by bacteria lies in obtaining sufficient nutrients to support growth. Competition is rife, and most microbial communities contain many different species, sometimes 100 or more, sharing the same site. Nutrients tend to concentrate at interfaces, and consequently the densest bacterial populations are located at interfaces of various kinds. In aquatic ecosystems, the major interfaces are the solid–liquid boundaries, such as the surfaces of submerged rocks or soil particles, and the air–water interface that is present in

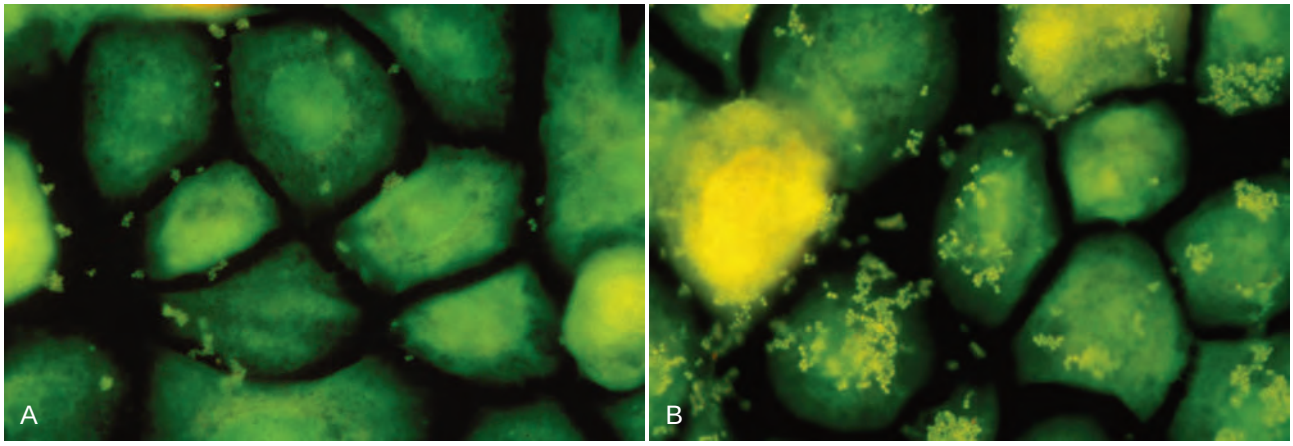

Figure 8-4 Microscopic confirmation of significant differences in the adhesion capacity of *P. gingivalis* (small green dots) to epithelial cells from a resistant patient *(left)* as compared with a patient with severe periodontitis *(right).*

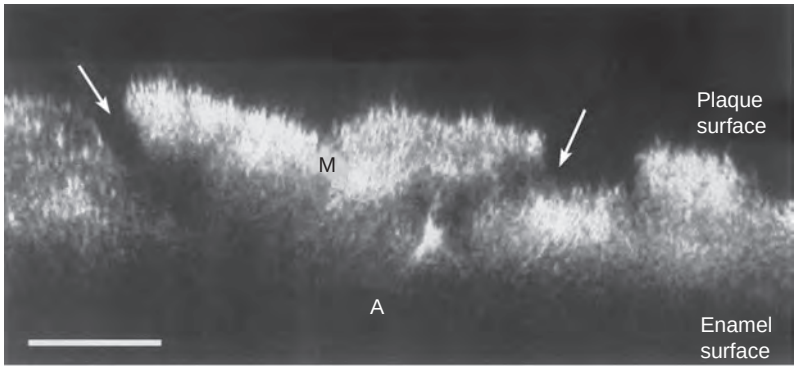

Figure 8-5 Vertical section through a 4-day human plaque sample. An intraoral device designed for the in vivo generation of plaque biofilms on enamel was used. Confocal microscopy enabled the visualization of the section of plaque without the dehydration steps used in conventional histologic preparations. Notice the open fluid-filled channels *(white arrows)* that traverse from the plaque surface through the bacterial mass (*M*; grey-white areas) to the enamel surface. An area in which the bacterial mass appears to attach to the enamel surface *(A)* is indicated. Scale bar = 25 µm. *(From Wood SR, Kirkham J, Marsh PD, et al:* J Dent Res *79:21, 2000.)*

open systems, such as oceans or lakes. Bacteria grow well in the laboratory at the solid–gas interface on the surface of an agar plate. However, desiccation rapidly kills most bacterial cells, and microbial growth at solid–gas interfaces is therefore generally restricted to areas where moisture is available. The human body provides several interfaces that support microbial populations, of which the most important in healthy individuals are the skin, gut, mouth, and female urogenital tract. As mentioned previously, the oral cavity is somewhat unique in this regard, because it provides hard, nonshedding surfaces (teeth) that are accessible for microbial colonization.

The importance of surfaces for microbial growth was recognized as early as the 1920s, when a number of workers independently noted that bacteria growing on glass slides submerged in soil were different from those that could be cultured in broth.[197] However, it was not until around 50 years later that sessile microbial populations were considered to be sufficiently different from free-living microorganisms to merit their own name, and the term *biofilms* was coined (Figure 8-5 and Figure 8-6, *B* and *C*). Biofilms are composed of microbial cells encased within a matrix of extracellular polymeric substances, such as polysaccharides, proteins, and nucleic acids.

Biofilm bacteria are often up to 1000 times more resistant to antimicrobial agents than their planktonic counterparts.[9,92] Bacteria that grow in multispecies biofilms interact closely with neighboring cells. Sometimes these interactions are mutually beneficial, as is the case when one organism removes another's waste products and uses them as an energy source. In other instances, bacteria compete with their neighbors by secreting antibacterial molecules such as inhibitory peptides (bacteriocins) or hydrogen peroxide (H_2O_2). In addition, the biofilm mode of growth facilitates cell–cell signaling and deoxyribonucleic acid (DNA) exchange between bacteria. It is clear that microbial ecology within biofilm communities is highly complex and that, in many cases, knowledge is only emerging at this point.

Biofilms are heterogeneous: variations in biofilm structure exist within individual biofilms and between different types of biofilms. However, a number of structural features that are common to many biofilms have been noted. For example, biofilms frequently contain microcolonies of bacterial cells. Water channels are commonly found in biofilms, and these can form a primitive circulatory system that removes waste products and brings fresh nutrients to the deeper layers of the film. Surface structures, such as fronds, can dissipate the energy of fluid flowing over the biofilm and lead to the rapid blockage of vessels.[81] In mixed-species biofilms, there is often heterogeneity in the distribution of different species. Steep chemical gradients exist, such as those of oxygen or pH, and these produce distinct microenvironments within the biofilm.

Microbial populations on the surfaces of teeth (dental plaque) are excellent examples of biofilm communities (Figure 8-7). The

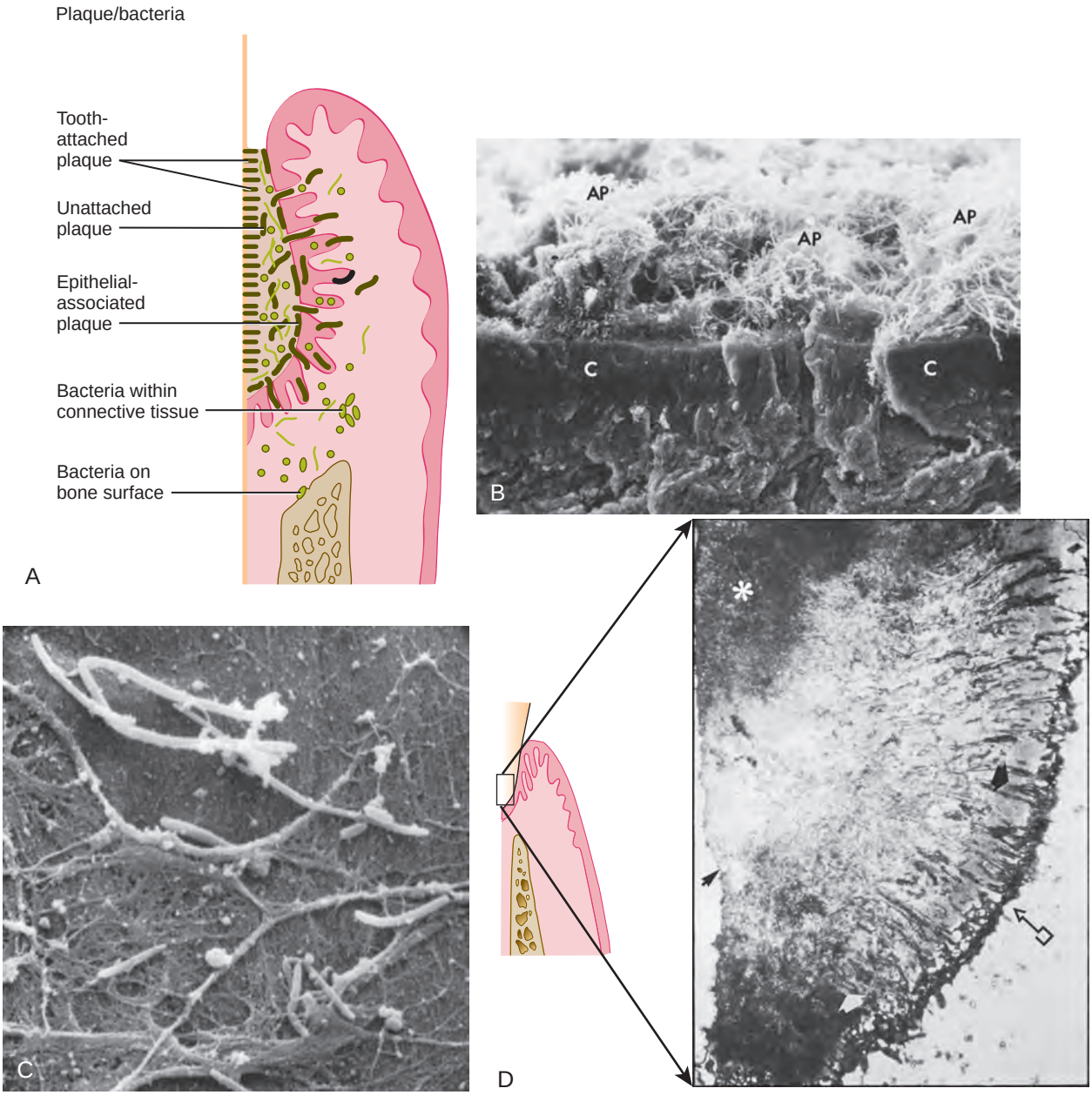

Figure 8-6 **A,** Diagram depicting the plaque–bacteria association between the tooth surface and the periodontal tissues. **B,** Scanning electron photomicrograph of a cross-section of cementum *(C)* with attached subgingival plaque *(AP)*. The area shown is within a periodontal pocket. **C,** Scanning electron micrograph of cocci and filaments associated with the surface of pocket epithelium in a case of marginal gingivitis. (×3000.) **D,** *Left,* Diagrammatic representation of the histologic structure of subgingival plaque. *Right,* Histologic section of subgingival plaque. *Arrow with box,* Sulcular epithelium. *White arrow,* Predominantly gram-negative unattached zone. *Black arrow,* Tooth surface. *Asterisk,* Predominantly gram-positive attached zone. *(**B** courtesy Dr. J. Sottosanti, La Jolla, CA.)*

architecture of a dental plaque biofilm has many features in common with other biofilms. It is heterogeneous in structure, with clear evidence of open fluid-filled channels running through the plaque mass[64,65,425] (Figure 8-5). Nutrients make contact with the sessile (attached) microcolonies by diffusion from the water channels to the microcolony rather than from the matrix. The bacteria exist and proliferate within the intercellular matrix through which the channels run. The matrix confers a specialized environment that distinguishes the bacteria that exist within the biofilm from those that are free-floating; this is the so-called "planktonic state" in solutions such as saliva or crevicular fluid. The biofilm matrix functions as a barrier. Substances produced by bacteria within the biofilm are retained and concentrated, which fosters metabolic interactions among the different bacteria.

The intercellular matrix consists of organic and inorganic materials derived from saliva, gingival crevicular fluid, and bacterial products.

Organic constituents of the matrix include polysaccharides, proteins, glycoproteins, lipid material, and DNA.[215] Albumin, which probably originates from crevicular fluid, has been identified as a component of the plaque matrix. The lipid material consists of debris from the membranes of disrupted bacterial and host cells,

Figure 8-7 Clinical picture of 10-day-old supragingival plaque. The first signs of gingival inflammation *(arrows)* are becoming visible.

Figure 8-8 Supragingival calculus is depicted on the buccal surface of the maxillary molars adjacent to the orifice of the parotid duct.

bacterial vesicles, and possibly food debris. *Glycoproteins* from the saliva are an important component of the pellicle that initially coats a clean tooth surface, but they also become incorporated into the developing plaque biofilm. Polysaccharides produced by bacteria also contribute to the organic portion of the matrix. They play a major role in maintaining the integrity of the biofilm.

The *inorganic components* of plaque are predominantly calcium and phosphorus, with trace amounts of other minerals such as sodium, potassium, and fluoride. The source of inorganic constituents of supragingival plaque is primarily saliva. As the mineral content increases, the plaque mass becomes calcified to form calculus (Figure 8-8). Calculus is frequently found in areas of the dentition adjacent to salivary ducts (e.g., the lingual surface of the mandibular incisors and canines, the buccal surface of the maxillary first molars), which reflects the high concentration of minerals available from saliva in those regions. The inorganic components of subgingival plaque are derived from crevicular fluid (a serum transudate). The calcification of subgingival plaque also results in calculus formation (Figure 8-9). Subgingival calculus is typically dark green or dark brown, which probably reflects the presence of blood products that are associated with subgingival hemorrhage.

The importance of these biofilms for oral diseases, such as dental caries and periodontitis—together with the relative ease with which tooth surface biofilms can be accessed—has led to dental plaque becoming one of the most highly studied biofilm systems. It is anticipated that, by understanding the mechanisms involved in the accumulation of dental plaque and the transition from health to disease, it will be possible to improve our control over these processes and to further restrict plaque-associated oral diseases.

Structure of a Mature Dental Plaque Biofilm

Dental plaque (see Figure 8-7) is defined clinically as a structured, resilient, yellow-grayish substance that adheres tenaciously to the intraoral hard surfaces, including removable and fixed restorations.[30] The tough extracellular matrix makes it impossible to remove plaque by rinsing or with the use of sprays. Plaque can thus be differentiated from other deposits that may be found on the tooth surface, such as materia alba and calculus. *Materia alba* refers to soft accumulations of bacteria, food matter, and tissue cells that lack the organized structure of dental plaque and that are easily displaced with a water spray. *Calculus* is a hard deposit that forms via the mineralization of dental plaque and that is generally covered by a layer of unmineralized plaque (Table 8-3).

Dental plaque is composed primarily of microorganisms. One gram of plaque (wet weight) contains approximately 10^{11}

Figure 8-9 Dark-pigmented deposits of subgingival calculus are shown on the distal root of an extracted lower molar.

bacteria.[340,361] The number of bacteria in supragingival plaque on a single tooth surface can exceed 10^9 cells. In a periodontal pocket, counts can range from 10^3 bacteria in a healthy crevice to more than 10^8 bacteria in a deep pocket. With the use of highly sensitive molecular techniques for microbial identification, it has been estimated that more than 500 distinct microbial phylotypes can be present as natural inhabitants of dental plaque.[1]

Any individual may harbor 150 or more different species. Nonbacterial microorganisms that are found in plaque include archaea, yeasts, protozoa, and viruses.[62,206]

Dental plaque is broadly classified as supragingival or subgingival on the basis of its position on the tooth surface toward the gingival margin.

- *Supragingival plaque* is found at or above the gingival margin; when in direct contact with the gingival margin, it is referred to as *marginal plaque.*
- *Subgingival plaque* is found below the gingival margin, between the tooth and the gingival pocket epithelium.

Supragingival plaque typically demonstrates the stratified organization of a multilayered accumulation of bacterial morphotypes (Figure 8-10).[437] Gram-positive cocci and short rods predominate at the tooth surface, whereas gram-negative rods and filaments as well as spirochetes predominate in the outer surface of the mature plaque mass.

In general, the subgingival microbiota differs in composition from the supragingival plaque, primarily because of the local availability of blood products and a low reduction–oxidation (redox) potential, which characterizes the anaerobic environment.

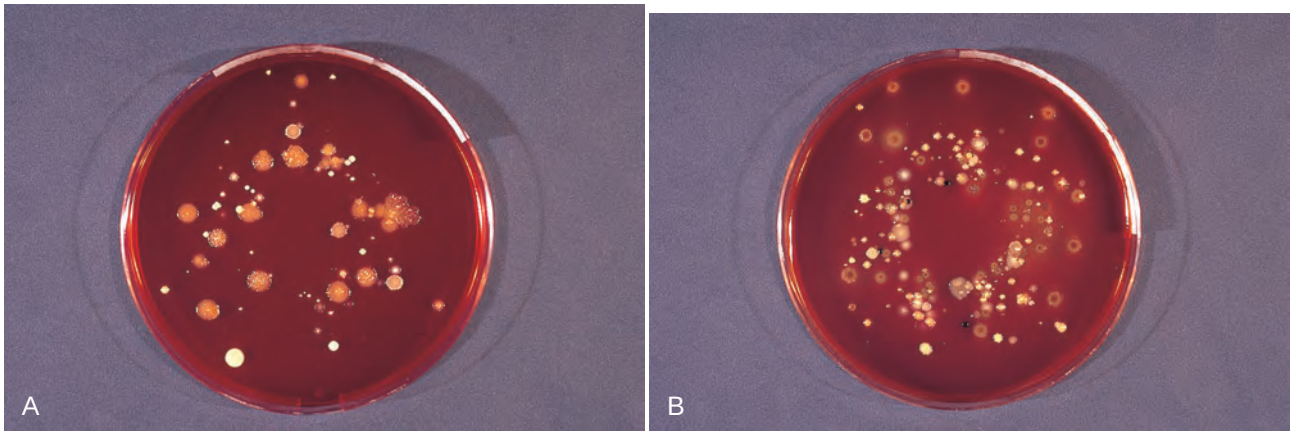

Figure 8-11 A plaque sample grown under **A,** aerobic and **B,** anaerobic conditions. A comparison of the culture plates shows different bacteria and different colony morphologies.

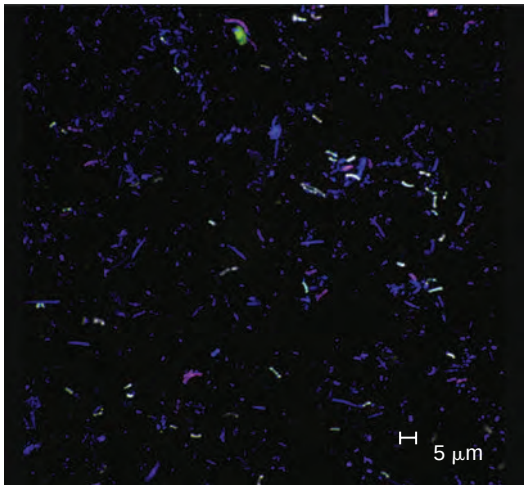

Figure 8-12 The identification of uncultured *Synergistetes* in subgingival dental plaque. Plaque was removed from deep (6 mm to 10 mm) periodontal pockets of volunteers with localized or generalized severe periodontitis. Bacteria were transferred to microscope slides, and intracellular DNA was hybridized with nucleic acid probes for all eubacteria (blue), *Synergistetes* cluster A (red), or a specific member of the *Synergistetes* cluster A, "3.3/BH007" (green). *Synergistetes* 3.3/BH007 appear white (blue + red + green), whereas other members of *Synergistetes* cluster A appear purple (blue + red). *Synergistetes* cluster A members were commonly detected in healthy and periodontally diseased sites, even though these organisms have never been cultured in the laboratory. *(Courtesy S. R. Vartoukian and W. G. Wade, King's College London Dental Institute, London. For more information, see Vartoukian SR, Palmer RM, Wade WG:* Appl Environ Microbiol *75:3777, 2009.)*

Many periodontopathogens are fastidious strict anaerobes and as such may contribute little to the initiation of disease in shallow gingival pockets. In deep periodontal pockets, however, they find their preferred habitat.

The identification of bacteria within intact dental plaque represents a significant challenge. Most of the previously cited studies of dental plaque microbiota used techniques that involved the disruption of the dental plaque matrix followed by microbial culture (Figure 8-11) or culture-independent identification. Techniques have been developed that allow for the specific visualization of individual bacteria within mixed populations. With these methods, specific labeling is achieved by using nucleic acid probes (fluorescence in situ hybridization [FISH]) or specific antibodies (immunofluorescence). FISH has been applied to identify particular species within plaque samples scraped from periodontal pockets.[111,265,401] With this methodology, it is even possible to image bacteria that have never been cultured in the laboratory, such as members of the phylum Synergistetes (Figure 8-12). Intact subgingival biofilms (Figure 8-13) have also been analyzed by FISH and shown to be composed of a heterogeneous structure with organisms such as *Actinomyces* spp. at the base, *F. nucleatum* and *Tannerella forsythia* in the middle layers, and periodontopathogens including members of the *Cytophaga–Flavobacterium–Bacteroides* cluster in the outer layers.[437] Supragingival biofilms have proved somewhat easier to visualize than subgingival plaque (Figure 8-14), and they have a somewhat different architecture.[437] Biofilms can be cultured on retrievable enamel chips held in intraoral devices in the mouths of volunteers. The enamel pieces can then be removed and processed for FISH or immunofluorescence. Images of biofilms can be captured by confocal laser scanning microscopy, which produces three-dimensional representations of the biofilm architecture. Labeling with nucleic acid probes requires the desiccation of the sample before hybridization, and therefore some structural information may be lost. Nevertheless, this technique has been applied successfully to determine the spatial relationships between *Actinomyces naeslundii* and *Streptococcus* spp. in dental plaque.[78] In these studies, *A. naeslundii* cells were frequently observed juxtaposed to *Streptococcus* spp. cells. Many strains of *Actinomyces* coaggregate with oral streptococci, and therefore the spatial organization of these organisms within dental plaque may be influenced by adhesin–receptor interactions.[175] In fact, a protein adhesin of *A. naeslundii* has been shown to colocalize with a cognate oral streptococcal receptor polysaccharide in in situ biofilms using specific antibody (immunofluorescence) labeling (Figure 8-15).[267] These studies clearly demonstrate that the interactions identified among bacteria isolated in the laboratory are relevant to the dental plaque biofilm.

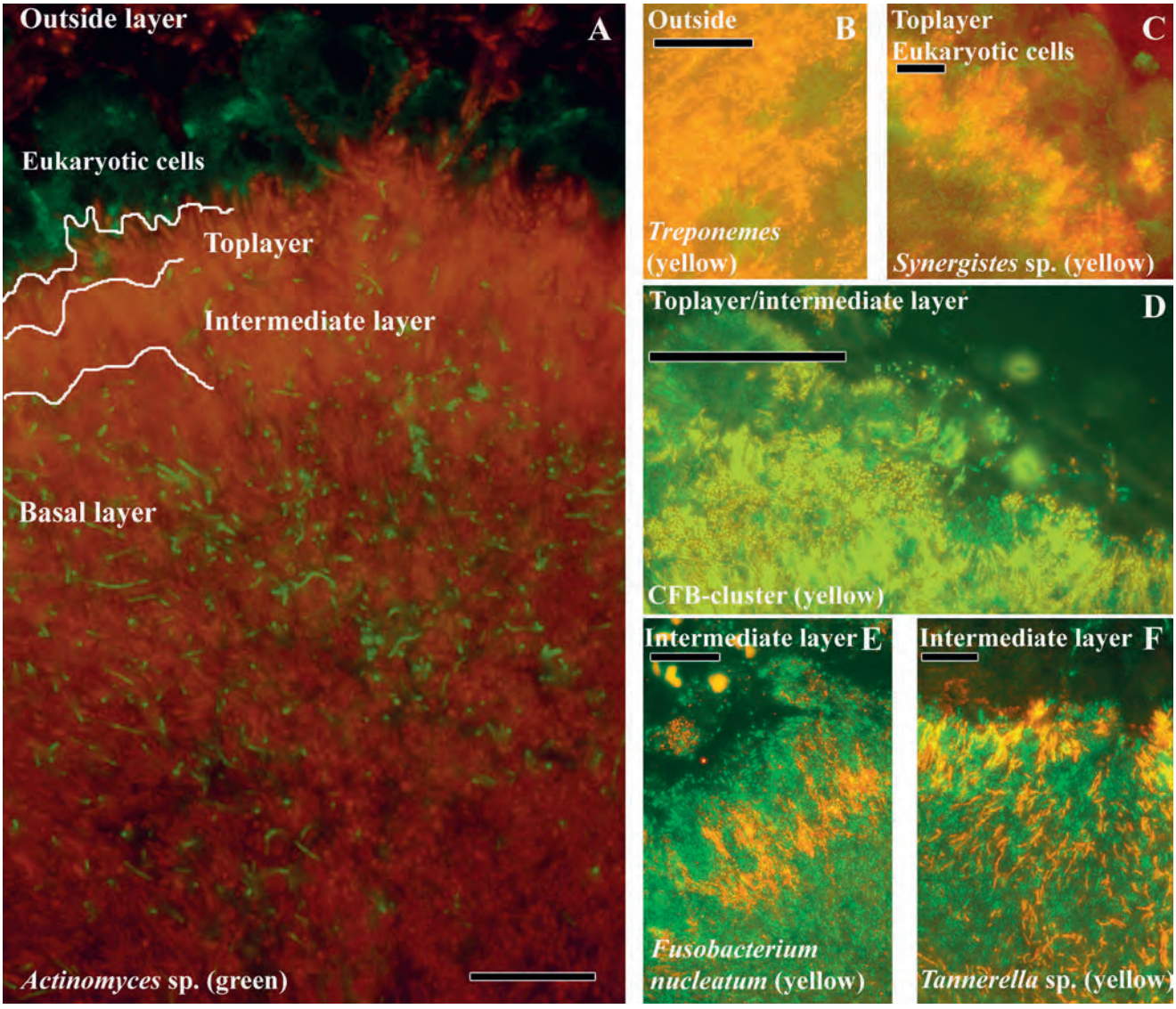

Figure 8-13 Localization of the most abundant species in subgingival biofilms. **A,** Overview of the subgingival biofilm with *Actinomyces* spp. (green bacteria), bacteria (red), and eukaryotic cells (large green cells on top). **B,** Spirochetes (yellow) outside of the biofilm. **C,** Detail of *Synergistetes* (yellow) in the top layer in close proximity to eukaryotic cells (green). **D,** Cytophaga-Flavobacterium-Bacteroides cluster (CFB-cluster) (yellow) in the top and intermediate layer. **E,** *F. nucleatum* in the intermediate layer. **F,** *Tannerella* spp. (yellow) in the intermediate layer. Each panel is double-stained with probe EUB338 labeled with FITC or Cy3. The yellow color results from the simultaneous staining with FITC- and Cy3-labeled probes. Bars = 10 µm.[437]

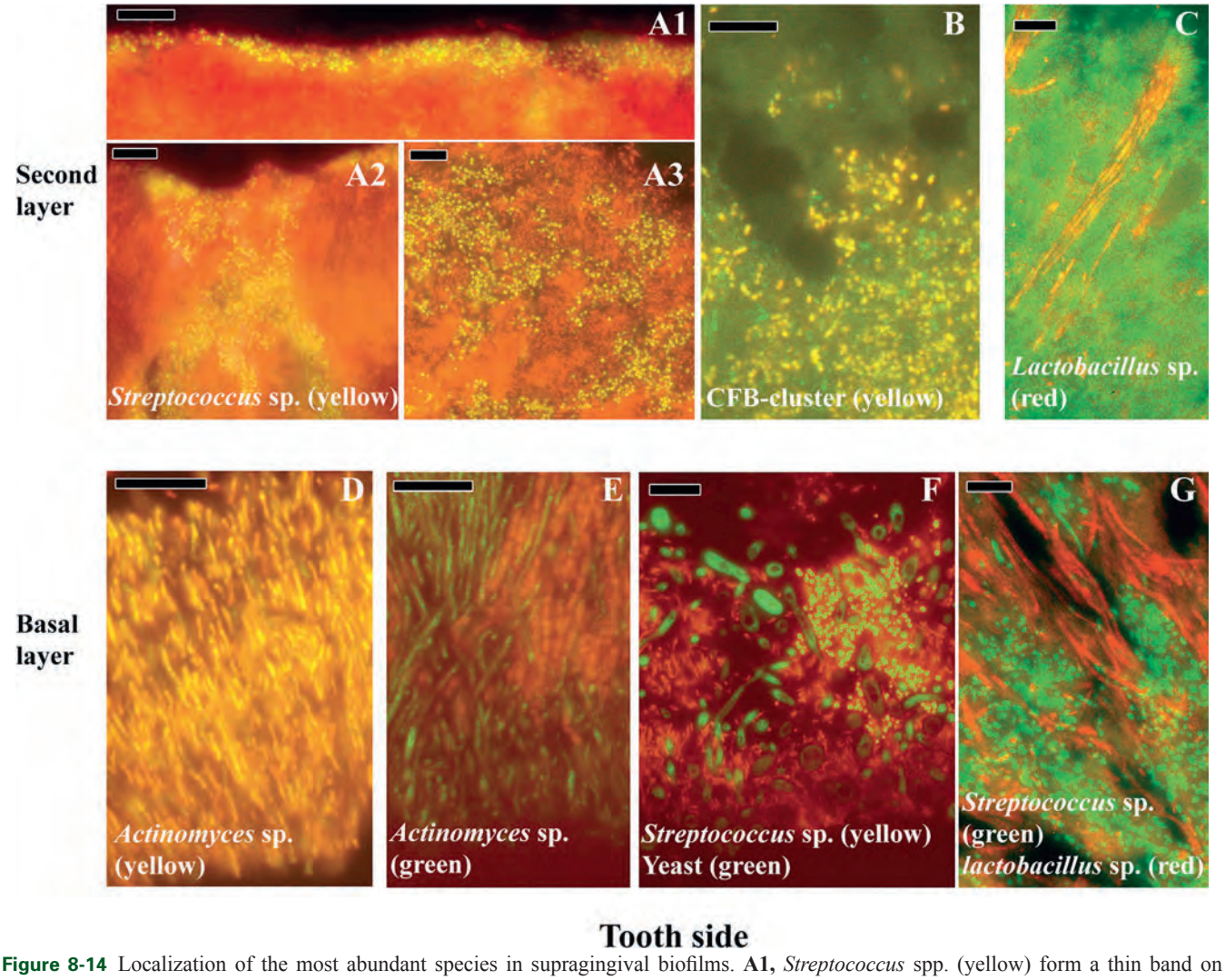

Figure 8-14 Localization of the most abundant species in supragingival biofilms. **A1,** *Streptococcus* spp. (yellow) form a thin band on top of the biofilm that **A2,** almost engulfs the biofilm or that **A3,** presents as small cells scattered throughout the top layer of the biofilm. **B,** Cells from the CFB cluster of bacteria in the top layer of the biofilm, without defined structure. **C,** *Lactobacillus* spp. (red) forming long strings through the top layer. **D,** *Actinomyces* spp. (yellow) plaque attached to the tooth. **E,** *Actinomyces* spp. (green) and cocci forming initial plaque. **F,** Multispecies initial plaque composed of *Streptococcus* spp. (yellow), yeast cells (green), and unidentified bacteria (red). **G,** *Streptococcus* spp. (green) and *Lactobacillus* spp. (red) forming initial plaque. The black holes may be channels through the biofilm. Panels **A, B, C, E,** and **F** are double stained with probe EUB338 labeled with FITC or Cy3. Bars = 10 µm.[437]

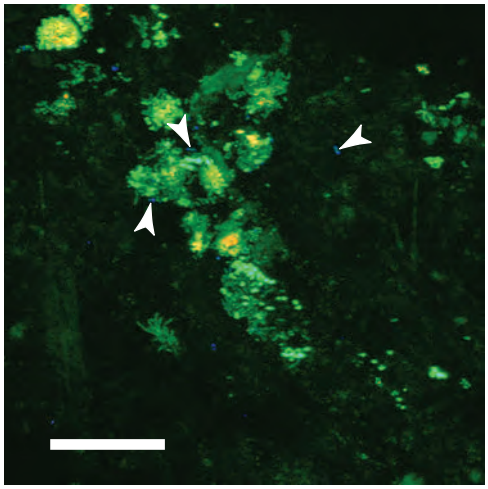

Figure 8-15 The visualization of specific bacteria in dental plaque biofilms with the use of specific antisera. Biofilms were developed on the surface of enamel chips held in the mouths of volunteers for 8 hours. Samples were labeled with acridine orange (stains all bacteria green), antibodies against streptococcal cell surface polysaccharides (orange), and antibodies against *Actinomyces oris* type 1 fimbriae (blue). *A. oris* cells (some indicated by *white arrowheads*) and polysaccharide-bearing streptococci can be seen in juxtaposition with other bacteria, which indicates that mixed-species interactions are common in dental plaque biofilms. Bar = 20 μm. *(Courtesy R. J. Palmer, Jr, National Institute of Dental and Craniofacial Research, Bethesda, MD.)*

TABLE 8-3 Differences Between Tooth Deposits

Materia Alba	Dental Plaque	Calculus
• White cheeselike accumulation • Soft accumulation of salivary proteins, some bacteria, many desquamated epithelial cells, and occasional disintegrating food debris • Lacks an organized structure and is therefore not as complex as dental plaque • Easily displaced with a water spray	• Resilient clear to yellow-grayish substance • Primarily composed of bacteria in a matrix of salivary glycoproteins and extracellular polysaccharides • Considered to be a biofilm • Impossible to remove by rinsing or with the use of sprays	• Hard deposit that forms via the mineralization of dental plaque • Generally covered by a layer of unmineralized dental plaque

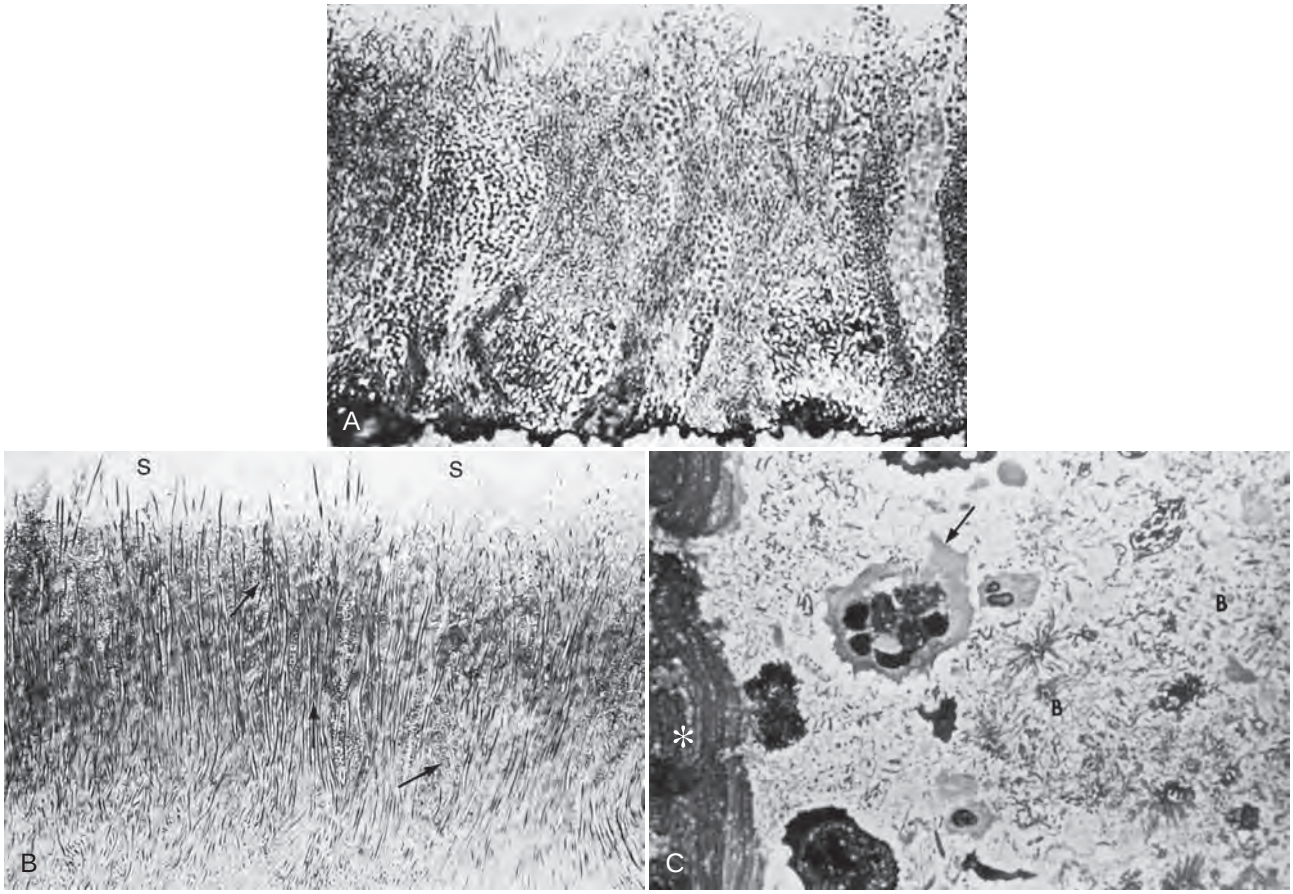

Figure 8-10 **A,** 1-day-old plaque. Microcolonies of plaque bacteria extend perpendicularly away from the tooth surfaces. **B,** Developed supragingival plaque showing the overall filamentous nature and the microcolonies *(arrows)* that extend perpendicularly away from the tooth surface. The saliva–plaque interface is shown *(S)*. **C,** A histologic section of plaque showing nonbacterial components such as white blood cells *(arrow)* and epithelial cells *(asterisk)* interspersed among bacteria *(B)*. *(Courtesy Dr. Max Listgarten, Philadelphia, PA.)*

The environmental parameters of the subgingival region differ from those of the supragingival region. The gingival crevice or pocket is bathed by the flow of crevicular fluid, which contains many substances that bacteria may use as nutrients. Host inflammatory cells and mediators are likely to have considerable influence on the establishment and growth of bacteria in the subgingival region. Both morphologic and microbiologic studies of subgingival plaque reveal distinctions between the tooth-associated regions and the soft-tissue–associated regions of subgingival plaque (see Figure 8-6, *A, B,* and *C*).[211,254]

The tooth-associated cervical plaque that adheres to the root cementum does not markedly differ from that observed in gingivitis. At this location, filamentous microorganisms dominate, but cocci and rods also occur. This plaque is dominated by gram-positive rods and cocci, including *S. mitis*, *S. sanguinis*, *Actinomyces oris*, *A. naeslundii*, and *Eubacterium* spp. (see Figure 8-1, *N*). However, in the deeper parts of the pocket, the filamentous organisms become fewer in number; in the apical portion, they seem to be virtually absent. Instead, the microbiota is dominated by smaller organisms without a particular orientation.[211] The apical border of the plaque mass is separated from the junctional epithelium by a layer of host leukocytes, and the bacterial population of this apical-tooth–associated region shows an increased concentration of gram-negative rods (see Figure 8-6, *D*).

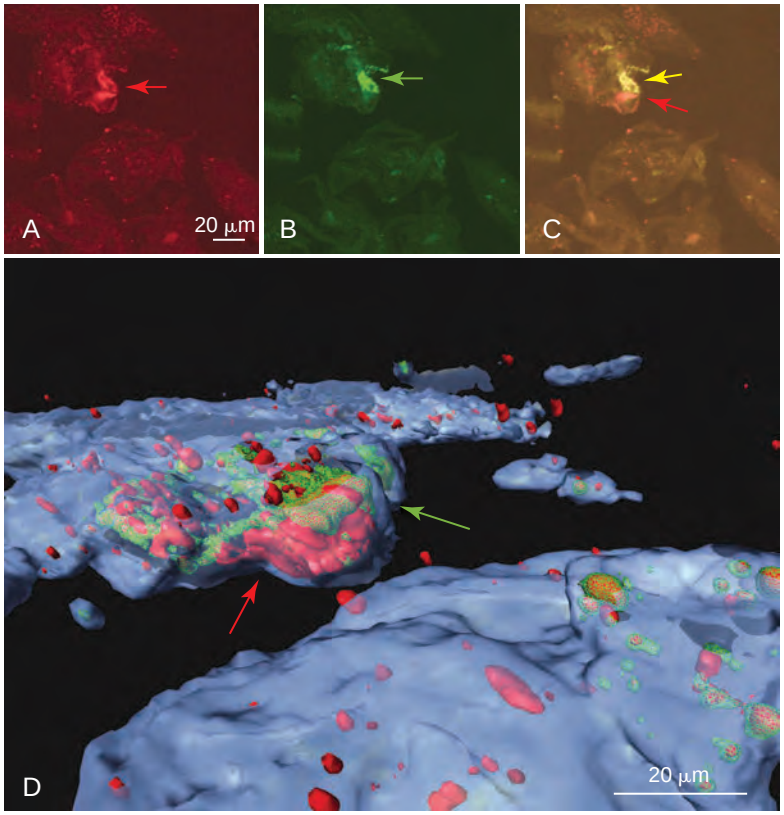

Figure 8-16 **A, B,** and **C** show images of z-section No. 39 from a stack of 74 0.2-μm z-sections (×600; the scale bar in **A** also applies to **B** and **C**). Buccal epithelial cells in this field were double-labeled with the *EUB338* universal probe **(A)** and with the *Aggregatibacter actinomycetemcomitans*–specific probe **(B).** The cell in the center of **A** contained a large mass of brightly fluorescent intracellular bacteria *(red arrow)*. Other cells in the field contained smaller bacterial masses (not marked). **B** shows that a portion of the large mass labeled with the universal probe also hybridized with the *A. actinomycetemcomitans*–specific probe *(green arrow)*. Images from **A** and **B** were superimposed in **C** to confirm that bacteria labeled with both probes *(yellow arrow)* were adjacent to other bacteria labeled only with the universal probe *(red arrow)*. **D,** A three-dimensional reconstruction of the same field. Bacteria recognized only by the universal probe are shown in solid red, whereas the colocalization of the *A. actinomycetemcomitans* and universal probes is depicted by a green wireframe over a red interior. Reconstructed buccal epithelial cell surfaces are presented in blue. The red and green colors are muted when bacterial masses are intracellular and brighter when bacteria appear to project out of the surface. The angle of view was rotated along the z-axis, and the image was zoomed. The large mass that appeared to have a lobular structure in z-section No. 39 was seen to be a cohesive unit that contained *A. actinomycetemcomitans* in direct proximity to other species *(red and green arrows)*. *(From Rudney JD, Chen R, Sedgewick GJ:* J Dent Res *84:59-63, 2005.)*

The layers of microorganisms that face the soft tissue lack a definite intermicrobial matrix and contain primarily gram-negative rods and cocci as well as large numbers of filaments, flagellated rods, and spirochetes. Studies of plaque associated with crevicular epithelial cells indicate a predominance of species such as *S. oralis, S. intermedius*, *Parvimonas micra* (formerly *Micromonas micra* and *Peptostreptococcus micros*), *P. gingivalis*, *P. intermedia*, *T. forsythia* (see Figure 8-10), and *F. nucleatum.*[77,82] Host-tissue cells (e.g., white blood cells, epithelial cells) may also be found in this region (see Figure 8-10, *C*). Bacteria are also found within the host tissues, such as in the soft tissues (see Figure 8-3), and within epithelial cells (Figure 8-16) as well as in the dentinal tubules (Figure 8-17).[326,327]

The composition of the subgingival plaque depends on the pocket depth. The apical part is more dominated by spirochetes, cocci, and rods, whereas in the coronal part more filaments are observed.

The site specificity of plaque is significantly associated with diseases of the periodontium. Marginal plaque, for example, is of prime importance during the initiation and development of gingivitis. Supragingival plaque and tooth-associated subgingival plaque



Figure 8-17 Scanning electron micrograph of bacteria within dentinal tubules.

are critical in calculus formation and root caries, whereas tissue-associated subgingival plaque is important in the tissue destruction that characterizes different forms of periodontitis. Biofilms also establish on artificial surfaces exposed to the oral environment, such as prostheses and implants. A large series of articles compared the microbiota in pockets around the teeth with those around implants of partially edentulous patients. The similarities were striking.*

Accumulation of a Dental Plaque Biofilm

The process of plaque formation can be divided into several phases: (1) the formation of the pellicle on the tooth surface; (2) the initial adhesion/attachment of bacteria; and (3) colonization/plaque maturation.

Formation of the Pellicle. All surfaces in the oral cavity, including the hard and soft tissues, are coated with a layer of organic material known as the *acquired pellicle.* The pellicle on tooth surfaces consists of more than 180 peptides, proteins, and glycoproteins, including keratins, mucins, proline-rich proteins, phosphoproteins (e.g., statherin), histidine-rich proteins, and other molecules that can function as adhesion sites (receptors) for bacteria.[347,348,429] The salivary pellicle can be detected on clean enamel surfaces within 1 minute after their introduction into the mouths of volunteers.[136] By 2 hours, the pellicle is essentially in equilibrium between adsorption and detachment, although further pellicle maturation can be observed for several hours.

Transmission electron microscopy shows the pellicle to be composed of two layers: a thin basal layer that is very difficult to remove, even with harsh chemical and mechanical treatments, and a thicker globular layer, up to 1 µm or more, that is easier to detach.[136,137] From these observations, it can be concluded that dental enamel is permanently covered with an acquired pellicle from the moment that teeth erupt.

Consequently, bacteria that adhere to tooth surfaces do not contact the enamel directly but interact with the acquired enamel pellicle. However, the pellicle is not merely a passive adhesion matrix. Many proteins retain enzymatic activity when they are incorporated into the pellicle, and some of these, such as peroxidases, lysozyme, and α-amylase, may affect the physiology and metabolism of adhering bacterial cells.[131,133-135]

In addition, a close ecological relationship between the pellicle and its associated microbiology seems to exist. Walker and coworkers reported that dental plaque samples will only produce in vitro biofilms if the surface on which they were grown contained a salivary pellicle belonging to the patient who donated the plaque sample. No biofilm could be grown on a pellicle that come from a different subject.[406]

Initial Adhesion/Attachment of Bacteria. Toothbrushing removes most but not all bacteria from the exposed surfaces of teeth.[393] However, recolonization begins immediately, and bacteria can be detected within 3 minutes of the introduction of sterile enamel into the mouth.[132]

The initial steps of transport and interaction with the surface are essentially nonspecific (i.e., they are the same for all bacteria). The proteins and carbohydrates that are exposed on the bacterial cell surface become important when the bacteria are in loose contact with the acquired enamel pellicle. The specific interactions between microbial cell surface "adhesin" molecules and receptors in the salivary pellicle determine whether a bacterial cell will remain associated with the surface. Only a relatively small proportion of oral bacteria possess adhesins that interact with receptors in the host pellicle, and these organisms are generally the most abundant bacteria in biofilms on tooth enamel shortly after cleaning. Over the first 4 to 8 hours, 60% to 80% of bacteria present are members of the genus *Streptococcus*.[78,259] Other bacteria that commonly present at this time include species that cannot survive without oxygen (obligate aerobes), such as *Haemophilus* spp. and *Neisseria* spp. as well as organisms that can grow in the presence or absence of oxygen (facultative anaerobes), including *Actinomyces* spp. and *Veillonella* spp.[1,75] These species are considered the "primary colonizers" of tooth surfaces. The primary colonizers provide new binding sites for adhesion by other oral bacteria. The metabolic activity of the primary colonizers modifies the local microenvironment in ways that can influence the ability of other bacteria to survive in the dental plaque biofilm. For example, by removing oxygen, the primary colonizers provide conditions of low oxygen tension that permit the survival and growth of obligate anaerobes.

The initial steps in colonization of teeth by bacteria occurs in three phases. Phase 1 is transport to the surface, phase 2 is initial adhesion, and phase 3 is strong attachment.

Colonization and Plaque Maturation. The primary colonizing bacteria (Table 8-4) adhered to the tooth surface provide new receptors for attachment by other bacteria as part of a process known as "coadhesion."[175] Together with the growth of adherent microorganisms, coadhesion leads to the development of microcolonies (Figure 8-18) and eventually to a mature biofilm.

Cell–cell adhesion between genetically distinct oral bacteria also occurs in the fluid phase (i.e., in saliva).

In the laboratory, interactions between genetically distinct cells in suspension result in clumps or "coaggregates" that are macroscopically visible (Figure 8-19).

Different species—or even different strains of a single species—have distinct sets of coaggregation partners (see Figure 8-20 online). Fusobacteria coaggregate with all other human oral bacteria, whereas *Veillonella* spp., *Capnocytophaga* spp. (see Figure 8-1, *Q*) and *Prevotella* spp. bind with streptococci and/or actinomyces.[174,176,418] Each newly accreted cell becomes itself a new surface and therefore may act as a coaggregation bridge to the next potentially accreting cell type that passes by.

Many coaggregations between strains of different genera are mediated by lectin like adhesins (proteins that recognize carbohydrates) and can be inhibited by lactose and other galactosides or by amino acids such as L-arginine. The significance of coaggregation in oral colonization has been documented in studies of biofilm formation in vitro as well as in animal model studies.[32,236]

Well-characterized interactions of secondary colonizers (see Table 8-4) with early colonizers include the coaggregation of *F. nucleatum* with *S. sanguinis, Prevotella loescheii* with *A. oris,* and *Capnocytophaga ochracea* with *A. oris.*[162,164,413-415] Streptococci show intrageneric coaggregation, which allows them to bind to the nascent monolayer of already bound streptococci.[148,171,260,349]

Secondary colonizers (see Table 8-4) such as *P. intermedia, Prevotella loescheii, Capnocytophaga* spp., *F. nucleatum,* and *P. gingivalis* do not initially colonize clean tooth surfaces but rather adhere to bacteria that are already in the plaque mass.[174] The transition from early supragingival dental plaque to mature plaque growing below the gingival margin involves a shift in the microbial population from primarily gram-positive organisms to high numbers of gram-negative bacteria. Therefore, during the later

*References 13, 151, 152, 166, 168, 201, 205, 237, 247, 268, 297, 334

Phase 1: Transport to the Surface. The first stage involves the initial transport of the bacterium to the tooth surface. Random contacts may occur, for example, through Brownian motion (average displacement, 40 µm/hour), through sedimentation of microorganisms, through liquid flow (several orders of magnitude faster than diffusion), or through active bacterial movement (chemotactic activity). It should be noted, however, that relatively few oral bacteria are motile, and forces such as saliva flow or mechanical contact between oral soft tissues and teeth are almost certainly more important than swimming for bringing the primary colonizing bacteria into contact with teeth.

Phase 2: Initial Adhesion. The second stage results in an initial reversible adhesion of the bacterium. This is initiated when the bacterial cell comes into close proximity to the surface (separation distance, ≈50 nm). Long- and short-range forces, including van der Waals attractive forces and electrostatic repulsive forces, operate at this distance. The behavior of bacterial cells can be reasonably described by the Derjaguin–Landau–Verwey–Overbeek theory of colloid stability.[141] According to this theory, the total interaction energy (also called the *total Gibbs energy* [G_{TOT}]), is the sum of the attractive forces (G_A) and the electrostatic repulsion (G_R). At the physiologic ionic strength of saliva, the van der Waals forces result in a net attraction of bacterial cells at distances of tens of nanometers from the surface. Approximately 10 nm from the surface, there is a secondary net energy minimum. Electrostatic repulsion prevents bacterial cells from getting even closer to the surface. At distances of approximately 10 nm from the surface, bacterial cells are reversibly bound. It is thought that stronger binding at this point is the consequence of interactions between bacterial adhesins and receptors in the salivary pellicle. It has been estimated that 10 to 50 ligand-receptor interactions are required to attain essentially irreversible binding of a bacterial cell to the pellicle.[44]

It is important to note that, although the Derjaguin-Landau-Verwey-Overbeek theory presents a neat picture of the initial stages of bacterial adhesion, in reality even these early steps in adhesion are extremely complex. Bacteria are not perfect spheres, and many cells possess structures, such as fimbriae, that protrude from the cell surface. Lewis acid-base interactions (hydrophobicity) also influence cell-surface interactions.[141] In addition, microbial cell surfaces are not uniformly coated with a negative charge. There may be regions of the cell surface that are positively charged, and, for these areas, electrostatic interactions with a negatively charged surface will tend to be attractive. Therefore, it is difficult to predict how initial attachment will be affected by modifying the prevailing environment.

Phase 3: Strong Attachment. After initial adhesion, a firm anchorage between the bacterium and the surface is established. On a rough surface, bacteria are more protected against shear forces so that a change from reversible to irreversible binding may occur more easily and more frequently. The substratum surface free energy becomes important, because the water film between the interacting surfaces has to be removed before short-range forces can be involved. The binding between the bacteria and the pellicle is mediated by specific adhesins on the bacterial cell surface (usually proteins) and complementary receptors (proteins, glycoproteins, or polysaccharides) in the acquired pellicle. Many proteins in the acquired pellicle can act as receptors for streptococci, including α-amylase, acid proline-rich proteins, statherin, and salivary agglutinin glycoprotein gp340.[335] The specific adhesins of primary colonizing bacteria have been the subject of many investigations, because these represent potential targets for interference with the formation of dental plaque. One of the best-characterized interactions is the binding between the antigen I/II family adhesins of oral streptococci and gp340.[159,160,285] Antigen I/II family adhesins are 160-kDa to 180-kDa proteins expressed on the surfaces of many oral streptococci, including *S. mutans, S. sobrinus* (see Figure 8-1, *P*), *S. gordonii,* and *S. intermedius.* Gp340 is present in fluid-phase saliva, and it is a component of the salivary pellicle. In the fluid phase, interactions between antigen I/II proteins and gp340 result in the aggregation of bacteria. Large clumps of bacterial cells do not stick well to surfaces, and they are probably removed by swallowing.[209] By contrast, bacterial binding to immobilized gp340 results in the retention of cells within the biofilm. Interestingly, the recognition of fluid-phase and immobilized gp340 by streptococci appears to involve different mechanisms.[224] It is likely that gp340 changes its conformation after adhesion to a surface and thus exposes different receptors for bacterial binding. Similar conformational changes have been noted for a number of host proteins, including proline-rich proteins and statherin.[89,112] The selective binding of fluid-phase or surface-bound proteins may modulate the ability of bacterial cells to colonize salivary pellicle-coated surfaces.

Coaggregation is a direct interaction; it is distinct from agglutination, which occurs when cells are stuck together by molecules in solution. At least 18 genera from the oral cavity have shown some form of coaggregation.[173] All oral bacteria possess surface molecules that foster some sort of cell–cell interaction (Figure 8-20).[174] The initial stages of coaggregation or coadhesion are essentially the same as the first steps involved in bacterial binding to surfaces: bacterial cells come into contact through passive or active transport and bind weakly through nonspecific hydrophobic, electrostatic, and van der Waals forces.[80,97,169,174] These steps can be dramatically accelerated in vitro by vigorously mixing dense suspensions of bacterial cells.[175] Strong cell–cell binding is then determined by the presence of adhesin proteins or carbohydrates on one partner and complementary receptor proteins or carbohydrates on the other. Note that adhesin–receptor interactions are mediated by the fundamental physicochemical forces (i.e., hydrophobic, electrostatic, and van der Waals), but they are highly specific.

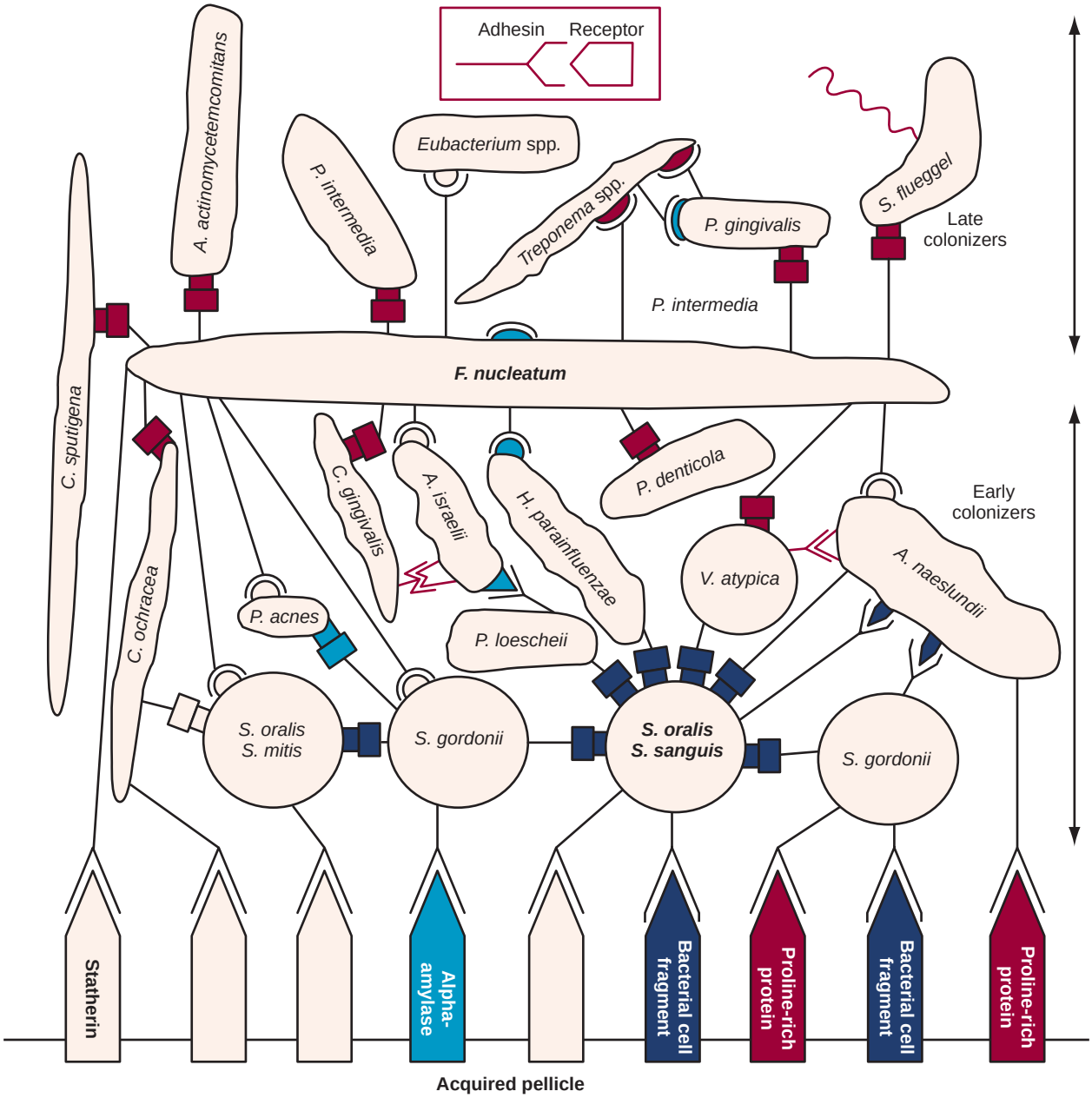

Figure 8-20 Diagrammatic representation of initial plaque formation. Early colonizers bind to receptors in the pellicle. Each adherent cell becomes in turn the nascent surface and bridge for additional species (secondary colonizers). The complementary sets of adhesin receptor symbols (example in box) represent the various kinds of coaggregations as well as the interactions with molecules in the pellicle. The symbol with a stem (adhesin) represents a cellular component that is heat inactivated (cell suspension heated to 85°C for 30 minutes) and sensitive to protease treatment. The cell type that exhibits the complementary symbol (receptor) is insensitive to either treatment. The symbols with a rectangular shape represent lactose-inhibitable coaggregations; the others are lactose-noninhibitable. *(Adapted from Kolenbrander PE, London J:* J Bacteriol *175:3247, 1993.)*

TABLE 8-4 Overview of Primary and Secondary Colonizers in Dental Plaque

Primary colonizers	*Streptococcus gordonii*
	Streptococcus intermedius
	Streptococcus mitis
	Streptococcus oralis
	Streptococcus sanguinis
	Actinomyces gerencseriae
	Actinomyces israelii
	Actinomyces naeslundii
	Actinomyces oris
	Aggregatibacter actinomycetemcomitans serotype a
	Capnocytophaga gingivalis
	Capnocytophaga ochracea
	Capnocytophaga sputigena
	Eikenella corrodens
	Actinomyces odontolyticus
	Veillonella parvula
Secondary colonizers	*Campylobacter gracilis*
	Campylobacter rectus
	Campylobacter showae
	Eubacterium nodatum
	Aggregatibacter actinomycetemcomitans serotype b
	Fusobacterium nucleatum spp *nucleatum*
	Fusobacterium nucleatum spp *vincentii*
	Fusobacterium nucleatum spp *polymorphum*
	Fusobacterium periodonticum
	Parvimonas micra
	Prevotella intermedia
	Prevotella loescheii
	Prevotella nigrescens
	Streptococcus constellatus
	Tannerella forsythia
	Porphyromonas gingivalis
	Treponema denticola

stages of plaque formation, coaggregation between different gram-negative species is likely to predominate. Examples of these types of interactions are the coaggregation of *F. nucleatum* with *P. gingivalis* or *Treponema denticola* (see Figure 8-1, *L*).[165,170,176]

Factors That Affect Supragingival Dental Plaque Formation

Clinically, early undisturbed plaque formation on teeth follows an exponential growth curve when measured planimetrically.[298] During the first 24 hours when starting with a clean tooth surface, plaque growth is negligible from a clinical viewpoint (i.e., <3% coverage of the vestibular tooth surface, which is an amount nearly undetectable clinically). This "lag time" is a result of the fact that the microbial population must reach a certain size before it can easily be detected by a clinician. During the following 3 days, coverage progresses rapidly to the point at which, after 4 days, an average of 30% of the total coronal tooth area will be covered with plaque (see Video 8-1: Plaque Growth).

Several reports have shown that the microbial composition of the dental plaque will change, with a shift toward a more anaerobic and a more gram-negative flora, including an influx of fusobacteria, filaments, spiral forms, and spirochetes (Figure 8-23). This was clearly illustrated in experimental gingivitis studies.[376,387] With this ecologic shift within the biofilm, there is a transition from the early aerobic environment, which is characterized by gram-positive facultative species, to a highly oxygen-deprived environment, in which gram-negative anaerobic microorganisms predominate. Bacterial growth in older plaque is much slower than in newly formed dental plaque, presumably because nutrients become limiting for much of the plaque biomass.[412]

Topography of Supragingival Plaque. Early plaque formation on teeth follows a typical topographic pattern (Figure 8-24), with initial growth along the gingival margin and from the interdental spaces (i.e., the areas protected from shear forces). Later, a further extension in the coronal direction can be observed.[241,302] This pattern may change severely when the tooth surface contains irregularities that offer a favorable growth path (Figure 8-25). Plaque formation may also originate from grooves,

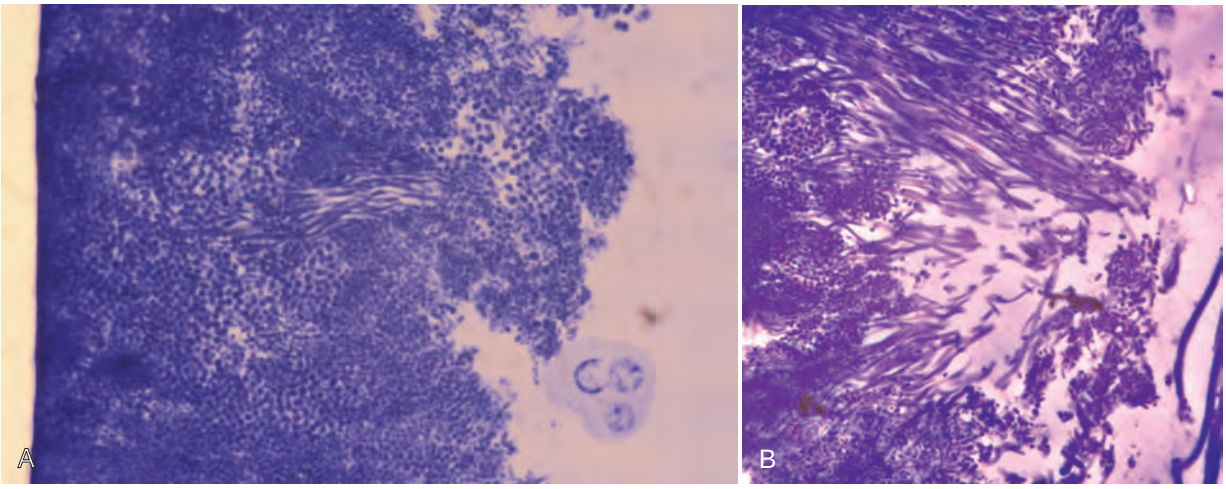

Figure 8-18 When a single microorganism adheres to the tooth surface, it can start to multiply, and it slowly forms a microcolony of daughter cells. These views were taken after plaque formation on a plastic strip (e.g., as shown in Figure 8-26) glued to a tooth surface.

The idea that coaggregation is important during the formation of oral biofilms opens new perspectives, especially for the use of probiotics. Special examples of coaggregations are the corncob formation (Figure 8-21), in which streptococci adhere to filaments of *Corynebacterium matruchotii* or *Actinomyces* spp., and the test-tube brush formation, composed of filamentous bacteria to which gram-negative rods adhere.[60,211,252]

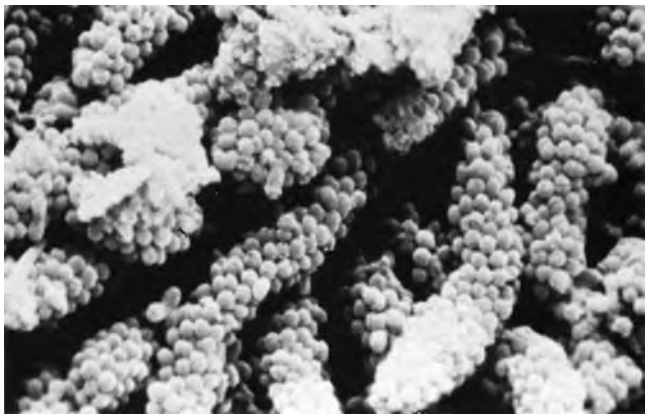

Figure 8-21 Long-standing supragingival plaque near the gingival margin demonstrates a "corn-cob" arrangement. A central gram-negative filamentous core supports the outer coccal cells, which are firmly attached by interbacterial adherence or coaggregation.

An analysis of more than 13,000 plaque samples that looked for 40 subgingival microorganisms using a DNA-hybridization methodology defined color-coded "complexes" of periodontal microorganisms that tend to be found together in health or disease. The composition of the different complexes was based on the frequency with which different clusters of microorganisms were recovered, and the complexes were color-coded for easy conceptualization (Figure 8-22).[365] Interestingly, the early colonizers are either independent of defined complexes *(A. naeslundii, A. oris)* or members of the yellow (*Streptococcus* spp.) or purple complexes *(A. odontolyticus)* (see Figure 8-1, *D*). The microorganisms primarily considered secondary colonizers fell into the green, orange, and red complexes. The green complex includes *Eikenella corrodens, A. actinomycetemcomitans* serotype a, and *Capnocytophaga* spp. The orange complex includes *Fusobacterium, Prevotella,* and *Campylobacter* spp. (see Figure 8-1, *R*). The green and orange complexes include species recognized as pathogens in periodontal and nonperiodontal infections. The red complex consists of *P. gingivalis, T. forsythia,* and *T. denticola.* This complex is of particular interest because it is associated with bleeding on probing.[365] The existence of complexes of species in plaque is another reflection of bacterial interdependency in the biofilm environment.

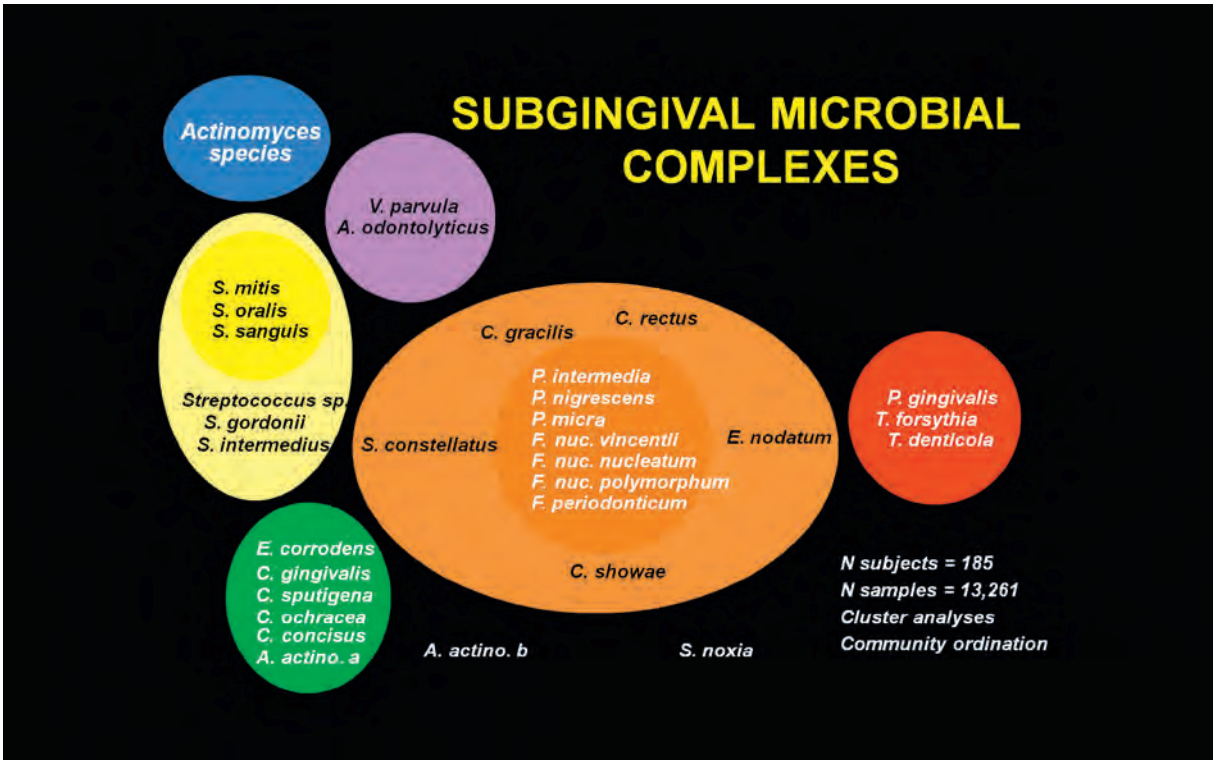

Figure 8-22 A diagram of the association among subgingival species The data were derived from 13,261 subgingival plaque samples taken from the mesial aspect of each tooth in 185 adult subjects. Each sample was individually analyzed for the presence of 40 subgingival species with the use of checkerboard DNA–DNA hybridization. Associations were sought among species via cluster analysis and community ordination techniques. The complexes to the left are comprised of species that are thought to colonize the tooth surface and to proliferate at an early stage. The orange complex becomes numerically dominant later; it is thought to bridge the early colonizers and the red complex species, which become numerically more dominant during the later stages of plaque development. *(Adapted from Socransky SS, Haffajee AD, Cugini MA, et al:* J Clin Periodontol *25:134, 1998.)*

Video 8-1: Plaque Growth This video shows undisturbed plaque formation on a central incisor after professional plaque removal over a period of 96 hours in the absence of oral hygiene. The plaque was visualized with erythrosin. After professional plaque removal, it takes—even in the absence of oral hygiene—at least 36 hours before plaque becomes detectable. Plaque first develops in irregularities on the tooth surface and at the gingival margin. Once established, the speed of plaque formation increases over time. Nevertheless, even in the absence of oral hygiene, no more than one fourth of the tooth surface is covered after 96 hours of undisturbed plaque growth.

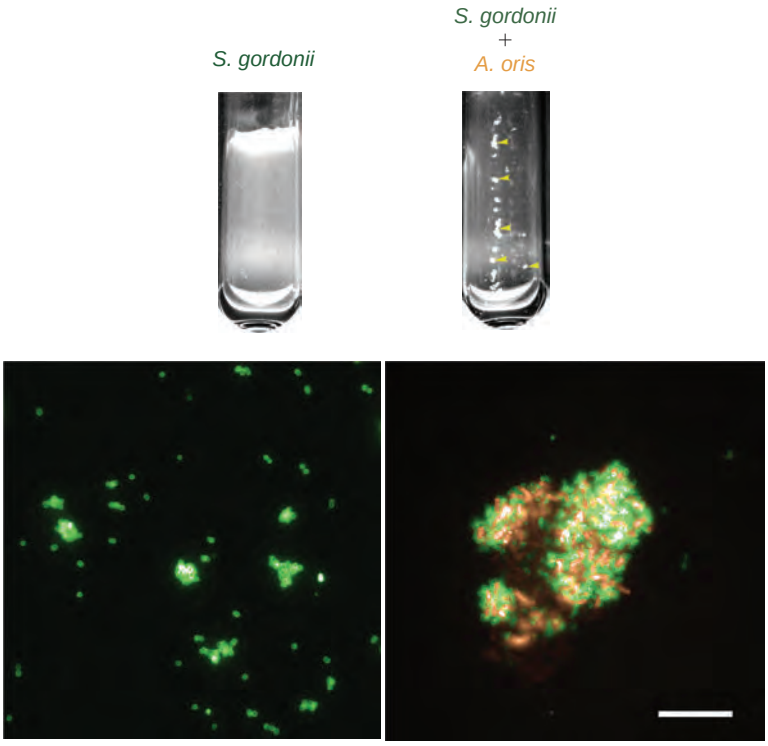

Figure 8-19 Coaggregation between *Streptococcus gordonii* DL1 and *Actinomyces oris* MG1 in vitro. A monoculture of *S. gordonii* appears uniformly turbid. Microscopically, cells labeled with specific anti-DL1 antibodies (green) are in small chains or clumps. After the addition of *A. oris,* cells clump together to form macroscopic coaggregates *(yellow arrows head).* Under the microscope, *S. gordonii* (green) are evenly distributed throughout the coaggregates with *A. oris* (orange). Bar = 20 µm. *(Image reproduced in part from Jakubovics NS, Gill SR, Iobst SE, et al:* J Bacteriol *190:3646, 2008.)*

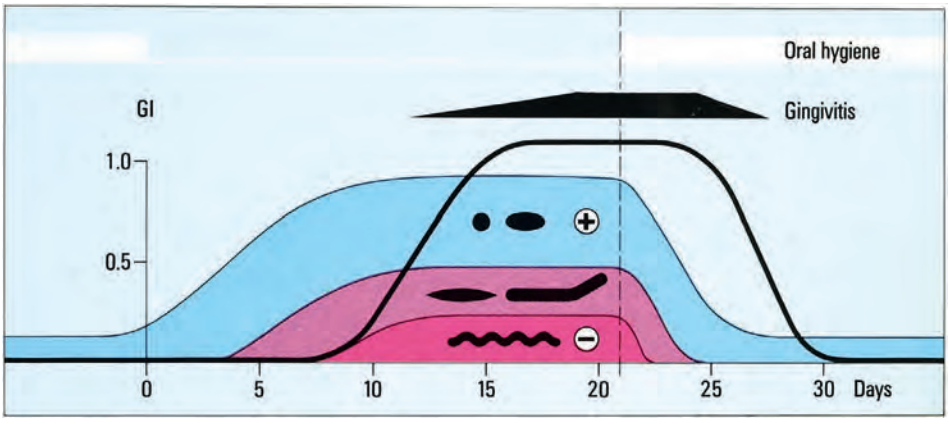

Figure 8-23 Artistic impression of the 1965 published classic experimental proof of the bacterial etiology of gingivitis using the experimental gingivitis model. In plaque-free subjects with clinically noninflamed gingiva, plaque will slowly develop on the teeth when all mechanical plaque control is stopped. With time, the plaque composition changes. During the first few days, the plaque is mainly composed of gram-positive (+) cocci and rods. Later on, the composition is shifted toward more gram-negative species and more rods and filaments; finally, gram-negative (–) spirochetes appear (see morphotypes in black). Within a few days, a mild gingivitis ensues (*black line;* gingival index of 1 according to Löe and Silness). From the moment that proper plaque control is reestablished *(vertical line)*, the plaque composition returns to the initial situation, and the symptoms of gingivitis disappear. *(From Löe H, Theilade E, Jensen SB: Experimental gingivitis in man,* J Periodontol *36:177, 1965.)*

cracks, perikymata, or pits. Scanning electron microscopy studies clearly revealed that the early colonization of the enamel surface starts from surface irregularities in which bacteria shelter from shear forces, thereby permitting them the time needed to change from reversible to irreversible binding.

By multiplication, the bacteria subsequently spread out from these starting up areas as a relatively even monolayer. Surface irregularities are also responsible for the so-called "individualized" plaque growth pattern (see Figure 8-25), which is reproduced in the absence of optimal oral hygiene.[241,242] This phenomenon

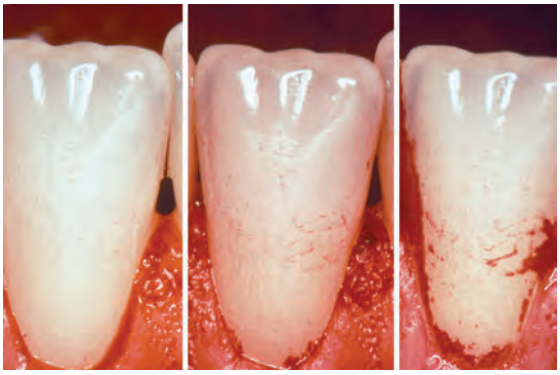

Figure 8-24 Clinical illustration of the typical topography of plaque growth. Initial growth starts along the gingival margins and from the interdental spaces (i.e., areas protected from shear forces) to further extend in a coronal direction. This pattern may fundamentally change, for example, if the tooth surface contains irregularities, such as those evident in Figure 8-25.

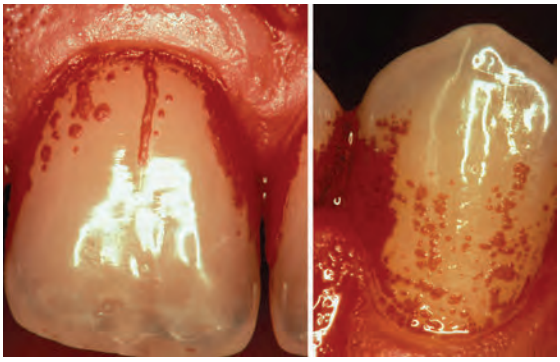

Figure 8-25 Important surface irregularities (i.e., a crack on the central upper incisor, several small pits on the canine) are also responsible for the so-called individualized plaque growth pattern.

illustrates the importance of surface roughness in plaque growth, which should lead to proper clinical treatment options.

Surface Microroughness. Rough intraoral surfaces (e.g., crown margins, implant abutments, denture bases) accumulate and retain more plaque and calculus in terms of thickness, area, and colony-forming units.[289] Ample plaque also reveals an increased maturity/pathogenicity of its bacterial components, which is characterized by an increased proportion of motile organisms and spirochetes and/or a denser packing of them (Figures 8-26 and 8-27). Smoothing an intraoral surface decreases the rate of plaque formation. Below a certain surface roughness ($R_a < 0.2$ µm), however, further smoothing does not result in an additional reduction in plaque formation.[28,291] There seems to be a threshold level for surface roughness ($R_a \approx 0.2$ µm) above which bacterial adhesion will be facilitated.[27] Although surface free energy and surface roughness are two factors that influence plaque growth, the latter predominates (see Figures 8-26 and 8-27).

Individual Variables That Influence Plaque Formation. The rate of plaque formation differs significantly between subjects, and these differences may overrule surface characteristics. A distinction is often made between "heavy" (fast) and "light" (slow) plaque formers (see Video 8-2: Difference in Plaque Growth Between Heavy and Light Plaque Formers).

A multiple regression analysis showed that the clinical wettability of the tooth surfaces, the saliva-induced aggregation of oral bacteria, and the relative salivary flow conditions around the sampled teeth explained 90% of the variation. Moreover, the saliva from light plaque formers reduced the colloidal stability of bacterial suspensions of, for example, *S. sanguinis*.[345]

In a study by Zee and colleagues, de novo plaque formation was followed on small enamel blocks that were bonded onto the teeth of slow and heavy plaque formers.[435] After 1 day, the heavy plaque formers showed more plaque with a more complex

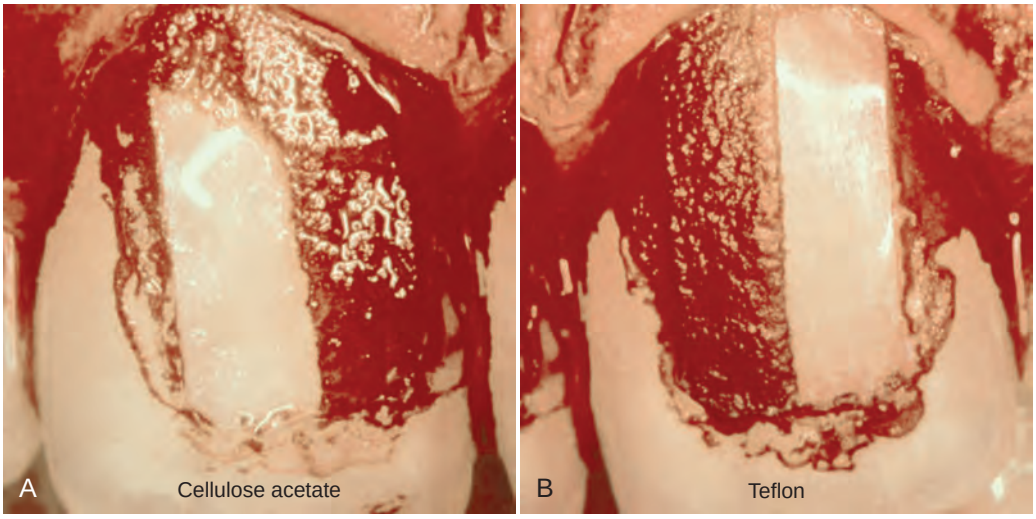

Figure 8-26 Photographs showing the clinical impact of surface roughness and surface free energy on de novo plaque formation. Two small strips were glued to the central upper incisors of a patient who refrained from oral hygiene for 3 days. Each strip was divided in two halves: a rough region (R_a 2.0 µm) located mesially and a smooth region (R_a 0.1 µm) located distally. The left strip was cellulose acetate (medium surface free energy [sfe]: 58 $ergcm^{-2}$), and the right strip was Teflon (low sfe: 20 $ergcm^{-2}$). Plaque was disclosed with 0.5% neutral red solution. The smooth regions show the decrease in biofilm formation because of the low sfe; the rough regions demonstrate the predominance of surface roughness (i.e., more plaque with no difference between the two surfaces), even with different sfe. *(From Quirynen M, Listgarten MA:* Clin Oral Implants Res *1:8, 1990.)*

Video 8-2: Difference in Plaque Growth Between Heavy and Light Plaque Formers This video shows undisturbed plaque formation after professional plaque removal over a period of 96 hours in the absence of oral hygiene. The left pane shows the visible plaque formation in a heavy, fast plaque-forming patient. The right pane shows the same process in a light, slow plaque-forming patient. Clear differences between patients are noted in the amount of plaque formed after 96 hours.

Simonsson and coworkers selected a group of heavy plaque formers and a group of light plaque formers.[346] Both groups were investigated for clinical, biochemical, biophysical, and microbiologic variables. In a comparative analysis, there were only minor differences between the groups, and no single variable was considered as the only explanation for the great differences in their rates of plaque formation.

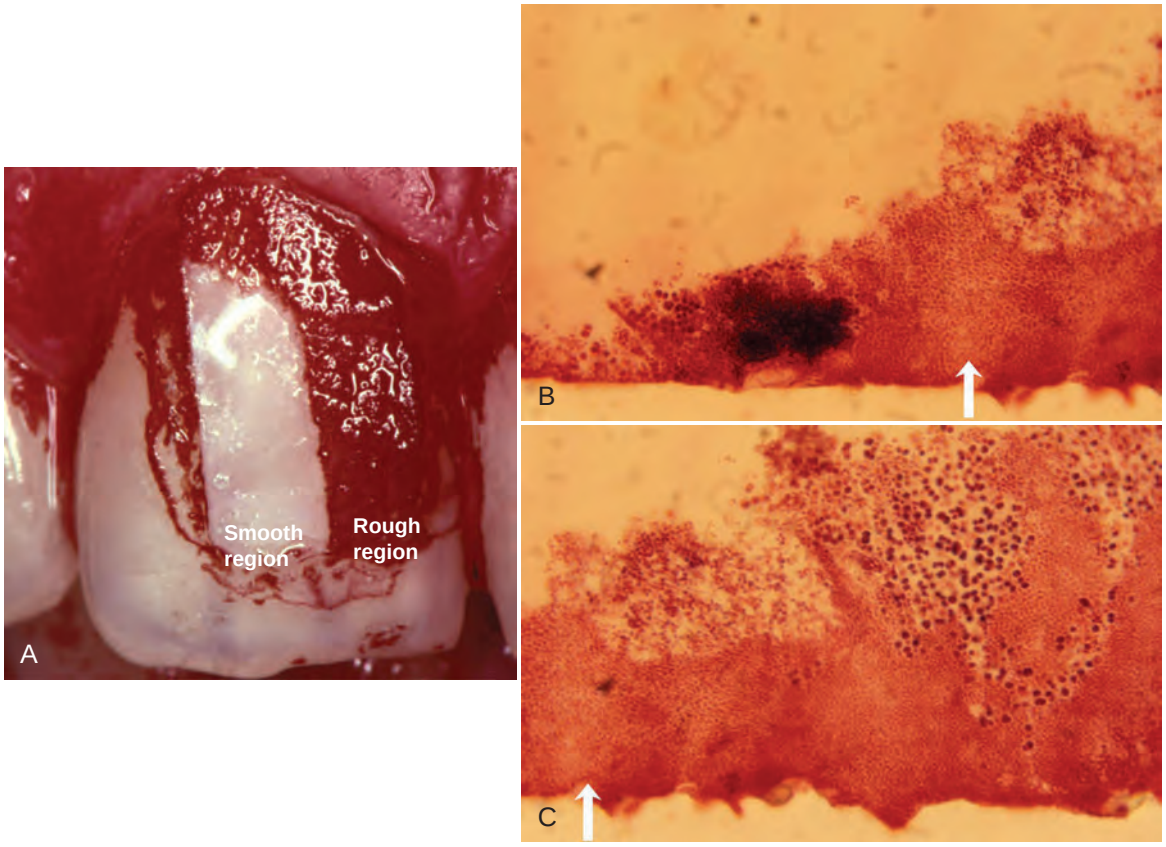

Figure 8-27 **A,** A small plastic strip, divided in half (a rough region [R_a 2.0 µm] located mesially and a smooth region [R_a 0.1 µm] located distally), had been glued to the central upper incisors of a patient who refrained from oral hygiene for 3 days. **B** and **C,** After removal, the strip had been cut into small slices for microscopic evaluation. It is obvious that the rough part **(C)** contains a thicker plaque layer than the smooth part **(B).** The *arrow* shows the border between the rough and smooth surfaces.

supragingival structure. However, from days 3 to 14, there were no discernible differences between both groups, except for a more prominent intermicrobial matrix in the group of fast growers. In another study by the same group of investigators, qualitative differences in the composition of the plaque between slow and rapid plaque formers were detected.[434] Rapid plaque formers demonstrated higher proportions of gram-negative rods (35% versus 17%) in 14-day-old plaque. The intersubject variation in plaque formation can also be explained by factors such as diet, chewing fibrous food, smoking, the presence of copper amalgam, tongue and palate brushing, the colloid stability of bacteria in the saliva, antimicrobial factors present in the saliva, the chemical composition of the pellicle, and the retention depth of the dentogingival area.[3,6,16,153,157,343,345,346]

Variation Within the Dentition. Within a dental arch, large differences in plaque growth rate can be detected. In general, early plaque formation occurs faster: in the lower jaw (as compared with the upper jaw); in molar areas; on the buccal tooth surfaces (as compared with palatal sites, especially in the upper jaw); and in the interdental regions (as compared with the buccal or lingual surfaces).[104,196,288]

Impact of Gingival Inflammation and Saliva. Several studies clearly indicate that early in vivo plaque formation is more rapid on tooth surfaces facing inflamed gingival margins than on those adjacent to healthy gingivae.[294,306,307] These studies suggest that the increase in crevicular fluid production enhances plaque formation. Probably some substances from this exudate (e.g., minerals, proteins, carbohydrates) favor both the initial adhesion and/or the growth of the early colonizing bacteria. In addition, it is known that, during the night, the plaque growth rate is reduced by some 50%.[302] This seems surprising, because one would expect that reduced plaque removal and the decreased salivary flow at night would enhance plaque growth. The fact that the supragingival plaque obtains its nutrients mainly from the saliva appears to be of greater significance than the antibacterial activity of saliva.[47]

Impact of Patient's Age. Although older studies were contradictory, more recent papers clearly indicate that a subject's age does not influence de novo plaque formation. In a study by Fransson and colleagues,[100] no differences could be detected in de novo plaque formation between a group of young (20 to 25 years old) patients and a group of older (65 to 80 years old) subjects who abolished mechanical tooth cleaning measures for 21 days, neither in amount nor in composition.[100] This observation largely confirms data by Holm-Pedersen and colleagues[147] and data by Winkel and coworkers.[422] However, the developed plaque in the older patient group resulted in more severe gingival inflammation, which seems to indicate an increased susceptibility to gingivitis with aging.

Spontaneous Tooth Cleaning. Many clinicians still think that plaque is removed spontaneously from the teeth, such as during eating. However, on the basis of the firm attachment between the bacteria and the surface, this seems unlikely. Even in the occlusal surfaces of the molars, plaque remains, even after chewing

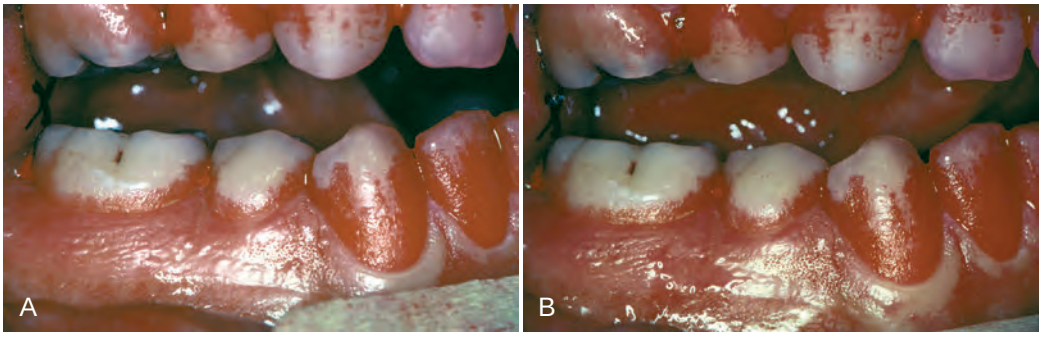

Figure 8-28 Lower premolars and molars from a dental student who refrained from oral hygiene for 100 hours to evaluate undisturbed plaque formation. **A,** Before dinner. **B,** After dinner, which included fibrous foods. Nearly no reduction in plaque extension could be observed, thereby illustrating the absence of spontaneous plaque removal.

fibrous food (e.g., carrots, apples, chips). The inefficiency of the spontaneous plaque removal is neatly illustrated by the clinical pictures in Figure 8-28, which were taken before and after dinner starting from 4 days of undisturbed plaque formation. Only negligible differences in plaque extent could be observed.

De Novo Subgingival Plaque Formation

It is technically impossible to record the dynamics of subgingival plaque formation in an established dentition for the simple reason that one cannot sterilize a periodontal pocket. Some early studies involving the use of culturing techniques examined the changes within the subgingival microbiota during the first week after mechanical debridement and reported an only partial reduction of around 3 logs (from 10^8 bacterial cells to 10^5 cells) followed by rapid regrowth toward nearly pretreatment levels (–0.5 log) within 7 days.[113,138,230] The fast recolonization was explained by several factors. A critical review of the effectiveness of subgingival debridement, for instance, revealed that a high proportion of treated tooth surfaces (5% to 80%) still harbored plaque and/or calculus after scaling. These remaining bacteria were considered the primary source for the subgingival recolonization.[278] Some pathogens penetrate the soft tissues or the dentinal tubules and eventually escape instrumentation (see Figure 8-17).[5,110,320] In a beagle dog study, Leknes and colleagues[204] studied the extent of subgingival colonization in 6-mm pockets with smooth or rough root surfaces. They also observed that smooth surfaces harbored significantly less plaque and concluded that subgingival irregularities shelter submerged microorganisms. Moreover, biopsies of the soft tissues showed an elevated proportion of inflammatory cells in the junctional epithelium (and the underlying connective tissue) facing the rough surfaces.[203] Finally, the same group reported higher rates of attachment loss around teeth with grooves in the root surface.[202]

The introduction of oral implants, especially of the two-stage type, provided a new experimental setup. When the transmucosal part of the implant (the abutment) is inserted on top of the osseointegrated endosseous part, a new "pristine" surface is created on which the intraoral translocation of bacteria can be investigated.[291] It has been demonstrated that a complex subgingival microbiota, including most periodontopathogens, is established within 1 week after abutment insertion. This is followed by a slow increase in the number of periodontopathogens.[103,303,304] Oral implants have also been used as a model to study the impact of surface roughness on subgingival plaque formation.[28,43,119,291,301,316] Smooth abutments (R_a < 0.2 μm) were found to harbor 25 times fewer bacteria than rough ones, with a slightly higher density of coccoid (i.e., nonpathogenic) cells. The subgingival microbiota was also largely dependent on the remaining presence of teeth and the degree of periodontitis in the remaining natural dentition (for a review, see Reference 293). These observations highlight the importance of intraoral bacterial translocation for subgingival biofilms.

Characteristics of Biofilm Bacteria (Life in "Slime City")

Metabolism of Dental Plaque Bacteria

The majority of nutrients for dental plaque bacteria originate from saliva or gingival crevicular fluid, although the host diet provides an occasional but nevertheless important food supply. The transition from gram-positive to gram-negative microorganisms observed in the structural development of dental plaque is paralleled by a physiologic transition in the developing plaque.

The early colonizers (e.g., *Streptococcus* and *Actinomyces* spp.) use oxygen and lower the redox potential of the environment, which then favors the growth of anaerobic species.[76,405] Many of the gram-positive early colonizers use sugars as an energy source. The bacteria that predominate in mature plaque are anaerobic and asaccharolytic (i.e., they do not break down sugars), and they use amino acids and small peptides as energy sources.[220]

Laboratory studies have demonstrated many metabolic interactions among the different bacteria found in dental plaque (Figure 8-29). For example, lactate and formate are byproducts of the metabolism of streptococci and *Actinomyces* spp.; they may be used in the metabolism of other plaque microorganisms, including *Veillonella* spp. and *A. actinomycetemcomitans*.[42,87]

The growth of *P. gingivalis* is enhanced by metabolic byproducts produced by other microorganisms, such as succinate from *C. ochracea* and protoheme from *Campylobacter rectus* (see Figure 8-1, *R*).[115,116,235] Overall, the total plaque population is more efficient than any one constituent organism at releasing energy from the available substrates.[419]

Metabolic interactions also occur between the host and the plaque microorganisms.

The bacterial enzymes that degrade host proteins mediate the release of ammonia, which may be used by bacteria as a nitrogen source.[48] Hemin iron from the breakdown of host hemoglobin may be important in the metabolism of *P. gingivalis*.[34]

Increases in steroid hormones are associated with significant increases in the proportions of *P. intermedia* found in subgingival plaque.[181] These nutritional interdependencies are probably critical to the growth and survival of microorganisms in dental plaque, and they may partly explain the evolution of the highly specific structural interactions observed among bacteria in plaque.

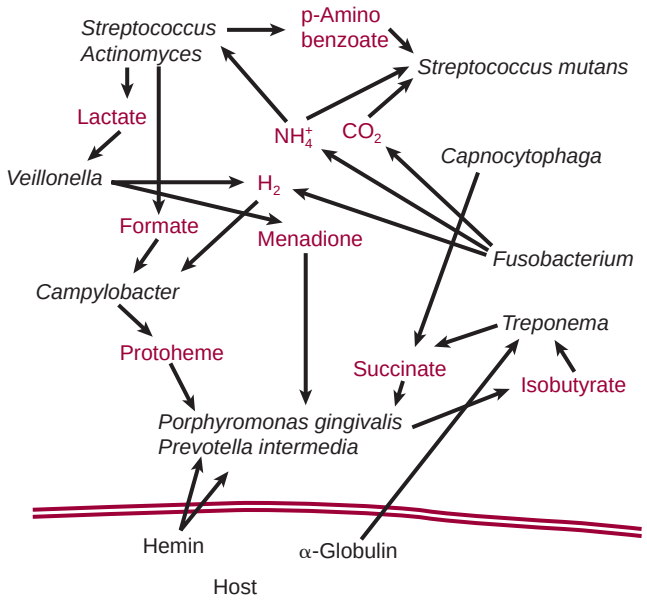

Figure 8-29 Schematic illustration of metabolic interactions among different bacterial species found in plaque and between the host and the plaque bacteria. These interactions are likely to be important to the survival of bacteria in the periodontal environment. *(Based on Carlsson J: Microbiology of plaque associated periodontal disease. In Lindhe J, ed:* Textbook of clinical periodontology, *Munksgaard, 1983, Munksgaard International Publishers; Grenier D:* Infect Immun *60:5298, 1992; Loesche WJ:* Periodontics *6:245, 1968; and Walden WC, Hentges DJ:* Appl Microbiol *30:781, 1975.)*

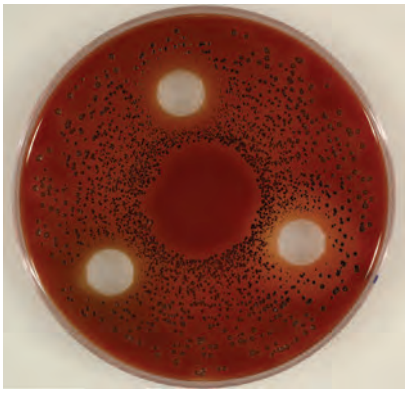

Figure 8-30 The growth of *Prevotella intermedia* (black colonies) is inhibited by the presence of *S. mitis, S. salivarius,* and *S. sanguinis* (in the white holes). This is represented by a zone of no growth (halo) around the white holes. This is a typical example of growth inhibition induced by streptococci.

Communication Between Biofilm Bacteria

Bacterial cells do not exist in isolation. In a biofilm, bacteria have the capacity to communicate with each other. One example of this is quorum sensing, in which bacteria secrete a signaling molecule that accumulates in the local environment and triggers a response such as a change in the expression of specific genes once they reach a critical threshold concentration. The threshold concentration is reached only at a high cell density, and therefore bacteria sense that the population has reached a critical mass or quorum. There is some evidence that intercellular communication can occur after cell–cell contact and that, in this case, communication may not involve secreted signaling molecules.[158] Two types of signaling molecules have been detected from dental plaque bacteria: peptides released by gram-positive organisms during growth and a "universal" signal molecule called *autoinducer 2* (AI-2).[172] Peptide signals are produced by oral streptococci; they are recognized by cells of the same strain that produced them and possibly also by different species of streptococci.[98] Responses are induced only when a threshold concentration of the peptide is attained, and thus the peptides act as cell density or quorum sensors. Local concentrations of signaling molecules may be enhanced in biofilms if the signals become trapped in the biofilm matrix. The streptococcal peptides are known as *competence-stimulating peptides,* because the major response to these signals is the induction of competence, a physiologic state during which cells are primed for DNA uptake and incorporation.

In some species, such as *S. mutans,* a small proportion of the cells in a population respond to competence-stimulating peptides by lysing.[276] Lysis is considered to be an altruistic behavior that helps to disseminate genetic information throughout the population of *S. mutans* cells.

In contrast with the strain-specific competence-stimulating peptides, AI-2 is produced and detected by many different bacteria. The detection of AI-2 produces wide-ranging changes in gene expression, in some cases affecting up to one third of the entire genome.[377]

Little is known about the specific functions of AI-2 in oral biofilms. However, this molecule has been demonstrated to play a role in mutualistic interactions between *S. oralis* and *A. oris (A. naeslundii)*.[315] Thus, in an in vitro model system, neither *S. oralis* nor *A. oris* formed biofilms in monoculture. When cultured together, these organisms grew abundantly on surfaces to form thick, confluent biofilms. This mutualistic behavior was only observed when AI-2 was present: disrupting the gene for AI-2 in *S. oralis* abrogated mutualistic growth. These data demonstrate that AI-2 is produced and sensed by oral bacteria and suggest that interbacterial communication is important for the development of dental plaque.

Quorum sensing therefore appears to play diverse roles in, for example, modulating the expression of genes for antibiotic resistance, encouraging the growth of beneficial species in the biofilm, and discouraging the growth of competitors.

Interactions Between Dental Plaque Bacteria

There is some evidence from laboratory studies that nonpathogenic organisms in subgingival dental plaque can modify the behavior of periodontal pathogens. For example, long and short fimbriae of *P. gingivalis* are required for adhesion and biofilm formation. The expression of long fimbriae is downregulated in the presence of *S. cristatus,* and short fimbriae are downregulated by *S. gordonii, S. mitis,* or *S. sanguinis*.[210,269] Changes in bacterial physiology after transitions from monoculture to mixed-species communities may be quite wide ranging.

With the use of a proteomics approach to probe the phenotype of *P. gingivalis*, it has been shown that the expression of almost 500 *P. gingivalis* proteins is changed in model oral microbial communities that contain *S. gordonii* and *F. nucleatum*.[187] At present, it is not clear how these changes affect the interaction between *P. gingivalis* and the host.

In multispecies biofilms in which many bacteria are juxtaposed to cells of different species, interactions between genetically distinct microorganisms can be mutually beneficial (see Figure 8-4, *A*). However, there are many examples of competitive interactions between different bacteria (Figure 8-30). For example, *S. mutans* produces antimicrobial peptides that have broad activity against bacteria in vitro.[185] Other oral streptococci compete with *S. mutans*

Several clinical studies followed the detection frequency and relative proportion of cariogenic species after periodontal therapy. They all suggest a relative increase in the number as well as the detection frequency of *S. mutans* up to 8 months after mechanical debridement.[74,296] In a cross-sectional study, subgingival plaque samples from chronic periodontitis patients were tested for the presence and levels of *S. mutans* and putative periodontal pathogens.[394] The patients were divided into four groups on the basis of the stage of periodontal treatment: untreated, after initial periodontal therapy, maintenance phase without periodontal surgery, and after periodontal surgery. The prevalence of mutans streptococci in the four study groups was equivalent. The shift toward a more cariogenic flora observed after initial and surgical periodontal therapy could be explained by a subgingival outgrowth by *S. mutans* occupying spots that became available after periodontal therapy (e.g., increased number of free adhesion/receptor sites), the creation of a new ecosystem in the subgingival area (i.e., a more anaerobic environment, changes in redox potential, pH, and nutrition) that allows or facilitates the growth of *S. mutans* species, and/or a downgrowth of *S. mutans* from the supragingival area in which the species could survive in the saliva. In addition, Socransky and coworkers showed that the total numbers of *P. gingivalis, T. forsythia,* and *T. denticola* are reduced 2 weeks after scaling and root planing and that concomitantly several orange complex organisms are also reduced in number at this point. However, the proportion of *S. sanguinis* in the population increased 2 weeks after treatment by scaling and root planing in conjunction with azithromycin or metronidazole and 3 months after treatment with doxycycline. Although these observations may be due to an antagonistic relationship between *S. sanguinis* and periodontal pathogens, they may also reflect the relatively high intrinsic antibiotic resistance of oral streptococci.

by excreting the strongly oxidizing molecule H_2O_2.[185] In fact, *S. oligofermentans* can convert lactic acid produced by *S. mutans* into H_2O_2, which then kills the *S. mutans* cells.[389]

In subgingival biofilms, oxygen is scarce, and therefore H_2O_2 production by bacteria is low. Oxidizing agents may be more important in the interaction between the host and the pathogen, because reactive oxygen species are a major component of the neutrophil response to bacteria.

Another example of competitive interaction exists between streptococci and periodontopathogens. *S. sanguinis*, *S. salivarius,* and *S. mitis* have been shown to inhibit hard- and soft-tissue colonization of *A. actinomycetemcomitans* (see Video 8-3: Colonization Inhibition), *P. gingivalis,* and *Prevotella intermedia* in vitro.[351,383,396]

Recent studies have shown that these interactions can also influence the host. Although in a study by Teughels and coworkers[384] no clinical effect was expected, a reduction in bleeding on probing was noted in pockets that received the streptococci. At that time, this observation was explained by the establishment of a more host-compatible microbiota. However, an interaction with the host via the immune system seems to be an additional interesting hypothesis. Oral streptococci have been shown to modulate bacteria–host interactions that involve both *F. nucleatum* and *A. actinomycetemcomitans*. Thus, *S. cristatus* and other oral streptococci attenuate the ability of *F. nucleatum* to stimulate interleukin-8 production by host oral epithelial cells.[436] Sliepen and coworkers recently demonstrated similar results for the streptococci that were used in the study by Teughels and coworkers.[352]

Another interesting example is the *S. gordonii*–induced increased expression of a complement resistance protein, ApiA, in *A. actinomycetemcomitans,* thereby resulting in a higher resistance to killing by host serum.[309]

Biofilms and Antimicrobial Resistance

Bacteria growing in microbial communities adherent to a surface do not "behave" the same way as bacteria growing suspended in a liquid environment (i.e., in a planktonic or unattached state). For example, the resistance of bacteria to antimicrobial agents is dramatically increased in the biofilm.[9,65,140,286] Almost without exception, organisms in a biofilm are 1000 to 1500 times more resistant as compared with antibiotics in their planktonic state. The mechanisms of this increased resistance differ from species to species, from antibiotic to antibiotic, and for biofilms growing in different habitats.

It is generally accepted that the resistance of bacteria to antibiotics is affected by their nutritional status, growth rate, temperature, pH, and prior exposure to subeffective concentrations of antimicrobial agents.[40,41,420] Variations in any of these parameters will lead to a varied response to antibiotics within a biofilm. An important mechanism of resistance appears to be the slower rate of growth of bacterial species in a biofilm, which makes them less susceptible to many but not all antibiotics.[18,38,65,428] The biofilm matrix, although not a significant physical barrier to the diffusion of antibiotics, does have certain properties that can retard antibiotic penetration. For example, strongly charged or chemically highly reactive agents can fail to reach the deeper zones of the biofilm, because the biofilm acts as an ion-exchange resin that removes such molecules from solution.[108,378]

In addition, extracellular enzymes such as β-lactamases, formaldehyde lyase, and formaldehyde dehydrogenase may become trapped and concentrated in the extracellular matrix, and as such inactivate some antibiotics (especially positively charged hydrophilic antibiotics).

Some antibiotics, such as the macrolides, which are positively charged but hydrophobic, are unaffected by this process.

Recently, "super-resistant" bacteria were identified within a biofilm. These cells have multidrug resistance pumps that can extrude antimicrobial agents from the cell.[38] Because these pumps place the antibiotics outside of the outer membrane, the process offers protection against antibiotics that target, for example, cell wall synthesis. The penetration and efficacy of antimicrobials against biofilm bacteria are critical issues for the treatment of periodontal infections.

Antibiotic resistance may be spread through a biofilm via the intercellular exchange of DNA. The high density of bacterial cells in a biofilm facilitates the exchange of genetic information among cells of the same species and across species and even across genera. Conjugation (i.e., the exchange of genes through a direct interbacteria connection formed by a sex pilus), transformation (i.e., the movement of small pieces of DNA from the environment into the bacterial chromosome), plasmid transfer, and transposon transfer have all been shown to occur in biofilms.

Bacterial Transmission and Translocation

The transmission of pathogens from one *locus* to another is an important aspect of infectious diseases. In theory, such transmission may jeopardize the outcome of periodontal therapy; in addition, the transmission of pathogens from one person to another may be important in terms of disease transmission. The significance of such an intraoral transmission or of a vertical or horizontal transmission is, however, difficult to prove or to quantify.

One of the first questions in this regard is, "Are oral bacteria transmissible between humans?" Molecular fingerprinting techniques have clearly illustrated that periodontal pathogens are transmissible within members of a family[431] (Figure 8-31).

This bacterial transmission between subjects (and even between animals and human beings) should not be confused with contagion (with the term *contagious* referring to the likelihood of a microorganism being transmitted from an infected to an uninfected host to create disease). Asikainen and coworkers used a genetic fingerprinting method called *arbitrarily primed-polymerase chain reaction* to genotype *A. actinomycetemcomitans* isolates from family members.[19] In 11 of 12 families, they found identical *A. actinomycetemcomitans* genotypes among family members. This suggests the transmission of this microorganism among family members. However, it was more often encountered that children carried a genotype identical to one of their parents than that spouses carried an identical genotype. This indicates that, in terms of *A. actinomycetemcomitans* transmission, vertical transmission is more important than horizontal transmission. Similar observations were made for the transmission of cariogenic species from mother to child.[167] The vertical or horizontal transmission of *P. gingivalis* has rarely been observed.[399]

The existence of an "intraoral" translocation of bacteria (i.e., from one niche to another) has been investigated more thoroughly. Intraoral transmission of bacteria was first examined in cariology. Loesche and coworkers showed that streptomycin-resistant strains of *S. mutans* grown on a dental inlay were spontaneously transmitted to the neighboring teeth (probably via saliva) and could even reach the contralateral quadrant after transmission with a dental explorer.[222] Previously, Edman and coworkers had successfully implanted the previously mentioned species in two volunteers by means of inoculated dental flosses.[85] Comparable observations have been made for periodontopathogens.

Christersson and coworkers demonstrated a translocation of *A. actinomycetemcomitans* via periodontal probes in localized

Video 8-3: Colonization Inhibition This video shows the colonization of a glass surface by a green fluorescent protein-labeled *A. actinomycetemcomitans* (green dots) strain over a 3-hour period. The colonization was visualized in a flow cell mounted on a confocal laser scanning microscope. The left panels show the colonization of a virgin surface, whereas the middle and right panels show the colonization of a glass surface that was coated with either *S. mitis* or *S. sanguinis*. It is clearly visible that both streptococci inhibit *A. actinomycetemcomitans* colonization over time. *S. sanguinis* was clearly the best inhibitor of *A. actinomycetemcomitans* colonization.

Surprisingly, when these bacteria were injected in freshly root-planed periodontal pockets in vivo, a significant inhibitory effect was observed with the recolonization of the periodontal pocket by periodontopathogens.[384] These observations highlight the importance of investigating nonpathogenic bacteria in periodontal biofilms in addition to studying the (putative) pathogens, and they may set the scene for new treatment approaches.

The clinical significance of intraoral translocation can be derived from several studies.

Nowzari and coworkers evaluated the amount of guided tissue regeneration and membrane contamination after the treatment of mandibular bony defects in either a group of patients with a healthy periodontium in the remaining dentition or a group of patients with multiple deep pockets and numerous pathogens.[258] The healthy group showed significantly less membrane contamination both immediately after insertion and at their removal after 6 weeks. The healthy group also showed significantly more clinical gain in attachment (3.4 mm versus 1.4 mm).

Mombelli and coworkers compared clinical and microbial changes when tetracycline fibers (local applications of antibiotics) were applied only to the two deepest pockets in the mouth (without further treatment to the remaining pockets) with the changes obtained when all teeth were cleaned and every pocket with a depth of more than 3 mm was treated.[246] After 6 months, significant "additional" improvements (clinical as well as microbiologic) were recorded in the group of patients with the more global approach. Their pockets showed a probing depth reduction (1.7 mm) and attachment gain (0.7 mm) that was significantly higher than that found in the pockets of patients with some remaining pockets (0.9 mm and 0.3 mm, respectively). The authors concluded that, most likely, pathogens were transferred via saliva from infected untreated periodontal lesions or other niches to the treated sites.

Quirynen and coworkers used a treatment strategy called "one-stage, full-mouth disinfection" to investigate the impact of intraoral translocation on the outcome of nonsurgical periodontal therapy.[292] This strategy attempted to suppress the translocation of periodontopathogens from all of their intraoral habitats (i.e., mucous membranes, tongue, and saliva) to root-planed periodontal pockets. Several comparative studies between the one-stage, full-mouth approach and the standard therapy from the Leuven group (i.e., root planing per quadrant with 2-week intervals that allow for translocation) illustrated the impact of bacterial translocation in relation to the obtained gain in attachment, pocket depth reduction, and changes in the microbiota.[293]

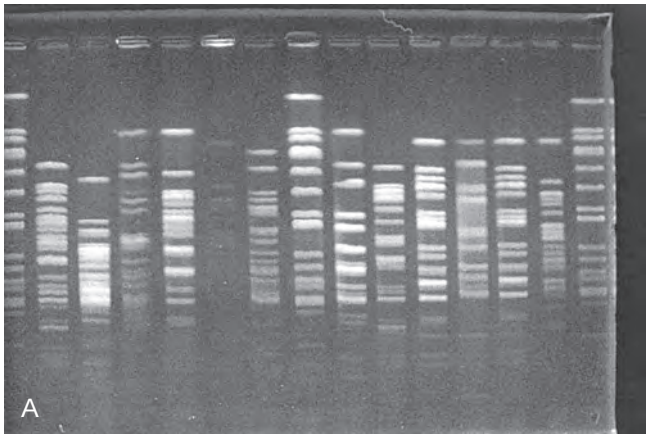

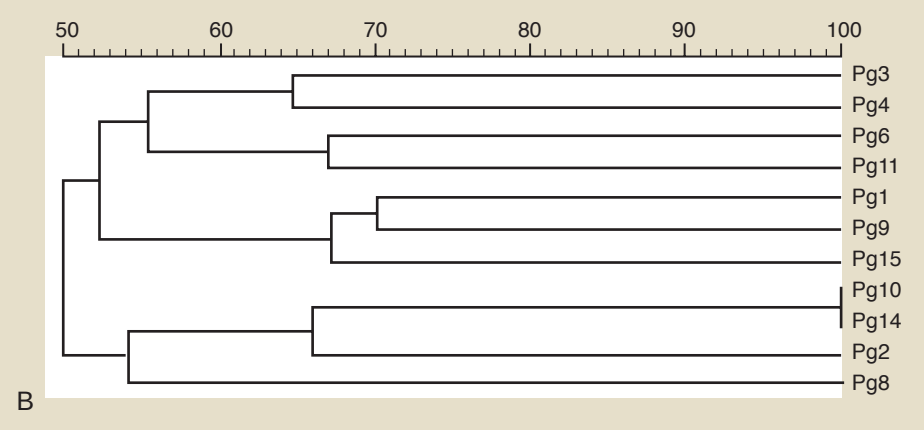

Figure 8-31 **A,** A band pattern of DNA isolated from multiple *Porphyromonas gingivalis* strains after pulsed-field gel electrophoresis. Lanes 1, 8, and 15 contain a reference strain of DNA (*Staphylococcus aureus*) cut with *Sma*I (a restriction endonuclease) in lanes 2 through 7 and 9 through 14; 12 different *P. gingivalis* strains are compared for their genetic similarity. **B,** The genetic similarity is expressed in a dendrogram. Bacteria are considered genetically similar when their band patterns are 80% similar.

juvenile periodontitis patients.[57] They were able to successfully colonize previously noninfected pockets with *A. actinomycetemcomitans* via a single course of probing with a probe that had been previously inserted in an infected pocket of the same patient. Although the colonization was only temporary, the question remained whether the colonization could not have become permanent if the site had offered more suitable growth conditions (e.g., a deep bleeding pocket, as frequently encountered immediately after initial periodontal therapy). It is well established that colonization of an already established microbial niche by a new species is difficult, because it is hampered by a variety of microbial interactions. Therefore, intraoral translocation to and the colonization of sterile surfaces may be different from the translocation and colonization of already colonized surfaces. Within the oral cavity, such sterile surfaces are not naturally occurring. However, at the moment of abutment placement on a dental implant, a sterile subgingival pocket is created. A large series of papers compared the microbiota in pockets around teeth with that found in periimplant pockets in partially edentulous patients and reported a striking similarity.* Several recent studies have investigated the subgingival colonization of such "sterile" periimplant pockets in partially edentulous patients. It has been shown that translocation to and the colonization of these pockets is extremely fast. Periodontopathogens could already be detected in this niche 30 minutes after abutment placement.[103] The initial colonization of these pockets with periodontopathogens is completed within 1 week. After 2 weeks, there are only minor additional changes in this newly developed microbiota.[103,303,305] These additional changes mainly reflect changes in the numbers of species. On the basis of the previously mentioned similarities between the microbial populations associated with teeth and implants, it has been suggested that, at least in partially edentulous patients, teeth may act as a reservoir for the (re)colonization of the subgingival area around implants. This hypothesis was supported by Sumida and coworkers, who detected similar intrasubject pulsed field gel electrophoresis patterns for *P. gingivalis* from teeth and implants (indicating that these locations contained precisely the same *P. gingivalis* strains) as compared with large intersubject variations.[375]

*References 13, 151, 152, 166, 168, 201, 205, 237, 247, 268, 297, 334

Nonbacterial Inhabitants of the Oral Cavity

Oral microbiology is often reduced to "oral bacteriology." However, the oral cavity comprises a much more diverse microbiota than merely a bacterial one. Viruses, fungi, archaea, and protozoa can be encountered in the oral cavity of humans. Many of these species can reside in the oral cavity in harmony with the host as commensals, similar to oral bacteria, but they can also cause several oral diseases.

Viruses

Viral diseases of the oral mucosa and the perioral region are often encountered in dental practice. Viruses are important ulcerogenic and tumorigenic agents of the human mouth. The finding of an abundance of mammalian viruses in periodontitis lesions may

Herpesviruses. Herpesvirus virions vary in size from 120 nm to 250 nm. They consist of a double-stranded linear DNA molecule surrounded by an icosahedral capsid, a proteinaceous tegument, and a lipid-containing envelope with embedded viral glycoproteins.[274] Eight human herpesvirus species with distinct biological and clinical characteristics have been described: herpes simplex virus-1, herpes simplex virus-2, varicella-zoster virus, Epstein-Barr virus (EBV), human cytomegalovirus (hCMV), human herpesvirus-6, human herpesvirus-7, and human herpesvirus-8 (see Table 8-5). Typically, after a primary infection, each herpesvirus subfamily maintains latent infection in specific cell populations. In the oral cavity, an infection with herpesviruses can present itself as a primary herpetic stomatitis, herpes labialis (cold sores), chickenpox (varicella), or shingles (zoster). In contrast with a chronic infection, this latency is not associated with the production of infectious virions. In addition, a single individual can simultaneously exhibit herpesvirus latent infection in some cells and active viral infection in other cells. Herpesviruses express proteins during the normal lytic and latent viral life cycle that can interfere with activities of the innate and adaptive immune systems and alter the cellular environment. The alteration of the host defense ensures a lifelong persistence of the viruses in the infected host, and it can contribute to disease development. Herpesvirus active infections can remain asymptomatic but still give rise to viral shedding, or they can cause illness that ranges from classic infectious diseases to benign and malignant tumors, especially in immunocompromised hosts (e.g., patients with acquired immunodeficiency syndrome [AIDS], organ transplant recipients).

Papillomaviruses. The papillomaviruses comprise a group of small, epitheliotropic, nonenveloped, icosahedral, double-stranded and circular DNA viruses (see Table 8-6). Human papillomaviruses are grouped within five genera, and they comprise more than 100 types. They can induce benign lesions of the skin (warts) and mucous membranes (condylomas), but they can also cause epithelial malignancies such as cancer of the uterine cervix, certain types of anal cancer, vulvar cancer, penile cancer, laryngeal cancer, and oral cancer. Type 16 papillomaviruses have been implicated in one third of oropharyngeal squamous cell carcinomas, and they show a particularly strong relationship with cancer of the tonsils.[130,145] Head and neck cancers related to papillomaviruses exhibit relatively high mortality rates despite early diagnosis and treatment.

Picornaviruses/Enteroviruses. Picornaviruses are nonenveloped, single-stranded, positive-sense RNA viruses with a virion diameter of approximately 30 nm.[266] This family of viruses consists of nine genera, and it contains several serious pathogens, including poliovirus, hepatitis A virus, rhinovirus, and the hand, foot, and mouth disease virus (see Table 8-7).

The enteroviruses form a specific genus in the picornavirus family. They include coxsackievirus, echovirus, poliovirus, and human enterovirus. Enteroviruses are common human pathogens that are associated with a broad spectrum of clinical presentations, including asymptomatic infections, various enanthems and exanthems, respiratory diseases, aseptic meningitis, severe illness in newborns and immunocompromised hosts, and fatal outcomes. They replicate in the alimentary tract.[262]

Retroviruses. Retroviral virions are composed of one or two copies (e.g., human immunodeficiency virus [HIV] has two copies) of single-stranded, positive-sense RNA enclosed by a conical capsid and a phospholipid envelope. A total of seven retrovirus genera have been established. HIV and T-lymphotropic virus are human pathogens. HIV belongs to the *Lentivirus* genus and includes two subspecies, HIV-1 and HIV-2. Lentiviruses are characterized by long incubation periods between the infection of the host and the manifestation of clinical disease. The course of HIV infection can be divided into primary (or acute) infection, chronic (asymptomatic) infection, and AIDS.[190] Early-stage secondary infections include oral and vulvovaginal candidiasis, pneumococcal infections, tuberculosis, and the reactivation of herpes simplex virus and varicella-zoster virus. Later-stage infections include *Pneumocystis jiroveci* (previously *Pneumocystis carinii*) pneumonia, *Candida* esophagitis, disseminated histoplasmosis, toxoplasma encephalitis, and cryptococcal meningitis. Late-stage diseases include disseminated *Mycobacterium avium* complex infection, recurrent or disseminated CMV infection, cryptosporidiosis, and microsporidiosis. CMV viremia predicts lower survival rates of AIDS patients who are receiving antiretroviral therapy.[423] Malignancies in patients with AIDS are generally virally related and include EBV lymphomas, human herpesvirus-8, Kaposi's sarcoma, and papillomavirus cervical and anal carcinomas.

suggest a role for viruses in more oral diseases than previously recognized.[342] A more in-depth review can be found in two articles by Slots.[356,357]

In contrast with most bacteria, viruses only replicate when they are present within eukaryotic (animals, plants, protists, and fungi) or prokaryotic (bacteria and archaea) cells and not on their own. The extracellular virion particle ranges in size from 20 nm to 300 nm and consists of either DNA or ribonucleic acid (RNA) contained within a protective protein coat or capsid (Figure 8-32).

Some viruses have an additional envelope that comprises a lipid bilayer derived from the outer cellular membrane, the internal nuclear membrane, or the endoplasmic reticulum membrane of the infected cell. In healthy individuals, the vast majority of viruses in the oral cavity are bacteriophages.[10] Four major viral families are associated with the main viral oral diseases of adults:

1. The group of herpesviruses contains eight different members that are all enveloped double-stranded DNA viruses (Table 8-5). In the oral cavity, they are related to different ulcers, tumors, and other oral pathoses.
2. Human papillomaviruses are grouped within five genera and are nonenveloped double-stranded DNA viruses (Table 8-6). In the oral cavity, they are related to ulcers, tumors, and oral pathoses.
3. Picornaviruses are all nonenveloped, single-stranded RNA viruses (Table 8-7). In the oral cavity, they are related to ulcers and different oral pathoses.
4. Retroviruses are divided into seven genera of which two are human pathogens. All retroviruses are enveloped single-stranded RNA viruses (Table 8-8). In the oral cavity, they are related to different tumors and oral pathoses.

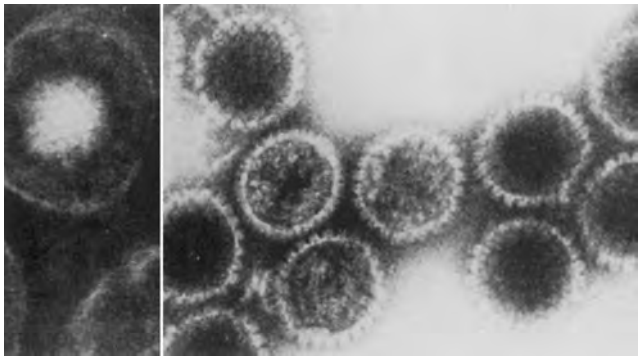

Figure 8-32 Electron micrographic picture of herpes simplex virus type 1, enveloped *(left)* and naked capsids *(right)*. (×198,000.) *(From Fields BN, Knipe DM: In Fields BN, eds:* Fields' virology, *New York, 1985, Raven Press.)*

Clinical Manifestations of Oral Viral Diseases

Oral Ulcers. Ulcers/erosions are relatively common in the oropharyngeal mucosa.[338] Although oral ulcers can have a variety of etiologies, a viral cause of oral ulcers has been established for primary and recurrent herpetic gingivostomatitis (primarily herpes simplex virus-1 but also herpes simplex virus-2), varicella/herpes zoster outbreak (varicella-zoster virus), herpangina (coxsackievirus), and hand, foot, and mouth disease (enteroviruses). Viruses may also play a role in some cases of recurrent aphthous stomatitis (varicella-zoster virus, CMV, other herpesviruses, adenoviruses, and measles virus) and in systemic diseases with an oral ulcerogenic component, such as erythema multiforme (herpes simplex virus), Behçet's syndrome (herpes simplex virus and CMV), pemphigus vulgaris (herpes simples virus and CMV), and systemic lupus erythematosus (EBV).

Oral Tumors. Viruses can be connected to a single or a limited number of tumor types (e.g., hepatitis B virus) or to multiple tumor types (e.g., EBV), a difference that probably reflects the extent of tissue tropism of the viruses. Viruses may cause cell transformation and proliferation by directly expressing oncogenic genes in infected cells or by acting as a necessary or noncompulsory cofactor in the development of malignancy. However, even though most individuals harbor oncogenic viruses in the oral cavity, cancer that occurs as a result of infection with such viruses is relatively rare. Risk factors apart from the viral infection are obviously important for cancer development, including family history, age, tobacco smoking, and alcohol consumption. The most important oncoviruses of the human mouth are EBV, herpesvirus-8, and papillomaviruses; the most common virally related malignancies in the oral cavity are epithelial neoplasms, lymphomas, and Kaposi's sarcoma.[330]

Other Oral Pathologies. In addition to oral ulcers and tumors, viruses have also been implicated in infectious mononucleosis (primary EBV infection and occasionally a primary CMV infection), Sjögren syndrome (hepatitis C virus, human T-lymphotropic virus type I, HIV, and herpesviruses), osteomyelitis (herpes zoster virus and CMV), osteonecrosis (herpes zoster), oral leukoplakia (papillomaviruses, mainly types 16 and 18), and oral lichen planus (papillomaviruses and hepatitis C virus).

Periodontitis. Bacteria are recognized as indispensable for the development of periodontitis, and the current hypotheses regarding the pathogenic mechanisms of periodontitis correctly emphasize the importance of assessing bacterial and host factors collectively. However, sole bacterial–host interactions appear insufficient to explain the clinical characteristics of the disease.[355] The localized distribution and intermittent exacerbations of periodontal breakdown and other issues remain a riddle. In response,

TABLE 8-5 Herpesviruses That Can Be Recovered in the Oral Cavity

Virus	Characteristics	Disease Association	Oral Pathoses
Herpes simplex virus-1	Latency in sensory ganglia Causes orolabial disease	Herpetic gingivostomatitis, recurrent orolabial lesions, herpetic whitlow, keratoconjunctivitis, eczema herpeticum, pharyngitis, mononucleosis-like syndrome, encephalitis, neonatal infections.	Adult herpetic gingivostomatitis HIV/AIDS-related oral ulcers Recurrent oral aphthous stomatitis Behçet's syndrome Oral pemphigus vulgaris Erythema multiforme Dry socket after tooth extraction
Herpes simplex virus-2	Latency in sensory ganglia Causes genital and newborn infections	Genital infection, aseptic meningitis, sacral autonomic nervous system dysfunction.	—

TABLE 8-5 Herpesviruses That Can Be Recovered in the Oral Cavity—cont'd

Virus	Characteristics	Disease Association	Oral Pathoses
Varicella-zoster virus	Latency in sensory ganglia Only three major genotypes of the wild-type virus are known More than 90% are infected before adolescence in an unvaccinated population	Varicella (chickenpox), herpes zoster (shingles), central nervous system involvement, pneumonia, secondary bacterial infections, and death Available varicella vaccines (about 90% effectiveness) include a single-antigen vaccine and a combination vaccine against MMRV	Recurrent oral aphthous stomatitis Osteomyelitis Herpes zoster (Hunt syndrome)
EBV	Identified initially in 1964 from African Burkitt's lymphoma Infects epithelial cells with a cytolytic infection and B lymphocytes with a latent infection	Infectious mononucleosis, hairy leukoplakia of the tongue, Burkitt's lymphoma, B lymphoproliferative disease, Hodgkin's lymphoma, X-linked lymphoproliferative disease, nasal T-cell lymphoma, nasopharyngeal carcinoma, gastric carcinoma, parotid carcinoma, and leiomyosarcoma	Recurrent oral aphthous stomatitis Erythema multiforme Various epithelial type tumors, such as lymphoepithelioma-like carcinoma, salivary gland lymphoepithelial carcinoma, Warthin's tumor (cystadenolymphoma) of the parotid gland, oral squamous cell carcinoma, tonsillar carcinoma, oral undifferentiated carcinomas, and oral hairy leukoplakia Various lymphoid type tumors, such as Hodgkin's lymphoma, T-cell/natural killer cell lymphoma, Burkitt's lymphoma, cyclosporine-related post-transplant lymphoproliferative disorder, oral post-transplant lymphoproliferative disorder/B-cell lymphoma, follicular lymphoid hyperplasia, and plasmablastic lymphoma Infectious mononucleosis
hCMV	Infects mainly T lymphocytes and macrophages The gB protein in the virion envelope participates in the virus–cell interaction and is a major target of the immune response	Preterm birth, preeclampsia, transplant rejection, immunosenescence, hemorrhagic retinal necrosis (patients with HIV), encephalitis, infectious mononucleosis, atherosclerosis, gastrointestinal disease, pneumonia, and encephalitis	HIV/AIDS-related oral ulcers Recurrent oral aphthous stomatitis Behçet's syndrome Oral pemphigus vulgaris Erythema multiforme Cyclosporine-steroid associated lymphoproliferative disorder Benign infantile hemangioendothelioma Kaposi's sarcoma Occasionally infectious mononucleosis Sialadenitis Osteomyelitis
Human herpesvirus-6	Cell tropism for T lymphocytes and neural cells Frequently shed in the saliva of healthy donors	Roseola infantum (sixth disease), meningitis, encephalitis, and possibly multiple sclerosis	Uvulopalatoglossal junctional ulcers Oral squamous cell carcinoma Oral leukoplakia Oral lichen planus
Human herpesvirus-7	Latency in macrophages and T lymphocytes Frequently shed in the saliva of healthy donors	Exanthema subitum, macular–papular rashes, and transplant–recipient pathogens	
Human herpesvirus-8	Six genetic subtypes with marked clustering to geographic areas B lymphocytes and monocytes serve as reservoirs	Kaposi's sarcoma, multicentric Castleman disease, primary effusion lymphoma, mononucleosis-like illness, and aplastic anemia (Unlike EBV, herpesvirus-8 is not involved in epithelial tumors)	Recurrent oral aphthous stomatitis Kaposi's sarcoma

Adapted from Slots J: *Periodontol 2000* 49:60, 2009.

EBV, Epstein-Barr virus; *hCMV,* human cytomegalovirus; *HIV,* human immunodeficiency virus; *AIDS,* acquired immunodeficiency syndrome; *MMRV,* measles, mumps, rubella, and varicella.

TABLE 8-6 Papillomaviruses That Can Be Recovered in the Oral Cavity

Virus	Characteristics	Disease Association	Oral Pathoses
Papillomavirus	Epithelial cell proliferation with specificity principally in the anogenital area, the urethra, the skin, the larynx, tracheobronchial region, and the oral mucosa	Genital and cutaneous warts, cervical and anogenital cancers, condylomata acuminate (sexually transmitted disease), and recurrent respiratory papillomatosis	Unspecified oral ulcers Recurrent oral aphthous stomatitis Focal epithelial hyperplasia Oral squamous cell carcinoma/verrucous carcinoma Oral leukoplakia Oral lichen planus

Adapted from Slots J: *Periodontol 2000* 49:60, 2009.

TABLE 8-7 Picornaviruses That Can Be Recovered in the Oral Cavity

Virus	Characteristics	Disease Association	Oral Pathoses
Coxsackievirus	Coxsackievirus A16 is closely related to enterovirus-71, and both belong to a discrete subgroup of type A enteroviruses that are prominently associated with hand, foot, and mouth disease	Uncomplicated hand, foot, and mouth disease (coxsackievirus A serotypes 10 and 16); herpangina (mostly coxsackievirus A); myocarditis; infectious type 1 diabetes (coxsackievirus B); and atherosclerosis	Herpangina Hand, foot, and mouth disease
Echovirus	Some echovirus replication occurs in the nasopharynx	Meningitis; pericarditis; myocarditis; herpangina; and Guillain-Barré syndrome	Herpangina
Enterovirus	Enterovirus-71 was first isolated in 1969 from a child with encephalitis Can cause large epidemics of acute disease Mutates readily	Hand, foot, and mouth disease (enterovirus-71); herpangina (enterovirus-71); poliomyelitis-like illness; meningoencephalitis (enterovirus-71); acute pulmonary edema (enterovirus-71); and hemorrhagic conjunctivitis	Herpangina Hand, foot, and mouth disease

Adapted from Slots J: *Periodontol 2000* 49:60, 2009.

TABLE 8-8 Retroviruses That Can Be Recovered in the Oral Cavity

Virus	Characteristics	Disease Association	Oral Pathoses
HIV-1	Global infection Infects cells that contain CD4 receptors, such as T-helper lymphocytes and cells of the macrophage lineage	Rank order of AIDS-defining pathoses is as follows:	Plasmablastic lymphoma
		Pneumocystis pneumonia (43%) Esophageal candidiasis (15%) Wasting (11%) Kaposi's sarcoma (11%) Disseminated *Mycobacterium avium* infection (5%) *Mycobacterium tuberculosis* infection (5%), cytomegalovirus disease (4%) HIV-associated dementia (4%) Recurrent bacterial pneumonia (3%) Toxoplasmosis (3%) Oral hairy leukoplakia	Kaposi's sarcoma Xerostomia (Sjögren's syndrome) Sialadenitis Osteomyelitis
HIV-2	Infection occurring mainly in West Central Africa (Guinea-Bissau)	HIV-2 is associated with similar types of diseases as HIV-1 but is generally less virulent	Oral hairy leukoplakia Plasmablastic lymphoma Kaposi's sarcoma Xerostomia (Sjögren's syndrome) Sialadenitis Osteomyelitis

Adapted from Slots J: *Periodontol 2000* 49:60, 2009.

HIV, Human immunodeficiency virus; *AIDS,* acquired immunodeficiency syndrome.

the involvement of herpesviruses in the etiology of periodontitis has been suggested on the basis of their increased presence in inflamed gingival tissue, crevicular fluid, and subgingival plaque in periodontally diseased sites and their potential to induce proinflammatory cytokines.[355,357] However, it remains unclear whether herpesvirus activation occurs spontaneously or as a result of concurrent infection, stress, or other immunosuppressive factors.[46] It is interesting to note that several risk factors for periodontitis also have the potential to reactivate herpesviruses.[66] Bacterioviral synergism may play an important role in the onset and progression of periodontitis.[357] However, the hypothesis that herpesviruses are involved in the etiology of periodontitis is still controversial.[46] However, there is no doubt that herpesviruses are present in the periodontal pocket. Next to herpesviruses, many other viruses have been detected in periodontal pockets. Papillomaviruses, HIV, human T-lymphotropic virus type I, hepatitis B and C viruses, and torque teno virus can all inhabit periodontitis lesions.[356] In addition, the inflamed periodontium may constitute the major oral reservoir for EBV, CMV, papillomaviruses, and hepatitis C virus.[356]

Yeasts

Many yeast species have been isolated from the oral cavity. The majority of isolates are *Candida*, and the most prevalent species is *C. albicans* (Figure 8-33). Together with *C. albicans*, some of the most common opportunistic fungal pathogens in humans are *C. tropicalis*, *C. glabrata*, *C. krusei*, *C parapsilosis*, *C. guilliermondii*, and *C. dubliniensis*. *Candida* spp. thrive in low-pH environments, and high *Candida* loads are associated with the presence of relatively low-diversity dental plaque that contains aciduric and acidogenic species such as *Streptococcus* spp. and *Lactobacillus* spp.[183] In addition to *C. albicans, C. glabrata* is now emerging as an important agent in both mucosal and bloodstream infections.[208,279]

Yeasts such as *Rhodotorula glutinis* and *Saccharomyces cerevisiae* are rarely found in the oral cavity and are not known to cause oral infections. *Cryptococcus neoformans* is occasionally isolated from the mouth but usually from patients with pulmonary cryptococcosis.[371]

C. albicans is the species that is most frequently encountered in infected tissues, including the oral mucosal layers. It is also the predominant species found during vaginal and invasive bloodstream infections. *C. albicans* infections are increasing in prevalence, especially among denture wearers and aging people; they may lead to invasive disease, which has a high mortality rate.[333]

In contrast with most other *Candida* spp., *C. albicans* is a pleomorphic fungus that exhibits different modes of growth. It can proliferate as unicellular budding yeast, and it may undergo morphologic switching when triggered by specific environmental conditions, thereby leading to elongated growth forms called *pseudohyphae* and *hypha* and collectively named *filamentous forms*.[374] Hyphae are characterized as unconstricted filaments with parallel-sided walls. In contrast, pseudohyphae seem to represent a growth form between those of yeast and hyphae in which the cells remain attached to each other but can vary in shape from elongated ellipsoidal cells to forms that superficially closely resemble hyphae. The various growth forms are important for the establishment of *Candida* infections, with specific roles proposed in the areas of adhesion, biofilm formation, tissue penetration, and organ colonization.[188]

A number of systemic mycotic diseases that were once considered exotic are now manifesting intraorally with increasing frequency as a result of the high prevalence of immunocompromised individuals in the community[228,329] (Table 8-9).

Protozoa

The mouth is the entry port for many parasites that have adapted to the human host. Only a few parasites affect the oral cavity, but an increasing body of literature indicates that oral protozoa are more common than previously appreciated.[24] Depending on the type of infection, the parasitic infectious agents can be divided into two categories: those that induce local infections and those that induce systemic infections with indirect effects on the oral cavity. The former group comprises saprophytes (e.g., *Entamoeba gingivalis, Trichomonas tenax*) (Figure 8-34) (see Video 8-4: Phase Contrast) that have the potential to turn into opportunistic pathogens or free-living amoebae that occasionally become invasive but that are seldom present clinically. Protozoa tend to be seen in cases of poor oral hygiene and poor periodontal health.

E. gingivalis is possibly less commonly found in the oral cavity than *T. tenax*. However, there are indications that *E. gingivalis* produces a particular progressive periodontal disease in immunocompromised patients, who often present with a necrotic gingival infection.

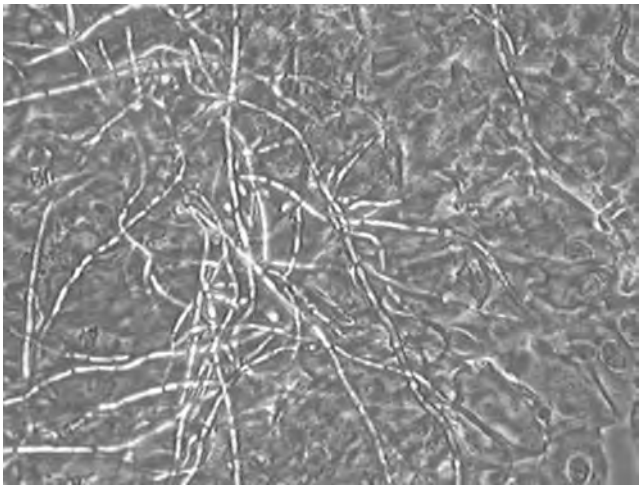

Figure 8-33 Sample of the palate of a patient with denture stomatitis with clear candidal mycelia visualized under a phase-contrast microscope.

TABLE 8-9 Etiologic Agents for Different Types of Oral Yeast Infections

Oral Mycoses	Etiologic Agent
Candidiasis	*Candida albicans, C. glabrata, C. tropicalis, C. dubliniensis, C. krusei,* and so on
Aspergillosis	*Aspergillus fumigatus*
Blastomycosis	*Blastomyces dermatitidis*
Coccidioidomycosis	*Coccidioides immitis*
Cryptococcosis	*Cryptococcus neoformans*
Fusariosis	*Fusarium moniliforme*
Geotrichosis	*Geotrichum candidum*
Histoplasmosis	*Histoplasma capsulatum*
Mucormycosis	Order *Mucorales*
Paracoccidiomycosis	*Paracoccidioides brasiliensis*
Penicilliosis	*Penicillium marneffei*
Sporotrichosis	*Sporothrix schenckii*

From Samaranayake LP, Keung LW, Jin L: *Periodontol 2000* 49:39, 2009.

Video 8-4: Phase Contrast Apathogenic (i.e., nonpathogenic): This phase-contrast image from a subgingival plaque sample of a healthy periodontal pocket shows an abundance of nonmotile cocci and rods. These bacteria can appear as single species, or they can be coaggregated in corn-cob–like structures. A clear absence of bacterial motion, except for Brownian movement, can be seen.

Pathogenic: This plaque sample originated from a deep periodontal pocket of a patient with chronic periodontitis. The presence of several motile plaque bacteria can be observed. These motile bacteria are typically spiral rods, comma-shaped rods, and spirochetes, and they should be considered to be high-risk species. Typically, in a pathogenic plaque sample, the percentage of motile organisms or spirochetes is more than 20% of the total number of bacteria, or the percentage of motile organisms and spirochetes together is more than 15%.

Very pathogenic: This plaque sample was derived from a deep periodontal pocket of a patient with aggressive periodontitis. Clearly a higher percentage of motile bacteria than was found in the patient with chronic periodontitis can be observed. Typically these high-risk motile bacteria are more large gliding and flexing rods and spirochetes.

Trichomonas: Oral trichomonas may be found in about 10% of persons with periodontal pockets. *Trichomonas tenax* is about 6 to 12 μm in length, and it is the type that is usually found in plaque specimens. Trichomonas of about 25 μm in length may be *Trichomonas vaginalis*. Trichomonas are transmitted through saliva or other bodily fluids. Although the periodontopathic potential of these trichomonas species is not known, they should not be given the benefit of the doubt.

We may be witnessing a genuine increase in the prevalence of *E. gingivalis* and *T. tenax,* but it is more probable that improved diagnostic techniques are contributing to the higher numbers that are being reported.

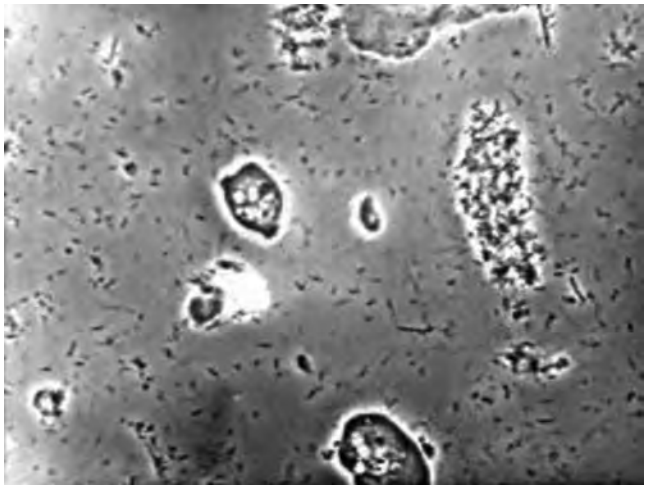

Figure 8-34 Trichomonas in dental plaque visualized under a phase-contrast microscope.

This type of painful oral lesion often has an unclear etiology, but, during the late 1990s, a Swedish study not only showed its association with HIV-1 but also reported that this parasite association seemed to be exclusive for HIV-1 in that no other parasite was ever found with this type of immunodeficiency.[227]

Among systemic parasitic infections, only the protozoan flagellate *Leishmania* can produce clinical symptoms that affect the oral cavity.[24] This effect is indirect, and it is caused by disfigurations produced by infections with the mucocutaneous form of the infection, thereby resulting in granulomatous growth that involves the mouth and nose. Although the distribution of the local oral parasites is worldwide, leishmaniasis only exists in certain areas.

Archaea

Archaea are single-celled organisms that are as distinct from bacteria as they are from eukaryotes. The role of archaea in oral diseases is only beginning to be explored. Methanogenic archaea produce methane from hydrogen gas (H_2)/carbon dioxide (CO_2) and sometimes from formate, acetate, methanol, or methylamine. These organisms have been isolated from patients with periodontal disease via the enrichment of cultures with H_2 and CO_2. They mainly occur in the anaerobic part of the subgingival biofilm and in infected root canals.[22,402,403] In addition, although they were not identified in periodontally healthy subjects, archaea were identified in 37 out of 48 samples from periodontal disease sites with the use of molecular detection methods.[206] Methanogenic archaea were found to thrive better in diseased sites as compared with healthy sites in patients with aggressive periodontitis, and a clear correlation was established with pathogenic microbiota.[94,234] It is postulated that these archaea may favor the growth of periodontopathogens by modulating the subgingival biofilm constitution inherent to their metabolism. However, the precise clinical relevance of archaea remains a matter of conjecture.[233]

Microbiologic Specificity of Periodontal Diseases

Nonspecific Plaque Hypothesis

During the mid-1900s, periodontal diseases were thought to result from an accumulation of plaque over time, eventually in conjunction with a diminished host response and increased host susceptibility with age. This theory, which is called the *nonspecific plaque hypothesis,* was supported by epidemiologic studies that correlated both age and the amount of plaque with evidence of periodontitis.[226,322,337]

According to the nonspecific plaque hypothesis, periodontal disease results from the "elaboration of noxious products by the entire plaque flora."[221] When only small amounts of plaque are present, the noxious products are neutralized by the host. Similarly, large amounts of plaque would cause a higher production of noxious products, which would essentially overwhelm the host's defenses.

Several observations contradicted these conclusions. First, some individuals with considerable amounts of plaque and calculus as well as gingivitis never developed destructive periodontitis. Furthermore, individuals who did present with periodontitis demonstrated considerable site specificity with regard to the pattern of disease. Some sites were unaffected, whereas advanced disease was found in adjacent sites. In the presence of a uniform host response, these findings were inconsistent with the concept that all plaque was equally pathogenic. Recognition of the differences in plaque at sites of different clinical status (i.e., disease versus health) led to a renewed search for specific pathogens in periodontal diseases and a conceptual transition from the nonspecific to the specific plaque hypothesis.[219,354,361]

Inherent to the nonspecific plaque hypothesis is the concept that the control of periodontal disease depends on the reduction of the total amount of plaque. The current standard treatment of periodontitis by debridement (nonsurgical or surgical) and oral hygiene measures still focuses on the removal of plaque and its products. Although the nonspecific plaque hypothesis has been discarded in favor of the specific plaque hypothesis and the ecologic plaque hypothesis, most of the therapeutic interventions are still based on the basic principles of the nonspecific plaque hypothesis.

Specific Plaque Hypothesis

The specific plaque hypothesis underlines the importance of the qualitative composition of the resident microbiota. The pathogenicity of dental plaque depends on the presence of or an increase in specific microorganisms.[221] This concept encapsulates that plaque that harbors specific bacterial pathogens may provoke periodontal disease because key organisms produce substances that mediate the destruction of host tissues. The association of specific bacterial species with disease came about during the early 1960s, when the microscopic examination of plaque revealed that different bacterial morphotypes were found in healthy versus periodontally diseased sites (see Video 8-4: Phase Contrast). At about the same time, major advances were made in the techniques used to isolate and identify periodontal microorganisms. These included improvements in procedures to sample subgingival plaque, in the handling of samples to prevent killing the bacteria, and in the media used to grow the bacteria in the laboratory.[363] The result was a tremendous increase in the ability to isolate periodontal microorganisms and considerable refinement in bacterial taxonomy.[186] Acceptance of the specific plaque hypothesis was spurred by the recognition of *A. actinomycetemcomitans* as a pathogen in localized aggressive periodontitis.[255,354] These advances led to a series of association studies focused on identifying specific periodontal pathogens by examining the microbiota associated with states of health and disease in cross-sectional and longitudinal studies.

The introduction of molecular methods for bacterial identification has greatly increased the power of association studies, because we are no longer constrained to analyzing those bacteria that can be cultured (i.e., <50% of the total oral microbiota). For example, specific members of the phylum *Synergistetes* that have never been cultured in isolation show a clear association with periodontal

Criteria for the Identification of Periodontopathogens

During the 1870s, Robert Koch developed the classic criteria by which a microorganism can be judged to be a causative agent in human infections. These criteria, known as *Koch's postulates,* stipulate that the causative agent must do the following:

1. Be routinely isolated from diseased individuals
2. Be grown in pure culture in the laboratory
3. Produce a similar disease when inoculated into susceptible laboratory animals
4. Be recovered from lesions in a diseased laboratory animal

Difficulties exist with regard to the application of these criteria to polymicrobial diseases, and the applicability of Koch's postulates has been increasingly challenged in recent years. In the case of periodontitis, there are three primary problems: (1) the inability to culture all of the organisms that have been associated with disease (e.g., many of the oral spirochetes); (2) the difficulties inherent in defining and culturing sites of active disease; and (3) the lack of a good animal model system for the study of periodontitis.[363] In fact, if the ecologic plaque hypothesis proves correct, it must be inherently impossible to fulfill Koch's postulates, because no single organism or group of organisms is responsible for all cases of disease.

Sigmund Socransky, a researcher at the Forsyth Dental Center in Boston, proposed criteria by which periodontal microorganisms may be judged to be potential pathogens.[363] According to these criteria, a potential pathogen must do the following:

1. Be associated with disease, as evidenced by increases in the number of organisms at diseased sites
2. Be eliminated or decreased in sites that demonstrate the clinical resolution of disease with treatment
3. Induce a host response in the form of an alteration in the host cellular or humoral immune response
4. Be capable of causing disease in experimental animal models
5. Produce demonstrable virulence factors that are responsible for enabling the microorganism to cause the destruction of the periodontal tissues

On the basis of these criteria, data that support the role of *A. actinomycetemcomitans* and *P. gingivalis* as periodontal pathogens have been presented earlier in this chapter. The association and elimination criteria are discussed in the preceding sections. The latter three criteria focus on the host–parasite interaction, which is discussed in Chapter 9.

disease.[401] Molecular identification techniques such as DNA checkerboard hybridization can identify and enumerate many different organisms simultaneously and are thus well-suited to high-throughput studies (see Figure 8-22 online). The association of Socranksy's "red complex" bacteria (*P. gingivalis*, *T. forsythia,* and *T. denticola*) with periodontal disease was based on the analysis of 40 different bacteria in more than 13,000 plaque samples.[365] Nevertheless, disease association studies do not reveal whether the presence of specific bacteria *causes* or *correlates with* the presence of disease. In addition, these studies have shown that periodontal disease can occur even in the absence of defined "pathogens," such as red complex bacteria, and conversely that "pathogens" may be present in the absence of disease.

Ecological Plaque Hypothesis

During the 1990s, Marsh and coworkers developed the "ecological plaque hypothesis" as an attempt to unify the existing theories regarding the role of dental plaque in oral disease (Figure 8-35). According to the ecological plaque hypothesis, both the total amount of dental plaque as well as the specific microbial composition of plaque may contribute to the transition from health to disease. The health-associated dental plaque microbiota is considered to be relatively stable over time and in a state of dynamic equilibrium or "microbial homeostasis." The host controls subgingival plaque to some extent by a tempered immune response and low levels of gingival crevicular fluid flow. Perturbations to the host response may be brought about by an excessive accumulation of nonspecific dental plaque, by plaque-independent host factors (e.g., the onset of an immune disorder, changes in hormonal balance [e.g., during pregnancy]), or by environmental factors (e.g., smoking, diet). Changes in the host status, such as inflammation, tissue degradation, and/or high gingival crevicular fluid flow, may lead to a shift in the microbial population in plaque. As a result of microenvironmental changes, the number of beneficial species may decrease, whereas the number of potentially pathogenic species increases. This gradual shift in the entire microbial community, known as *dysbiosis,* may result in a chronic disease state such as periodontitis.[23] The ecologic plaque hypothesis is entirely consistent with observations that disease-associated organisms are minor components of the oral microbiota in health; these organisms are kept in check by interspecies competition during microbial homeostasis. Disease is associated with the overgrowth of specific members of the dental plaque biofilm when the local microenvironment changes, but it is not necessarily the same species in each case. An important consideration of the ecological plaque hypothesis is that therapeutic intervention can be useful on a number of different levels. Eliminating the etiological stimulus—whether it is microbial, host, or environmental—will help to restore microbial homeostasis. Targeting specific microorganisms may be less effective, because the conditions for disease will remain.

Complicating Factors

The identification of bacterial pathogens in periodontal diseases has been difficult because of a number of factors.[363] The periodontal microbiota is a complex community of microorganisms, many of which are still difficult or impossible to cultivate or identify. The chronic nature of periodontal disease has complicated the search for bacterial pathogens. It was previously thought that periodontal diseases progressed at a slow but steady rate.[217] However, epidemiologic studies established that the disease progresses at different rates, with alternating episodes of rapid tissue destruction and periods of remission (Figure 8-36).[366] At this moment, by means of multilevel modeling, the linear and burst theories of periodontitis progression are considered to be a manifestation of the same phenomenon: some sites improve while others progress, and this occur in a cyclic manner.[109] Identification of the microorganisms found during the different phases of the disease progression is technically challenging. The interpretation of microbiological data is further complicated by the clinical classification of the disease status, which is an area that has undergone a number of recent revisions.[15,395] Previous and perhaps current classifications involve the grouping of potentially different disease states as a result of difficulties with accurately distinguishing them clinically. It is important to recognize that groupings such as this may obscure microbiological associations.

Periodontitis is currently considered a mixed infection. This has significant implications for both the diagnosis and treatment of periodontitis. For the diagnosis, some evaluate the presence of up to 40 species, but it still is unclear whether some combinations of species are more pathogenic than others. The treatment is directed toward the eradication or reduction of the number of key periodontopathogens. Because several species may be involved, the appropriate use of antimicrobials (especially antibiotics) is extremely difficult to define, because not all expected periodontopathogens are equally susceptible to the same antibiotic.

In fact, there is some evidence that certain pathogens may trigger the disruption of microbial homeostasis, thereby leading to the development of periodontal disease, even when they are present

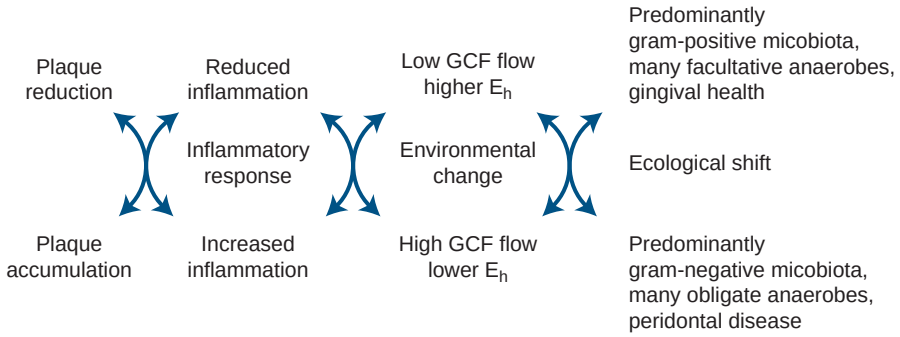

Figure 8-35 Ecologic plaque hypothesis in relation to periodontal diseases: gingivitis and periodontitis. The accumulation of plaque causes the inflammation of adjacent tissues (gingivitis) and other environmental changes that favor the growth of gram-negative anaerobes and proteolytic species, including periodontopathogens. The increased proportions of such species results in the destruction of periodontal tissues (i.e., periodontitis). *Eh,* Redox potential; *GCF,* gingival crevicular fluid. *(Adapted from Marsh PD:* Adv Dent Res *8:263, 1994.)*

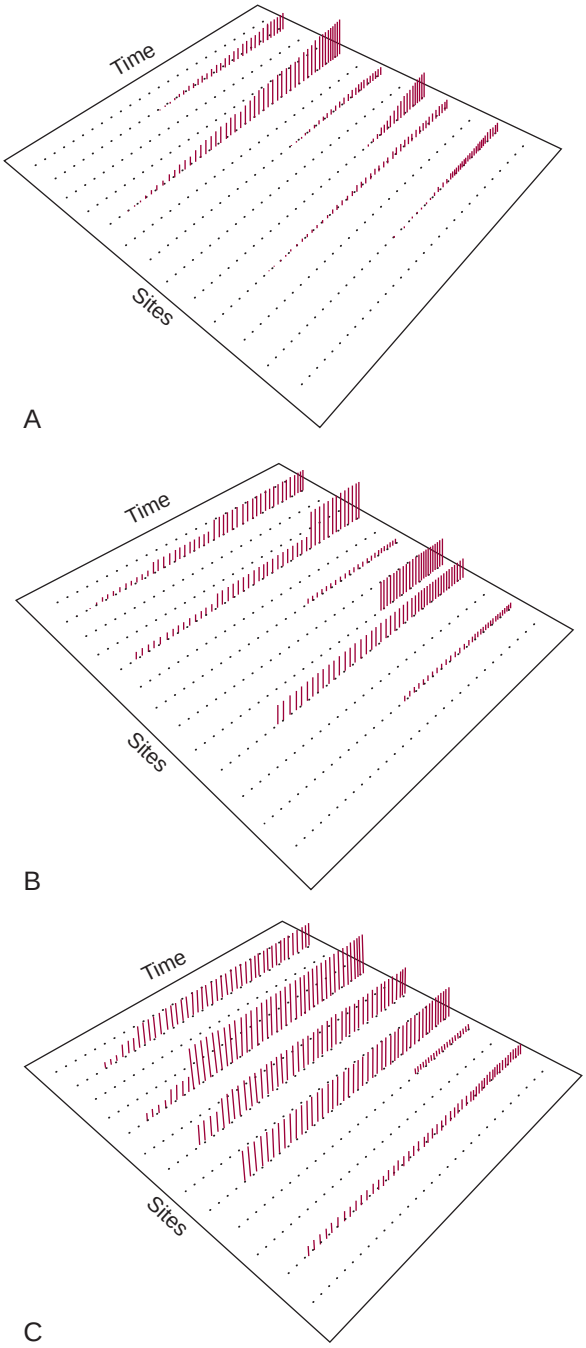

Figure 8-36 Diagrammatic representation of possible modes of progression of chronic destructive periodontal diseases. Sites on the x-axis are plotted against time on the y-axis, and activity is shown on the z-axis. **A,** Some sites show a progressive loss of attachment over time, whereas others show no destruction. The time of onset and the extent of destruction vary among sites. **B,** Random burst model. Activity occurs at random at any site. Some sites show no activity, whereas others show one or several bursts of activity. The cumulative extent of destruction varies among sites. **C,** Asynchronous multiple burst model. Several sites show bursts of activity over a finite period followed by prolonged periods of inactivity. Occasional bursts may occur infrequently at certain sites at later periods. Other sites show no periodontal disease activity at any time. The difference from the model shown in **B** is that, in **C,** the majority of destructive disease activity takes place within a few years of the individual's life. *(Courtesy Drs. S. Socransky, A. Haffajee, M. Goodson, and J. Lindhe; Boston, MA, and Göteborg, Sweden.)*

only low numbers. For example, specific pathogen-free mice exposed to *P. gingivalis* developed periodontal bone loss even when the pathogen was present in less than 0.1% of the total microbiota. Disease did not occur in the absence of other bacteria (i.e., in germ-free mice) or in mice lacking the C3a or C5a complement receptors. These data indicated that *P. gingivalis* subverts the host immune system and changes the microbial composition of dental plaque, ultimately leading to periodontal bone loss. On this basis, *P. gingivalis* was labeled a "keystone" pathogen; this means that it is an organism that is central to the disease process, even when it is at a relatively low abundance. This "keystone pathogen" hypothesis holds that certain low-abundance microbial pathogens can orchestrate inflammatory disease by remodeling a normally benign microbiota into a dysbiotic one. It may provide a novel conceptual basis for the development of targeted diagnostic and treatment modalities for complex dysbiotic diseases.[125,126]

Recent microbiological diagnostic tests indicated that the presence of periodontopathogens alone is not sufficient for the development of periodontitis. Because of the high sensitivity of these tests, several pathogens have been detected in periodontitis-free patients. Thus, merely the presence of pathogens is not sufficient for disease, and the amount of the pathogens plays a key role in relation to disease.[321] These observations have major clinical implications. First, the specificity of microbial detection is dramatically reduced (specificity in the sense that the presence of a specific pathogen means periodontitis). In other words, even though a microbiologic analysis is positive, the patient can be without disease.[225] In addition, the understanding of the etiology becomes more complicated, because the threshold level for periodontopathogens between health and disease is unknown and obviously subject dependent. Moreover, for several species, large intrastrain variations in genetic information have been detected (i.e., different genotypes) so that, in fact, genotypical information is necessary for pathogenicity assessment.[55,73,118,273] The quality of the host response also plays an essential role, but this cannot yet be correctly estimated. Finally, it might be questioned whether periodontopathogens are endogenous resident species or exogenous invaders. Indeed, the newer techniques have reported high detection frequencies of all pathogens in healthy subjects.[225,332] This has significant impact on the treatment strategies. For endogenous species, the endpoint of a therapy is the quantitative reduction of the species, whereas, for exogenous species, the endpoint is eradication and the prevention of reinfection.

It is currently impossible to alter the susceptibility of the host, so periodontal therapy must be focused on the reduction or elimination of periodontopathogens in combination with the reestablishment, often by surgical pocket elimination, of a more suitable (i.e., less anaerobic) environment for a more beneficial microbiota. Several studies have indicated that the presence of the previously mentioned periodontopathogens (that persist or are reestablished after treatment) is associated with a negative clinical outcome of periodontal treatment.[121,311,312] Because several species may be involved, the use of antimicrobials (especially antibiotics) is extremely difficult, because antibiotic susceptibility is very diverse among periodontopathogens and often depends on the geographic region.[300,400]

It is obvious that several key questions still remain unanswered. Some researchers question whether the presence of specific microorganisms in the periodontal pocket is a cause or a consequence of disease.[367] Because most periodontopathogens are fastidious strict anaerobes, they may contribute little to the initiation of disease in shallow gingival pockets and instead be found only in deep periodontal pockets, which is their preferred habitat.

The Transition From Health to Disease

The oral microbial ecology is dynamic. The presence and numbers of particular microorganisms, even as a part of a community colonizing a niche in a human being, are controlled by the type and quantity of nutrients present (nutritional determinant), their ability to tolerate the specific physicochemical factors (physicochemical determinants), and their ability to cope with antimicrobial compounds (biological determinants) or mechanical removal forces (mechanical determinants).[421] Although these determinants are well defined from a theoretical point of view, in practice they overlap each other, especially in more complex environments (i.e., multispecies environments). Inherent to their biological nature, bacteria interact with each other, with their environment, and vice versa. Therefore, the microbial ecology will change its composition or the composition of the microbial ecology will be changed when transitioning from a healthy status to a diseased status or vice versa. A change in the composition of a bacterial community as the result of external, nonmicrobial factors is termed *allogenic succession.* Smoking is a good example of such interaction. In *autogenic succession* (i.e., a change in the composition of a microbial community that arises from microbial activities), interbacterial and viral–bacterial interactions are involved.

Early microscopic studies clearly demonstrated that the number and proportions of different subgingival bacterial morphotypes differ between healthy and diseased sites (Figures 8-37 and 8-38; see Video 8-4: Phase Contrast).[212,354,361] The total number of bacteria, which was determined by microscopic counts per gram of plaque, was twice as high in periodontally diseased sites as compared with healthy sites.[361] Because considerably more plaque is found at diseased sites, this suggests that, in general, the total bacterial load in diseased sites is greater than that of healthy sites. Fewer coccal cells and more motile rods and spirochetes are found in diseased sites as compared with healthy sites.[212] Although this morphological criterion can be of diagnostic value, one should remember that nearly all key periodontal pathogens (except *Campylobacter rectus* and spirochetes) are immobile rods, which adds to the confusion regarding the bacterial etiology of periodontal diseases. Culturing has shown that the microbiota in periodontally healthy sites consists predominantly of gram-positive facultative rods and cocci (approximately 75%).[354] The recovery of this group of microorganisms is decreased proportionally in gingivitis (44%) and periodontitis (10% to 13%). These decreases are accompanied by increases in the proportions of gram-negative rods, from 13% in health to 40% in gingivitis and 74% in advanced periodontitis.

The current concept regarding the etiology of periodontal diseases considers three groups of factors that determine whether active periodontal destruction will occur in a subject: a susceptible host, the presence of pathogenic species, and the absence or small

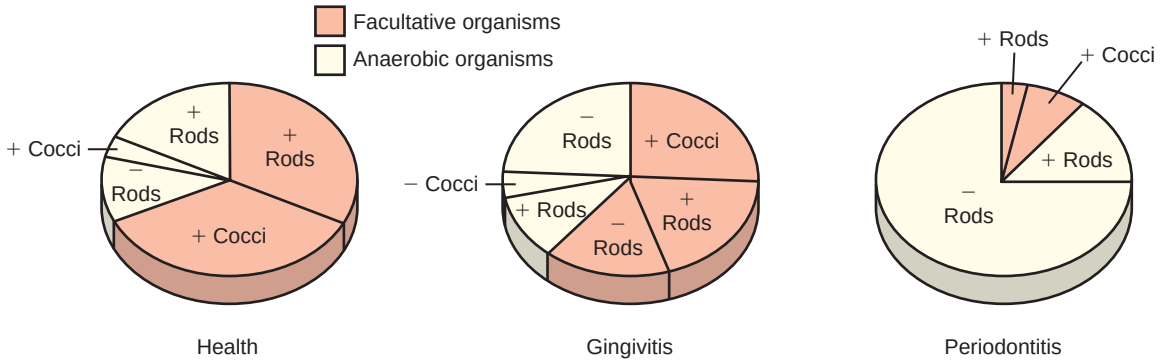

Figure 8-37 Pie charts based on culturing studies that represent the relative proportion of different morphotypes in subgingival samples in cases of periodontal health, gingivitis, and periodontitis. A clear distinction is made between facultative species and obligate anaerobic species. Spirochetes are not included.

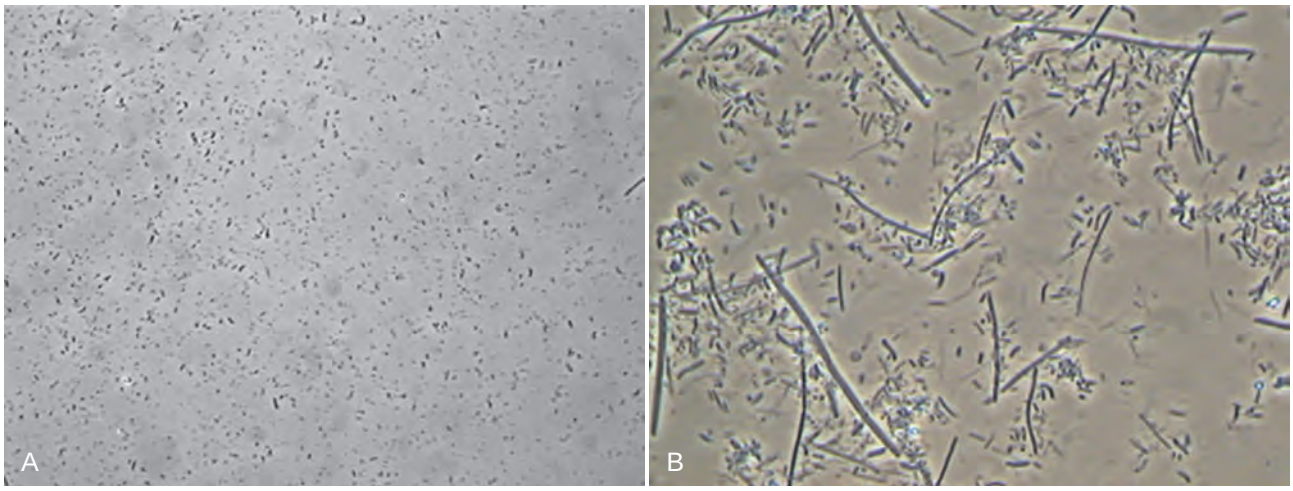

Figure 8-38 Phase-contrast micrographs of plaque samples from, **A,** a healthy patient and, **B,** a patient with periodontitis. Note the large rods and spirochetes in the periodontitis plaque sample.

proportion of so-called beneficial bacteria.[12,360,363,370,424] The clinical manifestations of periodontal destruction will result from a complex interplay between these etiologic agents. In general, small amounts of bacterial plaque can be controlled by the body's defense mechanisms without destruction; however, when dysbiosis happens (e.g., as a result of increased susceptibility, high bacterial load, or pathogenic infections), periodontal destruction might occur.[23]

Host Susceptibility

The susceptibility of the host is determined by genetic factors as well as by environmental and behavioral factors, such as smoking, stress, and viral infections.

Genetic factors seem important for patients with so-called early onset periodontitis, which is now referred to as *aggressive periodontitis.*[239] Reports regarding the familial nature of chronic forms of periodontitis are less conclusive. The aggregation of aggressive periodontitis within families is consistent with a genetic predisposition, although common environmental factors cannot be excluded (see Chapter 6).

Smoking is considered a behavioral factor and eventually an environmental factor. It dramatically increases host susceptibility to periodontal breakdown. Nevertheless, the exact nature of the relationship between periodontitis and smoking is unclear (see Chapter 10).There are conflicting reports regarding the effects of smoking on the oral microbiota. Some are in favor of an increased prevalence of *P. gingivalis*, *A. actinomycetemcomitans*, *T. forsythia, E. coli*, and *C. albicans* in smokers, whereas others report no difference.[29,123,287,373,391,398,432]

More recently, pyrosequencing revealed a lower subgingival taxonomic diversity in smokers as compared with nonsmokers.[26] Smoking cessation, on the other hand, can alter the subgingival biofilm and suggests a mechanism for improved periodontal health associated with smoking cessation.[102] There is some evidence that the epithelial cells of smokers are more prone to colonization by respiratory pathogens. Depending on the bacterial strain, the relative increase in the number of adhering pathogens in smokers versus nonsmokers ranged from 40% up to 150%.[93,324] Interestingly, cigarette smoke has recently been shown to modify the expression of *P. gingivalis* genes directly, including several virulence-associated genes.[20] After exposure to cigarette smoke extract, *P. gingivalis* cells induce a lower proinflammatory response than unexposed *P. gingivalis* cells.

Recently, viral infections have been added to the list of factors that modify host susceptibility. HIV and herpesviruses are often associated with periodontal infections.

With regard to periodontopathogen adhesion to virally infected cells, Teughels and coworkers showed a 100% increase in *A. actinomycetemcomitans* colonization when epithelial cells were infected with hCMV.[385]

Increasing evidence suggests that emotional stress and negative life events can play an important role in the development and progression of periodontitis and that they may also modify the response to periodontal treatment. Stress associated with financial strain is a significant risk indicator for more severe periodontitis in adults (odds ratio, 2.24; confidence interval, 1.15 to 4.38).[106] Emotional and psychological loads can influence the immune system, and they will also alter oral health behaviors.[68] Both factors increase the susceptibility to periodontitis.

Racial factors have also been implicated in the differences in prevalence of early-onset periodontitis and in the frequency of detection of putative periodontopathogens.[21,218]

Pathogenic Bacteria

The second essential factor for disease initiation and progression is the presence of one or more pathogens of the appropriate clonal type and in sufficient numbers. Despite the difficulties inherent in characterizing the microbiology of periodontal diseases, a small group of pathogens is recognized because of their close association with disease. There are obvious data to support the designation of *A. actinomycetemcomitans, T. forsythia, Treponema denticola,* and *P. gingivalis* as key pathogens, because they are strongly associated with periodontal disease status, disease progression, and unsuccessful therapy. For the following list of bacteria, moderate evidence for etiology has been reported, at least if their concentration passes a certain threshold level: *P. intermedia, Prevotella nigrescens* (see Figure 8-1, *I*), *C. rectus, Parvimonas micra* (see Figure 8-1, *J*), *F. nucleatum, Eubacterium nodatum* (see Figure 8-1, *N*), and various spirochetes.[12,360,363,370,424] The significance of the role of these key pathogens is largely based on epidemiologic data, the ability of these microorganisms to produce disease when inoculated in animals, and their capacity to produce virulence factors. However, the mere presence of putative periodontopathogens in the gingival crevice is not in itself sufficient to initiate or cause periodontal inflammation. An elevation in the relative proportion or number of these pathogens to reach a critical mass seems more crucial to mount an effective tissue-damaging process. Indeed, even in health, periodontopathogens are or can be present in the gingival crevice, albeit in low numbers, as members of the normal resident flora.[225] Table 8-10 gives a general overview of the detection frequency for most key pathogens in different forms of periodontal infections. It is immediately obvious that there is no black-and-white situation; there are no specific types of periodontitis for which any known pathogen is always present. This table also illustrates the difficulties with using the microbial composition

TABLE 8-10 Prevalence of Microbial Species Associated With Various Clinical Forms of Periodontitis

	FORMS OF PERIODONTITIS		
Species	**Chronic Periodontitis**	**Localized Aggressive Periodontitis**	**Aggressive Periodontitis**
Aggregatibacter actinomycetemcomitans	28.2%	81.8%	40.9%
Porphyromonas gingivalis	53.8%	13.3%	79.6%
Prevotella intermedia/nigrescens	50.2%	53.4%	71.4%
Tannerella forsythia	50.6%	0	50.8%
Campylobacter rectus	40.3%	12.5%	47.8%

Adapted from Haffajee AD, Socransky SS: *Periodontol 2000* 5:78, 1994; and Mombelli A, Casagni F, Madianos PN: *J Clin Periodontol* 29(Suppl 3):10, 2002.

0, Occasionally isolated.

Several studies show a clear association between HIV infection and some distinct forms of periodontal infection (i.e., necrotizing lesions).[271,281,341] The increased prevalence and severity of chronic periodontitis in HIV-positive subjects suggest that HIV infection predisposes affected individuals to chronic periodontitis.[323] A similar association has been shown for herpesviruses and periodontitis.[355] hCMV was positively associated with severe periodontitis (odds ratio, 4.65; confidence interval, 1.12 to 19.30).[63] Moreover, active hCMV replication in periodontal sites may suggest that hCMV reactivation triggers periodontitis activity.[61] However, caution is warranted in view of concerns regarding sampling, methods, and interpretation.[46]

It is thought that virus-associated periodontal destruction originates from virus-induced changes in the host response to the local subgingival microbiota.[355]

The influence of viral infections and of the bacterial colonization of cells was investigated by Sanford and coworkers, who first described an increased adhesion of bacteria to virally infected cultured cells.[331] Similar observations have been made since then for a wide variety of viruses, cells, and bacteria.[35] Viral infections relatively increase bacterial adhesion to cells by 20% to 362%.[88,127]

TABLE 8-11 Prevalence of Key Pathogens in Healthy Subjects and Patients with Periodontitis

Species	PREVALENCE		SIGNIFICANCE OF DIFFERENCE	
	Health	Periodontitis	*P* Value	Odds Ratio*
Aggregatibacter actinomycetemcomitans	12.8%	31.0%	.002	3.1
Porphyromonas gingivalis	10.6%	59.5%	<.001	12.3
Prevotella intermedia/nigrescens	69.1%	87.9%	.001	3.3
Tannerella forsythia	47.9%	90.5%	<.001	10.4
Fusobacterium nucleatum	85.1%	95.7%	.014	3.9
Parvimonas micra	67%	94%	<.001	7.7
Campylobacter rectus	13.8%	20.7%	NS	1.6

Adapted from Van Winkelhoff, Loos BG, van der Reijden WA, et al: *J Clin Periodontol* 29:1023, 2002.

NS, Not significant.

*The ratio of the probability of developing the disease to the probability of nonoccurrence. For example,"3" means that there is a threefold increased chance that the disease will develop if that species is present.

to differentiate between different forms of periodontal infections. Table 8-11 further highlights the complexity of the microbiology of periodontitis. Most periodontopathogens can also be detected in healthy subjects, with frequencies that range from 10% to 85%. It is obvious that this automatically reduces the specificity of microbiological testing in periodontology.

Beneficial Species

The role of "beneficial" species is less obvious in the development of periodontal diseases.[317,363] These bacteria can affect the pathogenic species in different ways and thus modify the disease process as follows: (1) by passively occupying a niche that may otherwise be colonized by pathogens; (2) by actively limiting a pathogen's ability to adhere to appropriate tissue surfaces; (3) by adversely affecting the vitality or growth of a pathogen; (4) by affecting the ability of a pathogen to produce virulence factors; or (5) by degrading the virulence factors produced by the pathogen. The often-used textbook example of such a beneficial action is the effect of *S. sanguinis* (formerly known as *S. sanguis*) on *A. actinomycetemcomitans*.[390] *S. sanguinis* produces H_2O_2, which either directly or by host enzyme amplification can kill *A. actinomycetemcomitans*.[144] Although these so-called beneficial bacteria may be of importance for maintaining a healthy subgingival ecosystem, evidence is limited.[317] Despite rapidly increasing knowledge of periodontopathogen–host interactions, the role of beneficial microbiota in this crosstalk remains obscure. In periodontal microbiology, a bacterial strain is considered beneficial when its prevalence is high in periodontal health and low in diseased situations. It has been shown for other fields in microbiology that direct and indirect microbial interactions can suppress the emergence of pathogens.[36] The importance of the latter is evidenced within the oral cavity by the development of yeast infections when the normal oral flora is reduced, such as after a period of systemic antibiotic usage.[407]

Because it has so far been impossible to alter the susceptibility of the host, periodontal therapy is necessarily focused on the reduction or elimination of periodontopathogens in combination with the reestablishment, often by surgical pocket elimination, of a more suitable (e.g., less anaerobic) environment for a more beneficial microbiota. Several studies have indeed indicated that the presence of the previously mentioned periodontopathogens (that have persisted or been reestablished after treatment) is associated with a negative clinical outcome of periodontal treatment.[67,122,311,312,365]

Taking all of this together, it is clear that the periodontal microbiota will shift when going from a periodontally healthy situation toward a periodontally diseased situation (Figure 8-39).

When comparing the microbiota among conditions of health, gingivitis, and periodontitis, the following microbial shifts can be identified as health progresses to periodontitis:

- From gram-positive to gram-negative
- From cocci to rods (and, at a later stage, to spirochetes)
- From nonmotile to motile organisms
- From facultative anaerobes to obligate anaerobes
- From fermenting to proteolytic species

Periodontal Health

The recovery of microorganisms from periodontally healthy sites is lower as compared with diseased sites (Table 8-12). The bacteria associated with periodontal health are primarily gram-positive facultative species and members of the genera *Streptococcus* and *Actinomyces* (e.g., *S. sanguinis, S. mitis, A. oris*, *A. israelii, A. gerencseriae, A. viscosus* [see Figure 8-1, *C*], *A. naeslundii*). Small proportions of gram-negative species are also found, most frequently *P. intermedia, F. nucleatum, F. nucleatum* spp. polymorphum, *F. periodonticum, Capnocytophaga* spp. *(C. gingivalis, C. ochracea,* and *C. sputigena*), *Neisseria* spp., and *Veillonella* spp. Microscopic analyses indicate that a few spirochetes and motile rods may also be present. On the basis of checkerboard DNA–DNA hybridization data, *Eubacterium saburreum, Propionibacterium acnes, S. anginosus, S. gordonii,* and *S. oralis* can also be considered as health-associated bacteria.[94,382,426,427]

Certain bacterial species have been proposed to be protective or beneficial to the host, including *S. sanguinis, Veillonella parvula* (see Figure 8-1, *B*), and *C. ochracea.* They are typically found in high numbers at periodontal sites that do not demonstrate attachment loss (inactive sites) but in low numbers at sites where active periodontal destruction occurs.[84,363] These species probably function to prevent the colonization or proliferation of pathogenic microorganisms. Clinical studies have shown that sites with high levels of *C. ochracea* and *S. sanguinis* are associated with a greater gain in attachment after therapy, thereby further supporting this concept.[363] A better understanding of plaque ecology and the interactions between bacteria and their products in plaque will undoubtedly reveal many other examples.

Gingivitis

The development of gingivitis has been extensively studied in a model system referred to as *experimental gingivitis* and initially described by Löe and coworkers.[219,387] Periodontal health is first established in human subjects via cleaning and rigorous oral hygiene measures that are followed by abstinence from oral

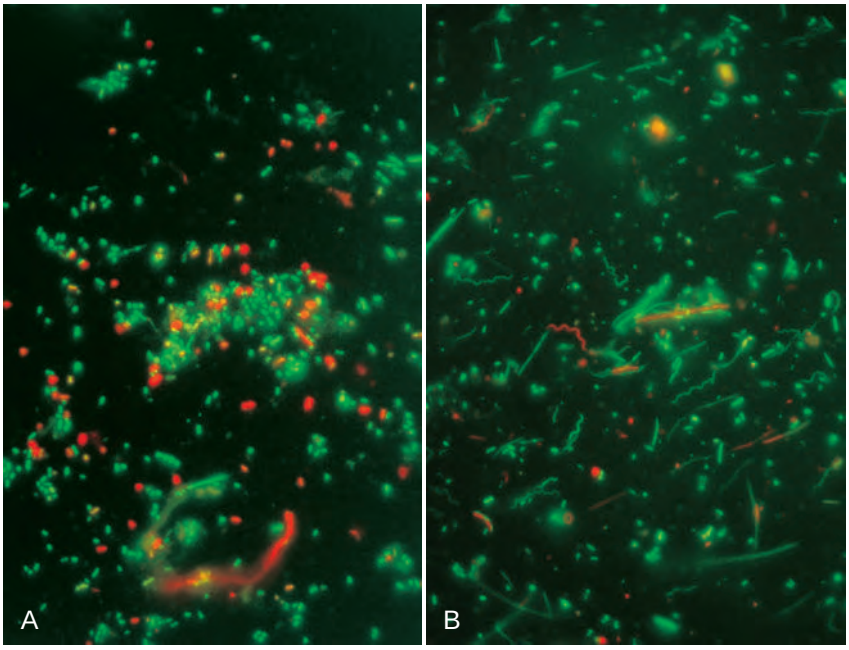

Figure 8-39 Vitality stain of subgingival plaque. **A,** Plaque derived from a healthy patient that primarily consists of cocci. **B,** Plaque derived from a patient with periodontitis. Note the important morphologic differences from **A.** Green bacteria are alive; red bacteria are dead.

hygiene for 21 days. After 8 hours without oral hygiene, bacteria may be found at concentrations of 10^3 to 10^4 per square millimeter of tooth surface, and they will increase in number by a factor of 100 to 1000 during the next 24-hour period.[368] After 36 hours, the plaque becomes clinically visible (see Video 8-1). The initial microbiota of experimental gingivitis (see Figure 8-23) consists of gram-positive rods, gram-positive cocci, and gram-negative cocci. The transition to gingivitis is evidenced by inflammatory changes; it is accompanied first by the appearance of gram-negative rods and filaments and then by spirochetal and motile microorganisms.[387]

The subgingival microbiota of dental-plaque–induced gingivitis (chronic gingivitis) differs from that of both health and chronic periodontitis (see Table 8-12). It consists of roughly equal proportions of gram-positive (56%) and gram-negative (44%) species as well as facultative (59%) and anaerobic (41%) microorganisms.[354] It should be noted that the majority of predominant species in chronic periodontitis are already present in the gingivitis state, but mostly in small numbers.

Predominant gram-positive species include *Streptococcus* spp. *(S. sanguinis, S. mitis, S. intermedius, S. oralis, S. anginosus), Actinomyces* spp. *(A. oris, A. naeslundii), Eubacterium nodatum,* and *Parvimonas micra*. The gram-negative microorganisms are predominantly *Capnocytophaga* spp., *Fusobacterium* spp., *Prevotella* spp., *Campylobacter gracilis, Campylobacter concisus, V. parvula, Haemophilus* spp., and *E. corrodens.* Both groups are commonly associated with gingivitis. The following gram-negative species are commonly found in periodontitis, and they are also associated with gingivitis but in fewer numbers: *P. gingivalis, T. forsythia, P. intermedia, Campylobacter rectus, Treponema* spp., and *A. actinomycetemcomitans* serotype a.[245,251,354] Pyrosequencing has identified additional taxa that are associated with gingivitis, including *Leptotrichia* spp. and *Selenomonas* spp.[150] In this study, *Streptococcus* spp. were more strongly associated with health than with gingivitis.

Pregnancy-associated gingivitis is an acute inflammation of the gingival tissues that is associated with pregnancy. This condition is accompanied by increases in steroid hormones in the crevicular fluid and dramatic increases in the levels of *P. intermedia* and *C. rectus*, which use the steroids as growth factors.[181,430]

Studies of gingivitis support the conclusion that disease development is associated with selected alterations in the microbial composition of dental plaque and not just the result of an accumulation of plaque. Gingivitis was generally thought to precede the development of chronic periodontitis; however, many individuals demonstrate long-standing gingivitis that never advances to the destruction of the periodontal attachment.[39,216]

Chronic Periodontitis

Numerous forms of periodontal disease are found in adult populations, and they are characterized by different rates of progression (see Figure 8-36) and different responses to therapy.[15] Studies in which untreated populations were examined over long time intervals indicate disease progression at mean rates that range from 0.05 mm to 0.3 mm of attachment loss per year (i.e., the gradual model).[39] When populations are examined over short time intervals, individual sites demonstrated short phases of attachment destruction interposed by periods of no disease activity (i.e., the burst model).[114] At this moment, by means of multilevel modeling, the linear and burst theories of periodontitis progression are considered to be manifestations of the same phenomenon: some sites improve whereas others progress, and this occurs in a cyclical manner.[109]

Microbiological examinations of chronic periodontitis have been carried out in both cross-sectional and longitudinal studies; the latter have been conducted with and without treatment. These studies support the concept that chronic periodontitis is associated with specific bacterial agents. The microscopic examination of plaque from sites with chronic periodontitis has consistently revealed elevated proportions of spirochetes (see Video 8-4).[212,223] The cultivation of plaque microorganisms from sites of chronic periodontitis reveals high percentages of anaerobic (90%) gram-negative (75%) bacterial species[353,354] (see Figure 8-29 and Table 8-12).

In patients with chronic periodontitis, the bacteria that are most often detected at high levels include *P. gingivalis, T. forsythia,*

TABLE 8-12 Summary of Bacterial Species Significantly Associated With Different Clinical Conditions Based on Culture, Polymerase Chain Reaction, and Checkerboard Data

Health	Gingivitis	Chronic Periodontitis	Localized Aggressive Periodontitis	Aggressive Periodontitis	Necrotizing Periodontal Diseases	Abscesses of the Periodontium	Periimplantitis
Actinomyces gerencseriae	*Actinomyces naeslundii* 1	*Aggregatibacter actinomycetemcomitans* serotype b	*Capnocytophaga* spp.	*Aggregatibacter actinomycetemcomitans* (serotype b)	*Fusobacterium nucleatum*	*Fusobacterium nucleatum*	*Capnocytophaga* spp
Actinomyces israelii	*Actinomyces viscosus*	*Campylobacter rectus*	*Aggregatibacter actinomycetemcomitans high* (leukotoxin clone)	*Eubacterium nodatum*	*Prevotella intermedia*	*Parvimonas micra*	*Aggregatibacter actinomycetemcomitans*
Actinomyces naeslundii 1	*Capnocytophaga* spp.	*Eikenella corrodens*	*Campylobacter rectus*	*Prevotella intermedia*	Spirochetes	*Prevotella intermedia*	*Campylobacter rectus*
Actinomyces oris	*Streptococcus anginosus*	*Eubacterium nodatum*	*Eikenella corrodens*	Spirochetes	*Treponema* spp.	Spirochetes	*Fusobacterium nucleatum*
Actinomyces viscosus	*Streptococcus mitis*	*Fusobacterium nucleatum*	*Eubacterium nodatum*	*Treponema* spp.		*Porphyromonas gingivalis*	*Parvimonas micra*
Capnocytophaga gingivalis	*Streptococcus oralis*	*Parvimonas micra*	*Fusobacterium nucleatum*	*Porphyromonas gingivalis*			*Prevotella intermedia*
Capnocytophaga ochracea	*Streptococcus sanguinis*	*Prevotella intermedia*	*Prevotella intermedia*	*Tannerella forsythia*			Spirochetes
Capnocytophaga spp.	*Veillonella parvula*	Spirochetes	Spirochetes	*Treponema denticola*			*Treponema* spp.
Capnocytophaga sputigena	*Aggregatibacter actinomycetemcomitans* serotype a	*Treponema* spp.	*Treponema* spp.	*Campylobacter gracilis*			*Enterobacter* spp.
Eubacterium saburreum	*Campylobacter concisus*	*Enterobacter* spp.	*Leptotrichia buccalis*	*Campylobacter showae*			*Porphyromonas gingivalis*
Fusobacterium periodonticum	*Campylobacter rectus*	*Leptotrichia buccalis*	*Porphyromonas gingivalis*	*Prevotella nigrescens*			*Tannerella forsythia*
Fusobacterium polymorphum	*Eikenella corrodens*	*Porphyromonas gingivalis*	*Tannerella forsythia*				*Treponema denticola*
Neisseria spp.	*Eubacterium nodatum*	*Selenomonas noxia*	*Treponema denticola*				*Pseudomonas aeruginosa*
Propionibacterium acnes	*Fusobacterium nucleatum*	*Tannerella forsythia*					*Staphylococcus aureus*
Streptococcus anginosus	*Haemophilus* spp.	*Treponema denticola*					*Staphylococcus epidermidis*
Streptococcus gordonii	*Parvimonas micra*	*Prevotella nigrescens*					
Streptococcus mitis	*Prevotella intermedia* spirochetes						
Streptococcus oralis	*Streptococcus intermedius*						
Streptococcus sanguinis	*Treponema* spp.						
Veillonella parvula							

P. intermedia, P. nigrescens, C. rectus, Eikenella corrodens (see Figure 8-1, *S*), *F. nucleatum, A. actinomycetemcomitans* (often serotype b), *P. micra, E. nodatum, Leptotrichia buccalis, Treponema (T. denticola), Selenomonas* spp. *(S. noxia),* and *Enterobacter* spp.* The introduction of pyrosequencing techniques for microbial community analysis has provided additional sensitivity for detecting periodontal pathogens, although the broad picture has not changed. Unculturable organisms such as *Synergistetes* appear to correlate with periodontal disease, whereas high proportions of *Actinomyces* spp., *Rothia* spp., and *Streptococcus* spp. are correlated with health.[2,117] When periodontally active sites (i.e., with recent attachment loss) were examined in comparison with inactive sites (i.e., with no recent attachment loss), concentrations of *C. rectus, P. gingivalis, P. intermedia, F. nucleatum,* and *T. forsythia* were found to be elevated in the active sites.[83] Furthermore, detectable levels of *P. gingivalis, P. intermedia, T. forsythia, C. rectus,* and *A. actinomycetemcomitans* are associated with disease progression, and their elimination via therapy is associated with an improved clinical response.[59,83,121,359,416] Both *P. gingivalis* and *A. actinomycetemcomitans* are known to invade host tissue cells, which may be significant in aggressive forms of periodontitis.[52,56,327]

Studies have documented an association between chronic periodontitis and viral microorganisms of the herpesviruses group, most notably EBV-1 and hCMV.[62] Furthermore, the presence of subgingival EBV-1 and hCMV are associated with high levels of putative bacterial pathogens, including *P. gingivalis, T. forsythia, P. intermedia,* and *T. denticola.* These data support the hypothesis that viral infection may contribute to periodontal pathogenesis, but the potential role of viral agents remains to be determined.

Localized Aggressive Periodontitis

Several forms of periodontitis are characterized by rapid and severe attachment loss that occurs in individuals during or before puberty. Localized aggressive periodontitis, which was previously referred to as *localized juvenile periodontitis* (LJP), develops around the time of puberty. It is observed in females more often than in males, and it typically affects the permanent first molars and incisors (Figure 8-40). This condition is almost uniformly seen in individuals who demonstrate some systemic defect in immune regulation, and often affected individuals demonstrate defective neutrophil function. Without treatment, the local form often extends to a more generalized form that involves severe attachment loss around many teeth. The first symptoms of localized juvenile periodontitis are already detectable in the deciduous dentition, especially via periodontal destruction around the canines and the second molars.[48]

The microbiota associated with localized aggressive periodontitis is predominantly composed of gram-negative, capnophilic (i.e., CO_2-requiring), anaerobic rods[255,256,354] (see Table 8-12). Microbiological studies indicate that almost all localized juvenile periodontitis sites harbor *A. actinomycetemcomitans,* which may comprise as much as 90% of the total cultivable microbiota.[182,248] Other organisms found in significant levels include *P. gingivalis, E. corrodens, C. rectus, F. nucleatum, B. capillus, Eubacterium brachy,* and *Capnocytophaga* spp. and spirochetes.[182,240,248,250] Recent checkerboard DNA–DNA hybridization studies have also shown high proportions of *E. nodatum, P. intermedia, Treponema* spp. *(T. denticola)*, *L. buccalis,* and *T. forsythia.*[94,426] In addition, herpesviruses, including EBV-1 and hCMV, have also been associated with localized aggressive periodontitis.[62,240,388]

A. actinomycetemcomitans is generally accepted as the primary etiologic agent in most but not all cases of localized aggressive periodontitis.[180,363] A high leukotoxic clone is uniquely associated with aggressive forms of periodontitis. However, the fact that not all aggressive periodontitis patients show this feature points to the possibility that several other factors may provoke this disease.[244] Studies of therapy indicate that mechanical debridement in combination with systemic antibiotic treatment is necessary to control the levels of *A. actinomycetemcomitans* associated with this disease.[182,313,314] The failure of mechanical therapy alone may relate to the ability of this organism to invade host tissues.[52,56,327]

Aggressive Periodontitis

Aggressive periodontitis, which is also known as *generalized aggressive periodontitis, early-onset periodontitis,* and *rapidly progressive periodontitis,* is a severe form of periodontitis that occurs at a relatively young age (i.e., between 20 to 40 years). It is characterized by a severe gingivitis, a large number of deepened pockets, and a high tendency for bleeding on probing. In relation to the patient's age, there is a lot of bone destruction. It is sometimes considered as a generalized form of localized aggressive periodontitis. From a microbiological point of view, it has a lot of similarities with localized aggressive periodontitis (see Table 8-12). However, aggressive periodontitis is clearly more dominated by *P. gingivalis, P. intermedia, T. forsythia,* and *Treponema* spp. *(T. denticola)* and less by *A. actinomycetemcomitans*. Recent

*References 184, 191, 220, 251, 354, 362, 363, 379, 382, 426, 437

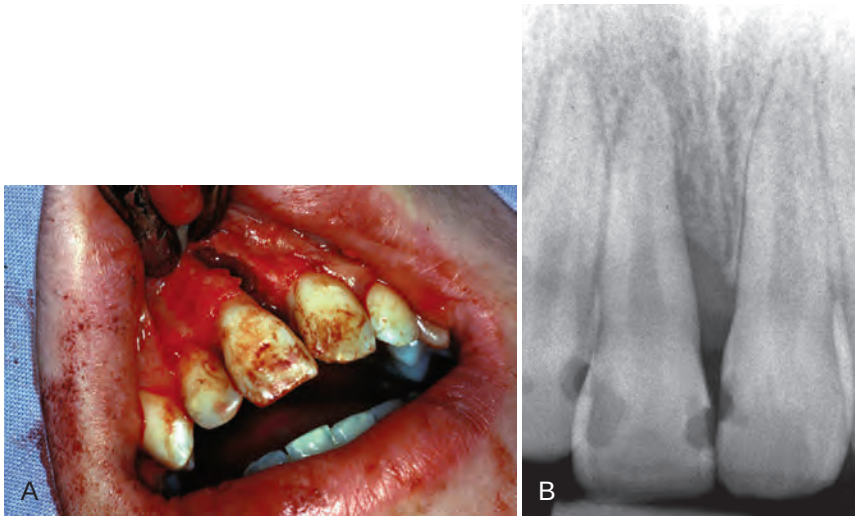

Figure 8-40 **A,** Clinical picture and, **B,** intraoral radiograph of the dramatic bone destruction in an adolescent patient with localized aggressive periodontitis.

checkerboard DNA–DNA hybridization studies also indicate high proportions of *E. nodatum, Campylobacter gracilis, Campylobacter showae,* and *P. nigrescens*.[94,426]

Necrotizing Periodontal Diseases

Necrotizing periodontal diseases (Figure 8-41) present as acute inflammation of the gingival and periodontal tissues that is characterized by the necrosis of the marginal gingival tissue and the interdental papillae. Clinically, these conditions are often associated with stress or HIV infection. They may be accompanied by malodor and pain and possibly systemic symptoms, including lymphadenopathy, fever, and malaise. Microbiological studies indicate that high levels of *P. intermedia* and especially of spirochetes and *F. nucleatum* are present in necrotizing ulcerative gingivitis lesions. Spirochetes are found to penetrate necrotic tissue and apparently unaffected connective tissue.[213,214]

Figure 8-41 Clinical picture of lower front teeth with necrotizing gingivitis.

Abscesses of the Periodontium

Periodontal abscesses (Figure 8-42) are acute lesions that may result in the very rapid destruction of the periodontal tissues. They often occur in patients with untreated periodontitis, but they also may be found in patients during maintenance or after the scaling and root planing of deep pockets. Periodontal abscesses may also occur in the absence of periodontitis; for example, they may be associated with the impaction of a foreign object (e.g., a popcorn kernel, dental floss) or with endodontic problems.[143] Typical clinical symptoms of periodontal abscesses include pain, swelling, suppuration, bleeding on probing, and mobility of the involved tooth. Signs of systemic involvement may be present, including cervical lymphadenopathy and an elevated white blood cell count.[142] Investigations reveal that bacteria that are recognized as periodontal pathogens are commonly found in significant numbers in periodontal abscesses. These microorganisms include *F. nucleatum, P. intermedia, P. gingivalis, P. micra,* and *T. forsythia.*[124,142,255] Periradicular lesions, which arise as a consequence of endodontic infections, appear to have a similar microbial composition, with a microbiota that is dominated by anaerobes. In addition, *Streptococcus* spp. can also be detected.[325]

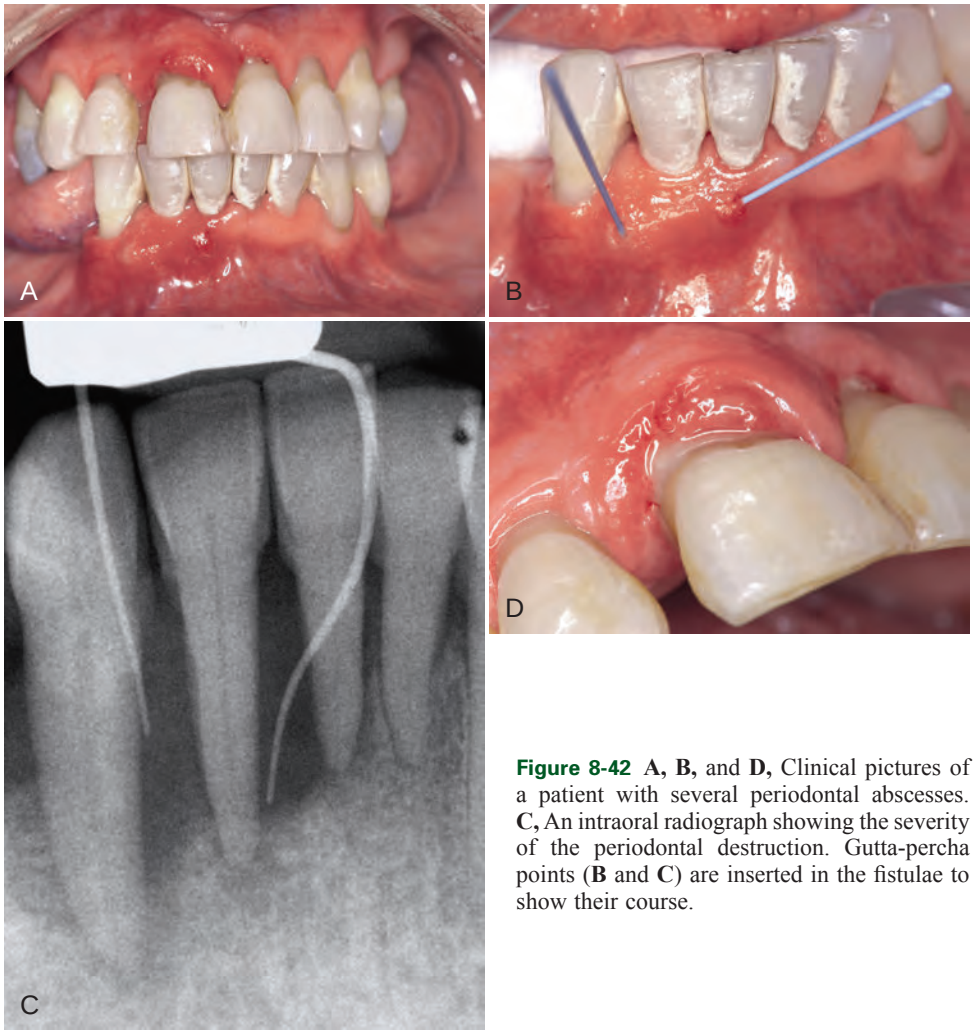

Figure 8-42 **A, B,** and **D,** Clinical pictures of a patient with several periodontal abscesses. **C,** An intraoral radiograph showing the severity of the periodontal destruction. Gutta-percha points (**B** and **C**) are inserted in the fistulae to show their course.

Periimplantitis

The term *periimplantitis* refers to an "inflammatory process" that affects the tissues around an already osseointegrated implant and that results in the loss of supporting bone.[15] Originally this inflammatory process was thought to be associated (e.g., in animal studies, in cross-sectional and longitudinal observations in man) with a microbiota comparable with that of periodontitis (i.e., a high proportion of anaerobic gram-negative rods, motile organisms, and spirochetes), but this association does not necessarily prove a causal relationship.[295] Recent evidence suggests a lower degree of bacterial complexity in the periimplant crevice.[189] Healthy periimplant pockets are characterized by high proportions of coccoid cells, a low ratio of anaerobic-to-aerobic species, a low number of gram-negative anaerobic species, and low detection frequencies for periodontopathogens.[4,31,201,264] Implants with periimplantitis reveal a microbiota that encompasses conventional periodontal pathogens (see Table 8-12) as well as the cariogenic bacterium *S. mutans*.[189,277] Species such as *A. actinomycetemcomitans, P. gingivalis, T. forsythia, P. micra, C. rectus, F. nucleatum, P. intermedia, T. denticola,* and *Capnocytophaga* are often isolated from failing sites, but they can also be detected around healthy periimplant sites.[344] Other species, such as *Pseudomonas aeruginosa*, *Enterobacter* spp., *C. albicans,* and staphylococci, are also frequently detected around implants.[8] These organisms are uncommon in the subgingival area, but they have been associated with refractory periodontitis.[360] High proportions of *Staphylococcus aureus* and *S. epidermidis* on oral implants have been reported.[308] The relative resistance of these organisms to commonly used antibiotics suggests that their presence may represent an opportunistic colonization that is caused by systemic antibiotic therapy.[359]

Some large-scale clinical follow-up studies seem to indicate that implant failures cluster within patients, with increased odd ratios for a second implant failure in patients who have already lost one implant.[397,417] These observations indicate that, within patients, systemic factors are important for the characterization of implant losses.

Virulence Factors of Periodontopathogens

It is clear that some organisms, such as *P. gingivalis, A. actinomycetemcomitans,* spirochetes, and *P. intermedia,* are strongly associated with a number of periodontal diseases. However, periodontal disease never occurs in the absence of a complex microbiota, and it is often difficult (if not impossible) to determine precisely how different organisms contribute to an individual case of disease. In fact, the contributions of specific bacteria to disease may be unimportant according to the ecological plaque hypothesis. Targeting one or more "pathogens" will not necessarily cure disease, because other organisms with similar activities may take their place. Therefore, it might make sense to focus on the specific molecules that contribute to disease (virulence factors) rather than on the microorganisms that produce them. In fact, it is often difficult to separate the virulence determinants from the organisms that produce them. For example, adhesins are produced by commensal organisms as well as by pathogens, yet only those adhesins that promote the attachment of a pathogenic organism could be considered virulence determinants. With this in mind, some of the known or putative virulence factors for periodontal disease are described in the following sections. It is important to note the following:

1. Only a proportion of periodontal bacteria have ever been isolated, and there are almost certainly many other virulence factors that are currently unknown.
2. Most of our understanding of virulence factors has come from studies of a very limited number of bacterial species and strains. It is far from clear that the molecules that have been studied in the greatest detail are truly representative of their classes.

Virulence factors of periodontal microorganisms can be subdivided as follows: (1) factors that promote colonization (adhesins); (2) toxins and enzymes that degrade host tissues; and (3) mechanisms that protect pathogenic bacteria from the host.

Adhesive Surface Proteins and Fibrils

To colonize the periodontal pocket, bacteria must adhere to cells or tissues in the region, such as teeth, the existing microbial biofilm, or the pocket epithelium. Bacterial cell surface structures provide the points of contact. Often these structures extend some distance from the cell surface. Fimbriae or pili are polymeric fibrils that are composed of repeating subunits that can extend several microns from the cell membrane. Pili were once thought to be unique to gram-negative bacteria, but they have now been identified in several gram-positive organisms, including streptococci and actinomyces.[231] Strains of *P. gingivalis* produce two types of fimbriae that are known as the *major fimbriae* and the *minor fimbriae.*[128]

The major fimbriae are single-stranded filaments approximately 5 nm in diameter and up to 3 µm in length. The backbone of major fimbriae is a chain of repeating subunits of the 43 kDa FimA protein. Minor fimbriae are composed of a 67 kDa protein, Mfa1, and they extend approximately 0.1 to 0.5 µm from the cell surface.[14] Major and minor fimbriae interact with oral streptococci such as *S. gordonii*. *P. gingivalis* FimA binds to glyceraldehyde-3-phosphate dehydrogenase, whereas Mfa1 interacts with the *S. gordonii* cell surface adhesin B.[229,270] Major fimbriae have also been shown to bind host extracellular matrix proteins fibronectin and type I collagen, salivary proline-rich proteins and statherin, and epithelial cells.[11,129,257] Extensive variation in the *fimA* gene that encodes the FimA fimbrial subunit has been observed, and six different genotypes have been designated (i.e., genotypes I, Ib, II, III, IV, and V).[91] Of these, genotypes II and IV are associated with periodontitis.[10,90] However, at present, there is no evidence that fimbriae of genotypes II and IV are functionally distinct from other major fimbriae.

Tissue-Destruction–Promoting Factors

Many bacterial proteins that interact with host cells are recognized by the immune system, and they may trigger immune responses. Fimbriae of *P. gingivalis* and *A. actinomycetemcomitans* are highly antigenic. Inflammation is a major contributor to tissue destruction in periodontal disease; this is considered separately in Chapter 5. However, a number of bacterial products directly promote tissue destruction in addition to modulating host immunity, with extracellular proteolytic enzymes being the most notable.

Bacterial proteolytic activity in dental plaque—and, in particular, trypsin like protease activity—is closely correlated with clinical markers of periodontal disease.[261]

However, the bulk of the host-tissue–degrading activity is restricted to a small number of these enzymes. In the case of *P. gingivalis*, three enzymes known as *gingipains* are responsible for at least 85% of the total host-protein–degradation activity.[283]

The gingipains belong to the cysteine protease family, and they use an active-site cysteine residue for catalysis. Gingipains are classed as "Arg-gingipains" (RgpA and RgpB) or "Lys-gingipains" (Kgp) on the basis of their ability to cleave Arg-Xaa or Lys-Xaa peptide bonds (Xaa represents any amino acid). Gingipains are multifunctional proteins that play important roles in adhesion, tissue degradation, and the evasion of host responses.

Adhesion is a fundamental process in the lifestyle of *A. actinomycetemcomitans*. On solid media, fresh isolates of *A. actinomycetemcomitans* generally form roughly star-shaped colonies that are embedded in the agar. In broth, these strains form clumps (autoaggregate) and grow firmly attached to the sides of the culture vessel, thus leaving the bulk fluid almost completely clear. After several laboratory subcultures, rough strains often revert to "smooth" colony variants. The conversion from a rough form to a smooth form is associated with the loss of pili. *A. actinomycetemcomitans* pili are encoded by a region of the chromosome that contains 14 genes, including the structural pilus subunit gene *flp-1* and an associated system for the secretion and modification of the fibrils. Twelve of these genes have been shown in gene disruption studies to be essential for biofilm formation.[275,280] In a rat model of periodontitis, genes in the *A. actinomycetemcomitans* pilus locus (*flp-1* and *tadA*) were essential for pathogenesis.[339] Despite these seemingly convincing data, there is still some debate regarding the exact role of pili in *A. actinomycetemcomitans* adhesion. Carbohydrates appear to be more important for the attachment of *A. actinomycetemcomitans* than proteins. Treatment with periodate (which disrupts carbohydrate structures) detaches cells from surfaces, whereas the degradation of cell surface proteins by trypsin does not.[96] During growth, *A. actinomycetemcomitans* produces a glycosidase enzyme, dispersin B, that degrades poly-N-acetylglucosamine and that releases even tightly adherent cells from surfaces.[163] In *A. actinomycetemcomitans,* poly-N-acetylglucosamine remains tightly bound to cells, and it co-purifies with lipopolysaccharides.[156] There is some evidence that the production of extracellular polysaccharides may be linked to pilus biosynthesis, because knocking out almost any gene in the pilus locus reduces extracellular polysaccharide production.[411]

Several nonpilus proteins from periodontopathogens have been shown to interact with host or bacterial receptors as well as, in some cases, with both. A relatively well-studied example is the major sheath protein (Msp) of *T. denticola*. Msp is a 53 kDa to 64 kDa protein that was originally thought to assemble into a hexagonal array in the outer sheath. However, careful analysis by electron microscopy indicated that Msp is predominantly a periplasmic protein and that some regions are exposed on the cell surface.[45] Purified Msp interacts with the host extracellular matrix proteins fibrinogen, fibronectin, and laminin.[86,95,120] In addition, Msp recognizes receptors on *P. gingivalis* and *F. nucleatum* and mediates coaggregation.[318] Therefore, Msp is a multifunctional adhesin that promotes binding to host and bacterial receptors.

Trypsin like proteases are produced by *P. gingivalis*, *T. denticola,* and *T. forsythia,* and these molecules have been the subject of a comprehensive review.[282] Proteases supply nutrition in the form of peptides or amino acids to the bacteria that produce them. During this process, they may cause the extensive degradation of host extracellular proteins. Periodontopathogens frequently produce complex proteolytic systems that consist of multiple peptide-degrading enzymes; at least 13 peptidases of *P. gingivalis* have been characterized, and a further 29 peptidases are predicted from the genome sequence of strain W83, for example.[253,282]

Protein domains involved in adhesion are located in the C-terminus of pro-RgpA and pro-Kgp, and they are subsequently removed by posttranslational proteolytic processing. The cleaved protease and adhesin domains sometimes reassociate noncovalently. By contrast, the gene that encodes RgpB does not contain the sequences for adhesin domains. The combination of adhesin functions and protease activity together in the same molecule provides an efficient mechanism for targeting substrates. Thus, the catalytic/adhesion domain complex of RgpA is more efficient than RgpB at binding and degrading fibrinogen.[154]

Proteases are produced by *A. actinomycetemcomitans,* but these appear to be less important for the virulence of this organism than the leukotoxin (LtxA). LtxA is a member of the repeats-in-toxin family of proteins. These toxins act by delivering an adenylate cyclase domain into cells, which catalyzes the uncontrolled conversion of adenosine triphosphate to cyclic adenosine monophosphate.

Most strains of *A. actinomycetemcomitans* produce low levels of LtxA. However, some strains are regarded as hyperleukotoxic, because they express high levels of the transcript from the *ltxA* gene, thereby encoding LtxA. Hyperleukotoxic strains include the JP2 clone of *A. actinomycetemcomitans*, which is uniquely associated with localized aggressive periodontitis.[139,244] Two distinct mechanisms that give rise to high levels of *ltxA* expression have been described.[336] The JP2 clone contains a deletion in a regulatory gene, designated *orfA*, that is upstream of the *ltxCABD* gene locus. Hyperleukotoxic *A. actinomycetemcomitans* strains isolated in Japan were not found to contain deletions in *orfA* but instead harbored a mobile genetic element (transposon), IS*1301*, that was upstream of the *orfA* gene. The sequence of IS*1301* contains elements that direct the enhanced transcription of the *orfA-ltxCABD* operon. From a diagnostic point of view, it is important to consider that simply detecting *A. actinomycetemcomitans,* LtxA, or both in the periodontal biofilm is by no means indicative of disease. However, the detection of a hyperleukotoxic strain of *A. actinomycetemcomitans* may be significant.

Strategies for Evading Host Immunity

Pathogenic bacteria have many and varied strategies for evading or subverting the host immune system, including the following: (1) the production of an extracellular capsule; (2) the proteolytic degradation of host innate or acquired immunity components; (3) the modulation of host responses by binding serum components on the bacterial cell surface; and (4) the invasion of gingival epithelial cells. A detailed description of bacteria–host interactions is given in Chapter 9. Selected examples of factors that mediate these processes are given in the following paragraphs.

Strains of *P. gingivalis* produce polysaccharide capsules (Figure 8-43) that surround the outer membrane. Six different antigenic capsule types have been described on the basis of the differences in the polysaccharide K antigen.[192] In a mouse model, capsular strains of *P. gingivalis* produced a spreading type of infection, whereas acapsular strains tended to form more localized abscesses.[194] The majority of *P. gingivalis* isolates from periodontitis patients are encapsulated.[193] It is hypothesized that the capsule protects cells from the host immune system. However, protection against the complement system appears to be mediated primarily by a branched phosphomannan polysaccharide that is independent of the K antigen.[350]

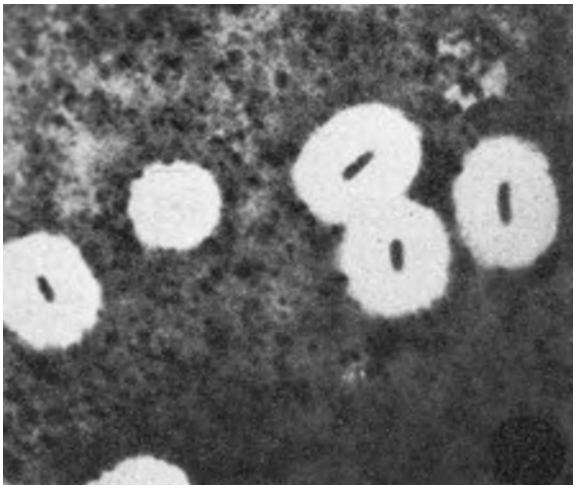

Figure 8-43 Glycocalyx or polysaccharide capsule of *Porphyromonas gingivalis* visualized with East Indian ink staining (clear halo).

Several periodontopathogens are resistant to complement-mediated phagocytosis, and it is thought that the proteolysis of complement components contributes to resistance to some extent. *P. gingivalis* gingipains have been shown to degrade complement components C3, C4, C5, and factor B.[282] More recently, a cysteine protease of *P. intermedia* called *interpain A* has also been shown to degrade C3.[284] In vitro, interpain A acts synergistically with gingipains to decrease the deposition of complement C3b.[284] These data fit with the hypothesis that periodontal disease processes are mediated by polymicrobial consortia rather than by individual periodontopathogens.

A novel mechanism for complement evasion has been identified in *A. actinomycetemcomitans*. This organism produces a 100-kDa protein on the outer membrane, Omp100 or ApiA, which mediates adhesion to and the invasion of host cells.[17,207] Mutants lacking ApiA were sensitized to killing by human serum: wild-type cells were almost completely resistant to 30% or 50% normal human serum, whereas 90% of ApiA mutant cells were killed. ApiA was shown to bind factor H, which is an inhibitor of the complement cascade. Interestingly, H_2O_2 produced by *S. gordonii* induces the expression of ApiA and enhances the serum resistance of *A. actinomycetemcomitans*.[309] It has been proposed that H_2O_2 derived from oral streptococci may stimulate the immune response and that the early detection of H_2O_2 by *A. actinomycetemcomitans* may provide an ecological advantage under these conditions.[309] Alternatively, the ability of *A. actinomycetemcomitans* to detect streptococcal H_2O_2 may be a fortuitous consequence of a system that has evolved primarily to detect and respond to the neutrophil oxidative burst.

Periodontal pathogens are notoriously difficult to eradicate completely. Despite aggressive antibacterial attacks from the host defenses and from clinical treatments, it is often impossible to prevent reinfection. One potential reservoir for periodontopathogens is inside gingival epithelial cells. *P. gingivalis* and *A. actinomycetemcomitans*, for example, can invade epithelial cells in vitro.[195,238] In vivo, *P. gingivalis*, *T. forsythia*, *P. intermedia*, *T. denticola,* and *A. actinomycetemcomitans* can be detected within the gingival epithelial cells of patients with periodontitis before and after periodontal therapy.[161] Adhesion to host cells is critical for invasion. However, it has been suggested that there may be factors that specifically control the ability of bacteria to invade cells. In *A. actinomycetemcomitans*, a screen for invasion-associated genes identified two loci, encoding ApiA (see previous paragraph) and ApiBC, which are related to known bacterial invasion proteins (invasins).[207] The ability of bacteria to invade cells may be influenced by their interactions with other organisms in the gingival sulcus. Thus, the coinfection of an epithelial cell line with *P. gingivalis* and a coaggregating strain of *F. nucleatum* resulted in increased invasion by *P. gingivalis* as compared with a monoculture control.[328] Coaggregation with *F. nucleatum* is mediated by the *P. gingivalis* capsular polysaccharide and lipopolysaccharide; therefore, these molecules may indirectly contribute to invasion.[318]

Future Advances in Periodontal Microbiology

Scientific progress at the end of the twentieth century, particularly in the field of molecular biology, has led to significant advances in

our understanding of periodontal microbiology. DNA-based methodologies for the identification and detection of specific bacteria and viruses offer remarkable time and cost advantages as compared with culturing techniques. A dramatic increase in the number of samples that can be examined and the number of microorganisms enumerated is now possible. Perhaps even more relevant is the present ability to detect microorganisms that cannot be cultivated so far, which has underscored the limitations of our knowledge of this complex ecologic niche. Greater awareness of the role of the host response in periodontal disease will further improve the understanding of the severity and therapy of periodontal infections. Finally, the recognition of the beneficial activity of several groups of commensal species may open new strategies for the treatment of periodontal disease, such as the use of probiotics or microbial replacement therapy.[386]

Suggested Readings

Berezow AB, Darveau RP: Microbial shift and periodontitis. *Periodontol 2000* 55:36–47, 2011.

Bergquist R: Parasitic infections affecting the oral cavity. *Periodontol 2000* 49:96–105, 2009.

Griffen AL, Beall CJ, Campbell JH, et al: Distinct and complex bacterial profiles in human periodontitis and health revealed by 16S pyrosequencing. *ISME J* 6:1176–1185, 2012.

Hajishengallis G, Darveau RP, Curtis MA: The keystone-pathogen hypothesis. *Nat Rev Microbiol* 10:717–725, 2012.

Jakubovics NS, Palmer RJ: Oral microbial ecology: current research and new perspectives, 2013, Caister Academic Press, p 1.

Samaranayake LP, Keung LW, Jin L: Oral mucosal fungal infections. *Periodontol 2000* 49:39–59, 2009.

Slots J: Oral viral infections of adults. *Periodontol 2000* 49:60–86, 2009.

Teles RP, Haffajee AD, Socransky SS: Microbiological goals of periodontal therapy. *Periodontol 2000* 42:180, 2006.

Zijnge V, van Leeuwen MB, Degener JE, et al: Oral biofilm architecture on natural teeth. *PLoS ONE* 5(2):e9321, 2010.

References

References for this chapter are found on the companion website www.expertconsult.com.

References

1. Aas JA, Paster BJ, Stokes LN, et al: Defining the normal bacterial flora of the oral cavity. *J Clin Microbiol* 43:5721, 2005.
2. Abusleme L, Dupuy AK, Dutzan N, et al: The subgingival microbiome in health and periodontitis and its relationship with community biomass and inflammation. *ISME J* 7:1016, 2013.
3. Adamson M, Carlsson J: Lactoperoxidase and thiocyanate protect bacteria from hydrogen peroxide. *Infect Immun* 35:20, 1982.
4. Adell R, Lekholm U, Rockler B, et al: Marginal tissue reactions at osseointegrated titanium fixtures (I). A 3-year longitudinal prospective study. *Int J Oral Maxillofac Surg* 15:39, 1986.
5. Adriaens PA, De Boever JA, Loesche WJ: Bacterial invasion in root cementum and radicular dentin of periodontally diseased teeth in humans. A reservoir of periodontopathic bacteria. *J Periodontol* 59:222, 1988.
6. Ainamo J, Asikainen S, Ainamo A, et al: Plaque growth while chewing sorbitol and xylitol simultaneously with sucrose flavored gum. *J Clin Periodontol* 6:397, 1979.
7. Alaluusua S, Renkonen OV: *Streptococcus mutans* establishment and dental caries experience in children from 2 to 4 years old. *Scand J Dent Res* 91:453, 1983.
8. Alcoforado GA, Slots J: *Actinobacillus actinomycetemcomitans* and black-pigmented bacteroides in advanced periodontitis in man. Theoretical and practical considerations. *Rev Port Estomatol Cir Maxilofac* 31:89, 1990.
9. Allison DG, Gilbert P: Modification by surface association of antimicrobial susceptibility of bacterial populations. *J Ind Microbiol* 15:311, 1995.
10. Amano A, Nakagawa I, Okahashi N, et al: Variations of *Porphyromonas gingivalis* fimbriae in relation to microbial pathogenesis. *J Periodontal Res* 39:136, 2004.
11. Amano A, Sharma A, Lee JY, et al: Structural domains of *Porphyromonas gingivalis* recombinant fimbrillin that mediate binding to salivary proline-rich protein and statherin. *Infect Immun* 64:1631, 1996.
12. American Academy of Periodontology: Proceedings of the 1996 World Workshop in Periodontics. Lansdowne, Virginia. July 13-17, 1996. *Ann Periodontol* 1:1, 1996.
13. Apse P, Ellen RP, Overall CM, et al: Microbiota and crevicular fluid collagenase activity in the osseointegrated dental implant sulcus: a comparison of sites in edentulous and partially edentulous patients. *J Periodontal Res* 24:96, 1989.
14. Arai M, Hamada N, Umemoto T: Purification and characterization of a novel secondary fimbrial protein from *Porphyromonas gingivalis* strain 381. *FEMS Microbiol Lett* 193:75, 2000.
15. Armitage GC: Development of a classification system for periodontal diseases and conditions. *Ann Periodontol* 4:1, 1999.
16. Arnim SS: The use of disclosing agents for measuring tooth cleanliness. *J Periodontol* 34:217, 1963.
17. Asakawa R, Komatsuzawa H, Kawai T, et al: Outer membrane protein 100, a versatile virulence factor of *Actinobacillus actinomycetemcomitans*. *Mol Microbiol* 50:1125, 2003.
18. Ashby MJ, Neale JE, Knott SJ, et al: Effect of antibiotics on non-growing planktonic cells and biofilms of *Escherichia coli*. *J Antimicrob Chemother* 33:443, 1994.
19. Asikainen S, Chen C, Slots J: Likelihood of transmitting *Actinobacillus actinomycetemcomitans* and *Porphyromonas gingivalis* in families with periodontitis. *Oral Microbiol Immunol* 11:387, 1996.
20. Bagaitkar J, Williams LR, Renaud DE, et al: Tobacco-induced alterations to *Porphyromonas gingivalis*-host interactions. *Environ Microbiol* 11:1242, 2009.
21. Beck JD, Koch GG, Zambon JJ, et al: Evaluation of oral bacteria as risk indicators for periodontitis in older adults. *J Periodontol* 63:93, 1992.
22. Belay N, Johnson R, Rajagopal BS, et al: Methanogenic bacteria from human dental plaque. *Appl Environ Microbiol* 54:600, 1988.
23. Berezow AB, Darveau RP: Microbial shift and periodontitis. *Periodontol 2000* 55:36, 2011.
24. Bergquist R: Parasitic infections affecting the oral cavity. *Periodontol 2000* 49:96, 2009.
25. Bik EM, Long CD, Armitage GC, et al: Bacterial diversity in the oral cavity of 10 healthy individuals. *ISME J* 4(8):962, 2010.
26. Bizzarro S, Loos BG, Laine ML, et al: Subgingival microbiome in smokers and non-smokers in periodontitis: an exploratory study using traditional targeted techniques and a next-generation sequencing. *J Clin Periodontol* 40:483, 2013.
27. Bollen CM, Mongardini C, Papaioannou W, et al: The effect of a one-stage full-mouth disinfection on different intra-oral niches. Clinical and microbiological observations. *J Clin Periodontol* 25:56, 1998.
28. Bollen CM, Papaioanno W, Van Eldere J, et al: The influence of abutment surface roughness on plaque accumulation and peri-implant mucositis. *Clin Oral Implants Res* 7:201, 1996.
29. Bostrom L, Bergstrom J, Dahlen G, et al: Smoking and subgingival microflora in periodontal disease. *J Clin Periodontol* 28:212, 2001.
30. Bowen WH: Nature of plaque. *Oral Sci Rev* 9:3, 1976.
31. Bower RC, Radny NR, Wall CD, et al: Clinical and microscopic findings in edentulous patients 3 years after incorporation of osseointegrated implant-supported bridgework. *J Clin Periodontol* 16:580, 1989.
32. Bradshaw DJ, Marsh PD, Watson GK, et al: Role of *Fusobacterium nucleatum* and coaggregation in anaerobe survival in planktonic and biofilm oral microbial communities during aeration. *Infect Immun* 66:4729, 1998.
33. Brailsford SR, Sheehy EC, Gilbert SC, et al: The microflora of the erupting first permanent molar. *Caries Res* 39:78, 2005.
34. Bramanti TE, Holt SC: Roles of porphyrins and host iron transport proteins in regulation of growth of *Porphyromonas gingivalis* W50. *J Bacteriol* 173:7330, 1991.
35. Brogden KA, Guthmiller JM: Polymicrobial diseases involving viruses and bacteria. In Brogden KA, Guthmiller JM, editors: *Polymicrobial diseases*, Washington DC, 2002, American Society Microbiology, p 201.
36. Brook I: Bacterial interference. *Crit Rev Microbiol* 25:155, 1999.
37. Brook I, Foote PA, Slots J: Immune response to *Fusobacterium nucleatum, Prevotella intermedia* and other anaerobes in children with acute tonsillitis. *J Antimicrob Chemother* 39:763, 1997.
38. Brooun A, Liu S, Lewis K: A dose-response study of antibiotic resistance in *Pseudomonas aeruginosa* biofilms. *Antimicrob Agents Chemother* 44:640, 2000.
39. Brown LJ, Loe H: Prevalence, extent, severity and progression of periodontal disease. *Periodontol 2000* 2:57, 1993.
40. Brown MR, Collier PJ, Gilbert P: Influence of growth rate on susceptibility to antimicrobial agents: modification of the cell envelope and batch and continuous culture studies. *Antimicrob Agents Chemother* 34:1623, 1990.
41. Brown MR, Williams P: The influence of environment on envelope properties affecting survival of bacteria in infections. *Annu Rev Microbiol* 39:527, 1985.
42. Brown SA, Whiteley M: A novel exclusion mechanism for carbon resource partitioning in *Aggregatibacter actinomycetemcomitans*. *J Bacteriol* 189:6407, 2007.
43. Brunette DM, Chehroudi B, Gould TRL: Electron microscopic observations on the effects of surface topography on the behaviour of cells attached to percutaneous and subcutaneous implants. In Laney WR, Tonato M, editors: *Tissue integration in oral, orthopedic and maxillofacial reconstruction*, Chicago, 1982, Quintessence Books, p 21.
44. Busscher HJ, Norde W, van der Mei HC: Specific molecular recognition and nonspecific contributions to bacterial interaction forces. *Appl Environ Microbiol* 74:2559, 2008.
45. Caimano MJ, Bourell KW, Bannister TD, et al: The *Treponema denticola* major sheath protein is predominantly periplasmic and has only limited surface exposure. *Infect Immun* 67:4072, 1999.
46. Cappuyns I, Gugerli P, Mombelli A: Viruses in periodontal disease—a review. *Oral Dis* 11:219, 2005.
47. Carlsson J: Symbiosis between host and microorganisms in the oral cavity. *Scand J Infect Dis Suppl Suppl* 24:74, 1980.

48. Carlsson J: Microbiology of plaque associated periodontal disease. In Lindhe J, editor: *Textbook of clinical periodontology*, Munksgaard, 1983, Munksgaard International Publishers.
49. Carlsson J, Grahnen H, Jonsson G: Lactobacilli and streptococci in the mouth of children. *Caries Res* 9:333, 1975.
50. Carlsson J, Grahnen H, Jonsson G, et al: Establishment of *Streptococcus sanguis* in the mouths of infants. *Arch Oral Biol* 15:1143, 1970.
51. Carlsson J, Soderholm G, Almfeldt I: Prevalence of *Streptococcus sanguis* and *Streptococcus mutans* in the mouth of persons wearing full-dentures. *Arch Oral Biol* 14:243, 1969.
52. Carranza FA, Jr, Saglie R, Newman MG, et al: Scanning and transmission electron microscopic study of tissue-invading microorganisms in localized juvenile periodontitis. *J Periodontol* 54:598, 1983.
53. Caufield PW, Dasanayake AP, Li Y, et al: Natural history of *Streptococcus sanguinis* in the oral cavity of infants: evidence for a discrete window of infectivity. *Infect Immun* 68:4018, 2000.
54. Caufield PW, Gibbons RJ: Suppression of *Streptococcus mutans* in the mouths of humans by a dental prophylaxis and topically-applied iodine. *J Dent Res* 58:1317, 1979.
55. Chen C, Slots J: Clonal analysis of *Porphyromonas gingivalis* by the arbitrarily primed polymerase chain reaction. *Oral Microbiol Immunol* 9:99, 1994.
56. Christersson LA, Albini B, Zambon JJ, et al: Tissue localization of *Actinobacillus actinomycetemcomitans* in human periodontitis. I. Light, immunofluorescence and electron microscopic studies. *J Periodontol* 58:529, 1987.
57. Christersson LA, Slots J, Zambon JJ, et al: Transmission and colonization of *Actinobacillus actinomycetemcomitans* in localized juvenile periodontitis patients. *J Periodontol* 56:127, 1985.
58. Christersson LA, Wikesjo UM, Albini B, et al: Tissue localization of *Actinobacillus actinomycetemcomitans* in human periodontitis. II. Correlation between immunofluorescence and culture techniques. *J Periodontol* 58:540, 1987.
59. Christersson LA, Zambon JJ, Genco RJ: Dental bacterial plaques. Nature and role in periodontal disease. *J Clin Periodontol* 18:441, 1991.
60. Cisar JO: Coaggregation reactions between oral bacteria: Studies of specific cell-to-cell adherence mediated by microbial lectins. In Genco RJ, Mergenhagen S, editors: *Host parasite interactions in periodontal diseases*, Washington DC, 1982, American Society for Microbiology, p 121.
61. Contreras A, Slots J: Active cytomegalovirus infection in human periodontitis. *Oral Microbiol Immunol* 13:225, 1998.
62. Contreras A, Slots J: Herpesviruses in human periodontal disease. *J Periodontal Res* 35:3, 2000.
63. Contreras A, Umeda M, Chen C, et al: Relationship between herpesviruses and adult periodontitis and periodontopathic bacteria. *J Periodontol* 70:478, 1999.
64. Costerton JW, Lewandowski Z, Caldwell DE, et al: Microbial biofilms. *Annu Rev Microbiol* 49:711, 1995.
65. Costerton JW, Stewart PS, Greenberg EP: Bacterial biofilms: a common cause of persistent infections. *Science* 284:1318, 1999.
66. Croen KD: Latency of the human herpesviruses. *Annu Rev Med* 42:61, 1991.
67. Cugini MA, Haffajee AD, Smith C, et al: The effect of scaling and root planing on the clinical and microbiological parameters of periodontal diseases: 12-month results. *J Clin Periodontol* 27:30, 2000.
68. Da Silva AM, Newman HN, Oakley DA: Psychosocial factors in inflammatory periodontal diseases. A review. *J Clin Periodontol* 22:516, 1995.
69. Danino J, Joachims HZ, Barak M: Predictive value of an adherence test for acute otitis media. *Otolaryngol Head Neck Surg* 118:400, 1998.
70. Danser MM, Timmerman MF, van Winkelhoff AJ, et al: The effect of periodontal treatment on periodontal bacteria on the oral mucous membranes. *J Periodontol* 67:478, 1996.
71. Danser MM, van Winkelhoff AJ, de Graaff J, et al: Short-term effect of full-mouth extraction on periodontal pathogens colonizing the oral mucous membranes. *J Clin Periodontol* 21:484, 1994.
72. Darveau RP, Hajishengallis G, Curtis MA: Porphyromonas gingivalis as a potential community activist for disease. *J Dent Res* 91(9):816–820, 2012.
73. Darveau RP, Tanner A, Page RC: The microbial challenge in periodontitis. *Periodontol 2000* 14:12, 1997.
74. De Soete M, De Keyser C, Pauwels M, et al: Outgrowth of cariogenic bacteria after initial periodontal therapy. *J Dent Res* 2005. submitted.
75. Diaz PI, Chalmers NI, Rickard AH, et al: Molecular characterization of subject-specific oral microflora during initial colonization of enamel. *Appl Environ Microbiol* 72:2837, 2006.
76. Diaz PI, Zilm PS, Rogers AH: The response to oxidative stress of *Fusobacterium nucleatum* grown in continuous culture. *FEMS Microbiol Lett* 187:31, 2000.
77. Dibart S, Skobe Z, Snapp KR, et al: Identification of bacterial species on or in crevicular epithelial cells from healthy and periodontally diseased patients using DNA-DNA hybridization. *Oral Microbiol Immunol* 13:30, 1998.
78. Dige I, Raarup MK, Nyengaard JR, et al: *Actinomyces naeslundii* in initial dental biofilm formation. *Microbiology* 155(Pt 7):2116, 2009.
79. Dominguez-Bello MG, Costello EK, Contreras M, et al: Delivery mode shapes the acquisition and structure of the initial microbiota across multiple body habitats in newborns. *Proc Natl Acad Sci U S A* 107:11971, 2010.
80. Doyle RJ, Rosenberg M, Drake D: Hydrophobicity of oral bacteria. In Doyle RJ, Rosenberg M, editors: *Microbial cell surface hydrophobicity*, Washington DC, 1990, American Society for Microbiology.
81. Drescher K, Shen Y, Bassler BL, et al: Biofilm streamers cause catastrophic disruption of flow with consequences for environmental and medical systems. *Proc Natl Acad Sci U S A* 110:4345, 2013.
82. Dzink JL, Gibbons RJ, Childs WC, III, et al: The predominant cultivable microbiota of crevicular epithelial cells. *Oral Microbiol Immunol* 4:1, 1989.
83. Dzink JL, Socransky SS, Haffajee AD: The predominant cultivable microbiota of active and inactive lesions of destructive periodontal diseases. *J Clin Periodontol* 15:316, 1988.
84. Dzink JL, Tanner AC, Haffajee AD, et al: Gram negative species associated with active destructive periodontal lesions. *J Clin Periodontol* 12:648, 1985.
85. Edman DC, Keene HJ, Shklair IL, et al: Dental floss for implantation and sampling of *Streptococcus mutans* from approximal surfaces of human teeth. *Arch Oral Biol* 20:145, 1975.
86. Edwards AM, Jenkinson HF, Woodward MJ, et al: Binding properties and adhesion-mediating regions of the major sheath protein of *Treponema denticola* ATCC 35405. *Infect Immun* 73:2891, 2005.
87. Egland PG, Palmer RJ, Jr, Kolenbrander PE: Interspecies communication in *Streptococcus gordonii-Veillonella atypica* biofilms: signaling in flow conditions requires juxtaposition. *Proc Natl Acad Sci U S A* 101:16917, 2004.
88. El Ahmer OR, Raza MW, Ogilvie MM, et al: Binding of bacteria to HEp-2 cells infected with influenza A virus. *FEMS Immunol Med Microbiol* 23:331, 1999.
89. Elangovan S, Margolis HC, Oppenheim FG, et al: Conformational changes in salivary proline-rich protein 1 upon adsorption to calcium phosphate crystals. *Langmuir* 23:11200, 2007.
90. Enersen M, Olsen I, Caugant DA: Genetic diversity of *Porphyromonas gingivalis* isolates recovered from single "refractory" periodontitis sites. *Appl Environ Microbiol* 74:5817, 2008.
91. Enersen M, Olsen I, Kvalheim O, et al: fimA genotypes and multilocus sequence types of *Porphyromonas gingivalis* from patients with periodontitis. *J Clin Microbiol* 46:31, 2008.
92. Evaldson G, Heimdahl A, Kager L, et al: The normal human anaerobic microflora. *Scand J Infect Dis Suppl* 35:9, 1982.
93. Fainstein V, Musher DM: Bacterial adherence to pharyngeal cells in smokers, nonsmokers, and chronic bronchitics. *Infect Immun* 26:178, 1979.
94. Faveri M, Figueiredo LC, Duarte PM, et al: Microbiological profile of untreated subjects with localized aggressive periodontitis. *J Clin Periodontol* 36:739, 2009.

95. Fenno JC, Muller KH, McBride BC: Sequence analysis, expression, and binding activity of recombinant major outer sheath protein (Msp) of *Treponema denticola*. *J Bacteriol* 178:2489, 1996.
96. Fine DH, Furgang D, Kaplan J, et al: Tenacious adhesion of *Actinobacillus actinomycetemcomitans* strain CU1000 to salivary-coated hydroxyapatite. *Arch Oral Biol* 44:1063, 1999.
97. Fletcher M: The physiological activity of bacteria attached to solid surfaces. *Adv Microb Physiol* 32:53, 1991.
98. Fontaine L, Goffin P, Dubout H, et al: Mechanism of competence activation by the ComRS signalling system in streptococci. *Mol Microbiol* 87:1113, 2013.
99. Frank RM: Bacterial penetration in the apical pocket wall of advanced human periodontitis. *J Periodontal Res* 15:563, 1980.
100. Fransson C, Berglundh T, Lindhe J: The effect of age on the development of gingivitis. Clinical, microbiological and histological findings. *J Clin Periodontol* 23:379, 1996.
101. Fujiwara T, Sasada E, Mima N, et al: Caries prevalence and salivary mutans streptococci in 0-2-year-old children of Japan. *Community Dent Oral Epidemiol* 19:151, 1991.
102. Fullmer SC, Preshaw PM, Heasman PA, et al: Smoking cessation alters subgingival microbial recolonization. *J Dent Res* 88:524, 2009.
103. Furst MM, Salvi GE, Lang NP, et al: Bacterial colonization immediately after installation on oral titanium implants. *Clin Oral Implants Res* 18:501, 2007.
104. Furuichi Y, Lindhe J, Ramberg P, et al: Patterns of de novo plaque formation in the human dentition. *J Clin Periodontol* 19:423, 1992.
105. Genco CA, Arko RJ: Animal chamber models for study of host-parasite interactions. *Methods Enzymol* 235:120, 1994.
106. Genco RJ, Ho AW, Grossi SG, et al: Relationship of stress, distress and inadequate coping behaviors to periodontal disease. *J Periodontol* 70:711, 1999.
107. Gibson GR, Roberfroid MB: Dietary modulation of the human colonic microbiota: introducing the concept of prebiotics. *J Nutr* 125:1401, 1995.
108. Gilbert P, Allison DG: Biofilms and their resistance towards antimicrobial agents. In Newman HN, Wilson M, editors: *Dental plaque revisited*, Cambridge, 1999, Cambridge University Press, p 125.
109. Gilthorpe MS, Zamzuri AT, Griffiths GS, et al: Unification of the "burst" and "linear" theories of periodontal disease progression: a multilevel manifestation of the same phenomenon. *J Dent Res* 82:200, 2003.
110. Giuliana G, Pizzo G, Milici ME, et al: In vitro antifungal properties of mouthrinses containing antimicrobial agents. *J Periodontol* 68:729, 1997.
111. Gmür R, Lüthi-Schaller H: A combined immunofluorescence and fluorescent in situ hybridization assay for single cell analyses of dental plaque microorganisms. *J Microbiol Methods* 69:402, 2007.
112. Goobes G, Goobes R, Schueler-Furman O, et al: Folding of the C-terminal bacterial binding domain in statherin upon adsorption onto hydroxyapatite crystals. *Proc Natl Acad Sci U S A* 103:16083, 2006.
113. Goodson JM, Tanner A, McArdle S, et al: Multicenter evaluation of tetracycline fiber therapy. III. Microbiological response. *J Periodontal Res* 26:440, 1991.
114. Goodson JM, Tanner AC, Haffajee AD, et al: Patterns of progression and regression of advanced destructive periodontal disease. *J Clin Periodontol* 9:472, 1982.
115. Grenier D: Nutritional interactions between two suspected periodontopathogens, *Treponema denticola* and *Porphyromonas gingivalis*. *Infect Immun* 60:5298, 1992.
116. Grenier D, Mayrand D: [Studies of mixed anaerobic infections involving *Bacteroides gingivalis*]. *Can J Microbiol* 29:612, 1983.
117. Griffen AL, Beall CJ, Campbell JH, et al: Distinct and complex bacterial profiles in human periodontitis and health revealed by 16S pyrosequencing. *ISME J* 6:1176, 2012.
118. Griffen AL, Leys EJ, Fuerst PA: Strain identification of *Actinobacillus actinomycetemcomitans* using the polymerase chain reaction. *Oral Microbiol Immunol* 7:240, 1992.
119. Guy SC, McQuade MJ, Scheidt MJ, et al: In vitro attachment of human gingival fibroblasts to endosseous implant materials. *J Periodontol* 64:542, 1993.
120. Haapasalo M, Muller KH, Uitto VJ, et al: Characterization, cloning, and binding properties of the major 53-kilodalton *Treponema denticola* surface antigen. *Infect Immun* 60:2058, 1992.
121. Haffajee AD, Cugini MA, Dibart S, et al: Clinical and microbiological features of subjects with adult periodontitis who responded poorly to scaling and root planing. *J Clin Periodontol* 24:767, 1997.
122. Haffajee AD, Cugini MA, Dibart S, et al: The effect of SRP on the clinical and microbiological parameters of periodontal diseases. *J Clin Periodontol* 24:324, 1997.
123. Haffajee AD, Socransky SS: Relationship of cigarette smoking to the subgingival microbiota. *J Clin Periodontol* 28:377, 2001.
124. Hafstrom CA, Wikstrom MB, Renvert SN, et al: Effect of treatment on some periodontopathogens and their antibody levels in periodontal abscesses. *J Periodontol* 65:1022, 1994.
125. Hajishengallis G, Darveau RP, Curtis MA: The keystone-pathogen hypothesis. *Nat Rev Microbiol* 10:717, 2012.
126. Hajishengallis G, Liang S, Payne MA, et al: Low-abundance biofilm species orchestrates inflammatory periodontal disease through the commensal microbiota and complement. *Cell Host Microbe* 10:497, 2011.
127. Hakansson A, Kidd A, Wadell G, et al: Adenovirus infection enhances *in vitro* adherence of *Streptococcus pneumoniae*. *Infect Immun* 62:2707, 1994.
128. Hamada N, Sojar HT, Cho MI, et al: Isolation and characterization of a minor fimbria from *Porphyromonas gingivalis*. *Infect Immun* 64:4788, 1996.
129. Hamada S, Amano A, Kimura S, et al: The importance of fimbriae in the virulence and ecology of some oral bacteria. *Oral Microbiol Immunol* 13:129, 1998.
130. Hammarstedt L, Lindquist D, Dahlstrand H, et al: Human papillomavirus as a risk factor for the increase in incidence of tonsillar cancer. *Int J Cancer* 119:2620, 2006.
131. Hannig C, Attin T, Hannig M, et al: Immobilisation and activity of human alpha-amylase in the acquired enamel pellicle. *Arch Oral Biol* 49:469, 2004.
132. Hannig C, Hannig M, Rehmer O, et al: Fluorescence microscopic visualization and quantification of initial bacterial colonization on enamel in situ. *Arch Oral Biol* 52:1048, 2007.
133. Hannig C, Hoch J, Becker K, et al: Lysozyme activity in the initially formed in situ pellicle. *Arch Oral Biol* 50:821, 2005.
134. Hannig C, Spitzmuller B, Hannig M: Characterisation of lysozyme activity in the in situ pellicle using a fluorimetric assay. *Clin Oral Investig* 13:15, 2009.
135. Hannig C, Spitzmuller B, Knausenberger S, et al: Detection and activity of peroxidase in the in situ formed enamel pellicle. *Arch Oral Biol* 53:849, 2008.
136. Hannig M: Ultrastructural investigation of pellicle morphogenesis at two different intraoral sites during a 24-h period. *Clin Oral Investig* 3:88, 1999.
137. Hannig M, Khanafer AK, Hoth-Hannig W, et al: Transmission electron microscopy comparison of methods for collecting in situ formed enamel pellicle. *Clin Oral Investig* 9:30, 2005.
138. Harper DS, Robinson PJ: Correlation of histometric, microbial, and clinical indicators of periodontal disease status before and after root planing. *J Clin Periodontol* 14:190, 1987.
139. Haubek D, Poulsen K, Kilian M: Microevolution and patterns of dissemination of the JP2 clone of *Aggregatibacter (Actinobacillus) actinomycetemcomitans*. *Infect Immun* 75:3080, 2007.
140. Helmerhorst EJ, Hodgson R, van't Hof W, et al: The effects of histatin-derived basic antimicrobial peptides on oral biofilms. *J Dent Res* 78:1245, 1999.
141. Hermansson M: The DLVO theory in microbial adhesion. *Colloids Surf B Biointerfaces* 14:105, 1999.
142. Herrera D, Roldan S, Gonzalez I, et al: The periodontal abscess (I). Clinical and microbiological findings. *J Clin Periodontol* 27:387, 2000.

143. Herrera D, Roldan S, Sanz M: The periodontal abscess: a review. *J Clin Periodontol* 27:377, 2000.
144. Hillman JD, Socransky SS, Shivers M: The relationships between streptococcal species and periodontopathic bacteria in human dental plaque. *Arch Oral Biol* 30:791, 1985.
145. Hobbs CG, Sterne JA, Bailey M, et al: Human papillomavirus and head and neck cancer: a systematic review and meta-analysis. *Clin Otolaryngol* 31:259, 2006.
146. Hoepelman AI, Tuomanen EI: Consequences of microbial attachment: directing host cell functions with adhesins. *Infect Immun* 60:1729, 1992.
147. Holm-Pedersen P, Agerbaek N, Theilade E: Experimental gingivitis in young and elderly individuals. *J Clin Periodontol* 2:14, 1975.
148. Hsu SD, Cisar JO, Sandberg AL, et al: Adhesive properties of viridans streptococcal species. *Microb Ecol Health Dis* 125:1994.
149. Hu YJ, Shao ZY, Wang Q, et al: Exploring the dynamic core microbiome of plaque microbiota during head-and-neck radiotherapy using pyrosequencing. *PLoS ONE* 8(2):e56343, 2013.
150. Huang S, Yang F, Zeng X, et al: Preliminary characterization of the oral microbiota of Chinese adults with and without gingivitis. *BMC Oral Health* 11:33, 2011.
151. Hultin M, Gustafsson A, Hallstrom H, et al: Microbiological findings and host response in patients with peri-implantitis. *Clin Oral Implants Res* 13:349, 2002.
152. Hultin M, Gustafsson A, Klinge B: Long-term evaluation of osseointegrated dental implants in the treatment of partly edentulous patients. *J Clin Periodontol* 27:128, 2000.
153. Hyyppä T, Paunio K: The plaque-inhibiting effects of copper amalgam. *J Clin Periodontol* 4:231, 1977.
154. Imamura T, Potempa J, Travis J: Comparison of pathogenic properties between two types of arginine-specific cysteine proteinases (gingipains-R) from *Porphyromonas gingivalis*. *Microb Pathog* 29:155, 2000.
155. Isogai E, Isogai H, Sawada H, et al: Bacterial adherence to gingival epithelial cells of rats with naturally occurring gingivitis. *J Periodontol* 57:225, 1986.
156. Izano EA, Sadovskaya I, Wang H, et al: Poly-N-acetylglucosamine mediates biofilm formation and detergent resistance in *Aggregatibacter actinomycetemcomitans*. *Microb Pathog* 44(1):52–60, 2008.
157. Jacobson SE, Crawford JJ, McFall WR, Jr: Oral physiotherapy of the tongue and palate: relationship to plaque control. *J Am Dent Assoc* 87:134, 1973.
158. Jakubovics NS, Gill SR, Iobst SE, et al: Regulation of gene expression in a mixed-genus community: stabilized arginine biosynthesis in *Streptococcus gordonii* by coaggregation with *Actinomyces naeslundii*. *J Bacteriol* 190:3646, 2008.
159. Jakubovics NS, Stromberg N, van Dolleweerd CJ, et al: Differential binding specificities of oral streptococcal antigen I/II family adhesins for human or bacterial ligands. *Mol Microbiol* 55:1591, 2005.
160. Jenkinson HF, Demuth DR: Structure, function and immunogenicity of streptococcal antigen I/II polypeptides. *Mol Microbiol* 23:183, 1997.
161. Johnson JD, Chen R, Lenton PA, et al: Persistence of extracrevicular bacterial reservoirs after treatment of aggressive periodontitis. *J Periodontol* 79:2305, 2008.
162. Kaplan CW, Lux R, Haake SK, et al: The *Fusobacterium nucleatum* outer membrane protein RadD is an arginine-inhibitable adhesin required for inter-species adherence and the structured architecture of multispecies biofilm. *Mol Microbiol* 71:35, 2009.
163. Kaplan JB, Ragunath C, Ramasubbu N, et al: Detachment of *Actinobacillus actinomycetemcomitans* biofilm cells by an endogenous beta-hexosaminidase activity. *J Bacteriol* 185:4693, 2003.
164. Kaufman J, DiRienzo JM: Isolation of a corncob (coaggregation) receptor polypeptide from *Fusobacterium nucleatum*. *Infect Immun* 57:331, 1989.
165. Kinder SA, Holt SC: Characterization of coaggregation between *Bacteroides gingivalis* T22 and *Fusobacterium nucleatum* T18. *Infect Immun* 57:3425, 1989.
166. Kohavi D, Greenberg RS, Raviv E, et al: Subgingival and supragingival microbial flora around healthy osseointegrated implants in partially edentulous patients. *Int J Oral Maxillofac Implants* 673:1994.
167. Kohler B, Krasse B, Carlen A: Adherence and *Streptococcus mutans* infections: in vitro study with saliva from noninfected and infected preschool children. *Infect Immun* 34:633, 1981.
168. Koka S, Razzoog ME, Bloem TJ, et al: Microbial colonization of dental implants in partially edentulous subjects. *J Prosthet Dent* 70:141, 1993.
169. Kolenbrander PE: Surface recognition among oral bacteria: multigeneric coaggregations and their mediators. *Crit Rev Microbiol* 17:137, 1989.
170. Kolenbrander PE, Andersen RN: Inhibition of coaggregation between *Fusobacterium nucleatum* and *Porphyromonas (Bacteroides) gingivalis* by lactose and related sugars. *Infect Immun* 57:3204, 1989.
171. Kolenbrander PE, Andersen RN, Moore LV: Intrageneric coaggregation among strains of human oral bacteria: potential role in primary colonization of the tooth surface. *Appl Environ Microbiol* 56:3890, 1990.
172. Kolenbrander PE, Egland PG, Diaz PI, et al: Genome-genome interactions: bacterial communities in initial dental plaque. *Trends Microbiol* 13:11–15, 2005.
173. Kolenbrander PE, Ganeshkumar N, Cassels FJ, et al: Coaggregation: specific adherence among human oral plaque bacteria. *FASEB J* 7:406, 1993.
174. Kolenbrander PE, London J: Adhere today, here tomorrow: oral bacterial adherence. *J Bacteriol* 175:3247, 1993.
175. Kolenbrander PE, Palmer RJ, Jr, Rickard AH, et al: Bacterial interactions and successions during plaque development. *Periodontol 2000* 42:47, 2006.
176. Kolenbrander PE, Parrish KD, Andersen RN, et al: Intergeneric coaggregation of oral *Treponema* spp. with *Fusobacterium* spp. and intrageneric coaggregation among *Fusobacterium* spp. *Infect Immun* 63:4584, 1995.
177. Kononen E: Oral colonization by anaerobic bacteria during childhood: role in health and disease. *Oral Dis* 5:278, 1999.
178. Kononen E: Development of oral bacterial flora in young children. *Ann Med* 32:107, 2000.
179. Kononen E, Asikainen S, Jousimies-Somer H: The early colonization of gram-negative anaerobic bacteria in edentulous infants. *Oral Microbiol Immunol* 7:28, 1992.
180. Kornman KS, Loe H: The role of local factors in the etiology of periodontal diseases. *Periodontol 2000* 2:83, 1993.
181. Kornman KS, Loesche WJ: Effects of estradiol and progesterone on *Bacteroides melaninogenicus* and *Bacteroides gingivalis*. *Infect Immun* 35:256, 1982.
182. Kornman KS, Robertson PB: Clinical and microbiological evaluation of therapy for juvenile periodontitis. *J Periodontol* 56:443, 1985.
183. Kraneveld EA, Buijs MJ, Bonder MJ, et al: The relation between oral Candida load and bacterial microbiome profiles in Dutch older adults. *PLoS ONE* 7(8):e42770, 2012.
184. Kremer BH, Loos BG, van d V, et al: *Peptostreptococcus micros* smooth and rough genotypes in periodontitis and gingivitis. *J Periodontol* 71:209, 2000.
185. Kreth J, Zhang Y, Herzberg MC: Streptococcal antagonism in oral biofilms: *Streptococcus sanguinis* and *Streptococcus gordonii* interference with *Streptococcus mutans*. *J Bacteriol* 190:4632, 2008.
186. Kroes I, Lepp PW, Relman DA: Bacterial diversity within the human subgingival crevice. *Proc Natl Acad Sci U S A* 96:14547, 1999.
187. Kuboniwa M, Hendrickson EL, Xia Q, et al: Proteomics of *Porphyromonas gingivalis* within a model oral microbial community. *BMC Microbiol* 9:98, 2009.
188. Kumamoto CA, Vinces MD: Alternative *Candida albicans* lifestyles: growth on surfaces. *Annu Rev Microbiol* 59:113, 2005.
189. Kumar PS, Mason MR, Brooker MR, et al: Pyrosequencing reveals unique microbial signatures associated with healthy and failing dental implants. *J Clin Periodontol* 39:425–433, 2012.

190. Kuritzkes DR, Walker BD: HIV-1 pathogenesis, clinical manifestations, and treatment. In Knipe DM, Howley PM, editors: *Fields virology*, Philadelphia, 2007, Lippincott Williams & Wilkins, p 2187.
191. Lai CH, Listgarten MA, Shirakawa M, et al: *Bacteroides forsythus* in adult gingivitis and periodontitis. *Oral Microbiol Immunol* 2:152, 1987.
192. Laine ML, Appelmelk BJ, van Winkelhoff AJ: Novel polysaccharide capsular serotypes in *Porphyromonas gingivalis*. *J Periodontal Res* 31:278, 1996.
193. Laine ML, Appelmelk BJ, van Winkelhoff AJ: Prevalence and distribution of six capsular serotypes of *Porphyromonas gingivalis* in periodontitis patients. *J Dent Res* 76:1840, 1997.
194. Laine ML, van Winkelhoff AJ: Virulence of six capsular serotypes of *Porphyromonas gingivalis* in a mouse model. *Oral Microbiol Immunol* 13:322, 1998.
195. Lamont RJ, Chan A, Belton CM, et al: *Porphyromonas gingivalis* invasion of gingival epithelial cells. *Infect Immun* 63:3878, 1995.
196. Lang NP, Cumming BR, Loe H: Toothbrushing frequency as it relates to plaque development and gingival health. *J Periodontol* 44:396, 1973.
197. Lappin-Scott HM, Claude E: Zobell—his life and contributions to biofilm microbiology. In Bell CR, Brylinsky M, Johnson-Green P, editors: *Microbial biosystems: new frontiers*, Halifax, Canada, 1999, Atlantic Canada Society for Microbial Ecology, p 45.
198. Law V, Seow WK: A longitudinal controlled study of factors associated with mutans streptococci infection and caries lesion initiation in children 21 to 72 months old. *Pediatr Dent* 28:58, 2006.
199. Law V, Seow WK, Townsend G: Factors influencing oral colonization of mutans streptococci in young children. *Aust Dent J* 52:93, 2007.
200. Lazarevic V, Whiteson K, Hernandez D, et al: Study of inter- and intra-individual variations in the salivary microbiota. *BMC Genomics* 11:523, 2011.
201. Lekholm U, Ericsson I, Adell R, et al: The condition of the soft tissues at tooth and fixture abutments supporting fixed bridges. A microbiological and histological study. *J Clin Periodontol* 13:558, 1986.
202. Leknes KN, Lie T, Selvig KA: Root grooves: a risk factor in periodontal attachment loss. *J Periodontol* 65:859, 1994.
203. Leknes KN, Lie T, Wikesjo UM, et al: Influence of tooth instrumentation roughness on gingival tissue reactions. *J Periodontol* 67:197, 1996.
204. Leknes KN, Lie T, Wikesjo UM, et al: Influence of tooth instrumentation roughness on subgingival microbial colonization. *J Periodontol* 65:303, 1994.
205. Leonhardt A, Renvert S, Dahlen G: Microbial findings at failing implants. *Clin Oral Implants Res* 10:339, 1999.
206. Lepp PW, Brinig MM, Ouverney CC, et al: Methanogenic Archaea and human periodontal disease. *Proc Natl Acad Sci U S A* 101:6176, 2004.
207. Li L, Matevski D, Aspiras M, et al: Two epithelial cell invasion-related loci of the oral pathogen *Actinobacillus actinomycetemcomitans*. *Oral Microbiol Immunol* 19:16, 2004.
208. Li L, Redding S, Dongari-Bagtzoglou A: *Candida glabrata:* an emerging oral opportunistic pathogen. *J Dent Res* 86:204, 2007.
209. Liljemark WF, Bloomquist CG, Germaine GR: Effect of bacterial aggregation on the adherence of oral streptococci to hydroxyapatite. *Infect Immun* 31:935, 1981.
210. Lin X, Lamont RJ, Wu J, et al: Role of differential expression of streptococcal arginine deiminase in inhibition of fimA expression in *Porphyromonas gingivalis*. *J Bacteriol* 190:4367, 2008.
211. Listgarten MA: Structure of the microbial flora associated with periodontal health and disease in man. A light and electron microscopic study. *J Periodontol* 47:1, 1976.
212. Listgarten MA, Hellden L: Relative distribution of bacteria at clinically healthy and periodontally diseased sites in humans. *J Clin Periodontol* 5:115, 1978.
213. Listgarten MA, Socransky SS: Ultrastructural characteristics of a spirochete in the lesion of acute necrotizing ulcerative gingivostomatitis (Vincent's infection). *Arch Oral Biol* 16:95, 1964.
214. Listgarten MA, Socransky SS: Electron microscopy as an aid in the taxonomic differentiation of oral spirochetes. *Arch Oral Biol* 10:127, 1965.
215. Liu YQ, Liu Y, Tay JH: The effects of extracellular polymeric substances on the formation and stability of biogranules. *Appl Microbiol Biotechnol* 65:143–148, 2004.
216. Loe H: Periodontal diseases: a brief historical perspective. *Periodontol 2000* 2:7, 1993.
217. Loe H, Anerud A, Boysen H, et al: The natural history of periodontal disease in man. The rate of periodontal destruction before 40 years of age. *J Periodontol* 49:607, 1978.
218. Loe H, Brown LJ: Early onset periodontitis in the United States of America. *J Periodontol* 62:608, 1991.
219. Loe H, Theilade E, Jensen SB: Experimental gingivitis in man. *J Periodontol* 36:177, 1965.
220. Loesche WJ: Importance of nutrition in gingival crevice microbial ecology. *Periodontics* 6:245, 1968.
221. Loesche WJ: Chemotherapy of dental plaque infections. *Oral Sci Rev* 9:65, 1976.
222. Loesche WJ, Svanberg ML, Pape HR: Intraoral transmission of *Streptococcus mutans* by a dental explorer. *J Dent Res* 58:1765, 1979.
223. Loesche WJ, Syed SA, Schmidt E, et al: Bacterial profiles of subgingival plaques in periodontitis. *J Periodontol* 56:447, 1985.
224. Loimaranta V, Jakubovics NS, Hytonen J, et al: Fluid- or surface-phase human salivary scavenger protein gp340 exposes different bacterial recognition properties. *Infect Immun* 73:2245, 2005.
225. Loomer PM: Microbiological diagnostic testing in the treatment of periodontal diseases. *Periodontol 2000* 34:49, 2004.
226. Lovdal A, Arno A, Waerhaug J: Incidence of clinical manifestations of periodontal disease in light of oral hygiene and calculus formation. *J Am Dent Assoc* 56:21, 1958.
227. Lucht E, Evengard B, Skott J, et al: *Entamoeba gingivalis* in human immunodeficiency virus type 1-infected patients with periodontal disease. *Clin Infect Dis* 27:471, 1998.
228. MacFarlane TW, Samaranayake LP: Systemic infections. In Jones JH, Manson DH, editors: *Oral manifestations of systemic disease*, London, 1990, Balliere Tindall, p 339.
229. Maeda K, Nagata H, Nonaka A, et al: Oral streptococcal glyceraldehyde-3-phosphate dehydrogenase mediates interaction with *Porphyromonas gingivalis* fimbriae. *Microbes Infect* 6:1163, 2004.
230. Maiden MF, Tanner A, McArdle S, et al: Tetracycline fiber therapy monitored by DNA probe and cultural methods. *J Periodontal Res* 26:452, 1991.
231. Mandlik A, Swierczynski A, Das A, et al: Pili in Gram-positive bacteria: assembly, involvement in colonization and biofilm development. *Trends Microbiol* 16:33, 2008.
232. Manor A, Lebendiger M, Shiffer A, et al: Bacterial invasion of periodontal tissues in advanced periodontitis in humans. *J Periodontol* 55:567, 1984.
233. Matarazzo F, Ribiero AC, Faveri M, et al: The domain Archaea in human mucosal surfaces. *Clin Microbiol Infect* 18:834–840, 2012.
234. Matarazzo F, Ribiero AC, Feres M, et al: Diversity and quantitative analysis of Archaea in aggressive periodontitis and periodontally healthy subjects. *J Clin Periodontol* 38:621–627, 2011.
235. Mayrand D, McBride BC: Exological relationships of bacteria involved in a simple, mixed anaerobic infection. *Infect Immun* 27:44, 1980.
236. McBride BC, Van der Hoeven JS: Role of interbacterial adherence in colonization of the oral cavities of gnotobiotic rats infected with S*treptococcus mutans* and *Veillonella alcalescens*. *Infect Immun* 33:467, 1981.
237. Mengel R, Stelzel M, Hasse C, et al: Osseointegrated implants in patients treated for generalized severe adult periodontitis. An interim report. *J Periodontol* 67:782, 1996.
238. Meyer DH, Sreenivasan PK, Fives-Taylor PM: Evidence for invasion of a human oral cell line by *Actinobacillus actinomycetemcomitans*. *Infect Immun* 59:2719, 1991.
239. Michalowicz BS: Genetic and heritable risk factors in periodontal disease. *J Periodontol* 65:479, 1994.

240. Michalowicz BS, Ronderos M, Camara-Silva R, et al: Human herpesviruses and *Porphyromonas gingivalis* are associated with juvenile periodontitis. *J Periodontol* 71:981, 2000.
241. Mierau HD: [Relations between plaque formation, tooth surface roughness and self-cleaning]. *Dtsch Zahnarztl Z* 39:691, 1984.
242. Mierau HD, Singer D: [Reproducibility of plaque formation in the dento-gingival region (3)]. *Dtsch Zahnarztl Z* 33:566, 1978.
243. Milgrom P, Riedy CA, Weinstein P, et al: Dental caries and its relationship to bacterial infection, hypoplasia, diet, and oral hygiene in 6- to 36-month-old children. *Community Dent Oral Epidemiol* 28:295, 2000.
244. Mombelli A, Casagni F, Madianos PN: Can presence or absence of periodontal pathogens distinguish between subjects with chronic and aggressive periodontitis? A systematic review. *J Clin Periodontol* 29(Suppl 3):10, 2002.
245. Mombelli A, Lang NP, Burgin WB, et al: Microbial changes associated with the development of puberty gingivitis. *J Periodontal Res* 25:331, 1990.
246. Mombelli A, Lehmann B, Tonetti M, et al: Clinical response to local delivery of tetracycline in relation to overall and local periodontal conditions. *J Clin Periodontol* 24:470, 1997.
247. Mombelli A, Marxer M, Gaberthuel T, et al: The microbiota of osseointegrated implants in patients with a history of periodontal disease. *J Clin Periodontol* 22:124, 1995.
248. Moore WE: Microbiology of periodontal disease. *J Periodontal Res* 22:335, 1987.
249. Moore WE, Holdeman LV: Special problems associated with the isolation and identification of intestinal bacteria in fecal flora studies. *Am J Clin Nutr* 27:1450, 1974.
250. Moore WE, Holdeman LV, Cato EP, et al: Comparative bacteriology of juvenile periodontitis. *Infect Immun* 48:507, 1985.
251. Moore WE, Moore LV: The bacteria of periodontal diseases. *Periodontol 2000* 5:66, 1994.
252. Mouton C, Reynolds HS, Genco RJ: Characterization of tufted streptococci isolated from the "corn cob" configuration of human dental plaque. *Infect Immun* 27:235, 1980.
253. Nelson KE, Fleischmann RD, DeBoy RT, et al: Complete genome sequence of the oral pathogenic *Bacterium porphyromonas gingivalis* strain W83. *J Bacteriol* 185:5591, 2003.
254. Newman HN: The approximal apical border of plaque on children's teeth. 1. Morphology, structure and cell content. *J Periodontol* 50:561, 1979.
255. Newman MG, Socransky SS: Predominant cultivable microbiota in periodontosis. *J Periodontal Res* 12:120, 1977.
256. Newman MG, Socransky SS, Savitt ED, et al: Studies of the microbiology of periodontosis. *J Periodontol* 47:373, 1976.
257. Nishiyama S, Murakami Y, Nagata H, et al: Involvement of minor components associated with the FimA fimbriae of *Porphyromonas gingivalis* in adhesive functions. *Microbiology* 153:1916, 2007.
258. Nowzari H, MacDonald ES, Flynn J, et al: The dynamics of microbial colonization of barrier membranes for guided tissue regeneration. *J Periodontol* 67:694, 1996.
259. Nyvad B, Fejerskov O: Scanning electron microscopy of early microbial colonization of human enamel and root surfaces in vivo. *Scand J Dent Res* 95:287, 1987.
260. Nyvad B, Kilian M: Microflora associated with experimental root surface caries in humans. *Infect Immun* 58:1628, 1990.
261. O'Brien-Simpson NM, Veith PD, Dashper SG, et al: Antigens of bacteria associated with periodontitis. *Periodontol 2000* 35:101, 2004.
262. Oberste MS, Maher K, Kilpatrick DR, et al: Molecular evolution of the human enteroviruses: correlation of serotype with VP1 sequence and application to picornavirus classification. *J Virol* 73:1941, 1999.
263. Ofek I, Doyle RJ, editors: *Bacterial adhesion to cells and tissues*, London, 1994, Chapman and Hall.
264. Ong ES, Newman HN, Wilson M, et al: The occurrence of periodontitis-related microorganisms in relation to titanium implants. *J Periodontol* 63:200, 1992.
265. Ouverney CC, Armitage GC, Relman DA: Single-cell enumeration of an uncultivated TM7 subgroup in the human subgingival crevice. *Appl Environ Microbiol* 69:6294, 2003.
266. Pallansch M, Roos R: Enteroviruses: polioviruses, coxsackieviruses, echoviruses, and newer enteroviruses. In Knipe DM, Howley PM, editors: *Fields virology*, Philadelphia, 2007, Lippincott, Williams and Wilkins, p 840.
267. Palmer RJ, Jr, Gordon SM, Cisar JO, et al: Coaggregation-mediated interactions of streptococci and actinomyces detected in initial human dental plaque. *J Bacteriol* 185:3400, 2003.
268. Papaioannou W, Quirynen M, van Steenberghe D: The influence of periodontitis on the subgingival flora around implants in partially edentulous patients. *Clin Oral Implants Res* 7:405, 1996.
269. Park Y, James CE, Yoshimura F, et al: Expression of the short fimbriae of *Porphyromonas gingivalis* is regulated in oral bacterial consortia. *FEMS Microbiol Lett* 262:65, 2006.
270. Park Y, Simionato MR, Sekiya K, et al: Short fimbriae of *Porphyromonas gingivalis* and their role in coadhesion with *Streptococcus gordonii*. *Infect Immun* 73:3983, 2005.
271. Patton LL, Phelan JA, Ramos-Gomez FJ, et al: Prevalence and classification of HIV-associated oral lesions. *Oral Dis* 8(Suppl 2):98, 2002.
272. Pearce C, Bowden GH, Evans M, et al: Identification of pioneer viridans streptococci in the oral cavity of human neonates. *J Med Microbiol* 42:67, 1995.
273. Pearce MA, Devine DA, Dixon RA, et al: Genetic heterogeneity in *Prevotella intermedia, Prevotella nigrescens, Prevotella corporis* and related species isolated from oral and nonoral sites. *Oral Microbiol Immunol* 15:89, 2000.
274. Pellett PE, Roizman B: The family Herpesviridae: a brief introduction. In Knipe DM, Howley PM, editors: *Fields virology*, Philadelphia, 2007, Lippincott, Williams and Wilkins, p 2479.
275. Perez BA, Planet PJ, Kachlany SC, et al: Genetic analysis of the requirement for flp-2, tadV, and rcpB in Actinobacillus actinomycetemcomitans biofilm formation. *J Bacteriol* 188:6361, 2006.
276. Perry JA, Jones MB, Peterson SN, et al: Peptide alarmone signalling triggers an auto-active bacteriocin necessary for genetic competence. *Mol Microbiol* 72:905, 2009.
277. Persson GR, Samuelsson E, Lindahl C, et al: Mechanical non-surgical treatment of peri-implantitis: a single-blinded randomized longitudinal clinical study. II. Microbiological results. *J Clin Periodontol* 37:563–573, 2010.
278. Petersilka GJ, Ehmke B, Flemmig TF: Antimicrobial effects of mechanical debridement. *Periodontol 2000* 28:56, 2002.
279. Pfaller MA: Nosocomial candidiasis: emerging species, reservoirs, and modes of transmission. *Clin Infect Dis* 22(Suppl 2):S89, 1996.
280. Planet PJ, Kachlany SC, Fine DH, et al: The widespread colonization island of *Actinobacillus actinomycetemcomitans*. *Nat Genet* 34:193, 2003.
281. Porter SR, Luker J, Scully C, et al: Orofacial manifestations of a group of British patients infected with HIV-1. *J Oral Pathol Med* 18:47, 1989.
282. Potempa J, Banbula A, Travis J: Role of bacterial proteinases in matrix destruction and modulation of host responses. *Periodontol 2000* 24:153, 2000.
283. Potempa J, Pike R, Travis J: Titration and mapping of the active site of cysteine proteinases from *Porphyromonas gingivalis* (gingipains) using peptidyl chloromethanes. *Biol Chem* 378:223, 1997.
284. Potempa M, Potempa J, Kantyka T, et al: Interpain A, a cysteine proteinase from *Prevotella intermedia,* inhibits complement by degrading complement factor C3. *PLoS Pathog* 5:e1000316, 2009.
285. Prakobphol A, Xu F, Hoang VM, et al: Salivary agglutinin, which binds *Streptococcus mutans* and *Helicobacter pylori,* is the lung scavenger receptor cysteine-rich protein gp-340. *J Biol Chem* 275:39860, 2000.
286. Pratten J, Barnett P, Wilson M: Composition and susceptibility to chlorhexidine of multispecies biofilms of oral bacteria. *Appl Environ Microbiol* 64:3515, 1998.

287. Preber H, Bergstrom J, Linder LE: Occurrence of periopathogens in smoker and non-smoker patients. *J Clin Periodontol* 19:667, 1992.
288. Quirynen M: *Anatomical and inflammatory factors influence bacterial plaque growth and retention in man*, 1986.
289. Quirynen M, Bollen CM: The influence of surface roughness and surface-free energy on supra- and subgingival plaque formation in man. A review of the literature. *J Clin Periodontol* 22:1, 1995.
290. Quirynen M, Bollen CM: The influence of surface roughness and surface-free energy on supra- and subgingival plaque formation in man. A review of the literature. *J Clin Periodontol* 22:1, 1995.
291. Quirynen M, Bollen CM, Papaioannou W, et al: The influence of titanium abutment surface roughness on plaque accumulation and gingivitis: short-term observations. *Int J Oral Maxillofac Implants* 11:169, 1996.
292. Quirynen M, Bollen CM, Vandekerckhove BN, et al: Full- vs. partial-mouth disinfection in the treatment of periodontal infections: short-term clinical and microbiological observations. *J Dent Res* 74:1459, 1995.
293. Quirynen M, De Soete M, Dierickx K, et al: The intra-oral translocation of periodontopathogens jeopardises the outcome of periodontal therapy. A review of the literature. *J Clin Periodontol* 28:499, 2001.
294. Quirynen M, Dekeyser C, van Steenberghe D: The influence of gingival inflammation, tooth type, and timing on the rate of plaque formation. *J Periodontol* 62:219, 1991.
295. Quirynen M, Gijbels F, Jacobs R: An infected jawbone site compromising successful osseointegration. *Periodontol 2000* 33:129, 2003.
296. Quirynen M, Gizani S, Mongardini C, et al: The effect of periodontal therapy on the number of cariogenic bacteria in different intra-oral niches. *J Clin Periodontol* 26:322, 1999.
297. Quirynen M, Listgarten MA: Distribution of bacterial morphotypes around natural teeth and titanium implants ad modum Brånemark. *Clin Oral Implants Res* 1:8, 1990.
298. Quirynen M, Marechal M, Busscher HJ, et al: The influence of surface free-energy on planimetric plaque growth in man. *J Dent Res* 68:796, 1989.
299. Quirynen M, Papaioannou W, van Steenbergen TJ, et al: Adhesion of *Porphyromonas gingivalis* strains to cultured epithelial cells from patients with a history of chronic adult periodontitis or from patients less susceptible to periodontitis. *J Periodontol* 72:626, 2001.
300. Quirynen M, Teughels W, De Soete M, et al: Topical antiseptics and antibiotics in the initial therapy of chronic adult periodontitis: microbiological aspects. *Periodontol 2000* 28:72, 2002.
301. Quirynen M, van der Mei HC, Bollen CM, et al: An in vivo study of the influence of the surface roughness of implants on the microbiology of supra- and subgingival plaque. *J Dent Res* 72:1304, 1993.
302. Quirynen M, van Steenberghe D: Is early plaque growth rate constant with time? *J Clin Periodontol* 16:278, 1989.
303. Quirynen M, Vogels R, Pauwels M, et al: Initial subgingival colonization of pristine pockets in an established environment. *J Dent Res* 84:340, 2005.
304. Quirynen M, Vogels R, Peeters W, et al: Dynamics of initial subgingival colonization of peri-implant pockets. *Clin Oral Implants Res* 17:25, 2005.
305. Quirynen M, Vogels R, Peeters W, et al: Dynamics of initial subgingival colonization of "pristine" peri-implant pockets. *Clin Oral Implants Res* 17:25, 2006.
306. Ramberg P, Axelsson P, Lindhe J: Plaque formation at healthy and inflamed gingival sites in young individuals. *J Clin Periodontol* 22:85, 1995.
307. Ramberg P, Lindhe J, Dahlen G, et al: The influence of gingival inflammation on de novo plaque formation. *J Clin Periodontol* 21:51, 1994.
308. Rams TE, Feik D, Slots J: Staphylococci in human periodontal diseases. *Oral Microbiol Immunol* 5:29, 1990.
309. Ramsey MM, Whiteley M: Polymicrobial interactions stimulate resistance to host innate immunity through metabolite perception. *Proc Natl Acad Sci U S A* 106:1578, 2009.
310. Reed WP, Williams RC: Bacterial adherence: first step in pathogenesis of certain infections. *J Chronic Dis* 31:67, 1978.
311. Renvert S, Dahlen G, Wikstrom M: Treatment of periodontal disease based on microbiological diagnosis. Relation between microbiological and clinical parameters during 5 years. *J Periodontol* 67:562, 1996.
312. Renvert S, Dahlen G, Wikstrom M: The clinical and microbiological effects of non-surgical periodontal therapy in smokers and non-smokers. *J Clin Periodontol* 25:153, 1998.
313. Renvert S, Wikstrom M, Dahlen G, et al: Effect of root debridement on the elimination of *Actinobacillus actinomycetemcomitans* and *Bacteroides gingivalis* from periodontal pockets. *J Clin Periodontol* 17:345, 1990.
314. Renvert S, Wikstrom M, Dahlen G, et al: On the inability of root debridement and periodontal surgery to eliminate *Actinobacillus actinomycetemcomitans* from periodontal pockets. *J Clin Periodontol* 17:351, 1990.
315. Rickard AH, Palmer RJ, Jr, Blehert DS, et al: Autoinducer 2: a concentration-dependent signal for mutualistic bacterial biofilm growth. *Mol Microbiol* 60:1446, 2006.
316. Rimondini L, Fare S, Brambilla E, et al: The effect of surface roughness on early in vivo plaque colonization on titanium. *J Periodontol* 68:556, 1997.
317. Roberts FA, Darveau RP: Beneficial bacteria of the periodontium. *Periodontol 2000* 30:40, 2002.
318. Rosen G, Genzler T, Sela MN: Coaggregation of *Treponema denticola* with *Porphyromonas gingivalis* and *Fusobacterium nucleatum* is mediated by the major outer sheath protein of *Treponema denticola*. *FEMS Microbiol Lett* 289:59, 2008.
319. Rotimi VO, Duerden BI: The development of the bacterial flora in normal neonates. *J Med Microbiol* 14:51, 1981.
320. Rudney JD, Chen R, Sedgewick GJ: Intracellular *Actinobacillus actinomycetemcomitans* and *Porphyromonas gingivalis* in buccal epithelial cells collected from human subjects. *Infect Immun* 69:2700, 2001.
321. Rudney JD, Chen R, Sedgewick GJ: *Actinobacillus actinomycetemcomitans, Porphyromonas gingivalis*, and *Tannerella forsythensis* are components of a polymicrobial intracellular flora within human buccal cells. *J Dent Res* 84:59, 2005.
322. Russel AL: Epidemiology of periodontal disease. *Int Dent J* 17:282, 1967.
323. Ryder MI: An update on HIV and periodontal disease. *J Periodontol* 73:1071, 2002.
324. Saadi AT, Blackwell CC, Essery SD, et al: Developmental and environmental factors that enhance binding of *Bordatella pertussis* to human epithelial cells in relation to sudden infant death syndrome (SIDS). *FEMS Immunol Med Microbiol* 16:51, 1996.
325. Saber MH, Schwarzberg K, Alonaizan FA, et al: Bacterial flora of dental periradicular lesions analyzed by the 454-pyrosequencing technology. *J Endod* 38:1484, 2012.
326. Saglie FR, Carranza FA, Jr, Newman MG, et al: Identification of tissue-invading bacteria in human periodontal disease. *J Periodontal Res* 17:452, 1982.
327. Saglie FR, Marfany A, Camargo P: Intragingival occurrence of *Actinobacillus actinomycetemcomitans* and *Bacteroides gingivalis* in active destructive periodontal lesions. *J Periodontol* 59:259, 1988.
328. Saito A, Inagaki S, Kimizuka R, et al: *Fusobacterium nucleatum* enhances invasion of human gingival epithelial and aortic endothelial cells by *Porphyromonas gingivalis*. *FEMS Immunol Med Microbiol* 54:349, 2008.
329. Samaranayake LP, Keung LW, Jin L: Oral mucosal fungal infections. *Periodontol 2000* 49:39, 2009.
330. Samonis G, Mantadakis E, Maraki S: Orofacial viral infections in the immunocompromised host. *Oncol Rep* 7:1389, 2000.
331. Sanford BA, Shelokov A, Ramsay MA: Bacterial adherence to virus-infected cells: a cell culture model of bacterial superinfection. *J Infect Dis* 137:176, 1978.
332. Sanz M, Quirynen M: Advances in the aetiology of periodontitis. Group A consensus report of the 5th European Workshop in Periodontology. *J Clin Periodontol* 32(Suppl 6):54, 2005.
333. Sardi JC, Scorzoni L, Bernardi T, et al: Candida species: current epidemiology, pathogenicity, biofilm formation, natural antifungal

products and new therapeutic options. *J Med Microbiol* 62(Pt 1):10, 2013.
334. Sbordone L, Barone A, Ciaglia RN, et al: Longitudinal study of dental implants in a periodontally compromised population. *J Periodontol* 70:1322, 1999.
335. Scannapieco FA: Saliva-bacterium interactions in oral microbial ecology. *Crit Rev Oral Biol Med* 5:203, 1994.
336. Schaeffer LM, Schmidt ML, Demuth DR: Induction of *Aggregatibacter actinomycetemcomitans* leukotoxin expression by IS1301 and orfA. *Microbiology* 154:528, 2008.
337. Schei O, Waerhaug J: Loval A: Alveolar bone loss as related to oral hygiene and age. *J Periodontol* 30:7, 1959.
338. Schneider LC, Schneider AE: Diagnosis of oral ulcers. *Mt Sinai J Med* 65:383, 1998.
339. Schreiner HC, Sinatra K, Kaplan JB, et al: Tight-adherence genes of *Actinobacillus actinomycetemcomitans* are required for virulence in a rat model. *Proc Natl Acad Sci U S A* 100:7295, 2003.
340. Schroeder HE, De Boever J: The structure of microbial dental plaque. In McHugh WD, editor: *Dental plaque*, Edinburgh, 1970, Livingstone, p 49.
341. Schuman P, Ohmit SE, Sobel JD, et al: Oral lesions among women living with or at risk for HIV infection. HIV Epidemiology Research Study (HERS) Group. *Am J Med* 104:559, 1998.
342. Scully C, Felix DH: Oral medicine—update for the dental practitioner. Aphthous and other common ulcers. *Br Dent J* 199:259, 2005.
343. Sheiham A: Periodontal disease and oral cleanliness in tobacco smokers. *J Periodontol* 42:259, 1971.
344. Shibli JA, Melo L, Ferrari DS, et al: Composition of supra- and subgingival biofilm of subjects with healthy and diseased implants. *Clin Oral Implants Res* 19:975, 2008.
345. Simonsson T: Aspects of dental plaque formation with special reference to colloid-chemical phenomena. *Swed Dent J Suppl* 58:1, 1989.
346. Simonsson T, Ronstrom A, Rundegren J, et al: Rate of plaque formation–some clinical and biochemical characteristics of "heavy" and "light" plaque formers. *Scand J Dent Res* 95:97, 1987.
347. Siqueira WL, Oppenheim FG: Small molecular weight proteins/peptides present in the in vivo formed human acquired enamel pellicle. *Arch Oral Biol* 54:437, 2009.
348. Siqueira WL, Zhang W, Helmerhorst EJ, et al: Identification of protein components in in vivo human acquired enamel pellicle using LC-ESI-MS/MS. *J Proteome Res* 6:2152, 2007.
349. Skopek RJ, Liljemark WF, Bloomquist CG, et al: Dental plaque development on defined streptococcal surfaces. *Oral Microbiol Immunol* 8:16, 1993.
350. Slaney JM, Gallagher A, Aduse-Opoku J, et al: Mechanisms of resistance of *Porphyromonas gingivalis* to killing by serum complement. *Infect Immun* 74:5352, 2006.
351. Sliepen I, Hofkens J, Van EM, et al: *Aggregatibacter actinomycetemcomitans* adhesion inhibited in a flow cell. *Oral Microbiol Immunol* 23:520, 2008.
352. Sliepen I, Van Damme J, Van Essche M, et al: Microbial interactions influence inflammatory host cell responses. *J Dent Res* 88:1026, 2009.
353. Slots J: The predominant cultivable microflora of advanced periodontitis. *Scand J Dent Res* 85:114, 1977.
354. Slots J: Subgingival microflora and periodontal disease. *J Clin Periodontol* 6:351, 1979.
355. Slots J: Herpesviruses in periodontal diseases. *Periodontol 2000* 38:33, 2005.
356. Slots J: Oral viral infections of adults. *Periodontol 2000* 49:60, 2009.
357. Slots J: Herpesviral-bacterial interactions in periodontal diseases. *Periodontol 2000* 52:117, 2010.
358. Slots J, Gibbons RJ: Attachment of *Bacteroides melaninogenicus* subsp. *asaccharolyticus* to oral surfaces and its possible role in colonization of the mouth and of periodontal pockets. *Infect Immun* 19:254, 1978.
359. Slots J, Listgarten MA: *Bacteroides gingivalis, Bacteroides intermedius* and *Actinobacillus actinomycetemcomitans* in human periodontal diseases. *J Clin Periodontol* 15:85, 1988.
360. Slots J, Rams TE: New views on periodontal microbiota in special patient categories. *J Clin Periodontol* 18:411, 1991.
361. Socransky SS, Gibbons RJ, Dale AC, et al: The microbiota of the gingival crevice area of man. I. Total microscopic and viable counts of specific microorganisms. *Arch Oral Biol* 8:275, 1963.
362. Socransky SS, Haffajee AD: Microbial mechanisms in the pathogenesis of destructive periodontal diseases: a critical assessment. *J Periodontal Res* 26:195, 1991.
363. Socransky SS, Haffajee AD: The bacterial etiology of destructive periodontal disease: current concepts. *J Periodontol* 63:322, 1992.
364. Socransky SS, Haffajee AD: The nature of periodontal diseases. *Ann Periodontol* 2:3, 1997.
365. Socransky SS, Haffajee AD, Cugini MA, et al: Microbial complexes in subgingival plaque. *J Clin Periodontol* 25:134, 1998.
366. Socransky SS, Haffajee AD, Goodson JM, et al: New concepts of destructive periodontal disease. *J Clin Periodontol* 11:21, 1984.
367. Socransky SS, Haffajee AD, Smith GL, et al: Difficulties encountered in the search for the etiologic agents of destructive periodontal diseases. *J Clin Periodontol* 14:588, 1987.
368. Socransky SS, Manganiello AD, Propas D, et al: Bacteriological studies of developing supragingival dental plaque. *J Periodontal Res* 12:90, 1977.
369. Socransky SS, Manganiello SD: The oral microbiota of man from birth to senility. *J Periodontol* 42:485, 1971.
370. Socransky SS, Smith C, Haffajee AD: Subgingival microbial profiles in refractory periodontal disease. *J Clin Periodontol* 29:260, 2002.
371. Stenderup A: Oral mycology. *Acta Odontol Scand* 48:3, 1990.
372. Stingu CS, Eschrich K, Rodloff AC, et al: Periodontitis is associated with a loss of colonization by *Streptococcus sanguinis*. *J Med Microbiol* 57:495, 2008.
373. Stoltenberg JL, Osborn JB, Pihlstrom BL, et al: Association between cigarette smoking, bacterial pathogens, and periodontal status. *J Periodontol* 64:1225, 1993.
374. Sudbery P, Gow N, Berman J: The distinct morphogenic states of *Candida albicans*. *Trends Microbiol* 12:317, 2004.
375. Sumida S, Ishihara K, Kishi M, et al: Transmission of periodontal disease-associated bacteria from teeth to osseointegrated implant regions. *Int J Oral Maxillofac Implants* 17:696, 2002.
376. Syed SA, Loesche WJ: Bacteriology of human experimental gingivitis: effect of plaque age. *Infect Immun* 21:821, 1978.
377. Sztajer H, Lemme A, Vilchez R, et al: Autoinducer-2-regulated genes in *Streptococcus mutans* UA159 and global metabolic effect of the luxS mutation. *J Bacteriol* 190:401, 2008.
378. Takenaka S, Trivedi HM, Corbin A, et al: Direct visualization of spatial and temporal patterns of antimicrobial action within model oral biofilms. *Appl Environ Microbiol* 74:1869, 2008.
379. Tanner AC, Haffer C, Bratthall GT, et al: A study of the bacteria associated with advancing periodontitis in man. *J Clin Periodontol* 6:278, 1979.
380. Tappuni AR, Challacombe SJ: Distribution and isolation frequency of eight streptococcal species in saliva from predentate and dentate children and adults. *J Dent Res* 72:31, 1993.
381. Taylor DC, Clancy RL, Cripps AW, et al: An alteration in the host-parasite relationship in subjects with chronic bronchitis prone to recurrent episodes of acute bronchitis. *Immunol Cell Biol* 72:143, 1994.
382. Teles RP, Haffajee AD, Socransky SS: Microbiological goals of periodontal therapy. *Periodontol 2000* 42:180, 2006.
383. Teughels W, Kinder Haake SA, Sliepen I, et al: Bacteria interfere with *A. actinomycetemcomitans* colonization. *J Dent Res* 87:611, 2007.
384. Teughels W, Newman MG, Coucke W, et al: Guiding periodontal pocket recolonization: a proof of concept. *J Dent Res* 86:1078, 2007.
385. Teughels W, Sliepen I, Quirynen M, et al: Human cytomegalovirus enhances *A. actinomycetemcomitans* adherence to cells. *J Dent Res* 86:2007.
386. Teughels W, Van EM, Sliepen I, et al: Probiotics and oral healthcare. *Periodontol 2000* 48:111, 2008.

387. Theilade E, Wright WH, Jensen SB, et al: Experimental gingivitis in man. II. A longitudinal clinical and bacteriological investigation. *J Periodontal Res* 1:1, 1966.
388. Ting M, Contreras A, Slots J: Herpesvirus in localized juvenile periodontitis. *J Periodontal Res* 35:17, 2000.
389. Tong H, Chen W, Merritt J, et al: *Streptococcus oligofermentans* inhibits *Streptococcus mutans* through conversion of lactic acid into inhibitory H2O2: a possible counteroffensive strategy for interspecies competition. *Mol Microbiol* 63:872, 2007.
390. Truper HG, De Clari L: Taxonomic note: necessary correction of specific epithets formed as substantives (nouns) "in apposition". *Int J Syst Bacteriol* 47:908, 1997.
391. Umeda M, Chen C, Bakker I, et al: Risk indicators for harboring periodontal pathogens. *J Periodontol* 69:1111, 1998.
392. Vaahtoniemi LH, Raisanen S, Stenfors LE: Attachment of bacteria to oral epithelial cells in vivo: a possible correlation to gingival health status. *J Periodontal Res* 28:308, 1993.
393. van der Mei HC, Rustema-Abbing M, Bruinsma GM, et al: Influence of weight on removal of co-adhering bacteria from salivary pellicles by different modes of brushing. *Caries Res* 38:85, 2004.
394. van der Reijden WA, Dellemijn-Kippuw N, Stijne-van Nes AM, et al: Mutans streptococci in subgingival plaque of treated and untreated patients with periodontitis. *J Clin Periodontol* 28:686, 2001.
395. Van der Velden U: Purpose and problems of periodontal disease classification. *Periodontol 2000* 39:13, 2005.
396. Van Hoogmoed CG, Geertsema-Doornbusch G, Teughels W, et al: Reduction of periodontal pathogens adhesion by antagonistic strains. *Oral Microbiol Immunol* 23:43, 2008.
397. van Steenberghe D, Jacobs R, Desnyder M, et al: The relative impact of local and endogenous patient-related factors on implant failure up to the abutment stage. *Clin Oral Implants Res* 13:617, 2002.
398. van Winkelhoff AJ, Bosch-Tijhof CJ, Winkel EG, et al: Smoking affects the subgingival microflora in periodontitis. *J Periodontol* 72:666, 2001.
399. van Winkelhoff AJ, Boutaga K: Transmission of periodontal bacteria and models of infection. *J Clin Periodontol* 32(Suppl 6):16, 2005.
400. van Winkelhoff AJ, Herrera D, Oteo A, et al: Antimicrobial profiles of periodontal pathogens isolated from periodontitis patients in The Netherlands and Spain. *J Clin Periodontol* 32:893, 2005.
401. Vartoukian SR, Palmer RM, Wade WG: Diversity and morphology of members of the phylum "synergistetes" in periodontal health and disease. *Appl Environ Microbiol* 75:3777, 2009.
402. Vianna ME, Conrads G, Gomes BP, et al: Identification and quantification of archaea involved in primary endodontic infections. *J Clin Microbiol* 44:1274, 2006.
403. Vickerman MM, Brossard KA, Funk DB, et al: Phylogenetic analysis of bacterial and archaeal species in symptomatic and asymptomatic endodontic infections. *J Med Microbiol* 56:110, 2007.
404. Wade WG, Addy M: In vitro activity of a chlorhexidine-containing mouthwash against subgingival bacteria. *J Periodontol* 60:521, 1989.
405. Walden WC, Hentges DJ: Differential effects of oxygen and oxidation-reduction potential on the multiplication of three species of anaerobic intestinal bacteria. *Appl Microbiol* 30:781, 1975.
406. Walker C, Sedlacek MJ: An in vitro biofilm model of subgingival plaque. *Oral Microbiol Immunol* 22:152, 2007.
407. Walker CB: Selected antimicrobial agents: mechanisms of action, side effects and drug interactions. *Periodontol 2000* 10:12, 1996.
408. Wan AK, Seow WK, Purdie DM, et al: Oral colonization of *Streptococcus mutans* in six-month-old predentate infants. *J Dent Res* 80:2060, 2001.
409. Wan AK, Seow WK, Purdie DM, et al: A longitudinal study of *Streptococcus mutans* colonization in infants after tooth eruption. *J Dent Res* 82:504, 2003.
410. Wan AK, Seow WK, Walsh LJ, et al: Association of *Streptococcus mutans* infection and oral developmental nodules in pre-dentate infants. *J Dent Res* 80:1945, 2001.
411. Wang Y, Chen C: Mutation analysis of the flp operon in *Actinobacillus actinomycetemcomitans*. *Gene* 351:61, 2005.
412. Weiger R, Netuschil L, von Ohle C, et al: Microbial generation time during the early phases of supragingival dental plaque formation. *Oral Microbiol Immunol* 10:93, 1995.
413. Weiss EI, Eli I, Shenitzki B, et al: Identification of the rhamnose-sensitive adhesin of *Capnocytophaga ochracea* ATCC 33596. *Arch Oral Biol* 35(Suppl):127S, 1990.
414. Weiss EI, London J, Kolenbrander PE, et al: Characterization of monoclonal antibodies to fimbria-associated adhesins of *Bacteroides loescheii* PK1295. *Infect Immun* 56:219, 1988.
415. Weiss EI, London J, Kolenbrander PE, et al: Localization and enumeration of fimbria-associated adhesins of *Bacteroides loescheii*. *J Bacteriol* 170:1123, 1988.
416. Wennstrom JL, Heijl L, Dahlen G, et al: Periodic subgingival antimicrobial irrigation of periodontal pockets (I). Clinical observations. *J Clin Periodontol* 14:541, 1987.
417. Weyant RJ, Burt BA: An assessment of survival rates and within-patient clustering of failures for endosseous oral implants. *J Dent Res* 72:2, 1993.
418. Whittaker CJ, Clemans DL, Kolenbrander PE: Insertional inactivation of an intrageneric coaggregation-relevant adhesin locus from *Streptococcus gordonii* DL1 (Challis). *Infect Immun* 64:4137, 1996.
419. Wickstrom C, Svensater G: Salivary gel-forming mucin MUC5B—a nutrient for dental plaque bacteria. *Oral Microbiol Immunol* 23:177, 2008.
420. Williams P: Role of the cell envelope in bacterial adaptation to growth in vivo in infections. *Biochimie* 70:987, 1988.
421. Wilson M: An introduction to the human-microbe symbiosis. In Wilson M, editor: *Microbial inhabitants of humans*, New York, 2005, Cambridge University Press, p 1.
422. Winkel EG, Abbas F, van d V, et al: Experimental gingivitis in relation to age in individuals not susceptible to periodontal destruction. *J Clin Periodontol* 14:499, 1987.
423. Wohl DA, Zeng D, Stewart P, et al: Cytomegalovirus viremia, mortality, and end-organ disease among patients with AIDS receiving potent antiretroviral therapies. *J Acquir Immune Defic Syndr* 38:538, 2005.
424. Wolff L, Dahlen G, Aeppli D: Bacteria as risk markers for periodontitis. *J Periodontol* 65:498, 1994.
425. Wood SR, Kirkham J, Marsh PD, et al: Architecture of intact natural human plaque biofilms studied by confocal laser scanning microscopy. *J Dent Res* 79:21, 2000.
426. Ximenez-Fyvie LA, Almaguer-Flores A, Jacobo-Soto V, et al: Subgingival microbiota of periodontally untreated Mexican subjects with generalized aggressive periodontitis. *J Clin Periodontol* 33:869, 2006.
427. Ximenez-Fyvie LA, Almaguer-Flores A, Jacobo-Soto V, et al: Description of the subgingival microbiota of periodontally untreated Mexican subjects: chronic periodontitis and periodontal health. *J Periodontol* 77:460, 2006.
428. Xu KD, McFeters GA, Stewart PS: Biofilm resistance to antimicrobial agents. *Microbiology* 146(Pt 3):547, 2000.
429. Yao Y, Berg EA, Costello CE, et al: Identification of protein components in human acquired enamel pellicle and whole saliva using novel proteomics approaches. *J Biol Chem* 278:5300, 2003.
430. Yokoyama M, Hinode D, Yoshioka M, et al: Relationship between *Campylobacter rectus* and periodontal status during pregnancy. *Oral Microbiol Immunol* 23:55, 2008.
431. Zambon JJ: Periodontal diseases: microbial factors. *Ann Periodontol* 1:879, 1996.
432. Zambon JJ, Grossi SG, Machtei EE, et al: Cigarette smoking increases the risk for subgingival infection with periodontal pathogens. *J Periodontol* 67:1050, 1996.
433. Zaura E, Keijser BJ, Huse SM, et al: Defining the healthy "core microbiome" of oral microbial communities. *BMC Microbiol* 9:259, 2009.

434. Zee KY, Samaranayake LP, Attstrom R: Predominant cultivable supragingival plaque in Chinese "rapid" and "slow" plaque formers. *J Clin Periodontol* 23:1025, 1996.
435. Zee KY, Samaranayake LP, Attstrom R: Scanning electron microscopy of microbial colonization of "rapid" and "slow" dental-plaque formers in vivo. *Arch Oral Biol* 42:735, 1997.
436. Zhang G, Chen R, Rudney JD: *Streptococcus cristatus* attenuates *Fusobacterium nucleatum*-induced interleukin-8 expression in oral epithelial cells. *J Periodontal Res* 43:408, 2008.
437. Zijnge V, van Leeuwen MB, Degener JE, et al: Oral biofilm architecture on natural teeth. *PLoS ONE* 5(2):e9321, 2010.

CHAPTER 9

Molecular Biology of Host-Microbe Interactions

Carlos Rossa Jr. and Keith L. Kirkwood

CHAPTER OUTLINE

Innate Immunity in Periodontal Diseases
Adaptive Immunity in Periodontal Diseases
Pathobiology of Periodontal Disease Progression
Therapeutic Strategies for Disrupting Host-Cell Signaling in the Treatment of Periodontal Diseases

For online-only content on defensins, inflammasomes, complement systems, and host-microbe interactions in adaptive immunity as well as expanded discussions of vigilance and tolerance, cell signaling pathways and the expression of biollogically active mediators in the innate immune response, the activation of adaptive immunity in periodontal diseases, and cell signaling events that modulate inflammatory mediator expression, please visit the companion website at www.expertconsult.com. Some figures may be out of numeric order in this printed chapter.

For the past two decades, the host response to the bacterial challenge that originates from the dental biofilm has been considered to play a major role in the initiation and tissue destruction of periodontal diseases.[196] The significance of host-microbial interactions is reinforced by epidemiological data indicating different susceptibilities to periodontal disease among individuals, despite the long-term presence of oral biofilm.[21,22,219] Other studies demonstrating increased susceptibility and greater severity of periodontal disease in individuals with impaired immune response due to systemic conditions also indicate the significance of the host response to the bacterial challenge.[95,237] In the current paradigm of periodontal disease, specific periodontal pathogens are essential for disease initiation; however, the extent and severity of tissue destruction are largely dependent on the nature of the host-microbial interactions. These interactions are dynamic, because the microbial composition of the dental biofilm and host immune competency can vary widely among patients, thereby resulting in differences in host responses and subsequent alveolar bone loss. This concept has evolved in parallel with a more advanced appreciation of the immune response that results in an increased emphasis on mechanisms of host-microbial interactions in periodontal disease pathobiology as well as on the development of novel therapeutic strategies.

Periodontal diseases provide a unique situation for the study of microbial-host interactions. More than 500 different microbial species can be found in the oral biofilm[268]; however, only a few of those are associated with periodontal disease.[332,333] This suggests that the recognition of both nonpathogenic/commensal bacteria and pathogenic bacteria by the host requires vigilance and tolerance mechanisms to mount an appropriate response that can prevent the dissemination of infection without inducing an exacerbated reaction that could result in damage to the host tissues. The direct recognition of microbes by the host is mediated by the recognition of microbial-associated molecular patterns (MAMPs) by pattern-recognition receptors (PRRs).[35,36]

The host response to periodontal infection requires the expression of a number of bioactive agents, including pro- and anti-inflammatory cytokines, growth factors, and enzymes, which are the result of the activation of multiple signaling pathways. This activation of intracellular signaling may be initiated exclusively as an innate immune response associated with the PRR-mediated sensing of MAMPs. However, because the oral cavity is one of the most readily colonized postnatal mucosal sites, the long-standing interactions between microbes (commensal and pathogenic) and the host results in a "priming" of the immune system with the common presence of adaptive immune cells in the periodontal tissues.

The biological mediators expressed as a result of PRR-signaling activation include costimulatory molecules involved in the induction of adaptive immunity.[36] This results in a cascade of events that will establish very complex cytokine and signaling networks. More recently, there is accumulating evidence for a direct role of "classical" innate immunity signaling through PRRs in adaptive immune cells that can modulate the function of these cells. Abundant evidence indicates a key role for the adaptive immune response—both the humoral and cellular aspects—in mediating the host response to microorganisms that exist within the oral biofilm as well as in the majority of tissue destruction associated with periodontal diseases.[23,26,92,93,139,140] Although cells participating in the adaptive immune response are considered to be primary sources of cytokines, thereby leading to bone resorption,[189] additional data exist that show how periodontal bone loss occurs in the absence of B and T cells, thus suggesting a role for the innate immune response in periodontal disease initiation or progression.[24-26]

Innate immunity and inflammation are not synonymous; however, inflammation arises primarily in response to infection. More importantly, innate and adaptive immune responses are not mutually exclusive, and the bridge between these arbitrarily and didactically distinguished arms of the immune response has been shortened in recent years. However, considering that this chapter focuses on host-microbe interaction and to avoid redundancy with other chapters, we will emphasize the direct recognition of MAMPs by cells participating in the immune response and the

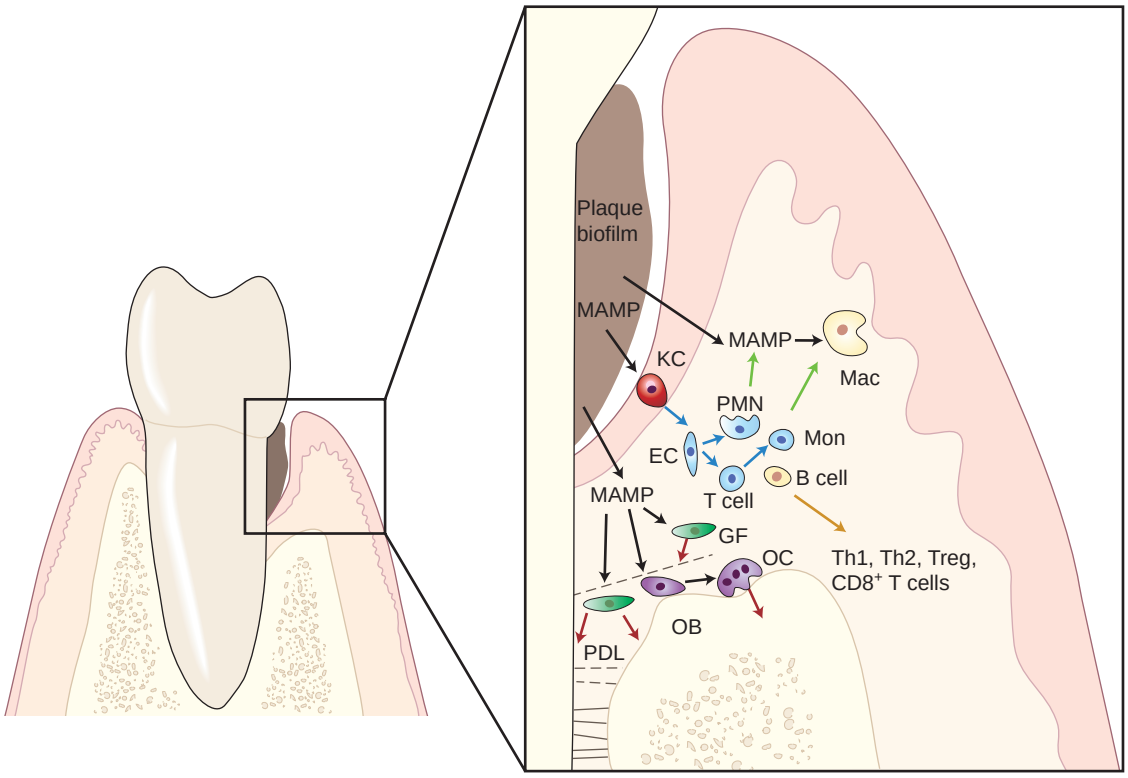

Figure 9-1 MAMPs from microorganisms in the dental biofilm activate inflammatory responses in periodontal tissues. Biological mediators will either affect neighboring cells *(blue arrows)* by inducing the expression of other mediators (e.g., RANKL) or by triggering chemotaxis *(green arrows)*. Direct damage to periodontal tissues may also result after MAMP stimulation *(red arrows)*; this may appear as metalloproteinase secretion by gingival and periodontal ligament fibroblasts. See the text for more details about the network of events initiated by MAMP stimulation. *MAMP,* Microbial-associated molecular pattern; *RANKL,* receptor activator of nuclear factor-κβ ligand; *IL-8,* interleukin-8; *KC,* keratinocyte; *DC,* dendritic cell; *Mac,* macrophage; *GF,* gingival fibroblast; *PDL,* periodontal ligament fibroblast; *OB,* osteoblast; *OC,* osteoclast; *EC,* endothelial cell; *PMN,* polymorphonuclear neutrophil; *Mon,* monocyte; *T cell,* T lymphocyte; *B cell,* B lymphocyte.

molecular mechanisms activated downstream from this recognition (Figure 9-1).

Innate Immunity in Periodontal Diseases

Vigilance and Tolerance

Although adaptive and innate immune responses are traditionally distinguished, in vivo they are integral parts of the host defenses against infections (i.e., innate immunity is not inactivated after the adaptive response is initiated). Innate immunity is required for the activation of a more specific adaptive immune response, but it also plays an important role in the management of host-microbial interactions. The innate immune system is rapidly activated (within minutes), and it is responsible for the defense during the initial hours and days of the infection. Alternatively, adaptive immunity requires at least 7 to 10 days before an adequate cellular or humoral response occurs. This role of innate immunity is especially important, considering that our host cells are outnumbered 10 : 1 by the microbial cells living on skin and mucosal surfaces. This coexistence, however, is usually pacific and even beneficial for one or both cohabitants; at the same time, it requires both vigilance and tolerance mechanisms that ultimately determine whether the host response clears the infection or is suppressed to maintain the homeostatic equilibrium between the host and the microbes.

With regard to periodontal diseases, the current paradigm indicates that some groups or complexes of bacteria are more strongly associated with the presence of periodontal diseases. However, this association is not universally true, because there are individuals who harbor the disease-associated complexes that are free of periodontal disease. Moreover, the microbiota of the oral cavity can include more than 500 different species, and there is no uniformity with regard to the level of infection that is sufficient to produce disease. The complexity of the oral microbiota is particularly intriguing given the limited number of receptors that are able to recognize microbial antigens. Tolerance mechanisms probably play a role in modulating the host response to commensal/nonpathogenic bacteria. One of the primary challenges of the innate immune system is to discriminate among a large number of periodontal pathogens from the host with a limited number of cell surface receptors. This challenge is compounded because microbial pathogens have the ability to mutate as a mechanism of escaping host recognition. The innate immune system has met this challenge through the recognition of evolutionary conserved structures on pathogens that are not present in higher eukaryotes: the PRRs. These molecular motifs—the MAMPs—have essential roles in the pathogen's ability to evade the host defense and thus are not subject to high mutation rates. MAMPs are shared among various species of microbes, but they are not expressed by the host. Although many PRRs have been known for years, it was not clear how the innate immune system functioned until the discovery of the Toll-like receptors (TLRs), which have proved to be critical for the recognition of microbes by the innate immune system and for bridging the

According to the current paradigm of the microbial etiology of periodontal disease, disease initiation depends on shifts in the microbial population of the dental biofilm toward a more complex flora that includes gram-negative and anaerobic species. This suggests that some bacterial species in the dental biofilm may not play a role in periodontal disease and that, in fact, periodontal clinical health is frequently observed despite the presence of a dental biofilm. However, the fact that different species of bacteria share common MAMPs (e.g., CpG DNA, lipopolysaccharides, peptidoglycans) that can potentially trigger an innate immune response suggests that tolerance mechanisms may counterbalance the vigilance aspect of innate immune responses to allow for the presence of these commensal, nonpathogenic bacteria. Tolerance mechanisms have been extensively studied in the gut epithelium, because the intestinal mucosa is continuously exposed to innocuous environmental antigens and commensal microorganisms that live in symbiosis with the host (for a review, see Reference 15). The critical importance of these tolerance mechanisms is exemplified by the fact that their dysregulation is associated with the pathogenesis of various inflammatory conditions, including inflammatory bowel disease and intestinal cancer.[43,187]

TABLE 9-1 Pattern-Recognition Receptors and the Host Cells (Mouse or Human) That Express Them and Their Ligands (Microbial-Associated Molecular Patterns) Present in Microorganisms Relevant to Periodontal Disease

Pattern-Recognition Receptors	Cells Where Expressed	Microbial-Associated Molecular Patterns	Periodontal Pathogens	References
TLR2	Monocytes, neutrophils, epithelial cells, fibroblasts, macrophages, T and B lymphocytes	Lipoproteins	*T. forsythia*	146
		Atypical LPS	*P. gingivalis, C. ochracea*	50,133,154,226,316,387
		Outer membrane proteins	Oral treponemes	16,148
		Fimbriae	*P. gingivalis*	17,129,134,136,137,153
		Non-endotoxic glycoprotein	*P. intermedium*	341
		Whole bacteria	*T. denticola*	301
		Cell-surface BspA protein	*T. forsythia*	262
TLR4	Monocytes, macrophages, epithelial cells, fibroblasts, neutrophils, T and B lymphocytes	LPS	*A. actinomycetemcomitans, F. nucleatum*	387
		HSP-60 (GroEL)	*P. gingivalis*	361
		Atypical LPS	*P. gingivalis*	32
TLR9	Epithelial cells, dendritic cells, T and B lymphocytes	CpG-containing DNA	*A. actinomycetemcomitans, P. gingivalis, P. micros*	251
Nod1	Cytotoxic T cells, dendritic cells, epithelial cells fibroblasts, osteoblasts, macrophages	Meso-diaminopimelic acid–containing peptidoglycan fragments (mostly gram-negative bacteria)		98,342,358,359
Nod2	Neutrophils, monocytes, dendritic cells, epithelial cells, fibroblasts, osteoblasts, macrophages	Muramyl dipeptide, which is found in the peptidoglycan of both gram-positive and gram-negative bacteria		98,342,358,359

innate and acquired immune responses. Interestingly, within the periodontal tissues, the expression of various TLRs appears to be increased in severe disease states.[29] Table 9-1 illustrates PRRs and the host cells that express them and their ligands (i.e., the MAMPs) present in microorganisms.

However, there are certain PRRs that can be secreted into the plasma as humoral proteins and others that are localized in the cytoplasm as intracellular sensors. Soluble PRRs include various proteins, such as collectins, ficolins and acute-phase pentraxins (e.g., C-reactive protein), which represent the functional ancestors of antibodies. These soluble mannose-binding receptors can interact with structures from microbes and activate the complement system via the mannan-binding lectin-associated serine kinase pathway.[303] In fact, direct interaction between complement precursors and microbes can initiate activation through an unclear mechanism that will culminate in the opsonization and lysis of the microbes. Another example of soluble PRRs is the lectin-complement system, which is involved in recognizing the microbe by the carbohydrate-binding lectin that leads to its subsequent opsonization and phagocytosis.[373]

Nucleotide-oligomerization domain (NOD) protein-like receptors represent cytoplasmic PRRs, and they are characterized by C-terminal leucine-rich repeats (similar to the TLRs), an N-terminal caspase-activating recruitment domain, and a nucleotide-binding domain (i.e., a NOD). These were initially described as cytosolic TLRs and were analogous to the R proteins present in plants.[76] NOD proteins are capable of recognizing different peptidoglycan molecules: Nod1 recognizes peptidoglycan that contains the meso-diaminopimelic acid fragments present in most gram-negative and some gram-positive bacteria,[114] whereas Nod2 recognizes muramyl dipeptide, which is found in peptidoglycan from both gram-negative and gram-positive bacteria.[235] More recent evidence indicates that NOD proteins (specifically Nod1 and Nod2) are involved in the activation of inflammatory gene expression[98] and even in lipopolysaccharide (LPS) recognition independently of TLR.[169] The relevance of NOD proteins for the immune response is demonstrated by the association between genetic mutations on Nod1 and Nod2 and the development of allergic conditions and Crohn's disease, respectively.[165,170] Another type of intracellular PRR is represented by another cytoplasmic protein family, the retinoic acid-inducible gene I–like receptors, which play a critical role in recognizing viral RNA as well as the induction of type I interferon expression. However, because the role of retroviruses in periodontal disease is not clear, these receptors will not be commented on here (for a review of retinoic acid-inducible gene I–like receptors, see Reference 385).

All of these different PRRs represent the necessary armamentaria for the recognition of MAMPs by the host, and they are expressed by a variety of cells that play a role in innate immunity. Importantly, the roles of PRRs in inflammation and the immune response have been expanded, so it is now appreciated that these receptors not only recognize various MAMPs to activate innate immune response but that they can also bind to endogenous molecules derived from damaged tissue and that they have a role in inflammation and adaptive immune response. The cells involved in innate immunity include the following:

- **Macrophages and polymorphonuclear cells,** as professional phagocytes with the primary function of engulfing and destroying microbes;
- **Dendritic cells,** as professional antigen-presenting cells and activators of adaptive immunity; and
- **Natural killer cells,** as innate cytotoxic lymphocytes that recognize and kill host cells that are altered (e.g., tumor cells) or infected with viruses.

However, other cell types can also play important roles in innate immunity, because they are able to recognize MAMPs through their

TABLE 9-2 Biological Mediators Elicited by Different Microbial-Associated Molecular Patterns in Resident and Nonresident Cells Involved in the Pathogenesis of Destructive Periodontal Disease

Cell Types	Pathogen-Associated Molecular Patterns	Biological Mediators	References
Epithelial cells	LPS, fimbriae, glycoprotein, whole bacteria, cell wall extracts, *P. gingivalis* gingipains	IL-8, G-CSF, GM-CSF, β-defensin-2, MMP-3, MMP-9, MMP-13, MIP-1α, IL-1β	59,78,127,141,163,164,255, 262,305,311,338,343,370
Dendritic cells	Fimbriae, LPS, CpG DNA, DNA	IFN-α, IL-6, IL-8, IL-10, IL-12, TNF-α, GM-CSF	172,183,184,283,335
Endothelial cells	LPS, heat shock proteins	IL-6, GM-CSF, ICAM-1	77,103,180,224
Gingival fibroblasts	LPS, peptidoglycans, CpG DNA, gingipains, *T. forsythia* detaching factor	IL-1β, IL-6, IL-8, TNF-α, PGE_2, MCP-1, MMP-2	13,39,89,149,251,255,259,261, 289,346,354,370,371
Periodontal ligament fibroblasts	LPS	IL-6, IL-8, MMP-13, RANKL	149,299,300,376
Cementoblasts	LPS	OPN, OCN, RANKL, IL-6	244,249
Macrophages	LPS, CpG DNA, leukotoxin	IL-1α, IL-1β, IL-6, IL-12, TNF-α, MMP-1, NO	191,195,234,251,259,348,374
Osteoblasts	LPS	IL-1β, IL-6, TNF-α, RANKL, PGE_2, NO, MMP-2, MMP-9	194,274,339,372-375,393
Neutrophils	DNA, LPS	IL-8, chemotaxis, shedding of L-selectin, MIP-1α	305,355,356
Monocytes	LPS, CpG DNA, fimbriae	IFN-γ, IL-1α, IL-1β, IL-6, IL-8, IL-12, TNF-α, LIF, RANKL, PGE_2	27,28,40,77,87,103,129,144, 175,206,222,243,289,293
B lymphocytes	CpG DNA, heat stress proteins, cell sonicate extracts	IL-6, IL-10, IL-12, TNF-α, proliferation, antibody production	54,258,367,389
T lymphocytes	LPS, CpG DNA, peptidoglycan	IFN-γ, IL-4, IL-10, IL-13, inhibition of apoptosis, decrease in Th2 cytokines	112,228,229,283,347,389

PRRs and to respond by expressing biologically active molecules (e.g., cytokines, matrix metalloproteases [MMPs]) that will have an effect on the homeostasis of the host tissues in the periodontal microenvironment. Resident "nonprofessional" cells (e.g., fibroblasts, osteoblasts) are also capable of producing a variety of cytokines (e.g., interleukin-6, prostaglandin E_2, MMPs, receptor activator of nuclear factor-κβ ligand [RANKL]). Table 9-2 presents these biological mediators elicited by different MAMPs in resident and nonresident cells involved in the pathogenesis of destructive periodontal disease. As a result of the sheer proportion of fibroblasts in the periodontal tissues and also of the proximity and relevance of both fibroblasts and osteoblasts to nonmineralized and mineralized tissue turnover, respectively, these cells can play important roles in innate immunity during periodontal diseases. Epithelial cells represent the initial point of contact with MAMPs in the periodontium, and they play an important role in innate immunity not only because of their function as a physical barrier but also because they are equipped with PRRs and respond to MAMPs by secreting various cytokines and chemokines, including interleukin-8 (IL-8) and antimicrobial peptides (i.e., β-defensins, cathelicidins).[173,73]

Despite the alleged nonspecificity of the innate immune response, it has long been known that cytokine release on stimulation with gram-positive or gram-negative bacteria has demonstrated important quantitative and qualitative differences.

There are some important differences between the oral epithelium and the intestinal mucosa, however, especially the presence of specialized immune cells subjacent to the mucosal epithelium in the intestines (i.e., gut-associated lymphoid tissues and Peyer's patches. However, the concept of a tolerance mechanism that renders the immune system hyporesponsive to commensal bacteria while retaining the capacity to respond to pathogenic organisms has also been investigated in oral epithelial cells. A comparison of the responses of oral epithelial cells to non-periodontopathic and periodontopathogenic bacteria demonstrated that, in general, commensal bacteria (e.g., *Streptococcus gordonii, Streptococcus sanguinis*) induce the expression of antimicrobial peptides without inducing the chemoattractant cytokine IL-8, whereas periodontopathogenic bacteria from the "orange complex" (i.e., *Fusobacterium nucleatum* and *Prevotella intermedia*) induce the strong expression of both antimicrobial peptides and IL-8. Interestingly, the bacteria that are more strongly associated with periodontitis (i.e., the "red complex" organisms *Treponema denticola, Tannerella forsythia,* and *Porphyromonas gingivalis*) tended to suppress the innate immune response by inhibiting the expression of antimicrobial peptides, of IL-8, or of both simultaneously.[173,202,364] Tolerance mechanisms may involve the activation of different signaling pathways, because the activation of nuclear factor-κβ (NF-κβ; associated with the expression of many inflammatory genes) was not required for the expression of antimicrobial peptides by oral epithelial cells after stimulation with commensal bacteria as opposed to the periodontopathogenic microorganisms.[59] There is still much to be explored in these tolerance mechanisms, but it is conceivable that commensal bacteria may be beneficial to the host, because they induce expression of antimicrobial peptides, which will clear some of the non-pathogenic and pathogenic bacteria while allowing non-pathogenic bacteria that are resistant to antimicrobial peptides (e.g., *S. gordonii, S. mutans*[173,285]) to establish themselves in the oral biofilm. The weak induction of IL-8 may function to maintain immune vigilance without causing too much collateral damage to the host tissues. On the other hand, pathogenic bacteria (e.g., the orange complex microorganisms, *F. nucleatum* and *P. intermedia*) that induce both antimicrobial peptides and IL-8 expression may be self-limiting their survival in the biofilm. Interestingly, the inhibition of the expression of antimicrobial peptides and IL-8 in epithelial cells by red complex bacteria (e.g., *P. gingivalis, T. denticola*) can represent host-evading strategies that allow them to survive and establish themselves in the oral biofilm.[48]

Cell Signaling Pathways and the Expression of Biologically Active Mediators in the Innate Immune Response

After MAMPs are recognized by the appropriate pattern-recognition receptors, a signal is initiated within the cell. This signal is transduced through the cytoplasm and the nucleus, more commonly by the sequential post-translational modification (e.g., phosphorylation) of a cascade of kinases that are constitutively expressed and that ultimately will determine the cell's response to the MAMPs that are detected.

TLRs are single-pass transmembrane proteins with N-terminals that present leucine-rich repeats that are responsible for the recognition of their ligands and with C-terminal cytoplasmic domains that are very similar to the cytoplasmic region of the interleukin-1 receptor,[4] which are called Toll/IL-1 receptor domains (TIR domains). Thus, subsequent to the recognition of a ligand by TLRs, the signal generated makes use of pathways similar to those used by the IL-1 receptor. TLR signaling was originally described in the context of the activation of interferon regulatory factors (IRF) family of transcription factors and NF-κβ, thereby leading to the expression of interferon-γ and early-response inflammatory genes, respectively.

Adaptive Immunity in Periodontal Diseases

Activation of Adaptive Immunity in Periodontal Diseases

In addition to its role in the immediate detection of infectious agents and toxic/degradation ("danger") products to elicit an inflammatory response and to activate effector processes aimed at the elimination or confinement of microbial invaders, innate immunity also has the pivotal role of initiating and modulating adaptive immune responses. Thus, adaptive immunity requires the innate "branch" of immunity to be activated; however, in vivo, this didactic distinction does not exist, and the immune response should be understood as a continuum and as a constantly adjusting host reaction to the presence of microbes and their MAMPs. In the context of this chapter and to avoid excessive overlap of information with other chapters in this book, only the signaling and molecular aspects of the host–microbe interactions related to the adaptive immune response will be emphasized.

Innate immune mechanisms and signaling are not "turned off" when the adaptive immune response is activated; rather, they are "supplemented" by the latter in their defense against microbes. On the other hand, cells from adaptive immune response also express PRRs and respond to MAMPs, which further stresses the dynamic interaction between the two "arms" of the immune response.

In T lymphocytes, TLR agonists have been shown to modulate the expression of co-stimulatory receptors (e.g., CD28, CD69, and CD152) and to increase their proliferation and interferon-γ production, thereby suggesting that microbes and their MAMPs may also have a direct functional role in the regulation of adaptive immunity.[51,331] This is especially important to realize in the periodontal disease context, which has been classically described as a chronic inflammatory condition and, as such, a condition that involves a dense lymphocytic infiltrate. Ever since the classical studies of the host response in periodontal disease—including the recognition of immunoglobulin-producing plasma cells in the gingival tissues of patients with periodontal disease[47]; the classical descriptions of initial, established, and advanced lesions[264]; and the characterization of the inflammatory infiltrate in the dog model[217]—the nature of the inflammatory infiltrate and its association with a certain type of inflammatory response and ultimately with the quiescence or progression of disease, as characterized by bone resorption, has been debated.

Pathobiology of Periodontal Disease Progression

The host response to periodontal infection requires the expression of a number of bioactive agents, including pro- and anti-inflammatory cytokines, growth factors, and enzymes that are the result of the activation of multiple signaling pathways. This activation of intracellular signaling may be initiated exclusively as an innate immune response associated with PRR-mediated sensing of MAMPs. However, the biological mediators expressed as a result of PRR signaling include co-stimulatory molecules involved in the induction of adaptive immunity.[36] This results in a cascade of events that will establish very complex cytokine and signaling networks.

Innate immunity and inflammation are not synonymous; however, inflammation arises primarily in response to infection. A better understanding of direct host–microbe interactions is especially important to understand how inflammation is initiated in response to microorganisms in the dental biofilm. In this sense, PRR signaling is considered the most important interface between the host and the microbes,[37] and, as discussed previously in this chapter, it can modulate both innate and adaptive aspects of the host response.

Cytokines and Mediators of Inflammation

Inflammation involves a number of biochemical and cellular alterations. An inappropriate inflammatory response is the cause of many common diseases, including periodontitis. The local inflammatory reaction, in response to bacteria in the dental biofilm, is characterized by an initial increase in blood flow, enhanced vascular permeability, and the influx of cells from the peripheral blood to the gingival crevice. These initial events are triggered by bioactive molecules (e.g., histamine, bradykinin, prostaglandin E2, nitric oxide) produced by innate immune cells and by resident non-immune cells that are present in the periodontal tissues. Polymorphonuclear leukocytes or neutrophils attracted to the area by other bioactive molecules (e.g., IL-8) migrate through the epithelial lining of the gingival sulcus to be the initial defense against invading plaque bacteria and their byproducts.[221] These cells are nonspecific phagocytes that are responsible for an acute and rapid defense. Subsequently, there is an increase in the number of monocytes and macrophages as well as an influx of T and B cells to the area.[105]

After they have been activated by cytokines, bioactive molecules, and MAMPs present in the area, these cells produce other inflammatory mediators that modulate the activity of other cells and affect the homeostasis of non-mineralized and mineralized tissues in the periodontium[63,121] (see Table 9-2 and Figure 9-5). Cytokines responsible for early responses to microbial aggression include IL-1α, IL-1β, IL-6, and TNF-α.[221] Other proinflammatory mediators include leukemia-inhibiting factor; interferon-γ; oncostatin M; ciliary neurotrophic factor; TGF-β; granulocyte macrophage colony-stimulating factor; IL-8, IL-11, IL-12, IL-17, and IL-18; and a variety of other chemokines that attract inflammatory cells.[53,257,310] The net effect of an inflammatory response is determined by the balance between proinflammatory and anti-inflammatory cytokines such as IL-4, IL-10, IL-13, IL-16, interferon-α, TGF-β, IL-1ra, granulocyte macrophage colony-stimulating factor, and soluble receptors for TNF or IL-6.[124,208]

Patients with periodontal inflammation have high concentrations of TNF-α, IL-1β, RANKL, and MMP-13[94,104,120,272,318,337] in

Defensins. Antimicrobial peptides are components of the innate immune response in eukaryotes, providing defense against a wide spectrum of gram-positive and gram-negative bacteria, viruses, and fungi.[142,372,391] In the oral cavity, at least 45 different antimicrobial peptides belonging to different biochemical classes are found in the saliva and the gingival crevicular fluid.[119] Defensins and the cathelicidin LL-37 are the most studied antimicrobial peptides (for comprehensive reviews of various antimicrobial peptides, the reader is referred to References 119 and 177). Defensins and LL-37 are cationic peptides that bind to negatively charged molecules on the microbial cell surface (e.g., LPS in gram-negative bacteria and lipoteichoic acid in gram-positive bacteria), thereby depolarizing and permeabilizing the cell membrane and leading to bacterial cell death.[199,322]

Defensins are the predominant type of antimicrobial peptides in humans, and, on the basis of the spacing and pairing of cysteine residues, they can be subdivided into α- and β-defensins. α-Defensins can be further subdivided into those produced by polymorphonuclear neutrophils (also called *human neutrophil peptides 1 through 4*), which are most predominant in infection sites, and those produced by the Paneth cells of the small intestine (HD5 and 6). β-Defensins were initially identified in upper respiratory mucosal epithelial cells 20 years ago,[85] and they are now known to be produced by a variety of epithelial cells, including cells from the skin, the upper respiratory tract mucosa, the kidneys, the pancreas, the lung, the uterus, the eye, and the urinary tract.[75]

The presence of defensins in the oral cavity of humans was first reported in 1995,[320] and they have since been confirmed by various studies describing the abundant production of human β-defensins by the tissues in the oral cavity and by salivary glands. These defensins—particularly the β-defensins 1, 2, and 3—can be found in the saliva and the gingival crevicular fluid.[75,91,197,277,306]

On the periodontium, β-defensins are located in different regions of the epithelium: β-defensins 1 and 2 are observed in the upper layers of the gingival and sulcular epithelium, adjacent to the microbial biofilm and external environment, which is consistent with the innate immune "barrier" function of the epithelium. Interestingly, neither β-defensin 1 nor β-defensin 2 are found in the junctional epithelium. Protection in the junctional epithelium may be provided by the higher concentration of α-defensins and LL-37 produced by granulocytes migrating toward the gingival sulcus.[75,74,233]

The expression of defensins induced by whole periodontopathogenic bacteria such as *F. nucleatum*, *P. gingivalis*, *A. actinomycetemcomitans,* and *T. denticola* is largely dependent on TLR signaling, as various studies have demonstrated by silencing TLR expression in epithelial cell lines.[174,278,328,364] For further information about the induction of defensins by periodontopathic bacteria, the reader is referred to Reference 118.

In addition to their primary antimicrobial function, defensins are modulated by immune response mediators and also present immunomodulatory functions of their own, which suggests that these peptides may actually function as an enhancer of innate immune response and even as a bridge between innate and adaptive immunity. Evidence that β-defensins 2, 3, and 4 induce the production of IL-6, IL-10, IL-18, IP-10, MCP1, MIP3, and RANTES by epithelial cells supports the idea of this immunoregulatory function of defensins.[248,247] On the other hand, defensins are also modulated by soluble mediators secreted by immune cells, such as proinflammatory cytokines IL-1β, tumor necrosis factor-α (TNF-α), interferon-γ, and IL-17, which induce the expression of β-defensins 1, 2, and 3 by epithelial cells[182,186,364]; anti-inflammatory IL-4 and IL-10 suppress their production.[186] Defensins also have a chemotactic effect on immune cells. The mechanisms are not fully understood and may involve direct interaction with unknown receptors in the target cells as well as indirectly inducing the production of chemokines. β-Defensins exert a chemotactic effect on macrophages, immature dendritic cells, memory T cells, and mastocytes via CCR6.[384] Neutrophil-derived α-defensins are also involved in the chemokine receptor 6 of naive T cells and immature dendritic cells as well as the degranulation of mastocytes and complement activation.[382,383]

In the periodontium, the expression of β-defensins 1, 2, and 3 is observed at the mRNA level both in clinically healthy and diseased tissues; the expression of these epithelium-derived peptides appears to be correlated with periodontal health, thereby suggesting a protective role.[38,46,365] On the other hand, the expression of neutrophil-derived defensins (α-defensins 1, 2, and 3) and LL-37 was significantly elevated in the gingival crevicular fluid of patients with chronic periodontitis[282,357]; however, the role of defensins and LL-37 in periodontal disease is currently not clear.

These antimicrobial and immunomodulatory roles of defensins have obvious attractiveness for therapeutic applications. However, the biochemical purification process is cost-inefficient and the synthesis process is complicated by the size and tridimensional structure of the peptides. Recently, novel analogs of defensins have shown even higher antibacterial activity than the endogenous β-defensins 1 and 3, without any cytotoxic effects on host cells,[321] thus indicating the promise of this approach. The issues with the direct use of antimicrobial peptides with therapeutic purposes may also be dealt with by stimulating the endogenous production of these peptides.

Activation of the innate immune system is critical for lymphocyte activation and other immune cells to help clear the infectious microorganisms. However, the exuberant production of proinflammatory cytokines leads to severe pathology, including periodontal bone loss.[18,81,82,122,123] To help prevent the deleterious effects of TLR activation, a number of signaling mechanisms have evolved. These mechanisms include the downregulation of surface TLR receptor expression; the transcriptional induction of negative regulators such as IL-1 receptor-associated kinase; the suppression of cytokine signaling-1 and SH2-containing inositol phosphatase; and the production of anti-inflammatory cytokines, including IL-10 and transforming growth factor-β (TGF-β).[216] In contrast with the release of proinflammatory cytokines and mediators, the production of these negative immune regulators occurs over a much longer time frame, thereby providing a vital role for controlling the extent of pro- and anti-inflammatory mediators in a proper temporal sequence.[216]

Interestingly, the participation of at least four adaptor proteins (MyD88, TRIF, Mal/TIRAP, and TRAM) that contain TIR domains and that can be recruited by activated TLRs results in important branching of the signal transduction and yields a significant flexibility to TLR signaling by allowing for cross-talk with other pathways, most notably the mitogen-activated protein kinase (MAPK) pathway. These adaptor proteins are recruited to TLRs by homophilic interactions between their TIR domains, and they are used differently by the TLRs. TLR5, TLR7, and TLR9 were shown to depend on the recruitment of MyD88 to signal,[152,159] whereas TLR3 is the only TLR that does not use MyD88.[379] TLR4, on the other hand, can use all four adaptor proteins: MyD88, TRIF, Mal/TIRAP, and TRAM.[378-380] Although the activation of the canonical NF-κβ pathway is usually affected by all TLRs, the timing of NF-κβ activation[188,190] as well as the additional signaling pathways that are activated by the branching of the signal varies among TLR receptors and with the participation of different adaptor proteins (Figure 9-2). These variations will ultimately affect the biological result in

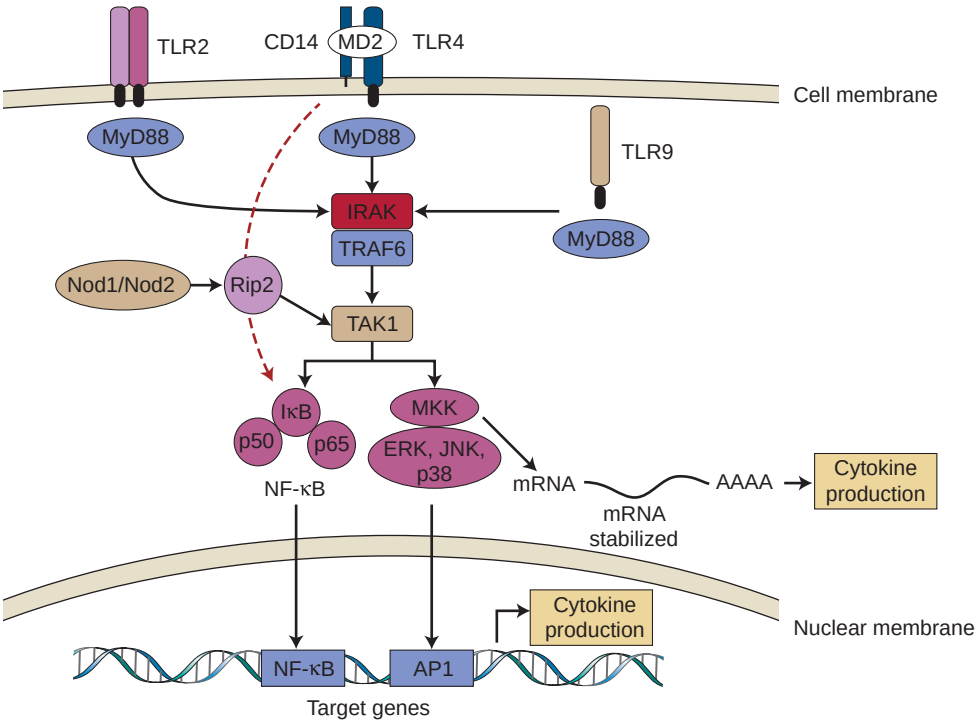

Figure 9-2 Pattern recognition receptors and innate immune signaling. TLR-2, TLR-4, and TLR-9 are depicted as examples of TLR receptors expressed in cells of the periodontal tissues. After ligand binding, all TLRs (except TLR3) recruit adaptor protein MyD88 and activate the common upstream activator (IRAK/TRAF6 and TAK1) of NF-κβ and MAP kinases. TLR-4 may also activate NF-κβ independently of MyD88, with delayed kinetics *(red dashed arrow)*. Nod1/Nod2 are cytosolic PRRs that recognize peptidoglycan fragments of the bacterial wall, and they may amplify the TLR-induced activation of signaling pathways. Activated NF-κβ and MAP kinases translocate to the nucleus and bind to their motifs (NF-κβ and AP-1, respectively) in the promoters of target genes (including early response and inflammatory genes) and induce their transcription into mRNA, which will ultimately lead to increased cytokine production. p38 MAP kinase is also involved after the transcriptional regulation of proinflammatory genes (e.g., IL-6, Cox-2) via the modulation of mRNA stability in the cytoplasm. *TLR;* Toll-like receptor; *CD14,* cluster of differentiation 14 molecule; *MD2,* myeloid differentiation protein-2; *MyD88,* myeloid differentiation primary response gene 88; *IRAK,* interleukin-1 receptor-associated kinase; *TRAF6,* tumor necrosis factor receptor associated factor-6; *TAK1,* transforming growth factor-β activated kinase 1; *MKK,* mitogen-activated protein kinase kinase; *ERK,* extracellular signal-regulated kinase; *JNK,* c-Jun N-terminal kinase; *AP-1,* activator protein-1.

terms of gene expression, as demonstrated by the finding that, even though NF-κβ activation is observed after TLR4 stimulation by LPS, this may or may not result in inflammatory gene expression, depending on the adaptor protein used. In wild-type cells, LPS stimulation results in inflammatory cytokine expression, whereas, in MyD88-deficient cells, LPS fails to induce cytokine expression. In the absence of MyD88, the activation of NF-κβ occurs with delayed kinetics as compared with wild-type cells.[188]

The shift of the microbial population present in the oral biofilm from predominantly gram-positive to gram-negative bacteria that is associated with the onset of periodontal disease may lead to different patterns of immune response as a result of the type of TLR predominantly activated. Gram-positive bacteria were shown to activate TLR2, which induced increased expression of IL-8, whereas gram-negative bacteria activated predominantly TLR4, thereby resulting in the increased expression of TNF-α.[351]

However, some gram-negative microorganisms that are present in the oral biofilm and associated with periodontal disease are rather unique in their capacity to activate NF-κβ via the preferential use of TLR2.[49] It has been reported that most gram-negative bacteria associated with periodontal disease—including *Porphyromonas gingivalis, Tannerella forsythensis, Prevotella intermedia, Prevotella nigrescens, Fusobacterium nucleatum, Aggregatibacter actinomycetemcomitans,* and *Veillonella parvula*—are all capable of activating TLR2, whereas the latter two microorganisms also activate TLR4.[193] Even though all of these disease-associated microorganisms activate TLR2 signaling, this pathway can also be activated in vitro by microorganisms that are present in an oral biofilm composed primarily of gram-positive bacteria, which are common colonizers of the oral biofilm and not associated with clinical signs of periodontal disease.[388] The fact that TLR2 is activated by both pathogenic and non-pathogenic microorganisms is an interesting finding and suggests differences in the use of adaptor proteins as well as the concomitant activation of other TLRs by different MAMPs expressed by the various bacterial species that are present in an oral biofilm associated with disease. These differences can lead to the activation of different signaling pathways and the subsequent modulation of the host response.

NOD-like receptors include 23 genes in humans, even though some of these genes are primarily expressed in macrophages and polymorphonuclear leukocytes; the best studied and best characterized members, Nod1 and Nod2, are expressed by a wide variety of cells, including epithelial cells,[358,360] monocytes/macrophages,[260] and dendritic cells[345] (see Table 9-1). The exact mechanism by which these proteins recognize their ligands is still unknown, and there is no evidence for direct interaction between ligands and NOD proteins. According to the proposed mechanism of activation of NOD proteins, they are kept in an inactive state via

intramolecular interactions among the C-terminal leucine-rich repeat domain, the N-terminal fragment caspase-activating recruitment domain, and the NOD domains. Ligand recognition results in conformational changes that relieve the autoinhibitory intramolecular interactions and that allow for NOD-domain dependent nucleotide binding and oligomerization.[162] The stimulation of Nod1 and Nod2 will result in the activation of NF-κβ and MAPKs, which is similar to the activation of TLRs (see Figure 9-2); however, the signal transduction pathways require different signaling intermediates. The activation of Nod2 leads to the recruitment of a kinase called *receptor-interacting protein 2* (Rip2, also known as *RICK*), which will bind directly to the inhibitor of NF-κβ kinase-γ (IKKγ; also known as *NF-κβ essential modulator* or *NEMO*) and promote its ubiquitination and the activation of the catalytic regulatory subunits of the inhibitor of the IKK complex. Once activated, IKK phosphorylates the inhibitor Iκβ, thereby leading to its degradation by the proteasome, releasing NF-κβ, and allowing for its translocation to the nucleus, where it will affect the expression of various inflammatory genes.[150,265] In this pathway, Rip2 has been shown to be required for Nod1 and Nod2 activation of NF-κβ,[265] but, interestingly, its kinase activity is not essential.[147] The same signaling intermediate Rip2 has also been shown to be involved in Nod1- and Nod2-induced MAPK activation by mediating the recruitment of the upstream activator of MAPK, TGF-β–activated kinase 1 (TAK1).[147] However, although Rip2 and TAK1 are required for Nod1- and Nod2-mediated activation of MAPKs, the intermediate steps in the activation of this pathway are not well known.[265,315]

Because TLRs and NOD proteins are PRRs involved in the recognition of bacteria and considering that the signals generated by their activation converge to the same signaling pathways, there may be a synergistic or "amplifying" effect for simultaneous NOD and TLR activation by MAMPs. This cooperation between different PRRs in the activation of NF-κβ and MAPK signaling pathways may increase the sensitivity and potency of the host response to the presence of bacteria.[98,99,363] Indeed, there is evidence that demonstrates that the activation of Nod1 and Nod2 has synergistic effects with TLR signaling on the production of proinflammatory cytokines, including IL-1, IL-4, IL-6, IL-10, IL-12, granulocyte macrophage colony-stimulating factor, and TNF.[99,265,345,363] Moreover, it has been suggested that Nod1 and Nod2 signaling augments Th1 polarization induced by TLR signaling, except for TLR2 signals, which inhibit Th1-type cytokines as a result of IL-10 production.[345]

In addition to their role as PRRs and their synergism with TLR signaling, other members of the NOD family of proteins can also affect innate immune response via their role in the formation of the inflammasome, which is a multi-protein complex that activates caspase-1. Activated caspase-1 will process the inactive pro-IL-1β and pro-IL-18 forms that are produced and convert them into the biologically active forms that will be secreted.[207]

Inflammasomes. Inflammasomes are multi-protein complexes that include a NOD leucine-rich repeat-containing receptor (NLR), caspase-1, and an adaptor protein. These complexes participate in the sensing of microbial-derived (MAMPs) and tissue-damage–derived (DAMPs) molecular patterns by the innate immunity. Caspase-1 is the central effector molecule in these protein complexes, and it participates in the processing of inflammatory cytokines and apoptosis.

The NLR proteins represent the "core" of the multi-protein complex, and they are reflected in the name of the inflammasome. NLRP1, NLRP3, and NLRC4 are the only inflammasomes with known physiological functions (Figure 9-3).[273] In addition to the core NLR protein, inflammasomes also include caspase-1 and the apoptosis-associated speck-like protein, which contain caspase-activating recruitment domains as central proteins. The relevance of inflammasomes to the immune response is supported by the associations between mutations in the genes that encoding the proteins of the inflammasome as well as inflammatory autoimmune conditions, including vitiligo, Muckle-Wells syndrome, cryopyrin-associated periodic syndrome, and type 2 diabetes.[179,156,210]

The different inflammasomes are "assembled" and activated in response to various exogenous and endogenous signals. MAMPs and DAMPs may activate NLRP3, whereas NLRC4 is preferentially activated by MAMPs, including double-stranded DNA and specific bacterial proteins. The protease caspase-1 is the effector protein of the inflammasomes; it plays an important role in cell death (specifically by pyroptosis) and also in the final processing and activation of the inflammatory cytokines IL-1β, IL-18, and IL-33. Thus, the gain of function caused by constitutive or prolonged activation of the inflammasomes and consequently of caspase-1 may lead to an exacerbation of the inflammatory response by increasing the bioavailability of active IL-1β. On the other hand, loss or reduced function of the inflammasomes can dampen inflammation and attenuate the immune response, thereby reducing the ability of the host to detect and respond to various MAMPs. Various microorganisms (e.g., *Salmonella typhimurium*) present evasion mechanisms to prevent the activation of the inflammasomes and to facilitate their invasion, thereby indicating the relevance of inflammasomes for the immune response and host–microbial interactions.[241]

With periodontal diseases, there is scarce evidence of the importance of inflammasomes. There is an increase in the gene expression of NLRP3 and its endogenous antagonist NLRP2 in human gingival tissues with various forms periodontal disease as compared with gingival biopsies of periodontally healthy sites. Moreover, the expression levels were positively correlated with the levels of IL-1 and IL-18 in the tissues,[41] thereby suggesting a role for NLRP3 inflammasome in inflammatory periodontal diseases. In vitro evidence indicates that microorganisms from the dental biofilm may modulate the expression of NLRP3 inflammasome and that this modulation was correlated with the production of IL-1 and IL-18.[42] Interestingly, some periodontopathogens from the subgingival biofilm may evade immune surveillance by avoiding the activation of inflammasomes, as was demonstrated in vitro for *P. gingivalis* that attenuated NLRP3 and IL-1 gene expression by gingival fibroblasts.[31]

The production of cytokines is crucial for the establishment of a competent innate immune response and also for the subsequent activation of adaptive immunity. Cytokines such as IL-1, IL-18, and IL-33 are processed by the inflammasomes, and they play an important role in the polarization of T-cell response toward Th17, Th1, and Th2, respectively.[60,209] Thus, inflammasome activation may bridge innate and adaptive immunity. An indication of the role played by inflammasomes on adaptive immunity comes from the experimental models of respiratory allergy and encephalitis. In these models, mice that are deficient in NLRP3, caspase-activating recruitment domains, or caspase-1 failed to develop an allergic reaction[97,200] and showed reduced progression of encephalitis[125,326] as a result of a marked shift in the adaptive response. Further evidence for the role of inflammasomes in the modulation of adaptive immunity includes models of host–microbial interactions that indicate a higher susceptibility for disseminated fungal infection in caspase-1–deficient animals; this is associated with the reduced Th1 and Th17 polarization of T cells.[362]

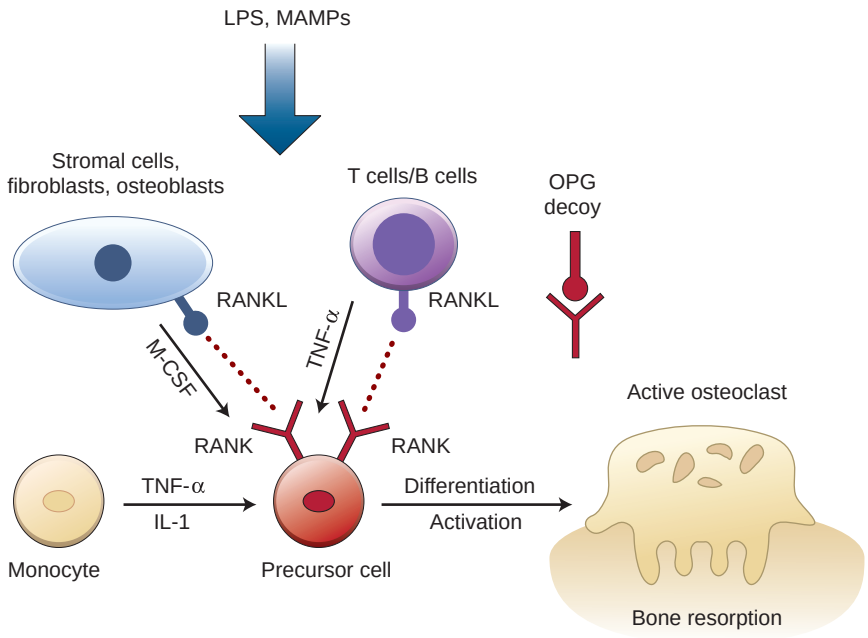

Figure 9-3 Inflammasome signaling. Schematic representation of the possible pathways leading to the activation of NLRP3 and NLRC4 inflammasomes. NLRP3 may be activated by a plethora of bacterial-derived stimuli, whereas NLRC4 is classically activated by microorganisms with type III or IV secretion systems, which are not usually associated with periodontal disease. However, other microorganisms as well as cytokines and biological mediators derived from the host may function as noncanonical activation pathways for both NLRC4 and NLRP3. In fact, bacterial infection can trigger the activation of several inflammasomes. Upon activation, the multiprotein complex recruits the adaptor protein ASC, which ultimately results in the activation of caspase-1 as the common effector molecule. Alternatively, ASC may also activate other signaling pathways (e.g., MAP kinases, NF-κβ) independently of the inflammasome, and this activation may also have an impact on the destruction of mineralized and nonmineralized tissues by modulating the expression of important biological mediators. Caspase-1 is the main effector protein of the inflammasomes, and it is responsible for the final processing of the inflammatory cytokines IL-1β, IL-18, and IL-33, which are not only relevant for the destruction of mineralized and nonmineralized tissues but which also can further activate signaling pathways that are important for the expression of other cytokines, inflammatory mediators, and protein constituents of the inflammasome itself in an autoregulatory positive feedback loop that amplifies the response. Active caspase-1 can also induce cell death by pyroptosis, which may reduce the number of viable osteoblasts in the periodontal microenvironment and aggravate the imbalance of the bone turnover.

Complement Systems. In cases of periodontal disease, the host defense also is dependent on a functional complement system, which coordinates the recruitment and activation of inflammatory cells, bacterial opsonization, phagocytosis, and lysis.[128,131] In addition, complement can amplify the TLR4-mediated inflammatory response toward bacterial LPS challenge (this was reviewed in Reference 291). The complement system is critical to the linking of innate and adaptive immunity by regulating the activation of both B cells and T cells, either directly or through effects on antigen-presenting cells.

The activation of the complement cascade involves the sequential activation and proteolytic cleavage of a series of serum proteins via three distinct mechanisms, namely the classical, lectin, and alternative (Figure 9-4).[128,291] Classical pathway activation occurs in response to antigen–antibody complexes that are recognized by the C1q subunit of C1. However, the lectin pathway is triggered through the interaction of a secreted pattern-recognition receptor (mannose-binding lectin) with specific carbohydrate groups on the surface of a variety of microorganisms. Both the classical and the lectin pathways then proceed through C4 and C2 cleavage for the generation of the classical/lectin C3 convertase (C4bC2b) (see Figure 9-4). The alternative pathway is initiated by the hydrolysis of C3 to C3(H_2O), which is a C3b analog that forms the initial alternative pathway for C3 convertase, or through bacterial lipopolysaccharide and lipooligosaccharide molecules in concert with microbial-derived properdin.[128] The alternative pathway also serves as a positive feedback loop for the classical and lectin pathways. All three pathways converge at the third component of complement (C3), which upon activation by pathway-specific C3 convertases leads to the generation of key effector molecules. These include the C3a and C5a anaphylatoxins, which activate specific G-protein–coupled receptors and which mediate the mobilization and activation of leukocytes. Also important are the C3b opsonins, which promote phagocytosis through complement receptors, and the C5b-9 membrane attack complex, which can lyse targeted pathogens (see Figure 9-4).[128]

The complement systems have also been shown to provide a barrier against the spread of bacterial infections; to facilitate clotting mechanisms[291]; to mobilize hematopoietic stem cells and progenitor cells from the bone marrow; to help replenish new leukocytes[211]; and to activate the differentiation of specific T-cell subsets.[220] The dysregulation of complement activities may lead to a failure to protect the host against pathogens and amplify inflammatory tissue damage (this was reviewed in Reference 128). In the context of periodontal inflammation, complement subversion appears to play a major role in periodontal pathogenesis.[132]

Activated complement components are found in the gingival crevicular fluid of patients with chronic periodontitis as compared with healthy sites. Virtually all of the complement components have been detected in chronically inflamed gingiva or in the

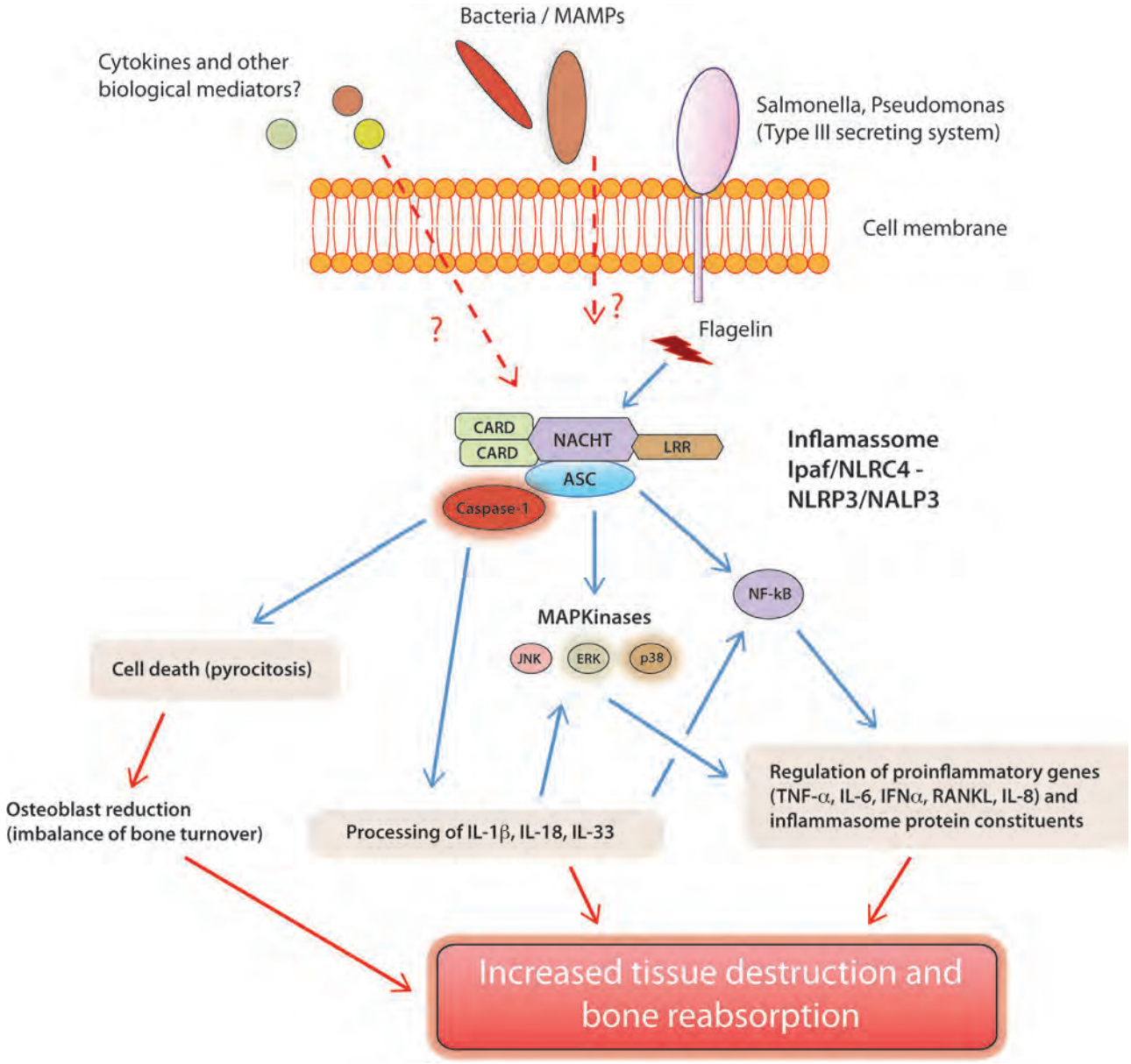

Figure 9-4 Activation and therapeutic blockade of the complement system. All three pathways converge at the third component of complement (C3). The classical pathway is activated by antigen–antibody complexes, and it requires C1, C2, and C4 components. MBL activates the lectin pathway through MASPs and C2 and C4 cleavage. The alternative pathway is propagated through hydrolyzed C3 by complexing with factor B (fB) and via the fB cleavage of factor D (fD). The alternative pathway can also be activated via bacterial LPS in a properdin-dependent manner. Downstream from C3, proteolytic cleavage generates C3a and C5a anaphylatoxins, which activate the receptors C3aR and C5aR. C5aR can also be activated via C5L2. C5b initiates the assembly of C5b-9 MAC, which can induce bacterial lysis. Therapeutic blockage is depicted with the C3 and C5 components. *MBL,* mannose-binding lectin; *MASPs,* MBL-associated serine proteases; *C5l2,* C5a receptor-like-2; *MAC,* membrane attack complex.

gingival crevicular fluid of patients as compared with healthy control samples. Finally, local complement activation may promote periodontal inflammation predominantly via C5a-induced vasodilation, increased vascular permeability and flow of inflammatory exudate, and chemotactic recruitment of inflammatory cells, especially neutrophils.[128]

Relative to periodontitis, therapeutic strategies are evolving that target either CR3 or CR5 (see Figure 9-4). Because C3 is a central component of all three activation pathways, blockade at this level is reasonable approach to treating complement-associated diseases, including periodontal diseases. CR3 antagonism through topical small molecule inhibitors has been shown to reduce *P. gingivalis*–induced alveolar bone loss.[130,135] The complement-generated fragment C5a functions as a potent mediator of complement signaling and neutrophil recruitment that may protect but also mediate excessive neutrophil activation, and it has the potential to augment tissue damage during periodontal disease progression. As such, C5aR inhibitors have been recently used in preclinical models to indicate that the potential to inhibit C5aR may be a viable option for the treatment and management of periodontal diseases.[1]

The adaptive immune response is characterized by the activities of pathogen-specific B and T lymphocytes; however, the cell type that is primarily responsible for translating innate signals into adaptive immunity is the dendritic cell (DC). In fact, the generation of adaptive immunity initiates with DCs recognizing MAMPs at the site of infection and subsequently migrating into the regional draining lymph nodes to present the processed antigen peptides in the context of MHC molecules to naïve T lymphocytes. Once inside the lymph nodes, DCs migrate to the T-cell areas, seek out antigen-specific T cells, and induce their activation and differentiation into effector cells (i.e., helper or cytotoxic cells).

The maturation process induced by MAMPs that leads to the migration of DCs to the lymph nodes involves the modulation of the expression of various chemokine receptors that renders DCs less responsive to inflammatory signals and more responsive to lymphocyte-derived signals. Notably, the LPS-induced maturation of DCs has been shown to result in the downregulation of "inflammatory" CCR1 and CCR5 (which responds to macrophage inflammatory protein-1α, for example) and the upregulation of CXCR4 and CCR7 (which respond to CXCL12 and CCL19, respectively).[309] These changes ultimately control DC trafficking and migration to the lymph nodes, and they represent one mechanism whereby the modulation of cell-signaling pathways (i.e., MAMPs activating PRR signaling versus inflammatory cytokine signaling) can influence the host response. The profound phenotypic changes that DC cells undergo during the process of activation by MAMPs and conversion into antigen-presenting cells is a multi-step process that includes not only trafficking and migration into lymph nodes but also the expression of high levels of major histocompatibility complex (MHC) bearing the processed microbial-derived peptides that will engage T-cell receptors in naïve T cells; the expression of co-stimulatory membrane-bound molecules (e.g., CD80, CD86), which are important for T-cell survival and proliferation; and finally the production of mediators (e.g., IL-12) that act on T cells and that induce their terminal differentiation into an effector cell type and their profile of cytokine expression. Ultimately, the integration of these signals (i.e., MHC antigens, co-stimulatory molecules, cytokines) will determine the fate and nature of the adaptive immune response.[181]

Interestingly, many of the features of DC activation can be induced by inflammatory cytokines in the absence of MAMPs and PRR signaling. This fact is interpreted by some as being supportive of the "danger model" of immunity, in which endogenous danger signals (e.g., toxic products from necrotic, apoptotic, or infected cells; inflammatory cytokines) can also trigger an immune response, similarly to exogenous MAMPs.[30,231] There are two important arguments against this concept:

1. Inflammatory cytokines may be synergistic with MAMP signaling to induce DC maturation, because cytokines are produced by various innate immune cells in response to the PRR signaling triggered by MAMPs. This would turn the inflammatory (or "danger") signals into "complementary" or surrogate signals of response to the MAMPs and not necessarily as alternatives.[250]
2. Activated or mature DCs defined by their high levels of expression of MHC class II molecules and co-stimulatory receptors CD80, CD86, and CD40 may not be fully competent for the activation of T-cell responses.[5,100]

The signaling aspects involved in DC maturation and activation are especially interesting, because most PRR and inflammatory receptor signals converge into similar pathways (e.g., NF-κβ, MAPKs). Despite similar signaling pathways activated by MAMPs and inflammatory cytokines, MyD88-defficient DCs stimulated with inflammatory cytokines fail to produce IL-12 and other inflammatory cytokines (e.g., IL-1β, IL-6, TNF-α, IFN-β),[160] which will have important consequences for the differentiation and activation of naïve $CD4^+$ and $CD8^+$ T cells[71] and also indirectly affect the activation of B cells and the humoral response.[336] Among the possible reasons for this differential role of MAMPs and inflammatory cytokines as external signals, despite the activation of similar signaling pathways, are the kinetics of the activation of the signaling pathways and also the other signaling pathways that are simultaneously activated by each external signal. The integration of multiple signal pathways may be required for a given profile of cytokine expression by DCs. Specifically, in patients with periodontal diseases, both MAMPs and inflammatory cytokines are usually present to fully activate the DCs, which suggests that there is no impairment to a competent activation of adaptive immunity.

Host–Microbe Interactions in Adaptive Immunity

Considering that humans are exposed to bacteria in various mucosal sites, including the oral mucosa, shortly after birth and that this exposure continues throughout our lives, it is reasonable to expect the chronic presence of adaptive immune cells as part of a vigilance mechanism in the sites that are chronically exposed to microbes and their MAMPs. The crucial role of adaptive immunity to periodontal disease progression is currently undisputed; however, the mechanisms are not fully understood. According to the current paradigm, DCs activated by MAMPs and inflammatory cytokines (also induced by MAMPs in innate immune and resident cells) will initiate an adaptive immune response by driving naïve T lymphocytes into a $CD8^+$ (for cytotoxic response) or $CD4^+$ with Th1 or Th2 phenotypes. Recently, more pieces have been added to the puzzle, including the regulatory T lymphocytes (Tregs), which appear to have their inhibitory functions suppressed by activated DCs. Activated T cells and their "specific" cytokine profiles will modulate the inflammatory response as well as the activation of B lymphocytes.

The helper subtype of T cells appears to be particularly relevant for periodontal diseases, as shown by studies in which mice lacking $CD4^+$ cells had decreased severity of bone loss induced by *P. gingivalis* challenge, whereas the depletion of $CD8^+$ cells did not have the same effect.[23] There has been a long debate about the cytokine profile associated with periodontal disease, and it is thought that the outcome (i.e., the progression of disease or a quiescent state) is determined by the predominant T lymphocyte cytokine profile (Th1 or Th2) of the inflamed tissues.[161] However, the cytokine profile associated with periodontal disease in vivo varies and includes both Th1- and Th2-type responses. Some studies involving in vivo models have associated a Th1-type cytokine profile with progressive periodontal diseases.[310,325,349] Compelling evidence for the role of Th1-type response in periodontal disease progression comes from studies in which periodontal bone loss in rats challenged with *A. actinomycetemcomitans* was associated with the introduction of T lymphocytes of the Th1 subtype but not with T lymphocytes of the Th2 subtype.[140] In fact, the introduction of T lymphocytes of the Th2 subtype in T-cell–depleted rats challenged with *P. gingivalis* resulted in decreased bone loss, thereby suggesting a protective role for Th2-type responses in periodontal disease.[92] Others reported that, even if the Th2 response is not protective of bone loss, it does not aggravate the bone loss induced

by *P. gingivalis* challenge as has been observed with the Th1-type response.[212] By contrast, a Th2 cytokine profile has also been reported as being associated with progressive periodontal disease by both in vitro[12,329] and in vivo[353,381] studies.

Both B and T lymphocytes were shown to express PRRs and, more specifically, certain types of TLRs. There is still some controversy regarding the type of TLR and the level of expression, which can be attributed to the various experimental methods used, including the procedure to purify lymphocytes, the model (murine or human), and the analysis method (e.g., flow cytometry, real-time polymerase chain reaction). Nevertheless, mRNA for TLR1, TLR2, TLR3, TLR4, TLR5, TLR7, and TLR9 was detected in human peripheral T lymphocytes, although the expression levels are highly variable among different studies.[51,88,158,390] Despite the controversy, there are some studies that have demonstrated a functional role for these PRRs expressed in lymphocytes. In naïve T cells, TLR2 and TLR4 may not be functional, because their expression was demonstrated intracellularly,[20,198,223] whereas TLR5 was detected in the cell surface.[68] However, the expression of cell-surface (and functional) TLR2 and TLR4 is regulated in naïve human T $CD4^+$ lymphocytes by T-cell receptor (TCR) activation, and the same is true for TLR2 in murine $CD4^+$ and $CD8^+$ T cells.[198,218] By contrast, TLR5 that is constitutively expressed on the cell surface of human $CD4^+$ T lymphocytes is downregulated by TCR stimulation.[68] The mechanism for the TCR-mediated modulation of TLR expression is not known; it may involve the induced translocation of intracellular TLRs to the cell surface or the de novo synthesis of membrane-bound TLRs.[185] Current evidence suggests that T cells can respond directly to MAMPs through TLR and that TLR signaling in T cells has a co-stimulatory effect with TCR activation. TLR2 signaling co-stimulates proliferation and cytokine production by $CD4^{+}$[198,218] and murine $CD8^+$ T cells.[66] TLR3 signaling increased the survival of activated murine $CD4^+$ T cells,[112] whereas TLR9 signaling increased not only survival but also the proliferation of $CD4^+$ T cells.[111] TLR4 stimulation increased perforin expression in $CD4^+$ T cells, thereby suggesting a role for LPS in the induction of a cytotoxic response.[284]

The expression of TLRs may also vary in different T-cell subsets. Regulatory T cells (i.e., Tregs, $CD25^+/CD4^+$) express higher levels of TLR5,[68] and, as opposed to $CD4^+/CD25^-$ T lymphocytes, they also express TLR8.[275] Treg cells have an important role as negative regulators of immune response and, consequently, in immune tolerance mechanisms. Their function requires precise control to maintain adequate and effective T-cell–mediated immunity.[307] Although the mechanisms for the suppressive effect of Tregs are not well known, they require the expression of transcriptional repressor FoxP3.[302] During the activation of adaptive immunity, activated DCs polarize naïve $CD4^+$ T lymphocytes to a Th1 or Th2-subtype in addition to inhibiting Tregs. There is evidence that this inhibition of the Treg suppressive function involves the production of IL-6 by activated DCs and other innate immune cells.[254,267] Interestingly, the direct stimulation of TLR2 or TLR8 together with TCR activation in Tregs results in increased proliferation and inhibition of FoxP3 expression and, consequently, of their immune suppressive activity.[218,275,344] There is also evidence of a modulation of Treg activity according to a dose-dependent stimulation of TLR signaling. Low concentrations of flagellin (a TLR5 ligand) enhanced the suppressive activity of Tregs (as in an immune tolerance mechanism), whereas higher concentrations of flagellin increased proliferation and cytokine production in $CD4^+$ T cells.[68] TLR4 signaling also appears to enhance Treg suppressive functions through IL-10 and TGF-β–dependent mechanisms.[214]

The proportion of B cells is reported to be larger than that of all subsets of T lymphocytes.[33] In fact, B-cell derived plasmocytes and B lymphocytes represent the absolute majority of infiltrating cells in diseased periodontal tissues, and their relative proportions appear to be higher in sites with severe periodontal disease as compared with sites with moderate to mild periodontitis. In addition to their classic role as producers of immunoglobulins that identify and bind to MAMPs, B cells also participate as antigen-presenting cells and modulators of host response through the production of cytokines such as TNF-α, IL-6, IL-10, TGF-β, and RANKL (for a review, see Reference 34). In fact, the relevance of B lymphocytes for the pathogenesis of periodontal disease and, in particular, for alveolar bone loss has been demonstrated in murine models.[139,143] The role of the humoral response in periodontal disease has not been clear until now, and the importance of B cells for periodontal disease pathogenesis is probably largely a result of cytokine production.[58,189] Antibodies are considered primarily as defense mechanisms that are aimed at neutralizing the microbes directly (through the inactivation of antigens with or without complement activation) or indirectly (through the opsonization of antigens and facilitating phagocytosis). However, there is no definite explanation as to why the elevated levels of immunoglobulins against periodontopathogenic bacteria are not sufficient to ameliorate periodontal disease or to prevent its recurrence. Elevated serum titers of antibodies against *P. gingivalis* were detected previously, but they did not prevent alveolar bone loss in a murine model of periodontal disease.[23] Indeed, elevated levels of immunoglobulins may actually aggravate the local destruction of periodontal tissues through complement activation or through self-reactive antibodies.[33] It has also been suggested that the high immunoglobulin G serum titers against periodontal bacteria may be implicated as one of the possible biological links between periodontal diseases and systemic diseases, such as cardiovascular diseases[256] and rheumatoid arthritis.[296] B cells have been shown to express various TLRs, including TLR1, TLR2, TLR4, TLR6, TLR7, TLR9 and TLR10.[158] Recent evidence indicates that a significantly higher proportion of B cells from periodontal tissues and blood from periodontal disease patients expressed TLR4 as compared with samples from periodontally healthy individuals.[327] This suggests that the expression of some TLRs may be induced, likely by the inflammatory environment that results from the initial activation of innate immunity by MAMPs. Thus, cytokines produced by the innate immune response and also by the presence of MAMPs would induce TLR expression in B cells, which in turn renders these cells more responsive to the ubiquitously present MAMPs in the periodontally diseased tissue. This concept is supported by the fact that resting B cells expressed primarily TLR1 and TLR9, with a lower proportion of resting B cells expressing TLR2, TLR3, and TLR4.[79] The activation of B cells in vitro by CD40 stimulation also increased the expression of TLR7, TLR9, and TLR10. Interestingly, co-stimulation with CD40 ligand and CpG bacterial DNA had a synergistic effect on this induction.[44]

It is important to note that TLR expression by B lymphocytes indicates that, similarly to the T lymphocytes, these cells can respond to MAMPs and play a role in the modulation of both the innate and adaptive arms of the immune response, thereby further stressing the continuity and cooperation between these two aspects of the host response. This cooperation is demonstrated by reduced antibody production in humans and mice with the reduced expression of TLR1 and TLR2[7]; increased proliferation; the activation of NF-κβ, p38, and JNK MAPKs; and increased expression of co-stimulatory molecules (e.g., CD86, CD40, MHC-II) and IL-6 by B cells that have been stimulated with a TLR9 agonist.[145]

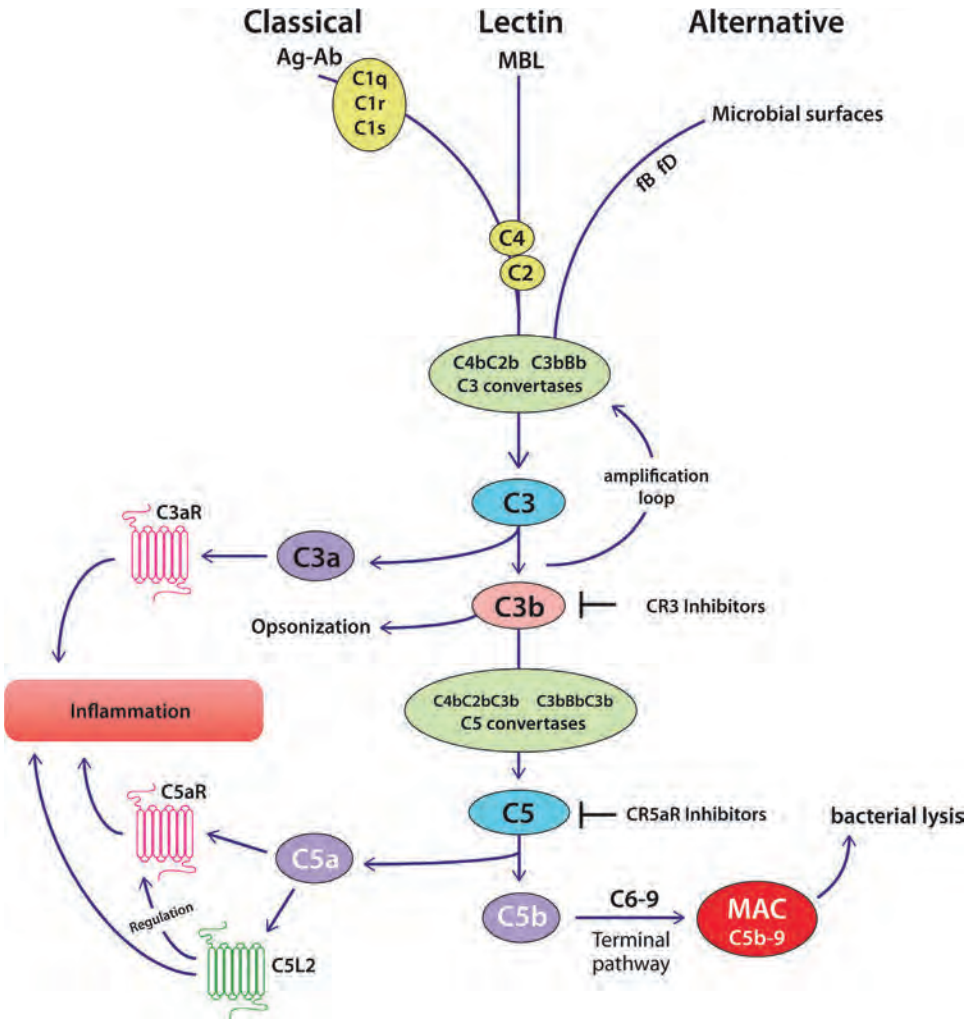

Figure 9-5 Stimuli factors that regulate osteoclastogenesis. Cytokines (e.g., IL-1β, TNF-α, M-CSF) produced by resident cells (e.g., bone stromal cells, fibroblasts, osteoblasts) and immune cells (e.g., monocytes, T-lymphocytes, B-lymphocytes) are key regulators of the process of osteoclastogenesis. OPG acts as a decoy receptor that prevents RANKL from binding to its receptor RANK on precursor cells, and it downregulates the process of osteoclastogenesis. Bacterial LPS and other MAMPs may directly or indirectly initiate the expression of RANKL and osteoclastogenesis. *LPS,* bacterial lipopolysaccharide; *MAMPs,* microbial-associated molecular patters; *M-CSF,* macrophage colony-stimulating factor; *IL-1,* interleukin-1; *TNF-α,* tumor necrosis factor-α; *RANK;* receptor activator of NF-κβ; *RANKL,* receptor activator of NF-κβ ligand; *OPG,* osteoprotegerin.

the gingival crevicular fluid. Increased levels of IL-1β, IL-2, IL-6, IL-17, TNF-α, and interferon-γ in the gingival tissues are also associated with destructive periodontal disease.[120,213]

However, despite the abundant literature about the cytokine profile associated with periodontal disease, there is still no definite answer. Among the reasons for the variability of the reports regarding the cytokine profile are the difficulties involved in defining periodontal disease and, especially, in the identification of actively progressing (i.e., ongoing attachment loss and alveolar bone resorption) disease sites. With the use of gene-expression profiling, mRNA levels of more than 38,000 genes with 54,000 DNA probes were performed in healthy and diseased periodontal tissues and demonstrated that more than 12,000 probes were differentially regulated in periodontally diseased tissues, including the genes involved in inflammation, apoptosis, and angiogenesis.[83] These data agree with the evidence that demonstrates that the cytokine profile associated with periodontal disease in vivo varies and includes both Th1- and Th2-type cytokines. IL-1β, IL-8, and TNF-α mRNA were detected in macrophages present in inflamed gingival tissues,[230] whereas Th2 cytokine IL-4 and pleiotropic IL-6 protein were also observed in diseased periodontal tissues.[381] A characteristic cytokine profile has been associated with each type of periodontal disease (i.e., inflammation of marginal soft tissues without active bone resorption [gingivitis] or with active bone resorption [periodontitis]). Thus, the expression of Th1-type cytokines has been associated with gingivitis, whereas Th2 cytokines were found in higher levels in periodontitis-affected tissues,[208,353] even though this distinction was not clear-cut, with both Th1 and Th2 cytokines being produced in gingivitis- and periodontitis-affected tissues; the predominant profile may actually represent the current activity of tissue destruction.[110,323,377] The relevance of cytokines as biological mediators of periodontal disease progression is demonstrated by studies showing that conventional periodontal therapy aimed at the reduction of the bacteria and associated metabolic byproducts result in their decrease, as has been shown for IL-1β[8,65,352] and TNF-α.[171]

After the immune and inflammatory processes are initiated and the complex cytokine network is established, various inflammatory molecules that play a direct role in the degradation of both non-mineralized and mineralized tissues of the periodontium are

produced in response to the MAMPs or to the host-derived cytokines.[63,121] One type of these inflammatory molecules is the matrix metalloproteases (MMPs), which are released from different cell types present in the lesion, including macrophages, leukocytes, and fibroblasts or other resident cells.[201] MMPs are a family of neutral proteases that are Zn/Ca-dependent, with an essential role in extracellular matrix turnover and degradation. Their activity is regulated at multiple levels (i.e., transcriptional, post-transcriptional, and post-translational) and also by endogenous inducible inhibitors, which are the tissue inhibitors of matrix metalloproteases. Collectively, MMPs are capable of degrading virtually all components of the extracellular matrix, and increased levels have been associated with periodontal disease in both human[65,94,96,203] and animal models.[80,109] The same difficulties associated with the determination of disease activity apply to the determination of MMPs in periodontal disease, although the trend seems to be of a positive correlation (i.e., MMPs increase with inflammation and disease activity,[116] and their detection in saliva has been recently suggested as one possible host-response biomarker of periodontal disease).[288] Interestingly, the role of individual MMPs in periodontal disease progression may differ: MMP-8 was recently shown to have a protective effect on alveolar bone loss induced by *P. gingivalis* infection in mice,[205] whereas MMP-13 expression was positively correlated with the severity of inflammation in ligature- and LPS-induced experimental periodontitis in rats[212] and also with the severity of periodontal disease in humans.[330]

The relevance of MMPs to the pathogenesis of periodontal diseases is supported by the decrease in bone loss associated with their non-selective inhibition in animal models of periodontal disease[286,287] and especially by the improved clinical results observed after periodontal treatment associated with the systemic inhibition of MMPs by a sub-antimicrobial dose of doxycycline.[107,115,280,281]

As periodontal disease progresses, the collagen fibers and the connective tissue attachment to the tooth are destroyed, and the junctional epithelial cells proliferate apically along the root surface; these structural changes are reflected clinically as attachment loss and increased probing pocket depth. These changes represent not only an increased severity of inflammation but also an apical displacement of the inflammatory infiltrate, which is in greater proximity to the alveolar bone. This affects the homeostasis of bone tissue by triggering the resorptive process that represents the main characteristic of destructive periodontal disease. According to current knowledge, the receptor-activator of NF-κβ ligand (RANKL) plays a pivotal role in bone resorption, because it is involved in osteoclast differentiation, activation, and survival.[45,192,350] Osteoprotegerin (OPG) is the endogenous inhibitor of RANKL, and it functions as RANKL's decoy receptor, preventing the binding of RANKL to the specific membrane-bound receptor expressed in osteoclast precursor cells (i.e., the receptor-activator of NF-κβ [RANK]).[45,155,340] RANKL is produced as either a membrane-bound or secreted protein by fibroblasts, osteoblasts, chondrocytes, mesenchymal cells, and T- and B-lymphocytes, whereas OPG is secreted primarily by osteoblastic cells, bone marrow stromal cells, and fibroblasts (see Figure 9-5). The ratio between RANKL and OPG is the current paradigm for the modulation of coupled bone turnover. Specifically in periodontal disease, this concept is supported by observations that demonstrate that patients with advanced periodontitis present higher levels of RANKL and lower levels of OPG as compared with periodontally healthy patients.[69,242] Further support to the relevance of the RANKL/OPG cytokine system for bone homeostasis comes from studies in which the local delivery of OPG decreases alveolar bone resorption in experimental periodontal disease models.[56,178] However, other biologically active mediators present in the complex network of cytokines established in the periodontal disease microenvironment can play important roles in periodontal disease pathogenesis and alveolar bone resorption, as indicated by studies targeting the inhibition of TNF-α.[61,86]

It is important to consider that there is significant heterogeneity with regard to the clinical presentation of periodontal disease in terms of its extent, severity, progression, and response to treatment. This heterogeneity is thought to reflect the high variability of the levels of inflammatory cytokines and bioactive molecules produced by different individuals, which cannot be completely explained by differences in the microbial population of the dental biofilm. On the basis of susceptibility analysis, individual differences in the host response to MAMPs and to host-derived cytokines that are the result of genetic variations may play an important role in modulating the pathogenesis of periodontal diseases (for a review, see Reference 386). This is supported by epidemiological studies of the association between various genetic syndromes and periodontal diseases[253] and the familial trend for the occurrence of some types of aggressive periodontal disease.[10,245] There are numerous studies correlating multiple variations of genetic-information–encoding genes and receptors involved in the immune response and inflammation with periodontal disease,[101,168] and these genetic variations are also heterogeneic according to race and ethnic aspects of human populations.[14,225,246,308,369] It is interesting to note that there is evidence that suggests that genetic polymorphisms for the "effector" genes of MMPs[19,57,279] and RANKL/OPG[266,334] are associated with the severity and extent of periodontal disease. However, the strength of this association, especially for MMPs, is still controversial; it may depend on specific types of MMPs, because other studies have failed to demonstrate an association between polymorphisms for some MMPs and periodontal disease status.[84,126,157]

Another important aspect to consider is how the external environment affects the production of inflammatory mediators by the host. Thus, even though there is a "personalized" genetic program that controls how each individual responds to microbial aggression, this program is further modulated by transitory aspects of each individual's life that can affect the production of cytokines and inflammatory mediators, including hormonal imbalances, stress, acquired diseases, medications, and smoking. These are all factors that come into play to determine the individual's response to microbial aggression and, ultimately, periodontal tissue destruction. Moreover, it has been recently suggested that genetic variances that modulate the host response may represent a common trait of susceptibility for periodontitis and systemic diseases, such as cardiovascular diseases.[317]

Cell Signaling Events That Modulate Inflammatory Mediator Expression

In the complex scenario of host-microbe interactions associated with periodontal disease, the signaling pathways originally shown to be relevant for the recognition of stress, inflammatory, and infectious extracellular stimuli are of special interest. The production of cytokines and inflammatory mediators is usually a tightly controlled process that is always initiated by external stimuli or "signals" that are rapidly transduced through the cytoplasm and into the nucleus, where gene expression starts with the transcription of DNA into pre-mRNA. From this very start to the final assembly of the biologically active protein, there are a great number of regulatory mechanisms that can affect gene expression, and various signaling pathways can participate in many of these mechanisms, both at transcriptional and post-transcriptional levels. Thus, cytokine production is a fast and transient process that is initiated and

The MAP kinases are a group of conserved cytoplasmic kinases that are organized in modules (MAPKKK → MAPKK → MAPK) that sequentially activated by dual phosphorylation at tyrosine/threonine residues. Of the four distinct classes of MAPKs described in mammals to date, p38 (α and β isoforms), c-Jun N-terminal activated kinases (JNK1, JNK2, and JNK3), and extracellular activated kinases (ERK1 and ERK2) are the most studied. Downstream substrates of MAP kinases include a variety of transcription factors, RNA-binding proteins, and other kinases (e.g., MAPK-activated protein kinases) that are involved in the regulation of gene expression by transcriptional, post-transcriptional, translational, and post-translational mechanisms (see Figure 9-2).

The STAT family of latent transcription factors is involved in many cytokine signaling pathways[166] and especially in those that use the gp130 receptor. Many cytokines and growth factors (i.e., interferons, interleukins, epidermal growth factor, growth hormone, erythropoietin, and others) exert their biological functions through the JAK-STAT signal transduction pathway.[263,319] Classically, interferons and interleukins, which are cytokines with key roles in regulating the immune response, activate enzymes called *Janus kinases* (JAK1, JAK2, JAK3, and Tyk2), which are associated with the cytoplasmic portion of the transmembrane receptors.[167] Activated JAKs phosphorylate the cytoplasmic domain of the receptor, thereby leading the activation of its substrates, especially the proteins known as STATs (STAT1, STAT2, STAT3, STAT4, STAT5a, STAT5b, and STAT6). After phosphorylation, STATs may form homodimers or heterodimers; this enables them to enter to the nucleus, where they can regulate gene transcription.[263] Although individual STAT proteins may be activated by multiple ligands, certain cytokines preferentially activate particular STATs. IFN-γ preferentially activates STAT1 through JAK1/JAK2, and IL-6 activates STAT3 through JAK1. The JAK-STAT pathway is the signaling target of many cytokines that play important roles in inflammation and thus could also be important to periodontal disease, including IFN-γ, IL-1, IL-2, IL-4, IL-6, IL-10, IL-12, and TNF-α.[33,293,368] STAT3 can be phosphorylated at tyrosine and serine residues. This dual phosphorylation is needed for full activation, although it is not known if the serine phosphorylation of STAT3 has a role in the DNA binding of STAT3.[374] Interestingly, deficient STAT3 signaling in innate immune cells has been recently shown to aggravate *P. gingivalis*–induced experimental periodontitis in mice by impairing IL-10 signaling and increasing a Th-1–type response characterized by elevated IL-12 and IL-1α.[313]

NF-κβ consists of five related transcription factors that can form multiple homodimers and heterodimers and regulate inducible gene expression in various physiological contexts.[113] Studies of animal and human diseases have indicated that the activation of NF-κβ is crucial for the expression of various inflammatory genes.[176,312] This role of NF-κβ for the inflammatory/immune response has been validated by other studies with the use of genetic approaches and chemical inhibitors.[6,239,324] The potential therapeutic applications of NF-κβ inhibition have been investigated in clinical trials of cancer[3] and in animal models of rheumatoid arthritis.[236] Collectively, this information suggests that NF-κβ signaling should play an important role in periodontal diseases; this concept is supported not only by a recent gene-profiling analysis that demonstrated the increased expression of both NF-κβ and NF-κβ–regulated inflammatory genes in diseased periodontal tissues[83] but also by studies in vitro.[56]

Despite a great deal of information available about the regulation and expression of inflammatory cytokines, there are only a few reports that address the signaling pathways activated specifically by periodontal disease in vivo. NF-κβ activation has been shown to be associated with increased periodontal disease severity.[9] Differences in the activation of signaling pathways in two frequently used murine models of experimentally induced periodontal disease were reported recently: in both the bacterial LPS injection model and the ligature model, p38 and ERK MAP kinases as well as NF-κβ were activated, but with different kinetics. On the other hand, the activation of JAK-STAT signaling was only observed with the ligature model.[108] However, to date, no studies involving NF-κβ or STAT inhibitors are available for periodontal disease models, despite the important role of these proteins in the regulation of various inflammatory genes.

Interestingly, the proteins that comprising many of the signaling pathways are much conserved among different species of organisms, thereby indicating their fundamental role in many essential physiological processes. Some of these signaling pathways also have a relevant role in diverse pathological conditions, thereby demonstrating their multivalency. For instance, the p38 MAPK pathway was originally described as being critically important to signal stress, inflammatory, and infectious stimuli, but it is also involved in the control of fundamental processes, including cell proliferation,[138] differentiation [215] and migration.[151] Nevertheless, many reports indicate its relevance and its potential therapeutic application in disease processes that involve inflammation and immunity, including rheumatoid arthritis,[232,238,366] ischemic heart disease,[62] allergies,[90,314] chronic obstructive pulmonary disease,[240] Alzheimer's disease,[70] and cancer.[290]

Surprisingly, despite evidence indicating a role of p38 MAPK in all of these diseases, there is a relative paucity of information regarding its role in oral-inflammation–related conditions, including temporomandibular joint disorders, chronic oral pain, and inflammatory changes of the oral mucosa.[271] Interest in its role in chronic inflammatory periodontal diseases has occurred only during the past few years. p38 MAPK is involved in the regulation of the expression of pro-inflammatory cytokines and enzymes induced by inflammatory and infectious signals in vitro, including IL-6,[269,270] MMP-13,[298,300] and RANKL[297] in periodontally relevant resident cells such as fibroblasts and osteoblasts. On the basis of its involvement in the regulation of these cytokines, it is expected that p38 MAP kinase will play a relevant role in disease progression. This signaling pathway is not only one of the main downstream effectors of TLR signaling,[35,36] but it is also particularly relevant for the activation and development of adaptive immune responses, as demonstrated by its role in T-cell proliferation and cytokine production[292,392] as well as in the differentiation of immature T cells into Th1 and Th2 effector cells.[64] p38 MAPK is also involved in B-cell activation[67] and the production of cytokines, including IL-10.[72] It even modulates IL-4–mediated responses in B cells via cross-talk with STAT6.[277] This illustrates the multiple roles of this signaling pathway and how the modulation of its activity may have multiple effects for both innate and adaptive immunity. Other signaling pathways that have been shown to be activated and involved in the regulation of gene expression during inflammation and immune response (e.g., Notch,[11,102] Wnt,[117,276] and PI3-kinase[375,295] pathways) participate in host-microbe interactions, but they have not been studied in the context of periodontal disease.

controlled by an even faster mechanism represented by the signaling pathways. The fact that a given signaling pathway regulates the expression of various inflammatory mediators is especially important for therapeutic applications if one considers that targeting the expression of a single cytokine may not be greatly effective as a result of the compensation of its biological role by other proinflammatory cytokines.

Therapeutic Strategies for Disrupting Host-Cell Signaling in the Treatment of Periodontal Diseases

A variety of treatment strategies have been developed to target the host response to LPS-mediated tissue destruction (see the article by Kirkwood and colleagues in the Suggested Readings list). Chapter 49 provides mechanistic overviews and clinical applications of host modulatory therapeutic regimens for periodontal disease management. MMP inhibitors (e.g., low-dose formulations of doxycycline) have been used in combination with scaling and root planing[52] or surgical therapy.[106] In addition, high-risk patient populations (e.g., diabetic patients, patients with refractory periodontal disease) have benefited from the systemic administration of MMP inhibitors.[55,252,304] Encouraging results have been shown with the use of soluble antagonists of TNF-α and IL-1β delivered locally to periodontal tissues in nonhuman primates.[18] Other therapeutic strategies that are being explored are aimed at inhibiting the signal transduction pathways involved in inflammation. Pharmacological inhibitors of NF-κβ and p38 MAPK pathways are actively being developed to manage rheumatoid arthritis and inflammatory bone diseases,[2,176,204] and they have been applied in periodontal disease models with noteworthy accomplishments.[196,294] With the use of this novel strategy, inflammatory mediators including proinflammatory cytokines (e.g., IL-1, TNF, IL-6), MMPs, and others would be inhibited at the level of the cell-signaling pathways required for the transcription factor activation necessary for inflammatory gene expression or mRNA stability. Indeed, the targeting of RNA-binding proteins that mediate the effects of inflammatory cytokines does have therapeutic value in small animal models of periodontal disease progression.[272] These therapies may provide the next wave of adjuvant chemotherapeutics that may be used to manage chronic periodontitis.

Suggested Readings

Akira S, Uematsu S, Takeuchi O: Pathogen recognition and innate immunity. *Cell* 124(4):783–801, 2006.

Artis D: Epithelial-cell recognition of commensal bacteria and maintenance of immune homeostasis in the gut. *Nat Rev Immunol* 8(6):411–420, 2008.

Boyle WJ, Simonet WS, Lacey DL: Osteoclast differentiation and activation. *Nature* 423(6937):337–342, 2003.

Graves D: Cytokines that promote periodontal tissue destruction. *J Periodontol* 79(8 Suppl):1585–1591, 2008.

Kabelitz D: Expression and function of Toll-like receptors in T lymphocytes. *Curr Opin Immunol* 19(1):39–45, 2007.

Karin M, Lawrence T, Nizet V: Innate immunity gone awry: linking microbial infections to chronic inflammation and cancer. *Cell* 124(4):823–835, 2006.

Kirkwood KL, Cirelli JA, Rogers JE, et al: Novel host response therapeutic approaches to treat periodontal diseases. *Periodontol 2000* 43:294–315, 2007.

Patil CS, Kirkwood KL: p38 MAPK signaling in oral-related diseases. *J Dent Res* 86(9):812–825, 2007.

Sarkar FH, Li Y, Wang Z, et al: NF-kappaB signaling pathway and its therapeutic implications in human diseases. *Int Rev Immunol* 27(5):293–319, 2008.

References

References for this chapter are found on the companion website www.expertconsult.com.

References

1. Abe T, Hosur KB, Hajishengallis E, et al: Local complement-targeted intervention in periodontitis: proof-of-concept using a C5a receptor (CD88) antagonist. *J Immunol* 189(11):5442–5448, 2012.
2. Adams JL, Badger AM, Kumar S, et al: p38 MAP kinase: molecular target for the inhibition of pro-inflammatory cytokines. *Prog Med Chem* 38:1–60, 2001.
3. Aghajanian C, Dizon DS, Sabbatini P, et al: Phase I trial of bortezomib and carboplatin in recurrent ovarian or primary peritoneal cancer. *J Clin Oncol* 23(25):5943–5949, 2005.
4. Akira S, Uematsu S, Takeuchi O: Pathogen recognition and innate immunity. *Cell* 124(4):783–801, 2006.
5. Albert ML, Jegathesan M, Darnell RB: Dendritic cell maturation is required for the cross-tolerization of CD8+ T cells. *Nat Immunol* 2(11):1010–1017, 2001.
6. Alcamo E, Mizgerd JP, Horwitz BH, et al: Targeted mutation of TNF receptor I rescues the RelA-deficient mouse and reveals a critical role for NF-kappa B in leukocyte recruitment. *J Immunol* 167(3):1592–1600, 2001.
7. Alexopoulou L, Thomas V, Schnare M, et al: Hyporesponsiveness to vaccination with *Borrelia burgdorferi* OspA in humans and in TLR1- and TLR2-deficient mice. *Nat Med* 8(8):878–884, 2002.
8. Al-Shammari KF, Giannobile WV, Aldredge WA, et al: Effect of nonsurgical periodontal therapy on C-telopeptide pyridinoline cross-links (ICTP) and interleukin-1 levels. *J Periodontol* 72(8):1045–1051, 2001.
9. Ambili R, Santhi WS, Janam P, et al: Expression of activated transcription factor nuclear factor-kappaB in periodontally diseased tissues. *J Periodontol* 76(7):1148–1153, 2005.
10. American Academy of Periodontology: Periodontal diseases of children and adolescents. *Pediatr Dent* 30(7 Suppl):240–247, 2008.
11. Ando K, Kanazawa S, Tetsuka T, et al: Induction of Notch signaling by tumor necrosis factor in rheumatoid synovial fibroblasts. *Oncogene* 22(49):7796–7803, 2003.
12. Aoyagi T, Sugawara-Aoyagi M, Yamazaki K, et al: Interleukin 4 (IL-4) and IL-6-producing memory T-cells in peripheral blood and gingival tissue in periodontitis patients with high serum antibody titers to *Porphyromonas gingivalis*. *Oral Microbiol Immunol* 10(5):304–310, 1995.
13. Ara T, Kurata K, Hirai K, et al: Human gingival fibroblasts are critical in sustaining inflammation in periodontal disease. *J Periodontal Res* 44(1):21–27, 2009.
14. Armitage GC, Wu Y, Wang HY, et al: Low prevalence of a periodontitis-associated interleukin-1 composite genotype in individuals of Chinese heritage. *J Periodontol* 71(2):164–171, 2000.
15. Artis D: Epithelial-cell recognition of commensal bacteria and maintenance of immune homeostasis in the gut. *Nat Rev Immunol* 8(6):411–420, 2008.
16. Asai Y, Jinno T, Ogawa T: Oral treponemes and their outer membrane extracts activate human gingival epithelial cells through toll-like receptor 2. *Infect Immun* 71(2):717–725, 2003.
17. Asai Y, Ohyama Y, Gen K, et al: Bacterial fimbriae and their peptides activate human gingival epithelial cells through Toll-like receptor 2. *Infect Immun* 69(12):7387–7395, 2001.
18. Assuma R, Oates T, Cochran D, et al: IL-1 and TNF antagonists inhibit the inflammatory response and bone loss in experimental periodontitis. *J Immunol* 160(1):403–409, 1998.
19. Astolfi CM, Shinohara AL, da Silva RA, et al: Genetic polymorphisms in the MMP-1 and MMP-3 gene may contribute to chronic periodontitis in a Brazilian population. *J Clin Periodontol* 33(10):699–703, 2006.
20. Babu S, Blauvelt CP, Kumaraswami V, et al: Cutting edge: diminished T cell TLR expression and function modulates the immune response in human filarial infection. *J Immunol* 176(7):3885–3889, 2006.
21. Baelum V, Fejerskov O, Karring T: Oral hygiene, gingivitis and periodontal breakdown in adult Tanzanians. *J Periodontal Res* 21(3):221–232, 1986.
22. Baelum V, Fejerskov O, Manji F: Periodontal diseases in adult Kenyans. *J Clin Periodontol* 15(7):445–452, 1988.
23. Baker PJ, Carter S, Dixon M, et al: Serum antibody response to oral infection precedes but does not prevent *Porphyromonas gingivalis*-induced alveolar bone loss in mice. *Oral Microbiol Immunol* 14(3):194–196, 1999.
24. Baker PJ, Evans RT, Roopenian DC: Oral infection with *Porphyromonas gingivalis* and induced alveolar bone loss in immunocompetent and severe combined immunodeficient mice. *Arch Oral Biol* 39(12):1035–1040, 1994.
25. Baker PJ, Garneau J, Howe L, et al: T-cell contributions to alveolar bone loss in response to oral infection with *Porphyromonas gingivalis*. *Acta Odontol Scand* 59(4):222–225, 2001.
26. Baker PJ, Howe L, Garneau J, et al: T cell knockout mice have diminished alveolar bone loss after oral infection with *Porphyromonas gingivalis*. *FEMS Immunol Med Microbiol* 34(1):45–50, 2002.
27. Baqui AA, Meiller TF, Chon JJ, et al: Granulocyte-macrophage colony-stimulating factor amplification of interleukin-1beta and tumor necrosis factor alpha production in THP-1 human monocytic cells stimulated with lipopolysaccharide of oral microorganisms. *Clin Diagn Lab Immunol* 5(3):341–347, 1998.
28. Barksby HE, Nile CJ, Jaedicke KM, et al: Differential expression of immunoregulatory genes in monocytes in response to *Porphyromonas gingivalis* and *Escherichia coli* lipopolysaccharide. *Clin Exp Immunol* 156(3):479–487, 2009.
29. Beklen A, Hukkanen M, Richardson R, et al: Immunohistochemical localization of Toll-like receptors 1-10 in periodontitis. *Oral Microbiol Immunol* 23(5):425–431, 2008.
30. Belardelli F, Ferrantini M: Cytokines as a link between innate and adaptive antitumor immunity. *Trends Immunol* 23(4):201–208, 2002.
31. Belibasakis GN, Guggenheim B, Bostanci N: Down-regulation of NLRP3 inflammasome in gingival fibroblasts by subgingival biofilms: involvement of *Porphyromonas gingivalis*. *Innate Immun* 19(1):3–9, 2013.
32. Berezow AB, Ernst RK, Coats SR, et al: The structurally similar, penta-acylated lipopolysaccharides of *Porphyromonas gingivalis* and *Bacteroides* elicit strikingly different innate immune responses. *Microb Pathog* 47(2):68–77, 2009.
33. Berglundh T, Donati M: Aspects of adaptive host response in periodontitis. *J Clin Periodontol* 32(Suppl 6):87–107, 2005.
34. Berglundh T, Donati M, Zitzmann N: B cells in periodontitis: friends or enemies? *Periodontol 2000* 45:51–66, 2007.
35. Beutler B: Toll-like receptors: how they work and what they do. *Curr Opin Hematol* 9(1):2–10, 2002.
36. Beutler B: Innate immune responses to microbial poisons: discovery and function of the Toll-like receptors. *Annu Rev Pharmacol Toxicol* 43:609–628, 2003.
37. Beutler B, Hoebe K, Du X, et al: How we detect microbes and respond to them: the Toll-like receptors and their transducers. *J Leukoc Biol* 74(4):479–485, 2003.
38. Bissell J, Joly S, Johnson GK, et al: Expression of beta-defensins in gingival health and in periodontal disease. *J Oral Pathol Med* 33(5):278–285, 2004.
39. Bodet C, Andrian E, Tanabe S, et al: *Actinobacillus actinomycetemcomitans* lipopolysaccharide regulates matrix metalloproteinase, tissue inhibitors of matrix metalloproteinase, and plasminogen activator production by human gingival fibroblasts: a potential role in connective tissue destruction. *J Cell Physiol* 212(1):189–194, 2007.
40. Bostanci N, Allaker R, Johansson U, et al: Interleukin-1alpha stimulation in monocytes by periodontal bacteria: antagonistic effects of *Porphyromonas gingivalis*. *Oral Microbiol Immunol* 22(1):52–60, 2007.
41. Bostanci N, Emingil G, Saygan B, et al: Expression and regulation of the NALP3 inflammasome complex in periodontal diseases. *Clin Exp Immunol* 157(3):415–422, 2009.
42. Bostanci N, Meier A, Guggenheim B, et al: Regulation of NLRP3 and AIM2 inflammasome gene expression levels in gingival fibroblasts by oral biofilms. *Cell Immunol* 270(1):88–93, 2011.

43. Bouma G, Strober W: The immunological and genetic basis of inflammatory bowel disease. *Nat Rev Immunol* 3(7):521–533, 2003.
44. Bourke E, Bosisio D, Golay J, et al: The toll-like receptor repertoire of human B lymphocytes: inducible and selective expression of TLR9 and TLR10 in normal and transformed cells. *Blood* 102(3):956–963, 2003.
45. Boyle WJ, Simonet WS, Lacey DL: Osteoclast differentiation and activation. *Nature* 423(6937):337–342, 2003.
46. Brancatisano FL, Maisetta G, Barsotti F, et al: Reduced human beta defensin 3 in individuals with periodontal disease. *J Dent Res* 90(2):241–245, 2011.
47. Brandtzaeg P, Kraus FW: Autoimmunity and periodontal disease. *Odontol Tidskr* 73:281–393, 1965.
48. Brissette CA, Pham TT, Coats SR, et al: *Treponema denticola* does not induce production of common innate immune mediators from primary gingival epithelial cells. *Oral Microbiol Immunol* 23(6):474–481, 2008.
49. Brozovic S, Sahoo R, Barve S, et al: *Porphyromonas gingivalis* enhances FasL expression via up-regulation of NFkappaB-mediated gene transcription and induces apoptotic cell death in human gingival epithelial cells. *Microbiology* 152(Pt 3):797–806, 2006.
50. Burns E, Bachrach G, Shapira L, et al: Cutting edge: TLR2 is required for the innate response to *Porphyromonas gingivalis:* activation leads to bacterial persistence and TLR2 deficiency attenuates induced alveolar bone resorption. *J Immunol* 177(12):8296–8300, 2006.
51. Caron G, Duluc D, Fremaux I, et al: Direct stimulation of human T cells via TLR5 and TLR7/8: flagellin and R-848 up-regulate proliferation and IFN-gamma production by memory $CD4^+$ T cells. *J Immunol* 175(3):1551–1557, 2005.
52. Caton JG, Ciancio SG, Blieden TM, et al: Subantimicrobial dose doxycycline as an adjunct to scaling and root planing: post-treatment effects. *J Clin Periodontol* 28(8):782–789, 2001.
53. Cavaillon JM: Cytokines and macrophages. *Biomed Pharmacother* 48(10):445–453, 1994.
54. Champaiboon C, Yongvanitchit K, Pichyangkul S, et al: The immune modulation of B-cell responses by Porphyromonas ginginvalis and interleukin-10. *J Periodontol* 71(3):468–475, 2000.
55. Chang K, Rani AS, Kumar S: Plasminogen activator activity is decreased in rat gingiva during diabetes. *J Periodontol* 67(8):743–747, 1996.
56. Chen D, Nie M, Fan MW, et al: Anti-inflammatory activity of curcumin in macrophages stimulated by lipopolysaccharides from *Porphyromonas gingivalis*. *Pharmacology* 82(4):264–269, 2008.
57. Chen D, Wang Q, Ma ZW, et al: MMP-2, MMP-9 and TIMP-2 gene polymorphisms in Chinese patients with generalized aggressive periodontitis. *J Clin Periodontol* 34(5):384–389, 2007.
58. Choi Y, Woo KM, Ko SH, et al: Osteoclastogenesis is enhanced by activated B cells but suppressed by activated CD8(+) T cells. *Eur J Immunol* 31(7):2179–2188, 2001.
59. Chung WO, Dale BA: Innate immune response of oral and foreskin keratinocytes: utilization of different signaling pathways by various bacterial species. *Infect Immun* 72(1):352–358, 2004.
60. Ciraci C, Janczy JR, Sutterwala FS, et al: Control of innate and adaptive immunity by the inflammasome. *Microbes Infect* 14(14):1263–1270, 2012.
61. Cirelli JA, Park CH, MacKool K, et al: AAV2/1-TNFR:Fc gene delivery prevents periodontal disease progression. *Gene Ther* 16(3):426–436, 2009.
62. Clark JE, Sarafraz N, Marber MS: Potential of p38-MAPK inhibitors in the treatment of ischaemic heart disease. *Pharmacol Ther* 116(2):192–206, 2007.
63. Cochran DL: Inflammation and bone loss in periodontal disease. *J Periodontol* 79(8 Suppl):1569–1576, 2008.
64. Cook R, Wu CC, Kang YJ, et al: The role of the p38 pathway in adaptive immunity. *Cell Mol Immunol* 4(4):253–259, 2007.
65. Correa FO, Goncalves D, Figueredo CM, et al: The short-term effectiveness of non-surgical treatment in reducing levels of interleukin-1beta and proteases in gingival crevicular fluid from patients with type 2 diabetes mellitus and chronic periodontitis. *J Periodontol* 79(11):2143–2150, 2008.
66. Cottalorda A, Verschelde C, Marcais A, et al: TLR2 engagement on CD8 T cells lowers the threshold for optimal antigen-induced T cell activation. *Eur J Immunol* 36(7):1684–1693, 2006.
67. Craxton A, Shu G, Graves J, et al: p38 MAPK is required for CD40-induced gene expression and proliferation in B lymphocytes. *J Immunol* 161:3225–3226, 1998.
68. Crellin NK, Garcia RV, Hadisfar O, et al: Human CD4+ T cells express TLR5 and its ligand flagellin enhances the suppressive capacity and expression of FOXP3 in CD4+CD25+ T regulatory cells. *J Immunol* 175(12):8051–8059, 2005.
69. Crotti T, Smith MD, Hirsch R, et al: Receptor activator NF kappaB ligand (RANKL) and osteoprotegerin (OPG) protein expression in periodontitis. *J Periodontal Res* 38(4):380–387, 2003.
70. Culbert AA, Skaper SD, Howlett DR, et al: MAPK-activated protein kinase 2 deficiency in microglia inhibits pro-inflammatory mediator release and resultant neurotoxicity. Relevance to neuroinflammation in a transgenic mouse model of Alzheimer disease. *J Biol Chem* 281(33):23658–23667, 2006.
71. Curtsinger JM, Lins DC, Mescher MF: Signal 3 determines tolerance versus full activation of naive CD8 T cells: dissociating proliferation and development of effector function. *J Exp Med* 197(9):1141–1151, 2003.
72. Dadgostar H, Zarnegar B, Hoffmann A, et al: Cooperation of multiple signaling pathways in CD40-regulated gene expression in B lymphocytes. *Proc Natl Acad Sci U S A* 99(3):1497–1502, 2002.
73. Dale BA: Periodontal epithelium: a newly recognized role in health and disease. *Periodontol 2000* 30:70–78, 2002.
74. Dale BA, Fredericks LP: Antimicrobial peptides in the oral environment: expression and function in health and disease. *Curr Issues Mol Biol* 7(2):119–133, 2005.
75. Dale BA, Kimball JR, Krisanaprakornkit S, et al: Localized antimicrobial peptide expression in human gingiva. *J Periodontal Res* 36(5):285–294, 2001.
76. Dangl JL, Jones JD: Plant pathogens and integrated defence responses to infection. *Nature* 411(6839):826–833, 2001.
77. Darveau RP, Arbabi S, Garcia I, et al: *Porphyromonas gingivalis* lipopolysaccharide is both agonist and antagonist for p38 mitogen-activated protein kinase activation. *Infect Immun* 70(4):1867–1873, 2002.
78. Darveau RP, Belton CM, Reife RA, et al: Local chemokine paralysis, a novel pathogenic mechanism for *Porphyromonas gingivalis*. *Infect Immun* 66(4):1660–1665, 1998.
79. Dasari P, Nicholson IC, Hodge G, et al: Expression of toll-like receptors on B lymphocytes. *Cell Immunol* 236(1-2):140–145, 2005.
80. de Aquino SG, Guimaraes MR, Stach-Machado DR, et al: Differential regulation of MMP-13 expression in two models of experimentally induced periodontal disease in rats. *Arch Oral Biol* 54(7):609–617, 2009.
81. Delima AJ, Karatzas S, Amar S, et al: Inflammation and tissue loss caused by periodontal pathogens is reduced by interleukin-1 antagonists. *J Infect Dis* 186(4):511–516, 2002.
82. Delima AJ, Oates T, Assuma R, et al: Soluble antagonists to interleukin-1 (IL-1) and tumor necrosis factor (TNF) inhibits loss of tissue attachment in experimental periodontitis. *J Clin Periodontol* 28(3):233–240, 2001.
83. Demmer RT, Behle JH, Wolf DL, et al: Transcriptomes in healthy and diseased gingival tissues. *J Periodontol* 79(11):2112–2124, 2008.
84. de Souza AP, Trevilatto PC, Scarel-Caminaga RM, et al: Analysis of the MMP-9 (C-1562 T) and TIMP-2 (G-418C) gene promoter polymorphisms in patients with chronic periodontitis. *J Clin Periodontol* 32(2):207–211, 2005.
85. Diamond G, Zasloff M, Eck H, et al: Tracheal antimicrobial peptide, a cysteine-rich peptide from mammalian tracheal mucosa: peptide isolation and cloning of a cDNA. *Proc Natl Acad Sci U S A* 88(9):3952–3956, 1991.
86. Di Paola R, Mazzon E, Muia C, et al: Effects of etanercept, a tumour necrosis factor-alpha antagonist, in an experimental model of periodontitis in rats. *Br J Pharmacol* 150(3):286–297, 2007.

87. Doherty DE, Zagarella L, Henson PM, et al: Lipopolysaccharide stimulates monocyte adherence by effects on both the monocyte and the endothelial cell. *J Immunol* 143(11):3673–3679, 1989.
88. Dolganiuc A, Garcia C, Kodys K, et al: Distinct Toll-like receptor expression in monocytes and T cells in chronic HCV infection. *World J Gastroenterol* 12(8):1198–1204, 2006.
89. Dongari-Bagtzoglou AI, Ebersole JL: Production of inflammatory mediators and cytokines by human gingival fibroblasts following bacterial challenge. *J Periodontal Res* 31(2):90–98, 1996.
90. Duan W, Wong WS: Targeting mitogen-activated protein kinases for asthma. *Curr Drug Targets* 7(6):691–698, 2006.
91. Dunsche A, Acil Y, Dommisch H, et al: The novel human beta-defensin-3 is widely expressed in oral tissues. *Eur J Oral Sci* 110(2):121–124, 2002.
92. Eastcott JW, Yamashita K, Taubman MA, et al: Adoptive transfer of cloned T helper cells ameliorates periodontal disease in nude rats. *Oral Microbiol Immunol* 9(5):284–289, 1994.
93. Ebersole JL, Taubman MA, Smith DJ, et al: Human serum antibody responses to oral microorganisms. IV. Correlation with homologous infection. *Oral Microbiol Immunol* 2(2):53–59, 1987.
94. Ejeil AL, Gaultier F, Igondjo-Tchen S, et al: Are cytokines linked to collagen breakdown during periodontal disease progression? *J Periodontol* 74(2):196–201, 2003.
95. Feller L, Lemmer J: Necrotizing periodontal diseases in HIV-seropositive subjects: pathogenic mechanisms. *J Int Acad Periodontol* 10(1):10–15, 2008.
96. Figueredo CM, Areas A, Miranda LA, et al: The short-term effectiveness of non-surgical treatment in reducing protease activity in gingival crevicular fluid from chronic periodontitis patients. *J Clin Periodontol* 31(8):615–619, 2004.
97. Franchi L, Nunez G: The Nlrp3 inflammasome is critical for aluminium hydroxide-mediated IL-1beta secretion but dispensable for adjuvant activity. *Eur J Immunol* 38(8):2085–2089, 2008.
98. Franchi L, Warner N, Viani K, et al: Function of Nod-like receptors in microbial recognition and host defense. *Immunol Rev* 227(1):106–128, 2009.
99. Fritz JH, Girardin SE, Fitting C, et al: Synergistic stimulation of human monocytes and dendritic cells by Toll-like receptor 4 and NOD1- and NOD2-activating agonists. *Eur J Immunol* 35(8):2459–2470, 2005.
100. Fujii S, Liu K, Smith C, et al: The linkage of innate to adaptive immunity via maturing dendritic cells in vivo requires CD40 ligation in addition to antigen presentation and CD80/86 costimulation. *J Exp Med* 199(12):1607–1618, 2004.
101. Fukusaki T, Ohara N, Hara Y, et al: Evidence for association between a Toll-like receptor 4 gene polymorphism and moderate/severe periodontitis in the Japanese population. *J Periodontal Res* 42(6):541–545, 2007.
102. Fung E, Tang SM, Canner JP, et al: Delta-like 4 induces notch signaling in macrophages: implications for inflammation. *Circulation* 115(23):2948–2956, 2007.
103. Galdiero M, de l'Ero GC: Marcatili A. Cytokine and adhesion molecule expression in human monocytes and endothelial cells stimulated with bacterial heat shock proteins. *Infect Immun* 65(2):699–707, 1997.
104. Gamonal J, Acevedo A, Bascones A, et al: Levels of interleukin-1 beta, -8, and -10 and RANTES in gingival crevicular fluid and cell populations in adult periodontitis patients and the effect of periodontal treatment. *J Periodontol* 71(10):1535–1545, 2000.
105. Gamonal J, Acevedo A, Bascones A, et al: Characterization of cellular infiltrate, detection of chemokine receptor CCR5 and interleukin-8 and RANTES chemokines in adult periodontitis. *J Periodontal Res* 36(3):194–203, 2001.
106. Gapski R, Barr JL, Sarment DP, et al: Effect of systemic matrix metalloproteinase inhibition on periodontal wound repair: a proof of concept trial. *J Periodontol* 75(3):441–452, 2004.
107. Gapski R, Hasturk H, Van Dyke TE, et al: Systemic MMP inhibition for periodontal wound repair: results of a multi-centre randomized-controlled clinical trial. *J Clin Periodontol* 36(2):149–156, 2009.
108. Garcia de Aquino S, Manzolli Leite FR, Stach-Machado DR, et al: Signaling pathways associated with the expression of inflammatory mediators activated during the course of two models of experimental periodontitis. *Life Sci* 84(21-22):745–754, 2009.
109. Garlet GP, Cardoso CR, Silva TA, et al: Cytokine pattern determines the progression of experimental periodontal disease induced by Actinobacillus actinomycetemcomitans through the modulation of MMPs, RANKL, and their physiological inhibitors. *Oral Microbiol Immunol* 21(1):12–20, 2006.
110. Garlet GP, Martins W, Jr, Ferreira BR, et al: Patterns of chemokines and chemokine receptors expression in different forms of human periodontal disease. *J Periodontal Res* 38(2):210–217, 2003.
111. Gelman AE, LaRosa DF, Zhang J, et al: The adaptor molecule MyD88 activates PI-3 kinase signaling in CD4+ T cells and enables CpG oligodeoxynucleotide-mediated costimulation. *Immunity* 25(5):783–793, 2006.
112. Gelman AE, Zhang J, Choi Y, et al: Toll-like receptor ligands directly promote activated CD4+ T cell survival. *J Immunol* 172(10):6065–6073, 2004.
113. Ghosh S, Hayden MS: New regulators of NF-kappaB in inflammation. *Nat Rev Immunol* 8(11):837–848, 2008.
114. Girardin SE, Boneca IG, Carneiro LA, et al: Nod1 detects a unique muropeptide from gram-negative bacterial peptidoglycan. *Science* 300(5625):1584–1587, 2003.
115. Golub LM, McNamara TF, Ryan ME, et al: Adjunctive treatment with subantimicrobial doses of doxycycline: effects on gingival fluid collagenase activity and attachment loss in adult periodontitis. *J Clin Periodontol* 28(2):146–156, 2001.
116. Goncalves LD, Oliveira G, Hurtado PA, et al: Expression of metalloproteinases and their tissue inhibitors in inflamed gingival biopsies. *J Periodontal Res* 43(5):570–577, 2008.
117. Gordon MD, Nusse R: Wnt signaling: multiple pathways, multiple receptors, and multiple transcription factors. *J Biol Chem* 281(32):22429–22433, 2006.
118. Gorr SU: Antimicrobial peptides of the oral cavity. *Periodontol 2000* 51:152–180, 2009.
119. Gorr SU: Abdolhosseini M. Antimicrobial peptides and periodontal disease. *J Clin Periodontol* 38(Suppl 11):126–141, 2011.
120. Gorska R, Gregorek H, Kowalski J, et al: Relationship between clinical parameters and cytokine profiles in inflamed gingival tissue and serum samples from patients with chronic periodontitis. *J Clin Periodontol* 30(12):1046–1052, 2003.
121. Graves D: Cytokines that promote periodontal tissue destruction. *J Periodontol* 79(8 Suppl):1585–1591, 2008.
122. Graves DT: The potential role of chemokines and inflammatory cytokines in periodontal disease progression. *Clin Infect Dis* 28(3):482–490, 1999.
123. Graves DT, Cochran D: The contribution of interleukin-1 and tumor necrosis factor to periodontal tissue destruction. *J Periodontol* 74(3):391–401, 2003.
124. Graves DT, Delima AJ, Assuma R, et al: Interleukin-1 and tumor necrosis factor antagonists inhibit the progression of inflammatory cell infiltration toward alveolar bone in experimental periodontitis. *J Periodontol* 69(12):1419–1425, 1998.
125. Gris D, Ye Z, Iocca HA, et al: NLRP3 plays a critical role in the development of experimental autoimmune encephalomyelitis by mediating Th1 and Th17 responses. *J Immunol* 185(2):974–981, 2010.
126. Gurkan A, Emingil G, Saygan BH, et al: Gene polymorphisms of matrix metalloproteinase-2, -9 and -12 in periodontal health and severe chronic periodontitis. *Arch Oral Biol* 53(4):337–345, 2008.
127. Gursoy UK, Kononen E, Uitto VJ: Stimulation of epithelial cell matrix metalloproteinase (MMP-2, -9, -13) and interleukin-8 secretion by fusobacteria. *Oral Microbiol Immunol* 23(5):432–434, 2008.
128. Hajishengallis G: Complement and periodontitis. *Biochem Pharmacol* 80(12):1992–2001, 2010.
129. Hajishengallis G, Genco RJ: Downregulation of the DNA-binding activity of nuclear factor-kappaB p65 subunit in *Porphyromonas gingivalis* fimbria-induced tolerance. *Infect Immun* 72(2):1188–1191, 2004.

130. Hajishengallis G, Harokopakis E: *Porphyromonas gingivalis* interactions with complement receptor 3 (CR3): innate immunity or immune evasion? *Front Biosci* 12:4547–4557, 2007.
131. Hajishengallis G, Lambris JD: Crosstalk pathways between Toll-like receptors and the complement system. *Trends Immunol* 31(4):154–163, 2010.
132. Hajishengallis G, Liang S, Payne MA, et al: Low-abundance biofilm species orchestrates inflammatory periodontal disease through the commensal microbiota and complement. *Cell Host Microbe* 10(5):497–506, 2011.
133. Hajishengallis G, Martin M, Schifferle RE, et al: Counteracting interactions between lipopolysaccharide molecules with differential activation of toll-like receptors. *Infect Immun* 70(12):6658–6664, 2002.
134. Hajishengallis G, Martin M, Sojar HT, et al: Dependence of bacterial protein adhesins on toll-like receptors for proinflammatory cytokine induction. *Clin Diagn Lab Immunol* 9(2):403–411, 2002.
135. Hajishengallis G, Shakhatreh MA, Wang M, et al: Complement receptor 3 blockade promotes IL-12-mediated clearance of *Porphyromonas gingivalis* and negates its virulence in vivo. *J Immunol* 179(4):2359–2367, 2007.
136. Hajishengallis G, Tapping RI, Harokopakis E, et al: Differential interactions of fimbriae and lipopolysaccharide from *Porphyromonas gingivalis* with the Toll-like receptor 2-centred pattern recognition apparatus. *Cell Microbiol* 8(10):1557–1570, 2006.
137. Hajishengallis G, Wang M, Liang S: Induction of distinct TLR2-mediated proinflammatory and proadhesive signaling pathways in response to *Porphyromonas gingivalis* fimbriae. *J Immunol* 182(11):6690–6696, 2009.
138. Han J, Lee JD, Bibbs L, et al: A MAP kinase targeted by endotoxin and hyperosmolarity in mammalian cells. *Science* 265(5173):808–811, 1994.
139. Han X, Kawai T, Eastcott JW, et al: Bacterial-responsive B lymphocytes induce periodontal bone resorption. *J Immunol* 176(1):625–631, 2006.
140. Han X, Kawai T, Taubman MA: Interference with immune-cell-mediated bone resorption in periodontal disease. *Periodontol 2000* 45:76–94, 2007.
141. Han YW, Shi W, Huang GT, et al: Interactions between periodontal bacteria and human oral epithelial cells: *Fusobacterium nucleatum* adheres to and invades epithelial cells. *Infect Immun* 68(6):3140–3146, 2000.
142. Hancock RE, Brown KL, Mookherjee N: Host defence peptides from invertebrates—emerging antimicrobial strategies. *Immunobiology* 211(4):315–322, 2006.
143. Harada Y, Han X, Yamashita K, et al: Effect of adoptive transfer of antigen-specific B cells on periodontal bone resorption. *J Periodontal Res* 41(2):101–107, 2006.
144. Hartmann G, Krieg AM: CpG DNA and LPS induce distinct patterns of activation in human monocytes. *Gene Ther* 6(5):893–903, 1999.
145. Hartmann G, Krieg AM: Mechanism and function of a newly identified CpG DNA motif in human primary B cells. *J Immunol* 164(2):944–953, 2000.
146. Hasebe A, Yoshimura A, Into T, et al: Biological activities of *Bacteroides forsythus* lipoproteins and their possible pathological roles in periodontal disease. *Infect Immun* 72(3):1318–1325, 2004.
147. Hasegawa M, Fujimoto Y, Lucas PC, et al: A critical role of RICK/RIP2 polyubiquitination in Nod-induced NF-kappaB activation. *EMBO J* 27(2):373–383, 2008.
148. Hashimoto M, Asai Y, Ogawa T: Treponemal phospholipids inhibit innate immune responses induced by pathogen-associated molecular patterns. *J Biol Chem* 278(45):44205–44213, 2003.
149. Hatakeyama J, Tamai R, Sugiyama A, et al: Contrasting responses of human gingival and periodontal ligament fibroblasts to bacterial cell-surface components through the CD14/Toll-like receptor system. *Oral Microbiol Immunol* 18(1):14–23, 2003.
150. Hayden MS, Ghosh S: Signaling to NF-kappaB. *Genes Dev* 18(18):2195–2224, 2004.
151. Hedges JC, Dechert MA, Yamboliev IA, et al: A role for p38(MAPK)/HSP27 pathway in smooth muscle cell migration. *J Biol Chem* 274(34):24211–24219, 1999.
152. Hemmi H, Kaisho T, Takeuchi O, et al: Small anti-viral compounds activate immune cells via the TLR7 MyD88-dependent signaling pathway. *Nat Immunol* 3(2):196–200, 2002.
153. Hiramine H, Watanabe K, Hamada N, et al: *Porphyromonas gingivalis* 67-kDa fimbriae induced cytokine production and osteoclast differentiation utilizing TLR2. *FEMS Microbiol Lett* 229(1):49–55, 2003.
154. Hirschfeld M, Weis JJ, Toshchakov V, et al: Signaling by toll-like receptor 2 and 4 agonists results in differential gene expression in murine macrophages. *Infect Immun* 69(3):1477–1482, 2001.
155. Hofbauer LC, Heufelder AE: Role of receptor activator of nuclear factor-kappaB ligand and osteoprotegerin in bone cell biology. *J Mol Med* 79(5-6):243–253, 2001.
156. Hoffman HM, Mueller JL, Broide DH, et al: Mutation of a new gene encoding a putative pyrin-like protein causes familial cold autoinflammatory syndrome and Muckle-Wells syndrome. *Nat Genet* 29(3):301–305, 2001.
157. Holla LI, Fassmann A, Vasku A, et al: Genetic variations in the human gelatinase A (matrix metalloproteinase-2) promoter are not associated with susceptibility to, and severity of, chronic periodontitis. *J Periodontol* 76(7):1056–1060, 2005.
158. Hornung V, Rothenfusser S, Britsch S, et al: Quantitative expression of toll-like receptor 1-10 mRNA in cellular subsets of human peripheral blood mononuclear cells and sensitivity to CpG oligodeoxynucleotides. *J Immunol* 168(9):4531–4537, 2002.
159. Hoshino K, Kaisho T, Iwabe T, et al: Differential involvement of IFN-beta in Toll-like receptor-stimulated dendritic cell activation. *Int Immunol* 14(10):1225–1231, 2002.
160. Hou B, Reizis B, DeFranco AL: Toll-like receptors activate innate and adaptive immunity by using dendritic cell-intrinsic and -extrinsic mechanisms. *Immunity* 29(2):272–282, 2008.
161. Houri-Haddad Y, Wilensky A, Shapira L: T-cell phenotype as a risk factor for periodontal disease. *Periodontol 2000* 45:67–75, 2007.
162. Hsu LC, Ali SR, McGillivray S, et al: A NOD2-NALP1 complex mediates caspase-1-dependent IL-1beta secretion in response to *Bacillus anthracis* infection and muramyl dipeptide. *Proc Natl Acad Sci U S A* 105(22):7803–7808, 2008.
163. Huang GT, Haake SK, Kim JW, et al: Differential expression of interleukin-8 and intercellular adhesion molecule-1 by human gingival epithelial cells in response to Actinobacillus actinomycetemcomitans or *Porphyromonas gingivalis* infection. *Oral Microbiol Immunol* 13(5):301–309, 1998.
164. Huang GT, Kim D, Lee JK, et al: Interleukin-8 and intercellular adhesion molecule 1 regulation in oral epithelial cells by selected periodontal bacteria: multiple effects of *Porphyromonas gingivalis* via antagonistic mechanisms. *Infect Immun* 69(3):1364–1372, 2001.
165. Hysi P, Kabesch M, Moffatt MF, et al: NOD1 variation, immunoglobulin E and asthma. *Hum Mol Genet* 14(7):935–941, 2005.
166. Ihle JN: The Stat family in cytokine signaling. *Curr Opin Cell Biol* 13(2):211–217, 2001.
167. Ihle JN, Kerr IM: Jaks and Stats in signaling by the cytokine receptor superfamily. *Trends Genet* 11(2):69–74, 1995.
168. Imamura Y, Fujigaki Y, Oomori Y, et al: Polymorphism of genes encoding toll-like receptors and inflammatory cytokines in periodontal disease in the Japanese population. *J Int Acad Periodontol* 10(3):95–102, 2008.
169. Inohara N, Ogura Y, Chen FF, et al: Human Nod1 confers responsiveness to bacterial lipopolysaccharides. *J Biol Chem* 276(4):2551–2554, 2001.
170. Inohara N, Ogura Y, Fontalba A, et al: Host recognition of bacterial muramyl dipeptide mediated through NOD2. Implications for Crohn's disease. *J Biol Chem* 278(8):5509–5512, 2003.
171. Iwamoto Y, Nishimura F, Soga Y, et al: Antimicrobial periodontal treatment decreases serum C-reactive protein, tumor necrosis factor-alpha, but not adiponectin levels in patients with chronic periodontitis. *J Periodontol* 74(8):1231–1236, 2003.

172. Jakob T, Walker PS, Krieg AM, et al: Activation of cutaneous dendritic cells by CpG-containing oligodeoxynucleotides: a role for dendritic cells in the augmentation of Th1 responses by immunostimulatory DNA. *J Immunol* 161(6):3042–3049, 1998.
173. Ji S, Kim Y, Min BM, et al: Innate immune responses of gingival epithelial cells to nonperiodontopathic and periodontopathic bacteria. *J Periodontal Res* 42(6):503–510, 2007.
174. Ji S, Shin JE, Kim YS, et al: Toll-like receptor 2 and NALP2 mediate induction of human beta-defensins by fusobacterium nucleatum in gingival epithelial cells. *Infect Immun* 77(3):1044–1052, 2009.
175. Jiang Y, Mehta CK, Hsu TY: Alsulaimani FF. Bacteria induce osteoclastogenesis via an osteoblast-independent pathway. *Infect Immun* 70(6):3143–3148, 2002.
176. Jimi E, Aoki K, Saito H, et al: Selective inhibition of NF-kappa B blocks osteoclastogenesis and prevents inflammatory bone destruction in vivo. *Nat Med* 10(6):617–624, 2004.
177. Jin L: An update on innate defense molecules of human gingiva. *Periodontol 2000* 56(1):125–142, 2011.
178. Jin Q, Cirelli JA, Park CH, et al: RANKL inhibition through osteoprotegerin blocks bone loss in experimental periodontitis. *J Periodontol* 78(7):1300–1308, 2007.
179. Jin Y, Mailloux CM, Gowan K, et al: NALP1 in vitiligo-associated multiple autoimmune disease. *N Engl J Med* 356(12):1216–1225, 2007.
180. Jirik FR, Podor TJ, Hirano T, et al: Bacterial lipopolysaccharide and inflammatory mediators augment IL-6 secretion by human endothelial cells. *J Immunol* 142(1):144–147, 1989.
181. Joffre O, Nolte MA, Sporri R, et al: Inflammatory signals in dendritic cell activation and the induction of adaptive immunity. *Immunol Rev* 227(1):234–247, 2009.
182. Joly S, Maze C, McCray PB, Jr, et al: Human beta-defensins 2 and 3 demonstrate strain-selective activity against oral microorganisms. *J Clin Microbiol* 42(3):1024–1029, 2004.
183. Jotwani R, Cutler CW: Fimbriated *Porphyromonas gingivalis* is more efficient than fimbria-deficient *P. gingivalis* in entering human dendritic cells in vitro and induces an inflammatory Th1 effector response. *Infect Immun* 72(3):1725–1732, 2004.
184. Jotwani R, Pulendran B, Agrawal S, et al: Human dendritic cells respond to *Porphyromonas gingivalis* LPS by promoting a Th2 effector response in vitro. *Eur J Immunol* 33(11):2980–2986, 2003.
185. Kabelitz D: Expression and function of Toll-like receptors in T lymphocytes. *Curr Opin Immunol* 19(1):39–45, 2007.
186. Kanda N, Kamata M, Tada Y, et al: Human beta-defensin-2 enhances IFN-gamma and IL-10 production and suppresses IL-17 production in T cells. *J Leukoc Biol* 89(6):935–944, 2011.
187. Karin M, Lawrence T, Nizet V: Innate immunity gone awry: linking microbial infections to chronic inflammation and cancer. *Cell* 124(4):823–835, 2006.
188. Kawai T, Adachi O, Ogawa T, et al: Unresponsiveness of MyD88-deficient mice to endotoxin. *Immunity* 11(1):115–122, 1999.
189. Kawai T, Matsuyama T, Hosokawa Y, et al: B and T lymphocytes are the primary sources of RANKL in the bone resorptive lesion of periodontal disease. *Am J Pathol* 169(3):987–998, 2006.
190. Kawai T, Takeuchi O, Fujita T, et al: Lipopolysaccharide stimulates the MyD88-independent pathway and results in activation of IFN-regulatory factor 3 and the expression of a subset of lipopolysaccharide-inducible genes. *J Immunol* 167(10):5887–5894, 2001.
191. Kelk P, Claesson R, Chen C, et al: IL-1beta secretion induced by *Aggregatibacter (Actinobacillus) actinomycetemcomitans* is mainly caused by the leukotoxin. *Int J Med Microbiol* 298(5-6):529–541, 2008.
192. Khosla S: Minireview: the OPG/RANKL/RANK system. *Endocrinology* 142(12):5050–5055, 2001.
193. Kikkert R, Laine ML, Aarden LA, et al: Activation of toll-like receptors 2 and 4 by gram-negative periodontal bacteria. *Oral Microbiol Immunol* 22(3):145–151, 2007.
194. Kikuchi T, Matsuguchi T, Tsuboi N, et al: Gene expression of osteoclast differentiation factor is induced by lipopolysaccharide in mouse osteoblasts via Toll-like receptors. *J Immunol* 166(5):3574–3579, 2001.
195. Kim SJ, Choi EY, Kim EG, et al: *Prevotella intermedia* lipopolysaccharide stimulates release of tumor necrosis factor-alpha through mitogen-activated protein kinase signaling pathways in monocyte-derived macrophages. *FEMS Immunol Med Microbiol* 51(2):407–413, 2007.
196. Kirkwood K, Li F, Rogers J, et al: A p38 alpha selective mitogen-activated protein kinase inhibitor prevents periodontal bone loss. *J Pharmacol Exp Ther* 320(1):56–63, 2007.
197. Kohlgraf KG, Pingel LC, Dietrich DE, et al: Defensins as anti-inflammatory compounds and mucosal adjuvants. *Future Microbiol* 5(1):99–113, 2010.
198. Komai-Koma M, Jones L, Ogg GS, et al: TLR2 is expressed on activated T cells as a costimulatory receptor. *Proc Natl Acad Sci U S A* 101(9):3029–3034, 2004.
199. Komatsuzawa H, Ouhara K, Kawai T, et al: Susceptibility of periodontopathogenic and cariogenic bacteria to defensins and potential therapeutic use of defensins in oral diseases. *Curr Pharm Des* 13(30):3084–3095, 2007.
200. Kool M, Petrilli V, De Smedt T, et al: Cutting edge: alum adjuvant stimulates inflammatory dendritic cells through activation of the NALP3 inflammasome. *J Immunol* 181(6):3755–3759, 2008.
201. Kornman KS, Page RC, Tonetti MS: The host response to the microbial challenge in periodontitis: assembling the players. *Periodontol 2000* 14:33–53, 1997.
202. Krisanaprakornkit S, Kimball JR, Weinberg A, et al: Inducible expression of human beta-defensin 2 by Fusobacterium nucleatum in oral epithelial cells: multiple signaling pathways and role of commensal bacteria in innate immunity and the epithelial barrier. *Infect Immun* 68(5):2907–2915, 2000.
203. Kubota T, Itagaki M, Hoshino C, et al: Altered gene expression levels of matrix metalloproteinases and their inhibitors in periodontitis-affected gingival tissue. *J Periodontol* 79(1):166–173, 2008.
204. Kumar S, Votta BJ, Rieman DJ, et al: IL-1- and TNF-induced bone resorption is mediated by p38 mitogen activated protein kinase. *J Cell Physiol* 187(3):294–303, 2001.
205. Kuula H, Salo T, Pirila E, et al: Local and systemic responses in matrix metalloproteinase 8-deficient mice during *Porphyromonas gingivalis*-induced periodontitis. *Infect Immun* 77(2):850–859, 2009.
206. Lai WC, Zhou M, Shankavaram U, et al: Differential regulation of lipopolysaccharide-induced monocyte matrix metalloproteinase (MMP)-1 and MMP-9 by p38 and extracellular signal-regulated kinase 1/2 mitogen-activated protein kinases. *J Immunol* 170(12):6244–6249, 2003.
207. Lamkanfi M, Kanneganti TD, Franchi L, et al: Caspase-1 inflammasomes in infection and inflammation. *J Leukoc Biol* 82(2):220–225, 2007.
208. Lappin DF, MacLeod CP, Kerr A, et al: Anti-inflammatory cytokine IL-10 and T cell cytokine profile in periodontitis granulation tissue. *Clin Exp Immunol* 123(2):294–300, 2001.
209. Lasiglie D, Traggiai E, Federici S, et al: Role of IL-1 beta in the development of human T(H)17 cells: lesson from NLPR3 mutated patients. *PLoS ONE* 6(5):e20014, 2011.
210. Lee HM, Kim JJ, Kim HJ, et al: Upregulated NLRP3 inflammasome activation in patients with type 2 diabetes. *Diabetes* 62(1):194–204, 2013.
211. Lee HM, Wysoczynski M, Liu R, et al: Mobilization studies in complement-deficient mice reveal that optimal AMD3100 mobilization of hematopoietic stem cells depends on complement cascade activation by AMD3100-stimulated granulocytes. *Leukemia* 24(3):573–582, 2010.
212. Leshem O, Kashino SS, Goncalves RB, et al: Th1 biased response to a novel *Porphyromonas gingivalis* protein aggravates bone resorption caused by this oral pathogen. *Microbes Infect* 10(6):664–672, 2008.
213. Lester SR, Bain JL, Johnson RB, et al: Gingival concentrations of interleukin-23 and -17 at healthy sites and at sites of clinical attachment loss. *J Periodontol* 78(8):1545–1550, 2007.

214. Lewkowicz P, Lewkowicz N, Sasiak A, et al: Lipopolysaccharide-activated CD4+CD25+ T regulatory cells inhibit neutrophil function and promote their apoptosis and death. *J Immunol* 177(10):7155–7163, 2006.
215. Li Y, Jiang B, Ensign WY, et al: Myogenic differentiation requires signalling through both phosphatidylinositol 3-kinase and p38 MAP kinase. *Cell Signal* 12(11-12):751–757, 2000.
216. Liew FY, Xu D, Brint EK, et al: Negative regulation of toll-like receptor-mediated immune responses. *Nat Rev Immunol* 5(6):446–458, 2005.
217. Lindhe J, Hamp SE, Loe H: Plaque induced periodontal disease in beagle dogs. A 4-year clinical, roentgenographical and histometrical study. *J Periodontal Res* 10(5):243–255, 1975.
218. Liu H, Komai-Koma M, Xu D, et al: Toll-like receptor 2 signaling modulates the functions of CD4+ CD25+ regulatory T cells. *Proc Natl Acad Sci U S A* 103(18):7048–7053, 2006.
219. Loe H, Anerud A, Boysen H, et al: Natural history of periodontal disease in man. Rapid, moderate and no loss of attachment in Sri Lankan laborers 14 to 46 years of age. *J Clin Periodontol* 13(5):431–445, 1986.
220. Longhi MP, Harris CL, Morgan BP, et al: Holding T cells in check–a new role for complement regulators? *Trends Immunol* 27(2):102–108, 2006.
221. Madianos PN, Papapanou PN, Sandros J: *Porphyromonas gingivalis* infection of oral epithelium inhibits neutrophil transepithelial migration. *Infect Immun* 65(10):3983–3990, 1997.
222. Mahanonda R, Sa-Ard-Iam N, Charatkulangkun O, et al: Monocyte activation by *Porphyromonas gingivalis* LPS in aggressive periodontitis with the use of whole-blood cultures. *J Dent Res* 83(7):540–545, 2004.
223. Mansson A, Adner M, Cardell LO: Toll-like receptors in cellular subsets of human tonsil T cells: altered expression during recurrent tonsillitis. *Respir Res* 7:36, 2006.
224. Mao S, Maeno N, Matayoshi S, et al: The induction of intercellular adhesion molecule-1 on human umbilical vein endothelial cells by a heat-stable component of *Porphyromonas gingivalis*. *Curr Microbiol* 48(2):108–112, 2004.
225. Maria de Freitas N, Imbronito AV, Neves AC, et al: Analysis of IL-1A(-889) and TNFA(-308) gene polymorphism in Brazilian patients with generalized aggressive periodontitis. *Eur Cytokine Netw* 18(3):142–147, 2007.
226. Martin M, Katz J, Vogel SN, et al: Differential induction of endotoxin tolerance by lipopolysaccharides derived from *Porphyromonas gingivalis* and *Escherichia coli*. *J Immunol* 167(9):5278–5285, 2001.
227. Mathews M, Jia HP, Guthmiller JM, et al: Production of beta-defensin antimicrobial peptides by the oral mucosa and salivary glands. *Infect Immun* 67(6):2740–2745, 1999.
228. Mattern T, Flad HD, Brade L, et al: Stimulation of human T lymphocytes by LPS is MHC unrestricted, but strongly dependent on B7 interactions. *J Immunol* 160(7):3412–3418, 1998.
229. Mattern T, Thanhauser A, Reiling N, et al: Endotoxin and lipid A stimulate proliferation of human T cells in the presence of autologous monocytes. *J Immunol* 153(7):2996–3004, 1994.
230. Matsuki Y, Yamamoto T, Hara K: Detection of inflammatory cytokine messenger RNA (mRNA)-expressing cells in human inflamed gingiva by combined in situ hybridization and immunohistochemistry. *Immunology* 76(1):42–47, 1992.
231. Matzinger P: Tolerance, danger, and the extended family. *Annu Rev Immunol* 12:991–1045, 1994.
232. Mbalaviele G, Anderson G, Jones A, et al: Inhibition of p38 mitogen-activated protein kinase prevents inflammatory bone destruction. *J Pharmacol Exp Ther* 317(3):1044–1053, 2006.
233. McCormick TS, Weinberg A: Epithelial cell-derived antimicrobial peptides are multifunctional agents that bridge innate and adaptive immunity. *Periodontol 2000* 54(1):195–206, 2010.
234. McCoy SL, Kurtz SE, Hausman FA, et al: Hefeneider SH. Activation of RAW264.7 macrophages by bacterial DNA and lipopolysaccharide increases cell surface DNA binding and internalization. *J Biol Chem* 279(17):17217–17223, 2004.
235. McDonald C, Inohara N, Nunez G: Peptidoglycan signaling in innate immunity and inflammatory disease. *J Biol Chem* 280(21):20177–20180, 2005.
236. McIntyre KW, Shuster DJ, Gillooly KM, et al: A highly selective inhibitor of I kappa B kinase, BMS-345541, blocks both joint inflammation and destruction in collagen-induced arthritis in mice. *Arthritis Rheum* 48(9):2652–2659, 2003.
237. Mealey BL, Rose LF: Diabetes mellitus and inflammatory periodontal diseases. *Curr Opin Endocrinol Diabetes Obes* 15(2):135–141, 2008.
238. Medicherla S, Ma JY, Mangadu R, et al: A selective p38 alpha mitogen-activated protein kinase inhibitor reverses cartilage and bone destruction in mice with collagen-induced arthritis. *J Pharmacol Exp Ther* 318(1):132–141, 2006.
239. Mendes Sdos S, Candi A, Vansteenbrugge M, et al: Microarray analyses of the effects of NF-kappaB or PI3K pathway inhibitors on the LPS-induced gene expression profile in RAW264.7 cells: synergistic effects of rapamycin on LPS-induced MMP9-overexpression. *Cell Signal* 21(7):1109–1122, 2009.
240. Mercer BA, D'Armiento JM: Emerging role of MAP kinase pathways as therapeutic targets in COPD. *Int J Chron Obstruct Pulmon Dis* 1(2):137–150, 2006.
241. Miao EA, Mao DP, Yudkovsky N, et al: Innate immune detection of the type III secretion apparatus through the NLRC4 inflammasome. *Proc Natl Acad Sci U S A* 107(7):3076–3080, 2010.
242. Mogi M, Otogoto J, Ota N, et al: Differential expression of RANKL and osteoprotegerin in gingival crevicular fluid of patients with periodontitis. *J Dent Res* 83(2):166–169, 2004.
243. Nagasawa T, Kobayashi H, Kiji M, et al: LPS-stimulated human gingival fibroblasts inhibit the differentiation of monocytes into osteoclasts through the production of osteoprotegerin. *Clin Exp Immunol* 130(2):338–344, 2002.
244. Nemoto E, Darveau RP, Foster BL, et al: Regulation of cementoblast function by *P. gingivalis* lipopolysaccharide via TLR2. *J Dent Res* 85(8):733–738, 2006.
245. Nibali L, Donos N, Brett PM, et al: A familial analysis of aggressive periodontitis—clinical and genetic findings. *J Periodontal Res* 43(6):627–634, 2008.
246. Nikolopoulos GK, Dimou NL, Hamodrakas SJ, et al: Cytokine gene polymorphisms in periodontal disease: a meta-analysis of 53 studies including 4178 cases and 4590 controls. *J Clin Periodontol* 35(9):754–767, 2008.
247. Niyonsaba F, Ushio H, Nagaoka I, et al: The human beta-defensins (-1, -2, -3, -4) and cathelicidin LL-37 induce IL-18 secretion through p38 and ERK MAPK activation in primary human keratinocytes. *J Immunol* 175(3):1776–1784, 2005.
248. Niyonsaba F, Ushio H, Nakano N, et al: Antimicrobial peptides human beta-defensins stimulate epidermal keratinocyte migration, proliferation and production of proinflammatory cytokines and chemokines. *J Invest Dermatol* 127(3):594–604, 2007.
249. Nociti FH, Jr, Foster BL, Barros SP, et al: Cementoblast gene expression is regulated by *Porphyromonas gingivalis* lipopolysaccharide partially via Toll-like receptor-4/MD-2. *J Dent Res* 83(8):602–607, 2004.
250. Nolte MA, Leibundgut-Landmann S, Joffre O, et al: Dendritic cell quiescence during systemic inflammation driven by LPS stimulation of radioresistant cells in vivo. *J Exp Med* 204(6):1487–1501, 2007.
251. Nonnenmacher C, Dalpke A, Zimmermann S, et al: DNA from periodontopathogenic bacteria is immunostimulatory for mouse and human immune cells. *Infect Immun* 71(2):850–856, 2003.
252. Novak MJ, Johns LP, Miller RC, et al: Adjunctive benefits of subantimicrobial dose doxycycline in the management of severe, generalized, chronic periodontitis. *J Periodontol* 73(7):762–769, 2002.
253. Nualart Grollmus ZC, Morales Chavez MC, Silvestre Donat FJ: Periodontal disease associated to systemic genetic disorders. *Med Oral Patol Oral Cir Bucal* 12(3):E211–E215, 2007.
254. Oberg HH, Wesch D, Grussel S, et al: Differential expression of CD126 and CD130 mediates different STAT-3 phosphorylation in CD4+CD25- and CD25high regulatory T cells. *Int Immunol* 18(4):555–563, 2006.

255. O'Brien-Simpson NM, Pathirana RD, Walker GD, et al: *Porphyromonas gingivalis* RgpA-Kgp proteinase-adhesin complexes penetrate gingival tissue and induce proinflammatory cytokines or apoptosis in a concentration-dependent manner. *Infect Immun* 77(3):1246–1261, 2009.
256. Offenbacher S, Beck JD: A perspective on the potential cardioprotective benefits of periodontal therapy. *Am Heart J* 149(6):950–954, 2005.
257. Offenbacher S, Salvi GE: Induction of prostaglandin release from macrophages by bacterial endotoxin. *Clin Infect Dis* 28(3):505–513, 1999.
258. Ogawa T: Immunobiological properties of chemically defined lipid A from lipopolysaccharide of *Porphyromonas (Bacteroides) gingivalis*. *Eur J Biochem* 219(3):737–742, 1994.
259. Ogawa T, Asai Y, Yamamoto H, et al: Immunobiological activities of a chemically synthesized lipid A of *Porphyromonas gingivalis*. *FEMS Immunol Med Microbiol* 28(4):273–281, 2000.
260. Ogura Y, Inohara N, Benito A, et al: Nod2, a Nod1/Apaf-1 family member that is restricted to monocytes and activates NF-kappaB. *J Biol Chem* 276(7):4812–4818, 2001.
261. Ohguchi Y, Ishihara Y, Ohguchi M, et al: Capsular polysaccharide from *Actinobacillus actinomycetemcomitans* inhibits IL-6 and IL-8 production in human gingival fibroblast. *J Periodontal Res* 38(2):191–197, 2003.
262. Onishi S, Honma K, Liang S, et al: Toll-like receptor 2-mediated interleukin-8 expression in gingival epithelial cells by the *Tannerella forsythia* leucine-rich repeat protein BspA. *Infect Immun* 76(1):198–205, 2008.
263. O'Shea JJ, Gadina M, Schreiber RD: Cytokine signaling in 2002: new surprises in the Jak/Stat pathway. *Cell* 109(Suppl):S121–S131, 2002.
264. Page RC, Schroeder HE: Pathogenesis of inflammatory periodontal disease. A summary of current work. *Lab Invest* 34(3):235–249, 1976.
265. Park JH, Kim YG, McDonald C, et al: RICK/RIP2 mediates innate immune responses induced through Nod1 and Nod2 but not TLRs. *J Immunol* 178(4):2380–2386, 2007.
266. Park OJ, Shin SY, Choi Y, et al: The association of osteoprotegerin gene polymorphisms with periodontitis. *Oral Dis* 14(5):440–444, 2008.
267. Pasare C, Medzhitov R: Toll pathway-dependent blockade of CD4+CD25+ T cell-mediated suppression by dendritic cells. *Science* 299(5609):1033–1036, 2003.
268. Paster BJ, Boches SK, Galvin JL, et al: Bacterial diversity in human subgingival plaque. *J Bacteriol* 183(12):3770–3783, 2001.
269. Patil C, Rossa C, Jr, Kirkwood KL: Actinobacillus actinomycetemcomitans lipopolysaccharide induces interleukin-6 expression through multiple mitogen-activated protein kinase pathways in periodontal ligament fibroblasts. *Oral Microbiol Immunol* 21(6):392–398, 2006.
270. Patil C, Zhu X, Rossa C, Jr, et al: p38 MAPK regulates IL-1beta induced IL-6 expression through mRNA stability in osteoblasts. *Immunol Invest* 33(2):213–233, 2004.
271. Patil CS, Kirkwood KL: p38 MAPK signaling in oral-related diseases. *J Dent Res* 86(9):812–825, 2007.
272. Patil CS, Liu M, Zhao W, et al: Targeting mRNA stability arrests inflammatory bone loss. *Mol Ther* 16(10):1657–1664, 2008.
273. Pedra JH, Cassel SL, Sutterwala FS: Sensing pathogens and danger signals by the inflammasome. *Curr Opin Immunol* 21(1):10–16, 2009.
274. Pelt P, Zimmermann B, Ulbrich N, et al: Effects of lipopolysaccharide extracted from Prevotella intermedia on bone formation and on the release of osteolytic mediators by fetal mouse osteoblasts in vitro. *Arch Oral Biol* 47(12):859–866, 2002.
275. Peng G, Guo Z, Kiniwa Y, et al: Toll-like receptor 8-mediated reversal of CD4+ regulatory T cell function. *Science* 309(5739):1380–1384, 2005.
276. Pereira C, Schaer DJ, Bachli EB, et al: Wnt5A/CaMKII signaling contributes to the inflammatory response of macrophages and is a target for the antiinflammatory action of activated protein C and interleukin-10. *Arterioscler Thromb Vasc Biol* 28(3):504–510, 2008.
277. Pesu M, Aittomaki S, Takaluoma K, et al: p38 Mitogen-activated protein kinase regulates interleukin-4-induced gene expression by stimulating STAT6-mediated transcription. *J Biol Chem* 277(41):38254–38261, 2002.
278. Peyret-Lacombe A, Brunel G, Watts M, et al: TLR2 sensing of F. nucleatum and S. sanguinis distinctly triggered gingival innate response. *Cytokine* 46(2):201–210, 2009.
279. Pirhan D, Atilla G, Emingil G, et al: Effect of MMP-1 promoter polymorphisms on GCF MMP-1 levels and outcome of periodontal therapy in patients with severe chronic periodontitis. *J Clin Periodontol* 35(10):862–870, 2008.
280. Preshaw PM, Hefti AF, Novak MJ, et al: Subantimicrobial dose doxycycline enhances the efficacy of scaling and root planing in chronic periodontitis: a multicenter trial. *J Periodontol* 75(8):1068–1076, 2004.
281. Preshaw PM, Novak MJ, Mellonig J, et al: Modified-release subantimicrobial dose doxycycline enhances scaling and root planing in subjects with periodontal disease. *J Periodontol* 79(3):440–452, 2008.
282. Puklo M, Guentsch A, Hiemstra PS, et al: Analysis of neutrophil-derived antimicrobial peptides in gingival crevicular fluid suggests importance of cathelicidin LL-37 in the innate immune response against periodontogenic bacteria. *Oral Microbiol Immunol* 23(4):328–335, 2008.
283. Pulendran B, Kumar P, Cutler CW, et al: Lipopolysaccharides from distinct pathogens induce different classes of immune responses in vivo. *J Immunol* 167(9):5067–5076, 2001.
284. Raffeiner B, Dejaco C, Duftner C, et al: Between adaptive and innate immunity: TLR4-mediated perforin production by CD28null T-helper cells in ankylosing spondylitis. *Arthritis Res Ther* 7(6):R1412–R1420, 2005.
285. Raj PA, Antonyraj KJ, Karunakaran T: Large-scale synthesis and functional elements for the antimicrobial activity of defensins. *Biochem J* 347(Pt 3):633–641, 2000.
286. Ramamurthy NS, Rifkin BR, Greenwald RA, et al: Inhibition of matrix metalloproteinase-mediated periodontal bone loss in rats: a comparison of 6 chemically modified tetracyclines. *J Periodontol* 73(7):726–734, 2002.
287. Ramamurthy NS, Xu JW, Bird J, et al: Inhibition of alveolar bone loss by matrix metalloproteinase inhibitors in experimental periodontal disease. *J Periodontal Res* 37(1):1–7, 2002.
288. Ramseier CA, Kinney JS, Herr AE, et al: Identification of pathogen and host-response markers correlated with periodontal disease. *J Periodontol* 80(3):436–446, 2009.
289. Reddi K, Poole S, Nair S, et al: associated proteins from periodontopathogenic bacteria induce interleukin-6 production by human gingival fibroblasts and monocytes. *FEMS Immunol Med Microbiol* 11(2):137–144, 1995.
290. Rennefahrt U, Janakiraman M, Ollinger R, et al: Stress kinase signaling in cancer: fact or fiction? *Cancer Lett* 217(1):1–9, 2005.
291. Ricklin D, Hajishengallis G, Yang K, et al: Complement: a key system for immune surveillance and homeostasis. *Nat Immunol* 11(9):785–797, 2010.
292. Rincon M, Enslen H, Raingeaud J, et al: Interferon-g expression by Th1 effector T cells mediated by the p38 MAP kinase signaling pathway. *EMBO J* 17:2817–2829, 1998.
293. Roberts FA, Richardson GJ, Michalek SM: Effects of *Porphyromonas gingivalis* and *Escherichia coli* lipopolysaccharides on mononuclear phagocytes. *Infect Immun* 65(8):3248–3254, 1997.
294. Rogers JE, Li F, Coatney DD, et al: A p38 mitogen-activated protein kinase inhibitor arrests active alveolar bone loss in a rat periodontitis model. *J Periodontol* 78(10):1992–1998, 2007.
295. Rommel C, Camps M, Ji H: PI3K delta and PI3K gamma: partners in crime in inflammation in rheumatoid arthritis and beyond? *Nat Rev Immunol* 7(3):191–201, 2007.
296. Rosenstein ED, Greenwald RA, Kushner LJ, et al: Hypothesis: the humoral immune response to oral bacteria provides a stimulus for the development of rheumatoid arthritis. *Inflammation* 28(6):311–318, 2004.
297. Rossa C, Ehmann K, Liu M, et al: MKK3/6-p38 MAPK signaling is required for IL-1beta and TNF-alpha-induced RANKL expression in

bone marrow stromal cells. *J Interferon Cytokine Res* 26(10):719–729, 2006.
298. Rossa C, Jr, Liu M, Bronson P, et al: Transcriptional activation of MMP-13 by periodontal pathogenic LPS requires p38 MAP kinase. *J Endotoxin Res* 13(2):85–93, 2007.
299. Rossa C, Jr, Liu M, Kirkwood KL: A dominant function of p38 mitogen-activated protein kinase signaling in receptor activator of nuclear factor-kappaB ligand expression and osteoclastogenesis induction by *Aggregatibacter actinomycetemcomitans* and *Escherichia coli* lipopolysaccharide. *J Periodontal Res* 43(2):201–211, 2008.
300. Rossa C, Jr, Liu M, Patil C, et al: MKK3/6-p38 MAPK negatively regulates murine MMP-13 gene expression induced by IL-1beta and TNF-alpha in immortalized periodontal ligament fibroblasts. *Matrix Biol* 24(7):478–488, 2005.
301. Ruby J, Rehani K, Martin M: *Treponema denticola* activates mitogen-activated protein kinase signal pathways through Toll-like receptor 2. *Infect Immun* 75(12):5763–5768, 2007.
302. Rudensky AY, Gavin M, Zheng Y: FOXP3 and NFAT: partners in tolerance. *Cell* 126(2):253–256, 2006.
303. Runza VL, Schwaeble W, Mannel DN: Ficolins: novel pattern recognition molecules of the innate immune response. *Immunobiology* 213(3-4):297–306, 2008.
304. Ryan ME, Usman A, Ramamurthy NS, et al: Excessive matrix metalloproteinase activity in diabetes: inhibition by tetracycline analogues with zinc reactivity. *Curr Med Chem* 8(3):305–316, 2001.
305. Ryu OH, Choi SJ, Linares AM, et al: Gingival epithelial cell expression of macrophage inflammatory protein-1alpha induced by interleukin-1beta and lipopolysaccharide. *J Periodontol* 78(8):1627–1634, 2007.
306. Sahasrabudhe KS, Kimball JR, Morton TH, et al: Expression of the antimicrobial peptide, human beta-defensin 1, in duct cells of minor salivary glands and detection in saliva. *J Dent Res* 79(9):1669–1674, 2000.
307. Sakaguchi S: Naturally arising Foxp3-expressing CD25+CD4+ regulatory T cells in immunological tolerance to self and non-self. *Nat Immunol* 6(4):345–352, 2005.
308. Sakellari D, Katsares V, Georgiadou M, et al: No correlation of five gene polymorphisms with periodontal conditions in a Greek population. *J Clin Periodontol* 33(11):765–770, 2006.
309. Sallusto F, Schaerli P, Loetscher P, et al: Rapid and coordinated switch in chemokine receptor expression during dendritic cell maturation. *Eur J Immunol* 28(9):2760–2769, 1998.
310. Salvi GE, Beck JD, Offenbacher S: PGE2, IL-1 beta, and TNF-alpha responses in diabetics as modifiers of periodontal disease expression. *Ann Periodontol* 3(1):40–50, 1998.
311. Sandros J, Karlsson C, Lappin DF, et al: Cytokine responses of oral epithelial cells to *Porphyromonas gingivalis* infection. *J Dent Res* 79(10):1808–1814, 2000.
312. Sarkar FH, Li Y, Wang Z, et al: NF-kappaB signaling pathway and its therapeutic implications in human diseases. *Int Rev Immunol* 27(5):293–319, 2008.
313. Sasaki H, Suzuki N, Kent R, Jr, et al: T cell response mediated by myeloid cell-derived IL-12 is responsible for *Porphyromonas gingivalis*-induced periodontitis in IL-10-deficient mice. *J Immunol* 180(9):6193–6198, 2008.
314. Sasaki Y, Aiba S: Dendritic cells and contact dermatitis. *Clin Rev Allergy Immunol* 33(1-2):27–34, 2007.
315. Sato S, Sanjo H, Takeda K, et al: Essential function for the kinase TAK1 in innate and adaptive immune responses. *Nat Immunol* 6(11):1087–1095, 2005.
316. Sawada N, Ogawa T, Asai Y, et al: Toll-like receptor 4-dependent recognition of structurally different forms of chemically synthesized lipid As of *Porphyromonas gingivalis*. *Clin Exp Immunol* 148(3):529–536, 2007.
317. Schaefer AS, Richter GM, Groessner-Schreiber B, et al: Identification of a shared genetic susceptibility locus for coronary heart disease and periodontitis. *PLoS Genet* 5(2):e1000378, 2009.
318. Schierano G, Pejrone G, Brusco P, et al: TNF-alpha TGF-beta2 and IL-1beta levels in gingival and peri-implant crevicular fluid before and after de novo plaque accumulation. *J Clin Periodontol* 35(6):532–538, 2008.
319. Schindler CW: Series introduction. JAK-STAT signaling in human disease. *J Clin Invest* 109(9):1133–1137, 2002.
320. Schonwetter BS, Stolzenberg ED, Zasloff MA: Epithelial antibiotics induced at sites of inflammation. *Science* 267(5204):1645–1648, 1995.
321. Scudiero O, Galdiero S, Nigro E, et al: Chimeric beta-defensin analogs, including the novel 3NI analog, display salt-resistant antimicrobial activity and lack toxicity in human epithelial cell lines. *Antimicrob Agents Chemother* 57(4):1701–1708, 2013.
322. Selsted ME, Ouellette AJ: Mammalian defensins in the antimicrobial immune response. *Nat Immunol* 6(6):551–557, 2005.
323. Seymour GJ, Gemmell E: Cytokines in periodontal disease: where to from here? *Acta Odontol Scand* 59(3):167–173, 2001.
324. Sha WC, Liou HC, Tuomanen EI, et al: Targeted disruption of the p50 subunit of NF-kappa B leads to multifocal defects in immune responses. *Cell* 80(2):321–330, 1995.
325. Shapira L, van Dyke TE, Hart TC: A localized absence of interleukin-4 triggers periodontal disease activity: a novel hypothesis. *Med Hypotheses* 39(4):319–322, 1992.
326. Shaw PJ, Lukens JR, Burns S, et al: Cutting edge: critical role for PYCARD/ASC in the development of experimental autoimmune encephalomyelitis. *J Immunol* 184(9):4610–4614, 2010.
327. Shin H, Zhang Y, Jagannathan M, et al: B cells from periodontal disease patients express surface Toll-like receptor 4. *J Leukoc Biol* 85(4):648–655, 2009.
328. Shin JE, Kim YS, Oh JE, et al: *Treponema denticola* suppresses expression of human β-defensin-3 in gingival epithelial cells through inhibition of the toll-like receptor 2 axis. *Infect Immun* 78(2):672–679, 2010.
329. Sigusch B, Klinger G, Glockmann E, et al: Early-onset and adult periodontitis associated with abnormal cytokine production by activated T lymphocytes. *J Periodontol* 69(10):1098–1104, 1998.
330. Silva N, Dutzan N, Hernandez M, et al: Characterization of progressive periodontal lesions in chronic periodontitis patients: levels of chemokines, cytokines, matrix metalloproteinase-13, periodontal pathogens and inflammatory cells. *J Clin Periodontol* 35(3):206–214, 2008.
331. Simone R, Floriani A, Saverino D: Stimulation of human CD4 T lymphocytes via TLR3, TLR5 and TLR7/8 up-regulates expression of costimulatory and modulates proliferation. *Open Microbiol J* 3:1–8, 2009.
332. Socransky SS, Haffajee AD, Cugini MA, et al: Microbial complexes in subgingival plaque. *J Clin Periodontol* 25(2):134–144, 1998.
333. Socransky SS, Haffajee AD, Ximenez-Fyvie LA, et al: Ecological considerations in the treatment of *Actinobacillus actinomycetemcomitans* and *Porphyromonas gingivalis* periodontal infections. *Periodontol 2000* 20:341–362, 1999.
334. Soedarsono N, Rabello D, Kamei H, et al: Evaluation of RANK/RANKL/OPG gene polymorphisms in aggressive periodontitis. *J Periodontal Res* 41(5):397–404, 2006.
335. Sparwasser T, Koch ES, Vabulas RM, et al: Bacterial DNA and immunostimulatory CpG oligonucleotides trigger maturation and activation of murine dendritic cells. *Eur J Immunol* 28(6):2045–2054, 1998.
336. Sporri R, Reis e Sousa C: Inflammatory mediators are insufficient for full dendritic cell activation and promote expansion of CD4+ T cell populations lacking helper function. *Nat Immunol* 6(2):163–170, 2005.
337. Stashenko P, Jandinski JJ, Fujiyoshi P, et al: Tissue levels of bone resorptive cytokines in periodontal disease. *J Periodontol* 62(8):504–509, 1991.
338. Stathopoulou PG, Benakanakere MR, Galicia JC, et al: The host cytokine response to *Porphyromonas gingivalis* is modified by gingipains. *Oral Microbiol Immunol* 24(1):11–17, 2009.
339. Suda K, Udagawa N, Sato N, et al: Suppression of osteoprotegerin expression by prostaglandin E2 is crucially involved in

lipopolysaccharide-induced osteoclast formation. *J Immunol* 172(4):2504–2510, 2004.
340. Suda T, Takahashi N, Udagawa N, et al: Modulation of osteoclast differentiation and function by the new members of the tumor necrosis factor receptor and ligand families. *Endocr Rev* 20(3):345–357, 1999.
341. Sugawara S, Yang S, Iki K, et al: Monocytic cell activation by Non-endotoxic glycoprotein from Prevotella intermedia ATCC 25611 is mediated by toll-like receptor 2. *Infect Immun* 69(8):4951–4957, 2001.
342. Sugawara Y, Uehara A, Fujimoto Y, et al: Toll-like receptors, NOD1, and NOD2 in oral epithelial cells. *J Dent Res* 85(6):524–529, 2006.
343. Sugiyama A, Uehara A, Iki K, et al: Activation of human gingival epithelial cells by cell-surface components of black-pigmented bacteria: augmentation of production of interleukin-8, granulocyte colony-stimulating factor and granulocyte-macrophage colony-stimulating factor and expression of intercellular adhesion molecule 1. *J Med Microbiol* 51(1):27–33, 2002.
344. Sutmuller RP, den Brok MH, Kramer M, et al: Toll-like receptor 2 controls expansion and function of regulatory T cells. *J Clin Invest* 116(2):485–494, 2006.
345. Tada H, Aiba S, Shibata K, et al: Synergistic effect of Nod1 and Nod2 agonists with toll-like receptor agonists on human dendritic cells to generate interleukin-12 and T helper type 1 cells. *Infect Immun* 73(12):7967–7976, 2005.
346. Takeshita A, Imai K, Hanazawa S: CpG motifs in *Porphyromonas gingivalis* DNA stimulate interleukin-6 expression in human gingival fibroblasts. *Infect Immun* 67(9):4340–4345, 1999.
347. Tam V, O'Brien-Simpson NM, Chen YY, et al: The RgpA-Kgp proteinase-adhesin complexes of *Porphyromonas gingivalis* Inactivate the Th2 cytokines interleukin-4 and interleukin-5. *Infect Immun* 77(4):1451–1458, 2009.
348. Tani Y, Tani M, Kato I: Extracellular 37-kDa antigenic protein from *Actinobacillus actinomycetemcomitans* induces TNF-alpha, IL-1 beta, and IL-6 in murine macrophages. *J Dent Res* 76(9):1538–1547, 1997.
349. Teng YT, Mahamed D, Singh B: Gamma interferon positively modulates *Actinobacillus actinomycetemcomitans*-specific RANKL+ CD4+ Th-cell-mediated alveolar bone destruction in vivo. *Infect Immun* 73(6):3453–3461, 2005.
350. Teitelbaum SL: Osteoclasts: what do they do and how do they do it? *Am J Pathol* 170(2):427–435, 2007.
351. Tietze K, Dalpke A, Morath S, et al: Differences in innate immune responses upon stimulation with gram-positive and gram-negative bacteria. *J Periodontal Res* 41(5):447–454, 2006.
352. Toker H, Poyraz O, Eren K: Effect of periodontal treatment on IL-1beta, IL-1ra, and IL-10 levels in gingival crevicular fluid in patients with aggressive periodontitis. *J Clin Periodontol* 35(6):507–513, 2008.
353. Tokoro Y, Matsuki Y, Yamamoto T, et al: Relevance of local Th2-type cytokine mRNA expression in immunocompetent infiltrates in inflamed gingival tissue to periodontal diseases. *Clin Exp Immunol* 107(1):166–174, 1997.
354. Tomi N, Fukuyo Y, Arakawa S, et al: Pro-inflammatory cytokine production from normal human fibroblasts is induced by *Tannerella forsythia* detaching factor. *J Periodontal Res* 43(2):136–142, 2008.
355. Trevani AS, Chorny A, Salamone G, et al: Bacterial DNA activates human neutrophils by a CpG-independent pathway. *Eur J Immunol* 33(11):3164–3174, 2003.
356. Tsukahara Y, Lian Z, Zhang X, et al: Gene expression in human neutrophils during activation and priming by bacterial lipopolysaccharide. *J Cell Biochem* 89(4):848–861, 2003.
357. Turkoglu O, Emingil G, Kutukculer N, et al: Gingival crevicular fluid levels of cathelicidin LL-37 and interleukin-18 in patients with chronic periodontitis. *J Periodontol* 80(6):969–976, 2009.
358. Uehara A, Fujimoto Y, Fukase K, et al: Various human epithelial cells express functional Toll-like receptors, NOD1 and NOD2 to produce anti-microbial peptides, but not proinflammatory cytokines. *Mol Immunol* 44(12):3100–3111, 2007.
359. Uehara A, Imamura T, Potempa J, et al: Gingipains from *Porphyromonas gingivalis* synergistically induce the production of proinflammatory cytokines through protease-activated receptors with Toll-like receptor and NOD1/2 ligands in human monocytic cells. *Cell Microbiol* 10(5):1181–1189, 2008.
360. Uehara A, Sugawara Y, Kurata S, et al: Chemically synthesized pathogen-associated molecular patterns increase the expression of peptidoglycan recognition proteins via toll-like receptors, NOD1 and NOD2 in human oral epithelial cells. *Cell Microbiol* 7(5):675–686, 2005.
361. Ueki K, Tabeta K, Yoshie H, et al: Self-heat shock protein 60 induces tumour necrosis factor-alpha in monocyte-derived macrophage: possible role in chronic inflammatory periodontal disease. *Clin Exp Immunol* 127(1):72–77, 2002.
362. van de Veerdonk FL, Joosten LA, Shaw PJ, et al: The inflammasome drives protective Th1 and Th17 cellular responses in disseminated candidiasis. *Eur J Immunol* 41(8):2260–2268, 2011.
363. van Heel DA, Ghosh S, Butler M, et al: Synergistic enhancement of Toll-like receptor responses by NOD1 activation. *Eur J Immunol* 35(8):2471–2476, 2005.
364. Vankeerberghen A, Nuytten H, Dierickx K, et al: Differential induction of human beta-defensin expression by periodontal commensals and pathogens in periodontal pocket epithelial cells. *J Periodontol* 76(8):1293–1303, 2005.
365. Vardar-Sengul S, Demirci T, Sen BH, et al: Human beta defensin-1 and -2 expression in the gingiva of patients with specific periodontal diseases. *J Periodontal Res* 42(5):429–437, 2007.
366. Wada Y, Nakajima-Yamada T, Yamada K, et al: R-130823, a novel inhibitor of p38 MAPK, ameliorates hyperalgesia and swelling in arthritis models. *Eur J Pharmacol* 506(3):285–295, 2005.
367. Wagner M, Poeck H, Jahrsdoerfer B, et al: IL-12p70-dependent Th1 induction by human B cells requires combined activation with CD40 ligand and CpG DNA. *J Immunol* 172(2):954–963, 2004.
368. Walker JG, Ahern MJ, Coleman M, et al: Expression of Jak3, STAT1, STAT4, and STAT6 in inflammatory arthritis: unique Jak3 and STAT4 expression in dendritic cells in seropositive rheumatoid arthritis. *Ann Rheum Dis* 65(2):149–156, 2006.
369. Walker SJ, Van Dyke TE, Rich S, et al: Genetic polymorphisms of the IL-1alpha and IL-1beta genes in African-American LJP patients and an African-American control population. *J Periodontol* 71(5):723–728, 2000.
370. Warner RL, Bhagavathula N, Nerusu KC, et al: Matrix metalloproteinases in acute inflammation: induction of MMP-3 and MMP-9 in fibroblasts and epithelial cells following exposure to pro-inflammatory mediators in vitro. *Exp Mol Pathol* 76(3):189–195, 2004.
371. Watanabe A, Takeshita A, Kitano S, et al: CD14-mediated signal pathway of *Porphyromonas gingivalis* lipopolysaccharide in human gingival fibroblasts. *Infect Immun* 64(11):4488–4494, 1996.
372. Weinberg A, Krisanaprakornkit S, Dale BA: Epithelial antimicrobial peptides: review and significance for oral applications. *Crit Rev Oral Biol Med* 9(4):399–414, 1998.
373. Weis WI, Taylor ME, Drickamer K: The C-type lectin superfamily in the immune system. *Immunol Rev* 163:19–34, 1998.
374. Wen Z, Darnell JE, Jr: Mapping of Stat3 serine phosphorylation to a single residue (727) and evidence that serine phosphorylation has no influence on DNA binding of Stat1 and Stat3. *Nucleic Acids Res* 25(11):2062–2067, 1997.
375. Williams DL, Ozment-Skelton T, Li C: Modulation of the phosphoinositide 3-kinase signaling pathway alters host response to sepsis, inflammation, and ischemia/reperfusion injury. *Shock* 25(5):432–439, 2006.
376. Yamaji Y, Kubota T, Sasaguri K, et al: Inflammatory cytokine gene expression in human periodontal ligament fibroblasts stimulated with bacterial lipopolysaccharides. *Infect Immun* 63(9):3576–3581, 1995.
377. Yamamoto M, Fujihashi K, Hiroi T, et al: Molecular and cellular mechanisms for periodontal diseases: role of Th1 and Th2 type cytokines in induction of mucosal inflammation. *J Periodontal Res* 32(1 Pt 2):115–119, 1997.

378. Yamamoto M, Sato S, Hemmi H, et al: Essential role for TIRAP in activation of the signalling cascade shared by TLR2 and TLR4. *Nature* 420(6913):324–329, 2002.
379. Yamamoto M, Sato S, Hemmi H, et al: Role of adaptor TRIF in the MyD88-independent toll-like receptor signaling pathway. *Science* 301(5633):640–643, 2003.
380. Yamamoto M, Sato S, Hemmi H, et al: TRAM is specifically involved in the Toll-like receptor 4-mediated MyD88-independent signaling pathway. *Nat Immunol* 4(11):1144–1150, 2003.
381. Yamazaki K, Nakajima T, Gemmell E, et al: IL-4- and IL-6-producing cells in human periodontal disease tissue. *J Oral Pathol Med* 23(8):347–353, 1994.
382. Yang D, Biragyn A, Kwak LW, et al: Mammalian defensins in immunity: more than just microbicidal. *Trends Immunol* 23(6):291–296, 2002.
383. Yang D, Chen Q, Chertov O, et al: Human neutrophil defensins selectively chemoattract naive T and immature dendritic cells. *J Leukoc Biol* 68(1):9–14, 2000.
384. Yang D, Chertov O, Bykovskaia SN, et al: Beta-defensins: linking innate and adaptive immunity through dendritic and T cell CCR6. *Science* 286(5439):525–528, 1999.
385. Yoneyama M, Fujita T: RNA recognition and signal transduction by RIG-I-like receptors. *Immunol Rev* 227(1):54–65, 2009.
386. Yoshie H, Kobayashi T, Tai H, et al: The role of genetic polymorphisms in periodontitis. *Periodontol 2000* 43:102–132, 2007.
387. Yoshimura A, Kaneko T, Kato Y, et al: Lipopolysaccharides from periodontopathic bacteria *Porphyromonas gingivalis* and *Capnocytophaga ochracea* are antagonists for human toll-like receptor 4. *Infect Immun* 70(1):218–225, 2002.
388. Yoshioka H, Yoshimura A, Kaneko T, et al: Analysis of the activity to induce toll-like receptor (TLR)2- and TLR4-mediated stimulation of supragingival plaque. *J Periodontol* 79(5):920–928, 2008.
389. Yun PL, DeCarlo AA, Collyer C, et al: Modulation of an interleukin-12 and gamma interferon synergistic feedback regulatory cycle of T-cell and monocyte cocultures by *Porphyromonas gingivalis* lipopolysaccharide in the absence or presence of cysteine proteinases. *Infect Immun* 70(10):5695–5705, 2002.
390. Zarember KA, Godowski PJ: Tissue expression of human Toll-like receptors and differential regulation of Toll-like receptor mRNAs in leukocytes in response to microbes, their products, and cytokines. *J Immunol* 168(2):554–561, 2002.
391. Zasloff M: Antimicrobial peptides of multicellular organisms. *Nature* 415(6870):389–395, 2002.
392. Zhang FX, Kirschning CJ, Mancinelli R, et al: Bacterial lipopolysaccharide activates nuclear factor-kappaB through interleukin-1 signaling mediators in cultured human dermal endothelial cells and mononuclear phagocytes. *J Biol Chem* 274(12):7611–7614, 1999.
393. Zou W, Bar-Shavit Z: Dual modulation of osteoclast differentiation by inallipopolysaccharide. *J Bone Miner Res* 17(7):1211–1218, 2002.

CHAPTER 10

Smoking and Periodontal Disease

Philip M. Preshaw, Leandro Chambrone, Karen F. Novak

CHAPTER OUTLINE

The Smoking Epidemic
Effects of Smoking on the Prevalence and Severity of Periodontal Diseases
Effects of Smoking on the Etiology and Pathogenesis of Periodontal Disease
Effects of Smoking on Response to Periodontal Therapy
Effects of Smoking Cessation on Periodontal Treatment Outcomes

The Smoking Epidemic

Smoking is highly prevalent and can be considered an epidemic in both developed and developing nations. In the United States in 1993, 25.4% of the population smoked; 27.0% of men smoked, and 24.0% of women smoked.[35] By 2010, this had decreased to 19.3% of the total population, with 21.5% of men smoking and 17.3% of women smoking.[19] Among dentate individuals during the period from 1988 to 1994, 27.9% of adults were current smokers, and 23.3% were former smokers.[2] Smoking was higher in younger age groups (i.e., ≤34 years old) as compared with older age groups (≥55 years old), and it was more common among men (30.9%) as compared with women (25.1%).[100] In 2012, roughly 43.4 million Americans were smokers, with 8.6 million people suffering from a severe smoking-related disease and 443,000 deaths (or 1 in 5 deaths) being attributable to smoking and exposure to secondhand smoke each year.[1] In the European Union in 2012, approximately 32.0% of the population were smokers (41% of men and 22% of women)[106]; this number ranged from 16% in Sweden to 48% in Greece. Smoking accounts for 650,000 deaths each year (or 1 in 7 deaths) in these countries.[4] Overall, around 16% of all deaths in European adults more than 30 old were related to tobacco smoking.[106] Furthermore, 79,000 nonsmoking Europeans die each year as a result of passive smoking. Worldwide, it is estimated that approximately 13% of the population 15 years old or older are smokers (i.e., there are >1.3 billion smokers [around 1 billion men and 300 million women]); that tobacco kills up to half of its users; and that more than 80% of smokers live in low- and middle-income countries.[107] Globally, smoking accounts for 1 in 5 deaths among men 30 years old and older and 1 in 20 deaths among women 30 years old and older.[107]

Smoking is harmful to almost every organ in the body, and it is associated with multiple diseases that reduce life expectancy and quality of life. Diseases associated with smoking include lung cancer, heart disease, stroke, emphysema, bronchitis, and cancers of the oral cavity, bladder, kidney, stomach, liver, and cervix. Approximately half of long-term smokers will die early as a result of smoking, and those who die before the age of 70 years will lose an average of 20 years of life.[30] Most deaths from smoking are due to lung cancer, chronic obstructive pulmonary disease, and coronary heart disease.

Tobacco smoke contains thousands of noxious chemicals, and it comprises a gaseous phase and a solid (particulate) phase. The gas phase contains carbon monoxide, ammonia, formaldehyde, hydrogen cyanide, and many other toxic and irritant compounds, including more than 60 known carcinogens such as benzo(a)pyrene and dimethylnitrosamine. The particulate phase includes nicotine, "tar" (itself made up of many toxic chemicals), benzene, and benzo(a)pyrene. Tar is inhaled with the smoke. In its condensate form, it is the sticky brown substance that stains fingers and teeth yellow and brown. Nicotine, which is an alkaloid, is found within the tobacco leaf and evaporates when the cigarette is lighted. It is quickly absorbed in the lungs, and it reaches the brain within 10 to 19 seconds. Nicotine is highly addictive. It causes a rise in blood pressure, increased heart and respiratory rates, and peripheral vasoconstriction.

All dental patients must be asked about their smoking status. Current smoking status is the minimal information that must be recorded (e.g., "Patient is currently smoking *X* cigarettes per day"), but the importance of cumulative exposure to cigarette smoke mandates that it is more appropriate to record pack-years of smoking (Box 10-1). Biochemical tests can also be used to assess smoking status, including exhaled carbon monoxide and the measurement of cotinine (the major metabolite of nicotine) in serum, saliva, or urine. Cotinine is measured in preference to nicotine because the half-life of nicotine is short (≈1 to 2 hours),[76] whereas that of cotinine is approximately 20 hours.[50] Plasma and saliva cotinine concentrations in smokers are approximately 300 ng/mL and the urine concentration is approximately 1500 ng/mL. Nonsmokers usually have plasma and saliva concentrations of less than 2 ng/mL, unless they are passive smokers.

Smoking is *the* major risk factor for periodontitis, and it affects the prevalence, extent, and severity of disease. In addition, smoking has an adverse impact on the clinical outcome of nonsurgical and surgical therapy as well as the long-term success of implant placement. With 41.9% of periodontitis cases in the United States reported as being *attributable* to smoking,[100] it is essential to understand the impact of smoking on the initiation, progression, and management of the disease. This chapter discusses the effects of smoking on the prevalence, severity, etiology, and pathogenesis of periodontal disease as well as its impact on treatment. The reader

BOX 10-1 The Challenge of Assessing Smoking Status

Current Smokers

Ask about current smoking and past smoking. Many smokers are trying to quit and therefore simply asking how many cigarettes they are smoking today may not give an accurate assessment of their lifetime exposure (e.g., a patient who is currently smoking 5 cigarettes per day may have been smoking 40 cigarettes per day until yesterday, when she decided to cut down). Try to get an indication of their approximate level of smoking (e.g., the average number of cigarettes per day for a certain number of years). It can also be useful to calculate the number of pack-years:

$$\text{Pack-years} = \text{Number of packs smoked per day} \times \text{Number of years of smoking}$$

In other words, 1 pack-year is the cumulative exposure that corresponds with the smoking of 1 pack of 20 cigarettes per day for 1 year. For example, a smoker who has smoked 20 cigarettes per day for 15 years has 15 pack-years of smoking.

Former Smokers

Ask the patient about his or her past smoking. A patient with periodontitis may have a significant smoking history that has had an impact on his periodontal status, even if he no longer smokes. Former smokers should always be congratulated for their achievement in quitting, but it is also very important to document the following:

- How much they used to smoke
- How many years they smoked
- When they quit

Is the Patient's Response Accurate?

The inaccurate or false reporting of smoking status is common; patients will tell you what they think you want to hear, or they may be embarrassed because they have not managed to cut down yet. Many patients report smoking 20 cigarettes per day, because this is the number of cigarettes in a pack in most countries, so 20 may be a convenient response rather than an accurate response. Cultural factors may also influence responses.[93]

When Is a Smoker not a Smoker?

- Smokers have smoked ≥100 cigarettes in their lifetime and currently smoke.
- Former smokers have smoked ≥100 cigarettes in their lifetime and do not currently smoke.
- Nonsmokers have not smoked ≥100 cigarettes in their lifetime and do not currently smoke.

It must be noted that many periodontal research studies have not used these definitions, and this can sometimes make it difficult to interpret the studies, particularly in the context of what constitutes a former smoker. For example, from an exposure point of view, there is a big difference between someone who smoked 5 cigarettes per day for 10 years and who quit 30 years ago as compared with someone who smoked 40 cigarettes per day for 20 years and quit 6 months ago. It is always best in clinical practice to gather full information about each patient's smoking history.

is referred to several excellent reviews of the topic for detailed results of specific studies.[44,1,54,53,69,70,83,101,21,105]

Effects of Smoking on the Prevalence and Severity of Periodontal Diseases

Gingivitis

Controlled clinical studies have demonstrated that, in human models of experimental gingivitis, the development of inflammation in response to plaque accumulation is reduced in smokers as compared with nonsmokers (Table 10-1).[15,26] In addition, cross-sectional studies have consistently demonstrated that smokers present with less gingival inflammation than nonsmokers.[13,8,9,78,77] These data suggest that smokers have a decreased expression of clinical inflammation in the presence of plaque accumulation as compared with nonsmokers. The microbiologic, immunologic, and physiologic factors that may account for this observation are discussed in detail later in this chapter.

Periodontitis

Although gingival inflammation in smokers appears to be reduced in response to plaque accumulation as compared with nonsmokers, an overwhelming body of data points to smoking as a major risk factor for increasing the prevalence and severity of periodontal destruction. Multiple cross-sectional and longitudinal studies have demonstrated that pocket depth, attachment loss, and alveolar bone loss are more prevalent and severe in patients who smoke as compared with nonsmokers.[54,53,83,101] An assessment of the relationship between cigarette smoking and periodontitis was performed in more than 12,000 dentate individuals who were more than 18 years old as part of the Third National Health and Nutrition Examination Survey.[100] Periodontitis was defined as one or more sites with clinical attachment loss of 4 mm or greater and pocket depth of 4 mm or greater. Smoking status was defined with the use of criteria established by the Centers for Disease Control and Prevention (see Box 10-1). Of the more than 12,000 individuals studied, 9.2% had periodontitis; this represented approximately 15 million cases of periodontitis in the United States. On average, smokers were four times as likely to have periodontitis as compared with persons who had never smoked after adjusting for age, gender, race/ethnicity, education, and income/poverty ratio. Former smokers were 1.7

TABLE 10-1 Effects of Smoking on the Prevalence and Severity of Periodontal Disease

Periodontal Disease	Impact of Smoking
Gingivitis	↓ Gingival inflammation and bleeding on probing
Periodontitis	↑ Prevalence and severity of periodontal destruction ↑ Pocket depth, attachment loss, and bone loss ↑ Rate of periodontal destruction ↑ Prevalence of severe periodontitis ↑ Tooth loss ↑ Prevalence with increased number of cigarettes smoked per day ↓ Prevalence and severity with smoking cessation

↓, Decreased; ↑, increased.

times more likely to have periodontitis than persons who had never smoked. This study also demonstrated a dose–response relationship between cigarettes smoked per day and the odds of having periodontitis. In subjects smoking nine or fewer cigarettes per day, the odds for having periodontitis were 2.8, whereas subjects who smoked 31 or more cigarettes per day were almost six times more likely to have periodontitis. In former smokers, the odds of having periodontitis declined with the number of years since quitting. These data indicated that approximately 42% of periodontitis cases (6.4 million cases) in the US adult population were attributable to current smoking and that approximately 11% (1.7 million cases) were attributable to former smoking. These data highlight the serious threat to dental public health posed by cigarette smoking and raise questions about the best methods for managing periodontitis in patients who smoke (Box 10-2).

These data are consistent with the findings of other cross-sectional studies performed in the United States and Europe. The odds ratio for periodontitis in current smokers has been estimated to range from as low as 1.5 to as high as 7.3, depending on the observed severity of periodontitis.[70] A meta-analysis of data from six such studies involving 2361 subjects indicated that current smokers were almost three times more likely to have severe periodontitis than nonsmokers.[69] The detrimental impact of long-term smoking on the periodontal and dental status of older adults has been clearly demonstrated. Older adult smokers are approximately three times more likely to have severe periodontal disease,[7,62] and the number of years of tobacco use is a significant factor in tooth loss, coronal root caries, and periodontal disease.[51,52]

Smoking has also been shown to affect periodontal disease severity in younger individuals. Cigarette smoking is associated with increased severity of generalized aggressive periodontitis in young adults,[92] and those who smoke are 3.8 times more likely to have periodontitis as compared with nonsmokers.[39] Longitudinal studies have demonstrated that young individuals who smoke more than 15 cigarettes per day showed the highest risk for tooth loss.[47] In addition, smokers are more than six times as likely as nonsmokers to demonstrate continued attachment loss.[49] Over a 10-year period, bone loss has been reported to be twice as rapid in smokers as in nonsmokers[16] and to proceed more rapidly even in the presence of excellent plaque control.[10] Less information is available about the effects of cigar and pipe smoking, but it appears that effects similar to those of cigarette smoking are observed with these forms of tobacco use.[3,31,32,60] The prevalence of moderate and severe periodontitis and the percentage of teeth with more than 5 mm of attachment loss were most severe in current cigarette smokers, but cigar and pipe smokers showed a severity of disease that was intermediate between that of current cigarette smokers and nonsmokers.[3] Tooth loss is also increased among cigar and pipe smokers as compared with nonsmokers.[60]

Former smokers have less risk for periodontitis than current smokers but more risk than nonsmokers, and the risk for periodontitis decreases with the increasing number of years since quitting smoking.[100] This suggests that the negative effects of smoking on the host are reversible with smoking cessation and therefore that smoking cessation programs must be an integral component of periodontal education and therapy (Box 10-3). Several tobacco intervention approaches can be used when helping the patient deal with the physiologic factors (i.e., nicotine withdrawal symptoms) and the psychologic factors associated with smoking cessation (Box 10-4).[71,85]

BOX 10-2 Should We Change How We Manage Periodontal Disease?

FACT 1: Smoking is *the* major risk factor for periodontal disease.

FACT 2: According to the literature, smoking may be responsible for more than half of periodontitis cases among adults in the United States.[2]

FACT 3: Depending on the study, approximately 10% to 15% of adults in most populations examined have advanced chronic periodontitis.

Questions:

- Would there be a benefit at the population level for periodontal health if all smokers in the population quit smoking today?
- Would dental professionals be able to more successfully manage periodontitis in smokers if we focused on smoking cessation as *the* primary treatment strategy for managing their periodontitis?

These questions are intended to be controversial! It is clear that smoking has a huge deleterious impact on periodontal status, and smoking cessation MUST be a core part of periodontal treatment protocols in patients with periodontitis who smoke. The answer to the first question is almost certainly a resounding "YES," but this probably will never be able to be tested. The answer to the second question is more difficult. Certainly smokers with periodontitis must be educated about the harm that they are causing to their periodontal tissues, and they must be encouraged and helped to quit smoking. Treatment outcomes are improved among smokers who quit as compared with those who continue to smoke.[81]

Two Final Points (These are contentious and designed to stimulate discussion!)

- If more than half of the cases of periodontitis are attributable to smoking, then patients who smoke may be better served if dental professionals put more than half of their efforts into treating these patients via smoking cessation treatments (as opposed to other forms of periodontal therapy).
- It is absurd for smokers in the Western world to worry about anything except stopping smoking.[75]

Effects of Smoking on the Etiology and Pathogenesis of Periodontal Disease

The increased prevalence and severity of periodontal destruction associated with smoking suggests that the host–bacterial interactions normally seen with chronic periodontitis are altered, thereby resulting in more extensive periodontal breakdown (Table 10-3). This imbalance between bacterial challenge and host response may be caused by changes in the composition of the subgingival plaque (e.g., increases in the numbers and virulence of pathogenic organisms), changes in the host response to the bacterial challenge, or a combination of both. This section discusses recent evidence of the effects of smoking on the microbiology, immune–inflammatory response, and physiology of periodontitis.

Microbiology

Studies have failed to demonstrate a difference in the rate of plaque accumulation of smokers as compared with nonsmokers. This suggests that, if an alteration in the microbial challenge in smokers exists, it results from a *qualitative* rather than a quantitative alteration in the plaque.[8] Several studies have explored the possible changes in subgingival plaque caused by smoking, with conflicting and inconclusive results. In a study of 142 patients with chronic periodontitis, plaque samples from deep pockets (i.e., ≥6 mm) demonstrated no differences in the counts of *Aggregatibacter actinomycetemcomitans*, *Porphyromonas gingivalis*, and *Prevotella*

BOX 10-3 Helping Your Patients to Quit Smoking

Smoking cessation is a public health priority for governments around the world. Excellent online resources are available to provide information about the harmful effects of smoking and to help people to quit, including the following:

- http://www.cdc.gov/tobacco
- http://www.ash.org.uk
- http://smokefree.nhs.uk
- http://www.tobacco-oralhealth.net

Smoking cessation must be an integral part of the management of dental patients who smoke, and it is the responsibility of all dental care professionals to address this issue with their patients. The dental team is well placed to provide this treatment, because they see patients on a regular basis as part of ongoing routine dental management. Furthermore, interventions to help patients quit smoking in dental practices are effective, with quit rates of 15% to 20% as compared with approximately 5% in control groups.[88] The whole dental team should therefore be involved in smoking cessation, but this is not always the case. Why? Some of the barriers to providing smoking cessation counseling in the dental practice are shown in Table 10-2.

Various methods for helping patients to quit smoking in the dental environment have been described, and these are typically referred to as *brief intervention programs.* One such program[8] is known as the "5 A's" and it laid out as follows:

ASK Ask the patient about his or her smoking status (see Box 10-1).
This should be part of the medical history.

ADVISE Advise smokers of the associations between oral disease and smoking.
Be informative, honest, and helpful but not judgmental.
The patient's response to this information will reveal his or her interest in quitting.

ASSESS Assess the patient's interest in and readiness to attempt smoking cessation.
Patients may not yet be in an action phase when it comes to quitting smoking, which is why it is always important to make these assessments every time you see the patient.

ASSIST Assist the patient with his or her quit attempt.
If you are trained, there are many techniques that can be used (see Box 10-4).
Alternatively, assist the patient with seeking the help that he or she needs.

ARRANGE Arrange for a follow-up visit or a referral to professional smoking cessation services.
The most important aspect of this is to keep in regular contact, particularly around the quit date and during the immediate period after the patient quits.

A simplified version that is particularly useful for the dental team is the AAR program, which is broken down as follows:

ASK Ask the patient about his or her smoking status.

ADVISE Advise smokers of the associations between oral disease and smoking.

REFER Refer the patient to a professional smoking cessation program.

BOX 10-4 Methods of Smoking Cessation

Set a Quit Date

This is the very first step, and it is highly important. The patient must set his or her own quit date on which he or she will stop smoking and will remove all tobacco products from the environment.

Willpower Alone

Success rate at 12 months is 3%. This is the least effective method of smoking cessation, with only 3% of smokers managing to quit after 12 months.

Self-Help Materials

Success rate at 12 months is 4%. This includes a variety of literature and online resources that patients can access. The dental team can be helpful by providing literature and guiding patients toward resources that they can access.

Brief Intervention Program in Primary Care

Success rate at 12 months is 5% to 10%.[85] Brief advice is very important and should always be given at every dental visit. Enhancing the role of specially trained dental hygienists and prevention auxiliaries in giving lifestyle advice is of major benefit. If the dental team gave even brief advice to most of their smoking patients and achieved a low cessation rate of 5% over time, a significant proportion of smokers in the population would be assisted to quit each year.

Nicotine Replacement Therapy

Success rate at 12 months is 10% to 20%. Nicotine replacement therapy (NRT) generally doubles the success rate of smoking cessation. For example, in primary care settings in which brief advice is given, 12-month success rates double from around 5% to around 10% if NRT is also used. In an intensive setting such as a smoker's clinic, success rates increase from around 10% to up to 20%. NRT is not a magic cure, but it helps with cravings and withdrawal when a person quits smoking. Although NRT products do contain nicotine, they do not contain the toxic products such as tar and carbon monoxide that are found in cigarette smoke. NRT products include the following:

- Patches (available in different doses and worn for 16 to 24 hours per day)
- Lozenges and gum (available in different flavors; should be chewed slowly to allow the nicotine to be absorbed through the mouth)
- Nasal spray (delivers nicotine solution via the nasal passages)
- Inhalator (a plastic mouthpiece with a supply of nicotine cartridges that fit on the end; nicotine is absorbed in the mouth by drawing on the inhalator like a cigarette).

Bupropion

Success rate at 12 months is 20% to 30%. This medication is used as an antidepressant at higher doses, but it is effective for smoking cessation at lower doses. It is usually prescribed to be started 1 to 2 weeks before the quit date, initially at 150 mg once per day for 6 days then 150 mg twice per day for 7 to 9 weeks. There are serious potential drug interactions and unwanted effects, so this medication should be prescribed by the patient's medical doctor.

Other Methods

Whatever works for the patient is good! In addition to combinations of the above, techniques for smoking cessation can include intensive counseling, motivational interviewing, cognitive behavioral therapy, hypnosis, and acupuncture.

TABLE 10-2 Barriers Against and Stimuli For the Provision of Smoking Cessation Advice by the Dental Team in Dental Practice

	Barriers	Stimuli
Professional characteristics	Perceived lack of efficacy	Self-efficacy
	Concerns about disturbing the patient–dentist relationship	Positive attitude toward giving advice as part of health care provider role
	Lack of knowledge about how to give the correct advice	Training
	Belief that counseling is unnecessary	Self-belief
	Perception that advising patients is frustrating and has a low success rate	
	Dental team member may be a smoker himself or herself	
	Lack of confidence in giving the advice	
Practice organization	Lack of time	Task delegation
	No organizational support in the practice to deliver advice	Focus on helping smokers quit
Health care system	No reimbursement	
	No referral options for further help	Local availability of smoking cessation clinics

Adapted from Rosseel JP, Jacobs JE, Hilberink SR, et al: *Br Dent J* 206:E13, 2009.[88]

TABLE 10-3 Effects of Smoking on the Etiology and Pathogenesis of Periodontal Disease

Etiologic Factor	Impact of Smoking
Microbiology	No effect on rate of plaque accumulation ↑ Colonization of shallow periodontal pockets by periodontal pathogens ↑ Levels of periodontal pathogens in deep periodontal pockets
Immune–inflammatory response	Altered neutrophil chemotaxis, phagocytosis, and oxidative burst ↑ Tumor necrosis factor-α and prostaglandin E_2 in gingival crevicular fluid ↑ Neutrophil collagenase and elastase in gingival crevicular fluid ↑ Production of prostaglandin E_2 by monocytes in response to lipopolysaccharide
Physiology	↓ Gingival blood vessels with ↑ inflammation ↓ Gingival crevicular fluid flow and bleeding on probing with ↑ inflammation ↓ Subgingival temperature ↑ Time needed to recover from local anesthesia

↓, Decreased; ↑, increased.

intermedia.[80] In a similar study of 615 patients involving the use of immunoassay, the prevalence of *A. actinomycetemcomitans*, *P. gingivalis*, *P. intermedia*, and *Eikenella corrodens* was not found to be significantly different between smokers and nonsmokers.[96] By contrast, other studies have demonstrated differences in the microbial composition of subgingival plaque of smokers and nonsmokers. In a study of 798 subjects with different smoking histories, it was found that smokers had significantly higher levels of *Tannerella forsythia* and that smokers were 2.3 times more likely to harbor *T. forsythia* as compared with nonsmokers and former smokers.[108] Of particular interest was the observation that smokers do not respond to mechanical therapy as well as nonsmokers do; this is associated with increased levels of *T. forsythia*, *A. actinomycetemcomitans*, and *P. gingivalis* remaining in the pockets after therapy in the smoking group as compared with nonsmokers.[36,37,42,84]

Many discrepancies between the findings of microbiologic studies are a function of the methodology involved, including bacterial counts versus proportions or prevalence of bacteria, the number of sites sampled and the pocket depths selected, the sampling technique, the disease status of the subject, and the methods of bacterial enumeration and data analysis. In an attempt to overcome some of these problems, one study sampled subgingival plaque from all teeth with the exception of third molars in 272 adult subjects, including 50 current smokers, 98 former smokers, and 124 nonsmokers.[41] Using checkerboard DNA–DNA hybridization technology to screen for 29 different subgingival species, it was found that members of the orange and red complexes—including *Eikenella nodatum*, *Fusobacterium nucleatum* ss *vincentii*, *P. intermedia*, *Peptostreptococcus micros*, *Prevotella nigrescens*, *T. forsythia*, *P. gingivalis*, and *Treponema denticola*—were significantly more prevalent in current smokers than in nonsmokers and former smokers. The increased prevalence of these periodontal pathogens was caused by an increased colonization of shallow sites (pocket depth ≤4 mm), with no differences among smokers, former smokers, and nonsmokers in pockets 4 mm or greater. In addition, these pathogenic bacteria were more prevalent in the maxilla than the mandible. These data suggest that smokers have a greater extent of colonization by periodontal pathogens than nonsmokers or former smokers and that this colonization may lead to an increased prevalence of periodontal breakdown.

Immune–Inflammatory Responses

The immune response of the host to plaque accumulation is essentially protective. In periodontal health, a balance exists between the bacterial challenge of plaque and the immune–inflammatory responses in the gingival tissues, with no resulting loss of periodontal support. By contrast, periodontitis is associated with an alteration in the host–bacterial balance that may be initiated by changes in the bacterial composition of the subgingival plaque, changes in the host responses, or a combination of both.

Smoking exerts a major effect on the immune–inflammatory response that results in an increase in the extent and severity of

periodontal destruction. The deleterious effects of smoking appear to result in part from the downregulation of the immune response to bacterial challenge. The neutrophil is an important component of the host response to the bacterial challenge, and alterations in neutrophil number or function may result in localized and systemic infections. Critical functions of neutrophils include *chemotaxis* (directed locomotion from the bloodstream to the site of infection), *phagocytosis* (internalization of foreign particles such as bacteria), and *killing* via oxidative and nonoxidative mechanisms.

Neutrophils obtained from the peripheral blood, oral cavity, or saliva of smokers or exposed in vitro to whole tobacco smoke or nicotine have been shown to demonstrate functional alterations in chemotaxis, phagocytosis, and the oxidative burst.[34,57] In vitro studies of the effects of tobacco products on neutrophils have shown detrimental effects on cell movement as well as on the oxidative burst.[25,56,61,89,94] In addition, levels of antibody to the periodontal pathogens essential for phagocytosis and killing of bacteria, specifically immunoglobulin G_2, have been reported to be reduced in smokers as compared with nonsmokers with periodontitis,[42,18,38,98] thereby suggesting that smokers may have reduced protection against periodontal bacteria. By contrast, elevated levels of tumor necrosis factor–α have been demonstrated in the gingival crevicular fluid of smokers,[17] and elevated levels of prostaglandin E_2, neutrophil elastase, and matrix metalloproteinase-8 have also been found.[95] In vitro studies have also shown that exposure to nicotine increases the secretion of prostaglandin E_2 by monocytes in response to lipopolysaccharide.[73]

These data suggest that smoking may impair the response of neutrophils to plaque bacteria but that it may also increase the release of tissue-destructive enzymes. The exact changes in the immunologic mechanisms involved in the rapid tissue destruction seen in smokers are currently unclear. Further studies are needed to define the effects of tobacco use on the immune–inflammatory response and tissue destruction in individuals with periodontitis.

Physiology

Previous studies have shown that the clinical signs of inflammation are less pronounced in smokers than in nonsmokers.[26,9] This may result from alterations in the inflammatory response in smokers, as described previously, or it may be caused by alterations in the vascular response of the gingival tissues. Although no significant differences in the vascular density of healthy gingiva have been observed between smokers and nonsmokers,[74] the response of the microcirculation to plaque accumulation appears to be altered in smokers as compared with nonsmokers. With developing inflammation, increases in gingival crevicular fluid flow, bleeding on probing,[15] and gingival blood vessels[14] are lower in smokers than in nonsmokers. In addition, the oxygen concentration in healthy gingival tissues appears to be lower in smokers than in nonsmokers, although this condition is reversed in the presence of moderate inflammation.[43] Subgingival temperatures are lower in smokers than nonsmokers,[28] and recovery from the vasoconstriction caused by local anesthetic administration takes longer in smokers.[58,103] These cumulative data suggest that significant alterations are present in the gingival microvasculature of smokers as compared with nonsmokers and that these changes lead to decreased blood flow and decreased clinical signs of inflammation. This explains the long-observed phenomenon of a transient increase in gingival bleeding when a smoker quits; patients need to be warned about this phenomenon.

TABLE 10-4 Effects of Smoking on Response to Periodontal Therapy

Therapy	Effects of Smoking
Nonsurgical	↓ Clinical response to root surface debridement ↓ Reduction in pocket depth ↓ Gain in clinical attachment levels ↓ Negative impact of smoking with ↑ level of plaque control
Surgery and implants	↓ Pocket depth reduction and ↓ gain in clinical attachment levels after access flap surgery ↑ Deterioration of furcations after surgery ↓ Gain in clinical attachment levels, ↓ bone fill, ↑ recession, and ↑ membrane exposure after guided tissue regeneration ↓ Root coverage after grafting procedures for localized gingival recession ↓ Pocket depth reduction after bone graft procedures ↑ Risk for implant failure and periimplantitis
Maintenance care	↑ Pocket depth and attachment loss during maintenance therapy ↑ Disease recurrence in smokers ↑ Need for retreatment in smokers ↑ Tooth loss in smokers after surgical therapy

↓, Decreased; ↑, increased.

Effects of Smoking on Response to Periodontal Therapy

Nonsurgical Therapy

Numerous studies have indicated that current smokers do not respond as well to periodontal therapy as nonsmokers or former smokers do (Table 10-4). The majority of clinical research supports the observation that pocket depth reduction is more effective in nonsmokers than in smokers after nonsurgical periodontal therapy, including oral hygiene instruction, scaling, and root surface debridement.[2,36,37,42,55,79,84] In addition, gains in clinical attachment as a result of nonsurgical treatment are less pronounced in smokers than in nonsmokers. In a study of patients with previously untreated advanced periodontal disease, nonsurgical therapy resulted in significantly greater mean reductions in pocket depth and bleeding on probing in nonsmokers than in smokers when evaluated 6 months after the completion of therapy.[84] Average pocket reductions of 2.5 mm for nonsmokers and 1.9 mm for smokers were observed in pockets that averaged 7 mm before treatment. In another study, the nonsurgical management of pockets of 5 mm or greater showed that smokers had less pocket depth reduction than nonsmokers after 3 months (1.29 mm versus 1.76 mm) as well as less gain in clinical attachment levels.[36] When a higher level of plaque control can be achieved as part of nonsurgical care, the differences in the resolution of 4- to 6-mm pockets between nonsmokers and smokers became clinically less significant.[79]

It can be concluded that smokers respond less well to nonsurgical therapy than nonsmokers. With excellent plaque control, these differences may be minimized, but the emphasis is on truly excellent plaque control. When comparing current smokers with former smokers and nonsmokers, the former and nonsmoking subjects appear to respond equally well to nonsurgical care,[36] thereby reinforcing the need for patients to be informed of the benefits of smoking cessation.

Surgical Therapy and Implants

The less favorable response of the periodontal tissues to nonsurgical therapy that is observed in current smokers is also observed after surgical therapy. In a longitudinal comparative study of the effects of four different treatment modalities (coronal scaling, root planing, modified Widman flap surgery, and osseous resection surgery), smokers (with "heavy" defined as ≥20 cigarettes/day and "light" defined as ≤19 cigarettes/day) consistently showed less pocket reduction and less gain in clinical attachment as compared with nonsmokers or former smokers.[55] These differences were evident immediately after the completion of therapy and continued throughout 7 years of supportive periodontal therapy. During the 7 years, deterioration at furcation areas was greater in heavy and light smokers than in former smokers and nonsmokers. Smoking has also been shown to have a negative impact on the outcomes of guided tissue regeneration[102,104] and the treatment of infrabony defects by bone grafts.[87] By 12 months after guided tissue regeneration therapy at deep infrabony defects, smokers demonstrated less than half the attachment gain that was observed in nonsmokers (2.1 mm versus 5.2 mm).[102] In a second study, 73 smokers also showed less attachment gain than nonsmokers (1.2 mm versus 3.2 mm), more gingival recession, and less bone infill of the defect. Similarly, after the use of bone grafts for the treatment of infrabony defects, smokers showed less reduction in pocket depths as compared with nonsmokers.[87]

Open flap access surgery without regenerative or grafting procedures is the most common surgical procedure used for accessing the root and bone surfaces. By 6 months after this procedure, smokers showed significantly less reduction of deep pockets (≥7 mm) than nonsmokers (3.0 mm for smokers versus 4.0 mm for nonsmokers) and significantly less gain in clinical attachment (1.8 mm for smokers versus 2.8 mm for nonsmokers), even though all of the patients received supportive periodontal therapy every month for 6 months.[91] Of clinical relevance was the observation that only 16% of deep pockets in smokers returned to 3 mm or less at 6 months after surgery, whereas 47% of deep pockets in nonsmokers were 3 mm or less after the completion of therapy.

Tobacco smoking also affects the outcomes of periodontal plastic surgery.[21,24] For instance, a systematic review assessed the influence of smoking on the outcomes achieved by root coverage procedures.[21] This review identified that significantly greater root coverage and greater gains in clinical attachment levels were recorded for nonsmokers as compared with smokers after the treatment of gingival recession defects by subepithelial connective-tissue grafts. Furthermore, smokers showed significantly less sites with complete root coverage than were seen in the nonsmokers.[24]

Four meta-analyses have investigated the influence of smoking on the short- and long-term outcomes of implant therapy and have identified that smoking increases the risk of implant failure.[46,59,97,22] These studies used various definitions to define implant failure, including implant loss, implant bone loss, mobility, pain, and peri-implantitis. Overall, the risk for implant failure in smokers appears to be approximately double the risk for failure in nonsmokers, and the risks appear to be higher in maxillary implants and when implants are placed in poor-quality bone. Smoking has also been shown to be a risk factor for periimplantitis, with a majority of studies showing a significant increase in periimplant bone loss as compared with nonsmokers.[45] Collectively, these data indicate that implant failure is more common among smokers than nonsmokers. However, because numerous factors can influence implant success, further controlled clinical trials are needed to address the role of smoking as an independent variable in implant failure. Given the current evidence, all patients who are considering implant therapy should be informed about the benefits of smoking cessation and the risks of smoking for the development of periimplantitis and implant failure.

Maintenance Therapy

The detrimental effect of smoking on treatment outcomes appears to be long lasting and independent of the frequency of maintenance therapy. After four different modalities of therapy, (scaling, scaling and root planing, modified Widman flap surgery, and osseous surgery), maintenance therapy was performed by a hygienist every 3 months for 7 years.[55] Smokers consistently had deeper pockets than nonsmokers and less gain in attachment when evaluated each year for the 7-year period. Even with more intensive maintenance therapy given every month for 6 months after flap surgery,[91] smokers had deeper and more residual pockets than nonsmokers, although no significant differences in plaque or bleeding on probing scores were found. These data suggest that the effects of smoking on the host response and the healing characteristics of the periodontal tissues may have a long-term effect on pocket resolution in smokers, possibly requiring more intensive management during the maintenance phase. Smokers also tend to experience more periodontal breakdown than nonsmokers after therapy.[63,65] In studies of patients who failed to respond to conventional therapy (including different combinations of oral hygiene instruction, scaling and root planing, surgery, and antibiotics), approximately 90% of these poorly responding patients were smokers.[63,64]

A systematic review that assessed the potential predictors of tooth loss during long-term periodontal maintenance care demonstrated that, although oral health and the prevention of tooth loss were achieved in the majority of patients, the long-term outcomes were also influenced by smoking.[20] Tobacco smoking was positively associated with tooth loss even when regular recall maintenance care was performed (overall, smokers had a risk of losing their teeth that was up to 380% higher than that of nonsmokers).[20] Similarly, smoking has a detrimental effect on periimplant tissue status, even when patients are under strict periimplant preventive maintenance care.[27] It has been also demonstrated in a practice-based study that the smoking status may be highly associated with periimplant tissue loss around 10-mm implants restored with single crowns.[27] For instance, when comparing nonsmokers and light smokers (i.e., subjects who smoked <10 cigarettes per day), it was found that the majority of patients who experienced bone loss were smokers (88.9%), with an odds ratio of 39.64 (95% confidence interval, 8.62 to 182.27) for increased risk of bone loss.[27]

It is clear from these studies that (1) smokers may present with periodontal disease at an early age; (2) that they may be difficult to treat effectively with conventional therapeutic strategies; (3) that they may continue to have progressive or recurrent periodontitis; and (4) that they may be at an increased risk of tooth loss or peri-implant bone loss, even when an adequate maintenance control is established. For these reasons, smoking cessation counseling must be a cornerstone of periodontal therapy in smokers.

Effects of Smoking Cessation on Periodontal Treatment Outcomes

The effect of smoking cessation on periodontal status has been studied in a large number of cross-sectional and cohort observational studies, in which the periodontal status of smokers, former smokers and nonsmokers is compared.[5,6,10-12,16,29,39,40,52,72,99,100] Similarly, periodontal treatment outcomes have been assessed in smokers, former smokers, and nonsmokers.[37,55,48,66,82,90] Collectively, these studies have demonstrated that smokers have

significantly worse periodontal status (i.e., deeper probing depths, more attachment loss and bone loss) than either former smokers or nonsmokers and usually have poorer treatment outcomes. The periodontal status of former smokers is intermediate to that of current smokers and nonsmokers, and it appears to usually be closer to that of nonsmokers.

There are very few intervention studies of the effect of smoking cessation on periodontal treatment outcomes (i.e., studies in which smokers were helped to quit and in which the effect on periodontal status was then assessed). Two short-term studies have indicated that smoking has a negative impact on the gingival vasculature and that these changes are reversible with smoking cessation.[67,68] However, most clinicians are probably more concerned with the clinical impact of quitting smoking on periodontal treatment outcomes. Two interventional studies have now been conducted that assessed the impact of smoking cessation on outcomes after nonsurgical periodontal treatment.[81,86] The first study employed dental hygienists who were trained as smoking cessation advisors and who achieved a 20% quit rate at 12 months in a population of smokers who also had periodontitis. The hygienists used a variety of strategies to assist these smokers, including counseling, nicotine replacement therapy, and bupropion. This confirms the effectiveness of dental health care professionals for providing smoking cessation counseling. All of the patients in the study received nonsurgical therapy as treatment for their periodontitis in addition to smoking cessation counseling. Those individuals who successfully quit smoking for the entire 12 months of the study had the best response to the periodontal treatment. The treatment responses in the nonquitters and the failed quitters (i.e., the "oscillators" who initially quit but who then resumed smoking) were significantly poorer than those seen in the quitters, and they did not differ significantly from each other. The second study was a 12-month prospective single-blinded study in which smoking cessation advice, nicotine replacement therapy, and medication were provided at four consecutive appointments, once a week, by a multidisciplinary team that included doctors, psychologists, and a dentist.[86] The confirmed continuous quit rate at 12 months was 18.3%, which was very similar to that reported in the previous study (20%). Similar to the study by Preshaw and colleagues,[81] a nonsurgical approach for the treatment of chronic periodontitis was performed. At the end of the 12-month follow-up period, it was identified that the quitters had improved clinical attachment gain as compared with the nonquitters. Both of these studies implemented similar inclusion criteria and used similar methodologies, and the second study[86] can be regarded as a replication of the previous one.[81] In addition, a supplementary study that described a set of meta-analyses performed with individual patient data from these two trials reported a highly significant beneficial impact of quitting smoking, with quitters demonstrating 30% more sites with probing depth reductions of 2 mm or more as compared with nonquitters.[23] Equally, quitters had 22% fewer sites with residual probing depths of 4 mm or greater as compared with nonquitters at the end of the 12-month follow-up period.[23]

The benefit of smoking cessation on the periodontium is likely to be mediated through various pathways, such as a shift toward a less pathogenic microbiota, the recovery of the gingival microcirculation, and improvements in certain aspects of the immune–inflammatory responses. In support of this, in the interventional study described previously,[81] plaque samples were collected as the study progressed. It became clear that subgingival microbial profiles differed significantly between smokers and quitters at 6 and 12 months after smoking cessation.[33] At 6 and 12 months after treatment, the microbial community in smokers was similar to that observed at baseline (i.e., before periodontal treatment/smoking cessation counseling), whereas the quitters demonstrated significantly divergent profiles; changes in bacterial levels contributed to this shift. These data suggest a critical role for smoking cessation in the alteration of the subgingival biofilm. Further research is now necessary to investigate the impact of quitting smoking on the immune–inflammatory mechanisms that drive tissue destruction in the periodontium.

In conclusion, smoking is the major risk factor for periodontitis, and smoking cessation should be an integral part of periodontal therapy among patients who smoke. Smoking cessation should be considered a priority for the management of periodontitis in smokers.

Suggested Readings

Chambrone L, Chambrone D, Lima LA, et al: Predictors of tooth loss during long-term periodontal maintenance: a systematic review of observational studies. *J Clin Periodontol* 37:675–684, 2010.

Chambrone L, Sukekava F, Araújo MG, et al: Root coverage procedures for the treatment of localized recession-type defects: A Cochrane systematic review. *J Periodontol* 81:452–478, 2010.

Chambrone L, Preshaw PM, Rosa EF, et al: Effects of smoking cessation on the outcomes of non-surgical periodontal therapy: a systematic review and individual patient data meta-analysis. *J Clin Periodontol* 40:607–615, 2013.

Heasman L, Stacey F, Preshaw PM, et al: The effect of smoking on periodontal treatment response: a review of clinical evidence. *J Clin Periodontol* 33:241–253, 2006.

Preshaw PM, Heasman L, Stacey F, et al: The effect of quitting smoking on chronic periodontitis. *J Clin Periodontol* 32:869–879, 2005.

Rosa EF, Corraini P, de Carvalho VF, et al: A prospective 12-month study of the effect of smoking cessation on periodontal clinical parameters. *J Clin Periodontol* 38:562–571, 2011.

Tomar SL, Asma S: Smoking-attributable periodontitis in the United States: findings from NHANES III. National Health and Nutrition Examination Survey. *J Periodontol* 71:743–751, 2000.

Warnakulasuriya S, Dietrich T, Bornstein MM, et al: Oral health risks of tobacco use and effects of cessation. *Int Dent J* 60:7–30, 2010.

References

References for this chapter are found on the companion website www.expertconsult.com.

References

1. AAP: Position paper: Tobacco use and the periodontal patient. *J Periodontol* 67:51–56, 1996.
2. Ah MK, Johnson GK, Kaldahl WB, et al: The effect of smoking on the response to periodontal therapy. *J Clin Periodontol* 21:91–97, 1994.
3. Albandar JM, Streckfus CF, Adesanya MR, et al: Cigar, pipe, and cigarette smoking as risk factors for periodontal disease and tooth loss. *J Periodontol* 71:1874–1881, 2000.
4. Ash website: Action on Smoking and Health. <http://www.ash.org.uk>. Accessed March 15, 2013.
5. Baljoon M, Natto S, Bergstrom J: The association of smoking with vertical periodontal bone loss. *J Periodontol* 75:844–851, 2004.
6. Baljoon M, Natto S, Bergstrom J: Long-term effect of smoking on vertical periodontal bone loss. *J Clin Periodontol* 32:789–797, 2005.
7. Beck JD, Koch GG, Rozier RG, et al: Prevalence and risk indicators for periodontal attachment loss in a population of older community-dwelling blacks and whites. *J Periodontol* 61:521–528, 1990.
8. Bergstrom J: Cigarette smoking as risk factor in chronic periodontal disease. *Community Dent Oral Epidemiol* 17:245–247, 1989.
9. Bergstrom J: Oral hygiene compliance and gingivitis expression in cigarette smokers. *Scand J Dent Res* 98:497–503, 1990.
10. Bergstrom J, Eliasson S, Dock J: A 10-year prospective study of tobacco smoking and periodontal health. *J Periodontol* 71:1338–1347, 2000.
11. Bergstrom J, Eliasson S, Dock J: Exposure to tobacco smoking and periodontal health. *J Clin Periodontol* 27:61–68, 2000.
12. Bergstrom J, Eliasson S, Preber H: Cigarette smoking and periodontal bone loss. *J Periodontol* 62:242–246, 1991.
13. Bergstrom J, Floderus-Myrhed B: Co-twin control study of the relationship between smoking and some periodontal disease factors. *Community Dent Oral Epidemiol* 11:113–116, 1983.
14. Bergstrom J, Persson L, Preber H: Influence of cigarette smoking on vascular reaction during experimental gingivitis. *Scand J Dent Res* 96:34–39, 1988.
15. Bergstrom J, Preber H: The influence of cigarette smoking on the development of experimental gingivitis. *J Periodontal Res* 21:668–676, 1986.
16. Bolin A, Eklund G, Frithiof L, et al: The effect of changed smoking habits on marginal alveolar bone loss. A longitudinal study. *Swed Dent J* 17:211–216, 1993.
17. Bostrom L, Linder LE, Bergstrom J: Clinical expression of TNF-alpha in smoking-associated periodontal disease. *J Clin Periodontol* 25:767–773, 1998.
18. Califano JV, Schifferle RE, Gunsolley JC, et al: Antibody reactive with *Porphyromonas gingivalis* serotypes K1-6 in adult and generalized early-onset periodontitis. *J Periodontol* 70:730–735, 1999.
19. Centers for Disease Control and Prevention website: Smoking and tobacco use, <http://www.cdc.gov/tobacco>. Accessed March 15, 2013.
20. Chambrone L, Chambrone D, Lima LA, et al: Predictors of tooth loss during long-term periodontal maintenance: a systematic review of observational studies. *J Clin Periodontol* 37:675–684, 2010.
21. Chambrone L, Chambrone D, Pustiglioni FE, et al: The influence of tobacco smoking on the outcomes achieved by root-coverage procedures: a systematic review. *J Am Dent Assoc* 140:294–306, 2009.
22. Chambrone L, Preshaw PM, Ferreira JD, et al: Effects of tobacco smoking on the survival rate of dental implants placed in areas of maxillary sinus floor augmentation: A systematic review. *Clin Oral Implants Res* 2013. [Epub ahead of print].
23. Chambrone L, Preshaw PM, Rosa EF, et al: Effects of smoking cessation on the outcomes of non-surgical periodontal therapy: a systematic review and individual patient data meta-analysis. *J Clin Periodontol* 40:607–615, 2013.
24. Chambrone L, Sukekava F, Araújo MG, et al: Root coverage procedures for the treatment of localized recession-type defects: A Cochrane systematic review. *J Periodontol* 81:452–478, 2010.
25. Codd EE, Swim AT, Bridges RB: Tobacco smokers' neutrophils are desensitized to chemotactic peptide-stimulated oxygen uptake. *J Lab Clin Med* 110:648–652, 1987.
26. Danielsen B, Manji F, Nagelkerke N, et al: Effect of cigarette smoking on the transition dynamics in experimental gingivitis. *J Clin Periodontol* 17:159–164, 1990.
27. De la Rosa-G M, Rodríguez A, Sierra K, et al: Predictors of peri-implant bone loss during long-term maintenance of patients treated with 10-mm implants and single crowns restorations. *Int J Oral Maxillofac Implants* 28:798–802, 2013.
28. Dinsdale CR, Rawlinson A, Walsh TF: Subgingival temperature in smokers and non-smokers with periodontal disease. *J Clin Periodontol* 24:761–766, 1997.
29. Do LG, Slade GD, Roberts-Thomson KF, et al: Smoking-attributable periodontal disease in the Australian adult population. *J Clin Periodontol* 35:398–404, 2008.
30. Doll R, Peto R, Wheatley K, et al: Mortality in relation to smoking: 40 years' observations on male British doctors. *BMJ* 309:901–911, 1994.
31. Feldman RS, Alman JE, Chauncey HH: Periodontal disease indexes and tobacco smoking in healthy aging men. *Gerodontics* 3:43–46, 1987.
32. Feldman RS, Bravacos JS, Rose CL: Association between smoking different tobacco products and periodontal disease indexes. *J Periodontol* 54:481–487, 1983.
33. Fullmer SC, Preshaw PM, Heasman PA, et al: Smoking cessation alters subgingival microbial recolonization. *J Dent Res* 88:524–528, 2009.
34. Eichel B, Shahrik HA: Tobacco smoke toxicity: loss of human oral leukocyte function and fluid-cell metabolism. *Science* 166:1424–1428, 1969.
35. Garfinkel L: Trends in cigarette smoking in the United States. *Prev Med* 26:447–450, 1997.
36. Grossi SG, Skrepcinski FB, DeCaro T, et al: Response to periodontal therapy in diabetics and smokers. *J Periodontol* 67:1094–1102, 1996.
37. Grossi SG, Zambon J, Machtei EE, et al: Effects of smoking and smoking cessation on healing after mechanical periodontal therapy. *J Am Dent Assoc* 128:599–607, 1997.
38. Gunsolley JC, Pandey JP, Quinn SM, et al: The effect of race, smoking and immunoglobulin allotypes on IgG subclass concentrations. *J Periodontal Res* 32:381–387, 1997.
39. Haber J, Wattles J, Crowley M, et al: Evidence for cigarette smoking as a major risk factor for periodontitis. *J Periodontol* 64:16–23, 1993.
40. Haffajee AD, Socransky SS: Relationship of cigarette smoking to attachment level profiles. *J Clin Periodontol* 28:283–295, 2001.
41. Haffajee AD, Socransky SS: Relationship of cigarette smoking to the subgingival microbiota. *J Clin Periodontol* 28:377–388, 2001.
42. Haffajee AD, Cugini MA, Dibart S, et al: Socransky SS: The effect of SRP on the clinical and microbiological parameters of periodontal diseases. *J Clin Periodontol* 24:324–334, 1997.
43. Hanioka T, Tanaka M, Ojima M, et al: Oxygen sufficiency in the gingiva of smokers and non-smokers with periodontal disease. *J Periodontol* 71:1846–1851, 2000.
44. Heasman L, Stacey F, Preshaw PM, et al: The effect of smoking on periodontal treatment response: a review of clinical evidence. *J Clin Periodontol* 33:241–253, 2006.
45. Heitz-Mayfield LJ: Peri-implant diseases: diagnosis and risk indicators. *J Clin Periodontol* 35:292–304, 2008.
46. Hinode D, Tanabe S, Yokoyama M, et al: Influence of smoking on osseointegrated implant failure: a meta-analysis. *Clin Oral Implants Res* 17:473–478, 2006.
47. Holm G: Smoking as an additional risk for tooth loss. *J Periodontol* 65:996–1001, 1994.
48. Hughes FJ, Syed M, Koshy B, et al: Prognostic factors in the treatment of generalized aggressive periodontitis: II: Effects of smoking on initial outcome. *J Clin Periodontol* 33:671–676, 2006.
49. Ismail AI, Morrison EC, Burt BA, et al: Natural history of periodontal disease in adults: findings from the Tecumseh Periodontal Disease Study, 1959-87. *J Dent Res* 69:430–435, 1990.

50. Jarvis MJ, Russell MA, Benowitz NL, et al: Elimination of cotinine from body fluids: implications for noninvasive measurement of tobacco smoke exposure. *Am J Public Health* 78:696–698, 1988.
51. Jette AM, Feldman HA, Douglass C: Oral disease and physical disability in community-dwelling older persons. *J Am Geriatr Soc* 41:1102–1108, 1993.
52. Jette AM, Feldman HA, Tennstedt SL: Tobacco use: a modifiable risk factor for dental disease among the elderly. *Am J Public Health* 83:1271–1276, 1993.
53. Johnson GK, Guthmiller JM: The impact of cigarette smoking on periodontal disease and treatment. *Periodontol 2000* 44:178–194, 2007.
54. Johnson GK, Hill M: Cigarette smoking and the periodontal patient. *J Periodontol* 75:196–209, 2004.
55. Kaldahl WB, Johnson GK, Patil KD, et al: Levels of cigarette consumption and response to periodontal therapy. *J Periodontol* 67:675–681, 1996.
56. Kalra J, Chaudhary AK, Prasad K: Increased production of oxygen free radicals in cigarette smokers. *Int J Exp Pathol* 72:1–7, 1991.
57. Kenney EB, Kraal JH, Saxe SR, et al: The effect of cigarette smoke on human oral polymorphonuclear leukocytes. *J Periodontal Res* 12:227–234, 1977.
58. Ketabi M, Hirsch RS: The effects of local anesthetic containing adrenaline on gingival blood flow in smokers and non-smokers. *J Clin Periodontol* 24:888–892, 1997.
59. Klokkevold PR, Han TJ: How do smoking, diabetes, and periodontitis affect outcomes of implant treatment? *Int J Oral Max Impl* 22(Suppl):173–202, 2007.
60. Krall EA, Garvey AJ, Garcia RI: Alveolar bone loss and tooth loss in male cigar and pipe smokers. *J Am Dent Assoc* 130:57–64, 1999.
61. Lannan S, McLean A, Drost E, et al: Changes in neutrophil morphology and morphometry following exposure to cigarette smoke. *Int J Exp Pathol* 73:183–191, 1992.
62. Locker D, Leake JL: Risk indicators and risk markers for periodontal disease experience in older adults living independently in Ontario, Canada. *J Dent Res* 72:9–17, 1993.
63. MacFarlane GD, Herzberg ML, Wolff LF, et al: Refractory periodontitis associated with abnormal polymorphonuclear leukocyte phagocytosis and cigarette smoking. *J Periodontol* 63:908–913, 1992.
64. Magnusson I, Low SB, McArthur WP, et al: Treatment of subjects with refractory periodontal disease. *J Clin Periodontol* 21:628–637, 1994.
65. Magnusson I, Walker CB: Refractory periodontitis or recurrence of disease. *J Clin Periodontol* 23:289–292, 1996.
66. Meinberg TA, Canarsky-Handley AM, McClenahan AK, et al: Outcomes associated with supportive periodontal therapy in smokers and nonsmokers. *J Dent Hyg* 75:15–19, 2001.
67. Morozumi T, Kubota T, Sato T, et al: Smoking cessation increases gingival blood flow and gingival crevicular fluid. *J Clin Periodontol* 31:267–272, 2004.
68. Nair P, Sutherland G, Palmer RM, et al: Gingival bleeding on probing increases after quitting smoking. *J Clin Periodontol* 30:435–437, 2003.
69. Papapanou PN: Periodontal diseases: epidemiology. *Ann Periodontol* 1:1–36, 1996.
70. Papapanou PN: Risk assessments in the diagnosis and treatment of periodontal diseases. *J Dent Educ* 62:822–839, 1998.
71. Parrott S, Godfrey C, Raw M, et al: Guidance for commissioners on the cost effectiveness of smoking cessation interventions. Health Educational Authority. *Thorax* 53(Suppl 5 Pt 2):S1–S38, 1998.
72. Paulander J, Wennstrom JL, Axelsson P, et al: Some risk factors for periodontal bone loss in 50-year-old individuals. A 10-year cohort study. *J Clin Periodontol* 31:489–496, 2004.
73. Payne JB, Johnson GK, Reinhardt RA, et al: Nicotine effects on PGE_2 and IL-1b release by LPS-treated human monocytes. *J Periodontal Res* 31:99–104, 1996.
74. Persson L, Bergstrom J: Smoking and vascular density of healthy marginal gingiva. *Eur J Oral Sci* 106:953–957, 1998.
75. Peto J: Cancer epidemiology in the last century and the next decade. *Nature* 411:390–395, 2001.
76. Pilotti A: Biosynthesis and mammalian metabolism of nicotine. *Acta Physiol Scand Suppl* 479:13–17, 1980.
77. Preber H, Bergström J: Cigarette smoking in patients referred for periodontal treatment. *Scand J Dent Res* 94:102–108, 1986.
78. Preber H, Bergström J: Occurrence of gingival bleeding in smoker and non-smoker patients. *Acta Odontol Scand* 43:315–320, 1985.
79. Preber H, Bergström J: The effect of non-surgical treatment on periodontal pockets in smokers and non-smokers. *J Clin Periodontol* 13:319–323, 1986.
80. Preber H, Bergström J, Linder L: Occurrence of periopathogens in smoker and non-smoker patients. *J Clin Periodontol* 19:667–671, 1992.
81. Preshaw PM, Heasman L, Stacey F, et al: The effect of quitting smoking on chronic periodontitis. *J Clin Periodontol* 32:869–879, 2005.
82. Preshaw PM, Lauffart B, Zak E, et al: Progression and treatment of chronic adult periodontitis. *J Periodontol* 70:1209–1220, 1999.
83. Ramseier CA: Potential impact of subject-based risk factor control on periodontitis. *J Clin Periodontol* 32:283–290, 2005.
84. Renvert S, Dahlen G, Wikstrom M: The clinical and microbiological effects of non-surgical periodontal therapy in smokers and non-smokers. *J Clin Periodontol* 25:153–157, 1998.
85. Richmond RL: Physicians can make a difference with smokers: evidence-based clinical approaches. *Int J Tuberc Lung Dis* 3:100–112, 1999.
86. Rosa EF, Corraini P, de Carvalho VF, et al: A prospective 12-month study of the effect of smoking cessation on periodontal clinical parameters. *J Clin Periodontol* 38:562–571, 2011.
87. Rosen PS, Marks MH, Reynolds MA: Influence of smoking on long-term clinical results of intrabony defects treated with regenerative therapy. *J Periodontol* 67:1159–1163, 1996.
88. Rosseel JP, Jacobs JE, Hilberink SR, et al: What determines the provision of smoking cessation advice and counselling by dental care teams? *Br Dent J* 206:E13, 2009.
89. Ryder MI, Fujitaki R, Johnson G, et al: Alterations of neutrophil oxidative burst by in vitro smoke exposure: implications for oral and systemic diseases. *Ann Periodontol* 3:76–87, 1998.
90. Ryder MI, Pons B, Adams D, et al: Effects of smoking on local delivery of controlled-release doxycycline as compared to scaling and root planing. *J Clin Periodontol* 26:683–691, 1999.
91. Scabbia A, Cho KS, Sigurdsson TJ, et al: Cigarette smoking negatively affects healing response following flap debridement surgery. *J Periodontol* 72:43–49, 2001.
92. Schenkein HA, Gunsolley JC, Koertge TE, et al: Smoking and its effects on early-onset periodontitis. *J Am Dent Assoc* 126:1107–1113, 1995.
93. Scott DA, Palmer RM, Stapleton JA: Validation of smoking status in clinical research into inflammatory periodontal disease. *J Clin Periodontol* 28:715–722, 2001.
94. Selby C, Drost E, Brown D, et al: Inhibition of neutrophil adherence and movement by acute cigarette smoke exposure. *Exp Lung Res* 18:813–827, 1992.
95. Soder B: Neutrophil elastase activity, levels of prostaglandin E2, and matrix metalloproteinase-8 in refractory periodontitis sites in smokers and non-smokers. *Acta Odontol Scand* 57:77–82, 1999.
96. Stoltenberg JL, Osborn JB, Pihlstrom BL, et al: Association between cigarette smoking, bacterial pathogens and periodontal status. *J Periodontol* 64:1225–1230, 1993.
97. Strietzel FP, Reichart PA, Kale A, et al: Smoking interferes with the prognosis of dental implant treatment: a systematic review and meta-analysis. *J Clin Periodontol* 34:523–544, 2007.
98. Tangada SD, Califano JV, Nakashima K, et al: The effect of smoking on serum IgG2 reactive with Actinobacillus actinomycetemcomitans in early-onset periodontitis patients. *J Periodontol* 68:842–850, 1997.
99. Thomson WM, Broadbent JM, Welch D, et al: Cigarette smoking and periodontal disease among 32-year-olds: a prospective study of a representative birth cohort. *J Clin Periodontol* 34:828–834, 2007.

100. Tomar SL, Asma S: Smoking-attributable periodontitis in the United States: findings from NHANES III. National Health and Nutrition Examination Survey. *J Periodontol* 71:743–751, 2000.
101. Tonetti MS: Cigarette smoking and periodontal diseases: etiology and management of disease. *Ann Periodontol* 3:88–101, 1998.
102. Tonetti MS, Pini Prato G, Cortellini P: Effect of cigarette smoking on periodontal healing following GTR in infrabony defects. A preliminary retrospective study. *J Clin Periodontol* 22:229–234, 1995.
103. Trikilis N, Rawlinson A, Walsh TF: Periodontal probing depth and subgingival temperature in smokers and non-smokers. *J Clin Periodontol* 26:38–43, 1999.
104. Trombelli L, Kim CK, Zimmerman GJ, et al: Retrospective analysis of factors related to clinical outcome of guided tissue regeneration procedures in intrabony defects. *J Clin Periodontol* 24:366–371, 1997.
105. Warnakulasuriya S, Dietrich T, Bornstein MM, et al: Oral health risks of tobacco use and effects of cessation. *Int Dent J* 60:7–30, 2010.
106. World Health Organization, regional office for Europe website: Smoking. <http://www.euro.who.int/en/what-we-do/health-topics/disease-prevention/tobacco/facts-and-figures>. Accessed March 15, 2013.
107. World Health Organization website: Tobacco. <http://www.who.int/mediacentre/factsheets/fs339/en/index.html>. Accessed March 15, 2013.
108. Zambon JJ, Grossi SG, Machtei EE, et al: Cigarette smoking increases the risk for subgingival infection with periodontal pathogens. *J Periodontol* 67:1050–1054, 1996.

CHAPTER 11

Influence of Systemic Conditions

Perry R. Klokkevold and Brian L. Mealey

CHAPTER OUTLINE

Endocrine Disorders and Hormonal Changes
Hematologic Disorders and Immune Deficiencies
Genetic Disorders
Stress and Psychosomatic Disorders
Nutritional Influences
Medications
Other Systemic Conditions *(e-only)*

For expanded discussions on female sex hormones, genetic disorders, and nutritional influences on periodontal disease as well as online only content on hyperparathyroidism, anemia, thrombocytopenia, antibody deficiency disorders, and other systemic conditions, please visit the companion website at www.expertconsult.com. Some figures and tables may be out of numeric order in this printed chapter.

Many systemic diseases, disorders, and conditions have been implicated as risk indicators or risk factors in periodontal disease. Clinical and basic science research over the past several decades has led to an improved understanding of and appreciation for the complexity and pathogenesis of periodontal diseases.[187] Although there is clear evidence for a bacterial etiology and there are specific bacteria (periodontal pathogens) associated with destructive periodontal disease, the presence of these pathogens does not invariably cause disease. Their absence, on the other hand, appears to be consistent with periodontal health. The role of bacteria in disease etiology and pathogenesis is discussed in Chapters 8 and 9.

Perhaps the most significant advance in our understanding of the pathogenesis of periodontitis is that the host response varies among individuals and that an altered, deficient, or exaggerated host immune response to bacterial pathogens may lead to more severe forms of the disease. In other words, the individual host immune response to periodontal pathogens is very important and likely explains many of the differences in disease severity observed from one individual to the next. Furthermore, systemic diseases, disorders, and conditions alter host tissues and physiology, which may impair the host's barrier function and immune defense against periodontal pathogens, thereby creating the opportunity for destructive periodontal disease to progress.

Recent evidence also suggests that periodontal infections can adversely affect systemic health with manifestations such as coronary heart disease, stroke, diabetes, preterm labor, low-birth-weight delivery, and respiratory disease.[167] The role of periodontal infections on these systemic health conditions is discussed in Chapter 12.

The interrelationships between periodontal infections and host defense are complex. A number of environmental, physical, and psychosocial factors have the potential to alter periodontal tissues and the host immune response, thereby resulting in more severe periodontal disease expression. It is important to recognize that the systemic diseases, disorders, or conditions themselves do not cause periodontitis; rather, they may predispose, accelerate, or otherwise increase the disease's progression. This chapter discusses important systemic diseases, disorders, and conditions that have the potential to influence periodontal health.

Endocrine Disorders and Hormonal Changes

Endocrine diseases such as diabetes and hormonal fluctuations that are associated with puberty and pregnancy are well-known examples of systemic conditions that adversely affect the condition of the periodontium. Endocrine disturbances and hormone fluctuations affect the periodontal tissues directly, modify the tissue response to local factors, and produce anatomic changes in the gingiva that may favor plaque accumulation and disease progression. This section describes the evidence that supports the relationship among endocrine disorders, hormonal changes, and periodontal disease.

Diabetes Mellitus

Diabetes mellitus is an extremely important disease from a periodontal standpoint. It is a complex metabolic disorder characterized by chronic hyperglycemia. Diminished insulin production, impaired insulin action, or a combination of both result in the inability of glucose to be transported from the bloodstream into the tissues, which in turn results in high blood glucose levels and the excretion of sugar in the urine. Lipid and protein metabolism are altered in diabetes as well. Uncontrolled diabetes (chronic hyperglycemia) is associated with several long-term complications, including microvascular diseases (retinopathy, nephropathy, or neuropathy), macrovascular diseases (cardiovascular and cerebrovascular conditions), an increased susceptibility to infections, and poor wound healing. An estimated 25.8 million individuals (both children and adults)—8.3% of the US population—have diabetes.[42] Approximately 7 million of these individuals are unaware that they have the disease.

There are two major types of diabetes, type 1 and type 2, with several less common secondary types. *Type 1 diabetes mellitus,* which was formerly known as *insulin-dependent diabetes mellitus,* is caused by a cell-mediated autoimmune destruction of the insulin-producing beta cells of the islets of Langerhans in the pancreas, which results in insulin deficiency. Type 1 diabetes accounts for 5% to 10% of all cases of diabetes and most often occurs in children and young adults. This type of diabetes results from a lack of insulin production, and it is very unstable and difficult to control. It has a marked tendency toward ketosis and coma, it is not preceded by obesity, and it requires the injection of insulin to be controlled. Patients with type 1 diabetes mellitus present with the symptoms that are traditionally associated with diabetes, including polyphagia, polydipsia, polyuria, and predisposition to infections.

Type 2 diabetes mellitus, which was formerly known as *non–insulin-dependent diabetes mellitus,* is caused by peripheral resistance to insulin action, impaired insulin secretion, and increased glucose production in the liver. The insulin-producing beta cells in the pancreas are not destroyed by cell-mediated autoimmune reaction. It typically begins as insulin resistance, which leads to the reduced pancreas production of insulin as the demand increases. Type 2 diabetes is the most common form of diabetes, and it accounts for 90% to 95% of all diagnosed cases in adults. Individuals are often not aware they have the disease until severe symptoms or complications occur. Type 2 diabetes generally occurs in obese individuals, and it can often be controlled by diet and oral hypoglycemic agents. Ketosis and coma are uncommon. Type 2 diabetes can present with the same symptoms as type 1 diabetes but typically in a less severe form.

An additional category of diabetes is *hyperglycemia* secondary to other diseases or conditions. A prime example of this type of hyperglycemia is gestational diabetes associated with pregnancy. *Gestational diabetes* develops in 2% to 10% of all pregnancies but disappears after delivery. Women who have had gestational diabetes are at increased risk of developing type 2 diabetes. Other secondary types of diabetes are those associated with diseases that involve the pancreas and the destruction of the insulin-producing cells. Endocrine diseases (e.g., acromegaly, Cushing's syndrome), tumors, pancreatectomy, and drugs or chemicals that cause altered insulin levels are included in this group. Experimentally induced types of diabetes generally belong in this category rather than in the categories of type 1 or 2 diabetes mellitus.

Oral Manifestations. Numerous oral changes have been described in patients with diabetes, including cheilosis, mucosal drying and cracking, burning mouth and tongue, diminished salivary flow, and alterations in the flora of the oral cavity, with greater predominance of *Candida albicans,* hemolytic streptococci, and staphylococci.[2,22,101,162] An increased rate of dental caries has also been observed in patients with poorly controlled diabetes.[76,86] It is important to note that these changes are not always present, that they are not specific, and that they are not pathognomonic for diabetes.[165] Furthermore, these changes are less likely to be observed in patients with well-controlled diabetes. Individuals with controlled diabetes have a normal tissue response, a normally developed dentition, a normal defense against infections, and no increase in the incidence of caries.[239]

The influence of diabetes on the periodontium has been thoroughly investigated. Although it is difficult to make definitive conclusions about the specific effects of diabetes on the periodontium, a variety of changes have been described, including a tendency toward an enlarged gingiva, sessile or pedunculated gingival polyps, polypoid gingival proliferations, abscess formation, periodontitis, and loosened teeth[114] (Figure 11-1). Perhaps the most striking changes in patients with uncontrolled diabetes are the reductions in the defense mechanisms and the increased susceptibility to infections, which lead to destructive periodontal disease. In fact, periodontal disease is considered to be the sixth complication of diabetes.[148] Periodontitis in patients with type 1 diabetes appears to start after the age of 12 years, and it has a fivefold increased prevalence in teenagers.[49] The prevalence of periodontitis has been reported as 9.8% in 13- to 18-year-old patients, and it increases to 39% in those who are 19 years old and older.

The extensive literature on this subject and the overall impression of clinicians indicate that *periodontal disease in patients with diabetes follows no consistent or distinct pattern.* Severe gingival inflammation, deep periodontal pockets, rapid bone loss, and frequent periodontal abscesses often occur in patients with poorly controlled diabetes and poor oral hygiene[3] (Figures 11-2 and 11-3). Children with type 1 diabetes tend to have more destruction around the first molars and incisors, but this destruction becomes more generalized at older ages.[48] In patients with juvenile diabetes, extensive periodontal destruction often occurs as a consequence of having more severe disease at a younger age.

Other investigators have reported that the rate of periodontal destruction appears to be similar for those with diabetes and those without diabetes up to the age of 30 years.[92,233] After 30, patients with diabetes have a greater degree of periodontal destruction, possibly related to more disease destruction over time. Patients who have had overt diabetes for more than 10 years have a greater loss of periodontal support than those with a diabetic history of less than 10 years.[92] This destruction may also be related to the diminished tissue integrity that continues to deteriorate over time (see later sections of this chapter for a description of altered collagen metabolism).

Although some studies have not found a correlation between the diabetic state and the periodontal condition, the majority of well-controlled studies show a higher prevalence and severity of periodontal disease in individuals with diabetes as compared with nondiabetic persons with similar local factors.[14,22,39,52,111,177,179,180,236] Findings include a greater loss of attachment, increased bleeding on probing, and increased tooth mobility. A study of risk indicators for a group of 1426 patients between the ages of 25 and 74 years revealed that individuals with diabetes are twice as likely to exhibit attachment loss as nondiabetic individuals.[108] The lack of consistency across studies is most likely related to the different degrees of diabetic involvement, variations in the level of disease control and the diversity of indices, and patient sampling from one study to another.

Recent studies have suggested that uncontrolled or poorly controlled diabetes is associated with an increased susceptibility to and severity of infections, including periodontitis.[16,211] Adults who are 45 years old or older with poorly controlled diabetes (i.e., with a glycated hemoglobin level of >9%) were 2.9 times more likely to have severe periodontitis than those without diabetes. The likelihood was even greater (4.6 times) among smokers with poorly controlled diabetes.[42] As with other systemic conditions associated with periodontitis, diabetes mellitus does not cause gingivitis or periodontitis, but evidence indicates that it alters the response of the periodontal tissues to local factors, thereby hastening bone loss and delaying postsurgical healing. Frequent periodontal abscesses appear to be an important feature of periodontal disease in patients with diabetes.

Approximately 40% of adult Pima Indians in Arizona have type 2 diabetes. A comparison of individuals with or without diabetes

Figure 11-1 Periodontal condition in patients with diabetes. **A,** Adult with diabetes (blood glucose level >400 mg/dL). Note the gingival inflammation, spontaneous bleeding, and edema. **B,** The same patient as shown in **A.** Improved control of diabetes was noted after 4 days of insulin therapy (blood glucose level <100 mg/dL). The clinical periodontal condition has improved without local therapy. **C,** Adult patient with uncontrolled diabetes. Note the enlarged, smooth, erythematous gingival margins and papilla in the anterior area. **D,** The same patient as shown in **C.** This is a lingual view of the right mandibular area. Note the inflamed and swollen tissues in the anterior and premolar areas. **E,** Adult patient with uncontrolled diabetes. There is a suppurating abscess on the buccal surface of the maxillary premolars.

in this Native American tribe has shown a clear increase in the prevalence of destructive periodontitis as well as a 15% increase in edentulousness among patients with diabetes.[222] The risk of developing destructive periodontitis increases threefold in these individuals.[73]

Bacterial Pathogens. The glucose content of gingival fluid and blood is higher in individuals with diabetes than in those without diabetes with similar plaque and gingival index scores.[79] The increased glucose in the gingival fluid and blood of patients with diabetes could change the environment of the microflora, thereby inducing qualitative changes in bacteria that may contribute to the severity of periodontal disease observed in those with poorly controlled diabetes.

Patients with type 1 diabetes mellitus and periodontitis have been reported to have a subgingival flora that is composed mainly of *Capnocytophaga*, anaerobic vibrios, and *Actinomyces* species. *Porphyromonas gingivalis, Prevotella intermedia,* and *Aggregatibacter actinomycetemcomitans*, which are common in periodontal lesions of individuals without diabetes, are present in low numbers in those with the disease.[110,163] However, other studies have found scarce *Capnocytophaga* and abundant *A. actinomycetemcomitans* and black-pigmented *Bacteroides* as well as *P. intermedia, P. melaninogenica,* and *Campylobacter rectus*.[162,214] Black-pigmented species—especially *P. gingivalis, P. intermedia,* and *C. rectus*—are prominent in severe periodontal lesions of Pima Indians with type 2 diabetes.[89,267] Although these results may suggest an altered flora in the periodontal pockets of patients with diabetes, the exact role of these microorganisms has not been determined. To date, there is insufficient evidence to support the role of a specific altered microflora that is responsible for periodontal disease destruction in patients with diabetes.

Polymorphonuclear Leukocyte Function. The increased susceptibility of patients with diabetes to infection has been hypothesized as being caused by polymorphonuclear leukocyte (PMN) deficiencies that result in impaired chemotaxis, defective phagocytosis, or impaired adherence.[166,236] In patients with

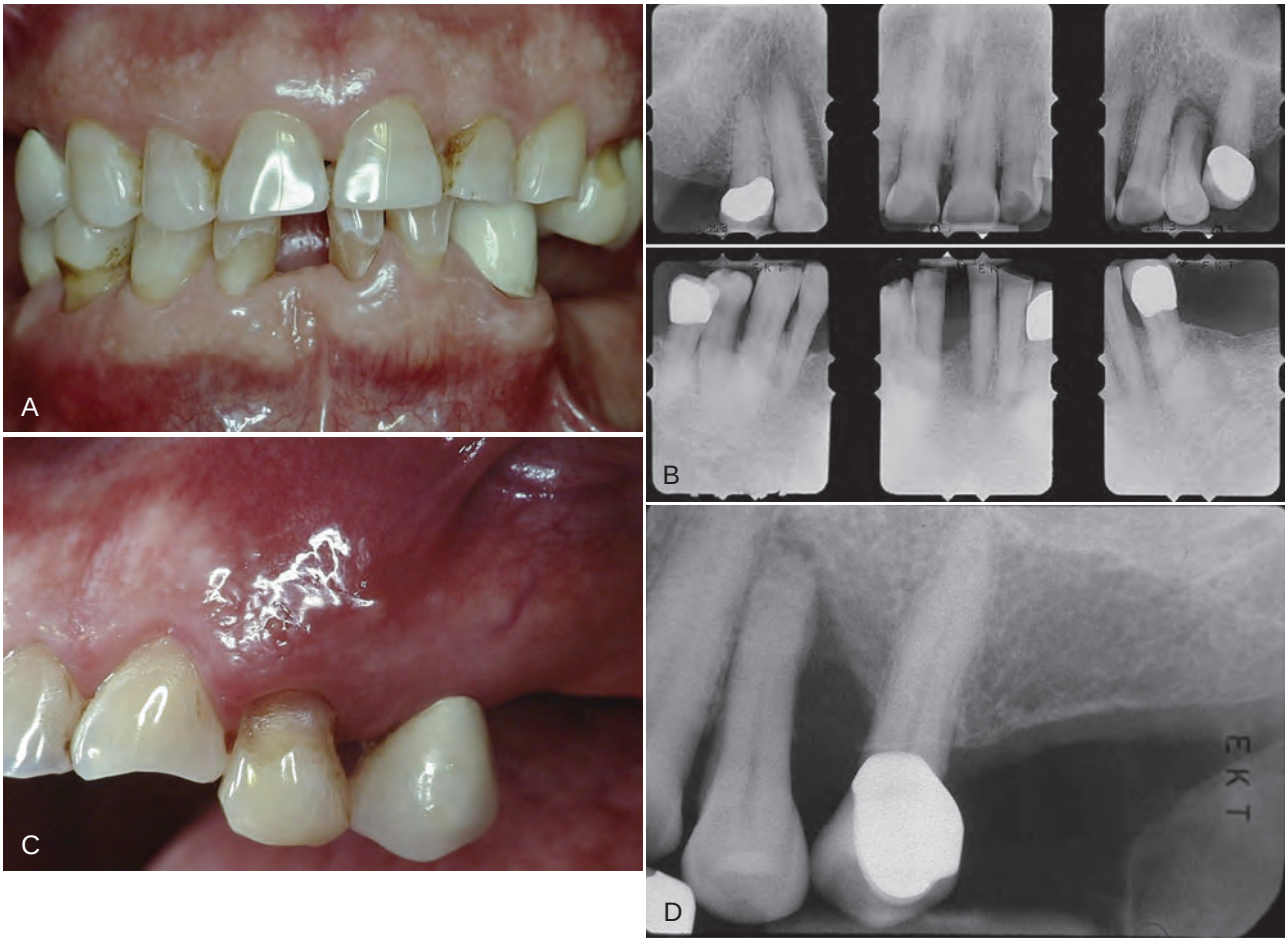

Figure 11-2 A 60-year-old patient with a long-term history of type 2 diabetes. **A,** Anterior retracted view of the patient's dental and periodontal condition. Note the missing posterior teeth, the supereruption of the premolars, and the mild generalized gingival inflammation. **B,** Periapical radiographs of the remaining teeth. Note the mild generalized bone loss with localized areas of severe bone loss. The failure to replace the posterior teeth adds to the occlusal burden of the remaining dentition. **C,** Clinical photograph of the maxillary premolar area presenting with abscess. Notice the diffuse erythema and inflammation surrounding the abscess area. **D,** Periapical radiograph of the maxillary premolar showing extensive bone loss associated with abscess.

poorly controlled diabetes, the function of PMNs, monocytes, and macrophages is impaired.[118] As a result, the primary defense mounted by PMNs against periodontal pathogens is diminished, and bacterial proliferation is more likely. No alteration of immunoglobulin A (IgA), G (IgG), or M (IgM) has been found in patients with diabetes.[204]

Altered Collagen Metabolism. Chronic hyperglycemia impairs collagen structure and function, which may directly impact the integrity of the periodontium. Decreased collagen synthesis, osteoporosis, and a reduction in alveolar bone height have been demonstrated in diabetic animals.[93,217] Chronic hyperglycemia adversely affects the synthesis, maturation, and maintenance of collagen and extracellular matrix. In the hyperglycemic state, numerous proteins and matrix molecules undergo a nonenzymatic glycosylation, thereby resulting in *accumulated glycation end-products* (AGEs). The formation of AGEs occurs at normal glucose levels as well; however, in hyperglycemic environments, AGE formation is excessive. Many types of molecules are affected, including proteins, lipids, and carbohydrates. Collagen is cross-linked by AGE formation, which makes the collagen less soluble and less likely to be normally repaired or replaced. Cellular migration through cross-linked collagen is impeded, and, perhaps more importantly, tissue integrity is impaired as a result of damaged collagen that remains in the tissues for longer periods (i.e., collagen is not renewed at a normal rate).[108] As a result, collagen in the tissues of patients with poorly controlled diabetes is older and more susceptible to pathogenic breakdown (i.e., less resistant to destruction by periodontal infections).

AGEs and receptors for AGEs (RAGEs) play a central role in the classic complications of diabetes,[33] and they may play a significant role in the progression of periodontal disease as well. Poor glycemic control, with the associated increase in AGEs, renders the periodontal tissues more susceptible to destruction.[216] The cumulative effects of altered cellular response to local factors, impaired tissue integrity, and altered collagen metabolism undoubtedly play a significant role in the susceptibility of patients with diabetes to infections and destructive periodontal disease.

Female Sex Hormones

Gingival alterations during puberty, pregnancy, and menopause are associated with physiologic hormonal changes in the female patient. During puberty and pregnancy, these changes are characterized by nonspecific inflammatory reactions with a predominant vascular component, which leads clinically to a marked hemorrhagic tendency. Oral changes during menopause may include thinning of the oral mucosa, gingival recession, xerostomia, altered taste, and burning mouth. The changes associated with each phase

Puberty. Puberty is often accompanied by an exaggerated response of the gingiva to plaque.[230] Pronounced inflammation, edema, and gingival enlargement result from local factors that might ordinarily elicit a comparatively mild gingival response (Figure 11-4). As adulthood approaches, the severity of the gingival reaction diminishes, even when local factors persist. However, the complete return to normal health requires the removal of these factors. Although the prevalence and severity of gingival disease are increased during puberty, gingivitis is not a universal occurrence for all adolescents. With good oral hygiene, it can be prevented (see Chapter 18).

Menstruation. During the menstrual period, the prevalence of gingivitis increases. Some patients may complain of bleeding gums or a bloated, tense feeling in the gums during the days preceding menstrual flow. The exudate from inflamed gingiva is increased during menstruation, which suggests that preexisting gingivitis is aggravated by menstruation; however, the crevicular fluid of normal, healthy gingiva is unaffected.[116] Tooth mobility does not change significantly during the menstrual cycle.[85] The salivary bacterial count is increased during menstruation and at ovulation, which occurs up to 14 days earlier.[196]

Figure 11-4 Gingivitis during puberty, with edema, discoloration, and enlargement of the entire gingival margin and papillary areas around the mandibular incisors.

Pregnancy. The gingival changes of pregnancy were described as early as the late 1800s, even before any knowledge about hormonal changes in pregnancy was available.[25,195] As with other systemic conditions, *pregnancy itself does not cause gingivitis*. Gingivitis during pregnancy is caused by bacterial plaque, just as it is in nonpregnant women. The hormonal changes of pregnancy accentuate the gingival response to plaque and modify the resultant clinical picture (Figure 11-5). *No notable changes occur in the gingiva during pregnancy in the absence of local factors.*

The reported incidence of gingivitis during pregnancy in well-conducted studies varies from 50% to 100%.[147,154] Pregnancy affects the severity of previously inflamed areas, but it does not alter healthy gingiva. Impressions of increased incidence may be created by the aggravation of previously inflamed but unnoticed areas. Tooth mobility, pocket depth, and gingival fluid are also increased during pregnancy.[117,144,198] The severity of gingivitis is increased during pregnancy beginning in the second or third month. Patients with mild chronic gingivitis that attracted no particular attention before the pregnancy become aware of the gingiva because previously inflamed areas become enlarged, edematous, and more notably discolored (Figure 11-5, *A* to *C*).

Gingivitis becomes more severe by the eighth month and decreases during the ninth month of pregnancy.[147] Plaque accumulation follows a similar pattern. Some investigators report that the greatest severity is between the second and third trimesters.[53] The correlation between gingivitis and the quantity of plaque is greater after parturition than during pregnancy, which suggests that pregnancy introduces other factors that aggravate the gingival response to local factors.[135]

Partial reduction in the severity of gingivitis occurs by 2 months postpartum, and, after 1 year, the condition of the gingiva is comparable to that of patients who have not been pregnant.[53] Tooth mobility, pocket depth, and gingival fluid are also reduced after pregnancy. In a longitudinal investigation of the periodontal changes that occurred during pregnancy and for 15 months postpartum, no significant loss of attachment was observed.[53]

Pronounced ease of bleeding is the most striking clinical feature. The gingiva is inflamed and varies in color from bright red to bluish red.[268,269] The marginal and interdental gingivae are edematous; they pit on pressure, appear smooth and shiny, are soft and pliable, and sometimes have a raspberry-like appearance. The extreme

Figure 11-5 Periodontal condition during pregnancy. **A,** Marginal erythema and easily bleeding gingiva in a woman who is 5 months pregnant. **B,** Localized incipient gingival enlargement between the maxillary central and lateral incisors in a woman who is 4 months pregnant. **C,** Generalized gingival enlargement of the interdental papilla and gingival margins on the facial surface of the maxillary incisors in a pregnant woman. **D,** Extensive gingival enlargement localized on the buccal surface of the mandibular premolars in a pregnant woman. These lesions are often referred to as "pregnancy tumors."

redness results from marked vascularity, and there is an increased tendency to bleed. The gingival changes are usually painless unless that are complicated by acute infection. In some cases, the inflamed gingiva forms discrete "tumorlike" masses, which are referred to as *pregnancy tumors* (Figure 11-5, *D*). Microscopically, gingival disease during pregnancy appears as nonspecific, vascularizing, and proliferative inflammation.[154,269] Marked inflammatory cellular infiltration occurs, with edema and degeneration of the gingival epithelium and connective tissue. The epithelium is hyperplastic, with accentuated rete pegs, reduced surface keratinization, and various degrees of intracellular and extracellular edema and infiltration by leukocytes.[244] Newly formed engorged capillaries are present in abundance.

The possibility that bacterial–hormonal interactions may change the composition of plaque and lead to gingival inflammation has not been extensively explored. Kornman and Loesche[136] reported that the subgingival flora changes to a more anaerobic flora as pregnancy progresses. *P. intermedia* appears to be the only microorganism that increases significantly during pregnancy. This increase appears to be associated with elevations in systemic levels of estradiol and progesterone and to coincide with the peak in gingival bleeding. It has also been suggested that, during pregnancy, a depression of the maternal T-lymphocyte response may be a factor in the altered tissue response to plaque.[181]

The aggravation of gingivitis during pregnancy has been attributed principally to the increased levels of progesterone, which produce dilation and tortuosity of the gingival microvasculature, circulatory stasis, and increased susceptibility to mechanical irritation, all of which favor the leakage of fluid into the perivascular tissues.[174,180] A marked increase in estrogen and progesterone occurs during pregnancy, with a reduction after parturition. Animal studies with radioactive estradiol have demonstrated that the gingiva is a target organ for female sex hormones.[82] The severity of gingivitis varies with the hormonal levels of pregnancy.[117]

It has also been suggested that the accentuation of gingivitis during pregnancy occurs has two peaks: during the first trimester, when there is an overproduction of gonadotropins, and during the third trimester, when estrogen and progesterone levels are highest.[147] The destruction of gingival mast cells by the increased sex hormones and the resultant release of histamine and proteolytic enzymes may also contribute to the exaggerated inflammatory response to local factors.[146]

Hormonal Contraceptives. Hormonal contraceptives aggravate the gingival response to local factors in a manner similar to that seen during pregnancy; when these drugs are taken for more than 1.5 years, there is an increase in periodontal destruction.[69,134,145] Although some brands of oral contraceptives produce more dramatic changes than others, no correlation has been found to exist on the basis of differences in the progesterone or estrogen content of various brands.[154,193] Cumulative exposure to oral contraceptives apparently has no effect on gingival inflammation or oral debris index scores.[125]

Menopause. During menopause, the usual rhythmic hormonal fluctuations of the female cycle are ended as estradiol ceases to be the major circulating estrogen.[168] As a result, females can develop a gingivostomatitis. This condition occurs during menopause or during the postmenopausal period. Mild signs and symptoms sometimes appear, and these are associated with the earliest menopausal changes. Menopausal gingivostomatitis is not a common condition. The term used for its designation has led to the erroneous impression that it invariably occurs in association with menopause, whereas the opposite is true. Oral disturbances are not a common feature of menopause.[260]

The gingiva and the remaining oral mucosa are dry and shiny, they vary in color from abnormal paleness to redness, and they bleed easily. Fissuring occurs in the mucobuccal fold in some women, and comparable changes may occur in the vaginal mucosa.[202] Microscopically, the gingiva exhibits atrophy of the germinal and prickle cell layers of the epithelium and, in some patients, areas of ulceration. The patient complains of a dry, burning sensation throughout the oral cavity that is associated with extreme sensitivity to thermal changes; abnormal taste sensations described as "salty," "peppery," or "sour"; and difficulty with removable partial prostheses.[164]

The signs and symptoms of menopausal gingivostomatitis are somewhat comparable with those of chronic desquamative gingivitis (see Chapter 19). Signs and symptoms similar to those of menopausal gingivostomatitis occasionally occur after ovariectomy or sterilization by radiation in the treatment of malignant neoplasms.

Hyperparathyroidism

Parathyroid hypersecretion produces generalized demineralization of the skeleton, increased osteoclasis with proliferation of the connective tissue in the enlarged marrow spaces, and the formation of bone cysts and giant cell tumors.[255] The disease is called *osteitis fibrosa cystica* or *von Recklinghausen's bone disease.* Loss of the lamina dura and giant cell tumors in the jaws are late signs of hyperparathyroid bone disease, which in itself is uncommon. The complete loss of the lamina dura does not occur often, and clinicians may attach too much diagnostic significance to it. The loss of lamina dura may also occur with Paget's disease, fibrous dysplasia, and osteomalacia.

Reports have suggested that 25% to 50% of patients with hyperparathyroidism have associated oral changes.[205,225,229] These changes include malocclusion and tooth mobility, radiographic evidence of alveolar osteoporosis with closely meshed trabeculae, widening of the periodontal ligament space, absence of the lamina dura (Figure 11-6), and radiolucent cystlike spaces (Figure 11-7). Bone cysts become filled with fibrous tissue with abundant hemosiderin-laden macrophages and giant cells. These cysts have been called *brown tumors,* but they are not tumors. More accurately, these cysts are reparative giant cell granulomas. In some cases, these lesions appear in the periapical region of teeth, and they can lead to a misdiagnosis of a lesion of endodontic origin.[149] A relationship has been suggested between periodontal disease in dogs and hyperparathyroidism secondary to calcium deficiency in the diet,[112] but this has not been confirmed by other studies.[231]

Figure 11-6 Secondary hyperparathyroidism in 35-year-old woman with advanced kidney disease. This periapical radiograph shows the ground-glass appearance of the bone and the loss of lamina dura. *(Courtesy Dr. L. Roy Eversole, San Francisco, CA.)*

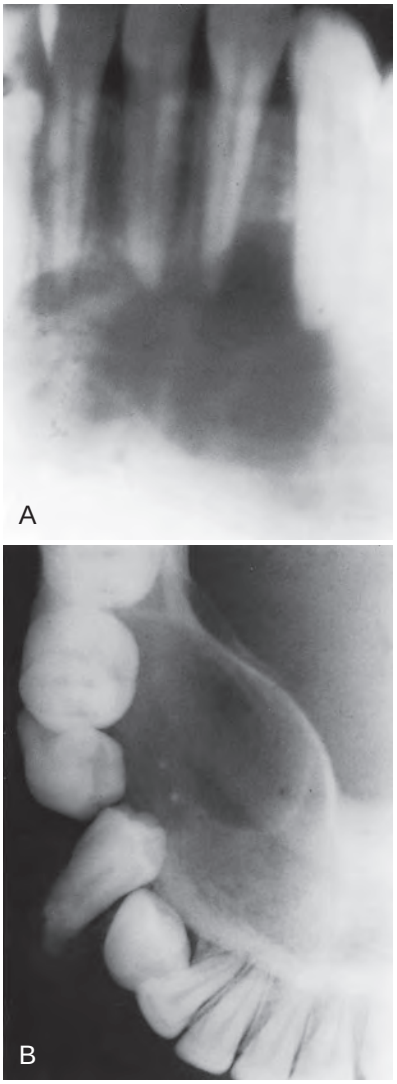

Figure 11-7 **A,** Periapical radiograph of a brown tumor in a patient with hyperparathyroidism. **B,** Occlusal radiographic view of the brown tumor. Note the expansion of the lingual cortical plate and the movement of the premolar. *(Courtesy Dr. L. Roy Eversole, San Francisco, CA.)*

Anemia

Anemia is a deficiency in the quantity or quality of the blood as manifested by a reduction in the number of erythrocytes and in the amount of hemoglobin. Anemia may be the result of blood loss, defective blood formation, or increased RBC destruction. Anemias are classified according to cellular morphology and hemoglobin content as follows: (1) macrocytic hyperchromic anemia (pernicious anemia); (2) microcytic hypochromic anemia (iron deficiency anemia); (3) sickle cell anemia; and (4) normocytic–normochromic anemia (hemolytic or aplastic anemia).

Pernicious anemia results in tongue changes in 75% of patients. The tongue appears red, smooth, and shiny as a result of atrophy of the papillae (Figure 11-21). There is also marked pallor of the gingiva (Figure 11-22). *Iron deficiency anemia* induces similar tongue and gingival changes. A syndrome that consists of glossitis and ulceration of the oral mucosa and oropharynx and that induces dysphagia (Plummer–Vinson syndrome) has been described in patients with iron deficiency anemia. *Sickle cell anemia* is a hereditary form of chronic hemolytic anemia that occurs almost exclusively in blacks. It is characterized by pallor, jaundice, weakness, rheumatoid manifestations, and leg ulcers. Oral changes include generalized osteoporosis of the jaws, with a peculiar stepladder

Figure 11-21 A smooth tongue in a patient with pernicious anemia.

Figure 11-22 The diffuse pallor of the gingiva in a patient with anemia. The discolored and inflamed gingival margin stands out in sharp contrast to the adjacent pale and attached gingiva.

alignment of the trabeculae of the interdental septa, along with pallor and yellowish discoloration of the oral mucosa. Periodontal infections may precipitate sickle cell crisis.[197] *Aplastic anemia* results from a failure of the bone marrow to produce erythrocytes. The etiology is usually the effect of toxic drugs on the marrow or the displacement of RBCs by leukemic cells. Oral changes include pale discoloration of the oral mucosa and increased susceptibility to infection because of the concomitant neutropenia.

Thrombocytopenia

Thrombocytopenia is a term that is used to describe the condition of a reduced platelet count that results from either a lack of platelet production or an increased loss of platelets. *Purpura* refers to the purplish appearance of the skin or mucous membranes where bleeding has occurred as a result of decreased platelets. *Thrombocytopenic purpura* may be idiopathic (i.e., of unknown etiology, as with Werlhof's disease), or it may occur secondary to some known etiologic factor that is responsible for a reduced amount of functioning marrow and a resultant reduction in the number of circulating platelets. Such etiologic factors include aplasia of the marrow; displacement of the megakaryocytes in the marrow, as with leukemia; replacement of the marrow by tumor; and destruction of the marrow by irradiation or radium or by drugs such as benzene, aminopyrine, and arsenical agents.

Thrombocytopenic purpura is characterized by a low platelet count, a prolonged clot retraction and bleeding time, and a normal or slightly prolonged clotting time. There is spontaneous bleeding into the skin or from the mucous membranes. Petechiae and hemorrhagic vesicles occur in the oral cavity, particularly in the palate, the tonsillar pillars, and the buccal mucosa. The gingivae are swollen, soft, and friable. Bleeding occurs spontaneously or with the slightest provocation, and it is difficult to control. *Gingival changes represent an abnormal response to local irritation.* The severity of the gingival condition is dramatically alleviated by removal of the local factors (Figure 11-23).

Antibody Deficiency Disorders

Agammaglobulinemia, or *hypogammaglobulinemia*, is an immune deficiency that results from inadequate antibody production caused by a deficiency in B cells. It can be congenital (X-linked or Bruton's agammaglobulinemia) or acquired (common variable immunodeficiency).

Congenital agammaglobulinemia is caused by an X-linked, recessive gene (Bruton's tyrosine kinase). It affects approximately 1 out of every 100,000 individuals. Because the defect is recessive and linked to the X chromosome, only males have the disease. The gene is responsible for B-cell development. In the absence of mature B cells, patients lack lymphoid tissue and fail to develop plasma cells. Thus, the production of antibodies is deficient. Germinal centers where B cells proliferate and differentiate are poorly developed in all lymphoid tissues. The tonsils, adenoids, and peripheral lymph nodes are small or absent.

Acquired or *late-onset* agammaglobulinemia is most often known as *common variable immunodeficiency disease* (CVID). The disorder is characterized by the onset of recurrent bacterial infections during the second and third decades of life as a result of drastic decreases in immunoglobulin and antibody levels. The basic immunologic defect of CVID is the failure of B-lymphocyte differentiation into plasma cells. In contrast with patients with the X-linked form of the disease, patients with CVID typically have an enlarged spleen and swollen glands or lymph nodes. Along with other autoimmune problems, some patients develop autoantibodies against their blood cells. Causes of the disease are unknown. Unlike the X-linked early onset form of the disease, CVID is not genetic, and both males and females are susceptible.

T-cell function remains normal in individuals with agammaglobulinemia. The disease, whether congenital or acquired, is characterized by recurrent bacterial infections, especially ear, sinus, and lung infections. Patients are also susceptible to periodontal infections. Aggressive periodontitis is a common finding in children who are diagnosed with agammaglobulinemia (see Figure 11-10).

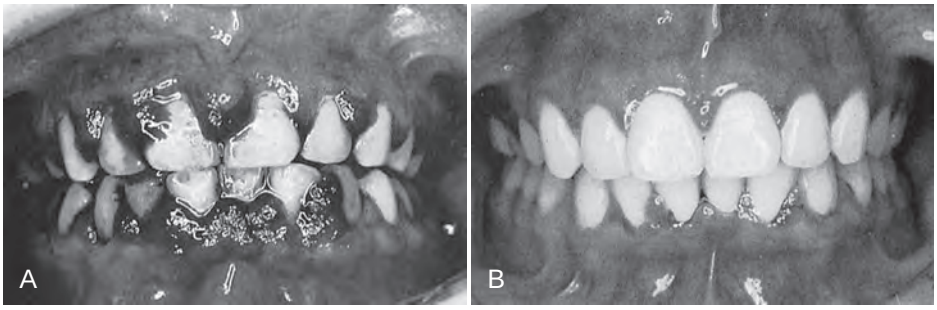

Figure 11-23 Thrombocytopenic purpura. **A,** Hemorrhagic gingivitis in a patient with thrombocytopenic purpura. **B,** The same patient as shown in **A.** There is a marked reduction in the severity of gingival disease after the removal of surface debris and careful scaling.

Figure 11-3 Abscess in a 28-year-old patient with poorly controlled type 1 diabetes. **A,** Periodontal abscess in a patient with poorly controlled diabetes. He presented with pain and abscess a few weeks after scaling and root planing of the area. **B,** Radiograph of the mandibular right premolar area demonstrating severe localized destruction of bone in the area of periodontal abscess. **C,** Radiograph of the mandibular right premolar area taken 2 months before the presentation of the abscess. Note the presence of calculus and the level of interproximal bone before the abscess occurred.

of the female life cycle from puberty to menopause are briefly addressed in the online materials associated with this book. See Chapter 38 for a detailed description of these changes, including management considerations for the periodontal manifestations of hormonal changes in the female patient.

Hematologic Disorders and Immune Deficiencies

All blood cells play an essential role in the maintenance of a healthy periodontium. White blood cells (WBCs) are involved in inflammatory reactions, and they are responsible for cellular defense against microorganisms as well as for proinflammatory cytokine release. Red blood cells (RBCs) are responsible for gas exchange and nutrient supply to the periodontal tissues and platelets, and they are necessary for normal hemostasis as well as for the recruitment of cells during inflammation and wound healing. Consequently, disorders of any blood cells or blood-forming organs can have a profound effect on the periodontium.

Certain oral changes (e.g., hemorrhage) may suggest the existence of a blood dyscrasia. However, a specific diagnosis requires a complete physical examination and a thorough hematologic study. Comparable oral changes occur in more than one form of blood dyscrasia, and secondary inflammatory changes produce a wide range of variation in the oral signs.

Gingival and periodontal disturbances associated with blood dyscrasias must be viewed in terms of fundamental interrelationships among the oral tissues, the blood cells, and the blood-forming organs rather than in terms of a simple association of dramatic oral changes with hematologic disease. Hemorrhagic tendencies occur when the normal hemostatic mechanisms are disturbed. Abnormal bleeding from the gingiva or other areas of the oral mucosa that is difficult to control is an important clinical sign that suggests a hematologic disorder. Petechiae (Figure 11-8) and ecchymosis (Figure 11-9) observed most often in the soft palate area are signs

Figure 11-8 Petechiae evident on the soft palate of a patient with an underlying bleeding disorder (thrombocytopenia).

Figure 11-9 Ecchymosis that is evident on the lateral aspects of the soft palate and tonsillar pillars of a patient with chemotherapy-induced thrombocytopenia.

of an underlying bleeding disorder. It is essential to diagnose the specific etiology to appropriately address any bleeding or immunological disorder.

Deficiencies in the host immune response may lead to severely destructive periodontal lesions. These deficiencies may be primary (inherited) or secondary (acquired) and caused by either immunosuppressive drug therapy or the pathologic destruction of the lymphoid system. Leukemia, Hodgkin's disease, lymphomas, and multiple myeloma may result in secondary immunodeficiency disorders. This section discusses common hematologic and certain immunodeficiency disorders that are not related to the human immunodeficiency virus or acquired immunodeficiency syndrome. See Chapter 26 for a detailed discussion of patients with human immunodeficiency virus infection.

Leukocyte (Neutrophil) Disorders

Disorders that affect the production or function of leukocytes may result in severe periodontal destruction. PMNs (neutrophils) in particular play a critical role in bacterial infections, because PMNs are the first line of defense (see Chapter 9). A quantitative deficiency of leukocytes (e.g., neutropenia, agranulocytosis) is typically associated with a more generalized periodontal destruction that affects all teeth.

Neutropenia. Neutropenia is a blood disorder that results in low levels of circulating neutrophils. It is a serious condition that may be caused by diseases, medications, chemicals, infections, idiopathic conditions, or hereditary disorders. It may be chronic or cyclic and severe or benign. It affects as many as one in three patients who are receiving chemotherapy for cancer. An absolute neutrophil count (ANC) of 1000 to 1500 cells/μL is diagnostic for mild neutropenia. An ANC of 500 to 1000 cells/μL is considered moderate neutropenia, and an ANC of less than 500 cells/μL indicates a severe neutropenia. Infections are sometimes difficult to manage and may be life threatening, particularly with severe neutropenia.

Agranulocytosis. Agranulocytosis is a more severe neutropenia that involves not only neutrophils but also basophils and eosinophils. It is defined as an ANC of less than 100 cells/μL. It is characterized by a reduction in the number of circulating granulocytes, and it results in severe infections, including ulcerative necrotizing lesions of the oral mucosa, the skin, and the gastrointestinal and genitourinary tracts. Less severe forms of the disease are called *neutropenia* or *granulocytopenia.*

Drug idiosyncrasy is the most common cause of agranulocytosis, but, in some cases, its cause cannot be explained. Agranulocytosis has been reported after the administration of drugs such as aminopyrine, barbiturates and their derivatives, benzene ring derivatives, sulfonamides, gold salts, and arsenical agents.[137,153,170,197] It generally occurs as an acute disease. It may be chronic or periodic, with recurring neutropenic cycles (e.g., cyclic neutropenia).[237]

The onset of disease is accompanied by fever, malaise, general weakness, and sore throat. Ulceration in the oral cavity, the oropharynx, and the throat is characteristic. The mucosa exhibits isolated necrotic patches that are black and gray and that are sharply demarcated from the adjacent uninvolved areas.[128,157] The absence of a notable inflammatory reaction caused by a lack of granulocytes is a striking feature. The gingival margin may or may not be involved. Gingival hemorrhage, necrosis, increased salivation, and fetid odor are accompanying clinical features. With cyclic neutropenia, the gingival changes recur with recurrent exacerbation of the disease.[51] The occurrence of generalized aggressive periodontitis has been described in patients with cyclic neutropenia[220] (Figure 11-10).

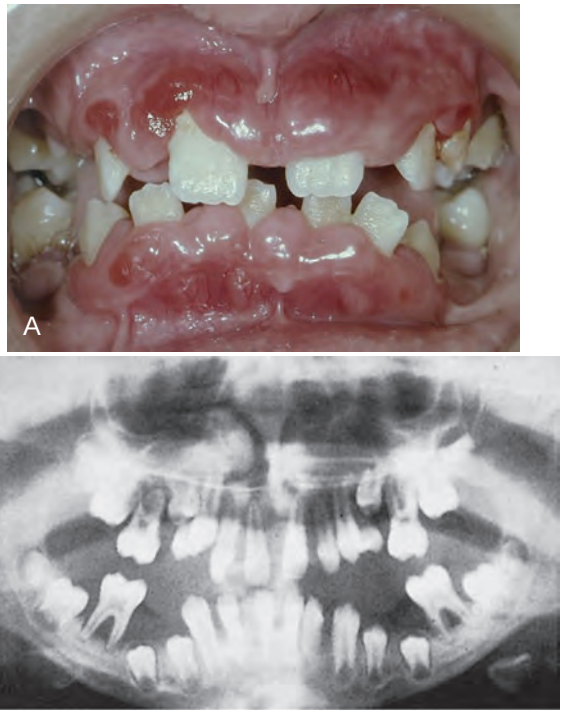

Figure 11-10 Aggressive periodontitis in 10-year-old boy with cyclic neutropenia and agammaglobulinemia. **A,** Clinical presentation of the periodontal condition. Note the severe swelling and inflammation of the marginal and papillary gingiva. There is gross migration of teeth caused by a loss of bone support. **B,** Panoramic radiograph demonstrating severe bone loss around all permanent teeth that have erupted into the oral cavity.

Because infection is a common feature of agranulocytosis, the differential diagnosis involves consideration of such conditions as necrotizing ulcerative gingivitis, noma, acute necrotizing inflammation of the tonsils, and diphtheria. Definitive diagnosis depends on the hematologic findings of pronounced leukopenia and the almost complete absence of neutrophils.

Leukemia

Leukemia is an important disease to understand and appreciate because of its seriousness and its periodontal manifestations. The leukemias are malignant neoplasias of WBC precursors that are characterized by the following: (1) the diffuse replacement of the bone marrow with proliferating leukemic cells; (2) abnormal numbers and forms of immature WBCs in the circulating blood; and (3) widespread infiltrates in the liver, spleen, lymph nodes, and other body sites.[203]

According to the cell type involved, leukemias are classified as *lymphocytic* or *myelogenous*. A subgroup of the myelogenous leukemias are the *monocytic* leukemias. The term *lymphocytic* indicates that the malignant change occurs in cells that normally form lymphocytes. The term *myelogenous* indicates that the malignant change occurs in cells that normally form RBCs, some types of WBCs, and platelets. According to their evolution, leukemias can be *acute* (which is rapidly fatal), *subacute,* or *chronic.* In acute leukemia, the primitive "blast" cells released into the peripheral circulation are immature and nonfunctional; in chronic leukemia, the abnormal cells tend to be more mature and to have normal morphologic characteristics and functions when released into the circulation.

Figure 11-11 Spontaneous bleeding from the gingival sulcus in a patient with thrombocytopenia. Normal coagulation is evident by the appearance of the large clot that forms in the mouth. However, platelets are inadequate to establish hemostasis at the site of hemorrhage.

All leukemias tend to displace normal components of the bone marrow elements with leukemic cells, thereby resulting in the reduced production of normal RBCs, WBCs, and platelets, which leads to anemia, *leukopenia* (a reduction in the number of *nonmalignant* WBCs), and thrombocytopenia. Anemia results in poor tissue oxygenation, thereby making tissues more friable and susceptible to breakdown. A reduction of normal WBCs in the circulation leads to a poor cellular defense and an increased susceptibility to infections. *Thrombocytopenia* leads to bleeding tendency, which can occur in any tissue but which in particular affects the oral cavity, especially the gingival sulcus (Figure 11-11). Some patients may have normal blood counts while leukemic cells reside primarily in the bone marrow. This type of disease is called *aleukemic leukemia*.[99]

The Periodontium in Leukemic Patients. Oral and periodontal manifestations of leukemia may include leukemic infiltration, bleeding, oral ulcerations, and infections. The expression of these signs is more common with acute and subacute forms of leukemia than with chronic forms.

Leukemic Infiltration. Leukemic cells can infiltrate the gingiva and, less frequently, the alveolar bone. Gingival infiltration often results in *leukemic gingival enlargement* (see Chapter 16).

A study of 1076 adult patients with leukemia showed that 3.6% of the patients with teeth had leukemic gingival proliferative lesions, with the highest incidence seen in patients with acute monocytic leukemia (66.7%), followed by those acute myelocytic–monocytic leukemia (18.7%) and acute myelocytic leukemia (3.7%).[65] It should be noted, however, that monocytic leukemia is an extremely rare form of the disease. Leukemic gingival enlargement is not found in edentulous patients or in patients with chronic leukemia, thereby suggesting that it is the accumulation of immature leukemic blast cells in the gingiva adjacent to tooth surfaces with bacterial plaque. Leukemic gingival enlargement consists of a basic infiltration of the gingival corium by leukemic cells that increases the gingival thickness and that creates gingival pockets in which bacterial plaque accumulates, thereby initiating a secondary inflammatory lesion that contributes to the enlargement of the gingiva. It may be localized to the interdental papilla area (Figure 11-12), or it may expand to include the marginal gingiva and partially cover the crowns of the teeth (Figure 11-13, *C* and *D*). Clinically, the gingiva appears bluish red and cyanotic, with a rounding and tenseness of the gingival margin. The abnormal accumulation

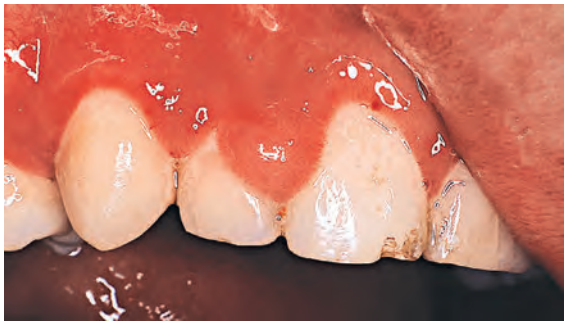

Figure 11-12 Leukemic infiltration that causes localized gingival swelling of the interdental papillae between the maxillary lateral and central incisors. Note the tense induration of the area.

of leukemic cells in the dermal and subcutaneous connective tissue is called *leukemia cutis,* and it forms elevated and flat macules and papules[65,203] (Figure 11-13, *A* and *B*).

Microscopically, the gingiva exhibits a dense, diffuse infiltration of predominantly immature leukocytes in the attached and marginal gingiva. Occasionally, mitotic figures indicative of ectopic hematopoiesis may be seen. The normal connective tissue components of the gingiva are displaced by the leukemic cells (Figure 11-14). The nature of the cells depends on the type of leukemia. The cellular accumulation is denser in the entire reticular connective tissue layer. In almost all cases, the papillary layer contains comparatively few leukocytes. The blood vessels are distended and contain predominantly leukemic cells, and the RBCs are reduced in number. The epithelium presents a variety of changes, and it may be thinned or hyperplastic. Common findings include degeneration associated with intercellular and intracellular edema and leukocytic infiltration with diminished surface keratinization.

The microscopic picture of the marginal gingiva differs from that of other gingival locations in that it usually exhibits a notable inflammatory component in addition to the leukemic cells. Scattered foci of plasma cells and lymphocytes with edema and degeneration are common findings. The inner aspect of the marginal gingiva is usually ulcerated, and marginal necrosis with pseudomembrane formation may also be seen.

The periodontal ligament and alveolar bone may also be involved in acute and subacute leukemia. The periodontal ligament may be infiltrated with mature and immature leukocytes. The marrow of the alveolar bone exhibits a variety of changes, such as localized areas of necrosis, thrombosis of the blood vessels, infiltration with mature and immature leukocytes, occasional RBCs, and the replacement of the fatty marrow with fibrous tissue.

In leukemic mice, the presence of infiltrate in marrow spaces and the periodontal ligament results in osteoporosis of the alveolar bone with destruction of the supporting bone and disappearance of the periodontal fibers[31,40] (Figure 11-15).

Bleeding. Gingival hemorrhage is a common finding in leukemic patients (see Figure 11-11), even in the absence of clinically detectable gingivitis. Bleeding gingiva can be an early sign of leukemia. It is caused by the thrombocytopenia that results from the replacement of the bone marrow cells with leukemic cells and from the inhibition of normal stem cell function by leukemic cells or their products.[203] This bleeding tendency can also manifest in the skin and throughout the oral mucosa, where petechiae are often found, with or without leukemic infiltrates. A more diffuse submucosal bleeding manifests as ecchymosis (see Figure 11-9). Oral bleeding has been reported as a presenting sign in 17.7% of patients with acute leukemia and in 4.4% of patients with chronic leukemia.[152]

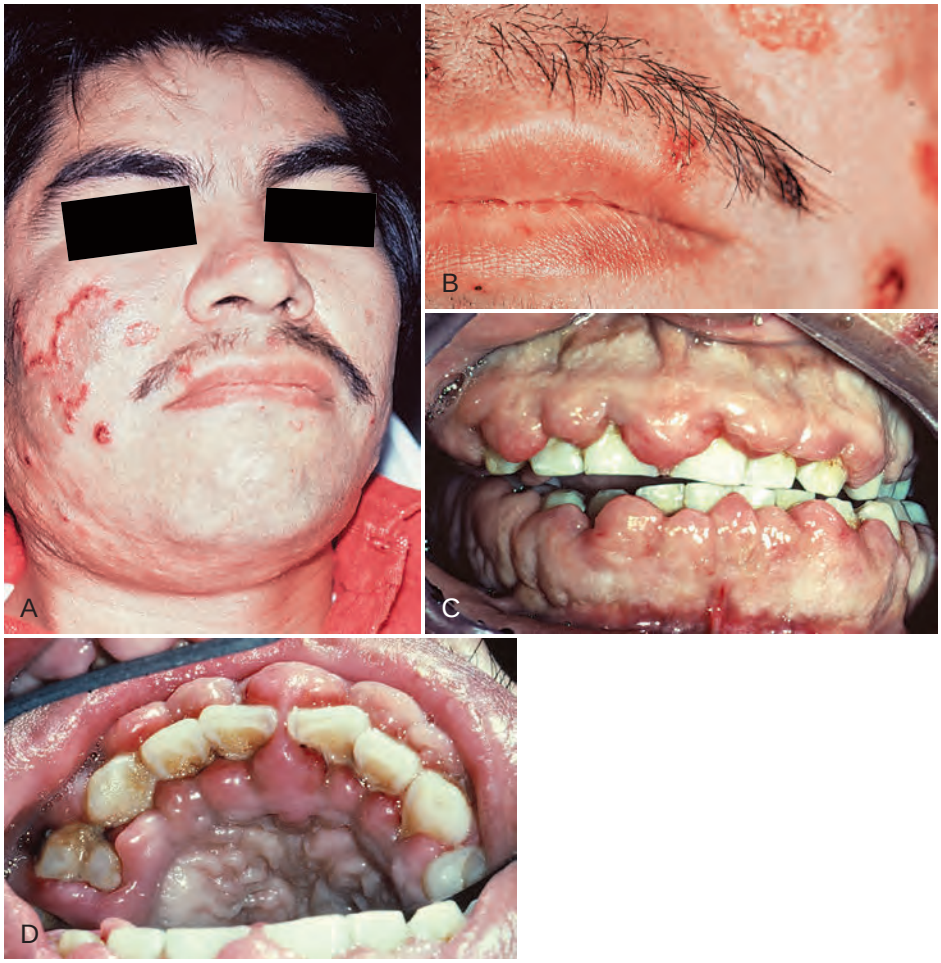

Figure 11-13 Adult male with acute myelocytic leukemia. **A,** A view of the patient's face. Note the elevated, flat macules and papules (leukemia cutis) on the right cheek. **B,** Close-up view of skin lesions. **C,** An intraoral view showing pronounced gingival enlargements of the entire gingival margin and interdental papilla areas of both arches. **D,** Occlusal view of the maxillary anterior teeth. Note the marked enlargement in both the facial and the palatal aspects. *(Courtesy Dr. Spencer Woolfe, Dublin, Ireland.)*

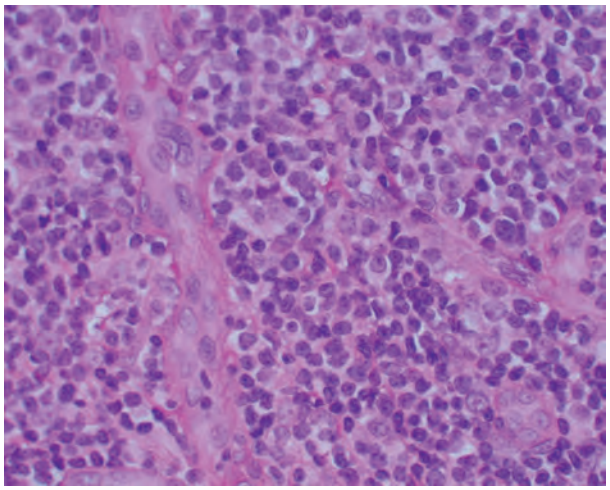

Figure 11-14 Human histologic appearance of leukemic infiltrate with dense diffuse infiltration of predominantly immature leukocytes. The normal connective tissue components of the gingiva are displaced by the leukemic cells. The cellular accumulation is denser in the entire reticular connective tissue layer. *(Courtesy Dr. Russell Christensen, University of California, Los Angeles, CA.)*

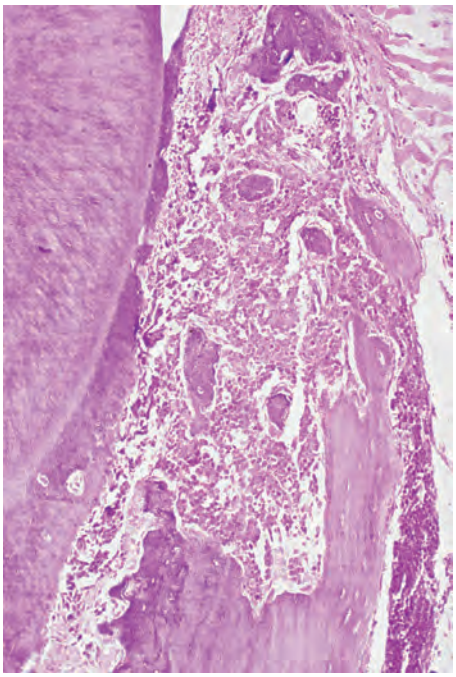

Figure 11-15 Leukemic infiltrate in alveolar bone in a leukemic mouse. Note the leukemic infiltrate causing destruction of the bone and a loss of the periodontal ligament.

Bleeding may also be a side effect of the chemotherapeutic agents used to treat leukemia.

Oral Ulceration and Infection. In patients with leukemia, the response to bacterial plaque or other local irritation is altered. The cellular component of the inflammatory exudate differs both quantitatively and qualitatively from that found in nonleukemic individuals in that there is a pronounced infiltration of immature leukemic cells in addition to the usual inflammatory cells. As a result, the normal inflammatory response may be diminished.

Granulocytopenia (diminished WBC count) results from the displacement of normal bone marrow cells by leukemic cells, which increases the host susceptibility to opportunistic microorganisms and leads to ulcerations and infections. Discrete, punched-out ulcers that penetrate deeply into the submucosa and that are covered by a firmly attached white slough can be found on the oral mucosa.[15] These lesions occur in sites of trauma (e.g., the buccal mucosa) in relation to the line of occlusion or on the palate. Patients with a history of herpesvirus infection may develop recurrent herpetic oral ulcers (often in multiple sites) and large atypical forms, especially after chemotherapy is instituted[104] (Figure 11-16).

A gingival (bacterial) infection in leukemic patients can be the result of an exogenous bacterial infection or an existing bacterial infection (e.g., gingival or periodontal disease). Acute gingivitis and lesions that resemble necrotizing ulcerative gingivitis are more frequent and severe in patients with terminal cases of acute leukemia[21] (Figures 11-17 and 11-18). The inflamed gingiva in patients with leukemia differs clinically from that found in nonleukemic individuals. The gingiva is a peculiar bluish red, it is spongelike and friable, and it bleeds persistently on the slightest provocation or even spontaneously in leukemic patients. This greatly altered and degenerated tissue is extremely susceptible to bacterial infection, which can be so severe as to cause acute gingival necrosis with pseudomembrane formation (Figure 11-19) or bone exposure (Figure 11-20). These are secondary oral changes that are superimposed on the oral tissues altered by the blood dyscrasia. They produce associated disturbances that may be a source of considerable difficulty to the patient, such as systemic toxic effects, loss of

Figure 11-16 Large ulcerations on the palate of a patient with granulocytopenia secondary to leukemia. These atypical ulcerations are caused by a herpesvirus opportunistic infection. Notice the smaller, discrete, round ulcerations that have coalesced into the larger lesion.

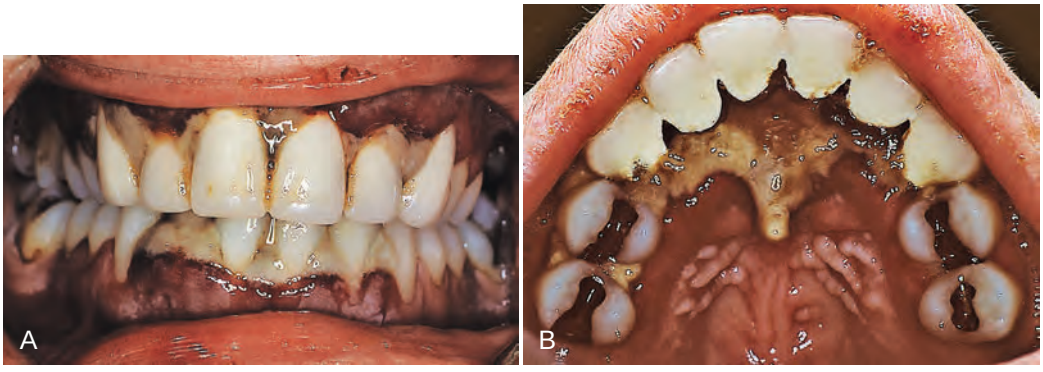

Figure 11-17 Adult female with acute myelocytic leukemia. **A,** Anterior view of a patient with acute myelocytic leukemia. The interdental papillae are necrotic, with highly inflamed and swollen gingival tissue at the base of the lesions. **B,** Palatal view demonstrating extensive necrosis of the interdental and palatal tissues behind the maxillary incisors.

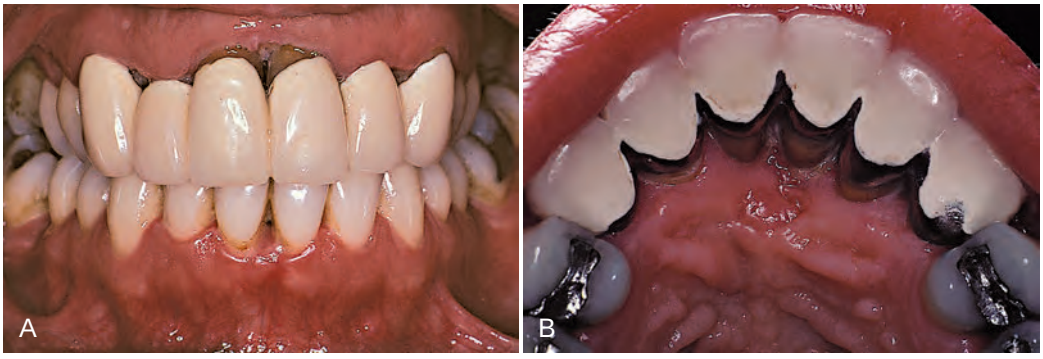

Figure 11-18 The same patient as was shown in Figure 11-17 after chemotherapy that resulted in the remission of her leukemia. **A,** An anterior view reveals dramatic improvement in gingival health after the remission of leukemia. Note the loss of interdental papillae as well as gingival recession in the anterior areas. **B,** A palatal view shows the extensive loss of gingival tissue around the maxillary incisors.

Figure 11-19 An opportunistic bacterial infection of the gingiva in a patient who has been hospitalized with leukemia. The gingival tissue is highly inflamed, bleeding, and necrotic, with pseudomembrane formation.

Figure 11-20 An opportunistic bacterial infection in the immunosuppressed patient caused the complete destruction of the gingiva, thus exposing the underlying alveolar bone.

appetite, nausea, blood loss from persistent gingival bleeding, and constant gnawing pain. Eliminating or reducing local factors (e.g., bacterial plaque) can minimize the severe oral changes associated with leukemia. In some patients with severe acute leukemia, symptoms may only be relieved by treatment that leads to the remission of the disease.

In those with chronic leukemia, oral changes that suggest a hematologic disturbance are rare. The microscopic changes of chronic leukemia may consist of replacing the normal fatty marrow of the jaws with islands of mature lymphocytes or lymphocytic infiltration of the marginal gingiva without dramatic clinical manifestations.

The existence of leukemia is sometimes revealed by a gingival biopsy performed to clarify the nature of a troublesome gingival condition. In such cases, the gingival findings must be corroborated by medical examination and hematologic study. In patients with diagnosed leukemia, gingival biopsy may indicate the extent to which leukemic infiltration is responsible for the altered clinical appearance of the gingiva. *Although such findings are of interest, their benefit to the patient is insufficient to warrant routine gingival biopsy studies in patients with leukemia.* Furthermore, it is important to note that the absence of leukemic involvement in a gingival biopsy specimen does not rule out the possibility of leukemia. A gingival biopsy in a patient with chronic leukemia may reveal typical gingival inflammation without any suggestion of a hematologic disturbance.

Genetic Disorders

Many systemic conditions associated with or that predispose an individual to periodontal destruction include genetic disorders that result in an inadequate number or reduced function of circulating neutrophils. This underscores the importance of the neutrophil in the protection of the periodontium against infection. Severe periodontitis has been observed in individuals with primary neutrophil disorders such as neutropenia, agranulocytosis, Chédiak–Higashi syndrome, and lazy leukocyte syndrome. In addition, severe periodontitis has also been observed in individuals who exhibit secondary neutrophil impairment, which is seen in those with Down syndrome, Papillon–Lefèvre syndrome, and inflammatory bowel disease. See the online material for this chapter as well as for Chapter 6 for detailed descriptions of the periodontal manifestations of these genetic disorders and syndromes.

Stress and Psychosomatic Disorders

Psychologic conditions, particularly psychosocial stress, have been implicated as risk indicators for periodontal disease.[87] The most notable example is the documented relationship between stress (e.g., experienced by soldiers at war or by students during examinations) and acute necrotizing ulcerative gingivitis (see Chapters 17 and 24). The presence of necrotizing ulcerative gingivitis among soldiers stressed by wartime conditions in the trenches led to one of the early diagnostic terms used to describe this condition: "trench mouth." Despite this well-known association between stress and necrotizing ulcerative gingivitis, confirming the connection between psychologic conditions and other forms of periodontal disease (e.g., chronic periodontitis) has been elusive. These relationships are difficult to elucidate, because, as with many common diseases, the etiology and pathogenesis of periodontal disease is multifactorial, and the role of individual risk factors is difficult to define.

Some studies have failed to recognize a relationship between psychological conditions and periodontal disease despite specific efforts to identify them. In a study of 80 patients (40 with aggressive periodontitis and 40 with chronic periodontitis), Monteiro da Silva and colleagues failed to find a relationship between psychologic factors and periodontal disease.[176] The researchers were able to identify depression and smoking as marginally significant in the aggressive periodontitis group. Their inability to find a relationship may be attributed to a lack of significant differences in psychologic characteristics between the two groups in the study. In an earlier study, the same group identified depression and loneliness as significant factors associated with aggressive periodontal disease in 50 patients as compared with 50 periodontally healthy individuals and 50 individuals with chronic periodontitis.[175] Another challenge when defining the relationship between psychosocial status and periodontitis is the myriad of confounding factors and the difficulty involved with controlling for them.[67]

Psychosocial Stress, Depression, and Coping

Recently, several clinical studies and a systematic review of the subject have documented a positive relationship between psychosocial stress and chronic forms of periodontal disease.[194] In case-control studies, individuals with stable lifestyles (based on family structure and employment status) and minimal negative life events had less periodontal disease destruction than individuals with less stable lifestyles (e.g., unmarried, unemployed) and more negative life events.[58] Interestingly, it is now becoming apparent that the effect is not simply a matter of the presence of stress versus a lack of stress but rather the type of stress as well as the ability of the individual to cope with stress that correlate with destructive periodontal disease.

All individuals experience stress, but these events do not invariably result in destructive periodontitis. The types of stress that lead to periodontal destruction appear to be more chronic or long term

Chédiak–Higashi Syndrome

Chédiak–Higashi syndrome is a rare disease that affects the production of organelles found in almost every cell. It affects mostly the melanocytes, platelets, and phagocytes. It causes partial albinism, mild bleeding disorders, and recurrent bacterial infections. Neutrophils contain abnormal, giant lysosomes that can fuse with the phagosome, but their ability to release their contents is impaired. As a result, the killing of ingested microorganisms is delayed. Patients with Chédiak–Higashi syndrome are susceptible to repeated infections that can be serious and life threatening. Aggressive periodontitis has been described in these patients. Chédiak–Higashi syndrome has been described as a genetically transmitted disease in ranch-raised mink[11,189] (see Chapter 6).

Lazy Leukocyte Syndrome

Lazy leukocyte syndrome is characterized by an individual's susceptibility to severe microbial infections, neutropenia, defective chemotactic response by neutrophils, and an abnormal inflammatory response.[192] Those who are diagnosed with lazy leukocyte syndrome are susceptible to aggressive periodontitis, with the destruction of bone and early tooth loss.

Leukocyte Adhesion Deficiency

Leukocyte adhesion deficiency (LAD) is a very rare genetic disorder; only a few hundred cases have been diagnosed. Because LAD is an inherited disease, it is categorized as a primary immunodeficiency that is most often diagnosed at birth. Many children with LAD do not survive.

LAD results from an inability to produce or a failure to normally express an important cell surface integrin (CD18), which is necessary for leukocytes to adhere to the vessel wall at the site of infection. When leukocytes cannot effectively adhere to the vessel wall near the site of infection, they cannot migrate to the infection. As a result, bacterial infections are able to continue to destroy host tissues unimpeded by the normal host immune response. Infections act similarly to those observed in neutropenic patients, because phagocytes are unable to reach the site of infection.

Cases of periodontal disease that are attributed to LAD are rare. They begin during or immediately after the eruption of the primary teeth. Extremely acute inflammation and proliferation of the gingival tissues with the rapid destruction of bone are found. Profound defects in peripheral blood neutrophils and monocytes and an absence of neutrophils in the gingival tissues have been noted in patients with LAD.[188,189] These patients also have frequent respiratory tract infections and sometimes otitis media. Both the primary and permanent teeth are affected, often resulting in early tooth loss.[253]

Papillon–Lefèvre Syndrome

Papillon–Lefèvre syndrome, which was first described by French physicians Papillon and Lefèvre,[190] is a very rare inherited condition that appears to follow an autosomal-recessive pattern. Parents are not affected, and both must carry the autosomal genes for the syndrome to appear in their offspring. It may occur in siblings, and it has no gender predilection. The estimated frequency is 1 to 4 cases per 1 million individuals. Rare cases of adult onset of this syndrome, although with mild periodontal lesions, have also been described.[36]

The syndrome is characterized by hyperkeratotic skin lesions, severe destruction of the periodontium, and, in some cases, calcification of the dura.[41,77] The cutaneous and periodontal changes usually appear together when the patient is between the ages of 2 and 4 years. The skin lesions consist of hyperkeratosis and ichthyosis of localized areas on the palms, soles, knees, and elbows (Figure 11-24).

Periodontal involvement consists of early inflammatory changes that lead to bone loss and exfoliation of teeth. The primary teeth are lost by 5 or 6 years of age. The permanent dentition then erupts normally, but, within a few years, the permanent teeth are also lost as a result of destructive periodontal disease (Figure 11-25). At a very early age (usually 15 to 20 years), patients are often edentulous except for the third molars. These may be lost as well a few years after eruption. Tooth extraction sites heal uneventfully.[78]

There are few case reports of successful tooth retention in patients with Papillon–Lefèvre syndrome.[241,258] The successful

Figure 11-24 Papillon-Lefèvre syndrome in a 17-year-old boy. **A,** A clinical view of the palms demonstrates hyperkeratosis of skin. **B,** A clinical view of the knees, which have hyperkeratotic scaly lesions.

Figure 11-25 The same patient as shown in Figure 11-24. This intraoral clinical view of a 17-year-old boy with Papillon-Lefèvre syndrome shows early tooth loss and severe bone loss around the remaining teeth as evidenced by gingival recession. The missing teeth were exfoliated.

retention of permanent teeth may be associated with timing treatment (i.e., antibiotics and the extraction of erupted teeth) with the severity of syndrome symptoms.[258] The extraction of all primary teeth followed by a period of edentulousness may partially explain the lack of recurrent infection. In their review of the literature, Wiebe and colleagues reported that the symptoms of Papillon–Lefèvre syndrome diminish with age and that teeth that erupt later may not be lost.[258]

The microscopic changes reported include marked chronic inflammation of the lateral wall of the pocket with a predominantly plasma cell infiltrate, considerable osteoclastic activity with an apparent lack of osteoblastic activity, and an extremely thin cementum.[158] Bacterial flora studies of plaque in a patient with Papillon–Lefèvre syndrome revealed a similarity to bacterial flora in patients with chronic periodontitis.[150] Spirochete-rich zones in the apical portion of the pockets as well as spirochete adherence to the cementum and microcolony formation of *Mycoplasma* species have been reported with Papillon–Lefèvre syndrome.[124] Gram-negative cocci and rods appear at the apical border of the plaque.[249] Although Schroeder and colleagues[219] failed to show defects in peripheral blood neutrophils in a 10-year-old male patient with Papillon–Lefèvre syndrome, others have implicated neutrophil defects as a contributing factor. Firatli and colleagues[80] reported depressed chemotaxis of peripheral neutrophils and suggested that this explained the pathogenesis of the Papillon–Lefèvre syndrome. Ghaffar and colleagues found significantly depressed neutrophil function in probands with Papillon–Lefèvre syndrome with respect to phagocytic and lytic activity.[91]

Down Syndrome

Down syndrome (mongolism, trisomy 21) is a congenital disease caused by a chromosomal abnormality and characterized by mental deficiency and growth retardation. The prevalence of periodontal disease in patients with Down syndrome is high, occurring in almost 100% of patients who are less than 30 years old.[54,61] Although plaque, calculus, and local irritants (e.g., diastemata, crowding of teeth, high frenum attachments, malocclusion) are present and oral hygiene is poor, the severity of periodontal destruction exceeds that explainable by local factors alone.[50,52,54,201,232]

Figure 11-26 Severe periodontal destruction in a 14-year-old patient with Down syndrome. Note the extensive loss of periodontal support around the mandibular incisors as evidenced by severe gingival recession. Moderate to heavy bacterial plaque is associated with moderate gingival inflammation in the area.

Periodontal disease in those with Down syndrome is characterized by the formation of deep periodontal pockets associated with substantial plaque accumulation and moderate gingivitis (Figure 11-26). These findings are usually generalized, although they tend to be more severe in the lower anterior region. Moderate recession is sometimes seen in this region as well. The disease progresses rapidly. The high prevalence and increased severity of periodontal destruction associated with Down syndrome is most likely explained by poor PMN chemotaxis, phagocytosis, and intracellular killing.[12,13,55,59,105,121,129]

and less likely to be controlled by the individual. Life events such as the loss of a loved one (e.g., spouse, family member), a failed relationship, loss of employment, and financial difficulties are examples of stressful life events that are typically not controllable by the individual or not perceived by the individual as being under his or her control, thereby rendering the person with a feeling of "helplessness." The duration of the stressful life event will also have an influence on the total impact of the stress-induced disease destruction.

Financial stress is an example of a long-term, constant pressure that may exacerbate periodontal destruction in susceptible individuals. Genco and colleagues[88] found that individuals with high levels of financial stress and poor coping skills had twice as much periodontal disease as those with minimal stress and good coping skills. Psychologic tests were used to identify and weigh the causes of stress, such as children, spouse, finances, single life, and work and to measure individual coping skills. Individuals with problem-focused (practical) coping skills fared better than individuals with emotion-focused (avoidance) coping skills with respect to periodontal disease. As part of their analysis, the researchers also found that chronic stress and inadequate coping could lead to changes in daily habits, such as poor oral hygiene, clenching, and grinding as well as physiologic changes such as decreased saliva flow and suppressed immunity.

When comparing 89 patients with periodontal disease to 63 periodontally healthy individuals, Wimmer and colleagues[259] found that patients with defensive (emotional) coping skills were more likely to refuse responsibility and to downplay their conditions. All patients completed a comprehensive stress assessment questionnaire (given in German) to evaluate their coping behavior. Patients with periodontal disease were less likely to use "active" coping skills (i.e., situation control) and more likely to cope with stress by averting blame (emotional) than were periodontally healthy individuals.

These studies support the concept that one of the most important aspects related to the influence of stress on periodontal disease destruction is the manner in which the individual copes with the stress. Emotional coping methods appear to render the host more susceptible to the destructive effects of periodontal disease than do practical coping methods. Furthermore, emotional coping is more common in situations that must be accepted and among individuals who feel helpless in the situation.

Stress-Induced Immunosuppression

Stress and psychosomatic disorders most likely impact periodontal health via changes in the individual's behavior and through complex interactions among the nervous, endocrine, and immune systems. Individuals under stress may have poorer oral hygiene, they may start or increase the clenching and grinding of their teeth, and they may smoke more frequently. All of these behavioral changes increase their susceptibility to periodontal disease destruction. Likewise, individuals who are under stress may be less likely to seek professional care.

In addition to the many behavioral changes that may influence periodontal disease destruction, psychosocial stress may also impact the disease through alterations in the immune system. The influence of stress on the immune system and systemic health conditions (e.g., cardiovascular disease) is well known. Stress-related immune system changes clearly have the potential to affect the pathogenesis of periodontal disease as well. One possible mechanism involves the production of cortisol. Stress increases cortisol production from the adrenal cortex by stimulating an increase in the release of adrenocorticotropic hormone from the pituitary gland. Increased cortisol suppresses the immune response directly through the suppression of neutrophil activity, immunoglobulin G production, and salivary immunoglobulin A secretion. All of these immune responses are critical for the normal immunoinflammatory response to periodontal pathogens (see Chapter 5). The resulting "stress-induced" immunosuppression increases the potential for destruction by periodontal pathogens. Stress may also affect the cellular immune response directly through an increased release of neurotransmitters, including epinephrine, norepinephrine, neurokinin, and substance P, which interact directly with lymphocytes, neutrophils, monocytes, and macrophages via receptors that cause an increase in their tissue-destructive function. Thus, in a manner similar to cortisol production, the "stress-induced" release of these neurotransmitters results in an upregulated immune response that increases the potential for destruction by the cellular response to periodontal pathogens.

It is important to remember that, although stress may predispose an individual to more destruction from periodontitis, the presence of periodontal pathogens remains as the essential etiologic factor. In other words, stress alone does not cause or lead to periodontitis in the absence of periodontal pathogens.

Influence of Stress on Periodontal Therapy Outcomes

Psychologic conditions such as stress and depression may also influence the outcome of periodontal therapy. In a large-scale retrospective study of 1299 dental records from a health maintenance organization database, 85 individuals with depression had post-therapy outcomes that were less favorable (below median) as compared with the outcomes of individuals without depression.[72] More than half of these records (697) were complete enough for a comprehensive evaluation that included both periodontal diagnosis and psychologic profiles. The authors concluded that depression might have a negative effect on periodontal treatment outcomes.

A recent study investigating the relationship between psychologic stress and wound repair in patients after routine surgery (in this case, inguinal hernia open incision repair) revealed that stress impairs the inflammatory response and matrix degradation.[30] Forty-seven adults were given a standardized questionnaire before surgery to assess their psychologic stress before surgery. Wound fluids were collected during the first 20 hours after surgery to measure inflammatory markers: interleukin-1, interleukin-6, and matrix metalloproteinase-9. Greater psychologic stress was significantly associated with lower levels of interleukin-1 and matrix metalloproteinase-9 as well as with a significantly more painful, poorer, and slower recovery.

Another study compared the psychiatric characteristics of individuals with different outcomes to periodontal therapy.[10] Two groups were compared to evaluate the psychologic characteristics of 11 individuals who were responsive to periodontal treatment as compared with 11 individuals who were not responsive to periodontal treatment. The members of the responsive group had more rigid personalities, whereas those in the nonresponsive group had more passive, dependent personalities. Furthermore, the nonresponsive group reported more stressful life events having occurred during their pasts.

These studies suggest that both stressful life events and the individual's personality and coping skills are factors to consider when assessing the risk of periodontal disease destruction and the potential for successful periodontal therapy. If patients with emotional or defensive coping skills are identified, care should be taken to ensure that they receive information in a manner that does not elicit a "defensive" reaction.

Psychiatric Influence of Self-Inflicted Injury

Psychosomatic disorders may result in harmful effects to the health of tissues in the oral cavity through the development of habits that are injurious to the periodontium. Neurotic habits such as grinding or clenching the teeth, nibbling on foreign objects (e.g., pencils, pipes), nail biting, and excessive use of tobacco are all potentially injurious to the teeth and the periodontium. Self-inflicted gingival injuries, such as gingival recession, have been described in both children and adults (Figure 11-27). However, these types of self-inflicted, factitious injuries do not appear to be common among psychiatric patients.[213]

Nutritional Influences

Some clinicians enthusiastically adhere to the theory in periodontal disease that assigns a key role to nutritional deficiencies and imbalances. Previous research did not support this view, but numerous problems in experimental design and data interpretation could be responsible for making these research findings inadequate.[5,212] The majority of opinions and research findings regarding the effects of nutrition on oral and periodontal tissues point to the following:

1. *There are no nutritional deficiencies that by themselves can cause gingivitis or periodontitis.* However, nutritional deficiencies can affect the condition of the periodontium and thereby may accentuate the deleterious effects of plaque-induced inflammation in susceptible individuals. Theoretically, one may presume that an individual with a nutritional deficiency is less able to defend against a bacterial challenge as compared with a nutritionally competent individual.
2. *There are nutritional deficiencies that produce changes in the oral cavity.* These changes include alterations of the tissues of the lips, oral mucosa, gingiva, and bone. These alterations are considered to be the periodontal and oral manifestations of nutritional disease.

The role of nutrition in periodontal disease may be related to the effect of nutrition on inflammation. A recent review of the literature evaluating the effect of nutritional factors on inflammation demonstrated that subtle shifts in nutritional status are associated with the prevalence of periodontitis.[45] More specifically, they reported that the results of contemporary animal and human studies have demonstrated the role of specific micronutrients in the modulation of the host's inflammatory response by reducing inflammatory biomarkers, which may in turn be responsible for periodontal destruction. The evidence for the effect of nutrition on inflammation is significant. Data suggest that diets that contain foods rich in antioxidants are beneficial, whereas foods that contain high levels of refined carbohydrates are detrimental to the inflammatory process.[45] See the online material for a review of the existing knowledge of the effects of vitamin and protein deficiencies on changes in the periodontium.

Medications

Some medications that are prescribed to cure, manage, or prevent diseases may have adverse effects on periodontal tissues, wound healing, or the host immune response. Bisphosphonates are a class of medications widely prescribed for the treatment of osteoporosis and various types of cancer. They have recently been implicated in osteonecrosis of the jaw (ONJ), a serious condition that is characterized by nonhealing, often painful exposure of nonvital and often sequestrating bone in the jaws. Corticosteroids have long been prescribed to suppress the immune system for the control and management of autoimmune disease, during cancer treatment, and as an anti-rejection medication for transplant patients. This section discusses the effect of bisphosphonates and corticosteroids on the periodontium. Readers are referred to Chapter 37 for additional information about these and other important medications.

Bisphosphonates

Bisphosphonate medications are primarily used to treat cancer (via intravenous [IV] administration) and osteoporosis (via oral administration). They act by inhibiting osteoclastic activity, which leads to less bone resorption, less bone remodeling, and less bone turnover.[210] The use of bisphosphonates in cancer treatment is aimed at preventing the often lethal imbalance of osteoclastic activity. During the treatment of osteoporosis, the goal is simply to harness osteoclastic activity to minimize or prevent bone loss and, in many cases, to increase bone mass by creating an advantage for osteoblastic activity. The major differences in the use of bisphosphonates for cancer versus osteoporosis are the potency and route of administration of the specific bisphosphonate medication used. Potency is influenced by the chemical properties as well as by the binding and release pharmacokinetic properties of these agents as they apply to bone. Specifically, the strength of binding and the ease of release of bisphosphonates with hydroxyapatite make these drugs more or less potent.

Bisphosphonates were first synthesized during the 1950s as a substitute for pyrophosphate, a compound used in detergent. The ability of bisphosphonates to increase bone mass was discovered after animal studies that took place in 1966, but the potential advantage of using bisphosphonates in humans with low bone mass was not appreciated until 1984.[250] The US Food and Drug Administration approved the use of alendronate for osteoporosis in 1995.

The chemical structure of bisphosphonate consists of two phosphate groups covalently bonded to a central carbon (Figure 11-28).

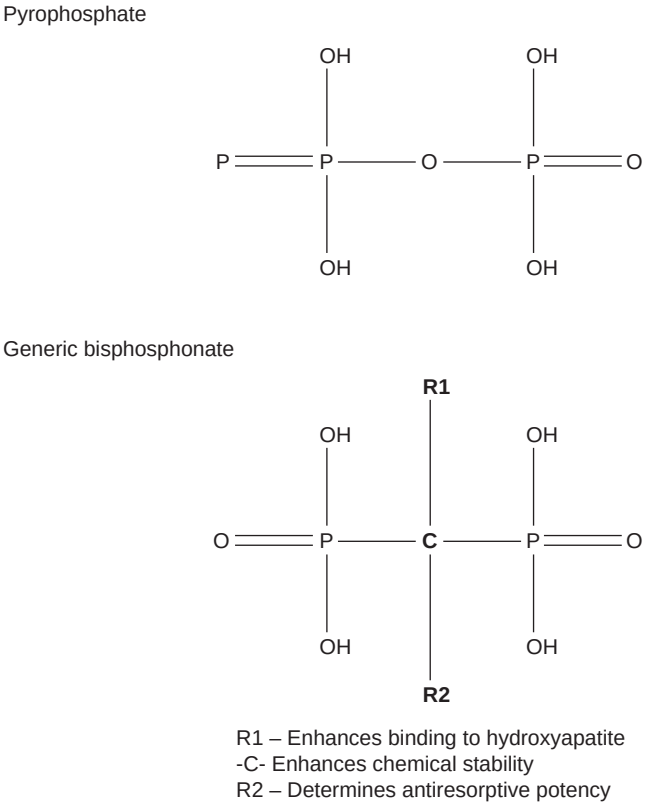

Figure 11-28 Chemical structure of a bisphosphonate molecule. Two phosphate groups are covalently bonded with a central carbon. The carbon also has two side chains, R1 and R2.

Figure 11-27 Severe gingival recession localized to the labial surface of all mandibular incisors. This finding was discovered in an uncooperative, institutionalized adult with mental disorders who had been placed under general anesthesia. The patient was known to pace around the home with all four fingers inside his lower lip.

Fat-Soluble Vitamin Deficiency

Vitamins A, D, and E are fat-soluble vitamins that are required in the human diet.

Vitamin A Deficiency. A major function of vitamin A is to maintain the health of the epithelial cells of the skin and mucous membranes. A deficiency of vitamin A results in dermatologic, mucosal, and ocular manifestations. In the absence of vitamin A, degenerative changes occur in epithelial tissues, thereby resulting in a keratinizing metaplasia. Because epithelial tissues provide a primary barrier function to protect against invading microorganisms, vitamin A may play an important role in protecting against microbial invasion by maintaining epithelial integrity.

Little information is available regarding the effects of vitamin A deficiency on the oral structures in humans. Several epidemiologic studies have failed to demonstrate any relationship between this vitamin and periodontal disease in humans.[252]

In experimental animals, vitamin A deficiency results in hyperkeratosis and hyperplasia of the gingiva, with a tendency toward increased periodontal pocket formation. The following periodontal changes have been reported in vitamin-A–deficient rats: hyperplasia and hyperkeratinization of the gingival epithelium, with proliferation of the junctional epithelium, and retardation of gingival wound healing.[63,84] In the presence of local factors, vitamin-A–deficient rats develop periodontal pockets that are deeper than those seen in animals that are not deficient in vitamin A and that exhibit associated epithelial hyperkeratosis.[29,96]

Vitamin D Deficiency. Vitamin D or calciferol is essential for the absorption of calcium from the gastrointestinal tract and the maintenance of the calcium–phosphorus balance. A deficiency of vitamin D and an imbalance in calcium–phosphorus intake result in rickets in young children and osteomalacia in adults. No studies have demonstrated a relationship between vitamin D deficiency and periodontal disease.

The effect of vitamin D deficiency or imbalance on the periodontal tissues of young dogs results in osteoporosis of alveolar bone. Osteoid forms at a normal rate but remains uncalcified and fails to resorb, which leads to excessive accumulation. A reduction in the width of the periodontal ligament space results from a normal rate of cementum formation coupled with defective calcification and distortion of the growth pattern of alveolar bone.[18,256]

In osteomalacic animals, there is rapid, generalized, severe osteoclastic resorption of alveolar bone, the proliferation of fibroblasts that replace bone and marrow, and new bone formation around the remnants of unresorbed bony trabeculae.[64] Radiographically, there is generalized partial to complete disappearance of the lamina dura and reduced density of the supporting bone, a loss of trabeculae, increased radiolucency of the trabecular interstices, and increased prominence of the remaining trabeculae. Microscopic and radiographic changes in the periodontium are almost identical to those seen with experimentally induced hyperparathyroidism.

Vitamin E Deficiency. Vitamin E serves as an antioxidant to limit free-radical reactions and to protect cells from lipid peroxidation. Cell membranes, which are high in polyunsaturated lipids, are the major site of damage in patients with vitamin E deficiency. No relationship has been demonstrated between deficiencies in vitamin E and oral disease, but systemic vitamin E appears to accelerate gingival wound healing in the rat.[130,191]

Water-Soluble Vitamin Deficiency

Vitamins B and C are water-soluble vitamins that are required in the human diet.

B-Complex Deficiency. The vitamin B complex includes thiamin, riboflavin, niacin, pyridoxine (B_6), biotin, folic acid, and cobalamin (B_{12}). Oral disease is rarely caused by a deficiency in just one component of the B-complex group; the deficiency is generally multiple.

Oral changes that are common to B-complex deficiencies are gingivitis, glossitis, glossodynia, angular cheilitis, and inflammation of the entire oral mucosa. The gingivitis in individuals with vitamin B deficiencies is nonspecific because it is caused by bacterial plaque rather than by the deficiency; however, gingivitis is subject to the deficiency's modifying effect.

The human manifestations of **thiamin deficiency,** called *beriberi,* are characterized by paralysis; cardiovascular symptoms, including edema; and loss of appetite. Frank beriberi is rare in the United States. Oral disturbances that have been attributed to thiamin deficiency include hypersensitivity of the oral mucosa; minute vesicles (simulating herpes) on the buccal mucosa, under the tongue, or on the palate; and erosion of the oral mucosa.[102,155]

The symptoms of **riboflavin deficiency** *(ariboflavinosis)* include glossitis, angular cheilitis, seborrheic dermatitis, and a superficial vascularizing keratitis. The glossitis is characterized by a magenta discoloration and atrophy of the papillae. In mild to moderate cases, the dorsum exhibits a patchy atrophy of the lingual papillae and engorged fungiform papillae, which project as pebble-like elevations.[162] With severe deficiency, the entire dorsum is flat, with a dry and often fissured surface. Changes observed in riboflavin-deficient monkeys include severe lesions of the gingiva, the periodontal tissues, and the oral mucosa, including noma.[44,243]

Angular cheilitis begins as an inflammation of the commissure of the lips, and this is followed by erosion, ulceration, and fissuring. Riboflavin deficiency is not the only cause of angular cheilitis. A loss of vertical dimension, together with the drooling of saliva into the angles of the lips, may produce a condition similar to angular cheilitis. Candidiasis may develop in the commissures of debilitated persons; this lesion has been termed *perlèche.*[100] Supplemental riboflavin is ineffective to resolve cases of glossitis and angular cheilitis that are not caused by vitamin deficiency.[264]

Niacin deficiency results in *pellagra,* which is characterized by symptoms of dermatitis, gastrointestinal disturbances, neurologic and mental disturbances (dermatitis, diarrhea, or dementia),

glossitis, gingivitis, and generalized stomatitis. This condition is rare, but it may occasionally result from malabsorption or alcoholism. Glossitis and stomatitis may be the earliest clinical signs of niacin deficiency.[156] The gingiva may be involved in *aniacinosis* with or without tongue changes.[132] The most common finding is necrotizing ulcerative gingivitis, usually in areas of local irritation.

Oral manifestations of vitamin-B–complex and niacin deficiency in experimental animals include black tongue and gingival inflammation, with destruction of the gingiva, the periodontal ligament, and the alveolar bone.[19,62] Necrosis of the gingiva and other oral tissues as well as leukopenia are terminal features of niacin deficiency in experimental animals.

Folic acid deficiency results in macrocytic anemia with megaloblastic erythropoiesis accompanied by oral changes, gastrointestinal lesions, diarrhea, and intestinal malabsorption.[63] Folic-acid–deficient animals demonstrate necrosis of the gingiva, the periodontal ligament, and the alveolar bone without inflammation.[221] The absence of inflammation is the result of deficiency-induced granulocytopenia. In humans with sprue and other folic acid deficiency states, generalized stomatitis occurs, which may be accompanied by ulcerated glossitis and cheilitis. Ulcerative stomatitis is an early indication of the toxic effect of the folic acid antagonists (e.g., methotrexate) used for the treatment of leukemia.

In a series of human studies, Vogel and colleagues[247,248] reported a significant reduction of gingival inflammation after the systemic or local use of folic acid as compared with placebo. This reduction occurred with no change in plaque accumulation. The authors also postulated that the gingival changes associated with pregnancy and oral contraceptives may be partly related to suboptimal levels of folic acid in the gingiva.[246] In a clinical study of pregnant women, a reduction in gingival inflammation occurred with the use of topical folate mouthrinses; no change was found with systemic folic acid.[186] A relationship has also been suggested between phenytoin-induced gingival overgrowth and folic acid on the basis of the interference of folic acid absorption and the use of phenytoin.[245] However, a more recent double-blind, randomized, placebo-controlled study of 20 institutionalized epileptic adults taking phenytoin found no difference in gingival conditions (i.e., gingival overgrowth and health or plaque index) between the group taking 3 mg of folic acid daily versus the placebo group at 4-week intervals over a 16-week period.[32]

Vitamin C (Ascorbic Acid) Deficiency. Severe vitamin C deficiency in humans results in scurvy, a disease that is characterized by hemorrhagic diathesis and delayed wound healing. Vitamin C is required in the human diet as well as in other primates, guinea pigs, and some rare flying mammals.[56] Because vitamin C is abundant in fruits and vegetables, scurvy is uncommon in developed countries. It may occur in infants during their first year of life if formulas are not fortified with vitamins and in older persons, especially those living alone and with restricted diets.[56] Malnutrition associated with alcoholism may predispose an individual to scurvy.

Scurvy results in the defective formation and maintenance of collagen, the impairment or cessation of osteoid formation, and impaired osteoblastic function.[81,261] Vitamin C deficiency is also characterized by increased capillary permeability, susceptibility to traumatic hemorrhages, hyporeactivity of the contractile elements of the peripheral blood vessels, and sluggishness of blood flow.[140] Clinical manifestations of scurvy include hemorrhagic lesions into the muscles of the extremities, the joints, and sometimes the nailbeds; petechial hemorrhages, often around the hair follicles; increased susceptibility to infections; and impaired wound healing.[56] Bleeding, swollen gingiva, and loosened teeth are common features of scurvy.

Possible Etiologic Factors. Ascorbic acid may play a role in periodontal disease through one or more of the following suggested mechanisms[262]:

1. Low levels of ascorbic acid influence the metabolism of collagen within the periodontium, thereby affecting the ability of the tissue to regenerate and repair itself. No experimental evidence supports this view of the role of ascorbic acid. Furthermore, it has been shown that collagen fibers in the periodontal ligament of scorbutic monkeys are the last to be affected before the death of the animals.[251]
2. Ascorbic acid deficiency interferes with bone formation and leads to the loss of periodontal bone. Changes that do occur in alveolar bone and other bones as a result of failure of the osteoblasts to form osteoid take place very late in the deficiency state.[94] Osteoporosis of alveolar bone in scorbutic monkeys results from increased osteoclastic resorption; it is not associated with periodontal pocket formation.[251]
3. Ascorbic acid deficiency increases the permeability of the oral mucosa to tritiated endotoxin and tritiated inulin and of normal human crevicular epithelium to tritiated dextran.[6,9] Optimal levels of vitamin C would therefore maintain the epithelium's barrier function to bacterial products.
4. Increasing levels of ascorbic acid enhance both the chemotactic and migratory actions of leukocytes without influencing their phagocytic activity.[98] Megadoses of vitamin C seem to impair the bactericidal activity of leukocytes.[223] The significance of these findings for the pathogenesis and treatment of periodontal diseases is not understood.
5. An optimal level of ascorbic acid is apparently required to maintain the integrity of the periodontal microvasculature as well as the vascular response to bacterial plaque and wound healing.[38]
6. The depletion of vitamin C may interfere with the ecologic equilibrium of bacteria in plaque and thus increase its pathogenicity. However, no evidence demonstrates this effect.

Epidemiologic Studies. Several studies in large populations have analyzed the relationship between gingival or periodontal status and ascorbic acid levels.[252] These studies used different methods for the biochemical analysis of ascorbic acid and various indices for the assessment of periodontal changes; they were made in persons of different socioeconomic statuses, races, and ages. All of the epidemiologic surveys failed to establish a causal relationship between the levels of vitamin C and the prevalence or severity of periodontal disease.[37,74,209] Megadoses of ascorbic acid have also been found to be unrelated to better periodontal health.[120,263]

Gingivitis. The legendary association of severe gingival disease with scurvy led to the presumption that vitamin C deficiency is an etiologic factor in gingivitis, which is common at all ages. Gingivitis with enlarged, hemorrhagic, bluish-red gingiva is described as one of the classic signs of vitamin C deficiency, but *gingivitis is not caused by vitamin C deficiency.* Vitamin-C–deficient patients do not necessarily have gingivitis. Acute vitamin C deficiency does not cause or increase the incidence of gingival inflammation, but it does increase its severity.[46,94,95] Gingivitis in vitamin-C–deficient patients is caused by bacterial plaque. Vitamin C deficiency may aggravate the gingival response to plaque and worsen the edema, enlargement, and bleeding. In addition, although correcting the deficiency may reduce the severity of the disorder, gingivitis will remain as long as bacterial factors are present.

Periodontitis. Changes in the supporting periodontal tissues and gingiva in individuals with vitamin C deficiency have been

documented extensively in experimental animals.[94,251] Acute vitamin C deficiency results in edema and hemorrhage in the periodontal ligament, osteoporosis of the alveolar bone, and tooth mobility; hemorrhage, edema, and degeneration of the collagen fibers occur in the gingiva. Vitamin C deficiency also impairs gingival healing. The periodontal fibers that are least affected by vitamin C deficiency are those just below the junctional epithelium and above the alveolar crest, which explains the infrequent apical downgrowth of the epithelium.[251]

Vitamin C deficiency alone does not cause periodontal destruction. Local bacterial factors are required for increased probing depth and attachment loss to occur. However, acute vitamin C deficiency accentuates the destructive effect of gingival inflammation on the underlying periodontal ligament and alveolar bone.[95]

Experimental studies conducted in humans failed to show the dramatic clinical changes that have traditionally been described with scurvy.[57,115,200] A case report by Charbeneau and Hurt[46] showed worsening of a preexisting moderate periodontitis with the development of scurvy. In a retrospective analysis of 12,419 adults studied in the Third National Health and Nutrition Examination Survey, Nishida and colleagues[178] found that there was a weak but statistically significant dose–response relationship between the levels of dietary vitamin C intake and periodontal disease in current and former smokers as measured by clinical attachment. This suggests that vitamin C deficiency has its greatest impact on periodontal disease when preexisting disease and other codestructive factors are present.

Summary. Analysis of the literature indicates that the microscopic signs of vitamin C deficiency are quite different from those that occur with plaque-induced periodontal disease in humans. Patients with acute or chronic vitamin-C–deficient states and no plaque accumulation demonstrate minimal (if any) changes in their gingival health status.

Protein Deficiency

Protein depletion results in hypoproteinemia with many pathologic changes, including muscular atrophy, weakness, weight loss, anemia, leukopenia, edema, impaired lactation, decreased resistance to infection, slow wound healing, lymphoid depletion, and reduced ability to form certain hormones and enzyme systems. Protein deprivation has been shown to cause changes in the periodontium of experimental animals.[47] The following observations have been made in protein-deprived animals: degeneration of the connective tissue of the gingiva and the periodontal ligament, osteoporosis of the alveolar bone, impaired deposition of the cementum, delayed wound healing, and atrophy of the tongue epithelium.[40,227,228] Similar changes occur in the periosteum and bone in other nonoral areas. Osteoporosis results from the reduced deposition of osteoid, a reduction in the number of osteoblasts, and impairment in the morphodifferentiation of connective tissue cells to form osteoblasts rather than from increased osteoclastic activity.

These observations are of interest in that they reveal a loss of alveolar bone that results from the inhibition of normal bone-forming activity rather than from the introduction of destructive factors. Protein deficiency also accentuates the destructive effects of bacterial plaque and occlusal trauma on the periodontal tissues, but the initiation of gingival inflammation and its severity depend on the bacterial plaque.[228] In other words, protein deprivation results in periodontal tissues that lack integrity and that, as a result, are more vulnerable to breakdown when challenged by bacteria.

Other Systemic Conditions

Osteoporosis

Osteoporosis is a disease that is characterized by low bone mass and structural deterioration that leads to an increased risk of bone fracture that affects approximately 10 million people in the United States. The condition has a higher predilection for females (80%) as compared with males (20%). An additional 34 million individuals in the United States are estimated to have osteopenia or low bone density. The loss of bone mass and the incidence of osteoporosis increases with age for both men and women, with women being affected earlier than men. The rate of bone loss is greatest for women during the perimenopausal years, when estrogen levels decrease.

A bone mineral density (BMD) test is used to measure an individual's bone mass. BMD is measured with the use of a dual-energy x-ray absorptiometry scan. The dual-energy x-ray absorptiometry value or T-score is a comparison of the patient's BMD to that of a healthy 30-year-old adult with peak bone mass. The World Health Organization defines osteoporosis and osteopenia by measures of "standard deviations" as compared with that of a normal, healthy, young adult. Thus, a T-score between +1 and –1 is considered normal, whereas a T-score between –1 and –2.5 indicates low bone density or osteopenia and a T-score of less than –2.5 (i.e., more than 2.5 standard deviations below normal) is diagnostic for osteoporosis (Table 11-2).

One of the most significant consequences of osteoporosis is the increased risk of bone fracture. All bones affected by osteoporosis are susceptible to fracture, but fractures of the pelvis and vertebrae carry the most serious risk of morbidity and mortality. Studies have reported that approximately 20% of patients with hip fractures die within a year and that 50% experience significant disability (e.g., an inability to walk unassisted).[141]

Although it is logical to surmise a relationship between osteoporosis and periodontitis, it has been a challenging hypothesis to prove. One of the difficulties is the fact that both osteoporosis and periodontitis are chronic, multifactorial diseases that result in bone loss, and bone loss in each condition is exacerbated by local and systemic factors.[183] Gender, genetic predisposition, inactivity, deficient diets (e.g., deficient in calcium or vitamin D), alcohol, smoking, hormones, and medications put individuals at risk for osteoporosis, with some of these factors putting them at risk for the progression of periodontitis as well. Variations in populations studied, measurements used to assess disease, and study design have also hindered the ability to clearly define a relationship between osteoporosis and periodontitis.

TABLE 11-2 Definitions of Osteoporosis and Osteopenia Indicated by T-Scores

T-Score	Bone Mineral Density Category
≥–1	Normal
–1 to –2.5	Low (osteopenia)
≤–2.5	Osteoporosis

Ranges of T-scores are based on standard deviations outside of normal, which is based on the bone mineral density of a healthy 30-year-old adult.

(Adapted from World Health Organization Definitions)

Attempts to use tooth loss as an indirect measure of periodontitis in individuals with osteoporosis have offered mixed conclusions. Several studies have reported greater tooth loss, more alveolar bone loss, and edentulism in individuals with osteoporosis.[60,66,109,266] However, some other studies have suggested that tooth loss is not correlated with osteoporosis or BMD.[27,68,172] One large study of 1365 Caucasian postmenopausal females that investigated systemic BMD (lumbar spine and proximal femur) and tooth loss found no significant correlation.[68] Part of the challenge and the reason for conflicting results in these studies may be attributed to differences in measurement methods. Another problem with translating any tooth loss study conclusions to address the question of whether osteoporosis contributes to periodontitis is that the cause of tooth loss in these studies is often unknown (i.e., tooth loss may or may not be related to periodontal disease).

Studies that attempt to correlate osteoporosis with periodontitis are fraught with similar if not greater challenges. Again, some studies have concluded or suggested that osteoporosis does contribute to the progression of periodontitis,[119,133,173,240] whereas others refute this conclusion.[71,151] One study by Elders and colleagues failed to show a correlation between lumbar BMD and clinical parameters of periodontitis in a dentate group of 46- to 55-year-old females.[71] The researchers used intraoral periodontal examinations (i.e., probing depth, bleeding on probing, and missing teeth) and bitewing radiographs to assess clinical parameters of periodontitis and interproximal alveolar bone loss. This study included edentulous subjects (286) as well, but no significant difference in BMD was found between edentulous (60) and dentate (226) subjects, thereby suggesting that neither periodontitis nor tooth loss was related to osteoporosis. The mean age of the subjects in this study was relatively young, which may have contributed to the lack of correlation.[90]

Most studies citing a positive correlation between osteoporosis or BMD and periodontitis are cross-sectional studies of postmenopausal females. Klemetti and colleagues evaluated 227 healthy postmenopausal women between the ages of 48 and 56 years and found that women with higher skeletal BMD were more likely to retain their teeth in the presence of periodontitis (i.e., deep periodontal pockets) as compared with those with osteoporosis.[133] Tezal and colleagues concluded that skeletal BMD (measured by dual-energy x-ray absorptiometry at multiple sites) is related to alveolar bone loss and, to a lesser extent, to clinical attachment loss, thereby implicating postmenopausal osteopenia as a risk indicator for periodontal disease in 70 postmenopausal white women between the ages of 51 and 78 years.[240] Periodontal parameters included probing depth, supragingival plaque, calculus, bleeding on probing, clinical attachment loss, and interproximal alveolar bone loss. Analysis was adjusted for age, age at menopause, estrogen supplementation, cigarette smoking, body mass, and supragingival plaque. Inagaki and colleagues evaluated the association between periodontal conditions, tooth loss, and metacarpal BMD in a cross-sectional study of 356 Japanese women: 171 premenopausal women (mean age, 37.9 years) and 185 postmenopausal women (mean age, 63.3 years). The authors concluded that periodontal status and tooth loss after menopause could be a useful indicator of metacarpal BMD loss in Japanese women.[119] These cross-sectional studies are suggestive but do not consider the periodontal condition or existence of periodontitis before the onset of osteoporosis or the loss of systemic bone mineral density.

The effect of estrogen deficiency and osteopenia or osteoporosis on periodontitis is not known, but it may be an important factor to consider. Reinhardt and colleagues[199] conducted a 2-year, prospective, longitudinal study of postmenopausal women (59 with moderate or advanced periodontitis and 16 with no periodontitis) to evaluate the effect of estrogen (serum estradiol) levels on periodontitis in these patients. Clinical measurements—including supragingival plaque, bleeding on probing, and relative clinical attachment—were taken at baseline and every 6 months for 2 years. The authors concluded that estrogen deficiency and osteopenia or osteoporosis together are risk factors for alveolar bone loss in postmenopausal women with a history of periodontitis.[199] Lerner[142] also proposed that estrogen deficiency may play a significant role in the progression of periodontitis in osteopenic or osteoporotic women, citing the fact that the cytokines thought to be involved in inflammation-induced remodeling are very similar to those suggested to play crucial roles in postmenopausal osteoporosis. In patients with periodontal disease and concomitant postmenopausal osteoporosis, the possibility exists that the lack of estrogen influences the activities of bone cells and immune cells in such a way that the progression of alveolar bone loss will be enhanced.[142] In fact, there are numerous studies that report less risk for tooth loss and improved oral health among postmenopausal women receiving hormone replacement therapy.[7,17,24,106,107,234] More prospective, longitudinal studies evaluating the effect of estrogen and osteopenia or osteoporosis on periodontitis are needed to improve the current understanding.

Congenital Heart Disease

Congenital heart disease occurs in about 1% of live births. Approximately 40% of individuals born with heart defects would die without treatment. However, the prognosis has been dramatically improved with advances in cardiac surgery. Cardiac defects can involve the heart, the adjacent vessels, or a combination of both. The most striking feature of congenital heart disease is cyanosis caused by the shunting of deoxygenated blood from the right to the left, thereby resulting in the return of poorly oxygenated blood to the systemic circulation. In severe cases, cyanosis is obvious at birth, particularly in the presence of tetralogy of Fallot. Chronic hypoxia causes impaired development, compensatory polycythemia (i.e., an increase in RBCs and hemoglobin), and clubbing edema of toes and fingers (Figure 11-32). Polycythemia is significant because it can result in hemorrhagic or thrombotic tendencies. Patients with congenital heart defects are often at risk for infective endocarditis as a result of turbulent blood flow in the heart and the associated cardiovascular defects. The need for prophylactic antibiotics should be evaluated before dental therapy.

In addition to the obvious cyanosis of the lips and the oral mucosa, oral abnormalities associated with cyanotic congenital heart disease include the delayed eruption of both the primary and

Figure 11-32 Characteristic clubbing of the fingers in an adolescent patient with tetralogy of Fallot. This is consistent with untreated congenital cyanotic heart disease.

permanent dentitions, increased positional abnormalities, and enamel hypoplasia. The teeth often have a bluish-white appearance with an increased pulp vascular volume. Gingival disease and other oral symptoms have been reported in children with congenital heart disease.[26,126] Reports seem to indicate more severe caries and periodontal disease in patients with cyanotic congenital heart defects. However, the apparent increase in dental disease may be attributed to poor oral hygiene and a general lack of dental care rather than a disease-related etiology.

Tetralogy of Fallot. As its name implies, tetralogy of Fallot is characterized by four cardiac defects: (1) ventricular septal defect; (2) pulmonary stenosis; (3) malposition of the aorta to the right; and (4) compensatory right ventricular enlargement. Clinical features include severe cyanosis, audible heart murmurs, and breathlessness. Cyanosis and breathlessness cause cerebral anoxia and syncope. Oral changes include a purplish-red discoloration of the lips and the gingiva. Severe marginal gingivitis and periodontal destruction have been reported (Figure 11-33). The discoloration of the lips and the gingiva corresponds to the general degree of cyanosis and returns to normal after corrective heart surgery. The tongue appears coated, fissured, and edematous, and there is extreme reddening of the fungiform and filiform papillae. The number of subepithelial capillaries is increased, but this also returns to normal after heart surgery.[83]

Eisenmenger's Syndrome. Among patients with ventricular septal defects, about half of those with large defects (i.e., those >1.5 cm in diameter) develop Eisenmenger's syndrome. This syndrome is distinguished by a greater blood flow from the stronger left ventricle to the right ventricle (backward flow) through the septal defect. This causes increased pulmonary blood flow, which in turn leads to progressive pulmonary fibrosis, small-vessel occlusion, and high pulmonary vascular resistance. With increasing pulmonary resistance, the right ventricle hypertrophies, the shunt becomes bidirectional, and ultimately, blood flow is reversed (i.e., it flows from right to left). The increased vascular resistance builds pressure in the right ventricle, thereby causing right ventricular hypertrophy, and a reverse in the direction of the blood flow, which results in a right-to-left shunt.

The natural history of a patient with untreated Eisenmenger's syndrome is a gradual increase in cyanosis over many years that eventually leads to cardiac failure. Cyanosis of the lips, cheeks, and buccal mucous membranes is observed in these patients, but it is much less severe than in those with tetralogy of Fallot. Severe, generalized periodontitis has been reported in patients with Eisenmenger's syndrome.[48] However, similar to patients with other types of congenital heart disease, the incidence of periodontal disease reported in those with Eisenmenger's syndrome may be related more to poor oral hygiene and a general lack of dental care than to any specific, syndrome-related etiology.

Figure 11-33 Extensive marginal inflammation with ulceronecrotic lesions and periodontal destruction in the same patient with tetralogy of Fallot as shown in Figure 11-31.

Hypophosphatasia

Hypophosphatasia is a rare familial skeletal disease that is characterized by rickets, poor cranial bone formation, craniostenosis, and the premature loss of the primary teeth, particularly the incisors. Patients have a low level of serum alkaline phosphatase, and phosphoethanolamine is present in serum and urine.

Teeth are lost with no clinical evidence of gingival inflammation, and they show reduced cementum formation.[23] In patients with minimal bone abnormalities, the premature loss of the deciduous teeth may be the only symptom of hypophosphatasia. In adolescents, this disease resembles localized "juvenile" (aggressive) periodontitis.[265]

Metal Intoxication

The ingestion of metals such as mercury, lead, and bismuth in medicinal compounds and through industrial contact may result in oral manifestations caused by either intoxication or absorption without evidence of toxicity.

Bismuth Intoxication. *Chronic* bismuth intoxication is characterized by gastrointestinal disturbances, nausea, vomiting, and jaundice as well as by an ulcerative gingivostomatitis, generally with pigmentation and accompanied by a metallic taste and burning sensation of the oral mucosa. The tongue may be sore and inflamed. Urticaria, different types of exanthematous eruptions, bullous and purpuric lesions, herpes-zoster–like eruptions, and pigmentation of the skin and mucous membranes are among the dermatologic lesions attributed to bismuth intoxication. Acute bismuth intoxication, which is seen less frequently, is accompanied by methemoglobin formation, cyanosis, and dyspnea.[113]

Bismuth pigmentation in the oral cavity usually appears as a narrow, bluish-black discoloration of the gingival margin in areas of preexisting gingival inflammation (Figure 11-34) (see Chapter 15). Such pigmentation results from the precipitation of particles of bismuth sulfide associated with vascular changes in inflammation; it is not evidence of intoxication but simply indicates the presence of bismuth in the bloodstream. Bismuth pigmentation in the oral cavity also occurs in cases of intoxication; it assumes a linear form if the marginal gingiva is inflamed.

Lead Intoxication. Lead is slowly absorbed, and toxic symptoms are not particularly definitive when they do occur.[123] There is a pallor of the face and lips and gastrointestinal symptoms that consists of nausea, vomiting, loss of appetite, and abdominal colic. Peripheral neuritis, psychologic disorders, and encephalitis have been reported. Oral signs include salivation, coated tongue, a peculiar sweetish taste, gingival pigmentation, and ulceration. Gingival pigmentation is linear (Burtonian line), steel gray, and associated with local inflammation. Oral signs may occur without toxic symptoms.

Mercury Intoxication. Mercury intoxication is characterized by headache, insomnia, cardiovascular symptoms, pronounced salivation (ptyalism), and a metallic taste.[4] Gingival pigmentation in linear form results from the deposition of mercuric sulfide. The chemical also acts as an irritant, which accentuates the preexisting inflammation and often leads to notable ulceration of the gingiva and the adjacent mucosa as well as the destruction of the underlying bone. Mercurial pigmentation of the gingiva also

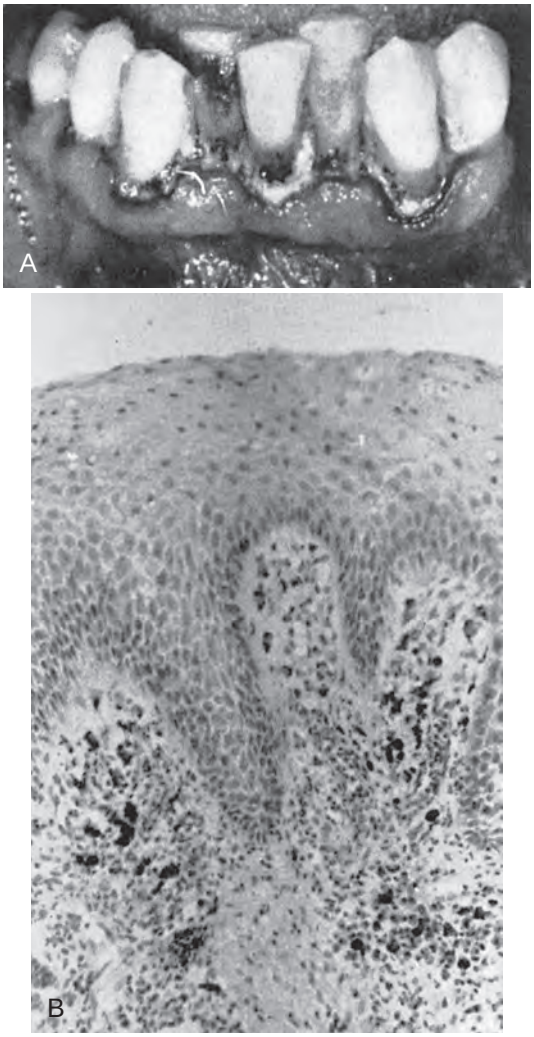

Figure 11-34 Bismuth line. **A,** Linear discoloration of the gingiva in relation to local irritation in a patient receiving bismuth therapy. **B,** Biopsy specimen showing bismuth particles engulfed by monocytes and macrophages.

occurs in areas of local irritation in patients without symptoms of intoxication.

Other Chemicals. Other chemicals (e.g., phosphorus, arsenic, chromium) may cause necrosis of the alveolar bone, with loosening and exfoliation of the teeth.[143,218] Inflammation and ulceration of the gingiva are usually associated with the destruction of the underlying tissues. Benzene intoxication is accompanied by gingival bleeding and ulceration with the destruction of the underlying bone.[218]

In addition to the two phosphate groups, the central carbon also has two side chains, R1 and R2. Both the short R1 side chain and the long R2 side chain influence the chemical properties and pharmacokinetics. The long R2 side chain also influences the mode of action and determines the strength or potency of the medication. Bisphosphonates inhibit osteoclasts by two mechanisms that depend on whether the R2 side chain contains nitrogen. Nonaminobisphosphonates are metabolized by osteoclasts to form an adenosine triphosphate analog that interferes with energy production and causes osteoclast apoptosis. Aminobisphosphonates (i.e., risedronate, zoledronate, ibandronate, and alendronate) are more potent and have multiple effects on osteoclasts, including the following: (1) inactivation of adenosine triphosphate; (2) osteoclast cytoskeletal disruption; (3) impairment of osteoclast recruitment; and (4) induction of osteoblasts to produce osteoclast-inhibiting factor.[185] Bisphosphonates also inhibit bone metabolism via antiangiogenic activity.[34]

Table 11-1 lists some of the common bisphosphonate medications used for osteoporosis and cancer treatment that are currently available in the United States.

There is growing evidence that bisphosphonates affect soft tissues as well and that they may contribute to osteonecrosis of the jaw via the inhibition of soft-tissue healing.[139] A recent in vitro study by Kim and colleagues suggests that bisphosphonates may act on oral keratinocytes to impair wound healing by inhibiting epithelial migration and wound closure.[131] Interestingly, the effects of bisphosphonates on oral mucosal cells and bone cells share the common mechanism of interference with products of the mevalonate pathway, which may be more significant to the overall problem than the reported apoptosis effects on osteoclasts. The inhibition of farnesyl pyrophosphate synthase leads to the inhibition of the mevalonate pathway end product, geranylgeranyl pyrophosphate (Figure 11-29). This bisphosphonate-inhibited pathway is required for many essential cellular functions in a variety of tissues. In the case of soft tissues, the bisphosphonate-induced senescence of human oral keratinocytes was found to be mediated, at least in part, by the inhibition of the mevalonate pathway. Similarly, Fisher and colleagues reported that bisphosphonates inhibit bone resorption via the prevention of protein prenylation in osteoclasts caused by the inhibition of farnesyl pyrophosphate synthase, thereby causing interference with the production of geranylgeranyl pyrophosphate.

Bisphosphonates have a high affinity for hydroxyapatite. They are rapidly absorbed in bone, especially in areas of high activity, which may help to explain why bisphosphonate-induced osteonecrosis is only found in the jaws.[250] The bisphosphonate molecule gets incorporated into bone without being metabolized or modified. During the osteoclastic resorption of bone, the trapped bisphosphonate is released and able to affect osteoclasts again. As a result, the half-life of bisphosphonates in the bone is estimated to be 10 years or more.

Osteonecrosis of the jaw associated with bisphosphonates was first reported in 2003 by Marx in a report of 36 patients with avascular necrosis of the jaw who were treated with IV bisphosphonate for malignant tumors.[159] Several case series reporting an association between bisphosphonates and osteonecrosis of the jaw were published during the months and years after this initial report.[161,208] Various terms have been used to describe this type of osteonecrosis of the jaw, including *avascular necrosis, bisphosphonate-associated ONJ, bisphosphonate-induced ONJ (BIONJ),* and *bisphosphonate-related ONJ (BRONJ).*[250] Today, with the widespread recognition of BRONJ, it is important to remember that necrotic bone exposure of the jaw (ONJ) is a condition with multiple possible etiopathogenic factors, including systemic medications, radiation, infection, trauma, direct chemical toxicity, and other idiopathic mechanisms; clinicians should carefully consider all factors before making a diagnosis of BRONJ.[8]

The condition of BRONJ has been defined as the exposure and necrosis of portions of the jaw bone in patients who have been exposed to bisphosphonates and that has persisted more than 8 weeks, with no history of radiation therapy to the jaws.[206] The stage of osteonecrosis is used to categorize patients and to make treatment decisions.[1,160,161,206] Stage 0 patients are patients at risk who have been treated with IV or oral bisphosphonates but who have no apparent exposed or necrotic bone. Stage 1 involves exposed or necrotic bone in patients who are asymptomatic, with no infection. Stage 2 involves exposed or necrotic bone in patients with pain and clinical evidence of infection. Stage 3 involves exposed or necrotic bone in patients with pain, infection, and one or more of the following: pathologic fracture, extraoral fistula, or osteolysis that extends to the inferior border.

Clinically, BRONJ presents as exposed alveolar bone that occurs spontaneously or after a traumatic event such as a dental procedure (Figures 11-30 and 11-31). The sites may be painful, with surrounding soft-tissue induration and inflammation. Infection with drainage may be present. Radiographically, lesions appear radiolucent, with sclerosis of the lamina dura, a loss of the lamina dura, or a widening of the periodontal ligament in areas where teeth are present. Histologically, bone appears necrotic, with empty lacunae demonstrating a lack of living osteocytes. In advanced cases, pathologic fracture may be present through the area of exposed or necrotic bone.

The high potency of nitrogen-containing bisphosphonates—especially those administered via IV for cancer treatment (e.g.,

TABLE 11-1 Current Nonaminobisphosphonate and Aminobisphosphonate Medications and Common Therapeutic Uses

Generic Name	Commercial Name	Route of Administration	Therapeutic Use	Nitrogen-Containing R2 Side Chain	Antiresorptive Potency
Etidronate	Didronel	PO	Paget's disease	No	1
Tiludronate	Skelid	PO	Paget's disease	No	10
Risedronate	Actonel	PO	Osteoporosis, Paget's disease	Yes	5000
Ibandronate	Boniva	PO	Osteoporosis	Yes	10,000
Alendronate	Fosamax	PO	Osteoporosis, Paget's disease	Yes	1000
Pamidronate	Aredia	IV	Paget's disease, cancer	Yes	100
Zoledronate	Zometa	IV	Cancer	Yes	10,000+

IV, Intravenous; *PO,* by mouth.

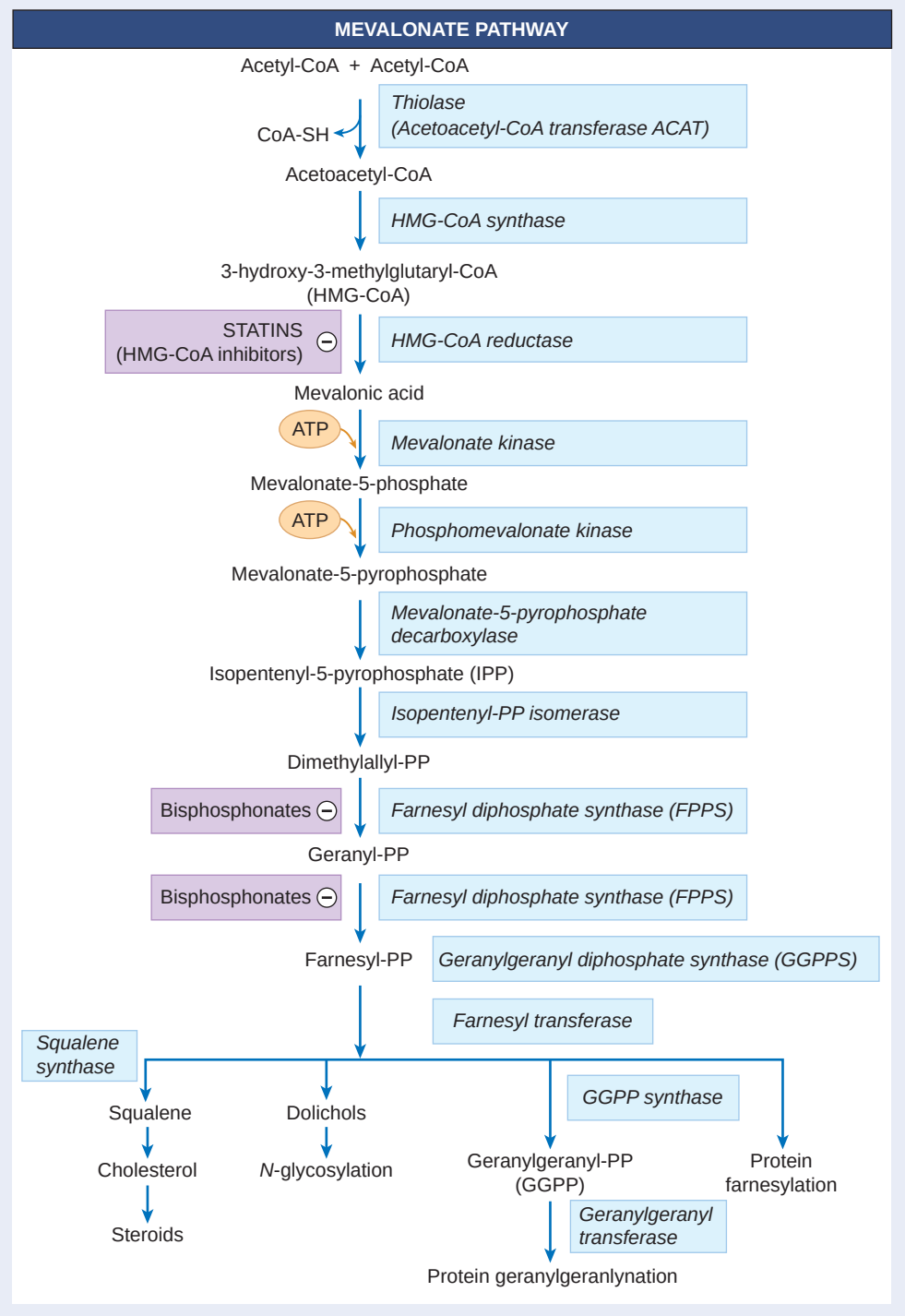

Figure 11-29 Mevalonate pathway. Bisphosphonates interfere with the farnesyl pyrophosphate synthase enzyme, which leads to the inhibition of geranylgeranyl pyrophosphate, an important end product for cellular functions.

zoledronate)—may explain the high incidence of BRONJ in these patients as compared with osteoporotic patients taking oral bisphosphonates. The incidence among patients who are being treated for cancer has been reported to range from 2.5% to 5.4%[254] or from 1% to 10%.[34] Estimating the incidence among patients who are taking oral bisphosphonates for osteoporosis is more difficult due to the large number of patients taking this prescription medication and a lack of good reporting or documentation for these patients. Some reports estimate the incidence of BRONJ from oral bisphosphonates to range from 0.007% to 0.04%,[250] whereas other reports suggest a slightly higher incidence that ranges from 0.004% to 0.11%.[226] Clearly, the incidence among patients taking oral bisphosphonates appears to be low.

It has been observed that BRONJ lesions occur most often in areas with dense bone and thin overlying mucosa, such as tori, bony exostoses, and the mylohyoid ridge.[161,208,207] Lesions are found more commonly in the mandible than in the maxilla at a 2 : 1 ratio.[206] Recent work by Schaudinn and colleagues suggests that there may be a toxic threshold of accumulated bisphosphonate in the bone that leads to the induction of BRONJ lesions and that

Figure 11-30 Clinical photograph of exposed bone on the palatal surface of the maxilla adjacent to the molar root in a 60-year-old female with bisphosphonate-induced osteonecrosis of the bone (maxilla). The bone exposures were noted after about 1 year of treatment with bisphosphonate (Aredia and Zometa). *(Courtesy Drs. Eric S. Sung and Evelyn M. Chung, University of California, Los Angeles, CA.)*

Figure 11-31 Clinical photograph of exposed bone on the lingual surface of the posterior mandible of a 70-year-old male with bisphosphonate-induced osteonecrosis of the bone (mandible). The bone exposure was noted after 3 years of bisphosphonate treatment (Aredia and Zometa) for multiple myeloma. *(Courtesy Drs. Eric S. Sung and Evelyn M. Chung, University of California, Los Angeles, CA.)*

measuring or calculating the concentration in bone may be a means of assessing an individual's risk for the development of BRONJ.[215]

In addition to bisphosphonate therapy, other factors are thought to increase individual susceptibility to BRONJ. Potential risk factors that may contribute to BRONJ include systemic corticosteroid therapy, smoking, alcohol, poor oral hygiene, chemotherapy, radiotherapy, diabetes, and hematologic disease.[28] The precipitating factors or trauma-inducing events that lead to BRONJ are reported to include extractions, root canal treatment, periodontal infections, periodontal surgery, and dental implant surgery; however, some cases appear to be idiopathic, with spontaneous exposures.[161] In a retrospective evaluation of patients treated with IV bisphosphonates for metastatic bone cancer from 1996 to 2006, Estilo and colleagues[75] found that the type of cancer, the duration of bisphosphonate therapy, sequential IV bisphosphonate treatment with pamidronate followed by zoledronate, comorbid osteoarthritis, rheumatoid arthritis, and benign hematologic conditions were significantly associated with an increased likelihood of ONJ. In their study, the systemic administration of corticosteroids was not found to be associated with an increased risk of BRONJ.[75]

As stated previously, patients who are being treated for cancer with IV bisphosphonates are at greater risk than patients being treated for osteoporosis with oral bisphosphonates. Dental health care providers should evaluate patients carefully, consider the risks, communicate with medical health care providers, inform patients, and consider treatment options and risks carefully.

Bisphosphonates and Periodontal Bone Loss Not surprisingly, the bone-preserving action of bisphosphonates has been studied and advocated for use in the prevention of bone loss from periodontal disease.[238] Several animal studies have shown that bisphosphonates, either applied topically or administered systemically, have the potential to prevent the alveolar bone loss caused by periodontitis.[43,103,169,171,182,224,257] The use of bisphosphonates for bone regeneration has been proposed as well.[238] Although some studies have demonstrated bone preservation with low doses of bisphosphonate, higher doses and longer administration may have a neutral or detrimental effect on bone loss caused by periodontitis.[35,43] In a 2- to 3-year follow-up report of four female patients with periodontitis treated with etidronate (200 mg daily for periods of 2 weeks with 10-week "off-drug" periods), the potential of this agent to prevent periodontal bone loss was reported.[235] In a 2-year, randomized, placebo-controlled clinical trial of 335 patients treated with alendronate (70 mg once weekly), no significant difference in alveolar bone loss or alveolar bone density was found.[122] Interestingly, alendronate was found to significantly reduce bone loss relative to controls in a subset of this group (i.e., patients with low mandibular bone mineral density at baseline), thereby suggesting that the effect may be more perceptible in cases with less bone mass or less bone density. In another clinical trial of 24 patients (12 experimental and 12 control), alendronate was shown to have a significant positive (bone-preserving) effect on bone density in jaws.[70] The bone mineral density of the maxilla and mandible was measured for all patients with the use of dual-energy x-ray absorptiometry at baseline and after 6 months of treatment (10 mg daily for 6 months).

Corticosteroids

In humans, the systemic administration of cortisone and adrenocorticotropic hormone appears to have no effect on the incidence or severity of gingival and periodontal disease. However, renal transplant patients receiving immunosuppressive therapy (prednisone or methylprednisone, azathioprine, or cyclophosphamide) have significantly less gingival inflammation than control subjects with similar amounts of plaque.[20,127,138,184,242]

Exogenous cortisone may have an adverse effect on bone quality and physiology. The systemic administration of cortisone in experimental animals resulted in the osteoporosis of alveolar bone.[97] There was capillary dilation and engorgement with hemorrhage into the periodontal ligament and gingival connective tissue; degeneration and a reduction in the number of collagen fibers in the periodontal ligament; and increased destruction of the periodontal tissues associated with inflammation.[97]

Stress increases circulating endogenous cortisol levels through the stimulation of the adrenal glands (i.e., the hypothalamic–pituitary–adrenal axis). This increased exposure to endogenous cortisol may have adverse effects on the periodontium by diminishing the immune response to periodontal bacteria (see the section about psychosocial stress).

Suggested Reading

Genco RJ: Current view of risk factors for periodontal diseases. *J Periodontol* 67:1041–1049, 1996.

Genco RJ, Ho AW, Grossi SG, et al: Relationship of stress, distress and inadequate coping behaviors to periodontal disease. *J Periodontol* 70:711–723, 1999.

Geurs NC, Lewis CE, Jeffcoat MK: Osteoporosis and periodontal disease progression. *Periodontol 2000* 32:105–110, 2003.

Iacopino AM: Periodontitis and diabetes interrelationships: role of inflammation. *Ann Periodontol* 6:125–137, 2001.

Loe H: Periodontal disease. The sixth complication of diabetes mellitus. *Diabetes Care* 16:329–334, 1993.

Mealey BL: Influence of periodontal infections on systemic health. *Periodontol 2000* 21:197–209, 1999.

Mealey BL, Moritz AJ: Hormonal influences: effects of diabetes mellitus and endogenous female sex steroid hormones on the periodontium. *Periodontol 2000* 32:59–81, 2003.

Ruggiero SL, Dodson TB, Assael LA, et al: American Association of Oral and Maxillofacial Surgeons position paper on bisphosphonate-related osteonecrosis of the jaws—2009 update. *J Oral Maxillofac Surg* 67(Suppl 5):2–12, 2009.

Schmidt AM, Weidman E, Lalla E, et al: Advanced glycation endproducts (AGEs) induce oxidant stress in the gingiva: a potential mechanism underlying accelerated periodontal disease associated with diabetes. *J Periodontal Res* 31:508–515, 1996.

Solomon DH, Mercer E, Woo SB, et al: Defining the epidemiology of bisphosphonate-associated osteonecrosis of the jaw: prior work and current challenges. *Osteoporos Int* 24(1):237–244, 2013.

Wimmer G, Janda M, Wieselmann-Penkner K, et al: Coping with stress: its influence on periodontal disease. *J Periodontol* 73:1343–1351, 2002.

References

References for this chapter are found on the companion website www.expertconsult.com.

References

1. Advisory Task Force on Bisphosphonate-Related Osteonecrosis of the Jaws, American Association of Oral and Maxillofacial Surgeons: American Association of Oral and Maxillofacial Surgeons position paper on bisphosphonate-related osteonecrosis of the jaws. *J Oral Maxillofac Surg* 65:369–376, 2007.
2. Adler P, Wegner H, Bohatka L: Influence of age and duration of diabetes on dental development in diabetic children. *J Dent Res* 52:535–537, 1973.
3. Ainamo J, Lahtinen A, Uitto VJ: Rapid periodontal destruction in adult humans with poorly controlled diabetes. A report of 2 cases. *J Clin Periodontol* 17:22–28, 1990.
4. Akers L: Ulcerative stomatitis following therapeutic use of mercury and bismuth. *J Am Dent Assoc* 23, 1936.
5. Alfano MC: Controversies, perspectives, and clinical implications of nutrition in periodontal disease. *Dent Clin North Am* 20:519–548, 1976.
6. Alfano MC, Miller SA, Drummond JF: Effect of ascorbic acid deficiency on the permeability and collagen biosynthesis of oral mucosal epithelium. *Ann N Y Acad Sci* 258:253–263, 1975.
7. Allen IE, Monroe M, Connelly J, et al: Effect of postmenopausal hormone replacement therapy on dental outcomes: systematic review of the literature and pharmacoeconomic analysis. *Manag Care Interface* 13:93–99, 2000.
8. Almazrooa SA, Woo SB: Bisphosphonate and nonbisphosphonate-associated osteonecrosis of the jaw: a review. *J Am Dent Assoc* 140:864–875, 2009.
9. Alvares O, Siegel I: Permeability of gingival sulcular epithelium in the development of scorbutic gingivitis. *J Oral Pathol* 10:40–48, 1981.
10. Axtelius B, Soderfeldt B, Nilsson A, et al: Therapy-resistant periodontitis. Psychosocial characteristics. *J Clin Periodontol* 25:482–491, 1998.
11. Babior B: Disorders of neutrophil function. In Wyngaarden JB, Smith LHJ, editors: *Cecil textbook of medicine*, Saunders, 1988, Philadelphia, p 18.
12. Barkin RM, Weston WL, Humbert JR, et al: Phagocytic function in Down syndrome—I. Chemotaxis. *J Ment Defic Res* 24(Pt 4):243–249, 1980.
13. Barkin RM, Weston WL, Humbert JR, et al: Phagocytic function in Down syndrome—II. Bactericidal activity and phagocytosis. *J Ment Defic Res* 24(Pt 4):251–256, 1980.
14. Barnett ML, Baker RL, Yancey JM, et al: Absence of periodontitis in a population of insulin-dependent diabetes mellitus (IDDM) patients. *J Periodontol* 55:402–405, 1984.
15. Barrett AP: Gingival lesions in leukemia. A classification. *J Periodontol* 55:585–588, 1984.
16. Bartolucci EG, Parkes RB: Accelerated periodontal breakdown in uncontrolled diabetes. Pathogenesis and treatment. *Oral Surg Oral Med Oral Pathol* 52:387–390, 1981.
17. Becker AR, Handick KE, Roberts WE, et al: Osteoporosis risk factors in female dental patients. A preliminary report. *J Indiana Dent Assoc* 76:15–19, quiz 20, 1997.
18. Becks H, Collins DA, Freytog RM: Changes in oral structures of the dog persisting after chronic overdoses of vitamin D. *Am J Orthod* 32:463, 1946.
19. Becks H, Wainwright WW, Morgan AF: Comparative study of oral changes in dogs due to deficiencies of pantothenic acid, nicotine acid and unknowns of vitamin B complex. *Am J Orthod* 29:183, 1943.
20. Been V, Engel D: The effects of immunosuppressive drugs on periodontal inflammation in human renal allograft patients. *J Periodontol* 53:245–248, 1982.
21. Bergmann OJ, Ellegaard B, Dahl M, et al: Gingival status during chemical plaque control with or without prior mechanical plaque removal in patients with acute myeloid leukaemia. *J Clin Periodontol* 19:169–173, 1992.
22. Bernick SM, Cohen DW, Baker L, et al: Dental disease in children with diabetes mellitus. *J Periodontol* 46:241–245, 1975.
23. Beumer J, 3rd, Trowbridge HO, Silverman S, Jr, et al: Childhood hypophosphatasia and the premature loss of teeth. A clinical and laboratory study of seven cases. *Oral Surg Oral Med Oral Pathol* 35:631–640, 1973.
24. Birkenfeld L, Yemini M, Kase NG, et al: Menopause-related oral alveolar bone resorption: a review of relatively unexplored consequences of estrogen deficiency. *Menopause* 6:129–133, 1999.
25. Biro S: Studies regarding the influence of pregnancy upon caries. *Vierteljahrschr Zahnheilk* 14:371, 1898.
26. Blitzer B, Sznajder N, Carranza FA: [Periodontal disease risks in children with congenital cardiopathies]. *Rev Asoc Odontol Argent* 63:169–172, 1975.
27. Bollen AM, Taguchi A, Hujoel PP, et al: Number of teeth and residual alveolar ridge height in subjects with a history of self-reported osteoporotic fractures. *Osteoporos Int* 15:970–974, 2004.
28. Borgioli A, Viviani C, Duvina M, et al: Biphosphonates-related osteonecrosis of the jaw: clinical and physiopathological considerations. *Ther Clin Risk Manag* 5:217–227, 2009.
29. Boyle P: Effect of Vitamin A deficiency on the periodontal tissues. *Am J Orthod* 33:744, 1947.
30. Broadbent E, Petrie KJ, Alley PG, et al: Psychological stress impairs early wound repair following surgery. *Psychosom Med* 65:865–869, 2003.
31. Brown LR, Roth GD, Hoover D, et al: Alveolar bone loss in leukemic and nonleukemic mice. *J Periodontol* 40:725–730, 1969.
32. Brown RS, Di Stanislao PT, Beaver WT, et al: The administration of folic acid to institutionalized epileptic adults with phenytoin-induced gingival hyperplasia. A double-blind, randomized, placebo-controlled, parallel study. *Oral Surg Oral Med Oral Pathol* 71:565–568, 1991.
33. Brownlee M: Glycation and diabetic complications. *Diabetes* 43:836, 1994.
34. Brozoski MA, Traina AA, Deboni MC, et al: Bisphosphonate-related osteonecrosis of the jaw. *Rev Bras Reumatol* 52(2):265–270, 2012.
35. Brunsvold MA, Chaves ES, Kornman KS, et al: Effects of a bisphosphonate on experimental periodontitis in monkeys. *J Periodontol* 63:825–830, 1992.
36. Bullon P, Pascual A, Fernandez-Novoa MC, et al: Late onset Papillon-Lefèvre syndrome? A chromosomic, neutrophil function and microbiological study. *J Clin Periodontol* 20:662–667, 1993.
37. Buzina R, Brodarec A, Jusic M, et al: Epidemiology of angular stomatitis and bleeding gums. *Int J Vitam Nutr Res* 43:401–415, 1973.
38. Cabrini RL, Carranza FA, Jr: Adenosine triphosphatase in normal and scorbutic wounds. *Nature* 200:1113, 1963.
39. Campbell MJ: Epidemiology of periodontal disease in the diabetic and the non-diabetic. *Aust Dent J* 17:274–278, 1972.
40. Carranza FA, Jr, Gravina O, Cabrini RL: Periodontal and pulpal pathosis in leukemic Mice. *Oral Surg Oral Med Oral Pathol* 20:374–379, 1965.
41. Carvel RI: Palmo-plantar hyperkeratosis and premature periodontal destruction. (Papillon-Lefèvre Syndrome: a 30 year study of two affected sisters). *J Oral Med* 24:73–82, 1969.
42. Centers for Disease Control and Prevention: National diabetes fact sheet: national estimates and general information on diabetes and prediabetes in the United States, 2011, Atlanta, GA, 2011, U.S. Department of Health and Human Services, Centers for Disease Control and Prevention.
43. Cetinkaya BO, Keles GC, Ayas B, et al: Effects of risedronate on alveolar bone loss and angiogenesis: a stereologic study in rats. *J Periodontol* 79:1950–1961, 2008.
44. Chapman O, Harris AE: Oral lesions associated with dietary deficiencies in monkeys. *J Infect Dis* 69:7, 1941.
45. Chapple IL: Potential mechanisms underpinning the nutritional modulation of periodontal inflammation. *J Am Dent Assoc* 140:178–184, 2009.
46. Charbeneau TD, Hurt WC: Gingival findings in spontaneous scurvy. A case report. *J Periodontol* 54:694–697, 1983.
47. Chawla TN, Glickman I: Protein deprivation and the periodontal structures of the albino rat. *Oral Surg Oral Med Oral Pathol* 4:578–602, 1951.

48. Chung EM, Sung EC, Sakurai KL: Dental management of the Down and Eisenmenger syndrome patient. *J Contemp Dent Pract* 5:70–80, 2004.
49. Cianciola LJ, Park BH, Bruck E, et al: Prevalence of periodontal disease in insulin-dependent diabetes mellitus (juvenile diabetes). *J Am Dent Assoc* 104:653–660, 1982.
50. Cichon P, Crawford L, Grimm WD: Early-onset periodontitis associated with Down's syndrome—clinical interventional study. *Ann Periodontol* 3:370–380, 1998.
51. Cohen DW, Friedman LA, Shapiro J, et al: Diabetes mellitus and periodontal disease: two-year longitudinal observations. I. *J Periodontol* 41:709–712, 1970.
52. Cohen DW, Friedman LA, Shapiro J, et al: Periodontal manifestations of cyclic neutropenia. *J Periodontal* 32:159, 1961.
53. Cohen DW, Shapiro J, Friedman L, et al: A longitudinal investigation of the periodontal changes during pregnancy and fifteen months postpartum. II. *J Periodontol* 42:653–657, 1971.
54. Cohen MM, Winer RA, Schwartz S, et al: Oral aspects of mongolism. I. Periodontal disease in mongolism. *Oral Surg Oral Med Oral Pathol* 14:92–107, 1961.
55. Costello C, Webber A: White cell function in Down's syndrome. *Clin Genet* 9:603–605, 1976.
56. Cotran R, Kumar V, Robbins SR: *Robbins' pathologic basis of disease*, 1989.
57. Crandon JH, Lund CC, Dill DB: Experimental human scurvy. *N Engl J Med* 223:353, 1940.
58. Croucher R, Marcenes WS, Torres MC, et al: The relationship between life-events and periodontitis. A case-control study. *J Clin Periodontol* 24:39–43, 1997.
59. Cutler CW, Wasfy MO, Ghaffar K, et al: Impaired bactericidal activity of PMN from two brothers with necrotizing ulcerative gingivoperiodontitis. *J Periodontol* 65:357–363, 1994.
60. Daniell HW: Postmenopausal tooth loss. Contributions to edentulism by osteoporosis and cigarette smoking. *Arch Intern Med* 143:1678–1682, 1983.
61. Deas DE, Mackey SA, McDonnell HT: Systemic disease and periodontitis: manifestations of neutrophil dysfunction. *Periodontol 2000* 32:82–104, 2003.
62. Denton J: A study of tissue changes in experimental black tongue of dogs compared with similar changes in pellagra. *Am J Pathol* 4:341, 1928.
63. Dreizen S: Oral manifestations of human nutritional anemias. *Arch Environ Health* 5:66–75, 1962.
64. Dreizen S, Levy BM, Bernick S, et al: Studies of the biology of the periodontium of marmosets. III. Periodontal bone changes in marmosets with osteomalacia and hyperparathyroidism. *Isr J Med Sci* 3:371, 1967.
65. Dreizen S, McCredie KB, Keating MJ, et al: Malignant gingival and skin "infiltrates" in adult leukemia. *Oral Surg Oral Med Oral Pathol* 55:572–579, 1983.
66. Drozdzowska B, Pluskiewicz W, Michno M: Tooth count in elderly women in relation to their skeletal status. *Maturitas* 55:126–131, 2006.
67. Dumitrescu AL: Psychological perspectives on the pathogenesis of periodontal disease. *Rom J Intern Med* 44:241–260, 2006.
68. Earnshaw SA, Keating N, Hosking DJ, et al: Tooth counts do not predict bone mineral density in early postmenopausal Caucasian women. EPIC study group. *Int J Epidemiol* 27:479–483, 1998.
69. El-Ashiry GM, El-Kafrawy AH, Nasr MF, et al: Comparative study of the influence of pregnancy and oral contraceptives on the gingivae. *Oral Surg Oral Med Oral Pathol* 30:472–475, 1970.
70. El-Shinnawi UM, El-Tantawy SI: The effect of alendronate sodium on alveolar bone loss in periodontitis (clinical trial). *J Int Acad Periodontol* 5:5–10, 2003.
71. Elders PJ, Habets LL, Netelenbos JC, et al: The relation between periodontitis and systemic bone mass in women between 46 and 55 years of age. *J Clin Periodontol* 19:492–496, 1992.
72. Elter JR, White BA, Gaynes BN, et al: Relationship of clinical depression to periodontal treatment outcome. *J Periodontol* 73:441–449, 2002.
73. Emrich LJ, Shlossman M, Genco RJ: Periodontal disease in non-insulin-dependent diabetes mellitus. *J Periodontol* 62:123–131, 1991.
74. Enwonwu CO, Edozien JC: Epidemiology of periodontal disease in Western Nigerians in relation to socio-economic status. *Arch Oral Biol* 15:1231–1244, 1970.
75. Estilo CL, Van Poznak CH, Wiliams T, et al: Osteonecrosis of the maxilla and mandible n patients with advanced cancer treated with bisphosphonate therapy. *Oncologist* 13:911–920, 2008.
76. Falk H, Hugoson A, Thorstensson H: Number of teeth, prevalence of caries and periapical lesions in insulin-dependent diabetics. *Scand J Dent Res* 97:198–206, 1989.
77. Fardal O, Drangsholt E, Olsen I: Palmar plantar keratosis and unusual periodontal findings. Observations from a family of 4 members. *J Clin Periodontol* 25:181–184, 1998.
78. Farzim I, Edalat M: Periodontosis with hyperkeratosis palmaris et plantaris (the Papillon Lefèvre syndrome): a case report. *J Periodontol* 45:316–318, 1974.
79. Ficara AJ, Levin MP, Grower MF, et al: A comparison of the glucose and protein content of gingival fluid from diabetics and nondiabetics. *J Periodontal Res* 10:171–175, 1975.
80. Firatli E, Gurel N, Efeoglu A, et al: Clinical and immunological findings in 2 siblings with Papillon-Lefèvre syndrome. *J Periodontol* 67:1210–1215, 1996.
81. Folis R: *The pathology of nutritional disease*, Springfield, 1948, Charles C. Thomas.
82. Formicola AJ, Weatherford T, 3rd, Grupe H, Jr: The uptake of H3-estradiol by the oral tissues of rats. *J Periodontal Res* 5:269–275, 1970.
83. Forsslund G: The occurrence of subepithelial gingival blood vessels in patients with morbus caeruleus (tetralogy of Fallot). *Acta Odontol Scand* 20:301–306, 1962.
84. Frandsen AM: Periodontal tissue changes in vitamin A deficient young rats. *Acta Odontol Scand* 21:19–34, 1963.
85. Friedman LA: Horizontal tooth mobility and the menstrual cycle. *J Periodontal Res* 7:125–130, 1972.
86. Galea H, Aganovic I, Aganovic M: The dental caries and periodontal disease experience of patients with early onset insulin dependent diabetes. *Int Dent J* 36:219–224, 1986.
87. Genco RJ: Current view of risk factors for periodontal diseases. *J Periodontol* 67:1041–1049, 1996.
88. Genco RJ, Ho AW, Grossi SG, et al: Relationship of stress, distress and inadequate coping behaviors to periodontal disease. *J Periodontol* 70:711–723, 1999.
89. Genco RJ, Shlossman M, Zambon JJ: Immunologic studies of periodontitis parents with type II diabetes. *J Dent Res* 66:257, 1987.
90. Geurs NC, Lewis CE, Jeffcoat MK: Osteoporosis and periodontal disease progression. *Periodontol 2000* 32:105–110, 2003.
91. Ghaffer KA, Zahran FM, Fahmy HM, et al: Papillon-Lefèvre syndrome: neutrophil function in 15 cases from 4 families in Egypt. *Oral Surg Oral Med Oral Pathol Oral Radiol Endod* 88:320–325, 1999.
92. Glavind L, Lund B, Loe H: The relationship between periodontal state and diabetes duration, insulin dosage and retinal changes. *J Periodontol* 39:341–347, 1968.
93. Glickman I: The periodontal structures in experimental diabetes. *NY J Dent* 16:226, 1946.
94. Glickman I: Acute vitamin C deficiency and periodontal disease; the periodontal tissues of the guinea pig in acute vitamin C deficiency. *J Dent Res* 27:9–23, 1948.
95. Glickman I: Acute vitamin C deficiency and the periodontal tissues; the effect of acute vitamin C deficiency upon the response of the periodontal tissues of the guinea pig to artificially induced inflammation. *J Dent Res* 27:201–210, 1948.
96. Glickman I, Stoller M: The periodontal tissues of the albino rat in vitamin A deficiency. *J Dent Res* 27:758, 1948.
97. Glickman I, Stone IC, Chawla TN: The effect of cortisol acetate upon the periodontium of white mice. *J Periodontal* 24:161, 1953.
98. Goetzl EJ, Wasserman SI, Gigli I, et al: Enhancement of random migration and chemotactic response of human leukocytes by ascorbic acid. *J Clin Invest* 53:813–818, 1974.

99. Goldman HM: Acute aleukemic leukemia. *Am J Orthod* 26:89, 1940.
100. Goodman H: Perleche: a consideration of its etiology and pathology. *Bull Johns Hopkins Hosp* 51:263, 1943.
101. Gottsegen R: Dental and oral considerations in diabetes mellitus. *N Y State J Med* 62:389–395, 1962.
102. Govier WM, Greig ME: Prevention of oral lesions in B1 avitaminotic dogs. *Science* 98:216–217, 1943.
103. Goya JA, Paez HA: Mandalunis PM: Effect of topical administration of monosodium olpadronate on experimental periodontitis in rats. *J Periodontol* 77:1–6, 2006.
104. Greenberg MS, Cohen SG, Boosz B, et al: Oral herpes simplex infections in patients with leukemia. *J Am Dent Assoc* 114:483–486, 1987.
105. Gregory L, Williams R, Thompson E: Leucocyte function in Down's syndrome and acute leukaemia. *Lancet* 1:1359–1361, 1972.
106. Grodstein F, Colditz GA, Stampfer MJ: Post-menopausal hormone use and tooth loss: a prospective study. *J Am Dent Assoc* 127:370–377, quiz 392, 1996.
107. Grodstein F, Colditz GA, Stampfer MJ: Tooth loss and hormone use in postmenopausal women. *Compend Contin Educ Dent Suppl* S9–S16, 1998.
108. Grossi SG, Zambon JJ, Ho AW, et al: Assessment of risk for periodontal disease. I. Risk indicators for attachment loss. *J Periodontol* 65:260–267, 1994.
109. Gur A, Nas K, Kayhan O, et al: The relation between tooth loss and bone mass in postmenopausal osteoporotic women in Turkey: a multicenter study. *J Bone Miner Metab* 21:43–47, 2003.
110. Gusberti FA, Syed SA, Bacon G, et al: Puberty gingivitis in insulin-dependent diabetic children. I. Cross-sectional observations. *J Periodontol* 54:714–720, 1983.
111. Hayden P, Buckley LA: Diabetes mellitus and periodontal disease in an Irish population. *J Periodontal Res* 24:298–302, 1989.
112. Henrikson PA: Periodontal disease and calcium deficiency. An experimental study in the dog. *Acta Odontol Scand* 26(Suppl 50):51–132, 1968.
113. Higgins W: Systematic poisoning with bismuth. *JAMA* 66:648, 1916.
114. Hirschfeld I: Periodontal symptoms associated with diabetes. *J Periodontal* 5:37, 1934.
115. Hodges RE, Baker EM, Hood J, et al: Experimental scurvy in man. *Am J Clin Nutr* 22:535–548, 1969.
116. Holm-Pederson P, Loe H: Flow of gingival exudate as related to menstruation and pregnancy. *J Periodontal* 2:13, 1967.
117. Hugoson A: Gingival inflammation and female sex hormones. A clinical investigation of pregnant women and experimental studies in dogs. *J Periodontal Res Suppl* 5:1–18, 1970.
118. Iacopino AM: Periodontitis and diabetes interrelationships: role of inflammation. *Ann Periodontol* 6:125–137, 2001.
119. Inagaki K, Kurosu Y, Yoshinari N, et al: Efficacy of periodontal disease and tooth loss to screen for low bone mineral density in Japanese women. *Calcif Tissue Int* 77:9–14, 2005.
120. Ismail AI, Burt BA, Eklund SA: Relation between ascorbic acid intake and periodontal disease in the United States. *J Am Dent Assoc* 107:927–931, 1983.
121. Izumi Y, Sugiyama S, Shinozuka O, et al: Defective neutrophil chemotaxis in Down's syndrome patients and its relationship to periodontal destruction. *J Periodontol* 60:238–242, 1989.
122. Jeffcoat MK, Cizza G, Shih WJ, et al: Efficacy of bisphosphonates for the control of alveolar bone loss in periodontitis. *J Int Acad Periodontol* 9:70–76, 2007.
123. Jones R: Symptoms in early stages of industrial plumbism. *JAMA* 104:105, 1935.
124. Jung J, Carranza FA, Jr, Newman MG: Scanning electron-microscopy of plague in Papillon-Lefèvre syndrome. *J Periodontol* 52:442–446, 1981.
125. Kalkwarf KL: Effect of oral contraceptive therapy on gingival inflammation in humans. *J Periodontol* 49:560–563, 1978.
126. Kaner A, Losch P, Green M: Oral manifestations of congenital heart disease. *J Pediatr* 29:269, 1946.
127. Kardachi BJ, Newcomb GM: A clinical study of gingival inflammation in renal transplant recipients taking immunosuppressive drugs. *J Periodontol* 49:307–309, 1978.
128. Kastlin G: Agranulocytic angina. *Am J Med Sci* 173:799, 1927.
129. Khan AJ, Evans HE, Glass L, et al: Defective neutrophil chemotaxis in patients with Down syndrome. *J Pediatr* 87:87–89, 1975.
130. Kim JE, Shklar G: The effect of vitamin E on the healing of gingival wounds in rats. *J Periodontol* 54:305–308, 1983.
131. Kim RH, Lee RS, Williams D, et al: Bisphosphonates induce senescence in normal human oral keratinocytes. *J Dent Res* 90:810–816, 2011.
132. King J: Vincent's disease treated with nicotinic acid. *Lancet* 2:32, 1940.
133. Klemetti E, Collin HL, Forss H, et al: Mineral status of skeleton and advanced periodontal disease. *J Clin Periodontol* 21:184–188, 1994.
134. Knight GM, Wade AB: The effects of hormonal contraceptives on the human periodontium. *J Periodontal Res* 9:18–22, 1974.
135. Kolodzinski E, Munoa N, Malatesta E: Clinical study of gingival tissue in pregnant women. *J Dent Res* 53:693, 1974.
136. Kornman KS, Loesche WJ: The subgingival microbial flora during pregnancy. *J Periodontal Res* 15:111–122, 1980.
137. Kracke R: *Granulopenia as associated with amidopyrine administration*. Presented at annual session of American Medical Association, 1934.
138. Krohn S: The effect of the administration of steroid hormones on the gingival tissues. *J Periodontal* 29:300, 1958.
139. Landesberg R, Cozin M, Cremers S, et al: Inhibition of oral mucosal cell wound healing by bisphosphonates. *J Oral Maxillofac Surg* 66(5):839–847, 2008.
140. Lee R, Lee NZ: The peripheral vascular system and its reactions in scurvy: an experimental study. *Am J Physiol* 149:465, 1947.
141. Leibson CL, Tosteson AN, Gabriel SE, et al: Mortality, disability, and nursing home use for persons with and without hip fracture: a population-based study. *J Am Geriatr Soc* 50:1644–1650, 2002.
142. Lerner UH: Inflammation-induced bone remodeling in periodontal disease and the influence of post-menopausal osteoporosis. *J Dent Res* 85:596–607, 2006.
143. Liberman H: Chromone ulcerations of the nose and throat. *N Engl J Med* 225:132, 1941.
144. Lindhe J: Attsfrom R: Gingival exudation during the menstrual cycle. *J Periodontal Res* 2:194–198, 1967.
145. Lindhe J, Bjorn AL: Influence of hormonal contraceptives on the gingiva of women. *J Periodontal Res* 2:1–6, 1967.
146. Lindhe J, Branemark PI: Changes in microcirculation after local application of sex hormones. *J Periodontal Res* 2:185–193, 1967.
147. Loe H: Periodontal changes in pregnancy. *J Periodontal* 36:209, 1965.
148. Loe H: Periodontal disease. The sixth complication of diabetes mellitus. *Diabetes Care* 16:329–334, 1993.
149. Loushine RJ, Weller RN, Kimbrough WF, et al: Secondary hyperparathyroidism: a case report. *J Endod* 29:272–274, 2003.
150. Lundgren T, Renvert S, Papapanou PN, et al: Subgingival microbial profile of Papillon-Lefèvre patients assessed by DNA-probes. *J Clin Periodontol* 25:624–629, 1998.
151. Lundstrom A, Jendle J, Stenstrom B, et al: Periodontal conditions in 70-year-old women with osteoporosis. *Swed Dent J* 25:89–96, 2001.
152. Lynch MA, Ship II: Initial oral manifestations of leukemia. *J Am Dent Assoc* 75:932–940, 1967.
153. Madison F, Squier TL: Primary granulocytopenia after administration of benzene chain derivatives. *JAMA* 102:755, 1934.
154. Maier AW, Orban B: Gingivitis in pregnancy. *Oral Surg Oral Med Oral Pathol* 2:334–373, 1949.
155. Mann A, Spies TD, Springer M: Oral manifestations of vitamin B complex deficiencies. *J Dent Res* 20:269, 1941.
156. Manson-Bahr P, Ransford ON: Stomatitis of vitamin B2 deficiency treated with nicotinic acid. *Lancet* 2:426, 1938.
157. Mark H: Agranulocytic angina: its oral manifestations. *J Am Dent Assoc* 21:119, 1934.
158. Martinez Lalis R, Lopez Otero R, Carranza FA, Jr: A case of Papillon-Lefèvre syndrome. *Periodontics* 3:292–295, 1965.

159. Marx RE: Pamidronate (Aredia) and zoledronate (Zometa) induced avascular necrosis of the jaws: a growing epidemic. *J Oral Maxillofac Surg* 61:1115–1117, 2003.
160. Marx RE: *Oral & intravenous bisphosphonate-induced osteonecrosis of the jaws: history, etiology, prevention, and treatment*, Chicago, 2007, Quintessence Pub. Co., p 150.
161. Marx RE, Sawatari Y, Fortin M, et al: Bisphosphonate-induced exposed bone (osteonecrosis/osteopetrosis) of the jaws: risk factors, recognition, prevention, and treatment. *J Oral Maxillofac Surg* 63:1567–1575, 2005.
162. Mascola RF, Jr: The oral manifestations of diabetes mellitus. A review. *N Y State Dent J* 36:139–142, 1970.
163. Mashimo PA, Yamamoto Y, Slots J, et al: The periodontal microflora of juvenile diabetics. Culture, immunofluorescence, and serum antibody studies. *J Periodontol* 54:420–430, 1983.
164. Massler M: Oral manifestations during the female climacteric (the postmenopausal syndrome). *Oral Surg Oral Med Oral Pathol* 4:1234–1243, 1951.
165. McCarthy P, Shklar G: *Disease of the oral mucosa*, ed 2, Philadelphia, 1980, Lea & Febiger.
166. McMullen JA, Van Dyke TE, Horoszewicz HU, et al: Neutrophil chemotaxis in individuals with advanced periodontal disease and a genetic predisposition to diabetes mellitus. *J Periodontol* 52:167–173, 1981.
167. Mealey BL: Influence of periodontal infections on systemic health. *Periodontol 2000* 21:197–209, 1999.
168. Mealey BL, Moritz AJ: Hormonal influences: effects of diabetes mellitus and endogenous female sex steroid hormones on the periodontium. *Periodontol 2000* 32:59–81, 2003.
169. Menezes AM, Rocha FA, Chaves HV, et al: Effect of sodium alendronate on alveolar bone resorption in experimental periodontitis in rats. *J Periodontol* 76:1901–1909, 2005.
170. Meyer AH: Agranulocytosis: report of case caused by sulfadiazine. *Cal West Med* 60:277, 1944.
171. Mitsuta T, Horiuchi H, Shinoda H: Effects of topical administration of clodronate on alveolar bone resorption in rats with experimental periodontitis. *J Periodontol* 73:479–486, 2002.
172. Mohammad AR, Bauer RL, Yeh CK: Spinal bone density and tooth loss in a cohort of postmenopausal women. *Int J Prosthodont* 10:381–385, 1997.
173. Mohammad AR, Hooper DA, Vermilyea SG, et al: An investigation of the relationship between systemic bone density and clinical periodontal status in post-menopausal Asian-American women. *Int Dent J* 53:121–125, 2003.
174. Mohammed A, Waterhouse JP, Friederici HH: The microvasculature of the rat gingiva as affected by progesterone, an ultrastructural study. *J Periodontal* 45:50, 1974.
175. Montiero da Silva A, Newman HN, Oakley DA, et al: Psychosocial factors and adult onset rapidly progressive periodontitis. *J Clin Periodontol* 23:789, 1996.
176. Montiero da Silva A, Newman HN, Oakley DA, et al: Psychosocial factors, dental plaque levels, and smoking in periodontitis patients. *J Clin Periodontol* 25:217, 1998.
177. Nichols C, Laster LL, Bodak-Gyovai LZ: Diabetes mellitus and periodontal disease. *J Periodontol* 49:85–88, 1978.
178. Nishida M, Grossi SG, Dunford RG, et al: Dietary vitamin C and the risk for periodontal disease. *J Periodontol* 71:1215–1223, 2000.
179. Novaes AB, Jr, Pereira AL, de Moraes N, et al: Manifestations of insulin-dependent diabetes mellitus in the periodontium of young Brazilian patients. *J Periodontol* 62:116–122, 1991.
180. O'Leary T, Shannon I, Prigmore JR: Clinical and systematic findings in periodontal disease. *J Periodontal* 32:243, 1962.
181. O'Neil TC: Maternal T-lymphocyte response and gingivitis in pregnancy. *J Periodontol* 50:178–184, 1979.
182. O'Uchi N, Nishikawa H, Yoshino T, et al: Inhibitory effects of YM175, a bisphosphonate, on the progression of experimental periodontitis in beagle dogs. *J Periodontal Res* 33:196–204, 1998.
183. Oh T-J, Bashutski J, Giannobile WV: The interrelationship between osteoporosis and oral bone loss. *Grand Rounds Oral Syst Med* 2, 2007.
184. Oshrain HI, Mender S, Mandel ID: Periodontal status of patients with reduced immunocapacity. *J Periodontol* 50:185–188, 1979.
185. Otomo-Corgel J: Implants and oral bisphosphonates: risky business? *J Periodontol* 78:373–376, 2007.
186. Pack AR, Thomson ME: Effects of topical and systemic folic acid supplementation on gingivitis in pregnancy. *J Clin Periodontol* 7:402–414, 1980.
187. Page RC: The pathobiology of periodontal diseases may affect systemic diseases: inversion of a paradigm. *Ann Periodontol* 3:108–120, 1998.
188. Page RC, Bowen T, Altman L, et al: Prepubertal periodontitis. I. Definition of a clinical disease entity. *J Periodontol* 54:257–271, 1983.
189. Page RC, Schroeder HE: Periodontitis in man and other animal a comparative review. *Basel Karger* 1982.
190. Papillion MM, Lefèvre LP: Deux cas de keratodermie palmaire et plantaire symmetrique famiale (maladie de Meleda) chez le frère et la soeur: coéxistance dans les deux cas d'altérations dentaires graves. *Bull Soc Derma Symp* 31:82–87, 1924.
191. Parrish JH, Jr, DeMarco TJ, Bissada NF: Vitamin E and periodontitis in the rat. *Oral Surg Oral Med Oral Pathol* 44:210–218, 1977.
192. Patrone F, Dallegri F, Rebora A, et al: Lazy leukocyte syndrome. *Blut* 39:265–269, 1979.
193. Perry DA: Oral contraceptives and periodontal health. *J West Soc Periodontol Periodontal Abstr* 29:72–80, 1981.
194. Peruzzo DC, Benatti BB, Ambrosano GM, et al: A systematic review of stress and psychological factors as possible risk factors for periodontal disease. *J Periodontol* 78:1491–1504, 2007.
195. Pinard A: Gingivitis in pregnancy. *Dent Register* 31:258, 1877.
196. Prout RE, Hopps RM: A relationship between human oral bacteria and the menstrual cycle. *J Periodontol* 41:98–101, 1970.
197. Randall C: Granulocytopenia following barbiturates and amidopyrine. *JAMA* 102:1137, 1934.
198. Rateitschak KH: Tooth mobility changes in pregnancy. *J Periodontal Res* 2:199–206, 1967.
199. Reinhardt RA, Payne JB, Maze CA, et al: Influence of estrogen and osteopenia/osteoporosis on clinical periodontitis in postmenopausal women. *J Periodontol* 70:823–828, 1999.
200. Restarski J, Pijoan M: Gingivitis and vitamin C. *J Am Dent Assoc* 31:1323, 1944.
201. Reuland-Bosma W, van Dijk J: Periodontal disease in Down's syndrome: a review. *J Clin Periodontol* 13:64–73, 1986.
202. Richman J, Abarbanel AR: Effects of estradiol, testosterone, diethylstilbestrol and several of their derivatives upon the human mucous membrane. *J Am Dent Assoc* 30:913, 1943.
203. Robbins SL, Cotran RS, Kumar V: *Pathologic basis of disease*, ed 4, Philadelphia, 1989, Saunders.
204. Robertson HD, Polk HC, Jr: The mechanism of infection in patients with diabetes mellitus: a review of leukocyte malfunction. *Surgery* 75:123–128, 1974.
205. Rosenberg E, Guralnick WC: Hyperparathyroidism. *Oral Surg* 15(Suppl 2):84, 1962.
206. Ruggiero SL, Dodson TB, Assael LA, et al: American Association of Oral and Maxillofacial Surgeons position paper on bisphosphonate-related osteonecrosis of the jaws—2009 update. *J Oral Maxillofac Surg* 67(Suppl 5):2–12, 2009.
207. Ruggiero SL, Fantasia J, Carlson E: Bisphosphonate-related osteonecrosis of the jaw: background and guidelines for diagnosis, staging and management. *Oral Surg Oral Med Oral Pathol Oral Radiol Endod* 102(4):433–441, 2006.
208. Ruggiero SL, Mehrotra B, Rosenberg TJ, et al: Osteonecrosis of the jaws associated with the use of bisphosphonates: a review of 63 cases. *J Oral Maxillofac Surg* 62:527–534, 2004.
209. Russell AL: International nutrition surveys: a summary of preliminary dental findings. *J Dent Res* 42(1)Pt 2:233–244, 1963.
210. Russell RG: Bisphosphonates: mode of action and pharmacology. *Pediatrics* 119(Suppl 2):S150–S162, 2007.
211. Safkan-Seppala B, Ainamo J: Periodontal conditions in insulin-dependent diabetes mellitus. *J Clin Periodontol* 19:24–29, 1992.

212. Salvi GE, Lawrence HP, Offenbacher S, et al: Influence of risk factors on the pathogenesis of periodontitis. *Periodontol 2000* 14:173–201, 1997.
213. Sandhu HS, Sharma V, Sidhu GS: Role of psychiatric disorders in self-inflicted periodontal injury: a case report. *J Periodontol* 68:1136–1139, 1997.
214. Sastrowijoto SH, Hillemans P, van Steenbergen TJ, et al: Periodontal condition and microbiology of healthy and diseased periodontal pockets in type 1 diabetes mellitus patients. *J Clin Periodontol* 16:316–322, 1989.
215. Schaudinn C, Gorur A, Webster P, et al: Quantification by energy dispersive x-ray spectroscopy of alendronate in the diseased jaw bone of patients with bisphosphonate-related jaw osteonecrosis. *Oral Surg Oral Med Oral Pathol Oral Radiol* 114:480–486, 2012.
216. Schmidt AM, Weidman E, Lalla E, et al: Advanced glycation end-products (AGEs) induce oxidant stress in the gingiva: a potential mechanism underlying accelerated periodontal disease associated with diabetes. *J Periodontal Res* 31:508–515, 1996.
217. Schneir M, Imberman M, Ramamurthy N, et al: Streptozotocin-induced diabetes and the rat periodontium: decreased relative collagen production. *Coll Relat Res* 8:221–232, 1988.
218. Schour I, Sarnat BG: Oral manifestations of occupational origin. *JAMA* 120:1197, 1942.
219. Schroeder HE, Seger RA, Keller HU, et al: Behavior of neutrophilic granulocytes in a case of Papillon-Lefèvre syndrome. *J Clin Periodontol* 10:618–635, 1983.
220. Scully C, MacFadyen E, Campbell A: Oral manifestations in cyclic neutropenia. *Br J Oral Surg* 20:96–101, 1982.
221. Shaw J: The relation of nutrition to periodontal disease. *J Dent Res* 41(Suppl 1):264, 1962.
222. Sheridan P: Diabetes and oral health. *J Am Dent Assoc* 115:741–742, 1987.
223. Shilotri PG, Bhat KS: Effect of mega doses of vitamin C on bactericidal activity of leukocytes. *Am J Clin Nutr* 30:1077–1081, 1977.
224. Shoji K, Horiuchi H, Shinoda H: Inhibitory effects of a bisphosphonate (risedronate) on experimental periodontitis in rats. *J Periodontal Res* 30:277–284, 1995.
225. Silverman S, Jr, Gordan G, Grant T, et al: The dental structures in primary hyperparathyroidism. Studies in forty-two consecutive patients. *Oral Surg Oral Med Oral Pathol* 15:426–436, 1962.
226. Solomon DH, Mercer E, Woo SB, et al: Defining the epidemiology of bisphosphonate-associated osteonecrosis of the jaw: prior work and current challenges. *Osteoporos Int* 24(1):237–244, 2013.
227. Stahl SS: The effect of a protein-free diet on the healing of gingival wounds in rats. *Arch Oral Biol* 7:551–556, 1962.
228. Stahl SS, Sandler HC, Cahn L: The effects of protein deprivation upon the oral tissues of the rat and particularly upon periodontal structures under irritation. *Oral Surg Oral Med Oral Pathol* 8:760–768, 1955.
229. Strock M: The mouth in hyperparathyroidism. *N Engl J Med* 224:1019, 1945.
230. Sutcliffe P: A longitudinal study of gingivitis and puberty. *J Periodontal Res* 7:52–58, 1972.
231. Svanberg G, Lindhe J, Hugoson A, et al: Effect of nutritional hyperparathyroidism on experimental periodontitis in the dog. *Scand J Dent Res* 81:155–162, 1973.
232. Sznajder N, Carraro JJ, Otero E, et al: Clinical periodontal findings in trisomy 21 (mongolism). *J Periodontal Res* 3:1–5, 1968.
233. Sznajder N, Carraro JJ, Rugna S, et al: Periodontal findings in diabetic and nondiabetic patients. *J Periodontol* 49:445–448, 1978.
234. Taguchi A, Sanada M, Suei Y, et al: Effect of estrogen use on tooth retention, oral bone height, and oral bone porosity in Japanese postmenopausal women. *Menopause* 11:556–562, 2004.
235. Takaishi Y, Miki T, Nishizawa Y, et al: Clinical effect of etidronate on alveolar pyorrhoea associated with chronic marginal periodontitis: report of four cases. *J Int Med Res* 29:355–365, 2001.
236. Tan JS, Anderson JL, Watanakunakorn C, et al: Neutrophil dysfunction in diabetes mellitus. *J Lab Clin Med* 85:26–33, 1975.
237. Telsey B, Beube FE, Zegarelli EV, et al: Oral manifestations of cyclical neutropenia associated with hypergammaglobulinemia; report of a case. *Oral Surg Oral Med Oral Pathol* 15:540–543, 1962.
238. Tenenbaum HC, Shelemay A, Girard B, et al: Bisphosphonates and periodontics: potential applications for regulation of bone mass in the periodontium and other therapeutic/diagnostic uses. *J Periodontol* 73:813–822, 2002.
239. Tervonen T, Knuuttila M, Pohjamo L, et al: Immediate response to nonsurgical periodontal treatment in subjects with diabetes mellitus. *J Clin Periodontol* 18:65–68, 1991.
240. Tezal M, Wactawski-Wende J, Grossi SG, et al: The relationship between bone mineral density and periodontitis in postmenopausal women. *J Periodontol* 71:1492–1498, 2000.
241. Tinanoff N, Tempro P, Maderazo EG: Dental treatment of Papillon-Lefèvre syndrome: 15-year follow-up. *J Clin Periodontol* 22:609–612, 1995.
242. Tollefsen T, Saltvedt E, Koppang HS: The effect of immunosuppressive agents on periodontal disease in man. *J Periodontal Res* 13:240–250, 1978.
243. Topping N, Fraser HF: Mouth lesions associated with dietary deficiencies in monkeys. *Public Health Rep* 54:416, 1939.
244. Turesky S, Fisher B, Glickman I: A histochemical study of the attached gingiva in pregnancy. *J Dent Res* 37:1115–1122, 1958.
245. Vogel RI: Relationship of folic acid to phenytoin-induced gingival overgrowth. In Hassel TM, Johnson M, Dudley K, editors: *Phenytoin-induced teratology and gingival pathology*, New York, 1980, Raven Press.
246. Vogel RI, Deasy M, Alfano M, et al: The effect of folic acid on gingival health of women taking oral contraceptives. *J Prev Dental* 6:221, 1980.
247. Vogel RI, Fink RA, Frank O, et al: The effect of topical application of folic acid on gingival health. *J Oral Med* 33:20–22, 1978.
248. Vogel RI, Fink RA, Schneider LC, et al: The effect of folic acid on gingival health. *J Periodontol* 47:667–668, 1976.
249. Vrahopoulos TP, Barber P, Liakoni H, et al: Ultrastructure of the periodontal lesion in a case of Papillon-Lefèvre syndrome (PLS). *J Clin Periodontol* 15:17–26, 1988.
250. Wade ML, Suzuki JB: Issues related to diagnosis and treatment of bisphosphonate-induced osteonecrosis of the jaws. *Grand Rounds Oral Syst Med* 2:46–53, 2007.
251. Waerhaug J: Effect of C-avitaminosis on the supporting structures of the teeth. *J Periodontal* 47:667, 1958.
252. Waerhaug J: *Epidemiology of periodontal disease*, 1966, American Academy of Periodontology, University of Michigan Press.
253. Waldrop TC, Anderson DC, Hallmon WW, et al: Periodontal manifestations of the heritable Mac-1, LFA-1, deficiency syndrome. Clinical, histopathologic and molecular characteristics. *J Periodontol* 58:400–416, 1987.
254. Wang EP, Kaban LB, Strewler GJ, et al: Incidence of osteonecrosis of the jaw in patients with multiple myeloma and breast or prostate cancer on intravenous bisphosphonate therapy. *J Oral Maxillofac Surg* 65:1328–1331, 2007.
255. Weinmann J, Schour I: The effect of parathyroid hormone on the alveolar bone and teeth of the normal and rachitic rat. *Am J Pathol* 21:857, 1945.
256. Weinmann J, Schour I: Experimental studies in calcification. *Am J Pathol* 21:821, 1945.
257. Weinreb M, Quartuccio H, Seedor JG, et al: Histomorphometrical analysis of the effects of the bisphosphonate alendronate on bone loss caused by experimental periodontitis in monkeys. *J Periodontal Res* 29:35–40, 1994.
258. Wiebe CB, Hakkinen L, Putnins EE, et al: Successful periodontal maintenance of a case with Papillon-Lefèvre syndrome: 12-year follow-up and review of the literature. *J Periodontol* 72:824–830, 2001.
259. Wimmer G, Janda M, Wieselmann-Penkner K, et al: Coping with stress: its influence on periodontal disease. *J Periodontol* 73:1343–1351, 2002.

260. Wingrove FA, Rubright WC, Kerber PE: Influence of ovarian hormone situation on atrophy, hypertrophy, and/or desquamation of human gingiva in premenopausal and postmenopausal women. *J Periodontol* 50:445–449, 1979.
261. Wolbach S, Bessey OA: Tissue changes in vitamin deficiencies. *Physiol Rev* 22:233, 1942.
262. Woolfe SN, Hume WR, Kenney EB: Ascorbic acid and periodontal disease: a review of the literature. *J West Soc Periodontol Periodontal Abstr* 28:44–56, 1980.
263. Woolfe SN, Kenney EB, Hume WR, et al: Relationship of ascorbic acid levels of blood and gingival tissue with response to periodontal therapy. *J Clin Periodontol* 11:159–165, 1984.
264. Wray D, Lowe GDO, Dagg JH, et al: *Systemic disease: oral manifestations and effects on oral health*, Edinburgh, 1999, Churchill Livingstone.
265. Yendt ER: *The parathyroids and calcium metabolism*, Philadelphia, 1986, Harper and Row.
266. Yoshihara A, Seida Y, Hanada N, et al: The relationship between bone mineral density and the number of remaining teeth in community-dwelling older adults. *J Oral Rehabil* 32:735–740, 2005.
267. Zambon JJ, Reynolds H, Fisher JG, et al: Microbiological and immunological studies of adult periodontitis in patients with noninsulin-dependent diabetes mellitus. *J Periodontol* 59:23–31, 1988.
268. Ziskin D, Blackberg SN: A study of the gingivae during pregnancy. *J Dent Res* 13:253, 1933.
269. Ziskin D, Blackberg SN, Stout A: The gingivae during pregnancy: an experimental study and a histopathological interpretation. *Surg Gynecol Obstet* 57:1933, 1933.

CHAPTER 12

Impact of Periodontal Infection on Systemic Health

Brian L. Mealey and Perry R. Klokkevold

CHAPTER OUTLINE

Pathobiology of Periodontitis
Focal Infection Theory Revisited
Evidence-Based Clinical Practice
Subgingival Environment as a Reservoir for Bacteria
Periodontal Disease and Mortality
Periodontal Disease and Coronary Heart Disease/Atherosclerosis
Periodontal Disease and Stroke
Periodontal Disease and Diabetes Mellitus
Periodontal Disease and Pregnancy Outcome *(online only)*
Periodontal Disease and Chronic Obstructive Pulmonary Disease *(online only)*
Periodontal Disease and Acute Respiratory Infections *(online only)*
Periodontal Medicine in Clinical Practice
Conclusions

For online-only content on periodontal disease and pregnancy outcome, periodontal disease and chronic obstructive pulmonary disease, and periodontal disease and acute respiratory infections, please visit the companion website at www.expertconsult.com.

Knowledge of the pathogenesis of periodontal diseases has evolved markedly over the last 50 years.[65] Periodontal disease is an inflammatory disease initiated by bacterial pathogens. Environmental, physical, social, and host stresses may affect and modify disease expression through a multitude of pathways. Certain systemic conditions can affect the initiation and progression of gingivitis and periodontitis (see Chapters 6 and 11). Systemic disorders that affect neutrophil, monocyte, macrophage, and lymphocyte function result in the altered production or activity of host inflammatory mediators.[65,102] These alterations may manifest clinically as the early onset of periodontal destruction or as a more rapid rate of destruction than would occur in the absence of such disorders.

Evidence has also shed light on the converse side of the relationship between systemic health and oral health: the potential effects of inflammatory periodontal diseases on a wide range of organ systems. This field of periodontal medicine addresses the following important questions:

- Can the inflammatory response to bacterial infection of the periodontium have an effect that is remote from the oral cavity?
- Is periodontal infection a risk factor for systemic diseases or conditions that affect human health?

Pathobiology of Periodontitis

Our understanding of the pathogenesis of periodontitis has changed remarkably over the last 30 years.[65,102,106] The nonspecific accumulation of bacterial plaque was once thought to be the cause of periodontal destruction, but it is now recognized that periodontitis is an infectious disease associated with a small number of predominantly gram-negative microorganisms that exist in a subgingival biofilm.[40] Furthermore, the importance of the host in disease initiation and progression is clearly recognized. Although pathogenic bacteria are necessary for periodontal disease, they are not sufficient alone to cause the disease. A susceptible host is also imperative. In a host who has relatively low susceptibility to disease, bacterial pathogens may have no clinical effect. This may be due to a particularly effective host immunoinflammatory response that eliminates pathogenic organisms while minimizing destruction of native tissues. Conversely, in a host with relatively high disease susceptibility, the marked destruction of periodontal tissues may result.

Recognition of the importance of host susceptibility opens a door to understanding the differences in the onset, natural history, and progression of periodontitis seen throughout the scientific literature. Because of differences in host susceptibility, not all individuals are equally vulnerable to the destructive effects of periodontal pathogens and the immunoinflammatory response to those organisms. Thus, patients may not necessarily have similar disease expression despite the presence of similar bacteria. Likewise, the response to periodontal treatment may vary depending on the wound-healing capacity and susceptibility of the host to further disease progression. The importance of host susceptibility is clearly evident in the medical literature. For example, respiratory tract pathogens may have minimal effect on many individuals, but in a susceptible host such as an elderly patient, these same pathogens may cause life-threatening respiratory tract illnesses.

There are many systemic conditions that can modify the host's susceptibility to periodontitis. For example, patients with immune suppression may not be able to mount an effective host response to subgingival microorganisms, thereby resulting in more rapid and severe periodontal destruction. Conversely, individuals with a significant increase in the production of proinflammatory mediators may respond to periodontal pathogens with an exuberant inflammatory response that results in the destruction of periodontal tissues. Although the potential impact of many systemic disorders on the periodontium is well documented, recent evidence suggests

Periodontal Disease and Pregnancy Outcome

Low-birth-weight (LBW) infants (i.e., those weighing <2500 g at birth) are 40 times more likely to die during the neonatal period than normal-birth-weight (NBW) infants.[85] LBW infants who survive the neonatal period are at increased risk for congenital anomalies, respiratory disorders, and neurodevelopmental disabilities. The social and financial costs of LBW infants are enormous, and an emphasis on the prevention of LBW is preferred to the high-cost intensive care often required to allow for the survival of LBW infants.

The primary cause of LBW deliveries is *preterm labor* or *premature rupture of membranes* (PROM). Factors such as smoking, alcohol, or drug use during pregnancy; inadequate prenatal care; race; low socioeconomic status; hypertension; high or low maternal age; diabetes; and genitourinary tract infections increase the risk of preterm LBW delivery. However, these risk factors are not present in approximately one fourth of preterm LBW cases, which results in the continued search for other causes.[36,100]

Research has examined the relationship between maternal infection and preterm labor, PROM, and LBW delivery. The true extent of this relationship is difficult to determine, because the majority of maternal infections may be subclinical. Genitourinary tract infections have been associated with adverse pregnancy outcomes. Women with bacteriuria have increased rates of preterm delivery, and the antibiotic treatment of bacteriuria has resulted in a significant decrease in preterm delivery rates as compared with placebo treatment.[47,100] Vaginal colonization with group B streptococci or *Bacteroides* species increases the risk of PROM, preterm delivery, and LBW infants.[86]

Bacterial Vaginosis

Bacterial vaginosis is the most common vaginal disorder in women of reproductive age. It is caused by changes in the vaginal microflora in which normally predominant facultative lactobacilli are replaced by *Gardnerella vaginalis*; anaerobic organisms, including species of *Prevotella*, *Bacteroides*, *Peptostreptococcus*, *Porphyromonas*, and *Mobiluncus*; and other organisms.[48] Bacterial vaginosis is a known risk factor for preterm labor, PROM, and LBW delivery.[40,133] The incidence of preterm birth is approximately three times greater among women with bacterial vaginosis as compared with those without.[5] In fact, the treatment of bacterial vaginosis with metronidazole in pregnant women resulted in decreased preterm birth rates as compared with placebo treatment.[96]

The exact mechanism by which vaginal colonization or genitourinary tract infection may cause PROM and preterm labor is not known.[133] The primary mechanism has traditionally been thought to be ascending infection from the vagina and the endocervix. Endotoxins (LPSs) and bioactive enzymes produced by many organisms associated with vaginosis may directly injure tissue and induce the release of proinflammatory cytokines and prostaglandins. Throughout normal gestation, amniotic prostaglandin levels rise steadily until a sufficient threshold is reached that induces labor and delivery. Maternal infection may cause increased amniotic prostaglandin production, and it may also result in labor-inducing levels being achieved before full gestation. In addition to prostaglandins, various proinflammatory cytokines (e.g., IL-1, IL-6, TNF) have been found in the amniotic fluid of women with preterm labor. Women with preterm labor often have culture-positive amniotic fluid, even in the absence of clinical infection. Among culture-positive patients, the species that is most often isolated is *Fusobacterium nucleatum*.[47] Although *F. nucleatum* is occasionally isolated from the vaginal flora in a patients with bacterial vaginosis, its prevalence among women with preterm labor is much higher than that found among women with vaginosis. *F. nucleatum* is even less frequently isolated from the vaginal flora of women without bacterial vaginosis. Many of the other species isolated from amniotic fluid in women with preterm labor are those often found with bacterial vaginosis, which supports an ascending route of infection. However, the frequency of *F. nucleatum* detection suggests other possible routes of infection. Some investigators have suggested infection by a hematogenous route from a location in which the organism is often detected.[47] *F. nucleatum* is a common oral species that is highly prevalent in patients with periodontitis, and it could reach the amniotic fluid via hematogenous spread from the oral cavity. This route is also suggested by the occasional isolation of *Capnocytophaga* species in the amniotic fluid of women with preterm labor; this is an organism that is rarely isolated from the vagina but that is common in the oral cavity. The species and subspecies of *F. nucleatum* isolated from the amniotic fluid cultures of women with preterm labor more closely match those found in subgingival plaque than strains identified from the lower genital tract. In addition to hematogenous spread, another possible route of infection is by oral–genital contact involving the transfer of oral organisms to the vagina.[47]

Although the direct effects of microorganisms may play an important role in many cases of preterm labor, PROM, and LBW delivery, indirect mechanisms may also be operative.[100] Bacterial infection of the chorioamnion or extraplacental membrane may lead to chorioamnionitis, a condition that is strongly associated with PROM and preterm delivery. However, many cases of histologic chorioamnionitis demonstrate negative bacterial cultures, which indicate that infection is not the sole cause of this condition. It is likely that an indirect mechanism may be active in which the cascade of host products produced in response to infection is often responsible for preterm labor. Maternal infection may lead to the presence of amniotic bacterial products, such as LPSs from gram-negative organisms, which stimulate the production of host-derived cytokines in the amnion and the decidua (Figure 12-8). These

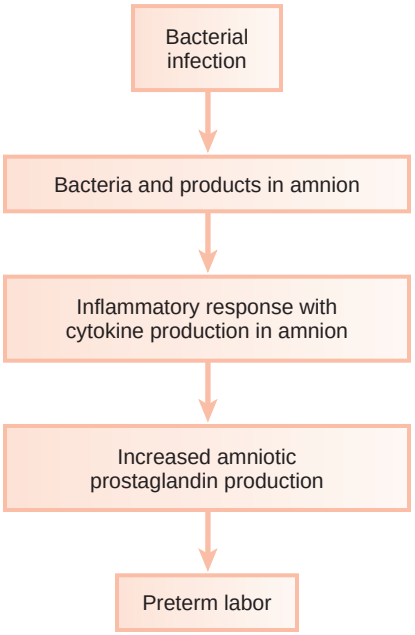

Figure 12-8 Mechanisms by which infection may induce preterm labor.

cytokines, including IL-1, TNF-α, and IL-6, stimulate increased prostaglandin production from the amnion and the decidua, which leads to the onset of preterm labor. A premature rise in PGE_2 and $PGF_{2\alpha}$ is characteristic of preterm labor, regardless of whether clinical or subclinical maternal genitourinary tract infection is detected.

The question then arises as to what stimulates the increased cytokine levels and the resultant increased prostaglandin levels seen during preterm delivery in patients with no evidence of genitourinary infection. Many cases of preterm LBW could result from infections of unknown origin, such as those that originate in areas other than the genitourinary tract.

Role of Periodontitis

Periodontitis is a remote gram-negative infection that may play a role in LBW infants. As discussed previously, periodontopathic organisms and their products may have wide-ranging effects that are most likely mediated through the stimulation of host cytokine production in target tissues. Animal studies suggest that remote reservoirs of gram-negative organisms and their products may have a negative impact on pregnancy outcome. *P. gingivalis* implanted in subcutaneous chambers during gestation caused significant increases in TNF-α and PGE_2 levels.[22] This localized subcutaneous infection resulted in a significant increase in fetal death and a decrease in fetal birth weight for those that remained viable as compared with control animals that were not inoculated. There was a significant correlation between both TNF-α and PGE_2 levels and between these levels and fetal death and growth retardation. These data suggest that a remote nondisseminated infection with *P. gingivalis* may result in abnormal pregnancy outcomes in this model.

Decreased fetal birth weight and increased fetal death were also seen after intravenous injections with LPSs derived from *P. gingivalis*.[21] This effect was greatly increased when *P. gingivalis* LPSs were administered before mating and during gestation, thereby indicating that repeated immunization with *P. gingivalis* LPSs does not provide protection during pregnancy but rather potentiates the negative effects of LPS exposure during gestation. *P. gingivalis*–induced experimental periodontitis in animal models resulted in decreased fetal birth weight and increased amniotic fluid levels of TNF-α and PGE_2 (Figure 12-9).[100] This provides direct evidence that periodontal infection can affect the fetal environment and pregnancy outcomes.

These animal studies have led to the examination of the potential effects of periodontitis on pregnancy outcome in humans. This relationship has been examined in numerous studies from many countries around the world. In an initial case-control study of 124 women in the United States (93 cases with at least one LBW delivery and 31 controls with at least one NBW delivery), Offenbacher and colleagues[101] found that women who had LBW infants also had significantly greater clinical attachment loss than women who had NBW infants. After adjusting for known risk factors for LBW delivery, women with periodontitis that resulted in more than 3 mm of attachment loss in at least 60% of sites had a 7.5-fold increased risk of having an LBW infant. In fact, periodontitis contributed to more preterm LBW cases than did smoking or alcohol use during pregnancy. In a large prospective study of more than 1300 pregnant women, subjects with generalized periodontitis had a fivefold increased risk of preterm birth before 35 weeks' gestation and a sevenfold increased risk of delivery before 32 weeks' gestation as compared with women without periodontitis.[57] These studies and others[27,74] indicate a strong association between periodontal infection and adverse pregnancy outcomes. However, not all studies demonstrate such a relationship. For example, a large case-control study that included more than 900 Brazilian women showed no significant differences in periodontal status among women with normal deliveries as compared with those who had preterm or LBW deliveries.[9]

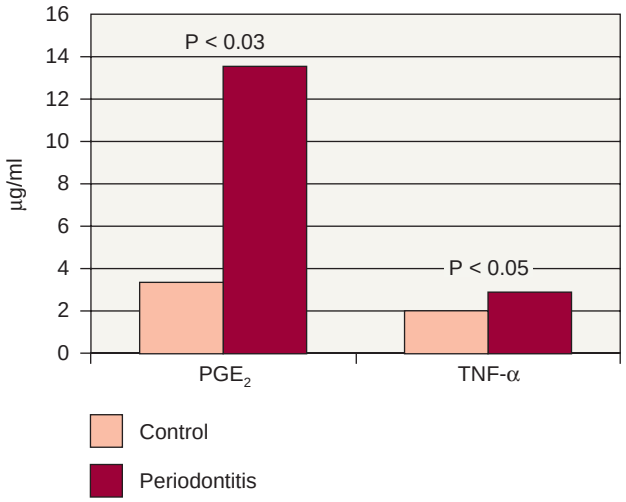

Figure 12-9 Amniotic fluid levels in experimental periodontitis. Experimental periodontitis resulted in increased amniotic fluid levels of tumor necrosis factor-α and prostaglandin E2 in the pregnant hamster model, thereby providing evidence that periodontal infection can affect the fetal environment. *(From Offenbacher S, Jarad HL, O'Reilly PG, et al:* Ann Periodontol *3:233, 1998.)*

Excellent systematic reviews have examined the wide range of studies evaluating the relationship between periodontitis and pregnancy outcomes. A meta-analysis of 17 studies that involved more than 7000 subjects confirmed a significant relationship between periodontitis and preterm or LBW infants.[132] The pooled estimate for the risk of having preterm or LBW infants in mothers with periodontal disease was 2.83 as compared with mothers without periodontal disease. In a systematic review and meta-analysis of 11 prospective studies involving more than 12,000 women, 9 of the studies showed a statistically significant increase in the risk of adverse pregnancy outcomes in women with maternal periodontitis.[16] Periodontitis was associated with a significantly increased risk of preterm birth (risk ratio, 1.70) and LBW (risk ratio, 2.11).

One potential mechanism by which periodontal disease could affect pregnancy outcome is via the systemic dissemination of periodontal pathogens. In a cross-sectional study, women who had LBW infants had significantly higher levels of *Aggregatibacter* (formerly *Actinobacillus*) *actinomycetemcomitans, Tannerella forsythia, P. gingivalis,* and *Treponema denticola* in their subgingival plaque than did the control women who had NBW infants.[100] Studies of fetal immunoglobulin M (IgM) antibody levels have found a remarkably high fetal antibody seropositivity to oral bacteria.[78] This indicates that the fetal immune response is activated in utero by bacterial antigens derived from the oral cavity. In fact, preterm babies have been shown to have a threefold increased prevalence of IgM seropositivity to many of the classic periodontopathogens as compared with full-term babies.[78] In particular, 20% of preterm infants had a positive IgM response to *Campylobacter rectus* as compared with 6.3% of term infants. The prevalence of fetal IgM seropositivity to other periodontopathogens such as *P. intermedia, P. micros,* and *F. nucleatum* was fourfold to eightfold higher in preterm infants as compared with normal term neonates. This suggests that the immune system of preterm infants is often challenged by organisms from the mother's oral cavity.

Women who had LBW infants also had higher levels of gingival crevicular fluid (GCF), PGE_2, and IL-1.[100] In primiparous women (those experiencing a first birth), GCF levels of PGE_2 were inversely related to their infants' birth weight. Women with higher PGE_2 levels in their GCF had smaller and more premature infants. GCF levels of IL-1 and PGE_2 have been shown to correlate highly with intraamniotic IL-1 and PGE_2 levels. In fact, measuring the GCF levels of these inflammatory mediators has been suggested as a means that is less invasive than amniocentesis for screening expectant mothers for elevated amniotic IL-1 and PGE_2 levels.[100] Thus, women who had LBW infants often had a higher prevalence and severity of periodontitis, more gingival inflammation, higher levels of putative periodontal pathogens, and an elevated subgingival inflammatory response as compared with women who had NBW infants; furthermore, the increased bacterial challenge may have broader systemic effects, thereby resulting in an elevated challenge to the fetal immune system.

Periodontal disease may increase the risk for preeclampsia. This hypertensive disorder affects about 5% to 10% of pregnancies, and it is a major cause of perinatal and maternal morbidity and mortality. Preeclampsia has multiple potential etiologies, several of which involve vascular changes in the placenta that are similar to those seen with atherosclerosis. The presence of periodontitis during pregnancy or a worsening of periodontal disease during pregnancy is associated with a twofold to 2.5-fold increased risk for preeclampsia.[13] In one study, women with severe preeclampsia were 3.8 times more likely to present with extensive periodontal disease than were normotensive women, whereas women with mild preeclampsia were 2.4 times more likely to have extensive periodontal disease than were normotensive women.[15] One systematic review found a significant relationship between periodontal disease and risk of preeclampsia in 8 of the 12 studies reviewed.[66] Another large systematic review found that periodontal disease was associated with a significant 76% overall increase in the risk of preeclampsia.[23]

Numerous intervention trials have examined the effects of treating periodontal disease during gestation rather than waiting until after parturition to provide needed care. In a study of 351 pregnant women with periodontitis, women who received scaling and root planing before 28 weeks' gestation, followed by prophylaxis every 2 weeks until parturition, had an LBW rate of 1.8%.[75] Conversely, women who did not receive periodontal therapy during gestation but instead were treated after parturition had an LBW rate of 10.1%. Similarly, Jeffcoat and colleagues[56] found a reduced preterm birth rate among women who received mechanical periodontal therapy during gestation. Conversely, other studies have shown that providing periodontal treatment during pregnancy improves periodontal health but has minimal impact on pregnancy outcome.[93]

Systematic reviews with meta-analyses have produced conflicting results regarding the impact of periodontal therapy on pregnancy outcome. They have also emphasized the difficulty inherent in analyzing such studies as a result of the variability among studies with regard to the definitions of periodontal disease used and the types of periodontal treatment provided to patients. In addition, there are large differences in the overall rate of adverse pregnancy outcomes in the various populations studied. For example, one systematic review of 13 randomized controlled trials that included more than 6800 live births and that examined the effect of maternal periodontal treatment or no periodontal treatment on birth weight and preterm delivery demonstrated that periodontal treatment was associated with a decreased adverse pregnancy outcome rate in 8 of the 13 studies.[17] However, meta-analysis of the total data set showed no significant effect of periodontal therapy on preterm birth or LBW. Another excellent systematic review of 11 randomized controlled trials distinguished between study subject populations with an overall low rate of adverse pregnancy outcomes and populations with a high rate of adverse outcomes.[61] Overall, periodontal therapy during gestation was not associated with decreased preterm birth rates. However, when studies with a high incidence of preterm birth (i.e., 22% to 62%) were compared with studies with a lower incidence (i.e., 4% to 10%), periodontal therapy was associated with a significant reduction in rate of preterm birth and LBW in the high-risk group but not in the low-risk group. This suggests that periodontal treatment during gestation may be most appropriate for women with a greater risk for adverse pregnancy outcomes.

Given the conflicting evidence, it is currently unclear whether periodontal therapy provided during gestation has a beneficial effect on pregnancy outcome. What is clear is that scaling and root planing provided during the second and third trimester of gestation are safe procedures. Every intervention trial published to date shows that scaling and root planing during pregnancy are associated with either a decrease or no change in adverse pregnancy outcome rates. Not a single study has shown an increase in adverse outcome rates. In addition, the children of women who received scaling and root planing during gestation have similar cognitive, motor, and language development during the first 2 years of life as compared with the children of women who did not receive periodontal therapy until the postpartum period.[94] Thus, the clinician should feel comfortable providing scaling and root planing during the second and third trimester of pregnancy.

Periodontal Disease and Chronic Obstructive Pulmonary Disease

Chronic obstructive pulmonary disease (COPD) is characterized by airflow obstruction that results from chronic bronchitis or emphysema. Bronchial mucous glands enlarge, and an inflammatory process occurs during which neutrophils and mononuclear inflammatory cells accumulate within the lung tissue.[43,128] About 14 million Americans have COPD, and tobacco smoking is the primary risk factor.

COPD shares similar pathogenic mechanisms with periodontal disease. With both diseases, a host inflammatory response is mounted in response to chronic challenge by bacteria in periodontal disease and by factors such as cigarette smoke associated with COPD. The resulting neutrophil influx leads to the release of oxidative and hydrolytic enzymes that cause tissue destruction directly. The recruitment of monocytes and macrophages leads to the further release of proinflammatory mediators.

Less is known about the clinical relationship between periodontal disease and COPD as compared with CHD and other systemic conditions. A longitudinal study of more than 1100 men showed that more severe bone loss found during the baseline dental examination was associated with an increased risk of subsequently developing COPD as compared with subjects who had less bone loss, independent of age, smoking status, and other known risk factors for COPD.[43] Individuals with poor oral hygiene have also been found to be at increased risk for chronic respiratory diseases such as bronchitis and emphysema.[116] Conversely, a large epidemiologic study revealed no significant overall association between periodontal disease and COPD.[52] Among nonsmokers and former smokers, even severe periodontitis did not increase the risk for COPD. In current smokers, however, the presence of severe periodontitis was associated with an increased risk of COPD. These results suggest that smoking may act as a major "effect modifier" in the relationship between COPD and periodontal disease and that this

modifier's presence may be required to generate an effect. A recent systematic review of 14 studies and almost 4000 subjects showed a significant twofold increased risk of COPD in those with periodontal disease as compared with those without.[141] However, more evidence is needed to establish a strong relationship between the two diseases.[115]

Periodontal Disease and Acute Respiratory Infections

The upper respiratory passages are often contaminated with organisms derived from the oral, nasal, and pharyngeal regions. Conversely, the lower airways, in which gas exchange occurs, are generally maintained free of microorganisms by a combination of host immune factors and mechanical clearance through the cough reflex, the ciliary transport of aspirated contaminants, and the movement of secretions from the lower airways into the trachea.[128] Pneumonia is an infection of the lungs that is caused by bacteria, viruses, fungi, or mycoplasma and that is broadly categorized as either community-acquired or hospital-acquired pneumonia. A wide variety of bacteria may cause pneumonia, and the spectrum of offending organisms differs greatly between community-acquired and hospital-acquired infections.

Community-acquired bacterial pneumonia is caused primarily by the inhalation of infectious aerosols or by the aspiration of oropharyngeal organisms. *Streptococcus pneumoniae* and *Haemophilus influenzae* are the most common, although numerous other species may be found, including anaerobic bacteria.[104] Antibiotic therapy is highly successful for the resolution of most cases of community-acquired bacterial pneumonia. To date, no associations have been found between oral hygiene or periodontal disease and the risk for acute respiratory conditions such as pneumonia in community-dwelling individuals.[116]

The same cannot be said for individuals in the hospital setting. *Hospital-acquired (nosocomial) bacterial pneumonia* has a very high morbidity and mortality rate. The incidence of nosocomial pneumonia is highest among severely ill patients, such as those in intensive care units or on ventilatory support. Although nosocomial pneumonia is most often caused by gram-negative aerobic organisms, many cases are the result of infection by anaerobic bacteria, including those that are typically found in the subgingival environment.

Hospital-acquired pneumonia is usually caused by the aspiration of oropharyngeal contents.[115] Oropharyngeal colonization with *potential respiratory pathogens* (PRPs) is generally a transient phenomenon; however, such colonization increases during hospitalization. The longer the hospital stay, the greater the prevalence of PRPs. PRPs are found predominantly in the gastrointestinal tract, and they may be passed via esophageal reflux into the oropharynx, where they colonize. Subsequent aspiration may lead to pneumonia. Patients whose posterior oropharynx becomes colonized with PRPs have a significantly increased risk of developing nosocomial pneumonia as compared with those without oropharyngeal colonization by PRPs.[117] Dental plaque has been shown to serve as a reservoir of PRPs; such colonization in plaque results in a persistent source of potential aspiration.[33]

Selective decontamination is a technique that combines systemic antibiotics with orally administered nonabsorbable antibiotics in an attempt to eradicate PRPs from the digestive tract and the oropharynx and to thereby minimize the risk of nosocomial respiratory infections. The technique is used primarily for patients who are intubated and on mechanical ventilators. Selective decontamination significantly decreases the incidence of nosocomial pneumonia.[119] The decontamination of only the digestive tract does not reduce the incidence of pneumonia, but decontamination of the oropharynx alone does.[107] This provides further evidence that the oropharynx is the primary site of PRP colonization, with the subsequent aspiration of causative organisms leading to pneumonia.

PRPs may also originate in the oral cavity, with dental plaque serving as a reservoir of these organisms.[7] Poor oral hygiene is common in the hospital and nursing home settings, especially among severely ill patients.[117] PRPs are more often isolated from the supragingival plaque and buccal mucosa of patients in intensive care units than in outpatient settings. Thus, organisms that are not routinely found in dental plaque become plaque colonizers after prolonged hospitalization. Subgingival plaque may also harbor PRPs, and putative periodontal pathogens have been associated with nosocomial pneumonia. Furthermore, anaerobic organisms from periodontal pockets may serve as the primary inoculum for suppurative respiratory diseases (e.g., pulmonary abscesses) that involve significant morbidity and mortality.

Systematic review of the evidence has determined that interventions that are used to improve oral hygiene, such as mechanical toothbrushing and chemical antimicrobial rinses, have the potential to decrease the risk of nosocomial pneumonia in high-risk patients, such as those in intensive care units or those on ventilators.[7,115] Improved oral hygiene by the patient in combination with frequent professional oral health care reduces both the incidence and the progression of respiratory diseases in older patients living in nursing homes, and these practices have a major impact on individuals in intensive care units in which the risks for nosocomial pneumonia are markedly elevated. One systematic review showed that mechanical oral hygiene performed in nursing homes and hospitals significantly decreased the occurrence and progression of respiratory tract infection and pneumonia; the review of evidence suggested that "one in 10 cases of death from pneumonia in elderly nursing home residents may be prevented by improving oral hygiene."[123]

BOX 12-1 Organ Systems and Conditions Possibly Influenced by Periodontal Infection

Cardiovascular/Cerebrovascular System
Atherosclerosis
Coronary heart disease
Angina
Myocardial infarction
Cerebrovascular accident (stroke)
Erectile Dysfunction

Endocrine System
Diabetes mellitus

Reproductive System
Preterm low-birth-weight infants
Preeclampsia

Respiratory System
Chronic obstructive pulmonary disease
Acute bacterial pneumonia

that periodontal infection may significantly enhance the risk for certain systemic diseases or alter the natural course of systemic conditions.[89,120] Conditions in which the influences of periodontal infection are documented include coronary heart disease (CHD) and CHD-related events such as angina, infarction, atherosclerosis, and other vascular conditions; stroke; diabetes mellitus; preterm labor, low-birth-weight delivery, and preeclampsia; and respiratory conditions such as chronic obstructive pulmonary disease[89,105] (Box 12-1).

Focal Infection Theory Revisited

Research in the area of periodontal medicine marks a resurgence in the concept of focal infection. In 1900, British physician William Hunter first developed the idea that oral microorganisms were responsible for a wide range of systemic conditions that were not easily recognized as being infectious in nature.[97,135] He claimed that the restoration of carious teeth instead of extraction resulted in the trapping of infectious agents under restorations. In addition to caries, pulpal necrosis, and periapical abscesses, Hunter also identified gingivitis and periodontitis as foci of infection. He advocated the extraction of teeth with these conditions to eliminate the source of sepsis. Hunter thought that teeth were prone to septic infection primarily because of their structure and their relationship to alveolar bone. He stated that the degree of systemic effect produced by oral sepsis depended on the virulence of the oral infection and the individual's degree of resistance. He also thought that oral organisms had specific actions on different tissues and that these organisms acted by producing toxins, thereby resulting in low-grade "subinfection" that produced systemic effects over prolonged periods. Finally, Hunter thought that the connection between oral sepsis and resulting systemic conditions could be shown via the removal of the causative sepsis through tooth extraction and observation of the improvement in systemic health. Because it explained a wide range of disorders for which there was no known explanation at the time, Hunter's theory became widely accepted in Britain and eventually the United States, thereby leading to the wholesale extraction of teeth.

The focal infection theory fell into disrepute during the 1940s and 1950s, when widespread extraction—often of the entire dentition—failed to reduce or eliminate the systemic conditions to which the supposedly infected dentition had been linked.[135] The theory, while offering a possible explanation for perplexing systemic disorders, had been based on very little (if any) scientific evidence. Hunter and other advocates of the theory were unable to explain how focal oral sepsis produced these systemic maladies. They were also unable to elucidate possible interactive mechanisms between oral and systemic health. Furthermore, the suggested intervention of tooth extraction often had no effect on the systemic conditions for which patients sought relief. However, Hunter's ideas did encourage extensive research in the areas of microbiology and immunology.

Evidence-Based Clinical Practice

Many of the precepts of the focal infection theory are being revived today in light of recent research demonstrating links between oral and systemic health. However, for the "hypothesis not to fall into disrepute for a second time, there must be no unsubstantiated attributions, no theories without evidence."[97] Today's era of evidence-based medicine and dentistry provides an excellent environment in which to examine the possible relationships between oral infection and systemic disorders. To establish a relationship between conditions A and B, different levels of evidence must be examined. All scientific evidence is not given the same weight.[49,92,98] The stronger the evidence, the more likely it is that a true relationship exists between the conditions. Table 12-1 describes these various levels of evidence.

For example, when examining the relationship between elevated cholesterol levels and CHD-related events, the literature might initially consist entirely of case reports or similar anecdotal information in which individual patients with recent myocardial infarction (MI) are found to have elevated cholesterol levels. These anecdotal reports suggest a possible relationship between elevated cholesterol and MI, but the evidence is weak. The case reports may lead to *cross-sectional studies* in which a large subject population is examined to determine whether those individuals who had an MI have higher cholesterol levels than other individuals (control subjects) who did not have an MI. Ideally, these cross-sectional studies are controlled for other potential causes or factors associated with MI, such as age, gender, and smoking history. In other words, the subjects with a previous MI would be retrospectively "matched" with subjects of similar age, gender, and smoking history, and their cholesterol levels would then be examined for similarities or differences. Significantly higher cholesterol levels in subjects with a previous MI as compared with those individuals without MI offer stronger evidence than case reports; such evidence further substantiates a possible link between elevated cholesterol and MI.

Even stronger evidence is provided by *longitudinal studies,* in which subject populations are examined over time. For example, a group of subjects might periodically have their cholesterol levels evaluated over several years. If individuals with elevated cholesterol levels have a significantly higher rate of MI over time as compared with subjects with normal cholesterol levels, then even stronger evidence is available to substantiate the link between cholesterol and MI. Finally, *intervention trials* may be designed to alter the potentially causative condition and to determine the effect of this change on the resultant condition. For example, patients with elevated cholesterol levels may be divided into two groups: a group that uses a cholesterol-lowering drug or diet and a control group that uses no intervention. These two groups might also be compared with a third group with normal cholesterol levels. Over time, the rate of MI in each group would be determined. If the group receiving the cholesterol-lowering regimen has a significantly lower rate of MI than the group with continued elevations in cholesterol level, strong evidence of a link between cholesterol and MI would be established.

TABLE 12-1 Evaluation of Evidence

Type of Evidence	Strength of Evidence	Description
Case report	+/–	• Provides relatively weak retrospective anecdotal evidence • May suggest that further study is needed
Cross-sectional study	+	• Compares groups of subjects at a single point in time • Stronger than a case report • Fairly easy to conduct • Relatively inexpensive to conduct
Longitudinal study	++	• Follows groups of subjects over time • Stronger than a cross-sectional study • Studies with a control group much stronger than studies without controls • More difficult and expensive to conduct
Intervention trial	+++	• Examines the effects of some intervention • Studies with a control group (i.e., placebo) much stronger than studies without controls • Strongest form of evidence is the randomized controlled intervention trial • Difficult and expensive to conduct
Systematic review	++++	• Systematically evaluates evidence from multiple studies, especially randomized controlled trials • Uses clearly defined guidelines for the selection of evidence to be included or excluded from the review • Examines for heterogeneity in the overall data to indicate variations in study design, sample populations, and assessment methodologies

Finally, the highest level of evidence is the systematic review. A systematic review is not a standard literature review in which the articles selected for review are based on the desires and search methods chosen by the author, often for convenience. In a systematic review, the topic in question is selected before the review begins. For example, the authors may state the question as follows: "As compared with subjects not taking cholesterol-lowering medications, do subjects taking such medications demonstrate a difference in the rate of myocardial infarction?" A specific search strategy is then determined to reveal as much potential data as possible to answer the stated question. The authors state specifically why research papers were included or excluded from the review. If possible, the data are subjected to meta-analysis; this is a statistical method that combines the results of multiple studies that address a similar research hypotheses. This provides a more robust evaluation of the overall data than one can glean from individual research articles.

At each level of evidence, it is important to determine whether a biologically plausible link exists between conditions A and B. For example, if case reports, cross-sectional studies, longitudinal studies, and intervention trials all support the link between cholesterol levels and MI, the following questions remain:

- How is cholesterol related to MI?
- What are the mechanisms by which cholesterol affects the cardiovascular system and thus increases the risk for MI?

These studies evaluate the mechanisms by which conditions A and B might be linked and provide explanatory data that further substantiate the association between the two conditions.

The focal infection theory, as proposed and defended during the early part of the twentieth century, was based on almost no evidence. Only the occasional case report and other anecdotes were available to substantiate the theory. Although explanatory mechanisms were proposed, none was validated with scientific research. Unfortunately, this theory predated current concepts of evidence-based clinical practice, thereby leading to the unnecessary extraction of millions of teeth. Currently, when reexamining the potential associations between oral infections and systemic conditions, it is important to determine what evidence (1) is available; (2) is still needed to substantiate the associations; and (3) validates the possible mechanisms of association. This chapter reviews current knowledge that relates periodontal infection to overall systemic health.

Subgingival Environment as a Reservoir for Bacteria

The subgingival microbiota in patients with periodontitis provides a significant and persistent gram-negative bacterial challenge to the host that is met by a potent immunoinflammatory response.[99] These organisms and their products, such as *lipopolysaccharide* (LPSs), have ready access to the periodontal tissues and to the circulation via the sulcular epithelium, which is frequently ulcerated and discontinuous. Even with treatment, the complete eradication of these organisms is difficult, and their reemergence is often rapid. The total surface area of pocket epithelium in contact with subgingival bacteria and their products in a patient with generalized moderate periodontitis has been estimated to be approximately the size of the palm of an adult hand, with even larger areas of exposure in cases of more advanced periodontal destruction.[106] Bacteremias are common after mechanical periodontal therapy, and they also occur frequently during normal daily function and oral hygiene procedures.[32,70,90] Just as the periodontal tissues mount an immunoinflammatory response to bacteria and their products, systemic challenge with these agents also induces a major vascular response.[28,46,109] This host response may offer explanatory mechanisms for the interactions between periodontal infection and a variety of systemic disorders.

Periodontal Disease and Mortality

The ultimate medical outcome measure is mortality. A number of studies suggest that an increased mortality rate is associated with inflammatory periodontal diseases.[30,34,55,68,113] The Normative Aging Study examined 2280 healthy men every 3 years for more than 30 years after baseline clinical, radiographic, laboratory, and electrocardiographic examinations. A subset of this population was

examined in the Veterans Affairs Dental Longitudinal Study to determine age-related changes in the oral cavity and to identify risk factors for oral disease. Clinical examinations were performed, and alveolar bone level measurements were determined from full-mouth radiographs. The mean percentage of alveolar bone loss and the mean probing depth were determined for each subject.

A study of data from this subject population sought to determine whether periodontal disease status was a significant predictor of mortality independent of other baseline characteristics within the population.[34] From the original sample of 804 dentate, medically healthy subjects, a total of 166 died during the study. Periodontal status at the baseline examination was a significant predictor of mortality independent of other factors, such as smoking, alcohol use, cholesterol levels, blood pressure, family history of heart disease, education level, and body mass. For those subjects with the most alveolar bone loss, who averaged more than 21% alveolar bone loss at baseline, the risk of dying during the follow-up period was 70% higher than for all other subjects. Interestingly, alveolar bone loss increased the risk of mortality more than smoking (52% increased risk), which is a well-known risk factor for mortality. A later evaluation of these same subjects confirmed a higher incidence of CHD-related events such as MI and unstable angina among men less than 60 years old with alveolar bone loss as compared with those without bone loss.[30]

In a prospective cohort study of 1400 dentate men from Northern Ireland, subjects were divided into thirds (tertiles) based on the average periodontal attachment loss.[68] Those with the highest level of periodontal attachment loss has a significantly higher risk of death as compared with those with the least attachment loss. The mortality rate over a 9-year period was 15.7% in those with the greatest attachment loss as compared with 7.9% in subjects with the lowest level of periodontal attachment loss. In these studies, periodontitis preceded and increased the risk of mortality. However, this only establishes an association; it does not confirm causation. It is possible that periodontal disease reflects other health behaviors not evaluated in this study rather than acting as a specific cause of mortality. In other words, patients with poor periodontal health may also have other risk factors that increase mortality rate (e.g., smoking).

When examining research that suggests oral health status as a possible risk factor for systemic conditions, it is important to recognize when other known risk factors for those systemic conditions have been accounted for in the analysis. Host susceptibility factors that place individuals at risk for periodontitis may also place them at risk for systemic diseases such as cardiovascular disease. In these patients, the association may actually be among the risk factors rather than among the diseases. For example, periodontitis and cardiovascular disease share such risk factors as smoking, age, race, male gender, and stress. Genetic risk factors may also be shared.[64] In the Veterans Affairs Dental Longitudinal Study, smoking was an independent risk factor for mortality. When examining the data to determine whether periodontal status was a risk factor, smoking status and other known risk factors for mortality were removed from the equation to allow for the independent evaluation of periodontal status. Other studies support the association between poor oral health and an increased risk for mortality.[113] In a prospective longitudinal study of subjects with type 2 diabetes, those with severe periodontitis had 3.2 times the risk of death from ischemic heart disease or kidney disease as compared with subjects without periodontitis or with only slight periodontitis after adjusting for other risk factors, including age, sex, duration of diabetes, glycemic control, macroalbuminuria, body mass index, serum cholesterol concentration, hypertension, and current smoking.[113]

Periodontal Disease and Coronary Heart Disease/Atherosclerosis

To further explore the association between periodontal disease and CHD/atherosclerosis, investigators have studied specific systemic disorders and medical outcomes to determine their relationship to periodontal status. CHD-related events are a major cause of death. MI has been associated with acute systemic bacterial and viral infections, and MI is sometimes preceded by influenza-like symptoms.[84,125] Is it possible that oral infection is similarly related to MI? Traditional risk factors such as smoking, dyslipidemia, hypertension, and diabetes mellitus do not explain the presence of coronary atherosclerosis in a large number of patients. Localized infection that results in a chronic inflammatory reaction has been suggested as a mechanism underlying CHD in these individuals.[91]

In cross-sectional studies of patients with acute MI or confirmed CHD who are compared with age- and gender-matched control patients, patients with MI had significantly worse dental health (e.g., periodontitis, periapical lesions, caries, pericoronitis) as compared with controls.[54,80,83] This association between poor dental health and MI was independent of known risk factors for heart disease, such as age, cholesterol levels, hypertension, diabetes, and smoking. Because atherosclerosis is a major determinant of CHD-related events, dental health has also been related to coronary atheromatosis. Mattila and colleagues[81] performed oral radiographic examinations and diagnostic coronary angiography on men with known CHD and found a significant correlation between the severity of dental disease and the degree of coronary atheromatosis. This relationship remained significant after accounting for other known risk factors for coronary artery disease. Similarly, Malthaner and colleagues[79] found an increased risk of angiographically defined coronary artery disease in subjects with greater bone loss and attachment loss; however, after adjusting for other known cardiovascular risk factors, the relationship between periodontal status and coronary artery disease was no longer statistically significant. There is evidence that the extent of periodontal disease may be associated with CHD. For example, there may be a greater risk for CHD-related events, such as MI, when periodontitis affects a greater number of teeth in the mouth as compared with subjects who have periodontitis that involves fewer teeth.[6]

Cross-sectional studies thus suggest a possible link between oral health and CHD; however, such studies cannot determine causality in this relationship. Rather, dental diseases may be indicators of general health practices. For example, periodontal disease and CHD are both related to lifestyle and share numerous risk factors, including smoking, diabetes, and low socioeconomic status. Bacterial infections have significant effects on endothelial cells, blood coagulation, lipid metabolism, and monocytes and macrophages. The research of Mattila and colleagues[80] showed that dental infections were the only factors—other than the classic and well-recognized coronary risk factors—that were associated independently with the severity of coronary atherosclerosis.

Longitudinal studies provide compelling data regarding this relationship. In a 7-year follow-up study of the patients from the study of Mattila and colleagues, dental disease was significantly related to the incidence of new fatal and nonfatal coronary events as well as to overall mortality.[82] In a prospective study of a national sample of adults, subjects with periodontitis had a 25% increase in the risk for CHD as compared with those with no or minimal periodontal disease, after adjusting for other known risk factors.[29] Among younger males between the ages of 25 and 49 years, periodontitis increased the risk of CHD by 70%. The level of oral

hygiene was also associated with heart disease. Patients with poor oral hygiene, as indicated by higher debris and calculus scores, had a twofold increased risk for CHD.

In another large prospective study, 1147 men were followed for 18 years.[10] During that time, 207 men (18%) developed CHD. When periodontal status at baseline was related to the presence or absence of CHD-related events during the follow-up period, a significant relationship was found. Subjects with more than 20% mean bone loss had a 50% increased risk of CHD as compared with those with up to 20% bone loss. The extent of sites with probing depths of more than 3 mm was strongly related to the incidence of CHD. Subjects with probing depths of more than 3 mm on at least half of their teeth had a twofold increased risk, whereas those with probing depths of more than 3 mm on all of their teeth had more than a threefold increased risk of CHD. This study and others in which the periodontal condition is known to have preceded the CHD-related events support the concept that periodontal disease is a risk factor for CHD, independent of other classic risk factors. Not all studies, however, support this concept; some show little independent effect of periodontal status on the risk for CHD after adjusting for commonly accepted cardiovascular risk factors.[50,51] It is particularly difficult to control for smoking as a confounding variable in these studies, because it is such an important risk factor for both periodontal disease and cardiovascular disease. This confounding influence of smoking makes it difficult to clarify the significance of the relationship between the diseases.

Perhaps the best evidence available comes from *systematic reviews* of studies examining the relationship between periodontal infection and cardiovascular diseases. A systematic review and meta-analysis of data from 15 studies showed a significant 14% to 222% increase in the risk of CHD-related events in patients with periodontal disease as compared with those without.[8] A similar systematic review of longitudinal cohort and case-control studies showed a significant increase in risk of incident MI, angina, or CHD-related death in subjects with periodontitis in five of the six studies reported.[31] This increased risk was noted mainly in younger subjects (i.e., <65 years old). Janket and colleagues[53] performed a meta-analysis of periodontal disease as a risk factor for future cardiovascular events and found an overall 19% increased risk of such events among individuals with periodontitis. The increase in risk was greater (44%) among people less than 65 years old. Although this increased risk is fairly modest, the extensive prevalence of periodontal disease in the population may increase the significance of the risk from a public health perspective. An extensive systematic review by Scannapieco and colleagues[114] concluded that a moderate degree of evidence exists to support an association between periodontal disease and atherosclerosis, MI, and cardiovascular disease; however, causality is unclear. A comprehensive review of the evidence was recently performed by an American Heart Association working group.[69] That group concluded that "periodontal disease is associated with atherosclerotic vascular disease independent of known confounders." However, the working group cautioned that evidence of a causal link between periodontitis and vascular diseases did not yet exist. Importantly, insufficient evidence exists to show that the treatment of periodontal disease has any impact on the risk of heart disease. Intervention trials are needed to make this determination.

Effect of Periodontal Infection

Although a direct causal link between periodontal diseases and vascular diseases has not been shown to date, there are numerous mechanisms—both direct and indirect—through which periodontal infection may affect the onset or progression of atherosclerosis and CHD.[59] Periodontitis and atherosclerosis both have complex etiologic factors that combine genetic and environmental influences. In addition to smoking, the diseases share many risk factors and have distinct similarities with regard to their basic pathogenic mechanisms.

Ischemic Heart Disease. Ischemic heart disease is associated with the processes of atherogenesis and thrombogenesis (Figure 12-1). Increased viscosity of blood may promote major ischemic heart disease and cerebrovascular accident (stroke) by increasing the risk of thrombus formation.[76] Fibrinogen is a major factor in the promotion of this hypercoagulable state. *Fibrinogen* is the precursor to fibrin, and increased fibrinogen levels increase blood viscosity. Increased plasma fibrinogen is a recognized risk factor for cardiovascular events and peripheral vascular disease[77] (Figure 12-2). Elevated white blood cell count is also a predictor of heart disease and stroke, and circulating leukocytes may promote the occlusion of blood vessels. Coagulation factor VIII/von Willebrand factor has likewise been associated with the risk of ischemic heart disease.[110]

Systemic Infections. Systemic infections are known to induce a hypercoagulable state and to increase blood viscosity

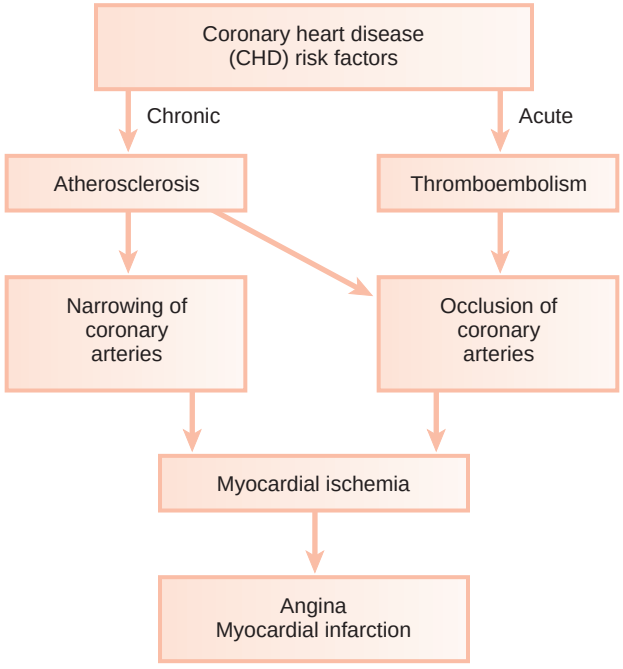

Figure 12-1 Acute and chronic pathways to ischemic heart disease. Coronary heart disease–related events, such as angina or myocardial infarction, may be precipitated by either pathway or both pathways.

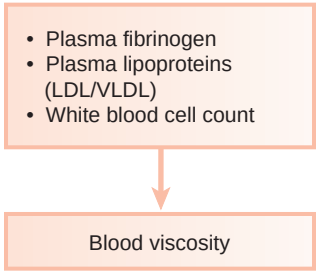

Figure 12-2 Factors that affect blood viscosity in health.

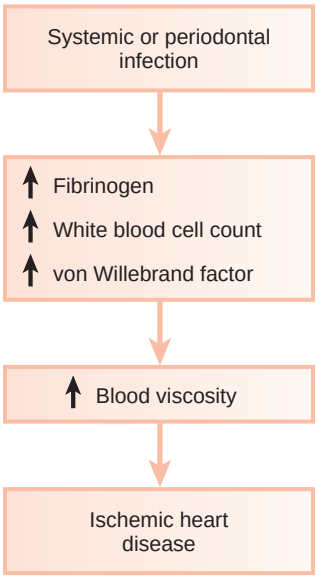

Figure 12-3 The effect of infection on blood viscosity. Increased plasma fibrinogen and von Willebrand factor cause hypercoagulability. When these are combined with an increased white blood cell count, the blood viscosity increases, thereby increasing the risk of coronary ischemia.

(Figure 12-3). Fibrinogen levels and white blood cell counts are often increased in patients with periodontal disease.[19,67] Individuals with poor oral health may also have significant elevations in coagulation factor VIII/von Willebrand factor antigen, thereby increasing the risk of thrombus formation. Thus, periodontal infection may also promote increased blood viscosity and thrombogenesis, which leads to an increased risk for central and peripheral vascular disease.

Daily Activity. Routine daily activities such as mastication and oral hygiene procedures result in frequent bacteremia with oral organisms.[70] Periodontal disease may predispose the patient to an increased incidence of bacteremia, including the presence of virulent gram-negative organisms associated with periodontitis. There is a greater risk of bacteremia after tooth brushing in patients with higher levels of plaque, calculus, and gingivitis as compared with those with minimal plaque and gingival inflammation.[71] In fact, subjects with generalized gingival bleeding after brushing showed an almost eightfold increase in their incidence of bacteremia as compared with those with minimal gingival bleeding. An estimated 8% of all cases of infective endocarditis are associated with periodontal or dental disease, without a preceding dental procedure.[32] The periodontium, when affected by periodontitis, also acts as a reservoir of *endotoxins* (LPSs) from gram-negative organisms. Endotoxins can pass readily into the systemic circulation during normal daily function, thereby inducing damage to the vascular endothelium and precipitating many negative cardiovascular effects. In a study of the incidence of endotoxemia after simple chewing, subjects with periodontitis were four times more likely to have endotoxin present in the bloodstream than subjects without periodontitis. Furthermore, the concentration of endotoxin present was more than fourfold greater in those with periodontitis as compared with healthy subjects.[35]

Thrombogenesis. Platelet aggregation plays a major role in thrombogenesis, and most cases of acute MI are precipitated by thromboembolism. Oral organisms may be involved in coronary thrombogenesis. Platelets selectively bind some strains of *Streptococcus sanguinis,* which is a common component of supragingival plaque, and *Porphyromonas gingivalis,* which is a pathogen closely associated with periodontitis.[44,45] The aggregation of platelets is induced by the *platelet-aggregation–associated protein* (PAAP) expressed on some strains of these bacteria.[111] In animal models, the intravenous infusion of PAAP-positive bacterial strains resulted in alterations of heart rate, blood pressure, cardiac contractility, and electrocardiogram readings consistent with MI. Platelet accumulation also occurred in the lungs, which lead to tachypnea. No such changes were seen with the infusion of PAAP-negative strains. PAAP-positive bacteria caused aggregation of circulating platelets, which resulted in the formation of thromboemboli and the resultant cardiac and pulmonary changes. Thus, periodontitis-associated bacteremia with certain strains of *S. sanguinis* and *P. gingivalis* may promote acute thromboembolic events via interaction with circulating platelets.

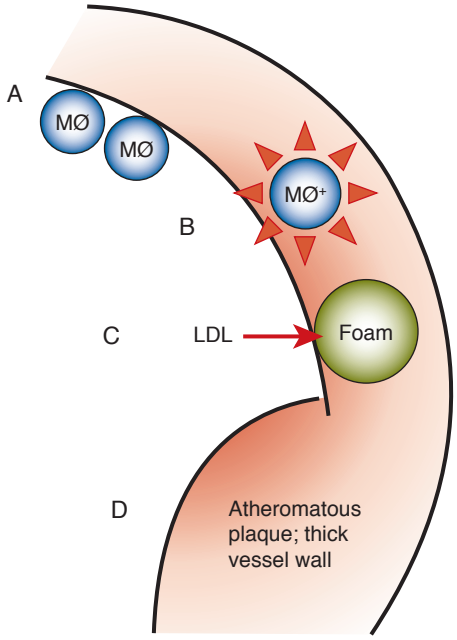

Figure 12-4 Pathogenesis of atherosclerosis. *A,* Monocytes and macrophages adhere to the vascular endothelium. *B,* Monocytes and macrophages penetrate into the arterial media and produce proinflammatory cytokines and growth factors. *C,* The ingestion of oxidized low-density lipoprotein enlarges monocytes to form foam cells. *D,* Smooth muscle proliferation and plaque formation thicken vessel walls and narrow the lumen. *MØ⁺,* Hyperinflammatory monocyte/macrophage phenotype.

Atherosclerosis. Atherosclerosis is a focal thickening of the arterial *intima,* the innermost layer lining the vessel lumen, and the *media,* the thick layer under the intima that consists of smooth muscle, collagen, and elastic fibers (Figure 12-4).[111] Early during the formation of atherosclerotic plaques, circulating monocytes adhere to the vascular endothelium. This adherence is mediated through several adhesion molecules on the endothelial cell surface, including intercellular adhesion molecule-1 (ICAM-1), endothelial leukocyte adhesion molecule-1 (ELAM-1), and vascular cell adhesion molecule-1 (VCAM-1).[12,62] These adhesion molecules are upregulated by a number of factors, including bacterial LPSs, prostaglandins, and proinflammatory cytokines. After binding to the endothelial cell lining, monocytes penetrate the endothelium and migrate under the arterial intima. The monocytes ingest circulating

low-density lipoprotein in its oxidized state and become engorged, thereby forming the foam cells that are characteristic of atheromatous plaques. After entering the arterial media, monocytes may also transform to macrophages. A host of proinflammatory cytokines such as interleukin-1 (IL-1), tumor necrosis factor-α (TNF-α), and prostaglandin-E_2 (PGE_2) are then produced, and these propagate the atheromatous lesion. Mitogenic factors such as fibroblast growth factor and platelet-derived growth factor stimulate smooth muscle and collagen proliferation within the media, thereby thickening the arterial wall.[77] Atheromatous plaque formation and thickening of the vessel wall narrow the lumen and dramatically decrease blood flow through the vessel.[111] Arterial thrombosis often occurs after an atheromatous plaque ruptures. Plaque rupture exposes circulating blood to arterial collagen and tissue factor from monocytes and macrophages that activate platelets and the coagulation pathway. Platelet and fibrin accumulation forms a thrombus that may occlude the vessel and result in ischemic events such as angina or MI. The thrombus may separate from the vessel wall and form an embolus, which may also occlude vessels, again leading to acute events such as MI or cerebral infarction (stroke).

Role of Periodontal Disease in Myocardial or Cerebral Infarction

In animal models, gram-negative bacteria and associated LPS cause the infiltration of inflammatory cells into the arterial wall, the proliferation of arterial smooth muscle, and intravascular coagulation. These changes are identical to those seen with naturally occurring atheromatosis. Patients with periodontitis are at increased risk for the thickening of the walls of the major coronary arteries.[10] In several studies of atheromas obtained from humans during endarterectomy, more than half of the lesions contained periodontal pathogens, and many atheromas contained multiple different periodontal species.[18,42,140] Periodontal diseases result in chronic systemic exposure to products of these organisms. Low-level bacteremia may initiate host responses that alter coagulability, endothelial and vessel wall integrity, and platelet function, thereby resulting in atherogenic changes and possible thromboembolic events (Figure 12-5).

Research has clearly shown a wide variation in host response to bacterial challenge. Some individuals with heavy plaque accumulation and high proportions of pathogenic organisms appear relatively resistant to bone and attachment loss. Others develop extensive periodontal destruction in the presence of small amounts of plaque and low proportions of putative pathogens. Patients with abnormally exuberant inflammatory responses often have a hyperinflammatory monocyte and macrophage phenotype ($MØ^+$). Monocytes and macrophages from these individuals secrete significantly increased levels of proinflammatory mediators (e.g., IL-1, TNF-α, PGE_2) in response to bacterial LPSs as compared with patients with a normal monocyte and macrophage phenotype. Patients with aggressive periodontitis, refractory periodontitis, and type 1 diabetes mellitus often possess the $MØ^+$ phenotype,[11] which appears to be under both genetic and environmental control. The monocyte and macrophage cell line is intimately involved in the pathogenesis of both periodontal disease and atherosclerosis. Diet-induced elevations in serum low-density lipoprotein levels upregulate monocyte and macrophage responsiveness to bacterial LPSs. Thus, elevated low-density lipoprotein levels, which are known risk factors for atherosclerosis and CHD, may increase the secretion of destructive and inflammatory cytokines by monocytes and macrophages. This may result not only in the propagation of atheromatous lesions but also in enhanced periodontal destruction in the presence of pathogenic organisms. This is one example of a potential shared mechanism in the pathogenesis of cardiovascular and periodontal diseases. The presence of an $MØ^+$ phenotype may place patients at risk for both CHD and periodontitis (Figure 12-6). Periodontal infections may contribute to atherosclerosis and thromboembolic events by repeatedly challenging the vascular endothelium and arterial wall with bacterial LPS and proinflammatory cytokines. Vascular monocytes and macrophages in patients with an $MØ^+$ phenotype meet this challenge with an abnormally elevated inflammatory response that may directly contribute to atherosclerosis and that may precipitate thromboembolic events.[89]

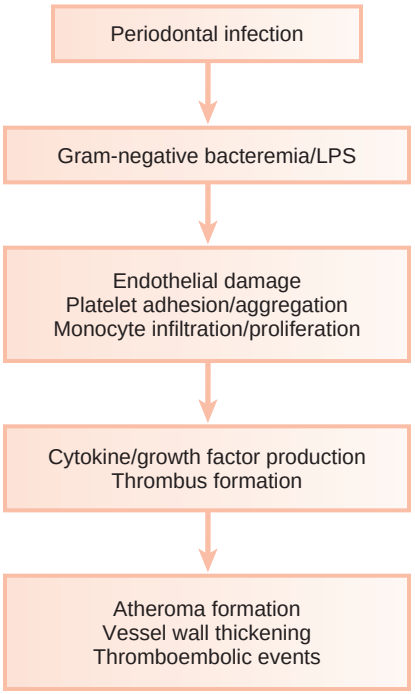

Figure 12-5 The influence of periodontal infection on atherosclerosis. Periodontal pathogens and their products result in damage to the vascular endothelium. Monocytes and macrophages enter the vessel wall and produce cytokines that further increase the inflammatory response and propagate the atheromatous lesion. Growth factor production leads to smooth muscle proliferation in the vessel wall. Damaged endothelium also activates platelets, thereby resulting in platelet aggregation and potentiating thromboembolic events. *LPS,* Lipopolysaccharide.

Cardiovascular diseases are increasingly recognized as having a major systemic inflammatory component, thereby further emphasizing possible similarities with inflammatory periodontal diseases.[111] As such, the detection of systemic inflammatory markers plays an increasingly important role in risk assessment for vascular events such as MI and cerebral infarction. Acute-phase proteins such as *C-reactive protein* (CRP) and fibrinogen are produced in the liver in response to inflammatory or infectious stimuli and act as inflammatory markers.[109] CRP induces monocytes and macrophages to produce tissue factor, which stimulates the coagulation pathway and increases blood coagulability. Increased fibrinogen levels may contribute to this process. CRP also stimulates the complement cascade, thereby further exacerbating inflammation.

Elevations in serum CRP and fibrinogen levels are well-accepted risk factors for cardiovascular disease.[108,109] Recent efforts have focused on periodontitis as a potential trigger for systemic inflammation. Serum CRP and fibrinogen levels are often elevated in

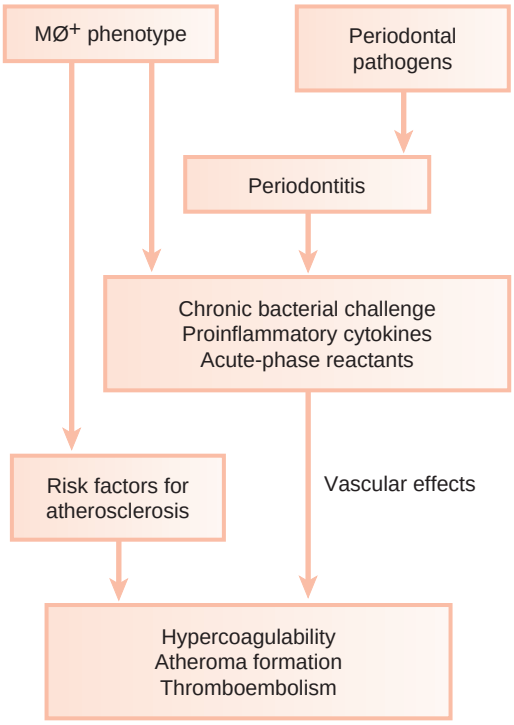

Figure 12-6 The cardiovascular and periodontal consequences of the hyperresponsive monocyte/macrophage phenotype. In combination with other risk factors, the MØ+ phenotype predisposes individuals to both atherosclerosis and periodontitis. Bacterial products and inflammatory mediators associated with periodontitis affect vascular endothelium, monocytes and macrophages, platelets, and smooth muscle, and they may increase blood coagulability. This may further increase atherosclerosis and result in thromboembolism and ischemic events.

subjects with periodontitis as compared with subjects without periodontitis.[24,73,136] These acute-phase proteins may act as intermediary steps in the pathway from periodontal infection to cardiovascular disease (see Figures 12-5 and 12-6). Thus, periodontal diseases may have both direct effects on the major blood vessels (e.g., atheroma formation) and indirect effects that stimulate changes in the cardiovascular system (e.g., the elevation of systemic inflammatory responses).

Interesting supportive evidence for these mechanisms can be derived from intervention trials in which serum levels of inflammatory mediators and markers are assessed before and after treatment that is aimed at decreasing periodontal inflammation. For example, in subjects with chronic periodontitis, serum levels of IL-6 and CRP are reduced after scaling and root planing.[25] Inflammatory periodontal disease is also associated with altered vascular endothelial function as compared with periodontally healthy individuals.[26] Altered vascular endothelial function is a major risk factor for acute thrombotic events. After scaling and root planing with a resultant decrease in periodontal inflammation, markers of vascular health also improve significantly over time.[26,131] The functional assessment of vascular endothelial function also returns to normal after scaling and root planing.[118,131] These results suggest that periodontal inflammation adversely affects the health of the vascular endothelium, whereas a reduction in inflammation improves endothelial health. Whether these changes directly impact the risk of acute cardiovascular events remains to be determined in prospective, controlled clinical intervention trials over long periods of time; these studies do not currently exist.

Role of Periodontal Disease in Erectile Dysfunction

Erectile dysfunction (ED) is associated with endothelial dysfunction, and elevated levels of oxidative stress and systemic inflammation are common to both periodontal diseases and ED. Recent studies have shown a relationship between ED and periodontitis. In a large case-control study of almost 200,000 subjects in Taiwan, those with ED were significantly more likely to have chronic periodontitis than those without ED, with an overall significant odds ratio of 3.35 after adjusting for confounding variables.[60] Other studies have supported these findings in smaller populations in other countries.[103,121,139] An intervention trial was conducted in 120 subjects with ED and chronic periodontitis; 60 subjects received scaling and root planing while 60 control subjects received no periodontal treatment.[1] Three months later, the treatment group has significant improvement in ED, whereas the control group had no change. These preliminary studies suggest a relationship between periodontitis and ED, but more research is needed to understand the mechanisms of interaction.

Periodontal Disease and Stroke

Ischemic cerebral infarction or stroke is often preceded by systemic bacterial or viral infection. In one study, patients with cerebral ischemia were five times more likely to have had a systemic infection within 1 week before the ischemic event than were nonischemic control subjects.[37] Recent infection was a significant risk factor for cerebral ischemia; it was independent of other known risk factors such as hypertension, history of a previous stroke, diabetes, smoking, and CHD. Interestingly, the presence of systemic infection before the stroke resulted in significantly greater ischemia and a more severe postischemic neurologic defect than did stroke not preceded by infection.[38] Stroke patients with a preceding infection had slightly higher levels of plasma fibrinogen and significantly higher levels of CRP as compared with those without infection.

Periodontal Infection Associated with Stroke

Stroke is classified as either hemorrhagic or nonhemorrhagic stroke. Nonhemorrhagic stroke or ischemic stroke is usually caused by thromboembolic events and cerebrovascular atherosclerosis, whereas hemorrhagic stroke often results from a vascular bleed such as an aneurysm. Periodontal disease has been associated primarily with an increased risk of nonhemorrhagic stroke. Numerous studies have shown that periodontal disease is associated with an increased risk of stroke. In a case-control study, subjects with severe periodontitis had a 4.3 times higher risk of stroke as compared with subjects with mild or no periodontitis.[39] Severe periodontitis was a risk factor in men but not women and in those less than 65 years old but not more than 65 years old. In a longitudinal study of 1137 dentate men who averaged more than 24 years old, subjects with more than 20% mean radiographic bone loss at baseline were more than three times as likely to have a stroke than subjects with less than 20% bone loss.[58] There was a stronger effect of periodontitis on the risk for stroke among men less than 65 years old as compared with those more than 65 years old. Both large epidemiologic studies and systematic reviews of the evidence suggest an approximate threefold increased risk of stroke in subjects with periodontitis.[53,137]

As previously discussed, periodontal infection may contribute directly to the pathogenesis of atherosclerosis by providing a persistent bacterial challenge to the arterial endothelium, thereby

contributing to the monocyte and macrophage–driven inflammatory process that results in atheromatosis and the narrowing of the vessel lumen. Furthermore, periodontal infection may stimulate a series of indirect systemic effects, such as the elevated production of fibrinogen and CRP, which serve to increase the risk of stroke (see Figures 12-5 and 12-6). Finally, bacteremia with PAAP-positive bacterial strains from the supragingival and subgingival plaque can increase platelet aggregation, thereby contributing to thrombus formation and subsequent thromboembolism, which is the leading cause of stroke.[89]

Periodontal Disease and Diabetes Mellitus

The relationship between diabetes mellitus and periodontal disease has been extensively examined. It is clear from epidemiologic research that diabetes increases the risk for and severity of periodontal diseases.[72] The biologic mechanisms through which diabetes influences the periodontium are discussed in Chapter 11. The increased prevalence and severity of periodontitis typically seen in patients with diabetes—especially those with poor metabolic control—led to the designation of periodontal disease as the "sixth complication of diabetes."[72] In addition to the five "classic" complications of diabetes (Box 12-2), the American Diabetes Association has officially recognized that periodontal disease is common among patients with diabetes, and the Association's Standards of Care include taking a history of current or past dental infections as part of the physician's examination.[4] In fact, since 2009, the American Diabetes Association's Standards of Medical Care in Diabetes have included the assessment of a patient's history of "dental disease" as part of the recommended medical history during the diabetic patient evaluation.[3] In addition, these standards specifically recommend that the physician refer patients with diabetes to a dentist for a comprehensive periodontal examination.

Many studies have examined the effects of diabetes on the periodontium, whereas others have examined the effect of periodontal infection on the control of diabetes.[87] Such studies are difficult to perform because of the influence of ongoing medical management on diabetes control during the study. The following questions remain:

- Does the presence or severity of periodontal disease affect the metabolic state of diabetic patients?
- Does periodontal treatment aimed at reducing the bacterial challenge and minimizing inflammation have a measurable effect on glycemic (blood glucose) control?

In a longitudinal study of patients with type 2 diabetes, severe periodontitis was associated with the significant worsening of glycemic control over time.[126] Individuals with severe periodontitis at the baseline examination had a greater incidence of worsening glycemic control over a 2- to 4-year period as compared with those without periodontitis at baseline. In this study, periodontitis is known to have preceded the worsening of glycemic control. Periodontitis has also been associated with the classic complications of diabetes. Diabetic adults with severe periodontitis at baseline had a significantly greater incidence of kidney and macrovascular complications over the subsequent 1 to 11 years than did diabetic adults with only gingivitis or mild periodontitis.[130] This was true despite both groups having similar glycemic control. One or more cardiovascular complications occurred in 82% of patients with severe periodontitis versus 21% of patients without severe periodontitis. Again, severe periodontitis preceded the onset of clinical diabetic complications in these subjects.

Among diabetic patients with periodontitis, periodontal therapy may have beneficial effects on glycemic control.[87] This may be especially true for patients with relatively poor glycemic control and more advanced periodontal destruction before treatment. Fifty years ago, the potential benefits of periodontal therapy were first described in young adults with type 1 diabetes and severe periodontitis.[134,135] Treatment with scaling and root planing, surgery, selected tooth extraction, and systemic antibiotics resulted in decreased insulin demand. In a case series evaluating scaling and root planing in combination with systemic doxycycline therapy for 2 weeks, a small group of type 1 diabetic patients with improved periodontal health also had significant improvements in glycemic control.[95] Conversely, those individuals who demonstrated little beneficial clinical effect from periodontal treatment had no change in glycemic control.

In a classic placebo-controlled study of individuals with poorly controlled type 2 diabetes and severe periodontitis, scaling and root planing in combination with systemic doxycycline for 14 days was compared with similar treatment in combination with systemic placebo.[41] All patient groups had significant improvements in periodontal status, with reduced probing depths and bleeding on probing. Those treated with doxycycline had a greater reduction in the prevalence of *P. gingivalis*, which was more sustained over time. The doxycycline-treated patients also demonstrated significant improvement in glycemic control 3 months after treatment, which gradually reverted to baseline levels at 6 months. Placebo-treated subjects had no significant improvements in glycemic control. These studies suggest that the combination of subgingival mechanical debridement and systemic doxycycline may result in short-term improvement in glycemia in diabetic patients with severe periodontitis and poor metabolic control. Conversely, individuals with moderately well-controlled or well-controlled diabetes and periodontitis who are treated with mechanical therapy alone may demonstrate no significant changes in glycemic control, despite improvement in their periodontal condition.

In studies of subjects treated by mechanical therapy without the adjunctive use of antibiotics, significant changes in glycemic control are less common.[2,20,124] Many patients in these studies had relatively good glycemic control before treatment, so less impact on metabolic control may be expected. However, some studies show improvements in glycemic control after scaling and root planing without antibiotics. In one such study, a group of well-controlled type 2 diabetic subjects with only gingivitis or mild periodontitis received scaling and root planing without antibiotics.[63] Three months after treatment, the subjects showed a 50% reduction in bleeding on probing that was accompanied by a significant improvement in glycemic control. A group of control subjects who received no periodontal treatment showed no change in glycemic control 3 months later, as one might expect given the continued presence of periodontal inflammation.

Systematic reviews of the evidence and meta-analyses support that periodontal treatment is associated with an improvement in glycemic control.[127,122] Most of the studies evaluating the treatment of periodontal disease and its impact on glycemic control have been performed in subjects with type 2 diabetes. However, research suggests that periodontal therapy may have a smaller impact on glycemic control in patients with type 1 diabetes than

BOX 12-2 Complications of Diabetes Mellitus

1. Retinopathy	4. Macrovascular disease
2. Nephropathy	5. Altered wound healing
3. Neuropathy	6. Periodontal disease

From Löe H: Periodontal disease: The sixth complication of diabetes mellitus *Diabetes Care* 16(Suppl 1):329, 1993.

those with type 2 disease.[14] In a study of subjects with type 1 and type 2 diabetes with periodontitis, periodontal therapy was associated with a significant improvement in glycemic control overall in those with type 2 diabetes but not in those with type 1 disease, despite improvement in the periodontal condition of both groups.[14]

It is common to observe wide interindividual variability in responses to various medical management approaches in patients with type 1 diabetes. Similarly, wide variability in the impact of periodontal therapy on glycemic control can be expected in the type 1 diabetic population. For example, a study of periodontal therapy in 65 people with type 1 diabetes and chronic periodontitis showed highly variable responses.[129] Although there was an overall improvement in periodontal health after therapy, approximately 35% of subjects had an improvement in glycemic control after treatment, 37% had no significant change, and 28% showed a worsening of glycemic control. In this study, subjects were divided into those with better baseline glycemic control (i.e., glycated hemoglobin values of <8.5%) and those with poorer glycemic control (i.e., glycated hemoglobin values of ≥8.5%). Interestingly, twice as many subjects showed improved glycemic control among those whose glycemic control before periodontal treatment was poor as compared with those among whom baseline glycemic control was good. Thus, the clinician may anticipate a greater glycemic response to periodontal therapy among those patients with type 1 diabetes whose glycemic control is relatively poor than among those whose glycemic control is already good before periodontal treatment.

Although the routine use of systemic antibiotics for treatment of chronic periodontitis is not justified, patients with poorly controlled diabetes and severe periodontitis may constitute one patient group for whom such therapy is appropriate. Antibiotics remain an adjunct to the necessary mechanical removal of plaque and calculus. The mechanisms by which adjunctive antibiotics may induce positive changes in glycemic control when they are combined with mechanical debridement are unknown at this time. Systemic antibiotics may eliminate residual bacteria after scaling and root planing, thereby further decreasing the bacterial challenge to the host. Tetracyclines are also known to suppress the glycation of proteins and to decrease the activity of tissue-degrading enzymes such as matrix metalloproteinases. These changes may contribute to improvements in the metabolic control of diabetes. A low-dose form of doxycycline (20 mg) has been introduced with the specific purpose of reducing the production of collagen-degrading matrix metalloproteinases (see Chapter 49). This dose has no antibiotic effects, and it does not induce antimicrobial resistance with long-term use. Because diabetes is associated with the greatly elevated production of collagenase, low-dose doxycycline has been used for the treatment of periodontitis in diabetic subjects. Further research is indicated to determine the adjunctive benefit of such host modulation therapies in the diabetic population, because little published evidence exists today.

Periodontal Infection Associated with Glycemic Control in Diabetes

An understanding of the effects of other infections is useful to delineate the mechanisms by which periodontal infection influences glycemia. It is well known that systemic inflammation plays a major role in insulin sensitivity and glucose dynamics. As discussed previously, periodontal diseases can induce or perpetuate an elevated systemic chronic inflammatory state, which is reflected in increased serum CRP, IL-6, and fibrinogen levels seen in many people with periodontitis.[25,73] Inflammation induces insulin resistance, and such resistance often accompanies systemic infections. For example, acute nonperiodontal bacterial and viral infections have been shown to increase insulin resistance and aggravate glycemic control.[112,138] This occurs in individuals both with and without diabetes. Systemic infections increase tissue resistance to insulin through a variety of mechanisms, thereby preventing glucose from entering target cells, causing elevated blood glucose levels, and requiring increased pancreatic insulin production to maintain normoglycemia. Insulin resistance may persist for weeks or even months after the patient has recovered clinically from their illness. In the individual with type 2 diabetes, who already has significant insulin resistance, further tissue resistance to insulin as a result of infection may considerably exacerbate poor glycemic control.

It is possible that chronic gram-negative periodontal infections may also result in increased insulin resistance and poor glycemic control.[40] In patients with periodontitis, persistent systemic challenge with periodontopathic bacteria and their products may act similar to well-recognized systemic infections (Figure 12-7). This mechanism would explain the worsening of glycemic control associated with severe periodontitis. Periodontal treatment designed to decrease the bacterial insult and reduce inflammation may restore insulin sensitivity over time, thereby resulting in improved metabolic control. The improved glycemic control seen in many studies of periodontal therapy would support such a hypothesis. This mechanism may also explain differences in the glycemic response to periodontal therapy between individuals with type 1 and type 2 diabetes.[14] Because type 2 diabetes is strongly associated with insulin resistance, periodontal therapy that reduces systemic inflammation may improve insulin sensitivity and result in improved glycemic control. Conversely, type 1 diabetes is not strongly associated with insulin resistance, so reduced inflammation after periodontal therapy may not have a major effect on insulin sensitivity in patients with type 1 disease, which would minimize the impact of periodontal treatment in these patients.

Periodontal Medicine in Clinical Practice

The concept of periodontal diseases as localized entities that affect only the teeth and the supporting apparatus is oversimplified. Rather than being confined to the periodontium, inflammatory periodontal diseases may have wide-ranging systemic effects. In most

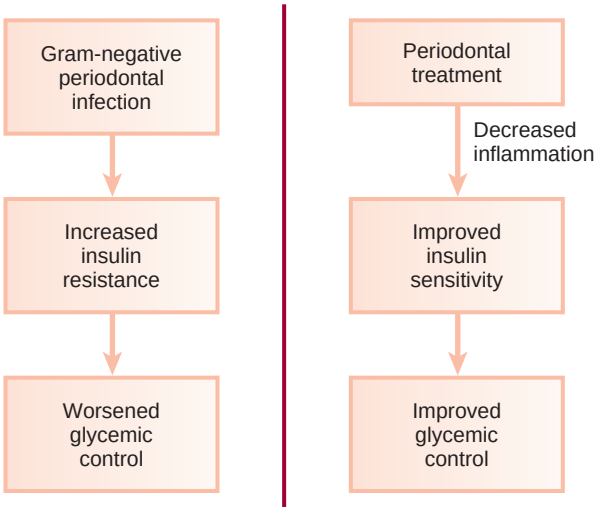

Figure 12-7 Potential effects of periodontal infection and periodontal therapy on glycemia in patients with diabetes.

persons, these effects may be relatively inconsequential or at least not clinically evident. In susceptible individuals, however, periodontal infection may act as an independent risk factor for systemic disease, and it may be involved in the basic pathogenic mechanisms of these conditions. Furthermore, periodontal infection may exacerbate existing systemic disorders.

Periodontal Disease and Systemic Health

The proper use of the knowledge of potential relationships between periodontal disease and systemic health requires the dental professional to recognize the oral cavity as one of many interrelated organ systems. An infection the size of one's palm on the leg of a pregnant woman would be a major concern to the patient and her health care provider, given the potential negative consequences of this localized infection on fetal and maternal health. A similar suppurating infection on the foot of a person with diabetes would be cause for immediate evaluation and aggressive treatment, considering the effects of such infections on the metabolic control of diabetes.

Periodontal infection must be viewed in a similar manner. Periodontitis is a gram-negative infection that often results in severe inflammation, and it potentially involves the intravascular dissemination of microorganisms and their products throughout the body. However, periodontitis tends to be a "silent" disease until destruction results in acute oral symptoms. Most patients—and many medical professionals—do not recognize the potential infection that may exist within the oral cavity.

Patient Education

Patient education is a priority. Only 30 years ago, the factors involved in CHD were unclear. At present, however, it would be difficult to find an individual who was unfamiliar with the link between cholesterol and heart disease. This change was precipitated by research clearly demonstrating the increased risk for heart disease among individuals with high cholesterol levels, and this was followed by intensive education efforts to spread the message from the scientific community to the public at large. It is important to recognize that high cholesterol levels have not been shown to *cause* heart disease in all individuals; rather, they significantly *increase the risk* of disease. Cholesterol has also been demonstrated to have a biologically plausible role in the pathogenesis of CHD.

Similarly, patient education efforts in the realm of periodontal medicine must emphasize the inflammatory nature of periodontal infections, the increased risk for systemic disease associated with the infection, and the biologically plausible role that periodontal infection may play in systemic disease. Few individuals had their cholesterol levels evaluated until the knowledge of the link between cholesterol and heart disease became widespread. Likewise, an increased appreciation of the potential effects of periodontal infection on systemic health may result in increased patient demand for periodontal evaluation.

Enhanced community awareness may be derived from newspapers, magazines, and other lay sources. However, the most reliable origin of information should be dental and medical professions through daily contact with patients. A pregnant woman usually knows that infections may adversely affect her pregnancy. Individuals with diabetes generally know that infections impair glycemic control. However, many of these patients do not know that occult periodontal infections can have the same effect as more clinically evident infections. The dentist is responsible for diagnosing periodontal infections, providing appropriate treatment, and preventing disease recurrence or progression. Because many medical professionals are unfamiliar with the oral cavity and oral health research, dentists must reach out to the medical community to improve patient care through education and communication.[88] Likewise, patients must be educated about disease prevention. Just as patients know that lowering their cholesterol levels may decrease their risk for heart disease, similar knowledge regarding the prevention of periodontal infection should be emphasized. A physician would be remiss if he or she did not provide education about decreasing the cholesterol level, losing weight, and ceasing a smoking habit to a patient at risk for CHD. Likewise, controlling the risk factor of periodontal infection requires the dentist to emphasize personal and professional preventive measures that are focused on thorough oral hygiene and regular recall.

Conclusions

Does periodontal disease *cause* CHD, COPD, or adverse pregnancy outcomes? This question may only be answered with the use of the evidence that is currently available and with the full knowledge that conclusions may change as future evidence dictates. Periodontal disease may increase the risk for many systemic disorders. Biologically plausible mechanisms support the role of periodontal infection in these conditions, but periodontal infection should not be presented as the cause of such systemic diseases any more than cholesterol should be said to cause heart disease. Periodontal infection is one of many potential risk factors for a number of systemic conditions. Fortunately, it is a readily modifiable risk factor, unlike age, gender, and genetic influences.

The focal infection theory of the early twentieth century was widely and appropriately discredited when treatment based on the theory, which consisted almost solely of tooth extraction, had no effect on the underlying diseases that oral sepsis supposedly caused. Similarly, the clinical utility of our current knowledge base is only now evolving. Future research will further delineate the role of periodontal infection in systemic health. The associations between periodontal infection and conditions such as LBW delivery, diabetes, cardiovascular and cerebrovascular diseases, and respiratory diseases may be further substantiated. Longitudinal studies and intervention trials are needed before any causative role can be assigned.

The emerging field of periodontal medicine offers new insights into the concept of the oral cavity as one system that is interconnected with the whole human body. For many years, the dental profession has recognized the effects of systemic conditions on the oral cavity. Only now, however, are dental professionals beginning to understand more fully the impact of the periodontium on systemic health.

Finally, it is important to appreciate the differences between the science and art of dental practice as it relates to periodontal medicine. Science is based, in general, on means and standard deviations or standard errors. Thus, science may determine that, on average, diabetic patients with periodontal disease have poorer glycemic control than diabetic patients who are periodontally healthy. However, the patient who is sitting in the dental chair at any given point in time may or may not be a "mean" patient: in other words, she may demonstrate the same relationship that science has determined to exist as an average within the population, or she may not. She may lie somewhere within or outside the standard deviation. She may have extremely poor glycemic control that is directly related to her extensive periodontal inflammation, she may have average glycemic control, or she may have good glycemic control. The clinical practice of periodontal medicine recognizes that, although using an evidence-based approach is absolutely key to modern dentistry, each patient is an individual, and he or she may not always fit the average determined by science.

Suggested Reading

Beck JD, Offenbacher S: The association between periodontal diseases and cardiovascular diseases: a state-of-the-art review. *Ann Periodontol* 6:9–15, 2001.

D'Aiuto F, Parkar M, Andreou G: Periodontitis and systemic inflammation: control of the local infection is associated with a reduction in serum inflammatory markers. *J Dent Res* 83:156–160, 2004.

Kebschull M, Demmer RT, Papapanou PN: "Gum bug, leave my heart alone"—epidemiologic and mechanistic evidence linking periodontal infections and atherosclerosis. *J Dent Res* 89:879–902, 2010.

Kornman KS: Mapping the pathogenesis of periodontitis: a new look. *J Periodontol* 79:1560–1568, 2008.

Lockhart PB, Bolger AF, Papapanou PN, et al; American Heart Association Rheumatic Fever, Endocarditis, and Kawasaki Disease Committee of the Council on Cardiovascular Disease in the Young, Council on Epidemiology and Prevention, Council on Peripheral Vascular Disease, and Council on Clinical Cardiology: Periodontal disease and atherosclerotic vascular disease: does the evidence support an independent association?: a scientific statement from the American Heart Association. *Circulation* 125:2520–2544, 2012.

Mealey BL, Oates TW: Diabetes mellitus and periodontal diseases. *J Periodontol* 77:1289–1303, 2006.

Ross RL: Atherosclerosis—an inflammatory disease. *N Engl J Med* 342:115–126, 1999.

Scannapieco FA, Bush RB, Paju S: Associations between periodontal disease and risk for nosocomial bacterial pneumonia and chronic obstructive pulmonary disease: a systematic review. *Ann Periodontol* 8:54–69, 2003.

Tonetti MS, D'Aiuto F, Nibali L: Treatment of periodontitis and endothelial function. *New Engl J Med* 356:911–920, 2007.

Williams RC: Understanding and managing periodontal diseases: a notable past, a promising future. *J Periodontol* 79:1552–1559, 2008.

Xiong X, Beukens P, Fraser WD, et al: Periodontal disease and adverse pregnancy outcomes: a systematic review. *BJOG* 113:135–143, 2006.

References

References for this chapter are found on the companion website www.expertconsult.com.

References

1. Abubekir E, Uguz F, Uslu MO, et al: The effect of periodontal treatment in improving erectile dysfunction: a randomized controlled trial. *J Clin Periodontol* 40:148–154, 2013.
2. Aldridge JP, Lester V, Watts TLP, et al: Single-blind studies of the effects of improved periodontal health on metabolic control in type 1 diabetes mellitus. *J Clin Periodontol* 22:271–275, 1995.
3. American Diabetes Association Standards of Medical Care in Diabetes—2013. *Diabetes Care* 36(Suppl 1):s11–s66, 2013.
4. American Diabetes Association: Report of the expert committee on the diagnosis and classification of diabetes mellitus. *Diabetes Care* 26(Suppl 1):s5–s20, 2003.
5. Andrews WW, Hauth JC, Goldenberg RL: Infection and preterm birth. *Am J Perinatol* 17:357–365, 2000.
6. Arbes SJ, Jr, Slade GD, Beck JD: Association between extent of periodontal attachment loss and self-reported history of heart attack: an analysis of NHANES III data. *J Dent Res* 78:1777–1782, 1999.
7. Azarpazhooh A, Leake JL: Systematic review of the association between respiratory diseases and oral health. *J Periodontol* 77:1465–1482, 2006.
8. Bahekar AA, Singh S, Saha S, et al: The prevalence and incidence of coronary heart disease is significantly increased in periodontitis: a meta-analysis *Am Heart J* 154:830–837, 2007. Epub 2007 Aug 20. Review. PubMed PMID: 17967586.
9. Bassani DG, Olinto MT, Kreiger N: Periodontal disease and perinatal outcomes: a case-control study. *J Clin Periodontol* 34:31–39, 2007.
10. Beck JD, Elter JR, Heiss G: Relationship of periodontal disease to carotid artery intima-media wall thickness: the Atherosclerosis Risk in Communities (ARIC) study. *Arterioscler Thromb Vasc Biol* 21:1816, 2001.
11. Beck JD, Offenbacher S, Williams R, et al: Periodontitis: a risk factor for coronary heart disease? *Ann Periodontol* 3:127–141, 1998.
12. Beck JD, Offenbacher S: The association between periodontal diseases and cardiovascular diseases: a state-of-the-art review. *Ann Periodontol* 6:9–15, 2001.
13. Boggess KA, Lieff S, Murtha AP, et al: Maternal periodontal disease is associated with an increased risk for preeclampsia. *Obstet Gynecol* 101:227–231, 2003.
14. Calabrese N, D'Aiuto F, Calabrese A, et al: Effects of periodontal therapy on glucose management in people with diabetes mellitus. *Diabetes Metab* 37:456–459, 2011.
15. Canakci V, Canakci CF, Yildrim A, et al: Periodontal disease increases the risk of severe pre-eclampsia among pregnant women. *J Clin Periodontol* 34:639–645, 2007.
16. Chambrone L, Guglielmetti MR, Pannuti CM, et al: Evidence grade associating periodontitis to preterm birth and/or low birth weight: I. A systematic review of prospective cohort studies. *J Clin Periodontol* 38:795–808, 2011.
17. Chambrone L, Pannuti CM, Guglielmetti MR, et al: Evidence grade associating periodontitis with preterm birth and/or low birth weight: II: a systematic review of randomized trials evaluating the effects of periodontal treatment. *J Clin Periodontol* 38:902–914, 2011.
18. Chiu B: Multiple infections in carotid atherosclerotic plaques. *Am Heart J* 138(Suppl):s534–s536, 1999.
19. Christan C, Dietrich T, Hagewald S, et al: White blood cell count in generalized aggressive periodontitis after non-surgical therapy. *J Clin Periodontol* 29:201–206, 2002.
20. Christgau M, Pallitzsch KD, Schmalz G, et al: Healing response to non-surgical periodontal therapy in patients with diabetes mellitus: clinical, microbiological and immunological results. *J Clin Periodontol* 25:112–124, 1998.
21. Collins JG, Smith MA, Arnold RR, et al: Effects of a *Escherichia coli* and *Porphyromonas gingivalis* lipopolysaccharide on pregnancy outcome in the golden hamster. *Infect Immun* 62:4652–4655, 1994.
22. Collins JG, Windley HW, III, Arnold RR, et al: Effects of a *Porphyromonas gingivalis* infection on inflammatory mediator response and pregnancy outcome in hamsters. *Infect Immun* 62:4356–4361, 1994.
23. Conde-Agudelo A, Villar J, Lindheimer M: Maternal infection and risk of preeclampsia: systematic review and metaanalysis. *Am J Obstet Gynecol* 198:7–22, 2008.
24. Craig RG, Yip JK, So MK, et al: Relationship of destructive periodontal disease to the acute-phase response. *J Periodontol* 74:1007–1016, 2003.
25. D'Aiuto F, Parkar M, Andreou G, et al: Periodontitis and systemic inflammation: control of the local infection is associated with a reduction in serum inflammatory markers. *J Dent Res* 83:156–160, 2004.
26. D'Aiuto F, Parkar M, Tonetti MS: Acute effects of periodontal therapy on bio-markers of vascular health. *J Clin Periodontol* 34:124–129, 2007.
27. Dasanayake AP: Poor periodontal health of the pregnant woman as a risk factor for low birth weight. *Ann Periodontol* 3:206–212, 1998.
28. DeNardin E: The role of inflammatory and immunological mediators in periodontitis and cardiovascular disease. *Ann Periodontol* 6:30–40, 2001.
29. DeStefano F, Andra RF, Kahn HS, et al: Dental disease and risk of coronary heart disease and mortality. *Br Med J* 306:688–691, 1993.
30. Dietrich T, Jimenez M, Krall Kaye EA, et al: Age dependent associations between chronic periodontitis: edentulism and risk of coronary heart disease. *Circulation* 117:1668–1674, 2008.
31. Dietrich T, Sharma P, Walter C, et al: The epidemiological evidence behind the association between periodontitis and incident atherosclerotic cardiovascular disease. *J Clin Periodontol* 40(Suppl 14):S70–S84, 2013.
32. Drangsholt MT: A new causal model of dental diseases associated with endocarditis. *Ann Periodontol* 3:184–196, 1998.
33. El-Solh AA, Pietrantoni C, Bhat A, et al: Colonization of dental plaques. A reservoir of respiratory pathogens for hospital-acquired pneumonia in institutionalized elders. *Chest* 126:1575–1582, 2004.
34. Garcia RI, Krall EA, Vokonas PS: Periodontal disease and mortality from all causes in the VA Dental Longitudinal Study. *Ann Periodontol* 3:339–349, 1998.
35. Geerts SO, Nys M, De MP, et al: Systemic release of endotoxins induced by gentle mastication: association with periodontitis severity. *J Periodontol* 73:73–78, 2002.
36. Gibbs RS: The relationship between infections and adverse pregnancy outcomes: an overview. *Ann Periodontol* 6:153–163, 2001.
37. Grau AJ, Buggle F, Heindl S, et al: Recent infection as a risk factor for cerebrovascular ischemia. *Stroke* 26:373–379, 1995.
38. Grau AJ, Buggle F, Steichen-Wiehn C, et al: Clinical and biochemical analysis in infection-associated stroke. *Stroke* 26:1520–1526, 1995.
39. Grau AJ, Becher H, Ziegler CM, et al: Periodontal disease as a risk factor for ischemic stroke. *Stroke* 35:496–501, 2004.
40. Grossi SG, Mealey BL, Rose LF: Effect of periodontal infection on systemic health and well-being. In Rose LF, Mealey BL, Genco RJ, et al, editors: *Periodontics: medicine, surgery and implants*, St Louis, 2004, Elsevier.
41. Grossi SG, Skrepcinski FB, DeCaro T, et al: Treatment of periodontal disease in diabetics reduces glycated hemoglobin. *J Periodontol* 68:713–719, 1997.
42. Haraszthy VI, Zambon JJ, Trevisan M, et al: Identification of periodontal pathogens in atheromatous plaques. *J Periodontol* 71:1554–1560, 2000.
43. Hayes C, Sparrow D, Cohen M, et al: The association between alveolar bone loss and pulmonary function: the VA Dental Longitudinal Study. *Ann Periodontol* 3:257–261, 1998.
44. Herzberg MC, Meyer MW: Dental plaque, platelets and cardiovascular diseases. *Ann Periodontol* 3:151–160, 1998.
45. Herzberg MC, Meyer MW: Effects of oral flora on platelets: possible consequences in cardiovascular disease. *J Periodontol* 67:1138–1142, 1996.
46. Herzberg MC: Coagulation and thrombosis in cardiovascular disease: plausible contributions of infectious agents. *Ann Periodontol* 6:16–19, 2001.
47. Hill GB: Preterm birth: associations with genital and possibly oral microflora. *Ann Periodontol* 3:222–232, 1998.

48. Hill GB: The microbiology of bacterial vaginosis. *Am J Obstet Gynecol* 169:450–454, 1993.
49. Hujoel P: Grading the evidence: the core of EBD. *J Evid Based Dent Pract* 8:116–118, 2008.
50. Hujoel PP, Drangsholt M, Spiekerman C, et al: Examining the link between coronary heart disease and the elimination of chronic dental infections. *J Am Dent Assoc* 132:883–889, 2001.
51. Hujoel PP, Drangsholt M, Spiekerman C, et al: Periodontal disease and coronary heart disease risk. *JAMA* 284:1406–1410, 2000.
52. Hyman JJ, Reid BC: Cigarette smoking, periodontal disease, and chronic obstructive pulmonary disease. *J Periodontol* 75:9–15, 2004.
53. Janket S, Baird AE, Chuang S, et al: Meta-analysis of periodontal disease and risk of coronary heart disease and stroke. *Oral Surg Oral Med Oral Pathol Oral Radiol Endod* 95:559–569, 2003.
54. Janket S, Qvarnstrom M, Muerman JH, et al: Asymptomatic dental score and prevalent coronary heart disease. *Circulation* 109:1095–1100, 2004.
55. Jansson L, Lavstedt S, Frithiof L: Relationship between oral health and mortality rate. *J Clin Periodontol* 29:1029–1034, 2002.
56. Jeffcoat MJ, Hauth JC, Guers N, et al: Periodontal disease and preterm birth: results of a pilot intervention study. *J Periodontol* 74:1214–1218, 2003.
57. Jeffcoat MK, Guers NC, Reddy MS, et al: Periodontal infection and preterm birth: results of a prospective study. *J Am Dent Assoc* 132:875–880, 2001.
58. Jimenez M, Krall EA, Garcia RI, et al: Periodontitis and incidence of cerebrovascular disease in men. *Ann Neurol* 66:505–512, 2009.
59. Kebschull M, Demmer RT, Papapanou PN: "Gum bug, leave my heart alone"—epidemiologic and mechanistic evidence linking periodontal infections and atherosclerosis. *J Dent Res* 89:879–902, 2010.
60. Keller JJ, Chung SD, Lin HC: A nationwide population-based study on the association between chronic periodontitis and erectile dysfunction. *J Clin Periodontol* 39:507–512, 2012.
61. Kim AJ, Lo AJ, Pullin DA, et al: Scaling and root planing treatment for periodontitis to reduce preterm birth and low birth weight: a systematic review and meta-analysis of randomized controlled trials. *J Periodontol* 83:1508–1519, 2012.
62. Kinane DF: Periodontal disease's contributions to cardiovascular disease: an overview of potential mechanisms. *Ann Periodontol* 3:142–150, 1998.
63. Kiran M, Arpak N, Unsal E, et al: The effect of improved periodontal health on metabolic control in type 2 diabetes mellitus. *J Clin Periodontol* 32:266–272, 2005.
64. Kornman KS, Duff GW: Candidates genes as potential links between periodontal and cardiovascular diseases. *Ann Periodontol* 6:48–57, 2001.
65. Kornman KS: Mapping the pathogenesis of periodontitis: a new look. *J Periodontol* 79:1560–1568, 2008.
66. Kunnen A, van Doormaal JJ, Abbas F, et al: Periodontal disease and pre-eclampsia: a systematic review. *J Clin Periodontol* 37:1075–1087, 2010.
67. Kweider M, Lowe GD, Murray GD, et al: Dental disease, fibrinogen and white cell counts: links with myocardial infarction? *Scott Med J* 38:73–74, 1993.
68. Linden GJ, Linden K, Yarnell J, et al: All-cause mortality and periodontitis in 60-70-year-old men: a prospective cohort study. *J Clin Periodontol* 39:940–946, 2012.
69. Lockhart PB, Bolger AF, Papapanou PN, et al; American Heart Association Rheumatic Fever, Endocarditis, and Kawasaki Disease Committee of the Council on Cardiovascular Disease in the Young, Council on Epidemiology and Prevention, Council on Peripheral Vascular Disease, and Council on Clinical Cardiology: Periodontal disease and atherosclerotic vascular disease: does the evidence support an independent association?: a scientific statement from the American Heart Association. *Circulation* 125:2520–2544, 2012.
70. Lockhart PB, Brennan MT, Sasser HC, et al: Bacteremia associated with toothbrushing and dental extraction. *Circulation* 117:3118–3125, 2008.
71. Lockhart PB, Brennan MT, Thornhill M, et al: Poor oral hygiene as a risk factor for infective endocarditis-related bacteremia. *J Am Dent Assoc* 140:1238–1244, 2009.
72. Löe H: Periodontal disease: the sixth complication of diabetes mellitus. *Diabetes Care* 16(Suppl 1):329–334, 1993.
73. Loos BG, Craandijk J, Hoek FJ, et al: Elevation of systemic markers related to cardiovascular diseases in the peripheral blood of periodontitis patients. *J Periodontol* 71:1528–1534, 2000.
74. Lopez NJ, Smith PC, Gutierrez J: Higher risk of preterm birth and low birth weight in women with periodontal disease. *J Dent Res* 81:58–63, 2002.
75. Lopez NJ, Smith PC, Gutierrez J: Periodontal therapy may reduce the risk of preterm low birth weight in women with periodontal disease: a randomized controlled trial. *J Periodontol* 73:911–924, 2002.
76. Lowe GD, Lee AJ, Rumley A, et al: Blood viscosity and risk of cardiovascular events: the Edinburgh Artery Study. *Br J Haematol* 96:168–173, 1997.
77. Lowe GD: Etiopathogenesis of cardiovascular disease: hemostasis, thrombosis, and vascular medicine. *Ann Periodontol* 3:121–126, 1998.
78. Madianos PN, Murtha AP, Boggess KA, et al: Maternal periodontitis and prematurity. Part II: maternal infection and fetal exposure. *Ann Periodontol* 6:175–182, 2001.
79. Malthaner SC, Moore S, Mills M, et al: Investigation of the association between angiographically defined coronary artery disease and periodontal disease. *J Periodontol* 73:1169–1176, 2002.
80. Mattila KJ, Nieminen MS, Valtonen VV, et al: Association between dental health and acute myocardial infarction. *Br Med J* 298:779–781, 1989.
81. Mattila KJ, Valle MS, Nieminen MS, et al: Dental infections and coronary atherosclerosis. *Atherosclerosis* 103:205–211, 1993.
82. Mattila KJ, Valtonen VV, Nieminen M, et al: Dental infection and the risk of new coronary events: prospective study of patients with documented coronary artery disease. *Clin Infect Dis* 20:588–592, 1995.
83. Mattila KJ: Dental infections as a risk factor for acute myocardial infarction. *Eur Heart J* 14:51–53, 1993.
84. Mattila KJ: Viral and bacterial infections in patients with acute myocardial infarction. *J Intern Med* 225:293–296, 1989.
85. McCormick MC: The contribution of low birth weight to infant mortality and childhood morbidity. *N Engl J Med* 312:82–90, 1985.
86. McDonald HM, O'Loughlin JA, Jolley P, et al: Vaginal infections and preterm labour. *Br J Obstet Gynecol* 98:427–435, 1991.
87. Mealey BL, Oates TW: Diabetes mellitus and periodontal diseases. *J Periodontol* 77:1289–1303, 2006.
88. Mealey BL: The interactions between physicians and dentists in managing the care of patients with diabetes mellitus. *J Am Dent Assoc* 139(Suppl):4s–7s, 2008.
89. Mealey BL: Influence of periodontal infections on systemic health. *Periodontol 2000* 21:197–209, 1999.
90. Mealey BL: Periodontal implications: medically compromised patients. *Ann Periodontol* 1:256–321, 1996.
91. Mehta JL, Saldeen TG, Rand K: Interactive role of infection, inflammation and traditional risk factors in atherosclerosis and coronary artery disease. *J Am Coll Cardiol* 31:1217–1225, 1998.
92. Merijohn GK, Bader JD, Frantsve-Hawley J, et al: Clinical decision support chairside tools for evidence-based dental practice. *J Evid Based Dent Pract* 8:119–132, 2008.
93. Michalowicz BS, Hodges JS, DiAngelis AJ, et al: Treatment of periodontal disease and the risk of preterm birth. *New Engl J Med* 355:1885–1894, 2006.
94. Michalowicz BS, Hodges JS, Lussky RC, et al: Maternal periodontitis treatment and child neurodevelopment at 24 to 28 months of age. *Pediatrics* 127:e1212–e1220, 2011.
95. Miller LS, Manwell MA, Newbold D, et al: The relationship between reduction in periodontal inflammation and diabetes control: a report of 9 cases. *J Periodontol* 63:843, 1992.
96. Morales WJ, Schorr S, Albritton J: Effect of metronidazole in patients with preterm birth in preceding pregnancy and bacterial vaginosis: a

placebo-controlled double-blind study. *Am J Obstet Gynecol* 171:345–347, 1994.
97. Newman HN: Focal infection. *J Dent Res* 75:1912–1919, 1996.
98. Newman MG, Caton JG, Gunsolley JC: The use of the evidence-based approach in a periodontal therapy contemporary science workshop. *Ann Periodontol* 8:1–11, 2003.
99. Offenbacher S, Barros SP, Beck JD: Rethinking periodontal inflammation. *J Periodontol* 79:1577–1584, 2008.
100. Offenbacher S, Jarad HL, O'Reilly PG, et al: Potential pathogenic mechanisms of periodontitis-associated pregnancy complications. *Ann Periodontol* 3:233–250, 1998.
101. Offenbacher S, Katz V, Fertik G, et al: Periodontal disease as a possible risk factor for preterm low birth weight. *J Periodontol* 67:1103–1113, 1996.
102. Offenbacher S: Periodontal diseases: pathogenesis. *Ann Periodontol* 1:821–878, 1996.
103. Oguz F, Eltas A, Beytur A, et al: Is there a relationship between chronic periodontitis and erectile dysfunction? *J Sex Med* 10:838–843, 2013.
104. Ostergaard L, Anderson PL: Etiology of community-acquired pneumonia: evaluation by transtracheal aspiration, blood culture, or serology. *Chest* 104:1400–1407, 1993.
105. Page RC, Beck JD: Risk assessment for periodontal diseases. *Int Dent J* 47:61–87, 1997.
106. Page RC: The pathobiology of periodontal diseases may affect systemic diseases: inversion of a paradigm. *Ann Periodontol* 3:108–120, 1998.
107. Pugin J, Auckenthaler R, Lew DP, et al: Oropharyngeal decontamination decreases incidence of ventilator-associated pneumonia: a randomized, placebo-controlled, double-blind clinical trial. *JAMA* 265:2704–2710, 1991.
108. Ridker PM, Rifai N, Rose L, et al: Comparison of C-reactive protein and low-density lipoprotein cholesterol levels in the prediction of first cardiovascular events. *N Engl J Med* 347:1557–1565, 2002.
109. Ridker PM, Silvertown JD: Inflammation, C-reactive protein and atherothrombosis. *J Periodontol* 79:1544–1551, 2008.
110. Ridker PM: Fibrinolytic and inflammatory markers for arterial occlusion: the evolving epidemiology of thrombosis and hemostasis. *Thromb Haemost* 78:53–59, 1997.
111. Ross RL: Atherosclerosis—an inflammatory disease. *N Engl J Med* 342:115–126, 1999.
112. Sammalkorpi K: Glucose intolerance in acute infections. *J Intern Med* 225:15–19, 1989.
113. Saremi A, Nelson RG, Tulloch-Reid M, et al: Periodontal disease and mortality in type 2 diabetes. *Diabetes Care* 28:27–32, 2005.
114. Scannapieco FA, Bush RB, Paju S: Associations between periodontal disease and risk for atherosclerosis, cardiovascular disease, and stroke: a systematic review. *Ann Periodontol* 8:38–53, 2003.
115. Scannapieco FA, Bush RB, Paju S: Associations between periodontal disease and risk for nosocomial bacterial pneumonia and chronic obstructive pulmonary disease: a systematic review. *Ann Periodontol* 8:54–69, 2003.
116. Scannapieco FA, Papandonatos GD, Dunford RG: Associations between oral conditions and respiratory disease in a national sample survey population. *Ann Periodontol* 3:251–265, 1998.
117. Scannapieco FA, Stewart EM, Mylotte JM: Colonization of dental plaque by respiratory pathogens in medical intensive care patients. *Crit Care Med* 20:740–745, 1992.
118. Seinost G, Wimmer G, Skerget M, et al: Periodontal treatment improves endothelial dysfunction in patients with severe periodontitis. *Am Heart J* 149:1050–1054, 2005.
119. Selective Decontamination of the Digestive Tract Trialist's Collaborative Group: Meta-analysis of randomised controlled trials of selective decontamination of the digestive tract. *Br Med J* 307:525–532, 1993.
120. Seymour GJ, Ford PJ, Cullinan MP, et al: Relationship between periodontal infections and systemic disease. *Clin Microbiol Infect* 13(Suppl 4):3–10, 2007.
121. Sharma A, Pradeep AR, Raju PA: Association between chronic periodontitis and vasculogenic erectile dysfunction. *J Periodontol* 82:1665–21669, 2011.
122. Simpson TC, Needleman I, Wild SH, et al: Treatment of periodontal disease for glycaemic control in people with diabetes. *Cochrane Database Syst Rev* 12(5):CD004714, 2010.
123. Sjogren P, Nilsson E, Forsell M, et al: A systematic review of the preventive effect of oral hygiene on pneumonia and respiratory tract infection in elderly people in hospitals and nursing homes: effect estimates and methodological quality of randomized controlled trials. *J Am Geriatr Soc* 56:2124–2130, 2008.
124. Smith GT, Greenbaum CJ, Johnson BD, et al: Short-term responses to periodontal therapy in insulin-dependent diabetic patients. *J Periodontol* 67:794–802, 1996.
125. Spodick DH, Flessas AP, Johnson MM: Association of acute respiratory symptoms with onset of acute myocardial infarction: prospective investigation of 150 consecutive patients and matched control patients. *Am J Cardiol* 53:481–482, 1984.
126. Taylor GW, Burt BA, Becker MP, et al: Severe periodontitis and risk for poor glycemic control in patients with non–insulin-dependent diabetes mellitus. *J Periodontol* 67:1085, 1996.
127. Teeuw WJ, Gerdes VE, Loos BG: Effect of periodontal treatment on glycemic control of diabetic patients: a systematic review and meta-analysis. *Diabetes Care* 33:421–427, 2010.
128. Terpenning M: The relationship between infection and chronic respiratory diseases: an overview. *Ann Periodontol* 6:66–70, 2001.
129. Tervonen T, Lamminsalo S, Hiltunen L, et al: Resolution of periodontal inflammation does not guarantee improved glycemic control in type 1 diabetic subjects. *J Clin Periodontol* 36:51–57, 2009.
130. Thorstensson H, Kuylensteirna J, Hugoson A: Medical status and complications in relation to periodontal disease experience in insulin-dependent diabetics. *J Clin Periodontol* 23:194, 1996.
131. Tonetti MS, D'Aiuto F, Nibali L, et al: Treatment of periodontitis and endothelial function. *New Engl J Med* 356:911–920, 2007.
132. Vergnes J-N, Sixou M: Preterm low birth weight and maternal periodontal status: a meta-analysis. *Am J Obstet Gynecol* 196:135.e1–135.e7, 2007.
133. Williams C, Davenport E, Sterne J, et al: Mechanisms of risk in preterm low-birthweight infants. *Periodontol 2000* 23:142–150, 2000.
134. Williams RC, Mahan CJ: Periodontal disease and diabetes in young adults. *JAMA* 172:776, 1960.
135. Williams RC: Understanding and managing periodontal diseases: a notable past, a promising future. *J Periodontol* 79:1552–1559, 2008.
136. Wu T, Trevisan M, Genco RJ, et al: Examination of the relation between periodontal health status and cardiovascular risk factors: serum total and high density lipoprotein cholesterol, C-reactive protein, and plasma fibrinogen. *Am J Epidemiol* 151:273–282, 2000.
137. Wu T, Trevisan M, Genco RJ, et al: Periodontal disease and risk of cerebrovascular disease: the first National Health and Nutrition Examination Survey and its follow-up study. *Arch Intern Med* 160:2749–2755, 2000.
138. Yki-Jarvinen H, Sammalkorpi K, Koivisto VA, et al: Severity, duration and mechanism of insulin resistance during acute infections. *J Clin Endocrinol Metab* 69:317–323, 1989.
139. Zadik Y, Bechor R, Galor S, et al: Erectile dysfunction might be associated with chronic periodontal disease: two ends of the cardiovascular spectrum. *J Sex Med* 6:1111–1116, 2009.
140. Zaremba M, Gorska R, Suwalski P, et al: Evaluation of the incidence of periodontitis-associated bacteria in the atherosclerotic plaque of coronary blood vessels. *J Periodontol* 78:322–327, 2007.
141. Zeng XT, Tu ML, Liu DY, et al: Periodontal disease and risk of chronic obstructive pulmonary disease: a meta-analysis of observational studies. *PLoS ONE* 7(10):e46508, 2012.

CHAPTER 13

Defense Mechanisms of the Gingiva

Jaime Bulkacz and Fermin A. Carranza

CHAPTER OUTLINE

Sulcular Fluid
Leukocytes in the Dentogingival Area
Saliva

The gingival tissue is constantly subjected to mechanical and bacterial aggressions. The saliva, the epithelial surface, and the initial stages of the inflammatory response provide resistance to these actions. Chapter 13 reviews the role of the epithelium, including its degree of keratinization and its turnover rate. This chapter describes the permeability of the junctional and sulcular epithelia and the role of the sulcular fluid, leukocytes, and saliva.

Sulcular Fluid

The presence of sulcular fluid, or *gingival crevicular fluid* (GCF), has been known since the nineteenth century, but its composition and its possible role in oral defense mechanisms were elucidated by the pioneering work of Waerhaug[107] and Brill and Krasse[13] during the 1950s. The latter investigators introduced filter paper into the gingival sulci of dogs that had previously been injected intramuscularly with fluorescein; within 3 minutes, the fluorescent material was recovered on the paper strips. This indicated the passage of fluid from the bloodstream through the tissues and the exiting of fluid via the gingival sulcus.

In subsequent studies, Brill[10,11] confirmed the presence of GCF in humans and considered it a "transudate." However, others[64,108] demonstrated that GCF is an inflammatory exudate rather than a continuous transudate. In strictly normal gingiva, little or no fluid can be collected.

More recently, interest in the development of tests for the detection or prediction of periodontal disease has resulted in numerous research papers about the components, origin, and function of GCF.[19]

Methods of Collection

The most difficult hurdle to overcome when collecting GCF is the scarcity of material that can be obtained from the sulcus. Many collection methods have been tried.[9,12,52,55,66,67,92] These methods include the use of absorbing paper strips, the placement of twisted threads around and into the sulcus, and techniques involving micropipettes and intracrevicular washings.

The absorbing paper strips are placed within the sulcus (intrasulcular method) or at its entrance (extrasulcular method) (Figure 13-1). The placement of the filter paper strip in relation to the sulcus or pocket is important. The Brill technique involves inserting it into the pocket until resistance is encountered (Figure 13-1, *A*). This method produces some degree of irritation of the sulcular epithelium that by itself can trigger the flow of fluid.

To minimize this irritation, Löe and Holm-Pedersen[64] placed the filter paper strip just at the entrance of the pocket or over the pocket entrance (Figure 13-1, *B* and *C*). In this way, fluid that seeps out is picked up by the strip, but the sulcular epithelium is not in contact with the paper.

Preweighed twisted threads were used by Weinstein and colleagues.[108] The threads were placed in the gingival crevice around the tooth, and the amount of fluid collected was estimated by weighing the sample thread.

The use of micropipettes permits the collection of fluid by capillarity. Capillary tubes of standardized length and diameter are placed in the pocket, and their content is later centrifuged and analyzed.[9,11,12]

Crevicular washings can be used to study GCF from clinically normal gingiva. One method involves the use of an appliance that consists of a hard acrylic plate that covers the maxilla, with soft borders and a groove that follows the gingival margins; it is connected to four collection tubes. The washings are obtained by rinsing the crevicular areas from one side to the other with the use of a peristaltic pump.[20]

A modification of the previous method involves the use of two injection needles that have been fitted one within the other so that, during sampling, the inside (ejection) needle is at the bottom of the pocket and the outside (collecting) needle is at the gingival margin. The collection needle is drained into a sample tube via continuous suction.[92]

Permeability of Junctional and Sulcular Epithelia

The initial studies by Brill and Krasse[13] involving the use of fluorescein were later confirmed with substances such as India ink[86] and saccharated iron oxide.[20] Substances that have been shown to penetrate the sulcular epithelium include albumin,[85] endotoxin,[84,89] thymidine,[43] histamine,[23] phenytoin,[102] and horseradish peroxidase.[70] These findings indicate permeability to substances with a molecular weight of up to 1000 kD.

Squier and Johnson[101] reviewed the mechanisms of penetration through an intact epithelium. The intercellular movement

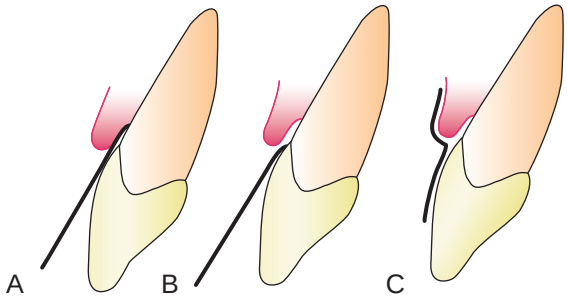

Figure 13-1 Placement of a filter strip in the gingival sulcus for the collection of fluid. **A,** Intrasulcular method. **B** and **C,** Extrasulcular methods.



Figure 13-2 Electronic device for measuring the amount of fluid collected on filter paper.

of molecules and ions along intercellular spaces appears to be a possible mechanism. Substances that take this route do not traverse the cell membranes.

Amount

The amount of GCF collected on a paper strip can be evaluated in a variety of ways. The wetted area can be made more visible by staining with ninhydrin; it is then measured planimetrically on an enlarged photograph or with a magnifying glass or a microscope.

An electronic method has been devised for measuring the fluid collected on a "blotter" (Periopaper) with the use of an electronic transducer (Periotron, Harco Electronics, Winnipeg, Manitoba, Canada) (Figure 13-2). The wetness of the paper strip affects the flow of an electronic current and provides a digital readout. A comparison of the ninhydrin-staining method and the electronic method performed in vitro revealed no significant differences between the two techniques.[104]

The amount of GCF collected is extremely small. Measurements performed by Cimasoni[20] showed that a strip of paper 1.5-mm wide and inserted 1 mm within the gingival sulcus of a slightly inflamed gingiva absorbs about 0.1 mg of GCF in 3 minutes. Challacombe[18] used an isotope dilution method to measure the amount of GCF present in a particular space at any given time. His calculations for human volunteers with mean gingival indices of less than 1 showed that the mean GCF volume in the proximal spaces from the molar teeth ranged from 0.43 to 1.56 μL.

Composition

The components of GCF can be characterized according to individual proteins,[64,76,93] specific antibodies, antigens,[30,83] and enzymes of several specificities.[14] The GCF also contains cellular elements.[23,26,110]

Many research efforts have attempted to use GCF components to detect or diagnose active disease or to predict patients who are at risk for periodontal disease.[2] So far, more than 40 compounds found in GCF have been analyzed,[80] but their origin is not known with certainty. These compounds can be derived from the host or produced by the bacteria in the gingival crevice, but their source can be difficult to elucidate; examples include β-glucuronidase, which is a lysosomal enzyme, and lactic acid dehydrogenase, which is a cytoplasmic enzyme. The sources of collagenases may be fibroblasts or polymorphonuclear leukocytes (PMNs [neutrophils]),[4,78] or collagenases may be secreted by bacteria.[30] Phospholipases are lysosomal and cytoplasmic enzymes, but they are also produced by microorganisms.[14] The majority of GCF elements detected thus far have been enzymes, but there are nonenzymatic substances as well.

Cellular Elements. Cellular elements found in GCF include bacteria, desquamated epithelial cells, and leukocytes (i.e., PMNs, lymphocytes, and monocytes/macrophages), which migrate through the sulcular epithelium.[23,26]

Electrolytes. Potassium, sodium, and calcium have been studied in the GCF. Most studies have demonstrated a positive correlation of calcium and sodium concentrations with the sodium/potassium ratio seen with inflammation.[49-51] (For more information, see References 12 and 13.)

Organic Compounds. Both carbohydrates and proteins have been investigated. Glucose hexosamine and hexuronic acid are two of the compounds that are found in GCF.[41] Blood glucose levels do not correlate with GCF glucose levels; glucose concentration in GCF is three to four times greater than that in serum.[41] This is interpreted not only as a result of the metabolic activity of adjacent tissues but also as a function of the local microbial flora.

The total protein content of GCF is much less than that of serum.[12,13] No significant correlations have been found between the concentration of proteins in GCF and the severity of gingivitis, pocket depth, or extent of bone loss.[7]

Metabolic and bacterial products identified in GCF include lactic acid,[42] urea,[36] hydroxyproline,[82] endotoxins,[98] cytotoxic substances, hydrogen sulfide,[100] and antibacterial factors.[22]

Many enzymes have also been identified.

The methodology used for the analysis of GCF components is as varied as the diversity of those components. Examples include fluorometry for the detection of metalloproteinases[23]; enzyme-linked immunosorbent assays to detect enzyme levels and interleukin-1β (IL-1β)[63]; radioimmunoassays for detecting cyclooxygenase derivatives[77] and procollagen III[105]; high-pressure liquid chromatography to detect timidazole[59]; and direct and indirect immunodot tests for the detection of acute-phase proteins.[97]

Cellular and Humoral Activity in Gingival Crevicular Fluid

Monitoring periodontal disease is a complicated task, because very few noninvasive procedures can follow the initiation and progress of the disease. The analysis of GCF constituents in health and disease may be extremely useful as a result of GCF's simplicity and because GCF can be obtained with noninvasive methods.

The analysis of GCF has identified cell and humoral responses in both healthy individuals and in those with periodontal disease.[56] The cellular immune response includes the appearance of cytokines in GCF, but there is no clear evidence of a relationship between cytokines and disease. However, IL-1α and IL-1β are known to increase the binding of PMNs and monocytes/macrophages to endothelial cells, to stimulate the production of prostaglandin E_2 and the release of lysosomal enzymes, and to stimulate bone resorption.[60] Preliminary evidence also indicates the presence of interferon-α in GCF,[56] which may have a protective role in periodontal disease because of its ability to inhibit the bone resorption activity of IL-1β.[38]

Because the amount of fluid recoverable from gingival crevices is small, only the use of very sensitive immunoassays permits the analysis of the specificity of antibodies.[22,24,25] A study that compared antibodies in different crevices with serum antibodies directed at specific microorganisms did not provide any conclusive evidence regarding the significance of the presence of antibodies in GCF among individuals with periodontal disease.[56]

Although the role of antibodies in the gingival defense mechanisms is difficult to ascertain, the consensus is that, in a patient with periodontal disease, a reduction in antibody response is detrimental, and an antibody response plays a protective role.[57]

Clinical Significance

As mentioned previously, GCF is an inflammatory exudate.[64] Its presence in clinically normal sulci can be explained, because gingiva that appears clinically normal invariably exhibits inflammation when it is examined microscopically.

The amount of GCF is greater when inflammation is present,[29,95] and it is sometimes proportional to the severity of inflammation.[79] GCF production is not increased by trauma from occlusion,[69] but it is increased by the mastication of coarse foods, toothbrushing and gingival massage, ovulation,[63] hormonal contraceptives,[62] prosthetic appliances,[74] and smoking.[71] Other factors that influence the amount of GCF are circadian periodicity and periodontal therapy.

Circadian Periodicity. There is a gradual increase in the amount of GCF from 6 AM to 10 PM and a decrease thereafter.[8]

Sex Hormones. Female sex hormones increase GCF flow, probably because they enhance vascular permeability.[60] Pregnancy, ovulation,[59] and hormonal contraceptives[61] all increase GCF production.

Mechanical Stimulation. Chewing[11] and vigorous gingival brushing stimulate the flow of GCF. Even the minor stimuli represented by the intrasulcular placement of paper strips increases the production of fluid.

Smoking. Smoking produces an immediate transient but marked increase in GCF flow.[71]

Periodontal Therapy. There is an increase in GCF production during the healing period after periodontal surgery.[3]

Drugs in Gingival Crevicular Fluid

Drugs that are excreted through the GCF may be used advantageously in periodontal therapy. Bader and Goldhaber[6] demonstrated in dogs that tetracyclines are excreted through the GCF; this finding triggered extensive research that showed a concentration of tetracyclines in GCF as compared with serum.[37] Metronidazole is another antibiotic that has been detected in human GCF[27] (see Chapter 48).

Leukocytes in the Dentogingival Area

Leukocytes have been found in clinically healthy gingival sulci in humans and experimental animals. The leukocytes found are predominantly PMNs. They appear in small numbers extravascularly in the connective tissue adjacent to the bottom of the sulcus; from there, they travel across the epithelium[17,39] to the gingival sulcus, where they are expelled (Figures 13-3 and 13-4).

Leukocytes are present in sulci even when histologic sections of adjacent tissue are free of inflammatory infiltrate.[88] Differential counts of leukocytes from clinically healthy human gingival sulci have shown 91.2% to 91.5% PMNs and 8.5% to 8.8% mononuclear cells.[99,110]

Mononuclear cells were identified as 58% B lymphocytes, 24% T lymphocytes, and 18% mononuclear phagocytes. The ratio of T lymphocytes to B lymphocytes was found to be reversed from the normal ratio of about 3 : 1 found in peripheral blood to about 1 : 3 in GCF.[110]

Leukocytes are attracted by different plaque bacteria,[47,109] but they can also be found in the dentogingival region of germ-free adult animals.[65,91] Leukocytes were reported in the gingival sulcus in nonmechanically irritated (resting) healthy gingiva, thereby indicating that their migration may be independent of an increase in vascular permeability.[5] The majority of these cells are viable and have phagocytic and killing capacity.[54,81,87] Therefore, leukocytes constitute a major protective mechanism against the extension of plaque into the gingival sulcus.

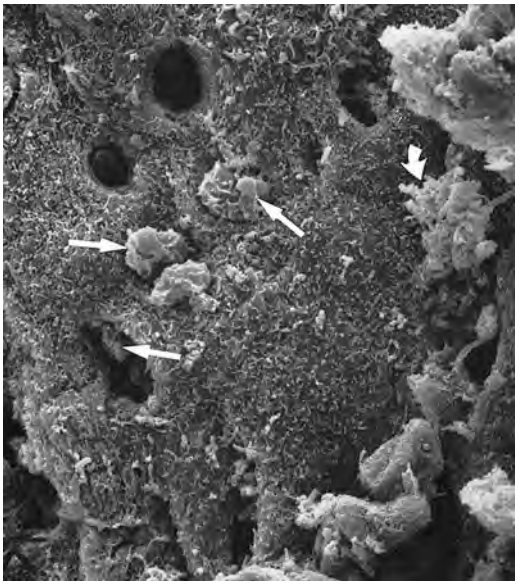

Figure 13-3 Scanning electron microscope view of the periodontal pocket wall. Several leukocytes are emerging *(straight arrows)*, some of which are partially covered by bacteria *(curved arrow)*. Empty holes correspond to tunnels through which leukocytes have emerged.

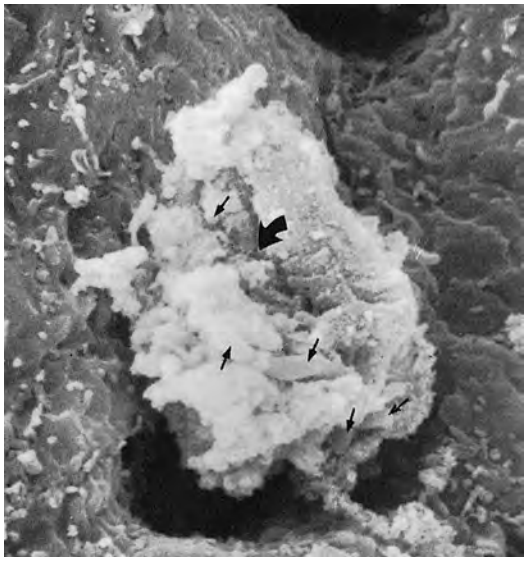

Figure 13-4 Scanning electron microscope view at higher magnification than shown in Figure 13-3. A leukocyte emerging from the pocket wall is covered with bacteria *(small arrows)*. The large, curved arrow points to a phagosomal vacuole through which bacteria are being engulfed.

TABLE 13-1 Role of Saliva In Oral Health

Function	Salivary Components	Probable Mechanism
Lubrication	Glycoproteins, mucoids	Coating similar to gastric mucin
Physical protection	Glycoproteins, mucoids	Coating similar to gastric mucin
Cleansing	Physical flow	Clearance of debris and bacteria
Buffering	Bicarbonate and phosphate	Antacids
Tooth integrity maintenance	Minerals	Maturation, remineralization
	Glycoprotein pellicle	Mechanical protection
Antibacterial action	Immunoglobulin A	Control of bacterial colonization
	Lysozyme	Breaks bacterial cell walls
	Lactoperoxidase	Oxidation of susceptible bacteria

Leukocytes are also found in saliva; this is discussed later in this chapter. The main port of entry of leukocytes into the oral cavity is the gingival sulcus.[94]

Saliva

Salivary secretions are protective in nature because they maintain the oral tissues in a physiologic state (Table 13-1). Saliva exerts a major influence on plaque by mechanically cleansing the exposed oral surfaces, by buffering acids produced by bacteria, and by controlling bacterial activity.[75]

Antibacterial Factors

Saliva contains numerous inorganic and organic factors that influence bacteria and their products in the oral environment. Inorganic factors include ions and gases, bicarbonate, sodium, potassium, phosphates, calcium, fluorides, ammonium, and carbon dioxide. Organic factors include lysozyme, lactoferrin, myeloperoxidase, lactoperoxidase, and agglutinins such as glycoproteins, mucins, β2-macroglobulins, fibronectins,[105] and antibodies.

Lysozyme is a hydrolytic enzyme that cleaves the linkage between structural components of the glycopeptide muramic acid–containing region of the cell wall of certain bacteria in vitro. Lysozyme works on both gram-negative and gram-positive organisms[44]; its targets include *Veillonella* species and *Actinobacillus actinomycetemcomitans*. It probably repels certain transient bacterial invaders of the mouth.[46]

The *lactoperoxidase–thiocyanate system* in saliva has been shown to be bactericidal to some strains of *Lactobacillus* and *Streptococcus*[73,90] by preventing the accumulation of lysine and glutamic acid, both of which are essential for bacterial growth. Another antibacterial finding is lactoferrin, which is effective against *Actinobacillus* species.[48]

Myeloperoxidase, which is an enzyme that is similar to salivary peroxidase, is released by leukocytes; it is bactericidal for *Actinobacillus,*[72] but it has the added effect of inhibiting the attachment of *Actinomyces* strains to hydroxyapatite.[15]

Salivary Antibodies

As with GCF, saliva contains antibodies that are reactive with indigenous oral bacterial species. Although immunoglobulins G (IgG) and M (IgM) are present, the preponderant immunoglobulin found in saliva is *immunoglobulin A* (IgA). However, IgG is more prevalent in GCF.[103] Major and minor salivary glands contribute all of the secretory IgA and lesser amounts of IgG and IgM. GCF contributes most of the IgG, complement, and PMNs that, in conjunction with IgG or IgM, inactivate or opsonize bacteria.

Salivary antibodies appear to be synthesized locally, because they react with strains of bacteria that are indigenous to the mouth but not with organisms that are characteristic of the intestinal tract.[31,33] Many bacteria found in saliva have been shown to be coated with IgA, and the bacterial deposits on teeth contain both IgA and IgG in quantities that are greater than 1% of their dry weight.[32] It has been shown that IgA antibodies present in parotid saliva can inhibit the attachment of oral *Streptococcus* species to epithelial cells.[28,107] Gibbons and colleagues[31-33] suggested that antibodies in secretions may impair the ability of bacteria to attach to mucosal or dental surfaces.

Enzymes

The *enzymes* that are normally found in the saliva are derived from the salivary glands, bacteria, leukocytes, oral tissues, and ingested substances; the major enzyme is parotid amylase. Certain salivary enzymes have been reported in increased concentrations in periodontal disease: hyaluronidase and lipase,[16] β-glucuronidase and chondroitin sulfatase,[35] aspartate aminotransferase and alkaline phosphatase,[106] amino acid decarboxylases,[35] catalase, peroxidase, and collagenase.[53]

Proteolytic enzymes in the saliva are generated by both the host and oral bacteria. These enzymes have been recognized as contributors to the initiation and progression of periodontal disease.[43,68] To combat these enzymes, saliva contains antiproteases that inhibit cysteine proteases such as cathepsins[45] and antileukoproteases that inhibit elastase.[78] Another antiprotease, which has been identified as a tissue inhibitor of matrix metalloproteinase, has been shown to inhibit the activity of collagen-degrading enzymes.[21]

High-molecular-weight mucinous glycoproteins in saliva bind specifically to many plaque-forming bacteria. The glycoprotein–bacteria interactions facilitate bacterial accumulation on the

exposed tooth surface.[28,31-33,109] The specificity of these interactions has been demonstrated. The interbacterial matrix of human plaque appears to contain polymers that are similar to salivary glycoproteins and that may aid in the maintenance of the integrity of plaque. In addition, these glycoproteins selectively adsorb to the hydroxyapatite to make up part of the acquired pellicle. Other salivary glycoproteins inhibit the sorption of some bacteria to the tooth surface and to epithelial cells of the oral mucosa. This activity appears to be associated with the glycoproteins that possess blood group reactivity.[1,28,31,33,107] Another effect of mucin is the deletion of bacterial cells from the oral cavity via aggregation with mucin-rich films.

Glycoproteins and a glycolipid that is present on mammalian cell surfaces appear to serve as receptors for the attachment of some viruses and bacteria. Thus, the close similarity between the glycoproteins of salivary secretions and the components of the epithelial cell surface suggests that the secretions can competitively inhibit antigen sorption and that they therefore may limit pathologic alterations.

Salivary Buffers and Coagulation Factors

The maintenance of the physiologic hydrogen ion concentration (pH) at the mucosal epithelial cell surface and the tooth surface is an important function of salivary buffers. The primary effect of these buffers has been studied in relationship to dental caries. In saliva, the most important salivary buffer is the bicarbonate–carbonic acid system.[67]

Saliva also contains coagulation factors (i.e., factors VIII, IX, and X; plasma thromboplastin antecedent; and Hageman factor) that hasten blood coagulation and that protect wounds from bacterial invasion.[58] An active fibrinolytic enzyme may also be present.

Leukocytes

In addition to desquamated epithelial cells, the saliva contains all forms of leukocytes, of which the principal cells are PMNs. The number of PMNs varies from person to person at different times of the day, and it is increased in the presence of gingivitis. PMNs reach the oral cavity by migrating through the lining of the gingival sulcus. Living PMNs in saliva are sometimes referred to as *orogranulocytes,* and their rate of migration into the oral cavity is termed the *orogranulocytic migratory rate.* Some investigators think that the rate of migration correlates with the severity of gingival inflammation and that it is therefore a reliable index for the assessment of gingivitis.[99]

Role in Periodontal Pathology

Saliva exerts a major influence on plaque initiation, maturation, and metabolism. Salivary flow and composition also influence calculus formation, periodontal disease, and caries. The removal of the salivary glands in experimental animals significantly increases the incidence of dental caries[34] and periodontal disease[40] in addition to delaying wound healing.[96]

In humans, an increase in inflammatory gingival diseases, dental caries, and rapid tooth destruction that is associated with cervical or cemental caries is partially a consequence of decreased salivary gland secretion (xerostomia). Xerostomia may result from sialolithiasis, sarcoidosis, Sjögren syndrome, Mikulicz disease, irradiation, the surgical removal of the salivary glands, and other factors (see Chapters 37 and 39).

Suggested Readings

Bader HJ, Goldhaber P: The passage of intravenously administered tetracycline in the gingival sulcus of dogs. *J Oral Ther* 2:324, 1966.

Brill N, Krasse B: The passage of tissue fluid into the clinically healthy gingival pocket. *Acta Odontol Scand* 16:223, 1958.

Bulkacz J: Enzymatic activities in gingival fluid with special emphasis on phospholipases. *J West Soc Periodontol Periodontal Abstr* 36:145, 1986.

Egelberg J: Cellular elements in gingival pocket fluid. *Acta Odontol Scand* 21:283, 1963.

Egelberg J: Gingival exudate measurements for evaluation of inflammatory changes of the gingiva. *Odont Rev* 15:381, 1964.

Lamster IB, Novak MJ: Host mediators in gingival crevicular fluid: implications for the pathogenesis of periodontal disease. *Crit Rev Oral Biol Med* 3:31, 1992.

Skougaard MR, Bay I, Klinkhamer JM: Correlation between gingivitis and orogranulocytic migratory rate. *J Dent Res* 48:716, 1994.

References

References for this chapter are found on the companion website www.expertconsult.com.

References

1. Adinolri M, Mollison PL, Polley MJ, et al: A blood group antibodies. *J Exp Med* 123:951, 1966.
2. Armitage G: Diagnostic tests for periodontal diseases. *Curr Opin Dent* 2:53, 1992.
3. Arnold R, Lunstad G, Bissada N, et al: Alterations in crevicular fluid flow during healing following gingival surgery. *J Periodontal Res* 1:303, 1966.
4. Attstrom R: Presence of leukocytes in the crevices of healthy and clinically inflamed gingiva. *J Periodontol* 5:42, 1970.
5. Attstrom R, Egelberg J: Emigration of blood neutrophils and monocytes into the gingival crevices. *J Periodontal Res* 5:48, 1970.
6. Bader HJ, Goldhaber P: The passage of intravenously administered tetracycline in the gingival sulcus of dogs. *J Oral Ther* 2:324, 1966.
7. Bang J, Cimasoni G: Total protein in human crevicular fluid. *J Dent Res* 50:1683, 1971.
8. Bissada NF, Schaffer EM, Haus E: Circadian periodicity of human crevicular fluid. *J Periodontol* 38:36, 1967.
9. Bjorn HL, Koch G, Lindhe J: Evaluation of gingival fluid measurements. *Odont Rev* 16:300, 1965.
10. Brill N: The gingival pocket fluid: studies of its occurrence, composition and effect. *Acta Odontol Scand* 20(Suppl 32):159, 1969.
11. Brill N: Effect of chewing on flow of tissue fluid into gingival pockets. *Acta Odontol Scand* 17:277, 1959.
12. Brill N, Bronnestam R: Immunoelectrophoretic study of tissue fluid from gingival pockets. *Acta Odontol Scand* 18:95, 1960.
13. Brill N, Krasse B: The passage of tissue fluid into the clinically healthy gingival pocket. *Acta Odontol Scand* 16:223, 1958.
14. Bulkacz J: Enzymatic activities in gingival fluid with special emphasis on phospholipases. *J West Soc Periodontol Periodontal Abstr* 36:145, 1986.
15. de Camargo PM, Miyasaki KT, Wolinsky LE: Host modulation of adherence: the effect of human neutrophil myeloperoxidase on the attachment of *Actinomyces viscosus* and *naeslundii* to saliva coated hydroxyapatite. *J Periodontal Res* 23:334, 1988.
16. Carlsson J, Egelberg J: Local effect of diet on plaque formation and development of gingivitis in dogs. II. Effect of high carbohydrate versus high protein/fat diets. *Odont Revy* 16:42, 1965.
17. Cattoni M: Lymphocytes in the epithelium of healthy gingiva. *J Dent Res* 30:627, 1951.
18. Challacombe SJ: Passage of serum immunoglobulin into the oral cavity. In Lehner T, Cimasoni G, editors: *Borderland between caries and periodontal disease*, vol 2, London, 1980, Academic Press.
19. Cimasoni G: The crevicular fluid. In Myers H, editor: *Monographs in oral science*, vol 3, Basel, 1974, S Karger.
20. Cimasoni G: Crevicular fluid updated. In Myers H, editor: *Monographs in oral science*, vol 12, Basel, 1983, S Karger.
21. Drouin L, Overall CM, Sodek J: Identification of matrix metalloendoproteinase inhibitor (TIMP) in human parotid and submandibular saliva: partial purification and characterization. *J Periodontal Res* 23:370, 1988.
22. Ebersole JL, Taubman MA, Smith DJ: Gingival crevicular fluid antibody to oral microorganisms. II. Distribution and specificity of local antibody responses. *J Periodontal Res* 20:349, 1985.
23. Egelberg J: Cellular elements in gingival pocket fluid. *Acta Odontol Scand* 21:283, 1963.
24. Egelberg J: Gingival exudate measurements for evaluation of inflammatory changes of the gingiva. *Odont Rev* 15:381, 1964.
25. Egelberg J: Permeability of the dentogingival vessels. II. Clinically healthy gingiva. *J Periodontal Res* 1:276, 1966.
26. Egelberg J, Attstrom R: Presence of leukocytes within crevices of healthy and inflamed gingiva and their immigration from the blood. *J Periodontal Res* 4(Suppl):23, 1969.
27. Eisenberg L, Suchow R, Coles RS, et al: The effects of metronidazole administration on clinical and microbiologic parameters of periodontal disease. *Clin Prev Dent* 13:28, 1991.
28. Ellen RP, Gibbons RJ: Protein associated adherence of *Streptococcus pyogenes* to epithelial surfaces: prerequisite for virulence. *Infect Immun* 5:826, 1972.
29. Garnick JJ, Pearson R, Harrell D: The evaluation of the Periotron. *J Periodontol* 50:424, 1979.
30. Genco RJ, Zambon JJ, Murray PA: Serum and gingival fluid antibodies as an adjunct in the diagnosis of *Actinobacillus actinomycetemcomitans*–associated periodontal disease. *J Periodontol* 56:41, 1985.
31. Gibbons RJ, van Houte J: Selective bacterial adherence to oral epithelial surfaces and its role as an ecological determinant. *Infect Immun* 3:567, 1971.
32. Gibbons RJ, van Houte J: On the formation of dental plaques. *J Periodontol* 44:347, 1973.
33. Gibbons RJ, van Houte J, Liljemark WF: Some parameters that affect the adherence of *S. salivarius* to oral epithelial surfaces. *J Dent Res* 51:424, 1972.
34. Gilda JE, Keyes PH: Increased dental caries activity in the Syrian hamster following desalivation. *Proc Soc Exp Biol Med* 66:28, 1947.
35. Gochman N, Meyer RK, Blackwell RQ, et al: The amino acid decarboxylase of salivary sediment. *J Dent Res* 38:998, 1959.
36. Golub LM, Borden SM, Kleinberg K: Urea content of gingival crevicular fluid and its relation to periodontal disease in humans. *J Periodontal Res* 6:243, 1971.
37. Gordon JM, Walker CB, Goodson JM, et al: Sensitive assay for measuring tetracycline levels in gingival crevice fluid. *Antimicrob Agents Chemother* 17:193, 1980.
38. Gowan M, Mundy GR: Actions of recombinant interleukin 1, interleukin 2 and interferon-gamma on bone resorption in vitro. *J Immunol* 136:2478, 1986.
39. Grant DA, Orban BJ: Leukocytes in the epithelial attachment. *J Periodontol* 31:87, 1960.
40. Gupta OH, Blechman H, Stahl SS: The effects of desalivation on periodontal tissues of the Syrian hamster. *Oral Surg Oral Med Oral Pathol* 13:470, 1960.
41. Hara K, Löe H: Carbohydrate components of the gingival exudate. *J Periodontal Res* 4:202, 1969.
42. Hasegawa K: Biochemical study of gingival fluid: lactic acid in gingival fluid. *Bull Tokyo Med Dent Univ* 14:359, 1967.
43. Holt SC, Bramanti TE: Factors in virulence expression and their role on periodontal disease pathogenesis. *Crit Rev Oral Biol Med* 2:177, 1991.
44. Iacono VC, Bolot PR, Mackay JB, et al: Lytic sensitivity of *Actinobacillus actinomycetemcomitans* to lysozyme. *Infect Immun* 40:773, 1983.
45. Isemura S, Ando K, Nakashizoka T, et al: Cystatin S: a cysteinproteinase inhibitor of human saliva. *J Biochem* 96:1311, 1984.
46. Jolles P, Petit JF: Purification and analysis of human saliva lysozyme. *Nature* 200:168, 1963.
47. Kahnberg KE, Lindhe J, Helden J: Initial gingivitis induced by topical application of plaque extract: a histometric study in dogs with normal gingiva. *J Periodontal Res* 11:218, 1976.
48. Kalmar JP, Arnold RP: Killing of *Actinobacillus actinomycetemcomitans* by human lactoferrin. *Infect Immun* 56:2552, 1988.
49. Kaslick RS, Mandel ID, Chasens AJ, et al: Concentration of inorganic ions in gingival fluid. *J Dent Res* 49:887, 1970.
50. Kaslick RS, Chasens AI, Mandel ID, et al: Quantitative analysis of sodium, potassium and calcium in gingival fluid from gingiva in varying degrees of inflammation. *J Periodontol* 41:93, 1970.
51. Kaslick RS, Chasens AI, Mandel ID, et al: Sodium, potassium and calcium in gingival fluid: a study of the relationship of the ions to one another, to circadian rhythms, gingival bleeding, purulence, and to conservative periodontal therapy. *J Periodontol* 41:442, 1970.
52. Kaslik RS, Chasens AI, Weinstein O, et al: Ultramicromethods for the collection of gingival fluid and quantitative analysis of its sodium content. *J Dent Res* 47:1192, 1986.
53. King JD: Experimental investigation of periodontal disease in the ferret and in man, with special reference to calculus formation. *Dent Pract* 4:157, 1954.

54. Kowolik MJ, Raeburn JA: Functional integrity of gingival crevicular neutrophil polymorphonuclear leukocytes as demonstrated by nitroblue tetrazolium reduction. *J Periodontal Res* 15:483, 1980.
55. Krekeler G: Quantitative determination of the gingival sulcus fluid by means of microcapillaries. *Dtsch Zahnaertzl Z* 30:544, 1975.
56. Lamster IB, Novak MJ: Host mediators in gingival crevicular fluid: implications for the pathogenesis of periodontal disease. *Crit Rev Oral Biol Med* 3:31, 1992.
57. Lamster IB, Celenti R, Ebersole J: The relationship of serum IgG antibody titers to periodontal pathogens to indicators of the host response in gingival crevicular fluid. *J Clin Periodontol* 17:419, 1990.
58. Leung SW, Jensen AT: Factors controlling the deposition of calculus. *Int Dent J* 8:613, 1958.
59. Liew V, Mack G, Tseng P, et al: Single-dose concentrations of timidazole in gingival crevicular fluid, serum and gingival tissue in adults with periodontitis. *J Dent Res* 70:910, 1991.
60. Life JS, Johnson NW, Powell JR, et al: Interleukin-1 beta (IL-1β) levels in gingival crevicular fluid from adults without previous evidence of destructive periodontitis: a cross sectional study. *J Clin Periodontol* 19:53, 1992.
61. Lindhe J, Attstrom R: Gingival exudation during the menstrual cycle. *J Periodontal Res* 2:194, 1967.
62. Lindhe J, Bjorn AL: Influence of hormonal contraceptives on the gingiva of women. *J Periodontal Res* 2:1, 1967.
63. Lindhe J, Attstrom R, Bjorn AL: Influence of sex hormones on gingival exudate of gingivitis-free female dogs. *J Periodontal Res* 3:273, 1968.
64. Löe H, Holm-Pedersen P: Absence and presence of fluid from normal and inflamed gingiva. *Periodontics* 3:171, 1965.
65. Magnusson B: Mucosal changes at erupting molars in germ-free rats. *J Periodontal Res* 4:181, 1969.
66. Marcus ER, Jooste CP, Driver HS, et al: The quantification of individual proteins in crevicular gingival fluid. *J Periodontal Res* 20:444, 1985.
67. Mandel I: Relation of saliva and plaque to caries. *J Dent Res* 53(Suppl):246, 1974.
68. Mandel ID: Markers of periodontal disease susceptibility and activity derived from saliva. In Johnson NW, editor: *Risk markers of oral diseases*, vol 3, New York, 1991, Cambridge University Press.
69. Martin LP, Noble WH: Gingival fluid in relation to tooth mobility and occlusal interferences. *J Periodontol* 45:444, 1974.
70. McDougall WA: Pathways of penetration and effects of horseradish peroxidase in rat molar gingiva. *Arch Oral Biol* 15:621, 1970.
71. McLaughlin WS, Lovat FM, Macgregor IDM, et al: The immediate effects of smoking on gingival fluid flow. *J Clin Periodontol* 20:448, 1993.
72. Miyasaki KT, Wilson ME, Genco RJ: Killing of *Actinobacillus actinomycetemcomitans* by the human peroxide chloride system. *Infect Immun* 53:161, 1986.
73. Muhlemann HR, Schroeder H: Dynamics of supragingival calculus formation. *Adv Oral Biol* 1:175, 1964.
74. Nagao M: Influence of prosthetic appliances upon the flow of crevicular tissue fluid. I. Relation between crevicular tissue fluid and prosthetic appliances. *Bull Tokyo Med Dent Univ* 14:241, 1967.
75. Nakamura M, Slots J: Salivary enzymes: origin and relationship to periodontal disease. *J Periodontal Res* 18:559, 1983.
76. Novaes AB, Jr, Ruben MP, Kramer GM: Proteins of the gingival exudate: a review and discussion of the literature. *J West Soc Periodontol Periodontal Abstr* 27:12, 1979.
77. Offenbacher S, Williams RC, Jeffcoat MK, et al: Effects of NSAIDs on beagle crevicular cyclo-oxygenase metabolites and periodontal bone loss. *J Periodontal Res* 27:207, 1992.
78. Ohlsson M, Rosengreen M, Tegner H, et al: Quantification of granulocyte elastase inhibitor in human mixed saliva and in pure parotid secretion. *Hoppe Seylers Z Physiol Chem* 364:1323, 1983.
79. Orban JE, Stallard RE: Gingival crevicular fluid: a reliable predictor of gingival health? *J Periodontol* 40:231, 1969.
80. Page RC: Host response tests designed for diagnosing periodontal disease. *J Periodontol* 63:356, 1992.
81. Passo SA, Tsai CC, McArthur WP, et al: Interaction of inflammatory cells and oral microorganisms. IX. The bacterial effect of human PMN leukocytes on isolated plaque microorganisms. *J Periodontal Res* 15:470, 1980.
82. Paunio K: On the hydroxyproline-containing components in the gingival exudate. *J Periodontal Res* 6:115, 1971.
83. Pollock JJ, Andors L, Gulumoglu A: Direct measurement of hepatitis B virus antibody and antigen markers in gingival crevicular fluid. *Oral Surg Oral Med Oral Pathol* 57:499, 1984.
84. Ranney RR, Montgomery EH: Vascular leakage resulting from topical application of endotoxin to the gingiva of the beagle dog. *Arch Oral Biol* 18:963, 1973.
85. Ranney RR, Zander HA: Allergic periodontal disease in sensitized squirrel monkeys. *J Periodontol* 41:12, 1970.
86. Ratcliff P: Permeability of healthy gingival epithelium by microscopically observable particles. *J Periodontol* 37:291, 1966.
87. Renggli HH: Phagocytosis and killing by crevicular neutrophils. In Lehner T, editor: *The borderland between caries and periodontal disease*, New York, 1977, Grune & Stratton.
88. Renggli HH, Regolatti B: Intracrevicular sampling of leukocytes using plastic strips. *Helv Odont Acta* 16:93, 1972.
89. Rizzo AA: Histologic and immunologic evaluation of antigen penetration into oral tissues after topical application. *J Periodontol* 41:210, 1970.
90. Rosebury R, Karshan M: *Salivary calculus: dental science and dental art*, Philadelphia, 1938, Lea & Febiger.
91. Rovin S, Costich ER, Gordon HA: The influence of bacteria and irritation in the initiation of periodontal disease in germfree and conventional rats. *J Periodontal Res* 1:193, 1966.
92. Salonen JI, Paunio KU: An intracrevicular washing method for collection of intracrevicular contents. *Scand J Dent Res* 99:406, 1961.
93. Sano K, Nakao M, Shiba A, et al: An ultra-micro assay for proteins in biological fluids other than blood using a combination of agarose gel isoelectric focusing and silver staining. *Clin Chim Acta* 137:115, 1984.
94. Schiott CR, Löe H: The origin and variation in the number of leukocytes in the human saliva. *J Periodontal Res* 4(Suppl):24, 1969.
95. Shapiro L, Goldman H, Bloom A: Sulcular exudate flow in gingival inflammation. *J Periodontol* 50:301, 1979.
96. Shen LS, Ghavamzadeh G, Shklar G: Gingival healing in sialadenectomized rats. *J Periodontol* 50:533, 1979.
97. Sibraa PD, Reinhardt AA, Dyer JK, et al: Acute-phase protein detection and quantification in gingival crevicular fluid by direct and indirect immuno-dot. *J Clin Periodontol* 18:101, 1991.
98. Simon B, Goldman HM, Ruben MP, et al: The role of endotoxin in periodontal disease. III. Correlation of the amount of endotoxin with the histologic degree of inflammation. *J Periodontol* 42:210, 1971.
99. Skougaard MR, Bay I, Klinkhamer JM: Correlation between gingivitis and orogranulocytic migratory rate. *J Dent Res* 48:716, 1994.
100. Solis Gaffar MC, Rustogi KN, Gaffar A: Hydrogen sulfide production from gingival crevicular fluid. *J Periodontol* 51:603, 1980.
101. Squier CA, Johnson NW: Permeability of oral mucosa. *Br Med Bull* 31:169, 1975.
102. Steinberg AD, Steinberg J, Allen P, et al: The effect of alteration in the sulcular environment upon the movement of 14C-diphenylhydantoin through rabbit sulcular tissues. *J Periodontal Res* 11:47, 1976.
103. Sueda T, Bang J, Cimasoni G: Collection of gingival fluid for quantitative analysis. *J Dent Res* 48:159, 1969.
104. Suppipat W, Suppipat N: Evaluation of an electronic device for gingival fluid quantitation. *J Periodontol* 48:388, 1977.
105. Talonopoika JT, Hamalainen MM: Collagen III aminoterminal propeptide in gingival crevicular fluid before and after periodontal disease. *Scand J Dent Res* 100:107, 1992.
106. Totan A, Greabu M, Totan C, et al: Salivary aspartate aminotransferase, alanine aminotransferase and alkaline phosphatase: possible markers in periodontal diseases? *Clin Chem Lab Med* 44:612, 2006.
107. Waerhaug J: The gingival pocket; anatomy, pathology, deepening and elimination. *Odontol Tidskr* 60(Suppl 1):1, 1952.

108. Weinstein E, Mandel ID, Salkind A, et al: Studies of gingival fluid. *Periodontics* 5:161, 1967.
109. Williams RW, Gibbons RG: Inhibition of bacterial adherence by secretory immunoglobulin A: a mechanism of antigen disposal. *Science* 177:697, 1972.
110. Wilton JMA, Renggli HH, Lehner T: The isolation and identification of mononuclear cells from the gingival crevice in man. *J Periodontal Res* 11:243, 1976.

CHAPTER 14

Gingival Inflammation

Joseph P. Fiorellini, David M. Kim, and Panagiota G. Stathopoulou

CHAPTER OUTLINE

Stage I Gingival Inflammation: The Initial Lesion
Stage II Gingival Inflammation: The Early Lesion
Stage III Gingival Inflammation: The Established Lesion
Stage IV Gingival Inflammation: The Advanced Lesion

The pathologic changes of gingivitis are associated with the presence of oral microorganisms attached to the tooth and perhaps in or near the gingival sulcus.

These organisms are capable of synthesizing products (e.g., collagenase, hyaluronidase, protease, chondroitin sulfatase, endotoxin) that cause damage to epithelial and connective tissue cells as well as to intercellular constituents such as collagen, ground substance, and glycocalyx (cell coat). The resultant widening of the spaces between the junctional epithelial cells during early gingivitis may permit injurious agents derived from bacteria or bacteria themselves to gain access to the connective tissue.[10,44,48] Microbial products activate monocytes and macrophages to produce vasoactive substances such as prostaglandin E2, interferon, tumor necrosis factor, and interleukin-1.[25,38] In addition, interleukin-1β alters the properties of gingival fibroblasts by delaying their death via mechanism-blocking apoptosis. This stabilizes the gingival fibroblast population during inflammation.[54]

Morphologic and functional changes in the gingiva during plaque accumulation have been thoroughly investigated, especially in beagle dogs and humans.[36] A useful framework for the organization and consideration of these data has been devised on the basis of histopathologic, radiographic, and ultrastructural features and biochemical measurements.[37,39] The sequence of events that culminates in clinically apparent gingivitis is categorized as the *initial, early,* and *established stages* of disease, with periodontitis designated as the *advanced stage*[38] (Table 14-1). One stage evolves into the next, with no clear-cut dividing lines.

Despite extensive research, we still cannot distinguish definitively between normal gingival tissue and the initial stage of gingivitis.[36] Most biopsies of clinically normal human gingiva contain inflammatory cells; these consist predominantly of T cells, with very few B cells or plasma cells.[36,49,50] These cells do not create tissue damage, but they appear to be important in the day-to-day host response to bacteria and other substances to which the gingiva is exposed.[36] Therefore, under normal conditions, a constant stream of neutrophils is migrating from the vessels of the gingival plexus through the junctional epithelium, to the gingival margin, and into the gingival sulcus and the oral cavity.[43]

Stage I Gingival Inflammation: The Initial Lesion

The first manifestations of gingival inflammation are vascular changes that consist of dilated capillaries and increased blood flow. These initial inflammatory changes occur in response to the microbial activation of resident leukocytes and the subsequent stimulation of endothelial cells. Clinically, this initial response of the gingiva to bacterial plaque (i.e., subclinical gingivitis[26]) is not apparent.

> Microscopically, some classic features of acute inflammation can be seen in the connective tissue beneath the junctional epithelium. Changes in blood vessel morphologic features (e.g., the widening of small capillaries or venules) and the adherence of neutrophils to vessel walls (margination) occur within 1 week and sometimes as early as 2 days after plaque has been allowed to accumulate[18,41] (Figure 14-1). Leukocytes—mainly polymorphonuclear neutrophils (PMNs)—leave the capillaries by migrating through the walls via diapedesis and emigration[25,50,51] (Figure 14-2). They can be seen in increased quantities in the connective tissue, the junctional epithelium, and the gingival sulcus[2,3,24,34,41,45,46] (Figures 14-3 and 14-4). The exudation of fluid from the gingival sulcus[18] and extravascular proteins are present.[20,21]

However, these findings are not accompanied by manifestations of tissue damage that are perceptible at the light microscopic or ultrastructural level; they do not form an infiltrate, and their presence is not considered to indicate pathologic change.[36]

Subtle changes can also be detected in the junctional epithelium and the perivascular connective tissue at this early stage. For example, the perivascular connective tissue matrix becomes altered, and there is exudation and deposition of fibrin in the affected area.[36] In addition, lymphocytes soon begin to accumulate (see Figure 14-2, *D*). The increase in the migration of leukocytes and their accumulation within the gingival sulcus may be correlated with an increase in the flow of gingival fluid into the sulcus.[4]

TABLE 14-1 Stages of Gingivitis

Stage	Time (Days)	Blood Vessels	Junctional and Sulcular Epithelia	Predominant Immune Cells	Collagen	Clinical Findings
I. Initial lesion	2 to 4	Vascular dilation Vasculitis	Infiltration by PMNs	PMNs	Perivascular loss	Gingival fluid flow
II. Early lesion	4 to 7	Vascular proliferation	Same as stage I Rete pegs Atrophic areas	Lymphocytes	Increased loss around infiltrate	Erythema Bleeding on probing
III. Established lesion	14 to 21	Same as stage II, plus blood stasis	Same as stage II but more advanced	Plasma cells	Continued loss	Changes in color, size, texture, and so on

PMNs, Polymorphonuclear leukocytes (neutrophils).

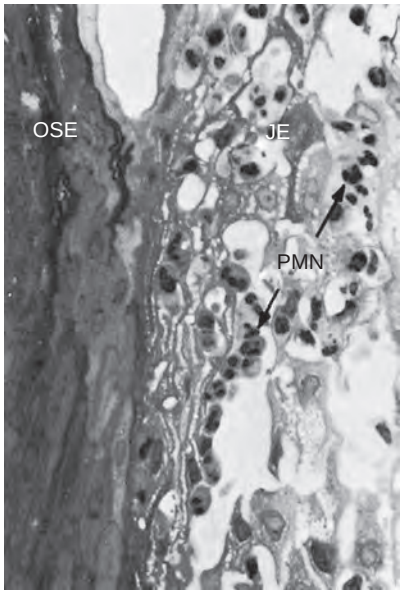

Figure 14-1 Human biopsy sample, experimental gingivitis. After 4 days of plaque accumulation, the blood vessels immediately adjacent to the junctional epithelium are distended and contain polymorphonuclear leukocytes (neutrophils) *(PMNs)*. Neutrophils have also migrated between the cells of the junctional epithelium *(JE). OSE,* Oral sulcular epithelium. (×500.) *(From Payne WA, Page RC, Ogilvie AL, et al:* J Periodontal Res *10:51, 1975.)*

The character and intensity of the host response determine whether this *initial lesion* resolves rapidly, with the restoration of the tissue to a normal state; alternatively, it may evolve into a chronic inflammatory lesion. If the latter occurs, an infiltrate of macrophages and lymphoid cells appears within a few days.

Stage II Gingival Inflammation: The Early Lesion

The *early lesion* evolves from the *initial lesion* within about 1 week after the beginning of plaque accumulation.[35,41] Clinically, the early lesion may appear as early gingivitis, and it overlaps with and evolves from the initial lesion with no clear-cut dividing line. As time goes on, clinical signs of erythema may appear, mainly because of the proliferation of capillaries and the increased formation of capillary loops between rete pegs or ridges (Figure 14-5). Bleeding on probing may also be evident.[1] Gingival fluid flow and the numbers of transmigrating leukocytes reach their maximum between 6 and 12 days after the onset of clinical gingivitis.[26]

Microscopic examination of the gingiva reveals leukocyte infiltration in the connective tissue beneath the junctional epithelium, which consists mainly of lymphocytes (75%, with the majority being T cells)[41,47] but that also includes some migrating neutrophils as well as macrophages, plasma cells, and mast cells. All of the changes seen in the initial lesion continue to intensify with the early lesion.[15,28,30,35,47] The junctional epithelium becomes densely infiltrated with neutrophils, as does the gingival sulcus, and the junctional epithelium may begin to show the development of rete pegs or ridges.

The amount of collagen destruction also increases[12,28,47]; 70% of the collagen is destroyed around the cellular infiltrate. The main fiber groups that are affected appear to be the circular and dentogingival fiber assemblies. Alterations in blood vessel morphologic features and vascular bed patterns have also been described.[18,19]

PMNs that have left the blood vessels in response to chemotactic stimuli from plaque components travel to the epithelium and cross the basement lamina; they are found in the epithelium, emerging in the pocket area (see Figure 14-3). PMNs are attracted to bacteria and engulf them during the process of phagocytosis (Figure 14-6). PMNs release their lysosomes in association with the ingestion of bacteria.[23] Fibroblasts show cytotoxic alterations,[40] with a decreased capacity for collagen.

Meanwhile, on the opposite side of molecular events, collagen degradation is related to matrix metalloproteinases (MMPs). Different MMPs are responsible for extracellular matrix remodeling within 7 days of inflammation, which is directly related to MMP-2 and MMP-9 production and activation.[54]

Stage III Gingival Inflammation: The Established Lesion

Over time, the *established lesion* evolves. It is characterized by a predominance of plasma cells and B lymphocytes, and it is probably in conjunction with the creation of a small gingival pocket lined with a pocket epithelium.[46] The B cells that are found in the established lesion are predominantly of the immunoglobulin G1 and G3 subclasses.[36]

With chronic gingivitis, which occurs 2 to 3 weeks after the beginning of plaque accumulation, the blood vessels become engorged and congested, venous return is impaired, and the blood flow becomes sluggish (Figure 14-7). The result is localized gingival *anoxemia,* which superimposes a somewhat bluish hue on the reddened gingiva.[17] The extravasation of erythrocytes into the connective tissue and the breakdown of hemoglobin into its component

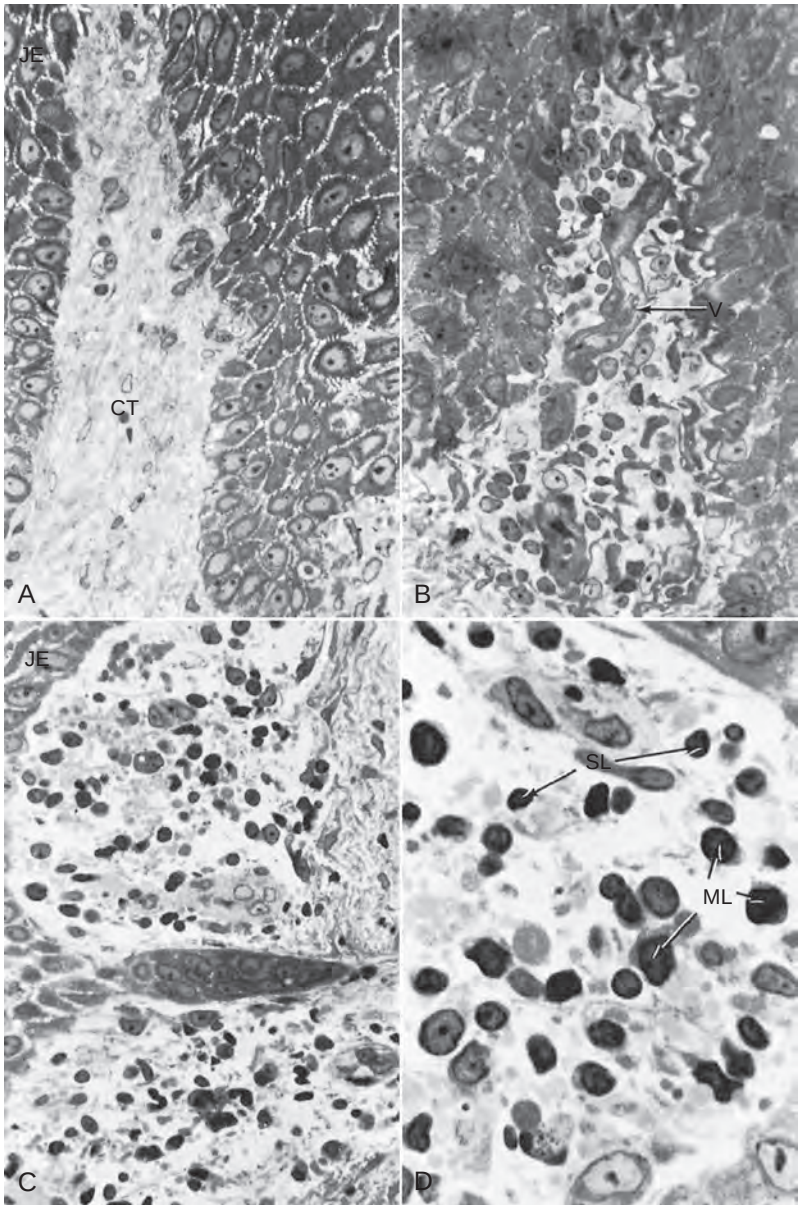

Figure 14-2 Human biopsy, experimental gingivitis. **A,** Control biopsy specimen from a patient with good oral hygiene and no detectable plaque accumulation. The junctional epithelium is on the left. The connective tissue *(CT)* shows few cells other than fibroblasts, blood vessels, and a dense background of collagen fibers. (×500.) **B,** Biopsy specimen taken after 8 days of plaque accumulation. The connective tissue is infiltrated with inflammatory cells, which displace the collagen fibers. A distended blood vessel *(V)* is seen in the center. (×500.) **C,** After 8 days of plaque accumulation, the connective tissue next to the junctional epithelium at the base of the sulcus shows a mononuclear cell infiltrate and evidence of collagen degeneration (i.e., clear spaces around the cellular infiltrate). (×500.) **D,** The inflammatory cell infiltrate at higher magnification (×1250). After 8 days of plaque accumulation, numerous small *(SL)* and medium-sized *(ML)* lymphocytes are seen within the connective tissue. Most of the collagen fibers around these cells have disappeared, presumably as a result of enzymatic digestion. *(From Payne WA, Page RC, Ogilvie AL, et al:* J Periodontal Res *10:51, 1975.)*

pigments can also deepen the color of the chronically inflamed gingiva. The established lesion can be described as moderately to severely inflamed gingiva.

In histologic sections, an intense and chronic inflammatory reaction is observed. Several detailed cytologic studies have been performed on chronically inflamed gingiva.[13-15,40,46,49,53] A key feature that differentiates the established lesion is the increased number of plasma cells, which become the preponderant inflammatory cell type. Plasma cells invade the connective tissue not only immediately below the junctional epithelium but also deep into the connective tissue, around the blood vessels, and between the bundles of collagen fibers.[6] The junctional epithelium reveals widened intercellular spaces that are filled with granular cellular debris, including lysosomes derived from disrupted neutrophils, lymphocytes, and monocytes (Figure 14-8). The lysosomes contain acid hydrolases that can destroy tissue components. The junctional epithelium develops rete pegs or ridges that protrude into the connective tissue, and the basal lamina is destroyed in some areas. In the connective tissue, collagen fibers are destroyed around the infiltrate of intact and disrupted plasma cells, neutrophils, lymphocytes, monocytes, and mast cells (Figure 14-9).

The predominance of plasma cells is thought to be a primary characteristic of the established lesion. However, several studies of human experimental gingivitis have failed to demonstrate plasma cell predominance in the affected connective tissues,[7,8,49] including one study of 6 months' duration.[1] Increases in the proportions of plasma cells were evident with longstanding gingivitis, but the time for the development of the classic "established lesion" may exceed 6 months.

An inverse relationship appears to exist between the number of intact collagen bundles and the number of inflammatory cells.[51]

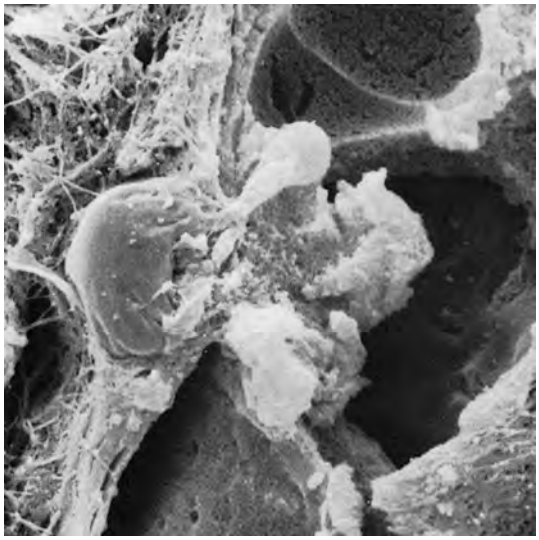

Figure 14-3 Scanning electron micrograph showing a leukocyte traversing the vessel wall to enter into the gingival connective tissue.

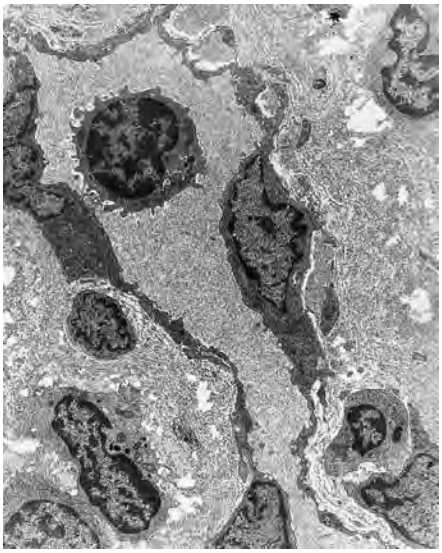

Figure 14-4 Early human gingivitis lesion. There is an area of lamina propria subjacent to the crevicular epithelium that shows a capillary with several extravascular lymphocytes and one lymphocyte within the lumen. The specimen also exhibits a considerable loss of perivascular collagen density. (×2500.) *(Courtesy Dr. Charles Cobb, Kansas City, MO.)*

Figure 14-5 Marginal gingivitis and irregular gingival contour.



Figure 14-6 Scanning electron micrograph of a leukocyte emerging to the pocket wall and covered with bacteria and extracellular lysosomes. *B,* Bacteria; *EC,* epithelial cells; *L,* lysosomes.

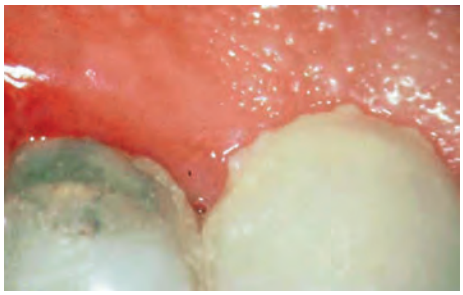

Figure 14-7 Marginal supragingival plaque and gingivitis.

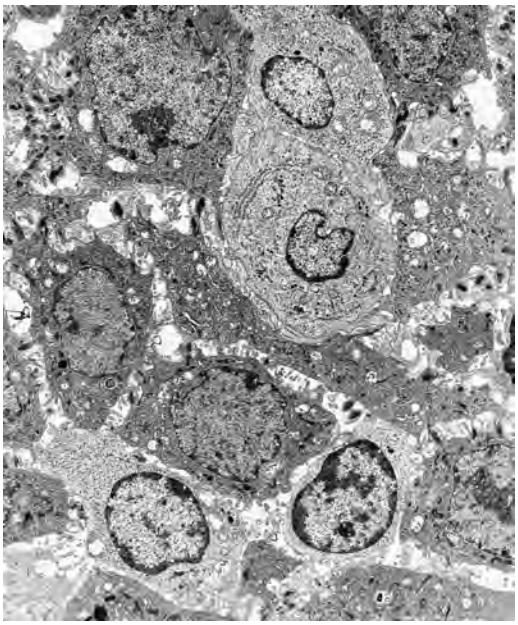

Figure 14-8 Established gingivitis in a human subject. An area of crevicular epithelium exhibits enlarged intercellular spaces with numerous microvilli and desmosomal junctions. Several lymphocytes, both small and large, are seen migrating through the epithelial layer. (×3000.)

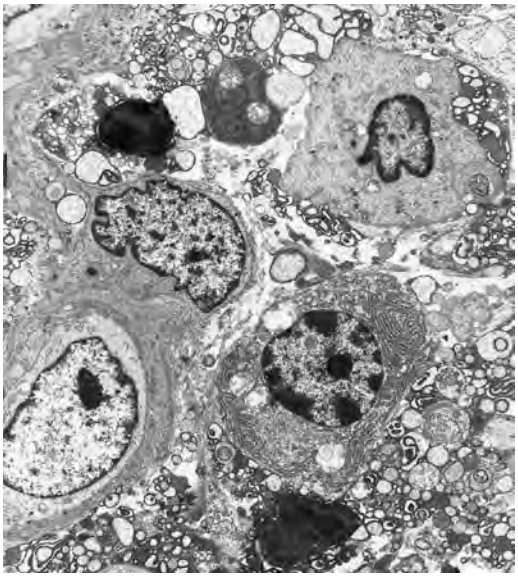

Figure 14-9 Advanced gingivitis in a human subject. This specimen from the lamina propria exhibits plasma cell degeneration, with abundant cellular debris visible. (×3000.) *(Courtesy Dr. Charles Cobb, Kansas City, MO.)*

Collagenolytic activity is increased in inflamed gingival tissue[16] by the enzyme collagenase. Collagenase is normally present in gingival tissues[5]; it is produced by some oral bacteria and by PMNs.

Enzyme histochemistry studies have shown that chronically inflamed gingivae have elevated levels of acid and alkaline phosphatase,[55] β-glucuronidase, β-glucosidase, β-galactosidase, esterases,[29] aminopeptidase,[33,42] and cytochrome oxidase.[9] Neutral mucopolysaccharide levels are decreased,[53] presumably as a result of degradation of the ground substance.

Established lesions of two types appear to exist; some remain stable and do not progress for months or years,[32,33,52] and others seem to become more active and to convert to progressively destructive lesions. In addition, the established lesions appear to be reversible in that the sequence of events that occurs in the tissues as a result of successful periodontal therapy seems to be essentially the reverse of the sequence of events observed as gingivitis develops. As the flora reverts from that characteristically associated with destructive lesions to that associated with periodontal health, the percentage of plasma cells decreases greatly, and the lymphocyte population increases proportionately.[27,31]

Stage IV Gingival Inflammation: The Advanced Lesion

The extension of the lesion into alveolar bone characterizes the fourth stage, which is known as the *advanced lesion*[40] or *phase of periodontal breakdown.*[26] This is described in detail in Chapters 21 and 23.

> Microscopically, fibrosis of the gingiva is present, and there are widespread manifestations of inflammatory and immunopathologic tissue damage.[36] At the advanced stage, the presence of plasma cells dominates the connective tissue, and neutrophils continue dominating the junctional epithelium.

Patients with experimental gingivitis had significantly more plaque accumulation, higher interleukin-1β levels, and lower interleukin-8 concentrations at 28 days.[11]

Gingivitis will progress to periodontitis only in individuals who are susceptible. Patients who had sites with consistent bleeding (gingival index = 2) had 70% more attachment loss as compared with sites that were not inflamed consistently (gingival index = 0). Teeth with noninflamed sites consistently had a 50-year survival rate of 99.5%, whereas teeth with consistently inflamed gingiva had a 63.4% survival rate over 50 years. On the basis of this longitudinal study of the natural history of periodontitis in a well-maintained male population, persistent gingivitis represents a risk factor for periodontal attachment loss and for tooth loss.[22] However, whether periodontitis can occur without a precursor of gingivitis is not known at this time.

Suggested Readings

Deinzer R, Weik U, Kolb-Bachofen V, et al: Comparison of experimental gingivitis with persistent gingivitis: differences in clinical parameters and cytokine concentrations. *J Periodontal Res* 2(4):318–324, 2007.

Lang NP, Schätzle MA, Löe H: Gingivitis as a risk factor in periodontal disease. *J Clin Periodontol* 36(Suppl 10):3–8, 2009.

Listgarten MA, Hellden L: Relative distribution of bacteria at clinically healthy and periodontal diseased sites in humans. *J Clin Periodontol* 5:115, 1978.

Lorencini M, Silva JA, de la Hoz CL, et al: Changes in MMPs and inflammatory cells in experimental gingivitis. *Histol Histopathol* 24(2):157–166, 2009.

Page RC, Schroeder HE: Pathogenesis of inflammatory periodontal disease: a summary of current work. *Lab Invest* 34:235, 1976.

References

References for this chapter are found on the companion website www.expertconsult.com.

References

1. Amato R, Caton J, Polson A, et al: Interproximal gingival inflammation related to the conversion of a bleeding to a nonbleeding state. *J Periodontol* 57:63, 1986.
2. Attström R: Studies on neutrophil polymorphonuclear leukocytes at the dento-gingival junction in gingival health and disease. *J Periodontal Res* 8(Suppl):1, 1971.
3. Attström R: The roles of gingival epithelium and phagocytosing leukocytes in gingival defense. *J Clin Periodontol* 2:25, 1975.
4. Attström R, Egelberg J: Emigration of blood neutrophils and monocytes into the gingival crevices. *J Periodontal Res* 5:48, 1970.
5. Beutner EH, Triftshauser C, Hazen SP: Collagenase activity of gingival tissue from patients with periodontal disease. *Proc Soc Exp Biol Med* 121:1082, 1966.
6. Brecx MC: Histophysiology and histopathology of the gingiva. *J West Soc Periodontol* 39:33, 1991.
7. Brecx MC, Frohlicher I, Gehr P, et al: Stereological observations on long-term experimental gingivitis in man. *J Clin Periodontol* 15:621, 1988.
8. Brecx MC, Lehmann B, Siegwart CM, et al: Observations on the initial stages of healing following human experimental gingivitis: a clinical and morphometric study. *J Clin Periodontol* 15:123, 1988.
9. Burstone MS: Histochemical study of cytochrome oxidase in normal and inflamed gingiva. *Oral Surg Oral Med Oral Pathol* 13:1501, 1960.
10. Caffesse RG, Nasjleti CE: Enzymatic penetration through intact sulcular epithelium. *J Periodontol* 47:391, 1976.
11. Deinzer R, Weik U, Kolb-Bachofen V, et al: Comparison of experimental gingivitis with persistent gingivitis: differences in clinical parameters and cytokine concentrations. *J Periodontal Res* 2(4):318–324, 2007.
12. Flieder DE, Sun CN, Schneider BC: Chemistry of normal and inflamed human gingival tissues. *Periodontics* 4:302, 1966.
13. Freedman HL, Listgarten MA, Taichman NS: Electron microscopic features of chronically inflamed human gingiva. *J Periodontal Res* 3:313, 1968.
14. Garant PR, Mulvihill JE: The fine structure of gingivitis in the beagle. III. Plasma cell infiltration of the subepithelial connective tissue. *J Periodontal Res* 7:161, 1971.
15. Gavin JB: Ultrastructural features of chronic marginal gingivitis. *J Periodontal Res* 5:19, 1970.
16. Hancock EB, Cray RJ, O'Leary TJ: The relationship between gingival crevicular fluid and gingival inflammation: a clinical and histologic study. *J Periodontol* 50:13, 1979.
17. Hanioka T, Shizukuishi S, Tsunemitsu A: Changes in hemoglobin concentration and oxygen saturation in human gingiva with decreasing inflammation. *J Periodontol* 62:366, 1991.
18. Hock J, Nuki K: A vital microscopy study of the morphology of normal and inflamed gingiva. *J Periodontal Res* 6:81, 1971.
19. Kindlova M: Changes in the vascular bed of the marginal periodontium in periodontitis. *J Dent Res* 44:456, 1965.
20. Lamster IB, Hartley LJ, Vogel RI: Development of a biochemical profile for gingival crevicular fluid: methodological considerations and evaluation of collagen-degrading and ground substance-degrading enzyme activity during experimental gingivitis. *J Periodontol* 56:13, 1985.
21. Lamster IB, Vogel RI, Hartley LJ, et al: Lactate dehydrogenase, beta-glucuronidase and arylsulfatase activity in gingival crevicular fluid associated with experimental gingivitis in man. *J Periodontol* 56:139, 1985.
22. Lang NP, Schätzle MA, Löe H: Gingivitis as a risk factor in periodontal disease. *J Clin Periodontol* 36(Suppl 10):3–8, 2009.
23. Lange D, Schroeder HE: Cytochemistry and ultrastructure of gingival sulcus cells. *Helv Odontol Acta* 15:65, 1971.
24. Levy BM, Taylor AC, Bernick S: Relationship between epithelium and connective tissue in gingival inflammation. *J Dent Res* 48:625, 1969.
25. Lindhe J, Socransky SS: Chemotaxis and vascular permeability produced by human periodontopathic bacteria. *J Periodontal Res* 14:138, 1979.
26. Lindhe J, Hamp SE, Löe H: Experimental periodontitis in the beagle dog. *Int Dent J* 23:432, 1973.
27. Lindhe J, Parodi R, Liljenberg B, et al: Clinical and structural alterations characterizing healing gingiva. *J Periodontal Res* 13:410, 1978.
28. Lindhe J, Schroeder HE, Page RC, et al: Clinical and stereologic analysis of the course of early gingivitis in dogs. *J Periodontal Res* 9:314, 1974.
29. Lisanti VF: Hydrolytic enzymes in periodontal tissues. *Ann N Y Acad Sci* 85:461, 1960.
30. Listgarten MA, Ellegaard B: Experimental gingivitis in the monkeys: relationship of leukocyte counts in junctional epithelium, sulcus depth, and connective tissue inflammation scores. *J Periodontal Res* 8:199, 1973.
31. Listgarten MA, Hellden L: Relative distribution of bacteria at clinically healthy and periodontal diseased sites in humans. *J Clin Periodontol* 5:115, 1978.
32. Lovdal A, Arno A, Waerhaug J: Incidence of clinical manifestations of periodontal disease in light of oral hygiene and calculus formation. *J Am Dent Assoc* 56:21, 1958.
33. Mori M, Kishiro A: Histochemical observation of aminopeptidase activity in the normal and inflamed oral epithelium. *J Osaka Univ Dent School* 1:39, 1961.
34. Oliver RC, Holm-Pederen P, Löe H: The correlation between clinical scoring, exudate measurements and microscopic evaluation of inflammation in the gingiva. *J Periodontol* 40:201, 1969.
35. Page RC: The role of inflammatory mediators in the pathogenesis of periodontal disease. *J Periodontal Res* 26:230, 1991.
36. Page RC: Gingivitis. *J Clin Periodontol* 13:345, 1986.
37. Page RC, Schroeder HE: Pathogenesis of inflammatory periodontal disease: a summary of current work. *Lab Invest* 34:235, 1976.
38. Page RC, Schroeder HE: Pathogenic mechanisms. In Schluger S, Youdelis R, Page RC, editors: *Periodontal disease: basic phenomena, clinical management and restorative interrelationships*, Philadelphia, 1977, Lea & Febiger.
39. Page RC, Schroeder HE: *Periodontitis in man and other animals: a comparative review*, Basel, 1982, S Karger.
40. Page RC, Simpson DM, Ammons WF: Host tissue response in chronic inflammatory periodontal disease. IV. The periodontal and dental status of a group of aged great apes. *J Periodontol* 46:144, 1975.
41. Payne WA, Page RC, Ogilvie AL, et al: Histopathologic features of the initial and early stages of experimental gingivitis in man. *J Periodontal Res* 10:51, 1975.
42. Quintarelli G: Histochemistry of the gingiva. III. The distribution of amino-peptidase in normal and inflammatory conditions. *Arch Oral Biol* 2:271, 1960.
43. Ryder MI: Histological ultrastructural characteristics of the periodontal syndrome in the rice rat. I. General light microscopic observations and ultrastructural observations of initial inflammatory changes. *J Periodontal Res* 15:502, 1980.
44. Saglie R, Newman MG, Carranza FA, Jr, et al: Bacterial invasion of gingiva in advanced periodontitis in humans. *J Periodontol* 53:217, 1982.
45. Schroeder HE: Transmigration and infiltration of leucocytes in human junctional epithelium. *Helv Odontol Acta* 17:6, 1973.
46. Schroeder HE, Graf-de Beer M, Attström R: Initial gingivitis in dogs. *J Periodontal Res* 10:128, 1975.
47. Schroeder HE, Munzel-Pedrazzoli S, Page RC: Correlated morphometric and biochemical analysis of gingival tissue in early chronic gingivitis in man. *Arch Oral Biol* 18:899, 1973.
48. Schwartz J, Stinson FL, Parker RB: The passage of tritiated bacterial endotoxin across intact gingival crevicular epithelium. *J Periodontol* 43:270, 1972.
49. Seymour GJ, Powell RN, Aitken JF: Experimental gingivitis in humans: a clinical and histological investigation. *J Periodontol* 54:522, 1983.
50. Seymour GJ, Powell RN, Cole KL, et al: Experimental gingivitis in humans: a histochemical and immunological characterization of the lymphoid cell subpopulations. *J Periodontal Res* 18:375, 1983.

51. Simpson DM, Avery BE: Histopathologic and ultrastructural features of inflamed gingiva in the baboon. *J Periodontol* 45:500, 1974.
52. Suomi JD, Smith LW, McClendon BJ: Marginal gingivitis during a sixteen-week period. *J Periodontol* 42:268, 1971.
53. Thilander H: Epithelial changes in gingivitis: an electron microscopic study. *J Periodontal Res* 3:303, 1968.
54. Vardar-Sengul S, Arora S, Baylas H, et al: Expression profile of human gingival fibroblasts induced by interleukin-1beta reveals central role of nuclear factor-kappa B in stabilizing human gingival fibroblasts during inflammation. *J Periodontol* 80(5):833–849, 2009.
55. Winer RA, O'Donnell LJ, Chauncey HH, et al: Enzyme activity in periodontal disease. *J Periodontol* 41:449, 1970.

CHAPTER 15

Clinical Features of Gingivitis

Joseph P. Fiorellini and Panagiota G. Stathopoulou

CHAPTER OUTLINE

Course and Duration
Description
Clinical Findings
Gingival Bleeding on Probing
Gingival Bleeding Caused by Local Factors
Gingival Bleeding Associated with Systemic Changes
Color Changes in the Gingiva
Color Changes Associated with Systemic Factors
Changes in the Consistency of the Gingiva
Changes in the Surface Texture of the Gingiva
Changes in the Position of the Gingiva
Changes in Gingival Contour

Experimental gingivitis studies provided the first empiric evidence that the accumulation of microbial biofilm on clean tooth surfaces results in the development of an inflammatory process around gingival tissue.[41,69] Research has also shown that the local inflammation will persist as long as the microbial biofilm is present adjacent to the gingival tissues and that the inflammation may resolve subsequent to a meticulous removal of the biofilm.[69]

The prevalence of gingivitis is evident worldwide. For example, epidemiologic studies indicate that more than 82% of adolescents in the United States have overt gingivitis and signs of gingival bleeding. A similar or higher prevalence of gingivitis is reported for children and adolescents in other parts of the world.[7] A significant percentage of adults also show signs of gingivitis; more than half of the US adult population is estimated to exhibit gingival bleeding, and other populations show even higher levels of gingival inflammation.[3,5,6,8,66] Whereas plaque remains the primary etiological factor that causes gingivitis, other factors may affect the development of periodontal diseases. Recent experimental gingivitis studies suggest an important role of the host response in the development and degree of gingival inflammation.[81]

In general, clinical features of gingivitis may be characterized by the presence of any of the following clinical signs: redness and sponginess of the gingival tissue, bleeding on provocation, changes in contour, and the presence of calculus or plaque with no radiographic evidence of crestal bone loss.[10] The histologic examination of inflamed gingival tissue reveals ulcerated epithelium. The presence of inflammatory mediators negatively affects epithelial function as a protective barrier. Repair of this ulcerated epithelium depends on the proliferative or regenerative activity of the epithelial cells. Removal of the etiologic agents that triggered the gingival breakdown is essential.

Course and Duration

Gingivitis can occur with sudden onset and short duration, and it can be painful. A less severe phase of this condition can also occur.

Chronic gingivitis is slow in onset and of long duration. It is painless, unless it is complicated by acute or subacute exacerbations, and it is the type that is most often encountered (Figure 15-1). Chronic gingivitis is a fluctuating disease in which inflammation persists or resolves and in which normal areas become inflamed.[30,36]

Recurrent gingivitis reappears after having been eliminated by treatment or disappearing spontaneously.

Description

Localized gingivitis is confined to the gingiva of a single tooth or group of teeth, whereas *generalized gingivitis* involves the entire mouth.

Marginal gingivitis involves the gingival margin, and it may include a portion of the contiguous attached gingiva. *Papillary gingivitis* involves the interdental papillae, and it often extends into the adjacent portion of the gingival margin. Papillae are involved more frequently than the gingival margin, and the earliest signs of gingivitis often occur in the papillae. *Diffuse gingivitis* affects the gingival margin, the attached gingiva, and the interdental papillae. Gingival disease in individual cases is described by combining the preceding terms as follows:

- *Localized marginal gingivitis* is confined to one or more areas of the marginal gingiva (Figure 15-2).
- *Localized diffuse gingivitis* extends from the margin to the mucobuccal fold in a limited area (Figure 15-3).
- *Localized papillary gingivitis* is confined to one or more interdental spaces in a limited area (Figure 15-4).
- *Generalized marginal gingivitis* involves the gingival margins in relation to all the teeth. The interdental papillae are usually affected (Figure 15-5).
- *Generalized diffuse gingivitis* involves the entire gingiva. The alveolar mucosa and the attached gingiva are affected, so the mucogingival junction is sometimes obliterated (Figure 15-6). Systemic conditions can be involved in the cause of generalized diffuse gingivitis and should be evaluated if they are suspected as an etiologic cofactor.

Clinical Findings

A *systematic* approach is required for the evaluation of the clinical features of gingivitis. The clinician should focus on subtle tissue alterations, because these may be of diagnostic significance. A

Figure 15-1 Chronic gingivitis. The marginal and interdental gingivae are smooth, edematous, and discolored. Isolated areas of acute response are seen.

Figure 15-2 Localized, diffuse, intensely red area on the facial surface of tooth #7 and dark-pink marginal changes in the remaining anterior teeth.

Figure 15-3 Generalized marginal gingivitis in the upper jaw with areas of diffuse gingivitis.

Figure 15-4 Generalized papillary gingivitis.

systematic clinical approach requires an orderly examination of the gingiva for color, contour, consistency, position, and ease and severity of bleeding and pain. This section discusses these clinical characteristics and the microscopic changes that are responsible for each.

Figure 15-5 Generalized marginal and papillary gingivitis.

Figure 15-6 Generalized diffuse gingivitis involves the marginal, papillary, and attached gingivae.

Gingival Bleeding on Probing

The two earliest signs of gingival inflammation that precede established gingivitis are as follows: (1) increased gingival crevicular fluid production rate; and (2) bleeding from the gingival sulcus on gentle probing (Figure 15-7). Chapter 13 discusses gingival crevicular fluid in detail.

Gingival bleeding varies with regard to severity, duration, and ease of provocation. Bleeding on probing is easily detected clinically and therefore is of value for the early diagnosis and prevention of more advanced gingivitis. It has been shown that bleeding on probing appears earlier than a change in color or other visual signs of inflammation[36,37,46]; in addition, the use of bleeding rather than color changes to diagnose early gingival inflammation is advantageous in that bleeding is a more objective sign that requires less subjective estimation by the examiner. For example, it is estimated that 53.2 million (50.3%) US adults who are 30 years old and older exhibit gingival bleeding.[6] Probing pocket depth measurements by themselves are of limited value for the assessment of the extent and severity of gingivitis. For example, gingival recession may result in a reduction of the probing depth and thus cause an inaccurate assessment of the periodontal status.[4] Therefore, bleeding on probing is widely used by clinicians and epidemiologists to measure disease prevalence and progression, to measure outcomes of treatment, and to motivate patients to perform necessary home care.[24] Several gingival indices that are based on bleeding have been developed,[2,16,53] as described in Chapter 4. (For further considerations of probing, see Chapter 29.)

In general, gingival bleeding on probing indicates an inflammatory lesion both in the epithelium and in the connective tissue that exhibits specific histologic differences as compared with healthy gingiva.[25] Even though gingival bleeding on probing may not be a good diagnostic indicator for clinical attachment loss, its absence is an excellent negative predictor of future attachment loss.[34] Therefore, the absence of gingival bleeding on probing is desirable and implies a low risk of future clinical attachment loss. Longitudinal findings revealed that sites with consistent bleeding (gingival

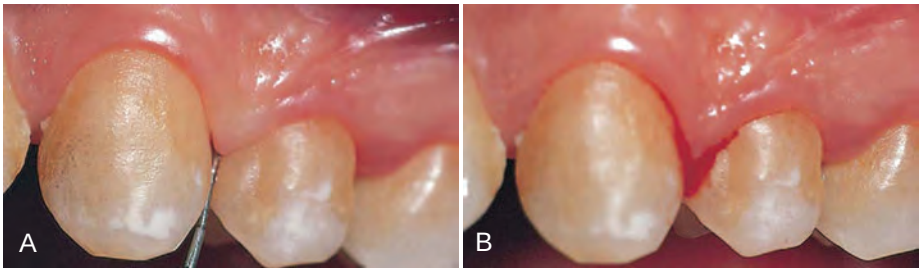

Figure 15-7 Bleeding on probing. **A,** Mild edematous gingivitis; a probe has been introduced to the bottom of the gingival sulcus. **B,** Bleeding appears after a few seconds.

index = 2) had 70% more attachment loss than sites that were noninflamed over a 26-year period in 565 males. Thus, persistent gingivitis can be considered as a risk factor for periodontal attachment loss that may lead to tooth loss.[35]

Interestingly, numerous studies have shown that current cigarette smoking suppresses the gingival inflammatory response, and smoking was found to exert a strong, chronic, dose-dependent suppressive effect on gingival bleeding with probing in the Third National Health and Nutrition Examination Survey.[19] In addition, recent research reveals an increase in gingival bleeding with probing in patients who quit smoking.[54] Thus, people who are committed to a smoking cessation program should be informed about the possibility of an increase in gingival bleeding associated with smoking cessation.

Gingival Bleeding Caused by Local Factors

Factors that contribute to plaque retention and that may lead to gingivitis include anatomic and developmental tooth variations, caries, frenum pull, iatrogenic factors, malpositioned teeth, mouth breathing, overhangs, partial dentures, lack of attached gingiva, and recession. In addition, orthodontic treatment and fixed retainers were associated with increased plaque retention and increased bleeding on probing.[38,78]

Chronic and Recurrent Bleeding. The most common cause of abnormal gingival bleeding on probing is chronic inflammation.[50] The bleeding is chronic or recurrent, and it is provoked by mechanical trauma (e.g., from toothbrushing, toothpicks, or food impaction) or by biting into solid foods (e.g., apples).

In gingival inflammation, histopathologic alterations that result in abnormal gingival bleeding include dilation and engorgement of the capillaries and thinning or ulceration of the sulcular epithelium (Figure 15-8). Because the capillaries are engorged and closer to the surface and because the thinned, degenerated epithelium is less protective, stimuli that are normally innocuous cause rupture of the capillaries and gingival bleeding. Sites that bleed on probing have a greater area of inflamed connective tissue (i.e., cell-rich, collagen-poor tissue) than sites that do not bleed. In most cases, the cellular infiltrate of sites that bleed on probing is predominantly lymphocytic, which is a characteristic of stage II (early) gingivitis.[9,17,25]

Histologic evaluations of animal specimens revealed that, during the early stages of gingivitis, the expression of the cytokines responsible for connective tissue breakdown—matrix metalloproteinases (MMPs)—is ubiquitous. Different MMPs play a role in this breakdown at different stages (e.g., a decrease of MMP-14 activity at 7 days of inflammation; an immediate increase in MMP-2, especially with fibroblastic stimulation). In addition, MMP-9 expression peaked 5 days after gingivitis occurrence, which was also regulated by macrophages and neutrophils. Thus, extracellular matrix remodeling was regulated with MMP-2 and MMP-9 production and activation by the host inflammatory response.[42]

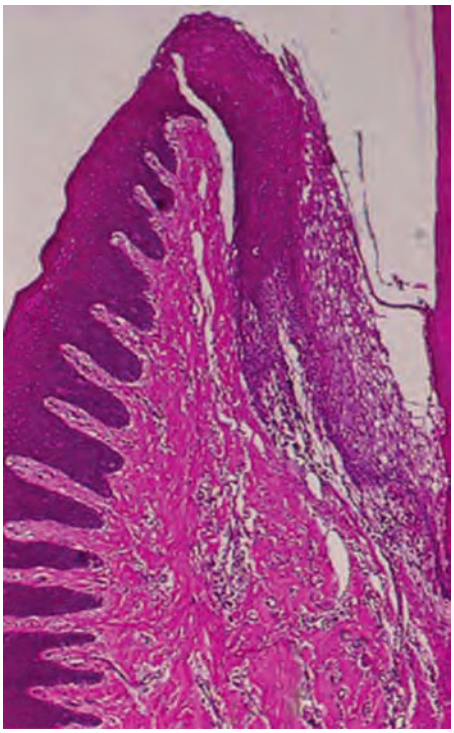

Figure 15-8 Microscopic view of the interdental space in a human autopsy specimen. Note the inflammatory infiltrate and the thinned epithelium in the area adjacent to the tooth as well as the collagenous tissue in the outer half of the section.

The severity of bleeding and the ease of its provocation depend on the intensity of the inflammation. After the vessels are damaged and ruptured, interrelated mechanisms induce hemostasis.[73] The vessel walls contract, blood flow diminishes, blood platelets adhere to the edges of the tissue, and a fibrous clot is formed that contracts and results in approximation of the edges of the injured area. Bleeding recurs when the area is irritated.

In cases of moderate or advanced periodontitis, the presence of bleeding on probing is considered a sign of active tissue destruction.

Acute episodes of gingival bleeding are caused by injury, and they can occur spontaneously in patients with gingival disease. Laceration of the gingiva by toothbrush bristles during aggressive

toothbrushing or by sharp pieces of hard food can cause gingival bleeding, even in the absence of gingival disease. Gingival burns from hot foods or chemicals increase the ease of gingival bleeding.

Spontaneous bleeding or bleeding on slight provocation can occur with acute necrotizing ulcerative gingivitis. With this condition, engorged blood vessels in the inflamed connective tissue are exposed via the ulceration of the necrotic surface epithelium.

Gingival Bleeding Associated with Systemic Changes

With some systemic disorders, gingival hemorrhage occurs spontaneously or after irritation, and it is excessive and difficult to control. These hemorrhagic diseases represent a wide variety of conditions that vary with regard to etiologic factors and clinical manifestations. Such conditions have the common feature of a hemostatic mechanism failure and result in abnormal bleeding in the skin, the internal organs, and other tissues, including the oral mucosa.[71]

Hemorrhagic disorders in which abnormal gingival bleeding is encountered include vascular abnormalities (vitamin C deficiency, allergy [e.g., Henoch–Schönlein purpura]), platelet disorders[27] (thrombocytopenic purpura), hypoprothrombinemia (vitamin K deficiency), other coagulation defects (hemophilia, leukemia, Christmas disease), deficient platelet thromboplastic factor as a result of uremia,[47] multiple myeloma,[12] and postrubella purpura.[30] The effects of hormonal replacement therapy, oral contraceptives, pregnancy, and the menstrual cycle are also reported to affect gingival bleeding.[43,65,79,80] In addition, in women, long-term depression-related stress exposure may increase concentrations of interleukin-6 in gingival crevicular fluid and worsen periodontal conditions with elevated gingival inflammation and increased pocket depths.[32]

In addition, changes in androgenic hormones have long been established as significant modifying factors in gingivitis, especially among adolescents. Several reports have shown notable effects of fluctuating estrogen and progesterone levels on the periodontium, starting as early as puberty.[1,55] Among pathologic endocrine changes, diabetes is an endocrine condition with a well-characterized effect on gingivitis.[78] In diabetes, marked inflammation affects both the epithelial and connective tissues, which leads to the degeneration of the dermal papilla, an increase in the number of inflammatory cells, the destruction of reticulin fibers, and an accumulation of dense collagen fibers that causes fibrosis.[70]

Several medications have also been found to have adverse effects on the gingiva. For example, anticonvulsants, antihypertensive calcium channel blockers, and immunosuppressant drugs are known to cause gingival enlargement (see Chapter 16), which secondarily can cause gingival bleeding. The American Heart Association has recommended over-the-counter aspirin as a therapeutic agent for cardiovascular disease, and aspirin is often prescribed for rheumatoid arthritis, osteoarthritis, rheumatic fever, and other inflammatory joint diseases.[28] Thus, it is important to consider aspirin's effect on bleeding during a routine dental examination to avoid false-positive readings, which could result in an inaccurate patient diagnosis.[67] (Chapter 11 discusses periodontal involvement in hematologic disorders.)

Color Changes in the Gingiva

The color of the gingiva is determined by several factors, including the number and size of blood vessels, the epithelial thickness, the quantity of keratinization, and the pigments within the epithelium.

Color Changes with Gingivitis. *Change in color is an important clinical sign of gingival disease.* The normal gingival color is "coral pink," and it is produced by the tissue's vascularity and modified by the overlying epithelial layers. For this reason, the gingiva becomes red when vascularization increases or when the degree of epithelial keratinization is reduced or disappears. The color becomes pale when vascularization is reduced (in association with fibrosis of the corium) or when epithelial keratinization increases. Thus, chronic inflammation intensifies the red or bluish-red color as a result of vascular proliferation and a reduction of keratinization. In addition, venous stasis will contribute a bluish hue. The gingival color changes with increasing chronicity of the inflammatory process. The changes start in the interdental papillae and the gingival margin and then spread to the attached gingiva (see Figure 22-1).

Proper diagnosis and treatment require an understanding of the tissue changes that alter the color of the gingiva at the clinical level.

Color changes in acute gingival inflammation differ with regard to both nature and distribution from those in patients with chronic gingivitis. The color changes may be marginal, diffuse, or patchlike, depending on the underlying acute condition. With acute necrotizing ulcerative gingivitis, the involvement is marginal; with herpetic gingivostomatitis, it is diffuse; and with acute reactions to chemical irritation, it is patchlike or diffuse.

Color changes vary with the intensity of the inflammation. Initially, there is an increase in erythema. If the condition does not worsen, this is the only color change until the gingiva reverts to normal. With severe acute inflammation, the red color gradually becomes a dull, whitish gray. The gray discoloration produced by tissue necrosis is demarcated from the adjacent gingiva by a thin, sharply defined erythematous zone. Chapter 10 provides detailed descriptions of the clinical and pathologic features of the various forms of acute gingivitis.

Metallic Pigmentation. Heavy metals (i.e., bismuth, arsenic, mercury, lead, and silver) that are absorbed systemically as a result of therapeutic use or occupational or household environments may discolor the gingiva and other areas of the oral mucosa.[45] These changes are rare, but they should still be ruled out in suspected cases.

Metals typically produce a black or bluish line in the gingiva that follows the contour of the margin (Figure 15-9). The pigmentation may also appear as isolated black blotches involving the interdental marginal and attached gingiva. This differs from the tattooing produced by the accidental embedding of amalgam or other metal fragments[15] (Figure 15-10).

Gingival pigmentation from systemically absorbed metals results from the perivascular precipitation of metallic sulfides in the subepithelial connective tissue. Gingival pigmentation is not a result of systemic toxicity. It occurs only in areas of inflammation

Figure 15-9 Bismuth gingivitis. Note the linear black discoloration of the gingiva in a patient who is receiving bismuth therapy.

Figure 15-10 Discoloration of the gingiva caused by embedded metal particles (amalgam).

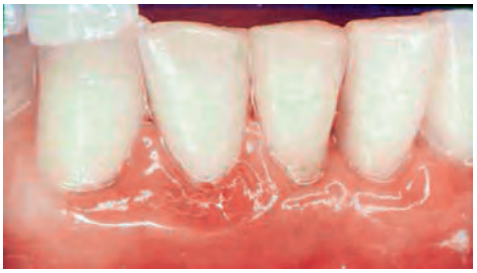

Figure 15-11 Chronic gingivitis. Swelling, loss of stippling, and discoloration occur when inflammatory exudate and edema are the predominant microscopic changes. The gingiva is soft and friable, and it bleeds easily.

in which the increased permeability of irritated blood vessels permits the seepage of the metal into the surrounding tissue. In addition to inflamed gingiva, mucosal areas that are irritated by biting or abnormal chewing habits (e.g., inner surface of lips, cheek at level of occlusal line, lateral border of tongue) are common sites of pigmentation. Pigmentation can be eliminated by treating the inflammatory changes without necessarily discontinuing the metal-containing medication.

Color Changes Associated with Systemic Factors

Many systemic diseases may cause color changes in the oral mucosa, including the gingiva.[22] In general, these abnormal pigmentations are nonspecific, and they should stimulate further diagnostic efforts or referral to the appropriate specialist.[68]

Endogenous oral pigmentations can be caused by melanin, bilirubin, or iron.[45] *Melanin* oral pigmentations can be normal physiologic pigmentations, and they are often found in highly pigmented ethnic groups (see Chapter 1). Diseases that increase melanin pigmentation include the following:

- *Addison's disease* is caused by adrenal dysfunction, and it produces isolated patches of discoloration that vary from bluish black to brown.
- *Peutz-Jeghers syndrome* produces intestinal polyposis and melanin pigmentation in the oral mucosa and the lips.
- *Albright's syndrome (polyostotic fibrous dysplasia)* and *von Recklinghausen's disease (neurofibromatosis)* produce areas of oral melanin pigmentation.

The skin and the mucous membranes can also be stained by *bile pigments.* Jaundice is best detected via the examination of the sclera, but the oral mucosa may also acquire a yellowish color. The deposition of *iron* in hemochromatosis may produce a blue-gray pigmentation of the oral mucosa. Several endocrine and metabolic disturbances, including diabetes and pregnancy, may result in color changes. Blood dyscrasias such as anemia, polycythemia, and leukemia may also induce color changes.

Exogenous factors that are capable of producing color changes in the gingiva include atmospheric irritants, such as coal and metal dust, and coloring agents in food or lozenges. Tobacco causes hyperkeratosis of the gingiva, and it may also induce a significant increase in melanin pigmentation of the oral mucosa.[56] Localized bluish-black areas of pigment are often caused by amalgam implanted in the mucosa (see Figure 15-10).

During recent years, the need for aesthetics in dentistry has increased, with a growing demand for a pleasing smile. This has made many individuals more aware of their gingival pigmentation, which may be apparent during smiling and speech.[20,21] Traditionally, gingival depigmentation has been carried out with the use of nonsurgical and surgical procedures, including chemical, cryosurgical, and electrosurgical techniques. However, those techniques were met with skepticism because of their varying degrees of success. More recently, lasers have been used to ablate cells that produce the melanin pigment; a nonspecific laser beam destroys the epithelial cells, including those at the basal layer. In addition, selective ablation with the use of a laser beam with a wavelength that is specifically absorbed in melanin effectively destroys the pigmented cells without damaging the nonpigmented cells. In both cases, radiation energy is transformed into ablation energy, thereby resulting in cellular rupture and vaporization with minimal heating of the surrounding tissue.[76]

Figure 15-12 Chronic gingivitis. Firm gingiva is produced when fibrosis predominates in the inflammatory process.

Changes in the Consistency of the Gingiva

Both chronic and acute inflammations produce changes in the normal firm and resilient consistency of the gingiva. As previously noted, in patients with chronic gingivitis, both destructive (edematous) and reparative (fibrotic) changes coexist, and the consistency of the gingiva is determined by their relative predominance (Figures 15-11 and 15-12). Table 15-1 summarizes the clinical alterations in the consistency of the gingiva and the microscopic changes that produce them.

Calcified Masses in the Gingiva. Calcified microscopic masses may be found in the gingiva.[14,52] These can occur alone or in groups, and they vary with regard to size, location, shape, and structure. Such masses may be calcified material that has been removed from the tooth and traumatically displaced into the gingiva during scaling,[52] root remnants, cementum fragments, or cementicles. Chronic inflammation and fibrosis, an occasional foreign body, and giant cell activity occur in relation to these masses. They are sometimes enclosed in an osteoidlike matrix. Crystalline foreign bodies have also been described in the gingiva, but their origin has not been determined.[60]

TABLE 15-1 Clinical and Histopathologic Changes in Gingival Consistency

Clinical Changes	Underlying Microscopic Features
Chronic Gingivitis	
1. Soggy puffiness that pits on pressure 2. Marked softness and friability, with ready fragmentation on exploration with probe and pinpoint surface areas of redness and desquamation 3. Firm, leathery consistency	1. Infiltration by fluid and cells of inflammatory exudate 2. Degeneration of connective tissue and epithelium associated with injurious substances that provoke the inflammation and the inflammatory exudate; change in the connective tissue–epithelium relationship, with inflamed, engorged connective tissue expanding to within a few epithelial cells of the surface; thinning of epithelium and degeneration associated with edema and leukocyte invasion, separated by areas in which rete pegs are elongated to connective tissue 3. Fibrosis and epithelial proliferation associated with long-standing chronic inflammation
Acute Forms of Gingivitis	
1. Diffuse puffiness and softening 2. Sloughing with grayish, flakelike particles of debris adhering to eroded surface 3. Vesicle formation	1. Diffuse edema of acute inflammatory origin; fatty infiltration in xanthomatosis 2. Necrosis with formation of pseudomembrane composed of bacteria, polymorphonuclear leukocytes, and degenerated epithelial cells in fibrinous meshwork 3. Intercellular and intracellular edema with degeneration of nucleus and cytoplasm and rupture of cell wall

Toothbrushing. Toothbrushing has various effects on the consistency of the gingiva, such as promoting keratinization of the oral epithelium, enhancing capillary gingival circulation, and thickening alveolar bone.[44,49,77] In animal studies, mechanical stimulation by toothbrushing was found to increase the proliferative activity of the junctional basal cells in dog gingiva by 2.5 times as compared with the use of a scaler.[31] These findings may indicate that toothbrushing causes an increased turnover rate and desquamation of the junctional epithelial surfaces. This process may repair small breaks in the junctional epithelium and prevent direct access to the underlying tissue by periodontal pathogens.[82]

Changes in the Surface Texture of the Gingiva

The surface of normal gingiva usually exhibits numerous small depressions and elevations that give the tissue an orange-peel appearance referred as *stippling.*[13] Stippling is restricted to the attached gingiva and predominantly localized to the subpapillary area, but it extends to a variable degree into the interdental papilla.[61] Although the biologic significance of gingival stippling is not known, some investigators conclude that the loss of stippling is an early sign of gingivitis.[33,61] However, clinicians must take into consideration that its pattern and extent vary in different mouth areas, among patients, and with age.

In patients with chronic inflammation, the gingival surface is either smooth and shiny or firm and nodular, depending on whether the dominant changes are exudative or fibrotic. Smooth surface texture is also produced by epithelial atrophy in atrophic gingivitis, and peeling of the surface occurs with chronic desquamative gingivitis. Hyperkeratosis results in a leathery texture, and drug-induced gingival overgrowth produces a nodular surface.

Changes in the Position of the Gingiva

Traumatic Lesions. One of the unique features of the most recent gingival disease classification is the recognition of non–plaque-induced traumatic gingival lesions as distinct gingival conditions.[11] Traumatic lesions—whether they are chemical, physical, or thermal—are among the most common lesions in the mouth. Sources of chemical injuries include aspirin, hydrogen peroxide, silver nitrate, phenol, and endodontic materials. Physical injuries can include lip, oral, and tongue piercings, which can result in gingival recession. Thermal injuries can result from hot drinks and foods. In acute cases, the appearance of slough (necrotizing epithelium), erosion, or ulceration and the accompanying erythema are common features. In chronic cases, permanent gingival defects are usually present in the form of gingival recession. Typically, the localized nature of the lesions and the lack of symptoms readily eliminate them from the differential diagnosis of systemic conditions that may be present with erosive or ulcerative oral lesions.[64]

Gingival Recession. Gingival recession is a common finding. The prevalence, extent, and severity of gingival recession increase with age, and this condition is more prevalent among males.[6]

Positions of the Gingiva. By clinical definition, recession is the exposure of the root surface by an apical shift in the position of the gingiva. To understand recession, it helps to distinguish between the actual and apparent positions of the gingiva. The *actual position* is the level of the coronal end of the epithelial attachment on the tooth, whereas the *apparent position* is the level of the crest of the gingival margin (Figure 15-13). *The severity of recession is determined by the actual position of the gingiva and not by its apparent position.* For example, in periodontal disease, the inflamed pocket wall covers part of the denuded root; thus, some of the recession is hidden, and some may be visible. The total amount of recession is the sum of the two.

Recession refers to the location of the gingiva rather than to its condition. Receded gingiva can be inflamed, but it may be normal except for its position (Figure 15-14). Recession may be localized to one tooth or to a group of teeth, or it may be generalized throughout the mouth.

Gingival recession increases with age; the incidence varies from 8% in children to 100% after the age 50 of years.[84] This has led some investigators to assume that recession may be a physiologic process related to aging. However, no convincing evidence has been presented for a physiologic shift of the gingival attachment.[39] The gradual apical shift is most likely the result of the cumulative

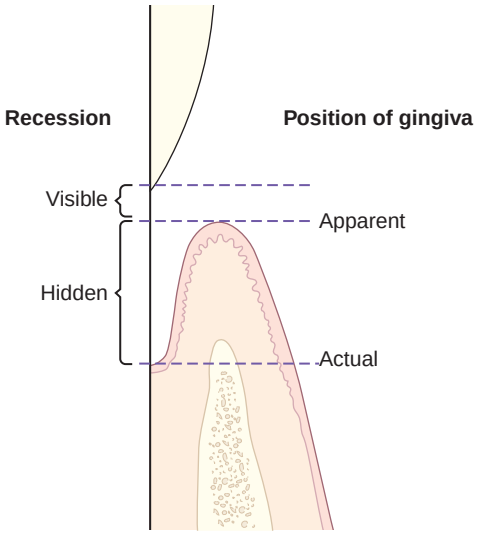

Figure 15-13 Diagram of apparent and actual positions of the gingiva and visible and hidden recession.

Figure 15-14 Different degrees of recession. Recession is slight in teeth #26 and #29 and marked in teeth #27 and #28. The change in gingival contour and the recession, as seen in tooth #28, are referred to as *Stillman's clefts.*

effect of minor pathologic involvement and repeated minor direct trauma to the gingiva. In some populations without access to dental care, however, recession may be the result of increasing periodontal disease.[29,40]

The following etiologic factors have been implicated in gingival recession: faulty toothbrushing technique (gingival abrasion), tooth malposition, friction from the soft tissues (gingival ablation),[72] gingival inflammation, abnormal frenum attachment, and iatrogenic dentistry. Trauma from occlusion has been suggested in the past, but its mechanism of action has never been demonstrated. For example, a deep overbite has been associated with gingival inflammation and recession. Excessive incisal overlap may result in a traumatic injury to the gingiva. Orthodontic movement in a labial direction in monkeys has been shown to result in the loss of marginal bone and connective tissue attachment as well as in gingival recession.[74]

Standard oral hygiene procedures, whether they involve toothbrushing or flossing, may lead to frequent transient and minimal gingival injury.[18,62] Although toothbrushing is important for gingival health, faulty toothbrushing technique or brushing with hard bristles may cause significant injury. This type of injury may present as lacerations, abrasions, keratosis, and recession, with the facial marginal gingiva being the most affected.[59] Thus, in these cases, recession tends to be more frequent and severe in patients with clinically healthy gingiva, little bacterial plaque, and good oral hygiene.[23,57,58]

Susceptibility to recession is also influenced by the position of teeth in the arch,[83] the root–bone angle, and the mesiodistal curvature of the tooth surface.[51] On rotated, tilted, or facially displaced teeth, the bony plate is thinned or reduced in height. Pressure from mastication or moderate toothbrushing damages the unsupported gingiva and produces recession. The effect of the angle of the root in the bone with recession is often observed in the maxillary molar area. If the lingual inclination of the palatal root is prominent or if the buccal roots flare outward, the bone in the cervical area is thinned or shortened, and recession results from repeated trauma of the thin marginal gingiva.

The health of the gingival tissue also depends on properly designed and placed restorative materials. Pressure from a poorly designed partial denture, such as an ill-fitting denture clasp, can cause gingival trauma and recession.[85] Overhanging dental restorations have long been viewed as a contributing factor to gingivitis because of plaque retention. In addition, there is general agreement that placing restorative margins within the biologic width frequently leads to gingival inflammation, clinical attachment loss, and, eventually, bone loss. Clinically, the violation of biologic width typically manifests as gingival inflammation, deepened periodontal pockets, and gingival recession.

A relationship may exist between smoking and gingival recession (see Chapter 10). The multifactorial mechanisms may include reduced gingival blood flow and altered immune response, but they are not as yet conclusive.[26,63]

Clinical Significance. Several aspects of gingival recession make it clinically significant. Exposed root surfaces are susceptible to caries. Abrasion or erosion of the cementum exposed by recession leaves an underlying dentinal surface that can be sensitive. Hyperemia of the pulp and associated symptoms may also result from the excessive exposure of the root surface.[48] Interproximal recession creates oral hygiene problems and resulting plaque accumulation.

Changes in Gingival Contour

Changes in gingival contour are primarily associated with gingival enlargement (see Chapter 16), but such changes may also occur with other conditions. Of historical interest are the descriptions of indentations of the gingival margin referred to as *Stillman's clefts* (see Figure 15-14)[75] and the *McCall festoons.* The term *Stillman's clefts* has been used to describe a specific type of gingival recession that consists of a narrow, triangular-shaped gingival recession. As the recession progresses apically, the cleft becomes broader, thereby exposing the cementum of the root surface. When the lesion reaches the mucogingival junction, the apical border of oral mucosa is usually inflamed because of the difficulty with maintaining adequate plaque control at this site.

The term *McCall festoons* has been used to describe a rolled, thickened band of gingiva that is usually seen adjacent to the cuspids when recession approaches the mucogingival junction. Initially, Stillman's clefts and McCall festoons were attributed to traumatic occlusion, and the recommended treatment was occlusal adjustment. However, this association was never proved, and these indentations merely represent peculiar inflammatory changes of the marginal gingiva.[14]

Suggested Readings

Bergström J: The topography of papillary gingiva in health and early gingivitis. *J Clin Periodontol* 11:423, 1984.

Danser MM, Timmerman MF, Ijzerman Y, et al: Evaluation of the incidence of gingival abrasion as a result of toothbrushing. *J Clin Periodontol* 25:701, 1998.

Dietrich T, Bernimoulin JP, Glynn RJ: The effect of cigarette smoking on gingival bleeding. *J Periodontol* 75:16, 2004.

Greenstein G: The role of bleeding upon probing in the diagnosis of periodontal disease: a literature review. *J Periodontol* 55:684, 1984.

Lang NP, Adler R, Joss A, et al: Absence of bleeding upon probing: an indicator of periodontal stability. *J Clin Periodontol* 17:714, 1990.

Löe H, Theilade E, Jensen SB: Experimental gingivitis in man. *J Periodontol* 36:177, 1965.

Machtei EE, Mahler D, Sanduri H, et al: The effect of menstrual cycle on periodontal health. *J Periodontol* 75:408, 2004.

Silva JA, Lorencini M, Reis JR, et al: The influence of type I diabetes mellitus in periodontal disease induced changes of the gingival epithelium and connective tissue. *Tissue Cell* 40:283, 2008.

Tal H, Oegiesser D, Tal M: Gingival depigmentation by erbium:YAG laser: clinical observations and patient responses. *J Periodontol* 74:1660, 2003.

Trombelli L, Tatakis DN, Scapoli C, et al: Modulation of clinical expression of plaque-induced gingivitis. II. Identification of "high-responder" and "low-responder" subjects. *J Clin Periodontol* 31:239, 2004.

References

References for this chapter are found on the companion website www.expertconsult.com.

References

1. Addy M, Hunter ML, Kingdon A, et al: An 8-year study of changes in oral hygiene and periodontal health during adolescence. *Int J Paediatr Dent* 4:75, 1994.
2. Ainamo J, Bay I: Problems and proposals for recording gingivitis and plaque. *Int Dent J* 25:229, 1975.
3. Albandar JM: Periodontal diseases in North America. *Periodontol 2000* 29:31, 2002.
4. Albandar JM, Rams TE: Global epidemiology of periodontal diseases: an overview. *Periodontol 2000* 29:7, 2002.
5. Albandar JM, Tinoco EM: Global epidemiology of periodontal diseases in children and young persons. *Periodontol 2000* 29:153, 2002.
6. Albandar JM, Brunelle JA, Kingman A: Destructive periodontal disease in adults 30 years of age and older in the United States, 1988-1994. *J Periodontol* 70:13, 1999.
7. Albandar JM, Brown LJ, Brunelle JA, et al: Gingival state and dental calculus in early-onset periodontitis. *J Periodontol* 67:953, 1996.
8. Albandar JM, Kingman A, Brown LJ, et al: Gingival inflammation and subgingival calculus as determinants of disease progression in early-onset periodontitis. *J Clin Periodontol* 25:231, 1998.
9. Amato R, Caton J, Polson A, et al: Interproximal gingival inflammation related to the conversion of a bleeding to a nonbleeding state. *J Periodontol* 57:63, 1986.
10. American Academy of Periodontology: Parameter on plaque-induced gingivitis. *J Periodontol* 71:851, 2000.
11. Armitage GC: Development of a classification system for periodontal diseases and conditions. *Ann Periodontol* 4:1, 1999.
12. Bennett JH, Shankar S: Gingival bleeding as the presenting feature of multiple myeloma. *Br Dent J* 157:101, 1984.
13. Bergström J: The topography of papillary gingiva in health and early gingivitis. *J Clin Periodontol* 11:423, 1984.
14. Box HK: Gingival clefts and associated tracts. *NY State Dent J* 16:3, 1950.
15. Buchner A, Hansen LS: Amalgam pigmentation (amalgam tattoo) of the oral mucosa: a clinicopathologic study of 268 cases. *Oral Surg Oral Med Oral Pathol* 49:139, 1980.
16. Carter HG, Barnes GP: The gingival bleeding index. *J Periodontol* 45:801, 1974.
17. Cooper PG, Caton JG, Polson AM: Cell populations associated with gingival bleeding. *J Periodontol* 54:497, 1983.
18. Danser MM, Timmerman MF, IJzerman Y, et al: Evaluation of the incidence of gingival abrasion as a result of toothbrushing. *J Clin Periodontol* 25:701, 1998.
19. Dietrich T, Bernimoulin JP, Glynn RJ: The effect of cigarette smoking on gingival bleeding. *J Periodontol* 75:16, 2004.
20. Dummett CO: Oral pigmentation: first symposium on oral pigmentation. *J Periodontol* 31:356, 1960.
21. Dummett CO: Overview of normal oral pigmentations. *Ala J Med Sci* 16:262, 1979.
22. Dummett CO: Oral tissue color changes. *Ala J Med Sci* 16:274, 1979.
23. Gorman WJ: Prevalence and etiology of gingival recession. *J Periodontol* 38:316, 1967.
24. Greenstein G: The role of bleeding upon probing in the diagnosis of periodontal disease: a literature review. *J Periodontol* 55:684, 1984.
25. Greenstein G, Caton J, Polson AM: Histologic characteristics associated with bleeding after probing and visual signs of inflammation. *J Periodontol* 52:420, 1981.
26. Gunsolley JC, Quinn SM, Tew J, et al: The effect of smoking on individuals with minimal periodontal destruction. *J Periodontol* 69:165, 1998.
27. Haeb HP: Postrubella thrombocytopenic purpura: a report of eight cases with discussion of hemorrhagic manifestations of rubella. *Clin Pediatr* 7:350, 1968.
28. Hennekens CH, Dyken ML, Fuster V: Aspirin as a therapeutic agent in cardiovascular disease: a statement for healthcare professionals from the American Heart Association. *Circulation* 96:2751, 1997.
29. Hirschfeld I: A study of skulls in the American Museum of Natural History in relation to periodontal disease. *J Dent Res* 5:241, 1923.
30. Hoover DR, Lefkowitz W: Fluctuation in marginal gingivitis. *J Periodontol* 36:310, 1965.
31. Horiuchi M, Yamamoto T, Tomofuji T, et al: Toothbrushing promotes gingival fibroblast proliferation more effectively than removal of dental plaque. *J Clin Periodontol* 29:791, 2002.
32. Johannsen A, Rydmark I, Söder B, et al: Gingival inflammation, increased periodontal pocket depth and elevated interleukin-6 in gingival crevicular fluid of depressed women on long-term sick leave. *J Periodontal Res* 42:546, 2007.
33. King JD: Gingival disease in Dundee. *Dent Rec* 56:9, 1945.
34. Lang NP, Adler R, Joss A, et al: Absence of bleeding upon probing: an indicator of periodontal stability. *J Clin Periodontol* 17:714, 1990.
35. Lang NP, Schätzle MA, Löe H: Gingivitis as a risk factor in periodontal disease. *J Clin Periodontol* 36(Suppl 10):3, 2009.
36. Larato DC, Stahl SS, Brown R, Jr, et al: The effect of a prescribed method of toothbrushing on the fluctuation of marginal gingivitis. *J Periodontol* 40:142, 1969.
37. Lenox JA, Kopczyk RA: A clinical system for scoring a patient's oral hygiene performance. *J Am Dent Assoc* 86:849, 1973.
38. Levin L, Samorodnitzky-Naveh GR, Machtei EE: The association of orthodontic treatment and fixed retainers with gingival health. *J Periodontol* 79:2087, 2008.
39. Löe H: The structure and physiology of the dentogingival junction. In Miles AE, editor: *Structural and chemical organization of teeth*, vol 2, New York, 1967, Academic Press.
40. Löe H, Anerud A, Boysen H: The natural history of periodontal disease in man: prevalence, severity and extent of gingival recession. *J Periodontol* 63:489, 1992.
41. Löe H, Theilade E, Jensen SB: Experimental gingivitis in man. *J Periodontol* 36:177, 1965.
42. Lorencini M, Silva JA, de la Hoz CL, et al: Changes in MMPs and inflammatory cells in experimental gingivitis. *Histol Histopathol* 24:157, 2009.
43. Machtei EE, Mahler D, Sanduri H, et al: The effect of menstrual cycle on periodontal health. *J Periodontol* 75:408, 2004.
44. Mackenzie IC: Does toothbrushing affect gingival keratinization? *Proc R Soc Med* 65:1127, 1972.
45. McCarthy FP, Shklar G: *Diseases of the oral mucosa*, New York, 1964, McGraw-Hill.
46. Meitner SW, Zander H, Iker HP, et al: Identification of inflamed gingival surfaces. *J Clin Periodontol* 6:93, 1979.
47. Merril A, Peterson LJ: Gingival hemorrhage secondary to uremia: review and report of a case. *Oral Surg Oral Med Oral Pathol* 29:530, 1970.
48. Merritt AA: Hyperemia of the dental pulp caused by gingival recession. *J Periodontol* 4:30, 1933.
49. Miake K, Agematsu H, Fukayama M, et al: An experimental study on histological changes occurring in rat-incisor alveolar bone during toothbrushing. In Ishikawa J, Kawasaki H, Ikeda K, editors: *Recent advances in clinical periodontology*, Amsterdam, 1988, Elsevier.
50. Milne AM: Gingival bleeding in 848 army recruits: an assessment. *Br Dent J* 122:111, 1967.
51. Morris ML: The position of the margin of the gingiva. *J Oral Surg* 11:969, 1958.
52. Moskow BS: Calcified material in human gingival tissue. *J Dent Res* 40:644, 1961.
53. Muhlemann HR, Son S: Gingival sulcus bleeding: a leading symptom in initial gingivitis. *Helv Odontol Acta* 15:107, 1971.
54. Nair P, Sutherland G, Palmer RM, et al: Gingival bleeding on probing increases after quitting smoking. *J Clin Periodontol* 30:435, 2003.
55. Nakagawa S, Fujii H, Machida Y, et al: A longitudinal study from prepuberty to puberty of gingivitis: correlation between the occurrence of *Prevotella intermedia* and sex hormones. *J Clin Periodontol* 21:658, 1994.
56. Neville BW, Damm DD, Allen CM, et al: *Oral and maxillofacial pathology*, Philadelphia, 1995, Saunders.
57. O'Leary TJ, Drake RB, Crump PP, et al: The incidence of recession in young males: further study. *J Periodontol* 42:264, 1971.

58. O'Leary TJ, Drake RV, Jividen GJ, et al: The incidence of recession in young males: relationship to gingival and plaque scores, SAM-TR-67-97. *Tech Rep SAM-TR* 1, 1967.
59. Offenbacher S, Barros SP, Singer RE, et al: Periodontal disease at the biofilm-gingival interface. *J Periodontol* 78:1911, 2007.
60. Orban B: Gingival inclusions. *J Periodontol* 16:16, 1945.
61. Orban B: Clinical and histological study of the surface characteristics of the gingiva. *Oral Surg Oral Med Oral Pathol Oral Radiol Endod* 1:827, 1948.
62. Pearlman BA: A mistaken health belief resulting in gingival injury: a case report. *J Periodontol* 65:284, 1994.
63. Preber H, Bergstrom J: Occurrence of gingival bleeding in smokers and non-smoker patients. *Acta Odontol Scand* 43:315, 1985.
64. Rawal SY, Claman LJ, Kalmar JR, et al: Traumatic lesions of the gingiva: a case series. *J Periodontol* 75:762, 2004.
65. Reinhardt RA, Payne JB, Maze CA, et al: Influence of estrogen and osteopenia/osteoporosis on clinical periodontitis in postmenopausal women. *J Periodontol* 70:823, 1999.
66. Rose G: *The strategy of preventive medicine*, Oxford, 1992, Oxford University Press.
67. Royzman D, Recio L, Badovinac RL, et al: The effect of aspirin intake on bleeding on probing in patients with gingivitis. *J Periodontol* 75:679, 2004.
68. Shklar G, McCarthy PL: *The oral manifestations of systemic disease*, Boston, 1976, Butterworth.
69. Silness J, Löe H: Periodontal disease in pregnancy. II. Correlation between oral hygiene and periodontal condition. *Acta Odontol Scand* 22:121, 1964.
70. Silva JA, Lorencini M, Reis JR, et al: The influence of type I diabetes mellitus in periodontal disease induced changes of the gingival epithelium and connective tissue. *Tissue Cell* 40:283, 2008.
71. Sodeman WA, Jr, Sodeman WA: *Pathologic physiology: mechanisms of disease*, ed 7, Philadelphia, 1985, Saunders.
72. Sognnaes RF: Periodontal significance of intraoral frictional ablation. *J West Soc Periodontol Periodontal Abstr* 25:112, 1977.
73. Stefanini M, Dameshek W: *The hemorrhagic disorders*, ed 2, New York, 1962, Grune & Stratton.
74. Steiner GG, Pearson JK, Ainamo J: Changes of the marginal periodontium as a result of labial tooth movement in monkeys. *J Periodontol* 52:314, 1981.
75. Stillman PR: Early clinical evidences of disease in the gingiva and pericementum. *J Dent Res* 3:25, 1921.
76. Tal H, Oegiesser D, Tal M: Gingival depigmentation by erbium:YAG laser: clinical observations and patient responses. *J Periodontol* 74:1660, 2003.
77. Tanaka M, Hanioka T, Kishimoto M, et al: Effect of mechanical toothbrush stimulation on microcirculatory functions in inflamed gingiva of dogs. *J Clin Periodontol* 25:561, 1998.
78. Tatakis DN, Trombelli L: Modulation of clinical expression of plaque-induced gingivitis. I. Background review and rationale. *J Clin Periodontol* 31:229, 2004.
79. Tilakaratne A, Soory M, Ranasinghe AW, et al: Effects of hormonal contraceptives on the periodontium, in a population of rural Sri-Lankan women. *J Clin Periodontol* 27:753, 2000.
80. Tilakaratne A, Soory M, Ranasinghe AW, et al: Periodontal disease status during pregnancy and 3 months post-partum, in a rural population of Sri-Lankan women. *J Clin Periodontol* 27:787, 2000.
81. Trombelli L, Tatakis DN, Scapoli C, et al: Modulation of clinical expression of plaque-induced gingivitis. II. Identification of "high-responder" and "low-responder" subjects. *J Clin Periodontol* 31:239, 2004.
82. Tomofuji T, Morita M, Horiuchi M, et al: The effect of duration and force of mechanical toothbrushing stimulation on proliferative activity of the junctional epithelium. *J Periodontol* 73:1149, 2002.
83. Trott JR, Love B: An analysis of localized gingival recession in 766 Winnipeg High School students. *Dent Pract Dent Rec* 16:209, 1966.
84. Woofter C: The prevalence and etiology of gingival recession. *Periodontal Abstr* 17:45, 1969.
85. Zlataric DK, Celebic A, Valentic-Peruzovic M: The effect of removable partial dentures on periodontal health of abutment and non-abutment teeth. *J Periodontol* 73:137, 2002.

CHAPTER 16

Gingival Enlargement

Fermin A. Carranza and Eva L. Hogan

CHAPTER OUTLINE

Inflammatory Enlargement
Drug-Induced Gingival Enlargement
Idiopathic Gingival Enlargement
Enlargements Associated with Systemic Diseases
Neoplastic Enlargement (Gingival Tumors)
False Enlargement

An increase in size of the gingiva is a common feature of gingival disease. The accepted current terms for this condition are *gingival enlargement* and *gingival overgrowth.* These are strictly clinical descriptive terms, and they avoid the erroneous pathologic connotations of terms used in the past, such as *hypertrophic gingivitis* and *gingival hyperplasia.*

The many types of gingival enlargement can be classified according to etiologic factors and pathologic changes as follows:

I. Inflammatory enlargement
   A. Chronic
   B. Acute
II. Drug-induced enlargement
   A. General information
   B. Anticonvulsants
   C. Immunosuppressants
   D. Calcium channel blockers
III. Enlargements associated with systemic diseases or conditions
   A. Conditioned enlargement
      1. Pregnancy
      2. Puberty
      3. Vitamin C deficiency
      4. Plasma cell gingivitis
      5. Nonspecific conditioned enlargement (pyogenic granuloma)
   B. Systemic diseases that cause gingival enlargement
      1. Leukemia
      2. Granulomatous diseases (e.g., Wegener's granulomatosis, sarcoidosis)
IV. Neoplastic enlargement (gingival tumors)
   A. Benign tumors
   B. Malignant tumors
V. False enlargement

With the use of the criteria of location and distribution, gingival enlargement is designated as follows:

- *Localized:* Limited to the gingiva adjacent to a single tooth or group of teeth
- *Generalized:* Involving the gingiva throughout the mouth
- *Marginal:* Confined to the marginal gingiva
- *Papillary:* Confined to the interdental papilla
- *Diffuse:* Involving the marginal and attached gingivae and papillae
- *Discrete:* An isolated sessile or a pedunculated, tumorlike enlargement

The degree of gingival enlargement can be scored as follows[16]:

- *Grade 0:* No signs of gingival enlargement
- *Grade I:* Enlargement confined to interdental papilla
- *Grade II:* Enlargement involves papilla and marginal gingiva
- *Grade III:* Enlargement covers three quarters or more of the crown

Inflammatory Enlargement

Gingival enlargement may result from chronic or acute inflammatory changes, although chronic changes are much more common. In addition, inflammatory enlargements are usually a secondary complication of any of the other types of enlargement, thereby creating a combined gingival enlargement. In these cases, it is important to understand the double etiology and to treat both causes adequately.

Chronic Inflammatory Enlargement

Clinical Features. Chronic inflammatory gingival enlargement originates as a slight ballooning of the interdental papilla and marginal gingiva. In the early stages, it produces a life-preserver–shaped bulge around the involved teeth. This bulge can increase in size until it covers part of the crowns. The enlargement may be localized or generalized; it progresses slowly and painlessly, unless it is complicated by acute infection or trauma (Figures 16-1 and 16-2).

Occasionally, chronic inflammatory gingival enlargement occurs as a discrete sessile or pedunculated mass that resembles a tumor. It may be interproximal or on the marginal or attached gingiva. The lesions are slow-growing masses, and they are usually painless. They may undergo a spontaneous reduction in size that is followed by exacerbation and continued enlargement. Painful ulceration sometimes occurs in the fold between the mass and the adjacent gingiva.

Histopathology. Chronic inflammatory gingival enlargements show the exudative and proliferative features of chronic inflammation (Figure 16-3). Lesions that are clinically deep red or bluish red are soft and friable with a smooth, shiny surface, and they bleed easily. They also have a preponderance of inflammatory cells and fluid, with vascular

Figure 16-1 Chronic inflammatory gingival enlargement localized to the anterior region.

Figure 16-2 Chronic inflammatory gingival enlargement.

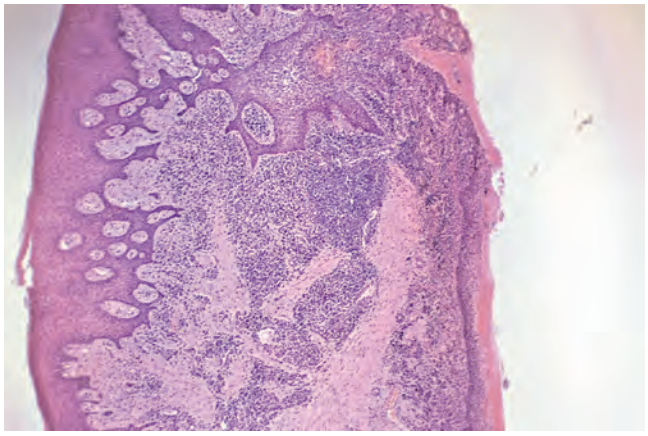

Figure 16-3 Survey section of chronic inflammatory gingival enlargement showing the inflamed connective tissue core and strands of proliferating epithelium.

engorgement, new capillary formation, and associated degenerative changes. Lesions that are relatively firm, resilient, and pink have a greater fibrotic component with an abundance of fibroblasts and collagen fibers.

Etiology. Chronic inflammatory gingival enlargement is caused by prolonged exposure to dental plaque. Factors that favor plaque accumulation and retention[48] include poor oral hygiene, irritation by anatomic abnormalities, and improper restorative and orthodontic appliances.

Gingival Changes Associated with Mouth Breathing. Gingivitis and gingival enlargement are often seen in patients who are mouth breathers. The gingiva appears red and edematous, with a diffuse surface shininess of the exposed area. The maxillary anterior region is the common site of such involvement. In many cases, the altered gingiva is clearly demarcated from the adjacent unexposed normal gingiva (Figure 16-4). The exact manner in which mouth breathing affects gingival changes has not been demonstrated. Its harmful effect is generally attributed to irritation from surface dehydration. However, comparable changes could not be produced by air drying the gingiva of experimental animals.[66]

Figure 16-4 Gingival enlargement in a mouth breather. Note the lesion that is sharply circumscribed to the anterior marginal and papillary areas.

Figure 16-5 Gingival abscess on the facial gingival surface in the space between the cuspid and the lateral incisor, unrelated to the gingival sulcus area.

Acute Inflammatory Enlargement

Gingival Abscess. A gingival abscess is a localized, painful, rapidly expanding lesion that usually has a sudden onset (Figure 16-5). It is generally limited to the marginal gingiva or the interdental papilla. In its early stages, it appears as a red swelling with a smooth, shiny surface. Within 24 to 48 hours, the lesion usually becomes fluctuant and pointed, with a surface orifice from which a purulent exudate may be expressed. The adjacent teeth are often sensitive to percussion. If permitted to progress, the lesion generally ruptures spontaneously.

Histopathology. The gingival abscess consists of a purulent focus in the connective tissue surrounded by a diffuse infiltration of polymorphonuclear leukocytes, edematous tissue, and vascular engorgement. The surface epithelium has varying degrees of intracellular and extracellular edema, invasion by leukocytes, and sometimes ulceration.

Etiology. Acute inflammatory gingival enlargement results from bacteria carried deep into the tissues when a foreign substance (e.g., toothbrush bristle, piece of apple core, lobster shell fragment) is forcefully embedded into the gingiva. The lesion is confined to the gingiva and should not be confused with periodontal or lateral abscesses.

Periodontal (Lateral) Abscess. Periodontal abscesses involve the supporting periodontal tissues and generally produce

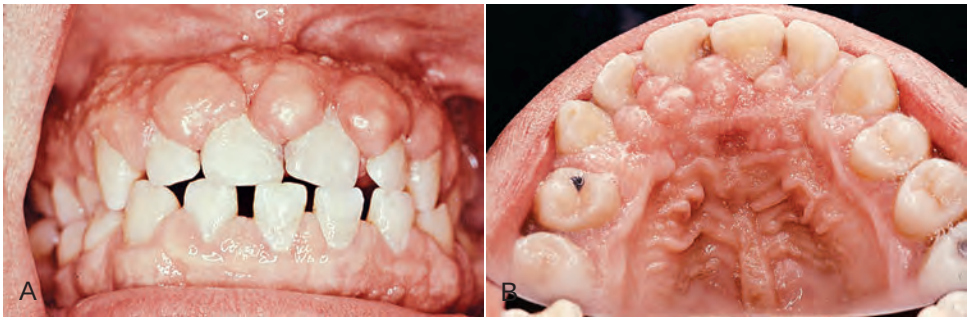

Figure 16-6 Gingival enlargement associated with phenytoin therapy. **A,** Facial view. Note the prominent papillary lesions and the firm, nodular surface. **B,** Occlusal view of the upper jaw.

Figure 16-7 Phenytoin gingival enlargement in a 5-year-old child covering most of the clinical crowns of the teeth.

Figure 16-8 Combined gingival enlargement resulting from the inflammatory involvement of a phenytoin-induced overgrowth.

enlargement of the gingiva. For a detailed description of periodontal abscesses, see Chapter 20.

Drug-Induced Gingival Enlargement

Gingival enlargement is a well-known consequence of the administration of some anticonvulsants, immunosuppressants, and calcium channel blockers. The condition may create speech, mastication, tooth eruption, and aesthetic problems.

Clinical and microscopic features of the enlargements caused by the different drugs are similar.[19,86] These are presented first, followed by a description of the particular features of each drug.

General Information

Clinical Features. The growth starts as a painless, beadlike enlargement of the interdental papilla that then extends to the facial and lingual gingival margins (Figure 16-6). As the condition progresses, the marginal and papillary enlargements unite, and they may develop into a massive tissue fold that covers a considerable portion of the crowns; this may interfere with occlusion (Figure 16-7).

When uncomplicated by inflammation, the lesion is mulberry shaped, firm, pale pink, and resilient, with a minutely lobulated surface and no tendency to bleed. The enlargement characteristically appears to project from beneath the gingival margin, from which it is separated by a linear groove. However, the presence of the enlargement makes plaque control difficult, often resulting in a secondary inflammatory process that complicates the gingival overgrowth caused by the drug.

The resultant enlargement then becomes a combination of the increase in size caused by the drug and the complicating inflammation caused by bacteria. Secondary inflammatory changes not only add to the size of the lesion caused by the drug but also produce a red or bluish-red discoloration, obliterate the lobulated surface demarcations, and increase bleeding tendency (Figure 16-8).

The enlargement is usually generalized throughout the mouth, but it is more severe in the maxillary and mandibular anterior regions. It occurs in areas in which teeth are present (not in edentulous spaces), and the enlargement disappears in areas from which teeth have been extracted. Hyperplasia of the mucosa in edentulous mouths has been reported but is rare.[26,27]

Drug-induced enlargement may occur in mouths with little or no plaque, and it may be absent in mouths with abundant deposits. However, some investigators believe that inflammation is a prerequisite for development of the enlargement, which therefore could be prevented by plaque removal and fastidious oral hygiene.[22,37,78,101] Oral hygiene by means of toothbrushing or the use of a chlorhexidine toothpaste[90] reduces the inflammation but does not lessen or prevent the overgrowth. Hassell and colleagues[42,44] have hypothesized that, in noninflamed gingiva, fibroblasts are less active or even quiescent and do not respond to circulating phenytoin, whereas fibroblasts within inflamed tissue are in an active state as a result of the inflammatory mediators and the endogenous growth factors that are present.

A genetic predisposition is a suspected factor[45,83] for determining whether a person treated with phenytoin will develop gingival enlargement.

The enlargement is chronic, and it slowly increases in size. Even if it is surgically removed, it recurs. Spontaneous disappearance occurs within a few months after the discontinuation of the drug. See Chapter 58 for more information about the treatment of gingival enlargements, including the substitution of drugs that do not induce gingival overgrowth.

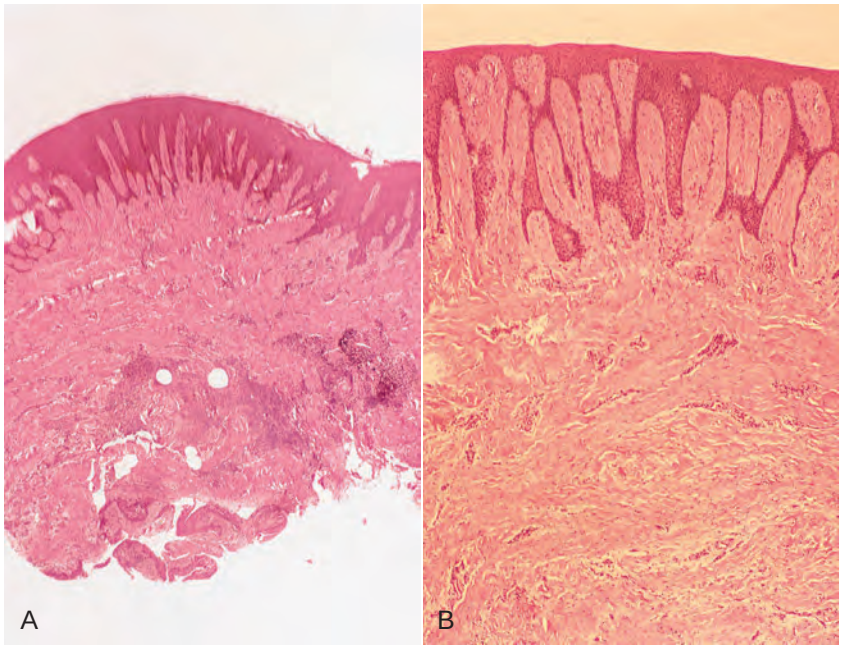

Figure 16-9 Microscopic view of gingival enlargement associated with phenytoin therapy. **A,** Hyperplasia and acanthosis of the epithelium and densely collagenous connective tissue, with evidence of inflammation in the area adjacent to the gingival sulcus (pocket). **B,** High-power view showing the extension of deep rete pegs into the connective tissue.

Histopathology. Drug-induced gingival enlargement consists of a pronounced hyperplasia of the connective tissue and epithelium (Figure 16-9). There is acanthosis of the epithelium, and elongated rete pegs extend deep into the connective tissue, which exhibits densely arranged collagen bundles with an increase in the number of fibroblasts and new blood vessels.[89] An abundance of amorphous ground substance has also been reported.[67] Structural changes in the outer epithelial cell surface have been reported with cyclosporine-induced enlargements.[3,94]

The enlargement begins as a hyperplasia of the connective tissue core of the marginal gingiva and increases by its proliferation and expansion beyond the crest of the gingival margin. An inflammatory infiltrate may be found at the bottom of the sulcus or pocket. Cyclosporine enlargements usually involve more highly vascularized connective tissue, with foci of chronic inflammatory cells (particularly plasma cells).[74]

The "mature" phenytoin enlargement has a fibroblast-to-collagen ratio that is equal to that of normal gingiva from normal individuals, which suggests that, at some point in the development of the lesion, fibroblastic proliferation must have been abnormally high.[43] Recurring phenytoin enlargements appear as granulation tissue composed of numerous young capillaries and fibroblasts and irregularly arranged collagen fibrils with occasional lymphocytes.

Anticonvulsants

The first drug-induced gingival enlargements reported were those produced by phenytoin (Dilantin). Dilantin is a hydantoin that was introduced by Merritt and Putnam[68] in 1938 for the treatment of all forms of epilepsy, except petit mal seizures. Shortly thereafter, its relationship with gingival enlargement was reported.[35,57]

Other hydantoins that are known to induce gingival enlargement are ethotoin (Peganone) and mephenytoin (Mesantoin). Other anticonvulsants that have the same side effect are the succinimides (ethosuximide [Zarontin], methsuximide [Celontin]) and valproic acid (Depakene).[38]

Gingival enlargement occurs in about 50% of patients receiving the drug,[109] although different authors have reported incidences from 3% to 84.5%.[2,35,79] It occurs more often in younger patients.[5] Its occurrence and severity are not necessarily related to the dosage after a threshold level has been exceeded.[96] Phenytoin appears in the saliva. There is no consensus, however, regarding whether the severity of the overgrowth is related to the levels of phenytoin in plasma or saliva.[2,5,6,41,115] Some reports indicate a relationship between the drug dosage and the degree of gingival overgrowth.[54,58]

Tissue culture experiments indicate that phenytoin stimulates the proliferation of fibroblast-like cells[97] and epithelium.[98] Two analogs of phenytoin (1-allyl-5-phenylhydantoinate and 5-methyl 5-phenylhydantoinate) have a similar effect on fibroblast-like cells.[98] Fibroblasts from a phenytoin-induced gingival overgrowth show increased synthesis of sulfated glycosaminoglycans in vitro.[53] Phenytoin may induce a decrease in collagen degradation as a result of the production of an inactive fibroblastic collagenase.[42]

Experimental attempts to induce gingival enlargement with phenytoin administration in laboratory animals have only been successful in the cat,[50] the ferret, and the *Macaca speciosa* monkey.[103] In experimental animals, phenytoin causes gingival enlargement that is independent of local inflammation.

In cats, one of the metabolic products of phenytoin is 5-(parahydroxyphenyl)-5-phenylhydantoin; the administration of this metabolite to cats also induces gingival enlargement in some cases. This led Hassell and colleagues[43] to hypothesize that gingival enlargement may result from the genetically determined ability or inability of the host to deal effectively with the prolonged administration of phenytoin.

The systemic administration of phenytoin accelerates the healing of gingival wounds in nonepileptic humans[100] and increases the tensile strength of healing abdominal wounds in rats.[25,99] The administration of phenytoin may precipitate megaloblastic anemia[65] and folic acid deficiency.[104]

In conclusion, the pathogenesis of gingival enlargement induced by phenytoin is not known, but some evidence links it to a direct effect on specific, genetically predetermined subpopulations of fibroblasts; the inactivation of collagenase; and plaque-induced inflammation.

Immunosuppressants

Cyclosporine is a potent immunosuppressive agent that is used to prevent organ transplant rejection and to treat several diseases of

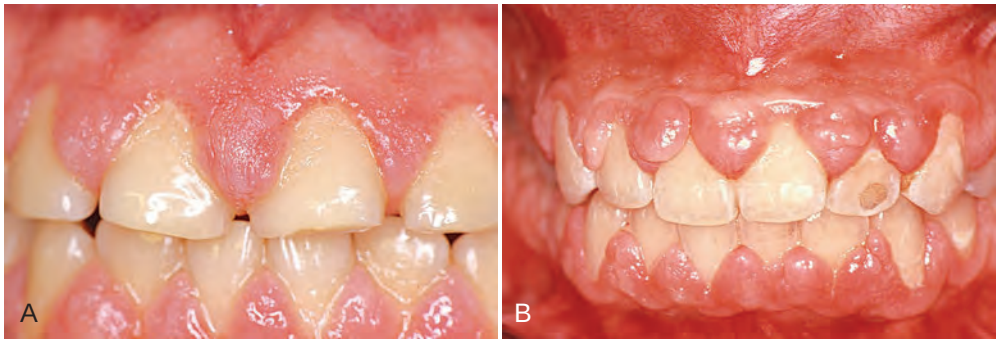

Figure 16-10 Cyclosporine-associated gingival enlargement. **A,** Mild involvement located particularly on the papillae between teeth #9 and #10 and teeth #10 and #11. **B,** Advanced generalized enlargement.

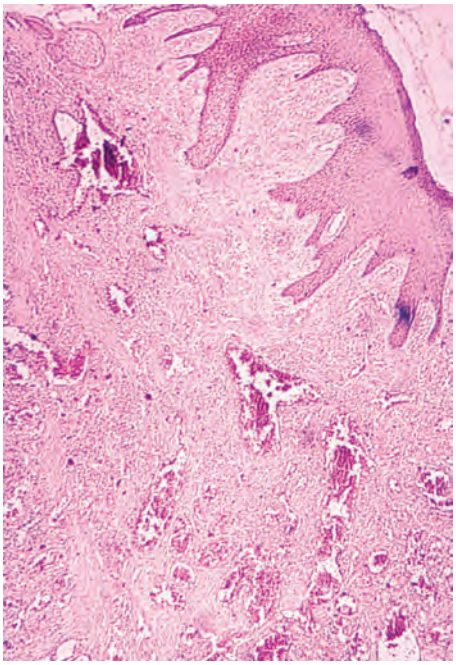

Figure 16-11 Microscopic view of cyclosporine-associated gingival enlargement. Note the epithelial hyperplasia and fibrous stroma with abundant vascularization.

autoimmune origin.[20] Its exact mechanism of action is not well known, but it appears to selectively and reversibly inhibit helper T cells, which play a role in cellular and humoral immune responses. Cyclosporine A (Sandimmune, Neoral) is administered intravenously or by mouth, and dosages of more than 500 mg/day have been reported to induce gingival overgrowth.[24]

Cyclosporine-induced gingival enlargement is more vascularized than phenytoin enlargement (Figures 16-10 and 16-11).[85,91,117] Its occurrence varies, according to different studies, from 25% to 70%.[88] It affects children more frequently, and its magnitude appears to be related more to the plasma concentration than to the patient's periodontal status.[95] Gingival enlargement is greater in patients who are medicated with both cyclosporine and calcium channel blockers.[101,111,112]

The microscopic finding of many plasma cells plus the presence of an abundant amorphous extracellular substance has suggested that the enlargement is a hypersensitivity response to the cyclosporine.[67]

In experimental animals (rats), the oral administration of cyclosporine was also reported to induce the abundant formation of new cementum.[4]

In addition to gingival enlargement, cyclosporine induces other major side effects such as nephrotoxicity, hypertension, and hypertrichosis. Another immunosuppressive drug, tacrolimus, has been used effectively; it is also nephrotoxic, but it results in much less severe hypertension, hypertrichosis, and gingival overgrowth.[7,70,102]

Calcium Channel Blockers

Calcium channel blockers are drugs that were developed for the treatment of cardiovascular conditions such as hypertension, angina pectoris, coronary artery spasms, and cardiac arrhythmias. They inhibit calcium ion influx across the cell membrane of heart and smooth muscle cells, thereby blocking the intracellular mobilization of calcium. This induces the direct dilation of the coronary arteries and arterioles and improves oxygen supply to the heart muscle; it also reduces hypertension by dilating the peripheral vasculature.

These drugs are the *dihydropyridine derivatives* (amlodipine [Lotrel, Norvasc], felodipine [Plendil], nicardipine [Cardene], nifedipine [Adalat, Procardia]); the *benzothiazine derivatives* (diltiazem [Cardizem, Dilacor XR, Tiazac]); and the *phenylalkylamine derivatives* (verapamil [Calan, Isoptin, Verelan, Covera HS]).[38]

Some of these drugs can induce gingival enlargement. Nifedipine, which is one of the most often used,[39,62,64,76] induces gingival enlargement in 20% of patients.[8] Diltiazem, felodipine, nitrendipine, and verapamil also induce gingival enlargement.[14,46] The dihydropyridine derivative isradipine can replace nifedipine in some cases; it does not induce gingival overgrowth.[114]

Nifedipine is also used with cyclosporine in kidney transplant recipients, and the combined use of both drugs induces larger overgrowths.[13] Nifedipine gingival enlargement has been induced experimentally in rats, where it appears to be dose dependent[32]; in humans, however, this dose dependency is not clear. One report indicates that nifedipine increases the risk of periodontal destruction in patients with type 2 diabetes mellitus.[63]

Idiopathic Gingival Enlargement

Idiopathic gingival enlargement is a rare condition of undetermined cause. It has been designated by such terms as *gingivostomatosis, elephantiasis, idiopathic fibromatosis, hereditary gingival hyperplasia,* and *congenital familial fibromatosis.*

General Information

Clinical Features. The enlargement affects the attached gingiva as well as the gingival margin and the interdental papillae. This is in contrast with phenytoin-induced overgrowth, which is often limited to the gingival margin and the interdental papillae (see Figure 16-6). The facial and lingual surfaces of the mandible and maxilla are generally affected, but the involvement may be limited to either jaw. The enlarged gingiva is pink, firm, and almost

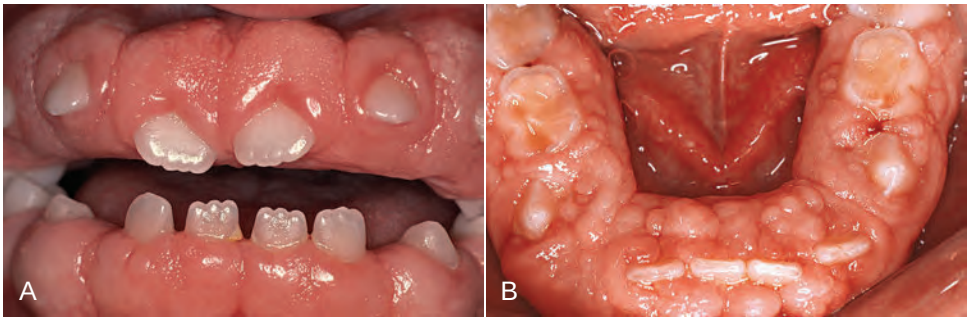

Figure 16-12 Idiopathic gingival enlargement in 14-year-old white male patient. **A,** Facial view. The gingiva is firm, with a nodular, pebbled surface and partially covering the crowns of the teeth. **B,** Occlusal view of the lower jaw.

leathery in consistency, and it has a characteristic minutely pebbled surface (Figure 16-12). In severe cases, the teeth are almost completely covered, and the enlargement projects into the oral vestibule. The jaws appear distorted as a result of the bulbous enlargement of the gingiva. Secondary inflammatory changes are common at the gingival margin.

Histopathology. Idiopathic gingival enlargement shows a bulbous increase in the amount of connective tissue that is relatively avascular and that consists of densely arranged collagen bundles and numerous fibroblasts. The surface epithelium is thickened and acanthotic, with elongated rete pegs.

Etiology. The cause is unknown, and thus the condition is designated as "idiopathic." Some cases have a hereditary basis,[28,118,119] but the genetic mechanisms involved are not well understood. A study of several families found the mode of inheritance to be autosomal recessive in some cases and autosomal dominant in others.[52,83] In some families, the gingival enlargement may be linked to the impairment of physical development.[56] The enlargement usually begins with the eruption of the primary or secondary dentition, and it may regress after extraction, which suggests that the teeth (or the plaque attached to them) may be initiating factors. The presence of bacterial plaque is a complicating factor.

Gingival enlargement has been described in tuberous sclerosis, which is an inherited condition characterized by a triad of epilepsy, mental deficiency, and cutaneous angiofibromas.[106,110]

Enlargements Associated with Systemic Diseases

Many systemic diseases can develop oral manifestations that may include gingival enlargement. These diseases and conditions can affect the periodontium via two different mechanisms:

1. *The magnification of an existing inflammation initiated by dental plaque.* This group of diseases, which are discussed in the Conditioned Enlargements section, includes some hormonal conditions (e.g., pregnancy, puberty), some nutritional diseases (e.g., vitamin C deficiency), and some cases in which the systemic influence is not identified (i.e., nonspecific conditioned enlargement).
2. *The manifestation of the systemic disease independently of the inflammatory status of the gingiva.* These mechanisms are described in the Systemic Diseases that Cause Gingival Enlargement section and the Neoplastic Enlargement (Gingival Tumors) section.

Conditioned Enlargements

Conditioned enlargements occur when the systemic condition of the patient exaggerates or distorts the usual gingival response to dental plaque. The specific manner in which the clinical picture of conditioned gingival enlargement differs from that of chronic gingivitis depends on the nature of the modifying systemic influence. *Bacterial plaque is necessary for the initiation of this type of enlargement.* However, plaque is not the sole determinant of the nature of the clinical features.

The three types of conditioned gingival enlargement are *hormonal* (pregnancy, puberty), *nutritional* (associated with vitamin C deficiency), and *allergic*. Nonspecific conditioned enlargement is also seen.

Enlargement in Pregnancy. Pregnancy gingival enlargement may be marginal and generalized, or it may occur as a single mass or multiple tumorlike masses (see Chapters 11 and 12).

During pregnancy, there is an increase in levels of both progesterone and estrogen, which by the end of the third trimester reach levels 10 and 30 times the levels present during the menstrual cycle, respectively.[1] These hormonal changes induce changes in vascular permeability, which leads to gingival edema and an increased inflammatory response to dental plaque. The subgingival microbiota may also undergo changes, including an increase in *Prevotella intermedia.*[60,82]

Marginal Enlargement. Marginal gingival enlargement during pregnancy results from the aggravation of previous inflammation, and its incidence has been reported as 10%[18] and 70%.[120]

The clinical picture varies considerably. The enlargement is usually generalized, and it tends to be more prominent interproximally than on the facial and lingual surfaces. The enlarged gingiva is bright red or magenta, soft, and friable, and it has a smooth, shiny surface. Bleeding occurs spontaneously or on slight provocation.

Tumorlike Gingival Enlargement. The so-called pregnancy tumor is not a neoplasm; it is an inflammatory response to bacterial plaque, and it is modified by the patient's condition. It usually appears after the third month of pregnancy, but it may occur earlier. The reported incidence is 1.8% to 5%.[66]

The lesion appears as a discrete, mushroomlike, flattened spherical mass that protrudes from the gingival margin or more often from the interproximal space, and it is attached by a sessile or pedunculated base (Figure 16-13). It tends to expand laterally, and pressure from the tongue and the cheek perpetuates its flattened appearance. It is generally dusky red or magenta in color; it has a smooth, glistening surface that often exhibits numerous deep-red, pinpoint markings. It is a superficial lesion that usually does not invade the underlying bone. The consistency varies; the mass is usually semifirm, but it may have varying degrees of softness and friability. It is usually painless unless its size and shape foster the accumulation of debris under its margin or interfere with occlusion, in which case painful ulceration may occur.

Figure 16-13 Localized gingival enlargement in a 27-year-old pregnant patient.

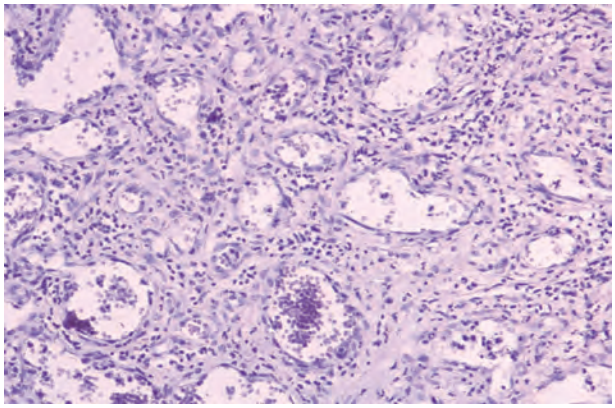

Figure 16-14 Microscopic view of gingival enlargement in pregnant patient showing an abundance of blood vessels and interspersed inflammatory cells.

Although the microscopic findings are characteristic of gingival enlargement during pregnancy, they are not pathognomonic, because they cannot be used to differentiate pregnant and nonpregnant patients.[66]

Histopathology. Gingival enlargement in pregnancy is called *angiogranuloma.* Both marginal and tumorlike enlargements consist of a central mass of connective tissue, with numerous diffusely arranged, newly formed, and engorged capillaries lined by cuboid endothelial cells (Figure 16-14) as well as a moderately fibrous stroma with varying degrees of edema and chronic inflammatory infiltrate. The stratified squamous epithelium is thickened, with prominent rete pegs and some degree of intracellular and extracellular edema, prominent intercellular bridges, and leukocytic infiltration.

Most gingival disease during pregnancy can be prevented by the removal of plaque and calculus as well as by the institution of fastidious oral hygiene at the outset. During pregnancy, treatment of the gingiva that is limited to the removal of tissue without the complete elimination of local irritants is followed by the recurrence of gingival enlargement. Although spontaneous reduction in the size of gingival enlargement typically follows the termination of pregnancy, complete elimination of the residual inflammatory lesion requires the removal of all plaque deposits and factors that favor its accumulation. For additional information about gingival disease during pregnancy, see Chapter 58.

Enlargement in Puberty. Enlargement of the gingiva is sometimes seen during puberty (see Chapter 11). It occurs in both male and female adolescents, and it appears in areas of plaque accumulation.

Figure 16-15 Conditioned gingival enlargement during puberty in a 13-year-old boy.

The size of the gingival enlargement greatly exceeds that usually seen in association with comparable local factors. It is marginal and interdental, and it is characterized by prominent bulbous interproximal papillae (Figure 16-15). Often, only the facial gingivae are enlarged, and the lingual surfaces are relatively unaltered; the mechanical action of the tongue and the excursion of food prevent a heavy accumulation of local irritants on the lingual surface.

Gingival enlargement during puberty has all of the clinical features that are generally associated with chronic inflammatory gingival disease. It is the degree of enlargement and its tendency to recur in the presence of relatively scant plaque deposits that distinguish pubertal gingival enlargement from uncomplicated chronic inflammatory gingival enlargement. After puberty, the enlargement undergoes spontaneous reduction, but does not disappear completely until the plaque and calculus are removed.

A longitudinal study of 127 children between the ages of 11 and 17 years demonstrated a high initial prevalence of gingival enlargement that tended to decline with age.[107] When the mean number of inflamed gingival sites per child was determined and correlated with the time at which the maximum number of inflamed sites was observed and with the oral hygiene index at that time, a pubertal peak in gingival inflammation unrelated to oral hygiene factors clearly occurred. A longitudinal study of the subgingival microbiota of children between the ages of 11 and 14 years and their association with clinical parameters implicated *Capnocytophaga* species in the initiation of pubertal gingivitis.[71] Other studies have reported that hormonal changes coincide with an increase in the proportion of *Prevotella intermedia* and *Prevotella nigrescens.*[73,116]

Histopathology. The microscopic appearance of gingival enlargement during puberty is chronic inflammation with prominent edema and associated degenerative changes.

Enlargement in Vitamin C Deficiency. The enlargement of the gingiva is generally included in classic descriptions of scurvy. Acute vitamin C deficiency itself does not cause gingival inflammation, but it does cause hemorrhage, collagen degeneration, and edema of the gingival connective tissue. These changes modify the response of the gingiva to plaque to the extent that the normal defensive delimiting reaction is inhibited and the extent of the inflammation is exaggerated,[33,34] thereby resulting in the massive gingival enlargement seen in patients with scurvy (Figure 16-16) (see Chapter 27).

Gingival enlargement with vitamin C deficiency is marginal; the gingiva is bluish red, soft, and friable, and it has a smooth, shiny surface. Hemorrhage that occurs either spontaneously or on slight provocation as well as surface necrosis with pseudomembrane formation are common features.

Histopathology. In patients with vitamin C deficiency, the gingiva has a chronic inflammatory cellular infiltration with a superficial acute response. There are scattered areas of hemorrhage with engorged capillaries. Marked diffuse edema, collagen degeneration, and a scarcity of collagen fibrils and fibroblasts are striking findings.

Plasma Cell Gingivitis. Plasma cell gingivitis consists of a mild marginal gingival enlargement that extends to the attached gingiva. The gingiva appears red, friable, and sometimes granular, and it bleeds easily; usually it does not induce a loss of attachment (Figure 16-17). This lesion is located in the oral aspect of the attached gingiva and therefore differs from plaque-induced gingivitis.

Histopathology. In patients with plasma cell gingivitis, the oral epithelium shows spongiosis and infiltration with inflammatory cells; ultrastructurally, there are signs of damage in the lower spinous layers and the basal layers. The underlying connective tissue contains a dense infiltrate of plasma cells that also extends to the oral epithelium, thereby inducing a dissecting type of injury.[75]

An associated cheilitis and glossitis have been reported.[55,93] Plasma cell gingivitis is thought to be allergic in origin and possibly related to components of chewing gum, dentifrices, or various diet components. The cessation of exposure to the allergen brings resolution of the lesion.

In rare instances, marked inflammatory gingival enlargements with a predominance of plasma cells can appear; these are associated with rapidly progressive periodontitis.[77]

Figure 16-16 Gingival enlargement in a patient with vitamin C deficiency. Note the prominent hemorrhagic areas. *(Courtesy Dr. Gerald Shklar, Boston, MA.)*

A solitary plasma cell tumor or *plasmocytoma* has been described in the nasopharynx and rarely in the oral mucosa.[12,91] It is a slow-growing pedunculated tumor with a pink and smooth surface, and it is composed of normal plasma cells. It is usually benign; however, in rare cases, it can be an oral manifestation of multiple myeloma, which is a malignant tumor of the bone marrow.

Nonspecific Conditioned Enlargement (Pyogenic Granuloma). *Pyogenic granuloma* is a tumorlike gingival enlargement that is considered an exaggerated conditioned response to minor trauma (Figure 16-18). The exact nature of the systemic conditioning factor has not been identified.[11] Pyogenic granuloma is similar in clinical and microscopic appearance to the conditioned gingival enlargement seen during pregnancy. The differential diagnosis is based on the patient's history.

Treatment consists of the removal of the lesions plus the elimination of irritating local factors. The recurrence rate is about 15%.

Systemic Diseases that Cause Gingival Enlargement

Several systemic diseases may result in gingival enlargement by different mechanisms. These are uncommon cases, and they are only briefly discussed.

Leukemia. Leukemic gingival enlargement may be diffuse or marginal and localized or generalized (see Chapter 11). It may appear as a diffuse enlargement of the gingival mucosa, an oversized extension of the marginal gingiva (Figure 16-19), or a discrete tumorlike interproximal mass.

Clinical Features. In patients with leukemic enlargement, the gingiva is generally bluish red, and it has a shiny surface. The consistency is moderately firm, but there is a tendency toward friability and hemorrhage that occur either spontaneously or with slight irritation. Acute painful necrotizing ulcerative inflammatory involvement may occur in the crevice formed at the junction of the enlarged gingiva and the contiguous tooth surfaces.

Patients with leukemia may also have a simple chronic inflammation without the involvement of leukemic cells, and they may present with the same clinical and microscopic features seen in patients without the systemic disease. Most cases, however, reveal features of both simple chronic inflammation and leukemic infiltrate.

True leukemic enlargement often occurs with acute leukemia, but it may also be seen with subacute leukemia. It seldom occurs with chronic leukemia.

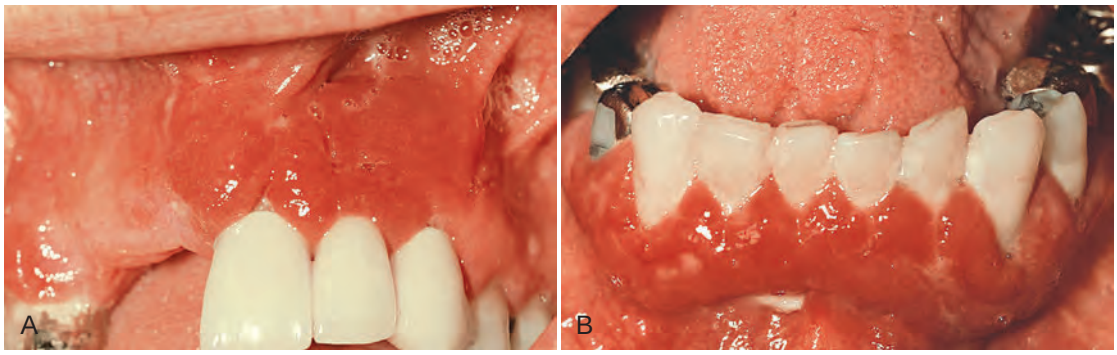

Figure 16-17 Plasma cell gingivitis. **A,** Diffuse lesions on the facial surface of the anterior maxilla. **B,** Mandibular lesions. *(Courtesy Dr. Kim D. Zussman, Thousand Oaks, CA.)*

Figure 16-18 Pyogenic granuloma. *(Courtesy Dr. Silvia Oreamuno, San José, Costa Rica.)*

Figure 16-19 Leukemic gingival enlargement (acute myelocytic leukemia). *(Courtesy Dr. Spencer Wolfe, Dublin, Ireland.)*

Histopathology. Gingival enlargements in leukemic patients show various degrees of chronic inflammation. Mature leukocytes and areas of connective tissue are infiltrated with a dense mass of immature and proliferating leukocytes, the specific nature of which varies with the type of leukemia. Engorged capillaries, edematous and degenerated connective tissue, and epithelium with various degrees of leukocytic infiltration and edema are found. Isolated surface areas of acute necrotizing inflammation with a pseudomembranous meshwork of fibrin, necrotic epithelial cells, polymorphonuclear leukocytes, and bacteria are often seen.

Granulomatous Diseases.

Wegener's Granulomatosis. Wegener's granulomatosis is a rare disease that is characterized by acute granulomatous necrotizing lesions of the respiratory tract, including nasal and oral defects. Renal lesions develop, and acute necrotizing vasculitis affects the blood vessels. The initial manifestations of Wegener's granulomatosis may involve the orofacial region and include oral mucosal ulceration, gingival enlargement,[47] abnormal tooth mobility, exfoliation of teeth, and delayed healing response.[17]

The granulomatous papillary enlargement is reddish purple and bleeds easily on stimulation (see Figure 19-30).

Histopathology. Chronic inflammation involves scattered giant cells, foci of acute inflammation, and microabscesses covered by a thin, acanthotic epithelium. Vascular changes have not been described with gingival enlargement in patients with Wegener's granulomatosis, probably because of the small size of the gingival blood vessels.[51]

The cause of Wegener's granulomatosis is unknown, but the condition is considered an immunologically mediated tissue injury.[23] At one time, the usual outcome for patients with this condition was death from kidney failure within a few months, but more recently the use of immunosuppressive drugs has produced prolonged remissions in more than 90% of patients.[59]

Sarcoidosis. Sarcoidosis is a granulomatous disease of unknown etiology. It starts in individuals during their twenties or thirties, it predominantly affects blacks, and it can involve almost any organ, including the gingiva, in which a red, smooth, painless enlargement may appear.

Histopathology. Sarcoid granulomas consist of discrete, noncaseating whorls of epithelioid cells and multinucleated, foreign-body–type giant cells with peripheral mononuclear cells.[87]

Neoplastic Enlargement (Gingival Tumors)

This section provides only a brief description of some of the more common neoplastic and pseudoneoplastic lesions of the gingiva. The reader is referred to oral pathology texts for more comprehensive coverage.[87,91]

Benign Tumors of the Gingiva

Epulis is a generic term that is used clinically to designate all discrete tumors and tumorlike masses of the gingiva. It serves to locate the tumor but not to describe it. Most lesions referred to by this term are inflammatory rather than neoplastic.

Neoplasms account for a comparatively small proportion of gingival enlargements, and they make up a small percentage of the total number of oral neoplasms. In a survey of 257 oral tumors, approximately 8% occurred on the gingiva.[69] In another study of 868 growths of the gingiva and palate (of which 57% were neoplastic and the remainder inflammatory), the following incidences of tumors were noted: carcinoma, 11.0%; fibroma, 9.3%; giant cell tumor, 8.4%; papilloma, 7.3%; leukoplakia, 4.9%; mixed tumor (salivary gland type), 2.5%; angioma, 1.5%; osteofibroma, 1.3%; sarcoma, 0.5%; melanoma, 0.5%; myxoma, 0.45%; fibropapilloma, 0.4%; adenoma, 0.4%; and lipoma, 0.3%.[9]

Fibroma. Fibromas of the gingiva arise from the gingival connective tissue or from the periodontal ligament. They are slow-growing spherical tumors that tend to be firm and nodular but that may be soft and vascular. Fibromas are usually pedunculated. Hard fibromas of the gingiva are rare; most of the lesions that are diagnosed clinically as "fibromas" are inflammatory enlargements.[92]

Histopathology. Fibromas are composed of bundles of well-formed collagen fibers with scattered fibrocytes and variable vascularity.

The so-called giant cell fibroma contains multinucleated fibroblasts. In another variant, mineralized tissue (bone, cementum-like material, and dystrophic calcifications) may be found; this type of fibroma is called *peripheral ossifying fibroma.*

Papilloma. Papillomas are benign proliferations of surface epithelium that are, in many (but not all) cases, associated with the human papillomavirus (HPV). Gingival papillomas appear as solitary wartlike or cauliflower-like protuberances (Figure 16-20). They may be small and discrete, or they may be broad, hard elevations with minutely irregular surfaces.

Histopathology. The papilloma lesion consists of fingerlike projections of stratified squamous epithelium that are often hyperkeratotic, with central cores of fibrovascular connective tissue.

Peripheral Giant Cell Granuloma. Giant cell lesions of the gingiva arise interdentally or from the gingival margin; they occur most frequently on the labial surface, and they may be sessile or pedunculated. They vary in appearance from smooth, regularly outlined masses to irregularly shaped, multilobulated

protuberances with surface indentations (Figure 16-21). The ulceration of the margin is occasionally seen. The lesions are painless, they vary in size, and they may cover several teeth. They may be firm or spongy, and their color varies from pink to deep red or purplish blue. There are no pathognomonic clinical features whereby these lesions can be differentiated from other forms of gingival enlargement. Microscopic examination is required for definitive diagnosis.

The prefix *peripheral* is needed to differentiate them from comparable lesions that originate within the jawbone (i.e., central giant cell granulomas).

In some cases, the giant cell granuloma of the gingiva is locally invasive and causes destruction of the underlying bone (Figure 16-22). Complete removal leads to uneventful recovery.

Figure 16-20 Papilloma of the gingiva in a 26-year-old man.

Figure 16-21 Gingival giant cell granuloma.

Histopathology. The giant cell granuloma has numerous foci of multinuclear giant cells and hemosiderin particles in a connective tissue stroma (see Figure 16-22). Areas of chronic inflammation are scattered throughout the lesion, with acute involvement occurring at the surface. The overlying epithelium is usually hyperplastic, with ulceration at the base. Bone formation occasionally occurs within the lesion (Figure 16-23).

Central Giant Cell Granuloma. Giant cell lesions arise within the jaws and produce central cavitation. They occasionally create a deformity of the jaw that makes the gingiva appear enlarged.

Mixed tumors, salivary gland types of tumors, and plasmacytomas of the gingiva have also been described but are not often seen.

Leukoplakia. *Leukoplakia* is a strictly clinical term defined by the World Health Organization as a white patch or plaque that does not rub off and that cannot be diagnosed as any other disease. The cause of leukoplakia remains obscure, although it is associated with the use of tobacco (smoke or smokeless). Other probable factors are *Candida albicans,* HPV-16 and HPV-18, and trauma. Leukoplakia of the gingiva varies in appearance from a grayish white, flattened, scaly lesion (Figure 16-24) to a thick, irregularly shaped, keratinous plaque.

Most leukoplakias (80%) are benign; the remaining 20% are malignant or premalignant, and only 3% of these are invasive carcinomas.[31] The biopsy of all leukoplakias is necessary, with the most suspicious area being selected, to arrive at a correct diagnosis and to then institute proper therapy.[31,91]

Histopathology. Leukoplakia exhibits hyperkeratosis and acanthosis. Premalignant and malignant cases have a variable degree of atypical epithelial changes that may be mild, moderate, or severe, depending on the extent of involvement of the epithelial layers. When dysplastic changes involve all layers, it is diagnosed as a *carcinoma in situ,* and this may become invasive carcinoma when the basement membrane is breached.[31] Inflammatory involvement of the underlying connective tissue is a common associated finding.

Gingival Cyst. Gingival cysts of microscopic proportions are common, but they seldom reach a clinically significant size.[72] When they do, they appear as localized enlargements that may involve the marginal and attached gingiva. The cysts occur in the

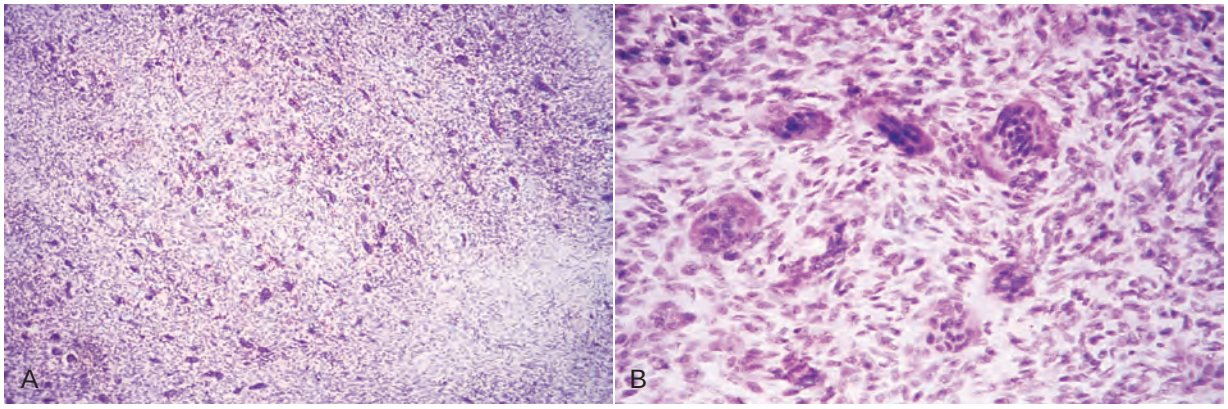

Figure 16-22 **A,** Microscopic survey of a peripheral giant cell granuloma. **B,** High-power study of the lesion demonstrating the giant cells and the intervening stroma that make up the major portion of the mass.

mandibular canine and premolar areas, most often on the lingual surface. They are painless, but, with expansion, they may cause erosion of the surface of the alveolar bone. The gingival cyst should be differentiated from the lateral periodontal cyst (see Chapter 20), which arises within the alveolar bone adjacent to the root and which is developmental in origin. Gingival cysts develop from odontogenic epithelium or from surface or sulcular epithelium traumatically implanted in the area. Removal is followed by uneventful recovery.

Figure 16-23 Bone destruction in the interproximal space between the canine and lateral incisor caused by the extension of a peripheral giant cell reparative granuloma of the gingiva. *(Courtesy Dr. Sam Toll.)*

Figure 16-24 Leukoplakia of the gingiva.

Histopathology. A gingival cyst cavity is lined by a thin, flattened epithelium with or without localized areas of thickening. Less frequently, the following types of epithelium can be found: unkeratinized stratified squamous epithelium, keratinized stratified squamous epithelium, and parakeratinized epithelium with palisading basal cells.[16]

Other Benign Masses. Other benign tumors have also been described as rare or infrequent findings in the gingiva. They include nevus,[10] myoblastoma,[36] hemangioma,[108] neurilemoma,[31] neurofibroma,[81] mucus-secreting cysts (mucoceles),[113] and ameloblastoma.[105]

Malignant Tumors of the Gingiva

Carcinoma. Oral cancer accounts for less than 3% of all malignant tumors in the body, but it is the sixth most common cancer in males and the twelfth most common in females.[74] The gingiva is not a frequent site of oral malignancy, accounting for only 6% of oral cancers.[61]

Squamous cell carcinoma is the most common malignant tumor of the gingiva. It may be *exophytic,* presenting as an irregular outgrowth, or *ulcerative,* appearing as flat, erosive lesions. It is often symptom free, going unnoticed until complicated by inflammatory changes that may mask the neoplasm but cause pain; sometimes it becomes evident after tooth extraction. These masses are locally invasive, and they involve the underlying bone and periodontal ligament of adjoining teeth and the adjacent mucosa (Figure 16-25). Metastasis is usually confined to the region above the clavicle; however, more extensive involvement may include the lung, liver, or bone.

Malignant Melanoma. Malignant melanoma is a rare oral tumor that tends to occur in the hard palate and maxillary gingiva of older persons.[74,84] It is usually darkly pigmented, and it is often preceded by localized pigmentation.[21] It may be flat or nodular, and it is characterized by rapid growth and early metastasis. It arises from melanoblasts in the gingiva, cheek, or palate. Infiltration into the underlying bone and metastasis to cervical and axillary lymph nodes are common.

Sarcoma. Fibrosarcoma, lymphosarcoma, and reticulum cell sarcoma of the gingiva are rare; only isolated cases have been described in the literature.[40,109] Kaposi's sarcoma often occurs in the oral cavity of patients with acquired immunodeficiency syndrome, particularly in the palate and the gingiva (see Chapter 26).

Metastasis. Tumor metastasis to the gingiva occurs infrequently. Such metastasis has been reported with various tumors, including adenocarcinoma of the colon,[49] lung carcinoma, melanoma,[30] renal

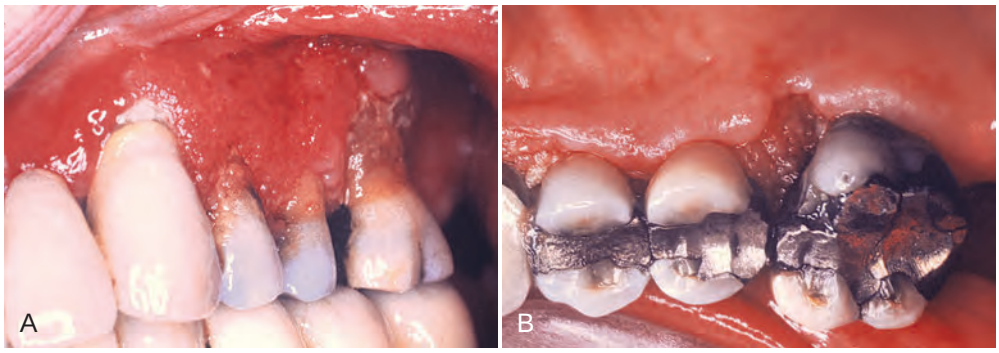

Figure 16-25 Squamous cell carcinoma of the gingiva. **A,** Facial view. Note the extensive verrucous involvement. **B,** Palatal view. Note the mulberry-like tissue emerging between the second premolar and the first molar.

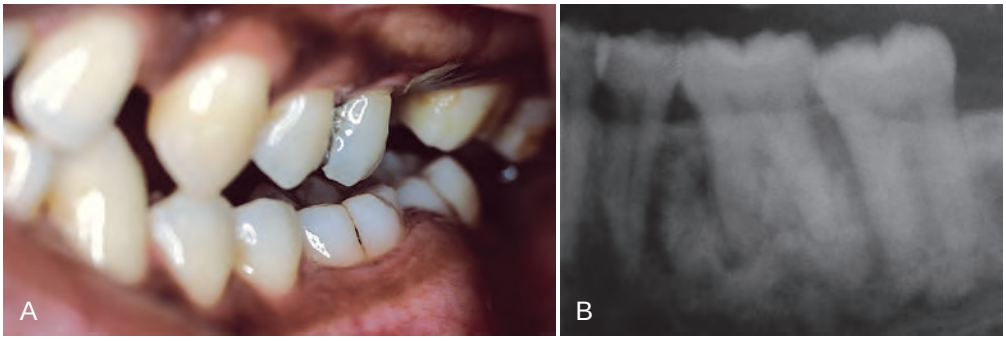

Figure 16-26 **A,** Apparent gingival enlargement associated with bone augmentation in a patient with fibrous dysplasia. **B,** Radiograph of the case shown in **A** depicting a ground-glass, mottled pattern.

cell carcinoma,[15] hypernephroma,[80] chondrosarcoma,[109] and testicular tumor.[29]

The low incidence of oral malignancy should not mislead the clinician. Ulcerations that do not respond to therapy in the usual manner as well as all gingival tumors and tumorlike lesions must be biopsied and submitted for microscopic diagnosis (see Chapter 34).

False Enlargement

False enlargements are not true enlargements of the gingival tissues, but they may appear as such as a result of increases in the size of the underlying osseous or dental tissues. The gingiva usually presents with no abnormal clinical features except the massive increase in the size of the area.

Underlying Osseous Lesions

Enlargement of the bone subjacent to the gingival area occurs most often with tori and exostoses, but it can also occur with Paget's disease, fibrous dysplasia, cherubism, central giant cell granuloma, ameloblastoma, osteoma, and osteosarcoma. Figure 16-26 shows fibrous dysplasia (florid type) in a 38-year-old black woman that induced an osseous enlargement in the mandibular molar area that appeared to be a gingival enlargement. The gingival tissue can appear normal, or it may have unrelated inflammatory changes.

Underlying Dental Tissues

During the various stages of eruption, particularly of the primary dentition, the labial gingiva may show a bulbous marginal distortion caused by the superimposition of the bulk of the gingiva on the normal prominence of the enamel in the gingival half of the crown. This enlargement has been called *developmental enlargement,* and often persists until the junctional epithelium has migrated from the enamel to the cementoenamel junction.

In a strict sense, developmental gingival enlargements are physiologic, and they usually present no problems. However, when such enlargement is complicated by marginal inflammation, the composite picture gives the impression of extensive gingival enlargement (Figure 16-27). Treatment to alleviate the marginal inflammation—rather than resection of the enlargement—is sufficient for these patients.

Figure 16-27 Developmental gingival enlargement. The normal bulbous contour of the gingiva around the incompletely erupted anterior teeth is accentuated by chronic inflammation.

NOTE: Chapter 85 in the online version of this book presents numerous examples of gingival enlargements.

Suggested Readings

Aas E: *Hyperplasia gingivae diphenylhydantoinea*, Oslo, 1963, Universitetsforlaget.

Fowler CB: Benign and malignant neoplasms of the periodontium. *Periodontol 2000* 21:33, 1999.

Hallmon WW, Rossmann JA: The role of drugs in the pathogenesis of gingival overgrowth. *Periodontol 2000* 21:176, 1999.

Kuffer R, Lombardi T: Premalignant lesions of the oral mucosa. A discussion about the place of oral intraepithelial neoplasia (OIN). *Oral Oncol* 38:125, 2002.

Nuki K, Cooper SH: The role of inflammation in the pathogenesis of gingival enlargement during the administration of diphenylhydantoin sodium in cats. *J Periodontal Res* 7:91, 1972.

Rees TD: Drugs and oral disorders. *Periodontol 2000* 18:21, 1998.

Sapp JP, Eversole LR, Wysocki GP: *Contemporary Oral and Maxillofacial Pathology*, ed 2, 2004, Mosby, Elsevier.

Seymour RA, Thomason JM, Ellis JS: The pathogenesis of drug-induced gingival overgrowth. *J Clin Periodontol* 23:165, 1996.

References

References for this chapter are found on the companion website www.expertconsult.com.

References

1. Amar S, Chung KM: Influence of hormonal variation on the periodontium in women. *Periodontol 2000* 6:79, 1994.
2. Angelopoulos AP, Goaz PW: Incidence of diphenylhydantoin gingival hyperplasia. *Oral Surg* 34:898, 1972.
3. Ashrafi SH, Slaski K, Thu K, et al: Scanning electron microscopy of cyclosporine-induced gingival overgrowth. *Scan Microsc* 10:219, 1996.
4. Ayanoglou CM, Lesty C: New cementum formation induced by cyclosporin A: a histological, ultrastructural and histomorphometric study in the rat. *J Periodontol* 32:543, 1997.
5. Babcock JR: Incidence of gingival hyperplasia associated with Dilantin therapy in a hospital population. *J Am Dent Assoc* 71:1447, 1965.
6. Babcock JR, Nelson GH: Gingival hyperplasia and Dilantin content of saliva. *J Am Dent Assoc* 68:195, 1964.
7. Bader G, Lejeune S, Messner M: Reduction of cyclosporine-induced gingival overgrowth following a change to tacrolimus: a case history involving a liver transplant patient. *J Periodontol* 69:729, 1988.
8. Barclay S, Thomason JM, Idle JR, et al: The incidence and severity of nifedipine-induced gingival overgrowth. *J Clin Periodontol* 19:311, 1992.
9. Bernick S: Growth of the gingiva and palate. II. Connective tissue tumors. *Oral Surg* 1:1098, 1948.
10. Bernier JL, Tiecke RW: Nevus of the gingiva. *J Oral Surg* 8:165, 1950.
11. Bhaskar SN, Jacoway JR: Pyogenic granuloma: clinical features, incidence, histology and result of treatment. *J Oral Surg* 24:391, 1966.
12. Bhaskar SN, Levin MP, Frisch J: Plasma cell granuloma of periodontal tissues: report of 45 cases. *Periodontics* 6:272, 1988.
13. Bökenkamp A, Bohnhorst B, Beier C, et al: Nifedipine aggravates cyclosporine A—induced hyperplasia. *Pediatr Nephrol* 8:181, 1994.
14. Brown RS, Sein P, Corio R, et al: Nitrendipine-induced gingival hyperplasia. *Oral Surg* 70:593, 1990.
15. Buchner A, Begleiter A: Metastatic renal cell carcinoma in the gingiva mimicking a hyperplastic lesion. *J Periodontol* 51:413, 1980.
16. Buchner A, Hansen AS: The histomorphologic spectrum of the gingival cyst in the adult. *Oral Surg* 48:532, 1979.
17. Buckley DJ, Barrett AP, Bilous AM, et al: Wegener's granulomatosis—are gingival lesions pathognomonic? *J Oral Med* 42:169, 1987.
18. Burket LW: *Oral medicine*, Philadelphia, 1946, Lippincott.
19. Butler RT, Kalkwarf KL, Kaldhal WB: Drug-induced gingival hyperplasia: phenytoin, cyclosporine and nifedipine. *J Am Dent Assoc* 114:56, 1987.
20. Calne R, Rolles K, White DJ, et al: Cyclosporin-A initially as the only immunosuppressant in 34 recipients of cadaveric organs: 32 kidneys, 2 pancreas and 2 livers. *Lancet* 2:1033, 1979.
21. Chaudry AP, Hampel A, Gorlin RJ: Primary malignant melanoma of the oral cavity: a review of 105 cases. *Cancer* 11:923, 1958.
22. Ciancio SG, Yaffe SJ, Catz CC: Gingival hyperplasia and diphenylhydantoin. *J Periodontol* 43:411, 1972.
23. Cotran RS, Kumar V, Robbins SL: *Robbins' pathologic basis of disease*, ed 4, Philadelphia, 1989, Saunders.
24. Daley TD, Wysocki GP, Day C: Clinical and pharmacologic correlations in cyclosporine-induced gingival hyperplasia. *Oral Surg* 62:417, 1986.
25. DaCosta ML, Regan MC, al Sader M, et al: Diphenyl hydantoin sodium promotes early and marked angiogenesis and results in increased collagen deposition and tensile strength in healing wounds. *Surgery* 123:287, 1988.
26. Dallas BM: Hyperplasia of the oral mucosa in an edentulous epileptic. *NZ Dent J* 59:54, 1963.
27. Dreyer WP, Thomas CJ: DPH-induced hyperplasia of the masticatory mucosa in an edentulous epileptic patient. *Oral Surg* 45:701, 1978.
28. Emerson TG: Hereditary gingival hyperplasia: a family pedigree of four generations. *Oral Surg* 19:1, 1965.
29. Fantasia JE, Chen A: A testicular tumor with gingival metastasis. *Oral Surg* 48:64, 1979.
30. Ferreti Bonan PR, Laranjeira AL, Martelli H, Jr, et al: Synchronous metastatic melanoma presenting as gingival and facial swelling: a case report and review of the literature. *J Periodontol* 79:2371, 2008.
31. Fowler CB: Benign and malignant neoplasms of the periodontium. *Periodontol 2000* 21:33, 1999.
32. Fu E, Nieh S, Hiao CT, et al: Nifedipine-induced gingival overgrowth in rats: brief review and experimental study. *J Periodontol* 69:765, 1988.
33. Glickman I: The periodontal tissues of the guinea pig in vitamin C deficiency. *J Dent Res* 27:9, 1948.
34. Glickman I: The effect of acute vitamin C deficiency upon the response of the periodontal tissues of the guinea pig to artificially induced inflammation. *J Dent Res* 27:201, 1948.
35. Glickman I, Lewitus M: Hyperplasia of the gingiva associated with Dilantin (sodium diphenyl hydantoinate) therapy. *J Am Dent Assoc* 28:1991, 1941.
36. Hagen JD, Soule EH, Gores RJ: Granular cell myoblastoma of the oral cavity. *Oral Surg* 14:454, 1961.
37. Hall WB: Dilantin hyperplasia: a preventable lesion. *J Periodontal Res* 4(Suppl):36, 1969.
38. Hallmon WW, Rossmann JA: The role of drugs in the pathogenesis of gingival overgrowth. *Periodontol 2000* 21:176, 1999.
39. Hancock RH, Swan RH: Nifedipine-induced gingival overgrowth. *J Clin Periodontol* 19:12, 1992.
40. Hardman FG: Secondary sarcoma presenting clinical appearance of fibrous epulis. *Br Dent J* 86:109, 1949.
41. Hassell TM: Epilepsy and the oral manifestations of phenytoin therapy. In *Monographs in Oral Science*, New York, 1981, S Karger.
42. Hassell TM: Evidence for production of an inactive collagenase by fibroblasts from phenytoin-enlarged human gingiva. *J Oral Pathol* 11:310, 1982.
43. Hassell TM, Burtner AP, McNeal D, et al: Oral problems and genetic aspects of individuals with epilepsy. *Periodontol 2000* 6:68, 1994.
44. Hassell TM, Page RC: The major metabolite of phenytoin (Dilantin) induces gingival overgrowth in cats. *J Periodontal Res* 13:280, 1978.
45. Hassell TM, Page RC, Lindhe J: Histologic evidence of impaired growth control in diphenylhydantoin gingival overgrowth in man. *Arch Oral Biol* 23:381, 1978.
46. Heijl L, Sundin Y: Nitrendipine-induced gingival overgrowth in dogs. *J Periodontol* 60:104, 1989.
47. Hernandez G, Serrano C, Porras L, et al: Strawberry-like gingival tumor as the first clinical sign of Wegener's granulomatosis. *J Periodontol* 79:1297, 2008.
48. Hirschfeld I: Hypertrophic gingivitis: its clinical aspect. *J Am Dent Assoc* 19:799, 1932.
49. Humphrey AA, Amos NH: Metastatic gingival adenocarcinoma from primary lesion of colon. *Am J Cancer* 28:128, 1936.
50. Ishikawa J, Glickman I: Gingival response to the systemic administration of sodium diphenyl hydantoinate (Dilantin) in cats. *J Periodontol* 32:149, 1961.
51. Israelson H, Binnie WH, Hurt WC: The hyperplastic gingivitis of Wegener's granulomatosis. *J Periodontol* 52:81, 1981.
52. Jorgenson RJ, Cocker ME: Variation in the inheritance and expression of gingival fibromatosis. *J Periodontol* 45:472, 1974.
53. Kantor ML, Hassell TM: Increased accumulation of sulfated glycosaminoglycans in cultures of human fibroblasts from phenytoin-induced gingival overgrowth. *J Dent Res* 62:383, 1983.
54. Kapur RN, Grigis S, Little TM, et al: Diphenylhydantoin-induced gingival hyperplasia: its relation to dose and serum level. *Dev Med Child Neurol* 15:483, 1973.
55. Kerr DA, McClatchey KD, Regezi JA: Allergic gingivostomatitis (due to gum chewing). *J Periodontol* 42:709, 1971.
56. Kilpinen E, Raeste AM, Collan Y: Hereditary gingival hyperplasia and physical maturation. *Scand J Dent Res* 86:118, 1978.
57. Kimball O: The treatment of epilepsy with sodium diphenylhydantoinate. *JAMA* 112:1244, 1939.
58. Klar LA: Gingival hyperplasia during Dilantin therapy: a survey of 312 patients. *J Public Health Dent* 33:180, 1973.

59. Kornblut AD, Wolff SM, de Fries HE, et al: Wegener's granulomatosis. *Laryngoscope* 90:1453, 1980.
60. Kornman KS, Loesche WJ: The subgingival microbial flora during pregnancy. *J Periodontal Res* 15:111, 1980.
61. Krolls SO, Hoffman S: Squamous cell carcinomas of the oral soft tissues: a statistical analysis of 14,253 cases by age, sex and race of patients. *J Am Dent Assoc* 92:571, 1976.
62. Lederman D, Lummerman H, Reuben S, et al: Gingival hyperplasia associated with nifedipine therapy. *Oral Surg* 57:620, 1984.
63. Li X, Luan Q, Wang X, et al: Nifedipine intake increases the risk of periodontal destruction in subjects with type 2 diabetes mellitus. *J Periodontol* 79:2054, 2008.
64. Lucas RM, Howell LP, Wall RA: Nifedipine-induced gingival hyperplasia: a histochemical and ultrastructural study. *J Periodontol* 56:211, 1985.
65. Lustberg A, Goldman D, Dreskin OH: Megaloblastic anemia due to Dilantin therapy. *Ann Intern Med* 54:153, 1961.
66. Maier AW, Orban B: Gingivitis in pregnancy. *Oral Surg* 2:334, 1949.
67. Mariani G, Calastrini C, Carinci F, et al: Ultrastructural features of cyclosporine A—induced gingival hyperplasia. *J Periodontol* 64:1092, 1993.
68. Merritt H, Putnam T: Sodium diphenylhydantoinate in the treatment of convulsive disorders. *JAMA* 111:1068, 1938.
69. McCarthy FP: A clinical and pathological study of oral disease. *JAMA* 116:16, 1941.
70. Mihatsch MJ, Kyo M, Morozumi K, et al: The side-effects of cyclosporine-A and tacrolimus. *Clin Nephrol* 49:356, 1988.
71. Mombelli A, Lang NP, Burgin WB, et al: Microbial changes associated with the development of puberty gingivitis. *J Periodontal Res* 25:331, 1990.
72. Moskow BS: The pathogenesis of the gingival cyst. *Periodontics* 4:23, 1966.
73. Nakagawa S, Fujii H, Machida Y, et al: A longitudinal study from prepuberty to puberty of gingivitis: correlation between the occurrence of *Prevotella intermedia* and sex hormones. *J Periodontol* 21:658, 1994.
74. Neville BW, Damm DD, Allen CM, et al: *Oral and maxillofacial pathology*, Philadelphia, 1995, Saunders.
75. Newcomb GM, Seymour GJ, Adkins KF: An unusual form of chronic gingivitis: an ultrastructural, histochemical and immunologic investigation. *Oral Surg* 53:488, 1982.
76. Nishikawa S, Tada H, Hamasaki A, et al: Nifedipine-induced gingival hyperplasia: a clinical and in vitro study. *J Periodontol* 62:30, 1991.
77. Nitta H, Kameyama Y, Ishikawa I: Unusual gingival enlargement with rapidly progressive periodontitis: report of a case. *J Periodontol* 64:1008, 1993.
78. Nuki K, Cooper SH: The role of inflammation in the pathogenesis of gingival enlargement during the administration of diphenylhydantoin sodium in cats. *J Periodontal Res* 7:91, 1972.
79. Panuska HJ, Gorlin RJ, Bearman JE, et al: The effect of anticonvulsant drugs upon the gingiva: a series of 1048 patients. *J Periodontol* 32:15, 1961.
80. Persson PA, Wallenino K: Metastatic renal carcinoma (hypernephroma) in the gingiva of the lower jaw. *Acta Odontol Scand* 19:289, 1961.
81. Pollack RP: Neurofibroma of the palatal mucosa: a case report. *J Periodontol* 61:456, 1990.
82. Raber-Durlacher JE, van Steenbergen TJM, van der Velde U, et al: Experimental gingivitis during pregnancy and postpartum: clinical, endocrinological and microbiological aspects. *J Clin Periodontol* 21:549, 1994.
83. Raeste AM, Collan Y, Kilpinen E: Hereditary fibrous hyperplasia of the gingiva with varying penetrance and expressivity. *Scand J Dent Res* 86:357, 1978.
84. Rapini RP, Golitz LE, Greer RO, Jr: Primary malignant melanoma of the oral mucosa. *Cancer* 55:1543, 1985.
85. Rateitschak-Pluss EM, Hefti A, Lortscher R, et al: Initial observation that cyclosporin A induces gingival enlargement in man. *J Clin Periodontol* 10:237, 1983.
86. Rees TD: Drugs and oral disorders. *Periodontol 2000* 18:21, 1998.
87. Rees TD: Disorders affecting the periodontium. *Periodontol 2000* 21:145, 1999.
88. Romito GA, Pustiglioni FE, Saraiva L, et al: Relationship of subgingival and salivary microbiota to gingival overgrowth in heart transplant patients following cyclosporine A therapy. *J Periodontol* 75:918, 2004.
89. Rostock MH, Fry HR, Turner JE: Severe gingival overgrowth associated with cyclosporine therapy. *J Periodontol* 57:294, 1986.
90. Russell BJ, Bay LM: Oral use of chlorhexidine gluconate toothpaste in epileptic children. *Scand J Dent Res* 86:52, 1978.
91. Sapp JP, Eversole LR, Wysocki GP: *Contemporary oral and maxillofacial pathology*, St Louis, 2004, Elsevier.
92. Schneider LC, Weisinger E: The true gingival fibroma: an analysis of 129 fibrous gingival lesions. *J Periodontol* 49:423, 1978.
93. Serio FG, Siegel MA, Slade BE: Plasma cell gingivitis of unusual origin: a case report. *J Periodontol* 49:423, 1978.
94. Seymour RA, Jacobs DJ: Cyclosporine and the gingival tissues. *J Clin Periodontol* 19:1, 1992.
95. Seymour RA, Smith DG, Rogers SR: The comparative effects of azathioprine and cyclosporine on some gingival health parameters of renal transplant patients. *J Clin Periodontol* 14:610, 1987.
96. Seymour RA, Thomason JM, Ellis JS: The pathogenesis of drug-induced gingival overgrowth. *J Clin Periodontol* 23:165, 1996.
97. Shafer WG: Effect of Dilantin sodium analogues on cell proliferation in tissue culture. *Proc Soc Exp Biol Med* 106:205, 1960.
98. Shafer WG: Effect of Dilantin sodium on various cell lines in tissue culture. *Proc Soc Exp Biol Med* 108:694, 1961.
99. Shafer WG, Beatty RE, Davis WB: Effect of Dilantin sodium on tensile strength of healing wounds. *Proc Soc Exp Biol Med* 98:348, 1958.
100. Shapiro M: Acceleration of gingival wound healing in nonepileptic patients receiving diphenylhydantoin sodium. *Exp Med Surg* 16:41, 1958.
101. Slavin J, Taylor J: Cyclosporine, nifedipine and gingival hyperplasia. *Lancet* ii:739, 1987.
102. Spencer CM, Goa KL, Gillis JC: Tacrolimus: an update of its pharmacology and drug efficacy in the management of organ transplantation. *Drugs* 54:925, 1997.
103. Staple PH, Reed MJ, Mashimo PA: Diphenylhydantoin gingival hyperplasia in *Macaca arctoides:* a new human model. *J Periodontol* 48:325, 1977.
104. Stein GM, Lewis H: Oral changes in a folic acid deficient patient precipitated by anticonvulsant drug therapy. *J Periodontol* 44:645, 1973.
105. Stevenson ARL, Austin BW: A case of ameloblastoma presenting as an exophytic gingival lesion. *J Periodontol* 61:378, 1990.
106. Stirrups D, Inglis J: Tuberous sclerosis with nonhydantoin gingival hyperplasia: report of a case. *Oral Surg* 49:211, 1980.
107. Sutcliffe P: A longitudinal study of gingivitis and puberty. *J Periodontal Res* 7:52, 1972.
108. Sznajder N, Dominguez FV, Carraro JJ, et al: Hemorrhagic hemangioma of the gingiva: report of a case. *J Periodontol* 44:579, 1973.
109. Taicher S, Mazar A, Hirschberg A, et al: Metastatic chondrosarcoma of the gingiva mimicking a reactive exophytic lesion: a case report. *J Periodontol* 623:223, 1991.
110. Thomas D, Rapley J, Strathman R, et al: Tuberous sclerosis with gingival overgrowth. *J Periodontol* 63:713, 1992.
111. Thomason JM, Seymour RA, Rice N: The prevalence and severity of cyclosporine and nifedipine-induced gingival overgrowth. *J Clin Periodontol* 20:37, 1993.
112. Thomason JM, Seymour RA, Ellis JS, et al: Determinants of gingival overgrowth severity in organ transplant patients. *J Clin Periodontol* 23:628, 1996.
113. Traeger KA: Cyst of the gingiva (mucocele): report of a case. *Oral Surg* 14:243, 1961.
114. Westbrook P, Bednarczyk EM, Carlson M, et al: Regression of nifedipine-induced gingival hyperplasia following switch to a same class calcium channel blocker, isradipine. *J Periodontol* 68:645, 1997.

115. Westphal P: Salivary secretion and gingival hyperplasia in diphenylhydantoin-treated guinea pigs. *Sven Tandlak Tidskr* 62:505, 1969.
116. Wojcicki CJ, Harper DS, Robinson PJ: Differences in periodontal-disease associated microorganisms in prepubertal, pubertal and post-pubertal children. *J Periodontol* 58:219, 1987.
117. Wysocki G, Gretsinger HA, Laupacis A, et al: Fibrous hyperplasia of the gingiva: a side effect of cyclosporin A therapy. *Oral Surg* 55:274, 1983.
118. Zackin SJ, Weisberger D: Hereditary gingival fibromatosis. *Oral Surg* 14:828, 1961.
119. Ziskin DE, Zegarelli E: Idiopathic fibromatosis of the gingivae. *Ann Dent* 2:50, 1943.
120. Ziskin DE, Blackberg SM, Stout AP: The gingivae during pregnancy. *Surg Gynecol Obstet* 57:719, 1933.

CHAPTER 17

Acute Gingival Infections

Perry R. Klokkevold and Fermin A. Carranza

CHAPTER OUTLINE

Necrotizing Ulcerative Gingivitis
Clinical Features
Relation of Bacteria to the Necrotizing Ulcerative Gingivitis Lesion
Diagnosis
Etiology
Epidemiology and Prevalence
Communicability
Primary Herpetic Gingivostomatitis
Clinical Features
Diagnosis
Differential Diagnosis
Communicability
Pericoronitis
Clinical Features
Complications

Necrotizing Ulcerative Gingivitis

Necrotizing ulcerative gingivitis (NUG) is a microbial disease of the gingiva in the context of an impaired host response. It is characterized by the necrosis and sloughing of gingival tissue, and it presents with characteristic signs and symptoms.

Clinical Features

NUG is usually identified as an *acute* disease. However, the term *acute* in this case is a clinical descriptor and should not be used as a diagnosis, because there is no chronic form of the disease. Although the acronym *ANUG* is frequently used, it is a misnomer.[57] NUG often undergoes a diminution in severity without treatment, thereby leading to a *subacute* stage with milder clinical symptoms. Thus, patients may have a history of repeated remissions and exacerbations, and the condition can also recur in previously treated patients. Involvement may be limited to a single tooth or group of teeth, or it may be widespread throughout the mouth (Figure 17-1).

NUG can cause tissue destruction that involves the periodontal attachment apparatus,[39] especially in patients with long-standing disease or severe immunosuppression. When bone loss occurs, the condition is called *necrotizing ulcerative periodontitis* (NUP) (see Chapter 24).

History. NUG is characterized by its sudden onset, sometimes after an episode of debilitating disease or acute respiratory tract infection. A change in living habits, protracted work without adequate rest, poor nutrition, tobacco use, and psychological stress are frequent features of the patient's history.

Oral Signs. Characteristic lesions are *punched-out, craterlike depressions at the crest of the interdental papillae* that subsequently extend to the marginal gingiva and rarely to the attached gingiva and oral mucosa. The surface of the gingival craters is covered by a *gray, pseudomembranous slough* that is demarcated from the remainder of the gingival mucosa by a pronounced *linear erythema* (Figure 17-1, *A*). In some cases, the lesions are denuded of the surface pseudomembrane, thereby exposing the gingival margin, which is red, shiny, and hemorrhagic. The characteristic lesions may progressively destroy the gingiva and the underlying periodontal tissues (see Figure 17-1, *B*).

Spontaneous gingival hemorrhage or pronounced bleeding after the slightest stimulation are additional characteristic clinical signs (see Figure 17-1, *B* and *C*). Other signs that are often found include a fetid odor and increased salivation.

NUG can occur in otherwise disease-free mouths, or it can be superimposed on chronic gingivitis or periodontal pockets. However, NUG or NUP does not usually lead to periodontal pocket formation, because the necrotic changes involve the junctional epithelium; a viable junctional epithelium is needed for pocket deepening (see Chapter 20). It is rare in edentulous mouths, but isolated spherical lesions occasionally occur in the soft palate.[56]

Oral Symptoms. The lesions are *extremely sensitive to touch,* and the patient often complains of a constant radiating, gnawing pain that is intensified by eating spicy or hot foods and chewing. There is a "metallic" foul taste, and the patient is conscious of an excessive amount of "pasty" saliva.

Extraoral and Systemic Signs and Symptoms. Patients are usually ambulatory and have a minimum of systemic symptoms. Local lymphadenopathy and a slight elevation in temperature are common features of the mild and moderate stages of the disease. In severe cases, there may be high fever, increased pulse rate, leukocytosis, loss of appetite, and general lassitude. Systemic reactions are more severe in children. Insomnia, constipation, gastrointestinal disorders, headache, and mental depression sometimes accompany the condition.

In very rare cases, severe sequelae such as gangrenous stomatitis and noma have been described.[1,2,17,31]

Clinical Course. The clinical course can vary. If untreated, NUG may lead to a progressive destruction of the periodontium as well as gingival recession accompanied by an increase in the severity of systemic complications.[29,49]

Histopathology. Microscopically, the NUG lesion is a nonspecific acute necrotizing inflammation of the gingival margin that involves both the stratified squamous epithelium and the underlying connective tissue.

Figure 17-1 Necrotizing ulcerative gingivitis. **A,** Typical punched-out papilla between the mandibular canine and the lateral incisor, covered by a grayish-white pseudomembrane. **B,** More advanced case showing the destruction of the papillae, which results in an irregular marginal contour. **C,** Typical lesions with spontaneous hemorrhage. **D,** Generalized involvement of the papillae and the marginal gingiva, with whitish necrotic lesions.

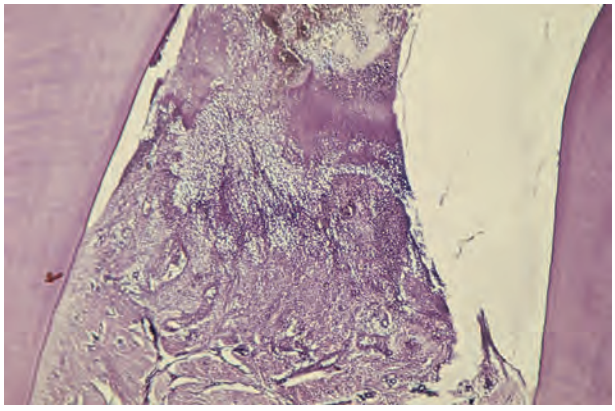

Figure 17-2 Survey section of interdental papilla in a patient with necrotizing ulcerative gingivitis. The top portion of the section shows the necrotic tissue that forms the gray marginal pseudomembrane. In the lower portion, note the ulceration and the accumulation of leukocytes and fibrin.

The surface epithelium is destroyed and replaced by a meshwork of fibrin, necrotic epithelial cells, polymorphonuclear leukocytes (neutrophils) (PMNs), and various types of microorganisms (Figure 17-2). This is the zone that appears clinically as the surface pseudomembrane. At the immediate border of the necrotic pseudomembrane, the epithelium is edematous, and the individual cells exhibit varying degrees of hydropic degeneration. In addition, there is an infiltration of PMNs in the intercellular spaces.

The underlying connective tissue is markedly hyperemic, with numerous engorged capillaries and a dense infiltration of PMNs. This acutely inflamed zone appears clinically as the linear erythema beneath the surface pseudomembrane. Numerous plasma cells may appear in the periphery of the infiltrate; this is interpreted as an area of established chronic gingivitis on which the acute lesion became superimposed.[28]

The epithelium and connective tissue alterations decrease as the distance from the necrotic gingival margin increases, blending gradually with the uninvolved gingiva.

It is noteworthy that the microscopic appearance of NUG is nonspecific. Comparable changes result from trauma, chemical irritation, or the application of caustic medications.

Relation of Bacteria to the Necrotizing Ulcerative Gingivitis Lesion

Light and electron microscopy have been used to study the relationship of bacteria to the characteristic lesion of NUG. Light microscopy shows that the exudate on the surface of the necrotic lesion contains microorganisms that morphologically resemble cocci, fusiform bacilli, and spirochetes.[71] The layer between the necrotic and living tissue contains enormous numbers of fusiform bacilli and spirochetes in addition to leukocytes and fibrin. Spirochetes and other bacteria invade the underlying living tissue.[4,12,16,36]

Spirochetes have been found as deep as 300 µm from the surface. The majority of spirochetes in the deeper zones are morphologically different from cultivated strains of *Treponema microdentium*. They occur in non-necrotic tissue before other types of bacteria, and they may be present in high concentrations intercellularly in the epithelium adjacent to the ulcerated lesion and in the connective tissue.[35]

Smears from the lesions (Figure 17-3) show scattered bacteria (predominantly spirochetes and fusiform bacilli), desquamated epithelial cells, and occasional PMNs. Spirochetes and fusiform bacteria are usually seen with other oral spirochetes, vibrios, and filaments.

Diagnosis

Diagnosis is based on clinical findings of gingival pain, ulceration, and bleeding. A bacterial smear is not necessary or definitive, because the bacterial picture is not appreciably different from that of patients with marginal gingivitis, periodontal pockets, pericoronitis, or primary herpetic gingivostomatitis.[55] However, bacterial studies are useful for the differential diagnosis of NUG and specific infections of the oral cavity (e.g., diphtheria, thrush, actinomycosis, streptococcal stomatitis).

The microscopic examination of a biopsy specimen is not sufficiently specific to be diagnostic. It can be used to differentiate

NUG from specific infections (e.g., tuberculosis) or from neoplastic disease, but it does not differentiate between NUG and other necrotizing conditions of nonspecific origin, such as those produced by trauma or caustic medications.

Differential Diagnosis. NUG should be differentiated from other conditions that resemble it in some respects, such as herpetic gingivostomatitis (Table 17-1); chronic periodontitis; desquamative gingivitis (Table 17-2); streptococcal gingivostomatitis; aphthous stomatitis; gonococcal gingivostomatitis; diphtheritic and syphilitic lesions (Table 17-3); tuberculous gingival lesions; candidiasis, agranulocytosis, and dermatoses (pemphigus, erythema multiforme, and lichen planus); and stomatitis venenata. Treatment options for these diseases vary dramatically, and improper treatment may exacerbate the condition. In the case of primary herpetic gingivostomatitis, early diagnosis may result in treatment with antiviral drugs that would be ineffective for NUG, whereas the treatment of a case of herpes with the debridement required for NUG could exacerbate the herpes. (See Chapter 19 for descriptions of most of these conditions.)

Streptococcal gingivostomatitis is a rare condition that is characterized by a diffuse erythema of the gingiva and other areas of the oral mucosa.[42] In some cases, it is confined as a marginal erythema with marginal hemorrhage. Necrosis of the gingival margin is not a feature of this disease, and there is no notable fetid odor. Bacterial smears show a preponderance of streptococcal forms, which were identified as *Streptococcus viridans,* but other studies report findings of group A β-hemolytic streptococcus.[37]

Agranulocytosis is characterized by a marked decrease in the number of circulating PMNs, lesions of the throat and other mucous membranes, and ulceration and necrosis of the gingiva that may resemble that of NUG and that occurs most commonly after chemotherapy in cancer patients or in patients with leukemia. The oral condition of patients with agranulocytosis is primarily necrotizing, but it lacks the severe inflammatory reaction seen with NUG. Blood studies serve to differentiate between NUG and the gingival necrosis associated with agranulocytosis.

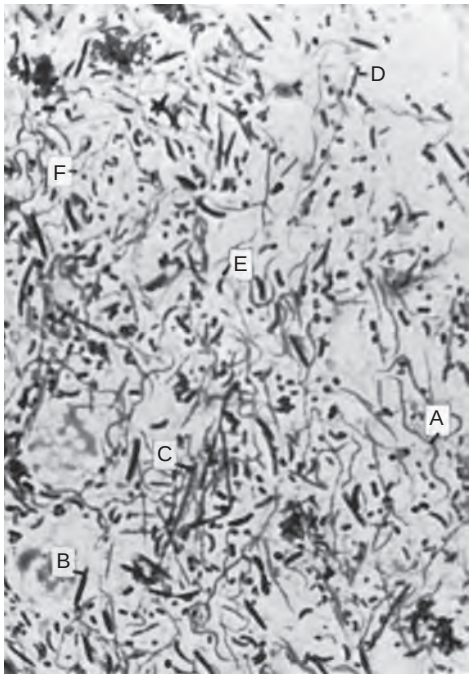

Figure 17-3 Bacterial smear from a lesion in a patient with necrotizing ulcerative gingivitis. *A,* Spirochete. *B, Bacillus fusiformis. C,* Filamentous organism (*Actinomyces* or *Leptotrichia*). *D, Streptococcus. E, Vibrio. F, Treponema microdentium.*

TABLE 17-1 Differentiation Between Necrotizing Ulcerative Gingivitis and Primary Herpetic Gingivostomatitis

Necrotizing Ulcerative Gingivitis	Primary Herpetic Gingivostomatitis
Etiology: interaction between host and bacteria, most probably fusospirochetes	Specific viral etiology
Necrotizing condition	Diffuse erythema and vesicular eruption
Punched-out gingival margin; pseudomembrane that peels off and leaves raw areas	Vesicles rupture and leave slightly depressed oval or spherical ulcer
Marginal gingiva affected; other oral tissues rarely affected	Diffuse involvement of gingiva; may include buccal mucosa and lips
Uncommon in children	Occurs more frequently in children
No definite duration	Duration of 7 to 10 days
No demonstrated immunity	Acute episode results in some degree of immunity
Contagion not demonstrated	Contagion

TABLE 17-2 Differentiation Among Necrotizing Ulcerative Gingivitis, Chronic Desquamative Gingivitis, and Chronic Periodontal Disease

Necrotizing Ulcerative Gingivitis	Desquamative Gingivitis	Chronic Destructive Periodontal Disease
Bacterial smears show fusospirochetal complex	Bacterial smears reveal numerous epithelial cells and few bacterial forms	Bacterial smears variable
Marginal gingiva affected	Diffuse involvement of marginal and attached gingivae and other areas of oral mucosa	Marginal gingiva affected
Acute history	Chronic history	Chronic history
Painful	May or may not be painful	Painless if uncomplicated
Pseudomembrane	Patchy desquamation of gingival epithelium	Generally no desquamation, but purulent material may appear from pockets
Papillary and marginal necrotic lesions	Papillae do not undergo necrosis	Papillae do not undergo noticeable necrosis
Affects adults of both genders and occasionally affects children	Affects adults, most often women	Generally found in adults, occasionally found in children
Characteristic fetid odor	No odor	Some odor present but not strikingly fetid

TABLE 17-3 Differentiation Among Necrotizing Ulcerative Gingivitis, Diphtheria, and Secondary Stage of Syphilis

Necrotizing Ulcerative Gingivitis	Diphtheria	Secondary Stage of Syphilis (Mucous Patch)
Etiology: interaction between host and bacteria, most probably fusospirochetes	Specific bacterial etiology: *Corynebacterium diphtheriae*	Specific bacterial etiology: *Treponema pallidum*
Affects marginal gingiva	Rarely affects marginal gingiva	Rarely affects marginal gingiva
Membrane removal easy	Membrane removal difficult	Membrane not detachable
Painful condition	Less painful	Minimal pain
Marginal gingivae affected	Throat, fauces, and tonsils affected	Any part of mouth affected
Serologic findings normal	Serologic findings normal	Serologic findings abnormal*
Immunity not conferred	Immunity conferred by an attack	Immunity not conferred
Doubtful contagiousness	Contagion	Only direct contact will communicate disease
Antibiotic therapy relieves symptoms	Antibiotic treatment has minimal effect	Antibiotic therapy has excellent results

*Wassermann, Kahn, Venereal Disease Research Laboratories.

Vincent's angina is a fusospirochetal infection of the oropharynx and throat as distinguished from NUG, which affects the marginal gingiva. Patients with Vincent's angina have a painful membranous ulceration of the throat, with edema and hyperemic patches breaking down to form ulcers that are covered with pseudomembranous material. The process may extend to the larynx and the middle ear.

NUG in the patient with *leukemia* is not produced by leukemia itself, but it may result from the reduced host defense mechanisms seen with leukemia. In addition, NUG may be superimposed on the gingival tissue alterations caused by leukemia. The differential diagnosis consists not of distinguishing between NUG and leukemic gingival changes but rather of determining whether leukemia is a predisposing factor in the mouth of a patient with NUG. For example, if a patient with necrotizing involvement of the gingival margin also has generalized diffuse discoloration and edema of the attached gingiva, the possibility of an underlying systemically induced gingival change should be considered. Leukemia is one of the conditions that would need to be ruled out (see Chapter 11).

NUG in the patient with *human immunodeficiency virus infection* has the same clinical features, although it often follows an extremely destructive course that leads to NUP, with a loss of soft tissue and bone and the formation of bony sequestra[25] (see Chapter 26).

Etiology

Role of Bacteria. Plaut[51] in 1894 and Vincent[73] in 1896 postulated that NUG was caused by specific bacteria: fusiform bacillus and a spirochetal organism.

Opinions still differ with regard to whether bacteria are the primary causative factors of NUG. Several observations support this concept, including that spirochetal organisms and fusiform bacilli are always found in patients with the disease, with other organisms also involved. Rosebury and colleagues[55] described a fusospirochetal complex that consists of *T. microdentium,* intermediate spirochetes, vibrios, fusiform bacilli, and filamentous organisms in addition to several *Borrelia* species.

Loesche and colleagues[38] described a predominant constant flora and a variable flora associated with NUG. The constant flora is composed of *Prevotella intermedia* in addition to *Fusobacterium, Treponema,* and *Selenomonas* species. The variable flora consists of a heterogeneous array of bacterial types.

Treatment with metronidazole results in a significant reduction of *Treponema* species, *Prevotella intermedia,* and *Fusobacterium,* with resolution of the clinical symptoms.[15,38] The antibacterial spectrum of this drug provides evidence for the anaerobic members of the flora as etiologic agents.

These bacteriologic findings have been supported by immunologic data[8] that demonstrated increased immunoglobulin G and M antibody titers for medium-sized spirochetes and *P. intermedia* in patients with NUG as compared with titers in those patients with chronic gingivitis and healthy controls.

Role of the Host Response. Regardless of whether specific bacteria are implicated in the etiology of NUG, the presence of these organisms appears to be insufficient to cause the disease.

In the first place, the fusiform–spirochete flora is frequently found in patients who do not have NUG. In addition, exudates from NUG lesions produce fusospirochetal abscesses rather than typical NUG when such exudates are inoculated subcutaneously into experimental animals.[54]

The role of an impaired host response in NUG has long been recognized. Even in the early descriptions of the disease, NUG was associated with physical and emotional stress[10,57] as well as decreased resistance to infection. NUG has not been produced experimentally in humans or animals by only the inoculation of bacterial exudates from the lesions. In the animal model, local or systemic immunosuppression with glucocorticoids (e.g., ketoconazole) results in more characteristic lesions of NUG in infected animals. Swenson and Muhler used Scillaren B, an amorphous glucoside, which reduced tissue resistance to create oral fusospirochetal infections in dogs.[68] Furthermore, NUG is not found in well-nourished individuals with a fully functional immune system. All of the predisposing factors for NUG are associated with immunosuppression. Cogen and colleagues[9] described a depression in host defense mechanisms, particularly in PMN chemotaxis and phagocytosis, in patients with NUG. (For further details regarding host–bacteria interactions in patients with NUG, see Chapters 7, 8, and 9.)

It is essential for the clinician to determine the predisposing factors that lead to immunodeficiency in patients with NUG to address the continued susceptibility of the patient and to determine whether an underlying systemic disease is present. Immunodeficiency may be related to varying levels of nutritional deficiency, fatigue caused by chronic sleep deprivation, other health habits (e.g., alcohol or drug abuse), psychosocial factors, or systemic disease. Importantly, NUG may be the presenting symptom for patients with immunosuppression related to human immunodeficiency virus infection.

Local Predisposing Factors. Preexisting gingivitis, injury to the gingiva, and smoking are important predisposing factors.

Although NUG may appear in an otherwise disease-free mouth, it most often occurs superimposed on preexisting chronic gingival disease and periodontal pockets. Deep periodontal pockets and pericoronal flaps are particularly vulnerable areas, because they offer a favorable environment for the proliferation of anaerobic fusiform bacilli and spirochetes. Areas of the gingiva that are traumatized by opposing teeth in malocclusion (e.g., the palatal surface behind the maxillary incisors, the labial gingival surface of the mandibular incisors) may predispose an individual to the development of NUG.

The relationship between NUG and *smoking* has often been mentioned in the literature. Pindborg[49] reported that 98% of his patients with NUG were smokers and that the frequency of this disease increases with increasing exposure to tobacco smoke. The effect of smoking on periodontal disease in general has been the subject of numerous studies during the past two decades, and smoking has been established as a high risk factor for disease (see Chapter 10).

Systemic Predisposing Factors. NUG is not found in a well-nourished individual with a fully functional immune system. Therefore, it is important for the clinician to determine the predisposing factors that lead to immunodeficiency. Again, immunodeficiency may be related to varying levels of nutritional deficiency; fatigue caused by chronic sleep deficiency; other health habits (e.g., alcohol or drug abuse); and systemic disease (e.g., diabetes, debilitating infection).

Nutritional Deficiency. Necrotizing gingivitis has been produced in animals by giving them nutritionally deficient diets.[6,32,45,69,72] Several researchers found an increase in the fusospirochetal flora in the mouths of the experimental animals, but the bacteria were regarded as opportunists that proliferate only when the tissues were altered by the deficiency. A poor diet has been cited as a predisposing factor for NUG and its sequelae in developing African countries, although the effects appear primarily to diminish the effectiveness of the immune response.[18,19,33]

Nutritional deficiencies (e.g., vitamin C, vitamin B_2) accentuate the severity of the pathologic changes induced when the fusospirochetal bacterial complex is injected into animals.[67]

Debilitating Disease. Debilitating systemic disease may predispose patients to the development of NUG. Such systemic disturbances include chronic diseases (e.g., syphilis, cancer), severe gastrointestinal disorders (e.g., ulcerative colitis), blood dyscrasias (e.g., leukemia, anemia), and acquired immunodeficiency syndrome. Nutritional deficiency that results from debilitating disease may be an additional predisposing factor. Experimentally induced leukopenia in animals may produce ulcerative gangrenous stomatitis.[45,70,71] Ulceronecrotic lesions appear in the gingival margins of hamsters that are exposed to total body irradiation[40]; these lesions can be prevented with systemic antibiotics.[41]

Psychosomatic Factors. Psychologic factors appear to be important in the etiology of NUG. The disease often occurs in association with stressful situations (e.g., induction into the armed forces, school examinations).[23] Psychologic disturbances[24] as well as increased adrenocortical secretion[62] are also common in patients with the disease.

A significant correlation between disease incidence and two personality traits—dominance and abasement—suggests the presence of a NUG-prone personality.[21]

The mechanisms whereby psychologic factors create or predispose an individual to gingival damage have not been established, but alterations in digital and gingival capillary responses that suggest increased autonomic nervous activity have been demonstrated in patients with NUG.[22]

It can be concluded that opportunistic bacteria are the primary etiologic agents of NUG in patients who demonstrate immunosuppression. Stress, smoking, and preexisting gingivitis are common predisposing factors.

Epidemiology and Prevalence

The prevalence of NUG appears to have been rather low in the United States and Europe before 1914. During World Wars I and II, numerous "epidemics" broke out among the Allied troops, but German soldiers did not seem to have been similarly affected. Epidemic-like outbreaks have also occurred among civilian populations. A study at a dental clinic in Prague, Czech Republic, reported the incidence of NUG as 0.08% among patients between the ages of 15 and 19 years old, 0.05% among those 20 to 24 years old, and 0.02% among those 25 to 29 years old.[65]

NUG occurs in individuals of all ages, with the highest incidence reported in patients between the ages of 15 and 30 years.[14,34,67,65] It is not common among children in the United States, Canada, and Europe, but it has been reported in children from low socioeconomic groups in underdeveloped countries.[31] In India, 54%[44] and 58%[50] of patients in two studies were less than 10 years old.

In a random school population in Nigeria, NUG occurred in 11.3% of children between the ages of 2 and 6 years old.[63] In a Nigerian hospital population, it was present in 23% of children who were less than 10 years old.[18] It has been reported in several members of the same family in low socioeconomic groups. NUG is more common among children with Down syndrome than among other children with mental deficiencies.[3]

Opinions differ with regard to whether NUG is more common during the winter,[34,47] summer, or fall[63] and whether there is a peak seasonal incidence.[13]

Communicability

NUG often occurs in groups in an epidemic pattern. At one time, NUG was considered contagious and involved required reporting to the community health department, but it was later concluded not to be communicable.[53,59] A distinction must be made between "communicability" and "transmissibility" when referring to the characteristics of disease. The term *transmissible* denotes a capacity for the maintenance of an infectious agent in successive passages through a susceptible animal host.[53] The term *communicable* signifies a capacity for the maintenance of infection by natural modes of spread, such as direct contact through drinking water, food, and eating utensils; via the airborne route; or by means of arthropod vectors. A disease that is communicable is described as *contagious.* It has been demonstrated that disease associated with the fusospirochetal bacterial complex is transmissible; however, *it has not been shown to be communicable or contagious.*

Attempts have been made to spread NUG from human to human, without success.[60] King[33] traumatized an area in his gingiva and introduced debris from a patient with a severe case of NUG. There was no response until he happened to fall ill shortly thereafter; subsequent to his illness, he observed the characteristic lesion in the experimental area. It may be inferred with reservation from this experiment that systemic debility is a prerequisite for the contagion of NUG.

It is a common impression that, because NUG often occurs among groups that use the same kitchen facilities, the disease is spread by bacteria on eating utensils. However, the growth of fusospirochetal organisms requires carefully controlled conditions

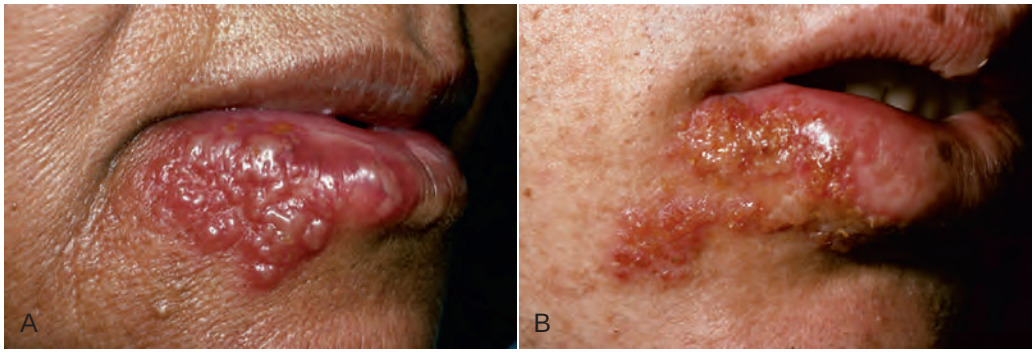

Figure 17-4 Recurrent herpetic vesicles in the lip. **A,** Early stage. **B,** Late stage showing brownish crusted lesions. *(From Sapp JP, Eversole, LR, Wysocki GP:* Contemporary oral and maxillofacial pathology, *ed 2, St Louis, 2002, Mosby.)*

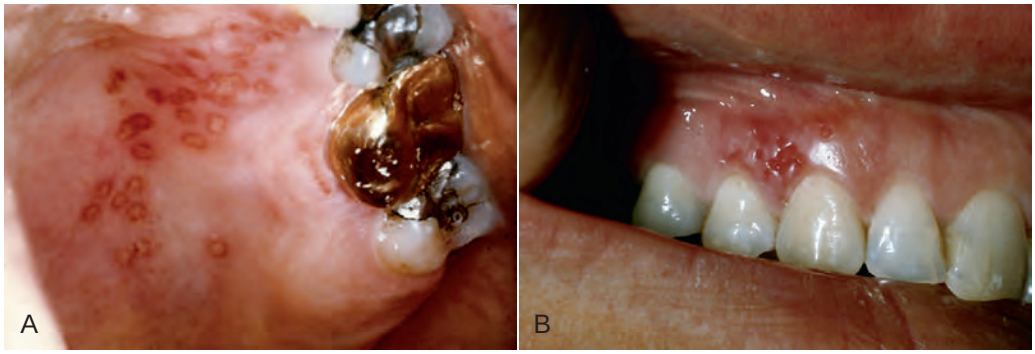

Figure 17-5 Recurrent intraoral herpetic vesicles, **A,** in the palate and, **B,** in the gingiva. The latter location is rare. *(From Sapp JP, Eversole, LR, Wysocki GP:* Contemporary oral and maxillofacial pathology, *ed 2, St Louis, 2002, Mosby.)*

and an anaerobic environment; they do not ordinarily survive on eating utensils.[11,27]

The occurrence of NUG in epidemic-like outbreaks does not necessarily mean that it is contagious. The affected groups may be afflicted by the disease as a result of common predisposing factors rather than because of its spread from person to person. In all likelihood, both a predisposed immunocompromised host and the presence of appropriate bacteria are necessary for the production of this disease.

Primary Herpetic Gingivostomatitis

Primary herpetic gingivostomatitis is an infection of the oral cavity caused by herpes simplex virus (HSV) type 1.[14,42,43,58] It occurs most often among infants and children who are less than 6 years old,[5,58,61] but it is also seen in adolescents and adults. It occurs with equal frequency in male and female patients. In most individuals, however, the primary infection is asymptomatic.

As part of the primary infection, the virus ascends through the sensory and autonomic nerves, where it persists as latent HSV in neuronal ganglia that innervate the site. In approximately one third of the world's population, secondary manifestations result from various stimuli, such as sunlight, trauma, fever, and stress. These secondary manifestations include herpes labialis (Figure 17-4), herpetic stomatitis, herpes genitalis, ocular herpes, and herpetic encephalitis. Secondary herpetic stomatitis can occur on the palate, on the gingiva (Figure 17-5), or on the mucosa as a result of dental treatment that traumatizes or stimulates the latent virus in the ganglia that innervate the area; it may present as pain away from the site of treatment 2 to 4 days later. Careful inspection for characteristic vesicles may be diagnostic (see Figure 17-4).

Figure 17-6 Primary herpetic gingivostomatitis in a 12-year-old boy, with diffuse erythematous involvement of the gingiva and a spherical gray vesicle in the lip. *(Courtesy Dr. Heddie Sedano, University of California, Los Angeles, and University of Minnesota.)*

Clinical Features

Oral Signs. Primary herpetic gingivostomatitis appears as a diffuse, erythematous, shiny involvement of the gingiva and the adjacent oral mucosa, with varying degrees of edema and gingival bleeding. During its initial stage, it is characterized by the presence of discrete, spherical gray vesicles, which may occur on the gingiva, the labial and buccal mucosae, the soft palate, the pharynx, the sublingual mucosa, and the tongue (Figure 17-6). After approximately 24 hours, the vesicles rupture and form painful small ulcers with red, elevated, halo-like margins and depressed yellowish or grayish-white central portions. These occur either in widely separated areas or in clusters where confluence occurs (Figure 17-7).

Figure 17-7 Involvement of the lip, gingiva, and tongue in primary herpetic gingivostomatitis. *(From Sapp JP, Eversole, LR, Wysocki GP:* Contemporary oral and maxillofacial pathology, *ed 2, St Louis, 2002, Mosby.)*

Occasionally, primary herpetic gingivitis may occur without overt vesiculation. The clinical picture consists of diffuse, erythematous, shiny discoloration and edematous enlargement of the gingivae with a tendency toward bleeding.

The course of the disease is limited to 7 to 10 days. The diffuse gingival erythema and edema that appear early during the course of the disease persist for several days after the ulcerative lesions have healed. Scarring does not occur in the areas of healed ulcerations.

Oral Symptoms. The disease is accompanied by generalized "soreness" of the oral cavity, which interferes with eating, drinking, and oral hygiene. The ruptured vesicles are the focal sites of pain; they are particularly sensitive to touch, thermal changes, foods such as condiments and fruit juices, and the action of coarse foods. In infants, the disease is marked by irritability and refusal to take food.

Extraoral and Systemic Signs and Symptoms. Cervical adenitis, fever as high as 101°F to 105°F (38°C to 40.6°C), and generalized malaise are common.

History. Primary herpetic gingivostomatitis is the result of an acute infection by HSV, and it has an acute onset.

Histopathology. The virus targets the epithelial cells, which show "ballooning degeneration" that consists of acantholysis, nuclear clearing, and nuclear enlargement. These cells are called *Tzanck cells.* Infected cells fuse to form multinucleated cells, and intercellular edema leads to the formation of intraepithelial vesicles that rupture and develop a secondary inflammatory response with a fibropurulent exudate[46] (Figure 17-8). Discrete ulcerations that result from the rupture of the vesicles have a central portion of acute inflammation, with varying degrees of purulent exudate surrounded by engorged blood vessels.

Diagnosis

It is critical to arrive at a diagnosis as early as possible in a patient with a primary herpetic infection. Treatment with antiviral medications can dramatically alter the course of the disease by reducing symptoms and potentially reducing recurrences. The diagnosis is usually established from the patient's history and the clinical findings. Material may be obtained from the lesions and submitted to the laboratory for confirmatory tests, including virus culture and immunologic tests that involve the use of monoclonal antibodies or deoxyribonucleic acid hybridization techniques.[5,52] This should not delay treatment if strong clinical evidence exists for primary gingivostomatitis.

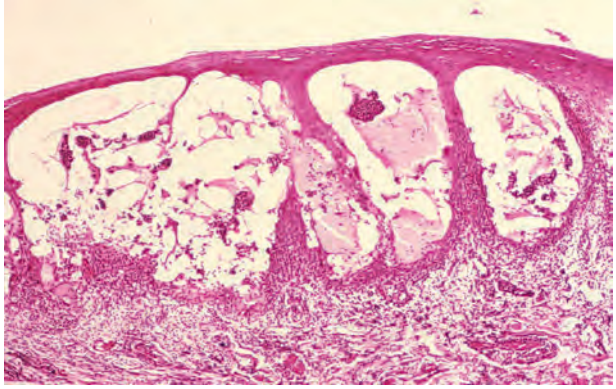

Figure 17-8 Biopsy showing intraepithelial viral vesicles that contain fluid and debris, with a large number of viruses and virally altered epithelial cells (i.e., Tzanck cells). *(Courtesy Dr. Heddie Sedano, University of California, Los Angeles, and University of Minnesota.)*

Differential Diagnosis

Primary herpetic gingivostomatitis should be differentiated from several conditions.

Lesions of *recurrent aphthous stomatitis* (RAS)[20] range from occasional small (0.5 cm to 1 cm in diameter), well-defined, round or ovoid shallow ulcers with a yellowish-gray central area surrounded by an erythematous halo, which heal in 7 to 10 days without scarring, to larger (1 cm to 3 cm in diameter) oval or irregular ulcers, which persist for weeks and heal with scarring (Figure 17-9). The cause is unknown, although immunopathologic mechanisms appear to play a role. RAS is a different clinical entity from primary herpetic gingivostomatitis. The ulcerations may look the same for the two conditions, but diffuse erythematous involvement of the gingiva and acute toxic systemic symptoms do not occur with RAS. A history of previous episodes of painful mucosal ulcerations suggests RAS rather than primary HSV.

Information about erythema multiforme, bullous lichen planus, and desquamative gingivitis can be found in Chapter 19.

Communicability

Primary herpetic gingivostomatitis is contagious.[7,37] Most adults have developed immunity to HSV as a result of infection during childhood, which, in most cases, is subclinical. For this reason, acute herpetic gingivostomatitis usually occurs in infants and children. Recurrent herpetic gingivostomatitis has been reported,[26] although it is not often clinically significant unless immunity is

Figure 17-9 Aphthous lesion in the lip. The depressed gray center is surrounded by an elevated red border. *(From Sapp JP, Eversole, LR, Wysocki GP:* Contemporary oral and maxillofacial pathology, *ed 2, St Louis, 2002, Mosby.)*

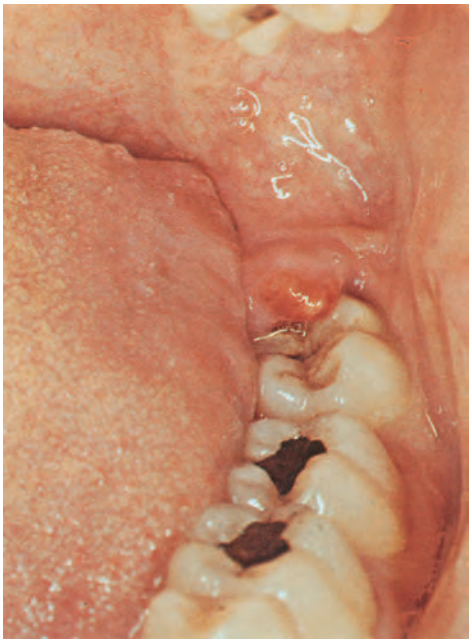

Figure 17-10 Pericoronitis. An inflamed coronal flap is covering the disto-occlusal surface of the impacted mandibular third molar. Note the swelling and redness. *(From Glickman I, Smulow J:* Periodontal disease: clinical, radiographic and histopathologic features, *Philadelphia, 1974, Saunders.)*

destroyed by debilitating systemic disease. Studies that have demonstrated HSV in periodontal pockets suggest more recurrence of viral replication than has previously been recognized.[66] Secondary herpetic infection of the skin, such as herpes labialis, does recur.[64]

Pericoronitis

The term *pericoronitis* refers to inflammation of the gingiva in relation to the crown of an incompletely erupted tooth (Figure 17-10). It occurs most often in the mandibular third molar area. Pericoronitis may be acute, subacute, or chronic.

Clinical Features

The partially erupted or impacted mandibular third molar is the most common site of pericoronitis. The space between the crown of the tooth and the overlying gingival flap (operculum) is an ideal area for the accumulation of food debris and bacterial growth. Even in patients with no clinical signs or symptoms, the gingival flap is often chronically inflamed and infected, and it has varying degrees of ulceration along its inner surface. Acute inflammatory involvement is a constant possibility; it may be exacerbated by trauma, occlusion, or a foreign body trapped underneath the tissue flap (e.g., popcorn husk, nut fragment).

Acute pericoronitis is identified by varying degrees of inflammatory involvement of the pericoronal flap and adjacent structures as well as by systemic complications. The inflammatory fluid and cellular exudate increase the bulk of the flap, which then may interfere with complete closure of the jaws and which can be traumatized by contact with the opposing jaw, thereby aggravating the inflammatory involvement.

The resultant clinical picture is a red, swollen, suppurating lesion that is exquisitely tender, with radiating pains to the ear, the throat, and the floor of the mouth. The patient is extremely uncomfortable as a result of pain, a foul taste, and an inability to close the jaws. Swelling of the cheek in the region of the angle of the jaw and lymphadenitis are common findings. Trismus may also be a presenting complaint. In addition, the patient may have systemic complications such as fever, leukocytosis, and malaise.

Complications

Involvement may be localized in the form of a pericoronal abscess. It may spread posteriorly into the oropharyngeal area and medially to the base of the tongue, thereby making it difficult for the patient to swallow. Depending on the severity and extent of the infection, there may be involvement of the submaxillary, posterior cervical, deep cervical, and retropharyngeal lymph nodes.[30,48] Peritonsillar abscess formation, cellulitis, and Ludwig's angina are infrequent but potential sequelae of acute pericoronitis.

Suggested Reading

Horning GM, Cohen ME: Necrotizing ulcerative gingivitis, periodontitis and stomatitis: clinical staging and predisposing factors. *J Periodontol* 66:990, 1995.

Johnson BD, Engel D: Acute necrotizing gingivitis. A review of diagnosis, etiology and treatment. *J Periodontol* 7:141, 1986.

Listgarten MA, Lewis DW: The distribution of spirochetes in the lesion of acute necrotizing ulcerative gingivitis: an electron microscopic and statistical survey. *J Periodontol* 38:379, 1967.

Loesche WJ, Syed SA, Langhorn BE, et al: The bacteriology of acute necrotizing ulcerative gingivitis. *J Periodontol* 53:223, 1982.

McCarthy PL, Shklar G: *Diseases of the oral mucosa*, ed 2, Philadelphia, 1980, Lea & Febiger.

Sapp JP, Eversole LR, Wysocki GP: *Contemporary oral and maxillofacial pathology*, ed 2, St. Louis, 2004, Mosby.

Shannon IL, Kilgore WG, Leary TJ: Stress as a predisposing factor in necrotizing ulcerative gingivitis. *J Periodontol* 40:240, 1969.

References

References for this chapter are found on the companion website www.expertconsult.com.

References

1. Berke JD: Experimental study of acute ulcerative stomatitis. *J Am Dent Assoc* 63:86, 1961.
2. Box HK: *Necrotic gingivitis*, Toronto, 1930, University of Toronto Press.
3. Brown RH: Necrotizing ulcerative gingivitis in mongoloid and non-mongoloid retarded individuals. *J Periodontal Res* 8:290, 1973.
4. Cahn LR: The penetration of the tissue by Vincent's organisms: a report of a case. *J Dent Res* 9:695, 1929.
5. Cawson RA: Infections of the oral mucous membrane. In Cohen B, Kramer IRH, editors: *Scientific foundations of dentistry*, Chicago, 1976, Year Book Medical Publishers.
6. Chapman OD, Harris AE: Oral lesions associated with dietary deficiencies in monkeys. *J Infect Dis* 69:7, 1941.
7. Chilton NW: Herpetic stomatitis. *Am J Orthod Oral Surg* 30:335, 1944.
8. Chung CP, Nisengard RJ, Slots J, et al: Bacterial IgG and IgM antibody titers in acute necrotizing ulcerative gingivitis. *J Periodontol* 54:557, 1983.
9. Cogen RB, Stevens AW, Jr, Cohen-Cole SA, et al: Leukocyte function in the etiology of acute necrotizing ulcerative gingivitis. *J Periodontol* 54:402, 1983.
10. Cohen-Cole SA, Cogen RD, Stevens AW, Jr, et al: Psychiatric, psychosocial and endocrine correlates of acute necrotizing ulcerative gingivitis (trench mouth): a preliminary report. *Psychiatr Med* 1:215, 1983.
11. Coutley RL: Vincent's infection. *Br Dent J* 74:34, 1943.
12. Curtois GJ, III, Cobb CM, Killoy WJ: Acute necrotizing ulcerative gingivitis: a transmission electron microscope study. *J Periodontol* 54:671, 1983.
13. Daley FH: Studies of Vincent's infection at the clinic of Tufts College Dental School from October 1926 to February 1928. *J Dent Res* 8:408, 1928.
14. Dodd K, Johnston LM, Budding GJ: Herpetic stomatitis. *J Pediatr* 12:95, 1938.
15. Duckworth R, Waterhouse JP, Britton DG, et al: Acute ulcerative gingivitis: a double blind controlled clinical trial with metronidazole. *Br Dent J* 120:599, 1966.
16. Ellerman V: Vincent's organisms in tissue. *Z Hyg Infekt Pr* 56:453, 1907.
17. Enwonwu CO: Epidemiological and biochemical studies of necrotizing ulcerative gingivitis and noma (cancrum oris) in Nigerian children. *Arch Oral Biol* 17:1357, 1972.
18. Enwonwu CO: Cellular and molecular effects of malnutrition and their relevance to periodontal diseases. *J Clin Periodontol* 21:643, 1994.
19. Enwonwu CO, Phillips RS, Savage KO: Inflammatory cytokine profile and circulating cortisol levels in malnourished children with necrotizing ulcerative gingivitis. *Eur Cytokine Netw* 16:240, 2005.
20. Eversole LR: Diseases of the oral mucous membranes. Review of the literature. In Millard HD, Mason DK, editors: *World workshop on oral medicine*, Chicago, 1989, Year Book Medical Publishers.
21. Formicola AJ, Witte ET, Curran PM: A study of personality traits and acute necrotizing ulcerative gingivitis. *J Periodontol* 41:36, 1970.
22. Giddon DB: Psychophysiology of the oral cavity. *J Dent Res* 45(Suppl 6):1627, 1966.
23. Giddon DB, Zackin SJ, Goldhaber P: Acute necrotizing gingivitis in college students. *J Am Dent Assoc* 68:381, 1964.
24. Goldhaber P, Giddon DB: Present concepts concerning the etiology and treatment of acute necrotizing ulcerative gingivitis. *Int Dent J* 14:468, 1964.
25. Greenspan D, Pindborg JJ, Greenspan JS, et al: *AIDS and the dental team*, Copenhagen, 1986, Munksgaard.
26. Griffin JW: Recurrent intraoral herpes simplex virus infection. *Oral Surg* 19:209, 1965.
27. Hampp EG, Mergenhagen SE: Experimental infection with oral spirochetes. *J Infect Dis* 109:43, 1961.
28. Hooper PA, Seymour GJ: The histopathogenesis of acute ulcerative gingivitis. *J Periodontol* 50:419, 1979.
29. Horning GM, Cohen ME: Necrotizing ulcerative gingivitis, periodontitis and stomatitis: clinical staging and predisposing factors. *J Periodontol* 66:990, 1995.
30. Jacobs MH: Pericoronal and Vincent's infections: bacteriology and treatment. *J Am Dent Assoc* 30:392, 1953.
31. Jimenez M, Baer PN: Necrotizing ulcerative gingivitis in children: a 9-year clinical study. *J Periodontol* 46:715, 1975.
32. Johnson BD, Engel D: Acute necrotizing gingivitis. A review of diagnosis, etiology and treatment. *J Periodontol* 7:141, 1986.
33. King JD: Nutritional and other factors in trench mouth with special reference to the nicotinic acid component of vitamin B complex. *Br Dent J* 74:113, 1943.
34. Lado RA, Carranza FA, Jr: Estudio sobre la incidencia de la gingivitis ulceronecrotizante. *Rev Asoc Odont Argentina* 49:87, 1961.
35. Listgarten MA: Electron microscopic observations on the bacterial flora of acute necrotizing ulcerative gingivitis. *J Periodontol* 36:328, 1965.
36. Listgarten MA, Lewis DW: The distribution of spirochetes in the lesion of acute necrotizing ulcerative gingivitis: an electron microscopic and statistical survey. *J Periodontol* 38:379, 1967.
37. Littner MM, Dayan D, Kaffe I, et al: Acute streptococcal gingivostomatitis: report of five cases. *Oral Surg Oral Med Oral Pathol Oral Radiol Endod* 53:144, 1982.
38. Loesche WJ, Syed SA, Langhorn BE, et al: The bacteriology of acute necrotizing ulcerative gingivitis. *J Periodontol* 53:223, 1982.
39. Lopez R, Baelum V: Necrotizing ulcerative gingival lesions and clinical attachment loss. *Eur J Oral Sci* 112:105, 2005.
40. Mayo J, Carranza FA, Jr, Cabrini RL: Comparative study of the effect of antibiotics, bone marrow and cysteamine on oral lesions produced in hamsters by total body irradiation. *Experientia* 20:403, 1964.
41. Mayo J, Carranza FA, Jr, Epper CE, et al: The effect of total-body irradiation on the oral tissues of the Syrian hamster. *Oral Surg* 15:739, 1962.
42. McCarthy PL, Shklar G: *Diseases of the oral mucosa*, ed 2, Philadelphia, 1980, Lea & Febiger.
43. McNair ST: Herpetic stomatitis. *J Dent Res* 29:647, 1950.
44. Miglani DC, Sharma OP: Incidence of acute necrotizing gingivitis and periodontosis among cases seen at the government hospital, Madras. *J All India Dent Assoc* 37:183, 1965.
45. Miller DK, Rhoads CP: The experimental production in dogs of acute stomatitis associated with leukopenia and a maturation defect of the myeloid elements of the bone marrow. *J Exp Med* 61:173, 1935.
46. Neville BW, Damm DD, Allen CM, et al: *Oral and maxillofacial pathology*, Philadelphia, 1995, Saunders.
47. Pedler JA, Radden BG: Seasonal influence of acute ulcerative gingivitis. *Dent Pract* 8:23, 1957.
48. Perkins AE: Acute infections around erupting mandibular third molar. *Br Dent J* 76:199, 1944.
49. Pindborg JJ: Gingivitis in military personnel with special reference to ulceromembranous gingivitis. *Odontol Tidskr* 59:407, 1951.
50. Pindborg JJ, Bhat M, Devanath KR, et al: Occurrence of acute necrotizing gingivitis in South Indian children. *J Periodontol* 37:14, 1966.
51. Plaut HC: Studienzur bakterielle diagnostik der diphtheriae un der aginen. *Dtsch Med Wochenschr* 20:920, 1894.
52. Regezi JA, Sciubba JJ: *Oral pathology: clinico-pathologic correlations*, Philadelphia, 1989, Saunders.
53. Rosebury T: Is Vincent's infection a communicable disease? *J Am Dent Assoc* 29:823, 1942.
54. Rosebury T, Foley G: Experimental Vincent's infection. *J Am Dent Assoc* 26:1939, 1978.
55. Rosebury T, MacDonald JB, Clark A: A bacteriologic survey of gingival scrapings from periodontal infections by direct examination, guinea pig inoculation and anaerobic cultivation. *J Dent Res* 29:718, 1950.
56. Rosenthal SL: Gootzeit EH: The incidence of *B. fusiformis* and spirochetes in the edentulous mouth. *J Dent Res* 21:373, 1942.
57. Rowland R: Necrotizing ulcerative gingivitis. *Ann Periodontol* 4:65, 1999.
58. Sapp JP, Eversole LR, Wysocki GP: *Contemporary oral and maxillofacial pathology*, ed 2, St. Louis, 2004, Mosby.

59. Schluger S: Necrotizing ulcerative gingivitis in the army: incidence, communicability, and treatment. *J Am Dent Assoc* 38:174, 1949.
60. Schwartzman J, Grossman L: Vincent's ulceromembranous gingivostomatitis. *Arch Pediatr* 58:515, 1941.
61. Scott TFM, Steigman AS, Convey JH: Acute infectious gingivostomatitis: etiology, epidemiology, and clinical picture of common disorders caused by virus of herpes simplex. *JAMA* 117:999, 1941.
62. Shannon IL, Kilgore WG, Leary TJ: Stress as a predisposing factor in necrotizing ulcerative gingivitis. *J Periodontol* 40:240, 1969.
63. Sheiham A: An epidemiological study of oral disease in Nigerians. *J Dent Res* 44:1184, 1965.
64. Ship II, Brightman VJ, Laster LL: The patient with recurrent aphthous ulcers and the patient with recurrent herpes labialis: a study of two population samples. *J Am Dent Assoc* 75:645, 1967.
65. Skach M, Zabrodsky S, Mrklas L: A study of the effect of age and season on the incidence of ulcerative gingivitis. *J Periodontal Res* 5:187, 1970.
66. Slots J, Contreras A: Herpesviruses: a unifying causative factor in periodontitis? *Oral Microbiol Immunol* 5:277, 2000.
67. Swenson HM: Induced Vincent's infection in dogs. *J Dent Res* 23:190, 1944.
68. Swenson HM, Muhler JC: Induced fusospirochetal infection in dogs. *J Dent Res* 26:161, 1947.
69. Topping NH, Fraser HF: Mouth lesions associated with dietary deficiencies in monkeys. *US Public Health Rep* 54:431, 1939.
70. Tunnicliff R, Fink EB, Hammond C: Significance of fusiform bacilli and spirilla in gingival tissue. *J Am Dent Assoc* 23:1936, 1959.
71. Tunnicliff R, Hammond C: Abscess production by fusiform bacilli in rabbits and mice by the use of scillaren-B or mucin. *J Dent Res* 16:479, 1937.
72. Underhill FP, Mendel LB: Further experiments on the pellagra-like syndrome in dogs. *Am J Physiol* 83:589, 1928.
73. Vincent H: Sur l'etiologie et sur les lesions anatomopathologiques de la pourritute d'hopital. *Ann l'Inst Pasteur* 10:448, 1896.

CHAPTER 18

Gingival Disease in Childhood

Clarice S. Law, Daniela R. Silva, Donald F. Duperon, and Fermin A. Carranza

CHAPTER OUTLINE

Periodontium of the Primary Dentition
Periodontal Changes Associated With Normal Development
Gingival Diseases of Childhood
Periodontal Diseases of Childhood
Gingival Manifestation of Systemic Disease in Children
Oral Mucosa in Childhood Diseases
Therapeutic Considerations in the Pediatric Patient
Conclusions

Periodontal disease in adults is partly precipitated by gingival inflammation during the formative years of childhood and early adolescence. Without appropriate intervention, the nondestructive gingival inflammation of childhood may progress to the more significant periodontal diseases seen in the adult population.

After first reviewing anatomic and physiologic changes in the periodontium and dentition, this chapter presents the gingival changes associated with childhood and adolescence. Periodontal diseases during these early periods of life are presented in the chapters that address the respective diseases (see Chapters 11, 23 to 25).

Periodontium of the Primary Dentition

In the edentulous infant, the gingival tissues present with thick gingival mucosa and segmentations that correspond with the primary buds (Figure 18-1). A high labial frenum attachment is a normal finding in almost 85% of infants, which may diminish in size with normal development.[58] During the primary dentition stage, the normal gingiva continues to be somewhat different from that found in adults. The tissues are pale pink, but they are pink to a lesser degree than the attached gingiva of adults, because the thinness of the keratinized layer causes the underlying vessels in children to be more visible.[41] Stippling appears at about 3 years of age and has been reported in 56% of children between ages 3 and 10 years, with little differences between maxillary and mandibular arches or between boys and girls throughout childhood[11] (Figure 18-2).

The *interdental gingiva* is broad buccolingually and narrow mesiodistally, which is consistent with the morphology of the primary dentition. Its structure and composition are similar to those of the adult gingiva.

Gingival sulcular depth is shallower in the primary dentition than in the permanent dentition. Probing depths range from 1 mm to 2 mm, with an increase in depth from anterior to posterior.[9,25,60]

The *attached gingiva* varies in width anteroposteriorly, with a range of 3 mm to 6 mm. On the buccal surfaces, the width decreases from anterior to posterior, with some data indicating a narrowing over the canines (Figure 18-3). The lingual attached gingiva shows an inverse relationship, with an increase in width from anterior to posterior.[25] The gingival width normally increases with age as children transition from the primary to the permanent dentition.[5,9,15,60] Interestingly, the junctional epithelium is thicker in the primary dentition than in the permanent dentition,[10] which is thought to reduce the permeability of the tissues to bacterial toxins.

Radiographically, the lamina dura is prominent in the primary dentition, with a wider periodontal space than in the permanent dentition. The marrow spaces of the bone are larger, and the crests of the interdental bony septa are flat, with bony crests within 1 mm to 2 mm of the cementoenamel junction[26] (Figure 18-4).

Periodontal Changes Associated With Normal Development

Significant changes occur in the periodontium as the dentition changes from the primary to the permanent teeth. Most of the changes are associated with eruption and are physiologic in nature. These changes should be distinguished from gingival disease, which may occur simultaneously.

Tooth Eruption

Before the eruption of a primary or permanent tooth, the gingiva reveals a bulge that is firm and pink or blanched as a result of the underlying tooth crown. An *eruption cyst* may occasionally be evident. This fluctuant mass may be filled with blood, and it generally presents as a bluish or deep red enlargement of the gingiva over the erupting tooth (Figure 18-5, *A*). The most common sites of these cysts are the primary first molars and the permanent first molars. Many resolve without treatment, but they may be marsupialized if they are painful or interfere with occlusion (Figure 18-5, *B*).[14]

As a tooth erupts, the gingival margin and the sulcus develop. At this point, the margin is rounded, edematous, and reddened. During the period of active tooth eruption, it is normal for the marginal gingiva that surrounds partially erupted teeth to appear prominent; this is most evident in the maxillary anterior region. The prominence is caused by the height of the contour of the erupting tooth and mild inflammation from mastication. Poor oral hygiene can contribute to the development of significant gingivitis in unprotected gingival areas.

Figure 18-1 Normal gingiva of an edentulous 1-month-old child showing a high labial frenulum and pink and healthy tissues. *(Copyright Dr. Daniela Silva. All rights reserved.)*

Figure 18-2 Normal gingiva of a 4-year-old child showing light stippling and flattened interproximal gingiva in areas of physiologic spacing. *(Copyright Dr. Daniela Silva. All rights reserved.)*

Figure 18-3 Normal gingiva of a 4-year-old African-American child demonstrating the width of the attached gingiva, as illustrated by the pigmentation that occurs only in the attached area. *(Copyright Dr. Daniela Silva. All rights reserved.)*

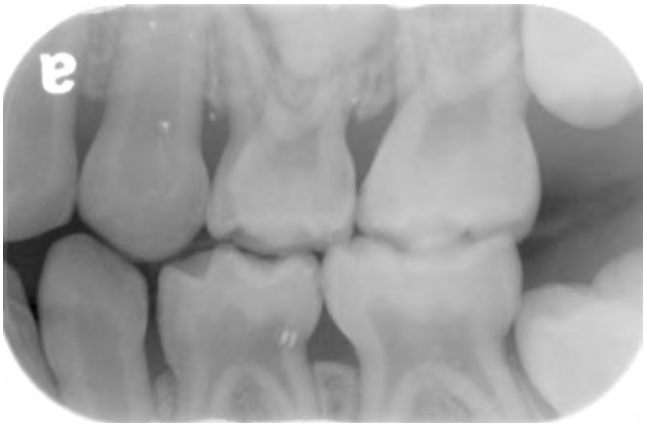

Figure 18-4 Bitewing radiograph of a 6-year-old child illustrating the flattened interseptal bone and bony crests within 1 mm to 2 mm of the cementoenamel junction. *(Copyright Dr. Daniela Silva. All rights reserved.)*

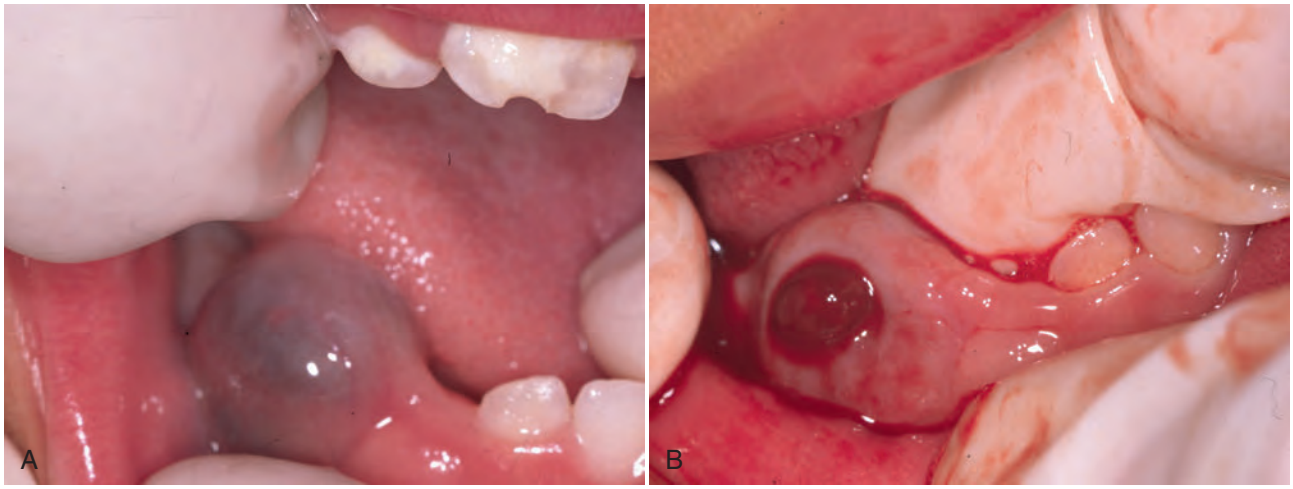

Figure 18-5 **A,** Eruption cyst at the lower right first primary molar area of a 16-month-old child. With this condition, there is transparent, bluish, blue, or blue-black swelling of the alveolar mucosa over a tooth in eruption. **B,** Eruption cyst at the lower right first primary molar area of a 16-month-old child. After a small incision of the mucosa, the hemorrhagic content was marsupialized. *(Copyright Dr. Daniela Silva. All rights reserved.)*

Teething

The effect of primary tooth eruption on infant health has been debated for centuries, but there is little scientific evidence regarding the diagnosis and management of the teething child. The period associated with the eruption of the primary teeth in infants can be difficult and stressful for both the child and the parents. The timing of primary incisor eruption (i.e., 5 to 12 months old) coincides with the diminution of the passive humoral immunity conferred by the transfer of maternal antibodies via the placenta and the establishment of the child's own immunity.[17,54] Pain is a common feature of teething as reported by parents and some health care providers. However, it is not the tooth that causes the pain but rather the follicle, which is a rich source of eicosanoids, cytokines, and growth factors and which results in a localized inflammatory response.[54,57]

Most medical and dental professionals agree that teething does not cause life-threatening illness, but they disagree about which symptoms may be associated with tooth eruption. A summary of the studies and systematic reviews of symptoms related to teething most commonly include decreased appetite, biting, drooling, gum rubbing, irritability, sucking, and abnormal temperature.[24,27,37,38,45,52,54,57,64,65] However, there is no evidence that any of the aforementioned symptoms can be diagnostic of teething in a child without excluding the possibility of other systemic diseases.

Primary Tooth Exfoliation

As with tooth eruption, the process of tooth exfoliation involves changes in the periodontium. The depth of the gingival sulcus increases as the junctional epithelium migrates down the resorbing root of an exfoliating tooth.[8,10] Microscopically, minor traumatic changes may demonstrate compression, ischemia, and the hyalinization of the periodontal ligament.[48] There may be changes in the permeability and integrity of the junctional epithelium, thereby making the exfoliating tooth more susceptible to inflammation.[10]

During the process of exfoliation, teeth may change position, which may lead to changes in occlusion. Malalignment caused by spacing and changes in skeletal relationships related to erupting teeth may also contribute to significant trauma of the periodontal structures. With more severe injury, crushing and necrosis of the periodontal ligament may occur. In most patients, these injuries are spontaneously resolved as the teeth exfoliate, erupt, and align through the normal growth and development processes.

Other Developmental Issues

Relation of Periodontal Status to Malocclusion. Data indicate an association between abnormal tooth position and gingivitis.[20] Crowding in the mixed dentition can often make plaque and food removal more difficult, thereby leading to an increased incidence of gingivitis. Severe changes may include gingival enlargement, discoloration, occasional ulceration, and the formation of deep pockets or pseudopockets. Generally, gingival health can be restored with orthodontic correction, but a failure to align the teeth does not necessarily have an effect on periodontal disease later in life.[20]

Mucogingival Problems. The prevalence of mucogingival problems and recession in children ranges from 1% to 19%, depending on the criteria used to assess the condition.[32] Evidence suggests that some mucogingival problems may start during the primary dentition as a consequence of developmental aberrations in eruption and deficiencies in the thickness of the periodontium.[41,42] A high frenum attachment may also be a factor in the development of mucogingival problems if there is excess tension at the marginal tissues.[51,61] During the mixed dentition, recession is most often found on the facial aspect of mandibular permanent incisors secondary to rotations or labial positioning related to space problems. Although erupting permanent lower incisors often show minimal attached gingiva, gingival width often increases as the teeth erupt and stimulate bone development[15] (Figure 18-6).

The maxillary canine region is also prone to localized gingival recession. Late-erupting canines in a crowded dentition may be displaced buccally, erupting into or near unattached gingiva or mucosa and increasing the risk of insufficient gingival tissue width and recession. Recession may also be associated with an anterior open bite as a result of the labial inclination of the teeth.[35] Orthodontic treatment and realignment may be necessary to protect the integrity of the attached gingiva.

Mucogingival problems can also result from factitious habits, like self-inflicted trauma from a fingernail (Figure 18-7) or excessive toothbrushing by either the parent or the child. Because the width of the attached gingiva increases with age, any of these problems may resolve spontaneously, thereby suggesting a cautious approach to treatment with judicious monitoring instead of immediate surgical intervention.[15,53]

Figure 18-6 Erupting permanent incisors showing minimal attached gingiva. *(Copyright Dr. Daniela Silva. All rights reserved.)*

Figure 18-7 Gingival recession on the maxillary and mandibular left primary canine areas caused by self-inflicted trauma from the patient's fingernail. *(Copyright Dr. Daniela Silva. All rights reserved.)*

Gingival Diseases of Childhood

Plaque-Induced Gingival Disease

Gingivitis is extremely common among children and adolescents, and it affects up to 70% of children who are more than 7 years old.[16,46] Inflammation is generally limited to the marginal gingiva (Figure 18-8), with undetectable loss of bone or connective tissue attachment in most cases. Although gingivitis does not always progress to periodontitis, the management of gingival disease in children and adolescents is important, because periodontitis is always preceded by gingivitis.[46]

In children as in adults, the primary cause of gingivitis is dental plaque, which is related to poor oral hygiene. The relationship between plaque and the gingival index, however, is weak and remains unclear.[8,37,40] Although gingivitis is highly prevalent in children, its severity is generally less intense than what is found in adults.[10] Similar oral hygiene conditions produce less severe forms of disease among children as compared with adults.[46]

As children age, their tendency to develop gingivitis increases.[10] The prevalence of disease is lowest during the preschool years and increases throughout childhood, peaking during puberty. However, increases in the degree of gingival inflammation do not fully correlate with the amount of plaque, thereby suggesting the influence of other factors.

Clinical Features. The most prevalent type of gingival disease in childhood is *chronic marginal gingivitis* (see Figure 18-8). The gingival tissues exhibit changes in color, size, consistency, and surface texture that are similar to those of chronic inflammation in the adult. Red, linear inflammation is accompanied by underlying chronic changes, including swelling, increased vascularization, and hyperplasia. Bleeding and increased pocket depth are not found as often in children as in adults, but they may be observed if severe gingival hypertrophy or hyperplasia occur.[8,46]

Chronic gingivitis in children is characterized by a loss of collagen in the area around the junctional epithelium and an infiltrate that consists mostly of lymphocytes, with small numbers of polymorphonuclear leukocytes, plasma cells, monocytes, and mast cells. Lesions generally have relatively few plasma cells, and they resemble the early nondestructive, nonprogressive lesions that are seen in adults. Furthermore, gingivitis in children differs from adult gingivitis in that the response is dominated by T lymphocytes, with few B lymphocytes and plasma cells in the infiltrate. This difference could explain why gingivitis in children rarely progresses to periodontitis.[33,34,40,55] Gingival histology in children also demonstrates other unique features that may contribute to a decreased tendency to progress to severe gingivitis. The junctional epithelium of the primary dentition tends to be thicker than in the permanent dentition,[10] which is thought to reduce the permeability of the gingival structures to bacterial toxins that initiate the inflammatory response.

Calculus. Calculus deposits are uncommon in infants and toddlers, but they may increase with age. About 9% of 4- to 6-year-old children exhibit calculus deposits. By the age of 7 to 9 years, 18% of children present with calculus deposits, and, by the age of 10 to 15 years, 33% to 43% have some calculus formation.[66] Within the category of special needs patients, children with cystic fibrosis[66] or chronic kidney disease[39] have a higher incidence of calculus deposits, which may be caused by increased calcium and phosphate concentrations in their saliva. Children who are fed exclusively with gastric or nasogastric tubes show significant calculus buildup as a result of a lack of function and increased oral pH (Figure 18-9).[23]

Microbiology of Disease. Because the intensity of gingival disease increases as a child develops into adulthood, it is important to understand the microbiology of disease, which is discussed more fully in Chapter 8. Interestingly, the composition of the oral microflora changes as the child matures.[10] Yang and colleagues[67] analyzed samples of dental plaque in children and reported that 71% of 18- to 48-month-old children were infected with at least one periodontal pathogen. Sixty-eight percent were infected with *Porphyromonas gingivalis,* and 20% exhibited *Bacteroides forsythus (Tannerella forsythia)*.[67] A moderate correlation also has been found between *B. forsythus* in children and periodontal disease in their mothers. *B. forsythus* also has been associated with gingival bleeding in children.

In a similar study, 60% of children between the ages of 2 and 18 years had detectable levels of *P. gingivalis* in their plaque, and 75% showed similar levels of *Actinobacillus actinomycetemcomitans*. The presence of *P. gingivalis* was most strongly associated

Figure 18-8 Plaque-induced gingivitis limited to the marginal gingiva in a 12-year-old girl. *(Copyright Dr. Daniela Silva. All rights reserved.)*

Figure 18-9 A 5-year-old boy with a history of liver transplant and gastric tube feeding showing generalized calculus deposit. *(Copyright Dr. Daniela Silva. All rights reserved.)*

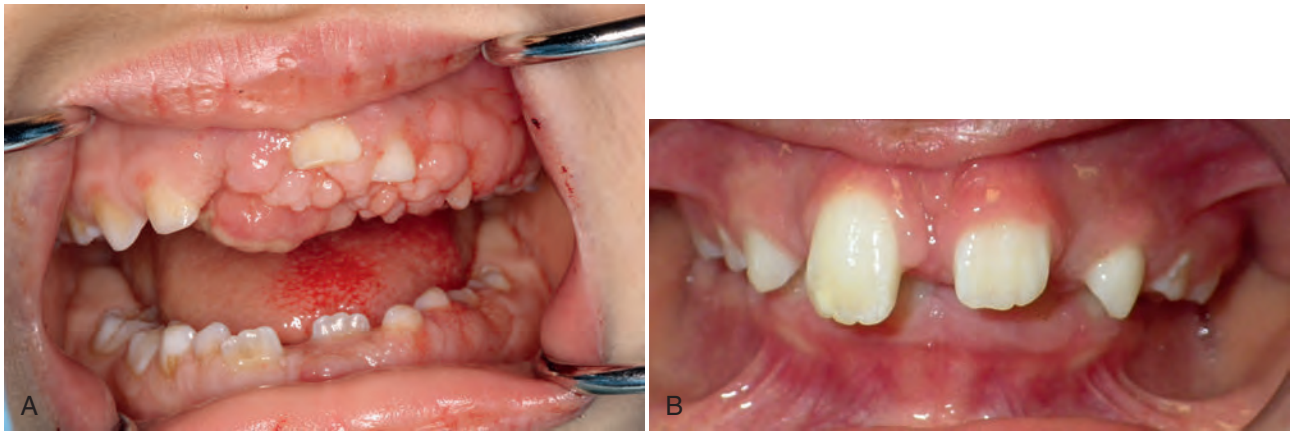

Figure 18-10 **A,** A 7-year-old boy with a history of aplastic anemia and cyclosporine-induced gingival hyperplasia. **B,** The same patient 1 year after gingivectomy and 6 months after the dosage of cyclosporine was decreased to half of the initial dosage. *(Copyright Dr. Daniela Silva. All rights reserved.)*

with the progression of gingivitis and the onset of periodontitis in healthy children.[44]

Experimental gingivitis models in children have demonstrated increased subgingival levels of *Actinomyces, Capnocytophaga, Leptotrichia,* and *Selenomonas*[16]—pathogens that are generally not seen in adult gingivitis—thereby raising interest in their potential role in the etiology of childhood gingivitis.

Eruption Gingivitis. Gingivitis associated with tooth eruption is so common that the term *eruption gingivitis* has come into common use. Tooth eruption per se does not cause gingivitis; however, inflammation associated with plaque accumulation around erupting teeth, perhaps secondary to discomfort caused by brushing these friable areas, may contribute to gingivitis.[10] The gingiva around erupting teeth may appear reddened because gingival margins have not yet keratinized fully and sulcus development is incomplete.

Exfoliating and severely carious primary teeth often contribute to gingivitis caused by plaque accumulation as a result of pain during brushing or food impaction in areas of cavitation. As a normal part of exfoliation, the junctional epithelium migrates under the resorbing tooth, thereby increasing pocket depth and potentially creating a niche for pathogenic bacteria.[10] The discomfort of chewing on severely infected teeth often leads to unilateral chewing on the unaffected side.

Puberty Gingivitis. As mentioned previously, the incidence of marginal gingivitis increases as a child matures, peaking when he or she is 9 to 14 years old and then decreasing slightly after puberty.[10] Gingival disease that behaves in such a manner is often referred to as *pubertal* (or *puberty*) *gingivitis.* Chapters 11 and 16 continue the discussion of this condition.

The most frequent manifestation of puberty gingivitis is bleeding and inflammation in interproximal areas. Inflammatory gingival enlargement may also be noted in both males and females, but it generally subsides after puberty[43] (Figure 18-8).

The altered gingival response during this developmental stage is thought to be the result of hormonal changes that magnify the vascular and inflammatory response to dental plaque[10,46] and that modify the reactions of dental plaque microbes.[22]

Drug-Induced Gingival Enlargement. Gingival enlargement, which is discussed in Chapter 16, may result from the use of certain drugs. Cyclosporine, phenytoin, and calcium channel blockers, which are used to treat conditions that are encountered during childhood (e.g., organ transplant, epilepsy, cardiac anomalies) result in a higher prevalence of gingival enlargement (Figure 18-10, *A* and *B*). A recent randomized clinical trial found an interesting and significant decrease in the incidence (21%) of phenytoin-induced gingival hyperplasia in children with epilepsy taking oral folic acid supplementation (0.5 mg/day) as compared with the control group (88%).[6] Although complicated by the plaque levels along the gingival margin, this form of gingival disease has features that are not typical of chronic marginal gingivitis.[46]

Figure 18-11 Chronic marginal gingivitis as a result of orthodontic therapy and inadequate oral hygiene. *(Copyright Dr. Daniela Silva. All rights reserved.)*

Gingival Changes Related to Orthodontic Appliances. Gingival enlargement can be related to the presence of fixed orthodontic appliances, which complicate plaque removal (Figure 18-11). Gingival changes can occur within 1 to 2 months of appliance placement; they are generally transient, and they only rarely produce long-term damage to periodontal tissues.[20] The fact that most orthodontic treatment is provided to individuals during puberty, when they are subject to the inflammatory changes associated with puberty gingivitis, may exacerbate the observed effect.

Mouth Breathing. Mouth breathing and lip incompetence, which are together referred to as an *open mouth posture,* are often

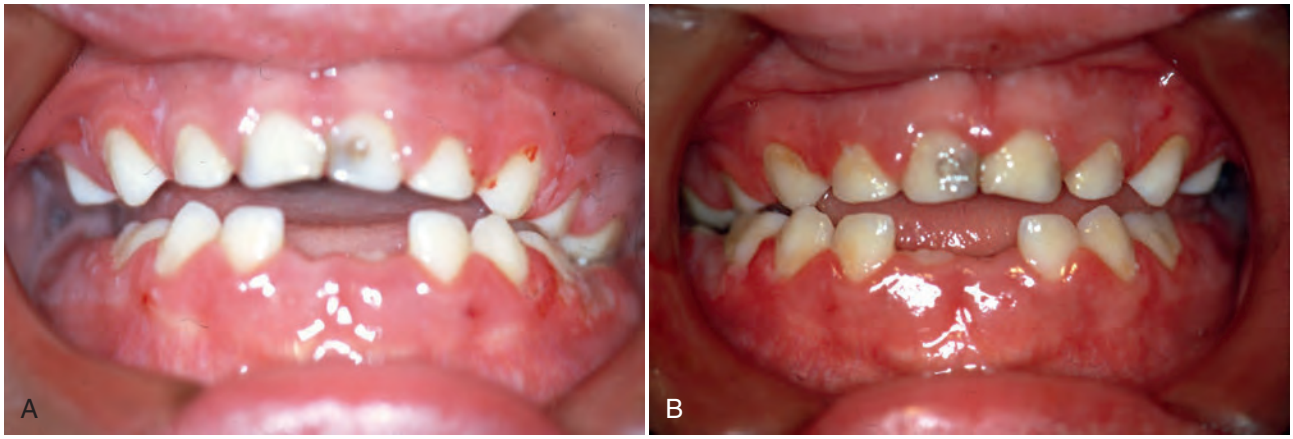

Figure 18-12 **A,** Acute herpetic gingivostomatitis in a 5-year-old girl with spontaneous bleeding. The infection is mostly limited to the attached gingiva, tongue, palate, and lips. **B,** The same patient 1 week later. The attached gingiva demonstrates initial healing. *(Courtesy Dr. Thomas K. Barber, University of California, Los Angeles Pediatric Dentistry.)*

associated with increased plaque and gingival inflammation.[20] The area of inflammation is often limited to the gingiva of the maxillary incisors. There is usually a clear line of demarcation where the gingiva is uncovered by the lip.

Non–Plaque-Induced Gingival Lesions

Intraoral soft-tissue lesions may be encountered in the pediatric population as they are in the adult population. The six most common pediatric intraoral lesions are primary herpetic gingivostomatitis, recurrent herpes simplex, recurrent aphthous stomatitis, candidiasis, angular cheilitis, and geographic tongue.[46] Most of these lesions present without significant differences between the pediatric and adult populations. However, two do have specific pediatric considerations.

Primary Herpetic Gingivostomatitis. Primary herpetic gingivostomatitis is an acute-onset viral infection that occurs early during childhood, with a heightened incidence between the ages of 1 and 3 years (see Chapter 17). In children with primary herpetic infections, 99% are symptom-free or have symptoms that are attributed to teething. The remaining 1% can develop significant gingival inflammation and ulceration of the attached gingiva, tongue, palate, and lips[27,46] (Figure 18-12, *A* and *B*). The most important measure is to control the child's hydration with bland, nonacetic fluids. Hospitalization may be necessary in some severe cases.

Candidiasis. Candidiasis results from an overgrowth of *Candida albicans*, usually after a course of antibiotics or as a result of congenital or acquired immunodeficiency. It is far less common in the child than the adult, and it is rarely associated with a healthy child.[13]

Localized Juvenile Spongiotic Gingival Hyperplasia. An additional condition that also appears to be unrelated to plaque accumulation is localized juvenile spongiotic gingival hyperplasia. This condition was only identified in recent years, and its pathogenesis is not yet well defined. The lesions are localized patches on the attached gingiva that present clinically as bright-red raised overgrowths; they are usually painless and associated with easy bleeding. These lesions are most commonly seen on the anterior labial maxillary and mandibular gingiva.[18] Most of the patients with this condition are between 8 and 14 years old (Figure 18-13).

Figure 18-13 Localized juvenile spongiotic gingival hyperplasia noted in an 11-year-old girl. The papillary gingiva is red, and the gingival overgrowth is prone to easy bleeding. *(Courtesy Dr. Chanel McCreedy. All rights reserved.)*

Periodontal Diseases of Childhood

Although gingivitis is considered to be "nearly universal" among children who are more than 7 years old,[16,46] frank periodontal disease with the loss of periodontal attachment and supporting bone is far less common in the pediatric population than in adults.[16] The incidence of disease begins increasing between the ages of 12 and 17 years, but the prevalence of severe attachment loss involving multiple teeth remains low, at 0.2% to 0.5%.[16] When comparing the different presentations of periodontal disease, chronic periodontitis has been shown to be more prevalent in adults, and aggressive periodontitis is more common in children and adolescents.[16]

Oral hygiene habits should be imprinted early during life, with instructions regarding proper technique and directions regarding the frequency of plaque removal procedures. These will form a foundation for a lifetime of dedication to periodontal health. Clinicians should be aware of the specific periodontal needs of children with particular abnormalities, such as gingival hyperplasia associated with immune suppression protocols used with organ transplants, antiseizure medications, and increased severity of periodontal disease in diabetic children. Physically and mentally

handicapped children deserve special care to ensure that appropriate preventive techniques are available; these may include the use of electric toothbrushes and antibacterial mouth rinses.

See Chapters 23 to 25 for detailed descriptions of the different types of periodontal disease.

Aggressive Periodontitis

Aggressive periodontitis is addressed in greater detail in Chapter 25. Because of the relatively early presentation of disease, which occurs around the time of puberty, former classifications include a mention of the developmental stage: early onset periodontitis, prepubertal periodontitis, and juvenile periodontitis.[16,46] The currently accepted designation of aggressive periodontitis may be further broken down into two forms: localized and generalized.

Localized aggressive periodontitis has been defined as "interproximal attachment loss on at least two permanent first molars and incisors, with attachment loss on no more than two teeth other than first molars and incisors."[16]

In young individuals, localized aggressive periodontitis is more common than the generalized form. The prevalence of the localized form has been reported to range from 0.1% to 15%, with most studies estimating less than 1%. Black and Hispanic individuals are reported to have a higher prevalence,[2,15,56] and some studies suggest a higher prevalence among Asian children as well.[2,48] Of relevance to the pediatric population is the finding that the classic presentation of localized aggressive periodontitis may be preceded by signs of bone loss around the teeth during the primary dentition.[16]

The generalized form of aggressive periodontitis, which is defined as a "generalized interproximal attachment loss, including at least three teeth that are not first molars and incisors," is rare among children (Figure 18-14, *A* and *B*). The onset of this form of periodontitis generally occurs after the initiation of adolescence. The general prevalence is 0.13% among 14- to 17-year-old children[16]; however, individuals with Down syndrome demonstrate a higher prevalence.[3,15,49] A purported genetic influence in the overall disease process suggests that any signs of disease in a child with a family history of generalized aggressive periodontitis should be investigated further.

Several studies have suggested the involvement of *A. actinomycetemcomitans*[2,31,59,56,18] and *P. gingivalis*[2] in the pathogenesis of aggressive periodontitis, with the former found at higher levels in children with the localized form and the latter found at higher levels with the generalized form. Both of these pathogens are relatively rare in healthy children, with a prevalence of 4.8%, but they are elevated in children with periodontitis, with a reported prevalence of 20%.[47] A recent study found a very strong association between localized aggressive periodontitis and the prevalence and abundance of *A. actinomycetemcomitans.* They also observed *A. actinomycetemcomitans* as being very site specific: it was more prevalent and abundant in diseased sites as compared with healthy sites in individuals with localized aggressive periodontitis.[56]

Chronic Periodontitis

Chronic periodontitis, which was formerly known as *adult periodontitis* or *chronic adult periodontitis*, is one of the most prevalent forms of periodontitis. It is characterized by a "slow to moderate rate of progression that may include periods of rapid destruction."[16] Although the disease can appear in children and adolescent populations as a result of retained plaque and calculus, it is far less prevalent in this population than it is in adults.[16]

Similar to the adult version, which is discussed in greater detail in Chapter 23, chronic periodontitis may occur in children in the localized form, in which less than 30% of the dentition is affected, as well the generalized form, in which more than 30% of the dentition is affected.

Although the microbiology of this disease is discussed in Chapters 8 and 23, it is important to note that recent studies suggest the familial transmission of certain bacteria associated with chronic periodontitis. Strains such as *T. forsythensis, P. intermedia*, and *P. nigrescens* are found more often in the children of individuals who have been shown to harbor these types.[63] Both *F. nucleatum* and *P. gingivalis* have been noted at significant levels in children of similarly affected parents.[12,29] Levels of these strains have been observed to increase with age, which suggests that *P. gingivalis* and *B. forsythus* may serve as early markers during screening for periodontal disease.[12,31,62] Thus, although chronic periodontitis may not be highly prevalent in children, early colonization may underscore the importance of early detection, particularly for those at elevated risk for adult forms of the disease.

Gingival Manifestation of Systemic Disease in Children

Systemic diseases that result in periodontitis occur more frequently in children than adults.[2] Chapter 11 discusses some of the general systemic diseases and disorders that affect periodontal health. However, many diseases are expressed differently in children than in adults and therefore merit special mention.

Acute necrotizing gingivitis is very rarely seen, except in cases of primary or secondary immune suppression, Down syndrome, or severe malnutrition.[19,49] The child's breath is fetid, and he or she complains of pain and discomfort when eating (see Chapter 17).

Endocrine Disorders and Hormonal Changes

Diabetes Mellitus. Type 1 or insulin-dependent diabetes mellitus occurs more frequently in children and young adults than type 2 or non–insulin-dependent diabetes mellitus. As in the diabetic adult, gingival inflammation and periodontitis are more prevalent in affected children than in unaffected individuals.[46,50] Clinical consequences include premature tooth loss and impaired immune response to the oral flora. The severity of periodontal disease is worse in children with poor metabolic control.

Although destructive changes are rather rare in healthy children, periodontal destruction can be observed in diabetic children, usually appearing around the time of puberty and becoming progressively worse as children mature into adulthood. Disease prevention and fastidious oral hygiene measures should be highly promoted.[30,31]

Hematologic Disorders and Immune Deficiencies

Leukemias. Leukemia is the most common type of cancer in children. Acute lymphocytic leukemia accounts for the majority of cases among children who are less than 7 years old. Leukemia must be considered as part of the differential diagnosis for children who present with the hallmark features of acute gingival enlargement, ulceration, bleeding, and infection (Figure 18-15).[1]

Leukocyte (Neutrophil) Disorders. As mentioned in greater detail in Chapter 11, neutrophil disorders impair defenses against infections, thereby making afflicted individuals susceptible to severe periodontal destruction. Many neutrophil disorders are genetic, including some forms of neutropenia, Chédiak–Higashi syndrome, leukocyte adhesion deficiency, and Papillon–Lefèvre syndrome. Therefore, the diagnosis of the systemic disorder generally will have occurred before any signs of periodontal destruction appear. Because periodontal changes are difficult to reverse in

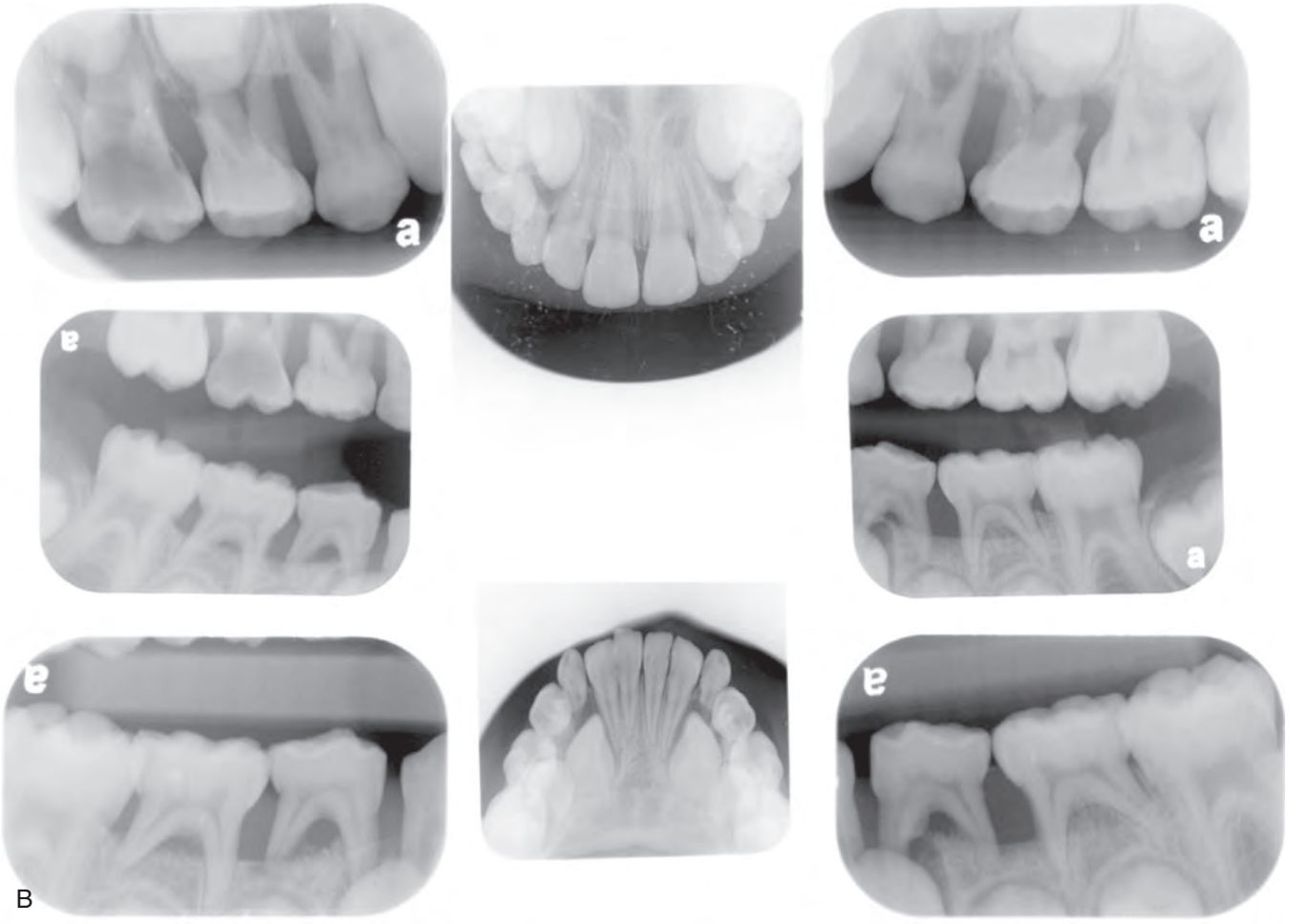

Figure 18-14 **A,** Aggressive periodontitis in an 8-year-old African-American girl. The clinical appearance of the mucosa is similar to normal tissue, but the primary canines and molars present with mobility, bleeding on probing, and deep pockets. **B,** Aggressive periodontitis in an 8-year-old African-American girl. Radiographs show advanced bone loss at the primary canine and molar areas. *(Copyright Dr. Daniela Silva. All rights reserved.)*

children with neutrophil disorders, disease management includes oral hygiene measures, mechanical debridement, antimicrobial therapy, and supportive care for any resultant tissue destruction or tooth loss. Treatment success is unpredictable as a result of the impact of systemic disease.[16]

Congenital Anomalies. Down syndrome is another congenital condition that would be diagnosed before the expression of periodontal disease. Afflicted individuals experience a high prevalence of severe aggressive periodontitis during early adulthood. The disease process is thought to be related to some kind of host susceptibility that results in an exaggerated immune–inflammatory response rather than a reaction to a specific causative microbe.[3,4,19]

Oral Mucosa in Childhood Diseases

Some childhood diseases present alterations or lesions of the oral mucosa and the underlying tissues, such as rubeola (rubella, measles), varicella (chickenpox), diphtheria, and scarlatina (scarlet fever). For a discussion of these diseases, the reader is referred to texts that discuss oral and pediatric pathology.

Therapeutic Considerations in the Pediatric Patient

The diagnostic process for pediatric patients follows the general outline described in Chapter 30. Medical and dental histories should be recorded for each child, with parents serving as the

Figure 18-15 A 12-year-old boy with acute lymphoblastic leukemia. There is generalized redness of the marginal gingiva, with spontaneous bleeding. *(Copyright Dr. Daniela Silva. All rights reserved.)*

primary historians. However, differences between the primary and permanent dentition and aspects related to development warrant some differences in clinical practices that involve the care of children.

Periodontal indices do not need to be recorded during the primary dentition unless a child exhibits signs of aggressive periodontitis or other unusual disease processes. More explicit periodontal assessments should begin during the mixed dentition, when children have permanent incisors and first molars. Rather than recording full-mouth probing depths, clinicians may elect to focus on selected teeth. For example, a rudimentary assessment of teeth #3, 8, 14, 19, 24, and 30 has been suggested,[20] with notes made regarding gingival health, bleeding on probing, and the presence of any calculus. This quick screening is generally sufficient for children up to the age of 11 years. Between the ages 12 to 19 years, when most individuals have a full permanent dentition, clinicians should also note pocket depths of more than 4 mm. By this stage of dental development, full-mouth pocket-depth probing may be warranted on the basis of general indicators of each patient's gingival health or risk of disease.

In-office professional plaque control procedures can vary in accordance with a patient's stage of development. As noted previously, calculus deposits are uncommon in infants and toddlers. Supragingival plaque removal with the use of simple rubber-cup coronal polishing or a toothbrush is usually sufficient during the primary dentition.[20] If calculus deposits are evident, selective supragingival scaling may be performed. As the permanent teeth erupt, the prevalence of calculus deposits increases, often necessitating targeted subgingival scaling in addition to supragingival plaque removal.[20]

Chapter 45 discusses plaque control for periodontal patients. In children, however, the dynamic process of developing manual dexterity affects the ability of a child to perform expected procedures. Each child requires an individualized home care program on the basis of his or her ability to actually perform the requested activities. For young children, plaque control should be a shared responsibility between children and their parents. Instruction in plaque control should be delivered to parents and children in language and terms that both understand.

For children who are less than 7 years old, parents should be asked to assist with toothbrushing.[20] Children may be encouraged to take a turn brushing their teeth using a simple scrub technique. However, parents should also take a turn to ensure the proper removal of plaque. By 7 years old, children generally possess the manual dexterity to brush their teeth on their own and may only require limited adult supervision.[20] More refined brushing techniques can be introduced during adolescence.

Mechanical toothbrushes with rotary heads have been shown to be effective for plaque removal.[20] The use of these devices can be encouraged as soon as children are able to tolerate the vibrating sensation, because many children initially dislike the feeling of the rotary movement. Mechanical toothbrushes are especially recommended for physically challenged children and individuals with fixed orthodontic appliances.[46]

Flossing is usually not indicated for children during the primary dentition stage, because most children have interdental spacing throughout most of their arches. However, as interdental contacts develop, flossing should be added to the home care routine. Studies have demonstrated both a decrease in gingival bleeding and the quantity of microbes associated with periodontal disease when tooth and tongue brushing are combined with flossing.[7,21] Again, limitations in manual dexterity may necessitate parental assistance with flossing during the mixed dentition stage. Adolescents with sufficient manual dexterity can be expected to floss on their own.[20]

Antimicrobial mouthrinses for chemical plaque control are not indicated for very young children because of the risk of ingestion of chemical agents.[20] However, rinses may be indicated for older children who demonstrate the ability to expectorate after rinsing.

Conclusions

- The periodontium of the primary dentition differs from that of the permanent dentition.
- Normal development can result in changes to the periodontium.
- Plaque-induced gingivitis is very common in children, although it may be less intense than in adults.
- With the exception of localized aggressive periodontitis, children rarely show signs of periodontitis.
- Some systemic disorders that are commonly associated with periodontal disease present initially during childhood.
- Recommendations regarding home plaque control routines should be individualized according to each patient's periodontal disease status and developmental stage.

Suggested Readings

Califano JV: Research Science and Therapy Committee American Academy of Periodontology: Position paper: periodontal diseases of children and adolescents. *Ped Dent Reference Manual* 34:304–311, 2012-13.

Clerehugh V, Tugnait A: Diagnosis and management of periodontal diseases in children and adolescents. *Periodontol 2000* 26:146–168, 2001.

Griffen AL: Periodontal problems in children and adolescents. In Casamassimo PS, Fields HW, McTigue DJ, Nowak AJ, editors: *Pediatric Dentistry Infancy Through Adolescence*, ed 5, Philadelphia, 2013, Elsevier.

Oh TJ, Eber R, Wang HL: Periodontal diseases in the child and adolescent. *J Clin Periodontol* 29:400–410, 2002.

References

References for this chapter are found on the companion website www.expertconsult.com.

References

1. Abdullah BH, Yahya HI, Kummoona RK, et al: Gingival fine needle aspiration cytology in acute leukemia. *J Oral Pathol Med* 31:55–58, 2002.
2. Albandar JM, Rams TE: Risk factors for periodontitis in children and young persons. *Periodontol 2000* 29:207–222, 2002.
3. Amano A, Kishima T, Kimura S, et al: Periodontopathic bacteria in children with Down syndrome. *J Periodontol* 71:249–255, 2000.
4. Amano A, Kishima T, Akiyama S, et al: Relationship of periodontopathic bacteria with early-onset periodontitis in Down's syndrome. *J Periodontol* 72:368–373, 2001.
5. Andlin-Sobocki A: Changes of facial gingival dimensions in children. A 2-year longitudinal study. *J Clin Periodontol* 20:212–218, 1993.
6. Arya R, Gulati S, Kabra M, et al: Folic acid supplementation prevents phenytoin-induced gingival overgrowth in children. *Neurology* 76:1338–1343, 2011.
7. Biesbrock A, Corby PM, Bartizek R, et al: Assessment of treatment responses to dental flossing in twins. *J Periodontol* 77:1386–1391, 2006.
8. Bimstein E, Lustmann J, Soskolne WA: A clinical and histometric study of gingivitis associated with the human deciduous dentition. *J Periodontol* 56:293–296, 1985.
9. Bimstein E, Eidelman E: Morphological changes in the attached and keratinized gingiva and gingival sulcus in the mixed dentition period. A 5-year longitudinal study. *J Clin Periodontol* 15:175–179, 1988.
10. Bimstein E, Matsson L: Growth and development considerations in the diagnosis of gingivitis and periodontitis in children. *Pediatr Dent* 21:186–191, 1999.
11. Bimstein E, Peretz B, Holan G: Prevalence of gingival stippling in children. *J Clin Pediatr Dent* 27:163–165, 2003.
12. Bimstein E, Sapir S, Houri-Haddad Y, et al: The relationship between *Porphyromonas gingivalis* infection and local and systemic factors in children. *J Periodontol* 75:1371–1376, 2004.
13. Blyth CC, Chen SC, Slavin MA, et al: Not just littler adults: candidemia epidemiology, molecular characterization and antifungal susceptibility in neonatal and pediatric patients. *Pediatrics* 123:1360–1368, 2009.
14. Bodner L, Goldstein J, Sarnat H: Eruption cysts: a clinical report of 24 new cases. *J Clin Pediatr Dent* 28:183–186, 2004.
15. Bosnjak A, Jorgic-Srdjak K, Maricevic T, et al: The width of clinically-defined keratinized gingiva in the mixed dentition. *ASDC J Dent Child* 69:266–270, 234, 2002.
16. Califano JV: Research Science and Therapy Committee American Academy of Periodontology: Position paper: periodontal diseases of children and adolescents. *Ped Dent Reference Manual* 34:304–311, 2012-13.
17. Carpenter JV: The relationship between teething and systemic disturbances. *J Dent Child* 45:381–384, 1978.
18. Chang JYF, Harvey P, Kessler HP, et al: Localized juvenile spongiotic gingival hyperplasia. *Oral Surg Oral Med Oral Pathol Oral Radiol Endod* 106:411–418, 2008.
19. Cichon P, Crawford L, Grimm WD: Early-onset periodontitis associated with Down's syndrome—clinical interventional study. *Ann Periodontol* 3:370–380, 1998.
20. Clerehugh V, Tugnait A: Diagnosis and management of periodontal diseases in children and adolescents. *Periodontol 2000* 26:146–168, 2001.
21. Corby PM, Biesbrock A, Bartizek R, et al: Treatment outcomes of dental flossing in twins: molecular analysis of the interproximal microflora. *J Periodontol* 79:1426–1433, 2008.
22. Demir T, Orbak R, Tezel A, et al: The changes in the T-lymphocyte subsets in a population of Turkish children with puberty gingivitis. *Int J Paediatr Dent* 19:206–212, 2009.
23. Dyment HA, Casas MJ: Dental care for children fed by tube: a critical review. *Spec Care Dentist* 19:220–224, 1999.
24. Feldens CA, Faraco IM, Ottoni AB, et al: Vítolo MR. Teething symptoms in the first year of life and associated factors: a cohort study. *J Clin Pediatr Dent* 34:201–206, 2010.
25. Gomes-Filho IS, Miranda DA, Trindade SC, et al: Relationship among gender, race, age, gingival width, and probing depth in primary teeth. *J Periodontol* 77:1032–1042, 2006.
26. Griffen AL: Periodontal problems in children and adolescents. In Pinkham JR, Cassamassimo PS, Field HW, editors: *Pediatric dentistry: infancy through adolescence*, ed 4, Philadelphia, PA, 2005, Saunders, pp 414–422.
27. King DL, Steinhauer W, Garcia-Godoy F, et al: Herpetic gingivostomatitis and teething difficulty in infants. *Pediatr Dent* 14:82–85, 1992.
28. Kiran K, Swati T, Kamala BK, et al: Prevalence of systemic and local disturbances in infants during primary teeth eruption: a clinical study. *Eur J Paediatr Dent* 12:249–252, 2011.
29. Kobayashi N, Ishihara K, Sugihara N, et al: Colonization pattern of periodontal bacteria in Japanese children and their mothers. *J Periodontal Res* 43:156–161, 2008.
30. Lalla E, Cheng B, Lal S, et al: Periodontal changes in children and adolescents with diabetes: a case-control study. *Diabetes Care* 29:295–299, 2006.
31. Lamell CW, Griffen AL, McClellan DL, et al: Acquisition and colonization stability of *Actinobacillus actinomycetemcomitans* and *Porphyromonas gingivalis* in children. *J Clin Microbiol* 38:1196–1199, 2000.
32. Loe H, Anerud A, Boysen H: The natural history of periodontal disease in man: prevalence, severity, and extent of gingival recession. *J Periodontol* 63:489–495, 1992.
33. Longhurst P, Johnson NW, Hopps RM: Differences in lymphocyte and plasma cell densities in inflamed gingiva from adults and young children. *J Periodontol* 48:705–710, 1977.
34. Longhurst P, Gillett R, Johnson NW: Electron microscope quantitation of inflammatory infiltrates in childhood gingivitis. *J Periodontal Res* 15:255–266, 1980.
35. Machtei EE, Zubery Y, Bimstein E, et al: Anterior open bite and gingival recession in children and adolescents. *Int Dent J* 40:369–373, 1990.
36. Mackler SB, Crawford JJ: Plaque development and gingivitis in the primary dentition. *J Periodontol* 44:18–24, 1973.
37. Macknin ML, Piedmonte M, Jacobs J, et al: Symptoms associated with infant teething: a prospective study. *Pediatrics* 105(4 Pt 1):747–752, 2000.
38. Markman L: Teething: facts and fiction. *Pediatr Rev* 30(8):e59–e64, 2009.
39. Martins C, Siqueira WL, Oliveira E, et al: Dental calculus formation in children and adolescents undergoing hemodialysis. *Pediatr Nephrol* 27:1961–1966, 2012.
40. Matsson L: Development of gingivitis in pre-school children and young adults. A comparative experimental study. *J Clin Periodontol* 5:24–34, 1978.
41. Maynard JG, Jr, Ochsenbein C: Mucogingival problems, prevalence and therapy in children. *J Periodontol* 46:543–552, 1975.
42. Maynard JG, Jr, Wilson RD: Diagnosis and management of mucogingival problems in children. *Dent Clin North Am* 24:683–703, 1980.
43. Modeer T, Wondimu B: Periodontal diseases in children and adolescents. *Dent Clin North Am* 44:633–658, 2000.
44. Morinushi T, Lopatin DE, Van Poperin N, et al: The relationship between gingivitis and colonization by *Porphyromonas gingivalis* and *Actinobacillus actinomycetemcomitans* in children. *J Periodontol* 71:403–409, 2000.
45. Noor-Mohammed R, Basha S: Teething disturbances; prevalence of objective manifestations in children under age 4 months to 36 months. *Med Oral Patol Oral Cir Bucal* 17:e491–e494, 2012.
46. Oh TJ, Eber R, Wang HL: Periodontal diseases in the child and adolescent. *J Clin Periodontol* 29:400–410, 2002.
47. Okada M, Hayashi F, Nagasaka N: Detection of *Actinobacillus actinomycetemcomitans* and *Porphyromonas gingivalis* in dental plaque samples from children 2 to 12 years of age. *J Clin Periodontol* 27:763–768, 2000.
48. Orban B, Weinmann J: Signs of traumatic occlusion in average human jaws. *J Dent Res* 13:216, 1933.

49. Pindborg JJ, Bhat M, Devanath KR, et al: Occurrence of acute necrotizing gingivitis in South Indian children. *J Periodontol* 37:14–19, 1966.
50. Pinson M, Hoffman WH, Garnick JJ, et al: Periodontal disease and type I diabetes mellitus in children and adolescents. *J Clin Periodontol* 22:118–123, 1995.
51. Powell RN, McEniery TM: A longitudinal study of isolated gingival recession in the mandibular central incisor region of children aged 6-8 years. *J Clin Periodontol* 9:357–364, 1982.
52. Ramos-Jorge J, Pordeus IA, Ramos-Jorge ML, et al: Prospective longitudinal study of signs and symptoms associated with primary tooth eruption. *Pediatrics* 128:471–476, 2011.
53. Saario M, Ainamo A, Mattila K, et al: The width of radiologically-defined attached gingiva over permanent teeth in children. *J Clin Periodontol* 21:666–669, 1994.
54. Sood S, Sood M: Teething: myths and facts. *J Clin Pediatr Dent* 35:9–14, 2010.
55. Seymour GJ, Crouch MS, Powell RN, et al: The identification of lymphoid cell subpopulations in sections of human lymphoid tissue and gingivitis in children using monoclonal antibodies. *J Periodontal Res* 17:247–256, 1982.
56. Shaddox LM, Huang H, Lin T, et al: Microbiological characterization in children with aggressive periodontitis. *J Dent Res* 91:927–933, 2012.
57. Shapira J, Berenstein-Ajzman G, Engelhard D, et al: Cytokine levels in gingival crevicular fluid of erupting primary teeth correlated with systemic disturbances accompanying teething. *Pediatr Dent* 25:441–448, 2003.
58. Silva CM, Ramos MM, Dalben GS: Oral characteristics of newborns. *J Dent Child (Chic)* 75:4–6, 2008.
59. Sjodin B, Arnrup K, Matsson L, et al: Periodontal and systemic findings in children with marginal bone loss in the primary dentition. *J Clin Periodontol* 22:214–224, 1995.
60. Srivastava B, Chandra S, Jaiswal JN, et al: Cross-sectional study to evaluate variations in attached gingiva and gingival sulcus in the three periods of dentition. *J Clin Pediatr Dent* 15:17–24, 1990.
61. Stoner JE, Mazdyasna S: Gingival recession in the lower incisor region of 15-year-old subjects. *J Periodontol* 51:74–76, 1980.
62. Suda R, Kurihara C, Kurihara M, et al: Determination of eight selected periodontal pathogens in the subgingival plaque of maxillary first molars in Japanese school children aged 8-11 years. *J Periodontal Res* 38:28–35, 2003.
63. Umeda M, Miwa Z, Takeuchi Y, et al: The distribution of periodontopathic bacteria among Japanese children and their parents. *J Periodontal Res* 39:398–404, 2004.
64. Wake M, Hesketh K, Lucas J: Teething and tooth eruption in infants: a cohort study. *Pediatrics* 106:1374–1379, 2000.
65. Wilson PHR, Mason C: The trouble with teething—misdiagnosis and misuse of a topical medicament. *Int J Paediatr Dent* 12:215–218, 2002.
66. Wotman S, Mercadante J, Mandel ID, et al: The occurrence of calculus in normal children, children with cystic fibrosis, and children with asthma. *J Periodontol* 44:278–280, 1973.
67. Yang EY, Tanner AC, Milgrom P, et al: Periodontal pathogen detection in gingiva/tooth and tongue flora samples from 18- to 48-month-old children and periodontal status of their mothers. *Oral Microbiol Immunol* 17:55–59, 2002.

CHAPTER 19

Desquamative Gingivitis

Alfredo Aguirre, Jose Luis Tapia Vazquez, and Russell J. Nisengard†

CHAPTER OUTLINE

Chronic Desquamative Gingivitis
Diagnosis of Desquamative Gingivitis: A Systematic Approach
Diseases that Present Clinically as Desquamative Gingivitis
Drug Eruptions
Miscellaneous Conditions that Mimic Desquamative Gingivitis

Chronic Desquamative Gingivitis

Although first recognized and reported in 1894,[157] the term *chronic desquamative gingivitis* was coined in 1932 by Prinz[122] to describe a peculiar condition characterized by intense erythema, desquamation, and ulceration of the free and attached gingiva[50,100] (Figure 19-1). Patients may be asymptomatic; when symptomatic, however, their complaints range from a mild burning sensation to an intense pain. Approximately 50% of desquamative gingivitis cases are localized to the gingiva, although patients can have involvement of the gingiva plus other intraoral and even extraoral sites.[56,112] Initially, the cause of this condition was unclear, with a variety of possibilities suggested. Because most cases were diagnosed in women during the fourth and fifth decades of life (although desquamative gingivitis may occur as early as puberty or as late as the seventh or eighth decade), a hormonal derangement was suspected. In 1960, however, McCarthy and colleagues[94] suggested that *desquamative gingivitis was not a specific disease entity but rather a gingival response associated with a variety of conditions.* This concept has been further supported by numerous immunopathologic studies.[77,114,130,151]

The use of clinical and laboratory parameters has revealed that approximately 75% of desquamative gingivitis cases have a dermatologic genesis. Cicatricial pemphigoid and lichen planus account for more than 95% of the dermatologic cases.[110] However, many other mucocutaneous autoimmune conditions (e.g., bullous pemphigoid, pemphigus vulgaris, linear immunoglobulin A [IgA] disease, dermatitis herpetiformis, lupus erythematosus, chronic ulcerative stomatitis) can clinically manifest as desquamative gingivitis.[138]

Other conditions that must be considered in the differential diagnosis of desquamative gingivitis include chronic bacterial, fungal, and viral infections as well as reactions to medications, mouthwashes, and chewing gum. Although less common, Crohn's disease, sarcoidosis, some leukemias, and even factitious lesions have also been reported to present clinically as desquamative gingivitis.[138,161]

Therefore, it is of paramount importance to ascertain the identity of the disease responsible for desquamative gingivitis to establish the appropriate therapeutic approach and management. To achieve this goal, the clinical examination must be coupled with a thorough history and routine histologic and immunofluorescence studies.[154,161] Despite this diagnostic approach, however, the cause of desquamative gingivitis cannot be elucidated in up to one third of the cases.[125]

Diagnosis of Desquamative Gingivitis: A Systematic Approach

Desquamative gingivitis is only a clinical term and not a diagnosis per se. Once the presence of this condition is determined, a series of laboratory procedures should be used to arrive at a final diagnosis. Thus, the success of any given therapeutic approach depends on the establishment of an accurate final diagnosis. The following discussion represents a systematic approach to elucidate the disease that is triggering desquamative gingivitis (Figure 19-2).

Clinical History

A thorough clinical history is mandatory to begin the assessment of desquamative gingivitis.[113] Data regarding the symptomatology associated with this condition as well as its historical aspects (i.e., when the lesion started, whether it has worsened, if there is a habit that exacerbates the condition) provide the foundation for a thorough examination. Information regarding previous therapy to alleviate the condition should also be documented.

Clinical Examination

Recognition of the pattern of distribution of the lesions (i.e., focal or multifocal, with or without confinement to the gingival tissues) provides leading information to begin the formulation of a differential diagnosis. In addition, a simple clinical maneuver such as Nikolsky's sign offers insight into the plausibility of the presence of a vesiculobullous disorder.[97]

Biopsy

Given the extent and number of lesions that may be present in an individual, an incisional biopsy is the best alternative to use to begin the microscopic and immunologic evaluation. An important consideration is the selection of the biopsy site. A perilesional incisional biopsy should avoid areas of ulceration, because necrosis and epithelial denudation severely hamper the diagnostic process. After the tissue is excised from the oral cavity, the specimen can be bisected and then submitted for microscopic examination. Buffered formalin (10%) should be used to fix the tissue for

†Deceased.

conventional hematoxylin-eosin (H&E) evaluation. Michel's buffer (ammonium sulfate buffer, pH 7.0) is used as transport solution for immunofluorescence assessment. In general, an incisional biopsy of uninvolved (normal) mucosa will show the same immunofluorescent findings as the biopsy of the perilesional tissue. However, there are notable exceptions, such as lichen planus and chronic cutaneous lupus erythematosus, in which only the lesional tissue will exhibit the corresponding immunologic markers (Table 19-1).

Microscopic Examination. Sections of approximately 5 µm of formalin-fixed, paraffin-embedded tissue stained with conventional H&E are obtained for light microscopy examination.

Immunofluorescence. For *direct* immunofluorescence, unfixed frozen sections are incubated with a variety of fluorescein-labeled, antihuman serum (i.e., anti-IgG, anti-IgA, anti-IgM, antifibrin, and anti-C3). With *indirect* immunofluorescence, unfixed frozen sections of oral or esophageal mucosa from an animal such as a monkey are first incubated with the patient's serum to allow for the attachment of any serum antibodies to the mucosal tissue. The tissue is then incubated with fluorescein-labeled antihuman serum. Immunofluorescence tests are positive if a fluorescent signal is observed in the epithelium, its associated basement membrane, or the underlying connective tissue (see Table 19-1).

Management

After the diagnosis is established, the dentist must choose the optimum management for the patient. This is accomplished in accordance with three factors: (1) the practitioner's experience; (2) the systemic impact of the disease; and (3) the systemic complications of the medications. A detailed consideration of these three factors dictates three different scenarios.

In the first scenario, the dental practitioner takes direct and exclusive responsibility for the treatment of the patient; this occurs with conditions such as erosive lichen planus, which is responsive to topical steroids (Figure 19-3).

In the second scenario, the dentist collaborates with another health care provider to evaluate and treat a patient concurrently. The classic example is seen with cicatricial pemphigoid, in which dentists and ophthalmologists work together (Figure 19-4). Although the dentist addresses the oral lesions, the ophthalmologist monitors the integrity of the ocular conjunctiva.

In the third scenario, the patient is immediately referred to a dermatologist for further evaluation and treatment. This occurs with conditions in which the systemic impact of the disease transcends the boundaries of the oral cavity and results in significant morbidity and even mortality. Pemphigus vulgaris is a clear example of a condition that, after diagnosis by the dentist, requires immediate referral to a dermatologist (Figure 19-5). In addition, the complications of chronically administered systemic medications that are indicated for the management of diseases such as pemphigus vulgaris or nonresponsive mucous membrane pemphigoid (e.g., diabetes mellitus, osteoporosis, methemoglobinemia) warrant referral to a dermatologist or a specialist in internal medicine.

When oral treatment is provided, periodic evaluation is needed to monitor the response of the patient to the selected therapy. Initially, the patient should be evaluated at 2 to 4 weeks after beginning treatment to ensure that the condition is under control. This observation should continue until the patient is free of discomfort. Appointments every 3 to 6 months would then be appropriate. Doses of any medications are usually adjusted during this interval.

Table 19-2 summarizes suggested contemporary therapeutic approaches that can be used to treat select conditions that clinically present as desquamative gingivitis. Dentists clearly play an important role in the diagnosis and management of desquamative gingivitis. The importance of being able to recognize and properly diagnose this condition is accentuated by the fact that a serious and life-threatening disease (e.g., squamous cell carcinoma) may mimic desquamative gingivitis.[127]

Figure 19-1 Chronic desquamative gingivitis. Irregular, conspicuous erythema involves the free and attached gingival tissues.

Diseases that Present Clinically as Desquamative Gingivitis

Lichen Planus

Lichen planus is an inflammatory mucocutaneous disorder that may involve the mucosal surfaces (e.g., oral cavity, genital tract, other mucosae) and the skin (including the scalp and the nails).[131]

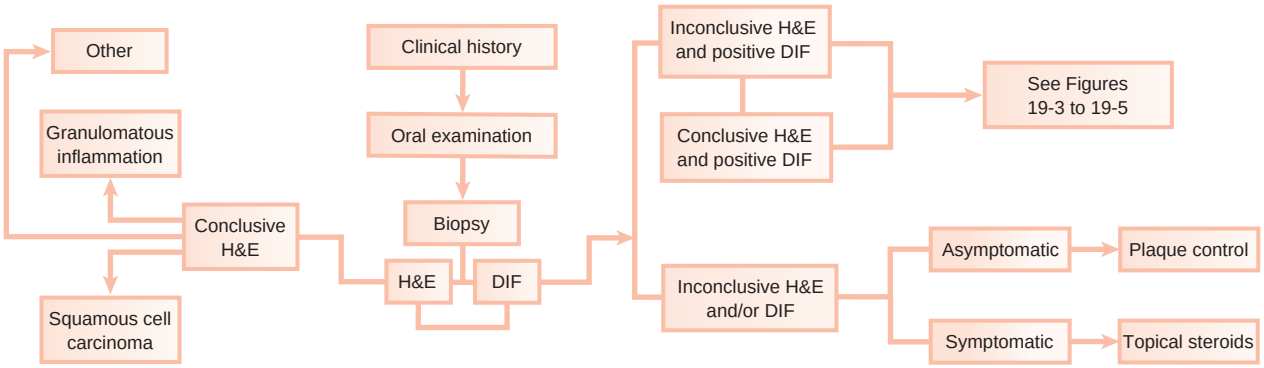

Figure 19-2 Diagnostic approach for desquamative gingivitis. *H&E,* Hematoxylin-eosin; *DIF,* direct immunofluorescence.

TABLE 19-1 Histopathologic, Direct, and Indirect Immunofluorescence Findings in Select Conditions that may Present Clinically as Desquamative Gingivitis

		DIRECT IMMUNOFLUORESCENCE		INDIRECT IMMUNOFLUORESCENCE
Disease	**Histopathology**	**Biopsy Perilesional Mucosa**	**Biopsy Uninvolved Mucosa**	**Serum**
Pemphigus	Intraepithelial clefting above the basal cell layer; basal cells have a characteristic "tombstone" appearance; acantholysis is present	Intercellular deposits in the epithelium; IgG in all cases and C3 in most cases	Same as for perilesional mucosa	Intercellular (IgG) antibodies in ≥90% of cases
Cicatricial pemphigoid	Subepithelial clefting with epithelial separation from the underlying lamina propria, leaving an intact basal layer	Linear deposits of C3 with or without IgG at the basement membrane zone in almost all cases	Same as for perilesional mucosa	Basement membrane zone (IgG) antibodies in 10% of cases
Bullous pemphigoid	Subepithelial clefting with epithelial separation from the underlying lamina propria, leaving an intact basal layer	Linear deposits of C3 with or without IgG at the basement membrane zone in almost all cases	Same as for perilesional mucosa	Basement membrane zone in 40% to 70% of cases
Epidermolysis bullosa acquisita	Similar to bullous and cicatricial pemphigoid	Linear deposits of IgG and C3 at the basement membrane zone in almost all cases	Same as for perilesional mucosa	Basement membrane zone (IgG) antibodies in 25% of cases
Lichen planus	Hyperkeratosis, hydropic degeneration of the basal layer, and sawtooth rete pegs; lamina propria exhibits dense, bandlike infiltrate, primarily of T lymphocytes; colloid bodies are present	Fibrillar deposits of fibrin at the dermal–epidermal junction	Negative	Negative
Chronic ulcerative stomatitis	Similar to erosive lichen planus; hyperkeratosis, acanthosis, basal cell layer liquefaction, subepithelial clefting, and lymphohistiocytic chronic infiltrate in a bandlike configuration	IgG deposits in the nuclei of the basal layer of epithelial cells	Same as for perilesional mucosa	ANA specific for basal cells of stratified squamous epithelium
Linear IgA disease	Similar to erosive lichen planus	Linear deposits of IgA at the basement membrane zone	Same as for perilesional mucosa	IgA basement membrane zone (IgA) antibodies in 30% of cases
Dermatitis herpetiformis	Collection of neutrophils, eosinophils, and fibrin in the connective tissue papillae	IgA deposits in the dermal papillae in 85% of cases	IgA deposits in dermal papillae in 100% of cases	IgA endomysial antibodies in 70% of cases; gliadin antibodies in 30% of cases
Systemic lupus erythematosus	Hyperkeratosis, basal cell degeneration, epithelial atrophy, and perivascular inflammation	IgG or IgM with or without C3 deposits at the dermal–epidermal junction	Same as for perilesional mucosa	ANA in >95% of cases; DNA and ENA antibodies in >50% of cases
Chronic cutaneous erythematosus	Hyperkeratosis, basal cell degeneration, epithelial atrophy, and perivascular inflammation	IgG or IgM with or without C3 deposits at the dermal–epidermal junction	Negative	Usually negative
Subacute lupus erythematosus	Less inflammatory cell infiltrate than systemic and chronic cutaneous forms but with similar microscopic features	IgG or IgM with or without C3 deposits at the dermal–epidermal junction in 60% of cases; granular IgG deposits in basal cell cytoplasm in 30% of cases	Same as for perilesional mucosa	ANA in 60% to 90% of cases; Ro (SSA) in 80% of cases; RF in 30% of cases; anti-RNP in 10% of cases

Modified from Rinaggio J, Neiders ME, Aguirre A, et al: *Compendium* 20:943, 1999.

ANA, Antinuclear antibodies; *C3,* complement 3; *DNA*, deoxyribonucleic acid; *ENA*, extractable nuclear antigens; *IgA*, immunoglobulin A; *IgG,* immunoglobulin G; *IgM,* immunoglobulin M; *RF*, rheumatoid factor; *RNP*, ribonucleoprotein.

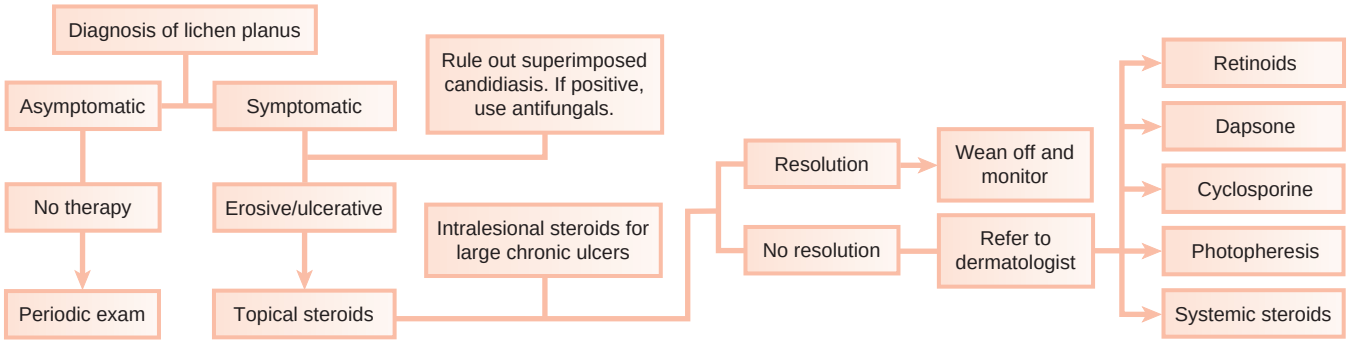

Figure 19-3 Treatment of lichen planus.

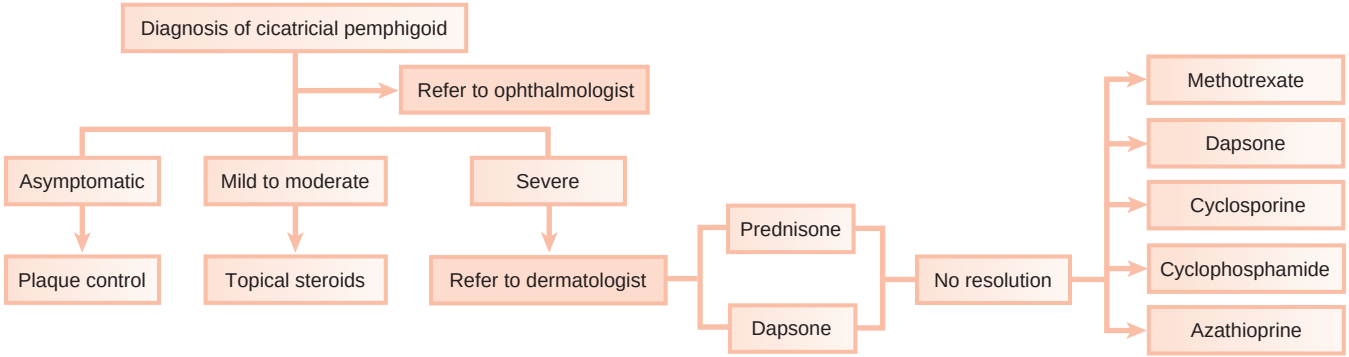

Figure 19-4 Treatment of cicatricial pemphigoid.

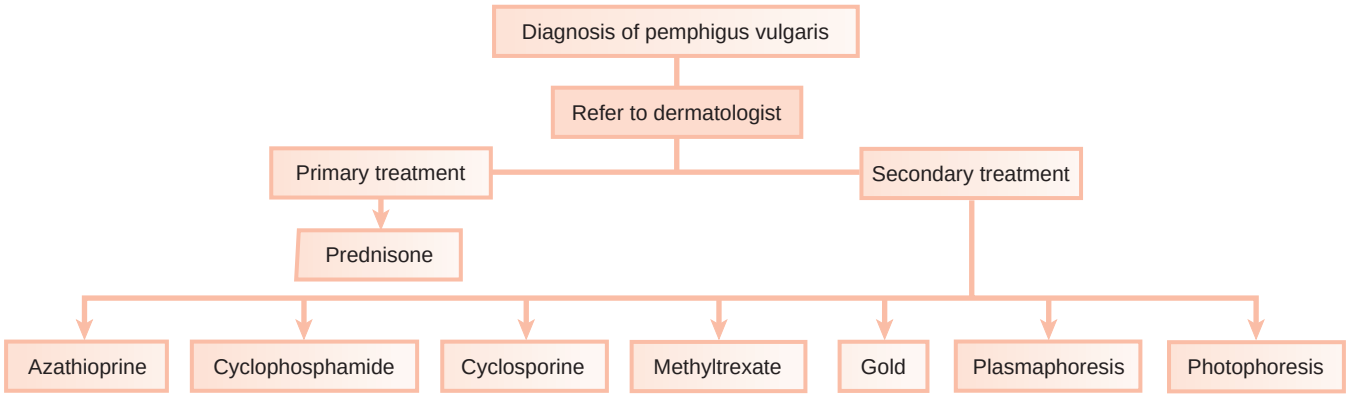

Figure 19-5 Treatment of pemphigus vulgaris.

Current evidence suggests that lichen planus is an immunologically mediated mucocutaneous disorder in which host T lymphocytes play a central role.[11,64,92] Although the oral cavity may present lichen planus lesions with a distinct clinical configuration and distribution, the clinical presentation may sometimes simulate other mucocutaneous disorders. Therefore, a clinical diagnosis of oral lichen planus should be accompanied by a broad differential diagnosis. Numerous epidemiologic studies have shown that oral lichen planus presents in 0.1% to 4% of the population.[139,142] The majority of patients with oral lichen planus are middle-aged and older women, with a 2:1 ratio of women to men. Children are rarely affected. In a dental setting, cutaneous lichen planus is observed in about one third of patients diagnosed with oral lichen planus.[88] By contrast, two thirds of patients seen in dermatologic clinics exhibit oral lichen planus.[136]

Oral Lesions. Although there are several clinical forms of oral lichen planus (i.e., reticular, patch, atrophic, erosive, and bullous), the most common are the reticular and erosive subtypes. The typical reticular lesions are asymptomatic and bilateral, and they consist of interlacing white lines on the posterior region of the buccal mucosa. The lateral border and dorsum of the tongue, the hard palate, the alveolar ridge, and the gingiva may also be affected. In addition, the reticular lesions may have an erythematous background, which is a feature that is associated with coexisting candidiasis. Oral lichen planus lesions follow a chronic course and have alternating, unpredictable periods of quiescence and flare-ups.

The erosive subtype of lichen planus is often associated with pain. It clinically manifests as atrophic, erythematous, and often ulcerated areas. Fine white radiating striations are observed

TABLE 19-2 Accepted Contemporary Therapeutic Approaches Used to Treat Select Conditions that Present Clinically as Desquamative Gingivitis

Disease	Therapy
Erosive lichen planus	*Mild cases:* Delivery of therapeutic agent can be enhanced with use of vacuum-formed custom trays **Rx:** Lidex (0.05% fluocinonide) gel **Disp:** One tube (1.5 g) **Sig:** Apply to affected area pc and hs Monitoring of the patient's oral cavity is warranted because candidiasis may develop after a few weeks of topical steroid use; concomitant use of antifungal may be necessary **Rx:** Nystatin oral pastilles (100,000 IU) **Disp:** 60 pastilles **Sig:** Dissolve in mouth bid, then expectorate for 30 consecutive days *Recalcitrant cases:* **Rx:** Protopic (0.1% tacrolimus) ointment **Disp:** One tube (15 g) **Sig:** Apply to affected area bid *Severe or refractory cases:* Refer to dermatologist for management with systemic corticosteroids
Cicatricial pemphigoid	*Mild cases:* **Rx:** Lidex (0.05% fluocinonide) gel **Disp:** One tube (1.5 g) **Sig:** Apply to affected area pc and hs **Rx:** Temovate (0.05% clobetasol propionate) **Disp:** One tube (1.5 g) **Sig:** Apply to affected area qid *Severe or refractory cases:* Refer to dermatologist for management with prednisone (20 to 30 mg/day); concomitant use of azathioprine may be needed; dapsone, sulfonamide, and tetracycline are other alternatives
Pemphigus	Refer to dermatologist for management with prednisone (20 to 30 mg/day); concomitant use of azathioprine may be needed
Chronic ulcerative stomatitis	*Mild cases:* **Rx:** Lidex (0.05% fluocinonide) gel **Disp:** One tube (1.5 g) **Sig:** Apply to affected area qid **Rx:** Temovate (0.05% clobetasol propionate) **Disp:** One tube (1.5 g) **Sig:** Apply to affected area qid

bid, Twice daily; *g,* grams; *hs,* at bedtime; *IU,* international units; *mg,* milligrams; *pc,* after meals; *qid,* four times daily.

bordering the atrophic and ulcerated zones. These areas may be sensitive to heat, acid, and spicy foods (Figure 19-6).

Gingival Lesions. Approximately 7% to 10% of patients with oral lichen planus have lesions restricted to the gingival tissue.[99,136] These may occur as one or more types of the following four distinctive patterns:

1. *Keratotic lesions.* These raised white lesions may present as groups of individual papules, linear or reticular lesions, or plaquelike configurations.
2. *Erosive or ulcerative lesions.* These extensive erythematous areas with a patchy distribution may present as focal or diffuse hemorrhagic areas. These lesions are exacerbated by slight trauma (e.g., toothbrushing) (Figure 19-7).
3. *Vesicular or bullous lesions.* These raised, fluid-filled lesions are uncommon and short lived on the gingiva, quickly rupturing and leaving ulcerations.
4. *Atrophic lesions.* Atrophy of the gingival tissues with ensuing epithelial thinning results in erythema that is confined to the gingiva.

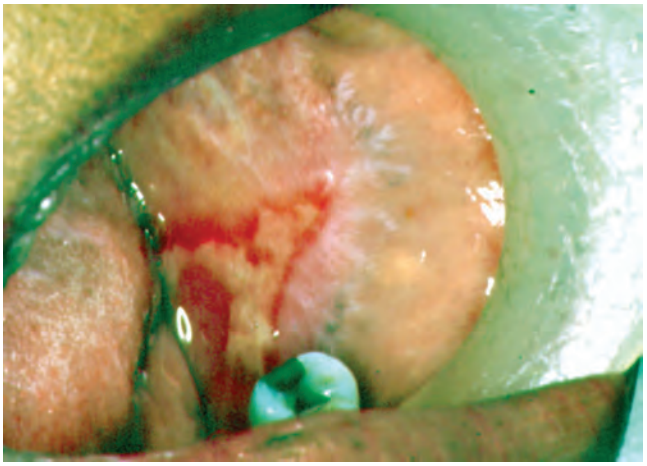

Figure 19-6 Erosive lichen planus. Note the large ulcerative lesion on the left buccal mucosa that exhibits bordering erythema. The typical white striations of lichen planus are evident in the periphery of the ulcer.

Figure 19-7 Erosive lichen planus presenting as desquamative gingivitis. The gingival tissues are erythematous, ulcerated, and painful. *(Courtesy Dr. Luis Gaitan, Oral Pathology Laboratory, Faculty of Odontology, National Autonomous University of Mexico, Mexico City, Mexico.)*

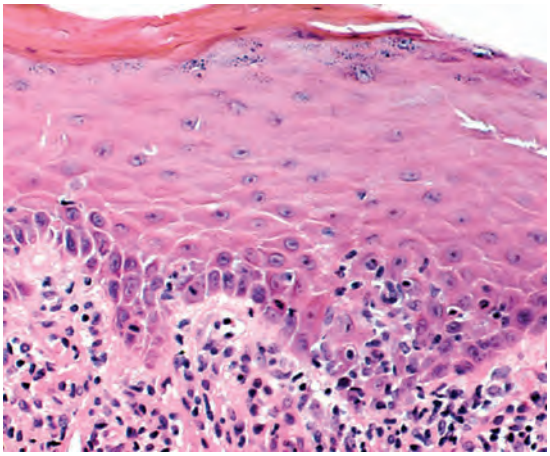

Figure 19-8 Microscopic appearance of lichen planus. A biopsy from a gingival lesion shows hyperkeratosis and mild hypergranulosis. Focal basal cell degeneration, lymphocytic exocytosis, and thickening of the basement membrane are apparent. The rete pegs exhibit a slight serrated configuration. The papillary lamina propria shows a bandlike infiltrate of lymphohistiocytic chronic inflammatory cells. (Hematoxylin-eosin stain; original magnification ×100.)

Histopathology. Microscopically, the three main features that characterize oral lichen planus are as follows: (1) hyperkeratosis or parakeratosis; (2) hydropic degeneration of the basal layer; and (3) a dense, bandlike infiltrate, primarily of T lymphocytes, in the lamina propria (Figure 19-8). Classically, the epithelial rete ridges have a "saw-tooth" configuration. Hydropic degeneration of the basal layer of the epithelium may be sufficiently extensive that the epithelium becomes thin and atrophic or detaches from the underlying connective tissue and produces either a subepithelial vesicle or an ulcer. Colloid bodies (Civatte bodies) are often seen at the epithelium–connective tissue interface. The microscopic diagnosis of oral lichen planus is straightforward in the keratotic lesions, and biopsy specimens should be obtained from these areas if possible. However, these classic histologic features may be obscured in areas of ulceration, thereby making a conclusive diagnosis of oral lichen planus difficult if it is based solely on conventional microscopy. Electron microscopy studies indicate that the separation of the basal lamina from the basal cell layer is an early manifestation of lichen planus.[61]

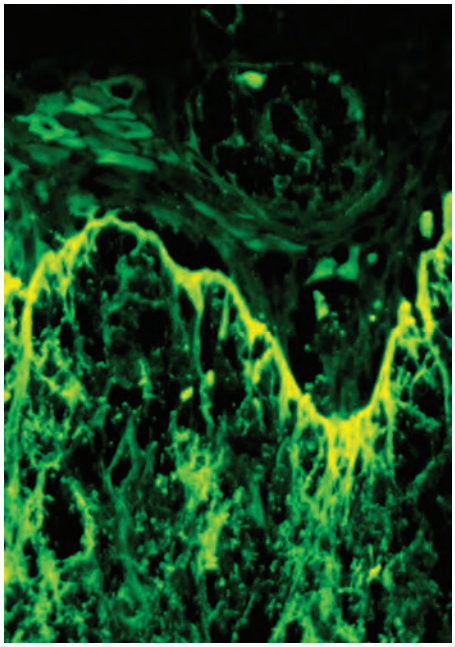

Figure 19-9 Direct immunofluorescence of lichen planus. Fibrin deposits along the basement membrane of the epithelium exhibit a "shaggy" configuration.

It is noteworthy that oral lesions of lichen planus may change in pattern, and, in certain unusual cases, a second or even a third biopsy may be necessary to arrive at a definitive diagnosis. More importantly, controversy exists regarding the malignant potential of oral lichen planus. In recent studies, it has been estimated that oral cancer emerges in up to 2% of patients with oral lichen planus.[41,55,62,63,150] By contrast, other researchers reject or question the connection between oral lichen planus and oral cancer.[42,66,87,123] Despite this controversy, biopsy and close follow up are warranted in these patients.

Immunopathology. Direct immunofluorescence of both lesional and perilesional oral lichen planus biopsy specimens reveals linear fibrillar ("shaggy") deposits of fibrin in the basement membrane zone (Figure 19-9), along with scattered immunoglobulin-staining cytoid bodies in the upper areas of the lamina propria (Figure 19-10). Serum tests involving the use of indirect immunofluorescence are negative in patients with lichen planus (see Table 19-1).

Differential Diagnosis. The classic clinical presentation of oral lichen planus can be simulated by other conditions and mainly by lichenoid mucositis. If oral lichen planus is confined to the gingival tissues (i.e., erosive oral lichen planus), then the identification of fine white radiating striations bordering the erosive areas support a clinical diagnosis of oral lichen planus. If the white striations are absent, the differential diagnosis should primarily include mucous membrane pemphigoid and pemphigus vulgaris. Other, less common possibilities include linear IgA disease (LAD) and chronic ulcerative stomatitis.

Treatment. The keratotic lesions of oral lichen planus are asymptomatic and do not require treatment after the microscopic diagnosis has been established. However, evaluation of the patient every 6 to 12 months is warranted to monitor suspicious clinical changes and to look for the emergence of an erosive component.

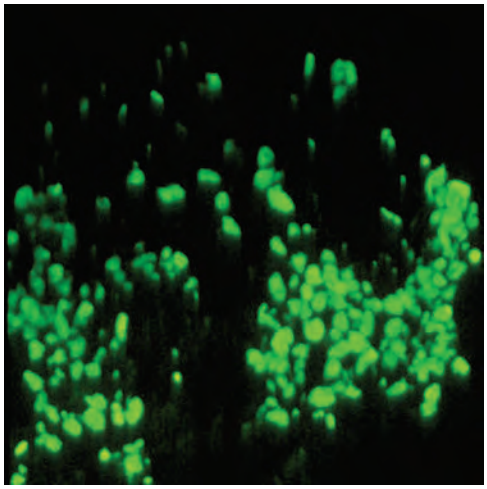

Figure 19-10 Direct immunofluorescence of lichen planus. Clusters of cytoid bodies exhibit immunoglobulin M deposits in the lamina propria.

By contrast, the erosive, bullous, or ulcerative lesions of oral lichen planus are treated with high-potency topical steroids, such as 0.05% fluocinonide gel (Lidex, three times daily). Lidex can also be mixed 1 : 1 with carboxymethylcellulose (Orabase) paste or another adhesive ointment. A gingival tray can also be used to deliver Lidex or 0.05% clobetasol propionate with 100,000 IU/ml of nystatin in Orabase. Three 5-minute applications of this mixture daily appear to be effective for controlling erosive lichen planus.[57] Intralesional injections of triamcinolone acetonide (10 mg to 20 mg) or short-term regimens of 40 mg of prednisone daily for 5 days, followed by 10 mg to 20 mg daily for an additional 2 weeks, have also been used in more severe cases.[112] Because of the potential side effects, the administration of systemic steroids should be prescribed and monitored by a dermatologist. Other treatment modalities (e.g., retinoids, hydroxychloroquine, cyclosporine, azathioprine, cyclophosphamide, free gingival grafts) have also been used.[112,119] A promising therapeutic agent, tacrolimus (0.1% Protopic ointment, twice daily), is an immunosuppressant that is effective for controlling the lesions of erosive lichen planus.[72,91,104,144]

Because candidiasis is often associated with symptomatic oral lichen planus and because topical steroid therapy promotes fungal growth, treatment should also include a topical antifungal agent.[16,52,67]

Pemphigoid

The term *pemphigoid* applies to a number of cutaneous, immune-mediated, subepithelial bullous diseases that are characterized by a separation of the basement membrane zone, including bullous pemphigoid, mucous membrane pemphigoid, and pemphigoid (herpes) gestationis.[118,140] Among these conditions, bullous pemphigoid and mucous membrane pemphigoid (also known as benign mucous membrane pemphigoid and cicatricial pemphigoid), have received considerable attention. Current molecular findings involving these two diseases clearly indicate that they are separate entities.[140] However, considerable histologic and immunopathologic overlap exists between the two diseases, so their differentiation may be impossible on the basis of these two criteria.[118] In many cases, the clinical findings are probably the best cognitive element to use to discriminate between them. Accordingly, the term *bullous pemphigoid* is preferred when the disease is nonscarring and mainly affects the skin. The term *cicatricial pemphigoid* is favored when scarring occurs and the disease is mainly confined to mucous membranes, although scarring may be absent with some subtypes of mucous membrane pemphigoid.[158] Until more research allows for the better understanding of this family of diseases, bullous pemphigoid and mucous membrane pemphigoid are discussed separately.

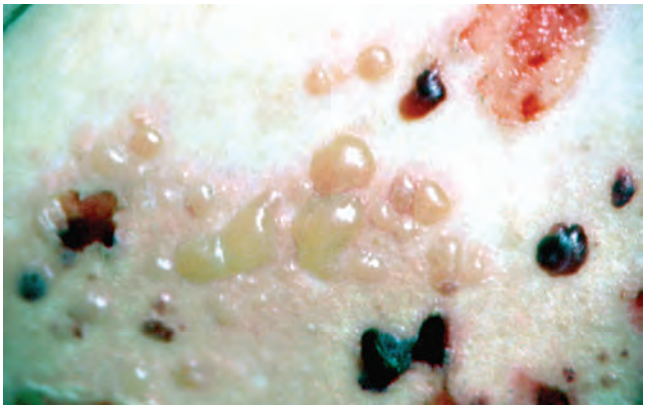

Figure 19-11 Bullous pemphigoid. Coalescing cutaneous bullae are seen, and some of them are hemorrhagic. Rupture of the bullae leads to the formation of serpiginous ulcers.

Bullous Pemphigoid. Bullous pemphigoid is a chronic, autoimmune, subepidermal bullous disease with tense cutaneous bullae that rupture and become flaccid (Figure 19-11). Oral involvement occurs in about a third of affected patients.[148]

Although the skin lesions of bullous pemphigoid clinically resemble those of pemphigus, the microscopic picture is quite distinct.

Histopathology. There is no evidence of acantholysis, and the developing vesicles are subepithelial rather than intraepithelial. The epithelium separates from the underlying connective tissue at the basement membrane zone. Electron microscopic studies show an actual horizontal splitting or replication of the basal lamina. The separating epithelium remains relatively intact, and the basal layer is present and appears to be regular. The two major antigenic determinants of bullous pemphigoid are the 230-kD protein plaque known as BP1 and the 180-kD collagen-like transmembrane protein BP2.[105,121,129]

Immunofluorescence. Immunologically, bullous pemphigoid is characterized by immunoglobulin G (IgG) and complement 3 (C3) immune deposits along the epithelial basement membranes and circulating IgG antibodies to the epithelial basement membrane.[71,109] Direct immunofluorescence is positive in 90% to 100% of these patients, whereas indirect immunofluorescence is positive in 40% to 70% of affected patients[110] (see Table 19-1).

Oral Lesions. Oral lesions have been reported to occur secondarily in up to 40% of cases. There is an erosive or desquamative gingivitis presentation and occasional vesicular or bullous lesions.[148]

Treatment. Because its etiologic factors are unknown, the treatment of bullous pemphigoid is designed to control its signs and symptoms.[71,109] The primary treatment is a moderate dose of systemic prednisone. Steroid-sparing strategies (i.e., prednisone plus other immunomodulatory drugs) are used when high doses of steroids are needed or when the steroid alone fails to control the disease.[38] For localized lesions of bullous pemphigoid, high-potency topical steroids or tetracycline with or without nicotinamide can be effective.[112]

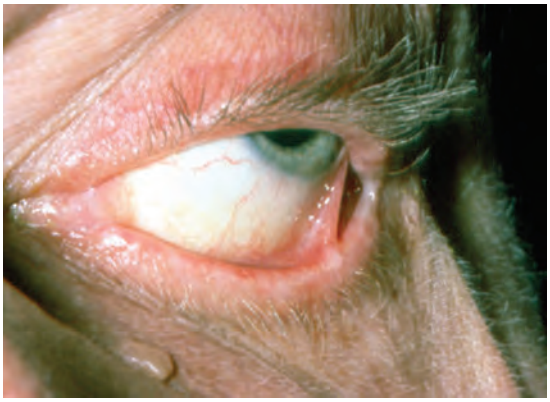

Figure 19-12 Mucous membrane pemphigoid. Characteristic ocular lesion (symblepharon) in a patient presenting with cicatricial pemphigoid. *(Courtesy Dr. Carl Allen, The Ohio State University, Columbus, OH.)*

Mucous Membrane Pemphigoid (Cicatricial Pemphigoid). Mucous membrane pemphigoid, which is also known as *cicatricial pemphigoid,* is a chronic vesiculobullous autoimmune disorder of unknown cause that predominantly affects women during the fifth decade of life. It has also rarely been reported in young children.[22,106,140]

Cicatricial pemphigoid involves the oral cavity, the conjunctiva, and the mucosa of the nose, vagina, rectum, esophagus, and urethra. In about 20% of patients, however, the skin may also be involved. Recent investigations suggest that cicatricial pemphigoid encompasses a group of heterogeneous conditions with distinct clinical and molecular features.[33,101,133] An elaborate cascade of events is involved in the pathogenesis of cicatricial pemphigoid. Initially, antigen–antibody complexing occurs at the basement membrane zone, and this is followed by complement activation and subsequent leukocyte recruitment. Next, proteolytic enzymes are released and dissolve or cleave the basement membrane zone, usually at the level of the lamina lucida.[45] The two major antigenic determinants for cicatricial pemphigoid are bullous pemphigoid 1 and 2 (BP1 and BP2). Most cases of cicatricial pemphigoid are the result of an immune response directed against BP2; less often, this response is mounted against BP1, epiligrin (laminin-5, a lamina lucida protein in basement membrane of stratified epithelium), and β4 integrins.[8,20,33]

Current research strongly suggests that there are at least five subtypes of cicatricial pemphigoid: oral pemphigoid, anti-epiligrin pemphigoid, anti-BP antigen mucosal pemphigoid, ocular pemphigoid, and multiple-antigens pemphigoid.[140] Recent studies have shown that the sera of ocular pemphigoid patients recognize the β4 integrin subunit, whereas the sera of patients with oral pemphigoid recognize the βα6 unit.[124]

Ocular Lesions. Among patients who first present to the dentist (mainly with desquamative gingivitis), the eyes are affected in approximately 25%.[110] By contrast, among patients who first present to the dermatologist, 66% present with conjunctival lesions; in ophthalmic studies, 100% of patients have ocular involvement.[51,81,102,103] The initial lesion is characterized by unilateral conjunctivitis that becomes bilateral within 2 years. Subsequently, there may be adhesions of eyelid to eyeball (symblepharon) (Figure 19-12). Adhesions at the edges of the eyelids (ankyloblepharon) may lead to a narrowing of the palpebral fissure. Small vesicular lesions may develop on the conjunctiva, which may eventually produce scarring, corneal damage, and blindness.

Figure 19-13 Gingival mucous membrane pemphigoid. Lesions are confined to the gingival tissues, where they produce a typical desquamative gingivitis appearance. *(Courtesy Dr. Stuart L. Fischman, State University of New York at Buffalo, Buffalo, NY.)*

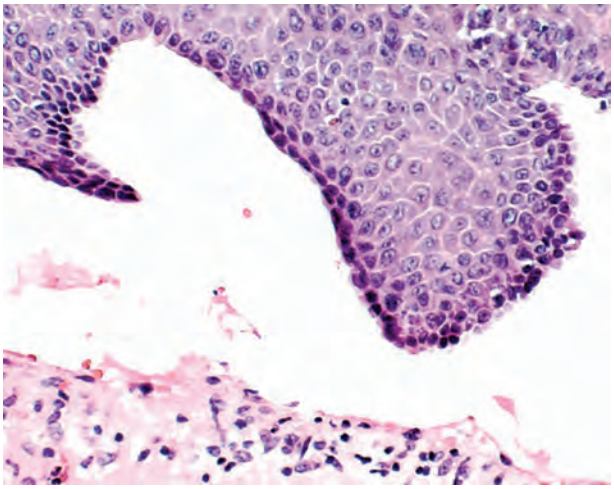

Figure 19-14 Microscopic features of oral mucous membrane pemphigoid. Note the separation of the epithelium from the subjacent connective tissue (subepithelial clefting). An intact basal cell layer remains attached to the epithelium. (Hematoxylin-eosin stain; original magnification ×100.)

Oral Lesions. The most characteristic feature of oral involvement is the presence of desquamative gingivitis, typically with areas of erythema, desquamation, ulceration, and vesiculation of the attached gingiva[53,146] (Figure 19-13). Vesiculobullous lesions may occur elsewhere in the mouth.[53] The bullae tend to have a relatively thick roof and to rupture within 2 to 3 days, leaving irregularly shaped areas of ulceration. Healing of these lesions may take 3 weeks or more.

Histopathology. The microscopic appearance of the oral lesions, although not completely diagnostic for mucous membrane pemphigoid, is sufficiently distinctive that a tentative diagnosis can be considered. A striking subepithelial vesiculation with the epithelium separated from the underlying lamina propria leaves an intact basal layer (Figure 19-14). The separation of the epithelium and the connective tissue occurs at the basement membrane zone. Electron microscopic studies demonstrate a split in the basal lamina.[155] A mixed inflammatory infiltrate (i.e., lymphocytes, plasma cells, neutrophils, and scarce eosinophils) is observed in the underlying fibrous connective tissue.

Immunofluorescence. Positive findings along the basement membrane area have been reported with the use of both direct and indirect immunofluorescence.[34,70,76] In biopsy tests by direct immunofluorescence, the main immunoreactants are IgG and C3, which

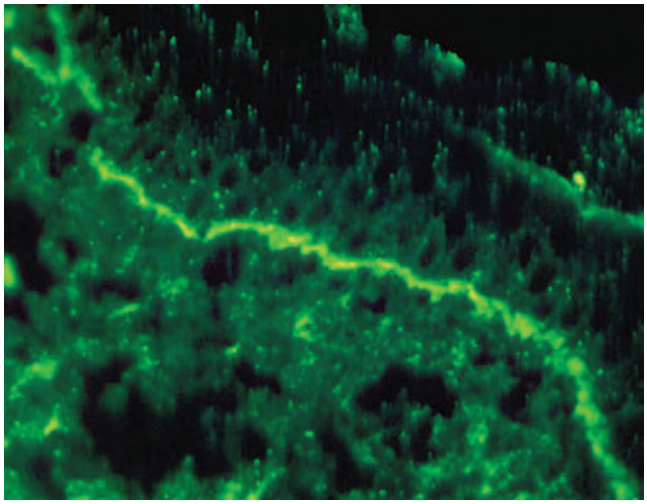

Figure 19-15 Direct immunofluorescence of mucous membrane pemphigoid. There are C3 deposits confined along the basement membrane.

are confined to the basement membrane (Figure 19-15). Some studies indicate that positive indirect immunofluorescence is rare in these patients (i.e., <25%).[96] The lack of indirect immunofluorescence findings may be caused by an earlier diagnosis of mucous membrane pemphigoid, thereby resulting in the identification of patients with less extensive disease.[2,79] In any event, circulating autoantibodies do not appear to play a role in the pathogenesis of the disease.

Differential Diagnosis. Several disease entities present with similar clinical and histologic (subepithelial bulla) features.[40] These include bullous pemphigoid, bullous lichen planus, dermatitis herpetiformis, LAD, erythema multiforme, herpes gestationis, and epidermolysis bullosa acquisita.

Pemphigus may be confined to the oral cavity during its early stage, and the vesicular and ulcerative lesions may resemble those of mucous membrane pemphigoid. An erosive or desquamative gingivitis may also be seen in pemphigus as a rare manifestation. Biopsy studies can quickly rule out pemphigus by revealing the absence or presence of acantholytic changes. In erythema multiforme, there are obvious vesiculobullous lesions. However, the onset is usually acute rather than chronic, labial involvement is severe, and the gingivae are usually not affected. Desquamative gingivitis is an unusual finding in erythema multiforme, although occasional vesicular lesions may develop. A biopsy study of an oral lesion reveals an unusual degeneration of the upper stratum spinosum that is characteristically seen in oral erythema multiforme lesions.

Cicatricial pemphigoid must be differentiated from epidermolysis bullosa acquisita, which can present with similar histopathology and immunopathology. When the biopsy is treated with salt to separate the dermis from the epidermis, basement membrane immunodeposits occur on the epidermal side with pemphigoid and on the dermal side with epidermolysis bullosa acquisita.[44]

Treatment. Topical steroids are the mainstay of treatment for mucous membrane pemphigoid, particularly when localized lesions are present. Fluocinonide (0.05%) and clobetasol propionate (0.05%) in an adhesive vehicle can be used three times a day for up to 6 months. When the oral lesions of mucous membrane pemphigoid are confined to the gingival tissues, topical corticosteroids are effectively delivered with vacuum-formed custom trays or

Figure 19-16 Cutaneous lesion of a patient with pemphigus vulgaris. A large bulla is present in the flexor surface of the wrist.

Figure 19-17 Pemphigus vulgaris of the oral cavity. Multiple and coalescent areas of ulceration are covered by pseudomembranes of necrotic epithelium. This patient presented with large ulcers of the labial mucosa, tongue, and soft palate.

veneers.[140] Optimal oral hygiene is essential because local irritants on the tooth surface result in an exaggerated gingival inflammatory response. Gingival irritation from any dental prosthesis should also be minimized.

If the disease is not severe and symptoms are mild, systemic corticosteroids may be omitted. If ocular involvement exists, systemic corticosteroids are indicated.

When lesions do not respond to steroids, systemic dapsone (4-4′-diaminodiphenylsulfone) has proved to be effective.[28,49,101,108] Because of the systemic side effects of dapsone, including hemolysis and methemoglobinemia and particularly in patients with glucose-6-phosphate dehydrogenase deficiency, referral to a dermatologist is often indicated.[115] Systemic steroids can also be combined with azathioprine or cyclophosphamide.[7,137] Some authors also advocate sulfonamides and tetracycline; although surgery is not a treatment for mucous membrane pemphigoid, it is used for some patients to prevent blindness as well as esophageal and upper airways stenosis.[140] Connective tissue grafting to alleviate root surface sensitivity and to improve aesthetics has been used with success to manage gingival recession in a patient with cicatricial pemphigoid.[84]

Pemphigus Vulgaris

The pemphigus diseases are a group of autoimmune bullous disorders that produce cutaneous and mucous membranes blisters (Figures 19-16 and 19-17). Pemphigus vulgaris is the most common

Figure 19-18 Pemphigus vulgaris of the gingiva. This image shows the clinical appearance of a patient with oral lesions that are confined to the gingivae and that were clinically diagnosed as "consistent with desquamative gingivitis." *(Courtesy Dr. Beatriz Aldape, Faculty of Odontology, National Autonomous University of Mexico, Mexico City, Mexico.)*

of the pemphigus diseases, which also include pemphigus foliaceus, pemphigus vegetans, and pemphigus erythematosus.[128] Pemphigus vulgaris is a potentially lethal chronic condition with a 10% mortality rate and a worldwide incidence of 0.1 to 0.5 cases per year per 100,000 individuals.[12,128,135] A predilection in women, usually after the fourth decade of life, has been observed.[112] However, pemphigus vulgaris has also been reported in unusually young children and even in newborns.[26,128,143,159]

The epidermal and mucous membrane blisters occur when the cell-to-cell adhesion structures are damaged by the action of circulating autoantibodies and by the in vivo binding of these autoantibodies to the pemphigus vulgaris antigens, which are cell-surface glycoproteins that are present in keratinocytes. These pemphigus vulgaris glycoproteins are members of the *desmoglein* (DSG) subfamily of the cadherin superfamily of cell–cell adhesion molecules, which are present in desmosomes.[78] Whereas high levels of desmoglein 3 (Dsg3) autoantibodies correlate with the severity of oral disease in patients with pemphigus vulgaris, elevated levels of desmoglein 1 (Dsg1) autoantibodies are associated with severity of cutaneous disease.[60] Recent evidence suggests that DSG3, which is the gene that codes for pemphigus vulgaris, is located in chromosome.[18]

Most cases of pemphigus vulgaris are idiopathic. However, medications such as penicillamine and captopril can produce drug-induced pemphigus, which is usually reversible after the withdrawal of the causative drug. Paraneoplastic pemphigus is antigenically distinct from pemphigus vulgaris, and it is associated with underlying malignancies.[107]

In approximately 60% of patients with pemphigus vulgaris, the oral lesions are the first sign of the disease; these lesions may herald the dermatologic involvement by a year or more.[98,149]

Oral Lesions. Oral lesions can range from small vesicles to large bullae. When the bullae rupture, they leave extensive areas of ulceration (Figure 19-18). Virtually any region of the oral cavity can be involved, but multiple lesions often develop at sites of irritation or trauma. The soft palate is most often involved (80%), and this is followed by the buccal mucosa (46%), the ventral aspect or dorsum of the tongue (20%), and the lower labial mucosa (10%). Oral lesions of pemphigus vulgaris are confined less often to the gingival tissues.[75] In these patients, a clinical diagnosis of erosive gingivitis or desquamative gingivitis is seen as the sole manifestation of oral pemphigus.

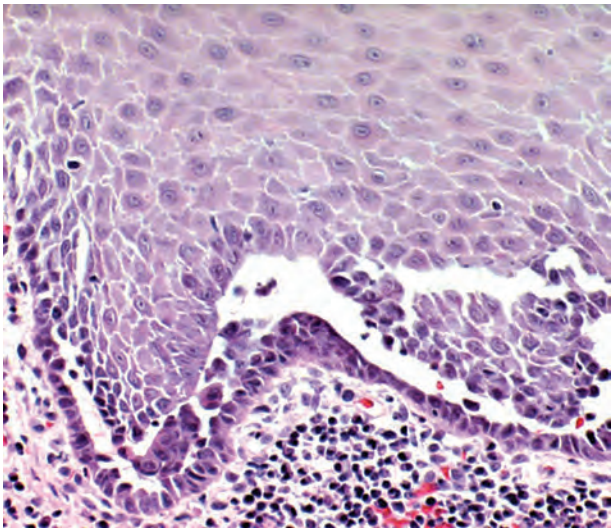

Figure 19-19 Microscopic features of pemphigus vulgaris. There is typical intraepithelial clefting with a "tombstone" appearance of the basal cells, which remain attached to the subjacent basement membrane and fibrous connective tissue. Acantholysis of epithelial cells with the formation of Tzanck cells is seen in the intraepithelial cleft. (Hematoxylin and eosin stain; original magnification ×100.)

Histopathology. The lesions of pemphigus demonstrate a characteristic intraepithelial separation that occurs above the basal cell layer. The intraepithelial vesiculation begins as a microscopic alteration (Figure 19-19) and gradually results in a grossly visible, fluid-filled bulla. Occasionally the entire superficial layers of epithelium are lost, leaving behind only the basal cells attached to the underlying lamina propria and conferring a characteristic "tombstone" appearance to the epithelial cells. *Acantholysis,* which involves the separation of the epithelial cells of the lower stratum spinosum, takes place; this condition is characterized by the presence of round rather than polyhedral epithelial cells. The intercellular bridges are lost, and the nuclei are large and hyperchromatic.[32,80,162] The underlying connective tissue usually presents as a mild to moderate, chronic inflammatory cell infiltrate. As the vesicle or bulla ruptures, the ulcerated lesion becomes infiltrated with polymorphonuclear leukocytes, and the surface may show suppuration.

Immunofluorescence. The presence of autoantibodies can be demonstrated in the oral mucosa of patients with oral pemphigus with the use of immunofluorescence techniques. For direct immunofluorescence, perilesional unfixed frozen sections are incubated with fluorescein-labeled human anti-IgG. With indirect immunofluorescence, unfixed frozen sections of oral or esophageal mucosa from an animal such as a monkey are first incubated with the patient's serum to allow for the attachment of any serum antibodies to the mucosal tissue. The tissue is then incubated with fluorescein-labeled antihuman IgG serum. The test is positive if immunofluorescence is observed in the intercellular spaces of the stratified squamous epithelium of the mucosa (Figure 19-20).

The indirect technique is less sensitive than the direct technique, and it may be negative during the early stages of the disease, particularly in its localized forms (see Table 19-1). In most cases, however, the indirect immunofluorescence titers are helpful for the monitoring of disease activity, and they have prognostic value.

Differential Diagnosis. The oral lesions of pemphigus vulgaris may be similar to those seen with erythema multiforme. In patients with erythema multiforme, however, recurrent active

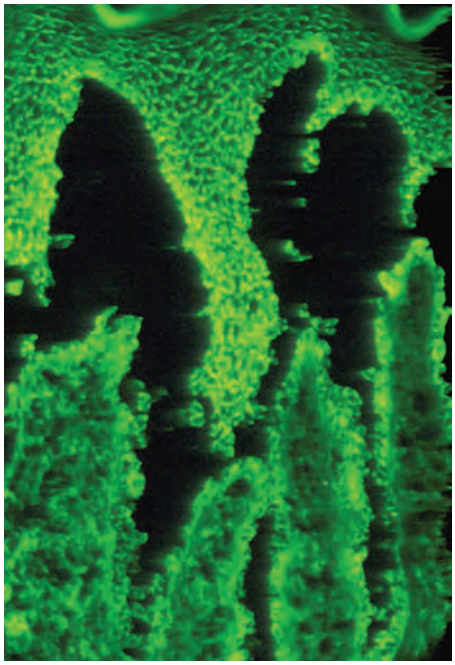

Figure 19-20 Direct immunofluorescence of oral pemphigus. The positive intercellular signal for immunoglobulin G deposits is seen in keratinocytes of the stratified squamous epithelium.

episodes of comparatively short duration are followed by long intervals that are free of skin or oral lesions. Erythema multiforme affects the lips with considerable severity. Microscopic examination with conventional H&E and direct immunofluorescence can discriminate between the oral lesions of pemphigus and those of erythema multiforme. Pemphigus vulgaris will show characteristic intraepithelial clefting at the basal–spinous cell layers and interface with acantholysis, whereas erythema multiforme shows microvesiculation of the superficial epithelial layers and numerous necrotic keratinocytes. Pemphigus vulgaris shows an intercellular and intraepithelial signal with direct immunofluorescence. By contrast, erythema multiforme exhibits negative immunofluorescence.

Pemphigoid may clinically resemble pemphigus. Microscopic examination and direct immunofluorescence studies are needed to establish a correct diagnosis. Bullous pemphigoid and mucous membrane pemphigoid exhibit detachment of the epithelium from the underlying connective tissue ("lifting off") rather than the acantholytic lesion characteristic of pemphigus.

Bullous lichen planus must also be considered during the differential diagnosis. The primary lesion of pemphigus may be of a bullous character, and this may be followed by erosion, with its associated pain and discomfort. In patients with lichen planus, however, the characteristic reticular lesions are invariably found associated with the bullae. Microscopic examination and direct immunofluorescence studies are necessary to differentiate this condition from pemphigus. Bullous lichen planus shows separation of the epithelium from the underlying fibrous connective tissue, "sawtooth" rete pegs, and a bandlike chronic inflammatory infiltrate in the lamina propria. Direct immunofluorescence reveals linear fibrillar deposits of fibrin in the basement membrane of bullous lichen planus, whereas pemphigus vulgaris has intercellular immunoglobulin deposition within the epithelium.

If the oral lesions of pemphigus vulgaris are restricted to the gingival tissues, then erosive lichen planus, pemphigoid, LAD, and chronic ulcerative stomatitis should be ruled out.

Treatment. The main therapy for pemphigus vulgaris is systemic corticosteroids with or without the addition of other immunosuppressive agents.[149] If the patient responds well to corticosteroids, the dosage can be gradually reduced, but a low maintenance dosage is usually necessary to prevent or minimize the recurrence of lesions. Many dermatologists monitor the dose of steroids via the periodic evaluation of the titers of DsG3 and DsG1 antibodies. Increasing titers are often associated with an impending exacerbation and warrant an increase of the steroid dose. A decrease in titer justifies a reduction of the steroid dose.[23] In patients who are not responsive to corticosteroids or who gradually adapt to them, "steroid-sparing" therapies are used; these consist of combinations of steroids plus other medications (e.g., azathioprine, cyclophosphamide, cyclosporine, dapsone, gold, methotrexate) as well as photoplasmapheresis and plasmapheresis.[112] Rituximab is an anti-CD20 monoclonal antibody that is aimed at the removal of desmoglein-reactive autoantibodies and that is currently being evaluated as an adjunct to treat pemphigus vulgaris.[43,141]

The maintenance phase aims to control the disease with the lowest dose of medication. To minimize the risk of morbidity associated with the long-term use of steroids, alternate-day steroid therapy, steroid-sparing drugs, and topical steroids can be combined. Because topical steroids may promote the development of candidiasis, topical antifungal medication may also be needed.[90]

The minimization of oral irritation is important for patients with oral pemphigus vulgaris. Optimal oral hygiene is essential with pemphigus vulgaris, because there is usually widespread involvement of the marginal and attached gingivae as well as of other areas of the mouth, which can be exacerbated by plaque-associated gingivitis and periodontitis. Periodontal care is an important issue in the overall management of patients with pemphigus vulgaris. To prevent flare-ups, patients in the maintenance phase should receive prednisone before professional oral prophylaxis and periodontal surgery.[128] In addition, the fit and design of removable prosthetic appliances should receive special attention, because even slight irritation from these prostheses can cause severe inflammation with vesiculation and ulceration.

Chronic Ulcerative Stomatitis

Chronic ulcerative stomatitis, which was first reported in 1990,[68] clinically presents with chronic oral ulcerations and has a predilection for women during their fourth decade of life. The erosions and ulcerations present predominantly in the oral cavity, with only a few cases exhibiting cutaneous lesions.[25,82,160]

Oral Lesions. Painful solitary small blisters and erosions with surrounding erythema are present mainly on the gingiva and the lateral border of the tongue. Because of the magnitude and clinical features of the gingival lesions, a diagnosis of desquamative gingivitis is considered (Figure 19-21). The buccal mucosae and hard palate may also present similar lesions.[152]

Histopathology. The microscopic features of chronic ulcerative stomatitis are similar to those observed with erosive lichen planus. Hyperkeratosis, acanthosis, and liquefaction of the basal cell layer with areas of subepithelial clefting are prominent features of the epithelium. The underlying lamina propria exhibits a lymphohistiocytic chronic infiltrate in a bandlike configuration.

Immunofluorescence. The direct immunofluorescence of normal and perilesional tissues reveals typical stratified epithelium–specific antinuclear antibodies. These are nuclear deposits of IgG

Figure 19-21 Chronic ulcerative stomatitis. Erythema and ulceration of the gingiva that are consistent with a clinical diagnosis of desquamative gingivitis are present. Direct and indirect immunofluorescence studies demonstrate the presence of stratified epithelium–specific antinuclear antibodies. *(Courtesy Dr. Douglas Damm, University of Kentucky, Lexington, KY.)*

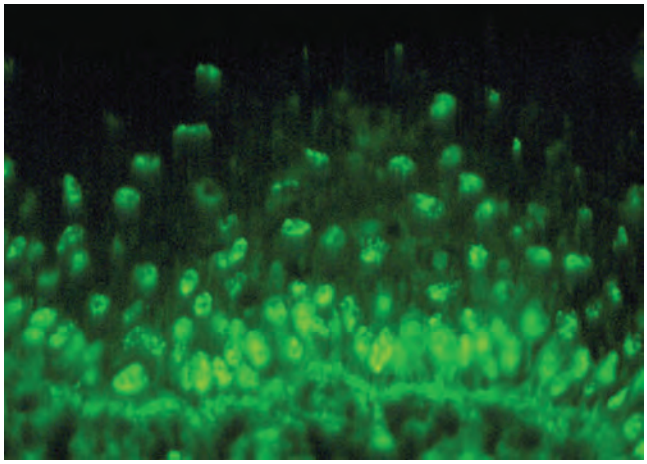

Figure 19-22 Direct immunofluorescence of chronic ulcerative stomatitis. Nuclear deposits of immunoglobulin G are prominent in the basal cell layer and fade toward the superficial layers. *(Courtesy Dr. Douglas Damm, University of Kentucky, Lexington, KY.)*

with a speckled pattern, and they are found mainly in the basal cell layer of the normal epithelium (Figure 19-22). In addition, fibrin deposits are visualized at the epithelial tissue–connective tissue interface. Indirect immunofluorescence studies involving the use of an esophageal substrate also reveal the presence of stratified epithelium–specific antinuclear antibodies.[153]

Diagnosis. Chronic ulcerative stomatitis is clinically similar to erosive lichen planus. In addition, pemphigus vulgaris, mucous membrane pemphigoid, LAD, bullous pemphigoid, and lupus erythematosus have to be included in the clinical differential diagnosis. Microscopic examination usually reduces the number of possibilities to chronic ulcerative stomatitis, LAD, and erosive lichen planus. Direct and indirect immunofluorescence studies are needed to arrive at the correct diagnosis.

Treatment. For mild cases, topical steroids (e.g., fluocinonide, clobetasol propionate) and topical tetracycline may produce clinical improvement; however, recurrences are common.[85] For severe cases, a high dose of systemic corticosteroids is needed to achieve remission. Unfortunately, the reduction of the corticosteroid dose results in relapse of the lesions. Hydroxychloroquine sulfate at a dosage of 200 mg to 400 mg per day seems to be the treatment

Figure 19-23 Linear immunoglobulin A disease. Intense erythema and ulceration of the gingiva consistent with desquamative gingivitis are present.

of choice to produce complete, long-lasting remission.[13,27,65,68] However, a long-term follow-up study demonstrated that combined therapy (i.e., small doses of corticosteroids and chloroquine) may be required because the initial good response to chloroquine ceases after several months or even years of treatment.[25]

Linear Immunoglobulin A Disease (Linear Immunoglobulin A Dermatosis)

LAD, which is also known as *linear IgA dermatosis,* is an uncommon mucocutaneous disorder with a predilection for women. The etiopathogenic aspects of LAD are not fully understood, although drug-induced LAD triggered by angiotensin-converting enzyme inhibitors has been reported.[48] LAD clinically presents as a pruritic vesiculobullous rash, usually during middle age and later, although younger individuals may be affected. Characteristic plaques or crops with an annular presentation surrounded by a peripheral rim of blisters affect the skin of the upper and lower trunk, the shoulders, the groin, and the lower limbs. The face and perineum may also be affected. Mucosal involvement, including that of the oral mucosa, ranges from 50% to 100% of the cases published.[21,29,69]

LAD may mimic lichen planus both clinically and histologically. Immunofluorescence studies are needed to establish the correct diagnosis.

Oral Lesions. Oral manifestations of LAD consist of vesicles, painful ulcerations or erosions, and erosive gingivitis or cheilitis. The hard and soft palates are affected more often; the tonsillar pillars, the buccal mucosa, the tongue, and the gingiva follow in frequency. Rarely, oral lesions may be the only manifestation of LAD for several years before the presentation of cutaneous lesions.[19] In addition, oral lesions of LAD have been clinically reported as desquamative gingivitis[37,116,120,121] (Figure 19-23).

Histopathology. The microscopic features of LAD are similar to those observed with erosive lichen planus.

Immunofluorescence. Linear deposits of IgA are observed at the epithelial tissue–connective tissue interface. They differ from the granular pattern that is observed with dermatitis herpetiformis.

Differential Diagnosis. The differential diagnosis of LAD includes erosive lichen planus, chronic ulcerative stomatitis, pemphigus vulgaris, bullous pemphigoid, and lupus erythematosus. Microscopic examination and immunofluorescence studies are necessary to establish the correct diagnosis.

Treatment. The primary treatment of LAD involves a combination of sulfones and dapsone. Small amounts of prednisone

(10 mg/day to 30 mg/day) can be added if the initial response is inadequate.[24] Alternatively, tetracycline (2 g/day) in combination with nicotinamide (1.5 g/day) has shown promising results.[117] Recently, mycophenolate (1 g twice daily) in combination with prednisolone (30 mg daily) resulted in the resolution of the refractory ulcerations associated with LAD.[83]

Dermatitis Herpetiformis

Dermatitis herpetiformis is a chronic condition that usually develops in young adults between the ages of 20 and 30 years, and it has a slight predilection for men.[39] Currently, evidence indicates that dermatitis herpetiformis is a cutaneous manifestation of celiac disease. Approximately 25% of patients with celiac disease have dermatitis herpetiformis. The etiology of celiac disease is obscure; however, tissue transglutaminase seems to be the predominant autoantigen in the intestine, the skin, and sometimes the mucosae.[31] Gluten enteropathy can be severe in about two thirds of patients, and it is mild or subclinical in the remaining third. In severe cases, patients may complain of dysphagia, weakness, diarrhea, and weight loss.[93]

Clinically, dermatitis herpetiformis presents with bilateral and symmetric pruritic papules or vesicles that are primarily restricted to the extensor surfaces of the extremities. The sacrum and the buttocks as well as occasionally the face and the oral cavity may also be affected.[15,39] The name *herpetic* is derived from the initial presentation of this disease, in which clusters of vesicles or papules arise on the skin. These vesicles or papules eventually resolve and are followed by hyperpigmentation of the skin, which ultimately wanes. The oral lesions of dermatitis herpetiformis range from painful ulcerations preceded by the collapse of ephemeral vesicles or bullae to erythematous lesions.[111]

Histopathology. The microscopic examination of the initial lesions of dermatitis herpetiformis reveals focal aggregates of neutrophils and eosinophils among deposits of fibrin at the apices of the dermal pegs.[163]

Immunofluorescence. Direct immunofluorescence shows that IgA and C3 are present at the dermal papillary apices. These findings are present in both perilesional tissue as well as normal, uninvolved tissue. By contrast, biopsies taken from lesional sites may fail to exhibit IgA or C3, thereby resulting in false-negative results.[163] Although no circulating autoantibodies to epithelial basement membrane are present in dermatitis herpetiformis, almost 80% of patients have anti-endomysial and gliadin antibodies.[14]

Treatment. A gluten-free diet is essential for the treatment of celiac disease and dermatitis herpetiformis. Oral dapsone is usually needed for patients with newly detected dermatitis herpetiformis to alleviate symptoms promptly.[19,31]

Lupus Erythematosus

Lupus erythematosus is an autoimmune disease with three different clinical presentations: systemic, chronic cutaneous, and subacute cutaneous.

Systemic Lupus Erythematosus. Systemic lupus erythematosus (SLE) is a severe disease with a 10 : 1 predilection for women as compared with men. SLE affects vital organs such as the kidneys and heart as well as the skin and mucosa. The classic cutaneous lesions characterized by the presence of a rash on the malar area with a butterfly distribution are actually uncommon[35] (Figure 19-24). The oral lesions of SLE are usually ulcerative or similar to lichen planus. Oral ulcerations are present in 36% of patients with SLE. In about 4% of patients, hyperkeratotic plaques reminiscent of lichen planus appear on the buccal mucosa and palate.[17] Direct immunofluorescence of both the perilesional and normal tissue reveals immunoglobulins and C3 deposits at the dermal–epidermal interface. Antinuclear antibodies are present in more than 95% of cases, whereas deoxyribonucleic acid and extractable nuclear antigen antibodies are present in more than 50% of patients (see Table 19-1).

Figure 19-24 Systemic lupus erythematosus producing erythema on the bridge of the nose, with a "butterfly" pattern. *(Courtesy Department of Dermatology, Hospital General Manuel Gea González, Mexico City, Mexico.)*

Figure 19-25 Chronic cutaneous lupus erythematosus. There are multiple facial lesions with irregular hyperpigmented borders, some of which exhibit central scarring with cutaneous atrophy. Other lesions consist of hyperpigmented cutaneous patches.

Chronic Cutaneous Lupus Erythematosus. Chronic cutaneous lupus erythematosus usually has no systemic signs or symptoms, with lesions being limited to the skin or the mucosal surfaces. The skin lesions are referred to as *discoid lupus erythematosus* (DLE). DLE merely describes the chronic scarring, atrophy-producing lesion that may develop into hyperpigmentation or hypopigmentation of the healing area (Figure 19-25). In the oral

Figure 19-26 Lupus erythematosus of the oral cavity presenting as desquamative gingivitis. Intense erythema with ulceration is bordered by white radial lines. *(Courtesy Dr. Stuart L. Fischman, State University of New York at Buffalo, NY.)*

cavity, about 9% of patients with chronic cutaneous lupus erythematosus present with lichen-planus–like plaques on the palate and the buccal mucosa.[5,17] The gingiva may be affected and present clinically as desquamative gingivitis (Figure 19-26).

Histopathology. The histopathology of the oral lesions of chronic cutaneous lupus erythematosus consists of hyperkeratosis, alternating acanthosis and atrophy, and hydropic degeneration of the basal layer of the epithelium. The lamina propria exhibits a chronic inflammatory cell infiltrate similar to that observed with lichen planus. However, a more diffuse and deeper inflammatory infiltrate with a perivascular pattern is typically observed.[147]

The direct immunofluorescence of lesional tissue reveals immunoglobulins and C3 deposits at the dermal–epidermal junction of the lesional or perilesional tissue but not in normal tissue. This seems to differentiate SLE from DLE. Indirect immunofluorescence reveals the presence of antinuclear antibodies in more than 95% of patients, whereas deoxyribonucleic acid– and extractable nuclear antigen–circulating antibodies are present in more than 50% of patients.

Subacute Cutaneous Lupus Erythematosus. Patients with subacute cutaneous lupus erythematosus present cutaneous lesions that are similar to DLE but that lack the development of scarring and atrophy.[18] In addition, arthritis and arthralgia, low-grade fever, malaise, and myalgia may present in up to 50% of patients with subacute cutaneous lupus erythematosus.[18,156] Direct immunofluorescence reveals immunoglobulins and C3 deposits at the dermal–epidermal junction in 60% of cases and granular IgG deposits in the cytoplasm of basal cells in 30% of cases. About 80% of patients with subacute cutaneous lupus erythematosus have Ro (SSA) antibodies to nuclear antigens, whereas 25% to 30% have La (SSB) antibodies to nuclear antigens. Rheumatoid factor is positive in about 30% of these patients, antinuclear antibodies are positive in 60% to 90% of these patients, and 10% of patients have anti-ribonucleoprotein antibodies to nuclear antigens (see Table 19-1).

Differential Diagnosis. Erosive lichen planus, erythema multiforme, and pemphigus vulgaris may sometimes simulate the lesions observed in patients with lupus erythematosus. The diagnosis of DLE confined to the oral cavity is difficult to make, but microscopic studies may suggest the characteristic histopathology.[4] Biopsy studies (i.e., H&E and direct immunofluorescence) help with differentiation between lupus erythematosus and other erosive diseases.

Treatment. The therapy for SLE depends on the severity and extent of the disease; it may range from topical steroids to nonsteroidal anti-inflammatory drugs to, for severe systemic organ involvement, moderate to high doses of prednisone. Immunosuppressive drugs (e.g., cytotoxic agents such as cyclophosphamide and azathioprine) and plasmapheresis alone or with steroids can be useful.[112] Recently, rituximab has been used, and it has produced dramatic long-term remissions.[35] For chronic cutaneous lupus erythematosus, topical steroids are effective to manage the cutaneous and oral lesions. For patients who are resistant to topical therapy, systemic antimalarial drugs may be used, with good results.[110]

Erythema Multiforme

Erythema multiforme is an acute bullous and macular inflammatory mucocutaneous disease that affects mainly young adults between the ages of 20 and 40 years; it is rarely seen in children (≤20%).[134] The genesis of the mucocutaneous lesions is believed to reside in the development of immune complex vasculitis. This is followed by complement fixation that leads to the leukocytoclastic destruction of vascular walls and small vessel occlusion. The culmination of these events produces ischemic necrosis of the epithelium and underlying connective tissue.[45] Target or "iris" lesions with central clearing are the hallmark of erythema multiforme. It may be a mild condition (erythema multiforme minor) or a severe and possibly life-threatening condition (erythema multiforme major or Stevens–Johnson syndrome). An underdiagnosed type of erythema multiforme is the oral form, with which most patients have chronic or recurrent oral lesions only.[6]

Erythema multiforme minor lasts approximately 4 weeks and exhibits moderate cutaneous and mucosal involvement. Stevens–Johnson syndrome may last a month or longer; it involves the skin, the conjunctiva, the oral mucosa, and the genitalia, and it requires more aggressive therapy. Some researchers consider toxic epidermal necrolysis to be the most severe form of erythema multiforme; however, other investigators believe that these are unrelated entities.[10] The two most common etiologic factors for the development of erythema multiforme are herpes simplex infection and drug reactions. The most common causative drugs are sulfonamides, penicillins, quinolones, chlormezanone, barbiturates, oxicam nonsteroidal anti-inflammatory drugs, anticonvulsant drugs, protease inhibitors, and allopurinol.[46]

Oral lesions in patients with erythema multiforme are common, and they are present in more than 70% of patients with skin involvement.[47,89,95] In rare instances, however, erythema multiforme may be confined to the mouth.[6,86,138] The oral lesions consist of multiple large, shallow, painful ulcers with an erythematous border. They affect the entire oral mucosa in approximately 20% of patients with erythema multiforme. The lesions are so painful that chewing and swallowing are impaired (Figure 19-27). The buccal mucosa and the tongue are the most frequently affected sites, and these are followed by the labial mucosa. Areas that are less often affected include the floor of the mouth, the hard and soft palates, and the gingiva.[47] There are rare instances in which erythema multiforme may be confined exclusively to the gingival tissues and result in a clinical diagnosis of desquamative gingivitis.[9] Hemorrhagic crusting of the vermilion border of the lips may occur, which is helpful for arriving at a clinical diagnosis of erythema multiforme.

Histopathology. Common microscopic findings of erythema multiforme include the liquefaction degeneration of the upper epithelium and the development of intraepithelial microvesicles but without the acantholysis that occurs with pemphigus.[145] In addition, acanthosis,

Figure 19-27 Erythema multiforme. There are large, shallow, and painful ulcers that involve the labial and buccal mucosae. Hemorrhagic crusting of the mandibular vermilion border of the lips is observed. *(Courtesy Dr. Stuart L. Fischman, State University of New York at Buffalo, NY.)*

pseudoepitheliomatous hyperplasia, and necrotic keratinocytes are observed in the epithelium. Degenerative changes also occur in the basement membrane. In some cases, the junction between the epithelium and the lamina propria is indistinct because of a dense inflammatory cell infiltrate. Edema of the lamina propria, vascular dilation, and congestion are also present. Deeper layers of the connective tissue stroma exhibit a perivascular chronic inflammatory cell infiltrate. However, neutrophils and eosinophils may also be present.

Immunofluorescence. Immunofluorescence examination is negative in patients with erythema multiforme. Its value resides in ruling out other vesiculobullous and ulcerative disorders.

Treatment. There is no specific treatment for erythema multiforme. For mild symptoms, systemic and local antihistamines together with topical anesthetics and the debridement of lesions with an oxygenating agent are adequate. In patients with bullous or ulcerative lesions and severe symptoms, corticosteroids are considered the drug of choice, although their use is controversial and not completely accepted.[46]

Drug Eruptions

An increase in the incidence of skin and oral manifestations of hypersensitivity to drugs has been noted since the advent of sulfonamides, barbiturates, and various antibiotics. The cutaneous and oral lesions are attributed to the drug acting as an allergen that sensitizes the tissues.

Eruptions in the oral cavity that result from sensitivity to drugs that have been taken by mouth or parenterally are called *stomatitis medicamentosa.* The local reaction from the use of a medicament in the oral cavity (e.g., stomatitis as a result of topical penicillin use) is referred to as *stomatitis venenata* or *contact stomatitis.* In many cases, skin eruptions may accompany the oral lesions.

In general, drug eruptions in the oral cavity are multiform. Vesicular and bullous lesions occur most often, but pigmented or nonpigmented macular lesions are also frequently observed. Erosions, which are often followed by deep ulceration with purpuric lesions, may also occur. The lesions are seen in different areas of the oral cavity, with the gingiva often being affected.[1,54]

The development of gingival lesions caused by contact allergy to the mercurial compounds present in dental amalgam has been clearly documented.[73] With regard to financial considerations, biopsy and patch testing may be indicated before the indiscriminate replacement of dental amalgam restorations. Similarly, desquamative gingivitis has been reported with the use of tartar control toothpaste. Pyrophosphates and flavoring agents have been identified as the main causative agents of this unusual condition.[36] Oral reactions to cinnamon compounds (i.e., cinnamon oil, cinnamic acid, or cinnamic aldehyde) that are used to mask the taste of pyrophosphates in tartar control toothpaste include an intense erythema of the attached gingival tissues that is characteristic of plasma cell gingivitis[3,74] (Figure 19-28). A thorough clinical history usually discloses the source of the gingival disturbance. Elimination of the offending agent (i.e., the tartar control toothpaste) leads to the resolution of the gingival lesions within a week, and challenge with the offending agent leads to recurrence of the oral lesions. If removal of the offending medication is not possible, topical corticosteroids and topical tacrolimus can be used to treat the lesions.[66]

Figure 19-28 Plasma cell gingivitis. The gingiva presents a band of moderate to severe inflammation that is reminiscent of desquamative gingivitis.

Miscellaneous Conditions that Mimic Desquamative Gingivitis

Another group of heterogeneous conditions may masquerade as desquamative gingivitis. Factitious lesions, candidiasis, graft-versus-host disease, Wegener's granulomatosis, foreign body gingivitis, Kindler syndrome, and even squamous cell carcinoma can divert the attention of the clinician and result in a diagnostic challenge.

Factitious lesions are injuries that are consciously and intentionally produced without a clear motive, although guilt, the seeking of sympathy, or monetary compensation may be the driving forces behind this abnormal behavior. Factitious desquamative gingivitis has been reported in the literature; it may be difficult to diagnose, and it may become apparent only after extensive and costly laboratory tests fail to reveal the genesis of the lesions.[96]

Candidiasis may rarely be limited to the gingival tissues, and it may simulate desquamative gingivitis. Linear gingival erythema is a *Candida*-associated lesion in individuals who are infected with human immunodeficiency virus in which a ribbonlike red band of the gingival margins is present and reminiscent of desquamative gingivitis.[132]

Graft-versus-host disease may occur in recipients of allogenic bone marrow transplants. The associated oral lesions may occasionally resemble desquamative gingivitis (Figure 19-29).

Wegener's granulomatosis is a systemic disease that may initially present with striking alterations that are confined to the gingival tissues. Classically, the gingival tissues exhibit erythema

Figure 19-29 Graft-versus-host disease in a recipient of an allogeneic bone marrow transplant. The maxillary gingiva exhibits features that are consistent with desquamative gingivitis. *(Courtesy Dr. Linda Lee, University of Toronto, Toronto, ON, Canada.)*

Figure 19-30 Wegener's granulomatosis affecting the gingival tissues. The classic "strawberry gums" appearance of the mandibular gingiva is seen in this patient. A slight resemblance with desquamative gingivitis is also evident.

and enlargement, and they are typically described as "strawberry gums"[30] (Figure 19-30).

Foreign body gingivitis is clinically characterized by red or red and white chronic lesions that may be painful and that are reminiscent of desquamative gingivitis. This condition is more common among women approaching the fifth decade of life. Microscopic analysis reveals small (<5 µm in diameter) foreign bodies associated with a chronic inflammatory cell response that may exhibit granulomatous and lichenoid characteristics. Energy-dispersive radiographic microanalysis has revealed that most of these foreign bodies originate from dental materials (specifically, abrasives, and restorative materials).[58,59]

Kindler syndrome, which involves cutaneous neonatal bullae, poikiloderma, photosensitivity, and acral atrophy, may also present with oral lesions that are clinically consistent with desquamative gingivitis.[126]

A clinical diagnosis of desquamative gingivitis requires a series of diagnostic steps before a precise diagnosis can be obtained. These steps include a comprehensive clinical history, a clinical–pathologic correlation, microscopic examination (e.g., H&E), and direct immunofluorescence studies.[155] The failure to properly and systematically evaluate a patient with a clinical condition that is consistent with desquamative gingivitis can lead to unpleasant outcomes. This is particularly true when therapy for a putative desquamative gingivitis is established before a biopsy of the lesional tissue is obtained. Every year we see in our laboratory at least two examples of clinically diagnosed desquamative gingivitis for which microscopic and immunofluorescence studies were not performed to rule out the genesis of the gingival lesions. In these cases, the patients have been either "carefully" followed up or prescribed topical steroids for several months. The lack of response of the gingival tissues eventually impels the clinician to obtain a biopsy, which reveals that the gingival lesions are squamous cell carcinomas. Thus, the clinician should be alert to the possibility of squamous cell carcinoma of the gingival tissues presenting initially as "desquamative gingivitis."

Suggested Readings

D'Cruz DP: Systemic lupus erythematosus. *Br Med J* 332:890, 2006.

Gonzalez-Moles MA, Ruiz-Avila I, Rodriguez-Archilla A, et al: Treatment of severe erosive gingival lesions by topical application of clobetasol propionate in custom trays. *Oral Surg Oral Med Oral Pathol Oral Radiol Endod* 95:688, 2003.

Gordon SC, Daley TD: Foreign body gingivitis: clinical and microscopic features of 61 cases. *Oral Surg Oral Med Oral Pathol Oral Radiol Endod* 83:562, 1997.

Ismail SB, Kumar SK, Zain RB: Oral lichen planus and lichenoid reactions: etiopathogenesis, diagnosis, management and malignant transformation. *J Oral Sci* 49:89, 2007.

Lodi G, Scully C, Carrozzo M, et al: Current controversies in oral lichen planus: report of an international consensus meeting. Part 2. Clinical management and malignant transformation. *Oral Surg Oral Med Oral Pathol Oral Radiol Endod* 100:164, 2005.

Nisengard RJ, Neiders M: Desquamative lesions of the gingiva. *J Periodontol* 52:500, 1981.

Robinson JC, Lozada-Nur F, Frieden I: Oral pemphigus vulgaris: a review of the literature and a report on the management of 12 cases. *Oral Surg Oral Med Oral Pathol Oral Radiol Endod* 84:349, 1997.

Scully C, Mignogna M: Oral mucosal disease: pemphigus. *Br J Oral Maxillofac Surg* 46:272, 2008.

Scully C, Muzio LL: Oral mucosal diseases: mucous membrane pemphigoid. *Br J Oral Maxillofac Surg* 46:358, 2008.

Solomon LW: Chronic ulcerative stomatitis. *Oral Dis* 14:383, 2008.

References

References for this chapter are found on the companion website www.expertconsult.com.

References

1. Abdollahl M, Rahimi R, Radfar M: Current opinion on drug-induced oral reactions: a comprehensive review. *Contemp Dent Pract* 9:1, 2008.
2. Ahmed AR, Kurgis BS, Rogers RS: Cicatricial pemphigoid. *J Am Acad Dermatol* 24:987, 1991.
3. Allen CM, Blozis GG: Oral mucosal reactions to cinnamon-flavored chewing gum. *J Am Dent Assoc* 116:664, 1988.
4. Andreasen JO, Poulsen HE: Oral manifestations in discoid and systemic lupus erythematosus: histologic investigation. *Acta Odontol Scand* 22:389, 1964.
5. Archard HO, Roebuck NF, Stanley HR: Oral manifestations of chronic discoid lupus erythematosus. *Oral Surg* 16:696, 1963.
6. Ayangco L, Rogers RS, 3rd: Oral manifestations of erythema multiforme. *Dermatol Clin* 21:195, 2003.
7. Bagan J, Muzio LL, Scully C: Number III. Mucous membrane pemphigoid. *Oral Dis* 11:197, 2005.
8. Balding SD, Prost C, Diaz LA: Cicatricial pemphigoid autoantibodies react with multiple sites on the BP 180 extracellular domain. *J Invest Dermatol* 106:141, 1996.
9. Barrett AW, Scully C, Eveson JW: Erythema multiforme involving gingiva. *J Periodontol* 64:910, 1993.
10. Bastuji-Garin S, Rzany B, Stern RS, et al: Clinical classification of cases of toxic epidermal necrolysis, Stevens-Johnson syndrome, and erythema multiforme. *Arch Dermatol* 129:92, 1993.
11. Baudet-Pommel M, Janin-Mercier A, Souteyrand P: Sequential immunopathologic study of oral lichen planus treated with tretinoin and etretinate. *Oral Surg* 71:197, 1991.
12. Becker BA, Gaspari AA: Pemphigus vulgaris and vegetants. *Dermatol Clin* 11:453, 1993.
13. Beutner EH, Chorzelski TP, Parodi A, et al: Ten cases of chronic ulcerative stomatitis with stratified epithelium-specific antinuclear antibody. *J Am Acad Dermatol* 24:781, 1991.
14. Beutner EH, Chorzelski TP, Reunala TL, et al: Immunopathology of dermatitis herpetiformis. *Clin Dermatol* 9:295, 1992.
15. Boh EE, Milikan LE: Vesiculobullous diseases with prominent immunologic features. *JAMA* 268:2893, 1992.
16. Brown RS, Bottomley WK, Puente E, et al: A retrospective evaluation of 193 patients with oral lichen planus. *J Oral Pathol Med* 22:69, 1993.
17. Burge SM, Frith PA, Juniper RP, et al: Mucosal involvement in systemic and chronic cutaneous lupus erythematosus. *Br J Dermatol* 121:727, 1989.
18. Callen JP, Kulick KB, Stelzer G, et al: Subacute cutaneous lupus erythematosus: clinical, serologic, and immunogenetic studies on 49 patients seen in a non-referral setting. *J Am Acad Dermatol* 15:1227, 1986.
19. Campisi G, Di Liberto C, Carrocio A, et al: Coeliac disease: Oral ulcer prevalence, assessment of risk and association with gluten-free diet in children. *Dig Liver Dis* 40:104, 2008.
20. Challacombe SJ, Setterfield J, Shirlaw P, et al: Immunodiagnosis of pemphigus and mucous membrane pemphigoid. *Acta Odontol Scand* 59:226, 2001.
21. Chan LS, Regezi JA, Cooper KD: Oral manifestations of linear IgA disease. *J Am Acad Dermatol* 22:362, 1990.
22. Chan LS, Ahmed AR, Anhalt GJ, et al: The first international consensus on mucous membrane pemphigoid: definition, diagnostic criteria, pathogenic factors, medical treatment, and prognostic indicators. *Arch Dermatol* 138:370, 2002.
23. Cheng SW, Obayashi M, Kinoshita-Kuroda K, et al: Monitoring disease activity in pemphigus with enzyme-linked immunosorbent assay using recombinant desmogleins 1 and 3. *Br J Dermatol* 147:261, 2002.
24. Chorzelski T, Jablonska S, Maciejowska E: Linear IgA bullous dermatosis of adults. *Clin Dermatol* 9:383, 1992.
25. Chorzelski T, Olszewska M, Jarzabek-Chorzelska M, et al: Is chronic ulcerative stomatitis an entity? Clinical and immunological findings in 18 cases. *Eur J Dermatol* 8:261, 1998.
26. Chowdhury MM, Natarajan S: Neonatal pemphigus vulgaris associated with mild oral pemphigus vulgaris in the mother during pregnancy. *Br J Dermatol* 139:500, 1998.
27. Church LF, Jr, Schosser RH: Chronic ulcerative stomatitis associated with stratified epithelial specific antinuclear antibodies: a case report of a newly described disease entity. *Oral Surg Oral Med Oral Pathol* 73:579, 1992.
28. Ciarrocca KN, Greenberg MS: A retrospective study of the management of oral mucous membrane pemphigoid with dapsone. *Oral Surg Oral Med Oral Pathol Oral Radiol Endod* 88:159, 1999.
29. Cohen DM, Bhattacharyya I, Zunt SL, et al: Linear IgA disease histopathologically and clinically masquerading as lichen planus. *Oral Surg Oral Med Oral Pathol Oral Radiol Endod* 88:196, 1999.
30. Cohen RE, Cardoza TT, Drinnan AJ, et al: Gingival manifestations of Wegener's granulomatosis. *J Periodontol* 61:705, 1990.
31. Collin P, Reunala T: Recognition and management of the cutaneous manifestations of celiac disease: a guide for dermatologists. *Am J Clin Dermatol* 4:13, 2003.
32. Combes FL, Canizares O: Pemphigus vulgaris, a clinicopathological study of one hundred cases. *Arch Dermatol Syph* 62:786, 1950.
33. Dabelsteen E: Molecular biological aspects of acquired bullous diseases. *Crit Rev Oral Biol Med* 9:162, 1998.
34. Dabelsteen E, Ullman S, Thomson K, et al: Demonstration of basement membrane autoantibodies in patients with benign mucous membrane pemphigoid. *Acta Derm Venereol* 54:189, 1974.
35. D'Cruz DP: Systemic lupus erythematosus. *Br Med J* 332:890, 2006.
36. DeLattre V: Factors contributing to adverse soft tissue reactions due to the use of tartar control toothpastes: report of a case and literature review. *J Periodontol* 70:803, 1999.
37. Del Valle AE, Martinez-Sahuquillo A, Padron JR, et al: Two cases of linear IgA disease with clinical manifestations limited to the gingiva. *J Periodontol* 74:879, 2003.
38. De Vita S, Neri R, Bombardieri S: Cyclophosphamide pulses in the treatment of rheumatic diseases: an update. *Clin Exp Rheumatol* 9:179, 1991.
39. Economopoulou P, Laskaris G: Dermatitis herpetiformis: oral lesions as an early manifestation. *Oral Surg Oral Med Oral Pathol* 62:77, 1986.
40. Eisen D, Ellis CN, Duell GA, et al: Effect of topical cyclosporin rinse on oral lichen planus. *N Engl J Med* 323:290, 1990.
41. Eisenberg E: Lichen planus and oral cancer: is there a connection between the two? *J Am Dent Assoc* 123:104, 1992.
42. Eisenberg E, Krutchkoff DJ: Lichenoid lesions of oral mucosa: diagnostic criteria and their importance in the alleged relationship to oral cancer. *Oral Surg Oral Med Oral Pathol* 73:699, 1992.
43. El Tal AK, Posner MR, Spigelman Z, et al: Rituximab: a monoclonal antibody to CD20 used in the treatment of pemphigus vulgaris. *J Am Acad Dermatol* 55:449, 2006.
44. Engel M, Ray HG, Orban B: The pathogenesis of desquamative gingivitis. *J Dent Res* 29:410, 1950.
45. Eversole LR: Immunopathology of oral mucosal ulcerative, desquamative and bullous diseases. *Oral Surg Oral Med Oral Pathol* 77:55, 1994.
46. Farthing P, Bagan JV, Scully C: Mucosal disease series. Number IV. Erythema multiforme. *Oral Dis* 11:261, 2005.
47. Farthing PM, Margou P, Coates M, et al: Characteristics of the oral lesions in patients with cutaneous recurrent erythema multiforme. *J Oral Pathol Med* 24:9, 1995.
48. Femiano F, Scully C, Gombos F: Linear IgA dermatosis induced by a new angiotensin-converting enzyme inhibitor. *Oral Surg Oral Med Oral Pathol Oral Radiol Endod* 95:169, 2003.
49. Fine JD: Management of acquired bullous diseases. *N Engl J Med* 5:33, 1995.
50. Foss CL, Grupe HE, Orban B: Gingivosis. *J Periodontol* 24:207, 1953.
51. Foster CS: Cicatricial pemphigoid. *Trans Am Ophthalmol Soc* 84:527, 1986.
52. Fotos PG, Vincent SD, Hellstein JW: Oral candidosis: clinical, historical and therapeutic features of 100 cases. *Oral Surg* 74:41, 1992.

53. Gallagher G, Shklar G: Oral involvement in mucous membrane pemphigoid. *Clin Dermatol* 5:19, 1987.
54. Gallagher GT: Oral mucous membrane reactions to drugs and chemicals. *Curr Opin Dent* 1:777, 1991.
55. Giovanni L, Scully C, Carrozzo M, et al: Current controversies in oral lichen planus: report of an international consensus meeting. Part 2. Clinical management and malignant transformation. *Oral Surg Oral Med Oral Pathol Oral Radiol Endod* 100:164, 2005.
56. Goadby K: *Diseases of the gums and oral mucous membrane*, London, 1923, Henry Froude and Hodder & Staughton.
57. Gonzalez-Moles MA, Ruiz-Avila I, Rodriguez-Archilla A, et al: Treatment of severe erosive gingival lesions by topical application of clobetasol propionate in custom trays. *Oral Surg Oral Med Oral Pathol Oral Radiol Endod* 95:688, 2003.
58. Gordon SC, Daley TD: Foreign body gingivitis: clinical and microscopic features of 61 cases. *Oral Surg Oral Med Oral Pathol Oral Radiol Endod* 83:562, 1997.
59. Gordon SC, Daley TD: Foreign body gingivitis: identification of the foreign material by energy-dispersive x-ray microanalysis. *Oral Surg Oral Med Oral Pathol Oral Radiol Endod* 83:571, 1997.
60. Harman KE, Seed PT, Gratian MJ, et al: The severity of cutaneous and oral pemphigus is related to desmoglein 1 and 3 antibody levels. *Br J Dermatol* 144:775, 2001.
61. Hashimoto K, Dibella R, Shklar G, et al: Electron microscopic studies of oral lichen planus. *G Ital Dermatol Minerva Dermatol* 107:765, 1966.
62. Holmstrup P: The controversy of a premalignant potential of lichen planus is over. *Oral Surg Oral Med Oral Pathol* 73:704, 1992.
63. Ingafou M, Leao JC, Porter Sr, et al: Oral lichen planus. A retrospective study of 690 British patients. *Oral Dis* 12:463, 2006.
64. Ishii T: Immunohistochemical demonstration of T cell subsets and accessory cells in oral lichen planus. *J Oral Pathol* 15:268, 1987.
65. Islam MN, Cohen DM, Ojha J, et al: Chronic ulcerative stomatitis: diagnostic and management challenges—four new cases and review of the literature. *Oral Surg Oral Med Oral Pathol Oral Radiol Endod* 104:194, 2007.
66. Ismail SB, Kumar SK, Zain RB: Oral lichen planus and lichenoid reactions: etiopathogenesis, diagnosis, management and malignant transformation. *J Oral Sci* 49:89, 2007.
67. Jainkittivong A, Kuvatanasuchati J, Pipattanagovit P, et al: Candida in oral lichen planus patients undergoing topical steroid therapy. *Oral Surg Oral Med Oral Pathol Oral Radiol Endod* 104:61, 2007.
68. Jaremko WM, Beutner EH, Kumar V, et al: Chronic ulcerative stomatitis associated with a specific immunologic marker. *J Am Acad Dermatol* 22:215, 1990.
69. Kelly SE, Frith PA, Millard PR, et al: A clinicopathological study of mucosal involvement in linear IgA disease. *Br J Dermatol* 119:161, 1988.
70. Komori A, Welton NA, Kelln EE: The behavior of the basement membrane of skin and oral lesions in patients with lichen planus, erythema multiforme, lupus erythematosus, pemphigus vulgaris, pemphigoid and epidermolysis bullosa. *Oral Surg* 22:752, 1966.
71. Korman NJ: Bullous pemphigoid. *Dermatol Clin* 11:483, 1993.
72. Laeijendecker R, Tank B, Dekker SK, et al: A comparison of treatment of oral lichen planus with topical tacrolimus and triamcinolone acetonide ointment. *Acta Derm Venereol* 86:227, 2006.
73. Laine J, Kalimo K, Happonen R: Contact allergy to dental restorative materials in patients with oral lichenoid lesions. *Contact Dermatitis* 36:141, 1997.
74. Lamey PJ, Lewis MAO, Ress TD, et al: Sensitivity reaction to the cinnamonaldehyde component of toothpaste. *Br Dent J* 168:115, 1990.
75. Lamey PJ, Rees TD, Binnie WH, et al: Oral presentation of pemphigus vulgaris and its response to systemic steroid therapy. *Oral Surg Oral Med Oral Pathol* 74:54, 1992.
76. Laskaris G, Angelopoulos A: Cicatricial pemphigoid: direct and indirect immunofluorescent studies. *Oral Surg* 51:48, 1981.
77. Laskaris G, Demetrou N, Angelopoulos A: Immunofluorescent studies in desquamative gingivitis. *J Oral Pathol* 10:398, 1981.
78. Lenz P, Amagai M, Volc-Platzer B, et al: Desmoglein 3-ELISA: a pemphigus vulgaris specific diagnostic tool. *Arch Dermatol* 135:142, 1999.
79. Leonard J: Immunofluorescent studies in ocular cicatricial pemphigoid. *Br J Dermatol* 118:209, 1988.
80. Lever WF: Pemphigus. *Medicine* 32:1, 1953.
81. Lever WF: Pemphigus and pemphigoid: a review of the advances made since 1964. *J Am Acad Dermatol* 1:2, 1979.
82. Lewis JE, Beutner EH, Rostami R, et al: Chronic ulcerative stomatitis with stratified epithelium-specific antinuclear antibodies. *Int J Dermatol* 35:272, 1996.
83. Lewis MAO, Yaqoob NA, Emanuel C, et al: Successful treatment of oral linear IgA disease using mycophenolate. *Oral Surg Oral Med Oral Pathol Oral Radiol Endod* 103:483, 2007.
84. Lorenzana ER, Rees TD, Hallmon WW: Esthetic management of multiple recession defects in a patient with cicatricial pemphigoid. *J Periodontol* 72:230, 2001.
85. Lorenzana ER, Rees TD, Glass M, et al: Chronic ulcerative stomatitis: a case report. *J Periodontol* 71:104, 2000.
86. Lozada F, Silverman S: Erythema multiforme: clinical characteristics and natural history in fifty patients. *Oral Surg* 46:628, 1978.
87. Lozada-Nur F: Oral lichen planus and oral cancer: is there enough epidemiologic evidence? *Oral Surg Oral Med Oral Pathol Oral Radiol Endod* 89:265, 2000.
88. Lozada-Nur F, Miranda C: Oral lichen planus: epidemiology, clinical characteristics, and associated diseases. *Semin Cutan Med Surg* 16:273, 1997.
89. Lozada-Nur F, Gorsky M, Silverman S, Jr: Oral erythema multiforme: clinical observations and treatment of 95 patients. *Oral Surg Oral Med Oral Pathol* 67:36, 1989.
90. Lozada-Nur F, Miranda C, Maliski R: Double-blind clinical trial of 0.05% clobetasole propionate ointment in orabase and 0.05% fluocinonide ointment in orabase in the treatment of patients with vesiculoerosive diseases. *Oral Surg Oral Med Oral Pathol* 77:598, 1994.
91. Lozada-Nur F, Sroussi HY: Tacrolimus powder in orabase 0.1% for the treatment of oral lichen planus and oral lichenoid lesions: an open clinical trial. *Oral Surg Oral Med Oral Pathol Oral Radiol Endod* 102:744, 2006.
92. Malmstrom M, Kontinnen YT, Jungell P, et al: Lymphocyte activation in oral lichen planus in situ. *Am J Clin Pathol* 89:329, 1988.
93. Marsh MN: The natural history of gluten sensitivity: defining, refining and re-defining. *Q J Med* 85:9, 1995.
94. McCarthy FP, McCarthy PL, Shklar G: Chronic desquamative gingivitis: a reconsideration. *Oral Surg* 13:1300, 1960.
95. McCarthy PL, Shklar G: *Diseases of the oral mucosa*, ed 2, Philadelphia, 1980, Lea & Febiger.
96. McGrath KG, Pick R, Leboff-Ries E, et al: Factitious desquamative gingivitis simulating a possible immunologic disease. *J Allergy Clin Immunol* 75:44, 1985.
97. Mignogna MD, Fortuna G, Leuci S, et al: Nikolsky's sign on the gingival mucosa: a clinical tool for oral health practitioners. *J Periodontol* 79:2241, 2008.
98. Mignogna MD, Lo Muzio L, Bucci E: Clinical features of gingival pemphigus vulgaris. *J Clin Periodontol* 28:489, 2001.
99. Mignogna MD, Lo Russo L, Fedele S: Gingival involvement of oral lichen planus in a series of 700 patients. *J Clin Periodontol* 32:1029, 2005.
100. Merritt AH: Chronic desquamative gingivitis. *J Periodontol* 4:30, 1933.
101. Mobini N, Nagarwalla N, Ahmed AR: Oral pemphigoid: subset of cicatricial pemphigoid? *Oral Surg Oral Med Oral Pathol Oral Radiol Endod* 85:37, 1998.
102. Mondino BJ, Brown SI: Ocular cicatricial pemphigoid. *Ophthalmology* 99:95, 1981.
103. Mondino BJ, Linstone FA: Ocular pemphigoid. *Clin Dermatol* 5:28, 1987.
104. Morrison L, Kratochvil FJ, 3rd, Gorman A: An open trial of topical tacrolimus for erosive oral lichen planus. *J Am Acad Dermatol* 47:617, 2002.

105. Muller S, Klaus-Kovtun V, Stanley JR: A 230-kD basic protein is the major bullous pemphigoid antigen. *J Invest Dermatol* 92:33, 1989.
106. Musa NJ, Kumar V, Humphreys L, et al: Oral pemphigoid masquerading as necrotizing ulcerative gingivitis in a child. *J Periodontol* 73:657, 2002.
107. Mutasim DF, Pelc DJ, Anhalt GJ: Paraneoplastic pemphigus. *Dermatol Clin* 11:473, 1993.
108. Mutasim DF, Pelc NJ, Anhalt GJ: Cicatricial pemphigoid. *Dermatol Clin* 11:499, 1993.
109. Nemeth AJ, Klein AD, Gould EW, et al: Childhood bullous pemphigoid: clinical and immunologic features, treatment, and prognosis. *Arch Dermatol* 127:378, 1991.
110. Neville BW, Damm DD, Allen C, et al: Dermatologic disease. In Neville BW, Damm DD, Allen C, et al, editors: *Oral and Maxillofacial Pathology*, ed 3, St Louis, 2009, Saunders, pp 741–815.
111. Nicolas MEO, Krause PK, Gibson LE, et al: Dermatitis herpetiformis. *Int J Dermatol* 42:588, 2003.
112. Nisengard R: Periodontal implications: mucocutaneous disorders. *Ann Periodontol* 1:401, 1996.
113. Nisengard R, Levine R: Diagnosis and management of desquamative gingivitis. *Periodontal Insights* 2:4, 1995.
114. Nisengard RJ, Neiders M: Desquamative lesions of the gingiva. *J Periodontol* 52:500, 1981.
115. Nisengard RJ, Rogers RS, III: The treatment of desquamative gingival lesions. *J Periodontol* 58:167, 1987.
116. O'Regan E, Bane A, Flint S, et al: Linear IgA disease presenting as desquamative gingivitis: a pattern poorly recognized in medicine. *Arch Otolaryngol Head Neck Surg* 130:469, 2004.
117. Peoples D, Fivenson DP: Linear IgA bullous dermatosis: successful treatment with tetracycline and nicotinamide. *J Am Acad Dermatol* 26:498, 1992.
118. Pleyer U, Bruckner-Tuderman L, Friedmann A, et al: The immunology of bullous oculo-muco-cutaneous disorders. *Immunol Today* 17:111, 1996.
119. Popovsky JL, Camisa C: New and emerging therapies for diseases of the oral cavity. *Dermatol Clin* 18:113, 2000.
120. Porter SR, Bain SE, Scully CM: Linear IgA disease manifesting as recalcitrant desquamative gingivitis. *Oral Surg Oral Med Oral Pathol* 74:179, 1992.
121. Porter SR, Scully C, Midda M, et al: Adult linear immunoglobulin A: a disease manifesting as desquamative gingivitis. *Oral Surg Oral Med Oral Pathol* 70:450, 1990.
122. Prinz H: Chronic diffuse desquamative gingivitis. *Dent Cosmos* 74:331, 1932.
123. Ramer MA, Altchek A, Deligdisch L, et al: Lichen planus and the vulvovaginal-gingival syndrome. *J Periodontol* 74:1385, 2003.
124. Rashid KA, Gürkcan HM, Ahmed AR: Antigen specificity in subsets of mucous membrane pemphigoid. *J Invest Dermatol* 126:2631, 2006.
125. Rees TD: Adjunctive therapy. In *Proceedings of the World Workshop in Clinical Periodontics*, Chicago, 1989, American Academy of Periodontology.
126. Ricketts DN, Morgan CL, McGregor JM, et al: Kindler syndrome: a rare cause of desquamative lesions of the gingiva. *Oral Surg Oral Med Oral Pathol Oral Radiol Endod* 84:488, 1997.
127. Rinaggio J, Neiders ME, Aguirre A, et al: Using immunofluorescence in the diagnosis of chronic ulcerative lesions of the oral mucosa. *Compendium* 20:943, 1999.
128. Robinson JC, Lozada-Nur F, Frieden I: Oral pemphigus vulgaris: a review of the literature and a report on the management of 12 cases. *Oral Surg Oral Med Oral Pathol Oral Radiol Endod* 84:349, 1997.
129. Robledo MA, Soo-Chan K, Korman NJ, et al: Studies of the relationship of the 230-kD and 180-kD bullous pemphigoid antigens. *J Invest Dermatol* 94:793, 1990.
130. Rogers RS, Sheridan PJ, Jordon RC: Desquamative gingivitis: clinical, histopathologic and immunopathologic investigations. *Oral Surg* 42:316, 1976.
131. Rogers RS, 3rd, Eisen D: Erosive oral lichen planus with genital lesions: the vulvovaginal-gingival syndrome and the peno-gingival syndrome. *Dermatol Clin* 21:91, 2003.
132. Samaranayake LP, Leung WK, Jin L: Oral mucosal infections. *Periodontol 2000* 49:39, 2009.
133. Sciubba JJ: Autoimmune aspects of pemphigus vulgaris and mucosal pemphigoid. *Adv Dent Res* 10:52, 1996.
134. Scully C, Bagan J: Oral mucosal diseases: erythema multiforme. *Br J Oral Maxillofac Surg* 46:90, 2008.
135. Scully C, Challacombe SJ: Pemphigus vulgaris: update on etiopathogenesis, oral manifestations, and management. *Crit Rev Oral Biol Med* 13:397, 2002.
136. Scully C, El-Kom M: Lichen planus: review and update on pathogenesis. *J Oral Pathol* 14:431, 1985.
137. Scully C, Muzio LL: Oral mucosal diseases: mucous membrane pemphigoid. *Br J Oral Maxillofac Surg* 46:358, 2008.
138. Scully C, Porter SR: The clinical spectrum of desquamative gingivitis. *Semin Cutan Med Surg* 16:308, 1997.
139. Scully C, Beyli M, Ferreiro MC, et al: Update on oral lichen planus: etiopathogenesis and management. *Crit Rev Oral Biol Med* 9:86, 1998.
140. Scully C, Carrozzo M, Gandolfo S, et al: Update on mucous membrane pemphigoid: a heterogeneous immune-mediated subepithelial blistering entity. *Oral Surg Oral Med Oral Pathol Oral Radiol Endod* 88:56, 1999.
141. Scully C, Mignogna M: Oral mucosal disease: pemphigus. *Br J Oral Maxillofac Surg* 46:272, 2008.
142. Setterfield JF, Black MM, Challacombe SJ: The management of oral lichen planus. *Clin Exp Dermatol* 25:176, 2000.
143. Shamin T, Varghese VI, Shameena PM, et al: Pemphigus vulgaris in oral cavity: clinical analysis of 71 cases. *Med Oral Patol Oral Cir Bucal* 13:E622, 2008.
144. Shen JT, Pedvis-Leftick A: Mucosal staining after using topical tacrolimus to treat erosive oral lichen planus. *J Am Acad Dermatol* 50:326, 2004.
145. Shklar G: Oral lesions of erythema multiforme: histologic and histochemical observations. *Arch Dermatol* 92:495, 1965.
146. Shklar G, McCarthy PL: The oral lesions of mucous membrane pemphigoid: a study of 85 cases. *Arch Otolaryngol* 93:354, 1971.
147. Shklar G, McCarthy PL: Histopathology of oral lesions of chronic discoid lupus erythematosus. *Arch Dermatol* 114:1031, 1978.
148. Shklar G, Meyer I, Zacarian S: Oral lesions in bullous pemphigoid. *Arch Dermatol* 99:663, 1969.
149. Siegel MA, Balciunas BA: Oral presentation and management of vesiculobullous disorders. *Semin Dermatol* 13:78, 1994.
150. Silverman S, Shachi B: Oral lichen planus update: clinical characteristics, treatment responses, and malignant transformation. *Am J Dent* 10:259, 1997.
151. Sklavounou A, Laskaris G: Frequency of desquamative gingivitis in skin disease. *Oral Surg Oral Med Oral Pathol* 56:141, 1983.
152. Solomon LW: Chronic ulcerative stomatitis. *Oral Dis* 14:383, 2008.
153. Solomon LW, Aguirre A, Neiders M, et al: Chronic ulcerative stomatitis: clinical, histopathologic, and immunopathologic findings. *Oral Surg Oral Med Oral Pathol Oral Radiol Endod* 96:718, 2003.
154. Suresh L, Neiders ME: Definitive and differential diagnosis of desquamative gingivitis through direct immunofluorescence studies. *J Periodontol* 83:1270, 2012.
155. Susi FR, Shklar G: Histochemistry and fine structure of oral lesions of mucous membrane pemphigoid. *Arch Dermatol* 104:244, 1971.
156. Tan EM, Cohen AS, Fries JR, et al: The 1982 revised criteria for the classification of systemic lupus erythematosus. *Arthritis Rheum* 25:1271, 1982.
157. Tomes J, Tomes G: *Dental surgery*, ed 4, London, 1894, Churchill.
158. Venning VA, Frith PA, Bron AJ, et al: Mucosal involvement in bullous and cicatricial pemphigoid: a clinical and immunopathological study. *Br J Dermatol* 118:7, 1988.
159. Weston WL, Morelli JG, Huff JC: Misdiagnosis, treatments and outcomes in the immunobullous diseases in children. *Pediatr Dermatol* 14:164, 1997.

160. Worle B, Wollenberg A, Schaller M, et al: Chronic ulcerative stomatitis. *Br J Dermatol* 137:262, 1997.
161. Yih WY, Maier T, Kratochvil FJ, et al: Analysis of desquamative gingivitis using direct immunofluorescence in conjunction with histology. *J Periodontol* 69:678, 1998.
162. Zegarelli DJ, Zegarelli EV: Intraoral pemphigus vulgaris. *Oral Surg* 44:384, 1977.
163. Zone JJ, Meyer LJ, Petersen MJ: Deposition of granular IgA relative to clinical lesions in dermatitis herpetiformis. *Arch Dermatol* 132:912, 1996.

CHAPTER 20

The Periodontal Pocket

Fermin A. Carranza and Paulo M. Camargo

CHAPTER OUTLINE

Classification
Clinical Features
Pathogenesis
Histopathology
Periodontal Disease Activity
Site Specificity
Pulp Changes Associated With Periodontal Pockets
Relationship of Attachment Loss and Bone Loss to Pocket Depth
Area Between Base of Pocket and Alveolar Bone
Relationship of Pocket to Bone
Periodontal Abscess
Lateral Periodontal Cyst

The periodontal pocket, which is defined as a pathologically deepened gingival sulcus, is one of the most important clinical features of periodontal disease. All different types of periodontitis, as outlined in Chapter 4, share histopathologic features, such as tissue changes in the periodontal pocket, mechanisms of tissue destruction, and healing mechanisms. However, they differ with regard to their etiology, natural history, progression, and response to therapy.[32]

Classification

Deepening of the gingival sulcus may occur as a result of coronal movement of the gingival margin, apical displacement of the gingival attachment, or a combination of the two processes (Figure 20-1). Pockets can be classified as follows:

Gingival pocket is formed by gingival enlargement without destruction of the underlying periodontal tissues. The sulcus is deepened because of the increased bulk of the gingiva (Figure 20-2, *A*).

Periodontal pocket produces destruction of the supporting periodontal tissues, thereby leading to the loosening and exfoliation of the teeth. The remainder of this chapter refers to this type of pocket.

Two types of periodontal pockets exist, as follows:

Suprabony (*supracrestal* or *supraalveolar*) occurs when the bottom of the pocket is coronal to the underlying alveolar bone (Figure 20-2, *B*).

Intrabony (*infrabony, subcrestal,* or *intraalveolar*) occurs when the bottom of the pocket is apical to the level of the adjacent alveolar bone. With this second type, the lateral pocket wall lies between the tooth surface and the alveolar bone (Figure 20-2, *C*).

Pockets can involve one, two, or more tooth surfaces, and they can be of different depths and types on different surfaces of the same tooth and on approximal surfaces of the same interdental space.[30,38] Pockets can also be spiral (i.e., originating on one tooth surface and twisting around the tooth to involve one or more additional surfaces) (Figure 20-3). These types of pockets are most common in furcation areas.

Clinical Features

Clinical signs that suggest the presence of periodontal pockets include a bluish-red thickened marginal gingiva; a bluish-red vertical zone from the gingival margin to the alveolar mucosa; gingival bleeding and suppuration; tooth mobility; diastema formation; and symptoms such as localized pain or pain "deep in the bone." The only reliable method of locating periodontal pockets and determining their extent is careful probing of the gingival margin along each tooth surface (Figure 20-4 and Table 20-1). On the basis of depth alone, however, it is sometimes difficult to differentiate between a deep normal sulcus and a shallow periodontal pocket. In such borderline cases, pathologic changes in the gingiva distinguish the two conditions.

For a more detailed discussion of the clinical aspects of periodontal pockets, see Chapter 30.

Pathogenesis

The initial lesion in the development of periodontitis is the inflammation of the gingiva in response to a bacterial challenge. Changes involved in the transition from the normal gingival sulcus to the pathologic periodontal pocket are associated with different proportions of bacterial cells in dental plaque. Healthy gingiva is associated with few microorganisms, mostly coccoid cells and straight rods. Diseased gingiva is associated with increased numbers of spirochetes and motile rods.[40,41,43] However, the microbiota of diseased sites cannot be used as a predictor of future attachment or bone loss, because their presence alone is not sufficient for disease to start or progress.[35]

> Pocket formation starts as an inflammatory change in the connective tissue wall of the gingival sulcus. The cellular and fluid inflammatory exudate causes degeneration of the surrounding connective tissue, including the gingival fibers. Just apical to the junctional epithelium, collagen fibers are destroyed,[20,61] and the area is occupied by inflammatory cells and edema (Figure 20-5).

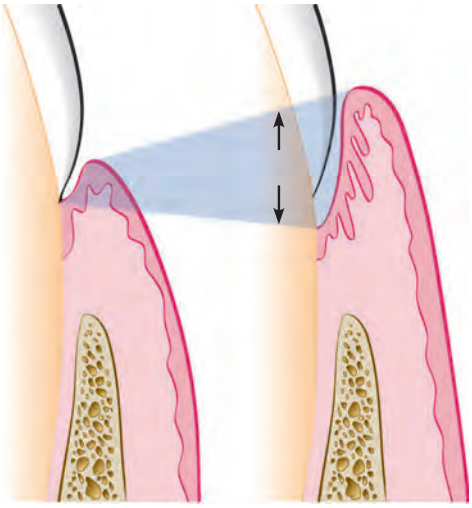

Figure 20-1 Illustration of pocket formation that indicates expansion in two directions *(arrows)* from the normal gingival sulcus *(left)* to the periodontal pocket *(right)*.

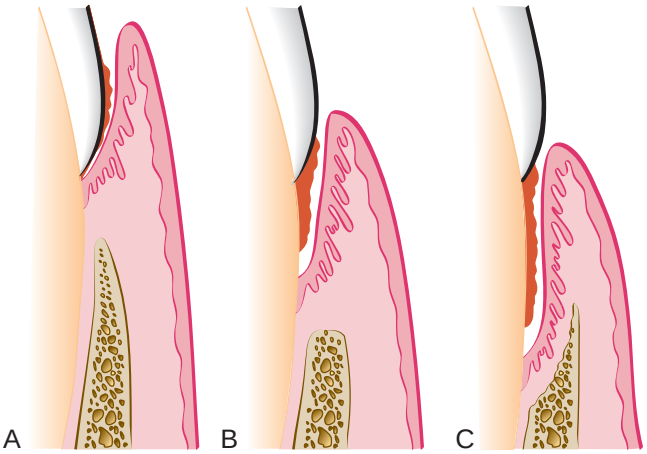

Figure 20-2 Different types of periodontal pockets. **A,** Gingival pocket. There is no destruction of the supporting periodontal tissues. **B,** Suprabony pocket. The base of the pocket is coronal to the level of the underlying bone. Bone loss is horizontal. **C,** Intrabony pocket. The base of the pocket is apical to the level of the adjacent bone. Bone loss is vertical.

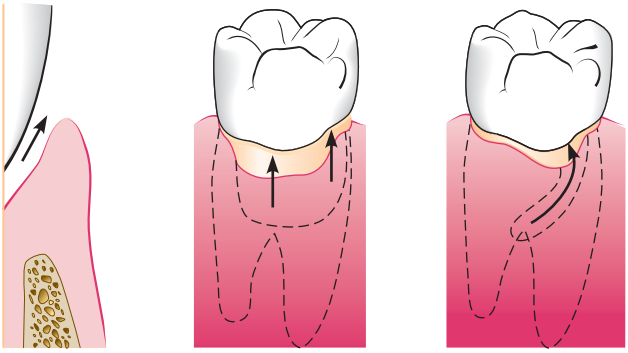

Figure 20-3 Classification of pockets according to involved tooth surfaces. **A,** Simple pocket. **B,** Compound pocket. **C,** Complex pocket.

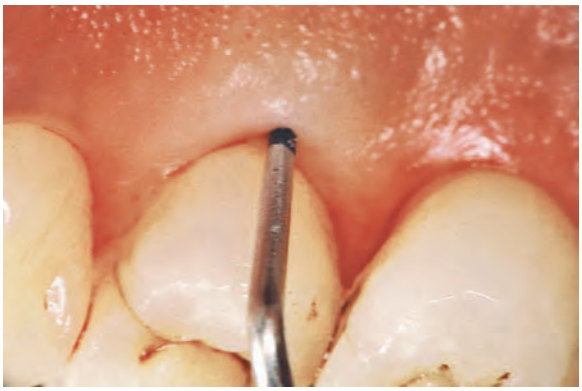

Figure 20-4 Probing of a deep periodontal pocket. The entire length of the periodontal probe has been inserted to the base of the pocket in the palatal surface of the first premolar.

TABLE 20-1 Correlation of Clinical and Histopathologic Features of the Periodontal Pocket

Clinical Features	Histopathologic Features
1. The gingival wall of the pocket presents various degrees of bluish-red discoloration; flaccidity; a smooth, shiny surface; and pitting on pressure.	1. The discoloration is caused by circulatory stagnation; the flaccidity by the destruction of gingival fibers and surrounding tissues; the smooth, shiny surface by atrophy of the epithelium and edema; and the pitting on pressure by edema and degeneration.
2. Less frequently, the gingival wall may be pink and firm.	2. In such cases, fibrotic changes predominate over exudation and degeneration, particularly in relation to the outer surface of the pocket wall. However, despite the external appearance of health, the inner wall of the pocket invariably presents some degeneration and is often ulcerated (see Figure 20-15).
3. Bleeding is elicited by gently probing the soft-tissue wall of pocket.	3. Ease of bleeding results from increased vascularity, the thinning and degeneration of the epithelium, and the proximity of engorged vessels to the inner surface.
4. When explored with a probe, the inner aspect of the pocket is generally painful.	4. Pain on tactile stimulation is caused by the ulceration of the inner aspect of the pocket wall.
5. In many cases, pus may be expressed with the application of digital pressure.	5. Pus occurs in pockets with suppurative inflammation of the inner wall.

Figure 20-5 Interdental papilla with suprabony pockets on proximal tooth surfaces. Note the densely inflamed connective tissue, with the infiltrate extending between the collagen fibers and the proliferating and ulcerated pocket epithelium.

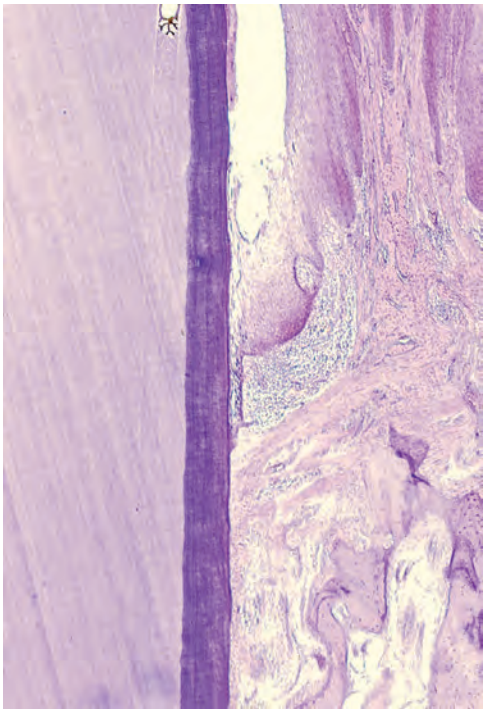

Figure 20-6 Low-power view of the base of the periodontal pocket and apical area. Note the dense inflammatory infiltrate on the area of destroyed collagen fibers and the thin, fingerlike extension of epithelium covering the cementum, which has been denuded of fibers.

Early concepts assumed that, after the initial bacterial attack, periodontal tissue destruction continued to be linked to bacterial action. More recently, it was established that the host's immunoinflammatory response to the initial and persistent bacterial attack unleashes mechanisms that lead to collagen and bone destruction. These mechanisms are related to various cytokines, some of which are produced normally by cells in noninflamed tissue and others by cells that are involved in the inflammatory process, such as polymorphonuclear leukocytes (PMNs), monocytes, and other cells, thereby leading to collagen and bone destruction. This chapter describes the histologic aspects of gingival inflammation and tissue destruction. For further information about the molecular biology aspects of these mechanisms of tissue destruction, please see Chapter 25 and www.expertconsult.com.

The two mechanisms associated with collagen loss are as follows: (1) collagenases and other enzymes secreted by various cells in healthy and inflamed tissue, such as fibroblasts,[74] PMNs,[73] and macrophages,[53] become extracellular and destroy collagen (these enzymes that degrade collagen and other matrix macromolecules into small peptides are called *matrix metalloproteinases*[75]); and (2) fibroblasts phagocytize collagen fibers by extending cytoplasmic processes to the ligament–cementum interface and degrading the inserted collagen fibrils and the fibrils of the cementum matrix.[20,21]

As a consequence of the loss of collagen, the apical cells of the junctional epithelium proliferate along the root and extend fingerlike projections that are two or three cells in thickness (Figure 20-6).

As a result of inflammation, PMNs invade the coronal end of the junctional epithelium in increasing numbers (Figure 20-7). The PMNs are not joined to one another or to the epithelial cells by desmosomes. When the relative volume of PMNs reaches approximately 60% or more of the junctional epithelium, the tissue loses cohesiveness and detaches from the tooth surface. Thus, the coronal portion of the junctional epithelium detaches from the root as the apical portion migrates, thereby resulting in its apical shift; the oral sulcular epithelium gradually occupies an increasing portion of the sulcus (then a pocket) lining.[62]

Extension of the junctional epithelium along the root requires the presence of healthy epithelial cells. Marked degeneration or necrosis of the junctional epithelium impairs rather than accelerates pocket formation. (This occurs in necrotizing ulcerative gingivitis, which results in an ulcer rather than pocket formation.)

Degenerative changes seen in the junctional epithelium at the base of periodontal pockets are usually less severe than those in the epithelium of the lateral pocket wall (see Figure 20-7). Because the migration of the junctional epithelium requires healthy, viable cells, it is reasonable to assume that the degenerative changes seen in this area occur after the junctional epithelium reaches its position on the cementum.

The degree of leukocyte infiltration of the junctional epithelium is independent of the volume of inflamed connective tissue; thus, this process may occur in gingiva with only slight signs of clinical inflammation.[61]

With continued inflammation, the gingiva increases in bulk, and the crest of the gingival margin extends coronally. The apical cells of the junctional epithelium continue to migrate along the root, and its coronal cells continue to separate from it. The epithelium of the lateral wall of the pocket proliferates to form bulbous, cordlike extensions into the inflamed connective tissue. Leukocytes and edema from the inflamed connective tissue infiltrate the epithelium that lines the pocket, thereby resulting in various degrees of degeneration and necrosis.

The transformation of a gingival sulcus into a periodontal pocket creates an area in which plaque removal becomes impossible, and a feedback mechanism is established. The rationale for pocket reduction is based on the need to eliminate areas of plaque accumulation.

Histopathology

Changes that occur during the initial stages of gingival inflammation are presented in Chapter 7. After the pocket is formed, several microscopic features are present, which will be discussed in this section.

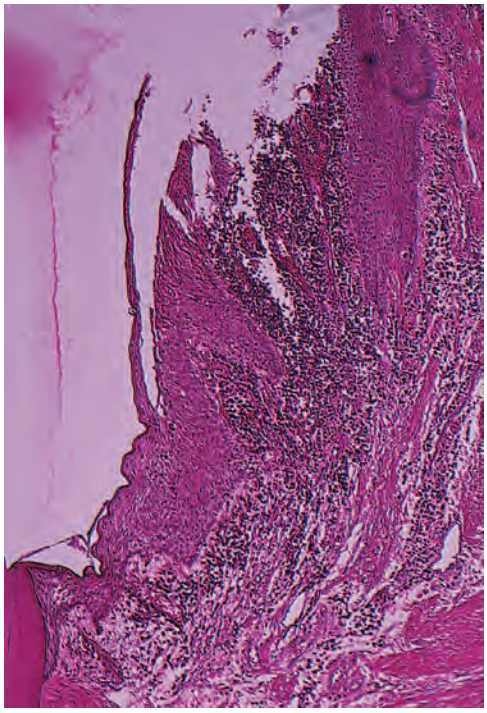

Figure 20-7 View of the ulcerated lateral pocket wall of a periodontal pocket. Note the extension of epithelial cells and the dense accumulation of leukocytes within the epithelium and in the connective tissue.

Soft-Tissue Wall. The connective tissue is edematous and densely infiltrated with plasma cells (approximately 80%), lymphocytes, and a scattering of PMNs.[82] The blood vessels are increased in number, dilated, and engorged, particularly in the subepithelial connective tissue layer.[10] The connective tissue exhibits varying degrees of degeneration. Single or multiple necrotic foci are occasionally present.[52] In addition to exudative and degenerative changes, the connective tissue shows proliferation of the endothelial cells, with newly formed capillaries, fibroblasts, and collagen fibers (see Figure 20-5).

The junctional epithelium at the base of the pocket is usually much shorter than that of a normal sulcus. Although marked variations are found with regard to the length, width, and condition of the epithelial cells,[63] usually the coronoapical length of the junctional epithelium is reduced to only 50 to 100 μm.[14] The cells may be well formed and in good condition, or they may exhibit slight to marked degeneration (see Figures 20-6 and 20-9).

The most severe degenerative changes in the periodontal pocket occur along the lateral wall (see Figure 20-7). The epithelium of the lateral wall of the pocket presents striking proliferative and degenerative changes. Epithelial buds or interlacing cords of epithelial cells project from the lateral wall into the adjacent inflamed connective tissue, and they may extend farther apically than the junctional epithelium (Figures 20-8, *A*, and 20-9). These epithelial projections, as well as the remainder of the lateral epithelium, are densely infiltrated by leukocytes and edema from the inflamed connective tissue. The cells undergo vacuolar degeneration and rupture to form vesicles. Progressive degeneration and necrosis of the epithelium lead to ulceration of the lateral wall, exposure of the underlying inflamed connective tissue, and suppuration. In some cases, acute inflammation is superimposed on the underlying chronic changes.

A comparative study of gingival changes in aggressive and chronic periodontitis revealed more pronounced degenerative changes in the epithelium of aggressive cases with more open intercellular spaces, including microclefts and necrotic areas.[35]

The severity of the degenerative changes is not necessarily related to pocket depth. Ulceration of the lateral wall may occur in shallow pockets, and deep pockets are occasionally observed in which the lateral epithelium is relatively intact or shows only slight degeneration.

The epithelium at the gingival crest of a periodontal pocket is generally intact and thickened, with prominent rete pegs.

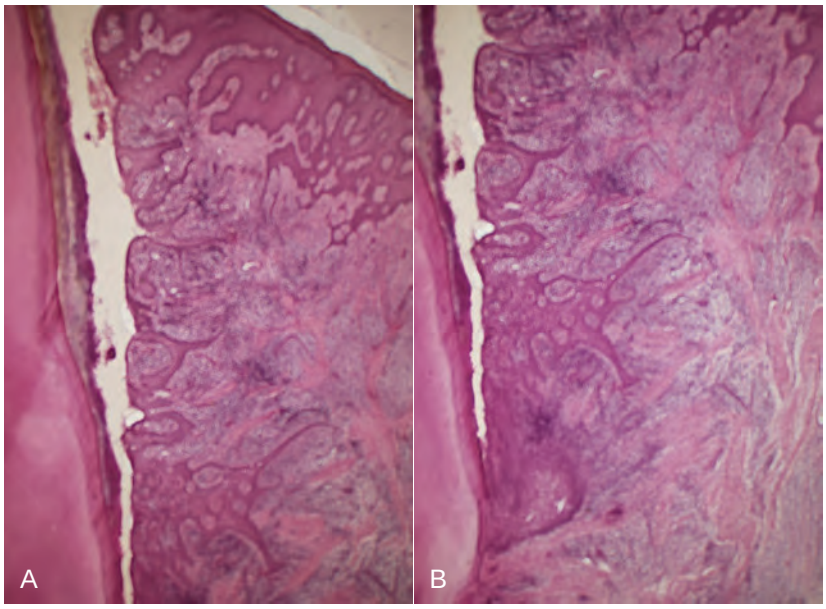

Figure 20-8 A, Lateral wall of a periodontal pocket showing epithelial proliferative and atrophic changes as well as marked inflammatory infiltrate and the destruction of collagen fibers. **B,** Slightly apical view of the same patient showing the shortened junctional epithelium.

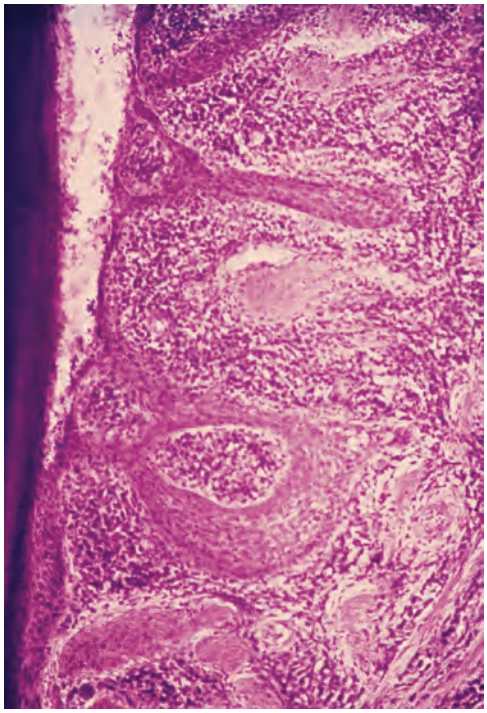

Figure 20-9 Base of periodontal pocket showing extensive proliferation of lateral epithelium next to atrophic areas, dense inflammatory infiltrate, remnants of destroyed collagen fibers, and the junctional epithelium, which is apparently in a less altered state than the lateral pocket epithelium.

For a detailed electron microscopic study of the pocket epithelium in experimentally induced pockets in dogs, see the article by Müller-Glauser and Schröder.[49]

Bacterial Invasion

Bacterial invasion of the apical and lateral areas of the pocket wall has been described in human chronic periodontitis. Filaments, rods, and coccoid organisms with predominant gram-negative cell walls have been found in intercellular spaces of the epithelium.[25,26] Hillmann and colleagues[35] have reported the presence of *Porphyromonas gingivalis* and *Prevotella intermedia* in the gingiva of aggressive periodontitis cases. *Actinobacillus actinomycetemcomitans* has also been found in the tissues.[16,47,58]

Bacteria may invade the intercellular space under exfoliating epithelial cells, but they are also found between deeper epithelial cells as well as accumulating on the basement lamina. Some bacteria traverse the basement lamina and invade the subepithelial connective tissue[60] (Figures 20-10 and 20-11).

The presence of bacteria in the gingival tissues has been interpreted by different investigators as bacterial invasion or as the "passive translocation" of plaque bacteria.[42] This important point has significant clinicopathologic implications and has not yet been clarified.[17,39,43]

Mechanisms of Tissue Destruction

The inflammatory response triggered by bacterial plaque unleashes a complex cascade of events aimed at destroying and removing bacteria, necrotic cells, and deleterious agents. However, this process is nonspecific; in an attempt to restore health, the host's cells (e.g., neutrophils, macrophages, fibroblasts, epithelial cells) produce proteinases, cytokines, and prostaglandins that can damage or destroy the tissues.

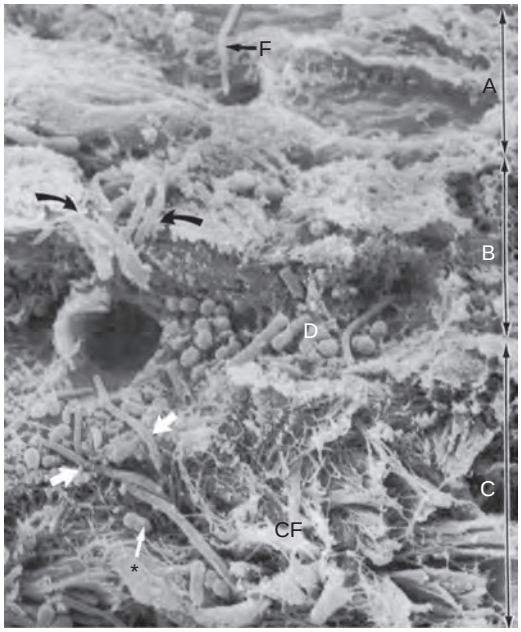

Figure 20-10 Scanning electron micrograph of a section of pocket wall in advanced periodontitis in a human specimen showing bacterial penetration into the epithelium and connective tissue. Scanning electron microscope view of the surface of the pocket wall *(A),* sectioned epithelium *(B),* and sectioned connective tissue *(C).* Curved arrows point to areas of bacterial penetration into the epithelium. Thick white arrows point to bacterial penetration into the connective tissue through a break in the continuity of the basal lamina. *CF,* Connective tissue fibers; *D,* accumulation of bacteria (rods, cocci, and filaments) on the basal lamina; *F,* filamentous organism on the surface of the epithelium. The asterisk points to coccobacillus in the connective tissue.

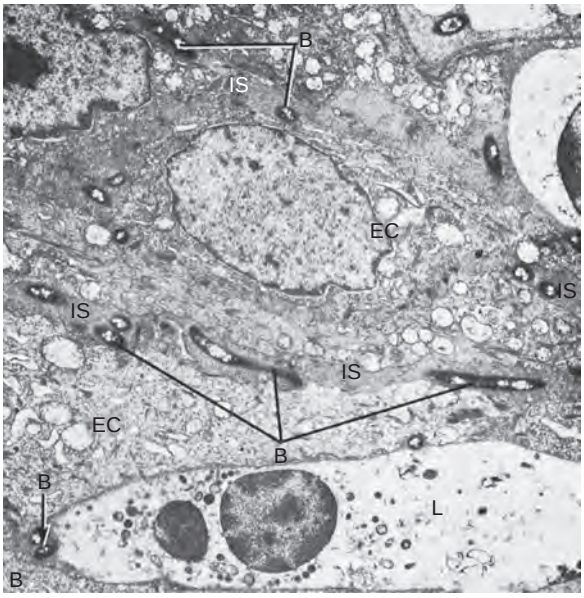

Figure 20-11 Transmission electron micrograph of the epithelium in the periodontal pocket wall showing bacteria in the intercellular spaces. *B,* Bacteria; *EC,* epithelial cell; *IS,* intercellular space; *L,* leukocyte about to engulf bacteria. (×8000.)



Figure 20-12 Scanning electron frontal micrograph of the periodontal pocket wall. Different areas can be seen in the pocket wall surface. *A,* Area of quiescence; *B,* bacterial accumulation; *C,* bacterial–leukocyte interaction; *D,* intense cellular desquamation. Arrows point to emerging leukocytes and holes left by leukocytes in the pocket wall. (×800.)

Chapter 25 describes in detail these aspects of inflammation and the mechanisms of tissue destruction at the molecular level.

Microtopography of the Gingival Wall

Scanning electron microscopy has permitted the description of several areas in the soft-tissue (gingival) wall of the periodontal pocket in which different types of activity take place.[59] These areas are irregularly oval or elongated and adjacent to one another, and they measure about 50 to 200 µm. These findings suggest that the pocket wall is constantly changing as a result of the interaction between the host and the bacteria. The following areas have been noted:

1. *Areas of relative quiescence,* showing a relatively flat surface with minor depressions and mounds and occasional shedding of cells (Figure 20-12, area *A*).
2. *Areas of bacterial accumulation,* which appear as depressions on the epithelial surface, with abundant debris and bacterial clumps penetrating into the enlarged intercellular spaces. These bacteria are mainly cocci, rods, and filaments, with a few spirochetes (Figure 20-12, area *B*).
3. *Areas of emergence of leukocytes,* in which leukocytes appear in the pocket wall through holes located in the intercellular spaces (Figure 20-13).
4. *Areas of leukocyte–bacteria interaction,* in which numerous leukocytes are present and covered with bacteria in an apparent process of phagocytosis. Bacterial plaque associated with the epithelium is seen either as an organized matrix covered by a fibrinlike material in contact with the surface of cells or as bacteria penetrating into the intercellular spaces (Figure 20-12, area *C*).
5. *Areas of intense epithelial desquamation,* which consist of semiattached and folded epithelial squames, which are sometimes partially covered with bacteria (Figure 20-12, area *D*).

Figure 20-13 Scanning electron micrograph of the periodontal pocket wall, frontal view, in a patient with advanced periodontitis. Note the desquamating epithelial cells and leukocytes *(white arrows)* emerging onto the pocket space. Scattered bacteria can also be seen *(black arrow).* (×1500.)

6. *Areas of ulceration,* with exposed connective tissue (Figure 20-14).
7. *Areas of hemorrhage,* with numerous erythrocytes.

The transition from one area to another could result from bacteria accumulating in previously quiescent areas and triggering the emergence of leukocytes and the leukocyte–bacteria interaction. This would lead to intense epithelial desquamation and finally to ulceration and hemorrhage.

Periodontal Pockets as Healing Lesions

Periodontal pockets are chronic inflammatory lesions and thus are constantly undergoing repair. Complete healing does not occur because of the persistence of the bacterial attack, which continues to stimulate an inflammatory response, thereby causing degeneration of the new tissue elements formed during the continuous effort at repair.

The condition of the soft-tissue wall of the periodontal pocket results from the interplay of the destructive and constructive tissue changes. Their balance determines clinical features such as color, consistency, and surface texture of the pocket wall. If the inflammatory fluid and cellular exudate predominate, the pocket wall is bluish-red, soft, spongy, and friable, with a smooth, shiny surface; at the clinical level, this is generally referred to as an *edematous pocket wall.* If there is a relative predominance of newly formed connective tissue cells and fibers, the pocket wall is more firm and pink and clinically referred to as a *fibrotic pocket wall* (see Table 20-1 and Chapter 30).

Edematous and fibrotic pockets represent opposite extremes of the same pathologic process rather than different disease entities. They are subject to constant modification, depending on the relative predominance of exudative and constructive changes.

Fibrotic pocket walls may be misleading, because they do not necessarily reflect what is taking place throughout the pocket wall. The most severe degenerative changes in periodontal tissues occur adjacent to the tooth surface and the subgingival plaque. In some cases, inflammation and ulceration on the inside of the pocket are



Figure 20-14 *Left,* Area of ulceration in the lateral wall of a deep periodontal pocket in a human specimen (×800). *A,* Surface of pocket epithelium in a quiescent state; *B,* area of hemorrhage. *Right,* Scanning electron microscopy (×3000) of the square on the left. Connective tissue fibers and cells can be seen in the bottom of the ulcer.

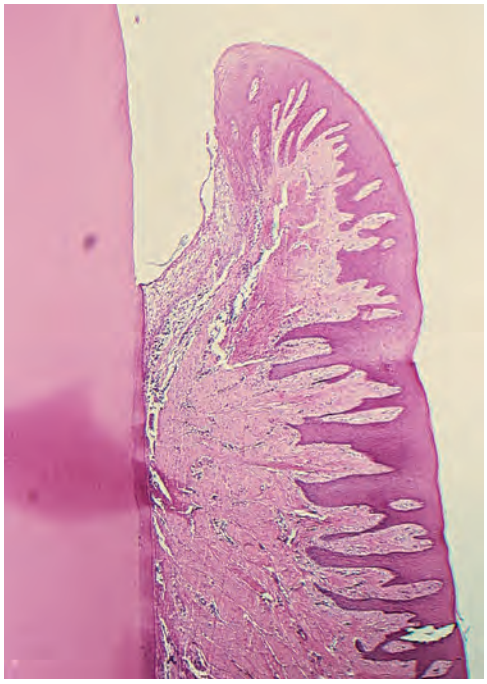

Figure 20-15 Periodontal pocket wall. The inner half is inflamed and ulcerated; the outer half is densely collagenous.

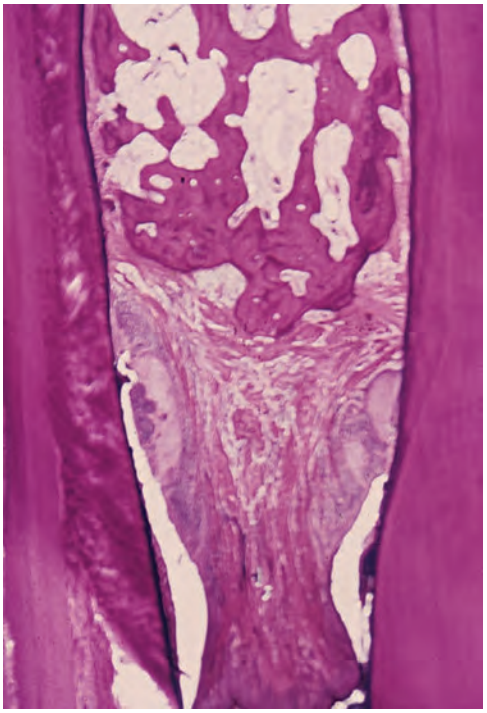

Figure 20-16 Interdental papilla with ulcerated suprabony periodontal pockets on its mesial and distal aspects. Calculus is present on the approximal tooth surfaces and within the gingiva.

walled off by fibrous tissue on the outer aspect (Figure 20-15). Externally the pocket appears pink and fibrotic, despite the inflammatory changes occurring internally.

Pocket Contents

Periodontal pockets contain debris that consists principally of microorganisms and their products (enzymes, endotoxins, and other metabolic products), gingival fluid, food remnants, salivary mucin, desquamated epithelial cells, and leukocytes. Plaque-covered calculus usually projects from the tooth surface (Figure 20-16). Purulent exudate, if present in the patient, consists of living, degenerated, and necrotic leukocytes; living and dead bacteria; serum; and a scant amount of fibrin.[46] The contents of periodontal pockets, when filtered free of organisms and debris, have been demonstrated to be toxic when injected subcutaneously into experimental animals.[31]

Pus is a common feature of periodontal disease, but it is only a secondary sign. The presence of pus or the ease with which it can be expressed from the pocket merely reflects the nature of the inflammatory changes in the pocket wall. It is not an indication of

the depth of the pocket or the severity of the destruction of the supporting tissues. Extensive pus formation may occur in shallow pockets, whereas deep pockets may exhibit little or no pus. The localized accumulation of pus constitutes an abscess, which is discussed later in this chapter.

Root Surface Walls

The root surface wall of periodontal pockets often undergoes changes that are significant because they may perpetuate the periodontal infection, cause pain, and complicate periodontal treatment.[11]

> As the pocket deepens, collagen fibers embedded in the cementum are destroyed, and cementum becomes exposed to the oral environment. Collagenous remnants of Sharpey fibers in the cementum undergo degeneration, thereby creating an environment favorable to the penetration of bacteria. Viable bacteria have been found in the roots of 87% of periodontally diseased noncarious teeth.[2] Bacterial penetration into the cementum can be found as deep as the cementodentinal junction,[1,19] and it may also enter the dentinal tubules.[29,31] Penetration and the growth of bacteria leads to fragmentation and breakdown of the cementum surface and results in areas of necrotic cementum that are separated from the tooth by masses of bacteria.

Pathologic granules[9] have been observed with light and electron microscopy,[6,7] and they may represent areas of collagen degeneration or areas in which collagen fibrils have not been fully mineralized initially.

In addition, bacterial products (e.g., endotoxins[3,5]) have also been detected in the cementum wall of periodontal pockets. When root fragments from teeth with periodontal disease are placed in tissue culture, they induce irreversible morphologic changes in the cells of the culture. Such changes are not produced by normal roots.[33] Diseased root fragments also prevent the in vitro attachment of human gingival fibroblasts, whereas normal root surfaces allow the cells to attach freely.[4] When placed in the oral mucosa of the patient, diseased root fragments induce an inflammatory response, even if they have been autoclaved.[44]

These changes manifest clinically as softening of the cementum surface; this is usually asymptomatic, but it can be painful when a probe or explorer penetrates the area. They also constitute a possible reservoir for reinfection of the area after treatment. During the course of treatment, these necrotic areas are removed by root planing until a hard, smooth surface is reached. Cementum is very thin in the cervical areas, and scaling and root planing often remove it entirely, exposing the underlying dentin. Sensitivity to cold may result until secondary dentin is formed by the pulp tissue.

Decalcification and Remineralization of Cementum Areas of *increased mineralization*[65] are probably a result of an exchange of minerals and organic components at the cementum–saliva interface after exposure to the oral cavity. The mineral content of exposed cementum increases,[64] and the minerals that are increased in diseased root surfaces include calcium,[67] magnesium,[50,67] phosphorus,[50] and fluoride.[50] Microhardness, however, remains unchanged.[55,81] The development of a highly mineralized superficial layer may increase the tooth's resistance to decay.[4]

The hypermineralized zones are detectable by electron microscopy, and they are associated with increased perfection of the crystal structure and organic changes that are suggestive of a subsurface cuticle.[64,65] These zones have also been seen in microradiographic studies[66] as a layer that is generally 10 to 20 mm thick, with areas as thick as 50 mm. No decrease in mineralization was found in deeper areas, thereby indicating that increased mineralization does not come from adjacent areas. A loss of or reduction in the crossbanding of collagen near the cementum surface[27,28] and a subsurface condensation of organic material of exogenous origin[64] have also been reported.

Areas of demineralization are often related to root caries. Exposure to oral fluid and bacterial plaque results in proteolysis of the embedded remnants of Sharpey fibers; the cementum may be softened, and it may undergo fragmentation and cavitation.[34] Unlike enamel caries, root surface caries tend to progress around rather than into the tooth.[48] Active root caries lesions appear as well-defined yellowish or light-brown areas; they are frequently covered by plaque, and they have a softened or leathery consistency on probing. Inactive lesions are well-defined darker lesions with a smooth surface and a harder consistency on probing.[24]

The dominant microorganism in root surface caries is *Actinomyces viscosus,*[72] although its specific role in the development of the lesion has not been established.[24] Other bacteria, such as *Actinomyces naeslundii, Streptococcus mutans, Streptococcus salivarius, Streptococcus sanguinis,* and *Bacillus cereus,* have been found to produce root caries in animal models. Quirynen and colleagues[54] reported that, when plaque levels and pocket depths decrease after periodontal therapy (both nonsurgical and surgical), a shift in oral bacteria occurs, thereby leading to a reduction in periodontal pathogens, an increase in *S. mutans,* and the development of root caries.

A prevalence rate study of root caries among 20- to 64-year-old individuals revealed that 42% had one or more root caries lesions and that these lesions tended to increase with age.[37]

The tooth may not be painful, but exploration of the root surface reveals the presence of a defect, and penetration of the involved area with a probe causes pain. Caries of the root may lead to pulpitis, sensitivity to sweets and thermal changes, or severe pain. Pathologic exposure of the pulp occurs in severe cases. Root caries may be the cause of toothache in patients with periodontal disease and no evidence of coronal decay.

Caries of the cementum requires special attention when the pocket is treated. The necrotic cementum must be removed by scaling and root planing until firm tooth surface is reached, even if this entails extension into the dentin.

Areas of cellular resorption of cementum and dentin are common in roots that are unexposed by periodontal disease.[68] These areas are of no particular significance because they are symptom free, and, as long as the root is covered by the periodontal ligament, they are likely to undergo repair. However, if the root is exposed by progressive pocket formation before repair occurs, these areas appear as isolated cavitations that penetrate into the dentin. These areas can be differentiated from caries of the cementum by their clear-cut outline and hard surface. They may be sources of considerable pain that require the placement of a restoration.

Surface Morphology of Tooth Wall.[78] The following zones can be found in the bottom of a periodontal pocket (Figure 20-17):

1. *Cementum covered by calculus,* in which all of the changes described in the preceding paragraphs can be found.
2. *Attached plaque,* which covers calculus and which extends apically from it to a variable degree (typically 100 to 500 µm).
3. The zone of *unattached plaque* that surrounds attached plaque and extends apically to it.

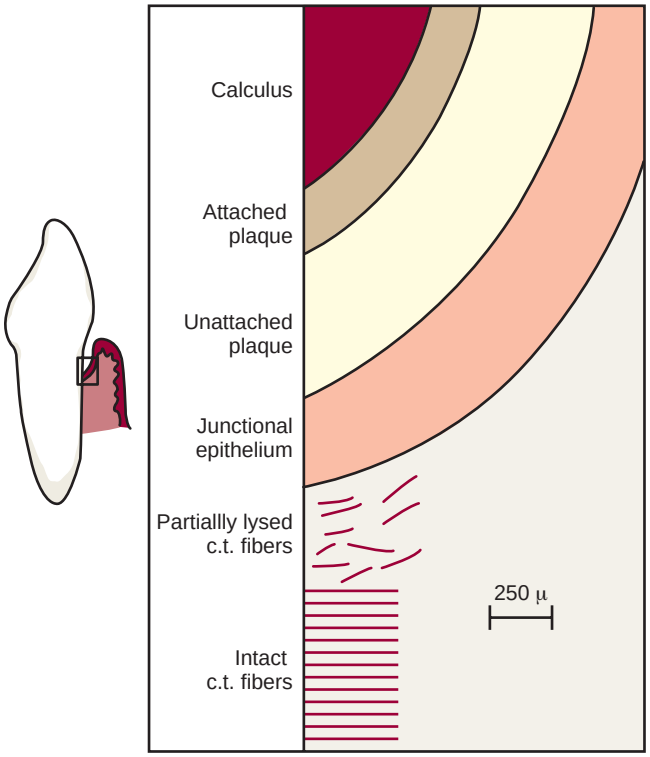

Figure 20-17 Diagram of the area at the bottom of a pocket. *c.t.,* Connective tissue.

4. The zone of *attachment of the junctional epithelium to the tooth.* The extension of this zone, which in normal sulci is more than 500 μm, is usually reduced in periodontal pockets to less than 100 μm.
5. A zone of *semidestroyed connective tissue fibers* may be apical to the junctional epithelium[60] (see the Pathogenesis section earlier in this chapter).

Zones 3, 4, and 5 make up the "plaque-free zone" seen in extracted teeth.[8,12,36,57,78] The total width of the plaque-free zone varies according to the type of tooth (i.e., it is wider in the molars than in the incisors) and the depth of the pocket (i.e., it is narrower in deeper pockets).[56] It is important to remember that the term *plaque-free zone* refers only to attached plaque, because unattached plaque contains a variety of gram-positive and gram-negative morphotypes, including cocci, rods, filaments, fusiforms, and spirochetes. The most apical zone contains predominantly gram-negative rods and cocci.[76]

Periodontal Disease Activity

For many years the loss of attachment produced by periodontal disease was thought to be a slow but continuously progressive phenomenon. More recently, as a result of studies of the specificity of plaque bacteria, the concept of periodontal disease activity has evolved.

According to this concept, periodontal pockets go through periods of exacerbation and quiescence as a result of episodic bursts of activity followed by periods of remission. *Periods of quiescence* are characterized by a reduced inflammatory response and little or no loss of bone and connective tissue attachment. A buildup of unattached plaque, with its gram-negative, motile, and anaerobic bacteria (see Chapter 23), starts a *period of exacerbation* during which bone and connective tissue attachment are lost and the pocket deepens. This period may last for days, weeks, or months, and it is eventually followed by a period of remission or quiescence during which gram-positive bacteria proliferate and a more stable condition is established. On the basis of a study of radioiodine^{125}I absorptiometry, McHenry and colleagues[45] confirmed that bone loss in patients with untreated periodontal disease occurs in an episodic manner.

These periods of quiescence and exacerbation are also known as *periods of inactivity* and *periods of activity.* Clinically, active periods show bleeding, either spontaneously or with probing, and greater amounts of gingival exudate. Histologically, the pocket epithelium appears thin and ulcerated, and an infiltrate composed predominantly of plasma cells,[19] PMNs,[53] or both is seen. Bacterial samples from the pocket lumen that are analyzed with dark-field microscopy show high proportions of motile organisms and spirochetes.[43]

Methods to detect periods of activity or inactivity are currently being investigated (see www.expertconsult.com).

Site Specificity

Periodontal destruction does not occur in all parts of the mouth at the same time; rather, it occurs on a few teeth at a time or even only on some aspects of some teeth at any given time. This is referred to as the *site specificity* of periodontal disease. Sites of periodontal destruction are often found next to sites with little or no destruction. Therefore, the severity of periodontitis increases with the development of new disease sites and with the increased breakdown of existing sites.

Pulp Changes Associated With Periodontal Pockets

The spread of infection from periodontal pockets may cause pathologic changes in the pulp. Such changes may give rise to painful symptoms, or they may adversely affect the response of the pulp to restorative procedures. Involvement of the pulp in periodontal disease occurs through either the apical foramen or the lateral pulp canals after pocket infection reaches them. Atrophic and inflammatory pulpal changes occur in such cases (see Chapters 52 and 63).

Relationship of Attachment Loss and Bone Loss to Pocket Depth

The severity of the attachment loss in pocket formation is generally but not always correlated with the depth of the pocket. This is because the degree of attachment loss depends on the location of the base of the pocket on the root surface, whereas pocket depth is the distance between the base of the pocket and the crest of the gingival margin. Pockets of the same depth may be associated with different degrees of attachment loss (Figure 20-18), and pockets of different depths may be associated with the same amount of attachment loss (Figure 20-19).

The severity of bone loss is generally but not always correlated with pocket depth. Extensive attachment and bone loss may be associated with shallow pockets if the attachment loss is accompanied by recession of the gingival margin, and slight bone loss can occur with deep pockets.

Area Between Base of Pocket and Alveolar Bone

Normally, the distance between the apical end of the junctional epithelium and the alveolar bone is relatively constant. The distance between the apical extent of calculus and the alveolar crest in human periodontal pockets is most constant, having a mean length of 1.97 mm (±33.16%).[71,77]

The distance from attached plaque to bone is never less than 0.5 mm and never more than 2.7 mm.[78-80] These findings suggest

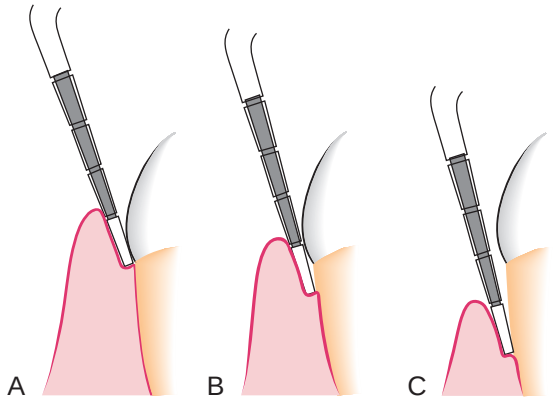

Figure 20-18 Same pocket depth with different amounts of recession. **A,** Gingival pocket with no recession. **B,** Periodontal pocket of similar depth as shown in **A** but with some degree of recession. **C,** Pocket depth the same as shown in **A** and **B** but with still more recession.

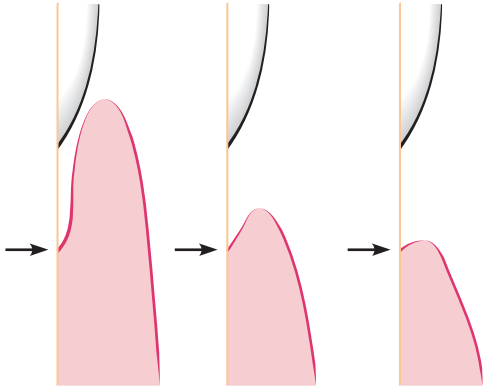

Figure 20-19 Different pocket depths with the same amount of attachment loss. Arrows point to the bottom of the pocket. The distance between the arrow and the cementoenamel junction remains the same despite different pocket depths.

that the bone-resorbing activity induced by the bacteria is exerted within these distances. However, the finding of isolated bacteria or clumps of bacteria in the connective tissue[60] and on the bone surface[26] may modify these considerations.

Relationship of Pocket to Bone

In infrabony pockets, the base of the pocket is apical to the crest of the alveolar bone, and the pocket wall lies between the tooth and the bone. The bone loss is in most cases vertical. Alternatively, in suprabony pockets, the base is coronal to the crest of the alveolar bone, and the pocket wall lies coronal to the bone. The type of bone loss is always horizontal.

This creates some microscopic differences that have some therapeutic importance. They are the relationship of the soft-tissue wall of the pocket to the alveolar bone, the pattern of bone destruction, and the direction of the transseptal fibers of the periodontal ligament[15] (Figures 20-20, 20-21, and 20-22).

In suprabony pockets, the alveolar crest gradually attains a more apical position in relation to the tooth, but it retains its general morphology and architecture. The interdental fibers that run over the bone from one tooth to the other maintain their usual horizontal direction. In infrabony pockets, the morphology of the alveolar crest changes completely, with the formation of an angular bony defect. The interdental fibers in this case run over the bone in an oblique direction between the two teeth of the interdental space.[15,80] This may affect the function of the area and also necessitate a modification in treatment techniques (see Chapters 60 and 62).[13,15] Table 20-2 summarizes the distinguishing features of suprabony and infrabony pockets. The classification of infrabony pockets is discussed in Chapter 14.

Periodontal Abscess

A periodontal abscess is a localized purulent inflammation in the periodontal tissues (Figure 20-23). It is also known as a *lateral abscess* or a *parietal abscess.* Abscesses that are localized in the gingiva, that are caused by injury to the outer surface of the gingiva, and that do not involve the supporting structures are called *gingival abscesses.* Gingival abscesses may occur in the presence or absence of a periodontal pocket (see Chapter 9).

Periodontal abscess formation may occur in the following ways:

1. *Extension of infection from a periodontal pocket deeply into the supporting periodontal tissues and localization of the suppurative inflammatory process along the lateral aspect of the root.*
2. *Lateral extension of inflammation from the inner surface of a periodontal pocket into the connective tissue of the pocket wall.* Formation of the abscess results when drainage into the pocket space is impaired.
3. *Formation in a pocket with a tortuous course around the root.* A periodontal abscess may form in the cul-de-sac, the deep end of which is shut off from the surface.
4. *Incomplete removal of calculus during treatment of a periodontal pocket.* The gingival wall shrinks, thereby occluding the pocket orifice, and a periodontal abscess occurs in the sealed-off portion of the pocket.
5. *After trauma to the tooth or with perforation of the lateral wall of the root in endodontic therapy.* In these situations, a periodontal abscess may occur in the absence of periodontal disease.

Periodontal abscesses are classified according to location as follows:

1. *Abscess in the supporting periodontal tissues along the lateral aspect of the root.* With this condition, a sinus generally occurs in the bone that extends laterally from the abscess to the external surface.
2. *Abscess in the soft-tissue wall of a deep periodontal pocket.*

> Microscopically, an abscess is a localized accumulation of viable and nonviable PMNs within the periodontal pocket wall. The PMNs liberate enzymes that digest the cells and other tissue structures, thereby forming the liquid product known as *pus,* which constitutes the center of the abscess. An acute inflammatory reaction surrounds the purulent area, and the overlying epithelium exhibits intracellular and extracellular edema and the invasion of leukocytes (Figure 20-24).
>
> The localized acute abscess becomes a chronic abscess when its purulent content drains through a fistula into the outer gingival surface or into the periodontal pocket and the infection that is causing the abscess is not resolved.

The bacterial invasion of tissues has been reported in abscesses; the invading organisms were identified as gram-negative cocci, diplococci, fusiforms, and spirochetes. Invasive fungi were also found and were interpreted as being "opportunistic invaders."[22] Microorganisms that colonize the periodontal abscess have been reported to be primarily gram-negative anaerobic rods.[51]

Lateral Periodontal Cyst

The periodontal cyst, which is also called *lateral periodontal cyst,* is an uncommon lesion that produces localized destruction of the

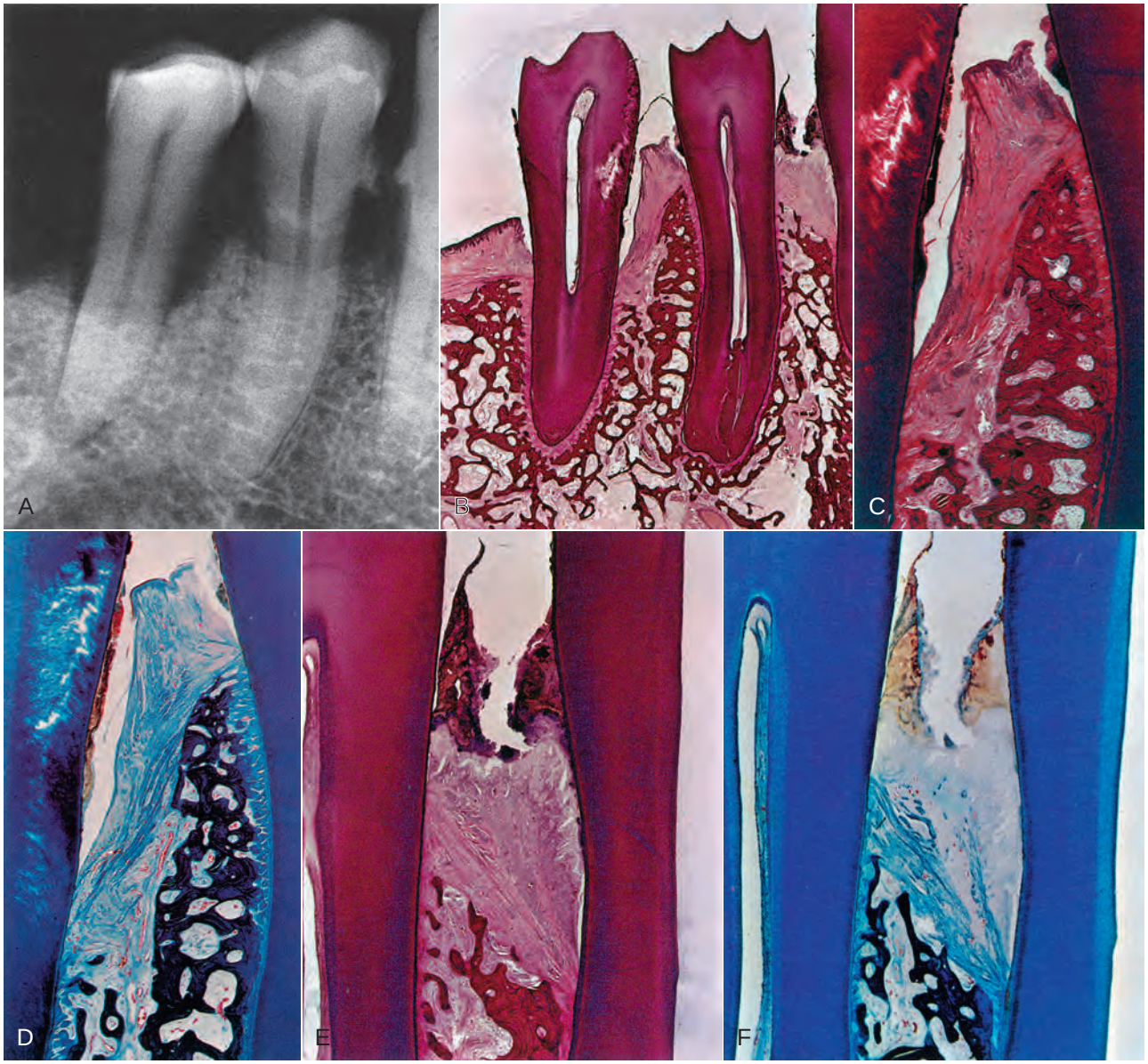

Figure 20-20 Radiographic and microscopic features of intrabony pockets. **A,** Radiograph of a mandibular canine and premolar area showing angular bone loss mesial to the second premolar. The type of bone loss between the first premolar and the canine is not radiographically apparent. **B,** Mesiodistal histologic section of the teeth seen in **A** showing an intrabony pocket mesial to the second premolar as well as suprabony pockets distal to the second premolar and mesial and distal to the first premolar. The mesial suprabony pocket of the first premolar appears to be coronal to a vertical bone loss. **C,** Higher-power view of the area between the premolars. Note the angular bone loss and the transseptal fibers that cover the bone. **D,** Higher-power view of the area between the premolars stained with Mallory connective tissue stain, clearly showing the direction of transseptal fibers. **E,** Higher-power view of the area between the first premolar and the canine. Note the abundant calculus, the dense leukocytic infiltration of the gingiva, and the angulation of the transseptal fibers and bone. The pocket is still suprabony. **F,** Mallory stain of a similar area to the one shown in **E.** Note the destruction of the gingival fibers caused by inflammation and the angular fibers formed over angular bone loss and less affected by the inflammation. Transseptal fibers extend from the distal surface of the premolar over the crest of the alveolar bone into the intrabony pocket. Note the leukocytic infiltration of the transseptal fibers. *(From Glickman I, Smulow J:* Periodontal disease: clinical, radiographic and histopathologic features, *Philadelphia, 1974, Saunders.)*

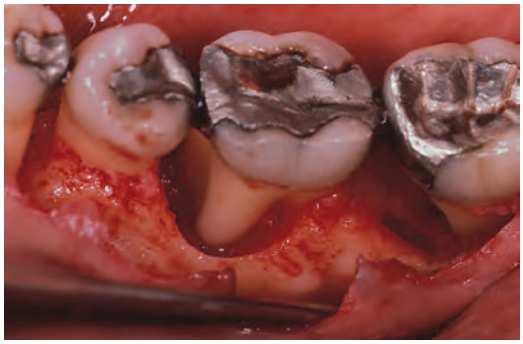

Figure 20-21 After raising a flap for the treatment of the infrabony pockets, the vertical bone loss around the mesial roots of the mandibular first and second molars can be seen.

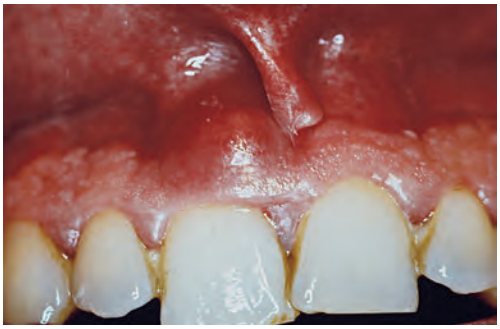

Figure 20-23 Periodontal abscess on an upper right central incisor.

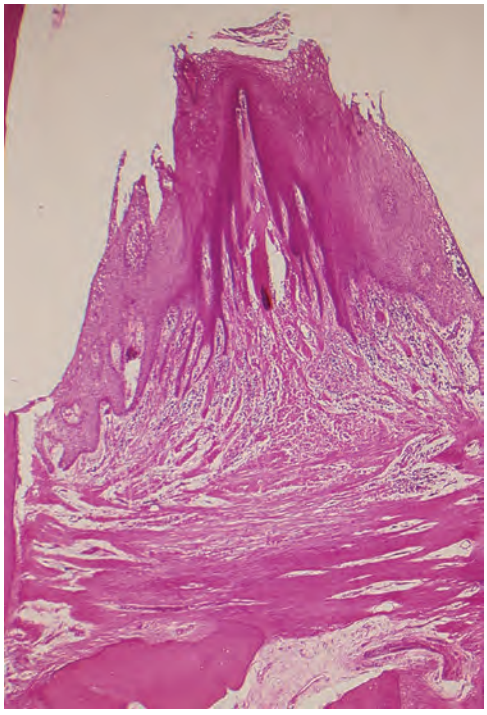

Figure 20-22 Two suprabony pockets in an interdental space. Note the normal horizontal arrangement of the transseptal fibers.

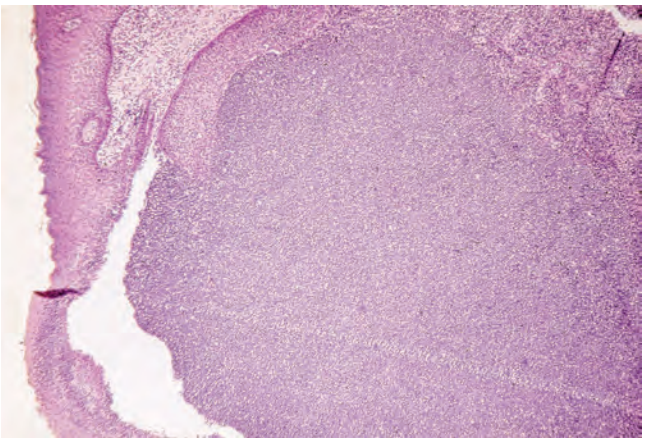

Figure 20-24 Microscopic view of a periodontal abscess showing the dense accumulation of polymorphonuclear leukocytes covered by squamous epithelium.

TABLE 20-2 Distinguishing Features of Suprabony and Intrabony Periodontal Pockets

Suprabony Pocket	Intrabony Pocket
1. The base of the pocket is coronal to the level of the alveolar bone.	1. The base of the pocket is apical to the crest of the alveolar bone so that the bone is adjacent to the soft-tissue wall (see Figure 20-2).
2. The pattern of destruction of the underlying bone is horizontal.	2. The pattern of bone destruction is vertical (angular) (see Figures 20-20 and 20-21).
3. Interproximally, transseptal fibers that are restored during progressive periodontal disease are arranged horizontally in the space between the base of the pocket and the alveolar bone (see Figure 20-22).	3. Interproximally, transseptal fibers are oblique rather than horizontal. They extend from the cementum beneath the base of the pocket along the alveolar bone and over the crest to the cementum of the adjacent tooth (see Figure 20-20).
4. On the facial and lingual surfaces, periodontal ligament fibers beneath the pocket follow their normal horizontal–oblique course between the tooth and the bone.	4. On the facial and lingual surfaces, periodontal ligament fibers follow the angular pattern of the adjacent bone. They extend from the cementum beneath the base of the pocket along the alveolar bone and over the crest to join with the outer periosteum.

periodontal tissues along a lateral root surface, most often in the mandibular canine–premolar area.[23,70] It is considered to be derived from the rests of Malassez or other proliferating odontogenic rests.[69]

A periodontal cyst is usually asymptomatic, without grossly detectable changes, but it may present as a localized, tender swelling. Radiographically, an interproximal periodontal cyst appears on the side of the root as a radiolucent area bordered by a radiopaque line. Its radiographic appearance cannot be differentiated from that of a periodontal abscess.

Microscopically, the cystic lining may be (1) a loosely arranged, thin, nonkeratinized epithelium, sometimes with thicker proliferating areas; or (2) an odontogenic keratocyst.[23]

Suggested Readings

Adriaens PA, DeBoever JA, Loesche WJ: Bacterial invasion in root cementum and radicular dentin of periodontally diseased teeth in humans: a reservoir of periodontopathic bacteria. *J Periodontol* 59:222, 1988.

Armitage GC, Christie TM: Structural changes in exposed cementum. I. Light microscopic observations. *J Periodontal Res* 8:343, 1973.

Armitage GC, Christie TM: Structural changes in exposed cementum. II. Electronmicroscopic observations. *J Periodontal Res* 8:356, 1973.

Lindhe J, Liljenberg B, Listgarten MA: Some microbiological and histopathological features of periodontal disease in man. *J Periodontol* 52:264, 1980.

Listgarten MA: Structure of the microbial flora associated with periodontal health and disease in man. *J Periodontol* 47:1, 1976.

Listgarten MA: Pathogenesis of periodontitis. *J Clin Periodontol* 13:418, 1986.

Newman MG, Sims TN: The predominant cultivable microbiota of the periodontal abscess. *J Periodontol* 50:350, 1979.

Page RC, Schroeder HH: Structure and pathogenesis. In Schluger S, Youdelis R, Page R, editors: *Periodontal disease*, Philadelphia, 1977, Lea & Febiger.

Quirynen M, Gizani S, Mongardini C, et al: The effect of periodontal therapy on the number of cariogenic bacteria in different intraoral niches. *J Clin Periodontol* 26:322, 1999.

Saglie FR, Newman MG, Carranza FA, Jr, et al: Bacterial invasion of gingiva in advanced periodontitis in humans. *J Periodontol* 53:217, 1982.

References

References for this chapter are found on the companion website www.expertconsult.com.

References

1. Adriaens PA, DeBoever JA: Ultrastructural study of bacterial invasion in roots of periodontally diseased, caries-free human teeth. *J Dent Res* 65:770, 1986.
2. Adriaens PA, DeBoever JA, Loesche WJ: Bacterial invasion in root cementum and radicular dentin of periodontally diseased teeth in humans: a reservoir of periodontopathic bacteria. *J Periodontol* 59:222, 1988.
3. Aleo JJ, Vandersall DC: Cementum: recent concepts related to periodontal disease therapy. *Dent Clin North Am* 24:627, 1980.
4. Aleo JJ, DeRenzis FA, Farber PA: In vitro attachment of human gingival fibroblasts to root surfaces. *J Periodontol* 46:639, 1975.
5. Aleo JJ, DeRenzis FA, Farber PA, et al: The presence and biologic activity of cementum-bound endotoxin. *J Periodontol* 45:672, 1974.
6. Armitage GC, Christie TM: Structural changes in exposed cementum. I. Light microscopic observations. *J Periodontal Res* 8:343, 1973.
7. Armitage GC, Christie TM: Structural changes in exposed cementum. II. Electronmicroscopic observations. *J Periodontal Res* 8:356, 1973.
8. Bass CC: A demonstrable line on extracted teeth indicating the location of the outer border of the epithelial attachment. *J Dent Res* 25:401, 1946.
9. Bass CC: A previously undescribed demonstrable pathologic condition in exposed cementum and the underlying dentine. *Oral Surg* 4:641, 1951.
10. Bonakdar MPS, Barber PM, Newman HN: The vasculature in chronic adult periodontitis: a qualitative and quantitative study. *J Periodontol* 68:50, 1997.
11. Bosshardt DD, Selvig KA: Dental cementum: the dynamic tissue covering the root. *Periodontol 2000* 13:41, 1997.
12. Brady JM: A plaque-free zone on human teeth: scanning and transmission electron microscopy. *J Periodontol* 44:416, 1973.
13. Carranza FA, Carranza FA, Jr: The management of alveolar bone in the treatment of the periodontal pocket. *J Periodontol* 27:29, 1956.
14. Carranza FA, Jr: Histometric evaluation of periodontal pathology: a review of recent studies. *J Periodontol* 38:741, 1967.
15. Carranza FA, Jr, Glickman I: Some observations on the microscopic features of the infrabony pockets. *J Periodontol* 28:33, 1957.
16. Christersson LA, Albini B, Zambon JJ, et al: Tissue localization of *Actinobacillus actinomycetemcomitans* in human periodontitis. I. Light, immunofluorescence and electronmicroscopic studies. *J Periodontol* 58:529, 1987.
17. Coons DB, Charbeneau TD, Rivera-Hidalgo F: Quantification of bacterial penetration in spontaneous periodontal disease in beagle dogs. *J Periodontol* 60:23, 1989.
18. Daly CG, Seymour GJ, Kieser JB, et al: Histological assessment of periodontally involved cementum. *J Clin Periodontol* 9:266, 1982.
19. Davenport RH, Jr, Simpson DM, Hassell TM: Histometric comparison of active and inactive lesions of advanced periodontitis. *J Periodontol* 53:285, 1982.
20. Deporter DA, Brown DJ: Fine structural observations on the mechanisms of loss of attachment during experimental periodontal disease in the rat. *J Periodontal Res* 15:304, 1980.
21. Deporter DA, Ten Cate AR: Collagen resorption by periodontal ligament fibroblasts at the hard tissue–ligament interfaces of the mouse molar periodontium. *J Periodontol* 51:429, 1980.
22. DeWitt GV, Cobb CM, Killoy WJ: The acute periodontal abscess: microbial penetration of the soft tissue wall. *Int J Periodont Restor Dent* 5:39, 1985.
23. Fantasia JE: Lateral periodontal cyst: an analysis of 46 cases. *Oral Surg Oral Med Oral Pathol* 48:237, 1979.
24. Fejerskov O, Nyvad B: Pathology and treatment of dental caries in the aging individual. In Holm-Pedersen P, Löe H, editors: *Geriatric dentistry*, Copenhagen, 1986, Munksgaard.
25. Frank RM: Bacterial penetration in the apical wall of advanced human periodontitis. *J Periodontal Res* 15:563, 1980.
26. Frank RM, Voegel RC: Bacterial bone resorption in advanced cases of human periodontitis. *J Periodontal Res* 13:251, 1978.
27. Furseth R: Further observations on the fine structure of orally exposed carious human dental cementum. *Arch Oral Biol* 16:71, 1971.
28. Furseth R, Johanson E: The mineral phase of sound and carious human dental cementum studies by electron microscopy. *Acta Odontol Scand* 28:305, 1970.
29. Giuliana G, Ammatuna P, Pizzo G, et al: Occurrence of invading bacteria in radicular dentin of periodontally diseased teeth: microbiological findings. *J Clin Periodontol* 24:478, 1997.
30. Glickman I, Smulow JB: *Periodontal disease: clinical, radiographic, and histopathologic features*, Philadelphia, 1974, Saunders.
31. Graham JW: Toxicity of sterile filtrate from parodontal pockets. *Proc R Soc Med* 30:1165, 1937.
32. Greenstein G, Lamster I: Changing periodontal paradigms: therapeutic implications. *Int J Periodont Restor Dent* 20:337, 2000.
33. Hatfield CG: Baumhammers A: Cytotoxic effects of periodontally involved surfaces of human teeth. *Arch Oral Biol* 16:465, 1971.
34. Herting HC: Electron microscope studies of the cementum surface structures of periodontally healthy and diseased teeth. *J Dent Res* 46(Suppl):127, 1967.
35. Hillmann G, Dogan S, Gewrtsen W: Histopathological investigation of gingival tissue from patients with rapidly progressive periodontitis. *J Periodontol* 69:195, 1998.
36. Hoffman ID, Gold W: Distances between plaque and remnants of attached periodontal tissues on extracted teeth. *J Periodontol* 42:29, 1971.
37. Katz RV, Hazen SP, Chilton NW, et al: Prevalence and intraoral distribution of root caries in an adult population. *Caries Res* 16:265, 1982.
38. Krayer JW, Rees TD: Histologic observations on the topography of a human periodontal pocket viewed in transverse step-serial sections. *J Periodontol* 64:585, 1993.
39. Liakoni H, Barber P, Newman HN: Bacterial penetration of pocket soft tissues in chronic adult and juvenile periodontitis cases: an ultrastructural study. *J Clin Periodontol* 14:22, 1987.
40. Lindhe J, Liljenberg B, Listgarten MA: Some microbiological and histopathological features of periodontal disease in man. *J Periodontol* 52:264, 1980.
41. Listgarten MA: Structure of the microbial flora associated with periodontal health and disease in man. *J Periodontol* 47:1, 1976.
42. Listgarten MA: Pathogenesis of periodontitis. *J Clin Periodontol* 13:418, 1986.
43. Listgarten MA, Hellden L: Relative distributions of bacteria at clinically healthy and periodontally diseased sites in humans. *J Clin Periodontol* 5:665, 1978.
44. Lopez NJ, Belvederessi M, de la Sotta R: Inflammatory effects of periodontally diseased cementum studied by autogenous dental root implants in humans. *J Periodontol* 51:582, 1980.
45. McHenry KR, Hausman E, Genco RJ, et al: 125I absorptiometry: alveolar bone mass measurements in untreated periodontal disease [abstract]. *J Dent Res* 60(Suppl A):387, 1981.
46. McMillan L, Burrill DY, Fosdick LS: An electron microscope study of particulates in periodontal exudate [abstract]. *J Dent Res* 37:51, 1958.
47. Meyer DH, Screenivasan PK, Fives-Taylor PM: Evidence for the invasion of a human oral cell line by *Actinobacillus actinomycetemcomitans*. *Infect Immun* 59:2719, 1991.
48. Mount GJ: Root surface caries: a recurrent dilemma. *Aust Dent J* 31:288, 1986.
49. Müller-Glauser W, Schröder HE: The pocket epithelium: a light and electron microscopic study. *J Periodontol* 53:133, 1982.
50. Nakata T, Stepnick R, Zipkin I: Chemistry of human dental cementum: the effect of age and exposure on the concentration of F, Ca, P and Mg. *J Periodontol* 43:115, 1972.
51. Newman MG, Sims TN: The predominant cultivable microbiota of the periodontal abscess. *J Periodontol* 50:350, 1979.
52. Orban B, Ray HG: Deep necrotic foci in the gingiva. *J Periodontol* 19:91, 1948.
53. Page RC, Schroeder HH: Structure and pathogenesis. In Schluger S, Youdelis R, Page R, editors: *Periodontal disease*, Philadelphia, 1977, Lea & Febiger.

54. Quirynen M, Gizani S, Mongardini C, et al: The effect of periodontal therapy on the number of cariogenic bacteria in different intraoral niches. *J Clin Periodontol* 26:322, 1999.
55. Rautiola CA, Craig RG: The micro hardness of cementum and underlying dentin of normal teeth and teeth exposed to periodontal disease. *J Periodontol* 32:113, 1961.
56. Saglie FR, Johansen JR, Flotra L: The zone of completely and partially destroyed periodontal fibers in pathologic pockets. *J Clin Periodontol* 2:198, 1975.
57. Saglie FR, Johansen JR, Tollefsen T: Plaque-free zones on human teeth in periodontitis. *J Clin Periodontol* 2:190, 1975.
58. Saglie FR, Marfany A, Camargo P: Intragingival occurrence of *Actinobacillus actinomycetemcomitans* and *Bacteroides gingivalis* in active destructive periodontal lesions. *J Periodontol* 59:259, 1988.
59. Saglie FR, Carranza FA, Jr, Newman MG, et al: Scanning electron microscopy of the gingival wall of deep periodontal pockets in humans. *J Periodontal Res* 17:284, 1982.
60. Saglie FR, Newman MG, Carranza FA, Jr, et al: Bacterial invasion of gingiva in advanced periodontitis in humans. *J Periodontol* 53:217, 1982.
61. Schroeder HE: Quantitative parameters of early human gingival inflammation. *Arch Oral Biol* 15:383, 1970.
62. Schroeder HE, Attstrom R: *The borderland between caries and periodontal disease*, vol 2, London, 1980, Grune & Stratton.
63. Schroeder HE: *The periodontium*, Berlin, 1986, Springer-Verlag.
64. Selvig KA: Ultrastructural changes in cementum and adjacent connective tissue in periodontal disease. *Acta Odontol Scand* 24:459, 1966.
65. Selvig KA: Biological changes at the tooth-saliva interface in periodontal disease. *J Dent Res* 48(Suppl):846, 1969.
66. Selvig KA, Hals E: Periodontally diseased cementum studied by correlated microradiography, electron probe analysis and electron microscopy. *J Periodontal Res* 12:419, 1977.
67. Selvig KA, Zander HA: Chemical analysis and microradiography of cementum and dentin from periodontally diseased human teeth. *J Periodontol* 33:303, 1962.
68. Sottosanti JS: A possible relationship between occlusion, root resorption, and the progression of periodontal disease. *J West Soc Periodontol* 25:69, 1977.
69. Spouge JD: A new look at the rests of Malassez: a review of their embryological origin, anatomy, and possible role in periodontal health and disease. *J Periodontol* 51:437, 1980.
70. Standish SN, Shafer WG: The lateral periodontal cyst. *J Periodontol* 29:27, 1958.
71. Stanley HR: The cyclic phenomenon of periodontitis. *Oral Surg Oral Med Oral Pathol* 8:598, 1955.
72. Syed SA, Loesche WJ, Pape HL, et al: Predominant cultivable flora isolated from human root surface caries plaque. *Infect Immun* 11:727, 1975.
73. Taichman N: Potential mechanisms of tissue destruction in periodontal disease. *J Dent Res* 47:928, 1968.
74. Takada T, Donath K: The mechanism of pocket formation: a light microscopic study of undecalcified human material. *J Periodontol* 59:215, 1988.
75. Ten Cate AR: Fibroblasts and their products. In Ten Cate JR, editor: *Oral histology: development, structure, and function*, ed 4, St Louis, 1994, Mosby.
76. Vrahopoulos TP, Barber PM, Newman HN: The apical border plaque in severe periodontitis: an ultrastructural study. *J Periodontol* 66:113, 1995.
77. Wade AB: The relation between the pocket base, the epithelial attachment and the alveolar process. In *Les Parodontopathies, 16th ARPA Congress*, Vienna, 1960.
78. Waerhaug J: The gingival pocket. *Odont Tidsk* 60(Suppl 1):1952.
79. Waerhaug J: The angular bone defect and its relationship to trauma from occlusion and downgrowth of subgingival plaque. *J Clin Periodontol* 6:61, 1979.
80. Waerhaug J: The infrabony pocket and its relationship to trauma from occlusion and subgingival plaque. *J Periodontol* 50:355, 1979.
81. Warren EB, Hanse NM, Swartz ML, et al: Effects of periodontal disease and of calculus solvents on microhardness of cementum. *J Periodontol* 35:505, 1964.
82. Wittwer JW, Dickler EH, Toto PD: Comparative frequencies of plasma cells and lymphocytes in gingivitis. *J Periodontol* 40:274, 1969.
83. Zander HA: The attachment of calculus to root surfaces. *J Periodontol* 24:16, 1953.

CHAPTER 21

Bone Loss and Patterns of Bone Destruction

Fermin A. Carranza, Paulo M. Camargo, and Henry H. Takei

CHAPTER OUTLINE

Bone Destruction Caused by the Extension of Gingival Inflammation
Bone Destruction Caused by Trauma from Occlusion
Bone Destruction Caused by Systemic Disorders
Factors Determining Bone Morphology in Periodontal Disease
Bone Destruction Patterns in Periodontal Disease

Editors Note: An animation (slide show) has been added as a supplement to the chapter by the Editors. This was produced by My Dental Hub as a patient education tool and covers the basic elements in a conceptual manner. It is not intended to be a procedural guide for dental professionals.

Although periodontitis is an infectious disease of the gingival tissue, changes that occur in bone are crucial, because the destruction of bone is responsible for tooth loss.

The height and density of the alveolar bone are normally maintained by an equilibrium, regulated by local and systemic influences, between bone formation and bone resorption.[12,14] When resorption exceeds formation, both bone height and bone density may be reduced (see Video 21-1: Vertical Bone Loss).

The level of bone is the consequence of past pathologic experiences, whereas changes in the soft tissue of the pocket wall reflect the present inflammatory condition. Therefore, the degree of bone loss is not necessarily correlated with the depth of periodontal pockets, the severity of ulceration of the pocket wall, or the presence or absence of pus.

Bone Destruction Caused by the Extension of Gingival Inflammation

The most common cause of bone destruction in periodontal disease is the extension of inflammation from the marginal gingiva into the supporting periodontal tissues. The inflammatory invasion of the bone surface and the initial bone loss that follows mark the transition from gingivitis to periodontitis.

Periodontitis is always preceded by gingivitis, but not all gingivitis progresses to periodontitis. Some cases of gingivitis apparently never become periodontitis, and other cases go through a brief gingivitis phase and rapidly develop into periodontitis. The factors that are responsible for the extension of inflammation to the supporting structures, thereby initiating the conversion of gingivitis to periodontitis, are not clearly understood at this time.

The transition from gingivitis to periodontitis is associated with changes in the composition of bacterial plaque. In advanced stages of disease, the number of motile organisms and spirochetes increases, whereas the number of coccoid rods and straight rods decreases.[34] The cellular composition of the infiltrated connective tissue also changes with increasing severity of the lesion (see Chapter 7). Fibroblasts and lymphocytes predominate in stage 1 gingivitis, whereas the number of plasma cells and blast cells increases gradually as the disease progresses. Seymour and colleagues[58,59] have postulated a stage of "contained" gingivitis in which T lymphocytes are preponderant; they think that, as the lesion becomes a B-lymphocyte lesion, it becomes progressively destructive.

Heijl and coworkers[22] were able to convert, in experimental animals, a confined, naturally occurring chronic gingivitis into a progressive periodontitis by placing a silk ligature into the sulcus and tying it around the neck of the tooth. This induced ulceration of the sulcular epithelium, a shift in the inflammatory infiltrate from predominantly plasma cells to predominantly polymorphonuclear leukocytes, and osteoclastic resorption of the alveolar crest. The recurrence of episodes of acute destruction over time may be one mechanism that leads to progressive bone loss in individuals with marginal periodontitis.

The extension of inflammation to the supporting structures of a tooth may be modified by the pathogenic potential of plaque and the resistance of the host. The latter includes immunologic activity and other tissue-related mechanisms, such as the degree of fibrosis of the gingiva, probably the width of the attached gingiva, and the reactive fibrogenesis and osteogenesis that occur peripheral to the inflammatory lesion.[52]

Histopathology. Gingival inflammation extends along the collagen fiber bundles and follows the course of the blood vessels through the loosely arranged tissues around them into the alveolar bone[67] (Figure 21-1). Although the inflammatory infiltrate is concentrated in the marginal periodontium, the reaction is a much more diffuse one, often reaching the bone and eliciting a response before evidence of crestal resorption or loss of attachment exists.[41] In the upper molar region, inflammation can extend to the maxillary sinus, thereby resulting in thickening of the sinus mucosa.[40]

Interproximally, inflammation spreads to the loose connective tissue around the blood vessels, through the fibers, and then into the bone through vessel channels that perforate the crest of the interdental

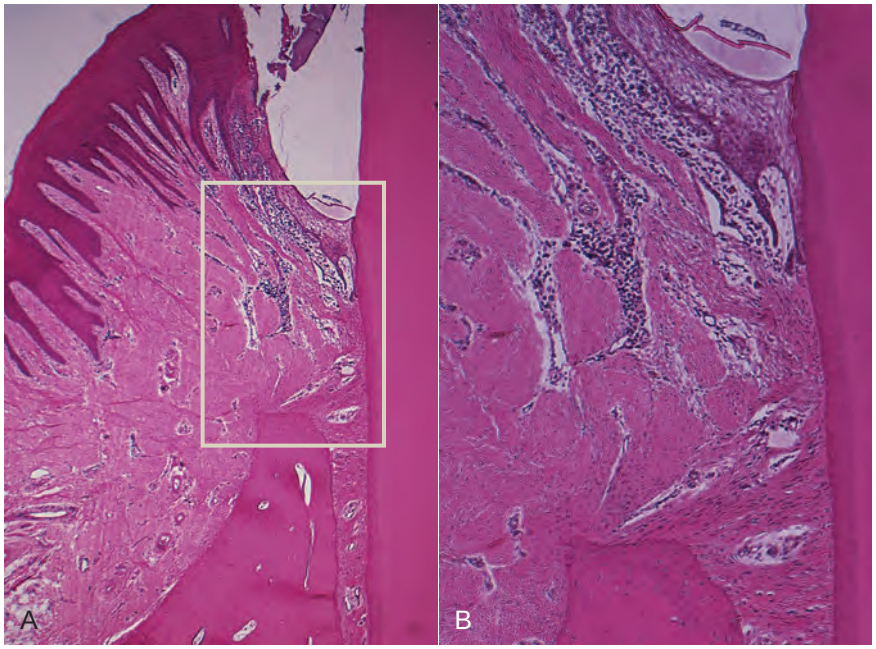

Figure 21-1 **A**, An area of inflammation extending from the gingiva into the suprabony area. **B,** Extension of inflammation along the blood vessels and between collagen bundles.

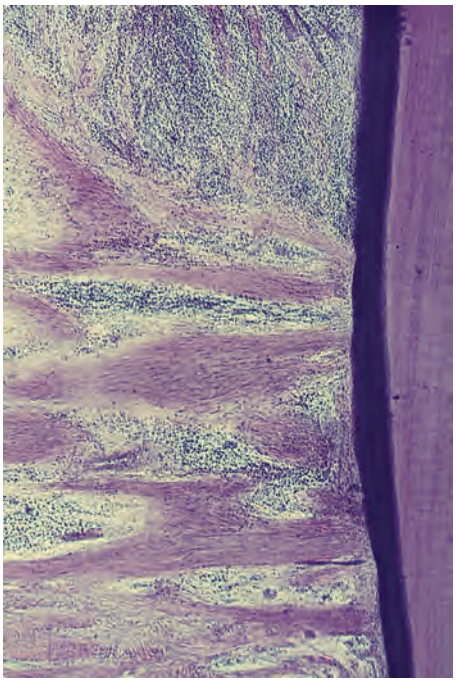

Figure 21-2 Inflammation that extends from the pocket area *(top)* between the collagen fibers, which are partially destroyed.

septum at the center of the crest (Figure 21-2), toward the side of the crest (Figure 21-3), or at the angle of the septum. In addition, inflammation may enter the bone through more than one channel. Less frequently, the inflammation spreads from the gingiva directly into the periodontal ligament and from there into the interdental septum[1] (Figure 21-4).

Facially and lingually, inflammation from the gingiva spreads along the outer periosteal surface of the bone (see Figure 21-4) and penetrates into the marrow spaces through vessel channels in the outer cortex.

Along its course from the gingiva to the bone, the inflammation destroys the gingival and transseptal fibers, reducing them to disorganized granular fragments interspersed among the inflammatory cells and edema.[45] However, there is a continuous tendency to recreate transseptal fibers across the crest of the interdental septum farther along the root as the bone destruction progresses (Figure 21-5). As a result, transseptal fibers are present, even in cases of extreme periodontal bone loss.

The dense transseptal fibers form a firm covering over the bone that is encountered during periodontal flap surgery after the superficial granulation tissue is removed.[50]

After inflammation reaches the bone via extension from the gingiva (Figure 21-6), it spreads into the marrow spaces and replaces the marrow with a leukocytic and fluid exudate, new blood vessels, and proliferating fibroblasts (Figure 21-7). Multinuclear osteoclasts and mononuclear phagocytes increase in number, and the bone surfaces appear to be lined with Howship lacunae (Figure 21-8).

In the marrow spaces, resorption proceeds from within and causes a thinning of the surrounding bony trabeculae and an enlargement of the marrow spaces; this is followed by the destruction of the bone and a reduction in bone height. Normally, fatty bone marrow is partially or totally replaced by a fibrous type of marrow in the vicinity of the resorption.

Bone destruction in periodontal disease is not a process of bone necrosis.[27] It involves the activity of living cells along viable bone. When tissue necrosis and pus are present in periodontal disease, they occur in the soft-tissue walls of periodontal pockets rather than along the resorbing margin of the underlying bone.

The amount of inflammatory infiltrate correlates with the degree of bone loss but not with the number of osteoclasts. However, the distance from the apical border of the inflammatory infiltrate to the alveolar bone crest correlates with both the number of osteoclasts on the alveolar crest and the total number of osteoclasts.[51] Similar findings have been reported in experimentally induced periodontitis in animals.[32]

Radius of Action

Garant and Cho[10] suggested that locally produced bone resorption factors may need to be present in the proximity of the bone surface to exert their action. Page and Schroeder,[49] on the basis of

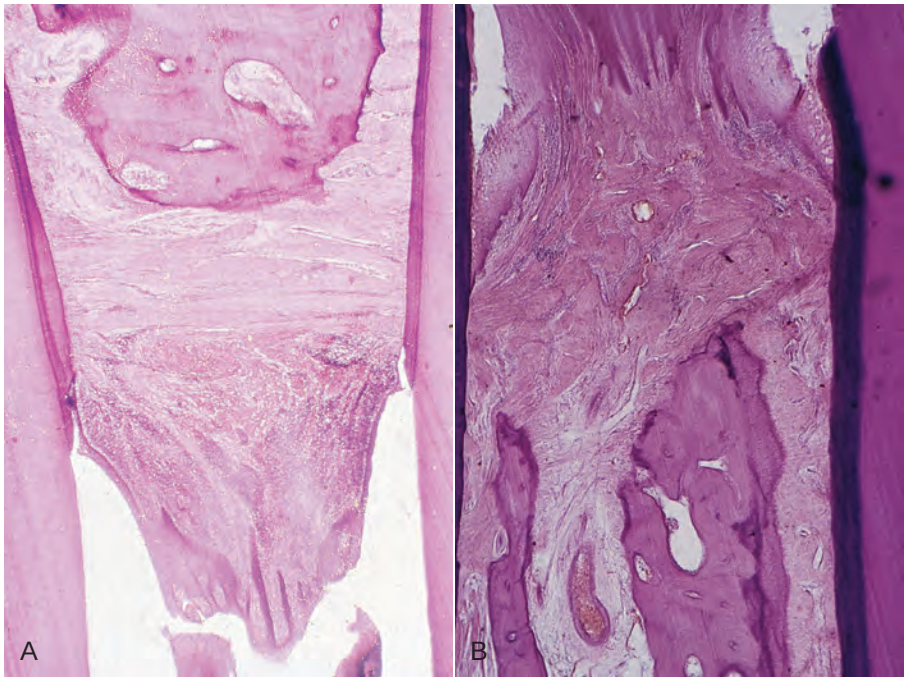

Figure 21-3 **A,** Extension of inflammation into the center of the interdental septum. Inflammation from the gingiva penetrates the transseptal fibers and enters the bone around the blood vessel in the center of the septum. **B,** The cortical layer at the top of the septum has been destroyed, and the inflammation penetrates into the marrow spaces.

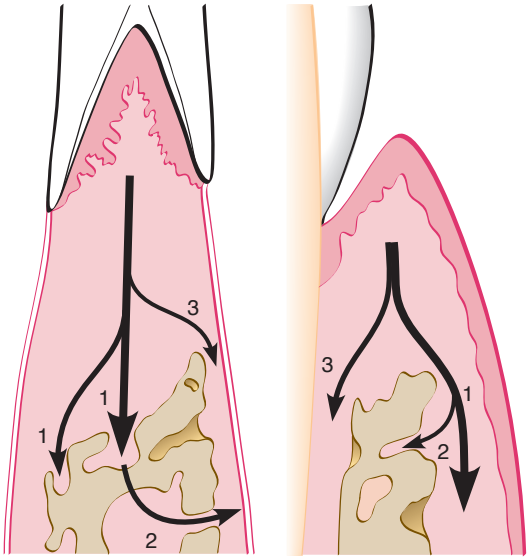

Figure 21-4 Pathways of inflammation from the gingiva into the supporting periodontal tissues in a patient with periodontitis. **A,** Interproximally, from the gingiva into the bone *(1),* from the bone into the periodontal ligament *(2),* and from the gingiva into the periodontal ligament *(3).* **B,** Facially and lingually, from the gingiva along the outer periosteum *(1),* from the periosteum into the bone *(2),* and from the gingiva into the periodontal ligament *(3).*

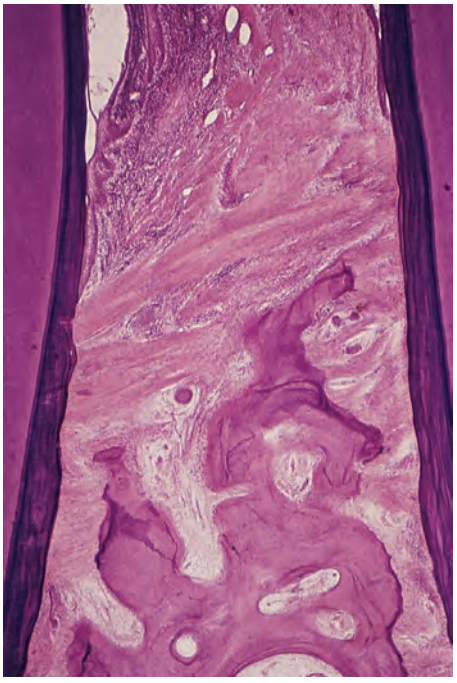

Figure 21-5 Reformation of transseptal fibers. A mesiodistal section through the interdental septum shows gingival inflammation and bone loss. Recreated transseptal fibers can be seen above the bone margin, where they have been partially infiltrated by the inflammatory process.

Waerhaug's measurements made on human autopsy specimens,[64,65] postulated a range of effectiveness of about 1.5 mm to 2.5 mm in which bacterial plaque can induce loss of bone. Beyond 2.5 mm, there is no effect; interproximal angular defects can appear only in spaces that are wider than 2.5 mm, because narrower spaces would be destroyed entirely. Tal[61] corroborated this with measurements in human patients.

Large defects that greatly exceed a distance of 2.5 mm from the tooth surface (as described in aggressive types of periodontitis) may be caused by the presence of bacteria in the tissues.[6,10,54]

Rate of Bone Loss

In a study of Sri Lankan tea laborers with no oral hygiene and no dental care, Löe and colleagues[36] found the rate of bone loss to

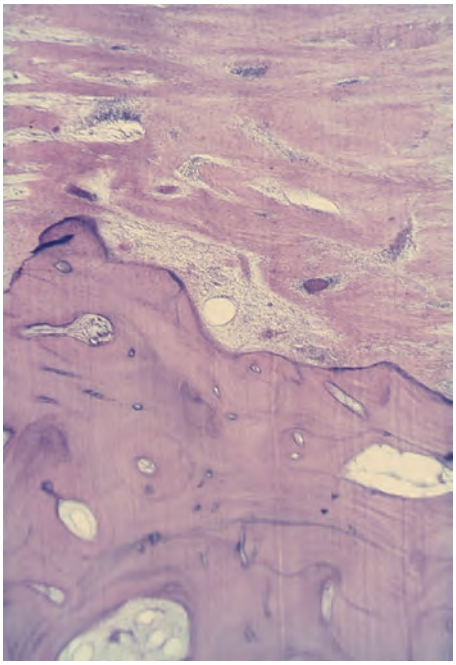

Figure 21-6 Extension of inflammation has reached the crestal bone surface.

Figure 21-7 Interdental septum in a human autopsy section. Extensive inflammatory infiltrate has invaded the marrow spaces, entering from both the mesial and distal aspects. Fatty bone marrow has been replaced by inflammatory cells and fibrous marrow.

average about 0.2 mm per year for facial surfaces and about 0.3 mm per year for proximal surfaces when periodontal disease was allowed to progress untreated. However, the rate of bone loss may vary, depending on the type of disease present. Löe and colleagues[35] also identified the following three subgroups of patients with periodontal disease on the basis of the interproximal loss of attachment and tooth mortality (loss of attachment can be equated with loss of bone, although attachment loss precedes bone loss by about 6 to 8 months[17]):

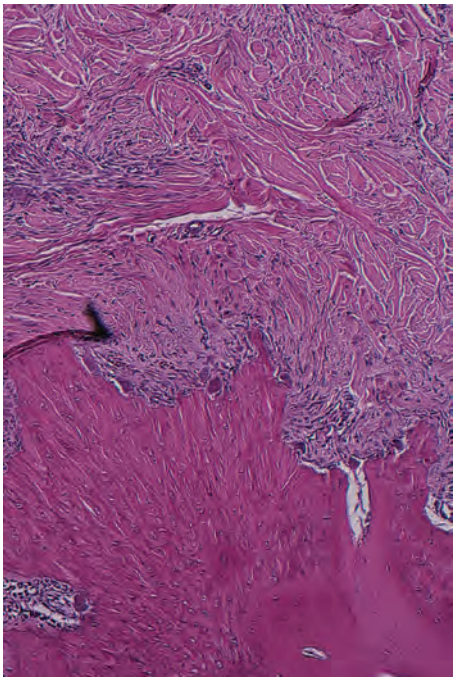

Figure 21-8 Osteoclasts and Howship lacunae in the resorption of crestal bone.

1. Approximately 8% of persons had a rapid progression of periodontal disease that was characterized by a yearly loss of attachment of 0.1 mm to 1.0 mm.
2. Approximately 81% of individuals had moderately progressive periodontal disease with a yearly loss of attachment of 0.05 mm to 0.5 mm.
3. The remaining 11% of persons had minimal or no progression of destructive disease with a yearly loss of attachment of 0.05 mm to 0.09 mm.

Periods of Destruction

Periodontal destruction occurs in an episodic, intermittent manner, with periods of inactivity or quiescence that alternate with destructive periods that result in the loss of collagen and alveolar bone and the deepening of the periodontal pocket.

Periods of destructive activity are associated with subgingival ulceration and an acute inflammatory reaction that results in the rapid loss of alveolar bone[49,56]; it has been hypothesized that this coincides with the conversion of a predominantly T-lymphocyte lesion to one with a predominantly B-lymphocyte–plasma cell infiltrate.[59] Microbiologically, these lesions are associated with an increase in the loose, unattached, motile, gram-negative, anaerobic pocket flora, whereas periods of remission coincide with the formation of a dense, unattached, nonmotile, gram-positive flora with a tendency to mineralize.[43]

It has also been suggested that the onset of periods of destruction coincide with tissue invasion by one or several bacterial species and that this is followed by an advanced local host defense that controls the attack.[54]

Mechanisms of Bone Destruction

The factors involved in bone destruction in periodontal disease are bacterial and host mediated. Bacterial plaque products induce the differentiation of bone progenitor cells into osteoclasts and stimulate gingival cells to release mediators that have the same effect.[21,57] Plaque products and inflammatory mediators can also act directly

on osteoblasts or their progenitors, thereby inhibiting their action and reducing their numbers.

In addition, in patients with rapidly progressing diseases (e.g., aggressive periodontitis), bacterial microcolonies or single bacterial cells have been found between collagen fibers and over the bone surface, which suggests a direct effect.[6,9,57]

Several host factors released by inflammatory cells are capable of inducing bone resorption in vitro, and they play a role in periodontal disease. These include host-produced prostaglandins and their precursors, interleukin-1α, interleukin-β, and tumor necrosis factor-α.

When injected intradermally, prostaglandin E_2 induces the vascular changes that are seen with inflammation; when injected over a bone surface, prostaglandin E_2 induces bone resorption in the absence of inflammatory cells, with few multinucleated osteoclasts.[18,26] In addition, nonsteroidal anti-inflammatory drugs (e.g., flurbiprofen, ibuprofen) inhibit prostaglandin E_2 production, thereby slowing bone loss in naturally occurring periodontal disease in beagle dogs and humans. This effect occurs without changes in gingival inflammation, and it rebounds 6 months after the cessation of drug administration.[25,68] (For more information about the host-mediated mechanisms of bone destruction, see Chapter 25.)

Bone Formation in Periodontal Disease

Areas of bone formation are also found immediately adjacent to sites of active bone resorption and along trabecular surfaces at a distance from the inflammation in an apparent effort to reinforce the remaining bone (i.e., buttressing bone formation). This osteogenic response is clearly found in experimentally produced periodontal bone loss in animals.[7] In humans, it is less obvious, but it has been confirmed by histometric[4,5] and histologic studies.[13]

Autopsy specimens from individuals with untreated disease occasionally show areas in which bone resorption has ceased and new bone is being formed on previously eroded bone margins. This confirms the intermittent character of bone resorption in periodontal disease, and it is consistent with the varied rates of progression observed clinically in individuals with untreated periodontal disease.

The periods of remission and exacerbation (or inactivity and activity, respectively) appear to coincide with the quiescence or exacerbation of gingival inflammation as manifested by changes in the extent of bleeding, the amount of exudate, and the composition of bacterial plaque (see Chapter 23).

The presence of bone formation in response to inflammation, even in those with active periodontal disease, has an effect on the outcome of treatment. The basic aim of periodontal therapy is the elimination of inflammation to remove the stimulus for bone resorption and therefore to allow the inherent constructive tendencies to predominate.

Bone Destruction Caused by Trauma from Occlusion

Another cause of bone destruction in periodontal disease is trauma from occlusion, which can occur in the absence or presence of inflammation (see Chapter 15).

In the absence of inflammation, the changes caused by trauma from occlusion vary from increased compression and tension of the periodontal ligament and increased osteoclasis of alveolar bone to necrosis of the periodontal ligament and bone and the resorption of bone and tooth structure. These changes are reversible in that they can be repaired if the offending forces are removed. However, persistent trauma from occlusion results in funnel-shaped widening of the crestal portion of the periodontal ligament with resorption of the adjacent bone.[33] These changes, which may cause the bony crest to have an angular shape, represent adaptation of the periodontal tissues aimed at "cushioning" increased occlusal forces; however, the modified bone shape may weaken tooth support and cause tooth mobility.

When it is combined with inflammation, trauma from occlusion aggravates the bone destruction caused by the inflammation[33] and results in bizarre bone patterns.

Bone Destruction Caused by Systemic Disorders

Local and systemic factors regulate the physiologic equilibrium of bone. When a generalized tendency toward bone resorption exists, bone loss initiated by local inflammatory processes may be magnified.

This systemic influence on the response of alveolar bone, as envisioned by Glickman[12] during the early 1950s, considers a systemic regulatory influence in all cases of periodontal disease. In addition to the virulence of plaque bacteria, the nature of the systemic component rather than its presence or absence influences the severity of the periodontal destruction. This concept of a role played by systemic defense mechanisms has been validated by the studies of immune deficiencies and host modulation in severely destructive types of periodontitis (see Chapters 25 and 37).

In recent years, interest has increased in the possible relationship between periodontal bone loss and osteoporosis.[11] Osteoporosis is a physiologic condition of postmenopausal women that results in the loss of bone mineral content as well as structural bone changes. Periodontitis and osteoporosis share a number of risk factors (e.g., aging, smoking, certain diseases, medications that interfere with healing). Some studies show a relationship between skeletal density and oral bone density; between crestal height and residual ridge resorption; and between osteopenia and periodontitis, tooth mobility, and tooth loss[19,23,24,55,63] (see Chapters 18 and 38).

Periodontal bone loss may also occur with generalized skeletal disturbances (e.g., hyperparathyroidism, leukemia, histiocytosis X) via mechanisms that may be totally unrelated to the usual periodontal problem.

Factors Determining Bone Morphology in Periodontal Disease

Normal Variation in Alveolar Bone

Considerable normal variation exists within the morphologic features of alveolar bone (see Chapter 2), and this affects the osseous contours produced by periodontal disease. The anatomic features that substantially affect the bone-destructive pattern of periodontal disease include the following:

- Thickness, width, and crestal angulation of the interdental septa
- Thickness of the facial and lingual alveolar plate
- Presence of fenestrations and dehiscences
- Alignment of the teeth
- Root and root trunk anatomy
- Root position within the alveolar process
- Proximity with another tooth surface

For example, angular osseous defects cannot form in thin facial or lingual alveolar plates, which have little or no cancellous bone between the outer and inner cortical layers. In such cases, the entire crest of the plate is destroyed, and the height of the bone is reduced (see Figure 21-9).

Exostoses

Exostoses are outgrowths of bone of varied size and shape. Palatal exostoses have been found in 40% of human skulls.[46] They can

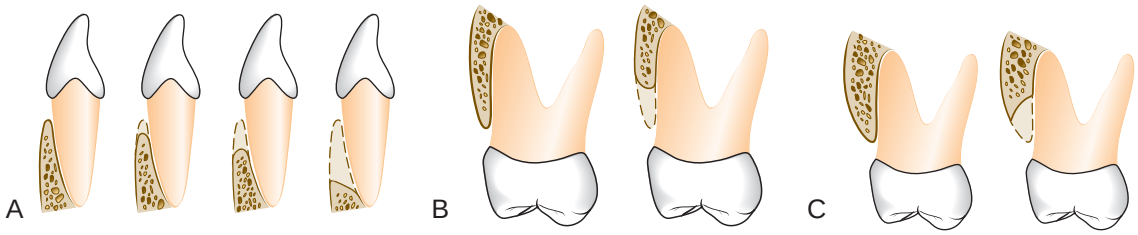

Figure 21-9 **A,** Lower incisor with thin labial bone. Bone loss can become vertical only when it reaches thicker bone in apical areas. **B,** Upper molars with thin facial bone, where only horizontal bone loss can occur. **C,** Upper molar with a thick facial bone that allows for vertical bone loss.

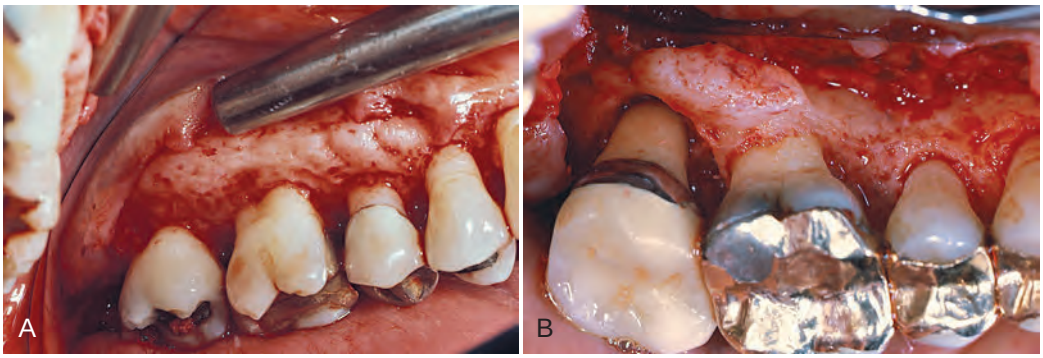

Figure 21-10 **A,** Exostosis in the facial aspect of the upper second premolar and molars. **B,** Exostosis in the palatal aspect of the first and second molars. Note also the circumferential defect in the second molar *(left)*.

occur as small nodules, large nodules, sharp ridges, spikelike projections, or any combination of these (Figure 21-10).[42] Exostoses have been described in rare cases as developing after the placement of free gingival grafts.[46]

Trauma from Occlusion

Trauma from occlusion may be a factor in determining the dimension and shape of bone deformities. It may cause a thickening of the cervical margin of alveolar bone or a change in bone morphology (e.g., angular defects, buttressing bone) on which inflammatory changes will later be superimposed.

Buttressing Bone Formation

Bone formation sometimes occurs in an attempt to buttress bony trabeculae that are weakened by resorption. When it occurs within the jaw, it is termed *central buttressing bone formation.* When it occurs on the external surface, it is referred to as *peripheral buttressing bone formation.*[13] The latter may cause bulging of the bone contour, which sometimes accompanies the production of osseous craters and angular defects (Figure 21-11).

Food Impaction

Interdental bone defects often occur where proximal contact is abnormal or absent. Pressure and irritation from food impaction contribute to the inverted bone architecture. In some cases, the poor proximal relationship may result from a shift in tooth position as a result of extensive bone destruction that precedes food impaction. In such patients, food impaction is a complicating factor rather than the cause of the bone defect.

Aggressive Periodontitis

A vertical or angular pattern of alveolar bone destruction is found around the first molars in aggressive periodontitis. The cause of the localized bone destruction with this type of periodontal disease is unknown (see Chapter 18).

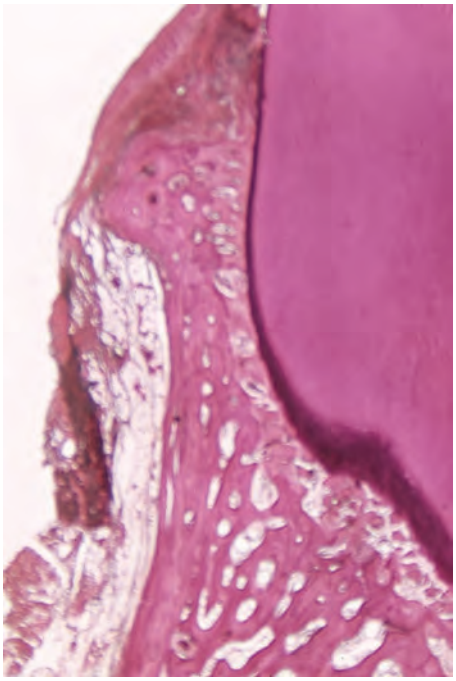

Figure 21-11 Lipping of facial bone. There is a peripheral buttressing bone formation along the external surface of the facial bony plate and at the crest. Note the deformity in the bone produced by the buttressing bone formation and the bulging of the mucosa.

Bone Destruction Patterns in Periodontal Disease

Periodontal disease alters the morphologic features of the bone in addition to reducing bone height. An understanding of the nature and pathogenesis of these alterations is essential for effective diagnosis and treatment.[48]

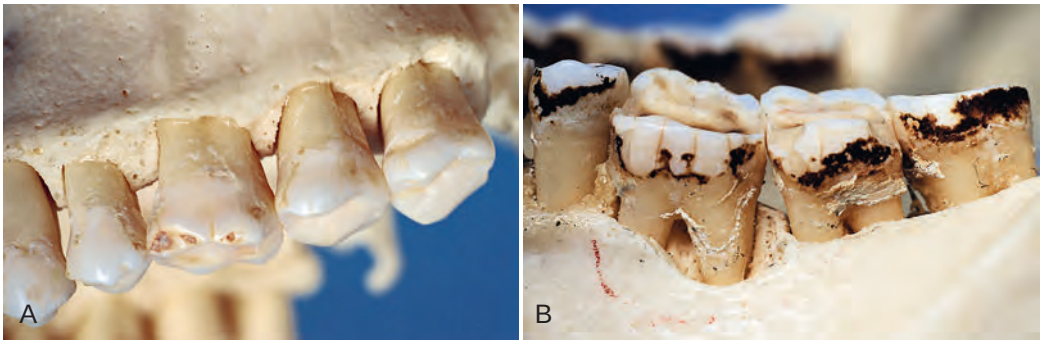

Figure 21-12 **A,** Horizontal bone loss. Note the reduction in height of the marginal bone that exposes cancellous bone and reaches the furcation of the second molar. **B,** Vertical (angular) bone loss on the distal root of the first molar.

Figure 21-13 Angular (vertical) defects of different depths.

Figure 21-14 Angular defect on the mesial surface of the first molar. Note also the furcation involvement.

Horizontal Bone Loss

Horizontal bone loss is the most common pattern of bone loss in periodontal disease. The bone is reduced in height, but the bone margin remains approximately perpendicular to the tooth surface. The interdental septa and the facial and lingual plates are affected but not necessarily to an equal degree around the same tooth (Figure 21-12, *A*).

Bone Deformities (Osseous Defects)

Different types of bone deformities can result from periodontal disease. These usually occur in adults, but they have also been reported in human skulls with deciduous dentitions.[28] Their presence may be suggested on radiographs, but careful probing and surgical exposure of the areas are required to determine their exact conformation and dimensions.

Vertical or Angular Defects

Vertical or angular defects are those that occur in an oblique direction, leaving a hollowed-out trough in the bone alongside the root; the base of the defect is located apical to the surrounding bone (Figures 21-12, *B*, 21-13, and 21-14). In most instances, angular defects have accompanying infrabony periodontal pockets; infrabony pockets, on the other hand, must always have an underlying angular defect.

Angular defects were classified by Goldman and Cohen on the basis of the number of osseous walls.[16] Angular defects may have one, two, or three walls (Figures 21-15 to 21-18). The number of walls in the apical portion of the defect is often greater than that in its occlusal portion, in which case the term *combined osseous defect* is used (Figure 21-19).

Vertical defects that occur interdentally can generally be seen on the radiograph, although thick, bony plates may sometimes obscure them. Angular defects can also appear on facial and lingual or palatal surfaces, but these defects are not seen on radiographs. Surgical exposure is the only sure way to determine the presence and configuration of vertical osseous defects.

Vertical defects increase with age.[44,47,69] Approximately 60% of persons with interdental angular defects have only a single defect.[44] Vertical defects detected radiographically have been reported to appear most often on the distal[44] and mesial surfaces.[47] However, three-wall defects are more frequently found on the mesial surfaces of the upper and lower molars.[29]

Osseous Craters

Osseous craters are concavities in the crest of the interdental bone that is confined within the facial and lingual walls (Figure 21-20). Craters have been found to make up about one third (35.2%) of all defects and about two thirds (62%) of all mandibular defects and to occur twice as often in posterior segments as in anterior segments.[37,38]

The heights of the facial and lingual crests of a crater have been found to be identical in 85% of cases, with the remaining 15% being almost equally divided between higher facial crests and higher lingual crests.[53]

The following reasons for the high frequency of interdental craters have been suggested[37,38,53]:

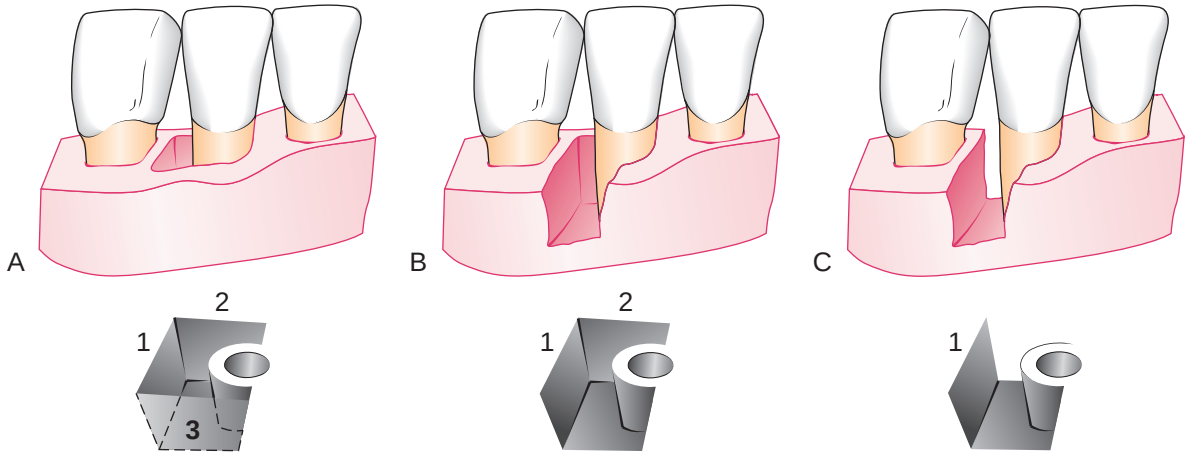

Figure 21-15 One-, two-, and three-walled vertical defects on the right lateral incisor. **A,** Three bony walls: distal *(1),* lingual *(2),* and facial *(3).* **B,** Two-wall defect: distal *(1)* and lingual *(2).* **C,** One-wall defect: distal wall only *(1).*

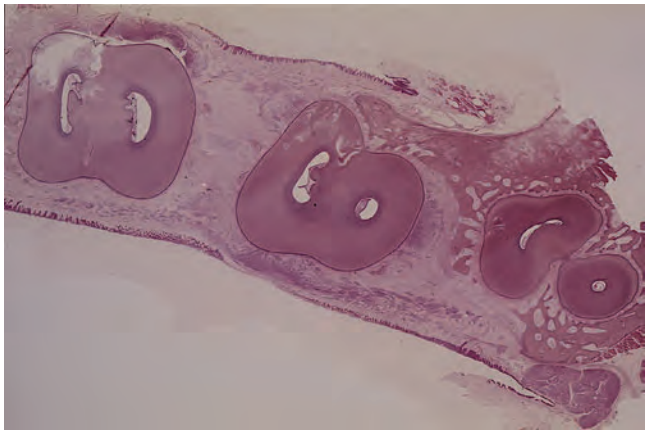

Figure 21-16 Horizontal section of the lower molars at the midroot level showing a two-wall osseous defect distal to second molar.

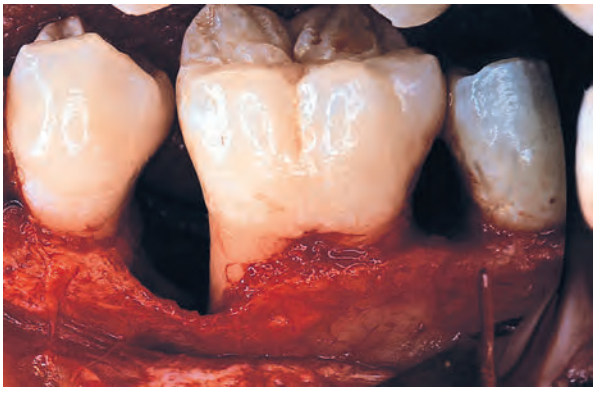

Figure 21-17 One-wall vertical defect on the mesial surface of the lower first molar.

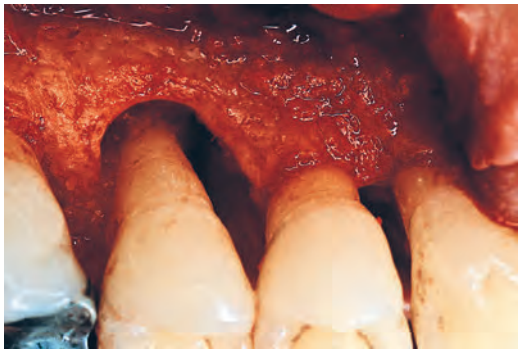

Figure 21-18 Circumferential vertical defect in relation to the upper premolar.

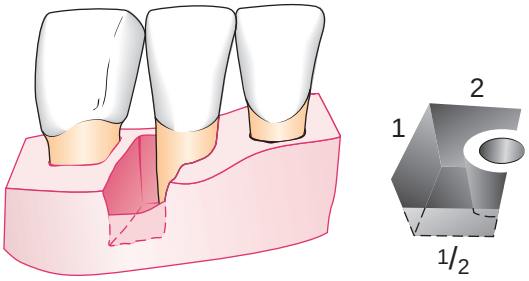

Figure 21-19 Combined type of osseous defect. Because the facial wall is half the height of the distal *(1)* and lingual *(2)* walls, this is an osseous defect with three walls in its apical half and two walls in its occlusal half.

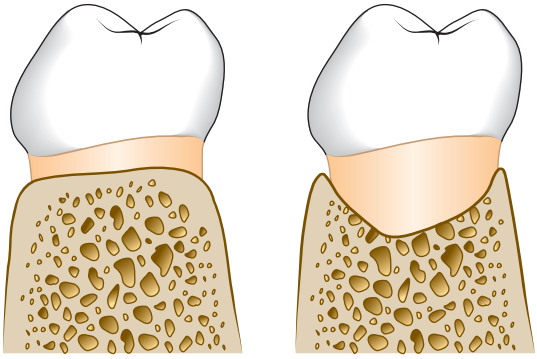

Figure 21-20 Diagrammatic representation of an osseous crater in a faciolingual section between two lower molars. *Left,* Normal bone contour. *Right,* Osseous crater.

Figure 21-21 Reversed architecture. The elevated flap shows the irregular bone margin.

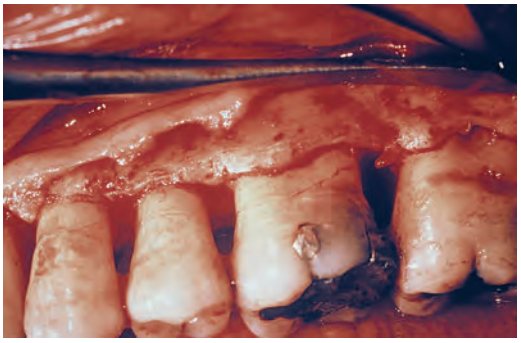

Figure 21-22 Ledge produced by interproximal resorption.

- The interdental area collects plaque and is difficult to clean.
- The normal flat or even slightly concave faciolingual shape of the interdental septum in the lower molars may favor crater formation.
- Vascular patterns from the gingiva to the center of the crest may provide a pathway for inflammation.

Bulbous Bone Contours

Bulbous bone contours are bony enlargements that are caused by exostoses (see Figure 21-10), adaptation to function, or buttressing bone formation. They are found more frequently in the maxilla than in the mandible.

Reversed Architecture

Reversed architecture defects are produced by a loss of interdental bone, including the facial plates and the lingual plates, without a concomitant loss of radicular bone, thereby reversing the normal architecture (Figure 21-21). Such defects are more common in the maxilla.[44]

Ledges

Ledges are plateaulike bone margins that are caused by the resorption of thickened bony plates (Figure 21-22).

Furcation Involvement

The term *furcation involvement* refers to the invasion of the bifurcation and trifurcation of multirooted teeth by periodontal disease. The prevalence of furcation-involved molars is not clear.[8,47] Although some reports indicate that the mandibular first molars are the most common sites and that the maxillary premolars are the least common,[30] other studies have found higher prevalence in the upper molars.[69] The number of furcation involvements increases with age.[30,31]

Figure 21-23 **A,** A molar with slightly inflamed gingiva that is seen clinically; however, it has a deep distal pocket. **B,** Flap elevation reveals extensive bone loss and furcation involvement. *(Courtesy Dr. Terry Fiori, Palo Alto, CA.)*

The denuded furcation may be visible clinically or covered by the wall of the pocket. The extent of involvement is determined by exploration with a blunt probe, along with a simultaneous blast of warm air to facilitate visualization (Figure 21-23).

Furcation involvements have been classified as grades I through IV according to the amount of tissue destruction. Grade I involves incipient bone loss; grade II involves partial bone loss (cul-de-sac); and grade III involves total bone loss with a through-and-through opening of the furcation. Grade IV is similar to grade III but includes gingival recession that exposes the furcation to view.

> Microscopically, furcation involvement presents no unique pathologic features. It is simply a phase in the rootward extension of the periodontal pocket. During its early stages, a widening of the periodontal space occurs with cellular and fluid inflammatory exudation, and this is followed by epithelial proliferation into the furcation area from an adjoining periodontal pocket. Extension of the inflammation into the bone leads to resorption and a reduction in bone height. The bone-destructive pattern may produce horizontal loss, or angular osseous defects associated with intrabony pockets may exist (Figure 21-24). Plaque, calculus, and bacterial debris occupy the denuded furcation space.

The destructive pattern of a furcation involvement varies in different cases and with the degree of involvement. Bone loss around each individual root may be horizontal or angular, and frequently a crater develops in the interradicular area (Figure 21-25). Probing to determine the presence of these destructive patterns must be done horizontally and vertically around each involved root and in the crater area to establish the depth of the vertical component.

Furcation involvement is a stage of progressive periodontal disease, and it has its same etiology. The difficulty and sometimes the impossibility[2,3] of controlling plaque in furcations are responsible for the presence of extensive lesions in this area.[66]

The role of trauma from occlusion in the etiology of furcation lesions is controversial. Some assign a key role to trauma, thinking that furcation areas are most sensitive to injury from excessive occlusal forces.[15] Others deny the initiating effect of trauma and consider that inflammation and edema caused by plaque in the furcation area tend to extrude the tooth, which then becomes traumatized and sensitive.[60,66]

Other factors that may play a role are the presence of enamel projections into the furcation,[39] which occurs in about 13% of multirooted teeth, and the proximity of the furcation to the cementoenamel junction, which occurs in about 75% of cases of furcation involvement.[31]

The presence of accessory pulpal canals in the furcation area may extend pulpal inflammation to the furcation.[20] This possibility should be carefully explored, particularly when mesial and distal bone retains its normal height. Accessory canals that connect the pulp chamber floor to the furcation have been found in 36% of maxillary first molars, 12% of maxillary second molars, 32% of mandibular first molars, and 24% of mandibular second molars.[62]

The diagnosis of furcation involvement is made by clinical examination and careful probing with a specially designed probe (see Chapter 30). Radiographic examination of the area is helpful, but lesions can be obscured by the angulation of the beam and the radiopacity of neighboring structures (see Chapter 31).

For more detailed clinical considerations involved with the diagnosis and treatment of furcation involvement, see Chapter 63.

Figure 21-24 Different degrees of furcation involvement in a human autopsy specimen. Furcation involvement is found in all three molars, with an advanced lesion in the second molar and an extremely severe lesion in the first molar that is exposing almost the entire mesial root.

Suggested Readings

Carranza FA, Jr, Simes RJ, Mayo J, et al: Histometric evaluation of periodontal bone loss in rats. I. The effect of marginal irritation, systemic irradiation and trauma from occlusion. *J Periodont Res* 6:65, 1971.

Garant PR, Cho MJ: Histopathogenesis of spontaneous periodontal disease in conventional rats. I. Histometric and histologic study. *J Periodont Res* 14:297, 1979.

Glickman I: Inflammation and trauma from occlusion, co-destructive factors in chronic periodontal disease. *J Periodontol* 34:5, 1963.

Goldman HM, Cohen DW: The intrabony pocket: classification and treatment. *J Periodontol* 29:272, 1958.

Goodson JM, Haffajee AD, Socransky SS: The relationship between attachment level loss and alveolar bone loss. *J Clin Periodontol* 11:348, 1984.

Heijl L, Rifkin BR, Zander HA: Conversion of chronic gingivitis to periodontitis in squirrel monkeys. *J Periodontol* 47:710, 1976.

Kronfeld R: Condition of alveolar bone underlying periodontal pockets. *J Periodontol* 6:22, 1935.

Lindhe J, Liljenberg B, Listgarten MA: Some microbiological and histopathological features of periodontal disease in man. *J Periodontol* 51:264, 1980.

Löe H, Anerud A, Boysen H, et al: Natural history of periodontal disease in man. Rapid, moderate and no loss of attachment in Sri Lankan laborers 14 to 46 years of age. *J Clin Periodontol* 13:431, 1986.

Löe H, Anerud A, Boysen H, et al: The natural history of periodontal disease in man. The rate of periodontal destruction before 40 years of age. *J Periodontol* 49:607, 1978.

Page RC, Schroeder HE: *Periodontitis in Man and Other Animals. A Comparative Review*, Basel, 1982, Karger.

Waerhaug J: The furcation problem. Etiology, pathogenesis, diagnosis, therapy and prognosis. *J Clin Periodontol* 7:73, 1980.

References

References for this chapter are found on the companion website www.expertconsult.com.

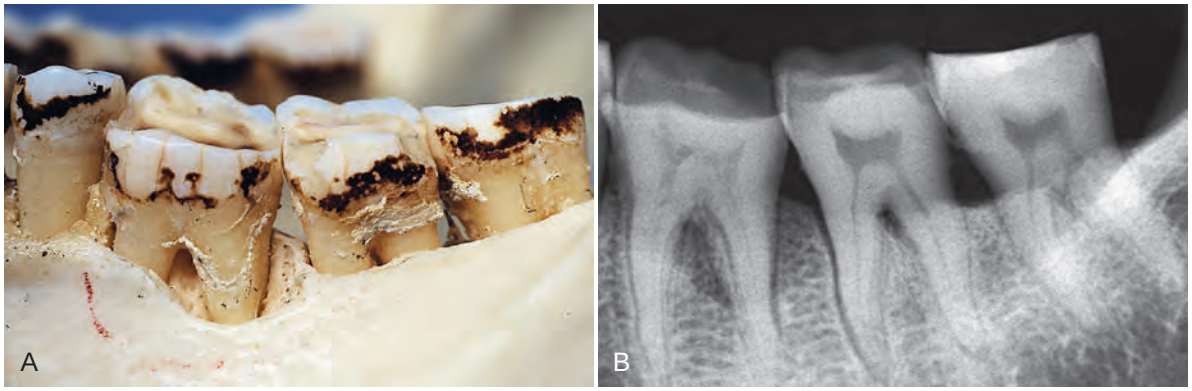

Figure 21-25 **A,** Photograph and, **B,** radiograph of different degrees of bone loss in a skull. There are furcation involvements in the first and second molars; deep angular bone loss in the distal root of the first molar; and interradicular and interdental craters in the second molar and between the second and third molars, respectively.

References

1. Akiyoshi M, Mori K: Marginal periodontitis: a histological study of the incipient stage. *J Periodontol* 38:45, 1967.
2. Bower RC: Furcation morphology relative to periodontal treatment: furcation entrance architecture. *J Periodontol* 50:23, 1979.
3. Bower RC: Furcation morphology relative to periodontal treatment: furcation root surface anatomy. *J Periodontol* 50:366, 1979.
4. Carranza FA, Jr: Histometric evaluation of periodontal pathology: a review of recent studies. *J Periodontol* 38:741, 1967.
5. Carranza FA, Jr, Cabrini RL: Histometric studies of periodontal tissues. *Periodontics* 5:308, 1967.
6. Carranza FA, Jr, Saglie R, Newman MG: Scanning and transmission electron microscopy study of tissue invading microorganisms in juvenile periodontitis. *J Periodontol* 54:598, 1983.
7. Carranza FA, Jr, Simes RJ, Mayo J, et al: Histometric evaluation of periodontal bone loss in rats. *J Periodontal Res* 6:65, 1971.
8. Easley JR, Drennan GA: Morphological classification of the furca. *J Can Dent Assoc* 35:104, 1969.
9. Frank RM, Voegel JC: Bacterial bone resorption in advanced cases of human periodontitis. *J Periodontal Res* 13:251, 1978.
10. Garant PR, Cho MJ: Histopathogenesis of spontaneous periodontal disease in conventional rats. I. Histometric and histologic study. *J Periodontal Res* 14:297, 1979.
11. Geurs NC: Osteoporosis and periodontal disease. *Periodontol 2000* 44:29, 2007.
12. Glickman I: The experimental basis for the "bone factor" concept in periodontal disease. *J Periodontol* 20:7, 1951.
13. Glickman I, Smulow J: Buttressing bone formation in the periodontium. *J Periodontol* 36:365, 1965.
14. Glickman I, Wood H: Bone histology in periodontal disease. *J Dent Res* 21:35, 1942.
15. Glickman I, Stein RS, Smulow JB: The effects of increased functional forces upon the periodontium of splinted and nonsplinted teeth. *J Periodontol* 32:290, 1961.
16. Goldman HM, Cohen DW: The intrabony pocket: classification and treatment. *J Periodontol* 29:272, 1958.
17. Goodson JM, Haffajee AD, Socransky SS: The relationship between attachment level loss and alveolar bone loss. *J Clin Periodontol* 11:348, 1984.
18. Goodson JM, McClatchy K, Revell C: Prostaglandin-induced resorption of the adult calvarium. *J Dent Res* 53:670, 1974.
19. Groen JJ, Menczel J, Shapiro S: Chronic destructive periodontal disease in patients with presenile osteoporosis. *J Periodontol* 39:19, 1968.
20. Gutman JL: Prevalence, location and patency of accessory canals in the furcation region of permanent molars. *J Periodontol* 49:21, 1978.
21. Hausmann E: Potential pathways for bone resorption in human periodontal disease. *J Periodontol* 45:338, 1974.
22. Heijl L, Rifkin BR, Zander HA: Conversion of chronic gingivitis to periodontitis in squirrel monkeys. *J Periodontol* 47:710, 1976.
23. Jeffcoat MK: Osteoporosis: a possible modifying factor in oral bone loss. *Ann Periodontol* 3:312, 1998.
24. Jeffcoat MK, Lewis CE, Reddy MS, et al: Post-menopausal bone loss and its relationship to oral bone loss. *Periodontol 2000* 23:94, 2000.
25. Jeffcoat MK, Williams RC, Wachter WJ, et al: Flurbiprofen treatment of periodontal disease in beagles. *J Periodontal Res* 21:624, 1986.
26. Klein DC, Raisz LG: Prostaglandins: stimulation of bone resorption in tissue culture. *Endocrinology* 86:1436, 1970.
27. Kronfeld R: Condition of alveolar bone underlying periodontal pockets. *J Periodontol* 6:22, 1935.
28. Larato DC: Periodontal bone defects in the juvenile skull. *J Periodontol* 41:473, 1970.
29. Larato DC: Intrabony defects in the dry human skull. *J Periodontol* 41:496, 1970.
30. Larato DC: Furcation involvements: incidence of distribution. *J Periodontol* 41:499, 1970.
31. Larato DC: Some anatomical factors related to furcation involvements. *J Periodontol* 46:608, 1975.
32. Lindhe J, Ericsson I: Effect of ligature placement and dental plaque on periodontal tissue breakdown in the dog. *J Periodontol* 49:343, 1978.
33. Lindhe J, Svanberg G: Influence of trauma from occlusion on progression of experimental periodontitis in beagle dogs. *J Clin Periodontol* 1:3, 1974.
34. Lindhe J, Liljenberg B, Listgarten MA: Some microbiological and histopathological features of periodontal disease in man. *J Periodontol* 51:264, 1980.
35. Löe H, Anerud A, Boysen H, et al: Natural history of periodontal disease in man: rapid, moderate and no loss of attachment in Sri Lankan laborers 14 to 46 years of age. *J Clin Periodontol* 13:431, 1986.
36. Löe H, Anerud A, Boysen H, et al: The natural history of periodontal disease in man: the rate of periodontal destruction before forty years of age. *J Periodontol* 49:607, 1978.
37. Manson JD: Bone morphology and bone loss in periodontal disease. *J Clin Periodontol* 3:14, 1976.
38. Manson JD, Nicholson K: The distribution of bone defects in chronic periodontitis. *J Periodontol* 45:88, 1974.
39. Masters DH, Hoskins SW: Projection of cervical enamel into molar furcations. *J Periodontol* 35:49, 1963.
40. Moskow BS: A histomorphologic study of the effects of periodontal inflammation on the maxillary sinus mucosa. *J Periodontol* 63:674, 1992.
41. Moskow BS, Polson AM: Histologic studies on the extension of the inflammatory infiltrate in human periodontitis. *J Clin Periodontol* 18:534, 1991.
42. Nery EB, Corn H, Eisenstein IL: Palatal exostoses in the molar region. *J Periodontol* 48:663, 1977.
43. Newman MG: The role of *Bacteroides melaninogenicus* and other anaerobes in periodontal infections. *Rev Infect Dis* 1:313, 1979.
44. Nielsen JI, Glavind L, Karring T: Interproximal periodontal intrabony defects: prevalence, localization and etiological factors. *J Clin Periodontol* 7:187, 1980.
45. Ooya K, Yamamoto H: A scanning electron microscopic study of the destruction of human alveolar crest in periodontal disease. *J Periodont Res* 13:498, 1978.
46. Pack ARC, Gaudie WM, Jennings AM: Bony exostosis as a sequela to free gingival grafting: two case reports. *J Periodontol* 62:269, 1991.
47. Papapanou PN, Tonetti MS: Diagnosis and epidemiology of periodontal osseous lesions. *Periodontol 2000* 22:8, 2000.
48. Papapanou PN, Wennström JL, Grondahl K: Periodontal status in relation to age and tooth type: a cross-sectional radiographic study. *J Clin Periodontol* 15:469, 1988.
49. Page RC, Schroeder HE: *Periodontitis in man and other animals: a comparative review*, Basel, 1982, S Karger.
50. Prichard JF: *Periodontal surgery: practical dental monographs*, Chicago, 1961, Year Book Medical.
51. Rowe DJ, Bradley LS: Quantitative analyses of osteoclasts, bone loss and inflammation in human periodontal disease. *J Periodontal Res* 16:13, 1981.
52. Ruben M, Cooper SJ: Tissue factors modifying the spread of periodontal inflammation: a perspective. *Contin Educ Dent* 2:387, 1981.
53. Saari JT, Hurt WC, Briggs NL: Periodontal bony defects on the dry skull. *J Periodontol* 39:278, 1968.
54. Saglie RF, Rezende M, Pertuiset J, et al: Bacterial invasion during disease activity as determined by significant loss of attachment. *J Periodontol* 58:336, 1987. (abstract).
55. Salvi GE, Lawrence HP, Offenbacher S, et al: Sequence of risk factors on the pathogenesis of periodontitis. *Periodontol 2000* 14:173, 1997.
56. Schroeder HE, Lindhe J: Conditions and pathological features of rapidly destructive experimental periodontitis in dogs. *J Periodontol* 51:6, 1980.
57. Schwartz Z, Goultschin J, Dean DD, et al: Mechanisms of alveolar bone destruction in periodontitis. *Periodontol 2000* 14:158, 1997.
58. Seymour GJ, Dockrell HM, Greenspan JS: Enzyme differentiation of lymphocyte subpopulations in sections of human lymph nodes, tonsils, and periodontal disease. *Clin Exp Immunol* 32:169, 1978.
59. Seymour GJ, Powell RN, Davies WJR: Conversion of a stable T cell lesion to a progressive B cell lesion in the pathogenesis of chronic

inflammatory periodontal disease: a hypothesis. *J Clin Periodontol* 6:267, 1979.
60. Svärdström G, Wennström JL: Prevalence of furcation involvements in patients referred for periodontal treatment. *J Clin Periodontol* 23:1093, 1996.
61. Tal H: Relationship between interproximal distance of roots and the prevalence of intrabony pockets. *J Periodontol* 55:604, 1984.
62. Vertucci FJ, Anthony RL: An SEM investigation of accessory foramina in the furcation and pulp chamber floor of molar teeth. *Oral Surg* 62:319, 1986.
63. Wactawski-Wende J, Grossi SG, Trevisan M, et al: The role of osteopenia in oral bone loss and periodontal disease. *J Periodontol* 67:1076, 1996.
64. Waerhaug J: The angular bone defect and its relationship to trauma from occlusion and downgrowth of subgingival plaque. *J Clin Periodontol* 6:61, 1979.
65. Waerhaug J: The infrabony pocket and its relationship to trauma from occlusion and subgingival plaque. *J Periodontol* 50:355, 1979.
66. Waerhaug J: The furcation problem: etiology, pathogenesis, diagnosis, therapy and prognosis. *J Clin Periodontol* 7:73, 1980.
67. Weinmann JP: Progress of gingival inflammation into the supporting structures of the teeth. *J Periodontol* 12:71, 1941.
68. Williams RC, Jeffcoat MK, Kaplan ML, et al: Flurbiprofen: a potent inhibitor of alveolar bone resorption in beagles. *Science* 227:640, 1985.
69. Wouters FR, Salonen LE, Helldén LB, et al: Prevalence of interproximal periodontal infrabony defects in an adult population in Sweden: a radiographic study. *J Clin Periodontol* 16:144, 1989.

CHAPTER 22

Periodontal Response to External Forces

Fermin A. Carranza

CHAPTER OUTLINE

Adaptive Capacity of the Periodontium to Occlusal Forces
Trauma from Occlusion
Stages of Tissue Response to Increased Occlusal Forces
Effects of Insufficient Occlusal Force
Reversibility of Traumatic Lesions
Effects of Excessive Occlusal Forces on Dental Pulp
Influence of Trauma from Occlusion on the Progression of Marginal Periodontitis
Pathologic Tooth Migration

Adaptive Capacity of the Periodontium to Occlusal Forces

The periodontium attempts to accommodate the forces exerted on the crown. This adaptive capacity varies in different persons and in the same person at different times. The effect of occlusal forces on the periodontium is influenced by the magnitude, direction, duration, and frequency of the forces.

When the *magnitude* of occlusal forces is increased, the periodontium responds with a widening of the periodontal ligament space, an increase in the number and width of periodontal ligament fibers, and an increase in the density of alveolar bone.

Changing the *direction* of occlusal forces causes a reorientation of the stresses and strains within the periodontium (Figure 22-1).[23] The principal fibers of the periodontal ligament are arranged so that they best accommodate occlusal forces along the long axis of the tooth. *Lateral* (horizontal) and *torque* (rotational) forces are more likely to injure the periodontium.

The response of alveolar bone is also affected by the *duration* and *frequency* of occlusal forces. Constant pressure on the bone is more injurious than intermittent forces. The more frequent the application of an intermittent force, the more injurious the force is to the periodontium.

Trauma from Occlusion

An inherent "margin of safety" that is common to all tissues permits some variation in occlusion without adversely affecting the periodontium. However, when occlusal forces exceed the adaptive capacity of the tissues, tissue injury results.[43,44] The resultant injury is termed *trauma from occlusion,* which is also known as *traumatism* or *occlusal trauma.*

Thus, trauma from occlusion refers to the *tissue injury* rather than the *occlusal force.* An occlusion that produces such an injury is called a *traumatic occlusion.*[2] Excessive occlusal forces may also disrupt the function of the masticatory musculature and cause painful spasms, injure the temporomandibular joints, or produce excessive tooth wear. However, the term *trauma from occlusion* is generally used in connection with injury in the periodontium.

Acute and Chronic Trauma

Trauma from occlusion may be acute or chronic. *Acute trauma* from occlusion results from an abrupt occlusal impact such as that produced by biting on a hard object (e.g., olive pit). Restorations or prosthetic appliances that interfere with or alter the direction of occlusal forces on the teeth may also induce acute trauma.

Acute trauma results in tooth pain, sensitivity to percussion, and increased tooth mobility. If the force is dissipated by a shift in the position of the tooth or by the wearing away or correction of the restoration, then the injury heals, and the symptoms subside. Otherwise, periodontal injury may worsen and develop into necrosis accompanied by periodontal abscess formation, or it may persist as a symptom-free chronic condition. Acute trauma can also produce cementum tears (Figure 22-2) (see Chapter 2).

Chronic trauma from occlusion is more common than the acute form, and it is of greater clinical significance. It most often develops from gradual changes in occlusion produced by tooth wear, drifting movement, and extrusion of the teeth in combination with parafunctional habits (e.g., bruxism, clenching) rather than as a sequela of acute periodontal trauma (see Chapter 20). The features of chronic trauma from occlusion and their significance are discussed in the following sections.

The criterion that determines if an occlusion is traumatic is whether it produces periodontal injury; this criterion is *not* how the teeth occlude. Any occlusion that produces periodontal injury is traumatic. Malocclusion is not necessary to produce trauma; periodontal injury may occur when the occlusion appears normal. The dentition may be anatomically and aesthetically acceptable but functionally injurious. Similarly, not all malocclusions are necessarily injurious to the periodontium. Traumatic occlusal relationships are referred to by such terms as *occlusal disharmony, functional imbalance,* and *occlusal dystrophy.* These terms refer to the effect of the occlusion on the periodontium rather than to the position of the teeth. Because trauma from occlusion refers to the tissue injury rather than the occlusion, an increased occlusal force is not traumatic if the periodontium can accommodate it.

Primary and Secondary Trauma from Occlusion

Trauma from occlusion may be caused by alterations in occlusal forces, a reduced capacity of the periodontium to withstand occlusal forces, or both. When trauma from occlusion is the result of alterations in occlusal forces, it is called *primary trauma from occlusion.* When it results from the reduced ability of the tissues to resist the occlusal forces, it is known as *secondary trauma from occlusion.*

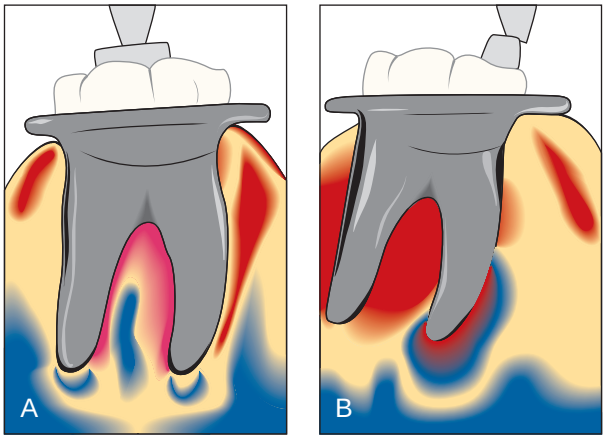

Figure 22-1 Stress patterns around the roots changed by shifting the direction of occlusal forces (experimental model using photoelastic analysis). **A,** Buccal view of an ivorine molar subjected to an axial force. The shaded fringes indicate that the internal stresses are at the root apices. **B,** Buccal view of an ivorine molar subjected to a mesial tilting force. The shaded fringes indicate that the internal stresses are along the mesial surface and at the apex of the mesial root.

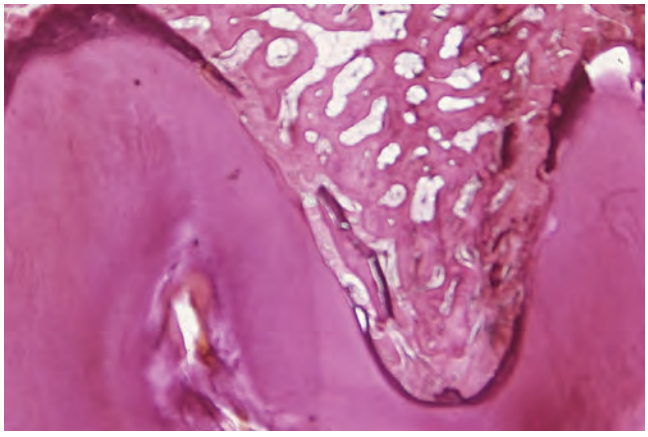

Figure 22-2 Cemental tear, presumably caused by acute trauma from occlusion in a human autopsy specimen. Note the repair process depositing bone on the displaced, torn cementum and recreating a periodontal ligament.

Primary trauma from occlusion occurs if trauma from occlusion is considered the primary etiologic factor in periodontal destruction and if the only local alteration to which a tooth is subjected is a result of occlusion. Examples include periodontal injury produced around teeth with a previously healthy periodontium after the following: (1) the insertion of a "high filling"; (2) the insertion of a prosthetic replacement that creates excessive forces on abutment and antagonistic teeth; (3) the drifting movement or extrusion of the teeth into spaces created by unreplaced missing teeth; or (4) the orthodontic movement of teeth into functionally unacceptable positions. Most studies of the effect of trauma from occlusion involving experimental animals have examined the primary type of trauma. Changes produced by primary trauma do not alter the level of connective tissue attachment and do not initiate pocket formation. This is probably because the supracrestal gingival fibers are not affected and therefore prevent the apical migration of the junctional epithelium.[48]

Secondary trauma from occlusion occurs when the adaptive capacity of the tissues to withstand occlusal forces is impaired by bone loss that results from marginal inflammation. This reduces the periodontal attachment area and alters the leverage on the remaining tissues. The periodontium becomes more vulnerable to injury, and previously well-tolerated occlusal forces become traumatic.

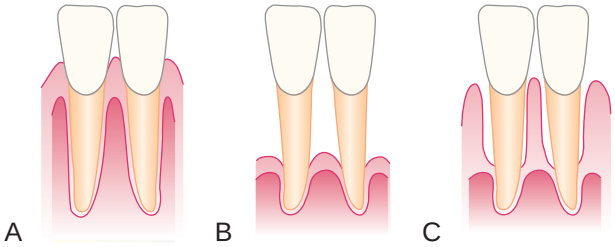

Figure 22-3 Traumatic forces can occur on, **A,** normal periodontium with normal height of bone; **B,** normal periodontium with reduced height of bone; or, **C,** marginal periodontitis with reduced height of bone.

Figure 22-3 depicts three different situations on which excessive occlusal forces can be superimposed:

1. Normal periodontium with normal height of bone
2. Normal periodontium with reduced height of bone
3. Marginal periodontitis with reduced height of bone

The first case is an example of primary trauma from occlusion, whereas the last two represent secondary trauma from occlusion. The effects of trauma from occlusion in these different situations are analyzed in the following discussion.

It has been found in experimental animals that systemic disorders can reduce tissue resistance and that previously tolerable forces may become excessive.[21,51,61] This could theoretically represent another mechanism by which tissue resistance to increased forces is lowered, thereby resulting in secondary trauma from occlusion.

Stages of Tissue Response to Increased Occlusal Forces

Tissue response occurs in three stages[4,8]: injury, repair, and adaptive remodeling of the periodontium.

Stage I: Injury

Tissue injury is produced by excessive occlusal forces. The body then attempts to repair the injury and restore the periodontium. This can occur if the forces are diminished or if the tooth drifts away from them. If the offending force is chronic, however, the periodontium is remodeled to cushion its impact. The ligament is widened at the expense of the bone, which results in angular bone defects without periodontal pockets, and the tooth becomes loose.

Under the forces of occlusion, a tooth rotates around a fulcrum or axis of rotation, which in single-rooted teeth is located in the junction between the middle third and the apical third of the clinical root and in multirooted teeth in the middle of the interradicular bone (Figure 22-4). This creates areas of pressure and tension on opposite sides of the fulcrum. Different lesions are produced by different degrees of pressure and tension. If jiggling forces are exerted, these different lesions may coexist in the same area.

> *Slightly excessive pressure* stimulates resorption of the alveolar bone, with a resultant widening of the periodontal ligament space. *Slightly excessive tension* causes elongation of the periodontal ligament fibers and the apposition of alveolar bone. In areas of increased pressure, the blood vessels are numerous and reduced in size; in areas of increased tension, they are enlarged.[67]

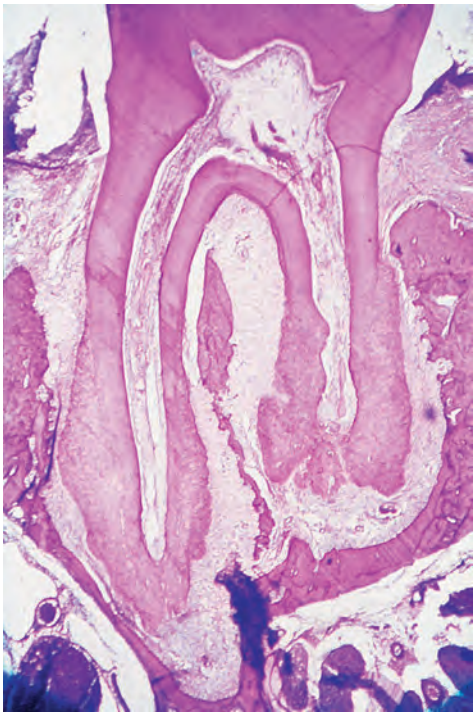

Figure 22-4 Areas of tension and pressure in opposite sites of the periodontal ligament caused by experimentally induced orthodontic movement in a rat molar.

Greater pressure produces a gradation of changes in the periodontal ligament, starting with compression of the fibers, which produces areas of hyalinization.[54-56] Subsequent injury to the fibroblasts and other connective tissue cells leads to necrosis of areas of the ligament.[52,56] Vascular changes are also produced: within 30 minutes, impairment and stasis of blood flow occur; at 2 to 3 hours, blood vessels appear to be packed with erythrocytes, which start to fragment; and between 1 and 7 days, disintegration of the blood vessel walls and release of the contents into the surrounding tissue occur.[53,63] In addition, increased resorption of alveolar bone and resorption of the tooth surface occur.[29,34]

Severe tension causes widening of the periodontal ligament, thrombosis, hemorrhage, tearing of the periodontal ligament, and resorption of alveolar bone.

Pressure severe enough to force the root against bone causes necrosis of the periodontal ligament and bone. The bone is resorbed from viable periodontal ligament adjacent to necrotic areas and from marrow spaces; this process is called *undermining resorption.*[25,43]

The areas of the periodontium that are most susceptible to injury from excessive occlusal forces are the furcations.[22]

Injury to the periodontium produces a temporary depression in mitotic activity, in the rate of proliferation and differentiation of fibroblasts,[62] in collagen formation, and in bone formation.[29,58,60,62] These return to normal levels after the dissipation of the forces.

Stage II: Repair

Repair occurs constantly in the normal periodontium, and trauma from occlusion stimulates increased reparative activity.

The damaged tissues are removed, and new connective tissue cells and fibers, bone, and cementum are formed in an attempt to restore the injured periodontium (Figure 22-5). Forces remain traumatic only as long as the damage produced exceeds the reparative capacity of the tissues.

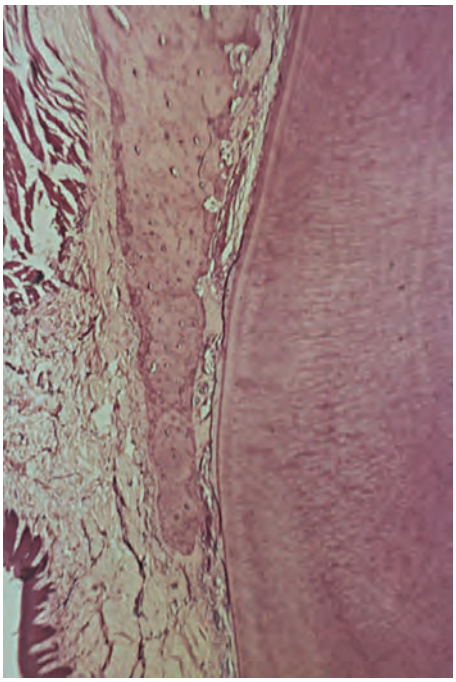

Figure 22-5 Experimental occlusal trauma in rats. Note the area of necrosis of the marginal periodontal ligament and resorption and remodeling in the more apical periodontal sites.

When bone is resorbed by excessive occlusal forces, the body attempts to reinforce the thinned bony trabeculae with new bone (Figure 22-6). This attempt to compensate for lost bone is called *buttressing bone formation,* and it is an important feature of the reparative process associated with trauma from occlusion.[16] It also occurs when bone is destroyed by inflammation or osteolytic tumors.

Buttressing bone formation occurs within the jaw (central buttressing) and on the bone surface (peripheral buttressing). During *central buttressing,* the endosteal cells deposit new bone, which restores the bony trabeculae and reduces the size of the marrow spaces. *Peripheral buttressing* occurs on the facial and lingual surfaces of the alveolar plate. Depending on its severity, peripheral buttressing may produce a shelflike thickening of the alveolar margin, which is referred to as *lipping* (Figure 22-7), or a pronounced bulge in the contour of the facial and lingual bone[8,16] (see Chapter 14).

Cartilage-like material sometimes develops in the periodontal ligament space as an aftermath of the trauma.[13] The formation of crystals from erythrocytes has also been demonstrated.[57]

Stage III: Adaptive Remodeling of the Periodontium

If the repair process cannot keep pace with the destruction caused by the occlusion, the periodontium is remodeled in an effort to create a structural relationship in which the forces are no longer injurious to the tissues.[18] *This results in a widened periodontal ligament, which is funnel shaped at the crest, and angular defects in the bone, with no pocket formation. The involved teeth become loose.*[67] Increased vascularization has also been reported.[9]

The three stages in the evolution of traumatic lesions have been differentiated histometrically by the relative amounts of

periodontal bone surface undergoing resorption or formation[5,8] (Figure 22-8). The injury phase shows an increase in areas of resorption and a decrease in bone formation, whereas the repair phase demonstrates decreased resorption and increased bone formation. After adaptive remodeling of the periodontium, resorption and formation return to normal.

Effects of Insufficient Occlusal Force

Insufficient occlusal force may also be injurious to the supporting periodontal tissues.[6,36] Insufficient stimulation causes thinning of the periodontal ligament, atrophy of the fibers, osteoporosis of the alveolar bone, and a reduction in bone height. Hypofunction can result from an open-bite relationship, an absence of functional antagonists, or unilateral chewing habits that neglect one side of the mouth.

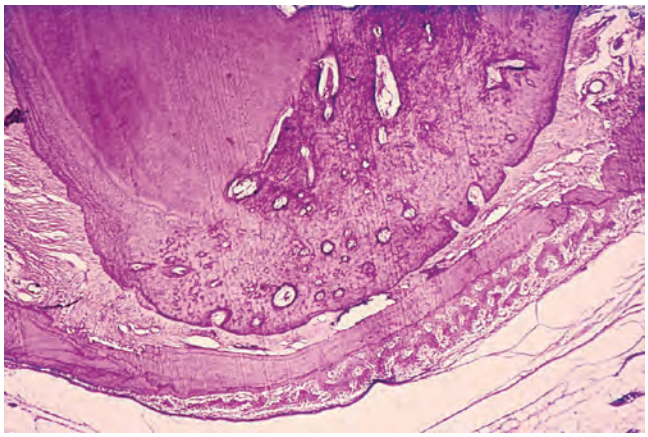

Figure 22-6 Apical area of a premolar subjected to experimental occlusal trauma in a dog causing intrusion of the tooth and areas of necrosis in the periodontal ligament. Note the active bone formation on the outer aspect of the bone and the resorptive activity in the periphery of the necrotic site.

Reversibility of Traumatic Lesions

Trauma from occlusion is reversible. When trauma is artificially induced in experimental animals, the teeth move away or intrude into the jaw. When the impact of the artificially created force is relieved, the tissues undergo repair. Although trauma from occlusion is reversible under such conditions, it does not always correct itself, and therefore it is not always temporary or of limited clinical significance. The injurious force must be relieved for repair to occur.[22,49] If conditions in humans do not permit the teeth to escape from or adapt to excessive occlusal force, periodontal damage persists and worsens.

The presence of inflammation in the periodontium as a result of plaque accumulation may impair the reversibility of traumatic lesions.[30,49]

Effects of Excessive Occlusal Forces on Dental Pulp

The effects of excessive occlusal forces on the dental pulp have not been established. Some clinicians report the disappearance of pulpal symptoms after the correction of excessive occlusal forces. Pulpal reactions have been noted in animals subjected to increased occlusal forces,[7,35] but these did not occur when the forces were minimal and occurred over short periods.[35]

Influence of Trauma from Occlusion on the Progression of Marginal Periodontitis

The clinical impressions of early investigators and clinicians assigned an important role to trauma from occlusion in the etiology of periodontal lesions. Since then, numerous studies have been performed that have attempted to determine the mechanisms by which trauma from occlusion may affect periodontal disease.

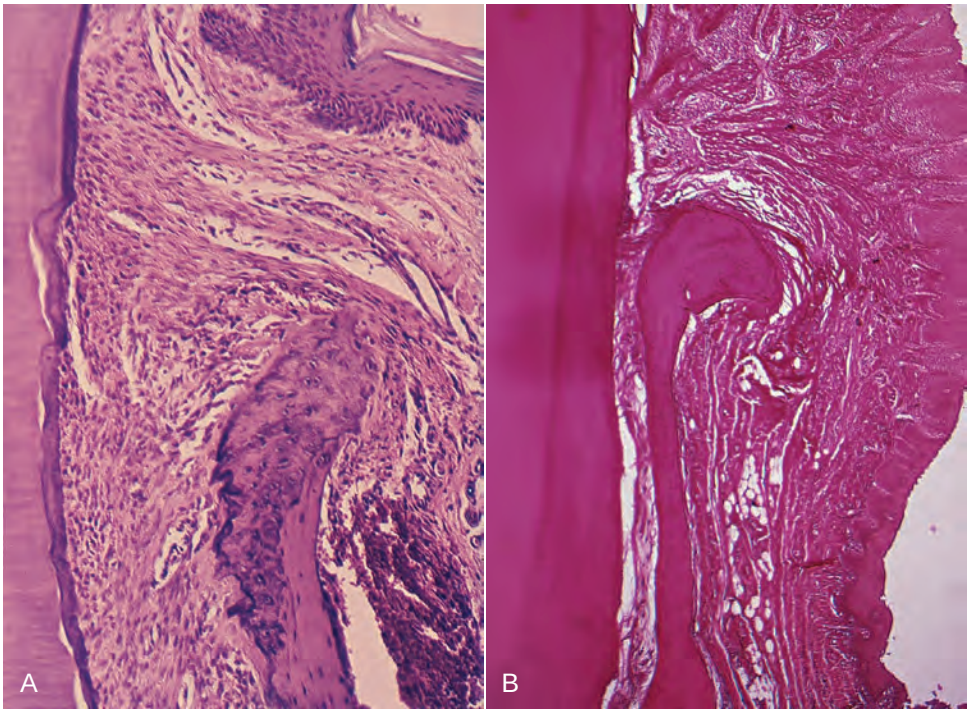

Figure 22-7 **A,** Widening of the periodontal ligament space in the cervical area and a change in the shape of the marginal alveolar bone as a result of chronic prolonged trauma from occlusion in rats. **B,** Comparable changes in the shape of the marginal bone found in a human autopsy case.

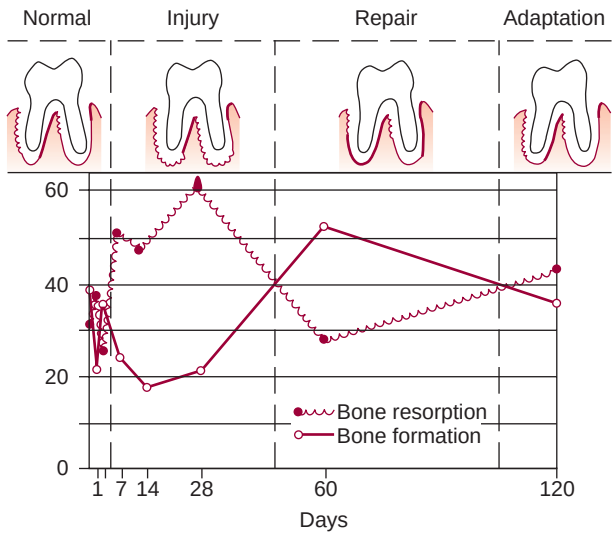

Figure 22-8 Evolution of traumatic lesions as depicted experimentally in rats by variations in relative amounts of areas of bone formation and bone resorption in periodontal bone surfaces. The horizontal axis shows the number of days after the initiation of traumatic interference. The vertical axis shows the percentage of bone surface undergoing resorption or formation. The stages in the evolution of the lesions are represented in the top drawings, which show the average amount of bone activity for each group.[4]

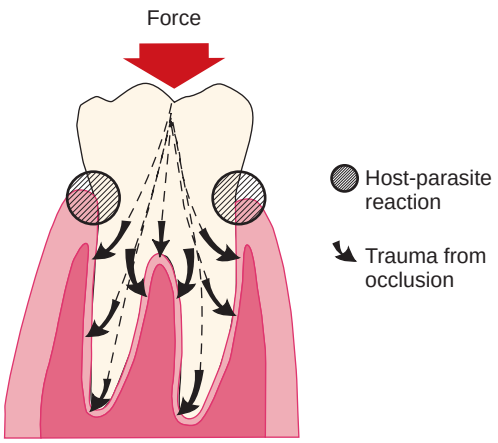

Figure 22-9 The reaction between dental plaque and the host takes place in the gingival sulcus region. Trauma from occlusion appears in the tissues that are supporting the tooth.

Initial studies involved the placement of high crowns or restorations on the teeth of dogs or monkeys, thereby resulting in a continuous or intermittent force in one direction.[2,20] These investigations provided an orthodontic type of force and gave clear descriptions of changes that were occurring in pressure zones and tension zones. These procedures usually resulted in tooth displacement and consolidation in a new, nontraumatized position.

Trauma from occlusion in humans, however, is the result of forces that act alternatively in opposing directions. These were analyzed in experimental animals with "jiggling forces," which were usually produced by a high crown in combination with an orthodontic appliance that would bring the traumatized tooth back to its original position when the force was dissipated by separating the teeth. With another method, the teeth were separated by wooden or elastic material wedged interproximally to displace a tooth toward the opposite proximal side. After 48 hours, the wedge was removed, and the procedure was repeated on the opposite side.

These studies resulted in a combination of changes produced by pressure and tension on both sides of the tooth, with an increase in the width of the ligament and increased tooth mobility. None of these methods caused gingival inflammation or pocket formation, and the results essentially represented different degrees of functional adaptation to increased forces.[48,67]

To mimic the problem in humans more closely, studies were then conducted on the effect produced by jiggling trauma and simultaneous plaque-induced gingival inflammation.

The accumulation of bacterial plaque that initiates gingivitis and results in periodontal pocket formation affects the marginal gingiva, but trauma from occlusion occurs in the supporting tissues and does not affect the gingiva (Figure 22-9). The marginal gingiva is unaffected by trauma from occlusion because its blood supply is not affected, even when the vessels of the periodontal ligament are obliterated by excessive occlusal forces.[24] It has been repeatedly proved that trauma from occlusion does not cause pockets or gingivitis[2,20,50,65,66,68] and that it also does not increase gingival fluid flow.[27,33,36,41,42,50] Furthermore, experimental trauma in dogs does not influence the bacterial repopulation of pockets after scaling and root planing.[31] However, mobile teeth in humans harbor significantly higher proportions of *Campylobacter rectus* and *Peptostreptococcus micros* than nonmobile teeth.[26]

As long as inflammation is confined to the gingiva, the inflammatory process is not affected by occlusal forces.[32] When inflammation extends from the gingiva into the supporting periodontal tissues (i.e., when gingivitis becomes periodontitis), plaque-induced inflammation enters the zone that is influenced by occlusion, which Glickman has called the *zone of co-destruction.*[14,15,17]

Two groups have studied this topic experimentally, with conflicting results, probably because of the different methods used. The Eastman Dental Center group in Rochester, NY, used squirrel monkeys, produced trauma by repetitive interdental wedging, and added mild to moderate gingival inflammation; experimental times were up to 10 weeks. They reported that the presence of trauma did not increase the loss of attachment induced by periodontitis.[42,45-47] The University of Gothenburg group in Sweden used beagle dogs, produced trauma by placing cap splints and orthodontic appliances, and induced severe gingival inflammation; experimental times were up to 1 year. This group found that occlusal stresses increase the periodontal destruction induced by periodontitis.[11,12,39]

When trauma from occlusion is eliminated, a substantial reversal of bone loss occurs, except in the presence of periodontitis. This indicates that inflammation inhibits the potential for bone regeneration.[30,38,48,49] *Thus, it is important to eliminate the marginal inflammatory component in cases of trauma from occlusion, because the presence of inflammation affects bone regeneration after the removal of the traumatizing contacts.*[30] It has also been shown in experimental animals that trauma from occlusion does not induce progressive destruction of the periodontal tissues in regions that are kept healthy after the elimination of preexisting periodontitis.[11]

Trauma from occlusion also tends to change the shape of the alveolar crest. The change in shape consists of a widening of the marginal periodontal ligament space, a narrowing of the interproximal alveolar bone, and a shelflike thickening of the alveolar margin.[9,39,42] Therefore, although trauma from occlusion does not alter the inflammatory process, it changes the architecture of the area around the inflamed site.[17,39] *Thus, in the absence of inflammation, the response to trauma from occlusion is limited to adaptation to the increased forces. In the presence of inflammation, however, the changes in the shape of the alveolar crest may be*

conducive to angular bone loss, and existing pockets may become intrabony.

Other theories that have been proposed to explain the interaction of trauma and inflammation include the following:

- Trauma from occlusion may alter the pathway of the extension of gingival inflammation to the underlying tissues. This may be favored by the reduced collagen density and the increased number of leukocytes, osteoclasts, and blood vessels in the coronal portion of increasingly mobile teeth.[3] Inflammation may then proceed to the periodontal ligament rather than to the bone. Resulting bone loss would be angular, and pockets could become intrabony.[1,17,19,40]
- Trauma-induced areas of root resorption uncovered by apical migration of the inflamed gingival attachment may offer a favorable environment for the formation and attachment of plaque and calculus and therefore may be responsible for the development of deeper lesions.[59]
- Supragingival plaque can become subgingival if the tooth is tilted orthodontically or if it migrates into an edentulous area, which results in the transformation of a suprabony pocket into an intrabony pocket.[10,12,17]
- Increased mobility of traumatically loosened teeth may have a pumping effect on plaque metabolites, thereby increasing their diffusion.[64]

Clinical and Radiographic Signs of Trauma from Occlusion Alone

The most common clinical sign of trauma to the periodontium is *increased tooth mobility.* During the injury stage of trauma from occlusion, the destruction of periodontal fibers occurs, which increases tooth mobility. During the final stage, the accommodation of the periodontium to increased forces entails a widening of the periodontal ligament, which also leads to increased tooth mobility. Although this tooth mobility is greater than the so-called normal mobility, it cannot be considered pathologic, because it is an adaptation and not a disease process. If it does become progressively worse, it can then be considered pathologic.

Other causes of increased tooth mobility include advanced bone loss, inflammation of the periodontal ligament of periodontal or periapical origin, and some systemic causes (e.g., pregnancy). The destruction of surrounding alveolar bone, such as occurs with osteomyelitis or jaw tumors, may also increase tooth mobility (see Chapter 30).

Radiographic signs of trauma from occlusion may include the following:

1. Increased width of the periodontal space, often with thickening of the lamina dura along the lateral aspect of the root, in the apical region, and in bifurcation areas. These changes do not *necessarily* indicate destructive changes, because they may result from thickening and strengthening of the periodontal ligament and alveolar bone, thereby constituting a favorable response to increased occlusal forces.
2. A "vertical" rather than "horizontal" destruction of the interdental septum.
3. Radiolucency and condensation of the alveolar bone.
4. Root resorption (see Chapter 13).

In summary, trauma from occlusion does not initiate gingivitis or periodontal pockets, but it may constitute an additional risk factor for the progression and severity of the disease. An understanding of the effect of trauma from occlusion on the periodontium is useful during the clinical management of periodontal problems.

Pathologic Tooth Migration

Pathologic migration refers to tooth displacement that results when the balance among the factors that maintain physiologic tooth position is disturbed by periodontal disease. Pathologic migration is relatively common. It may be an early sign of disease, or it may occur in association with gingival inflammation and pocket formation as the disease progresses.

Pathologic migration occurs most frequently in the anterior region, but posterior teeth may also be affected. The teeth may move in any direction, and the migration is usually accompanied by mobility and rotation. Pathologic migration in the occlusal or incisal direction is termed *extrusion.* All degrees of pathologic migration are encountered, and one or more teeth may be affected (Figure 22-10). It is important to detect migration during its early stages and to prevent more serious involvement by eliminating the causative factors. Even during the early stage, some degree of bone loss occurs.

Pathogenesis

Two major factors play a role in maintaining the normal position of the teeth: the health and normal height of the periodontal attachment apparatus and the forces exerted on the teeth. The latter includes the forces of occlusion and pressure from the lips, cheeks, and tongue. Factors that are important in relation to the forces of occlusion include the following: (1) tooth morphologic features and cuspal inclination; (2) the presence of a full complement of teeth; (3) a physiologic tendency toward mesial migration; (4) the nature and location of contact point relationships; (5) proximal, incisal, and occlusal attrition; and (6) the axial inclination of the teeth. Alterations in any of these factors start an interrelated sequence of changes in the environment of a single tooth or group of teeth that may result in pathologic migration. Thus, pathologic migration occurs under conditions that weaken the periodontal support, that increase or modify the forces exerted on the teeth, or both.

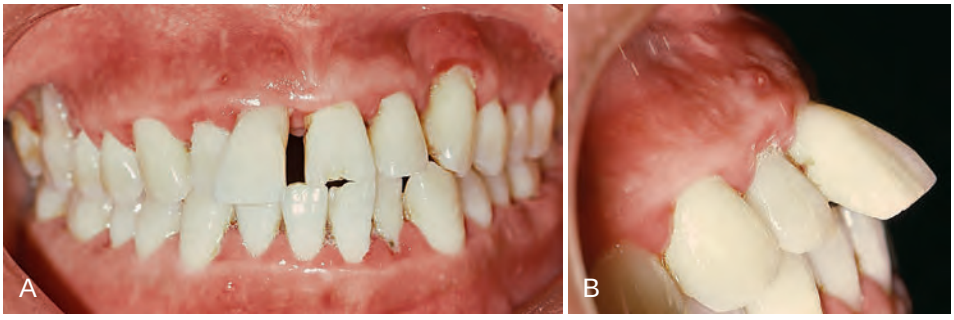

Figure 22-10 Labial migration of the maxillary central incisors, especially the right incisor. **A,** Frontal view. **B,** Lateral view.

Weakened Periodontal Support. The inflammatory destruction of the periodontium in patients with periodontitis creates an imbalance between the forces that maintain the tooth in position and the occlusal and muscular forces the tooth ordinarily needs to bear. The tooth with weakened support is unable to maintain its normal position in the arch and moves away from the opposing force unless it is restrained by proximal contact. The force that moves the weakly supported tooth may be created by factors such as occlusal contacts or pressure from the tongue.

It is important to understand that the abnormality of pathologic migration rests with the weakened periodontium; the force itself is not necessarily abnormal. Forces that are acceptable to an intact periodontium become injurious when periodontal support is reduced, as in the tooth with abnormal proximal contacts. Abnormally located proximal contacts convert the normal anterior component of force to a wedging force that moves the tooth occlusally or incisally. The wedging force, which can be withstood by the intact periodontium, causes the tooth to extrude when the periodontal support is weakened by disease. *As its position changes, the tooth is subjected to abnormal occlusal forces, which aggravate the periodontal destruction and the tooth migration.*

Pathologic migration may continue after a tooth no longer contacts its antagonist. Pressures from the tongue, the food bolus during mastication, and the proliferating granulation tissue provide the force.

Pathologic migration is also an early sign of localized aggressive periodontitis. Weakened by the loss of periodontal support, the maxillary and mandibular anterior incisors drift labially and extrude, thereby creating diastemata between the teeth (see Chapter 18).

Changes in the Forces Exerted on the Teeth. Changes in the magnitude, direction, or frequency of the forces exerted on the teeth can induce the pathologic migration of a tooth or group of teeth. These forces do not have to be abnormal to cause migration if the periodontium is sufficiently weakened. Changes in the forces may result from unreplaced missing teeth or other causes.

Unreplaced Missing Teeth. The drifting of teeth into the spaces created by unreplaced missing teeth often occurs. Drifting differs from pathologic migration in that it does not result from the destruction of the periodontal tissues. However, it usually creates conditions that lead to periodontal disease, and thus the initial tooth movement is aggravated by a loss of periodontal support (Figure 22-11).

Drifting generally occurs in a mesial direction in combination with tilting or extrusion beyond the occlusal plane. The premolars frequently drift distally (Figure 22-12). Although drifting is a common sequela when missing teeth are not replaced, it does not always occur (Figure 22-13).

Failure to Replace First Molars. The pattern of changes that may follow the failure to replace missing first molars is characteristic. In extreme cases, it consists of the following:

1. The second and third molars tilt mesially, which results in a decrease in vertical dimension (Figure 22-14).
2. The premolars move distally, and the mandibular incisors tilt or drift lingually. While drifting distally, the mandibular premolars lose their intercuspating relationship with the maxillary teeth, and they may tilt distally.
3. Anterior overbite is increased. The mandibular incisors strike the maxillary incisors near the gingiva or traumatize the gingiva.
4. The maxillary incisors are pushed labially and laterally (Figure 22-15).

Figure 22-11 Calculus and bone loss on the mesial surface of a canine that has drifted distally.

Figure 22-12 Maxillary first molar that has tilted and extruded into the space created by a missing mandibular tooth.

Figure 22-13 No drifting or extrusion is present here, despite 4 years' absence of the mandibular teeth.

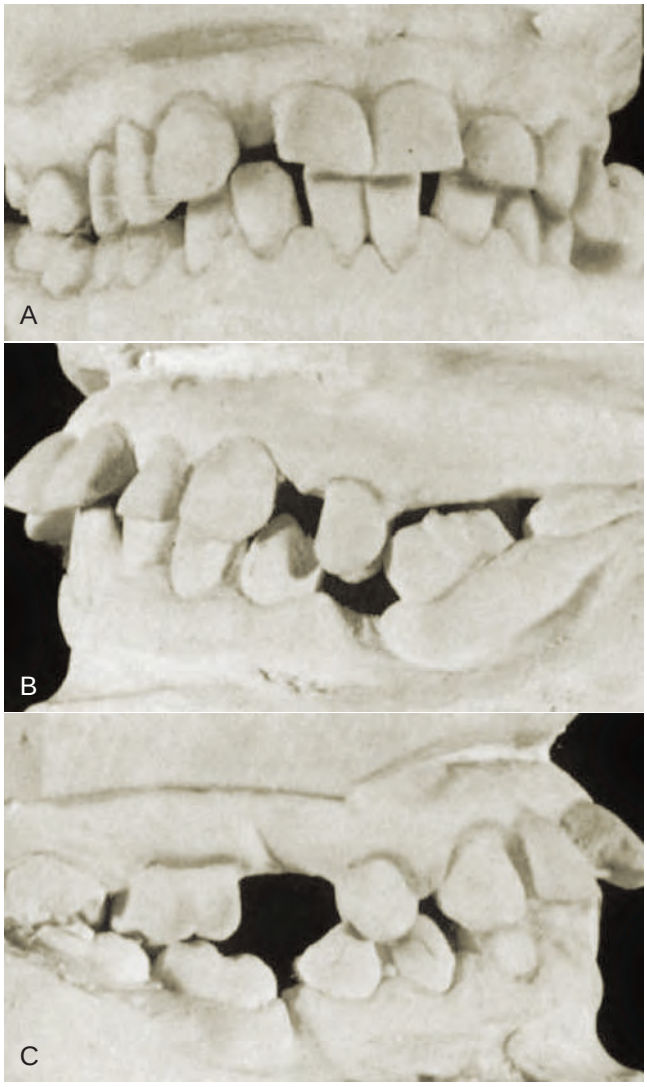

Figure 22-14 Examples of the mutilation of occlusion associated with unreplaced missing teeth. Note pronounced pathologic migration, disturbed proximal contacts, and functional relationships with closing of the bite.

5. The anterior teeth extrude because the incisal apposition has largely disappeared.
6. Diastemata are created by the separation of the anterior teeth (see Figure 22-14).

The disturbed proximal contact relationships lead to food impaction, plaque accumulation that results in gingival inflammation, and pocket formation, which are followed by bone loss and tooth mobility. Occlusal disharmonies created by the altered tooth positions traumatize the supporting tissues of the periodontium and aggravate the destruction caused by the inflammation. The reduction in periodontal support leads to the further migration of the teeth and the mutilation of the occlusion.

Other Causes. *Trauma from occlusion* may cause a shift in tooth position either by itself or in combination with inflammatory periodontal disease. The direction of movement depends on the occlusal force.

Pressure from the tongue may cause drifting of the teeth in the absence of periodontal disease, or it may contribute to the pathologic migration of teeth with reduced periodontal support (Figure 22-16).

Figure 22-15 Maxillary incisors pushed labially in a patient with bilateral unreplaced mandibular molars. Note the extrusion of the maxillary molars.

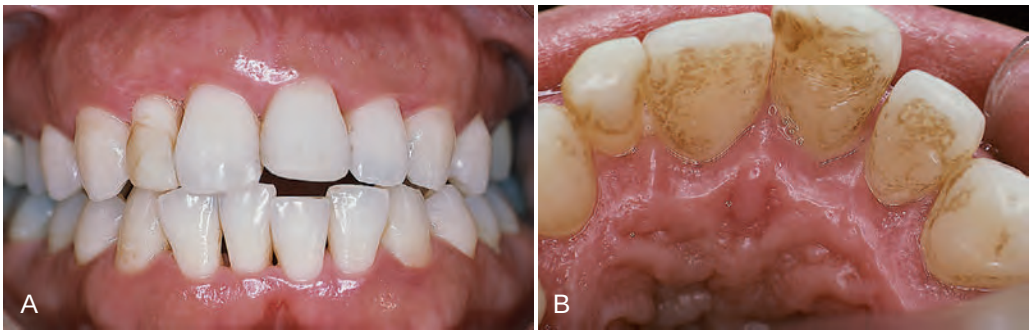

Figure 22-16 Pathologic migration associated with tongue pressure. **A,** Facial view. **B,** Palatal view.

When tooth support has been weakened by periodontal destruction, *pressure from the granulation tissue of periodontal pockets* has been mentioned as contributing to pathologic migration.[28,37] The teeth may return to their original positions after the pockets are eliminated, but, if more destruction has occurred on one side of a tooth than on the other, the healing tissues tend to pull in the direction of the lesser destruction.

Suggested Readings

Glickman I, Smulow JB: Adaptive alterations in the periodontium of the rhesus monkey in chronic trauma from occlusion. *J Periodontol* 39:101, 1968.

Glickman I, Roeber F, Brion M, et al: Photoelastic analysis of internal stresses in the periodontium created by occlusal forces. *J Periodontol* 41:30, 1970.

Lindhe J, Ericsson I: The influence of trauma from occlusion on reduced but healthy periodontal tissues in dogs. *J Clin Periodontol* 3:110, 1976.

Lindhe J, Svanberg G: Influence of trauma from occlusion on progression of experimental periodontitis in the beagle dog. *J Clin Periodontol* 1:3, 1974.

Meitner S: Co-destructive factors of marginal periodontitis and repetitive mechanical injury. *J Dent Res* 54:C78, 1975.

Polson AM: The relative importance of plaque and occlusion in periodontal disease. *J Clin Periodontol* 13:923, 1986.

Stahl SS: Accommodation of the periodontium to occlusal trauma and inflammatory periodontal disease. *Dent Clin North Am* 19:531, 1975.

References

References for this chapter are found on the companion website www.expertconsult.com.

References

1. Ballbe R, Carranza FA, Erausquin R: Los paradencios del caso ocho. *Rev Odont (Buenos Aires)* 26:606, 1938.
2. Bhaskar SN, Orban B: Experimental occlusal trauma. *J Periodontol* 26:270, 1955.
3. Biancu S, Ericsson I, Lindhe J: Periodontal ligament tissue reactions to trauma and gingival inflammation: an experimental study in the beagle dog. *J Clin Periodontol* 22:772, 1995.
4. Carranza FA, Jr: Histometric evaluation of periodontal pathology. *J Periodontol* 38:741, 1967.
5. Carranza FA, Jr, Cabrini RL: Histometric studies of periodontal tissues. *Periodontics* 5:308, 1967.
6. Cohn SA: Disuse atrophy of the periodontium in molar teeth of mice. *J Dent Res* 40:707, 1961.
7. Cooper MB, Landay MA, Seltzer S: The effects of excessive occlusal forces on the pulp. II. Heavier and longer term forces. *J Periodontol* 42:353, 1971.
8. Dotto CA, Carranza FA, Jr, Itoiz ME: Efectos mediatos del trauma experimental en ratas. *Rev Asoc Odontol Argent* 54:48, 1966.
9. Dotto CA, Carranza FA, Jr, Cabrini RL, et al: Vascular changes in experimental trauma from occlusion. *J Periodontol* 38:183, 1967.
10. Ericsson I: The combined effects of plaque and physical stress on periodontal tissues. *J Clin Periodontol* 13:918, 1986.
11. Ericsson I, Lindhe J: Lack of effect of trauma from occlusion on the recurrence of experimental periodontitis. *J Clin Periodontol* 4:115, 1977.
12. Ericsson I, Lindhe J: Effect of longstanding jiggling on experimental marginal periodontitis in the beagle dog. *J Clin Periodontol* 9:497, 1982.
13. Everett FG, Bruckner RJ: Cartilage in the periodontal ligament space. *J Periodontol* 41:165, 1970.
14. Glickman I: Occlusion and the periodontium. *J Dent Res* 46(Suppl):53, 1967.
15. Glickman I, Smulow JB: Alterations in the pathway of gingival inflammation into the underlying tissues induced by excessive occlusal forces. *J Periodontol* 33:7, 1962.
16. Glickman I, Smulow JB: Buttressing bone formation in the periodontium. *J Periodontol* 36:365, 1965.
17. Glickman I, Smulow JB: Effect of excessive occlusal forces upon the pathway of gingival inflammation in humans. *J Periodontol* 36:141, 1965.
18. Glickman I, Smulow JB: Adaptive alterations in the periodontium of the rhesus monkey in chronic trauma from occlusion. *J Periodontol* 39:101, 1968.
19. Glickman I, Smulow JB: The combined effects of inflammation and trauma from occlusion to periodontitis. *Int Dent J* 19:393, 1969.
20. Glickman I, Weiss L: Role of trauma from occlusion in initiation of periodontal pocket formation in experimental animals. *J Periodontol* 26:14, 1955.
21. Glickman I, Smulow JB, Moreau J: Effect of alloxan diabetes upon the periodontal response to excessive occlusal forces. *J Periodontol* 37:146, 1966.
22. Glickman I, Stein RS, Smulow JB: The effects of increased functional forces upon the periodontium of splinted and nonsplinted teeth. *J Periodontol* 32:290, 1961.
23. Glickman I, Roeber F, Brion M, et al: Photoelastic analysis of internal stresses in the periodontium created by occlusal forces. *J Periodontol* 41:30, 1970.
24. Goldman H: Gingival vascular supply in induced occlusal traumatism. *Oral Surg Oral Med Oral Pathol* 9:939, 1956.
25. Gottlieb B, Orban B: *Changes in the tissue due to excessive force upon the teeth*, Leipzig, 1931, G Thieme.
26. Grant DA, Grant DA, Flynn MJ, et al: Periodontal microbiota of mobile and nonmobile teeth. *J Periodontol* 66:386, 1985.
27. Hakkarainen K: Relative influence of scaling and root influence and occlusal adjustment on sulcular fluid flow. *J Periodontol* 57:681, 1986.
28. Hirschfeld I: The dynamic relationship between pathologically migrating teeth and inflammatory tissue in periodontal pockets: a clinical study. *J Periodontol* 4:35, 1933.
29. Itoiz ME, Carranza FA, Jr, Cabrini RL: Histologic and histometric study of experimental occlusal trauma in rats. *J Periodontol* 34:305, 1963.
30. Kantor M, Polson AN, Zander HA: Alveolar bone regeneration after removal of inflammatory and traumatic factors. *J Periodontol* 46:687, 1976.
31. Kaufman H, Carranza FA, Jr, Enders B, et al: The influence of trauma from occlusion on the bacterial repopulation of periodontal pockets in dogs. *J Periodontol* 55:86, 1984.
32. Kenney EB: A histopathologic study of incisal dysfunction and gingival inflammation in the rhesus monkey. *J Periodontol* 42:3, 1971.
33. Kobayashi K, Kobayashi K, Soeda W, et al: Gingival crevicular pH in experimental gingivitis and occlusal trauma in man. *J Periodontol* 69:1036, 1998.
34. Kvam E: Scanning electron microscopy of tissue changes on the pressure surface of human premolars following tooth movement. *Scand J Dent Res* 80:357, 1972.
35. Landay MA, Nazimov H, Seltzer S: The effects of excessive occlusal forces on the pulp. *J Periodontol* 41:3, 1970.
36. Levy G, Mailland ML: Etude quantitative des effets de l'hypofonction occlusale sur la largeur desmodontale et la resorption osteoclastique alveolaire chez le rat. *J Biol Buccale* 8:17, 1980.
37. Lindhe J, Ericsson I: The influence of trauma from occlusion on reduced but healthy periodontal tissues in dogs. *J Clin Periodontol* 3:110, 1976.
38. Lindhe J, Ericsson I: The effect of elimination of jiggling forces on periodontally exposed teeth in the dog. *J Periodontol* 53:562, 1982.
39. Lindhe J, Svanberg G: Influence of trauma from occlusion on progression of experimental periodontitis in the beagle dog. *J Clin Periodontol* 1:3, 1974.
40. Macapanpan LC, Weinmann JP: The influence of injury to the periodontal membrane on the spread of gingival inflammation. *J Dent Res* 33:263, 1954.
41. Martin LP, Noble WH: Gingival fluid in relation to tooth mobility and occlusal interferences. *J Periodontol* 45:444, 1974.
42. Meitner S: Co-destructive factors of marginal periodontitis and repetitive mechanical injury. *J Dent Res* 54:C78, 1975.
43. Orban B: Tissue changes in traumatic occlusion. *J Am Dent Assoc* 15:2090, 1928.
44. Orban B, Weinmann JP: Signs of traumatic occlusion in average human jaws. *J Dent Res* 13:216, 1933.
45. Polson AM: Trauma and progression of marginal periodontitis in squirrel monkeys. II. Codestructive factors of periodontitis and mechanically produced injury. *J Periodontal Res* 9:108, 1974.
46. Polson AM: The relative importance of plaque and occlusion in periodontal disease. *J Clin Periodontol* 13:923, 1986.
47. Polson AM, Zander HA: Effect of periodontal trauma upon intrabony pockets. *J Periodontol* 54:586, 1983.
48. Polson AM, Meitner SW, Zander HA: Trauma and progression of marginal periodontitis in squirrel monkeys. III. Adaption of interproximal alveolar bone to repetitive injury. *J Periodontal Res* 11:279, 1976.
49. Polson AM, Meitner SW, Zander HA: Trauma and progression of marginal periodontitis in squirrel monkeys. IV. Reversibility of bone loss due to trauma alone and trauma superimposed upon periodontitis. *J Periodontal Res* 11:290, 1976.
50. Ramfjord SP, Kohler CA: Periodontal reaction to functional occlusal stress. *J Periodontol* 30:95, 1959.
51. Rothblatt JM, Waldo CM: Tissue response to tooth movement in normal and abnormal metabolic states. *J Dent Res* 32:678, 1953.
52. Rygh P: Ultrastructural cellular reactions in pressure zones of rat molar periodontium incident to orthodontic movement. *Acta Odontol Scand* 30:575, 1972.
53. Rygh P: Ultrastructural vascular changes in pressure zones of rat molar periodontium incident to orthodontic movement. *Scand J Dent Res* 80:307, 1972.

54. Rygh P: Ultrastructural changes in pressure zones of human periodontium incident to orthodontic tooth movement. *Acta Odontol Scand* 31:109, 1973.
55. Rygh P: Ultrastructural changes of the periodontal fibers and their attachment in rat molar periodontium incident to orthodontic tooth movement. *Scand J Dent Res* 81:467, 1973.
56. Rygh P: Elimination of hyalinized periodontal tissues associated with orthodontic tooth movement. *Scand J Dent Res* 82:57, 1974.
57. Rygh P, Selvig KA: Erythrocytic crystallization in rat molar periodontium incident to tooth movement. *Scand J Dent Res* 81:62, 1973.
58. Solt CW, Glickman I: A histologic and radioautographic study of healing following wedging interdental injury in mice. *J Periodontol* 39:249, 1968.
59. Sottosanti JS: A possible relationship between occlusion, root resorption and the progression of periodontal disease. *J West Soc Periodontol* 25:69, 1977.
60. Stahl SS: Accommodation of the periodontium to occlusal trauma and inflammatory periodontal disease. *Dent Clin North Am* 19:531, 1975.
61. Stahl SS, Miller SC, Goldsmith ED: The effects of vertical occlusal trauma on the periodontium of protein deprived young adult rats. *J Periodontol* 28:87, 1957.
62. Stallard RE: The effect of occlusal alterations on collagen formation within the periodontium. *Periodontics* 2:49, 1964.
63. Svanberg G, Lindhe J: Vascular reactions to the periodontal ligament incident to trauma from occlusion. *J Clin Periodontol* 1:58, 1974.
64. Vollmer WH, Rateitschak KH: Influence of occlusal adjustment by grinding on gingivitis and mobility of traumatized teeth. *J Clin Periodontol* 2:113, 1975.
65. Waerhaug J, Hansen ER: Periodontal changes incidental to prolonged occlusal overload in monkeys. *Acta Odontol Scand* 24:91, 1966.
66. Wentz FM, Jarabak J, Orban B: Experimental occlusal trauma imitating cuspal interferences. *J Periodontol* 29:117, 1958.
67. Zaki AE, Van Huysen G: Histology of the periodontium following tooth movement. *J Dent Res* 42:1373, 1963.
68. Zander HA, Muhlemann HR: The effect of stresses on the periodontal structures. *Oral Surg Oral Med Oral Pathol* 9:380, 1956.

CHAPTER 23

Chronic Periodontitis

H. Dommisch and M. Kebschull

CHAPTER OUTLINE

Clinical Features
Risk Factors for Disease

Chronic periodontitis is the most prevalent form of periodontitis, and it generally demonstrates the characteristics of a slowly progressing inflammatory disease. However, systemic and environmental factors (e.g., diabetes mellitus, smoking) may modify the host's immune response to the dental biofilm so that periodontal destruction becomes more progressive. Although chronic periodontitis is most frequently observed in adults, it can occur in children and adolescents in response to chronic plaque and calculus accumulation.

Chronic periodontitis has been defined as "an infectious disease resulting in inflammation within the supporting tissues of the teeth, progressive attachment loss, and bone loss."[18] This definition outlines the major clinical and etiologic characteristics of the disease: (1) microbial biofilm formation (dental plaque); (2) periodontal inflammation (e.g., gingival swelling, bleeding on probing); and (3) attachment as well as alveolar bone loss.

In addition to the local immune response caused by the dental biofilm, periodontitis may also be associated with a number of systemic disorders and defined syndromes. In most cases, patients with systemic diseases that lead to impaired host immunity may also show periodontal destruction. Therefore, periodontitis is a disease that is not only limited to the area of the oral cavity; it is also associated with severe systemic diseases (e.g., cardiovascular disorders, diabetes mellitus).[40]

This chapter discusses clinical features that have been described for chronic periodontitis. In addition, the disease's etiology is summarized with the use of categories that explain the known factors (i.e., microbiologic, immunologic, and genetic) involved in the pathology of chronic periodontitis.

Clinical Features

General Characteristics

Characteristic clinical findings in patients with untreated chronic periodontitis include the following (see also the case presentation in Figures 23-1 through 23-6):

- Supragingival and subgingival plaque and calculus
- Gingival swelling, redness, and loss of gingival stippling
- Altered gingival margins (e.g., rolled, flattened, cratered papillae, recessions)
- Pocket formation
- Bleeding on probing
- Attachment loss (angular or horizontally)
- Bone loss
- Root furcation involvement (exposure)
- Increased tooth mobility
- Change in tooth position
- Tooth loss

Chronic periodontitis can be clinically revealed with periodontal screening and recording, which results in a periodontal screening index rating. The condition is diagnosed via the assessment of the clinical attachment level and the detection of inflammatory changes in the marginal gingiva (see Figure 23-1). Measurements of periodontal pocket depth in combination with the location of the marginal gingiva allow for conclusions to be drawn regarding the loss of clinical attachment (see Figures 23-2 and 23-6). Dental radiographs display the extent of bone loss, which is indicated by the distance between the cementoenamel junction and the alveolar bone crest (see Figure 23-3). The distinction between aggressive and chronic periodontitis is sometimes difficult, because the clinical features may be similar at the time of the first examination. At later time points during treatment, aggressive and chronic periodontitis may be differentiated by the rate of disease progression over time, the familial nature of aggressive disease, the disease's resistance to periodontal anti-infective therapy, and the presence of local factors.

Disease Distribution

Chronic periodontitis is considered a site-specific disease. Local inflammation, pocket formation, attachment loss, and bone loss are the consequences of direct exposure to the subgingival plaque (biofilm). As a result of this local effect, pocket formation and attachment as well as bone loss may occur on one surface of a tooth, whereas other surfaces maintain normal attachment levels. As a result of the site-specific nature, the number of teeth with clinical attachment loss classifies chronic periodontitis into the following types:

- **Localized chronic periodontitis:** less than 30% of the sites show attachment and bone loss
- **Generalized chronic periodontitis:** 30% or more of the sites show attachment and bone loss

During chronic periodontitis, the local inflammatory response may lead to different patterns of bone loss, including vertical (angular) and horizontal bone destruction. Although vertical bone loss is associated with intrabony pocket formation, horizontal

Text continued on p. 314

Figure 23-1 Clinical features of generalized chronic periodontitis in a 49-year-old, medically healthy, male patient. The patient reported a smoking habit of 15 cigarettes per day. At the first visit, the periodontal photostatus displays untreated chronic periodontitis with abundant dental plaque and calculus deposits, gingival redness and swelling, and an alteration of the gingival texture (i.e., loss of gingival stippling). The patient noticed multiple recessions. In this case, recessions were the result of a loss of clinical attachment and alveolar bone. **A,** Right lateral view. **B,** Frontal view. **C,** Left lateral view. **D,** Maxillary view. **E,** Mandibular view. *(Reprinted from Kebschull and Dommisch, Thieme, 2012.)*

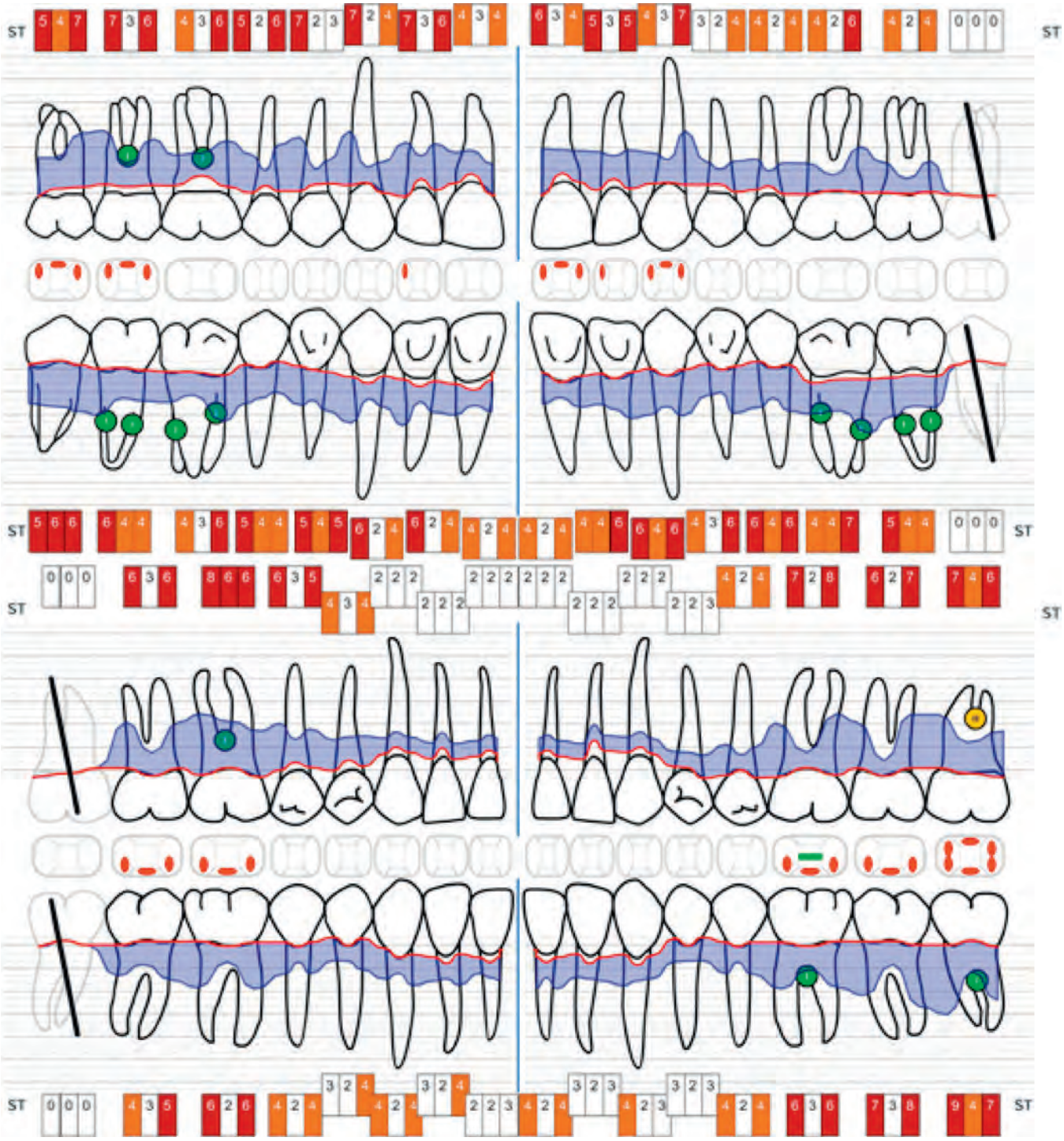

Figure 23-2 Documentation of the periodontal attachment level in the same patient as shown in Figure 23-1 at the time of the first visit. The red line displays the gingival margin as it reflects the recessions. Clinical attachment loss is illustrated by the filled *(blue)* area on the root surfaces. The deepest periodontal pocket was measured at 9 mm. Class I *(green)* and Class II *(yellow)* furcation involvements were documented. Bleeding with periodontal probing (i.e., gingival inflammation) is reflected by red dots. As a result of the patient's history of smoking, the bleeding on probing score was relatively low, although the patient presented advanced attachment loss. Tooth mobility is indicated by the green line (tooth #19). *(Reprinted from Kebschull and Dommisch, Thieme, 2012.)*

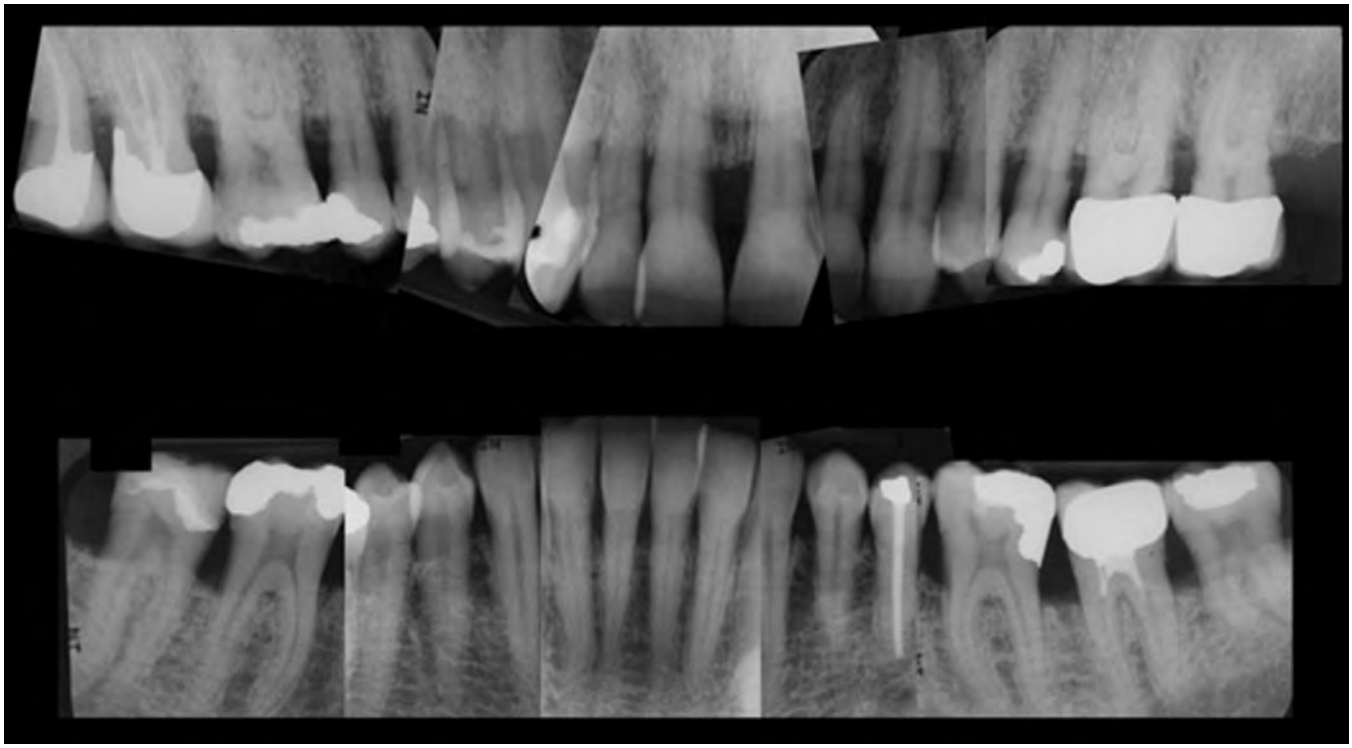

Figure 23-3 Collage of a total of 11 radiographs showing the radiographic periodontal status at the time of diagnosis. Compare this with Figures 23-1 and 23-2. Note the generalized horizontal and localized angular and vertical bone loss on the mesial and distal sites of the molars. The radiographs show deep subgingival restorations (teeth #2 and #19), overhanging margins of restorations (teeth #14 and #15), a carious lesion (tooth #14), and insufficient root canal treatment (tooth #18). *(Reprinted from Kebschull and Dommisch, Thieme, 2012.)*

Figure 23-4 After the anti-infective therapy and periodontal reevaluation, resective periodontal surgery was performed for the patient introduced in Figures 23-1, 23-2, and 23-3. The surgical method involved an apically repositioned flap. **A,** Intrasulcular incisions at the buccal sites. Notice the Class I furcation involvement on tooth #14. **B,** Paramarginal incision at the palatal sites, with the excision of a distal wedge. **C** and **D,** Suturing with the use of 5-0 Prolene; buccal and palatal views, respectively. **E,** Occlusal view after suturing. **F,** Occlusal view 1 week after surgery. Tooth #14 received endodontic therapy and crown restoration before periodontal surgery. *(Reprinted from Kebschull and Dommisch, Thieme, 2012.)*

Figure 23-5 After the anti-infective therapy and periodontal reevaluation, resective periodontal surgery was performed for the patient introduced in Figures 23-1 through 23-4. The surgical method involved an apically repositioned flap. **A,** Intrasulcular incisions at the buccal sites. Note the Class I furcation involvement on tooth #19 and the horizontal bone loss affecting teeth #18, #19, and #20. **B,** Suturing with the use of 5-0 Prolene; buccal view. *(Reprinted from Kebschull and Dommisch, Thieme, 2012.)*

bone loss is usually associated with suprabony (supra-alveolar) pockets.

Disease Severity

The severity of periodontal destruction that occurs as a result of chronic periodontitis is generally considered a function of time in combination with systemic disorders that impair or enhance host immune responses. With increasing age, attachment loss and bone loss become more prevalent and more severe as a result of an accumulation of destruction. Disease severity may be described as mild, moderate, or severe (see Chapter 4):

- **Mild chronic periodontitis:** when no more than 1 mm to 2 mm of clinical attachment loss has occurred
- **Moderate chronic periodontitis:** when 3 mm to 4 mm of clinical attachment loss has occurred
- **Severe periodontitis:** when 5 mm or more of clinical attachment loss has occurred

Symptoms

Chronic periodontitis is commonly a slowly progressive disease that does not cause the affected individual to feel pain. Therefore, most patients are unaware that they have developed a chronic disease that is also associated with other systemic diseases (e.g., cardiovascular disease). For the majority of the patients, gingival bleeding during oral hygiene procedures or eating may be the first self-reported sign of disease occurrence. As a result of gingival recession, patients may notice black triangles between the teeth or tooth sensibility in response to temperature changes (i.e., cold and heat). In patients with advanced attachment and bone loss, tooth mobility, tooth movement, and, in rare occasions, tooth loss may be reported. In those individuals with advanced disease progression, areas of localized dull pain or pain sensations that radiate to other areas of the mouth or head may occur. The presence of areas of food impaction may add to the patient's discomfort. Gingival tenderness or "itchiness" may also be found.

Disease Progression

Patients appear to have the same susceptibility to plaque-induced chronic periodontitis throughout their lives. The rate of disease progression is usually slow, but it may be modified by systemic, environmental, and behavioral factors. The onset of chronic periodontitis can occur at any time, and the first signs may be detected during adolescence in the presence of chronic plaque and calculus accumulation. Because of its slow rate of progression, however, chronic periodontitis usually becomes clinically significant when a patient reaches his or her mid-30s or later.

Chronic periodontitis does not progress at an equal rate in all affected sites throughout the mouth. Some involved areas may remain static for long periods,[33] whereas others may progress more rapidly. More rapidly progressive lesions occur most frequently in interproximal areas,[32,34] and they may also be associated with areas of greater plaque accumulation and inaccessibility to plaque-control measures (e.g., furcation areas, overhanging margins of restorations, sites of malposed teeth, areas of food impaction).

Further factors that influence disease progression may be of systemic origin. Patients with poorly adjusted diabetes mellitus show a significantly higher risk of developing a severe progression of chronic periodontitis.[43,61]

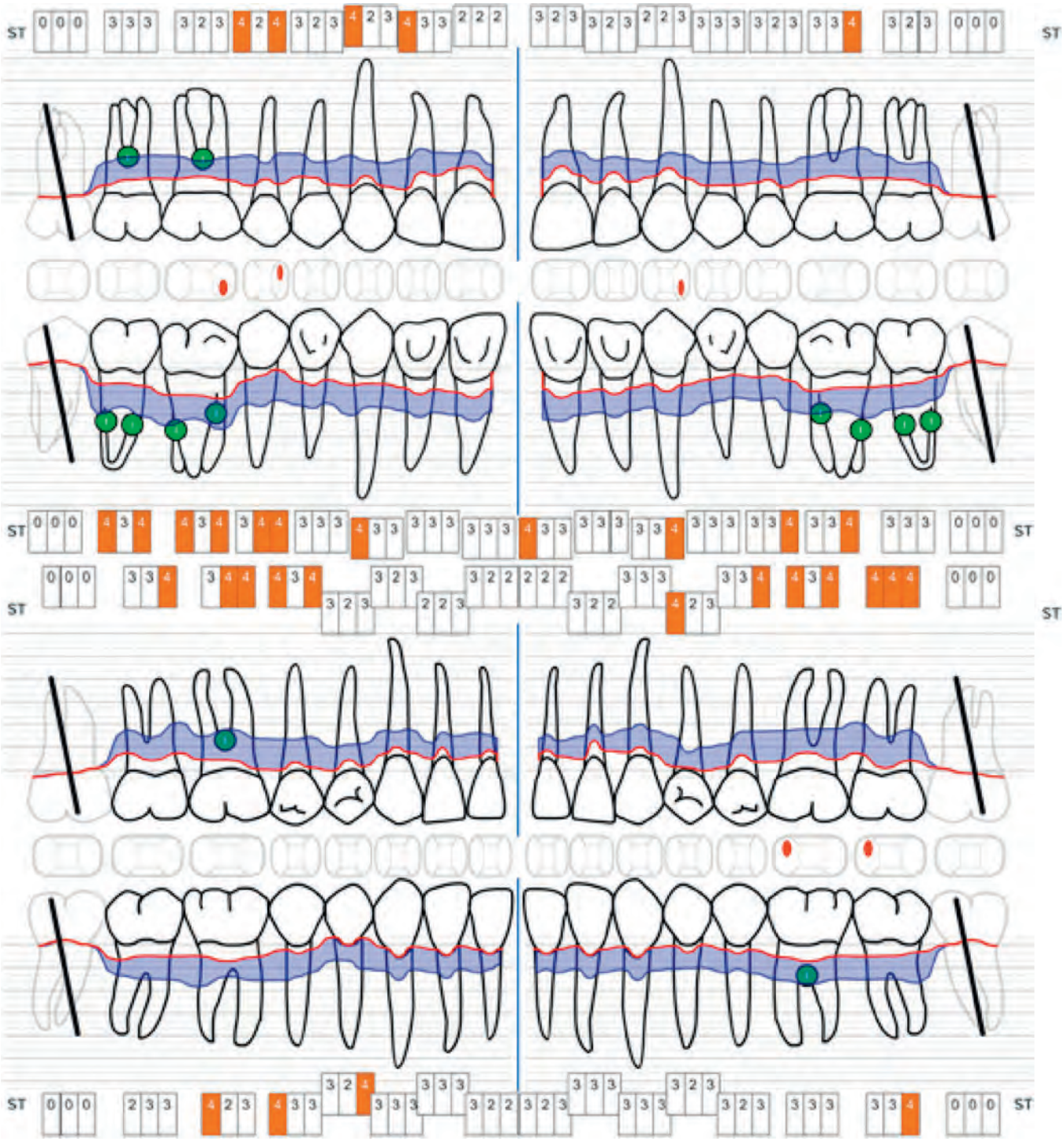

Figure 23-6 Documentation of the periodontal attachment level in the same patient introduced in Figures 23-1 through 23-5 after active periodontal therapy was completed and the supportive periodontal therapy was initiated. The red line displays the gingival margin as it reflects recessions after therapy. Clinical attachment loss is illustrated by the filled *(blue)* area on the root surfaces. The deepest periodontal pocket was measured at 4 mm. *(Reprinted from Kebschull and Dommisch, Thieme, 2012.)*

Several models have been proposed to describe the rate of disease progression.[57] In these models, progression is measured by determining the amount of attachment loss during a given period as follows:

- The **continuous model** suggests that disease progression is slow and continuous, with affected sites showing a constantly progressive rate of destruction throughout the duration of the disease.
- The **random or episodic-burst model** proposes that periodontal disease progresses by short bursts of destruction followed by periods of no destruction. This pattern of disease is random with respect to the tooth sites affected and the chronology of the disease process.
- The **asynchronous, multiple-burst model** of disease progression suggests that periodontal destruction occurs around affected teeth during defined periods of life and that these bursts

of activity are interspersed with periods of inactivity or remission. The chronology of these bursts of disease is asynchronous for individual teeth or groups of teeth.

Prevalence

Chronic periodontitis increases in prevalence and severity with age, and it generally affects both genders equally. Periodontitis is an age-associated (not an age-related) disease. Nonetheless, the prevalence of periodontitis increases with age so that 40% of patients who are 50 years old or older and almost 50% of patients who are 65 years old or older show moderate periodontal destruction. The prevalence of severe forms of periodontitis also increases with age. Up to 30% of patients develop severe periodontitis by the time they are 40 years old or older. Generally, 50% of the human population experiences at least one form of periodontal disease (Figures 23-7 and 23-8).[9,16,20,25,58]

Risk Factors for Disease

A number of different factors influence the etiopathology of chronic periodontitis. The composition of the oral microflora is a major etiologic factor that leads to periodontal destruction. In this context, the extent of the periodontal destruction depends on the host's immune competence as well as genetic predispositions that influence individual susceptibility to disease. In addition, both systemic diseases and environmental factors interfere with the development and progression of chronic periodontitis.

Microbiological Aspects

Plaque accumulation on tooth and gingival surfaces at the dentogingival junction is considered the primary initiating agent in the etiology of gingivitis and chronic periodontitis.[34] Attachment and bone loss are associated with an increase in the proportion of gram-negative organisms in the subgingival biofilm, with specific increases in organisms that are known to be exceptionally pathogenic and virulent. *Porphyromonas gingivalis*, *Tannerella forsythia*, and *Treponema denticola*—otherwise known as the "red complex"—are frequently associated with ongoing attachment and bone loss in patients with chronic periodontitis. The development and progression of chronic periodontitis may not depend on the presence of one specific bacterium or bacterial complex alone. It is assumed that chronic periodontitis is the result of a multispecies infection with a number of different bacteria that influence the pro-inflammatory immune response of the host.[50] Periodontal pathogens may invade the periodontal tissue and thus induce an immune response with increasing concentrations of pro-inflammatory mediators that may enhance periodontal breakdown. In addition, a number of periodontal pathogens are capable of producing proteases that directly influence tissue stability and host immune responses.[40]

As the dental biofilm develops, early signs of an inflammatory reaction occur in the gingival margin (i.e., gingivitis), without actual attachment loss. Generally, optimal plaque control leads to the complete resolution of this early gingival inflammation. Alternatively, with neglected oral hygiene, inflammation will progress and eventually result in the loss of attachment around teeth.[32] Although not all patients with gingivitis develop periodontitis, it is known that all patients with periodontitis experienced prior gingivitis. The occurrence of periodontitis depends on the individual immune response that modifies the onset and progression of the disease.[32,39,40]

Local Factors

Plaque accumulation and biofilm development are the primary causes of periodontal inflammation and destruction. Therefore,

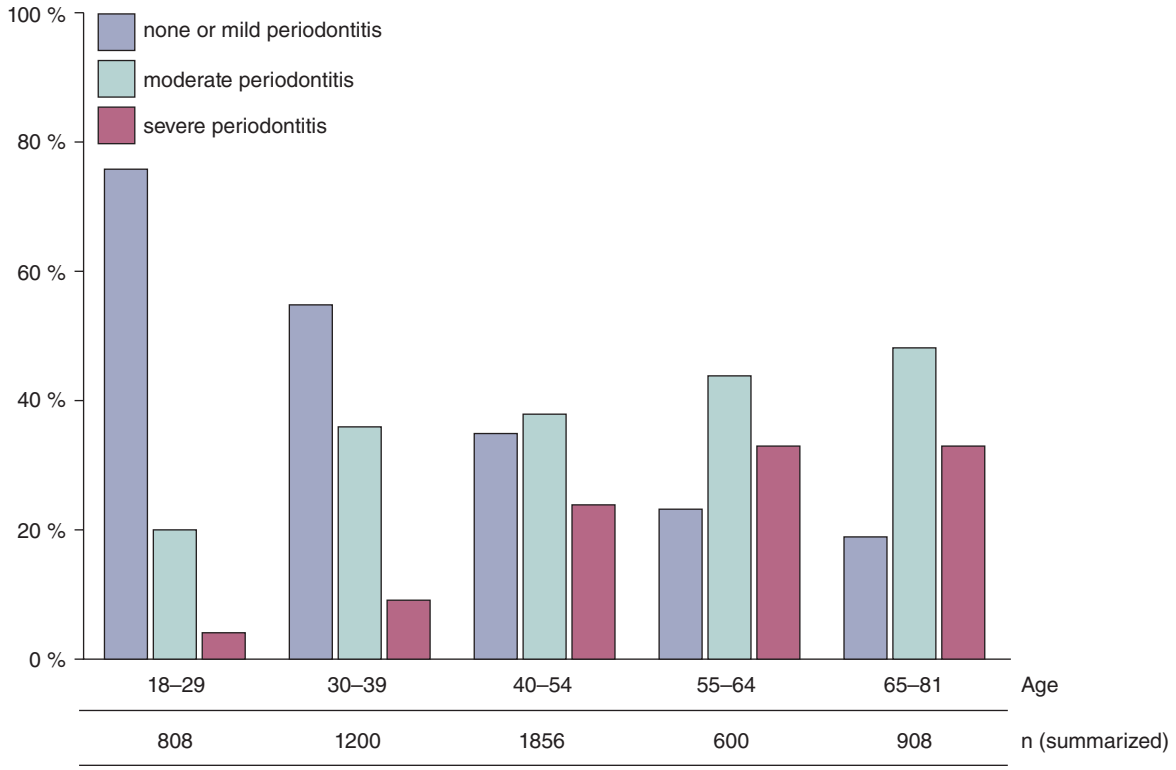

Figure 23-7 Prevalence of periodontitis in the United States and Germany, 2007-2009. *((Eke PI, Dye BA, Wei L, et al: Prevalence of periodontitis in adults in the United States: 2009 and 2010.* J Dent Res *91:914–920, 2012.)*

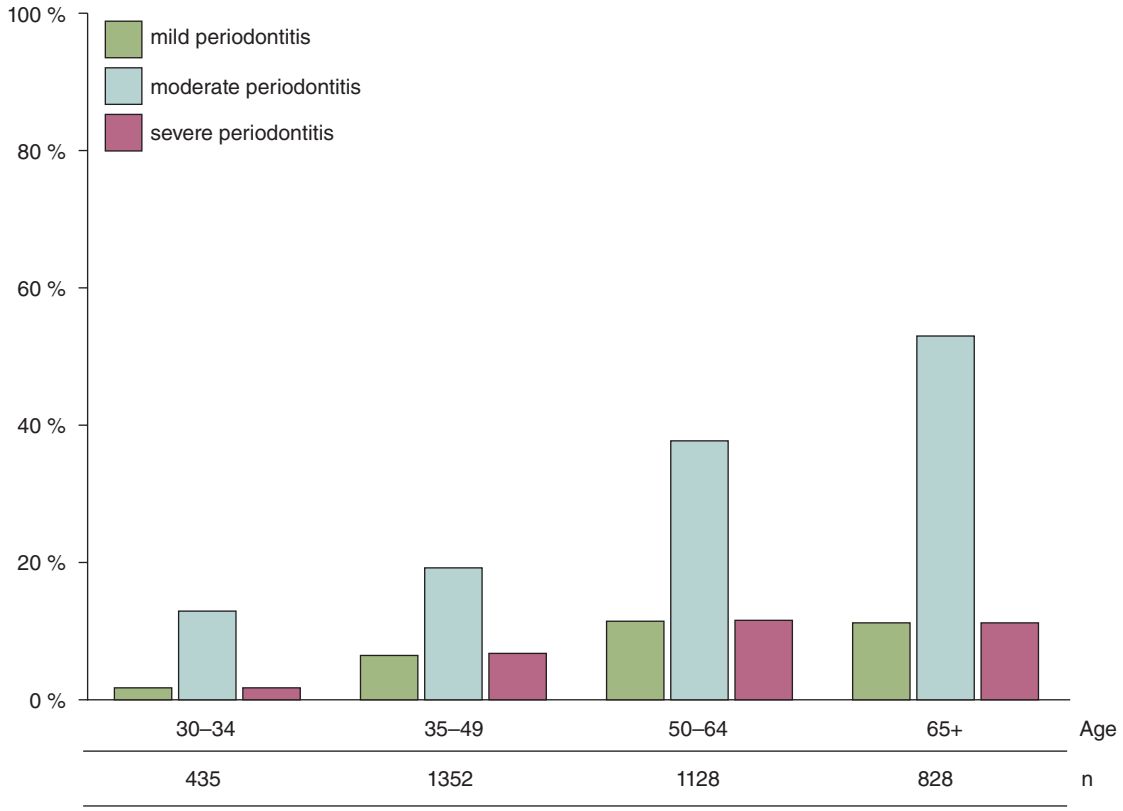

Figure 23-8 Prevalence of periodontitis in the United States, 2009-2010. *(Eke PI, Dye BA, Wei L, et al: Prevalence of periodontitis in adults in the United States: 2009 and 2010.* J Dent Res *91:914–920, 2012.)*

factors that facilitate plaque accumulation or that prevent plaque removal by oral hygiene procedures can be detrimental to the patient. Plaque-retentive factors are important for the development and progression of chronic periodontitis, because they retain microorganisms in proximity to the periodontal tissues, thereby providing an ecologic niche for biofilm maturation. Calculus is considered the most important plaque-retentive factor as a result of its ability to retain and harbor plaque bacteria on its rough surface as well as inside.[56] As a consequence, calculus removal is essential for the maintenance of a healthy periodontium. In addition, tooth morphology may influence plaque retention. Roots may show grooves or concavities, and, in some instances, enamel projections on the surface or the furcation entrances. These morphologic variations may facilitate plaque retention, subgingival calculus formation, and disease progression.[21,26,48] In addition, subgingival and overhanging margins of restorations, carious lesions that extend subgingivally, and furcations exposed by loss of bone promote plaque retention.[31,62] These potential risk factors for periodontitis are discussed further in Chapter 32, and their impact on the prognosis of periodontal treatment is discussed in Chapter 33.

Systemic Factors

Chronic periodontitis is a complex disease that may not only be limited to the infection of local sites. In several instances, periodontitis is also associated with other systemic disorders, such as Haim–Munk syndrome, Papillon–Lefèvre syndrome, Ehlers–Danlos syndrome, Kindlers syndrome, and Cohen syndrome. Patients with diseases that impair the host immune response (e.g., human immunodeficiency virus, acquired immunodeficiency syndrome) may also show periodontal destruction. It is also known that osteoporosis, a severely unbalanced diet, and stress as well as dermatologic, hematologic, and neoplastic factors interfere with periodontal inflammatory responses.

In addition to being associated with defined syndromes, periodontitis also occurs with severe systemic diseases, such as diabetes mellitus, cardiovascular disorders, stroke, and lung disorders.[1,28,38,40,60]

For diabetes mellitus and periodontitis, it is known that there is an interaction during which both diseases mutually correlate with each other. Patients with diabetes mellitus exhibit a higher risk for the development of periodontitis, and periodontal infection and inflammation may negatively interfere with the glycemic control of the diabetic patient.[43] A number of studies showed that the prevalence, severity, and prognosis of periodontitis are associated with the incidence of diabetes mellitus. It was found that the average pocket depth as well as the clinical attachment loss was increased in patients with diabetes mellitus (independent of the type of diabetes mellitus).[10,43] Patients with poor glycemic control (i.e., a glycated hemoglobin level of >9%) tend to experience a more severe progression of periodontitis as compared with patients with good glycemic control (i.e., a glycated hemoglobin level of <9%). With regard to the progression of severe periodontitis, no difference was found between patients with good glycemic control and non-diabetic patients.[61] With diabetes mellitus, advanced glycation end products may arise and lead to the release of free oxygen and pro-inflammatory mediators (i.e., cytokines). Advanced glycation end products may also promote chemotaxis and the adhesion of inflammatory cells to periodontal tissues, and the increased apoptosis of fibroblasts and osteoblasts may occur.[23] Furthermore, patients with diabetes mellitus tend to show a higher body mass index; therefore, increased concentrations of adipokines that

directly influence inflammatory responses will likely be found.[44] Hyperglycemia itself leads to the release of pro-inflammatory mediators in the bloodstream, which in turn promote increased glycose concentration.[43] Periodontal therapy may contribute to the glycemic control of the diabetic patient. It has been shown that systematic periodontal therapy leads a 0.4% reduction of glycated hemoglobin. Each therapy regimen that contributes to achieve a reduction in the glycated hemoglobin level decreases the risk of diabetes-related long-term consequences, such as myocardial infarction, microvascular complications, and many others. [43]

Immunologic Factors

Chronic periodontitis is a disease that is induced by bacteria organized in the dental biofilm. However, the onset, progression, and severity of the disease depend on the individual host's immune response.[19,39] Patients may show alterations in their peripherial monocytes, which are related to the reduced reactivity of lymphocytes or an enhanced B-cell response.[39,40] B-cells, macrophages, periodontal ligament cells, gingival fibroblasts, and epithelial cells synthesize pro-inflammatory mediators (e.g., interleukin-1β, interleukin-6, interleukin-8, prostaglandin E2, tumor necrosis factor-α) that modify innate and adaptive immune responses at periodontal sites.[7,12-14,29,45] Pro-inflammatory mediators regulate the synthesis and secretion of, for example, matrix metalloproteinases and receptor activator of nuclear factor-κβ ligand (RANKL). In periodontal lesions, matrix metalloproteinases contribute to soft- and hard-tissue degradation during active inflammatory reactions.[19] RANKL binds to its receptor activator of nuclear factor-κβ on the cell surface of premature osteoclasts, thereby initiating osteoclast differentiation that leads to the degradation of alveolar bone.[19,29,45] Physiologically, osteoprotegerin is the opponent of RANKL; during periodontitis, an imbalance between osteoprotegerin and RANKL promotes further bone degradation.[19]

In addition, reduced neutrophil counts influence the degree of periodontal inflammation. Congenital neutropenia (Kostman syndrome) leads not only to an increased susceptibility to infection in general but also to severe chronic periodontitis. Patients with Kostman syndrome show reduced levels of antimicrobial peptides, such as the cathelicidin LL-37 and neutrophil peptides (α-defensins), which impair the innate immune response.[5,46] LL-37 is an effective antimicrobial peptide that is synthesized from inactive precursors. Mutations in the cathepsin C gene hinder cleavage and thus the activation of LL-37. Such genetic alterations contribute to the severity and progression of chronic periodontitis (i.e., Papillon–Lefèvre syndrome; Haim–Munk syndrome).[8,24]

Genetic Factors

Periodontitis is considered to be a multifactorial disease that is influenced by local, systemic, and immunologic factors, as described previously. Each factor is in turn directly related to individual genetic conditions. Genetic variations such as single nucleotide polymorphisms (SNPs) and genetic copy number variations may directly influence innate and adaptive immune responses as well as the structure of periodontal tissues. Periodontal destruction has been found among family members and across different generations within a family, thereby suggesting a genetic basis for the susceptibility to periodontal disease. In a number of studies, the prevalence of aggressive and chronic periodontitis has been investigated in families with a history of one or more family members with periodontitis. The data from those studies have demonstrated variable results, with a likelihood of heritability of up to 50%. Variations are mainly the result of different study designs as well as the number of evaluated individuals.[2,35,51]

Studies of SNPs in the interleukin-1 gene led to early conclusions that alterations in sequences of immunologically relevant genes may explain the heritability of periodontitis.[30] Conflicting data in the literature indicate inconclusive knowledge of SNPs in the interleukin-1 gene as well as of SNPs' potential role in the heritability and etiopathology of periodontitis. [15,17]

Genome-wide association studies have revealed a significant association between periodontitis and coronary heart disease as a result of a variation in the CDKN2BAS gene (cyclin-dependent kinase inhibitor 2B antisense [formerly antisense non-coding RNA in the INK4 locus, ANRIL]). In vitro studies have shown that the periodontal pathogen *Porphyromonas gingivalis* induced the gene expression of ANRIL in human gingival fibroblasts, thereby suggesting the potential regulation of ANRIL during periodontal infection and inflammation.[52] Another study identified a SNP in an untranslated region of the human β-defensin-1 gene DEFB1, and this genetic alteration was significantly associated with aggressive and chronic periodontitis. Human β-defensin-1 is an antimicrobial peptide that plays an important role in innate immune responses.[7,54] In a different genome-wide association study, a SNP in the glycosyltransferase gene GLT6D1 was found to be associated with aggressive periodontitis. The exact physiological role of GLT6D1 is currently unknown.[55] In addition, genetic alterations in the cyclooxygenase-2 gene (COX-2) were also significantly associated with aggressive periodontitis. COX-2 is involved in eicosanoid metabolism and therefore important during inflammatory reactions.[53] Although four different genetic variations have been identified and validated, it is most likely that a higher number of genes require variations to result in the development of periodontitis.[36]

Environmental and Behavioral Factors

In addition to microbial, immunologic, and genetic factors, the development and progression of chronic periodontitis is further influenced by environmental and behavioral factors, such as smoking and psychological stress.[39,40] Smoking is a major risk factor for the development and progression of generalized chronic periodontitis.[4] Periodontitis is influenced by smoking in a dose-dependent manner. The intake of more than 10 cigarettes per day tremendously increases the risk of disease progression as compared with non-smokers and former smokers.[59]

As compared with non-smokers, the following features are found in smokers[3,27,42,49]:

- Increased periodontal pocket depth of more than 3 mm
- Increased attachment loss
- More recessions
- Increased loss of alveolar bone
- Increased tooth loss
- Fewer signs of gingivitis (e.g., less bleeding with probing)
- Greater incidence of furcation involvement

As a result of the consumption of tobacco, reactive oxygen (i.e., radicals) is released that chemically irritates periodontal tissues via DNA damage, the lipid peroxidation of cell membranes, the damage of endothelial cells, and the induction of smooth muscle cell growth.[37]

Psychological factors (e.g., stress, depression) also negatively influence the progression of chronic periodontitis.[22] Patients with periodontitis often report the experience of family- or work-related stress.[41] Positive correlations between cortisol levels and periodontal indices (e.g., plaque index, gingival index), bone loss, and missing teeth have been recorded.[11,22,47] In addition, stress as an etiologic factor was even more strongly associated with periodontitis when patients were smokers as compared with non-smokers.[6]

Suggested Readings

Chung WO, Dommisch H, Yin L, et al: Expression of defensins in gingiva and their role in periodontal health and disease. *Curr Pharm Des* 13:3073–3083, 2007.

Eke PI, Dye BA, Wei L, et al: Prevalence of periodontitis in adults in the United States: 2009 and 2010. *J Dent Res* 91:914–920, 2012.

Flemmig TF: Periodontitis. *Ann Periodontol* 4:32–38, 1999.

Kebschull M, Demmer RT, Papapanou PN: "Gum bug, leave my heart alone!"—epidemiologic and mechanistic evidence linking periodontal infections and atherosclerosis. *J Dent Res* 89:879–902, 2010.

Lang NP, Schatzle MA, Loe H: Gingivitis as a risk factor in periodontal disease. *J Clin Periodontol* 36(Suppl 10):3–8, 2009.

Lindhe J, Okamoto H, Yoneyama T, et al: Longitudinal changes in periodontal disease in untreated subjects. *J Clin Periodontol* 16:662–670, 1989.

Pihlstrom BL, Michalowicz BS, Johnson NW: Periodontal diseases. *Lancet* 366:1809–1820, 2005.

Preshaw PM, Alba AL, Herrera D, et al: Periodontitis and diabetes: a two-way relationship. *Diabetologia* 55:21–31, 2012.

Schaefer AS, Richter GM, Nothnagel M, et al: A 3′ UTR transition within DEFB1 is associated with chronic and aggressive periodontitis. *Genes Immun* 11:45–54, 2010.

Tonetti MS: Cigarette smoking and periodontal diseases: etiology and management of disease. *Ann Periodontol* 3:88–101, 1998.

References

References for this chapter are found on the companion website www.expertconsult.com.

References

1. Azarpazhooh A, Tenenbaum HC: Separating fact from fiction: use of high-level evidence from research syntheses to identify diseases and disorders associated with periodontal disease. *J Can Dent Assoc* 78:c25, 2012.
2. Beaty TH, Boughman JA, Yang P, et al: Genetic analysis of juvenile periodontitis in families ascertained through an affected proband. *Am J Hum Genet* 40:443–452, 1987.
3. Bergstrom J: Influence of tobacco smoking on periodontal bone height. Long-term observations and a hypothesis. *J Clin Periodontol* 31:260–266, 2004.
4. Bergstrom J: Tobacco smoking and chronic destructive periodontal disease. *Odontology* 92:1–8, 2004.
5. Carlsson G, Andersson M, Putsep K, et al: Kostmann syndrome or infantile genetic agranulocytosis, part one: celebrating 50 years of clinical and basic research on severe congenital neutropenia. *Acta Paediatr* 95:1526–1532, 2006.
6. Chiou LJ, Yang YH, Hung HC, et al: The association of psychosocial factors and smoking with periodontal health in a community population. *J Periodontal Res* 45:16–22, 2010.
7. Chung WO, Dommisch H, Yin L, et al: Expression of defensins in gingiva and their role in periodontal health and disease. *Curr Pharm Des* 13:3073–3083, 2007.
8. de Haar SF, Hiemstra PS, van Steenbergen MT, et al: Role of polymorphonuclear leukocyte-derived serine proteinases in defense against *Actinobacillus actinomycetemcomitans*. *Infect Immun* 74:5284–5291, 2006.
9. Demmer RT, Papapanou PN: Epidemiologic patterns of chronic and aggressive periodontitis. *Periodontol 2000* 53:28–44, 2010.
10. Deschner J, Haak T, Jepsen S, et al: Diabetes mellitus and periodontitis. Bidirectional relationship and clinical implications. A consensus document. *Der Internist* 52:466–477, 2011.
11. Dolic M, Bailer J, Staehle HJ, et al: Psychosocial factors as risk indicators of periodontitis. *J Clin Periodontol* 32:1134–1140, 2005.
12. Dommisch H, Chung WO, Jepsen S, et al: Phospholipase C, p38/MAPK, and NF-kappaB-mediated induction of MIP-3alpha/CCL20 by *Porphyromonas gingivalis*. *Innate Immun* 16:226–234, 2010.
13. Dommisch H, Chung WO, Rohani MG, et al: Protease-activated receptor 2 mediates human beta-defensin 2 and CC chemokine ligand 20 mRNA expression in response to proteases secreted by *Porphyromonas gingivalis*. *Infect Immun* 75:4326–4333, 2007.
14. Dommisch H, Reinartz M, Backhaus T, et al: Antimicrobial responses of primary gingival cells to *Porphyromonas gingivalis*. *J Clin Periodontol* 39:913–922, 2012.
15. Ehmke B, Kress W, Karch H, et al: Interleukin-1 haplotype and periodontal disease progression following therapy. *J Clin Periodontol* 26:810–813, 1999.
16. Eke PI, Dye BA, Wei L, et al: Prevalence of periodontitis in adults in the United States: 2009 and 2010. *J Dent Res* 91:914–920, 2012.
17. Fiebig A, Jepsen S, Loos BG, et al: Polymorphisms in the interleukin-1 (IL1) gene cluster are not associated with aggressive periodontitis in a large Caucasian population. *Genomics* 92:309–315, 2008.
18. Flemmig TF: Periodontitis. *Ann Periodontol* 4:32–38, 1999.
19. Garlet GP: Destructive and protective roles of cytokines in periodontitis: a re-appraisal from host defense and tissue destruction viewpoints. *J Dental Res* 89:1349–1363, 2010.
20. Genco RJ, Falkner KL, Grossi S, et al: Validity of self-reported measures for surveillance of periodontal disease in two western New York population-based studies. *J Periodontol* 78:1439–1454, 2007.
21. Gher ME, Vernino AR: Root morphology—clinical significance in pathogenesis and treatment of periodontal disease. *J Am Dent Assoc* 101:627–633, 1980.
22. Goyal S, Jajoo S, Nagappa G, et al: Estimation of relationship between psychosocial stress and periodontal status using serum cortisol level: a clinico-biochemical study. *Indian J Dent Res* 22:6–9, 2011.
23. Graves DT, Liu R, Oates TW: Diabetes-enhanced inflammation and apoptosis: impact on periodontal pathosis. *Periodontol 2000* 45:128–137, 2007.
24. Hart TC, Hart PS, Michalec MD, et al: Haim-Munk syndrome and Papillon-Lefevre syndrome are allelic mutations in cathepsin C. *J Med Genet* 37:88–94, 2000.
25. Holtfreter B, Schwahn C, Biffar R, et al: Epidemiology of periodontal diseases in the Study of Health in Pomerania. *J Clin Periodontol* 36:114–123, 2009.
26. Hou GL, Tsai CC: Cervical enamel projection and intermediate bifurcational ridge correlated with molar furcation involvements. *J Periodontology* 68:687–693, 1997.
27. Johnson GK, Hill M: Cigarette smoking and the periodontal patient. *J Periodontology* 75:196–209, 2004.
28. Kebschull M, Demmer RT, Papapanou PN: "Gum bug, leave my heart alone!"—epidemiologic and mechanistic evidence linking periodontal infections and atherosclerosis. *J Dent Res* 89:879–902, 2010.
29. Kinane DF, Preshaw PM, Loos BG, et al: Host-response: understanding the cellular and molecular mechanisms of host-microbial interactions—consensus of the Seventh European Workshop on Periodontology. *J Clin Periodontol* 38(Suppl 11):44–48, 2011.
30. Kornman KS, Crane A, Wang HY, et al: The interleukin-1 genotype as a severity factor in adult periodontal disease. *J Clin Periodontol* 24:72–77, 1997.
31. Kuonen P, Huynh-Ba G, Krummen VS, et al: Restoration margins in young adolescents: a clinical and radiographic study of Swiss Army recruits. *Oral Health Prev Dent* 7:377–382, 2009.
32. Lang NP, Schatzle MA, Loe H: Gingivitis as a risk factor in periodontal disease. *J Clin Periodontol* 36(Suppl 10):3–8, 2009.
33. Lindhe J, Okamoto H, Yoneyama T, et al: Longitudinal changes in periodontal disease in untreated subjects. *J Clin Periodontol* 16:662–670, 1989.
34. Lindhe J, Okamoto H, Yoneyama T, et al: Periodontal loser sites in untreated adult subjects. *J Clin Periodontol* 16:671–678, 1989.
35. Llorente MA, Griffiths GS: Periodontal status among relatives of aggressive periodontitis patients and reliability of family history report. *J Clin Periodontol* 33:121–125, 2006.
36. Loos BG, John RP, Laine ML: Identification of genetic risk factors for periodontitis and possible mechanisms of action. *J Clin Periodontol* 32(Suppl 6):159–179, 2005.
37. Moller P, Jacobsen NR, Folkmann JK, et al: Role of oxidative damage in toxicity of particulates. *Free Radic Res* 44:1–46, 2010.
38. Offenbacher S, Barros SP, Altarawneh S, et al: Impact of tooth loss on oral and systemic health. *Gen Dent* 60:494–500, quiz p 501-592, 2012.
39. Ohlrich EJ, Cullinan MP, Seymour GJ: The immunopathogenesis of periodontal disease. *Aust Dent J* 54(Suppl 1):S2–S10, 2009.
40. Pihlstrom BL, Michalowicz BS, Johnson NW: Periodontal diseases. *Lancet* 366:1809–1820, 2005.
41. Pistorius A, Krahwinkel T, Willershausen B, et al: Relationship between stress factors and periodontal disease. *Eur J Med Res* 7:393–398, 2002.
42. Preber H, Bergstrom J: Occurrence of gingival bleeding in smoker and non-smoker patients. *Acta Odontol Scand* 43:315–320, 1985.
43. Preshaw PM, Alba AL, Herrera D, et al: Periodontitis and diabetes: a two-way relationship. *Diabetologia* 55:21–31, 2012.
44. Preshaw PM, Foster N, Taylor JJ: Cross-susceptibility between periodontal disease and type 2 diabetes mellitus: an immunobiological perspective. *Periodontol 2000* 45:138–157, 2007.
45. Preshaw PM, Taylor JJ: How has research into cytokine interactions and their role in driving immune responses impacted our understanding of periodontitis? *J Clin Periodontol* 38(Suppl 11):60–84, 2011.
46. Putsep K, Carlsson G, Boman HG, et al: Deficiency of antibacterial peptides in patients with morbus Kostmann: an observation study. *Lancet* 360:1144–1149, 2002.
47. Rai B, Kaur J, Anand SC, et al: Salivary stress markers, stress, and periodontitis: a pilot study. *J Periodontol* 82:287–292, 2011.
48. Roussa E: Anatomic characteristics of the furcation and root surfaces of molar teeth and their significance in the clinical management of marginal periodontitis. *Clin Anat* 11:177–186, 1998.
49. Salem A, Hilow H, Khraisat A, et al: Association between intensity of smoking and periodontal pockets among young university students. *Odontostomatol Trop* 31:5–10, 2008.

50. Sanz M, van Winkelhoff AJ, Working Group 1 of Seventh European Workshop on Periodontology: Periodontal infections: understanding the complexity—consensus of the Seventh European Workshop on Periodontology. *J Clin Periodontol* 38(Suppl 11):3–6, 2011.
51. Saxen L: Heredity of juvenile periodontitis. *J Clin Periodontol* 7:276–288, 1980.
52. Schaefer AS, Richter GM, Dommisch H, et al: CDKN2BAS is associated with periodontitis in different European populations and is activated by bacterial infection. *J Med Genet* 48:38–47, 2011.
53. Schaefer AS, Richter GM, Nothnagel M, et al: COX-2 is associated with periodontitis in Europeans. *J Dent Res* 89:384–388, 2010.
54. Schaefer AS, Richter GM, Nothnagel M, et al: A 3′ UTR transition within DEFB1 is associated with chronic and aggressive periodontitis. *Genes Immun* 11:45–54, 2010.
55. Schaefer AS, Richter GM, Nothnagel M, et al: A genome-wide association study identifies GLT6D1 as a susceptibility locus for periodontitis. *Hum Mol Genet* 19:553–562, 2010.
56. Schroeder HE: Formation and inhibition of dental calculus. *J Periodontol* 40:643–646, 1969.
57. Socransky SS, Haffajee AD, Goodson JM, et al: New concepts of destructive periodontal disease. *J Clin Periodontol* 11:21–32, 1984.
58. Taylor GW, Borgnakke WS: Self-reported periodontal disease: validation in an epidemiological survey. *J Periodontol* 78:1407–1420, 2007.
59. Tonetti MS: Cigarette smoking and periodontal diseases: etiology and management of disease. *Ann Periodontol* 3:88–101, 1998.
60. Tonetti MS: Periodontitis and risk for atherosclerosis: an update on intervention trials. *J Clin Periodontol* 36(Suppl 10):15–19, 2009.
61. Tsai C, Hayes C, Taylor GW: Glycemic control of type 2 diabetes and severe periodontal disease in the US adult population. *Community Dent Oral Epidemiol* 30:182–192, 2002.
62. Valderhaug J: Periodontal conditions and carious lesions following the insertion of fixed prostheses: a 10-year follow-up study. *Int Dent J* 30:296–304, 1980.

CHAPTER 24

Necrotizing Ulcerative Periodontitis

Perry R. Klokkevold and Fermin A. Carranza

CHAPTER OUTLINE

Clinical Features
Microscopic Findings
Patient with HIV/Acquired Immunodeficiency Syndrome
Etiology of Necrotizing Ulcerative Periodontitis
Malnutrition
Conclusion

Necrotizing ulcerative periodontitis (NUP) may be an extension of *necrotizing ulcerative gingivitis* (NUG) into the periodontal structures that leads to periodontal attachment and bone loss. Alternatively, NUP and NUG may be different diseases. To date, there is little evidence to support the progression of NUG to NUP or to establish a relationship between the two conditions as a single disease entity. However, numerous clinical descriptions and case reports of NUP clearly demonstrate many clinical similarities between the two conditions. Until a distinction between NUG and NUP can be proved or disproved, it has been suggested that NUG and NUP be classified together under the broader category of *necrotizing periodontal diseases,* although with differing levels of severity.[1,19]

NUG has been recognized and described in the literature for centuries.[22] The features of NUG are presented in Chapter 10.

The lesions of NUG are confined to the gingiva without a loss of periodontal attachment or alveolar bone support; this is the feature that distinguishes NUG from NUP.

The term *necrotizing ulcerative periodontitis* was first adopted at the 1989 World Workshop in Clinical Periodontics.[3] It was changed from the 1986 term *necrotizing ulcerative gingivoperiodontitis,* which represented the condition of recurrent NUG that progresses to a chronic form of periodontitis that includes attachment and bone loss. The adoption of NUP as a disease entity occurred in 1989 when there was a heightened awareness and an increase in the number of necrotizing periodontitis cases being diagnosed and described in the literature. Specifically, more cases of NUP were being described among immunocompromised patients, especially those who were human immunodeficiency virus (HIV) positive or who had acquired immunodeficiency syndrome (AIDS). In 1999, the subclassifications of NUG and NUP were included as separate diagnoses under the broader classification of "necrotizing ulcerative periodontal diseases."[1]

Clinical Features

Similar to NUG, clinical cases of NUP are defined by necrosis and ulceration of the coronal portion of the interdental papillae and gingival margin, with a painful, bright-red marginal gingiva that bleeds easily.

The distinguishing feature of NUP is the *destructive progression* of the disease, which includes periodontal attachment and bone loss. Deep interdental osseous craters typify periodontal lesions of NUP (Figure 24-1). However, "conventional" periodontal pockets with deep probing depth are not found, because the ulcerative and necrotizing nature of the gingival lesion destroys the marginal epithelium and connective tissue, thereby resulting in gingival recession. Periodontal pockets are formed because the junctional epithelial cells remain viable and can therefore migrate apically to cover areas of lost connective-tissue attachment. The necrosis of the junctional epithelium in patients with NUG and NUP creates an ulcer that prevents this epithelial migration, and a pocket cannot form. Advanced lesions of NUP lead to severe bone loss, tooth mobility, and ultimately tooth loss. In addition to these manifestations, as previously mentioned, patients with NUP may present with oral malodor, fever, malaise, or lymphadenopathy.

Microscopic Findings

In a study involving the use of transmission electron microscopy and scanning electron microscopy of the microbial plaque overlying the necrotic gingival papillae, Cobb and colleagues[4] demonstrated striking histologic similarities between NUP in HIV-positive patients and previous descriptions of NUG in HIV-negative patients. Microscopic examination revealed a surface biofilm composed of a mixed microbial flora with different morphotypes and a subsurface flora with dense aggregations of spirochetes (i.e., the bacterial zone). Below the bacterial layers were dense aggregations of polymorphonuclear leukocytes (PMNs) (i.e., the neutrophil-rich zone) and necrotic cells (necrotic zone). The biopsy technique used in this study did not allow for the observation of the deepest layer and thus was not able to identify the spirochetal infiltration zone, which is classically described in NUG lesions. In addition to the NUG-like microscopic features of NUP described in this study, high levels of yeasts and herpes-like viruses were observed. This latter finding is most likely indicative of the conditions afforded to opportunistic microbes in the immunocompromised host (i.e., HIV-positive patients).

Patients with Human Immunodeficiency Virus/Acquired Immunodeficiency Syndrome

Gingival and periodontal lesions with distinctive features are frequently found in patients with HIV infection and AIDS. Many of these lesions are atypical manifestations of inflammatory periodontal diseases that arise during the course of HIV infection

Figure 24-1 Necrotizing ulcerative periodontitis in a 45-year-old, HIV-negative, white, male patient. **A,** Buccal view of the maxillary cuspid–bicuspid area. **B,** Palatal view of the same area shown in **A. C,** Buccal view of the mandibular anteriors. Note the deep craters associated with bone loss.

and as a result of the patient's concomitant immunocompromised state. Linear gingival erythema, NUG, and NUP are the most common HIV-associated periodontal conditions reported in the literature.[20] Chapter 19 provides detailed descriptions of these and other atypical periodontal diseases that occur in the patient with HIV.

NUP lesions found in patients with HIV or AIDS can present with features similar to those seen in HIV-negative patients. Alternatively, NUP lesions in patients with HIV or AIDS can be much more destructive and frequently result in complications that are extremely rare among patients without HIV or AIDS. For example, periodontal attachment and bone loss associated with NUP in an HIV-positive patient may be extremely rapid. Winkler and colleagues[30] described cases of NUP in HIV-positive patients with teeth that lost more than 90% of periodontal attachment and 10 mm of bone over a 3- to 6-month period. Ultimately, many of these lesions resulted in tooth loss. Other complications reported in this population included the progression of the lesions to involve large areas of soft-tissue necrosis, with the exposure of bone and the sequestration of bone fragments. This type of severe, progressive lesion with extension into the vestibular area and the palate is referred to as *necrotizing ulcerative stomatitis* (see Figure 19-31).

The reported prevalence of NUP among patients with HIV infection varies.[6,13,20,22] Riley and colleagues[23] described only two cases of NUP in 200 HIV-positive patients (1%), whereas Glick and colleagues[13] found a prevalence of 6.3% for NUP cases in a prospective study of 700 HIV-positive patients. Variations in reported findings may be related to differences in the populations studied (e.g., intravenous drug users versus homosexuals versus patients with hemophilia) and differences in the immune statuses of the study subjects.

Necrotizing forms of periodontitis appear to be more prevalent among patients with more severe immunosuppression.[20,21] Case reports have depicted NUP as a progressive extension of HIV periodontitis (i.e., chronic to necrotic progression).[24] Glick and colleagues[13,14] found a high correlation between the diagnosis of NUP and immunosuppression in HIV-positive patients. Those patients who presented with NUP were 20.8 times more likely to have CD4+ counts of less than 200 cells/mm^3 as compared with HIV-positive patients without NUP. The authors consider a diagnosis of NUP to be a marker of immune deterioration and a predictor of the diagnosis of AIDS.[13] Others have suggested that NUP may be used as an indicator of HIV infection in undiagnosed patients. Shangase and colleagues[27] reported that a diagnosis of NUG or NUP in systemically healthy, asymptomatic South-African patients was strongly correlated with HIV infection. Of patients presenting with NUG or NUP, 39 of 56 (69.6%) were subsequently found to be infected with HIV (see Chapter 19).

Etiology of Necrotizing Ulcerative Periodontitis

The etiology of NUP has not been determined, although a mixed fusiform–spirochete bacterial flora appears to play a key role. Because bacterial pathogens are not solely responsible for causing the disease, some predisposing "host" factors may be necessary. Numerous predisposing factors have been attributed to NUG, including poor oral hygiene, preexisting periodontal disease, smoking, viral infections, immunocompromised status, psychosocial stress, and malnutrition.

NUG and NUP are more prevalent and more severe among patients with HIV. These patients require urgent treatment, because untreated lesions can progress rapidly; within a few days, severe bone loss around affected teeth can be seen.

Smoking, malnutrition, and high plaque levels all increase the risk of NUG and need to be changed so that treatment success is obtained.

Clinicians should check all patients who present with NUP to ascertain their HIV status. NUP can progress rapidly and lead to tooth exfoliation, so treatment should include local debridement, local antiplaque agents, and systemic antibiotics. The early diagnosis and treatment of NUP are crucial, because the osseous defects

that occur during the late stages of the disease are extremely difficult to resolve.

Microbial Flora

Assessment of the microbial flora of NUP lesions is almost exclusively limited to studies involving patients with HIV or AIDS, with some conflicting evidence. Murray and colleagues[19] reported that cases of NUP in HIV-positive patients demonstrated significantly greater numbers of the opportunistic fungus *Candida albicans* and a higher prevalence of *Aggregatibacter actinomycetemcomitans, Prevotella intermedia, Porphyromonas gingivalis, Fusobacterium nucleatum,* and *Campylobacter* species as compared with HIV-negative controls. In addition, they reported a low or variable level of spirochetes, which is inconsistent with the flora associated with NUG. Citing differences in microbial flora, they refuted the notion that the destructive lesions seen in HIV-positive patients were related to NUG lesions; they suggested that the flora of NUP lesions in HIV-positive patients is comparable to that of chronic periodontitis lesions, thus supporting their concept that necrotizing periodontitis in the HIV-positive patient is an aggressive manifestation of chronic periodontitis in the immunocompromised host.

In contrast with these findings, Cobb and colleagues[4] reported that the microbial composition of NUP lesions in HIV-positive patients was very similar to that of NUG lesions, as discussed previously. With the use of electron microscopy, the researchers described a mixed microbial flora with various morphotypes in 81.3% of specimens. The subsurface microbial flora featured dense aggregations of spirochetes in 87.5% of specimens. The authors also reported opportunistic yeasts and herpes-like viruses in 65.6% and 56.5% of NUP lesions, respectively. The differences between these reports may be explained by the limitations of obtaining viable cultures of spirochetes[19] as compared with the more definitive electron microscopic observation of spirochetes.[4]

In a recent review article, Feller and Lemmer suggested that spirochetes, herpesviruses, candida, and HIV all have potentially pathogenic roles in NUP lesions in the HIV-seropositive individual.[12] Spirochetes have the ability to modulate the host's innate and adaptive immune responses and to stimulate host inflammatory reactions,[8] which may reduce the local immune competence and facilitate the development of necrotizing disease.[12] Activated herpesviruses have the capacity to deregulate the host's immune system, which may lead to an increase in the colonization and activity of other pathogenic microorganisms. *Candida albicans* has been reported to produce eicosanoids, thereby leading to the release of proinflammatory mediators, which may facilitate spirochete colonization and invasion and promote the development of necrotizing periodontal diseases.[11,12]

Immunocompromised Status

Clearly, both NUG and NUP lesions are more prevalent among patients with compromised or suppressed immune systems. Numerous studies—particularly those evaluating patients with HIV or AIDS—support the concept that a diminished host response is present in those individuals who have been diagnosed with necrotizing ulcerative periodontal diseases.[30] Whereas a compromised immune system (i.e., "immune compromise") in the HIV-infected patient is driven by impaired T-cell function and altered T-cell ratios, evidence indicates that other forms of compromised immunity predispose individuals to NUG and NUP as well.

Cutler and colleagues[6] described the impaired bactericidal activity of PMNs in two children with NUP. In a comparative assay of PMNs and periodontal pathogens, two brothers who were 9 and 14 years old showed significant depression of PMN phagocytosis and killing function as compared with gender- and age-matched controls. Furthermore, Batista and colleagues[2] reported periodontal findings and NUP in an adolescent patient with a rare genetic disease (multifactorial congenital immunodeficiency) that causes the impaired secretion of immunoglobulin; the oral lesions resolved with the administration of intravenous immunoglobulin.

Psychologic Stress

Most studies evaluating the role of stress on necrotizing periodontal disease have involved subjects with NUG[7,15,28,29] and thus have not specifically addressed the role of stress on NUP.

Patients with NUG have been found to have had significantly more anxiety, higher depression scores, a greater magnitude of recent stressful events, more overall distress and adjustments related to these events, and more negative life events.[5,14] Although the role of stress in the development of NUP has not been reported specifically, the many similarities between NUG and NUP would suggest that similar relationships to stress may exist.

The mechanisms that predispose an individual with stress to necrotizing ulcerative periodontal diseases have not been established. However, it is well known that stress increases the systemic cortisol levels, and sustained increases in cortisone have a suppressive effect on the immune response. In an investigation of 474 military personnel, Shannon and colleagues[28] found that urinary levels of 17-hydroxycorticosteroid were higher among subjects with NUG than in all other subjects who had been diagnosed with periodontal health, gingivitis, or periodontitis. Experimentally, noma-like lesions have been produced in rats by administering cortisone[26] and causing mechanical injury to the gingiva[25] and in hamsters via total body irradiation.[18] Thus, stress-induced immunosuppression may be one mechanism that impairs the host response and leads to necrotizing periodontal disease. The scientific evidence supporting an etiologic role of stress in chronic periodontitis is not as clear (see Chapter 27).

Malnutrition

Direct evidence of the relationship between malnutrition and necrotizing periodontal disease is limited to descriptions of necrotizing infections in severely malnourished children. Lesions resembling NUG but that progress to become *gangrenous stomatitis* or noma have been described in children with severe malnutrition in underdeveloped countries. Jimenez and Baer[17] reported cases of NUG among malnourished children and adolescents between the ages of 2 and 14 years in Colombia. In the advanced stages, NUG lesions extended from the gingiva to other areas of the oral cavity, becoming gangrenous stomatitis (noma) and causing exposure, necrosis, and sequestration of the alveolar bone. Later, Jimenez and colleagues reported that 44 of the 45 cases of necrotizing disease (NUG = 29, NUP = 7, and noma = 9) documented from 1965 to 2000 were from a low socioeconomic group and that malnutrition was associated with nearly all of the necrotizing conditions (29/29 NUG cases, 6/7 NUP cases, and 9/9 noma cases).[16] In a study of socioeconomically deprived Nigerian children with NUG (153 cases), Enwonwu and colleagues confirmed malnutrition by measuring circulating micronutrients.[10] As compared with neighborhood counterparts, the children with NUG and micronutrient deficiencies demonstrated dysregulated cytokine production with a complex interplay of elevated proinflammatory and anti-inflammatory mediators.

A possible explanation is that malnutrition, particularly when extreme, contributes to a diminished host resistance to infection and necrotizing disease. It is well documented that many of the host defenses—including phagocytosis; cell-mediated immunity;

and complement, antibody, and cytokine production and function—are impaired in malnourished individuals.[9] The depletion of nutrients to cells and tissues results in immunosuppression and increases disease susceptibility. Thus, it is reasonable to conclude that malnutrition can predispose an individual to opportunistic infections or intensify the severity of existing oral infections.

Conclusion

NUP and NUG share many clinical and microbiologic features, but NUP is distinguished by a more severe condition with periodontal attachment and bone loss. Indeed, some patients with NUP, particularly those with compromised immunity, can have severe and rapidly progressive disease. It appears that an impaired immune response and a lowered host resistance to infection are significant factors in the onset and progression of NUP. The best example of an immunocompromised host with a predisposition for NUP is the patient with HIV or AIDS. As with the other infection-related complications of HIV and AIDS, the immunocompromised status of affected patients renders them vulnerable to opportunistic periodontal infections, including NUP. Several other factors have been identified in cases of NUG that may also play a role in NUP, including smoking, viral infections, psychosocial stress, and malnutrition. Although none of these factors alone is sufficient to cause necrotizing disease, in combination with other immunocompromising conditions, they undoubtedly have the potential to adversely influence the host response or resistance to infection.

Suggested Readings

Cobb CM, Ferguson BL, Keselyak NT, et al: A TEM/SEM study of the microbial plaque overlying the necrotic gingival papillae of HIV-seropositive, necrotizing ulcerative periodontitis. *J Periodontal Res* 38(2):147–155, 2003.

Feller L, Lemmer J: Necrotizing periodontal diseases in HIV-seropositive subjects: pathogenic mechanisms. *J Int Acad Periodontol* 10(1):10–15, 2008.

Glick M, Muzyka BC, Salkin LM, et al: Necrotizing ulcerative periodontitis: a marker for immune deterioration and a predictor for the diagnosis of AIDS. *J Periodontol* 65(5):393–397, 1994.

Jimenez LM, Duque FL, Baer PN, et al: Necrotizing ulcerative periodontal diseases in children and young adults in Medellin, Colombia, 1965-2000. *J Int Acad Periodontol* 7(2):55–63, 2005.

Novak MJ: Necrotizing ulcerative periodontitis. *Ann Periodontol* 4(1):74–78, 1999.

Winkler JR, Grassi M, Murray PA: *Clinical description and etiology of HIV-associated periodontal diseases*, Littleton, MA, 1988, PSG Publishing.

References

References for this chapter are found on the companion website www.expertconsult.com.

References

1. Armitage GC: Development of a classification system for periodontal diseases and conditions. *Ann Periodontol* 4(1):1–6, 1999.
2. Batista EL, Jr, Novaes AB, Jr, Calvano LM, et al: Necrotizing ulcerative periodontitis associated with severe congenital immunodeficiency in a prepubescent subject: clinical findings and response to intravenous immunoglobulin treatment. *J Clin Periodontol* 26(8):499–504, 1999.
3. Caton J: Consensus report on periodontal diagnosis and diagnostic aids. Paper presented at: Proceedings of the World Workshop in Clinical Periodontics, Chicago, 1989.
4. Cobb CM, Ferguson BL, Keselyak NT, et al: A TEM/SEM study of the microbial plaque overlying the necrotic gingival papillae of HIV-seropositive, necrotizing ulcerative periodontitis. *J Periodontal Res* 38(2):147–155, 2003.
5. Cohen-Cole SA, Cogen RB, Stevens AW, Jr, et al: Psychiatric, psychosocial, and endocrine correlates of acute necrotizing ulcerative gingivitis (trench mouth): a preliminary report. *Psychiatr Med* 1(2):215–225, 1983.
6. Cutler CW, Wasfy MO, Ghaffar K, et al: Impaired bactericidal activity of PMN from two brothers with necrotizing ulcerative gingivoperiodontitis. *J Periodontol* 65(4):357–363, 1994.
7. Da Silva AM, Newman HN, Oakley DA: Psychosocial factors in inflammatory periodontal diseases: a review. *J Clin Periodontol* 22(7):516–526, 1995.
8. Ellen RP, Galimanas VB: Spirochetes at the forefront of periodontal infections. *Periodontol 2000* 38:13–32, 2005.
9. Enwonwu CO, Phillips RS, Falkler WA, Jr: Nutrition and oral infectious diseases: state of the science. *Compend Contin Educ Dent* 23(5):431–434, 436, 438 passim; quiz 448, 2002.
10. Enwonwu CO, Phillips RS, Savage KO: Inflammatory cytokine profile and circulating cortisol levels in malnourished children with necrotizing ulcerative gingivitis. *Eur Cytokine Netw* 16(3):240–248, 2005.
11. Feller L, Buskin A, Blignaut E: A review of candida and periodontal disease in immunocompetent and HIV-infected subjects. *SADJ* 60(4):152–154, 2005.
12. Feller L, Lemmer J: Necrotizing periodontal diseases in HIV-seropositive subjects: pathogenic mechanisms. *J Int Acad Periodontol* 10(1):10–15, 2008.
13. Glick M, Muzyka BC, Lurie D, et al: Oral manifestations associated with HIV-related disease as markers for immune suppression and AIDS. *Oral Surg Oral Med Oral Pathol* 77(4):344–349, 1994.
14. Glick M, Muzyka BC, Salkin LM, et al: Necrotizing ulcerative periodontitis: a marker for immune deterioration and a predictor for the diagnosis of AIDS. *J Periodontol* 65(5):393–397, 1994.
15. Hildebrand HC, Epstein J, Larjava H: The influence of psychological stress on periodontal disease. *J West Soc Periodontol Periodontal Abstr* 48(3):69–77, 2000.
16. Jimenez LM, Duque FL, Baer PN, et al: Necrotizing ulcerative periodontal diseases in children and young adults in Medellin, Colombia, 1965-2000. *J Int Acad Periodontol* 7(2):55–63, 2005.
17. Jimenez M, Baer PN: Necrotizing ulcerative gingivitis in children: a 9 year clinical study. *J Periodontol* 46(12):715–720, 1975.
18. Mayo J, Carranza FA, Jr, Epper CE, et al: The effect of total-body irradiation on the oral tissues of the Syrian hamster. *Oral Surg Oral Med Oral Pathol* 15:739–745, 1962.
19. Murray PA, Winkler JR, Sadkowski L, et al: *Microbiology of HIV-associated gingivitis and periodontitis*, Littleton, MA, 1988, PSG Publishing.
20. Novak MJ: Necrotizing ulcerative periodontitis. *Ann Periodontol* 4(1):74–78, 1999.
21. Pistorius A, Willershausen B: Cases of HIV-associated characteristic periodontal diseases. *Eur J Med Res* 4(3):121–125, 1999.
22. Plaut HC: [Bacterial diagnostic studies of diphtheria and oral diseases]. *Dtsch Med Wochnschr* 20, 1894.
23. Riley C, London JP, Burmeister JA: Periodontal health in 200 HIV-positive patients. *J Oral Pathol Med* 21(3):124–127, 1992.
24. Rowland RW: Necrotizing ulcerative gingivitis. *Ann Periodontol* 4(1):65–73, discussion 78, 1999.
25. SanGiacomo TR, Tan PM, Loggi DG, et al: Progressive osseous destruction as a complication of HIV-periodontitis. *Oral Surg Oral Med Oral Pathol* 70(4):476–479, 1990.
26. Selye H: Effect of cortisone and somatotrophic hormone upon the development of a noma-like condition in the rat. *Oral Surg Oral Med Oral Pathol* 6(4):557–561, 1953.
27. Shangase L, Feller L, Blignaut E: Necrotising ulcerative gingivitis/periodontitis as indicators of HIV-infection. *SADJ* 59(3):105–108, 2004.
28. Shannon IL, Kilgore WG, O'Leary TJ: Stress as a predisposing factor in necrotizing ulcerative gingivitis. *J Periodontol* 40(4):240–242, 1969.
29. Shields WD: Acute necrotizing ulcerative gingivitis. A study of some of the contributing factors and their validity in an Army population. *J Periodontol* 48(6):346–349, 1977.
30. Winkler JR, Grassi M, Murray PA: *Clinical description and etiology of HIV-associated periodontal diseases*, Littleton, MA, 1988, PSG Publishing.

CHAPTER 25

Aggressive Periodontitis

Moritz Kebschull and Henrik Dommisch

CHAPTER OUTLINE

Historical Background *(e-only)*
Classification and Clinical Characteristics
Epidemiology
Pathobiology and Risk Factors
Diagnosis
Therapeutic Considerations for Patients With Aggressive Periodontitis

For online only content about the historical background of aggressive periodontitis, please visit the companion website at www.expertconsult.com.

Periodontitis is the pathological manifestation of the host response against bacterial challenge that stems from a polymicrobial biofilm at the biofilm–gingival interface.[51]

There are several subforms of the disease, and they are mainly characterized by their clinical phenotype (i.e., the rate of disease progression and other features) rather than their (still partially unknown) etiology. This chapter addresses aggressive periodontitis, which features the rapid loss of periodontal attachment and tooth-supporting bone in otherwise healthy patients.

Classification and Clinical Characteristics

Features

The 1999 International Workshop for the Classification of Periodontal Diseases and Conditions defined the entity of aggressive periodontitis as being characterized by three primary features[38] (see Table 25-1):

1. *The rapid loss of attachment and tooth-supporting bone*
   With aggressive periodontitis, as compared with the more common variant chronic periodontitis, the loss of attachment progresses significantly faster. To evaluate this rapid course of destruction, the evaluation of clinical or radiographic data from earlier points in time is necessary, thereby allowing for the making of an estimate of the start of the disease. Note that the age of the patient per se is not a primary criterion for the diagnosis of aggressive periodontitis. Because earlier clinical records are often not available, many clinicians argue that a severe loss of attachment in young patients may conceivably be the result of a rapid course of disease progression. However, this is not generally true; the neglect of all oral hygiene in a periodontitis-susceptible individual over a decade will lead to severe attachment loss, even with a slow rate of progression. On the other hand, severe attachment loss in an older individual is not necessarily the result of long-lasting, slowly progressing disease. It is therefore inappropriate to use the age of an affected individual as a primary diagnostic criterion for the distinction of aggressive and chronic periodontitis. Note that, with chronic periodontitis, there are reportedly periods of rapid disease progression that can by themselves be misinterpreted as aggressive periodontitis.
2. *The subject is otherwise healthy (i.e., not suffering from any systemic disease or condition that could be responsible for the present periodontitis)*
   There are systemic diseases that lead to severely altered host defenses against periodontal pathogens, often resulting in the rapid loss of attachment and tooth loss at early age. This disease is designated "periodontitis as a manifestation of systemic disease" (see Chapter 4). Note that the specific properties or abnormalities of some types of immune cells listed later in this chapter and reported to be often associated with the diagnosis of aggressive periodontitis do not themselves qualify for the aforementioned diagnosis.
3. *The presence of familiar aggregation*
   The familiar aggregation of aggressive periodontitis cases is a feature that can be evaluated via medical and dental history questionnaires and by interviewing the patient. However, it is advisable to verify similar cases in the family, if possible, because many individuals may not be fully aware of their diagnoses. Many cases of "bad teeth that run in the family" turn up to be caries related or likely due to chronic periodontitis.

In addition, the Workshop defined several secondary features that are generally found in aggressive periodontitis cases but that are not universally necessary to diagnose the disease entity:

1. Inconsistency of the low amounts of present etiological factors (i.e., plaque) and the observed pronounced tissue destruction
2. Strong colonization by *Aggregatibacter actinomycetemcomitans* and, in some populations, *Porphyromonas gingivalis*
3. Immunological differences that do not entail the diagnosis of periodontitis as a manifestation of systemic disease
   a. Hyperresponsive macrophages
   b. Abnormalities of neutrophil function
4. Self-limiting disease

Subgroups

Aggressive periodontitis can be subclassified into localized and generalized forms. The diagnosis of the subcategory is based on

Historical Background

In 1923, Gottlieb described a patient with a fatal case of epidemic influenza and a disease that he called "diffuse atrophy of the alveolar bone."[25] This disease was characterized by a loss of collagen fibers in the periodontal ligament and their replacement by loose connective tissue and extensive bone resorption, which resulted in a widened periodontal space. The gingiva apparently was not involved. In 1928, Gottlieb attributed this condition to the inhibition of continuous cementum formation, which he considered essential for the maintenance of the periodontal fibers.[26] At that time, he called the disease "deep cementopathia," and he hypothesized that this was a "disease of eruption" and that the cementum initiated a foreign-body response. As a result, it was postulated that the host attempted to exfoliate the tooth, thereby resulting in the observed bone resorption and pocket formation.

In 1938, Wannenmacher described incisor and first molar involvement and called the disease "parodontitis marginalis progressiva."[78] Several explanations evolved for the etiology and pathogenesis of this type of disease. Many authors considered this to be a degenerative, noninflammatory disease process and therefore gave it the name *periodontosis.*[24,52,75] Other investigators denied the existence of a degenerative type of periodontal disease and attributed the changes observed to trauma from occlusion.[10,46] Finally, in 1966, the World Workshop in Periodontics concluded that the concept of periodontosis as a degenerative entity was unsubstantiated and that the term should be eliminated from periodontal nomenclature.[58] The committee did recognize that a clinical entity different from adult periodontitis may occur among adolescents and young adults.

The term *juvenile periodontitis* was introduced by Chaput and colleagues in 1967 and by Butler in 1969.[9] In 1971, Baer defined it as "a disease of the periodontium occurring in an otherwise healthy adolescent which is characterized by a rapid loss of alveolar bone about more than one tooth of the permanent dentition.[5] The amount of destruction manifested is not commensurate with the amount of local irritants." In 1989, the World Workshop in Clinical Periodontics categorized this disease as localized juvenile periodontitis and as a subset of the broad classification of early-onset periodontitis.[11] Under this classification system, age of onset and distribution of lesions were of primary importance when making a diagnosis of this condition.

In 1999, the World Workshop in Periodontics introduced a novel classification that was meant to eliminate the shortcomings of earlier endeavors to classify periodontal disease. Most importantly, the new 1999 classification sought "to discard classification terminologies that were age-dependent or required knowledge of rates of progression."[2] In the new classification scheme, several rapidly progressing periodontitis forms were united under the term *aggressive periodontitis.*

TABLE 25-1 Diagnostic Criteria to Distinguish Chronic and Aggressive Periodontitis

Criterion	Aggressive Periodontitis	Chronic Periodontitis
Rate of progression	Rapid	Slow, but rapid episodes are possible
Familiar aggregation	Typical	Can be present when families share imperfect oral hygiene habits
Presence of etiological factors (e.g., plaque, calculus, overhanging restorations)	Often minimal	Often commensurate with observed periodontal destruction
Age	Often in young patients (i.e., <35 years old) but can be found in all age groups	Often in older patients (i.e., >55 years old) but can be found in all age groups
Clinical inflammation signs	Sometimes lacking (especially in patients with localized aggressive periodontitis)	Commensurate with amount of etiological factors present

TABLE 25-2 Diagnostic Criteria for Localized and Generalized Aggressive Periodontitis

Criterion	Localized Aggressive Periodontitis	Generalized Aggressive Periodontitis
Age of onset	Circumpubertal	Most often <30 years of age, but can also occur in older individuals
Serum antibody response against infecting agents	Robust	Poor
Destruction pattern	Localized attachment loss at incisors and first molars; interproximal attachment loss at two or more permanent teeth, one of which is a first molar, and involvement of two or fewer teeth other than the first molars and incisors	Generalized interproximal attachment loss at three or more permanent teeth other than the first molars and incisors
Additional		Episodic nature of attachment loss

clinical, radiographic, and historical data. These include the age of onset, the involvement of teeth other than first molars and incisors (i.e., the first permanent teeth to erupt), and the presence of a systemic antibody response against periodontal pathogens (see Table 25-2).

Generalized Aggressive Periodontitis. Generalized aggressive periodontitis (GAP) is the subgroup of periodontal disease that is characterized by the highest severity and extent of disease and also by its large heterogeneity. The diagnosis of GAP encompasses the diseases that were previously classified as generalized juvenile periodontitis and rapidly progressive periodontitis.

Two gingival tissue responses can be found in cases of GAP (see Figures 25-1 and 25-2). One involves severe, acutely inflamed tissue that is often proliferating, ulcerated, and fiery red. Bleeding may occur spontaneously or with slight stimulation, and suppuration may be an important feature. This tissue response is thought to occur during the destructive stage, in which attachment and bone are actively lost.

In other cases, the gingival tissues may appear pink, free of inflammation, and occasionally with some degree of stippling, although stippling may be absent. However, despite the apparently mild clinical appearance, deep pockets can be demonstrated by probing. Page and Schroeder thought that this tissue response coincides with periods of quiescence in which the bone level remains stationary.[53]

Localized Aggressive Periodontitis. Localized aggressive periodontitis (LAP) is usually found in younger individuals than GAP (see Figures 25-3 and 25-4). It is characterized by more pronounced systemic antibody titers against periodontal pathogens than are found in patients with GAP. This could indicate that, in individuals who are susceptible to disease but who also have the ability to enact a robust response against pathogens, the disease might be limited in extent (i.e., LAP). Alternatively, in individuals with a lesser humoral response, the disease would not be limited to the first permanent teeth, and the patient would develop GAP. This would mean that LAP and GAP would merely be phenotypic variations of the same underlying disease. This assumption is backed by several reports that show a sequence of LAP and GAP in the same individuals over time.[8,31,69]

At the same time, there exist several lines of evidence that support the claim that LAP constitutes a disease on its own, with dissimilar underlying molecular and cellular mechanisms.

Epidemiology

The question of the prevalence of aggressive periodontitis in different populations is complicated by the fact that the currently used classification[2] is relatively young and not easy to apply in epidemiological studies. Therefore, many available studies either (1) report on older, previously used entities of periodontitis that showed early onset or rapid progression but that are not interchangeable with aggressive periodontitis or (2) report only on periodontitis severity and not on diagnosis (for a detailed review, see reference 15).

Case Definition

The diagnosis of aggressive periodontitis in epidemiological studies is difficult, because all primary criteria for the disease, rapid progression, systemic health, and familiar aggregation are difficult to reliably assess in the setting of such a study. Both the criteria for systemic health and familiar aggregation would require extensive interviews and thorough verification. The rapid progression of

Text continued on p. 330

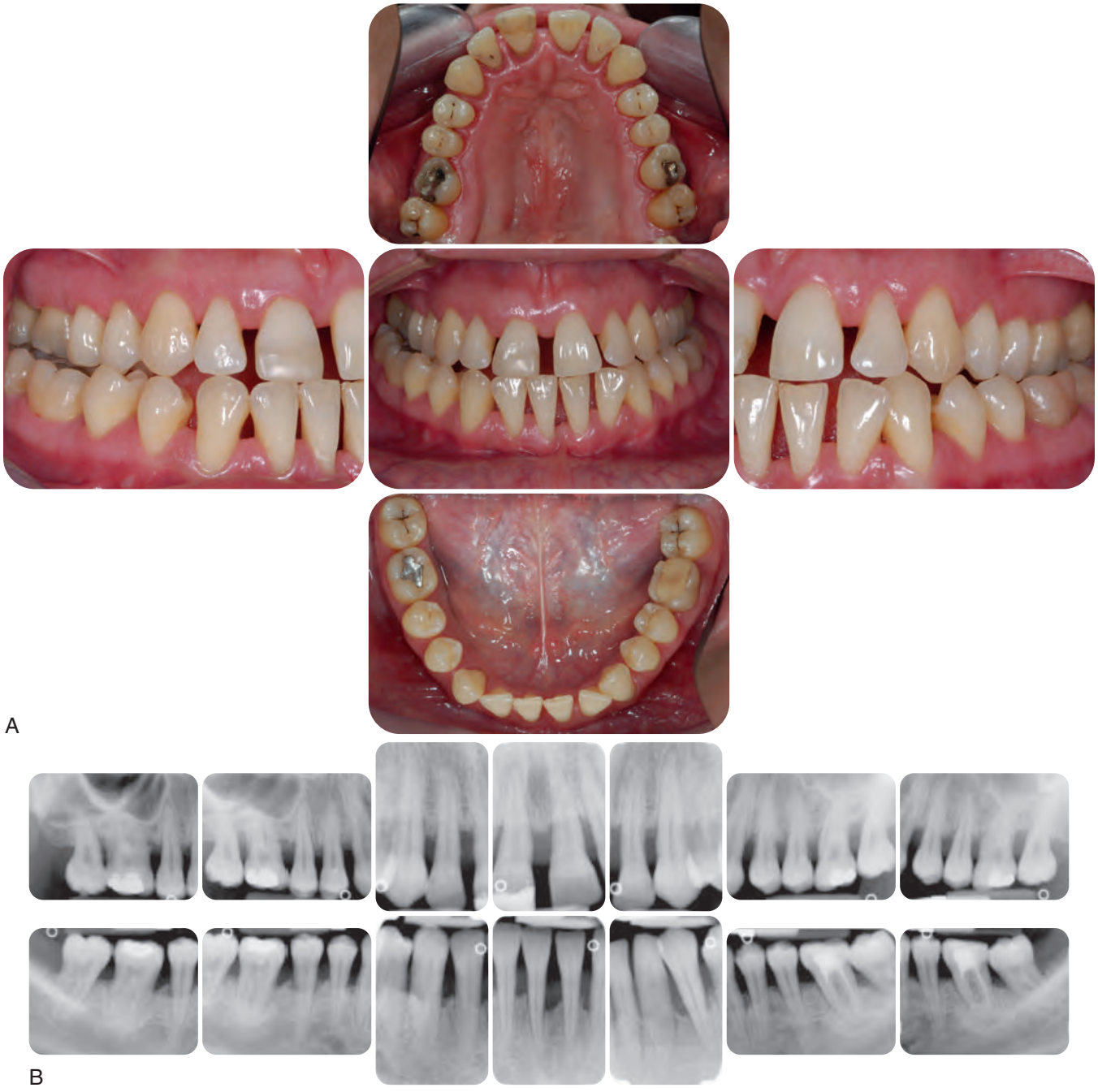

Figure 25-1 Generalized aggressive periodontitis. Generalized aggressive periodontitis in a 28-year-old Caucasian, female, nonsmoking patient. **A,** Clinical views with minimal amounts of calculus and plaque. **B,** Radiographically, bone loss of 50% or more was present at all teeth.

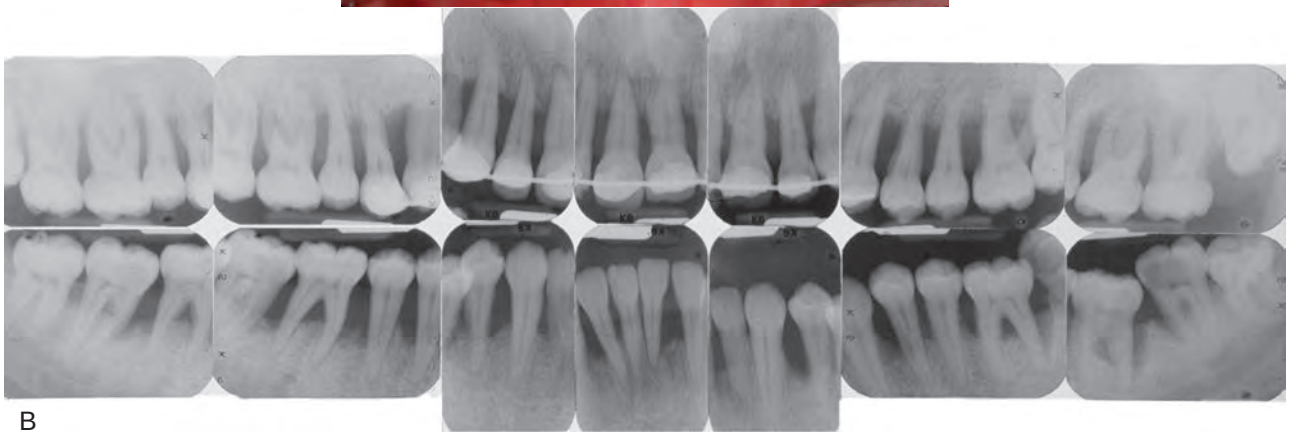

Figure 25-2 Generalized aggressive periodontitis. Severe generalized aggressive periodontitis in a 22-year-old black, male patient with a family history of early tooth loss through periodontal disease. **A,** Clinical view showing minimal plaque and inflammation. A provisional wire-and-resin splint had been placed by the general practice dentist to stabilize the teeth. **B,** Radiographs showing the severe and generalized nature of the disease, with all erupted teeth affected.

Figure 25-3 Localized aggressive periodontitis. Localized aggressive periodontitis in 15-year-old black, female patient who had a twin with similar disease. **A,** Clinical view showing minimal plaque and inflammation, except for localized inflammation on the distal side of the maxillary left central incisor and the mandibular right central incisor. **B,** Radiographs showing localized, vertical, angular bone loss associated with the maxillary and mandibular first molars and the mandibular central incisors. The maxillary incisors show no apparent involvement. **C,** Surgical appearance of the localized, vertical, angular bony defects affecting the mandibular incisors. Note the wide circumferential nature of the defects and the lack of calculus on the root surfaces.

A

Figure 25-4 Localized aggressive periodontitis. Localized aggressive periodontitis in an 18-year-old Caucasian, female, nonsmoking patient. Familiar aggregation was reported. **A,** Clinical view showing recessions at the incisors and first molars.

Continued

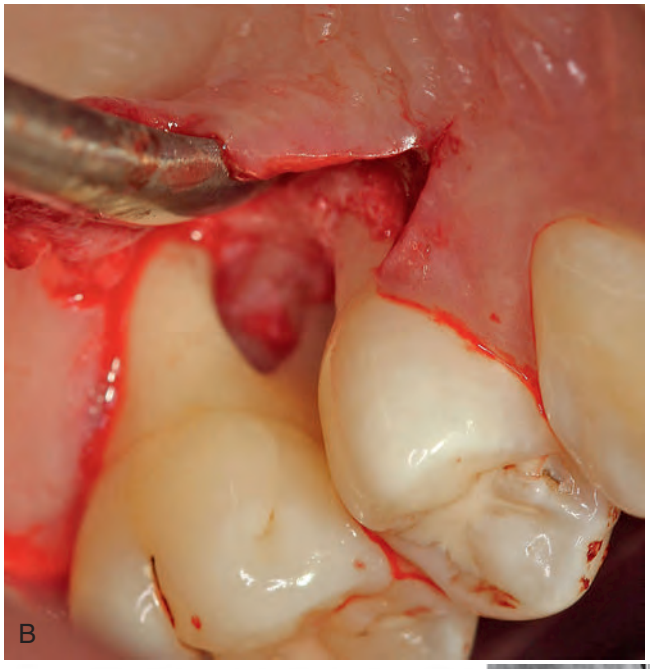

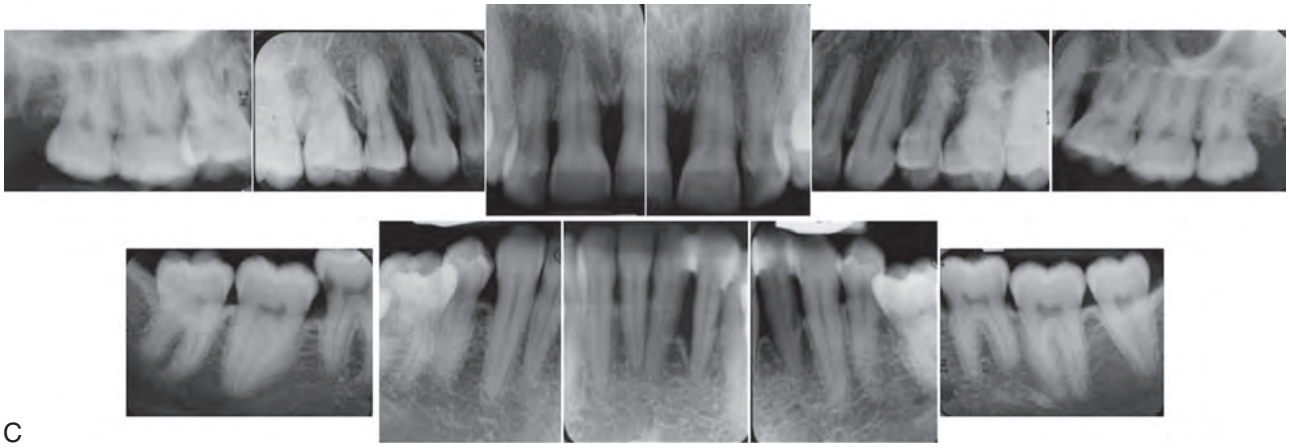

Figure 25-4, cont'd **B,** Intraoperative view showing advanced, localized, angular bony defect associated with a first molar. **C,** Radiographs showing pronounced localized, angular bone loss. *(Courtesy Dr. Hendrik Schulze, Bonn, Germany.)*

disease can consistently only be documented by following a subject longitudinally and performing at least two subsequent examinations within a reasonable time frame; alternatively (and as noted previously), it may be extrapolated from older clinical or radiographic records. These, however, are frequently not available, and they would add extensive bias to the study, because prior providers of oral care were not calibrated.

As a result, to date, the authors are only aware of a single methodologically sound epidemiological study of aggressive periodontitis that was performed in a population of young Israeli army recruits.[40]

Thus, to be able to assess the prevalence of aggressive periodontitis in other populations, Demmer and Papapanou[15] proposed the use of the generally accepted case definition (see Chapter 5) for periodontitis that was proposed by a working group of the U.S. Centers for Disease Control and Prevention and the American Academy of Periodontology[17,54] in combination with the age of the study subject. Specifically, they assessed available studies for the proportion of subjects 25 years old or younger who suffered from moderate or severe periodontitis as well as the proportion of subjects between the ages of 26 and 35 years who suffered from severe periodontitis, both according to the definition proposed by the U.S. Centers for Disease Control and Prevention.

Localized Aggressive Periodontitis

The prevalence of LAP in an Israeli army population between the ages of 18 and 30 years old was 4.3%. In this cohort, presence of LAP was highly correlated with North African origin and current smoking.[40]

In addition to these recent data, there exist several studies on the prevalence of localized juvenile periodontitis (LJP) among diverse populations. LJP is the predecessor of LAP, although the two conditions are not exactly interchangeable. The prevalence of this disease in geographically diverse adolescent populations was estimated at less than 1%. Most reports suggested a low prevalence of about 0.2%.[41] Two independent radiographic studies of 16-year-old adolescents (one in Finland[62] and the other in Switzerland[34]) followed the strict diagnostic criteria delineated by Baer[5] and reported a prevalence rate of 0.1%. A clinical and radiographic study of 7266 English adolescents who were 15 to 19 years old

also showed a prevalence rate of 0.1%.[61] In the United States, a national survey of adolescents between the ages of 14 and 17 years reported that 0.53% had LJP.[41] Blacks were at much higher risk for LJP, and black male teenagers were 2.9 times more likely to have the disease than black female adolescents. By contrast, white female teenagers were more likely to have LJP than white male adolescents. Several other studies have found the highest prevalence of LJP among black males,[8,61,44] who are followed in descending order by black females, white females, and white males.[44]

LJP was reported to affect both males and females, and it is seen most frequently in the period between puberty and 20 years of age. Some studies have suggested a predilection for female patients, particularly in the youngest age groups,[31] whereas others reported no male or female differences in incidence when studies are designed to correct for ascertainment bias.[28]

Generalized Aggressive Periodontitis

Among the young Israeli army recruits, it was found that 1.8% suffered from GAP.[40] When using extrapolation, as proposed by Demmer and Papapanou, a prevalence of about 1% to a maximum of 15% in individuals aged 25 to 35 years was found, depending on the study.

Specifically, data from the German Study of Health in Pomerania indicated an extrapolated prevalence within different age groups of 13% (≤29 years) and 7% (30 to 39 years), whereas the highest extrapolated prevalence was found in the Erie County Study, with up to 15% of individuals aged 25 to 35 years being affected.

As indicated previously, the use of prior epidemiological data for the heterogeneous predecessors of GAP (generalized juvenile periodontitis and rapidly progressive periodontitis) to assess GAP prevalence is not possible, because these entities are not interchangeable with GAP. By contrast, LJP—although still different from LAP, by definition—can be used as a surrogate for LAP.

Current Understanding

Taken together, these data primarily show that the discrimination of aggressive periodontitis from other forms of periodontitis is not always easy, especially when seeing the patient only for a single examination, as it is the case in most epidemiological studies. The prevalence of aggressive periodontitis of approximately 1% to 15% among subjects who are 35 years old or younger, in combination with the severity and tendency for the rapid progression of this disease, strongly suggest that all patients in this age group should be screened regularly for the presence of periodontal disease.

Pathobiology and Risk Factors

All forms of periodontitis share certain common pathobiological principles as polymicrobial, biofilm-mediated, chronic inflammatory diseases at the biofilm–gingival interface. For now, we will focus on the biological reasons for the rapid course of destruction in patients with aggressive periodontitis, including looking at research that has investigated the specific properties of aggressive periodontitis in periodontal microbiology, immunology, and genetics.

Microbiology

Periodontitis is caused by specific microorganisms in a susceptible host.[57] In the subgingival biofilm, up to 700 bacterial species have been identified,[35] some of which have been identified as being causative.[13]

The observed higher rate of disease progression in aggressive versus chronic periodontitis could possibly be explained by the presence of specific microorganisms that cause and perpetuate tissue destruction. In addition, the reported familiar aggregation of aggressive periodontitis cases could be also to a certain point explained by an infection or the within-family transmission of specific microorganisms.

Therefore, several studies have sought to identify the specific microbial properties of aggressive periodontitis cases. However, when evaluating GAP and LAP as a single entity and solely focusing on a small number of "classic" pathogens, it has been concluded that microbiological infection patterns could not reliably distinguish between this entity and chronic periodontitis cases.[49]

However, data from a limited number of studies involving both classic microbiological tools and more recent molecular techniques suggest that there exist differences in microbiological composition between both (1) LAP and both GAP and chronic periodontitis, and (2) CAP and chronic periodontitis[23,20,36,59] (for a review of this information, see reference 3).

Specific Bacteria in Localized Aggressive Periodontitis. In patients with LAP, the situation seems to be different. In these cases, several lines of evidence point to a strong role of specific microorganisms, most notably *A. actinomycetemcomitans.* For decades, this bacterial species has been associated with LAP,[6,12,71] and its presence predicted the development of LAP in two longitudinal studies.[21,30] Longitudinal studies are of critical importance for the demonstration of a causal relationship, whereas cross-sectional studies can by definition only show correlations that cannot be used to infer causality.

In the first longitudinal study, age-, gender- and race-matched juvenile carriers and noncarriers of *A. actinomycetemcomitans* (serotypes a, b, and c were equally distributed, with no presence of *A. actinomycetemcomitans* strain JP2) were followed longitudinally. After 1 year of follow-up, 80% of the carriers and only 10% of the noncarriers had developed periodontitis.[21]

In the second and larger longitudinal study, the highly leukotoxic *A. actinomycetemcomitans* (serotype b) strain JP2, which has a 530-bp deletion in its leukotoxin gene operon that leads to a 10- to 20-fold higher production of leukotoxin,[29] was found to be directly related to the occurrence of LAP in children in Northern Africa. Specifically, the odds ratio for future attachment loss among carriers of the JP2 strain was 18.0 as compared to 3.0 for carriers of other, non-JP2 strains of *A. actinomycetemcomitans*.[30] Similar findings can also be found in West African countries such as Ghana.[1] This is in contrast with the eastern parts of Africa, where no studies have reported the presence of JP2 clone strains in patients with periodontitis.[18]

A recent study of the occurrence of JP2 clone strains in patients with aggressive periodontitis demonstrated a high incidence of both LAP and GAP, which suggests that both subclasses could be more related than initially thought.[19]

In addition, it needs to be noted that LAP is clearly not a monoinfection with *A. actinomycetemcomitans;* as with all entities involving periodontitis, LAP features a polymicrobial biofilm. In support of this notion is the fact that there are also reports of confirmed cases of LAP that did not involve *A. actinomycetemcomitans*.[36,47]

Host Response to Bacterial Challenge

The inflammatory host response toward pathogens is generally attributed to be responsible for a larger proportion of the tissue

destruction in periodontitis than the invading periodontal pathogens themselves. The rapid progression of aggressive periodontitis implies that—in addition to the aforementioned composition of the subgingival microbiological flora—specific properties of this inflammatory response render the individuals with aggressive periodontitis both more susceptible to disease and more prone to lose more attachment in a shorter amount of time.

Host Response Specific to Aggressive Periodontitis. With regard to GAP, a recent review concluded that "there appears to be no difference between aggressive and chronic periodontitis in terms of their histopathology and immunopathology."[72] Still, it has to be acknowledged that this could mean that there exist no differences or, rather, that "the differences between both disease entities only reflect variations in the degree of severity of susceptibility rather than actual different immune-pathologies."[22]

Most recently, the stronger activation of natural killer cells and natural killer T cells in patients with aggressive periodontitis was suggested to be causative for the more pronounced tissue destruction that has been observed in these patients.[33,50]

Abnormalities in Localized Aggressive Periodontitis. Earlier work suggested that individuals with LAP were characterized by an inherited defect of neutrophil function that led to a dampened immune response against the microflora inhabiting the periodontal pocket.[77] Specifically, when challenged with periodontal pathogens, the LAP neutrophils were reported to show impaired chemotaxis, phagocytosis, and killing of bacteria. Alternatively, it was also hypothesized that these impaired defense properties were in fact acquired defects caused by prolonged exposure to an inflammatory microenvironment.

Today, the understanding of neutrophil biology is that neutrophils arriving at a site with uncontrolled periodontal inflammation are primed to attack the invading pathogens by releasing lytic enzymes. These enzymes may, on the other hand, accelerate tissue destruction. It is hypothesized that the observed dampened neutrophil function in deep aggressive periodontitis lesions is due to the heavy commitment of primed neutrophils to debridement so that less potency remains for chemotaxis and defense.[60]

Genetics: Family Studies. A familiar aggregation of aggressive periodontitis cases is a secondary feature of the disease entity; it is often (but not always) found with aggressive periodontitis. To assess the familiar component of the disease, twin studies were performed,[7,43] and these demonstrated a strong genetic component with a likely autosomal-dominant inheritance pattern and a 70% (African-Americans) to 73% (Caucasians) penetrance.[43]

Genetics: Polymorphisms. Accordingly, there has been extensive work to determine the inherent genetic traits that underlie this familiar aggregation.[37,73]

First, it was suspected that an inherent susceptibility to periodontitis would be likely the result of mutations in the DNA encoding for proteins of inflammatory mediators; this is the candidate gene approach. DNA regions that were selected on the basis of a priori knowledge of the disease pathobiology were assessed for sequence variations, and these were most often single nucleotide polymorphisms. On the basis of small sample sizes and often suboptimal study designs that conceivably led to false-positive results,[37,63] single nucleotide polymorphisms within genes that encoded for cytokines such as interleukins-1α, -1β, -6, and so on were reported to be associated with aggressive periodontitis. However, with current knowledge, it has to be realized that these findings were possibly spurious or the result of confounding: all of the "classical" candidate gene associations could not be replicated in today's larger and better controlled cohorts.[65] Note that, in the case of genetic association studies, meta-analyses are not generally suitable tools to overcome the problems of small, heterogeneous cohorts.

During recent years, a consortium investigating a large number of aggressive periodontitis cases and controls identified a common susceptibility locus for aggressive periodontitis and myocardial infarction, and these findings were able to be replicated in independent cohorts.[64,66,67]

Taken together, these data indicate that there is evidence for a strong genetic component in aggressive periodontitis. It is very likely that the low number of identified and replicated susceptibility loci for aggressive periodontitis are the result of too low sample numbers and issues in study design than to a lacking biological association (for a review of the information, see reference 37).

Environmental Factors That Affect Susceptibility. The amount and duration of smoking are important variables that can influence the extent of destruction seen in young adults.[76] Patients with GAP who smoke have more affected teeth and more loss of clinical attachment than nonsmoking patients with GAP.[27] However, smoking may not have the same impact on attachment levels in younger patients with LAP.[68]

Current Developments. On the basis of the aforementioned still incomplete current understanding of the specific microbiological, immunological, and genetic properties of the clinical symptom-based periodontitis entities aggressive and chronic periodontitis, research now focuses on the assessment whether these entities are in fact sufficiently distinct with respect to their underlying pathobiology to form etiology-based clinical classes. For these analyses, novel, unbiased, high-throughput methodologies such as microarrays and next-generation sequencing are employed.[32]

Diagnosis

Assessment of Clinical Presentation

The most reliable diagnostic marker for periodontitis is periodontal probing.[48] However, this technique merely assesses a loss of attachment; it does not classify subcategories of periodontal disease.

The diagnosis of aggressive periodontitis in the clinic is therefore made by jointly assessing the primary and secondary features of aggressive periodontitis, as described previously.

As a result of the small but significant prevalence of this severe category of periodontal disease, it is recommended to also routinely screen for the presence of attachment loss in younger patients with the use of Periodontal Screening and Recording or the Periodontal Screening Index every year. In patients with significant findings, a more thorough clinical assessment that includes the evaluation of periodontal probing depth and attachment loss at six sites per tooth should be performed.

In addition, patients who are at risk for developing aggressive periodontitis should be more closely monitored. These are primarily subjects with a known familiar aggregation of aggressive periodontitis (e.g., the child of a patient with aggressive periodontitis who is already being treated in the practice).

The diagnosis of systemic health is made by checking the medical history of the patient, usually with the use of a questionnaire and a short interview; this process is repeated every other year. In subjects with suspected aggressive periodontitis, the

primary care physician can be consulted to rule out underlying systemic illnesses or conditions.

Assessment of Radiographic Presentation

Radiographic evidence of periodontal bone loss is a very specific but not very sensitive diagnostic sign of periodontitis.[39]

It has been suggested to screen for bone loss in younger children and adolescents with the use of the bite-wing radiographs that are regularly obtained for the early detection of dental caries; in this population with erupting permanent teeth, periodontal probing can be difficult. A distance of 2 mm between the cementoenamel junction and the alveolar bone crest in these patients could be a sign of periodontitis and may warrant a more thorough examination.[70]

For the routine management of a patient with aggressive periodontitis, periapical radiographs should be obtained, because they provide a better estimate of osseous destruction than panoramic radiographs do.[56] The use of cone-beam computed tomography offers some intriguing possibilities when assessing three-dimensional defects, but its use for the diagnosis of aggressive periodontitis is limited. To avoid unnecessary radiation exposure of the patient, the routine use of cone-beam imaging is not recommended.[16]

The vertical loss of alveolar bone around the first molars and incisors, which begins around puberty in otherwise healthy teenagers, is a classic diagnostic sign of LAP. Radiographic findings may include an "arc-shaped loss of alveolar bone extending from the distal surface of the second premolar to the mesial surface of the second molar."[46] Bone defects are usually wider than those that are usually seen with chronic periodontitis.

Assessment of Microbiological Burden

There exists a wealth of commercially available tests for sampling the subgingival microbiota. These tests most often assess the presence and estimate the relative numbers of 3 to 20 prominent periodontal pathogens.

However, the sensitivity and specificity of these tests is disputed. In addition, in patients with aggressive periodontitis, the test results will likely not change standard treatment protocols, which most often include the prescription of systemic antibiotics as adjuncts to anti-infective therapy. Therefore, some authors suggest that microbial testing can be omitted.

Assessment of Genetic Features

Because recent large-scale and well-controlled studies could not replicate earlier reports from smaller collectives of an association of candidate genes (e.g., interleukin-1) with aggressive periodontitis, it seems unwarranted at the present time to test putative aggressive periodontitis patients for the presence of DNA polymorphisms or other genetic markers.

Assessment of Host Defense

In a suspect case of rapidly progressing aggressive periodontitis, one may consider the use of one of the commercially available tests for markers of ongoing periodontal inflammation and tissue breakdown in either gingival crevicular fluid or saliva (e.g., matrix metalloproteinase-8) or other areas. Still, none of the available tests to date can reliably discriminate aggressive periodontitis from other conditions, and thus the utility of these tests to assess ongoing tissue breakdown is disputed. Furthermore, their value (if any) lies primarily in screening individuals for the recurrence of disease during the maintenance phase rather than providing an initial diagnosis. Therefore, the use of these tests for the diagnosis of aggressive periodontitis is not recommended at present.

Therapeutic Considerations for Patients With Aggressive Periodontitis

Considerations for the Anti-infective Therapy of Aggressive Periodontitis

Anti-infective therapy in patients with aggressive periodontitis seems to benefit strongly from the adjunctive use of systemic antibiotics.[14]

Considerations for the Surgical Therapy of Aggressive Periodontitis

In general, individuals with aggressive periodontitis, especially LAP, have to undergo surgical therapy more often than the average patient with periodontitis.[14] This is due to the following: (1) the often much more pronounced loss of attachment with deep periodontal pockets that are challenging to instrument[4,42]; and (2) the high prevalence of vertical defects, most notably in patients with LAP, that need to be resolved.[55]

Considerations for the Supportive Periodontal Therapy of Patients With Aggressive Periodontitis

It is the current view that patients with aggressive periodontitis suffer from a combination of an especially virulent microbiological burden in combination with alterations in their host defense that render them more prone to rapid attachment loss, even in the absence of seemingly "adequate" amounts of etiological factors. This suggests that, during the maintenance phase, utmost care needs to be taken to optimize self-performed oral hygiene to minimize the amount of plaque that could eventually lead to a new and rapid loss of attachment. Therefore, many clinicians recommend performing supportive periodontal therapy, including the regular assessments of periodontal parameters, at least every 3 months. This should even be the schedule for patients who show particularly high levels of oral hygiene proficiency, and it should be independent of the Periodontal Risk Assessment tool, which seems to be of limited use in patients with aggressive periodontitis.[45]

Considerations for Oral Rehabilitation and Implant Therapy in Patients With Aggressive Periodontitis

Dental implants today allow for the routine and predictable functional and aesthetic replacement of lost teeth. Still, there are concerns about the incidence of peri-implantitis; this is an inflammatory condition of dental implants that has parallels with periodontal disease and for which no defined, predictable treatment protocols exist to date. Peri-implantitis risk is linked to a history of periodontal disease in the individual with dental implants. There exist limited data that show an even stronger risk for the development of the disease among patients with aggressive periodontitis as compared with patients with chronic periodontitis or periodontally healthy controls.[74]

Suggested Readings

Armitage GC: Comparison of the microbiological features of chronic and aggressive periodontitis. *Periodontol 2000* 53:70–88, 2010.

Armitage GC, Cullinan MP: Comparison of the clinical features of chronic and aggressive periodontitis. *Periodontol 2000* 53:12–27, 2010.

Demmer RT, Papapanou PN: Epidemiologic patterns of chronic and aggressive periodontitis. *Periodontol 2000* 53:28–44, 2010.

Fine DH, Markowitz K, Furgang D, et al: *Aggregatibacter actinomycetemcomitans* and its relationship to initiation of localized aggressive

periodontitis: longitudinal cohort study of initially healthy adolescents. *J Clin Microbiol* 45(12):3859–3869, 2007.

Haubek D, Ennibi OK, Poulsen K, et al: Risk of aggressive periodontitis in adolescent carriers of the JP2 clone of *Aggregatibacter (Actinobacillus) actinomycetemcomitans* in Morocco: a prospective longitudinal cohort study. *Lancet* 371(9608):237–242, 2008.

Kebschull M, Guarnieri P, Demmer RT, et al: Molecular differences between chronic and aggressive periodontitis. *J Dent Res* 92(12):1081–1088, 2013.

Laine ML, Crielaard W, Loos BG: Genetic susceptibility to periodontitis. *Periodontol 2000* 58(1):37–68, 2012.

Nowak M, Kramer B, Haupt M, et al: Activation of invariant NK T cells in periodontitis lesions. *J Immunol* 190(5):2282–2291, 2013.

Schaefer AS, Richter GM, Dommisch H, et al: CDKN2BAS is associated with periodontitis in different European populations and is activated by bacterial infection. *J Med Genet* 48(1):38–47, 2011.

Smith M, Seymour GJ, Cullinan MP: Histopathological features of chronic and aggressive periodontitis. *Periodontol 2000* 53:45–54, 2010.

References

References for this chapter are found on the companion website www.expertconsult.com.

References

1. Aberg CH, Kwamin F, Claesson R, et al: Presence of JP2 and Non-JP2 genotypes of *Aggregatibacter actinomycetemcomitans* and attachment loss in adolescents in Ghana. *J Periodontol* 83(12):1520–1528, 2012.
2. Armitage GC: Development of a classification system for periodontal diseases and conditions. *Ann Periodontol* 4(1):1–6, 1999.
3. Armitage GC: Comparison of the microbiological features of chronic and aggressive periodontitis. *Periodontol 2000* 53:70–88, 2010.
4. Badersten A, Nilveus R, Egelberg J: Effect of nonsurgical periodontal therapy. II. Severely advanced periodontitis. *J Clin Periodontol* 11(1):63–76, 1984.
5. Baer PN: The case for periodontosis as a clinical entity. *J Periodontol* 42(8):516–520, 1971.
6. Berthold P, Listgarten MA: Distribution of *Actinobacillus actinomycetemcomitans* in localized juvenile periodontitis plaque: an electron immunocytochemical study. *J Periodontal Res* 21(5):473–485, 1986.
7. Boughman JA, Astemborski JA, Suzuki JB: Phenotypic assessment of early onset periodontitis in sibships. *J Clin Periodontol* 19(4):233–239, 1992.
8. Burmeister JA, Best AM, Palcanis KG, et al: Localized juvenile periodontitis and generalized severe periodontitis: clinical findings. *J Clin Periodontol* 11(3):181–192, 1984.
9. Butler JH: A familial pattern of juvenile periodontitis (periodontosis). *J Periodontol* 40(2):115–118, 1969.
10. Carranza F, Carranza F: A suggested classification of common periodontal disease. *J Periodontol* 30(140), 1959.
11. Caton J: Consensus report: periodontal diagnosis and diagnostic aids. In *Proceedings of the World Workshop in Clinical Periodontics*, Chicago, 1989, American Academy of Periodontology.
12. Cortelli JR, et al: Prevalence of periodontal pathogens in Brazilians with aggressive or chronic periodontitis. *J Clin Periodontol* 32(8):860–866, 2005.
13. Darveau R: Periodontitis: a polymicrobial disruption of host homeostasis. *Nat Rev Microbiol* 8(7):481–490, 2010.
14. Deas DE, Mealey BL: Response of chronic and aggressive periodontitis to treatment. *Periodontol 2000* 53:154–166, 2010.
15. Demmer RT, Papapanou PN: Epidemiologic patterns of chronic and aggressive periodontitis. *Periodontol 2000* 53:28–44, 2010.
16. du Bois AH, Kardachi B, Bartold PM: Is there a role for the use of volumetric cone beam computed tomography in periodontics? *Aust Dent J* 57(Suppl 1):103–108, 2012.
17. Eke PI, et al: Update of the case definitions for population-based surveillance of periodontitis. *J Periodontol* 83(12):1449–1454, 2012.
18. Elamin A, et al: Prevalence of Aggregatibacter actinomycetemcomitans in Sudanese patients with aggressive periodontitis: a case-control study. *J Periodontal Res* 46(3):285–291, 2011.
19. Ennibi OK, et al: The highly leukotoxic JP2 clone of Aggregatibacter actinomycetemcomitans in localized and generalized forms of aggressive periodontitis. *Acta Odontol Scand* 70(4):318–322, 2012.
20. Faveri M, et al: Microbiological diversity of generalized aggressive periodontitis by 16S rRNA clonal analysis. *Oral Microbiol Immunol* 23(2):112–118, 2008.
21. Fine DH, et al: Aggregatibacter actinomycetemcomitans and its relationship to initiation of localized aggressive periodontitis: longitudinal cohort study of initially healthy adolescents. *J Clin Microbiol* 45(12):3859–3869, 2007.
22. Ford PJ, Gamonal J, Seymour GJ: Immunological differences and similarities between chronic periodontitis and aggressive periodontitis. *Periodontol 2000* 53:111–123, 2010.
23. Gajardo M, et al: Prevalence of periodontopathic bacteria in aggressive periodontitis patients in a Chilean population. *J Periodontol* 76(2):289–294, 2005.
24. Goldman HM: A similar condition to periodontosis found in two spider monkeys. *Am J Orthod* 33(10):749–755, 1947.
25. Gottlieb B: Die diffuse Atrophie des Alveolarknochens. *Z Stomatol* 21(195):1923.
26. Gottlieb B: The formation of the pocket: diffuse atrophy of alveolar bone. *J Am Dent Assoc* 15(462):1928.
27. Haber J, Kent RL: Cigarette smoking in a periodontal practice. *J Periodontol* 63(2):100–106, 1992.
28. Hart TC, et al: No female preponderance in juvenile periodontitis after correction for ascertainment bias. *J Periodontol* 62(12):745–749, 1991.
29. Haubek D: The highly leukotoxic JP2 clone of Aggregatibacter actinomycetemcomitans: evolutionary aspects, epidemiology and etiological role in aggressive periodontitis. *APMIS Suppl* 130:1–53, 2010.
30. Haubek D, et al: Risk of aggressive periodontitis in adolescent carriers of the JP2 clone of Aggregatibacter (Actinobacillus) actinomycetemcomitans in Morocco: a prospective longitudinal cohort study. *Lancet* 371(9608):237–242, 2008.
31. Hormand J, Frandsen A: Juvenile periodontitis. Localization of bone loss in relation to age, sex, and teeth. *J Clin Periodontol* 6(6):407–416, 1979.
32. Kebschull M, et al: Molecular Differences between Chronic and Aggressive Periodontitis. *J Dent Res* 2013. **in press**.
33. Kramer B, et al: Role of the NK Cell-Activating Receptor CRACC in Periodontitis. *Infect Immun* 81(3):690–696, 2013.
34. Kronauer E, Borsa G, Lang NP: Prevalence of incipient juvenile periodontitis at age 16 years in Switzerland. *J Clin Periodontol* 13(2):103–108, 1986.
35. Kumar PS, et al: Identification of candidate periodontal pathogens and beneficial species by quantitative 16S clonal analysis. *J Clin Microbiol* 43(8):3944–3955, 2005.
36. Lafaurie GI, et al: Demographic, clinical, and microbial aspects of chronic and aggressive periodontitis in Colombia: a multicenter study. *J Periodontol* 78(4):629–639, 2007.
37. Laine ML, Crielaard W, Loos BG: Genetic susceptibility to periodontitis. *Periodontol 2000* 58(1):37–68, 2012.
38. Lang N, et al: Consensus Report: Aggressive Periodontitis. *Ann Periodontol* 4(1):53–53, 1999.
39. Lang NP, Hill RW: Radiographs in periodontics. *J Clin Periodontol* 4(1):16–28, 1977.
40. Levin L, et al: Aggressive periodontitis among young Israeli army personnel. *J Periodontol* 77(8):1392–1396, 2006.
41. Loe H, Brown LJ: Early onset periodontitis in the United States of America. *J Periodontol* 62(10):608–616, 1991.
42. Loos B, et al: Clinical effects of root debridement in molar and non-molar teeth. A 2-year follow-up. *J Clin Periodontol* 16(8):498–504, 1989.
43. Marazita ML, et al: Evidence for autosomal dominant inheritance and race-specific heterogeneity in early-onset periodontitis. *J Periodontol* 65(6):623–630, 1994.
44. Melvin WL, Sandifer JB, Gray JL: The prevalence and sex ratio of juvenile periodontitis in a young racially mixed population. *J Periodontol* 62(5):330–334, 1991.
45. Meyer-Baumer A, et al: Prognostic value of the periodontal risk assessment in patients with aggressive periodontitis. *J Clin Periodontol* 39(7):651–658, 2012.
46. Miller SC: Precocious advanced alveolar atrophy. *J Periodontol* 19(4):146, 1948.
47. Moore WE, Moore LV: The bacteria of periodontal diseases. *Periodontol 2000* 5:66–77, 1994.
48. Mombelli A: Clinical parameters: biological validity and clinical utility. *Periodontol 2000* 39:30–39, 2005.
49. Mombelli A, Casagni F, Madianos PN: Can presence or absence of periodontal pathogens distinguish between subjects with chronic and aggressive periodontitis? A systematic review. *J Clin Periodontol* 29(Suppl 3):10–21, discussion 37-8, 2002.
50. Nowak M, et al: Activation of Invariant NK T Cells in Periodontitis Lesions. *J Immunol* 2013.
51. Offenbacher S, et al: Periodontal disease at the biofilm-gingival interface. *J Periodontol* 78(10):1911–1925, 2007.
52. Orban B, Weinmann J: Diffuse atrophy of alveolar bone. *J Periodontol* 13(31):1943.
53. Page R, Schroeder H: *Periodontitis in man and other animals: a comparative review*, Basel, 1982, Karger.
54. Page RC, Eke PI: Case definitions for use in population-based surveillance of periodontitis. *J Periodontol* 78(7 Suppl):1387–1399, 2007.

55. Papapanou PN, Wennstrom JL: The angular bony defect as indicator of further alveolar bone loss. *J Clin Periodontol* 18(5):317–322, 1991.
56. Pepelassi EA, Diamanti-Kipioti A: Selection of the most accurate method of conventional radiography for the assessment of periodontal osseous destruction. *J Clin Periodontol* 24(8):557–567, 1997.
57. Pihlstrom BL, Michalowicz BS, Johnson NW: Periodontal diseases. *Lancet* 366(9499):1809–1820, 2005.
58. Ramfjord S, Ash M, Kerr D: *World Workshop in Periodontics*, Ann Arbor, 1966, University of Michigan.
59. Riep B, et al: Are putative periodontal pathogens reliable diagnostic markers? *J Clin Microbiol* 47(6):1705–1711, 2009.
60. Ryder MI: Comparison of neutrophil functions in aggressive and chronic periodontitis. *Periodontol 2000* 53:124–137, 2010.
61. Saxby MS: Juvenile periodontitis: an epidemiological study in the west Midlands of the United Kingdom. *J Clin Periodontol* 14(10):594–598, 1987.
62. Saxen L: Prevalence of juvenile periodontitis in Finland. *J Clin Periodontol* 7(3):177–186, 1980.
63. Schafer AS, Jepsen S, Loos BG: Periodontal genetics: a decade of genetic association studies mandates better study designs. *J Clin Periodontol* 38(2):103–107, 2011.
64. Schaefer AS, et al: Identification of a shared genetic susceptibility locus for coronary heart disease and periodontitis. *PLoS Genet* 5(2):e1000378, 2009.
65. Schaefer AS, et al: A genome-wide association study identifies GLT6D1 as a susceptibility locus for periodontitis. *Hum Mol Genet* 19(3):553–562, 2010.
66. Schaefer AS, et al: CDKN2BAS is associated with periodontitis in different European populations and is activated by bacterial infection. *J Med Genet* 48(1):38–47, 2011.
67. Schaefer AS, et al: Validation of reported genetic risk factors for periodontitis in a large-scale replication study. *J Clin Periodontol* 2013.
68. Schenkein HA, et al: Smoking and its effects on early-onset periodontitis. *J Am Dent Assoc* 126(8):1107–1113, 1995.
69. Shapira L, et al: Sequential manifestation of different forms of early-onset periodontitis. A case report. *J Periodontol* 65(6):631–635, 1994.
70. Sjodin B, Matsson L: Marginal bone level in the normal primary dentition. *J Clin Periodontol* 19(9 Pt 1):672–678, 1992.
71. Slots J, Ting M: Actinobacillus actinomycetemcomitans and Porphyromonas gingivalis in human periodontal disease: occurrence and treatment. *Periodontol 2000* 20:82–121, 1999.
72. Smith M, Seymour GJ, Cullinan MP: Histopathological features of chronic and aggressive periodontitis. *Periodontol 2000* 53:45–54, 2010.
73. Stabholz A, Soskolne WA, Shapira L: Genetic and environmental risk factors for chronic periodontitis and aggressive periodontitis. *Periodontol 2000* 53:138–153, 2010.
74. Swierkot K, et al: Mucositis, Periimplantitis, Implant Success and Survival of Implants in Subjects With Treated Generalized Aggressive Periodontitis: 3 to 16 Year Results of a Prospective Long-Term Cohort Study. *J Periodontol* 2012.
75. Thoma K, Goldman H: Wandering and elongation of the teeth and pocket formation in paradontosis. *J Am Dent Assoc* 27(335):1940.
76. Tonetti MS, Mombelli A: Early-onset periodontitis. *Ann Periodontol* 4(1):39–53, 1999.
77. Van Dyke TE, et al: Neutrophil chemotaxis in families with localized juvenile periodontitis. *J Periodontal Res* 20(5):503–514, 1985.
78. Wannenmacher, E., Ursachen auf dem Gebiet der Paradentopathien. *Zbl Gesant Zahn Mund Kieferheilk* 3(81), 1938.

CHAPTER 26

Pathology and Management of Periodontal Problems in Patients with Human Immunodeficiency Virus Infection

Terry D. Rees

CHAPTER OUTLINE

Pathogenesis *(e-only)*
Epidemiology and Demographics *(e-only)*
Classification and Staging *(e-only)*
Oral and Periodontal Manifestations of Human Immunodeficiency Virus Infection
Dental Treatment Complications
Gingival and Periodontal Diseases
Periodontal Treatment Protocol

For online-only content on pathogenesis, epidemiology and demographics, classification and staging, adverse drug effects, and necrotizing ulcerative stomatitis as well as expanded content about the oral and periodontal manifestations of human immunodeficiency virus infection and gingival and periodontal diseases, please visit the companion website at www.expertconsult.com. Some figures may be out of numeric order in this printed chapter.

Acquired immunodeficiency syndrome (AIDS) is characterized by profound impairment of the immune system. The condition was first reported in 1981, and a viral pathogen, the *human immunodeficiency virus* (HIV), was identified in 1984.[221] The condition was originally thought to be restricted to male homosexuals. Subsequently, it was also identified in male and female heterosexuals and bisexuals who participated in unprotected sexual activities or who abused injected drugs.[187] Currently, sexual activity and drug abuse remain the primary means of transmission.

HIV has a strong affinity for cells of the immune system, most specifically those that carry the CD4 cell surface receptor molecule. Thus, helper T lymphocytes (T4 cells) are most profoundly affected, but monocytes, macrophages, Langerhans cells, and some neuronal and glial brain cells may also be involved.[125] Viral replication occurs continuously in the lymphoreticular tissues of the lymph nodes, the spleen, the gut-associated lymphoid cells, and the macrophages.[282,283]

In 1986, a second type of HIV was isolated in Western Africa, and subsequently the two were named HIV-1 and HIV-2. Infection with HIV-2 was first reported in the United States in 1987 in an individual who had migrated from Western Africa. The two viruses apparently originated in different simian species. HIV-2 is very similar to HIV-1, but it appears to be less virulent, and it causes AIDS much more slowly. Infection with HIV-2 is rarely identified outside of Africa and countries that have been intimately associated with that area. During subsequent years, various subgroups of the viruses have been identified. HIV-1 consists of three named subgroups: M (main or major), N (new or non-M) and O (outlier). HIV-1 subgroup M is primarily responsible for the worldwide HIV epidemic. There are at least 10 subtypes of HIV-1 M, with subtype B being the most common. It has also been learned that co-infection with varying groups or subgroups can result in circulating recombinant forms of viral strains. There are also eight known HIV-2 subgroups. There is evidence that this growing plethora of viral mutations may play a role in the increasing resistance to antiretroviral therapy. It is known, for example, that HIV-2 possesses a natural resistance to non-nucleoside reverse transcriptase inhibitor antiretroviral drugs, and circulating recombinant forms may also develop resistance to drugs that are being used for treatment.[126,163,217]

During recent years, combined therapeutic regimens that consist of antiretroviral agents and protease-inhibiting drugs have resulted in marked improvement in the health status of HIV-infected individuals and occasionally a reduction in viral plasma bioloads to below detectable levels (i.e., <50 copies/ml), although the infection may still be transmissible.[79,108,114,290] Current evidence indicates that the virus is never completely eradicated; rather, it is sequestered at low levels in resting CD4 cells, even in individuals with no detectable plasma viral ribonucleic acid (RNA).[49,78] These findings suggest that effective combination drug therapy may be necessary for the lifetime of infected individuals. Long-term control of the infection may be difficult, because the antiviral agents that are currently used have many adverse side effects and readily develop drug-resistant variant viral strains.[282] In addition, growing evidence suggests that oral pathogenic microorganisms (including putative periodontal pathogens) may help to induce HIV recrudescence by reactivating latently infected dendritic cells, macrophages, or T cells.[97,123,124]

Oral and Periodontal Manifestations of Human Immunodeficiency Virus Infection

Oral lesions are common in HIV-infected patients, although geographic and environmental variables may exist. Previous reports

Pathogenesis

In patients with untreated or inadequately treated HIV infection, the overall effect is the gradual impairment of the immune system via interference with T4 (CD4) lymphocytes and other immune cell functions.[283] Recent evidence indicates that innate immune response may play a role in controlling HIV replication. Chemokine receptor type 5 (CCR5) is found on the surface of CD4 cells, and it often serves as a point of entry for HIV into the cell. A genetic variation associated with the expression of CCR5 and its ligand has been found to decrease an individual's susceptibility to HIV infection and to delay clinical progression independent of their effects on viral replication. This may serve to partially explain the lack of progression of HIV infection in some individuals, and it may ultimately lead to a cure for HIV infection.[125,253]

B lymphocytes are not infected, but the altered function of infected T4 lymphocytes secondarily results in B-cell dysregulation and altered neutrophil function.[147] This may place the HIV-positive individual at increased risk for malignancy and disseminated infections with microorganisms such as viruses, mycobacterioses, and mycoses.[107,202,210] HIV-positive individuals are also at increased risk for adverse drug reactions as a result of altered antigenic regulation.[196]

Epithelial cells of the mucosa may become infected, and they may allow for the access of the virus into the bloodstream. Some evidence suggests that oral epithelial cells may harbor HIV virions and infect CD4+ cells by direct cell-to-cell transfer or by transporting and releasing low levels of infectious virions.[271] Most evidence, however, indicates that oral transmucosal viral transmission occurs after mild or severe traumatic injury or punctures of the mucous membranes. This allows for the infection of circulating host defense cells such as lymphocytes, macrophages, and dendritic cells.[43,244]

HIV has been detected in most body fluids, although it is found in high quantities only in blood, semen, and cerebrospinal fluid. Transmission occurs almost exclusively by sexual contact, the illicit use of injection drugs, or exposure to blood or blood products. Transmission after human bites has been reported, although the risk is extremely low.[207,277]

The high-risk population includes homosexual and bisexual men; users of illegal injection drugs; persons with hemophilia or other coagulation disorders; recipients of blood transfusions before April 1985; infants of HIV-infected mothers (in whom transmission occurs by fetal transmission, at delivery, or by breastfeeding); promiscuous heterosexuals; and individuals who engage in unprotected sex with HIV-positive cohorts.[113] Heterosexual transmission is a common cause of AIDS in the world population, and it is increasing significantly in the United States.[38,197] Transmission is more likely to occur through contact with HIV-infected individuals harboring a high plasma bioload of the virus.[197,223] HIV transmission has also been reported to occur through organ transplantation and artificial insemination.[46]

Some short-term studies have suggested that HIV-positive individuals who have been successfully treated with antiretroviral therapy (i.e., who have no detectable viral load) cease to be infectious to others.[32,208] However, Wilson and colleagues[284] have developed a mathematical model that indicates that the potential for HIV transmission to an uninfected individual by a heterosexual partner with an undetectable viral load is low but not without some risk. This risk appears to increase with more frequent exposure and the presence of other sexually transmitted diseases. Incomplete adherence to antiretroviral therapy could further increase the risk of transmission. Unprotected sex in this scenario creates a risk of HIV transmission that is four times greater than that associated with condom use.

The concept of serosorting has been advocated with increasing frequency in an effort to allow unprotected sex among male homosexuals who are both HIV positive or both HIV negative. This is the practice of preferentially having sex only with partners of concordant HIV status while selectively using condoms with HIV-discordant partners. There does appear to be some reduction in risk to others by HIV-positive individuals who only have sex with other seropositive individuals. However, the degree of risk for other sexually transmitted diseases remains high. Among HIV-negative individuals, serosorting presents an increased risk of the transmission of HIV and other sexually transmitted diseases, because some HIV-infected individuals are not aware of their disease status or do not reveal their status. Consequently, the consistent use of condoms is strongly recommended for both HIV concordant and HIV discordant sexual activity.[95,122,140]

Epidemiology and Demographics

In November 2012, the Foundation for AIDS Research provided worldwide estimates that indicated that more than 34 million people were living with HIV/AIDS, 3.3 million of whom were less than 15 years old. In 2011, an estimated 2.5 million individuals were newly infected, and 1.7 million people had died from AIDS that year. Since the beginning of the epidemic, more than 60 million have contracted HIV, and approximately 30 million have died. Sub-Saharan Africa continues to be the global epicenter of the AIDS pandemic, and 23.5 million individuals in that area (69% of the worldwide total) are living with HIV/AIDS. Ninety-one percent of the world's HIV-positive children live in the area, and 71% of the worldwide AIDS deaths occurred there in 2011.[82] The increase in the numbers of patients living with AIDS in the United States and other developed countries has resulted in part from prolonged survival since the advent of multidrug highly active antiretroviral therapy (HAART).[23,79,198,273,276] Thus, AIDS represents the most serious medical crisis in world history.[41,82,269]

AIDS affects individuals of all ages, but more than 98% of cases occur among adults and adolescents who are more than 12 years old. Centers for Disease Control and Prevention (CDC) estimates indicate that, in 2010, approximately 29,800 newly infected adult victims in the United States were men who had sex with men (MSM), who accounted for 63% of all new infections. Disturbingly, the greatest increase in HIV-infected MSM was seen in the youngest age group (13 to 24 years old), and it was especially prevalent among young black MSM. An additional 4% of the MSM group also used illicit injection drugs. HIV transmission through injection drug use alone infected 12%, whereas 25% of all new HIV infections in the United States were contracted through heterosexual contact, usually with a high-risk individual.[35,38] More than 25% of newly infected people were women, the majority of whom had sex with intravenous drug users or bisexual men.[39-41,82]

Other women with AIDS were born in countries such as Haiti or one of several high-incidence African nations in which heterosexual contact is the major mode of transmission. Only one individual contracted AIDS from blood products or blood transfusions in the United States in 2007 as a result of stringent blood bank controls; this data is no longer maintained as a single entity. This mode of transmission continues to be a threat, however, in undeveloped countries. A disproportionately high number of black/African-American and Hispanic male homosexuals, male and female heterosexuals, and children of affected women have HIV infection. The major risk factor for this disparity appears to be a more frequent history of the use of injection drugs and needle

sharing as well as unprotected sexual activity in these groups.[35,38,154] It is of interest to note that the mother-to-child transmission of HIV in the United States has progressively decreased since its peak in 1992 because of the use of antiretroviral therapy.[264]

Transmission from health care workers to patients has been documented on three occasions, with one dentist infecting six patients either accidentally or deliberately.[146,161] Conversely, seroconversion has been documented in 103 health care workers after occupational injury, usually related to the management of patients with high plasma viral loads. The majority of these incidents involved nurses, and no documented seroconversion has been reported among dental health care workers.[81,128,161,289]

Classification and Staging

The World Health Organization (WHO) and the CDC each have published guidelines regarding the definition of HIV infection and HIV disease staging. In both sets of guidelines, HIV infection is confirmed, if possible, with the use of laboratory criteria. However, in many parts of the world, laboratory testing is not available. Consequently, in the WHO concept, clinical findings may be used to establish the diagnosis and to determine a patient's eligibility for antiretroviral therapy.

The WHO staging and case definition system was developed in 1990 and revised in 2007. Staging is primarily based on the clinical appearance of the disease, and it includes the following:

Clinical stage 1: Asymptomatic infection or persistent generalized lymphadenopathy

Clinical stage 2: Mild symptoms such as mild unexplained weight loss, angular cheilitis, herpes zoster, recurrent oral ulcerations, papular pruritic eruptions, seborrheic dermatitis, fungal infections, and recurrent respiratory infections

Clinical stage 3: Advanced symptoms such as severe weight loss, chronic diarrhea, persistent intermittent or constant fever, pulmonary tuberculosis, severe bacterial infections, unexplained anemia, neutropenia, chronic thrombocytopenia persistent oral candidiasis, oral hairy leukoplakia, acute necrotizing stomatitis, gingivitis, and periodontitis

Clinical stage 4: Severe symptoms such as HIV wasting syndrome, *Pneumocystis* pneumonia, chronic herpes simplex infection of more than 1 month's duration, esophageal candidiasis, extrapulmonary tuberculosis, Kaposi's sarcoma, cytomegalovirus (CMV) infection, lymphoma, candidiasis (of the trachea, bronchi, or lungs), invasive cervical carcinoma, and others[281]

AIDS may be present with either clinical stage 3 or stage 4 disease. A CD4 count of less than 350/mm^3 is considered diagnostic for AIDS in adults and in children who are 5 years old or older. Advanced HIV infection in infants is based on a CD4+ cell value of less than 30% if the patient is less than 12 months old; of less than 25% among those between 12 and 35 months old; and of less than 20% among those between the ages of 36 and 59 months. (These are the WHO case definitions of HIV for surveillance and the revised clinical staging and immunologic classifications of HIV-related disease in adults and children.[3,36])

In 1982, the CDC developed a surveillance case definition for AIDS based on the presence of opportunistic illnesses or malignancies secondary to defective cell-mediated immunity in HIV-positive individuals.[36,37] The 1993 revision added invasive cervical cancer in women, bacillary tuberculosis, and recurrent pneumonia to the AIDS designation. Currently, any of 25 specific clinical conditions found in HIV-positive individuals can establish the diagnosis of AIDS (Box 26-1). The most significant change in the most recent CDC case definition was the inclusion of severe immunodeficiency (CD4+ T lymphocyte count of <200/mm^3 or CD+ T lymphocyte percentage of <14% of total lymphocytes) as being definitive for AIDS. This change was based on the recognition that severe immunodeficiency results in an increased risk for opportunistic, life-threatening conditions. Many HIV-positive individuals have been designated as patients with AIDS solely because of a low CD4 cell count or percentage, even in the absence of life-threatening conditions. More recently, HIV plasma bioload has been identified as a significant factor related to the transmissibility and severity of the disease.

BOX 26-1 Centers for Disease Control and Prevention Acquired Immunodeficiency Syndrome Surveillance Case Definition Conditions

- Candidiasis of bronchi, trachea, or lungs
- Candidiasis, esophageal
- Cervical cancer, invasive
- Coccidioidomycosis, disseminated or extrapulmonary
- Cryptococcosis, extrapulmonary
- Cryptosporidiosis, chronic intestinal (>1 month's duration)
- Cytomegalovirus disease (other than liver, spleen, or nodes)
- Cytomegalovirus retinitis (with loss of vision)
- Encephalopathy, human immunodeficiency virus related
- Herpes simplex: chronic ulcer(s) (>1 month's duration) or bronchitis, pneumonitis, or esophagitis
- Histoplasmosis, disseminated or extrapulmonary
- Isosporiasis, chronic intestinal (>1 month's duration)
- Kaposi's sarcoma
- Lymphoma, Burkitt's (or equivalent term)
- Lymphoma, immunoblastic (or equivalent term)
- Lymphoma, primary, of brain
- *Mycobacterium avium* complex or *Mycobacterium kansasii,* disseminated or extrapulmonary
- *Mycobacterium tuberculosis,* any site (pulmonary or extrapulmonary)
- Mycobacterium, other species or unidentified species, disseminated or extrapulmonary
- *Pneumocystis jiroveci* pneumonia
- Pneumonia, recurrent
- Progressive multifocal leukoencephalopathy
- Salmonella septicemia, recurrent
- Toxoplasmosis of brain
- Wasting syndrome caused by human immunodeficiency virus

From the Centers for Disease Control and Prevention: *MMWR* 41:RR-17, 1993.

HIV infection among children less than 13 years old is based on immunologic categories. Category N infected children show no evidence of suppression; category A designates evidence of mild suppression; category B designates moderate suppression; and category C represents severe symptomatic suppression. Perinatally exposed infants are usually not categorized until their HIV status is determined at the age of 18 months, because standard anti-HIV immunoglobulin G antibody tests are not reliable for patients younger than this age. Infants born to HIV-positive mothers usually possess maternal anti-HIV immunoglobulin G antibodies, which cross the placental barrier and offer some perinatal protection. Despite this, 15% to 30% of these infants ultimately become infected with HIV.[41]

Testing for Human Immunodeficiency Virus Infection

The enzyme-linked immunosorbent assay (ELISA) and Western blot (WB) tests were the original methods for determining the

presence of HIV-1 and HIV-2 antibodies in serum or plasma, and they are still considered the gold standard of confirmatory testing. The ELISA test is performed first, and it is repeated if the first test is positive. If it is positive a second time, WB is performed, and a positive finding is considered diagnostic for the infection. The WB is based on the reactivity of antibodies to specific viral proteins. It tests for the proteins p24 (capsid protein), gp41, and gp120 through gp160. In many laboratories, a positive band to two of these three proteins is considered positive, whereas anything less is considered indeterminate or negative if no antigenic proteins are detected. Both ELISA and WB require the presence of circulating HIV antibodies, which may take several weeks or even months to become detectible. Thus, false-negative tests are possible and repeat testing may be required, although modern testing methods are highly accurate. Today, several other test methods are based on the presence of an HIV antigen. Although these tests are expensive, they may be of benefit, especially for early diagnosis after exposure.[42,65,75]

The window of time between exposure and the development of antibodies can lead to an increased risk for disease transmission, and some evidence suggests that early treatment during that window can significantly minimize the intensity of the infection and positively influence treatment outcomes. Consequently, during recent years, several test methods have been developed that detect the presence of HIV genes, RNA, or deoxyribonucleic acid (DNA). These tests may offer the advantage of the earlier confirmation of recent exposure and infection. Several rapid HIV tests are currently available that can provide results in minutes as opposed to days. In some instances, collection kits are available for personal use, including one that collects oral fluids. At this time, the US Food and Drug Administration has approved approximately seven of these rapid tests as well as three that test for HIV and for coinfection with the hepatitis C virus; one of these also tests for hepatitis B virus. Rapid tests may require the collection of oral fluids, plasma, serum, or whole blood, and the CDC encourages their use in most health care settings. It must be recognized that rapid tests may have a relatively high number of false-negative results as well as some false-positive results, so repeat testing and follow-up testing with ELISA and WB are often indicated.[75] Rapid tests may be of special benefit in undeveloped countries, where medical laboratory testing may not be readily available.[42,58,65]

The number of individuals living with AIDS in the United States has greatly increased during recent years as a result of the development of HAART, which combines various types of antiretroviral drugs, protease inhibitors, and fusion inhibitors.[110,132] Infected individuals treated with HAART may experience a marked rise in CD4 cell levels and a decreased plasma viral load. CD4 counts may reach normal levels, and viral bioload may decrease to a point below the level of detection.[19,201] Despite this improvement, these individuals are still considered to have AIDS, because the virus is apparently sequestered somewhere in the body. The patient remains potentially infectious to others, and viral activity may resume if medications are discontinued or if severe coinfections with sexually transmitted diseases or other diseases occur.[78,83,127,221,272,273] Some evidence suggests that severe oral infections, including periodontal diseases, may sometimes represent a significant coinfection.

A few weeks to a few months after initial exposure, some HIV-infected individuals may experience acute symptoms, such as the sudden onset of an acute mononucleosis-like illness that is characterized by malaise, fatigue, fever, myalgia, erythematous cutaneous eruption, oral candidiasis, oral ulcerations, and thrombocytopenia.[83,160,272] This acute phase may last for up to 2 weeks, with seroconversion occurring 3 to 8 weeks later.[273] However, antigenic viremia may sometimes be present for an extended time before seroconversion occurs.[127,145] Some individuals experience asymptomatic HIV infection, whereas others may become asymptomatic after the initial acute infection. In either case, infected individuals eventually become seropositive for HIV antibody, but the mean time from infection until the development of AIDS is now estimated to be up to 15 years or more.[127,145]

Centers for Disease Control and Prevention Surveillance Case Classification

Patients with AIDS have been grouped as follows, according to the 1993 CDC Surveillance Case Classification[36]:

- **Category A** includes patients with acute symptoms or asymptomatic diseases as well as individuals with persistent generalized lymphadenopathy with or without malaise, fatigue, or low-grade fever (Figure 26-1).
- **Category B** patients have symptomatic conditions such as oropharyngeal or vulvovaginal candidiasis, herpes zoster, oral hairy leukoplakia, and idiopathic thrombocytopenia or constitutional symptoms of fever, diarrhea, and weight loss.
- **Category C** patients are those with outright AIDS as manifested by life-threatening conditions or as identified by CD4+ T lymphocyte levels of less than 200 cells/mm^3.

The CDC staging categories reflect progressive immunologic dysfunction, but patients do not necessarily progress serially through the three stages, and the predictive value of these categories is not known. However, because HAART drugs may cause severe adverse side effects, many AIDS treatment centers continue to follow these guidelines to determine when to initiate or discontinue multidrug therapy.[15,27,30,111]

Antiretroviral Therapy

To date, 36 drugs or drug combinations from six separate drug classes have been approved by the US Food and Drug Administration for the treatment of HIV and AIDS infection (Box 26-2). However, two of these drugs, Hivid and Fortovase, are no longer marketed.[1] The goals of therapy are to reduce morbidity and

Figure 26-1 Cervical lymphadenopathy in an asymptomatic individual with human immunodeficiency virus.

BOX 26-2 Antiretroviral Drugs Approved for Use by the US Food and Drug Administration

Nucleoside Reverse Transcriptase Inhibitors (NRTIs)
Abacavir (Ziagen, ABC)
Abacavir plus lamivudine (Epzicom)
Abacavir plus lamivudine plus zidovudine (Trizivir)
Didanosine (Videx, DDI)
Emtricitabine (Emtriva, FTC, Coviracil)
Emtricitabine plus tenofovir DF (Truvada)
Lamivudine (Epivir, 3TC)
Lamivudine plus zidovudine (Combivir)
Stavudine (Zerit, d4T)
Tenofovir (Viread, TDF)
Zalcitabine (Hivid, ddC)
Zidovudine (Retrovir, AZT, ZDM)

Non-Nucleoside Reverse Transcriptase Inhibitors (NNRTIs)
Delavirdine (Rescriptor, DLV)
Etravirine (Intelence)
Efavirenz (Sustiva, EFV)
Nevirapine (Viramune, NVP)

Protease Inhibitors (PIs)
Amprenavir (Agenerase, APV)
Atazanavir (Reyataz, ATV)
Darunavir (Prezista)
Fosamprenavir (Lexiva, FPV)
Indinavir (Crixivan, IDV)
Lopinavir/ritonavir (Kaletra, LPV/r)
Nelfinavir (Viracept, NFV)
Ritonavir (Norvir, RTV)
Saquinavir (SQV, Invirase)
Tipranavir (Aptivus)

Fusion Inhibitor (FI)
Enfuvirtide (Fuzeon, T20)

Entry Inhibitor/Chemokine Receptor Type 5 Co-Receptor Antagonist
Maraviroc (Selzentry)

Human Immunodeficiency Virus Integrase Strand Transfer Inhibitor
Raltegravir (Isentress)

Multiclass Combination Product
Efavirenz plus emtricitabine plus tenofovir (Atripla)

From the US Food and Drug Administration: http://www.fda.gov.

mortality and to improve and prolong life. To achieve this, it is necessary to suppress plasma viremia and to improve or preserve immunologic function. However, the total eradication of HIV does not appear to currently be possible, because reservoirs of latently infected CD4 cells are established early during the infection and persist even with treatment.[185] Anatomic reservoirs of infection have been located in the gastrointestinal and reproductive tracts and in breast, lung, and brain tissue. Recently, the oral cavity has been proposed as an anatomic reservoir, because a small percentage of HIV-infected individuals were found to be salivary hyperexcretors of HIV.[244]

Nucleoside reverse transcriptase inhibitors (NRTI) were the first class of antiretrovirals to be developed. They act by competing for incorporation into the proviral chain, thereby eliminating chain elongation. They are effective against both HIV-1 and HIV-2. NRTIs are the principal drugs in use today in drug combinations.

Non-nucleoside reverse transcriptase inhibitors (NNRTI) bind to the active site in the developing HIV-1 viral chain and arrest its development. These drugs are quite effective, but they rapidly develop resistance via a single-step mutation.

Protease inhibitors are active against both HIV-1 and HIV-2. They bind to the HIV protease enzyme and result in the formation of noninfectious HIV virions. Fusion inhibitors bind to the gp41 glycoprotein membrane on HIV and prevent virus fusion into susceptible CD4 cells. The drugs are administered by subcutaneous injection.[83,188,268] Some entry inhibitors block the access of HIV to CCR5 receptors on macrophages and to T cells that are helping to preserve immune function and reduce viral load.[2] Integrase inhibitors block the incorporation of viral DNA into CD4 cell DNA after viral RNA has been converted into DNA by the reverse transcription enzyme.[252] Combination antiviral agents are composed of multiple drugs with various sites of viral disruption of incorporation into CD4 cells. These combinations represent the transformation of antiretroviral therapy into HAART.[188]

Drugs in each category potentially have adverse effects. NRTIs may induce a nonspecific gastrointestinal syndrome that begins with nausea, vomiting, and abdominal pain but that may rapidly progress to hepatic or respiratory failure and pancreatitis. Other NRTIs may induce bone marrow suppression, peripheral neuropathy, pancreatitis, hepatotoxicity, and visceral adiposity (lipodystrophy).

NNRTIs are potent, but they may lead to the rapid development of resistance and cross-resistance to all drugs in the category. The NNRTIs have the potential for adverse interactions with other HIV drugs, especially protease inhibitors, and adverse drug interactions are common with all drugs that are metabolized by the hepatic p450 system, principally the CYP3A4 enzyme. Stevens–Johnson syndrome may develop, and hepatic and central nervous system manifestations are common.[196]

Protease inhibitors are potent antiretrovirals that also are metabolized by the CYP3A4 isoenzyme of the hepatic p450 system, which means that adverse drug interactions are common to other antiretroviral agents and non-HIV agents. Gastrointestinal intolerance, hyperlipidemia, insulin resistance, and lipodystrophy are common.[188,268]

The only fusion inhibitor that has currently been approved is enfuvirtide. Because it is administered subcutaneously, injection site reactions are common. Enfuvirtide is rarely used alone for the management of HIV infection.[283]

Combined antiretroviral drug therapy has been extremely successful for changing HIV infection from a rapidly progressive fatal disease to a chronic condition that often can be managed successfully. This type of therapy has improved survival rates to nearly normal while suppressing or eliminating susceptibility to some opportunistic diseases and disorders.

Highly Active Antiretroviral Therapy

With HAART therapy, combinations of three or more antiretroviral drugs are administered simultaneously for long periods of time in an effort to block HIV replication and plasma viral load and to restore immune function while minimizing antiretroviral drug resistance and adverse drug effects. The goals are the improvement of the patient's quality of life and the reduction of HIV-related morbidity and mortality. Three commonly used combinations are one NNRTI plus two NRTIs; one or two protease inhibitors plus two NRTIs; or three NRTIs. One NRTI three-drug combination is available in a single tablet, but this antiretroviral therapy does not necessarily qualify as HAART.[80,196]

It is now nearly 20 years since the advent of HAART, and some authorities propose that drug combinations be personalized for each HIV-positive individual on the basis of the specific characteristics of the drugs (e.g., toxicity, potency, central nervous system/sanctuary site penetration); the virus (e.g., resistance pattern, history of antiretroviral use, CCR5 tropism); and the host (e.g., lifestyle, compliance, drug interactions, non-AIDS comorbidities, organ dysfunction, pregnancy).[196]

Considerable controversy has existed for several years with regard to determining the best time to initiate HAART. Some authorities felt that the drugs should not be administered until significant immune suppression occurred. It was thought that this approach would minimize the side effects as well as the risk of developing drug resistance. Others advocated the initiation of therapy as soon as the diagnosis was established. More recently, evidence has indicated that early treatment is far more successful than delayed treatment.[20,196]

HAART has to be proven very successful for achieving a significant increase in the survival and quality of life of HIV-infected individuals, and life expectancy is markedly increased for many individuals using this therapy.[4] However, not everyone benefits equally from HAART. Survival time is shorter despite HAART among individuals who are injected drug abusers, in those with AIDS before the initiation of therapy, in those with a very high viral load before the initiation of therapy (i.e., >100,000 copies/ml), in those who are inconsistent in their adherence to the drug regimen, and in those who discontinue the drugs. Other factors that affect life expectancy in the era of HAART include smoking; excessive alcohol consumption; older age at initiation of therapy; comorbidities such as hepatitis C or other viral, bacterial, or fungal infections; chronic liver, kidney, or cardiovascular conditions; and diabetes mellitus. Low socioeconomic status is also a negative factor that is perhaps related to access to care, and HIV-related death continues to occur earlier among Hispanics and non-Hispanic blacks.[69,97]

Before the advent of antiretroviral therapy, opportunistic infections were the principal cause of morbidity and mortality among HIV-infected persons. Even today, opportunistic infections continue to occur among those who are unaware of their HIV infection, those who do not take recommended medications, and those who are resistant or who react adversely to recommended medications. In some instances, HAART has not altered the rate of occurrence or severity of certain opportunistic infections, whereas it is associated with the increased occurrence of others. Commonly described systemic conditions that may be found more often after HAART are lipodystrophy, increased insulin resistance, gynecomastia, blood dyscrasias, and dermatologic disorders. In the oral cavity, candidal infections are markedly reduced among individuals who are responsive to antiretroviral therapy[261]; hairy leukoplakia, Kaposi's sarcoma, deep mycoses, necrotizing ulcerative gingivitis (NUG), and necrotizing ulcerative periodontitis (NUP) are reduced in these patients as well. Conversely, the incidence and severity of oral condylomata and HSV infection appear unchanged, whereas neutropenia-associated oral aphthous-like ulcers; lichenoid reactions; and oral melanotic macules of the lip, gingiva, palate, or buccal mucosa may increase.[238] On the basis of these observations, the presence or absence of oral opportunistic infections associated with HIV infection or its treatment may serve as markers for the success or failure of antiretroviral therapy.[6,9,18,56,67,102,107,175,219,233,255,259]

Immune Reconstitution Inflammatory Syndrome

Complications from rapid immune recovery have been described for many years, usually among individuals with bone marrow transplants and cancer chemotherapy. However, this phenomenon has been identified as a common complication associated with the recovery of immunity that occurs with HAART, and it has been termed the *immune reconstitution inflammatory syndrome* (IRIS). In patients with this syndrome, pre-existing subclinical or minimally symptomatic infections worsen. Recurrent lesions of Kaposi's sarcoma may be particularly ominous. More often, infectious diseases (e.g., tuberculosis, disseminated *Mycobacterium avium* complex disease, hepatitis B, hepatitis C, herpes zoster viruses) are reactivated, which causes an overwhelming inflammatory response that makes the symptoms of infection more severe. The triggering antigen may be a viable infectious agent (i.e., unmasking form) or even a dead or dying infectious organism; a tumor antigen; or a host autoimmune antigen (i.e., paradoxical form).[266] In most instances, a single antigen is responsible for the condition. However, it occasionally presents with multiple manifestations.[2] IRIS seems to occur among individuals with low baseline CD4 counts who are responsive to HAART, and it causes a rapid increase in the CD4 cell numbers and a hyperinflammatory response that may cause fever and worsening of an existing bacterial, viral, or fungal infection.[248] In the oral cavity, IRIS lesions could include CMV infection, varicella-zoster virus infection, histoplasmosis, cryptococcal infections, Kaposi's sarcoma, and other conditions. Although sometimes described years after the initiation of ART, IRIS most often occurs within the first 2 to 12 weeks after starting ART in individuals with rapidly decreasing HIV viremia and rapidly increasing CD4+ T lymphocyte counts; in individuals who are starting ART for the first time; in those who are changing their treatment regime; or in those who were not compliant and discontinued their ART treatment for a period of time and then restarted therapy. The condition is difficult to diagnosis and manage, and it may take months to subside, but it does not appear to affect patient survival in most instances.[1] However, as mentioned previously, recurrent Kaposi's sarcoma may indicate a grim prognosis. At this time, the implications of IRIS as the apply to oral opportunistic infections are largely unknown, but parotid enlargement has been reported as a common oral manifestation for reasons that have not yet been elucidated.[120,184,185,216]

However, some medical protocols delay the use of HAART drugs until immune suppression is relatively severe. These protocols also discontinue HAART if immune stability has been achieved or if the targeted virus becomes drug resistant.[74,167,233,262] In theory, these protocols suggest that patients with HIV and AIDS may experience a greater number of oral manifestations than patients who start HAART therapy earlier. The dental practitioner must continue to be prepared to diagnose and manage these conditions in coordination with the patient's physician. However, HIV resistance to antiretroviral drug therapy is an ongoing problem, and this resistance may even be transmitted to newly infected sexual partners or to newborns of infected mothers.[87]

Candida, a fungus that is found in the normal oral flora, proliferates on the surface of the oral mucosa under certain conditions. A major factor associated with the overgrowth of *Candida* is diminished host resistance, which is seen in debilitated patients or in patients who have received immunosuppressive therapy. The incidence of candidal infection has been demonstrated to increase progressively in relationship to diminishing immune competency.[158,159,249] Most oral candidal infections (i.e., 85% to 95%) are associated with *Candida albicans,* but other species of *Candida* may also be involved. Currently, at least 11 strains of *Candida* have been identified, and non–*Candida albicans* infections are more common among immunocompromised individuals who are already receiving antifungal therapy for *C. albicans.*[155,236]

Although oropharyngeal candidiasis occurs with some frequency among immunocompetent individuals, it and esophageal candidiasis are especially common among HIV-infected people. Some evidence suggests that the Th17 subset of T helper cells may be very important to the resistance of infections caused by common oral commensal microorganisms. Its selective loss in HIV infection may allow candidal species to express their pathogenic potential by creating an environment that allows for the overexpression of fungal virulence factors that can degrade host defense components, such as histatin-5 and E-cadherin. Some evidence suggests that the fungus may actually bind to the HIV proteins.[31] Because non–*C. albicans* candidal species appear to be especially prone to the development of azole resistance, species identification may become more important for the control of candidiasis.[136] A study from India reported that oral candidiasis infections are more common among males as compared with females, although 92% of infected men and 95% of infected women reported acquiring the infection through heterosexual contact.[215] Others have shown that previous ART reduced the risk for oral candidiasis, whereas smoking and the presence of removable full or partial dentures increased the risk.[285] Although the incidence of oral candidiasis has been reported to be significantly decreased after HAART treatment, colonization and oral infection remain common among HIV-positive individuals of all ages, either as evidence of unsuccessful therapy or as a result of IRIS.[180,192,205,260]

Although candidiasis in HIV-infected patients may respond to antifungal therapy, it is often refractory or recurrent. In the past, 30% of patients with AIDS-related candidiasis relapsed within 4 weeks of treatment, and 60% to 80% relapsed within 3 months. This relapse may have resulted from decreasing immunocompetency or the development of antifungal-resistant candidal strains.[117] As many as 10% of candidal organisms become resistant to long-term fluconazole therapy, and cross-resistance to other azoles (i.e., ketoconazole, itraconazole, miconazole, or clotrimazole) and amphotericin B may develop.[51,135,176,184,186,198,200,210,230,278] Resistant candidiasis is more common among late-presenting individuals with AIDS who have low CD4 counts and high viral loads at baseline.[117] Non–*C. albicans* candidal species in HIV-positive individuals most often include *Candida glabrata, Candida tropicalis, Candida krusei, Candida parapsilosis, Candida lusitaniae, Candida guilliermondii*, and other as yet unidentified strains. Individuals with recurrent episodes of oropharyngeal candidiasis and previous exposure to antifungal drugs were more likely to colonize non–*C. albicans* species and to develop azole resistance.[170]

Recent reports indicate that the administration of HAART to patients with HIV infection has resulted in a significant decrease in the incidence of oropharyngeal candidiasis and oral candidal carriage, and it has also reduced the rate of fluconazole resistance.[33,55,67,155,176,179,220] When esophageal candidiasis is present during HAART, there is an increased incidence of non–*C. albicans* species and fluconazole-resistant organisms.[263] Early oral lesions of HIV-related candidiasis are usually responsive to topical antifungal therapy (Figure 26-9). More advanced lesions, including hyperplastic candidiasis, may require systemic antifungal drugs; systemic therapy is mandatory for esophageal candidiasis[235,242] (Figure 26-10).

With any therapy, lesions tend to recur after the drug is discontinued, and resistant strains of candidal organisms have been described, especially with the use of systemic agents.[62,235,274] Box 26-3 identifies the therapeutic agents that are often prescribed for the treatment of candidal infections. Most oral topical antifungal agents contain large quantities of sucrose, which may be cariogenic after long-term use. For this reason, some authorities recommend the oral use of vaginal tablets because they do not contain sucrose. However, such tablets are relatively low in active units (100,000) as compared with usual oral dosages of 200,000 to 600,000 units. Sucrose-free nystatin is also available in a powder form, which may be mixed extemporaneously with water at each use (i.e., 1 teaspoon of powder in a glass of water). In addition, many compounding pharmacies can provide sucrose-free nystatin on request. Recently, sucrose-free oral suspensions of itraconazole and amphotericin B oral rinse have become available. To date, few comparative studies have been performed to address the effectiveness of these products. Amphotericin B oral suspension is more effective against *C. albicans* than it is against other species. Patients should be instructed to rinse with the oral suspension for several minutes and then swallow it.[206] Fluconazole oral suspension has been reported to be more effective as an antifungal than liquid nystatin. Chlorhexidine and cetylpyridinium chloride oral rinses may also be of some prophylactic value against oral candidal infection.[88] The long-term prophylactic effectiveness of once-weekly systemic fluconazole also has been described.[235]

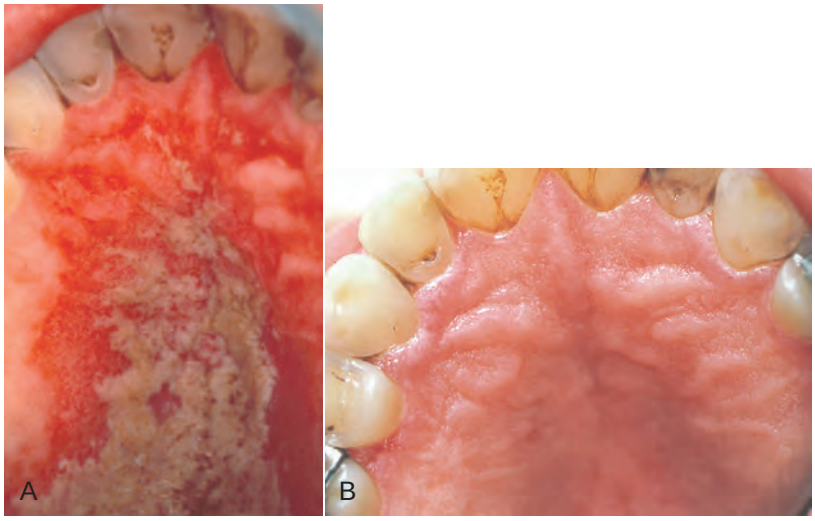

Figure 26-9 Palatal pseudomembranous candidiasis. **A,** Before treatment with nystatin oral suspension. **B,** Remission after 2 weeks of treatment.

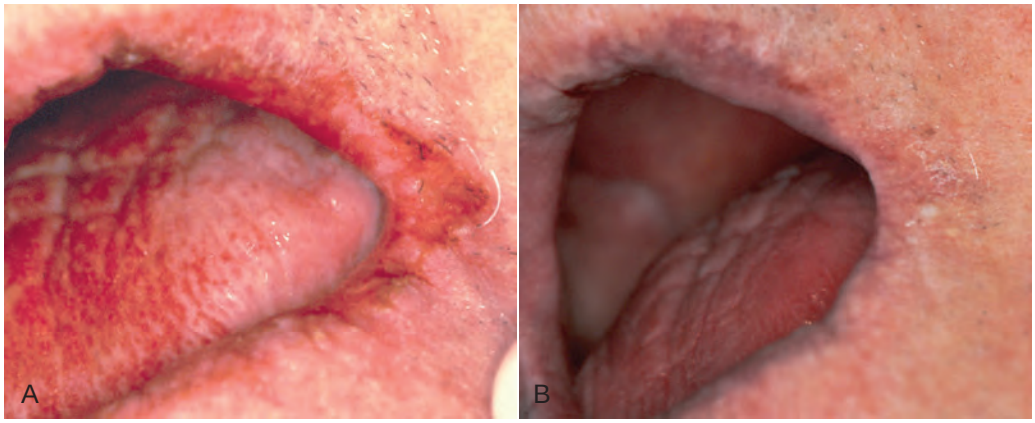

Figure 26-10 Severe angular cheilitis. **A,** Before treatment. **B,** After treatment with systemic fluconazole.

BOX 26-3 Common Antifungal Therapeutic Agents for Oral Candidiasis

Topical Drugs

1. Clotrimazole (Mycelex), 10-mg tablets: Dissolve 3 to 5 tables in mouth daily for 7 to 14 days.
2. Nystatin (Mycostatin, Nilstat)
   a. Oral suspension
      - 100,000 U/ml: Administer 240 ml.
      - Rinse with 1 tsp (5 ml) qid.
   b. Oral suspension (extemporaneous)
      - Administer 2 to 4 billion U.
      - Mix 1 tsp (500,000 U) in 4 oz of water in a cup.
      - Rinse qid.
      - NOTE: Extemporaneous nystatin is sucrose free.
   c. Tablets (500,000 U): Dissolve 1 tablet in mouth 4 or 5 times daily.
   d. Pastilles (200,000 U): Dissolve 1 or 2 pastilles in mouth 4 or 5 times daily.
   e. Vaginal tablets (100,000 U): Dissolve 1 tablet in mouth tid.
      - NOTE: Vaginal tablets are sucrose free.
   f. Ointment (for angular cheilitis), 15-g tube: Apply to the affected area tid or qid.
3. Clotrimazole ointment, 15-g tube: Apply to the affected area qid.
4. Miconazole 2% ointment, 15-g tube: Apply to the affected area qid.
5. Itraconazole oral suspension (Sporanox): Take 100 mg to 200 mg once daily for 7 to 14 days.
6. Fluconazole oral suspension (Diflucan): Take 3 mg/kg to 6 mg/kg (max, 400 mg/dose) once daily for 7 to 14 days.
7. Amphotericin B oral suspension (Fungizone): Take 100 mg qid for 2 weeks.

Systemic Drugs

1. Ketoconazole (Nizoral), 200-mg tablets: Take 2 tablets immediately and then 1 or 2 tablets daily with food for 5 to 14 days.
2. Fluconazole (Diflucan), 100-mg tablets: Take 2 tablets immediately and then 1 tablet daily for 7 to 14 days.
3. Itraconazole (Sporanox), 100-mg capsules: Take 200 mg once daily with meals for 7 to 14 days. Patients with acquired immunodeficiency syndrome or neutropenia should take this medication as described for 4 weeks.

max, Maximum; *mg,* milligrams; *ml,* milliliters; *qid,* four times daily; *tid,* three times daily; *tsp,* teaspoon; *U,* Units.

Systemic antifungal agents such as ketoconazole, fluconazole, itraconazole, and amphotericin B are effective for the treatment of oral candidiasis[186] (see Box 26-3). Fluconazole may be the agent of choice when systemic therapy is required.[7,61,241,246] As previously mentioned, however, resistant strains of candidal organisms may develop with the prolonged use of any systemic agent, potentially rendering the drugs ineffective against life-threatening candidal infections during the later stages of immunosuppression.[29,211] In addition, significant adverse side effects may occur with the long-term use of any systemic antifungal agent. For example, the long-term use of ketoconazole may induce liver damage in individuals with pre-existing liver disease. The increased risk of chronic hepatitis B or hepatitis C infection in immunosuppressed individuals may put some patients at risk for ketoconazole-induced liver damage. If ketoconazole is prescribed, patients should receive liver function tests at baseline and at least monthly during therapy. The drug is contraindicated if the patient's aspartate transaminase level is more than 2.5 times higher than normal.[270] Ketoconazole absorption may also be impaired by the gastropathy experienced by many HIV-infected individuals.[141]

Microscopically, the OHL lesion shows a hyperparakeratotic surface with projections that often resemble hairs. Beneath the parakeratotic surface, acanthosis and some characteristic "balloon cells" that resemble koilocytes are seen (Figure 26-11, *B*). It has been demonstrated that these cells contain viral particles of the human herpesvirus group; these particles have been interpreted as EBV.[101,105]

Epithelial dysplasia is not a feature, and, in most OHL lesions, little or no inflammatory infiltrate in the underlying connective tissue is present.[232]

OHL is found almost exclusively on the lateral borders of the tongue, although it has been reported on the dorsum of the tongue, the buccal mucosa, the floor of the mouth, the retromolar area, and the soft palate.[72,101,135] In addition, most of these lesions reveal surface colonization by *Candida* organisms, which are secondary invaders and not the cause of the lesion.

OHL was originally thought to be caused by the human papillomavirus, but subsequent evidence has indicated an association with EBV.[72,101,103,279] During the late 1980s, so-called pseudo–hairy leukoplakia was described in HIV-negative and EBV-negative individuals with lesions that are clinically identical to OHL. In addition, several case reports have described OHL in EBV-infected but HIV-negative individuals with a variety of immunosuppressed conditions (e.g., acute myelogenous leukemia) or who develop immunosuppression as a result of organ transplantation or extensive

systemic corticosteroid therapy.[103,257] Regardless of the cause, biopsy identification of a lesion that is suggestive of OHL should dictate that HIV testing be performed. It should be emphasized that the severity of the lesion is not correlated with the likelihood of developing AIDS; thus, small lesions are as diagnostically significant as extensive lesions.[190]

The differential diagnosis of OHL includes several white lesions of the mucosa, such as dysplasia, carcinoma, frictional and idiopathic keratosis, lichen planus, tobacco-related leukoplakia, secondary syphilis, psoriasiform lesions (e.g., geographic tongue), and hyperplastic candidiasis.[5,191] The microscopic confirmation of OHL of the tongue in a high-risk patient is considered to be a specific early sign of HIV infection and an indication that the patient will develop AIDS.[104,225] Before the advent of effective therapy for HIV, survival analysis indicated that 83% of HIV-infected patients with hairy leukoplakia would develop AIDS within 31 months, and the number of patients with hairy leukoplakia who eventually developed AIDS approached 100%.[104] The use of HAART, however, has resulted in a greatly diminished incidence of OHL[18,34,74,262,280] (Figure 26-12).

If OHL occurs despite HAART, it may represent an increasing immunodeficiency resulting from therapeutic failure, a failure to take medications as prescribed, or a reduced dosage of medications that are used to prevent adverse side effects.[71] The vigorous treatment of OHL is usually not indicated. However, the lesions are often responsive to HIV drug therapy or to the use of antiviral agents such as acyclovir, desciclovir, ganciclovir, foscarnet, or valacyclovir.[280,282] Lesions can be successfully removed with laser or conventional surgery. Some have advocated the topical application of podophyllin, retinoids, oral acyclovir, or interferon, but these agents can induce unwanted local or systemic side effects. Regardless of the choice of treatment, OHL lesions tend to recur when therapy is discontinued.[7,279,280]

As far as is known, HHV-8 seroconversion precedes the development of epidemic KS by 5 to 10 years. It has been associated with both AIDS-related and non–AIDS-related KS.[84,223] However, untreated HIV-infected individuals are 7000-fold more likely to develop KS.[4] HHV-8 seroconversion is common, and the virus has been isolated from 29% of American adults and 8% of children in the general population without AIDS. It has also been isolated from lesions of NHL, multicentric Castleman's disease, primary effusion lymphoma, and other lymphoproliferative disorders as well as from those of a variety of additional abnormalities, although these findings may coincide with those of the healthy general population.[96,130,247] By contrast, one study identified HHV-8 in more than 90% of HIV-related and non–HIV-related KS lesions.[138] Thus, it appears that decreasing immunocompetence results in the activation of latent HHV-8. As mentioned previously, the virus may be sexually transmitted, but it may also be transmitted from infected mothers to their children.[237,258]

AIDS-related KS may develop at any age, even in newborns, and oral lesions are more common in children than adults in sub-Saharan Africa.[189] Although KS is a malignant tumor, in its classic and endemic forms, it is a localized and usually slowly growing lesion. The KS that occurs in HIV-infected patients presents different clinical features (Figures 26-14 and 26-15). In these individuals, KS is a much more aggressive lesion, and the majority of patients (71%) develop lesions of the oral mucosa, particularly the palate, the gingiva, and the tongue[189,133] (Figure 26-16). Oral lesions may be unifocal or multifocal. The oral cavity may often be the first or only site of the lesion.[13]

Lymphedema of the neck and face has been reported in association with oral lesions. The cause of the lymphedema has not been determined, but it may result from the compression of lymphatics by expanding lesions. The presence of facial lymphedema is considered to be an ominous sign that is associated with a fatal outcome.[189]

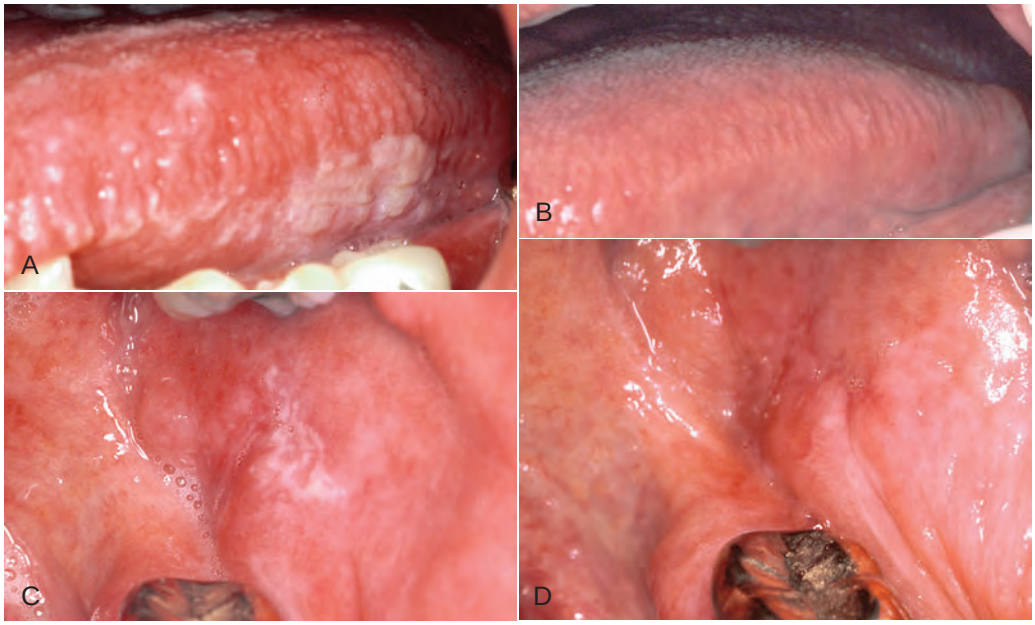

Figure 26-12 **A,** Oral hairy leukoplakia of the tongue before the initiation of highly active antiretroviral therapy (HAART). **B,** Oral hairy leukoplakia of the buccal mucosa before the initiation of HAART. **C,** Tongue lesion in remission after the initiation of HAART. **D,** Remission of a lesion on the buccal mucosa after HAART.

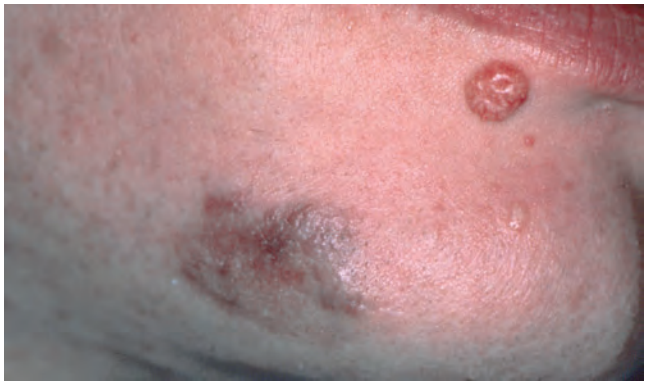

Figure 26-14 Cutaneous Kaposi's sarcoma on the right chin.

Figure 26-15 Ocular Kaposi's sarcoma causing a loss of vision.

During the early stages, the oral lesions are painless, reddish-purple macules of the mucosa. As they progress, the lesions frequently become nodular, and they can easily be confused with other oral vascular entities, such as hemangioma, hematoma, varicosity, and pyogenic granuloma (when occurring in the gingiva).[237]

Lesions may manifest as nodules, papules, or non-elevated macules that are usually brown, blue, or purple, although occasionally the lesions may display normal pigmentation. The lesions may become painful if they become ulcerated or traumatized by opposing teeth as they enlarge. Diagnosis is based on histologic findings.[218]

Gingival KS lesions may be exacerbated by existing periodontal lesions, or necrotizing periodontal diseases may be superimposed on existing gingival KS. On occasion, the expansion of gingival lesions may result in bone resorption, and increased tooth mobility and loss has been reported.[189]

Regional and gender differences are apparent; oral KS is more common in the United States than in Europe, and the male-to-female ratio is 20 : 1.[265] KS has also been reported in patients with lupus erythematosus who are receiving immunosuppressant therapy as well as in renal transplant patients and other individuals receiving corticosteroid or cyclosporine therapy. Case reports describe gingival KS in HIV-negative patients experiencing cyclosporine-induced gingival enlargement.[209,272] In an HIV-positive individual, the presence of KS signifies the transition to outright AIDS. Before the advent of combined drug therapy for AIDS, the median survival time after the onset of KS ranged from 7 to 31 months.[52]

The differential diagnosis of oral KS includes pyogenic granuloma, hemangioma, atypical hyperpigmentation, sarcoidosis, bacillary angiomatosis, angiosarcoma, pigmented nevi, and cat-scratch disease of the skin.[223]

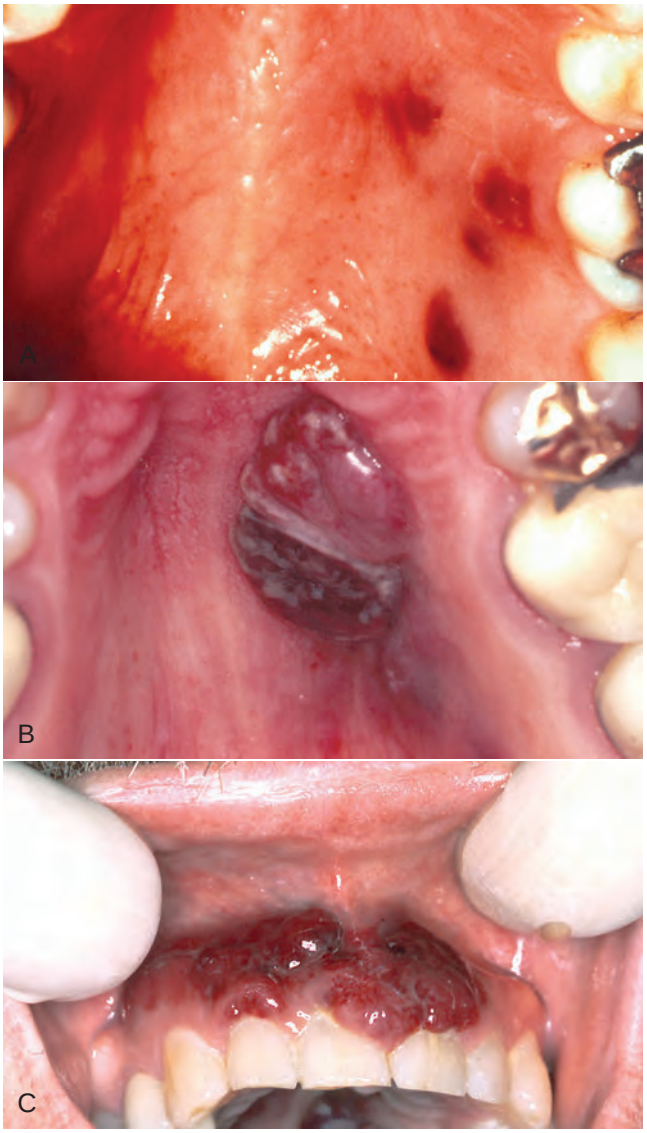

Figure 26-16 Intraoral Kaposi's sarcoma. **A,** Multiple painless, non-elevated palatal lesions. **B,** A palatal Kaposi's lesion that interfered with function and required treatment. **C,** A gingival lesion that created an aesthetic concern for the patient.

The advent of HAART has resulted in a marked reduction in the incidence of KS. However, the lesions may still be found in severely immunocompromised individuals who are unaware of their HIV-positive status or who are untreated or unresponsive to therapy.[84] HHV-8 may be found more frequently in the saliva of HIV-positive individuals with higher CD4 cell counts, which suggests that viral shedding may occur relatively early during the disease process.[52,118] The treatment of oral KS includes antiretroviral agents, laser excision, cryotherapy, radiation therapy, and intralesional injection with vinblastine, interferon-γ, sclerosing agents, or other chemotherapeutic drugs.[7,71,242,265] Nichols and colleagues[177] described the successful use of intralesional injections of vinblastine at a dose of 0.1 mg/cm^2 with the use of a 0.2 mg/ml solution of vinblastine sulfate in saline (Figure 26-18). In responsive patients, treatment was repeated at 2-week intervals until resolution or stabilization of the lesions occurred. Side effects included some post-treatment pain and occasional ulceration of the lesions, but in general the therapy was well tolerated. Total resolution was achieved in 70% of 82 intraoral KS lesions with 1 to 6 treatments.

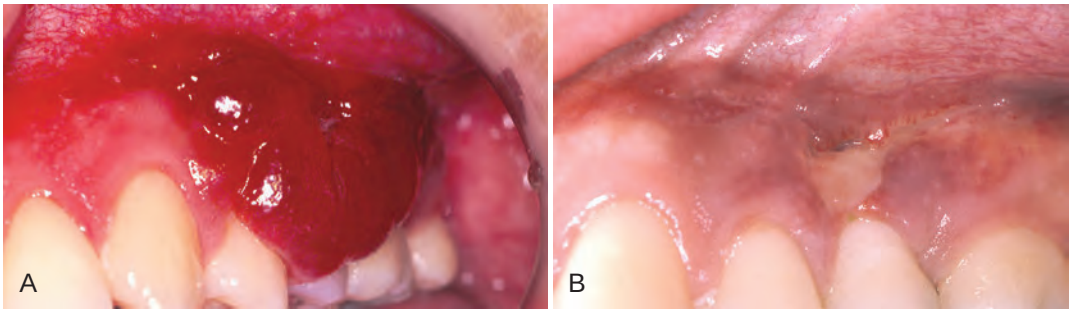

Figure 26-18 **A,** The management of gingival Kaposi's sarcoma interfering with function. **B,** The nearly complete resolution of the lesion after intralesional injection with vinblastine.

Lesions tended to recur, however, thereby indicating that treatment probably should be reserved for oral KS lesions that are easily traumatized or that interfere with chewing or swallowing. Occasionally, treatment may be indicated when KS lesions create an unsightly appearance on the lips or in the anterior oral cavity. In a double-blind, randomized, clinical trial involving a small group of patients with oral KS lesions, the authors concluded that vinblastine injections remain the most effective treatment for the management of localized lesions.[211] However, comparable results may be obtained with the use of injections of 3% sodium tetradecyl sulfate, a sclerosing agent that was previously used for the treatment of varicose veins. The sclerosing agent offers the advantage of being relatively inexpensive and easy to use. Destructive periodontitis has also been reported in conjunction with gingival KS. In such patients, scaling and root planing as well as other periodontal therapy may be indicated in addition to intralesional or systemic chemotherapy.[242,265]

Today, some authorities recommend the treatment of oral KS with the use of a combination of HAART and systemic cytotoxic therapy.

The incidence of KS among HIV-positive individuals has decreased precipitously since its peak in 1989 as a result of the emphasis on safer sexual practices as well as the introduction of HAART. Today, AIDS-related KS is uncommon except in those who are unaware of their HIV-positive status, those who are not taking HAART, or those who have discontinued HAART for one reason or another.[26,158] However, approximately 7% of individuals with KS who begin treatment with HAART for the first time may experience a flare of existing KS lesions or have new lesions may develop.[77] In sub-Saharan Africa, which is resource poor when it comes to treating HIV infection, HSV-8 is endemic; the incidence of KS is very high among HIV-positive individuals, and its presence may represent the first recognized indication that HIV infection has occurred. Although oral KS may regress with ART, it may flare as part of the immune reconstitution inflammatory syndrome and increase mortality among individuals who were in the late stages of AIDS when diagnosed.[48]

The risk of NHL is associated with a number of infections; EBV-associated lesions may include Burkitt's lymphoma and HIV-associated lymphoma. However, the role of EBV in tumor formation has not been clarified, and a viral etiology has not been confirmed. NHL is characterized by the malignancy of B or T lymphocytes, and tumors are typed by the WHO classification system as indolent, aggressive, or highly aggressive. NHL is treated by chemotherapy, and HAART does not appear to significantly reduce the incidence or prognosis of the malignancies, although HIV-associated NHL may be less common.[157]

Patients with HIV and benign lymphoepithelial involvement of the salivary glands may have a markedly increased risk of developing benign or malignant lymphoma.[71] NHL of the diffuse B-cell type with plasmoblastic differentiation (i.e., plasmoblastic lymphoma) is a particularly aggressive form of lymphoma that occurs most often in the oral cavity and jaws. Prognosis is guarded, especially in patients with AIDS, but HAART has somewhat reduced the incidence of this malignancy. Some evidence suggests that HHV-8 may have a role in its development. The tumor must be differentiated from plasma cell myeloma via its plasmoblastic features.[112,121]

Patients with AIDS and NHL may require the management of HIV-related opportunistic infections, chemotherapy-induced mucositis and thrombocytopenia, and possibly graft-versus-host disease, if hematopoietic cell transplantation is performed.[71,157]

The condition is more prevalent in HIV-positive individuals with low CD4 levels.[165]

The diagnosis of BA is based on biopsy, which reveals an "epithelioid" proliferation of angiogenic cells accompanied by an acute inflammatory cell infiltrate. The causative organism in the biopsy specimen may be identified with the use of Warthin–Starry silver staining or electron microscopy.[86]

The differential diagnosis of BA includes KS, angiosarcoma, hemangioma, pyogenic granuloma, and nonspecific vascular proliferation.[45] BA is usually treated with the use of broad-spectrum antibiotics such as erythromycin or doxycycline. Gingival lesions may be managed by using the antibiotic in conjunction with conservative periodontal therapy and possibly the excision of the lesion.[45,91,92,220] To date, no reports have been found regarding the effect of HAART on BA incidence among HIV-positive individuals. However, one case report described a fatal outcome of *B. quintana*–derived BA during HAART-induced immunity restoration.[171]

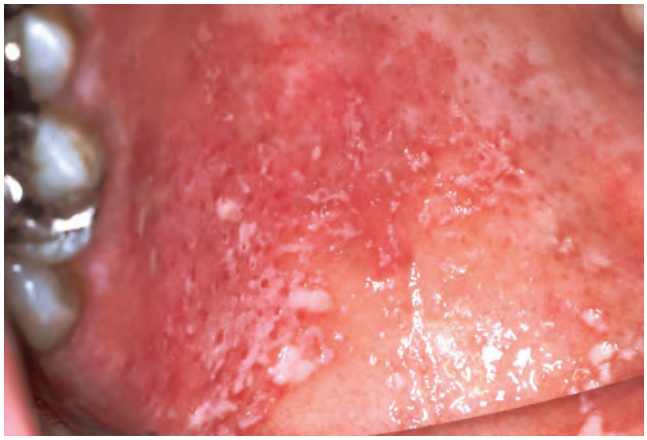

Figure 26-2 Palatal pseudomembranous candidiasis.

have indicated that most patients with AIDS have head and neck lesions,[223] whereas oral lesions are quite common among HIV-positive individuals who do not yet have AIDS.[16,93] Several reports have identified a strong correlation between HIV infection and oral candidiasis, oral hairy leukoplakia, atypical periodontal diseases, oral Kaposi's sarcoma, and oral non-Hodgkin's lymphoma.[68,71,153]

Oral lesions less strongly associated with HIV infection include melanotic hyperpigmentation, mycobacterial infections, necrotizing ulcerative stomatitis (NUS), miscellaneous oral ulcerations, and viral infections (e.g., herpes simplex virus [HSV], herpes zoster, and condyloma acuminatum). Lesions that are seen in HIV-infected individuals with undetermined frequency include less common viral infections (e.g., CMV, molluscum contagiosum), recurrent aphthous stomatitis, and bacillary angiomatosis (epithelioid angiomatosis).[68]

The advent of HAART has resulted in the greatly diminished frequency of oral lesions associated with HIV infection and AIDS.[34,179,261]

Oral Candidiasis

Candidiasis is the most common oral lesion associated with HIV disease, and it has been found in approximately 90% of patients with AIDS.[194,246] It usually has one of four clinical presentations: pseudomembranous, erythematous, or hyperplastic candidiasis or angular cheilitis.[115,178]

Pseudomembranous candidiasis ("thrush") presents as painless or slightly sensitive, yellow-white, curdlike lesions that can be readily scraped and separated from the surface of the oral mucosa. This type is most common on the hard and soft palate and the buccal or labial mucosa, but it can occur anywhere in the oral cavity (Figure 26-2).

Erythematous candidiasis may be present as a component of the pseudomembranous type, appearing as red patches on the buccal or palatal mucosa, or it may be associated with depapillation of the tongue. If the gingiva is affected, it may be misdiagnosed as desquamative gingivitis (Figures 26-3, 26-4, and 26-5). Some evidence suggests that erythematous candidiasis in more common among HIV-positive individuals with CD4+ counts between 200 and 500 cells/µl, whereas the pseudomembranous form occurs in patient with less than 200 CD4+ cells/µl. Viral load is most often elevated to more than 100,000 copies/ml. However, it should be emphasized that any form of candidiasis can be found in individuals who are only minimally immunocompromised.[181]

Hyperplastic candidiasis is the least common form, and it may be seen in the buccal mucosa and the tongue. It is more resistant to removal than the other types (Figures 26-6 and 26-7).

Figure 26-3 Palatal erythematous candidiasis.

Figure 26-4 Gingival erythematous candidiasis that is suggestive of desquamative gingivitis.

Figure 26-5 Mixed erythematous and pseudomembranous candidiasis of the palate.

In *Candida*-related *angular cheilitis,* the commissures of the lips appear erythematous, with surface crusting and fissuring.

The diagnosis of candidiasis is made by the clinical evaluation, culture analysis, or microscopic examination of a tissue sample or smear of material scraped from the lesion (oral cytology), which shows hyphae and yeast forms of the organisms (Figure 26-8). When oral candidiasis appears in patients with no apparent predisposing causes, the clinician should be alerted to the possibility of HIV infection.[68] Many patients who are at risk for HIV infection

Figure 26-6 Mixed erythematous and hyperplastic candidiasis of the corner of the mouth.

Figure 26-7 Hyperplastic candidiasis in the corner of the mouth. The lesion persisted despite the use of systemic antifungal drugs.

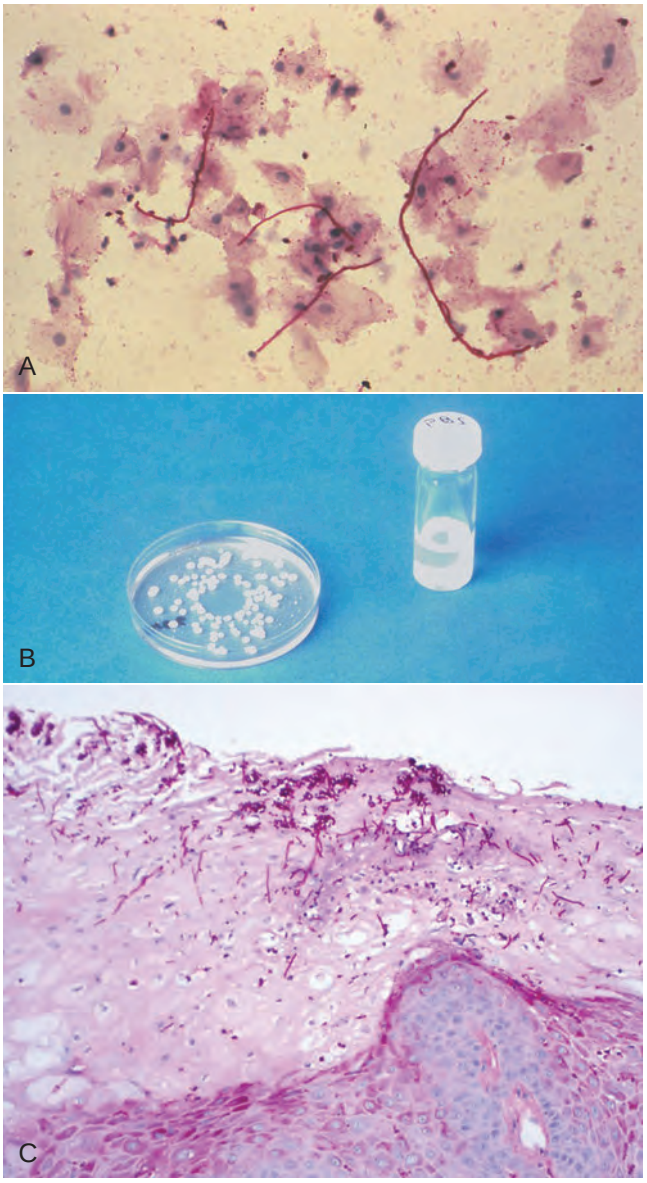

Figure 26-8 Techniques for the diagnosis of candidiasis. **A,** Candidal hyphae in a tissue smear after periodic acid–Schiff staining. **B,** Culture media specific for *Candida* species. **C,** Candidal hyphae in the epithelium of biopsied tissue.

who present with oral candidiasis also have esophageal candidiasis, which is a diagnostic sign of AIDS.[263]

Oral Hairy Leukoplakia

Oral hairy leukoplakia (OHL) primarily occurs in persons with HIV infection.[101,104] It is found on the lateral borders of the tongue, it frequently has a bilateral distribution, and it may extend to the ventrum. OHL is caused by the Epstein–Barr virus (EBV), and it is the only EBV lesion with which viral shedding in saliva is common.[181] The lesion is characterized by an asymptomatic, poorly demarcated, keratotic area that ranges in size from a few millimeters to several centimeters (Figure 26-11, *A*). Often, characteristic vertical striations are present, and these impart a corrugated appearance; the surface may also be shaggy and appear "hairy" when dried. The lesion does not rub off, and it may resemble other keratotic oral lesions.

Kaposi's Sarcoma and Other Malignancies

Oral malignancies occur more frequently in severely immunocompromised individuals than in the general population. An HIV-positive individual with non-Hodgkin's lymphoma (NHL) or Kaposi's sarcoma (KS) is categorized as having AIDS (Figure 26-13). Oral lesions are reported in approximately 4% of individuals with NHL, and the gingiva and palate are common sites. The incidence of oral squamous cell carcinoma may also increase among HIV-infected individuals.[22] KS was a very rare disease until the early 1980s. In its classic form, it is found in older men and occasionally in patients after organ transplants, and it is endemic in parts of Africa. An epidemic form has subsequently been described in HIV-positive individuals, and it is an AIDS-defining condition.[193]

KS is the most common oral malignancy associated with AIDS. This angioproliferative tumor is a rare, multifocal, vascular neoplasm; it was originally described in 1872 as occurring in the skin of the lower extremities of older men of Mediterranean origin. Today, it is closely associated with homosexual and heterosexual transmission, but occurs five to ten times more often among male homosexuals than in other groups that have a high risk for HIV. The causative agent has been identified as human herpesvirus-8 (HHV-8).

Microscopically, Kaposi's sarcoma consists of four components: (1) endothelial cell proliferation with the formation of atypical vascular channels; (2) extravascular hemorrhage with hemosiderin deposition; (3) spindle cell proliferation in association with atypical vessels; and (4) a mononuclear inflammatory infiltrate that consists mainly of plasma cells[99] (Figure 26-17).

Non-Hodgkin's Lymphoma

Lymphoma represents a heterogeneous malignancy that is characterized by the proliferation of lymphoid cells. It is broadly classified as Hodgkin's disease (14%) or NHL. NHL in individuals with HIV infection is an AIDS-defining condition, and elevated cumulative viremia may be a strong predictor of AIDS-related lymphoma.[292]

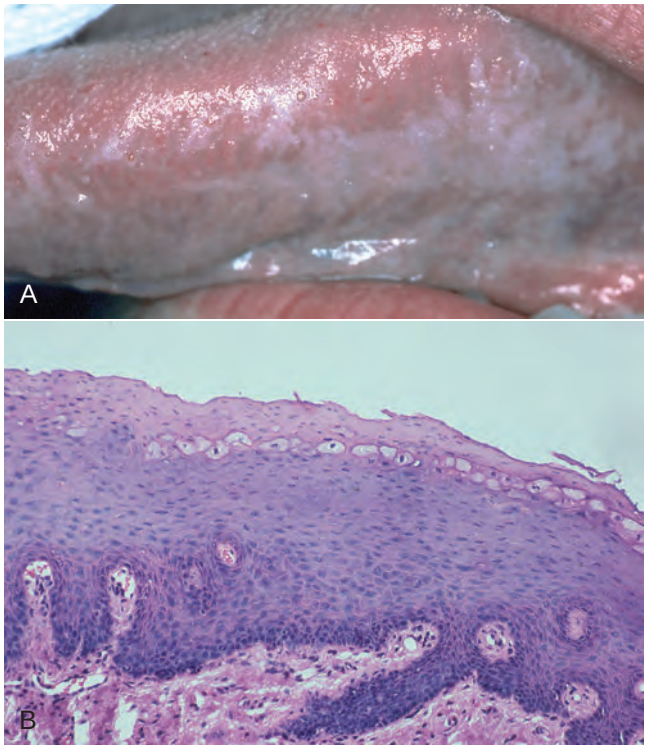

Figure 26-11 Oral hairy leukoplakia on the left lateral border of the tongue. **A,** Clinical view. **B,** Biopsy confirmation of oral hairy leukoplakia. Note the ballooned epithelial cells near the surface of the epithelium.

Oral lesions usually appear as erythematous, painless enlargements that may become ulcerated as a result of traumatic injury (Figure 26-19). In some cases, bone involvement occurs, although this is rare in the United States. Lesions commonly affect the gingival, palatal, and alveolar mucosa, and they may mimic dental infections. Diagnosis is based on physical examination, complete blood count with differential, imaging studies, and lymph node and tissue biopsy.[172]

Bacillary (Epithelioid) Angiomatosis

Bacillary (epithelioid) angiomatosis (BA) is an infectious vascular proliferative disease with clinical and histologic features similar to those of KS. BA is caused by facultative intracellular gram-negative mobile bacilli of the genus *Bartonella* and the order Rickettsia (e.g., *Bartonella henselae, Bartonella quintana*).[68,212,230] Cats are the primary host of *B. henselae,* and the infection is usually transmitted to humans by bites, scratches, or fleas (i.e., cat-scratch fever). Man is the primary reservoir for *B. quintana,* and it is usually transmitted by human lice. BA can occur in immunocompetent persons, but it is most commonly associated with AIDS. Skin lesions are similar to those associated with KS or cat-scratch disease. [57,254] Gingival BA manifests as red, purple, or blue edematous soft-tissue lesions that may cause the destruction of periodontal ligament and bone[91] (see Figure 26-19).

Oral Hyperpigmentation

An increased incidence of **oral hyperpigmentation** has been described in HIV-infected individuals.[50,139,143,291] Oral pigmented

Figure 26-13 Non-Hodgkin's lymphoma of the anterior mandibular gingiva.

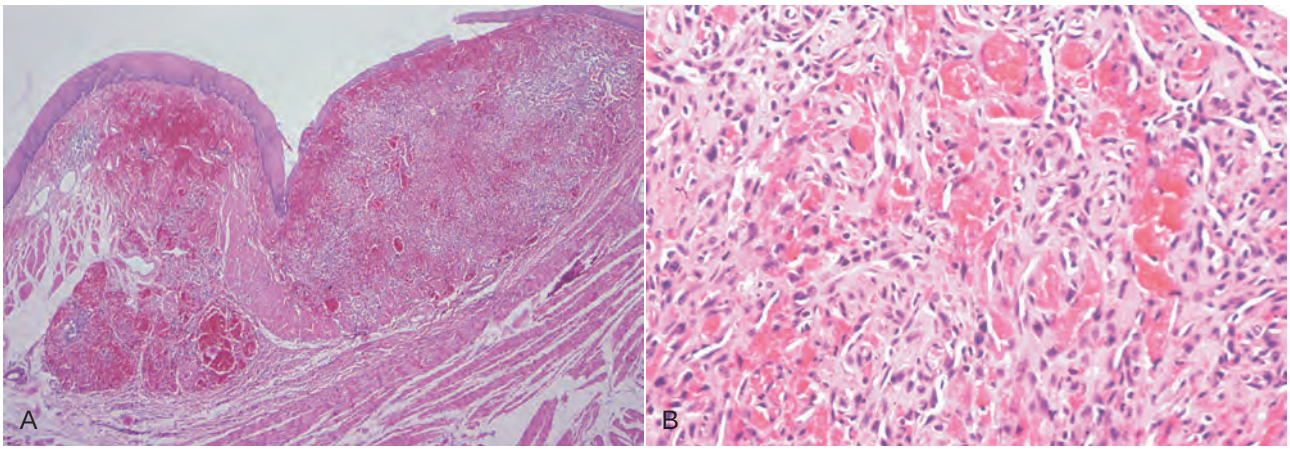

Figure 26-17 **A,** Histologic view of Kaposi's sarcoma. This lesion is exophytic and only minimally inflamed (low magnification). **B,** Note the sheets of endothelial cells and the numerous small blood vessels (high magnification).

Figure 26-19 Bacillary angiomatosis mimicking Kaposi's sarcoma.

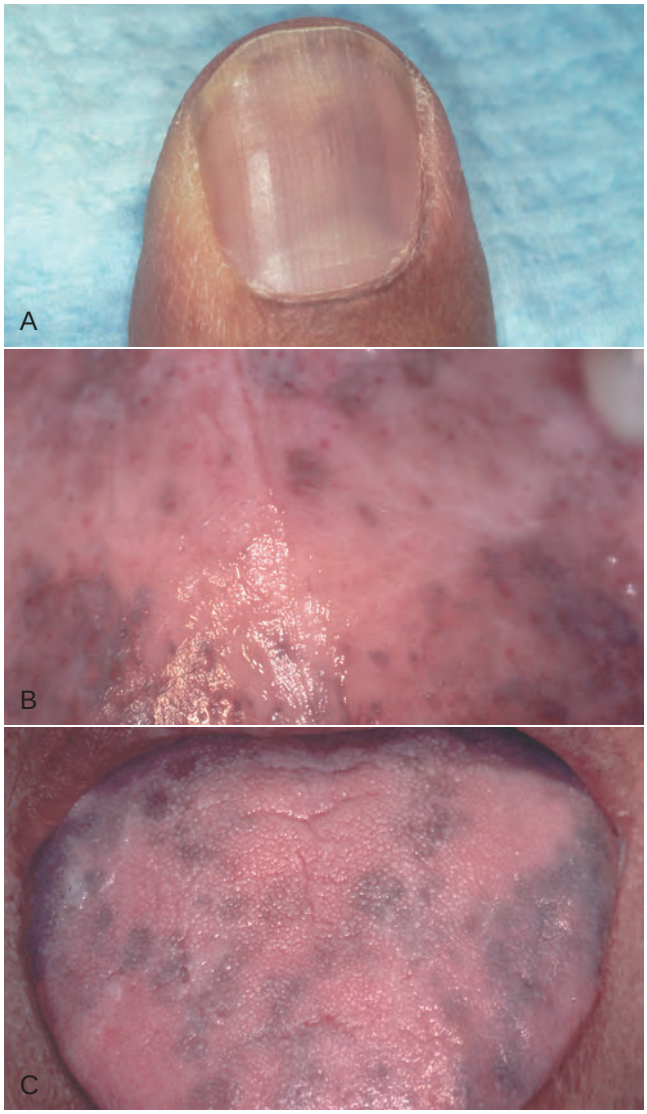

Figure 26-20 Drug-induced hyperpigmentation as a result of zidovudine use. **A,** Fingernail bed discoloration. **B,** Palatal hyperpigmentation in the same patient. **C,** Tongue hyperpigmentation in the same patient. Note the similarity between the oral lesions and those caused by adrenal cortex hypofunction (i.e., Addison's disease).

areas often appear as spots or striations on the buccal mucosa, the palate, the gingiva, or the tongue (Figure 26-20). At present, most reports describing the oral features of HIV/AIDS or post-HAART HIV/AIDS come from areas of the world in which racial pigmentation may be common. In these areas, oral evaluation may often be accomplished by non-dental health care workers. Consequently, it is not possible to accurately assess the degree of HIV-related oral hyperpigmentation before or after ART.

Atypical Ulcers

Atypical ulcers (nonspecific oral ulcerations) in HIV-infected individuals may have multiple etiologies that include neoplasms such as lymphoma, KS, and squamous cell carcinoma. HIV-associated neutropenia may also feature oral ulcerations.

HIV-infected patients have a higher incidence of recurrent herpetic lesions and aphthous stomatitis (Figures 26-21 and 26-22). Approximately 10% of HIV-infected patients have herpes infection,[199] and multiple episodes are common. The CDC HIV classification system indicates that mucocutaneous herpes that lasts more than 1 month is diagnostic of AIDS in HIV-infected individuals.[36] Aphthae and aphthae-like lesions are common when patients are followed throughout the course of their immunosuppression.[93]

Salivary Gland Disorders and Xerostomia

Salivary gland hypofunction and xerostomia may be most common among HIV-infected men during both the early and advanced stages of HIV infection and immunosuppression. Salivary function does not appear to be affected by HAART, despite the fact that some individual antiretroviral medications are reported to induce xerostomia. However, it is clear that xerostomia is a relatively common condition among HIV-infected individuals and that up to 10% of these patients may be affected. Xerostomia appears to become more severe as immunosuppression worsens, and increased candidal carriage is associated with reduced salivary flow rate.[131]

Dental Treatment Complications

Concerns have been expressed regarding the potential for postoperative complications (e.g., hemorrhage, infection, delayed wound healing) in individuals with HIV or AIDS. Medically compromised patients must be carefully managed in the dental office to avoid undue treatment complications.[60] However, *systematic reviews of the literature indicate that special precautions are usually not necessary based simply on the HIV status of patients when performing periodontal treatment procedures such as dental prophylaxis, scaling and root planing, periodontal surgery, extractions, and the placement of implants.* On occasion, the poor overall health status of an individual with AIDS may limit periodontal therapy to conservative, minimally invasive procedures, and antibiotic therapy may be required.[10,63,64,90,195] When possible, antibiotics should be avoided in significantly immunocompromised individuals to minimize the risk of opportunistic infections (i.e., candidiasis), superinfection, and microorganism drug resistance.[169]

Gingival and Periodontal Diseases

Considerable research has focused on the nature and incidence of periodontal diseases in HIV-infected individuals. Some studies suggest that chronic periodontitis is more common in this patient population, but others do not. Periodontal diseases are more common among HIV-infected users of injection drugs, but this may relate to poor oral hygiene and a lack of dental care rather than decreased CD4 cell counts. However, some unusual types of periodontal diseases do seem to occur with greater frequency among HIV-positive individuals.[12,106,142,199,214,259]

Linear Gingival Erythema

A persistent, linear, easily bleeding, erythematous gingivitis has been described in some HIV-positive patients. The intensity of the

In some cases, the pigmentation may relate to the prolonged use of drugs such as zidovudine, ketoconazole, or clofazimine.[291] Zidovudine is also associated with the excessive pigmentation of the skin and nails, although similar hyperpigmentation has been reported in some individuals who have never taken zidovudine. On occasion, oral pigmentation may be the result of adrenocorticoid insufficiency that has been induced in an HIV-positive individual via the prolonged use of ketoconazole or by *Pneumocystis jiroveci,* CMV, or other viral infections[143] (see Figure 26-20).

Neutropenia has been successfully treated with the use of recombinant human granulocyte colony-stimulating factor, with the resultant resolution of oral ulcers.[148] Severe and prolonged oral ulcers have been successfully managed with the use of prednisone or thalidomide, a drug that inhibits tissue necrosis factor-α. Recurrence is likely, however, if either drug is discontinued.[96,132]

In healthy patients, herpetic and aphthous lesions are self-limiting and relatively easy to diagnose as a result of their characteristic clinical features (i.e., herpes on the keratinizing mucosa and aphthae on the non-keratinizing surfaces). In HIV-infected patients, the clinical presentation and course of these lesions may be altered. Herpes may involve all mucosal surfaces and extend to the skin, and it may persist for months[73] (see Figure 26-21). Atypical large, persistent, nonspecific, and painful ulcers are common in immunocompromised individuals. If healing is delayed, these lesions are secondarily infected, and they may become indistinguishable from persistent herpetic or aphthous lesions.[220]

A wide variety of bacterial and viral infections may produce severe oral ulcerations in HIV-infected individuals.[258] Essentially, immunocompromised individuals are at risk from infectious agents that are endemic to the patient's geographic location.[21,286] Atypical or non-healing ulcers may require biopsy, microbial cultures, or both to determine the etiology. Oral ulcerations have been described in association with enterobacterial organisms such as *Klebsiella pneumoniae, Enterobacter cloacae,* and *Escherichia coli.*[220] Such infections are rare, and they are usually associated with systemic involvement. Specific antibiotic therapy is indicated, and the close coordination of oral therapy with the patient's physician is usually necessary.[220]

HSV, varicella-zoster virus, EBV, and CMV are frequently retrieved from nonspecific oral ulcers, thereby indicating a possible etiologic role.[258] Recently, some atypical ulcers were found to be coinfected with both HSV and CMV or with both EBV and CMV.[222,267] These ulcers may be more common in individuals who are neutropenic in conjunction with their HIV infection. Neutropenia may also be induced by drugs such as zidovudine, trimethoprim-sulfamethoxazole, and gancyclovir.[148] Atypical ulcers may be more severe and persistent in individuals with low CD4 cell counts, and the presence of oral CMV-induced ulcers may be indicative of systemic CMV infection.[93]

Herpes labialis in HIV-infected individuals may be responsive to topical antiviral therapy (e.g., acyclovir, penciclovir, docosanol), thus reducing the healing time of lesions. In other patients, however, oral or labial herpetic lesions may require the use of systemic antiviral agents (e.g., acyclovir, valacyclovir, famciclovir).[8,70,73]

Recurrent aphthous stomatitis has been described in HIV-infected individuals, but the overall incidence may be no greater than that found in the general population.[68] Recurrent aphthous stomatitis may occur, however, as a component of the initial acute illness of HIV seroconversion. The incidence of major aphthae may be increased, and the oropharynx, esophagus, or other areas of the gastrointestinal tract may be involved[8] (see Figure 26-22).

Available evidence indicates that the incidence of herpesvirus infections is not reduced by HAART, whereas the incidence of neutropenic ulcerations may actually increase.

Proven methods for the treatment of recurrent aphthous stomatitis include topical or intralesional corticosteroids, chlorhexidine or other antimicrobial mouthrinses, oral tetracycline rinses, and topical amlexanox. Systemic corticosteroid therapy may be necessary in some cases. Consequently, in patients with HIV infection and recurrent aphthae, closely coordinated medical and dental therapy may be necessary.[70,73]

Recent evidence indicates that many nonspecific oral ulcerations may be of viral origin, with HSV, EBV, and CMV being the most common[93] (Figure 26-23). For this reason, the practitioner should consider the viral culturing of such lesions and the use of antiviral agents in treatment where appropriate.

Oral viral infections in immunocompromised individuals are often treated with acyclovir (200 mg to 800 mg administered five times daily for at least 10 days). Subsequent daily maintenance therapy (200 mg two to five times daily) may be required to prevent recurrence. Resistant viral strains are treated with foscarnet, ganciclovir, or valacyclovir.[7,263]

Topical corticosteroid therapy (fluocinonide gel applied three to six times daily) is safe and efficacious for the treatment of recurrent aphthous ulcers or other mucosal lesions in immunocompromised individuals.[70] However, topical corticosteroids may predispose immunocompromised individuals to candidiasis. Consequently, prophylactic antifungal medications should be prescribed.

Occasionally, large aphthae in HIV-positive individuals may prove to be resistant to conventional topical therapy. In these patients, medical consultation is recommended, and the administration of systemic corticosteroids (e.g., prednisone, 40 mg to 60 mg daily) or alternative therapy (e.g., thalidomide, levamisole, pentoxifylline) should be considered.[44,129] These agents may have significant side effects, however, and the clinician should remain alert for any evidence that is suggestive of an adverse drug reaction or interaction with currently prescribed medications.[68] Because virtually all antiviral agents used for the treatment of HIV infection have the potential for adverse side effects or drug interactions, the dental clinician should consider topical therapy when appropriate.

Saliva is an important component of the oral mucosal immune system, and it contains many HIV inhibitors, such as HIV-1–specific antibodies, lysozyme, peroxidases, cystatins, lactoferrin, histatins, and others.[11,243] Saliva may also contain a specific salivary anti-HIV factor known as *secretory leukocyte protease inhibitor.* Its immune properties plus its flushing action may help to explain why HIV concentrations are low in saliva and why the oral cavity is rarely a site of HIV transmission. Conversely, dryness of the mouth (xerostomia) is common in HIV-positive individuals, and it worsens as the viral load increases to more than 100,000 copies/mm^3. In addition, the enlargement of the major salivary glands, particularly the parotids, is more common in HIV-positive individuals.[147]

Figure 26-23 A solitary ulcer in the soft palate. Culture confirmed the presence of cytomegalovirus.

One longitudinal study indicated that submandibular and sublingual hypofunction occurs earlier than parotid hypofunction, but the parotid glands become progressively less functional over time.

Reports of a possible interrelationship between salivary gland function and HIV infection have been difficult to assess, because there is little standardization of protocols to study salivary hypofunction, and many medications used for the treatment of HIV infection and associated conditions may induce xerostomia. Despite these limitations, a carefully conducted study of xerostomia in HIV-positive and HIV-negative women indicated that HIV-positive individuals were nearly three times as likely to have zero unstimulated salivary flow rate as HIV-negative individuals. Zero unstimulated salivary flow rate was significantly associated with a CD4 count of less than 200, but no differences were found relative to viral load.[173]

Although some antiretroviral medications are reported to contribute to xerostomia, the overall effect of antiretroviral therapy may indicate that the drugs serve to prevent salivary gland hypofunction by controlling HIV replication.[173] Parotid enlargement associated with HIV infection may occur as the result of a condition described as diffuse infiltrative lymphocytosis syndrome, which is characterized by persistent circulating CD8+ lymphocytosis as well as visceral lymphocytic infiltration and parotid infiltration.[76] Other causes include cystic lymphoepithelial lesions, hyperplastic lymphadenopathy, bacterial and viral infections, Sjögren's syndrome, and lymphoma.[76] In addition, HAART is associated with lipodystrophy syndrome, which may result in fat hypertrophy in the parotid glands in association with facial thinning and visceral fatty deposits. This syndrome is associated with dyslipidemia and increased insulin resistance.[124]

Adverse Drug Effects

A number of adverse drug-induced effects have been reported in HIV-positive patients, and the dentist may be the first to recognize an oral drug reaction. Foscarnet, interferon, and 2-3-dideoxycytidine occasionally induce oral ulcerations, and erythema multiforme has been reported with the use of didanosine.[54] Zidovudine and ganciclovir may induce leukopenia, which results in oral ulcers.[161] Xerostomia and altered taste sensation have been described in conjunction with diethyldithiocarbamate (Ditiocarb). HIV-positive patients are thought to be generally more susceptible to drug-induced mucositis and lichenoid drug reactions than the general population.[14,54,164] In some patients, mouth ulcers and mucositis resolve if drug therapy is continued beyond 2 to 3 weeks, but when drug effects are severe or persistent, alternative therapy with different drugs should be used.

HAART drugs may induce adverse side effects, which range from relatively mild conditions such as nausea to the development of kidney stones. Individuals with hepatitis and HIV coinfection are susceptible to liver cirrhosis.[219] A newly identified adverse effect is lipodystrophy, a condition that features the redistribution of body fat. Affected individuals may develop gaunt facial features yet display excessive abdominal fat or even a fat pad on the rear of the shoulders (i.e., buffalo hump). This may be accompanied by severe systemic hyperlipidemia.[15,25,28,30,55,79,149,151] Other adverse effects of HAART include increased insulin resistance,[111] gynecomastia,[152] toxic epidermal necrolysis, blood dyscrasias,[236] and possibly an increased incidence of oral warts.[27,100,222,278] Other reported oral or perioral adverse effects include oral lichenoid reactions, xerostomia, altered taste sensation, perioral paresthesia, and exfoliative cheilitis[24,25,30,166] (Figures 26-24 and 26-25).

The affected gingiva may be exquisitely painful, and caution must be taken to avoid undue patient discomfort. Basic treatment may consist of the cleaning and debridement of affected areas with a cotton pellet soaked in peroxide after the application of a topical anesthetic. Escharotic oral rinses such as hydrogen peroxide should only rarely be used for any patient, and they are especially contraindicated in immunocompromised individuals. The patient should be seen daily or every other day for the first week, and the debridement of affected areas is repeated at each visit. Plaque-control methods are gradually introduced. A meticulous plaque-control program should be taught and started as soon as the sensitivity of the area allows it. After initial healing has occurred, the patient should be able to tolerate scaling and root planing, if needed.

The patient should avoid tobacco, alcohol, and condiments. An antimicrobial oral rinse such as chlorhexidine gluconate 0.12% should be prescribed.

Systemic antibiotics such as metronidazole or amoxicillin may be prescribed for patients with moderate to severe tissue destruction, localized lymphadenopathy, or systemic symptoms. Metronidazole may be the antibiotic of choice, because it has been demonstrated to be effective for the treatment of NUG, and its narrow bactericidal spectrum may minimize the risk of secondary opportunistic infections such as candidiasis.[288] The use of prophylactic antifungal medication should be considered if antibiotics are prescribed.

Figure 26-24 Exfoliative cheilitis associated with highly active antiretroviral therapy.

Figure 26-25 Condyloma acuminatum in the left buccal mucosa of a patient with human immunodeficiency virus who is receiving highly active antiretroviral therapy. Available evidence suggests that such human papillomavirus–induced lesions occur with increased frequency the after initiation of multidrug therapy for acquired immunodeficiency syndrome.

The periodontium should be reevaluated 1 month after the resolution of acute symptoms to assess the results of treatment and to determine whether further therapy will be necessary.

Some evidence suggests slight differences between the microbial flora found in NUP lesions and that found in chronic periodontitis,[169,190] but most data implicate a similar microbial component in both diseases. An increasing number of studies, however, have identified the presence of candidal organisms and human herpesviruses of various types in individuals with necrotizing ulcerative periodontal diseases. The exact role of these organisms is not yet fully understood.[51,250] As discussed previously, the reported periodontal health of HIV-infected individuals is subject to wide variations.[224,287] Riley and colleagues[224] examined 200 HIV-positive patients and found that 85 were periodontally healthy; none had NUG; 59 had gingivitis; 54 were experiencing mild, moderate, or advanced periodontitis; and only two had NUP. Glick and colleagues[94] reported the prevalence of NUP as 6.3% in an HIV-positive population, and they described a positive correlation between the presence of NUP and outright AIDS.[94]

Necrotizing Ulcerative Stomatitis

NUS has occasionally been reported in HIV-positive patients. NUS may be severely destructive and acutely painful, and it may affect significant areas of oral soft tissue and underlying bone. It may occur separately or as an extension of NUP,[119,203] and it is often associated with the severe suppression of CD4 immune cells and an elevated viral load. The condition appears to be identical to cancrum oris (noma), a rare necrotizing destructive process that has been variously described as stomatitis gangrenosa, cancrum oris, or noma but that was originally reported in nutritionally deprived individuals, especially in Africa. However, today noma is very common in sub-Saharan African children with HIV.[47] NUS may be associated with severe immunodeficiency, regardless of the cause of onset.[9,17,225]

Treatment for NUS may include an antibiotic such as metronidazole and the use of an antimicrobial mouth rinse such as chlorhexidine gluconate. If osseous necrosis is present, it is often necessary to remove the affected bone to promote wound healing[9] (Figure 26-31).

Despite these limitations, most studies of chronic periodontitis (CP) in HIV-positive individuals report that the incidence is similar to that found in the general population. In addition, the periodontal pathogenic organisms that are routinely found in conventional CP are also found in HIV-associated CP. However, numerous studies have also reported a high prevalence of microorganisms in HIV-associated CP that are not found in the general population, including *Acinetobacter baumannii, Candida* spp., *Clostridium difficile, Clostridium clostridioforme, Entamoeba gingivalis, Enterobacter* spp., *Enterococcus faecalis, Enterococcus avium, Klebsiella pneumoniae, Mycoplasma salivarium,* and *Pseudomonas aeruginosa*.[268,59] Viral organisms such as EBV-1, HHV-7 and CMV have previously been found in gingivitis and mild to moderate periodontitis in systemically healthy individuals as well as in HIV-positive individuals. However, EBV and HHV-6 were reported at a higher frequency among HIV-positive patients. Even HHV-8, which is the KS virus, has been found in HIV-associated CP in the absence of KS. Whether or not these rare organisms influence periodontal pathogenesis has not been determined. However, it is certainly possible that these microorganisms may alter the subgingival biofilm environment and cause an HIV-infected individual to experience more rapid CP progression.[268,59] Many of these organisms are also associated with systemic diseases, thereby suggesting the possibility that CP in HIV-positive individuals may increase the risk for nosocomial infections as well as the development of antimicrobial resistance in affected individuals.

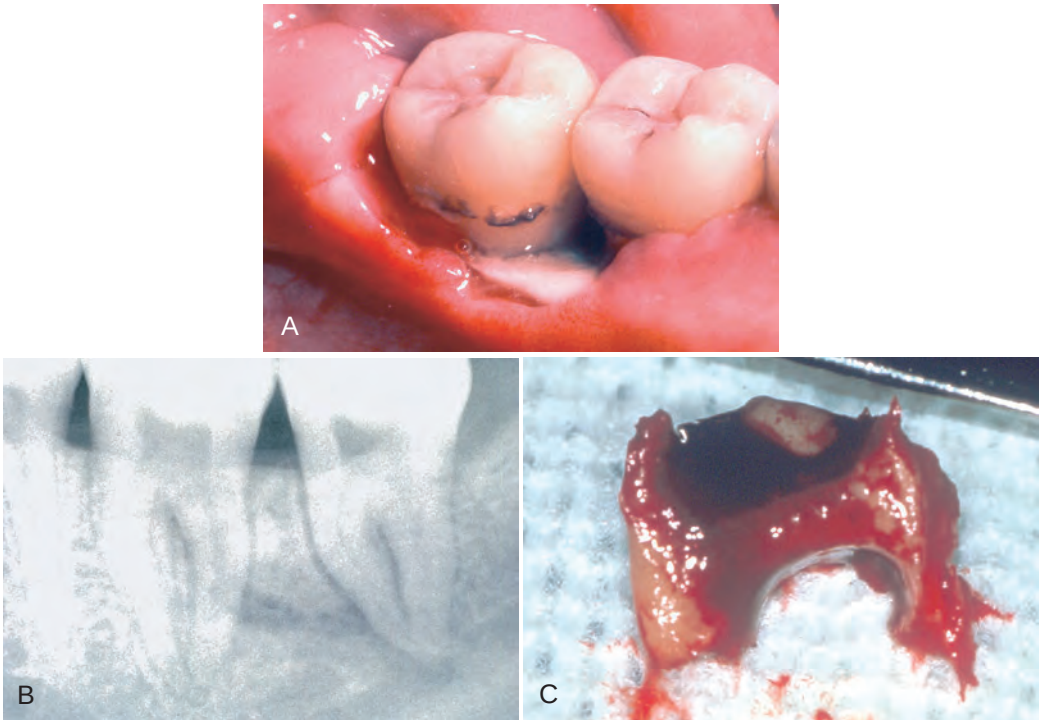

Figure 26-31 **A,** Necrotizing ulcerative stomatitis in the left mandibular molar area. **B,** Radiographic view. Note the large osseous sequestrum. **C,** The osseous sequestrum has been removed.

In previous studies, Shugars and colleagues reported that HIV-1 RNA was detectable in the saliva of some seropositive individuals and that both salivary and plasma levels were higher in those with HIV-associated periodontal diseases, leading some to suggest that periodontal infections may contribute to HIV viremia, as discussed previously.[245]

EBV-1 has been reported to be present more frequently in HIV-positive patients than in HIV-negative patients.[98] Lamster and colleagues[142] compared the frequency of oral lesions and periodontal diseases between HIV-positive and HIV-negative individuals, some of whom were IDUs. Those researchers concluded that the lifestyles of IDUs may play a larger role in oral disease than the individual's HIV status. They also found that tongue lesions consistent with hairy leukoplakia were most common among seropositive homosexual males, whereas oral candidiasis and LGE were most common among IDUs.

Others have reported that the incidence and severity of chronic periodontitis are similar in HIV-positive and HIV-negative groups.[227,229] Klein and colleagues[137] evaluated heterosexuals with AIDS and found a larger percentage of women (91%) than men (73%) with gingivitis or periodontitis. Overall, most heterosexuals with AIDS had only gingivitis (70%), whereas others had moderate (27%) to severe (27%) periodontitis. This study suggests that periodontal diseases are no more frequent among heterosexuals with AIDS than they are among the general population. The finding of more frequent disease in women may reflect more women with AIDS being IDUs.

Drinkard and colleagues[66] evaluated the periodontal status of asymptomatic HIV-positive individuals and those with signs and symptoms of declining immune status. They reported that both groups were generally in good periodontal health, with no significant differences seen between groups. Others have described similar findings.[222,226,227,229,231]

A well-controlled study indicated that gingival recession and early attachment loss are more common in HIV groups than matched groups from the general population.[226] This appears to affirm that immunocompromised individuals are slightly more susceptible to chronic periodontitis than those with robust immune systems. In support of this, Ceballos-Salobrena and colleagues[34] reported a 30% decrease in the prevalence of chronic periodontitis among patients with AIDS who were receiving HAART. The majority of HIV-positive individuals experience gingivitis and chronic periodontitis in a manner similar to the general population. However, several studies have suggested that proinflammatory cytokines are increased in HIV-positive individuals, which suggests that chronic periodontitis may tend to be more severe in this population should it be present.[288]

Recently, there has been considerable interest in comparing the periodontal health of HIV-positive individuals before and after HAART.[156] At present, HAART appears to have significantly modified the course of HIV disease by changing it into a manageable chronic disease with improved quality of life for infected individuals and a life expectancy approaching that of individuals without HIV. HAART appears to have significantly reduced the incidence and severity of periodontal diseases in adults but not in children.[65] However, studies that have followed the post-HAART era for an extended period of time report that the potential for oral opportunistic infections such as candidiasis may still be present, whereas others note that comorbid conditions such as chronic obstructive pulmonary disease, cardiovascular disease, and diabetes may affect life expectancy among HAART-maintained individuals. Liberali and colleagues have suggested that early methods of identifying periodontal diseases in HIV-positive individuals may have underestimated their prevalence, because these methods did not measure the clinical attachment loss that may be markedly increased in the presence of necrotizing gingival and periodontal diseases but without a significant increase in probing depths.[144] By using current diagnostic criteria, those researchers determined that moderate to severe periodontal disease and gingivitis continue to be elevated in HIV-positive patients as compared with age-matched controls.[144] This information—in combination with the realization that ongoing periodontal diseases may adversely affect some systemic conditions and that CP may influence HIV recrudescence—indicates that achieving periodontal health in populations with HIV and AIDS is extremely important.

Figure 26-21 Abnormal herpetic lesions in individuals with human immunodeficiency virus. **A,** The lip crusting of primary herpetic gingivostomatitis. **B,** Ulcerations of the gingiva, the alveolar mucosa, and the vestibule in the same patient. **C,** Severe herpes labialis in the commissures of the lip. **D,** A close-up view of herpes labialis. Note the fluid-filled vesicles.

erythema is disproportionate to the amount of plaque present. There is no ulceration, pocketing, or attachment loss,[268] and the condition does not respond predictably to conventional periodontal therapy. Lesions that are clinically identical to linear gingival erythema were observed before the advent of HIV in association with severely immunocompromised individuals or in those with NUG.

Linear gingival erythema (LGE) may or may not serve as a precursor to rapidly progressive NUP[92,94] (Figures 26-26 and 26-27). The microflora of LGE may closely mimic that of periodontitis rather than gingivitis. However, *Candida* infection has been implicated as a major etiologic factor, and human herpesviruses have been proposed as possible triggers or cofactors.[7,53,226,250,268] Linear gingivitis lesions may be localized or generalized in nature. The erythematous gingivitis may be limited to marginal tissue, extend into attached gingiva in a punctate or diffuse erythema, or extend into the alveolar mucosa.

The diagnosis of LGE may be difficult, because it can be mistaken for conventional marginal gingivitis. This may be especially true in studies from undeveloped countries or countries with newly identified and largely untreated patients with HIV and AIDS. This makes it very difficult to identify the true prevalence of LGE in HIV-infected and non-infected individuals. This prompted the report from the Fifth World Workshop on Oral Health and Disease in AIDS to limit a diagnosis of LGE only to those individuals who do not respond to conventional periodontal debridement procedures.[268]

Although LGE may sometimes be unresponsive to corrective therapy, such lesions may undergo spontaneous remission. Concomitant oral candidiasis and LGE lesions have been identified, which suggests a possible etiologic role for candidal species in LGE.[142] In one study, direct microscopic cultures from LGE lesions implicated *Candida dubliniensis* in four patients, all of whom experienced complete or partial remission after systemic antifungal therapy.[274] It is not yet known whether candidal infections are etiologic in all LGE cases. A recent systematic review indicates that LGE is more common among HIV-infected populations but that most individuals who are HIV-positive do not experience LGE.[194]

Others have reported that LGE is most often found in HIV-positive individuals whose CD4+ counts are depressed (i.e., 200 to 500 cells/mm^3 or <200 cells/mm^3) or whose viral loads are elevated, thereby suggesting that it may represent an early marker of progressive immunodeficiency or even the transition to outright AIDS.[194,251]

LGE-like lesions can sometimes be adequately managed by following the therapeutic principles associated with marginal gingivitis. However, as mentioned previously, it has been suggested that gingivitis lesions that respond to conventional therapy do not represent LGE.[264] The affected sites should be scaled and polished. Subgingival irrigation with chlorhexidine or 10% povidone–iodine may be beneficial. The patient should be carefully instructed regarding the performance of meticulous oral hygiene procedures. The condition should be reevaluated 2 to 3 weeks after initial

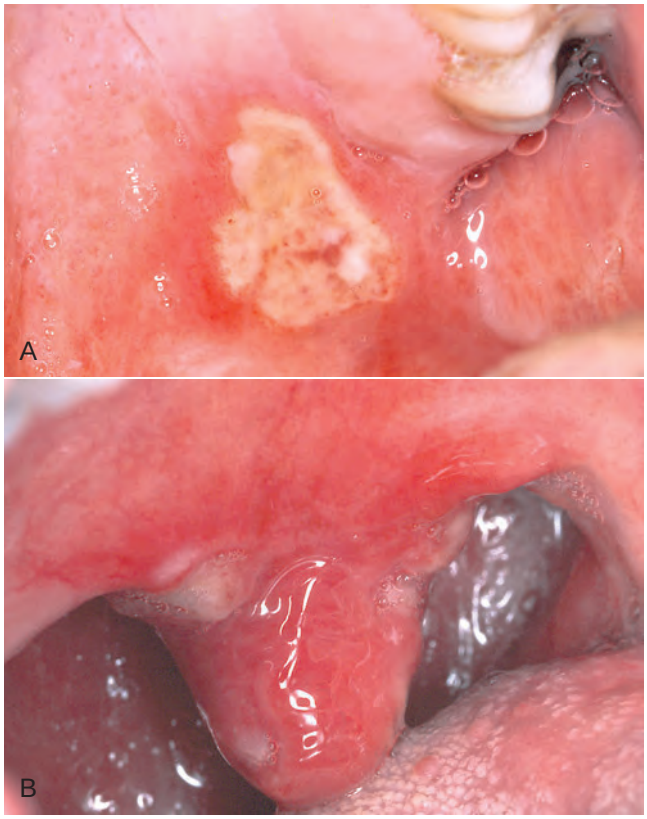

Figure 26-22 Intraoral aphthous stomatitis in a patient with acquired immunodeficiency syndrome. **A,** Major aphthous lesion in the left soft palate. **B,** Ulcerations of the uvula in the same patient.

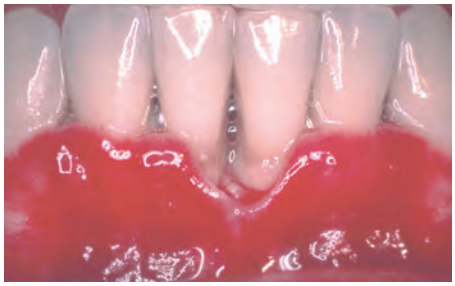

Figure 26-26 Linear gingival erythema and necrotizing ulcerative gingivitis in a patient with acquired immunodeficiency syndrome.

Figure 26-27 Mild linear gingival erythema. The patient had a T4 count of 9 and a viral load that was too numerous to count.

therapy. If the patient is compliant with home care procedures and the lesions persist, the possibility of a candidal infection should be considered. It is doubtful that topical antifungal rinses will reach the base of the gingival crevices. Consequently, the treatment of choice may be the empiric administration of a systemic antifungal agent, such as fluconazole, for 7 to 10 days.[116]

It is important to remember that LGE is often refractory to treatment. If so, the patient should be carefully monitored for developing signs of more severe periodontal conditions (e.g., NUG, NUP, NUS). The patient should be placed on a 2- to 3-month recall maintenance interval and re-treated as necessary. As mentioned previously, despite the occasional resistance of LGE to conventional periodontal therapy, spontaneous remission may occur for reasons that are not yet known.

Necrotizing Ulcerative Gingivitis

Some reports have described an increased incidence of NUG among HIV-infected individuals, although this has not been substantiated by other studies.[66,93,94,119,228,256]

There is no consensus regarding whether the incidence of NUG increases in HIV-positive patients.[191,195,219,239] However, a recent study evaluated the HIV status of individuals who presented with necrotizing periodontal diseases, and 69% were found to be HIV seropositive.[239] The treatment of NUG in these patients does not differ from that used for HIV-negative individuals (see Chapter 41).

Necrotizing Ulcerative Periodontitis

A necrotizing, ulcerative, rapidly progressive form of periodontitis occurs more frequently among HIV-positive individuals, although such lesions were described long before the onset of the AIDS epidemic. NUP appears to represent an extension of NUG in which bone loss and periodontal attachment loss occur.[182,239]

NUP is characterized by soft-tissue necrosis, rapid periodontal destruction, and interproximal bone loss[94,204] (Figures 26-28, 26-29, and 26-30). Lesions may occur anywhere in the dental arches; they are usually localized to a few teeth, although generalized NUP is sometimes present after marked CD4+ cell depletion. Bone is often exposed, which results in necrosis and subsequent sequestration. NUP is severely painful at onset, and immediate treatment is necessary. Occasionally, however, patients undergo spontaneous resolution of the necrotizing lesions, which leave painless, deep interproximal craters that are difficult to clean and that may lead to conventional periodontitis.[92]

Figure 26-28 Necrotizing ulcerative periodontitis. Note the adjacent linear gingival erythema.

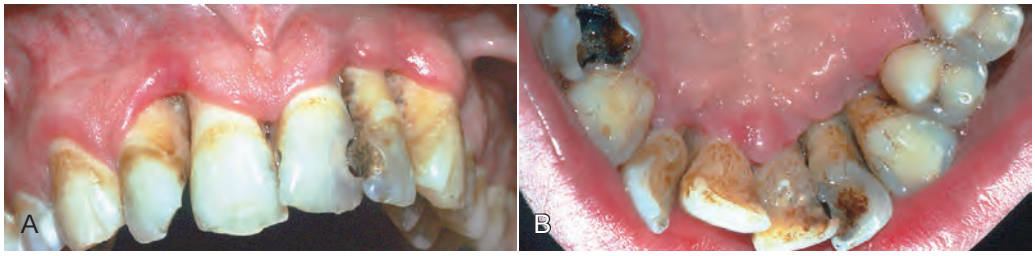

Figure 26-29 Necrotizing ulcerative periodontitis in an otherwise healthy 19-year-old man without human immunodeficiency virus. **A,** Anterior maxilla. **B,** Palatal view.

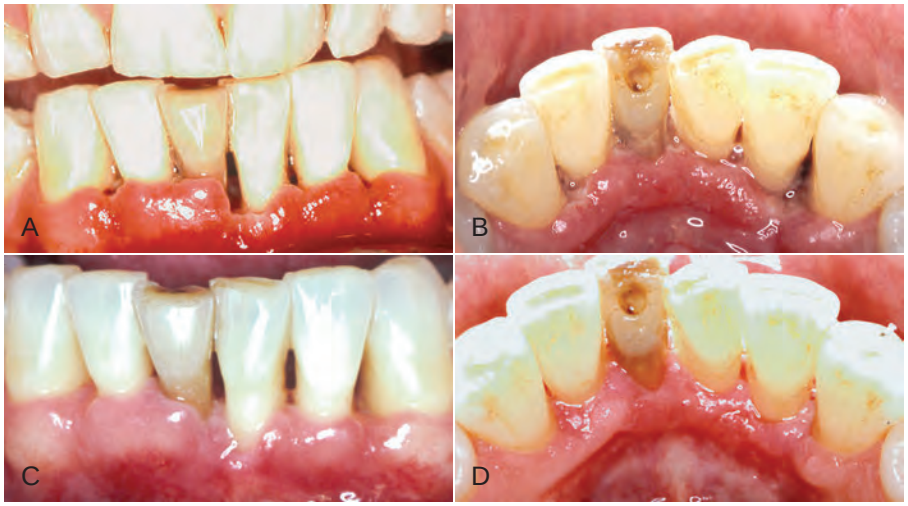

Figure 26-30 Early necrotizing ulcerative periodontitis in a patient with acquired immunodeficiency syndrome. **A,** Facial view. **B,** Lingual view. **C,** Facial view of the complete resolution of necrotizing ulcerative periodontitis after treatment. **D,** Lingual view.

Therapy for NUP includes local debridement; scaling and root planing; in-office irrigation with an effective antimicrobial agent such as chlorhexidine gluconate or povidone–iodine (Betadine); and the establishment of meticulous oral hygiene, including the home use of antimicrobial rinses or irrigation.[195,203,229] This therapeutic approach is based on reports that involved only a small number of patients.

In patients with severe NUP, antibiotic therapy may be necessary, but it should be used with caution in HIV-infected patients to avoid an opportunistic and potentially serious localized candidiasis or even candidal septicemia.[166] If an antibiotic is necessary, metronidazole (250 mg, with two tablets taken immediately and then two tablets taken four times daily for 5 to 7 days) is the drug of choice. The prophylactic prescription of a topical or systemic antifungal agent is prudent if an antibiotic is used.

Chronic Periodontitis

A number of longitudinal studies and prevalence studies have suggested that HIV-positive individuals are more likely to experience chronic periodontitis than the general population.[12,162,174,213] Most studies, however, do not take into account the level of oral hygiene, the presence of pre-existing gingivitis, poor diet, the age of the patient, smoking, other periodontal disease risk factors, the degree of immunodeficiency in the population studied, or whether the individuals in the study are injection drug users (IDUs); these confounding factors cloud the issue.

With proper home care and appropriate periodontal treatment and maintenance, HIV-positive individuals can anticipate reasonably good periodontal health throughout the course of their disease.[134] The median period between initial HIV infection and outright AIDS is approximately 15 years, and the life expectancy of persons living with AIDS has been significantly prolonged with current anti-HIV drug therapy.[23,38]

Figure 26-32 Periodontal health in an individual with advanced acquired immunodeficiency syndrome.

This indicates that HIV-infected patients are potential candidates for conventional periodontal treatment procedures, including periodontal surgery and implant placement. Treatment decisions should be based on the overall health status of the patient, the degree of periodontal involvement, and the motivation and ability of the patient to perform effective oral hygiene (Figure 26-32).

Clearly, some less common periodontal diseases do occur more frequently in HIV-positive individuals, but these same conditions are also reported among HIV-negative persons. Consequently, definitions for these conditions and the discussion of their management

should not be construed as limiting them to individuals with HIV or AIDS.

Periodontal Treatment Protocol

It is imperative that medically compromised patients, including those with HIV or AIDS, be safely and effectively managed in dental practice.[240] Several universal treatment considerations are important to ensure that this is achieved.

Health Status

The patient's health status should be determined from the health history, the physical evaluation, and consultation with the patient's physician. Treatment decisions will vary, depending on the patient's state of health. For example, delayed wound healing and an increased risk of postoperative infection are possible complicating factors in patients with AIDS, but neither concern should significantly alter treatment planning for an otherwise healthy, asymptomatic, HIV-infected patient with a normal or near-normal CD4 count and a low viral bioload.[85,109,153,207]

It is important to obtain information about the patient's immune status with questions such as the following:

- What is the CD4+ T4 lymphocyte level?
- What is the current viral load?
- How do current CD4+ T4 cell and viral load counts differ from previous evaluations? How often are such tests performed?
- How long ago was the HIV infection identified? Is it possible to identify the approximate date of original exposure?
- Is there a history of drug abuse, sexually transmitted diseases, multiple infections, or other factors that may alter immune response? For example, does the patient have a history of chronic hepatitis B, hepatitis C, neutropenia, thrombocytopenia, nutritional deficiency, or adrenocorticoid insufficiency?
- What medications is the patient taking?
- Does the patient describe or present with possible adverse side effects from medications?

Infection Control Measures

The clinical management of HIV-infected periodontal patients requires strict adherence to established methods of infection control, which should be based on guidance from the American Dental Association and the CDC. Compliance, especially with universal precautions, will eliminate or minimize risks to both patients and the dental staff.[85,150,275] Immunocompromised patients are potentially at risk for acquiring as well as transmitting infections in the dental office and other health care facilities.[146,168,183]

Goals of Therapy

A thorough oral examination will determine the patient's dental treatment needs. The primary goals of dental therapy should be the restoration and maintenance of oral health, comfort, and function. At the very least, periodontal treatment goals should be directed toward the control of HIV-associated mucosal diseases, such as chronic candidiasis and recurrent oral ulcerations. Acute periodontal and dental infections should be managed, and the patient should receive detailed instructions regarding the performance of effective oral hygiene procedures.[90,116]

Conservative nonsurgical periodontal therapy should be a treatment option for virtually all HIV-positive patients, and the performance of elective surgical periodontal procedures, including implant placement, has been reported.[89,229] NUP or NUS can be severely destructive to periodontal structures, but a history of these conditions does not automatically dictate the extraction of involved teeth, unless the patient is unable to maintain effective oral hygiene in the affected areas. Decisions regarding elective periodontal procedures should be made with the informed consent of the patient and after medical consultation, when possible.

Maintenance Therapy

It is imperative that the patient maintain meticulous personal oral hygiene. In addition, periodontal maintenance recall visits should be conducted at short intervals (i.e., every 2 to 3 months), and any progressive periodontal disease should be treated vigorously.[288]

As mentioned previously, systemic antibiotic therapy should be administered with caution. Blood and other medical laboratory tests may be required to monitor the patient's overall health status, and close consultation and coordination with the patient's physician are necessary.

Psychologic Factors

HIV infection of neuronal cells may affect brain function and lead to dementia. This may profoundly influence the responsiveness of affected patients to dental treatment. However, psychologic factors are numerous in virtually all HIV-infected patients, even in the absence of neuronal lesions.

Patients may be greatly concerned with the maintenance of medical confidentiality, and such confidentiality must be upheld. Coping with a life-threatening disease may elicit depression, anxiety, and anger in such patients, and this anger may be directed toward the dentist and the staff. It is important to display concern and understanding for the patient's situation. Treatment should be provided in a calm, relaxed atmosphere, and stress to the patient must be minimized.[6]

The dentist should be prepared to advise and counsel patients regarding their oral health status. Dentists often encounter HIV-infected patients who are unaware of their disease status. The early diagnosis and treatment of HIV infection can have a profound effect on the patient's life expectancy and quality of life, and the dentist should be prepared to assist the patient with obtaining testing.[234,241] Any patient with oral lesions that are suggestive of HIV infection should be informed of the findings and, if appropriate, questioned about any previous exposure to HIV. If HIV testing is requested, it must be accompanied by patient counseling; therefore, it may be best to obtain such tests through medical referral. However, if the dentist elects to request testing for HIV antibody, the patient must be informed. In most circumstances, written informed consent is desirable before testing.

Suggested Readings

AIDS Education and Training Centers: HIV classification: CDC and WHO staging systems, 2006. <http://www.aidsetc.org>.

Gonzalez OA, Ebersole JL, Huang CB: Oral infectious diseases: a potential risk factor for HIV virus recrudescence? *Oral Dis* 15:313–332, 2009.

Kaplan JE, Benson C, Holmes KK, et al: Centers for Disease Control and Prevention (CDC); National Institutes of Health; HIV Medicine Association of the Infectious Diseases Society of America, Guidelines for prevention and treatment of opportunistic infections in HIV-infected adults and adolescents: recommendations from CDC, the National Institutes of Health and the HIV Medicine Association of the Infectious Diseases Society of America. *MMWR* 58(RR–4):1–207, 2009.

Matafsi M, Skoura L, Sakellari D: HIV infection and periodontal diseases: an overview of the post-HAART era. *Oral Dis* 17:13–25, 2011.

Mosca NG, Hathorn AR: HIV-positive patients: dental management considerations. *Dent Clin North Am* 50:635–657, 2006.

Noak RM, Richardson JT, Buchacz K, et al: HIV outpatient study (HOPS) investigators. Immune reconstitution inflammatory syndrome: incidence and implications for mortality. *AIDS* 27:720–730, 2012.

Pantanowitz L, Khammissa RAG, Lemmer J, et al: Oral HIV-associated Kaposi sarcoma. *J Oral Pathol Med* 42:201–207, 2013.
Patton LL: HIV disease. *Dent Clin North Am* 47:467, 2003.
Pavlos R, Phillips EJ: Individualization of antiretroviral therapy. *Pharmgenomics Pers Med* 5:1–17, 2012.
Toppuni AR: Immune reconstitution inflammatory syndrome. *Adv Dent Res* 23:90–96, 2011.
Umadevi M, Adeyemi O, Patel M, et al: Periodontal diseases and other bacterial infections. *Adv Dent Res* 19:139–145, 2006.
Vacharajsa A, Asrani AC, Gebhard KH, et al: Oral keratinocytes support non-replicative infection and transfer or harbored HIV-1 to permissive cells. *Retrovirology* 5:66, 2008.

References

References for this chapter are found on the companion website www.expertconsult.com.

References

1. Abel S, Beck DJ, Vourvahis M: Maraviroc: pharmacokinetics and drug interactions. *Antivir Ther* 14:607–618, 2009.
2. Achappa B, Madi D, Shetty N, et al: A patient with multiple immune reconstitution inflammatory syndrome (IRIS) following initiation of antiretroviral therapy. *J Clin Diagn Res* 6:1547–1549, 2012.
3. AIDS Education and Training Centers: HIV Classification: CDC and WHO staging systems. <http://www.aidsetc.org>.
4. Antiretroviral Therapy Cohort Collaboration: Life expectancy of individuals on combination antiretroviral therapy in high-income countries: a collaborative analysis of 14 cohort studies. *Lancet* 372:293–299, 2008.
5. Aquilina C, Viraben R, Denis P: Secondary syphilis simulating oral hairy leukoplakia. *J Am Acad Dermatol* 49:749–751, 2003.
6. Asher RS, McDowell JD, Winquist H: HIV-related neuropsychiatric changes: concerns for dental professionals. *J Am Dent Assoc* 124:80–84, 1993.
7. Baccaglini L, Atkinson JC, Patton LL, et al: Management of oral lesions in HIV-positive patients. *Oral Surg Oral Med Oral Pathol Oral Radiol Endod* 103(Suppl 1):S50.e1–S50.e23, 2007.
8. Bach MC, Valenti AJ, Howell DA, et al: Odynophagia from aphthous ulcers of the pharynx and oesophagus in the acquired immunodeficiency syndrome (AIDS). *Ann Intern Med* 108:338–339, 1990.
9. Barasch A, Gordon S, Geist RY, et al: Necrotizing stomatitis: report of 3 *Pseudomonas aeruginosa*–positive patients. *Oral Surg Oral Med Oral Pathol Oral Radiol Endod* 96:136–140, 2003.
10. Baron M, Gritsch F, Hansy AM, et al: Implants in an HIV-positive patient: a case report. *Int J Oral Maxillofac Implants* 19:425–430, 2004.
11. Baron S: Oral transmission of HIV, a rarity: emerging hypotheses. *J Dent Res* 80:1602–1604, 2001.
12. Barr C, Lopez MR, Rua-Dobles A: Periodontal changes by HIV serostatus in a cohort of homosexual and bisexual men. *J Clin Periodontol* 19:794–801, 1992.
13. Barrett AP, Bilous AM, Buckley DJ, et al: Clinicopathological presentations of oral Kaposi's sarcoma in AIDS. *Aust Dent J* 33:395–399, 1988.
14. Bayard PJ, Berger TG, Jacobson MA: Drug hypersensitivity reactions and human immunodeficiency virus disease. *J Acquir Immune Defic Syndr* 5:1237–1257, 1992.
15. Behrens GM, Stoll M, Schmidt RE: Lipodystrophy syndrome in HIV infection: what is it, what causes it and how can it be managed? *Drug Saf* 23:57–76, 2000.
16. Bendick C, Scheifele C, Reichart PA: Oral manifestations in 101 Cambodians with HIV and AIDS. *J Oral Pathol Med* 31:1–4, 2002.
17. Berthold P: Noma, a forgotten disease. *Dent Clin North Am* 47:559–574, 2003.
18. Birnbaum W, Hodgson TA, Reichart PA, et al: Prognostic significance of HIV-associated oral lesions and their relation to therapy. *Oral Dis* 8(Suppl 2):110–114, 2002.
19. Blankson JN, Persaud D, Siliciano RF: The challenge of viral reservoirs in HIV-1 infection. *Annu Rev Med* 53:557, 2002.
20. Braithwaite RS, Roberts MS, Goetz MB, et al: Do benefits of earlier antiretroviral treatment initiation outweigh harms for individuals at risk for poor adherence? *Clin Infect Dis* 48:827–828, 2009.
21. Bulterys PL, Le T, Quang VM, et al: Environmental predictors and incubation period of AIDS-associated *Penicillium marneffei* infection in Ho Chi Minh City, Vietnam. *Clin Infect Dis* 56:1273–1279, 2013.
22. Butt FM, Chindia ML, Rana F, et al: Pattern of head and neck malignant neoplasms in HIV-infected patients in Kenya. *Int J Oral Maxillofac Surg* 37:907–911, 2008.
23. Buve A, Rogers MF: Epidemiology. *AIDS* 2(Suppl A):S53–S54, 1998.
24. Calista D, Boschini A: Cutaneous side effects induced by indinavir. *Eur J Dermatol* 10:292–296, 2000.
25. Calista D, Morri M, Stagno A, et al: Changing morbidity of cutaneous diseases in patients with HIV after introduction of highly active antiretroviral therapy including a protease inhibitor. *Am J Clin Dermatol* 3:59–62, 2002.
26. Campo-Trapero J, Del Romero-Guerrero J, Cano-Sanchez J, et al: Relationship between oral Kaposi's sarcoma and HAART: contribution of two case reports. *Med Oral Patol Oral Cir Bucal* 13:E709–E713, 2008.
27. Carr A, Cooper DA: Adverse effects of antiretroviral therapy. *Lancet* 356:1423–1430, 2000.
28. Carr A, Samaras K, Thorisdottir A, et al: Diagnosis, prediction, and natural course of HIV-1 protease-inhibitor–associated lipodystrophy, hyperlipidaemia, and diabetes mellitus: a cohort study. *Lancet* 353:2093–2099, 1999.
29. Casado JL, Quereda C, Oliva J, et al: Candidal meningitis in HIV-infected patients: analysis of 14 cases. *Clin Infect Dis* 25:673–676, 1997.
30. Casariego Z, Pombo T, Perez H, et al: Eruptive cheilitis: a new adverse effect in reactive HIV-positive patients subjected to high activity antiretroviral therapy (HAART). Presentation of six clinical cases. *Med Oral* 6:19–30, 2001.
31. Cassone A, Cauda R: Candida and candidiasis in HIV-infected patient: where commensalism, opportunistic behavior and frank pathogenicity lose their borders. *AIDS* 26:1457–1472, 2012.
32. Castilla J, Del Romero J, Hernando V, et al: Effectiveness of highly active antiretroviral therapy in reducing heterosexual transmission of HIV. *J Acquir Immune Defic Syndr* 40:96–101, 2005.
33. Ceballos-Salobrena A, Gaitain-Cepeda L, Ceballos-Garcia L, et al: The effect of antiretroviral therapy on the prevalence of HIV-associated oral candidiasis in a Spanish cohort. *Oral Surg Oral Med Oral Pathol Oral Radiol Endod* 97:345–350, 2004.
34. Ceballos-Salobrena A, Gaitain-Cepeda LA, Ceballos-Garcia L, et al: Oral lesions in HIV/AIDS patients undergoing highly active antiretroviral treatment including protease inhibitors: a new face of oral AIDS? *AIDS Patient Care STDS* 14:627–635, 2000.
35. Centers for Disease Control and Prevention, HIV/AIDS Statistics and Surveillance: Cases of HIV infection and AIDS in the United States and Dependent Areas, 2007. <http://www.cdc.gov/hiv/topics/surveillance/basic.htm> Accessed May 13, 2009.
36. Centers for Disease Control and Prevention: 1993 revised classification system for HIV infection and expanded surveillance case definition for AIDS among adolescents and adults. *MMWR* 41:RR–17, 1993.
37. Centers for Disease Control and Prevention: Update on acquired immune deficiency syndrome (AIDS)—United States. *MMWR* 31:507–508, 513–514, 1982.
38. Centers for Disease Control and Prevention–NCHSTP-DHAP: *HIV/AIDS surveillance report. Addendum: cases of HIV infection and AIDS in the United States, 2002*, Atlanta, 2003, Centers for Disease Control and Prevention.
39. Centers for Disease Control and Prevention: HIV/AIDS among women. <http://www.cdc.gov/hiv/topics/women/resources/factsheets/women.htm>. Accessed May 14, 2009.
40. Centers for Disease Control and Prevention. <http://www.cdc.gov/hiv/topics/women/index.htm>.
41. Centers for Disease Control and Prevention: CDC classification system for children under 13 years of age. MCWP 6 (Rev 5/10).
42. Centers for Disease Control and Prevention: Rapid HIV testing, <http://www.cdc.gov/hiv/topics/testing/rapid/>.
43. Challacombe SJ, Sweet SP: Salivary and mucosal immune responses to HIV and its co-pathogens. *Oral Dis* 3(Suppl 1):S79–S84, 1997.
44. Chandrasekhar J, Liem AA, Cox NH, et al: Oxpentifylline in the management of recurrent aphthous oral ulcers. *Oral Surg Oral Med Oral Pathol Oral Radiol Endod* 87:564–567, 1999.
45. Cheuk W, Wong KO, Wong CS, et al: Immunostaining for human herpesvirus 8 latent nuclear antigen 1 helps distinguish Kaposi sarcoma from its mimickers. *Am J Clin Pathol* 121:335–342, 2004.
46. Chiasson MA, Stoneburner RL, Joseph SC: Human immunodeficiency virus transmission through artificial insemination. *J Acquir Immune Defic Syndr* 3:69–72, 1990.

47. Chidzonga MM, Mabomva L: Noma (cancrum oris) in human immunodeficiency virus infection and acquired immunodeficiency syndrome (HIV and AIDS): clinical experience in Zimbabwe. *J Oral Maxillofac Surg* 66:475–485, 2008.
48. Chu KM, Mahlangeni G, Swannet S, et al: AIDS-associated Kaposi's sarcoma is linked to advanced disease and high mortality in a primary care HIV programme in South Africa. *J Int AIDS Soc* 8:13–23, 2010.
49. Chun T-W, Carruth L, Finzi D, et al: Quantification of latent tissue reservoirs and total body viral load in HIV-1 infection. *Nature* 387:183–188, 1997.
50. Cicek Y: The normal and pathological pigmentation of oral mucous membrane: a review. *J Contemp Dent Pract* 3:76–86, 2003.
51. Cobb CM, Ferguson BL, Keselyak NT, et al: A TEM/SEM study of the microbial plaque overlying the necrotic gingival papillae of HIV-seropositive, necrotizing ulcerative periodontitis. *J Periodontal Res* 38:147–155, 2003.
52. Conant MA, Opp KM, Paretz D, et al: Reduction on Kaposi's sarcoma lesions following treatment of AIDS with ritonavir. *AIDS* 11:1300–1301, 1997.
53. Consensus Report: Non-plaque-induced gingival lesions. *Ann Periodontol* 4:30–31, 1999.
54. Coopman SA, Stern RS: Cutaneous drug reactions in human immunodeficiency virus infection. *Arch Dermatol* 27:714–717, 1991.
55. Cossarizza A, Mussini C, Vigano A: Mitochondria in the pathogenesis of lipodystrophy induced by anti-HIV antiretroviral drugs: actors or bystanders? *Bioessays* 23:1070–1080, 2001.
56. da Silva CA, Dourado I, Dahia SR, et al: Oral manifestations of HIV infection in patients receiving highly active antiretroviral therapy (HAART) in Bahia, Brazil. *J Public Health Dent* 68:178–181, 2008.
57. de Justa RF, Carneiro AB, Rodrigues JLN, et al: Bacillary angiomatosis in HIV-positive patient from Northeastern Brazil: a case report. *Rev Soc Bras Med Trop* 44:641–643, 2011.
58. De Simone JA, Pomerantz RJ: New methods for the detection of HIV. *Clin Lab Med* 32:573–579, 2002.
59. de Souza Goncalves L, Souto R, Colombo APV: Detection of *Helicobacter pylori, Enterococcus faecalis,* and *Pseudomonas aeruginosa* in the subgingival biofilm of HIV-infected subjects undergoing HAART with chronic periodontitis. *Eur J Clin Microbiol Infect Dis* 28:1335–1342, 2009.
60. Diz Dios P, Fernandez Feijoo J, Vazquez Garcia E: Tooth extraction in HIV sero-positive patients. *Int Dent J* 9:317–321, 1999.
61. Diz Dios P, Hermida AO, Alvarez CM, et al: Fluconazole-resistant oral candidosis in HIV-infected patients. *AIDS* 9:809–810, 1995.
62. Diz Dios P, Ocampo A, Miralles C, et al: Frequency of oropharyngeal candidiasis in HIV-infected patients on protease inhibitor therapy. *Oral Surg Oral Med Oral Pathol Oral Radiol Endod* 87:437–441, 1999.
63. Diz Dios P, Vazquez Garcia E, Fernandez Feijoo L: Letter to the editor. *J Dent Res* 77:533–534, 1998.
64. Dodson TB: HIV status and the risk of post-extraction complications. *J Dent Res* 76:1644–1652, 1997.
65. Dowshen N, Pierce VM, Zanno A, et al: Acute HIV infection in a critically ill 15-year old male. *Pediatrics* 131:e-959–e-963, 2013.
66. Drinkard CR, Decher L, Little JW, et al: Periodontal status of individuals in early stages of human immunodeficiency virus infection. *Commun Dent Oral Epidemiol* 9:281–285, 1991.
67. Dunic I, Vesic S, Jevtovic DJ: Oral candidiasis and seborrheic dermatitis in HIV-infected patients on highly active antiretroviral therapy. *HIV Med* 5:50–54, 2004.
68. EC-Clearinghouse on Oral Problems Related to HIV Infection, WHO Collaborating Centre on Oral Manifestations of the Immunodeficiency Virus: Classification and diagnostic criteria for oral lesions in HIV infection. *J Oral Pathol Med* 22:289–291, 1993.
69. Effos RB, Fletcher CV, Gebo K, et al: Aging and infectious diseases: workshop on HIV infection and aging: what is known and future research directions. *Clin Infect Dis* 47:542–553, 2008.
70. Elish D, Singh F, Weinberg JM: Therapeutic options for herpes labialis. I. Oral agents. *Cutis* 74:31–34, 2004.
71. Epstein JB: Oral malignancies associated with HIV. *J Can Dent Assoc* 73:953–956, 2007.
72. Eversole LR, Jacobsen P, Stone CE, et al: Oral condyloma planus (hairy leukoplakia) among homosexual men: a clinico-pathologic study of thirty-six cases. *Oral Surg* 61:249–255, 1986.
73. Eversole LR: Viral infections of the head and neck among HIV-seropositive patients. *Oral Surg Oral Med Oral Pathol* 73:155–163, 1992.
74. Eyeson JD, Tenant-Flowers M, Cooper DJ, et al: Oral manifestations of an HIV-positive cohort in the era of highly active anti-retroviral therapy (HAART) in South London. *J Oral Pathol Med* 31:169–174, 2002.
75. Faraoni S, Rocchetti A, Gotta F, et al: Evaluation of a rapid antigen and antibody combination test in acute HIV infection. *J Clin Virol* 57:84–87, 2013.
76. Feller L, White JP, Bouckaert M, et al: Diffuse infiltrative CD8+ lymphocytosis syndrome; review of the literature and report of a case. *SADJ* 62:314–317, 2007.
77. Feller L, Anagnostopoulos C, Wood NH, et al: Human immunodeficiency virus-associated Kaposi sarcoma as an immune reconstitution inflammatory syndrome: a literature review and case report. *J Periodontol* 79:362–468, 2008.
78. Finzi D, Blankson J, Siliciano JD, et al: Latent infection of CD+4 T cells provides a mechanism for lifelong persistence of HIV-1, even in patients on effective combination therapy. *Nature Med* 5:512–517, 1999.
79. Fleming PL, Ward JW, Karon JM, et al: Declines in AIDS incidence and deaths in the USA: a signal change in the epidemic. *AIDS* 12(Suppl A):S55–S61, 1998.
80. Flint SR, Tappuni A, Leigh J, et al: B3 markers of immunodeficiency and mechanisms of highly active antiretroviral therapy HAART therapy on oral lesions. *Adv Dent Res* 19:146–151, 2006.
81. Flint SR, Croser D, Reznik D, et al: HIV transmission in the dental setting and the HIV-infected oral health care professional: workshop 1C. *Adv Dent Res* 23:106–111, 2011.
82. Foundation for AIDS Research: <www.amfar.org/about_hiv_and_aids/facts-and-stats/statistics>. 2012.
83. Gaines H, Von Sydow M, Pehrson PO, et al: Clinical picture of primary HIV infection presenting as a glandular-fever-like illness. *Br Med J* 97:1363–1368, 1988.
84. Gazouli M, Papaconstantinou I, Zavos G, et al: Human herpesvirus type 8 genotypes in iatrogenic, classic and AIDS-associated Kaposi's sarcoma from Greece. *Anticancer Res* 24:1597–1602, 2004.
85. Gennaro S, Naidoo S, Berthold P: Oral health and HIV. *MCN Am J Matern Child Nurs* 33:50–57, 2008.
86. Ghidoni JJ: Role of *Bartonella henselae* endocarditis in the nucleation of aortic valvular calcification. *Ann Thorac Surg* 77:704–706, 2004.
87. Girardi E: Epidemiological aspects of transmitted HIV drug resistance. *Scand J Infect Dis Suppl* 5(106):17–20, 2003.
88. Giuliana G, Pizzo G, Milici ME, et al: In vitro activities of antimicrobial agents against *Candida* species. *Oral Surg Oral Med Oral Pathol Oral Radiol Endod* 87:44–49, 1999.
89. Glick M: Clinical protocol for treating patients with HIV disease. *Gen Dent* 38:418–425, 1990.
90. Glick M, Abel SN, Muzyka BC, et al: Dental complications after treating patients with AIDS. *J Am Dent Assoc* 125:296–301, 1994.
91. Glick M, Cleveland DB: Oral mucosal bacillary epithelioid angiomatosis in a patient with AIDS associated with rapid alveolar bone loss: a case report. *J Oral Pathol Med* 2:235–239, 1993.
92. Glick M, Holmstrup P: HIV infection and periodontal diseases. In Genco R, Mealey B, Rose L, editors: *Periodontal medicine*, Hamilton, Ontario, Canada, 2000, BC Decker.
93. Glick M, Muzyka BC, Lurie D, et al: Oral manifestations associated with HIV disease as markers for immune suppression and AIDS. *Oral Surg Oral Med Oral Pathol* 77:344–349, 1994.
94. Glick M, Muzyka BC, Salkin LM, et al: Necrotizing ulcerative periodontitis: a marker for immune deterioration and a predictor for the diagnosis of AIDS. *J Periodontol* 65:393–397, 1994.

95. Golden MR, Stekler J, Hughes JP, et al: HIV serosorting in men who have sex with men: is it safe? *J Acquir Immune Defic Syndr* 49:212–218, 2008.
96. Gompels UA, Kasolo FC: HHV-8 serology and Kaposi's sarcoma. *Lancet* 348:1587–1588, 1996.
97. Gonzalez OA, Ebersole JL, Huang CB: Oral infectious diseases: a potential risk factor for HIV virus recrudescence? *Oral Dis* 15:313–327, 2009.
98. Grande SR, Imbronito AV, Okuda OS, et al: Herpes viruses in periodontal compromised sites: comparison between HIV-positive and negative patients. *J Clin Periodontol* 35:838–845, 2008.
99. Green TS, Beckstead JH, Lozada-Nur F, et al: Histopathologic spectrum of oral Kaposi's sarcoma. *Oral Surg* 58:306–314, 1984.
100. Greenspan D, Canchola AJ, MacPhail LA, et al: Effect of highly active antiretroviral therapy on frequency of oral warts. *Lancet* 357:1411–1412, 2001.
101. Greenspan D, Conant M, Silverman S, Jr, et al: Oral hairy leukoplakia in male homosexuals: evidence of association with both papilloma virus and a herpes-group virus. *Lancet* 2(8407):831–834, 1984.
102. Greenspan D, Gange SJ, Phelan JA, et al: Incidence of oral lesions in HIV-1-infected women: reduction with HAART. *J Dent Res* 83:145–150, 2004.
103. Greenspan D, Greenspan JS, de Souza Y, et al: Oral hairy leukoplakia in an HIV-negative renal transplant recipient. *J Oral Pathol Med* 18:32–34, 1989.
104. Greenspan D, Greenspan JS, Hearst NG, et al: Relations of oral hairy leukoplakia with HIV and the risk of developing AIDS. *J Infect Dis* 155:475–481, 1987.
105. Greenspan JS, Greenspan D, Lennette ET, et al: Replication of Epstein-Barr virus within the epithelial cells of oral hairy leukoplakia, and AIDS associated lesion. *N Engl J Med* 313:1564–1571, 1985.
106. Guarinos J, Bagan JV, Martinez-Canut P: Dental health in patients infected by human immunodeficiency virus (HIV). A study of 94 cases. *Bull Group Int Rech Sci Stomatol Odontol* 39:119–122, 1996.
107. Gupta G: Viral pathogenesis and opportunistic infections. *J Calif Dent Assoc* 21:29–36, 1993.
108. Haase AT, Schacker TW: Potential for the transmission of HIV-1 despite highly active antiretroviral therapy. *N Engl J Med* 17(339):1846–1848, 1998.
109. Hammer SM: Advances in antiretroviral therapy and viral load monitoring. *AIDS* 10(Suppl 3):S1–S11, 1996.
110. Handforth J, Sharland M: Triple nucleoside reverse transcriptase inhibitor therapy in children. *Paediatr Drugs* 6:147–159, 1999.
111. Hardy H, Esch LD, Morse GD: Glucose disorders associated with HIV and its drug therapy. *Ann Pharmacother* 35:343–351, 2001.
112. Hassman LM, Ellison TJ, Kedes DH: KSHV infects a subset of human tonsillar B cells, driving proliferation and plasmablast differentiation. *J Clin Invest* 12:752–768, 2011.
113. HIV InfoSource: Demographics of HIV. <http://www.hivinfosource.org/hivis/hivbasics/demographics/>.
114. Ho DD, Neumann AU, Perelson AS, et al: Rapid turnover of plasma virions and CD4 lymphocytes in HIV-1 infection. *Nature* 373:123–126, 1995.
115. Hodgson TA, Rachanis CC: Oral fungal and bacterial infections in HIV-infected individuals: an overview in Africa. *Oral Dis* 8(Suppl 2):80–87, 2002.
116. Hofer D, Hammerle CH, Grassi M, et al: Long-term results of supportive periodontal therapy (SPT) in HIV-seropositive and HIV-seronegative patients. *J Clin Periodontol* 29:630–637, 2002.
117. Hood SV, Hollis S, Percy M, et al: Assessment of therapeutic response of oropharyngeal and esophageal candidiasis in AIDS with use of a new clinical scoring system: studies with D0870. *Clin Infect Dis* 28:587–596, 1999.
118. Horenstein MG, Moontasri NJ, Cesarman EJ: The pathobiology of Kaposi's sarcoma: advances since the onset of the AIDS epidemic. *J Cutan Pathol* 35(Suppl 2):40–44, 2008.
119. Horning GM, Cohen ME: Necrotizing ulcerative gingivitis, periodontitis and stomatitis: clinical staging and predisposing factors. *J Periodontol* 66:990–998, 1995.
120. Hornik A, Rodriquez-Porcel F, Wallery S, et al: Late onset CNS immune reconstitution inflammatory syndrome in an immunocompetent patient. *Front Neurol* 4:12, 2013.
121. Horvath E, Krenacs L, Bagdi E, et al: Plasmoblastic lymphoma associated with human immunodeficiency virus. *Rom J Morphol Embryol* 49:309–314, 2008.
122. Hotton AL, Gratzer B, Hehta SD: Association between serosorting and bacterial sexually transmitted infection among HIV-negative men who have sex with men at an urban lesbian, gay, bisexual, and transgender health center. *Sex Transm Dis* 39:959–964, 2012.
123. Huang CB, Emerson KA, Gonzalez OA, et al: Oral bacteria induce a differential activation of human immunodeficiency virus-1 promoter in T cells, macrophages and dendritic cells. *Oral Microbiol Immunol* 24:401–407, 2009.
124. Huang CB, Emerson KA, Gonzalez OA, et al: Supernatants from oral epithelial cells and gingival fibroblasts modulate human immunodeficiency virus promoter activation induced by type 1 periodontopathogens in monocytes/macrophages. *Mol Oral Microbiol* 25:136–149, 2010.
125. Hunt PW, Carrington M: Host genetic determinants of HIV pathogenesis: an immunologic perspective. *Curr Opin HIV AIDS* 3:342–348, 2008.
126. Hunt R: Virology-Chapter seven Human Immunodeficiency virus and AIDS Part six Types Sub-types and Co-receptors. *Microbiol Immunol On-Line*. University of South Carolina School of Medicine. 2013.
127. Imagawa DT, Lee MH, Wolinsky SM, et al: Human immunodeficiency virus type 1 infection in homosexual men who remain seronegative for prolonged periods. *N Engl J Med* 320:1458–1462, 1989.
128. Ippolito G, Puro V, Heptonstall J, et al: Occupational human immunodeficiency virus infection in health care workers: worldwide cases through September 1997. *Clin Infect Dis* 28:365–383, 1999.
129. Jacobson JM, Greenspan JS, Spritzler J, et al: Thalidomide for the treatment of oral aphthous ulcers in patients with human immunodeficiency virus infection. *N Engl J Med* 336:1487–1493, 1997.
130. Jaffe HW, Pellett PE: Human herpesvirus 8 and Kaposi's sarcoma—some answers, more questions. *N Engl J Med* 340:1912–1913, 1999.
131. Jainkittivong A, Lin AL, Johnson DA, et al: Salivary secretion, mucin concentrations and *Candida* carriage in HIV-infected patients. *Oral Dis* 15:229–234, 2009.
132. Jamjian MC, McNicholl IR: Enfuvirtide: first fusion inhibitor for treatment of HIV infection. *Am J Health Syst Pharm* 61:1242–1247, 2004.
133. Jin Y-T, Tsai S-T, Yan J-J, et al: Presence of human herpesvirus–like DNA sequence in oral Kaposi's sarcoma. A preliminary PCR study. *Oral Surg Oral Med Oral Pathol Oral Radiol Endod* 81:442–444, 1996.
134. Jordan RA, Gangler P, Johren HP: Clinical treatment outcomes of periodontal therapy in HIV-seropositive patients undergoing highly active antiretroviral therapy. *Eur J Med Res* 11:232–235, 2006.
135. Kabani S, Greenspan D, DeSouza YD, et al: Oral hairy leukoplakia with extensive oral mucosal involvement: report of two cases. *Oral Surg Oral Med Oral Pathol* 67:411–415, 1989.
136. Kantheti LP, Reddy B, Ravikumar S, et al: Isolation, identification, and carriage of candidal species in PHLAs and their correlation with immunological status in cases with and without HAART. *J Oral Maxillofac Pathol* 16:38–44, 2012.
137. Klein RS, Quart AM, Small CB: Periodontal disease in heterosexuals with acquired immunodeficiency syndrome. *J Periodontol* 62:535–540, 1991.
138. Knowles DM, Cesarman E: The Kaposi's sarcoma-associated herpesvirus (human herpesvirus-8) in Kaposi's sarcoma, malignant lymphoma, and other diseases. *Ann Oncol* 8(Suppl 2):123–129, 1997.
139. Kumar SN, Sarswathi TR, Ranganathan K: Intra-oral hypermelanosis in an HIV sero-positive patient—a case report. *Indian J Dent Res* 14:131–134, 2003.
140. Kurtz SP, Buttram ME, Surratt HL, et al: Resilience, syndemic factors, and serosorting behavior among HIV-positive and HIV-negative substance-using MSM. *AIDS Educ Prev* 24:193–205, 2012.

141. Lake-Bakaar G, Tom W, Lake-Bakaar D, et al: Gastropathy and ketoconazole malabsorption in the acquired immunodeficiency syndrome (AIDS). *Ann Intern Med* 109:471–473, 1998.
142. Lamster IB, Begg MD, Mitchell-Lewis D, et al: Oral manifestations of HIV infection in homosexual men and intravenous drug users. *Oral Surg Oral Med Oral Pathol* 78:163–174, 1994.
143. Langford A, Pohle HD, Gelderblum HR, et al: Oral hyperpigmentation in HIV-infected patients. *Oral Surg Oral Med Oral Pathol* 67:301–307, 1989.
144. Liberali SA, Coates EA, Freeman AD, et al: Oral conditions and their social impact among HIV dental patients, 18 years on. *Aust Dent J* 58:18–25, 2013.
145. Lindhardt BO, Ulrich K, Sindrup JH, et al: Seroconversion to human immunodeficiency virus (HIV) in persons attending an STD clinic in Copenhagen. *Acta Derm Venereol (Stockh)* 68:250–253, 1998.
146. Lot F, Seguier J-C, Fegueux S, et al: Probable transmission of HIV from an orthopedic surgeon to a patient in France. *Ann Intern Med* 30:1–6, 1999.
147. Lu FX, Jacobson RS: Oral mucosal immunity and HIV/SIV infection. *J Dent Res* 86:216–226, 2007.
148. Luzzi GA, Jones BJ: Treatment of neutropenic oral ulceration in human immunodeficiency virus infection with G-CSF. *Oral Surg Oral Med Oral Pathol Oral Radiol Endod* 81:53–54, 1996.
149. Mallon PW, Cooper DA, Carr A: HIV-associated lipodystrophy. *HIV Med* 2:166–173, 2001.
150. Mandel ID: Occupational risks in dentistry: comforts and concerns. *J Am Dent Assoc* 124:41–49, 1993.
151. Mandel L, Alfi D: Drug-induced paraparotid fat deposition in patients with HIV: case reports. *J Am Dent Assoc* 139:152–157, 2008.
152. Manfredi R, Calza L, Chiodo F: Gynecomastia associated with highly active antiretroviral therapy. *Ann Pharmacother* 35:438–439, 2001.
153. Margiotta V, Campisi G, Mancuso S, et al: HIV infection: oral lesions, CD4+ cell count and viral load in an Italian study population. *J Oral Pathol Med* 28:173–177, 1999.
154. Marmor M, Krasinski K, Sanchez M, et al: Sex, drugs, and HIV infection in a New York city hospital outpatient population. *J Acquir Immune Defic Syndr* 3:307–318, 1990.
155. Martins MD, Lozano-Chiu M, Rex JH: Declining rates of oropharyngeal candidiasis and carriage of *Candida albicans* associated with trends toward reduced rates of carriage of fluconazole-resistant *C. albicans* in human immunodeficiency virus–infected patients. *Clin Infect Dis* 27:1291–1294, 1998.
156. Matafsi M, Skoura L, Sakellari D: HIV infection and periodontal diseases: an overview of the post-HAART era. *Oral Dis* 17:13–25, 2011.
157. Mawardi H, Cutler C, Treister N: Medical management update: non-Hodgkin lymphoma. *Oral Surg Oral Med Oral Pathol Oral Radiol Endod* 107:e19–e33, 2009.
158. Mayor AM, Gomez MA, Rios-Olivares E, et al: AIDS-defining neoplasm prevalence in a cohort of HIV-infected patients, before and after highly active antiretroviral therapy. *Ethn Dis* 18(2 Suppl 2):189–194, 2008.
159. McCarthy GM: Host factors associated with HIV-related oral candidiasis. *Oral Surg Oral Med Oral Pathol* 73:181–186, 1992.
160. McCarthy GM, Mackie ID, Koval J, et al: Factors associated with increased frequency of HIV-related oral candidiasis. *J Oral Pathol Med* 20:332–336, 1991.
161. McCarthy GM, Ssali CS, Bednarsh H, et al: Transmission of HIV in the dental clinic and elsewhere. *Oral Dis* 8(Suppl 2):126–135, 2002.
162. McKaig RG, Patton LL, Thomas JC, et al: Factors associated with periodontitis in an HIV-infected southeast USA study. *Oral Dis* 6:158–165, 2000.
163. McCutchan FE: Global epidemiology of HIV. *J Med Virol* 78(Suppl 1):S7–S12, 2006.
164. Medical Letter: Drugs for AIDS and associated infections. *Med Lett Drugs Ther* 35:79, 1993.
165. Michael NL, Brown AD, Voigt RF, et al: Rapid disease progression without seroconversion following primary human immunodeficiency virus type 1 infection: evidence for highly susceptible human hosts. *J Infect Dis* 175:1352–1359, 1997.
166. Miziara ID, Filho BC, Weber R: Oral lesions in Brazilian HIV-infected children undergoing HAART. *Int J Pediatr Otorhinolaryngol* 70:1086–1096, 2006.
167. Modrzejewski KA, Herman RA: Emtricitabine: a once-daily nucleoside reverse transcriptase inhibitor. *Ann Pharmacother* 38:1006–1014, 2004.
168. Molinari JA: HIV, health care workers and patients: how to ensure safety in the dental office. *J Am Dent Assoc* 124:51–53, 1993.
169. Mosca NG, Hathorn AR: HIV-positive patients: dental management considerations. *Dent Clin North Am* 50:635–657, 2006.
170. Mulu A, Kassu A, Anagaw B, et al: Frequent detection of "azole" resistant *Candida* species among late presenting AIDS patients in northwest Ethiopia. *BMC Infect Dis* 13:82, 2013.
171. Murillo O, Mimbrera D, Petit A, et al: Fatal bacillary angiomatosis mimicking an infiltrative vascular tumour in the immune restoration phase of an HIV-infected patient. *Antivir Ther* 17:405–407, 2012.
172. Navarro CM, Shibli JA, Ferrari RB, et al: Gingival primary extranodal non-Hodgkin's lymphoma as the first manifestation of acquired immunodeficiency syndrome. *J Periodontol* 79:562–566, 2008.
173. Navazesh M, Mulligan R, Komaroff E, et al: The prevalence of xerostomia and salivary gland hypofunction in a cohort of HIV-positive and at-risk women. *J Dent Res* 79:1502–1507, 2000.
174. Ndiaye CF, Critchlow CW, Leggot PJ, et al: Periodontal status of HIV1 and HIV2 seropositive female commercial sex workers in Senegal. *J Periodontol* 68:827–831, 1997.
175. Nesti M, Carli E, Giaquinto C, et al: Correlation between viral load, plasma levels of CD4-CD8 T lymphocytes and AIDS-related oral diseases: a multicenter study on 30 HIV+ children in the HAART era. *J Biol Regul Homeost Agents* 26:527–537, 2012.
176. Nguyen MT, Weiss PJ, LaBarre RC, et al: Orally administered amphotericin B in the treatment of oral candidiasis in HIV-infected patients caused by azole-resistant *Candida albicans*. *AIDS* 10:1745–1747, 1996.
177. Nichols CM, Flaitz CM, Hicks MJ: Treating Kaposi's lesions in the HIV-infected patient. *J Am Dent Assoc* 124:78–79, 1993.
178. Nicolatou O, Theodoridou M, Mostrou G, et al: Oral lesions in children with perinatally acquired human immunodeficiency virus infection. *J Oral Pathol Med* 28:49–53, 1999.
179. Nicolatou-Galitis O, Velegraki A, Paikos S, et al: Effect of PI-HAART on the prevalence or oral lesions in HIV-1 infected patients: a Greek study. *Oral Dis* 10:145–150, 2004.
180. Noak RM, Richardson JT, Buchacz K, et al: HIV outpatient study (HOPS) investigators. Immune reconstitution inflammatory syndrome: incidence and implications for mortality. *AIDS* 27:720–730, 2012.
181. Nokta M: Oral manifestations associated with HIV infection. *Curr HIV/AIDS Rep* 5:5–12, 2008.
182. Novak MJ: Necrotizing ulcerative periodontitis. *Ann Periodontol* 4:74–78, 1999.
183. Olsen RJ, Lynch P, Coyle MB, et al: Examination gloves as barriers to hand contamination in clinical practice. *JAMA* 270(3):350–353, 1993.
184. Ortega KL, Ceballos-Salobrena A, Gaitan-Cepeda LA, et al: Oral manifestations after immune reconstitution in HIV patients on HAART. *Int J STD AIDS* 19:305–308, 2008.
185. Ortiz AM, Silvestri G: Immunopathogenesis of AIDS. *Curr Infect Dis Rep* 11:239–245, 2009.
186. Oude Lashof AM, De Bock R, Herbrecht R, et al: An open multicentre comparative study of the efficacy, safety and tolerance of fluconazole and itraconazole in the treatment of cancer patients with oropharyngeal candidiasis. *Eur J Cancer* 40:1314–1319, 2004.
187. Padian NS, Shiboski SC, Glass SO, et al: Heterosexual transmission of human immunodeficiency virus in northern California: results from a ten-year study. *Am J Epidemiol* 146:350–357, 1997.
188. Pang W, Tam S-C, Zheng Y-T: Current peptide HIV type1 fusion inhibitors. *Antivir Chem Chemother* 20:18–27, 2009.

189. Pantanowitz L, Khammissa RAG, Lemmer J, et al: Oral HIV-associated Kaposi sarcoma. *J Oral Pathol Med* 42:201–207, 2013.
190. Paster BJ, Russell MK, Alpagot T, et al: Bacterial diversity in necrotizing ulcerative periodontitis in HIV-positive subjects. *Ann Periodontol* 7:8–16, 2002.
191. Patel AS, Glick M: Oral manifestations associated with HIV infection: evaluation, assessment, and significance. *Gen Dent* 51:153–156, 121, 2003.
192. Patel PK, Erlandsen JE, Kirkpatrick WR, et al: The changing epidemiology of oropharyngeal candidiasis in patients with HIV/AIDS in the era of antiretroviral therapy. *AIDS Res Treat* 2012:262471, 2012.
193. Patrikidou A, Vahtsevanos K, Charambidou M, et al: Non-AIDS Kaposi's sarcoma in the head and neck area. *Head Neck* 31:260–268, 2009.
194. Patton LL: HIV disease. *Dent Clin North Am* 47:467–492, 2003.
195. Patton LL, Shugars DA, Bonito AJ: A systematic review of complication risks for HIV-positive patients undergoing dental treatment. *J Am Dent Assoc* 133:195–203, 2000.
196. Pavlos R, Phillips EJ: Individualization of antiretroviral therapy. *Pharmgenomics Pers Med* 5:1–17, 2012.
197. Pedraza MA, del Romero J, Roldan F, et al: Heterosexual transmission of HIV-1 is associated with high plasma viral load levels and a positive viral isolation in the infected partner. *J Acquir Immune Defic Syndr* 21:120–125, 1999.
198. Pezzotti P, Napoli PA, Acciai S, et al: Increasing survival time after AIDS in Italy: the role of new combination antiretroviral therapies. *AIDS* 3:249–255, 1999.
199. Phelan JA, Saltzman BR, Friedland GH, et al: Oral findings in patients with acquired immunodeficiency syndrome. *Oral Surg* 64:50–56, 1987.
200. Phillips P: Refractory mucosal candidiasis in patients with human immunodeficiency virus infection. *Clin Infect Dis* 28:407–408, 1999.
201. Pierson T, Hoffman T, Blankson J, et al: Characterization of chemokine receptor utilization of viruses in the latent reservoir for human immunodeficiency virus type 1. *J Virol* 74:7824–7833, 2000.
202. Piliero PJ, Faragon JJ: Hepatitis B virus and HIV coinfection. *AIDS Read* 12:448–449, 1993.
203. Pistorius A, Willershausen B: Cases of HIV-associated characteristic periodontal diseases. *Eur J Med Res* 4:121–126, 1999.
204. Plemons JM, Benton E, Rankin KV, et al: Necrotizing ulcerative periodontitis: a case report. *Tex Dent J* 120:508–513, 2003.
205. Ponnam SR, Srivastava G, Theruru K: Oral manifestations of human immunodeficiency virus in children: an institutional study at highly active antiretroviral therapy centre in India. *J Oral Maxilllofac Pathol* 16:195–202, 2012.
206. Pons V, Greenspan D, Lozada-Nur F, et al: Oropharyngeal candidiasis in patients with AIDS: randomized comparison of fluconazole versus nystatin oral suspensions. *Clin Infect Dis* 44:1204–1207, 1997.
207. Pretty IA, Anderson GS, Sweet DJ: Human bites and the risk of human immunodeficiency virus transmission. *Am J Forensic Med Pathol* 20:232–239, 1999.
208. Quinn TC, Wawer MJ, Sewamkambo N, et al: Viral load and heterosexual transmission of human immunodeficiency virus type 1. Rakai Project Study Group. *N Engl J Med* 342:921–929, 2000.
209. Qunibi WY, Akhtar M, Ginn E, et al: Kaposi's sarcoma in cyclosporine-induced gingival hyperplasia. *Am J Kidney Dis* 11:349–352, 1988.
210. Rahman MA, Kingsley LA, Breinig MK, et al: Enhanced antibody responses to Epstein-Barr virus in HIV-infected homosexual men. *J Infect Dis* 159:472–479, 1989.
211. Ramirez-Amador V, Esquivel-Pedraza L, Lozada-Nur F, et al: Intralesional vinblastine vs 3% sodium tetradecyl sulfate for the treatment of oral Kaposi's sarcoma: a double blind, randomized clinical trial. *Oral Oncol* 38:460–467, 2002.
212. Ramirez CR, Saavedra S, Ramirez Ronda C: Bacillary angiomatosis: microbiology, histopathology, clinical presentation, diagnosis and management. *Bol Asoc Med P R* 8:46–51, 1996.
213. Ranganathan K, Magesh KT, Kumarasamy N, et al: Greater severity and extent of periodontal breakdown in 136 south Indian human immunodeficiency virus seropositive patients than in normal control: a comparative study using community periodontal index of treatment needs. *Indian J Dent Res* 18:55–59, 2007.
214. Ranganathan AT, Saraswathi PK, Albert V, et al: Route of transmission might influence the clinical expression of periodontal lesions in "human immunodeficiency virus" positive patients. *Niger J Clin Pract* 15:349–353, 2012.
215. Rao UK, Ranganathan K, Kumarasamy N: Gender differences in oral lesions among persons with HIV disease in Southern India. *J Oral Maxillofac Pathol* 16:388–394, 2012.
216. Recommendations from CDC, the National Institutes of Health and the HIV Medicine Association of the Infectious Diseases Society of America: Guidelines for prevention and treatment of opportunistic infections in HIV-infected adults and adolescents. *MMWR* 58 (RR–4):1–207, 2009.
217. Reeves JD, Doms RW: Human immunodeficiency virus type 2. *J Gen Virol* 83:1253–1265, 2002.
218. Regezi JA, Eversole LR, Barker BF, et al: Herpes simplex and cytomegalovirus coinfected oral ulcers in HIV-positive patients. *Oral Surg Oral Med Oral Pathol Oral Radiol Endod* 81:55–62, 1996.
219. Reichart PA: Oral manifestations in HIV infection: fungal and bacterial infections, Kaposi's sarcoma. *Med Microbiol Immunol* 192:165–169, 2003.
220. Reichart PA: Oral ulceration and iatrogenic disease in HIV infection. *Oral Surg Oral Med Oral Pathol* 73:212–214, 1992.
221. Relman AS: Pathogenic human retroviruses. *N Engl J Med* 318:243–245, 1998.
222. Reznik DA, O'Daniels C: Oral manifestations of HIV/AIDS in the HAART era, 2002. <http://www.hivdent.org/oralm/oralmOMHAH052002.htm>.
223. Richards JM: Notes on AIDS. *Br Dent J* 158:199–201, 1985.
224. Riley C, London JP, Burmeister JA: Periodontal health in 200 HIV-positive patients. *J Oral Pathol Med* 21:124–127, 1992.
225. Rivera-Hidalgo F, Stanford T: Oral mucosal lesions caused by infective microorganisms. 1. Lesions caused by viruses and bacteria. *Periodontol 2000* 21:125–144, 1999.
226. Robinson PG: The significance and management of periodontal lesions in HIV infection. *Oral Dis* 8(Suppl 2):91–97, 2002.
227. Robinson PG, Boulter A, Birnbaum W, et al: A controlled study of relative attachment loss in people with HIV infection. *J Clin Periodontol* 25:278–285, 2000.
228. Rowland RW, Escobar MR, Friedman RB, et al: Painful gingivitis may be an early sign of infection with the human immunodeficiency virus. *Clin Infect Dis* 16:233–236, 1993.
229. Ryder MI: Periodontal management of HIV-infected patients. *Periodontol 2000* 23:85–93, 2000.
230. Sanchez-Vargas LO, Ortiz-Lopez NG, Villar M, et al: Oral *Candida* isolates colonizing or infecting human immunodeficiency virus-infected and healthy persons in Mexico. *J Clin Microbiol* 43:4159–4162, 2005.
231. Scheutz F, Matee MIN, Andsager L, et al: Is there an association between periodontal condition and HIV infection? *J Clin Periodontol* 22:580–587, 1997.
232. Schiodt M, Greenspan D, Daniels TE, et al: Clinical and histologic spectrum of oral hairy leukoplakia. *Oral Surg Oral Med Oral Pathol* 64:716–720, 1987.
233. Schmidt-Westhausen AM, Priepke F, Bergmann FJ, et al: Decline in the rate of oral opportunistic infections following introduction of highly active antiretroviral therapy. *J Oral Pathol Med* 29:336–341, 2000.
234. Schulman DJ: The dentist, HIV and the law: duty to treat, need to understand. *J Calif Dent Assoc* 21(9):45–50, 1993.
235. Schuman P, Capps L, Peng G, et al: Weekly fluconazole for the prevention of mucosal candidiasis in women with HIV infection. *Ann Intern Med* 126:689–696, 1997.
236. Schuman P, Sobel JD, Ohmit SE, et al: Mucosal candidal colonization and candidiasis in women with or without risk for human immunodeficiency virus infection. *Clin Infect Dis* 27:1161–1167, 1998.

237. Sciubba JJ: Recognizing the oral manifestations of AIDS. *Oncology* 6:64–70, discussion 75–76, 1992.
238. Scully C, Diz Dios P: Orofacial effects of antiretroviral therapies. *Oral Dis* 7:205–210, 2001.
239. Shangase L, Feller L, Blignaut E: Necrotising ulcerative gingivitis/periodontitis as indicators of HIV infection. *SADJ* 59:105–108, 2004.
240. Shaw D: Dentistry and the ethics of infection. *J Med Ethics* 34:184–187, 2008.
241. Sheehan DJ, Hitchcock CA, Sibley CM: Current and emerging azole antifungal agents. *Clin Microbiol Rev* 12:40–79, 1999.
242. Shibosky CH, Winkler JR: Gingival Kaposi's sarcoma and periodontitis. *Oral Surg Oral Med Oral Pathol* 76:49–53, 1993.
243. Shine N, Konopka K, Duzgunes N: The anti-HIV-1 activity associated with saliva. *J Dent Res* 76:634–640, 1997.
244. Shugars DC, Wahl SM: The role of the oral environment in HIV-1 transmission. *J Am Dent Assoc* 129:851–858, 1998.
245. Shugars DC, Slade GD, Patton LL, et al: Oral and systemic factors associated with increased levels of human immunodeficiency virus type 1 RNA in saliva. *Oral Surg Oral Med Oral Pathol Oral Radiol Endod* 8:432–440, 2000.
246. Silverman S, Jr, Gallo JW, McKnight ML, et al: Clinical characteristics and management responses in 85 HIV-infected patients with oral candidiasis. *Oral Surg Oral Med Oral Pathol Oral Radiol Endod* 82:402, 1996.
247. Sitas F, Newton R, Boshoff C: Increasing probability of mother-to-child transmission of HHV-8 with increasing maternal antibody titer for HHV-8. *N Engl J Med* 340:1923, 1999.
248. Skolasky RL, Phair J, Detels R, et al: Thrush and fever as markers of immune competence in the era of highly active antiretroviral therapy. *AIDS Res Hum Retroviruses* 17:1311–1316, 2001.
249. Slots J: Update on human cytomegalovirus in destructive periodontal disease. *Oral Microbiol Immunol* 19:217–223, 2004.
250. Soares LF, de Araujo Castro GFB, De Souza IPR, et al: Pediatric HIV-related oral manifestations: a five-year retrospective study. *Braz Oral Res* 18:6–11, 2004.
251. Sontakke SA, Umarji H, Karhodkar F: Comparison of oral manifestations with CD4 count in HIV infected patients. *Indian J Dent Res* 22:732–734, 2011.
252. Steigbigel RT, Cooper DA, Kumar PN, et al: Raltegravir with optimized background therapy for resistant HIV-1-infection. *New Engl J Med* 359:339–354, 2008.
253. Stone D, Kiem HP, Jerome KR: Targeted gene disruption to cure HIV. *Curr Opin HIV AIDS* 8:217–223, 2013.
254. Stutzer B, Hartmann K: Chronic bartonellosis in cats: what are the potential implications? *J Feline Med Surg* 14:612–621, 2012.
255. Swango PA, Kleinman DV, Konzelman JL: HIV and periodontal health: a study of military personnel with HIV. *J Am Dent Assoc* 122:49–54, 1991.
256. Syrjanen S, Laine P, Niemela M, et al: Oral hairy leukoplakia is not a specific sign of HIV infection but related to immunosuppression in general. *J Oral Pathol Med* 18:28–31, 1989.
257. Syrjanen S, Leimola-Virtanen R, Schmidt-Westhausen A, et al: Oral ulcers in AIDS patients frequently associated with cytomegalovirus (CMV) and Epstein-Barr virus (EBV) infection. *J Oral Pathol Med* 28:204–209, 1999.
258. Tacconelli E, Bertagnolio S, Posteraro B, et al: Azole susceptibility patterns and genetic relationship among oral *Candida* strains isolated in the era of highly active antiretroviral therapy. *J Acquir Immune Defic Syndr* 31:38–44, 2002.
259. Taiwo OO, Hassan Z: The impact of highly active antiretroviral therapy (HAART) on the clinical features of HIV-related oral lesions in Nigeria. *AIDS Res Ther* 25:7–19, 2010.
260. Tami-Maury IM, Willig JH, Jolly PD, et al: Prevalence, incidence and recurrence of oral lesions among HIV-infected patients on HART in Alabama: a two-year longitudinal study. *South Med J* 104:561–566, 2011.
261. Tappuni AR, Fleming GJ: The effect of antiretroviral therapy on the prevalence of oral manifestations in HIV-infected patients: a UK study. *Oral Surg Oral Med Oral Pathol Oral Radiol Endod* 92:623–628, 2001.
262. Tavitian A, Raufman JP, Rosenthal LE: Oral candidiasis as a marker for esophageal candidiasis in the acquired immunodeficiency syndrome. *Ann Intern Med* 104:54–55, 2007.
263. The Henry J. Kaiser Family Foundation: HIV/AIDS policy fact sheet, 2007.
264. Thomas CJ: Triazole therapy for mucocutaneous candidiasis in HIV-infected patients. *J Assoc Nurses AIDS Care* 9:36–44, 1998.
265. Tomlinson DR, Coker RJ, Fisher M: Management and treatment of Kaposi's sarcoma in AIDS. *Int J STD AIDS* 7:466–470, 1996.
266. Toppuni AR: Immune reconstitution inflammatory syndrome. *Adv Dent Res* 23:90–96, 2011.
267. Traeder C, Kowoll S, Arasteh K: *Candida* infection in HIV positive patients 1985-2007. *Mycoses* 51(Suppl 2):58–61, 2008.
268. Umadevi M, Adeyemi O, Patel M, et al: Periodontal diseases and other bacterial infections. *Adv Dent Res* 19:139–145, 2006.
269. UNAIDS Joint United Nations Programme on HIV/AIDS: Report on the global AIDS epidemic. UNAIDS/08.27E/JC 1511E (English original), 2008.
270. Ustianowski AP, Leake H, Evans S: Outpatient therapy of HIV-associated oral and oesophageal candidosis. *Int J STD AIDS* 8:592–594, 1997.
271. Vacharajsa A, Asrani AC, Gebhard KH, et al: Oral keratinocytes support non-replicative infection and transfer or harbored HIV-1 to permissive cells. *Retrovirology* 5:66, 2008.
272. Vanhems P, Allard R, Toma E, et al: Prognostic value of the CD4-T cell count for HIV-1 infected patients with advanced immunosuppression. *Int J STD AIDS* 7:495–501, 1996.
273. Vanhems P, Dassa C, Lambert J, et al: Comprehensive classification of symptoms and signs reported among 218 patients with acute HIV-1 infection. *J Acquir Immune Defic Syndr* 21:99–106, 1999.
274. Velegraki A, Nicolatou O, Theodoridou M, et al: Paediatric AIDS-related linear gingival erythema: a form of erythematous candidiasis? *J Oral Pathol Med* 28:178–182, 1999.
275. Verrusio AC: Risk of transmission of the human immunodeficiency virus to health care workers exposed to HIV-infected patients: a review. *J Am Dent Assoc* 118:339–342, 1989.
276. Veugelers PJ, Cornelisse PG, Craib KJ, et al: Models of survival in HIV infection and their use in the quantification of treatment benefits. *Am J Epidemiol* 148:487–496, 1998.
277. Vidmar L, Poljak M, Tomazic J, et al: Transmission of HIV-1 by human bite. *Lancet* 347:1762, 1996.
278. Walli R, Goebel FD: Impaired glucose tolerance and protease inhibitors. *Ann Intern Med* 129:837–838, 1998.
279. Walling DM, Etienne W, Ray AJ, et al: Persistence and transition of Epstein-Barr virus genotypes in the pathogenesis of oral hairy leukoplakia. *J Infect Dis* 190:387–395, 2004.
280. Walling DM, Flaitz CM, Nichols CM: Epstein-Barr virus replication in oral hairy leukoplakia: response, persistence, and resistance to treatment with valacyclovir. *J Infect Dis* 188:383–395, 2003.
281. Weerasuriya N, Snape J: Oesophageal candidiasis in elderly patients: risk factors, prevention and management. *Drugs Aging* 25:119–130, 2008.
282. Wei X, Ghosh SK, Taylor ME, et al: Dynamics in human immunodeficiency virus type 1 infection. *Nature* 12:117–122, 1995.
283. Weisman Z, Kalinkovich A, Borkow G, et al: Infection by different HIV-1 subtypes (B and C) results in a similar immune activation profile despite distinct immune backgrounds. *J Acquir Immune Defic Syndr* 21:157–163, 1999.
284. Wilson DP, Law MG, Grulich AE, et al: Relation between HIV viral load and infectiousness: a model-based analysis. *Lancet* 372:314–320, 2008.
285. Witzel AL, Pires Mde F, de Carli ML, et al: *Candida albicans* isolation from buccal mucosa of patients with HIV wearing removable dental prostheses. *Int J Prosthodont* 25:127–131, 2012.
286. Wu TC, Chan JW, Ng CK, et al: Clinical presentations and outcomes of *Penicillium marneffei* infections: a series from 1994 to 2004. *Hong Kong Med J* 14:103–109, 2008.

287. Yeung SC, Stewart GJ, Cooper DA, et al: Progression of periodontal disease in HIV seropositive patients. *J Periodontol* 64:651–657, 1993.
288. Yin MT, Dobkin JF, Grbic JT: Epidemiology, pathogenesis, and management of human immunodeficiency virus infection in patients with periodontal disease. *Periodontol 2000* 44:55–81, 2007.
289. Younai FS, Murphy DC, Kotelchuck D: Occupational exposures to blood in a dental teaching environment: results of a ten-year surveillance study. *J Dent Educ* 65:436–448, 2001.
290. Zhang H, Dornadula G, Beumont M, et al: Human immunodeficiency virus type 1 in the semen of men receiving highly active antiretroviral therapy. *N Engl J Med* 339:186–188, 1998.
291. Zhang X, Langford A, Gelderblom H, et al: Ultrastructural findings in oral hyperpigmentation of HIV-infected patients. *J Oral Pathol Med* 18:471–474, 1989.
292. Zoufaly A, Stellbrink HJ, Heiden MA, et al: Cumulative HIV viremia during highly active antiretroviral therapy is a strong predictor of AIDS-related lymphoma. *J Infect Dis* 200:79–87, 2009.

CHAPTER 27

Masticatory System Disorders that Influence the Periodontium

Michael J. McDevitt

CHAPTER OUTLINE

Temporomandibular Joint
Muscles and Nerves of the Masticatory System
Centric Relation
Biomechanics of the Masticatory System *(e-only)*
Dysfunction and Deterioration
Orofacial Pain
Comprehensive Evaluation
Diagnostic Decision Making

For online-only content about the biomechanics of the masticatory system as well as expanded discussions of the muscles and nerves of the masticatory system, dysfunction and deterioration, orofacial pain, and clinical examination, please visit the companion website at www.expertconsult.com. Some figures may be out of numeric order in this printed chapter.

The masticatory system consists of the temporomandibular joints (TMJs), the masticatory muscles, the teeth in occlusion, and the neurologic and vascular supplies that support all of these structures. Research suggests that masticatory system disorders include many varied conditions with multiple possible contributing factors rather than different manifestations of a single disease or syndrome.[2,84,129] The ability to understand the anatomy and function of the masticatory system and to correctly interpret relevant diagnostic information is a prerequisite to fulfilling comprehensive standards of care. Our diagnostic process must have a broad enough base and be inclusive enough to determine the most appropriate cause of masticatory dysfunction.[137]

Temporomandibular Joint

Harmonious function of the TMJs is a product of the coordination of the muscles of mastication by intricate mechanisms of neurologic control. Understanding the dynamics and the relationship of the TMJ to the associated muscles and nerves provides the working knowledge required for effective assessment and diagnosis.

The TMJ is one of the most complex joints in the human body. It is capable of providing both hinging (rotation) and gliding (translation) movements, and it is able to resist incredible forces of mastication. The TMJ is formed by the head of the condyle of the mandible as it fits into the articular fossa of the temporal bone (Figure 27-1). The body of the mandible effectively connects both condyles so that neither condyle functions independently of the other. Interposed between the head of the condyle and the articular surface of the temporal bone is the articular disc, which consists of dense connective tissue; this results in a compound joint with two joint cavities (Figure 27-2). The articulating surfaces of the osseous structures are essentially convex in a healthy situation, so the biconcave configuration of the articular disc compensates for the opposing convexities. The articular surfaces of the condyles and the temporal bones consist of fibrous connective tissue, which renders them resistant to breakdown and capable of repair. Deep to the superficial connective tissue layer, articular cartilage provides the cellular and structural basis for the response to the functional loading and movement of the TMJs.[84,137,186] The discal ligaments and attachments to the capsule, along with the disc itself, become the means of separating the joint into superior and inferior joint spaces (see Figures 27-1 and 27-2). Synovial lubrication of the articular surfaces is a function of the production of synovial fluid by endothelial cells along the borders of each joint cavity and at the anterior extent of the retrodiscal tissues.[42,43,84,137,181,183,186]

Muscles and Nerves of the Masticatory System

The muscles and nerves of the masticatory system are extensively reviewed elsewhere. They are only briefly discussed here for the purpose of understanding the mechanisms involved. Appropriate references are provided for further reading.

Centric Relation

The mandible is suspended from the cranial base by ligaments and muscles. The understanding of mandibular movement begins with an initial reference point for each condyle, which is usually referred to as *centric relation;* this clinically determined relationship of the mandible to the maxilla occurs when both condyle–disc assemblies are positioned in their most superior position in the maxillary (or glenoid) fossa and against the slope of the articular eminence of the temporal bone. Verification of centric relation is obtained by loading the TMJs bilaterally with the teeth apart via the bimanual mandibular manipulation technique advocated by Dawson and others.[42,43,44,45,172] When both condyles are in this relationship, rotation or hinging action occurs around an axis defined by the medial poles of each condyle (Figure 27-3).

The term *centric relation* is limited to the rotation axis through both condyles while they are seated in their respective glenoid

The muscles of mastication consist principally of two groups: the *elevator muscles* and the *depressor muscles*. The muscles responsible for elevating the mandible are the masseter, the internal pterygoid, and much of the temporal muscle. The posteriorly oriented fibers of the temporal muscle also retrude the mandible. The superficial muscle bundle of the masseter muscle may also assist with protruding the mandible, whereas the deeper bundle serves to stabilize the condylar head against the articular eminence. Juxtaposed with the masseter muscle, the medial pterygoid forms a muscular support for the mandible at its angle. Although its primary function is elevation of the mandible, it is also active during protrusion.[84,137] The lateral pterygoid muscle is now known to function as two distinct muscles, the inferior and superior lateral pterygoid muscles, with independent and almost opposite functions.[6,15] The inferior lateral pterygoid muscle depresses and protrudes the mandible. The superior lateral pterygoid muscle does not contract during depression of the mandible but rather contracts along with the elevator muscles, thereby bracing the condyle anteromedially.[116,125,135,137,157]

Physiologic mandibular posture and movement are products of harmonious muscular contraction among masticatory and supportive muscles. The neurologic input needed to produce the synergy of complementary and antagonistic muscles is extremely complex.

The motor and sensory innervation of the TMJs and the rest of the masticatory system are provided by structures of the trigeminal nerve.

Mechanoreceptors in the skin, the muscle, and the ligamentous structures, especially the periodontal ligament (PDL), discern pressure differences at sensitive degrees of discrimination. Painful stimuli are perceived by nociceptors and result in both pain perception and reflex responses.

The innervation of both the capsular ligaments and the discal ligaments provide essential proprioceptive input with regard to joint position. Efferent or motor neurons cause muscle contraction in response to central cortical stimulation and in response to afferent stimuli during reflex activity.[42,137,186]

Sensory input from the PDL offers the potential to be an important component of the complex neurologic management of the masticatory system. Currently, little evidence of the existence of proprioceptive sensory organs within the neuroanatomy of the PDL is available, although it was once considered likely.

Pain perception causes the nociceptive reflex to open the mouth rapidly via the contraction of depressor muscles and the suppression of elevator muscles; this is consistent with other protective reflexes within the musculoskeletal system.[137] Protective reflexes may be suppressed in individuals who are experiencing chronic occlusal parafunction (i.e., clenching or grinding of the teeth).[27,53] Pressure perception is a function of the numerous mechanoreceptors within the PDL of teeth that are in contact. Discrimination within the dentition on the basis of the specific teeth in contact, the direction of force, the intensity of force, and their influence on muscle activity have been demonstrated in human study populations and animal studies.[23,39,105,115,160] Both research and clinical observations suggest that elevator muscle contraction is suppressed when anterior teeth promote disclusion or the separation of posterior teeth during excursive mandibular movements.[182]

The loss of attachment that results from periodontitis involves the loss of some mechanoreceptors.

Patients with significant bone loss, significant inflammatory disruption of the integrity of the PDL, or chronic occlusal parafunction may experience the compromised regulation of muscle activity.[2,26,53,81,84,130,137,155]

Biomechanics of the Masticatory System

The biomechanics of mandibular movement are a function of neurologic input from cortical and stomatognathic sources acting to initiate or restrict muscular contraction. Muscular action either stabilizes the condyle against the articular eminence or directs its rotational and translational movements relative to each respective temporal bone. The position and functional movement of one condyle always depend on the status or activity of the other.

Because the maxillary teeth have a fixed relationship with the cranial base (just as mandibular teeth have a fixed relationship with the condyle), the contact of their respective occlusal surfaces may directly influence condylar position or movement.[42,43,137]

The mandible can move within a range of motion that is limited by skeletal, muscular, and ligamentous structures. Pure rotation of up to approximately 25 mm can occur before translation of the condyle is required to continue toward the maximal opening of the jaw. Movement of the condyle is relative to the disc, so rotation effectively occurs within the inferior joint space (Figure 27-5, *A*). Strict translation protrudes the mandible, whereas the condyle–disc assembly moves anterior and inferior toward the articular eminence of the temporal bone.

The disc moves relative to the temporal bone, and movement occurs within the upper joint space (see Figure 27-5, *B*). During combination translation/rotation movement of the condyle, the axis of rotation for each condyle changes as the condyle translates down the articular eminence to a position inferior to its fossa (see Figure 27-5, *C*). Harmonious muscle function and ligament attachments keep the condyle–disc assembly properly related so that the articular disc remains loaded in its concave avascular central portion between the condyle and the articular surface of the temporal bone. The elasticity and vascularity of the retrodiscal tissues permit anterior movement of the disc during the translation of each respective condyle.

Rotation and translation of the condyle can occur in the absence of any tooth-to-tooth contact, because the condyle–disc assembly can be supported by the muscles of mastication against the articular eminence during rotation, translation, and combination movements.

When the teeth are in contact, their ability to influence both the position and the direction of movement of condyle–disc assemblies is defined by the intensity of muscle activity and the steepness of the inclines of those teeth.[42,43,78,90,109,137]

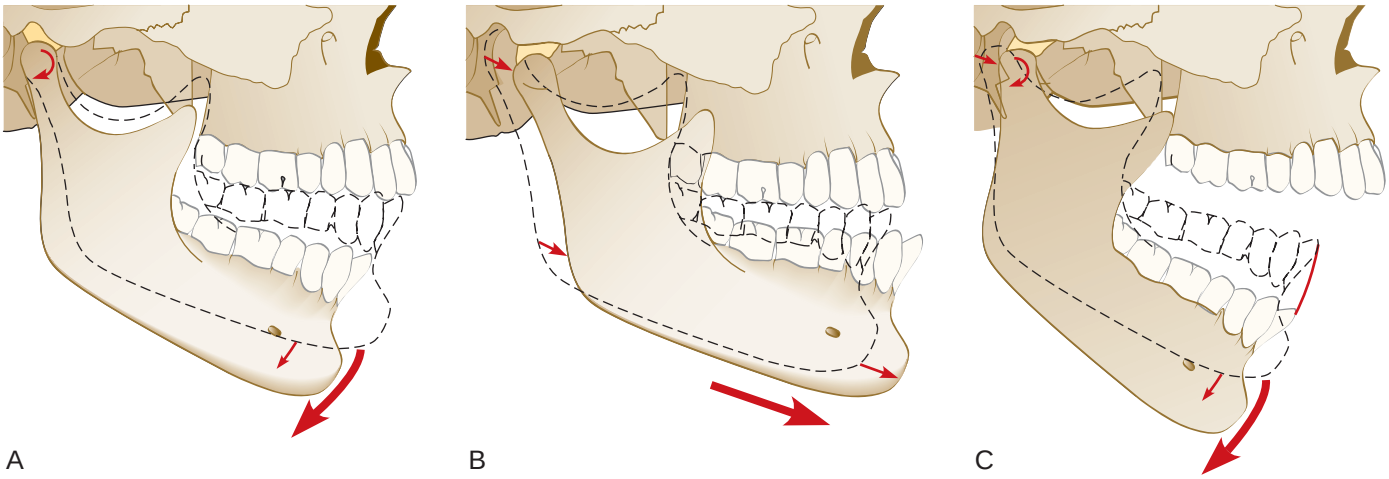

Figure 27-5 **A,** Rotational movement of the mandible with the condyles in centric relation. This pure rotational opening can occur until the anterior teeth are about 20 mm to 25 mm apart. **B,** Translational movement of the condyle–disc assembly during protrusion of the mandible. **C,** Second stage of rotational movement during opening. Note the dual activity relative to the articular disc. *1,* Rotation of the condylar head, relative to the disc, occurs in the inferior space. *2,* Movement of the disc anteriorly and inferiorly along the articular surface of the temporal bone. The articular disc moves anteriorly and inferiorly with the head of the condyle, which continues to rotate against the disc. Translation occurs in the superior joint space, and rotation occurs in the inferior joint space. *(From Okeson JP:* Management of temporomandibular joint disorders and occlusion, *ed 4, St Louis, 1998, Mosby.)*

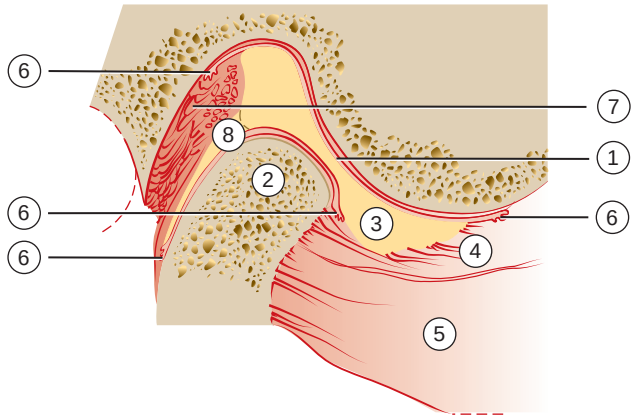

Figure 27-1 Lateral view of a cross-section through the temporomandibular joint. *1,* Posterior slope of the articular eminence of the temporal bone; *2,* head of the condyle; *3,* articular disc (note the biconcave shape); *4,* superior lateral pterygoid muscle (note the attachment to both the head of the condyle and the articular disc); *5,* inferior lateral pterygoid muscle; *6,* synovial tissue; *7,* retrodiscal tissue; and *8,* discal ligament attachment to the posterior surface of head of condyle. *(Modified from Dawson PE:* Evaluation, diagnosis, and treatment of occlusal problems, *ed 2, St Louis, 1989, Mosby.)*

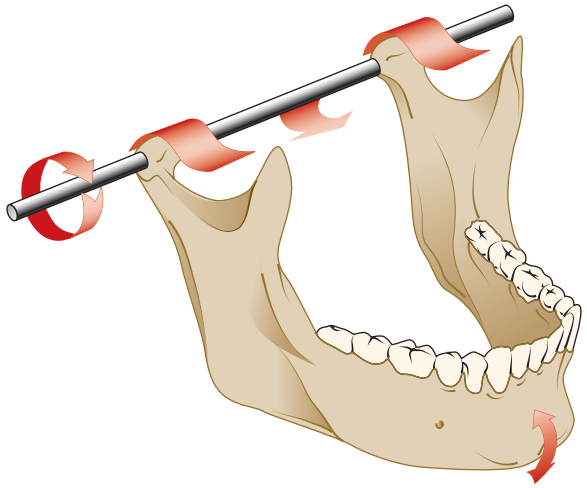

Figure 27-3 When they are in centric relation, the condyles can rotate on a fixed axis. As long as the rotational axis stays fixed at the most superior position against the eminentiae, the mandible can open or close and still be in centric relation. If the condyle axis moves forward, it is no longer in centric relation. *(From Dawson PE:* Evaluation, diagnosis, and treatment of occlusal problems, *ed 2, St Louis, 1989, Mosby.)*

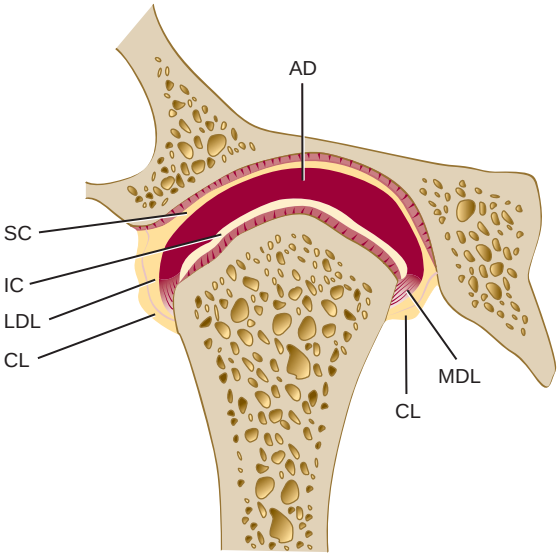

Figure 27-2 Anterior view of the temporomandibular joint showing the collateral ligaments. *AD,* Articular disc; *CL,* capsular ligament; *IC,* inferior joint cavity; *LDL,* lateral discal ligament; *MDL,* medial discal ligament; *SC,* superior joint cavity. *(From Okeson JP:* Management of temporomandibular joint disorders and occlusion, *ed 4, St Louis, 1998, Mosby.)*

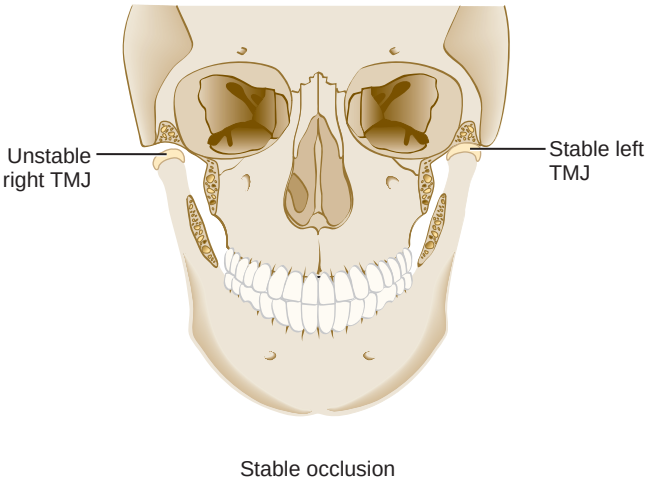

Figure 27-4 Example of orthopedic instability. Note that, with the teeth in their stable position (i.e., maximum intercuspation), the left temporomandibular joint is in a stable relationship with the fossa. The right temporomandibular joint, however, is not in a stable position with the fossa. When the elevator muscles contract, the right condyle moves superiorly to seek a more stable relationship with the articular disc and fossa (i.e., the musculoskeletally stable position). This type of loading can lead to an intracapsular disorder. *(From Okeson JP:* Management of temporomandibular joint disorders and occlusion, *ed 4, St Louis, 1998, Mosby.)*

fossae. The only occlusal consideration relative to centric relation occurs when rotation of the mandible initiates the first contact of opposing occlusal surfaces. The term *initial contact* in centric relation can be used to define this relationship (see Chapter 49). If the contraction of elevator muscles occurs at the point of initial occlusal contact and results in the distraction of one or both condyle–disc assemblies from their seated relationship, then centric relation is no longer occurring.[42,43,44]

For TMJs to maintain orthopedic stability, the condyles must remain fully seated in their respective fossae when the teeth occlude in maximal intercuspation. Orthopedic instability occurs when the occlusal relationships are such that the contraction of elevator muscles is required to achieve stable occlusion in the maximal intercuspal position, which results in the unseating of one or both condyles from their respective fossae (Figure 27-4).

The strain on the discal ligaments caused by a loaded joint being displaced from the fossa can lead to internal derangement of that joint, which will be described later in this chapter. Postural and parafunctional stress can also be a source of the orthopedic instability of a TMJ.

An individual's susceptibility to masticatory system disorders determines whether that person adapts with minimal consequence or develops dysfunction or degeneration.[26,42,43,137,172]

Dysfunction and Deterioration

Ideally, function never exceeds the integrity or adaptive limits of the structural elements of the masticatory system. Clinical experience shows that the tolerance of the components of the masticatory system can be exceeded by both acute trauma and chronic trauma. *Acute trauma* to the head and neck region can range from a distinct event, such as an accident or a blow to the face, to a sustained overuse experience, such as a long dental appointment. Acute trauma can serve as an initiating event that leads to a chronic condition, so accurate documentation and careful monitoring may prove extremely valuable should symptoms or dysfunction persist.[13,20,47]

Chronic trauma is defined as any experience that repeatedly exceeds the tolerances of the affected masticatory system structure. Postural stresses and parafunctional occlusal habits, with or without occlusal discrepancies, may produce musculoskeletal disharmony and orthopedic instability of the TMJ.

The general terms for occlusal parafunction used in this text include *bruxism,* which is the grinding of the teeth, and *clenching,* which is when a person holds the teeth firmly together with significant force. Bruxism is usually confirmed by the observation of excessive tooth wear. The clenching type of parafunction can be distinguished from the grinding of the teeth, and it seems to be more often associated with masticatory system disorders than does bruxism.[31,61,63,83,140,145] Sleep bruxism may include both tooth grinding and clenching, and it seems to occur primarily during stage 1 and stage 2 (i.e., non–rapid eye movement) sleep. These episodes often occur in association with short brain and cardiac reactivations called "microarousals." Rhythmic masticatory muscle activity is relatively common among non-bruxers, but the frequency and intensity of the muscle contraction is substantially greater for the sleep bruxer. The central pattern generator of the primate brain stem does not modulate or reduce muscle contraction during sleep as it does during waking hours. In addition, the amplification of oral parafunction has been reported in association with a patient's intake of selective serotonin reuptake inhibitors (e.g., Prozac).[10,42,43,137,148,174]

Discrimination between occlusal-function–related and parafunction-related masticatory system disorders and those with other etiologies requires exacting standards of occlusal evaluation.

If sufficient evidence exists to suspect that the occlusal relationships in function or parafunction may have exceeded the tolerances of that individual's masticatory system, responsible intervention or monitoring can be initiated.[43,66,140,147]

Disruption of the relationship or alignment of the condyle, the disc, and the articular surface of the temporal bone is typically called an *intracapsular disorder* or an *internal derangement of the TMJ.* The articular disc can be displaced as a result of an acute blow to the jaw, chronic trauma, or the uncoordinated contraction of the lateral pterygoid muscle. When the disc cannot return to its normal relationship to the condyle with full closure of the mouth, it is considered to be displaced or dislocated.

Orofacial Pain

Discomfort associated with masticatory system disorders falls under the larger umbrella of orofacial pain. Pain associated with TMJ dysfunction is most frequently muscular in origin,[42] and it may be amplified by both occlusal parafunction and stress.[64] Although pain itself is a complex entity,[168] a working knowledge of even the uncommon sources of pain perceived in the region of the masticatory system is essential to providing comprehensive diagnosis and treatment.

BOX 27-1 Differential Diagnosis of Orofacial Pain

Intracranial Pain Disorders[70,76,84,123,136,142]
Neoplasm, aneurysm, abscess, hemorrhage, hematoma, edema

Primary Headache Disorders (Neurovascular Disorders)[92,124]
Migraine, migraine variants, cluster headache, paroxysmal hemicrania, cranial arteritis, carotidynia, tension-type headache[4,93,100,137]

Neurogenic Pain Disorders[123,124]
Paroxysmal neuralgias: Trigeminal, glossopharyngeal, nervus intermedius, and superior laryngeal neuralgias[162]
Continuous pain disorders: Deafferentation pain syndromes (peripheral neuritis, postherpetic neuritis, posttraumatic and postsurgical neuralgia, neuralgia-inducing cavitation osteonecrosis[17,18])
Sympathetically maintained pain[21]

Intraoral Pain Disorders
Dental pulp, periodontium, mucogingival tissues, tongue[14,110,123,185]

Temporomandibular Disorders
Masticatory muscle, temporomandibular joint, associated structures

Associated Structures[38,40,131,136,137]
Ears, eyes, nose, paranasal sinuses, throat, lymph nodes, salivary glands, neck

Axis II Mental Disorders
Somatoform disorders
Pain syndromes of psychogenic origin

Compiled by the American Academy of Orofacial Pain.

Sources of dental or periodontal pain should be identified by clinical, radiographic, and historic information. Nondental sources of pain include TMJ structures, muscles, cervical structures, neuropathies, vascular inflammation, all types of headache, sleep disorders, systemic disorders, and psychoimmune neurologic sources.[136] A survey of 45,700 American households revealed that 22% of respondents had experienced some type of orofacial pain during the previous 6 months, thereby establishing a meaningful probability that the periodontal patient's list of symptoms includes pain.[11]

Box 27-1 provides the current list of possible sources of orofacial pain. This list was prepared by the American Academy of Orofacial Pain.[136]

Headache pain is perceived primarily within the trigeminal nerve pathways, although other cranial and cervical nerves may offer painful sensory input.[84,136,158] Pain that originates in masticatory system structures, which are also innervated by the trigeminal nerve, requires diagnostic differentiation from headache pain.[159]

Headache can present in a myriad of forms, and it can influence the perception of pain and the diagnosis of the origin of pain.[84,136]

Pain of dental and periodontal origin must be clearly defined and differentiated from heart attack, sinus pain, and myofascial pain.[136,137]

Pain that originates in pulpal or periodontal nociceptors can be differentiated with a comprehensive clinical and radiographic evaluation. Orofacial pain that originates in the TMJs or the muscles of mastication can result from neoplasm, macrotrauma, repeated microtrauma, systemic disease, and anatomic predisposition.

Sleep-disordered breathing may also play a role in a patient's orofacial pain through various potential mechanisms.[8] Sleep bruxism has been associated with hypoxia and arousals during

Occlusal relationships that disrupt the condyle during the physiologic movement of rotation or translation require muscular and TMJ compensation. The extent to which the repeated loading of the teeth and the condyles during function and parafunction exceeds the tolerance of an individual will determine whether structural or muscular compromise occurs.[137]

Recently completed prospective research found only a weak association with occlusal disharmonies but significant correlations of both reported bruxism and tooth wear index with symptoms of temporomandibular disorders.[24,118] When TMJ dysfunction could be correlated with specific occlusal relationships, the trend was to recognize that, when inclines of posterior teeth dominated occlusal function, masticatory system harmony was disrupted.[1,30,44,56,71,77,82,128,137,180,182] Other researchers have found that various occlusal interferences and relationships are common among individuals with and without masticatory system disorders.

The researchers could not distinguish a particular occlusal feature as a specific etiologic or predisposing factor for the development of masticatory system disorders, although some found that several factors occurring together encouraged dysfunction.[37,77,146,147,171] There seems to be less correlation between static references (e.g., the class of the malocclusion) and masticatory system disorders than when functional or extrafunctional occlusal forces exceed the tolerance of the TMJ and the masticatory musculature.[137,159]

Progressive disc displacement most often begins on its lateral aspect and occurs in an anterior and medial direction as a result of the insertion of muscle fibers into the anteromedial aspect of the disc and the reported variability in resistance of the attachment of the lateral aspect of the disc.[12,161] Stretching of the retrodiscal tissues and collateral ligaments permits the disc to be displaced and function to be limited in response to pain that results from compressive forces on the retrodiscal tissues. At some stage of opening, the remaining elasticity of the retrodiscal tissues and the tension of the capsular ligaments can pull the disc onto the head of the condyle, often with a discernible sound. Closing then results in the disc again becoming dislocated anteriorly, which results in a common joint sound that is often referred to as a *reciprocal click*[36,85,86,103,104,113] (Figure 27-6).

When the disc remains anterior to the head of the condyle during rotation and the limited range of translation possible, the condition is called *closed lock* or *disc displacement (dislocation) without reduction*[42,137] (Figure 27-7).

The entire disc need not be locked anterior to the head of the condyle for this condition to limit function and cause pain. The lateral aspect of the disc would be more likely than the medial aspect to be displaced anteriorly if a partial anterior disc displacement without reduction were to occur. A history of joint sounds is usually reported, although this state of the condyle–disc assembly may not result in currently discernible sounds.[42,137]

The vascular portion of the retrodiscal tissues being loaded between the condyle and the articular surface of the eminentia accounts for most current pain or a history of pain originating within the TMJ. The adaptation of the retrodiscal tissues to completely nonvascular fibrous tissue or perforation of the disc may account for the cessation of the painful symptoms.[141]

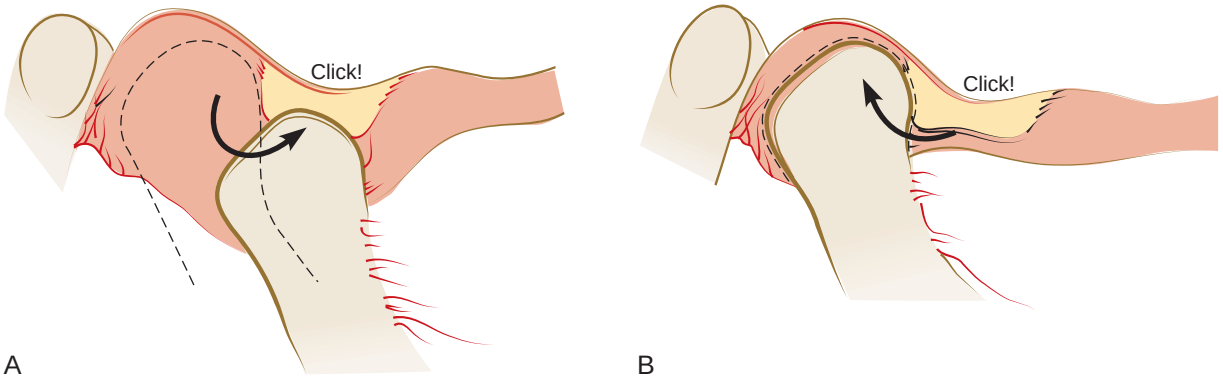

Figure 27-6 Reciprocal click. **A,** Reciprocal click occurs when the condyle moves onto the articular disc from a position behind the posterior band of the disc and then, **B,** clicks off of the disc when the condyle moves back. This occurs as the condyle translates forward and back during the opening and closing movements. *(From Dawson PE:* Evaluation, diagnosis, and treatment of occlusal problems, *ed 2, St Louis, 1989, Mosby.)*

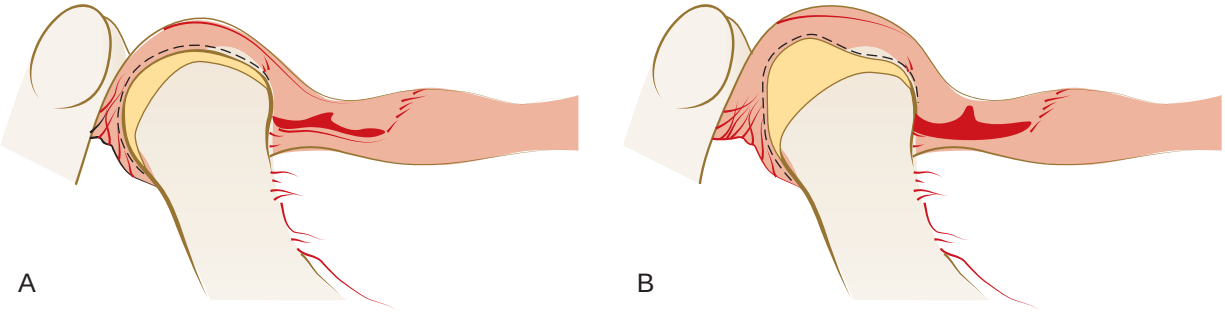

Figure 27-7 Anterior disc displacement without reduction. **A,** Condyle positioned in the fossa on the retrodiscal tissues, with the disc remaining anterior to the head of the condyle. **B,** During translation, the disc is further misshapen, thereby restricting the full opening of the mandible. *(From Dawson PE:* Evaluation, diagnosis, and treatment of occlusal problems, *ed 2, St Louis, 1989, Mosby.)*

The presence of abnormal anatomic features of the condyle and fossa results in deviations in the shape of the affected articular surface to which the disc then must adapt its normal anatomy, thereby resulting in deviations in form and function. If this type of functional limitation or irregularity is observed at a consistently occurring point during jaw opening and closing, it is often within the compensatory mechanisms of the patient and should be distinguished from the disc derangements that were described previously.[137]

When the intensity and duration of the functional and dysfunctional loading of the TMJs result in injury, molecular agents appear to be active in the degeneration of joints. Free radicals, various catabolic enzymes, neuropeptides, estrogen, cytokines, and prostaglandins are implicated in inflammatory reactions that have an impact on the articular surfaces and the synovial fluid.[58,69,94,97,99,126,127,133,151,163] The loss of the ability of the synovial fluid to lubricate articular surfaces can result in adherence of the disc. The limitation of rotation occurs with adherence between the disc and the condyle, whereas fixation of the disc against the fossa permits rotation but does not allow the disc to move forward during translation.[137]

Hypermobility (subluxation) of the TMJ can permit the condyle to translate beyond the eminentia, with both the disc and the condyle located beyond its prominence. The combination of anatomic features that predisposes individuals to subluxation often allows for the self-reduction of the condyles. When the condyles translate beyond the eminentia but the discs are trapped posteriorly, the combined steepness of the disc and the eminentia prevents the reduction of each condyle, and the mandible is locked open.[137]

Within the joint structures, the inflammation and compression of vascularized components are the direct sources of pain. Synovitis or capsulitis with or without osteoarthritis and the polyarthritides are characterized by local pain, which increases with function while limiting the range of motion of the affected TMJ. In addition to the potential for pain, symptoms of arthritis can include limited mandibular opening, the disruption of other jaw mechanics, and joint sounds that are characteristic of degenerative change to and direct contact between articular surfaces.[47,48,52,65,67,79,95,96,114,117,120,136,187]

Orofacial pain that originates in the muscles of mastication may be perceived in that region, or it may be referred to other structures, such as individual teeth.

Similarly, pain referral to the region of certain muscles requires definition of the origin. Because local provocation at the origin of pain should produce symptoms at the site of pain perception, movement of the jaw would be expected to elicit pain in the painful muscles of mastication.

Cranial nerves experience referral on the same side, whereas skeletal nerve referral can occur to the opposite side; both sources generally refer pain centrally or superiorly.[84,137,164]

The muscles of mastication are subject to a variety of disorders and dysfunction, many of which can be painful.

The American Academy of Orofacial Pain designates myofascial pain, myositis, muscle spasm (myospasm), local myalgia, and myofibrotic contracture as major categories of these conditions.

Muscle palpation that reveals a taut band of muscle or fascia and that results in pain, which is also frequently referred, is virtually diagnostic for myofascial pain. Myositis of the masticatory muscles arises from direct trauma or infection close to the muscle. Associated pain increases with mandibular movement, thereby limiting the range of motion. Muscle spasm is the sustained involuntary contraction that results in the pain and dramatic shortening of the affected muscle. Myospasm of the masticatory muscles greatly limits mandibular movement, and it can change that occlusion suddenly as a result of its rapid onset. Local myalgia, which is pain that is specific to individual muscles, may result from ischemia or fatigue, and it may present as delayed-onset muscle soreness and protective co-contraction.

Occlusal parafunction, extended dental appointments, metabolic imbalances, and sympathetic nervous system influences have been associated with this painful muscular reaction. An extended period of a limited range of mandibular movement can result in fibrosis of the muscle and related attachments, thereby creating a painless condition called myofibrotic contracture.[136]

Otolaryngologic symptoms associated with masticatory system disorders have been reported and include degrees of deafness, tinnitus, and vertigo.[16,22,28,29,38,40,60,89,131,137,139,153,154,184] Trauma and postural stress in the cervical spine can be responsible for both the perception and the origin of pain within the masticatory system.[13,20,84,137]

sleep disruption.[25,55,178,177] Pain tolerance appears to be diminished with sleep deprivation.[165] Oral appliances that have been prescribed for sleep-disordered breathing have the potential to cause at least transient symptoms of temporomandibular disorders as a result of the mandibular advancement that needs to be experienced for them to be effective.[51,46] Oral appliances prescribed for sleep bruxism may represent an additional airway obstruction for the patient with obstructive sleep apnea.[59] In the light of the increasing emphasis on the effects of sleep-disordered breathing in both medicine and dentistry, Chapter 28 has been developed for this text to serve as a reference for the reader.

Comprehensive Evaluation

Patient History and Interview

The written history and personal interview should be designed to invite open-ended responses and reflection by the patient on past experiences and the current condition.

Standard dental or medical history forms may require modification to include questions about any history of limited or painful jaw movement, noise in either joint, and masticatory muscle symptoms (Box 27-2).

These issues should be documented with regard to timing, duration, frequency, and relationship to any history of trauma.[136]

BOX 27-2 Examples of Questions About the Masticatory System to Include in the Patient History

Are you now experiencing or have you ever experienced:

1. Pain in either jaw joint or pain when opening or closing your mouth?[9]
2. Acute or direct trauma to the face, jaw, head, or neck, such as during an accident?
3. Any locking or restricted movement of either jaw joint?[50,166]
4. The inability to bite or close the teeth together completely without discomfort in one or both jaw joints?
5. Earache without infection, especially if it is recurring?
6. Ringing or rushing sounds in either ear?
7. Any type of neuralgia (nerve pain), especially with trigger points?[123,176]
8. Tooth pain without a diagnosed dental problem or after tooth removal?[121,122,169]
9. Fibromyalgia (muscle pain)?[41,144,149,164]
10. Sleep apnea or any sleep disturbance?
11. Any sounds, such as clicks or pops, in either jaw joint, especially when opening or while eating?
12. Chronic or frequently recurring headaches, especially migraines or cluster headaches?[4]
13. Shingles or any painful infection of the face or neck?
14. Having to "adjust" the jaw or manipulate the jaw joint with your hand to be able to open or close your mouth?
15. An occupation or activity that requires a regular stressful posture, such as cradling a telephone between the head and shoulder, working at a computer, playing a musical instrument, or scuba diving?[170,188]
16. An awareness of frequently keeping your teeth together, maintaining a clenched jaw, or holding your jaw in an assumed position, such as holding a pipe?
17. Lyme disease?[70]
18. Neck muscles that are often tired or sore?
19. A sleep position or posture that maintains pressure on your lower jaw?

Clinical Examination

The clinical examination continues the interview process through the co-discovery of the patient's masticatory system status. The dentist leads the patient to understand the meaning of signs and symptoms of dysfunction or deterioration and seeks opportunities to expand the patient's responses to questions.

The physical examination actually begins during the interview, when asymmetries in facial form, head posture, and mandibular movement patterns can be observed. The clinical evaluation of the various structures of the masticatory system, although individual to each practitioner, should afford the patient opportunities for understanding and include the following[10,42,137]:

1. The observation and measurement of the full range of motion of the mandible
2. The auscultation and light palpation of each TMJ in its full range of motion
3. The load testing of each TMJ
4. The palpation of each muscle of mastication and the related head and neck muscles
5. The evaluation of all of the soft tissues of the face, oral cavity, and oropharynx
6. Periodontal and dental examinations
7. Complete occlusal analysis, including accurately mounted diagnostic models

Imaging

When the clinical evaluation, panoramic radiographs, and patient history indicate the possibility of structural masticatory system disorders or the possible presence of pathology (especially neoplasm), appropriate imaging of the TMJ is warranted.[108] The state-of-the-art technique for the imaging of soft tissue, especially the articular disc, is magnetic resonance imaging. The current highest standard for the imaging of hard tissue, such as the condyle or the temporal bone, is computed tomography (CT). Cone-beam CT has become much more readily available to dentistry during the last few years, with software systems able to display the data gathered as both anteroposterior and cross-sectional depictions of the condyle and cranial structures, with image quality that is the same as or better than spiral CT. Less radiation exposure and lower cost to the patient are both reasons to favor cone-beam CT over conventional CT. The interpretation of magnetic resonance and CT images usually requires specialized training for the clinician or access to a radiologist. Arthrography is still being used for certain diagnostic situations, such as the suspected perforation of the articular disc, and nuclear medicine has developed protocols to image the TMJ to determine if active deterioration is occurring.[10,19,72,75,88,102,120,143]

Although plain-film tomography is occasionally a feature of some of the newer radiographic equipment, the technique that is most readily available to a majority of practitioners is panoramic radiography. The image produced depicts only general relationships and gross anatomy, so the information provided should be used only for screening purposes. When pathology or marked deformation is suggested by a panoramic radiograph, further diagnostic imaging and procedures may be warranted.[19,84]

Diagnostic Decision Making

The complete evaluation of every patient's periodontal status must include the diagnostic components required to reveal any form of masticatory system disorder. The existence of factors that are responsible for the historical, current, or potential impairment of masticatory system function can be integrated into a

The determination of a specific origin or source of pain can become more difficult with pain referral and the modulation of painful experiences by the central nervous system.

The sensitization of peripheral nociceptors by higher neural centers and inflammation at the site of the origin of pain can alter pain perception.[87,119,162] Persistent inflammation may therefore be a contributing factor to chronic pain.[87,119,162] Systemic conditions that may contribute to or predispose an individual to compromised pain regulation include sleep disorders, fibromyalgia, chronic depression, chronic fatigue syndrome, hypothyroidism, insufficient thyroid receptor activity, prolactin feedback disorder, epinephrine sensitivity related to mitral valve prolapse, premenstrual syndrome, androgen excess in women, and post-traumatic stress disorder.

Although some of these situations exhibit gender bias in response to hormonal factors, the influence of stress on pain experiences and the effect of variable coping skills have been reported for both genders.[5,21,107,134,136,144,156,157]

Evaluation of the TMJ begins with range-of-motion analysis. The observation of a departure from a straight path of opening and closing the mandible suggests an intracapsular disorder or masticatory muscle incoordination.[42,43,137] An average maximal opening of 50 mm is common; findings of less than 40 mm of opening suggest limited opening caused by a masticatory system disorder. The range of right and left lateral excursions is usually about 9 mm, and the protrusion of mandible is typically 7 mm. Limitation in the range of motion may be normal for some patients, but, for most, these observations are of diagnostic value.[10,50,74,137,167] *Auscultation* of the joint by listening with a stethoscope or Doppler instrument, which amplifies joint sound for both the patient and the dentist, can reveal noises that are diagnostic for numerous conditions. The intensity and nature of any sounds, clicks, pops, or crepitus (i.e., grinding, grating, or rubbing sounds) should be recorded accurately. Any sound that is detected as part of the initial evaluation should be tracked consistently to detect any change. Diagnostic interpretation and management on the basis of specific sounds correlated with the status of the TMJ can be found in other reference texts.[7,10,42,43,137,179]

Firm palpation of the TMJ with the mouth closed can be uncomfortable for the patient with inflammation in joint structures or superficial muscles.

Palpation while opening may become more uncomfortable if retrodiscal tissues are also inflamed.

Load testing of the TMJ is essentially a means to palpate the head of the condyle, the surface of the glenoid fossa, and the tissue interposed between them, except in the case of bone-to-bone contact. With bimanual mandibular manipulation, the dentist loads the joints equally and may detect resistance or tension on either side. The patient is in a supine position in the dental chair to minimize postural influence on muscle activity. The patient's head is braced by the support of the chair and by being cradled against the dentist's arm or abdomen. The dentist's middle fingers locate the notch in the mandible just anterior to the angle, and the thumbs are placed near the midline in the mental region of the mandible (Figure 27-8). Initially, the dentist provides very gentle guidance to the hinging action of the mandible, with a slight lifting force applied with the fingers and a slight depressing force applied with the thumbs. If the patient remains comfortable, increasing force can be applied at both points, ultimately with enough pressure to load test the joints. With the avascular fibrous discs interposed, the condyles are in centric relation, and the loading of both joints is comfortable. Discomfort may occur with muscle incoordination or bracing or with an anterior displaced disc and the attempted loading of vascular retrodiscal tissues of either TMJ.

Figure 27-8 Bimanual manipulation load testing in centric relation, with the teeth apart.

When performed properly, the patient can bite firmly as part of guided loading of the TMJs and report the nature or absence of pain or tension.[10,42,68,137]

Muscle palpation is also a learned technique that requires both experience and expertise so that it may help to derive the most reliable information. Too little pressure is not diagnostic of modest muscle pain or spasm, whereas too much pressure can hurt even when normal musculature is palpated.[62] Externally, the muscles that are palpated include the anterior, middle, and posterior temporalis; the superficial masseter; the anterior and posterior digastric; the sternocleidomastoid; the trapezius; the posterior cervical muscles; and the insertion of the medial pterygoid muscle. Intraorally, the deep masseter is tested with moderate squeezing pressure, and the medial pterygoid muscle is palpated directly in the general region of the insertion point for local anesthesia with a mandibular block. The lateral pterygoid is difficult to palpate because of the dominance of the medial pterygoid in the same region. Its palpation superior and distal to the palpation point for the medial pterygoid can be attempted distal to the maxillary tuberosity. Offering manual resistance to the patient's efforts to protrude the mandible is also a test of the lateral pterygoid muscle. Neither method of evaluation of the possible soreness of the lateral pterygoid muscle is completely reliable, although both provide some insight into the patient's muscle status.[3,10,42,43,54,57,84,137,167]

During muscle palpation, the dentist may be able to detect a particularly taut and uncomfortable band of muscle fibers. This condition represents regional myofascial pain or trigger point myalgia, which can be responsible for the referral of pain to the teeth and to other orofacial regions. The diagnostic injection of local anesthesia can be effective for identifying trigger point pain and pain referral patterns.[137,164]

The *occlusal analysis* is a logical extension of the evaluation of the teeth and the periodontium. Tooth mobility is assessed in both static and dynamic modes. Pressure applied to a tooth with a firm object allows for the detection of movement through both visual and tactile evaluation (see Chapters 30 and 49). Asking the patient to perform excursions of the mandible while maintaining firm contact with the opposing teeth also permits visual and tactile assessment.

Sources of tooth mobility include inadequate periodontal support, inflammation of the periodontium, and excessive occlusal loading of the teeth with adequate periodontium, thereby resulting in adaptive mobility.

The physical evaluation of the teeth and any restorations can reflect a history of trauma or wear. Visual observation, registration with marking paper or wax, and the electronic assessment of tooth contacts as the patient moves in all excursions may reveal disharmonies that are sufficient to cause the orthopedic instability of either TMJ.

If the teeth are found to be relatively firm, the relationship between the maxillary and mandibular teeth may influence the direction of condylar movement as soon as tooth-to-tooth contact is made.

While maintaining centric relation, the dentist continues the physical examination by positioning the condyles in a fully seated relationship without tooth-to-tooth contact by using bimanual manipulation or a leaf gauge technique. The mandible is manually guided to close until the first tooth-to-tooth contact is made. If that position is also maximum intercuspation, the optimum seating of the condyles is maintained. If the initial contact in centric relation is not maximum intercuspation, the condyles will be directed from a fully seated position to an inferior position relative to their respective fossae, which results in an orthopedic instability.

The direction and extent of the accommodation of the mandible should be carefully measured and recorded during the initial evaluation and consistently evaluated at subsequent appointments to discover any trend.[10,32,33,42-44,80,82,91,92,98,111,112,137,138,150,152,159,175]

To increase the reliability of this evaluation, a muscle-deprogramming effort may be employed. The simplest approach is to use cotton rolls that can be placed between the anterior teeth for 5 to 15 minutes to allow for possible muscle relaxation through the avoidance of proprioceptive or pressure neurologic input. A prefabricated or directly fabricated acrylic or composite bite stop for the anterior teeth offers the same advantage.[10,11,137] A more complex means of confirming the seating of the condyles in centric relation is achieved with a maxillary or mandibular muscle relaxation occlusal appliance. These appliances provide full coverage for the respective arch and occlusal contact for at least one cusp or incisal edge of the opposing teeth so that the teeth are protected from spontaneous shifting. The occlusal design provides immediate disclusion of all of the posterior teeth in every protrusive or lateral excursion. This allows for the progressive deprogramming of muscles through the advantage of reduced muscle contractions and limited noxious neurologic input.[44,101,181]

Models of the dentition must be accurately mounted to be diagnostic. The facebow transfer relates the maxillary cast to the axis of rotation of the articulator as the maxillary teeth relate to the cranial case. With careful bimanual manipulation or the use of an anterior bite stop, a transfer wafer is generated with the condyles fully seated in their glenoid fossa. The maxillary and mandibular teeth of each diagnostic model then relate to one another in centric relation as determined by condylar position. They may reveal an occlusal discrepancy in centric relation, which would require compensation by the patient.[10,42]

comprehensive treatment plan. Patients who require substantial periodontal therapy or who have advanced periodontal disease may be at increased risk for masticatory system disorders, so diagnostic processes must remain consistently thorough and inclusive for all patients.[26,155] For the patient who presents with a symptomatic masticatory system disorder, the diagnostic strategy would logically begin with the inclusion of all potential sources of pain or dysfunction and be followed by the systematic exclusion of possible causative or contributing factors, beginning with the least likely. When no symptoms are reported, the history and clinical examination still need to be thorough, because some patients tend to tolerate modest dysfunction or mild transient discomfort. The diagnostic strategy for the patient who presents with minimal or no signs and symptoms of masticatory system disorders is to attempt to confirm a stable condition while identifying risk factors. The careful documentation of past or current trauma and disharmony provides the basis for the trend analysis and anticipation of possible future problems.[34,35,49,62,73,106,124,129,130,132,173]

Consistent professional maintenance care has been clearly demonstrated to be a key ingredient in the successful management of a patient's periodontal condition.[73,124] By complementing any treatment sequence, these appointments afford dentists the opportunity at every stage of comprehensive care to provide continuing evaluation of the status of the entire masticatory system and to provide timely and appropriate intervention when needed (see Chapter 49).

Acknowledgments

I would like to acknowledge the encouragement and the recommendation of references provided by Dr. Henry Gremillion during the revision of this chapter.

Suggested Readings

Carra MC, Huynh N, Lavigne G: Sleep bruxism: a comprehensive overview for the clinician interested in sleep medicine. *Dent Clin North Am* 56:387, 2012.

Dawson PE: *Functional occlusion from TMJ to smile design*, St. Louis, 2007, Mosby.

Glaros AG, Williams K, Lausten L: The role of parafunctions, emotions and stress in predicting facial pain. *J Am Dent Assoc* 136:451, 2005.

Gremillion HA: TMD and maladaptive occlusion: does a link exist? *Cranio* 13:205, 1995.

Jacobs R, van Steenberghe D: Role of periodontal ligament receptors in the tactile function of teeth: a review. *J Periodont Res* 29:153, 1994.

Lavigne GJ, Khoury S, Abe S, et al: Bruxism physiology and pathology: an overview for clinicians. *J Oral Rehabil* 35:476, 2008.

Lewis EL, Dolwick MF, Abramowicz S, et al: Contemporary imaging of the temporomandibular joint. *Dent Clin N Am* 52:875, 2008.

Magnusson T, Egermark I, Carlsson GE: A prospective investigation over two decades on signs and symptoms of temporomandibular disorders and associated variables. A final summary. *Acta Odontol Scand* 63:99, 2005.

Okeson JP: *Orofacial pain: guidelines for assessment, diagnosis, and management*, Carol Stream, IL, 1996, Quintessence.

Okeson JP: *Management of temporomandibular joint disorders and occlusion*, ed 4, St Louis, 1998, Mosby.

References

References for this chapter are found on the companion website www.expertconsult.com.

References

1. Al-Hadi LA: Prevalence of temporomandibular disorders in relation to some occlusal parameters. *J Prosthet Dent* 70:345, 1993.
2. Allen EP, Bayne SC, Becker IM, et al: Annual review of selected dental literature: report of the Committee of Scientific Investigation of the American Academy of Restorative Dentistry. *J Prosthet Dent* 82:39, 1999.
3. Atwood MJ, Dixon DC, Talcott GW, et al: Comparison of two scales in the assessment of muscle and joint palpation tenderness in chronic temporomandibular disorders. *J Orofac Pain* 7:403, 1993.
4. Austin DG: Special considerations in orofacial pain and headache. *Dent Clin North Am* 41:325, 1997.
5. Auvenshine RC: Psychoneuroimmunology and its relationship to the differential diagnosis of temporomandibular disorders. *Dent Clin North Am* 41:279, 1997.
6. Aziz MA, Cowie RJ, Skinner CE, et al: Are the two heads of the human lateral pterygoid separate muscles? A perspective based on their nerve supply. *J Orofac Pain* 12:226, 1998.
7. Bade DM, Lovasko JH, Dimitroff M, et al: Clinical comparison of temporomandibular joint sound auscultation and emission imaging studies. *J Orofac Pain* 8:55, 1994.
8. Bailey DB: Sleep disorders. Overview and relationship to orofacial pain. *Dent Clin North Am* 41:189, 1997.
9. Bates RE, Gremillion HA, Stewart CM: Degenerative joint disease. Part II. Symptoms and examination findings. *Cranio* 12:88, 1994.
10. Becker IM, Tarantola GJ: *Parameters of care: temporomandibular disorders*, Key Biscayne, FL, 1994, Pankey Institute of Advanced Dental Education.
11. Becker I, Tarantola G, Zambrano J, et al: Effect of a prefabricated anterior bite stop on electromyographic activity of masticatory muscles. *J Prosthet Dent* 82:22, 1999.
12. Ben Amor F, Carpentier P, Foucart JM, et al: Anatomic and mechanical properties of the lateral disc attachment of the temporomandibular joint. *J Oral Maxillofac Surg* 56:1164, 1998.
13. Benoliel R, Eliav E, Elishoov H, et al: Diagnosis and treatment of persistent pain after trauma to the head and neck. *J Oral Maxillofac Surg* 52:1138, 1994.
14. Bergdahl J, Anneroth G, Anneroth I: Clinical study of patients with burning mouth. *Scand J Dent Res* 102:229, 1994.
15. Bertilsson O, Ström D: A literature survey of a hundred years of anatomic and functional lateral pterygoid muscle research. *J Orofac Pain* 9:17, 1995.
16. Bjorne A, Agerberg G: Craniomandibular disorders in patients with Ménière's disease: a controlled study. *J Orofac Pain* 10:28, 1996.
17. Bouquot J, Roberts A: NICO (neuralgia-inducing cavitational osteonecrosis): radiographic appearance of the "invisible" osteomyelitis. *Oral Surg* 74:600, 1992.
18. Bouquot JE, Roberts AM, Person P, et al: NICO (neuralgia-inducing cavitational osteonecrosis): osteomyelitis in 224 jawbone samples from patients with facial neuralgias. *Oral Surg* 73:307, 1992.
19. Brooks SL, Brand JW, Gibbs SJ, et al: Imaging of the temporomandibular joint: a position paper of the American Academy of Oral and Maxillofacial Radiology. *Oral Surg Oral Med Oral Pathol Oral Radiol Endod* 83:609, 1997.
20. Burgess JA, Kolbinson DA, Lee PT, et al: Motor vehicle accidents and TMDs: assessing the relationship. *J Am Dent Assoc* 127:1767, 1996.
21. Bush FM, Harkins SW: Pain-related limitation in activities of daily living in patients with chronic orofacial pain: psychometric properties of a disability index. *J Orofac Pain* 9:57, 1995.
22. Bush FM, Harkins SW, Harrington WG: Otalgia and aversive symptoms in temporomandibular disorders. *Ann Otol Rhinol Laryngol* 108:884, 1999.
23. Byers MR, Dong WK: Comparison of trigeminal receptor location and structure in the periodontal ligament of different types of teeth from the rat, cat, and monkey. *J Comp Neurol* 279:117, 1989.
24. Carlsson GA, Egermark I, Magnusson T: Predictors of signs and symptoms of temporomandibular disorders: a 20-year follow-up study form childhood to adulthood. *Acta Odontol Scand* 60:180, 2002.
25. Carra MC, Huynh N, Lavigne G: Sleep bruxism: a comprehensive overview for the clinician interested in sleep medicine. *Dent Clin North Am* 56:387, 2012.
26. Carranza FA, Newman MG: *Clinical periodontology*, ed 8, Philadelphia, 1996, Saunders.
27. Cathelineau G, Yardin M: The relationship between tooth vibratory sensation and periodontal disease. *J Periodontol* 53:704, 1982.
28. Chan SWY, Reade PC: Tinnitus and temporomandibular pain-dysfunction disorder. *Clin Otolaryngol* 19:370, 1994.
29. Chole RA, Parker WS: Tinnitus and vertigo in patients with temporomandibular disorder. *Arch Otolaryngol Head Neck Surg* 118:817, 1992.
30. Christensen GJ: Abnormal occlusal conditions: a forgotten part of dentistry. *J Am Dent Assoc* 126:1667, 1995.
31. Christensen GJ: Treating bruxism and clenching. *J Am Dent Assoc* 131:233, 2000.
32. Christensen LV, Rassouli NM: Experimental occlusal interferences. Part I. A review. *J Oral Rehabil* 22:515, 1995.
33. Christensen LV, Rassouli NM: Experimental occlusal interferences. Part V. Mandibular rotations versus hemimandibular translations. *J Oral Rehabil* 22:865, 1995.
34. Christensen LV, McKay DC: TMD diagnostic decision-making and probability theory. Part I. *Cranio* 14:240, 1996.
35. Christensen LV, McKay DC: TMD diagnostic decision-making and probability theory. Part II. *Cranio* 14:312, 1996.
36. Clark GT, Ram S: Four oral motor disorders: bruxism, dystonia, dyskinesia and drug-induced dystonic extrapyramidal reactions. *Dent Clin North Am* 51:225, 2007.
37. Clark GT, Tsukiyama Y, Baba K, et al: Sixty-eight years of experimental occlusal interference studies: what have we learned? *J Prosthet Dent* 82:704, 1999.
38. Ciancaglini R, Loreti P, Radaelli G: Ear, nose, and throat symptoms in patients with TMD: the association of symptoms according to severity of arthropathy. *J Orofac Pain* 8:293, 1994.
39. Coffey JP, Williams WN, Turner GE, et al: Human bite force discrimination using specific maxillary and mandibular teeth. *J Oral Rehabil* 16:529, 1989.
40. Cooper BC, Cooper DL: Recognizing otolaryngologic symptoms in patients with temporomandibular disorders. *Cranio* 11:260, 1993.
41. Dao TTT, Reynolds WJ, Tenenbaum HC: Comorbidity between myofascial pain of the masticatory muscle and fibromyalgia. *J Orofac Pain* 11:232, 1997.
42. Dawson PE: *Evaluation, diagnosis, and treatment of occlusal problems*, ed 2, St Louis, 1989, Mosby.
43. Dawson PE: *Functional occlusion from TMJ to smile design*, St Louis, 2007, Mosby.
44. Dawson PE: New definition for relating occlusion to varying conditions of the temporomandibular joint. *J Prosthet Dent* 74:619, 1995.
45. Dawson PE: A classification system that relates maximal intercuspation to the position and condition of the temporomandibular joint. *J Prosthet Dent* 75:60, 1996.
46. de Almdeida FR, Lowe AA, Tsuiki S, et al: Long-term compliance and side effects of oral appliances used for treatment of snoring and obstructive sleep apnea syndrome. *J Clin Sleep Med* 15:143, 2005.
47. De Boever JA, Keersmaeker K: Trauma in patients with temporomandibular disorders: frequency and treatment outcomes. *J Oral Rehabil* 23:91, 1996.
48. De Bont LGM, Stengenga B: Pathology of temporomandibular joint internal derangement and osteoarthrosis. *Int J Oral Maxillofac Surg* 22:71, 1993.
49. De Wijer A, Lobbezoo-Scholte AM, Steenks MH, et al: Reliability of clinical findings in temporomandibular disorders. *J Orofac Pain* 9:181, 1995.
50. Dimitroulis G, Dolwick MF, Gremillion HA: Temporomandibular disorders. 1. Clinical evaluation. *Aust Dent J* 40:301, 1995.
51. Doff MH, Veldhuis SK, Hoekema A, et al: Long-term oral appliance therapy in obstructive sleep apnea syndrome: a controlled study on temporomandibular side effects. *Clin Oral Investig* 16:689, 2012.

52. Donaldson KW: Rheumatoid diseases and the temporomandibular joint: a review. *Cranio* 13:264, 1995.
53. Dong WK, Shiwaku T, Kawakami Y, et al: Static and dynamic responses of periodontal ligament mechanoreceptors and intradental mechanoreceptors. *J Neurophysiol* 69:1567, 1993.
54. Ehrlich R, Garlick D, Ninio M: The effect of jaw clenching on the electromyographic activities of 2 neck and 2 trunk muscles. *J Orofac Pain* 13:115, 1999.
55. Fernandes G, Franco AL, Siqueira JT, et al: Sleep bruxism increases the risk for painful temporomandibular disorder, depression and nonspecific physical symptoms. *J Oral Rehabil* 39:538, 2012.
56. Ferrario VF, Sforza C, Sigurta D, et al: Temporomandibular joint dysfunction and flat lateral guidances: a clinical association. *J Prosthet Dent* 75:534, 1996.
57. Ferrario VF, Sforza C, Colombo A, et al: An electromyographic investigation of masticatory muscle symmetry in normo-occlusion subjects. *J Oral Rehabil* 27:33, 2000.
58. Fu K, Ma X, Zhang Z, et al: Interleukin-6 in synovial fluid and HLA-DR expression in synovium from patients with temporomandibular disorders. *J Orofac Pain* 9:131, 1995.
59. Gagnon Y, Mayer P, Morrison F, et al: Aggravation of respiratory disturbances by the use of an occlusal splint in apneic patients: a pilot study. *Int J Prosthodont* 17:447, 2004.
60. Gelb H, Gelb ML, Wagner ML: The relationship of tinnitus to craniocervical mandibular disorders. *Cranio* 15:136, 1997.
61. Glaros AG, Baharloo L, Glass EG: Effect of parafunctional clenching and estrogen on temporomandibular disorder pain. *Cranio* 16:78, 1998.
62. Glaros AG, Glass EG, Williams KB: Clinical examination findings of temporomandibular disorder patients: a factor analytic study. *J Orofac Pain* 12:193, 1998.
63. Glaros AG, Tabacchi KN, Glass EG: Effect of parafunctional clenching on TMD pain. *J Orofac Pain* 12:145, 1998.
64. Glaros AG, Williams K, Lausten L: The role of parafunctions, emotions and stress in predicting facial pain. *J Am Dent Assoc* 136:451, 2005.
65. Goupille P, Fouquet B, Goga D, et al: The temporomandibular joint in rheumatoid arthritis: correlations between clinical and tomographic features. *J Dent* 21:141, 1993.
66. Gremillion HA: TMD and maladaptive occlusion: does a link exist? *Cranio* 13:205, 1995.
67. Gynther GW, Holmlund AB, Reinholt FP, et al: Temporomandibular joint involvement in generalized osteoarthritis and rheumatoid arthritis: a clinical, arthroscopic, histologic, and immunohistochemical study. *Int J Oral Maxillofac Surg* 26:10, 1997.
68. Harper RP, Schneiderman E: Condylar movement and centric relation in patients with internal derangement of the temporomandibular joint. *J Prosthet Dent* 75:67, 1996.
69. Haskin CL, Milam SB, Cameron IL: Pathogenesis of degenerative joint disease in the human temporomandibular joint. *Crit Rev Oral Biol Med* 6:248, 1995.
70. Heir GM: Differentiation of orofacial pain related to Lyme disease from other dental and facial pain disorders. *Dent Clin North Am* 41:243, 1997.
71. Hickman DM, Cramer R: The effect of different condylar positions on masticatory muscle electromyography activity in humans. *Oral Surg Oral Med Oral Pathol Radiol Endod* 85:18, 1998.
72. Hintze H, Weise M, Wenzel A: Cone beam CT and conventional tomography for the detection of morphological temporomandibular joint changes. *Dentomaxillofac Radiol* 36:192, 2007.
73. Hirschfield L, Wasserman B: A long-term survey of tooth loss in 600 treated periodontal patients. *J Periodontol* 49:225, 1978.
74. Hochstedler JL, Allen JD, Follmar MA: Temporomandibular joint range of motion: a ratio of interincisal opening to excursive movement in a healthy population. *Cranio* 14:296, 1996.
75. Honey OB, Scarfe WC, Hilgers MJ, et al: Accuracy of cone-beam computed tomography imaging of the temporomandibular joint: comparisons with panoramic radiology and linear tomography. *Am J Orthod Dentofacial Orthop* 132:429, 2007.
76. Huntley TA, Wiesenfeld D: Delayed diagnosis of the cause of facial pain in patients with neoplastic disease: a report of eight cases. *J Oral Maxillofac Surg* 52:81, 1994.
77. Ingervall B, Hähner R, Kessi S: Pattern of tooth contacts in eccentric mandibular positions in young adults. *J Prosthet Dent* 66:169, 1991.
78. Isberg A, Westesson PL: Steepness of articular eminence and movement of the condyle and disk in asymptomatic temporomandibular joints. *Oral Surg Oral Med Oral Pathol Oral Radiol Endod* 86:152, 1998.
79. Israel HA, Diamond B, Saed-Nejad F, et al: Osteoarthritis and synovitis as major pathoses of the temporomandibular joint: comparison of clinical diagnosis with arthroscopic morphology. *J Oral Maxillofac Surg* 56:1023, 1998.
80. Ito T, Gibbs CH, Marguelles-Bonnet R, et al: Loading on the temporomandibular joints with five occlusal conditions. *J Prosthet Dent* 56:478, 1986.
81. Jacobs R, van Steenberghe D: Role of periodontal ligament receptors in the tactile function of teeth: a review. *J Periodont Res* 29:153, 1994.
82. Kahn J, Tallents RH, Katzberg RW, et al: Association between dental occlusal variables and intraarticular temporomandibular joint disorders: horizontal and vertical overlap. *J Prosthet Dent* 79:658, 1998.
83. Kampe T, Tagdae T, Bader G, et al: Reported symptoms and clinical findings in a group of subjects with longstanding bruxing behavior. *J Oral Rehabil* 24:581, 1997.
84. Kaplan AS, Assaed LA: *Temporomandibular disorders: diagnosis and treatment*, Philadelphia, 1991, Saunders.
85. Kato T, Rompre P, Montplaisir JY, et al: Sleep bruxism: an oromotor activity secondary to micro-arousal. *J Dent Res* 80:1940, 2001.
86. Kato T, Thie NMR, Huynh N, et al: Topical review: sleep bruxism and the role of peripheral sensory influences. *J Orofac Pain* 17:191, 2003.
87. Katz MA: Approach to the management of nonmalignant pain. *Am J Med* 101(Suppl 1A):54S, 1996.
88. Katzberg RW, Westesson P: *Diagnosis of the temporomandibular joint*, Philadelphia, 1993, Saunders.
89. Keersmaeker K, De Boever JA, van Den Berghe L: Otalgia in patients with temporomandibular joint disorders. *J Prosthet Dent* 75:72, 1996.
90. Kenworthy CR, Morrish RB, Mohn C, et al: Bilateral condylar movement patterns in adult subjects. *J Orofac Pain* 11:328, 1997.
91. Kerstein RB: Disclusion time measurement studies: a comparison of disclusion time between chronic myofascial pain dysfunction patients and nonpatients: a population analysis. *J Prosthet Dent* 72:473, 1994.
92. Kerstein R: Disclusion time measurement studies: stability of disclusion time—a 1-year follow-up. *J Prosthet Dent* 72:164, 1994.
93. Kleinegger CL, Lilly GE: Cranial arteritis: a medical emergency with orofacial manifestations. *J Am Dent Assoc* 130:1203, 1999.
94. Kelmetti E, Vainio P, Kroger H: Craniomandibular disorders and skeletal mineral status. *Cranio* 13:89, 1995.
95. Koh ET, Yap AU, Koh CK, et al: Temporomandibular disorders in rheumatoid arthritis. *J Rheumatol* 26:1918, 1999.
96. Könönen M, Wenneberg B, Kallenberg A: Craniomandibular disorders in rheumatoid arthritis, psoriatic arthritis, and ankylosing spondylitis: a clinical study. *Acta Odontol Scand* 50:281, 1992.
97. Kopp S: The influence of neuropeptides, serotonin, and interleukin 1B on temporomandibular joint pain and inflammation. *J Oral Maxillofac Surg* 56:189, 1998.
98. Kuboki T, Azuma Y, Orsini MG, et al: Effects of sustained unilateral molar clenching on the temporomandibular joint space. *Oral Surg Oral Med Oral Pathol Oral Radiol Endod* 82:616, 1996.
99. Kubota E, Kubota T, Matsumoto J, et al: Synovial fluid cytokines and proteinases as markers of temporomandibular joint disease. *J Oral Maxillofac Surg* 56:192, 1998.
100. Kumar KL, Cooney TG: Headaches. *Med Clin North Am* 79:261, 1995.
101. Kurita H, Ikeda K, Kurashina K: Evaluation of the effect of a stabilization splint on occlusal force in patient occlusions with masticatory muscle disorders. *J Oral Rehabil* 27:79, 2000.
102. Larheim TA: Current trends in temporomandibular joint imaging. *Oral Surg Oral Med Oral Pathol Oral Radiol Endod* 80:555, 1995.

103. Lavigne GJ, Kato T, Koltra A, et al: Neurobiological mechanisms involved in sleep bruxism. *Crit Rev Oral Biol Med* 14:30, 2003.
104. Lavigne GJ, Khoury S, Abe S, et al: Bruxism physiology and pathology: an overview for clinicians. *J Oral Rehabil* 35:476, 2008.
105. Lavigne G, Kim JS, Valiquette C, et al: Evidence that periodontal pressoreceptors provide positive feedback to jaw closing muscles during mastication. *J Neurophysiol* 58:342, 1987.
106. Levitt SR, McKinney MW: Appropriate use of predictive values in clinical decision making and evaluating diagnostic tests for TMD. *J Orofac Pain* 8:298, 1994.
107. Levitt SR, McKinney MW: Validating the TMJ scale in the national sample of 10,000 patients: demographic and epidemiologic characteristics. *J Orofac Pain* 8:25, 1994.
108. Lewis EL, Dolwick MF, Abramowicz S, et al: Contemporary imaging of the temporomandibular joint. *Dent Clin North Am* 52:875, 2008.
109. Lindauer SJ, Sabol G, Isaccson RJ, et al: Condylar movement and mandibular rotation during jaw opening. *Am J Orthod Dentofacial Orthop* 107:573, 1995.
110. Lipton JA, Ship JA, Larach-Robinson D: Estimated prevalence and distribution of reported orofacial pain in the United States. *J Am Dent Assoc* 124:115, 1993.
111. Liu ZJ, Yamagata K, Kashara Y, et al: Electromyographic examination of jaw muscles in relation to symptoms and occlusion of patients with temporomandibular joint disorders. *J Oral Rehabil* 26:33, 1999.
112. Lobbezoo F, Lavigne GJ: Do bruxism and temporomandibular disorders have a cause-and-effect relationship? *J Orofac Pain* 11:15, 1997.
113. Lobbezoo F, Naeije M: Bruxism is regulated centrally not peripherally. *J Oral Rehabil* 28:1085, 2001.
114. Locher MC, Felder M, Sailer HF: Involvement of the temporomandibular joints in ankylosing spondylitis (Bechterew's disease). *J Craniomaxillofac Surg* 24:205, 1996.
115. Louca C, Cadden SW, Linden RWA: The roles of periodontal ligament mechanoreceptors in the reflex control of human jaw-closing muscles. *Brain Res* 731:63, 1996.
116. Loughner BA, Gremillion HA, Larkin LH, et al: Muscle attachment to the lateral aspect of the articular disc of the human temporomandibular joint. *Oral Surg Oral Med Oral Pathol Oral Radiol Endod* 82:139, 1996.
117. Lyssy KJ, Escalante A: Perioperative management of rheumatoid arthritis: areas of concern for primary care physicians. *Postgrad Med* 99:191, 1996.
118. Magnusson T, Egermark I, Carlsson GE: A prospective investigation over two decades on signs and symptoms of temporomandibular disorders and associated variables. A final summary. *Acta Odontol Scand* 63:99, 2005.
119. Maixner W, Fillingham R, Kincaid S, et al: Relationship between pain sensitivity and resting arterial blood pressure in patients with painful temporomandibular disorders. *Psychosom Med* 59:503, 1997.
120. Major P, Ramos-Remus C, Suarez-Almazor ME, et al: Magnetic resonance imaging and clinical assessment of temporomandibular joint pathology in ankylosing spondylitis. *J Rheumatol* 26:616, 1999.
121. Marbach JL: Is phantom tooth pain a deafferentation (neuropathic) syndrome? *Oral Surg Oral Med Oral Pathol* 75:225, 1993.
122. Marbach JL: Orofacial phantom pain: theory and phenomenology. *J Am Dent Assoc* 127:221, 1996.
123. Marbach JJ: Medically unexplained chronic orofacial pain: temporomandibular pain and dysfunction syndrome, orofacial phantom pain, burning mouth syndrome, and trigeminal neuralgia. *Med Clin North Am* 83:691, 1999.
124. McGuire MK, Nunn ME: Prognosis versus actual outcome: a long-term survey of 100 treated periodontal patients under maintenance care. *J Periodontol* 62:51, 1991.
125. Merida-Velasco JR, Rodriguez-Vazquez JF, Jimenez-Collado J: The relationships between the temporomandibular joint disc and related masticatory muscles in humans. *J Oral Maxillofac Surg* 51:390, 1993.
126. Milam SB, Schmitz JP: Molecular biology of temporomandibular joint disorders: proposed mechanisms of disease. *J Oral Maxillofac Surg* 53:1448, 1995.
127. Milam SB, Zardeneta G, Schmitz JP: Oxidative stress and degenerative temporomandibular joint disease: a proposed hypothesis. *J Oral Maxillofac Surg* 56:214, 1998.
128. Minagi S, Ohtsuki H, Sato T, et al: Effect of balancing-side occlusion on the ipsilateral TMJ dynamics under clenching. *J Oral Rehabil* 24:57, 1997.
129. Mohl ND: Reliability and validity of diagnostic modalities for temporomandibular disorders. *Adv Dent Res* 7:113, 1993.
130. Mohl ND, Ohrbach R: Clinical decision making for temporomandibular disorders. *J Dent Educ* 56:823, 1992.
131. Morgan DH, Goode RL, Christiansen RL, et al: The TMJ-ear connection. *Cranio* 13:42, 1995.
132. Moses AJ: Scientific methodology in temporomandibular disorders. Part I. Epidemiology. *Cranio* 12:114, 1994.
133. Murakami K, Kubota E, Maeda H, et al: Intraarticular levels of prostaglandin E2, hyaluronic acid, and chrondroitin-4 and -6 sulfates in the temporomandibular joint synovial fluid of patients with internal derangements. *J Oral Maxillofac Surg* 56:199, 1998.
134. Murray H, Locker D, Mock D, et al: Pain and the quality of life in patients referred to a craniofacial pain unit. *J Orofac Pain* 10:316, 1996.
135. Neff PA: *TMJ occlusion and function*, Washington, DC, 1975, Georgetown University School of Dentistry.
136. Okeson JP: *Orofacial pain: guidelines for assessment, diagnosis, and management*, Carol Stream, IL, 1996, Quintessence.
137. Okeson JP: *Management of temporomandibular joint disorders and occlusion*, ed 4, St Louis, 1998, Mosby.
138. Parker MW: The significance of occlusion in restorative dentistry. *Dent Clin North Am* 37:341, 1993.
139. Parker WS, Chole RA: Tinnitus, vertigo, and temporomandibular disorders. *Am J Orthod Dentofacial Orthop* 107:153, 1995.
140. Pavone BW: Bruxism and its effect on the natural teeth. *J Prosthet Dent* 53:692, 1985.
141. Pereira FL, Lundh H, Eriksson L, et al: Microscopic changes in the retrodiscal tissues of painful temporomandibular joints. *J Oral Maxillofac Surg* 54:461, 1996.
142. Pertes RA: Differential diagnosis of orofacial pain. *Mt Sinai J Med* 65:348, 1998.
143. Pharoah MJ: The prescription of diagnostic images for temporomandibular joint disorders. *J Orofac Pain* 13:251, 1999.
144. Pleash O, Wolfe F, Lane N: The relationship between fibromyalgia and temporomandibular disorders: prevalence and symptom severity. *J Rheumatol* 23:1948, 1996.
145. Pullinger AG, Seligman DA: The degree to which attrition characterizes differentiated patient groups of temporomandibular disorders. *J Orofac Pain* 7:196, 1993.
146. Pullinger AG, Seligman DA: Quantification and validation of predictive values of occlusal variables in temporomandibular disorders using multifactorial analysis. *J Prosthet Dent* 83:66, 2000.
147. Pullinger AG, Seligman DA, Gornbein JA: A multiple logistic regression analysis of the risk and relative odds of temporomandibular disorders as a function of common occlusal features. *J Dent Res* 72:968, 1993.
148. Rammelsberg P, Pospiech PR, Jäger L, et al: Variability of disc position in asymptomatic volunteers and patients with internal derangements of the TMJ. *Oral Surg Oral Med Oral Pathol Oral Radiol Endod* 83:393, 1997.
149. Raphael KG, Marbach JJ, Klausner J: Myofascial face pain: clinical characteristics of those with regional versus widespread pain. *J Am Dent Assoc* 131:161, 2000.
150. Rassouli NM, Christensen LV: Experimental occlusal interferences. Part III. Mandibular rotations induced by a rigid interference. *J Oral Rehabil* 22:781, 1995.
151. Ratcliffe A, Israel H, Saed-Nejad F, et al: Proteoglycans in the synovial fluid of the temporomandibular joint as an indicator of changes in cartilage metabolism during primary and secondary osteoarthritis. *J Oral Maxillofac Surg* 56:204, 1998.
152. Raustia AM, Pirttiniemi PM, Pyhtinen J: Correlation of occlusal factors and condyle position asymmetry with signs and symptoms of temporomandibular disorders in young adults. *Cranio* 13:152, 1995.

153. Ren Y, Isberg A: Tinnitus in patients with temporomandibular joint internal derangement. *Cranio* 13:75, 1995.
154. Rodriguez-Vazquez JF, Merida-Velasco JR, Merida-Velasco JA, et al: Anatomical considerations on the discomalleolar ligament. *J Anat* 192:617, 1998.
155. Rosenbaum RS: The possible effects of periodontal disease on occlusal function. *Curr Opin Periodontol* 163–169, 1993.
156. Ruf S, Cecere F, Kupfer J, et al: Stress-induced changes in the functional electromyographic activity of the masticatory muscles. *Acta Odontol Scand* 55:44, 1997.
157. Sarnat BG, Laskin DM: *The temporomandibular joint: biologic basis for clinical practice*, ed 4, Philadelphia, 1992, Saunders.
158. Schiffman E, Haley D, Baker C, et al: Diagnostic criteria for screening headache patients for temporomandibular disorders. *Headache* 35:121, 1995.
159. Schiffman EL, Fricton JR, Haley D: The relationship of occlusion, parafunctional habits and recent life events to mandibular dysfunction in a nonpatient population. *J Oral Rehabil* 19:201, 1992.
160. Schindler JH, Stengel E, Spiess WE: Feedback control during mastication of solid food textures: a clinical-experimental study. *J Prosthet Dent* 80:330, 1998.
161. Schmolke C: The relationship between the temporomandibular joint capsule, articular disc, and jaw muscles. *J Anat* 184:335, 1994.
162. Sessle BJ: The neural basis of the temporomandibular joint and masticatory muscle pain. *J Orofac Pain* 13:238, 1999.
163. Shibata T, Murakami K, Kubota E, et al: Glycosaminoglycan components in temporomandibular joint synovial fluid as markers of joint pathology. *J Oral Maxillofac Surg* 56:209, 1998.
164. Simons DG, Travell JG, Simons LS: *Myofascial pain and dysfunction: the trigger point manual*, Baltimore, 1999, Williams & Wilkins.
165. Smith MT, Wickwire EM, Grace EG, et al: Sleep disorders and their association with laboratory pain sensitivity in temporomandibular joint disorder. *Sleep* 32:779, 2009.
166. Stegenga B, de Bont LGM, de Leeuw R, et al: Assessment of mandibular function impairment associated with temporomandibular joint osteoarthrosis and internal derangement. *J Orofac Pain* 7:183, 1993.
167. Stratmann U, Mokyrs K, Meyer U, et al: Clinical anatomy and palpability of the inferior lateral pterygoid muscle. *J Prosthet Dent* 83:548, 2000.
168. Suvinen TI, Reade PC: Temporomandibular disorders: a critical review of the nature of pain and its assessment. *J Orofacial Pain* 9:317, 1995.
169. Svensson P, Jadidi F, Arima T, et al: Relationships between craniofacial pain and bruxism. *J Oral Rehabil* 35:524, 2008.
170. Taddey JJ: Musicians and temporomandibular disorders: prevalence and occupational etiologic considerations. *Cranio* 10:241, 1992.
171. Tanne K, Tanaka E, Sakuda M: Association between malocclusion and temporomandibular disorders in orthodontic patients before treatment. *J Orofacial Pain* 7:156, 1993.
172. Tarantola GJ, Becker IM, Gremillion H: The reproducibility of centric relation: a clinical approach. *J Am Dent Assoc* 128:1245, 1997.
173. Tasaki MM, Westesson P, Isberg AM, et al: Classification and prevalence of temporomandibular joint disc displacement in patients and symptom-free volunteers. *Am J Orthod Dentofacial Orthop* 109:249, 1996.
174. Tenenbaum HC, Freeman BV, Psutka DJ, et al: Temporomandibular disorders: disc displacements. *J Orofac Pain* 13:285, 1999.
175. Tsolka P, Walter JD, Wilson RF, et al: Occlusal variables, bruxism and temporomandibular disorders: a clinical and kinesiographic assessment. *J Oral Rehabil* 22:849, 1995.
176. Turp JG, Gobetti JP: Trigeminal neuralgia: an update. *Compendium* 21:279, 2000.
177. van Selms MKA, Lobbezoo F, Visscher CM, et al: Myofascial temporomandibular disorder pain, parafunctions and psychological stress. *J Oral Rehabil* 35:45, 2008.
178. van Selms MKA, Lobbezoo F, Wicks DJ, et al: Craniomandibular pain, oral parafunctions and psychological stress in a longitudinal case study. *J Oral Rehabil* 31:738, 2004.
179. Wabeke KB, Spruijt RJ, van der Zaag J: The reliability of clinical methods for recording temporomandibular joint sounds. *J Dent Res* 73:1157, 1994.
180. Watanabe EK, Yatani H, Kuboki T, et al: The relationship between signs and symptoms of temporomandibular disorders and bilateral occlusal contact patterns in lateral excursions. *J Oral Rehabil* 25:409, 1998.
181. Wilkinson TM, Crowley CM: A histologic study of retrodiscal tissues of the human temporomandibular joint in the open and closed position. *J Orofac Pain* 8:7, 1994.
182. Williamson EH, Ludquist DO: Anterior guidance: its effect on electromyographic activity of the temporal and masseter muscles. *J Prosthet Dent* 49:816, 1983.
183. Wish-Baratz S, Ring GD, Hiss J, et al: The microscopic structure and function of the vascular retrodiscal pad of the human temporomandibular joint. *Arch Oral Biol* 38:265, 1993.
184. Wright EF, Bifano SL: Tinnitus improvement through TMD therapy. *J Am Dent Assoc* 128:1424, 1997.
185. Wright EF, Gullickson DC: Identifying acute pulpalgia as a factor in TMD pain. *J Am Dent Assoc* 127:773, 1996.
186. Zarb GA, Carlsson GE, Sessle BJ, et al: *Temporomandibular joint and masticatory muscle disorders*, St Louis, 1994, Mosby.
187. Zarb GA, Carlsson GE: Temporomandibular disorders: osteoarthritis. *J Orofac Pain* 13:295, 1999.
188. Zimers PL, Gobetti JP: Head and neck lesions commonly found in musicians. *J Am Dent Assoc* 125:1487, 1994.

CHAPTER 28

Sleep-Disordered Breathing

Adrian Zacher and Michael McDevitt

CHAPTER OUTLINE

A New and Evolving Role for the Dentist
Sleep-Related Breathing Disorders and the Periodontium
Dental Identification of Signs and Symptoms
Sleep, Breathing, and Apnea
Diagnosis of Obstructive Sleep Apnea
Treatment Options for Obstructive Sleep Apnea
Oral Devices (Mandibular Repositioning Devices)
Device Design and Compliance *(e-only)*
Conclusions
Glossary *(e-only)*

For an expanded discussion of the diagnosis of obstructive sleep apnea as well as online-only content about device design and compliance, please visit the companion website at www.expertconsult.com.

A New and Evolving Role for the Dentist

Everyone sleeps, and no one thinks much about sleep until something goes wrong. When sleep does go wrong—and it can, in many ways—the effects can be more than just feeling a little tired in the morning. This chapter explores the exciting and evolving role of the dentist with an interest in sleep-disordered breathing (SDB): helping patients to breathe, sleep, and ultimately function better each day.

Snoring and sleep apnea (*apnea* means cessation of breathing) are points along a spectrum that extends from benign or simple snoring with no sleep disturbance to obstructive sleep apnea (OSA) with excessive daytime sleepiness and the physiologic consequences of recurrent asphyxia.[21] Over the years, there have been many dubious claims made regarding snoring cures. However, our knowledge has now greatly improved,[13] and much can be done to manage OSA and its associated consequences. It is in the provision of oral devices for OSA that a key role for suitably trained dentists is developing.

Sleep apnea can be caused by a lack of central drive to breathe. Later in this chapter is an overview of the less common types of apnea: central, mixed, and complex.

Professor Colin Sullivan was the inventor of the mainstay therapy for sleep apnea: positive airway pressure (PAP) therapy. He was also an internationally renowned key opinion leader, and he advocated[5] for dentists, as part of a multidisciplinary team, to play a critical role in four areas:

1. Treating adults with oral devices for snoring and mild to moderate OSA to slow the progression of the disease
2. Identifying patients at risk (both children and adults) by looking at their upper airways on a regular basis
3. Treating children with rapid maxillary expansion and avoiding deleterious orthodontic treatments
4. Recognizing the need for bimaxillary osteotomy among young adults with a need for maxillofacial correction

Sleep-Related Breathing Disorders and the Periodontium

The prevalence of impaired breathing in patients who are also susceptible to periodontal disease and whose periodontitis experience may be affected by a sleep-related breathing disorder is sufficient to compel dentists and their teams to develop recognition strategies.

Whereas diagnosing OSA is the responsibility of a qualified physician, the dentist is capable of identifying and differentiating clinical signs of possible airway issues, often before the patient becomes suspicious of a potential health risk. Information shared by the patient regarding his or her overall health status should be reviewed and correlated with clinical observations of oral indicators of attempted compensation by the patient for any significant degree of airway obstruction or resistance.

The value of early recognition and intervention cannot be overstated. The growing understanding of the deleterious effects of sleep-related breathing disorders and resultant periods of asphyxia on cardiovascular health, endocrine function, neurologic function, and masticatory system integrity adds to the urgency of dentists including recognition protocols during their initial and recurring evaluations of their patients.

It is important to state that a multidisciplinary team approach[25] that incorporates respect for each team member's professional role is essential for accurate diagnosis and to facilitate the provision of the most appropriate treatment.

The following sections discuss sleep, apnea, and the dentist's role in the provision of oral devices, which is one of the increasingly favored OSA treatment options.

Dental Identification of Signs and Symptoms

Review of Health Status and Systems

The frequency with which dentists see their patients places them in a unique position to recognize the symptoms of OSA. Consequently, at the beginning of every dental appointment, the dentist or a member of the dental team should conduct an effective review and recording of the patient's health status. In addition to addressing specific items that may have been discussed previously, the inclusion of questions about breathing issues may alert the dentist to look for clinical indicators of sleep-related breathing disorders. Conversely, the identification of clinical signs may reframe future discussions of the patient's overall health so as to not overlook possible correlations with observations. For example, snoring or gasping reported to the patient by his or her bed partner may correlate with the unexpected mobility of occluding anterior teeth. Conditions of note reported by a patient would include the following:

- Hypertension
- Gastroesophageal reflux disease
- Excessive daytime sleepiness
- Cardiovascular disease, including arrhythmias
- Type 2 diabetes
- Hypothyroidism
- Obesity
- Sudden onset of snoring
- Awareness of snoring or SDB
- Use of a snore appliance from a dentist or another source

Dental Clinical Signs and Symptoms of Possible Obstructed Breathing

Neither the clinical indicators nor the health or breathing status reported by the patient can define the degree or implications of a sleep-related breathing disorder for the dentist. Developing a list of observations to discuss with the patient may allow the patient to confirm the possibility of a breathing disorder and to communicate these signs to his or her physician for further assessment and diagnosis.

Sleep Bruxism. Although patients are commonly reported to experience both SDB and sleep bruxism, there is currently only a suspected association, because no evidence-based clinical trial has established a specific relationship. The bruxing patient's repeated patterns of mandibular movement are primarily mediated by the central nervous system. It has been hypothesized that the advancement of the mandible opens the oropharynx, which could relieve some of the consequences of SDB.[27,28]

Clinical Signs and Symptoms

- Wear patterns on opposing incisors may suggest that the patient postures the mandible anteriorly to open the airway.[42,43]
- The mobility of the anterior teeth may be in excess of what might be estimated on the basis of the patient's health and the support available from supporting periodontal structures.
- In the periodontitis-susceptible patient, progressive bone loss may be located or exaggerated in sites of unusual wear or mobility. The possible role of occlusal trauma in the amplification of the consequences of periodontitis is described in depth in the online version of Chapter 50 of this edition of this textbook.
- Tongue crenulations (scalloped borders) suggest that the patient is depressing the tongue forward against the mandibular teeth regularly to open their oral airway.
- The development of an anterior or lateral open-bite relationship of the opposing teeth may result from tongue posturing.
- Sleep bruxism may develop or increase.
- The dimpling of the cusps and lingual surfaces of the teeth may be an indicator of related gastroesophageal reflux.
- The development of orofacial pain, temporomandibular joint (TMJ) dysfunction symptoms, masticatory muscle fatigue noted on awakening, or morning headache can be related to the positioning of the mandible to open a person's airway. This topic is addressed in Chapter 27 of this edition of this textbook, where comprehensive diagnostic references can also be found.
- During the evaluation of the oropharynx, prominent tonsils, a large uvula, or a narrow or tongue-obstructed airway may be noted. The patient's age may contribute to the loss of tone of the pharyngeal muscles.
- Evidence of mouth breathing while sleeping may take the form of drying of the surface of the gingiva.

Sleep, Breathing, and Apnea

A basic understanding of sleep physiology, normal sleep cycles, and the variety of sleep disorders will provide the dentist with the means for effective communication with patients and patients' physicians.

Sleep is classically defined as a cyclic, temporary, and physiologic loss of consciousness that is readily, promptly, and completely reversed with appropriate stimuli. Not being able to breathe would seem to qualify as an appropriate stimulus; however, affected individuals are rarely aware of any difficulty.

Normal sleep progresses through different stages that are typically depicted on a hypnogram (Figure 28-1).

Snoring is a vibratory noise that is generated by the back of the relaxed tongue, pharynx, and soft palate. Further loss of tone or narrowing produces not only louder snoring but also labored inspiration. Still further narrowing may cause complete collapse of the airway. This obstruction is known as an *apneic episode.*

There comes a point at which the increased inspiratory effort or the oxygen desaturation that may accompany the apneic episode is sensed by the sleeping brain, and a transient arousal will be provoked. This is a brief awakening to breathe before the individual returns to sleep. These arousals can be seen in Figure 28-2 as decreased-duration periods and increasingly frequent interruptions in the descent into deeper more refreshing sleep. Disregarding complaints about the snoring noise, these repetitive arousals occur for the most part without the individual being aware, sometimes several hundred times a night.

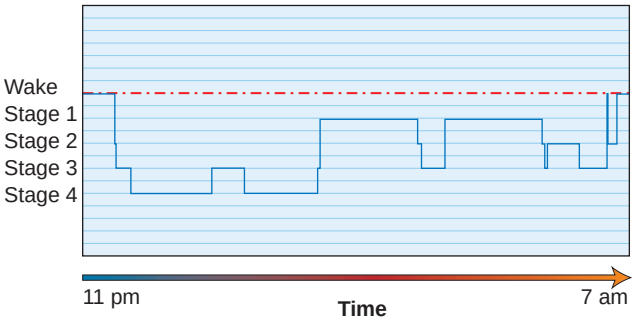

Figure 28-1 Simplified hypnogram of a normal adult's sleep. *(Courtesy Adrian Zacher, 2013, Snorer.com.)*

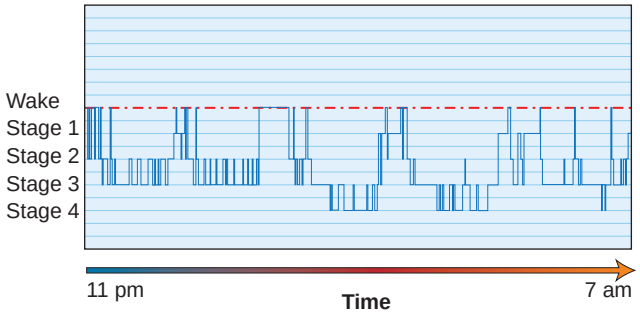

Figure 28-2 Simplified hypnogram of an adult's fragmented sleep. *(Courtesy Adrian Zacher, 2013, Snorer.com.)*

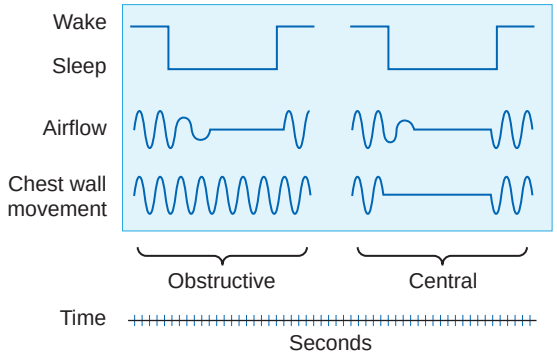

Figure 28-3 Obstructive versus central apnea. *(Courtesy Learning Center, ResMed.)*

Each apneic episode may last from a few seconds to approximately 2 minutes. The individual's descent into the deeper and more restorative slow-wave stages of sleep is interrupted, because he or she has partially awakened to restore the airway. Sleep becomes highly fragmented, and the consequent daytime sleepiness known as *hypersomnolence* increases the individual's risk of accidents at home, at work, and on the road.[50]

OSA has a significant impact on an individual's quality of life.[10] If left untreated, it has neurologic and physiologic consequences,[37] including increased morbidity and mortality[35] and, particularly for men, impaired cardiovascular[51] and metabolic[18] function.

Prevalence of Obstructive Sleep Apnea

Sleep apnea affects a large number of people, but it continues to be largely unrecognized. Estimates suggest that 24% of men and 9% of women who are 30 to 60 years old with an average body mass index of 25 kg/m^2 to 28 kg/m^2 are affected.[49] When considered within the context of the concurrent metabolic dysfunction epidemic (which is manifest in obesity, cardiovascular disease,[31,26] and type 2 diabetes in men[12,40,39]), the prevalence of sleep apnea becomes alarming. Indeed, the International Diabetes Federation urges health care professionals to ensure that a person diagnosed with OSA is considered for the presence of type 2 diabetes and vice versa.[41]

Central, Mixed, and Complex Apnea

In contrast with OSA, central sleep apnea (CSA) occurs without a physical obstruction of the airway. CSA is caused by a group of disorders that are characterized by the intermittent loss of the respiratory drive (in Figure 28-3, note the lack of chest wall movement in the patient with CSA). Cheyne-Stokes respirations as a form of CSA are most often seen in patients with heart failure. Mixed apnea is, as expected, a combination of OSA and CSA. Complex apnea occurs when CSA events emerge in response to PAP therapy for OSA.[17]

This chapter is confined to OSA because it is by far the most common form of apnea, and it is in the provision of oral devices (also known as *mandibular repositioning devices* [MRDs]) for OSA that the suitably trained dentist may play a role.[22]

Chronic Disease

The maintenance of a separate "silo" approach and viewing one aspect of an individual's symptomatology in isolation could be argued to be flawed thinking. OSA in isolation and as a potential component of metabolic syndrome (i.e., syndrome Z[47]) requires a multidisciplinary chronic disease management approach. The World Health Organization[48] states that chronic diseases are projected to be the leading cause of disability; if they are not successfully prevented and managed by 2020, they will become the most expensive problems for health care systems.

Diagnosis of Obstructive Sleep Apnea

Snoring is a symptom of a partially impeded airway, the walls of which are vibrating as the air passes. Simplistically, how frequently the walls of the airway vibrate (i.e., snoring noise) or collapse (i.e., apnea events of varying duration) indicates the severity of the OSA.

As mentioned at the beginning of this chapter, a multidisciplinary team approach for the diagnosis and treatment of OSA is necessary. Dentists are experts when it comes to mouths and should be recognized as such. For OSA treatment, dentists need to build relationships with physicians so that they may, when appropriate, provide a dental solution to a medical condition; however, it is important to recognize that the diagnosis of OSA is not within the purview of dentistry.[7]

Treatment Options for Obstructive Sleep Apnea

Otolaryngology or Oromaxillofacial Surgery

Surgical options for snoring and OSA are largely outside of the scope of this text. However, it is important to note that, when physical obstructions to the airway are present (e.g., tonsils, deviated septum, nasal polyps) surgical correction may improve breathing. For example, if adenotonsillar hypertrophy exists, then childhood correction is considered advantageous.[30]

Limited evidence for adult palatal surgery, which is known as *uvulopalatopharyngoplasty,* exists; this surgery should be considered only after PAP therapy has failed.[6] Maxillary or bimaxillary orthognathic surgery is rarely considered, whereas tracheotomy is an effective option of last resort, because it completely bypasses the affected area.

Positive Airway Pressure

PAP (Figure 28-6) is considered the first-line treatment for OSA, and it is very effective in terms of helping the patient to overcome daytime sleepiness symptoms. Individuals with severe sleep apnea do well with this therapy, despite the forbidding appearance. Possibly considered an arduous therapy, it involves wearing a mask over the nose (and sometimes both the mouth and nose) at night while being connected to a quiet blower. It works by slightly pressurizing the upper airway, thereby pneumatically splinting it open and thus preventing it from collapsing. PAP is particularly useful when there is a need for the rapid control of OSA.

The sleep laboratory may also suggest that oral device therapy is appropriate. This depends on the severity of the OSA and the existence of other comorbidities. Oral devices may be used to provide therapy for sleep apnea of all severities; however, effective

The closest thing to internationally accepted practice parameters, which are those issued by the American Academy of Sleep Medicine,[14] state that the "presence or absence and severity of OSA must be determined before initiating treatment." In practice, this means that a dentist must not initiate treatment with an oral device unless the patient has been assessed, medically diagnosed, and then referred to the dentist (Figure 28-4).

If OSA is suspected, then a referral is made for a sleep study. This may involve spending a night in a sleep laboratory or at home with an electronic monitoring device to wear while sleeping. A sleep laboratory is essentially a bedroom with monitoring equipment.

In a sleep laboratory, the patient undergoes what is known as *polysomnography* (PSG), during which multiple parameters are monitored while the patient is asleep. These include (but are not limited to) sound, video, oxygen saturation, respiratory effort, electrocardiography, electroencephalography, and body position. Attended overnight PSG is an expensive assessment to perform, with varying levels of availability and access that are dependent on geography.

Several screening protocols have been proposed over the years.[24,20] In January 2012, the California Dental Association[8] determined that it is appropriate for dentists to screen patients for the signs and symptoms of SDB and to work with physicians to diagnose and treat SDB. The Association also stated that SDB is a medical condition, and its diagnosis is outside of the scope of the practice of dentistry.

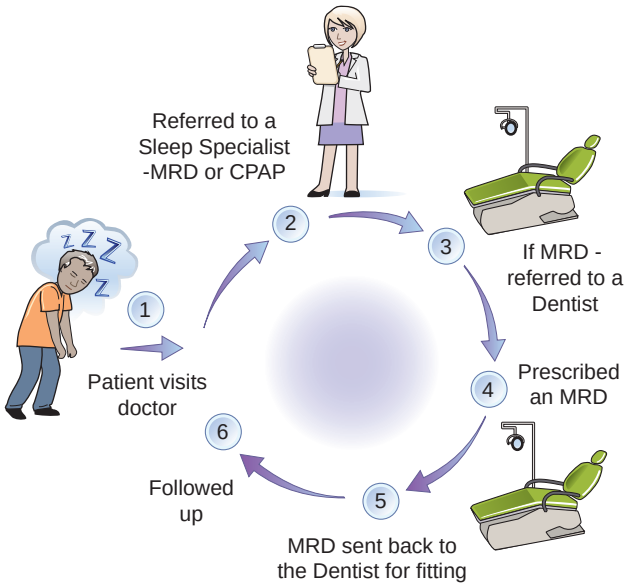

Figure 28-4 Obstructive sleep apnea diagnosis and treatment route. *(Courtesy ResMed, San Diego, CA, 2011.)*

Whether a PSG is essential to diagnose OSA is now being questioned.[36] Since 2009 in the United Kingdom, a general dental practitioner working as part of a multidisciplinary team (including a sleep medicine specialist) may in certain defined circumstances screen, recognize, and initiate treatment with an MRD *without* a prior medical diagnosis.[45] Currently in the United States, both PSG and home study monitor results need to be interpreted by a physician.

The role of home sleep testing and who should interpret the data that it produces are points of contention and perhaps fuel the debate surrounding PSG. This questioning of the need for mandatory PSG may be in response to the following:

- Increasingly valid and competitively priced home sleep testing equipment
- Increase in the number of patients requiring assessment
- Perception that PSG is the point of contention in the treatment process
- Realization that oral devices are appropriate for milder forms of OSA and that dentists are uniquely placed to provide them because they may see the patient more frequently than sleep medicine specialists will see the patient
- Realization that a trained dentist, as part of a multidisciplinary team, may filter referrals to the sleep medicine specialist

A sleep laboratory's main function is to diagnose OSA and then to offer treatment to those who are likely to benefit from it. If the symptoms are fairly disabling and if the diagnosis is confirmed by a sleep study, then PAP therapy is routinely offered. Increasingly around the world, oral devices are becoming a first-line treatment for mild to moderate OSA when they can be prescribed and monitored by a multidisciplinary team.

Figure 28-5 provides definitions and diagnostic criteria for SDB.[44]

Apnea	Cessation of airflow > 10 seconds
Hypopnea	> 50% reduction in airflow for > 10 seconds
AHI	Apnea Hypopnea Index: the number of apneas and hypopneas per hour of sleep
Severity	Normal: AHI < 5 Mild: AHI 5-15 Moderate: AHI 15-30 Severe: AHI > 30
Sleep Apnea Syndrome (SAS)	AHI of > 5 with symptoms
Cheyne Stokes Respiration	> 3 consecutive cyclical crescendo-decrescendo changes in breathing apmplitude during 10 consecutive minutes and/or an AHI > 5

Figure 28-5 Sleep-related disorders in adults: definitions and diagnostic criteria.

results are considered less certain with increasing severity.[19] PAP and MRD therapies are complementary; in patients with moderate OSA, the two modalities may, in some circumstances, be considered equally appropriate. Figure 28-7 illustrates this point in broad terms. Treatment of severe sleep apnea with an oral device necessitates careful patient monitoring, because things such as small weight changes may negate the effect.[34]

The technology of both PAP and oral devices is fast developing, with particular focus on improving the patient's ability to tolerate their use and minimize their side effects. PAP development is focusing on better mask design, the inclusion of air humidifiers, and the sensitive electronically controlled variation of air pressure in response to inspiration and expiration. Oral devices have become increasingly adjustable and thinner, and they can now be designed to minimize some common side effects (e.g., hypersalivation, incisor sensitivity). Future developments in oral devices may focus on objective compliance monitoring and treatment efficacy.

Oral Devices (Mandibular Repositioning Devices)

The developing role of dentistry in the provision of oral devices for snoring and OSA has given rise to concerns about training and professional indemnity. Dentists may be asked to place anti-snoring devices; consequently, state boards of dentistry are now issuing position statements regarding whether the provision of such devices falls within the practice of dentistry, and so are insurance providers, which will determine if such devices are within the scope of the assistance normally provided.

The reader should check with his or her own state board of dentistry and professional indemnity insurer to clarify the situation. Most insurers suggest that dentists are well placed to construct any oral device, provided that they have appropriate training to do so. However, the treatment of snoring and OSA does *not* routinely fall within the definition of the practice of dentistry and therefore would fall outside of the scope of assistance normally provided by the insurer.

The reader should undergo a documented training course in the provision of anti-snoring devices that includes training in the appropriate screening for OSA. Candidates for oral devices should be properly assessed for the signs and symptoms of OSA in accordance with contemporary standards, and such assessment should be documented. If the patient exhibits signs or symptoms of OSA, then there must be a referral for a medical assessment. Patients should be advised about the risks and benefits of anti-snoring devices, including any potential impact on the occlusion, the periodontium, and the TMJs. Documentary evidence of the consent process must be retained. When OSA is present, any anti-snoring device should be supplied only as part of an integrated treatment plan provided by a multidisciplinary team of which the dentist is one part.

Devices Pertinent to the Dentist

Oral devices for snoring and OSA aim to maintain the upper airway during sleep. Tongue-retaining devices and MRDs do this either directly by acting on the tongue and holding it in a forward position or indirectly via the forward repositioning of the mandible, which in turn maintains upper airway patency (Figure 28-8). MRDs are the most researched type of oral device for OSA, and they are the focus of this chapter.

Custom-made adjustable devices are generally associated with better treatment outcomes[46] as compared with universal "boil and bite" MRDs. Adjustable MRDs are more likely to provide

Figure 28-6 Positive airway pressure therapy. *(Courtesy ResMed, San Diego, CA, 2011.)*

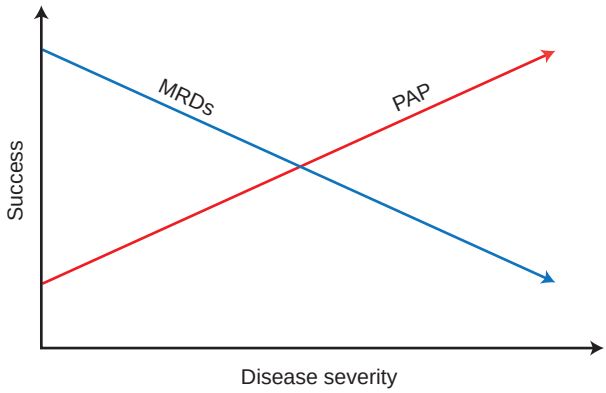

Figure 28-7 Complementary therapies. *(Courtesy Adrian Zacher, 2013, Snorer.com.)*

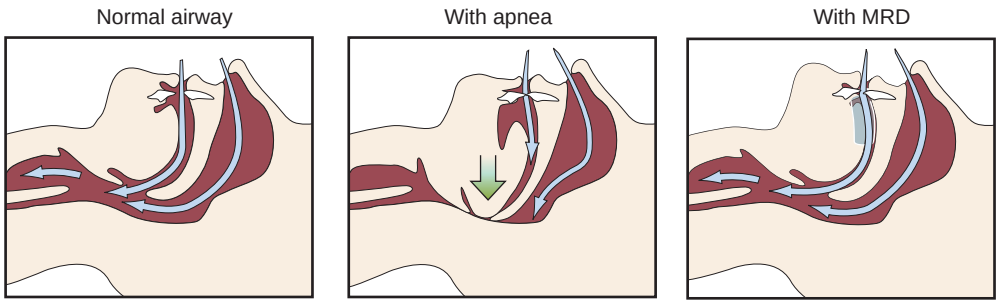

Figure 28-8 Airway status: healthy and apneic, with a mandibular repositioning device. *(Courtesy ResMed, San Diego, CA, 2011.)*

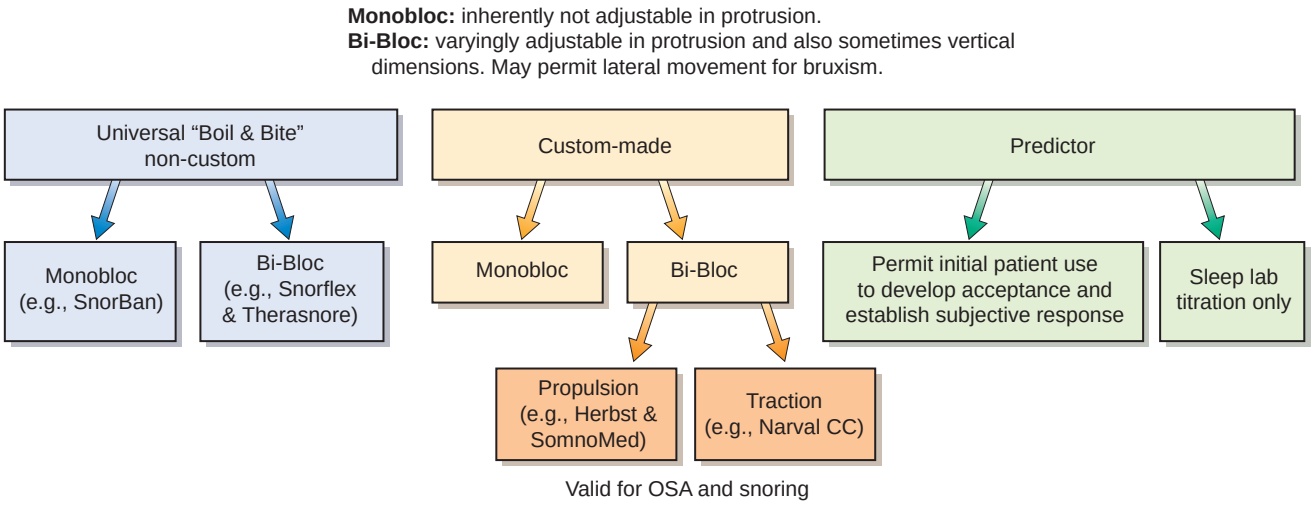

Figure 28-9 Mandibular repositioning device taxonomy. *(Courtesy Adrian Zacher, 2013, Snorer.com.)*

successful therapy in patients with moderate to severe OSA than nonadjustable MRDs.[29]

Predictor Devices. Sleep medicine specialists charged with caring for patients with OSA are understandably desirous of certainty that a patient has been effectively treated. This has historically represented a legitimate concern when considering an MRD for a patient with OSA and has resulted in MRDs being confined to use with mild to moderate OSA. Predictor devices, which are sometimes known as *titration devices,*[11] seek to do the following:

- Establish both whether the patient can tolerate an intraoral device and whether it is subjectively effective
- Objectively determine whether mandibular repositioning delivers adequate therapy
- Subsequently provide a "prescription" jaw relationship for custom MRD manufacture if the outcome is positive

The use of predictor devices has been an area of MRD technologic innovation during recent years. In this role, it is important that predictor devices not be confused with thermoplastic universal treatment devices. Predictor devices are expressly designed for use for a limited number of nights; they are self-limiting, and they sacrifice patient convenience for functionality. A basic taxonomy for the oral devices of MRDs is shown in Figure 28-9.

Characteristics of the Ideal Oral Device

From an individual wearer's perspective, any intraoral device will feel foreign and invasive. Indeed, the individual may seek treatment largely for his or her partner and may perceive little or no personal benefit, because hypersomnolence symptoms correlate poorly with OSA severity.[10] Affected individuals may have forgotten what it feels like to be fully awake.

Side effects of early devices included hypersalivation or dry mouth when worn, dental sensitivity, and perhaps a claustrophobic locking of the jaws in a protrusive position and a morning postwear TMJ ache; for these reasons, early oral devices required development. Some MRD manufacturers have reduced or eliminated these side effects; however, there is no single perfect device.[2] Consequently, knowledge of a range of MRDs to suit different individuals is necessary. The characteristics of the ideal MRD vary for each patient, and some characteristics may preclude others. Table 28-1 presents several options.

Important note: Recognizing that a child may benefit from an SDB investigation is important. MRDs are *not* recommended for children unless the children are under the supervision of an orthodontist who is working as part of a multidisciplinary team.

Communication

Effective communication among the referring sleep laboratory, the patient, and the patient's general dental practitioner is essential and may be commenced before the patient is seen (Box 28-1).

Sleep Laboratory and Primary Care Physician Communication. Confirmation of the OSA diagnosis and the requirement for revaluation should be confirmed. Relevant medical history information should be exchanged. The existence of positional apnea (i.e., apnea that is worsened when sleeping supine) should also be noted.

Patient Communication. Valid informed consent for treatment (including a risk-benefit analysis, information about side effects, and therapy limitations) and permission to obtain dental records from the general dental practitioner should be obtained.

General Dental Practitioner. With reference to the patient's existing dental records, a recent orthopantomogram may be considered valuable.

General Indications and Contraindications

When a patient who has been diagnosed with OSA is referred to a dentist, dental assessment to determine the suitability of MRD therapy is required on the basis of an individual analysis of indications and contraindications. It is essential to obtain valid informed consent and baseline records and to retain any pre-MRD therapy casts. Uncontrolled epilepsy is an absolute contraindication.

Any MRD, which is also known as a *mandibular advancement device* (MAD) or an *oral appliance,* will protrude the mandible; however, each MRD has a different feature set. In 2010, Ahrens stated that "no [one] MAD design most effectively influences subjectively perceived treatment efficacy, but efficacy depends on many factors including materials and method used for fabrication, type of MAD (monobloc or twin-block [bi-bloc]), and the degree of protrusion."[1] Understanding the differences among these devices enables the dentist to prescribe appropriately, with knowledge of the indications, features, and design limitations allowing

TABLE 28-1 Characteristics of the Ideal Mandibular Repositioning Device

Acceptance, Adherence, and Efficacy	Mitigation of Side Effects	Practical Considerations
Two separate piece construction (To give the patient time to accept wearing the mandibular repositioning device, half is worn alone before the complete device is worn.)	Metal free; no parts that can fatigue, fracture, and then be inhaled or ingested to create a galvanic reaction with other dental restorations	Low cost
Ability to titrate anteroposteriorly for tolerability and effect	Minimal bulk for less impact on phonetic function and reduced hypersalivation	East to fit for both the patient and the dental practitioner
Ability to start titration from zero protrusion to improve comfort throughout the titration process	Does not dictate a protrusive path or a final protruded position to the temporomandibular joints	Titratable in the sleep laboratory without waking the patient
Encourages the mouth to close and certainly prevents the mouth from falling open at sleep onset	No unwanted orthodontic effects (e.g., incisor tilting)	Instant device; no impressions or laboratory work required
Permits lip seal and encourages nasal breathing		Minimal follow-up appointments
Ability to titrate the vertical opening (i.e., <5 mm measured at the incisors) considered optimal for acceptance and adherence[38]		Easy to modify
Easy to clean		Does not necessitate a remake should a dental restoration be necessary
Permits lateral movement where there is evidence of parafunction		
Does not encroach on tongue space or impede the forward movement of the tongue		
Includes compliance and efficacy monitoring		
Is it worn and does it work?		

From Adrian Zacher, 2013, Snorer.com.

BOX 28-1 The "Take Home" Message

1. Has the presence (and severity) or absence of obstructive sleep apnea been established?
2. Is the patient at least partially dentate? Does he or she have sufficient alveolar bone to withstand lateral loads?
3. Are you satisfied that there is no severe periodontal condition that the device would prejudice? Does the patient possess the competence to maintain his or her oral hygiene?
4. Are you satisfied there is no gross temporomandibular disorder?
5. Have you ensured that there is an absence of a pronounced gag reflex?
6. Does the patient have a competent nasal airway?
7. Does the patient comprehend the costs of therapy?
8. Have the patient's expectations of therapy been managed appropriately?

him or her to maximize treatment efficacy and minimize unwanted side effects.

Temporomandibular Joint Dysfunction. Severe TMJ dysfunction, limited opening, and reports of jaw locking should be considered contraindications. A limited protrusive range (i.e., <5 mm) would suggest a low likelihood of OSA treatment efficacy with an MRD.

Although a basic assessment for TMJ dysfunction is essential, consideration of the validity of certain TMJ theories and diagnostic tools is necessary. Thorough record keeping is advised. Referral to a dental practitioner who has advanced training in the diagnosis and management of TMJ dysfunction may be indicated if symptoms are present at the initial evaluation or if they develop at any time during treatment.

Reports of diffuse tenderness, ear canal stuffiness, clicks, significant deviation with opening or protruding, and pain associated with these movements necessitate referral to an expert.

Dentate State. The individual must have sound teeth. Edentulous patients are unable to use MRDs. MRDs function by retaining the teeth, and they use this retention to reposition the mandible anteriorly. The minimum number and distribution of teeth varies by device. The placement of the adjustment mechanism routinely needs to be on the teeth and not in an edentulous area. The 8 to 10 teeth distributed around the arch, to avoid excessive lateral load, may serve as a general guide. The shape and inclination of the teeth may affect the retention of the MRD and the dentist's ability to provide effective MRD therapy (e.g., nil or grossly undercut teeth may be problematic). Difficulty taking impressions in the presence of a pronounced gag reflex may suggest that the patient will have difficulty adhering to MRD therapy.

Periodontal Condition and Tooth Mobility. A healthy periodontium with evidence of adequate oral hygiene is essential before therapy with an MRD commences. Anything worn in the mouth may be prejudicial to oral hygiene if it is not kept clean.

Bruxism. The management of sleep bruxism is an important role for the dentist. Bruxism is not necessarily a contraindication for MRD therapy. An assessment for TMJ dysfunction is recommended. The individual should be advised that the parafunction will most likely negatively affect his or her life expectancy and choice of MRD.

Gastroesophageal Reflux Disease. Dentinal pooling that results from gastroesophageal reflux disease may be a symptom of OSA, and it is one that a dentist is ideally positioned to recognize.

Summary

Long-term complications of MRD therapy are not well documented, which—given the intricacies of the determination of which device is most likely to be successful, the role of titration, and the management of complications—demands that the dentist seek advanced training before supplying an MRD.

A thorough and complete periodontal assessment should precede the decision to fit a patient with an MRD. The management of any inflammation may be made more difficult with an MRD that the patient must use consistently when sleeping. Bacterial biofilm formation and retention are likely to be encouraged on the tissues and on the device, so additional instruction and encouragement regarding effective bacterial biofilm removal are often necessary. The careful and frequent monitoring of the periodontal status with the ongoing use of the MRD is essential to confirm sustained health and tooth stability, to recognize any negative changes, and to recommend intervention and the consideration of an alternative treatment modality.

Conclusions

Around the world, the future of sleep medicine is being debated. In the United States, the American Academy of Sleep Medicine has published a white paper on its website.[4] The aim of this publication is to devise "frameworks for healthcare delivery such as the patient-centered medical home (PCMH), patient registries, and new outcomes measures and tools for the diagnosis and treatment of sleep disorders." With the rise in the awareness of how obesity, cardiology, diabetes, and OSA are interrelated, it may be hypothesized that sleep laboratories may perhaps in the future evolve into "metabolism centers."

In 1997, Loube and Strauss[32] concluded that "future efforts at enhancing cooperation between dentists and sleep disorders physicians in the treatment of OSA with oral appliances should be promoted as a means of standardizing treatment." Empowering appropriately trained team members to perform functions that they are well positioned to undertake would seem logical and, in the face of an epidemic and global financial crisis, a necessity.

The role of dentistry in sleep medicine is developing to include increased emphasis on screening, and it may include patient evaluation (e.g., monitoring MRD compliance and objective efficacy). This may also include blood pressure and weight monitoring in an effort to recognize the best time to transition from oral devices to PAP.

The correlation of clinical indicators (e.g., incisal wear, tooth mobility) as signs of SDB with a patient's hypertension, for example, may help the patient's physician develop a more broad-based strategy of intervention. The possible role of breathing obstruction in its various forms in the amplification of periodontal damage (see Chapter 50) and masticatory system disorders (see Chapter 27) will also be addressed in the chapters in this text dedicated to those topics.

In conclusion, perspective is essential and may be gained through working as part of a multidisciplinary team. Tooth movement that, in isolation, may appear to be significant may be considered relatively unimportant when placed within the context of breathing and sleeping.

Suggested Readings

Both undertaking a recognized course of training and joining a national or international dental sleep medicine society are highly recommended. A selection of works that may be of interest to those who are interested in additional information about the topics discussed in this chapter is provided here.

Almeida FR, Lowe AA, Sung JO, et al: Long-term sequellae of oral appliance therapy in obstructive sleep apnea patients: part 1. Cephalometric analysis. *Am J Orthod Dentofacial Orthop* 129:195, 2006.

American Academy of Sleep Medicine: Future of sleep medicine, 2011. Available at: <www.aasmnet.org/articles.aspx?id=2392>. Accessed November 7, 2011.

Bradley TD, Floras JS: Obstructive sleep apnoea and its cardiovascular consequences. *Lancet* 373:82–93, 2009.

California Dental Association: Sleep disordered breathing, Available at: <www.cda.org/library/pdfs/sleep_disordered_breathing.pdf>. Accessed January 10, 2012.

Chan AS, Cistulli PA: Oral appliance treatment of obstructive sleep apnea: an update. *Curr Opin Pulm Med* 16:591–596, 2009.

Dieltjens M, Vanderveken OM, Heyning PH, et al: Current opinions and clinical practice in the titration of oral appliances in the treatment of sleep-disordered breathing. *Sleep Med Rev* 16:177, 2011.

Epstein LJ, Kristo D, Strollo PJ, Jr, et al: Clinical guideline for the evaluation, management and long-term care of obstructive sleep apnea in adults. *J Clin Sleep Med* 5:263, 2009.

Ferguson KR, Cartwright R, Rogers R, et al: Oral appliances for snoring and obstructive sleep apnea: a review. *Sleep* 29:244, 2006.

Fleury B, Rakotonanahary D, Petelle B, et al: Mandibular advancement titration for obstructive sleep apnea: optimization of the procedure by combining clinical and oximetric parameters. *Chest* 125:1761, 2004.

Journal of the California Dental Association: http://www.cda.org/DesktopModules/SearchBoost/DownloadDoc.ashx?filepid=0&file=39. Accessed March 2014.

Lavigne GJ, Cistulli PA, Smith MT: *Sleep medicine for dentists*, Chicago, 2009, Quintessence.

Lavigne GJ, Khoury S, Abe S, et al: Bruxism physiology and pathology: an overview for clinicians. *J Oral Rehabil* 35:476, 2008.

Marklund M, Stenlund H, Franklin KA: Mandibular advancement devices in 630 men and women with obstructive sleep apnea and snoring: tolerability and predictors of treatment success. *Chest* 125:1270, 2004.

Phillips CL, Grunstein RR, Darendeliler MA, et al: A comparative effectiveness trial of continuous positive airway pressure (CPAP) versus oral appliance (OA) therapy in obstructive sleep apnea (OSA). *Sleep Biol Rhythms* 9:294, 2011.

Shaw JE, Punjabi NM, Wilding JP, et al: Sleep-disordered breathing and type 2 diabetes. A report from the International Diabetes Federation Taskforce on Epidemiology and Prevention. *Diabetes Res Clin Pract* 81:2, 2008.

Simmons JH, Prehn RS: Airway protection: the missing link between nocturnal bruxism and obstructive sleep apnea. *Sleep* 32:A218, 2009.

Stradling J, Dookun R: Snoring and the role of the GDP: British Society of Dental Sleep Medicine (BSDSM) pre-treatment screening protocol. *Br Dent J* 206:301, 2009.

Sullivan CE, Issa FG, Berthon-Jones M, et al: Reversal of obstructive sleep apnoea by continuous positive airway pressure applied through the nares. *Lancet* 1:862, 1981.

University of Wisconsin School of Medicine and Public Health: *Wisconsin Sleep Cohort website*, 2011, Board of Regents of the University of Wisconsin System. Available at: <www.pophealth.wisc.edu/Research/WSC>.

Vanderveken OM, Devolder A, Marklund M, et al: Comparison of a custom-made and a thermoplastic oral appliance for the treatment of mild sleep apnea. *Am J Respir Crit Care Med* 178:197, 2008.

Vanderveken O, Hoekema A: How to treat patients that do not tolerate continuous positive airway pressure. *Breathe* 7:157, 2010.

Young T, Palta M, Dempsey J, et al: The occurrence of sleep-disordered breathing among middle-aged adults. *N Engl J Med* 328:1230–1235, 1993.

References

References for this chapter are found on the companion website www.expertconsult.com.

Device Design and Compliance

Considerations

Table 28-2 proposes factors to consider when selecting an adjustable custom-made MRD for a patient.

Bulk, Xerostomia, and Hypersalivation. Logically, the least presence in the mouth the MRD represents, the easier the patient will find it to tolerate. Depending on the bulk of the device and the patient's ability to close the mouth while wearing the device, dry mouth (xerostomia) and hypersalivation are common initial responses to MRD wear. These conditions normally resolve over the first few weeks as the patient adapts to the device. A nonbulky MRD that permits lip seal would therefore be considered superior and may also encourage nasal breathing.

Initial Protrusive Position. To overcome an inherent design limitation, some MRDs have to start from approximately 50% to 70% of the patient's maximum protrusion. Ideally, the MRD would start from zero protrusion and be gradually protruded to maximize acceptance and minimize unnecessary protrusion to achieve effect.

Tongue Space Invasion. An MRD protrudes the jaw and effectively pulls the tongue away from the back of the throat. Placing a mechanism where the tongue is to be placed may be considered counterproductive.

Adjustable Protrusion: Placement of the Mechanism. MRDs may be broadly subdivided into those that place the mechanism in the buccal sulcus, incisally, or inside the tongue space. Proponents of each subdivision vociferously defend their design logic. The assessment of the suitability of one MRD over another requires a comprehensive assessment of the individual in context with any proposed MRD indications and contraindications.

TABLE 28-2 Factors to Consider When Selecting a Mandibular Repositioning Device

Feature	Benefit
Discreet	Hypersalivation reduced and acceptance improved
Permits full lip seal	Eliminates dry mouth or dribbling when worn
Adjustable from zero protrusion and over a wide range	Time to adapt to wearing the device and ability to titrate for maximum effect
Does not load the incisor teeth	Dental morbidity
Retentive	Stays in place so it works
Controls vertical opening	Does not permit the effect of protrusion to be lost by mouth opening
Permits lateral movement	Useful for patients with bruxism
Does not invade the tongue space	Ability to tolerate the device and to speak discernibly
Easy for the dental clinician	Improved chance of success
Long life and robust	Value for money
Biocompatible and without metal components	Allergic and galvanic reaction; bad taste when worn
Easy to keep clean	Useful life
Compliance and obstructive sleep apnea efficacy monitoring	Evidence of device wear and effect

From Adrian Zacher, 2013, Snorer.com.

Freedom of Lateral Movement. When evidence of bruxism is found during an examination, the use of an MRD that permits lateral movement and that can withstand the forces imposed on it is advisable. Mechanisms that may potentially fatigue and fracture should be considered carefully.

Durability and Ease of Cleaning. An inherently robust design and fabrication method is important, because the device will be used to maintain an unconscious individual's airway. The consequences of metal fatigue should be considered. Complex mechanisms and materials that absorb saliva may present difficulty when it comes to cleaning and thus adversely affect the MRD's useful life.

Effect of Vertical Opening. Interincisal opening of more than 5 mm has been associated with lower patient adherence, perhaps as a result of discomfort.[38] However, a recent product trend based on empiric reporting may suggest that, in certain patients, increased occlusal vertical dimension may be more comfortable and permit the tongue to flow over the occlusal surfaces (i.e., allow the tongue to expand laterally). This may be relevant for patients with macroglossia or micrognathia.

Macroglossia and Micrognathia. Adding to an already crowded oral cavity makes wearing the MRD a challenge for the patient. In such an individual, empiric evidence suggests that permitting the tongue to expand over the occlusal surface by increasing the vertical dimension (with protrusion of the mandible) may, in selected cases, be of benefit.

Side Effects

Maximizing the positive effect of MRD therapy while minimizing the side effects is the unstated aim of MRD design. The following sections highlight the primary side effects. Common side effects may include incisor tilting; when identified, this should be discussed with the patient. Placing detected undesired tooth movement in context with OSA treatment benefits requires a risk–benefit analysis with the consideration of treatment alternatives at review appointments. Valid informed consent is advisable.

Hypersalivation or Xerostomia (Dry Mouth). Immediate short-term side effects of the wearing of MRDs include hypersalivation or dry mouth if lip seal is impossible as a result of vertical opening, bulk, or both.

Undesired Orthodontic Effects. Tooth movement may complicate MRD therapy, and it "may be predictable on the basis of initial characteristics in dental occlusion and the design."[33] Some degree of retroclination of the upper incisors and proclination of the lower incisors is thought to occur with most MRDs.[9] This may manifest in long-term use as a mild reduction in either overjet or overbite,[3] and it may be undetectable by the patient. Exceptionally, dental changes may occur that require remedial dentistry to restore the occlusion. After wearing an MRD, some patients may experience a temporary sensation of bite change. Empiric reporting has led to the creation of morning-wear devices that may lessen this. In addition, the morning-wear device may be designed to reverse the lateral load applied to the teeth by the MRD and in addition to the potential overbite and overjet changes.

Change in Occlusal Relationship. Obtaining valid informed consent and retaining pre-MRD therapy study casts are highly recommended, because, in rare instances, a change in the occlusal relationship may be observed. Careful and frequent dental follow-up appointments are suggested. Communication with the patient regarding detected changes about which he or she may be unaware is recommended and should be discussed in context with a risk–benefit assessment and the consideration of alternative treatment modalities.

A posterior open bite may develop in some MRD users for unknown reasons. Theories include the following:

- The device "frees the bite": the MRD may eliminate interdigitation with opposing teeth and the influence of physiologic TMJ function on tooth position, either or both of which could destabilize the occlusion.
- The condylar head is moved anteriorly and off of the meniscus.
- Premature incisal contact results from inclination that appears as a posterior open bite.

Temporomandibular Joint Ache. An aggressive titration rate (increasing protrusion) or commencing MRD therapy in an excessively protruded or incorrect position (i.e., the bite registration is not observed when the laboratory constructs the device) may cause TMJ ache. Frequent evaluation with gradual incremental titration from a minimal or zero protrusion starting point is advisable. TMJ ache may perhaps occur even with proper fitting and management, and the dentist should always ask the patient to communicate even seemingly minor and transient symptoms, because their occurrence may indicate a developing complication.

Tooth Pain. Diffuse low-level discomfort of the teeth may also be reported.

Recording the Jaw Relationship

What. A protrusive bite registration may be considered a three-dimensional prescription to be given to the MRD manufacturer. It relates the position of the jaws, and it is the position to which the MRD is constructed. It can be merely a wax horseshoe shape into which the patient bites, or it may be a more sophisticated product with added functionality (e.g., the George Gauge, the IST bite fork, Airway Metrics.)

Why. Every patient is unique; consequently, an approach of "X millimeters of protrusion to be effective" will not work. When registering the protrusive bite, the intention is to record the relationship of the jaws in a position that is 50% to 70% of the maximum comfortable protrusion in anticipation that this will be close to the final effective position. The MRD will be constructed to this position; however, therapy may ideally commence with less or no protrusion. The ideal bite registration position relates to and minimizes the vertical opening to permit lip seal and encourage nasal breathing. MRD designs vary, as does the impact of an incorrectly constructed or used protrusive bite registration.

How. Various products are available to assist the dentist with providing accurate bite registrations, including orthodontic bite forks, the George Gauge, and the IST bite fork. Alternatives include wax or putty. YouTube videos are available to show how these products can best be used. See the section about determining the optimum protrusion for more information.

When or If. It is always necessary to provide a protrusive bite registration for MRD construction to ensure the following:

- That even and balanced contact is present between the occlusal surfaces (Note that some MRDs may have incisal contact only [e.g., Thornton Adjustable Positioner, MDSA]; however, a bite registration is still required.)
- That deviation to the left or right on protrusion is reflected in the MRD

Other Factors. Factors to communicate to the laboratory include the following:

- When the dental midlines do not coincide
- When the dental and facial midlines do not coincide
- When there is an acute condylar angle (commonly associated with skeletal class II)
- When there is a steep curve of Spee that leads to posterior interference on protrusion
- Overerupted or unopposed molars that may interfere with protrusion
- Marked facial or condylar asymmetry

Some MRD manufacturers may also ask for the following:

- A record of the maximum comfortable protrusion
- A record of the maximum opening (measured interincisally)
- Whether the device should include all of the molar teeth

It is important to ensure that the vertical space between the most posterior molar teeth is sufficient to include two devices (upper and lower) of adequate material thickness for robustness.

Fitting

Ensure that both parts of the device are appropriately retentive and that, when the MRD design incorporates posterior support, it is even and balanced. Be sure that, where the gingiva is covered, it does not blanche. It is essential to establish that the patient can insert and remove the individual parts of and subsequently the complete device. He or she must understand how the pieces of the device interrelate to achieve effect. This discussion should include the requirement for titration and regular follow-up appointments.

Determining the Optimum Protrusion

Establishing the optimum jaw advancement, which is also known as *protrusion,* to deliver OSA therapy is challenging. Each patient has a unique maximum response to protrusion, which must be balanced against increasing the load on the teeth and the TMJs. This process, which is known as *titration,* has to be performed while providing sufficient time for the wearer to adapt to the device, and it must be balanced against both the individual's desire and his or her bed partner's desire for a rapid resolution.

Simplistically, increased protrusion yields improved resolution of OSA symptoms. However, subjective and objective symptom improvements are poorly correlated.[16] A nonlinear dose–response relationship exists between protrusion and response (Figure 28-10).[23] Increased protrusion improves response until a certain patient-specific optimum has been established. Protrusion beyond this position yields no further benefit and is even hypothesized to diminish response.

Titration is complicated by the interindividual heterogeneous response (i.e., note the difference between patient A and patient B with regard to both response and protrusion) and the detrimental effects of increasing the load directed toward the teeth and the TMJs, which is concomitant with increased protrusion.

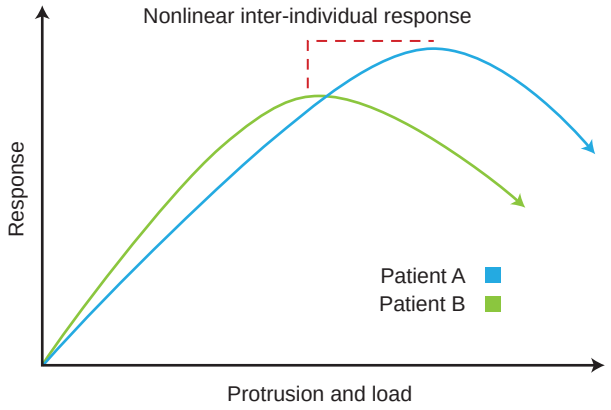

Figure 28-10 Nonlinear dose–response relationship for two patients. *(Courtesy Adrian Zacher, 2013, Snorer.com.)*

Several MRD titration protocols exist, and there is no consensus regarding what is optimal.[11] A multiparametric titration protocol as described by Dieltjens is suggested as ideal. Subjective titration should be performed by the dental practitioner over time in response to patient and partner reporting, provided that the patient has had time to adapt to the device. Subsequently, the patient's maximum tolerable protrusion is established before further titration is performed in an objective assessment environment. This may then occur up to the patient's physiologic or tolerable limit.

Dental Evaluation

The dentist should provide regular follow-up appointments to monitor patients for side effects and possible complications, particularly during the early weeks and months of therapy; to promote compliance[15]; and to titrate for subjective or objective improvement in the patient's symptoms. The consideration of an alternate type of MRD may also be necessary.

References

1. Ahrens A, McGrath C, Hägg U: Subjective efficacy of oral appliance design features in the management of obstructive sleep apnea: a systematic review. *Am J Orthod Dentofacial Orthop* 138:559, 2010.
2. Ahrens A, McGrath C, Hägg U: A systematic review of the efficacy of oral appliance design in the management of obstructive sleep apnoea. *Eur J Orthod* 33:318, 2011.
3. Almeida FR, Lowe AA, Sung JO, et al: Long-term sequellae of oral appliance therapy in obstructive sleep apnea patients: part 1. Cephalometric analysis. *Am J Orthod Dentofacial Orthop* 129:195, 2006.
4. American Academy of Sleep Medicine: Future of sleep medicine, 2011. Available at: <www.aasmnet.org/articles.aspx?id=2392>. Accessed November 7, 2011.
5. *At a Dental Sleep Medicine Congress in Bremen*, Germany, 2010.
6. Aurora RN, Casey KR, Kristo D, et al: Practice parameters for the surgical modifications of the upper airway for obstructive sleep apnea in adults. *Sleep* 33:1408, 2010.
7. Barsh L: Dentistry's role in the recognition and treatment of sleep-breathing disorders: the need for cooperation with the medical community. *J Calif Dent Assoc* 26:591, 1998.
8. California Dental Association: Sleep disordered breathing, Available at: http://www.cda.org/DesktopModules/SearchBoost/DownloadDoc.ashx?filepid=0&file=39. Accessed March 2014.
9. Cistulli PA, Gotsopoulos H, Marklund M, et al: Treatment of snoring and obstructive sleep apnea with mandibular repositioning appliances. *Sleep Med Rev* 8:443, 2004.
10. D'Ambrosio C, Bowman T, Mohsenin V: Quality of life in patients with obstructive sleep apnea: effect of nasal continuous positive airway pressure—a prospective study. *Chest* 115:123, 1999.
11. Dieltjens M, Vanderveken OM, Heyning PH, et al: Current opinions and clinical practice in the titration of oral appliances in the treatment of sleep-disordered breathing. *Sleep Med Rev* 16:177, 2011.
12. Einhorn D, Stewart DA, Erman MK, et al: Prevalence of sleep apnea in population of adults with type 2 diabetes mellitus. *Endocr Pract* 13:355, 2007.
13. Engleman HM, Douglas NJ: Sleepiness, cognitive function, and quality of life in obstructive sleep apnoea/hypopnoea syndrome. *Thorax* 59:618, 2004.
14. Epstein LJ, Kristo D, Strollo PJ, Jr, et al: Clinical guideline for the evaluation, management and long-term care of obstructive sleep apnea in adults. *J Clin Sleep Med* 5:263, 2009.
15. Ferguson KR, Cartwright R, Rogers R, et al: Oral appliances for snoring and obstructive sleep apnea: a review. *Sleep* 29:244, 2006.
16. Fleury B, Rakotonanahary D, Petelle B, et al: Mandibular advancement titration for obstructive sleep apnea: optimization of the procedure by combining clinical and oximetric parameters. *Chest* 125:1761, 2004.
17. Gilmartin GS, Daly RW, Thomas RJ: Recognition and management of complex sleep-disordered breathing. *Curr Opin Pulm Med* 11:485, 2005.
18. Gottlieb DJ, Yenokyan G, Newman AB, et al: Prospective study of obstructive sleep apnea and incident coronary heart disease and heart failure: the Sleep Heart Health Study. *Circulation* 122:352–360, 2010.
19. Holley A, Lettieri CJ, Shah AA: Efficacy of an adjustable oral appliance and comparison with continuous positive airway pressure for the treatment of obstructive sleep apnea syndrome. *Chest* 140:1511, 2011.
20. Jauhar R, Orchardson SW, Banham E, et al: The Kushida Index as a screening tool for obstructive sleep apnoea-hypopnoea syndrome. *Br Dent J* 212:E2, 2012.
21. Javaheri S, Parker TJ, Liming JD, et al: Sleep apnea in 81 ambulatory male patients with stable heart failure. Types and their prevalences, consequences, and presentations. *Circulation* 97:2154, 1998.
22. Javaheri S, Smith J, Chung E: The prevalence and natural history of complex sleep apnea. *J Clin Sleep Med* 5:205–211, 2009.
23. Kato J, Isono S, Tanaka A, et al: Dose dependent effects of mandibular advancement on pharyngeal mechanics and nocturnal oxygenation in patients with sleep disordered breathing. *Chest* 117:1065, 2000.
24. Kushida CA, Efron B, Guilleminault C: A predictive morphometric model for the obstructive sleep apnea syndrome. *Ann Intern Med* 127:581, 1997.
25. Kushida CA, Morgenthaler TI, Littner MR, et al: Practice parameters for the treatment of snoring and obstructive sleep apnea with oral appliances: an update for 2005. *Sleep* 29:240, 2006.
26. Lavie P, Herer P, Hoffstein V: Obstructive sleep apnoea syndrome as a risk factor for hypertension: population study. *BMJ* 320:479, 2000.
27. Lavigne GJ, Cistulli PA, Smith MT: *Sleep medicine for dentists*, Chicago, 2009, Quintessence.
28. Lavigne GJ, Khoury S, Abe S, et al: Bruxism physiology and pathology: an overview for clinicians. *J Oral Rehabil* 35:476, 2008.
29. Lettieri CJ, Paolino N, Eliasson AH, et al: Comparison of adjustable and fixed oral appliances for the treatment of obstructive sleep apnea. *J Clin Sleep Med* 7:439, 2011.
30. Lim J, McKean M: Adenotonsillectomy for obstructive sleep apnea in children. *Cochrane Database Syst Rev* (4):CD003136, 2003.
31. Logan AG, Perlikowski SM, Mente A, et al: High prevalence of unrecognized sleep apnoea in drug-resistant hypertension. *J Hypertens* 19:2271, 2001.
32. Loube MD, Strauss AM: Survey of oral appliance practice among dentists treating obstructive sleep apnea patients. *Chest* 111:382, 1997.
33. Marklund M: Predictors of long-term orthodontic side effects from mandibular advancement devices in patients with snoring and obstructive sleep apnea. *Am J Orthod Dentofacial Orthop* 129:214, 2006.
34. Marklund M, Stenlund H, Franklin K: Mandibular advancement devices in 630 men and women with obstructive sleep apnea and snoring—tolerability and predictors of treatment success. *Chest* 125:1270, 2004.
35. Martínez-García MA, Soler-Cataluña JJ, Ejarque-Martínez L, et al: Continuous positive airway pressure treatment reduces mortality in patients with ischemic stroke and obstructive sleep apnea: a 5-year follow up study. *Am J Respir Crit Care Med* 180:36, 2009.
36. McNicholas WT, Levy P: Portable monitoring in sleep apnoea: the way forward? *Eur Respir J* 37:749, 2011.
37. Morgan B: Acute and chronic cardiovascular responses to sleep disordered breathing. *Sleep* 19(10 Suppl):S206, 1996.
38. Pitsis AJ, Darendeliler MA, Gotsopoulos H, et al: Effect of vertical dimension on efficacy of oral appliance therapy in obstructive sleep apnea. *Am J Respir Crit Care Med* 166:860, 2002.
39. Punjabi NM, Shahar E, Redline S, et al: Sleep-disordered breathing, glucose intolerance and insulin resistance: the Sleep Heart Health Study. *Am J Epidemiol* 160:521, 2004.
40. Resnick HE, Redline S, Shahar E, et al: Diabetes and sleep disturbances: findings from the Sleep Heart Health Study. *Diabetes Care* 26:702–709, 2003.
41. Shaw JE, Punjabi NM, Wilding JP, et al: Sleep-disordered breathing and type 2 diabetes: 1 report from the International Diabetes Federation Taskforce on Epidemiology and Prevention. *Diabetes Res Clin Pract* 81:2, 2008.
42. Simmons JH, Prehn RS: Bruxing as a compensatory mechanism for a collapsing airway. *Sleep* 31:A199, 2008.
43. Simmons JH, Prehn RS: Airway protection: the missing link between nocturnal bruxism and obstructive sleep apnea. *Sleep* 32:A218, 2009.
44. Sleep-related breathing disorders in adults: recommendations for syndrome definition and measurement techniques in clinical research. The Report of an American Academy of Sleep Medicine Task Force. *Sleep* 22:667, 1999.
45. Stradling J, Dookun R: Snoring and the role of the GDP: British Society of Dental Sleep Medicine (BSDSM) pre-treatment screening protocol. *Br Dent J* 206:307, 2009.
46. Vanderveken OM, Devolder A, Marklund M, et al: Comparison of a custom-made and a thermoplastic oral appliance for the treatment of mild sleep apnea. *Am J Respir Crit Care Med* 178:197, 2008.
47. Wilcox I, McNamara SG, Collins FL, et al: "Syndrome Z": the interaction of sleep apnoea, vascular risk factors and heart disease. *Thorax* 53:S25, 1998.
48. World Health Organization: Integrating prevention into healthcare, Factsheet no. 172, revised Oct 2002. *Indian J Med Sci* 56:619, 2002.

49. Young T: Epidemiology of obstructive sleep apnea, a population health perspective. *Am J Respir Crit Care Med* 165:1217, 2002.
50. Young T, Blustein J, Finn L, et al: Sleep-disordered breathing and motor vehicle accidents in a population-based sample of employed adults. *Sleep* 20:608, 1997.
51. Young T, Finn L, Peppard PE, et al: Sleep disordered breathing and mortality: eighteen-year follow-up of the Wisconsin Sleep Cohort. *Sleep* 31:1071, 2008.

GLOSSARY

Apneic (ap-knee-ic) episode A period of not breathing while asleep that usually lasts for more than 10 seconds.

Hypercapnia (high-per-cap-nee-ah) A raised level of carbon dioxide in the blood. Carbon dioxide is the gas that is normally breathed out, but its blood level rises if breathing is inadequate. It is usually measured by taking an arterial blood sample.

Hypersomnolence (high-per-som-no-lence) Excessive daytime sleepiness.

Hypnogram (hip-no-gram) The final printout of the all-night sleep stages (i.e., both rapid eye movement and non–rapid eye movement) after an overnight study.

Hypopnea (high-pop-nee-ah) A period of underbreathing that usually lasts for more than 10 seconds.

Hypothyroidism (high-po-thy-royd-ism) Also known as *myxedema* (mix-si-dee-ma). Hypothyroidism occurs when the thyroid gland fails to make enough thyroid hormone, and it can present as obstructive sleep apnea.

Hypoxia (high-pox-ee-a) The state during which the body is short of oxygen and therefore the level in the blood falls.

Hypoxic (high-pox-ic) dips The falls in oxygen levels, seen on the oximeter, that usually accompany apneas. These are also known as *desaturations* because, when it is not hypoxic, the blood is described as fully saturated with oxygen.

Insomnia (in-som-nee-ah) The state of being awake when one wants to be asleep. This is often thought of as a problem, but it may not be.

Mandibular repositioning device An intraoral device that is used to maintain upper airway patency during sleep. This is also known as a mandibular advancement device, an oral appliance, or a splint.

Manometer (ma-nom-i-ter) A device used to measure the pressure being delivered by a continuous positive airway pressure machine; this is usually measured in centimeters of water (cm H_2O), with a common pressure being about 10 cm H_2O.

Microarousals Very brief "awakenings" that may only be seen when the brain waves are being monitored via encephalography.

Movement arousals Short awakenings that involve minor body movements about which the sleeper is unaware.

Narcolepsy (nar-co-lep-see) A cause of daytime sleepiness that results from an inherited disorder of the control of dreaming sleep. Narcolepsy has to be differentiated from sleep apnea, periodic leg movements, and other rarer causes of daytime sleepiness.

Obstructive sleep apnea (ap-knee-ah) This syndrome is commonly referred to as OSA (obstructive sleep apnea) or OSAS (obstructive sleep apnea syndrome). It usually involves 30 or more periods of not breathing when asleep. Each period or apneic episode lasts for more than 10 seconds.

Positive airway pressure (PAP) The process of delivering a continuously raised airway pressure via a mask worn on the face to pneumatically splint open the airway.

Sleep-disordered breathing (SDB) The collective term for a group of disorders that are characterized by abnormalities of the respiratory pattern (i.e., pauses in breathing) or the quantity of ventilation during sleep.

CHAPTER 29

Clinical Diagnosis

Henry H. Takei, Fermin A. Carranza, and Jonathan H. Do

CHAPTER OUTLINE

First Visit
Second Visit
Laboratory Aids to Clinical Diagnosis

Proper diagnosis is essential to intelligent treatment. Periodontal diagnosis should first determine whether disease is present; it should then identify the disease's type, extent, distribution, and severity, and it should finally provide an understanding of the underlying pathologic processes and their causes. Sections 1 and 2 of Part 3 of this book provide a detailed description of the different diseases that can affect the periodontium. In general, they fall into the following three broad categories:

1. The gingival diseases (Box 29-1)
2. The various types of periodontitis (Table 29-1)
3. The periodontal manifestations of systemic diseases (see Chapter 11)

The periodontal diagnosis is determined after the careful analysis of the case history and the evaluation of the clinical signs and symptoms as well as the results of various tests (e.g., probing, mobility assessment, radiographs, blood tests, and biopsies).

The interest should be in the patient who has the disease and not simply in the disease itself. Diagnosis must therefore include a general evaluation of the patient and a consideration of the oral cavity.

Diagnostic procedures must be systematic and organized for specific purposes. It is not enough to assemble facts; the findings must be pieced together so that they provide a meaningful explanation of the patient's periodontal problem. The following is a recommended sequence of procedures for the diagnosis of periodontal diseases.

First Visit

Overall Appraisal of the Patient

From the first meeting, the clinician should attempt an overall appraisal of the patient. This includes the consideration of the patient's mental and emotional status, temperament, attitude, and physiologic age.

Medical History

Most of the medical history is obtained at the first visit, and it can be supplemented by pertinent questioning at subsequent visits. The health history can be obtained verbally by questioning the patient and recording his or her responses on a blank piece of paper or by means of a printed questionnaire that the patient completes. Figure 29-1 is the medical questionnaire form recommended by the American Dental Association.

The importance of the medical history should be clearly explained, because patients often omit information that they cannot relate to their dental problems. The patient should be made aware of the following: (1) the possible role that some systemic diseases, conditions, or behavioral factors may play in the cause of periodontal disease; (2) the presence of conditions that may require special precautions or modifications of the treatment procedure (see Chapter 37); and (3) the possibility that oral infections may have a powerful influence on the occurrence and severity of a variety of systemic diseases and conditions (see Chapter 12).

The medical history should include reference to the following:

1. If the patient is under the care of a physician, the nature and duration of the problem and its therapy should be discussed. The name, address, and telephone number of the physician should be recorded, because direct communication with him or her may be necessary.
2. Details regarding hospitalizations and operations, including the diagnosis, the type of operation, and any untoward events (e.g., anesthetic, hemorrhagic, or infectious complications) should be provided.
3. A list of all medications being taken and whether they were prescribed or obtained over the counter should be included. All of the possible effects of these medications should be carefully analyzed to determine their effect, if any, on the oral tissues and also to avoid administering medications that would interact adversely with them. Special inquiry should be made regarding the dosage and duration of therapy with anticoagulants and corticosteroids. Patients who are taking the family of drugs called bisphosphonates (e.g., Actonel, Fosamax, Boniva, Aredia, Zometa), which are often prescribed for patients with osteoporosis, should be cautioned about possible problems related to osteonecrosis of the jaw after undergoing any form of oral surgery involving the bone.
4. All medical problems (e.g., cardiovascular, hematologic, endocrine), including infectious diseases, sexually transmitted diseases, and high-risk behavior for human immunodeficiency virus infection, should be listed. Chapter 26 discusses the subject of human immunodeficiency virus infection.

TABLE 29-1 Features of Types of Periodontitis

Parameter	Chronic	Aggressive	Prepubertal	Localized Aggressive Periodontitis	Necrotizing Ulcerative Periodontitis
Age (years)	35+	20 to 35	<11	11 to 19	15 to 35
Calculus	Moderate to abundant	Scanty to moderate	Scanty	Moderate	Scanty
Disease progression	Slow	Rapid	Rapid	Rapid	Rapid
Distribution	Generalized; associated with etiologic factors	Generalized; no consistent pattern	Primary molars and incisors	First molars and incisors, and no more than two other teeth	?
Prevalence*	United States, >50%; Sri Lanka, 81%	United States, 4% to 5%; Sri Lanka, 11%	?	<0.50%	?
Racial predilection	No	No	No	More common among blacks	No
Familial tendency	No	?	Yes	Yes	?
Gender distribution	More severe among men	?	?	?	?
Polymorphonuclear leukocyte/macrophage defects	No	Yes	Yes	Yes	Yes
Association with systemic problems	No	Some cases	Yes	Yes	Yes
Response to therapy	Very good	Variable	Poor	Good	Variable

*Prevalence among adolescents between the ages of 14 and 17 years in the United States.

BOX 29-1 Gingival Diseases

- Chronic marginal gingivitis
- Acute necrotizing ulcerative gingivitis
- Acute herpetic gingivostomatitis
- Allergic gingivitis
- Gingivitis associated with skin diseases
- Gingivitis associated with endocrine–metabolic disturbances
- Gingivitis associated with hematologic–immunologic disturbances
- Gingival enlargement associated with medications
- Gingival tumors

5. Any possibility of occupational disease should be noted.
6. Abnormal bleeding tendencies, such as nosebleeds, prolonged bleeding from minor cuts, spontaneous ecchymoses, a tendency toward excessive bruising, and excessive menstrual bleeding, should be cited. These symptoms should be correlated with the medications that the patient is taking.
7. The patient's allergy history should be taken, including that related to hay fever, asthma, sensitivity to foods, sensitivity to drugs (e.g., aspirin, codeine, barbiturates, sulfonamides, antibiotics, procaine, laxatives), and sensitivity to dental materials (e.g., eugenol, acrylic resins).
8. Information is needed regarding the onset of puberty and for females, menopause, menstrual disorders, hysterectomy, pregnancies, and miscarriages.
9. A family medical history should be taken, including that of bleeding disorders and diabetes.

Dental History

Current Illness. Some patients may be unaware of any problems, but many may report bleeding gums; loose teeth; spreading of the teeth with the appearance of spaces where none existed before; foul taste in the mouth; and an itchy feeling in the gums that is relieved by digging with a toothpick. There may also be pain of varied types and duration, including constant, dull, gnawing pain; dull pain after eating; deep radiating pains in the jaws; acute throbbing pain; sensitivity when chewing; sensitivity to hot and cold; burning sensation in the gums; and extreme sensitivity to inhaled air.

A preliminary oral examination is done to explore the source of the patient's chief complaint and to determine whether immediate emergency care is required. If this is the case, the problem is addressed after the consideration of the medical history (see Chapters 41 and 42).

The dental history should include reference to the following:

1. Visits to the dentist should be listed, including their frequency, the date of the most recent visit, the nature of the treatment, and oral prophylaxis or cleaning by a dentist or hygienist, including the frequency and date of most recent cleaning.
2. The patient's oral hygiene regimen should be described, including toothbrushing frequency, time of day, method, type of toothbrush and dentifrice, and interval at which brushes are replaced. Other methods for mouth care, such as mouthwashes, interdental brushes, other devices, water irrigation, and dental floss, should also be listed.
3. Any orthodontic treatment, including its duration and the approximate date of termination, should be noted.
4. If the patient is experiencing pain in the teeth or in the gingiva, the manner in which the pain is provoked, its nature and duration, and the manner in which it is relieved should be described.
5. Note the presence of any gingival bleeding, including when it first occurred; whether it occurs spontaneously, on brushing or eating, at night, or with regular periodicity; whether it is associated with the menstrual period or other specific factors; and the duration of the bleeding and the manner in which it is stopped.
6. A bad taste in the mouth and areas of food impaction should be mentioned.

Health History Form

ADA
American Dental Association
www.ada.org

E-mail: Today's Date:

As required by law, our office adheres to written policies and procedures to protect the privacy of information about you that we create, receive or maintain. Your answers are for our records only and will be kept confidential subject to applicable laws. Please note that you will be asked some questions about your responses to this questionnaire and there may be additional questions concerning your health. This information is vital to allow us to provide appropriate care for you. This office does not use this information to discriminate.

Name: Last First Middle | Home Phone: *Include area code* ( ) | Business/Cell Phone: *Include area code* ( )

Address: Mailing address | City: | State: | Zip:

Occupation: | Height: | Weight: | Date of birth: | Sex: M F

SS# or Patient ID: | Emergency Contact: | Relationship: | Home Phone: ( ) | Cell Phone: ( ) *Include area codes*

If you are completing this form for another person, what is your relationship to that person?

Your Name Relationship

Do you have any of the following diseases or problems: *(Check DK if you Don't Know the answer to the question)*	Yes	No	DK
Active tuberculosis	☐	☐	☐
Persistent cough greater than a 3 week duration	☐	☐	☐
Cough that produces blood	☐	☐	☐
Been exposed to anyone with tuberculosis	☐	☐	☐

If you answer yes to any of the 4 items above, please stop and return this form to the receptionist.

Dental Information *For the following questions, please mark (X) your responses to the following questions.*

	Yes	No	DK
Do your gums bleed when you brush or floss?	☐	☐	☐
Are your teeth sensitive to cold, hot, sweets or pressure?	☐	☐	☐
Does food or floss catch between your teeth?	☐	☐	☐
Is your mouth dry?	☐	☐	☐
Have you had any periodontal (gum) treatments?	☐	☐	☐
Have you ever had orthodontic (braces) treatment?	☐	☐	☐
Have you had any problems associated with previous dental treatment?	☐	☐	☐
Is your home water supply fluoridated?	☐	☐	☐
Do you drink bottled or filtered water?	☐	☐	☐
If yes, how often? Circle one: DAILY / WEEKLY / OCCASIONALLY			
Are you currently experiencing dental pain or discomfort?	☐	☐	☐

	Yes	No	DK
Do you have earaches or neck pains?	☐	☐	☐
Do you have any clicking, popping or discomfort in the jaw?	☐	☐	☐
Do you brux or grind your teeth?	☐	☐	☐
Do you have sores or ulcers in your mouth?	☐	☐	☐
Do you wear dentures or partials?	☐	☐	☐
Do you participate in active recreational activities?	☐	☐	☐
Have you ever had a serious injury to your head or mouth?	☐	☐	☐

Date of your last dental exam:
What was done at that time?

Date of last dental x-rays:

What is the reason for your dental visit today?

How do you feel about your smile?

Medical Information *Please mark (X) your response to indicate if you have or have not had any of the following diseases or problems.*

	Yes	No	DK
Are you now under the care of a physician?	☐	☐	☐

Physician Name: | Phone: *Include area code* ( )

Address/City/State/Zip:

Are you in good health?	☐	☐	☐
Has there been any change in your general health within the past year?	☐	☐	☐

If yes, what condition is being treated?

Date of last physical exam:

	Yes	No	DK
Have you had a serious illness, operation or been hospitalized in the past 5 years?	☐	☐	☐

If yes, what was the illness or problem?

Are you taking or have you recently taken any prescription or over the counter medicine(s)?	☐	☐	☐

If so, please list all, including vitamins, natural or herbal preparations and/or diet supplements:

_____
_____
_____
_____

© 2007 American Dental Association
Form S500

SAMPLE

Figure 29-1 Medical history form from the American Dental Association. *(Form © American Dental Association. Reprinted with permission.)*

Continued

Medical Information

Please mark (X) your response to indicate if you have or have not had any of the following diseases or problems.

(Check DK if you Don't Know the answer to the question)	Yes	No	DK
Do you wear contact lenses?	☐	☐	☐
Joint Replacement. Have you had an orthopedic total joint (hip, knee, elbow, finger) replacement?	☐	☐	☐
Date: _____ If yes, have you had any complications? _____			
Are you taking or scheduled to begin taking either of the medications, alendronate (Fosamax®) or risedronate (Actonel®) for osteoporosis or Paget's disease?	☐	☐	☐
Since 2001, were you treated or are you presently scheduled to begin treatment with the intravenous bisphosphonates (Aredia® or Zometa®) for bone pain, hypercalcemia or skeletal complications resulting from Paget's disease, multiple myeloma or metastatic cancer?	☐	☐	☐
Date Treatment began: _____			

	Yes	No	DK
Do you use controlled substances (drugs)?	☐	☐	☐
Do you use tobacco (smoking, snuff, chew, bidis)?	☐	☐	☐
If so, how interested are you in stopping? (Circle one) VERY / SOMEWHAT / NOT INTERESTED			
Do you drink alcoholic beverages?	☐	☐	☐
If yes, how much alcohol did you drink in the last 24 hours? _____			
If yes, how much do you typically drink In a week? _____			
WOMEN ONLY Are you:			
Pregnant?	☐	☐	☐
Number of weeks: _____			
Taking birth control pills or hormonal replacement?	☐	☐	☐
Nursing?	☐	☐	☐

Allergies - Are you allergic to or have you had a reaction to: To all **yes** responses, specify type of reaction.	Yes	No	DK
Local anesthetics _____	☐	☐	☐
Aspirin _____	☐	☐	☐
Penicillin or other antibiotics _____	☐	☐	☐
Barbiturates, sedatives, or sleeping pills _____	☐	☐	☐
Sulfa drugs _____	☐	☐	☐
Codeine or other narcotics _____	☐	☐	☐

	Yes	No	DK
Metals _____	☐	☐	☐
Latex (rubber) _____	☐	☐	☐
Iodine _____	☐	☐	☐
Hay fever/seasonal _____	☐	☐	☐
Animals _____	☐	☐	☐
Food _____	☐	☐	☐
Other _____	☐	☐	☐

Please mark (X) your response to indicate if you have or have not had any of the following diseases or problems.

	Yes	No	DK
Artificial (prosthetic) heart valve	☐	☐	☐
Previous infective endocarditis	☐	☐	☐
Damaged valves in transplanted heart	☐	☐	☐
Congenital heart disease (CHD)			
Unrepaired, cyanotic CHD	☐	☐	☐
Repaired (completely) in last 6 months	☐	☐	☐
Repaired CHD with residual defects	☐	☐	☐

Except for the conditions listed above, antibiotic prophylaxis is no longer recommended for any other form of CHD.

	Yes	No	DK
Cardiovascular disease.	☐	☐	☐
Angina	☐	☐	☐
Arteriosclerosis	☐	☐	☐
Congestive heart failure	☐	☐	☐
Damaged heart valves	☐	☐	☐
Heart attack	☐	☐	☐
Heart murmur	☐	☐	☐
Low blood pressure	☐	☐	☐
High blood pressure	☐	☐	☐
Other congenital heart defects	☐	☐	☐

	Yes	No	DK
Mitral valve prolapse	☐	☐	☐
Pacemaker	☐	☐	☐
Rheumatic fever	☐	☐	☐
Rheumatic heart disease	☐	☐	☐
Abnormal bleeding	☐	☐	☐
Anemia	☐	☐	☐
Blood transfusion	☐	☐	☐
If yes, date: _____			
Hemophilia	☐	☐	☐
AIDS or HIV infection	☐	☐	☐
Arthritis	☐	☐	☐

	Yes	No	DK
Autoimmune disease	☐	☐	☐
Rheumatoid arthritis	☐	☐	☐
Systemic lupus erythematosus.	☐	☐	☐
Asthma	☐	☐	☐
Bronchitis	☐	☐	☐
Emphysema	☐	☐	☐
Sinus trouble	☐	☐	☐
Tuberculosis	☐	☐	☐
Cancer/Chemotherapy/ Radiation Treatment	☐	☐	☐
Chest pain upon exertion	☐	☐	☐
Chronic pain	☐	☐	☐
Diabetes Type I or II	☐	☐	☐
Eating disorder	☐	☐	☐
Malnutrition	☐	☐	☐
Gastrointestinal disease	☐	☐	☐
G.E. Reflux/persistent heartburn	☐	☐	☐
Ulcers	☐	☐	☐
Thyroid problems	☐	☐	☐
Stroke	☐	☐	☐
Glaucoma	☐	☐	☐

	Yes	No	DK
Hepatitis, jaundice or liver disease	☐	☐	☐
Epilepsy	☐	☐	☐
Fainting spells or seizures	☐	☐	☐
Neurological disorders	☐	☐	☐
If yes, specify: _____			
Sleep disorder	☐	☐	☐
Mental health disorders	☐	☐	☐
Specify: _____			
Recurrent infections	☐	☐	☐
Type of infection: _____			
Kidney problems	☐	☐	☐
Night sweats	☐	☐	☐
Osteoporosis	☐	☐	☐
Persistent swollen glands in neck	☐	☐	☐
Severe headaches/ migraines	☐	☐	☐
Severe or rapid weight loss	☐	☐	☐
Sexually transmitted disease	☐	☐	☐
Excessive urination	☐	☐	☐

	Yes	No	DK
Has a physician or previous dentist recommended that you take antibiotics prior to your dental treatment?	☐	☐	☐

Name of physician or dentist making recommendation: | Phone:

	Yes	No	DK
Do you have any disease, condition, or problem not listed above that you think I should know about?	☐	☐	☐

Please explain:

NOTE: Both doctor and patient are encouraged to discuss any and all relevant patient health issues prior to treatment.
I certify that I have read and understand the above and that the information given on this form is accurate. I understand the importance of a truthful health history and that my dentist and his/her staff will rely on this information for treating me. I acknowledge that my questions, if any, about inquiries set forth above have been answered to my satisfaction. I will not hold my dentist, or any other member of his/her staff, responsible for any action they take or do not take because of errors or omissions that I may have made in the completion of this form.

Signature of Patient/Legal Guardian: | Date:

FOR COMPLETION BY DENTIST

Comments: _____

SAMPLE

Figure 29-1, cont'd *(Form © American Dental Association. Reprinted with permission.)*

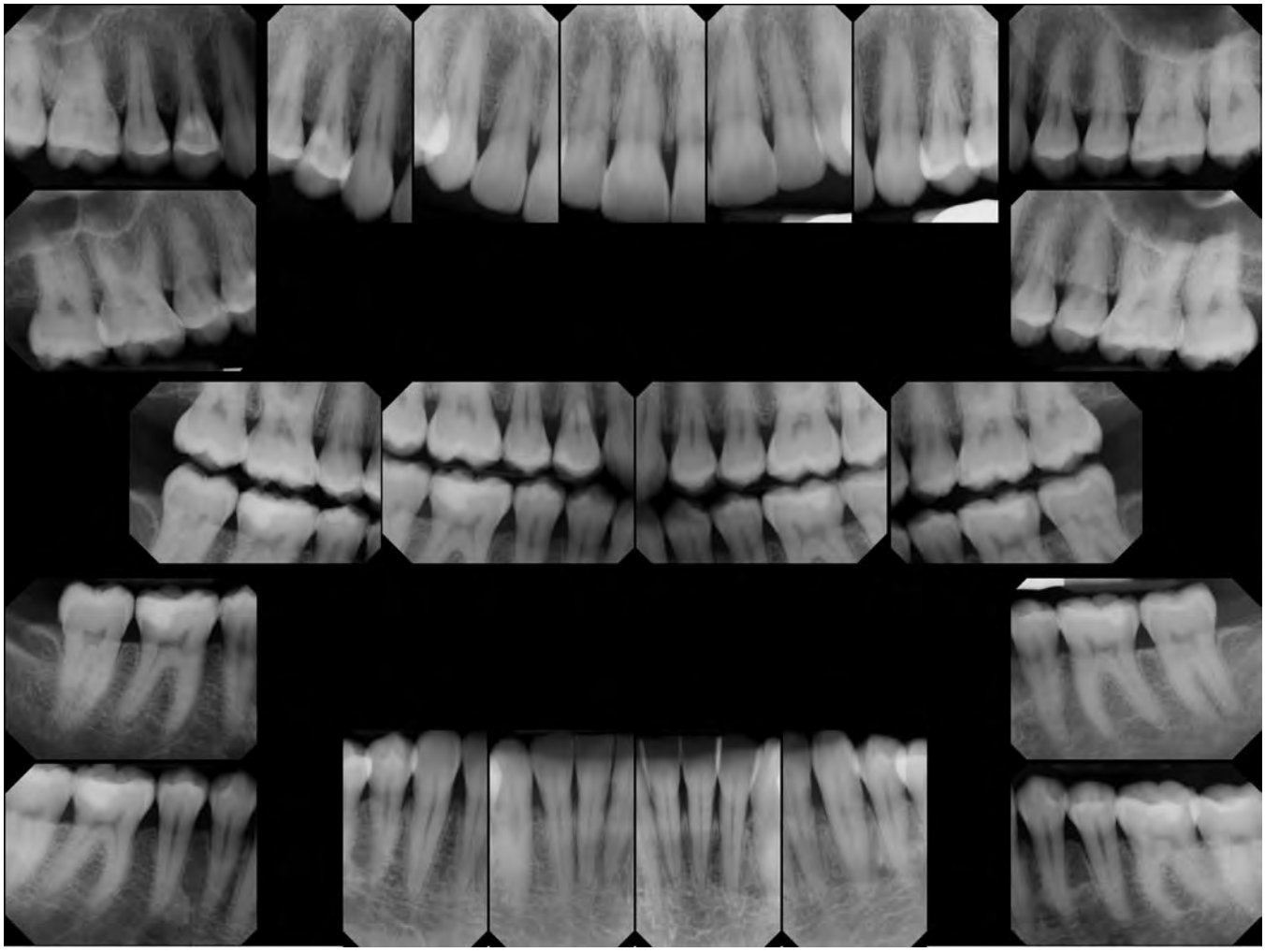

Figure 29-2 A full-mouth intraoral radiographic series (17 periapical films and 4 bite-wing films) used as an adjunct for periodontal diagnosis.

7. Assess whether the patient's teeth feel "loose" or insecure, if he or she has any difficulty chewing, and whether there is any tooth mobility.
8. Note the patient's general dental habits, such as grinding or clenching of the teeth during the day or at night. Do the teeth or jaw muscles feel "sore" in the morning? Are there other habits to address, such as tobacco smoking or chewing, nail biting, or biting on foreign objects?
9. Discuss the patient's history of previous periodontal problems, including the nature of the condition, and, if it was previously treated, the type of treatment received (surgical or nonsurgical) and the approximate period of termination of the previous treatment. If, in the opinion of the patient, the present problem is a recurrence of previous disease, what does he or she think caused it?
10. Note whether the patient wears any removable prosthesis. Does the prosthesis enhance or is it a detriment to the existing dentition or the surrounding soft tissues?
11. Does the patient have implants to replace any of the missing teeth?

Intraoral Radiographic Survey

The radiographic survey should consist of a minimum of 14 intraoral films and 4 posterior bite-wing films (Figure 29-2).

Panoramic radiographs are a simple and convenient method of obtaining a survey view of the dental arch and the surrounding structures (Figure 29-3). They are helpful for the detection of developmental anomalies, pathologic lesions of the teeth and jaws, and fractures as well as for the dental screening examinations of large groups. They provide an informative overall radiographic picture of the distribution and severity of bone destruction with periodontal disease, but *a complete intraoral series is required for periodontal diagnosis and treatment planning.* Chapter 31 gives a detailed description of radiographic interpretation in periodontics.

Casts

Casts from dental impressions are useful adjuncts during the oral examination. They indicate the position of the gingival margins (recession) and the position and inclination of the teeth, the proximal contact relationships, and the food impaction areas. In addition, they provide a view of the lingual–cuspal relationships. Casts are important records of the dentition before it is altered by treatment. Finally, casts also serve as visual aids during discussions with the patient, and they are useful for pretreatment and posttreatment comparisons as well as for reference at recall visits. They are also helpful to determine the position of implant placement if the case will require it.

Figure 29-3 A panoramic radiograph showing temporomandibular joints and "cystic" spaces in the jaw. Areas of periodontal bone loss are not seen in detail. (Compare this with Figure 29-2.)

Figure 29-4 Poor oral hygiene. The gingival inflammation is associated with plaque and calculus.

Clinical Photographs

Color photographs are useful for recording the appearance of the tissue before and after treatment. Photographs cannot always be relied on for the comparison of subtle color changes in the gingiva, but they do depict gingival morphologic changes. With the advent of digital clinical photography, record keeping for mucogingival problems (e.g., areas of gingival recession, frenum involvement, papilla loss) has become important.

Review of the Initial Examination

If no emergency care is required, the patient is dismissed and instructed about when to report for the second visit. Before this visit, a correlated examination is made of the radiographs, photographs, and casts to relate the radiographic changes to unfavorable conditions represented on the casts. The casts are checked for evidence of abnormal wear, plunger cusps, uneven marginal ridges, malposed or extruded teeth, crossbite relationships, and other conditions that could cause occlusal disharmony or food impaction. Such areas are marked on the casts to serve as a reference during the detailed examination of the oral cavity. The radiographs, photographs, and casts are valuable diagnostic aids; however, it is *the clinical findings in the oral cavity that constitute the basis for diagnosis.*

Second Visit

Oral Examination

Oral Hygiene. The cleanliness of the oral cavity is appraised in terms of the extent of accumulated food debris, plaque, and tooth surface stains (Figure 29-4). Disclosing solution may be used to detect plaque that would otherwise be unnoticed. The amount of plaque detected, however, is not necessarily related to the severity of the disease present. For example, aggressive periodontitis is a destructive type of periodontitis in which plaque is minimal. Qualitative assessments of plaque are more meaningful, and their value for diagnosis is discussed in Chapter 8.

Oral Malodor. Oral malodor, which is also termed *fetor ex ore, fetor oris,* or *halitosis,* is a foul or offensive odor that emanates from the oral cavity. Mouth odors may be of diagnostic significance, and their origin may be either oral or extraoral (remote).[58] Chapter 52 discusses in detail the problems related to oral malodor.

Examination of the Oral Cavity. The entire oral cavity should be carefully examined. The examination should include the lips, the floor of the mouth, the tongue, the palate, and the oropharyngeal region as well as the quality and quantity of saliva. Although findings may not be related to the periodontal problem, the dentist should detect all pathologic changes that are present in the mouth. Textbooks that address oral medicine and oral diagnosis cover these topics in detail.

Examination of the Lymph Nodes. Because periodontal, periapical, and other oral diseases may result in lymph node changes, the diagnostician should routinely examine and evaluate the lymph nodes of the head and neck. Lymph nodes can become enlarged or indurated as a result of an infectious episode, malignant metastases, or residual fibrotic changes.

Inflammatory nodes become enlarged, palpable, tender, and fairly immobile. The overlying skin may be red and warm. Patients are often aware of the presence of "swollen glands." Primary herpetic gingivostomatitis, necrotizing ulcerative gingivitis, and acute periodontal abscesses may produce lymph node enlargement. After successful therapy, lymph nodes return to normal in a matter of days to weeks.

Examination of the Teeth and Implants

The teeth are examined for caries, poor restorations, developmental defects, anomalies of tooth form, wasting, hypersensitivity, and proximal contact relationships. The stability, position, and number of implants and their relationship to the adjacent natural dentition are also examined.

Wasting Disease of the Teeth. *Wasting* is defined as any gradual loss of tooth substance, which is characterized by the formation of smooth, polished surfaces without regard to the possible mechanism of this loss. The forms of wasting are erosion, abrasion, and attrition.[42,60]

Erosion, which is also called *corrosion,* is a sharply defined wedge-shaped depression in the cervical area of the facial tooth

Figure 29-5 An abrasion attributed to aggressive toothbrushing *(arrow)*. The involvement of the roots is followed by the undermining of the enamel.

surface.[50] The long axis of the eroded area is perpendicular to the vertical axis of the tooth. The surfaces are smooth, hard, and polished. Erosion generally affects a group of teeth. During the early stages, it may be confined to the enamel, but it generally extends to involve the underlying dentin as well as the cementum.

The etiology of erosion is not known. Decalcification by acidic beverages[40] or citrus fruits in combination with the effect of acid salivary secretion are suggested causes. Sognnaes[66] refers to these lesions as *dentoalveolar ablations* and attributes them to forceful frictional actions between the oral soft tissues and the adjacent hard tissues. In patients with erosion, the salivary pH, the buffering capacity, and the calcium and phosphorus content have been reported as normal, and the mucin level is elevated.[39]

Abrasion refers to the loss of tooth substance that is induced by mechanical wear other than that of mastication. Abrasion results in saucer-shaped or wedge-shaped indentations with a smooth, shiny surface. Abrasion starts on the exposed cementum surfaces rather than on the enamel, and it extends to involve the dentin of the root. A sharp "ditching" around the cementoenamel junction appears to be the result of the softer cemental surface as compared with the much harder enamel surface.

Continued exposure to the abrasive agent in combination with decalcification of the enamel by locally formed acids may result in a loss of enamel followed by a loss of the dentin of the crown.

Toothbrushing[22] with an abrasive dentifrice (Figure 29-5) and the action of clasps are frequently mentioned, but aggressive toothbrushing is the most common cause.[30] Tooth position (facial) is also a major factor in the abrasive loss of the root surface. The degree of tooth wear from toothbrushing depends on the abrasive effect of the dentifrice and the angle of brushing.[37,38] Horizontal brushing at right angles to the vertical axis of the teeth results in the severest loss of tooth substance. Occasionally, abrasion of the incisal edges occurs as a result of habits such as holding objects (e.g., bobby pins, tacks) between the teeth.

Attrition is occlusal wear that results from functional contacts with opposing teeth. Such physical wear patterns may occur on incisal, occlusal, and approximal tooth surfaces. A certain amount of tooth wear is physiologic, but accelerated wear may occur when abnormal anatomic or unusual functional factors are present.

Occlusal or incisal surfaces worn by attrition are called *facets*. When active tooth grinding occurs, the enamel rods are fractured and become highly reflective to light.[74] Thus, shiny, smooth, and curviplanar facets are usually the best indicator of ongoing frictional activity. If dentin is exposed, a yellowish brown discoloration is frequently present (Figure 29-6). Facets vary with regard to size and location, depending on whether they are produced by physiologic or abnormal wear.[12,72] At least one significant wear

Figure 29-6 Flat, shiny, discolored surfaces produced by occlusal wear.

facet has been reported in 92% of adults,[63] and facet prevalence approaches universality.[10,73] Facets are usually not sensitive to thermal or tactile stimulation.

Facets generally represent functional or parafunctional wear as well as iatrogenic dental treatment through coronoplasty (occlusal adjustment). However, coronoplasty does not appear to contribute to higher ratings of wear.[64] Excessive wear may result in the obliteration of the cusps and the formation of either a flat or a cuneiform (cupped-out) occlusal surface. Contrary to earlier thought, attrition in young adults from modern societies is not age related.[15,64] This suggests that a significant amount of attrition, when present in young adults, is unlikely to occur as a result of functional wear,[32] and it is probably the result of bruxing activity.[64] Attrition has been correlated with age when older adults are considered.[7,62]

The angle of the facet on the tooth surface is potentially significant to the periodontium. Horizontal facets tend to direct forces on the vertical axis of the tooth to which the periodontium can adapt most effectively. Angular facets direct occlusal forces laterally and increase the risk of periodontal damage. However, gradual attrition may be compensated for by continuous tooth eruption without alveolar bone growth, and it is characterized by a lack of inflammatory changes on the alveolar bone surfaces.[69]

Another mechanism of tooth wear that has been studied recently is called *abfraction,* and it results from occlusal loading surfaces causing tooth flexure and mechanical microfractures and tooth substance loss in the cervical area.[24]

These four mechanisms of tooth wear (corrosion, abrasion, attrition, and abfraction) can combine with each other to result in an increased degree of tooth wear.

Dental Stains. Dental stains are pigmented deposits on the teeth. They should be carefully examined to determine their origin (see Chapter 7).

Hypersensitivity. Root surfaces exposed by gingival recession may be hypersensitive to thermal changes or tactile stimulation. Patients often direct the clinician to the sensitive areas. These may be located by gentle exploration with a probe or cold air.

Proximal Contact Relations. Open contacts allow for food impaction. The tightness of contacts should be checked by means of clinical observation and with dental floss. Abnormal contact relationships may also initiate occlusal changes, such as a shift in

the median line between the central incisors with labial flaring of the maxillary canine; buccal or lingual displacement of the posterior teeth; and an uneven relationship of the marginal ridges. Teeth opposite an edentulous site may supererupt, thereby opening the proximal contacts.

Tooth Mobility. All teeth have a slight degree of physiologic mobility, which varies for different teeth and at different times of the day.[47,51] It is greatest when arising in the morning, and it progressively decreases. The increased mobility in the morning is attributed to slight extrusion of the tooth as a result of limited occlusal contact during sleep. During the waking hours, mobility is reduced by chewing and swallowing forces, which intrude the teeth in the sockets. These 24-hour variations are less marked in persons with a healthy periodontium than in those with occlusal habits such as bruxism and clenching.

Single-rooted teeth have more mobility than multi-rooted teeth, with incisors having the most mobility. Mobility occurs primarily in a horizontal direction, although some axial mobility occurs to a lesser degree.[49]

Tooth mobility occurs in the following two stages:

1. The initial or intrasocket stage occurs when the tooth moves within the confines of the periodontal ligament. This is associated with viscoelastic distortion of the ligament and the redistribution of the periodontal fluids, interbundle content, and fibers.[31] This initial movement occurs with forces of about 100 lb, and it is on the order of 0.05 mm to 0.10 mm (50 µm to 100 µm).[43]
2. The secondary stage occurs gradually and entails the elastic deformation of the alveolar bone in response to increased horizontal forces.[45] When a force of 500 g is applied to the crown, the resulting displacement is about 100 µm to 200 µm for incisors, 50 µm to 90 µm for canines, 8 µm to 10 µm for premolars, and 40 µm to 80 µm for molars.[43]

When a force such as that applied to teeth in occlusion is discontinued, the teeth return to their original position in two stages: the first is an immediate, springlike elastic recoil; the second is a slow, asymptomatic recovery movement. The recovery movement is pulsating, and it is apparently associated with the normal pulsation of the periodontal vessels, which occurs in synchrony with the cardiac cycle.[44]

Many attempts have been made to develop mechanical or electronic devices for the precise measurement of tooth mobility.[44,48,50,63] Although standardization of grading mobility would be helpful for the diagnosis of periodontal disease and for evaluating treatment outcomes, these devices are not widely used. As a general rule, mobility is graded clinically by holding the tooth firmly between the handles of two metallic instruments or with one metallic instrument and one finger (Figure 29-7). An effort is then made to move it in all directions. Abnormal mobility most often occurs faciolingually. Mobility is graded according to the ease and extent of tooth movement as follows:

- Normal mobility
- Grade I: Slightly more than normal
- Grade II: Moderately more than normal
- Grade III: Severe mobility faciolingually, mesiodistally, or both in combination with vertical displacement

Mobility beyond the physiologic range is termed *abnormal* or *pathologic.* It is pathologic in that it exceeds the limits of normal mobility values; however, the periodontium is not *necessarily* diseased at the time of examination.

Increased mobility is caused by one or more of the following factors:

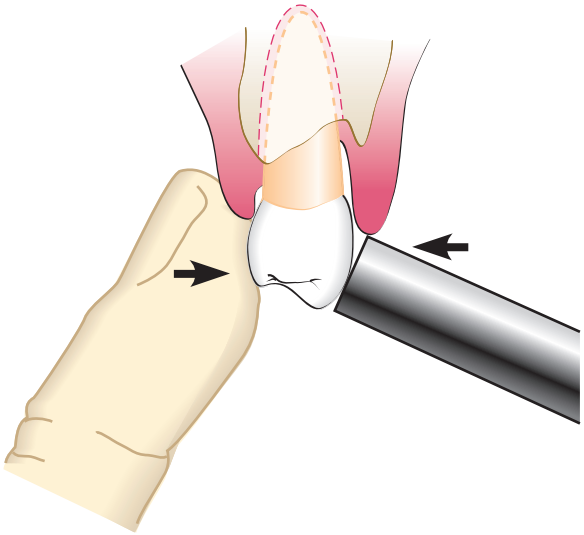

Figure 29-7 Tooth mobility is checked with a metal instrument and one finger.

1. *Loss of tooth support (bone loss)* can result in mobility. The amount of mobility depends on the severity and distribution of bone loss at individual root surfaces, the length and shape of the roots, and the root size as compared with that of the crown.[50] A tooth with short, tapered roots is more likely to loosen than one with normal-size or bulbous roots with the same amount of bone loss. One should carefully evaluate post-orthodontic cases for possible apical shortening of the root, which may lead to excessive mobility. Because bone loss usually results from a combination of factors and does not occur as an isolated finding, the severity of tooth mobility does not necessarily correspond to the amount of bone loss.
2. *Trauma from occlusion* (i.e., injury produced by excessive occlusal forces or incurred as a result of abnormal occlusal habits such as bruxism and clenching) is a common cause of tooth mobility. Mobility is also increased by hypofunction. Mobility produced by trauma from occlusion occurs initially as a result of resorption of the cortical layer of bone, which leads to reduced fiber support, and later as an adaptation phenomenon that results in a widened periodontal space.
3. *Extension of inflammation* from the gingiva or from the periapex into the periodontal ligament results in changes that increase mobility. The spread of inflammation from an acute periapical abscess may increase tooth mobility in the absence of periodontal disease.
4. *Periodontal surgery* temporarily increases tooth mobility immediately after the intervention and for a short period.[53-56]
5. Tooth mobility is increased during *pregnancy,* and it is sometimes associated with the *menstrual cycle* or the use of *hormonal contraceptives.* This is unrelated to periodontal disease, and it occurs presumably because of physicochemical changes in the periodontal tissues.
6. *Pathologic processes of the jaws* that destroy the alveolar bone or the roots of the teeth can also result in mobility. Osteomyelitis and tumors of the jaws belong in this category.

One study[20] has suggested that pockets around mobile teeth harbor higher proportions of *Campylobacter rectus* and *Peptostreptococcus micros* and possibly of *Porphyromonas gingivalis* as compared with nonmobile teeth. This hypothesis requires further verification.

Trauma from Occlusion. *Trauma from occlusion* refers to *tissue injury* produced by occlusal forces rather than to the occlusal forces themselves (see Chapter 22). The criterion that determines that an occlusion is traumatic is whether it causes damage in the periodontal tissues; therefore, the diagnosis of trauma from occlusion is made from the condition of the periodontal tissues. The periodontal findings are then used as a guide for locating the responsible occlusal relationships.

Periodontal findings that suggest the presence of trauma from occlusion include excessive tooth mobility, particularly in teeth that show radiographic evidence of a widened periodontal space; vertical or angular bone destruction; infrabony pockets; and pathologic migration, especially of the anterior teeth. These are discussed in more detail in the following sections.

Pathologic Migration of the Teeth. Alterations in tooth position should be carefully noted, particularly with a view toward identifying abnormal forces, a tongue-thrusting habit, or other habits that may be contributing factors (see Chapter 22). Premature tooth contacts in the posterior region that deflect the mandible anteriorly contribute to the destruction of the periodontium of the maxillary anterior teeth and to pathologic migration (Figure 29-8; see also Chapter 22). The loss of posterior teeth can lead to the facial "flaring" of the maxillary anterior dentition. This is due to the increased trauma that the mandibular anterior dentition places against the palatal surface of the maxillary anterior dentition. Pathologic migration of the anterior teeth in young persons may be a sign of localized aggressive (juvenile) periodontitis.

Sensitivity to Percussion. Sensitivity to percussion is a feature of acute inflammation of the periodontal ligament. Gentle percussion of a tooth at different angles to the long axis often helps with the localization of the site of inflammatory involvement.

Dentition With the Jaws Closed. Examination of the dentition with the jaws closed can detect conditions, such as irregularly aligned teeth, extruded teeth, improper proximal contacts, and areas of food impaction, all of which may favor plaque accumulation.

Excessive *overbite,* which is seen most often in the anterior region, may cause the impingement of the teeth on the gingiva and food impaction, followed by gingival inflammation, gingival enlargement, and pocket formation. The real significance of the detrimental effect of an excessive anterior overbite on gingival health is still controversial.[2]

In *open-bite* relationships, abnormal vertical spaces exist between the maxillary and mandibular teeth. The condition occurs most often in the anterior region, although posterior open bite is occasionally seen. Reduced mechanical cleansing by the passage of food may lead to the accumulation of plaque, debris, calculus formation, and the extrusion of teeth.

With *crossbite,* the normal relationship of the mandibular teeth to the maxillary teeth is reversed, with the maxillary teeth being lingual to the mandibular teeth. Crossbite may be bilateral or unilateral, or it may affect only a pair of antagonists. Trauma from occlusion, food impaction, spreading of the mandibular teeth, and associated gingival and periodontal disturbances may be caused by crossbite.

Figure 29-8 Periodontal disease with pathologic migration of the anterior teeth. **A,** Clinical photograph. **B,** Radiographic view.

Functional Occlusal Relationships. The examination of functional occlusal relationships is an important part of the diagnostic procedure. Dentitions that appear to be normal when the jaws are closed may present marked functional abnormalities. Systematic procedures for the detection and correction of functional abnormalities are presented in Chapter 50.

Examination of the Periodontium

The periodontal examination should be systematic, starting in the molar region in either the maxilla or the mandible and proceeding around the arch. This prevents the overemphasis of unusual findings at the expense of other conditions that, although less striking, may be equally important. It is important to detect the earliest signs of gingival and periodontal disease.

Charts to record the periodontal and associated findings provide a guide for a thorough examination and record of the patient's condition (Figure 29-9, *A* and *B*). They are also used to evaluate the response to treatment and for comparison at recall visits. However, excessively complicated mouth charting may lead to a frustrating maze of minutiae rather than clarification of the patient's problem.

During the last decade, electronic clinical records have been developed and are increasingly being used by general dentists and periodontists. Most systems provide rapid and easy access to information and allow for the incorporation of digital clinical and radiographic images.[59] Computerized dental examination systems that make use of high-resolution graphics and voice-activated technology allow for the easy retrieval and comparison of data.[11]

Plaque and Calculus. There are many methods available for assessing plaque and calculus accumulation.[17] The presence of supragingival plaque and calculus can be directly observed, and the amount can be measured with a calibrated probe. For the detection of subgingival calculus, each tooth surface is carefully checked to the level of the gingival attachment with a no. 17 or no. 3A explorer (Figure 29-10). Warm air may be used to deflect the gingiva and to aid in the visualization of the calculus.

Although radiographs may sometimes reveal heavy calculus deposits interproximally and even on the facial and lingual surfaces, they cannot be relied on for the thorough detection of calculus.

Gingiva. The gingiva must be dried before accurate observations can be made (Figure 29-11). Light reflection from moist gingiva obscures detail. In addition to visual examination and exploration with instruments, firm but gentle palpation should be used to detect pathologic alterations in normal resilience as well as to locate areas of exudate.

Features of the gingiva to consider include color, size, contour, consistency, surface texture, position, ease of bleeding, and pain (see Chapter 15). Any deviation from the norm should be evaluated and not overlooked. The distribution of gingival disease and its acute or chronic nature should also be noted.

Clinically, gingival inflammation can produce two basic types of tissue response: edematous and fibrotic. *Edematous* tissue response is characterized by a smooth, glossy, soft, red gingiva. With the *fibrotic* tissue response, some of the characteristics of normalcy persist; the gingiva is more firm, stippled, and opaque; it is usually thicker, and the margin appears rounded.

Use of Clinical Indices in Dental Practice. There has been a tendency to extend the use of indices that were originally designed for epidemiologic studies into dental practice (see Chapter 4). Of all of the indices proposed, the gingival index and the sulcus bleeding index appear to be the most useful and the most easily transferred to clinical practice.

The *gingival index*[35] provides an assessment of the gingival inflammatory status that can be used in practice to compare gingival health before and after phase 1 therapy or before and after surgical therapy. It can also be used to compare the gingival status at recall visits. Attaining good intraexaminer and interexaminer calibration is imperative in the dental office.

The *sulcus bleeding index*[46] provides an objective and easily reproducible assessment of the gingival status. It is extremely useful for detecting early inflammatory changes and the presence of inflammatory lesions located at the base of the periodontal pocket, which is an area inaccessible to visual examination. Patients can easily understand this index; therefore, it can be used to enhance the patient's motivation for plaque control.

Periodontal Pockets. Examination for periodontal pockets must include their presence and distribution on each tooth surface, the pocket depth, the level of attachment on the root, and the type of pocket (i.e., suprabony or infrabony).

Signs and Symptoms. Although probing is the only reliable method of detecting pockets, clinical signs such as color changes (i.e., a bluish-red marginal gingiva or a bluish-red vertical zone that extends from the gingival margin to the attached gingiva); a "rolled" edge separating the gingival margin from the tooth surface; or an enlarged, edematous gingiva may suggest their presence. The presence of bleeding, suppuration, and loose, extruded teeth may also denote the presence of a pocket (Figures 29-12).

Periodontal pockets are generally painless, but they may give rise to symptoms such as localized or sometimes radiating pain or the sensation of pressure after eating that gradually diminishes. A foul taste in localized areas, sensitivity to hot and cold, and toothache in the absence of caries is also sometimes present.

Detection of Pockets. The only accurate method of detecting and measuring periodontal pockets is careful exploration with a periodontal probe. Pockets are not detected by radiographic examination. The periodontal pocket is a soft-tissue change. Radiographs indicate areas of bone loss in which pockets may be suspected, but they do not show pocket presence or depth, and consequently they show no difference before and after pocket elimination unless bone has been modified.

Gutta-percha points or calibrated silver points[26] can be used with the radiograph to assist with determining the level of attachment of the periodontal pockets (Figure 29-13). They may be used effectively for individual pockets or in clinical research, but their routine use throughout the mouth would be difficult to manage. Clinical examination and probing are more direct and efficient. See Chapter 31 for detailed information about radiographic examination.

Pocket Probing. There are two different pocket depths: (1) the biologic or histologic depth; and (2) the clinical or probing depth[25] (Figure 29-14).

The *biologic depth* is the distance between the gingival margin and the base of the pocket (i.e., the coronal end of the junctional epithelium). This can be measured only in carefully prepared and adequately oriented histologic sections. The *probing depth* is the distance to which a probe penetrates into the pocket. Probes that are presently used are described in Chapter 46.

Probe penetration can vary, depending on the force of introduction, the shape and size of the probe tip, the direction of penetration, the resistance of the tissues, the convexity of the crown, and the degree of tissue inflammation.[4] Several studies have been made

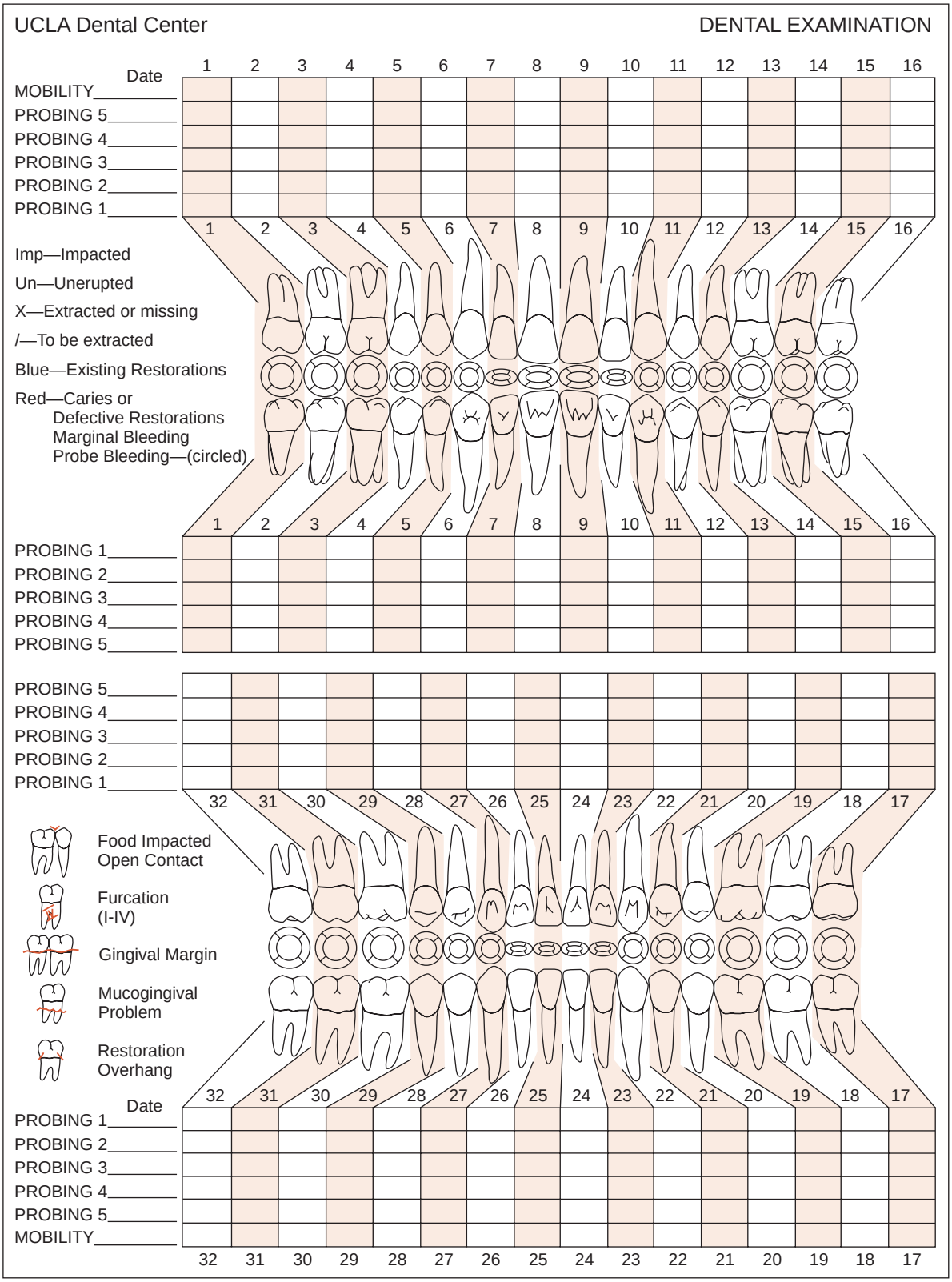

A

Figure 29-9 **A,** University of California, Los Angeles, periodontal chart.

Continued

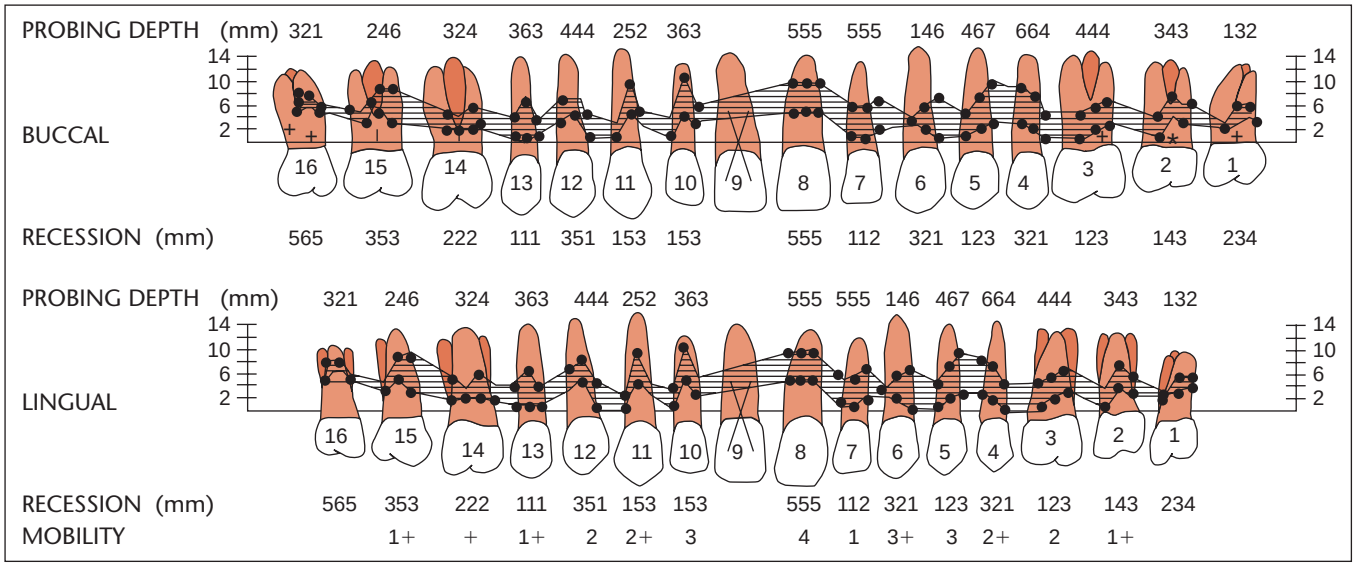

B

Figure 29-9, cont'd **B,** Computerized diagram showing various periodontal parameters. *(Courtesy University of California, Los Angeles, School of Dentistry.)*

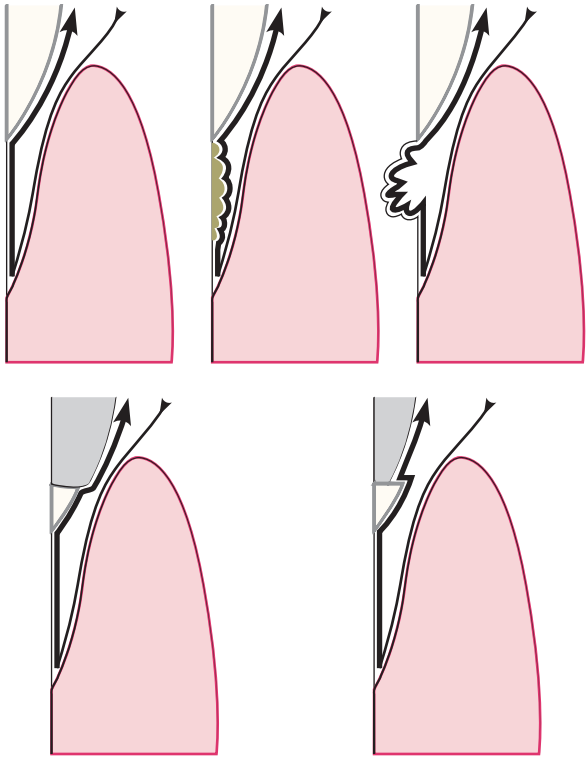

Figure 29-10 *Top left,* Detection of the smoothness of various irregularities on the root surface with the outward motion of a probe or explorer. *Top center,* Calculus. *Top right,* Caries. *Bottom left and right,* Irregular margins of restorations.

Figure 29-11 Normal gingiva with incipient gingivitis in teeth #11 and #22. Normal surface features are better revealed by drying gingiva.

Figure 29-12 Periodontal pockets around the mandibular anterior teeth showing rolled margins, edematous inflammatory changes, and abundant calculus and plaque. Note the suppuration from tooth #6.

to determine the depth of penetration of a probe in a sulcus or pocket. Armitage and colleagues[6] used beagle dogs to evaluate the penetration of a probe with the use of a standardized force of 25 g. They reported that, in patients with healthy gingiva, the probe penetrated the epithelium to about two thirds of its length; in patients with gingivitis, it stopped 0.1 mm short of its apical end; and in patients with periodontitis, the probe tip consistently went past the most apical cells of the junctional epithelium (Figure 29-15).

In human periodontal pockets, the probe tip penetrates to the most coronal intact fibers of the connective tissue attachment.[34,67] The depth of penetration of the probe in the connective tissue apical to the junctional epithelium in a periodontal pocket is about 0.3 mm.[34,61,67] This is important when evaluating differences in probing depth before and after treatment, because the reduction in

Figure 29-13 Blunted silver points assist with locating the base of the pocket.

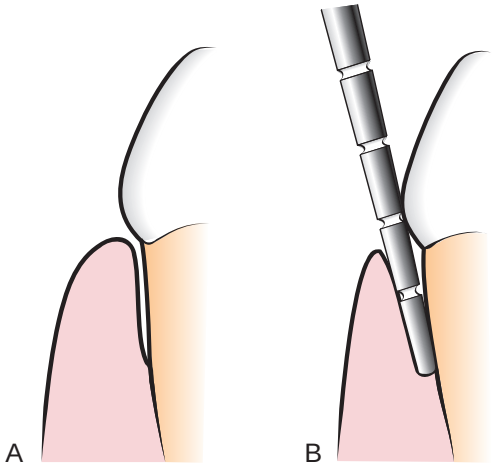

Figure 29-14 **A,** The biologic or histologic pocket depth is the actual distance between the gingival margin and the attached tissues (i.e., the bottom of the pocket). **B,** The probing or clinical pocket depth is the depth of penetration of the probe.

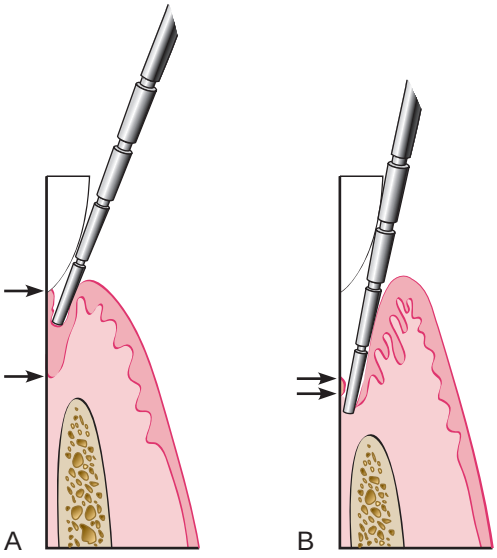

Figure 29-15 **A,** In a normal sulcus with a long junctional epithelium (between *arrows*), the probe penetrates about one third to half the length of the junctional epithelium. **B,** In a periodontal pocket with a short junctional epithelium (between *arrows*), the probe penetrates beyond the apical end of the junctional epithelium.

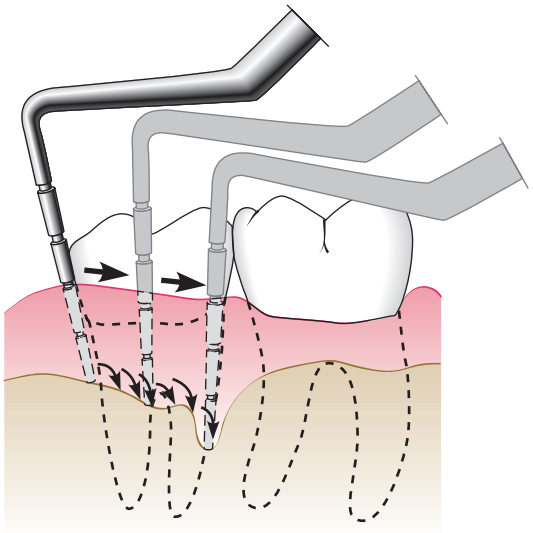

Figure 29-16 "Walking" the probe to explore the entire pocket.

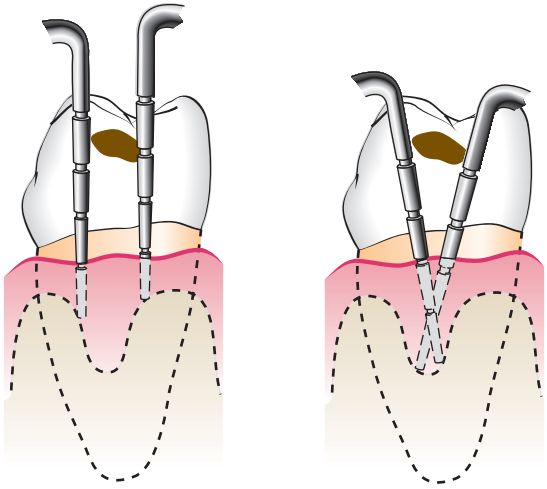

Figure 29-17 Vertical insertion of the probe *(left)* may not detect interdental craters; oblique positioning of the probe *(right)* reaches the depth of the crater.

probe penetration may be a result of reduced inflammatory response rather than of a gain in attachment.[33,36]

The probing forces have been explored by several investigators[18,70,71]; forces of 0.75 N have been found to be well tolerated and accurate.[68] Interexaminer error (i.e., depth discrepancies between examiners) was reported to be as much as 2.1 mm (with an average of 1.5 mm) in the same areas.[25]

Probing Technique. The probe should be inserted parallel to the vertical axis of the tooth and "walked" circumferentially around each surface of each tooth to detect the areas of deepest penetration (Figure 29-16).

In addition, special attention should be directed to detecting the presence of interdental craters and furcation involvements. To detect an *interdental crater,* the probe should be placed obliquely from both the facial and lingual surfaces to explore the deepest point of the pocket located beneath the contact point (Figure 29-17). In multi-rooted teeth, the possibility of *furcation involvement* should be carefully explored. The use of specially designed probes (e.g., Nabers probes) allows for an easier and more accurate exploration of the horizontal component of furcation lesions (Figure 29-18).

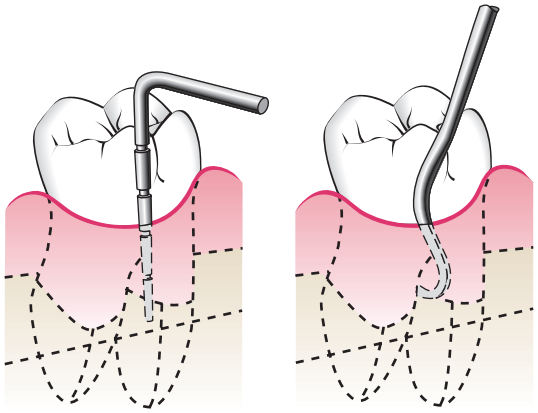

Figure 29-18 Exploring with a periodontal probe *(left)* may not detect furcation involvement; specially designed instruments (i.e., Nabers probes) *(right)* can enter the furcation area.

Level of Attachment Versus Pocket Depth. *Pocket depth* is the distance between the base of the pocket and the gingival margin. It may change from time to time, even in patients with untreated periodontal disease, as a result of changes in the position of the gingival margin. Therefore, it may be unrelated to the existing attachment of the tooth.

Alternatively, the level of attachment is the distance between the base of the pocket and a fixed point on the crown, such as the cementoenamel junction (CEJ). Changes in the level of attachment can be the result of a gain or loss of attachment, and they can afford a better indication of the degree of periodontal destruction or gain. *Shallow pockets attached at the level of the apical third of the root connote more severe destruction than deep pockets attached at the coronal third of the roots* (see Chapter 20 and Figures 20-17, 20-18, and 20-19).

Determining the Level of Attachment. When the *gingival margin is located on the anatomic crown,* the level of attachment is determined by subtracting from the depth of the pocket the distance from the gingival margin to the CEJ. If both are the same, the loss of attachment is zero.

When the gingival margin coincides with the CEJ, the loss of attachment equals the pocket depth.

When the gingival margin is located apical to the CEJ, the loss of attachment is greater than the pocket depth. Therefore, the distance between the CEJ and the gingival margin should be added to the pocket depth. Drawing the gingival margin on the chart where pocket depths are entered helps to clarify this important point.[65]

Bleeding on Probing. The insertion of a probe to the bottom of the pocket elicits bleeding if the gingiva is inflamed and if the pocket epithelium is atrophic or ulcerated. Noninflamed sites rarely bleed. In most cases, bleeding on probing is an earlier sign of inflammation than gingival color changes[41] (see Chapter 15). However, color changes may present without bleeding on probing.[22] Depending on the severity of inflammation, bleeding can vary from a tenuous red line along the gingival sulcus to profuse bleeding.[1] If periodontal treatment is successful, bleeding on probing will cease.[3]

To test for bleeding after probing, the probe is carefully introduced to the bottom of the pocket and gently moved laterally along the pocket wall. Sometimes bleeding appears immediately after the removal of the probe; other times, it may be delayed for a few seconds. Therefore, the clinician should recheck for bleeding 30 to 60 seconds after probing.

As a single test, bleeding on probing is not a good predictor of progressive attachment loss; however, its absence is an excellent predictor of periodontal stability.[4] When bleeding is present in multiple sites of advanced disease, bleeding on probing is a good indicator of progressive attachment loss.[4,19] Armitage analyzed the literature on this subject up to 1996; he performed a meta-analysis of the various papers and concluded that the presence of bleeding on probing in a "treated and maintained patient population" is an important risk predictor for increased loss of attachment.[4]

The insertion of a soft wooden interdental stimulator in the interdental space produces a similar bleeding response.[3] This tool can be used by the patient to self-examine the gingiva for the presence of inflammation.[13]

When to Probe. The probing of pockets is performed at various times for diagnosis and to monitor the course of treatment and maintenance. The initial probing of moderate or advanced cases is usually hampered by the presence of heavy inflammation and abundant calculus, and it cannot be done very accurately. Probing at this stage is also difficult as a result of the discomfort and pain that occurs when the gingival tissues are inflamed.

The purpose of this initial probing, together with the clinical and radiographic examination, is to determine whether the tooth should be saved or extracted. After the patient has performed adequate plaque control for some time and the calculus has been removed, the major inflammatory changes disappear, and an accurate probing of the pockets can be performed. The purpose of this second probing is to accurately establish the level of attachment and the degree of involvement of roots and furcations. Data obtained from this probing provides valuable information for treatment decisions.

Later during periodontal treatment, probings are done to determine changes in pocket depth and to ascertain healing progress after different procedures.

Probing Around Implants. Because implants are susceptible to bone loss, probing around them becomes part of examination and diagnosis. A traditional periodontal probe may be used under light force (e.g., 0.25 N) without damaging the periimplant mucosal seal.[16]

Automatic and Electronic Periodontal Probing. The use of the periodontal probe is the classic method to detect pocket depth and loss of attachment. However, it presents some problems in terms of reproducibility of the measurements. Accuracy and reproducibility depend not only on root morphology and tissue changes but also, very importantly, on the probing technique, the probing force, the size of the probe, the angle of insertion of the probe, and the precision of the probe's calibration (Figure 29-19).

Probing Force. One of the main problems of reproducibility has been the variation of probing force. The development of pressure-sensitive probes has helped to overcome this. It has been shown that, with forces of up to 30 g, the tip of the probe remains within the junctional epithelium,[5] whereas forces of up to 50 g are necessary to reach the bone level.[28]

Probe Angulation. Standardization of the probe tip (i.e., <1 mm) and the addition of registration stents to maintain reproducible probe angulation have been used to overcome this error.[8] New, commercially available, computer-assisted technology has been used to improve probing accuracy and reproducibility. In addition to more accurate measurement, the data derived from automatic probing can become part of the electronic record. Once incorporated, clinical changes and patterns of disease activity can be easily determined. These records also provide feedback to the patient. The Florida Probe System[2] (Figure 29-20) consists of a probe handpiece, a digital readout, a foot switch, a computer

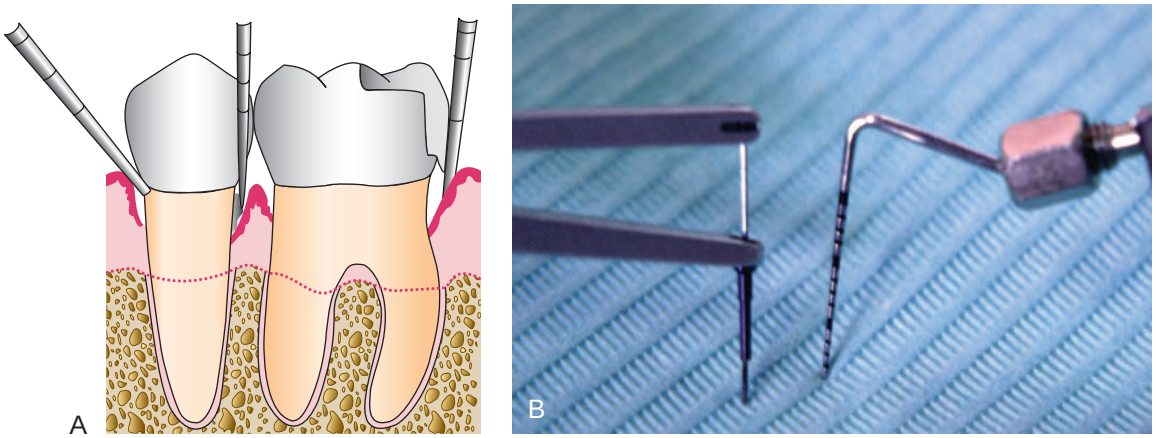

Figure 29-19 **A,** The limitations of periodontal probing. **B,** Probing pressure caused by probe angulation, the presence of subgingival calculus, and the presence of overhanging restorations. *(**A,** Courtesy Dr. J. Frontan.)*

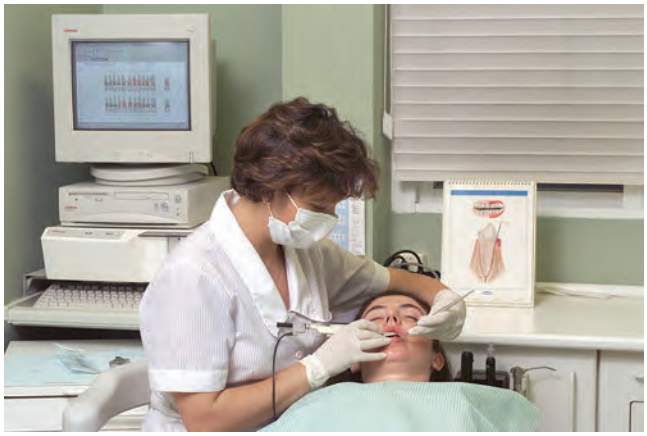

Figure 29-20 Automated periodontal probes: Florida Probe System. Integration of direct electronic measurements with constant probing force, with computer storage and online data readout.

interface, and a computer. The end of the probe is 0.4 mm, and it reciprocates through a sleeve that provides a reference by which measurements are made.

These measurements are made electronically and transferred automatically when the foot switch is pressed or when a voice command is given. Constant probing force is provided by coil springs inside the probe handpiece and a digital readout (Figure 29-21). This method combines the advantages of a constant probing force with precise electronic measurement and computer storage of data, thereby eliminating the potential errors associated with visual reading and the need for an assistant to record the measurements.

Several studies have been made comparing the Florida Probe with conventional probing. The automatic probe appears to underestimate deep probing depths[52] but to show less variability than conventional probing.[14,57,75] The automatic probe also has the problem of providing little tactile sensitivity, thereby making it more difficult to "walk" the probe.

Electronic systems such as the Interprobe and the Periprobe provide constant probing force and computer storage of data, but their reproducibility is only slightly better than that of conventional methods.[57,75]

The lack of standardization between probings by different individuals and at different times by the same individual depend not only on root morphology and tissue changes but also on the probing technique, the probing force, the size of the probe, the angle of insertion of the probe, and the precision of the probe's calibration. For measurements of clinical attachment loss, it is necessary to identify the location of the CEJ, and this offers another hurdle for the standardization of measurements.

Determination of Disease Activity. Currently, there are no accurate methods to determine the activity or inactivity of a lesion. Inactive lesions may show little or no bleeding with probing and minimal amounts of gingival fluid. Active lesions bleed more readily with probing and have large amounts of fluid and exudates, although active and nonactive sites may show no differences with regard to bleeding with probing, even in patients with aggressive periodontitis.[28] The bacterial flora in a healthy gingival sulcus, as revealed by dark-field microscopy, consists mostly of coccoid cells. The bacterial flora of a periodontal pocket shows a greater number of spirochetes and motile bacteria.[23]

For the determination of pocket depth or attachment levels to provide information about whether the lesion is in an active or inactive state, measurements taken at different times have to be compared. The precise assessment and comparison of the clinical attachment level at different intervals of time can determine whether the attachment is being lost, which indicates that the lesion is active. The exact measurement of this important clinical parameter is done from the CEJ to the bottom of the pocket and therefore requires that the location of this landmark be determined exactly and reproducibly.

The Florida Probe provides a means of recording relative clinical attachment level changes over time. A later model of the probe has a modified sleeve with a prominent 0.125-mm edge to facilitate a "catch" of the CEJ. The width of this edge is considered small enough not to interfere with probing-depth measurements, thus providing concurrent measurements of clinical attachment level and pocket depth.[29,62] Of course, this measurement does not predict the future but only shows what happened during the period of time between the two measurements. See Chapters 8 and 9 for descriptions of other methods used to determine disease activity that is still in a developmental stage. The precise determination of disease activity will have a direct effect on diagnosis, prognosis, and therapy. The goals of therapy may change, depending on the state of the periodontal lesion.

Amount of Attached Gingiva. It is important to establish the relationship between the bottom of the pocket and the

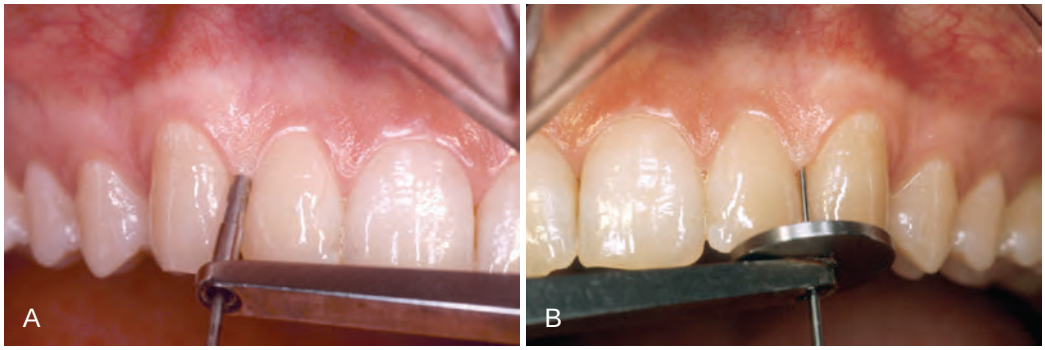

Figure 29-21 Florida Probe System. **A,** Handpiece for assessing probing pocket depths. **B,** Handpiece for assessing relative clinical attachment levels.

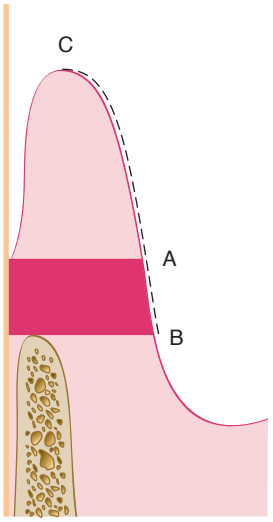

Figure 29-22 The shaded area shows the attached gingiva, which extends between the projection on the external surface of the bottom of the pocket *(A)* and the mucogingival junction *(B)*. The keratinized gingiva may extend from the mucogingival junction *(B)* to the gingival margin *(C)*.

mucogingival line. The width of the attached gingiva is the distance between the mucogingival junction and the projection on the external surface of the bottom of the gingival sulcus or the periodontal pocket. It should not be confused with the width of the keratinized gingiva, because the latter also includes the marginal gingiva (Figure 29-22).

The width of the attached gingiva is determined by subtracting the sulcus or pocket depth from the total width of the gingiva (i.e., the gingival margin to the mucogingival line). This is done by stretching the lip or cheek to demarcate the mucogingival line while the pocket is being probed (Figure 29-23). The amount of attached gingiva is generally considered to be insufficient when the stretching of the lip or cheek induces the movement of the free gingival margin.

Other methods that are used to determine the amount of attached gingiva include pushing the adjacent mucosa coronally with a dull instrument or painting the mucosa with Schiller's potassium iodide solution, which stains keratin.

Degree of Gingival Recession. During periodontal examination, it is necessary to record the data regarding the amount of gingival recession. This measurement is taken with a periodontal probe from the CEJ to the gingival crest, and it is drawn on the patient's chart.

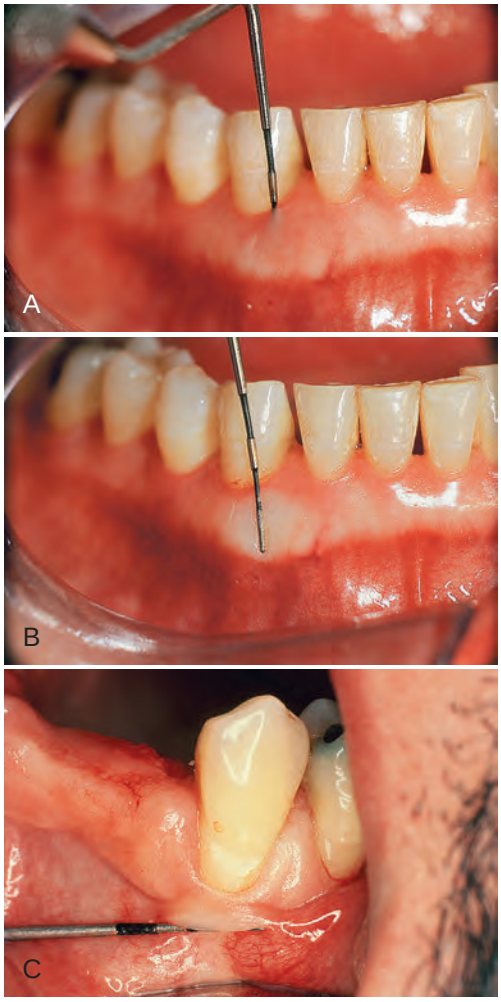

Figure 29-23 To determine the width of the attached gingiva, **A,** the pocket is probed, and then **B,** the probe is placed on the outer surface while the lip or cheek is extended to demarcate the mucogingival line. **C,** Another method that can be used to demarcate the mucogingival line is pushing the lip or cheek coronally.

Alveolar Bone Loss. Alveolar bone levels are evaluated via both clinical and radiographic examination. Probing is helpful for determining the following: (1) the height and contour of the facial and lingual bones, which are obscured on the radiograph by the roots; and (2) the architecture of the interdental bone. Transgingival probing, which is performed after the area is anesthetized, is a more accurate method of evaluation, and it provides additional information about bone architecture.[21,30,68]

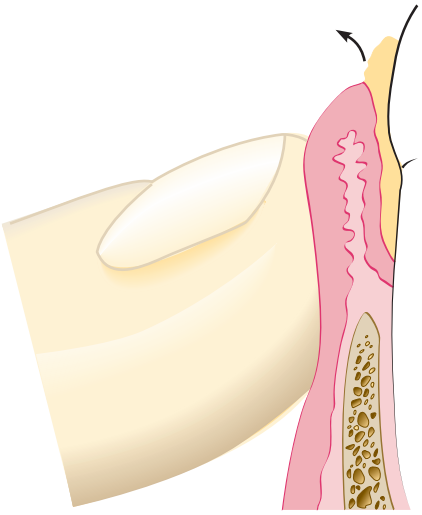

Figure 29-24 Purulent exudate expressed from a periodontal pocket by digital pressure.

Palpation. Palpating the oral mucosa in the lateral and apical areas of the tooth may help to locate the origin of radiating pain that the patient cannot localize. Infection deep in the periodontal tissues and the early stages of a periodontal abscess may also be detected by palpation.

Suppuration. The presence of an abundant number of neutrophils in the gingival fluid transforms it into a purulent exudate.[4] Several studies[9,10,13,27] have evaluated the association between suppuration and the progression of periodontitis, and they have reported that this sign is present in a very low percentage of diseased sites (i.e., 3% to 5%).[4] Therefore, it is not by itself a good indicator.

Clinically, the presence of exudate in a periodontal pocket is determined by placing the ball of the index finger along the lateral aspect of the marginal gingiva and applying pressure in a rolling motion toward the crown (Figure 29-24). Visual examination without digital pressure is not enough. The purulent exudate is formed in the inner pocket wall, and therefore the external appearance may give no indication of its presence. Exudate formation does not occur in all periodontal pockets, but digital pressure often reveals it in pockets where its presence is not suspected.

Periodontal Abscess. A periodontal abscess is a localized accumulation of exudate within the gingival wall of a periodontal pocket (see Chapters 20 and 42). Periodontal abscesses may be acute or chronic.

The *acute periodontal abscess* appears as an ovoid elevation of the gingiva along the lateral aspect of the root (Figures 29-25). The gingiva is edematous and red, with a smooth, shiny surface. The shape and consistency of the elevated area vary; the area may be domelike and relatively firm, or it may be pointed and soft. In most cases, exudate may be expressed from the gingival margin with gentle digital pressure.

The acute periodontal abscess is accompanied by symptoms such as throbbing, radiating pain, and tenderness of the gingiva to palpation. Other symptoms may include sensitivity of the tooth to palpation; tooth mobility and lymphadenitis; and, less frequently, systemic effects such as fever, leukocytosis, and malaise. Occasionally the patient may have symptoms of an acute periodontal abscess without any notable clinical lesion or radiographic changes.

Figure 29-25 Acute periodontal abscesses on **A,** the buccal aspect of tooth #19 and **B,** the lingual aspect of tooth #20 in the same patient.

The *chronic periodontal abscess* usually presents a sinus that opens onto the gingival mucosa along the length of the root. There may be a history of intermittent exudation. The orifice of the sinus may appear as a difficult-to-detect pinpoint opening, which, when probed, reveals a sinus tract that leads deep into the periodontium. The sinus may be covered by a small, pink, beadlike mass of granulation tissue. The chronic periodontal abscess is usually asymptomatic. However, the patient may report episodes of dull, gnawing pain; a slight elevation of the tooth; and a desire to bite down and grind the tooth. The chronic periodontal abscess often undergoes acute exacerbations, with all of the associated symptoms.

Diagnosis of the periodontal abscess requires the correlation of the history with the clinical and radiographic findings. The suspected area should be probed carefully along the gingival margin in relation to each tooth surface to detect a channel from the marginal area to the deeper periodontal tissues. Continuity of the lesion with the gingival margin is clinical evidence that the abscess is periodontal.

The abscess is not necessarily located on the same surface of the root as the pocket from which it is formed. A pocket at the facial surface may give rise to a periodontal abscess interproximally. It is common for a periodontal abscess to be located at a root surface other than that along which the pocket originated, because drainage is more likely to be impaired when a pocket follows a tortuous course.

In children, a sinus orifice along the lateral aspect of a root is usually the result of periapical infection of a deciduous tooth. In the permanent dentition, such an orifice may be caused by a periodontal abscess or by apical involvement. The orifice may be patent and draining, or it may be closed and appear as a red, nodular mass (Figure 29-26). The exploration of such masses with a probe

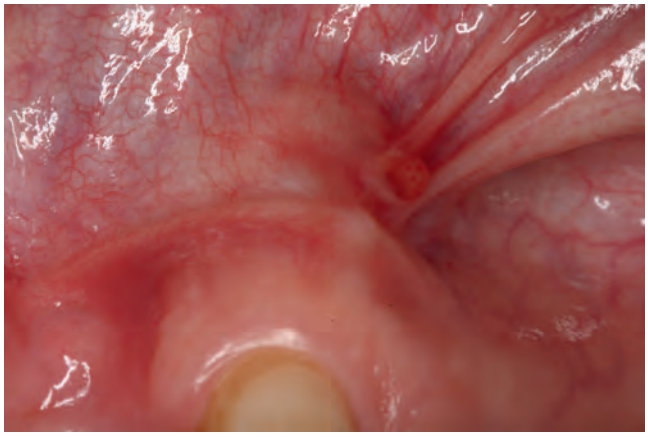

Figure 29-26 Nodular mass at the orifice of a draining sinus.

usually reveals a pinpoint orifice that communicates with an underlying sinus.

Periodontal Abscess and Gingival Abscess. The principal differences between the periodontal abscess and the gingival abscess are location and history (see Chapters 20 and 42). The gingival abscess is confined to the marginal gingiva, and it often occurs in previously disease-free areas. It is usually an acute inflammatory response to the forcing of foreign material into the gingiva. The periodontal abscess involves the supporting periodontal structures, and it generally occurs during the course of chronic destructive periodontitis.

Periodontal Abscess and Periapical Abscess. Several characteristics can be used as guidelines when differentiating a periodontal abscess from a periapical abscess. If the tooth is nonvital, the lesion is most likely periapical. However, a previously nonvital tooth can have a deep periodontal pocket that can abscess. Moreover, a deep periodontal pocket can extend to the apex and cause pulpal involvement and necrosis.

An apical abscess may spread along the lateral aspect of the root to the gingival margin. However, when the apex and lateral surface of a root are involved with a single lesion that can be probed directly from the gingival margin, the lesion is more likely to have originated as a periodontal abscess.

Radiographic findings are helpful for differentiating between a periodontal lesion and a periapical lesion (see Chapter 31). Early acute periodontal and periapical abscesses present no radiographic changes. Ordinarily, a radiolucent area along the lateral surface of the root suggests the presence of a periodontal abscess, whereas apical rarefaction suggests a periapical abscess. However, acute periodontal abscesses that show no radiographic changes often cause symptoms in teeth with long-standing, radiographically detectable periapical lesions that are not contributing to the patient's complaint. Clinical findings such as the presence of extensive caries, pocket formation, lack of tooth vitality, and the existence of continuity between the gingival margin and the abscess area often prove to be of greater diagnostic value than the radiographic appearance.

A draining sinus on the lateral aspect of the root suggests periodontal rather than apical involvement; a sinus from a periapical lesion is more likely to be located further apically. However, sinus location is not conclusive. In many instances, particularly in children, the sinus from a periapical lesion drains on the side of the root rather than at the apex (see Chapter 43).

Laboratory Aids to Clinical Diagnosis

When unusual gingival or periodontal problems are detected that cannot be explained by local causes, the possibility of contributing systemic factors must be explored. The signs and symptoms of oral manifestations of systemic disease have to be clearly understood and analyzed and their presence discussed with the patient's physician. Parts 3 and 5 of this book present discussions of many of these problems, and the reader is also directed to standard texts that discuss medical diagnosis for more detailed descriptions of the necessary tests and their interpretation.

Numerous laboratory tests aid in the diagnosis of systemic diseases that may contribute to periodontal and oral diseases; these tests will also be needed for the making of treatment decisions when dealing with medically compromised patients (see Chapter 37). Analyses of blood smears, blood cell counts, white blood cell differential counts, and erythrocyte sedimentation rates are used to evaluate the presence of blood dyscrasias and generalized infections. Determinations of coagulation time, bleeding time, clot retraction time, prothrombin time, and capillary fragility as well as bone marrow studies may be required at times. The reader is referred to books about medical diagnoses for a consideration of this subject.

Suggested Readings

Abrams K, Caton J, Polson AM: Histologic comparisons of interproximal gingival tissues related to the presence or absence of bleeding. *J Periodontol* 55:629, 1984.

Armitage GC: Periodontal diseases: diagnosis. *Ann Periodontol* 1:37, 1996.

Badersten A, Nilveus R, Egelberg J: Reproducibility of probing attachment levels measurements. *J Clin Periodontol* 11:475, 1984.

Badersten A, Nilvéus R, Egelberg J: Effect of nonsurgical therapy. VII. Bleeding, suppuration and probing depth in sites with probing attachment loss. *J Clin Periodontol* 12:432, 1985.

Badersten A, Nilvéus R, Egelberg J: Scores of plaque, bleeding, suppuration and probing depth to predict probing attachment loss. Five years of observation following nonsurgical periodontal therapy. *J Clin Periodontol* 7:102, 1990.

Egermark-Erikson I, Carlsson GE, Ingervall B: Prevalence of mandibular dysfunction and orofacial parafunction in 7-, 11-, and 15-year old Swedish children. *Eur J Orthop* 13:163, 1981.

Greenberg J, Laster L, Listgarten MA: Transgingival probing as a potential estimator of alveolar bone level. *J Periodontol* 47:514, 1976.

Greenstein G: The role of bleeding upon probing in the diagnosis of periodontal disease. A literature review. *J Periodontol* 55:684, 1984.

References

References for this chapter are found on the companion website www.expertconsult.com.

References

1. Abrams K, Caton J, Polson AM: Histologic comparisons of interproximal gingival tissues related to the presence or absence of bleeding. *J Periodontol* 55:629, 1984.
2. Alexander AG, Tipnis AK: The effect of irregularity of teeth and the degree of overbite and overjet on the gingival health. *Br Dent J* 128:539, 1970.
3. Amato R, Caton J, Polson A, et al: Interproximal gingival inflammation related to the conversion of a bleeding to a non-bleeding state. *J Periodontol* 57:63, 1986.
4. Armitage GC: Periodontal diseases: diagnosis. *Ann Periodontol* 1:37, 1996.
5. Armitage GC, Jeffcoat MK, Chadwick DE, et al: Longitudinal evaluation of elastase as a marker for the progression of periodontitis. *J Clin Periodontol* 65:120, 1994.
6. Armitage GC, Svanberg GK, Löe H: Microscopic evaluation of clinical measurements of connective tissue attachment levels. *J Clin Periodontol* 4:173, 1977.
7. Arstad T: *The capsular ligaments of the temporomandibular joint and retrusion facets of the dentition in relationship to mandibular movements*, Oslo, Norway, 1954, Akademisk Forlag.
8. Badersten A, Nilveus R, Egelberg J: Reproducibility of probing attachment levels measurements. *J Clin Periodontol* 11:475, 1984.
9. Badersten A, Nilvéus R, Egelberg J: Effect of nonsurgical therapy. VII. Bleeding, suppuration and probing depth in sites with probing attachment loss. *J Clin Periodontol* 12:432, 1985.
10. Badersten A, Nilvéus R, Egelberg J: Scores of plaque, bleeding, suppuration and probing depth to predict probing attachment loss. Five years of observation following nonsurgical periodontal therapy. *J Clin Periodontol* 7:102, 1990.
11. Baumgartner HS: A voice-input computerized dental examination system using high resolution graphics. *Compend Contin Educ Dent* 9:446, 1988.
12. Beyron HI: Occlusal changes in the adult dentition. *J Am Dent Assoc* 48:674, 1954.
13. Caton J, Polson A: The interdental bleeding index: a simplified procedure to monitor gingival health. *Compend Contin Educ Dent* 6:89, 1985.
14. Clark WB, Yang MC, Magnusson I: Measuring clinical attachment level reproducibility and relative measurements with an electronic probe. *J Periodontol* 63:831, 1992.
15. Egermark-Erikson I, Carlsson GE, Ingervall B: Prevalence of mandibular dysfunction and orofacial parafunction in 7-, 11-, and 15-year old Swedish children. *Eur J Orthop* 13:163, 1981.
16. Etter TH, Håkanson I, Lang NP, et al: Healing after standardized clinical probing of the perlimplant soft tissue seal: a histomorphometric study in dogs. *Clin Oral Implants Res* 13:571, 2002.
17. Fischman SL, Picozzi A: Review of the literature: the methodology of clinical calculus evaluation. *J Periodontol* 40:607, 1969.
18. Gabathuler H, Hassel TM: A pressure sensitive periodontal probe. *Helv Odontol Acta* 15:114, 1971.
19. Gibbs RA: DNA amplification by the polymerase chain reaction. *Anal Chem* 62:1202, 1990.
20. Grant DA, Grant DA, Flynn MJ, et al: Periodontal microbiota of mobile and non-mobile teeth. *J Periodontol* 66:386, 1995.
21. Greenberg J, Laster L, Listgarten MA: Transgingival probing as a potential estimator of alveolar bone level. *J Periodontol* 47:514, 1976.
22. Greenstein G: The role of bleeding upon probing in the diagnosis of periodontal disease. A literature review. *J Periodontol* 55:684, 1984.
23. Greenstein G, Caton J, Polson AM: Histologic characteristics associated with bleeding after probing and visual signs of inflammation. *J Periodontol* 52:420, 1981.
24. Grippo JO, Simring M, Schreiner S: Attrition, abrasion, corrosion and abfraction revisited. *J Am Dent Assoc* 135:1109, 2004.
25. Hassel TM, German MA, Saxer UP: Periodontal probing: interinvestigator discrepancies and correlations between probing force and recorded depth. *Helv Odontol Acta* 17:38, 1973.
26. Hirschfeld L: A calibrated silver point for periodontal diagnosis and recording. *J Periodontol* 24:94, 1953.
27. Kaldahl WB, Kalkwarf KL, Patil KD, et al: Relationship of gingival bleeding, gingival suppuration and supragingival plaque to attachment loss. *J Periodontol* 61:347, 1990.
28. Kalkwarf KI, Kahldal WD, Patil KD: Comparison of manual and pressure controlled periodontal probing. *J Periodontol* 57:467, 1986.
29. Karpinia K, Magnusson I, Gibbs C, et al: Accuracy of probing attachment levels using CEJ probe versus traditional probes. *J Clin Periodontol* 31:173, 2004.
30. Kim HY, Yi SW, Choi SH, et al: Bone probing measurement as a reliable evaluation of the bone level in periodontal defects. *J Periodontol* 71:729, 2000.
31. Kurashima K: Viscoelastic properties of periodontal tissue. *Bull Tokyo Med Dent Univ* 12:240, 1965.
32. Lambrechts P, Braem M, Vuylsteke-Wanters M, et al: Quantitative in vivo wear of human enamel. *J Dent Res* 68:1752, 1989.
33. Listgarten MA: Periodontal probing: what does it mean? *J Clin Periodontol* 7:165, 1980.
34. Listgarten MA, Mao R, Robinson PJ: Periodontal probing: the relationship of the probe tip to periodontal tissues. *J Periodontol* 47:511, 1976.
35. Löe H, Silness J: Periodontal Disease in Pregnancy. I. Prevalence and Severity. *Acta Odontol Scand* 21:533, 1963.
36. Magnusson I, Listgarten MA: Histological evaluation of probing depth following periodontal treatment. *J Clin Periodontol* 7:26, 1980.
37. Manly RS: Abrasion of cementum and dentin by modern dentifrices. *J Dent Res* 20:583, 1941.
38. Manly RS: Factors influencing tests on the abrasion of dentin by brushing with dentifrices. *J Dent Res* 23:59, 1944.
39. Mannerberg F: Saliva factors in cases of erosion. *Odont Rev* 14:156, 1963.
40. McCay CM, Wills L: Erosion of molar teeth by acid beverages. *J Nutr* 39:313, 1949.
41. Meitner SW, Zander HA, Iker HP, et al: Identification of inflamed gingival surfaces. *J Clin Periodontol* 6:93, 1979.
42. Miller WD: Experiments and observations on the wasting of tooth tissue variously designated as erosion, abrasion, chemical abrasion, denudation, etc. *Dent Cosmos* 49:1, 1907.
43. Mühlemann HR: Ten years of tooth mobility measurements. *J Periodontol* 31:110, 1960.
44. Mühlemann HR: Tooth mobility: a review of clinical aspects and research findings. *J Periodontol* 38:686, 1967.
45. Mühlemann HR, Savdir S, Rateitschak KH: Tooth mobility—its causes and significance. *J Periodontol* 36:148, 1965.
46. Mühlemann HR, Son S: Gingival Sulcus Bleeding. A Leading Symptom in Initial Gingivits. *Heiv Odontol Acta* 15:107, 1971.
47. O'Leary TJ: Tooth mobility. *Dent Clin North Am* 3:567, 1969.
48. O'Leary TJ, Rudd KD: An instrument for measuring horizontal mobility. *Periodontics* 1:249, 1963.
49. Parfitt GJ: Measurement of the physiologic mobility of individual teeth in an axial direction. *J Dent Res* 39:608, 1960.
50. Parfitt GJ: The dynamics of a tooth in function. *J Periodontol* 32:102, 1961.
51. Perlitsch MJ: A systematic approach to the interpretation of tooth mobility and clinical implications. *Dent Clin North Am* 24:177, 1980.
52. Perry DA, Taggart EJ, Leung A, et al: Comparison of a conventional probe with electronic and manual pressure-regulated probes. *J Periodontol* 65:908, 1994.
53. Persson R: Assessment of tooth mobility using small loads. II. Effect of oral hygiene procedures. *J Clin Periodontol* 7:506, 1980.
54. Persson R: Assessment of tooth mobility using small loads. III. Effect of periodontal treatment including a gingivectomy procedure. *J Clin Periodontol* 8:4, 1981.
55. Persson R: Assessment of tooth mobility using small loads. IV. The effect of periodontal treatment including gingivectomy and flap procedures. *J Clin Periodontol* 8:88, 1981.
56. Persson R, Svensson A: Assessment of tooth mobility using small loads. I. Technical devices and calculations of tooth mobility in periodontal health and disease. *J Clin Periodontol* 7:259, 1980.

57. Quyrinen M, Callens A, van Steenberghe D, et al: Clinical evaluation of a constant force electronic probe. *J Periodontol* 64:35, 1993.
58. Ratcliff PA, Johnson PW: The relationship between malodor, gingivitis and periodontitis. A review. *J Periodontol* 70:485, 1999.
59. Rhodes PR: The electronic patient record. In Rose LF, Mealey BL, Genco RJ, et al, editors: *Periodontics: medicine, surgery and implants*, St Louis, 2004, Elsevier Mosby.
60. Robinson HBG: Abrasion, attrition and erosion of teeth. *Health Center J Ohio State Univ* 3:21, 1949.
61. Saglie R, Johanson JR, Flotra L: The zone of completely and partially destructed periodontal fibers in pathological pockets. *J Clin Periodontol* 2:198, 1975.
62. Salonen L, Hellden L: Prevalence of signs and symptoms of dysfunction in the masticatory system: an epidemiologic study in an adult Swedish population. *J Craniomandib Disord* 4:241, 1990.
63. Schulte W, D'Hoedt B, Scholz F, et al: Periotest-neues messverfahren der funktion des parodontiums. *Zahnarztl Mitt* 73:1229, 1983.
64. Seligman DA, Pullinger AG, Solberg AK: The prevalence of dental attrition and its association with factors of age, gender and TMJ symptomatology. *J Dent Res* 67:1323, 1988.
65. Sivertson JF, Burgett FG: Probing of pockets related to the attachment level. *J Periodontol* 47:281, 1976.
66. Sognnaes RF: Periodontal significance of intraoral frictional ablation. *J West Soc Periodontol* 25:112, 1977.
67. Spray JR, Garnick JJ, Doles LR, et al: Microscopic demonstration of the position of periodontal probes. *J Periodontol* 49:148, 1978.
68. Tibbetts LS: Use of diagnostic probes for detection of periodontal disease. *J Am Dent Assoc* 78:549, 1969.
69. Van der Bilt A, Olthoff LW, Bosman F, et al: The effect of missing postcanine teeth on chewing performance in man. *Arch Oral Biol* 38:423, 1993.
70. Van der Velden U: Probing force and the relationship of the probe tip to the periodontal tissues. *J Clin Periodontol* 6:106, 1979.
71. Van der Velden U, De Vries JH: Introduction of a new periodontal probe. The pressure probe. *J Clin Periodontol* 5:188, 1978.
72. Weinberg LA: Diagnosis of facets in occlusal equilibration. *J Am Dent Assoc* 52:26, 1956.
73. Woda A, Gourdon AM, Faraj M: Occlusal contact and tooth wear. *J Prosthet Dent* 57:85, 1987.
74. Xhonga FA: Bruxism and its effect on teeth. *J Oral Rehabil* 4:65, 1977.
75. Yang MCK, Bochacki V, Genco RJ: Immunological assays for putative periodontal pathogens. *Oral Microbiol Immunol* 1:39, 1986.

CHAPTER 30

Significance of Clinical and Biologic Information

Philippe P. Hujoel

CHAPTER OUTLINE

Tangible versus Intangible Benefits
Size of the Treatment Effect
Defining Four Levels of Clinical Significance
Conclusion

In one study of the topic of periodontal tissue regeneration, investigators reported that a treatment that resulted in a gain of 1.2 mm in clinical attachment level and a reduction of 1 mm in probing pocket depth "may not have a great clinical impact."[4] In another study of a local antimicrobial, the investigators reported that a treatment that resulted in a gain of 0.0 mm in clinical attachment level and a reduction of 0.2 mm in probing depth had such clinical significance that it should "be used universally."[28] This example illustrates that different individuals will reach different decisions regarding what is meant by the term *clinical significance.* As a result, the term *clinically significant* has become more useful to marketers than to clinicians.

The term *clinically significant* could be made more relevant by recognizing the nature of the benefits (i.e., tangible/intangible) and the size of the treatment effect (i.e., large/small). The presence or absence of these two criteria can be used to classify clinical significance into four levels. Before these levels are introduced, each classification term will be described.

Tangible versus Intangible Benefits

The clinical significance of a treatment depends on whether the benefits identified are tangible or intangible to the patient who undergoes the procedure.

Tangible benefits are those treatment outcomes that reflect how a patient feels, functions, or survives. The word *tangible* is defined as "capable of being precisely identified or realized by the mind." Examples of tangible benefits could include improved oral health–related quality of life,[14,15] a decrease in self-reported symptoms (e.g., bleeding) after brushing, the prevention of tooth loss, or the elimination of a painful periodontal abscess. These examples of treatment benefits can be precisely identified or realized by the *patient's mind;* in other words, they are tangible. Tangible benefits can also be referred to as "clinically relevant" benefits or "clinically meaningful" benefits.

Intangible benefits cannot be realized or perceived by the patient's mind. Changes in the probing attachment level as a result of scaling, changes in the enamel mineralization level as a result of fluoride application, and changes in the size of a periapical radiolucency as a result of a root canal treatment are examples of changes that the patient's mind cannot identify or realize; thus, they are described as *intangible treatment benefits.* Intangible treatment benefits can often be measured objectively by the clinician or by laboratory methods.

A first step in assessing the clinical significance of a treatment is to determine whether the documented treatment benefits are tangible or intangible. This distinction is important, because intangible benefits often do not necessarily translate into tangible benefits. A medication that lowers elevated blood lipid levels (an intangible benefit) may also shorten the life span (a tangible patient harm).[28] A treatment that increases bone density (an intangible benefit) can increase fracture risk (a tangible patient harm).[11] A treatment that provides extensive periodontal bone regeneration (an intangible benefit) can lead to tooth loss (a tangible harm).[13]

A treatment that has been shown to provide tangible benefits has a higher level of clinical significance than a treatment for which only evidence of intangible benefits exists. The finding that implant-supported dentures improve quality of life[1] has a higher level of clinical significance than the finding that scaling increases probing attachment levels. The finding that an endodontic treatment reliably eliminates tooth pain has a higher level of clinical significance than the finding that chlorhexidine reduces *Streptococcus mutans* levels.

Size of the Treatment Effect

A second important criterion for the assessment of clinical significance is the size of the treatment effect. The size of the treatment effect is a comparison of the success rates of the experimental treatment and the control treatment. This comparison of treatments can be a subtraction of the success rates, a division of the success rates, or some other mathematical operation. The size of the treatment effect, regardless of how it is calculated, has long been recognized as an important part of the assessment of clinical significance. The larger the likelihood of obtaining an expected benefit of a treatment (relative to a control treatment), the more clinically significant the treatment. We suggest that the number needed to treat (NNT) may be a good measure to separate large from small treatment effects.

The likelihood of obtaining a treatment benefit (relative to the control) determines to a large extent the methodologic and analytic rigor required to establish treatment effectiveness. At one extreme, in all-or-none situations, reliable evidence may result from observations of a small number of patients. For example, no concurrent

controlled trials were conducted to assess the effectiveness of general anesthesia. Determining effectiveness for treatments that achieve a dramatic and immediate effect is straightforward, and only essential scientific principles (e.g., consistency of observations across different operators) are considered sufficient evidence of treatment effectiveness. Reportedly, the statement "Gentlemen, this is no humbug" was sufficient to convince an audience that general anesthesia was effective.

At another extreme, if the likelihood of obtaining an expected treatment benefit is small, substantial rigor in both the design and analysis of controlled clinical trials is required. The benefit of mammography screening for the early detection of breast cancer,[9] the benefit of one "clot-buster" drug over another after a myocardial event, and the benefit of local antibiotics for the treatment of periodontitis are all so small that large randomized controlled trials (RCTs) are required to provide reliable evidence of whether small benefits are indeed associated with treatment.

The likelihood of obtaining a treatment benefit is a determinant of clinical significance; the larger the likelihood, the more confident a patient can feel that a treatment will be successful. Although it is possible to have a clear, unequivocal definition of what constitutes a tangible benefit associated with treatment, it is not possible to have a similar rigorous definition of what can be considered a large likelihood. We define a "large treatment effect" as an NNT of 5, which, under fortuitous circumstances, can be reliably identified with nonexperimental study designs.[5,26]

Defining Four Levels of Clinical Significance

On the basis of the nature of the benefit (i.e., tangible/intangible) and the size of the treatment effect (i.e., large/small), four levels of clinical significance can be defined (Table 30-1). These are numbered from 1 to 4 in order of decreasing levels of significance.

Clinical Significance Level 1

Treatments of clinical significance level 1 are the "magic bullets" or the "miracle cures" that provide a tangible benefit with a large treatment effect. Examples of such treatments include the use of vitamin C to treat scurvy, bone marrow transplantation to treat leukemia, and dental implants to improve the oral health–related quality of life of edentulous individuals. In all three examples, the benefits of the treatment are tangible, and the size of the treatment effect is large.

An understanding of the biologic mechanisms of treatment actions is not required to establish that a treatment has clinical significance level 1. Lemon juice was identified as an effective method to prevent scurvy in 1601, but it was not until the beginning of the twentieth century that vitamin C was isolated.[23] Digitalis was discovered as a treatment for "dropsy" long before physicians became aware of the drug's cardiac effects.[27] Lithium is an effective drug for bipolar disorder, but its mechanism of action remains largely unknown.[25] By contrast, hormone replacement therapy, for which the biologic mechanisms of the drug's benefits were supposedly so well understood, resulted in more harm than good.[12]

Treatments of clinical significance level 1 are not always immediately accepted or widely used. It took the British Navy 264 years from the time of the observations of Captain James until a universal preventive policy was established to prevent scurvy.[3] This lack of appreciation for this treatment of clinical significance level 1 was unfortunate: "It is estimated that 5000 lives a year were needlessly lost from scurvy during this period: that is a total of nearly 800,000. In the 200 years from 1600 to 1800 nearly 1,000,000 men died of an easily preventable disease. There are in the whole of human history few more notable examples of official indifference and stupidity producing such disastrous consequence to human life."[22] Although it is easy to determine clinical significance level 1 in retrospect, it may be difficult to recognize at the time of discovery.

Clinical Significance Level 2

Treatments of clinical significance level 2 have demonstrated tangible benefits, but the likelihood of obtaining the benefit from the treatment is small. As the size of the benefit of one therapy over another decreases in size, RCTs that are large in size and rigorous in execution and analysis are required to provide unequivocal evidence that the treatment provides tangible patient benefits. Examples of such treatments include the advantage of tissue plasminogen activator (t-PA) over streptokinase[10] and the benefits of penciclovir for the treatment of herpetic lesions.[19]

Determining the clinical relevance of treatments of clinical significance level 2 is an individual choice in which issues such as cost and side effects often play a more important role. For example, the mortality rate with t-PA is 6.3%, whereas the mortality rate with streptokinase is 7.3%.[10] In other words, there is a 1% increased chance for survival associated with t-PA (i.e., 100 patients need to be treated with t-PA instead of streptokinase to save one life). During the 1990s, when this treatment was introduced, the increased cost for t-PA was $2000. Is a 1% increased survival probability worth $2000? Different individuals, different governments, and different health insurance companies may make different decisions regarding this important question. Indeed, some individuals may believe that, if large RCTs are required to determine treatment effectiveness, the clinical significance of the treatment comes into question.

The use of penciclovir for the treatment of herpetic lesions provides another example of a drug of clinical significance level 2. When applying a 1% penciclovir cream, 70% of patients reported lesion healing by day 6. When applying a placebo cream, 59% of patients reported lesion healing by day 6.[19] Is an 11% increased probability of lesion healing (NNT of 9) by day 6 of sufficient magnitude to refer to the treatment as "clinically relevant"? Once again, the answer to this question is highly individual; the cream may be worth its weight in gold for a young teenager when prom night is approaching, but it may be clinically irrelevant for a more sedate adult. By using the terminology "clinical significance level 2," the concept of a small tangible patient benefit can quickly be communicated without becoming trapped in meaningless discussions about the clinical relevance of small benefits.

TABLE 30-1 Definition of Levels of Significance Based on the Size and Nature of the Benefit

		Size of the Benefit	
Clinical significance		Large[‡]	Small[§]
Nature of the benefit	*Tangible**	Level 1	Level 2
	Intangible[†]	Level 3	Level 4

*Tangible benefits are outcomes that directly measure how a patient feels, functions, or survives.

[†]Intangible benefits are outcomes that are not perceivable by the patient's mind.

[‡]A large benefit is defined as one that can reliably be identified with the use of epidemiologic methodology.

[§]A small benefit is defined as one that requires the conduct of randomized controlled trials for reliable identification.

Clinical Significance Level 3

Treatments of clinical significance level 3 are the magic bullets or miracle cures in the surrogate world in which the beneficial but intangible effects of treatment are so convincing that the need for RCTs may appear unethical. Examples of such treatments include the use of highly active antiretroviral therapy (HAART) for patients with acquired immunodeficiency syndrome (AIDS),[16] the use of imatinib (Gleevec) for the treatment of chronic myeloid leukemia,[17] and the use of chlorhexidine varnish for the prevention of caries.[24]

With a treatment that has the label of "clinical significance level 3," there is always uncertainty regarding whether the intangible benefits will translate into real, tangible patient benefits. It has been a common observation that the larger the effect size observed on the surrogate, the more likely the surrogate benefit translates into a real, tangible patient benefit.[6]

For certain treatments, such as HAART for AIDS or Gleevec for chronic leukemia, the opportunity may exist to avoid RCTs. Instead, treatments of clinical significance level 3 can become treatments of clinical significance level 1 by means of epidemiologic studies in which the tangible benefits associated with the intangible surrogate changes are identified. For example, drastic changes in the viral load of human immunodeficiency virus have been shown to lead to large reductions in the risk of AIDS and death. With the use of historic controls, it was shown that HAART treatment reduced AIDS risk by 38% and the associated mortality risk by 34%.[16] A large surrogate benefit (clinical significance level 3) translated into a large survival benefit (clinical significance level 1).

However, assuming that large, intangible treatment benefits invariably translate into tangible treatment benefits remains dangerous, no matter how large the effect on the surrogate end point. A 40% chlorhexidine varnish used for the prevention of caries was reported to result in a 99.9% reduction of *Streptococcus mutans* in all 20 subjects that were treated, and the amount of streptococci stayed below detectable levels for at least 4 weeks in 9 subjects. By contrast, the placebo varnish/sealant led to only a 32% reduction of *Streptococcus mutans,* and none of the 20 treated subjects had amounts of streptococci that stayed below detectable levels for 4 weeks.[24] On the basis of these data, it was reported that "Chlorzoin will wipe out dental decay much like smallpox." A subsequent RCT in 1240 children at high risk for caries did not translate into a reduction of large cavities in the teeth: the Chlorzoin group had 6.8 D3 lesions (standard deviation, 6.2), and the placebo group had 6.4 D3 lesions (standard deviation, 6.4). In other words, the placebo group demonstrated fewer lesions.[7] It has become clear since then that most forms of chlorhexidine are contraindicated for the treatment of caries[21] and that they may even harm systemic health by eliminating nitrite-producing organisms on the tongue.[8] A large treatment effect on a surrogate, in this instance, did not translate into a tangible benefit.

Clinical Significance Level 4

Treatments of clinical significance level 4 are those treatments that have reliable evidence from large RCTs of small intangible treatment benefits. Because the treatment effects are small, epidemiologic studies are almost always incapable of identifying treatments of clinical significance level 4. In other words, rigorously conducted RCTs are a necessity to reliably identify a small surrogate benefit. Examples of treatments of clinical significance level 4 include those that cause a small decrease in lipid level, a small drop in blood pressure, or a small decrease in pocket depth. Large leaps of faith are often required to jump from the observations that small changes in surrogate endpoints translate into real, tangible benefits.

The use of clofibrate to lower lipid levels is an example of a drug of clinical significance level 4. Clofibrate reduced mean cholesterol levels from 324 mg to 224 mg and mean values of triglycerides from 271 to 125 (it can be argued that these mean changes are, in actuality, not so small).[2] Clofibrate was the most widely prescribed lipid-lowering agent in the United States, but uncertainty remained regarding whether clofibrate actually provided a tangible patient benefit. Advertisements that were widely used in medical journals accurately reflected the clinical uncertainty surrounding the use of this drug. A text box within the advertisement stated the following: "It has not been established whether the drug-induced lowering of serum cholesterol or lipid levels has a detrimental, beneficial, or no effect on the mortality and the morbidity due to atherosclerosis or coronary heart disease. Several years will be required before current investigations will yield an answer to this question." A subsequent World Health Organization cooperative trial of clofibrate revealed the wisdom of this disclaimer. The trial results showed that clofibrate resulted in excess mortality of 47%, thereby providing yet another example of a misleading surrogate.[20]

Treatment of clinical significance level 4 may cause more harm than good, and there is debate about whether the drug-approval process should be changed.[18] If such a change were to occur, it could have significant consequences for periodontal therapies. Approved periodontal therapies are almost without exception of clinical significance level 4, and information about their long-term safety and lack of harm is minimal.

Conclusion

Two important determinants of clinical significance are the nature of the benefit (i.e., tangible/intangible) and the likelihood of obtaining the benefit (as compared with the control treatment). These two characteristics can be used to define four hierarchic levels of clinical significance. Treatments that provide a tangible patient benefit (levels 1 and 2) are of greater value and should correspond to a higher level of clinical significance than treatments with evidence of only intangible benefits (levels 3 and 4). Similarly, treatments with a large likelihood of clinical improvement (levels 1 and 3) are clinically more significant than treatments with a small likelihood of clinical improvement (levels 2 and 4). Providing four hierarchical levels of clinical significance may help clinicians and patients to communicate more effectively about the clinical significance of a treatment. In particular, the dental clinician should inform his or her periodontal patients that no unequivocal evidence is available that periodontal treatments provide a tangible patient benefit. We hope that we provide tangible benefits to our patients, but RCTs that ensure that we really do are lacking. It is our hope that the RCTs that have been asked for since the 1960s to address the effect of periodontal therapy on tooth loss will be conducted during the coming years.

Suggested Readings

Hujoel PP: Endpoints in periodontal trials: the need for an evidence-based research approach. *Periodontol 2000* 36:196–204, 2004.

Hujoel PP, DeRouen TA: A survey of endpoint characteristics in periodontal clinical trials published 1988-1992, and implications for future studies. *J Clin Periodontol* 22(5):397–407, 1995. Review.

Hujoel PP, Leroux BG, DeRouen TA, et al: Evaluating the validity of probing attachment loss as a surrogate for tooth mortality in a clinical trial on the elderly. *J Dent Res* 76(4):858–866, 1997.

References

References for this chapter are found on the companion website www.expertconsult.com.

References

1. Awad MA, Locker D, Korner-Bitensky N, et al: Measuring the effect of intra-oral implant rehabilitation on health-related quality of life in a randomized controlled clinical trial. *J Dent Res* 79:1659, 2000.
2. Berkowitz D: Long-term treatment of hyperlipidemic patients with clofibrate. *JAMA* 218:1002, 1971.
3. Berwick DM: Disseminating innovations in health care. *JAMA* 289:1969, 2003.
4. Esposito M, Coulthard P, Worthington HV: Enamel matrix derivative (Emdogain) for periodontal tissue regeneration in intrabony defects. *Cochrane Database Syst Rev* CD003875, 2003.
5. Feinstein AR: Scientific standards in epidemiologic studies of the menace of daily life. *Science* 242:1257, 1988.
6. Fleming TR, Prentice RL, Pepe MS, et al: Surrogate and auxiliary endpoints in clinical trials, with potential applications in cancer and AIDS research. *Stat Med* 13:955, 1994.
7. Forgie AH, Paterson M, Pine CM, et al: A randomised controlled trial of the caries-preventive efficacy of a chlorhexidine-containing varnish in high-caries-risk adolescents. *Caries Res* 34:432, 2000.
8. Gilchrist M, Winyard PG, Benjamin N: Dietary nitrate—good or bad? *Nitric Oxide* 22:104, 2010.
9. Giles J: Study warns of "avoidable" risks of CT scans. *Nature* 431:391, 2004.
10. GUSTO Investigators: An international randomized trial comparing four thrombolytic strategies for acute myocardial infarction. *N Engl J Med* 329:673, 1993.
11. Haguenauer D, Welch V, Shea B, et al: Fluoride for treating postmenopausal osteoporosis. *Cochrane Database Syst Rev* CD002825, 2000.
12. Hogervorst E: Estrogen plus progestin use did not improve global cognitive function in older postmenopausal women. *Evid Based Obstet Gynecol* 5:189, 2003.
13. Hujoel PP: Endpoints in periodontal trials: the need for an evidence-based research approach. *Periodontol 2000* 36:196, 2004.
14. Leao A, Sheiham A: The development of a socio-dental measure of dental impacts on daily living. *Community Dent Health* 13:22, 1996.
15. McGrath C, Bedi R: An evaluation of a new measure of oral health related quality of life: OHQoL-UK(W). *Community Dent Health* 18:138, 2001.
16. Mocroft A, Ledergerber B, Katlama C, et al: Decline in the AIDS and death rates in the EuroSIDA study: an observational study. *Lancet* 362:22, 2003.
17. O'Brien SG, Deininger MW: Imatinib in patients with newly diagnosed chronic-phase chronic myeloid leukemia. *Semin Hematol* 40:26, 2003.
18. Psaty BM, Weiss NS, Furberg CD, et al: Surrogate end points, health outcomes, and the drug-approval process for the treatment of risk factors for cardiovascular disease. *JAMA* 282:786, 1999.
19. Raborn GW, Martel AY, Lassonde M, et al: Effective treatment of herpes simplex labialis with penciclovir cream: combined results of two trials. *J Am Dent Assoc* 133:303, 2002.
20. Report of the Committee of Principal Investigators: WHO cooperative trial on primary prevention of ischaemic heart disease with clofibrate to lower serum cholesterol: final mortality follow-up. *Lancet* 2:600, 1984.
21. Rethman MP, Beltran-Aguilar ED, Billings RJ, et al: Nonfluoride caries-preventive agents: executive summary of evidence-based clinical recommendations. *J Am Dent Assoc* 142:1065, 2011.
22. Roddis LH: *A short history of nautical medicine*, New York, 1941, Hoeber.
23. Rosenfeld L: Vitamine—vitamin: the early years of discovery. *Clin Chem* 43:680, 1997.
24. Sandham HJ, Brown J, Chan KH, et al: Clinical trial in adults of an antimicrobial varnish for reducing mutans streptococci. *J Dent Res* 70:1401, 1991.
25. Shaldubina A, Agam G, Belmaker RH: The mechanism of lithium action: state of the art, ten years later. *Prog Neuropsychopharmacol Biol Psychiatry* 25:855, 2001.
26. Taubes G: Epidemiology faces its limits. *Science* 269:164, 1995.
27. Wade OL: Digoxin 1785-1985. I. Two hundred years of digitalis. *J Clin Hosp Pharm* 11:3, 1986.
28. Williams RC, Paquette DW, Offenbacher S, et al: Treatment of periodontitis by local administration of minocycline microspheres: a controlled trial. *J Periodontol* 72:1535, 2001.

CHAPTER 31

Radiographic Aids in the Diagnosis of Periodontal Disease

Sotirios Tetradis, Sanjay Mallya, and Henry H. Takei

CHAPTER OUTLINE

Normal Interdental Bone
Radiographic Techniques
Bone Destruction in Periodontal Disease
Radiographic Appearance of Periodontal Disease
Digital Intraoral Radiography
Advanced Imaging Modalities
Conclusion

Radiographs are valuable for diagnosis of periodontal disease, estimation of severity, determination of prognosis, and evaluation of treatment outcome.[1-3] *However, radiographs are an adjunct to the clinical examination, not a substitute for it.*

Radiographs demonstrate changes in calcified tissue; they do not reveal current cellular activity but rather reflect the effects of past cellular experience on the bone and roots.

Normal Interdental Bone

Evaluation of bone changes in periodontal disease is based mainly on the appearance of the interdental bone because the relatively dense root structure obscures the facial and lingual bony plates. The interdental bone normally is outlined by a thin, radiopaque line adjacent to the periodontal ligament (PDL) and at the alveolar crest, referred to as the *lamina dura* (Figure 31-1). *Because the lamina dura represents the cortical bone lining the tooth socket, the shape and position of the root and changes in the angulation of the x-ray beam produce considerable variations in its appearance.*

The width and shape of the interdental bone and the angle of the crest normally vary according to the convexity of the proximal tooth surfaces and the level of the cementoenamel junction (CEJ) of the approximating teeth. The faciolingual diameter of the bone is related to the width of the proximal root surface. The angulation of the crest of the interdental septum is generally parallel to a line between the CEJs of the approximating teeth (see Figure 31-1). When there is a difference in the level of the CEJs, the crest of the interdental bone appears angulated rather than horizontal.

Radiographic Techniques

In conventional radiographs, periapical and bite-wing projections offer the most diagnostic information and are most commonly used in the evaluation of periodontal disease. To properly and accurately depict periodontal bone status, proper techniques of exposure and processing are required. The bone level, pattern of bone destruction, PDL space width, as well as the radiodensity, trabecular pattern, and marginal contour of the interdental bone, vary by modifying exposure and development time, type of film, and x-ray angulation.[4] Standardized, reproducible techniques are required to obtain reliable radiographs for pretreatment and posttreatment comparisons.

Prichard[5] established the following four criteria to determine adequate angulation of periapical radiographs:

1. The radiograph should show the tips of molar cusps with little or none of the occlusal surface showing.
2. Enamel caps and pulp chambers should be distinct.
3. Interproximal spaces should be open.
4. Proximal contacts should not overlap unless teeth are out of line anatomically.

For periapical radiographs, the long-cone paralleling technique most accurately projects the alveolar bone level (Figure 31-2). The bisection-of-the-angle technique elongates the projected image, making the bone margin appear closer to the crown; the level of the facial bone is distorted more than that of the lingual. Inappropriate horizontal angulation results in tooth overlap, changes the shape of the interdental bone image, alters the radiographic width of the PDL space and the appearance of the lamina dura, and may distort the extent of furcation involvement (see Figure 31-2).

Periapical radiographs frequently do not reveal the correct relationship between the alveolar bone and the CEJ.[6] This is particularly true in cases in which a shallow palate or floor of the mouth does not allow ideal placement of the periapical film. Bite-wing projections offer an alternative that better images periodontal bone levels. For bite-wing radiographs, the film is placed behind the crowns of the upper and lower teeth parallel to the long axis of the teeth. The x-ray beam is directed through the contact areas of the teeth and perpendicular to the film. Thus the projection geometry of the bite-wing films allows the evaluation of the relationship between the interproximal alveolar crest and the CEJ without distortion[7] (Figures 31-3 and 31-4). If the periodontal bone loss is severe and the bone level cannot be visualized on regular bite-wing radiographs, films can be placed vertically to cover a larger area of the jaws (Figure 31-5). More than two vertical bite-wing films might be necessary to cover all the interproximal spaces of the area of interest.

Bone Destruction in Periodontal Disease

Early destructive changes of bone that do not remove sufficient mineralized tissue cannot be captured on radiographs. Therefore

slight radiographic changes of the periodontal tissues suggest that the disease has progressed beyond its earliest stages.[8] *The earliest signs of periodontal disease must be detected clinically.*

Bone Loss

The radiographic image tends to underestimate the severity of bone loss. The difference between the alveolar crest height and the radiographic appearance ranges from 0 to 1.6 mm, mostly accounted for by x-ray angulation.

Amount. Radiographs are an indirect method for determining the amount of bone loss in periodontal disease; they image the amount of remaining bone rather than the amount lost. The amount of bone lost is estimated to be the difference between the physiologic bone level and the height of the remaining bone.

The distance from the CEJ to the alveolar crest has been analyzed by several investigators.[9-11] Most studies, conducted in adolescents, suggest a distance of 2 mm to reflect normal periodontium; this distance may be greater in older patients.

Distribution. The distribution of bone loss is an important diagnostic sign. It points to the location of destructive local factors in different areas of the mouth and in relation to different surfaces of the same tooth.

Figure 31-1 Crest of interdental bone normally parallel to a line drawn between the cementoenamel junction of adjacent teeth *(arrow)*. Note also the radiopaque lamina dura around the roots and interdental bone.

Pattern of Bone Destruction

In periodontal disease the interdental bone undergoes changes that affect the lamina dura, crestal radiodensity, size and shape of the medullary spaces, and height and contour of the bone. Height of interdental bone may be reduced, with the crest perpendicular to the long axis of the adjacent teeth (*horizontal* bone loss; Figure 31-6), or angular or arcuate defects (*angular,* or *vertical,* bone loss; Figure 31-7) could form.

Radiographs do not indicate the internal morphology or depth of craterlike defects. Also, radiographs do not reveal the extent of involvement on the facial and lingual surfaces. Bone destruction of facial and lingual surfaces is masked by the dense root structure, and bone destruction on the mesial and distal root surfaces may be partially hidden by superimposed anatomy, such as a dense mylohyoid ridge (Figure 31-8). In most cases, it can be assumed that bone losses seen interdentally continue in either the facial or the lingual aspect, creating a troughlike lesion.

Dense cortical facial and lingual plates of interdental bone obscure destruction of the intervening cancellous bone. Thus a deep craterlike defect between the facial and lingual plates might not be depicted on conventional radiographs. To record destruction of the interproximal cancellous bone radiographically, the cortical bone must be involved. A reduction of only 0.5 to 1.0 mm in the thickness of the cortical plate is sufficient to permit radiographic visualization of the destruction of the inner cancellous trabeculae.

Interdental bone loss may continue facially and/or lingually to form a troughlike defect that could be difficult to appreciate radiographically. These lesions may terminate on the radicular surface or may communicate with the adjacent interdental area to form one continuous lesion (Figure 31-9).

Figure 31-10 shows two adjacent interdental lesions connecting on the radicular surface to form one interconnecting osseous lesion. Along with clinical probing of these lesions, the use of a radiopaque pointer placed in these radicular defects will demonstrate the extent of the bone loss.

Periodontal bone loss should be differentiated from normal anatomy or anatomic variants that can resemble disease. For example, nutrient canals in the alveolar bone can appear as linear

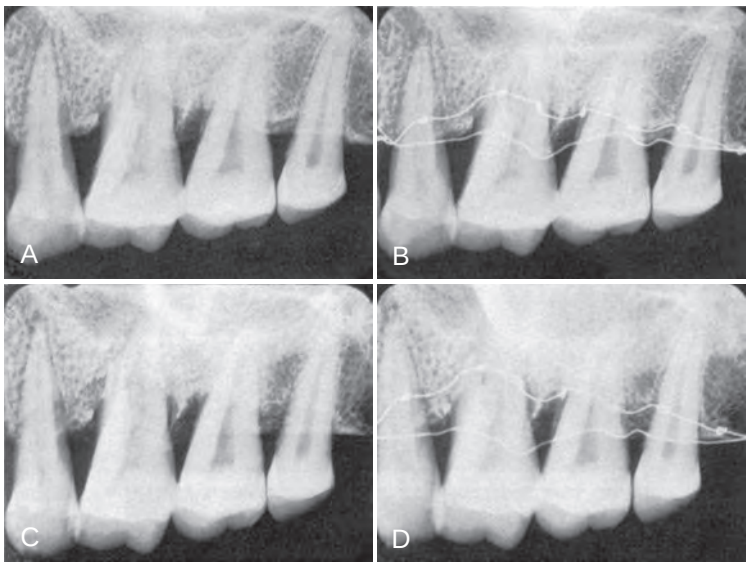

Figure 31-2 Comparison of long-cone paralleling and bisection-of-the-angle techniques. **A,** Long-cone paralleling technique, radiograph of dried specimen. **B,** Long-cone paralleling technique, same specimen as **A.** Smooth wire is on margin of the facial plate and knotted wire is on the lingual plate to show their relative positions. **C,** Bisection-of-the-angle technique, same specimen as **A** and **B. D,** Bisection-of-the-angle technique, same specimen. Both bone margins are shifted toward the crown, the facial margin (smooth wire) more than the lingual margin (knotted wire), creating the illusion that the lingual bone margin has shifted apically. *(Courtesy Dr. Benjamin Patur, Hartford, CT.)*

and circular radiolucent areas (Figure 31-11). These canals can be seen more frequently in the anterior mandible, although they can be present throughout the alveolar ridge.

Finally, it should be emphasized that radiographs can only assess the amount of periodontal bone that is present and deduce the extent of bone loss. However, it is sometimes necessary to determine whether the reduced bone level is the result of periodontal disease that is no longer destructive (usually after treatment and proper maintenance) or whether destructive periodontal disease is present. Differentiation between treated versus active periodontal disease can only be achieved clinically. Radiographically detectable changes in the normal cortical outline of the interdental bone are corroborating evidence of destructive periodontal disease.

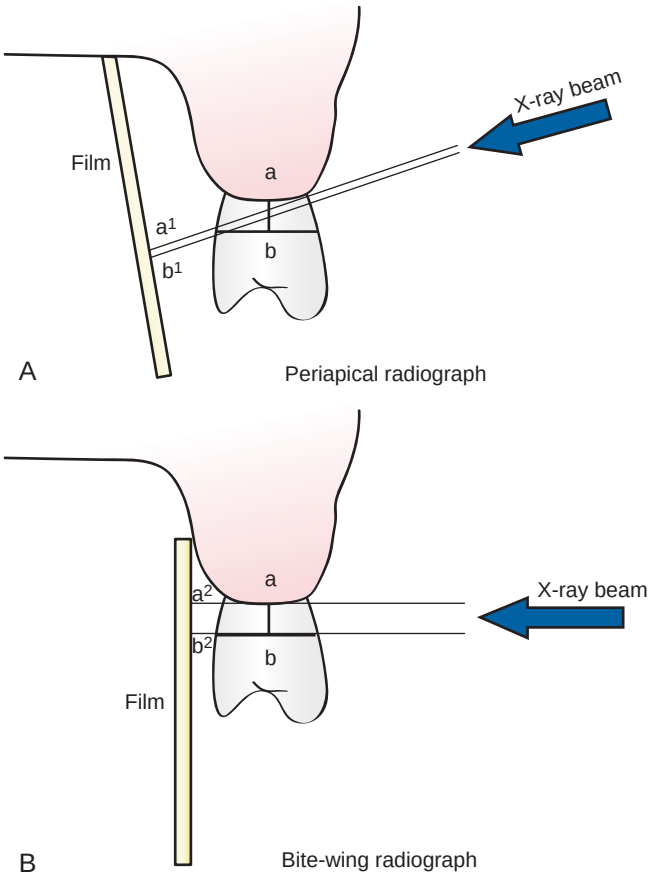

Figure 31-3 Schematic diagram of periapical **(A)** and bite-wing **(B)** radiographs. Angulation of the x-ray beam and the film on the periapical radiograph distort the distance between the alveolar crest and the cementoenamel junction (CEJ) (compare a-b versus a^1-b^1). In contrast, the projection geometry of the bite-wing radiograph allows a more accurate depiction (a^2-b^2) of the distance between the alveolar crest and the CEJ (a-b).

Radiographic Appearance of Periodontal Disease

Periodontitis

Radiographic changes in periodontitis follow the pathophysiology of periodontal tissue destruction and include the following:

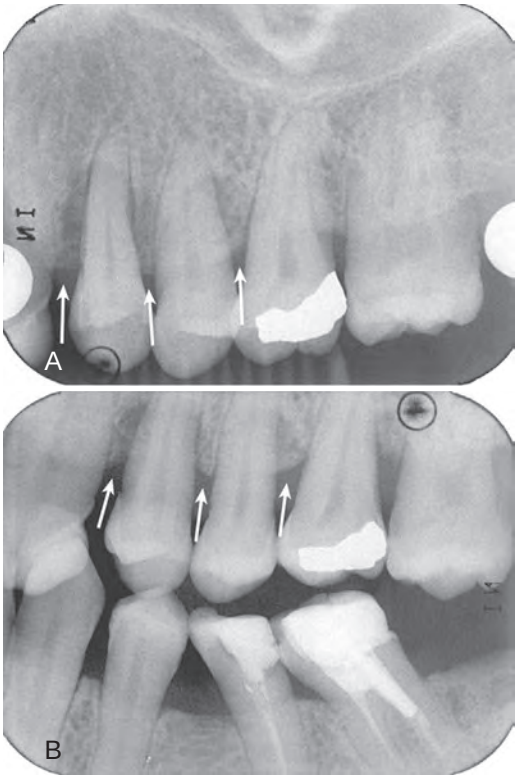

Figure 31-4 Periapical **(A)** and bite-wing **(B)** radiographs from full-mouth series of a patient with periodontitis. The periapical film clearly underestimates the amount of bone loss *(white arrows)*. Because of appropriate projection geometry, the alveolar crest height is accurately depicted on the bite-wing radiograph *(white arrows)*.

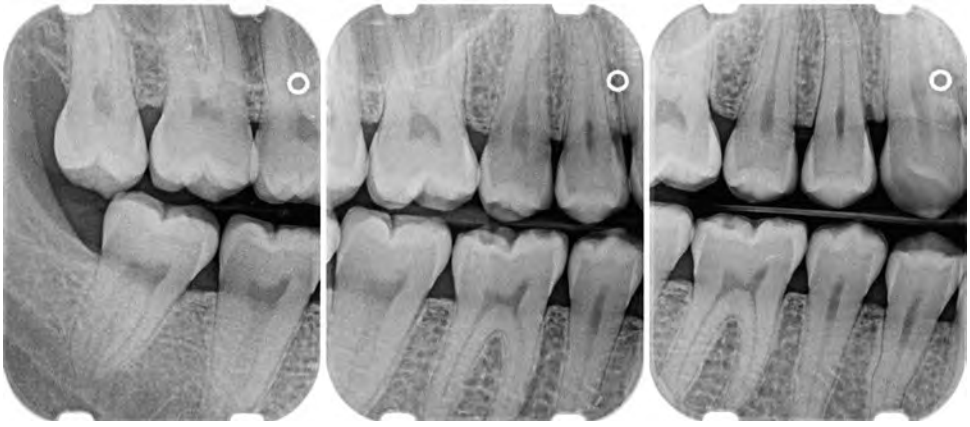

Figure 31-5 Vertical bite-wing films can be used to cover a larger area of the alveolar bone.

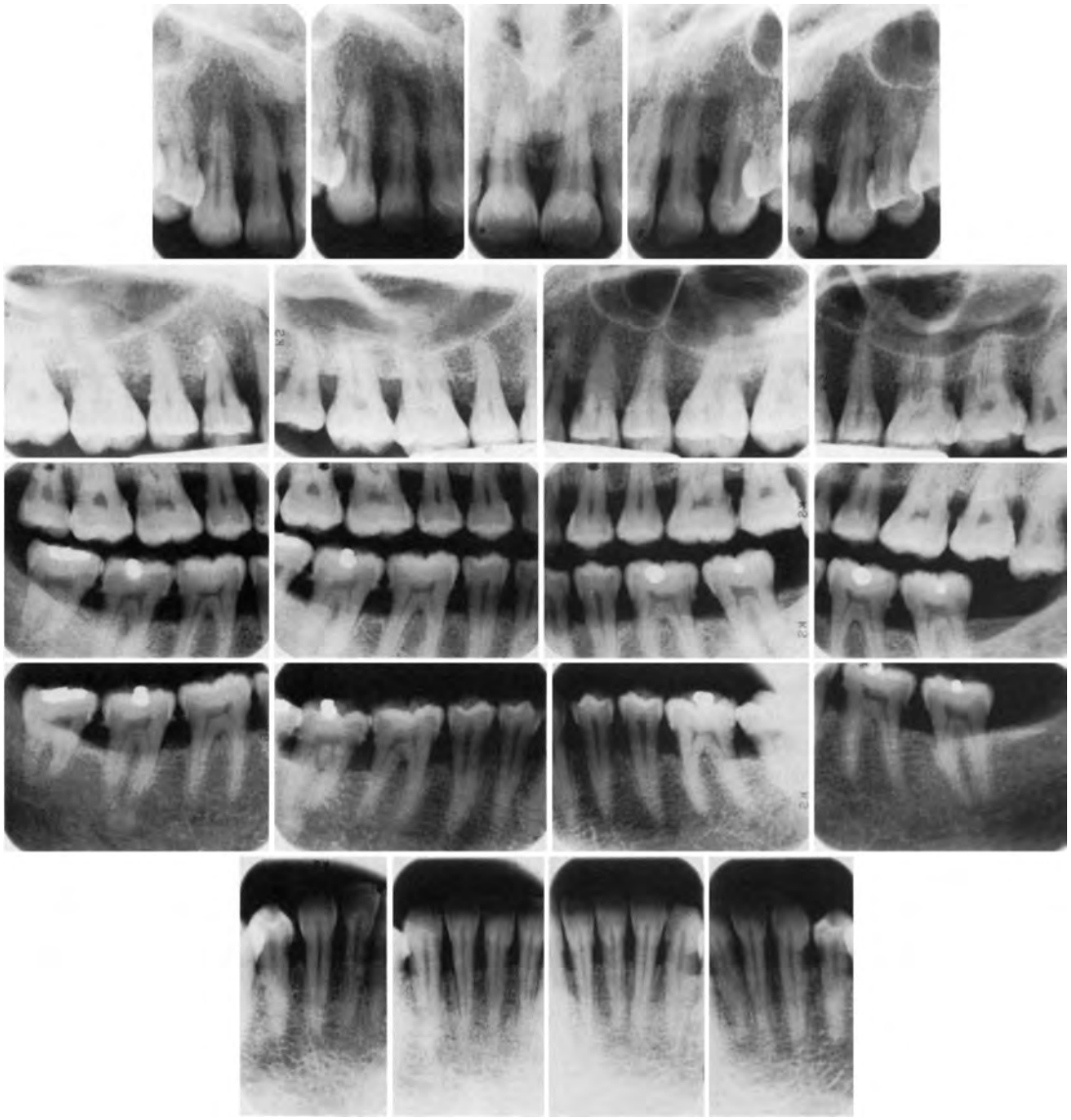

Figure 31-6 Generalized horizontal bone loss.

Figure 31-7 Angular bone loss on first molar with involvement of the furcation.

Figure 31-8 Angular bone loss on mandibular molar partially obscured by a dense mylohyoid ridge.

1. *Fuzziness and disruption of lamina dura* crestal cortication continuity is the earliest radiographic change in periodontitis (Figure 31-12, *A* and *B*) and results from bone resorption activated by extension of gingival inflammation into the periodontal bone. Depicting these early changes depends greatly on the radiographic technique, as well as on anatomic variations (thickness and density of interdental bone, position of adjoining teeth). No correlation has been found between crestal lamina dura in radiographs and the presence or absence of clinical inflammation, bleeding on probing, periodontal pockets, or loss of attachment.[12] Therefore it can be concluded that the presence of an intact crestal lamina dura may be an indicator of periodontal health, whereas its absence lacks diagnostic relevance.[13,14]
2. Continued periodontal bone loss and widening of the periodontal space results in a wedge-shaped radiolucency at the mesial or distal aspect of the crest (Figure 31-12, *B*). The apex of the area is pointed in the direction of the root.
3. Subsequently, the destructive process extends across the alveolar crest, thus reducing the height of the interdental bone. As increased osteoclastic activity results in increased bone resorption along the endosteal margins of the medullary spaces, the remaining interdental bone can appear partially eroded (Figure 31-12, *C*).
4. The height of the interdental septum is progressively reduced by the extension of inflammation and the resorption of bone (Figure 31-12, *D*).
5. Frequently a radiopaque horizontal line can be observed across the roots of a tooth. This opaque line demarcates the portion of the root where the labial or lingual bony plate has been partially or completely destroyed from the remaining bone-supported portion (Figure 31-13).

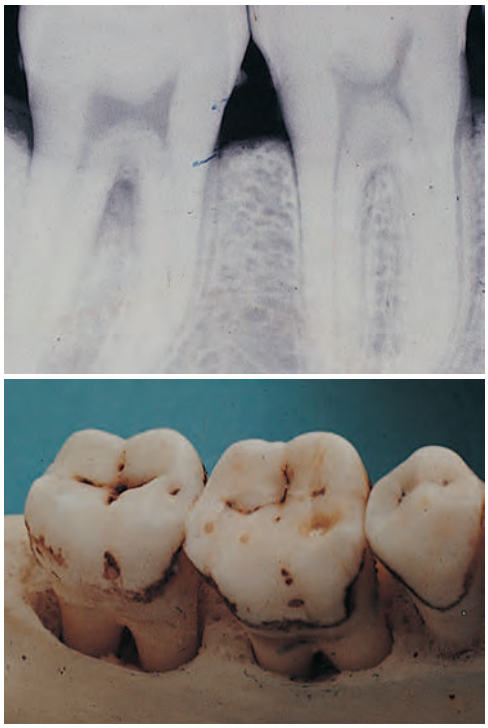

Figure 31-9 Interdental lesion that extends to the facial or lingual surfaces in a troughlike manner.

Interdental Craters

Interdental craters are seen as irregular areas of reduced density on the alveolar bone crests. Craters are generally not sharply demarcated but gradually blend with the rest of the bone. Conventional radiographs do not accurately depict the morphology or depth of interdental craters, which sometimes appear as vertical defects.

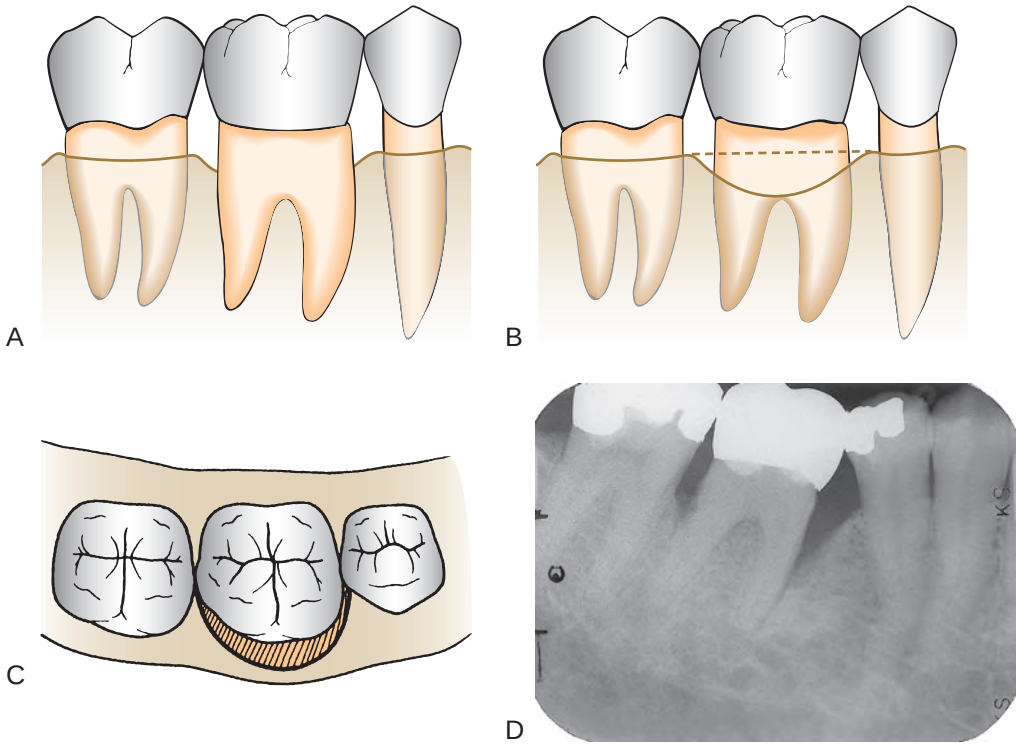

Figure 31-10 **A,** Interdental mesial and distal lesions. **B,** Facial or lingual outlines of actual lesion. **C,** Occlusal view of lesion. **D,** Radiograph of mesial and facial lesions.

Figure 31-11 Prominent nutrient canals in the mandible.

Furcation Involvement

Definitive diagnosis of furcation involvement is made by clinical examination, which includes careful probing with a specially designed probe (e.g., Nabers). Radiographs are helpful, but root superimposition, caused by anatomic variations and/or improper technique, can obscure radiographic representation of furcation involvement. As a general rule, bone loss is greater than it appears in the radiograph. A tooth may present marked bifurcation involvement in one film (Figure 31-14, *A*) but appear to be uninvolved in another (Figure 31-14, *B*). Radiographs should be taken at different angles to reduce the risk of missing furcation involvement.

The recognition of a large, clearly defined radiolucency in the furcation area is easy to identify (see Figure 31-14, *A*), but less clearly defined radiographic changes are often overlooked. To assist in the radiographic detection of furcation involvement, the following diagnostic criteria are suggested:

1. The slightest radiographic change in the furcation area should be investigated clinically, especially if there is bone loss on adjacent roots (Figure 31-15).
2. Diminished radiodensity in the furcation area in which outlines of bony trabeculae are visible suggests furcation involvement (Figure 31-16).
3. Whenever there is marked bone loss in relation to a single molar root, it may be assumed that the furcation is also involved (Figure 31-17).

Periodontal Abscess

The typical radiographic appearance of the periodontal abscess is a discrete area of radiolucency along the lateral aspect of the root (Figures 31-18 and 31-19). However, the radiographic picture is often not characteristic (Figure 31-20). This can be due to the following:

1. *The stage of the lesion.* In the early stages the acute periodontal abscess is extremely painful but presents no radiographic changes.
2. *The extent of bone destruction and the morphologic changes of the bone.*
3. *The location of the abscess.* Lesions in the soft tissue wall of a periodontal pocket are less likely to produce radiographic changes than those deep in the supporting tissues. Abscesses on the facial or lingual surface are obscured by the radiopacity of the root; interproximal lesions are more likely to be visualized radiographically.

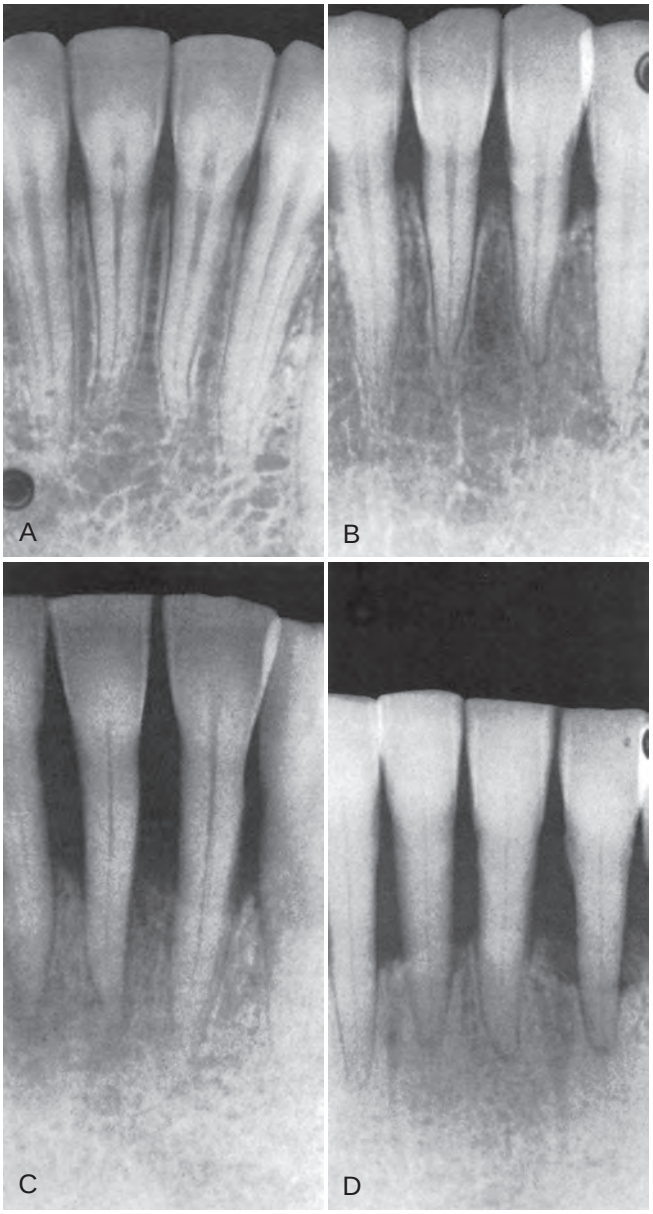

Figure 31-12 Radiographic changes in periodontitis. **A,** Normal appearance of interdental bone. **B,** Fuzziness and a break in the continuity of the lamina dura at the crest of the bone distal to the central incisor *(left)*. There are wedge-shaped radiolucent areas at the crest of the other interdental bone. **C,** Radiolucent projections from the crest into the interdental bone indicate extension of destructive processes. **D,** Severe bone loss.

Therefore radiographs alone cannot provide final diagnosis of a periodontal abscess but need to be accompanied by careful clinical examination.

Clinical Probing

Regenerative and resective flap designs and incisions require prior knowledge of the underlying osseous topography. Careful probing of these pocket areas after scaling and root planing often require local anesthesia and definitive radiographic evaluation of the osseous lesions. Radiographs taken with periodontal probes, gutta-percha points or other indicators (e.g., Hirschfeld pointers) placed into the anesthetized pocket show the true extent of the bone lesion. As indicated previously, the attachment level on the

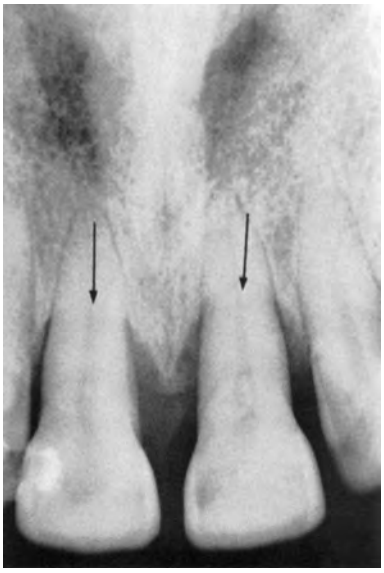

Figure 31-13 Horizontal lines across the roots of the central incisors *(arrows)*. The area of the roots below the horizontal lines is partially or completely denuded of the facial and lingual bony plates.

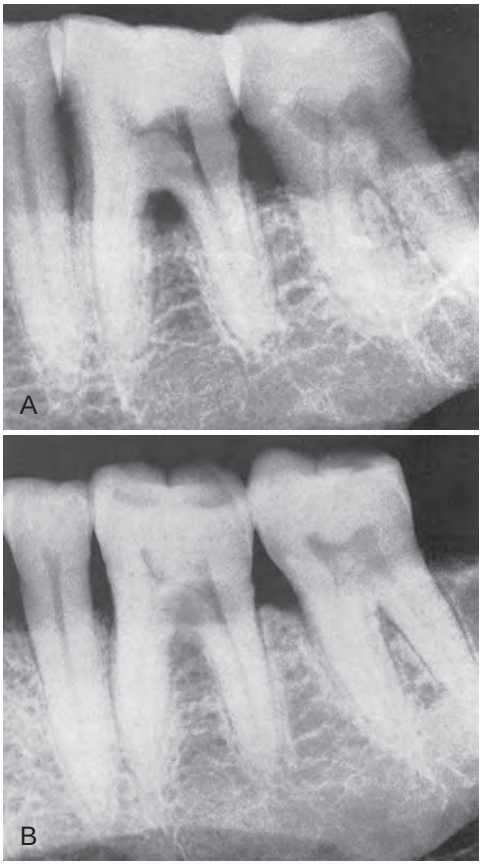

Figure 31-14 **A,** Furcation involvement indicated by triangular radiolucency in bifurcation area of mandibular first molar. The second molar presents only a slight thickening of the periodontal space in the bifurcation area. **B,** Same area as **A,** different angulation. The triangular radiolucency in the bifurcation of the first molar is obliterated, and involvement of the second molar bifurcation is apparent.

Figure 31-15 Early furcation involvement suggested by fuzziness in the bifurcation of the mandibular first molar, particularly when associated with bone loss on the roots.

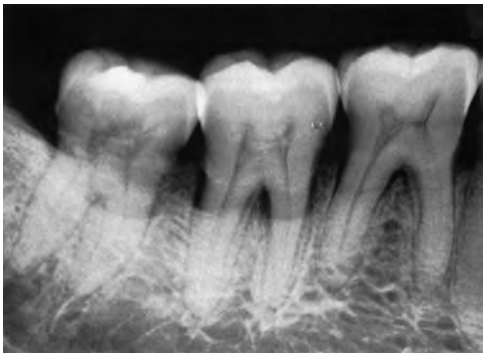

Figure 31-16 Furcation involvement of mandibular first and second molars indicated by thickening of periodontal space in furcation area. The furcation of the third molar is also involved, but the thickening of the periodontal space is partially obscured by the external oblique line.

Figure 31-17 Furcation involvement of the first molar partially obscured by the radiopaque lingual root. The horizontal line across the distobuccal root demarcates the apical portion *(arrow),* which is covered by bone, from the remainder of the root, where the bone has been destroyed.

radicular surface or interdental lesions with thick facial or lingual bone cannot be visualized in the radiograph. The use of radiopaque indicators is an efficient and necessary diagnostic aid (Figure 31-21).

Localized Aggressive Periodontitis

Localized aggressive (formerly "localized juvenile") periodontitis is characterized by the following:

1. Initially, bone loss in the maxillary and mandibular incisor and/or first molar areas, usually bilaterally, resulting in vertical, arclike destructive patterns (Figure 31-22).
2. As the disease progresses, loss of alveolar bone may become generalized but remains less pronounced in the premolar areas.

Figure 31-18 Radiolucent area on lateral aspect of root with chronic periodontal abscess.

Trauma from Occlusion

Trauma from occlusion can produce radiographically detectable changes in the thickness of the lamina dura, morphology of the alveolar crest, width of the PDL space, and density of the surrounding cancellous bone.[15]

Traumatic lesions manifest more clearly in faciolingual aspects because mesiodistally, the tooth has the added stability provided by the contact areas with adjacent teeth. Therefore slight variations in the proximal surfaces may indicate greater changes in the facial and lingual aspects. *The radiographic changes listed next are not pathognomonic of trauma from occlusion and must be interpreted in combination with clinical findings,* particularly tooth mobility, presence of wear facets, pocket depth, and analysis of occlusal contacts and habits.

The *injury phase* of trauma from occlusion produces a loss of the lamina dura that may be noted in apices, furcations, and marginal areas. This loss of lamina dura results in widening of the PDL space (Figure 31-23). *The repair phase* of trauma from occlusion results in an attempt to strengthen the periodontal structures to better support the increased loads. Radiographically, this is manifested by a widening of the PDL space, which may be generalized or localized.

Figure 31-19 Typical radiographic appearance of periodontal abscess on right central incisor.

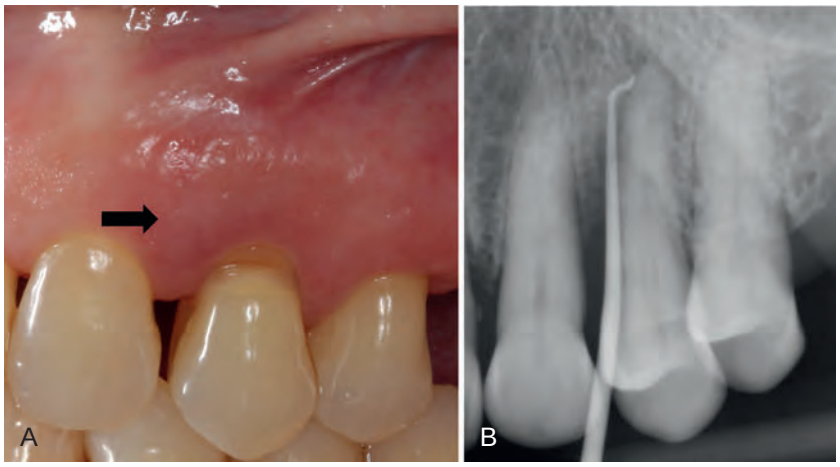

Figure 31-20 Chronic periodontal abscess. **A,** Periodontal abscess in the left maxillary first premolar area. **B,** Extensive bone destruction on the mesial surface of the first premolar. Gutta-percha point traces to the root apex.

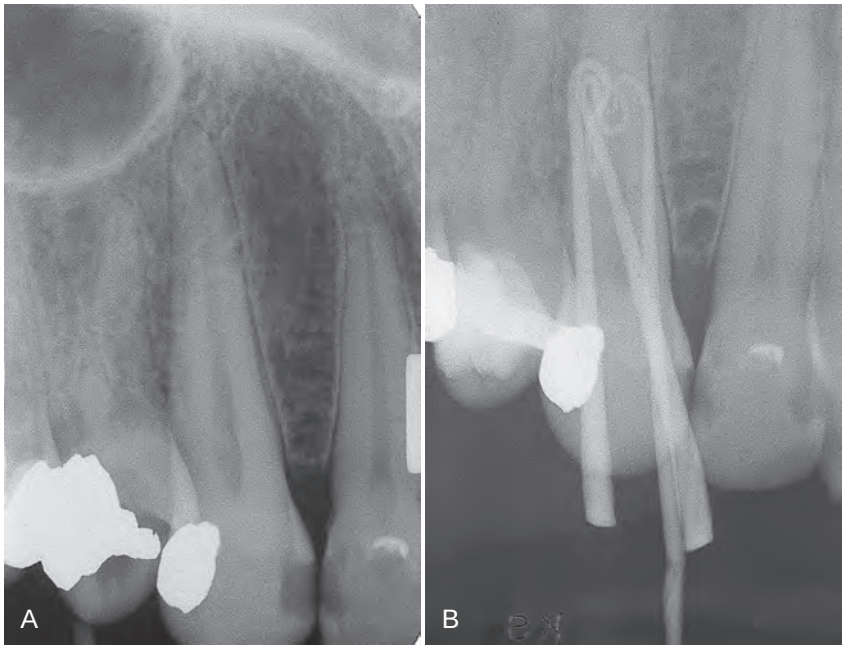

Figure 31-21 **A,** Radiograph of maxillary cuspid. This view does not show facial bone loss. **B,** Radiograph of same maxillary cuspid as **A,** with gutta-percha points placed in the facial pocket to indicate bone loss.

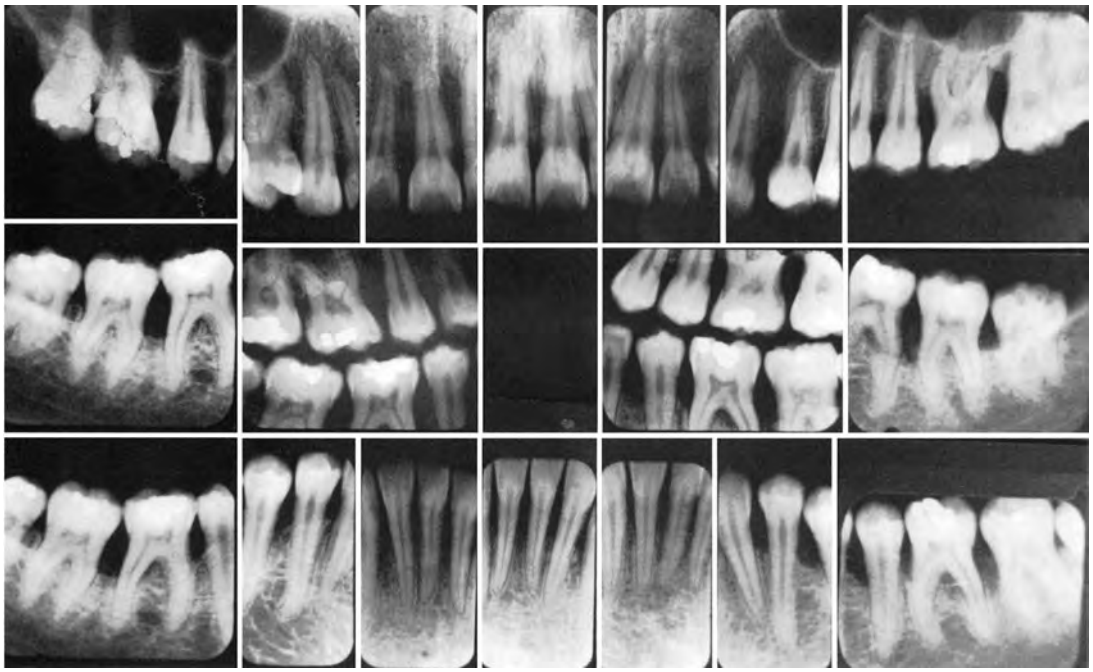

Figure 31-22 Localized aggressive periodontitis. The accentuated bone destruction in the anterior and first molar areas is considered to be characteristic of this disease.

Although microscopic measurements have determined normal variations in the PDL space width along the root surface, these are generally not detected radiographically. Thus, when seen on the radiographs, PDL space variations in width suggest that the tooth is being subjected to increased forces. Successful attempts to reinforce the periodontal structures by widening the PDL space is accompanied by increased width of the lamina dura and sometimes by condensation of the perialveolar cancellous bone.

More advanced traumatic lesions may result in deep angular bone loss, which, when combined with marginal inflammation, may lead to intrabony pocket formation. In terminal stages, these lesions extend around the root apex, producing a wide, radiolucent periapical image (cavernous lesions).

Root resorption may also result from excessive forces on the periodontium, particularly those caused by orthodontic appliances. Although trauma from occlusion produces many areas of root resorption, these areas are usually of a magnitude insufficient to be detected radiographically.

Digital Intraoral Radiography

Over the last two decades, advances in digital imaging technology have driven a rapid growth of digital intraoral radiography as a

Figure 31-23 Widened periodontal space caused by trauma from occlusion. Note the increased density of the surrounding bone caused by new bone formation in response to increased occlusal forces.

convenient alternative to conventional film-based radiography.[2,16-18] These technologies have been integrated into patient management systems, enabling dental offices to maintain a fully electronic patient record (Figure 31-24, *A*). The digital records can be easily shared among dentists and other healthcare providers enabling telediagnosis, and also facilitating transmission to third parties for reimbursement.

Digital intraoral radiographic systems use either solid-state detectors or photostimulable phosphor (PSP) plates.[18-20] Systems with solid-state detectors use either charge-coupled devices (CCDs) or complementary metal oxide semiconductor (CMOS) chips as image receptors. These receptors are typically wired and connected to a computer using a universal serial bus (USB) connection. Wireless sensors are also available and require the use of disposable batteries. With CCD/CMOS-based receptors, images are recorded and displayed on a computer monitor virtually in real time. These sensors are bulkier than film, and the active image-recording area is slightly smaller than that of film. A second technology for intraoral radiography is PSP plates. These receptors are the same size as intraoral radiographic film. Unlike CCD/CMOS receptors, PSP plates do not provide a real-time display of the radiographic image. On interaction with x-ray photons, PSP crystals in the plate store energy, creating a latent radiographic image. The stored energy is then released by stimulating the plate with an appropriate wavelength of light. With PSP systems, the workflow is somewhat similar to that of silver halide emulsion film. Following radiographic exposure, the PSP plate is scanned by a laser beam, converting the latent radiographic image into a digital image.

Following capture, digital radiographic images can be enhanced to augment radiographic diagnosis. The brightness and contrast of the image can be altered to highlight specific anatomic regions, depending on the diagnostic task. The images can be magnified to allow closer examination of a specific area of interest. Importantly, a variety of image enhancement filters can be applied, for example to sharpen (enhance edges) images. Some software programs have preprogrammed algorithms that can be applied for specific diagnostic tasks. For example, to enhance interproximal caries, periodontal bone, pulp canals, and so forth (Figure 31-24, *B*). However, it is important to recognize that such image manipulations can produce artifacts that may be misinterpreted as disease. Clinicians should be aware of such artifacts produced by digital image manipulation. In addition to the image manipulation features, digital radiographic images facilitate patient education, allow for easy storage, and sharing with other healthcare providers, and can be easily integrated into electronic patient records.

Advanced Imaging Modalities

In the last decade, cone-beam computed tomography (CBCT) has revolutionized the field of oral and maxillofacial imaging. CBCT technology and its use in evaluation of the implant patient are discussed in Chapter 73. However, CBCT finds application in almost every diagnostic task of clinical dentistry, including evaluation of periodontal and periapical structures.[21] CBCT offers many advantages over conventional radiography, including the accurate three-dimensional imaging of teeth and supporting structures. Although not recommended for every dental patient, CBCT avoids the problems of geometric superimposition and unpredictable magnification and can provide valuable diagnostic information in periodontal evaluation.

As discussed earlier, periapical and bite-wing radiographs provide information mostly for the interdental bone. However, a three-wall defect that preserves the buccal and/or lingual cortices can be difficult to diagnose, and the buccal, lingual, and furcational periodontal bone levels are hard to evaluate in conventional radiographs. When clinical examination raises concerns for such areas, CBCT imaging can add diagnostic value. Figure 31-25 illustrates the CBCT diagnostic advantage in the evaluation of a three-wall defect in the distal surface of tooth #32. Periapical radiograph (Figure 31-25, *A*) presents normal bone height at the mesial and distal surface of #32. CBCT sections (Figure 31-25, *A* to *C*) clearly demonstrate a three-wall defect on the distal surface of #32. Note that the buccal and lingual cortical plates are well preserved. For this reason, the periodontal defect is not depicted by the periapical radiograph. Similarly, Figure 31-26 depicts a vertical defect in the interproximal area between the two right maxillary premolars extending from the alveolar crest to the apical third of the roots toward the palatal aspect of the alveolar ridge. This defect cannot be appreciated on the periapical radiograph.

Conclusion

Periapical radiographic examination should be part of each patient's periodontal evaluation and should be coupled with a detailed recording of pocket depths, gingival margin location, and bleeding on probing. Radiographic evaluation should be updated every 2 years. Periapical radiographs often underestimate the amount of periodontal bone loss, and early changes are usually not detected. Significant interdental bone loss can occur and may not be detectable on periapical radiographs because the density of the intact buccal and lingual or palatal bone plates obscure changes that occur as the result of periodontitis. Comparison of periapical radiographs of the same area taken at different times will only be reliable in documenting dramatic changes in bone levels since variations in angulation of the beam, placement of the film, and development of the image make accurate measurements taken over time very difficult and unreliable.

Recent use of three-dimensional radiographic techniques with CBCT gives a much more accurate picture of periodontal bone loss

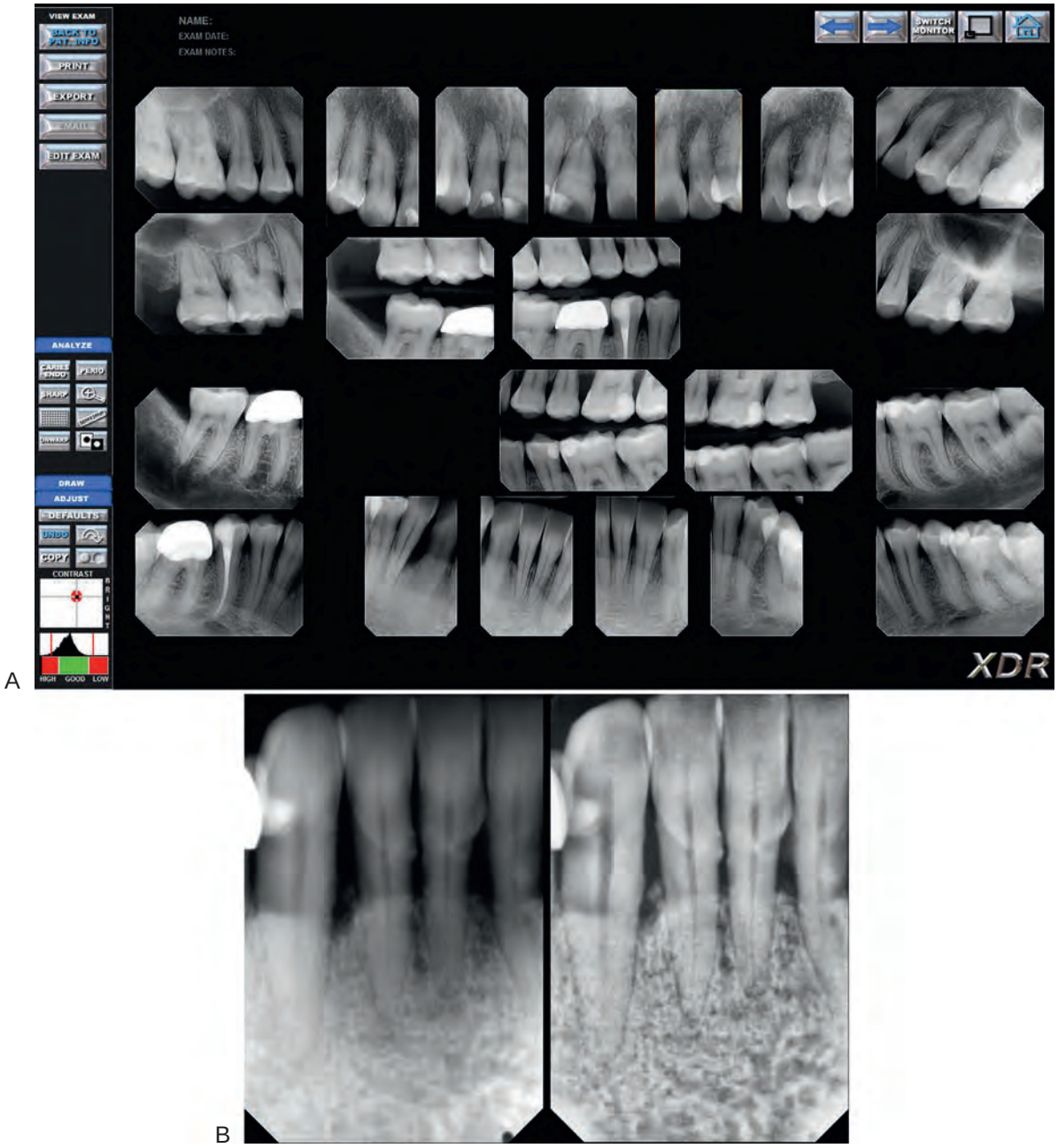

Figure 31-24 **A,** Image display of a full-mouth radiographic series acquired using complementary metal oxide semiconductor (CMOS) receptors. Specific features of the software program allow for image manipulation, measurements, and annotations. **B,** The "perio" image enhancement filtration applied to highlight the contrast of alveolar bone. Note the presence of calculus and the better depiction of the alveolar crestal bone.

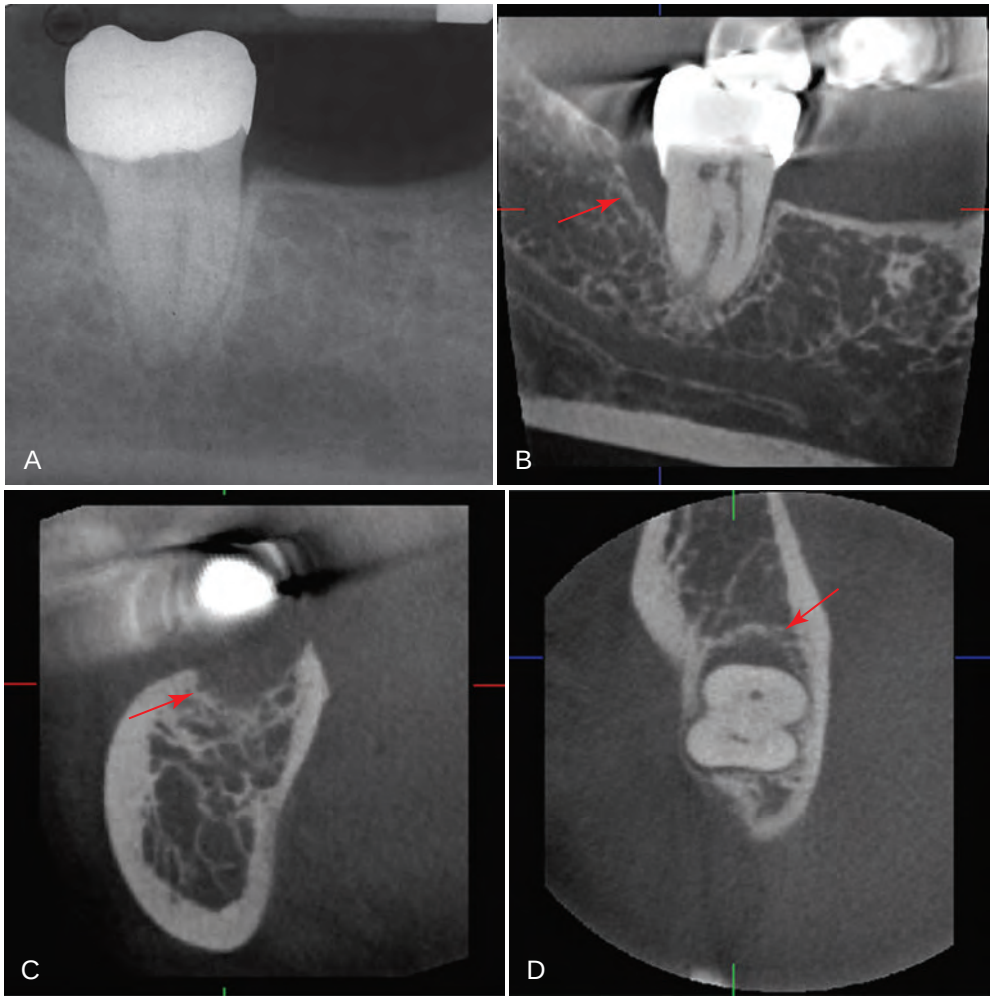

Figure 31-25 Periapical radiograph **(A)** and sagittal **(B),** cross-sectional **(C),** and axial **(D)** cone-beam computed tomography (CBCT) sections of the mandibular right second molar. No pathology is detected on the periapical radiograph. However, CBCT images clearly illustrate a deep, vertical, three-wall defect on the distal surface of the mandibular right second molar *(red arrow)*.

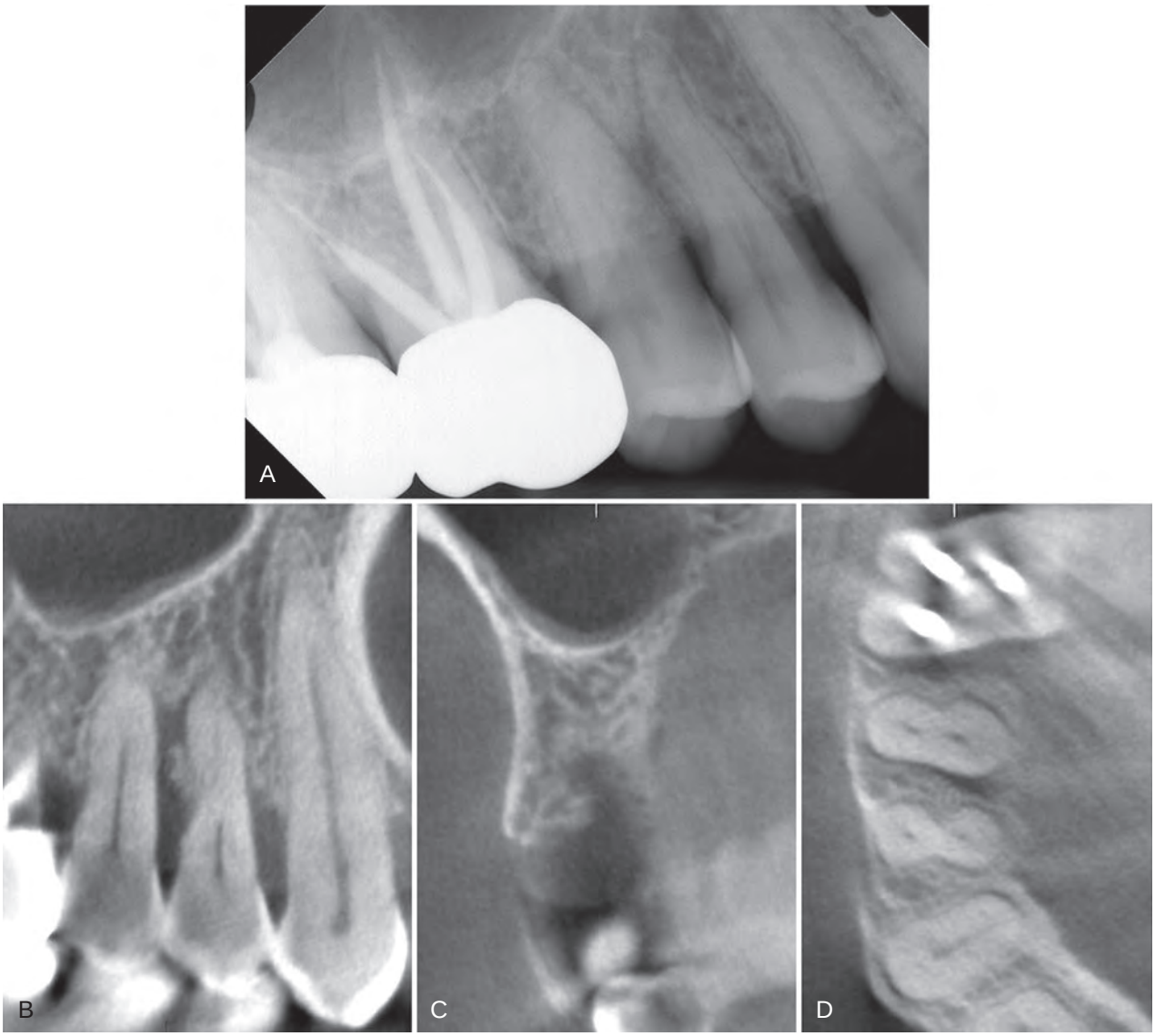

Figure 31-26 Periapical radiograph **(A)** and sagittal **(B),** cross-sectional **(C),** and axial **(D)** cone-beam computed tomography (CBCT) sections of the maxillary premolar region. The periapical radiograph demonstrates horizontal bone loss. The CBCT images reveal the presence of a vertical defect in between the premolars that extends from the palatal crest to the apical third of the roots. The extent of the bone loss is underestimated on the periapical radiograph.

than do two-dimensional radiographs and will be more widely used as this technology becomes available in more clinics.

Suggested Readings

Misch KA, Yi ES, Sarment DP: Accuracy of conebeam computed tomography for periodontal defect measurements. *J Periodontol* 77:1261–1266, 2006.

Tetradis S, Anstey P, Graff-Radford S: Cone beam computed tomography in the diagnosis of dental disease. *J Calif Dent Assoc* 38:27–32, 2010.

Tyndall A, Rathore S: Cone-beam CT diagnostic applications: caries, periodontal bone assessment, and endodontic applications. *Dent Clin North Am* 52:825, 2008.

Vandenberghe B, Jacobs R, Bosmans H: Modern dental imaging: a review of the current technology and clinical applications in dental practice. *Eur Radiol* 20:2637–2655, 2010.

Van der Stelt PF: Filmless imaging: the uses of digital radiography in dental practice. *J Am Dent Assoc* 136:1379–1387, 2005.

White SC, Pharoah MJ: *Oral radiology: principles and interpretation*, ed 6, St. Louis, 2009, Mosby, Elsevier.

References

References for this chapter are found on the companion website www.expertconsult.com.

References

1. Corbet EF, Ho DK, Lai SM: Radiographs in periodontal disease diagnosis and management. *Aust Dent J* 54(Suppl 1):S27–S43, 2009.
2. Mol A: Imaging methods in periodontology. *Periodontol 2000* 34:34–48, 2004.
3. Tugnait A, Hirschmann PN, Clerehugh V: Validation of a model to evaluate the role of radiographs in the diagnosis and treatment planning of periodontal diseases. *J Dent* 34:509–515, 2006.
4. Tyndall A, Rathore S: Cone-beam CT diagnostic applications: caries, periodontal bone assessment, and endodontic applications. *Dent Clin North Am* 52:825, 2008.
5. Prichard JF: *Advanced periodontal disease: surgical and prosthetic management*, ed 2, Philadelphia, 1972, Saunders.
6. Gutteridge DL: The use of radiographic techniques in the diagnosis and management of periodontal diseases. *Dentomaxillofac Radiol* 24:107–113, 1995.
7. Reed BE, Polson AM: Relationships between bitewing and periapical radiographs in assessing crestal alveolar bone levels. *J Periodontol* 55:22–27, 1984.
8. Bragger U: Radiographic parameters: biological significance and clinical use. *Periodontol 2000* 39:73–90, 2005.
9. Greenstein G, Polson A, Iker H, et al: Associations between crestal lamina dura and periodontal status. *J Periodontol* 52(7):362–366, 1981.
10. Hausmann E, Allen K, Clerehugh V: What alveolar crest level on a bite-wing radiograph represents bone loss? *J Periodontol* 62:570, 1991.
11. Källestål C, Matsson L: Criteria for assessment of interproximal bone loss on bite-wing radiographs in adolescents. *J Clin Periodontol* 16:300, 1989.
12. Rams TE, Listgarten MA, Slots J: Utility of radiographic crestal lamina dura for predicting periodontal disease activity. *J Clin Periodontol* 21:571, 1995.
13. Armitage G: Periodontal diseases: diagnosis. *Ann Periodontol* 1:37, 1996.
14. Bragger I: Radiographic diagnosis of periodontal disease progression. *Curr Opin Periodontol* 3:59–67, 1996.
15. Burgett FG: Trauma from occlusion. Periodontal concerns. *Dent Clin North Am* 39:301–311, 1995.
16. Hausmann E: Radiographic and digital imaging in periodontal practice. *J Periodontol* 71:497–503, 2000.
17. Jeffcoat MK, Reddy MS: Advances in measurements of periodontal bone and attachment loss. *Monogr Oral Sci* 17:56–72, 2000.
18. White SC, Yoon DC, Tetradis S: Digital radiography in dentistry: what it should do for you? *J Calif Dent Assoc* 27:942, 1999.
19. Vandenberghe B, Jacobs R, Bosmans H: Modern dental imaging: a review of the current technology and clinical applications in dental practice. *Eur Radiol* 20:2637–2655, 2010.
20. White SC, Pharoah MJ: *Oral radiology: principles and interpretation*, ed 6, St. Louis, 2009, Mosby, Elsevier.
21. Tetradis S, Anstey P, Graff-Radford S: Cone beam computed tomography in the diagnosis of dental disease. *J Calif Dent Assoc* 38:27–32, 2010.

CHAPTER 32

Clinical Risk Assessment

Karen F. Novak and M. John Novak

CHAPTER OUTLINE

Definitions
Risk Factors for Periodontal Disease
Risk Determinants/Background Characteristics for Periodontal Disease
Risk Indicators for Periodontal Disease *(e-only)*
Risk Markers/Predictors for Periodontal Disease *(e-only)*
Clinical Risk Assessment for Periodontal Disease *(e-only)*
Conclusion

For online-only content on risk indicators, risk markers/predictors, and clinical risk assessment for periodontal disease, please visit the companion website at www.expertconsult.com.

Definitions

Risk assessment is defined by numerous components.[1,2] Risk is the probability that an individual will develop a specific disease in a given period. The risk of developing the disease will vary from individual to individual.

Risk factors may be environmental, behavioral, or biologic factors that, when present, increase the likelihood that an individual will develop the disease. Risk factors are identified through longitudinal studies of patients with the disease of interest. Exposure to a risk factor or factors may occur at a single point in time; over multiple, separate points in time; or continuously. However, to be identified as a risk factor, the exposure must occur before disease onset. Interventions often can be identified and when implemented, can help modify risk factors.

The term *risk determinant/background characteristic*, which is sometimes substituted for the term *risk factor*, should be reserved for those risk factors that cannot be modified.

Risk indicators are *probable* or *putative* risk factors that have been identified in cross-sectional studies but not confirmed through longitudinal studies.

Risk predictors/markers, although associated with increased risk for disease, do not cause the disease.

These factors also are identified in cross-sectional and longitudinal studies.

Box 32-1 lists elements of these categories of risk for periodontal disease.

Risk Factors for Periodontal Disease

Tobacco Smoking

Tobacco smoking is a well-established risk factor for periodontitis.[1,3] A direct relationship exists between smoking and the prevalence of periodontal disease (see Chapter 10). This association is independent of other factors such as oral hygiene or age.[4] Studies comparing the response to periodontal therapy in smokers, previous smokers, and nonsmokers have shown that smoking has a negative impact on the response to therapy. However, former smokers respond similarly to nonsmokers.[5] These studies demonstrate the therapeutic impact of intervention strategies on patients who smoke (see Chapter 10).

Diabetes

Diabetes is a clear risk factor for periodontitis.[1] Epidemiologic data demonstrate that the prevalence and severity of periodontitis are significantly higher in patients with type 1 or type 2 diabetes mellitus than in those without diabetes, and that the level of diabetic control is an important variable in this relationship (see Chapter 11).

Pathogenic Bacteria and Microbial Tooth Deposits

It is well documented that accumulation of bacterial plaque at the gingival margin results in the development of gingivitis and that the gingivitis can be reversed with the implementation of oral hygiene measures.[6] These studies demonstrate a causal relationship between accumulation of bacterial plaque and gingival inflammation. However, a causal relationship between *plaque accumulation* and *periodontitis* has been more difficult to establish. Often, patients with severe loss of attachment have minimal levels of bacterial plaque on the affected teeth, indicating that the *quantity* of plaque is not of major importance in the disease process. However, although quantity may not indicate risk, there is evidence that the composition, or *quality,* of the complex plaque biofilm is of importance.

In terms of quality of plaque, three specific bacteria have been identified as etiologic agents for periodontitis: *Aggregatibacter actinomycetemcomitans* (formerly *Actinobacillus actinomycetemcomitans*), *Porphyromonas gingivalis,* and *Tannerella forsythia* (formerly *Bacteroides forsythus*).[7] *Porphyromonas gingivalis* and *T. forsythia* are often found in chronic periodontitis, whereas *A. actinomycetemcomitans* is often associated with aggressive

BOX 32-1 Categories of Risk Elements for Periodontal Disease

Risk Factors
Tobacco smoking
Diabetes
Pathogenic bacteria
Microbial tooth deposits

Risk Determinants/Background Characteristics
Genetic factors
Age
Gender
Socioeconomic status
Stress

Risk Indicators
HIV/AIDS
Osteoporosis
Infrequent dental visits

Risk Markers/Predictors
Previous history of periodontal disease
Bleeding on probing

HIV, Human immunodeficiency virus; *AIDS,* acquired immunodeficiency syndrome.

periodontitis. Cross-sectional and longitudinal studies support the delineation of these three bacteria as risk factors for periodontal disease. Additional evidence that these organisms are causal agents includes the following[8]:

1. Their elimination or suppression impacts the success of therapy.
2. There is a host response to these pathogens.
3. Virulence factors are associated with these pathogens.
4. Inoculation of these bacteria into animal models induces periodontal disease.

Although not completely supported by these criteria for causation, moderate evidence also suggests that *Campylobacter rectus*, *Eubacterium nodatum*, *Fusobacterium nucleatum*, *Prevotella intermedia, Prevotella nigrescens*, *Peptostreptococcus micros*, *Streptococcus intermedius*, and *Treponema denticola* are etiologic factors in periodontitis.[7]

Therefore the quantity of plaque present may not be as important as the quality of the plaque in determining risk for periodontitis.

Anatomic factors, such as furcations, root concavities, developmental grooves, cervical enamel projections, enamel pearls, and bifurcation ridges, may predispose the periodontium to disease as a result of their potential to harbor bacterial plaque and present a challenge to the clinician during instrumentation. Similarly, the presence of subgingival and overhanging margins can result in increased plaque accumulation, increased inflammation, and increased bone loss. Although not clearly defined as risk factors for periodontitis, anatomic factors and *restorative factors* that influence plaque accumulation may play a role in disease susceptibility for specific teeth.[9]

The presence of *calculus,* which serves as a reservoir for bacterial plaque, has been suggested as a risk factor for periodontitis. Although the presence of some calculus in healthy individuals receiving routine dental care does not result in significant loss of attachment, the presence of calculus in other groups of patients, such as those not receiving regular care and patients with poorly controlled diabetes, can have a negative impact on periodontal health.[2]

Risk Determinants/Background Characteristics for Periodontal Disease

Genetic Factors

Evidence indicates that genetic differences between individuals may explain why some patients develop periodontal disease and others do not. Studies conducted in twins have shown that genetic factors influence clinical measures of gingivitis, probing pocket depth, attachment loss, and interproximal bone height.[10-12] The familial aggregation seen in localized and generalized aggressive periodontitis also is indicative of genetic involvement in these diseases (see Chapter 6).

Kornman et al[13] demonstrated that alterations in specific genes encoding the inflammatory cytokines interleukin-1α (IL-1α) and interleukin-1β (IL-1β) were associated with severe chronic periodontitis in nonsmoking subjects.[13] However, results of other studies have shown limited association between these altered genes and the presence of periodontitis. Overall, it appears that changes in the IL-1 genes may be only one of several genetic changes involved in the risk for chronic periodontitis. Therefore, although the alteration in the IL-1 genes may be a valid marker for periodontitis in defined populations, its usefulness as a genetic marker in the general population may be limited.[14]

Immunologic alterations, such as neutrophil abnormalities,[15] monocytic hyperresponsiveness to lipopolysaccharide stimulation in patients with localized aggressive periodontitis,[16] and alterations in the monocyte/macrophage receptors for the Fc portion of antibody,[14,17] also appear to be under genetic control. In addition, genetics play a role in regulating the titer of the protective immunoglobulin G2 (IgG2) antibody response to *A. actinomycetemcomitans* in patients with aggressive periodontitis[18] (see Chapter 25).

Age

Both the prevalence and severity of periodontal disease increase with age.[3,19,20] It is possible that degenerative changes related to aging may increase susceptibility to periodontitis. However, it also is possible that the attachment loss and bone loss seen in older individuals are the result of prolonged exposure to other risk factors over a person's life, creating a cumulative effect over time. In support of this, studies have shown minimal loss of attachment in aging subjects enrolled in preventive programs throughout their lives.[21,22] Therefore it is suggested that periodontal disease is not an inevitable consequence of the aging process and that aging alone does not increase disease susceptibility. However, it remains to be determined whether changes related to the aging process, such as intake of medications, decreased immune function, and altered nutritional status, interact with other well-defined risk factors to increase susceptibility to periodontitis.

Evidence of loss of attachment may have more consequences in younger patients. The younger the patient, the longer the patient has for exposure to causative factors. In addition, aggressive periodontitis in young individuals often is associated with an unmodifiable risk factor such as a genetic predisposition to disease.[3] Therefore young individuals with periodontal disease may be at greater risk for continued disease as they age.

Gender

Gender plays a role in periodontal disease.[1] Surveys conducted in the United States since 1960 demonstrate that men have more loss of attachment than women.[23-25] In addition, men have poorer oral hygiene than women, as evidenced by higher levels of plaque and calculus.[25-27] Therefore gender differences in prevalence and

severity of periodontitis appear to be related to preventive practices rather than any genetic factor.

Socioeconomic Status

Gingivitis and poor oral hygiene can be related to lower socioeconomic status (SES).[1,23,24] This can most likely be attributed to decreased dental awareness and decreased frequency of dental visits compared with more educated individuals with higher SES. After adjusting for other risk factors, such as smoking and poor oral hygiene, lower SES alone does not result in increased risk for periodontitis (see Chapter 4).

Stress

The incidence of necrotizing ulcerative gingivitis increases during periods of emotional and physiologic stress, suggesting a link between the two.[28,29] Emotional stress may interfere with normal immune function[30,41] and may result in increased levels of circulating hormones, which can affect the periodontium.[32] Stressful life events, such as bereavement and divorce, appear to lead to a greater prevalence of periodontal disease,[33] and an apparent association exists between psychosocial factors and risk behaviors such as smoking, poor oral hygiene, and chronic periodontitis.[34] Adult patients with periodontitis who are resistant to therapy are more stressed than those who respond to therapy.[35] Individuals with financial strain, distress, depression, or inadequate coping mechanisms have more severe loss of attachment.[36] Although epidemiologic data on the relationship between stress and periodontal disease are limited, stress may be a putative risk factor for periodontitis.[3]

Conclusion

Risk assessment involves identifying elements that either may predispose a patient to developing periodontal disease or may influence the progression of disease that already exists. In either case, these patients may require modification of their prognosis and treatment plan. In addition to an evaluation of the factors contributing to their risk, these patients should be educated concerning their risk, and when appropriate, suitable intervention strategies should be implemented.

Suggested Readings

Genco RJ, Ho AW, Grossi SG, et al: Relationship of stress, distress and inadequate coping behaviors to periodontal disease. *J Periodontol* 70(7):711–723, 1999.

Haber J, Wattles J, Crowley M, et al: Evidence for cigarette smoking as a major risk factor for periodontitis. *J Periodontol* 64(1):16–23, 1993.

Ismail AI, Burt BA, Eklund SA: Epidemiologic patterns of smoking and periodontal disease in the United States. *J Am Dent Assoc* 106(5):617–621, 1983.

Löe H, Theilade E, Jensen SB: Experimental gingivitis in man. *J Periodontol* 36:177–187, 1965.

Michalowicz BS, Diehl SR, Gunsolley JC, et al: Evidence of a substantial genetic basis for risk of adult periodontitis. *J Periodontol* 71(11):1699–1707, 2000.

Papapanou PN, Lindhe J, Sterrett JD, et al: Considerations on the contribution of ageing to loss of periodontal tissue support. *J Clin Periodontol* 18(8):611–615, 1991.

Stanford TW, Rees TD: Acquired immune suppression and other risk factors/indicators for periodontal disease progression. *Periodontol 2000* 32:118–135, 2003.

References

References for this chapter are found on the companion website www.expertconsult.com.

Risk Indicators for Periodontal Disease

Human Immunodeficiency Virus/Acquired Immunodeficiency Syndrome

It has been hypothesized that the immune dysfunction associated with human immunodeficiency virus (HIV) infection and acquired immunodeficiency syndrome (AIDS) increases susceptibility to periodontal disease (see Chapter 26). Early reports on the periodontal status of patients with AIDS or individuals who are HIV seropositive revealed that these patients often had severe periodontal destruction characteristic of necrotizing ulcerative periodontitis.[37] More recent reports, however, have failed to demonstrate significant differences in the periodontal status of individuals with HIV infection and healthy controls.[38,39] The apparent discrepancy in these reports may have been caused by the inclusion of patients with AIDS (versus patients who were exclusively HIV seropositive) in some studies.[3]

Conflicting results also exist in studies examining the level of immunosuppression and severity of periodontal destruction. Some studies support that as the degree of immunosuppression increases in adults with AIDS, periodontal pocket formation and loss of clinical attachment also increase. Results of other studies have found no relationship between periodontal diseases and HIV/AIDS status. Evidence also suggests that AIDS-affected individuals who practice good preventive oral health measures, including effective home care and seeking appropriate professional therapy, can maintain periodontal health.[40] Therefore, although it seems reasonable to hypothesize that HIV infection and immunosuppression are risk factors for periodontal disease, the evidence is not conclusive.[1,3]

Osteoporosis

Osteoporosis has been suggested as another risk factor for periodontitis. Although studies in animal models indicate that osteoporosis does not initiate periodontitis, evidence indicates that the reduced bone mass seen in osteoporosis may aggravate periodontal disease progression.[41,42] However, reports in humans are conflicting. In a study of 12 women with osteoporosis and 14 healthy women, von Wowern et al[43] reported that the women with osteoporosis had greater loss of attachment than the control subjects. In contrast, Kribbs[44] examined pocket depth, bleeding on probing, and gingival recession in women with and without osteoporosis. Although the two groups had significant differences in bone mass, no differences in periodontal status were noted. However, it appears that a link may exist between osteoporosis and periodontitis, and additional studies may need to be conducted to determine whether osteoporosis is a true risk factor for periodontal disease.[45,46]

Infrequent Dental Visits

Identifying failure to visit the dentist regularly as a risk factor for periodontitis is controversial.[2] One study demonstrated an increased risk for severe periodontitis in patients who had not visited the dentist for 3 or more years, whereas another demonstrated that there was no more loss of attachment or bone loss in individuals who did not seek dental care compared with those who did over a 6-year period. However, differences in the ages of the subjects in these two studies may explain the different results. Additional longitudinal and intervention studies are necessary to determine whether infrequency of dental visits is a risk factor for periodontal disease.

Risk Markers/Predictors for Periodontal Disease

Previous History of Periodontal Disease

A history of previous periodontal disease is a good clinical predictor of risk for future disease.[2] Patients with the most severe existing loss of attachment are at the greatest risk for future loss of attachment. Conversely, patients currently free of periodontitis have a decreased risk for developing loss of attachment compared with those who currently have periodontitis (see Chapter 4).

Bleeding on Probing

Bleeding on probing is the best clinical indicator of gingival inflammation.[2] Although this indicator alone does not serve as a predictor for loss of attachment, bleeding on probing coupled with increasing pocket depth may serve as an excellent predictor for future loss of attachment. Lack of bleeding on probing does appear to serve as an excellent indicator of periodontal health.

Clinical Risk Assessment for Periodontal Disease

Information concerning individual risk for developing periodontal disease is obtained through careful evaluation of the patient's demographic data, medical history, dental history, and clinical examination (Box 32-2). The elements that contribute to increased risk can be identified through the collection of demographic data, including the patient's age, gender, and SES. The medical history may reveal elements such as a history of diabetes, smoking, HIV/AIDS, or osteoporosis, as well as the perceived level of stress. The dental history can reveal a family history of early tooth loss (suggestive of a genetic predisposition for aggressive periodontitis), a previous history of periodontal disease, and information concerning the frequency of oral health care in the past. Important elements identified during the clinical examination can include the location and extent of bacterial plaque accumulation, presence of plaque-retentive factors (e.g., overhanging restorations, subgingival margins), presence of anatomic plaque-retentive areas (e.g., grooves, furcation involvements), presence of calculus, extent of attachment loss, and presence or absence of bleeding on probing.

Once the social, demographic, medical history, dental history, and clinical presentation data are collected, they must be analyzed to identify patients at risk for developing periodontal disease. This analysis can be accomplished by the healthcare provider and/or through the use of a computer-based risk assessment tool. One example of this type of tool is the Periodontal Assessment Tool (PAT), which is one component of the PreViser Oral Health Information Suite (OHIS). The PAT utilizes input from 23 items that are part of a routine periodontal examination to generate both a quantification of current disease and a risk score for future disease. The score, which is based on an individual patient's set of risk factors and history, ranges from 1 (lowest risk) to 5 (highest risk). It has been proposed that utilizing this tool will provide a more objective, quantitative way to assess risk for periodontitis than clinical opinion.[47,48] Ultimately, a thorough risk assessment should improve clinical decision making, as well as patient outcomes.

Once an at-risk patient is identified and a diagnosis is made, the treatment plan may be modified accordingly (Figure 32-1). For example, patients with a history of cigarette smoking should be

BOX 32-2 Clinical Risk Assessment for Periodontal Disease

Demographic Data

Age
Duration of exposure to risk elements
Postmenopausal women
Evidence of aggressive disease
Male gender
Preventive practices
Frequency of care
Socioeconomic status
Dental awareness
Frequency of care

Medical History

Diabetes
Tobacco smoking
HIV/AIDS
Osteoporosis
Stress
Dental History
Family history of early tooth loss
Genetic predisposition to aggressive disease
Previous history of periodontal disease
Frequency of dental care
Clinical Examination
Plaque accumulation
Microbial sampling for putative periodontal pathogens
Calculus
Bleeding on probing
Extent of loss of attachment
Aggressive forms of disease
Tooth examination
Plaque retentive areas
Anatomic factors
Restorative factors

HIV, Human immunodeficiency virus; *AIDS,* acquired immunodeficiency syndrome.

informed of the relationship between smoking and periodontitis. They also should be informed of the impact of smoking on their prognosis and the likelihood of success of their periodontal therapy if they continue to smoke. Part of their recommended treatment plan for initial therapy may include referral to a smoking cessation program or implementation of self-administered smoking cessation aids. As another example, a patient diagnosed with severe, chronic periodontitis may be encouraged to be tested for the IL-1–positive genotype. If positive, the patient's treatment may involve the administration of systemic antimicrobial agents and host modifiers that would not be used in a patient without this genetic marker. If alterations in the host response are identified, the prognosis and treatment plan may be modified. Previously identified risk elements also may need to be reassessed at the reevaluation stage of treatment. This is especially important in patients who do not respond favorably to periodontal therapy (see Figure 32-1).

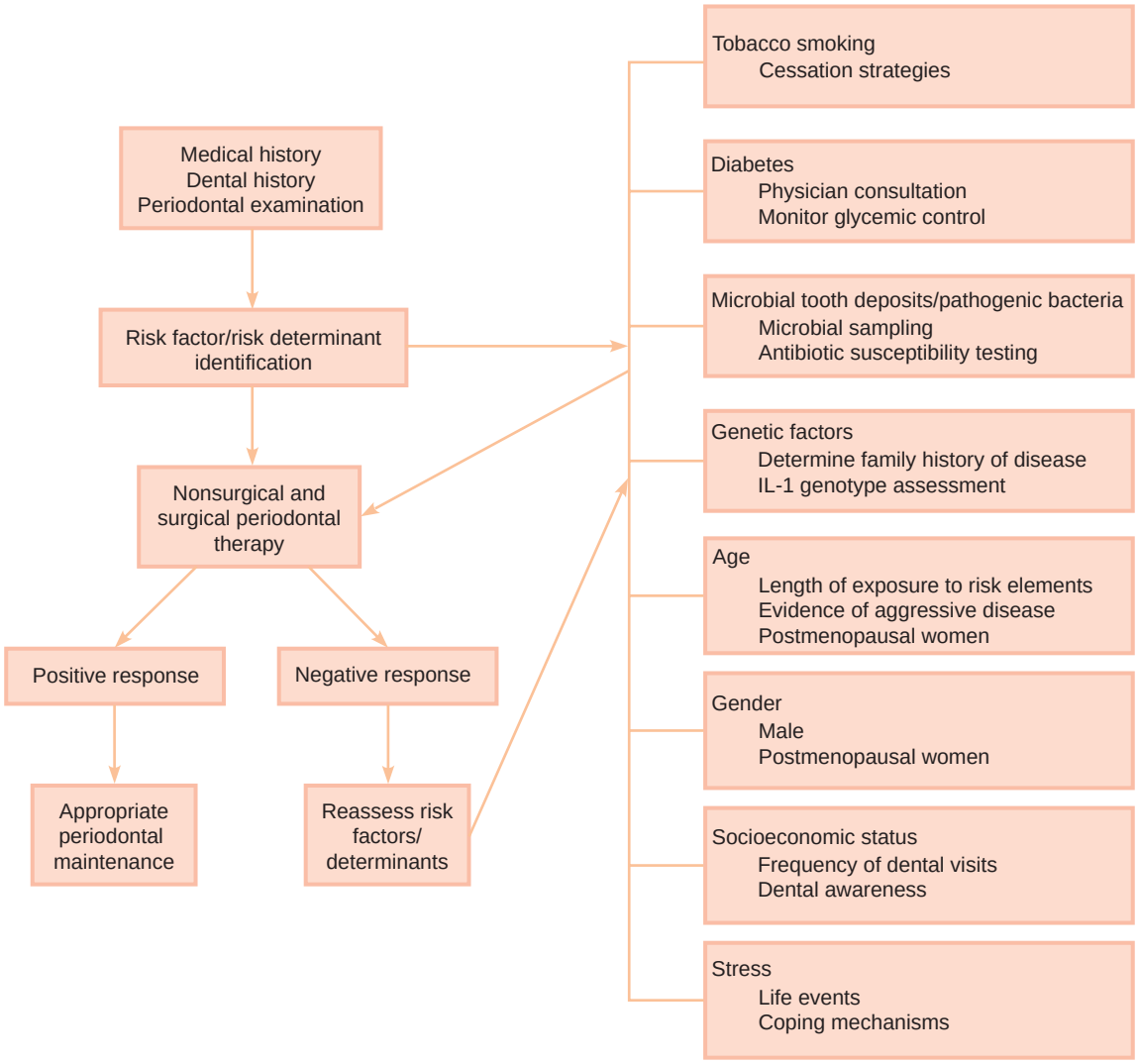

Figure 32-1 Risk assessment in periodontal therapy. The major risk elements to be considered in the diagnosis and treatment of periodontal disease are indicated. The importance of risk assessment before the initiation of therapy is highlighted, as well as the need for reassessment after a negative response to therapy.

References

1. American Academy of Periodontology: Position paper: epidemiology of periodontal diseases. *J Periodontol* 67:935, 1996.
2. Page RC, Beck JD: Risk assessment for periodontal diseases. *Int Dent J* 47:61, 1997.
3. Papapanou PN: Risk assessments in the diagnosis and treatment of periodontal diseases. *J Dent Educ* 62:822, 1998.
4. Ismail AI, Burt BA, Eklund SA: Epidemiologic patterns of smoking and periodontal disease in the United States. *J Am Dent Assoc* 106:617, 1983.
5. American Academy of Periodontology: Position paper: tobacco use and the periodontal patient. *J Periodontol* 70:1419, 1999.
6. Löe H, Theilade E, Jensen SB: Experimental gingivitis in man. *J Periodontol* 36:177, 1965.
7. Genco R, Kornman K, Williams R, et al: Consensus report: periodontal diseases: pathogenesis and microbial factors. *Ann Periodontol* 1:926, 1996.
8. Haffajee AD, Socransky SS: Microbial etiological agents of destructive periodontal diseases. *Periodontol 2000* 5:78, 1994.
9. Blieden TM: Tooth-related issues. *Ann Periodontol* 4:91, 1999.
10. Michalowicz BS, Aeppli DP, Kuba RK, et al: A twin study of genetic variation in proportional radiographic alveolar bone height. *J Dent Res* 70:1431, 1991.
11. Michalowicz BS, Aeppli DP, Virag JG, et al: Risk findings in adult twins. *J Periodontol* 62:293, 1991.
12. Michalowicz BS, Diehl SR, Gunsolley JC, et al: Evidence for a substantial genetic basis for risk of adult periodontitis. *J Periodontol* 71:2000, 1699.
13. Kornman KS, Crane S, Wang HY, et al: The interleukin-1 genotype as a severity factor in adult periodontal disease. *J Clin Periodontol* 24:72, 1997.
14. Kinane DF, Hart TC: Genes and gene polymorphisms associated with periodontal disease. *Crit Rev Oral Biol Med* 14:430, 2003.
15. Hart TC, Shapira L, Van Dyke TE: Neutrophil defects as risk factors for periodontal diseases. *J Periodontol* 65:521, 1994.
16. Shapira L, Soskolone WA, Van Dyke TE, et al: Prostaglandin E2 secretion, cell maturation, and CD14 expression by monocyte-derived macrophages from localized juvenile periodontitis patients. *J Periodontol* 67:224, 1996.
17. Wilson ME, Kalmar JR: FcγIIa (CD32): a potential marker defining susceptibility to localized juvenile periodontitis. *J Periodontol* 76:323, 1996.
18. Gunsolley JC, Tew JG, Gooss CM, et al: Effects of race, smoking and immunoglobulin allotypes on IgG subclass concentrations. *J Periodontal Res* 32:381, 1997.
19. Burt BA: Periodontitis and aging: reviewing recent evidence. *J Am Dent Assoc* 125:273, 1994.
20. Papapanou PN: Epidemiology and natural history of periodontal disease. In Lang NP, Karring T, editors: *Proceedings of the first European workshop on periodontology*, London, 1994, Quintessence.
21. Papapanou PN, Lindhe J: Preservation of probing attachment and alveolar bone levels in two random population samples. *J Clin Periodontol* 19:583, 1992.
22. Papapanou PN, Lindhe J, Sterrett JD, et al: Considerations on the contribution of aging to loss of periodontal tissue support. *J Clin Periodontol* 18:611, 1991.
23. US Public Health Service, National Center for Health Statistics: *Periodontal disease in adults, United States, 1960-1962*, PHS Pub No 1000, Series 11, No 12, Washington, DC, 1965, US Government Printing Office.
24. US Public Health Service, National Center for Health Statistics: *Basic data on dental examination findings of persons 1-74 years, United States, 1971-1974*, DHEW PHS Pub No 79-1662, Series 11, No 214, Washington, DC, 1979, US Government Printing Office.
25. US Public Health Service, National Institute of Dental Research (NIDR): *Oral health of United States adults: national findings*, NIH Pub No 87-2868, Bethesda, MD, 1987, NIDR.
26. Abdellatif HM, Burt BA: An epidemiological investigation into the relative importance of age and oral hygiene status as determinants of periodontitis. *J Dent Res* 66:13, 1987.
27. US Public Health Service, National Center for Health Statistics: *Oral hygiene in adults, United States, 1960-1962*, PHS Pub No 1000, Series 11, No 16, Washington, DC, 1966, US Government Printing Office.
28. Enwonwu CO: Epidemiological and biochemical studies of necrotizing ulcerative gingivitis and noma (cancrum oris) in Nigerian children. *Arch Oral Biol* 17:1357, 1972.
29. Shields WD: Acute necrotizing ulcerative gingivitis: a study of some of the contributing factors and their validity in an Army population. *J Periodontol* 48:346, 1977.
30. Ballieux RE: Impact of mental stress on the immune response. *J Clin Periodontol* 18:427, 1991.
31. Sternberg EM, Chrousos GP, Wilder RL, et al: The stress response and the regulation of inflammatory disease. *Ann Intern Med* 117:854, 1992.
32. Rose RM: Endocrine responses to stressful psychological events. *Psychiatr Clin North Am* 3:251, 1980.
33. Green LW, Tryon WW, Marks B, et al: Periodontal disease as a function of life events stress. *J Stress* 12:32, 1986.
34. Croucher R, Marcenes WS, Torres MC, et al: The relationship between life-events and periodontitis: a case-control study. *J Clin Periodontol* 24:39, 1997.
35. Axtelius B, Söderfeldt B, Nilsson A, et al: Therapy-resistant periodontitis: psychosocial characteristics. *J Clin Periodontol* 25:482, 1998.
36. Genco RJ, Ho AW, Grossi SG, et al: Relationship of stress, distress, and inadequate coping behaviors to periodontal disease. *J Periodontol* 70:711, 1999.
37. Winkler JR, Herrera C, Westenhouse J, et al: Periodontal disease in HIV-infected and uninfected homosexual and bisexual men. *AIDS* 6:1041, 1992. (letter).
38. Lamster IB, Begg MD, Mitchell L, et al: Oral manifestations of HIV infection in homosexual men and intravenous drug users: study design and relationship of epidemiologic, clinical, and immunologic parameter to oral lesions. *Oral Surg Oral Med Oral Pathol* 78:163, 1994.
39. Swango PA, Kleinman DV, Konzelman JL: HIV and periodontal health: a study of military personnel with HIV. *J Am Dent Assoc* 122:49, 1991.
40. Stanford TW, Rees TD: Acquired immune suppression and other risk factors/indicators for periodontal disease progression. *Periodontol 2000* 32:118, 2003.
41. Aufdemorte TB, Boyan BD, Fox WC, et al: Diagnostic tools and biologic markers: animal models in the study of osteoporosis and oral bone loss. *J Bone Miner Res* 8(Suppl 1):S29, 1993.
42. Krook L, Whalen JP, Lesser GV, et al: Experimental studies on osteoporosis. *Methods Achiev Exp Pathol* 7:72, 1975.
43. von Wowern J, Klausen B, Kollerup G: Osteoporosis: a risk factor in periodontal disease. *J Periodontol* 65:134, 1994.
44. Kribbs PJ: Comparison of mandibular bone in normal and osteoporotic women. *J Prosthet Dent* 63:218, 1990.
45. Guers NC, Lewis CE, Jeffcoat MJ: Osteoporosis and periodontal disease progression. *Periodontol 2000* 32:105, 2003.
46. Kinane DF: Periodontitis modified by systemic factors. *Ann Periodontol* 4:55, 1999.
47. Page RC, Martin JA, Loeb CF: The oral health information suite (OHIS): its use in the management of periodontal disease. *J Dent Educ* 69:509, 2005.
48. Persson GR, Mancl LS, Martin J, et al: Assessing periodontal disease risk. A comparison of clinicians' assessment versus a computerized tool. *J Am Dent Assoc* 134:575, 2003.

CHAPTER 33

Determination of Prognosis

Karen F. Novak, Henry H. Takei, and Jonathan H. Do

CHAPTER OUTLINE

Definitions
Types of Prognosis
Factors in Determination of Prognosis
Relationship Between Diagnosis and Prognosis
Reevaluation of Prognosis After Phase I Therapy

Definitions

The *prognosis* is a prediction of the probable course, duration, and outcome of a disease based on a general knowledge of the pathogenesis of the disease and the presence of risk factors for the disease. It is established after the diagnosis is made and before the treatment plan is established. The prognosis is based on specific information about the disease and the manner in which it can be treated, but it also can be influenced by the clinician's previous experience with treatment outcomes (successes and failures) as they relate to the particular case. It is important to note that determination of prognosis is a dynamic process. As such, the prognosis initially assigned should be reevaluated after completion of all phases of therapy, including periodontal maintenance.

Prognosis is often confused with the term *risk.* Risk generally deals with the likelihood that an individual will develop a disease in a specified period (see Chapter 5). *Risk factors* are those characteristics of an individual that put the person at increased risk for developing a disease (see Chapter 4). In contrast, *prognosis* is the prediction of the course or outcome of a disease. *Prognostic factors* are characteristics that predict the outcome of disease once the disease is present. In some cases, risk factors and prognostic factors are the same. For example, patients with diabetes or patients who smoke are more at risk for acquiring periodontal disease, and once they have it, they generally have a worse prognosis.

Types of Prognosis

Although some factors may be more important than others when assigning a prognosis[1,2] (Box 33-1), consideration of each factor may be beneficial to the clinician.

Historically, prognosis classification schemes have been designed based on studies evaluating tooth mortality.[1,3-6] One scheme[1,5] assigns the following classifications:

Good prognosis: Control of etiologic factors and adequate periodontal support ensure the tooth will be easy to maintain by the patient and clinician.

Fair prognosis: Approximately 25% attachment loss and/or Class I furcation involvement (location and depth allow proper maintenance with good patient compliance).

Poor prognosis: 50% attachment loss, Class II furcation involvement (location and depth make maintenance possible but difficult).

Questionable prognosis: >50% attachment loss, poor crown-to-root ratio, poor root form, Class II furcations (location and depth make access difficult) or Class III furcation involvements; >2+ mobility; root proximity.

Hopeless prognosis: Inadequate attachment to maintain health, comfort, and function.

It should be recognized that good, fair, and hopeless prognoses in this classification system could be established with a reasonable degree of accuracy. However, poor and questionable prognoses were likely to change to other categories because they depend on a large number of factors that can interact in an unpredictable number of ways.[7-9]

In contrast to schemes based on tooth mortality, Kwok and Caton[5] have proposed a scheme based on "the probability of obtaining stability of the periodontal supporting apparatus." This scheme is based on the probability of disease progression as related to local and systemic factors (see Box 33-1). Although some of these factors may affect disease progression more than others, consideration of each factor is important in assigning a prognosis. This scheme is as follows:

Favorable prognosis: Comprehensive periodontal treatment and maintenance will stabilize the status of the tooth. Future loss of periodontal support is unlikely.

Questionable prognosis: Local and/or systemic factors influencing the periodontal status of the tooth may or may not be controllable. If controlled, the periodontal status can be stabilized with comprehensive periodontal treatment. If not, future periodontal breakdown may occur.

Unfavorable prognosis: Local and/or systemic factors influencing the periodontal status cannot be controlled. Comprehensive periodontal treatment and maintenance are unlikely to prevent future periodontal breakdown.

Hopeless prognosis: The tooth must be extracted.

Because periodontal stability is assessed on a regular basis using clinical measures, it may be more useful in making treatment decisions and prognosis predictions than trying to determine the likelihood that the tooth will be lost.

In many of these cases, it may be advisable to establish a *provisional prognosis* until phase I therapy is completed and evaluated. The provisional prognosis allows the clinician to initiate treatment of teeth that have a doubtful outlook in the hope that a favorable response may tip the balance and allow teeth to be

BOX 33-1 Factors to Consider When Determining a Prognosis

Overall Clinical Factors
Patient age
Disease severity
Plaque control
Patient compliance

Systemic and Environmental Factors
Smoking
Systemic disease or condition
Genetic factors
Stress

Local Factors
Plaque and calculus
Subgingival restorations

Anatomic Factors
Short, tapered roots
Cervical enamel projections
Enamel pearls
Bifurcation ridges
Root concavities
Developmental grooves
Root proximity
Furcation involvement
Tooth mobility

Prosthetic and Restorative Factors
Abutment selection
Caries
Nonvital teeth
Root resorption

retained. The reevaluation phase in the treatment sequence allows the clinician to examine the tissue response to scaling, oral hygiene, and root planing, as well as to the possible use of chemotherapeutic agents where indicated. The patient's compliance with the proposed treatment plan also can be determined.

Overall Versus Individual Tooth Prognosis

Prognosis can be divided into overall prognosis and individual tooth prognosis. The *overall prognosis* is concerned with the dentition as a whole. Factors that may influence the overall prognosis include patient age; current severity of disease; systemic factors; smoking; the presence of plaque, calculus, and other local factors; patient compliance; and prosthetic possibilities (see Box 33-1). The overall prognosis answers the following questions:

- Should treatment be undertaken?
- Is treatment likely to succeed?
- When prosthetic replacements are needed, are the remaining teeth able to support the added burden of the prosthesis?

The *individual tooth prognosis* is determined after the overall prognosis and is affected by it.[6] For example, in a patient with a poor overall prognosis, the dentist likely would not attempt to retain a tooth that has a questionable prognosis because of local conditions. Many of the factors listed under local factors and prosthetic and restorative factors in Box 33-1 have a direct effect on the prognosis for individual teeth, in addition to any overall systemic or environmental factors that may be present.

Factors in Determination of Prognosis

Overall Clinical Factors

Patient Age. For two patients with comparable levels of remaining connective tissue attachment and alveolar bone, the prognosis is generally better for the older of the two. For the younger patient, the prognosis is not as good because of the shorter time frame in which the periodontal destruction has occurred; the younger patient may have an aggressive type of periodontitis, or disease progression may have increased because of systemic disease or smoking. In addition, although the younger patient would ordinarily be expected to have a greater reparative capacity, the occurrence of so much destruction in a relatively short period would exceed any naturally occurring periodontal repair.

Disease Severity. Studies have demonstrated that a patient's history of previous periodontal disease may be indicative of their susceptibility for future periodontal breakdown (see Chapter 4). Therefore the following variables should be carefully recorded because they are important for determining the patient's past history of periodontal disease: pocket depth, level of attachment, degree of bone loss, and type of bony defect. These factors are determined by clinical and radiographic evaluation (see Chapters 29 and 31).

The determination of the level of clinical attachment reveals the approximate extent of root surface that is devoid of periodontal ligament; the radiographic examination shows the amount of root surface still invested in bone. Pocket depth is less important than level of attachment because it is not necessarily related to bone loss. In general, a tooth with deep pockets and little attachment and bone loss has a better prognosis than one with shallow pockets and severe attachment and bone loss. However, deep pockets are a source of infection and may contribute to progressive disease.

Prognosis is adversely affected if the base of the pocket (level of attachment) is close to the root apex. The presence of apical disease as a result of endodontic involvement also worsens the prognosis. However, surprisingly good apical and lateral bone repair can sometimes be obtained by combining endodontic and periodontal therapy (see Chapter 43).

The prognosis also can be related to the height of remaining bone. Assuming bone destruction can be arrested, is there enough bone remaining to support the teeth? The answer is readily apparent in extreme cases, that is, when there is so little bone loss that tooth support is not in jeopardy (Figure 33-1), or when bone loss is so severe that the remaining bone is obviously insufficient for proper tooth support (Figure 33-2). Most patients, however, do not fit into these extreme categories. The height of remaining bone is usually somewhere in between, making bone level assessment alone insufficient for determining the overall prognosis.

The type of defect also must be determined. The prognosis for horizontal bone loss depends on the height of the existing bone because it is unlikely that clinically significant bone height regeneration will be induced by therapy. In the case of angular, intrabony defects, if the contour of the existing bone and the number of osseous walls are favorable, there is an excellent chance that therapy could regenerate bone to approximately the level of the alveolar crest.[10]

When greater bone loss has occurred on one surface of a tooth, the bone height on the less involved surfaces should be taken into consideration when determining the prognosis. Because of the greater height of bone in relation to other surfaces, the center of rotation of the tooth will be nearer the crown (Figure 33-3). This results in a more favorable distribution of forces to the periodontium and less tooth mobility.[11]

In dealing with a tooth with a questionable prognosis, the chances of successful treatment should be weighed against any benefits that would accrue to the adjacent teeth if the tooth under consideration were extracted. Strategic extraction of teeth was first proposed as a means of improving the overall prognosis of adjacent teeth and/or enhancing the prosthetic treatment plan.[12] It has now been expanded to include the extraction of teeth with a questionable prognosis to enhance the likelihood of partial restoration of the bone supporting of the adjacent teeth (Figure 33-4, *A* to *D*) or successful implant placement. With the growing evidence of the long-term success of dental implants, it is proposed that a "watch and wait" approach may allow an area to deteriorate to the point that placing an implant is no longer a viable option. This means that the practitioner should weigh the potential success of one

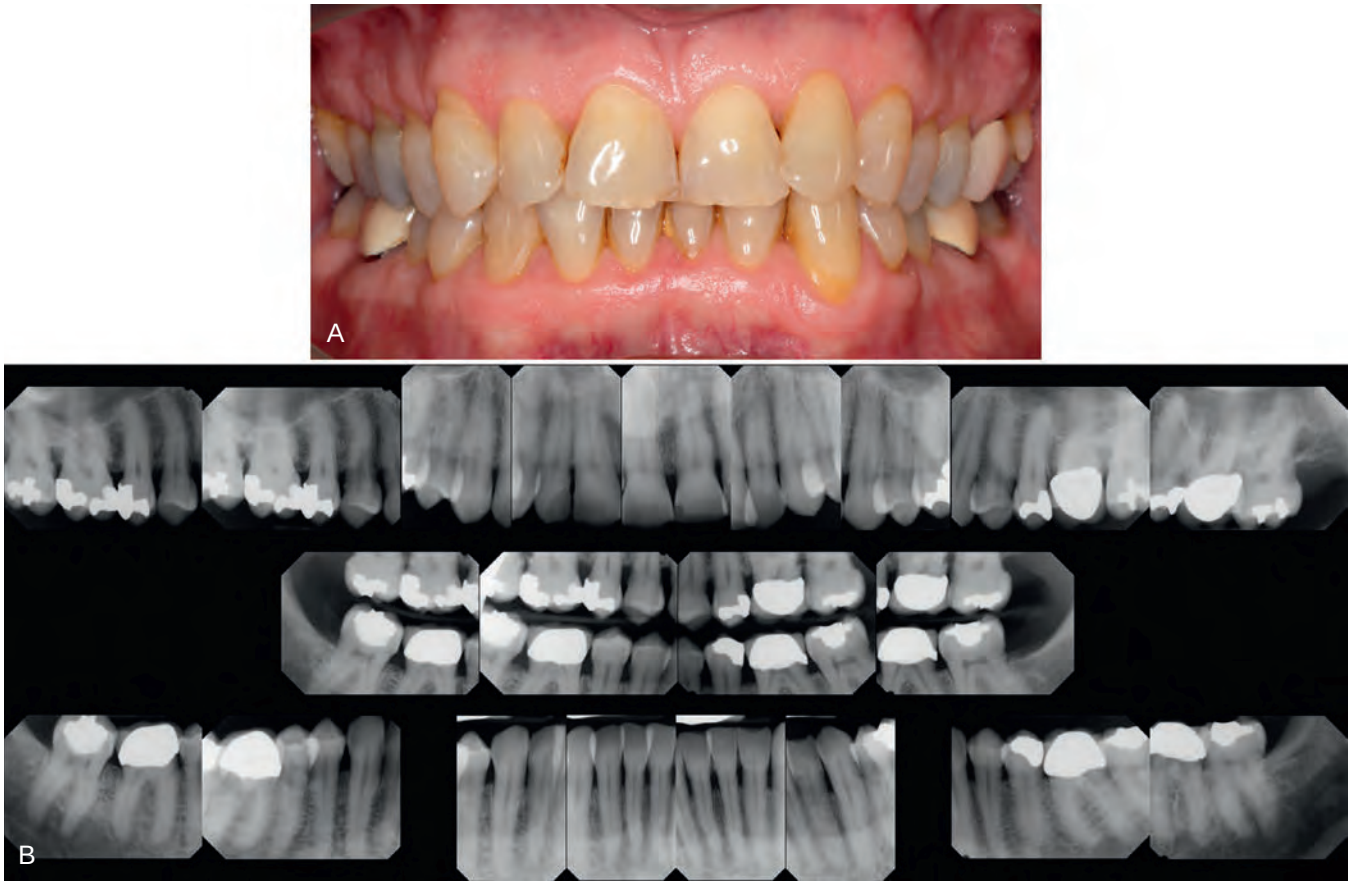

Figure 33-1 Chronic periodontitis in systemically healthy, nonsmoking 60-year-old male; overall prognosis is good. **A,** Gingival inflammation and fair oral hygiene. **B,** Although local factors are present, the patient presents with adequate remaining bone support and a good prognosis, provided local factors can be controlled.

treatment option (extraction and implant placement) versus the other (periodontal therapy and maintenance) carefully when assigning a prognosis to questionable teeth.[13]

Plaque Control. Bacterial plaque is the primary etiologic factor associated with periodontal disease (see Chapter 8). Therefore effective removal of plaque on a daily basis by the patient is critical to the success of periodontal therapy and to the prognosis.

Patient Compliance and Cooperation. The prognosis for patients with gingival and periodontal disease is critically dependent on the patient's attitude, desire to retain the natural teeth, and willingness and ability to maintain good oral hygiene. Without these, treatment cannot succeed. Patients should be clearly informed of the important role they must play for treatment to succeed. If patients are unwilling or unable to perform adequate plaque control and to receive the timely periodic maintenance checkups and treatments that the dentist deems necessary, the dentist can (1) refuse to accept the patient for treatment or (2) extract teeth that have a hopeless or poor prognosis and perform scaling and root planing on the remaining teeth. The dentist should make it clear to the patient and in the patient record that further treatment is needed but will not be performed because of a lack of patient cooperation.

Systemic and Environmental Factors

Smoking. Epidemiologic evidence suggests that smoking may be the most important environmental risk factor impacting the development and progression of periodontal disease (see Chapter 10). Therefore it should be made clear to the patient that a direct relationship exists between smoking and the prevalence and incidence of periodontitis. In addition, patients should be informed that smoking affects not only the severity of periodontal destruction but also the healing potential of the periodontal tissues. As a result, patients who smoke do not respond as well to conventional periodontal therapy as patients who have never smoked.[14,15] Therefore the prognosis in patients who smoke and have slight to moderate periodontitis is generally fair to poor. In patients with severe periodontitis, the prognosis may be poor to hopeless.

However, it should be emphasized that smoking cessation can affect the treatment outcome and therefore the prognosis.[16,17] Patients with slight-to-moderate periodontitis who stop smoking can often be upgraded to a good prognosis, whereas those with severe periodontitis who stop smoking may be upgraded to a fair prognosis.

Systemic Disease or Condition. The patient's systemic background affects overall prognosis in several ways. For example, evidence from epidemiologic studies clearly demonstrates that the prevalence and severity of periodontitis are significantly higher in patients with type 1 and type 2 diabetes than in those without diabetes and that the level of control of the diabetes is an important variable in this relationship (see Chapter 4). Therefore patients at risk for diabetes should be identified as early as possible and informed of the relationship between periodontitis and diabetes. Similarly, patients diagnosed with diabetes must be informed of the impact of diabetic control on the development and progression

Figure 33-2 Generalized severe chronic periodontitis; overall prognosis is poor. **A,** Gingival inflammation, periodontal pockets, and pathologic migration. **B,** Severe bone destruction. Note several hopeless teeth.

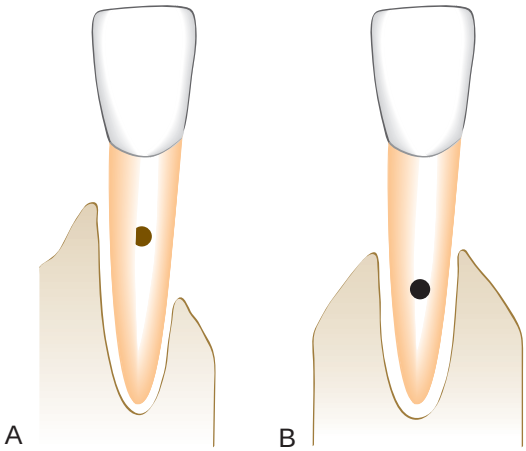

Figure 33-3 Prognosis for tooth **A** is better than for tooth **B,** despite less bone on one of the surfaces of A. Because the center of rotation of tooth **A** is closer to the crown, the distribution of occlusal forces to the periodontium is more favorable than in **B.**

of periodontitis. It follows that the prognosis in these cases depends on patient compliance relative to both medical and dental status. Well-controlled diabetic patients with slight-to-moderate periodontitis who comply with their recommended periodontal treatment should have a good prognosis. Similarly, in patients with other systemic disorders that could affect disease progression, prognosis improves with correction of the systemic problem.

The prognosis is questionable when surgical periodontal treatment is required but cannot be provided because of the patient's health (see Chapter 37). Incapacitating conditions that limit the patient's performance of oral procedures (e.g., Parkinson disease) also adversely affect the prognosis. Newer "automated" oral hygiene devices, such as electric toothbrushes, may be helpful for these patients and may improve their prognosis (see Chapter 45).

Genetic Factors. Periodontal diseases represent a complex interaction between a microbial challenge and the host's response to that challenge, both of which may be influenced by environmental factors such as smoking. In addition to these external factors, evidence also indicates that genetic factors may play an important role in determining the nature of the host response.[18] Evidence for this type of genetic influence exists for patients with both chronic and aggressive periodontitis. Genetic polymorphisms in the interleukin-1 (IL-1) genes, resulting in increased production of IL-1β, have been associated with a significant increase in risk for severe, generalized, and chronic periodontitis.[19,20] It has been demonstrated that knowledge of the patient's IL-1 genotype and smoking status can aid the clinician in assigning a prognosis.[21] Genetic factors also appear to influence serum immunoglobulin G2 (IgG2) antibody titers and the expression of FcγRII receptors on the neutrophil, both of which may be significant in aggressive periodontitis.[18] Other genetic disorders, such as leukocyte adhesion deficiency type 1, can influence neutrophil function, creating an additional risk factor for aggressive periodontitis.[18] Finally,

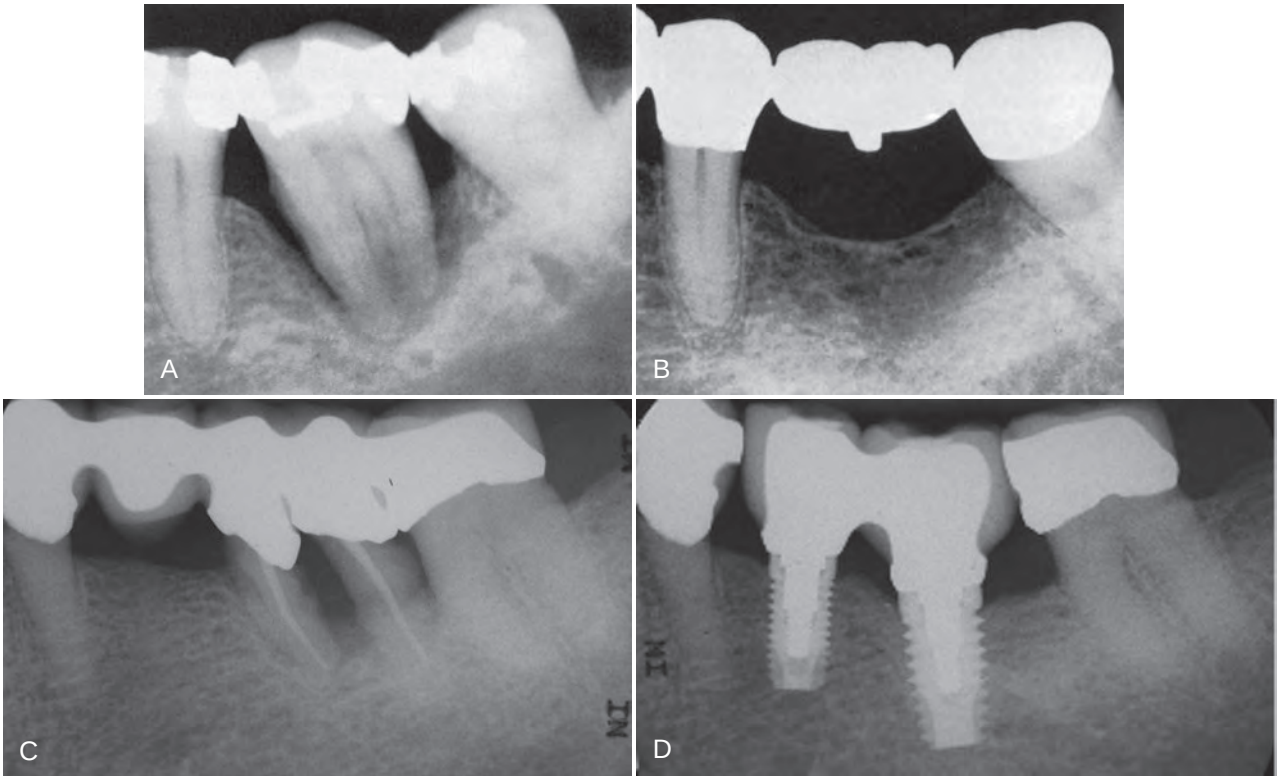

Figure 33-4 Extraction of severely involved tooth to preserve bone on adjacent teeth. **A,** Extensive bone destruction around the mandibular first molar. **B,** Radiograph made years after extraction of the first molar and replacement by a prosthesis. Note the excellent bone support. **C,** Extraction of periodontally involved bicuspid and molar. **D,** Implant replacement of both teeth. *(Courtesy Dr. S. Angha, University of California, Los Angeles.)*

the familial aggregation that is characteristic of aggressive periodontitis indicates that additional, as yet unidentified genetic factors may be important in susceptibility to this form of disease (see Chapter 25).

The influence of genetic factors on prognosis is not simple. Although microbial and environmental factors can be altered through conventional periodontal therapy and patient education, genetic factors currently cannot be altered. However, detection of genetic variations linked to periodontal disease can potentially influence the prognosis in several ways. First, early detection of patients at risk because of genetic factors can lead to early implementation of preventive and treatment measures for these patients. Second, identification of genetic risk factors later in the disease or during the course of treatment can influence treatment recommendations, such as the use of adjunctive antibiotic therapy or increased frequency of maintenance visits. Third, identification of young individuals who have not been evaluated for periodontitis, but who are recognized as being at risk because of the familial aggregation seen in aggressive periodontitis, can lead to the development of early intervention strategies. In each of these cases, early diagnosis, intervention, and alterations in the treatment regimen may lead to an improved prognosis for the patient.

Stress. Physical and emotional stress, as well as substance abuse, may alter the patient's ability to respond to the periodontal treatment performed (see Chapter 4). These factors must be realistically faced when attempting to establish a prognosis.

Local Factors

Plaque and Calculus. The microbial challenge presented by bacterial plaque and calculus is the most important local factor in periodontal diseases. Therefore, in most cases, having a good prognosis depends on the ability of the patient and the clinician to remove these etiologic factors (see Chapters 7 and 8).

Subgingival Restorations. Subgingival margins may contribute to increased plaque accumulation, increased inflammation, and increased bone loss[22-24] when compared with supragingival margins. Furthermore, discrepancies in these margins (e.g., overhangs) can negatively impact the periodontium (see Chapter 7). The size of these discrepancies and duration of their presence are important factors in the amount of destruction that occurs. In general, however, a tooth with a discrepancy in its subgingival margins has a poorer prognosis than a tooth with well-contoured supragingival margins.

Anatomic Factors. Anatomic factors that may predispose the periodontium to disease and therefore affect the prognosis include short, tapered roots with large crowns; cervical enamel projections and enamel pearls; intermediate bifurcation ridges; root concavities; and developmental grooves. The clinician must also consider root proximity and the location and anatomy of furcations when developing a prognosis.

Prognosis is poor for teeth with short, tapered roots and relatively large crowns (Figure 33-5). Because of the disproportionate crown-to-root ratio and the reduced root surface available for periodontal support,[25] the periodontium may be more susceptible to injury by occlusal forces.

Cervical enamel projections (CEPs) are flat, ectopic extensions of enamel that extend beyond the normal contours of the cementoenamel junction.[26] CEPs extend into the furcation of 28.6% of mandibular molars and 17% of maxillary molars.[26] CEPs are most

Figure 33-5 Generalized aggressive periodontitis and poor crown-to-root ratio in 28-year-old patient; overall prognosis is poor. **A,** generalized periodontal attachment loss and pocket formation. **B,** Moderate to advanced bone destruction. The contrast between the well-formed crowns and the relatively short, tapered roots worsens the prognosis.

likely to be found on buccal surfaces of maxillary second molars.[27,28] Enamel pearls are larger, round deposits of enamel that can be located in furcations or other areas on the root surface.[29] Enamel pearls are seen less frequently (1.1% to 5.7% of permanent molars; 75% appearing in maxillary third molars[29]) than CEPs. An intermediate bifurcation ridge has been described in 73% of mandibular first molars, crossing from the mesial to the distal root at the midpoint of the furcation.[30] The presence of these enamel projections on the root surface interferes with the attachment apparatus and may prevent regenerative procedures from achieving their maximum potential. Therefore their presence may have a negative effect on the prognosis for an individual tooth.

Scaling with root planing is a fundamental procedure in periodontal therapy. Anatomic factors that decrease the efficiency of this procedure can have a negative impact on the prognosis. Therefore the morphology of the tooth root is an important consideration when discussing prognosis. *Root concavities* exposed through loss of attachment can vary from shallow flutings to deep depressions. They appear more marked on maxillary first premolars, the mesiobuccal root of the maxillary first molar, both roots of mandibular first molars, and the mandibular incisors[31,32] (Figures 33-6 and 33-7). Any tooth, however, can have a proximal concavity.[33] Although these concavities increase the attachment area and produce a root shape that may be more resistant to torquing forces, they also create areas that can be difficult for both the dentist and the patient to clean.

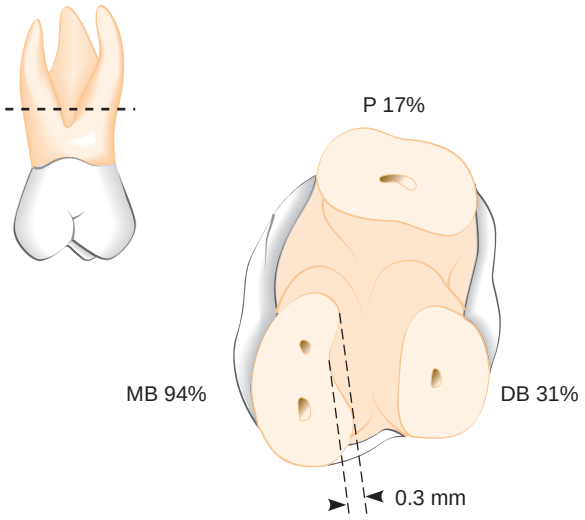

Figure 33-6 Root concavities in maxillary first molars sectioned 2 mm apical to the furca. The furcal aspect of the root is concave in 94% of the mesiobuccal *(MB)* roots, 31% of the distobuccal *(DB)* roots, and 17% of the palatal *(P)* roots. The deepest concavity is found in the furcal aspects of the mesiobuccal root (mean concavity, 0.3 mm). The furcal aspect of the buccal roots diverges toward the palate in 97% of teeth (mean divergence, 22 degrees). *(Redrawn from Bower RC:* J Periodontol *50:366, 1979.)*

Other anatomic considerations that present accessibility problems are developmental grooves, root proximity, and furcation involvements. The presence of any of these can worsen the prognosis. *Developmental grooves,* which sometimes appear in the maxillary lateral incisors (palatogingival groove[34]; Figure 33-8) or in the lower incisors, create an accessibility problem.[35,36] They initiate on enamel and can extend a significant distance on the root surface, providing a plaque-retentive area that is difficult to instrument. These palatogingival grooves are found on 5.6% of maxillary lateral incisors and 3.4% of maxillary central incisors.[37] Similarly, *root proximity* can result in interproximal areas that are difficult for the clinician and patient to access. Finally, *access to the furcation area* is usually difficult to obtain. In 58% of maxillary and mandibular first molars, the furcation entrance diameter is narrower than the width of conventional periodontal curettes[32] (Figure 33-9). Maxillary first premolars present the greatest difficulties, and therefore their prognosis is usually unfavorable when the lesion reaches the mesiodistal furcation. Maxillary molars also present some difficulty; sometimes their prognosis can be improved by resecting one of the buccal roots (see Chapter 62), thereby improving access to the area. When mandibular first molars or buccal furcations of maxillary molars offer good access to the furcation area, their prognosis is usually better.

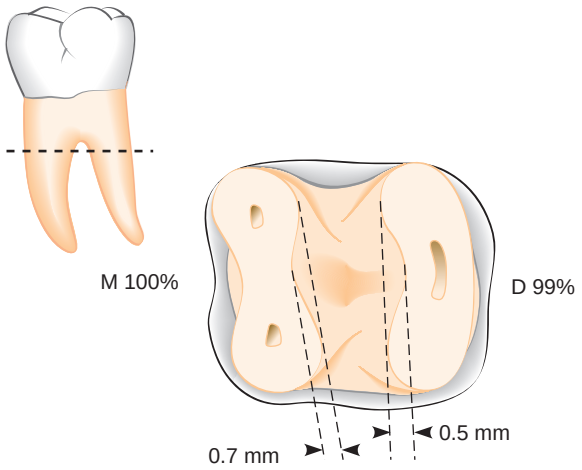

Figure 33-7 Root concavities in mandibular first molars sectioned 2 mm apical to the furca. Concavity of the furcal aspect was found in 100% of mesial *(M)* roots and 99% of distal *(D)* roots. Deeper concavity was found in the mesial roots (mean concavity, 0.7 mm). *(Redrawn from Bower RC:* J Periodontol *50:366, 1979.)*

Tooth Mobility. The principal causes of tooth mobility are loss of alveolar bone, inflammatory changes in the periodontal ligament, and trauma from occlusion. Tooth mobility caused by inflammation and trauma from occlusion may be correctable.[38] However, tooth mobility resulting from loss of alveolar bone is not likely to be corrected. The likelihood of restoring tooth stability is inversely proportional to the extent to which mobility is caused by loss of supporting alveolar bone. A longitudinal study of the response to treatment of teeth with different degrees of mobility revealed that pockets on clinically mobile teeth do not respond as well to periodontal therapy as pockets on nonmobile teeth exhibiting the same initial disease severity.[39] Another study, however, in which ideal plaque control was attained, found similar healing in both hypermobile and firm teeth.[10] The stabilization of tooth mobility through the use of splinting may have a beneficial impact on the overall and individual tooth prognosis.

Prosthetic and Restorative Factors

The overall prognosis requires a general consideration of bone levels (evaluated radiographically) and attachment levels (determined clinically) to establish whether enough teeth can be saved either to provide a functional and aesthetic dentition or to serve as abutments for a useful prosthetic replacement of the missing teeth.

At this point, the overall prognosis and the individual tooth prognosis overlap because the prognosis for key individual teeth

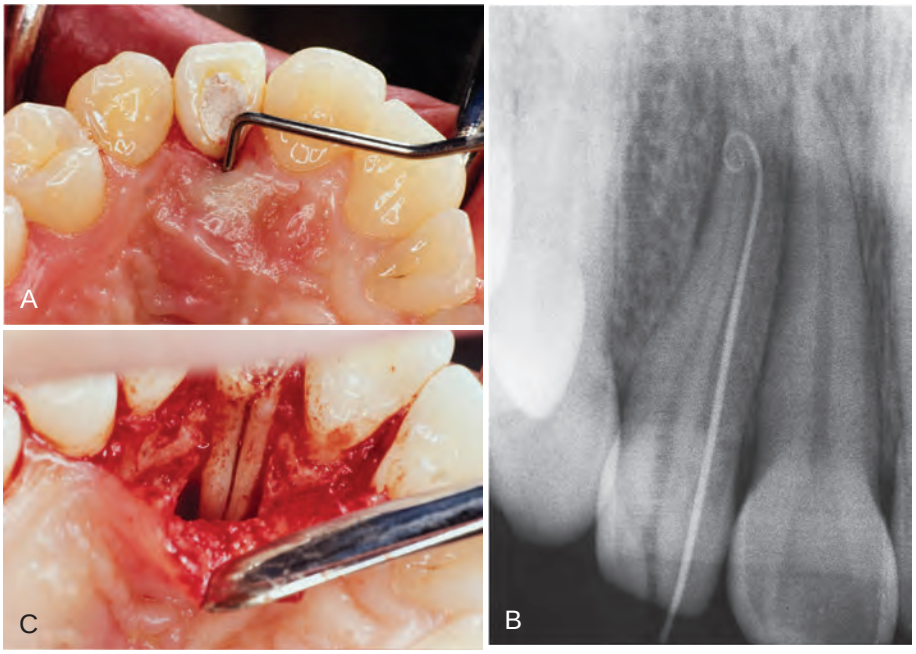

Figure 33-8 Palatogingival groove. **A,** Probe in place to indicate a deep pocket along the palatogingival groove. **B,** Radiograph with a gutta-percha point placed in the pocket. **C,** The area is surgically opened. Note the palatogingival groove along the entire palatal portion of the root. *(Courtesy Dr. Nadia Chugal, University of California, Los Angeles.)*

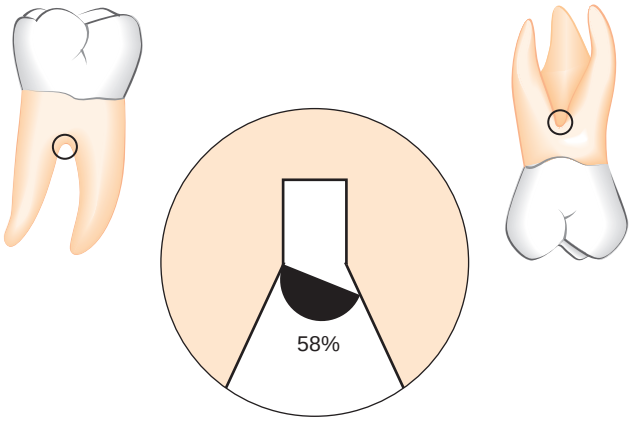

Figure 33-9 The furcation entrance is narrower than a standard curette in 58% of first molars. *(Redrawn from Bower RC:* J Periodontol *50:366, 1979.)*

may affect the overall prognosis for prosthetic rehabilitation. For example, saving or losing a key tooth may determine whether other teeth are saved or extracted or whether the prosthesis used is fixed or removable (see Figure 33-4). When few teeth remain, the prosthodontic needs become more important, and sometimes periodontally treatable teeth may have to be extracted if they are not compatible with the design of the prosthesis.

Teeth that serve as abutments are subjected to increased functional demands. More rigid standards are required when evaluating the prognosis of teeth adjacent to edentulous areas. A tooth with a post that has undergone endodontic treatment is more likely to fracture when serving as a distal abutment supporting a distal removable partial denture. Additionally, special oral hygiene measures must be instituted in these areas.

Caries, Nonvital Teeth, and Root Resorption. For teeth mutilated by extensive caries, the feasibility of adequate restoration and endodontic therapy should be considered before undertaking periodontal treatment. Extensive idiopathic root resorption or root resorption resulting from orthodontic therapy jeopardizes the stability of teeth and adversely affects the response to periodontal treatment. The periodontal prognosis of treated nonvital teeth does not differ from that of vital teeth. New attachment can occur to the cementum of both nonvital and vital teeth.

Relationship Between Diagnosis and Prognosis

Many of the criteria used in the diagnosis and classification of the different forms of periodontal disease[40] (see Chapter 3) are also used in developing a prognosis (see Box 33-1). Factors such as patient age, severity of disease, genetic susceptibility, and presence of systemic disease are important criteria in the diagnosis of the condition, as well as important in developing a prognosis. These common factors suggest that for any given diagnosis, there should be an expected prognosis under ideal conditions. This section discusses the potential prognoses of the various periodontal diseases outlined in Chapter 3.

Prognosis for Patients with Gingival Disease

Dental Plaque–Induced Gingival Diseases

Gingivitis Associated with Dental Plaque Only. Plaque-induced gingivitis is a reversible disease that occurs when bacterial plaque accumulates at the gingival margin.[41,42] This disease can occur on a periodontium that has experienced no attachment loss or on a periodontium with nonprogressing attachment loss. In either case, the prognosis for patients with gingivitis associated with dental plaque only is good, provided all local irritants are eliminated, other local factors contributing to plaque retention are eliminated, gingival contours conducive to the preservation of health are attained, and the patient cooperates by maintaining good oral hygiene.

Plaque-Induced Gingival Diseases Modified by Systemic Factors. The inflammatory response to bacterial plaque at the gingival margin can be influenced by systemic factors, such as endocrine-related changes associated with puberty, menstruation, pregnancy, and diabetes, and the presence of blood dyscrasias. In many cases, the frank signs of gingival inflammation that occur in these patients are seen in the presence of relatively small amounts of bacterial plaque. Therefore the long-term prognosis for these patients depends not only on control of bacterial plaque but also on control or correction of the systemic factor(s).

Plaque-Induced Gingival Diseases Modified by Medications. Gingival diseases associated with medications include drug-influenced *gingival enlargement,* often seen with phenytoin, cyclosporine, and nifedipine and in oral contraceptive–associated gingivitis. In drug-influenced gingival enlargement, reductions in dental plaque can limit the severity of the lesions. However, plaque control alone does not prevent development of the lesions, and surgical intervention is usually necessary to correct the alterations in gingival contour. Continued use of the drug usually results in recurrence of the enlargement, even after surgical intervention (see Chapter 16). Therefore the long-term prognosis depends on whether the patient's systemic problem can be treated with an alternative medication that does not have gingival enlargement as a side effect.

In oral contraceptive–associated gingivitis, frank signs of gingival inflammation can be seen in the presence of relatively little plaque. Therefore, as seen in plaque-induced gingival diseases modified by systemic factors, the long-term prognosis in these patients depends on not only the control of bacterial plaque but also on the likelihood of continued use of the oral contraceptive.

Gingival Diseases Modified by Malnutrition. Although malnutrition has been suspected to play a role in the development of gingival diseases, most clinical studies have not shown a relationship between the two. One possible exception is severe vitamin C deficiency. In early experimental vitamin C deficiency, gingival inflammation and bleeding on probing were independent of plaque levels present. The prognosis in these patients may depend on the severity and duration of the deficiency and on the likelihood of reversing the deficiency through dietary supplementation.

Non–Plaque-Induced Gingival Lesions. Non–plaque-induced gingivitis can be seen in patients with a variety of bacterial, fungal, and viral infections.[43] Since the gingivitis in these patients is not usually attributed to plaque accumulation, prognosis depends on elimination of the source of the infectious agent. Dermatologic disorders, such as lichen planus, pemphigoid, pemphigus vulgaris, erythema multiforme, and lupus erythematosus, also can manifest in the oral cavity as atypical gingivitis (see Chapter 19). Prognosis for these patients is linked to management of the associated dermatologic disorder. Finally, allergic, toxic, and foreign body reactions, as well as mechanical and thermal trauma, can result in gingival lesions. Prognosis for these patients depends on elimination of the causative agent.

Prognosis for Patients with Periodontitis

Chronic Periodontitis. Chronic periodontitis is a slowly progressive disease associated with well-known local environmental

factors.[44] It can present in a localized or generalized form (see Chapter 23). In cases in which the clinical attachment loss and bone loss are not very advanced (slight-to-moderate periodontitis), the prognosis is generally good, provided the inflammation can be controlled through good oral hygiene and the removal of local plaque-retentive factors (see Figure 33-1). In patients with more severe disease, as evidenced by furcation involvement and increasing clinical mobility, or in patients who are noncompliant with oral hygiene practices, the prognosis may be downgraded to fair to poor.

Aggressive Periodontitis. Aggressive periodontitis can present in a localized or a generalized form.[45] Two common features of both forms are (1) rapid attachment loss and bone destruction in an otherwise clinically healthy patient and (2) a familial aggregation. These patients often present with limited microbial deposits that seem inconsistent with the severity of tissue destruction. However, the deposits that are present often have elevated levels of *Aggregatibacter actinomycetemcomitans* or *Porphyromonas gingivalis*. These patients also may present with phagocyte abnormalities and a hyperresponsive monocyte/macrophage phenotype. These clinical, microbiologic, and immunologic features would suggest that patients diagnosed with aggressive periodontitis would have a poor prognosis.

However, the clinician should consider additional specific features of the localized form of disease when determining the prognosis (see Figure 33-2). Localized aggressive periodontitis usually occurs around the age of puberty and is localized to first molars and incisors. The patient often exhibits a strong serum antibody response to the infecting agents, which may contribute to localization of the lesions (see Chapter 25). When diagnosed early, these cases can be treated conservatively with oral hygiene instruction and systemic antibiotic therapy,[46] resulting in an excellent prognosis. When more advanced disease occurs, the prognosis can still be good if the lesions are treated with debridement, local and systemic antibiotics, and regenerative therapy.[47,48]

In contrast, although patients with generalized aggressive periodontitis also are young patients (usually under age 30), they present with generalized interproximal attachment loss and a poor antibody response to infecting agents. Secondary contributing factors, such as cigarette smoking, are often present. These factors, coupled with the alterations in host defense seen in many of these patients, may result in a case that does not respond well to conventional periodontal therapy (scaling with root planing, oral hygiene instruction, and surgical intervention). Therefore these patients often have a fair, poor, or questionable prognosis, and the use of systemic antibiotics should be considered to help control the disease (see Chapter 48).

Periodontitis as Manifestation of Systemic Diseases. Periodontitis as a manifestation of systemic diseases can be divided into the following two categories:[49,50]

1. Periodontitis associated with hematologic disorders such as leukemia and acquired neutropenias.
2. Periodontitis associated with genetic disorders such as familial and cyclic neutropenia, Down syndrome, Papillon-Lefèvre syndrome, and hypophosphatasia.

Although the primary etiologic factor in periodontal diseases is bacterial plaque, systemic diseases that alter the ability of the host to respond to the microbial challenge presented may affect the progression of disease and therefore the prognosis for the case. For example, decreased numbers of circulating neutrophils (as in acquired neutropenias) may contribute to widespread destruction of the periodontium. Unless the neutropenia can be corrected, these patients present with a fair-to-poor prognosis. Similarly, genetic disorders that alter the way the host responds to bacterial plaque (as in leukocyte adhesion deficiency [LAD] syndrome) also can contribute to the development of periodontitis. Because these disorders generally manifest early in life, the impact on the periodontium may be clinically similar to generalized aggressive periodontitis. The prognosis in these cases will be fair to poor.

Other genetic disorders do not affect the host's ability to combat infections but still affect the development of periodontitis. Examples include hypophosphatasia, in which patients have decreased levels of circulating alkaline phosphatase, severe alveolar bone loss, and premature loss of deciduous and permanent teeth, and the connective tissue disorder, Ehlers-Danlos syndrome, in which patients may present with the clinical characteristics of aggressive periodontitis. In both examples the prognosis is fair to poor.

Necrotizing Periodontal Diseases. Necrotizing periodontal disease can be divided into necrotic diseases that affect the gingival tissues exclusively (necrotizing ulcerative gingivitis [NUG]) and necrotic diseases that affect deeper tissues of the periodontium, resulting in loss of connective tissue attachment and alveolar bone (necrotizing ulcerative periodontitis [NUP]).[51,52] In NUG, the primary predisposing factor is bacterial plaque. However, this disease is usually complicated by the presence of secondary factors such as acute psychologic stress, tobacco smoking, and poor nutrition, all of which can contribute to immunosuppression. Therefore superimposition of these secondary factors on a preexisting gingivitis can result in the painful, necrotic lesions characteristic of NUG. With control of both the bacterial plaque and the secondary factors, the prognosis for a patient with NUG is good. However, the tissue destruction in these cases is not reversible, and poor control of the secondary factors may make these patients susceptible to recurrence of the disease. With repeated episodes of NUG, the prognosis may be downgraded to fair.

The clinical presentation of NUP is similar to that of NUG, except the necrosis extends from the gingiva into the periodontal ligament and alveolar bone. In systemically healthy patients, this progression may have resulted from multiple episodes of NUG, or the necrotizing disease may occur at a site previously affected with periodontitis. In these patients, the prognosis depends on alleviating the plaque and secondary factors associated with NUG. However, many patients presenting with NUP are immunocompromised through systemic conditions, such as human immunodeficiency virus (HIV) infection. In these patients the prognosis depends on not only reducing local and secondary factors, but also on dealing with the systemic problem (see Chapter 40).

In advanced cases, prognosis may be better established after reviewing the effectiveness of phase I therapy.

Determination of the prognosis of a tooth or teeth can be difficult, particularly for teeth with previous disease. Many factors can influence disease progression and the response to therapy, and the specific influence of any one factor is unknown and likely different from one patient to another. In addition, each patient can respond differently at different times. All these issues make determination of a prognosis difficult.

Therefore the prognosis is often determined after initial treatment is provided, assuming a favorable outcome. The prognosis is delayed until after initial therapy because the etiology depends on the host response. During initial therapy, the patient's motivation and commitment, acknowledged as critical in all periodontal therapy, also can be determined, as well as the host response and healing capacity of the patient. Clearly, enhancing the host response

to plaque's microbial challenge will significantly and positively influence the periodontal prognosis. Likewise, an *inability* to enhance the host response will negatively influence the prognosis. Either outcome, however, will allow the clinician to determine a more accurate prognosis.

Reevaluation of Prognosis After Phase I Therapy

A frank reduction in pocket depth and inflammation after phase I therapy indicates a favorable response to treatment and may suggest a better prognosis than previously assumed. If the inflammatory changes present cannot be controlled or reduced by phase I therapy, the overall prognosis may be unfavorable. In these patients, the prognosis can be directly related to the severity of inflammation. Given two patients with comparable bone destruction, the prognosis may be better for the patient with the greater degree of inflammation because a larger component of that patient's bone destruction may be attributable to local irritants. In addition, phase I therapy allows the clinician an opportunity to work with the patient and the patient's physician to control systemic and environmental factors such as diabetes and smoking, which may have a positive effect on prognosis if adequately controlled.

The progression of periodontitis generally occurs in an episodic manner, with alternating periods of quiescence and shorter destructive stages (see Chapter 20). No methods are available at present to determine accurately whether a given lesion is in a stage of remission or exacerbation. Advanced lesions, if active, may progress rapidly to a hopeless stage, whereas similar lesions in a quiescent stage may be maintainable for long periods. Phase I therapy will, at least temporarily, transform the prognosis of the patient with an active advanced lesion, and the lesion should be reanalyzed after completion of phase I therapy.

Suggested Readings

Bower RC: Furcation morphology relative to periodontal treatment. Furcation entrance architecture. *J Periodontol* 50(1):23–27, 1979.

Bower RC: Furcation morphology relative to periodontal treatment. Furcation root surface anatomy. *J Periodontol* 50(7):366–374, 1979.

Kwok V, Caton JG: Commentary: prognosis revisited: a system for assigning periodontal prognosis. *J Periodontol* 78(11):2063–2071, 2007.

McGuire MK: Prognosis versus actual outcome: a long-term survey of 100 treated periodontal patients under maintenance care. *J Periodontol* 62(1):51–58, 1991.

McGuire MK, Nunn ME: Prognosis versus actual outcome. II. The effectiveness of clinical parameters in developing an accurate prognosis. *J Periodontol* 67(7):658–665, 1996.

McGuire MK, Nunn ME: Prognosis versus actual outcome. III. The effectiveness of clinical parameters in accurately predicting tooth survival. *J Periodontol* 67(7):666–674, 1996.

McGuire MK, Nunn ME: Prognosis versus actual outcome. IV. The effectiveness of clinical parameters and IL-1 genotype in accurately predicting prognoses and tooth survival. *J Periodontol* 70(1):49–56, 1999.

Miyamoto T, Kumagai T, Jones JA, et al: Compliance as a prognostic indicator: retrospective study of 505 patients treated and maintained for 15 years. *J Periodontol* 77(2):223–232, 2006.

Miyamoto T, Kumagai T, Lang MS, et al: Compliance as a prognostic indicator. II. Impact of patient's compliance to the individual tooth survival. *J Periodontol* 81(9):1280–1288, 2010. doi: 10.1902/jop.2010.100039.

Nunn ME, Fan J, Su X, et al: Development of prognostic indicators using classification and regression trees for survival. *Periodontol 2000* 58(1):134–142, 2012. doi: 10.1111/j.1600-0757.2011.00421.x.

References

References for this chapter are found on the companion website www.expertconsult.com.

References

1. McGuire MK, Nunn ME: Prognosis versus actual outcome. II. The effectiveness of clinical parameters in developing an accurate prognosis. *J Periodontol* 67:658, 1996.
2. McGuire MK, Nunn ME: Prognosis versus actual outcome. III. The effectiveness of clinical parameters in accurately predicting tooth survival. *J Periodontol* 67:666, 1996.
3. Becker W, Becker B, Berg L: Periodontal treatment without maintenance. A retrospective study in 44 patients. *J Periodontol* 55:505, 1984.
4. Becker W, Berg L, Becker B: The long-term evaluation of periodontal treatment and maintenance in 95 patients. *Int J Periodontics Restorative Dent* 4:54, 1984.
5. Kwok V, Caton J: Prognosis revisited: a system for assigning periodontal prognosis. *J Periodontol* 78:2063, 2007.
6. McGuire MK: Prognosis versus actual outcome: a long-term survey of 100 treated periodontal patients under maintenance care. *J Periodontol* 62:51, 1991.
7. Chace R, Sr, Low SB: Survival characteristics of periodontally involved teeth: a 40-year study. *J Periodontol* 64:701, 1993.
8. Ghaia S, Bissada NF: Prognosis and actual treatment outcome of periodontally involved teeth. *Periodontal Clin Investig* 18:7, 1996.
9. Shapiro N: Retaining periodontally "hopeless" teeth: a case report. *J Am Dent Assoc* 125:596, 1994.
10. Rosling B, Nyman S, Lindhe J: The effect of systematic plaque control on bone regeneration in infrabony pockets. *J Clin Periodontol* 3:38, 1976.
11. Sorrin S, Burman LR: A study of cases not amenable to periodontal therapy. *J Am Dent Assoc* 31:204, 1944.
12. Corn H, Marks MH: Strategic extractions in periodontal therapy. *Dent Clin North Am* 13:817, 1969.
13. Kao RT: Strategic extraction: a paradigm shift that is changing our profession. *J Periodontol* 79:971, 2008.
14. Preber J, Bergström J: The effect of non-surgical treatment on periodontal pockets in smokers and non-smokers. *J Clin Periodontol* 13:319, 1986.
15. Renvert S, Dahlen G, Wikström M: The clinical and microbiological effects of non-surgical periodontal therapy in smokers and non-smokers. *J Clin Periodontol* 25:153, 1998.
16. Bolin A, Eklund G, Frithiof L, et al: The effect of changed smoking habits on marginal alveolar bone loss: a longitudinal study. *Swed Dent J* 17:211, 1993.
17. Grossi SD, Zambon J, Machtei EE, et al: Effects of smoking and smoking cessation on healing after mechanical therapy. *J Am Dent Assoc* 128:599, 1997.
18. Hart TC, Kornman KS: Genetic factors in the pathogenesis of periodontitis. *Periodontol 2000* 14:202, 1997.
19. Kornman KS, di Giovine FS: Genetic variations in cytokine expression: a risk factor for severity of adult periodontitis. *Ann Periodontol* 3:327, 1998.
20. Michalowicz BS, Diehl SR, Gunsolley JC, et al: Evidence of a substantial genetic basis for risk of adult periodontitis. *J Periodontol* 71:2000, 1699.
21. McGuire MK, Nunn ME: Prognosis versus actual outcome. IV. The effectiveness of clinical parameters and IL-1 genotype in accurately predicting prognoses and tooth survival. *J Periodontol* 70:49, 1999.
22. Bjorn AL, Bjorn H, Grkovic B: Marginal fit of restorations and its relation to periodontal bone level. I. Metal fillings. *Odontol Revy* 20:311, 1969.
23. Newcomb GM: The relationship between the location of subgingival crown margins and gingival inflammation. *J Periodontol* 45:151, 1974.
24. Silness J: Periodontal conditions in patients treated with dental bridges. III. The relationship between the location of the crown margin and the periodontal condition. *J Periodontal Res* 5:225, 1970.
25. Kay S, Forscher BK, Sackett LM: Tooth root length-volume relationships: an aid to periodontal prognosis. I. Anterior teeth. *Oral Surg* 7:735, 1954.
26. Masters DH, Hoskins SW: Projection of cervical enamel into molar furcations. *J Periodontol* 35:49, 1964.
27. Grewe JM, Meskin LH, Miller T: Cervical enamel projections: prevalence, location, and extent; with associated periodontal implications. *J Periodontol* 36:460, 1965.
28. Tsatsas B, Mandi F, Kerani S: Cervical enamel projections in the molar teeth. *J Periodontol* 44:312, 1973.
29. Moskow BS, Canut PM: Studies on root enamel. 2. Enamel pearls: a review of their morphology, localization, nomenclature, occurrence, classification, histogenesis and incidence. *J Clin Periodontol* 17:275, 1990.
30. Everett FG, Jump EB, Holder TD, et al: The intermediate bifurcational ridge: a study of the morphology of the bifurcation of the lower first molar. *J Dent Res* 37:162, 1958.
31. Bower RC: Furcation morphology relative to periodontal treatment: furcation entrance architecture. *J Periodontol* 50:23, 1979.
32. Bower RC: Furcation morphology relative to periodontal treatment–furcation root surface anatomy. *J Periodontol* 50:366, 1979.
33. Fox SC, Bosworth BL: A morphological study of proximal root concavities: a consideration in periodontal therapy. *J Am Dent Assoc* 114:811, 1987.
34. Withers JA, Brunsvold MA, Killoy WJ, et al: The relationship of palato-gingival grooves to localized periodontal disease. *J Periodontol* 52:41, 1981.
35. Everett FG, Kramer GN: The distolingual groove in the maxillary lateral incisor: a periodontal hazard. *J Periodontol* 43:352, 1972.
36. Gher ME, Vernino AR: Root morphology: clinical significance in pathogenesis and treatment of periodontal disease. *J Am Dent Assoc* 101:627, 1980.
37. Kogan SL: The prevalence, location and conformation of palato-radicular grooves in maxillary incisors. *J Periodontol* 57:2312, 1986.
38. Morris ML: The diagnosis, prognosis and treatment of loose tooth. *Oral Surg* 6:1037, 1953.
39. Flezar TJ, Knowles JW, Morrison EC, et al: Tooth mobility and periodontal therapy. *J Clin Periodontol* 7:495, 1980.
40. Armitage GC: Development of a classification system for periodontal diseases and conditions. *Ann Periodontol* 4:1, 1999.
41. Löe H, Theilade E, Jensen SB: Experimental gingivitis in man. *J Periodontol* 36:177, 1965.
42. Mariotti A: Dental plaque–induced gingival disease. *Ann Periodontol* 4:7, 1999.
43. Holmstrup P: Non–plaque-induced gingival lesions. *Ann Periodontol* 4:20, 1999.
44. Lindhe J, Ranney R, Lamster I, et al: Consensus report: chronic periodontitis. *Ann Periodontol* 4:38, 1999.
45. Lang N, Bartold PM, Cullinan M, et al: Consensus report: aggressive periodontitis. *Ann Periodontol* 4:53, 1999.
46. Novak MJ, Polson AM, Adair SM: Tetracycline therapy in patients with early juvenile periodontitis. *J Periodontol* 59:366, 1988.
47. Mabry T, Yukna R, Sepe W: Freeze-dried bone allografts with tetracycline in the treatment of juvenile periodontitis. *J Periodontol* 56:74, 1985.
48. Yukna R, Sepe W: Clinical evaluation of localized periodontosis defects with freeze-dried bone allografts combined with local and systemic tetracyclines. *Int J Periodontics Restorative Dent* 5:9, 1982.
49. Kinane D: Periodontitis modified by systemic factors. *Ann Periodontol* 4:54, 1999.
50. Lindhe J, Ranney R, Lamster I, et al: Consensus report: periodontitis as a manifestation of systemic diseases. *Ann Periodontol* 4:64, 1999.
51. Novak MJ: Necrotizing ulcerative periodontitis. *Ann Periodontol* 4:74, 1999.
52. Rowland RW: Necrotizing ulcerative gingivitis. *Ann Periodontol* 4:65, 1999.

CHAPTER 34

Rationale for Periodontal Treatment

Fermin A. Carranza and Henry H. Takei

CHAPTER OUTLINE

What Does Periodontal Therapy Accomplish?
Factors That Affect Healing
Healing After Periodontal Therapy
Periodontal Reconstruction

What Does Periodontal Therapy Accomplish?

The effectiveness of periodontal therapy is made possible by the remarkable healing capacity of the periodontal tissues. Periodontal therapy can restore chronically inflamed gingiva so that, from a clinical and structural point of view, it is almost identical with gingiva that has never been exposed to excessive plaque accumulation[1] (see Part 8).

Properly performed, periodontal treatment can eliminate pain, exudate, gingival inflammation,[2] and bleeding. It can also reduce periodontal pockets, eliminate infection, arrest the destruction of soft tissue and bone,[3] and reduce abnormal tooth mobility.[4] Other benefits are to establish optimal occlusal function, restore tissue destroyed by disease, reestablish physiologic gingival contour, and prevent the recurrence of disease, which will all help to maintain the natural dentition[5] (Figure 34-1).

Local Therapy

The cause of periodontitis and gingivitis is bacterial plaque accumulation on the tooth surface close to the gingival tissue. The accumulation of plaque can be favored by a variety of local factors, such as calculus, overhanging margins of restorations, and food impaction. *The removal of plaque and all of the factors that favor its accumulation is the primary goal in local therapy.*

Abnormal forces on the tooth can increase tooth mobility. The thorough elimination of plaque and the prevention of its formation can help maintain periodontal health, even if traumatic forces are allowed to persist.[6, 7] However, the elimination of trauma may increase the chances for bone regeneration and the gain of attachment.[8] Although this point is not widely accepted,[9] it appears that creating occlusal relationships that are more tolerable to the periodontal tissues increases the margin of safety of the periodontium to the buildup of plaque, in addition to reducing tooth mobility. It should be remembered that total plaque elimination as obtained in experimental studies may not be possible in human subjects.

Systemic Therapy

Systemic therapy may be employed as an adjunct to local measures for specific purposes such as controlling systemic complications from acute infections or chemotherapy and preventing harmful effects of posttreatment bacteremia. The control of systemic diseases that aggravate the patient's periodontal condition is always a consideration so proper precautions can be instituted during therapy (see Chapters 37, 38, and 39).

Systemic therapy for treatment of the periodontal condition in conjunction with local therapy is indicated in patients with aggressive periodontitis. In these diseases, systemic antibiotics are used to eliminate the bacteria that invade the gingival tissues and can repopulate the pocket after scaling and root planing (see Chapters 40 and 47).

In addition, periodontal manifestations of systemic diseases (see Chapter 28) are treated primarily by other local measures.

In the late twentieth century, the concept of *host modulation* was introduced as a medical approach to periodontal treatment. The classic 1979 paper by Nyman, Schroeder, and Lindhe[10] reported that it was possible to block periodontal bone loss in animals with the aspirin-like drug indomethacin. Evidence was then presented that some *nonsteroidal antiinflammatory drugs* (NSAIDs), such as flurbiprofen and ibuprofen, can reduce the development of experimental gingivitis,[11] as well as the loss of alveolar bone in periodontitis.[12-15] These drugs are propionic acid derivatives and act by inhibiting the cyclooxygenase pathway of arachidonic acid metabolism, thereby reducing prostaglandin formation. These NSAIDs can be administered by mouth[16] or applied topically.[13]

Another drug that has a strong inhibitory effect on bone resorption is alendronate, a *bisphosphonate,* which is currently used to treat metabolic diseases in humans, such as Paget disease or hypercalcemia of malignancy, which result in bone resorption. Experimental studies in monkeys have shown that alendronate reduced the bone loss associated with periodontitis.[17,18]

Host modulation is still in its experimental stages, and protocols for its clinical use have not been established. However, current studies indicates that future treatment modalities may attempt not only to control the bacterial cause of the disease but also to suppress the self-destructive components of the host inflammatory response[12] (see Chapter 49).

Factors That Affect Healing

In the periodontium, as elsewhere in the body, healing is affected by local and systemic factors.

Local Factors

Systemic conditions that impair healing may reduce the effectiveness of local periodontal treatment and should be corrected before

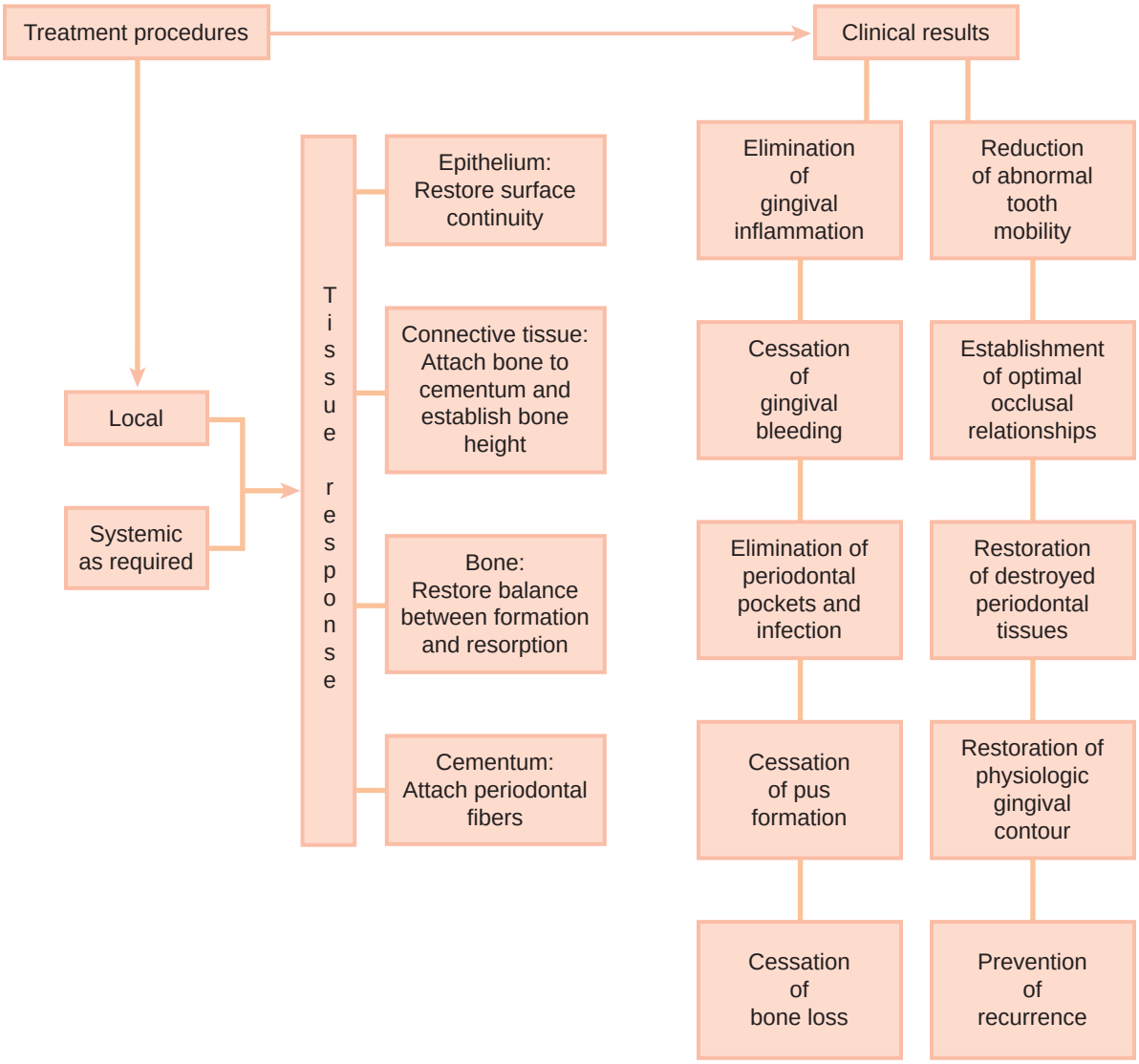

Figure 34-1 Tissue response and clinical results after periodontal treatment.

or during local procedures. However, local factors, particularly plaque microorganisms, are the most common deterrents to healing after periodontal treatment.

Healing is also delayed by (1) excessive tissue manipulation during treatment, (2) trauma to the tissues, (3) the presence of foreign bodies, and (4) repetitive treatment procedures that disrupt the orderly cellular activity in the healing process. An adequate blood supply is needed for the increased cellular activity during healing. If the blood supply is impaired or insufficient, areas of necrosis will develop and delay the healing process.

Healing is improved by debridement (removal of degenerated and necrotic tissue), immobilization of the healing area, and pressure on the wound. The cellular activity in healing entails an increase in oxygen consumption, but healing of the gingiva is not accelerated by artificially increasing the oxygen supply beyond the normal requirements.[19]

Systemic Factors

The effects of systemic conditions on healing have been extensively documented in animal experiments but are less clearly defined in humans. Healing capacity diminishes with age,[20,21] probably because of the atherosclerotic vascular changes common in aging and the resulting reduction in blood circulation. Healing is delayed in patients with generalized infections and in those with diabetes and other debilitating diseases.

Healing is impaired by insufficient food intake; bodily conditions that interfere with the use of nutrients; and deficiencies in vitamin C,[22,23] proteins,[24] and other nutrients. However, the nutrient requirements of the healing tissues in minor wounds, such as those created by periodontal surgical procedures, are usually satisfied by a well-balanced diet.

Healing is also affected by hormones. Systemically administered glucocorticoids such as cortisone hinder repair by depressing the inflammatory reaction or by inhibiting the growth of fibroblasts, the production of collagen, and the formation of endothelial cells. Systemic stress,[25] thyroidectomy, testosterone, adrenocorticotropic hormone (ACTH), and large doses of estrogen suppress the formation of granulation tissue and impair healing.[20] Progesterone increases and accelerates the vascularization of immature granulation tissue[26] and appears to increase the susceptibility of the gingiva to mechanical injury by causing dilation of the marginal vessels.[27]

Healing After Periodontal Therapy

The basic healing processes are the same after all forms of periodontal therapy. These processes consist of the removal of degenerated tissue debris and the replacement of tissues destroyed by

disease. This implies regeneration and repair of the periodontal structures but not necessarily a gain in attachment. Techniques to gain attachment and bone level are discussed in the sections on new attachment and periodontal reconstruction.

Regeneration

Regeneration is the natural renewal of a structure, produced by growth and differentiation of new cells and intercellular substances to form new tissues or parts. Regeneration occurs through growth from the same type of tissue that has been destroyed or from its precursor. In the periodontium, gingival epithelium is replaced by epithelium, and the underlying connective tissue and periodontal ligament are derived from connective tissue. Bone and cementum are replaced by connective tissue, which is the precursor of both. Undifferentiated connective tissue cells develop into osteoblasts and cementoblasts, which form bone and cementum.

Regeneration of the periodontium is a continuous physiologic process. Under normal conditions, new cells and tissues are constantly being formed to replace those that mature and die; this is termed *wear and tear repair.*[28] It is manifested by (1) mitotic activity in the epithelium of the gingiva and the connective tissue of the periodontal ligament, (2) the formation of new bone, and (3) the continuous deposition of cementum.

Regeneration is occurring even during destructive periodontal disease. Most gingival and periodontal diseases are chronic inflammatory processes and as such are *healing* lesions. Regeneration is part of healing. However, bacteria and bacterial products that perpetuate the disease process, along with the resulting inflammatory exudate, are injurious to the regenerating cells and tissues, thus preventing completion of the healing process.

By removing bacterial plaque and creating the conditions to prevent its new formation, periodontal treatment removes the obstacles to regeneration and enables the patient to benefit from the inherent regenerative capacity of the tissues. A brief "spurt" in regenerative activity occurs immediately after periodontal treatment, but no local treatment procedures promote or accelerate regeneration.

Repair

Repair simply restores the continuity of the diseased marginal gingiva and reestablishes a normal gingival sulcus at the same level on the root as the base of the preexisting periodontal pocket (Figure 34-2, *B*). This process, called *healing by scar,*[29] arrests bone destruction but does not result in gain of gingival attachment or bone height. This return of the destroyed periodontium to health involves regeneration and mobilization of epithelial and connective tissue cells into the damaged area and increased local mitotic divisions to provide sufficient numbers of cells (Figure 34-3).

For the diseased gingiva and attachment apparatus to regain (totally or partially) their level on the root (Figure 34-2, *C*), therapy must include special materials and techniques. If these are not used or are not successful, tissues undergo repair only, which involves regeneration of tissue to remodel the attachment apparatus but does not include regaining attachment level or new bone height. For this reason, we prefer to use the term *reconstruction of the periodontium* to refer to the crucial therapeutic techniques that seek to rebuild the periodontium and result in a significant gain of attachment and bone height (see Chapter 61).

New Attachment

New attachment is the embedding of new periodontal ligament fibers into new cementum and the attachment of the gingival epithelium to a tooth surface previously denuded by disease.

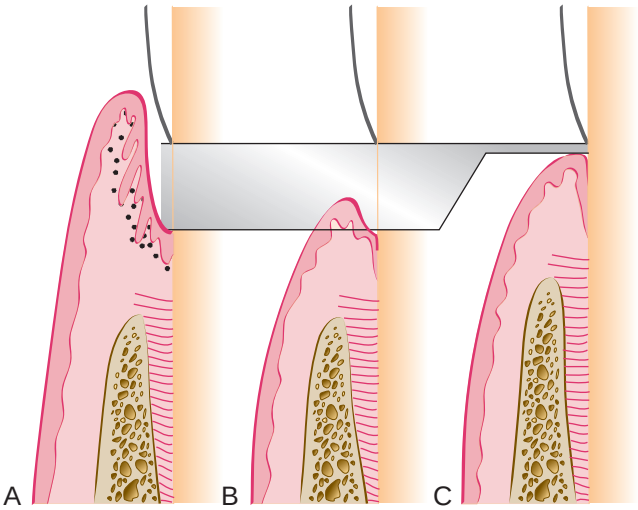

Figure 34-2 Two possible outcomes of pocket elimination. **A,** Periodontal pocket before treatment. **B,** Normal sulcus reestablished at the level of the base of the pocket. **C,** Periodontium restored on the root surface previously denuded by disease; this is called *new attachment.* Shaded areas show denudation caused by periodontal disease.

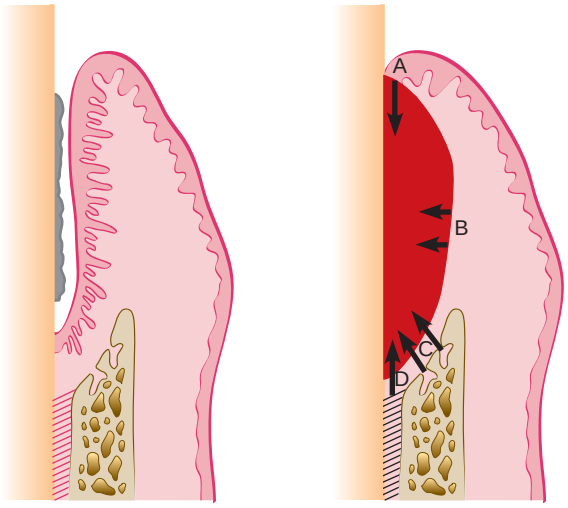

Figure 34-3 Sources of regenerating cells in the healing stages of a periodontal pocket. *Left,* Intrabony pocket. *Right,* After therapy the clot formed is invaded by cells from, *A,* the marginal epithelium; *B,* the gingival connective tissue; *C,* the bone marrow; and, *D,* the periodontal ligament.

The critical phrase in this definition is "tooth surface previously denuded by disease" (Figure 34-4, area *B*). The attachment of the gingiva or the periodontal ligament to areas of the tooth from which they have been removed in the course of treatment (or during preparation of teeth for restorations) represents simple healing or reattachment of the periodontium, not new attachment.[30] The term *reattachment* refers to repair in areas of the root not previously exposed to the pocket such as after surgical detachment of the tissues or following traumatic tears in the cementum, tooth fractures, or the treatment of periapical lesions (Figure 34-4, area *D*).

Epithelial adaptation differs from new attachment in that it is the close apposition of the gingival epithelium to the tooth surface, with no gain in height of gingival fiber attachment. The pocket is not completely obliterated, although it may not permit passage of a probe (Figure 34-5).

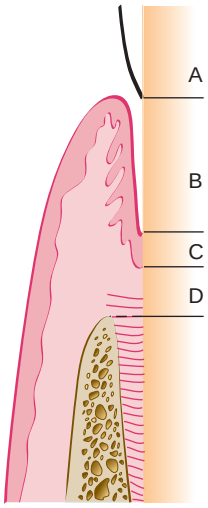

Figure 34-4 Enamel surface *(A)*. Area of cementum denuded by pocket formation *(B)*. Area of cementum covered by junctional epithelium *(C)*. Area of cementum apical to junctional epithelium *(D)*. The term *new attachment* refers to a new junctional epithelium and attached connective tissue fibers formed on area *B*.

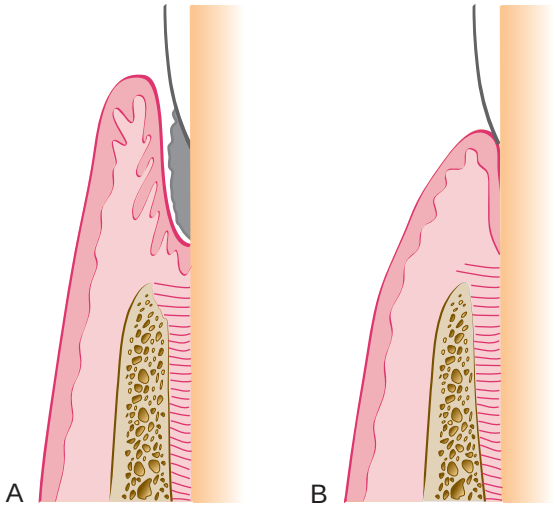

Figure 34-5 Epithelial adaptation after periodontal treatment. **A,** Periodontal pocket. **B,** After treatment. The pocket epithelium is closely adapted to but not attached to the root.

However, studies have shown that these deep sulci lined by long, thin epithelium may be as resistant to disease as true connective tissue attachments.[31,32] The absence of bleeding or secretion on probing, the absence of clinically visible inflammation, and the absence of stainable plaque on the root surface when the pocket wall is deflected from the tooth may indicate that the "deep sulcus" persists in an inactive state, causing no further loss of attachment.[15,33] A posttherapy depth of 4 mm or even 5 mm may therefore be acceptable in these cases.

Periodontal Reconstruction

As previously discussed, the term *periodontal reconstruction* refers to the process of regeneration of cells and fibers and remodeling of the lost periodontal structures that results in (1) gain of attachment level, (2) formation of new periodontal ligament fibers, and (3) a level of alveolar bone significantly coronal to that present before treatment.

A technique to attain these ideal results has been a constant but elusive goal of periodontal therapy for centuries.[34] Since the 1970s, renewed laboratory and clinical research efforts have resulted in new concepts and techniques that have moved us much closer to attaining this ideal result of therapy. Melcher[35] pointed out that the regeneration of the periodontal ligament is the key to periodontal reconstruction because it "provides continuity between the alveolar bone and the cementum and also because it contains cells that can synthesize and remodel the three connective tissues of the alveolar part of the periodontium." Chapter 61 discusses growth factors that help the maturation of these tissues.

During the healing stages of a periodontal pocket, the area is invaded by cells from four different sources (see Figure 34-3): oral epithelium, gingival connective tissue, bone, and periodontal ligament.

The final outcome of periodontal pocket healing depends on the sequence of events during the healing stages.[35] If the epithelium proliferates along the tooth surface before the other tissues reach the area, the result will be a long junctional epithelium. If the cells from the gingival connective tissue are the first to populate the area, the result will be fibers parallel to the tooth surface and remodeling of the alveolar bone with no attachment to the cementum. If bone cells arrive first, root resorption and ankylosis may occur. Finally, only when cells from the periodontal ligament proliferate coronally is there new formation of cementum and periodontal ligament.[35]

Several methods, based on different concepts and resulting in various techniques, have been recommended to improve the likelihood of gaining new attachment and increased bone levels, as discussed in Chapter 61.

Suggested Readings

Beaumont RH, O'Leary TJ, Kafrawy AH: Relative resistance of long junctional epithelial adhesions and connective tissue attachments to plaque-induced inflammation. *J Periodontol* 55:213, 1984.

Caffesse RG, Ramfjord SP, Nasjleti CE: Reverse bevel periodontal flaps in monkeys. *J Periodontol* 39:219, 1968.

Kantor M, Polson AM, Zander HA: Alveolar bone regeneration after removal of inflammatory and traumatic factors. *J Periodontol* 47:687, 1976.

Lindhe J, Ericsson I: The influence of trauma from occlusion on reduced but healthy periodontal tissues in dogs. *J Clin Periodontol* 3:110, 1976.

Lindhe J, Nyman S: The effect of plaque control and surgical pocket elimination on the establishment and maintenance of periodontal health: a longitudinal study of periodontal therapy in cases of advanced periodontal disease. *J Clin Periodontol* 2:67, 1975.

Magnusson I, Runstad L, Nyman S, et al: A long junctional epithelium: a locus minoris resistentiae in plaque infection? *J Clin Periodontol* 10:33, 1983.

Melcher AH: On the repair potential of periodontal tissues. *J Periodontol* 47:256, 1976.

Polson AM: Interrelationship of inflammation and tooth mobility (trauma) in pathogenesis of periodontal disease. *J Clin Periodontol* 7:351, 1980.

References

References for this chapter are found on the companion website www.expertconsult.com.

References

1. Lindhe J, Parodi R, Liljenberg B, et al: Clinical and structural alterations characterizing healing gingiva. *J Periodontal Res* 13:410, 1978.
2. Rateitschak K: The therapeutic effect of local treatment on periodontal disease assessed upon evaluation of different diagnostic criteria. 2. Changes in gingival inflammation. *J Periodontol* 35:155, 1964.
3. Rateitschak K, Engelberger A, Marthaler TM: The therapeutic effect of local treatment on periodontal disease assessed upon evaluation of different diagnostic criteria. 3. Radiographic changes in appearance of bone. *J Periodontol* 35:263, 1964.
4. Ferris RT: Quantitative evaluation of tooth mobility following initial periodontal therapy. *J Periodontol* 37:190, 1966.
5. Oliver RC: Tooth loss with and without periodontal therapy. *Periodont Abstr* 17:8, 1969.
6. Lindhe J, Ericsson I: The influence of trauma from occlusion on reduced but healthy periodontal tissues in dogs. *J Clin Periodontol* 3:110, 1976.
7. Lindhe J, Nyman S: The effect of plaque control and surgical pocket elimination on the establishment and maintenance of periodontal health: a longitudinal study of periodontal therapy in cases of advanced periodontal disease. *J Clin Periodontol* 2:67, 1975.
8. Kantor M, Polson AM, Zander HA: Alveolar bone regeneration after removal of inflammatory and traumatic factors. *J Periodontol* 47:687, 1976.
9. Polson AM: Interrelationship of inflammation and tooth mobility (trauma) in pathogenesis of periodontal disease. *J Clin Periodontol* 7:351, 1980.
10. Nyman S, Schroeder HE, Lindhe J: Suppression of inflammation and bone resorption by indomethacin during experimental periodontitis in dogs. *J Periodontol* 50:450, 1979.
11. Heasman PA, Seymour RA: The effect of a systemically administered non-steroidal anti-inflammatory drug (flurbiprofen) on experimental gingivitis in humans. *J Clin Periodontol* 16:551, 1989.
12. Howell TH, Williams RC: Nonsteroidal antiinflammatory drugs as inhibitors of periodontal disease progression. *Crit Rev Oral Biol Med* 4:177, 1993.
13. Williams RC, Jeffcoat MK, Howell TH, et al: Topical flurbiprofen treatment of periodontitis in beagles. *J Periodontal Res* 23:166, 1988.
14. Williams RC, Jeffcoat MK, Howell H, et al: Altering the progression of human alveolar bone loss with the non-steroidal anti-inflammatory drug flurbiprofen. *J Periodontol* 60:485, 1989.
15. Williams RC, Jeffcoat MK, Kaplan ML, et al: Flurbiprofen: a potent inhibitor of alveolar bone resorption in beagles. *Science* 227:640, 1985.
16. Jeffcoat MK, Williams RC, Reddy MS, et al: Flurbiprofen treatment of human periodontitis: effect on alveolar bone height and metabolism. *J Periodontal Res* 23:381, 1988.
17. Brunsvold MA, Chaves ES, Kornman KS, et al: Effects of a bisphosphonate on experimental periodontitis in monkeys. *J Periodontol* 63:825, 1992.
18. Weinreb M, Quartuccio H, Seedor JG, et al: Histomorphometrical analysis of the effects of the bisphosphonate alendronate on bone loss caused by experimental periodontitis in monkeys. *J Periodontal Res* 29:35, 1994.
19. Glickman I, Turesky SS: Manhold J: The oxygen consumption of healing gingiva. *J Dent Res* 29:429, 1950.
20. Butcher EO, Klingsberg J: Age, gonadectomy, and wound healing in the palatal mucosa. *J Dent Res* 40:694, 1961.
21. Holm-Pedersen P, Löe H: Wound healing in the gingiva of young and old individuals. *Scand J Dent Res* 79:40, 1971.
22. Barr CE: Oral healing in ascorbic acid deficiency. *Periodontics* 3:286, 1965.
23. Turesky SS, Glickman I: Histochemical evaluation of gingival healing in experimental animals on adequate and vitamin C deficient diets. *J Dent Res* 33:273, 1954.
24. Stahl SS: The effect of a protein-free diet on the healing of gingival wounds in rats. *Arch Oral Biol* 7:551, 1962.
25. Stahl SS: Healing gingival injury in normal and systemically stressed young adult male rats. *J Periodontol* 32:63, 1961.
26. Lindhe J, Branemark PI: The effect of sex hormones on vascularization of a granulation tissue. *J Periodontal Res* 3:6, 1968.
27. Hugoson A: Gingival inflammation and female sex hormones. *J Periodontal Res* 5(Suppl):1, 1970.
28. Leblond CP, Walker BE: Renewal of cell populations. *Physiol Rev* 36:255, 1956.
29. Ratcliff PA: An analysis of repair systems in periodontal therapy. *Periodont Abstr* 14:57, 1966.
30. Kalkwarf KL: Periodontal new attachment without the placement of osseous potentiating grafts. *Periodont Abstr* 22:53, 1974.
31. Beaumont RH, O'Leary TJ, Kafrawy AH: Relative resistance of long junctional epithelial adhesions and connective tissue attachments to plaque-induced inflammation. *J Periodontol* 55:213, 1984.
32. Magnusson I, Runstad L, Nyman S, et al: A long junctional epithelium: a locus minoris resistentiae in plaque infection? *J Clin Periodontol* 10:33, 1983.
33. Caffesse RG, Ramfjord SP, Nasjleti CE: Reverse bevel periodontal flaps in monkeys. *J Periodontol* 39:219, 1968.
34. Carranza F, Shklar G: *History of periodontology*, Chicago, 2003, Quintessence.
35. Melcher AH: On the repair potential of periodontal tissues. *J Periodontol* 47:256, 1976.

CHAPTER 35

The Treatment Plan

Fermin A. Carranza and Henry H. Takei

CHAPTER OUTLINE

Master Plan for Total Treatment
Sequence of Therapeutic Procedures
Explaining Treatment Plan to the Patient

After the diagnosis and prognosis have been established, the treatment is planned. The plan should encompass short- and long-term goals.

The *short-term goals* are the elimination of all infectious and inflammatory processes that cause periodontal and other oral problems that may hinder the patient's general health. Basically, the short-term goals are to bring the oral cavity to a state of health. This may require periodontal procedures, as well as other dental therapy, such as endodontics and correcting oral mucous membrane pathology. Referral to other dental and medical specialties will be necessary.

From a periodontal viewpoint, the short-term goals are important, since they consist of the elimination of gingival inflammation and correction of the conditions that cause and perpetuate it. These include not only elimination of root accretions but also pocket eradication or reduction and establishment of good gingival contours and mucogingival relationships conducive to good periodontal health. Restoration of carious areas and the correction of poor existing restorations may also be necessary.

The *long-term goals* are the reconstruction of a healthy dentition that fulfills all functional and esthetic requirements. Long-term planning involves consideration of prosthetic reconstruction of the dentition, which may require implant therapy, including surgical preparation of the implant site. Also, the need for orthodontic treatment should be evaluated. The financial impact of long-term treatment requires careful consideration and understanding by the patient. The age and medical health status of the patient must also be considered.

The treatment plan is the blueprint for case management. It includes all procedures required for the establishment and maintenance of oral health and involves the following decisions:

- Need for emergency treatment (pain, acute infections)
- Teeth that will require removal
- Periodontal pocket therapy techniques (surgical or nonsurgical)
- Endodontic therapy
- The need for occlusal correction, including orthodontic therapy
- The use of implant therapy
- The need for caries removal and the placement of temporary and final restorations
- Prosthetic replacements that may be needed and which teeth will be abutments if a fixed prosthesis is used
- Decisions regarding esthetic considerations in periodontal therapy
- Sequence of therapy

Unforeseen developments during treatment may necessitate modification of the initial treatment plan. However, *except for emergencies, no therapy should be initiated until a treatment plan has been established*.

Master Plan for Total Treatment

The aim of the treatment plan is total treatment, that is, the coordination of all the short- and long-term goals for the purpose of creating a well-functioning dentition in a healthy periodontal environment. The master plan of periodontal treatment encompasses different areas of therapeutic objectives for each patient according to his or her needs. It is based on the diagnosis, disease severity, risk factors, and other factors outlined in previous chapters.

Extracting or Preserving a Tooth

Periodontal treatment requires long-range planning. Its value to the patient is measured in years of healthy functioning of the entire dentition and not by the number of teeth retained at the time of treatment. *Treatment is directed to establishing and maintaining the health of the periodontium throughout the mouth rather than attempting spectacular efforts to "tighten loose teeth."*

In the past two decades, implant replacement of missing teeth has become a predictable course of therapy. Therefore attempts to save questionable teeth may jeopardize adjacent teeth and may lead to the loss of bone needed for implant therapy. Teeth on the borderline of a hopeless prognosis do not contribute to the overall usefulness of the dentition. Such teeth become sources of recurrent problem to the patient and detract from the value of the greater service rendered by the establishment of periodontal health in the remainder of the oral cavity.

Removal, retention, or temporary (interim) retention of one or more teeth is a very important part of the overall treatment plan. A tooth should be extracted under the following conditions:

- It is so mobile that function becomes painful.
- It can cause acute abscesses during therapy.
- There is no use for it in the overall treatment plan.

In some cases, a tooth can be retained temporarily, postponing the decision to extract until after treatment is completed. A tooth in this category can be retained under the following conditions:

- It maintains posterior stops; the tooth can be removed after treatment when it can be replaced by an implant or another type of prosthesis.
- It maintains posterior stops and may be functional after implant placement in adjacent areas. When the implant is restored, these teeth can be extracted.
- In the anterior esthetic zone, a tooth can be retained during periodontal therapy and removed when treatment is completed and a permanent restorative procedure can be performed. The retention of this tooth should not jeopardize the adjacent teeth. This approach avoids the need for temporary appliances during therapy.
- Extraction of hopeless teeth can also be performed during periodontal surgery of the adjacent teeth. This approach reduces the number of appointments needed for surgery in the same area.

In the formulation of the treatment plan, in addition to the proper function of the dentition, esthetic considerations play an important role. Different patients value esthetics differently, according to their age, gender, profession, and social status. The clinician should carefully evaluate and consider a final esthetic outcome of treatment that will be acceptable to the patient without jeopardizing the basic need of attaining health.

With the predictable use of implants, questionable teeth should be carefully evaluated as to whether their removal and replacement with an implant may be a better and more satisfactory course of therapy.

In complex cases, interdisciplinary consultation with other specialty areas is necessary before a final plan can be made. The opinion of orthodontists and prosthodontists is especially important for the final decision in these patients.

Occlusal evaluation and therapy may be necessary during treatment, which may necessitate planning for occlusal adjustment (see Chapters 50 and 51), orthodontics, and splinting. The correction of bruxism and other occlusal habits may also be necessary.

Systemic conditions should be carefully evaluated because they may require special precautions during the course of periodontal treatment. The tissue response to treatment procedures may be affected, or the preservation of periodontal health may be threatened after treatment is completed. The patient's physician should always be consulted when the patient presents with medical and systemic problems that may affect the periodontal therapy.

Supportive periodontal care is also of paramount importance for case maintenance. Such care entails all procedures for maintaining periodontal health after it has been attained. It consists of instruction in oral hygiene and recall therapy at regular intervals, according to the patient's needs.

Sequence of Therapeutic Procedures

Periodontal therapy is an inseparable part of dental therapy. The list of procedures presented in Box 35-1 includes periodontal procedures (in italics) and other procedures not considered to be within the province of the periodontist. These procedures are listed together in Box 35-1 to emphasize the close relationship of periodontal therapy with other phases of therapy performed by general dentists or other specialists.

The sequence in which these phases of therapy are performed may vary to some extent in response to the requirements of the case. However, the preferred sequence, which covers the vast majority of cases, is shown in Figure 35-1.

Although the phases of treatment have been numbered, the recommended sequence does not follow the numbers. Phase I, or the *nonsurgical phase,* is directed to the elimination of the etiologic

BOX 35-1 Phases of Periodontal Therapy

Preliminary Phase

Treatment of emergencies:
- Dental or periapical
- *Periodontal*
- Other

Extraction of hopeless teeth and provisional replacement if needed (may be postponed to a more convenient time)

Nonsurgical Phase (Phase I Therapy)

Plaque control and patient education:
- Diet control (in patients with rampant caries)
- *Removal of calculus and root planing*
- *Correction of restorative and prosthetic irritational factors*
- Excavation of caries and restoration (temporary or final, depending on whether a definitive prognosis for the tooth has been determined and the location of caries)
- *Antimicrobial therapy (local or systemic)*
- *Occlusal therapy*
- *Minor orthodontic movement*
- *Provisional splinting and prosthesis*

Evaluation of Response to Nonsurgical Phase

Rechecking:
- Pocket depth and gingival inflammation
- Plaque and calculus, caries

Surgical Phase (Phase II Therapy)
- Periodontal therapy, including placement of implants
- Endodontic therapy

Restorative Phase (Phase III Therapy)
- Final restorations
- Fixed and removable prosthodontic appliances
- Evaluation of response to restorative procedures
- Periodontal examination

Maintenance Phase (Phase IV Therapy)

Periodic rechecking:
- Plaque and calculus
- Gingival condition (pockets, inflammation)
- Occlusion, tooth mobility
- Other pathologic changes

Periodontal procedures are in italics.

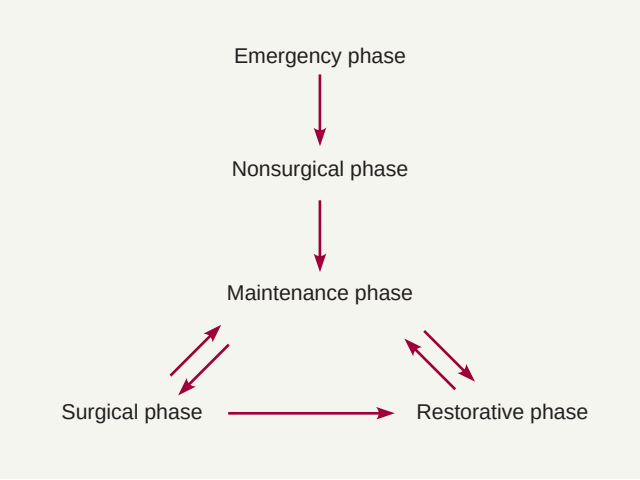

Figure 35-1 Preferred sequence of periodontal therapy.

factors of gingival and periodontal diseases. When successfully performed, this phase stops the progression of dental and periodontal disease.

Immediately after completion of phase I therapy, the patient should be placed on the *maintenance phase* (phase IV) to preserve the results obtained and prevent any further deterioration and recurrence of disease. While on the maintenance phase, with its periodic evaluation, the patient enters into the *surgical phase* (phase II) and the *restorative phase* (phase III) of treatment. These phases include periodontal surgery to treat and improve the condition of the periodontal and surrounding tissues. This may include regeneration of the gingiva and bone for function and esthetics, placement of implants, and restorative therapy.

Explaining Treatment Plan to the Patient

The following discussion includes suggestions for explaining the treatment plan to the patient.

Be specific. Tell your patient, "You have gingivitis" or "You have periodontitis," then explain exactly what these conditions are.

Avoid vague statements. Do not use statements such as, "You have trouble with your gums" or "Something should be done about your gums." Patients may not understand the significance of such statements and may disregard them.

Begin your discussion on a positive note. Talk about the teeth that can be retained and the long-term service they can be expected to render. Do not begin your discussion with the statement, "The following teeth have to be extracted." This creates a negative impression, which adds to the erroneous attitude of hopelessness the patient already may have regarding his or her mouth. Make it clear that every effort will be made to retain as many teeth as possible, but do not dwell on the patient's loose teeth. Emphasize that the important purpose of the treatment is to prevent the other teeth from becoming as severely diseased as the loose teeth.

Present the entire treatment plan as a unit. Avoid creating the impression that treatment consists of separate procedures, some or all of which may be selected by the patient. Make it clear that dental restorations and prostheses contribute as much to the health of the gingiva as the elimination of inflammation and periodontal pockets. Do not speak in terms of "having the gums treated and then taking care of the necessary restorations later" as if these were unrelated treatments.

Patients often seek guidance from the dentist with questions such as the following:

- "Are my teeth worth treating?"
- "Would you have them treated if you had my problem?"
- "Why don't I just go along the way I am until the teeth really bother me and then have them all extracted?"

Explain that "doing nothing" or holding onto hopelessly diseased teeth as long as possible is inadvisable for the following reasons:

1. Periodontal disease is a microbial infection, and research has clearly shown it to be an important risk factor for severe life-threatening diseases such as stroke, cardiovascular disease, pulmonary disease, and diabetes, as well as for premature low-birth-weight babies in women of childbearing age. Correcting the periodontal condition eliminates a serious potential risk of systemic disease, which in some cases ranks as high on the danger list as smoking.
2. It is not feasible to place restorations or fixed bridges on teeth with untreated periodontal disease because the usefulness of the restoration would be limited by the uncertain condition of the supporting structures.
3. Failure to eliminate periodontal disease not only results in the loss of teeth already severely involved, but also shortens the life span of other teeth. With proper treatment, these teeth can serve as the foundation for a healthy, functioning dentition.

Therefore the dentist should make it clear to the patient that if the periodontal condition is treatable, the best results are obtained by prompt treatment. If the condition is not treatable, the teeth should be extracted.

It is the dentist's responsibility to advise the patient of the importance of periodontal treatment. However, if treatment is to be successful, the patient must be sufficiently interested in retaining his or her natural teeth and to maintain the necessary oral hygiene. Individuals who are not particularly perturbed by the thought of losing their teeth are generally not good candidates for periodontal treatment.

CHAPTER 36

Conscious Sedation

Robert L. Merin and Perry R. Klokkevold

CHAPTER OUTLINE

Rationale for Sedation during Periodontal and Implant Surgical Procedures
ADA Policy Statement and Guidelines for Conscious Sedation
Definitions and Levels of Sedation
Mild Sedation (Anxiolysis) *(e-only)*
Moderate (Conscious) Sedation *(e-only)*
Sedation Failures
Emergency Preparedness
Conclusion

For online-only content on mild sedation/anxiolysis and moderate (conscious) sedation, please visit the companion website at www.expertconsult.com. Some figures, boxes, and tables may be out of numeric order in this printed chapter.

Periodontal and implant surgery should be performed painlessly and with minimal or no apprehension. The patient should be assured of this at the outset and throughout the procedure. The most reliable means of providing painless surgery is with effective administration of local anesthesia. However, patients who are apprehensive may require treatment under mild or moderate sedation. The use of sedation can help make patients more comfortable during periodontal and implant surgery, especially when the procedure is expected to continue for 2 hours or more. Routes of administration for sedation agents include inhalation, oral, intramuscular, and intravenous (IV). The specific agent(s) and modality of administration are based on the desired level of sedation, anticipated length of the procedure, overall condition of the patient, and training of the clinician and staff. This chapter reviews the rationale, definitions, techniques, and guidelines for the use of mild-to-moderate conscious sedation in the dental office for periodontal and implant surgical procedures.

Rationale for Sedation During Periodontal and Implant Surgical Procedures

Many patients delay or avoid having needed dental treatment because of fear and anxiety. This avoidance behavior often results in compromised health and quality of life. Anxiety toward dental therapy has not changed significantly over the past 50 years; publications report that about 30% to 50% of patients are at least somewhat fearful of dental procedures.[1-4] New evidence suggests that genetic variations are associated with anxiety related to dental care, which could help to explain the consistent avoidance patterns despite improved treatment methods.[5] According to a national survey of the Canadian population, more than 68% of patients would prefer to have sedation or general anesthesia for periodontal surgery[6] (Figure 36-1). Anxiety reduction is an important part of delivering advanced periodontal services.[7] Furthermore, since dental anxiety results in avoidance behavior and is associated with more dental and periodontal problems,[8,9] it is likely that a disproportionate number of patients referred to periodontal specialists will have dental anxiety. Interestingly, there appears to be a close relationship between anxiety and postoperative pain. In fact, preoperative anxiety may be considered a predictor of postoperative pain.[10,11] In addition, high levels of anxiety (stress) can affect wound healing after periodontal treatment[12-14] (see Chapter 11). Sedation techniques have been shown to be effective in reducing physiologic markers of stress.[15] For these reasons, it is important for clinicians who provide advanced periodontal and implant therapy to be knowledgeable and skilled in providing sedation in order to reduce anxiety in their patients.

ADA Policy Statement and Guidelines for Conscious Sedation

In 2007, the American Dental Association (ADA) released three documents related to the use of sedation and general anesthesia in dentistry, including (1) the *ADA Policy Statement: The Use of Sedation and General Anesthesia by Dentists*,[16] (2) the *ADA Guidelines for the Use of Sedation and General Anesthesia by Dentists*,[17] and (3) *ADA Guidelines for Teaching Pain Control and Sedation to Dentists and Dental Students*.[18] The *ADA Policy Statement* and the *ADA Guidelines* provide educational and practice standards for anxiety control in dental practice. The ADA Committee on Anesthesiology, consisting of representatives from dental organizations involved with sedation and anesthesia (Table 36-1), produced these documents after review of the relevant scientific evidence, expert opinion, and comment by all communities of interest. The following paragraphs describe the important elements of these documents as they relate to treating anxious periodontal patients.

ADA Policy Statement: The Use of Sedation and General Anesthesia by Dentists

The dental profession's continued ability to control anxiety and pain effectively depends on a strong educational foundation in the discipline. Training to competency in minimal and moderate

Mild Sedation/Anxiolysis

Oral Sedation

Oral sedation can help reduce anesthetic failures and decrease anxiety in a large percentage of dental patients.[22,23] Oral premedication is cost-effective and requires minimal monitoring when correct doses are used.[2,3] Most states do not require special permits for dentists who are prescribing sedatives to achieve mild sedation/anxiolysis. State laws do vary, and dentists need to check with their own dental board. Mild sedation dosages are generally defined as less than or equal to the single maximum recommended dose that can be prescribed for home use. Generally, these maximum doses can be found in references such as the package inserts, pharmaceutical websites, articles in the dental literature, and yearly updated books such as the *Physicians' Desk Reference.*

The use of oral sedation premedication is both an art and a science. It is wise for dentists to become very familiar with a small number of oral sedative regimens. In this way, one has a better chance of accurately predicting the correct dose for each patient and understanding the precautions and side effects of each agent. Although there are a large number of oral sedative agents available by prescription, recent dental articles have concentrated on the use of zaleplon, triazolam, and lorazepam.[24-29] As an example, diazepam has been recommended for dental anxiety in several references.[30-32] Its duration of action is 6 to 8 hours. However, it has a primary half-life of 20 to 80 hours and a 40- to 120-hour half-life for active secondary metabolites. In addition, two head-to-head comparisons of diazepam and triazolam found triazolam to be a more effective anxiolytic agent.[33,34] The remainder of this section discusses guidelines and protocols for the use of these three oral sedative agents.

Zaleplon is a short-acting hypnotic in the pyrazolopyrimidine class. The onset of action of zaleplon is usually within 30 minutes, and it is rapidly eliminated with a half-life of approximately 1 hour. Zaleplon is a relatively new agent, and there are relatively few articles on its use in dentistry. Both triazolam and lorazepam are benzodiazepine medications, and the main difference is the effective time of sedation. The duration of action of triazolam is 2 to 4 hours compared to 4 to 8 hours for lorazepam (Table 36-6). It is important for the dentist to carefully review the patient's past medical history to rule out any contraindications to these medications before the treatment appointment.

Suggested patient pretreatment instructions are presented in Box 36-3. Patients must understand that they will need a responsible adult to escort them home when they take a sedative medication. *Patients who are not reliable at following directions are not good candidates for oral sedative premedication.*

Guidelines for Mild Sedation with Oral Medications. This section provides guidelines for the mild sedation/anxiolytic doses for these medications, but these recommendations should not be a substitute for good clinical judgment and direct patient assessment. Patient factors, such as diminished liver enzyme function, extremes of age, and drug tolerance as the result of past drug use may cause alterations in the proposed protocol. Precautions and drug interactions for zaleplon, triazolam, and lorazepam are presented in Boxes 36-5, 36-6, and 36-7, respectively. If the calculated amount of medication is ineffective, the dentist can choose to terminate the dental appointment or continue if the patient is willing. If the patient's anxiety is not sufficiently diminished, the dentist must follow all normal dismissal procedures, including releasing the patient to a responsible adult because the sedative agent may impair motor activity even when not relieving dental anxiety. A failure to produce anxiolysis may require changing future prescriptions, using the services of a dental anesthesiologist in your office, or referring the patient to an office that provides conscious sedation or general anesthesia.

Anxiolytic dosing guidelines for zaleplon, triazolam, and lorazepam are presented in Table 36-7. A recent review of the dental literature suggests a maximum dose of 0.625 mg of triazolam or 2.5 mg of lorazepam for anxiolysis.[28] However, it is important to recognize that individual tolerance and responses vary and that

BOX 36-5 Zaleplon Precautions and Drug Interactions*

Relative and Absolute Contraindications

Pregnancy, liver impairment, severe renal disease, respiratory disease, mental depression, children

Drug Interactions That May Increase Effects

Imipramine, thioridazine, cimetidine, erythromycin, ketoconazole, other CNS depressants

Drug Interactions That May Decrease Effect

Hepatic cytochrome P450 enzyme inducers such as carbamazepine, phenobarbital, phenytoin, rifampin

Foods That May Increase Effect

Alcohol, valerian, kava, gotu kola

Foods That May Decrease Effect

St. John's wort, caffeine. A high-fat or heavy meal can reduce the peak blood levels by 35% and the time to peak plasma levels by 2 hours.

*Note this is a relatively new drug and there are many potential drug interactions that have not been studied.
CNS, Central nervous system.

TABLE 36-6 Comparison of Zaleplon, Triazolam, and Lorazepam

	Zaleplon	Triazolam	Lorazepam
Available dosages	5 and 10 mg capsules	0.125 and 0.25 mg tablets	0.5, 1, and 2 mg tablets
Onset of hypnotic effect	15-30 minutes	30 minutes	30-60 minutes
Peak plasma concentration	1 hour	<2 hours	1-6 hours
Duration of action	1 hour	2-4 hours	4-8 hours
Mean half-life	1 hour	2.5 hours	12-16 hours

Data from Donaldson M, Goodchild JH: *Gen Dent* 55:143-148; quiz 149, 167-148, 2007; Ganzberg SI, Dietrich T, Valerin M, et al: *Anesth Prog* 52:128-131, 2005; Goodchild, JH, Donaldson, M: *Gen Dent* 54:54-57; quiz 58, 2006; Wynn RL, Meiller TF, Crossley HI: *Drug information handbook for dentistry,* Hudson, OH, 2009, Lexi-Comp.

BOX 36-6 Triazolam Precautions and Drug Interactions

Relative and Absolute Contraindications

Acute narrow angle glaucoma; uncorrected open angle glaucoma; myasthenia gravis; respiratory diseases, including severe sleep apnea and severe COPD; pregnancy; lactation; severe liver impairment; renal impairment; children; mental depression; hypersensitivity to this drug or other benzodiazepines.

Drug Interactions That May Increase Effect

Other CNS depressants, isoniazid, oral contraceptives, ranitidine, CYP3A4 inhibitors such as macrolide antibiotics (erythromycin, clarithromycin), azole antifungals, doxycycline, some calcium channel blockers.

Drug Interactions That May Decrease Effect

Theophylline, CYP3A4 inducers such as aminoglutethimide, carbamazepine, nafcillin, nevirapine, phenobarbital, phenytoin, and rifamycins.

Foods That May Increase Effect

Grapefruit juice, alcohol, kava, gotu kola, star fruit, melatonin, valerian, chamomile

Foods That May Decrease Effect

St. John's wort, caffeine.

BOX 36-7 Lorazepam Precautions and Drug Interactions

Relative and Absolute Contraindications

Acute narrow angle glaucoma; uncorrected open angle glaucoma; myasthenia gravis; respiratory diseases, including severe sleep apnea and severe COPD; pregnancy; lactation; severe liver impairment; renal impairment; children; mental depression, hypersensitivity to this drug or other benzodiazepines.

Drug Interactions That May Increase Effect

Other CNS depressants, probenecid (used for gout). Drugs that inhibit the oxidative metabolism of triazolam are less likely to affect lorazepam, which undergoes direct glucuronide conjugation.

Drug Interactions That May Decrease Effect

Theophylline. Drugs that induce the oxidative metabolism of triazolam are less likely to affect lorazepam, which undergoes direct glucuronide conjugation.

Foods That May Increase Effect

Alcohol, valerian, St. John's wort, kava, gotu kola.

Foods That May Decrease Effect

Caffeine.

COPD, Chronic obstructive pulmonary disease; *CNS,* central nervous system.

TABLE 36-7 Total Anxiolytic Dosing Guidelines for Zaleplon,* Triazolam,† and Lorazepam‡

	Zaleplon	Triazolam	Lorazepam
Weight (lb):	Age 41-64 years	Age 41-64 years	Age 41-64 years
<100	5 mg	0.250 mg	1.0 mg
150	10 mg	0.375 mg	1.5 mg
200+	10-15 mg	0.500 mg	2.0 mg
Notes§	Elderly and debilitated patients are more sensitive to hypnotics; recommended dose for these patients is 5 mg. Doses >10 mg in elderly and debilitated patients are not recommended. Maximum dose in package insert is 20 mg for sleep.	Dose for debilitated or elderly patients should be reduced by 50%. Doses for healthy adults under 40 years can be increased by 25%. With sublingual administration, systemic availability is approximately 27% higher compared with the same dose taken by the conventional oral route. Maximum single dose listed in the package insert is 0.5 mg for sleep.	Dose for debilitated or elderly patients should be reduced by 30%-50%. Doses for healthy adults younger than 40 years can be increased by 25%. Maximum single dose listed in the package insert is 4.0 mg.

*Zaleplon capsules; FDA-approved package insert, Aurobindo Pharma USA, 2008.

†Triazolam tablets: FDA-approved package insert, Pharmacia and Upjohn Company Division of Pfizer, 2008.

‡Lorazepam tablets: FDA-approved package insert, Ranbaxy Pharmaceuticals, 2009.

§Adapted from Goodchild JH, Donaldson M: *Gen Dent* 54:54-57, quiz 58, 2006.

maximum and average doses are not appropriate for all patients. It is necessary to adjust dosages according to weight, age, health status, and other prescribed medications, as well as previous patient experiences with sedative agents. The literature shows that age-related changes can impair benzodiazepine metabolism, and the maximum anxiolytic dose for elderly patients should be reduced by 50% for triazolam and 30% to 50% for lorazepam.[35] The opposite is true for younger adult patients (younger than 40 years of age) who may need a 25% increase in their weight-related anxiolytic dose. Sample prescriptions for zaleplon, triazolam, and lorazepam are presented in Figures 36-7, 36-8, and 36-9, respectively.

When using a very short-acting agent, such as zaleplon, there is a risk that recovery of psychomotor functions may take longer than 1 hour after the onset of action despite the reported duration of action. Also, when using triazolam with anxiolytic doses (generally higher than the hypnotic dose), there is a risk that full recovery to a normal state of consciousness may take longer than 4 hours. Ganzberg et al found that 28.5% of the zaleplon-sedated patients and 78.5% of the triazolam-sedated patients felt that the sedation effects lingered for the rest of the day.[27] Consequently, zaleplon and triazolam patients must be accompanied by a responsible adult and not resume normal activities for the remainder of the day. The opposite problem can occur when using short-acting sedative agents. Namely, the sedation effects of the short-acting agent may wear off quickly. For this reason, the dentist must prevent delays or interruptions so that treatment can be completed in a timely manner. If procedures are expected to be longer than 2 hours, it may be best to use a longer acting agent such as lorazepam.

Rx #2

Patient characteristics:

Age 68 Weight 160 lbs Health is good

Rx Zaleplon 5 mg

Tabs #2

Sig Take one tablet at bedtime the night before dental procedure and come 45 minutes early to your dental appointment and take one tablet in the office. This is for sedation, and you need to be accompanied by a responsible adult. Do not drive.

Figure 36-7 Sample zaleplon prescription. *(Modified from Merin RL:* J Calif Dent Assoc *34:959-968, 2006.)*

Rx #2

Patient characteristics:

Age 68 Weight 160 lbs Health is good

Appointment is in the morning

Rx Triazolam 0.125 mg

Tabs #2

Sig Take one tablet at bedtime the night before dental procedure and one tablet 1 hour before dental procedure. This is for sedation, and you need to be accompanied by a responsible adult. Do not drive.

Rx #3

Patient characteristics:

Age 45 Weight 160 lbs Health is good

Appointment is in the afternoon

Rx Triazolam 0.25 mg

Tabs #1

Sig One hour before your dental appointment, place tablet under tongue and do NOT swallow for at least 2 minutes to allow tablet to dissolve. This is for sedation, and you need to be accompanied by a responsible adult. Do not drive.

Rx #4

Patient characteristics:

Age 68 Weight 160 lbs Health is good

Appointment is in the afternoon

Rx Triazolam 0.125 mg

Tabs #1

Sig One hour before dental treatment, place tablet under tongue and do NOT swallow for at least 2 minutes to allow tablet to dissolve. This is for sedation, and you need to be accompanied by a responsible adult. Do not drive.

Figure 36-8 Sample triazolam prescription. *(Modified from Merin RL:* J Calif Dent Assoc *34:959-968, 2006.)*

Rx #2
Patient characteristics:
Age 68 Weight 160 lbs Health is good
Appointment is in the morning
Rx Lorazepam 0.5 mg
Tabs #3
Sig Take one tablet at bedtime the night before dental procedure, and two tablets 2 hours before dental procedure. This is for sedation, and you need to be accompanied by a responsible adult. Do not drive.

Rx #3
Patient characteristics:
Age 45 Weight 160 lbs Health is good
Appointment is in the afternoon
Rx Lorazepam 0.5 mg
Tabs #3
Sig Take three tablets 2 hours before dental procedure. This is for sedation, and you need to be accompanied by a responsible adult. Do not drive.

Rx #4
Patient characteristics:
Age 68 Weight 160 lbs Health is good
Appointment is in the afternoon
Rx Lorazepam 0.5 mg
Tabs #2
Sig Take two tablets 2 hours before dental procedure. This is for sedation, and you need to be accompanied by a responsible adult. Do not drive.

Figure 36-9 Sample lorazepam prescriptions. *(Modified from Merin RL:* J Calif Dent Assoc *34:959-968, 2006.)*

Inhalation Sedation

This section is a general description of the N_2O technique. To be competent in N_2O sedation, the ADA recommends a minimum course of 14 hours, including a clinical component.[18]

In 1844, Dr. Horace Wells (Hartford, CT) was the first to recognize and introduce the use of N_2O as an analgesic, sedative agent to perform dental surgical procedures. Since that time, N_2O has been used with a long safety record in numerous dental procedures. Advantages of N_2O are a rapid onset of action and rapid recovery. There are few contraindications (e.g., chronic obstructive pulmonary diseases, severe emotional disturbances, and early pregnancy). Obstacles to the use of N_2O include the initial cost of equipment, the need for effective scavenging equipment, periodic maintenance, and the concern that long-term exposure to trace amounts of N_2O can be hazardous to dental personnel.

The N_2O/O_2 inhalation sedation is divided into three phases.[36] The technique begins with an induction phase, which leads to a treatment phase and ends with a recovery phase. Each of these phases is described in the following:

Induction Phase.

1. A flow rate of 100% oxygen is started, and a nasal hood is placed on the patient and adjusted.
2. The correct flow rate is established while the patient is breathing 100% oxygen.
3. The scavenging system is adjusted and checked for function.
4. The N_2O flow is started usually at 20% and titrated in 10% increments every 60 seconds until patients state that they feel relaxed and display the signs of relaxation.

Treatment Phase.

1. Once the ideal level of sedation is achieved, local anesthetic may be given and the dental procedure may be started.
2. The flow of N_2O can be reduced when patients are comfortable with the procedure, or increased if more local anesthetic is required (and they have not been given any other sedation medication).

Recovery Phase.

1. When the patient no longer requires sedation, the N_2O flow is terminated and the patient is given 100% oxygen for 5 minutes or until the patient is recovered from the sedation.
2. Patients may leave the office unescorted if they are completely recovered from the sedative effects of the N_2O.

BOX 36-8 ADA Guidelines for Teaching Moderate Enteral and Moderate Parental Sedation 2007

Moderate Enteral Sedation Course

1. Minimum of 24 hours of instruction.
2. At least 10 adult case experiences by the enteral and/or enteral-N_2O/O_2 route.
3. At least 3 of the 10 cases must be live patient clinical experiences.
4. Seven of the cases may be simulations and/or video presentations but must include one experience in returning (rescuing) a patient from deep to moderate sedation.
5. Demonstrate competence in airway management

Moderate Parental Sedation Course

1. Minimum of 60 hours of instruction.
2. Manage at least 20 patients by the intravenous route.
3. Experience in managing a compromised airway.
4. Demonstrate competence in airway management.

*Data from ADA guidelines for teaching pain control and sedation to dentists and dental students, 2007, www.ada.org. Current policies adopted 1954-2008 © 2009.
N_2O/O_2, Nitrous oxide/oxygen.

Moderate (Conscious) Sedation

The ADA recognizes that moderate sedation requires more training and knowledge than minimal sedation and recommends that moderate sedation providers have current certification in Advanced cardiac life support (ACLS) and/or appropriate training in a dental sedation/anesthesia emergency management course.[17] Guidelines for course content and adult case experiences recommended for teaching moderate sedation are summarized in Box 36-8.

Before performing any moderate sedation technique, practitioners must satisfy all state laws and regulations for the provision of this service. The following discussion is meant to be an overview of some of the popular moderate sedation techniques used to treat periodontal and implant patients. Practitioners must follow the clinical and educational guidelines previously presented in this chapter.

Oral Sedation

Most medications available for moderate enteral sedation are used in an "off-label" manner and have no determined MRD for that purpose.[24] The most frequently reported agent used is triazolam. A typical regimen would include a dose of triazolam 1 hour before a dental appointment followed by an incremental dose to achieve an adequate level of sedation.[24] Since it takes 30 to 90 minutes to reach maximum serum levels, dentists cannot accurately titrate sedation levels with oral and sublingual administration. Donaldson and Goodchild have calculated 24-hour maximum cumulative doses (MCDs) for triazolam as 2.0 mg for a young healthy 200-pound patient.[24] This dosage needs to be adjusted for patients by weight and health. For healthy ASA PS 1 patients, their weight is divided by 100 to calculate the MCD of triazolam.

In a study on the effects of multidose sublingual triazolam in 10 healthy volunteers, subjects were given 0.25 mg followed by additional doses after 60 minutes (0.5 mg) and 90 minutes (0.25 mg) for a total dose of 1.0 mg. Plasma concentrations of triazolam, sedation scores, and bispectral index scores were greatest at the end of the 3-hour observation period.[37] Although all subjects were able to maintain a patent airway independently, eight of the subjects had Observer's Assessment of Alertness/Sedation scores (see Table 36-4) consistent with the definition of deep sedation or general anesthesia. Incremental dosing of this short-acting benzodiazepine results in long-lasting sedation, which is dose dependent. In addition, the sedation produced by supplemental dosing of triazolam cannot be reversed by a single submucosal injection of the reversal agent, flumazenil.[38] Supplemental doses should only follow an observation period sufficient to assess the drug effects, and the decision to administer additional doses of oral sedatives should be based on direct patient observation.

TABLE 36-8 Intravenous Midazolam and Diazepam

	Midazolam	Diazepam
Average dose: Periodontal patients[42]	3.3 mg	12.1 mg
Average dose: Dental patients[58]	2.5-7.5 mg	10 mg
Maximum dose	10 mg	20 mg
Duration of action	20-45 minutes	30-60 minutes
Half-life	1.7-2.4 h	31.3 h
Active metabolites	No	Yes
Anterograde amnesia	Good	Fair
Ease of titration	Good	Very good
Recovery	Abrupt	Slow/smoother
Phlebitis potential	Minimal/water soluble	High/not water soluble

Combined Oral and Inhalation Sedation

Combining oral benzodiazepines with N_2O/O_2 inhalation has been shown in both human and animal studies to produce safe and effective sedation.[39-42] The technique is to prescribe a minimal sedation dose of an appropriate benzodiazepine and then titrate N_2O/O_2 to the appropriate level of moderate sedation. The majority of the published studies used triazolam as the sedative agent. Again, it is important to remember that N_2O/O_2, when used in combination with sedative agents, may produce sedation that is minimal, moderate, or deep and in some cases may produce general anesthesia. Patients should be monitored carefully to avoid going beyond the intended level of sedation.

Intravenous Sedation

The desired endpoint of IV sedation is drowsiness, tranquility, and loss of anxiety. The classical sign of drooping of the eyelid may represent unnecessarily deep sedation.[43] The correct level of sedation has been achieved when the patient rests with his or her eyes closed, responds to verbal commands or mild physical stimulation, and shows signs of relaxation.

Single Benzodiazepine Intravenous Sedation Techniques

Midazolam Technique. An initial test dose of 0.2 mg is given and then midazolam is titrated at a rate of 0.5 mg per minute until the desired level of sedation is achieved.[44,45] The effective loading dose (ELD) is defined as the dose required to reach the level of moderate sedation. Additional IV midazolam can be administered as needed during surgical procedures up to a maximum dose of 10 mg (Table 36-8).

Diazepam Technique. An initial test dose of 1.0 mg is given to determine if there is any unusual drug sensitivity, and then diazepam is titrated at a rate of 2.5 mg per minute until the desired level of sedation is achieved.[45] Additional IV diazepam can be

administered as needed during the surgical procedures up to a maximum of 20 mg (see Table 36-8).

Combination Intravenous Sedation. When little clinical effect is produced with the usual maximum safe doses of a single sedative agent, further administration of the same drug is unlikely to provide acceptable sedation until extremely large doses are given.[46,47] To help prevent sedation failures, combination techniques are required. Administration of two or more sedative agents increases the likelihood of drug synergism and reduces the dose required to render 50% of the patients unconscious (ED-50). When using combination techniques, the clinician must carefully monitor the patient for increased depth of sedation beyond that which is desired, and be prepared to stop the periodontal procedure until the patient is returned to the appropriate level of sedation. Opioids are frequently combined with benzodiazepines to produce analgesia, drowsiness, changes in mood, and mental clouding. All opioids produce dose-related respiratory depression, which is a major factor in morbidity and mortality related to IV sedation.

Meperidine Combined with Diazepam or Midazolam. The benzodiazepine is titrated in the usual manner until the desired (minimal to moderate) sedation is produced. A small test dose of meperidine is given initially to see if there is any unusual reaction. Meperidine is titrated at a rate of 5 mg per minute until moderate sedation is produced (up to a maximum dose of 50 mg). The dose can be estimated on the basis of the effective loading dose of the benzodiazepine given. The clinical effects of meperidine are exhibited 2 to 4 minutes after IV administration, which may lead to excessive sedation if administered too rapidly.[36] For this reason, all narcotics should be administered slowly when the goal is moderate sedation in order to avoid deep sedation or general anesthesia. The rate of administration determines the initial depth of anesthesia.

Fentanyl Combined with Midazolam. Fentanyl is a rapid-onset, short-acting opioid agonist. After IV administration the onset of analgesia and sedation occurs in less than a minute, although the maximal analgesic and respiratory depressant effects do not develop for several minutes. The respiratory depressant effects of fentanyl last longer than its analgesic and sedative properties, and this can be a problem for patients dismissed from the office.[48] Fentanyl techniques usually recommend that the fentanyl be administered prior to the midazolam.[44,45] Fentanyl is administered first in a fixed dose of 0.001 mg/kg via slow IV infusion over 2 minutes. The time between injection and clinical effect is the lead-time for that patient. Later in the procedure, knowledge of the lead-time is useful in timing the administration of subsequent doses. Midazolam is then administered at a rate of 0.5 mg per minute until the appropriate level of sedation is produced.

Combined Oral and Intravenous Sedation

In reviewing the dental literature, there were five reports of combining oral and IV sedation or general anesthesia in dental patients.[49-52] All of these studies found that oral sedation reduced the preoperative anxiety and improved overall patient comfort.

Patients are prescribed a minimal sedation dose of lorazepam (described in this chapter) to be taken at home. As patients walk into the operatory, they are assessed as to how sedated they are from the oral lorazepam, which is interpreted as their sensitivity to benzodiazepines. Vital signs are measured, and an IV drip is started. Midazolam is titrated to the level of moderate sedation. The amount of IV midazolam required is generally small (1 to 2 mg) because the patient is already sedate from the oral lorazepam. Midazolam generally produces good amnesia, but at times, the patient can be talkative and not feel sleepy. At this time, small amounts of IV pentobarbital (12.5 to 50 mg) can be titrated to provide the patient with a feeling of more profound sedation.

Rationale for Technique. One author (RM) has been using the combined oral and IV sedation technique for more than 10 years, and has found it to be very effective. Lorazepam was selected for oral premedication for several reasons. The duration of action is appropriate for periodontal procedures, and several studies have shown that it works well to relieve anxiety before surgical procedures.[53-56] When anxious patients are sedated without oral premedication, they usually cannot be slowly titrated. They need to be given a slightly larger dose and put into a deeper level of sedation temporarily to overcome their initial anxiety. With effective oral premedication, they can be slowly titrated to the desired level of sedation. Although midazolam produces good amnesia, it has been this author's and other authors' experience that midazolam is sometimes difficult to smoothly titrate to a light sedation level.[45] This is sometimes referred to as "reading the patient." After administering IV midazolam, many patients will be talkative and say "I don't feel sedated," even though the dentist knows they are already affected by the midazolam and will probably not remember what they are saying. By adding a small amount of sodium pentobarbital, the patients will state that they feel the effects of sedation and are slightly sleepy. Only small amounts of pentobarbital are required since barbiturates increase the affinity of benzodiazepine receptors to midazolam and are supra additive in producing increased sedation.[57] Although pentobarbital has no reversal agent, it has been used safely for many years as a dental sedative.[36]

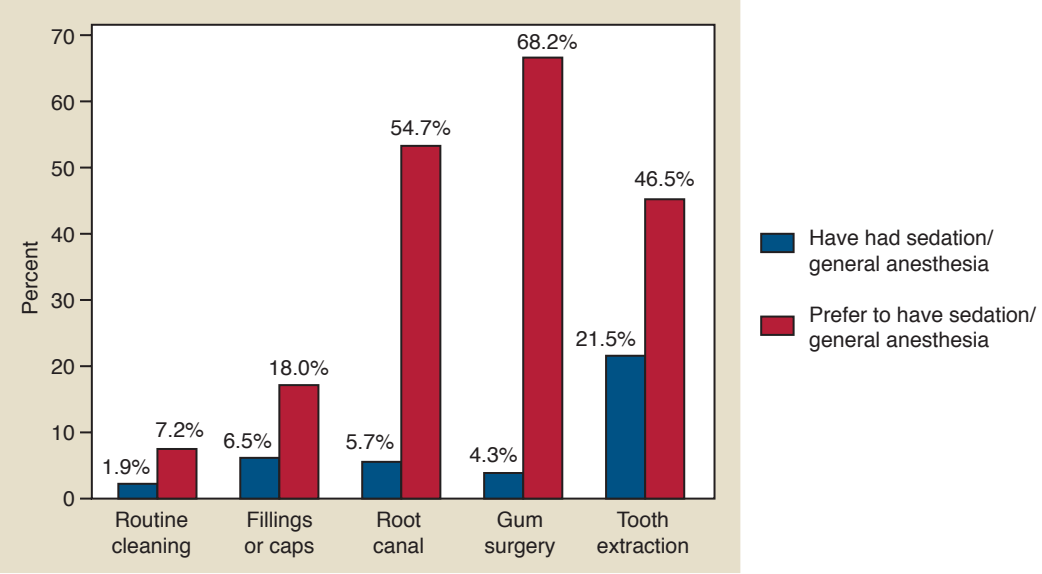

Figure 36-1 Patient preference for sedation or general anesthesia by dental procedure. *(From Chanpong B, Haas DA, Locker D: Need and demand for sedation or general anesthesia in dentistry: a national survey of the Canadian population,* Anesth Prog *52:3-11, 2005.)*

TABLE 36-1 American Dental Association Committee on Anesthesiology: 2007 Policy and Guidelines

Dr. Guy Shampaine, Chairperson	Dr. David Moyer
American Dental Association	American Association of Oral and Maxillofacial Surgeons
Oral and Maxillofacial Surgeon	Oral and Maxillofacial Surgeon
Annapolis, MD	South Portland, ME
Dr. Michael Edwards	Dr. Mort Rosenberg
American Dental Association	American Dental Society of Anesthesia
General Dentist	Dental Anesthesiologist, Tufts University School of Dental Medicine
Wedowee, AL	Boston, MA
Dr. Dee Isackson	Dr. David Rothman
American Society of Anesthesiologists	American Association of Pediatric Dentists
M.D. Anesthesiologist	Pediatric Dentist
Bothell, WA	San Francisco, CA
Dr. Michael Mashni	
American Association of Dental Anesthesiologists	
Dental Anesthesiologist	
Fullerton, CA	
Dr. Robert Merin	
American Academy of Periodontology	
Periodontist	
Woodland Hills, CA	

sedation techniques may be acquired at the predoctoral, postgraduate, graduate, or continuing education level. Dentists who wish to utilize minimal or moderate sedation are expected to successfully complete formal training, which is structured in accordance with the *ADA Guidelines for Teaching Pain Control and Sedation for Dentists and Dental Students*.[18] The knowledge and skills required for administration of deep sedation and general anesthesia are beyond the scope of predoctoral and continuing education. Only dentists who have completed an advanced education program accredited by the Commission on Dental Accreditation (CODA) that provides training in deep sedation and general anesthesia are considered educationally qualified to use these modalities in practice.

ADA Guidelines for the Use of Sedation and General Anesthesia by Dentists

Unlike previous ADA documents, the 2007 *ADA Guidelines* refer to the effects of sedation on the central nervous system and are not dependent on the route of administration. The ADA adopted the American Society of Anesthesiologists (ASA) definitions for levels of sedation (Figure 36-2) and expanded and commented on them specifically as they relate to treating dental patients.[19]

Definitions and Levels of Sedation

Pediatric Sedation

Children (aged 12 and younger) can become moderately sedated despite an intended level of minimal sedation. The use of preoperative sedatives for children (ages 12 and younger) except in extraordinary situations must be avoided because of the risk of unobserved respiratory obstruction during transport by untrained individuals. The management of children with conscious sedation is beyond the scope of this chapter and is not covered. For children 12 years of age and younger, the reader is referred to the *American Academy of Pediatrics/American Academy of Pediatric Dentists Guidelines for Monitoring and Management of Pediatric Patients During and After Sedation for Diagnostic and Therapeutic Procedures*.[20]

Adult Sedation

Minimal Sedation. Minimal sedation is defined as a minimally depressed level of consciousness produced by a pharmacologic method that retains the patient's ability to independently and continuously maintain an airway and to respond normally to tactile stimulation and verbal command. Although cognitive function and coordination may be modestly impaired, respiratory and cardiovascular functions are unaffected. When the intent is minimal sedation, the appropriate initial dosing of a single enteral drug is no more than the maximum recommended dose of a drug that can be prescribed for unmonitored home use.

CONTINUUM OF DEPTH OF SEDATION: DEFINITION OF GENERAL ANESTHESIA AND LEVELS OF SEDATION/ANALGESIA*
Committee of Origin: Quality Management and Departmental Administration (Approved by the ASA House of Delegates on October 13, 1999, and amended on October 27, 2004)

	Minimal Sedation/ Analgesia	Moderate Sedation/ "Conscious Sedation"	Deep Sedation/Anxiolysis	General Anesthesia/ Analgesia
Responsiveness	Normal response to verbal stimulation	Purposeful† response to verbal or tactile stimulation	Purposeful† response following repeated or painful stimulation	Unarousable even with painful stimulus
Airway	Unaffected	No intervention required	Intervention may be required	Intervention often required
Spontaneous ventilation	Unaffected	Adequate	May be inadequate	Frequently inadequate
Cardiovascular function	Unaffected	Usually maintained	Usually maintained	May be impaired

Minimal Sedation (Anxiolysis) is a drug-induced state during which patients respond normally to verbal commands. Although cognitive function and coordination may be impaired, ventilatory and cardiovascular functions are unaffected.

Moderate Sedation/Analgesia ("Conscious Sedation") is a drug-induced depression of consciousness during which patients respond purposefully† to verbal commands, either alone or accompanied by light tactile stimulation. No interventions are required to maintain a patent airway, and spontaneous ventilation is adequate. Cardiovascular function is usually maintained.

Deep Sedation/Analgesia is a drug-induced depression of consciousness during which patients cannot be easily aroused but respond purposefully† following repeated or painful stimulation. The ability to independently maintain ventilatory function may be impaired. Patients may require assistance in maintaining a patent airway, and spontaneous ventilation may be inadequate. Cardiovascular function is usually maintained.

General Anesthesia is a drug-induced loss of consciousness during which patients are not arousable, even by painful stimulation. The ability to independently maintain ventilatory function is often impaired. Patients often require assistance in maintaining a patent airway, and positive pressure ventilation may be required because of depressed spontaneous ventilation or drug-induced depression of neuromuscular function. Cardiovascular function may be impaired.

Because sedation is a continuum, it is not always possible to predict how an individual patient will respond. Hence, practitioners intending to produce a given level of sedation should be able to rescue†† patients whose level of sedation becomes deeper than initially intended. Individuals administering Moderate Sedation/Analgesia ("Conscious Sedation") should be able to rescue†† patients who enter a state of Deep Sedation/Analgesia, while those administering Deep Sedation/Analgesia should be able to rescue†† patients who enter a state of General Anesthesia.

*Monitored anesthesia care does not describe the continuum of depth of sedation, rather it describes "a specific anesthesia service in which an anesthesiologist has been requested to participate in the care of a patient undergoing a diagnostic or therapeutic procedure."
†Reflex withdrawal from a painful stimulus is NOT considered a purposeful response.
††Rescue of a patient from a deeper level of sedation than intended is an intervention by a practitioner proficient in airway management and advanced life support. The qualified practitioner corrects adverse physiologic consequences of the deeper-than-intended level of sedation (such as hypoventilation, hypoxia, and hypotension) and returns the patient to the originally intended level of sedation.

Figure 36-2 Continuum of depth of sedation: definition of general anesthesia and levels of sedation/analgesia. *(Approved by the ASA House of Delegates on October 27, 2004, and last amended on October 21, 2009. http://www.asahq.org/publicationsAndServices/standards/20.pdf is reprinted with permission of the American Society of Anesthesiologists, 520 N. Northwest Highway, Park Ridge, Illinois 60068-2573.)*

Inhalation sedation with nitrous oxide/oxygen (N_2O/O_2) may be used in combination with a single enteral drug in minimal sedation. It is important to recognize that N_2O/O_2, when used in combination with one or more sedative agent(s), is capable of producing sedation that is minimal, moderate, or deep and in some cases may produce general anesthesia.

Maximum Recommended Dose. The maximum recommended dose (MRD) is the maximum Food and Drug Administration (FDA)-recommended dose of a drug as printed in FDA-approved labeling for unmonitored home use.

Incremental Dosing. Incremental dosing is the administration of multiple doses of a drug until a desired effect is reached.

Supplemental Dosing. During minimal sedation, supplemental dosing is a single additional dose of the sedative drug being used that may be necessary for prolonged procedures. The supplemental dose should not exceed one-half of the initial total dose and should not be administered until the dentist has determined that the clinical half-life of the initial dose has passed. The total aggregate dose must not exceed 1.5 times the MRD on the day of treatment.

Moderate Sedation. Moderate sedation is a drug-induced depression of consciousness during which patients respond purposefully to verbal commands, either alone or accompanied by light tactile stimulation. No interventions are required to maintain a patent airway, and spontaneous ventilations are adequate. Cardiovascular function is usually maintained. In accord with this particular definition, the drugs and/or techniques used should carry a margin of safety wide enough to render unintended loss of consciousness unlikely. Repeated dosing of an agent before the effects of previous dosing can be fully appreciated may result in greater alteration of the state of consciousness than is the intent of the dentist. Further, a patient whose only response is reflex withdrawal

from a painful stimulus is not considered to be in a state of moderate sedation.

Titration. Titration is the administration of incremental doses of a drug until a desired effect is reached. Knowledge of each drug's time of onset, peak response, and duration of action is essential to avoid oversedation. The concept of titration to effect is critical for patient safety. Thus it is important to know whether the previous dose has taken full effect before administering an additional drug increment when the intent is moderate sedation.

Deep Sedation. Deep sedation is a drug-induced depression of consciousness during which patients cannot be easily aroused but respond purposefully following repeated or painful stimulation. The ability to independently maintain respiratory function may be impaired. Patients may require assistance in maintaining a patent airway, and spontaneous ventilation may be inadequate. Cardiovascular function is usually maintained.

General Anesthesia. General anesthesia is a drug-induced loss of consciousness during which patients are not aroused, even by painful stimulation. The ability to independently maintain respiratory function is often impaired. Patients often require assistance in maintaining a patent airway, and positive pressure ventilation may be required because of depressed spontaneous ventilation or drug-induced depression of neuromuscular function. Cardiovascular function may be impaired.

Clinical Guidelines for Minimal and Moderate Sedation

The following clinical guidelines apply to both minimal and moderate sedation.[17] These guidelines include (1) patient evaluation, (2) preoperative preparation, (3) personnel and equipment, (4) monitoring and documentation, and (5) recovery and discharge. Differences between guidelines for minimal and moderate sedation are indicated as appropriate.

Patient Evaluation. Patients must be evaluated to assess their current health status before any sedation procedure. This should include a determination of their ASA physical status (ASA PS) (Table 36-2). In healthy or medically stable individuals (ASA PS 1 or 2), a review of their medical history and medication use may be adequate. However, for patients with significant medical considerations (ASA PS 3 or 4), a consultation with their primary care physician or consulting medical specialist is indicated. The evaluation should also include baseline vital signs and a focused physical examination of alertness, respiratory function, airway, and appearance, as well as a specific evaluation of any identified medical conditions (Box 36-1 and Figure 36-3).

Preoperative Preparation. The patient (parent, guardian, or caregiver, if patient is a minor) must be informed about the planned procedure under sedation, including benefits, risks, and instructions for sedation (Figure 36-4). An informed consent for the proposed procedure and sedation must be obtained.

Preoperative dietary restrictions must be considered based on the sedative technique prescribed (Boxes 36-2 and 36-3; see also Figure 36-4).

TABLE 36-2 ASA Physical Status Classification System

ASA 1	A normal healthy patient
ASA 2	A patient with mild systemic disease
ASA 3	A patient with severe systemic disease
ASA 4	A patient with severe systemic disease that is a constant threat to life
ASA 5	A moribund patient who is not expected to survive without the operation
ASA 6	A declared brain-dead patient whose organs are being removed for donor purposes

From American Society of Anesthesiologists: ASA physical status classification system: www.asahq.org, 2009.

BOX 36-1 Preoperative Physical Evaluation

1. Blood pressure and pulse
2. Oxygen saturation and respiration; able to breathe deeply and cough
3. Mallampati airway classification and neck flexibility
4. Appearance and skin color
5. Alertness
6. Exercise tolerance and ambulation

Class 1; soft palate, fauces, uvula, pillars
Class 2; soft palate, fauces, portion of uvula
Class 3; soft palate, base of uvula
Class 4; hard palate only

Figure 36-3 Mallampati classification. *(Adapted from Mallampati SR, Gatt SP, Gugino LD, et al:* Can Anaesth Soc J *32:429-434, 1985.)*

An explanation of IV conscious sedation, its purpose, benefits, possible risks, and complications as well as alternative methods of anesthesia has been discussed with you at your consultation, and we obtained your verbal consent to undergo treatment planned for you. Please read this document, which repeats issues we discussed, and provide the appropriate signatures. Please ask us to clarify anything that you do not understand.

PRESEDATION INFORMATION

1. The premedication you will receive by vein is NOT sodium pentothal. Its purpose is not to put you to sleep but to relax and sedate you. In addition, local anesthetics will be administered in your mouth.
2. You must have a responsible adult bring you to the office and drive you home, and you must remain in the company of a responsible adult until you are fully alert. Make arrangements for the person driving you home to come to the waiting room.
3. You should not have any solid food for 6 hours before your appointment. You can have clear liquids up to 2 hours before your appointment. Examples of clear liquids are apple juice, lemonade, Jell-O, or decaffeinated coffee without cream or cream substitutes.
4. Please wear short sleeves or sleeves that may be raised above the elbows.
5. No alcoholic beverages for 12 hours before sedation.
6. Possible risks and side effects: I have been informed and understand that occasionally there are complications associated with IV conscious sedation including, but not limited to, pain, phlebitis (inflammation of the vein), infection, swelling, bleeding, numbness, discoloration, nausea, vomiting, allergic reaction, depressed breathing, and, in extremely rare instances, intraarterial injection with damage to the part of the body supplied by the artery.
7. I have read and understand the presedation instructions and have also read the enclosed postsedation instructions.

Patient's Signature _____ Date _____

Figure 36-4 Consent form for and explanation of intravenous conscious sedation.

BOX 36-2 Mild Sedation: Suggested Protocol for the Use of Adult Oral Sedative Premedication for Anxious or Fearful Dental Patients

1. The dentist needs to determine the extent of dental treatment, evaluate the patient's medical history, research potential drug interactions, consult with the patient's physician if appropriate, and obtain informed consent.
2. The patient must have a responsible adult companion for travel to and from the dental office. The patient must be escorted by this companion to and from the parking lot to prevent the patient from stumbling.
3. Patients take the prescribed medication according to directions and are instructed to have a light meal such as toast and beverage without caffeine.
4. Patients who have received oral sedatives are monitored visually and never left alone.
5. After the treatment is complete, postoperative directions are given to both the patient and responsible adult, and the patient is released into the care of his or her companion for travel home. The companion is informed that the patient may have psychomotor and cognitive impairment for the rest of the day.

From Merin RL: *J Calif Dent Assoc* 34:959-968, 2006.

BOX 36-3 Mild Sedation: Example of Suggested Patient Pretreatment Instructions

1. The sedative _____ (name of medication) is being prescribed to help reduce your anxiety before and during a dental procedure.
2. The medication may make you sleepy and impair your thinking and coordination. You must have a responsible adult companion for travel to and from the dental office.
3. You must be escorted by this companion to and from the parking lot to prevent you from stumbling.
4. You should take the prescribed medication according to directions. You can have a light meal (no fat) such as toast without butter or margarine and beverage without caffeine. No grapefruit juice.
5. After the treatment is complete, a responsible adult must escort you out of the office and take you home. The sedative effects may linger for the rest of the day so you should not plan to do anything and it is advisable to have a responsible adult stay until you are able to take care of yourself.

From Merin RL: *J Calif Dent Assoc* 34:959-968, 2006.

Personnel and Equipment. At least one additional person trained in basic life support (BSL) for healthcare providers must be present in addition to the dentist.

Determination of adequate oxygen supply and equipment necessary to deliver oxygen under positive pressure must be completed. A positive-pressure oxygen delivery system suitable for the patient being treated must be immediately available. An appropriate scavenging system must be available if gases other than oxygen or air are used.

When inhalation equipment is used, it must have a fail-safe system that is appropriately checked and calibrated. The equipment must also have either (1) a functioning device that prohibits the delivery of less than 30% oxygen or (2) an appropriately calibrated and functioning in-line oxygen analyzer with audible alarm.

For moderate sedation, the equipment necessary to establish IV access must be available. This includes a catheter or butterfly needle, an IV drip line, a solution bag (saline or dextrose), tourniquet, and appropriate antiseptic/dermal disinfectant (Figure 36-5).

Monitoring. The dentist or an appropriately trained individual, directed by the dentist, must remain in the operatory during active dental treatment with sedation to monitor the patient continuously until the criteria for discharge is met (Box 36-4). The appropriately trained individual must be familiar with monitoring techniques and equipment.

In the case of moderate sedation, a qualified dentist administering moderate sedation must remain in the operatory room to monitor the patient continuously until the patient meets the criteria for recovery. When active treatment concludes and the patient recovers to a minimally sedated level, a qualified auxiliary may be

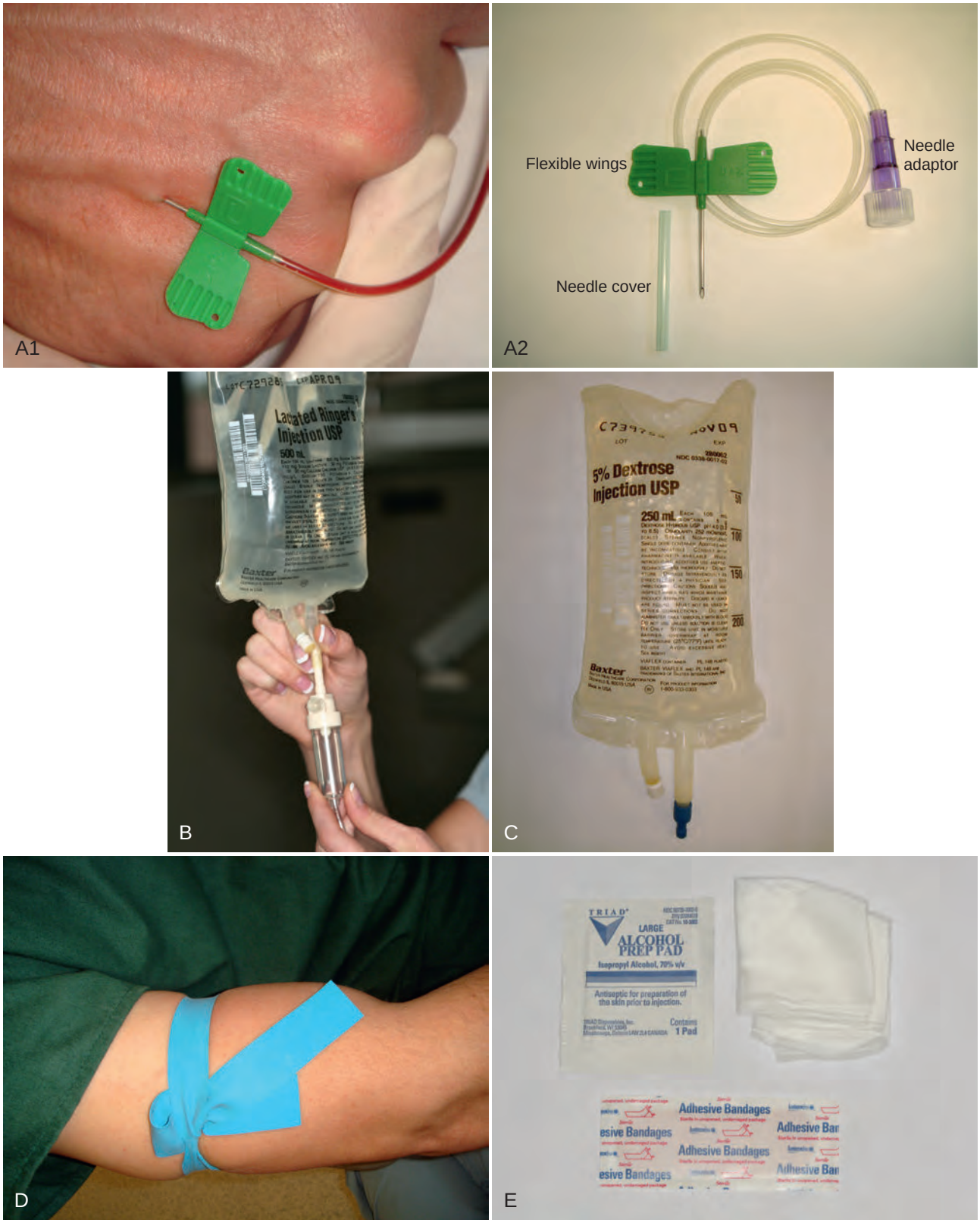

Figure 36-5 Equipment and supplies needed for the administration of moderate intravenous (IV) sedation includes an indwelling catheter **(A),** an IV drip line **(B),** a solution bag-saline or dextrose **(C),** tourniquet **(D),** and appropriate antiseptic/dermal disinfectant **(E).** *(From Malamed SF:* Sedation: a guide to patient management, *ed 5, St. Louis, 2010, Elsevier.)*

directed by the dentist to remain with the patient and continue to monitor him or her as explained in the guidelines until discharged from the facility. The dentist must not leave the facility until the patient meets the criteria for discharge and is discharged to go home with a responsible adult (see Box 36-4).

Monitoring equipment must include a sphygmomanometer, positive pressure oxygen delivery system, suction, and if inhalation sedation is used, a fail-safe and scavenging system. In the case of moderate sedation, a pulse oximeter, equipment for IV access, and reversal agents for drugs used must also be available (Table 36-3).

In the case of moderate sedation, the level of consciousness (e.g., responsiveness to verbal command) must be continually assessed (Table 36-4).

The color of the mucosa, skin, or blood must be evaluated continuously to assess oxygenation. Oxygen saturation by pulse oximetry is clinically useful and should be considered for minimal sedation. For moderate sedation, oxygen saturation must be continuously evaluated by pulse oximetry. Approximately 98% to 99% of the total oxygen content in arterial blood is bound to hemoglobin within red blood cells. The pulse oximeter measures the degree hemoglobin is saturated with oxygen (SpO_2). The remaining 1% to 2% of oxygen is dissolved in plasma and produces a gas pressure referred to as arterial oxygen tension (PaO_2). The PaO_2 level is what determines how much oxygen is entering the body tissues and is referred to as *oxygenation*. Normally, the SpO_2 level is at 98% to 99% and sustains a PaO_2 level of about 95%. Normal oxygenation is defined as a PaO_2 of 80 to 100 mm Hg. There is a nonlinear relationship between the SpO_2 and the PaO_2. SpO_2 readings of 95% and higher maintain PaO_2 at or above 80 mm Hg and prevent hypoxemia (Table 36-5).

The dentist and/or appropriately trained individual must monitor respirations continually to ensure adequate ventilation. This can be accomplished by auscultation of breath sounds with a precordial stethoscope, by verbal communication with the patient, or monitoring end-tidal carbon dioxide (CO_2). The latter method, referred to as capnography, is the monitoring of CO_2 concentrations in exhaled respiratory gases. Capnography monitors provide a graphic representation of the partial pressure of carbon dioxide that is more effective than other clinical assessments of ventilation. A recent report of a randomized, controlled clinical trial in patients undergoing moderate sedation demonstrated that capnography improved patient monitoring with earlier detection of respiratory compromise prompting intervention to minimize hypoxemia as compared to current standard of care methods.[21]

Blood pressure and heart rate should be evaluated preoperatively, postoperatively, and intraoperatively as necessary in cases

BOX 36-4 Discharge Criteria

Alertness: Able to Answer Three Simple Questions Such as the Following:

Who is driving you home?
Where are you?
What day is it?

Breathing

Normal oxygen saturation on room air
Able to breathe deeply and cough

Circulation

Systolic blood pressure within 20% of baseline

Ambulation

Able to walk with minimal assistance

Color

Normal skin color and appearance

TABLE 36-3 Equipment Required for Mild or Moderate Sedation

Mild or Moderate Sedation	Moderate Sedation
• Sphygmomanometer. • Positive pressure oxygen delivery system. • Suction equipment. • When inhalation equipment is used, it must have a fail-safe system and scavenging system.	• Pulse oximeter. • Equipment necessary to establish intravenous access. • Reversal agents for drugs used.

TABLE 36-4 The Observer's Assessment of Alertness/Sedation Scale

Category	Observation	Score
Responsiveness	Responds readily to name spoken in normal tone	5
	Lethargic response to name spoken in normal tone	4
	Responds only after name is called loudly and/or repeatedly	3
	Responds only after mild prodding or shaking	2
	Does not respond to mild prodding or shaking	1
Speech	Normal	5
	Mild slowing or thickening	4
	Slurring or prominent slowing	3
	Few recognizable words	2
Facial expression	Normal	5
	Mild relaxation	4
	Marked relaxation (slack jaw)	3
Eyes	Clear, no ptosis	5
	Glazed or mild ptosis (less than half of the eye)	4
	Glazed and marked ptosis (half of the eye or more)	3

Adapted from Chernik DA, Gillings D, Laine H, et al: Validity and reliability of the Observer's Assessment of Alertness/Sedation Scale: study with intravenous midazolam, *J Clin Psychopharmacol* 10: 244-251, 1990.

of minimal sedation. For moderate sedation, the dentist must continually evaluate blood pressure and heart rate. Continuous electrocardiograph (ECG) monitoring of patients with significant cardiovascular disease should be considered.

Documentation. An appropriate, time-oriented anesthetic record must be maintained with the names and dosages of all drugs administered (including local anesthetics) and monitored physiologic parameters, including blood pressure, pulse, and respiratory rate (Figure 36-6). In cases of moderate sedation, oxygen saturation must be monitored and recorded continuously (e.g., pulse oximetry).

Recovery and Discharge. Oxygen and suction equipment must be immediately available in the treatment room and the recovery room (if a separate recovery area is utilized). The qualified dentist or appropriately trained clinical staff must continually monitor the patient's blood pressure, heart rate, and respirations. In cases of moderate sedation, oxygen saturation and level of consciousness must be evaluated continuously. The qualified dentist must determine and document that the level of consciousness, oxygenation, ventilation, and circulation are satisfactory before discharge (see Box 36-4).

Postoperative verbal and written instruction must be given to the patient and a responsible adult (e.g., parent, escort, guardian, or caregiver).

If a reversal agent is administered before discharge criteria have been met, the patient must be monitored until recovery is assured. A potential problem when using reversal agents is the possibility that the duration of action of the reversal agent may be shorter than the sedative agent used, and the patient may become sedated again. It is critical for the clinician to understand and appreciate the duration of action of all sedative and reversal agents used.

TABLE 36-5 Pulse Oximeter Reading and Arterial Oxygen Tension (Pa_{O_2}) Tissue Oxygenation

Oximeter Arterial Oxyhemoglobin Saturation (Sp_{O_2})	Pa_{O_2}	Interpretation
95%-99%	80-100 mm Hg	Normal oxygenation
90%	60 mm Hg	Alarm goes off; patient hypoxemia
80%	45-50 mm Hg	Severe hypoxemia

Sedation Failures

When performing outpatient mild or moderate sedation, the clinician must realize that sedation success will not be 100% effective for all patients. A certain percentage of patients will not respond appropriately to minimal and moderate sedation protocols (Table 36-9). If a patient is not responding to the sedation procedure, it is extremely hazardous to go beyond dose limits or to attempt putting the patient into a deeper level of sedation. It is best to abort the

Patient's Name: S.S. #: Age: DATE ____/____/____

Medical Hx: CVS
Respiratory System
CNS
Liver
Kidneys
Other

Current Medications:

Allergy:

IV started at ____ a.m./p.m.
Venipuncture Site ____
Type of Needle ____
IV d/c'd at ____ a.m./p.m.
IV solution & volume ____ ml

DRUGS ADMINISTERED – SUMMARY –

Base Line Vital Signs:
Date of V.S.:
B.P.: P.R.:
R.: T.:
Ht.: Wt.:
Age:

ASA: I, II, III, IV

Reason for Sedation:

Evaluator:

Name of Driver:

	PREOPERATIVE time	INTRAOPERATIVE time	time	time	time	time	POSTOP time	DISCHARGE time
Blood Pressure								
Heart Rate								
Respirations								
O_2 LPM								
N_2O LPM								
(mg)								
(mg)								
(mg)								
(mg)								
(mg)								
(mg)								
(mg)								

List all drugs and route of administration (IV, IM)

DRUGS DISCARDED – SUMMARY –

DENTISTRY TREATMENT

Start ____ Finish ____
Name of person discharged to: ____
Post-Op Medications (if any) ____

Additional Monitoring: *(check as appropriate)* precordial stethoscope ____ pulse oximeter ____ ECG ____ automatic blood pressure ____

COMMENTS

Student Doctor: ____ AMED Faculty: ____ ☐ Informed Consent
IV Student: ____ Assistants: ____ ☐ Postoperative Instructions

SAM/USC/SOD 02/85

Figure 36-6 Moderate sedation record sample. *(From Malamed SF:* Sedation: a guide to patient management, *ed 5, St. Louis, 2010, Elsevier.)*

TABLE 36-9 Sedation Failures in Dentistry by Route of Administration[59]

Technique	Expected Failure Rate (%)
Oral (child): older	40-50
Oral (child): younger	50-65
Oral (adult)	20-50
Inhalation	15-20
Oral + inhalation	5-10
Intravenous	5
Oral + intravenous	2-3
Deep sedation/general anesthesia	1.6[43]

Data from Malamed SF: *Alpha Omegan* 99:70, 2006.

procedure, and reschedule the appointment for another day with a different technique or with a dental anesthesiologist.

Emergency Preparedness

Because sedation and general anesthesia are a continuum of drug-induced depression of consciousness to loss of consciousness, it is not always possible to predict how an individual patient will respond. Thus practitioners intending to produce a given level of sedation should be able to diagnose and manage the physiologic consequences (rescue) for patients whose level of sedation becomes deeper than initially intended. For all levels of sedation, the practitioner must have the training, skills, drugs, and equipment to identify and manage such an occurrence until either assistance arrives (emergency medical service) or the patient returns to the intended level of sedation without airway or cardiovascular complications. The qualified dentist is responsible for the sedation management, the adequacy of the facility, the competence of the staff, the diagnosis and treatment of emergencies related to the administration of sedation, and for providing and maintaining the equipment and protocols for patient rescue.

If a patient enters a deeper level of sedation than the dentist is qualified to provide, the dentist must stop the dental procedure and focus his or her attention on managing the patient until the patient's condition returns to the intended level of sedation. This could involve simply monitoring the patient, airway management and support, reversal agents, or activating the emergency medical services.

Conclusion

As periodontal procedures become more complex, there is an increased need for the use of conscious sedation techniques for patients with fear and anxiety. The ADA has guidelines and policy outlined in documents that need to be followed. The use of mild sedation with N_2O inhalation techniques must be done with appropriate patient monitoring; the doctor should have a minimum of 14 hours instruction including a clinical component. After appropriate recovery, patients can generally be allowed to function normally and do not need another adult to manage them. Mild sedation using oral agents, such as triazolam in one dose, should not exceed the MRD for home use, but these patients, when recovered, cannot drive and need another adult to supervise them. Moderate-to-deep sedation should only be performed by practitioners with appropriate postdoctoral training in an accredited advanced education program, which carries with it additional responsibilities for patient monitoring, restrictions on food and liquid intake, recovery, and additional trained support staff.

Patients with systemic problems should get preoperative evaluations from a physician, and elderly patients frequently need downward adjustments of normal dosage. Children require special care from trained doctors, and preoperative sedation in children younger than 12 years of age should be carried out by specialists in pediatric anesthesia. Patients with significant systemic problems are best treated in a hospital environment rather than in an outpatient surgical center.

Suggested Readings

American Academy of Pediatric Dentists and American Academy of Pediatrics: *Guideline for monitoring and management of pediatric patients during and after sedation for diagnostic and therapeutic procedures*: www.aapd.org, 2006.

American Dental Association (ADA): *Policy statement: The use of sedation and general anesthesia by dentists*: www.ada.org, October 2007.

Ganzberg SI, Dietrich T, Valerin M, et al: Zaleplon (Sonata) oral sedation for outpatient third molar extraction surgery. *Anesth Prog* 52:128, 2005.

Hosaka K, Jackson D, Pickrell JE, et al: Flumazenil reversal of sublingual triazolam. A randomized controlled clinical trial. *J Am Dent Assoc* 140:559, 2009.

Malamed SF: *Sedation: a guide to patient management*, ed 5, St. Louis, 2009, Elsevier.

Merin RL: Adult oral sedation in California: what can a dentist do without a special permit or certificate from the Dental Board of California? *J Calif Dent Assoc* 34:959, 2006.

References

References for this chapter are found on the companion website www.expertconsult.com.

References

1. Dental Organization for Conscious Sedation (DOCS): *Oral sedation in dentistry*: www.docseducation.org, 2009.
2. Dionne RA, Gordon SM, McCullagh LM, et al: Assessing the need for anesthesia and sedation in the general population. *J Am Dent Assoc (1939)* 129:167–173, 1998.
3. Dionne RA, Yagiela JA, Cote CJ, et al: Balancing efficacy and safety in the use of oral sedation in dental outpatients. *J Am Dent Assoc* 137:502–513, 2006.
4. Smith TA, Heaton LJ: Fear of dental care: are we making any progress? *J Am Dent Assoc* 134:1101–1108, 2003.
5. Binkley CJ, Beacham A, Neace W, et al: Genetic variations associated with red hair color and fear of dental pain, anxiety regarding dental care and avoidance of dental care. *J Am Dent Assoc* 140:896–905, 2009.
6. Chanpong B, Haas DA, Locker D: Need and demand for sedation or general anesthesia in dentistry: a national survey of the Canadian population. *Anesth Prog* 52:3–11, 2005.
7. Ruggerio AC: Intravenous sedation of the periodontal surgical patient. *J Periodontol* 46:319–327, 1975.
8. Eitner S, Wichmann M, Paulsen A, et al: Dental anxiety—an epidemiological study on its clinical correlation and effects on oral health. *J Oral Rehab* 33:588–593, 2006.
9. Locker D, Liddell A: Clinical correlates of dental anxiety among older adults. *Community Dent Oral Epidemiol* 20:372–375, 1992.
10. Feeney SL: The relationship between pain and negative affect in older adults: anxiety as a predictor of pain. *J Anxiety Dis* 18:733–744, 2004.
11. Fox E, O'Boyle C, Barry H, et al: Repressive coping style and anxiety in stressful dental surgery. *Brit J Med Psychol* 62(Pt 4):371–380, 1989.
12. Johannsen A, Asberg M, Soder PO, et al: Anxiety, gingival inflammation and periodontal disease in non-smokers and smokers—an epidemiological study. *J Clin Periodontol* 32:488–491, 2005.
13. Kloostra PW, Eber RM, Wang HL, et al: Surgical versus non-surgical periodontal treatment: psychosocial factors and treatment outcomes. *J Periodontol* 77:1253–1260, 2006.
14. Vettore M, Quintanilha RS, Monteiro da Silva AM, et al: The influence of stress and anxiety on the response of non-surgical periodontal treatment. *J Clin Periodontol* 32:1226–1235, 2005.
15. Shepherd SR, Sims TN, Johnson BW, et al: Assessment of stress during periodontal surgery with intravenous sedation and with local anesthesia only. *J Periodontol* 59:147–154, 1988.
16. American Dental Association: *Policy statement: the use of sedation and general anesthesia by dentists*: www.ada.org, 2007.
17. American Dental Association: *Guidelines for the use of sedation and general anesthesia by dentists*: www.ada.org, 2007.
18. American Dental Association: *Guidelines for teaching pain control and sedation to dentists and dental students*: www.ada.org, 2007.
19. American Society of Anesthesiologists: *Continuum of depth of sedation*: www.asahq.org, 2004.
20. American Academy of Pediatric Dentists and American Academy of Pediatrics: *Guideline for monitoring and management of pediatric patients during and after sedation for diagnostic and therapeutic procedures*: www.aapd.org, 2006.
21. Lightdale JR, Goldmann DA, Feldman HA, et al: Microstream Capnography improves patient monitoring during moderate sedation: a randomized, controlled trial. *Pediatrics* 117(6):e1170–e1178, 2006.
22. Feck AS, Goodchild JH: The use of anxiolytic medications to supplement local anesthesia in the anxious patient. *Compend Contin Educ Dent* 26:183–186, 188, 190; quiz 191, 209, 2005.
23. Quarnstrom FW, Donaldson M: Triazolam use in the dental setting: a report of 270 uses over 15 years. *Gen Dent* 52:496–501, 2004.
24. Donaldson M, Goodchild JH: Maximum cumulative doses of sedation medications for in-office use. *Gen Dent* 55:143–148, quiz 149, 167–148, 2007.
25. Flanagan D: Oral triazolam sedation in implant dentistry. *J Oral Implantol* 30:93–97, 2004.
26. Flanagan D, Goodchild JH: Comparison of triazolam and zaleplon for sedation of dental patients. *Dent Today* 24:64–66, 68–69, 2005.
27. Ganzberg SI, Dietrich T, Valerin M, et al: Zaleplon (Sonata) oral sedation for outpatient third molar extraction surgery. *Anesth Prog* 52:128–131, 2005.
28. Goodchild JH, Donaldson M: Calculating and justifying total anxiolytic doses of medications for in-office use. *Gen Dent* 54:54–57, quiz 58, 2006.
29. Yagiela JA: Recent developments in local anesthesia and oral sedation. *Compend Contin Educ Dent* 25:697–706, quiz 708, 2004.
30. Cianco SG: *ADA Guide to Dental Therapeutics*, ed 4, 2006.
31. Jacobsen PL: *The Little Dental Drug Booklet*, 2007–2008.
32. Wynn RL, Meiller TF, Crossley HI: *Drug information handbook for dentistry*, Hudson, OH, 2009, Lexi-Comp.
33. Ehrich DG, Lundgren JP, Dionne RA, et al: Comparison of triazolam, diazepam, and placebo as outpatient oral premedication for endodontic patients. *J Endod* 23:181–184, 1997.
34. Penttila HJ, Nuutinen LS, Kiviluoma KT, et al: Sublingual triazolam versus peroral diazepam as a premedication for general anaesthesia. *Cana J Anaesth* 42:862–868, 1995.
35. Greenblatt DJ: Pharmacologic management of dental anxiety: conscious versus unconscious sedation. *J Clin Psychopharmacol* 26:1–3, 2006.
36. Malamed SF: *Sedation: a guide to patient management*, ed 5, St. Louis, 2009, Elsevier.
37. Jackson DL, Milgrom P, Heacox GA, et al: Pharmacokinetics and clinical effects of multidose sublingual triazolam in healthy volunteers. *J Clin Psychopharmacol* 26:4–8, 2006.
38. Hosaka K, Jackson D, Pickrell JE, et al: Flumazenil reversal of sublingual triazolam: a randomized controlled clinical trial. *J Am Dent Assoc* 140:559–566, 2009.
39. Gries DA, Condouris GA, Shey Z, et al: Anxiolytic-like action in mice treated with nitrous oxide and oral triazolam or diazepam. *Life Sci* 76:1667–1674, 2005.
40. Jackson DL, Johnson BS: Inhalational and enteral conscious sedation for the adult dental patient. *Dent Clin North Am* 46:781–802, 2002.
41. Kaufman E, Hargreaves KM, Dionne RA: Comparison of oral triazolam and nitrous oxide with placebo and intravenous diazepam for outpatient premedication. *Oral Surg Oral Med Oral Pathol* 75:156–164, 1993.
42. Vallerand WP, Vallerand AH, Hall MB: Evaluation of the sedative combination of nitrous oxide and orally administered diazepam. *Oral Surg Oral Med Oral Pathol* 71:660–664, 1991.
43. Skehan SJ, Malone DE, Buckley N, et al: Sedation and analgesia in adult patients: evaluation of a staged-dose system based on body weight for use in abdominal interventional radiology. *Radiology* 216:653–659, 2000.
44. Dionne RA, Yagiela JA, Moore PA, et al: Comparing efficacy and safety of four intravenous sedation regimens in dental outpatients. *J Am Dent Assoc* 132:740–751, 2001.
45. Staretz LR, Otomo-Corgel J, Lin JI: Effects of intravenous midazolam and diazepam on patient response, percentage of oxygen saturation, and hemodynamic factors during periodontal surgery. *J Periodontol* 75:1319–1326, 2004.
46. Venchard GR, Thomson PJ, Boys R: Improved sedation for oral surgery by combining nitrous oxide and intravenous Midazolam: a randomized, controlled trial. *Int J Oral Maxillofac Surg* 35:522–527, 2006.
47. Vinik HR, Bradley EL, Jr, Kissin I: Triple anesthetic combination: propofol-midazolam-alfentanil. *Anesth Analg* 78:354–358, 1994.
48. Malamed SF: Sedation and safety: 36 years of perspective. *Alpha Omegan* 99:70–74, 2006.
49. Luyk NH, Whitley BD: Efficacy of oral midazolam prior to intravenous sedation for the removal of third molars. *Int J Oral Maxillofac Surg* 20:264–267, 1991.
50. Manani G, Alberton L, Bazzato MF, et al: Analysis of an anxiolytic technique applied in 1179 patients undergoing oral surgery. *Minerva Stomatol* 54:551–568, 2005.
51. Manani G, Baldinelli L, Cordioli G, et al: Premedication with chlordemethyldiazepam and anxiolytic effect of diazepam in implantology. *Anesth Prog* 42:107–112, 1995.

52. Stopperich PS, Moore PA, Finder RL, et al: Oral triazolam pretreatment for intravenous sedation. *Anesth Prog* 40:117–121, 1993.
53. Conner JT, Parson N, Katz RL, et al: Evaluation of lorazepam and pentobarbital as surgical premedicants. *Clin Pharmacol Ther* 19:24–29, 1976.
54. Fragen RJ, Caldwell N: Lorazepam premedication: lack of recall and relief of anxiety. *Anesth Anal* 55:792–796, 1976.
55. Gale GD, Galloon S, Porter WR: Sublingual lorazepam: a better premedication? *Br J Anaesth* 55:761–765, 1983.
56. Rubin J, Schweggmann I, Uys P: Lorazepam as a premedicant in dental surgery. *S Afr Med J* 58:124–126, 1980.
57. Kissin I, Mason JO, 3rd, Bradley EL, Jr: Pentobarbital and thiopental anesthetic interactions with midazolam. *Anesthesiology* 67:26–31, 1987.
58. Mallampati SR, Gatt SP, Gugino LD, et al: A clinical sign to predict difficult tracheal intubation: a prospective study. *Can Anaesth Soc J* 32:429–434, 1985.
59. Senel FC, Buchanan JM, Jr, Senel AC, et al: Evaluation of sedation failure in the outpatient oral and maxillofacial surgery clinic. *J Oral Maxillofac Surg* 65:645–650, 2007.

CHAPTER 37

Periodontal Treatment of Medically Compromised Patients

Perry R. Klokkevold, Brian L. Mealey, and Joan Otomo-Corgel

CHAPTER OUTLINE

Cardiovascular Diseases
Endocrine Disorders
Hemorrhagic Disorders
Renal Diseases *(Online Only)*
Liver Diseases *(Online Only)*
Pulmonary Diseases *(Online Only)*
Medications and Cancer Therapies
Prosthetic Joint Replacement
Pregnancy *(Online Only)*
Infectious Diseases *(Online Only)*

For online-only content on thyroid and parathyroid disorders, adrenal insufficiency, thrombocytopenic purpuras, nonthrombocytopenic purpuras, blood dyscrasias, renal diseases, liver diseases, and pulmonary diseases, please visit the companion website at www.expertconsult.com.

Many patients seeking dental care have significant medical conditions that may alter both the course of their oral disease and the therapy provided. Older periodontal patients will have a greater likelihood of having underlying disease. Therefore the therapeutic responsibility of the clinician includes identification of the patient's medical problems to formulate proper treatment plans. Thorough medical histories are paramount.[1] If significant findings are unveiled, consultation with or referral of the patient to an appropriate physician may be indicated. This ensures correct patient management and provides medicolegal coverage to the clinician.

This chapter covers common medical conditions and associated periodontal management. Review of each topic area is general, and the reader is encouraged to consult other references for more detailed coverage of specific disorders. Understanding these conditions will enable the clinician to treat the total patient, not merely the periodontal reflection of underlying disease.

Cardiovascular Diseases

Cardiovascular diseases are the most prevalent category of systemic disease in the United States and many other countries, and they are more common with increasing age.[2] Health histories should be closely scrutinized for cardiovascular problems. These conditions include hypertension, angina pectoris, myocardial infarction (MI), previous cardiac bypass surgery, previous cerebrovascular accident (CVA), congestive heart failure (CHF), presence of cardiac pacemakers or automatic cardioverter-defibrillators, and infective endocarditis (IE).

In most cases the patient's physician should be consulted, especially if stressful or prolonged treatment is anticipated. Short appointments and a calm, relaxing environment help minimize stress and maintain hemodynamic stability.

Hypertension

Hypertension, the most common cardiovascular disease, affects more than 50 million American adults, many of whom are undiagnosed.[3] In 2003, the National Heart, Lung and Blood Institute issued revised guidelines for evaluation and management of hypertension.[4-6] The *Seventh Report of the Joint National Committee on Prevention, Detection, Evaluation, and Treatment of High Blood Pressure* (JNC-7) guidelines[4] simplified the classification of blood pressure (Table 37-1).

Compared with previous classification[7,8] schemes that focused on diastolic blood pressure (BP), the JNC-7 guidelines[4] emphasize the importance of systolic BP greater than 140 mm Hg. Systolic blood pressure greater than 140 mm Hg is considered a greater risk factor for cardiovascular disease than elevated diastolic pressure. JNC-7 also introduced a category known as *prehypertension* to replace the more innocuous terms "high normal" and "borderline" hypertension. People with systolic BP between 120 and 139 mm Hg or diastolic BP between 80 and 89 mm Hg are classified as "prehypertensive." Hypertension is now classified into only two categories versus three under past classification schemes for simplicity and because treatment for categories 2 and 3 was essentially the same. *Stage 1 hypertension* is defined by systolic pressure of 140 to 159 mm Hg or diastolic pressure of 90 to 99 mm Hg. *Stage 2 hypertension* is defined by a systolic pressure greater than 160 mm Hg or diastolic pressure greater than 100 mm Hg.

Hypertension is not diagnosed on a single elevated BP recording. Rather, classification is usually based on the average value of two or more BP readings taken at two or more appointments. The higher value of either the systolic or diastolic pressure determines the patient's classification. Patients with hypertension enter the dental practice every day and are particularly common among the older population seen in most periodontal practices. Evidence from the Framingham Heart Study revealed that people with normal BP at age 55 still have a 90% risk of becoming hypertensive later in life.[9]

Hypertension is divided into primary and secondary types. *Primary* (essential) *hypertension* occurs when no underlying pathologic abnormality can be found to explain the disease.

Thyroid and Parathyroid Disorders

Periodontal therapy requires minimal alterations in the patient with adequately managed thyroid disease.[49,50] Patients with *thyrotoxicosis* and those with inadequate medical management should not receive periodontal therapy until their conditions are stabilized. Patients with a history of *hyperthyroidism* should be carefully evaluated to determine the level of medical management, and they should be treated in a way that limits stress and infection. Hyperthyroidism may cause tachycardia and other arrhythmias, increased cardiac output, and myocardial ischemia. Medications such as epinephrine and other vasopressor amines should be given with caution in patients with treated hyperthyroidism, although the small amounts used in dental anesthetics rarely cause problems.[18,50] These drugs should not be given to patients with thyrotoxicosis or poorly controlled thyroid disorders. Patients with *hypothyroidism* require careful administration of sedatives and narcotics because of the potential for excessive sedation.

Routine periodontal therapy may be provided to patients with parathyroid disease once that disorder has been identified and the proper medical treatment given. However, patients who have not received medical care may have significant renal disease, uremia, and hypertension. Also, if hypercalcemia or hypocalcemia is present, the patient may be more prone to cardiac arrhythmias.

Adrenal Insufficiency

Acute adrenal insufficiency is associated with significant morbidity and mortality as a result of peripheral vascular collapse and cardiac arrest. Therefore, the periodontist should be aware of the clinical manifestations (Box 37-5) and ways of preventing acute adrenal insufficiency in patients with histories of *primary* adrenal insufficiency (Addison disease) or *secondary* adrenal insufficiency (most often caused by use of exogenous glucocorticosteroids).

The use of systemic corticosteroids is common in patients with allergic, endocrine, respiratory, joint, intestinal, neurologic, renal, liver, skin, and connective tissue disorders. Significant complications associated with corticosteroid use include alterations in glucose metabolism (steroid-induced diabetes), increased risk of infection, altered wound healing, osteoporosis, skin disorders, cataracts, glaucoma, and suppression of the hypothalamic-pituitary-adrenal (HPA) axis.[10,51] In the normal healthy patient, stress activates the HPA axis, stimulating increased endogenous cortisol production by the adrenal glands. Exogenous steroids may suppress the HPA axis and impair the patient's ability to respond to stress with increased endogenous cortisol production, leading to the potential for acute adrenal crisis (see Box 37-5). The degree of adrenal suppression depends on the drugs used, dose, duration of administration, time elapsed since steroid therapy was terminated, and route of administration.

It has been common practice in the past to administer prophylactic systemic steroids before dental treatment for patients who are taking or who recently have taken exogenous steroids. Such steroid supplementation may not be required for many periodontal procedures.[3] In fact, *adrenal crisis* is rare in dentistry, especially when associated with secondary adrenal suppression caused by steroid use.[52] Shapiro et al[53] found that patients taking 5 to 20 mg/day of prednisone maintained at least some adrenal reserve after immediate termination of steroid therapy. Higher doses may suppress the adrenal glands to a greater degree. Although exogenous steroids may suppress normal adrenal cortisol secretion for an extended period, the ability of the adrenal gland to respond to stress may return quickly after termination of steroid therapy.

Despite its rarity, the severe consequences of adrenal crisis suggest caution in patient management. Before providing extensive dental treatment to a patient with a history of recent or current steroid use, physician consultation is indicated to determine whether the patient's treatment needs warrant supplemental steroids. Use of a stress reduction protocol and profound local anesthesia will help minimize the physical and psychologic stress associated with therapy and reduce the risk of acute adrenal crisis.

Current evidence indicates that a vast majority of individuals with adrenal insufficiency can receive routine dental treatment without the need for supplemental glucocorticosteroids.[54,55] Patients currently taking corticosteroids generally have enough exogenous and endogenous cortisol to handle routine dental procedures if their usual dose is taken within 2 hours of the planned procedure. Thus, for most patients, supplemental corticosteroid administration is not required when uncomplicated minor surgical procedures, including periodontal surgery, are performed with local anesthesia with or without sedation.[55]

Individuals who may be at risk for adrenal crisis requiring supplementation include those who are undergoing lengthy, major surgical procedures, those expected to have significant blood loss, and those who have extremely low adrenal function. For these individuals, consultation with their physician and steroid supplementation is indicated. Low adrenal function can be identified with an adrenocorticotropic hormone (ACTH) stimulation test. A rapid assay is also available to determine the degree of adrenal reserve by measurement of serum cortisol levels 30 and 60 minutes after IV administration of synthetic corticotropin.[53]

For the patient who is identified as being at risk, the need for corticosteroid prophylaxis depends on the drug used because of the variance in equivalent therapeutic doses (Table 37-7).

Glucocorticosteroid coverage regimens vary, but most provide a twofold to fourfold increase in coverage, depending on the stress produced by the procedure. In an emergency situation, when testing is not possible, increasing the steroid dose before the procedure can decrease the chances of acute adrenal crisis.

BOX 37-5 Manifestations of Acute Adrenal Insufficiency (Adrenal Crisis)

- Mental confusion, fatigue, and weakness
- Nausea and vomiting
- Hypertension
- Syncope
- Intense abdominal pain, lower back pain, and leg pain
- Loss of consciousness
- Coma

TABLE 37-7 Equivalent Doses of Corticosteroids

Corticosteroid	Equivalent Dose (mg)
Cortisone	25
Hydrocortisone	20
Prednisone	5
Prednisolone	5
Methyl prednisone	5
Methylprednisolone	4
Triamcinolone	4
Dexamethasone	0.75
Betamethasone	0.6

Management of the patient in an acute adrenal insufficiency crisis is as follows:

1. Terminate periodontal treatment.
2. Summon medical assistance.
3. Give oxygen.
4. Monitor vital signs.
5. Place the patient in a supine position.
6. Administer 100 mg of hydrocortisone sodium succinate (Solu-Cortef) IV over 30 seconds or intramuscularly.

Thrombocytopenic Purpuras

Thrombocytopenia is defined as a platelet count of less than 100,000/mm^3. Bleeding caused by thrombocytopenia may be seen with idiopathic thrombocytopenic purpuras, radiation therapy, myelosuppressive drug therapy (e.g., chemotherapy), leukemia, or infections. Purpuras are hemorrhagic diseases characterized by extravasation of blood into the tissues under the skin or mucosa, producing spontaneous petechiae (small red patches) or ecchymoses (bruises).

Periodontal therapy for patients with thrombocytopenia should be directed toward reducing inflammation by removing local irritants to avoid the need for more aggressive therapy.[10,57] Oral hygiene instructions and frequent maintenance visits are paramount. Physician referral is indicated for a definitive diagnosis and to determine any alterations in planned therapy. Scaling and root planing are generally safe unless platelet counts are less than 60,000/mm^3. No surgical procedures should be performed unless the platelet count is greater than 80,000/mm^3. Platelet transfusion may be required before surgery. Surgical technique should be as atraumatic as possible, and local hemostatic measures should be applied.

Nonthrombocytopenic Purpuras

Nonthrombocytopenic purpuras result from either vascular wall fragility or thrombasthenia (impaired platelet aggregation). Vascular wall fragility may result from hypersensitivity reactions, scurvy, infections, chemicals (phenacetin, aspirin), dysproteinemia, and other causes. Thrombasthenia occurs in uremia, Glanzmann disease, aspirin ingestion, and von Willebrand disease.[57] Both types of nonthrombocytopenic purpura may result in immediate bleeding after gingival injury. Treatment consists primarily of direct pressure applied for at least 15 minutes. This initial pressure should control the bleeding unless coagulation times are abnormal or reinjury occurs. Surgical therapy should be avoided until the qualitative and quantitative platelet problems are resolved.

Blood Dyscrasias

Numerous disorders of red and white blood cells may affect the course of periodontal therapy. Alterations in wound healing, bleeding, tissue appearance, and susceptibility to infection may occur. Clinicians should be aware of the clinical signs and symptoms of blood dyscrasias, availability of screening laboratory tests, and need for physician referral.

Renal Diseases

The most common causes of renal failure are glomerulonephritis, pyelonephritis, kidney cystic disease, renovascular disease, drug nephropathy, obstructive uropathy, and hypertension.[68,69] Renal failure may result in severe electrolyte imbalances, cardiac arrhythmias, pulmonary congestion, CHF, and prolonged bleeding.[10] Because the dental management of patients with renal disease may need to be drastically altered, physician consultation is necessary to determine the stage of renal disease, regimen for medical management, and alterations in periodontal therapy. The patient in chronic renal failure has a progressive disease that ultimately may require kidney transplantation or dialysis. It is preferable to treat the patient before, rather than after, transplant or dialysis.

The following treatment modifications should be used:

1. Consult the patient's physician.
2. Monitor BP (patients in end-stage renal failure are usually hypertensive).
3. Check laboratory values: PTT, PT, bleeding time, and platelet count; hematocrit; blood urea nitrogen (do not treat if <60 mg/dL); and serum creatinine (do not treat if <1.5 mg/dL).
4. Eliminate areas of oral infection to prevent systemic infection.
   - Good oral hygiene should be established.
   - Periodontal treatment should aim at eliminating inflammation or infection and providing easy maintenance. Questionable teeth should be extracted if medical parameters permit.
   - Frequent recall appointments should be scheduled.
5. Drugs that are nephrotoxic or metabolized by the kidney should not be given (e.g., phenacetin, tetracycline, aminoglycoside antibiotics). Acetaminophen may be used for analgesia and diazepam for sedation. Local anesthetics, such as lidocaine, are generally safe.[10,70]

The patient who is receiving dialysis requires modifications in treatment planning.[6,68] The three modes of dialysis are intermittent peritoneal dialysis (IPD), chronic ambulatory peritoneal dialysis (CAPD), and hemodialysis. Only hemodialysis patients require special precautions. These patients have a high incidence of viral hepatitis, anemia, and prolonged hemorrhage. The risk for hemorrhage is related to anticoagulation during dialysis, platelet trauma from dialysis, and the uremia that develops with renal failure.[10] Hemodialysis patients have either an internal arteriovenous fistula or an external arteriovenous shunt. This shunt is often located in the arm and must be protected from trauma. Thus, in addition to guidelines for patients with chronic renal disease, the following recommendation are made for those receiving hemodialysis:

1. Screen for hepatitis B and hepatitis C antigens and antibody before any treatment.
2. Provide antibiotic prophylaxis to prevent endarteritis of the arteriovenous fistula or shunt. (IPD and CAPD patients do not generally require prophylactic antibiotics.)
3. Patients receive heparin anticoagulation on the day of hemodialysis. Therefore periodontal treatment should be provided on the day *after* dialysis, when the effects of heparinization have subsided. Hemodialysis treatments are generally performed three or four times a week. (IPD and CAPD patients are not systemically heparinized; therefore they usually do not have the potential bleeding problems associated with hemodialysis.)
4. Be careful to protect the hemodialysis shunt or fistula when the patient is in the dental chair. If the shunt or fistula is placed in the arm, do not cramp the limb; *BP readings should be taken from the other arm.* Do not use the limb for the injection of medication. Patients with leg shunts should avoid sitting with the leg dependent for longer than 1 hour. If appointments last longer, allow the patient to walk about for a few minutes, then resume therapy.
5. Refer the patient to the physician if uremic problems develop, such as uremic stomatitis. To prevent systemic dissemination, refer to the physician if oral infections do not resolve promptly.

The renal transplant patient's greatest foe is infection. Transplant patients take immunosuppressive drugs that greatly reduce

resistance to infection.[70] Excessive bleeding may occur during or after periodontal treatment because of drug-induced thrombocytopenia, anticoagulation, or both. A periodontal abscess is a potentially life-threatening situation; therefore a dental team approach should be used *before* transplantation to determine which teeth can be easily maintained. Many organ transplant centers now include dental examination in their standard pretransplant protocol. Teeth with severe bone and attachment loss, furcation invasion, periodontal abscesses, or extensive surgical requirements should be extracted, leaving an easily maintainable dentition. In addition to the recommendations for patients with chronic renal failure, the following should be considered for the renal transplant patient:

1. Hepatitis B and C screening.
2. Determination of level of immune system compromise resulting from antirejection drug therapy.
3. Prophylactic antibiotics (using AHA recommendations or specific regimens based on physician consultation). Not all transplant patients require antibiotic coverage, and physician consultation is warranted before prescribing.

Liver Diseases

Liver diseases may range from mild conditions to complete liver failure. Major causes of liver disease include drug toxicity, cirrhosis, viral infections (e.g., hepatitis B and C), neoplasms, and biliary tract disorders.[71] Because the liver is the site of production for most of the clotting factors, excessive bleeding during or after periodontal treatment may occur in patients with severe liver disease. Many drugs are metabolized in the liver; thus liver disease alters normal drug metabolism. Treatment recommendations for patients with liver disease include the following:

1. Consultation with the physician concerning current stage of disease, risk for bleeding, potential drugs to be prescribed during treatment, and required alterations to periodontal therapy.
2. Screening for hepatitis B and C.
3. Check laboratory values for PT and PTT.
4. Check laboratory values for INR.

For the liver transplant patient, as with kidney and other organ transplantation, infection is a major concern. Transplant patients take immunosuppressive drugs that greatly reduce resistance to infection.[70] Excessive bleeding may occur during or after periodontal treatment because of drug-induced thrombocytopenia, anticoagulation, or both. Dental or periodontal infections are potentially life-threatening. A pretransplantation evaluation is recommended to determine which teeth can be maintained without risk of infection. Teeth with severe bone and attachment loss, furcation invasion, periodontal abscesses, or extensive surgical requirements should be extracted.

Pulmonary Diseases

The periodontal treatment of a patient with pulmonary disease may require alteration, depending on the nature and the severity of the respiratory problem. Pulmonary diseases range from obstructive lung diseases (e.g., asthma, emphysema, bronchitis, or acute obstruction) to restrictive ventilatory disorders caused by muscle weakness, scarring, obesity, or any condition that could interfere with effective lung ventilation.[72,73] Combined restrictive-obstructive lung disease may also develop.

The clinician should be aware of the signs and symptoms of pulmonary disease, such as increased respiratory rate, cyanosis, clubbing of the fingers, chronic cough, chest pain, hemoptysis, dyspnea or orthopnea, and wheezing. Patients with these problems should be referred for medical evaluation and treatment. Most patients with chronic lung disease may undergo routine periodontal therapy if they are receiving adequate medical management. Caution should be practiced in relation to any treatment that may depress respiratory function.

Acute respiratory distress may be caused by slight airway obstruction or depression of respiratory function. Because of their limited vital lung capacity, these patients also have decreased cough effectiveness.[73] They must continually deal with the mental anxiety caused by air hunger and alter their position in attempts to improve their ventilatory efficiency.

The following guidelines should be used during periodontal therapy:

1. Identify and refer patients with signs and symptoms of pulmonary disease to their physician.
2. In patients with known pulmonary disease, consult with their physician regarding medications (antibiotics, steroids, chemotherapeutic agents) and the degree and severity of pulmonary disease.
3. Avoid elicitation of respiratory depression or distress:
   - Minimize the stress of a periodontal appointment. The patient with emphysema should be treated in the afternoon, several hours after sleep, to allow for airway clearance.
   - Avoid medications that could cause respiratory depression (e.g., narcotics, sedatives, or general anesthetics).
   - Avoid bilateral mandibular block anesthesia, which could cause increased airway obstruction.
   - Position the patient to allow maximal ventilatory efficiency, be careful to prevent physical airway obstruction, keep the patient's throat clear, and avoid excess periodontal packing.
4. In a patient with a history of asthma, especially if asthma attacks are frequent, make sure the patient's medication (inhaler) is available. The inhaler should be readily accessible on the countertop in the dental treatment room.
5. Patients with active fungal or bacterial respiratory diseases should not be treated unless the periodontal procedure is an emergency.

Pregnancy

The aim of periodontal therapy for the pregnant patient is to minimize the potential exaggerated inflammatory response related to pregnancy-associated hormonal alterations. Meticulous plaque control, scaling, root planing, and polishing should be the only nonemergency periodontal procedures performed.

The second trimester is the safest time to perform treatment. However, long, stressful appointments, as well as periodontal surgical procedures, should be delayed until the postpartum period. As the uterus increases in size during the second and third trimesters, obstruction of the vena cava and aorta may occur if the patient is placed in a supine position. The reduction in return cardiac blood supply may cause *supine hypotensive syndrome,* with decreased placental perfusion.[116] Decreasing BP, syncope, and loss of consciousness may occur. This can be prevented by placing the patient on her left side or simply by elevating the right hip 5 to 6 inches during treatment. Appointments should be short, and the patient should be allowed to change positions frequently. A fully reclined position should be avoided if possible.

Other precautions during pregnancy relate to the potential toxic or teratogenic effects of therapy on the fetus. Ideally, no medications should be prescribed. However, analgesics, antibiotics, local anesthetics, and other drugs may be required during pregnancy, depending on the patient's needs. Before being prescribed, all drugs should be reviewed for potential adverse effects on the fetus.[10,116]

As for all patients, use of dental radiographs during pregnancy should be kept to a minimum. The small amount of radiation exposure during diagnostic dental radiography poses little, if any, risk to the fetus as long as the mother is properly shielded.[106,117] The ADA has stated that "normal radiographic guidelines do not need to be altered because of pregnancy."[117] Use of a properly positioned lead apron is an absolute requirement. Chapter 38 includes a detailed discussion of the management of the female patient, including pregnancy.

Infectious Diseases

Because many infectious diseases are occult in nature and because medical histories are often inaccurate or incomplete, all periodontal patients should be treated as though they have an infectious disease.[118] Protection of patients, clinicians, and office staff requires use of universal (standard) precautions for all patients, maximizing prevention of infection and cross-contamination. This section provides a brief discussion of hepatitis, human immunodeficiency virus (HIV) and acquired immunodeficiency syndrome (AIDS), and tuberculosis in relation to the precautions required in periodontal therapy.

Hepatitis

To date, six distinct viruses causing viral hepatitis have been identified: hepatitis A, B, C, D, E, and G viruses.[119-121] In addition, a single-stranded deoxyribonucleic acid (DNA) virus known as *transfusion-transmitted virus* has recently been identified in cases of acute and chronic hepatitis[121,122]; its role as an etiologic agent is still undetermined. These forms of viral hepatitis differ in their virology, epidemiology, and prophylaxis (Table 37-12). Because the majority of hepatitis infections are undiagnosed, the clinician must be aware of high-risk groups, such as renal dialysis patients, healthcare workers, immunosuppressed patients, patients who have received multiple blood transfusions, homosexuals, drug users, and institutionalized patients.

Hepatitis A virus (HAV) and *hepatitis E virus* (HEV) are both self-limiting infections with no associated chronic liver disease. These viruses are primarily transmitted via the fecal-oral route. HAV transmission in the United States usually results from close personal household, sexual, or day care center contact. Conversely, HEV is transmitted mainly through fecally contaminated drinking water and is thus relatively uncommon in the United States.

TABLE 37-12 Comparison of Hepatitis Viruses

	VIRUS						
Source	**HAV**	**HBV**	**HCV**	**HDV**	**HEV**	**HGV**	**TTV**
Feces	Blood and body fluids	Blood and body fluids	Blood and body fluids	Feces	Blood	Blood, possibly feces	
Primary modes of transmission	Fecal-oral	Percutaneous, permucosal; sexual	Percutaneous, permucosal	Percutaneous, permucosal (occurs only after previous infection with HBV or as coinfection with HBV)	Fecal-oral	Percutaneous (usually occurs as co infection with other hepatitis viruses)	Blood (transfusion), possible fecal-oral
Incubation period	15-50 days	50-160 days	15-150 days	15-150 days	15-60 days	Unknown	Unknown
Risk of chronic infection	No chronic infection	Varies with age: adults 5%-10%; children 25%-50%; infants >85%	Very high (>85%)	5% when acquired as co infection with HBV; >70% when acquired as a second infection in chronic HBV carrier	No chronic infection	Unknown whether chronic infection occurs	Unclear
Protective immunity after infection?	Yes; anti-HAV antibody	Usually; antibody to core antigen, e antigen, and surface antigen (HBsAg) are produced; anti-HBsAg is most protective; chronic carrier state exists.	No; anti-HCV antibody is produced but is usually not protective.	Because HDV infection requires previous infection or coinfection with HBV, protective immunity is similar to hepatitis B.	Unknown	Unknown	Unknown
Vaccine available?	Yes	Yes	No	Yes (HBV vaccine protects against HDV)	No	No	No

HAV, Hepatitis A virus; *HBsAg*, hepatitis B surface antigen; *HBV*, hepatitis B virus; *HCV*, hepatitis C virus; *HDV*, hepatitis D virus; *HEV*, hepatitis E virus; *HGV*, hepatitis G virus; *TTV*, transfusion-transmitted virus.

Currently, a vaccination is available to protect against HAV infection but not HEV infection.

Hepatitis B virus (HBV) infection may result in chronic liver disease and a chronic carrier state. Chronic HBV infection develops in about 5% to 10% of infected individuals, with much higher rates among infants and children. Because it is transmitted primarily through a hematogenous route, HBV is a major concern for healthcare workers; the highest rates of HBV infection are found among dentists and oral surgeons.[120] Percutaneous or permucosal injury with contaminated instruments or needles is the most common route of infection in the dental office. The HBV vaccine is recommended for all healthcare workers.

Hepatitis D virus (HDV) is a defective virus that requires the presence of HBV for its survival, replication, and infectivity. The HDV genetic material is packaged within the HBV surface-antigen coating. Thus prevention of HDV infection is similar to prevention of HBV and relies strongly on HBV vaccination. Once antibody titers to HBV are elevated to a protective level, the patient is also protected against HDV infection.

Hepatitis C virus (HCV) is probably the most serious of all viral hepatitis infections because of its high chronic infection rate. Only 15% of patients infected with HCV recover completely; 85% develop chronic HCV infection, which dramatically increases the risk for cirrhosis, hepatocellular carcinoma, and liver failure. In fact, HCV infection is the leading cause of liver transplantation in the United States. Unfortunately, no vaccine is available for HCV. Because HCV is transmitted primarily through a percutaneous or permucosal route, healthcare workers are at risk from injury with contaminated instruments.

Hepatitis G virus (HGV) is a ribonucleic acid (RNA) virus, and its epidemiology and virology are not fully understood. HGV rarely occurs as a solitary infection, usually appearing as a coinfection with hepatitis A, B, or C. HGV is known to be transmitted through the blood and has frequently been associated with transfusions.

Transfusion-transmitted virus (TTV) was first identified in 1997 and is common in the general population.[121,123] The virus is often present in patients with hepatitis and chronic liver disease. Similar to HGV, TTV may not actually cause a specific form of hepatitis. Patients infected with TTV may develop a chronic carrier state without having clinically evident disease, or they may develop frank disease. Evidence indicates that TTV can be transmitted not only by the blood (e.g., transfusions) but also via a fecal-oral route and from mother to child. Also, as with HGV, TTV is often associated with HCV.

The following guidelines are offered for treating hepatitis patients:

1. If the disease, regardless of type, is active, do not provide periodontal therapy unless the situation is an emergency. In an emergency case, follow the protocol for patients positive for hepatitis B surface antigen (HBsAg).
2. For patients with a past history of hepatitis, consult the physician to determine the type of hepatitis, course and length of the disease, mode of transmission, and any chronic liver disease or viral carrier state.
3. For recovered HAV or HEV patients, perform routine periodontal care.
4. For recovered HBV and HDV patients, consult with the physician and order HBsAg and anti-HBs (antibody to HBV surface antigen) laboratory tests.
   - If HBsAg and anti-HBs tests are negative but HBV is suspected, order another HBs determination.
   - Patients who are HBsAg positive are probably infective (chronic carriers); the degree of infectivity is measured by an HBsAg determination.
   - Patients who are anti-HBs positive may be treated routinely (they have antibody to HBsAg).
   - Patients who are HBsAg negative may be treated routinely.
5. For HCV patients, consult with the physician to determine the patient's risk for transmissibility and current status of chronic liver disease.
6. If a patient with active hepatitis, positive-HBsAg (HBV carrier) status, or positive-HCV carrier status requires emergency treatment, use the following precautions:
   - Consult the patient's physician regarding status.
   - If bleeding is likely during or after treatment, measure PT and bleeding time. Hepatitis may alter coagulation; change treatment accordingly.
   - All personnel in clinical contact with the patient should use full barrier technique, including masks, gloves, glasses or eye shields, and disposable gowns.
   - Use as many disposable covers as possible, covering light handles, drawer handles, and bracket trays. Headrest covers should also be used.
   - All disposable items (e.g., gauze, floss, saliva ejectors, masks, gowns, or gloves) should be placed in one lined wastebasket. After treatment, these items and all disposable covers should be bagged, labeled, and disposed of, following proper guidelines for biohazardous waste.
   - Aseptic technique should be followed at all times. Minimize aerosol production by not using ultrasonic instrumentation, air syringe, or high-speed handpieces; remember that saliva contains a distillate of the virus. Prerinsing with chlorhexidine gluconate for 30 seconds is highly recommended.
   - When the procedure is completed, all equipment should be scrubbed and sterilized. If an item cannot be sterilized or disposed of, it should not be used.

If a percutaneous or permucosal injury occurs during dental treatment of a HBV carrier, current Centers for Disease Control and Prevention (CDC) guidelines recommend administration of *hepatitis B immune globulin* (HBIG).[124] The HBV vaccine should also be administered if the injured individual has not previously received it. Unfortunately, postexposure prophylaxis with immune globulin or antiviral agents is generally ineffective if a percutaneous injury occurs during treatment of a hepatitis C carrier.[119,125]

HIV and AIDS

Since the beginning of the AIDS epidemic, a wide range of oral lesions has been associated with HIV infection; these lesions are discussed in Chapter 26.

As with hepatitis, not all HIV-infected patients know that they are infected when they report for dental treatment. Furthermore, individuals with known HIV infection may not admit their status on the medical history. Therefore every patient receiving dental treatment should be managed as a potentially infected person, using universal precautions for all therapy.

Extensive periodontal treatment plans must be considered in regard to the patient's systemic health, prognosis, and survival time.[10] Large variations in progression of HIV disease exist among individuals, and selection of an appropriate treatment plan depends on the state of the patient's overall health. Although there appear to be few contraindications to routine dental treatment for many HIV-infected patients, the periodontal treatment plan is influenced by the patient's overall systemic health and coincident oral infections or diseases. An awareness of oral disorders associated with HIV infection may allow the clinician to recognize previously undiagnosed disease or to modify treatment protocols appropriately.

Tuberculosis

The patient with tuberculosis should receive only emergency care, following the guidelines listed in the section on hepatitis. If the patient has completed chemotherapy, the patient's physician should be consulted regarding infectivity and the results of sputum cultures for *Mycobacterium tuberculosis*. When medical clearance has been given and the sputum culture results are negative, these patients may be treated normally. Any patient who gives a history of poor medical follow-up (e.g., lack of yearly chest radiographs) or shows signs or symptoms indicative of tuberculosis should be referred for evaluation. Adequate treatment of tuberculosis requires a minimum of 18 months, and thorough posttreatment follow-up should include chest radiographs, sputum cultures, and a review of the patient's symptoms by the physician at least every 12 months.

TABLE 37-1 Classification of Adult Blood Pressure

Classification	Systolic BP (mm Hg)	Diastolic BP (mm Hg)	Dental Treatment Modifications
Normal	<120	and <80	No changes in dental treatment.
Prehypertension	120-139	or 80-89	No changes in dental treatment. Monitor BP at each appointment.
Stage 1 hypertension	140-159	or 90-99	Inform patient of findings. Routine medical consultation/referral. Monitor BP at each appointment. No changes in dental treatment; minimize stress.
Stage 2 hypertension	≥160	≥100	Inform patient. Medical consultation/referral. Monitor BP at each appointment. If systolic BP is <180 mm Hg and diastolic is <110 mm Hg, perform selective dental care (routine exam, prophylaxis, restorative nonsurgical endodontics and periodontics); minimize stress. If systolic BP ≥ 180 mm Hg or diastolic ≥100 mm Hg, give immediate medical consultation/referral, and perform emergency dental care only (to alleviate pain, bleeding, infection)*; minimize stress. Consider stress reduction protocol.

BP, Blood pressure.

*Risk of providing emergency dental care must outweigh risk of possible hypertensive complications.[4-6]

Approximately 95% of all hypertensive patients have primary hypertension. The remaining 5% have *secondary hypertension,* in which an underlying etiology can be found and often treated. Examples of the conditions responsible for secondary hypertension are renal disease, endocrinologic changes, and neurogenic disorders.

In early hypertension, the patient may be asymptomatic. If not identified and diagnosed, hypertension may persist and increase in severity, leading eventually to coronary artery disease, angina, MI, CHF, CVA, or kidney failure.[10] The dental office can play a vital role in the detection of hypertension and maintenance care of the patient with hypertensive disease. The first dental office visit should include two BP readings spaced at least 10 minutes apart, which are averaged and used as a baseline. Before the clinician refers a patient to a physician because of elevated BP, readings should be taken at a minimum of two appointments, unless the measurements are extremely high (i.e., systolic pressure >180 mm Hg or diastolic pressure >100 mm Hg). The periodontal recall system is an ideal method for hypertension detection and monitoring. Almost three of every four adult patients with hypertension in the United States do not control their BP well enough to attain the goal of systolic pressure less than 140 mm Hg and diastolic pressure less than 90 mm Hg.[11] Lack of compliance with antihypertensive therapy is the primary reason for this failure. Dentists can help achieve greater success in managing hypertension by taking BP readings at each periodontal recall visit.

Periodontal procedures should not be performed until accurate BP measurements and histories have been taken to identify those patients with significant hypertensive disease. The time of day also should be recorded because BP varies significantly throughout the day.[12] Table 37-1 outlines appropriate medical referral or consultation and dental treatment modifications, depending on the patient's stage of hypertension.

Dental treatment for hypertensive patients is generally safe as long as stress is minimized.[10,13] If a patient is currently receiving antihypertensive therapy, consultation with the physician may be warranted regarding the current medical status, medications, periodontal treatment plan, and patient management. Many physicians are not knowledgeable about the nature of specific periodontal procedures. The dentist must inform the physician regarding the estimated degree of stress, length of the procedures, and complexity of the individualized treatment plan. Morning dental appointments were once suggested for hypertensive patients. However, recent evidence indicates that BP generally increases around awakening and peaks at midmorning.[12,14,15] Lower BP levels occur in the afternoon; therefore afternoon dental appointments may be preferred.

No routine periodontal treatment should be given to a patient who is hypertensive and not under medical management. For patients with systolic BP greater than 180 mm Hg or diastolic BP greater than 110 mm Hg, treatment should be limited to emergency care until hypertension is controlled. Analgesics are prescribed for pain and antibiotics for infection. Acute infections may require surgical incision and drainage, although the surgical field should be limited because excessive bleeding may be seen with elevated BP.

When treating hypertensive patients, the clinician should not use a local anesthetic containing an epinephrine concentration greater than 1 : 100,000 nor should a vasopressor be used to control local bleeding. Local anesthesia without epinephrine may be used for short procedures (<30 minutes). In a patient with hypertensive disease, however, it is important to minimize pain by providing profound local anesthesia to avoid an increase in endogenous epinephrine secretion.[10,13]

The benefits of the small doses of epinephrine used in dentistry far outweigh the potential for hemodynamic compromise. The smallest possible dose of epinephrine should be used, and aspiration before injection of local anesthetics is critical. Intraligamentary injection is generally contraindicated because hemodynamic changes are similar to intravascular injection.[16] If the hypertensive patient exhibits anxiety, use of conscious sedation in conjunction with periodontal procedures may be warranted[17] (see Chapter 36).

Beta-adrenergic receptor antagonists, or β-blockers, are typically used to treat hypertension (Table 37-2). β-blockers are either *cardioselective,* blocking only β-1 cardiac receptors (β1 receptors), or *nonselective,* blocking both β-1 cardiac receptors and β-2

TABLE 37-2 Nonselective and Selective β-Adrenergic Receptor Antagonists (β-Blockers)

Generic Name	Trade Name
Nonselective β-Blockers	
Carvedilol	Coreg
Carteolol hydrochloride	Cartrol
Nadolol	Corgard
Penbutolol sulfate	Levatol
Pindolol	Visken
Propranolol hydrochloride	Inderal; Inderal LA
Timolol maleate	Blocadren
Selective β-Blockers	
Acebutolol hydrochloride	Sectral
Atenolol	Tenormin
Betaxolol hydrochloride	Kerlone
Bisoprolol fumarate	Zebeta
Metoprolol tartrate	Lopressor
Metoprolol succinate	Toprol-XL

peripheral receptors (β2 receptors). Epinephrine, an α-adrenergic and β-adrenergic agonist, produces an increase in heart rate through direct stimulation of cardiac β-1 receptors. Epinephrine also stimulates α-adrenergic receptors, producing vasoconstriction of arteries, as well as β-2 receptors, causing vasodilation of skeletal muscle arterioles. Administration of local anesthetics containing epinephrine to patients taking nonselective β-blockers (e.g., propranolol, nadolol) may cause elevated BP.[18] Epinephrine-induced α-adrenergic stimulation results in vasoconstriction and increased BP. Because the patient's nonselective medication has blocked the β-2 receptors, epinephrine will not stimulate the normal compensatory β-2 receptor–induced vasodilation. This may result in dramatically increased BP, followed by reflex bradycardia mediated by the vagus nerve and carotid baroreceptors. The end result is a patient with severe hypertension and bradycardia, resulting in a dangerous decrease in vascular perfusion and possible death. Because of this potential complication, epinephrine-containing local anesthetics should be used cautiously and only in very small amounts in patients taking nonselective β-blockers, with careful monitoring of vital signs.[10,18]

The clinician should be aware of the many side effects of various antihypertensive medications. *Postural hypotension* is common and can be minimized by slow positional changes in the dental chair.[10] *Depression* is a side effect of which many patients are unaware. Nausea, sedation, oral dryness, lichenoid drug reactions, and gingival overgrowth are associated with certain classes of antihypertensive agents.[13]

Ischemic Heart Diseases

Ischemic heart disease (Figure 37-1) includes disorders such as angina pectoris and myocardial infarction. Angina pectoris occurs when myocardial oxygen demand exceeds supply, resulting in temporary myocardial ischemia.[5] Patients with a history of unstable angina pectoris (angina that occurs irregularly or on multiple occasions without predisposing factors) should be treated only for emergencies and then in consultation with their physician. Patients with stable angina (angina that occurs infrequently, is associated with exertion or stress, and is easily controlled with medication and rest) can undergo elective dental procedures. Because stress often induces an acute anginal attack, stress reduction is important. Profound local anesthesia is vital, and conscious sedation may be

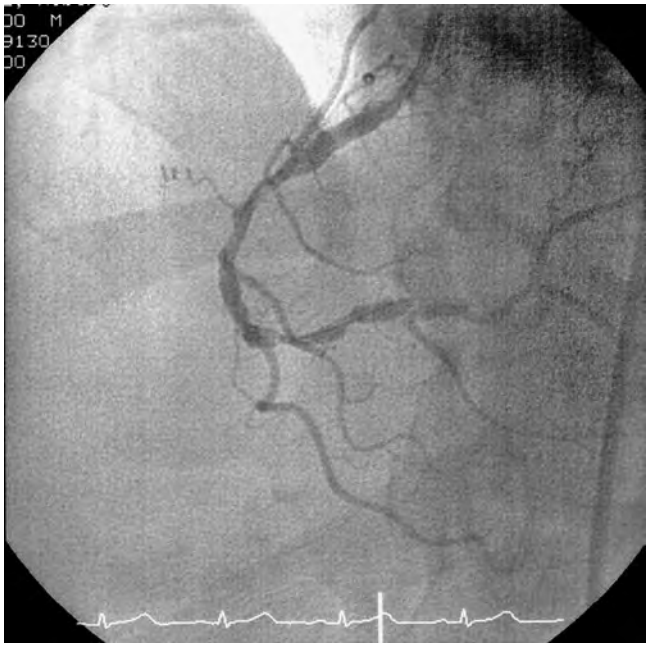

Figure 37-1 Coronary angiogram. Atherosclerosis can result in narrowing of the coronary arteries and onset of signs and symptoms of ischemic heart disease.

indicated for anxious patients[17] (see Chapter 36). Supplemental oxygen delivered by nasal cannula may also help prevent intraoperative anginal attacks.

Patients who treat acute anginal attacks with nitroglycerin should be instructed to bring their medication to dental appointments. Nitroglycerin should also be kept in the office emergency medical kit. For particularly stressful procedures, the patient may take a nitroglycerin tablet preoperatively to prevent angina, although this generally is not necessary. The patient's nitroglycerin should be readily accessible on the dental tray in case it is needed during treatment. Because the shelf life of nitroglycerin is relatively short, the expiration date of the patient's nitroglycerin should be noted, as should the expiration date of the nitroglycerin in the office's emergency medical kit. Also, patients with angina may be taking longer-acting forms of nitroglycerin (tablet, patch), β-blockers, or calcium channel blockers (also used in treatment of hypertension) for prevention of angina. Restrictions on use of local anesthetics containing epinephrine are similar to those for the patient with hypertension. In addition, intraosseous injection with epinephrine-containing local anesthetics using special systems (e.g., Stabident, Fairfax Dental) should be done cautiously in patients with ischemic heart disease, because it results in transient increases in heart rate and myocardial oxygen demand.[19]

If the patient becomes fatigued or uncomfortable or has a sudden change in heart rhythm or rate during a periodontal procedure, the procedure should be discontinued as soon as possible. A patient who has an anginal episode in the dental chair should receive the following emergency medical treatment:

1. Discontinue the periodontal procedure.
2. Administer 1 tablet (0.3 to 0.6 mg) of nitroglycerin sublingually.
3. Reassure the patient, and loosen restrictive garments.
4. Administer oxygen with the patient in a reclined position.
5. If the signs and symptoms cease within 3 minutes, complete the periodontal procedure if possible, making sure that the patient is comfortable. Terminate the procedure at the earliest convenient time.

6. If the anginal signs and symptoms do not resolve with this treatment within 2 to 3 minutes, administer another dose of nitroglycerin, monitor the patient's vital signs, call the patient's physician, and be ready to accompany the patient to the emergency department.
7. A third nitroglycerin tablet may be given 3 minutes after the second. Chest pain that is not relieved by three tablets of nitroglycerin indicates likely myocardial infarction. The patient should be transported to the nearest emergency medical facility immediately.

In recent years, nitroglycerin lingual spray formulations have been popular in hospital pharmacies because of the increased shelf life as compared to nitroglycerin tablets.[20] The lingual spray has been reported to provide a greater and more rapid vasodilation with a longer duration of action.[21,22] The convenience and advantages of a nitroglycerin lingual spray are appealing, but the accuracy of dose delivery has been questioned and warrants additional studies before it can be recommended to replace the known tablet regimen.[20]

Myocardial infarction (MI) is the other category of ischemic heart disease encountered in dental practice. Dental treatment is generally deferred for at least 6 months after MI because peak mortality occurs during this time.[23] After 6 months, MI patients can usually be treated using techniques similar to those for the stable angina patient.

Cardiac (aortocoronary) bypass, femoral artery bypass, angioplasty, and endarterectomy have become common surgical procedures in patients with ischemic heart disease. If one of these procedures was performed recently, the physician should be consulted before elective dental therapy to determine the degree of heart damage or arterial occlusive disease, the stability of the patient's condition, and the potential for infective endocarditis or graft rejection. Prophylactic antibiotics are not usually necessary for cardiac bypass patients unless recommended by the cardiologist.

Congestive Heart Failure

Congestive heart failure (CHF) is a condition in which the pump function of the heart is unable to supply sufficient amounts of oxygenated blood to meet the body's needs.[23] CHF usually begins with left ventricular failure caused by a disproportion between the hemodynamic load and the capacity to handle that load. CHF may be caused by a chronic increase in workload (as in hypertension or aortic, mitral, pulmonary, or tricuspid valvular disease), direct damage to the myocardium (as in MI or rheumatic fever), or an increase in the body's oxygen requirements (as in anemia, thyrotoxicosis, or pregnancy).

Patients with poorly controlled or untreated CHF are not candidates for elective dental procedures. These individuals are at risk for sudden death, usually from ventricular arrhythmias.[24] For patients with treated CHF, the clinician should consult with the physician regarding the severity of CHF, underlying etiology, and current medical management. Medical management of CHF may include use of calcium channel blockers, direct vasodilators, diuretics, angiotensin-converting enzyme (ACE) inhibitors, α-receptor blockers, and cardiotonic agents such as digoxin.[25,26] Each of these medications has potential side effects that may have an impact on periodontal therapy. Because of the presence of orthopnea (inability to breathe unless in an upright position) in some CHF patients, the dental chair should be adjusted to a comfortable level for the patient rather than being placed in a supine position. Short appointments, stress reduction with profound local anesthesia and possibly conscious sedation, and use of supplemental oxygen should be considered.[10,23]

Cardiac Pacemakers and Implantable Cardioverter-Defibrillators

Cardiac arrhythmias are most often treated with medications; however, some are also treated with implantable pacemakers or automatic cardioverter-defibrillators.[10,24,27] Pacemakers are usually implanted in the chest wall and enter the heart transvenously. Automatic cardioverter-defibrillators are more often implanted subcutaneously near the umbilicus and have electrodes passing into the heart transvenously or directly attached to the epicardium. Consultation with the patient's physician allows determination of the underlying cardiac status, the type of pacemaker or automatic cardioverter-defibrillator, and any precautionary measures to be taken. Older pacemakers were unipolar and could be disrupted by dental equipment that generated electromagnetic fields, such as ultrasonic and electrocautery units. Newer units are bipolar and are generally not affected by dental equipment. Automatic cardioverter-defibrillators activate without warning when certain arrhythmias occur. This may endanger the patient during dental treatment because such activation often causes sudden patient movement. Stabilization of the operating field during periodontal treatment with bite blocks or other devices can prevent unexpected trauma.

Infective Endocarditis

Infective endocarditis (IE) is a disease in which microorganisms colonize the damaged endocardium or heart valves.[28] Although the incidence of IE is low, it is a serious disease with a poor prognosis, despite modern therapy. The term *infective endocarditis* is preferred to the previous term *bacterial endocarditis* because the disease can also be caused by fungi and viruses. The organisms most often encountered in IE are α-hemolytic streptococci (e.g., *Streptococcus viridans*). However, nonstreptococcal organisms often found in the periodontal pocket have been increasingly implicated, including *Eikenella corrodens, Aggregatibacter actinomycetemcomitans, Capnocytophaga,* and *Lactobacillus* species.[29]

IE has been divided into acute and subacute forms. The *acute* form involves virulent organisms, generally nonhemolytic streptococci and strains of staphylococci, which invade normal cardiac tissue, produce septic emboli, and cause infections that run a rapid, generally fatal course. The *subacute* form, conversely, results from colony formation on damaged endocardium or heart valves by low-grade pathogenic organisms; the classic example is rheumatic carditis consequent to rheumatic fever.

Since the last American Heart Association (AHA) publication on prevention of IE in 1997,[30] many have questioned the efficacy of antimicrobial prophylaxis to prevent IE in patients who undergo dental or other procedures and have suggested that the AHA guidelines should be revised.[31,32] Members of the Rheumatic Fever, Endocarditis, and Kawasaki Disease Committee of the AHA Council on Cardiovascular Disease in the Young, and a national and international group of experts on IE extensively reviewed data published on the prevention of IE. The committee concluded that only an extremely small number of IE cases might be prevented by antibiotic prophylaxis for dental procedures (even if such therapy was 100% effective). Consequently, the guidelines were changed and published in a 2008 report.[33] The new guidelines advise that IE prophylaxis should only be recommended for cardiac conditions with the highest risk of adverse outcome from IE (Box 37-1). For these patients, antibiotic prophylaxis is recommended for all dental procedures that involve manipulation of the gingival tissues, periapical tissues, or perforation of the oral mucosa. Antibiotic prophylaxis is not indicated for individuals on the basis of an increased lifetime risk of contracting IE.

The practice of periodontics is intimately concerned with the prevention of IE. However, bacteremia may occur even in the absence of dental procedures, especially in individuals with poor oral hygiene and significant periodontal inflammation. In fact, IE is much more likely to result from frequent exposure to random bacteremias associated with daily activities than caused by a dental procedure.[33] Thus the prevention of periodontal inflammation is paramount. The AHA states that patients who are at risk for IE should "establish and maintain the best possible oral health to reduce potential sources of bacterial seeding." To provide adequate preventive measures for IE, the clinician's major concern should be to reduce the microbial population in the oral cavity so as to minimize soft tissue inflammation and bacteremia.

Preventive measures to reduce the risk of IE should consist of the following:

1. *Define the susceptible patient.* A careful medical history will disclose the previously mentioned susceptible patients. Health questioning should cover history of all potential categories of risk. If any doubt exists, the patient's physician should be consulted.
2. *Provide oral hygiene instruction.* Oral hygiene should be practiced with methods that improve gingival health. In patients with significant gingival inflammation, oral hygiene should initially be limited to gentle procedures (i.e., oral rinses and gentle toothbrushing with a soft brush) to minimize bleeding. As gingival health improves, more aggressive oral hygiene may be initiated. Oral irrigators are generally not recommended because their use may induce bacteremia.[34] Susceptible patients should be encouraged to maintain the highest level of oral hygiene once soft tissue inflammation is controlled.
3. *During periodontal treatment, currently recommended antibiotic prophylactic regimens* (Table 37-3) *should be practiced with all high-risk patients.* If any doubt regarding susceptibility exists, the patient's physician should be consulted. In patients who have been receiving continuous oral penicillin for secondary prevention of rheumatic fever, penicillin-resistant α-hemolytic streptococci are occasionally found in the oral cavity. It therefore is recommended that an alternate regimen be followed instead. Likewise, if the periodontal patient is taking a systemic antibiotic as part of periodontal therapy, changes in the IE prophylaxis regimen may be indicated. For example, a patient currently taking a penicillin agent after regenerative therapy may be placed on azithromycin before the next periodontal procedure. Patients with early-onset forms of periodontitis often have high levels of *A. actinomycetemcomitans* in the subgingival plaque. This organism has been associated with IE and is often resistant to penicillins. Therefore, in patients with aggressive periodontitis who should be given prophylaxis, Slots et al[35] suggested using tetracycline, 250 mg, four times daily for 14 days to eliminate or reduce *A. actinomycetemcomitans,* followed by the conventional prophylaxis protocol at the time of dental treatment.
4. *Periodontal treatment should be designed for susceptible patients to accommodate their particular degree of periodontal involvement.* The nature of periodontal therapy enhances the problems related to the prophylaxis of subacute

BOX 37-1 Cardiac Conditions Associated with the Highest Risk of Adverse Outcome from Endocarditis for Which Prophylaxis with Dental Procedures Is Recommended*

Previous history of infective endocarditis
Prosthetic cardiac valves or prosthetic material used for cardiac valve repair
Congenital heart disease (CHD), with the following conditions:
- Unrepaired cyanotic CHD, including palliative shunts and conduits
- Completely repaired congenital heart defect with prosthetic material or device, whether placed by surgery or by catheter intervention, during the first 6 months after the procedure
- Repaired CHD with residual defects at the site or adjacent to the site of a prosthetic patch or prosthetic device (which inhibit endothelialization)

Cardiac transplantation recipients who develop cardiac valvulopathy

*Recommendations by the American Heart Association.[33]

From Takahashi M, et al: Prevention of Infective Endocarditis: Guidelines from the American Heart Association, 116:1736, 2007.

TABLE 37-3 Recommended Antibiotic Prophylaxis Regimens for Periodontal Procedures in Adults at Risk for Infective Endocarditis

Regimen	Antibiotic	Dosage*
Standard oral regimen	Amoxicillin	2.0 g 30-60 minutes before procedure
Alternate regimen for patients allergic to amoxicillin/penicillin	Clindamycin	600 mg 30-60 minutes before procedure
	or	
	Azithromycin or clarithromycin	500 mg 30-60 minutes before procedure
	or	
	Cephalexin or cefadroxil*	2.0 g 30-60 minutes before procedure
Patients unable to take oral medications	Ampicillin	2.0 g intramuscularly or intravenously within 30 minutes before procedure
Patients unable to take oral medications and allergic to penicillin	Clindamycin	600 mg intravenously within 30 minutes before procedure (must be diluted and injected slowly)
	or	
	Cefazolin†	1.0 g intramuscularly or intravenously within 30 minutes before procedure

*Cephalosporins should not be used in patients with immediate-type hypersensitivity reactions to penicillins (e.g., urticaria, angioedema, anaphylaxis).

†Adult dosages listed. Children's dosages are lower.

IE. Patients are faced with long-term therapy, healing periods that extend beyond a 1-day antibiotic regimen, multiple visits, and procedures that easily elicit gingival bleeding.

The following guidelines should aid in the development of periodontal treatment plans for patients susceptible to IE:

- Periodontal disease is an infection with potentially wide-ranging systemic effects. In patients at risk for IE, every effort should be made to eliminate this infection. Teeth with severe periodontitis and a poor prognosis may require extraction. Teeth with less severe involvement in a motivated patient should be retained, treated, and maintained closely.
- All periodontal treatment procedures (including probing) require antibiotic prophylaxis; gentle oral hygiene methods are excluded. Pretreatment chlorhexidine rinses are recommended before all procedures, including periodontal probing, because these oral rinses significantly reduce the presence of bacteria on mucosal surfaces.[30]
- To reduce the number of visits required and thereby minimize the risk of developing resistant bacteria, numerous procedures may be accomplished at each appointment, depending on the patient's needs and ability to tolerate dental treatment.[10]
- When possible, allow at least 7 days between appointments (preferably 10 to 14 days). If this is not possible, select an alternative antibiotic regimen for appointments within a 7-day period.
- Evidence does not support or refute a need to place patients at risk for IE on extended antibiotic regimens after treatment.[10] Therefore patients who have had periodontal surgery are not generally placed on antibiotics for the first week of healing (unless there are specific indications to do so). If patients are placed on such regimens, the dosages are inadequate to prevent endocarditis during ensuing appointments. Therefore the standard prophylactic antibiotic dose is still needed. For example, if a patient was placed on 250 mg of amoxicillin three times a day for 10 days after periodontal surgery and was returning to the office for more treatment on the seventh day, the patient would still require a full 2.0-g dose of amoxicillin before that treatment. Alternatively, clindamycin or azithromycin could be used at the second appointment.
- Regular recall appointments, with an emphasis on oral hygiene reinforcement and maintenance of periodontal health, are extremely important for patients susceptible to IE.

Cerebrovascular Accident

A cerebrovascular accident (CVA), or stroke, results from ischemic changes (e.g., cerebral thrombosis caused by an embolus) or hemorrhagic phenomena. Hypertension and atherosclerosis are predisposing factors for CVA and should alert the clinician to evaluate the patient's medical history carefully for the possibility of early cerebrovascular insufficiency and to be aware of symptoms of the disease. A physician's referral should precede periodontal therapy if the signs and symptoms of early cerebrovascular insufficiency are evident.

To prevent a repeat stroke, active infections should be treated aggressively because even minor infection may alter blood coagulation and trigger thrombus formation and ensuing cerebral infarction. The clinician should counsel the patient about the importance of thorough oral hygiene.[36] Poststroke weakness of the facial area or paralysis of extremities may make oral hygiene procedures extremely difficult.[37] The clinician may need to modify oral hygiene instruments for ease of use, perhaps in consultation with an occupational therapist. Long-term chlorhexidine rinses may greatly aid in plaque control.

Dental clinicians should treat post-CVA patients with the following guidelines in mind:

1. No periodontal therapy (unless for an emergency) should be performed for 6 months because of the high risk of recurrence during this period.
2. After 6 months, periodontal therapy may be performed using short appointments with an emphasis on minimizing stress. Profound local anesthesia should be obtained using the minimal effective dose of local anesthetic agents. Concentrations of epinephrine greater than 1 : 100,000 are contraindicated.
3. Light conscious sedation (inhalation, oral, or parenteral) may be used for anxious patients. Supplemental oxygen is indicated to maintain thorough cerebral oxygenation.
4. Stroke patients are frequently placed on oral anticoagulants. Previously, it was thought that for procedures entailing significant bleeding, such as periodontal surgery or tooth extraction, the anticoagulant regimen may need adjustment, depending on the level of anticoagulation at which the patient is maintained. However, recent evidence regarding the risks of altering anticoagulation therapy suggests that it may be more prudent to provide treatment without changing it (see later section on anticoagulant/antiplatelet therapy). Any changes in anticoagulant therapy regimens for a stroke patient should always be done in consultation with the patient's physician.
5. BP should be monitored carefully. Recurrence rates for CVAs are high, as are rates of associated functional deficits.

Endocrine Disorders

Diabetes

The diabetic patient requires special precautions before periodontal therapy. The two major types of diabetes are *type 1* (formerly known as "insulin-dependent diabetes") and *type 2* (formerly called "non–insulin-dependent diabetes").[38] Over the past decade, the medical management of diabetes has changed significantly in an effort to minimize the debilitating complications associated with this disease.[39,40] Patients are more tightly managing their blood glucose levels (glycemia) through diet, oral agents, and insulin therapy.[41]

If the clinician detects intraoral signs of undiagnosed or poorly controlled diabetes, a thorough history is indicated.[42] The classic signs of diabetes include *polydipsia* (excessive thirst), *polyuria* (excessive urination), and *polyphagia* (excessive hunger, often with unexplained concurrent weight loss). If the patient has any of these signs or symptoms, or if the clinician's index of suspicion is high, further investigation with laboratory studies and physician consultation is indicated. Periodontal therapy has limited success in the presence of undiagnosed or poorly controlled diabetes.

If a patient is suspected of having undiagnosed diabetes, the following procedures should be performed:

1. Consult the patient's physician.
2. Analyze laboratory tests (Box 37-2): fasting blood glucose and casual glucose.[43]
3. Rule out acute orofacial infection or severe dental infection; if present, provide emergency care immediately.

BOX 37-2 Diagnostic Criteria for Diabetes Mellitus

Diabetes mellitus may be diagnosed by any one of three different laboratory methods. Whichever method is used, it must be confirmed on a subsequent day by using any one of the following three methods.

1. Symptoms of diabetes plus casual (nonfasting) plasma glucose ≥200 mg/dL. Casual glucose may be drawn at any time of day without regard to time since the last meal. Classic symptoms of diabetes include polyuria, polydipsia, and unexplained weight loss.
2. Fasting plasma glucose ≥126 mg/dL. "Fasting" is defined as no caloric intake for at least 8 hours. (Normal fasting glucose is 70-100 mg/dL.)
3. Two-hour postprandial glucose ≥200 mg/dL during an oral glucose tolerance test.* The test should be performed using a glucose load containing the equivalent of 75 g of anhydrous glucose dissolved in water. (Normal 2-hour postprandial glucose is <140 mg/dL.)

Data from American Diabetes Association: *Diabetes Care* 26(suppl 1):5, 2003.

*The third method is not recommended for routine clinical use.

BOX 37-3 Laboratory Evaluation of Diabetes Control: Glycosylated Hemoglobin (HbA1c) Assay*

4%-6%	Normal
<7%	Good diabetes control
7%-8%	Moderate diabetes control
>8%	Action suggested to improve diabetes control

*American Diabetes Association guidelines.

4. Establish best possible oral health through nonsurgical debridement of plaque and calculus; institute oral hygiene instruction. Limit more advanced care until diagnosis has been established and good glycemic control obtained.

If a patient is known to have diabetes, it is critical that the level of glycemic control be established before initiating periodontal treatment. The fasting glucose and casual glucose tests provide "snapshots" of the blood glucose concentration at the time the blood was drawn; these tests reveal nothing about long-term glycemic control. The primary test used to assess glycemic control in a known diabetic individual is the *glycosylated* (or glycated) *hemoglobin* (Hb) *assay* (Box 37-3). Two different tests are available, the HbA1 and the HbA1c assay; the HbA1c is used more often.[41] This assay has been shown by a large international study to provide an accurate measure of the average blood glucose concentrations over the preceding 2 to 3 months.[44] Table 37-4 lists the average blood glucose concentrations for HbA1c values from that study, and Figure 37-2 is a simplified graphic representation of the data. The therapeutic goal for many patients is to achieve and maintain an HbA1c below 8%. Patients with relatively well-controlled diabetes (HbA1c < 8%) usually respond to therapy in a manner similar to nondiabetic individuals.[45-47] Poorly controlled patients (HbA1c > 10%) often have a poor response to treatment, with more postoperative complications and less favorable long-term results[38,46] (see Figure 11-3). Improvements in HBA1c values after periodontal therapy may provide an indication of the potential response.

As discussed in Chapter 11, periodontal infection may worsen glycemic control and should be managed aggressively. Diabetic patients with periodontitis should receive oral hygiene instructions, mechanical debridement to remove local factors, and regular maintenance. When possible, an HbA1c of less than 10% should be established before surgical treatment is performed. Systemic antibiotics are not needed routinely, although recent evidence indicates that tetracycline antibiotics in combination with scaling and root planing may positively influence glycemic control. If the patient has poor glycemic control and surgery is absolutely needed, prophylactic antibiotics may be given; penicillins are most often used for this purpose. Frequent reevaluation after active therapy is needed to assess treatment response and prevent recurrence of periodontitis.

Almost all diabetic patients use glucometers for immediate blood glucose self-monitoring. These devices use capillary blood from a simple fingerstick to provide blood glucose readings in seconds. Diabetic patients should be asked whether they have glucometers and how often they use them. Because these devices provide instantaneous assessment of blood glucose, they are highly

TABLE 37-4 Comparison of HbA1c Values to Estimated Average Glucose Measurements

HbA1c (%)	Estimated Average Glucose (mg/dL)
5.0	97
5.5	111
6.0	126
6.5	140
7.0	154
7.5	169
8.0	183
8.5	197
9.0	212
9.5	226
10.0	240
10.5	255
11.0	269
11.5	283
12.0	298

HbA1c, glycosylated hemoglobin A1c.

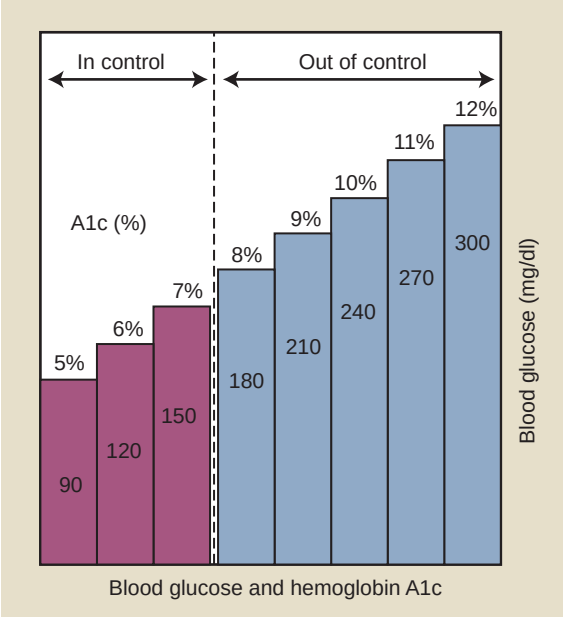

Figure 37-2 Graphic representation of glycosylated hemoglobin (Hb) A1c values and estimated average blood glucose.

beneficial in the dental office environment. The following guidelines should be observed:

1. Patients should be asked to bring their glucometer to the dental office at each appointment.
2. Patients should check their blood glucose before any long procedure to obtain a baseline level. Patients with blood glucose levels at or below the lower end of normal before the procedure may become hypoglycemic intraoperatively. It is advisable to have such a patient consume some carbohydrate before starting treatment. For example, if a 2-hour procedure is planned and the pretreatment glucose level is 70 mg/dL (lower end of normal range), providing 4 oz of juice preoperatively may help prevent hypoglycemia during treatment. If pretreatment glucose levels are excessively high, the clinician should determine whether or not the patient's glycemic control has been poor recently. This can be done by thorough patient questioning and by determining the most recent HbA1c values. If glycemic control has been poor over the preceding few months, the procedure may need to be postponed until better glycemic control is established. If glycemic control has been good, and the currently high glucometer reading is a fairly isolated event, the surgical procedure may proceed.
3. If the procedure lasts several hours, it is often beneficial to check the glucose level during the procedure to ensure that the patient does not become hypoglycemic.
4. After the procedure, the blood glucose can be checked again to assess fluctuations over time.
5. Any time the patient feels symptoms of hypoglycemia, blood glucose should be checked immediately. This may prevent onset of severe hypoglycemia, a medical emergency.

The most common dental office complication seen in diabetic patients taking insulin is symptomatic low blood glucose, or *hypoglycemia* (Box 37-4). Hypoglycemia is also associated with the use of numerous oral agents (Table 37-5). In patients receiving conscious sedation, the warning signs of an impending hypoglycemic episode may be masked, making the patient's glucometer one of the best diagnostic aids. Hypoglycemia does not usually occur until blood glucose levels fall below 60 mg/dL. However, in patients with poor glycemic control who have prolonged *hyperglycemia* (high blood glucose levels), a rapid drop in glucose can precipitate signs and symptoms of hypoglycemia at levels well above 60 mg/dL.

As medical management of diabetes has intensified over the last decade, the incidence of severe hypoglycemia has risen.[48] The clinician should question diabetic patients about past episodes of hypoglycemia. Hypoglycemia is more common in patients with better glycemic control. When planning dental treatment, it is best to schedule appointments before or after periods of peak insulin activity. This requires knowledge of the pharmacodynamics of the drugs being taken by the diabetic patient. Patients taking insulin are at greatest risk, followed by those taking sulfonylurea agents.

BOX 37-4 Signs and Symptoms of Hypoglycemia

Shakiness or tremors	Dizziness
Confusion	Feeling of "impending doom"
Agitation and anxiety	Unconsciousness
Sweating	Seizures
Tachycardia	

TABLE 37-5 Oral Agents Used in Management of Diabetes

Agent	Action	Risk of Hypoglycemia
Sulfonylureas (first generation): Chlorpropamide Tolbutamide Tolazamide	Stimulate pancreatic insulin secretion	++
Sulfonylureas (second generation): Glyburide Glipizide	Stimulate pancreatic insulin secretion	+++
Sulfonylureas (third generation): Glimepiride	Stimulate pancreatic insulin secretion	+
Meglitinides: Repaglinide Nateglinide	Stimulate rapid pancreatic insulin secretion (different mechanism than sulfonylureas)	+
Biguanides: Metformin	Block production of glucose by liver; improve tissue sensitivity to insulin	–
Thiazolidinediones: Rosiglitazone Pioglitazone	Improve tissue sensitivity to insulin	–
α-Glucosidase inhibitors: Acarbose Miglitol	Slow absorption of some carbohydrates from gut, decreasing postprandial peaks in glycemia	–
Dipeptidyl peptidase-4 (DPP-4) inhibitors: Sitagliptin Saxagliptin	Inhibit the enzyme DPP-4; enable the pancreas to produce more insulin but only after food ingestion	–
Combination agents	Combine two different oral agents into single drug	Risk depends on which drugs are combined

TABLE 37-6 Types of Insulin

Type	Classification	ACTIVITY		
		Onset	Peak	Duration
Lispro; Aspart; Glulisine	Rapid acting	15 minutes	30-90 minutes	<5 hours
Regular	Short acting	30-60 minutes	2-3 hours	4-12 hours
NPH	Intermediate acting	2-4 hours	4-10 hours	14-18 hours
Levemir	Long acting	1-2 hours	Relatively flat	up to 24 hours
Glargine	Long acting	6-8 hours	"Peakless" (has no peak in activity)	20-24+ hours

Metformin and thiazolidinediones generally do not cause hypoglycemia (see Table 37-5).

Insulins are classified as rapid-acting, short-acting, intermediate-acting, or long-acting agents (Table 37-6). The categories vary in their onset, peak, and duration of activity. It is important that the clinician establish exactly which insulins the diabetic patient takes, the amount, the number of times per day, and the time of the last dose. Periodontal treatment often can be timed to avoid peak insulin activity. Many diabetic patients take multiple injections each day, in which case it is difficult, if not impossible, to avoid peak insulin activity. Checking the pretreatment glucose with the patient's glucometer, checking again during long procedures, and checking again at the end of the procedure provides a better understanding of the patient's insulin pharmacodynamics and help prevent hypoglycemia.

If hypoglycemia occurs during dental treatment, therapy should be immediately terminated. If a glucometer is available, the blood glucose level should be checked. Treatment guidelines include the following[41]:

1. Provide approximately 15 g of oral carbohydrate to the patient:
   - 4 to 6 oz of juice or soda
   - 3 or 4 tsp of table sugar
   - Hard candy with 15 g of sugar
2. If the patient is unable to take food or drink by mouth, or if the patient is sedated:
   - Give 25 to 30 mL of 50% dextrose intravenous (IV), which provides 12.5 to 15.0 g of dextrose, or
   - Give 1 mg of glucagon IV (glucagon results in rapid release of stored glucose from the liver), or
   - Give 1 mg of glucagon intramuscularly or subcutaneously (if no IV access).

Emergencies resulting from hyperglycemia are rare in the dental office. They generally take days to weeks to develop. However, the glucometer may be used to rule out hyperglycemic emergencies such as diabetic ketoacidosis, a life-threatening event.

Because periodontal therapy may render the patient unable to eat for some time, adjustment in insulin or oral agent dosages may be required. It is absolutely critical that patients eat their normal meal before dental treatment. Taking insulin without eating is the primary cause of hypoglycemia. If the patient is restricted from eating before treatment (e.g., for conscious sedation), normal insulin doses will need to be reduced. As a general guideline, *well-controlled diabetic patients having routine periodontal treatment may take their normal insulin doses as long as they also eat their normal meal.* If the procedures are going to be particularly long, the insulin dose before treatment may need to be reduced. Likewise, if the patient will have dietary restrictions after treatment, insulin or sulfonylurea dosages may need to be reduced.

Consultation with the patient's physician is prudent and allows both practitioners to review the proposed treatment plan and determine any modifications needed. When periodontal surgery is indicated, it is usually best to limit the size of the surgical fields so that the patient will be comfortable enough to resume a normal diet immediately.

Hemorrhagic Disorders

Patients with a history of bleeding problems caused by disease or drugs should be managed to minimize risks of hemorrhage. Identification of these patients through the health history, clinical examination, and clinical laboratory tests is paramount. Health questioning should cover (1) history of bleeding after previous surgery or trauma, (2) past and present drug history, (3) history of bleeding problems among relatives, and (4) illnesses associated with potential bleeding problems.

Clinical examination should detect the presence of jaundice, ecchymosis, spider telangiectasia, hemarthrosis, petechiae, hemorrhagic vesicles, spontaneous gingival bleeding, and gingival hyperplasia. Laboratory tests should include methods to measure the hemostatic, coagulation, or lytic phases of the clotting mechanism, depending on clues regarding which phase is involved (Table 37-8). These tests include bleeding time, tourniquet test, complete blood cell count, prothrombin time (PT), partial thromboplastin time (PTT), and coagulation time.

Bleeding disorders may be classified as coagulation disorders, thrombocytopenic purpuras, or nonthrombocytopenic purpuras.

Coagulation Disorders

The main inherited coagulation disorders include hemophilia A, hemophilia B, and von Willebrand disease[42,56] (Table 37-9). *Hemophilia A* results in a deficiency of coagulation factor VIII, and the clinical severity of the disorder depends on the level of factor VIII remaining.[57] Patients with severe hemophilia who have less than 1% of normal factor VIII levels may have severe bleeding on the slightest provocation, whereas those with more moderate hemophilia (1% to 5% factor VIII) have less frequent spontaneous hemorrhage but still bleed with minimal trauma.[10] Patients with mild hemophilia (6% to 30% factor VIII) rarely bleed spontaneously but may still have hemorrhage after severe trauma or during surgical procedures. The clinician should consult the patient's physician before dental treatment to determine the risk for bleeding and treatment modifications required. To prevent surgical hemorrhage, factor VIII levels of at least 30% are needed.[10,57] Parenteral 1-deamino-8-D-arginine vasopressin (DDAVP; desmopressin) can be used to raise factor VIII levels twofold to threefold in patients with mild or moderate hemophilia. DDAVP has the significant advantage of avoiding the risk of viral disease transmission from factor VIII infusion and is considered the drug of choice in responsive patients. Most patients with moderate and severe hemophilia require infusion of factor VIII concentrate before surgical procedures. Before 1985, the risk of viral disease transmission from

TABLE 37-8 Laboratory Tests for Bleeding Disorders

HEMOSTATIC TESTS			
Vascular	**Platelet**	**Coagulation**	**Lytic**
1. Tourniquet test *N:* 10 petechiae *Abn:* >10 petechiae	1. Platelet count *N:* 150,000-300,000/mm^3 *Abn:* Thrombocytopenia occurs at <100,000/mm^3; clinical bleeding occurs at <80,000/mm^3; spontaneous bleeding occurs at <20,000/mm^3. 2. Bleeding time 3. Clot retraction 4. Complete blood cell count	1. PT measures extrinsic and common pathways: factors I, II, V, VII, and X. *N:* 11-14 s (depending on laboratory) measured against control PT reported as international normalized ratio (INR): *N:* INR = 1.0 *Abn:* INR >1.5	1. Euglobin clot lysis time *N:* <90 min *Abn:* >90 min
2. Bleeding time *N:* 1-6 min *Abn:* >6 min		2. PTT measures intrinsic and common pathways: factors III, IX, XI, and low levels of factors I, II, V, X, and XII. *N:* 25-40 s (depending on laboratory) measured against control *Abn:* >1.5 times normal 3. Clotting (coagulation) time *N:* 30-40 min *Abn:* >1 h	
Clinical Disease Association			
Vascular (capillary) wall defect *Rule out:* Thrombocytopenia Purpuras Telangiectasia Aspirin or NSAID therapy Leukemia Renal dialysis	Thrombocytopenia *Rule out:* Vascular wall defect Acute/chronic leukemia Aplastic anemia Liver disease Renal dialysis	*All three tests:* Liver disease Warfarin therapy Aspirin or NSAID therapy Malabsorption syndrome or long-term antibiotic therapy (lack of vitamin K utilization) PT: Factor VII deficiency PTT: Hemophilia Renal dialysis	Increase in fibrinolytic activity

N, Normal; *Abn,* abnormal; *PT,* prothrombin time; *PTT,* partial thromboplastin time; *NSAID,* nonsteroidal antiinflammatory drug.

TABLE 37-9 Inherited Coagulation Disorders

Type	Prolonged	Normal	Treatment
Hemophilia A	PTT	PT Bleeding time	DDAVP (desmopressin) factor VIII concentrate or cryoprecipitate Fresh-frozen plasma Fresh whole blood ε-Aminocaproic acid (Amicar) Tranexamic acid
Hemophilia B	PTT	PT Bleeding time	Purified prothrombin complex concentrates Factor IX concentrates Fresh-frozen plasma
Von Willebrand disease	Bleeding time PTT Variable factor VIII deficiency	PT Platelet count	DDAVP (desmopressin) factor VIII concentrate or cryoprecipitate

PT, Prothrombin time; *PTT,* partial thromboplastin time; *DDAVP,* 1-deamino-8-D-arginine vasopressin.

these infusions was high. In recent years, virally safe, highly purified monoclonal antibody or recombinant DNA factor VIII products have come into widespread use.

Hemophilia B, or Christmas disease, results in a deficiency of factor IX. The severity of the disorder depends on the relative amount of existing factor IX. Surgical therapy requires a factor IX level of 30% to 50% and is usually achieved by administration of purified prothrombin complex concentrates or factor IX concentrates.[57]

von Willebrand disease results from a deficiency of von Willebrand factor, which mediates adhesion of platelets to the injured vessel wall and is required for primary hemostasis. von Willebrand factor also carries the coagulant portion of factor VIII in the plasma. The disorder has three major subtypes with a wide range of clinical severity. In fact, many cases of von Willebrand disease go undiagnosed, and bleeding during dental treatment may be the first sign of the underlying disease. More severe forms require preoperative factor VIII concentrate or cryoprecipitate infusion. Patients with milder forms respond favorably to administration of DDAVP before periodontal surgery or tooth extraction.[57,58]

Periodontal treatment may be performed in patients with these coagulation disorders, provided that sufficient precautions are taken. Probing, scaling, and prophylaxis can usually be done without medical modification. More invasive treatment, such as local block anesthesia, root planing, or surgery, dictate prior physician consultation.

During treatment, local measures to ensure clot formation and stability are of major importance. Complete wound closure and application of pressure will reduce hemorrhage. Antihemostatic agents, such as oxidized cellulose or purified bovine collagen, may be placed over surgical sites or into extraction sockets. The antifibrinolytic agent *ε-aminocaproic acid* (Amicar), given orally or via IV, is a potent inhibitor of initial clot dissolution.[59] *Tranexamic acid* is a more potent antifibrinolytic agent than Amicar and has been shown to prevent excessive oral hemorrhage after periodontal surgery and tooth extraction.[60] It is available as an oral rinse and may be used either alone or in combination with systemic tranexamic acid for several days after surgery.[61]

Not all coagulation disorders are hereditary. Liver disease may affect all phases of blood clotting because most coagulation factors are synthesized and removed by the liver. Long-term alcohol abusers or chronic hepatitis patients often demonstrate inadequate coagulation. Coagulation may be impaired by vitamin K deficiency, often caused by malabsorption syndromes, or by prolonged antibiotic administration, which alters the intestinal microflora that produces vitamin K. Dental treatment planning for patients with liver disease should include the following:

1. Physician consultation.
2. Laboratory evaluations: PT, bleeding time, platelet count, and PTT (in patients in later stages of liver disease).
3. Conservative, nonsurgical periodontal therapy, whenever possible.
4. If surgery is required (may require hospitalization):
   - International normalized ratio (INR; PT) should generally be less than 2.0. For simple surgical procedures, INR less than 2.5 is generally safe.[62]
   - Platelet count should be *more* than 80,000/mm^3.

Anticoagulant Medications. The most common cause of abnormal coagulation may be drug therapy. Patients with prosthetic heart valves or histories of MI, CVA, or thromboembolism are frequently placed on anticoagulant therapy using coumarin derivatives such as dicumarol and warfarin.[62,63] These drugs are vitamin K antagonists that decrease production of vitamin K–dependent coagulation factors II, VII, IX, and X. The effectiveness of anticoagulation therapy is monitored by PT laboratory test. The recommended level of therapeutic anticoagulation for most patients is an INR of 2.0 to 3.0, with prosthetic heart valve patients generally in the 2.5 to 3.5 range.[62] Traditional recommendations for periodontal treatment are as follows:

1. Consult the patient's physician to determine the nature of the underlying medical problem and the degree of required anticoagulation.
2. The procedure to be done determines the acceptable INR. Infiltration anesthesia, scaling, and root planing may be done safely in patients with an INR less than 3.0. Block anesthesia, minor periodontal surgery, and simple extractions usually require an INR less than 2.0 to 2.5. Complex surgery or multiple extractions may require an INR less than 1.5 to 2.0.
3. The physician must be consulted about any changes (discontinuing or reducing) in anticoagulant dosage until the desired INR is achieved. The dentist must inform the physician what degree of intraoperative and postoperative bleeding is usually expected with the procedures planned. If the INR is higher than the level at which significant bleeding is likely to accompany a particular procedure, the physician may elect to change anticoagulant therapy. Often, the anticoagulant is discontinued for 2 to 3 days before periodontal treatment (clearance half-life of warfarin is 36 to 42 hours), and the INR is checked on the day of therapy. If the INR is within the acceptable target range, the procedure is done and the anticoagulant resumed immediately after treatment.
4. Careful technique and complete wound closure are paramount. For all procedures, application of pressure can minimize hemorrhage. Use of oxidized cellulose, microfibrillar collagen, topical thrombin, and tranexamic acid should be considered for persistent bleeding.

NOTE: Discontinuing anticoagulant therapy before dental surgery (as previously stated) was common in the past. However, many clinicians may no longer recommend discontinuing anticoagulation for many procedures because this has significant potential risks to patient health.[64,65] Recent evidence related to the risks of altering anticoagulant therapy along with the lack of evidence for bleeding complications suggest that treating patients without reducing or discontinuing medications may be more prudent. See later section on anticoagulant/antiplatelet therapy under section for a detailed explanation of these more recent considerations.

Heparin is generally used for short-term anticoagulation and is given IV (usually in a hospital environment). It is a powerful anticoagulant with a duration of action of 4 to 8 hours. Periodontal treatment is rarely required while a patient is taking heparin.

Antiplatelet Medications. Aspirin interferes with normal platelet aggregation and can result in prolonged bleeding. Because it binds irreversibly to platelets, the effects of aspirin last at least 4 to 7 days. Aspirin is generally used in small doses of 325 mg or less per day, which usually does not alter bleeding time. In general, patients taking low doses of aspirin daily do not need to discontinue aspirin therapy before periodontal procedures.[65] However, higher doses may increase bleeding time and predispose the patient to postoperative bleeding.[10] For patients taking more than 325 mg of aspirin per day, aspirin may need to be discontinued 7 to 10 days before surgical therapy that might result in significant bleeding, in consultation with the physician. Nonsteroidal antiinflammatory drugs (NSAIDs), such as ibuprofen, also inhibit platelet function.

Because NSAIDs bind reversibly, the effect is transitory, lasting only a short time after the last drug dose. The bleeding time is used when questions arise about the potential effect of aspirin or NSAIDs. Aspirin should not be prescribed for patients who are receiving anticoagulation therapy or who have illnesses related to bleeding tendencies.

Leukemia

Altered periodontal treatment for patients with leukemia is based on their enhanced susceptibility to infections, bleeding tendency, and the effects of chemotherapy.[10] The treatment plan for leukemia patients is as follows:

1. Refer the patient for medical evaluation and treatment. Close cooperation with the physician is required.
2. Before chemotherapy, a complete periodontal treatment plan should be developed with a physician (see previous discussion).
   - Monitor hematologic laboratory values daily: bleeding time, coagulation time, PT, and platelet count.
   - Administer antibiotic coverage before any periodontal treatment because infection is a major concern.
   - Extract all hopeless, nonmaintainable, or potentially infectious teeth at least 10 days before the initiation of chemotherapy, if systemic conditions allow.
   - Periodontal debridement (scaling and root planing) should be performed and thorough oral hygiene instructions given if the patient's condition allows. Twice-daily rinsing with 0.12% chlorhexidine gluconate is recommended after oral hygiene procedures. Recognize the potential for bleeding caused by thrombocytopenia. Use pressure and topical hemostatic agents as indicated.
3. During the acute phases of leukemia, patients should receive only emergency periodontal care. Any source of potential infection must be eliminated to prevent systemic dissemination. Antibiotic therapy is frequently the treatment of choice, combined with nonsurgical or surgical debridement as indicated.
4. Oral ulcerations and mucositis are treated palliatively with agents such as viscous lidocaine. Systemic antibiotics may be indicated to prevent secondary infection.
5. Oral candidiasis is common in the leukemic patient and can be treated with nystatin suspensions (100,000 U/mL four times daily) or clotrimazole vaginal suppositories (10 mg four or five times daily).[66]
6. For patients with chronic leukemia and those in remission, scaling and root planing can be performed without complication, but periodontal surgery should be avoided if possible.
   - Platelet count and bleeding time should be measured on the day of the procedure. If either is low, postpone the appointment and refer the patient to a physician.

Agranulocytosis

Patients with agranulocytosis (cyclic neutropenia and granulocytopenia) have an increased susceptibility to infection. The total white blood cell count is reduced, and granular leukocytes (neutrophils, eosinophils, basophils) are reduced or disappear. These disorders are often marked by early, severe periodontal destruction.[67] When possible, periodontal treatment should be done during periods of disease remission. At such times, treatment should be as conservative as possible while reducing potential sources of systemic infection. After physician consultation, severely affected teeth should be extracted. Oral hygiene instruction should include use of chlorhexidine rinses twice daily. Scaling and root planing should be performed carefully under antibiotic protection.

Medications and Cancer Therapies

Some medications prescribed to cure, manage, or prevent diseases have effects on periodontal tissues, wound healing, or the host immune response that require an understanding, appreciation, and in some cases, modification of treatment. Bisphosphonates, anticoagulation medications, antiplatelet medications, steroids, chemotherapy, and radiation therapy are briefly addressed here. Readers are encouraged to seek additional information and advice from other sources.

Bisphosphonates

Bisphosphonate medications are primarily used to treat cancer (IV administration) and osteoporosis (oral administration). They act by inhibiting osteoclastic activity, which leads to less bone resorption, less bone remodeling, and less bone turnover.[74] The use of bisphosphonates in cancer treatment is aimed at preventing the often lethal imbalance of osteoclastic activity. In the treatment of osteoporosis, the goal is simply to harness osteoclastic activity to minimize or prevent bone loss. The major difference in the use of bisphosphonates for cancer versus osteoporosis is the potency and route of administration. Potency is influenced by the chemical properties and pharmacokinetics of these agents with bone. See Chapter 11 for a description of the chemical structure, activity, and role of bisphosphonates in the development of bisphosphonate-related osteonecrosis of the jaw (BRONJ).

Clinically, BRONJ presents as exposed alveolar bone occurring spontaneously or after a dental procedure (see Figures 11-29 and 11-30). Individuals treated with high potency, nitrogen-containing bisphosphonates, especially those administered via IV for cancer treatment (e.g., zoledronate), appear to be at greater risk for BRONJ than individuals taking oral bisphosphonates for prevention and treatment of osteoporosis. The incidence in patients treated for cancer has been reported to range from 2.5% to 5.4%.[75] Estimating the incidence in patients taking oral bisphosphonates for osteoporosis is more difficult but appears to range from 0.007% to 0.04%.[76] Even if this is an underestimation of the actual risk for individuals taking oral bisphosphonates, the incidence appears to be low. The risk for individuals treated with oral bisphosphonates for a period of less than 3 years appears to be minimal or zero.[77] Regular use of oral bisphosphonates for a period greater than 3 years suggests a risk profile that increases with time and length of use.[77]

As with many multifactorial diseases and conditions, it is likely that factors in addition to bisphosphonate therapy contribute to the individual risk of BRONJ. Potential risk factors thought to contribute to the development of BRONJ include systemic corticosteroid therapy, smoking, alcohol, poor oral hygiene, chemotherapy, radiotherapy, diabetes, and hematologic disease.[21] Reported factors or conditions leading to BRONJ include extractions, root canal treatment, periodontal infections, periodontal surgery, and dental implant surgery.[78] Clearly, both periodontal disease and treatment (especially surgery) pose a risk for patients treated with bisphosphonates. The bacterial-induced inflammatory process of periodontitis that causes bone resorption can lead to bone necrosis. Likewise, periodontal treatment, especially surgery, may cause bone necrosis in the presence of bisphosphonates. Caution is warranted for any patient who has been or will be treated with bisphosphonates.

Healthcare providers need to evaluate patients carefully, communicate with medical healthcare providers, inform patients, and consider treatment options and risks carefully. A careful intraoral examination is prudent for all patients treated with bisphosphonate therapy (IV or oral) to determine whether bone exposures exist and to assess any local conditions that might predispose them to the

TABLE 37-10 C-Terminal Telopeptide Laboratory Risk Assessment for Bisphosphonate Therapy

C-Terminal Telopeptide (CTX) Value	Risk for BRONJ
300-600 pg/mL (normal)	None
150-299 pg/mL	None or minimal
101-149 pg/mL	Moderate
≤100 pg/mL	High

BRONJ, Bisphosphonate-related osteonecrosis of the jaw.

Data from Marx RE: *Oral and intravenous bisphosphonate-induced osteonecrosis of the jaws,* Hanover Park, MD, 2007, Quintessence.

development of BRONJ. A thorough medical history should be reviewed, evaluated, and recorded with details about any bisphosphonate treatment, including medication type, dose, route of administration, and duration. Comorbidities, such as previous and current medications, treatments, and existing disease or pathology, should be considered. Radiographs should be carefully evaluated for signs of bisphosphonate toxicity. Finally, Marx has suggested that a laboratory blood test for the serum C-terminal telopeptide fragment of type I collagen (CTX) can be used as a means of assessing an individual's risk of developing BRONJ.[77] Marx reports that lower CTX values are associated with greater risk (Table 37-10). It is important to recognize that these values are based on retrospective evaluation of patients with osteonecrosis of the jaws and that prospective studies to validate these findings have not been done. The CTX laboratory test is a measure of the specific C-terminal fragment of type I collagen cleaved by osteoclasts and serves as a good indicator of bone resorption activity. However, its use as a measure of risk for BRONJ is controversial and not confirmed by prospective studies.

Optimal periodontal/oral health should be achieved and maintained for all patients. For individuals treated with IV bisphosphonates, invasive treatment, such as extractions, periodontal surgery, implant surgery, and bone augmentation procedures, should be avoided. Caution and careful consideration of risks must be considered before any treatment for individuals with a history of taking oral bisphosphonates for periods longer than 3 years. This is an area of current research that will undoubtedly continue to evolve as the pathophysiology is better understood. Providers are encouraged to consult other sources for updates on this important topic.

Anticoagulant/Antiplatelet Therapy

Many patients with a variety of conditions are placed on anticoagulant or antiplatelet medications to prevent thrombosis (blood clotting) or thromboembolism. Examples of patients at risk who may be on anticoagulant or antiplatelet therapy include those with heart value replacements, heart rhythm disorders, and congenital heart defects, as well as individuals with a history or risk of myocardial infarction, stroke, or deep vein thrombosis. These medications, although effective in reducing the risk of thrombosis, may increase the risk for bleeding complications, especially in patients undergoing surgical procedures.

As stated earlier, traditional management of patients on anticoagulant or antiplatelet therapy was to discontinue therapy about 3 to 5 (antiplatelet) or 7 to 10 (anticoagulant) days before planned surgical procedures. Recent evidence and new thoughts regarding the management of patients on anticoagulant or antiplatelet therapy suggest that treating them (e.g., periodontal surgery, extractions, etc) without altering their anticoagulant/antiplatelet mediations is safe and does not lead to intraoperative or postoperative bleeding complications. Furthermore, the increased risk of morbidity and mortality in those individuals discontinuing the anticoagulant or antiplatelet therapy may be significant.

Controlled clinical studies have demonstrated that intraoperative bleeding is not likely to be a problem with simple extractions or periodontal surgery if antiplatelet therapy (e.g., aspirin) is continued.[79,80] In these studies, there were no episodes of uncontrolled bleeding, all bleeding was controlled with local measures, and there were no cases of postoperative bleeding problems. Conversely, the risk of stopping antiplatelet therapy may be serious. In a retrospective evaluation of 52 patients undergoing cataract surgery, 1 in 10 whose antiplatelet therapy was stopped or reduced suffered a stroke.[81]

Similarly, clinical studies of patients on anticoagulant therapy undergoing extractions and other oral surgical procedures have demonstrated minimal bleeding problems when therapy is continued.[82-86] In a review of the literature, Wahl et al[85] reported that only 12 patients (<1.3%, 950 total) receiving continuous anticoagulant therapy required more than local measures to control hemorrhage after minor oral surgical procedures (2400 total). Most of the 950 patients had anticoagulation levels that were well above currently recommended therapeutic levels. Only three patients (<0.31%) had anticoagulation levels within or below currently recommended therapeutic levels. In contrast, 5 of 526 (0.95%) patients who experienced 575 interruptions of continuous anticoagulant therapy, suffered serious embolic complications; 4 of these patients died. In a prospective study of 131 patients undergoing 511 extractions, patients whose oral anticoagulant therapy was reduced 72 hours before surgery to achieve an INR of 1.5 to 2.0 (target 1.8) were found to have postoperative bleeding warranting subsequent local intervention in 10 cases (15.1%).[87] There were only six cases (9.2%) in the group that continued their oral anticoagulant therapy (mean INR = 2.9).

These studies suggest that the risks of serious morbidity associated with discontinuing anticoagulant or antiplatelet therapy should be avoided and that the risk of bleeding while maintaining this therapy is minimal.

Corticosteroids

Approximately 5% of the adults in the United States habitually take corticosteroids for the treatment of various conditions, potentially putting them at risk for secondary adrenal insufficiency.[55] Patients who habitually use corticosteroids have an increased likelihood of developing hypertension, osteoporosis, and peptic ulcer disease. Care should be taken to minimize the risk of adverse outcomes in these patients. BP should be monitored, and medications that may exacerbate peptic ulceration (e.g., acetylsalicylic acid [ASA], NSAIDs) should be avoided.

Stressful events, such as trauma, illness, surgery, emotional upset, or athletic events, normally increase circulating endogenous cortisol levels through stimulation of the HPA axis. Pain appears to increase the requirement for cortisol release.[88] There is concern that the normal release of cortisol in response to stressful events, such as a dental procedure, may be impaired in patients exposed to habitual corticosteroid use. Hence the concern for whether patients who are habitually taking corticosteroids require perioperative supplementation for dental procedures. Historically, recommendations were based on the medication type, amount, and duration of corticosteroid use. However, current thinking about the need for perioperative corticosteroid supplementation has been adjusted.

Studies investigating the stress response to minor general and oral surgical procedures conclude that significant increases in

cortisol are generally not seen until 1 to 5 hours after surgery and appear to be associated more with postoperative pain and the loss of local anesthesia than with the preoperative and intraoperative stress of the procedure.[89-91] In fact, the administration of adequate analgesics in the postoperative period can diminish the release (requirement) of cortisol.[89]

Evidence indicates that a vast majority of individuals with adrenal insufficiency can receive routine dental treatment without the need for supplemental glucocorticosteroids.[54,55] Patients currently taking corticosteroids generally have enough exogenous and endogenous cortisol to handle routine dental procedures if their usual dose is taken within 2 hours of the planned procedure. Thus, for most patients, supplemental corticosteroid administration is not required when uncomplicated minor surgical procedures, including periodontal surgery, are performed with local anesthesia with or without sedation.[55] Topical corticosteroids generally have minimal HPA effect, and steroid supplementation is not required for these patients.

Individuals who may be at risk for adrenal crisis requiring supplementation include those who are undergoing lengthy, major surgical procedures, those expected to have significant blood loss and those who have extremely low adrenal function. Low adrenal function can be identified with an ACTH stimulation test. For these individuals, consultation with the physician and steroid supplementation is indicated.

Immunosuppression and Chemotherapy

Immunosuppressed patients have impaired host defenses as a result of an underlying immunodeficiency or drug administration (primarily related to organ transplantation or cancer chemotherapy).[92,93] Because chemotherapy is often cytotoxic to bone marrow, destruction of platelets and red and white blood cells results in thrombocytopenia, anemia, and leukopenia. Immunosuppressed individuals are at greatly increased risk for infection, and even minor periodontal infections can become life threatening if immunosuppression is severe.[42,94] Intraorally, bacterial, viral, and fungal infections may manifest. Patients receiving bone marrow transplantation require special attention because these patients receive extremely high-dose chemotherapy and are particularly susceptible to dissemination of oral infections.

Treatment in these patients should be directed toward the prevention of oral complications that could be life threatening. The greatest potential for infection occurs during periods of extreme immunosuppression; therefore treatment should be conservative and palliative. It is always preferable to evaluate the patient before initiation of chemotherapy.[92,93] Teeth with a poor prognosis should be extracted, with thorough debridement of remaining teeth to minimize the microbial load. The clinician must teach and emphasize the importance of good oral hygiene. Antimicrobial rinses, such as chlorhexidine, are recommended, especially for patients with chemotherapy-induced mucositis, to prevent secondary infection.

Chemotherapy is usually performed in cycles, with each cycle lasting several days, followed by intervening periods of myelosuppression and recovery. If periodontal therapy is needed during chemotherapy, it is best done the day *before* chemotherapy is given, when white blood cell counts are relatively high. Coordination with the oncologist is critical. Dental treatment should be done when white cell counts are above 2000/mm^3, with an absolute granulocyte count of 1000 to 1500/mm^3.[10]

Radiation Therapy

The use of radiotherapy, alone or in conjunction with surgical resection, is common in the treatment of head and neck tumors. The side effects of ionizing radiation include dramatic perioral changes of significant concern to dental health personnel.[5,66,95] The extent and severity of mucositis, dermatitis, xerostomia, dysphagia, gustatory alteration, radiation caries (Figure 37-3), vascular changes, trismus, temporomandibular joint degeneration, and periodontal change depend on the type of radiation used, fields of irradiation, number of ports, types of tissues in the fields, and dosage.

Patients scheduled to receive head and neck radiation therapy require dental consultation *at the earliest possible time* to reduce the morbidity of the known perioral side effects.[96] *Preirradiation treatment* depends on the patient's prognosis, compliance, and residual dentition in addition to the fields, ports, dose, and immediacy of radiotherapy. The initial visit should include panoramic and intraoral radiographs, a clinical dental examination, a periodontal evaluation, and a physician consultation. The physician should be asked about the amount of radiation to be administered, extent and location of the lesion, nature of any surgical procedures already performed or to be performed, number of radiation ports, exact fields to be irradiated, mode of radiation therapy, and patient's prognosis (i.e., likelihood of metastasis). Preirradiation treatment should commence immediately after the physician consultation. The first decision should involve possible extractions because radiation can cause side effects that interfere with healing.

For head and neck squamous cell carcinomas, the radiation dose is usually 5000 to 7000 cGy (centigray; 1 cGy = 1 rad) delivered in a fractionated method (150-200 cGy/day over a 6- to 7-week course).[66,97] This is considered "full-course" radiation treatment, and the degree of perioral side effects depends on which tissues are irradiated, that is, the radiation fields. If this dose is administered to the salivary gland tissues, xerostomia will ensue. The parotid is the most radiosensitive of the salivary glands; saliva may become extremely viscous or nonexistent, depending on the dose delivered to the particular gland. Xerostomia causes a decrease in the normal salivary cleansing mechanisms, buffering capacity of saliva, and pH of oral fluids.[66] Oral bacterial populations shift to a preponderance of cariogenic forms (e.g., *Streptococcus mutans, Actinomyces* spp., *Lactobacillus* spp.). Radiation-induced caries may progress rapidly and primarily affects smooth tooth surfaces (see Figure 37-3).

High-dose radiation therapy results in hypovascularity of irradiated tissues with a reduction in wound-healing capacity.[37,98,99] Most severe among the resulting oral complications is *osteoradionecrosis* (ORN). Decreased vascularity renders the bone less capable of resolving trauma or infection. Such events may cause severe destruction of bone. The risk of ORN continues for the remainder of the patient's life and does not decrease with time.[100]

Periodontal disease can be a precipitating factor in ORN.[101,102] Tooth extraction after radiation treatment involves a high risk for developing ORN, and surgical flap procedures are generally discouraged after radiation. For these reasons, it is important that the clinician address the patient's periodontal disease *before* radiation begins, whenever possible. Teeth that are nonrestorable or severely periodontally diseased should be extracted, ideally at least 2 weeks before radiation.[66] Extractions should be performed in a manner that allows primary closure. Mucoperiosteal flaps should be gently elevated; teeth should be extracted in segments; alveolectomy should be performed, allowing no rough bony spicules to remain; and primary closure should be provided without tension. It is unnecessary to extract teeth that can be retained with conservative restorative, endodontic, or periodontal therapy. However, prudence dictates extraction of questionable teeth because periodontal

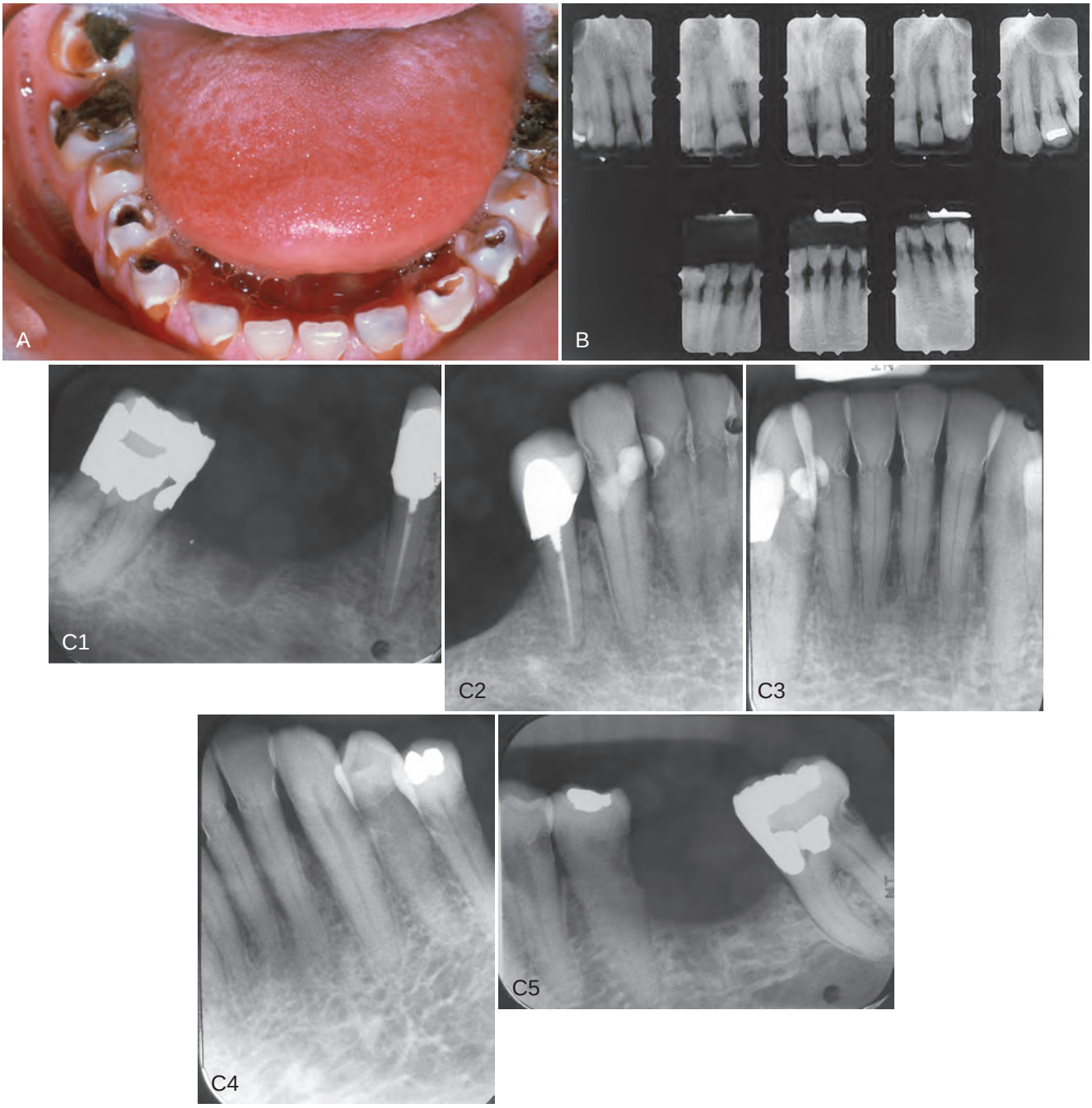

Figure 37-3 **A,** Clinical view of patient with radiation caries. Notice how the caries primarily affects the smooth tooth surfaces and the cusp tips. **B,** Radiographs of anterior teeth of 52-year-old male with postradiation caries. Patient received 6000-cGy radiation treatment to the posterior mandible and base of tongue for squamous cell carcinoma. Radiation caries developed within 1 year after radiation treatment, affecting the cervical areas and incisal edges of the anterior teeth. **C,** Radiographs of the mandibular teeth of 60-year-old male with postradiation caries. Patient received chemotherapy and 65-Gy intensity modulated radiation therapy (IMRT) to the lower head and neck for pharyngeal carcinoma. Radiation caries affecting the cervical areas of most remaining teeth. Notice the radiopaque layer on the outer surface of carious areas attributed to remineralization treatment with fluoride. *(**A** and **C** courtesy Dr. Eric Sung, Hospital Dentistry, University of California Los Angeles.)*

treatment after irradiation may be limited to nonsurgical forms of therapy. Flap surgery or extraction of teeth after radiation may lead to ORN. Management of ORN is often difficult and costly, involving progressively more aggressive treatment if bone does not respond to conservative therapy. Costly hyperbaric oxygen therapy is frequently required for complete resolution.

During radiation therapy, patients should receive weekly prophylaxis, oral hygiene instruction, and professionally applied fluoride treatments, unless mucositis prevents such treatment. Patients should be instructed to brush daily with a 0.4% stannous or 1.0% sodium fluoride gel. Custom gel trays allow optimum fluoride application.[98] All remaining teeth should receive thorough debridement (scaling and root planing).

Postirradiation follow-up consists of palliative treatment given as indicated. Viscous lidocaine may be prescribed for painful mucositis, and salivary substitutes may be given for xerostomia.

Daily topical fluoride application and oral hygiene are the best means of preventing radiation caries over time. A long-term, 3-month recall interval is ideal.

Prosthetic Joint Replacement

The main treatment consideration for patients with prosthetic joint replacements relates to the potential need for antibiotic prophylaxis before periodontal therapy. Currently, no scientific evidence indicates that prophylactic antibiotics prevent late prosthetic joint infections, which might occur from transient bacteremia induced by dental treatment.[10,103,104] Furthermore, although dental-induced bacteremia could theoretically cause prosthetic joint infection, scant reports demonstrate dental treatment as a source of joint infection, and none of these actually documents a cause-and-effect relationship.[1,45,105] Thus, in previous reports, the American Dental Association (ADA), American Academy of Orthopedic Surgeons (AAOS), American Academy of Oral Medicine (AAOM), and British Society for Antimicrobial Chemotherapy (BSAC) all agreed that routine antibiotic prophylaxis before dental treatment was not indicated for most patients with prosthetic joint replacements.[106-110] However, antibiotic prophylaxis was indicated for almost all patients within the first 2 years after joint replacement and for so-called high-risk patients, including those with previous prosthetic joint infections, immunosuppression, rheumatoid arthritis, systemic lupus erythematosus, type 1 diabetes, hemophilia, and malnourishment.[107] Importantly, many authors consider patients with severe periodontal disease or other potential dental infections to be "high risk," and antibiotic prophylaxis may be indicated for these patients before dental treatment.[110,111]

In February 2009, the AAOS released an "information statement" regarding antibiotic prophylaxis for bacteremia in patients with joint replacements.[112] Their earlier information statement, developed jointly with the ADA, was published in 1997[107] and revised in 2003.[108] It intended to reduce the risk to patients from unnecessary use of antibiotics. The 2009 information statement, which was not developed collaboratively with the ADA, will greatly increase the number of patients exposed to antibiotics because it states that all patients with prosthetic joint replacements should be given antibiotic prophylaxis prior to invasive procedures. Commentaries that challenge the statement have been published in the *Journal of the American Dental Association*[113] and the *Journal of the Canadian Dental Association*.[114]

Most recently, in December 2012, AAOS and ADA released new joint recommendations for the routine use of antibiotics for joint replacement patients. According to this document, there is insufficient evidence to recommend the routine use of antibiotics for patients with orthopaedic implants to prevent infections prior to having dental procedures. Here are their evidence-based recommendations:

Recommendation 1.

The practitioner might consider discontinuing the practice of routinely prescribing prophylactic antibiotics for patients with hip and knee prosthetic implants undergoing dental procedures.

The strength of evidence for this recommendation was classified as **Limited**, meaning that the quality of the supporting evidence that exists is unconvincing, or that well-conducted studies show little clear advantage to one approach versus another. The guidelines also stated that "practitioners should be cautious in deciding whether to follow a recommendation classified as **Limited**, and should exercise judgment and be alert for emerging publications that report evidence. Patient preference should have a substantial influencing role."

Recommendation 2.

The work group was unable to recommend for or against the use of topical oral antimicrobials in patients with prosthetic joint implants or other orthopaedic implants undergoing dental procedures.

The strength of evidence for this recommendation was classified as **Inconclusive**, meaning that there is a lack of compelling evidence resulting in an unclear balance between benefits and potential harm. The guidelines also stated that practitioners should feel little constraint in deciding whether to "follow a recommendation labeled as **Inconclusive** and should exercise judgment and be alert to future publications that clarify existing evidence for determining balance of benefits versus potential harm. Patient preference should have a substantial influencing role."

Recommendation 3.

In the absence of reliable evidence linking poor oral health to prosthetic joint infection, it is the opinion of the work group that patients with prosthetic joint implants or other orthopaedic implants maintain appropriate oral hygiene.

The strength of evidence for this recommendation was classified as **Consensus**, meaning that expert opinion supports the guideline recommendation even though there is no available empirical evidence that meets the inclusion criteria. The guidelines also stated that "practitioners should be flexible in deciding whether to follow a recommendation classified as **Consensus**, although they may set boundaries on alternatives. Patient preference should have a substantial influencing role."

Although the evidence demonstrates no need for antibiotic prophylaxis in most patients, many orthopedic surgeons still prefer such treatment,[115] most likely because of the high morbidity and potential mortality associated with prosthetic joint infections. Consultation with the patient's orthopedic surgeon before periodontal treatment is in the patient's best interest and may help assess the risk for joint infection relative to current dental status and type of periodontal treatment planned. Because individuals with significant periodontal disease are considered "high risk," antibiotic prophylaxis before treatment is common in the periodontal practice (Table 37-11).[107]

Providers are encouraged to monitor the status of these important statements and implied guidelines from other resources.

TABLE 37-11 Antibiotic Regimens for Prevention of Prosthetic Joint Infections*

Patient Characteristics	Drug Regimen
Patients not allergic to penicillins	Cephalexin, cephradine, or amoxicillin: 2 g orally 1 hour before dental procedure
Patients allergic to penicillins	Clindamycin: 600 mg orally 1 hour before dental procedure
Patients not allergic to penicillins, but unable to take oral medication	Cefazolin 1 g or ampicillin 2 g intramuscularly or intravenously 1 hour before dental procedure
Patients allergic to penicillins, and unable to take	Clindamycin 600 mg intravenously 1 hour before dental oral medications procedure (must be diluted and injected slowly)

*No second doses were recommended.

Data from American Dental Association and American Academy of Orthopedic Surgeons: *Am Dent Assoc J* 128:1004-1008, 1997.

Suggested Readings

American Academy of Orthopaedic Surgeons and the American Dental Association: Evidence-Based Guideline and Evidence Report. Prevention of Orthopaedic Implant Infection in Patients undergoing Dental Procedures. December 7, 2012. http://www.aaos.org/research/guidelines/PUDP/PUDP_guideline.pdf.

Lenfant C, Chobanian AV, Jones DW, et al: Joint National Committee on the Prevention, Detection, Evaluation, and Treatment of High Blood Pressure: Seventh report of the Joint National Committee on the Prevention, Detection, Evaluation, and Treatment of High Blood Pressure (JNC 7): resetting the hypertension sails. *Hypertension* 41:1178–1179, 2003.

Marx RE: *Oral and intravenous bisphosphonate-induced osteonecrosis of the jaws*, Hanover Park, 2007, Quintessence.

Mealey BL: Periodontal implications: medically compromised patients. *Ann Periodontol* 1:256–321, 1996.

Mealey BL: Impact of advances in diabetes care on dental treatment of the diabetic patient. *Compend Contin Educ Dent* 19:41–44, 46–48, 50 passim; quiz 60, 1998.

Pallasch TJ, Slots J: Antibiotic prophylaxis and the medically comprised patient. *Peridontol 2000* 10:107, 1996.

The sixth report of the Joint National Committee on prevention, detection, evaluation, and treatment of high blood pressure (JNC VI). *Arch Intern Med* 157:2413–2446, 1997.

Wade ML, Suzuki JB: Issues related to diagnosis and treatment of bisphosphonate-induced osteonecrosis of the jaws. *Grand Rounds Oral Systemic Medicine* 2:46–53, 2007.

Wilson W, Taubert KA, Gewitz M, et al: Prevention of infective endocarditis: guidelines from the American Heart Association: a guideline from the American Heart Association Rheumatic Fever, Endocarditis and Kawasaki Disease Committee Council on Cardiovascular Disease in the Young, and the Council on Clinical Cardiology Council on Cardiovascular Surgery and Anesthesia, and the Quality of Care and Outcomes Research Interdisciplinary Working Group. *J Am Dent Assoc* 139(Suppl):3S–24S, 2008.

Yagiela JA: Adverse drug interactions in dental practice: interactions associated with vasoconstrictors. Part V of a series. *J Am Dent Assoc* 130:701–709, 1999.

References

References for this chapter are found on the companion website www.expertconsult.com.

References

1. Rose L, Steinberg B: Clinical history and laboratory tests. In Rose L, Genco R, Cohen D, et al, editors: *Periodontal medicine*, Hamilton, 2000, BC Decker.
2. Umino M, Nagao M: Systemic diseases in elderly dental patients. *Int Dent J* 43:213, 1993.
3. Hajjar I, Kotchen TA: Trends in prevalence, awareness, treatment, and control of hypertension in the United States, 1988-2000. *JAMA* 290:199–206, 2003.
4. Chobanian AV, Bakris GL, Black HR, et al: The Seventh Report of the Joint National Committee on Prevention, Detection, Evaluation, and Treatment of High Blood Pressure: the JNC 7 report. *JAMA* 289:2560–2572, 2003.
5. Herman WW, Konzelman JL, Jr, Prisant LM: New national guidelines on hypertension: a summary for dentistry. *J Am Dent Assoc* 135:576–584, quiz 653–574, 2004.
6. Lenfant C, Chobanian AV, Jones DW, et al: Seventh report of the Joint National Committee on the Prevention, Detection, Evaluation, and Treatment of High Blood Pressure (JNC 7): resetting the hypertension sails. *Hypertension* 41:1178–1179, 2003.
7. Joint National Committee on Detection, Evaluation, and Treatment of High Blood Pressure: The fifth report of the Joint National Committee on Detection, Evaluation, and Treatment of High Blood Pressure (JNC V). *Arch Intern Med* 153:154–183, 1993.
8. Joint National Committee on Prevention, Detection, Evaluation, and Treatment of High Blood Pressure: The sixth report of the Joint National Committee on prevention, detection, evaluation, and treatment of high blood pressure (JNC VI). *Arch Intern Med* 157:2413–2446, 1997.
9. Vasan RS, Beiser A, Seshadri S, et al: Residual lifetime risk for developing hypertension in middle-aged women and men: the Framingham Heart Study. *JAMA* 287:1003–1010, 2002.
10. Mealey BL: Periodontal implications: medically compromised patients. *Ann Periodontol* 1:256–321, 1996.
11. Burt VL, Whelton P, Roccella EJ, et al: Prevalence of hypertension in the US adult population. Results from the Third National Health and Nutrition Examination Survey, 1988-1991. *Hypertension* 25:305–313, 1995.
12. Raab FJ, Schaffer EM, Guillaume-Cornelissen G, et al: Interpreting vital sign profiles for maximizing patient safety during dental visits. *J Am Dent Assoc* 129:461–469, 1998.
13. Muzyka BC, Glick M: The hypertensive dental patient. *J Am Dent Assoc* 128:1109–1120, 1997.
14. Black HR: The coronary artery disease paradox. *Am J Hypertens* 9:2S–10S, 1996.
15. Smolensky MH: Chronobiology and chronotherapeutics. Applications to cardiovascular medicine. *Am J Hypertens* 9:11S–21S, 1996.
16. Smith G: Periodontal ligament injection: evaluation of systematic effects. *Oral Surg Oral Med Oral Pathol* 56:571, 1983.
17. Tibbetts LS: Conscious sedation. In Rose LF, Genco RJ, Mealey BL, et al, editors: *Periodontics: medicine, surgery, and implants*, St. Louis, 2004, Mosby, Elsevier.
18. Yagiela JA: Adverse drug interactions in dental practice: interactions associated with vasoconstrictors. Part V of a series. *J Am Dent Assoc* 130:701–709, 1999.
19. Replogle K, Reader A, Nist R, et al: Cardiovascular effects of intraosseous injections of 2 percent lidocaine with 1:100,000 epinephrine and 3 percent mepivacaine. *J Am Dent Assoc* 130:649–657, 1999.
20. Price JW, Price JR: Accuracy and precision of metered doses of nitroglycerin lingual spray. *Am J Health Syst Pharm* 65:1556–1559, 2008.
21. Ducharme A, Dupuis J, McNicoll S, et al: Comparison of nitroglycerin lingual spray and sublingual tablet on time of onset and duration of brachial artery vasodilation in normal subjects. *Am J Cardiol* 84:952–954, A958, 1999.
22. Sato H, Koretsune Y, Taniguchi T, et al: Studies on the response of nitroglycerin oral spray compared with sublingual tablets for angina pectoris patients with dry mouth. A multicenter trial. *Arzneimittelforschung* 47:128–131, 1997.
23. Findler M, Garfunkel AA, Galili D: Review of very high-risk cardiac patients in the dental setting. *Compendium* 15(58):60–64, 1994.
24. Estes NA, 3rd, Weinstock J, Wang PJ, et al: Use of antiarrhythmics and implantable cardioverter-defibrillators in congestive heart failure. *Am J Cardiol* 91:45D–52D, 2003.
25. Eisenberg MJ, Brox A, Bestawros AN: Calcium channel blockers: an update. *Am J Med* 116:35–43, 2004.
26. Konstam MA: Improving clinical outcomes with drug treatment in heart failure: what have trials taught? *Am J Cardiol* 91:9D–14D, 2003.
27. Rhodus NL, Little JW: Dental management of the patient with cardiac arrhythmias: an update. *Oral Surg Oral Med Oral Pathol Oral Radiol Endod* 96:659–668, 2003.
28. Genco RJ, Offenbacher S, Beck J, et al: Cardiovascular diseases and oral infections. In Rose LF, Genco RJ, Cohen DW, et al, editors: *Periodontal medicine*, Toronto, 1999, BC Decker.
29. Barco CT: Prevention of infective endocarditis: a review of the medical and dental literature. *J Periodontol* 62:510–523, 1991.
30. Dajani AS, Taubert KA, Wilson W, et al: Prevention of bacterial endocarditis: recommendations by the American Heart Association. *J Am Dent Assoc* 128:1142–1151, 1997.
31. Durack DT: Antibiotics for prevention of endocarditis during dentistry: time to scale back? *Ann Intern Med* 129:829–831, 1998.
32. Strom BL, Abrutyn E, Berlin JA, et al: Dental and cardiac risk factors for infective endocarditis. A population-based, case-control study. *Ann Intern Med* 129:761–769, 1998.
33. Wilson W, Taubert KA, Gewitz M, et al: Prevention of infective endocarditis: guidelines from the American Heart Association: a guideline from the American Heart Association Rheumatic Fever, Endocarditis and Kawasaki Disease Committee Council on Cardiovascular Disease in the Young, and the Council on Clinical Cardiology Council on Cardiovascular Surgery and Anesthesia, and the Quality of Care and Outcomes Research Interdisciplinary Working Group. *J Am Dent Assoc* 139(Suppl):3S–24S, 2008.
34. Pallasch TJ, Slots J: Antibiotic prophylaxis and the medically comprised patient. *Periodontol 2000* 10:107, 1996.
35. Slots J, Rosling BG, Genco RJ: Suppression of penicillin-resistant oral *Actinobacillus actinomycetemcomitans* with tetracycline. Considerations in endocarditis prophylaxis. *J Periodontol* 54:193–196, 1983.
36. Rose LF, Mealey B, Minsk L, et al: Oral care for patients with cardiovascular disease and stroke. *J Am Dent Assoc* 133(Suppl):37S–44S, 2002.
37. Ostuni E: Stroke and the dental patient. *J Am Dent Assoc* 125:721–727, 1994.
38. Mealey BL: Diabetes mellitus. In Rose LF, Genco RJ, Cohen DW, et al, editors: *Periodontal medicine*, Hamilton, 2000, BC Decker.
39. The Diabetes Control and Complications Trial Research Group: The effect of intensive treatment of diabetes on the development and progression of long-term complications in insulin-dependent diabetes mellitus. *N Engl J Med* 329:977–986, 1993.
40. United Kingdom Prospective Diabetes Study (UKPDS) Group: Intensive blood-glucose control with sulphonylureas or insulin compared with conventional treatment and risk of complications in patients with type 2 diabetes (UKPDS 33). *Lancet* 352:837–853, 1998.
41. Mealey BL: Impact of advances in diabetes care on dental treatment of the diabetic patient. *Compend Contin Educ Dent* 19:41–44, 46–48, 50 passim; quiz 60, 1998.
42. Rees TD, Mealey BL: Periodontal treatment of the medically compromised patient. In Rose LF, Mealey BL, Genco RJ, et al, editors: *Periodontics: medicine, surgery, and implants*, St. Louis, 2004, Mosby Elsevier.
43. American Diabetes Association: Report of the Expert Committee on the Diagnosis and Classification of Diabetes Mellitus. *Diabetes Care* 5(Suppl 1):5, 2003.
44. Nathan DM, Kuenen J, Borg R, et al: Translating the A1C assay into estimated average glucose values. *Diabetes Care* 31:1473–1478, 2008.

45. Christgau M, Palitzsch KD, Schmalz G, et al: Healing response to non-surgical periodontal therapy in patients with diabetes mellitus: clinical, microbiological, and immunologic results. *J Clin Periodontol* 25:112–124, 1998.
46. Tervonen T, Karjalainen K: Periodontal disease related to diabetic status. A pilot study of the response to periodontal therapy in type 1 diabetes. *J Clin Periodontol* 24:505–510, 1997.
47. Westfelt E, Rylander H, Blohme G, et al: The effect of periodontal therapy in diabetics. Results after 5 years. *J Clin Periodontol* 23:92–100, 1996.
48. The Diabetes Control and Complications Trial Research Group: Hypoglycemia in the Diabetes Control and Complications Trial. *Diabetes* 46:271–286, 1997.
49. Pinto A, Glick M: Management of patients with thyroid disease: oral health considerations. *J Am Dent Assoc* 133:849–858, 2002.
50. Sherman RG, Lasseter DH: Pharmacologic management of patients with diseases of the endocrine system. *Dent Clin North Am* 40:727–752, 1996.
51. Glick M: Glucocorticosteroid replacement therapy: a literature review and suggested replacement therapy. *Oral Surg Oral Med Oral Pathol* 67:614–620, 1989.
52. Miller CS, Little JW, Falace DA: Supplemental corticosteroids for dental patients with adrenal insufficiency: reconsideration of the problem. *J Am Dent Assoc* 132:1570–1579, quiz 1596–1577, 2001.
53. Shapiro R, Carroll PB, Tzakis AG, et al: Adrenal reserve in renal transplant recipients with cyclosporine, azathioprine, and prednisone immunosuppression. *Transplantation* 49:1011–1013, 1990.
54. Bromberg JS, Baliga P, Cofer JB, et al: Stress steroids are not required for patients receiving a renal allograft and undergoing operation. *J Am Coll Surg* 180:532–536, 1995.
55. Little JW, Falace DA, Miller CS, et al: *Dental management of the medically compromised patient*, St. Louis, 2002, Mosby.
56. Schardt-Sacco D: Update on coagulopathies. *Oral Surg Oral Med Oral Pathol Oral Radiol Endod* 90:559–563, 2000.
57. Patton LL, Ship JA: Treatment of patients with bleeding disorders. *Dent Clin North Am* 38:465–482, 1994.
58. Petrover M, Cohen CI: The use of desmopressin in the management of two patients with von Willebrand's disease undergoing periodontal surgery: 2 case reports. *J Periodontal* 61:239, 1990.
59. Johnson WT, Leary JM: Management of dental patients with bleeding disorders: review and update. *Oral Surg Oral Med Oral Pathol* 66:297–303, 1988.
60. Ramstrom G, Sindet-Pedersen S, Hall G, et al: Prevention of postsurgical bleeding in oral surgery using tranexamic acid without dose modification of oral anticoagulants. *J Oral Maxillofac Surg* 51:1211–1216, 1993.
61. Sindet-Pedersen S, Stenbjerg S, Ingerslev J: Control of gingival hemorrhage in hemophilic patients by inhibition of fibrinolysis with tranexamic acid. *J Periodontal Res* 23:72–74, 1988.
62. Herman WW, Konzelman JL, Jr, Sutley SH: Current perspectives on dental patients receiving coumarin anticoagulant therapy. *J Am Dent Assoc* 128:327–335, 1997.
63. Martinowitz U, Mazar AL, Taicher S, et al: Dental extraction for patients on oral anticoagulant therapy. *Oral Surg Oral Med Oral Pathol* 70:274–277, 1990.
64. Jeske AH, Suchko GD: Lack of a scientific basis for routine discontinuation of oral anticoagulation therapy before dental treatment. *J Am Dent Assoc* 134:1492–1497, 2003.
65. Scully C, Wolff A: Oral surgery in patients on anticoagulant therapy. *Oral Surg Oral Med Oral Pathol Oral Radiol Endod* 94:57–64, 2002.
66. Mealey BL, Semba SE, Hallmon WW: The head and neck radiotherapy patient: Part 2–management of oral complications. *Compendium* 15:442, 444, 446–452 passim; quiz 458, 1994.
67. Watanabe K: Prepubertal periodontitis: a review of diagnostic criteria, pathogenesis, and differential diagnosis. *J Periodontal Res* 25:31–48, 1990.
68. Gudapati A, Ahmed P, Rada R: Dental management of patients with renal failure. *Gen Dent* 50:508–510, 2002.
69. Kerr AR: Update on renal disease for the dental practitioner. *Oral Surg Oral Med Oral Pathol Oral Radiol Endod* 92:9–16, 2001.
70. Rhodus NL, Little JW: Dental management of the renal transplant patient. *Compendium* 14:518–524, 526, 528 passim; quiz 532, 1993.
71. Ziccardi VB, Abubaker AO, Sotereanos GC, et al: Maxillofacial considerations in orthotopic liver transplantation. *Oral Surg Oral Med Oral Pathol* 71:21–26, 1991.
72. Phillips YY, Hnatiuk OW: Diagnosing and monitoring the clinical course of chronic obstructive pulmonary disease. *Respir Care Clin N Am* 4:371–389, 1998.
73. Scannapieco FA: Respiratory diseases. In Rose LF, Genco RJ, Mealey BL, editors: *Periodontal medicine*, Toronto, 1999, BC Decker.
74. Russell RG: Bisphosphonates: mode of action and pharmacology. *Pediatrics* 119(Suppl 2):S150–S162, 2007.
75. Wang EP, Kaban LB, Strewler GJ, et al: Incidence of osteonecrosis of the jaw in patients with multiple myeloma and breast or prostate cancer on intravenous bisphosphonate therapy. *J Oral Maxillofac Surg* 65:1328–1331, 2007.
76. Wade ML, Suzuki JB: Issues related to diagnosis and treatment of bisphosphonate-induced osteonecrosis of the jaws. *Grand Rounds Oral Systemic Med* 2:46–53, 2007.
77. Marx RE: *Oral and intravenous bisphosphonate-induced osteonecrosis of the jaws*, Hanover Park, 2007, Quintessence.
78. Marx RE, Sawatari Y, Fortin M, et al: Bisphosphonate-induced exposed bone (osteonecrosis/osteopetrosis) of the jaws: risk factors, recognition, prevention, and treatment. *J Oral Maxillofac Surg* 63:1567–1575, 2005.
79. Ardekian L, Gaspar R, Peled M, et al: Does low-dose aspirin therapy complicate oral surgical procedures? *J Am Dent Assoc* 131:331–335, 2000.
80. Madan GA, Madan SG, Madan G, et al: Minor oral surgery without stopping daily low-dose aspirin therapy: a study of 51 patients. *J Oral Maxillofac Surg* 63:1262–1265, 2005.
81. Saitoh AK, Saitoh A, Taniguchi H, et al: Anticoagulation therapy and ocular surgery. *Ophthalmic Surg Lasers* 29:909–915, 1998.
82. Blinder D, Manor Y, Martinowitz U, et al: Dental extractions in patients maintained on oral anticoagulant therapy: comparison of INR value with occurrence of postoperative bleeding. *Int J Oral Maxillofac Surg* 30:518–521, 2001.
83. Campbell JH, Alvarado F, Murray RA: Anticoagulation and minor oral surgery: should the anticoagulation regimen be altered? *J Oral Maxillofac Surg* 58:131–135, discussion 135–136, 2000.
84. Wahl MJ: Dental surgery in anticoagulated patients. *Arch Intern Med* 158:1610–1616, 1998.
85. Wahl MJ: Myths of dental surgery in patients receiving anticoagulant therapy. *J Am Dent Assoc* 131:77–81, 2000.
86. Zanon E, Martinelli F, Bacci C, et al: Safety of dental extraction among consecutive patients on oral anticoagulant treatment managed using a specific dental management protocol. *Blood Coagul Fibrinolysis* 14:27–30, 2003.
87. Sacco R, Sacco M, Carpenedo M, et al: Oral surgery in patients on oral anticoagulant therapy: a randomized comparison of different INR targets. *J Thromb Haemost* 4:688–689, 2006.
88. Raff H, Norton AJ, Flemma RJ, et al: Inhibition of the adrenocorticotropin response to surgery in humans: interaction between dexamethasone and fentanyl. *J Clin Endocrinol Metab* 65:295–298, 1987.
89. Banks P: The adreno-cortical response to oral surgery. *Br J Oral Surg* 8:32–44, 1970.
90. Shannon IL, Isbel GM, Hester WR: Stress in dental patients. IV. Effect of local anesthetic administration on serum free 17-hydroxycorticosteroid patterns. *J Oral Surg Anesth Hosp Dent Serv* 21:50–54, 1963.
91. Shannon IL, Isbell GM, Prigmore JR, et al: Stress in dental patients. II. The serum free 17-hydroxycorticosteroid response in routinely appointed patients undergoing simple exodontia. *Oral Surg Oral Med Oral Pathol* 15:1142–1146, 1962.
92. Mealey BL, Semba SE, Hallmon WW: Dentistry and the cancer patient: Part 1–oral manifestations and complications of chemotherapy. *Compendium* 15:1252, 1254, 1256 passim; quiz 1262, 1994.

93. Semba SE, Mealey BL, Hallmon WW: Dentistry and the cancer patient: Part 2–Oral health management of the chemotherapy patient. *Compendium* 15:1378, 1380–1377; quiz 1388, 1994.
94. Raber-Durlacher JE, Epstein JB, Raber J, et al: Periodontal infection in cancer patients treated with high-dose chemotherapy. *Support Care Cancer* 10:466–473, 2002.
95. Semba SE, Mealey BL, Hallmon WW: The head and neck radiotherapy patient: Part 1–Oral manifestations of radiation therapy. *Compendium* 15:250, 252–260; quiz 261, 1994.
96. Schiodt M, Hermund NU: Management of oral disease prior to radiation therapy. *Support Care Cancer* 10:40–43, 2002.
97. Blaha PJ, Reeve CM: Periodontal treatment for patients with cancer. *Curr Opin Periodontol* 64–70, 1994.
98. Vissink A, Burlage FR, Spijkervet FK, et al: Prevention and treatment of the consequences of head and neck radiotherapy. *Crit Rev Oral Biol Med* 14:213–225, 2003.
99. Vissink A, Jansma J, Spijkervet FK, et al: Oral sequelae of head and neck radiotherapy. *Crit Rev Oral Biol Med* 14:199–212, 2003.
100. Marx RE, Johnson RP: Studies in the radiobiology of osteoradionecrosis and their clinical significance. *Oral Surg Oral Med Oral Pathol* 64:379–390, 1987.
101. Carl W: Local radiation and systemic chemotherapy: preventing and managing the oral complications. *J Am Dent Assoc* 124:119–123, 1993.
102. Galler C, Epstein JB, Guze KA, et al: The development of osteoradionecrosis from sites of periodontal disease activity: report of 3 cases. *J Periodontol* 63:310–316, 1992.
103. Deacon JM, Pagliaro AJ, Zelicof SB, et al: Prophylactic use of antibiotics for procedures after total joint replacement. *J Bone Joint Surg Am* 78:1755–1770, 1996.
104. Seymour RA, Whitworth JM: Antibiotic prophylaxis for endocarditis, prosthetic joints, and surgery. *Dent Clin North Am* 46:635–651, 2002.
105. Tong DC, Rothwell BR: Antibiotic prophylaxis in dentistry: a review and practice recommendations. *J Am Dent Assoc* 131:366–374, 2000.
106. Council on Dental Therapeutics: Management of dental patients with prosthetic joints. *J Am Dent Assoc* 121:537–538, 1990.
107. American Dental Association and American Academy of Orthopaedic Surgeons: Advisory statement. Antibiotic prophylaxis for dental patients with total joint replacements. *J Am Dent Assoc* 128:1004–1008, 1997.
108. American Dental Association and American Academy of Orthopaedic Surgeons: Antibiotic prophylaxis for dental patients with total joint replacements. *J Am Dent Assoc* 134:895–899, 2003.
109. Eskinazi D, Rathbun W: Is systematic antimicrobial prophylaxis justified in dental patients with prosthetic joints? *Oral Surg Oral Med Oral Pathol* 66:430–431, 1988.
110. Thyne GM, Ferguson JW: Antibiotic prophylaxis during dental treatment in patients with prosthetic joints. *J Bone Joint Surg Br* 73:191–194, 1991.
111. Norden CW: Antibiotic prophylaxis in orthopedic surgery. *Rev Infect Dis* 13(Suppl 10):S842–S846, 1991.
112. American Association of Orthopaedic Surgeons: Information statement: antibiotic prophylaxis for bacteremia in patients with joint replacements: www.aaos.org/about/papers/advistmt/1033.asp, 2009.
113. Glick M: Clinical guidelines: to follow or folly? You decide. *J Am Dent Assoc* 140:824–826, 2009.
114. Napenas JJ, Lockhart PB, Epstein JB: Comment on the 2009 American Academy of Orthopaedic Surgeons' information statement on antibiotic prophylaxis for bacteremia in patients with joint replacements. *J Can Dent Assoc* 75:447–449, 2009.
115. Shrout MK, Scarbrough F, Powell BJ: Dental care and the prosthetic joint patient: a survey of orthopedic surgeons and general dentists. *J Am Dent Assoc* 125:429–436, 1994.
116. Tarsitano BF, Rollings RE: The pregnant dental patient: evaluation and management. *Gen Dent* 41:226–234, quiz 233–224, 1993.
117. American Dental Association Council on Dental Materials, IaE: Recommendations in radiographic practices: an update. *J Am Dent Assoc* 118:115, 1989.
118. DePaola LG: Managing the care of patients infected with bloodborne diseases. *J Am Dent Assoc* 134:350–358, 2003.
119. Cleveland JL, Gooch BF, Shearer BG, et al: Risk and prevention of hepatitis C virus infection. Implications for dentistry. *J Am Dent Assoc* 130:641–647, 1999.
120. Gillchrist J: Hepatitis viruses A, B, C, D, E, and G: implications for dental personnel. *J Am Dent Assoc* 130:509, 1999.
121. Lodi G, Bez C, Porter SR, et al: Infectious hepatitis C, hepatitis G, and TT virus: review and implications for dentists. *Spec Care Dentist* 22:53–58, 2002.
122. Winsom C, Siegel MA: Advances on the diagnosis and management of human viral hepatitis. *Dent Clin North Am* 47:431, 2003.
123. Naoumov NV: TT virus–highly prevalent, but still in search of a disease. *J Hepatol* 33:157–159, 2000.
124. Immunization of health-care workers: recommendations of the Advisory Committee on Immunization Practices (ACIP). *MMWR Morb Mortal Wkly Rep* 60(RR-7):1–45, 2011.
125. Centers for Disease Control and Prevention: Recommendations for follow-up of health-care workers after occupational exposure to hepatitis C virus. *MMWR Morb Mortal Wkly Rep* 46:603, 1997.

CHAPTER 38

Periodontal Therapy in the Female Patient

Joan Otomo-Corgel

CHAPTER OUTLINE

Puberty
Menses
Pregnancy
Oral Contraceptives
Menopause *(e-only)*
Conclusion

For online-only content on menopause, please visit the companion website at www.expertconsult.com.

Throughout a woman's life cycle, hormonal influences affect therapeutic decision making in periodontics. Historically, therapies have been gender biased. However, the advent of new research has provided keener appreciation of the unique systemic influences on oral, periodontal, and implant tissues. Oral health care professionals have greater awareness of and better capabilities for dealing with hormonal influences associated with the reproductive process. Periodontal and oral tissue responses may be altered, creating diagnostic and therapeutic dilemmas. Therefore it is imperative that the clinician recognize, customize, and appropriately alter periodontal therapy according to the individual woman's needs based on the stage of her life cycle.

This chapter reviews phases of the female life cycle from puberty through menopause. Periodontal manifestations, systemic effects, and clinical management are presented.

Puberty

Puberty occurs between the average ages of 11 to 14 in most women. The production of sex hormones (estrogen and progesterone) increases, then remains relatively constant during the remainder of the reproductive phase. Also, the prevalence of gingivitis increases, without an increase in the amount of plaque. Gram-negative anaerobes, especially *Prevotella intermedia,* have been implicated in association with puberty gingivitis. Kornman and Loesche[57] postulated that this anaerobic organism may use ovarian hormone as a substitute for vitamin K growth factor. Levels of black-pigmented *Bacteroides,* especially *P. intermedia* (formerly known as *Bacteroides intermedius*), are thought to increase with increased levels of gonadotropic hormones in puberty. *Capnocytophaga* species also increase in incidence, as well as in proportion. These organisms have been implicated in the increased bleeding tendency observed during puberty.

Recent studies associated with pubertal gingivitis indicate proportionately elevated motile rods, spirochetes, and *P. intermedia.*[81] Statistically significant increases in gingival inflammation and in the proportions of *P. intermedia* and *Prevotella nigrescens* have been seen in pubertal gingivitis.[85] A recent study of 11- to 17-year-old adolescents found higher levels of *Actinobacillus actinomycetemcomitans* and *Fusobacterium nucleatum,* which were associated with bleeding indices, probing depth, and attachment loss.[70]

During puberty, periodontal tissues may have an exaggerated response to local factors. A hyperplastic reaction of the gingiva may occur in areas where food debris, materia alba, plaque, and calculus are deposited. The inflamed tissues become erythematous, lobulated, and retractable. Bleeding may occur easily with mechanical debridement of the gingival tissues. Histologically, the appearance is consistent with inflammatory hyperplasia.

During the reproductive years, women tend to have a more vigorous immune response, including higher immunoglobulin concentrations, stronger primary and secondary responses, increased resistance to the induction of immunologic tolerance, and a greater ability to reject tumors and homografts.[116] Allergy, sensitivity, and asthma occur more often in young men, but after puberty, women become more susceptible than their male counterparts.

Management

During puberty, education of the parent or caregiver is part of successful periodontal therapy. Preventive care, including a vigorous program of oral hygiene, is also vital.[5] Milder gingivitis cases respond well to scaling and root planing, with frequent oral hygiene reinforcement. Severe cases of gingivitis may require microbial culturing, antimicrobial mouthwashes and local site delivery, or antibiotic therapy. Periodontal maintenance appointments may need to be more frequent when periodontal instability is noted.

The clinician should recognize the periodontal manifestations and/or intraoral lesions reflected by systemic diseases (i.e., diabetes).[24,92] Thorough review of the patient's medical history and medical referral should occur when deemed necessary. The clinician should be aware of the effects of chronic regurgitation of gastric contents on intraoral tissues; this age group also is susceptible to eating disorders, namely, bulimia and anorexia nervosa. *Perimolysis* (smooth erosion of enamel and dentin), typically on the lingual surfaces of maxillary anterior teeth, varies with the duration and frequency of the behavior.[16] Also, enlargement of the parotid glands (occasionally sublingual glands) has been estimated to occur in 10% to 50% of patients who "binge and purge."[75] Therefore a diminished salivary flow rate may also be present,

Menopause

Female life expectancy is 80+ years, so many women will live 40% of their lives in menopause. This cohort represents a large number of the patients that present in clinical practices. Therefore dental clinicians must be aware of the effects of reduced hormones on the periodontal tissues, as well as the systemic changes that may manifest.

Throughout a woman's lifetime, the number of oocytes steadily diminishes. Menopause is associated with symptoms of estrogen deficiency. Estradiol levels fall gradually in the years before menopause. Levels of FSH and LH begin to rise, and levels of sex hormones begin to fluctuate. This stage of "perimenopause" is characterized by increasing ovarian unresponsiveness, and thus sporadic ovulation ensues. Anovulatory cycles indicate low estradiol and progesterone because of absent corpus luteum function.

Oral Changes

It is important for the clinician to recognize the effect of hormonal alterations on the oral cavity as well as systemic and psychologic changes. Oral changes in menopause include thinning of the oral mucosa, oral discomfort ("burning mouth"), gingival recession, xerostomia, altered taste sensation, alveolar bone loss, and alveolar ridge resorption.

Fluctuations of sex hormones during menopause have been implicated as factors in inflammatory changes in the human gingiva, hypertrophy, or atrophy. Estrogen affects cellular proliferation, differentiation, and keratinization of the gingival epithelium. Hormone receptors have been identified in basal and spinous layers of the epithelium and connective tissue, implicating gingiva and other oral tissues as targets to manifest hormone deficiencies. Sex steroids are known to have a direct effect on connective tissue, with estrogens increasing the intracellular fluid content. Estrogen deficiency can lead to a reduction in collagen formation in connective tissues, resulting in a decrease in skin thickness.[136]Alterations in collagen affect tissues such as joints, hair, nails, and glands. Mohammed et al[79] noted significantly increased recession in postmenopausal patients with low bone density. A recent study of postmenopausal women indicated that those who were overweight with *T. forsythia* infections were more likely to have oral bone loss.[14]

Osteopenia and osteoporosis have been associated with the menopausal patient. *Osteopenia* is a reduction in bone mass caused by an imbalance between bone resorption and formation, favoring resorption and resulting in demineralization and osteoporosis. *Osteoporosis* is a disease characterized by low bone mass and fragility and a consequent increase in fracture risk.[133] In most women, peak bone mass occurs between 20 and 30 years of age, then declines. Menopause accelerates declining bone mass.[131] An estimated 25 million Americans have osteoporosis, 80% of whom are female. Ongoing studies are examining the association of postmenopausal primary osteoporosis with mandibular and maxillary bone mineral density (BMD), tooth loss, alveolar ridge atrophy, and clinical periodontal attachment loss[41,49]; however, problems in extrapolation and application of data arise as a result of small sample size, study design, and inadequately controlled confounding factors and limited understanding of the relationship between the two diseases. The effects of hormone replacement therapy (HRT) or estrogen replacement therapy (ERT) on the oral bone and tooth loss also are under investigation. Evidence indicates a probable association between osteoporosis and maxillary tooth loss, as well as alveolar bone loss.[51,97,107,108]

Studies show the greatest association when evaluating tooth loss and alveolar ridge atrophy with osteoporosis.[26,42,140] There is also less risk of tooth loss when postmenopausal women are placed on HRT.[40,123] Improved BMD with HRT has been a recognized benefit. Krall et al found that the odds of being edentulous were reduced by 6% for each 1-year increase in duration of HRT use.[59] It is also apparent that there is increased alveolar ridge resorption in edentulous patients with osteoporosis.

Current knowledge regarding the effects of osteoporosis/osteopenia on periodontal diseases and alveolar bone loss are inconclusive. Articles have presented an association of osteoporosis in postmenopausal women with periodontitis, attachment loss, and gingival recession.[47,125] Greater alveolar crestal height loss is noted with osteoporosis and osteopenia.[79,134] However, studies evaluating the association of clinical attachment loss and osteoporosis have mixed results. Several studies indicate decreasing BMD was associated with increased clinical attachment loss.[80,111,140] Others have found weak or no significant association of systemic BMD and clinical attachment loss.[32,100] Further clinical trials with greater numbers, longer time intervals, male patients, and accounting for confounding variables needs to be performed. Most studies indicate improved periodontal status in women on HRT/ERT.[17,108,123] Increased alveolar bone mass with associated improved alveolar crestal height, reduced clinical attachment loss, or reduced periodontal inflammation has been reported with patients on hormone therapy. A recent review found that research supports the idea that osteoporosis independently influences alveolar bone height loss and that strategies for reducing osteoporosis may help retard alveolar bone loss.[53]

Clinical Management

It is the clinician's responsibility to review the patient's medical history and keep information up to date. Because of possible alterations in oral soft and osseous tissues during perimenopause and after menopause, appropriate questioning regarding hormone changes should be performed and documented. The many available therapies for HRT/ERT, from prescriptions to holistic approaches, need to be followed. Many medications may alter clotting times, prolong the effects of other medications, and interfere with absorption or effectiveness of prescription medications. If gingival and mucosal tissue thinning occurs, soft tissue augmentation may be performed.

Brushing with an extrasoft toothbrush using the "toe" or "heel" of the brush may prevent "scrubbing" the thinning gingiva. Dentifrices with minimal abrasive particles should be used. Rinses should have low alcohol concentration. During periodontal maintenance, root surfaces should be debrided gently with minimal soft tissue trauma. Oral pain may result from thinning tissues, xerostomia, inadequate nutritional intake, or hormone depletion. In patients with oral symptoms who receive HRT, symptoms may be significantly reduced.

If the patient is susceptible to osteoporosis (menopausal, white or Asian, smoker, minimal physical activity, low calcium intake, thin build or low body weight [<58 kg], systemic disease associated with predisposition, and genetic history),[49] the dentist should consult the patient's physician as to the risks versus benefits of HRT/ERT and calcium/vitamin D supplementation for the individual patient. Sodium fluoride, bisphosphonates (e.g., alendronate), selective estrogen receptor modulators, and parathyroid hormone may be other therapies for the osteoporotic patient. Close monitoring of the patient's periodontal stability, performing titrated periodontal maintenance, informing the patient about potential

risks of hormone depletion on the oral tissues, and consulting the treating physician are advised. The National Institutes of Health (NIH; 1994 Conference on Optimal Calcium Intake) recommends 1000 mg of elemental calcium per day for premenopausal women and 1500 mg/day for postmenopausal women (Box 38-3). Vitamin D_3 recommendations are 400 IU daily for premenopausal women and 800 IU for postmenopausal women.

To date, no data are available regarding success or failure with periodontal regeneration procedures in osteoporotic versus non-osteoporotic individuals. Also, no scientific data are available to contraindicate the use of osseointegrated implants in osteoporotic patients, despite articles stating osteoporosis as a risk factor. Much research is needed to address the increasing number of patients who may present to periodontal practices with osteoporosis or osteopenia, most of whom will be undiagnosed.

BOX 38-3 National Institutes of Health (NIH) Consensus Conference Recommendations for Optimal Calcium Intake

Premenopausal women (25-50 years old): 1000 mg/day
Postmenopausal women (estrogen therapy): 1000 mg/day
Postmenopausal women (no estrogen therapy): 1500 mg/day
Men (25-65 years old): 1000 mg/day
Women and men >65 years old: 1500 mg/day

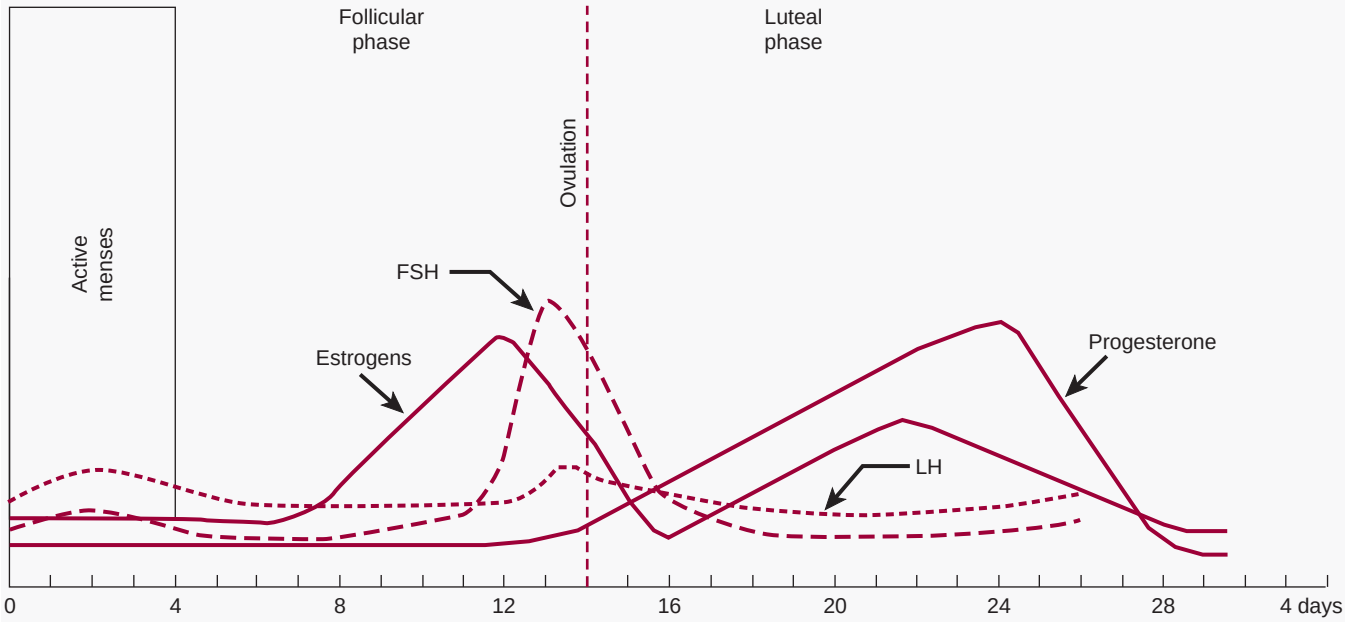

Figure 38-1 Female reproductive cycle. Note the peak levels of progesterone and estrogen compared with follicle-stimulating hormone *(FSH)* and luteinizing hormone *(LH)*.

which will increase oral mucous membrane sensitivity, gingival erythema, and caries susceptibility.

Menses

Periodontal Manifestations

During the reproductive years, the ovarian cycle is controlled by the anterior pituitary gland. The gonadotropin follicle-stimulating hormone (FSH) and luteinizing hormone (LH) are produced from the anterior pituitary gland. The secretion of gonadotropins also depends on the hypothalamus. Ongoing changes in the concentration of the gonadotropins and ovarian hormones occur during the monthly menstrual cycle (Figure 38-1). Under the influence of FSH and LH, estrogen and progesterone are steroid hormones produced by the ovaries during the menstrual cycle. During the reproductive cycle, the purpose of estrogen and progesterone is to prepare the uterus for implantation of the egg.

The monthly reproductive cycle has two phases. The first phase is referred to as the *follicular phase.* Levels of FSH are elevated, and estradiol (E2), the major form of estrogen, is synthesized by the developing follicle and peaks approximately 2 days before ovulation. The effect of estrogen stimulates the egg to move down the fallopian tubules (ovulation) and stimulates proliferation of the stroma cells, blood vessels, and glands of the endometrium.

The second phase is called the *luteal phase*. The developing corpus luteum synthesizes both estradiol and progesterone. Estrogen peaks at 0.2 ng/mL and progesterone at 10.0 ng/mL to complete the rebuilding of the endometrium for implantation of the fertilized egg. The corpus luteum involutes, ovarian hormone levels drop, and menstruation ensues. It has been postulated that ovarian hormones may increase inflammation in gingival tissues and exaggerate the response to local irritants. Gingival inflammation seems to be aggravated by an imbalance or increase in sex hormones. Numerous studies have demonstrated in vitro and in vivo that sex hormones affect and modify the actions of cells of the immune system. In addition, evidence suggests that the interaction between estrogen and cells of the immune system can have nonimmune regulatory effects.[7,20] Possible mechanisms have been suggested for the increase in hormonal gingival interaction in the menstrual cycle. Tumor necrosis factor alpha (TNF-α), which fluctuates during the menstrual cycle[13]; elevated prostaglandin E_2 (PGE_2) synthesis[77]; and angiogenetic factors, endothelial growth factors, and receptors may be modulated by progesterone and estrogen, contributing to increases in gingival inflammation during certain stages of the menstrual cycle.

Progesterone has been associated with increased permeability of the microvasculature, altering the rate and pattern of collagen production in the gingiva,[71] increasing folate metabolism,[96,126] and altering the immune response. During menses, progesterone increases from the second week, peaks at approximately 10 days, and dramatically drops before menstruation. (Note that this is based on a 28-day cycle; individual cycles are variable.) Progesterone plays a role in stimulating the production of prostaglandins that mediate the body's response to inflammation. PGE_2 is one of the major secretory products of monocytes and is increased in inflamed gingiva. Miyagi et al[78] found that the chemotaxis of polymorphonuclear leukocytes (PMNs, neutrophils) was enhanced by progesterone but reduced by estradiol. Testosterone did not have a measurable effect on PMN chemotaxis. The researchers suggested that the altered PMN chemotaxis associated with gingival inflammation may be caused by the effects of sex hormones. Physiologic, experimental, and clinical data confirm differences in immune responses between the two sexes.[135]

Gingival tissues have been reported to be more edematous during menses and erythematous before the onset of menses in some women. A recent study reported higher gingival indices during ovulation and before menstruation despite reported increases in oral symptoms during menses.[72] In addition, an increase of gingival exudate has been observed during the menstrual period and is sometimes associated with a minor increase in tooth mobility.[39] The incidence of postextraction osteitis is also higher during initiation of menses. No significant hematologic laboratory findings accompany this, other than a slightly reduced platelet count and a slight increase in clotting time.

When the progesterone level is highest (during luteal phase of cycle), intraoral recurrent aphthous ulcers,[33] herpes labialis lesions,

and candidal infections occur in some women as a cyclic pattern. Because the esophageal sphincter is relaxed by progesterone, women may be more susceptible to *gastroesophageal reflux disease* (GERD) during this time of the cycle as well. Symptoms of GERD include heartburn, regurgitation, and chest pain, and when reflux is severe, some patients develop unexplained coughing, hoarseness, sore throat, gingivitis, and asthma.[109]

Management

During the peak level of progesterone (about 7 to 10 days before menstruation), *premenstrual syndrome* (PMS) may also occur. There appears to be no significant difference in the estrogen and progesterone levels between women with PMS and those without PMS. However, women with PMS seem to have lower levels of certain neurotransmitters such as enkephalins, endorphins, γ-aminobutyric acid (GABA), and serotonin. Depression, irritability, mood swings, and difficulty with memory and concentration may be symptoms of neurotransmitter reduction. Patients are more sensitive and less tolerant of procedures, have a heightened gag reflex, and may have an exaggerated response to pain.

Increased gingival bleeding and tenderness associated with the menstrual cycle require closer periodontal monitoring. Periodontal maintenance should be titrated to the individual patient's need and if problematic, 3- to 4-month intervals should be recommended. An antimicrobial oral rinse before cyclic inflammation may be indicated. Emphasis should be placed on oral hygiene. For the patient with a history of excessive postoperative hemorrhage or menstrual flow, scheduling surgical visits after cyclic menstruation is prudent. Anemia is common, and appropriate consultation with a physician and recent laboratory tests, when indicated, should be maintained.

During PMS, many women exhibit physical symptoms that include fatigue, sweet and salty food cravings, abdominal bloating, swollen hands or feet, headaches, breast tenderness, nausea, and gastrointestinal upset. GERD may make it more uncomfortable for the patient to lay fully supine, especially after a meal, and the woman may have a more sensitive gag reflex. The clinician should be aware that nonsteroidal antiinflammatory drugs (NSAIDs), infection, and acidic foods exacerbate GERD. Patients taking over-the-counter antacids, H_2-receptor antagonists (cimetidine, famotidine, nizatidine, ranitidine), prokinetic agents (cisapride, metoclopramide), and proton pump inhibitors (lansoprazole, omeprazole, pantoprazole, or rabeprazole)[110] may be GERD patients. These medications interact with some antibiotics and antifungals, and thus a review of their pharmacology is necessary. Fluoride rinses and trays, frequent periodontal debridement, and avoidance of mouthwashes with high alcohol content may reduce the associated gingival and caries sequelae.

PMS is often treated by antidepressants. *Selective serotonin reuptake inhibitors* (SSRIs) are generally the first-line choice because they have fewer side effects than other antidepressants, do not require blood monitoring, and are safe in overdoses. Women with PMS taking the SSRI fluoxetine were reported to have a 70% response rate. Fluoxetine was ranked the fifth most dispensed prescription (new and refills) in the United States in 1998, but when the patent was lifted, its sales slowed. However, overall SSRIs ranked second in total dollar sales in the 2000s. (Sertraline was ranked twelfth and is the drug of choice for treatment of PMS.[143]) The clinician should be aware that patients taking fluoxetine have increased side effects with highly protein-bound drugs (e.g., aspirin), and the half-life of diazepam and other central nervous system (CNS) depressants is increased. Additional common SSRIs are fluvoxamine, paroxetine, and citalopram. Other antidepressants that may be prescribed are the selective serotonin-norepinephrine reuptake inhibitors (SNRIs), tricyclics, trazodone, mirtazapine, nefazodone, and maprotiline.

The PMS patient may be difficult to treat because of emotional and physiologic sensitivity. The dentist should treat the gingival and oral mucosal tissues gently. Gauze pads or cotton rolls should be moistened with a lubricant, chlorhexidine rinse, or water before placing them in the aphtha-prone patient. Careful retraction of the oral mucosa, cheeks, and lips is necessary in patients prone to aphthous or herpetic lesions. Because the hypoglycemic threshold is elevated, the clinician should advise the patient to have a light snack before her appointment. Of menstruating women, 70% have PMS symptoms, but only 5% meet the strict diagnostic criteria.

Pregnancy

Periodontal Manifestations

The link between pregnancy and periodontal inflammation has been known for many years. In 1778, Vermeeren discussed "toothpains" in pregnancy. In 1818, Pitcarin[102] described gingival hyperplasia in pregnancy. Despite awareness regarding pregnancy and its effect on periodontal disease, only recently has evidence indicated an inverse relationship to systemic health. Current research implies periodontal disease may alter the systemic health of the patient and adversely affect the well-being of the fetus by elevating the risk for low-birth-weight, preterm infants.

In 1877, Pinard[101] recorded the first case of "pregnancy gingivitis." Only recently has periodontal research begun to focus on causative mechanisms. The occurrence of pregnancy gingivitis is extremely common, occurring in 30% to 100% of all pregnant women.[45,62,66,114] It is characterized by erythema, edema, hyperplasia, and increased bleeding. Histologically, the description is the same as for gingivitis. However, the etiologic factors are different despite clinical and histologic similarities. Cases range from mild-to-severe inflammation (Figure 38-2), which can progress to severe hyperplasia, pain, and bleeding (Figures 38-3 and 38-4).

Other growths that resemble pregnancy granulomas must be ruled out, such as central giant cell granulomas or underlying systemic diseases. Periodontal status before pregnancy may influence the progression or severity as the circulating hormones fluctuate. The anterior region of the mouth is affected more often, and interproximal sites tend to be most involved.[25] Increased tissue edema may lead to increased pocket depths and may be associated with transient tooth mobility.[103] Anterior site inflammation may be exacerbated by increased mouth breathing, primarily in the third trimester, from pregnancy rhinitis. The gingiva is the most common site involved (approximately 70% of all cases), followed by the tongue and lips, buccal mucosa, and palate.[114] An increase in attachment loss may represent active periodontal infection accelerated by pregnancy.[61]

Figure 38-2 Moderate form of pregnancy gingivitis.

Pyogenic granulomas ("pregnancy tumors," pregnancy epulis) occur in 0.2% to 9.6% of pregnancies. They are clinically and histologically indistinguishable from pyogenic granulomas occurring in nonpregnant women or in men. Pyogenic granulomas appear most often during the second or third month of pregnancy. Clinically, they bleed easily and become hyperplastic and nodular. When excised, the lesions usually do not leave a large defect. They may be sessile or pedunculated and ulcerated, ranging in color from purplish red to deep blue, depending on the vascularity of the lesion and degree of venous stasis.[10] The lesion classically occurs in an area of gingivitis and is associated with poor oral hygiene and calculus. Alveolar bone loss is usually not associated with pyogenic granulomas of pregnancy.

Role of Pregnancy Hormones

Subgingival Plaque Composition. Epidemiologic studies indicate a relationship between the level of home care and the severity of gingival inflammation. It appears that the association between signs of gingival inflammation and the amount of plaque is greater after parturition than during pregnancy. An alteration in the compositions of subgingival plaque occurs during pregnancy. As mentioned, Kornman and Loesche[58] found that during the second trimester, gingivitis and gingival bleeding increased, without an increase in plaque levels. Bacterial anaerobic/aerobic ratios increased, in addition to proportions of *Bacteroides melaninogenicus* and *P. intermedia* (2.2% to 10.1%). The authors suggested that estradiol or progesterone can substitute for menadione (vitamin K) as an essential growth factor for *P. intermedia* but not *Porphyromonas gingivalis* or *Eikenella corrodens.* There was also an increase in *P. gingivalis* during the twenty-first through twenty-seventh weeks of gestation, but this was not statistically significant. The relative increase in the numbers of *P. intermedia* may be a more sensitive indicator of an altered systemic hormonal situation than clinical parameters of gingivitis.[119] A recent study concluded subgingival levels of bacteria associated with periodontitis did not change. *P. gingivalis* and *Tannerella forsythia* counts were higher and associated with bleeding on probing at week 12.[2]

Figure 38-3 Pyogenic granuloma of pregnancy ("pregnancy tumor").

Periodontal Disease and Preterm, Low-Birth-Weight Infant. Although the greatest majority of studies support a causal relationship regarding the hypothesis that periodontitis during pregnancy poses an increased risk for adverse pregnancy outcomes, there are conflicting results. Variation in study results may be due to confounding factors, effect modifiers, population studied, timing of intervention or evaluation, and severity of periodontal disease caused by varying definitions.

Several systematic reviews indicate periodontal disease[115,130,137,139] may adversely affect pregnancy outcomes. Intervention trials have shown a positive effect with periodontal therapy and reduction of adverse pregnancy outcomes,[50,68,69,91,124] but three large multicenter trials in the United States did not support these results.[76,88,120] Studies do indicate that routine nonsurgical periodontal therapy after the first trimester is not associated with adverse pregnancy outcomes.[76]

Initially, Offenbacher et al[90] provided evidence that untreated periodontal disease in pregnant women may be a significant risk factor for preterm (<37 weeks' gestation), low-birth-weight (<2500 g) infants. The relationship between genitourinary tract infection and preterm, low-birth-weight (PLBW) infants is well documented in human and animal studies. Periodontal researchers, suspecting periodontal disease as another source of infection, found that otherwise low-risk mothers of PLBW infants had significantly more periodontal attachment loss than control mothers having normal-weight infants at birth.

The current opinion is that the correlation of periodontal disease to PLBW births may occur as a result of infection and is mediated indirectly, principally by the translocation of bacterial products such as endotoxin (lipopolysaccharide [LPS]) and the action of maternally produced inflammatory mediators.[36] Jared et al[48] noted in utero fetal exposure to oral pathogens increases the risk of neonatal intensive care unit admission and length of stay. Biologically active molecules, such as PGE_2 and TNF-α, which are normally involved in normal parturition, are raised to artificially high levels by the infection process, which may foster premature labor.[3] Gram-negative bacteria in periodontal diseases therefore may permit selective overgrowth or invasion of gram-negative bacteria within the genitourinary tract. Han et al[44] documented hematogenous spread of oral bacteria to the amnion, while Madianos et al[73] showed that oral bacteria crosses the placental barrier and triggered an immune response by the fetus.

Gingival crevicular fluid (GCF) levels of PGE_2 were positively associated with intraamniotic PGE_2 levels ($p = 0.018$), suggesting

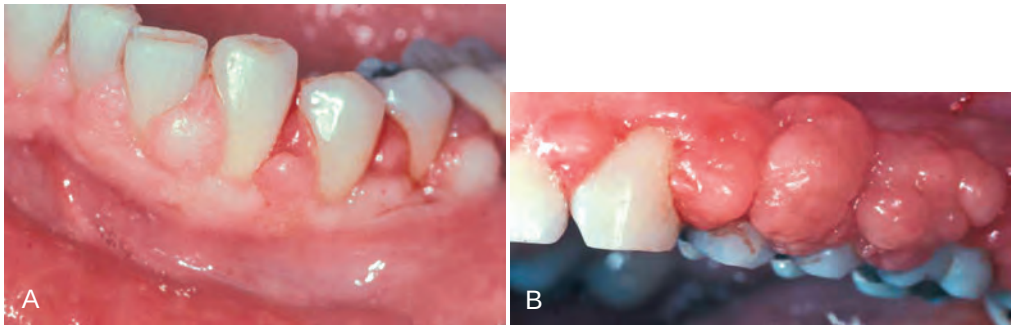

Figure 38-4 Severe pregnancy gingivitis with hyperplasia in patients with poorly controlled non–insulin-dependent diabetes mellitus. **A,** Moderate gingival enlargement. **B,** Severe gingival enlargement.

that gram-negative periodontal infection may present a systemic challenge sufficient to initiate the onset of premature labor as a source of LPS, or through stimulation of secondary inflammatory mediators such as PGE_2 and interleukin-1 beta (IL-1β).[21] Offenbacher et al[89] suggested a dose-response relationship for increasing GCF PGE_2 as a marker of current periodontal disease activity and decreasing birth weight. Four organisms associated with mature plaque and progressing periodontitis—*T. forsythia, P. gingivalis, A. actinomycetemcomitans,* and *Treponema denticola*—were detected at higher levels in PLBW mothers compared with normal-birth-weight controls (see Chapter 28). Despite research supporting the association of periodontal disease and PLBW,[22,23] more studies with improved methodology are needed to assess the validity of the association.

Preeclampsia. A systematic review of preeclampsia and periodontitis indicated an increased risk during pregnancy. Preeclampsia is a life-threatening condition in late pregnancy characterized by high blood pressure and excess urine protein. High C-reactive protein levels also are associated with preeclampsia in this population.[112,117,129]

Maternal Immunoresponse

The maternal immune system is thought to be suppressed during pregnancy. This response may allow the fetus to survive as an allograft. Documentation of immunosuppressive factors in the sera of pregnant women can be noted by marked increase of monocytes (which in large numbers inhibit in vitro proliferative responses to mitogens, allogenic cells, and soluble antigen),[128] and pregnancy-specific β_1-glycoproteins contribute to diminished lymphocyte responsiveness to mitogens and antigens.[11] In addition, a decrease in the ratio of peripheral T helper cells to T suppressor cells (CD4/CD8) has been reported to occur throughout pregnancy.[105] These changes in maternal immunoresponsiveness suggest an increased susceptibility to developing gingival inflammation. In one study, the gingival index was higher, but percentages of T3, T4, and B cells appeared to decrease in peripheral blood and gingival tissues during pregnancy compared with a control group.[1] Other studies report decreased PMN (neutrophil) chemotaxis, depression of cell-mediated immunity, phagocytosis, and a decreased T-cell response with elevated ovarian hormone levels, especially progesterone.[104] Decreased in vitro responses of peripheral blood lymphocytes to several mitogens and to a preparation of *P. intermedia* have been reported.[12,67,87] Also, evidence suggests a decrease in the absolute numbers of CD4+ cells in peripheral blood during pregnancy compared with the number of these cells postpartum.[80,88] Lapp et al[60] suggested that high levels of progesterone during pregnancy affect the development of localized inflammation by downregulation of IL-6 production, rendering the gingiva less efficient at resisting the inflammatory challenges produced by the bacteria. A recent study indicated live preterm birth is associated with decreased levels of immunoglobulin G (IgG) antibody to periodontal pathogens in women with periodontitis when assessed during the second trimester but not associated with birth outcomes.[27]

Also, ovarian hormone stimulates the production of prostaglandins, in particular PGE_1 and PGE_2, which are potent mediators of the inflammatory response. With the prostaglandin acting as an immunosuppressant, gingival inflammation may increase when the mediator level is high.[30,93] Kinnby et al[55] found that high progesterone levels during pregnancy influenced plasminogen activator inhibitor type 2 (PAI-2) and disturbed the balance of the fibrinolytic system. Because PAI-2 serves as an important inhibitor of tissue proteolysis, this research implies that components of the fibrinolytic system may be involved in the development of pregnancy gingivitis.

During pregnancy, sex hormonal levels rise dramatically (Box 38-1). Progesterone reaches levels of 100 ng/mL, 10 times the peak luteal phase of menses. Estradiol in the plasma may reach 30 times higher levels than during the reproductive cycle. In early pregnancy and during the normal ovarian cycle, the corpus luteum is the major source of estrogen and progesterone. During pregnancy the placenta begins to produce estrogens and progesterone.

Estrogen may regulate cellular proliferation, differentiation, and keratinization, whereas progesterone influences the permeability of the microvasculature,[63,64] alters the rate and pattern of collagen production, and increases the metabolic breakdown of folate (necessary for tissue maintenance).[141] High concentration of sex hormones in gingival tissues, saliva, serum, and GCF also may exaggerate the response.

Regulation of most cellular processes by hormones occurs through the interaction of these products with intracellular

BOX 38-1 Etiology of Gingival Responses to Elevated Estrogen and Progesterone during Pregnancy

Subgingival Plaque Composition

Increase in anaerobic/aerobic ratio
Higher concentrations of *Prevotella intermedia* (substitutes sex hormone for vitamin K growth factor)
Higher concentrations of *Bacteroides melaninogenicus*
Higher concentrations of *Porphyromonas gingivalis*

Maternal Immunoresponse

Depression of cell-mediated immunity
Decreased neutrophil chemotaxis
Depression of antibody and T-cell responses
Decrease in ratio of peripheral T helper cells to T suppressor-cytotoxic cells (CD4/CD8 ratio)
Cytotoxicity directed against macrophages and B cells may result in diminished immunoresponsiveness.
Decrease in absolute numbers of CD3+, CD4+, and CD19+ cells in peripheral blood during pregnancy versus postpartum
Stimulation of prostaglandin production

Sex Hormone Concentration

Estrogen

Increases cellular proliferation in blood vessels (known in the endometrium).
Decreases keratinization, while increasing epithelial glycogen.
Specific receptors are found in gingival tissues.

Progesterone

Increases vascular dilation, and thus increases permeability (resulting in edema and accumulation of inflammatory cells).
Increases proliferation of newly formed capillaries in gingival tissues (increased bleeding tendency).
Alters rate and pattern of collagen production.
Increased metabolic breakdown of folate (folate deficiency can inhibit tissue repair).
Specific receptors are found in gingival tissues.
Decreases plasminogen activator inhibitor type 2, and thus increases tissue proteolysis.

Estrogen and Progesterone

Affect ground substance of connective tissue by increasing fluidity.
Concentrations increase in saliva and fluid with increased concentrations in serum.

receptors. The resulting effects depend on the concentration of unbound hormone diffused through the cell membrane. Vittek et al[132] demonstrated specific estrogen and progesterone receptors in gingival tissues, providing direct biochemical evidence that this tissue may function as a target organ for sex hormones. Muramatsu and Takaesu[83] found increasing concentration of sex hormones in saliva from the first month and peaking in the ninth month of gestation, along with increasing percentages of *P. intermedia.* Probing depth, number of gingival sites with bleeding, and redness increased until 1 month postpartum. Also, evidence indicates sex hormone concentration in GCF, providing a growth media for periodontal pathogens.

Other Oral Manifestations of Pregnancy

As previously mentioned, perimolysis (acid erosion of teeth) may occur if "morning sickness" or esophageal reflux is severe and involves repeated vomiting of the gastric contents. Severe reflux may cause scarring of the esophageal sphincter, and the patient may become a more likely candidate for GERD later in life.

Xerostomia is a frequent complaint among pregnant women. One study found this persistent dryness in 44% of pregnant participants.[28]

A rare finding in pregnancy is *ptyalism,* or *sialorrhea.* This excessive secretion of saliva usually begins at 2 to 3 weeks of gestation and may abate at the end of the first trimester. The etiology of ptyalism has not been identified, but it may result from the inability of nauseated gravid women to swallow normal amounts of saliva, rather than from a true increase in saliva production.[19]

Because pregnancy places the woman in an immunocompromised state, the clinician must be aware of the patient's total health. Gestational diabetes, leukemia, and other medical conditions may appear during pregnancy.

Clinical Management

A thorough medical history is an imperative component of the periodontal examination, especially in the pregnant patient. Because of immunologic alterations, increased blood volume (ruling out mitral valve prolapse and heart murmurs), and fetal interactions, the clinician must diligently and consistently monitor the patient's medical and periodontal stability. Medical history dialog should include pregnancy complications, previous miscarriages, and recent history of cramping, spotting, or pernicious vomiting. The patient's obstetrician should be contacted to discuss her medical status, periodontal or dental needs, and the proposed treatment plan.

Establishing a healthy oral environment and maintaining optimal oral hygiene levels are primary objectives in the pregnant patient. A preventive periodontal program consisting of nutritional counseling and rigorous plaque control measures in the dental office and at home should be reinforced.

Plaque Control. The increased tendency for gingival inflammation during pregnancy should be clearly explained to the patient so that acceptable oral hygiene techniques may be taught, reinforced, and monitored throughout pregnancy. Scaling, polishing, and root planing may be performed whenever necessary during pregnancy. Some practitioners avoid the use of high-alcohol-content antimicrobial rinses in pregnant women and prefer to use non–alcohol-based oral rinses.

Prenatal Fluoride. The prescribing of prenatal fluoride supplements has been an area of controversy. Although two studies have claimed beneficial results,[37,38] others suggest that the clinical efficacy of prenatal fluoride supplements is uncertain and that the mechanism by which prenatal fluorides might impart cariostasis is unclear.[99] The American Dental Association (ADA) does not recommend the use of prenatal fluoride because its efficacy has not been demonstrated. The American Academy of Pediatric Dentistry supports this position as well. The American Academy of Pediatrics has no stated position on prescribing prenatal fluorides.

Treatment

Elective Dental Treatment. Other than good plaque control, it is prudent to avoid elective dental care if possible during the first trimester and the last half of the third trimester. The first trimester is the period of organogenesis, when the fetus is highly susceptible to environmental influences. In the last half of the third trimester, a hazard of premature delivery exists because the uterus is very sensitive to external stimuli. Prolonged chair time may need to be avoided because the woman is most uncomfortable at this time. Further, *supine hypotensive syndrome* may occur. In a semireclining or supine position, the great vessels, particularly the inferior vena cava, are compressed by the gravid uterus. By interfering with venous return, this compression will cause maternal hypotension, decreased cardiac output, and eventual loss of consciousness. Supine hypotensive syndrome can usually be reversed by turning the patient on her left side, thereby removing pressure on the vena cava and allowing blood to return from the lower extremities and pelvic area. A preventive 6-inch soft wedge (rolled towel) should be placed on the patient's right side when she is reclined for clinical treatment.

Early in the second trimester is the safest period for providing routine dental care. The emphasis at this time is on controlling active disease and eliminating potential problems that could arise in late pregnancy. Major elective oral or periodontal surgery may be postponed until after delivery. "Pregnancy tumors" that are painful, interfere with mastication, or continue to bleed or suppurate after mechanical debridement may require excision and biopsy before delivery.

The American Academy of Periodontology (www.perio.org) has developed a position statement regarding the need for providing proper periodontal therapy for pregnant patients (Figure 38-5). Because of research indicating possible impact on the fetus, the presence of acute infection, abscesses, or other potential disseminating sources of sepsis may warrant prompt intervention irrespective of the stage of pregnancy.[4] A consensus report of the Joint EFP/AAP Workshop indicated that "although periodontal therapy has been shown to be safe and leads to improved periodontal conditions in pregnant women, case-related periodontal therapy, without systemic antibiotics does not reduce overall rates of pre-term birth and low birthweight."[113]

Dental Radiographs. The safety of dental radiography during pregnancy has been well established, provided features such as high-speed film, filtration, collimation, and lead aprons are used. However, it is most desirable not to have *any* irradiation during pregnancy, especially during the first trimester, because the developing fetus is particularly susceptible to radiation damage.[65] When radiographs are needed for diagnosis, the most important aid for the patient is the protective lead apron. Studies have shown that when an apron is used during contemporary dental radiography, gonadal and fetal radiation is virtually immeasurable.[9]

Even with the obvious safety of dental radiography, x-ray films should be taken selectively during pregnancy and only when necessary and appropriate to aid in diagnosis and treatment. In most cases, only bite-wing, panoramic, or selected periapical films are indicated.

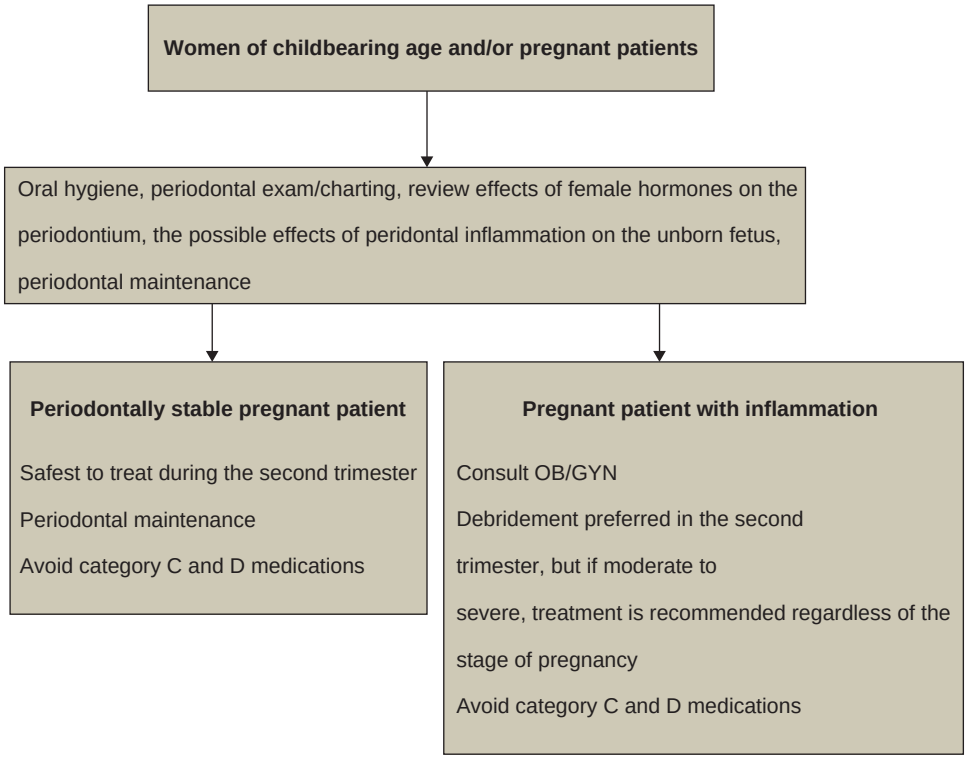

Figure 38-5 Treatment algorithm for the pregnant patient.

Medications. Drug therapy in the pregnant patient is controversial because drugs can affect the fetus by diffusion across the placenta. Prescriptions should be only the duration absolutely essential for the pregnant patient's well-being and only after careful consideration of potential side effects. The classification system established by the U.S. Food and Drug Administration (FDA) in 1979 to rate fetal risk levels associated with many prescription drugs provides safety guidelines (Box 38-2). The prudent practitioner should consult references, such as Briggs et al's *Drugs in Pregnancy and Lactation*[15] and Olin's *Drug Facts and Comparisons,*[94] for information on the FDA pregnancy risk factor associated with prescription drugs. Ideally, no drug should be administered during pregnancy, especially the first trimester.[65] However, it is sometimes impossible to adhere to this rule. Fortunately, most common drugs in dental practice can be given during pregnancy with relative safety, although there are a few important exceptions. Tables 38-1, 38-2, and 38-3 present general guidelines for anesthetic and analgesic, antibiotic, and sedative-hypnotic drugs, respectively.[106,127]

In particular, antibiotics are often needed in periodontal therapy. The effect of a particular medication on the fetus depends on the type of antimicrobial, dosage, trimester, and duration of the course of therapy.[95] Research regarding subgingival irrigation and local site delivery in relation to the developing fetus is inadequate at this date.

Breastfeeding. Usually, there is a risk that the drug can enter breast milk and be transferred to the nursing infant, in whom exposure could have adverse effects (Tables 38-4 and 38-5). Unfortunately, there is little conclusive information about drug dosage and effects through breast milk; however, retrospective clinical studies and empiric observations coupled with known pharmacologic pathways allow recommendations to be made.[65] The amount of drug excreted in breast milk is usually not more than 1% to 2% of the maternal dose; therefore it is highly unlikely that most drugs have any pharmacologic significance for the infant.[138]

The mother should take prescribed drugs just after breastfeeding and then avoid nursing for 4 hours or more, if possible,[65,121] to decrease the drug concentration in breast milk.

BOX 38-2 FDA Drug Classification System Based on Potential for Causing Birth Defects

A Controlled studies in women fail to demonstrate a risk to the fetus in the first trimester (there is no evidence of a risk in later trimesters), and the possibility of fetal harm appears remote.

B Either animal reproduction studies have not demonstrated a fetal risk but there are no controlled studies in pregnant women, or animal reproduction studies have shown an adverse effect (other than a decrease in fertility) that was not confirmed in controlled studies in women in the first trimester (and there is no evidence of a risk in later trimesters).

C Either studies in animals have revealed adverse effects on the fetus (teratogenic, embryocidal, or other) and there are no controlled studies in women, or studies in women and animals are not available. Drugs should be given only if the potential benefit justifies the potential risk to the fetus.

D There is positive evidence of human fetal risk, but the benefits from use in pregnant women may be acceptable despite the risk (e.g., if the drug is needed in a life-threatening situation or for a serious disease for which safer drugs cannot be used or are ineffective).

X Studies in animals or humans have demonstrated fetal abnormalities, or there is evidence of fetal risk based on human experience, or both, and the risk of using the drug in pregnant women clearly outweighs any possible benefit. The drug is contraindicated in women who are or who may become pregnant.

TABLE 38-1 Local Anesthetic and Analgesic Administration during Pregnancy

Drug	FDA Category (Prescription Drug)	During Pregnancy
Local Anesthetics*		
Lidocaine	B	Yes
Mepivacaine	C	Use with caution; consult physician.
Prilocaine	B	Yes
Bupivacaine	C	Use with caution; consult physician.
Etidocaine	B	Yes
Procaine	C	Use with caution; consult physician.
Articaine	B	Yes; no blocks
Analgesics		
Aspirin	C/D, third trimester	Caution; avoid in third trimester.
Acetaminophen	B	Yes
Ibuprofen	B/D, third trimester	Caution; avoid in third trimester.
Codeine†	C	Use with caution; consult physician.
Hydrocodone†	B	Use with caution; consult physician.
Oxycodone†	B	Use with caution; consult physician.
Propoxyphene	C	Use with caution; consult physician.

*Can use vasoconstrictors if necessary.

†Avoid prolonged use.

FDA, U.S. Food and Drug Administration.

TABLE 38-3 Sedative-Hypnotic Drug Administration during Pregnancy

Drug(s)	FDA Category	During Pregnancy
Benzodiazepines	D	Avoid
Barbiturates	D	Avoid
Nitrous oxide	Not assigned	Avoid in first trimester; otherwise use with caution; consult physician.

FDA, U.S. Food and Drug Administration.

TABLE 38-4 Local Anesthetic and Analgesic Administration during Breastfeeding

Drug	During Breastfeeding
Local Anesthetics	
Lidocaine	Yes
Mepivacaine	Yes
Prilocaine	Yes
Bupivacaine	Yes
Etidocaine	Yes
Procaine	Yes
Analgesics	
Aspirin	Avoid
Acetaminophen	Yes
Ibuprofen	Yes
Codeine	Yes
Hydrocodone	No data
Oxycodone	Yes
Propoxyphene	Yes

TABLE 38-2 Antibiotic Administration during Pregnancy

Drug(s)	FDA Category (Prescription Drug)	During Pregnancy	Risks
Penicillins	B	Yes	Diarrhea
Erythromycin	B	Yes; avoid estolate form	Intrahepatic jaundice in mother
Clindamycin	B	Yes, with caution	Drug concentrated in fetal bone, spleen, lung, and liver
Cephalosporins	B	Yes	Limited information
Tetracycline	D	Avoid	Depression of bone growth, enamel hypoplasia, gray-brown tooth discoloration
Ciprofloxacin	C	Avoid	Possible developing cartilage erosion
Metronidazole	B	Avoid; controversial	Theoretic carcinogenic data in animals
Gentamicin	C	Caution; consult physician	Limited information
Ototoxicity			
Vancomycin	C	Caution; consult physician	Limited information
Clarithromycin	D	Avoid; use only if potential benefit justifies risk to fetus	Limited information
			Adverse effects on pregnancy, outcome, and embryo/fetal development in animals

FDA, U.S. Food and Drug Administration.

TABLE 38-5 Antibiotic and Sedative-Hypnotic Administration during Breastfeeding

Drug(s)	During Breastfeeding
Antibiotics*	
Penicillins	Yes
Erythromycin	Yes
Clindamycin	Yes, with caution
Cephalosporins	Yes
Tetracycline	Avoid
Ciprofloxacin	Avoid
Metronidazole	Avoid
Gentamicin	Avoid
Vancomycin	Avoid
Sedative-Hypnotics	
Benzodiazepines	Avoid
Barbiturates	Avoid
Nitrous oxide	Yes

*Antibiotics have the risk of diarrhea and sensitization in the mother and infant.

Oral Contraceptives

Women may have responses to oral contraceptives (OCs) similar to those seen in pregnant patients. Mullally et al found that current users of OCs had poorer periodontal health.[82] An exaggerated response to local irritants occurs in gingival tissues. Inflammation ranges from mild edema and erythema to severe inflammation with hemorrhagic or hyperplasic gingival tissues. It has been reported that more exudate is present in inflamed gingival tissues of OC users than in pregnant women.[118,142] Investigators have suggested several mechanisms for the heightened response in gingival tissues. Kalkwarf[54] reported that the response may be caused by an altered microvasculature, increased gingival permeability, and increasing synthesis of prostaglandin. PGE, a potent mediator of inflammation,[31] appears to rise significantly with increasing levels of sex hormones. Jensen et al[52] found dramatic microbial changes in pregnant and OC groups compared with a nonpregnant group. A sixteenfold increase in *Bacteroides* species was noted in the OC group versus the nonpregnant group, despite no statistically significant clinical differences in gingival index or GCF flow. The authors stated that the increased female sex hormones substituting for the naphthoquinone requirement of certain *Bacteroides* species were most likely responsible for this increase.

The OC-associated gingival inflammation may become chronic (versus the acute inflammation of pregnancy) because of the extended periods that women are exposed to elevated levels of estrogen and progesterone.[56,98] Some have reported that the inflammation increases with prolonged use of OCs. Kalkwarf[54] did not find that duration of use made a significant difference; however, the brand used resulted in different responses. Further studies need to be performed in relation to dosage, duration, and type of OC used in association with the periodontium. The concentration of female sex hormones in current OCs is significantly less than that of the 1970s, with the same level of contraceptive efficacy.

Salivary composition changed notably in patients taking OCs in studies from the 1970s. A decreased concentration of protein, sialic acid, hexosamine fucose, hydrogen ions, and total electrolytes has been reported. Salivary flow rates were increased in one report[74] and decreased in 30% of subjects in another report.[29]

The dental literature reports that women taking OCs experience a two- to threefold increase in the incidence of localized osteitis after extraction of mandibular third molars.[122] The higher incidence of osteitis is these patients may be attributed to the effects of OCs (estrogens) on clotting factors. However, a number of studies refutes these findings.[18] Evidence thus far is inconclusive on osteitis after third molar extraction and OC use. Also, a spotty melanotic pigmentation of the skin may occur with OC use. This suggests a relationship between the use of OCs and the occurrence of gingival melanosis,[46] especially in fair-skinned individuals.

Management

Medical histories should include OCs under medications, and an oral dialog should include questions regarding OCs in women of childbearing age. The patient should be informed of the oral and periodontal side effects of OCs and the need for meticulous home care and compliance with periodontal maintenance. Treatment of gingival inflammation exaggerated by OCs should include establishing an oral hygiene program and eliminating local predisposing factors. Periodontal surgery may be indicated if resolution after initial therapy (scaling and root planing) is inadequate. It may be advisable to perform extraction of teeth (especially of third molars) on nonestrogenic days (days 23 to 28) of the OC cycle to reduce the risk of a postoperative localized osteitis[34]; however, evidence of this association is inconclusive and warrants further investigation.

Although the results from animal studies have demonstrated antibiotic interference adversely affecting contraceptive sex hormone levels, several human studies have failed to support such an interaction.[8,35,84,86] This issue is controversial, and antibiotics possibly could render OCs ineffective in preventing pregnancies. In 1991, an ADA report stated that all women of childbearing age should be informed of possible reduced efficacy of steroid OCs during antibiotic therapy and advised women to use additional forms of contraception during short-term antibiotic therapy.[6] During long-term antibiotic therapy, they should consult their physician about using high-dose OC preparations. Although only research regarding oral manifestations attributed to OCs has been reported in the literature, the same effects presumably could occur with the use of contraceptive implants. Similarly, the remote possibility of reduced efficacy of the contraceptive implant with concurrent antibiotic administration also exists, and women can adhere to the same precautions as with OC use.

Conclusion

Clinical periodontal therapy includes an understanding of the clinician's role in the total health and well-being of female patients. Dentists do not treat localized infections without affecting other systems (and the fetus or the breastfed infant). Therefore female patients may present with periodontal and systemic considerations that alter conventional therapy.

The cyclic nature of the female sex hormones often is reflected in the gingival tissues as initial signs and symptoms. Medical histories and dialogs should include thoughtful investigation of the individual patient's problems and needs. Questioning should reflect hormonal stability and medications associated with regulation. Patients should be educated regarding the profound effects the sex hormones may play on periodontal and oral tissues, as well as the consistent need for home and office removal of local irritants.

Research regarding female issues and medical/periodontal therapy is in process. In the near future, information regarding specific management and etiology of sex hormone–mediated infections will enhance our ability to provide quality care to our patients.

Suggested Readings

Armitage GC: Bi-directional relationship between pregnancy and periodontal disease. *Periodontol 2000* 61:160–176, 2013.

Chang HH, Larson J, Biencowe H, et al: Preventing preterm births: analysis of trends and potential reductions with interventions in 39 countries with very high human development index. *Lancet* 381:223–234, 2013.

De Rossi SS, Sollecito TP: The oral-medical disease connection: pregnancy, cardiovascular disease, and diabetes. *Compendium* 33:406–413, 2012.

Ide M, Papapanou P: Epidemiology of association between maternal periodontal disease and adverse pregnancy outcomes—systematic review. *J Clin Periodontol* 40(Suppl 14):181–194, 2013.

Kumar PS: Sex and the subgingival microbiome: do female sex steroids affect periodontal bacteria? *Periodontol 2000* 61:103–124, 2013.

Madianos PN, Bobetsis YA, Offenbacher S: Adverse pregnancy outcomes (APOs) and periodontal disease pathogenic mechanisms. *J Clinical Periodontol* 40(Suppl 14):170–180, 2013.

Mariotti A, Mawhinney M: Endocrinology of sex steroid hormones and cell dynamics in the periodontium. *Periodontol 2000* 6:69–88, 2013.

Otomo-Corgel J: Dental management of the female patient. *Periodontol 2000* 61:219–231, 2013.

Otomo-Corgel J, Steinberg B: Periodontal medicine and the female patient. In Rose LF, Genco R, Cohen D, et al, editors: *Periodontal medicine*, St. Louis, 2000, BC Decker.

Preshaw P: Oral contraceptives and the periodontium. *Periodontol 2000* 61:124–159, 2013.

Sanz M, Kornman K, Working Group 3 of the joint EFP/AAP Workshop: Periodontitis and adverse pregnancy outcomes: consensus report of the Joint EFT/AAP Workshop on Periodontitis and Systemic Diseases. *J Periodontol* 84:S164–S169, 2013.

Xiong X, Buekens P, Vastardis S, et al: Periodontal disease and pregnancy outcomes: state-of-the-science. *Obstet Gynecol Surv* 62:605–612, 2007.

References

References for this chapter are found on the companion website www.expertconsult.com.

References

1. Aboul-Dahab OM, el-Sherbiny MM, Abdel-Rahman R, et al: Identification of lymphocytes subsets in pregnancy. *Egypt Dent J* 40:653, 1994.
2. Adriaens LM, Alessandri R, Sporri S, et al: Does pregnancy have an impact on the subgingival microbiota? *J Periodontol* 80:72, 2009.
3. American Academy of Periodontology: Position paper: periodontal disease as a potential risk factor for systemic disease. *J Periodontol* 69:841, 1998.
4. American Academy of Periodontology: Statement regarding periodontal management of the pregnant patient. *J Periodontol* 75:495, 2004.
5. American Dental Association (ADA): *Council on Access, Prevention, and Interpersonal Relations: women's oral health issues*, Chicago, 1995, ADA.
6. American Dental Association Health Foundation Research Institute, Department of Toxicology: Antibiotic interference with oral contraceptives. *J Am Dent Assoc* 122:79, 1991.
7. Aschkenazi S, Naftolin F, Mor G: Menopause, sex hormones and the immune system. *Menopause Manag* 9:6, 2000.
8. Back DJ, Orme M: Pharmacokinetic drug interactions with oral contraceptives. *Clin Pharmacokinet* 18:472, 1990.
9. Bean LR, Jr, Devore WD: The effects of protective aprons in dental roentgenography. *Oral Surg* 28:505, 1969.
10. Bhashkar SN, Jacoway JR: Pyogenic granuloma: clinical features, incidence, histology, and results of treatment report of 242 cases. *J Oral Surg* 24:391, 1966.
11. Bischof P, Lauber K, Girard JP, et al: Circulating levels of pregnancy proteins and depression of lymphoblastogenesis during pregnancy. *J Clin Lab Immunol* 12:93, 1983.
12. Brabin BJ: Epidemiology of infection in pregnancy. *Rev Infect Dis* 7:579, 1985.
13. Brannstrom M, Friden BE, Jasper M, et al: Variations in peripheral blood levels of immunoreactive tumor necrosis factor alpha throughout the menstrual cycle and secretion of TNF-a from the human corpus luteum. *Eur J Obstet Gynecol Reprod Biol* 83:213, 1999.
14. Brennan RM, Genco RJ, Wilding G, et al: Bacterial species in subgingival plaque and oral bone loss in postmenopausal women. *J Periodontol* 78:1051, 2007.
15. Briggs GG, Freeman RK, Yaffe SJ: *Drugs in pregnancy and lactation*, ed 4, Baltimore, 1994, Williams & Wilkins.
16. Brown S, Bonifaz DZ: An overview of anorexia and bulimia nervosa and the impact of eating disorders on the oral cavity. *Compend Contin Educ Dent* 14:1594, 1993.
17. Civitelli R, Pilgram TK, Dotson M, et al: Alveolar and postcranial bone density in postmenopausal women receiving hormone/estrogen replacement therapy: a randomized, double-blind, placebo-controlled trial. *Arch Intern Med* 162:1409, 2002.
18. Cohen ME, Simecek JW: Effects of gender-related factors on the Incidence of localized alveolar osteitis. *Oral Surg Oral Med Oral Pathol* 79:416, 1995.
19. Cruikshank O, Hayes PM: Maternal physiology. In Gabbe S, Niebyl JR, Simpson JL, editors: *Pregnancy in obstetrics: normal and problem pregnancies*, New York, 1986, Churchill Livingstone.
20. Cutolo M, Sulli A, Seriolo B, et al: Estrogens, the immune response and autoimmunity. *Clin Exp Rheumatol* 13:217, 1995.
21. Damare SM, Wells S, Offenbacher S: Eicosanoids in periodontal diseases: potential for systemic involvement. *Adv Exp Med Biol* 433:23, 1997.
22. Dasanayake AP: Poor periodontal health of the pregnant woman as a risk. *Ann Periodontol* 3:206, 1998.
23. Davenport ES, Williams CE, Sterne JA, et al: The East London study of maternal chronic periodontal disease and preterm low birth weight infants: study design and prevalence. *Ann Periodontol* 3:213, 1998.
24. Dakovic D, Pavlovic MD: Periodontal disease in children and adolescents with type 1 diabetes in Serbia. *J Periodontol* 79:987, 2008.
25. DeLiefde B: The dental care of pregnant women. *NZ Dent J* 80:41, 1984.
26. Drozdzowska B, Pluskiewicz W, Michno M: Tooth count in elderly women in relation to their skeletal status. *Maturitas* 55:126, 2006.
27. Ebersole JL, Novak MJ, Michalowicz BS, et al: Systemic immune responses in pregnancy and periodontitis: relationship to pregnancy outcome in the obstetrics and periodontal therapy (OPT) study. *J Periodontol* 80:953, 2009.
28. El-Ashiry G: Comparative study of the influence of pregnancy and oral contraceptives on the gingivae. *Oral Surg* 30:472, 1970.
29. El-Ashiry G, El-Kafrawy AH, Nasr MF, et al: Effects of oral contraceptives on the gingiva. *J Periodontol* 42:273, 1971.
30. El-Attar TM: Prostaglandin F2 in human gingiva in health and disease and its stimulation by female sex steroids. *Prostaglandins* 11:331, 1976.
31. El-Attar TM, Roth GD, Hugoson A: Comparative metabolism of 4-C progesterone in normal and chronically inflamed human gingival tissue. *J Periodontal Res* 8:79, 1973.
32. Famili P, Cauley J, Suzuki JB, et al: Longitudinal study of periodontal disease and edentulism with rates of bone loss in older women. *J Periodontol* 76:11, 2005.
33. Ferguson MM, Carter J, Boyle P: An epidemiological study of factors associated with recurrent aphthae in women. *J Oral Med* 39:212, 1984.
34. Fleisher AB, Jr, Resnick SD: The effect of antibiotics in the efficacy of oral contraceptives. *Arch Dermatol* 125:1582, 1980.
35. Fraser IS, Jansen RP: Why do inadvertent pregnancies occur in oral contraceptive users? Effectiveness of oral contraceptive regimens and interfering factors. *Contraception* 27:531, 1983.
36. Gibbs RS, Romero R, Hillier SL, et al: A review of premature birth and subclinical infections. *Am J Obstet* 166:1515, 1992.
37. Glenn FB: Immunity conveyed by a fluoride supplement during pregnancy. *J Dent Child* 44:391, 1977.
38. Glenn FB, Glenn WD, III, Duncan RC: Fluoride tablet supplementation during pregnancy for caries immunity: a study of the offspring produced. *Am J Obstet Gynecol* 143:560, 1982.
39. Grant D, Stern J, Listgarten M: The epidemiology, etiology, and public health aspects of periodontal disease. In Grant D, Stern J, Listegarten M, editors: *Periodontics*, St. Louis, 1988, Mosby.
40. Grodstein F, Colditz GA, Stamfer MJ: Post-menopausal hormone use and tooth loss: a prospective study. *J Am Dent Assoc* 127:370, 1996.
41. Grossi SG, Jeffcoat MK, Genco RJ: Osteopenia, osteoporosis, and oral disease. In Rose LR, Genco RJ, Cohen DW, et al, editors: *Periodontal medicine*, New York, 2000, BC Decker.
42. Gur A, Nas K, Kayhan O, et al: The relation between tooth loss and bone mass in postmenopausal osteoporotic women in Turkey: a multicenter study. *J Bone Miner Metab* 21:43, 2003.
43. Gusberti FA, Mombelli A, Lang NP, et al: Changes in subgingival microbiota during puberty. *J Clin Periodontol* 17:685, 1990.
44. Han YL, Shen T, Chung P, et al: Uncultivated bacteria as etiologic agents of intra-amniotic inflammation leading to preterm birth. *J Clin Microbiol* 47:38, 2008.
45. Hanson L, Sobol SM, Abelson T: The otolaryngologic manifestations of pregnancy. *J Fam Pract* 23:151, 1986.
46. Hertz RS, Beckstead PC, Brown WJ: Epithelial melanosis of the gingiva possibly resulting from the use of oral contraceptives. *J Am Dent Assoc* 100:173, 1980.
47. Inagaki K, Kurosu Y, Sakano M, et al: Oral osteoporosis: a review and its dental implications. *Clin Calcium* 17:157, 2007.
48. Jared H, Boggess KA, Moss K, et al: Fetal exposure to oral pathogens and subsequent risk for neonatal intensive care admission. *J Periodontol* 80:878, 2009.
49. Jeffcoat MK: Osteoporosis: a possible modifying factor in oral bone loss. *Ann Periodontol* 3:312, 1998.
50. Jeffcoat MK, Hauth JC, Geurs NC, et al: Periodontal disease and preterm birth: results of a pilot intervention study. *J Periodontol* 74:1214, 2003.
51. Jeffcoat MK, Lewis CE, Reddy MS, et al: Postmenopausal bone loss and its relationship to oral bone loss. *Periodontol 2000* 23:94, 2000.
52. Jensen J, Lilijmack W, Blookquist C: The effect of female sex hormones on subgingival plaque. *J Periodontol* 52:599, 1981.

53. Kaye EK: Bone health and oral health. *J Am Dent Assoc* 138:616, 2007.
54. Kalkwarf KL: Effect of oral contraceptive therapy on gingival inflammation in humans. *J Periodontol* 49:560, 1978.
55. Kinnby B, Matsson L, Astedt B: Aggravation of gingival inflammatory symptoms during pregnancy associated with the concentration of activator inhibitor type 2 (PAI-2) in gingival fluid. *J Periodontal Res* 31:271, 1996.
56. Knight GM, Wade AB: The effects of oral contraceptives on the human periodontium. *J Periodontol Res* 9:18, 1974.
57. Kornman K, Loseche JF: Direct interaction of estradiol and progesterone with *Bacteroides melaninogenicus*. *J Dent Res* 58A:10, 1979.
58. Kornman KS, Loesche WJ: The subgingival flora during pregnancy. *J Periodontol* 15:111, 1980.
59. Krall EA, Dawson-Hughes B, Hannan MT, et al: Postmenopausal estrogen replacement and tooth retention. *Compend Contin Educ Dent Suppl* 22:S17, 1998.
60. Lapp CA, Thomas ME, Lewis JB: Modulation by progesterone of interleukin-6 production by gingival fibroblasts. *J Periodontol* 66:279, 1995.
61. Lieff S, Boggess KA, Murtha AP, et al: The oral conditions and pregnancy study: periodontal status of a cohort of pregnant women. *J Periodontol* 75:116, 2004.
62. Levin RP: Pregnancy gingivitis. *J Md State Dent Assoc* 30:27, 1987.
63. Lindhe J, Branemark P: Changes in microcirculation after local application of sex hormones. *J Periodontal Res* 2:185, 1967.
64. Lindhe J, Branemark P: Changes in vascular permeability after local application of sex hormones. *J Periodontal Res* 2:259, 1967.
65. Little JW, Falace DA: *Dental management of the medically compromised patient*, ed 4, St. Louis, 1993, Mosby.
66. Löe H, Silness J: Periodontal disease in pregnancy. 1. Prevalence and severity. *Acta Odontol Scand* 21:533, 1984.
67. Lopatin DE, Kornman KS, Loesche WJ: Modulation of immunoreactivity to periodontal disease-associated microorganisms during pregnancy. *Infect Immun* 28:713, 1980.
68. Lopez NJ, Da Silva I, Ipinza J, et al: Periodontal therapy reduces the rate of preterm low birth weight in women with pregnancy-associated gingivitis. *J Periodontol* 76:2144, 2005.
69. Lopez NJ, Smith PC, Guiterrez J: Periodontal therapy may reduce the risk of preterm low birth weight in women with periodontal disease: a randomized controlled trial. *J Periodontol* 73:2011, 2002.
70. Lu SY, Shi Q, Yang SH: Bacterial analysis of subgingival plaque in adolescents. *ZhonghuaKou Qiang Yi Xue Za Zhi* 43:737, 2008. (Chinese).
71. Lundgren D, Magnssen B, Lindhe J: Connective tissue alterations in gingiva of rats treated with estrogens and progesterone. *Odontology* 24:49, 1973.
72. Machtei EE, Mahler D, Sanduri H, et al: The effect of the menstrual cycle on periodontal health. *J Periodontol* 75:408, 2004.
73. Madianos PN, Lieff S, Murtha AP, et al: Maternal periodontitis and prematurity. Part II: Maternal infection and fetal exposure. *Periodontol 2000* 6:175, 2001.
74. Magnusson T, Ericson T, Hugoson A: The effect of oral contraceptives on some salivary substance in women. *Arch Oral Biol* 20:119, 1975.
75. Mandel L, Kaynar A: Bulimia and parotid swelling: a review and case report. *J Oral Maxillofac Surg* 50:1122, 1992.
76. Michalowicz BS, Di Angelis AJ, Novak MJ, et al: Examining the safety of dental treatment in pregnant women. *J Am Dent Assoc* 139:685, 2008.
77. Miyagi M, Morishita M, Iwamoto Y: Effect of sex hormones on production of prostaglandin E2 by human peripheral monocytes. *J Periodontol* 64:1075, 1993.
78. Miyagi M, Aoyama H, Morishita M, et al: Effects of sex hormones on chemotaxis of polymorphonuclear leukocytes and monocytes. *J Periodontol* 63:28, 1992.
79. Mohammed AR, Brunsvold M, Bauer R: The strength of association between systemic postmenopausal osteoporosis and periodontal disease. *Int J Prosthet* 9:479, 1996.
80. Mohammad AR, Hooper DA, Vermilyea SG, et al: An investigation of the relationship between system bone density and clinical periodontal status in post-menopausal Asian-American women. *In Dent J* 53:121, 2003.
81. Mombelli A, Rutar A, Lan NP: Correlation of the periodontal status 6 years after puberty with clinical and microbiological conditions during puberty. *J Clin Periodontol* 22:300, 1995.
82. Mullally BH, Coulter WA, Hutchinson JD, et al: Current oral contraceptive status and periodontitis in young adults. *J Periodontol* 78:1031, 2007.
83. Muramatsu Y, Takaesu Y: Oral health status related to subgingival bacterial flora and sex hormones in saliva during pregnancy. *Bull Tokyo Dent Coll* 35:139, 1994.
84. Murphy AA, Zacur HA, Charache P, et al: The effect of tetracycline on levels of oral contraceptives. *Am J Obstet Gynecol* 164:28, 1991.
85. Nakagawa S, Fujii H, Machida Y, et al: A longitudinal study from prepuberty to puberty of gingivitis: correlation between the occurrence of Prevotella intermedia and sex hormones. *J Clin Periodontol* 21:658, 1994.
86. Neely JL, Abate M, Swinker M, et al: The effect of doxycycline on serum levels on ethinyl estradiol, norethindrone, and endogenous progesterone. *Obstet Gynecol* 77:416, 1991.
87. O'Neil TC: Maternal T-lymphocyte response and gingivitis in pregnancy. *J Periodontol* 50:178, 1979.
88. Offenbacher S, Beck J, Jared H, et al: Maternal oral therapy to reduce obstetric risk (MOTOR): a report of a multi-centered periodontal therapy randomized-controlled trial on rate of preterm delivery. *BJOG* 199:S2, 2008.
89. Offenbacher S, Jared HL, O'Reilly PG, et al: Potential pathogenic mechanisms of periodontitis associated pregnancy complications. *Ann Periodontol* 3:233, 1998.
90. Offenbacher S, Katz V, Fertik G, et al: Periodontal infection as a possible risk factor for preterm low birthweight. *J Periodontol* 67(Suppl):1103, 1996.
91. Offenbacher S, Lin D, Strauss R, et al: Effects of periodontal therapy during pregnancy on periodontal status, biologic parameters, and pregnancy outcomes: a pilot study. *J Periodontol* 77:2011, 2006.
92. Oh Tj, ber R, Wang L: Periodontal disease in the child and adolescent. *J Clin Periodontol* 29:400, 2002.
93. Ojanotko-Harri AO, Harri MP, Hurrita HP, et al: Altered tissue metabolism of progesterone in pregnancy gingivitis and granuloma. *J Clin Periodontol* 18:262, 1991.
94. Olin BR: *Drug facts and comparisons*, St. Louis, 1994, Kluwer.
95. Otomo-Corgel J: *Systemic considerations for female patients. In Antibiotic/antimicrobial use in dental practice*, Tokyo, 1990, Quintessence.
96. Pack AR, Thomson ME: Effects of topical and systemic folic acid supplementation on gingivitis in pregnancy. *J Clin Periodontol* 7:402, 1980.
97. Paganini-Hill A: Benefits of estrogen replacement therapy on oral health: the leisure world cohort. *Arch Intern Med* 155:2325, 1995.
98. Pankhurst CL: The influence of oral contraceptive therapy on the periodontium: duration of drug therapy. *J Periodontol* 52:617, 1981.
99. Pediatric Dentistry special issue: Reference manual. *Pediatr Dent* 16(7), 1994.
100. Pilgram TK, Hildebolt CF, Dotson M: Relationships between clinical attachment level and spine and hip bone mineral density: data from healthy postmenopausal women. *J Periodontol* 73:298, 2002.
101. Pinard A: Gingivitis in pregnancy. *Dent Register* 31:258, 1877.
102. Pitcarin J: A case of disease of the gums [that] occurred during pregnancy. *Dubing Hosp Rep* 2:309, 1818.
103. Raber-Durlacher JE, van Steenbergen TJ, van der Velden U: Experimental gingivitis during pregnancy and postpartum: clinical, endocrinological and microbiological aspects. *J Clin Periodontol* 21:549, 1994.
104. Raber-Durlacher JE, Leene W, Palmer-Bouva CC, et al: Experimental gingivitis during pregnancy and postpartum: immunohistochemical aspects. *J Periodontol* 64:211, 1993.

105. Raber-Durlacher JE, Zeylemaker WP, Meinesz AA, et al: CD4 to CD8 ratio and in vitro lymphoproliferative responses during experimental gingivitis in pregnancy and postpartum. *J Periodontol* 62:663, 1991.
106. Reese RE, Betts RF: *Handbook of antibiotics*, ed 2, Boston, 1993, Little, Brown.
107. Reinhardt RA, Payne JB, Maze C, et al: Gingival fluid IL-beta in postmenopausal females on supportive periodontal therapy: a longitudinal 2-year study. *J Clin Periodontol* 25:1029, 1998.
108. Reinhardt RA, Payne JB, Maze CA, et al: Influence of estrogen and osteopenia/osteoporosis on clinical periodontitis in postmenopausal women. *J Periodontol* 70:823, 1999.
109. Robb-Nicholson C: PMS: it's real. *Harv Women Health Watch* 1(11):2, 1994.
110. Robb-Nicholson C: Gastroesophageal reflux disease. *Harv Women Health Watch* 4(6):4, 1999.
111. Ronderos M, Jacobs DR, Himes JH, et al: Associations of periodontal disease with femoral bone mineral density and estrogen replacement therapy: cross-sectional evaluation of U.S. adults from NHANES III. *J Clin Periodontol* 27:778, 2000.
112. Ruma M, Moss K, Jared H: Maternal periodontal disease, systemic inflammation and eclampsia. *Am J Obstet Gynecol* 19:389, 2008.
113. Sanz M, Kornman K, et al: Periodontitis and adverse pregnancy outcomes: consensus report of the Joint EFP/AAP Workshop on Periodontitis and Systemic Diseases. *J Periodontol* 201;84(4 Suppl):164, 2013.
114. Samant A, Malik CP, Chabra SK, et al: Gingivitis and periodontal disease in pregnancy. *J Periodontol* 47:415, 1976.
115. Scannapieco FA, Bush RB, Paju S: Periodontal disease as a risk factor for adverse pregnancy outcomes: a systematic review. *Ann Periodontol* 8:70, 2003.
116. Schuurs A, Verheul H: Effects of gender and sex steroids on the immune response and autoimmune disease. *J Steroid Biochem* 35:157, 1990.
117. Siqueira FM, Cota LO, Costa JE: Maternal periodontitis as a potential risk variable for preeclampsia: a case-control study. *J Periodontol* 79:207, 2008.
118. Sooriyamoorthy M, Gower DB: Hormonal influences on gingival tissues: relationship to periodontal disease. *J Clin Periodontol* 16:201, 1989.
119. Sridama V, Pacini F, Yang SL, et al: Decreased levels of helper T cells: a possible cause of immunodeficiency in pregnancy. *N Engl J Med* 307:352, 1982.
120. Srinivas SK, Aauuel MD, Stamilio DM, et al: Periodontal disease and adverse pregnancy outcomes: is there an association? *Am J Obstet Gynecol* 200:297, 2009.
121. Steinberg BJ: Sex hormonal alterations. In Rose LD, Kay D, editors: *Internal medicine for dentistry*, ed 2, St. Louis, 1990, Mosby.
122. Sweet JB, Butler DP: Increased incidence of postoperative localized osteitis in mandibular 3rd molar surgery associated with patients using oral contraceptives. *Am J Obstet Gynecol* 127:518, 1977.
123. Taguchi A, Sandada M, Suei Y, et al: Effect of estrogen use on tooth retention, oral bone height, and oral bone porosity in Japanese postmenopausal women. Post menopausal estrogen replacement and tooth retention. *Menopause* 11:556, 2004.
124. Tarannum F, Faizuddin M: Effect of periodontal therapy on pregnancy outcome in women affected by periodontitis. *J Periodontol* 78:2095, 2007.
125. Tezal M, Wactawski-Wende J, Grossi SG, et al: The relationship between bone mineral density and periodontitis in postmenopausal women. *J Periodontol* 71:149, 2000.
126. Thomson ME, Pack AR: Effects of extended systemic and topical folate supplementation on gingivitis in pregnancy. *J Clin Periodontol* 9:275, 1982.
127. Turner M, Aziz SR: Management of the pregnant oral and maxillofacial surgery patient. *J Oral Maxillofac Surg* 60:1479, 2002.
128. Valdimarsson H, Mulholland C, Fridriksdottir V, et al: A longitudinal study of leukocyte blood counts and lymphocyte responses in pregnancy: a marked early increase of monocyte-lymphocyte ratio. *Clin Exp Immunol* 53:437, 1983.
129. Vergnes JN: Studies suggest an association between maternal periodontal diseases and pre-eclampsia. *Evid Based Dent* 9:46, 2008.
130. Vetorre MV, Leal M, Leao AT, et al: The relationship between periodontitis and preterm low birthweight. *J Dent Res* 87:73, 2008.
131. Vinco L, Prallet B, Chappard D, et al: Contributions of chronological age, age at menarche and menopause and of anthropometric parameters to axial and peripheral bone densities. *Osteoporosis Int* 2:153, 1992.
132. Vittek J, Gordon G, Rappaport C, et al: Specific progesterone receptors in rabbit gingiva. *J Periodontal Res* 17:657, 1982.
133. Wactawski-Wende J, Grossi SG, Trevisan M, et al: The role of osteopenia in oral bone loss and periodontal disease. *J Periodontol* 67:1076, 1996.
134. Wactawski-Wende J, Hauwmann E, Hovey K, et al: The association between osteoporosis and alveolar crestal height in postmenopausal women. *J Periodontol* 76(11 Suppl):2116, 2000.
135. Whitacre CC, Reingold SC, O'Looney PA: A gender gap in autoimmunity. *Science* 283:1277, 1999.
136. Whitehear MI, Whitcroft SI, Hillard TC: *An atlas of the menopause*, New York, 1993, Parthenon.
137. Wimmer G, Pihlstrom BL: A critical assessment of adverse pregnancy outcomes and periodontal disease. *J Clin Periontol* 35:380, 2008.
138. Wilson JT, Brown RD, Cherek DR, et al: Drug excretion in human breast milk: principles, pharmacokinetics and projects consequences. *Clin Pharmacokinet* 5:1, 1980.
139. Xiong X, Buekens P, Fraser WD, et al: Periodontal disease and adverse pregnancy outcomes: a systemic review. *BJOG* 61:307, 2006.
140. Yoshihara A, Seida Y, Hanada N, et al: The relationship between bone mineral density and the number of remaining teeth in community-dwelling older adults. *J Oral Rehabil* 32:735, 2005.
141. Zachariasen RD: Ovarian hormones and oral health: pregnancy gingivitis. *Compend Contin Educ Dent* 10:508, 1989.
142. Zachariasen RD: The effects of elevated ovarian hormones on periodontal health: oral contraceptives and pregnancy. *Women Health* 20(2):21, 1993.
143. Zoeller J: The top 200 drugs. *Am Druggist* 41:1999.

CHAPTER 39

Periodontal Treatment for Older Adults

Sue S. Spackman and Janet G. Bauer

CHAPTER OUTLINE

The Aging Periodontium
Demographics *(e-only)*
Dental and Medical Assessments *(e-only)*
Periodontal Diseases in Older Adults
Periodontal Treatment Planning
Prevention of Periodontal Disease and Maintenance of Periodontal Health in Older Adults
Conclusion

For online-only content on demographics, dental and medical assessment, and risk reduction, please visit the companion website at **www.expertconsult.com.**

Older adults are expected to compose a larger proportion of the population than in the past. Population growth among long-lived older adults contributes to this increase worldwide. For dentistry, this means that older adults are retaining more of their natural dentition. Currently, almost 70% of older adults in the United States have natural teeth.[27] However, retention of teeth may result in more teeth at risk for periodontal disease, and thus the prevalence of periodontal disease may be associated with aging. This association was addressed by Beck[20] at the 1996 World Workshop on Periodontics: "It may be that risk factors do change as people age or at least the relative importance of risk factors change."

This chapter focuses on the interrelationship between aging and oral health, with an emphasis on periodontal health.

The Aging Periodontium

Normal aging of the periodontium is a result of cellular aging. In general, cellular aging is the basis for the intrinsic changes seen in oral tissues over time. The aging process does not affect every tissue in the same way. For example, muscle tissue and nerve tissue undergo minimal renewal, whereas epithelial tissue, which is one of the primary components of the periodontium, always renews itself.

Intrinsic Changes

In epithelium, a progenitor population of cells (stem cells), situated in the basal layer, provides new cells. These cells of the basal layer are the least differentiated cells of the oral epithelium. A small subpopulation of these cells produces basal cells and retains proliferative potential of the tissue. A larger subpopulation of these cells (amplifying cells) produces cells available for subsequent maturation. This maturing population of cells continually undergoes a process of differentiation or maturation.

By definition, this differentiated cell, or epithelial cell, can no longer divide. Conversely, the basal cell remains as part of the progenitor population of cells ready to return to the mitotic cycle and again produce both types of cells. Thus there is a constant source of renewal (Figure 39-1). In the aging process, cell renewal takes place at a slower rate and with fewer cells, so the effect is to slow down the regenerative processes. As the progenitor cells wear out and die, there are fewer and fewer of these cells to renew the dead ones. This effect is characteristic of the age-related and biologic changes that occur with aging.

By the action of gerontogene(s) or replicative senescence (Hayflick's limit and telomere shortening), the number of progenitor cells decreases. Hayflick, an American microbiologist, observed that fetal cells (i.e., fibroblasts) displayed a consistently greater growth potential (approximately 50 cumulative population doublings) than those derived from adult tissues (20 to 30 cumulative population doublings). As a result, the decreased cellular component has a concomitant effect to decrease cellular reserves and protein synthesis. This affects the oral epithelium in that the tissue becomes thin, with reduced keratinization.

Stochastic Changes

Stochastic changes occurring within cells also affect tissue (e.g., glycosylation and cross-linking produce morphologic and physiologic changes). Structures become stiffer, with a loss of elasticity and increased mineralization (fossilization). With a loss of regenerative power, structures become less soluble and more thermally stable. Somatic mutations lead to decreased protein synthesis and structurally altered proteins. Free radicals contribute to the accumulation of waste in the cell.

All these changes produce a decline in the physiologic processes of tissue. Most changes are primarily a result of aging, although some are secondary to physiologic deterioration. For example, loss of elasticity and increased resistance of the tissue may lead to decreased permeability, decreased nutrient flow, and the accumulation of wastes in the cell. Thus vascular peripheral resistance (decreased blood supply) may secondarily decrease cellular function.

Physiologic Changes

In the periodontal ligament, a decrease in the number of collagen fibers leads to a reduction or loss in tissue elasticity.

Demographics

Population Distribution

In 2010, adults 65 years of age and older were 12.0% of the U.S. population or 40 million people. By 2050, this population will grow 55% to 88.5 million people due to aging of the baby boomer generation and immigration into the United States. The greatest percentage of population growth will occur in those aged 85 and older (29%) and those 100 and older (65%). At the same time, the U.S. population is expected to increase from 312 million to 439 million or by 40%. Of the 65+ age group, the number of those 85 and older are expected to increase by 13.3 million people (300%) with centenarians (age 100+) increasing by 500,000 people or at a rate of 20 times greater than that of other segments of the aging population (900%).[62,63]

The increase in the aging population is the result of the dramatic increase in life expectancy during the past and present centuries. Average life expectancy was 77 years in 2010, an increase of 30 years since 1900. In 2010, life expectancy (at birth) was projected to be 80 years. Adults who reached the age of 65 in 2010 could expect to live an average of 18 additional years.[62,63]

Differences in population growth between urban and rural older adults have special significance for oral health. The expected increase in the proportion of older adults will be 3% larger in rural areas. Because rural older adults use dental services less than their urban counterparts, the risk for adverse changes in oral health and self-care may be greater.[67]

Health Status

Increased life expectancy has changed the way the public and healthcare policy makers and providers think about "aging." Instead of controlling chronic disease and morbidity, aging is seen in terms of "successful aging" or "healthy aging." This paradigm shift is based on study of what promotes health and longevity. Current research is now examining aging in terms of the physical, mental, and social well-being of older adults, not just disease or morbidity. The MacArthur Studies of Successful Aging asked the fundamental question, "What genetic, biomedical, behavioral, and social factors are crucial to maintaining health and functional capacities in the later years?"[42]

Despite this paradigm shift, the number of older adults with acute and chronic diseases continues to increase.[63] Visual impairments, cataracts, glaucoma, and hearing impairments increase in frequency with advancing age. Almost half of people age 65 and older have arthritis.[65] Most older adults have at least one chronic condition, and many have several chronic conditions. In 1994 the chronic conditions that occurred most often in older adults were arthritis, hypertension, heart disease, hearing impairment, cataract, orthopedic impairment, sinusitis, and diabetes (Figure 39-2). Although heart disease remains the leading cause of death among older adults, cancer may become the leader during the twenty-first century. Currently, among older adults, approximately 7 in 10 deaths are caused by heart disease, cancer, or stroke.[63]

In the early 1900s, Dr. Ignatz Leo was the first to recognize that older adults had health needs and concerns that set them apart from younger adults.[47] Not until the latter half of the twentieth century, however, did geriatrics (medicine for older adults) become a discipline in healthcare. A "geriatric" patient is an older adult who is frail, dependent, or both and who requires health and social support services to attain an optimal level of physical, psychologic, and social functioning. Thus the treatment plan must reflect the professional knowledge to resolve physical and psychologic aspects of health status, as well as being sensitive to an individual's all-encompassing social functioning. This functioning may include aspects of race, ethnicity, culture, personal relationships, esthetics, and social and economic conditions.

The main focus of geriatrics is *frail and functionally dependent older adults.* Functionally independent older adults are included but only to make them aware of services that they may need if they experience functional deficits that impair their daily activities (Table 39-1). Specialists in geriatric medicine, *geriatricians,* have additional training in healthcare for frail and functionally dependent older adults. In geriatric medicine, numerous assessment instruments have been developed to assist the geriatrician, and some aspects of these are important to dentists in identifying risks and functional declines. These instruments include activities of daily living (ADLs), Tinetti Balance and Gait Evaluation, geriatric depression scale (GDS), and Mini-Mental State Questionnaire. Each assesses risks to morbidity and mortality in maintaining a patient's optimal health and functional independence.

Care for geriatric patients crosses many disciplines. Thus, an interdisciplinary team is formed to care for and treat geriatric patients and may include the dentist. Including dentistry in the interdisciplinary effort has benefits for the patient; for example, oral care has been incorporated into nursing educational programs

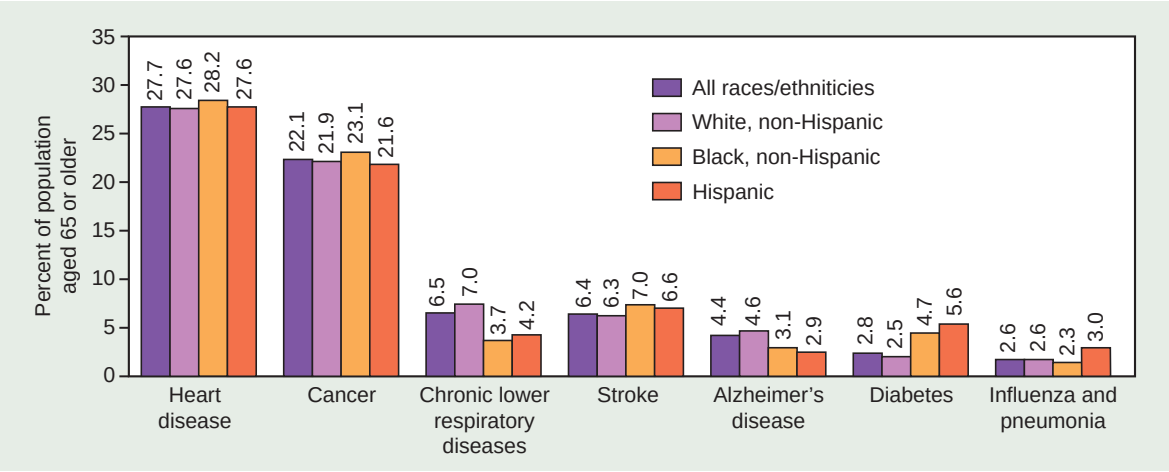

Figure 39-2 Centers for Disease Control and Prevention. *The State of Aging and Health in America 2013.* Atlanta: Centers for Disease Control and Prevention, US Dept of Health and Human Services, 2013.

TABLE 39-1 Functional Categories for Older Adults

Category	Description	Issues	Limitations
Functionally independent	Those who reside in the community and receive little or no assistance.	Majority of older adults fall into this category.	Access and use dental services similar to younger adults in the community.
Frail	Those who reside in the community and maintain some degree of independence with assistance from others.	Include those who are "homebound," or spend most of their time in their homes, and those at risk for being institutionalized.	Need assistance with some ADLs and are dependent on another for most IADLs.
Bathing, dressing, and transportation problems were the three limitations that most homebound elderly experienced.			
Functionally dependent	Those who cannot maintain any level of independence and are totally dependent on assistance.	Include those who are institutionalized or are a at highest risk for institutionalization.	Dependent on another for most if not all the IADLs and basic ADLs.

ADLs, Activities of daily living; *IADLs,* instrumental ADLs.

and practice for the geriatrician nurse practitioner.[49] Likewise, dieticians have educational content in oral care. The focus is to include oral health as part of *medical nutrition therapy* (MNT) in achieving the patient's total health needs.[7] A "last frontier" for the interdisciplinary team is the community. When geriatric patients require multidisciplinary strategies to improve their conditions at the community level, efforts have been less than satisfactory. Problems have been encountered when coordination is needed for geriatric patients to access multiple providers across a range of healthcare settings. Shared decision making and patient education are needed to improve access and realize successful outcomes.[33] A detailed computer-based model on multidisciplinary and interdisciplinary decision making in the geriatric population can be found in Bauer et al.[13-19]

Functional Status

In dentistry, prevention of oral diseases and improvements in healthy lifestyles have contributed to older adults keeping and maintaining their dentition. Dentistry for geriatric patients, or *geriatric dentistry,* emphasizes an interdisciplinary approach to diagnosis, treatment, and prevention of dental and oral diseases.[31] Specialists in geriatric dentistry are *geriatric dentists.* Similar geriatric health and functional instruments used in medicine assist geriatric dentists in assessing risks that compromise oral health.

Functional impairments have a significant impact on oral health and self-care. Sensory impairments and arthritis make it more difficult for older adults to understand dental outcomes, communicate oral healthcare needs and concerns, and perform effective oral self-care. Functional testing or measuring instruments may become part of the dentist's armamentarium to assess an older adult's ability to perform oral care tasks in achieving and maintaining oral health. The index of Activities of Daily Oral Hygiene (ADOH) is one such dental assessment instrument that quantifies the functional ability of older adults, specifically frail and functionally dependent older adults, in performing oral self-care tasks.[10] The index of ADOH provides the dentist or dental assistant with the means to determine the functional ability of an older adult to manipulate aids used in daily oral hygiene care. From these findings, strategies may be developed to rehabilitate and then remeasure for improvements in functional deficits. If improvements are not forthcoming, alternative strategies and assistive devices are recommended.

Accommodating dentists in the interdisciplinary team is increasing, including their participation in primary care. For example, edentulism and denture wearing in older adults may be related to poor quality of life and risk for undiagnosed oral disease. They may also indicate other medical comorbidities. Thus medical and dental geriatricians must incorporate knowledge of comorbidities to identify risks that manifest as reciprocation of disease and poor quality of life.[68,73] In managing periodontal disease, the dental geriatrician is challenged with integrating primary care, oral health, and patient and caregiver education in nontraditional settings such as residential, institutional, and hospital practice settings.

Although geriatric medicine training programs have grown remarkably over the past three decades, this growth is still not producing the number of geriatricians needed to care for the growing older adult population. Comparatively, the training of dental geriatricians is much less. In response, the geriatric dentistry community has advocated the use of dental geriatricians to train general dentists in the care of geriatric dental patients. Kayak and Brudvik[40] see this type of training essential to "successful aging" and periodontal healthcare in both dental practice and nontraditional settings. Thus dental geriatricians as faculty are needed to train practitioners.[68]

In an article on periodontal dental education, Wilder et al stated "that dental schools are confident about the knowledge of their students regarding oral-systemic content. However, much work is needed to educate dental students to work in a collaborative fashion with other healthcare providers to co-manage patients at risk for oral-systemic conditions."[75]

Nutritional Status

Whereas "diet" refers to the consumption of types and varieties of food resources, *nutrition* is the process by which food is used to provide energy and sustain, restore, and maintain tissue of living organisms. With aging, there is an increased risk of nutritional deficiencies among older adults. However, the real risk is not malnutrition; among older adults in the United States, the rate of malnutrition is low. The real risk is attributed to *unbalanced diets.*

An older adult's dietary patterns may be associated with numerous factors, including the aging process, diseases and the medications used in their treatment, and social and economic conditions. In general, energy needs and intake in older adults decline with age.

Beyond middle age, body weight and lean body mass decline with age, in part because of primary aging. Age changes in physiologic functioning, including metabolic, hormonal, and neural changes, have been associated with poor quality diets in older adults.

Older adults do not compensate well, or take in more food, when bodily changes alter their energy levels. For example, a slower metabolic rate accompanied with decreased levels of

physical activity explains why older adults have reduced food intake. This is also associated with altered sensations of hunger, thirst, and satiety or fullness. Reductions are seen in fluid intake, uncompensated by increased thirst. The variety of foods eaten is reduced, or characteristic bland diets may result from lowered sensory-specific satiety. In other words, older adults have a lowered enjoyment of foods because of deficits in smell and possibly taste. More than half of people age 65 to 80 have a major olfactory impairment, with 75% of those age 80 and older affected. Thus food recognition diminishes with age.

All these factors may place the older adult at risk for serious problems. *Anorexia,* or low food intake, increases the risk of nutrition-related illnesses. *Electrolytic imbalances* (e.g., salt and water imbalances) are associated with age-related changes in regulatory systems, such as changes in central nervous system (CNS) receptors that detect changes in the level of sodium in blood. Dehydration, which can lead to illness and death, is a common cause of fluid and electrolyte disturbance. *Deconditioning* is an almost complete disturbance of physical functioning. These conditions may present when a frail older adult comes to the dental office seeking care and are seen more often in homebound persons, hospitalized patients, and nursing home residents.

Poor nutrition and low body weight may often precede and predispose older adults to secondary age changes. *Secondary aging changes* are a result of acute and chronic disease and medication use. The most common age-associated chronic diseases are hypertension, hyperlipidemia, atherosclerosis, and diabetes. Compounding effects of secondary aging may include impaired mobility, inability to feed oneself, poor oral health, and the use of dentures, all of which may affect the amount and types of foods consumed. Age-associated decreases in saliva production and swallowing problems may also make eating difficult. In addition, nutrient malabsorption can be caused by altered gastric acid secretion or by interaction with medications. The cumulative effect of these changes may account for taste loss in the older adult.

Economic and social factors have also been linked with significant changes in eating patterns, such as loss of appetite. *Economic factors* include a lower economic status resulting from retirement, failing health, living on a fixed income, or death of a spouse. *Social factors* include isolation, loneliness, and the effects of depression or dementia. All these factors may affect the type and quality of food consumed. For example, socialization at meals may increase the amount of food consumed by older adults.

In addition, *impaired chewing* can cause changes in food selection, such as decreasing the variety in the diet, which may contribute to nutritional problems. Currently, 42% of older adults have no natural teeth. Rehabilitation with complete dentures may restore only 25% of normal chewing effectiveness.[54] Of those with teeth, 60% have tooth decay and 90% have periodontal disease, which may contribute to impaired chewing ability or loss of appetite.

These aging-related disease states and social factors may result in inadequate consumption of nutrient-dense foods or inadequate intake of some vitamins and minerals. Minerals are important to the absorption and utilization of vitamins. Both are important to antibody formation and the immune system in combating infection, foreign substances, and toxins (Table 39-2).[23]

Psychosocial Factors

Dental diseases have their greatest effect on behaviors and mental and social well-being. In other words, dental diseases impact psychologic and social functioning and thus are almost always preventable by behavioral and social means. On average, older adults use fewer dental services, perhaps because of conflicting economic priorities between medical and dental needs. For many older adults, dental services are a discretionary choice and not part of their primary care options. This may result in part from their poorer health status, lack of dental insurance or coverage by government-sponsored healthcare programs, or simply their functional status or independence.

Older adults with positive attitudes toward oral health have predictably better dental behaviors that translate into higher utilization rates of dental services. Positive attitudes are highly associated with educational level.[12] The education level of older adults is increasing. In 1995, only 64% of noninstitutionalized older adults completed at least high school, and 13% possessed a bachelor's degree. By 2015, it is estimated that 76% of older adults will have completed at least high school, with 20% obtaining a bachelor's degree. Those with more education were three to four times more likely to have visited a dentist in the past year, indicating that an informed and knowledgeable public provides a culture of healthy behaviors that guide older adults toward the long-term preservation of teeth and function.

Impediments to the utilization of dental services are associated with low income and an associated lack of a regular source of care. Those with higher education tend to be better off financially than those with low education. Poverty is less prevalent today among older adults for all race, gender, and ethnic groups.[63,64] In general, older adults have the highest disposable income of all ages.[71] Thus higher educational achievement with lower poverty levels is a predictor for an increase in demand for oral healthcare among older adults.[39]

However, differences in the prevalence of periodontal disease were seen in relation to race. Among dentate non-Hispanic blacks, non-Hispanic whites, and Mexican Americans 50 years of age and older, blacks had higher levels of periodontal disease, even those in higher income groups. Thus Borrell et al[22] suggested that race and ethnicity are important factors in combating health disparities.

Reciprocally, oral disease may affect behaviors, and behavioral problems may adversely affect oral health. Adverse oral health conditions affect three aspects of daily living: (1) systemic health, (2) quality of life, and (3) economic productivity.

Both systemic health and quality of life are compromised when edentulism, xerostomia, soft tissue lesions, and poorly fitting dentures affect eating and food choices. Conditions, such as oral clefts, missing teeth, severe malocclusion, and severe caries, are associated with feelings of embarrassment, withdrawal, and anxiety. Oral and facial pain from dentures, temporomandibular joint disorders, and oral infections affect social interaction and daily behaviors.[38]

Behavioral problems may worsen oral conditions. Older adults today grew up during Prohibition or the Great Depression, when *alcohol consumption* was much lower. Since then, alcohol consumption has increased, especially in women, along with alcohol-related health problems. Alcohol-related disorders include alcohol abuse and dependence and alcoholic liver disease, psychoses, cardiomyopathy, gastritis, and polyneuropathy.

A general consensus states that light drinking, or one drink per day, is not harmful as long as the older adult is reasonably healthy and not taking medications that interact with alcohol. However, alcohol may react differently in older than younger adults. A decrease in body water content may produce higher peak serum ethanol levels. In particular, alcohol intake may make older adults vulnerable to changes in the capacity of the liver to metabolize drugs and to symptomatic behaviors such as confusion, depression, and dementia.

TABLE 39-2 Nutrient Effects on the Immune Response

Nutrient	Component in Biologic Processes	EFFECT OF INSUFFICIENT INTAKE OF NUTRIENT	
		Increase Function	Decrease Function
Protein energy intake	Energy metabolism DNA/RNA synthesis	Bacterial adhesion	Salivary antimicrobial properties Immunoglobulin production Lysozymes Activation of lymphocytes Production of antibodies
Vitamin A	Cellular differentiation and proliferation Integrity of immune system	Bacterial adhesion	Immune cell differentiation Response to antigens Antibody production Immunoglobulin production Production of lymphocytes
Vitamin E	Antioxidant protecting lipid membranes from oxidation	—	Antibody synthesis Response of lymphocytes Phagocytic function
Vitamin C	Antioxidant that reduces free radicals that cause DNA damage to immune cells	—	Phagocytic function of neutrophils and macrophages Antibody response Cytotoxic T-cell activity
Riboflavin, vitamin B_6, and pantothenic acid	Coenzymes in metabolic processes	—	Antibody synthesis Cytotoxic T-cell activity Lymphocyte response
Folic acid and vitamin B_{12}	Involved in DNA/RNA synthesis	—	Production of lymphocytes Cytotoxic T-cell activity Phagocytic function of neutrophils
Zinc	More than 100 enzymes associated with carbohydrate and energy metabolism Protein catabolism and synthesis Nucleic acid synthesis	—	Antibody response Phagocytic function of macrophages B-cell and T-cell proliferation
Iron	Involved in hemoglobin, myoglobin, and cytochrome systems	—	Lymphocyte proliferation Neutrophil cytotoxic activity Antibody response

Data from Boyd LD, Madden TE: *Dent Clin North Am* 47:337, 2003.

DNA, Deoxyribonucleic acid; *RNA,* ribonucleic acid.

The patterns of drinking and alcohol-related problems may not differ between older and younger problem drinkers. However, numerous reports suggest that alcohol as the primary substance of abuse is higher in the older than in the younger adult. A peak onset for alcohol-related problems is 65 to 74 years. Unfortunately, alcohol consumption is directly correlated with clinical attachment loss in periodontal disease.[61]

Periodontal disease may also be exacerbated in those with depression.[4,41] *Depression* is a common public health problem among elderly persons, affecting 15% of adults over age 65 in the United States. The suicide rate for those older than 85 is about 2 times the national rate. Geriatric depression is treatable, so recognition of this disorder is a vital step in the prevention of disability and mortality.[56] However, depression is not easy to recognize. Depression may also accompany a wide variety of physical illnesses such as fatigue, poor appetite, sleep disturbances, cardiovascular disease, and cancer. It may be the primary cause of somatic complaints, including oral discomfort. The classic signs and symptoms for depression include sadness, decreased appetite, weight loss, confusion, difficulty in decision making, dissatisfaction, and irritability. Many older adults, however, present with a less dramatic level of actual sadness and frequently have apparent cognitive impairment, especially memory deficits, and therefore differentiation from dementia is important. Recognizing the signs of depression can significantly reduce depression, by about 70%, in those older than 65 years of age.

Dentate Status

In dentistry the level of illness is measured as "tooth mortality" or tooth loss. Still among the most ubiquitous of human diseases, dental disease places all segments of the population at risk. Older adults are at greatest risk, especially those older than 85 years of age. Oral health changes in health and functional well-being (functional disabilities) potentiate risks to oral disease, including dental caries (particularly root caries), periodontal disease, oral cancer, xerostomia (dry mouth), disorders associated with denture wearers, and systemic disease with oral symptoms.

Over a 30-year period, edentulism and partial tooth loss declined substantially.[27] The most current estimates of tooth loss and tooth retention in the U.S. population indicate that 75% of older adults age 65 to 69 and more than half of adults age 75 and older are dentate (Table 39-3).

By the year 2030, the number of teeth retained by older adults is expected to double, which is an estimated 800 million increase in tooth retention. It is expected that over the next 3 decades the average number of retained teeth will increase from

TABLE 39-3 Percentage of Dentate Older Adults: United States, 1988 to 1991

Age Group	All Older Adults	Male	Female
50-54	88	90	86
55-59	82	82	83
60-64	76	77	76
65-69	74	73	75
70-74	69	71	67
75+	56	53	58

Data from U.S. Census Bureau: US interim projections by age, sex, race and Hispanic origin, 2004: http://www.census.gov/ipc/www/usinterimproj/.

the current 20 to 25.9 teeth.[30] Thus the risk of periodontal disease and dental caries is expected to be a major problem of older adults. Because few older adults are covered by dental insurance,[11] payment for treatments will be the responsibility of the geriatric patient. Costs and the inability to afford care will always affect healthcare utilization, particularly dentistry, which is often considered discretionary.

Periodontal Status

The classic periodontal disease model suggested that virtually all older adults would, at some time in their life, become susceptible to severe periodontitis. This result was attributed to an insidious process in which gingivitis slowly progressed into periodontitis, with probable bone and tooth loss. Thus it was asserted that susceptibility to periodontitis increased with age, resulting in tooth loss seen predominantly after age 35 years.

The current periodontal disease model suggests that only a small proportion of adults have advanced periodontal destruction. Mild gingivitis is common, as is mild-to-moderate periodontitis. Most adults show some loss of probing attachment while maintaining a functional dentition. In addition, severe periodontal disease is not a part of normal aging and is not the major cause of tooth loss. There may be exceptions to this, but when disease occurs, it is usually in those age 85 and older.

The model asserts that gingivitis does precede periodontitis, but relatively few sites with gingivitis develop periodontitis. The bacterial flora associated with gingivitis and periodontitis shows similarities but does not reciprocate causally. In all, the current model of periodontal disease indicates the following:

- The prevalence of periodontal disease is low and possibly decreasing.
- The progress of periodontal disease is episodic and infrequent.
- Active and inactive disease sites coexist.
- Most of the reported cases of periodontal disease occur in a small, high-risk population of older adults.
- There is a continued effort to identify risk factors for periodontal disease.

The current risk factors suggested for periodontal disease include age, smoking, diabetes mellitus, and the presence of subgingival *Porphyromonas gingivalis* and *Tannerella forsythia.*

The prevalence of periodontal disease is therefore expected to increase with age 20 as a result of a cumulative disease progression over time, not susceptibility.[5,44] In a 30-year preventive home care study, periodontal findings showed a 75% improvement in the number of healthy periodontal sites in the 51- to 65-year-old age group.[5] Thus recent data suggest that older adults who maintain optimum oral self-care are less susceptible to periodontitis.[25]

Figure 39-3 Severe periodontal disease with potential danger of tooth aspiration.

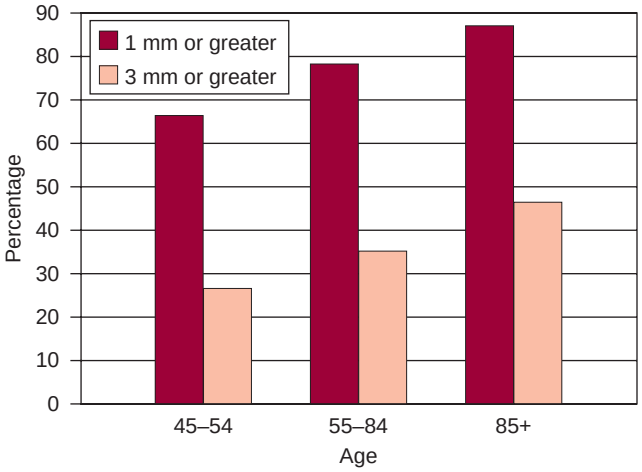

Figure 39-4 Percentage of older persons with gingival recession, 1988 to 1991. *(From Brown LJ, Brunelle JA, Kingman A:* J Dent Res *75:672, 1996.)*

Advanced periodontal disease among older adults is not as common as once thought.[15] Moderate levels of attachment loss are seen in a high proportion of older adults, but severe loss is detected in only a small proportion of older adults (Figure 39-3). The amount of periodontal disease associated with age does not appear to be clinically significant, and it is unclear whether the higher prevalence of periodontal disease is a function of age or time.[44] Figures 39-4 to 39-6 illustrate periodontal disease data from phase I of the Third National Health and Nutrition Examination Survey (NHANES III) conducted in the United States from 1988 to 1991.[14] Gingival recession increased with advancing age, with one third (35%) of persons age 55 to 84 and less than half (46%) of persons age 85 and older having 3 mm or more of gingival recession (see Figure 39-4). Pocket depth of 6 mm or greater was detected in 7% of persons 45 to 54 years of age, 8% of persons age 55 to 64, and 7% of persons age 65 and older (see Figure 39-5). Attachment loss increases with age, although less than half of persons age 65 and older had loss of attachment measuring 5 mm or greater (see Figure 39-6).

Periodontal regenerative therapies for aging periodontal tissue is being investigated by Benatti and others. Deciphering the biologic properties of periodontal ligament cell (PDLC) regeneration with the use of aging periodontal ligament cells in the laboratory will likely change the way periodontal disease is treated.[21]

Caries Status

Root caries is a disease that has a particular predilection for older adults. Exposed root surfaces in combination with compromised

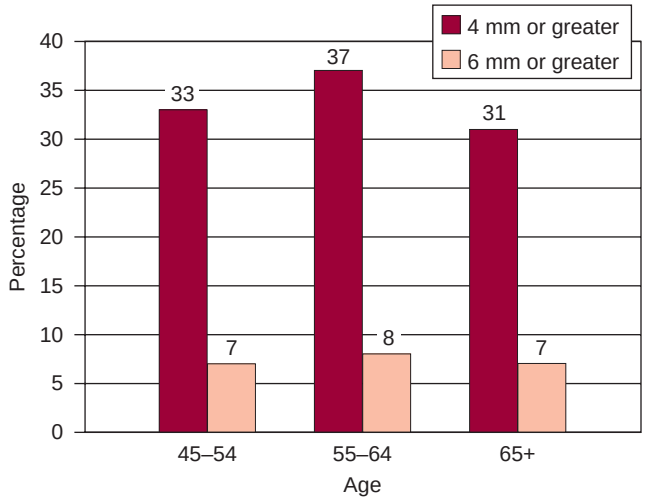

Figure 39-5 Percentage of older persons with pocket depths by age, 1988 to 1991. *(From Brown LJ, Brunelle JA, Kingman A:* J Dent Res *75:672, 1996.)*

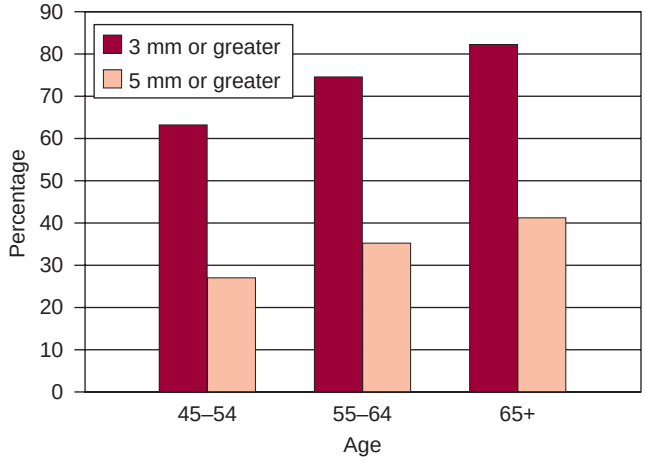

Figure 39-6 Percentage of older persons with loss of attachment by age, 1988 to 1991. *(From Brown LJ, Brunelle JA, Kingman A:* J Dent Res *75:672, 1996.)*

health status and use of multiple medications make older adults at high risk for root caries. Caries examinations from phase I of NHANES III indicate that root caries prevalence increases greatly with age. Decayed or filled root surfaces were detected in 47% of persons age 65 to 74 and in 55.9% of those 75 and older.[78]

The majority of older adults are at low risk for developing root caries, but mediating factors increase this risk, including immune system dysfunction and ineffective oral self-care. With the prospect of older adults retaining more of their teeth through improved access, prevention programs, and personal oral hygiene, it is likely that a sound root surface will remain caries free. Once a lesion is present, however, one-surface and multiple-surface lesions progress aggressively to infect other adjoining tooth surfaces rather than cavitating the infected surface. This natural occurrence in older adults is caused by dentinal sclerosis; caries progression spreads without cavitation. In older adults the active four-surface lesion produces a characteristic "apple coring," or collar of caries extending circumferentially along the cementoenamel junction, below the clinical enamel crown of the tooth. The four-surface lesion becomes chronic, with morphologic loss dependent on the

Figure 39-7 Root tips remain after coronal portion of the tooth is lost as a result of root caries, leaving a pathway for infection.

balance of forces during demineralization and remineralization. Loss of the root structure may be so significant that it undermines the support of the clinical crown. When tooth structure is compromised, the tooth is at a high risk for fracture, and oral or tooth function is impaired (Figure 39-7). The tooth may then be lost because of clinical outcomes that disallow its rehabilitation.

Dental Visits

Fundamentally, dental visits by older adults are correlated with having teeth, not age.[77] Data from the 1995 Behavioral Risk Factor Surveillance System (BRFSS), which is a continuous state-based, random-digit-dialed telephone survey of the U.S. noninstitutionalized population age 18 years and older, indicate that older adults are frequent users of dental services.[26]

Although their total consumption of dental services approximates that of younger adults, older adults make fewer dental visits: 21% to 53% of dentate adults visited the dentist in the last 12 months. Approximately 40% of these older adults use these visits for episodic care, indicating a lack of sustained and consistent care. Those least likely to visit a dentist were older adults who were either homebound or institutionalized.

When dentate and edentulous adults express positive attitudes regarding the efficacy of dental care, their care-seeking behaviors translate into use, continuous use, and recent use of dental services. However, the belief among dentate and edentulous older adults that their dental problems are a result of aging prevails. Despite clinically evident disease or problems, beliefs and values of older adults regarding the usefulness of dental care to resolve oral problems are limited. They have difficulty incorporating their perceived need into care-seeking behaviors. In addition, nursing home residents often refuse dental care, even when cost is not a barrier, and believe prevention or treatment would not be efficacious in solving their oral problems.

Recent studies report dramatic increases in dentate older adults accessing dental care, with older adults now using dental services to the same extent as dentate adults between ages 35 and 44. Among adults age 65 and older, 62% of all respondents reported having a dental visit during the previous year, and 75% of those with natural teeth reported a dental visit in the past year.[26]

As the trend for tooth retention in older adults continues, older adults will account for a greater proportion of dental practice income and visits. Even the oldest persons in the elderly population have reversed earlier, negative attitudes and demonstrated increased awareness and concern for oral health.[41,43,74] Dental expenditure data indicate that older adults have a higher cost per visit than younger persons and are willing to make a significant investment in dental care.[71] Despite these trends, older adults in nursing homes seldom access dental services.

Figure 39-8 Severe xerostomia after radiation therapy when the parotid glands were not spared.

Xerostomia

Saliva plays an essential role in maintaining oral health. Besides a loss of acinar cells occurring with aging, many older adults take medications for chronic medical conditions and disorders. When challenged with medications that cause dry mouth, older adults are more adversely affected than younger adults, which supports the secretory reserve hypothesis of salivary function.[25,36]

More than 500 prescription and over-the-counter (OTC) medications are associated with decreased saliva, dry mouth, and xerostomia. The medications most often associated with xerostomia and decreased saliva are the tricyclic antidepressants, antihistamines, antihypertensives, and diuretics. Medication use is frequently associated with dry mouth; however, certain medical diseases, disorders, or conditions are also associated with dry mouth, such as radiation treatment for oral, head, neck, and thyroid cancers; Sjögren syndrome; poorly controlled diabetes; bone marrow transplantation; thyroid disorders; and depression (Figure 39-8).

Symptomatic and corrective therapies, such as parotid-sparing radiation therapy, have been suggested. The effect of this treatment has been shown to reduce xerostomia in each of four domains of quality of life: eating, communication, pain, and emotion. Both xerostomia and quality-of-life scores improved significantly over time during the first year after therapy. These results suggest that the efforts to reduce xerostomia using parotid-sparing radiation therapy may improve broad aspects of quality of life.[43]

Medications that induce xerostomia may also be associated with compromised chewing, speaking, tasting, or swallowing and increased risk for caries, periodontal disease, and candidiasis.

Future research directions include (1) gene therapy approaches to direct salivary growth and differentiation or modify remaining tissues to promote secretion, (2) creation of a biocompatible artificial salivary gland, and (3) salivary transplantation. With improved secretagogues, the effects of conditions that result in reduced salivary function and increased caries will be ameliorated.[34]

Candidiasis

Candidiasis is caused by an overproliferation of *Candida albicans.* A pathogenic infection occurs when *C. albicans* infiltrates into the oral mucosal layers. Candidiasis can be both local and systemic.[37]

Any condition compromising a patient's immune system can be considered a risk factor for candidiasis. Oral candidiasis can occur with long-term use of antibiotics, steroid therapies, or chemotherapy. Diabetes mellitus, head and neck radiation therapy, and human immunodeficiency virus (HIV) are risk factors for acute pseudomembranous candidal infection. *Pseudomembranous candidiasis* presents as white lesions that can be wiped away with gauze, leaving an erythematous area.[37]

BOX 39-1 Dental Patient Interview

Older Adult

Medical (Physical) History

Assess for endocrine and nutritional disorders.
Assess for systemic disease.

Behavior History

Assess *overdependence:* Is the patient demanding, repetitious, or expressing urgency in his or her demands?
Assess *pseudocooperativeness:* Is the patient noncompliant in maintaining daily self-care?
Assess *perfectionism:* Is the patient unrealistic in his or her expectations yet noncompliant in maintaining oral self-care regimens?

Social History

Assess the presence or lack of a support system for the frail and dependent older adult.

Chronic atrophic candidiasis presents most often as an erythematous area under a maxillary denture and is associated with poor oral hygiene. In patients without a prosthesis, chronic atrophic candidiasis may present as a generalized redness or even generalized burning of the mouth.[37]

Chronic atrophic candidiasis, or *angular cheilitis,* can also manifest itself in the creases or commissures of the lips. This occurs when a patient has a tendency to pool saliva around the corners of the mouth or constantly lick the lips in some cases.[37]

A new treatment for candidiasis is being investigated using bioadhesive nanoparticles as modulators of adherence to buccal epithelial cells.[48]

Dental and Medical Assessments

Review of Dental History

Initially, the patient interview assists the patient in disclosing needs, desires, preferences, and values for dental treatment. The dental history includes dates of the last dental examination and visit, radiographs taken, and the frequency of tooth prophylaxis. Also included is a review of past restorations, endodontic therapies, extractions, oral surgeries, prosthetic appliances (including single and multiple, removable and fixed units), periodontal therapies, and gnathologic treatments. Other useful information may include daily oral self-care regimens, fluoride status of the drinking water (bottled, well, and community sources), and type of toothpaste used (fluoride versus nonfluoride).

Review of Medical History

The medical history of the older adult should be detailed and should include a careful review of past and current medical and mental conditions, including emergency and hospital visits and any serious illnesses (Box 39-1). The review should focus on a careful evaluation of systemic diseases and disorders, particularly those that influence dental treatment, such as bleeding disorders and use of anticoagulants,[29] diabetes, heart valve problems,[1,45] certain cardiovascular conditions, stroke, artificial joints,[5] and use of corticosteroids. A consultation with the patient's physician is advisable, especially for older adults with medical problems, or if complicated or invasive procedures are planned. The medical history review should also include medications taken regularly and allergies to medications, metals, and environmental allergens. The social history is reviewed to determine the patient's age, tobacco use (type and pack-years estimate), alcohol use, and caregiver status.

TABLE 39-4 Twenty Most Frequently Mentioned Drugs by Therapeutic Drug Category at Office Visits: United States, 2010

Therapeutic Drug Category[1]	Number of Occurrences in Thousands (Standard Error in Thousands)		Percent of Drug Mentions[2] (Standard Error of Percent)	
Analgesics[3]	278,720	(18,134)	10.9	(0.2)
Antihyperlipidemic agents	147,191	(11,036)	5.7	(0.2)
Antidepressants	108,760	(7,799)	4.2	(0.2)
Immunostimulants	101,579	(9,883)	4.0	(0.4)
Antidiabetic agents	99,741	(9,710)	3.9	(0.3)
Anxiolytics, sedatives, and hypnotics	92,522	(6,794)	3.6	(0.2)
Antiplatelet agents	92,246	(7,247)	3.6	(0.2)
Beta-adrenergic blocking agents	87,322	(6,046)	3.4	(0.1)
Bronchodilators	85,327	(6,853)	3.3	(0.2)
Anticonvulsants	74,246	(5,644)	2.9	(0.1)
Dermatological agents	74,004	(5,146)	2.9	(0.2)
Angiotensin converting enzyme inhibitors	73,280	(4,999)	2.9	(0.1)
Proton pump inhibitors	71,701	(5,730)	2.8	(0.1)
Diuretics	65,361	(5,383)	2.6	(0.1)
Antihistamines	58,293	(5,342)	2.3	(0.1)
Vitamins	55,470	(4,992)	2.2	(0.1)
Vitamin and mineral combinations	51,886	(4,484)	2.0	(0.1)
Thyroid hormones	48,688	(4,352)	1.9	(0.1)
Minerals and electrolytes	47,482	(4,020)	1.9	(0.1)
Adrenal cortical steroids	46,638	(3,978)	1.8	(0.1)

[1]Based on Multum Lexicon second level therapeutic drug category (see www.multum.com/lexicon.htm).

[2]Based on an estimated 2,562,072,000 drug mentions at office visits in 2010.

[3]Includes narcotic and nonnarcotic analgesics and nonsteroidal anti-inflammatory drugs.

SOURCE: CDC/NCHS. National Ambulatory Medical Care Survey.

Caregiver status indicates the functional level of the patient as functionally independent, frail, or functionally dependent.

Obtaining a complete medical history may take longer in severely compromised older adults. However, the time spent to disclose conditions will determine if the use of the interdisciplinary team is indicated. Coordinating and managing oral healthcare in this manner may increase the success of dental outcomes.[58]

Review of Medication Use

Older adults are high users of prescription and OTC medications. Table 39-4 lists the top 20 drugs prescribed in the United States in 2003. Many medications used by older adults can have a negative impact on oral health. To obtain a complete list of prescription and OTC medications, ask patients to bring each medication bottle or package to the dental office. This not only helps to obtain a complete medication list but also provides additional information such as medication dose and number of physicians prescribing medications.

Extraoral and Intraoral Examinations

The *extraoral examination* provides assessments of the head and neck. The head and neck examination determines if the skull is normal in shape with no traumatic injuries. Also included are assessments of the skin, nodes, and cranial nerves involved in oral function. The temporomandibular joint is also assessed at this time. Findings include changes from normal, apparent lesions, and dysfunction.

The *intraoral examination* provides assessment of soft and hard tissue of the oral cavity (Box 39-2). Assessments help to determine the state of the teeth: past restorations, caries, occlusal dysfunction, and missing teeth. The periodontal examination includes gingival bleeding points and pocket depths. The remaining intraoral examination assesses the lips, cheeks, tongue, gingiva, floor of the mouth, palate, retromolar region, and oropharyngeal area for tissue abnormalities, red or white patches, ulcerations, and swellings. A major focus of these examinations is the assessment for oral and pharyngeal cancer.

It can be difficult to differentiate between a benign lesion and either a precancerous or early cancerous lesion. For this reason, a product called *OralCDx* has been developed; this computer-assisted brush biopsy test can aid in screening for cancer.[28,55]

Oral cancer may appear as an ulceration, a swelling, or a red or white sore that does not heal in 1 to 2 weeks. Other signs of oral cancer may be swollen lymph nodes and difficulty swallowing and speaking.[32] Particularly alarming, oral and pharyngeal cancer lesions may not be painful. Unfortunately, the 5-year survival of patients with oral cancer has not improved.[6]

Xerostomia screening may be done by sialometry or by oral examination. With *sialometry,* depending on the type of gland, the precise collection of saliva may require 5 to 15 minutes (Table 39-5). Specific screening tools may be required for different gland types. For example, modified Carlson-Crittenden collectors are used to suction saliva from the parotid gland through Stensen's duct, and specialized equipment is used for the submandibular gland (through Wharton's ducts) and the minor salivary glands.

A less quantitative measure of saliva for xerostomia is by oral examination using a tongue blade (Figure 39-9). The saliva collected from either the floor of the mouth or the buccal vestibules is absorbed onto the tongue blade (see Figure 39-9, *A* and *B*). If only the tip of the tongue blade demonstrates wetness rather than a greater portion of the end of the blade, then an abnormal finding is noted (see Figure 39-9, *C*).

Assessment of Risk

Assessment of risk is determined after completion of the patient interview and the extraoral and intraoral examinations. Oral and medical problems may influence the risk for disease, pain, oral dysfunction, and nutritional disorders, both in quality and quantity of foods.[53] Risk assessments may also serve as predictors for successful treatment outcomes, maintenance protocols, and patient compliance. For example, the risk factors that influence periodontal therapy are smoking, genetic susceptibility, compliance, and diabetes.[76]

Assessment tests use genetic markers to demonstrate susceptibility to periodontal disease. Specific genetic markers associated with increased levels of interleukin-1 (IL-1) production indicate a strong susceptibility to severe periodontitis in older adults. When the genotype for polymorphic IL-1 gene cluster was identified, it was correlated with an odds ratio of 18.9, indicating severe periodontitis in nonsmoking adults.

Risk factors for oral and pharyngeal cancer are age, tobacco use, frequent use of alcohol, and exposure to sunlight (lip). Oral cancer is treatable if discovered and treated early. Most dentists can easily identify an early carcinoma in situ (Figure 39-10). At this stage, however, the lesion may have already spread to the lymph nodes. Oral and pharyngeal cancer detected at later stages can cause disfigurement, loss of function, decreased quality of life, and death. Surveillance, Epidemiology, and End Results (SEER) data indicated that more than 50% of tongue and floor of mouth cancers had metastasized to a distant site at the time of diagnosis.[57]

BOX 39-2 Dental Examination

Assessments for Older Adult Patients

Oral Epithelium

Assess a decrease in intracellular water content, amount of subcutaneous fat, elasticity and vascularity of tissue, muscle tone, and vertical dimension.

Assess for a thin, waxy appearance of the tissue.

Assess for a hyperkeratosis of keratin areas.

Tongue

Assess for defoliation of papillae, fissures (dorsum side), and varicosities (ventral side).

Assess for alteration in taste.

Assess clinical complaints of the following:

- Smooth, glossy, and painful tongue (may indicate vitamin B_{12} deficiency)
- Geographic tongue (erythema migrans)
- Oral infections (e.g., candidiasis)

Saliva

Assess for xerostomia (altered salivary flow) that produces a decrease in the following:

- Antibacterial activity
- Buffering capacity
- Transport of taste sensors
- Lubrication of the oral cavity
- Digestive function

Note any signs of xerostomia, including the following:

- Intraoral dryness
- Burning sensations
- Altered tongue surface
- Dysphagia
- Cheilosis
- Alterations in taste
- Difficulty with speech
- Root caries

Immune System

Assess for pronounced inflammatory responses of the gingiva to infection.

Quality of Life

The conditions predisposing the older patient to disease or changes in oral health status may result from physical or psychologic problems, or both. These problems may be the result of the older person's social conditions. Whatever the cause, these underlying problems must be addressed so that dental outcomes will be positive. This may require the dentist first to address the patient's fears and expectations about treatment outcomes. For example, older adults who are experiencing the loss of teeth and the adjustment to removable appliances or dentures can experience tremendous difficulty in accepting a reduced level of oral functioning. Their coping mechanism may also be stressed because of other socially important factors, such as esthetics and social esteem. Thus the

TABLE 39-5 Sialometry for Xerostomia Screening: Salivary Flow Rates

Category	Normal	Abnormal
Whole saliva	0.5-1.2 mL/min	0.0-0.2 mL/min
Whole saliva, stimulated	1.0-2.0 mL/min	0.01-0.4 mL/min

Figure 39-9 Tongue blade screen for saliva testing. **A,** Screening begins by placing the tongue blade in the sublingual area at the mandibular anterior quadrant. **B,** For the saliva screen, wet the tongue blade for about 5 seconds. **C,** Tongue blade screen showing minimal wetness, an indication of xerostomia.

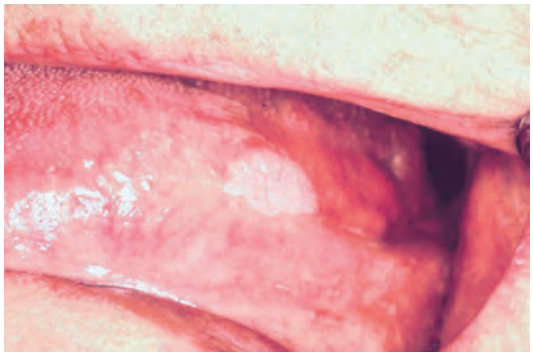

Figure 39-10 Early carcinoma in situ.

patient's presenting conditions may affect the rendering of the treatment plan.

Many conditions limit an older person's ability to withstand or cope with dental treatment. For example, some older adults with physically or psychologically based behavior problems may require premedication in order for the dentist to deliver treatment. Other conditions may limit the dentist's ability to render treatment. For example, an older patient may not tolerate a reclining chair position for restorative procedures because of a chronic heart ailment or arthritis.

With treatment, there is a concomitant risk for causing problems, referred to as *iatrogenic effects*. Iatrogenic problems arise from side effects of treatment or from treatment procedures and range from drug interactions to medical emergencies.

Under certain conditions, the most appropriate care is to do nothing. In some severely compromised patients, treatment is only rendered if the potential for sepsis is suspected. Otherwise, treatment is withheld. In less serious situations, a dentist may decide not to treat a cracked tooth but to dome it and leave its root intact in tissue. This maintains the bone in the area and allows for a prosthetic appliance to be placed. In general, the dentist uses a determination of the risk/benefit of treatment for patient-related outcomes in deciding whether to provide treatment.

In addition, the dentist often may not have the special skills, equipment, or training to meet the needs of poorly functioning or nonfunctioning older adults. This may require the dentist to obtain the additional training and equipment to treat this population, especially in a rural community where access to services is extremely limited. Alternatively, the dentist may need to become familiar with the referral resources to contact clinicians who can treat such patients. One major referral base would be a trained hospital dentist who is capable of managing and treating the patient impaired by dementia or some physical problem or disease.

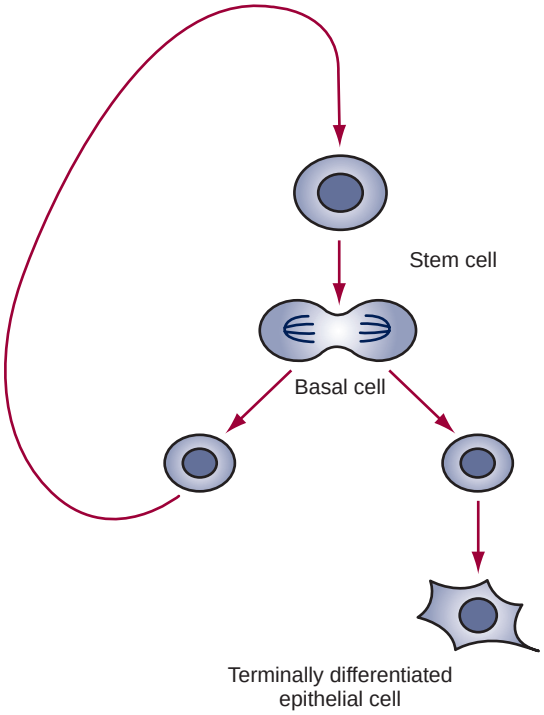

Figure 39-1 Cell renewal cycle in which the basal cell produces the epithelial cell and returns to the progenitor cell population.

A decrease in vascularity results in decreased production of mucopolysaccharides.

All these types of changes are seen in the alveolar bone. With aging, the alveolar bone shows a decrease in bone density and an increase in bone resorption and a decrease in vascularity also occurs. In contrast, however, cementum shows cemental thickness.

Functional Changes

With aging, the cells of the oral epithelium and periodontal ligament have reduced mitotic activity, and all cells experience a reduction in metabolic rate. These changes also affect the immune system and affect healing in the periodontium. There is a reduction in healing capacity and rate. Inflammation, when present, develops more rapidly and more severely. Individuals are highly susceptible to viral and fungal infections because of abnormalities in T-cell function.

Clinical Changes

Compensatory changes occur as a result of aging or disease. These changes affect the tooth or periodontium that presents the clinical condition. Gingival recession and reductions in bone height are common conditions. Attrition is a compensatory change that acts as a stabilizer between loss of bony support and excessive leveraging from occlusal forces imposed on the teeth.

In addition, a reduction in "overjet" of the teeth is seen, manifesting as an increase in the edge-to-edge contact of the anterior teeth. Typically, this is related to the approximal wear of the posterior teeth. An increase is seen in the food table area, with loss of "sluiceways," and in mesial migration.

Functional changes are associated with reduced efficiency of mastication. Although effectiveness of mastication may remain, efficiency is reduced because of missing teeth, loose teeth, poorly fitting prostheses, or noncompliance of the patient, who may refuse to wear prosthetic appliances.

Periodontal Diseases in Older Adults

Etiology

Periodontal disease in older adults is usually referred to as *chronic periodontitis.*[37,60] Because periodontitis is a chronic disease, much of the ravages of the disease detected in older adults results from an accumulation of the disease over time. Research has shown that the advanced stages of periodontitis are less prevalent than the moderate stages in the older adult population.[24] One theory is that many sites of advanced periodontal disease have resulted in tooth loss earlier in life, suggesting that older age is not a risk factor for periodontal disease.[37,60]

Evidence is limited on whether the risk factors for periodontal disease differ with age.[20] General health status, immune status, diabetes, nutrition, smoking, genetics, medications, mental health status, salivary flow, functional deficits, and finances may modify the relationship between periodontal disease and age.[20,76]

Some frequently prescribed medications for older adults can alter the gingival tissues. *Steroid-induced gingivitis* has been associated with postmenopausal women receiving steroid therapy. *Gingival overgrowth* can be induced by such medications as cyclosporines, calcium channel blockers, and anticonvulsants (e.g., nifedipine, phenytoin) in the presence of poor oral hygiene. This gingival overgrowth further decreases a person's ability to maintain good oral hygiene.[37]

Relationship to Systemic Disease

In Padilha et al,[52] using data from the Baltimore Longitudinal Study of Aging, the conclusion is reached that "the number of teeth is a significant risk indicator for mortality … and that improving oral health and preventing tooth decay may substantially improve the oral status of the population and increase longevity."

A review of the literature by Loesche and Lopatin[46] indicates that poor oral health has been associated with medical conditions such as aspiration pneumonia and cardiovascular disease. In particular, periodontal disease can be associated with coronary heart disease and cerebrovascular accident (CVA; stroke). In addition, the Surgeon General's Report on Oral Health emphasizes that animal and population-based studies demonstrate an association between periodontal disease and diabetes, cardiovascular disease, and stroke.[66]

Recent investigations confirm these associations. For example, a periodontal examination may assist cardiovascular risk assessment in hypertensive patients. Angeli et al[8] reported an association between periodontal disease and left ventricular mass in untreated patients with essential hypertension.

Pneumonia is a common cause of morbidity and mortality in the older adult. Improvements in oral care have greatly reduced the incidence of pneumonia in elderly nursing home patients. Although the mechanism is currently under investigation, it is thought that the cough reflex can be improved by reducing the oropharyngeal microbial pathogens present.[69] Expanding on these findings, studies have been conducted on the prevention of ventilator-associated pneumonia. Providing oral therapy for intensive care patients to reduce bacterial colonization in the mouth and teeth can reduce mortality and morbidity by 42%.[35]

The presence and extent of periodontal disease may be related to increased risk of weight loss in older, well-functioning adults. This association is independent of smoking and diabetes mellitus. Changes in nutrient intake may be related to periodontal disease and a higher systemic inflammatory burden.[74]

Periodontal Treatment Planning

Generally, periodontal disease in older adults is not a rapidly progressive disease but often presents as long-standing chronic disease. Because periodontal disease has periods of exacerbation and remission, understanding and documenting periods of active disease versus quiescent periods are essential to the formulation of the treatment plan and prognosis.[60]

Periodontal disease must be diagnosed regardless of age. The goal of periodontal treatment for both young and old patients is to preserve function and eliminate or prevent the progression of inflammatory disease.[72]

The goal of clinically managing periodontal disease in older adults is based on specific, individualized care. The major consideration is improving or maintaining function, with an emphasis on quality-of-life issues. Emphasizing care over cure is the cornerstone of any proposed treatment plan. Prevention, comfort, function, esthetics, and ease of maintenance are the criteria for successful management of an older adult, particularly a frail or functionally dependent older patient.

Several factors must be considered during treatment planning for older individuals.[60] It is important first to remember that periodontal healing and recurrence of disease are *not* influenced by age.[20] Factors to consider in the older patient are medical and mental health status, medications, functional status, and lifestyle behaviors that influence periodontal treatment, outcome, or progression of disease.[72] Periodontal disease severity, ability to perform oral hygiene procedures, and ability to tolerate treatment should be evaluated during treatment planning. The risks and benefits of both surgical and nonsurgical therapy should be considered.[46] The amount of remaining periodontal support or past periodontal destruction, tooth type, number of occlusal contacts, and individual patient preferences are also important.[72] Dental implants are a reliable replacement for missing teeth in older adults[77]; age alone is not a contraindication for implant placement. Risk factors for success of implants has been investigated. While aging is a factor in decision making, the majority of the failures are associated with smoking, diabetes, head and neck radiation, and postmenopausal estrogen therapy.[51]

For older adults, a nonsurgical approach is often the first treatment choice. Depending on the nature and extent of periodontal disease, surgical therapy may be indicated. Surgical technique should minimize the amount of additional root exposure. Individuals responding best to surgical therapy are those who are able to maintain the surgical result. Age alone is not a contraindication to surgery. For individuals who are unable to comply with treatment, who have poor oral hygiene, or who are medically or mentally compromised or functionally impaired, palliative supportive periodontal care instead of surgical periodontal treatment is often the optimal treatment approach.[46,58]

A common goal for all older adults is to decrease bacteria through oral hygiene and mechanical debridement. Clinical trials with older adults show that the development or progression of periodontal disease can be prevented or arrested by the control of plaque. For certain patients, topical antibiotic therapy may complement repeated subgingival instrumentation during supportive care. Oral hygiene maintenance should also focus on root surfaces susceptible to caries.[72]

Decision making for frail and functionally dependent older adults may be challenging to the general dentist. For this reason, dentists, other healthcare professionals, and other scientists are creating high-quality office-based methods to access evidence-based decision-making programs and accommodating websites to help with complicated oral healthcare issues.[3,59,70]

Prevention of Periodontal Disease and Maintenance of Periodontal Health in Older Adults

For both younger and older persons, the most important factors determining a successful outcome of periodontal treatment are plaque control and frequency of professional care. Advanced age does not decrease plaque control[9]; however, older adults may have difficulty performing adequate oral hygiene because of compromised health, altered mental status, medications, or altered mobility and dexterity.[72] Older adults may change toothbrush habits because of disabilities such as hemiplegia secondary to CVA, visual difficulties, dementia, and arthritis. The newer, lightweight, electric-powered toothbrushes may be more beneficial than a manual toothbrush for older adults with physical and sensory limitations. The proportion of people who floss their teeth decreases after age 40 years.[71] This may be partly caused by impairment of fine motor skills secondary to disease or injury. Interproximal brushes, shaped wooden toothpicks, and mechanical flossing devices often can be used in place of traditional flossing with satisfactory outcomes.

In addition, multidisciplinary strategies are increasingly becoming part of periodontal healthcare promotion. Assessments of overall health, functional status, and patient education are fundamental to promoting and maintaining optimum periodontal health. Older adults, their families, and caregivers need to be informed and trained by dentists in the appropriate devices, chemotherapeutic agents, and techniques to provide oral self-care and maintain healthy lifestyles. The outcomes are instrumental in achieving overall health, oral and periodontal health, self-esteem, nutrition, and quality of life. Barriers to achieving these benefits are access and costs. For those older adults who are homebound or institutionalized, these barriers inhibit their achieving and maintaining optimum oral and periodontal health.

Chemotherapeutic Agents

Antiplaque Agents. Patients who are unable to remove plaque adequately secondary to disease or disability may benefit from antiplaque agents such as chlorhexidine, sub-antimicrobial tetracycline, and Listerine or its generic counterparts.[50,60,72]

Chlorhexidine is a cationic bisbiguanide that has been used as a broad-spectrum antiseptic in medicine since the 1950s. In Europe, a 0.2% concentration of chlorhexidine has been used for years as a preventive and therapeutic agent.[46,71] Chlorhexidine is either bacteriostatic or bactericidal, depending on the dose. Adverse effects of chlorhexidine include an increase in calculus formation, dysgeusia (altered taste), and permanent staining of teeth.[6] Chlorhexidine is a prescription rinse for short-term use (<6 months); long-term use (>6 months) has not been extensively studied.[71] The American Dental Association (ADA) Council on Dental Therapeutics[4] has approved chlorhexidine to help prevent and reduce supragingival plaque and gingivitis. Although chlorhexidine has not been studied in older adults, outcomes in younger persons, including those with disabilities, suggest that it is also effective in older adults. Chlorhexidine may be particularly useful for older adults who have difficulty with plaque removal and those who take phenytoin, calcium channel blockers, or cyclosporines and who are at risk for gingival hyperplasia.[60,71]

Sub-antimicrobial tetracycline (Periostat) is useful in treating moderate to severe chronic periodontitis. The active ingredient in

Periostat is *doxycycline hyclate*. In concert with scaling and root planing, Mohammad et al[50] have shown this treatment to be effective in institutionalized older adults. Periostat is contraindicated for those patients with an allergy to tetracycline.

Listerine antiseptic and its generic counterparts are approved by the ADA Council on Dental Therapeutics[6] to help prevent and reduce supragingival plaque and gingivitis. The active ingredients in Listerine are *methyl salicylate* and three essential oils (eucalyptol, thymol, and menthol). Listerine has been shown to be effective in reducing plaque and gingivitis compared with placebo rinses in young healthy adults. Listerine may exacerbate xerostomia because of its high alcohol content, ranging from 21.6% to 26.9%. Listerine is generally contraindicated in patients under treatment for alcoholism who take Antabuse (disulfiram). Listerine may benefit patients who do not tolerate the taste or staining of chlorhexidine and who prefer OTC medicaments that are less expensive and easier to obtain.[60,71]

The use of inorganic polyphosphate (*p*-phenylene vinylene [Poly P]) to treat periodontal disease in the aging is being investigated in Japan and points to an alternative method for reduction of bone loss. What is interesting is that the Poly P is considered safe as a food additive and is low risk to harm the patient. Since it is not an antibiotic, bacteria are unlikely to become resistant to it.[80]

Fluoride. Fluoride, "nature's cavity fighter," is the most effective caries-preventive agent currently available. Fluoride's effects are as follows[60,71]:

1. Reduces enamel solubility.
2. Promotes remineralization of early carious lesions.
3. Is bactericidal to bacterial plaque.

Topical fluorides are recommended for the prevention and treatment of dental caries. OTC fluorides include fluoride dentifrices, rinses, and gels that contain concentrations of 230 to 1500 parts per million (ppm) of fluoride ions. Prescription 1.1% neutral sodium fluoride gels are available with a fluoride concentration of 5000 ppm fluoride ion. Professionally applied fluoride gel, foam, or varnish products are between 9050 and 22,600 ppm fluoride ion.[6]

Saliva Substitutes. Saliva substitutes, which are intended to match the chemical and physical traits of saliva, are available to relieve the symptoms of dry mouth. Their composition is varied; however, they usually contain salt ions, a flavoring agent, paraben (preservative), cellulose derivative or animal mucins, and fluoride. The ADA's seal of approval has been granted for some artificial saliva products (e.g., Saliva Substitute, Salivart).[6] Most saliva substitutes can be used as desired by patients and are dispensed in spray bottle, rinse/swish bottle, or oral swab stick.[6,71] In addition, products, such as dry-mouth toothpastes and moisturizing gels, are also available. Biotene products are marketed to relieve the symptoms of xerostomia.

Patients with dry mouth may also benefit by stimulating saliva flow with sugarless candies and sugarless gum. Xylitol chewing gum has been shown to have anticariogenic properties in children. Medicated chewing gum with xylitol and chlorhexidine or xylitol alone has the added benefits of reducing oral plaque scores and gingivitis in elderly persons who live in residential facilities.[7]

Salivary substitutes and stimulants are only effective in the short term. Under investigation is acupuncture-like transcutaneous nerve stimulation (Codetron), a method to treat radiation-induced xerostomia. Unlike traditional acupuncture therapy, Codetron does not use invasive needles to achieve stimulation. This method helps patients produce their own saliva and reduce symptoms of xerostomia for several months. Acupuncture therapy has demonstrated improvements lasting up to 3 years.[79]

Conclusion

Future oral healthcare trends will see increased numbers of older adults seeking periodontal therapy. Dental practitioners of the twenty-first century should be comfortable providing comprehensive periodontal care for this segment of the population. Aging dental patients have particular oral and general health conditions that dentists should be familiar with detecting, consulting, and treating. Medical diseases and conditions that occur more often with age may require modification to periodontal preventive tools, as well as for the planning and treatment phases of periodontal care.

Suggested Readings

Gluzman R, Katz RV, Frey B, et al: Prevention of root caries: a literature review of primary and secondary preventive agents. *Special Care Dentistry* 33(3):133–140, 2012.

Huttner EA, Machado DC, De Oliveira RB, et al: Effects of human aging on periodontal tissues. *Special Care Dentistry* 29:149-155, 2009.

Lamster I, Northridge M, editors: *Improving oral health for the elderly: an interdisciplinary approach*, New York, 2008, Springer Science + Business Media.

Little J, Falace, DA, Miller CS, et al: Neurological diseases. In *Dental management of the medically compromised patient*, ed 6, St. Louis, 2007, Mosby.

Shay K: Identifying the needs of the elderly dental patient. The geriatric dental assessment. *Dent Clin North Am* 38(3):499–523, 1994.

References

References for this chapter are found on the companion website www.expertconsult.com.

Risk Reduction

Cessation of tobacco use has been primarily an issue of patient compliance. Most smokers (90%) quit "cold turkey." However, nicotine replacement therapy may help strongly addicted patients. The transdermal nicotine patch or nicotine polacrilex (gum) can reduce the symptoms of nicotine withdrawal. For behavioral modification, the four steps to tobacco cessation are as follows:

1. Ask the patient about tobacco.
2. Advise the patient to stop using tobacco.
3. Assist the patient in stopping by selecting a quitting date (usually within the next 4 weeks).
4. Arrange patient follow-up services.

Clinical studies show that all four components, used routinely, result in much higher patient cessation rates than if only two or three are used. Both forms of nicotine replacement have been shown to increase cessation rates when used in combination with behavioral interventions.

Nicotine replacement therapy is intended to be used for a few (6 to 12) weeks so that patients can learn psychologic and social coping skills without going through nicotine withdrawal at the same time. It is not recommended for use for more than 6 months.

Nicotine replacement therapy should probably not be considered for the following persons:

- Individuals who have not previously tried to quit.
- Individuals who use only small amounts of tobacco or who are occasional users.
- Individuals who have tried to quit and have not had significant physical symptoms of nicotine withdrawal.
- Individuals who do not receive behavioral support from clinic staff.

Alcoholism and alcohol abuse are diagnosed using the *Diagnostic and Statistical Manual of Mental Disorders,* third edition, revised *(DSM-IIIR),* and fourth edition *(DSM-IV).* The tests suggested to screen for alcohol abuse are the self-administered questionnaire, the Michigan Alcoholism Screening Test (MAST), and the CAGE (from a series of four questions about drinking: *c*ut down, *a*nnoyed, *g*uilty, and *e*ye-opener) questionnaire, which is a four-item screening tool (Figure 39-11). A score of 2 (an affirmative answer to 2 questions) in the elderly patient provides clinical evidence or suspicion of alcohol abuse, with a sensitivity of about 50% and a specificity over 90%. The MAST, with a cutoff score of 5, produces sensitivity ranging from 50% to 70% and a specificity above 90%.

CAGE Test

- Have you ever felt the need to **Cut** down on drinking?
- Have you ever felt **Annoyed** by criticism of drinking?
- Have you ever had **Guilty** feelings about drinking?
- Have you ever taken a morning **Eye**-opener?

Figure 39-11 Method of determining alcohol abuse using the modified CAGE test. The acronym CAGE is derived from a series of four questions about drinking: *c*ut down; *a*nnoyed; *g*uilty; and *e*ye-opener. *(From Mallin R:* Am Fam Physician *65:1107, 2002.)*

The most common treatment for alcoholism is referral to a substance abuse facility. For the older adults, the most effective treatment is a program that emphasizes older adult–specific groups using nonconfrontational therapy and encouraging reminiscence, as well as discussion of current problems. Discussion of current problems is relevant because of the role that stress plays in recent widowhood, recent retirement, or disruption or removal from one's residence.

References

1. ACC/AHA 2008 Guideline Update on Valvular Heart Disease: focused update on infective endocarditis: a report of the American College of Cardiology/American Heart Association Task Force on Practice Guidelines. *Circulation* 118:887, 2008.
2. Centers for Disease Control and Prevention: *The State of Aging and Health in America 2013*, Atlanta, GA, 2013, US Dept of Health and Human Services. <http://www.cdc.gov/features/agingandhealth/state_of_aging_and_health_in_america_2013.pdf>. Accessed 3-20-2014.
3. Agency for Healthcare Research and Quality: *Patient-Centered Care Through Health IT: Enabling Patient-Centered Care through Health Information*, Rockville, MD, June 2012. <http://www.ahrq.gov/research/findings/evidence-based-reports/er206-abstract.html>. Accessed 3-20-2014.
4. *Alliance for Aging Research, task force on aging research funding*, Washington, DC, 2004, The Alliance.
5. *American Academy of Orthopaedic Surgeons and the American Dental Association; AAOS-ADA clinical practice guideline, Prevention of Orthopaedic Implant Infection in Patients Undergoing Dental Procedures. AAOS Clinical Practice Guideline Unit 1 v0.2 2.2.2012*, Rosemont, 2012.
6. American Dental Association: *Guide to dental therapeutics*, ed 2, Chicago, 2000, ADA.
7. American Dietetic Association: Oral health and nutrition. *J Am Diet Assoc* 103:615, 2003.
8. Angeli F, Verdecchia P, Pellegrino C, et al: Association between periodontal disease and left ventricle mass in essential hypertension. *Hypertension* 41:488, 2003.
9. Axelsson P, Nystrom B, Lindhe J: The long-term effect of a plaque control program on tooth mortality, caries and periodontal disease in adults: results after 30 years of maintenance. *J Clin Periodontol* 31:749, 2004.
10. Bauer JG: The index of ADOH: concept of measuring oral self-care functioning in the elderly. *Spec Care Dentist* 21:63, 2001.
11. Bauer JG, Spackman S: financing dental services in the US: best practice model. *Braz J Oral Sci* 2:187, 2003.
12. Bauer JG, Spackman S, Chiappelli F, et al: Issues in dentistry for patients with Alzheimer-related dementia. *Long-Term Care—Interface* 6:30, 2005.
13. Bauer JG, Spackman S: The clinical decision tree of oral health in geriatrics. In Weiss JW, Weiss DJ, editors: *A science of decision making*, Oxford, 2009, Oxford University Press.
14. Bauer JG, Spackman S, Chiappelli F, et al: Interdisciplinary resources optimize evidence-based dental practice. *J Evid Based Dent Pract* 5:67, 2005.
15. Bauer JG, Spackman S, Chiappelli F, et al: Evidence-based decision-making in private practice. *J Evid Based Dent Pract* 5:125, 2005.
16. Bauer JG, Spackman S, Chiappelli F, et al: Model of evidence-based dental decision-making. *J Evid Based Dent Pract* 5:189, 2005.
17. Bauer J, Chiappelli F, Spackman S, et al: Evidence-based dentistry: fundamentals for the dentist. *J Calif Dent Assoc* 34:427, 2006.
18. Bauer JG, Spackman S, Chiappelli F, et al: Evidence-based dentistry: a clinician's perspective. *J Calif Dent Assoc* 34:427, 2006.
19. Bauer JG, Spackman S, Chiappelli F, et al: Making clinical decisions using a clinical practice guideline. *J Calif Dent Assoc* 34:427, 2006.
20. Beck JD: Periodontal implications: older adults. *Ann Periodontol* 1:322, 1996.
21. Benatti BB, Silvério KG, Casati MZ, et al: Influence of aging on biological properties of periodontal ligament cells. *Connect Tissue Res* 49:401, 2008.
22. Borrell LN, Burt BA, Neighbors HW, et al: Social factors and periodontitis in an older population. *Am J Public Health* 94:748, 2004.
23. Boyd LD, Madden TE: Nutrition, infection, and periodontal disease. *Dent Clin North Am* 47:337, 2003.
24. Brown LJ, Brunelle JA, Kingman A: Periodontal status in the United States, 1988-1991: prevalence, extent, and demographic variation. *J Dent Res* 75:672, 1996. (special issue).
25. Burt BA, Eklund SA: *Dentistry, dental practice, and the community*, Philadelphia, 1999, Saunders.
26. Centers for Disease Control and Prevention: Dental service use and dental insurance coverage—United States, behavioral risk factor surveillance system, 1995. *MMWR Morb Mortal Wkly Rep* 46:1199, 1997.
27. Centers for Disease Control and Prevention: Public health and aging: retention of natural teeth among older adults—United States, 2002. *MMWR Morb Mortal Wkly Rep* 52:1226, 2003.
28. Christian DC: Computer-assisted analysis of oral brush biopsies at an oral cancer screening program. *J Am Dent Assoc* 133:357, 2002.
29. du Breuil AL, Umland EM: Outpatient management of anticoagulation therapy. *Am Fam Physician* 75:1031, 2007.
30. Ettinger RL: The unique oral health needs of an aging population. *Dent Clin North Am* 41:633, 1997.
31. Ettinger RL, Mulligan R: The future of dental care for the elderly population. *J Calif Dent Assoc* 27:687, 1999.
32. Fedele DJ, Jones JA, Niessen LC: Oral cancer screening in the elderly. *J Am Geriatr Soc* 39:920, 1991.
33. Fortinsky RH, Iannuzzi-Sucich M, Baker D, et al: Fall—risk assessment and management in clinical practice: views from healthcare providers. *J Am Geriatr Soc* 52:1522, 2004.
34. Fox PC: Salivary enhancement therapies. *Caries* 38:241, 2004.
35. Garcia R, Jendresky l, Colbert L: Reduction of microbial colonization in the oropharynx and dental plaque reduces ventilator-associated pneumonia. Poster presented at Association for Professionals in Infection Control (APIC) Conference and Epidemiology Annual Educational Conference and International Meeting, Phoenix, 2004.
36. Ghezzi EM, Ship JA: Aging and secretory reserve capacity of major salivary glands. *J Dent Res* 82:844, 2003.
37. Gibson G, Niessen LC, Cassel CK, et al, editors: *Geriatric medicine*, New York, 1997, Springer-Verlag.
38. Hollister MC, Weintraub JA: The association of oral status with systemic health, quality of life, and economic productivity. *J Dent Educ* 57:901, 1993.
39. Jones JA, Fedele DJ, Bolden AJ, et al: Gains in dental care use not shared by minority elders. *J Public Health Dent* 54:39, 1994.
40. Kayak HA, Brudvik J: Dental students' self-assessed competence in geriatric dentistry. *J Dent Educ* 56:728, 1992.
41. Kiecolt-Glaser JK, Glaser R: Depression and immune function: central pathways to morbidity and mortality. *J Psychosom Res* 53:873, 2002.
42. Kiyak HA: Successful aging: implications for oral health. *J Public Health Dent* 60:276, 2000.
43. Lin A, Kim HM, Terrell JE, et al: Quality of life after parotid-sparing IMRT for head and neck cancer: a prospective longitudinal study. *Int J Radiat Oncol Biol Phys* 57:61, 2003.
44. Locker D, Slade GD, Murray H: Epidemiology of periodontal disease among older adults: a review. *Periodontol 2000* 16:16, 1998.
45. Lockhart PB: Guidelines for prevention of infective endocarditis: an explanation of the changes. *J Am Dent Assoc* 2S:139, 2008. <http://www.ada.org/prof/resources/topics/infective_endocarditis.asp>. (Accessed 3-20-2014)
46. Loesche WJ, Lopatin DE: Interaction between periodontal disease, medical disease and immunity in the older individual. *Periodontol 2000* 16:80, 1998.
47. Macfayden D: International geriatric health promotion study/activities. In Abdellah FG, Moore SR, editors: *Proceedings of the Surgeon General's Workshop on Health Promotion and Aging*, Washington, DC, 1988, US Department of Health and Human Services.
48. McCarron PA: Bioadhesive, non-drug-loaded nanoparticles as modulators of candidal adherence to buccal epithelial cells: a potentially novel prophylaxis for candidosis. *Biomaterials* 25:2399, 2004.
49. Mezey M, Capezuti E, Fulmer T: Care of older adults. *Nurs Clin North Am* 39(3):xiii, 2004.
50. Mohammad AR, Preshaw PM, Hefti AF, et al: Subantimicrobial-dose doxycycline for treatment of periodontitis in an institutionalized geriatric population. Presented at 81st General Session of International Association for Dental Research (IADR), Goteborg, Sweden, 2003.
51. Moy PK, Medina D, Shetty V, et al: Dental implant failure rates and associated risk factors. *Int J Oral Maxillofac Implants* 20:569, 2005.

52. Padilha DM, Hilgert JB, Hugo FN, et al: Number of teeth and mortality risk in the Baltimore Longitudinal Study of Aging. *J Gerontol A Biol Sci Med Sci* 63:739, 2008.
53. Ritchie CS: Oral health, taste, and olfaction. *Clin Geriatr Med* 18:709, 2002.
54. Ritchie CS, Joshipura K, Hung HC, et al: Nutrition as a mediator in the relation between oral and systemic disease: associations between specific measures of adult oral health and nutrition outcomes. *Crit Rev Oral Biol Med* 13:291, 2002.
55. Sciubba JJ: Improving detection of precancerous and cancerous oral lesions: computer-assisted analysis of the oral brush biopsy, US Collaborative OralCDx Study Group. *J Am Dent Assoc* 130:1445, 1999.
56. Serby M, Yu M: Overview: depression in the elderly. *Mt Sinai J Med* 70:38, 2003.
57. Shiboski CH, Shiboski SC, Silverman S, Jr: Trends in oral cancer rates in the United States, 1973-1996. *Community Dent Oral Epidemiol* 28:249, 2000.
58. Ship JA, Duffy V, Jones JA, et al: Geriatric oral health and its impact on eating. *J Am Geriatr Soc* 44:456, 1996.
59. Sutherland SE, Matthews DC: Conducting systemic reviews and creating clinical practice guidelines in dentistry: lessons learned. *J Am Dent Assoc* 135:747, 2004.
60. Suzuki JB, Niessen LC, Fedele DJ: Periodontal diseases in the older adult. In Papas AS, Niessen LC, Chauncey HH, editors: *Geriatric dentistry: aging and oral health*, St. Louis, 1991, Mosby.
61. Tezal M, Grossi SG, Ho AW, et al: Alcohol consumption and periodontal disease: the third National Health and Nutrition Examination Survey. *J Clin Periodontol* 31:484, 2004.
62. Vincent GK, Velkoff VA: *THE NEXT FOUR DECADES, The Older Population in the United States: 2010 to 2050*, Current Population Reports, P25-1138, Washington, DC, 2010, U.S. Census Bureau.
63. US Department of Commerce, Bureau of the Census: Statistical Abstracts of the United States. Section 2-Births, Deaths, Marriages, and Divorces, 2012. <http://www.census.gov/compendia/statab/cats/births_deaths_marriages_divorces/life_expectancy.html>. Accessed 3-20-2014.
64. US Department of Commerce, Bureau of the Census: Comprehensive Analysis of Fast-Growing 90-and-Older Population, Nov., 2011. <http://www.census.gov/newsroom/releases/archives/aging_population/cb11-194.html>. Accessed 3-20-2014.
65. U.S. Department of Health and Human Services, Public Health Service: *Current estimates from the National Health Interview Survey, 1991. Series 10, No 184, DHHS Pub No (PHS) 93-1512*, Hyattsville, Md, 1992, DHHS, Public Health Service.
66. U.S. Department of Health and Human Services: *Oral health in America: a report of the surgeon general. NIH Pub No 00-4713*, Rockville, Md, 2000, DHHS, National Institute of Dental and Craniofacial Research, National Institutes of Health.
67. Vargas CM, Yellowitz JA, Hayes KL: Oral health status of older rural adults in the United States. *J Am Dent Assoc* 134:479, 2003.
68. Warshaw GA, Bragg EJ: The training of geriatricians in the United States: three decades of progress. *J Am Geriatr Soc* 51(7 Suppl):S338, 2003.
69. Watando A, Ebihara S, Ebihara T, et al: Daily oral care and cough reflex sensitivity in elderly nursing home patients. *Chest* 126:1066, 2004.
70. WebCampus of Dentistry for Seniors: Professional and Student Learning Centers, 2014. <http://www.webddsseniors.com>. accessed 3-20-2014.
71. Wells LM, Kolavic S, Niessen LC, et al: Caring for older adults: maintaining oral health for a lifetime. In Hardin JF, editor: *Clark's clinical dentistry*, vol 1, Philadelphia, 1996, Lippincott.
72. Wennstrom JL: Treatment of periodontal disease in older adults. *Periodontol 2000* 16:106, 1998.
73. Weyant RJ, Pandav RS, Plowman JL: Medical and cognitive correlates of denture wearing in older community-dwelling adults. *J Am Geriatr Soc* 2:596, 2004.
74. Weyant RJ, Newman AB, Kritchevsky SB, et al: Periodontal disease and weight loss in older adults. *J Am Geriatr Soc* 52:547, 2004.
75. Wilder RS, Iacopino AM, Feldman CA, et al: Periodontal-systemic disease education in U.S. and Canadian dental schools. *J Dent Educ* 73:38, 2009. Erratum in: *J Dent Educ* 73:e646, 2009.
76. Wilson TG: Using risk assessment to customized periodontal treatment. *J Calif Dent Assoc* 27:627, 1999.
77. Wilson TG, Higginbottom FL: Periodontal disease and dental implants in older adults. *J Esthet Dent* 10:265, 1998.
78. Winn DM, Brunelle JA, Selwitz RH, et al: Coronal and root caries in the dentition of adults in the United States, 1988-1991. *J Dent Res* 75:642, 1996. (special issue).
79. Wong RK, Jones GW, Sagar SM, et al: Phase I-II study in the use of acupuncture-like transcutaneous nerve stimulation in the treatment of radiation-induced xerostomia in head-and-neck cancer patients treated with radical radiotherapy. *Int J Radiat Oncol Biol Phys* 57:472, 2003.
80. Yamaoka M, Uematsu T, Shiba T, et al: Effect of inorganic polyphosphate in periodontitis in the elderly. *Gerodontology* 25:10, 2008.

CHAPTER 40

Treatment of Aggressive and Atypical Forms of Periodontitis

Perry R. Klokkevold

CHAPTER OUTLINE

Aggressive Periodontitis
Periodontitis Refractory to Treatment *(e-only)*
Necrotizing Ulcerative Periodontitis

For online-only content on periodontitis refractory to treatment, please visit the companion website at www.expertconsult.com.

The majority of patients with common forms of periodontal disease respond predictably well to conventional therapy, including oral hygiene instruction, nonsurgical debridement, surgery, and supportive periodontal maintenance. However, patients diagnosed with aggressive and some atypical forms of periodontal disease often do not respond as predictably or as favorably to conventional therapy. Fortunately, only a small percentage of patients with periodontal disease are diagnosed with aggressive periodontitis. Patients who are diagnosed with periodontal disease (any type) that is *refractory* to treatment present in small numbers as well. Even fewer patients are diagnosed with necrotizing ulcerative periodontitis. Each of these atypical disease entities poses significant challenges for the clinician not only because they are infrequently encountered, but also because they may not respond favorably to conventional periodontal therapy.[24,40] Furthermore, the severe loss of periodontal support associated with these cases leaves the clinician faced with uncertainty about treatment outcomes and difficulty in making decisions about whether to save compromised teeth or to extract them.

Aggressive Periodontitis

Aggressive periodontitis, by definition, causes rapid destruction of the periodontal attachment apparatus and the supporting alveolar bone (see Chapter 25). The responsiveness of aggressive periodontitis to conventional periodontal treatment is unpredictable, and the overall prognosis for these patients is poorer than for patients with chronic periodontitis. Because these patients do not respond "normally" to conventional methods and their disease progresses unusually fast, the logical question is whether there are problems associated with an impaired host immune response that may contribute to such a *different* disease and result in a *limited* response to the usual therapeutic measures. Indeed, defects in polymorphonuclear leukocyte (PMN, neutrophil) function have been identified in some patients with aggressive periodontitis.[30,31] Also, in a small number of cases, a systemic disease, such as neutropenia, can be identified that clearly explains the unusual severity of the periodontal disease for that individual.[12,13] In most patients with aggressive periodontitis, however, systemic diseases or disorders cannot be identified. In fact, the irony is that these patients are typically quite healthy. Numerous attempts to examine immunologic profiles in patients with aggressive periodontitis have failed to identify any specific etiologic factors common to all patients.

The prognosis for patients with aggressive periodontitis depends on (1) whether the disease is generalized or localized, (2) the degree of destruction present at the time of diagnosis, and (3) the ability to control future progression. *Generalized* aggressive periodontitis rarely undergoes spontaneous remission, whereas *localized* forms of the disease have been known to arrest spontaneously.[29] This unexplained curtailment of disease progression has sometimes been referred to as a "burnout" of the disease. It appears that cases of localized aggressive periodontitis often have a limited period of rapid periodontal attachment and alveolar bone loss, followed by a slower, more chronic phase of disease progression. Overall, patients with generalized aggressive periodontitis tend to have a poorer prognosis because they typically have more teeth affected by the disease and because the disease is less likely to go spontaneously into remission compared with patients with localized forms of aggressive periodontitis.

Therapeutic Modalities

Early detection is critically important in the treatment of aggressive periodontitis (generalized or localized) because preventing further destruction is often more predictable than attempting to regenerate lost supporting tissues. Therefore, at the initial diagnosis, it is helpful to obtain any previously taken radiographs to assess the rate of progression of the disease. Together with future radiographs, this documentation will also facilitate the clinician's assessment of treatment success and control of the disease.

Treatment of aggressive periodontitis must be pursued with a logical and regimented approach. Several aspects of treatment must be particularly considered when managing a patient with aggressive periodontitis. One of the most important aspects of treatment success is to educate the patient about the disease, including the causes and the risk factors for disease, and to stress the importance

of the patient's role in the success of treatment.[1] Essential therapeutic considerations for the clinician are to control the infection, arrest disease progression, correct anatomic defects, replace missing teeth, and ultimately help the patient maintain periodontal health with frequent periodontal maintenance care. Educating family members is another important factor because aggressive periodontitis is known to have familial aggregation. Thus family members, especially younger siblings, of the patient diagnosed with aggressive periodontitis should be examined for signs of disease, educated about preventive measures, and monitored closely. It cannot be stressed enough that early diagnosis, intervention, and if possible, prevention of disease is more desirable than attempting to reverse the destruction that results from aggressive periodontitis.

Conventional Periodontal Therapy. Conventional periodontal therapy for aggressive periodontitis consists of patient education, oral hygiene improvement, scaling and root planing, and regular (frequent) recall maintenance. It may or may not include periodontal flap surgery.[3] Unfortunately, the response of aggressive periodontitis to conventional therapy alone has been limited and unpredictable. Patients who are diagnosed with aggressive periodontitis at an early stage and who are able to enter therapy may have a better outcome than those who are diagnosed at an advanced stage of destruction. In general, the earlier the disease is diagnosed, the more conservative the therapy and the more predictable the outcome.

Teeth with moderate to advanced periodontal attachment loss and bone loss often have a poor prognosis and pose the most difficult challenge. Depending on the condition of the remaining dentition, treatment of these teeth may have a limited prospect for improvement and may even diminish the overall treatment success for the patient. Clearly, some of these teeth should be extracted; however, other teeth may be pivotal to the stability of that individual's dentition, and thus it may be desirable to attempt treatment to maintain them. Treatment options for teeth with deep periodontal pockets and bone loss may be nonsurgical or surgical. Surgery may be purely resective, regenerative, or a combination of these approaches.

Surgical Resective Therapy. Resective periodontal surgery can be effective to reduce or eliminate pocket depth in patients with aggressive periodontitis. However, it may be difficult to accomplish if adjacent teeth are unaffected, as often seen in cases of localized aggressive periodontitis. If a significant height discrepancy exists between the periodontal support of the affected tooth and the adjacent unaffected tooth, the gingival transition (following the bone) will often result in deep probing pocket depth around the affected tooth despite surgical efforts. A less-than-ideal outcome must be taken into consideration before deciding to treat increased pocket depth surgically.

It is important to realize the limitations of surgical therapy and to appreciate the possible risk that surgical therapy may further compromise teeth that are mobile because of extensive loss of periodontal support. For example, in a patient with severe horizontal bone loss, surgical resective therapy may result in increased tooth mobility that is difficult to manage, and a nonsurgical approach may be indicated. Therefore careful evaluation of the risks versus the benefits of surgery must be considered on a case-by-case basis.

Regenerative Therapy. The concept and application of periodontal regeneration has been established in patients with chronic forms of periodontal disease (see Chapter 61). The use of regenerative materials, including bone grafts, barrier membranes, and wound-healing agents, are well documented and often used. Intrabony defects, particularly vertical defects with multiple osseous walls, are often amenable to regeneration with these techniques. Most of the success and predictability of periodontal regeneration have been achieved in patients with chronic periodontitis; much less evidence is available about the use of periodontal regeneration for patients with aggressive periodontitis.

Periodontal regenerative procedures have been successfully demonstrated in patients with localized aggressive periodontitis in some clinical case reports. Dodson et al[14] demonstrated the regenerative potential of a severe, localized osseous defect around a mandibular incisor in a healthy, 19-year-old black man diagnosed with localized aggressive periodontitis. The patient presented with severe bone loss localized around one of the mandibular incisors. Using open-flap surgical debridement, root surface conditioning (tetracycline solution), and an allogenic bone graft reconstituted with sterile saline and tetracycline powder, the surgeons reduced the probing pocket depth from 9 to 12 mm down to 1 to 3 mm (3 mm of recession was noted), and significant bone fill of the defect (about 80%) was reported (Figure 40-1). This case illustrates the potential for healing severe defects in patients with localized aggressive periodontitis, especially when local factors are controlled and sound surgical principles are followed. The authors cited several factors that likely contributed to the success of this case, including a probable transition of disease activity from aggressive to chronic, tooth stabilization before surgery, sound surgical management of hard and soft tissues, and good postoperative care.[14]

It is important to note that although the potential for regeneration in patients with aggressive periodontitis appears to be good, expectations are limited for patients with severe bone loss. This is especially true if the bone loss is horizontal and if it has progressed to involve furcations.

Antimicrobial Therapy. The presence of periodontal pathogens, specifically *Aggregatibacter actinomycetemcomitans,* has been implicated as the reason that aggressive periodontitis does not respond to conventional therapy alone. These pathogens are known to remain in the tissues after therapy to reinfect the pocket.[9,57] In the late 1970s and early 1980s, the identification of *A. actinomycetemcomitans* as a major culprit and the discovery that this organism penetrates the tissues offered another perspective to the pathogenesis of aggressive periodontitis and offered new hope for therapeutic success, namely, antibiotics.[9] The use of systemic antibiotics was thought to be necessary to eliminate pathogenic bacteria (especially *A. actinomycetemcomitans*) from the tissues. Indeed, several authors have reported success in the treatment of aggressive periodontitis using antibiotics as adjuncts to standard therapy.[33,34,35,70]

There is compelling evidence that adjunctive antibiotic treatment frequently results in a more favorable clinical response than mechanical therapy alone.[65] In a systematic review, Herrera et al[23] found that systemic antimicrobials in conjunction with scaling and root planing offer benefits over scaling and planing alone in terms of clinical attachment level, probing pocket depth, and reduced risk of additional attachment loss. Patients with deeper, progressive pockets seem to benefit the most from systemic administration of adjunctive antibiotics. Many different antibiotic types and regimens were reviewed. Because of limitations in comparing data from different studies, however, definitive recommendations were not possible. In a meta-analysis of the literature (six randomized clinical trials were included), Sgolastra et al[59] found that the systemic use of combined amoxicillin and metronidazole as an adjunct to scaling and root planing for the treatment of generalized

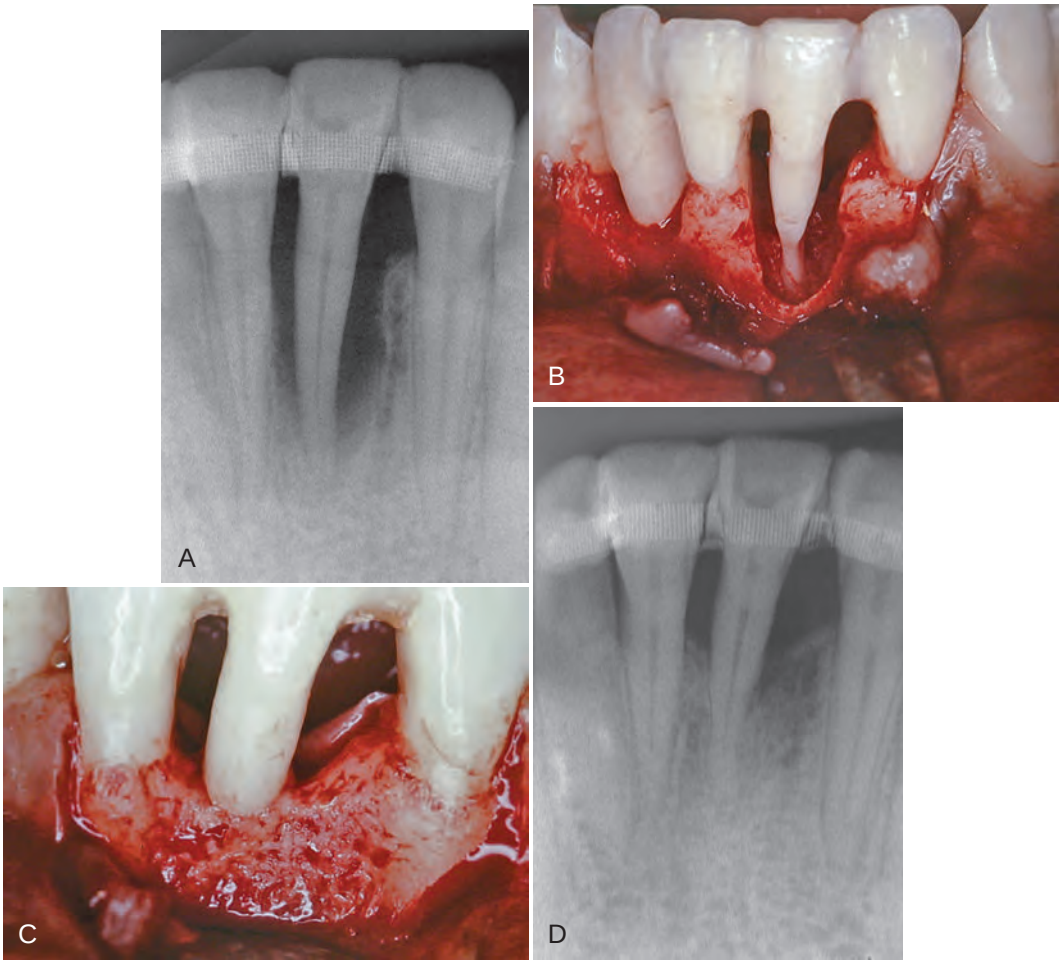

Figure 40-1 Clinical photographs and periapical radiographs demonstrating regenerative success in patient with localized aggressive periodontitis. **A,** Periapical radiograph of the right lateral incisor at the initial diagnosis. Notice the severe, vertical bone loss associated with the right lateral incisor. Tooth has been splinted to adjacent teeth for stability. **B,** Facial view of the circumferential osseous defect around the lower right lateral incisor during open flap surgery. There is complete loss of buccal, lingual, mesial, and distal bone around the lateral incisor, with minimal bone support limited to the apical few millimeters. **C,** Facial view of reentered surgical site 1 year after treatment. Bone fill around all surfaces demonstrates remarkable potential for regeneration of a large osseous defect in a young patient with localized aggressive periodontitis. **D,** Periapical radiograph taken 1 year after regenerative therapy. Note the increased radiopacity and bone fill. *(From Dodson SA, Takei HH, Carranza FA Jr:* Int J Periodont Restor Dent *16:455, 1996.)*

aggressive periodontitis showed significant clinical attachment gain ($p < 0.05$) and pocket reduction ($p < 0.05$) as compared to scaling and root planing alone.

Figure 40-2 shows the before and after results of an aggressive periodontitis case treated nonsurgically with scaling and root planing and adjunctive antibiotic therapy. The patient, a 34-year-old Asian male, presented with a complaint of loose teeth and bleeding gums. He requested treatment to save his teeth. Treatment consisted of patient education including oral hygiene instructions and nonsurgical therapy with adjunctive antibiotics. All teeth were thoroughly scaled and root planed under local anesthesia over two treatment appointments, and the patient was treated with systemic amoxicillin (500 mg, 3 times a day for 2 weeks) during the period of treatment. All areas responded favorably with probing pocket depths decreasing from 3 to 13 mm down to 2 to 5 mm. Bleeding on probing diminished from generalized to very few isolated areas. He has been on periodontal maintenance with good results for more than 5 years.

Genco et al[18] treated localized aggressive periodontitis patients with scaling and root planing plus systemic administration of tetracycline (250 mg, four times daily for 14 days every 8 weeks). Measurements of vertical defects were made at intervals of up to 18 months after the initiation of therapy. Bone loss had stopped, and one-third of the defects demonstrated an increase in bone level, whereas in the control group, bone loss continued.

Liljenberg and Lindhe[33] treated patients with localized aggressive periodontitis with systemic administration of tetracycline (250 mg, four times daily for 2 weeks), modified Widman flaps, and periodic recall visits (one visit every month for 6 months, then one visit every 3 months). The lesions healed more rapidly and more completely than similar lesions in control patients. These investigators reevaluated their results after 5 years and found that the treatment group continued to demonstrate resolution of gingival inflammation, gain of clinical attachment, and refill of bone in angular defects.[34] Figures 40-3 and 40-4 show radiographs of a case with similar treatment and results.[4]

Clearly, numerous studies support the use of adjunctive tetracycline along with mechanical debridement for the treatment of *A. actinomycetemcomitans*–associated aggressive periodontitis (Box 40-1). Given the possible emergence of tetracycline-resistant *A. actinomycetemcomitans,* there is concern that tetracycline may not be effective. In these cases the combination of metronidazole and

Figure 40-2 Intraoral clinical photographs and full-mouth radiographs (before and after treatment) of a 34-year-old Asian male with aggressive periodontitis. **A, B,** Intraoral clinical photographs of pretreatment periodontal condition. Note the gingival edema, inflammation, and bleeding. Probing pocket depths ranged from 3 to 13 mm with generalized bleeding on probing and purulent exudate. **C,** Pretreatment full-mouth radiographs demonstrating generalized severe horizontal bone loss. Note the periapical radiolucency at the apex of the upper left premolar indicating pulpal disease.

Figure 40-2, cont'd **D, E,** Intraoral clinical photographs of posttreatment (5 years) results. Treatment included nonsurgical scaling and root planing along with adjunctive systemic antibiotics (amoxicillin). Patient improved oral hygiene and continued to be seen for professional maintenance every 3 months. Probing pocket depths have been maintained in the range of 2 to 5 mm with only a few localized areas of bleeding on probing. **F,** Posttreatment (5 years) full-mouth radiographs demonstrating no additional bone loss. Endodontically involved maxillary premolar was extracted and replaced with a removable partial denture.

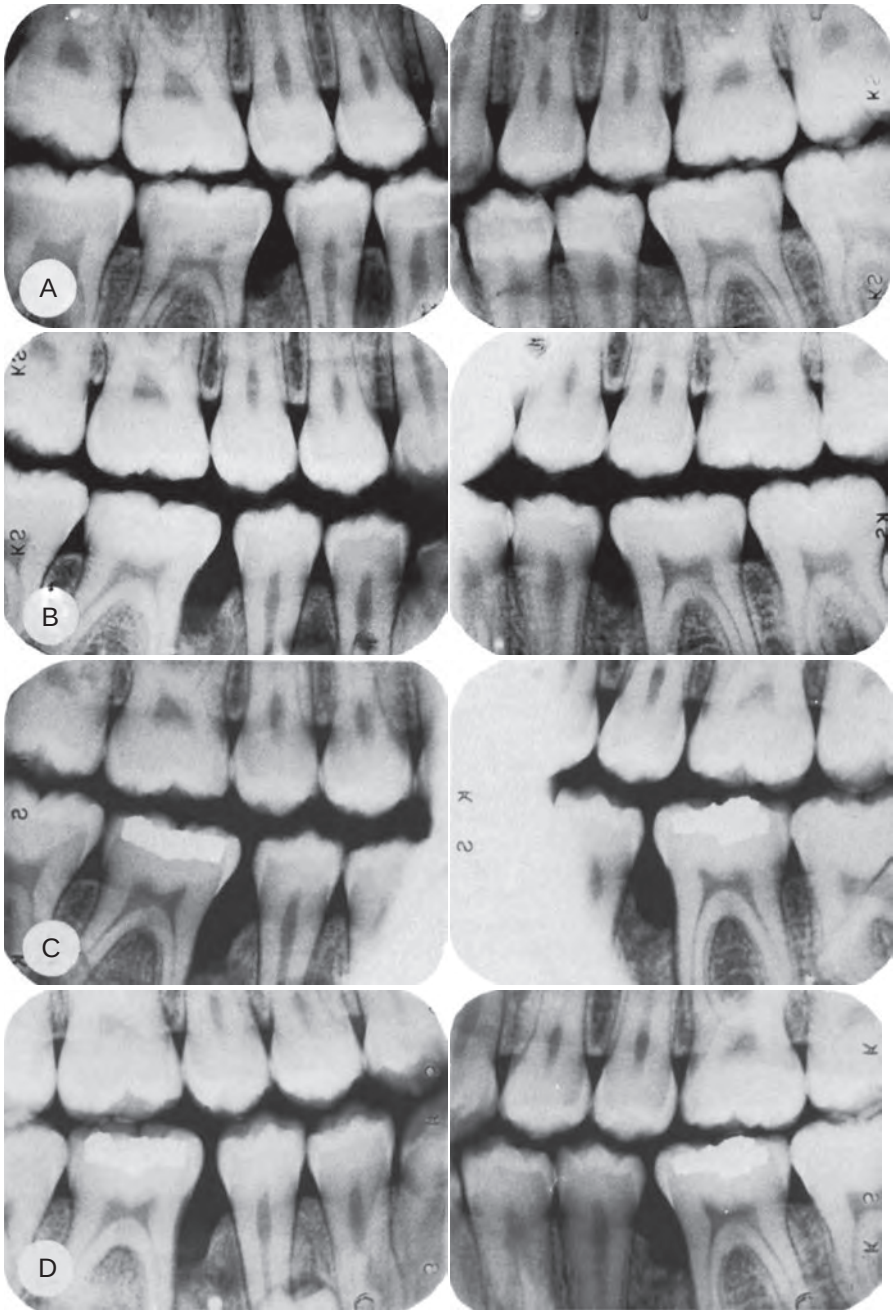

Figure 40-3 Radiographs depicting progression of the osseous lesion in patient with localized aggressive periodontitis (formerly "localized juvenile periodontitis"). **A,** January 29, 1979; **B,** August 16, 1979; **C,** February 22, 1980; **D,** May 15, 1981. Note the progressive deterioration of the osseous level. *(From Barnett ML, Baker RL:* J Periodontol *54:148, 1983.)*

amoxicillin may be advantageous. The combination of these two antibiotics with conventional periodontal therapy[21,22] provides better disease control and better clinical improvement in attachment levels in difficult-to-manage periodontitis cases than similar periodontal therapy without antibiotics. Similar effects were seen for a variety of antibiotic types. However, a lack of sufficient sample sizes among studies makes it difficult to offer specific recommendations about which antibiotics were most effective.[23]

The criteria for selection of antibiotics are not clear. Good clinical and microbiologic responses have been reported with several individual antibiotics and antibiotic combinations (Table 40-1). The optimal antibiotic or combination for any particular infection probably depends on the case. Choices must be made based on patient-related and disease-related factors.

Microbial Testing. Some investigators and clinicians advocate microbial testing to identify the specific periodontal pathogens responsible for disease and to select an appropriate antibiotic based on sensitivity and resistance. There may be specific cases in which bacterial identification and antibiotic-sensitivity testing is invaluable. For example, in localized aggressive periodontitis cases, tetracycline-resistant *Actinobacillus* species have been suspected. If antibiotic susceptibility tests determine that tetracycline-resistant species exist in the lesion, the clinician may be advised to consider another antibiotic or an antibiotic combination, such as amoxicillin and metronidazole.[15,50,61]

In practice, antibiotics are often used empirically without microbial testing. One study evaluated and compared the results of microbial testing offered by two independent laboratories.[41,58] Two microbiologic cultures, sampled simultaneously from the same sites in 20 patients, were submitted separately to each of the two laboratories for bacterial identification and antibiotic-sensitivity testing. The reported presence of bacterial species varied from one

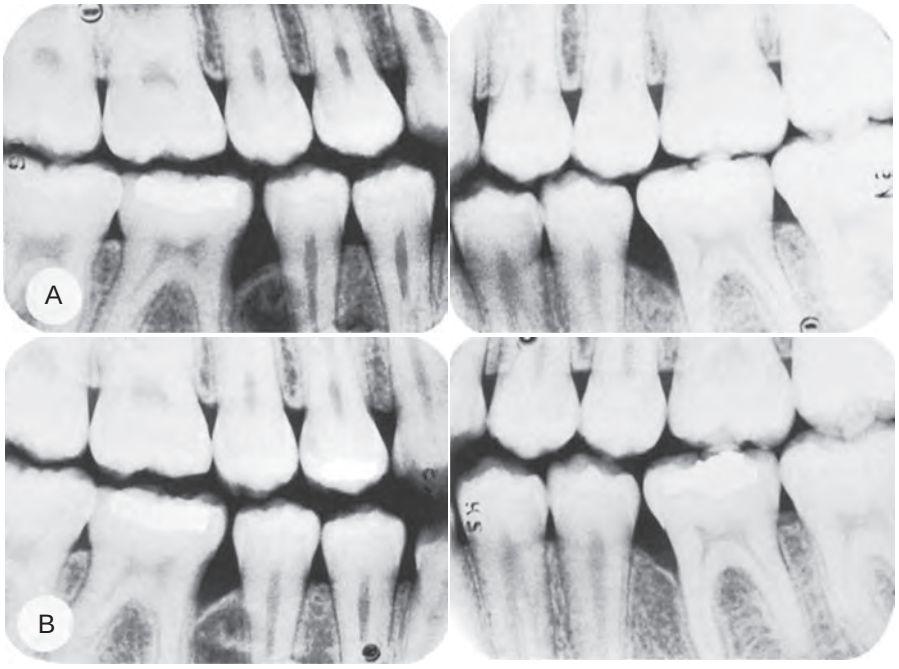

Figure 40-4 Postoperative radiographs of the patient in Figure 40-3. **A,** November 6, 1981; **B,** March 3, 1982. Treatment consisted of oral hygiene instruction, scaling and root planing concurrently with 1 g of tetracycline per day for 2 weeks, and modified Widman flaps. *(From Barnett ML, Baker RL:* J Periodontol *54:148, 1983.)*

BOX 40-1 Systemic Tetracycline in Treatment of Aggressive Periodontitis

Systemic tetracycline (250 mg of tetracycline hydrochloride four times daily for at least 1 week) should be given in conjunction with local mechanical therapy. If surgery is indicated, systemic tetracycline should be prescribed and the patient instructed to begin taking the antibiotic approximately 1 hour before surgery. Doxycycline, 100 mg/day, may be used instead of tetracycline. Chlorhexidine rinses should be prescribed and continued for several weeks to enhance plaque control and facilitate healing.

TABLE 40-1 Antibiotic Therapy for Aggressive Periodontitis

Associated Microflora	Antibiotic of Choice
Gram-positive organisms	Amoxicillin–clavulanate potassium (Augmentin)[10,67]
Gram-negative organisms	Clindamycin[19,20,63,67]
Nonoral gram-negative, facultative rods	Ciprofloxacin[36]
Pseudomonads, staphylococci	
Black-pigmented bacteria and spirochetes	Metronidazole[19,60]
Prevotella intermedia, Porphyromonas gingivalis	Tetracycline[50]
Aggregatibacter actinomycetemcomitans	Metronidazole-amoxicillin[19,60]
	Metronidazole-ciprofloxacin
	Tetracycline[48]
P. gingivalis	Azithromycin[49]

laboratory to another, as did their antimicrobial recommendations. Interestingly, the combination of amoxicillin and metronidazole yielded the highest level of agreement (80%). This is likely attributed to the effectiveness of this combination, as well as a clinical predisposition to favor a known regimen. These findings suggest that the usefulness of microbial testing may be limited and led the authors to conclude that the empiric use of antibiotics, such as a combination of amoxicillin and metronidazole, may be more clinically sound and cost-effective than bacterial identification and antibiotic-sensitivity testing.[41,58]

Nonetheless, the use of microbial testing should be considered whenever a case of aggressive periodontitis is not responding or if the destruction continues despite good therapeutic efforts.

Local Delivery. The use of local delivery to administer antibiotics offers a novel approach to the management of periodontal "localized" infections. The primary advantage of local therapy is that smaller total dosages of topical agents can be delivered inside the pocket, avoiding the side effects of systemic antibacterial agents while increasing the exposure of the target microorganisms to higher concentrations, and therefore more therapeutic levels, of the medication. Local delivery agents have been formulated in many different forms, including solutions, gels, fibers, and chips[16,17,27] (see Chapter 48).

Full-Mouth Disinfection. Another approach to antimicrobial therapy in the control of infection associated with periodontitis is the concept of full-mouth disinfection. The concept, described by Quirynen et al,[51] consists of full-mouth debridement (removal of all plaque and calculus) completed in two appointments within a 24-hour period. In addition to scaling and root planing, the tongue is brushed with a chlorhexidine gel (1%) for 1 minute, the mouth is rinsed with a chlorhexidine solution (0.2%) for 2 minutes, and periodontal pockets are irrigated with a chlorhexidine solution (1%).

In a clinical and microbiologic study, 10 patients with advanced chronic periodontitis were randomly assigned to test or control groups. Test patients were treated as just described while control patients received scaling and root planing by quadrant at 2-week intervals along with oral hygiene instructions. At 1 and 2 months after treatment, the test group showed significantly higher reduction in probing pocket depth, especially for deeper pockets (7 to 8 mm). Patients in the test group also had significantly lower pathogenic microorganisms after treatment compared with controls.

Several follow-up studies by the same center demonstrated similar results for up to 6 months after therapy.[5,6,62] In another study, the same group included a test group who did *not* use chlorhexidine as part of the one-stage, full-mouth disinfection.[52] Interestingly, the results of both test groups (with and without chlorhexidine) were similar and were significantly better than for controls. The authors concluded that the beneficial effects of one-stage, full-mouth disinfection probably result from the full-mouth debridement within 24 hours rather than the adjunctive chlorhexidine treatment.

A few reports have included patients with aggressive (early-onset) periodontitis in their evaluation of the one-stage, full-mouth disinfection protocol.[11,45,53] As with the advanced chronic periodontitis group, De Soete et al[11] found a significant reduction in probing pocket depth and gain in clinical attachment in patients with aggressive periodontitis up to 8 months after treatment compared with controls (scaling and root planing by quadrant at 2-week intervals). They also found significant reductions in periodontal pathogens up to 8 months after therapy. *Porphyromonas gingivalis* and *Tannerella forsythia* were reduced to levels below detection.

Host Modulation. A novel approach in the treatment of aggressive periodontitis and difficult-to-control forms of periodontal disease is the administration of agents that modulate the host response. Several agents have been used or evaluated to modify the host response to disease (see Chapter 49).

Treatment Planning and Restorative Considerations

Successful management of patients with aggressive periodontitis must include tooth replacement as part of the treatment plan. In some advanced cases of aggressive periodontitis, the overall treatment success for the patient may be enhanced if severely compromised teeth are extracted. The outcome of treatment for these teeth is limited, and more importantly, the retention of severely diseased teeth over time may result in additional bone loss and teeth that are further compromised. The risk of further bone loss is even a greater concern now with the current success and predictability of dental implants and the desire to preserve bone for implant placement. Any additional alveolar bone loss in an area that has already undergone severe bone loss may further compromise residual anatomy and impair the opportunity for tooth replacement with a dental implant. This is especially true for certain areas with poor bone quality or limited bone volume, such as the posterior maxilla. Fortunately, healing of extraction sites is typically uneventful in patients with aggressive periodontitis, and bone augmentation of defect sites is predictable.

In the patient with aggressive periodontitis, the approach to restorative treatment should be made based on a single premise: extract severely compromised teeth early and plan treatment to accommodate future tooth loss. The teeth with the best prognosis should be identified and considered when planning the restorative treatment. The lower cuspids and first premolars are generally more resistant to loss, probably because of the favorable anatomy (single roots, no furcations) and easier access for patient oral hygiene. As a rule, an extensive fixed prosthesis should be avoided, and removable partial dentures should be planned in such a way as to allow for the addition of teeth.

When hopeless teeth are extracted, they need to be replaced. The desire to replace missing teeth in a permanent manner without preparation of adjacent teeth for a fixed partial denture motivated clinicians to attempt transplantation of teeth from one site to another. Transplantation of developing third molars to the sockets of hopeless first molars has been attempted with limited success.[7,32,39] Clearly, the success and predictability of dental implants have obviated the need for attempting to transplant teeth to edentulous sites.

Use of Dental Implants. Initially, the use of dental implants was suggested and implemented with much caution in patients with aggressive periodontitis because of an unfounded fear of bone and implant loss. However, evidence to the contrary appears to support the use of dental implants in patients treated for aggressive periodontal disease.[37,42,44,46,69] Thus it is possible to consider the use of dental implants in the overall treatment plan for patients with aggressive periodontitis.

There is scant evidence to support the use of bone augmentation procedures in preparation for or in combination with implant placement in patients treated for aggressive periodontitis. One case report with short-term follow-up suggests it is successful.[25] A prospective study of 10 patients treated for generalized aggressive periodontitis undergoing guided bone regeneration followed by implant placement found that the implant survival rate was 100% after 3 years.[43] However, a slightly greater attachment (0.65 mm) and bone (1.78 mm) loss was observed in the aggressive periodontitis group as compared to 10 periodontally healthy controls who received implants without bone augmentation.

Clinical Consideration. It is important to recognize that special consideration must be given to the risk of occlusal overload of implants placed in a periodontally compromised dentition. This is especially true when only one or a few implants are used to replace a limited number of teeth with an implant-supported fixed crown or bridge in a patient with a majority of the remaining dentition being mobile. The immobility of implants in a dentition that does not have a stable vertical occlusal stop may lead to implant overloaded.

Periodontal Maintenance

When patients with aggressive periodontitis are transferred to maintenance care, their periodontal condition must be stable (i.e., no clinical signs of disease and no periodontal pathogens). Each maintenance visit should consist of a medical history review, an inquiry about any recent periodontal problems, assessment risk of factors, a comprehensive periodontal and oral examination, thorough root debridement, and prophylaxis, followed by a review of oral hygiene instructions. If oral hygiene is not good, patients may benefit most from a review of oral hygiene instructions and visualization of plaque in their own mouth before debridement and prophylaxis.

Frequent maintenance visits appear to be one of the most important factors in the control of disease and the success of treatment in patients with aggressive periodontitis.[31,63] In a study of 25 individuals with aggressive (early-onset) periodontitis followed with maintenance every 3 to 6 months for 5 years, it was concluded that patients with aggressive periodontitis could be effectively maintained with clinical and microbiologic improvements after active periodontal therapy.[26] The presence of high bacterial counts (particularly *P. gingivalis* and *Treponema denticola*), number of acute episodes, number of teeth lost, smoking, and stress appear to be significant factors in the small percentage of sites that showed progressive bone loss. In a 5-year follow-up study of 13 patients with aggressive periodontitis, comprehensive mechanical, surgical, and antimicrobial therapy with supportive periodontal maintenance every 3 to 4 months, periodontal disease progression was arrested in 95% of the initially affected lesions. Only 2% to 5% experienced discrete episodes of loss of periodontal support.[8]

A supportive periodontal maintenance program aimed at early detection and treatment of sites that begin to lose attachment should be established. The duration between these recall visits is usually short during the first period after the patient's completion of therapy, generally no longer than 3-month intervals. Acute episodes of gingival inflammation can be detected and managed earlier when the patient is on a frequent monitoring cycle. Monitoring as frequently as every 3 to 4 weeks may be necessary when the disease is thought to be active. If signs of disease activity and progression persist despite therapeutic efforts, frequent visits and good patient compliance, microbial testing may be indicated. The rate of disease progression may be faster in younger individuals, and therefore the clinician should monitor such patients more frequently. Over time the recall maintenance interval can be adjusted (more or less often) to suit the patient's level of oral hygiene and control of disease, as determined by each examination.

Close collaboration between members of the treatment team, including the periodontist, general dentist, dental hygienist, and patient's physician, is required for continuity of care and for patient motivation and encouragement. It is important to monitor and observe the patient's overall physical status as well, because weight loss, depression, and malaise have been reported in patients with generalized aggressive periodontitis. Finally, there is a constant need to reinforce patient education about disease etiology and preventive practices (i.e., oral hygiene and control of risk factors).

Necrotizing Ulcerative Periodontitis

Necrotizing ulcerative periodontitis (NUP) is a rare disease, especially in developed countries. Often, NUP is diagnosed in individuals with a compromised host immune response (see Chapter 24). The incidence of NUP in specific populations, such as patients who are positive for human immunodeficiency virus (HIV) or who have acquired immunodeficiency syndrome (AIDS), has been reported as 0% to 6%. Most patients diagnosed with NUP apparently have diseases or conditions that impair their host immune response. These patients often have an underlying predisposing systemic factor that renders them susceptible to necrotizing ulcerative periodontal disease. For this reason, patients presenting with NUP should be treated in consultation with their physician.

A comprehensive medical evaluation and diagnosis of any condition that may be contributing to an altered host immune response should be completed. It is also important to rule out any hematologic disease (e.g., leukemia) before initiating treatment of a case that has a similar presentation to NUP (see Chapter 11 and Figures 11-17 and 11-19).

Treatment can be initiated only after a thorough medical history and examination to identify the existence of any systemic diseases. Treatment for NUP includes local debridement of lesions with scaling and root planing, lavage, and instructions for good oral hygiene. It may be necessary to use local anesthesia during the debridement because lesions are frequently painful. The use of ultrasonic instrumentation with profuse irrigation may enhance debridement and flushing of the deep lesions. Achieving good oral hygiene may be challenging as well until the lesions and associated pain resolve.

Antimicrobial adjuncts, such as chlorhexidine, added to the oral hygiene regimen may be effective in contributing to the daily reduction of bacterial loads. Patients frequently complain of pain. The use of locally applied topical antimicrobials and systemic antibiotics, as well as systemic analgesics, should be used as indicated by signs and symptoms.

Patients with NUP often harbor bacteria, fungi, viruses, and other nonoral microorganisms, complicating the selection of antimicrobial therapy. Superinfection or overgrowth of fungi and viruses may be propagated by antibiotic therapy. Antifungal and/or antiviral agents can be considered prophylactically against these infections or after they are diagnosed. Because oral hygiene for these patients is complicated by the painful lesions, alternative methods should be encouraged. In such patients, irrigation with diluted cleansing and antibacterial agents can be of some benefit.

Ultimately, the successful treatment of NUP may depend on the resolution or treatment of the systemic condition (e.g., immune compromise) that predisposed the individual to the disease. Evaluation and treatment of patients with known systemic conditions, such as HIV infection, should be coordinated with the patient's physician.

Suggested Readings

Al-Zahrani MS: Implant therapy in aggressive periodontitis patients: a systematic review and clinical implications. *Quintessence Int* 39:211–215, 2008.

Bollen CM, Mongardini C, Papaioannou W, et al: The effect of a one-stage full-mouth disinfection on different intra-oral niches. Clinical and microbiological observations. *J Clin Periodontol* 25:56–66, 1998.

Buchmann R, Nunn ME, Van Dyke TE, et al: Aggressive periodontitis: 5-year follow-up of treatment. *J Periodontol* 73:675–683, 2002.

Haffajee AD, Uzel NG, Arguello EI, et al: Clinical and microbiological changes associated with the use of combined antimicrobial therapies to treat "refractory" periodontitis. *J Clin Periodontol* 31:869–877, 2004.

Herrera D, Sanz M, Jepsen S, et al: A systematic review on the effect of systemic antimicrobials as an adjunct to scaling and root planing in periodontitis patients. *J Clin Periodontol* 29(Suppl 3):136–159, discussion 160–162, 2002.

Lang N, Bartold PM, Cullinan M, et al: Consensus report: aggressive periodontitis. *Ann Periodontol* 4:1999.

Lindhe J, Liljenberg B: Treatment of localized juvenile periodontitis. Results after 5 years. *J Clin Periodontol* 11:399–410, 1984.

Nevins M, Langer B: The successful use of osseointegrated implants for the treatment of the recalcitrant periodontal patient. *J Periodontol* 66:150–157, 1995.

Quirynen M, Mongardini C, de Soete M, et al: The role of chlorhexidine in the one-stage full-mouth disinfection treatment of patients with advanced adult periodontitis. Long-term clinical and microbiological observations. *J Clin Periodontol* 27:578–589, 2000.

Waerhaug J: Subgingival plaque and loss of attachment in periodontosis as evaluated on extracted teeth. *J Periodontol* 48:125–130, 1977.

References

References for this chapter are found on the companion website www.expertconsult.com.

Periodontitis Refractory to Treatment

Although refractory periodontitis is not currently considered a separate disease entity (see Chapter 3), patients who fail to respond to conventional therapy are considered to have periodontitis that is "refractory" to treatment. It is possible to characterize any form of periodontal disease (e.g., chronic periodontitis, aggressive periodontitis) as refractory to treatment.

These cases are difficult to manage because the etiology behind their lack of response to therapy is unknown. Initially, because contributing factors may have been overlooked, it is important to evaluate the adequacy of treatment attempts thoroughly and to consider other possible etiologies before concluding that a case truly is refractory. A patient with periodontitis that is refractory to treatment often does not have any distinguishing clinical characteristics on initial examination compared with cases of periodontitis that respond normally. Therefore the initial treatment would follow conventional therapeutic modalities for periodontitis. After treatment, if the patient has not responded as expected, the clinician should rule out the following conditions:

1. *Inadequately treated periodontitis.* Most forms of periodontitis can be treated effectively with currently available modalities if they are performed properly. After treatment, if it is determined that the patient has not responded, the clinician must evaluate whether the therapy was adequately performed. Undetected or inaccessible subgingival calculus may be present in one or more areas. Retreatment may be the best way to ensure that therapy was adequately performed. All root surfaces must be meticulously inspected.
2. *Poor plaque control.* Plaque control is essential to the success of periodontal therapy.[47,55,56] Patients must understand the role of bacterial plaque in their disease process, and they must comply with daily oral hygiene instructions. Thus patient compliance and the adequacy of their daily plaque control should be assessed before concluding that a case of periodontitis is refractory to treatment.
3. *Endodontic infection.* The presence of nonperiodontal infections in the area can perpetuate periodontal disease activity and prevent a normal healing response to conventional periodontal therapy. Endodontic infection of teeth in the area should be suspected and ruled out before concluding that a case is refractory to treatment. The clinician should suspect an endodontic etiology especially in those patients with localized recurrent disease.

A case may be considered *refractory* to treatment only when loss of periodontal attachment and bone continues after well-executed treatment in a patient with good oral hygiene and no other infections or etiologic factors.

Clinicians are in a quandary when presented with a patient who is not responding to periodontal therapy. Therapeutic means must be broad in scope and thorough to ensure that all aspects of the host response are addressed. At a minimum, a frequent and intensive recall maintenance and home care program is necessary. Mechanical debridement with scaling and root planing can reduce total supragingival and subgingival bacterial masses, but major periodontal pathogens may persist. Surgical treatment may aid in providing access for debridement and in elimination of bacterial pathogens.[57] In addition, the morphology of the gingival tissues should be modified to facilitate daily plaque removal by the patient.

Systemic antibiotic therapy is administered to reinforce mechanical periodontal treatment and support the host defense system in overcoming the infection by killing subgingival pathogens that remain after conventional mechanical periodontal therapy. Many antibiotics have been used according to the target microflora with various degrees of success[20] (see Table 40-1). For patients with refractory disease who fail to respond to initial antibiotic therapy, subsequent treatment should include microbial testing with bacterial identification and antimicrobial susceptibility.

Antibiotic resistance is a potential problem. Patients with periodontitis that is refractory to treatment often present with a history of previous tetracycline therapy, and thus they may have a microflora that is resistant to this drug.[28,38,65,66] Tetracycline-resistant bacteria have been isolated from patients with periodontitis refractory to treatment.[48] However, some patients with refractory disease may still benefit from the use of tetracycline or one of its derivatives.

Cases of periodontitis (refractory) in which the associated microflora consists primarily of gram-positive microorganisms have been successfully treated with *amoxicillin–clavulanate potassium.* Many efforts have been made to establish the most appropriate regimen of antibiotic therapy for these patients. Similar antimicrobial regimens, consisting of 250 mg of amoxicillin and 125 mg of clavulanate potassium, have been administered three times daily for 14 days, with scaling and root planing, and produced a reduction in attachment loss for at least 12 months. A regimen of one capsule containing the same amount of drug every 6 hours for 2 weeks, with intrasulcular full-mouth lavage using a 10% povidone-iodine solution and chlorhexidine oral rinses twice daily, resulted in a reduction in attachment loss that persisted at approximately 34 months.[10] A regimen of 500 mg of metronidazole three times daily for 7 days was shown to be effective in treating periodontitis (refractory) in patients who were culture positive for *T. forsythia* in the absence of *A. actinomycetemcomitans.*[68]

Clindamycin is a potent antibiotic that penetrates well into gingival fluid, although it is not usually effective against *A. actinomycetemcomitans* and *Eikenella corrodens.*[65] However, clindamycin has been effective in controlling the extent and rate of disease progression in refractory cases in patients who have a microflora susceptible to this antibiotic.[20,36,64] A regimen of clindamycin hydrochloride, 150 mg, four times daily for 7 days, combined with scaling and root planing produced a decrease in the incidence of disease activity from an annual rate of 8% to an annual rate of 0.5% of sites per patient.[19] Clindamycin should be prescribed with caution because of the potential for pseudomembranous colitis from superinfections with *Clostridium difficile.* Patients should be warned and advised to discontinue the antibiotic if symptoms of diarrhea develop.

Azithromycin may be effective in periodontitis that is refractory to treatment, especially in patients infected with *P. gingivalis.*[49]

Combinations of antibiotic therapy may offer greater promise as adjunctive treatment for the management of refractory periodontitis.[2,10,15,38] The rationale is based on the diversity of putative pathogens[18,61] and no single antibiotic being bactericidal for all known pathogens. Combination antibiotic therapy may help broaden the antimicrobial range of the therapeutic regimen beyond that attained by any single antibiotic. Other advantages include lowering the dose of individual antibiotics by exploiting possible synergy between two drugs against targeted organisms. In addition, combination therapy may prevent or forestall the emergence of bacterial resistance. Many combinations of antibiotics have demonstrated significant improvement in the clinical aspects of the disease.[38] Examples of combinations include amoxicillin-clavulanate[15] or metronidazole-amoxicillin for the treatment of *A. actinomycetemcomitans*–associated periodontitis; metronidazole-doxycycline for the prevention of recurrent periodontitis; metronidazole-ciprofloxacin[54] for the treatment of recurrent cases containing a microflora associated with enteric rods and

pseudomonads; and amoxicillin-doxycycline[38] in the treatment of periodontitis associated with *A. actinomycetemcomitans* and *P. gingivalis*.

Some cases of periodontitis that are refractory to treatment may not respond to a given antibiotic regimen. When this occurs, the clinician should consider a different antimicrobial therapy based on microbial susceptibility analysis. At this point in the therapy, strong consideration should be given to consulting with the patient's physician for an evaluation of a possible host immune system deficiency or a metabolic problem such as diabetes.

References

1. Parameter on aggressive periodontitis. American Academy of Periodontology. *J Periodontol* 71:867–869, 2000.
2. Atiken S, Birek P, Kulkarni GV, et al: Serial doxycycline and metronidazole in prevention of recurrent periodontitis in high-risk patients. *J Periodontal* 63:1993.
3. Baer PN, Socransky SS: Periodontosis: case report with long-term follow-up. *Periodontal Case Rep* 1:1–6, 1979.
4. Barnett ML, Baker RL: The formation and healing of osseous lesions in a patient with localized juvenile periodontitis, case report. *J Periodontol* 54:148–150, 1983.
5. Bollen CM, Mongardini C, Papaioannou W, et al: The effect of a one-stage full-mouth disinfection on different intra-oral niches. Clinical and microbiological observations. *J Clin Periodontol* 25:56–66, 1998.
6. Bollen CM, Vandekerckhove BN, Papaioannou W, et al: Full- versus partial-mouth disinfection in the treatment of periodontal infections. A pilot study: long-term microbiological observations. *J Clin Periodontol* 23:960–970, 1996.
7. Borring-Moller G, Frandsen A: Autologous tooth transplantation to replace molars lost in patients with juvenile periodontitis. *J Clin Periodontol* 5:152–158, 1978.
8. Buchmann R, Nunn ME, Van Dyke TE, et al: Aggressive periodontitis: 5-year follow-up of treatment. *J Periodontol* 73:675–683, 2002.
9. Carranza FA, Jr, Saglie R, Newman MG, et al: Scanning and transmission electron microscopic study of tissue-invading microorganisms in localized juvenile periodontitis. *J Periodontol* 54:598–617, 1983.
10. Collins JG, Offenbacher S, Arnold RR: Effects of a combination therapy to eliminate *Porphyromonas gingivalis* in refractory periodontitis. *J Periodontol* 64:998–1007, 1993.
11. de Soete M, Mongardini C, Peuwels M, et al: One-stage full-mouth disinfection: long-term microbiological results analyzed by checkerboard DNA-DNA hybridization. *J Periodontal* 72:1983.
12. Deas DE, Mackey SA, McDonnell HT: Systemic disease and periodontitis: manifestations of neutrophil dysfunction. *Periodontal 2000* 32, 2003.
13. Delcourt-Debruyne EM, Boutigny HR, Hildebrand HF: Features of severe periodontal disease in a teenager with Chediak-Higashi syndrome. *J Periodontol* 71:816–824, 2000.
14. Dodson SA, Takei HH, Carranza FA, Jr: Clinical success in regeneration: report of a case. *Int J Periodontics Restorative Dent* 16:455–461, 1996.
15. Flemmig TF, Milian E, Karch H, et al: Differential clinical treatment outcome after systemic metronidazole and amoxicillin in patients harboring *Aggregatibacter actinomycetemcomitans* and/or *Porphyromonas gingivalis*. *J Clin Periodontol* 25:380–387, 1998.
16. Fourmousis I, Tonetti MS, Mombelli A, et al: Evaluation of tetracycline fiber therapy with digital image analysis. *J Clin Periodontol* 25:737–745, 1998.
17. Garrett S, Johnson L, Drisko CH, et al: Two multi-center studies evaluating locally delivered doxycycline hyclate, placebo control, oral hygiene, and scaling and root planing in the treatment of periodontitis. *J Periodontol* 70:490–503, 1999.
18. Genco RJ, Ciancio SG, Rosling B: Treatment of localized juvenile periodontitis. *J Dent Res* 60(abstract):1981.
19. Gordon J, Walker C, Hovliaras C, et al: Efficacy of clindamycin hydrochloride in refractory periodontitis: 24-month results. *J Periodontol* 61:686–691, 1990.
20. Gordon JM, Walker CB: Current status of systemic antibiotic usage in destructive periodontal disease. *J Periodontol* 64:760–771, 1993.
21. Haffajee AD, Socransky SS, Gunsolley JC: Systemic anti-infective periodontal therapy. A systematic review. *Ann Periodontol* 8:115–181, 2003.
22. Haffajee AD, Uzel NG, Arguello EI, et al: Clinical and microbiological changes associated with the use of combined antimicrobial therapies to treat "refractory" periodontitis. *J Clin Periodontol* 31:869–877, 2004.
23. Herrera D, Sanz M, Jepsen S, et al: A systematic review on the effect of systemic antimicrobials as an adjunct to scaling and root planing in periodontitis patients. *J Clin Periodontol* 29(Suppl 3):136–159, discussion 160–162, 2002.
24. Hirschfeld L, Wasserman B: A long-term survey of tooth loss in 600 treated periodontal patients. *J Periodontol* 49:225–237, 1978.
25. Hoffmann O, Beaumont C, Zafiropoulos GG: Combined periodontal and implant treatment of a case of aggressive periodontitis. *J Oral Implantol* 33:288–292, 2007.
26. Kamma JJ, Baehni PC: Five-year maintenance follow-up of early-onset periodontitis patients. *J Clin Periodontol* 30:562–572, 2003.
27. Killoy WJ: The use of locally delivered chlorhexidine in the treatment of periodontitis. Clinical results. *J Clin Periodontol* 25:953–958, discussion 978–979, 1998.
28. Kornman KS, Karl EH: The effect of long-term low-dose tetracycline therapy on the subgingival microflora in refractory adult periodontitis. *J Periodontol* 53:604–610, 1982.
29. Lang N, Bartold PM, Cullinan M, et al: Consensus report: aggressive periodontitis. *Ann Periodontol* 1999.
30. Lavine WS, Maderazo EG, Stolman J, et al: Impaired neutrophil chemotaxis in patients with juvenile and rapidly progressing periodontitis. *J Periodontal Res* 14:10–19, 1979.
31. Leino L, Hurttia H: A potential role of an intracellular signaling defect in neutrophil functional abnormalities and promotion of tissue damage in patients with localized juvenile periodontitis. *Clin Chem Lab Med* 37:215–222, 1999.
32. Levine RA: Twenty-five month follow-up of an autogenous third molar transplantation in a localized juvenile periodontitis patient: a case report. *Compendium* 8:560, 1987, 563, 566 passim.
33. Liljenberg B, Lindhe J: Juvenile periodontitis. Some microbiological, histopathological and clinical characteristics. *J Clin Periodontol* 7:48–61, 1980.
34. Lindhe J, Liljenberg B: Treatment of localized juvenile periodontitis. Results after 5 years. *J Clin Periodontol* 11:399–410, 1984.
35. Mabry TW, Yukna RA, Sepe WW: Freeze-dried bone allografts combined with tetracycline in the treatment of juvenile periodontitis. *J Periodontol* 56:74–81, 1985.
36. Magnusson I, Low SB, McArthur WP, et al: Treatment of subjects with refractory periodontal disease. *J Clin Periodontol* 21:628–637, 1994.
37. Malmstrom HS, Fritz ME, Timmis DP, et al: Osseo-integrated implant treatment of a patient with rapidly progressive periodontitis. A case report. *J Periodontol* 61:300–304, 1990.
38. Matisko MW, Bissada NF: Short-term sequential administration of amoxicillin/clavulanate potassium and doxycycline in the treatment of recurrent/progressive periodontitis. *J Periodontol* 64:553–558, 1993.
39. Mattout P, Moskow BS, Fourel J: Repair potential in localized juvenile periodontitis. A case in point. *J Periodontol* 61:653–660, 1990.
40. McFall WT, Jr: Tooth loss in 100 treated patients with periodontal disease. A long-term study. *J Periodontol* 53:539–549, 1982.
41. Mellado JR, Freedman AL, Salkin LM, et al: The clinical relevance of microbiologic testing: a comparative analysis of microbiologic samples secured from the same sites and cultured in two independent laboratories. *Int J Periodontics Restorative Dent* 21:232–239, 2001.
42. Mengel R, Behle M, Flores-de-Jacoby L: Osseointegrated implants in subjects treated for generalized aggressive periodontitis: 10-year results of a prospective, long-term cohort study. *J Periodontol* 78:2229–2237, 2007.
43. Mengel R, Flores-de-Jacoby L: Implants in regenerated bone in patients treated for generalized aggressive periodontitis: a prospective longitudinal study. *Int J Periodontics Restorative Dent* 25:331–341, 2005.
44. Mengel R, Schroder T, Flores-de-Jacoby L: Osseointegrated implants in patients treated for generalized chronic periodontitis and generalized aggressive periodontitis: 3- and 5-year results of a prospective long-term study. *J Periodontol* 72:977–989, 2001.
45. Mongardini C, van Steenberghe D, Dekeyser C, et al: One stage full- versus partial-mouth disinfection in the treatment of chronic adult or generalized early-onset periodontitis. I. Long-term clinical observations. *J Periodontol* 70:632–645, 1999.

46. Nevins M, Langer B: The successful use of osseointegrated implants for the treatment of the recalcitrant periodontal patient. *J Periodontol* 66:150–157, 1995.
47. Nyman S, Lindhe J, Rosling B: Periodontal surgery in plaque-infected dentitions. *J Clin Periodontol* 4:240–249, 1977.
48. Olsvik B, Tenover FC: Tetracycline resistance in periodontal pathogens. *Clin Infect Dis* 16(Suppl 4):S310–S313, 1993.
49. Pajukanta R: In vitro antimicrobial susceptibility of *Porphyromonas gingivalis* to azithromycin, a novel macrolide. *Oral Microbiol Immunol* 8:325–326, 1993.
50. Pavicic MJ, van Winkelhoff AJ, Pavivic-Temming YA, et al: Metronidazole susceptibility factors in Aggregatibacter actinomycetemcomitans. *J Antimicrob Chemother* 35:1995.
51. Quirynen M, Bollen CM, Vandekerckhove BN, et al: Full- vs. partial-mouth disinfection in the treatment of periodontal infections: short-term clinical and microbiological observations. *J Dent Res* 74:1459–1467, 1995.
52. Quirynen M, Mongardini C, de Soete M, et al: The role of chlorhexidine in the one-stage full-mouth disinfection treatment of patients with advanced adult periodontitis. Long-term clinical and microbiological observations. *J Clin Periodontol* 27:578–589, 2000.
53. Quirynen M, Mongardini C, Pauwels M, et al: One stage full- versus partial-mouth disinfection in the treatment of chronic adult or generalized early-onset periodontitis. II. Long-term impact on microbial load. *J Periodontol* 70:646–656, 1999.
54. Rams TE, Feik D, Slots J: Ciprofloxacin/metronidazole treatment of recurrent adult periodontitis. *J Dent Res* 70:1992.
55. Rosling B, Nyman S, Lindhe J: The effect of systematic plaque control on bone regeneration in infrabony pockets. *J Clin Periodontol* 3:38–53, 1976.
56. Rosling B, Nyman S, Lindhe J, et al: The healing potential of the periodontal tissues following different techniques of periodontal surgery in plaque-free dentitions. A 2-year clinical study. *J Clin Periodontol* 3:233–250, 1976.
57. Saglie FR, Carranza FA, Jr, Newman MG, et al: Identification of tissue-invading bacteria in human periodontal disease. *J Periodontal Res* 17:452–455, 1982.
58. Salkin LM, Freedman AL, Mellado JR, et al: The clinical relevance of microbiologic testing. Part 2: a comparative analysis of microbiologic samples secured simultaneously from the same sites and cultured in the same laboratory. *Int J Periodontics Restorative Dent* 23:121–127, 2003.
59. Sgolastra F, Petrucci A, Gatto R, et al: Effectiveness of systemic amoxicillin/metronidazole as an adjunctive therapy to full-mouth scaling and root planing in the treatment of aggressive periodontitis: a systematic review and meta-analysis. *J Periodontol* 83(6):731–743, 2012.
60. Thomas JG, Metheny RJ, Karakiozis JM, et al: Long-term sub-antimicrobial doxycycline (Periostat) as adjunctive management in adult periodontitis: effects on subgingival bacterial population dynamics. *Adv Dent Res* 12:32–39, 1998.
61. van Winkelhoff AJ, Tijhof CJ, de Graaff J: Microbial and clinical results of metronidazole amoxicillin therapy in *Aggregatibacter actinomycetemcomitans*-associated periodontitis. *J Periodontal* 63:1992.
62. Vandekerckhove BN, Bollen CM, Dekeyser C, et al: Full- versus partial-mouth disinfection in the treatment of periodontal infections. Long-term clinical observations of a pilot study. *J Periodontol* 67:1251–1259, 1996.
63. Waerhaug J: Subgingival plaque and loss of attachment in periodontosis as evaluated on extracted teeth. *J Periodontol* 48:125–130, 1977.
64. Walker C, Gordon J: The effect of clindamycin on the microbiota associated with refractory periodontitis. *J Periodontol* 61:692–698, 1990.
65. Walker C, Karpinia K: Rationale for use of antibiotics in periodontics. *J Periodontol* 73:1188–1196, 2002.
66. Walker CB, Gordon JM, Magnusson I, et al: A role for antibiotics in the treatment of refractory periodontitis. *J Periodontol* 64:772–781, 1993.
67. Walker CB, Pappas JD, Tyler KZ, et al: Antibiotic susceptibilities of periodontal bacteria. In vitro susceptibilities to eight antimicrobial agents. *J Periodontol* 56:67–74, 1985.
68. Winkel EG, Van Winkelhoff AJ, Timmerman MF, et al: Effects of metronidazole in patients with "refractory" periodontitis associated with *Bacteroides forsythus*. *J Clin Periodontol* 24:573–579, 1997.
69. Yalcin S, Yalcin F, Gunay Y, et al: Treatment of aggressive periodontitis by osseointegrated dental implants. A case report. *J Periodontol* 72:411–416, 2001.
70. Yukna RA, Sepe WW: Clinical evaluation of localized periodontosis defects treated with freeze-dried bone allografts combined with local and systemic tetracyclines. *Int J Periodontics Restorative Dent* 2:8–21, 1982.

CHAPTER 41

Treatment of Acute Gingival Disease

Perry R. Klokkevold and Fermin A. Carranza

CHAPTER OUTLINE

Acute Necrotizing Ulcerative Gingivitis
Acute Pericoronitis
Acute Herpetic Gingivostomatitis

The treatment of acute gingival disease entails the alleviation of the acute symptoms and elimination of all other periodontal disease, both chronic and acute, throughout the oral cavity. Treatment is not complete if periodontal pathologic changes or factors capable of causing them are still present.

Acute Necrotizing Ulcerative Gingivitis

Necrotizing ulcerative gingivitis (NUG) results from an impaired host response to a potentially pathogenic microflora. Depending on the degree of immunosuppression, NUG may occur in a mouth essentially free of other gingival involvement or may be superimposed on underlying chronic gingival disease. Treatment should include the alleviation of the acute symptoms and the correction of the underlying chronic gingival disease. The former is the simpler part of the treatment, whereas the latter requires more comprehensive procedures.

The treatment of NUG consists of (1) alleviation of the acute inflammation by reducing the microbial load and removal of necrotic tissue, (2) treatment of chronic disease either underlying the acute involvement or elsewhere in the oral cavity, (3) alleviation of generalized symptoms such as fever and malaise, and (4) correction of systemic conditions or factors that contribute to the initiation or progression of the gingival changes. Chapter 26 provides further information on the management and treatment of NUG in patients with acquired immunodeficiency syndrome (AIDS).

Treatment of NUG should follow an orderly sequence, according to specific steps at three clinical visits.

First Visit

At the first visit, the clinician should do a complete evaluation of the patient, including a comprehensive medical history with special attention to recent illness, living conditions, dietary background, cigarette smoking, type of employment, hours of rest, risk factors for human immunodeficiency virus (HIV), and psychosocial parameters (e.g., stress, depression). The patient is questioned regarding the history of the acute disease and its onset and duration, as follows:

- Is the disease recurrent?
- Are the recurrences associated with specific factors such as menstruation, particular foods, exhaustion, or mental stress?
- Has there been any previous treatment? When and for how long?

The clinician should also inquire as to the type of treatment received and the patient's impression regarding its effect.

The examination of the patient should include general appearance, presence of halitosis, presence of skin lesions, vital signs including temperature, and palpation for the presence of enlarged lymph nodes, especially submaxillary and submental nodes.

The oral cavity is examined for the characteristic lesion of NUG (see Chapters 17 and 24), its distribution, and the possible involvement of the oropharyngeal region. Oral hygiene is evaluated, with special attention to the presence of pericoronal flaps, periodontal pockets, and local factors (e.g., poor restorations, distribution of calculus). Periodontal probing of NUG lesions is likely to be very painful and may need to be deferred until after the acute lesions are resolved.

The goals of initial therapy are to reduce the microbial load and remove necrotic tissue to the degree that repair and regeneration of normal tissue barriers are reestablished. Treatment during this initial visit is confined to the acutely involved areas, which are isolated with cotton rolls and dried. A topical anesthetic is applied, and after 2 or 3 minutes the areas are gently swabbed with a moistened cotton pellet to remove the pseudomembrane and nonattached surface debris. Bleeding may be profuse. Each cotton pellet is used in a small area, then discarded; sweeping motions over large areas with a single pellet are not recommended. After the area is cleansed with warm water, the superficial calculus is removed. Ultrasonic scalers are very useful for this purpose because they do not elicit pain, and the water jet and cavitation aid in lavage of the area.

Subgingival scaling and curettage are contraindicated at this time because these procedures may extend the infection into the deeper tissues and may also cause bacteremia. *Unless an emergency exists, procedures, such as extractions or periodontal surgery, are postponed until the patient has been symptom free for 4 weeks, to minimize the likelihood of exacerbating the acute symptoms.*

Patients with moderate or severe NUG and local lymphadenopathy or other systemic signs or symptoms are placed on an antibiotic regimen of amoxicillin, 500 mg orally every 6 hours for 10 days. For amoxicillin-sensitive patients, other antibiotics are prescribed, such as erythromycin (500 mg every 6 hours) or metronidazole

(500 mg twice daily for 7 days). Systemic complications should subside in 1 to 3 days. *Antibiotics are not recommended in NUG patients who do not have systemic complications.*

Instructions to the Patient. The patient is discharged with the following instructions:

1. Avoid tobacco, alcohol, and condiments.
2. Rinse with a glassful of an equal mixture of 3% hydrogen peroxide and warm water every 2 hours and/or twice daily with 0.12% chlorhexidine solution.
3. Get adequate rest. Pursue usual activities, but avoid excessive physical exertion or prolonged exposure to the sun, as in golf, tennis, swimming, or sunbathing.
4. Confine toothbrushing to the removal of surface debris with a bland dentifrice and an ultrasoft brush; overzealous brushing and the use of dental floss or interdental cleaners will be painful. Chlorhexidine mouth rinses are also helpful in controlling plaque throughout the mouth.
5. An analgesic, such as a nonsteroidal antiinflammatory drug (NSAID; e.g., ibuprofen), is appropriate for pain relief.
6. Patients who have systemic complications, such as high fever, malaise, anorexia, and general debility and who have been put on an antibiotic treatment are told that bed rest is necessary, as well as copious fluid consumption and administration of analgesics for relief of pain.

Patients are asked to report back to the clinician in 1 to 2 days. The patient should be advised of the extent of total treatment that the condition requires and warned that treatment is not complete when pain stops. The patient should be informed of the presence of chronic gingival or periodontal disease, which must be eliminated to reduce the likelihood of recurrence of the acute symptoms.

A large variety of drugs have been used in the treatment of NUG.[3] Topical drug therapy, however, is only an adjunctive measure; no drug, when used alone, can be considered complete therapy. Systemic antibiotics, when used, also reduce the oral bacterial flora and alleviate the oral symptoms,[11,12] but they are only an adjunct to the complete local treatment that the disease requires. In patients treated by drugs alone or by systemic antibiotics alone the acute painful symptoms often recur after treatment is discontinued.

Second Visit

At the second visit, 1 or 2 days after the first visit, the patient is evaluated for amelioration of signs and symptoms. The patient's condition is usually improved; the pain is diminished or no longer present. The gingival margins of the involved areas are erythematous but without a superficial pseudomembrane.

Scaling is performed if necessary and sensitivity permits. Shrinkage of the gingiva may expose previously covered calculus, which is gently removed. The instructions to the patient are the same as those given previously.

Third Visit

At the next visit, approximately 5 days after the second visit, the patient is evaluated for resolution of symptoms, and a comprehensive plan for the management of the patient's periodontal conditions is formulated. The patient should be essentially symptom free. Some erythema may still be present in the involved areas, and the gingiva may be slightly painful on tactile stimulation (Figure 41-1, *A* and *B*). The patient is instructed in plaque control procedures (see Chapter 46), which are essential for the success of the treatment and the maintenance of periodontal health. The patient is further counseled on nutrition, smoking cessation, and other conditions or habits associated with a potential recurrence. The hydrogen peroxide rinses are discontinued, but chlorhexidine rinses can be maintained for 2 or 3 weeks. Scaling and root planing are repeated if necessary. Unfortunately, the patient often discontinues treatment because the acute condition has subsided; however, this is when comprehensive treatment of the patient's chronic periodontal problem should start.

Appointments should be scheduled for the treatment of chronic gingivitis, periodontal pockets, and pericoronal flaps, as well as for the elimination of all forms of local irritation. The patient should be reevaluated at 1 month to determine compliance with oral hygiene, health habits, psychosocial factors, the potential need for reconstructive or esthetic surgery, and the interval of subsequent recall visits.

Figure 41-1 **A,** Initial view of the anterior gingival tissues in a 22-year-old white female smoker with acute necrotizing ulcerative gingivitis (NUG). **B,** Palatal view of the same patient. **C,** Facial view of the same patient, 2 days after initial scaling and cessation of smoking. **D,** Palatal view of the same patient, 2 days after initial scaling and cessation of smoking. *(From Rose LF, Mealey BL, Genco RJ, Cohen DW:* Periodontics: medicine, surgery, and implants*, Mosby, St. Louis, 2005.)*

Gingival Changes with Healing

The characteristic lesion of NUG undergoes the following changes in the course of healing in response to treatment:

1. Removal of the surface pseudomembrane exposes the underlying red, hemorrhagic, craterlike depressions in the gingiva, indicating inflammation caused by necrosis and microbial infiltration of tissue that has lost the normal barrier function of the epithelium.
2. In the next stage, the bulk and redness of the crater margins are reduced, indicating a reduction in inflammation and re-epithelialization, but the surface remains shiny (Figure 41-1, *C* and *D*).
3. This is followed by the early signs of restoration of normal gingival contour and color, indicating reestablishment of the normal barrier function of the epithelium, including keratinization, and further reduction of inflammation.
4. In the final stage, the normal gingival color, consistency, surface texture, and contour may be restored. Portions of the root exposed by the acute disease may be covered by healthy gingiva (Figure 41-2).

Additional Treatment Considerations

Contouring of Gingiva as Adjunctive Procedure. Even in cases of severe gingival necrosis, healing often leads to restoration of the normal gingival contour, although normal architecture of the gingiva may be achieved only after several weeks or months. However, if there has been loss of interdental bone, if the teeth are irregularly aligned, or if the entire papilla is lost, healing sometimes results in the formation of a shelflike gingival margin, which favors retention of plaque and recurrence of gingival inflammation as well as being an esthetic problem. This can be corrected by an attempt to restore lost tissue through periodontal plastic procedures or by reshaping the gingiva surgically (Figure 41-3). Effective plaque control by the patient is particularly important to establish and maintain the normal gingival contour in areas of tooth irregularity.

Role of Drugs. A large variety of drugs have been used for topical treatment of NUG. Topical drug therapy is only an adjunctive measure. *No drug, when used alone, can be considered complete treatment.*

Escharotic drugs, such as phenol, silver nitrate, chromic acid, or potassium bichromate, should not be used. They are necrotizing agents that alleviate pain by destroying the nerve endings of the ulcerated gingiva. However, they also destroy young cells needed for repair and delay healing. Repeated use of these agents results in loss of gingival tissue that is not restored when the disease subsides.[4]

Persistent or Recurrent Cases

Adequate local therapy with optimal home care will resolve most cases of NUG. If a case of NUG persists despite therapy or if it recurs, the patient should be reevaluated, with a focus on the following factors:

1. *Reassessment of differential diagnosis to rule out diseases that resemble NUG.* Several diseases and conditions may initially present with a similar appearance as NUG, such as

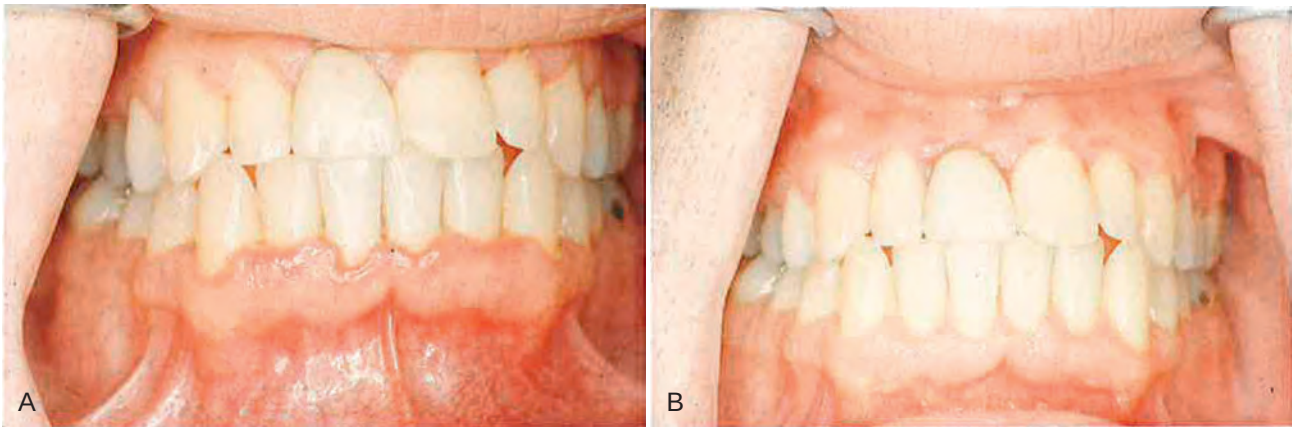

Figure 41-2 Treatment of acute NUG. **A,** Before treatment. Note the characteristic interdental lesions. **B,** After treatment, showing restoration of healthy gingival contour.

Figure 41-3 Reshaping the gingiva in the treatment of acute NUG. **A,** Before treatment, showing bulbous gingiva and interdental necrosis in the mandibular anterior area. **B,** After treatment. Gingival contours still undesirable. **C,** Final result. Physiologic contours obtained by reshaping the gingiva.

desquamative gingivitis. A renewed search for skin lesions and other signs or symptoms should be undertaken, with a biopsy if warranted (see Chapters 19 and 24).

2. *Underlying systemic disease causing immunosuppression.* In particular, HIV infection may frequently present with symptoms of NUG or necrotizing ulcerative periodontitis (NUP). The patient should be reassessed for risk factors and may need counseling about testing for HIV or other suspected underlying systemic diseases (e.g., lymphoproliferative disease). The patient will likely need referral to his or her physician for further evaluation.
3. *Inadequate local therapy.* Too often, treatment is discontinued when the symptoms have subsided, without eliminating the chronic gingival disease and periodontal pockets that remain after the superficial acute condition is relieved. Remaining calculus and other local factors that predispose to gingival inflammation may permit recurrence. Recurrent acute involvement in the mandibular anterior area can be associated with persistent pericoronal inflammation arising from partial eruption and pericoronal inflammation of third molars.[8] The anterior involvement is less likely to recur after the third molar situation is corrected.
4. *Inadequate compliance.* Poor plaque control, heavy use of tobacco, ineffective stress management, and continued malnutrition can also contribute to persistence or recurrence of NUG.

The clinician should evaluate the quality and consistency of plaque control. Further assessment and counseling on tobacco use will also determine the role of tobacco in this patient. If the clinician perceives that psychosocial factors are unresolved and are complicating health behaviors and contributing to immunosuppression, the patient should be referred to the appropriate professional. A reassessment of the patient's nutritional state, with potential dietary analysis or nutritional testing, may be required.[5,7]

Acute Pericoronitis

The treatment of pericoronitis depends on the severity of the inflammation, the systemic complications, and the advisability of retaining the involved tooth. All pericoronal flaps should be viewed with suspicion. Persistent symptom-free pericoronal flaps should be removed as a preventive measure against subsequent acute involvement.

The treatment of acute pericoronitis consists of (1) gently flushing the area with warm water to remove debris and exudate and (2) swabbing with antiseptic after elevating the flap gently from the tooth with a scaler. The underlying debris is removed, and the area is flushed with warm water (Figure 41-4). The occlusion is evaluated to determine if an opposing tooth is occluding with the pericoronal flap. It may be necessary to reduce soft tissue surgically and/or to adjust the opposing tooth to alleviate pain. Antibiotics can be prescribed in severe cases and for patients who may have clinical evidence of diffuse microbial infiltration of the tissue. If the gingival flap is swollen and fluctuant, an incision may be necessary to establish drainage and relieve pressure.

Once the acute symptoms have subsided, the prognosis of the tooth can be evaluated. The decision will be governed by the likelihood of whether the tooth will continue eruption into a functional position or if impaction and the factors predisposing to pericoronitis will persist. Bone loss on the distal surface of the second molar is a concern when third molars are impacted along the distal surface.[2] The problem is significantly greater if the third molars are extracted after the roots are formed or when patients are older (i.e., mid-twenties or later). To reduce the risk of bone loss around second molars, partially or completely impacted third molars should be extracted early in their development.

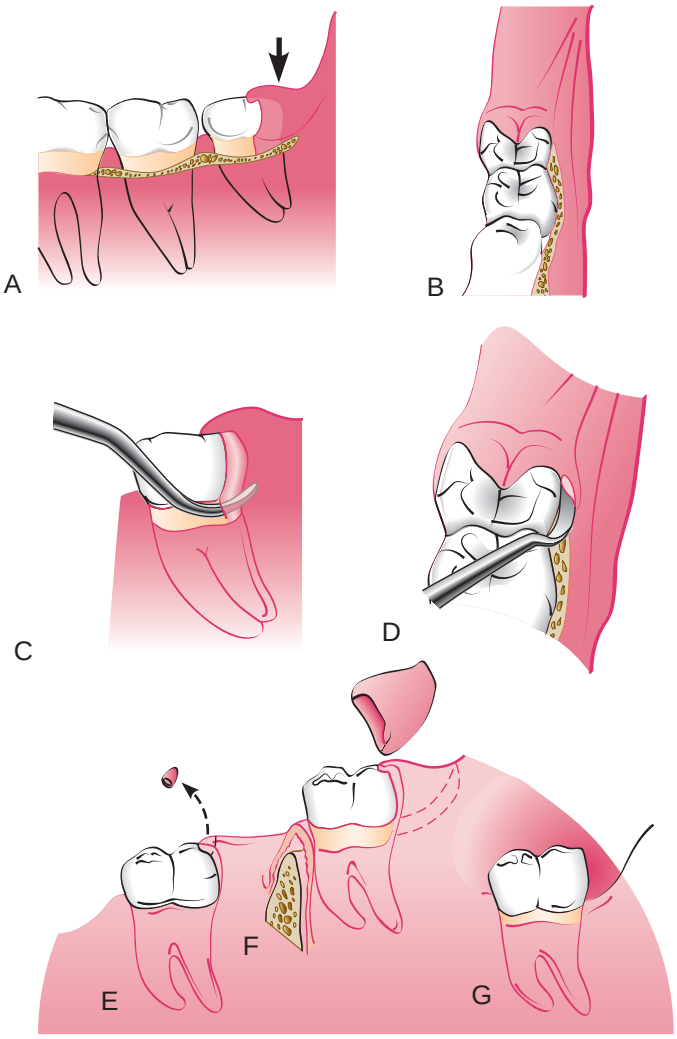

Figure 41-4 Treatment of acute pericoronitis. Osseous surgery may be necessary in some cases. **A,** Inflamed pericoronal flap *(arrow)* in relation to the mandibular third molar. **B,** Anterior view of third molar and flap. **C,** Lateral view with scaler in position to gently remove debris under flap. **D,** Anterior view of scaler in position. **E,** Incorrect removal of the tip of the flap, permitting the deep pocket to remain distal to the molar. **F,** Removal of section of the gingiva distal to the third molar, after the acute symptoms subsided. The line of incision is indicated by the broken line. **G,** Appearance of the healed area.

If the decision is made to retain the tooth, the pericoronal flap is surgically reduced (see Figure 41-4). It is necessary to remove the tissue distal to the tooth, as well as the flap on the occlusal surface. Incising only the occlusal portion of the flap leaves a deep distal pocket, which invites recurrence of acute pericoronal involvement. It is critical to leave the patient with a cleansable site. On healing, the patient needs appropriate instruction in long-term maintenance.

Acute Herpetic Gingivostomatitis

Primary infection with herpes simplex virus in the oral cavity results in a condition known as acute herpetic gingivostomatitis, which is an oral infection often accompanied by systemic signs and symptoms (see Chapter 17). This infection typically occurs in children, but it can occur in adults as well. It runs a 7- to 10-day course

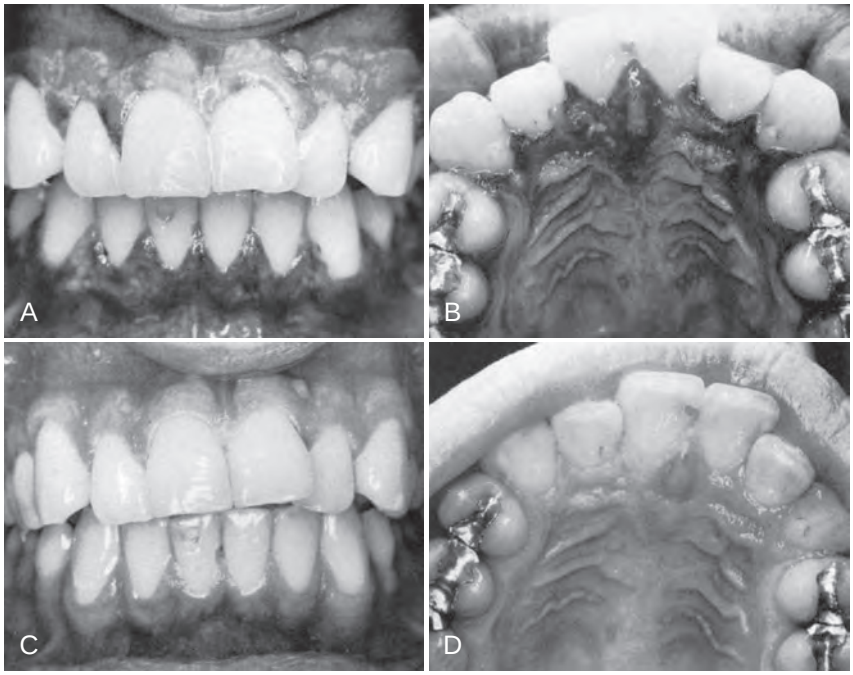

Figure 41-5 Treatment of acute herpetic gingivostomatitis. **A,** Before treatment. Note diffuse erythema and surface vesicles. **B,** Before treatment, palatal view, showing gingival edema and ruptured vesicle on palate. **C,** One month after treatment, showing restoration of normal gingival contour and stippling. **D,** One month after treatment, palatal view.

and usually heals without scarring. A recurrent herpetic episode may be precipitated in individuals with a history of herpesvirus infections by dental treatment,[13] respiratory infections, sunlight exposure, fever, trauma, exposure to chemicals, and emotional stress.

Treatment consists of early diagnosis and immediate initiation of antiviral therapy. Until recently, therapy for primary herpetic gingivostomatitis consisted of palliative care. With the development of antiviral therapy, however, the standard of care has changed. in a randomized double-blind placebo-controlled study, Amir et al[1] demonstrated that antiviral therapy with 15 mg/kg of an acyclovir suspension given five times daily for 7 days substantially changes the course of the disease without significant side effects. Acyclovir reduced symptoms, including fever, from 3 days to 1 day; decreased new extraoral lesions from 5.5 to 0 days; and reduced difficulty with eating from 7 to 4 days. Furthermore, viral shedding stopped at 1 day for the acyclovir group compared with 5 days for the control group. Overall, oral lesions were present for only 4 days in the acyclovir group but for 10 days in the control group. Although no clear clinical evidence indicates that this regimen will reduce recurrences, research data suggest that a greater number of latent virus copies incorporated into ganglia will increase the severity of recurrences.[1]

In summary, if primary herpetic gingivostomatitis is diagnosed within 3 days of onset, acyclovir suspension should be prescribed: 15 mg/kg 5 times daily for 7 days. If diagnosis occurs after 3 days in an immunocompetent patient, acyclovir therapy may have limited value. All patients, including those presenting more than 3 days after disease onset, may receive palliative care, including removal of plaque and food debris. An NSAID (e.g., ibuprofen) can be given systemically to reduce fever and pain. Patients may use either nutritional supplements or topical anesthetics (e.g., viscous lidocaine) before eating to aid in proper nutrition during the early phases in acute herpetic gingivostomatitis. Periodontal therapy should be postponed until the acute symptoms subside to avoid the possibility of exacerbation (Figure 41-5).

Local or systemic application of antibiotics is sometimes advised to prevent opportunistic infection of ulcerations, especially in the immunocompromised patient. If the condition does not resolve within 2 weeks, the patient should be referred to a physician for medical consultation.[6] The patient should be informed that herpetic gingivostomatitis is contagious at certain stages such as when vesicles are present (highest viral titer). All individuals exposed to an infected patient should take precautions. Herpetic infection of a clinician's finger, referred to as *herpetic whitlow,* can occur if a seronegative clinician becomes infected with a patient's herpetic lesions.[9,10]

Suggested Readings

Amir J, Harel L, Smetana Z, et al: Treatment of herpes simplex gingivostomatitis with acyclovir in children: a randomised double-blind placebo-controlled study. *BMJ* 314:1800, 1997.

Ash MM, Jr, Costich ER, Hayward JR: A study of periodontal hazards of third molars. *J Periodontol* 33:209, 1962.

Corbet EF: Diagnosis of acute periodontal lesions. *Periodontol 2000* 34:204–216, 2004.

Johnson BD, Engel D: Acute necrotizing ulcerative gingivitis: a review of diagnosis, etiology and treatment. *J Periodontol* 57(3):141–150, 1986.

Kureishi A, Chow AW: The tender tooth. Dentoalveolar, pericoronal, and periodontal infections. *Infect Dis Clin North Am* 2(1):163–182, 1988.

Langlais RP, Miller CS: *Color atlas of common oral diseases*, ed 2, New York, 1998, Williams & Wilkins.

Matusow RJ: Acute primary herpetic gingivostomatitis in non-immunocompromised adults and an HSV-1 isolation technique. *Compendium* 13(8):662–666, 1992.

Regezi JA, Sciubba JJ: *Oral pathology: clinical-pathologic correlations*, Philadelphia, 1989, Saunders.

Wade DN, Kerns DG: Acute necrotizing ulcerative gingivitis-periodontitis: a literature review. *Mil Med* 163(5):337–342, 1998.

Williamson RT: Diagnosis and management of recurrent herpes simplex induced by fixed prosthodontic tissue management: a clinical report. *J Prosthet Dent* 82:1, 1999.

References

References for this chapter are found on the companion website www.expertconsult.com.

References

1. Amir J, Harel L, Smetana Z, et al: Treatment of herpes simplex gingivostomatitis with acyclovir in children: a randomised double-blind placebo-controlled study. *BMJ* 314:1997, 1800.
2. Ash MM, Jr, Costich ER, Hayward JR: A study of periodontal hazards of third molars. *J Periodontol* 33:209, 1962.
3. Burket LW: *Oral medicine*, ed 3, Philadelphia, 1946, Lippincott.
4. Glickman I, Johannessen LB: The effect of a six percent solution of chromic acid on the gingiva of the albino rat: a correlated gross, biomicroscopic, and histologic study. *J Am Dent Assoc* 41:674, 1950.
5. King JD: Nutritional and other factors in "trench mouth" with special reference to the nicotinic acid component of the vitamin B2 complex. *Br Dent J* 74:113, 1943.
6. Langlais RP, Miller CS: *Color atlas of common oral diseases*, ed 2, New York, 1998, Williams & Wilkins.
7. Linghorne WJ, McIntosh WG, Tice JW, et al: The relation of ascorbic acid intake to gingivitis. *J Can Dent Assoc* 12:49, 1946.
8. Mitchell DF, Baker BR: Topical antibiotic control of necrotizing gingivitis. *J Periodontol* 39:81, 1968.
9. Regezi JA, Sciubba JJ: *Oral pathology: clinical-pathologic correlations*, Philadelphia, 1989, Saunders.
10. Snyder ML, Church DH, Rickles NH: Primary herpes infection of right second finger. *Oral Surg* 27:598, 1969.
11. Wade AB, Blake G, Mirza K: Effectiveness of metronidazole in treating the acute phase of ulcerative gingivitis. *Dent Pract* 16:440, 1966.
12. Wade AB, Blake GC, Manson JD, et al: Treatment of the acute phase of ulcerative gingivitis (Vincent's type). *Br Dent J* 115:372, 1963.
13. Williamson RT: Diagnosis and management of recurrent herpes simplex induced by fixed prosthodontic tissue management: a clinical report. *J Prosthet Dent* 82:1, 1999.

CHAPTER 42

Treatment of Periodontal Abscess

Philip R. Melnick and Henry H. Takei

CHAPTER OUTLINE

Classification of Abscesses
Specific Treatment Approaches

Classification of Abscesses

The periodontal abscess is a localized purulent inflammation of the periodontal tissues.[6] It has been classified into three diagnostic groups: gingival abscess, periodontal abscess, and pericoronal abscess. The *gingival abscess* involves the marginal gingival and interdental tissues. The *periodontal abscess* is an infection located contiguous to the periodontal pocket and may result in destruction of the periodontal ligament and alveolar bone. The *pericoronal abscess* is associated with the crown of a partially erupted tooth.[22]

Periodontal Abscess

The periodontal abscess is typically found in patients with untreated periodontitis and in association with moderate-to-deep periodontal pockets.[5,25] Periodontal abscesses often arise as an acute exacerbation of a preexisting pocket[6] (Figure 42-1). Primarily related to incomplete calculus removal, periodontal abscesses have been linked to a number of clinical situations.[8,15,16,24] They have been identified in patients after periodontal surgery,[12] after preventive maintenance (Figure 42-2),[7,10,17,21] after receiving systemic antibiotic therapy,[26] and as the result of recurrent disease.[15,16] Conditions in which periodontal abscess is not related to inflammatory periodontal disease include tooth perforation or fracture[2,24] (Figure 42-3) and foreign body impaction.[1,23] Poorly controlled diabetes mellitus has been considered a predisposing factor for periodontal abscess formation[22] (Figure 42-4). Formation of periodontal abscess has been reported as a major cause of tooth loss[12-21]; however, with proper treatment followed by consistent preventive periodontal maintenance, teeth with significant bone loss may be retained for many years[7] (see Figure 42-10).

Gingival Abscess

The gingival abscess is a localized, acute inflammatory lesion that may arise from a variety of sources, including microbial plaque infection, trauma, and foreign body impaction.[22] Clinical features include a red, smooth, sometimes painful, often fluctuant swelling (Figure 42-5).

Pericoronal Abscess

The pericoronal abscess results from inflammation of the soft tissue operculum, which covers a partially erupted tooth. This situation is most often observed around the mandibular third molars. As with the gingival abscess, the inflammatory lesion may be caused by the retention of microbial plaque, food impaction, or trauma.

Acute Versus Chronic Abscess

Abscesses are categorized as acute or chronic. The acute abscess is often an exacerbation of a chronic inflammatory periodontal lesion. Influencing factors include increased number and virulence of bacteria present, combined with lowered tissue resistance and lack of spontaneous drainage.[11,25] The drainage may have been prevented by a deep, tortuous pocket morphology, debris, or closely adapted pocket epithelium blocking the pocket orifice. Acute abscesses are characterized by painful, red, edematous, smooth, and ovoid swelling of the gingival tissues.[15,16,25] Exudate may be expressed with gentle pressure; the tooth may be percussion sensitive and feel elevated in the socket (Figure 42-6). Fever and regional lymphadenopathy are occasional findings.[22]

The *chronic abscess* forms after the spreading infection has been controlled by spontaneous drainage, host response, or therapy. Once homeostasis between the host and infection has been reached, the patient may have few or no symptoms.[9] However, dull pain may be associated with the clinical findings of a periodontal pocket, inflammation, and a fistulous tract.[22]

Box 42-1 compares the signs and symptoms of the acute and chronic abscess.

Periodontal Versus Pulpal Abscess

To determine the cause of an abscess and thus establish a proper treatment plan, it is often necessary to perform a differential diagnosis between a periodontal and pulpal abscess[4] (Box 42-2 and Figures 42-7 and 42-8).

Specific Treatment Approaches

Treatment of the periodontal abscess includes two phases: resolving the acute lesion, followed by the management of the resulting chronic condition[24] (Box 42-3).

Acute Abscess

The acute abscess is treated to alleviate symptoms, control the spread of infection, and establish drainage.[19] Before treatment, the patient's medical history, dental history, and systemic condition are reviewed and evaluated to assist in the diagnosis and to determine the need for systemic antibiotics[3] (Boxes 42-4 and 42-5).

Drainage through Periodontal Pocket. The peripheral area around the abscess is anesthetized with sufficient topical and local anesthetic to ensure comfort. The pocket wall is gently retracted with a periodontal probe or curette in an attempt to initiate

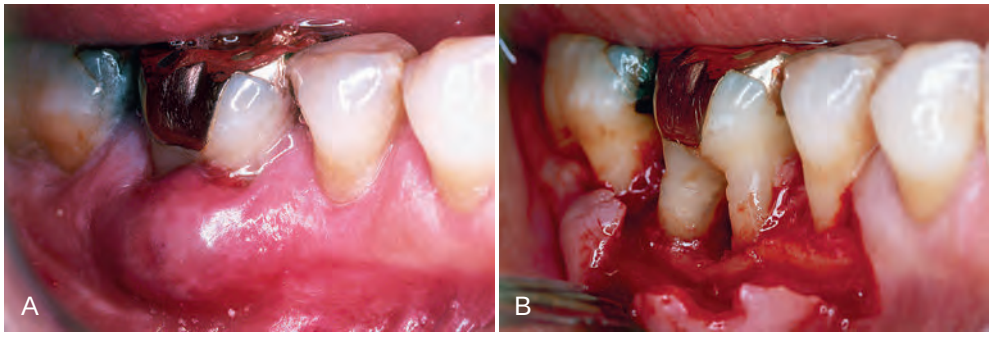

Figure 42-1 **A,** Deep furcation invasions are a common location for the periodontal abscess. **B,** Furcation anatomy often prevents the definitive removal of calculus and microbial plaque.

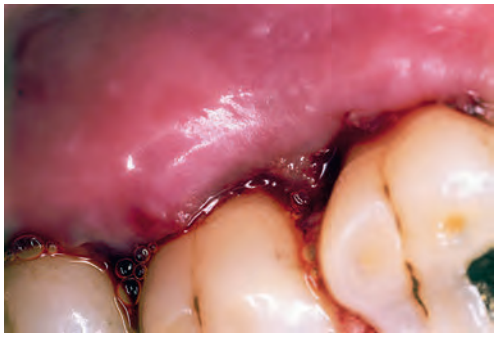

Figure 42-2 Postprophylaxis periodontal abscess resulting from partial healing of a periodontal pocket over residual calculus.

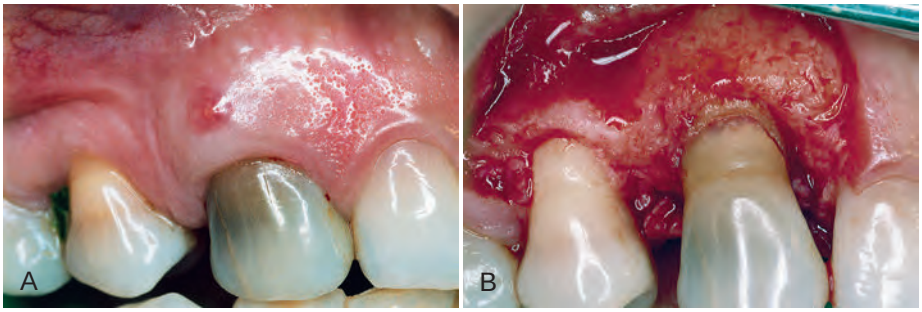

Figure 42-3 **A,** Fistula is observed in attached gingiva of maxillary right canine. **B,** Elevated flap shows the cause to be a root fracture.

Figure 42-4 Localized periodontal abscess of mandibular right canine of male adult with poorly controlled type 2 diabetes mellitus. For some patients, periodontal abscess formation may be the first sign of the disease.

Figure 42-5 Plaque-associated gingival abscess of mandibular right canine.

Figure 42-6 Patient presenting with acute abscess complained of dull pain and a sensation of tooth elevation in the socket. Signs of tissue distention and exudation are evident.

drainage through the pocket entrance (see Figure 42-8). Gentle digital pressure and irrigation may be used to express exudates and clear the pocket (Figure 42-9). If the lesion is small and access uncomplicated, debridement in the form of scaling and root planing may be undertaken.

If the lesion is large and drainage cannot be established, root debridement by scaling and root planing or surgical access should be delayed until the major clinical signs have abated.[18] In these patients, use of adjunctive systemic antibiotics[13-16] with short-term high-dose regimens is recommended[20] (see Box 42-5). Antibiotic therapy alone without subsequent drainage and subgingival scaling is contraindicated.[14]

Drainage through External Incision. The abscess is dried and isolated with gauze sponges. Topical anesthetic is applied, followed by local anesthetic injected peripheral to the lesion. A vertical incision through the most fluctuant center of the abscess is made with a No. 15 surgical blade. The tissue lateral to the incision can be separated with a curette or periosteal elevator. Fluctuant matter is expressed, and the wound edges approximated under light digital pressure with a moist gauze pad.

BOX 42-1 Signs and Symptoms of Periodontal Abscess

Acute Abscess
- Mild to severe discomfort
- Localized red, ovoid swelling
- Periodontal pocket
- Mobility
- Tooth elevation in socket
- Tenderness to percussion or biting
- Exudation
- Elevated temperature*
- Regional lymphadenopathy*

Chronic Abscess
- No pain or dull pain
- Localized inflammatory lesion
- Slight tooth elevation
- Intermittent exudation
- Fistulous tract often associated with a deep pocket
- Usually without systemic involvement

*May indicate the need for systemic antibiotics.
Data from Dahlen G: *Periodontol 2000* 28:206, 2002; Meng HX: *Ann Periodontol* 4:79, 1999; and Sanz M, Herrera D, van Winkelhoff AJ: The periodontal abscess. In Lindhe, J: *Clinical periodontology*, Copenhagen, 2000, Munksgaard

BOX 42-2 Differential Diagnosis of Periodontal and Pulpal Abscess

Periodontal Abscess
- Associated with preexisting periodontal pocket.
- Radiographs show periodontal angular bone loss and furcation radiolucency.
- Tests show vital pulp.
- Swelling usually includes gingival tissue, with occasional fistula.
- Pain usually dull and localized.
- Sensitivity to percussion may or may not be present.

Pulpal Abscess
- Offending tooth may have large restoration.
- May have no periodontal pocket, or if present, probes as a narrow defect.
- Tests show nonvital pulp.
- Swelling often localized to apex, with a fistulous tract.
- Pain often severe and difficult to localize.
- Sensitivity to percussion.

Modified from Corbet EF: *Periodontol 2000* 34:204, 2004.

Figure 42-7 **A,** Maxillary right first molar with fistula on the attached gingiva. **B,** Using local anesthesia, periodontal probe is introduced through the fistula and angled toward the root end. **C,** Surgical flap elevation demonstrates failed endodontic therapy and tooth fracture as causing the fistula.

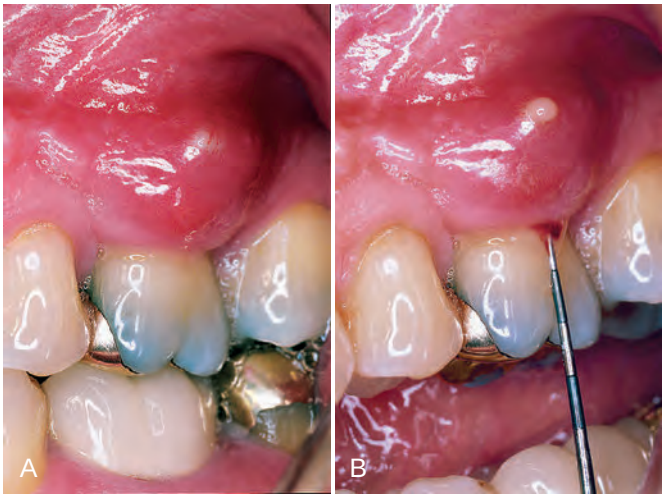

Figure 42-8 **A,** Periodontal abscess of maxillary left first molar. **B,** Periodontal probe is used to gently retract the pocket wall.

Figure 42-9 Gentle digital pressure may be sufficient to express purulent discharge.

BOX 42-3 Treatment Options for Periodontal Abscess

1. Drainage through pocket retraction or incision
2. Scaling and root planing
3. Periodontal surgery
4. Systemic antibiotics
5. Tooth removal

Modified from Sanz M, Herrera D, van Winkelhoff AJ: The periodontal abscess. In Lindhe, J: *Clinical periodontology,* Copenhagen, 2000, Munksgaard.

BOX 42-4 Indications for Antibiotic Therapy in Patients with Acute Abscess

1. Cellulitis (nonlocalized, spreading infection)
2. Deep, inaccessible pocket
3. Fever
4. Regional lymphadenopathy
5. Immunocompromised patient

BOX 42-5 Antibiotic Options for Periodontal Infections

Antibiotic of Choice

Amoxicillin, 500 mg

- 1.0-g loading dose, then 500 mg 3 times a day for 3 days.
- Reevaluation after 3 days to determine need for continued or adjusted antibiotic therapy.

Penicillin Allergy

Clindamycin

- 600-mg loading dose, then 300 mg 4 times a day for 3 days.

Azithromycin (or clarithromycin).*

- 1.0-g loading dose, then 500 mg 4 times a day for 3 days.

*To be used with caution in patients with high baseline cardiovascular risk.
Data from American Academy of Periodontology: *J Periodontol* 67:1553, 2004.

In abscesses presenting with severe swelling and inflammation, aggressive mechanical instrumentation should be delayed in favor of antibiotic therapy so as to avoid damage to healthy contiguous periodontal tissues.[24]

Once bleeding and suppuration have ceased, the patient may be dismissed. For those who do not need systemic antibiotics, post-treatment instructions include frequent rinsing with warm salt water (1 tbsp/8-oz glass) and periodic application of chlorhexidine gluconate either by rinsing or locally with a cotton-tipped applicator. Reduced exertion and increased fluid intake are often recommended for patients showing systemic involvement. Analgesics may be prescribed for comfort. By the following day, the signs and symptoms have usually subsided. If not, the patient is instructed to continue the previously recommended regimen for an additional 24 hours. This often results in satisfactory healing, and the lesion can be treated as a chronic abscess.[25]

Chronic Abscess

As with a periodontal pocket, the chronic abscess is usually treated with scaling and root planing or surgical therapy. Surgical treatment is suggested when deep vertical or furcation defects are encountered that are beyond the therapeutic capabilities of nonsurgical instrumentation (Figure 42-10). The patient should be advised of the possible postoperative sequelae usually associated with periodontal nonsurgical and surgical procedures. As with the acute abscess, antibiotic therapy may be indicated.[25]

Gingival Abscess

Treatment of the gingival abscess is aimed at reversal of the acute phase and when applicable, immediate removal of the cause. To ensure procedural comfort, topical or local anesthesia by infiltration is administered. When possible, scaling and root planing are completed to establish drainage and remove microbial deposits. In more acute situations the fluctuant area is incised with a No. 15 scalpel blade, and exudate may be expressed by gentle digital pressure. Any foreign material (e.g., dental floss, impression material) is removed. The area is irrigated with warm water and covered with moist gauze under light pressure.

Once bleeding has stopped, the patient is dismissed with instructions to rinse with warm salt water every 2 hours for the remainder of the day. After 24 hours the area is reassessed, and if resolution is sufficient, scaling not previously completed is undertaken. If the residual lesion is large or poorly accessible, surgical access may be required.

Pericoronal Abscess

As with the other abscesses of the periodontium, the treatment of the pericoronal abscess is aimed at management of the acute phase, followed by resolution of the chronic condition. The acute pericoronal abscess is properly anesthetized for comfort, and drainage

Figure 42-10 **A,** Chronic periodontal abscess of maxillary right canine. **B,** Using local anesthesia, periodontal probe is inserted to determine severity of the lesion. **C,** Using mesial and distal vertical incisions, a full-thickness flap is elevated, exposing severe bone dehiscence, a subgingival restoration, and root calculus. **D,** Root surface has been planed free of calculus and the restoration smoothed. **E,** Full-thickness flap has been replaced to its original position and sutured with absorbable sutures. **F,** At 3 months, gingival tissues are pink, firm, and well adapted to the tooth, with minimal periodontal probing depth.

is established by gently lifting the soft tissue operculum with a periodontal probe or curette. If the underlying debris is easily accessible, it may be removed, followed by gentle irrigation with sterile saline. If there is regional swelling, lymphadenopathy, or systemic signs, systemic antibiotics may be prescribed.

The patient is dismissed with instructions to rinse with warm salt water every 2 hours, and the area is reassessed after 24 hours. If discomfort was one of the original complaints, appropriate analgesics should be employed. Once the acute phase has been controlled, the partially erupted tooth may be definitively treated with either surgical excision of the overlying tissue or removal of the offending tooth.

Suggested Readings

American Academy of Periodontology: Parameter on acute periodontal diseases. *J Periodontol* 71(5 Suppl):863–866, 2000.

Corbet EF: Diagnosis of acute periodontal lesions. *Periodontol 2000* 34:204, 2004.

Dahlen G: Microbiology and treatment of dental abscesses and periodontal-endodontic lesions. *Periodontol 2000* 28:206, 2002.

Herrera D, Roldan S, Gonzalez I, et al: The periodontal abscess. I. Clinical and microbiology findings. *J Clin Periodontol* 27:287, 2000.

Herrera D, Roldan S, Sanz M: The periodontal abscess: a review. *J Clin Periodontol* 27:377, 2000.

Lang N, Soskolne WA, Greenstein G, et al: Consensus report: abscesses of the periodontium. *Ann Periodontol* 4(1):83, 1999.

Meng HX: Periodontal abscess. *Ann Periodontol* 4:79, 1999.

Minsk L: Diagnosis and treatment of acute periodontal conditions. *Compend Contin Educ Dent* 27(1):8–11, 2006.

Sanz M, Herrera D, van Winkelhoff AJ: The periodontal abscess. In Lindhe J: *Clinical periodontology*, Copenhagen, 2000, Munksgaard.

References

References for this chapter are found on the companion website www.expertconsult.com.

References

1. Abrams H, Kopczyk R: Gingival sequela from a retained piece of dental floss. *J Am Dent Assoc* 106:57, 1983.
2. Abrams H, Cunningham C, Lee S: Periodontal changes following coronal/root perforation and formocresol pulpotomy. *J Endod* 18:399, 1992.
3. American Academy of Periodontology: Position paper: systemic antibiotics in periodontics. *J Periodontol* 67:1553, 2004.
4. Ammons WF, Jr, Harrington GW: The periodontic-endodontic continuum. In Newman MG, Takei HH, Carranza FA, editors: *Carranza's clinical periodontology*, ed 9, Philadelphia, 2002, Saunders.
5. Becker W, Berg L, Becker B: The long-term evaluation of periodontal treatment and maintenance in 95 patients. *Int J Periodont Restor Dent* 2:55, 1984.
6. Carranza FA, Camargo PM: The periodontal pocket. In Newman MG, Takei HH, Carranza FA, editors: *Carranza's clinical periodontology*, ed 9, Philadelphia, 2002, Saunders.
7. Chace R, Low SB: Survival characteristics of periodontally involved teeth: a 40-year study. *J Periodontol* 64:701, 1993.
8. Corbet EF: Diagnosis of acute periodontal lesions. *Periodontol 2000* 34:204, 2004.
9. Dahlen G: Microbiology and treatment of dental abscesses and periodontal-endodontic lesions. *Periodontol 2000* 28:206, 2002.
10. Dello Russo NM: The post-prophylaxis periodontal abscess: etiology and treatment. *Int J Periodont Restor Dent* 5:29, 1985.
11. Epstein S, Scopp IW: Antibiotics and the intraoral abscess. *J Periodontol* 48:236, 1977.
12. Garrett S, Polson A, Stoller N, et al: Comparison of a bioabsorbable GTR barrier to a non-absorbable barrier in treating human class II furcation defects: a multi-center parallel design randomized single-blind study. *J Periodontol* 668:667, 1997.
13. Genco RJ: Using antimicrobials agents to manage periodontal diseases. *J Am Dent Assoc* 122:31, 1991.
14. Hafstrom CA, Wikstrom MB, Renvert SN, et al: Effect of treatment on some periodontopathogens and their antibody levels in periodontal abscesses. *J Periodontol* 65:1022, 1994.
15. Herrera D, Roldan S, Sanz M: The periodontal abscess: a review. *J Clin Periodontol* 27:377, 2000.
16. Herrera D, Roldan S, Gonzalez I, et al: The periodontal abscess. I. Clinical and microbiology findings. *J Clin Periodontol* 27:287, 2000.
17. Kaldahl WB, Kalwarf KL, Patil KD, et al: Long-term evaluation of periodontal therapy. I. Response to 4 therapeutic modalities. *J Periodontol* 67:93, 1996.
18. Lewis MA, MacFarlane TW: Short-course high dosage amoxicillin in the treatment of acute dento-alveolar abscess. *Br Dent J* 161:299, 1986.
19. Manson JD: Periodontics, ed 3, Philadelphia, 1975, Lea & Febiger.
20. Martin MV, Longman LP, Hill JB, et al: Acute dentoalveolar infections: an investigation of the duration of antibiotic therapy. *Br Dent J* 183:135, 1997.
21. McLeod DE, Lainson PA, Spivey JD: Tooth loss due to periodontal abscess: a retrospective study. *J Periodontol* 68:963, 1997.
22. Meng HX: Periodontal abscess. *Ann Periodontol* 4:79, 1999.
23. O'Leary TJ, Standish SM, Bloomer RS: Severe periodontal destruction following impression procedures. *J Periodontol* 44:43, 1973.
24. Sanz M, Herrera D, van Winkelhoff AJ: The periodontal abscess. In Lindhe J: *Clinical periodontology*, Copenhagen, 2000, Munksgaard.
25. Takei HH: Treatment of the periodontal abscess. In Newman MG, Takei HH, Carranza FA, editors: *Carranza's clinical periodontology*, ed 9, Philadelphia, 2002, Saunders.
26. Topoll H, Lange D, Muller R: Multiple periodontal abscesses after systemic antibiotic therapy. *J Clin Periodontol* 17:268, 1990.

CHAPTER 43

Diagnosis and Management of Endodontic-Periodontic Lesions

Kenneth C. Trabert and Mo K. Kang

CHAPTER OUTLINE

Anatomic Considerations of the Pulpal and Periodontal Continuum
Factors Initiating Pulpal and Apical Diseases
Classification of Pulpal and Apical Diseases
Biologic Effects of Pulpal Infection on Periodontal Tissues
Biologic Effects of Periodontal Infection on the Dental Pulp
Differential Diagnosis of Pulpal and Periodontal Infection
Treatment Considerations of Endodontic-Periodontic Lesions
Effect on the Periodontium of Endodontic Procedural Complications and Dental Anomalies
Conclusion

For online-only content on perforations, tooth fractures (video 43-1), sodium hypochlorite accident, resorptive defects, dental anomalies, and ultrasonic devices in the section on the effect on the periodontium of endodontic procedural complications and dental anomalies as well as expanded discussions of the factors initiating pulpal and apical diseases and classification of pulpal and periradicular apical diseases, go to the companion website at www.expertconsult.com. Some figures may be out of numeric order in this printed chapter. Editors Note: An animation (slide show) has been added as a supplement to the chapter by the Editors. This was produced by My Dental Hub as a patient education tool and covers the basic elements in a conceptual manner. It is not intended to be a procedural guide for dental professionals.

Anatomic Considerations of the Pulpal and Periodontal Continuum

Conversations occur daily between periodontists, endodontists, and general practitioners to try and ascertain whether a lesion surrounding one or more teeth is of periodontal or endodontic origin or is possibly is a true combined lesion that impacts both compartments and will require endodontic as well as subsequent periodontal treatment. The purpose of this chapter will be to discuss the proper diagnosis of these various conditions and to offer treatment modalities to ensure the retention of teeth that might otherwise be extracted.

Persistent infection in the pulp tissue leads to secondary infection and breakdown of tissues in the periodontium. Conversely, severe periodontal disease may initiate or exacerbate inflammatory changes in the pulp tissue. This mutuality of infection between pulp and periodontium is mediated through physical routes, allowing for communication between the two structures. The main and obvious route of communication is the apical foramina. Advanced pulpitis will lead to pulp necrosis, which often is accompanied by inflammatory bone resorption at the root apex, as found in cases of apical periodontitis or an apical abscess (Figure 43-1). This is also known as *retrograde periodontitis* because it represents the periodontal tissue breakdown from an apical to a cervical direction and is the opposite of *orthograde periodontitis* that results from a sulcular infection. This is typically identified as a periapical radiolucency (PARL) (Figure 43-2). Retrograde periodontitis is the most common example of pulpal diseases leading to secondary periodontal breakdown. The presence of patent apical foramina can also lead to pulpal inflammatory changes secondary to a severe periodontitis in cases where the periodontal defect reaches the apical foramina.

Alternatively, lateral or accessory canals may also be the route of periodontal and pulpal communications. Prevalence of accessory root canals in various human teeth and their contribution to the complexity of the root canal system have been well established. Accessory canals are found along the length of the root canals, albeit to varying frequencies depending on their location. Earlier studies, using the "clearing technique" for transparent root canal visualization, showed that 59.5% of maxillary second premolars possess lateral canals; 78.2% of those are located in the apical regions of the root canals.[156] Notably, accessory canals were also found in both midroot and cervical regions, albeit with reduced frequencies at 16.2% and 4.0%, respectively. A subsequent study showed that 28.4% of permanent molars exhibit patent accessory canals in furcation regions,[51] suggesting that these accessory canals allow a pulpal and periodontal communication to exist. Root canal therapies fail frequently in maxillary molars because of unidentified second mesial canals. These canals are found in a surprisingly high percentage (80.8%) of teeth.[67] Clearly, accessory canals can lead to asymptomatic apical periodontitis resulting from chronic pulpal diseases. This can be readily detected in periapical radiographs (Figure 43-3) and the periodontal lesions usually heal after the successful completion of endodontic therapy. Questions also arise as to whether pulpal disease can develop from periodontal infections through accessory root canals. Kirkham[76] reported that out of 100 permanent human teeth extracted as the result of

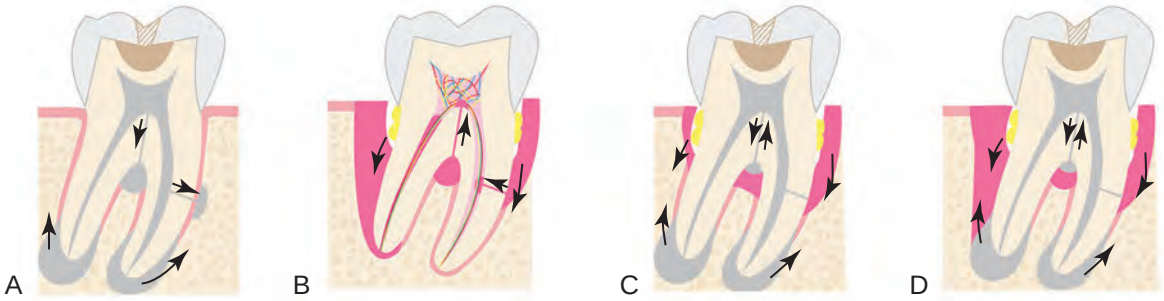

Figure 43-1 Classification of endodontic-periodontic lesions. **A,** Primary pulpal infection can lead to chronic periradicular periodontitis by which a periapical radiolucency (PARL) can develop and migrate cervically. Mandibular molars can also have accessory canals in lateral orientation or in the furcation area. These accessory canals can allow migration of the primary pulpal infection and cause secondary breakdown of the periodontium at their respected loci. **B,** Primary periodontal infection can lead to extensive breakdown of alveolar crest bone that migrates from the cervical area to the apex. In these lesions, one would find generalized bone loss around a single tooth or often might involve multiple adjacent teeth. Because of the pulpal-periodontal continuum through main root canal foramina or through accessory canals, extensive periodontal infection can cause irritation in the pulp tissues. **C,** Both primary pulpal and primary periodontal infection can occur simultaneously in an "independent" endodontic-periodontic lesion, exhibiting the characteristics of both. **D,** Primary pulpal and primary periodontal infections can occur extensively in this "combined" endodontic-periodontic lesion.

Figure 43-2 Retrograde periodontitis. **A,** Large periapical lesion extending around the periapex of tooth #31. No visible fractures were detected on the mesial or distal marginal ridges. The tooth tested nonvital. A sinus tract was visible on the buccal gingiva. **B,** Endodontic therapy was completed in two visits, and the canals were obturated. **C,** Healing of the periradicular bone is evident at 6 months, and a crown providing complete coverage has been placed. *(Courtesy Dr. Thomas Rauth.)*

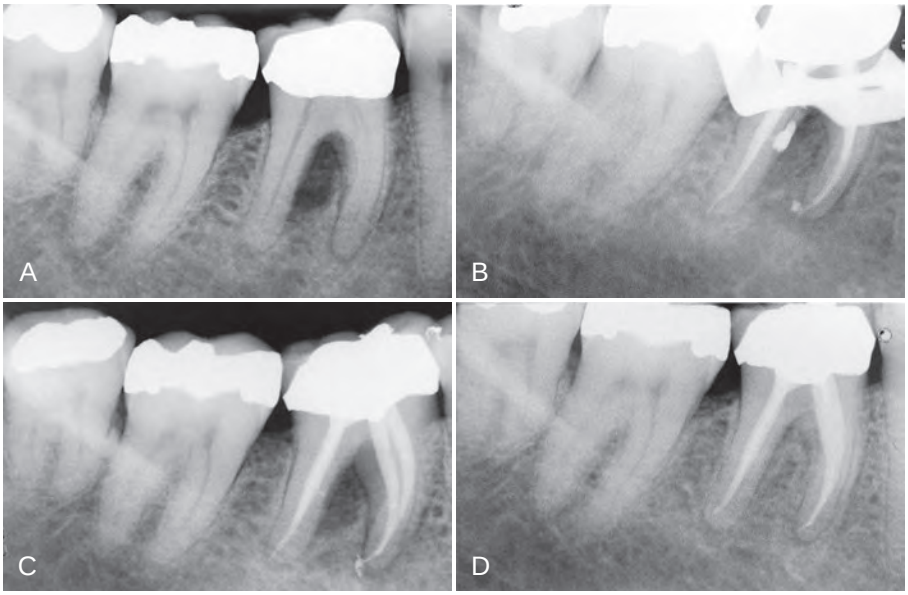

Figure 43-3 Lateral canal-led periodontal defect from a primary endodontic infection. **A,** Bone loss is present in the furcation with sinus tract present on the buccal mucosa. Tooth #30 tested nonvital. **B,** During condensation, a large amount of sealer was expressed through a large lateral canal in the distal root. **C,** Sealer was removed after obturation by curettage of the furcation and irrigation with anesthetic solution through the sinus tract. **D,** Healing at 12 months demonstrates complete repair of periradicular bone. *(Courtesy Dr. Thomas Rauth.)*

severe periodontal disease, only 2 teeth possessed accessory canals within the periodontal pockets. Thus, the likelihood that primary periodontal infections will reach the dental pulp through accessory canals is rare.

The third route of communication between the periodontium and the pulp is through the dentinal tubules. Dentinal tubules maintain a tapered structure along the length from the pulpodentinal complex (PDC) to the dentinoenamel junction (DEJ) with the diameter of 2.5 µm at PDC and 0.9 µm at the DEJ.[149] It is therefore conceivable that dentin is a permeable structure, and that the permeability changes at different locations along the root surface according to the size and density of the dentinal tubules. Bacterial colonization in the tubules from infected root canals has been well documented.[132] Also, bacterial invasion into dentinal tubules from the periodontal pocket has been demonstrated,[50] suggesting that dentinal tubules may allow pulpal irritation from chronic periodontal infections.

Dentin permeability through dentinal tubules is a clinically important issue. The permeability may be measured through hydraulic conductance described earlier.[121] Subsequently, investigators have studied the effects of various agents and stresses on dentin permeability. Root planing, as part of routine periodontal therapy, for example, is shown to decrease dentin permeability and result in the formation of a smear layer that is acid-labile.[38] However, dentin permeability may increase on removal of the smear layer, resulting in tubular penetration of oral pathogens and subsequent pulpal irritation. Further study is necessary to delineate the role of dentinal tubules in causing a secondary infection in either the pulpal or periodontal tissues. Clinicians need to be cognizant of the fact that patent dentinal tubules can provide effective irritant conduits between these two otherwise distinct tissues.

In addition to the above routes of anatomical communication between pulpal and periodontal tissues, there are instances in which communication is established between the pulp and periodontium by iatrogenic defects such as vertical root fractures and tooth perforations. Both of these situations represent nonanatomic communication between the pulp and periodontium and result in the spread of infection from one compartment to the other.

Factors Initiating Pulpal and Apical Diseases

Pulpal and apical diseases are initiated by numerous external factors that may include microorganisms, trauma, excessive heat, restorative procedures, restorative agents, and malocclusion. These insults lead to inflammatory changes in the pulp, starting from a reversible or irreversible pulpitis and ultimately progressing to pulpal necrosis and subsequent breakdown of the periodontium. Dental caries is a prominent cause of pulpal disease, and bacterial infection is the primary form of microbial insult to the pulp. A systematic review of literature from 1966 to 2000 showed causative effects of mutans streptococci and the lactobacilli for human dental caries, whereas others like sanguinis streptococci, *Streptococcus salivarius*, or enterococci could not be associated with the disease.[145] Recent understanding in the caries process has adopted the importance of the homeostatic balance in biofilm, which describes the microbial ecosystem on tooth surfaces, rather than the virulence of individual bacterial species.[141] Regardless, pulpal infection is polymicrobial and often starts from incipient caries causing localized pulpal inflammation or pulpitis.

Classification of Pulpal and Apical Diseases

The diagnosis of endodontic lesions that may often have a periodontal component can be confusing. The diagnostic terminology used in various dental schools and textbooks further compounds the confusion for students and practitioners alike. In an attempt to simplify and unify a standardized diagnostic terminology, the American Association of Endodontists established a new endodontic diagnosis terminology in 2009. The reader is referred to this revised terminology published in 2009 in volume 35 of the *Journal of Endodontics* (page 1634) for a more complete discussion of this subject. Throughout this chapter we will be referring to this new terminology, which is also summarized in Tables 43-1 and 43-2.

To make a proper endodontic diagnosis, the clinician must evaluate the symptoms of the patient; the radiographic and clinical findings; and the presence, absence, and location of any swelling or drainage. Given all of these variables, it is easy to understand why a lack of clarity exists and mistakes are made as to whether the lesion is primarily endodontic, periodontal, or a true combined lesion.

Biologic Effects of Pulpal Infection on Periodontal Tissues

The effects of the pulpal disease on the surrounding periodontal tissues are widely accepted by both clinicians and researchers and has been studied for more than 50 years. Early inflammatory changes in the pulp exert very little effect on the periodontium. Even a pulp that is significantly inflamed may have little or no

TABLE 43-1 Classification of Pulpal Diseases*

Pulpal State	Symptom	Vitality	Response to Cold
Normal pulp	Asymptomatic	Vital	Within normal limits
Reversible pulpitis	Sensitive to pressure or temperature†	Vital	Hypersensitive to cold
Symptomatic Irreversible pulpitis‡	Spontaneous, throbbing pain	Vital	Hypersensitive to cold and lingering response
Asymptomatic irreversible pulpitis§	None	Vital	Within normal limits
Pulp necrosis¶	Asymptomatic¶	Nonvital	No response
Previously treated	Variable	Nonvital	No Response
Previously initiated therapy	Variable	Variable	Variable

*Different pulpal conditions cannot be discerned by periapical radiographs. Symptoms and responses to cold explained herein are the general findings, but exceptions can occur.

†Patients' response to pressure may be due to hyperocclusion in reversible pulpitis cases. In the absence of such factors, patients' complaints mainly revolve around thermal sensitivity.

‡Symptomatic irreversible pulpitis may be symptomatic and painful as described or may be asymptomatic and nonpainful.

§Asymptomatic irreversible pulpitis is based on presence of pulpal inflammation, e.g., extensive caries, hyperemia, or traumatic injuries, in the absence of patients' subjective symptoms.

¶Necrotic pulp may cause acute exacerbation of symptom, including spontaneous throbbing pain. However, such sensitivity results from periradicular inflammation.

This diagnostic terminology is based on the recommendations of the AAE Consensus Conference, as shown in the *Journal of Endodontics*, 35:1634, 2009.

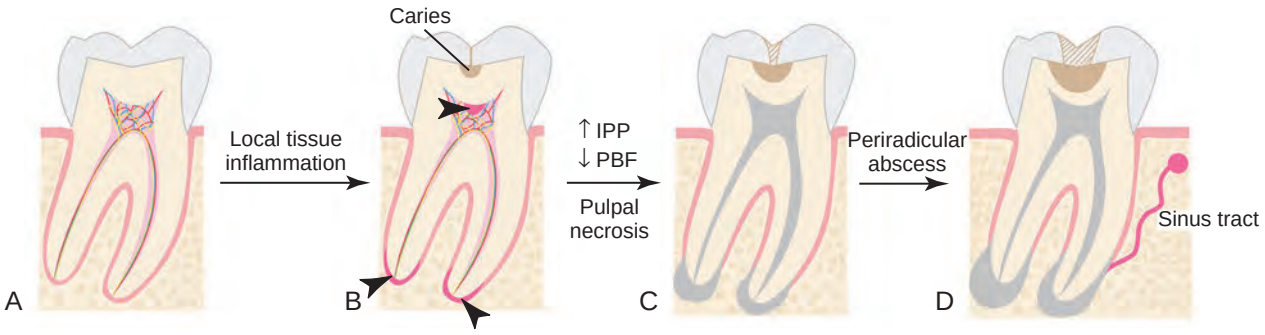

Figure 43-4 Progression of the pulpal and periradicular pathosis. **A,** Normal tooth without any pulpal pathosis is richly vascularized and innervated. **B,** With microbial challenges, such as caries, local tissue inflammation can occur in the pulp adjacent to the site of carious lesions as well as in the apical regions *(arrowheads).* **C,** Pulpal inflammation can lead to reduction in pulpal blood flow *(PBF)* caused by an increase in intrapulpal pressure *(IPP),* causing pulpal necrosis (shown in gray). **D,** Pulpal necrosis, if left untreated, can lead to the chronic inflammation of periradicular tissues and abscess formation, leading to a draining sinus tract.

Local invasion of the cariogenic bacteria or a shift in the bacterial content of biofilm can lead to inflammatory changes in the dental pulp. This frequently happens in the absence of caries extension into the pulp chamber. Bacterial by-products relevant to pulpitis include lactic acid, ammonia, urea, lipopolysaccharide (LPS), and lipoteichoic acid (LTA). It is notable that the dental pulp is capable of managing numerous microbial insults because of its extensive intrapulpal lymphatic system. However, an overwhelming pulpal inflammatory response may be induced through various mechanisms and numerous microbial challenges. LPS and LTA bind toll-like receptors (TLRs). These are present on the surface of some immune cells in the pulp, and induce the release of inflammatory mediators such as prostaglandins, cytokines, and chemokines.[64] In particular, tumor necrosis factor alpha (TNF-α), interleukin-1 (IL-1), IL-8, IL-12, and chemokines CCL2 and CXCL2 are well described for their role in pulpitis.[52] IL-1 is known to be released from macrophages after stimulation with LPS and responsible for bone resorption leading to apical periodontitis.[59] During acute pulpitis, the inflammatory mediators trigger vasodilation, transient increase of pulpal blood flow (PBF), inflammatory cell infiltration, increased intrapulpal pressure, and finally ischemic necrosis of the pulp (Figure 43-4).

In an acute apical abscess, anaerobic bacteria are predominant over aerobic strains and anaerobes, and microaerophiles were predominant in 82% of the cases studied.[72] The most prevalent isolated bacteria are *Fusobacterium nucleatum, Parvimonas micra,* and *Porphyromonas endodontalis.*[133] Depending on the virulence of the organisms and host resistance, a lesion that has been chronic may exacerbate and become an acute apical abscess. The presence of spirochetes is also well documented in apical, as well as periodontal abscesses and has been studied by various identification techniques.[27] Spirochetes most often isolated in root canal infections are *Treponema denticola* and *Treponema maltophilium.*[66,123] When comparing chronic and acute apical abscesses, Baumgartner found that there was a significantly higher incidence of spirochetes in acute abscesses or cellulitis than in asymptomatic infected root canals. *Treponema socranskii* was the most frequently encountered species.[10]

Thermomechanical irritants can induce altered pulpal circulation and pulp tissue damage. Earlier studies demonstrated that thermal changes caused by dental procedures, such as tooth preparation, led to marked diminution of PBF and plasma extravasation, resulting in an inflammatory response.[74,120] Extreme heat caused by dry tooth preparation triggers vascular stasis and hemorrhage in the subodontoblastic vascular plexus.[105] It was noted that even a small increase in pulpal temperature (5° to 6°C [41° to 42.8°)F] is capable of inducing necrotic changes in the pulp.[171] Pulpal necrosis will eventually lead to apical periodontitis. Likewise, chemical irritants impose measurable changes in the pulp status. A recent study showed the cytotoxicity of dental resin material (2-hydroxyethyl methacrylate [HEMA]) on pulp stromal cells through induction of apoptotic cell death.[116] Etching the dentin surface with high phosphoric acid content yields deleterious effects on dental pulp.[129] Also, bonding resins used as pulp capping materials led to acute pulpitis and varying degrees of necrosis in human teeth.[2] Root canal overfills with gutta-percha and sealers invariably cause severe inflammatory reactions in the apical tissues, even though patients may be completely asymptomatic.[122] Thus dental materials often contain chemical irritants that affect both the pulpal and periodontal tissues, and one must be cognizant of the potential iatrogenic endodontic pathosis associated with their misuse.

The classification of diseases of the dental pulp depends on the extent of pulpal injury and its ability to repair. Many factors influence whether a tooth will be classified as normal, develop a reversible pulpitis, an irreversible pulpitis, or will become totally necrotic.

Previous studies have found little correlation between the histology of pulpal disease and the symptoms that the patient experienced before treatment.[84,154] More recently, a review of the diagnosis of pulpal pain by Bender found that 80% of patients who give a previous history of pain manifested histopathologic evidence of chronic partial pulpitis with partial necrosis. This symptomatology would indicate that either endodontic therapy or extraction would be the indicated treatment choices. Bender concluded that a clinician is able to determine the degree of pulp histopathosis by asking patients about their previous pain history and symptoms related to the involved tooth.[12] There still remains controversy, however, as to the degree of correlation between pulpal symptoms and the histopathology of the pulpal tissues and additional studies are needed to confirm the correlation between the two.

Apical diseases of endodontic origin are inflammatory processes occurring in the tissues that surround the tooth. They result from various infectious agents that originate in the root canal system and create a series of both inflammatory and immunologic responses. These agents exit through the apical foramen, lateral canals, or dentinal tubules.[76,117] It is an infectious process caused by a large number of microbial species unlike classic infectious diseases occurring elsewhere in the body that may consist of only one or two specific organisms. These species reside in ecologically balanced communities discussed previously and referred to as *biofilms.*[114] The different characteristics of pulpal and periodontal lesions are summarized in Table 43-3.[43]

TABLE 43-3 Different Characteristics of Pulpal and Periodontal Lesions*

	Primary Pulpal	Primary Periodontal	Independent Endodontic-Periodontic	Combined Endodontic-Periodontic
Patient symptom	Varies†	Mild discomfort	Varies†	Varies†
Coronal integrity	Compromised	Intact	Compromised	Compromised
Radiographic lesions	PARL	Crestal bone loss	Separate PARL and crestal lesions	Continuous bony lesions from alveolar crest to apex
Vitality	Nonvital	Vital	Nonvital	Nonvital
Periodontal probing	Narrow probing to apex‡	Generalized bone loss	Generalized bone loss	Generalized bone loss with narrow probing to apex

PARL, Periapical radiolucency.

*These are generalized summaries, and deviations can occur.

†Patient symptom for pulpal lesions may vary, depending on the type of pathosis. Chronic lesions can be completely asymptomatic, whereas acute symptoms without any radiographic lesions can trigger pain.

‡Primary pulpal lesions may not present with any periodontal defect. Narrow probing in pulpal lesions may indicate sinus tract through sulcus.

TABLE 43-2 Classification of Periradicular Diseases*

Periradicular State	Symptom	Pulpal Status	Percussion Response	Palpation Response	PARL	Sinus Tract
Normal periapex	None	Varies[†]	None	None	Not present	Not present
Symptomatic apical periodontitis[‡]	Painful	Inflamed	Painful	Varies[§]	Not present	Not present
Asymptomatic apical periodontitis	None	Nonvital	None	None	Present	Not present
Acute apical abscess[‡]	Painful	Inflamed	Painful	Painful	Varies[¶]	Not present
Chronic apical abscess	None	Nonvital	None	None	Present	Present
Condensing osteitis	None/pain	Inflamed	None	None	Radiopaque	Not present

PARL, Periapical radiolucency.

*Symptom and other descriptions of the individual periradicular pathosis are the general findings to which deviations can occur.

[†]Normal periapex can be associated with either normal, inflamed, or necrotic pulp.

[‡]Difference between acute periradicular periodontitis and acute periradicular abscess is that the former is confined to the involved tooth and the latter is more generalized and frequently presents with gross swelling in the affected periradicular tissues.

[§]Palpation in acute periradicular periodontitis may elicit tenderness after progression of the disease through the cortical plate.

[¶]PARL may be present in advanced acute periradicular abscess.

This diagnostic terminology is based on the recommendations of the AAE Consensus Conference, as shown in Journal of Endodontics, 35:1634, 2009.

effect on the surrounding periodontal tissues. It is thought that this initial pulpal inflammatory response is an attempt by the body to prevent the spread of infection to the apical tissues.

When the pulp becomes necrotic, however, it produces a significant inflammatory response involving extremely complex inflammatory and immune reactions. This response can traverse the apical foramen, the furcation, lateral canals, dentinal tubules, or areas of trapped necrotic tissue along the surface of the root that extend past the periodontal ligament (PDL) and into the surrounding apical tissues.[130] This initial inflammatory response of the pulp and subsequent necrosis that permeates through the numerous spaces of the canal system includes various bacterial strains, spirochetes, fungi, yeasts, and viruses.[107] The nature and extent of the periodontal destruction that follows depends on the virulence of the pathogens in the canal system, the duration of the disease, and the defense mechanisms of the host.[20]

In a classic study by Kakehashi et al,[68] the infected pulps of germ-free rats remained vital, whereas the infected pulps of normal rats that were left open to the oral environment developed pulpal necrosis with subsequent inflammation and formation of periapical lesions. Other investigators reported similar results using other animal models.[102]

Bacteria play a critical role in both endodontic and periodontal disease. Most bacteria grow in biofilms. The biofilm is composed of a 15% cellular component and a matrix material that comprises the remaining 85%. The formation of biofilm communities is under the control of complex chemical signals that both regulate and guide the formation of the slime-enclosed colonies and water channels.[24] Proteolytic bacteria predominate in early root canal infections and then change over time to a flora that contains a greater number of anerobes.[34,138]

Fungi and yeasts are also present in pulpal infections.[158] Studies by various investigators report that the incidence of cultured samples of fungi and yeasts from untreated root canals vary from 0.5% to 26%,[125] whereas the percentage in teeth that have been previously endodontically treated showed an even greater increase of these organisms. *Candida albicans* was the most prevalent isolated species.[159]

Current evidence suggests the important role that viruses may play in the pathogenesis of both periodontal and endodontic disease. Viruses have been isolated from both patients with periodontal disease and from the dental pulp.[22,45] A study by Contreras et al[23] demonstrated that gingival herpes viruses were associated with the increased growth of pathogenic periodontal bacteria. Even with the numerous studies that have been published, additional research is needed to demonstrate the causal relationship between viral infections in both periodontal and pulpal disease.[125]

Several nonliving pathogens have also been implicated in the inflammatory process as well. These include foreign bodies, epithelial rests, cholesterol crystals, Russell bodies, Rushton hyaline bodies, and Charcot-Leyden crystals. These nonliving pathogens have not only been implicated in the inflammatory process but may also be responsible for the lack of healing of apical lesions in teeth that have received appropriate endodontic treatment.[125] If the growth of the epithelial cells is stimulated by any of these living or nonliving pathogens, then the integrity of the periodontal tissues may be affected as well.

As the degree of pulpal inflammation becomes more extensive, a greater amount of destruction of the periodontal tissues ensues. Extension of the infection through the PDL space, tooth socket, and surrounding bone occurs and the patient begins to experience a localized or diffuse swelling that may result in cellulitis that invades the various facial spaces. Most often, however, the infection erupts through the labial, buccal, or lingual mucosa and results in a draining sinus tract. In cases where the path of least resistance for the infectious process is along the attached gingiva, the infection may dissect the PDL space and result in the formation of a deep but narrow periodontal pocket. This pocket usually extends to the main site of the infection when probed or traced with a gutta-percha point. Confusion often results among both general dentists and specialists as to whether the probing defect is the result of an endodontic or periodontal problem. In general, a narrow probing defect combined with a nonvital pulpal response indicates that the problem is usually of endodontic origin rather than periodontal.

In a few situations, adjacent teeth, their root surfaces, or furcation areas may also probe deeply. Care must be taken to thoroughly test all maxillary and mandibular teeth to correctly assess whether the problem is endodontic or periodontal. Once the correct diagnosis is made, only then should the treatment plan be formulated and discussed with the patient. When endodontic therapy is the main

cause of the swelling or breakdown of the periodontium, successful endodontic treatment usually results in healing of both the periapical and periodontal tissues. There are times, however, when trauma to the tooth, severe loss of adjacent periodontal tissues, continued tooth mobility, and occlusal trauma do not provide an environment that allows for apical healing to occur. In these cases, splinting is sometimes necessary to help stabilize the tooth and allow for potential repair of the apical tissues (Figure 43-5).

If an endodontic infection is left untreated, the progression of periodontal disease continues. Untreated and unresolved infections of endodontic origin can sustain the growth of various endodontic pathogens that may lead to increased pocket formation, and bone loss, calculus deposition, osteoclastic activity, and subsequent bone and tooth resorption. They may additionally impair wound healing and aggravate the development and progression of the periodontal disease state.[31]

The ability of the periodontium to regenerate and heal the lost attachment apparatus has been controversial. This is especially true when the teeth have been endodontically treated and the cement layer is no longer present.[71] A study by Sanders et al[127] demonstrated a 60% osseous regeneration rate in teeth that had not undergone endodontic treatment compared with a regeneration rate of only 33% in teeth that had endodontic treatment completed. One study compared the loss of attached gingival tissue and found that there was a 0.2 mm greater loss of attached tissue in the presence of teeth with a root canal infection and a periapical radiolucency.[62] These same investigators in a later study found a three times greater loss of marginal proximal bone using radiographic measurements in teeth with endodontic infections compared to those without endodontic infections or subsiding endodontic involvement.[61] Other investigators, however, have reported that all periodontal tissues have the ability to regenerate, regardless of whether the tooth is vital, partially treated and medicated, partially filled, or whether endodontic treatment has been successfully completed.[30] Additional research needs to be completed to better understand the relationship between the presence of endodontic infection and the increased loss of marginal bone and attached tissue in patients prone to periodontal disease.

It is clearly apparent that the endodontium and periodontium are closely related and that microorganisms and nonliving pathogens play an important role in both infections. Diseases in one area can lead to a secondary disease in the other. Diagnosis therefore is critically important and will dictate the appropriate course of treatment.

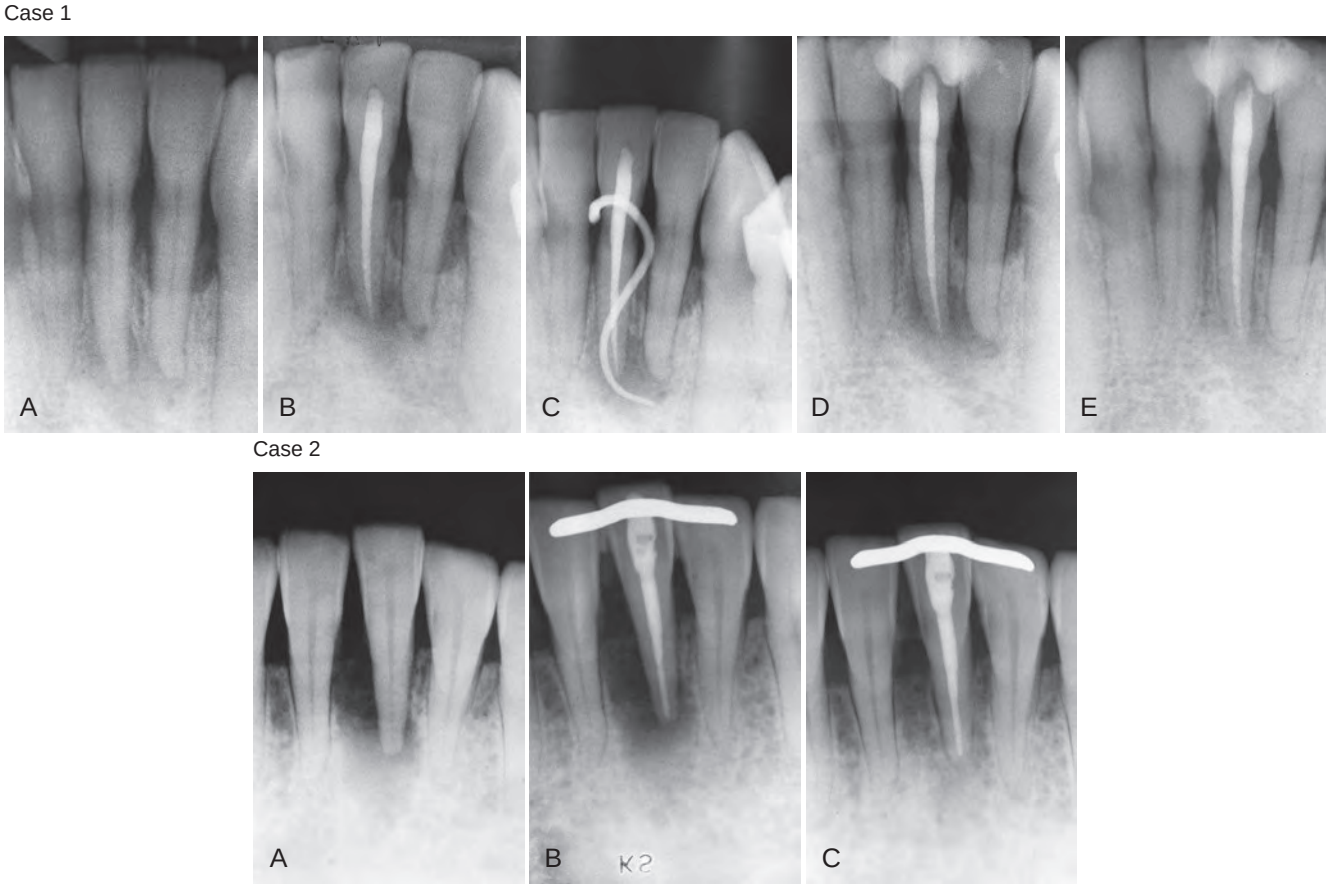

Figure 43-5 *Case 1.* **A,** Previous trauma of tooth #25 with complaints of pain to biting and chewing. The tooth tested nonvital and tooth #26 probed 6 mm on the lingual. **B,** Postoperative radiograph after obturation of the canal. Treatment was completed in two appointments with the interappointment placement of calcium hydroxide. **C,** 4 months later the tooth was mobile, and there was a sinus tract present. **D,** The occlusion was adjusted, and composite resin was bonded to the mesial and distal surfaces to stabilize both teeth #25 and #26. **E,** Healing of the periradicular lesion is apparent after 13 months and tooth #26 probed only 4 mm.
Case 2. **A,** Previously traumatized tooth #25. The tooth was Class III mobile and tested nonvital to both CO_2 and electric pulp testing. **B,** After obturation of the tooth with gutta-percha, a cast gold splint was bonded to the lingual surface to stabilize the tooth. **C,** Thirteen-month recall demonstrates repair of the periradicular bone and no mobility as a result of the placement of stabilization and splint. *(Case 1 courtesy Dr. Thomas Rauth.)*

Biologic Effects of Periodontal Infection on the Dental Pulp

The effects of periodontal disease on the dental pulp appear to be more controversial compared to the effects of pulpal disease on the periodontium.[11,131] Not all researchers agree about the effect of periodontal disease on the pulp. Even though inflammation and localized pulpal necrosis have been observed next to lateral canals exposed by periodontal disease,[126,130,131] other research studies have not confirmed a correlation between periodontal disease and changes within the pulp.[25,97,148] Langeland et al[84] indicated that when pathologic changes do occur in the pulp of a tooth as a result of advanced periodontal disease, the pulp does not usually undergo degenerative changes as long as the main canal has not been involved. If the vasculature of the pulp remains vital, no inflammatory reaction occurs and there are no symptoms of pulpal pathosis. An animal study conducted by Bergenholtz[14] found that 70% of animal specimens showed no pathologic changes even when 30% to 40% of the periodontal attachment was lost. The remainder showed only minor inflammatory changes, formation of reparative dentin, or resorptive defects where the root had been exposed.[14]

Researchers and clinicians, however, have observed the spread of advanced periodontal lesions that extend to the apical foramen and result in pulpal necrosis. This retrograde infection may proliferate through large accessory canals on the lateral surfaces of the tooth, canals positioned closer to the apical foramen, and the area where the main canal exits the tooth apex.[126] Kobayashi et al[81] compared the microflora from root canals and periodontal pockets of caries-free teeth that were necrotic and tested nonvital with an electric pulp tester. The aerobic/anaerobic ratio in the periodontal pocket was 0.23 compared to 0.0022 in the root canal. Although there were far fewer bacteria in the root canal, both areas demonstrated similar bacterial strains. The authors concluded that the similarity of strains in both areas suggested that the periodontal pocket may be the source of bacteria found in infections within the root canal system.[79]

Protection and preservation of the cementum and dentin surrounding the tooth also play important roles in preserving the health of the pulp and prevent the ingress of periodontal pathogens. The presence of an intact layer of cementum is important in protecting the pulp from dental plaque and other periodontal pathogens that migrate along the root surface during the development of advanced periodontal disease. Excessive root planing and curettage that remove the cementum and dentin from the root surface, encourages narrowing of the pulp canals. This process is thought to be reparative rather than inflammatory.[11,85] Several studies also suggest that periodontal disease is degenerative to pulpal tissues resulting in continued calcification, fibrosis, collagen resorption and inflammation.[84,94]

Dentin thickness also contributes to the protection of the pulp. Stanley[137] stated that if a 2-mm thickness of dentin remains between the pulp and irritating stimulus, there is little chance of pulpal damage.[137] Weine[164] summarized the precautions that can be taken during the course of periodontal therapy as (1) avoid using irritating chemicals on the root surface, (2) minimize the use of ultrasonic scalers when there is less than 2 mm of remaining dentin, and (3) allow minor pulpal irritations to subside before completing additional procedures.[164] When these precautions are not followed and the microvasculature of the pulp is damaged during periodontal procedures that involve deep curettage or periodontal surgical efforts to save the tooth, necrosis may result.[165]

The healing success and failure rates after endodontic microsurgery were studied in teeth that had lesions of only endodontic origin compared to those teeth that had lesions of a combined endodontic-periodontal origin. Lesions only of endodontic origin had a success outcome of 95.2%, whereas those teeth with combined lesions had a success outcome of only 77.5%. This suggests that bone and tissue healing are negatively affected after endodontic surgery with lesions of combined origin.[73]

It appears, therefore, that both the pulp and periodontal compartments influence the other. Periodontal disease, however, seems to have less of an influence on the pulpal tissues compared to the influence of pulpal disease on the periodontium. Clearly, advanced periodontal disease has some effect on the pulpal state (Figure 43-6). Unless the microvasculature of the pulp is compromised during aggressive periodontal procedures or excessively deep curettage severs the apical vessels, most periodontal interventions result in only a localized pulpal response and dentin hypersensitivity.[155]

Differential Diagnosis of Pulpal and Periodontal Infection

Acute infection of both the periodontium and the pulp must be differentiated from one another for clinicians to be able to establish a correct diagnosis with reasonable certainty and to initiate appropriate therapy. A thorough understanding of both disease processes and the correct interpretation of clinical and radiographic findings will aid the dentist in establishing a diagnosis that results in the rapid relief of the acute and painful condition.

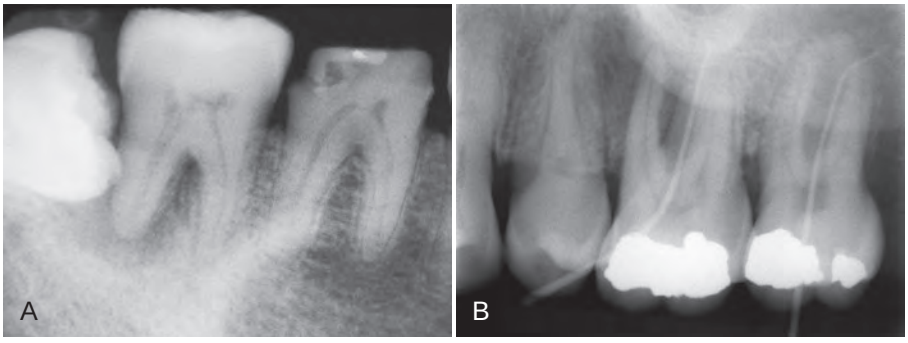

Figure 43-6 Primary periodontal defects causing periradicular bony lesions and pulpal irritation. **A,** Primary periodontal lesion is evident on the distal of tooth #31. The defect was probed to a depth of 7 mm, and the tooth tested vital to both thermal and electrical pulp testing. The defect was most likely the result of the impacted third molar and formation of a chronic periodontal abscess. **B,** Primary periodontal lesions both probing 12 mm into the furcation. Teeth #14 and #15 tested vital to thermal and electrical testing. The patient's chief complaint was discomfort to cold, thus exemplifying pulpitis secondary to the primary periodontal infection. *(**B,** Courtesy Dr. Gregory Kolber.)*

When the pulpal and periodontal abscesses are separate from one another, most clinicians feel that the diagnosis is usually easier. There are instances, however, when each primary disease may have similar clinical characteristics and make the diagnosis more difficult. In other situations, there may be no demarcation between the two areas of pathosis that both clinically and radiographically appear as one large and continuous lesion with extreme pain and swelling. When this occurs, the clinician must avoid classifying these continuous lesions as true combined lesions. One must rely on all available clinical testing methods to help clarify the correct clinical diagnosis prior to beginning treatment.[71]

Making the accurate differentiation between pulpal and periodontal lesions can be challenging. If the lesion originates from a pulpal infection and yet was treated by extensive periodontal therapy, it will not resolve. Conversely, performing endodontic therapy on a tooth that has an extensive periodontal defect and a vital pulp will result in the persistence of the periodontal infection. Thus, identifying the primary cause of infection is a critical determinant of treatment outcome. Perhaps the most important consideration when making such a distinction is to base the diagnosis on multiple findings. Those include patients' symptoms, coronal integrity, shape and size of the radiographic lesions, periodontal probing, and tooth vitality. It is possible that one or more of these findings suggest a pulpal or periodontal infection, whereas others point to the contrary. For example, a tooth may exhibit extensive failing restorations, recurring decay, and radiographic lesions, suggesting probable pulpal involvement. However, the tooth may test completely vital and lack any evidence of an irreversible pulpitis upon thermal testing. Under these circumstances, one would rule out the primary pulpal infection and examine the patient for periodontal involvement. Thus, making the distinction between pulpal or periodontal infection requires collectively dissecting the multiple findings and synthesizing the most probable diagnosis (Table 43-3).

Patients' Subjective Symptoms

Patients suffering from the acute phase of pulpal infection present with the symptoms that are generally absent in chronic periodontal infection. During the initial stage of pulpitis, patients may complain about sensitivity and pain exacerbated by certain stimuli, including temperature changes, pressure, and/or biting. If the symptoms result from reversible pulpitis, they will usually resolve spontaneously with time as the result of various mechanisms such as closure of dentinal tubules, clearance of microbial irritants and toxins, and reparative dentin formation. Persistent inflammation leads to a symptomatic irreversible pulpitis, which is often associated with sharp and spontaneous pain, although asymptomatic irreversible pulpitis may also occur as described previously. Acute pain to thermal stimuli may subside after several days as the pulp becomes necrotic, and the bacteria and their by-products migrate down the complex canal system. As the infection extends to and then past the apical foramen or a lateral root canal, the tooth becomes particularly sensitive to bite pressure and percussion. After several days, the necrotic tooth may develop an acute apical abscess that results in the elevation of the tooth from the dentoalveolar complex. Patients frequently report that the tooth feels "high" on occlusion. However, patients with irreversible pulpitis or a necrotic pulp may be asymptomatic. Thus, making the diagnosis of primary pulpal infection must be based on multiple objective findings, such as the patients' responses to percussion, palpation, biting, periodontal probing, and vitality testing as well as thorough evaluation of the patients' subjective symptoms.

In apical and periodontal abscesses, the extent of pain may vary. In general, an acute apical abscess causes extreme pain to pressure, bite, percussion and, at times, to palpation if the infection has penetrated the cortical bone. Periodontal abscesses are thought to cause less pain because there is little or no elevation of the periosteum. Edema and swelling are characteristics that may be shared by both conditions. The swelling and edema with a periodontal abscess is generally confined to the cervical portion of the tooth. An apical abscess is usually more sensitive to palpation around the tooth apex if the infection has penetrated through the bony cortical plate. Redness and a smooth appearance of the marginal gingival tissues is more common with abscesses of periodontal origin, whereas redness can be detected more apically if a pulpal abscess has started to swell and elevate surrounding tissues. Objective findings in periodontal abscesses include bleeding on probing, suppuration, increased pocket depth, increased tooth mobility, and occasionally, lymphadenopathy.[57] Abscesses of endodontic origin usually probe normally but may also display increased mobility, depending on the amount of bone loss. Patients may describe the tooth as feeling longer or higher than the adjacent teeth.[48]

Suppuration and drainage from periradicular and periodontal abscesses may also differ. Periodontal abscesses are associated with severe periodontal destruction. In a study investigating the incidence of anaerobes in periodontal abscesses, approximately 66% were determined to have a suppurative exudate that was evident during probing. In the same study, 100% of the patients had bleeding during probing, more than 75% had severe edema, redness and swelling, and 78% of the patients had some degree of mobility. Only a few of the patients suffered from lymphadenopathy. Over 60% of the patients had not received previous periodontal therapy and nearly 70% of the teeth were molars. The average measured pocket depth was 7.28 mm.[57] In another study that cultured facultative anaerobic bacteria, the teeth most affected were maxillary and mandibular anteriors and mandibular molars. One of the typical features in this study, as in the previous one, was the fact that most of the teeth had been previously untreated.[96] Other aspects of periodontal therapy that correlate highly with the development of acute periodontal abscess formation are (1) patients undergoing current periodontal treatment,[135] (2) incomplete removal of calculus,[29] (3) a history of a previous abscess at the same site,[99] and (4) the previous use of antibiotics for dental or nondental reasons.[56]

Drainage from apical abscesses usually comes from one of two sites. The most prevalent area of drainage is a sinus tract that develops when the area of swelling breaks through the mucoperiosteum and exits the mucosal tissue either near or at some distance from the site of the infection. Additionally, the path of least resistance may be along the PDL, and the infection may dissect the ligament along the surface of the root and exit the tooth at the height of the epithelial attachment. This results in a periodontal defect that probes along a narrow path to the apex of the root as previously discussed. Both the sinus tract and narrow sulcular lesions can usually be traced to the infected tooth or offending root using a gutta-percha point.

Coronal Integrity

Periodontal infection without pulpal involvement may present with intact crown structure and absence of coronal defects. Conversely, endodontic infection is almost always associated with loss of coronal integrity such as caries, failing restorations, extensive restorations, and the existence of cracks or fractures that extend to the pulpal tissues. However, this does not mean that all periodontal infections are devoid of coronal defects nor that all endodontic lesions exhibit loss of coronal integrity. When pulp tissue is severed by trauma, for example, one might expect to find a necrotic pulp

in the absence of coronal defects. If left untreated, such lesions originating from primary pulpal infection lead to the breakdown of the periodontium as in asymptomatic apical periodontitis or apical abscess. Of course, primary periodontal lesions can develop in teeth with coronal defects. Furthermore, combined lesions (so-called endo-perio lesions) would present with a periodontal infection and extensive coronal destruction. However, careful examination of the coronal status either during the intraoral or radiographic examination can provide supportive information in deciding whether the lesion originates from an endodontic or periodontal infection.

Radiographic Appearance

Periapical radiographs can provide distinguishing information whether the lesion is of pulpal or periodontal origin. Although radiographic findings are objective data, *interpretation* of radiographs can be highly subjective, depending on who is reading the radiograph. Thus, it is important to *understand* to focus on specific entities on a radiograph. These should include the coronal status, crestal bone height and shape, presence of an apical or lateral radiolucency, bony trabeculation, integrity of the lamina dura, and careful evaluation of the obturation of the root canal if present. Coronal status as revealed on a radiograph can also help in the differential diagnosis as described previously. Also, apical lesions originating from a primary pulpal infection lead to a retrograde periodontitis that migrates from the root apex in a cervical direction. On the contrary, periodontal infections will lead to the loss of crestal bone from the cervical area of the tooth in an apical direction. Thus, radiographic lesions appear different in endodontically treated teeth compared to periodontal lesions and the shape of the bony lesions can help distinguish between the two. For example, radiographic lesions representing severe periodontitis will appear wider at the cervical end than the apical portion of the lesion. Apical or lateral radiolucencies may also result from differences in trabeculation patterns not associated with pulpal infection. For this reason, it is critical to consider the integrity of the lamina dura. A break in the lamina dura, accompanied by an apical or lateral radiolucency, is usually indicative of a chronic or acute pulpal infection. If the tooth had been endodontically treated, assessment of the previous obturation qualities (i.e., voids, short fills or overfills, missed canals, etc.) is also important. These radiographic features will provide very useful and often distinguishing information in making the differential diagnosis between pulpal and periodontal lesions more accurate.

Vitality

Testing of tooth vitality often becomes one of the most important tests that can differentiate between periodontal and endodontic infections. Teeth with periodontal infection usually test vital to thermal testing unless the acute condition is a combined lesion in which both endodontic and periodontal compartments have become diseased. Teeth with both endodontic infection and periodontal abscess usually test nonvital. Exceptions to this are extremely calcified canals, extensively restored teeth, or multirooted teeth where canals may be partly necrotic as a result of either pulpal or periodontal disease. Other canals may still retain vital tissue that responds to thermal or electric pulp testing. Thermal testing is usually the most reliable way of determining pulpal health or disease. Patients with symptomatic irreversible pulpitis often report a lingering painful response to a thermal stimulus. In later stages of pulpitis, heat exacerbates the symptom more than the cold, and the application of cold may even cause short-term pain relief.[70] Although thermal testing can be informative as to the status of the pulp, a patient's response to thermal stimuli may be confused with hypersensitivity resulting from exposed dentin and patent dentinal tubules in the absence of pulpitis.[3] Therefore, thermal testing must be combined with other diagnostic criteria as discussed previously to distinguish between the lesions originating from pulpal or periodontal infection.

Treatment Considerations of Endodontic-Periodontic Lesions

In managing the lesions of pulpal or periodontal origin, making an accurate diagnosis as to the source of infection is a critical determinant of the treatment outcome. *Primary* pulpal lesions combined with *secondary* periodontal defects would completely resolve by conventional root canal therapy (RCT) alone. Figure 43-3 shows a chronic pulpal infection associated with a necrotic pulp that led to a periodontal defect via the apical foramen. This is a classic example of primary pulpal infection causing a secondary periodontal defect. In this case, RCT alone led to complete resolution of the chronic apical periodontitis involving the furcal defect. In fact, this type of lesion and the healing pattern are observed in almost all secondary periodontal defects resulting from primary pulpal infection and rapid bone loss in the periodontal tissues.

Lesions originating from pulpal infections require endodontic therapy and would not resolve from periodontal treatment alone. This is exemplified in Figure 43-7, a preoperative radiograph of an "independent" endodontic-periodontic lesion shows an apical radiolucency spanning the entire length of the distal root of tooth #19 and moderate bone loss at the mesial aspect. On completion of endodontic therapy, the periodontal breakdown around the distal root completely resolved, whereas the mesial bony defect remained unchanged. Case 2 shows a "combined" endodontic-periodontic lesion involving extensive apical defects around the apices of tooth #19 and a periodontal defect in the bifurcation. After successful endodontic therapy alone, the apical lesions and the furcation defect have resolved, but incomplete healing is noted in the coronal aspect of the furcation. This finding presumes that the unhealed defect originates from a primary periodontal infection.

Therefore, endodontic-periodontic lesions require both endodontic and periodontal therapies for complete healing to occur. This is true whether the endodontic-periodontic lesions are independent or combined. One important consideration is the sequence of therapies: Which of the two should be performed first? As discussed earlier, endodontic lesions are often associated with more pronounced symptoms than periodontal lesions. More importantly, in combined endodontic-periodontic lesions, some periodontal defects will resolve on completion of the endodontic treatment, whereas the opposite would not be the case. After resolution of the secondary periodontal defect stemming from a primary pulpal infection, the residual periodontal disease may be more accurately and predictably managed. These considerations indicate that combined endodontic-periodontic lesions are best treated by first performing the necessary endodontic treatment followed by periodontal therapy.

When patients present with an abscess, the periodontal and apical abscesses are managed differently. Previous studies have suggested that the treatment of the patient with an acute periodontal abscess should be performed in two stages. In the first stage, the management of the acute lesion is performed. In the second stage, a more comprehensive treatment of the original and any residual lesions are accomplished. The management of the acute periodontal abscess involves establishing drainage via the periodontal pocket and subgingival scaling and root planning.

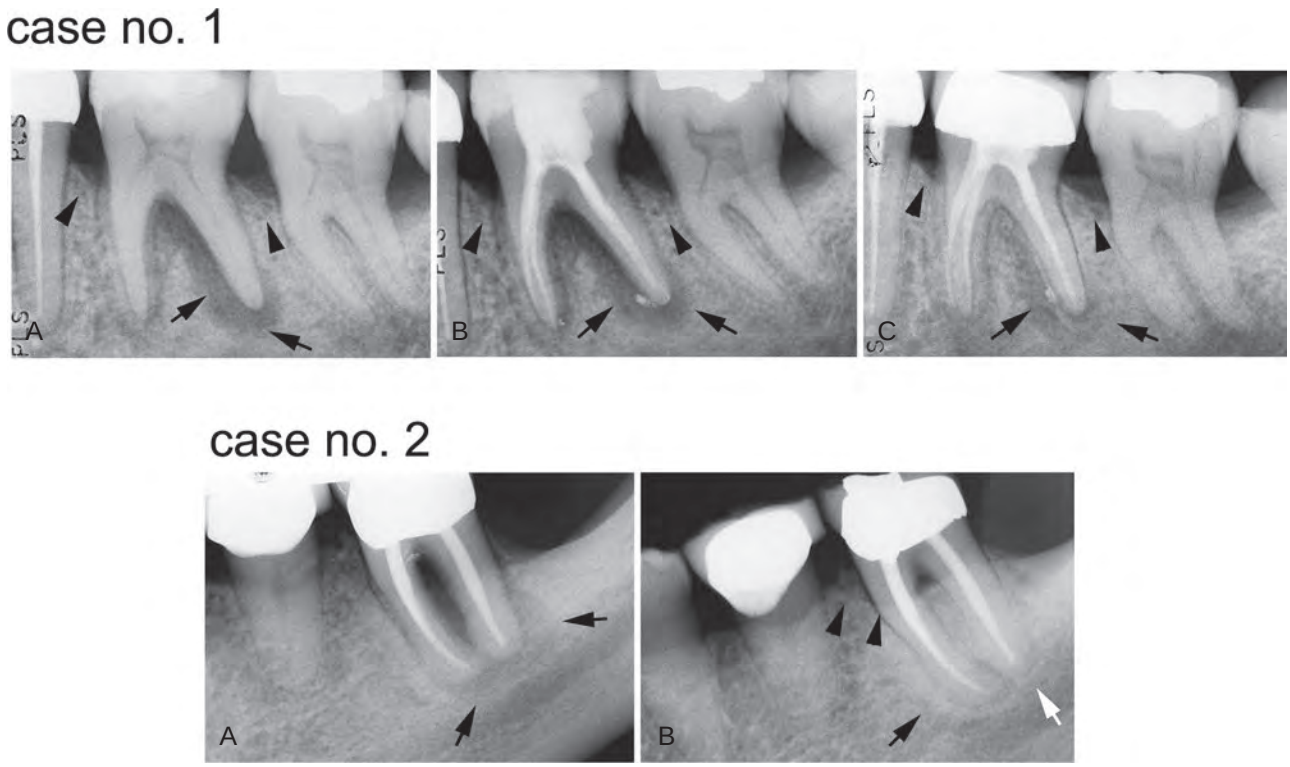

Figure 43-7 *Case 1.* "Independent" endodontic-periodontic lesion. **A,** "Truly separate" endodontic-periodontic lesions. Vertical periodontal bone loss can be seen at the mesial surface of both teeth #18 and #19. A large endodontic lesion extends around the apex and into the bifurcation. An apical and furcal defect is evident radiographically. **B,** Final condensation film 2 weeks after initiating treatment. **C,** Nearly complete healing of the endodontic lesion at 6 months and restoration of the tooth with a PFM crown. The areas of vertical bone loss from the periodontal lesions are still present.
Case 2. "Combined" endodontic-periodontic lesion. **A,** Nonvital tooth with a narrow 9-mm probing defect in the bifurcation of tooth #19 and a large periapical lesion. Normal probing depths were found on the remaining tooth surfaces. **B,** 9-month healing demonstrates significant bone repair in the furcation and periapical areas. A small amount of bone loss in the furcation still remains because of a persistent periodontal defect. *(Case 1 courtesy Dr. Thomas Rauth.)*

Curettage of the epithelium lining, the pocket, and surrounding connective tissue is then accomplished followed by compression of the pocket wall. If the swelling is large and fluctuant, flap surgery or incision and drainage may be necessary to relieve the pressure. In cases in which the bone loss is too extensive and the prognosis for the tooth is hopeless, extraction may be required.[153]

Rationale use of antibiotics should be considered in acute periodontal abscesses.[63] The use of systemic antibiotics may be indicated when patients have elevated temperatures, cellulitis, or systemic disease and are immunocompromised.[153] In a study by Jaramillo,[63] some periodontal pathogens showed resistance to tetracycline, metronidazole, and amoxicillin but not azithromycin. In the management of acute apical abscesses, the abscess should first be drained by performing a pulpectomy or incision and drainage. The choice of which technique to use may be based on time constraints. Incision and drainage procedures require less time to accomplish and yet relieve the pressure that has accumulated under the subperiosteal tissues that results in a fluctuant, swollen, and painful lesion. Pulpectomy removes the infected pulp tissues and microorganisms within the canal system, and calcium hydroxide is placed into each of the canals. Its use has proved to be a suitable intracanal medicament because of its stability and bactercidal effect in a limited space.[69]

If adequate drainage is achieved via incision and drainage and debridement and medication of the canal system, antibiotics generally are of no additional benefit. In the event of systemic complications, such as fever, lymphadenopathy, cellulitis, or in an immunocompromised patient, antibiotics may be prescribed in addition to drainage of the abscess.[95]

Penicillin V or amoxicillin are still the antibiotics of choice against the majority of bacteria isolated from acute endodontic infections. If penicillin V therapy is ineffective, the combination of penicillin V with metronidazole or amoxicillin–clavulanate potassium is recommended. The use of clindamycin is another excellent alternative.[72] The management of pain associated with acute apical periodontitis is well controlled by prescribing systemic nonsteroidal antiinflammatory drugs (NSAIDs) with or without the additional use of Tylenol. Narcotics are usually unnecessary unless an acute flare-up occurs.[139] The correct diagnosis of periodontal and apical abscesses is the most critical step in the resolution of the disease process. Failure to properly diagnose and treat these often encountered conditions result in the progression of the disease, continued loss of bone and periodontal attachment apparatus, and a poor prognosis and possible loss of the tooth.

Effect on the Periodontium of Endodontic Procedural Complications and Dental Anomalies

There are a number of procedural complications and anatomic anomalies that present treatment challenges for both the endodontist and periodontist. Two that are routinely discussed in the literature are perforations and vertical fractures. Both create diagnostic and treatment concerns for both disciplines. Besides these, sodium hypochlorite accidents, resorptive defects, dental anomalies, and

Perforations

Perforations may occur due to extensive caries or resorptive defects that have perforated through the dentin and into the periradicular tissues. Iatrogenic perforations may also occur during the preparation of the access cavity, instrumentation of the canal space, preparation of the tooth for a post, and extensive gouging of a tooth with rotary instruments during periodontal surgical procedures.

Perforations occurring during access preparation may be located either on the external surface of the tooth or perforate the furcation of multirooted teeth. Errors in instrumentation are usually the result of either overinstrumentation, stripping of the internal root curvature or "danger zone,"[1] or canal transportation sometimes resulting in a perforation defect that extends into the periradicular tissues.

After endodontic therapy, a final restoration is placed to protect the tooth from further breakdown or fracture. Because most of the coronal tooth structure may have been previously destroyed, a post and core is often required to provide retention for the placement of a crown. Improper post space preparation may needlessly result in a perforation or stripping defect of the root and result in a guarded-to-hopeless prognosis for the tooth and exposure of the periradicular tissues to necrotic debris and oral pathogens. This will result in the additional loss of bone at the perforation site and future endodontic and periodontal complications.

The most important consideration in repair of a perforation defect is to minimize the time from the occurrence of the perforation until it is successfully sealed and to control any infection present. Keeping this time as short as possible ensures a more predictable result and minimizes the amount of periodontal destruction adjacent to the perforative defect.[39,118] This may be done nonsurgically, surgically, or a combination of the two techniques, depending on the size of the defect, the amount of bone loss, and the location of the perforation. Surgical procedures that involve bicuspidation, hemisection, root amputation, reimplantation, and guided tissue regeneration are more complex, have a more guarded prognosis, and demand that the patient becomes diligent in their oral hygiene.[5,9] In some cases, the placement of an implant may be a more predictable choice and better preserve the surrounding bone structure.

Numerous materials have been previously used for the repair of these perforations. Cavit, intermediate restorative material (IRM), super-ethoxy benzoic acid (EBA), amalgam, composites, glass ionomer cements, and iridium foil have been used with varying degrees of success.[4] Most of the recent studies, however, have demonstrated the wide use of mineral trioxide aggregate (MTA) as the material of choice because of its biocompatibility, ability to be sealed, and its high degree of success.[93,112,169]

The location of the perforation, its size, and the condition of the pulpal and periradicular tissues has a profound effect on the prognosis of the tooth. Teeth that are nonvital with periradicular lesions demonstrate a less favorable prognosis compared to those that are vital and have intact PDLs with no apical pathosis present.[104,113] Additionally, furcal perforations, perforations slightly below crestal bone, stripping perforations in the coronal third of the root, or older perforations with increased loss of bone demonstrate a poorer prognosis than those perforations that are small and situated more apically or above crestal bone.[113]

Prevention of root perforations depends on a thorough clinical examination. The examination should include the knowledge of tooth morphology and the angulation of the tooth being treated. Multiple-angled radiographs can help determine the position of the perforation defect, and the use of a fiberoptic light can aid in the proper diagnosis and the possible presence of any preexisting fractures. Magnifying loupes or an operating microscope aid the operator in observing small details that may otherwise go unnoticed and better allow microsurgical procedures to be completed more quickly and accurately. This usually results in more rapid healing and a repair procedure that has a higher degree of success.

Tooth Fractures

Whenever trauma occurs, patients will usually be examined first by their general dentist and then possibly referred to either a periodontist or endodontist for further evaluation and treatment. It is extremely important for the generalist or specialist to determine if the tooth has received a simple concussion, luxation, or fracture of the crown or root. Multiple radiographs are helpful in distinguishing between these various injury types. It is suggested that a steep occlusal and two conventional periapical bisecting angled films are taken from both mesial and distal directions.[7] If a tooth fracture is detected, a thorough diagnosis and treatment plan needs to be developed to render the appropriate treatment for the patient.

Teeth can fracture for a variety of reasons, and the fracture site and severity may be situated along any area of the tooth from the crown to the apical portion of the root. The treatment and prognosis of each of these fracture types vary greatly. The discussion of tooth fracture is divided into three separate categories that affect both the endodontic and periodontal treatment. The causes, clinical observations and diagnosis, treatment, and prognosis are discussed for each type of fracture modality.

Crown-Root Fractures. Crown-root fractures are of endodontic and periodontal concern when the fracture extends slightly below the marginal gingiva or crestal bone. These fractures are usually the result of a traumatic incident and are usually horizontal or oblique because of the direction and the intensity of force sustained during the trauma. Anterior teeth are most frequently involved, but premolars and molars may also be fractured, depending on the type of injury sustained. Teeth that are badly shattered in both the coronal and root areas and have sustained multiple fractures cannot be successfully treated endodontically or periodontally. They are most often extracted and restored using a fixed bridge or an implant. Most of the time, however, a chisel-type fracture will occur that splits the crown and the root in an oblique direction and extends 2 to 3 mm below the marginal gingival and crestal bone, which generally results in the exposure of the pulp and often presents a challenge to the periodontist, endodontist, and restorative dentist to successfully retain the tooth.

The depth to which the fracture extends determines the restorability of the tooth and the type of restorative treatment employed. In cases in which the tooth is immature and development of the root is incomplete, the fractured segments may be temporarily bonded to allow for future root development and apical closure. Sound clinical judgment, the length of time from the occurrence of the fracture, and pulpal status must be taken into account to arrive at a proper course of treatment.[35-37]

If the root has completely developed, the fractured segment should be removed to determine the depth of the fracture defect. Questions that need to be answered during treatment planning are as follows:

1. Is the amount of remaining tooth structure adequate to support a final restoration?
2. Is the root length adequate to allow for the orthodontic extrusion and restoration of the tooth?
3. Should the tooth be removed and an implant or bridge placed?

4. Can orthodontic movement close the space and provide an esthetic result for the patient?[8]

These cases usually necessitate a multidisciplinary approach using the talents of four to five different specialty areas.

Horizontal Root Fractures. Horizontal fractures most often occur in the region of the anterior maxilla. Many of these fractures go undiagnosed and heal without any treatment.[26] Usually it is not until these patients visit a dental office years later that a radiograph reveals the presence of the previous trauma and subsequent healing of the fractured tooth segments. In a study by Andreasen et al,[7] 400 horizontal root–fractured teeth were studied in young individuals from 7 to 17 years of age. Their findings demonstrated that 30% of the teeth healed by hard tissue fusion, 20% healed with the interposition of the PDL and bone, 43% healed with the interposition of PDL alone, and only 22% became necrotic and exhibited inflammatory changes between the fragments. Variables that correlated positively with healing were (1) younger age, (2) immature root formation, (3) vital pulp, and (4) no tooth mobility or displacement of the coronal segment. Healing of the segments was also progressively worse as the separation between the fragments increased.[7] Horizontal root fractures are usually categorized as coronal, midroot, or apical. The diagnosis of horizontal fractures is mostly based on information gained during the clinical and radiographic examinations.

Horizontal Fractures in the Coronal Area. Coronal fractures may require only endodontic treatment if the fracture is at the level of the gingival tissue. This is necessary only when the coronal portion of the tooth is missing and endodontics is necessary to allow for the placement of a final restoration. If the position of the fracture is below crestal bone and the crown is intact, the mobility of the coronal segment dictates whether to splint the teeth and wait to evaluate the traumatized tooth at a later appointment or remove the coronal segment, complete endodontic treatment, and then proceed with either periodontal crown lengthening or extrusion of the apical segment.[54] Cvek[26] reported that when comparing transverse fractures in the coronal third of the root to oblique fractures, the frequency of healing did not differ. Only 16% of the teeth in this study became necrotic with radiolucent areas adjacent to the fracture site.

When the crown has been lost and the coronal segment of the root is submerged below the marginal gingiva, periodontal treatment is necessary and the tissues may be apically repositioned around the submerged root segment. In complex crown fractures in younger patients, a multidisciplined approach is often needed to surgically treat the tissues around the fractured segment using guided bone regeneration followed by endodontic treatment and the placement an esthetic post to increase retention of the crown and more equally distribute the stresses of mastication.[6] If the root has fully developed and has adequate root length, another common approach is to orthodontically extrude the root to preserve both the height of bone and contour of the surrounding tissue. Both these tissues migrate coronally with the root during the extrusion process. Following extrusion, the coronal fibers of the PDL are surgically released and the root is stabilized to prevent intrusion or relapse. After stabilization has occurred, the final restoration is fabricated and permanently cemented.[54]

Horizontal Fractures in the Midroot Area. Midroot fractures usually require no periodontal intervention with the possible exception of the patient who requires emergency repositioning and splinting of the teeth by a periodontist rather than a general dentist or endodontist. Midroot fractures that are stable usually require no endodontic intervention or splinting. As with midroot fractures in the coronal area, luxated teeth should be repositioned and passively splinted for 1 to 4 weeks. The exact time of stabilization varies between different investigators.[7,110] Figure 43-8 illustrates the successful use of a large metal Thermafil carrier to stabilize both the coronal and apical segments of a tooth with a horizontal midroot fracture. Delays in splinting of several days did not result in reduced healing.[7] Frequent pulp testing and radiographic evaluation for resorptive defects should be done with all fractured teeth.

Necrosis of the coronal potion of the fracture necessitates endodontic therapy of usually just the coronal segment. Gutta-percha or MTA are used to seal the coronal portion of the root, depending

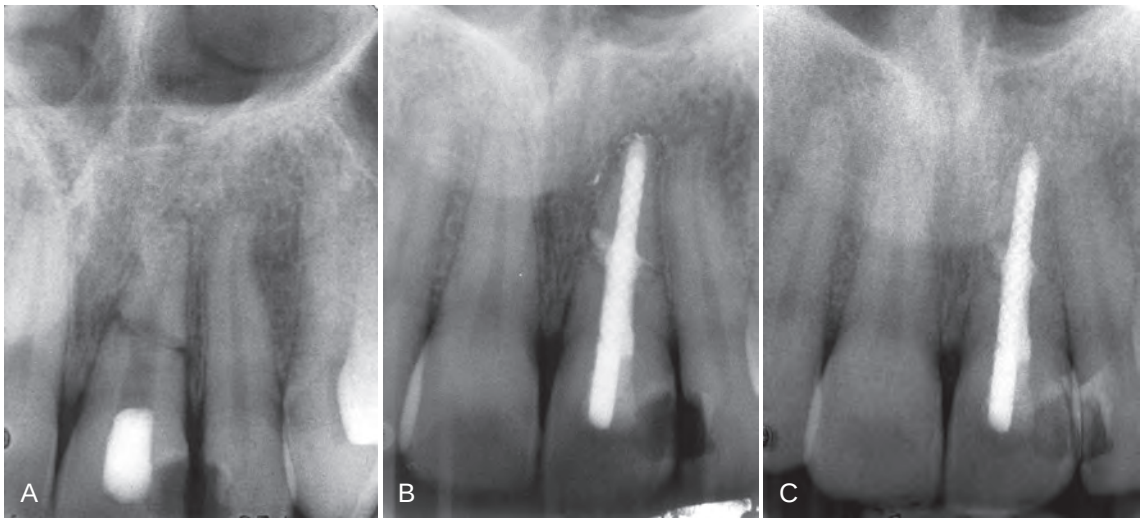

Figure 43-8 Horizontal root fracture. **A,** Radiograph of tooth #9, 4 weeks after instrumentation. The radiograph shows a midroot intraalveolar horizontal root fracture with separation of the coronal and apical segments. Resorptive defects are evident at the fracture site and slight periapical bone loss is present at the periapex and mesial root surfaces. The tooth displayed slight mobility with normal probing depths. **B,** The segments were stabilized using a size #140 Thermafil obturator with a metal carrier. The tooth was restored with an acid-etched composite restoration. **C,** 12-year recall radiograph shows excellent long-term treatment success and a normal periradicular appearance. *(Courtesy Dr. Nadia Chugal.)*

on the apical diameter and the presence, severity, and type of resorption. The apical segment usually remains vital.[168] If both segments become nonvital, fixation using various post types and designs may be employed[80] (see Figure 43-8).

Horizontal Fractures in the Apical Area. Fractures occurring in the apical portion of the root are evaluated and treated similar to coronal and midroot fractures. The mobility of the coronal segment may be less due to the more apical position of the fracture site. This depends on the direction and severity of the trauma and the presence and degree of tooth luxation. Factors previously discussed regarding splinting and frequent evaluation of vitality and root resorption apply to apical fractures as well. Most coronal and apical segments remain vital and do not require either endodontic or periodontal intervention.[7] If the apical segment does become necrotic, it is usually removed surgically and the necrotic coronal portion of the root is endodontically treated in the same manner as horizontal fractures occurring in the midroot area of the tooth.

Vertical Root Fractures. The early detection and diagnosis of vertical root fractures presents a challenge to both general dentists and specialists. Failure to properly diagnose this type of fracture usually results in prolonged patient suffering and frustration for both the patient and treating dentist. An accurate diagnosis can often be established by listening to the patients chief complaint, careful examination of both periapical and bitewing radiographs, and a thorough clinical examination.[21] These steps help in accurately locating the involved tooth, correctly identifying the source of the problem, and decreasing the rapid breakdown of bone surrounding the tooth. Taking these necessary steps will have a profound effect on the success of the placement of a subsequent implant.[151]

Definition. Dentin is anisotropic and fractures usually extend perpendicular to the orientation of the dentinal tubules. Vertical root fractures result from internal and external stresses that exceed the elastic modulus of dentin. These stresses ultimately result in structural failure (Figure 43-9).

Incidence. The incidence of vertical root fractures in endodontically treated teeth has been reported to vary from 3.69% to as high as 10.9%.[41,103,172] Fuss et al[40] feel that this large difference may be due to the difficulty in making an accurate diagnosis before sending patients to have the tooth extracted. This concept may be valid because one study found that general dentists correctly diagnosed vertically fractured teeth only 33% of the time.[142] The remaining 67% were referred for either periodontal therapy or endodontic retreatment.[142]

There are many factors that predispose teeth to vertical root fractures. These etiologic factors include previous endodontic treatment, extensive restorative procedures, morphologic tooth differences, age, sex, ethnicity, cultural differences, resorptive defects, and heavy masticatory forces. Most vertically fractured teeth have undergone previous endodontic treatment. In fact, the most common etiology associated with vertical root fractures is previous endodontic treatment and post placement. Vertical root fractures in teeth that have not been treated endodontically are uncommon. The only reported studies are investigations of Chinese and Thai populations. These studies point to differences in dietary habits,

Figure 43-9 Vertical root fracture. **A,** Patient whose chief complaint is pain from bite pressure irritation, bleeding, and redness on the lingual marginal tissues. The radiograph reveals a slight loss of bone on the distal surface of tooth #13 and a short screw post. A lingual periodontal pocket probing 6 mm was present. A diagnosis of vertical root fracture was made. **B,** After extraction of the tooth, a vertical root fracture extending two-thirds of the root is evident. **C,** Lower molar previously diagnosed with an incomplete fracture tested vital and was referred back to the dentist for restoration with a full crown. The tooth was restored with an onlay, and an endodontic procedure was needed less than a year later because of pulpal necrosis. Initial healing was observed at 6 months, but the tooth required extraction 18 months later. This photograph shows the extension of the vertical fracture apically. **D,** A cross-sectional view at the cementoenamel junction demonstrates the presence of both a mesiodistal, as well as a lingual, fracture.

consumption of abrasive foods, and chewing betel nut. The incidence of fractures in males was 70% to 100% greater compared with females.[18,19,42]

The Chinese and Thai studies reported that vertical fractures occurred 78% more frequently in the mesial or mesiobuccal roots of first molars and in patients between the ages of 40 and 69 years. One study found that 40% of all vertical fractures occurred in teeth that have not been treated endodontically. The majority of the patients studied had relatively intact dentitions. Fractured teeth frequently had no previous restorative procedures and showed excessive wear on the occlusal surfaces.[18,19,42]

Both endodontic and restorative procedures remove valuable tooth structure that is critical to the stability of the tooth and its ability to resist constant masticatory loading. Stresses generated during these procedures may not appear for many years until the vertical fracture becomes apparent both clinically and radiographically.[40] An investigation of instrumented compared to noninstrumented teeth demonstrated that instrumented mandibular premolars showed a higher risk to fracture than those that were not instrumented. This further emphasizes the role that structural integrity plays in reducing the possibility of tooth fracture.[167]

As with nonendodontically treated teeth, endodontically treated teeth with narrow mesiodistal diameters have a greater tendency to vertically fracture. This includes maxillary premolars, the mesial or mesiobuccal roots of molars, and lower anterior teeth.[142] Tamse reported that the incidence of vertical fractures was greatest in maxillary second premolars (27%) and the mesial roots of mandibular molars (24%).[142] Other investigations have included lower premolars and distal roots of maxillary molars as well.[77,150] Overpreparation of the canal system[111,128] and the cementation of posts of improper design, length, and diameter increase stresses within the tooth and the propensity for the root to vertically fracture as well.[101,124] All fractures extend from the internal root surface to at least one external surface. but occasionally some fractures extend to both surfaces. Most often, fractures will be oriented in a facial or buccolingual direction in anterior and premolar teeth and mesiodistally oriented in molars. When both the buccal and lingual surfaces of a tooth have deep and narrow probing defects, it is generally pathognomonic of a vertical fracture. Vertical forces applied to an endodontic spreader during lateral condensation cause stresses to be generated throughout the prepared canal. If the spreader load is too great, the spreader is too large or the canal has been overinstrumented, both in vitro and photoelastic investigations have demonstrated that these internal stresses can result in vertical root fracture.[28,58,65,106,166]

Clinical Findings. The subjective findings associated with vertical fractures are usually minimal. The patient often presents with reported discomfort to bite and chewing pressure and signs of mild inflammation. In general, there is minimal swelling unless a flare-up has occurred. Flare-ups are usually the primary reason for the patient seeking dental care. When this happens, the tooth will appear to have all the signs and symptoms of a periodontal abscess. This is the most probable reason that so many vertical fractures are referred first for periodontal or endodontic treatment.

The fracture space contains various irritants that result in the inflammation of the surrounding periodontal tissues. Bacteria may be present either in the dentinal tubules or enter the fracture site from the oral environment. Sealer may be found in the fracture or adjacent tissues, especially when the fracture resulted from excessive condensation forces or forceful tapping of a post during the cementation procedure.[160]

Objective findings include periodontal probing patterns that are usually very deep and narrow at the fracture site.[91,142] This is probably one the most common findings when a vertical root fracture is diagnosed. Periodontal defects tend to probe more widely because of the broader and more extensive loss of bone. Often, it is possible to retract the tissues, transilluminate the root, and successfully identify the fracture. At other times, the tooth may probe normally, but a sinus tract may be evident close to the gingival margin rather than at the apical area. Tamse et al[142] found that a solitary, narrow buccal pocket existed in 67% of the vertical fractures examined and a sinus tract was evident 34% of the time. If a fracture is suspected but cannot be seen, a surgical flap may be necessary to positively identify its presence or absence.[119]

Fractures in maxillary premolars, mesial and mesiobuccal roots of molars, and lower anteriors usually extend in a faciolingual direction.[91,142,144] Mandibular molar teeth with large intracoronal restorations may be transilluminated to diagnose the presence a fracture. These fractures may extend varying distances both pulpally, as well as down both mesial and distal or buccal and lingual tooth surfaces. Teeth with shallow but wide restorations that test necrotic and are painful to percussion generally have vertical fractures that have extended into the pulpal space and may not be salvageable and will subsequently require extraction.

Vertical root fractures extend varying lengths from the coronal or apical portions of the root. The degree of extension depends on both the amount and location of stress concentration within the root. Most of these fractures probably begin on the internal root surface caused by the stresses generated during restoration, endodontic instrumentation and condensation, or the placement of a post. Probing depths may vary, depending on the length of time the fracture has been present, although some vertically fractured teeth have probing depths that are normal.

Radiographic bone loss is significantly greater in teeth with periodontal or combined endodontic-periodontal lesions compared to teeth that are vertically fractured.[108] In vertically fractured teeth, radiographic findings in maxillary and mandibular premolars and mesial and mesiobuccal roots of molars typically display one of three typical patterns that depend on the time the fracture has been present and the amount of bone loss that has occurred. Early patterns may appear as just a slight widening of the PDL space on the lateral tooth surface. As bone loss becomes more progressive, a more angular loss of crestal bone, or "halo" or "**J**-shaped" radiographic appearance, may become evident. Only a few teeth display the actual separation of tooth segments. Radiolucencies in the bifurcation area are more typical of vertical root fractures in mandibular molars.[143,151] The use of computed tomography (CT) scans and the newer cone-beam CT (CBCT) scans have been shown to be superior to periapical radiographs in the identification and diagnosis of vertical root fractures.[53,170]

Prevention of vertical root fractures relies on two basic concepts: (1) the preservation of radicular dentin and (2) the reduction of dentinal stresses resulting from forces encountered during instrumentation, condensation, and restorative procedures. Overinstrumentation of the canal space and the use of progressively larger hand or rotary instruments result in the loss of valuable tooth structure. Preservation of this tooth structure is necessary to prevent tooth fracture after the restoration of the tooth and years of masticatory function.[83] Instrumentation and, in particular, underinstrumentation exposes the tooth to greater forces during condensation with inflexible and larger spreader and plugger designs.[65,106] More research is needed to arrive at an ideal instrumentation and filling technique based on the dimensions of the root, its curvature, and the stresses transmitted during endodontic treatment of the tooth.

Research of various post designs demonstrated that posts should be used only when there is too little tooth structure left to support

the final restoration. Posts that transfer stresses throughout the entire root surface have a vented surface to allow for even cementation pressures, do not weaken root structure caused by excessive post width, and do not result in a wedging effect during cementation should be used. Post width should be no greater than one-third the width of the root. Post designs that are least likely to result in excessive stress production are currently prefabricated, passively cemented parallel designs of either metal or the newer more flexible carbon-fiber design.[124,134,136] Cast posts and cores with minimal taper may be needed in certain cases as the result of canal morphology and the necessity for a protective ferrule to further prevent the possibility of root fracture.[140,144]

Treatment of vertical root fractures involved the use of composite resin bonding techniques in an attempt to repair the fractured root surface, continuous wave carbon dioxide (CO_2) lasers to fuse bioactive glass paste in an attempt to fuse the fractured surfaces, and the use of various filling materials in an attempt to seal the fractured segments.[161] Most of these techniques have had varying success and still need to be further evaluated before their acceptance as a viable way to retain a vertically fractured tooth.

The prognosis for the vertically fractured tooth is virtually hopeless, and attempts to bond the fractured segments together, use CO_2 lasers to fuse the segments, and use of other filling materials have met with met with varying success.[161] The usual solution in single-rooted teeth is to remove the tooth and replace it with a fixed or removable appliance or a dental implant. In multirooted teeth, either an amputation or hemisection of the involved root is surgically performed.[82] An alternate procedure is removal of the tooth, maintenance of the bony architecture, and placement of an implant.

Sodium Hypochlorite Accident

Sodium hypochlorite is the most commonly used irrigant in endodontic treatment. Concentrations that have been recommended range from 0.5% to 6%, but 2.5% is the most commonly used concentration.[173] Extrusion of sodium hypochlorite into the periradicular tissues results in a rapid diffuse swelling and extreme pain. Tightly wedging the irrigating needle into the canal and forcing the irrigant into the surrounding periradicular tissues is the most common cause of extrusion. Other mishaps that result in the extrusion of sodium hypochlorite are caused by overinstrumentation of the canal, iatrogenic perforations that occur during access preparation, or the inadvertent injection of sodium hypochlorite into the tissues during patient anesthesia.[100] In a recent survey of diplomats of the American Board of Endodontics, approximately one-third reported experiencing a sodium hypochlorite accident at some time during their years of practice. In the survey, findings indicated that accidents were more positively correlated with women, maxillary compared to mandibular teeth, posterior compared to anterior teeth, and necrotic compared to teeth with no necrosis or periapical lesions present. Sodium hypochlorite accidents may involve both the endodontist and periodontist if the general dentist refers the patient for further consultation. The endodontist may monitor the case for several weeks and subsequently obturate the canal when the swelling subsides. The periodontist may be asked to monitor scar tissue formation that often forms and causes continued discomfort and surgically intervene if necessary.

Avoidance of sodium hypochlorite accidents is best accomplished by the use of side-vented needles and loose insertion of the irrigation needle into the canal. Using light pressure to deliver the sodium hypochlorite and remove the debris created during canal instrumentation is also useful. If an accident does occur, the patient should be checked frequently, the tooth should be closely monitored and left open for drainage to occur, and referral to an endodontist is advised. The occurrence of a sodium hypochlorite accident by itself does not adversely affect the endodontic prognosis, and most signs and symptoms from the accident usually resolve within a month.[78]

Resorptive Defects

Resorption of tooth structure occurs as pathologic events leading to destruction of root canal and periradicular structural integrity. However, it is important to recognize that the resorptive process itself is a normal, physiologic event. In bone, for example, there is constant osteoclast-mediated bone resorption coupled with new bone formation as part of routine bone remodeling process.[146] Even in dental tissues, physiologic root resorption is found in primary teeth without any inflammatory events. Thus resorption of mineralized tissues, whether bone, dentin, or cementum, is not pathologic at all. What is surprising is that such remodeling of hard tissue is not meant to occur in the permanent dentition under normal conditions. The mechanisms leading to resorption are essentially identical in pathologic root resorption as that for bone that involve the activation of odontoclast cells expressing tartrate-resistant acid phosphatase.[75] In normal conditions, root resorption does not occur as the result of resistance of dental tissues to the physiologic bone remodeling process. The resistance may be explained by the fact that organic matrix of demineralized dentin or unmineralized predentin contain inhibitors of root resorption.[163] This may be associated with the fact that dentin matrix possesses significantly reduced amount of osteopontin (OPN) compared with bone matrix,[17] and OPN plays a critical role in odontoclast maturation during root resorption.[152] Furthermore, predentin and cementoid covering the most inner and outer layers of the root, respectively, provide protection against the physiologic bone remodeling and resorptive activities.[90,162] Therefore pathologic root resorption would entail disruption of these protective layers as can be evinced in cases of trauma, excessive heat, chemical injuries, and infection. Trauma, such as luxation, avulsion, or excessive pressure applied by orthodontic appliances, can lead to cemental tears, exposing deeper cementum and/or dentin. Minor injuries of this kind can be repaired without gross structural alteration by formation of a new cemental layer covering the injured sites and prevent further progression of the resorption. However, traumatic injuries causing larger denudation of the protective cementoid or predentin layers would allow progressive external or internal root resorption, respectively. *External root resorption* is also known as *replacement resorption, osseous replacement,* or *ankylosis,* which can be detected in routine radiographs as radicular defects replaced with bony trabeculation. On the contrary, *internal root resorption* frequently appears as a circular radiolucent lesion centered within the root canal in the absence of osseous replacement. After trauma, external root resorption may also be aggressive in nature and lead to the rapid destruction of dental tissues.[55] These lesions are known as *invasive cervical resorption* because of the typical location that involves the cervical region of the root by fibrovascular tissues causing the resorptive defect. The etiology of these lesions may be linked with a history of trauma. Cervical root resorption is also associated with damage in the cementoid layer located at the cervical attachment apparatus.[47] Other causes of root resorption include chemical injuries. Intracoronal bleaching may cause external cervical root resorption by cemental damage caused by the release of hydrogen peroxide or carbamide peroxide through the dentinal tubules.[46] Excessive heat generated by ultrasonic instrumentation during RCT may also cause external root resorption due to the necrotic changes in the cemental layer and PDL cell damage. As described in greater detail elsewhere in this chapter, ultrasonic devices are frequently used for

post removal during orthograde root canal retreatments, and the device setting and the contact time with the intracanal post system may influence the risk of external resorption. Perhaps the most frequent cause of root resorption is the presence of chronic inflammation of the pulp and periradicular tissues. This is known as *inflammatory root resorption,* can be internal or external, and is located mostly at the root apex associated with apical periodontitis.[87] The presence of apical inflammatory root resorption may drastically alter the course of the endodontic therapy as it may shorten the root length and compromise the apical constriction (Figure 43-10, *A*).

Root resorptions have been treated by various means. If the cause of the resorption is chronic inflammation originating from pulpal infection, conventional RCT may lead to complete resolution of the internal resorptive process, although the defect cannot be restored (see Figure 43-10, *B*). These resorptive defects result from loss of internal tooth structure caused by multinucleated giant cells and the granulation tissues in the radicular pulp. Internal resorptive lesions with perforating defects or external root resorption not resulting from pulpal infection have limited treatment options and their outcome is highly variable. Root canal therapy combined with perforation repair using MTA has been effective in some cases.[13,113] Recent studies also assessed the potential use of bisphosphonate, which inhibits bone resorption by acting directly on osteoclasts.[115] Preclinical studies evaluating the bisphosphonate's ability to inhibit root resorption has resulted in partial success and demonstrated that the topical application of bisphosphonate reduced the extent of root resorption but not ankylosis.[81,92] On the contrary, intracanal application of bisphosphonate did not have any effect on replacement resorption.[147] Further research is necessary to elucidate the potential benefit of this novel approach in preventing root resorption.

Dental Anomalies

Dental malformations that occur during tooth development can result in the loss of periradicular bone and the possible loss of the tooth. Malformations include dens invaginatus (dens in dente), dens evaginatus, and lingual dental grooves.

Dens Invaginatus. Dens invaginatus is one of the more common developmental defects that occurs when the inner enamel epithelium invaginates into the dental papilla before calcification.[49] Its etiology is unknown, but it may be genetic in origin. The lateral incisor is the most commonly affected tooth, and bilateral occurrence is not uncommon. It may often be detected by observance of an increased labiolingual or mesiodistal diameter, labial notching, a peg or conical morphology, and the presence of an exaggerated or "talon cusp."[15] Its presence increases the risk of pulpal disease and severe periodontal destruction.

The severity of dens invaginatus varies, and the classification by Oehlers is generally the most widely accepted.[109] The classification increases in morphologic severity from Class I to Class III with Class III being the most anatomically complex and the most difficult to treat endodontically. If pulpal necrosis and periapical

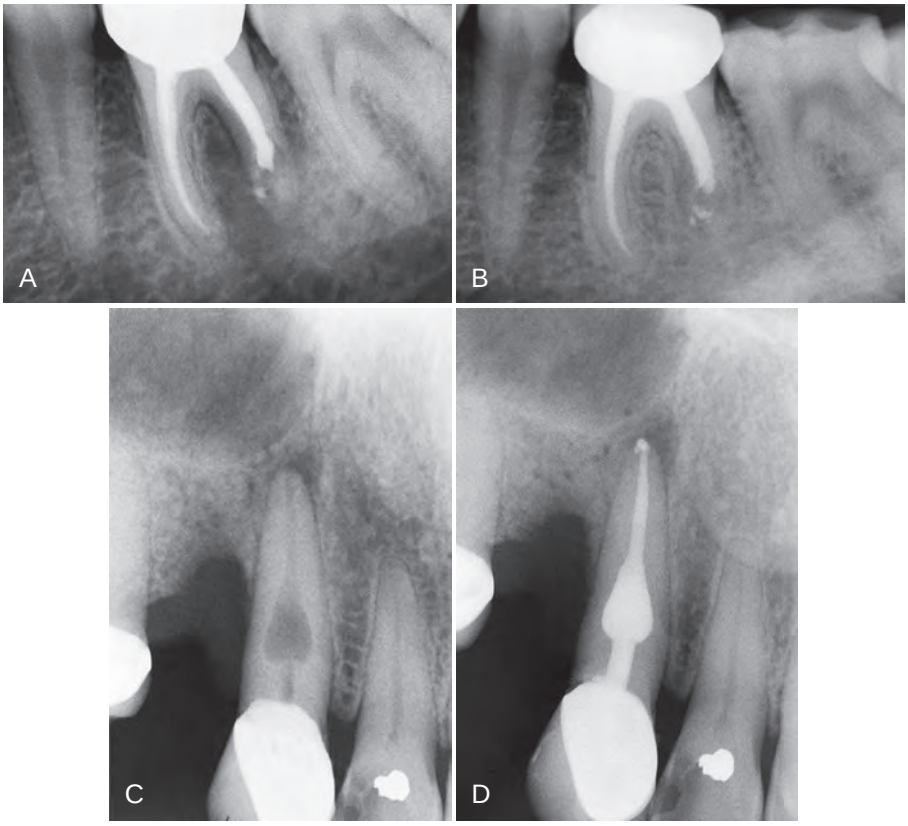

Figure 43-10 Root resorption. **A,** Radiograph of tooth #19 after obturation of the canals. The shortened distal root is the result of apical inflammatory root resorption. A large radiolucent lesion extending into the bifurcation is evident. **B,** A 1-year recall radiograph shows complete repair of periradicular bone and some additional resorption of extruded filling material at the root apex. **C,** An internal resorptive lesion of relatively large size. The expansion of the canal space is diagnostic of a resorptive defect inside the tooth. However, it is not possible to diagnose the possibility of a possible external perforation from a two-dimensional radiograph. **D,** The final obturation film seems to indicate that the lesion and filling material appears to be confined to the canal space. *(Courtesy Dr. Thomas Rauth.)*

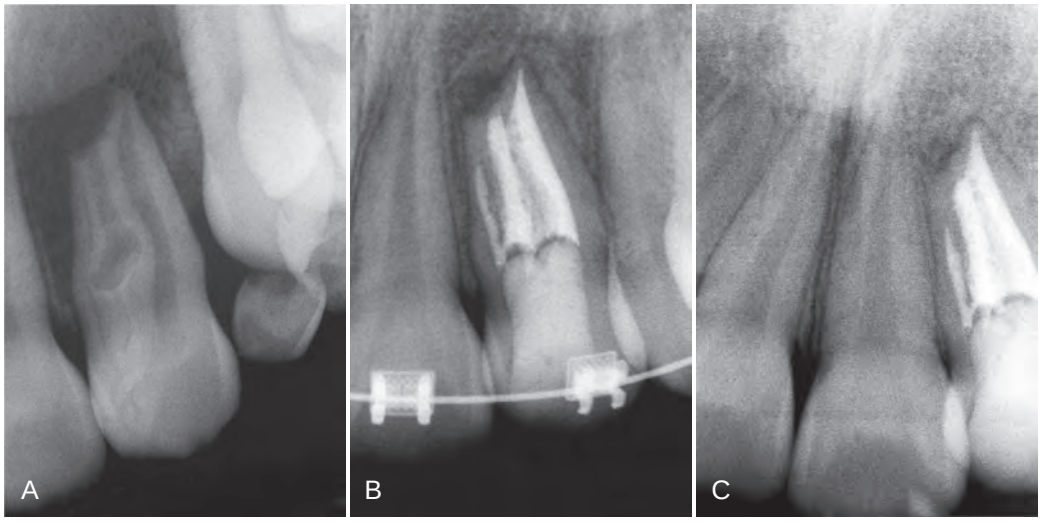

Figure 43-11 Case of dens invaginatus causing primary endodontic infection. **A,** Preoperative radiograph of tooth #10 demonstrating a complex dens invaginatus with extensive apical bone loss. **B,** Significant bone healing is apparent and orthodontic therapy has been initiated **C,** A 4-year follow-up demonstrated continued bone repair. *(Courtesy Dr. Nadia Chugal.)*

disease result from the exposure of the defect to the oral environment, either orthograde endodontic treatment or a combination of orthograde and surgical treatment may be necessary. Both gutta-percha and MTA have been used to render orthograde treatment of complex defects[16] (Figure 43-11).

Dens Evaginatus. Dens evaginatus is another dental anomaly that has been well documented since 1925.[88] The defect manifests itself as a tubercle or protrusion of enamel from the occlusal tooth surface that has a core of dentin usually containing a thin extension of pulpal tissue. It occurs in at least 2% of patients of Asian or Native American descent and is located mostly on mandibular premolar teeth but may also be found on molars and anteriors.[98] The tubercles are susceptible to pulpal exposure caused by fracture, wear, orthodontic movement, or occlusal equilibration. Many of these teeth become necrotic before the root of the tooth has developed and require apexification procedures to allow for apical closure.

Prevention or prophylactic treatment before pulpal involvement is of paramount importance in the treatment of dens invaginatus. If the pulp is not exposed after removal of the tubercle, an alloy or a composite resin restoration may be used. If the pulp is exposed during removal of the tubercle, pulp capping may be accomplished by using either calcium hydroxide or MTA. Therefore, early recognition and timely treatment can prevent pulpal necrosis, extensive loss of periodontal supporting tissues, and the possible loss of the tooth.

Lingual Groove. Sometimes referred to as palatogingival grooves, lingual grooves are found most often on the distolingual surface of the maxillary lateral incisor, although other incisor teeth can be involved as well. The groove is a developmental anomaly where there is an infolding of the inner enamel epithelium and Hertwig's epithelial root sheath. The groove may extend varying distances from the cingulum of the incisor in a cervicoapical direction toward the apex of the root. Microscopic investigation of teeth with lingual grooves demonstrates that more than 75% show deformation of the pulp chamber adjacent to the groove, diminished enamel and dentin thickness, and extension of the groove to the apical third of the root. Direct communication between the between the pulp and periodontium is rarely observed.[86]

Lingual grooves are associated with both periodontal and pulpal pathosis. A study[43] using scanning electron microscopy traced the communication between the lingual groove and the pulp cavity. Accessory foramina were located in both areas. These accessory foramina could provide a pathway for infectious materials to migrate from the lingual groove to the pulp cavity resulting in pulpal necrosis.[43] The presence of a lingual groove frequently results in a deep narrow periodontal defect. There are occasional pulpal communications that result in both periodontal and pulpal pathosis. Bonded restorative materials in combination with guided tissue regeneration have been used with variable results. The prognosis of these teeth is usually guarded to poor. Many are lost to extraction with the subsequent placement of an implant or bridge. Figure 43-12 demonstrates a lateral incisor with two roots and a deep lingual groove that was successfully treated.

Ultrasonic Devices

The retreatment of teeth that have been restored with various post designs has attracted researchers to study how to best remove these posts without weakening, fracturing, or perforating the surrounding tooth structure. Today, the use of ultrasonic devices to remove obstructions, cements, and metallic posts from within the canal space is used frequently when retreatment becomes necessary or a crown and post have fractured leaving the root and remaining post exposed and in need of further treatment.

Early studies suggested that the removal of posts without water spray could produce heat that could seriously affect the mineralized tissues that surround the tooth if temperatures in the periradicular tissues exceeded 50° C (122° F).[32] Temperatures exceeding 10 degrees above body temperature are usually cited as a threshold beyond which vital tissues become irreversibly damaged. Resorptive defects resulting from the excessive heat generated from the ultrasonic tip to the metal post and the damage to both the cemental layer and PDL have been previously discussed.

More recent observations and case reports have clearly shown that if the intensity of the device and the contact time with the post is too long, significant heat conduction occurs through the dentin and into the surrounding PDL, bone, and soft tissue; it results in the necrosis of both the periodontal tissues surrounding the tooth and may cause the loss of the tooth and permanent damage to the

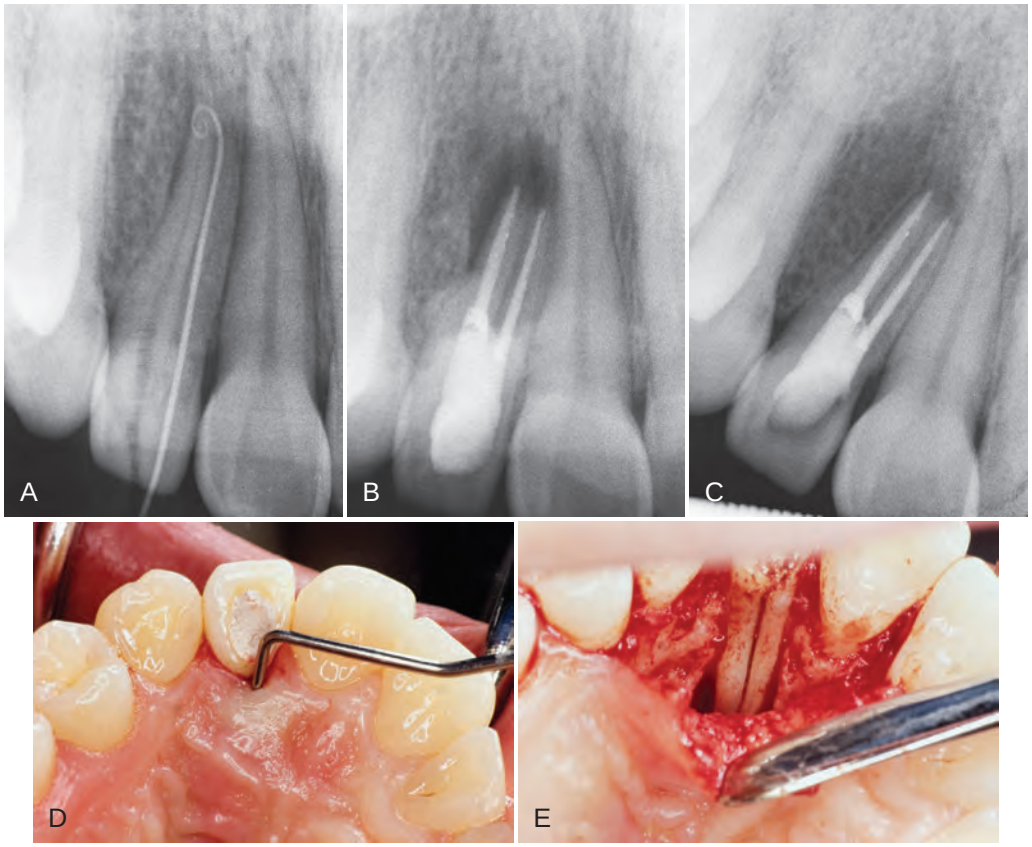

Figure 43-12 Case of developmental lingual groove causing primary endodontic infection. **A,** Preoperative radiograph of tooth #7. A gutta-percha marker extends to the apex. The radiograph is suggestive of a deep lingual groove or two separate roots. No caries or other abnormalities were present. **B,** A large lingual and periradicular defect developed after gutta-percha obturation of both canals (see photo in **D**). **C,** One-year recall after surgery showed radiographic healing, no symptoms, and a 3-mm probing depth. **D,** A 12-mm probing depth is demonstrated before surgical exploration. **E,** A large area of bone loss on the palatal and a deep lingual groove are evident during reflection of the flap. The groove was eliminated and Geristore resin was bonded to the lingual surface to repair the defect. *(Courtesy Dr. Nadia Chugal.)*

periodontium.[33,157] Most of these studies have concluded that there is a significant increase in root temperature that can reach values of more than 50° C (122° F) if the contact time exceeds 15 to 30 seconds and there is no coolant used during the removal of the post.[44,60] It therefore seems prudent to use a water coolant and intermittent contact times between the ultrasonic tip and the post of no more than 30 seconds. This should ensure that damage to the surrounding periodontal tissues is minimized.

Not using a local anesthetic when removing a post from a tooth is often the best way to evaluate when the patient is beginning to experience discomfort. The ultrasonic tip can be removed as soon as the patient indicates any painful sensation and replaced once it has disappeared. Using this technique can avoid problems or damage to the surrounding periodontal structures.

To demonstrate the amount of heat transferred to the surrounding tissues, various in vitro studies have further investigated the effects of ultrasonic contact time with the post, the intensity setting of the device, the use of air and water coolants, and the amount of remaining tooth structure.[33] Most of these studies have concluded that there is a significant increase in root temperature that can reach values of more than 50° C (122° F) if the contact time exceeds 15 to 30 seconds and there is no coolant used during the removal of the post.[44,60] It therefore seems prudent to use a water coolant and intermittent contact times between the ultrasonic tip and the post of no more than 30 seconds. This should ensure that damage to the surrounding periodontal tissues is minimized.

Minimizing or avoiding these various procedural complications will benefit the endodontist, periodontist, patient, and generalist in maintaining teeth that would have a guarded to poor prognosis and might be lost because of tooth-related defects such as resorption or operator-related errors resulting in the extraction of the tooth and loss of the supporting periodontal structures.

the improper use of ultrasonic devices may all result in problems that may require treatment by both specialties.

All of these topics are discussed in detail in the online section of this chapter and it is the hope of the authors that the discussion of these problems that affect both specialties will give the reader a more complete understanding of appropriate treatment solutions

Numerous complications may arise during and following endodontic therapy. Some of these complications may be iatrogenic such as perforations, root fractures, sodium hypochlorite accidents, or the improper use of ultrasonic devices. The remainder may be the result of excessive masticatory forces, resorptive defects on either or both the internal or external periradicular surfaces, or dental malformations that occur during tooth development.

Many complications are difficult to avoid because of the complex morphology of the tooth and calcification of the root canal system. All of these complications result in the increased risk of treatment failure and the destruction of periodontal tissues surrounding the tooth. Lin et al[89] remind us, however, that errors or complications encountered during endodontic therapy are not the direct cause of treatment failure. Instead, it is the inability to completely remove the pathogens during treatment of these complications that have a negative effect on surrounding periodontal tissues.[89] Therefore, appropriate treatment is required to minimize the loss of these periodontal supporting structures and maximize the prognosis for tooth retention.

Conclusion

Bacterial-induced inflammations of the pulpal and periodontal tissues often occur together. Endodontic lesions are more likely to spread to surrounding periodontal tissues with subsequent bone and tissue destruction compared to the less frequent involvement of periodontal infections on the pulpal tissues resulting in a retrograde pulpitis.

The etiology and diagnosis of dental abscesses are based on patient history and clinical and radiographic findings. Pulpal pathosis often results in significant pain to thermal stimuli, tissue swelling, or may be totally asymptomatic. Radiographic evaluation may demonstrate a circumscribed periapical lesion when the tooth tests necrotic and the origin of the lesion is pulpal. Vitality testing can detect changes of sensation caused by pulpal inflammation and necrosis. If there is evidence of pulpal disease and the possibility of associated periodontal bone loss, the endodontic treatment should be completed first and then the patient should be reevaluated. In many cases, apparent periodontal pathology, including bone loss, suppuration, and pocket depth resolves if there has been a pulpal lesion that has been successfully treated endodontically.

Residual periodontal problems can be treated after completion of successful endodontic treatment, and in many cases, successful regeneration of periodontal defects is possible in endodontically treated teeth.

The importance of the knowledge of these two disciplines is necessary for a successful treatment outcome for the patient.

Suggested Readings

Andreasen JO, Andreasen FM, Mejare I, et al: Healing of 400 intra-alveolar root fractures. Effect of treatment factors such as treatment delay, repositioning, splinting type and period and antibiotics. *Dent Traumatol* 20:203–211, 2004.

Bender IB, Seltzer S: The effect of periodontal disease on the pulp. *Oral Surg Oral Med Oral Pathol* 33:458–474, 1972.

Chen SY, Wang HL, Glickman GN: The influence of endodontic treatment upon periodontal wound healing. *J Clin Periodontol* 24:449–456, 1997.

Costerton JW, Stewart PS, Greenberg EP: Bacterial biofilms: a common cause of persistent infections. *Science* 284:1318–1322, 1999.

Czarnecki RT, Schilder H: A histological evaluation of the human pulp in teeth with varying degrees of periodontal disease. *J Endod* 5:242–253, 1979.

González-Moles MA, González NM: Bacterial infections of pulp and periodontal origin. *Med Oral Patol Oral Cir Bucal* 9(Suppl):32–36, 2004.

Herrera D, Roldán S, González I, et al: The periodontal abscess (I). Clinical and microbiological findings. *J Clin Periodontol* 27:387–394, 2000.

Hong CY, Lin SK, Kok SH, et al: The role of lipopolysaccharide in infectious bone resorption of periapical lesion. *J Oral Pathol Med* 33:162–169, 2004.

Jansson LE, Ehnevid H, Lindskog S, et al: The influence of endodontic infection on progression of marginal bone loss in periodontitis. *J Clin Periodontol* 22:729–734, 1995.

Jaramillo A, Arce RM, Herrera D, et al: Clinical and microbiological characterization of periodontal abscesses. *J Clin Periodontol* 32:1213–1218, 2005.

Kerns DG, Glickman GN: Endodontic and periodontal interrelationships. In Cohen S, Hargreaves K, editors: *Pathways of the pulp*, ed 9, St. Louis, 2006, Elsevier Mosby.

Kobayashi T, Hayashi A, Yoshikawa R, et al: The microbial flora from root canals and periodontal pockets of non-vital teeth associated with advanced periodontitis. *Int Endod J* 23:100–106, 1990.

Mazur B, Massler M: Influence of periodontal disease of the dental pulp. *Oral Surg Oral Med Oral Pathol* 17:592–603, 1964.

Nair PN: Pathogenesis of apical periodontitis and the causes of endodontic failures. *Crit Rev Oral Biol Med* 15:348–381, 2004.

Rothstein I, Simon JH: The endo-perio lesion: a critical appraisal of the disease condition. *Endod Topics* 13:34–56, 2006.

Torabinejad M, Kiger RD: A histologic evaluation of dental pulp tissue of a patient with periodontal disease. *Oral Surg Oral Med Oral Pathol* 59:198–200, 1985.

Whyman RA: Endodontic-periodontic lesions. Part II: Management. *N Z Dent J* 84:109–111, 1988.

References

References for this chapter are found on the companion website www.expertconsult.com.

References

1. Abou-Rass M, Frank AL, Glick DH: The anticurvature filing method to prepare the curved root canal. *J Am Dent Assoc* 101:792–794, 1980.
2. Accorinte Mde L, Loguercio AD, Reis A, et al: Adverse effects of human pulps after direct pulp capping with the different components from a total-etch, three-step adhesive system. *Dent Mater* 21:599–607, 2005.
3. Addy M: Tooth brushing, tooth wear and dentine hypersensitivity—are they associated? *Int Dent J* 4(Suppl 1):261–267, 2005.
4. Aguirre R, El Deeb ME, El Deeb ME: Evaluation of the repair of mechanical furcation perforations using amalgam, gutta-percha, or indium foil. *J Endod* 12:249–256, 1986.
5. Alhadainy HA: Root perforations. A review of literature. *Oral Surg Oral Med Oral Pathol* 78:368–374, 1994.
6. Altun C, Tozum TF, Guven G: Multidisciplinary approach to the rehabilitation of a crown fracture with glass-fibre-reinforced composite: a case report. *J Can Dent Assoc* 74:363–366, 2008.
7. Andreasen JO, Andreasen FM, Mejare I, et al: Healing of 400 intra-alveolar root fractures. Effect of treatment factors such as treatment delay, repositioning, splinting type and period and antibiotics. *Dent Traumatol* 20:203–211, 2004.
8. Bakland LK, Flores MT: Management of traumatic dental injuries. In Torabinejad M, Walton RE, editors: *Endodontics: principles and practice*, ed 4, St. Louis, 2009, Elsevier Saunders.
9. Barkhordar RA, Javid B: Treatment of endodontic perforations by guided tissue regeneration. *Gen Dent* 48:422–426, 2000.
10. Baumgartner JC, Khemaleelakul SU, Xia T: Identification of spirochetes (treponemes) in endodontic infections. *J Endod* 29:794–797, 2003.
11. Bender IB, Seltzer S: The effect of periodontal disease on the pulp. *Oral Surg Oral Med Oral Pathol* 33:458–474, 1972.
12. Bender IB: Pulp pain diagnosis—a review. *J Endod* 26:175–179, 2000.
13. Benenati FW: Treatment of a mandibular molar with perforating internal resorption. *J Endod* 27:474–475, 2001.
14. Bergenholtz G, Lindhe J: Effect of experimentally induced marginal periodontitis and periodontal scaling on the dental pulp. *J Clin Periodontol* 5:59–73, 1978.
15. Bishop K, Alani A: Dens invaginatus. Part 2: clinical, radiographic features and management options. *Int Endod J* 41:1137–1154, 2008.
16. Bogen G, Kuttler S: Mineral trioxide aggregate obturation: a review and case series. *J Endod* 35:777–790, 2009.
17. Butler WT, Brunn JC, Qin C: Dentin extracellular matrix (ECM) proteins: comparison to bone ECM and contribution to dynamics of dentinogenesis. *Connect Tissue Res* 44:171–178, 2003.
18. Chan CP, Lin CP, Tseng SC, et al: Vertical root fracture in endodontically versus nonendodontically treated teeth: a survey of 315 cases in Chinese patients. *Oral Surg Oral Med Oral Pathol Oral Radiol Endod* 87:504–507, 1999.
19. Chan CP, Tseng SC, Lin CP, et al: Vertical root fracture in nonendodontically treated teeth—a clinical report of 64 cases in Chinese patients. *J Endod* 24:678–681, 1998.
20. Chen SY, Wang HL, Glickman GN: The influence of endodontic treatment upon periodontal wound healing. *J Clin Periodontol* 24:449–456, 1997.
21. Cohen S, Blanco L, Berman L: Vertical root fractures: clinical and radiographic diagnosis. *J Am Dent Assoc* 134:434–441, 2003.
22. Contreras A, Slots J: Typing of herpes simplex virus from human periodontium. *Oral Microbiol Immunol* 16:63–64, 2001.
23. Contreras A, Umeda M, Chen C, et al: Relationship between herpesviruses and adult periodontitis and periodontopathic bacteria. *J Periodontol* 70:478–484, 1999.
24. Costerton JW, Stewart PS, Greenberg EP: Bacterial biofilms: a common cause of persistent infections. *Science* 284:1318–1322, 1999.
25. Czarnecki RT, Schilder H: A histological evaluation of the human pulp in teeth with varying degrees of periodontal disease. *J Endod* 5:242–253, 1979.
26. Cvek M, Mejare I, Andreasen JO: Healing and prognosis of teeth with intra-alveolar fractures involving the cervical part of the root. *Dent Traumatol* 18:57–65, 2002.
27. Dahle UR, Tronstad L, Olsen I: Characterization of new periodontal and endodontic isolates of spirochetes. *Eur J Oral Sci* 104:41–47, 1996.
28. Dang DA, Walton RE: Vertical root fracture and root distortion: effect of spreader design. *J Endod* 15:294–301, 1989.
29. Dello Russo NM: The post-prophylaxis periodontal abscess: etiology and treatment. *Int J Periodontics Restorative Dent* 5:28–37, 1985.
30. Diem CR, Bowers GM, Ferrigno PD, et al: Regeneration of the attachment apparatus on pulpless teeth denuded of cementum in the rhesus monkey. *J Periodontol* 45:18–22, 1974.
31. Ehnevid H, Jansson L, Lindskog S, et al: Endodontic pathogens: propagation of infection through patent dentinal tubules in traumatized monkey teeth. *Endod Dent Traumatol* 11:229–234, 1995.
32. Eriksson AR, Albrektsson T: Temperature threshold levels for heat-induced bone tissue injury: a vital-microscopic study in the rabbit. *J Prosthet Dent* 50:101–107, 1983.
33. Ettrich CA, Labossiere PE, Pitts DL, et al: An investigation of the heat induced during ultrasonic post removal. *J Endod* 33:1222–1226, 2007.
34. Fabricius L, Dahlén G, Holm SE, et al: Influence of combinations of oral bacteria on periapical tissues of monkeys. *Scand J Dent Res* 90:200–206, 1982.
35. Flores MT, Andersson L, Andreasen JO, et al: Guidelines for the management of traumatic dental injuries. I. Fractures and luxations of permanent teeth. *Dent Traumatol* 23:66–71, 2007.
36. Flores MT, Andersson L, Andreasen JO, et al: Guidelines for the management of traumatic dental injuries. II. Avulsion of permanent teeth. *Dent Traumatol* 23:130–136, 2007.
37. Flores MT, Malmgren B, Andersson L, et al: Guidelines for the management of traumatic dental injuries. III. Primary teeth. *Dent Traumatol* 23:196–202, 2007.
38. Fogel HM, Pashley DH: Effect of periodontal root planing on dentin permeability. *J Clin Periodontol* 20:673–677, 1993.
39. Fuss Z, Trope M: Root perforations: classification and treatment choices based on prognostic factors. *Endod Dent Traumatol* 12:255–264, 1996.
40. Fuss Z, Lustig J, Katz A, et al: An evaluation of endodontically treated vertical root fractured teeth: impact of operative procedures. *J Endod* 27:46–48, 2001.
41. Fuss Z, Lustig J, Tamse A: Prevalence of vertical root fractures in extracted endodontically treated teeth. *Int Endod J* 32:283–286, 1999.
42. Gao YJ, Yin XM, Wu HJ: Relationship between vertical root fracture and the habits of chewing betel nut. *Hunan Yi Ke Da Xue Xue Bao* 26:161–162, 2001.
43. Gao ZR, Shi JN, Wang Y, et al: Scanning electron microscopic investigation of maxillary lateral incisors with a radicular lingual groove. *Oral Surg Oral Med Oral Pathol* 68:462–466, 1989.
44. Garrido AD, Fonseca TS, Silva-Sousa YT, et al: Evaluation of root external temperature during the application of ultrasound in removal of intraradicular posts. *Gen Dent* 55:121–124, 2007.
45. Glick M, Trope M, Pliskin ME: Detection of HIV in the dental pulp of a patient with AIDS. *J Am Dent Assoc* 119:649–650, 1989.
46. Gokay O, Ziraman F, Cali Asal A, et al: Radicular peroxide penetration from carbamide peroxide gels during intracoronal bleaching. *Int Endod J* 41:556–560, 2008.
47. Gonzales JR: Rodekirchen H: Endodontic and periodontal treatment of an external cervical resorption. *Oral Surg Oral Med Oral Pathol Oral Radiol Endod* 104:e70–e77, 2007.
48. González-Moles MA, González NM: Bacterial infections of pulp and periodontal origin. *Med Oral Patol Oral Cir Bucal* 9(Suppl):32–36, 2004.
49. Gound TG: Dens invaginatus—a pathway to pulpal pathology: a literature review. *Pract Periodontics Aesthet Dent* 9:585–594, 1997.
50. Guiliana G, Ammatuna P, Pizzo G, et al: Occurrence of invading bacteria in radicular dentin of periodontally diseased teeth: microbiological findings. *J Clin Periodontol* 24:478–485, 1997.

51. Gutman JL: Prevalence, location, and patency of accessory canals in the furcation region of permanent molars. *J Periodontol* 49:21–26, 1978.
52. Hahn CL, Liewehr FR: Relationships between caries bacteria, host responses, and clinical signs and symptoms of pulpitis. *J Endod* 33:213–219, 2007.
53. Hassan B, Metska ME, Ozok AR, et al: Detection of vertical root fractures in endodontically treated teeth by a cone beam computed tomography scan. *J Endod* 35:719–722, 2009.
54. Heithersay GS: Combined endodontic-orthodontic treatment of transverse root fractures in the region of the alveolar crest. *Oral Surg Oral Med Oral Pathol* 36:404–415, 1973.
55. Heithersay GS: Invasive cervical resorption following trauma. *Aust Endod J* 25:79–85, 1999.
56. Helovuo H, Hakkarainen K, Paunio K: Changes in the prevalence of subgingival enteric rods, staphylococci and yeasts after treatment with penicillin and erythromycin. *Oral Microbiol Immunol* 8:75–79, 1993.
57. Herrera D, Roldán S, González I, et al: The periodontal abscess (I). Clinical and microbiological findings. *J Clin Periodontol* 27:387–394, 2000.
58. Holcomb JQ, Pitts DL, Nicholls JI: Further investigation of spreader loads required to cause vertical root fracture during lateral condensation. *J Endod* 13:277–284, 1987.
59. Hong CY, Lin SK, Kok SH, et al: The role of lipopolysaccharide in infectious bone resorption of periapical lesion. *J Oral Pathol Med* 33:162–169, 2004.
60. Huttula AS, Tordik PA, Imamura G, et al: The effect of ultrasonic post instrumentation on root surface temperature. *J Endod* 32:1085–1087, 2006.
61. Jansson LE, Ehnevid H, Lindskog S, et al: The influence of endodontic infection on progression of marginal bone loss in periodontitis. *J Clin Periodontol* 22:729–734, 1995.
62. Jansson LE, Ehnevid H, Lindskog SF, et al: Radiographic attachment in periodontitis-prone teeth with endodontic infection. *J Periodontol* 64:947–953, 1993.
63. Jaramillo A, Arce RM, Herrera D, et al: Clinical and microbiological characterization of periodontal abscesses. *J Clin Periodontol* 32:1213–1218, 2005.
64. Jiang HW, Zhang W, Ren BP, et al: Expression of toll like receptor 4 in normal human odontoblasts and dental pulp tissue. *J Endod* 32:747–751, 2006.
65. Joyce AP, Loushine RJ, West LA, et al: Photoelastic comparison of stress induced by using stainless-steel versus nickel-titanium spreaders in vitro. *J Endod* 24:714–715, 1998.
66. Jung IY, Choi B, Kum KY, et al: Identification of oral spirochetes at the species level and their association with other bacteria in endodontic infections. *Oral Surg Oral Med Oral Pathol Oral Radiol Endod* 92:329–334, 2001.
67. Jung IY, Seo MA, Fouad AF, et al: Apical anatomy in mesial and mesiobuccal roots of permanent first molars. *J Endod* 31:364–368, 2005.
68. Kakehashi S, Stanley HR, Fitzgerald RJ: The effects of surgical exposures of dental pulps in germ-free and conventional laboratory rats. *Oral Surg Oral Med Oral Pathol* 20:340–349, 1965.
69. Kawashima N, Wadachi R, Suda H, et al: Root canal medicaments. *Int Dent J* 59:5–11, 2009.
70. Keenan JV, Farman AG, Fedorowicz Z, et al: Antibiotic use for irreversible pulpitis. *Cochrane Database Syst Rev* (18):CD004969, 2005.
71. Kerns DG, Glickman GN: Endodontic and periodontal interrelationships. In Cohen S, Hargreaves K, editors: *Pathways of the pulp*, ed 9, St. Louis, 2006, Elsevier Mosby.
72. Khemaleelakul S, Baumgartner JC: Pruksakorn S: Identification of bacteria in acute endodontic infections and their antimicrobial susceptibility. *Oral Surg Oral Med Oral Pathol Oral Radiol Endod* 94:746–755, 2002.
73. Kim E, Song JS, Jung IY, et al: Prospective clinical study evaluating endodontic microsurgery outcomes for cases with lesions of endodontic origin compared with cases with lesions of combined periodontal-endodontic origin. *J Endod* 34:546–551, 2008.
74. Kim S, Dorscher-Kim JE, Liu M, et al: Functional alterations in pulpal microcirculation in response to various dental procedures and materials. *Proc Finn Dent Soc* 88(Suppl 1):65–71, 1992.
75. Kimura R, Anan H, Matsumoto A, et al: Dental root resorption and repair: histology and histometry during physiological drift of rat molars. *J Periodontal Res* 38:525–532, 2003.
76. Kirkham DB: The location and incidence of accessory pulpal canals in periodontal pockets. *J Am Dent Assoc* 91:353–356, 1975.
77. Kishen A: Mechanisms and risk factors for fracture predilection in endodontically treated teeth. *Endod Topics* 13:57, 2006.
78. Kleier DJ, Averbach RE, Mehdipour O: The sodium hypochlorite accident: experience of diplomates of the American Board of Endodontics. *J Endod* 34:1346–1350, 2008.
79. Kobayashi T, Hayashi A, Yoshikawa R, et al: The microbial flora from root canals and periodontal pockets of non-vital teeth associated with advanced periodontitis. *Int Endod J* 23:100–106, 1990.
80. Kocak S, Cinar S, Kocak MM, et al: Intraradicular splinting with endodontic instrument of horizontal root fracture—case report. *Dent Traumatol* 24:578–580, 2008.
81. Komatsu K, Shimada A, Shibata T, et al: Long-term effects of local pretreatment with alendronate on healing of replanted rat teeth. *J Periodontal Res* 43:194–200, 2008.
82. Kurtzman GM, Silverstein LH, Shatz PC: Hemisection as an alternative treatment for vertically fractured mandibular molars. *Compend Contin Educ Dent* 27:126–129, 2006.
83. Lam PP, Palamara JE, Messer HH: Fracture strength of tooth roots following canal preparation by hand and rotary instrumentation. *J Endod* 31:529–532, 2005.
84. Langeland K, Rodrigues H, Dowden W: Periodontal disease, bacteria, and pulpal histopathology. *Oral Surg Oral Med Oral Pathol* 37:257–270, 1974.
85. Lantelme RL, Handelman SL, Herbison RJ: Dentin formation in periodontally diseased teeth. *J Dent Res* 55:48–51, 1976.
86. Lara VS, Consolaro A, Bruce RS: Macroscopic and microscopic analysis of the palato-gingival groove. *J Endod* 26:345–350, 2000.
87. Laux M, Abbott PV, Pajarola G, et al: Apical inflammatory root resorption: a correlative radiographic and histologic assessment. *Int Endod J* 33:483–493, 2000.
88. Leigh R: Dental pathology of the Eskimo. *Dent Cosmos* 67:884–898, 1925.
89. Lin LM, Rosenberg PA, Lin J: Do procedural errors cause endodontic treatment failure? *J Am Dent Assoc* 136:187–193, 2005.
90. Loe H, Waerhaug J: Experimental replantation of teeth in dogs and monkeys. *Arch Oral Biol* 3:176–184, 1961.
91. Lustig JP, Tamse A, Fuss Z: Pattern of bone resorption in vertically fractured, endodontically treated teeth. *Oral Surg Oral Med Oral Pathol Oral Radiol Endod* 90:224–227, 2000.
92. Lustosa-Pereira A, Garcia RB, de Moraes IG, et al: Evaluation of the topical effect of alendronate on the root surface of extracted and replanted teeth. Microscopic analysis on rats' teeth. *Dent Traumatol* 22:30–35, 2006.
93. Main C, Mirzayan N, Shabahang S, et al: Repair of root perforations using mineral trioxide aggregate: a long term study. *J Endod* 30:80, 2004.
94. Mandi FA: Histological study of the pulp changes caused by periodontal disease. *J Br Endod Soc* 6:80–82, 1972.
95. Matthews DC, Sutherland S, Basrani B: Emergency management of acute apical abscesses in the permanent dentition: a systematic review of the literature. *J Can Dent Assoc* 69:660, 2003.
96. Matthews DC, Tabesh M: Detection of localized tooth-related factors that predispose to periodontal infections. *Periodontol 2000* 34:136–150, 2004.
97. Mazur B, Massler M: Influence of periodontal disease of the dental pulp. *Oral Surg Oral Med Oral Pathol* 17:592–603, 1964.
98. McCulloch KJ, Mills CM, Greenfeld RS, et al: Dens evaginatus: review of the literature and report of several clinical cases. *J Can Dent Assoc* 64:104–106, 110–113, 1998.
99. McLeod DE, Lainson PA, Spivey JD: Tooth loss due to periodontal abscess: a retrospective study. *J Periodontol* 68:963–966, 1997.

100. Mehdipour O, Kleier DJ, Averbach RE: Anatomy of sodium hypochlorite accidents. *Compend Contin Educ Dent* 28:544–546, 548, 550, 2007.
101. Meister F, Jr, Lommel TJ, Gerstein H: Diagnosis and possible causes of vertical root fractures. *Oral Surg Oral Med Oral Pathol* 49:243–253, 1980.
102. Möller AJ, Fabricius L, Dahlén G, et al: Influence on periapical tissues of indigenous oral bacteria and necrotic pulp tissue in monkeys. *Scand J Dent Res* 89:475–484, 1981.
103. Morfis AS: Vertical root fractures. *Oral Surg Oral Med Oral Pathol* 69:631–635, 1990.
104. Motamedi MH: Root perforations following endodontics: a case for surgical management. *Gen Dent* 55:19–21, 2007.
105. Mullaney TP, Laswell HR: Iatrogenic blushing of dentin following full crown preparation. *J Prosthet Dent* 22:354–359, 1969.
106. Murgel CA, Walton RE: Vertical root fracture and dentin deformation in curved roots: the influence of spreader design. *Endod Dent Traumatol* 6:273–278, 1990.
107. Nair PN: Pathogenesis of apical periodontitis and the causes of endodontic failures. *Crit Rev Oral Biol Med* 15:348–381, 2004.
108. Nicopoulou-Karayianni K, Bragger U, Lang NP: Patterns of periodontal destruction associated with incomplete root fractures. *Dentomaxillofac Radiol* 26:321–326, 1997.
109. Oehlers FA: Dens invaginatus. II. Associated posterior crown forms and pathogenesis. *Oral Surg Oral Med Oral Pathol* 10:1302–1316, 1957.
110. Oikarinen K: Tooth splinting: a review of the literature and consideration of the versatility of a wire-composite splint. *Endod Dent Traumatol* 6:237–250, 1990.
111. Okitsu M, Takahashi H, Yoshioka T, et al: Effective factors including periodontal ligament on vertical root fractures. *Dent Mater J* 24:66–69, 2005.
112. Oliveira TM, Sakai VT, Silva TC, et al: Repair of furcal perforation treated with mineral trioxide aggregate in a primary molar tooth: 20-month follow-up. *J Dent Child (Chic)* 75:188–191, 2008.
113. Pace R, Giuliani V, Pagavino G: Mineral trioxide aggregate as repair material for furcal perforation: case series. *J Endod* 34:1130–1133, 2008.
114. Palmer R: Oral bacterial biofilms—history in progress. *Microbiology* 155(Pt 7):2113, 2009. [Epub ahead of print].
115. Papapoulos SE: Bisphosphonates: how do they work? *Best Pract Res Clin Endocrinol Metab* 22:831–847, 2008.
116. Paranjpe A, Cacalano NA, Hume WR, et al: N-acetylcysteine protects dental pulp stromal cells from HEMA-induced apoptosis by inducing differentiation of the cells. *Free Radic Biol Med* 43:1394–1408, 2007.
117. Paul BF, Hutter JW: The endodontic-periodontal continuum revisited: new insights into etiology, diagnosis and treatment. *J Am Dent Assoc* 128:1541–1548, 1997.
118. Pitt Ford TR, Torabinejad M, McKendry DJ, et al: Use of mineral trioxide aggregate for repair of furcal perforations. *Oral Surg Oral Med Oral Pathol Oral Radiol Endod* 79:756–763, 1995.
119. Pitts DL, Natkin E: Diagnosis and treatment of vertical root fractures. *J Endod* 9:338–346, 1983.
120. Raab WH: Temperature related changes in pulpal microcirculation. *Proc Finn Dent Soc* 88:469–479, 1992.
121. Reeder OW, Jr, Walton RE, Livingston MJ, et al: Dentin permeability: determinants of hydraulic conductance. *J Dent Res* 57:187–193, 1978.
122. Ricucci D, Langeland K: Apical limit of root canal instrumentation and obturation, part 2. A histological study. *Int Endod J* 31:394–409, 1998.
123. Rôças IN, Siqueira JF, Jr, Santos KR, et al: "Red complex" (Bacteriodes forsythus, Porphyromonas gingivalis, and Treponema denticola) in endodontic infections: a molecular approach. *Oral Surg Oral Med Oral Pathol Oral Radiol Endod* 91:468–471, 2001.
124. Ross RS, Nicholls JI, Harrington GW: A comparison of strains generated during placement of five endodontic posts. *J Endod* 17:450–456, 1991.
125. Rothstein I, Simon JH: The endo-perio lesion: a critical appraisal of the disease condition. *Endod Topics* 13:34–56, 2006.
126. Rubach WC, Mitchell DF: Periodontal disease, accessory canals and pulp pathosis. *J Periodontol* 36:34–38, 1965.
127. Sanders JJ, Sepe WW, Bowers GM, et al: Clinical evaluation of freeze-dried bone allografts in periodontal osseous defects. Part III. Composite freeze-dried bone allografts with and without autogenous bone grafts. *J Periodontol* 54:1–8, 1983.
128. Sathorn C, Palamara JE, Palamara D, et al: Effect of root canal size and external root surface morphology on fracture susceptibility and pattern: a finite element analysis. *J Endod* 31:288–292, 2005.
129. Schuurs AH, Gruythuysen RJ, Wesselink PR: Pulp capping with adhesive resin-based composite vs. calcium hydroxide: a review. *Endod Dent Traumatol* 16:240–250, 2000.
130. Seltzer S, Bender IB, Nazimov H, et al: Pulpitis-induced interradicular periodontal changes in experimental animals. *J Periodontol* 38:124–129, 1967.
131. Seltzer S, Bender IB: Ziontz M: The interrelationship of pulp and periodontal disease. *Oral Surg Oral Med Oral Pathol* 16:1474–1490, 1963.
132. Shovelton DH: The presence and distribution of microorganisms within non-vital teeth. *Br Dent J* 117:101–107, 1964.
133. Siqueira JF, Jr, Rôças IN: The microbiota of acute apical abscesses. *J Dent Res* 88:61–65, 2009.
134. Sirimai S, Riis DN, Morgano SM: An in vitro study of the fracture resistance and the incidence of vertical root fracture of pulpless teeth restored with six post-and-core systems. *J Prosthet Dent* 81:262–269, 1999.
135. Smith RG, Davies RM: Acute lateral periodontal abscesses. *Br Dent J* 161:176–178, 1986.
136. Standlee JP, Caputo AA, Collard EW, et al: Analysis of stress distribution by endodontic posts. *Oral Surg Oral Med Oral Pathol* 33:952–960, 1972.
137. Stanley HR: Design for a human pulp study. II. *Oral Surg Oral Med Oral Pathol* 25:756–764, 1968.
138. Sundqvist G: Ecology of the root canal flora. *J Endod* 18:427–430, 1992.
139. Sutherland S, Matthews DC: Emergency management of acute apical periodontitis in the permanent dentition: a systematic review of the literature. *J Can Dent Assoc* 69:160, 2003.
140. Tan PL, Aquilino SA, Gratton DG, et al: In vitro fracture resistance of endodontically treated central incisors with varying ferrule heights and configurations. *J Prosthet Dent* 93:331–336, 2005.
141. Takahashi N, Nyvad B: Caries ecology revisited: microbial dynamics and the caries process. *Caries Res* 42:409–418, 2008.
142. Tamse A, Fuss Z, Lustig J, et al: An evaluation of endodontically treated vertically fractured teeth. *J Endod* 25:506–508, 1999.
143. Tamse A, Fuss Z, Lustig J, et al: Radiographic features of vertically fractured, endodontically treated maxillary premolars. *Oral Surg Oral Med Oral Pathol Oral Radiol Endod* 88:348–352, 1999.
144. Tamse A: Vertical root fractures in endodontically treated teeth: diagnostic signs and clinical management. *Endod Topics* 13:84, 2006.
145. Tanzer JM, Livingston J, Thompson A: The microbiology of primary dental caries in humans. *J Dent Ed* 65:1028–1037, 2001.
146. Teitelbaum SL: Bone resorption by osteoclasts. *Science* 289:1504–1508, 2000.
147. Thong YL, Messer HH, Zain RB, et al: Intracanal bisphosphonate does not inhibit replacement resorption associated with delayed replantation of monkey incisors. *Dent Traumatol* 2009. [Epub ahead of print].
148. Torabinejad M, Kiger RD: A histologic evaluation of dental pulp tissue of a patient with periodontal disease. *Oral Surg Oral Med Oral Pathol* 59:198–200, 1985.
149. Torneck CD: Dentin-pulp complex. In Ten Cate R, editor: *Oral histology: development, structure, and function*, St. Louis, 1998, Mosby.
150. Trope M, Ray HL, Jr: Resistance to fracture of endodontically treated roots. *Oral Surg Oral Med Oral Pathol* 73:99–102, 1992.
151. Tsesis I, Tamse A, Lustig J, et al: Vertical root fractures in endodontically treated teeth part I: clinical and radiographic diagnosis. *Refuat Hapeh Vehashinayim* 23:13–17, 2006.

152. Tyrovola JB, Spyropoulos MN, Makou M, et al: Root resorption and the OPG/RANKL/RANK system: a mini review. *J Oral Sci* 50:367–376, 2008.
153. Valgi P, Gorzo I: Periodontal abscess: etiology, diagnosis and treatment. *Fogorv* 97:151–155, 2004.
154. Van Hassel HJ: Physiology of the human dental pulp. *Oral Surg Oral Med Oral Pathol* 32:126–134, 1971.
155. Vandenwijngaert S, Vanlerberghe K: Effects of periodontal disease and its treatment on the condition of the pulp. *Rev Belge Med Dent* 55:313–320, 2000.
156. Vertucci F, Seelig A, Gillis R: Root canal morphology of the human maxillary second premolar. *Oral Surg Oral Med Oral Pathol* 38:456–464, 1974.
157. Walters JD, Rawal SY: Severe periodontal damage by an ultrasonic endodontic device: a case report. *Dent Traumatol* 23:123–127, 2007.
158. Waltimo TM, Sen BH, Meurman JH, et al: Yeasts in apical periodontitis. *Crit Rev Oral Biol Med* 14:128–137, 2003.
159. Waltimo TM, Sirén EK, Torkko HL, et al: Fungi in therapy-resistant apical periodontitis. *Int Endod J* 30:96–101, 1997.
160. Walton RE, Michelich RJ, Smith GN: The histopathogenesis of vertical root fractures. *J Endod* 10:48–56, 1984.
161. Wang YL, Lee BS, Tseng CL, et al: In vitro study of root fracture treated by CO2 laser and DP—bioactive glass paste. *J Formos Med Assoc* 107:46–53, 2008.
162. Wedenberg C, Lindskog S: Macrophage colonization of infected and noninfected dental tissues in vitro. *Scan J Dent Res* 94:311–319, 1986.
163. Wedenberg C, Yumita S: Evidence for an inhibitor of osteoclast attachment in dentinal matrix. *Endod Dent Traumatol* 6:255–259, 1990.
164. Weine FS: Endodontic-periodontal problems. In Weine FS, editor: *Endodontic therapy*, ed 5, St. Louis, 1995, Mosby.
165. Whyman RA: Endodontic-periodontic lesions. Part II: Management. *N Z Dent J* 84:109–111, 1988.
166. Wilcox LR, Roskelley C, Sutton T: The relationship of root canal enlargement to finger-spreader induced vertical root fracture. *J Endod* 23:533–534, 1997.
167. Wu MK, van der Sluis LW, Wesselink PR: Comparison of mandibular premolars and canines with respect to their resistance to vertical root fracture. *J Dent* 32:265–268, 2004.
168. Yates JA: Root fractures in permanent teeth: a clinical review. *Int Endod J* 25:150–157, 1992.
169. Yildirim G, Dalci K: Treatment of lateral root perforation with mineral trioxide aggregate: a case report. *Oral Surg Oral Med Oral Pathol Oral Radiol Endod* 102:e55–e58, 2006.
170. Youssefzadeh S, Gahleitner A, Dorffner R, et al: Dental vertical root fractures: value of CT in detection. *Radiol* 210:545–549, 1999.
171. Zach L, Cohen G: Pulp response to externally applied heat. *Oral Surg Oral Med Oral Pathol* 19:515–530, 1962.
172. Zadik Y, Sandler V, Bechor R, et al: Analysis of factors related to extraction of endodontically treated teeth. *Oral Surg Oral Med Oral Pathol Endod* 106:e31–e35, 2008.
173. Zehnder M: Root canal irrigants. *J Endod* 32:389, 2006.

CHAPTER 44

Phase I Periodontal Therapy

Dorothy A. Perry and Henry H. Takei

CHAPTER OUTLINE

Rationale
Treatment Sessions
Sequence of Procedures
Results
Healing
Decision to Refer for Specialist Treatment
Conclusion

Phase I therapy or cause-related therapy[10] is the first in the chronologic sequence of procedures that constitute periodontal treatment. The objective of phase I therapy is to alter or eliminate the microbial etiology and factors that contribute to gingival and periodontal diseases to the greatest extent possible, therefore halting the progression of disease and returning the dentition to a state of health and comfort.[5] Phase I therapy is referred to by a number of names, including *initial therapy,*[5,10] *nonsurgical periodontal therapy,*[18] *cause-related therapy.*[10] All terms refer to the procedures performed to treat gingival and periodontal infections, up to and including tissue reevaluation, which is the point at which the course of ongoing care is determined.

Rationale

Phase I therapy is defined by the evidence-based American Association of Periodontology practice guidelines[5] as the initiation of a comprehensive daily plaque control regimen, management of periodontal-systemic interrelationships as needed, thorough removal of supra and subgingival bacterial plaque biofilm and calculus, chemotherapeutic agents as necessary, and elimination of local factors[1,2,3,4,6] such as defective restorations and treatment of carious lesions.[7,9,15,16,20] These procedures are a required part of periodontal therapy, regardless of the extent of disease present. In many cases, only phase I therapy will required to restore periodontal health, or it will constitute the preparatory phase for surgical therapy. Figures 44-1 and 44-2 show the results of phase I therapy in two patients with chronic periodontitis. The goal of cause-related phase I periodontal therapy has been succinctly stated as the approach *aimed at removal of pathogenic biofilms, toxins and calculus, and the reestablishment of a biologically acceptable root surface*.[10]

Phase I therapy is a critical aspect of periodontal treatment. Data from clinical research indicate that the long-term success of periodontal surgical treatment is dependent upon maintaining the plaque biofilm control results achieved with phase I therapy. In fact, patients who do not have adequate plaque biofilm control will continue to lose attachment regardless of what surgical procedures are performed.[12] In addition, phase I therapy provides an opportunity for the dentist to evaluate tissue response and provide reinforcement about home care, both of which are crucial elements to the overall success of treatment.

Based on the knowledge that microbial plaque biofilm is the major etiologic agent in gingival inflammation, one specific aim of phase I therapy for every patient is *effective daily plaque biofilm removal* at home. These home care procedures can be complex, time consuming, and often require changing long-standing habits. Good oral hygiene is more easily accomplished if the tooth surfaces are free of calculus deposits and other irregularities so that surfaces are easily accessible. Management of contributing all local factors is required in phase I therapy. The following list of elements makes up phase I therapy:

1. Complete removal of calculus (see Chapters 46 and 47)
2. Correction or replacement of poorly fitting restorations and prosthetic devices (see Chapter 67)
3. Restoration or temporization of carious lesions
4. Orthodontic tooth movement (see Chapter 51)
5. Treatment of food impaction areas
6. Treatment of occlusal trauma (see Chapter 50)
7. Extraction of hopeless teeth
8. Possible use of antimicrobial agents including necessary plaque sampling and sensitivity testing (see Chapters 8 and 48)

Treatment Sessions

After careful analysis and diagnosis of the specific periodontal condition present, the dentist must develop a treatment plan that includes all required procedures and estimates the number of appointments necessary to complete phase I therapy. In most cases, patients require several treatment sessions for the complete debridement of tooth surfaces. All of the following conditions must be considered when determining the phase I treatment plan[18]:

- General health and tolerance of treatment
- Number of teeth present
- Amount of subgingival calculus
- Probing pocket depths
- Attachment loss
- Furcation involvements
- Alignment of teeth
- Margins of restorations
- Developmental anomalies
- Physical barriers to access (i.e., limited opening or tendency to gag)
- Patient cooperation and sensitivity (requiring use of anesthesia or analgesia)

Figure 44-1 Results of phase I therapy, severe chronic periodontitis. **A,** 45-year-old patient with deep probe depths, bone loss, severe swelling, and redness of the gingival tissues. **B,** Results 3 weeks after the completion of phase I therapy. Note that the gingival tissue has returned to a normal contour, with redness and swelling dramatically reduced.

Figure 44-2 Results of phase I therapy, moderate chronic periodontitis. **A,** 52-year-old patient with moderate attachment loss and probe depths in the 4- to 6-mm range. Note that the gingiva appears pink because it is fibrotic. Inflammation is present in the periodontal pockets but disguised by the fibrotic tissue. Bleeding occurs on probing. **B,** Lingual view of the patient with more visible inflammation and heavy calculus deposits. **C** and **D,** 18 months after phase I therapy the same areas show significant improvement in gingival health. The patient returned for regular maintenance visits at 4-month intervals.

Sequence of Procedures

Step 1: Plaque Biofilm Control Instruction. Plaque biofilm control is the essential component to successful periodontal therapy, and instruction should begin at the first treatment appointment. The patient must learn to correctly brush the teeth, focusing on applying the bristles at the gingival third of the clinical crowns of the teeth, and begin using floss or other aids for interdental cleaning. This is sometimes referred to as *targeted oral hygiene*[22] and emphasizes thorough biofilm removal around the periodontal tissues. The multiple appointment approach to phase I therapy permits the dentist to evaluate, reinforce, and improve the patient's oral hygiene skills. (Chapter 45 details plaque control options.)

Step 2. Removal of Supragingival and Subgingival Plaque Biofilm and Calculus. Removal of calculus is accomplished using scalers, curettes, ultrasonic instrumentation, or combinations of these devices during one or more appointments. Evidence suggests that the treatment results for chronic periodontitis are similar for all instruments.[12,13] In addition to calculus removal, bacterial plaque biofilm and some cementum are removed by instrumentation procedures as a matter of course. At one time it was thought that all cementum had to be systematically planed off of root surfaces in order to leave a glassy hard surface free of accumulated bacterial toxins. The rationale was that cementum became necrotic from penetration of lipopolysaccharide endotoxins from the microbial biofilm and would interfere with healing. Lipopolysaccharides are loosely attached and easily removed from cementum so that instrumentation beyond the thorough removal of calculus and plaque biofilm will not improve treatment outcomes. As a consequence the term *debridement* is now used as commonly than root planing.[12]

Laser treatment has also been advocated for periodontal therapy by and some dentists.[8] However, recent reviews suggest that further well-designed studies are needed to confirm improved outcomes. In addition, gingival curettage, the systematic removal of the soft tissue lining of the pockets has not been shown to improve results of treatment, and there is little if any change in outcomes from performing irrigation or lavage of periodontal pockets during phase I treatment appointments.[12]

Photodynamic therapy has also been posited as an adjunct to scaling and root planing. This therapy uses lasers at specific wavelengths to "target microorganisms treated with a photosensitizer." Studies have not found this intervention to be useful as an alternative to scaling and root planing, or to improve treatment outcomes, and further research needs to be conducted to ascertain the efficacy of this treatment.[12]

One other interesting approach to calculus removal and debridement is full mouth disinfection. The technique is to perform the full mouth treatment at one session, or multiple sessions within a day or so, and using disinfectants with the intention preventing reinfection of treated sites from untreated sites.[14,17,19] This treatment approach may also be used for phase I therapy, but it has not been shown to be superior to any other phase I therapy treatment plan.[11,12,21]

There are multiple approaches to planning and performing nonsurgical phase I therapy. Decisions as to how to proceed should be discussed and agreed upon by the patient and the dentist based on amount of disease present and patient comfort.[11] Staged therapy permits the advantage of evaluating and reinforcing oral hygiene care, and the one or two appointment therapies can be more efficient in reducing the number of office visits the patient is required to attend.

Step 3. Recontouring Defective Restorations and Crowns. Corrections for restorative defects, which are plaque traps, may be made by smoothing surfaces and overhangs with burs or hand instruments or by replacing restorations. These procedures can be completed concurrently with other phase I procedures.

Step 4. Management of Carious Lesions. Removal of the carious tissue and placement with either temporary or permanent restorations is indicated in phase I therapy because of the infectious nature of the caries process. Healing of the periodontal tissues will be maximized by removing the reservoir of bacteria in these lesions so that they cannot repopulate the microbial plaque.

Step 5. Tissue Reevaluation. After scaling, root planing, and other phase I procedures, the periodontal tissues require approximately 4 weeks to heal so that the connective tissues have time to heal and accurate probe depths can be measured. Patients also need the opportunity to improve their home care skills required to reduce inflammation and adopt new habits that ensure the success of treatment. At the reevaluation appointment, periodontal tissues are probed, and all related anatomic conditions are carefully evaluated to determine if further treatment, including periodontal surgery, is indicated. Additional improvement from periodontal surgical procedures can be expected only if phase I therapy resulted in the gingiva being free of overt inflammation and the patient has adopted effective daily plaque biofilm control procedures.

Results

Scaling and root planing therapy has been studied extensively to evaluate its effects on periodontal disease. Many studies indicated that this treatment is both effective and reliable. Studies ranging from 1 month to 2 years in length demonstrated up to 80% reduction in bleeding on probing and mean probing depth reductions of 2 to 3 mm. Others demonstrated that the percentage of periodontal pockets of 4-mm or greater depth was reduced more than 50% and up to 80%.[9] Figures 44-1 and 44-2 show examples of the effectiveness of phase I therapy.

It is also important to recognize that deeper probing depths present the dentist with greatly increased instrumentation challenges due to the complexity of root anatomy and difficulty of access. Badersten and colleagues[7] showed in the 1980s that more residual calculus remained in deeper pockets on up to 44% of the surfaces. Other studies have confirmed these findings, including those comparing the use of hand instruments to powered scaling instruments.[12]

Additional individual treatments, such as caries control and correction of poorly fitting restorations, clearly augment the healing gained through good plaque biofilm control and debridement by making tooth surfaces accessible to cleaning procedures. Figure 44-3 demonstrates the effects of an overhanging amalgam restoration on gingival inflammation in an otherwise healthy periodontium. Maximal healing from phase I treatment is not possible when local conditions retain biofilm and provide reservoirs for repopulation of periodontal pathogens.

Healing

Healing of the gingival epithelium consists of the formation of a long junctional epithelium rather than new connective tissue attachment to the root surfaces. The attachment epithelium reappears about 1 week after therapy. Gradual reductions in inflammatory cell population, crevicular fluid flow, and repair of connective tissue result in decreased clinical signs of inflammation, including less redness and swelling. One or two millimeters of recession is often apparent as the result of tissue shrinkage.[9] Connective tissue fibers are disrupted and lysed by the disease process and also by the inflammatory reaction to treatment. These tissues requires 4 or more weeks to reorganize and heal, and complete healing can take months.

Transient root sensitivity frequently accompanies the healing process. Although evidence suggests that relatively few teeth in a few patients become highly sensitive, this development is common and can be disconcerting to patients. The extent of the sensitivity can be diminished through good plaque biofilm removal.[23] Warning patients about the potential outcomes of the teeth appearing longer because of shrinkage of periodontal tissues and tooth root sensitivity at the beginning of the treatment sequence will avoid surprise if these changes occur. Unexpected and possibly uncomfortable consequences to treatment may result in distrust and loss of motivation to continue therapy.

Decision to Refer for Specialist Treatment

Often, periodontal conditions heal sufficiently well after phase I therapy that no further treatment is required beyond routine maintenance, making treatment of most periodontal patients the responsibility of the general dentist. However, advanced or complicated cases benefit from specialist care. It has been demonstrated by Heitz-Mayfield and coworkers[12] that surgical treatment in deep pockets, those >6 mm, gained 0.6 mm more probing depth reduction and 0.2 mm more clinical attachment gain than did deep pockets treated with scaling and root planing alone. That group also confirmed that in pockets of 4 to 6 mm probing depth, scaling and root planing resulted in 0.4 mm more attachment gain than surgical procedures, and shallow pockets of 1 to 3 mm had 0.5 mm less attachment loss compared to surgical results.[12] It is critical to be skilled in determining which patients would benefit from specialist care and should be referred.

The concept of the *critical probing depth* of 5.4 mm has been advanced to assist in making the determination to proceed to surgical intervention. This is the measurement above which therapy will result in clinical attachment gain, and below it will result in clinical attachment loss. This determination was made based on statistical analysis of surgical outcomes data.[12] A similar *5-mm standard* has

Figure 44-3 Effects of overhanging amalgam margin on interproximal gingiva of maxillary first molar in otherwise healthy mouth. **A,** Clinical appearance of rough, irregular, and overcontoured amalgam. **B,** Gentle probing of interproximal pocket. **C,** Extensive bleeding elicited by gentle probing indicating severe inflammation in the area.

been commonly used as a guideline for identifying candidates for surgical referral based on the understanding that the typical root length is about 13 mm and the crest of the alveolar bone is at a level approximately 2 mm apical to the bottom of the pocket. When there is 5 mm of clinical attachment loss, the crest of bone is about 7 mm apical to the cementoenamel junction, therefore only about half the bony support for the tooth remains. Periodontal surgery can help improve support for teeth in these cases through pocket reduction, bone augmentation, and regeneration procedures . Figure 44-4 depicts the relationship of clinical attachment loss to tooth support.

In addition to consideration of 5-mm probing depths, other factors must also be factored into the decision to refer:

1. *Extent of disease and generalized or localized deep involvement.* Extensive bone loss, even in localized areas, suggest the need for specialized surgical techniques.
2. *Root length.* Short roots are more seriously jeopardized by 5 mm of clinical attachment loss than long roots.
3. *Hypermobility.* Excessive tooth mobility suggests contributing factors and a more guarded prognosis.
4. *Difficulty of scaling and root planing.* The presence of deep pockets and furcations makes instrumentation much more difficult and results can often be improved with surgical access.
5. *Restorability and importance of particular teeth for reconstruction.* Long-term prognosis of each tooth is important when considering extensive restorative work.
6. *Age of the patient.* Younger patients with extensive attachment loss are more likely to have aggressive forms of disease that require extensive therapy.
7. *Lack of resolution of inflammation after scaling and planing.* If inflammation persists, further therapy is often necessary to gain the most positive results.

Every patient is unique, and the decision process for each patient is complex. The considerations presented in this chapter should provide guidance understanding the significance of phase I therapy and in making referral decisions.

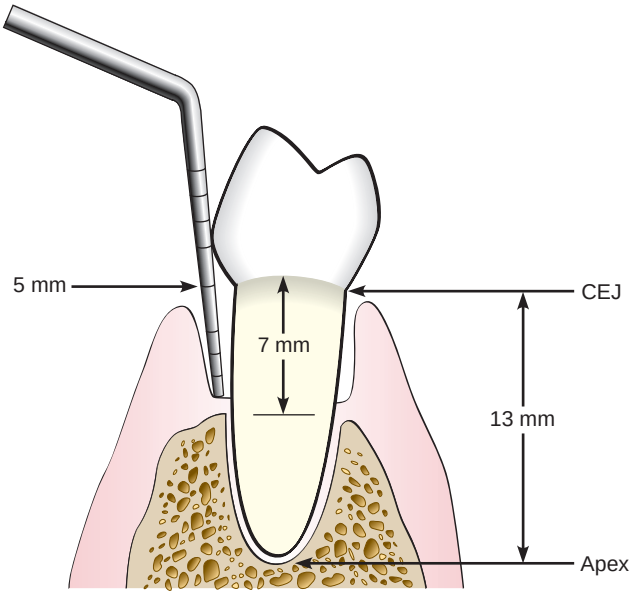

Figure 44-4 The 5-mm standard for referral to a periodontist is based on root length, probing depth, and clinical attachment loss. The standard serves as a reasonable guideline to analyze the case for referral for specialist care. *CEJ,* Cementoenamel junction. *(Redrawn with permission from Armitage G, editor:* Periodontal maintenance therapy*, Berkeley, Calif, 1974, Praxis.)*

Conclusion

The major goal of phase I therapy is to control the factors responsible for the periodontal inflammation; the removal of subgingival bacterial biofilms and the subsequent control of plaque biofilm

levels by patients are particularly significant. Phase I therapy should be comprehensive and include scaling, root planing, and oral hygiene instructions, as well as other therapies such as caries control, replacement of defective restorations, occlusal therapy, orthodontic tooth movement, and cessation of confounding habits such as tobacco use. Comprehensive reevaluation after phase I therapy is essential to determine treatment options and to estimate prognosis. Many patients can have their periodontal disease controlled with phase I therapy alone and not require further surgical intervention. For patients who do need surgical intervention, phase I therapy is an advantageous element of treatment in that it permits tissue healing, thus improving the surgical management and healing response of the tissues.

Periodontal surgical intervention should be considered for patients with critically deep pocket depths and those with 5 mm or more of attachment loss still present after phase I therapy. Periodontal specialists can best provide treatment to preserve the teeth for these patients with advanced disease. It is also important to note that patients who do not demonstrate the ability to successfully control plaque biofilm at home, on a daily basis, are poor candidates for successful surgical outcomes and should be closely monitored on a recall maintenance program unless conditions change.

Suggested Readings

American Academy of Periodontology, Ad Hoc Committee on the Parameters of Care: Phase I therapy. *J Periodontol* 71(Suppl):856, 2000.

American Academy of Periodontology, Task Force to Update the Guidelines for Periodontal Therapy: Comprehensive periodontal therapy: a statement by the American Academy of Periodontology. *J Periodontol* 82:943, 2011.

Dentino A, Lee S, Mailhot J, et al: Principles of periodontology. *Periodontol 2000* 61:16, 2013.

Heitz-Mayfield LJA, Lang NP: Surgical and nonsurgical periodontal therapy. Learned and unlearned concepts. *Periodontol 2000* 62:218, 2013.

References

References for this chapter are found on the companion website www.expertconsult.com.

References

1. American Academy of Periodontology, Ad Hoc Committee on the Parameters of Care: Chronic periodontitis with slight to moderate loss of periodontal support. *J Periodontol* 71(Suppl):853, 2000.
2. American Academy of Periodontology, Ad Hoc Committee on the Parameters of Care: Chronic periodontitis with advanced loss of periodontal support. *J Periodontol* 71(Suppl):856, 2000.
3. American Academy of Periodontology, Ad Hoc Committee on the Parameters of Care: Periodontal maintenance. *J Periodontol* 71(Suppl):849, 2000.
4. American Academy of Periodontology, Ad Hoc Committee on the Parameters of Care: Refractory periodontitis. *J Periodontol* 71(Suppl):859, 2000.
5. American Academy of Periodontology, Ad Hoc Committee on the Parameters of Care: Phase I therapy. *J Periodontol* 71(Suppl):856, 2000.
6. American Academy of Periodontology, Task Force to Update the Guidelines for Periodontal Therapy: Comprehensive periodontal therapy: a statement by the American Academy of Periodontology. *J Periodontol* 82:943, 2011.
7. Badersten A, Nilveus R, Egelberg J: Effect of non-surgical periodontal therapy II: severely advanced periodontitis. *J Clin Periodontol* 11:63, 1984.
8. Cobb CM: Lasers in periodontics: a review of the literature. *J Periodontol* 77:545, 2006.
9. Cobb CM: Non-surgical pocket therapy: mechanical. *Ann Periodontol* 1:443, 1996.
10. Dentino A, Lee S, Mailhot J, et al: Principles of periodontology. *Periodontol 2000* 61:16, 2013.
11. Eberhard J, Jepsen S, Jervøe-Storm PM, et al: Full mouth disinfection for the treatment of adult chronic periodontitis. *Cochrane Database Syst Rev* (1):CD004622, January 23, 2008.
12. Heitz-Mayfield LJA, Lang NP: Surgical and nonsurgical periodontal therapy. Learned and unlearned concepts. *Periodontol 2000* 62:218, 2013.
13. Ioannou I, Dimitriadis N, Papadimitriou K, et al: Hand instrumentation versus ultrasonic debridement in the treatment of chronic periodontitis: a randomized clinical and microbiological trial. *J Clin Periodontol* 36:132, 2009.
14. Lang N, Tan WC, Krahenmann MA, et al: A systematic review of the effects of full-mouth debridement with and without antiseptics in patients with chronic periodontitis. *J Clin Periodontol* 35:8, 2008.
15. Lightner LM, O'Leary TJ, Drake RB, et al: Preventive periodontics treatment procedures: results over 46 months. *J Periodontol* 42:555, 1971.
16. Lindhe J, Kock G: The effect of supervised oral hygiene on the gingiva of children: progression and inhibition of gingivitis. *J Periodontal Res* 1:260, 1966.
17. Mongardini C, van Steenberghe D, Dekeyser C, et al: One stage full- versus partial-mouth disinfection in the treatment of chronic adult or generalized early-onset periodontitis. I. Long-term clinical observations. *J Periodontol* 70:632, 1999.
18. Perry DA, Beemsterboer PB: *Periodontology for the dental hygienist*, ed 4, Chapter 13, Philadelphia, 2013, Elsevier.
19. Quirynen M, Mongardini C, Pauwels M, et al: One stage full- versus partial-mouth disinfection in the treatment of chronic adult or generalized early-onset periodontitis. II. Long-term impact on microbial load. *J Periodontol* 70:646, 1999.
20. Suomi JD, Greene JC, Vermillion JR, et al: The effect of controlled oral hygiene procedures on the progression of periodontal disease in adults: results after third and final year. *J Periodontol* 42:152, 1971.
21. Swierkot K, Nonnenmacher CI, Mutters R, et al: One-stage full-mouth disinfection versus quadrant and full-mouth root planing. *J Clin Periodontol* 36:240, 2009.
22. Takei H: Personal communication, 2009.
23. Tommaro S, Wennstrom JL, Bergenholtz G: Root-dentin sensitivity following non-surgical periodontal treatment. *J Clin Periodontol* 27:690, 2001.

CHAPTER 45

Plaque Biofilm Control for the Periodontal Patient

Dorothy A. Perry

CHAPTER OUTLINE

The Toothbrush
Powered Toothbrushes
Dentifrices
Toothbrushing Methods
Interdental Cleaning Aids
Gingival Massage
Oral Irrigation *(e-only)*
Caries Control *(e-only)*
Chemical Plaque Biofilm Control with Oral Rinses *(e-only)*
Disclosing Agents *(e-only)*
Frequency of Plaque Biofilm Removal *(e-only)*
Patient Motivation and Education *(e-only)*
Conclusion

For online-only content on oral irrigation, caries control, chemical plaque biofilm control with oral rinses, disclosing agents, frequency of plaque biofilm removal, and patient motivation and education, please visit the companion website at www.expertconsult.com.

Microbial plaque biofilm control is an effective way of treating and preventing gingivitis and is an essential part of all the procedures involved in the treatment and prevention of periodontal diseases,[47] It is critical to the long-term success of all periodontal and dental treatment.[3] In 1965, Löe et al[86] conducted the classic study demonstrating the relationship between microbial plaque biofilm accumulation and the development of experimental gingivitis in humans. Subjects in the study stopped brushing and other plaque biofilm control procedures, resulting in the development of gingivitis in every person within 7 to 21 days. The composition of the biofilm bacteria also shifted so that more virulent gram-negative organisms predominated, and these changes were shown to be reversible within 7 days. Good supragingival biofilm control has also been shown to affect the growth and composition of subgingival plaque, so that it favors a healthier microflora and reduces calculus formation.[117] Carefully performed daily home plaque biofilm control, combined with frequent professionally delivered plaque biofilm and calculus removal, reduces the amount of supragingival biofilm; decreases the total number of microorganisms in moderately deep pockets, including furcation areas; and greatly reduces the quantity of periodontal pathogens.[27,58] Reviews of home care procedures in 2011 and 2013 confirm the positive effects of daily plaque biofilm removal but cautions that these gains appear to be small and best results also require professional maintenance care.[30,103]

Microbial biofilm growth occurs within hours, and it must be completely removed at least once every 48 hours in the experimental setting with periodontally healthy subjects to prevent inflammation.[116] The American Dental Association (ADA) recommends that individuals brush twice per day and use floss or other interdental cleaners once per day to effectively remove microbial plaque biofilms and prevent gingivitis.[3] They recommend twice daily brushing because most individuals do not adequately remove microbial biofilms at one brushing and doing it a second time improves the results.

Periodontal lesions are predominantly found in interdental locations, so toothbrushing alone is not sufficient to control gingival and periodontal diseases.[72] It has been demonstrated in healthy subjects that plaque biofilm formation begins on the interproximal surfaces where the toothbrush does not reach. Masses of biofilm first develop in the molar and premolar areas, followed by the proximal surfaces of the anterior teeth and the facial surfaces of the molars and premolars. Lingual surfaces accumulate the least amount of biofilm. Patients consistently leave more plaque biofilm on the posterior teeth than the anterior teeth, with interproximal surfaces retaining the highest amounts of biofilm, exactly the places in which periodontal infections begin.[116] In addition, periodontal patients have increased susceptibility to disease,[120] complex defects in gingival architecture, and long exposed root surfaces to clean, compounding the difficulty of doing a thorough job of cleaning.

Chemical inhibitors of plaque biofilm and calculus that are incorporated in mouthwashes or dentifrices also play important roles in controlling microbial biofilms.[30] Fluorides delivered through toothpastes and mouthrinses are essential for caries control.[36] Many products are available as adjunctive agents to mechanical techniques. These medicaments, as with any drug, should be recommended and prescribed according to the needs of individual patients.

Daily plaque biofilm control permits each patient to assume responsibility for oral health every day. Without it, optimal oral health through periodontal treatment cannot be attained or preserved. Elements of biofilm control include mechanical cleaning and chemical adjuncts.

The Toothbrush

Toothbrushes vary in size and design as well as in length, hardness, and arrangement of the bristles[111] (Figure 45-1). Some toothbrush manufacturers claim superiority of design for such factors as minor modifications of bristle placement, length, and stiffness. These

Figure 45-1 Manual toothbrushes. **A,** Toothbrushes from the nineteenth and twentieth centuries, one with an ivory handle from about 1890 *(left),* one with a composition handle from the 1950s *(center),* and one with a sterling silver handle from the early twentieth century *(right).* The ivory-handled brush belonged to a dental student who used the handle to practice cutting preparations and filling the "preps" with amalgam or gold foil. **B,** Various types of toothbrushes are available; note the variation in brush head and handle design. **C,** Brush heads, showing various bristle configurations. *(Antique brushes courtesy Dean John D.B. Featherstone, University of California, San Francisco School of Dentistry Historical Collection, San Francisco.)*

claims are primarily based on plaque biofilm removal shown to be significantly superior to other toothbrushes in short-term clinical studies. However, the research does not show significant differences in gingivitis scores or bleeding indices, which are the more important measures of improved gingival health. In fact, at least one study compared four commercially available toothbrushes for total plaque biofilm removal at a single brushing; all four toothbrushes removed biofilms equally, and the authors concluded that no one design was superior to others.[23] In addition, systematic review of multiple studies did not identify any one superior design.[30]

When recommending a particular toothbrush, ease of use by the patient and the perception that the brush works well are the important considerations. The effectiveness of and potential injury from different types of brushes depend to a great degree on how the brushes are used. Data from in vitro studies of abrasion by different manual toothbrushes suggest that brush designs permitting the bristles to carry more toothpaste while brushing contribute to abrasion more than brush bristles themselves.[31] However, it has been shown that use of hard toothbrushes, vigorous horizontal brushing, and use of extremely abrasive dentifrices may lead to cervical abrasions of teeth and recession of gingiva.[71]

Toothbrush Design

Toothbrush bristles are grouped in tufts that are usually arranged in three or four rows. Rounded bristle ends cause fewer scratches on the gingiva than flat-cut bristles with sharp ends[26,111] (see Figure 45-1). Two types of bristle material are used in toothbrushes: natural bristles from hogs and artificial filaments made of nylon. Both remove microbial plaque biofilms, but nylon bristle brushes vastly predominate in the market. Bristle hardness is proportional to the square of the diameter and inversely proportional to the square of bristle length.[53] Diameters of common bristles range from 0.007 inch (0.2 mm) for soft brushes to 0.012 inch (0.3 mm) for medium brushes and 0.014 inch (0.4 mm) for hard brushes.[60] Soft bristle brushes of the type described by Bass[11] have gained wide acceptance. Handle design characteristics are entirely a matter of personal preference.

Softer bristles are more flexible, clean slightly below the gingival margin when used with a sulcular brushing technique,[12] and reach farther onto the proximal surfaces.[42] Use of hard-bristled toothbrushes is associated with more gingival recession.[71] However, the manner in which a brush is used and the abrasiveness of the dentifrice affect the abrasion to a greater degree than the bristle hardness itself.[90] Bristle hardness does not significantly affect wear on enamel surfaces.[104]

The amount of force used to brush is not critical for effective plaque biofilm removal.[122] Vigorous brushing is not necessary and can lead to gingival recession, wedge-shaped defects in the cervical area of root surfaces,[105] and painful ulceration of the gingiva.[98]

Toothbrushes must also be replaced periodically, although the amount of visible bristle wear does not appear to affect plaque biofilm removal for up to 9 weeks.[25] Most clinicians recommend that toothbrushes be replaced every 3 to 4 months.

Recommendations

- Soft, nylon bristle toothbrushes clean effectively when used properly, remain effective for a reasonable time, and tend not to traumatize the gingiva or root surfaces.
- Toothbrushes should be replaced about every 3 to 4 months.
- If patients perceive a benefit from a particular brush design, they should use it.

Powered Toothbrushes

Electrically powered toothbrushes designed to mimic back-and-forth brushing techniques were invented in 1939. Subsequent models featured circular or elliptical motions, and some had combinations of motions. Currently, powered toothbrushes have oscillating and rotating motions (Figure 45-2), and some brushes use low-frequency acoustic energy to enhance cleaning ability. Powered toothbrushes rely primarily on mechanical contact between the bristles and the tooth to remove plaque biofilm. The addition of low-frequency acoustic energy generates dynamic fluid movement and provides cleaning slightly away from the bristle tips.[41] The vibrations have also been shown to interfere with bacterial adherence to oral surfaces. Neither the sonic vibration nor the mechanical motion of powered toothbrushes has been shown to affect bacterial cell viability.[88] Hydrodynamic shear forces created by these brushes disrupt biofilms a short distance from the bristle tips, explaining the additional interproximal biofilm removal.[64]

Typically, comparison studies of powered toothbrushes, manual toothbrushes, or other powered devices demonstrate slightly improved plaque biofilm removal for the device of interest in short-term clinical trials.[92,102] A recent Cochrane review reported that mechanical brushes with oscillating and rotating motions reduced microbial plaque biofilm 11% and demonstrated 6% greater reduction in gingival bleeding than manual brushing. These improvements were maintained over 3 months. Although long-term benefits have not been established, this particular style of mechanical brush resulted in better microbial plaque biofilm and gingivitis reduction in a number of well-controlled studies.[30,55]

Figure 45-2 Powered toothbrush designs offer options in head shape and size.

Patient acceptance of powered toothbrushes is good. One study reported that 88.9% of patients introduced to a powered toothbrush would continue to use it.[124] However, patients have also been reported to quit using powered toothbrushes after 5 or 6 months, presumably when the novelty is gone. Powered toothbrushes have been shown to improve oral health for (1) children and adolescents, (2) children with physical or mental disabilities, (3) hospitalized patients, including older adults who need to have their teeth cleaned by caregivers, and (4) patients with fixed orthodontic appliances. Powered brushes have not been shown to provide benefits routinely for patients with rheumatoid arthritis, children who are well-motivated brushers, or patients with chronic periodontitis.[56]

Recommendations

- Powered toothbrushes with oscillating and rotating motions remove plaque biofilm and reduce gingival bleeding slightly better than manual toothbrushes.
- Patients who want to use powered toothbrushes should be encouraged to do so.
- Patients need to be instructed in the proper use of powered devices.
- Patients who are poor brushers, children, and caregivers may particularly benefit from using powered toothbrushes.

Dentifrices

Dentifrices aid in cleaning and polishing tooth surfaces. They are used mostly in the form of pastes, although tooth powders and gels are also available. Dentifrices are made up of abrasives (e.g., silicon oxides, aluminum oxides, and granular polyvinyl chlorides), water, humectants, soap or detergent, flavoring and sweetening agents, therapeutic agents (e.g., fluorides, pyrophosphates), coloring agents, and preservatives.[54,115] Abrasives are insoluble inorganic salts that enhance the abrasive action of toothbrushing as much as 40 times and make up 20% to 40% of dentifrices.[90] Tooth powders are much more abrasive than pastes and contain about 95% abrasive materials. The abrasive quality of dentifrices affects enamel only slightly and is a much greater concern for patients with exposed roots. Dentin is abraded 25 times faster and cementum 35 times faster than enamel, so root surfaces are easily worn away, leading to notching and tooth sensitivity.[115] Oral hygiene procedures mainly cause hard tissue damage from abrasive dentifrices, although gingival lesions can also be produced[98,104] (Figure 45-3). Dentifrices are very useful for delivering therapeutic agents to the teeth and gingiva. The pronounced caries-preventive effect of *fluorides* incorporated in dentifrices has been proved beyond question.[114] Fluoride ion must be available in the amount of 1000 to 1100 parts per million (ppm) to achieve caries reduction effects. Toothpaste products that have been tested by the ADA and have fluoride ion available in the appropriate amount carry the ADA seal of approval for caries control and can be relied on to provide caries protection.[5]

"Calculus control toothpastes," also referred to as "tartar control toothpastes," contain *pyrophosphates* and have been shown to reduce the deposition of new calculus on teeth. These ingredients interfere with crystal formation in calculus but do not affect the fluoride ion in the paste or increase tooth sensitivity. Dentifrice with pyrophosphates has been shown to reduce the formation of new supragingival calculus by 30% or more.[67,89,129] Pyrophosphate-containing toothpastes do not affect subgingival calculus formation

or gingival inflammation. The inhibitory effects reduce the deposition of new supragingival calculus but do not affect existing calculus deposits. To achieve the greatest effect from calculus control toothpaste, the patient's teeth must be cleaned and completely free of supragingival calculus when adding these products to the daily home care regimen.

Recommendations

- Dentifrices increase the effectiveness of brushing but should cause a minimum of abrasion to root surfaces.
- Products containing fluorides and antimicrobial agents provide additional benefits for controlling caries and gingivitis.
- Patients who form significant amounts of supragingival calculus benefit from the use of a calculus control dentifrice.

Figure 45-3 Vigorous toothbrushing with an abrasive dentifrice can result in trauma to the gingiva and wearing away of the tooth surfaces, especially root surfaces, and can contribute to gingival recession.

Toothbrushing Methods

Many methods for brushing the teeth have been described and promoted as being efficient and effective. These methods can be categorized primarily according to the pattern of motion when brushing and are primarily of historic interest, as follows[65]:

Roll: Roll[2] or modified Stillman technique[61]
Vibratory: Stillman,[113] Charters,[20] and Bass[12] techniques
Circular: Fones technique[40]
Vertical: Leonard technique[79]
Horizontal: Scrub technique[126]

Patients with periodontal disease are most frequently taught a sulcular brushing technique using a vibratory motion to improve access to the gingival margin areas. It is important for patients to understand that the plaque biofilm removal at the dento-gingival junction is necessary to prevent caries as well as periodontal disease. This is referred to as "target hygiene."[118] The method most often recommended is the *Bass technique* because it emphasizes the placement of the bristles at this most important area. This sulcular placement of the bristle and adapting the bristle tips to the gingival margin to reach the supragingival plaque biofilm and accessing some of the subgingival biofilm may be the most important aspect of "target hygiene." A controlled vibrating motion is used to dislodge microbial plaque biofilm and avoid trauma. The brush is systematically placed on all the teeth in both arches. Figures 45-4 and 45-5 illustrate this brushing technique.

Bass Technique[11]

1. Place the head of a soft brush parallel with the occlusal plane, with the brush head covering three to four teeth, beginning at the most distal tooth in the arch.
2. Place the bristles at the gingival margin, pointing at a 45-degree angle to the long axis of the teeth.
3. Exert gentle vibratory pressure, using short, back-and-forth motions without dislodging the tips of the bristles. This motion forces the bristle ends into the gingival sulcus area (see Figure 45-4), as well as partly into the interproximal embrasures. The pressure should be firm enough to blanch the gingiva

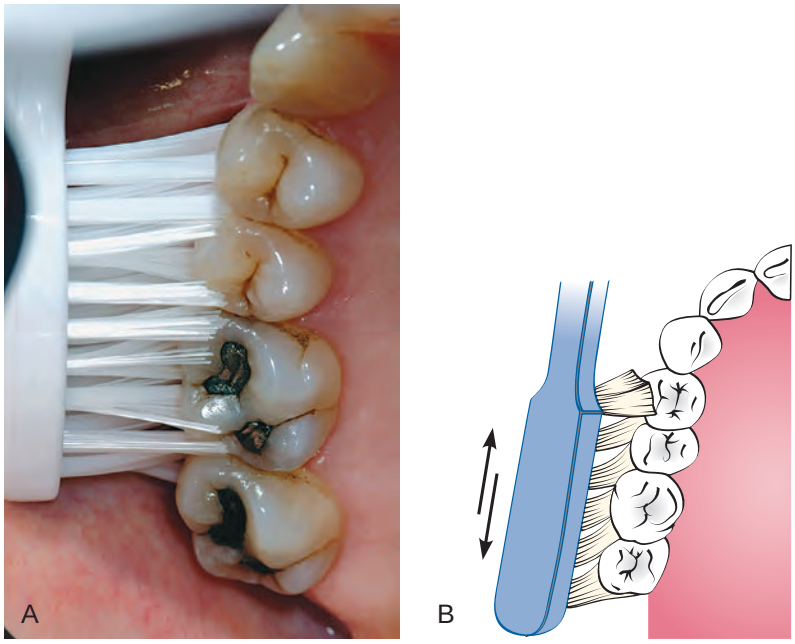

Figure 45-4 Bass method. **A,** Place the toothbrush so that the bristles are angled approximately 45 degrees from the tooth surfaces. **B,** Start at the most distal tooth in the arch, and use a vibrating, back-and-forth motion to brush.

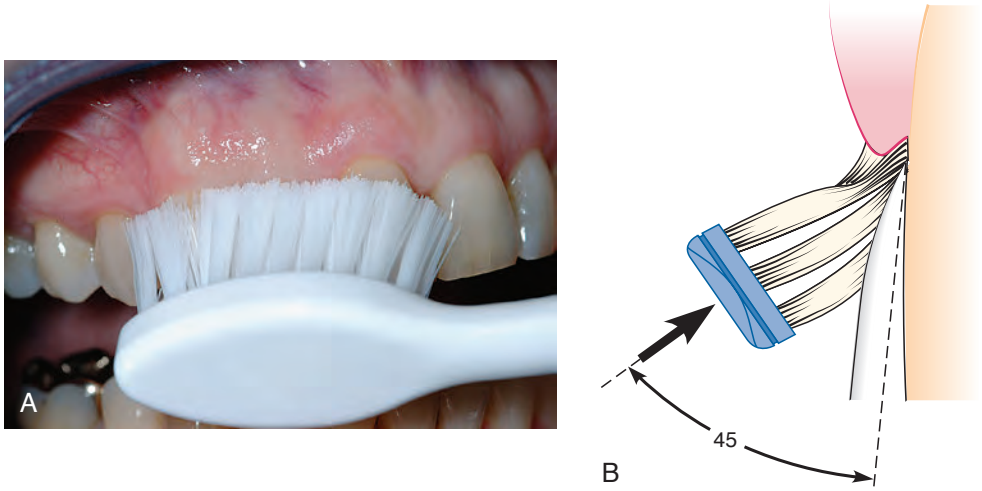

Figure 45-5 Bass method. **A,** Proper position of the brush in the mouth aims the bristle tips toward the gingival margin. **B,** Diagram shows the ideal placement, which permits slight subgingival penetration of the bristle tips.

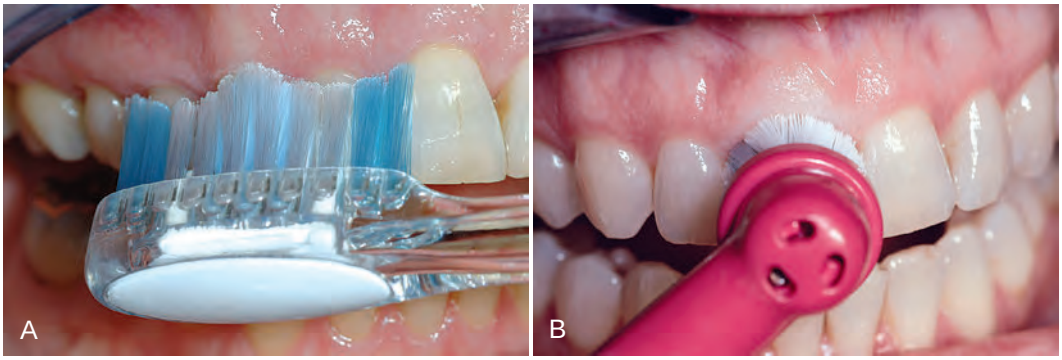

Figure 45-6 Positioning the powered toothbrush head and bristle tips so that they reach the gingival margin is critical to achieving the most effective cleaning results. **A,** Straight-head placement. **B,** Round-head placement.

Brushing with Powered Toothbrushes

The various mechanical motions built into powered toothbrushes do not require special techniques. The patient needs only place the brush head next to the teeth at the gingival margin, using a targeted hygiene approach, and proceed systematically around the dentition.[121] A routine method of brushing all the teeth, similar to the method described for manual brushing, should also be used with powered toothbrushes (Figure 45-6).

Recommendations

- Targeted hygiene[118] focuses brushing efforts on the cervical and interproximal portions of the teeth, where microbial plaque biofilm accumulates first.
- Brushing with either a manual or a powered toothbrush requires a systematic routine to clean all the accessible areas.[92]
- Patients will modify any technique to their needs but must achieve the goal of brushing effectively until the teeth are free of plaque biofilm on all accessible surfaces.

Interdental Cleaning Aids

Any toothbrush, regardless of the brushing method used, does not completely remove interdental plaque biofilms. This is true for all brushers, even periodontal patients with wide-open embrasures.[44,107] Daily interdental plaque biofilm removal is crucial to augment the effects of toothbrushing because most dental and periodontal diseases originate in interproximal areas.[1]

Tissue destruction associated with periodontal disease often leaves large, open spaces between teeth and long, exposed root surfaces with anatomic concavities and furcations. These areas shelter plaque biofilms and are both difficult for patients to clean and poorly accessible to the toothbrush.[72] Patients need to understand that the purpose of interdental cleaning is to remove microbial plaque biofilms, not just dislodge food wedged between teeth. Many tools are available for interproximal cleaning and they should be recommended based on the size of interdental spaces, presence of furcations, tooth alignment, and presence of orthodontic appliances or fixed prostheses. Also, ease of use and patient cooperation are important considerations. Common aids are dental floss and interdental cleaners such as wooden or plastic tips, and interdental brushes.

Dental Floss

Dental floss is the most widely recommended tool for removing biofilm from proximal tooth surfaces.[43] Floss is made from nylon filaments or plastic monofilaments, and comes in waxed, unwaxed, thick, thin, and flavored varieties. Some prefer monofilament flosses made of a nonstick material because they are slick and do not fray. Clinical research has demonstrated no significant differences in the ability of the various types of floss to remove dental plaque biofilm; they all work equally well.[38,59,69,70] Waxed dental floss was thought to leave a waxy film on proximal surfaces, thus contributing to biofilm accumulation and gingivitis. It has been shown, however, that wax is not deposited on tooth surfaces[99] and

that improvement in gingival health is unrelated to the type of floss used.[38] Factors influencing the choice of dental floss include the tightness of tooth contacts, roughness of proximal surfaces, and the patient's manual dexterity, not the superiority of any one product. Therefore recommendations about type of floss should be based on ease of use and personal preference.

Technique. The floss must contact the proximal surface from line angle to line angle to clean effectively. It must also clean the entire proximal surface, including accessible subgingival areas, not just be slipped apical into the contact area. Flossing technique requires the following:

1. Start with a piece of floss long enough to grasp securely; 12 to 18 inches is usually sufficient. It may be wrapped around the fingers, or the ends may be tied together in a loop.
2. Stretch the floss tightly between the thumb and forefinger (Figure 45-7), or between both forefingers, and pass it gently through each contact area with a firm back-and-forth motion. Do not snap the floss past the contact area because this may injure the interdental gingiva. In fact, zealous snapping of floss through contact areas creates proximal grooves in the gingiva.
3. Once the floss is apical to the contact area between the teeth, wrap the floss around the proximal surface of one tooth, and slip it under the marginal gingiva. Move the floss firmly along the tooth up to the contact area and gently down into the sulcus again, repeating this up-and-down stroke two or three times (Figure 45-8). Then, move the floss across the interdental gingiva, and repeat the procedure on the proximal surface of the adjacent tooth.
4. Continue through the whole dentition, including the distal surface of the last tooth in each quadrant. When the working portion of the floss shreds or becomes dirty, move to a fresh portion of floss.

Flossing can be facilitated by using a *floss holder* (Figure 45-9, *A*). Floss holders are helpful for patients lacking manual dexterity and for caregivers assisting patients in cleaning their teeth. A floss holder should be rigid enough to keep the floss taut when penetrating into tight contact areas, and it should be simple to string with floss. The disadvantage is that floss tools are time-consuming because they must be rethreaded frequently when the floss shreds.

Disposable, single-use floss holders with prethreaded floss are also available. Short-term clinical studies suggest that plaque biofilm reduction and improvement in gingivitis scores are similar

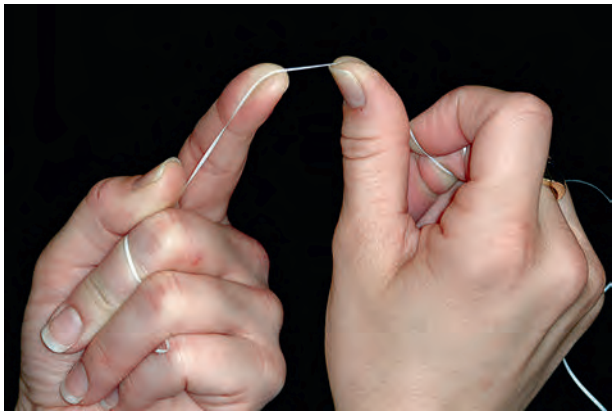

Figure 45-7 Dental floss should be held securely in the fingers or tied in a loop.

Figure 45-8 Dental floss technique. The floss is slipped between the contact area of the teeth (in this case, teeth #7 and #8), is wrapped around the proximal surface, and removes plaque by using several up-and-down strokes. The process must be repeated for the distal surface of tooth #8.

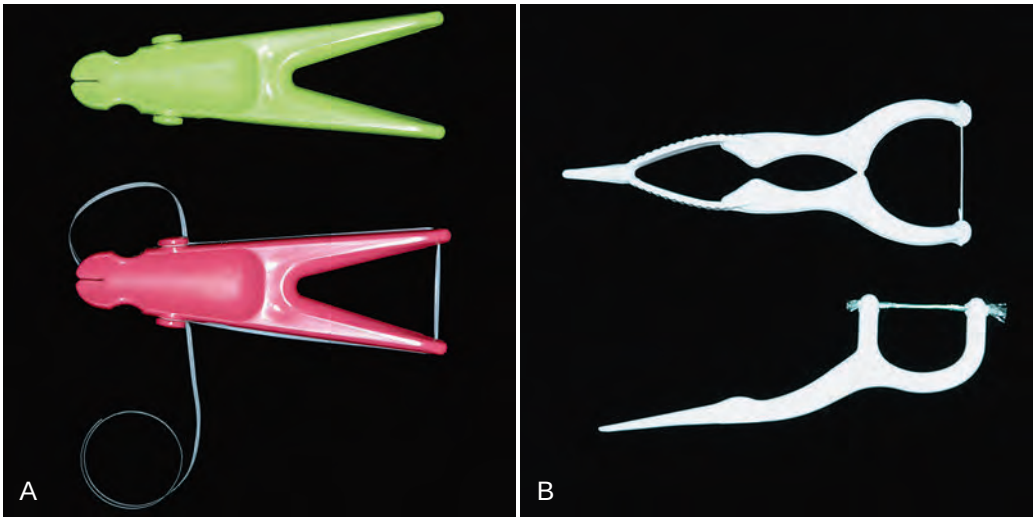

Figure 45-9 Floss holders can simplify the manipulation of dental floss. **A,** Reusable floss tools require stringing the floss around a series of knobs and grooves to secure it. **B,** Disposable floss tools have prestrung floss and are easy to use, but the floss may shred and break, requiring several tools to complete flossing the teeth.

Figure 45-10 Powered flossing devices can be easier for some patients to use than handheld floss. The tip is inserted into the proximal space, and a bristle or wand comes out of the tip and moves in a circular motion when the device is turned on *(left)*. Alternately, the device moves the prestrung floss in short motions to provide interproximal cleaning *(right)*.

for patients using disposable floss devices as for patients who hold the floss with their fingers[18,112] (Figure 45-9, *B*).

Powered flossing devices are also available (Figure 45-10). The devices have been shown to be safe and effective, but no better at plaque biofilm removal than holding the floss in the fingers.[24,49]

Establishing a lifelong habit of flossing the teeth is difficult to achieve for both patients and dentists, regardless of whether one uses a tool or flosses with the fingers. In fact, the daily use of floss is universally low. It has been reported that only about 8% of young teenagers in Great Britain flossed daily,[87] with similar percentages reported for other countries.[72] No information is available about the establishment of long-term flossing habits comparing the various tools to finger flossing. However, the tools may be useful to help some individuals begin flossing or to make flossing possible if patients have limited dexterity.

Recommendations

- The benefits of interproximal cleaning using dental floss are undisputed.
- Flossing tools work as well as flossing with the traditional method.
- The flossing habit is difficult to establish.

Interdental Cleaning Devices

Concave root surfaces such as the mesial aspect of the maxillary first bicuspid and furcations are often present in periodontal patients who have experienced significant attachment loss and recession, and they are not cleaned well with dental floss. A comparison study of dental floss and interdental brushes used by patients with moderate to severe periodontal disease showed that the interproximal brushes removed slightly more interproximal plaque biofilm and that subjects found them easier to use than dental floss. However, no differences were seen in probe depth reductions or bleeding indices.[21] Therefore interproximal cleaning aids, such as interdental brushes, are adequate for proximal cleaning of teeth when interdental spaces permit access.[72]

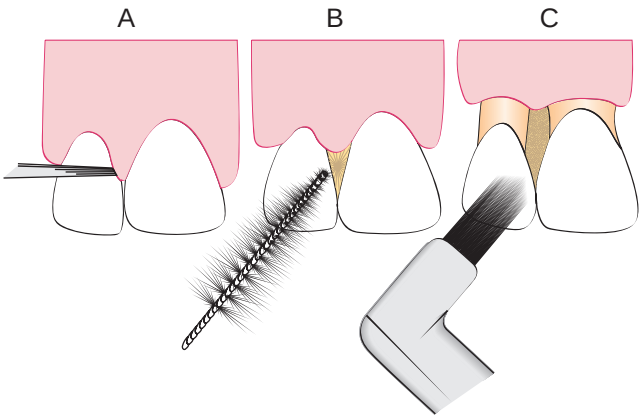

Figure 45-11 Interproximal embrasure spaces vary greatly in patients with periodontal disease. In general, **A,** embrasures with no gingival recession are adequately cleaned using dental floss; **B,** larger spaces with exposed root surfaces require the use of an interproximal brush; and **C,** single-tufted brushes clean efficiently in interproximal spaces with no papillae.

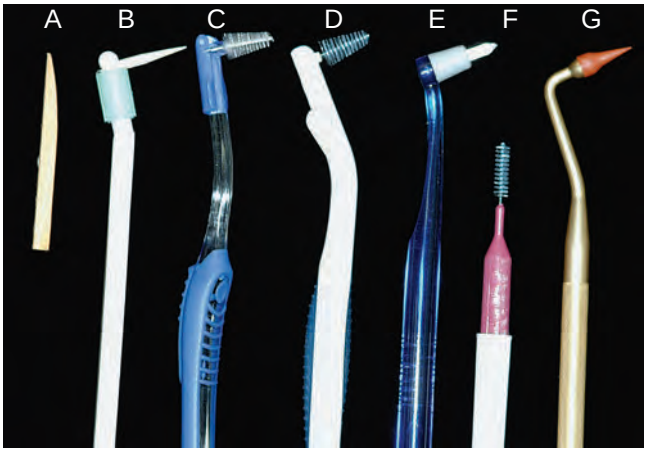

Figure 45-12 Interproximal cleaning devices include wooden tips (**A** and **B**), interproximal brushes (**C** to **F**), and rubber tip stimulators **(G)**.

Embrasure spaces vary greatly in size and shape. Figure 45-11 provides a representation of the size and anatomy of three types of embrasures and the type of interdental cleaner often recommended for each. As a general rule, the larger the space, the larger the device needed to clean it.

Interdental Brushes. A wide variety of interdental cleaning devices are available for removing microbial plaque biofilm from between the teeth (Figure 45-12). The most common types are conical or cylindrical brushes, tapered wooden toothpicks that are round or triangular in cross section, and single-tufted brushes. Many interdental devices have handles for convenient manipulation around the teeth and in posterior areas. Clinical research has shown that the devices are effective on lingual and facial tooth surfaces as well as on proximal surfaces.[72,107]

Figure 45-13 Wooden toothpick. **A,** The tip is a common wooden toothpick held in a handle and broken off. It is used to clean subgingivally and reach into periodontal pockets. **B,** The tip can also be used to clean along the gingival margins of the teeth and reach under the gingiva.

Technique. Interdental brushes of any style are inserted through interproximal spaces and moved back and forth between the teeth with short strokes. The diameter of brush should be slightly larger than the gingival embrasures to be cleaned. This size permits bristles to exert pressure on both proximal tooth surfaces, working their way into concavities on the roots.

Single-tufted brushes provide access to furcation areas, or isolated areas of deep recession, and work well on the lingual surfaces of mandibular molars and premolars. These areas are often missed when using a toothbrush and floss.

Wooden or Rubber Tips. Wooden toothpicks are used either with or without a handle (see Figure 45-12, *A* and *B*). Access is easier from the buccal surfaces for tips without handles but is limited primarily to the anterior and bicuspid areas. Wooden toothpicks used on handles improve access to all areas and have been shown to be as effective as dental floss in reducing plaque biofilm and bleeding scores in subjects with gingivitis.[81] Triangular wooden tips are also available; this design is most useful in the anterior areas when used from the buccal surfaces of the teeth. Rubber tips are conical and are mounted on handles or the ends of toothbrushes; they are reusable and can be easily adapted to all proximal surfaces in the mouth. Plastic tips that resemble wooden or rubber tips are also available and are used in the same way.

Technique. Toothpicks are common devices and readily available in most homes. They can be used around all surfaces of the teeth when attached to commercially available handles (see Figure 45-12, *B*). Once mounted on the handle, the toothpick is broken off so that it is only 5- or 6-mm long. The tip of the toothpick is used to trace along the gingival margin and into the proximal areas from both the facial and the lingual surface of each tooth (Figure 45-13). Toothpicks mounted on handles are efficient for cleaning along the gingival margin,[43] can penetrate into periodontal pockets and furcations, and permit patients to target their hygiene efforts at the gingival margin.[118]

Soft, triangular wooden picks or plastic picks are placed in the interdental space with the base of the triangle resting on the gingiva and the sides in contact with the proximal tooth surfaces (Figure 45-14). The pick is then repeatedly moved in and out of the embrasure several times to remove the biofilm. The disadvantage of triangular wooden or plastic tips is that they do not reach well into the posterior areas or on the lingual surfaces.

Rubber tips should be placed into the embrasure space, resting on the gingiva, and used in a circular motion. They can be applied to interproximal spaces and other defects throughout the mouth and are easily adaptable to lingual surfaces.

Figure 45-14 Triangular wooden tips are also popular with patients. The tip is inserted between the teeth, with the triangular portion resting on the gingival papilla. The tip is moved in and out to remove plaque; however, it is very difficult to use on posterior teeth and from the lingual aspect of all teeth.

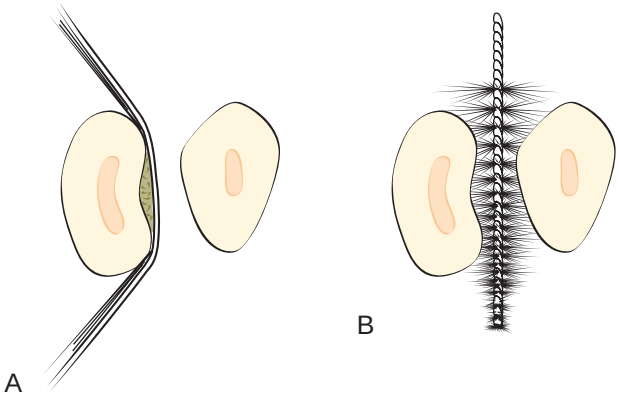

Figure 45-15 Cleaning of concave or irregular proximal tooth surfaces. Dental floss **(A)** may be less effective than an interdental brush **(B)** on long root surfaces with concavities.

Recommendations

- Often a toothbrush and dental floss are not sufficient to clean interdental spaces adequately, so it is extremely important to find an interdental device that the patient likes and will use.
- Many interdental cleaning aids are available for patients. The patient might need to try several devices before finding one that is acceptable and cleans adequately.
- In general, the largest brush or device that fits into a space will clean most efficiently (Figure 45-15).

Gingival Massage

Massaging the gingiva with a toothbrush or an interdental cleaning devices produces epithelial thickening, increased keratinization, and increased mitotic activity in the epithelium and connective tissue.[16,19,46] The increased keratinization occurs only on the gingiva facing the oral cavity and not on the areas more vulnerable to microbial attack, which are the sulcular epithelium and the interdental areas where the gingival col is present. Epithelial thickening, increased keratinization, and increased blood circulation have not been shown to be beneficial for restoring gingival health.[45] Improved gingival health associated with interdental stimulation is much more likely the result of microbial plaque biofilm removal than gingival massage.

Conclusion

- All patients require the regular use of a toothbrush, either manual or electric, at least once per day. The brushing method should emphasize access to the gingival margins (dento-gingival junction) of all accessible tooth surfaces, referred to as *targeted hygiene,* and extension as far onto the proximal surfaces as possible.
- Dental floss should be used in all interdental spaces that are filled with gingiva.
- Interdental aids such as interproximal brushes, wooden tips, rubber tips, or toothpicks should be used in all areas where the toothbrush and floss techniques cannot adequately remove the plaque biofilm. This includes large embrasure spaces and furcation areas as well as the mesial surface of the maxillary first bicuspid, which presents a concavity on the root surface near the cemento enamel junction.
- Daily at-home subgingival irrigation is useful for reduction of inflammation and maintenance for patients with residual deep pockets and those who struggle with mechanical interproximal cleaning devices. The effectiveness of irrigation is enhanced by the addition of a chlorhexidine or essential oil rinse as an irrigant.
- Caries control requires the daily use of a dentifrice with low-concentration fluoride. Topical oral rinses and gels with higher concentrations of fluoride should be used if the patient demonstrates caries risk, and chlorhexidine rinses should be used in a caries risk management program for patients at high risk for caries.
- Chemical antimicrobial agents, such as chlorhexidine and essential oils, can be used to disinfect the patient's mouth and control infection. These oral rinses may be continued indefinitely. Staining of teeth and taste alteration are side effects that may limit the use of these products.
- Reinforcement of daily plaque biofilm control practices and routine visits to the dental office for maintenance care are essential to successful microbial plaque biofilm control and the long-term success of therapy.

Suggested Readings

Drisko CL: Periodontal self-care: evidence-based support. *Periodontol 2000* 62:243, 2013.

Featherstone JD: Prevention and reversal of dental caries: role of low level fluoride. *Community Dent Oral Epidemiol* 27:31, 1999.

Lindhe J, Nyman S: The effect of plaque control and surgical pocket elimination on the establishment and maintenance of periodontal health: a longitudinal study of periodontal therapy in cases of advanced disease. *J Clin Periodontol* 2:67, 1975.

Robinson P, Deacon SA, Deery C, et al: Manual versus powered toothbrushing for oral health. *Cochrane Database Syst Rev* (2):CD002281, April 18, 2005.

Sambunjak D, Nickerson JW, Poklepovic T, et al: Flossing for the management of periodontal diseases and dental caries in adults. *Cochrane Database Syst Rev* (12):CD008829, 2011. doi: 10.1002/14651858.CD008829.pub2.

Wilson TG, Jr, Glover ME, Schoen J, et al: Compliance with maintenance therapy in a private dental practice. *J Periodontol* 55:468, 1984.

References

References for this chapter are found on the companion website www.expertconsult.com.

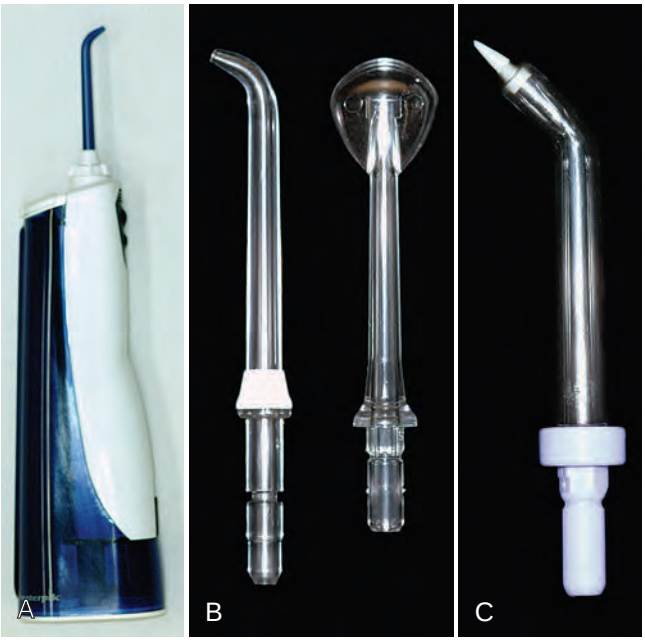

Figure 45-16 Oral irrigation. **A,** The most common oral irrigators have a built-in pump and reservoir. **B,** Conventional plastic tips are used for daily supragingival irrigation at home by the patient. *Left,* Tip for gingival irrigation. *Right,* Tip for cleaning dorsal surface of the tongue. **C,** Soft rubber tip is used for daily subgingival irrigation by the patient at home.

Oral Irrigation

Supragingival Irrigation

Oral irrigators for daily home use by patients work by directing a pulsating stream of water through a nozzle to the tooth surfaces. Most often, a device with a built-in pump generates the pressure (Figure 45-16, *A*). Oral irrigators clean nonadherent bacteria and debris from the oral cavity more effectively than toothbrushes and mouth rinses. They are particularly helpful for removing debris from inaccessible areas around orthodontic appliances and fixed prostheses. When used as adjuncts to toothbrushing, these devices can have a beneficial effect on periodontal health by reducing the accumulation of microbial plaque biofilm and calculus[63,84,101] and decreasing inflammation and pocket depth.[17,101]

Oral irrigation has been shown to disrupt and detoxify subgingival plaque biofilm and can be useful in delivering antimicrobial agents into periodontal pockets.[4] Daily supragingival irrigation with dilute chlorhexidine for 6 months resulted in significant reductions in bleeding and gingivitis compared with water irrigation and chlorhexidine rinse controls. Irrigation with water alone also reduced gingivitis significantly but not as much as the dilute chlorhexidine.[39]

Technique.

1. The common home-use irrigator tip is a plastic nozzle with a 90-degree bend at the tip (see Figure 45-16, *B*), attached to a pump providing pulsating beads of water at speeds regulated by a dial. Patients should be instructed to aim the pulsating jet across the proximal papilla, hold it there for 10 to 15 seconds, then trace along the gingival margin to the next proximal space, and repeat the procedure.
2. The irrigator should be used from both the buccal and the lingual surface.
3. Patients with gingival inflammation should start at low pressure and they can increase the pressure comfortably to about medium as tissue health improves. Some individuals like to use the device on the highest pressure setting, with no reported harm. Patient comfort should be the guide for pressure setting.

Subgingival Irrigation

Subgingival irrigation can be performed both in the dental office and at home by the patient, to apply antimicrobial agents. Home irrigation is performed by aiming or placing the irrigation tip or a blunt syringe tip into the periodontal pocket, attempting to insert the tip at least 3 mm.[29] A soft rubber irrigator tip is shown in Figure 45-16, *C*. Irrigation performed in the dental office, also called *lavage* or *flushing of the periodontal pocket,* as a one-time treatment after scaling and root planing, has not been shown to improve clinical healing, and data do not support its use in improving therapeutic results.[4,51,108]

Subgingival irrigation performed with an oral irrigator using chlorhexidine diluted to one-third strength and performed regularly at home and after scaling, root planing, and in-office irrigation therapy has produced significant gingival improvement compared with controls.[51,66,108] Subgingival irrigation has been shown to disrupt more than half the subgingival plaque biofilm[62] and reach about half the depth of pockets, up to 7 mm, much further apically than a toothbrush or floss can reach.[32] These data suggest that patients can benefit from daily subgingival irrigation, particularly in difficult sites such as furcations and residual pockets. A more detailed discussion of irrigation is presented in Chapter 47.

Technique.

The soft rubber irrigator tip reduces the pressure and flow of the pulsating jet of water (see Figure 45-16, C) when inserted subgingivally and permits penetration of irrigant of up to 70% of pocket depth in laboratory simulation.[22,62] The subgingival irrigation tip should be gently inserted into pockets or furcation areas, 3 mm if possible, and each pocket should be flushed for a few seconds.

One caution must be considered. Transient bacteremia has been reported after water irrigation in patients with periodontitis[37] and patients receiving periodontal maintenance therapy.[123] However, bacteremia has also been found after toothbrushing[96] and is known to occur in a significant number of patients after scaling alone.[123] Subgingival irrigation at home is not the oral hygiene procedure of choice for patients requiring antibiotic prophylaxis before dental treatment, particularly if extensive inflammation is present.[29] For these patients, supragingival irrigation used in combination with toothbrushing and other interdental cleaning aids is recommended.

Recommendations

- Supragingival irrigation reduces gingival inflammation and is easier for some patients than using mechanical interdental aids.
- Subgingival irrigation with specialized tips for deep pockets and furcation areas is effective when used daily as part of the home care routine.
- Patients requiring antibiotic premedication for dental procedures should use supragingival techniques.

Caries Control

Dental caries, particularly root caries, is a problem for periodontal patients because of attachment loss and exposed root surfaces associated with the disease process and periodontal therapeutic

procedures. *Root caries* develops through a process similar to coronal caries, involving the alternating cycle of demineralization and remineralization of the surfaces and other risk factors associated with diet and salivary flow. The demineralization process requires the fermentation of carbohydrates in the plaque biofilm by oral bacteria, resulting in loss of mineral from the root surface. *Lactobacillus* and *Streptococcus* species are involved in the root caries process, as with coronal caries. The major difference is that the amount of organic material in the root surfaces is greater than in enamel, so once the demineralization has occurred, the organic matrix—mostly collagen—is exposed. Organic material is then further broken down by bacterial enzymes, resulting in rapid destruction of the root surface.[34,125]

Fluoride works primarily by topical effects to prevent and reverse the caries process, whether in enamel, cementum, or dentin. Low concentrations of topical fluoride inhibit demineralization, enhance remineralization, and inhibit the enzyme activity in bacteria by acidifying the cells.[35,36] Adult patients benefit from the prevention and reversal of root caries provided by low-concentration topical fluoride delivered by toothpastes or other topical applications.[35] It also has been demonstrated that the use of fluoride dentifrice containing 5000 ppm of fluoride was more effective in reversing active root caries lesions than the fluoride level of 1100 ppm found in conventional toothpastes.[13]

Recommendations

- All periodontal patients should be encouraged to use a fluoride-containing toothpaste daily, 1000 to 1100 ppm, to reduce demineralization and enhance remineralization of tooth surfaces.
- Patients at high risk for caries, including those with a history of root lesions or who have active lesions, should use higher-concentration fluoride toothpaste or gels, 5000 ppm, daily until the risk for caries is controlled, then maintain with the lower concentration toothpastes and mouthrinses.
- Periodic chlorhexidine rinsing to control cariogenic bacteria in the oral cavity should also be used as part of a caries risk management program.[36]
- Other considerations in caries control, such as diet and reduced salivary flow, should be evaluated as with all dental patients.

Chemical Plaque Biofilm Control with Oral Rinses

Improved understanding of the infectious nature of dental diseases has dramatically increased interest in chemical methods of plaque biofilm control and holds great promise for advances in disease control and prevention. The ADA Council on Scientific Affairs has adopted a program for acceptance of chemical plaque biofilm control agents. The agents must be evaluated in placebo-controlled clinical trials of 6 months or longer that demonstrate significantly improved gingival health compared with controls. To date, the ADA has accepted two agents for treatment of gingivitis: prescription solutions of chlorhexidine digluconate oral rinse and nonprescription essential oil mouthrinse.

Prescription Chlorhexidine Rinse

The agent that has shown the most positive antibacterial results to date is chlorhexidine, a diguanidohexane with pronounced antiseptic properties. Several clinical investigations confirmed the initial finding that two daily rinses with 10 mL of a 0.2% aqueous solution of chlorhexidine digluconate almost completely inhibited the development of microbial plaque biofilm, calculus, and gingivitis in the human model for experimental gingivitis.[52] Clinical studies of several months' duration have reported plaque biofilm reductions of 45% to 61% and more importantly, gingivitis reductions of 27% to 67%.[52,76] The 0.12% chlorhexidine digluconate preparation available in the United States for reducing plaque biofilm and gingivitis has been shown to be equally effective as the higher-concentration product.[68,74]

Localized, reversible side effects to chlorhexidine use occur, primarily brown staining of the teeth, tongue, and silicate and resin restorations[76] and transient impairment of taste perception.[85] Chlorhexidine has very low systemic toxic activity in humans, has not produced any appreciable resistance of oral microorganisms, and has not been associated with teratogenic alterations.[74] The preparation contains 12% alcohol, which may be of interest to clinicians and patients over concerns that alcohol increases the risk of oropharyngeal cancer.[33] However, an extensive review of the available epidemiologic evidence associating alcohol-containing oral rinse preparations with cancer concluded that existing data do not support this association.[110] A nonalcoholic form of chlorhexidine mouthrinse is also available. It has been shown to be equally effective for microbial plaque biofilm control[10,82] and may be preferred by patients.

Nonprescription Essential Oil Rinse

Essential oil mouthrinses contain thymol, eucalyptol, menthol, and methyl salicylate. These preparations have been evaluated in long-term clinical studies and demonstrated plaque biofilm reductions of 20% to 35% and gingivitis reductions of 25% to 35%.[28,48,73] This type of oral rinse has a long history of daily use and safety since the nineteenth century, and many patients have used the products for decades. These products also contain alcohol (up to 24% depending on the preparation), so some patients prefer not to use them.

Other Products

A preparation containing *triclosan* has shown some effectiveness in reducing plaque biofilm and gingivitis. It is available in toothpaste form, and the active ingredient is more effective in combination with zinc citrate or a copolymer of methoxyethylene.[8] Other oral rinse products on the market have shown some evidence of plaque biofilm reduction, although long-term improvement in gingival health has not been substantiated. These include stannous fluoride, cetylpyridinium chloride (quaternary ammonia compounds), and sanguinarine. Evidence suggests that these and other available mouth rinse products do not possess the antimicrobial potential of either chlorhexidine products or essential oil preparations.[91,97]

One type of agent has been marketed as a prebrushing oral rinse to improve the effectiveness of toothbrushing. The active ingredient is sodium benzoate. Research to support its effectiveness is contradictory, but the preponderance of evidence suggests that using a prebrushing rinse is no more effective than brushing alone.[14,15]

Chemical plaque biofilm control has been shown to be effective for both plaque biofilm reduction and improved wound healing after periodontal surgery.[106] Both chlorhexidine[6] and essential oil[128] mouthrinses have significant positive effects when prescribed for use after periodontal surgery for 1 to 4 weeks.

Recommendations

- Chemical plaque biofilm control can augment mechanical plaque biofilm control procedures and reduce gingivitis and caries.

- Chlorhexidine rinses can be used to augment plaque biofilm control during phase I therapy, for patients with recurrent disease, for use after periodontal or oral surgery, and for caries management.
- Essential oil rinses are effective as irrigants, have fewer side effects, and are available without prescriptions.
- Oral irrigators used with dilute solutions of effective antimicrobial agents reduce gingivitis.
- Oral rinse preparations are also available with no alcohol content, which may be preferable to some clinicians and patients.
- The use of cosmetic oral rinses and prebrushing rinses should not be used to replace proven mechanical and chemical means of plaque biofilm removal, but can be useful if patients perceive benefits from them.

Disclosing Agents

Disclosing agents are solutions or wafers capable of staining bacterial biofilms on the surfaces of teeth, tongue, and gingiva. These can be used as educational and motivational tools to improve the efficiency of plaque biofilm control procedures[7] (Figure 45-17). Solutions are applied to the teeth as concentrates on cotton swabs or diluted as rinses. They usually produce heavy staining of bacterial plaque biofilm, gingiva, tongue, lips, and fingers, as well as the sink. Wafers are crushed between the teeth and swished around the mouth for a few seconds and then spit out. Either form can be used for plaque biofilm control instruction in the office and dispensed for home use to aid periodontal patients in evaluating the effectiveness of their oral hygiene routines.

Frequency of Plaque Biofilm Removal

In the controlled and supervised environment of clinical research, where well-trained individuals remove all visible plaque biofilm, gingival health can be maintained by one thorough cleaning with brush, floss, and toothpicks every 24 to 48 hours.[27,65,72,75] However, most patients fall far short of this goal. The average daily home care routine lasts less than 2 minutes and removes only 40% of plaque biofilm.[29] It has been reported that improved plaque biofilm removal and therefore improved periodontal health is associated with increasing the frequency of brushing to twice per day.[65,93] Cleaning three or more times per day does not appear to further improve periodontal conditions.

Recommendations

- Emphasis should be placed on cleaning the teeth meticulously once daily with all necessary tools.
- If plaque control is not adequate, a second daily brushing will help.

Patient Motivation and Education

In periodontal therapy, plaque biofilm control has two important purposes: to minimize gingival inflammation and to prevent the recurrence or progression of periodontal diseases and caries. Daily mechanical removal of plaque biofilm by the patient, including the use of appropriate antimicrobial agents, is the only practical means for improving oral health on a long-term basis. The process requires interest on the part of the patient and education and instruction from the dentist, followed by encouragement and reinforcement. Keeping records of patient performance facilitates this process. Figure 45-18 provides an example of a plaque biofilm control record that permits repeated measures and comparison over time.

Motivation for Effective Plaque Biofilm Control

Motivating patients to perform effective plaque biofilm control is one of the most critical and difficult elements of long-term success in periodontal therapy. It requires both commitment by the patient to change daily habits and regular return visits for maintenance and reinforcement. The scope of this compliance problem is immense. It has been shown that patients stop using interproximal cleaning aids after a very short time. Heasman et al[57] followed 100 patients treated for moderate to severe periodontal disease and taught to use one or more interdental cleaning aids. It was found that only 20% used the aids after 6 months. Of those who had started using three devices, one-third had stopped all interdental cleaning at 6 months; the others used one or two of the aids.[63] The situation is no better when looking at patient willingness to return for office visits. In one study of 1280 patients, most of whom had periodontal surgery in multiple sites after intensive scaling, root planing, and home care instruction, 25% never returned for a follow-up visit; only 40% returned regularly.[94] Wilson et al[127] reported that 67% of periodontal patients were noncompliant with return visits in a 20-year retrospective of a private periodontal practice.

Adopting new habits and returning for office visits is not an impossible task. To be successful, the patient (1) must be receptive and understand the concepts of pathogenesis, treatment, and prevention of periodontal disease; (2) must be willing to change the habits of a lifetime; and (3) must be able to adjust personal beliefs, practices, and values to accommodate new regimens. Manual skills must be developed to establish an effective plaque biofilm control regimen. In addition, the patient must understand the dentist's critical role in treating and maintaining periodontal health.[100] If not, long-term success of treatment is much less likely.

Figure 45-17 Effect of a disclosing agent. **A,** Unstained, the teeth look clean, but close inspection shows subtle signs of gingivitis. **B,** Plaque shows as dark-red particulate matter when stained with a disclosing dye. It is useful to demonstrate toothbrushing in the patient's mouth with the teeth disclosed and plaque visible.

Plaque Control Record

	1	2	3	4	5	6	7	8	9	10	11	12	13	14	15	16	Plaque Score:
Date: _____	32	31	30	29	28	27	26	25	24	23	22	21	20	19	18	17	_____
	1	2	3	4	5	6	7	8	9	10	11	12	13	14	15	16	Plaque Score:
Date: _____	32	31	30	29	28	27	26	25	24	23	22	21	20	19	18	17	_____
	1	2	3	4	5	6	7	8	9	10	11	12	13	14	15	16	Plaque Score:
Date: _____	32	31	30	29	28	27	26	25	24	23	22	21	20	19	18	17	_____

Figure 45-18 The plaque control record can be an effective motivator for patients. This form permits easy comparison of scores over time. *(Courtesy Dean John D.B. Featherstone, University of California, San Francisco School of Dentistry, San Francisco.)*

Education and Scoring Systems

Many patients prefer to believe that treatment is a passive process, so it is incumbent on the dentist to educate and reinforce to each patient their personal role in long-term success of therapy. Our health-conscious society is an advantage with regard to patient education. Most patients know what gingivitis is because they have heard about it on television or read about it in magazines or on the web. They are willing to spend time and money to try new products such as toothbrushes and mouthrinses.

Patients must also be informed that periodic assessment and debridement of the teeth in the dental office are required to prevent recurrence of periodontal diseases and identify problems that may arise. These procedures work best when combined with an individualized oral hygiene regimen practiced daily at home. Therefore time spent in the dental office teaching the patient how to perform microbial plaque biofilm control procedures is central to care. Patients sometimes have the concept that "cleanings" every few months are sufficient for calculus and biofilm removal and disease control. Only the combination of regular office visits with conscientious home care has been shown to significantly reduce gingivitis and loss of supporting periodontal tissues over the long term.[83,120]

Periodontal patients should be shown how periodontal disease has manifested in their own mouth. Stained plaque biofilm, the bleeding of inflamed gingiva, and demonstrations of the periodontal probe inserted into pockets are impressive demonstrations of the presence of pathogens and symptoms of disease. It also is of educational value to patients to have their oral cleanliness and periodontal condition recorded periodically[9] so that improvements in performance can be used for positive reinforcement. The plaque biofilm control record and the bleeding points index are simple indices and useful for patient education and motivation.

Plaque Biofilm Control Record (O'Leary Index).[95]

Have the patient use a disclosing solution or tablet and examine each tooth surface (except occlusal surfaces) for the presence or absence of stained biofilm at the dentogingival junction. Plaque biofilm is recorded on the appropriate box in a diagram for four surfaces on each tooth. After all teeth have been scored, the index number is calculated for the percentage of surfaces with biofilm by dividing the number of surfaces with microbial plaque biofilm by the total number of surfaces scored and then multiplying by 100. A reasonable goal for patients is 10% or fewer surfaces with plaque biofilm. If biofilm is always present in the same areas, provide instructions to improve cleaning procedures in those areas. It is extremely difficult to achieve a perfect score of 0, so patients should be rewarded for approaching it.

Some frequently used plaque biofilm indices do not require staining the teeth including the Plaque Index of Silness and Löe.[109] These are more convenient to use and often more acceptable to patients, but they are not as dramatic for patient education.

Bleeding Points Index.[78]

The bleeding points index provides an evaluation of gingival inflammation around each tooth in the patient's mouth. Retract the cheek, and place the periodontal probe 1 mm into the sulcus or pocket at the distal aspect of the most posterior tooth in the quadrant on the buccal surface. Carry the probe lightly across the length of the sulcus to the mesial interproximal area on the facial aspect. Continue along all the teeth in the quadrant from the facial aspect. Wait 30 seconds, and record the presence of bleeding on the distal, facial, and mesial surfaces on the chart. Repeat on the lingual-palatal aspect, recording bleeding only for the direct lingual surface, not for the mesial or distal surfaces. This results in four separate scores for each tooth and does not score the mesial and distal surfaces twice. Repeat the steps for each quadrant. The percentage of the number of bleeding surfaces is calculated by dividing the number of surfaces that bled by the total number of tooth surfaces (four per tooth) and by multiplying by 100 to convert the score to a percentage. This index is designed to demonstrate gingival inflammation characterized by bleeding rather than presence of microbial plaque biofilm. Again, a goal of 10% or fewer bleeding points is good, but 0 is ideal. If a few bleeding points repeatedly occur in the same areas, cleaning procedures for those areas should be reinforced or modified.

Significance of Plaque Biofilm Scores and Bleeding Scores.

Plaque biofilm scores are helpful as indicators of patient compliance and success with daily home care procedures. However, biofilm levels themselves do not necessarily reflect gingival health or risk of disease progression, even though the location of the plaque biofilm is highly correlated with the presence of gingivitis.[86] Bleeding is a much better indicator of predicting success in controlling inflammation and reducing the chance of disease progression. Although bleeding on probing is not the most specific or sensitive measures of health, it has a strong negative correlation to disease progression. If bleeding is absent at any given site in the mouth, reflecting good plaque biofilm control and disease management, it is unlikely that periodontal disease will progress.[77]

Instruction and Demonstration

Patients can reduce the incidence of plaque biofilm and gingivitis with repeated instruction and encouragement much more effectively than with self-acquired oral hygiene habits.[50,107] However, instruction in how to clean teeth must be more than a cursory chairside demonstration on the use of a toothbrush. It is a painstaking procedure that requires patient participation, careful supervision with correction of mistakes, and reinforcement during return

visits, until the patient achieves the necessary proficiency.[80] Any strategy for introducing plaque biofilm control to the periodontal patient includes several elements. At the first instruction visit, the patient should be given a new toothbrush, an interdental cleaner, and a disclosing agent. The patient's plaque biofilm should be disclosed otherwise it is difficult for the patient to see (see Figure 45-17). Polished dental restorations do not take up the stain, but the oral mucosa and the lips may retain it for up to several hours. Use petroleum jelly to keep the dye off the patient's lips.

Toothbrushing should be demonstrated in the patient's mouth while the patient observes using a hand mirror. The patient then repeats the procedures with the dentist giving assistance, correction, and positive reinforcement. Repeat the demonstration and instruction process with dental floss and interdental cleaning aids according to the patient's needs.

Encourage patients to clean the teeth thoroughly at least once a day. Be sure to inform them that home care procedures on a full dentition take 5 to 10 minutes, and for complex periodontal cases, home care procedures may take 30 minutes. The patient should set aside a convenient time and place in the daily schedule to perform the procedures reliably every day. Subsequent instruction visits should be used to reinforce or modify previous instructions, periodically recording the state of gingival health and amount of plaque biofilm.

Some strategies simply do not work. Waiting until the end of the appointment, for example, when the patient is sore, exhausted, and possibly anesthetized is not conducive to learning. Failing to provide positive reinforcement, handing the patient too many tools, and relying only on pamphlets and printed material to provide education are likely to result in an insufficient or ineffective instruction process.

Recommendations

The following list provides some strategies that will assist you in educating and motivating your patients:

- Provide encouragement.
- Demonstrate how devices work, and allow the patient to practice with them.
- Provide samples so that the patient does not have to stop and buy products on the way home; the patient may not follow through with the purchase.
- Show improvements at subsequent appointments, even if they are modest.
- Use positive reinforcement[119]; threats are not effective.

References

1. Addy M, Adriaens P: Epidemiology and etiology of periodontal diseases and the role of plaque control in dental caries. In Lang NP, Ättstrom R, Löe H, editors: *Proceedings of the European workshop on mechanical plaque control*, Chicago, 1998, Quintessence.
2. American Academy of Periodontology, Committee Report: The tooth brush and methods of cleaning the teeth. *Dent Items Int* 42:193, 1920.
3. American Academy of Periodontology: Position paper: guidelines for periodontal therapy. *J Periodontol* 72:1624, 2001.
4. American Academy of Periodontology: Position paper: the role of supra- and subgingival irrigation in the treatment of periodontal diseases. *J Periodontol* 76:2015, 2005.
5. American Dental Association: ADA seal shopping list: www.ada.org/ada/seal/shoppinglist.aspx, June 3, 2013.
6. Anderson L, Sanz M, Newman MG, et al: Clinical effects of a 0.12% chlorhexidine mouthrinse on periodontal surgical wounds without periodontal dressing. *J Dent Res* 67:329, 1988 (abstract 1728).
7. Arnim SS: The use of disclosing agents for measuring tooth cleanliness. *J Periodontol* 34:227, 1963.
8. Arweiler NB, Henning G, Reich E, et al: Effect of an amine-fluoride-triclosan mouthrinse on plaque regrowth and biofilm vitality. *J Clin Perio* 29:358, 2002.
9. Barrikman R, Penhall O: Graphing indexes reduce plaque. *J Am Dent Assoc* 87:1404, 1973.
10. Bascones A, Morante S, Mateos L, et al: Influence of additional active ingredients on the effectiveness of non-alcoholic chlorhexidine mouthwashes: a randomized controlled trial. *J Periodontol* 76:1469, 2005.
11. Bass CC: The optimum characteristics of toothbrushes for personal oral hygiene. *Dent Items Int* 70:697, 1948.
12. Bass CC: An effective method of personal oral hygiene. Part II. *J La State Med Soc* 106:100, 1954.
13. Baysan A, Lynch E, Ellwood R, et al: Reversal of primary root caries using dentifrices containing 5000 and 1100 ppm fluoride. *Caries Res* 35:41, 2001.
14. Beiswander BB, Mallott MC, Mau MS, et al: The relative plaque removal effect of a prebrushing mouthrinse. *J Am Dent Assoc* 120:190, 1990.
15. Binney A, Addy M, Newcombe RG: The plaque removal effects of single rinsings and brushings. *J Periodontol* 64:181, 1993.
16. Cantor MT, Stahl SS: The effects of various interdental stimulators upon the keratinization of the interdental col. *Periodontics* 3:243, 1965.
17. Cantor MT, Stahl SS: Interdental col tissue responses to the use of a water pressure device. *J Periodontol* 40:292, 1969.
18. Carter-Hanson C, Gadbury-Amyot C, Killoy WJ: Comparison of the plaque removal efficacy of a new flossing aid (Quik-Floss) to finger flossing. *J Clin Periodontol* 23:873, 1996.
19. Castenfelt T: *Toothbrushing and massage in periodontal disease: an experimental clinical histologic study*, Stockholm, 1952, Nordisk Rotegravyr.
20. Charters WJ: Eliminating mouth infections with the toothbrush and other stimulating instruments. *Dent Digest* 38:130, 1932.
21. Christou V, Timmerman MF, van der Velden U, et al: Comparison of different approaches of interdental oral hygiene: interdental brushes versus dental floss. *J Periodontol* 69:759, 1998.
22. Ciancio SC: Clinical benefits of powered subgingival irrigation. *Biol Ther Dent* 8:13, 1992.
23. Claydon N, Addy M: Comparative single-use plaque removal by toothbrushes of different designs. *J Clin Periodontol* 23:1112, 1996.
24. Cronin M, Dembling W: An investigation of the efficacy and safety of a new electric interdental plaque remover for the reduction of interproximal plaque and gingivitis. *J Clin Dent* 7:74, 1996.
25. Daly CG, Chapple CC, Cameron AC: Effect of toothbrush wear on plaque control. *J Clin Periodontol* 23:45, 1996.
26. Danser MM, Timmerman MF, Ijzerman Y, et al: Evaluation of the incidence of gingival abrasion as a result of toothbrushing. *J Clin Periodontol* 25:701, 1998.
27. De la Rosa MR, Guerra JZ, Johnston DA, et al: Plaque growth and removal with daily toothbrushing. *J Periodontol* 50:661, 1979.
28. De Paola LG, Overholser CD, Meiller TF, et al: Chemotherapeutic reduction of plaque and gingivitis development: a 6 month investigation. *J Dent Res* 65:274, 1986 (abstract 941).
29. Drisko CL: Nonsurgical periodontal therapy: pharmacotherapeutics. *Ann Periodontol* 1:491, 1996.
30. Drisko CL: Periodontal self-care: evidence-based support. *Periodontol 2000* 62:243, 2013.
31. Dyer D, Addy M, Newcombe RG: Studies in vitro of abrasion by different manual toothbrush heads and a standard toothpaste. *J Clin Periodontol* 27:99, 2000.
32. Eakle WS, Ford C, Boyd RL: Depth of penetration in periodontal pockets with oral irrigation. *J Clin Periodontol* 13:39, 1986.
33. Elmore JG, Horwitz JI: Oral cancer and mouthwash use: evaluation of the epidemiologic evidence. *Otolaryngol Head Neck Surg* 113:253, 1995.
34. Featherstone JD: Fluoride, remineralization and root caries. *Am J Dent* 7:271, 1994.
35. Featherstone JD: Prevention and reversal of dental caries: role of low level fluoride. *Community Dent Oral Epidemiol* 27:31, 1999.
36. Featherstone JD: The science and practice of caries prevention. *J Am Dent Assoc* 131:887, 2000.
37. Felix JA, Rosen S, App GR: Detection of bacteremia after the use of an oral irrigation device in subjects with periodontitis. *J Periodontol* 42:785, 1971.
38. Finkelstein P, Grossman E: The effectiveness of dental floss in reducing gingival inflammation. *J Dent Res* 58:1034, 1979.
39. Flemmig TF, Newman MG, Doherty FM, et al: Supragingival irrigation with 0.06% chlorhexidine in naturally occurring gingivitis. I. Six month clinical observations. *J Periodontol* 61:112, 1990.
40. Fones AC: *Mouth hygiene*, ed 4, Philadelphia, 1934, Lea & Febiger.
41. Forgas-Brockmann LB, Carter-Hanson C, Killoy WJ: The effects of an ultrasonic toothbrush on plaque accumulation and gingival inflammation. *J Clin Periodontol* 25:375, 1998.
42. Gilson CM, Charbeneau GT, Hill HC: A comparison of physical properties of several soft toothbrushes. *J Mich Dent Assoc* 51:347, 1969.
43. Gjermo P, Flotra L: The plaque removing effect of dental floss and toothpicks: a group comparison study. *J Periodontal Res* 4:170, 1969 (abstract).
44. Gjermo P, Flotra L: The effect of different methods of interdental cleaning. *J Periodontal Res* 5:230, 1970.
45. Glickman I, Petralis R, Marks R: The effect of powered toothbrushing plus interdental stimulation upon the severity of gingivitis. *J Periodontol* 35:519, 1964.
46. Glickman I, Petralis R, Marks R: The effect of powered toothbrushing and interdental stimulation upon microscopic inflammation and surface keratinization of the interdental gingiva. *J Periodontol* 36:108, 1965.
47. Goodson JM, Palys MD, Carpino E, et al: Microbiological changes associated with dental prophylaxis. *J Am Dent Assoc* 135:1159, 2004.
48. Gordon JM, Lamster IV, Seiger MC: Efficacy of Listerine antiseptic in inhibiting the development of plaque and gingivitis. *J Clin Periodontol* 12:697, 1985.
49. Gordon JM, Frascella JA, Reardon RC: A clinical study of the safety and efficacy of a novel electric interdental cleaning device. *J Clin Dent* 7:70, 1996.
50. Gravelle HR, Shackelford NF, Lovett JT: The oral hygiene of high school students as affected by three different educational programs. *J Public Health Dent* 27:91, 1967.
51. Greenstein G: Effects of subgingival irrigation on periodontal status. *J Periodontol* 58:827, 1987.
52. Grossman E, Reiter G, Sturzenberger OP, et al: Six-month study of the effects of a chlorhexidine mouthrinse on gingivitis in adults. *J Periodontal Res* 21(Suppl):33, 1986.
53. Harrington JH, Terry IA: Automatic and hand toothbrushing abrasion studies. *J Am Dent Assoc* 68:343, 1964.

54. Harris NO: Dentifrices, mouth rinses, and oral irrigators. In Harris NO, Christen AG, editors: *Primary preventive dentistry*, ed 3, East Norwalk, Conn, 1991, Appleton & Lange.
55. Heanue M, Deacon SA, Deery C, et al: Manual versus powered toothbrushing for oral health. *Cochrane Database Syst Rev* (2):CD00281, 2005.
56. Heasman PA, McCracken GI: Powered toothbrushes: a review of clinical trials. *J Clin Periodontol* 26:407, 1999.
57. Heasman PA, Jacobs DJ, Chapple IL: An evaluation of the effectiveness and patient compliance with plaque control methods in the prevention of periodontal disease. *J Clin Prev Dent* 11:24, 1989.
58. Hellstrom MK, Ramberg P, Krok L, et al: The effects of supragingival plaque control on subgingival microflora in human periodontitis. *J Clin Periodontol* 23:934, 1996.
59. Hill HC, Levi PA, Glickman I: The effects of waxed and unwaxed dental floss on interdental plaque accumulation and interdental gingival health. *J Periodontol* 44:411, 1973.
60. Hine MK: Toothbrush. *Int Dent J* 6:15, 1956.
61. Hirschfeld I: The toothbrush, its use and abuse. *Dent Items Int* 3:833, 1931.
62. Hollander BN, Boyd RL, Eakle WS: Comparison of subgingivally placed cannula oral irrigator tip with a supragingivally placed standard irrigator tip. *J Clin Periodontol* 19:340, 1992.
63. Hoover DR, Robinson HB, Billingsley A: The comparative effectiveness of the Water-Pik in a noninstructed population. *J Periodontol* 39:43, 1968 (abstract).
64. Hope CK, Petrie A, Wilson M: In vitro assessment of the plaque-removing ability of hydrodynamic shear forces produces beyond the bristles by 2 electric toothbrushes. *J Periodontol* 1017:2003.
65. Jepson S: The role of manual toothbrushes in effective plaque control: advantages and limitations. In Lang NP, Ättstrom R, Löe H, editors: *Proceedings of the European workshop on mechanical plaque control*, Chicago, 1998, Quintessence.
66. Jolkovsky DL, Waki MY, Newman MN, et al: Clinical and microbiological effects of subgingival and gingival marginal irrigation with chlorhexidine gluconate. *J Periodontol* 61:663, 1990.
67. Kazmierczak M, Mather M, Ciancio S, et al: A clinical evaluation of anticalculus dentifrices. *J Clin Prev Dent* 12:13, 1990.
68. Keijser J, Verkade H, Timmerman M, et al: Comparison of 2 commercially available chlorhexidine mouthrinses. *J Periodontol* 74:214, 2003.
69. Keller SE, Manson-Hing LR: Clearance studies of proximal tooth surfaces. Part II. In vivo removal of interproximal plaque. *Ala J Med Sci* 6:266, 1969.
70. Keller SE, Manson-Hing LR: Clearance studies of proximal tooth surfaces. Parts III and IV. In vivo removal of interproximal plaque. *Ala J Med Sci* 6:399, 1969.
71. Khocht A, Simon G, Person P, et al: Gingival recession in relation to history of hard toothbrush use. *J Periodontol* 64:900, 1993.
72. Kinane DF: The role of interdental cleaning in effective plaque control: need for interdental cleaning in primary and secondary prevention. In Lang NP, Ättstrom R, Löe H, editors: *Proceedings of the European workshop on mechanical plaque control*, Chicago, 1998, Quintessence.
73. Lamster IB, Alfano MC, Seiger MC, et al: The effect of Listerine antiseptic on reduction of existing plaque and gingivitis. *J Clin Prev Dent* 5:12, 1983.
74. Lang NP, Brecx MC: Chlorhexidine digluconate: an agent for chemical plaque control and prevention of gingival inflammation. *J Periodontal Res* 21(Suppl):74, 1986.
75. Lang NP, Cumming BR, Löe H: Toothbrushing frequency as it relates to plaque development and gingival health. *J Periodontol* 44:396, 1973.
76. Lang NP, Hotz P, Graf H, et al: Effects of supervised chlorhexidine mouthrinses in children: a longitudinal clinical trial. *J Periodontal Res* 17:101, 1982.
77. Lang NP, Joss A, Orsanic T, et al: Bleeding on probing: a predictor for the progression of periodontal diseases? *J Clin Periodontol* 13:590, 1986.
78. Lenox JA, Kopczyk RA: A clinical system for scoring a patient's oral hygiene performance. *J Am Dent Assoc* 86:849, 1973.
79. Leonard JF: Conservative treatment of periodontoclasia. *J Am Dent Assoc* 26:1308, 1939.
80. Less W: Mechanics of teaching plaque control. *Dent Clin North Am* 16:647, 1972.
81. Lewis MW, Holder-Ballard C, Selders RJ, Jr, et al: Comparison of the use of a toothpick holder to dental floss in improvement of gingival health in humans. *J Periodontol* 75:551, 2004.
82. Leyes Borrajo JL, Garcia Varela L, Lopez Castro G, et al: Efficacy of chlorhexidine mouthrinses with and without alcohol: a clinical study. *J Periodontol* 73:317, 2002.
83. Lindhe J, Nyman S: The effect of plaque control and surgical pocket elimination on the establishment and maintenance of periodontal health: a longitudinal study of periodontal therapy in cases of advanced disease. *J Clin Periodontol* 2:67, 1975.
84. Lobene RR: The effect of a pulsed water pressure cleaning device on oral health. *J Periodontol* 40:667, 1969.
85. Löe H: Does chlorhexidine have a place in the prophylaxis of dental disease? *J Periodontal Res* 8(Suppl 12):93, 1973.
86. Löe H, Theilade E, Jensen SB: Experimental gingivitis in man. *J Periodontol* 36:177, 1965.
87. Macgregor ID, Balding JW, Regis D: Flossing behaviour in English adolescents. *J Clin Periodontol* 25:291, 1998.
88. MacNeill S, Walter DM, Day A, et al: Sonic and mechanical toothbrushes an in vitro study showing altered microbial surface structures but lack of effect on viability. *J Clin Periodontol* 25:988, 1998.
89. Mallatt ME, Beiswanger BB, Stookey GK, et al: Influence of soluble pyrophosphates on calculus formation in adults. *J Dent Res* 64:1159, 1985.
90. Manly RS, Brudevold F: Relative abrasiveness of natural and synthetic toothbrush bristles on cementum and dentin. *J Am Dent Assoc* 55:779, 1957.
91. Mauriello SM, Bader JD: Six-month effects of a sanguinarine dentifrice on plaque and gingivitis. *J Periodontol* 59:238, 1988.
92. McKendrick AJ, Barbenel LM, McHugh WD: A two-year comparison of hand and electric toothbrushes. *J Periodontal Res* 3:224, 1968.
93. McKendrick AJ, Barbenel LM, McHugh WD: The influence of time of examination, eating, smoking, and frequency of brushing on the oral debris index. *J Periodontal Res* 5:205, 1970.
94. Novaes AB, Novaes AB, Jr, Moraes N, et al: Compliance with supportive periodontal therapy. *J Periodontol* 67:213, 1996.
95. O'Leary TJ, Drake RB, Naylor JE: The plaque control record. *J Periodontol* 43:38, 1972.
96. O'Leary TJ, Shafer WG, Swenson HM, et al: Possible penetration of crevicular tissue from oral hygiene procedures. II. Use of the toothbrush. *J Periodontol* 41:158, 1970.
97. Parsons LG, Thomas LG, Southard GL, et al: Effect of sanguinaria extract on established plaque and gingivitis when supragingivally delivered as a manual rinse or under pressure in an oral irrigator. *J Clin Periodontol* 14:381, 1987.
98. Pattison GA: Self-inflicted gingival injuries: literature review and case report. *J Periodontol* 54:299, 1983.
99. Perry DA, Pattison G: The investigation of wax residue on tooth surfaces after the use of waxed dental floss. *Dent Hygiene* 60:16, 1986.
100. Renvert S, Glavind L: Individualized instruction and compliance in oral hygiene practices: recommendations and means of delivery. In Lang NP, Ättstrom R, Löe H, editors: *Proceedings of the European workshop on mechanical plaque control*, Chicago, 1998, Quintessence.
101. Robinson HB, Hoover PR: The comparative effectiveness of a pulsating oral irrigator as an adjunct in maintaining oral health. *J Periodontol* 42:37, 1971.
102. Robinson P, Deacon SA, Deery C, et al: Manual versus powered toothbrushing for oral health. *Cochrane Database Syst Rev* (2):CD002281, 2005.
103. Sambunjak D, Nickerson JW, Poklepovic T, et al: Flossing for the management of periodontal diseases and dental caries in adults.

Cochrane Database Syst Rev (12):CD008829, 2011. doi: 10.1002/14651858.CD008829.pub2.
104. Sangnes G: Traumatization of teeth and gingiva related to habitual tooth cleaning procedures. *J Clin Periodontol* 3:94, 1976.
105. Sangnes G, Gjermo P: Prevalence of oral soft and hard tissue lesions related to mechanical tooth cleaning procedures. *Community Dent Oral Epidemiol* 4:77, 1976.
106. Sanz M, Herrera D: Role of oral hygiene during the healing phase of periodontal therapy. In Lang NP, Ättstrom R, Löe H, editors: *Proceedings of the European workshop on mechanical plaque control*, Chicago, 1998, Quintessence.
107. Schmid MO, Balmelli O, Saxer UP: The plaque removing effect of a toothbrush, dental floss and a toothpick. *J Clin Periodontol* 3:157, 1976.
108. Shiloah J, Hovious LA: The role of subgingival irrigations in the treatment of periodontitis. *J Periodontol* 64:835, 1993.
109. Silness J, Löe H: Periodontal disease in pregnancy. II. Correlation between oral hygiene and periodontal condition. *Acta Odontol Scand* 22:121, 1964.
110. Silverman S, Jr, Wilder R: Antimicrobial mouthrinse as part of a comprehensive oral care regimen. *J Am Dent Assoc* 137(Suppl 3):22s, 2006.
111. Silverstone LM, Featherstone MJ: A scanning electron microscope study of the end rounding of bristles in eight toothbrush types. *Quintessence Int* 19:87, 1988.
112. Spolsky VA, Perry DA, Meng Z, et al: Evaluating the efficacy of a new flossing aid. *J Clin Periodontol* 20:490, 1993.
113. Stillman PR: A philosophy of the treatment of periodontal disease. *Dent Digest* 38:314, 1932.
114. Stookey G: Are all fluoride dentifrices the same? In Wei SHY, editor: *Clinical uses of fluorides*, Philadelphia, 1985, Lea & Febiger.
115. Stookey GK, Muhler JC: Laboratory studies concerning the enamel and dentin abrasion properties of common dentifrice polishing agents. *J Dent Res* 47:524, 1968.
116. Straub AM, Salvi GE, Lang NP: Supragingival plaque formation in the human dentition. In Lang NP, Ättstrom R, Löe H, editors: *Proceedings of the European workshop on mechanical plaque control*, Chicago, 1998, Quintessence.
117. Suomi JD, Green JC, Vermillion JR, et al: The effect of controlled oral hygiene procedures on the progression of periodontal disease in adults: results after two years. *J Periodontol* 40:416, 1969.
118. Takei HH: Targeted hygiene. Personal communication, June 2009.
119. Tedesco LA, Keffler MA, Davis EL, et al: Effect of a social cognitive intervention on oral health status, behavior reports, and cognition. *J Periodontol* 63:567, 1992.
120. Teles RP, Patel M, Socransky SS, et al: Disease progression in periodontally healthy and maintenance subjects. *J Periodontol* 79:784, 2008.
121. Tritten CB, Armitage GA: Comparison of a sonic and a manual toothbrush for efficacy in supragingival plaque removal and reduction of gingivitis. *J Clin Periodontol* 23:641, 1996.
122. Van der Weijden GA, Timmerman MF, Danser MM, et al: Relationship between the plaque removal efficacy of a natural toothbrush and brushing force. *J Clin Periodontol* 25:413, 1998.
123. Waki MY, Jolkovsky DL, Otomo-Corgel J, et al: Effects of subgingival irrigation on bacteremia following scaling and root planing. *J Periodontol* 61:405, 1990.
124. Warren PR, Ray TS, Cugini M, et al: A practice-based study of a power toothbrush: assessment of effectiveness and acceptance. *J Am Dent Assoc* 131:389, 2000.
125. Wefel JS: Root caries histopathology and chemistry. *Am J Dent* 7:261, 1994.
126. Raposa K: Oral infections control: toothbrushes and toothbrushing. In Wilkins EM, editor: *Clinical practice of the dental hygienist*, ed 11, Philadelphia, 2013, Lippincott, Williams & Wilkins.
127. Wilson TG, Jr, Glover ME, Schoen J, et al: Compliance with maintenance therapy in a private dental practice. *J Periodontol* 55:468, 1984.
128. Yukna RA, Broxson AW, Mayer ET, et al: Comparison of Listerine mouthwash and periodontal dressing following periodontal flap surgery. *Clin Prev Dent* 4:14, 1986.
129. Zacheri WA, Pheiffer HJ, Swancar JR: The effect of soluble pyrophosphates on dental calculus in adults. *J Am Dent Assoc* 110:737, 1985.

CHAPTER 46

Scaling and Root Planing

Anna M. Pattison and Gordon L. Pattison

CHAPTER OUTLINE

Classification of Periodontal Instruments
General Principles of Instrumentation *(e-only)*
Principles of Scaling and Root Planing *(e-only)*
Instrument Sharpening *(e-only)*

For online-only content on general principles of instrumentation, principles of scaling and root planing, and instrument sharpening, please visit the companion website at www.expertconsult.com.

Periodontal instruments are designed for specific purposes such as removing calculus, planing root surfaces, curetting the gingiva, and removing diseased tissue. On first investigation, the variety of instruments available for similar purposes appears confusing. With experience, however, clinicians select a relatively small set that fulfills all requirements.

Classification of Periodontal Instruments

Periodontal instruments are classified according to the purposes they serve, as follows:

1. *Periodontal probes* are used to locate, measure, and mark pockets, as well as determine their course on individual tooth surfaces.
2. *Explorers* are used to locate calculus deposits and caries.
3. *Scaling, root-planing, and curettage instruments* are used for removal of biofilm and calcified deposits from the crown and root of a tooth, removal of altered cementum from the subgingival root surface, and debridement of the soft tissue lining the pocket. Scaling and curettage instruments are classified as follows:
   - *Sickle scalers* are heavy instruments used to remove supragingival calculus.
   - *Curettes* are fine instruments used for subgingival scaling, root planing, and removal of the soft tissue lining the pocket.
   - *Hoe, chisel, and file scalers* are used to remove tenacious subgingival calculus and altered cementum. Their use is limited compared with that of curettes.
   - *Ultrasonic and sonic instruments* are used for scaling and cleansing tooth surfaces and curetting the soft tissue wall of the periodontal pocket.[41,42,61]
4. *Periodontal endoscopes* are used to visualize deeply into subgingival pockets and furcations, allowing the detection of deposits.
5. *Cleansing and polishing instruments*, such as rubber cups, brushes, and dental tape, are used to clean and polish tooth surfaces. Also available are air-powder abrasive systems for tooth polishing.

The wearing and cutting qualities of some types of steel used in periodontal instruments have been tested,[83,84,146] but specifications vary among manufacturers.[146] Stainless steel is used most often in instrument manufacture. High-carbon-content steel instruments are also available and are considered by some clinicians to be superior.

Each group of instruments has characteristic features; individual therapists often develop variations with which they operate most effectively. Small instruments are recommended to fit into periodontal pockets without injuring the soft tissues.[109,111,112,163]

The parts of each instrument are referred to as the working end, shank, and handle (Figure 46-1).

Periodontal Probes

Periodontal probes are used to measure the depth of pockets and to determine their configuration. The typical probe is a tapered, rodlike instrument calibrated in millimeters, with a blunt, rounded tip (Figure 46-2). There are several other designs with various millimeter calibrations (Figure 46-3). The World Health Organization (WHO) probe has millimeter markings and a small, round ball at the tip (Figure 46-3, *E*). Ideally, these probes are thin, and the shank is angled to allow easy insertion into the pocket. Furcation areas can best be evaluated with the curved, blunt Nabers probe (Figure 46-4).

When measuring a pocket, the probe is inserted with a firm, gentle pressure to the bottom of the pocket. The shank should be aligned with the long axis of the tooth surface to be probed. Several measurements are made to determine the level of attachment along the surface of the tooth.

Explorers

Explorers are used to locate subgingival deposits and carious areas and to check the smoothness of the root surfaces after root planing. Explorers are designed with different shapes and angles, with various uses (Figure 46-5), as well as limitations (Figure 46-6). The periodontal probe can also be useful in the detection of subgingival deposits (Figure 46-6, *D*).

Material in this chapter was derived from Pattison A, Pattison G, Matsuda S: Periodontal Instrumentation, ed 3, Pearson Education, (in press).

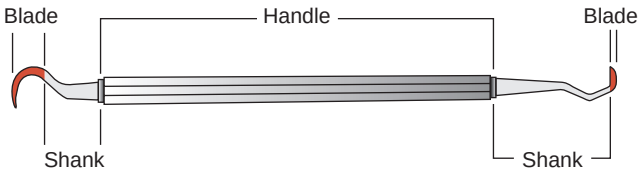

Figure 46-1 Parts of a typical periodontal instrument.

Figure 46-2 Periodontal probe is composed of the handle, shank, and calibrated working end.

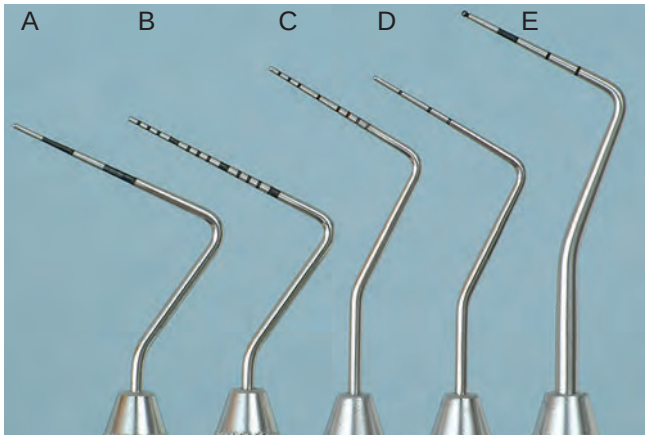

Figure 46-3 Types of periodontal probes. **A,** Marquis color-coded probe. Calibrations are in 3-mm sections. **B,** University of North Carolina-15 probe, a 15-mm long probe with millimeter markings at each millimeter and color coding at the fifth, tenth, and fifteenth millimeters. **C,** University of Michigan "O" probe, with Williams markings (at 1, 2, 3, 5, 7, 8, 9, and 10 mm). **D,** Michigan "O" probe with markings at 3, 6, and 8 mm. **E,** World Health Organization (WHO) probe, which has a 0.5-mm ball at the tip and millimeter markings at 3.5, 8.5, and 11.5 mm and color coding from 3.5 to 5.5 mm.

Figure 46-4 Curved #2 Nabers probe for detection of furcation areas, with color-coded markings at 3, 6, 9, and 12 mm.

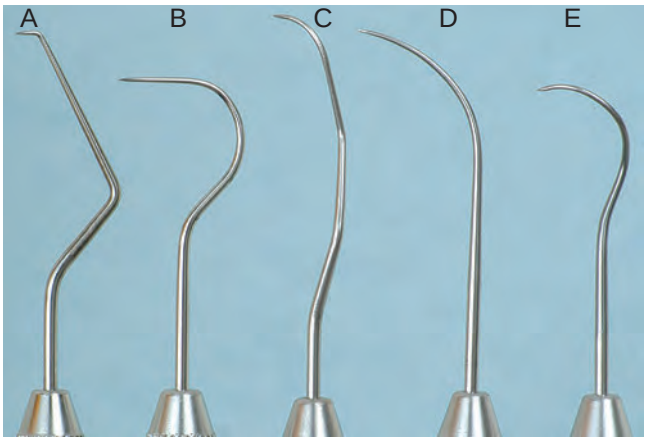

Figure 46-5 Five typical explorers. **A,** #17; **B,** #23; **C,** EXD 11-12; **D,** #3; **E,** #3CH Pigtail.

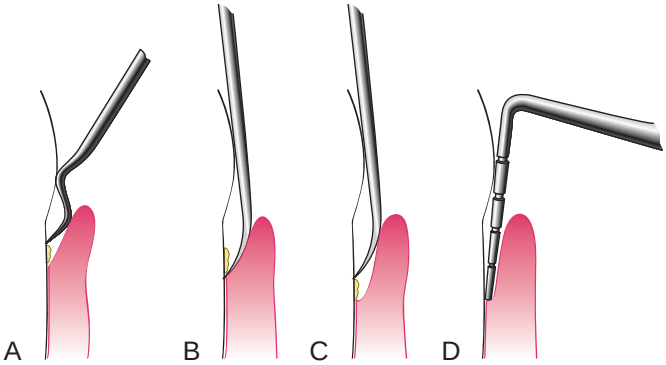

Figure 46-6 Insertion of two types of explorers and a periodontal probe in a pocket for calculus detection. **A,** The limitations of the pigtail explorer in a deep pocket. **B,** Insertion of the #3 explorer. **C,** Limitations of the #3 explorer. **D,** Insertion of the periodontal probe.

Scaling and Curettage Instruments

Scaling and curettage instruments are illustrated in Figure 46-7.

Sickle Scalers. Sickle scalers have a flat surface and two cutting edges that converge in a sharply pointed tip. The shape of the instrument makes the tip strong so that it will not break off during use (Figure 46-8). The sickle scaler is used primarily to remove supragingival calculus (Figure 46-9). Because of the design of this instrument, it is difficult to insert a large sickle blade under the gingiva without damaging the surrounding gingival tissues (Figure 46-10). Small, curved sickle scaler blades such as the 204SD can be inserted under ledges of calculus several millimeters below the gingiva. Sickle scalers are used with a pull stroke.

It is important to note that sickle scalers with the same basic design can be obtained with different blade sizes and shank types to adapt to specific uses. The U15/30 (Figure 46-11), Ball, and Indiana University sickle scalers are large. The Jaquette sickle scalers #1, 2, and 3 have medium-size blades. The curved 204 posterior sickle scalers are available with large, medium, or small blades (Figure 46-12). The Montana Jack sickle scaler and the Nevi 2, Nevi 3, and Nevi 4 curved posterior sickle scalers are all thin enough to be inserted several millimeters subgingivally for removal of light to moderate ledges of calculus. The selection of these instruments should be based on the area to be scaled. Sickle scalers

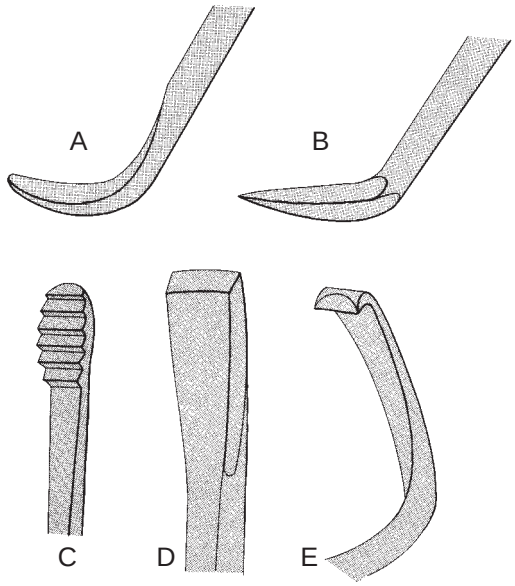

Figure 46-7 The five basic scaling instruments. **A,** Curette; **B,** sickle; **C,** file; **D,** chisel; E, hoe.

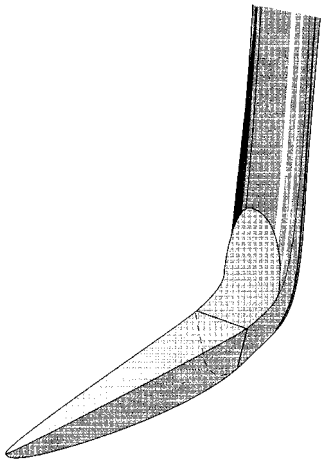

Figure 46-8 Basic characteristics of a sickle scaler: triangular shape, double-cutting edge, and pointed tip.

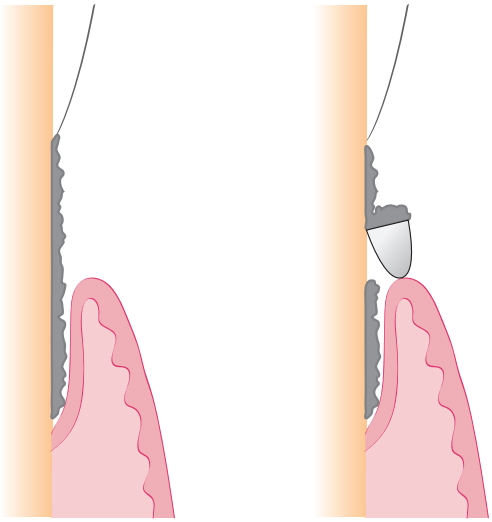

Figure 46-9 Use of a sickle scaler for removal of supragingival calculus.

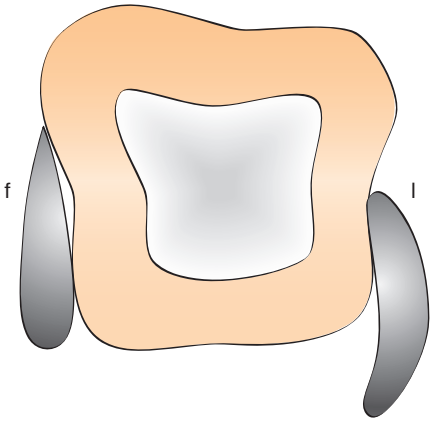

Figure 46-10 Subgingival adaptation around the root is better with the curette than with the sickle; *f,* facial; *l,* lingual.

Figure 46-11 Both ends of a U15/30 scaler.

Figure 46-12 Three different sizes of 204 sickle scalers.

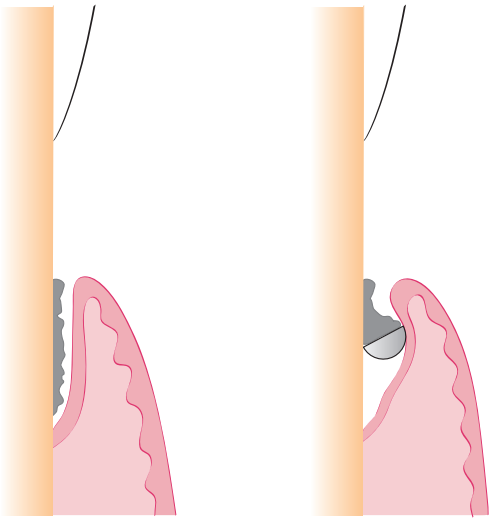

Figure 46-13 The curette is the instrument of choice for subgingival scaling and root planing.

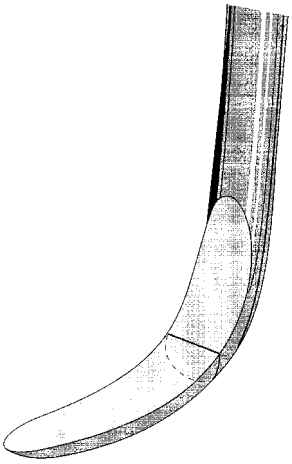

Figure 46-14 Basic characteristics of a curette: spoon-shaped blade and rounded tip.

with straight shanks are designed for use on anterior teeth and premolars. Sickle scalers with contra-angled shanks adapt to posterior teeth.

Curettes. The curette is the instrument of choice for removing deep subgingival calculus, root planing altered cementum, and removing the soft tissue lining the periodontal pocket (Figure 46-13). Each working end has a cutting edge on both sides of the blade and a rounded toe. The curette is finer than the sickle scalers and does not have any sharp points or corners other than the cutting edges of the blade (Figure 46-14). Therefore curettes can be adapted and provide good access to deep pockets, with minimal soft tissue trauma (see Figure 46-10). In cross-section, the blade appears semicircular with a convex base. The lateral border of the convex base forms a cutting edge with the face of the semicircular blade. There are cutting edges on both sides of the blade. Both single- and double-end curettes may be obtained, depending on the preference of the operator.

As shown in Figure 46-10, the curved blade and rounded toe of the curette allow the blade to adapt better to the root surface, unlike the straight design and pointed end of a sickle scaler, which can cause tissue laceration and trauma. There are two basic types of curettes: universal and area specific.

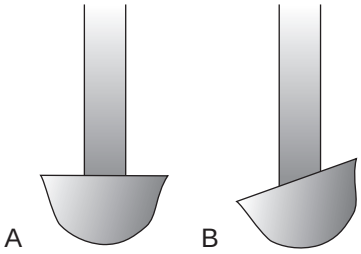

Figure 46-15 Principal types of curettes as seen from the toe of the instrument. **A,** Universal curette. **B,** Gracey curette. Note the offset blade angulation of the Gracey curette.

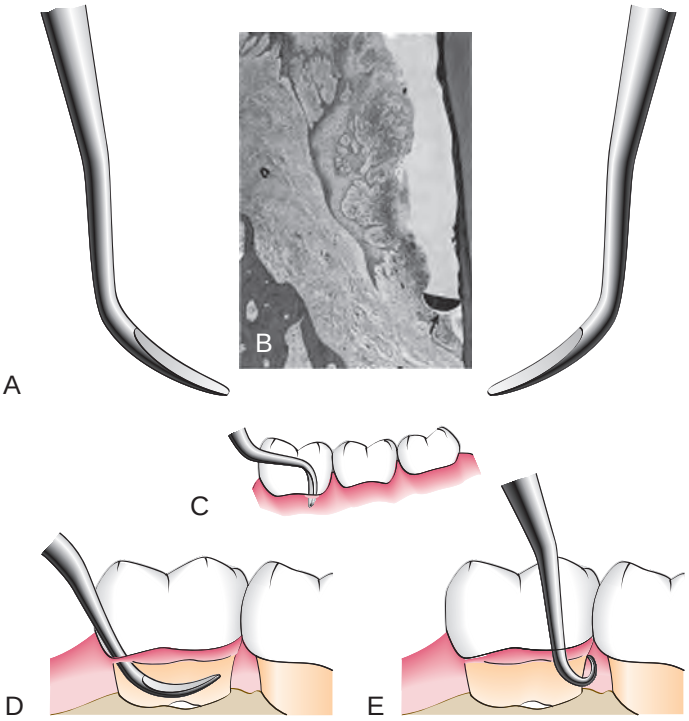

Figure 46-16 **A,** Double-ended curette for the removal of subgingival calculus. **B,** Cross-section of the curette blade *(arrow)* against the cemental wall of a deep periodontal pocket. **C,** Curette in position at the base of a periodontal pocket on the facial surface of a mandibular molar. **D,** Curette inserted in a pocket with the tip directed apically. **E,** Curette in position at the base of a pocket on the distal surface of the mandibular molar.

Universal Curettes. Universal curettes have cutting edges that may be inserted in most areas of the dentition by altering and adapting the finger rest, fulcrum, and hand position of the operator. The blade size and the angle and length of the shank may vary, but the face of the blade of every universal curette is at a 90-degree angle (perpendicular) to the lower shank when seen in cross-section from the tip (Figure 46-15, *A*). The blade of the universal curette is curved in one direction from the head of the blade to the toe. The Barnhart curettes #1-2 and 5-6 and the Columbia curettes #13-14, 2R-2L, and 4R-4L (Figures 46-16 and 46-17, *A*) are examples of universal curettes. Other popular universal curettes are the Younger-Good #7-8, McCall's #17-18, and the Indiana University #17-18 (Figure 46-17, *B*).

Area-Specific Curettes

Gracey Curettes. Gracey curettes are representative of the area-specific curettes, a set of several instruments designed and angled

Figure 46-17 **A,** Columbia #4R-4L universal curette. **B,** Younger-Good #7-8, McCall's #17-18, and Indiana University #17-18 universal curettes.

Figure 46-19 Gracey #11-12 curette. Note the double turn of the shank.

Figure 46-18 Reduced set of Gracey curettes. *Left to right,* #5-6, #7-8, #11-12, and #13-14.

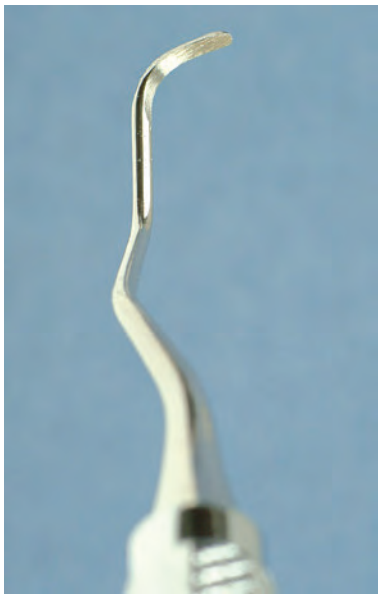

Figure 46-20 Gracey #13-14 curette. Note the acute turn of the blade.

to adapt to specific anatomic areas of the dentition (Figure 46-18). These curettes and their modifications are probably the best instruments for subgingival scaling and root planing because they provide the best adaptation to complex root anatomy.

Double-ended Gracey curettes are paired in the following manner:

Gracey #1-2 and 3-4: Anterior teeth
Gracey #5-6: Anterior teeth and premolars
Gracey #7-8 and 9-10: Posterior teeth: facial and lingual
Gracey #11-12: Posterior teeth: mesial (Figure 46-19)
Gracey #13-14: Posterior teeth: distal (Figure 46-20)

Single-ended Gracey curettes can also be obtained; a set of these curettes comprises 14 instruments. Although these curettes are designed to be used in specific areas, an experienced operator can adapt each instrument for use in several different areas by altering the position of his or her hand and the position of the patient.

The Gracey curettes also differ from the universal curettes in that the blade is not at a 90-degree angle to the lower shank. The term *offset blade* is used to describe Gracey curettes because they are angled approximately 60 to 70 degrees from the lower shank (see Figure 46-15, *B*). This unique angulation allows the blade to be inserted in the precise position necessary for subgingival scaling and root planing, provided that the lower shank is parallel with the long axis of the tooth surface being scaled.

Area-specific curettes also have a curved blade. Whereas the blade of the universal curette is curved in one direction (Figure 46-21, *A*), the Gracey blade is curved from head to toe and also along the side of the cutting edge (Figure 46-21, *B*). Thus only a pull stroke can be used. Table 46-1 lists some of the major

differences between Gracey (area-specific) curettes and universal curettes.

Gracey curettes are available with either a "rigid" or a "finishing" type of shank. The rigid Gracey has a larger, stronger, and less flexible shank and blade than the standard finishing Gracey. The rigid shank allows the removal of moderate to heavy calculus without using a separate set of heavy scalers, such as sickles and hoes. Although some clinicians prefer the enhanced tactile sensitivity that the flexible shank of the finishing Gracey provides, both types of Gracey curettes are suitable for root planing.

Recent additions to the Gracey curette set have been the Gracey #15-16 and 17-18. The Gracey #15-16 is a modification of the standard #11-12 and is designed for the mesial surfaces of posterior teeth (Figure 46-22). It consists of a Gracey #11-12 blade combined with the more acutely angled #13-14 shank. When the clinician is using an intraoral finger rest, it is often difficult to position the lower shank of the Gracey #11-12 so that it is parallel with the mesial surfaces of the posterior teeth, especially on the mandibular molars. The new shank angulation of the Gracey #15-16 allows better adaptation to posterior mesial surfaces from a front position with intraoral rests. If alternative fulcrums, such as extraoral or opposite-arch rests, are used, the Gracey #11-12 works well and the new #15-16 is not essential. The Gracey #17-18 is a modification of the #13-14. It has a terminal shank elongated by 3 mm and a more accentuated angulation of the shank to provide complete occlusal clearance and better access to all posterior distal surfaces. The horizontal handle position minimizes interference from opposing arches and allows a more relaxed hand position when scaling distal surfaces. In addition, the blade is 1 mm shorter to allow better adaptation of the blade to distal tooth surfaces.

Extended-Shank Curettes. Extended-shank curettes, such as the *After Five* curettes (Hu-Friedy, Chicago), are modifications of the standard Gracey curette design. The terminal shank is 3 mm longer, allowing extension into deeper periodontal pockets of 5 mm or more (Figures 46-23 and 46-24). Other features of the After Five curette include a thinned blade for smoother subgingival insertion and reduced tissue distention and a large-diameter, tapered shank. All standard Gracey numbers except for the #9-10 (i.e., #1-2, #3-4, #5-6, #7-8, #11-12, or #13-14) are available in the After

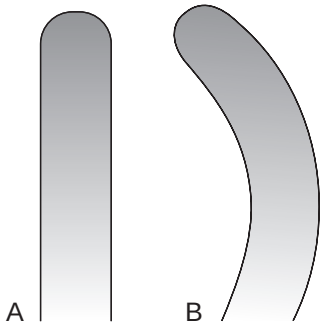

Figure 46-21 **A,** Universal curette as seen from the blade. Note that the blade is straight. **B,** Gracey curette as seen from the blade. The blade is curved; only the convex cutting edge is used.

Figure 46-22 Gracey #15-16. New Gracey curette, designed for mesioposterior surfaces, combines a Gracey #11-12 blade with a Gracey #13-14 shank. *(© A. Pattison)*

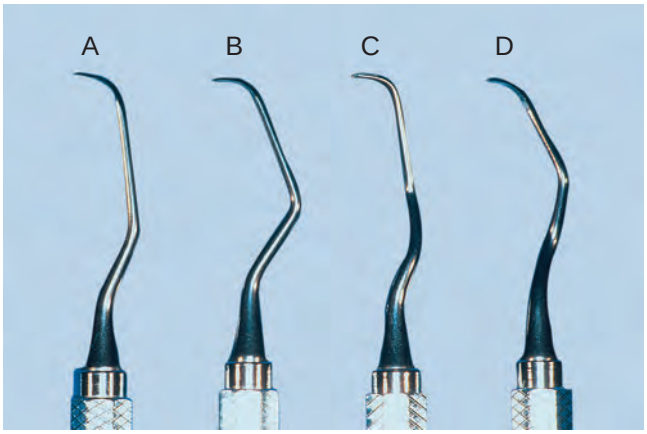

Figure 46-23 After Five curette. Note the extra 3 mm in the terminal shank of the After Five curette compared with the standard Gracey curette. **A,** #5-6; **B,** #7-8; **C,** #11-12; **D,** #13-14. *(© A. Pattison)*

TABLE 46-1 Comparison of Area-Specific (Gracey) and Universal Curettes

	Gracey Curette	Universal Curette
Area of use	Set of many curettes designed for specific areas and surfaces.	One curette designed for all areas and surfaces.
Cutting Edge		
Use	One cutting edge used; work with outer edge only.	Both cutting edges used; work with either outer or inner edge.
Curvature	Curved in two planes; blade curves up and to the side.	Curved in one plane; blade curves up, not to the side.
Blade angle	Offset blade; face of blade beveled at 60 degrees to shank.	Blade not offset; face of blade beveled at 90 degrees to shank.

Modified from Pattison G, Pattison A: *Periodontal instrumentation*, ed 2, Norwalk, CT, 1992, Appleton & Lange.

Figure 46-24 Comparison of After Five curette with standard Gracey curette. Rigid Gracey #13-14 adapted to the distal surface of the first molar and rigid After Five #13-14 adapted to the distal surface of the second molar. Notice the extra-long shank of the After Five curette, which allows deeper insertion and better access. *(© A. Pattison)*

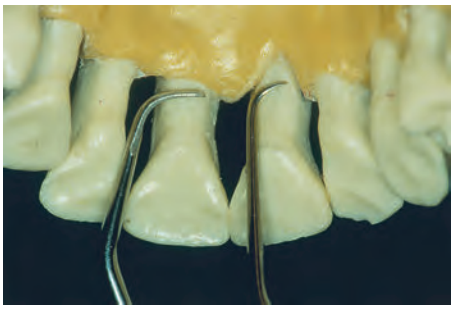

Figure 46-26 Comparison of standard rigid Gracey #5-6 with rigid Mini Five #5-6 on the palatal surfaces of the maxillary central incisors. Mini Five curette can be inserted to the base of these tight anterior pockets and used with a straight vertical stroke. Standard Gracey or After Five curette usually cannot be inserted vertically in this area because the blade is too long. *(© A. Pattison)*

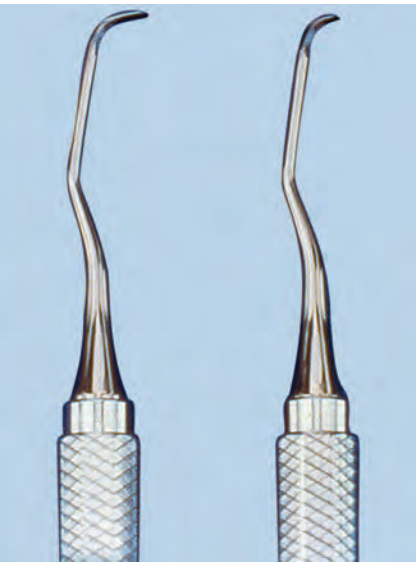

Figure 46-25 Comparison of After Five curette and Mini Five curette. The shorter Mini Five blade (half the length) allows increased access and reduced tissue trauma.

Figure 46-27 Micro Mini Five Gracey curettes. *Left to right,* #1-2, #7-8, #11-12, #13-14.

Five series. The After Five curettes are available in finishing or rigid designs. For heavy or tenacious calculus removal, rigid After Five curettes should be used. For light scaling or deplaquing in a periodontal maintenance patient, the thinner, finishing After Five curettes will insert subgingivally more easily.

Mini-Bladed Curettes. Mini-bladed curettes, such as the Hu-Friedy *Mini Five* curettes, are modifications of the After Five curettes. The Mini Five curettes feature blades that are half the length of the After Five or standard Gracey curettes (Figure 46-25). The shorter blade allows easier insertion and adaptation in deep, narrow pockets; furcations; developmental grooves; line angles; and deep, tight, facial, lingual, or palatal pockets. In any area in which root morphology or tight tissue prevents full insertion of the standard Gracey or After Five blade, the Mini Five curettes can be used with vertical strokes, with reduced tissue distention, and without tissue trauma (Figure 46-26).

In the past the only solution in most of these areas of difficult access was to use the Gracey curettes with a toe-down horizontal stroke. The Mini Five curettes, along with other short-bladed instruments relatively recently introduced, open a new chapter in the history of root instrumentation by allowing access to areas that previously were extremely difficult or impossible to reach with standard instruments. The Mini Five curettes are available in both finishing and rigid designs. Rigid Mini Five curettes are recommended for calculus removal. The more flexible, shanked, finishing Mini Five curettes are appropriate for light scaling and deplaquing in periodontal maintenance patients with tight pockets. As with the After Five series, the Mini Five curettes are available in all standard Gracey numbers, except the #9-10.

The recently introduced *Micro Mini Five* Gracey curettes (Hu-Friedy, Chicago) have blades that are 20% thinner and smaller than the Mini Five curettes (Figures 46-27 and 46-28) These are the smallest of all curettes, and they provide exceptional access and adaptation to tight, deep, or narrow pockets; narrow furcations; developmental depressions; line angles; and deep pockets on facial, lingual, or palatal surfaces. In areas in which root morphology or tight, thin tissue prevents easy insertion of other mini-bladed curettes, the Micro Mini Five curettes can be used with vertical strokes without causing tissue distension or tissue trauma.

The *Gracey Curvettes* are another set of four mini-bladed curettes; the Sub-0 and the #1-2 are used for anterior teeth and premolars, the #11-12 is used for posterior mesial surfaces, and the #13-14 for posterior distal surfaces. The blade length of these instruments is 50% shorter than that of the conventional Gracey curette, and the blade has been curved slightly upward (Figure 46-29). This curvature allows the Gracey Curvettes to adapt more closely to the tooth surface than any other curettes, especially on

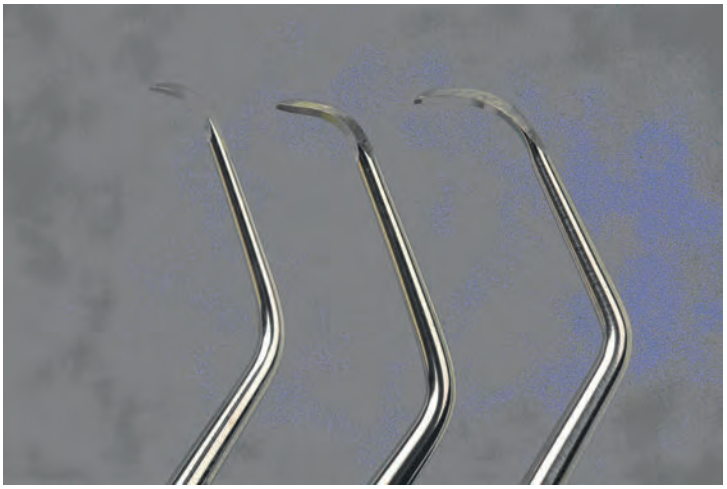

Figure 46-28 Comparison of Gracey curette blades. *Left to right,* Micro Mini Five #7-8, Mini Five #7-8, Standard #7-8.

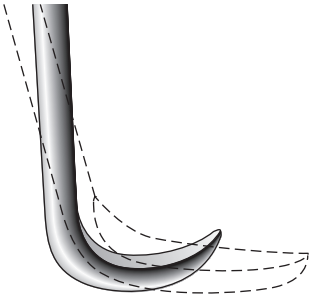

Figure 46-29 Gracey Curvette blade. This diagram shows the 50% shorter blade of the Gracey Curvette superimposed on the standard Gracey curette blade *(dotted lines)*. Notice the upward curvature of the Curvette blade and blade tip. *(Redrawn from Pattison G, Pattison A:* Periodontal instrumentation, *ed 2, Norwalk, Conn, 1992, Appleton & Lange.)*

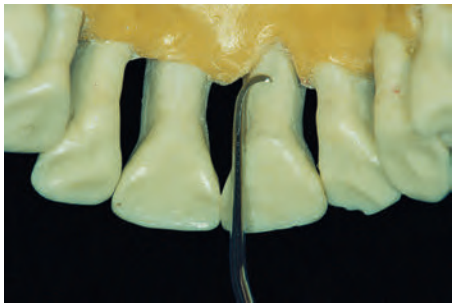

Figure 46-30 Gracey Curvette Sub-0 on the palatal surface of a maxillary central incisor. The long shank and short, curved, and blunted tip make this a superior instrument for deep anterior pockets. This curette provides excellent blade adaptation to the narrow root curvatures of the maxillary and mandibular anterior teeth. *(© A. Pattison)*

the anterior teeth and on line angles (Figure 46-30). However, this curvature also carries the risk of gouging or "grooving" into the root surfaces on the proximal surfaces of the posterior teeth when the Gracey Curvette #11-12 or 13-14 is used. Additional features that represent improvements on the standard Gracey curettes are a precision-balanced blade tip in direct alignment with the handle, a blade tip perpendicular to the handle, and a shank closer to parallel with the handle.

Figure 46-31 Comparison of three different mini-bladed instruments designed for use on the maxillary and mandibular anterior teeth. **A,** Hu-Friedy Mini Five #5-6; **B,** Hu-Friedy Curvette Sub-0; **C,** Hartzell Sub-0. *(© A. Pattison)*

For many years, the *Morse scaler,* a miniature sickle, was the only mini-bladed instrument available. However, the mini-bladed curettes have largely replaced this instrument (Figure 46-31).

Langer and Mini-Langer Curettes. The Langer and Mini Langer curettes are a set of three curettes combining the shank design of the standard Gracey #5-6, 11-12, and 13-14 curettes with a universal blade honed at 90 degrees rather than the offset blade of the Gracey curette. This marriage of the Gracey and universal curette designs allows the advantages of the area-specific shank to be combined with the versatility of the universal curette blade. The Langer #5-6 curette adapts to the mesial and distal surfaces of anterior teeth; the Langer #1-2 curette (Gracey #11-12 shank) adapts to the mesial and distal surfaces of mandibular posterior teeth; and the Langer #3-4 curette (Gracey #13-14 shank) adapts to the mesial and distal surfaces of maxillary posterior teeth (Figure 46-32). These instruments can be adapted to both mesial and distal tooth surfaces without changing instruments. The standard Langer curette shanks are heavier than a finishing Gracey but less rigid than the rigid Gracey. Langer curettes are also available with either

Figure 46-32 Langer curettes combine Gracey-type shanks with universal curette blades. *Left to right,* #5-6, #1-2, and #3-4. *(© A. Pattison)*

Figure 46-33 Schwartz Periotriever tip designs. The long blade is for general use in pockets, and the contra-angled tip is for use in furcations. *(From Pattison G, Pattison A:* Periodontal instrumentation, *ed 2, Norwalk, CT, 1992, Appleton & Lange.)*

rigid or finishing shanks and can be obtained in the extended-shank (After Five) and mini-bladed (Mini Five) versions.

Schwartz Periotrievers. The Schwartz Periotrievers are a set of two double-ended, highly magnetized instruments designed for the retrieval of broken instrument tips from the periodontal pocket (Figures 46-33 and 46-34). They are indispensable when the clinician has broken a curette tip in a furcation or deep pocket.[138]

Plastic and Titanium Instruments for Implants. Several different companies are manufacturing plastic and titanium instruments for use on titanium and other implant abutment materials. It is important that plastic or titanium instruments be used to avoid scarring and permanent damage to the implants* (Figures 46-35, 46-36, and 46-37).

Hoe Scalers. Hoe scalers are used for scaling of ledges or rings of calculus (Figure 46-38). The blade is bent at a 99-degree angle; the cutting edge is formed by the junction of the flattened terminal surface with the inner aspect of the blade. The cutting edge is beveled at 45 degrees. The blade is slightly bowed so that it can

*References 22, 38, 42, 45, 54, 91, and 132.

Figure 46-34 Broken instrument tip attached to the magnetic tip of the Schwartz Periotriever. *(From Pattison G, Pattison A:* Periodontal instrumentation, *ed 2, Norwalk, CT, 1992, Appleton & Lange.)*

Figure 46-35 Plastic probe: Colorvue (Hu-Friedy, Chicago).

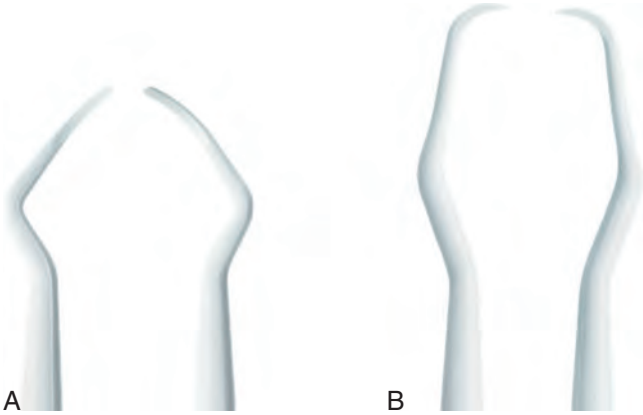

Figure 46-36 New Implacare II implant instruments (Hu-Friedy, Chicago) These implant instruments have autoclavable stainless steel handles and five different cone-socket plastic tip designs. Shown here: A. New Barnhart 5-6 curette tips B. New Langer 1-2 curette tips

Figure 46-37 Titanium Implant Curettes (Paradise Dental Technologies, Missoula, MT). *Left to right,* Barnhart #5-6, Langer #1-2, and NEB 128B-L5 Mini.

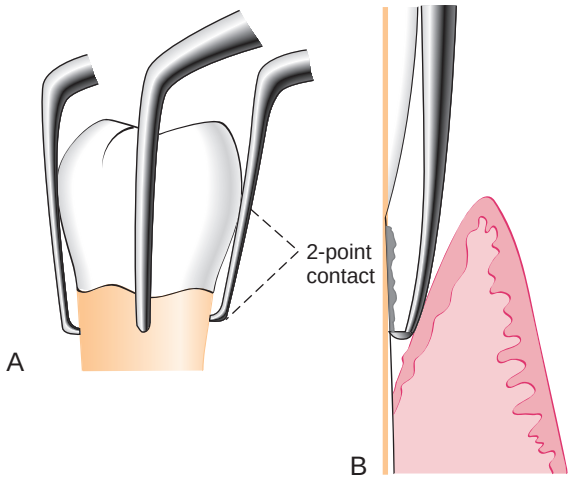

Figure 46-38 **A,** Hoe scalers designed for different tooth surfaces, showing "two-point" contact. **B,** Hoe scaler in a periodontal pocket. The back of the blade is rounded for easier access. The instrument contacts the tooth at two points for stability.

maintain contact at two points on a convex surface. The back of the blade is rounded, and the blade has been reduced to minimal thickness to permit access to the roots without interference from the adjacent tissues.

Hoe scalers are used in the following manner:

1. The blade is inserted to the base of the periodontal pocket so that it makes two-point contact with the tooth (see Figure 46-38). This stabilizes the instrument and prevents nicking of the root.
2. The instrument is activated with a firm pull stroke toward the crown, with every effort being made to preserve the two-point contact with the tooth.

McCall's #3, 4, 5, 6, 7, and 8 are a set of six hoe scalers designed to provide access to all tooth surfaces. Each instrument has a different angle between the shank and handle.

Files. Files have a series of blades on a base (Figure 46-39). Their primary function is to fracture or crush large deposits of tenacious calculus or burnished sheets of calculus. Files can easily gouge and roughen root surfaces when used improperly. Therefore they are not suitable for fine scaling and root planing. Mini-bladed curettes

Figure 46-39 Chisel scaler **(A)** and file scaler **(B).**

Figure 46-40 Quétin furcation curettes: BL2 (larger) and BL1 (smaller). *(© A. Pattison)*

are currently preferred for fine scaling in areas where files were once used. Files are sometimes used for removing overhanging margins of dental restorations.

Chisel Scalers. The chisel scaler, designed for the proximal surfaces of teeth too closely spaced to permit the use of other scalers, is usually used in the anterior part of the mouth. It is a double-ended instrument with a curved shank at one end and a straight shank at the other (see Figure 46-39); the blades are slightly curved and have a straight cutting edge beveled at 45 degrees.

The chisel is inserted from the facial surface. The slight curve of the blade makes it possible to stabilize it against the proximal surface, whereas the cutting edge engages the calculus without nicking the tooth. The instrument is activated with a push motion while the side of the blade is held firmly against the root.

Quétin Furcation Curettes. The Quétin furcation curettes are actually hoes with a shallow, half-moon radius that fits into the roof or floor of the furcation. The curvature of the tip also fits into developmental depressions on the inner aspects of the roots. The shanks are slightly curved for better access, and the tips are available in two widths (Figure 46-40). The BL1 *(buccal-lingual)* and MD1 *(mesial-distal)* instruments are small and fine, with a 0.9-mm

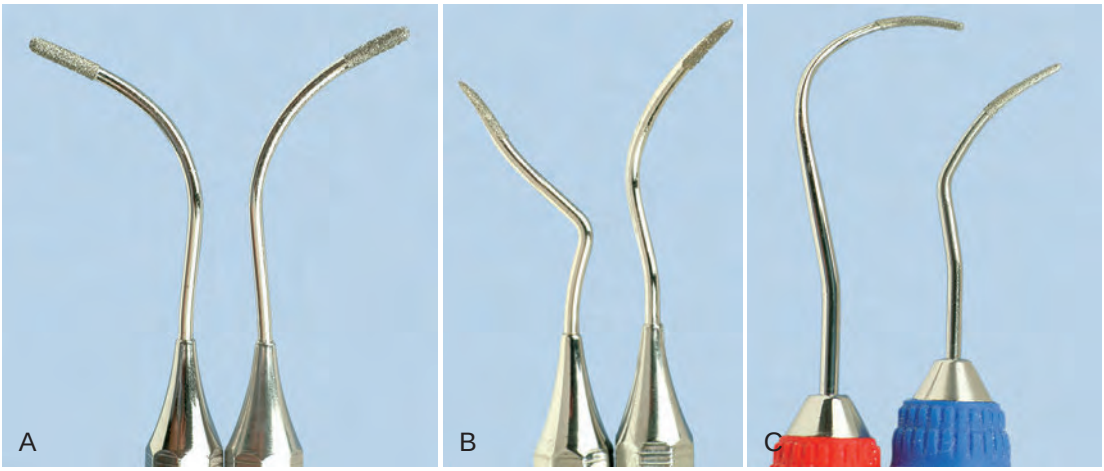

Figure 46-41 Diamond files. **A,** #1,2 (Brasseler, Savannah, GA); **B,** #3,4 (Brasseler). **C,** SDCN 7, SDCM/D 7. *(© A. Pattison)*

blade width. The BL2 and MD2 instruments are larger and wider, with a 1.3-mm blade width.

These instruments remove burnished calculus from recessed areas of the furcation where curettes, even the mini-bladed curettes, are often too large to gain access. Using mini-bladed Gracey curettes and Gracey Curvettes in the roof or floor of the furcation may unintentionally create gouges and grooves. The Quétin instruments, however, are well suited for this area and lessen the likelihood of root damage.

Diamond-Coated Files. Diamond-coated files are unique instruments used for final finishing of root surfaces. These files do not have cutting edges; instead, they are coated with very-fine-grit diamond (Figure 46-41). The most useful diamond files are the buccal-lingual instruments, which are used in furcations and also adapt well to many other root surfaces.

New diamond files are sharply abrasive and should be used with light, even pressure against the root surface to avoid gouging or grooving. When viewing the root surface with the dental endoscope after all tactilely detectable deposits are gone, small embedded remnants of calculus in the root surface can be observed. Diamond files are used similar to an emery board to remove these minute remnants of calculus from the root, creating a surface that is free of all visible accretions. Diamond files can produce a smooth, even, clean, and highly polished root surface.

Diamond files must be used carefully because they can cause overinstrumentation of the root surface. They will remove too much root structure if they are used with excessive force, are poorly adapted to root morphology, or used too long in one place.

Diamond files are particularly effective when used with the dental endoscope, which reveals residual deposits and directs the clinician to the exact area for instrumentation.

Ultrasonic and Sonic Instruments. Ultrasonic instruments may be used for removing plaque, scaling, curetting, and removing stain (see Chapter 47).

Dental Endoscope. A dental endoscope has been introduced for use subgingivally in the diagnosis and treatment of periodontal disease (Figure 46-42). The *Perioscopy* system (Perioscopy, Inc., Oakland, CA) consists of a 0.99-mm-diameter, reusable fiberoptic endoscope over which is fitted a disposable, sterile sheath. The fiberoptic endoscope fits onto periodontal probes and ultrasonic instruments that have been designed to accept it (Figure 46-43).

Figure 46-42 Perioscopy system, dental endoscope. *(Courtesy Perioscopy Incorporated, Oakland, CA.)*

The sheath delivers water irrigation that flushes the pocket while the endoscope is being used, keeping the field clear. The fiberoptic endoscope attaches to a medical-grade charged-coupled device (CCD) video camera and light source that produces an image on a flat-panel monitor for viewing during subgingival exploration and instrumentation. This device allows clear visualization deeply into subgingival pockets and furcations (Figure 46-44). It permits operators to detect the presence and location of subgingival deposits and guides them in the thorough removal of these deposits. Magnification ranges from 24 to 48 times, enabling visualization of even minute deposits of plaque and calculus. Using this device, operators can achieve levels of root debridement and cleanliness that are much more difficult or impossible to produce without it.[149,150,167,168] The Perioscopy system can also be used to evaluate

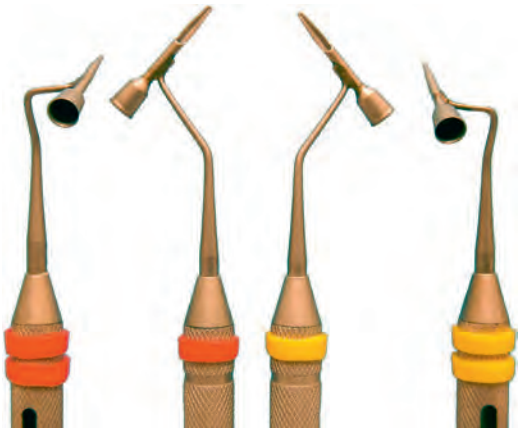

Figure 46-43 Viewing periodontal explorers (left/right/full viewing) for the Perioscopy system. *(Courtesy Perioscopy Incorporated, Oakland, CA.)*

Figure 46-44 Perioscopic instrumentation permits deep subgingival visualization in pockets and furcations. *(Courtesy Perioscopy Incorporated, Oakland, CA.)*

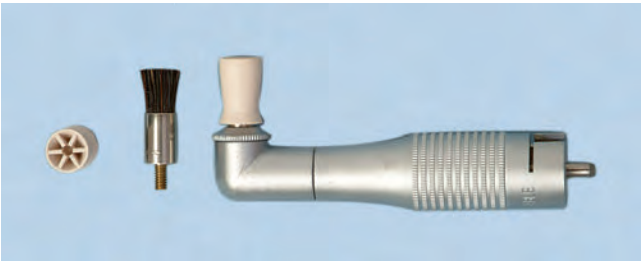

Figure 46-45 Metal prophylaxis angle with rubber cup and brush.

subgingival areas for caries, defective restorations, root fractures, and resorption.

Cleansing and Polishing Instruments

Rubber Cups. Rubber cups consist of a rubber shell with or without webbed configurations in the hollow interior (Figure 46-45). They are used in the handpiece with a special prophylaxis angle. The handpiece, prophylaxis angle, and rubber cup must be sterilized after each patient use, or a disposable plastic prophylaxis angle and rubber cup may be used and then discarded (Figure 46-46). A good cleansing and polishing paste that contains fluoride should be used and kept moist to minimize frictional heat as the cup revolves. Polishing pastes are available in fine, medium, or coarse grits and are packaged in small, convenient, single-use

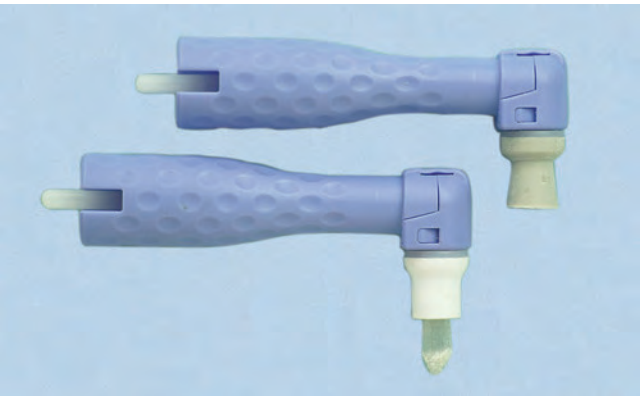

Figure 46-46 Disposable plastic prophylaxis angle with rubber cup and with brush.

containers. Aggressive use of the rubber cup with any abrasive may remove the layer of cementum, which is thin in the cervical area.

Bristle Brushes. Bristle brushes are available in wheel and cup shapes (see Figure 46-45). The brush is used in the prophylaxis angle with a polishing paste. Because the bristles are stiff, use of the brush should be confined to the crown to avoid injuring the cementum and the gingiva.

Dental Tape. Dental tape with polishing paste is used for polishing proximal surfaces that are inaccessible to other polishing instruments. The tape is passed interproximally while being kept at a right angle to the long axis of the tooth and is activated with a firm labiolingual motion. Particular care is taken to avoid injury to the gingiva. The area should be cleansed with warm water to remove all remnants of paste.

Air-Powder Polishing. The first specially designed handpiece to deliver an air-powered slurry of warm water and sodium bicarbonate for polishing was introduced in the early 1980s. This device, called the *Prophy-Jet* (Dentsply International, York, PA) is very effective for the removal of extrinsic stains and soft deposits (Figure 46-47). The slurry removes stains rapidly and efficiently by mechanical abrasion and provides warm water for rinsing and lavage. The flow rate of abrasive cleansing power can be adjusted to increase the amount of powder for heavier stain removal. Currently, many manufacturers produce air-powder polishing systems that use various powder formulas.

The results of studies on the abrasive effect of the air-powder polishing devices using sodium bicarbonate and aluminum trihydroxide on cementum and dentin show that significant tooth substance can be lost.[2,19,110,118] Damage to gingival tissue is transient and insignificant clinically, but amalgam restorations, composite resins, cements, and other nonmetallic materials can be roughened.[13,43,67,89,161] Polishing powders containing glycine rather than sodium bicarbonate recently have been introduced for subgingival biofilm removal from root surfaces.[97,117] Air-powder polishing can be used safely on titanium implant surfaces.[74,91,126]

Patients with medical histories of respiratory illnesses and hemodialysis are not candidates for the use of the air-powder polishing device.[145,165] Powders containing sodium bicarbonate should not be used on patients with histories of hypertension, sodium-restricted diets, or medications affecting the electrolyte balance.[125] Patients with infectious diseases should not be treated with this device because of the large quantity of aerosol created. A preprocedural rinse with 0.12% chlorhexidine gluconate should be used

Figure 46-47 Cavitron ProphyJet air-powder polishing device. *(Courtesy Dentsply International, York, PA.)*

to minimize the microbial content of the aerosol.[17] High-speed evacuation should also be used to eliminate as much of the aerosol as possible.[57]

Suggested Readings

Cadosch J, Zimmermann U, Ruppert M, et al: Root surface debridement and endotoxin removal. *J Periodontal Res* 38:229, 2003.

Claffey N: Decision making in periodontal therapy: the reevaluation. *J Clin Periodontol* 18:364, 1991.

Drisko CL, Cochran DL, Blieden T, et al: Position paper: sonic and ultrasonic scalers in periodontics. Research, Science and Therapy Committee of the American Academy of Periodontology. *J Periodontol* 71:1792, 2000.

Greenstein G: Nonsurgical periodontal therapy in 2000: a literature review. *J Am Dent Assoc* 131:1580, 2000.

Kaldahl WB, Kalkwarf KL, Patil KD, et al: Long-term evaluation of periodontal therapy. I. Response to 4 therapeutic modalities. *J Periodontol* 67:93, 1996.

Lindhe J, Nyman S: Long-term maintenance of patients treated for advanced periodontal disease. *J Clin Periodontol* 11:504, 1984.

Lindhe J, Nyman S, Karring T: Scaling and root planing in shallow pockets. *J Clin Periodontol* 9:415, 1982.

Magnusson I, Lindhe J, Yoneyama T, et al: Recolonization of a subgingival microbiota following scaling in deep pockets. *J Clin Periodontol* 11:193, 1984.

Pattison AM: The use of hand instruments in supportive periodontal treatment. *Periodontol 2000* 12:71, 1996.

Quirynen M, Mongardini C, Pauwels M, et al: One stage full- versus partial-mouth disinfection in the treatment of chronic adult or generalized early-onset periodontitis. II. Long-term impact on microbial load. *J Periodontol* 70:646, 1999.

References

References for this chapter are found on the companion website www.expertconsult.com.

General Principles of Instrumentation

Effective instrumentation is governed by a number of general principles that are common to all periodontal instruments. Proper position of the patient and the operator, illumination and retraction for optimal visibility, and sharp instruments are fundamental prerequisites. A constant awareness of tooth and root morphologic features and of the condition of the periodontal tissues is also essential. Knowledge of instrument design enables the clinician to select the proper instrument for the procedure and the correct area in which it will be performed. In addition to these principles, the basic concepts of grasp, finger rest, adaptation, angulation, and stroke must be understood before clinical instrument-handling skills can be mastered.

Accessibility: Positioning of Patient and Operator

Accessibility facilitates thoroughness of instrumentation. The position of the patient and operator should provide maximal accessibility to the area of operation. Inadequate accessibility impedes thorough instrumentation, prematurely tires the operator, and diminishes his or her effectiveness.

The clinician should be seated on a comfortable operating stool that has been positioned so that the clinician's feet are flat on the floor with the thighs parallel to the floor. The clinician should be able to observe the field of operation while keeping the back straight and the head erect.

The patient should be in a supine position and placed so that the mouth is close to the resting elbow of the clinician. For instrumentation of the maxillary arch, the patient should be asked to raise the chin slightly to provide optimal visibility and accessibility. For instrumentation on the mandibular arch, it may be necessary to raise the back of the chair slightly and request that the patient lower the chin until the mandible is parallel to the floor. This will especially facilitate work on the lingual surfaces of the mandibular anterior teeth.

Visibility, Illumination, and Retraction

Whenever possible, *direct vision* with *direct illumination* from the dental light is most desirable (Figure 46-48). If this is not possible, *indirect vision* may be obtained by using the mouth mirror (Figure 46-49) and *indirect illumination* may be obtained by using the mirror to reflect light to where it is needed (Figure 46-50). Indirect vision and indirect illumination are often used simultaneously (Figure 46-51).

Figure 46-48 Direct vision and direct illumination in the mandibular left premolar area.

Retraction provides visibility, accessibility, and illumination. Depending on the location of the area of operation, the fingers and/or the mirror are used for retraction. The *mirror* may be used for retraction of the cheeks or the tongue; the *index finger* is used for retraction of the lips or cheeks. The following methods are effective for retraction:

Figure 46-49 Indirect vision using the mirror for the lingual surfaces of the mandibular anterior teeth.

Figure 46-50 Indirect illumination using the mirror to reflect light onto the maxillary left posterior lingual region.

Figure 46-51 Combination of indirect illumination and indirect vision for the lingual surfaces of the maxillary anterior teeth.

Figure 46-52 Retracting the cheek with the mirror.

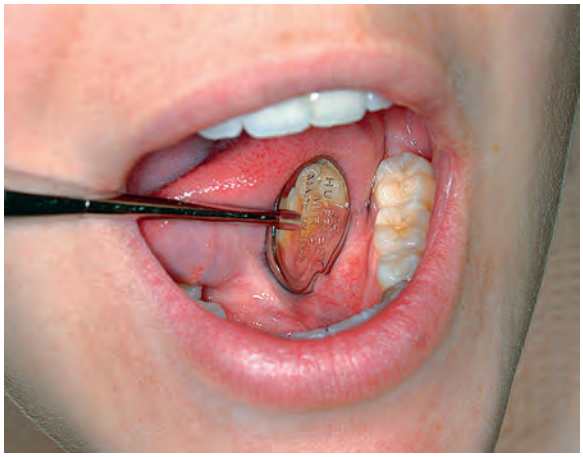

Figure 46-54 Retracting the tongue with the mirror.

Figure 46-53 Retracting the lip with the index finger of the nonoperating hand.

1. Use of the mirror to deflect the cheek while the fingers of the nonoperating hand retract the lips and protect the angle of the mouth from irritation by the mirror handle.
2. Use of the mirror alone to retract the lips and cheek (Figure 46-52).
3. Use of the fingers of the nonoperating hand to retract the lips (Figure 46-53).
4. Use of the mirror to retract the tongue (Figure 46-54).
5. Combinations of the preceding methods.

When retracting, care should be taken to avoid irritation to the angles of the mouth. If the lips and skin are dry, softening the lips with petroleum jelly before instrumentation is a helpful precaution against cracking and bleeding. Careful retraction is especially important for patients with a history of recurrent *herpes labialis* because these patients may easily develop herpetic lesions after instrumentation.

Condition and Sharpness of Instruments

Before any instrumentation, all instruments should be inspected to make sure that they are clean, sterile, and in good condition. The working ends of pointed or bladed instruments must be sharp to be effective. Sharp instruments enhance tactile sensitivity and allow the clinician to work more precisely and efficiently (see later discussion). Dull instruments may lead to incomplete calculus removal and unnecessary trauma because of the excess force usually applied to compensate for their ineffectiveness.

Maintaining a Clean Field

Despite good visibility, illumination, and retraction, instrumentation can be hampered if the operative field is obscured by saliva, blood, and debris. The pooling of saliva interferes with visibility during instrumentation and impedes control because a firm finger rest cannot be established on wet, slippery tooth surfaces. Adequate suction is essential and can be achieved with a saliva ejector or, if working with an assistant, an aspirator.

Gingival bleeding is an unavoidable consequence of subgingival instrumentation. In areas of inflammation, bleeding is not necessarily an indication of trauma from incorrect technique but rather may indicate ulceration of the pocket epithelium. Blood and debris can be removed from the operative field with suction and by wiping or blotting with gauze squares. The operative field should also be flushed occasionally with water.

Compressed air and gauze squares can be used to facilitate visual inspection of tooth surfaces just below the gingival margin during instrumentation. A jet of air directed into the pocket deflects a retractable gingival margin. Retractable tissue can also be deflected away from the tooth by gently packing the edge of a gauze square into the pocket with the back of a curette. Immediately after the gauze is removed, the subgingival area should be clean, dry, and clearly visible for a brief interval.

Instrument Stabilization

Stability of the instrument and the hand is the primary requisite for controlled instrumentation. Stability and control are essential for effective instrumentation and avoidance of injury to the patient or clinician. The two factors of major importance in providing stability are the instrument grasp and the finger rest.

Instrument Grasp. A proper grasp is essential for precise control of movements made during periodontal instrumentation. The most effective and stable grasp for all periodontal instruments is the *modified pen grasp* (Figure 46-55). Although other grasps are possible, this modification of the *standard pen grasp* (Figure 46-56) ensures the greatest control in performing intraoral procedures.

The thumb, index finger, and middle finger are used to hold the instrument as a pen is held, but the middle finger is positioned so that the side of the pad next to the fingernail is resting on the

Figure 46-55 Modified pen grasp. The pad of the middle finger rests on the shank. *(© A. Pattison)*

Figure 46-56 Standard pen grasp. The side of the middle finger rests on the shank. *(© A. Pattison)*

instrument shank. The index finger is bent at the second joint from the fingertip and is positioned well above the middle finger on the same side of the handle.

The pad of the thumb is placed midway between the middle and index fingers on the opposite side of the handle. This creates a triangle of forces, or *tripod effect,* that enhances control because it counteracts the tendency of the instrument to turn uncontrollably between the fingers when scaling force is applied to the tooth. This stable modified pen grasp enhances control because it enables the clinician to roll the instrument in precise degrees with the thumb against the index and middle fingers to adapt the blade to the slightest changes in tooth contour. The modified pen grasp also enhances tactile sensitivity because slight irregularities on the tooth surface are best perceived when the tactile-sensitive pad of the middle finger is placed on the shank of the instrument.

The *palm and thumb grasp* (Figure 46-57) is useful for stabilizing instruments during sharpening and for manipulating air and water syringes, but it is not recommended for periodontal instrumentation. Maneuverability and tactile sensitivity are so inhibited by this grasp that it is unsuitable for the precise, controlled movements necessary during periodontal procedures.

Finger Rest. The finger rest serves to stabilize the hand and the instrument by providing a firm fulcrum as movements are made to

Figure 46-57 Palm and thumb grasp, used for stabilizing instruments during sharpening. *(© A. Pattison)*

activate the instrument. A good finger rest prevents injury and laceration of the gingiva and surrounding tissues by poorly controlled instruments. The fourth (ring) finger is preferred by most clinicians for the finger rest. Although it is possible to use the third (middle) finger for the finger rest, this is not recommended because it restricts the arc of movement during the activation of strokes and severely curtails the use of the middle finger for both control and tactile sensitivity. Maximal control is achieved when the middle finger is kept between the instrument shank and the fourth finger. This "built-up" fulcrum is an integral part of the wrist-forearm action that activates the powerful working stroke for calculus removal. Whenever possible, these two fingers should be kept together to work as a one-unit fulcrum during scaling and root planing. Separation of the middle and fourth fingers during scaling strokes results in a loss of power and control because it forces the clinician to rely solely on finger flexing for activation of the instrument.

Finger rests may be generally classified as intraoral finger rests or extraoral fulcrums. Intraoral finger rests on tooth surfaces ideally are established close to the working area. Variations of intraoral finger rests and extraoral fulcrums are used whenever good angulation and a sufficient arc of movement cannot be achieved by a finger rest close to the working area. The following examples illustrate the different variations of the intraoral finger rest:

1. *Conventional:* The finger rest is established on tooth surfaces immediately adjacent to the working area (Figure 46-58).
2. *Cross-arch:* The finger rest is established on tooth surfaces on the other side of the same arch (Figure 46-59).
3. *Opposite arch:* The finger rest is established on tooth surfaces on the opposite arch (e.g., mandibular arch finger rest for instrumentation on the maxillary arch) (Figure 46-60).
4. *Finger on finger:* The finger rest is established on the index finger or thumb of the nonoperating hand (Figure 46-61).

Extraoral fulcrums are essential for effective instrumentation of some aspects of the maxillary posterior teeth. When properly established, they allow optimal access and angulation while providing adequate stabilization. Extraoral fulcrums are not "finger rests" in the literal sense because the tips or pads of the fingers are not used for extraoral fulcrums as they are for intraoral finger rests.

Figure 46-58 Intraoral conventional finger rest. The fourth finger rests on the occlusal surfaces of adjacent teeth.

Figure 46-59 Intraoral cross-arch finger rest. The fourth finger rests on the incisal surfaces of teeth on the opposite side of the same arch.

Figure 46-60 Intraoral opposite-arch finger rest. The fourth finger rests on the mandibular teeth while the maxillary posterior teeth are instrumented.

Figure 46-61 Intraoral finger-on-finger rest. The fourth finger rests on the index finger of the nonoperating hand.

Figure 46-62 Extraoral palm-up fulcrum. The backs of the fingers rest on the right lateral aspect of the mandible while the maxillary right posterior teeth are instrumented.

Instead, as much of the front or back surface of the fingers as possible is placed on the patient's face to provide the greatest degree of stability. The two most common extraoral fulcrums are used as follows:

1. *Palm up:* The palm-up fulcrum is established by resting the backs of the middle and fourth fingers on the skin overlying the lateral aspect of the mandible on the right side of the face (Figure 46-62).
2. *Palm down:* The palm-down fulcrum is established by resting the front surfaces of the middle and fourth fingers on the skin overlying the lateral aspect of the mandible on the left side of the face (Figure 46-63).

Both intraoral finger rests and extraoral fulcrums may be reinforced by applying the index finger or thumb of the nonoperating hand to the handle or shank of the instrument for added control and pressure against the tooth. The reinforcing finger is usually employed for opposite-arch or extraoral fulcrums when precise control and pressure are compromised by the longer distance between the fulcrum and the working end of the instrument. Figure 46-64 shows the index finger–reinforced rest, and Figure 46-65 shows the thumb-reinforced rest.

Figure 46-63 Extraoral palm-down fulcrum. The front surfaces of the fingers rest on the left lateral aspect of the mandible while the maxillary left posterior teeth are instrumented.

Figure 46-64 Index finger-reinforced rest. The index finger is placed on the shank for pressure and control in the maxillary left posterior lingual region.

Figure 46-65 Thumb-reinforced rest. The thumb is placed on the handle for control in the maxillary right posterior lingual region.

Instrument Activation

Adaptation. *Adaptation* refers to the manner in which the working end of a periodontal instrument is placed against the surface of a tooth. The objective of adaptation is to make the working end of the instrument conform to the contour of the tooth surface. Precise adaptation must be maintained with all instruments to avoid trauma to the soft tissues and root surfaces and to ensure maximum effectiveness of instrumentation.

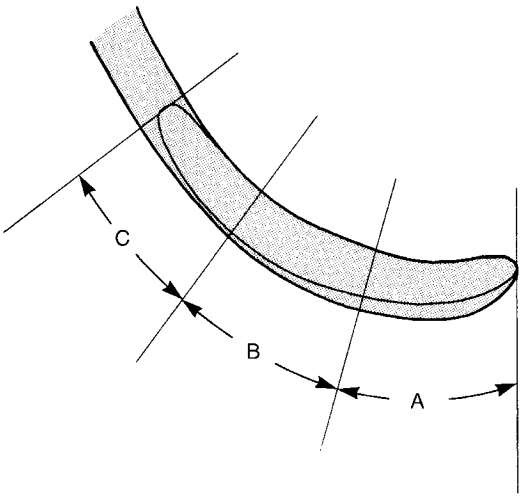

Figure 46-66 Gracey curette blade divided into three segments: **A,** the lower one-third of the blade, consisting of the terminal few millimeters adjacent to the toe; **B,** the middle one-third; and, **C,** the upper one-third, which is adjacent to the shank.

Correct adaptation of the probe is quite simple. The tip and side of the probe should be flush against the tooth surface as vertical strokes are activated within the crevice. Bladed instruments (e.g., curettes) and sharp-pointed instruments (e.g., explorers) are more difficult to adapt. The ends of these instruments are sharp and can lacerate tissue, so adaptation in subgingival areas becomes especially important. The lower third of the working end, which is the last few millimeters adjacent to the toe or tip, must be kept in constant contact with the tooth while it is moving over varying tooth contours (Figure 46-66). Precise adaptation is maintained by carefully rolling the handle of the instrument against the index and middle fingers with the thumb. This rotates the instrument in slight degrees so that the toe or tip leads into concavities and around convexities. On convex surfaces such as line angles, it is not possible to adapt more than 1 or 2 mm of the working end against the tooth. Even on what appear to be broader, flatter surfaces, no more than 1 or 2 mm of the working end can be adapted because the tooth surface, although it may seem flat, is actually slightly curved.

If only the middle third of the working end is adapted on a convex surface so that the blade contacts the tooth at a tangent, the toe or sharp tip will jut out into soft tissue, causing trauma and discomfort (Figure 46-67).

If the instrument is adapted so that only the toe or tip is in contact, the soft tissue can be distended or compressed by the back of the working end, also causing trauma and discomfort. A curette that is improperly adapted in this manner can be particularly damaging because the toe can gouge or groove the root surface.

Angulation. *Angulation* refers to the angle between the face of a bladed instrument and the tooth surface. It may also be called the *tooth-blade relationship.*

Correct angulation is essential for effective calculus removal. For subgingival insertion of a bladed instrument such as a curette, angulation should be as close to 0 degree as possible (Figure 46-68, *A*). The end of the instrument can be inserted to the base of the pocket more easily with the face of the blade flush against the tooth. During scaling and root planing, optimal angulation is between 45 and 90 degrees (Figure 46-68, *B*). The exact blade angulation



Figure 46-67 Blade adaptation. The curette on the left is properly adapted to the root surface. The curette on the right is incorrectly adapted; the toe juts out, lacerating the soft tissues.

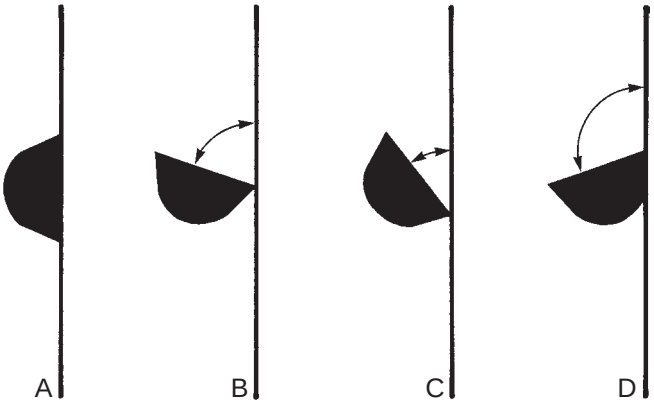

Figure 46-68 Blade angulation. **A,** 0 degrees: correct angulation for blade insertion. **B,** 45 to 90 degrees: correct angulation for scaling and root planing. **C,** Less than 45 degrees: incorrect angulation for scaling and root planing. **D,** More than 90 degrees: incorrect angulation for scaling and root planing, correct angulation for gingival curettage.

depends on the amount and nature of the calculus, the procedure being performed, and the condition of the tissue. Blade angulation is diminished or closed by tilting the lower shank of the instrument toward the tooth. It is increased or opened by tilting the lower shank away from the tooth. During scaling strokes on heavy, tenacious calculus, angulation should be just less than 90 degrees so that the cutting edge "bites" into the calculus. With angulation of less than 45 degrees, the cutting edge will not bite into or engage the calculus properly (Figure 46-68, *C*). Instead, it will slide over the calculus, smoothing or "burnishing" it. If angulation is more than 90 degrees, the lateral surface of the blade, rather than the cutting edge, will be against the tooth, and the calculus will not be removed and may become burnished (Figure 46-68, *D*). After the calculus has been removed, angulation of just less than 90 degrees may be maintained, or the angle may be slightly closed as the root surface is smoothed with light, root-planing strokes.

When gingival curettage is indicated, angulation greater than 90 degrees is deliberately established so that the cutting edge will engage and remove the pocket lining (Figure 46-68, *D*).

Lateral Pressure. *Lateral pressure* refers to the pressure created when force is applied against the surface of a tooth with the cutting edge of a bladed instrument. The exact amount of pressure applied must be varied according to the nature of the calculus and according to whether the stroke is intended for initial scaling to remove calculus or for root planing to smooth the root surface.

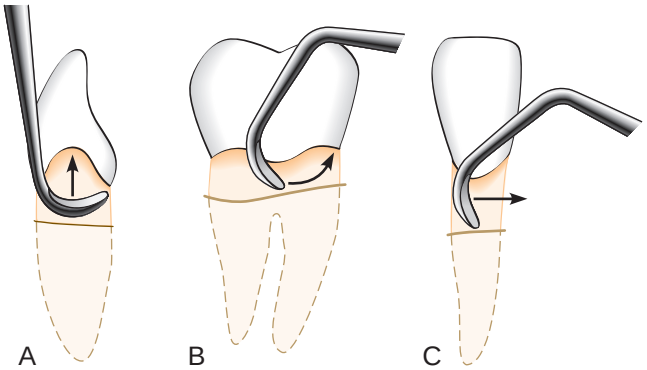

Figure 46-69 Three basic stroke directions. **A,** Vertical; **B,** oblique; **C,** horizontal.

Lateral pressure may be firm, moderate, or light. When removing calculus, lateral pressure is initially applied firmly or moderately and is progressively diminished until light lateral pressure is applied for the final root-planing strokes. When insufficient lateral pressure is applied for the removal of heavy calculus, rough ledges or lumps may be shaved to thin, smooth sheets of burnished calculus that are difficult to detect and remove. This burnishing effect often occurs in areas of developmental depressions and along the cementoenamel junction.

Although firm lateral pressure is necessary for the thorough removal of calculus, indiscriminate, unwarranted, or uncontrolled application of heavy forces during instrumentation should be avoided. Repeated application of excessively heavy strokes often nicks or gouges the root surface.

The careful application of varied and controlled amounts of lateral pressure during instrumentation is an integral part of effective scaling and root-planing techniques and is critical to the success of both these procedures.

Strokes. Three basic types of strokes are used during instrumentation: the exploratory stroke, the scaling stroke, and the root-planing stroke. Any of these basic strokes may be activated by a pull or a push motion in a vertical, oblique, or horizontal direction (Figure 46-69). *Vertical* and *oblique* strokes are used most frequently. *Horizontal* strokes are used selectively on line angles or deep pockets that cannot be negotiated with vertical or oblique strokes. The direction, length, pressure, and number of strokes necessary for either scaling or root planing are determined by four major factors: (1) gingival position and tone, (2) pocket depth and shape, (3) tooth contour, and (4) the amount and nature of the calculus or roughness.

The **exploratory stroke** is a light, "feeling" stroke that is used with probes and explorers to evaluate the dimensions of the pocket and to detect calculus and irregularities of the tooth surface. With bladed instruments such as the curette, the exploratory stroke is alternated with scaling and root-planing strokes for these same purposes of evaluation and detection. The instrument is grasped lightly and adapted with light pressure against the tooth to achieve maximal tactile sensitivity.

The **scaling stroke** is a short, powerful pull stroke that is used with bladed instruments for the removal of both supragingival and subgingival calculus. The muscles of the fingers and hands are tensed to establish a secure grasp, and lateral pressure is firmly

applied against the tooth surface. The cutting edge engages the apical border of the calculus and dislodges it with a firm movement in a coronal direction. The scaling motion should be initiated in the forearm and transmitted from the wrist to the hand with a slight flexing of the fingers. Rotation of the wrist is synchronized with movement of the forearm. The scaling stroke is not initiated in the wrist or fingers, nor is it carried out independently without the use of the forearm.

It is possible to initiate the scaling motion by rotating the wrist and forearm or by flexing the fingers. The use of wrist and forearm action versus finger motion has long been debated among clinicians. Perhaps the strong opinions on both sides should be the most valid indication that there is a time and a place for each. Neither method can be advocated exclusively because a careful analysis of effective scaling and root-planing technique reveals that both types of stroke activation are necessary for complete instrumentation. The wrist and forearm motion, pivoting in an arc on the finger rest, produces a more powerful stroke and is therefore preferred for scaling. *Finger flexing* is indicated for precise control over stroke length in areas such as line angles and when horizontal strokes are used on the lingual or facial aspects of narrow-rooted teeth.

The *push scaling* motion has been advocated by some clinicians. In the push stroke, the instrument engages the lateral or coronal border of the calculus, and the fingers provide a thrust motion that dislodges the deposit. Because the push stroke may force calculus into the supporting tissues, its use, especially in an apical direction, is not recommended.

The **root-planing stroke** is a moderate to light pull stroke that is used for final smoothing and planing of the root surface. Although hoes, files, and ultrasonic instruments have been used for root planing, curettes are widely acknowledged to be the most effective and versatile instruments for this procedure.* The design of the curette, which allows it to be more easily adapted to subgingival tooth contours, makes curettes particularly suitable for root planing in periodontal patients. With a moderately firm grasp, the curette is kept adapted to the tooth with even, lateral pressure. A continuous series of long, overlapping shaving strokes is activated. As the surface becomes smoother and resistance diminishes, lateral pressure is progressively reduced.

Instruments for Scaling and Root Planing

Universal Curettes. The working ends of the universal curette are designed in pairs so that all surfaces of the teeth can be treated with one double-ended instrument or a matched pair of single-ended instruments (see Figure 46-16).

In any given quadrant, when approaching the tooth from the facial aspect, one end of the universal curette adapts to the mesial surfaces, and the other end adapts to the distal surfaces. When approaching from the lingual aspect in the same quadrant, the double-ended universal curette must be turned end for end because the blades are mirror images. This means that the end that adapts to the mesial surfaces on the facial aspect also adapts to the distal surfaces on the lingual aspect, and vice versa. Both ends of the universal curette are used for instrumentation of the anterior teeth. On posterior teeth, however, because of the limited access to distal surfaces, a single working end can be used to treat both mesial and distal surfaces by using both its cutting edges. To do this, the instrument is first adapted to the mesial surface with the handle nearly parallel to the mesial surface. Because the face of the universal curette blade is honed at 90 degrees to the lower shank, if the lower shank is positioned so that it is absolutely parallel to the surface being instrumented, the tooth-blade angulation is 90 degrees. To close this angle and thus obtain proper working angulation, the lower shank must be tilted slightly toward the tooth. The distal surface of the same posterior tooth can be instrumented with the opposite cutting edge of the same blade. This cutting edge can be adapted at proper working angulation by positioning the handle so that it is *perpendicular* to the distal surface (Figure 46-70).

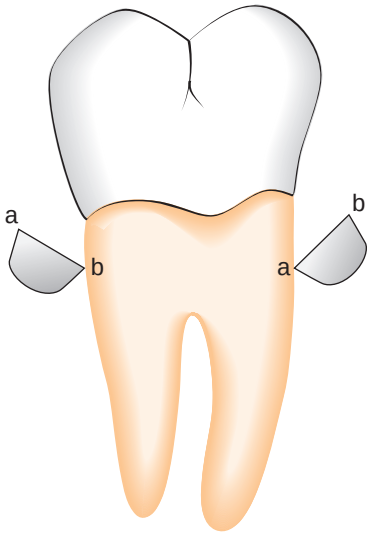

Figure 46-70 Adaptation of the universal curette on a posterior tooth. Cross-sectional representations of the same universal curette blade as its cutting edges (*a* and *b*) are adapted to the mesial and distal surfaces of a posterior tooth.

When adapting the universal curette blade, as much of the cutting edge as possible should be in contact with the tooth surface, except on narrow convex surfaces such as line angles. Although the entire cutting edge should contact the tooth, pressure should be concentrated on the lower third of the blade during scaling strokes. During root-planing strokes, however, lateral pressure should be distributed evenly along the cutting edge.

The primary advantage of these curettes is that they are designed to be used universally on all tooth surfaces, in all regions of the mouth. However, universal curettes have limited adaptability for the treatment of deep pockets in which apical migration of the attachment has exposed furcations, root convexities, and developmental depressions. For this reason, many clinicians prefer the Gracey curettes and the new modifications of Gracey curettes, which are area specific and specially designed for subgingival scaling and root planing in periodontal patients.

Gracey Curettes. As discussed earlier, Gracey curettes are a set of area-specific instruments that were designed by Dr. Clayton H. Gracey of Michigan in the mid-1930s (see Figure 46-18). Four design features make the Gracey curettes unique: (1) they are area specific, (2) only one cutting edge on each blade is used, (3) the blade is curved in two planes, and (4) the blade is "offset" (see Table 46-1.) Each of these features directly influences the manner in which the Gracey curettes are used, as discussed next.

Area Specificity. There are seven pairs of curettes in the set. The Gracey curettes #1-2 and 3-4 are used on anterior teeth. The Gracey #5-6 may be used on both anterior and premolar teeth. The facial and lingual surfaces of posterior teeth are instrumented with Gracey curettes #7-8 and 9-10. The Gracey #11-12 is designed for mesial surfaces of posterior teeth, and the #13-14 adapts to the

*References 15, 46, 47, 48, 50, 70, 109, 135, 137, 158, and 166.

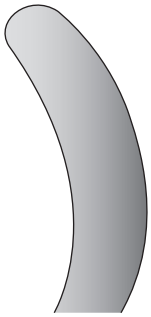

Figure 46-71 Determining the correct cutting edge of a Gracey curette. When viewed from directly above the face of the blade, the correct cutting edge is the one forming the larger, outer curve on the right.

distal surfaces of posterior teeth. Although these guidelines for areas of use were originally established by Dr. Gracey, it is possible to use a Gracey curette in an area of the mouth other than the one for which it was specifically designed if the general principles regarding these curettes are understood and applied. Gracey curettes need not be reserved exclusively for periodontal patients. In fact, many clinicians prefer Gracey curettes for general scaling because of their excellent adaptability.

Single Cutting Edge Used. As with a universal curette, the Gracey curette has a blade with two cutting edges. Unlike the universal curette, however, the Gracey instrument is designed so that only one cutting edge is used. To determine which of the two is the correct cutting edge to adapt to the tooth, the blade should be held face up and parallel to the floor. When viewed from this angle, the blade can be seen to curve to the side. One cutting edge forms a larger outer curve, and the other forms a shorter, small inner curve. The larger outer curve, which has also been described as the "inferior cutting edge" or as the cutting edge farther away from the handle, is the correct cutting edge (Figure 46-71).

Blade Curves in Two Planes. As with the toe of the universal curette, the toe of the Gracey curette curves upward. However, the toe of the Gracey curette also curves to the side, as previously mentioned. This unique curvature enhances the blade's adaptation to convexities and concavities as the working end is advanced around the tooth. Only the lower third or half of the Gracey blade is in contact with the tooth during instrumentation. The cutting edge of a universal curette blade, however, is straight and does not curve to the side, making it less adaptable to root concavities.

Offset Blade. Gracey curette blades are honed at an *offset angle,* which means that the face of the blade is not perpendicular to the lower shank as it is on a universal curette. Instead, Gracey curettes are designed so that the tooth-blade working angulation is 60 to 70 degrees when the lower shank is held parallel to the tooth surface. Gracey curettes were originally designed to be used with *push strokes* and were beveled to provide a tooth-blade angulation of 40 degrees when the lower shank was parallel to the tooth surface; for many years, Gracey curettes were available only in this form. Currently, Gracey curettes are available not only in the original push design but also in a modified version to be used with pull strokes. It is important to understand this when purchasing Gracey curettes to avoid obtaining instruments that are not properly designed for *pull strokes.* If Gracey curettes that are designed to be used with push strokes are used with pull strokes instead, they are likely to burnish calculus rather than completely remove it. The design of the Gracey curette was modified in response to requests from clinicians who liked the shank design and adaptability of the original Gracey instruments but were opposed to the use of push strokes

Figure 46-72 Correct cutting edge of a Gracey curette adapted to the tooth.

Figure 46-73 Incorrect cutting edge of a Gracey curette adapted to the tooth.

for scaling and root planing. The push stroke is not recommended, especially for the novice clinician, because it is likely to cause undue trauma to the junctional epithelium and to embed fragments of dislodged calculus in the soft tissues.

Principles of Use. The following general principles of use of the Gracey curettes are essentially the same as those for the universal curette; italicized principles apply only to Gracey curettes:

1. *Determine the correct cutting edge.* The correct cutting edge should be determined by visually inspecting the blade and confirmed by lightly adapting the chosen cutting edge to the tooth with the lower shank parallel to the surface of the tooth. With the toe pointed in the direction to be scaled (e.g., mesially with a #7-8 curette), only the back of the blade can be seen if the correct cutting edge has been selected (Figure 46-72). If the wrong cutting edge has been adopted, the flat, shiny face of the blade will be seen instead (Figure 46-73).
2. *Make sure the lower shank is parallel to the surface to be instrumented.* The lower shank of a Gracey curette is that portion of the shank between the blade and the first bend in the shank. Parallelism of the handle or upper shank is not an acceptable guide with Gracey curettes because the angulations of the shanks vary. On anterior teeth the lower shank of the Gracey #1-2, 3-4, or 5-6 should be parallel to the mesial, distal, facial, or lingual surfaces of the teeth (Figure 46-74). On posterior teeth the lower shank of the #7-8 or 9-10 should be parallel to the facial or lingual surfaces of the teeth (Figure 46-75); the lower shank of the #11-12 should

Figure 46-74 Gracey #5-6 curette adapted to an anterior tooth. *(© A. Pattison)*

Figure 46-75 Gracey #7-8 curette adapted to the facial surface of a posterior tooth. *(© A. Pattison)*

Figure 46-76 Gracey #11-12 curette adapted to the mesial surface of a posterior tooth. *(© A. Pattison)*

be parallel to the mesial surfaces of the teeth (Figure 46-76); and the lower shank of the #13-14 should be parallel to the distal surfaces of the teeth (Figure 46-77).

3. When using intraoral finger rests, keep the fourth and middle fingers together in a built-up fulcrum for maximum control and wrist-arm action.
4. Use extraoral fulcrums or mandibular finger rests for optimal angulation when working on the maxillary posterior teeth.
5. Concentrate on using the lower third of the cutting edge for calculus removal, especially on line angles or when attempting to remove a calculus ledge by breaking it away in sections, beginning at the lateral edge.
6. Allow the wrist and forearm to carry the burden of the stroke, rather than flexing the fingers.

Figure 46-77 Gracey #13-14 curette adapted to the distal surface of a posterior tooth. *(© A. Pattison)*

7. Roll the handle slightly between the thumb and fingers to keep the blade adapted as the working end is advanced around line angles and into concavities.
8. Modulate lateral pressure from firm to moderate to light depending on the nature of the calculus, and reduce pressure as the transition is made from scaling to root-planing strokes.

Extended-Shank Gracey Curettes. Extended-shank Gracey curettes, such as the After Five curettes, are 3 mm longer in the terminal shank than the standard Gracey curettes but are used with the same technique (see Figure 46-23). They are most useful for deep pockets on maxillary and mandibular posterior teeth, where the longer terminal shank allows better access, especially to deep mesial and distal pockets (see Figure 46-24). Although the longer lower shank makes access easier while using a conventional intraoral finger rest, the use of an extraoral fulcrum allows better access and adaptation to all the maxillary posterior teeth. Extended shank Gracey curettes with rigid shanks should be used for scaling of heavy calculus; those with regular, finishing shanks should be used for periodontal maintenance patients with deep residual pockets.

Mini-Bladed Gracey Curettes. Mini-bladed Gracey curettes, such as the Mini Five curettes and the Gracey Curvettes, have a terminal shank that is 3 mm longer than the standard Gracey curettes and a blade that is 50% shorter. Micro Mini Five curette blades are 20% smaller than Mini Five curette blades (see Figures 46-28 and 46-29). These mini-bladed instruments are generally used in the same manner as the Gracey curettes, except for the following specific differences:

1. Mini-bladed curettes should not be used routinely in place of standard Gracey or extended shank Gracey curettes. Instead, they should be used to supplement conventional curettes and ultrasonic instruments in areas difficult to access, such as furcations, line angles, and deep, tight, or narrow pockets (see Figure 46-30).
2. Large #4 handles are recommended for any mini-bladed instruments because the larger diameter of the handles allows better control of the small blades.
3. Mini-bladed curettes can be used to scale with the toe directed either mesially or distally. In fact, these curettes often adapt more effectively to the root curvatures of many posterior teeth when the blade is inserted with the toe pointed distally and when strokes are activated from the mesial toward the distal line angle (Figure 46-78).
4. Use rigid-shank mini-bladed curettes for calculus removal. Use the thinner, standard-shank mini-bladed curettes for deplaquing during maintenance.

Figure 46-78 Mini Five #13-14 curette adapted to the palatal surface of a maxillary molar with the toe directed distally. *(© A. Pattison)*

5. When using mini-bladed curettes for calculus removal, use intraoral finger rests close to the working area. When performing light root planing or deplaquing, either intraoral rests or extraoral fulcrums may be used. Extraoral fulcrums are usually necessary to gain access to deep pockets on maxillary second and third molars.
6. Mini-bladed curettes are generally used with straight, vertical strokes. They may also be used with oblique or horizontal strokes, but because of the shortness of the blade, these strokes might not extend far enough subgingivally unless the tissue is very retractable. Horizontal strokes with mini-bladed curettes are most effective when used in the cementoenamel junction or in developmental depressions just below it.

When properly used, mini-bladed Gracey curettes allow unprecedented access and effectiveness for both nonsurgical and surgical root debridement. One study showed that Gracey Curvettes performed better than standard Gracey curettes in deep anterior pockets.[76] In areas such as line angles, furcations, and narrow, curved, facial, or palatal root surfaces, these miniature curettes provide excellent adaptation with better tactile sensitivity than modified, slim ultrasonic tips. Studies also demonstrated that Gracey Curvette curettes performed better than ultrasonic slim tips on deep mandibular anterior pockets, furcations, and furcation entrances.[111,112] No comparison of hand instruments and modified, slim ultrasonic tips can be made unless mini-bladed curettes have been fully employed. To date, some research has been done to compare the effectiveness of mini-bladed instruments with the modified, slim ultrasonic tips. More of these studies need to be performed in vivo to guide clinicians in the optimal utilization of these newer types of instruments.[116]

Principles of Scaling and Root Planing

Definitions and Rationale

Scaling is the process by which biofilm and calculus are removed from both supragingival and subgingival tooth surfaces. No deliberate attempt is made to remove tooth substance along with the calculus. *Root planing* is the process by which residual embedded calculus and portions of cementum are removed from the roots to produce a smooth, hard, clean surface.

The primary objective of scaling and root planing is to restore gingival health by completely removing elements that provoke gingival inflammation (i.e., biofilm, calculus, and endotoxin) from the tooth surface (Figure 46-79). Instrumentation has been shown to reduce dramatically the numbers of subgingival microorganisms and produce a shift in the composition of subgingival biofilm from one with high numbers of gram-negative anaerobes to one dominated by gram-positive facultative bacteria compatible with health.[†] After thorough scaling and root planing, a profound reduction in spirochetes, motile rods, and putative pathogens, such as *Actinobacillus actinomycetemcomitans, Porphyromonas gingivalis,* and *Prevotella intermedia,* and an increase in coccoid cells occur.[‡] These changes in the microbiota are accompanied by a reduction or elimination of inflammation clinically.[§] This positive microbial change must be sustained by the periodic scaling and root planing performed during supportive periodontal therapy.[‖]

Scaling and root planing are not separate procedures; all the principles of scaling apply equally to root planing. The difference between scaling and root planing is only a matter of degree. The nature of the tooth surface determines the degree to which the surface must be scaled or planed.

Biofilm and calculus on enamel surfaces provoke gingival inflammation. Unless they are grooved or pitted, enamel surfaces are relatively smooth and uniform. When biofilm and calculus form on enamel, the deposits are usually superficially attached to the surface and are not locked into irregularities. Scaling alone is sufficient to remove biofilm and calculus completely from enamel, leaving a smooth, clean surface.

Root surfaces exposed to biofilm and calculus pose a different problem. *Deposits of calculus on root surfaces are frequently embedded in cemental irregularities.*[1,26,100,139,170] Subgingival calculus is porous and harbors bacteria and endotoxin and therefore should be removed completely.[24,25,153] When dentin is exposed, biofilm bacteria may invade dentinal tubules.[1] Therefore scaling alone is insufficient to remove them, and a portion of the root surface must be removed to eliminate these deposits. Furthermore, when the root surface is exposed to biofilm and the pocket environment, its surface is contaminated by toxic substances, notably endotoxins.[3,4,59] Evidence suggests that these toxic substances are only superficially attached to the root and do not permeate it deeply.[¶] Removal of extensive amounts of dentin and cementum is not necessary to render the roots free of toxins and should be avoided.[47,88,116] In areas where cementum is thin, however, instrumentation may expose dentin. Although this is not the aim of treatment, such exposure may be unavoidable.[135,158]

Scaling and root planing should not be viewed as separate procedures unrelated to the rest of the treatment plan. These procedures belong in the initial phase of an orderly sequence of treatment. After careful analysis of a case, the number of appointments needed to complete this phase of treatment is estimated. Patients with small amounts of calculus and relatively healthy tissues can be treated in one appointment. Most other patients require several treatment sessions. The dentist should estimate the number of appointments needed on the basis of the number of teeth in the mouth, severity of inflammation, amount and location of calculus, depth and activity of pockets, presence of furcation invasions, patient's comprehension of and compliance with oral hygiene instructions, and need for local anesthesia.

When the rationale for scaling and root planing is thoroughly understood, it becomes apparent that mastery of these skills is essential to the ultimate success of any course of periodontal therapy. Of all clinical dental procedures, subgingival scaling and root planing in deep pockets are the most difficult and exacting

[†]References 87, 90, 101, 127, 130, 140, and 142.
[‡]References 90, 127, 134, 140, 159, and 169.
[§]References 11, 47, 50, 65, 69, 88, 98, 120, 122, and 123.
[‖]References 10, 18, 85, 116, 140, and 164.
[¶]References 27, 28, 63, 64, 99, 103, 104, and 143.

Figure 46-79 Results of Phase I therapy. **A** to **F,** Moderate chronic periodontitis. **A,** Patient presenting with moderate attachment loss and probe depths in the 4- to 6-mm range. Note the gingiva appears pink because it is fibrotic and the inflammation is deep in the periodontal pockets. **B,** Lingual view before treatment, with more visible inflammation and heavy deposits of calculus. **C** and **D,** The same areas with significant improvement in gingival health 18 months after scaling, root planing, and plaque control therapy were provided; the patient returned for regular maintenance visits. **E** and **F,** Presenting radiographs of the lower anterior teeth. Radiograph taken 18 months after Phase I therapy and maintenance shows no increase in bone loss.

skills to master. It has been argued that such proficiency in instrumentation cannot be attained, and therefore periodontal surgery is necessary to gain access to root surfaces. Others have argued that although proficiency is possible, it need not be developed because access to the roots can be gained more easily with surgery. However, without mastering subgingival scaling and root-planing skills, the clinician will be severely hampered and unable to treat adequately those patients for whom surgery is contraindicated.

Detection Skills

Good visual and tactile detection skills are required for the accurate initial assessment of the extent and nature of deposits and root irregularities before scaling and root planing. Valid evaluation of results of instrumentation depends on these detection skills.

Visual examination of supragingival and subgingival calculus just below the gingival margin is not difficult with good lighting and a clean field. Light deposits of supragingival calculus are often difficult to see when they are wet with saliva. Compressed air may be used to dry supragingival calculus until it is chalky white and readily visible. Air also may be directed into the pocket in a steady stream to deflect the marginal gingiva away from the tooth so that subgingival deposits near the surface can be seen.

Tactile exploration of the tooth surfaces in subgingival areas of pocket depth, furcations, and developmental depressions is much

more difficult than visual examination of supragingival areas and requires the skilled use of a fine-pointed explorer or probe. The explorer or probe is held with a light but stable modified pen grasp. This provides maximal tactile sensitivity for detection of subgingival calculus and other irregularities. The pads of the thumb and fingers, especially the middle finger, should perceive the slight vibrations conducted through the instrument shank and handle as irregularities in the tooth surface are encountered.

After a stable finger rest is established, the tip of the instrument is carefully inserted subgingivally to the base of the pocket. Light exploratory strokes are activated vertically on the root surface. When calculus is encountered, the tip of the instrument should be advanced apically over the deposit until the termination of the calculus on the root is felt. The distance between the apical edge of the calculus and the bottom of the pocket usually ranges from 0.2 to 1.0 mm. The tip is adapted closely to the tooth to ensure the greatest degree of tactile sensitivity and avoid tissue trauma. When a proximal surface is being explored, strokes must be extended at least halfway across that surface past the contact area to ensure complete detection of interproximal deposits. When an explorer is used at line angles, convexities, and concavities, the handle of the instrument must be rolled slightly between the thumb and fingers to keep the tip constantly adapted to the changes in tooth contour.

Although exploration technique and good tactile sensitivity are important, *interpreting various degrees of roughness and making clinical judgments based on these interpretations* also require much expertise. The beginning student usually has difficulty detecting fine calculus and altered cementum. Such detection must begin with the recognition of ledges, lumps, or spurs of calculus, then smaller spicules, then slight roughness, and finally a slight graininess that feels like a sticky coating or film covering the tooth surface. Overhanging or deficient margins of dental restorations, caries, decalcification, and root roughness caused by previous instrumentation are all typically found during exploration. These and other irregularities must be recognized and differentiated from subgingival calculus. Because this requires a great deal of experience and a high degree of tactile sensitivity, many clinicians agree that the development of detection skills is as important as the mastery of scaling and root-planing technique.

Supragingival Scaling Technique

Supragingival calculus is generally less tenacious and less calcified than subgingival calculus. Because instrumentation is performed coronal to the gingival margin, scaling strokes are not confined by the surrounding tissues. This makes adaptation and angulation easier. It also allows direct visibility, as well as a freedom of movement not possible during subgingival scaling.

Sickles, curettes, and ultrasonic and sonic instruments are most often used for the removal of supragingival calculus; hoes and chisels are less frequently used. To perform supragingival scaling, the sickle or curette is held with a modified pen grasp, and a firm finger rest is established on the teeth adjacent to the working area. The blade is adapted with an angulation of slightly less than 90 degrees to the surface being scaled. The cutting edge should engage the apical margin of the supragingival calculus while short, powerful, overlapping scaling strokes are activated coronally in a vertical or an oblique direction. The sharply pointed tip of the sickle can easily lacerate marginal tissue or gouge exposed root surfaces, so careful adaptation is especially important when this instrument is being used. The tooth surface is instrumented until it is visually and tactilely free of all supragingival deposits. If the tissue is retractable enough to allow easy insertion of the bulky blade, the sickle may be used slightly below the free gingival margin. If the sickle is used in this manner, final scaling and root planing with the curette should always follow.

Subgingival Scaling and Root-Planing Technique

Subgingival scaling and root planing are much more complex and difficult to perform than supragingival scaling. *Subgingival calculus* is usually harder than supragingival calculus and is often locked into root irregularities, making it more tenacious and therefore more difficult to remove.[26,100,139,170] The overlying tissue creates significant problems in subgingival instrumentation. Vision is obscured by the bleeding that inevitably occurs during instrumentation and by the tissue itself. The clinician must rely heavily on tactile sensitivity to detect calculus and irregularities, guide the instrument blade during scaling and root planing, and evaluate the results of instrumentation.

In addition, the adjacent pocket wall limits the direction and length of the strokes. The confines of the soft tissue make careful adaptation to tooth contours imperative to avoid trauma. Such precise adaptation cannot be accomplished without a thorough knowledge of tooth morphologic features. The clinician must form a mental image of the tooth surface to anticipate variations in contour, continually confirming or modifying the image in response to tactile sensations and visual cues, such as the position of the instrument handle and shank. The clinician then must instantaneously adjust the adaptation and angulation of the working end to the tooth. It is this complex and precise coordination of visual, mental, and manual skills that makes subgingival instrumentation one of the most difficult of all dental skills. *The curette is preferred by most clinicians for subgingival scaling and root planing because of the advantages afforded by its design.* Its curved blade, rounded toe, and curved back allow the curette to be inserted to the base of the pocket and adapted to variations in tooth contour with minimal tissue displacement and trauma.

Sickles, hoes, files, and ultrasonic instruments also are used for subgingival scaling of heavy calculus. Some small files (e.g., Hirschfeld file) may be inserted to the base of the pocket to crush or initially fracture tenacious deposits. Larger files, hoes, sickles, and standard ultrasonic tips for supragingival use are too bulky and cannot be inserted easily into deep pockets or areas where tissue is firm and fibrotic. Hoes and files cannot be used to produce as smooth a surface as curettes. Hoes, files, and standard large ultrasonic tips are all more hazardous than the curette in terms of trauma to the root surface and surrounding tissues.[15,109,135] Although thin ultrasonic tips designed for scaling of deep pockets and furcations can be inserted more easily subgingivally, they must be used on low power.[41,42,60] When low-power scaling is performed on heavy calculus or tenacious sheets of calculus, thin ultrasonic tips are likely to burnish the calculus rather than thoroughly remove it. Therefore ultrasonic scaling should be followed by careful assessment with an explorer and further instrumentation with curettes when necessary.

Subgingival scaling and root planing are accomplished with either universal or area-specific (Gracey) curettes using the following basic procedure. The curette is held with a modified pen grasp, and a stable finger rest is established. The correct cutting edge is slightly adapted to the tooth, with the lower shank kept parallel to the tooth surface. The lower shank is moved toward the tooth so that the face of the blade is nearly flush with the tooth surface. The blade is then inserted under the gingiva and advanced to the base of the pocket by a light exploratory stroke. When the cutting edge reaches the base of the pocket, a working angulation of between 45 and 90 degrees is established, and pressure is applied laterally against the tooth surface. Calculus is removed by a series of

controlled, overlapping, short, powerful strokes primarily using wrist-arm motion (Figure 46-80). As calculus is removed, resistance to the passage of the cutting edge diminishes until only a slight roughness remains. Longer, lighter root-planing strokes are then activated with less lateral pressure until the root surface is completely smooth and hard. The instrument handle must be rolled carefully between the thumb and fingers to keep the blade adapted closely to the tooth surface as line angles, developmental depressions, and other changes in tooth contour are followed. Scaling and root-planing strokes should be confined to the portion of the tooth where calculus or altered cementum is found; this area is known as the *instrumentation zone.* Sweeping the instrument over the crown where it is not needed wastes operating time, dulls the instrument, and causes loss of control.

The amount of lateral pressure applied to the tooth surface depends on the nature of the calculus and whether the strokes are for initial calculus removal or final root planing. If heavy lateral pressure is continued after the bulk of calculus has been removed and the blade is repeatedly readapted with short, choppy strokes, the result will be a root surface roughened by numerous nicks and gouges, resembling the rippled surface of a washboard.[115] If heavy lateral pressure is continued with long, even strokes, the result will be excessive removal of root structure, producing a smooth but "ditched" or "riffled" root surface. To avoid these hazards of over-instrumentation, a deliberate transition from short, powerful scaling strokes to longer, lighter root-planing strokes must be made as soon as the calculus and initial roughness have been eliminated.

When scaling strokes are used to remove calculus, force can be maximized by concentrating lateral pressure onto the lower third of the blade (see Figure 46-66). This small section, the terminal few millimeters of the blade, is positioned slightly apical to the lateral edge of the deposit, and a short vertical or oblique stroke is used to split the calculus from the tooth surface. Without withdrawing the instrument from the pocket, the lower third of the blade is advanced laterally and repositioned to engage the next portion of the remaining deposit. Another vertical or oblique stroke is made, slightly overlapping the previous stroke. This process is repeated in a series of powerful scaling strokes until the entire deposit has been removed. The overlapping of these pathways or "channels" of instrumentation[115] ensures that the entire instrumentation zone is covered (Figure 46-81).

Engaging a large, tenacious ledge or piece of calculus with the entire length of the cutting edge is not recommended because the force is distributed through a longer section of the cutting edge rather than concentrated. Much more lateral pressure is required to dislodge the entire deposit in one stroke. Although some clinicians may possess the strength to remove calculus completely in this manner, the heavier forces required diminish tactile sensitivity and contribute to a loss of control that results in tissue trauma. A single heavy stroke usually is not sufficient to remove calculus entirely. Instead, the blade skips over or skims the surface of the deposit. Subsequent strokes made with the entire cutting edge tend to shave the deposit down layer by layer. When a series of these repeated whittling strokes is applied, the calculus may be reduced to a thin,

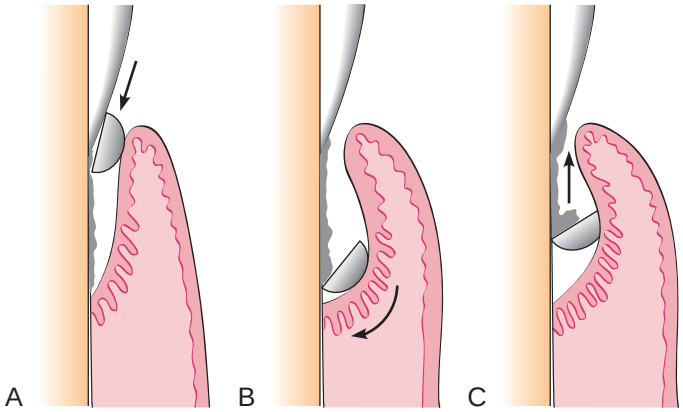

Figure 46-80 Subgingival scaling procedure. **A,** Curette inserted with the face of the blade flush against the tooth. **B,** Working angulation (45 to 90 degrees) is established at the base of the pocket. **C,** Lateral pressure is applied, and the scaling stroke is activated in the coronal direction.

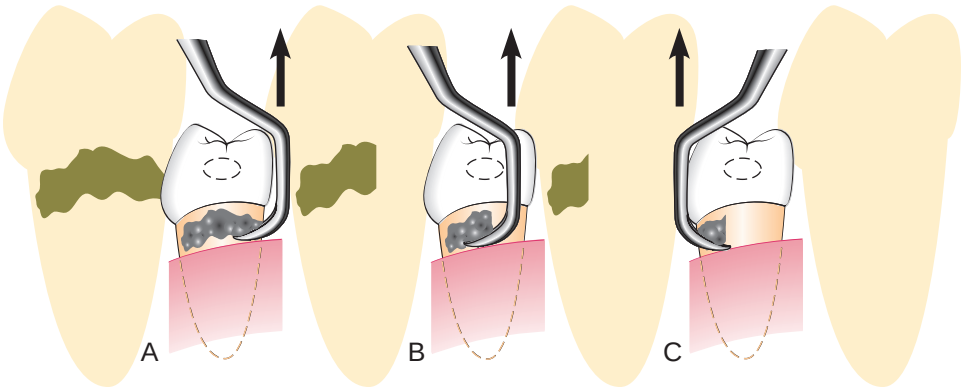

Figure 46-81 Instrumentation for calculus removal. **A,** Calculus is removed by engaging the apical or lateral edge of the deposit with the cutting edge of a scaler; vertical movement of the instrument will remove the fragment of calculus engaged by the instrument, as seen in the shaded drawing. **B,** The instrument is moved laterally and again engages the edge of the calculus, overlapping the previous stroke to some extent; the shaded drawing shows further removal. **C,** The final portion of the deposit is engaged and removed. Note how the procedure is performed in an interdental space by entering facially and lingually.

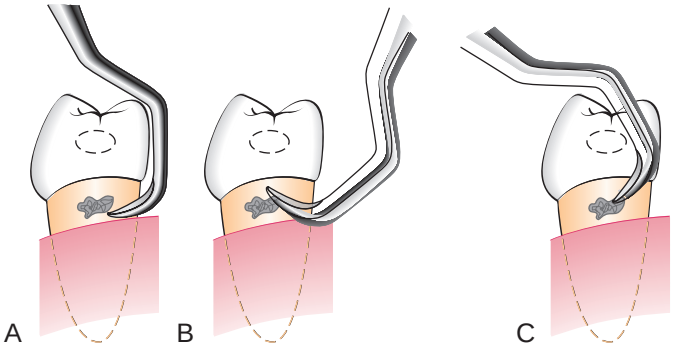

Figure 46-82 Shank position for scaling proximal surfaces. **A,** Correct shank position, parallel with the long axis of the tooth. **B,** Incorrect shank position, tilted away from the tooth. **C,** Incorrect shank position, tilted too far toward the tooth. Sextant: lingual aspect.

Figure 46-83 Maxillary right posterior sextant: facial aspect.

Figure 46-84 Maxillary right posterior sextant, premolar region only: facial aspect.

smooth, burnished sheet that is difficult to distinguish from the surrounding root surface.

A common error in instrumenting proximal surfaces is failing to reach the midproximal region apical to the contact. This area is relatively inaccessible, and the technique requires more skill than instrumentation of buccal or lingual surfaces. It is extremely important to extend strokes at least halfway across the proximal surface so that no calculus or roughness remains in the interproximal area. With properly designed curettes, this can be accomplished by keeping the lower shank of the curette parallel with the long axis of the tooth (Figure 46-82, *A*). With the lower shank parallel to the long axis, the blade of the curette will reach the base of the pocket and the toe will extend beyond the midline as strokes are advanced across the proximal surface. This extension of strokes beyond the midline ensures thorough exploration and instrumentation of these surfaces. If the lower shank is angled or tilted away from the tooth, the toe will move toward the contact area. Because this prevents the blade from reaching the base of the pocket, calculus apical to the contact will not be detected or removed. Strokes will be hampered because the toe tends to become lodged in the contact. If the instrument is angled or tilted too far toward the tooth, the lower shank will hit the tooth or the contact area, preventing extension of strokes to the midproximal region (Figure 46-82, *B* and *C*).

The relationship between the location of the finger rest and the working area is important for two reasons. First, the finger rest or fulcrum must be positioned to allow the lower shank of the instrument to be parallel or nearly parallel to the tooth surface being treated. This parallelism is a fundamental requirement for optimal working angulation. Second, the finger rest must be positioned to enable the operator to use wrist-arm motion to activate strokes. On some aspects of the maxillary posterior teeth, these requirements can be met only with the use of extraoral or opposite-arch fulcrums. When intraoral finger rests are used in other regions of the mouth, the finger rest must be close enough to the working area to fulfill these two requirements. A finger rest that is established too far from the working area forces the clinician to separate the middle finger from the fourth finger in an effort to obtain parallelism and proper angulation. Effective wrist-arm motion is possible only when these two fingers are kept together in a built-up fulcrum. Separation of the fingers commits the clinician to the exclusive use of finger flexing for the activation of strokes.

As instrumentation proceeds from one tooth to the next, the body position of the operator and the location of the finger rest must be frequently adjusted or changed to allow parallelism and wrist-arm motion. Various approaches to instrumentation in different areas of the mouth are illustrated here. The examples shown provide maximal efficiency for the clinician and comfort for the patient. For most areas, more than one approach is presented. Other approaches are possible and are acceptable if they provide equal efficiency and comfort. The following approaches may be used:

Maxillary right posterior sextant: facial aspect (Figure 46-83).
Operator position: Side position.
Illumination: Direct.
Visibility: Direct (indirect for distal surfaces of molars).
Retraction: Mirror or index finger of the nonoperating hand.
Finger rest: Extraoral, palm up. Backs of the middle and fourth fingers on the lateral aspect of the mandible on the right side of the face.

Maxillary right posterior sextant, premolar region only: Facial aspect (Figure 46-84).
Operator position: Side or back position.
Illumination: Direct.
Visibility: Direct.
Retraction: Mirror or index finger of the nonoperating hand.
Finger rest: Intraoral, palm up. Fourth finger on the occlusal surfaces of the adjacent maxillary posterior teeth.

Maxillary right posterior sextant: Lingual aspect (Figure 46-85).
Operator position: Side or front position.
Illumination: Direct and indirect.
Visibility: Direct or indirect.

Figure 46-85 Maxillary right posterior sextant: lingual aspect.

Figure 46-86 Maxillary right posterior sextant: lingual aspect.

Retraction: None.
Finger rest: Extraoral, palm up. Backs of the middle and fourth fingers on the lateral aspect of the mandible on the right side of the face.
Maxillary right posterior sextant: Lingual aspect (Figure 46-86).
Operator position: Front position.
Illumination: Direct.
Visibility: Direct.
Retraction: None.
Finger rest: Intraoral, palm up, finger on finger. Index finger of the nonoperating hand on the occlusal surfaces of the maxillary right posterior teeth; fourth finger of the operating hand or the index finger of the nonoperating hand.
Maxillary anterior sextant: Facial aspect, surfaces away from the operator (Figure 46-87).
Operator position: Back position.
Illumination: Direct.
Visibility: Direct.
Retraction: Index finger of the nonoperating hand.
Finger rest: Intraoral, palm up. Fourth finger on the incisal edges or occlusal surfaces of adjacent maxillary teeth.
Maxillary anterior sextant: Facial aspect, surfaces toward the operator (Figure 46-88).
Operator position: Front position.
Illumination: Direct.
Visibility: Direct.
Retraction: Index finger of the nonoperating hand.

Figure 46-87 Maxillary anterior sextant: facial aspect, surfaces away from the operator.

Figure 46-88 Maxillary anterior sextant: facial aspect, surfaces toward the operator.

Figure 46-89 Maxillary anterior sextant: lingual aspect, surfaces away from the operator (surfaces toward the operator are scaled from a front position).

Finger rest: Intraoral, palm down. Fourth finger on the incisal edges or the occlusal or facial surfaces of adjacent maxillary teeth.
Maxillary anterior sextant: Lingual aspect, surfaces away from the operator (surfaces toward the operator are scaled from a front position) (Figure 46-89).

Operator position: Back position.
Illumination: Indirect.
Visibility: Indirect.
Retraction: None.
Finger rest: Intraoral, palm up. Fourth finger on the incisal edges or the occlusal surfaces of adjacent maxillary teeth.
Maxillary left posterior sextant: Facial aspect (Figure 46-90).
Operator position: Side or back position.
Illumination: Direct or indirect.
Visibility: Direct or indirect.
Retraction: Mirror.
Finger rest: Extraoral, palm down. Front surfaces of the middle and fourth fingers on the lateral aspect of the mandible on the left side of the face.
Maxillary left posterior sextant: Facial aspect (Figure 46-91).
Operator position: Back or side position.
Illumination: Direct or indirect.
Visibility: Direct or indirect.
Retraction: Mirror.
Finger rest: Intraoral, palm up. Fourth finger on the incisal edges or the occlusal surfaces of adjacent maxillary teeth.
Maxillary left posterior sextant: Lingual aspect (Figure 46-92).
Operator position: Front position.
Illumination: Direct.
Visibility: Direct.
Retraction: None.
Finger rest: Intraoral, palm down, opposite arch, reinforced. Fourth finger on the incisal edges of the mandibular anterior teeth or the facial surfaces of the mandibular premolars, reinforced with the index finger of the nonoperating hand.
Maxillary left posterior sextant: Lingual aspect (Figure 46-93).
Operator position: Front position.
Illumination: Direct and indirect.
Visibility: Direct and indirect.
Retraction: None.
Finger rest: Extraoral, palm down. Front surfaces of the middle and fourth fingers on the lateral aspect of the mandible on the left side of the face. The nonoperating hand holds the mirror for indirect illumination.
Maxillary left posterior sextant: Lingual aspect (Figure 46-94).
Operator position: Side or front position.
Illumination: Direct.
Visibility: Direct.
Retraction: None.
Finger rest: Intraoral, palm up. Fourth finger on the occlusal surfaces of adjacent maxillary teeth.
Mandibular left posterior sextant: Facial aspect (Figure 46-95).
Operator position: Side or back position.
Illumination: Direct.
Visibility: Direct or indirect.
Retraction: Index finger or mirror of the nonoperating hand.

Figure 46-90 Maxillary left posterior sextant: facial aspect.

Figure 46-92 Maxillary left posterior sextant: lingual aspect.

Figure 46-91 Maxillary left posterior sextant: facial aspect.

Figure 46-93 Maxillary left posterior sextant: lingual aspect.

Figure 46-94 Maxillary left posterior sextant: lingual aspect.

Figure 46-95 Mandibular left posterior sextant: facial aspect.

Figure 46-96 Mandibular left posterior sextant: lingual aspect.

Finger rest: Intraoral, palm down. Fourth finger on the incisal edges or the occlusal or facial surfaces of adjacent mandibular teeth.
Mandibular left posterior sextant: Lingual aspect (Figure 46-96).
Operator position: Front or side position.
Illumination: Direct and indirect.
Visibility: Direct.
Retraction: Mirror retracts tongue.

Figure 46-97 Mandibular anterior sextant: facial aspect, surfaces toward the operator.

Figure 46-98 Mandibular anterior sextant: facial aspect, surfaces away from the operator.

Finger rest: Intraoral, palm down. Fourth finger on the incisal edges or the occlusal surfaces of adjacent mandibular teeth.
Mandibular anterior sextant: Facial aspect, surfaces toward the operator (Figure 46-97).
Operator position: Front position.
Illumination: Direct.
Visibility: Direct.
Retraction: Index finger of the nonoperating hand.
Finger rest: Intraoral, palm down. Fourth finger on the incisal edges or the occlusal surfaces of adjacent mandibular teeth.
Mandibular anterior sextant: Facial aspect, surfaces away from the operator (Figure 46-98).
Operator position: Back position.
Illumination: Direct.
Visibility: Direct.
Retraction: Index finger or thumb of the nonoperating hand.
Finger rest: Intraoral, palm down. Fourth finger on the incisal edges or the occlusal surfaces of adjacent mandibular teeth.
Mandibular anterior sextant: Lingual aspect, surfaces away from the operator (Figure 46-99).
Operator position: Back position.
Illumination: Direct and indirect.
Visibility: Direct and indirect.
Retraction: Mirror retracts tongue.

Figure 46-99 Mandibular anterior sextant: lingual aspect, surfaces away from the operator.

Figure 46-101 Mandibular right posterior sextant: facial aspect.

Figure 46-100 Mandibular anterior sextant: lingual aspect, surfaces toward the operator.

Figure 46-102 Mandibular right posterior sextant: lingual aspect.

Finger rest: Intraoral, palm down. Fourth finger on the incisal edges or the occlusal surfaces of adjacent mandibular teeth.
Mandibular anterior sextant: Lingual aspect, surfaces toward the operator (Figure 46-100).
Operator position: Front position.
Illumination: Direct and indirect.
Visibility: Direct and indirect.
Retraction: Mirror retracts tongue.
Finger rest: Intraoral, palm down. Fourth finger on the incisal edges or the occlusal surfaces of adjacent mandibular teeth.
Mandibular right posterior sextant: Facial aspect (Figure 46-101).
Operator position: Side or front position.
Illumination: Direct.
Visibility: Direct.
Retraction: Mirror or index finger of the nonoperating hand.
Finger rest: Intraoral, palm down. Fourth finger on the incisal edges or the occlusal surfaces of adjacent mandibular teeth.
Mandibular right posterior sextant: Lingual aspect (Figure 46-102).
Operator position: Front position.
Illumination: Direct and indirect.
Visibility: Direct and indirect.
Retraction: Mirror retracts tongue.
Finger rest: Intraoral, palm down. Fourth finger on the incisal edges or the occlusal surfaces of adjacent mandibular teeth.

Ultrasonic and Sonic Scaling

Instruments. Ultrasonic scalers may be used for removing plaque and stain, scaling, root planing, curetting, and surgical debridement. The two types of ultrasonic units are magnetostrictive and piezoelectric. In both types, alternating electrical current generates oscillations in materials in the handpiece that cause the scaler tip to vibrate. Depending on the manufacturer, these ultrasonic vibrations at the tip of the instruments of both types range from 18,000 to 50,000 cycles per second (cps; also referred to as Hertz [Hz]). In magnetostrictive units the pattern of vibration of the tip is elliptical, which means that all sides of the tip are active and will work when adapted to the tooth. In piezoelectric units the pattern of vibration of the tip is linear, or back and forth, meaning that the two sides of the tip are the most active.

Sonic units consist of a handpiece that attaches to a compressed-air line and uses a variety of specially designed tips. Vibrations at the sonic tip range from 2500 to 7000 cps, which provides less power for calculus removal than ultrasonic units.

Ultrasonic and sonic tips of different shapes and sizes are available. Larger tips are used for removal of heavy supragingival calculus and heavy subgingival calculus where tissue is inflamed and retractable. Thinner tips are designed for more definitive subgingival debridement. All tips are designed to operate in a wet field with a water spray directed at the end of the tip. Vibrational energy dislodges calculus and biofilm from the tooth surfaces and acoustic streaming and acoustic turbulence of the water serves to flush these

deposits from the pocket. Magnetostrictive ultrasonic inserts generate heat and require water for cooling. Sonic and piezoelectric units do not generate heat but still utilize water for cooling of frictional heat and for flushing away debris.

Ultrasonic Instruments

Ultrasonic instruments have been used as a valuable adjunct to conventional hand instrumentation for many years. In the early era of ultrasonic scaling, most tips were large and bulky, making them generally suitable only for supragingival scaling. Currently, many thinner ultrasonic tips allow better access to subgingival areas that were previously accessible only with hand instruments.[40] It is important to understand this historical perspective when attempting to interpret the literature comparing the effects of hand and ultrasonic instruments on root surfaces. Earlier studies using older tip designs generally showed that ultrasonic instruments left a rougher, more damaged surface than curettes.* More recent studies, especially those using the newer, thinner tips, show that ultrasonic instruments can produce root surfaces as smooth or smoother than those produced by curettes.[40,41,46,128] Whether these relative degrees of smoothness are important has not been clearly established.† It is evident, however, that both methods of instrumentation are able to provide satisfactory clinical results, as measured by removal of biofilm and calculus, reduction of bacteria, reduction of inflammation and pocket depth, and gain in clinical attachment.‡

Ultrasonic instruments have been shown to be more effective than hand instruments at reducing spirochetes and motile rods in class II and III furcations.[81] Two in vitro studies found that ultrasonic and sonic scalers do not kill periodontal pathogenic bacteria by cavitation, rather they suggest an antimicrobial effect from an increase in temperature or from acoustic streaming.[106,136] Other in vitro studies found that the mini-bladed Gracey Curvettes were more effective than slim ultrasonic inserts in debriding root trunks, furcation entrances, and furcation areas of mandibular first molars.[111,112] Mini-bladed hand instruments—such as the Gracey Curvettes and the mini-bladed or micro mini-bladed Gracey Curvettes—allow excellent, unprecedented access to narrow furcations and they can be followed by thin, curved ultrasonic inserts for final debridement and lavage.

The selection of either ultrasonic or hand instrumentation should be determined by the clinician's preference and experience and the needs of each patient. The success of either treatment method is determined by the time devoted to the procedure and the thoroughness of root debridement. In practice, clinicians typically use a combination of both ultrasonic and hand instrumentation to achieve thorough debridement.

The vibrational energy produced by the ultrasonic instrument makes it useful for removing heavy, tenacious deposits of calculus and stain. Such deposits can be removed more quickly and with less effort ultrasonically than manually. When ultrasonic instruments are properly manipulated, less tissue trauma and, therefore, less postoperative discomfort occur. This makes ultrasonic instrumentation useful for initial debridement in patients with acute painful conditions such as necrotizing ulcerative gingivitis. This same quality can be used to advantage with the new, thin ultrasonic tips for subgingival root debridement and deplaquing in maintenance patients with residual pocket depth. Ultrasonic scaling devices also have been used for gingival curettage and to remove overhangs and excess cement after cementing orthodontic appliances. Opinions differ regarding the effectiveness of ultrasonic instruments for removing stain compared with conventional polishing methods.[23]

There are some contraindications for the use of ultrasonic and sonic scaling devices. Magnetostrictive devices have been reported to interfere with the function of older cardiac pacemakers.[171] In a recent independent study, a piezoelectric dental scaler produced no electromagnetic interference with defibrillators.[21] Patients with newer pacemakers can be treated safely; however, there may be a risk if the patient is medically fragile or if electronically defective ultrasonic devices are used.[93,156,171] Medical consultation is advised when treating patients with such conditions.

Patients with known communicable diseases that can be transmitted by aerosols should not be treated with ultrasonic or sonic scaling devices. The water spray creates a contaminated aerosol that fills the operating area, exposing personnel and surfaces.[77,102] Even when treating patients without known communicable diseases, it is especially important that proper infection control measures be observed (i.e., use of protective clothing, eyewear, masks, and gloves) and proper surface decontamination be performed afterward. Prerinsing for 1 minute with an antimicrobial mouthwash such as 0.12% chlorhexidine significantly reduces the number of bacteria in the aerosol for approximately 1 hour.[160]

Patients at risk for respiratory disease should not be treated with ultrasonic or sonic devices, including patients who are immunosuppressed or have chronic pulmonary disorders.[141,152] Finally, metal ultrasonic and sonic inserts are contraindicated for titanium implants, which can be etched or gouged, and for porcelain or bonded restorations, which can be fractured or removed.[20,39,78,124,161] Magnetostrictive and piezoelectric plastic-tipped ultrasonic inserts that do not cause damage to titanium implants are available.[75] Also, plastic and Teflon-coated sonic scaler tips have been developed for titanium implants and for deplaquing and subgingival polishing of root surfaces.[72,73,132]

Technique. Ultrasonic instrumentation is accomplished with a light-to-moderate grasp and varying pressures depending on the amount and tenacity of the deposit. Excessive pressure is not recommended because it can cause dampening of the vibration of the tip. The tip should be kept constantly in motion and parallel to the tooth surface.[41,60,119] Leaving the tip in one place for too long or using the point of the tip against the tooth can produce gouging and roughening of the root surface or overheating of the tooth.[40] Using a lower-power setting and applying only slight pressure reduces the volume and depth of tooth structure removal.[31,119]

The ultrasonic tip must come in direct physical contact with calculus to fracture and remove it. The tip must also contact all aspects of the root surface to remove biofilm and toxins thoroughly. Although as much as 10 mm or more of the length of the ultrasonic tip vibrates, only the terminal few millimeters of the tip produce maximum vibration. At any point in time, it is only possible for this terminal 1 to 2 millimeter portion of the tip to be in contact with the tooth because of the curved anatomy of the tooth. A series of focused, overlapping strokes must be activated to keep this small active portion of the tip adapted to the root surface at all times.[60] The handpiece and the blunt working end of the ultrasonic tip impair tactile sensitivity, and the constant water spray hampers visibility. For these reasons, during ultrasonic instrumentation, the tooth surface should be frequently examined with an explorer to evaluate the completeness of debridement.

The aerosol produced by sonic and ultrasonic instrumentation may contain potentially infectious blood-borne and airborne

*References 5, 31, 46, 48, 66, 70, 151, 158, and 166.
†References 46, 47, 60, 71, 80, 105, and 137.
‡References 8-12, 37, 42, 50, 86, 107, 120, and 151.

pathogens.* Pneumococci, staphylococci, α-hemolytic streptococci, and *Mycobacterium tuberculosis* are among the bacteria that have been found in dental aerosols.[68,82] Aerosols also subject dental personnel and patients to many viruses, including herpes simplex, hepatitis, influenza, common cold, Epstein-Barr, and cytomegalovirus.[29,32,33,34,35,92,154] Of additional concern are pathogens that do not originate from patients but are from the contaminated waterlines of the dental unit or the ultrasonic device.[36,44,113] Putative pathogens such as *Pseudomonas* species and *Legionella pneumophila* have been isolated from dental unit water and can become aerosolized by an ultrasonic scaler.[34,44,51,108] Aerosol from ultrasonic instrumentation always contains blood[14,94] and lingers in the air for 30 minutes or longer in the entire operatory and in areas of the dental office outside the operatory.[77,79,95,96] Unprotected patients may be more susceptible to infection from the aerosol than dental personnel who are wearing protective barriers, such as masks, gloves, eyewear, and clinical clothing.[16,29,141] High-speed evacuation, preprocedural rinsing with chlorhexidine, flushing of the handpiece and waterlines or a self-contained sterile water source, thorough disinfection of environmental surfaces, and adequate ventilation and air filtration units with high-efficiency particulate air (HEPA) filters are all important precautions to minimize the potential hazards of ultrasonic aerosols.[55,56,58,133]

With these points in mind, the ultrasonic device is used in the following manner:

1. Thoroughly wipe the ultrasonic unit with a disinfectant. Use a sterile, autoclavable ultrasonic handpiece, or wipe the handpiece with disinfectant. Cover the ultrasonic unit or control knobs and the handpiece with plastic or latex barriers. Flush the waterlines and handpiece for 2 minutes to decrease the number of microorganisms in the lines.[165] Use waterline filters or sterile water whenever possible.
2. Direct the patient to rinse for 1 minute with an antimicrobial oral rinse such as 0.12% chlorhexidine to reduce the contaminated aerosol.[160,165]
3. The clinician and the assistant should wear protective eyewear or face shield and masks. Use high-speed evacuation to minimize contaminated aerosol produced during instrumentation.[55,56,58]
4. Turn on the unit, select an insert, place it into the handpiece, and then adjust the water control knob to produce a light mist of water at the working tip. Adequate aspiration is necessary to remove this water as it accumulates in the mouth. The power setting should begin on low and be adjusted no higher than necessary to remove calculus. Medium-to-high-power settings have been shown to cause damage to roots when the tip is not parallel to the root surface.
5. The instrument is grasped with a light to moderate pen or modified pen grasp, and a finger rest or extraoral fulcrum should be established to allow a light touch. Extraoral hand rests should be used for the maxillary teeth. For the mandibular teeth, either intraoral or extraoral fulcrums may be used.
6. Use short, light, vertical, horizontal, or oblique overlapping strokes. Keep the working tip adapted to the tooth surface as it is passed over the deposit. Heavy lateral pressure is unnecessary because the vibrational energy of the instrument dislodges the calculus. However, the working end must touch the deposit for this to occur.
7. The working end should be kept in constant motion, and the tip should be kept parallel to the tooth surface or at no more than a 15-degree angle to avoid etching or grooving the tooth surface.[165]
8. The instrument should be switched off periodically to allow for aspiration of water, and the tooth surface should be examined frequently with an explorer.
9. Any remaining irregularities of the root surface may be removed with sharp standard or mini-bladed curettes if necessary.

See Chapter 47 for additional information on ultrasonic and sonic scaling.

Evaluation

The adequacy of scaling and root planing is evaluated when the procedure is performed and again later, after a period of soft tissue healing.

Immediately after instrumentation, the tooth surfaces should be carefully inspected visually with optimal lighting and the aid of a mouth mirror and compressed air; surfaces also should be examined with a fine explorer or probe. Subgingival surfaces should be hard and smooth. Although complete removal of calculus is definitely necessary for the health of the adjacent soft tissue,[164] little documented evidence of the necessity for root smoothness is available.[47,50,155] Nevertheless, relative smoothness is still the best immediate clinical indication that calculus has been completely removed.[47]

Although smoothness is the criterion by which scaling and root planing are immediately evaluated, the ultimate evaluation is based on *tissue response*.[162] Clinical evaluation of the soft tissue response to scaling and root planing, including probing, should not be conducted earlier than 2 weeks postoperatively. Reepithelialization of the wounds created during instrumentation takes 1 to 2 weeks.[121,147,148] Until then, gingival bleeding on probing can be expected even when calculus has been completely removed because the soft tissue wound is not epithelialized. Any gingival bleeding on probing noted after this interval is more likely the result of persistent inflammation produced by residual deposits not removed during the initial procedure or inadequate plaque control. Positive clinical changes after instrumentation often continue for weeks or months. Therefore a longer period of evaluation may be indicated before deciding whether to intervene with further instrumentation or surgery.[30]

Occasionally, the clinician may find that some slight root roughness remains after scaling and root planing.[39,92,104] If sound principles of instrumentation have been followed, the roughness may not be calculus. Because calculus removal, not root smoothness, has been shown to be necessary for tissue health, it might be more prudent in such a case to stop short of perfect smoothness and reevaluate the patient's tissue response after 2 to 4 weeks or longer. This avoids overinstrumentation and removal of excessive root structure in the pursuit of smoothness for its own sake. If the tissue is healthy after an interval of 2 to 4 weeks or longer, no further root planing is necessary. If the tissue is inflamed, the clinician must determine to what extent this is caused by biofilm accumulation or the presence of residual calculus and to what degree further root planing is necessary.

Instrument Sharpening

It is impossible to carry out periodontal procedures efficiently with dull instruments. A sharp instrument cuts more precisely and quickly than a dull instrument. To do its job at all, a dull instrument must be held more firmly and pressed harder than a sharp

*References 7,51, 52, 53, 62, 77, 95, 96, 129, 152, and 157.

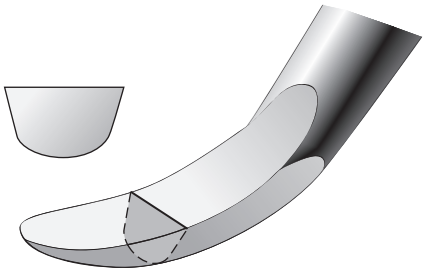

Figure 46-103 The cutting edge of a curette is formed by the angular junction of the face and the lateral surfaces of the instrument. When the instrument is sharp, the cutting edge is a fine line.

Figure 46-104 The cutting edge of a dull curette is rounded.

instrument. This reduces tactile sensitivity and increases the possibility that the instrument will inadvertently slip. *Therefore, to avoid wasting time and operating haphazardly, clinicians must be thoroughly familiar with the principles of sharpening and able to apply them to produce a keen cutting edge on the instruments they are using.* Development of this skill requires patience and practice, but clinical excellence cannot be attained without it.

Evaluation of Sharpness

The *cutting edge* of an instrument is formed by the angular junction of two surfaces of its blade. The cutting edges of a curette, for example, are formed where the face of the blade meets the lateral surfaces (Figure 46-103).

When the instrument is sharp, this junction is a fine line running the length of the cutting edge. As the instrument is used, metal is worn away at the cutting edge, and the junction of the face and lateral surface becomes rounded or dulled[6,84] (Figure 46-104). Thus the cutting edge becomes a rounded surface rather than an acute angle, which is why a dull instrument cuts less efficiently and requires more pressure to do its job.[48]

Sharpness can be evaluated by sight and touch in one of the following ways:

1. When a dull instrument is held under a light, the rounded surface of its cutting edge reflects light back to the observer. It appears as a bright line running the length of the cutting edge (Figure 46-105). The acutely angled cutting edge of a sharp instrument, conversely, has no surface area to reflect light. When a sharp instrument is held under a light, no bright line can be observed (see Figure 46-103).
2. Tactile evaluation of sharpness is performed by drawing the instrument lightly across an acrylic rod known as a "sharpening test stick." A dull instrument will slide smoothly, without "biting" into the surface and raising a light shaving as a sharp instrument would.[165]

Objective of Sharpening

The objective of sharpening is to restore the fine, thin, linear cutting edge of the instrument. This is done by grinding the surfaces of the blade until their junction is once again sharply angular rather than rounded. For any given instrument, several sharpening techniques may produce this result. A technique is acceptable if it produces a sharp cutting edge without unduly wearing the instrument or altering its original design. To maintain the original design, the operator must understand the location and course of the cutting edges and the angles between the surfaces that form them. It is important to restore the cutting edge without distorting the original angles of the instrument. When these angles have been altered, the instrument does not function as it was designed to function, which limits its effectiveness.



Figure 46-105 Light reflected from the rounded cutting edge of a dull instrument appears as a bright line.

Figure 46-106 Sharpening stones. *Top* to *bottom,* A flat India stone, a flat Arkansas stone, a cone-shaped Arkansas stone, and a ceramic stone.

Sharpening Stones

Sharpening stones may be quarried from natural mineral deposits or produced artificially. In either case, the surface of the stone is made up of abrasive crystals that are harder than the metal of the instrument to be sharpened. Coarse stones have larger particles and cut more rapidly; they are used on instruments that are dull. Finer stones with smaller crystals cut more slowly and are reserved for final sharpening to produce a finer edge and for sharpening instruments that are only slightly dull.[131,144] India and Arkansas oilstones are examples of natural abrasive stones. Carborundum, ruby, and ceramic stones are synthetically produced (Figure 46-106).

Sharpening stones can also be categorized by their method of use.

Mounted Rotary Stones. These stones are mounted on a metal mandrel and used in a motor-driven handpiece. They may be cylindrical, conical, or disc shaped. These stones are generally not recommended for routine use because they (1) are difficult to

control precisely and can ruin the shape of the instrument, (2) tend to wear down the instrument quickly, and (3) can generate considerable frictional heat, which may affect the temper of the instrument.

Unmounted Stones. Unmounted stones come in a variety of sizes and shapes. Some are rectangular with flat or grooved surfaces, whereas others are cylindrical or cone shaped. Unmounted stones may be used in two ways: the instrument may be stabilized and held stationary while the stone is drawn across it, or the stone may be stabilized and held stationary while the instrument is drawn across it.

Principles of Sharpening

1. Choose a stone suitable for the instrument to be sharpened—one that is of an appropriate shape and abrasiveness.
2. Use a sterilized sharpening stone if the instrument to be sharpened will not be resterilized before it is used on a patient.
3. Establish the proper angle between the sharpening stone and the surface of the instrument on the basis of an understanding of its design.
4. Maintain a stable, firm grasp of both the instrument and the sharpening stone. This ensures that the proper angulation is maintained throughout the controlled sharpening stroke. In this manner, the entire surface of the instrument can be reduced evenly, and the cutting edge is not improperly beveled.
5. Avoid excessive pressure. Heavy pressure causes the stone to grind the surface of the instrument more quickly and may shorten the instrument's life unnecessarily.
6. Avoid the formation of a "wire edge," characterized by minute filamentous projections of metal extending as a roughened ledge from the sharpened cutting edge.[6,49,114,165] When the instrument is used on root surfaces, these projections produce a grooved surface rather than a smooth surface. A wire edge is produced when the direction of the sharpening stroke is away from, rather than into or toward, the cutting edge.[6,114] When back-and-forth or up-and-down sharpening strokes are used, formation of a wire edge can be avoided by finishing with a down stroke toward the cutting edge.[83,84]
7. Lubricate the stone during sharpening. This minimizes clogging of the abrasive surface of the sharpening stone with metal particles removed from the instrument.[49,114,165] It also reduces heat produced by friction. Oil should be used for natural stones and water for synthetic stones.
8. Sharpen instruments at the first sign of dullness. A grossly dull instrument is inefficient and requires more pressure when used, which hinders control. Furthermore, sharpening such an instrument requires the removal of a great deal of metal to produce a sharp cutting edge. This shortens the effective life of the instrument.

Sharpening Individual Instruments

Universal Curettes. Several techniques will produce a properly sharpened curette. Regardless of the technique used, the clinician must keep in mind that the angle between the face of the blade and the lateral surface of any curette is 70 to 80 degrees (Figure 46-107). This is the most effective design for removing calculus and root planing (Figure 46-108, *left*). Changing this angle distorts the design of the instrument and makes it less effective. A cutting edge of less than 70 degrees is quite sharp but also thin (Figure 46-108, *center*). It wears down quickly and becomes dull. A cutting edge of 90 degrees or more requires heavy lateral pressure to remove deposits (Figure 46-108, *right*). Calculus removal with such an instrument is often incomplete, and root planing cannot be done effectively.

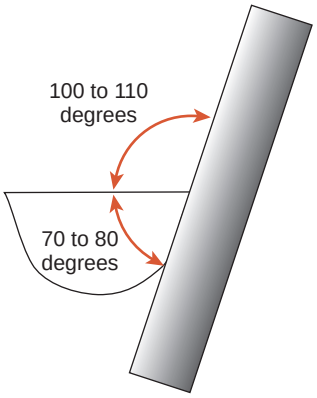

Figure 46-107 When the sharpening stone forms a 100- to 110-degree angle with the face of the blade, the 70- to 80-degree angle between the face and the lateral surface is automatically preserved.

Figure 46-108 *Left,* Properly sharpened curette maintains a 70- to 80-degree angle between its face and lateral surface. *Center,* Curette has been sharpened so that one of its cutting edges is less than 70 degrees. This fine edge is quite sharp but dulls easily. *Right,* One of the cutting edges of the curette has been sharpened to 90 degrees. Heavy lateral pressure must be applied to the tooth to remove deposits with such an instrument.

The following technique is recommended because it enables the clinician to visualize the critical 70- to 80-degree angle easily and thereby consistently restores an effective cutting edge:

Sharpening the Lateral Surface. When a flat, handheld stone is correctly applied to the lateral surface of a curette to maintain the 70- to 80-degree angle, the angle between the face of the blade and the surface of the stone will be 100 to 110 degrees (see Figure 46-107). This can best be visualized by holding the curette so that the face of the blade is parallel with the floor. A palm grasp should be used and the upper arm braced against the body for support.

1. Apply the sharpening stone to the lateral surface of the curette so that the angle between the face of the blade and the stone is 100 to 110 degrees (Figure 46-109; see also Figure 46-107).
2. Beginning at the shank end of the cutting edge and working toward the toe, activate the stone with short, up-and-down strokes. Use consistent, light pressure and keep the stone continuously in contact with the blade. Make sure that the 100- to 110-degree angle is constantly maintained (see Figure 46-109).
3. Check for sharpness as previously described, and continue sharpening as necessary. To prevent the toe of the curette from becoming pointed, sharpen the entire blade from shank end to toe. When approaching the toe, be sure to sharpen around it to preserve its rounded form (Figure 46-110).
4. As the stone is moved along the cutting edge, finish each section with a down stroke into or toward the cutting edge;

Figure 46-109 Using a palm grasp, operator holds the universal curette so that the face of the blade is parallel to the floor. The stone makes a 100- to 110-degree angle with the face of the blade.

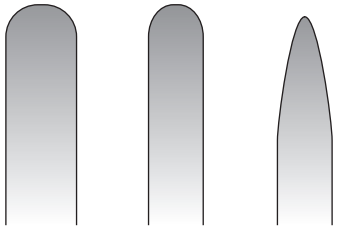

Figure 46-110 *Left,* new, unsharpened curette viewed from directly above the face of the blade. *Center,* curette has been correctly sharpened to maintain the rounded toe. *Right,* curette has been incorrectly sharpened, producing a pointed toe.

Figure 46-111 *Left,* Angulation is difficult to control when sharpening the face of the blade and often results in unwanted beveling. *Right,* Sharpening the face also weakens the blade by narrowing it from face to back.

this will minimize the formation of a wire edge. Check the cutting edge under a light.

5. Sharpening the curette in this manner tends to flatten the lateral surface. This can be corrected by lightly grinding the lateral surface and the back of the instrument, away from the cutting edge, each time the instrument is sharpened.
6. When one edge has been properly sharpened, the opposite cutting edge can be sharpened in the same manner.

Sharpening the Face of the Blade. This may be done by moving a handheld cylindrical or cone-shaped stone back and forth across the face of the blade. A similar stone mounted in a handpiece may also be used by applying it to the face of the blade with the stone rotating toward the toe. These methods are not recommended for routine use for the following reasons:

1. The angulation between the instrument and the stone is difficult to maintain, and therefore the blade may be improperly beveled[6] (Figure 46-111, *left*).
2. Sharpening the face of the blade narrows the working end from face to back. This weakens the blade and makes it likely to bend or break while in use[6,84,114,138] (Figure 46-111, *right*).
3. Sharpening the face of the blade with a handheld stone using a back-and-forth motion produces a wire edge that interferes with the sharpness of the blade.[6]

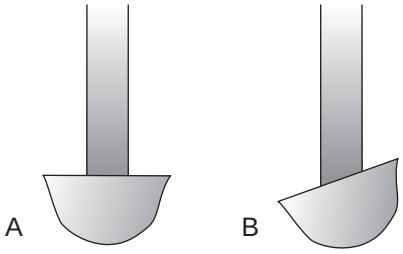

Figure 46-112 **A,** Face of a universal curette is at 90 degrees to its shank. **B,** Face of a Gracey curette is offset, forming a 70-degree angle with its shank.

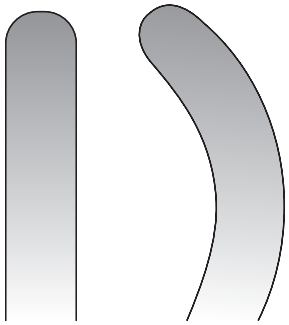

Figure 46-113 Cutting edges of a universal curette extend straight from shank to toe. The cutting edges of a Gracey curette gently curve from shank to toe. Only the larger, outer cutting edge at the right is used for scaling and needs to be sharpened.

Area-Specific (Gracey) Curettes. As with a universal curette, a Gracey curette has an angle of 70 to 80 degrees between the face and lateral surface of its blade. Therefore the technique described for sharpening a universal curette can be used to sharpen a Gracey curette. However, several unique design features that distinguish a Gracey from a universal curette must be understood to avoid distorting the design of the instrument while sharpening (see earlier discussion).

As previously noted, Gracey curettes have an offset blade; that is, the face of the blade is not perpendicular to the shank of the instrument, as it is on a universal curette but is offset at a 70-degree angle (Figure 46-112). A Gracey curette is further distinguished by the curvature of its cutting edges. When viewed from directly above the face of the blade, the cutting edges of a universal curette extend in straight lines from shank to toe; both cutting edges can be used for scaling and root planing. The cutting edges of a Gracey curette, conversely, curve gently from shank to toe, and only the larger, outer cutting edge is used for scaling and root planing (Figure 46-113).

With these points in mind, a Gracey curette is sharpened in the following manner:

1. Hold the curette so that the face of the blade is parallel with the floor. Because the blade is offset, the shank of the instrument will not be perpendicular to the floor, as it is with universal curettes (Figure 46-114).
2. Identify the edge to be sharpened. Remember that only one cutting edge is used, so only that edge must be sharpened (Figure 46-115, *left*). Apply the stone to the lateral surface so that the angle between the face of the blade and the stone is 100 to 110 degrees.
3. Activate short, up-and-down strokes, working from the shank end of the blade to the curved toe. Finish with a down stroke.

Figure 46-114 Note that when a Gracey curette is held in proper sharpening position, its shank is not perpendicular to the floor because of its offset blade angle. The stone meets the blade at an angle of 100 to 110 degrees. Compare this position with the sharpening position of a universal curette, as shown in Figure 46-109.

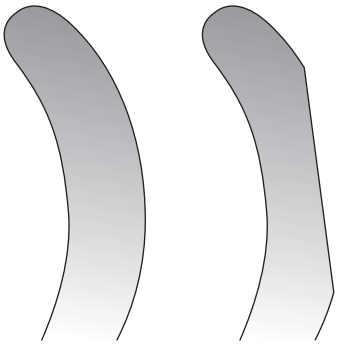

Figure 46-115 Gracey curette on the left has been properly sharpened to maintain a symmetric curve on its outer cutting edge. For the curette on the right, the sharpening stone was activated too long in one place, thereby flattening the blade.

4. Remember that the cutting edge is curved. Preserve the curve by turning the stone while sharpening from shank to toe. If the stone is kept in one place for too many strokes, the blade will be flattened (Figure 46-115, *right*).
5. Evaluate sharpness as previously described. Continue sharpening as necessary.

Extended-Shank and Mini-Bladed Gracey Curettes. Extended-shank Gracey curettes, such as the After Five curettes, are sharpened in exactly the same manner as the standard Gracey curettes. Although the terminal shank is 3 mm longer, the blade size and shape are very similar, and thus there is no difference in the sharpening technique.

Mini-bladed Gracey curettes, such as the Mini Five curettes, Micro Mini curettes, or Gracey Curvettes, are also sharpened with the same technique. These blades are only half the length of a standard Gracey blade, but the angle between the face and the lateral surface of the blade is still 70 to 80 degrees. However, sharpening too heavily or too often around the toe of a mini-bladed curette should be avoided to prevent excessive shortening of the blade.

Sickle Scalers. The two types of sickle scalers are the straight sickle and curved sickle. On a straight sickle the face of the blade is flat from shank to tip, whereas on a curved sickle the face of the blade forms a gentle curve (Figure 46-116). However, the straight and curved sickles have similar cross-sectional designs. As in the curette, the angle between the face of the blade and the lateral surface of a sickle is 70 to 80 degrees (Figure 46-117). When a sharpening stone is correctly applied to the lateral surface to preserve this angle, the angle between the face of the blade and the surface of the stone is 100 to 110 degrees. With this in mind, the sickle scaler can be sharpened in a manner similar to that described for the curette, except that the sickle has a sharp, pointed toe that must not be rounded.



Figure 46-116 Face of the blade on a straight sickle is flat from shank to tip *(left),* whereas on the curved sickle the blade face forms a gentle arc *(right).*

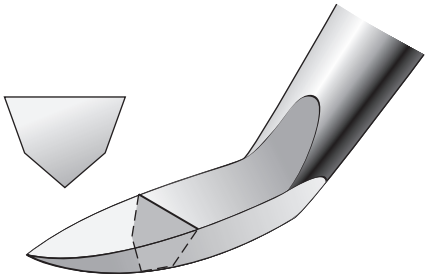

Figure 46-117 As with the curette, the sickle has an angle of 70 to 80 degrees between the face of the blade and the lateral surface.



Figure 46-118 Large, flat stone may also be used to sharpen the sickle. The stone is stabilized on a flat surface. The fourth finger of the right hand guides the sharpening stroke as the instrument is pulled across the face of the stone toward the operator.

A large, flat stone may also be used to sharpen sickles (Figure 46-118). The stone is stabilized on a table or cabinet with the left hand. The sickle is held in the right hand with a modified pen grasp and applied to the stone so that the angle between the face of the blade and the stone is 100 to 110 degrees. The fourth finger is

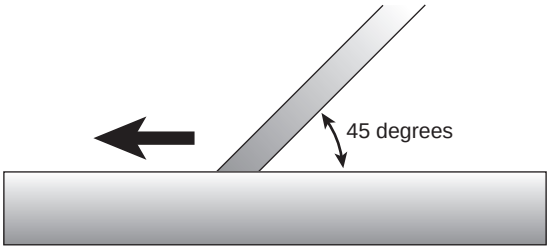

Figure 46-119 When the entire bevel on a chisel contacts the sharpening stone, the angle between the instrument and the stone is 45 degrees. The cutting edge will be properly sharpened if this angle is maintained as the instrument is pushed across the stone.

Figure 46-120 Chisel also can be sharpened on a stationary, flat sharpening stone.

placed on the right-hand edge of the stone to stabilize and guide the sharpening movement. The right hand then pushes and pulls the sickle across the surface of the stone.

To avoid a wire edge, the operator finishes with a pull stroke, being sure that the proper angulation is always maintained.

Chisels and Hoes. Chisels have a single, straight cutting edge that is perpendicular to the shank. The face of the blade is continuous with the shank of the instrument, which may be directly in line with the handle or slightly curved. The end of the blade is beveled at 45 degrees to form the cutting edge.

To sharpen a chisel, stabilize a flat sharpening stone on a flat surface. Grasp the instrument with a modified pen grasp. Establish a finger rest with the pads of the third and fourth fingers against the straight edge of the sharpening stone. Apply the flat beveled surface of the chisel to the surface of the stone. If the entire surface of the bevel is contacting the stone, the 45-degree angle between the beveled surface and the face of the blade will be maintained, and the design of the instrument will not be altered (Figures 46-119 and 46-120).

Using moderate, steady pressure, with the hand and arm acting as a unit and the finger resting on the edge of the stone as a guide, push the instrument across the surface of the sharpening stone. Release pressure slightly, and draw the instrument back to its starting point. Repeat the sharpening stroke until a sharp edge has been obtained. Remember to finish with a push stroke to prevent the formation of a wire edge. Check for sharpness as previously described. Examine the instrument carefully to be sure that its design has not been inadvertently altered.

Back-action surgical chisels and hoe scalers are sharpened with exactly the same technique described for chisels except that a pull stroke is used rather than a push stroke (Figure 46-121).

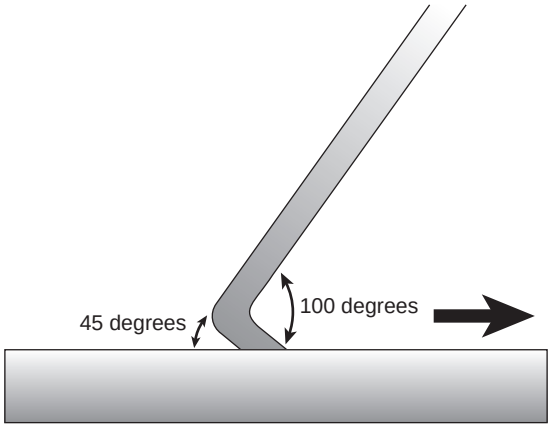

Figure 46-121 Back-action chisels and hoes are sharpened with a pull stroke.

Figure 46-122 Flat-bladed gingivectomy knives, such as this Kirkland knife, have a cutting edge that extends around the entire blade. The entire cutting edge must be sharpened.

Periodontal Knives. There are two general types of periodontal knives. The first type includes the disposable scalpel blades that come prepackaged and are presharpened and sterilized by the manufacturer. These knives are not resharpened when they become dull but are discarded and replaced.

The second type of periodontal knife is reusable and must be sharpened when it becomes dull. The most common knives in this group are the flat-bladed gingivectomy knives (e.g., Kirkland knives #15K and 16K) and the narrow, pointed interproximal knives.

Flat-Bladed Gingivectomy Knives. These knives have broad, flat blades that are nearly perpendicular to the lower shank of the instrument. The curved cutting edge extends around the entire outer edge of the blade and is formed by bevels on both the front and the back surface of the blade (Figure 46-122).

When sharpening these instruments, only the bevel on the back surface of the instrument needs to be ground. This can be done by drawing the blade across a stationary, flat sharpening stone or by holding the instrument stationary and drawing the stone across its blade.

Interproximal Knives. The blades of interproximal knives have two long, straight cutting edges that come together at the sharply pointed tip of the instrument. The cutting edges are formed by bevels on the front and back surfaces of the blade. The entire blade is roughly perpendicular to the lower shank of the instrument (Figure 46-123).

As with the flat-bladed gingivectomy knives, only the bevels on the back surface of the interproximal knives need to be sharpened. Again, this can be accomplished by drawing the instrument across a stationary stone or by holding the instrument stationary and moving the stone across it.

Stationary Stone Technique. Stabilize a flat sharpening stone on a flat surface. Grasp the handle of the instrument with a modified

Figure 46-123 The two cutting edges of an interproximal knife are formed by bevels on the front and back surfaces of the blade.

Figure 46-125 Interproximal knife may be sharpened on a flat stationary stone. The blade is drawn toward the operator.

Figure 46-124 Gingivectomy knife may be sharpened on a stationary flat stone. The instrument is held with a modified pen grasp. The fourth finger guides the sharpening stroke as the instrument is rolled between the fingers so that all sections of the blade are sharpened.

Figure 46-126 Interproximal knife may also be sharpened with a handheld stone. The instrument is held with a palm grasp, and the stone is applied to the entire cutting edge.

pen grasp, and apply the bevel on the back surface of the blade to the flat surface of the sharpening stone. With moderate pressure, pull the instrument toward you (Figures 46-124 and 46-125). Release pressure slightly, and return to the starting point. Begin at one end of the cutting edge, and continue around the blade by rolling the handle of the instrument slightly between the thumb and the first and second fingers. Finish each section of the blade with a pull stroke to prevent formation of a wire edge. Check for sharpness as described previously.

Stationary Instrument Technique. Grasp the instrument with the palm. Apply the flat surface of a handheld sharpening stone to the bevel on the back surface of the blade (Figure 46-126). Begin at one end of the cutting edge, and with moderate pressure, draw the stone back and forth across the instrument. To prevent the formation of a wire edge, finish each section with a stroke into or toward the cutting edge. Proceed around the entire length of the cutting edge by gradually rotating the instrument and the stone in relation to one another.

References

1. Adriaens P, Edwards C, DeBoever J, et al: Ultrastructural observations on bacterial invasion in cementum and radicular dentin of periodontally diseased human teeth. *J Periodontol* 59:493, 1988.
2. Agger MS, Horsted-Bindslev P, Hovgaard O: Abrasiveness of an air-powder polishing system on root surfaces in vitro. *Quintessence Int* 32:407, 2001.
3. Aleo J, DeRenzis F, Farber P: In vitro attachment of human gingival fibroblasts to root surfaces. *J Periodontol* 46:639, 1975.
4. Aleo J, DeRenzis F, Farber P, et al: The presence and biological activity of cementum-bound endotoxin. *J Periodontol* 45:672, 1974.
5. Allen EF, Rhoads RH: Effects of high-speed periodontal instruments on tooth surfaces. *J Periodontol* 34:352, 1963.
6. Antonini CJ, Brady JM, Levin MP, et al: Scanning electron microscope study of scalers. *J Periodontol* 48:45, 1977.
7. Ashimoto A, Chen C, Bakker I, et al: Polymerase chain reaction detection of 8 putative periodontal pathogens in subgingival plaque of gingivitis and advanced periodontitis lesions. *Oral Microbiol Immunol* 11:266, 1996.
8. Axelsson P, Lindhe J: Effect of controlled oral hygiene procedures on caries and periodontal disease in adults: results after 6 years. *J Clin Periodontol* 8:239, 1981.
9. Baderstein A, Nilveus R, Egelberg J: Effect of nonsurgical periodontal therapy. I. Moderately advanced periodontitis. *J Clin Periodontol* 8:57, 1981.
10. Baderstein A, Nilveus R, Egelberg J: 4-year observations of basic periodontal therapy. *J Clin Periodontol* 14:438, 1987.
11. Baderstein A, Nilveus R, Egelberg J: Scores of plaque, bleeding, suppuration, and probing depth to predict probing attachment loss: 5 years of observation following nonsurgical periodontal therapy. *J Clin Periodontol* 17:102, 1990.
12. Baehni P, Thilo P, Chapuis B, et al: Effects of ultrasonic and sonic scalers on dental plaque microflora in vitro and in vivo. *J Clin Periodontol* 19:455, 1992.
13. Barnes C, Hayes E, Leinfelder K: Effects of an air abrasive polishing system on restored surfaces. *Gen Dent* 35:186, 1987.
14. Barnes JB, Harrel SK, Rivera-Hidalgo F: Blood contamination of the aerosols produced by in vivo use of ultrasonic scalers. *J Periodontol* 69:434, 1998.
15. Barnes JE, Schaffer EM: Subgingival root planing: a comparison using files, hoes, and curets. *J Periodontol* 31:300, 1960.
16. Basu MK, Browne RM, Potts AJ, et al: A survey of aerosol-related symptoms in dental hygienists. *J Soc Occup Med* 38:23, 1988.
17. Bay N, Overman P, Krust-Bray K, et al: Effectiveness of antimicrobial mouthrinses on aerosols produced by an air polisher. *J Dent Hyg* 67:312, 1993.
18. Becker W, Berg LE, Becker BE: Long-term evaluation of periodontal treatment and maintenance in 95 patients. *Int J Periodont Restor Dent* 4:54, 1984.
19. Berkstein S, Reiff RL, McKinney JF, et al: Supragingival root surface removal during maintenance procedures utilizing an air-powder abrasive system or hand scaling: an in vitro study. *J Periodontol* 58:327, 1987.
20. Bjornson EJ, Collins DE, Engler WO: Surface alteration of composite resins after curette, ultrasonic and sonic instrumentation: an in vitro study. *Quintessence Int* 21:381, 1990.
21. Brand HS, Entjes ML, Nieuw Amerongen AV, et al: Interference of electrical dental equipment with implantable cardioverter-defibrillators. *Br Dent J* 203(10):577–579, 2007.
22. Brookshire FV, Nagy WW, Dhuru VB, et al: The qualitative effects of various types of hygiene instrumentation on commercially pure titanium and titanium alloy implant abutments: an in vitro and scanning electron microscope study. *J Prosthet Dent* 78:286, 1997.
23. Burman LR, Alderman NE, Ewen SJ: Clinical application of ultrasonic vibrations for supragingival calculus and stain removal. *J Dent Med* 13:156, 1968.
24. Cadosch J, Zimmermann U, Ruppert M, et al: Root surface debridement and endotoxin removal. *J Periodontal Res* 38:229, 2003.
25. Calabrese N, Galgut P, Mordan N: Identification of *Actinobacillus actinomycetemcomitans, Treponema denticola* and *Porphyromonas gingivalis* within human dental calculus: a pilot investigation. *J Int Acad Periodontol* 9(4):118–128, 2007.
26. Canis MF, Kramer GM, Pameijer CM: Calculus attachment: review of the literature and findings. *J Periodontol* 50:406, 1979.
27. Checchi L, Pelliccioni GA: Hand versus ultrasonic instrumentation in the removal of endotoxin from root surface in vitro. *J Periodontol* 59:398, 1998.
28. Cheetham WA, Wilson M, Kieser JB: Root surface debridement: an in vitro assessment. *J Clin Periodontol* 15:228, 1988.
29. Chen SK, Vesley D, Brosseau LM, et al: Evaluation of single-use masks and respirators for protection of health care workers against mycobacterial aerosols. *Am J Infect Control* 22:65, 1994.
30. Claffey N: Decision making in periodontal therapy: the reevaluation. *J Clin Periodontol* 18:364, 1991.
31. Clark S, Group H, Mabler D: The effect of ultrasonic instrumentation on root surfaces. *J Periodontol* 39:125, 1968.
32. Contreras A, Slots J: Active cytomegalovirus infection in human periodontitis. *Oral Microbiol Immunol* 13:225, 1998.
33. Contreras A, Slots J: Herpesviruses in human periodontal disease. *J Periodontal Res* 35:3, 2000.
34. Contreras A, Slots J: Mammalian viruses in human periodontitis. *Oral Microbiol Immunol* 11:381, 1996.
35. Contreras A, Umeda M, Chen C, et al: Relationship between herpesviruses and adult periodontitis and periodontopathic bacteria. *J Periodontol* 70:478, 1999.
36. Council on Dental Materials, Instruments and Equipment, American Dental Association: Dental units and water retraction. *J Am Dent Assoc* 16:417, 1988.
37. Copulos TA, Low SB, Walker CB, et al: Comparative analysis between a modified ultrasonic tip and hand instruments on clinical parameters of periodontal disease. *J Periodontol* 64:694, 1993.
38. Cross-Poline GN, Shaklee RL, Stach DJ: Effect of implant curets on titanium implant surfaces. *Am J Dent* 10:41, 1997.
39. Cutler BJ, Goldstein GR, Simonelli G: The effect of dental prophylaxis instruments on the surface roughness of metals used for metal ceramic crowns. *J Prosthet Dent* 73:219, 1995.
40. Dragoo MR: A clinical evaluation of hand and ultrasonic instruments on subgingival debridement. Part I. With unmodified and modified ultrasonic inserts. *Int J Periodontol* 12:311, 1992.
41. Drisko CL: Scaling and root planing without overinstrumentation: hand versus power-driven scalers. *Curr Opin Periodontol* 3:78, 1993.
42. Drisko CL, Cochran DL, Blieden T, et al: Position paper: sonic and ultrasonic scalers in periodontics. Research, Science and Therapy Committee of the American Academy of Periodontology. *J Periodontol* 71:1792, 2000.
43. Eliades GC, Tzoutzas JG, Vougiouklakis GJ: Surface alterations on dental restorative materials subjected to an air-powder abrasive instrument. *J Prosthet Dent* 65:27, 1991.
44. Fitzgibbon EJ, Bartzokas CA, Martin MV, et al: The source, frequency and extent of bacterial contamination of dental unit water systems. *Br Dent J* 157:98, 1984.
45. Fox SC, Moriarty JD, Kusy RP: The effects of scaling a titanium implant surface with metal and plastic instruments: an in vitro study. *J Periodontol* 61:485, 1990.
46. Garnick JJ, Dent J: A scanning electron micrographical study of root surfaces and subgingival bacteria after hand scaling and ultrasonic instrumentation. *J Periodontol* 60:441, 1989.
47. Garrett JS: Effects of nonsurgical periodontal therapy on periodontitis in humans: a review. *J Clin Periodontol* 10:515, 1983.
48. Green E, Ramfjord SR: Tooth roughness after subgingival root planing. *J Periodontol* 37:396, 1966.
49. Green E, Seyer PC: Sharpening curets and sickle scalers, ed 2, Berkeley, Calif, 1972, Praxis.
50. Greenstein G: Nonsurgical periodontal therapy in 2000: a literature review. *J Am Dent Assoc* 131:1580, 2000.
51. Gross A, Devine MJ, Cutright DE: Microbial contamination of dental units and ultrasonic scalers. *J Periodontol* 47:670, 1976.

52. Gross KB, Overman PR, Cobb C, et al: Aerosol generation by two ultrasonic scalers and one sonic scaler. A comparative study. *J Dent Hyg* 66:314, 1992.
53. Haffajee AD, Socransky SS: Microbial etiological agents of destructive periodontal diseases. *Periodontol 2000* 5:78, 1994.
54. Hallmon WW, Waldrop TC, Meffert RM, et al: A comparative study of the effects of metallic, nonmetallic, and sonic instrumentation on titanium abutment surfaces. *Int J Oral Maxillofac Implants* 11:96, 1996.
55. Hannan MM, Azadian BS, Gazzard BG, et al: Hospital infection control in an era of HIV infection and multi-drug resistant tuberculosis. *J Hosp Infect* 44:5, 2000.
56. Harrel SK, Barnes JB, Rivera-Hidalgo F: Reduction of aerosols produced by ultrasonic scalers. *J Periodontol* 67:28, 1996.
57. Harrel SK, Barnes JB, Rivera-Hidalgo F: Aerosol reduction during air polishing. *Quintessence Int* 30(9):623–628, 1999.
58. Harrel SK, Barnes JB, Rivera-Hidalgo F: Aerosol and splatter contamination from the operative site during ultrasonic scaling. *J Am Dent Assoc* 129:1241, 1998.
59. Hatfield CG, Baumhammers A: Cytotoxic effects of periodontally involved surfaces of human teeth. *Arch Oral Biol* 16:465, 1971.
60. Holbrook T, Low S: Power-driven scaling and polishing instruments. *Clin Dent* 3:1, 1989.
61. Holbrook T, Low S: Power-driven scaling and polishing instruments. In Hardin JF, editor: *Clarke's clinical dentistry*, Philadelphia, 1991, Lippincott.
62. Holbrook WP, Muir KF, MacPhee IT, et al: Bacteriological investigation of the aerosol from ultrasonic scalers. *Br Dent J* 144:245, 1978.
63. Hughes FJ, Smales FC: Immunohistochemical investigation of the presence and distribution of cementum-associated lipopolysaccharides in periodontal disease. *J Periodont Res* 21:660, 1986.
64. Hughes FJ, Auger DW, Smales FC: Investigation of the distribution of cementum-associated lipopolysaccharides in periodontal disease with scanning electron microscope immunohistochemistry. *J Periodontal Res* 23:100, 1988.
65. Hughes TP, Caffesse RG: Gingival changes following scaling root planing and oral hygiene: a biometric evaluation. *J Periodontol* 49:245, 1978.
66. Johnson WN, Wilson JR: The application of the ultrasonic dental units to scaling procedures. *J Periodontol* 28:24, 1957.
67. Johnson WW, Barnes CM, Covey DA, et al: The effects of a commercial aluminum airpolishing powder on dental restorative materials. *J Prosthodont* 13:166, 2004.
68. Jokit W, editor: *Zinsser's microbiology*, ed 20, Norwalk, Conn, 1992, Appleton & Lange.
69. Kaldahl WB, Kalkwarf KL, Patil KD, et al: Long-term evaluation of periodontal therapy. I. Response to 4 therapeutic modalities. *J Periodontol* 67:93, 1996.
70. Kerry GJ: Roughness of root surfaces after use of ultrasonic instruments and hand curets. *J Periodontol* 38:340, 1967.
71. Khatiblou FA, Ghodssi A: Root surface smoothness or roughness in periodontal treatment: a clinical study. *J Peridontol* 54:365, 1983.
72. Kocher T, Konig J, Hansen P, et al: Subgingival polishing compared to scaling with steel curettes: a clinical pilot study. *J Clin Periodontol* 28:194, 2001.
73. Kocher T, Langenbeck M, Ruhling A, et al: Subgingival polishing with a Teflon-coated sonic scaler insert in comparison to conventional instruments as assessed on extracted teeth. I. Residual deposits. *J Clin Periodontol* 27:243, 2000.
74. Koka S, Han J, Razzoog ME, et al: The effects of two air-powder abrasive prophylaxis systems on the surface of machined titanium: a pilot study. *Implant Dent* 1:259, 1992.
75. Kwan J, Zablotsky MH, Meffert RM: Implant maintenance using a modified ultrasonic instrument. *J Dent Hyg* 64:422, 1990.
76. Landry C, Long B, Singer D, et al: Comparison between a short and a conventional blade periodontal curet: an in vitro study. *J Clin Periodontol* 26:548, 1999.
77. Larato DC, Ruskin PF, Martin A: Effect of an ultrasonic scaler on bacterial counts in air. *J Periodontol* 38:550, 1967.
78. Lee SY, Lai YL, Morgano SM: Effects of ultrasonic scaling and periodontal curettage on surface roughness of porcelain. *J Prosthet Dent* 73:227, 1995.
79. Legnani P, Checchi L, Pelliccioni GA, et al: Atmospheric contamination during dental procedures. *Quintessence Int* 25:435, 1994.
80. Leknes KN, Lie T, Wikesjo UM, et al: Influence of tooth instrumentation roughness on subgingival microbial colonization. *J Periodontol* 65:303, 1994.
81. Leon LE, Vogel RI: A comparison of the effectiveness of hand scaling and ultrasonic debridement in furcations as evaluated by differential dark-field microscopy. *J Periodontol* 58:86, 1987.
82. Lever MS, Williams A, Bennett AM: Survival of mycobacterial species in aerosols generated from artificial saliva. *Lett Appl Microbiol* 31:238, 2000.
83. Lindhe J: Evaluation of periodontal scalers. II. Wear following standardized or diagonal cutting tests. *Odontol Rev* 17:121, 1966.
84. Lindhe J, Jacobson L: Evaluation of periodontal scalers. I. Wear following clinical use. *Odontol Rev* 17:1, 1966.
85. Lindhe J, Nyman S: Long-term maintenance of patients treated for advanced periodontal disease. *J Clin Periodontol* 11:504, 1984.
86. Lindhe J, Nyman S, Karring T: Scaling and root planing in shallow pockets. *J Clin Periodontol* 9:415, 1982.
87. Listgarten MA, Lindhe J, Hellden L: Effect of tetracycline and/or scaling on human periodontal disease: clinical microbiological and histological observations. *J Clin Periodontol* 5:246, 1978.
88. Lowenguth RA, Greenstein G: Clinical and microbiological response to nonsurgical mechanical periodontal therapy. *Periodontol 2000* 9:14, 1995.
89. Lubow RM, Cooley RL: Effect of air-powder abrasive instrument on restorative materials. *J Prosthet Dent* 55:462, 1986.
90. Magnusson I, Lindhe J, Yoneyama T, et al: Recolonization of a subgingival microbiota following scaling in deep pockets. *J Clin Periodontol* 11:193, 1984.
91. Mengel R, Buns CE, Mengel C, et al: An in vitro study of the treatment of implant surfaces with different instruments. *Int J Oral Maxillofac Implants* 13:91, 1998.
92. Michalowicz BS, Ronderos M, Camara-Silva R, et al: Human herpesviruses and Porphyromonas gingivalis are associated with juvenile periodontitis. *J Periodontol* 71:981, 2000.
93. Miller CS, Leonelli FM, Latham E: Selective interference with pacemaker activity by electrical dental devices. *Oral Surg Oral Med Oral Pathol Oral Radiol Endod* 85:33, 1998.
94. Miller RL: Characteristics of blood-containing aerosols generated by common powered dental instruments. *Am Ind Hyg Assoc J* 56:670, 1995.
95. Miller RL, Micik RE: Air pollution and its control in the dental office. *Dent Clin North Am* 22:453, 1978.
96. Miller RL, Micik RE, Abel C, et al: Studies on dental aerobiology. II. Microbial splatter discharged from the oral cavity of dental patients. *J Dent Res* 50:621, 1971.
97. Moëne R, Décaillet F, Andersen E, et al: Subgingival plaque removal using a new air-polishing device. *J Periodontol* 81(1):79–88, 2010.
98. Mongardini C, van Steenberghe D, Dekeyser C, et al: One stage full-versus partial-mouth disinfection in the treatment of chronic adult or generalized early-onset periodontitis. I. Long-term clinical observations. *J Periodontol* 70:632, 1999.
99. Moore J, Wilson M, Kieser JB: The distribution of bacterial lipopolysaccharide (endotoxin) in relation to periodontally involved root surfaces. *J Clin Periodontol* 13:748, 1986.
100. Moskow BS: Calculus attachment in cemental separations. *J Periodontol* 40:125, 1969.
101. Mousques T, Listgarten MA, Phillips RW: Effect of scaling and root planing on the composition of human subgingival microbial flora. *J Periodontal Res* 7:199, 1980.
102. Muir KF, Ross PW, MacPhee IT, et al: Reduction of microbial contamination from ultrasonic scalers. *Br Dent J* 145:760, 1978.
103. Nakib NM, Bissada NF, Simmelink JW, et al: Endotoxin penetration into root cementum of periodontally healthy and diseased human teeth. *J Periodontol* 53:368, 1982.

104. Nyman S, Westfelt E, Sarhed G, et al: Role of "diseased" root cementum in healing following treatment of periodontal disease: a clinical study. *J Clin Periodontol* 15:464, 1988.
105. Oberholzer R, Rateitschak KH: Root cleaning or root smoothing: an in vivo study. *J Clin Periodontol* 23:326, 1996.
106. O'Leary R, Sved AM, Davies EH, et al: The bactericidal effects of dental ultrasound on Actinobacillus actinomycetemcomitans and Porphyromonas gingivalis: an in vitro investigation. *J Clin Periodontol* 24:432, 1997.
107. Oosterwall PJ, Matee MI, Mikx FHM, et al: The effect of subgingival debridement with hand and ultrasonic instruments on subgingival microflora. *J Clin Periodontol* 14:528, 1987.
108. Oppenheim BA, Sefton AM, Gill ON, et al: Widespread Legionella pneumophila contamination of dental stations in a dental school without apparent human infection. *Epidemiol Infect* 99:159, 1987.
109. Orban B, Manella V: Macroscopic and microscopic study of instruments designed for root planing. *J Periodontol* 27:120, 1956.
110. Orton GS: Clinical use of an air-powder abrasive system. *Dent Hyg* 75:513, 1987.
111. Otero-Cagide FJ, Long BA: Comparative in vitro effectiveness of closed root debridement with fine instruments on specific areas of mandibular first molar furcations. I. Root trunk and furcation entrance. *J Periodontol* 68:1093, 1997.
112. Otero-Cagide FJ, Long BA: Comparative in vitro effectiveness of closed root debridement with fine instruments on specific areas of mandibular first molar furcations. I. Furcation area. *J Periodontol* 68:1098, 1997.
113. Pankhurst CL, Johnson NW, Woods RG: Microbial contamination of dental unit waterlines: the scientific argument. *Int Dent J* 48:359, 1998.
114. Paquette OE, Levin MP: The sharpening of scaling instruments. I. An examination of principles. *J Periodontol* 48:163, 1977.
115. Parr R, Green E, Madsen L, et al: Subgingival scaling and root planing, Berkeley, Calif, 1976, Praxis.
116. Pattison AM: The use of hand instruments in supportive periodontal treatment. *Periodontol 2000* 12:71, 1996.
117. Petersilka GJ, Bell M, Haberlein I, et al: In vitro evaluation of novel low abrasive air polishing powders. *J Clin Periodontol* 30:9, 2003.
118. Petersilka GJ, Bell M, Mehl A, et al: Root defects following air polishing. *J Clin Periodontol* 30:165, 2003.
119. Petersilka GJ, Flemmig TF, Mehl A, et al: Comparison of root substance removal by magnetostrictive and piezoelectric ultrasonic and sonic scalers in vitro. *J Clin Periodontol* 24:864, 1997.
120. Pihlstrom BL, McHugh RB, Oliphant TH, et al: Comparison of surgical and nonsurgical treatment of periodontal disease: a review of current studies and additional results after 6 years. *J Clin Periodontol* 10:524, 1983.
121. Proye M, Caton J, Polson A: Initial healing of periodontal pockets after a single episode of root planing monitored by controlled probing force. *J Periodontol* 53:296, 1982.
122. Quirynen M, Mongardini C, de Soete M, et al: The role of chlorhexidine in the one-stage full-mouth disinfection treatment of patients with advanced adult periodontitis: long-term clinical and microbiological observations. *J Clin Periodontol* 27:578, 2000.
123. Quirynen M, Mongardini C, Pauwels M, et al: One stage full- versus partial-mouth disinfection in the treatment of chronic adult or generalized early-onset periodontitis. II. Long-term impact on microbial load. *J Periodontol* 70:646, 1999.
124. Rajstein J, Tal M: The effects of ultrasonic scaling on the surface of Class V amalgam restorations: a scanning electron microscope study. *J Oral Rehabil* 11:299, 1984.
125. Rawson RD, Nelson BN, Jewell BD, et al: Alkalosis as a potential complication of air polishing systems: a pilot study. *Dent Hyg* 59:500, 1985.
126. Razzoog ME, Koka S: In vitro analysis of the effects of two air-abrasive prophylaxis systems and inlet air pressure on the surface of titanium abutment cylinders. *J Prosthodont* 3:103, 1994.
127. Renvert S, Wikström M, Dahlén G, et al: Effect of root debridement on the elimination of Actinobacillus actinomycetemcomitans and Bacteroides gingivalis from periodontal pockets. *J Clin Periodontol* 17:345, 1990.
128. Ritz L, Hefti AF, Rateitschak KH: An in vitro investigation on the loss of root substance in scaling with various instruments. *J Clin Peridontol* 18:643, 1991.
129. Rivera-Hidalgo F, Barnes JB, Harrel SK: Aerosol and splatter production by focused spray and standard ultrasonic inserts. *J Periodontol* 70:473, 1999.
130. Rosenberg ES, Evian CI, Listgarten M: The composition of the subgingival microbiota after periodontal therapy. *J Periodontol* 52:435, 1981.
131. Rossi R, Smukler H: A scanning electron microscope study comparing the effectiveness of different types of sharpening stones and curets. *J Peridontol* 66:956, 1995.
132. Ruhling A, Kocher T, Kreusch J, et al: Treatment of subgingival implant surfaces with Teflon-coated sonic and ultrasonic scaler tips and various implant curettes: an in vitro study. *Clin Oral Implants Res* 5:19, 1994.
133. Rutala WA, Jones SM, Worthington JM, et al: Efficacy of portable filtration units in reducing aerosolized particles in the size range of Mycobacterium tuberculosis. *Infect Control Hosp Epidemiol* 16:391, 1995.
134. Sbordone L, Ramaglia L, Guletta E, et al: Recolonization of the subgingival microflora after scaling and root planing in human periodontitis. *J Periodontol* 61:579, 1990.
135. Schaffer EM: Histologic results of root curettage on human teeth. *J Periodontol* 27:269, 1956.
136. Schenk G, Flemmig TF, Lob S, et al: Lack of antimicrobial effect on periodontopathic bacteria by ultrasonic and sonic scalers in vitro. *J Clin Periodontol* 27:116, 2000.
137. Schlageter L, Rateitschak-Pluss EM, Schwarz JP: Root surface smoothness or roughness following open debridement: an in vivo study. *J Clin Periodontol* 23:460, 1996.
138. Schwartz M: The prevention and management of the broken curet. *Compend Contin Educ Dent* 19:418, 1998.
139. Selvig KA: Attachment of plaque and calculus to tooth surfaces. *J Periodontal Res* 5:8, 1970.
140. Shiloah J, Patters M: Repopulation of periodontal pockets by microbial pathogens in the absence of supportive therapy. *J Peridontol* 67:130, 1996.
141. Shreve WB, Hoerman KC, Trautwein CA: Illness in patients following exposure to dental aerosols. *J Public Health Dent* 32:34, 1972.
142. Slots J, Mashimo P, Levine MJ, et al: Periodontal therapy in humans. I. Microbiological and clinical effects of a single course of periodontal scaling and root planing, and of adjunctive tetracycline therapy. *J Periodontol* 50:495, 1979.
143. Smart GJ, Wilson M, Davis EH, et al: The assessment of ultrasonic root surface debridement by determination of residual endotoxin levels. *J Clin Periodontol* 17:174, 1990.
144. Smith BA, Setter MS, Caffesse RG, et al: The effect of sharpening stones upon curette surface roughness. *Quintessence Int* 18:603, 1987.
145. Snyder JA, McVay JT, Brown FH, et al: The effect of air abrasive polishing on blood pH and electrolyte concentrations in healthy mongrel dogs. *J Periodontol* 64:81, 1990.
146. Stach DJ, Cross-Poline GN, Newmand SM, et al: Effect of repeated sterilization and ultrasonic cleaning on curet blades. *J Dent Hyg* 69:31, 1995.
147. Stahl SS, Slavkin HC, Yamada L, et al: Speculations about gingival repair. *J Periodontol* 43:395, 1972.
148. Stahl SS, Weiner JM, Benjamin S, et al: Soft tissue healing following curettage and root planing. *J Periodontol* 42:678, 1971.
149. Stambaugh RV: A clinician's 3-year experience with perioscopy. *Compend Contin Educ Dent* 23(11A):1061–1070, 2002.
150. Stambaugh RV, Myers G, Stambaugh RV, et al: Endoscopic visualization of the submarginal gingiva dental sulcus and tooth root surfaces. *J Periodontol* 73(4):374–382, 2002.
151. Stende GW, Schaffer EM: A comparison of ultrasonic and hand scaling. *J Periodontol* 32:312, 1961.

152. Suzuki JB, Delisle AL: Pulmonary actinomycosis of periodontal origin. *J Periodontol* 55:581, 1984.
153. Tan B, Gillam DG, Mordan NJ, et al: A preliminary investigation into the ultrastructure of dental calculus and associated bacteria. *J Clin Periodontol* 31:364, 2004.
154. Ting M, Contreras A, Slots J: Herpesvirus in localized juvenile periodontitis. *J Periodontal Res* 35:17, 2000.
155. Torfason T, Kiger R, Selvig KA, et al: Clinical improvement of gingival conditions following ultrasonic versus hand instrumentation of periodontal pockets. *J Clin Periodontol* 6:165, 1979.
156. Trenter SC, Walmsley AD: Ultrasonic dental scaler: associated hazards. *J Clin Periodontol* 30:95, 2003.
157. Umeda M, Contreras A, Chen C, et al: The utility of whole saliva to detect the oral presence of periodontopathic bacteria. *J Periodontol* 69:828, 1998.
158. Van Volkinburg J, Green E, Armitage G: The nature of root surfaces after curette, cavitron, and alpha-sonic instrumentation. *J Periodontal Res* 11:374, 1976.
159. van Winkelhoff AJ, van der Velden U, de Graaff J: Microbial succession in recolonizing deep periodontal pockets after a single course of supra- and subgingival debridement. *J Clin Periodontol* 15:116, 1988.
160. Veksler AE, Kayrouz GA, Newman MG: Reduction of salivary bacteria by pre-procedural rinses with chlorhexidine 0.12%. *J Periodontol* 62:649, 1991.
161. Vermilyea SG, Prasanna MK, Agar JR: Effect of ultrasonic cleaning and air polishing on porcelain labial margin restorations. *J Prosthet Dent* 71:447, 1994.
162. Waerhaug J: Healing of the dentoepithelial junction following subgingival plaque control. *J Periodontol* 49:1, 1978.
163. Waerhaug J, Arno A, Lovdal A: The dimension of instruments for removal of subgingival calculus. *J Periodontol* 25:281, 1954.
164. Westfelt E, Nyman S, Socransky SS, et al: Significance of frequency of professional tooth cleaning following periodontal surgery. *J Clin Periodontol* 10:148, 1983.
165. Wilkins EM: Clinical practice of the dental hygienist, ed 10, Philadelphia, 2009, Lippincott, Williams & Wilkins.
166. Wilkinson RF, Maybury J: Scanning electron microscopy of the root surface following instrumentation. *J Periodontol* 44:559, 1973.
167. Wilson TG, Carnio J, Schenk R, et al: Absence of histologic signs of chronic inflammation following closed subgingival scaling and root planing using the dental endoscope: human biopsies—a pilot study. *J Periodontol* 79(11):2036–2041, 2008.
168. Wilson TG, Harrel SK, Nunn ME, et al: The relationship between the presence of tooth-borne subgingival deposits and inflammation found with a dental endoscope. *J Periodontol* 79(11):2029–2035, 2008.
169. Ximenez-Fyvie LA, Haffajee AD, Socransky SS: Comparison of the microbiota of supra- and subgingival plaque in health and periodontitis. *J Clin Periodontol* 27:648, 2000.
170. Zander HA: The attachment of calculus to root surfaces. *J Periodontol* 24:16, 1953.
171. Zappa U, Studer M, Merkle A, et al: Effect of electrically powered dental devices on cardiac parameter function in humans. *Periodontology* 2:299, 1991.

CHAPTER 47

Sonic and Ultrasonic Instrumentation and Irrigation

Carol A. Jahn

CHAPTER OUTLINE

Mechanism of Action of Power Scalers
Type and Benefit of Power Instruments
Clinical Outcomes of Power-Driven Instruments
Special Considerations
Principles of Instrumentation
Home/Self-Applied Irrigation
Mechanism of Action of Irrigation
Clinical Outcomes of Irrigation
Individuals with Special Considerations
Conclusion

For many years, practitioners have sought ways to enhance and prolong the outcomes from scaling and root planing. In the office setting, technologic advances and new designs of ultrasonic and sonic power scalers have transformed the role of power-driven oscillating instruments in periodontal therapy. At home, the pulsating dental water has been clinically proven to help patients maintain periodontal health by removing biofilm supragingivally and subgingivally and reducing inflammation.

Mechanism of Action of Power Scalers

Various physical factors play a role in the mechanism of action of power scalers. These factors include frequency, stroke, and water flow. In addition to rate of flow, the physiologic effects of water may play a contributing role in the efficacy of power instruments.

Water contributes to three physiologic effects that play a role in the efficacy. These are acoustic streaming, acoustic turbulence, and cavitation. Acoustic steaming is the unidirectional fluid flow caused by ultrasound waves. Acoustic turbulence is created when the movement of the tip causes the coolant to accelerate, producing an intensified swirling effect. This turbulence continues until cavitation occurs. Cavitation is the formation of bubbles in water caused by the high turbulence. The bubbles implode and produce shock waves in the liquid, creating further shock waves throughout the water. In vitro, the combination of acoustic streaming, acoustic turbulence, and cavitation has been shown to disrupt microflora.[52,83-85]

Type and Benefit of Power Instruments

Sonic units work at a frequency of 2000 to 6500 cycles per second and use a high- or low-speed air source from the dental unit. Water is delivered via the same tubing used to deliver water to a dental handpiece. Sonic scaler tips are large in diameter and universal in design. A sonic scaler tip travels in an elliptical or orbital stroke pattern. This stroke pattern allows the instrument to be adapted to all tooth surfaces. Box 47-1 outlines the advantages and disadvantages of mechanized instruments as compared to manual instruments.

Magnetostrictive ultrasonic devices work in a frequency range of 18,000 to 50,000 cycles per second (Figures 47-1 and 47-2). Metal stacks that change dimension when electrical energy is applied power magnetostrictive technology. Vibrations travel from the metal stack to a connecting body that causes the vibration of the working tip. Tips move in an elliptical or orbital stroke pattern. This allows the tip four active working surfaces (Figure 47-3).

Piezoelectric ultrasonic units work in a frequency range of 18,000 to 50,000 cycles per second (Figure 47-4). They have ceramic discs that are located in the handpiece power piezoelectric technology. They change in dimension as electrical energy is applied to the tip. Piezoelectric tips move in a linear pattern, giving the tip two active surfaces (Figure 47-5). A variety of insert tip designs and shapes are available for use.

Efficiency

Power instrumentation has the potential to make scaling less demanding, more time efficient, and more ergonomically friendly. Modified tip designs allow for improved access in many areas, including furcations. Newer, slimmer designs operate effectively at lower power settings, thus improving patient comfort. Sonic and ultrasonic tips can reduce the time needed for scaling.

Tip Designs

There are tips designed to remove heavy supragingival calculus or to definitively debride periodontal pockets. Large diameter tips are created in a universal design and are indicated for the removal of large, tenacious deposits. A high power setting is generally recommended. Thinner diameter tips may be site specific in design. The straight tip design is ideal for use in treating patients with gingivitis and deplaquing maintenance patients (Figure 47-6). The right and left contra-angled instruments allow for greater access and adaptation to root morphology. These inserts are designed to work in a low power setting. They can be used for exploration. The amount

BOX 47-1 Advantages and Disadvantages of Mechanized Instruments as Compared with Manual Instruments

Advantages
Increased efficiency
Multiple surfaces of tip are capable of removing deposits
No need to sharpen
Less chance for repetitive stress injuries
Handpiece size large
Reduced lateral pressure
Less tissue distention
Water
Lavage
Irrigation
Acoustic microstreaming

Disadvantages
More precautions and limitations
Client comfort (water spraying)
Aerosol production
Temporary hearing shifts
Noise
Less tactile sensation
Reduced visibility

From Darby ML, Walsh MM: *Dental hygiene,* ed 3, Saunders, St Louis, 2010.

Figure 47-1 Magnetostrictive ultrasonic device. *(Courtesy DENTSPLY International, York, PA.)*

of water delivered for lavage can be controlled through the selection of either traditional flow or a focused tip delivery flow. Contra-angled designs and larger, ergonomic grips enhance comfort and ergonomics (Figures 47-7 and 47-8).

Clinical Outcomes of Power-Driven Instruments

Numerous clinical outcomes have been evaluated from the use of power-driven instruments. A systematic review of the literature on the treatment of chronic periodontitis found no difference in the efficacy of subgingival debridement using ultrasonic/sonic scalers versus hand instruments in the treatment of single-rooted teeth. A benefit for multirooted teeth could not be determined because of a lack of clinical data.[81] Likewise, a review by the American Academy

Figure 47-2 A magnetostrictive ultrasonic device. *(Courtesy Hu-Friedy, Chicago.)*

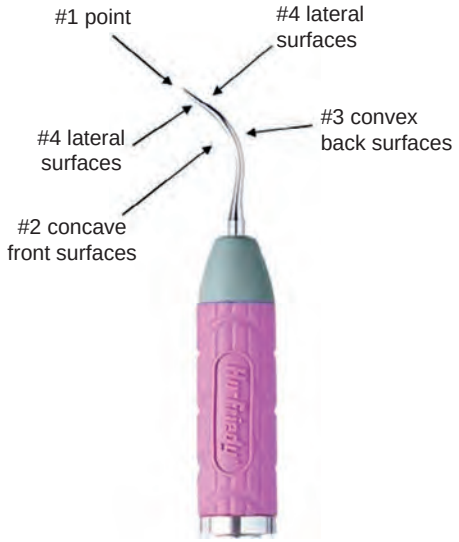

Figure 47-3 Working sides of a magnetostrictive tip. *(Courtesy Hu-Friedy, Chicago.)*

of Periodontology found no differences in outcomes between sonic, magnetostrictive, and piezoelectric scalers.[28]

It is well established that power-driven instruments remove biofilms, bacteria, and calculus through mechanical action.* With the advent of new designs and thinner tips, deplaquing of root surfaces may be effectively accomplished by power-scalers.[2,28,80] Both sonic and ultrasonic instruments have been shown to be effective in removing calculus similar to hand instrumentation.* Ultrasonic instruments through high-speed action produce a cavitational activity and acoustic microstreaming that some believe may help enhance the disruption of the bacteria in subgingival biofilms.

The primary expected clinical outcomes from scaling and root planing are a reduction in bleeding and probing depth and a gain in clinical attachment. In comparing power scalers to hand instruments, both types demonstrate similar outcomes for reductions in bleeding on probing and probing depth and gains in clinical attachment (see Table 47-1).†

*References 2, 15, 18, 27, 37, 48, 50, 53, 55, 58, 70, 71, 75, and 78.
†References 2, 5, 6, 11, 23, 25, 38, 51, 54, 55, 60, 61, 67, 68, 75, 81, 82 and 88.

Figure 47-4 A piezoelectric ultrasonic device. *(Courtesy Hu-Friedy, Chicago.)*

Figure 47-5 Working sides of a piezoelectric tip. *(Courtesy Hu-Friedy, Chicago.)*

Figure 47-6 An ultrasonic insert with universal design. *(Courtesy DENTSPLY International, York, PA.)*

Figure 47-7 Site-specific designed insert. *(Courtesy DENTSPLY International, York, PA.)*

Figure 47-8 Site-specific designed insert. *(Courtesy DENTSPLY International, York, PA.)*

Special Considerations

Furcations present one of the greatest scaling challenges. In many instances, the opening of the furcation is narrower than the conventional hand instrument. For this reason, power scalers may be recommended as a means to improve access when scaling furcations (see Table 47-2).

Aerosol Production

Universal infection control procedures can help minimize the amount of aerosol produced. Harrel and Molinari[45] recommend three levels of defense in the reduction of dental aerosols. The first recommended layer of defense is personal protective barriers such as a mask, gloves, and safety glasses. The second layer is routine use of an antiseptic preprocedural rinse. The final layer is the use of a high-speed evacuation device either by a dental assistant or attached to the instrument being used.[44] In all cases and with all patients, the Centers for Disease Control and Prevention (CDC) guidelines for infection control should be adhered to.

Cardiac Pacemakers

Newer models of cardiac pacemakers often have bipolar titanium insulation that shields the units from the effects of sonic-type devices making magnetostrictive, piezoelectric, and sonic instruments generally safe for use on people with pacemakers.[74] However, a 1998 study by Miller et al[63] found atrial and ventricular pacing was inhibited by electromagnetic interference produced by a magnetostrictive ultrasonic scaler. A sonic scaler was also tested but did not produce the same effect.[63] In light of this, as a precaution, some practitioners have advocated using only hand instruments on individuals with pacemakers.[36] There are no Food and Drug Administration (FDA) warnings or precautions on the devices that prevent them from being used on patients with pacemakers. If in doubt, consult with the physician regarding any precautions or warnings from the manufacturer of the product. Box 47-2 outlines the indications, precautions, and contraindications of using mechanized instrumentation.

Principles of Instrumentation

Ultrasonic technique is different from instrumentation with hand scalers. A modified pen grasp is used with an ultrasonic scaler along with an extraoral fulcrum (Figure 47-9). The purpose of the extraoral fulcrum is that it allows the operator to maintain a light grasp and easier access physically and visually to the oral cavity. Alternate fulcrums of cross arch or opposite arch fulcrums are acceptable alternatives.

Light pressure is needed with a power instrument. The tip is traveling at a set frequency in a set stroke pattern. Increased clinician pressure on the tip causes decreased clinical efficacy.

Sonic/ultrasonic instrumentation requires removal from the coronal to the apical portion of the deposit. This stroke pattern allows the insert to work at its optimal stroke pattern and frequency for quick effective deposit removal. A deplaquing stroke should be used when the focus is removal of biofilm and soft debris for the resolution of gingival inflammation. This stroke entails accessing every square millimeter of the tooth surface during ultrasonic deplaquing as a result of the limited lateral dispersion of the lavage subgingivally (see Videos 47-1: Pulsating Action of Jet Tip, and Video 47-2: Depth of Penetration with a Dental Water Jet).

Home/Self-Applied Irrigation

The body of evidence on the dental water jet (also called oral irrigator and water flosser) consistently has been shown to significantly

Video clip 47-1. Using the universal insert. *(Courtesy of Hu-Friedy, Chicago.)*

Video clip 47-2. Using site-specific inserts. *(Courtesy of Hu-Friedy, Chicago.)*

TABLE 47-1 Increased Understanding of the Benefits of a Dental Water Jet

Understanding of Periodontal Diseases (Approximate Years)	Significant Developments and Research in Dental Water Jet (DWJ) Technology
Nonspecific Plaque Era (1965)	
Plaque was considered to be a homogenous, toxic substance that caused gingivitis. Gingivitis could progress slowly to periodontitis. Amount of plaque and length of time plaque attached to tooth were paramount factors in disease. All plaque was considered essentially the same, and all plaque was considered bad.[62]	DWJ initially introduced to dental community in early 1960s. Clinical and laboratory studies showed the following: • DWJ is a significant aid to oral hygiene procedures.[8] • DWJ can decrease plaque formation.[39,42] • Use of DWJ significantly reduces gingivitis[20] and calculus formation as adjunct to tooth brushing.[59] • These devices do not produce bacteremia.[40,79]
Specific Plaque Hypothesis Era (1975)	
Supragingival and subgingival plaque shown to be different. Supragingival plaque begins first, then with time can grow apically and evolve into subgingival plaque, which can cause bone destruction around a tooth.[69]	Clinical studies in the 1970s through 1990s continued to show significant clinical reductions in bleeding, inflammation, and plaque formation using DWJ and marginal irrigation with water, chlorhexidine gluconate, and essential oils.*
Elevation of specific bacterial species associated with specific periodontal diseases. Periodontal pathogens are located subgingivally.[65]	Studies show that DWJ irrigation with a jet tip can reach subgingival areas inhabited by periodontal pathogens.[12,24,29,30]
Host Bacteria Interrelationship Era (1985) and Era of Periodontal Medicine (Present)	
Diabetes and other systemic diseases shown to make patient more susceptible to periodontal diseases.[41]	There is an improvement in clinical parameters in diabetic patients using DWJ and reduced inflammatory mediators over traditional routine oral hygiene regimens.[1] Moderate-to-severe periodontitis increases systemic inflammation, which is associated with cardiovascular disease and gram-negative bacteria in periodontal pockets (biofilms) have been associated with arthromas.[35] In 2009, at a consensus meeting, the *American Journal of Cardiology* and *Journal of Periodontology* issued guidelines for patients with atherosclerotic cardiovascular disease who have untreated or uncontrolled periodontitis that stated these patients should be treated with a focus on *reducing and controlling the bacterial accumulations and eliminating inflammation.*[35] Clinical benefits of oral irrigation found to be related to reduction of proinflammatory mediators in serum (i.e., reduces systemic inflammation).[26] Efficiency of DWJ irrigation at removing biofilm ex vivo and in vivo shown in scanning electron microscopy studies.[42] DWJ irrigation (along with toothbrushing) is an effective alternative to dental floss for the reduction of bleeding, gingivitis, and plaque and in some cases, may provide superior results for reducing bleeding and gingivitis.[7,73]

*References 4, 13, 16, 17, 21, 33, 34, 49, 50, 86, 87.

reduce gingivitis, bleeding on probing, and periodontal pathogens.* These oral health improvements have been demonstrated with the use of either water or an antimicrobial agent. Emerging evidence indicates the dental water jet effectively removes biofilm[39,42] and is as effective as dental floss when added to toothbrushing.[8,73,77] Table 47-1 compares the understanding of periodontal disease to significant developments in dental water jet technology.

Mechanism of Action of Irrigation

The mechanism of action of irrigation occurs through the direct application of a pulsed stream of water or other solution. Studies have found pulsation and pressure to be critical components of an irrigation device.[9,10,76] Pulsating devices have been shown to be three times as effective as a continuous-stream irrigating syringe.[76] Pulsation provides for a compression and decompression phase that may account for expedient clearing of bacteria from the pocket.[9] A pulsating device allows for control of the pressure rate. The majority of studies on home irrigation that have demonstrated clinical efficacy have been done using a dental water jet with 1200 pulsations per minute set on a medium to a high pressure setting (50 to 90 psi)[9,10,76] (Figures 47-10 and 47-11). Dental water jets with varying pulsation and pressure are available, but like other self-care products, research from one product brand should not be extrapolated to other brands since they may have used a different pressure setting and pulsation rate.

A pulsation rate of 1200 per minute has been shown to create two zones of hydrokinetic activity[24]: the impact zone, in which the solution initially contacts, and the flushing zone, in which the solution reaches into the subgingival sulcus[43] (Figure 47-12). The outcome of hydrokinetic activity is subgingival penetration.

Home irrigation has been demonstrated to penetrate subgingivally with both a jet tip[30] (Figure 47-13) and a soft, site-specific, subgingival tip[14] (Pik Pocket subgingival irrigation tip, Water Pik, Inc., Fort Collins, CO) (Figure 47-14). Supragingival irrigation is irrigation with a jet tip placed above the gingival margin resulting in penetration of a solution into the subgingival sulcus to approximately 50% (Video clips 47-3 and 47-4).[12,30]

*References 1, 4, 8, 13, 16, 17, 19-21, 22, 24, 26, 29, 31, 33, 34, 46, 49, 50, 57, 59, 64, 66, 72, 73,77, 86, and 87.

Video clip 47-3. Pulsating action of a jet tip. *(Animation courtesy of Water Pik, Inc., Fort Collins, CO.)*

Video clip 47-4. Depth of penetration with a dental water jet. *(Animation courtesy of Water Pik, Inc., Fort Collins, CO.)*

TABLE 47-2 Reduction of Inflammation and Plaque Biofilm

Study	Duration	*N*	Agent Used	% Bleeding Reduction	% Gingivitis Reduction	% Plaque Biofilm Reduction
Al-Mubarak et al[1]	3 months	50	Water	43.8	66.9	64.9
Barnes et al[8]	4 weeks	105	Water	36.2-59.2	10.8-15.1	8.8-17.3
Brownstein et al[16]	8 weeks	44	CHX (0.06%)	52-59	25.4-31.1*	14.3-19*
			Water	NR		NR
Burch et al[17]	2 months	47	Water	57.1-76.6	NR	52-55.7
Chaves et al[20]	6 months	105	CHX (0.04%)	54	26	35
			Water	50	26	16
Ciancio et al[21]	6 weeks	61	Essential oils†	27.6	54-55.7	23-24
			Water and alcohol 5%	13.6-31.2	59.8-61.9	9/6-13.3
Cutler et al[26]	2 weeks	52	Water	56	50	40
Flemmig et al[34]	6 months	175	CHX (0.06%)	35.4	42.5	53.2
			Water	24	23.1	0.1
Flemmig et al[33]	6 months	60	Acetylsalicylic acid 3%		8.9	55.6
			Water	50	29.2	0
Felo et al[31]	3 months	24	CHX (0.06%)	62	45	29
Fine et al[32]	6 weeks	50	Essential oils†	14.8-21.7	NR	36.8-37.7
			Water	7.5-10.6	NR	15.5-18.4
Jolkovsky et al[50]	3 months	58	CHX (0.4%)	NR	33.1	51.6
			Water	NR	18.6	25.6
Lobene et al[59]	5 months	155	Water	NR	52.9	7.9
Newman et al[64]	6 months	155	Water	22.8	17.8	6.1
			Water and zinc sulfate (0.57%)	8.8	6.5	9.2
Rosema et al[73]	30 days	104	Water	17%	NR	?
Sharma et al[77]	4 weeks	128	Water	84.5	NR	38.9
Walsh et al[86]	8 weeks	8	CHX (0.2%)	NR	45	77
			Quinine salt	NR	14	0

CHX, Chlorhexidine; *NR,* not reported.

*Percentages were reported for differences between CHX and water irrigation groups.

†Reported the range for prophy and nonprophy groups.

Data from Cianco SG: *Compendium Contin Educ Dent* 30:7-14, 2009.

The jet tip is generally used for full-mouth irrigation. Recently, other types of supragingival tips enhanced with soft, tapered bristles (Figure 47-15) have been introduced and shown to be effective in increasing the removal of plaque.[42,73,77] Irrigation with the soft, site-specific tip is called *subgingival irrigation.* This refers to the placement of the tip, which is placed slightly below the gingival margin (Figure 47-16). The subgingival tip is used for the localized irrigation of a specific site such as a deep pocket, furcation, implant, or crown and bridge. Studies with this site-specific, subgingival tip show that it can deliver a solution into a pocket of 6 mm or less up to 90% of its depth.[14] In pockets deeper than 6 mm, the depth of penetration has been shown to be 64%.[14]

Safety

Concerns regarding the safety of oral irrigation with regard to soft tissue damage and penetration of bacteria into the pocket have been voiced; although no scientific evidence exists to support these claims. Several investigators have evaluated the soft tissue and found no trauma or adverse reaction from using a pulsating oral irrigator. Researchers have found that irrigation reduces the amount of bacteria in the gingival crevice or periodontal pocket.* Specifically, Cobb et al[24] and Drisko et al[29] found that bacteria was reduced up to 6 mm.

*References 16, 20, 21, 24, 29, 34, 49, 50, and 66.

Clinical Outcomes of Irrigation

Table 47-2 highlights the body of evidence on the dental water jet. Evaluated outcomes include removal of plaque biofilm and reductions in calculus, gingivitis, bleeding on probing, probing depth, periodontal pathogens, and inflammatory mediators.* Home irrigation has been studied and found safe and effective for those with gingivitis,† implants,[31] crown and bridge,[56] orthodontics,[17,49,77] intermaxillary fixation,[72] and diabetes[1]; patients who are noncompliant with dental floss[7,73]; and in periodontal maintenance.‡

Early studies found that irrigation with water leads to a reduction in calculus[46,59]: up to as much as 50% over brushing alone.[59] A study conducted with the scanning electron microscope found that a 3-second pulsating lavage at a 60 psi with either a jet tip or small brush tip removed 99% of plaque biofilm[42] (Figures 47-17 and 47-18). A single-use study that compared irrigation to string floss in addition each in addition to manual brushing found irrigation to be 29% more effective at whole mouth plaque removal.[39]

As early as the 1960s, it was shown that oral irrigation with water added to toothbrushing reduced gingivitis by 52% compared

*References 1, 4, 8, 13, 16, 17, 20, 21, 26, 31-34, 46, 47, 49, 56, 59, 64, 72, 77, 86, and 87.

†References 16, 20, 21, 34, and 59.

‡References 26, 32, 33, 50, 64, and 86.

BOX 47-2 Indications, Precautions, and Contraindications for Use of Mechanized Instruments

Indications

- Supragingival debridement of dental calculus and extrinsic stain
- Subgingival debridement of calculus, oral biofilm, root surface constituents, and periodontal pathogens
- Removal of orthodontic cement
- Gingival and periodontal conditions and diseases
- Surgical interventions
- Margination (reduces amalgam overhangs)

Precautions

- Unshielded pacemakers
- Infectious diseases: human immunodeficiency virus, hepatitis, tuberculosis (active stages)
- Demineralized tooth surface
- Exposed dentin (especially associated with sensitivity)
- Restorative materials (porcelain, amalgam, gold, composite)
- Titanium implant abutments unless using special insert, e.g., Quixonic SofTip Prophy Tips
- Children (primary teeth)
- Immunosuppression from disease or chemotherapy
- Uncontrolled diabetes mellitus

Contraindications

- Chronic pulmonary disease: asthma, emphysema, cystic fibrosis, pneumonia
- Cardiovascular disease with secondary pulmonary disease
- Swallowing difficulty (dysphagia)

From Darby ML, Walsh MM: *Dental hygiene,* ed 3, Saunders, St Louis, 2010.

Figure 47-9 Modified pen grasp with tip. *(Courtesy Hu-Friedy, Chicago.)*

to a 30% reduction for toothbrushing alone.[59] Throughout the years, other researchers have found concurring results with the use of plain water.[§] The use of an antimicrobial agent, such as diluted chlorhexidine (Table 47-3), or an essential oil, generally enhances reductions in gingivitis and bleeding.*

Emerging evidence indicates that home irrigation may play a role in modulating the host response, particularly the inflammatory mediators associated with clinical attachment loss and alveolar bone loss.[1,26] This evidence lends support to the safety of irrigation, as well as its potential for helping periodontal maintenance patients maintain stability.

[§]References 1, 8, 20, 26, 34, 46, 47, 59, 64, and 77.
*References 4, 16, 20, 21, 31-34, 50, and 86.

Figure 47-10 A dental water jet with 1200 ppm and a pressure setting that ranges from 20 to 90 psi. *(Courtesy Water Pik, Inc., Fort Collins, CO.)*

Figure 47-11 A cordless dental water jet, which also has 1200 ppm. *(Courtesy Water Pik, Inc., Fort Collins, CO.)*

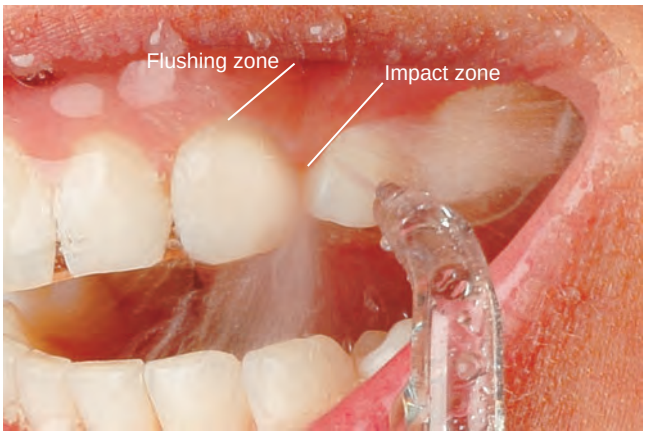

Figure 47-12 Pulsation creates two zones of hydrokinetic activity: the impact zone and the flushing zone. *(Courtesy Water Pik, Inc., Fort Collins, CO.)*

Figure 47-13 Jet tip. *(Courtesy Water Pik, Inc., Fort Collins, CO.)*

Figure 47-14 Site-specific tip. *(Courtesy Water Pik, Inc., Fort Collins, CO.)*

Figure 47-15 Tip with soft tapered bristles. *(Courtesy Water Pik, Inc., Fort Collins, CO.)*

Figure 47-16 The Pik Pocket tip is gently placed slightly subgingivally. *(Courtesy Water Pik, Inc., Fort Collins, CO.)*

Figure 47-17 The use of the Pik Pocket tip around an implant. *(Courtesy Water Pik, Inc., Fort Collins, CO.)*



Figure 47-18 Control tooth with no irrigation. *(Courtesy Water Pik, Inc., Fort Collins, CO.)*

TABLE 47-3 Chlorhexidine Dilutions (Based on 0.12% Concentration) Shown Effective in Clinical Trials

Concentrations	Amount of Water	Amount of Chlorhexidine
0.02%[3,86]	5 parts	1 part
0.04%[20,50]	3 parts	1 part
0.06%[16,31,34,66]	1 part	1 part

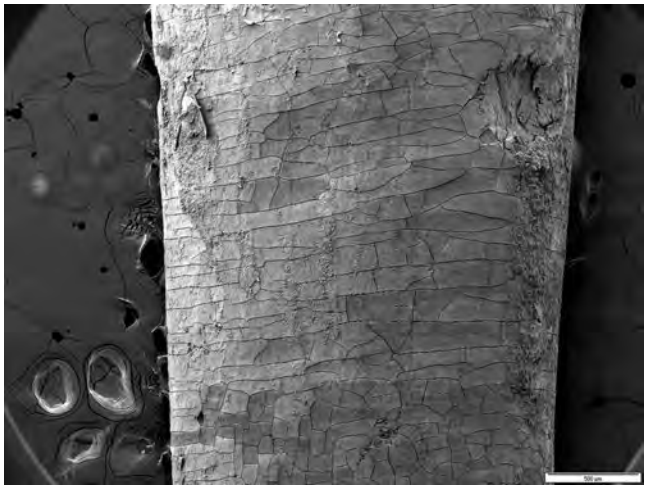

Figure 47-19 Tooth after a 3-second pulsating lavage with a jet tip at medium pressure. *(Courtesy Water Pik, Inc., Fort Collins, CO.)*

Individuals with Special Considerations

Some clinical trials have focused on groups with special oral or medical health needs. Both children and adults undergoing orthodontic therapy have shown significant benefits from using a dental water jet.[17,77] A new, small brush tip that cleans and irrigates simultaneously has been shown to remove 3.76 times more plaque than brushing and flossing with a floss threader.[77] For individuals with implants, a soft, site-specific subgingival tip used with 0.06% chlorhexidine improved oral health better than rinsing with 0.12% chlorhexidine[31] (Figure 47-19). For those with special medical considerations, home irrigation has been studied and shown safe and effective in a group of individuals with either type 1 or type 2 diabetes.[1]

Conclusion

Power scalers have emerged from adjuncts for removing heavy supragingival calculus to a tool that may be used for all aspects of scaling: deplaquing, supragingival scaling, and subgingival scaling. The clinical outcomes achieved are similar to those for hand instrumentation. The advantages gained from using power instruments are potentially greater access subgingivally and in furcation areas and increased efficiency in time needed for scaling.

Home irrigation is safe and effective for a wide variety of patients, including those in periodontal maintenance; those with calculus buildup, gingivitis, orthodontic appliances, maxillary fixation, crown and bridge, implants, and diabetes; and those who are noncompliant with floss. Clinical outcomes include the reduction of plaque, calculus, gingivitis, bleeding on probing, probing depth, periodontal pathogens, and inflammatory mediators.

Suggested Readings

Arabaci T, Cicek Y, Canakci CF: Sonic and ultrasonic scalers in periodontal treatment: a review. *Int J Dent Hygiene* 5:2, 2007.

Ciancio SG: The dental water jet: a product ahead of its time. *Compend Contin Educ Dent* 30(special 1):7, 2009.

Cobb CM, Rodgers RL, Killoy WJ: Ultrastructural examination of human periodontal pockets following the use of an oral irrigation device in vivo. *J Periodontol* 59:155, 1988.

Drisko C: Academy report: sonic and ultrasonic scalers in periodontics. *J Periodontol* 71:1792, 2000.

Gorur A, Lyle DM, Schaudinn C: Biofilm removal with a dental water jet. *Compend Contin Educ Dent* 30(special issue 1):1–6, 2009.

Harrel SK, Barnes JB, Rivera-Hidalgo F: Reduction of aerosols produced by ultrasonic scalers. *J Periodontol* 67:28, 1996.

Khambay BS, Walmsley AD: Acoustic microstreaming: detection and measurement around ultrasonic scalers. *J Periodontol* 70:626, 1999.

Newman MG, Cattabriga M, Etienne D, et al: Effectiveness of adjunctive irrigation in early periodontitis: multi-center evaluation. *J Periodontol* 65:224, 1994.

Obeid PR, D'Hoore W, Bercy P: Comparative clinical responses related to the use of various periodontal instrumentation. *J Clin Periodontol* 31:193, 2004.

Rosema NAM, Hennequin Hoenderdos NL, Berchier CE et al: The effect of different interdental cleaning devices on gingival bleeding. *J Int Acad Periodontol* 13:2–10, 2011.

References

References for this chapter are found on the companion website www.expertconsult.com.

References

1. Al-Mubarek S, Ciancio S, Aljada A, et al: Comparative evaluation of adjunctive oral irrigation in diabetics. *J Clin Periodontol* 29:295, 2002.
2. Arabaci T, Cicek Y, Canakci CF: Sonic and ultrasonic scalers in periodontal treatment: a review. *Int J Dent Hygiene* 5:2, 2007.
3. Auplish G, Needleman IG, Moles DR, et al: Diamond-coated sonic tips are more efficient for open debridement of molar furcations. A comparative manikin study. *J Clin Periodontol* 27:302, 2000.
4. Aziz-Gandour IA, Newman HN: The effects of simplified oral hygiene regime plus supragingival irrigation with chlorhexidine or metronidazole on chronic inflammatory periodontal disease. *J Clin Periodontol* 13:228, 1986.
5. Badersten A, Nilveus R, Egelberg J: Effect of nonsurgical periodontal therapy. I. Moderately advanced periodontitis. *J Clin Periodontol* 8:57, 1981.
6. Badersten A, Nilveus R, Egelberg J: Effect of nonsurgical periodontal therapy. II. Severely advanced periodontitis. *J Clin Periodontol* 11:63, 1984.
7. Baehni P, Thilo B, Chapuis B, et al: Effects of ultrasonic and sonic scalers on dental plaque microflora in vitro and in vivo. *J Clin Periodontol* 19:455, 1992.
8. Barnes CM, Russell CM, Reinhardt RA, et al: Comparison of irrigation to floss as an adjunct to tooth brushing: effect on bleeding, gingivitis, and supragingival plaque. *J Clin Dent* 16:71–77, 2005.
9. Bhaskar SN, Cutright DE, Gross A, et al: Water jet devices in dental practice. *J Periodontol* 42:593, 1971.
10. Bhaskar SN, Cutright DE, Frisch J: Effect of high-pressure water jet on oral mucosa of varied density. *J Periodontol* 40:593, 1969.
11. Boretti G, Zappa U, Graf H, et al: Short-term effects of phase I therapy on crevicular cell populations. *J Periodontol* 66:235, 1995.
12. Boyd RL, Hollander BN, Eakle WS: Comparison of a subgingivally placed cannula oral irrigator tip with a supragingivally placed standard irrigator tip. *J Clin Periodontol* 19:340, 1992.
13. Boyd RL, Leggott R, Quinn S, et al: Effect of self-administrated daily irrigation with 0.03% SnF2 on periodontal disease activity. *J Clin Periodontol* 12:420, 1985.
14. Braun RE, Ciancio SG: Subgingival delivery by an oral irrigation device. *J Periodontol* 63:469, 1992.
15. Breininger DR, O'Leary TJ, Blumenshine RV: Comparative effectiveness of ultrasonic and hand scaling for the removal of subgingival calculus. *J Periodontol* 58:9, 1987.
16. Brownstein CN, Briggs SD, Schweitzer KL, et al: Irrigation with chlorhexidine to resolve naturally occurring gingivitis: a methodologic study. *J Clin Periodontol* 17:588, 1990.
17. Burch JG, Lanese R, Ngan P: A two-month study of the effects of oral irrigation and automatic toothbrush use in an adult orthodontic population with fixed appliances. *Am J Orthod Dentofac Orthop* 106:121, 1994.
18. Busslinger A, Lampe K, Beuchat M, et al: A comparative in vitro study of a magnetostrictive and a piezoelectric ultrasonic scaling instrument. *J Clin Periodontol* 28:642, 2001.
19. Cantor MT, Stahl SS: Interdental col tissue responses to the use of water pressure cleansing device. *J Periodontol* 40:292, 1969.
20. Chaves ES, Kornman KS, Manwell MA, et al: Mechanism of irrigation effects on gingivitis. *J Periodontol* 65:1016, 1994.
21. Ciancio SG, Mather ML, Zambon JJ, et al: Effect of a chemotherapeutic agent delivered by an oral irrigation device on plaque, gingivitis, and subgingival microflora. *J Periodontol* 60:310, 1989.
22. Ciancio SG: The dental water jet: a product ahead of its time. *Compend Contin Educ Dent* 30(special 1):7, 2009.
23. Clifford LR, Needleman IG, Chan YK: Comparison of periodontal pocket penetration by conventional and microultrasonic inserts. *J Clin Periodontol* 26:124, 1996.
24. Cobb CM, Rodgers RL, Killoy WJ: Ultrastructural examination of human periodontal pockets following the use of an oral irrigation device in vivo. *J Periodontol* 59:155, 1988.
25. Copulos TA, Low SB, Walker CB, et al: Comparative analysis between a modified ultrasonic tip and hand instruments on clinical parameters of periodontal disease. *J Periodontol* 64:694, 1993.
26. Cutler CW, Stanford TW, Cederberg A, et al: Clinical benefits of oral irrigation for periodontitis are related to reduction of pro-inflammatory cytokine levels and plaque. *J Clin Periodontol* 27:134, 2000.
27. Dragoo M: A clinical evaluation of hand and ultrasonic instruments on subgingival debridement. I. With unmodified and modified ultrasonic inserts. *Int J Perio Res Dent* 12:311, 1992.
28. Drisko C: Academy report: sonic and ultrasonic scalers in periodontics. *J Periodontol* 71:1792, 2000.
29. Drisko C, White C, Killoy W, et al: Comparison of dark-field microscopy and a flagella stain for monitoring the effect of a Water Pik on bacterial motility. *J Periodontol* 58:381, 1987.
30. Eakle WS, Ford C, Boyd RL: Depth of penetration in periodontal pockets with oral irrigation. *J Clin Periodontol* 13:39, 1986.
31. Felo A, Shibly O, Ciancio SG, et al: Effects of subgingival chlorhexidine irrigation on perio-implant maintenance. *Am J Dent* 10:107, 1997.
32. Fine JB, Harper S, Gordon JM, et al: Short-term microbiological and clinical effects of subgingival irrigation with an antimicrobial mouthrinse. *J Periodontol* 65:30, 1994.
33. Flemmig TF, Epp B, Funkenhauser Z, et al: Adjunctive supragingival irrigation with acetylsalicylic acid in periodontal supportive therapy. *J Clin Periodontol* 22:427, 1995.
34. Flemmig TF, Newman MG, Doherty FM, et al: Supragingival irrigation with 0.06% chlorhexidine in naturally occurring gingivitis I. 6 month clinical observations. *J Periodontol* 61:112, 1990.
35. Friedewalk VE, Kornman KS, Beck JD, et al: The American Journal of Cardiology and Journal of Periodontology Editors' Consensus: periodontitis and atherosclerotic cardiovascular disease. *J Periodontol* 80:1021, 2009.
36. Friedlander AH, Yoshikawa TT, Change DS, et al: Atrial fibrillation: pathogenesis, medical-surgical management and dental implications. *J Am Dent Assoc* 140:167, 2009.
37. Gagnot G, Mora F, Poblete MG, et al: Comparative study of manual and ultrasonic instrumentation of cementum surfaces: influence of lateral pressure. *Int J Periodontics Restorative Dent* 24:137, 2004.
38. Garnick JJ, Dent J: A scanning electron micrographical study of root surfaces and subgingival bacteria after hand and ultrasonic instrumentation. *J Periodontol* 60:441, 1989.
39. Goyal CR, Lyle DM, Qaqish JG, et al: Evaluation of the plaque removal efficacy of a water flosser compared to string floss in adults after a single use. *J Clin Dent* 24:37–42, 2013.
40. Gross A, Bhaskar SN, Cutright DE: A study of bacteremia after wound lavage. *Oral Surg* 31:720, 1971.
41. Grossi SG, Skrepcinski FB, DeCaro T, et al: Treatment of periodontal disease in diabetics reduces glycated hemoglobin. *J Periodontol* 68:713, 1997.
42. Gorur A, Lyle DM, Schaudinn C: Biofilm removal with a dental water jet. *Compend Contin Educ Dent* 30(special1):1–6, 2009.
43. Greenstein G: Supragingival and subgingival irrigation: practical application in the treatment of periodontal diseases. *Compend Contin Educ Dent* 12:1098, 1992.
44. Harrel SK, Barnes JB, Rivera-Hidalgo F: Reduction of aerosols produced by ultrasonic scalers. *J Periodontol* 67:28, 1996.
45. Harrel SK, Molinari J: Aerosols and splatter in dentistry: a brief review of the literature and infection control implications. *J Am Dent Assoc* 135:429, 2004.
46. Hoover DR, Robinson HBG: The comparative effectiveness of a pulsating oral irrigator as an adjunct in maintaining oral health. *J Periodontol* 42:37, 1971.
47. Hugoson A: Effect of the Water Pik device on plaque accumulation and development of gingivitis. *J Clin Periodontol* 5:95, 1978.
48. Hunter RK, O'Leary TJ, Kafrawy AH: The effectiveness of hand versus ultrasonic instrumentation in open flap root planing. *J Periodontol* 697:1984.
49. Hurst JE, Macedonia JV: The effect of an oral irrigating device on the oral hygiene of orthodontic patients. *J Am Dent Assoc* 81:678, 1970.

50. Jolkovsky DL, Waki M, Newman MG, et al: Clinical and microbiological effects of subgingival and gingival marginal irrigation with chlorhexidine gluconate. *J Periodontol* 61:663, 1990.
51. Jotikasthira NE, Lie T, Leknes KN: Comparative in vitro studies of sonic, ultrasonic, and reciprocating scaling instruments. *J Clin Periodontol* 19:560, 1992.
52. Khambay BS, Walmsley AD: Acoustic microstreaming: detection and measurement around ultrasonic scalers. *J Periodontol* 70:626, 1999.
53. Kocher T, Konig J, Hansen P, et al: Subgingival polishing compared to scaling with steel curettes: a clinical pilot study. *J Clin Periodontol* 28:194, 2001.
54. Kocher T, Plagmann HC: Root debridement of molars with furcations involvement using diamond-coated sonic scaler inserts during flap surgery—a pilot study. *J Clin Periodontol* 26:525, 1999.
55. Kocher T, Ruhling A, Momsen H, et al: Effectiveness of subgingival instrumentation with power driven instruments in the hands of experienced and inexperienced operators: a study on manikins. *J Clin Periodontol* 24:498, 1997.
56. Krajewski J, Giblin J, Gargiulo AW: Evaluation of a water pressure-cleansing device as an adjunct to periodontal treatment. *Periodontics* 2:76, 1964.
57. Lainson PA, Bergquist JJ, Fraleigh CM: A longitudinal study of pulsating water pressure cleansing devices. *J Periodontol* 43:444, 1972.
58. Lie T, Leknes KN: Evaluation of the effect on root surfaces of air turbine scalers and ultrasonic instrumentation. *J Periodontol* 56:522, 1985.
59. Lobene RR: The effect of a pulsed water pressure-cleansing device on oral health. *J Periodontol* 40:51, 1969.
60. Loos B, Kiger R, Egelberg J: An evaluation of basic periodontal therapy using sonic and ultrasonic scalers. *J Clin Periodontol* 14:29, 1987.
61. Loos B, Nylund K, Claffey N, et al: Clinical effects of root debridement in molar and non-molar teeth: a 2-year follow-up. *J Clin Periodontol* 16:498, 1989.
62. Maynard G: *Eras in Periodontology. Periodontology disease management. A publication based on presentations at Periodontal Disease Management: A Conference for the Dental Team, Boston Massachusetts, July 1993*, Chicago, IL, 1994, American Academy of Periodontology.
63. Miller CS, Leonelli FM, Latham E: Selective interference with pacemaker activity by electrical dental devices. *Oral Surg Oral Med Oral Pathol Oral Radio Endod* 85:33, 1998.
64. Newman MG, Cattabriga M, Etienne D, et al: Effectiveness of adjunctive irrigation in early periodontitis: multi-center evaluation. *J Periodontol* 65:224, 1994.
65. Newman MG, Socransky SS: Predominant cultivable microflora in periodontosis. *J Periodontol Res* 12:120, 1977.
66. Newman MG, Flemmig TF, Nachnani S, et al: Irrigation with 0.06% chlorhexidine in naturally occurring gingivitis. II. 6 months microbiological observations. *J Periodontol* 61:427, 1990.
67. Obeid PR, D'Hoore W, Bercy P: Comparative clinical responses related to the use of various periodontal instrumentation. *J Clin Periodontol* 31:193, 2004.
68. Oosterwaal PJ, Matee MI, Mikx FH, et al: The effect of subgingival debridement with hand and ultrasonic instruments on the subgingival microflora. *J Clin Periodontol* 14:528, 1987.
69. Page RC, Schroeder HC: Pathogenesis of inflammatory periodontal disease. A summary of current work. *Lab Invest* 33:235, 1976.
70. Patterson M, Eick JD, Eberhart AB, et al: The effectiveness of two sonic and two ultrasonic scaler tips in furcations. *J Periodontol* 60:325, 1989.
71. Petersilka GJ, Draenert M, Mehl A, et al: Safety and efficiency of novel sonic scaler tips in vitro. *J Clin Periodontol* 30:551, 2003.
72. Phelps-Sandall BA, Oxford SJ: Effectiveness of oral hygiene techniques on plaque and gingivitis in patients placed in intermaxillary fixation. *Oral Surg Oral Med Oral Path* 56:487, 1983.
73. Rosema NAM, Hennequin Hoenderdos NL, Berchier CE, et al: The effect of different interdental cleaning devices on gingival bleeding. *J Int Acad Periodontol* 13:2–10, 2011.
74. Rees T: Academy report: Periodontal management of patients with cardiovascular diseases. *J Periodontol* 73:954, 2002.
75. Sculean A, Schwarz F, Berakdar M, et al: Non-surgical periodontal treatment with a new ultrasonic device (Vector™—ultrasonic system) or hand instruments: a prospective, controlled clinical study. *J Clin Periodontol* 31:428, 2004.
76. Selting WJ, Bhaskar SN, Mueller RP: Water jet direction and periodontal pocket debridement. *J Periodontol* 43:569, 1972.
77. Sharma NC, Lyle DM, Qaquish JG, et al: Effect of a dental water jet with orthodontic tip on plaque and bleeding in adolescent patients with fixed orthodontic appliances. *Am J Orthod Dentofacial Orthop* 133:565–571, 2008.
78. Sherman PR, Hutchens LH, Jewson LG, et al: The effectiveness of subgingival scaling and root planing, I. Clinical detection of residual calculus. *J Periodontol* 61:65, 1990.
79. Tamimi GA, Thomassen PR, Moser EH: Bacteremia study using a water irrigation device. *J Periodontol* 40:424, 1969.
80. Thornton S, Garnick J: Comparison of ultrasonic to hand instruments in the removal of subgingival plaque. *J Periodontol* 53:35, 1982.
81. Torfason T, Kiger R, Selvig A, et al: Clinical improvement of gingival conditions following ultrasonic versus hand instrumentation of periodontal pockets. *J Clin Periodontol* 6:165, 1979.
82. Tunkel J, Heinecke A, Flemmig TF: A systematic review of efficacy of machine-driven and manual subgingival debridement in the treatment of chronic periodontitis. *J Clin Periodontol* 29(Suppl 3):72, 2002.
83. Walmsley AD, Laird WR, Williams AR: Dental plaque removal by cavitational activity during ultrasonic scaling. *J Clin Periodontol* 15:539, 1988.
84. Walmsley AD, Laird WR, Williams AR: A model system to demonstrate the role of cavitational activity in ultrasonic scaling. *J Dent Res* 63:62, 1984.
85. Walmsley AD, Walsh TF, Laird WRE, et al: Effects of cavitational activity on the root surface of teeth during ultrasonic scaling. *J Clin Periodontol* 17:306, 1990.
86. Walsh TF, Glenwright HD, Hull PS: Clinical effects of pulsed oral irrigation with 0.0% chlorhexidine digluconate in patients with adult periodontitis. *J Clin Periodontol* 19:245, 1992.
87. Wolff LF, Bakdash MB, Pihlstrom BL, et al: The effect of professional and home subgingival irrigation with antimicrobial agents on gingivitis and early periodontitis. *J Dent Hyg* 63:224, 1989.
88. Yukna RA, Scott JB, Aichelmann-Reidy ME, et al: Clinical evaluation of the speed and effectiveness of subgingival calculus removal on single-rooted teeth with diamond-coated ultrasonic tips. *J Clin Periodontol* 68:436, 1997.

CHAPTER 48

Anti-infective Therapy

Sebastian G. Ciancio and Angelo Mariotti

CHAPTER OUTLINE

Definitions
Systemic Administration of Antibiotics
Serial and Combination Antibiotic Therapy
Local Delivery Agents
Overview of Local Delivery of Antimicrobial Agents and Periimplant Mucositis/Implantitis
Conclusion

SYSTEMIC ADMINISTRATION OF ANTIBIOTICS
Tetracyclines
Metronidazole
Penicillins
Cephalosporins
Clindamycin
Ciprofloxacin
Macrolides

LOCAL DELIVERY AGENTS
Subgingival Chlorhexidine
Tetracycline-Containing Fibers
Subgingival Doxycycline
Subgingival Minocycline
Subgingival Metronidazole

It is well established that the various periodontal diseases are caused by bacterial infection. Bacteria begin reattaching to the crowns of teeth soon after the teeth have been cleaned and begin to form a *biofilm.* Over time, this supragingival plaque biofilm becomes more complex, which leads to a succession of bacteria that are more pathogenic. Bacteria grow in an apical direction and become subgingival. Eventually, as bone is destroyed, a periodontal pocket is formed. In a periodontal pocket, the bacteria form a highly structured and complex biofilm. As this process continues, the bacterial biofilm extends so far subgingivally that the patient cannot reach it during oral hygiene efforts. In addition, this complex biofilm may now offer some protection from the host's immunologic mechanisms in the periodontal pocket as well as from antibiotics used for treatment. It has been suggested that an antibiotic strength that is 500 times greater than the usual therapeutic dose may be needed to be effective against bacteria that have become arranged in biofilms.[40]

It is therefore logical to treat periodontal pockets via the mechanical removal of local factors (including the calculus that harbors bacteria) and also by the disruption of the subgingival plaque biofilm itself. Mechanical removal includes manual instrumentation (e.g., scaling and root planing) and machine-driven instrumentation (e.g., ultrasonic scalers), and these procedures can be considered "anti-infective therapy." Many chemotherapeutic agents are now available to clinicians who treat periodontal diseases. *Systemic* anti-infective therapy (oral antibiotics) and *local* anti-infective therapy (placing anti-infective agents directly into the periodontal pocket) can reduce the bacterial challenge to the periodontium. It is also possible that systemically administered nonsteroidal anti-inflammatory agents may play a role in future adjunctive therapy.[68,93]

Bacteria and their toxic products cause a loss of attachment and a loss of bone. Ultimately, however, the host's own immunologic response to this bacterial infection can cause even more bone destruction (i.e., indirect bone loss) than that caused by pathogenic bacteria and their by-products. This immunologic response can be influenced by environmental (e.g., tobacco use), acquired (e.g., systemic disease), and genetic risk factors.[77] Chemotherapeutic agents can modulate the host's immune response to bacteria and reduce the host's self-destructive immunologic response to bacterial pathogens, thereby reducing bone loss.[71,72,75] It is also incumbent on health care providers to counsel patients about the detrimental effects of systemic factors, including medications, stress, and tobacco use.[40]

This chapter reviews the indications and protocols for optimizing the use of anti-infective agents during the treatment of periodontal diseases.

It is important to note that significant work has been performed with the use of a systematic *evidence-based approach* to evaluate the various anti-infective and host modulation therapies[99] (see Chapters 78 and 79). The meta-analysis of similar research studies has given power to statistical analysis to evaluate anti-infective chemotherapeutic agents for the treatment of periodontal diseases. Unfortunately, a standardized research protocol has not yet been implemented. As a result, some studies—although relevant—have not been used in the evidence-based approach because of their study design. Further evidence-based and similar research is needed to define protocols more precisely for the use of anti-infective agents to treat periodontal diseases.

Definitions

An anti-infective agent is a *chemotherapeutic agent* that acts by reducing the number of bacteria present. An antibiotic is a naturally

TABLE 48-1 Antibiotics Used to Treat Periodontal Diseases

Category	Agent	Major Features
Penicillin*	Amoxicillin	Extended spectrum of antimicrobial activity; excellent oral absorption; used systemically
	Augmentin†	Effective against penicillinase-producing microorganisms; used systemically
Tetracyclines	Minocycline	Effective against a broad spectrum of microorganisms; used systemically and applied locally (subgingivally)
	Doxycycline	
	Tetracycline	Effective against a broad spectrum of microorganisms; used systemically and applied locally (subgingivally)
		Chemotherapeutically used in subantimicrobial doses for host modulation (Periostat)
		Effective against a broad spectrum of microorganisms
Quinolone	Ciprofloxacin	Effective against gram-negative rods; promotes health-associated microflora
Macrolide	Azithromycin	Concentrates at sites of inflammation; used systemically
Lincomycin derivative	Clindamycin	Used in penicillin-allergic patients; effective against anaerobic bacteria; used systemically
Nitroimidazole‡	Metronidazole	Effective against anaerobic bacteria; used systemically and applied locally (subgingivally) as gel

*Indications: localized aggressive periodontitis, generalized aggressive periodontitis, medically related periodontitis, and refractory periodontitis.

†Amoxicillin and clavulanate potassium.

‡Indications: localized aggressive periodontitis, generalized aggressive periodontitis, medically related periodontitis, refractory periodontitis, and necrotizing ulcerative periodontitis.

occurring, semisynthetic, or synthetic type of anti-infective agent that destroys or inhibits the growth of selective microorganisms, generally at low concentrations. An antiseptic is a chemical antimicrobial agent that can be applied topically or subgingivally to mucous membranes, wounds, or intact dermal surfaces to destroy microorganisms and to inhibit their reproduction or metabolism. In dentistry, antiseptics are widely used as the active ingredient in anti-plaque and anti-gingivitis oral rinses and dentifrices. Disinfectants (a subcategory of antiseptics) are antimicrobial agents that are generally applied to inanimate surfaces to destroy microorganisms.[21]

Anti-infective agents can be administered *locally* or *orally.* When administered orally, many of these agents can be found in gingival crevicular fluid (GCF). With either approach, their purpose is to reduce the number of bacteria present in the diseased periodontal pocket. The *systemic administration* of antibiotics may be a necessary adjunct for the controlling of bacterial infection, because bacteria can invade periodontal tissues, thereby making mechanical therapy alone sometimes ineffective.[4,18,20,31,76] The *local administration* of anti-infective agents, generally directly to the pocket, has the potential to provide greater concentrations directly to the infected area and thus reduce possible systemic side effects.

A single chemotherapeutic agent can also have a dual mechanism of action. For example, tetracyclines (especially doxycycline) are chemotherapeutic agents that can reduce collagen and bone destruction via their ability to inhibit the enzyme collagenase. As antibiotic agents, they can also reduce periodontal pathogens in periodontal tissues.[20]

Systemic Administration of Antibiotics

Background and Rationale

The treatment of periodontal diseases is based on the infectious nature of these diseases (Table 48-1). Ideally, the causative microorganisms should be identified, and the most effective agent should be selected with the use of antibiotic-sensitivity testing. Although this appears simple, the difficulty lies primarily in identifying the specific etiologic microorganisms rather than the microorganisms that are simply associated with various periodontal disorders.[19,20]

TABLE 48-2 Common Antibiotic Regimens Used to Treat Periodontal Diseases*

	Regimen	Dosage/Duration
Single Agent		
Amoxicillin	500 mg	Three times daily for 8 days
Azithromycin	500 mg	Once daily for 4 to 7 days
Ciprofloxacin	500 mg	Twice daily for 8 days
Clindamycin	300 mg	Three times daily 10 days
Doxycycline or minocycline	100 mg to 200 mg	Once daily for 21 days
Metronidazole	500 mg	Three times daily for 8 days
Combination Therapy		
Metronidazole + amoxicillin	250 mg of each	Three times daily for 8 days
Metronidazole + ciprofloxacin	500 mg of each	Twice daily for 8 days

Data from Jorgensen MG, Slots J: *Compend Contin Educ Dent* 21:111, 2000.

*These regimens are prescribed after a review of the patient's medical history, periodontal diagnosis, and antimicrobial testing. Clinicians must consult pharmacology references such as *Mosby's GenRx*[67] or the manufacturer's guidelines for warnings, contraindications, and precautions.

An ideal antibiotic for use in the prevention and treatment of periodontal diseases should be specific for periodontal pathogens, allogenic, nontoxic, substantive, not in general use for the treatment of other diseases, and inexpensive.[32] Currently, however, an ideal antibiotic for the treatment of periodontal diseases does not exist.[49] Although oral bacteria are susceptible to many antibiotics, no single antibiotic at the concentrations achieved in body fluids inhibits all putative periodontal pathogens.[97] Indeed, a combination of antibiotics may be necessary to eliminate all putative pathogens from some periodontal pockets[70] (Table 48-2).

As always, the clinician—in concert with the patient—must make the final decision regarding any treatment. Thus, the treatment of the individual patient must be based on the patient's clinical status, the nature of the colonizing bacteria, the ability of the agent to reach the site of infection, and the risks and benefits

associated with the proposed treatment plan. The clinician is responsible for choosing the correct antimicrobial agent. Some adverse reactions include allergic or anaphylactic reactions, superinfections of opportunistic bacteria, the development of resistant bacteria, interactions with other medications, upset stomach, nausea, and vomiting.[6] Most adverse reactions take the form of gastrointestinal upset.[49] Other concerns include the cost of the medication and the patient's willingness and ability to comply with the proposed therapy.

No consensus exists regarding the magnitude of the risk for the development of bacterial resistance. The common and indiscriminate use of antibiotics worldwide has contributed to increasing numbers of resistant bacterial strains over the last 15 to 20 years, and this trend is likely to continue given the widespread use of antibiotics.[96] The overuse, misuse, and widespread prophylactic application of anti-infective drugs are some of the factors that have led to the emergence of resistant microorganisms. Increasing levels of resistance of subgingival microflora to antibiotics has been correlated with the increased use of antibiotics in individual countries.[91] However, researchers have noted that the subgingival microflora tends to revert to similar proportions of antibiotic-resistant isolates 3 months after therapy.[29,43]

Tetracyclines

Tetracyclines have been widely used for the treatment of periodontal diseases. They have been frequently used to treat refractory periodontitis, including *localized aggressive periodontitis* (LAP)[100] (see Table 48-1). Tetracyclines have the ability to concentrate in the periodontal tissues and to inhibit the growth of *Aggregatibacter actinomycetemcomitans.* In addition, tetracyclines exert an anticollagenase effect that can inhibit tissue destruction and that may help with bone regeneration.[17,59,95]

Pharmacology. The tetracyclines are a group of antibiotics that are produced naturally from certain species of *Streptomyces* or that are derived semi-synthetically. These antibiotics are bacteriostatic, and they are effective against rapidly multiplying bacteria. They generally are more effective against gram-positive bacteria than gram-negative bacteria. Tetracyclines are effective for the treatment of periodontal diseases in part because their concentration in the gingival crevice is 2 to 10 times that found in serum.[2,7,37] This allows a high drug concentration to be delivered into the periodontal pockets. In addition, several studies have demonstrated that tetracyclines at a low GCF concentration (i.e., 2 µg/ml to 4 µg/ml) are very effective against many periodontal pathogens.[8,9]

Clinical Use. Tetracyclines have been investigated as adjuncts for the treatment of LAP.[82] *A. actinomycetemcomitans* is a frequent microorganism that is associated with LAP, and it invades tissue. Therefore, the mechanical removal of calculus and plaque from root surfaces may not eliminate this bacterium from the periodontal tissues. Systemic tetracycline can eliminate tissue bacteria, and it has been shown to arrest bone loss and to suppress *A. actinomycetemcomitans* levels in conjunction with scaling and root planing.[81] This combination therapy allows for the mechanical removal of root surface deposits and for the elimination of pathogenic bacteria from within the tissues. Increased posttreatment bone levels have been noted with the use of this method.[85] As a result of increased resistance to tetracyclines, metronidazole or amoxicillin with metronidazole has been found to be more effective for the treatment of aggressive periodontitis in children. Some investigators think that metronidazole in combination with amoxicillin–clavulanic acid is the preferable antibiotic.[94]

The long-term use of low antibacterial doses of tetracyclines has been advocated in the past. One long-term study of patients taking low doses of tetracycline (i.e., 250 mg/day for 2 to 7 years) demonstrated the persistence of deep pockets that did not bleed after probing. These sites contained high proportions of tetracycline-resistant, gram-negative rods *(Fusobacterium nucleatum).* After the antibiotic was discontinued, the flora was characteristic of sites with disease.[49] Therefore, it is not advisable to prescribe long-term regimens of tetracyclines because of the possible development of resistant bacterial strains.[55] Although tetracyclines were often used in the past as anti-infective agents, especially for LAP and other types of aggressive periodontitis, they are now frequently replaced by more effective combination antibiotics.[49]

Specific Agents. Tetracycline, minocycline, and doxycycline are semisynthetic members of the tetracycline group that have been used in periodontal therapy.

Tetracycline. Treatment with tetracycline hydrochloride requires the administration of 250 mg four times daily. It is inexpensive, but compliance may be reduced by the need to take the medication so frequently. Side effects include gastrointestinal disturbances, photosensitivity, hypersensitivity, increased blood urea nitrogen levels, blood dyscrasias, dizziness, and headache. In addition, tooth discoloration occurs when this drug is administered to children who are 12 years old or younger.

Minocycline. Minocycline is effective against a broad spectrum of microorganisms. In patients with adult periodontitis, it suppresses spirochetes and motile rods as effectively as scaling and root planing, with suppression evident up to 3 months after therapy. Minocycline can be given twice daily, thereby facilitating compliance as compared with tetracycline. Although it is associated with less phototoxicity and renal toxicity than tetracycline, minocycline may cause reversible vertigo. Minocycline administered at a dose of 200 mg/day for 1 week results in a reduction in total bacterial counts, the complete elimination of spirochetes for up to 2 months, and the improvement of all clinical parameters.[21,24]

Side effects are similar to those of tetracycline; however, there is an increased incidence of vertigo. It is the only tetracycline that can discolor permanently erupted teeth and gingival tissue when administered orally.

Doxycycline. Doxycycline has the same spectrum of activity as minocycline, and it may be equally as effective.[20] Because doxycycline can be given only once daily, patients may be more compliant. Compliance is also favored because its absorption from the gastrointestinal tract is only slightly altered by calcium, metal ions, or antacids, as is absorption of other tetracyclines. Side effects are similar to those of tetracycline hydrochloride; however, it is the most photosensitizing agent in the tetracycline category.

The recommended dosage when doxycycline is used as an anti-infective agent is 100 mg twice daily the first day, which is then reduced to 100 mg daily. To reduce gastrointestinal upset, 50 mg can be taken twice daily after the initial dose. When given as a sub-antimicrobial dose (to inhibit collagenase), 20 mg of doxycycline twice daily is recommended.[17,26] Periostat (CollaGenex Pharmaceuticals Inc, Newtown, PA) and generic forms are currently available for a dose of 20 mg of doxycycline.

Metronidazole

Pharmacology. Metronidazole is a nitroimidazole compound that was developed in France to treat protozoal infections. It is bactericidal to anaerobic organisms, and it is thought to disrupt bacterial DNA synthesis in conditions with a low reduction

potential. Metronidazole is not the drug of choice for treating *A. actinomycetemcomitans* infections. However, metronidazole is effective against *A. actinomycetemcomitans* when it is used in combination with other antibiotics.[69,70] Metronidazole is also effective against anaerobes such as *Porphyromonas gingivalis* and *Prevotella intermedia*.[39]

Clinical Use. Metronidazole has been used clinically to treat gingivitis, acute necrotizing ulcerative gingivitis, chronic periodontitis, and aggressive periodontitis. It has been used as monotherapy and also in combination with both root planing and surgery or with other antibiotics. Metronidazole has been used successfully to treat necrotizing ulcerative gingivitis.[61]

Studies in humans have demonstrated the efficacy of metronidazole for the treatment of gingivitis and periodontitis.[60] A single dose of metronidazole (250 mg orally) appears in both serum and GCF in sufficient quantities to inhibit a wide range of suspected periodontal pathogens. When it is administered systemically (i.e., 750 mg/day to 1000 mg/day for 2 weeks), metronidazole reduces the growth of anaerobic flora, including spirochetes, and it decreases the clinical and histopathologic signs of periodontitis.[60] The most common regimen is 250 mg three times daily for 7 days.[61] Currently, the critical level of spirochetes that is needed to diagnose an anaerobic infection, the appropriate time to give metronidazole, and the ideal dosage or duration of therapy are unknown.[39] As monotherapy (i.e., with no concurrent root planing), metronidazole is inferior and at best only equivalent to root planing. Therefore, if it is used, metronidazole should not be administered as monotherapy.

Soder and colleagues[83] demonstrated that metronidazole was more effective than placebo for the management of sites that were unresponsive to root planing. Nevertheless, many patients still had sites that bled with probing, despite metronidazole therapy. The existence of refractory periodontitis as a diagnostic consideration indicates that some patients do not respond to conventional therapy, which may include root planing, surgery, or both.

Studies have suggested that, when it is combined with amoxicillin or amoxicillin–clavulanate potassium (Augmentin), metronidazole may be of value for the management of patients with LAP or refractory periodontitis. This is discussed in more detail later in this chapter.

Side Effects. Metronidazole has an Antabuse effect when alcohol is ingested. The response is generally proportional to the amount ingested, and it can result in severe cramps, nausea, and vomiting. Products that contain alcohol should be avoided during therapy and for at least 1 day after therapy is discontinued. Metronidazole also inhibits warfarin metabolism. Patients who are undergoing anticoagulant therapy should avoid metronidazole, because it prolongs prothrombin time.[61] It also should be avoided in patients who are taking lithium. This drug produces a metallic taste in the mouth, which may affect compliance.

Penicillins

Pharmacology. Penicillins are the drugs of choice for the treatment of many serious infections in humans, and they are the most widely used antibiotics. Penicillins are natural and semisynthetic derivatives of broth cultures of the *Penicillium* mold. They inhibit bacterial cell wall production and therefore are bactericidal.

Clinical Use. Penicillins other than amoxicillin and amoxicillin–clavulanate potassium (Augmentin) have not been shown to increase periodontal attachment levels, and their use in periodontal therapy does not appear to be justified.

Side Effects. Penicillins may induce allergic reactions and bacterial resistance; up to 10% of patients may be allergic to penicillin.

Amoxicillin. Amoxicillin is a semi-synthetic penicillin with an extended anti-infective spectrum that includes gram-positive and gram-negative bacteria. It demonstrates excellent absorption after oral administration. Amoxicillin is susceptible to penicillinase, which is a β-lactamase produced by certain bacteria that breaks the penicillin ring structure and thus renders penicillins ineffective.

Amoxicillin may be useful for the management of patients with aggressive periodontitis in both localized and generalized forms. The recommended dosage is 500 mg three times daily for 8 days.[49,50]

Amoxicillin–Clavulanate Potassium. The combination of amoxicillin with clavulanate potassium makes this anti-infective agent resistant to penicillinase enzymes produced by some bacteria. Amoxicillin with clavulanate (Augmentin) may be useful for the management of patients with LAP or refractory periodontitis.[68] Bueno and colleagues[13] reported that Augmentin arrested alveolar bone loss in patients with periodontal disease that was refractory to treatment with other antibiotics, including tetracycline, metronidazole, and clindamycin.

Cephalosporins

Pharmacology. The family of β-lactams known as cephalosporins is similar in action and structure to the penicillins. These drugs are frequently used in medicine, and they are resistant to a number of β-lactamases that are normally active against penicillin.

Clinical Use. Cephalosporins are generally not used to treat dental-related infections. The penicillins are superior to cephalosporins with regard to their range of action against periodontal pathogenic bacteria.

Side Effects. Patients who are allergic to penicillins must be considered to be allergic to all β-lactam products. Rashes, urticaria, fever, and gastrointestinal upset have all been associated with cephalosporins.[96]

Clindamycin

Pharmacology. Clindamycin is effective against anaerobic bacteria, and it has a strong affinity for osseous tissue.[89] It is effective for situations in which the patient is allergic to penicillin.

Clinical Use. Clindamycin has demonstrated efficacy in patients with periodontitis that is refractory to tetracycline therapy. Walker and colleagues[96] showed that clindamycin assisted with the stabilization of refractory patients; the dosage used was 150 mg four times daily for 10 days. Jorgensen and Slots[50] recommend a regimen of 300 mg twice daily for 8 days.

Side Effects. Clindamycin has been associated with pseudomembranous colitis, but the incidence is higher with cephalosporins and ampicillin. When needed, however, clindamycin can be used with caution, but it is not indicated for patients with a history of colitis. Diarrhea or cramping that develops during clindamycin therapy may be indicative of colitis, and clindamycin should be

discontinued. If symptoms persist, the patient should be referred to an internist.

Ciprofloxacin

Pharmacology. Ciprofloxacin is a quinolone that is active against gram-negative rods, including all facultative and some anaerobic putative periodontal pathogens.[80]

Clinical Use. Because it demonstrates a minimal effect on *Streptococcus* species, which are associated with periodontal health, ciprofloxacin therapy may facilitate the establishment of a microflora that is associated with periodontal health. At present, ciprofloxacin is the only antibiotic in periodontal therapy to which all strains of *A. actinomycetemcomitans* are susceptible. It has also been used in combination with metronidazole.[70]

Side Effects. Nausea, headache, metallic taste in the mouth, and abdominal discomfort have been associated with ciprofloxacin. Quinolones inhibit the metabolism of theophylline, and caffeine and concurrent administration can produce toxicity. Quinolones have also been reported to enhance the effect of warfarin and other anticoagulants.[96]

Macrolides

Pharmacology. Macrolide antibiotics contain a many-membered lactone ring to which one or more deoxy sugars are attached. They inhibit protein synthesis by binding to the 50S ribosomal subunits of sensitive microorganisms. Macrolides can be bacteriostatic or bactericidal, depending on the concentration of the drug and the nature of the microorganism. The macrolide antibiotics used for periodontal treatment include erythromycin, spiramycin, and azithromycin.

Clinical Use. Erythromycin does not concentrate in GCF, and it is not effective against most putative periodontal pathogens. For these reasons, erythromycin is not recommended as an adjunct to periodontal therapy.

Spiramycin is active against gram-positive organisms; it is excreted in high concentrations in saliva. It is used as an adjunct to periodontal treatment in Canada and Europe, but it is not available in the United States. Spiramycin has a minimal effect on increasing attachment levels.

Azithromycin is a member of the azalide class of macrolides. It is effective against anaerobes and gram-negative bacilli. After an oral dosage of 500 mg four times daily for 3 days, significant levels of azithromycin can be detected in most tissues for 7 to 10 days.[10,47] The concentration of azithromycin in tissue specimens from periodontal lesions is significantly higher than that of normal gingiva.[62] It has been proposed that azithromycin penetrates fibroblasts and phagocytes in concentrations that are 100 to 200 times greater than that of the extracellular compartment. The azithromycin is actively transported to sites of inflammation by phagocytes, where it is then released directly into the sites of inflammation as the phagocytes rupture during phagocytosis.[33] Therapeutic use requires a single dose of 250 mg/day for 5 days after an initial loading dose of 500 mg.[96]

Data have suggested that azithromycin may be an effective adjunctive therapy for increasing attachment levels in patients with aggressive periodontitis[41] as well as for reducing the degree of gingival enlargement.[25] At this time, these data must be carefully considered, because the data were derived from small subject populations. Currently, the literature presents conflicting reports regarding the efficacy of this antibiotic as an adjunct to periodontal therapy. A recent study concluded that adjunctive azithromycin provides no additional benefit over nonsurgical periodontal treatment for the parameters investigated in patients with severe generalized chronic periodontitis. Furthermore, a study in the *New England Journal of Medicine* in 2012 reported that there was an increase in cardiovascular deaths among patients who were receiving azithromycin; this increase was most pronounced among patients with a high baseline risk of cardiovascular disease. As a result of this study, the U.S. Food and Drug Administration issued a warning that the drug can alter the electrical activity of the heart, which may lead to a potentially fatal heart rhythm known as *prolonged QT interval.* This rhythm causes the timing of the heart's contractions to become irregular. The warning stated that physicians should use caution when giving the antibiotic to patients who are known to have this condition or who are at risk for cardiovascular problems.

To ascertain the efficacy of azithromycin for the management of periodontal diseases, future studies will need to increase the number of subjects, improve diagnostic methods and tools, and determine the appropriate dose, duration, and frequency of azithromycin therapy.

Serial and Combination Antibiotic Therapy

Rationale

Because periodontal infections may contain a wide diversity of bacteria, no single antibiotic is effective against all putative pathogens. Indeed, differences exist in the microbial flora associated with the various periodontal disease syndromes.[100] These "mixed" infections can include a variety of aerobic, microaerophilic, and anaerobic bacteria, which may be both gram negative and gram positive. In these cases, it may be necessary to use more than one antibiotic, either serially or in combination.[69] Before combinations of antibiotics are used, however, the periodontal pathogens being treated must be identified and antibiotic-susceptibility testing performed.[98]

Clinical Use

Antibiotics that are bacteriostatic (e.g., tetracycline) generally require rapidly dividing microorganisms to be effective. They do not function well if a bactericidal antibiotic (e.g., amoxicillin) is given concurrently. *When both types of drugs are required, they are best given serially rather than in combination.*

Rams and Slots[69] reviewed combination therapy involving the use of systemic metronidazole along with amoxicillin, amoxicillin–clavulanate (Augmentin), or ciprofloxacin. The metronidazole–amoxicillin and metronidazole–Augmentin combinations provided excellent elimination of many organisms in adults with LAP who had been treated unsuccessfully with tetracyclines and mechanical debridement. These drugs have an additive effect that involves the suppression of *A. actinomycetemcomitans*. Tinoco and colleagues[87] found metronidazole and amoxicillin to be clinically effective for the treatment of LAP, although 50% of patients who were treated with this regimen harbored *A. actinomycetemcomitans* 1 year later. The metronidazole–ciprofloxacin combination is effective against *A. actinomycetemcomitans;* metronidazole targets obligate anaerobes, and ciprofloxacin targets facultative anaerobes. This is a powerful combination against mixed infections. Studies of this drug combination for the treatment of refractory periodontitis have documented marked clinical improvement. This combination may provide a therapeutic benefit by reducing or eliminating pathogenic organisms and a prophylactic benefit by giving rise to a predominantly streptococcal microflora.[70]

Systemic antibiotic therapy in combination with mechanical therapy appears to be valuable for the treatment of recalcitrant periodontal infections and LAP infections that involve *A. actinomycetemcomitans*. Antibiotic treatment should be reserved for specific subsets of periodontal patients who do not respond to conventional therapy. The selection of specific agents should be guided by the results of cultures and sensitivity tests for subgingival plaque microorganisms.

Pharmacologic Implications

Principles of antibiotic therapy for the proper selection of an antibiotic minimally require the identification of the causative organism, the determination of the antibiotic sensitivity, and an effective method of administration.[45] The use of antibiotics to treat gingival diseases is contraindicated, because this is a local infection that can be easily treated with scaling and appropriate home care by the patient.[86] With regard to destructive periodontal diseases, there are limited data to support the use of systemic antibiotic treatment. Although bacterial infections of the periodontium are considered to be important for the initiation of the disease, currently there is no one microbe or group of microbes that has been demonstrated to be the cause of these diseases. It is therefore not surprising that systemic antibiotics have had only a modest effect on the management of periodontal diseases. At this time, systemic antibiotics for the treatment of periodontal diseases have been indicated primarily for adjunctive use in the treatment of aggressive periodontal diseases[40,43] (Table 48-3).

Guidelines for the use of antibiotics in periodontal therapy include the following:

1. The clinical diagnosis and situation dictate the need for possible antibiotic therapy as an adjunct for controlling active periodontal disease (Figure 48-1). The patient's diagnosis can change over time. For example, a patient who presents with generalized, mild chronic periodontitis can return to a diagnosis of periodontal health after initial therapy. However, if this patient has been treated and continues to have active disease, the diagnosis may change to generalized severe chronic periodontitis.
2. Disease activity as measured by continuing attachment loss, purulent exudate, and bleeding on probing[56,57] may be an indication for periodontal intervention and possible microbial analysis through plaque sampling.
3. When they are used to treat periodontal disease, antibiotics are selected on the basis of the patient's medical and dental status, his or her current medications,[49] and the results of microbial analysis, if it is performed.
4. Microbiologic plaque sampling may be performed according to the instructions of the reference laboratory. The samples are usually taken at the beginning of an appointment before instrumentation of the pocket. Supragingival plaque is removed, and an endodontic paper point is inserted subgingivally into the deepest pockets present to absorb bacteria in the loosely associated plaque. This endodontic point is placed in reduced transfer fluid or a sterile transfer tube and sent overnight to the laboratory. The laboratory will then send the referring dentist a report that includes the pathogens that are present and any appropriate antibiotic regimen. At this time, there are scant data to suggest that microbial identification from a plaque sample can be used to clinically improve the periodontal condition of the patient.
5. Meta-analyses of randomized clinical trials and quasi-experimental studies have shown that systemic antibiotics can improve attachment levels when they are used as adjuncts to scaling and root planing. The same benefits could not be demonstrated when antibiotics were used as a stand-alone therapy.[43]
6. When systemic antibiotics were used as adjuncts to scaling and root planing, improvements were observed in the attachment levels of patients with chronic and aggressive periodontitis, although patients with aggressive periodontitis experienced greater benefits.[43] The mean attachment level change depended on the antibiotic used; it ranged from 0.09 mm to 1.10 mm.[43]
7. The identification of which antibiotics were most effective for the treatment of destructive periodontal diseases was limited by the insufficient sizes of the samples found in the randomized clinical trials used as part of a systematic review.[43] With the use of a meta-analysis to evaluate eight different antibiotics or antibiotic combinations, only tetracycline and metronidazole were shown to significantly improve attachment levels when they were used as adjuncts to scaling and root planing for patients with destructive periodontal diseases.[43]
8. Debridement of root surfaces, optimal oral hygiene, and frequent periodontal maintenance therapy are important parts of comprehensive periodontal therapy. As mentioned previously, an antibiotic strength that is 500 times greater than the systemic therapeutic dose may be required to be effective against bacteria that has been arranged into biofilms. It is therefore important to disrupt this biofilm physically so that the antibiotic agents can have access to the periodontal pathogens.[40]

TABLE 48-3 Therapeutic Uses of Systemic Antimicrobial Agents for Various Periodontal Diseases

Disease	Systemic Antimicrobial Agents	Adjunct or Stand-Alone Therapy
Gingival diseases	Antibiotic use not recommended	Not applicable
Necrotizing ulcerative gingivitis	Antibiotics use not recommended unless accompanied by systemic complications (e.g., fever, swollen lymph nodes)	As an adjunct when necessary
Chronic periodontitis	Limited benefit; antibiotic use not recommended	Not applicable
Aggressive periodontitis	Antibiotic use recommended; for greatest benefit, therapeutic levels of antibiotics should be achieved by the time scaling and root planing are completed (all debridement should be completed within a week); the optimal antibiotic type, dose, frequency, and duration have not been identified	As an adjunct
Necrotizing ulcerative periodontitis	Antibiotic use dependent on the systemic condition of the patient	As an adjunct when necessary
Periodontitis as a manifestation of systemic diseases	Antibiotic use dependent on the systemic condition of the patient	As an adjunct when necessary
Periodontal abscess	Antibiotic use not recommended	Not applicable

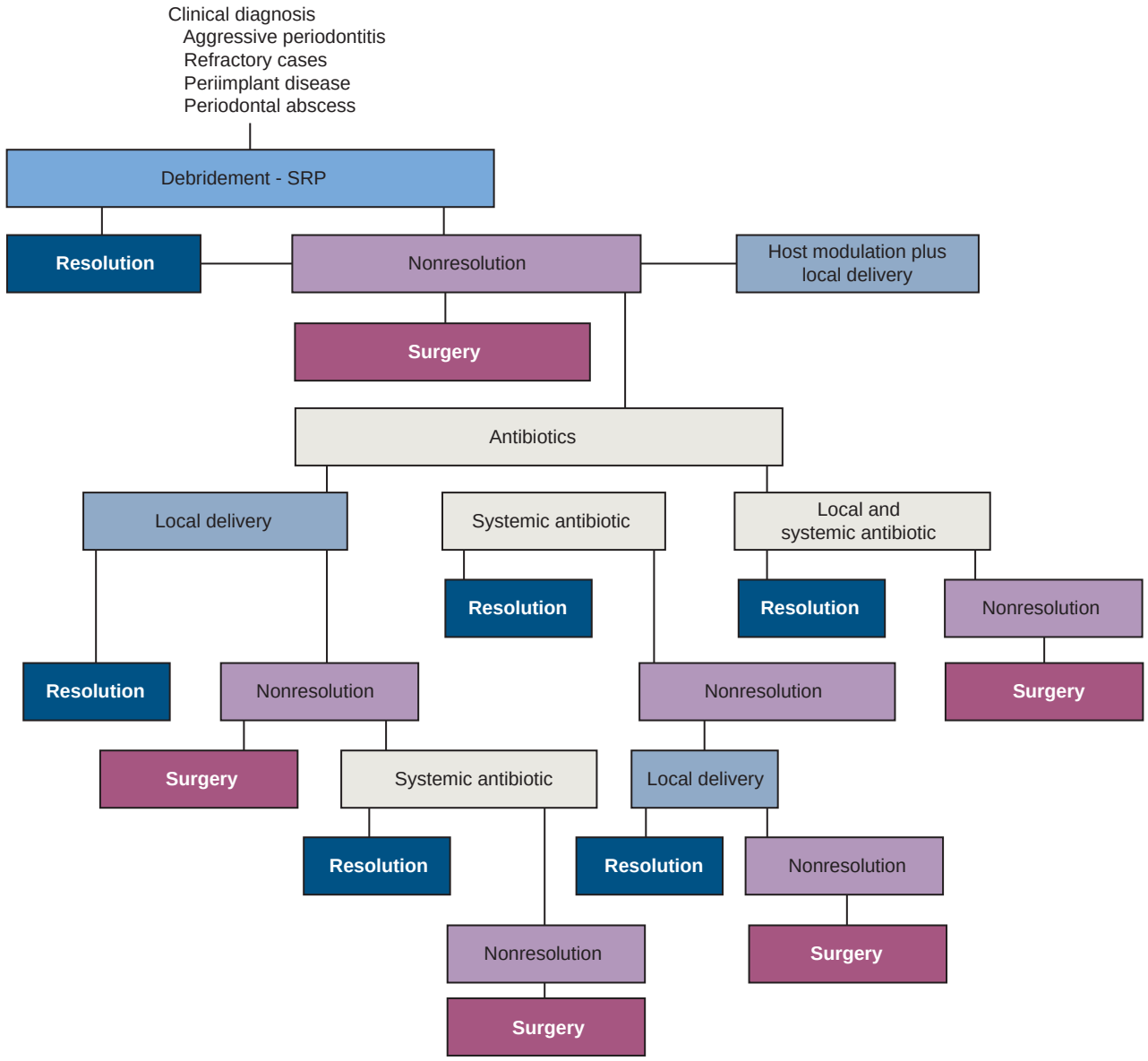

Figure 48-1 A decision tree for the selection of antibiotic therapy.

9. Although there are adequate data to suggest that systemic antibiotics can be of benefit for the treatment of destructive periodontal diseases, there are limited data available to identify which antibiotics are suitable for which infection; the optimum dosage, frequency, and duration of antibiotic therapy; when the regimen with antibiotics should be introduced during the treatment schedule; the long-term outcomes of antibiotic use; the potential hazards of these agents (e.g., antibiotic resistance, changes in oral microflora)[43]; and the economic ramifications of this type of pharmacologic intervention.

The selection of an antibiotic must be made on the basis of factors other than the empirical decisions made by the clinician. Unfortunately, there is no one best choice of antibiotic at present (i.e., there is no "silver bullet"). Therefore, the clinician must integrate the history of the patient's disease, the clinical signs and symptoms, and the results of radiographic examinations and possibly of microbiologic sampling to determine the course of periodontal therapy. The clinician must obtain a thorough medical history, including current medications and the possible adverse effects of combining these medicines, before prescribing any antibiotic therapy. The clinician must make the final decision with the patient. Risks and benefits concerning antibiotics as adjuncts to periodontal therapy should be discussed with the patient before antibiotics are used.

Local Delivery Agents

Locally delivered antimicrobial agents are available as adjuncts to scaling and root planing and as aids for the control of growth of bacteria on barrier membranes.[67] Although they are not discussed in this chapter, locally delivered nonsteroidal anti-inflammatory agents are also being evaluated as adjunctive agents for the treatment of periodontal disease.[44,92] When they are placed into periodontal pockets, they reduce the subgingival microflora, the probing depths, and the clinical signs of inflammation. A recent systematic review concluded that "adjunctive local therapy generally reduced probing depth levels. Differences between treatment and SRP-only groups in the baseline to follow-up period typically favored treatment groups but usually only modestly (e.g., from about 0.1 mm to nearly 0.5 mm). Effects for clinical attachment level gains were smaller and statistical significance less common."[11]

A report about locally delivered agents that was prepared by the American Academy of Periodontology stated that "the clinician's decision to use locally delivered agents . . . should be based upon a consideration of clinical findings, the patient's dental and medical history, scientific evidence, patient preferences and advantages and disadvantages of alternative therapies." The report also stated that use of locally delivered agents may be of value when probing depths of more than 5 mm with inflammation are still present after conventional therapy. However, if multiple sites are present in the same quadrant, therapy other than locally delivered agents should be considered.[5]

Subgingival Chlorhexidine

A resorbable delivery system has been tested for the subgingival placement of chlorhexidine gluconate with positive clinical results (Figure 48-2). This product is available in the United States as well as in a number of other countries. The PerioChip is a small chip (4.0 mm × 5.0 mm × 0.35 mm) that is composed of a biodegradable hydrolyzed gelatin matrix. It is cross-linked with glutaraldehyde, and it also contains glycerin and water into which 2.5 mg of chlorhexidine gluconate has been incorporated per chip. This delivery system releases chlorhexidine and maintains drug concentrations in the GCF of more than 100 µg/ml for at least 7 days[84]; these concentrations are well above the tolerance of most oral bacteria.[12] Because the chip biodegrades within 7 to 10 days, a second appointment for removal is not needed.

Two multicenter, randomized, double-blind, parallel-group, controlled clinical trials of this chip were conducted in the United States and included a total of 447 patients from 10 centers.[48] In these studies, patients received supragingival prophylaxis for up to 1 hour, which was followed by scaling and root planing for 1 hour. Chips were placed in target sites with probing depths of 5 mm to 8 mm at baseline that bled with probing and again at 3 and 6 months if the probing depth remained at 5 mm or more. Sites in control subjects received either a placebo chip (inactive) with scaling and root planing or scaling and root planing alone. Sites in test subjects received either a chlorhexidine chip (active) with scaling and root planing or scaling and root planing alone. Examinations were performed at baseline and again at 3, 6, and 9 months. At 9 months, significant decreases in probing depth from baseline that favored the active chip as compared with controls were observed: chlorhexidine chip with scaling and root planing, –0.95 ± 0.05 mm; placebo chip with scaling and root planing, –0.69 ± 0.05 mm ($P = .001$); and scaling and root planing alone, –0.65 ± 0.05 mm ($P = .00001$). Although statistically significant, the net clinical changes were limited. The proportion of pocket sites with a probing depth reduction of 2 mm or more was increased in the chlorhexidine chip group (30%) as compared with scaling and root planing alone (16%); this was a statistically significant difference on a per-patient basis ($P < .0001$).

No signs of staining were noted in any of the previous three studies as a result of the chlorhexidine chip treatment as measured by a stain index. Adverse effects were minimal, although a few patients complained of slight pain and swelling during the first 24 hours after chip placement.

Tetracycline-Containing Fibers

The first local delivery product available in the United States—an ethylene/vinyl acetate copolymer fiber (diameter, 0.5 mm) that contained tetracycline (12.7 mg per 9 inches)—was extensively studied. When packed into a periodontal pocket, it was well tolerated by the oral tissues. For 10 days, it sustained tetracycline concentrations that exceeded 1300 µg/ml, which was well beyond the 32 µg/ml to 64 µg/ml required to inhibit the growth of the pathogens that had been isolated from periodontal pockets.[34,35,64,65,88,99] By contrast, GCF concentrations of only 4 µg/ml to 8 µg/ml were reported after systemic tetracycline administration (250 mg four times daily for 10 days for a total oral dose of 10 g).[36,37]

Studies demonstrated that tetracycline fibers applied with or without scaling and root planing reduced probing depth, bleeding with probing, and periodontal pathogens and provided gains in clinical attachment level. Such effects were significantly better than those attained with scaling and root planing alone or with placebo fibers. No change in antibiotic resistance to tetracycline was found after tetracycline fiber therapy among the tested putative periodontal pathogens. However, these fibers are no longer commercially available.

Subgingival Doxycycline

A gel system involving the use of a syringe with 10% doxycycline (Atridox) (Figure 48-3) is available. It was the only local delivery system accepted by the American Dental Association when the Association had an acceptance program for professional products, although that program was terminated in 2008. This product is available in the United States and in a number of other countries.

During a 9-month multicenter study of 180 patients, treatment with 10% doxycycline gel alone was more effective than the other treatments at all time periods, with the exception of the 3-month clinical attachment level value. For the 10% doxycycline gel group, the reduction in clinical attachment level at 9 months showed a gain of 0.4 mm as compared with vehicle control; the reduction in probing depth was 0.6 mm greater than with vehicle control; and

Figure 48-2 Placement of a chlorhexidine gluconate chip (PerioChip).

Figure 48-3 Placement of 10% doxycycline (Atridox) gel.

the reduction of bleeding with probing was 0.2 units greater than with vehicle control. The differences were clinically small but statistically significant. Although resistance was not evaluated in this study, the local application of doxycycline has previously been reported to show transient increases in resistance in oral microbes and no overgrowth of foreign pathogens.[58]

Two multicenter clinical trials each studied 411 patients with moderate to severe periodontitis.[30] At baseline, patients were randomized to one of four treatment groups: 10% doxycycline gel, vehicle control, oral hygiene only, and scaling and root planing. Sites with probing depths of 5 mm or more that bled with probing were treated at baseline and then again with the same treatment at 4 months. Clinical assessments were made for 9 months, and clinical attachment level, probing depth, and bleeding on probing were measured. All treatment groups in both studies showed clinical improvements as compared with baseline over the 9-month period. The results for all parameters measured were significantly better in the 10% doxycycline gel group as compared with vehicle control and oral hygiene only. As compared with scaling and root planing, the effects of 10% doxycycline gel as monotherapy on clinical attachment level gain and probing depth reduction were equivalent (see Chapter 48). Most recently, a 6-month, randomized, multicenter, placebo-controlled examiner-masked study[66] of 171 subjects evaluated the combined use of systemically delivered doxycycline hyclate (20 mg twice daily) plus locally delivered doxycycline hyclate gel (10%) in combination with scaling and root planing versus scaling and root planing plus placebo. The results of the study showed that the combination therapy provided statistically significantly greater clinical benefits than control therapy for all clinical measures at both 3 and 6 months. The clinical parameters measured were probing depth, clinical attachment level, bleeding with probing, and gingival health.[66]

Subgingival Minocycline

A locally delivered, sustained-release form of minocycline microspheres (Arestin) is available for subgingival placement as an adjunct to scaling and root planing (Figure 48-4). The 2% minocycline is encapsulated into bioresorbable microspheres in a gel carrier. This product is available in the United States and in a number of other countries. As compared with controls (i.e., scaling and root planing with nonactive vehicle as subgingival irrigant), there was a statistically significant increase in the clinical attachment levels among patients who presented with pockets with probing depths of 6 mm or more.[22]

In a four-center, double-blind, randomized trial, patients with periodontal pockets at least 5 mm deep were selected, and either 2% minocycline gel or vehicle was applied once every 2 weeks for four applications after initial scaling and root planing.[90] A total of 343 teeth (976 sites) were included in the minocycline group, with 299 teeth (810 sites) being included in the control group. Reductions in *P. gingivalis* and *P. intermedia* at weeks 2, 4, 6, and 12 and at weeks 6 and 12 for *A. actinomycetemcomitans* were statistically significant. These results demonstrated the advantages of supplementing standard subgingival debridement with the application of minocycline gel. The three primary clinical efficacy variables in this study were probing depth, clinical attachment level, and bleeding index. There was a trend toward clinical improvement in both treatment groups for all three measures, and the reduction in probing depth was significantly greater with minocycline gel. When sites with probing depth of at least 7 mm and significant bleeding at baseline were considered, the improvements were greater than those seen with 5-mm pockets. The improvements with minocycline were statistically significantly better than those seen in the control group.

Applications of 2% minocycline were also evaluated in a 3-month study in 30 patients.[38] Active or placebo gel was placed subgingivally at planed sites in each subject, according to a double-blind protocol, immediately after scaling and root planing and again 2 and 4 weeks later. Differences between groups with regard to mean probing depth did not reach statistical significance at any visit, but mean clinical attachment levels favored the minocycline group ($P < .05$) at both reassessments. The number of sites that bled after deep probing at 12 weeks also favored the minocycline group ($P < 0.05$).

Figure 48-4 Placement of minocycline microspheres (Arestin).

Subgingival Metronidazole

A topical medication that contains an oil-based metronidazole 25% dental gel (glyceryl monooleate and sesame oil) has been tested in a number of studies.[1] This product is not available in the United States. It is applied in a viscous consistency to the pocket, where it is liquidized by the body heat and then hardens again, forming crystals when it comes in contact with water. As a precursor, the preparation contains metronidazole–benzoate, which is converted into the active substance by esterases in GCF. Two 25% gel applications at a 1-week interval have been used.[54]

Studies have shown that metronidazole gel is equivalent to scaling and root planing, but they have not shown adjunctive benefits with scaling and root planing. In a 6-month study of 30 patients, treatment consisted of two applications of the dental gel in two randomly selected quadrants at 1-week intervals as well as simultaneous subgingival scaling of the remaining quadrants.[85] Oral hygiene instructions were given on day 21. Statistical analyses showed that both treatments effectively reduced probing depth and bleeding with probing over the 6-month period. At the end of the follow-up period, the mean reduction in probing depth was 1.3 mm after gel treatment and 1.5 mm after subgingival scaling. Bleeding with probing was reduced by 35% and 42%, respectively. No significant differences between the two treatments were detected. Dark-field microscopy showed a shift toward a seemingly healthier microflora for both treatment modalities; this effect persisted throughout the 6-month period.

A large, multicenter study of 206 subjects investigated two applications of metronidazole gel in two randomly selected quadrants versus two quadrants of scaling.[1] Probing depths were reduced by 1.2 mm in the gel and by 1.5 mm in the scaling group. At 6 months, the differences between treatments were statistically but not clinically significant. In addition, bleeding on probing was reduced by 88% for both treatment groups.

Comparative Studies

Few researchers have attempted to compare these devices side by side. However, in one study, doxycycline polymer, metronidazole gel, and PerioChip were compared in 47 periodontal patients. The study found that all controlled-release polymer devices increased gingival attachment levels but that there was a slightly greater improvement among patients who were treated with the doxycycline polymer.[78]

Subgingival Moxifloxacin

Moxifloxacin is a fourth-generation synthetic fluoroquinolone with broad-spectrum antibacterial activity. This antibiotic inhibits cell replication by modifying the actions of DNA gyrase and topoisomerase IV. Because moxifloxacin has been shown to have antimicrobial activity against aerobic and anaerobic bacteria, including a number of periodontal pathogens, it has been introduced as a local delivery agent for the treatment of destructive periodontal diseases. A recent study in Europe suggested that the local delivery of 0.4% moxifloxacin may be of benefit as an adjunct to scaling and root planning for the treatment of periodontitis. It should be noted that the mean incremental reduction in probing depth as compared with placebo was 0.4 mm, which is similar to the reduction found with other commercially available local delivery agents. As of this writing, this drug is not available in the United States, but it is available in other parts of the world.

Overview of Local Delivery of Antimicrobial Agents and Periimplant Mucositis/Implantitis

Because there are a number of similarities between the pathogens involved in periodontitis periimplant mucositis and periimplantitis, it is logical that similar clinical approaches should be implemented for these two conditions. An early study by Mombelli and colleagues[63] that made use of tetracycline-containing fibers that are no longer available demonstrated in 25 patients with periimplant mucositis that there was a significant reduction of four periopathogenic species; however, other species (e.g., *P. gingivalis, A. actinomycetemcomitans*) had very low baseline levels and were not significantly affected. There was a slight but not significant improvement in the probing depth at 12 months. The study showed that the local delivery of tetracycline from polymeric fibers may be used to improve the clinical and microbiologic parameters around infected implants as compared with scaling and root planing alone.

In another study,[14] investigators applied controlled-release doxycycline (Atridox) into periimplant pockets and noted differences as compared with scaling and root planing alone. This study also showed the efficacy of such devices for the treatment of periimplant mucositis. Patients who received the doxycycline treatment showed significantly greater probing attachment levels and lesser pocket probing depths and bleeding indexes ($P < .05$) as compared with those who received scaling and root planing alone.[14]

A study by Persson and colleagues[79] evaluated 31 implants with periimplantitis in 25 patients and monitored clinical and radiographic changes over 12 months after the adjunctive placement of minocycline microspheres (Arestin). Minocycline microspheres (Arestin) were locally delivered to each implant site with bone loss and with a probing pocket depth (PPD) of 5 mm or more. Rescue therapy with Arestin was allowed at days 180 and 270 at any site exhibiting an increase in PPD of 2 mm or more as compared with the previous visit. Six implants in six subjects were either rescued or exited as a result of persisting active periimplantitis. Successful implants showed a statistically significant reduction in both PPD and the percentage of sites with bleeding with probing between baseline and day 360 ($P < .05$). At mesial implant sites, the mean PPD reduction amounted to 1.6 mm (95% confidence interval, 0.9 mm to 2.2 mm; $P < .001$), and this was accompanied by a statistically significant reduction of the bleeding with probing value ($P < .001$).

Although studies evaluating the use of the PerioChip (chlorhexidine) for periimplant mucositis were not identified, one 12-month study compared the clinical and microbiologic results after the application of minocycline microspheres as an adjunct to the mechanical treatment of incipient periimplant infections as compared with an adjunctive treatment involving the application of 1 ml of a 1% chlorhexidine gel.[73] Sixteen patients in the minocycline group and 14 patients in the chlorhexidine group completed the study. The findings of the study were that the adjunctive use of minocycline microspheres resulted in improvements of probing depths and bleeding scores, whereas the adjunctive use of chlorhexidine only resulted in the limited reduction of bleeding scores. For the deepest sites of the treated implants in the minocycline group, the mean probing depth was reduced from 5.0 mm to 4.4 mm at 12 months. This study did not demonstrate any significant difference in the levels of bacterial species or groups at any time point between the two antimicrobial agents tested.

Conclusion

Scaling and root planing alone are effective for reducing pocket depths, gaining increases in periodontal attachment levels, and decreasing inflammation levels (i.e., bleeding with probing). When scaling and root planing are combined with the subgingival placement of sustained-release vehicles, however, additional clinical benefits are possible, including the further reduction of pocket depths, additional gains in clinical attachment levels (e.g., 0.39 mm with minocycline gel), and further decreases in inflammation. Improvements in clinical attachment levels also occur with the chlorhexidine chip (0.16 mm) and doxycycline gel (0.34 mm).[42] When systemic antibiotics are used as adjuncts to scaling and root planing, the evidence indicates that some systemic antibiotics (e.g., metronidazole, tetracycline) provide additional improvements in attachment levels (0.35 mm for metronidazole; 0.40 mm for tetracycline) when used as adjuncts to scaling and root planing.[43] The use of anti-infective chemotherapeutic treatment adjuncts does not result in significant patient-centered adverse effects.

The decision regarding when to use local or systemic antimicrobials should be made on the basis of the clinician's consideration of the clinical findings, the patient's medical and dental history,[27,28] the patient's preferences, and the potential benefits of adjunctive therapy with these agents.

There are extensive reviews of the local delivery agents that are available for the treatment of periodontitis.[42,46,52,53,74]

References

References for this chapter are found on the companion website www.expertconsult.com.

References

1. Ainamo J, Lie T, Ellingsen BH, et al: Clinical responses to subgingival application of a metronidazole 25% gel compared to the effect of subgingival scaling in adult periodontitis. *J Clin Periodontol* 19(Pt II):723, 1992.
2. Alger FA, Solt CW, Vuddhankanok S, et al: The histologic evaluation of new attachment in periodontally diseased human roots treated with tetracycline hydrochloride and fibronectin. *J Periodontol* 61:447, 1990.
3. American Academy of Periodontology: Parameters of care. *J Periodontol* 71(Suppl):847, 2000.
4. American Academy of Periodontology, Research, Science and Therapy Committee: Systemic antibiotics in periodontics. *J Periodontol* 75:1553, 2004.
5. American Academy of Periodontology statement on local delivery of sustained or controlled release antimicrobials as adjunctive therapy in the treatment of periodontitis. *J Periodontol* 77:1458, 2006.
6. American Dental Association, Council on Scientific Affairs: Combating antibiotic resistance. *J Am Dent Assoc* 135:484, 2004.
7. Bader HI, Goldhaber P: The passage of intravenously administered tetracycline into the gingival sulcus of dogs. *J Oral Ther Pharmacol* 2:324, 1968.
8. Baker PJ, Evans RT, Slots J, et al: Antibiotic susceptibility of anaerobic bacteria from the oral cavity. *J Dent Res* 65:1233, 1985.
9. Baker PJ, Evans RT, Slots J, et al: Susceptibility of human oral anaerobic bacteria to antibiotics suitable for topical use. *J Clin Periodontol* 12:201, 1985.
10. Blandizzi C, Tecla M, Lupetti A, et al: Periodontal tissue disposition of azithromycin in patients affected by chronic inflammatory periodontal diseases. *J Periodontol* 70:960, 1999.
11. Bonito A, Lux L, Lohr KN: Impact of local adjuncts to scaling and root planing in periodontal disease therapy: a systematic review. *J Periodontol* 76:1227, 2005.
12. Briner WW, Kayrouz GA, Chanak MX: Comparative antimicrobial effectiveness of a substantive (0.12% chlorhexidine) and a nonsubstantive (phenolic) mouthrinse in vivo and in vitro. *Compend Contin Educ Dent* 15:1158, 1994.
13. Bueno L, Walker C, van Ness W, et al: Effect of Augmentin on microbiota associated with refractory periodontitis. *J Dent Res* 67:246, 1988.
14. Buchter A, Meyer U, Kruse-Losler B, et al: Sustained release of doxycycline for the treatment of periimplantitis: randomised controlled trial. *Br J Oral Maxillofac Surg* 42:439, 2004.
15. Carranza FA, Jr, Saglie R, Newman MG, et al: Scanning and transmission electron microscopic study of tissue-invading microorganisms in localized juvenile periodontitis. *J Periodontol* 54:598, 1983.
16. Caton J, Bleiden T, Adams D, et al: Subantimicrobial doxycycline therapy for periodontitis. *J Dent Res* 76:1307, 1997.
17. Caton JG, Ciancio SG, Blieden TM, et al: Treatment with subantimicrobial dose doxycycline improves the efficacy of scaling and root planing in patients with adult periodontitis. *J Periodontol* 71:521, 2000.
18. Christersson LA, Slots J, Rosling BG, et al: Microbiological and clinical effects of surgical treatment of localized juvenile periodontitis. *J Clin Periodontol* 12:465, 1985.
19. Ciancio SG: Use of antibiotics in periodontal therapy. In Newman MG, Goodman A, editors: *Antibiotics in dentistry*, Chicago, 1983, Quintessence.
20. Ciancio SG: Antibiotics in periodontal therapy. In Newman MG, Kornman K, editors: *Antibiotic/antimicrobial use in dental practice*, Chicago, 1990, Quintessence.
21. Ciancio SG: Antiseptics and antibiotics as chemotherapeutic agents for periodontitis management. *Compend Contin Educ Dent* 21:59, 2000.
22. Ciancio SG, editor: FDA approves Arestin marketing. In *Biological therapies in dentistry*, 17(suppl 1):s1, Hamilton, Ontario, Canada, 2001, BC Decker (newsletter).
23. Ciancio SG, Adams D, Blieden T, et al: Subantimicrobial dose doxycycline: a new adjunctive therapy for adult periodontitis. Presented at the annual meeting of the American Academy of Periodontology, Boston, 1998.
24. Ciancio SG, Slots J, Reynolds HS, et al: The effect of short-term administration of minocycline HCl administration on gingival inflammation and subgingival microflora. *J Periodontol* 53:57, 1982.
25. Clementini M, Vittorini G, Crea A, et al: Efficacy of AZM therapy in patients with gingival overgrowth induced by cyclosporine A: a systematic review. *BMC Oral Health* 8:34, 2008.
26. Crout R, Adams D, Blieden T, et al: Safety of doxycycline hyclate 20 mg bid in patients with adult periodontitis. Presented at the annual meeting of the American Academy of Periodontology, Boston, 1998.
27. Edelson H, Kaplan H, Korchak H: Differing effects of nonsteroidal anti-inflammatory agents on neutrophil functions. *Clin Res* 30:469A, 1982.
28. Feldman R, Szeto B, Chauncey H, et al: Nonsteroidal anti-inflammatory drugs in the reduction of human alveolar bone loss. *J Clin Periodontol* 10:131, 1983.
29. Feres M, Haffajee AD, Allard K, et al: Antibiotic resistance of subgingival species during and after periodontal therapy. *J Clin Periodontol* 28:12, 2002.
30. Garrett S, Adams D, Bandt C, et al: Two multicenter clinical trials of subgingival doxycycline in the treatment of periodontitis. *J Dent Res* 76:153, 1997.
31. Genco RJ, Cianciola JJ, Rosling H: Treatment of localized juvenile periodontitis. *J Dent Res* 60:527, 1981.
32. Gibson W: Antibiotics and periodontal disease: a selective review of the literature. *J Am Dent Assoc* 104:213, 1982.
33. Gladue RP, Snyder ME: Intracellular accumulation of azithromycin by cultured human fibroblasts. *Antimicrob Agents Chemother* 34:1056, 1990.
34. Goodson JM, Tanner A: Antibiotic resistance of the subgingival microbiota following local tetracycline therapy. *Oral Microbiol Immunol* 7:113, 1992.
35. Goodson JM, Cugini M, Kent RL, et al: Multicenter evaluation of tetracycline fiber therapy. II. Clinical response. *J Periodontal Res* 26:371, 1991.
36. Gordon JM, Walker CB, Murphy JC: Concentration of tetracycline in human gingival fluid after single doses. *J Clin Periodontol* 8:117, 1981.
37. Gordon JM, Walker CB, Murphy CJ, et al: Tetracycline: levels achievable in gingival crevice fluid and in vitro effect on subgingival organisms. Part I. Concentrations in crevicular fluid after repeated doses. *J Periodontol* 52:609, 1981.
38. Grace MA, Watts TL, Wilson RF, et al: A randomized controlled trial of a 2% minocycline gel as an adjunct to nonsurgical periodontal treatment, using a design with multiple matching criteria. *J Clin Periodontol* 24:249, 1997.
39. Greenstein G: The role of metronidazole in the treatment of periodontal diseases. *J Periodontol* 64:1, 1993.
40. Greenstein G: Changing periodontal concepts: treatment considerations. *Compend Contin Educ Dent* 26:81, 2005.
41. Haas AN, de Castro GD, Moreno T, et al: Azithromycin as an adjunctive treatment of aggressive periodontitis: 12-months randomized clinical trial. *J Clin Periodontol* 35:696, 2008.
42. Hanes PJ, Purvis JP: Local anti-infective therapy: pharmacological agents. A systematic review. *Ann Periodontol* 8:79, 2003.
43. Haffajee AD, Socransky SS, Gunsolley JC: Systemic anti-infective periodontal therapy: a systematic review. *Ann Periodontol* 8:115, 2003.
44. Heasam PA, Benn DK, Kelly PJ, et al: The use of topical flurbiprofen as an adjunct to non-surgical management of periodontal disease. *J Clin Periodontol* 20:457, 1993.
45. Hessen MT, Kaye D: Principles of use of antibacterial agents. *Infect Dis Clin North Am* 18:435, 2004.
46. Hill M, Moore R: Locally acting oral chemotherapeutic agents. In Rose LF, Mealey BL, Genco RJ, et al, editors: *Periodontics: medicine, surgery, and implants*, St. Louis, 2004, Elsevier.

47. Hoepelman IM, Schneider MM: Azithromycin: the first of the tissue-selective azalides. *Int J Antimicrob Agents* 5:145, 1995.
48. Jeffcoat M, Bray KS, Ciancio SG, et al: Adjunctive use of a subgingival controlled-release chlorhexidine chip reduces probing depth and improves attachment level compared with scaling and root planing alone. *J Periodontol* 69:989, 1998.
49. Jorgensen MG, Slots J: Practical antimicrobial periodontal therapy. *Compend Contin Educ Dent* 21:111, 2000.
50. Jorgensen MG, Slots J: Responsible use of antimicrobials in periodontics. *J Cal Dent Assoc* 28:185, 2000.
51. Kaplan H, Edelson H, Korchak H, et al: Effects of nonsteroidal anti-inflammatory agents on neutrophil functions in vitro and in vivo. *Biochem Pharmacol* 33:371, 1984.
52. Killoy WJ: Chemical treatment of periodontitis: local delivery of antimicrobials. *Int Dent J* 48(Suppl 1):305, 1998.
53. Killoy WJ, Polson AM: Controlled local delivery of antimicrobials in the treatment of periodontitis. *Dent Clin North Am* 42:263, 1998.
54. Klinge B, Attström R, Karring T, et al: Three regimens of topical metronidazole compared with subgingival scaling on periodontal pathology in adults. *J Clin Periodontol* 19(Pt II):708, 1992.
55. Kornman KS, Karl EH: The effect of long-term low-dose tetracycline therapy on the subgingival microflora in refractory adult periodontitis. *J Periodontol* 53:604, 1982.
56. Lang NP, Adler R, Joss A, et al: The absence of bleeding on probing: an indicator of periodontal stability. *J Clin Periodontol* 17:7144, 1990.
57. Lang NP, Joss A, Orsanic T, et al: Bleeding on probing: a predictor for the progression of periodontal disease? *J Clin Periodontol* 13:590, 1986.
58. Larsen T: Occurrence of doxycycline-resistant bacteria in the oral cavity after local administration of doxycycline in patients with periodontal disease. *Scand J Infect Dis* 23:89, 1991.
59. Lee HM, Ciancio SG, Tuter G, et al: Subantimicrobial dose doxycycline efficacy as a matrix metalloproteinase inhibitor in chronic periodontitis is enhanced when combined with a non-steroidal anti-inflammatory drug. *J Periodontol* 75:453, 2004.
60. Lekovic V, Kenney EB, Carranza FA, Jr, et al: Effect of metronidazole on human periodontal disease: a clinical and microbiologic study. *J Periodontol* 54:476, 1983.
61. Lozdan J, Sheiham A, Pearlman BA, et al: The use of nitroimidazine in the treatment of acute ulcerative gingivitis: a double-blind controlled trial. *Br Dent J* 130:294, 1971.
62. Malizia T, Tejada MR, Ghelardi E, et al: Periodontal tissue disposition of azithromycin. *J Periodontol* 68:1206, 1997.
63. Mombelli A, Feloutzis A, Bragger U, et al: Treatment of peri-implantitis by local delivery of tetracycline. Clinical, microbiological and radiological results. *Clin Oral Implants Res* 4:287, 2001.
64. Morrison SL, Cobb CM, Kazakos GM, et al: Root surface characteristics associated with subgingival placement of monolithic tetracycline-impregnated fibers. *J Periodontol* 63:137, 1992.
65. Niederman R, Holborow D, Tonetti M, et al: Reinfection of periodontal sites following tetracycline fiber therapy. *J Dent Res* 69:277, 1990.
66. Novak MJ, Dawson DR, 3rd, Magnusson I, et al: Combining host modulation and topical antimicrobial therapy in the Management of moderate to severe periodontitis: a randomized multicenter trial. *J Periodontal* 79(1):33, 2008.
67. Nowzari H, McDonald ES, Flynn J, et al: The dynamics of microbial colonization of barrier membranes for guided tissue regeneration. *J Periodontol* 67:694, 1996.
68. Offenbacher S, Braswell L, Loos A, et al: Effects of flurbiprophen on the progression of periodontitis in *Macaca mulatta*. *J Periodontal Res* 22:473, 1987.
69. Rams TE, Slots J: Antibiotics in periodontal therapy: an update. *Compend Contin Educ Dent* 13:1130, 1992.
70. Rams TE, Feik D, Slots J: Ciprofloxacin/metronidazole treatment of recurrent adult periodontitis. *J Dent Res* 71:319, 1992.
71. Reddy MS, Geurs NC, Gunsolley JC: Periodontal host modulation with antiproteinase, anti-inflammatory, and bone sparing agents: a systematic review. *Ann Periodontol* 8:12, 2003.
72. Research, Science and Therapy Committee: *Pharmacologic blocking of host responses as an adjunct in the management of periodontal diseases: a research update*, Chicago, 1992, American Academy of Periodontology.
73. Renvert S, Lessem J, Dahlén G, et al: Topical minocycline microspheres versus topical chlorhexidine gel as an adjunct to mechanical debridement of incipient peri-implant infections: a randomized clinical trial. *J Clin Periodontol* 33:362, 2006.
74. Rose LF, Mealey BL, Genco RJ, et al, editors: *Periodontics: medicine, surgery, and implants*, St. Louis, 2004, Elsevier.
75. Rosling BG, Slots J, Christersson LA, et al: Topical antimicrobial therapy and diagnosis of subgingival bacteria in the management of inflammatory periodontal disease. *J Clin Periodontol* 13:975, 1986.
76. Saglie FR, Carranza FA, Jr, Newman MG, et al: Identification of tissue invading bacteria in human periodontal disease. *J Periodontal Res* 17:452, 1982.
77. Salvi GE, Lawrence HP, Offenbacher S, et al: Influence of risk factors on the pathogenesis of periodontal disease. *Periodontol 2000* 14:173, 1997.
78. Salvi GE, Mombelli A, Mayfield L, et al: Local antimicrobial therapy after initial periodontal treatment. *J Clin Periodontol* 29:540, 2002.
79. Persson GR, Salvi GE, Heitz-Mayfield LJ, et al: Antimicrobial therapy using a local drug delivery system (Arestin) in the treatment of peri-implantitis. I. Microbiological outcomes. *Clin Oral Implants Res* 17(4):386, 2006.
80. *Mosby's GenRx*, ed 10, St Louis, 2001, Mosby.
81. Slots J, Rams TE: Antibiotics and periodontal therapy: advantages and disadvantages. *J Clin Periodontol* 17:479, 1990.
82. Slots J, Rosling BG: Suppression of periodontopathic microflora in localized juvenile periodontitis by systemic tetracycline. *J Clin Periodontol* 10:465, 1983.
83. Soder P, Frithiof L, Wikner S, et al: The effects of systemic metronidazole after non-surgical treatment in moderate and advanced periodontitis in young adults. *J Periodontol* 61:281, 1990.
84. Soskolne WA, Heasman PA, Stabholz A, et al: Sustained local delivery of chlorhexidine in the treatment of periodontitis: a multi-center study. *J Periodontol* 68:32, 1997.
85. Stelzel M, Flores-De-Jacoby L: Topical metronidazole application compared with subgingival scaling: a clinical and microbiological study on recall patients. *J Clin Periodontol* 23:24, 1996.
86. Tatakis DN, Trombelli L: Modulation of clinical expression of plaque-induced gingivitis. L. Background review and rationale. *J Clin Periodontol* 31:220, 2004.
87. Tinoco EM, Beldi M, Campedelli F, et al: Clinical and microbiologic effects of adjunctive antibiotics in treatment of localized aggressive periodontitis: a controlled clinical study. *J Periodontol* 69:1355, 1998.
88. Tonetti M, Cugini AM, Goodson JM: Zero order delivery with periodontal placement of tetracycline loaded ethylene vinyl acetate fibers. *J Periodontal Res* 25:243, 1990.
89. Tyler K, Walker CB, Gordon J, et al: Evaluation of clindamycin in adult refractory periodontitis: antimicrobial susceptibilities. *J Dent Res* 64:360, 1985.
90. Van Steenberghe D, Bercy P, Kohl J: Subgingival minocycline hydrochloride ointment in moderate to severe chronic adult periodontitis: a randomized, double-blind, vehicle-controlled, multicenter study. *J Periodontol* 64:637, 1993.
91. Van Winkelhoff AJ, Gonzales DH, Winkel EG, et al: Antimicrobial resistance in the subgingival microflora in patients with adult periodontitis: a comparison between the Netherlands and Spain. *J Clin Periodontol* 27:79, 2000.
92. Vogel R, Schneider L, Goteinter D: The effects of a topical nonsteroidal anti-inflammatory drug on ligature induced periodontal disease in the squirrel monkey. *J Clin Periodontol* 12:139, 1986.
93. Waite I, Saxon C, Young A, et al: The periodontal status of subjects receiving nonsteroidal anti-inflammatory drugs. *J Periodontal Res* 16:100, 1981.
94. Walker C, Karpinia K: Rationale for use of antibiotics in periodontics. *J Periodontol* 73:1188, 2002.

95. Walker C, Thomas J: The effect of subantimicrobial doses of doxycycline on the microbial flora and antibiotic resistance in patients with adult periodontitis. Presented at the annual meeting of the American Academy of Periodontology, Boston, 1998.
96. Walker CB: Selected antimicrobial agents: mechanisms of action, side effects and drug interactions. *Periodontol 2000* 10:12, 1996.
97. Walker CB: The acquisition of resistance of antibiotic resistance in the periodontal microflora. *Periodontol 2000* 10:79, 1996.
98. Walker CB, Gordon JM, Socransky SS: Antibiotic susceptibility testing of subgingival plaque samples. *J Clin Periodontol* 10:422, 1983.
99. Walker CB, Gordon JM, McQuilkin SJ, et al: Tetracycline: levels achievable in gingival crevice fluid and in vitro effect on subgingival organisms. Part II. Susceptibilities of periodontal bacteria. *J Periodontol* 52:613, 1981.
100. Walker CB, Gordon JM, Magnusson I, et al: A role for antibiotics in the treatment of refractory periodontitis. *J Periodontol* 64:772, 1993.

CHAPTER 49

Host Modulation

Maria Emanuel Ryan and Ying Gu

CHAPTER OUTLINE

Systemically Administered Agents
Locally Administered Agents
Host Modulation and Comprehensive Periodontal Management
Sub-Antimicrobial-Dose Doxycycline
Emerging Host Modulatory Therapies *(e-only)*
Host Modulation Factors in Systemic Disorders *(e-only)*
Conclusion

For an expanded introduction to host modulation, as well as online only content on emerging host modulatory therapies and host modulation factors in systemic disorders, please visit the companion website at www.expertconsult.com. Some figures, boxes, and tables may be out of numeric order in this printed chapter.

HMT is a *means of treating the host side of the host-bacteria interaction*. The host response is responsible for most of the tissue breakdown that occurs, leading to the clinical signs of periodontitis (i.e., loss of connective tissue attachment and bone). HMTs offer the opportunity for modulating or reducing this destruction by treating aspects of the chronic inflammatory response. HMTs do not "switch off" normal defense mechanisms or inflammation; instead, they ameliorate excessive or pathologically elevated inflammatory processes to enhance the opportunities for wound healing and periodontal stability.

HMT can be used to reduce excessive levels of enzymes, cytokines, and prostanoids and should not reduce levels below constitutive levels. HMTs can also modulate osteoclast and osteoblast function (Figure 49-3) but should not impact normal tissue turnover. HMT is key to addressing many of the risk factors that have adverse effects on the host response, which are either not easily managed (e.g., smoking, diabetes) or cannot be changed (e.g., genetic susceptibility). In addition, host modulatory agents might be used to increase the levels of a person's own protective or anti-inflammatory mediators. Use of systemic HMTs for treatment of a patient's periodontal condition may also provide benefits for other inflammatory disorders such as arthritis, cardiovascular disease, dermatologic conditions, diabetes, rheumatoid arthritis, and osteoporosis. Also, patients who are currently taking host modulatory agents, such as nonsteroidal antiinflammatory drugs (NSAIDs), bisphosphonates, or tetracyclines, as well as newer agents targeting specific cytokines for the management of medical conditions, may be experiencing periodontal benefits from these systemic medications prescribed for the management of other chronic inflammatory conditions.

A variety of different drug classes have been evaluated as host modulation agents, including the NSAIDs, bisphosphonates, tetracyclines, enamel matrix proteins, growth factors, and bone morphogenetic proteins. This section discusses chemotherapeutics developed as HMTs researched as adjuncts to treat periodontitis to date, use of HMTs in clinical practice, and what the future might hold for HMTs.

Systemically Administered Agents

Nonsteroidal Antiinflammatory Drugs

NSAIDs inhibit the formation of prostaglandins, including PGE_2, which is produced by neutrophils, macrophages, fibroblasts, and gingival epithelial cells in response to the presence of LPS, a component of the cell wall of gram-negative bacteria. PGE_2 has been extensively studied in periodontal disease because it upregulates bone resorption by osteoclasts.[36,47,69] Levels of PGE_2 have been shown to be elevated in patients with periodontal disease compared with healthy patients.[38,69] PGE_2 also inhibits fibroblast function and has inhibitory and modulatory effects on the immune response.[39]

NSAIDs inhibit prostaglandins and therefore reduce tissue inflammation. They are used to treat pain, acute inflammation, and a variety of chronic inflammatory conditions. NSAIDs include the salicylates (e.g., aspirin), indomethacin, and the propionic acid derivatives (e.g., ibuprofen, flurbiprofen, and naproxen). The ability of NSAIDs to block PGE_2 production, thereby reducing inflammation and inhibiting osteoclast activity in the periodontal tissues, has been investigated in patients with periodontitis. Studies have shown that systemic NSAIDs, such as indomethacin,[103] flurbiprofen,[102] and naproxen[46] administered daily for up to 3 years, significantly slowed the rate of alveolar bone loss compared with placebo. However, NSAIDs have some serious disadvantages when considered for use as a HMT for periodontitis. Daily administration for extended periods is necessary for periodontal benefits to become apparent, and NSAIDs are associated with significant side effects, including gastrointestinal problems, hemorrhage (from decreased platelet aggregation), and renal and hepatic impairment. Furthermore, research shows that the periodontal benefits of taking long-term NSAIDs are lost when patients stop taking the drugs, with a return to or even an acceleration of the rate of bone loss

Host modulation is a relatively new term that has been incorporated into our dental jargon, but it has not been well defined. *Host* can be defined as "the organism from which a parasite obtains its nourishment," or in the transplantation of tissue, "the individual who receives the graft." *Modulation* is defined as "the alteration of function or status of something in response to a stimulus or an altered chemical or physical environment" (*Taber's Medical Dictionary,* 2004). In diseases of the periodontium that are initiated by bacteria, the "host" clearly is the individual who harbors these pathogens; however, it was not clear for many years whether it was possible to modulate the host response to these pathogens and other stimuli leading to the breakdown of the attachment apparatus. Host modulation with chemotherapeutic agents or drugs is the latest adjunctive therapeutic option for the management of periodontal diseases. The concept of host modulation is fairly new to the field of dentistry but is universally understood by most physicians who routinely apply the principles of host modulation to the management of a number of chronic progressive disorders such as arthritis and osteoporosis. The concept of host modulation was first introduced to dentistry by Williams[101] and Golub et al[35] and then expanded on by many other scholars in the dental profession. In 1990, Williams concluded "there are compelling data from studies in animals and human trials indicating that pharmacologic agents, that modulate the host responses believed to be involved in the pathogenesis of periodontal destruction, may be efficacious in slowing the progression of periodontitis."[101] In 1992, Golub and colleagues discussed "host modulation with tetracyclines and their chemically modified analogues."[35] The future that these authors described has arrived, and to better understand this new era in disease management, we must first look to the pathogenesis of periodontitis.

Many clinicians previously believed that periodontal disease was an inevitable consequence of aging and was uniformly distributed in the population. They thought that disease severity was directly correlated with plaque levels (i.e., the worse the oral hygiene, the worse the periodontal disease) and that disease progression occurred in a continuous, linear manner throughout life. Now, as a result of better epidemiologic data, there has been a paradigm shift in how clinicians and scientists view the prevalence and progression of this common disease. It has been well established that periodontal disease is not a natural consequence of aging and disease severity is not necessarily correlated with plaque levels. Theories about the pathogenesis of periodontitis have evolved from a purely plaque-associated disease to the more recent hypotheses that place considerable emphasis on the host's response to the bacteria.[10] The first Surgeon General's report on "Oral Health in America," published in 2000, recognized the importance of dental health in the overall general health and well-being of a patient.[93] Recent research findings indicate possible associations between chronic oral infections, such as periodontitis, and systemic disorders, such as diabetes, cardiovascular and lung diseases, stroke, osteoporosis, and rheumatoid arthritis. The Surgeon General's report assesses these emerging associations and explores factors that may underlie oral-systemic disease connections. Along with these findings and the emergence of the discipline of periodontal medicine, there have been many developments in therapeutic approaches to the management of periodontitis. The development of the chemotherapeutic approach known as "host modulation" required a thorough understanding of the host response and the impact of a variety of risk factors.

Anecdotally, many dentists have identified patients with abundant plaque and calculus deposits which may manifest itself as gingivitis with shallow pocketing. By contrast, other patients, despite maintaining a high standard of plaque control, succumb to aggressive forms of periodontitis, with deep pocketing, tooth mobility, and early tooth loss. The former group of patients is *periodontal disease resistant,* whereas the latter group is *periodontal disease susceptible.* Clearly, the response of the periodontal tissues to plaque is different in these two types of patients, and certain patients undergo advanced periodontal breakdown even though they achieve a high standard of oral hygiene. The previous observations led researchers to realize that the *host response* to the bacterial challenge presented by subgingival plaque is perhaps the *most* important determinant of disease severity, progression, and even response to therapy. Although plaque bacteria are capable of causing direct damage to the periodontal tissues (e.g., by release of H_2S, butyric acid, and other enzymes and mediators), it is now recognized that the great majority of the destructive events occurring in the periodontal tissues result from activation of destructive processes that occur as part of the host immune-inflammatory response to plaque bacteria. The host response is essentially protective by intent but paradoxically can also result in significant tissue damage, including breakdown of connective tissue fibers in the periodontal ligament and resorption of alveolar bone.

In 1985, research began to focus on bacterial-host interactions.[58] It had been recognized that although bacterial pathogens initiate the periodontal inflammation, the host response to these pathogens is equally, if not more, important in mediating connective tissue breakdown, including bone loss. It has become clear that the host-derived enzymes known as the *matrix metalloproteinases* (MMPs), as well as changes in osteoclast activity driven by cytokines and prostanoids, cause most of the tissue destruction in the periodontium.[68] This shift in paradigms, with a focus on the host response, led to the development of *host modulatory therapies* to improve therapeutic outcomes, slow the progression of disease, and allow for more predictable management of patients with periodontitis. This therapeutic strategy not only may be relevant to individuals at greater risk for periodontal disease but also may be important in the management of those at risk for a number of related systemic conditions. To better understand the host factors that clinicians are attempting to modulate, we need a more detailed assessment of the role of the host response in periodontal pathogenesis (Figure 49-1). After the accumulation of subgingival plaque bacteria, a variety of microbial substances, including chemotactic factors such as *lipopolysaccharide* (LPS), microbial peptides, and other bacterial antigens, diffuse across the junctional epithelium into the gingival connective tissues. The periodontium is anatomically unique in that the junctional epithelium ends on the tooth surface, which is nonliving tissue; there is no other such discontinuous lining over the entire surface of the body. The dentogingival junction indicates a priori vulnerability to bacterial attack. Epithelial and connective tissue cells are thus stimulated to produce inflammatory mediators that result in an inflammatory response in the tissues. The gingival vasculature dilates (vasodilation) and becomes increasingly permeable to fluid and cells. Fluid accumulates in the tissues, and defense cells migrate from the circulation toward the source of the chemotactic stimulus (bacteria and their products) in the gingival crevice. Neutrophils, or polymorphonuclear leukocytes (PMNs), predominate in the early stages of gingival inflammation to phagocytose and kill plaque bacteria. Bacterial killing by PMNs involves both intracellular mechanisms (after phagocytosis of bacteria within membrane-bound structures inside the cell) and extracellular mechanisms (by release of PMN enzymes and oxygen radicals outside the cell). As bacterial products enter the circulation, committed lymphocytes return to the site of infection, and B lymphocytes are transformed to plasma cells, which produce antibodies against

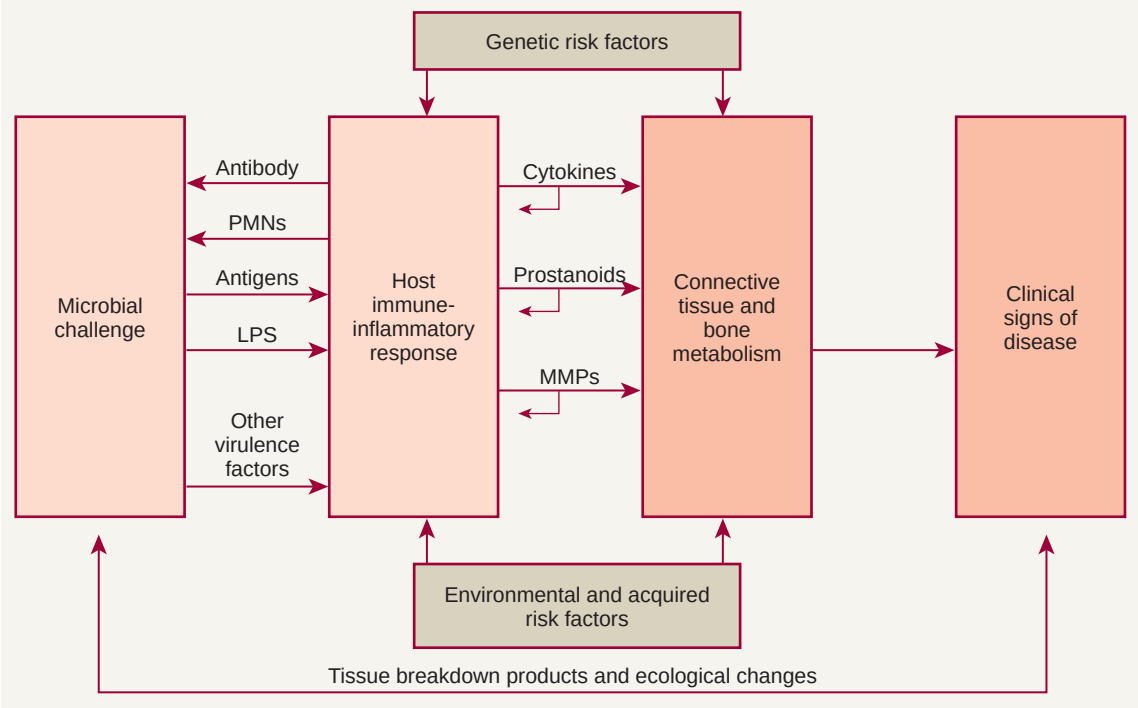

Figure 49-1 Schematic illustration of the pathogenesis of periodontitis. The microbial challenge presented by subgingival plaque bacteria results in an upregulated host immune-inflammatory response in the periodontal tissues that is characterized by the excessive production of inflammatory cytokines (e.g., interleukins, tumor necrosis factor), prostanoids (e.g., prostaglandin E_2) and enzymes, including the matrix metalloproteinases *(MMPs)*. These proinflammatory mediators are responsible for the majority of periodontal breakdown that occurs, leading to the clinical signs and symptoms of periodontitis. The process is modified by environmental (e.g., tobacco use) and acquired risk factors (e.g., systemic diseases) and genetic susceptibility. *PMNs,* Polymorphonuclear leukocytes; *LPS*, lipopolysaccharide. *(Modified from Page RC, Kornman KS: The pathogenesis of human periodontitis: an introduction, Periodontology 20:127, 2009.)*

specific bacterial antigens. Antibodies are released in the gingival tissues and, in the presence of complement, facilitate and enhance PMN phagocytosis and bacterial killing.

Thus a host immune-inflammatory response is established in the gingival tissues, and the clinical signs of gingivitis develop as the tissues become more edematous and erythematous. This response is essentially protective in intent, to combat the bacterial infection and prevent ingress of bacteria into the tissues. In persons who are not susceptible to periodontitis *(disease resistant),* these primary defense mechanisms control the infection, and chronic inflammation (i.e., chronic gingivitis) may persist indefinitely. In *disease-susceptible* individuals, however, inflammatory events extend apically and laterally to involve deeper connective tissues and alveolar bone. There is proliferation of the junctional epithelium, which becomes increasingly permeable and ulcerated, thus accelerating the ingress of bacterial products, and the inflammation worsens. Further defense cells are recruited to the area, including macrophages and lymphocytes. Large numbers of PMNs migrate into the tissues, secreting excessive quantities of destructive enzymes and inflammatory mediators indiscriminately into the tissues. These enzymes include the MMPs, such as collagenase and gelatinase, which break down collagen fibers in the gingival and periodontal tissues. The infiltrating inflammatory and immune cells are accommodated by the breakdown of structural components of the periodontium. MMPs are a primary target for host modulation. Pharmacologic agents or chemotherapeutics can be administered to suppress excessive levels of MMPs.

Macrophages are recruited to the area and are activated (by binding to LPS) to produce prostaglandins (e.g., prostaglandin E_2 [PGE_2]), interleukins (e.g., IL-1α, IL-1β, IL-6), tumor necrosis factor alpha (TNF-α), and MMPs. The cytokines (interleukins and TNF-α) and prostanoids are additional targets for host modulatory therapeutics. Interleukins and TNF-α bind to fibroblasts, which are stimulated to produce additional quantities of PGE_2, interleukins, TNF-α, and MMPs in positive-feedback cycles. The concentration of these enzymes and inflammatory mediators becomes pathologically high in the periodontal tissues. Host modulatory therapy (HMT) can be used to interrupt these positive-feedback loops and ultimately reduce the excessive levels of cytokines, prostanoids, and enzymes resulting in tissue destruction. MMPs break down collagen fibers, disrupting the normal anatomy of the gingival tissues ultimately resulting in destruction of the periodontal ligament. The inflammation extends apically, and osteoclasts are stimulated to resorb alveolar bone by the high levels of prostaglandins, interleukins, and TNF-α in the tissues. The osteoclasts themselves are targets for host modulation. Drugs can be administered to downregulate osteoclastic activity and ultimately to inhibit bone resorption by these cells.

The elevations in the proinflammatory or destructive mediators in response to bacterial challenge are counterbalanced by elevations in antiinflammatory or protective mediators such as the cytokines IL-4 and IL-10, as well as other mediators, such as IL-1ra (receptor antagonist), and tissue inhibitors of metalloproteinases (TIMPs) (Figure 49-2). Under conditions of health, the antiinflammatory or protective mediators serve to control tissue destruction. If there are adequate levels of these antiinflammatory or protective mediators to keep the host response to the bacterial challenge in check, the individual will be disease resistant. If an imbalance occurs, with excessive levels of the proinflammatory or destructive mediators present in the host tissues, tissue destruction will ensue

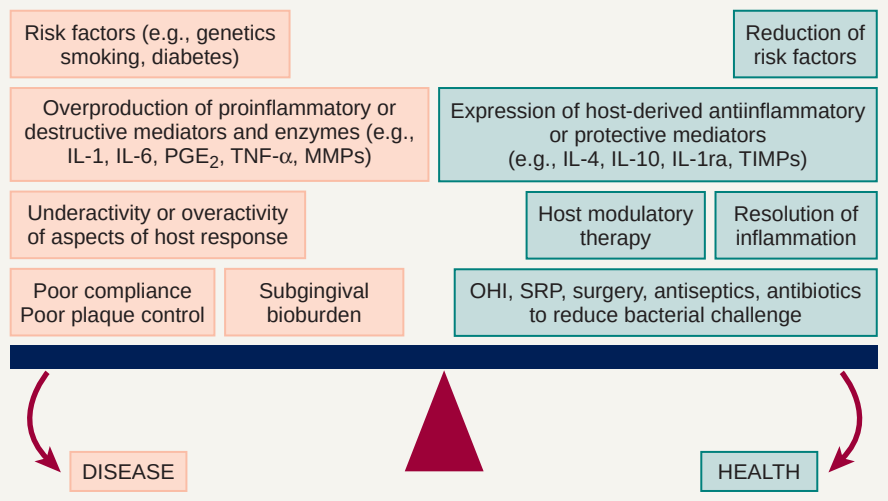

Figure 49-2 The periodontal balance. The balance between periodontal breakdown ("disease") and periodontal stability ("health") is tipped toward disease by risk factors, excessive production of inflammatory cytokines and enzymes (e.g., *IL-1* and *IL-6,* interleukin-1 and -6; PGE_2, prostaglandin E_2; *TNF-α,* tumor necrosis factor alpha; *MMPs,* matrix metalloproteinases), underactivity or overactivity of aspects of the immune-inflammatory host response, poor compliance, and a pathogenic microflora. The balance can be tipped toward health by risk factor modification, upregulation, and restoration of balance between naturally occurring inhibitors of inflammation (e.g., *IL-4* and *IL-10,* interleukins-4 and -10; *IL-1ra,* interleukin-1 receptor antagonist; *TIMPs,* tissue inhibitors of metalloproteinases), *HMT* (host modulatory therapy), and antibacterial treatments such as *OHI* (oral hygiene instructions), *SRP* (scaling and root planing), surgery, antiseptics, and antibiotics.

in the susceptible host. Another potential target for host modulation could entail the use of pharmacologic agents, which either mimic or result in elevations of endogenous antiinflammatory or protective mediators.

Thus plaque bacteria initiate the disease, and bacterial antigens that cross the junctional epithelium drive the inflammatory process. Therefore bacteria are essential for periodontitis to occur, but they are insufficient by themselves to cause disease. For periodontitis to develop, a susceptible host is also required. The majority of periodontal breakdown (bone loss, attachment loss) is caused by host-derived destructive enzymes (MMPs) and inflammatory mediators (prostaglandins, interleukins) that are released during the cascade of destructive events that occur as part of the inflammatory response[71] (see Figure 49-1). Paradoxically, the inflammatory response, which is essentially protective in design, is responsible for much of the breakdown of the soft and hard periodontal tissues. Periodontal disease is characterized by high concentrations of MMPs, cytokines, and prostanoids in the periodontal tissues, whereas periodontal health is characterized by the opposite.[70] The purpose of HMT is to restore the balance of proinflammatory or destructive mediators and antiinflammatory or protective mediators to that seen in healthy individuals. Pocket formation occurs as coronal junctional epithelium is broken down and restored at a more apical location. Plaque bacteria then migrate apically along the root surface deeper into the pocket, where the physical conditions favor the proliferation of gram-negative anaerobic species. Bacterial products continue to challenge the host, and the host continues its frustrated response against these bacteria and their products. Inflammation extends further and further apically, more bone is resorbed, and periodontal ligament (PDL) is broken down. The pocket deepens, and the associated attachment and bone loss result in clinical and radiographic signs of periodontitis. Intervention is required to prevent eventual tooth loss and other sequelae of the disease.

The nature of the host response to the presence of plaque is modified by genetic factors (helping to explain why aggressive periodontitis tends to have a familial aggregation) and systemic and environmental factors (e.g., smoking, diabetes, stress). These risk factors may lead to the imbalance between the proinflammatory and antiinflammatory mediators seen in susceptible individuals (see Figure 49-2). Risk factors can affect onset, rate of progression, and severity of periodontal disease, as well as response to therapy[24,41,86] (Box 49-1). Risk assessment is extremely important as we now recognize that some of these risk factors can be modified to reduce a patient's susceptibility to periodontitis. Risk reduction strategies may include smoking cessation, improved control of diabetes, nutritional supplementation, improved oral hygiene, changes in medication, stress management, weight loss, and more frequent dental visits (Box 49-2). The use of chemotherapeutic agents or drugs specifically designed to treat periodontal diseases is emerging to aid as a risk reduction strategy. Intervention in periodontal disease can now include HMT as one of the available adjunctive treatment options. The term *adjunctive* is meant to imply "in addition to conventional therapies" or "in addition to

BOX 49-1 Risk Factors for Periodontal Disease

- Heredity: family history, PST test
- Smoking: frequency, current history, past history
- Diabetes: duration, control
- Obesity
- Stress: reported by patient
- Medications: calcium channel blockers, phenytoin (Dilantin), cyclosporin, drugs known to cause dry mouth
- Nutrition
- Poor oral hygiene: plaque and calculus
- Faulty dentistry: overhangs, subgingival margins
- Hormonal variations: *pregnancy* (increased estradiol and progesterone), *menopause* (decreased estrogen, osteoporosis)
- Immunocompromise: HIV, neutropenia
- Connective tissue diseases
- Previous history of periodontitis

PST, Periodontal screening test; *HIV,* human immunodeficiency virus.

BOX 49-2 Risk Reduction Strategies

- Heredity: HMT chemotherapeutics
- Smoking: cessation, HMT chemotherapeutics
- Diabetes: improved control, work with physician; HMT chemotherapeutics
- Obesity: weight loss
- Stress: management, HMT chemotherapeutics
- Medications: change medications, work with physician; HMT chemotherapeutics
- Nutrition: supplements
- Poor oral hygiene: improved oral hygiene, HMT chemotherapeutics
- Faulty dentistry: corrective dentistry
- Hormonal variations: consult with physician, HMT chemotherapeutics
- Immunocompromise: consult with physician, HMT chemotherapeutics
- Connective tissue diseases: consult with physician, HMT chemotherapeutics

HMT, Host modulatory therapy.

other established therapies." For the management of periodontal diseases, conventional approaches were initially mechanical in nature, that is, surgery, as well as scaling and root planing (SRP). Initially, adjunctive therapies were solely antimicrobial such as the use of antiseptics and antibiotics (local and/or systemic). New adjunctive approaches involve modulation of the host response. Researchers are also investigating HMTs, which aim to modify or reduce destructive aspects of the host response so that the immune-inflammatory response to plaque is less damaging to the periodontal tissues. Removal of plaque by SRP targets one aspect of the pathogenic process by reducing the bacterial burden and therefore the antigenic challenge that drives the inflammatory response in the host tissues. However, the bacterial challenge is never completely eliminated after SRP, and recolonization by bacterial species occurs. HMTs offer the potential for downregulating destructive aspects and upregulating protective aspects of the host response so that, in combination with conventional treatments to reduce the bacterial burden, the balance between health (resolution of inflammation and wound healing) and disease progression (continued proinflammatory events) is tipped in the direction of a healing response.

Emerging Host Modulatory Therapies

In the future, a variety of HMTs will likely be developed as adjunctive treatments for periodontitis. One of the most promising groups of potential HMTs is the *chemically modified tetracyclines* (CMTs). These nonantibiotic tetracycline analogs are tetracycline molecules that have been modified to remove all antibiotic properties, but which retain host modulatory, anticollagenolytic effects. The CMTs are also designed to be more potent inhibitors of proinflammatory mediators and can increase levels of antiinflammatory mediators such as IL-10. Because they have no antimicrobial properties, the clinician would be able to increase the dose for more susceptible patients with more risk factors and who might be more difficult to manage without getting side effects seen with antibiotics. CMTs, such as CMT-3 and CMT-8 (both of which lack antibiotic activity but retain anti-MMP activity), have been shown to inhibit osteoclastic bone resorption and promote bone formation,[87] enhance wound healing,[74] and inhibit proteinases produced by periodontal pathogens.[38] CMTs also are being studied for other effects, such as inhibition of tumor cell invasion[54] and attenuation of intimal thickening after arterial injury.[48] CMTs will likely emerge as drugs that have beneficial effects in a variety of disease states because of their host modulation capabilities.

Other potential HMTs include the novel *anticytokine drugs* developed for the management of rheumatoid arthritis, a disease with a pathobiology similar to that of periodontitis.[62] Cytokines such as TNF-α have been targeted by TNF-α antagonists (e.g., infliximab, etanercept), which have been shown to be effective in treating rheumatoid arthritis.[96] As yet, such drugs have not been evaluated in the treatment of periodontal disease, but they could offer potential benefits given the importance of inflammatory cytokines, such as TNF-α, in periodontal pathogenesis. In addition, drugs designed to increase the levels of antiinflammatory or protective mediators, such as IL-1ra, can perform similar functions. In addition, evidence is emerging to support the benefits of combining HMTs that target different aspects of the disease processes. For example, the combination of SDD with bisphosphonates has also showed synergy in animal models of bone loss.

Recent research has indicated that there is an active biochemical resolution phase involved in inflammation. Failure of this resolution pathway may play a role in the pathogenesis of periodontal diseases.[94] Restoration of the resolution pathway by the introduction of resolving molecules may provide new potential therapeutic methods for the management of inflammatory periodontitis.[7] In rabbit animal models of periodontitis, topical application of Resolvin E1 has been shown to protect bone loss mediated by osteoclasts.[44] In the future, a combination of antiinflammatory drugs with resolving agents tested in human clinical trials may provide evidence to support a brand new host modulation therapy for the management of periodontal diseases.

As the concept of host modulation has become more widely accepted, we have seen much research looking toward the development of new HMTs. Some have focused in the efficacy of available nutritional supplements such as fish oils. Studies have indicated that n-3 polyunsaturated fatty acid (n-3 PUFA; fish oil), as an adjunct to oral hygiene instructions, can significantly lower GCF, IL-8, IL-6, and PGE_2 levels compared to placebo controls.[16] Other studies have found that a combination therapy with n-3 PUFA and low-dose aspirin as an adjunct to regenerative procedures using decalcified freeze-dried bone allografts result in greater mean probing depth reductions ($P < 0.001$) and gains in clinical attachment ($P < 0.05$) accompanied by a trend for modulation of the cytokine profile of IL-1β and IL-10 in GCF compared to placebo controlled regenerative therapy.[17] New collagenase (MMP) inhibitors known as poly-enolic zinc-binding compounds (PEZBINs; methoxycarbonyl curcumin) for periodontitis have also been investigated. In vitro and in vivo findings demonstrate that these potential new host modulatory agents can decrease pathologically elevated MMP levels in the plasma and gingiva of animal models of periodontitis.[31] Other approaches recently reported indicate the therapeutic potential of a novel semi-synthetic sulfated polysaccharide to suppress inflammatory mediators in high-risk individuals, such as those with diabetes and smokers, based on their ability to reduce the impact of advanced glycation end products (AGEs) thereby resulting in reductions of proinflammatory mediators of disease.[42]

Host Modulation Factors in Systemic Disorders

In susceptible patients demonstrating an excessive local inflammatory response to the bacterial stimuli leading to periodontal disease, another consideration involves the loss of epithelial integrity in the

periodontal pocket. This tissue response allows for bacterial penetration into the inflamed tissues and eventual entry of the bacteria into the systemic circulation. Patients with untreated periodontitis have an increased risk for transient bacteremias. Bacteremia and associated endotoxemia may incite the overproduction of destructive proinflammatory mediators at distant sites in the periodontitis patient. Therefore patients with periodontitis may be at greater risk for developing a number of systemic conditions associated with a similar overactive host response to external stimuli such as cardiovascular disease and diabetic complications. Elevated levels of cytokines, prostanoids, and enzymes are evident in all these conditions.

In the era of periodontal medicine, systemic host modulatory approaches need to be considered. As mentioned, host modulators used to manage periodontal disease, such as an MMP, cytokine, and prostanoid inhibitors, may have additional beneficial effects on systemic diseases that have been linked to periodontal disease, such as CVD and diabetes. In CVD, preliminary studies have indicated that individuals with periodontal disease are almost twice as likely to have a fatal heart attack and three times as likely to have a stroke.[4] MMPs and cytokines have been found to play a major role in weakening the plaques formed with CVD, leading to rupture and eventual thrombosis and infarction.[25] In fact, Golub et al[28] suggested that tetracyclines could reduce the incidence of acute myocardial infarction[61] by blocking collagenase and stabilizing the collagen cap on the atheroscleromatous arterial plaques. In diabetes, the same MMPs and cytokines involved in the development of periodontitis as the sixth long-term complication of diabetes[60] also play a role in the development of other well-known complications of diabetes such as nephropathy, angiopathy, retinopathy, and wound-healing problems.[83] Modulation of these proinflammatory mediators in patients with diabetes may impede the development of multiple long-term complications. An inhibitor of MMPs, cytokines, and prostanoids used in the treatment of periodontitis may have an indirect effect on these disease processes if a patient's risk for developing these disorders is increased by the presence of untreated periodontitis. HMT may also directly aid in the treatment and prevention of CVD and diabetic complications.

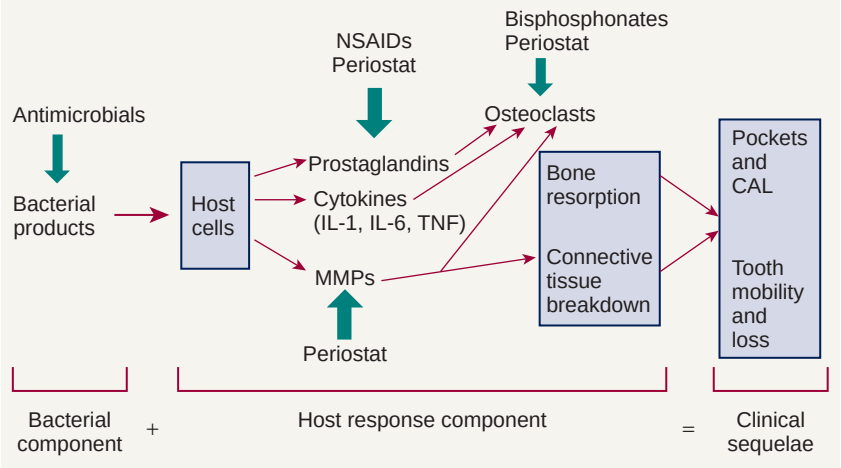

Figure 49-3 Potential adjunctive therapeutic approaches. Possible adjunctive therapies and points of intervention in the treatment of periodontitis are presented related to the pathologic cascade of events. *CAL,* Clinical attachment loss.

seen before NSAID therapy, often referred to as a "rebound effect."[104] For these reasons, the long-term use of NSAIDs as an adjunctive treatment for periodontitis has never really developed beyond research studies.

It was previously anticipated that the selective cyclooxygenase-2 (COX-2) inhibitors may offer promise as adjunctive treatments in the management of periodontitis. The enzyme cyclooxygenase, which converts arachidonic acid to prostaglandins, exists in two functionally distinct isoforms, COX-1 and COX-2. COX-1 is constitutively expressed and has antithrombogenic and cytoprotective functions. Therefore, inhibition of COX-1 by nonselective NSAIDs causes side effects such as gastrointestinal ulceration and impaired hemostasis. COX-2 is induced after stimulation by various cytokines, growth factors, and LPS and results in the production of elevated quantities of prostaglandins. Inhibition of COX-2 by selective COX-2 inhibitors results in reduction of inflammation. Researchers considered that the use of selective COX-2 inhibitors offered the prospect for reducing periodontal inflammation without the side effects typically observed after long-term (nonselective) NSAID therapy, and preliminary studies identified that selective COX-2 inhibitors slowed alveolar bone loss in animal models[5,45] and modified prostaglandin production in human periodontal tissues.[95] However, the selective COX-2 inhibitors were later identified to be associated with significant and life-threatening adverse effects (i.e., myocardial infarction), resulting in some drugs being withdrawn from the market. In summary, NSAIDs (including the selective COX-2 specific inhibitors) are presently not indicated as adjunctive HMTs in the treatment of periodontal disease.

Bisphosphonates

The bisphosphonates are bone-seeking agents that inhibit bone resorption by disrupting osteoclast activity. Their precise mechanism of action is unclear, but research has shown that bisphosphonates interfere with osteoblast metabolism and secretion of lysosomal enzymes.[100] More recent evidence has suggested that bisphosphonates also possess anticollagenase properties.[64] The ability of bisphosphonates to modulate osteoclast activity clearly may be useful in the treatment of periodontitis. Research has demonstrated that in naturally occurring periodontitis in beagle dogs, treatment with the bisphosphonate, alendronate, significantly increased bone density compared with placebo.[80] In animal models of experimentally induced periodontitis, bisphosphonates reduced alveolar bone resorption.[88,100] In human studies, these agents resulted in enhanced alveolar bone status and density.[18,82]

Some bisphosphonates have the unwanted effects of inhibiting bone calcification and inducing changes in white blood cell counts. Also, there have been recent reports of avascular necrosis of the jaws following bisphosphonate therapy, with the resultant risk of bone necrosis following dental extractions.[11] The recent reports of bisphosphonate-related osteonecrosis of the jaw (BRONJ), although primarily associated with intravenous administration of bisphosphonates rather than oral administration, has impeded the development of bisphosphonates as an HMT to manage periodontitis. As with NSAIDs, at present there are no bisphosphonate drugs that are approved and indicated for treatment of periodontal diseases.

Sub-Antimicrobial-Dose Doxycycline

Sub-antimicrobial-dose doxycycline (SDD) is a 20-mg dose of doxycycline (Periostat) that is approved and indicated as an adjunct to SRP in the treatment of chronic periodontitis. It is taken twice daily for 3 months, up to a maximum of 9 months of continuous dosing. The 20-mg dose exerts its therapeutic effect by enzyme, cytokine, and osteoclast inhibition rather than by any antibiotic effect. Research studies have found no detectable antimicrobial effect on the oral flora or the bacterial flora in other regions of the body and have identified clinical benefit when used as an adjunct to SRP. At present, SDD (Periostat) is the only systemically administered HMT specifically indicated for the treatment of chronic periodontitis that is approved by the U.S. Food and Drug Administration (FDA) and accepted by the American Dental Association (ADA). In addition, a modified-release SDD was recently approved by the FDA (Oracea) for the treatment of the common skin disorder rosacea and is routinely prescribed within the dermatology community. Studies conducted by Preshaw et al,[79] using this same modified-release SDD versus placebo in 266 subjects with periodontitis as an adjunct to SRP resulted in significantly greater clinical benefits than SRP alone in the treatment of periodontitis. It will be interesting to see what the long-term benefits to oral health will be in rosacea patients being prescribed this new drug. There has also been considerable off-label use of this new modified-release SDD for the treatment of periodontal diseases based on the understanding that once-a-day administration can increase the level of compliance as compared to twice-a-day oral administration.

Locally Administered Agents

Nonsteroidal Antiinflammatory Drugs

Topical NSAIDs have shown benefit in the treatment of periodontitis. One study of 55 patients with chronic periodontitis who

received topical ketorolac mouth rinse reported that gingival crevicular fluid (GCF) levels of PGE_2 were reduced by approximately half over 6 months and that bone loss was halted.[49] In addition, locally administered ketoprofen has been investigated. To date, topically administered NSAIDs have not been approved as local HMTs for the management of periodontitis.

Enamel Matrix Proteins, Growth Factors, and Bone Morphogenetic Proteins

A number of local HMTs have been investigated for potential use as adjuncts to surgical procedures, not only to improve wound healing but also to stimulate regeneration of lost bone, periodontal ligament, and cementum, restoring the complete periodontal attachment apparatus. These have included enamel matrix proteins, bone morphogenetic proteins (BMP-2, BMP-7), growth factors (platelet-derived growth factor, insulin-like growth factor), and tetracyclines. The locally applied HMTs currently approved by the FDA for adjunctive use during surgery are enamel matrix proteins (Emdogain), recombinant human platelet-derived growth factor-BB (GEM 21S), and BMP-2 (INFUSE), which are covered in much greater detail in other chapters. The initial local host modulatory agent approved by the FDA for adjunctive use during surgery to assist with clinical attachment gain and wound healing was Emdogain; this has been followed by platelet-derived growth factor combined with a resorbable synthetic bone matrix (GEM 21S) to assist in regenerative procedures approved recently by the FDA, as well as rhBMP-2 (INFUSE) soaked onto an absorbable collagen sponge to assist with ridge and sinus augmentation. The technology behind GEM 21 has also been approved and marketed for use in wound healing, particularly in patients with diabetes, and INFUSE has been used for quite some time for the healing of fractures by the orthopedic community.

The remainder of this chapter focuses on the clinical utility of host modulation for nonsurgical procedures in clinical practice and the use of SDD (Periostat) in clinical practice.

Host Modulation and Comprehensive Periodontal Management

The term *periodontal management* suggests a much broader concept of periodontal care than the term *periodontal treatment.* This concept is extremely important considering the chronic nature of the disease. Management includes thorough medical and dental history and examination (clinical charting and radiographs), assessment of risk factors, diagnosis, development of a treatment strategy, initial and definitive treatment planning, review of treatment outcomes and reevaluation, long-term supportive periodontal therapy (maintenance care), and assessment of prognosis. In addition, as new data continue to emerge regarding biochemical assessments of disease activity (measuring levels of proinflammatory mediators, bone and connective tissue breakdown products in the GCF, saliva, and tissues of the oral cavity), new diagnostic and prognostic tests may become part of our established protocols for comprehensive periodontal disease management in the future. However, controlling the bacteria that cause periodontal infections remains a central focus of effective periodontal treatment. Understanding the importance of the host response and the impact of risk factors now allows clinicians to provide complementary treatment strategies simultaneously for their patients (Figure 49-4).

Those patients most likely requiring the use of HMT include those with risk factors that are either nonmodifiable or not easily modified. If the decision is made to use HMT, this must be discussed with the patient and the rationale for treatment thoroughly explained. This takes time at the chair side, but it is time well spent;

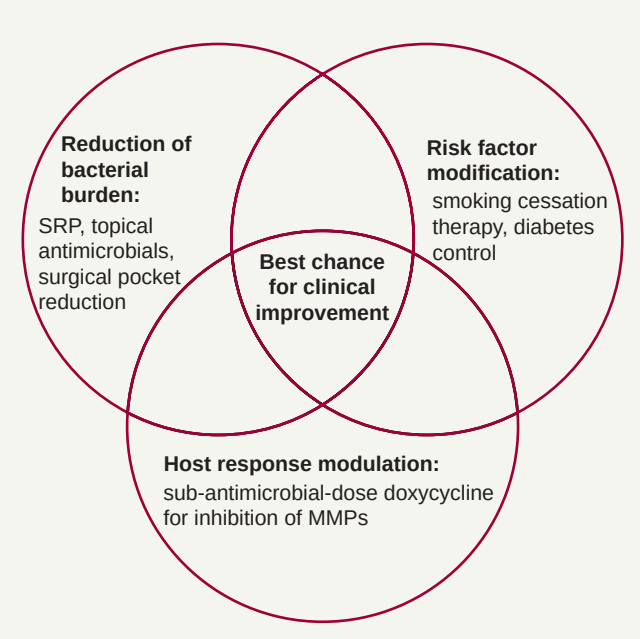

Figure 49-4 Complementary treatment strategies in periodontitis. The best chance for clinical improvement may come from implementing complementary treatment strategies that target different aspects of the periodontal balance. Reduction of the bacterial burden by scaling and root planing *(SRP)* is the cornerstone of treatment and can be augmented by the use of topical antimicrobials and surgical pocket therapy. In addition to this antibacterial treatment approach, the host response can be treated by the use of host modulatory therapy, such as sub-antimicrobial-dose doxycycline, for the inhibition of matrix metalloproteinases *(MMPs)*. Risk factor assessment and modification must form a key part of any periodontal treatment strategy, including smoking cessation counseling. These different but complementary treatment strategies can be used together as part of a comprehensive management approach.

patients become increasingly interested in their periodontal status and are more likely to develop ownership of their management, thereby enhancing compliance with all aspects of care, including plaque control, risk reduction, and treatment protocols. Compliance with HMT is greatly facilitated if the rationale for prescribing is clearly explained. The need for compliance with the prescribed drug regimen is important because with SDD, for example, a tablet must be taken twice daily (once in the morning and once in the evening) and should not be taken with calcium supplements. Compliance may be improved by administration of a modified-release SDD capsule taken only once a day. It should be emphasized to the patient that the use of HMT is not a substitute for excellent plaque control (just as it is not a substitute for excellent debridement and root surface instrumentation by the treating clinician). To achieve the best results, patients must be interested and well informed about their condition so that compliance is maximized. Furthermore, patients must also be convinced that comprehensive and frequent recall appointments are absolutely necessary in the maintenance phase of this chronic and often progressive disease, which can be very well controlled with adequate follow-up.

In addition to patient motivation, oral hygiene instruction, and SRP to reduce the bacterial challenge, a key treatment strategy when managing periodontitis patients is *risk factor modification.* The harmful effects of smoking on the periodontal tissues are well documented,[51] and successful smoking cessation therapy will likely be a major benefit to patients with periodontitis. Smoking cessation

counseling can be undertaken in the dental office (if staff are appropriately trained) or through collaboration with the patient's physician or specialized clinics. Given the evidence that smokers have worse periodontal disease than nonsmokers[89,105] and that the magnitude and predictability of clinical improvements after treatment are significantly reduced in smokers,[1,75] smoking cessation counseling should form a major part of treatment for smokers with periodontitis. Patients with poorly controlled diabetes are also at increased risk for periodontitis,[59] and periodontal therapy may have an impact on diabetic control.[39] Collaboration with medical colleagues when treating diabetic patients with periodontitis is warranted to ascertain the degree of diabetic control.[23] Other possible risks for periodontitis include nonmodifiable factors such as genetics, gender, and race. As the relevance of different risk factors is established through epidemiologic research, clinicians must remain aware of their responsibilities for informing and attempting to change patients' behaviors in relation to modifiable risks.

The management of patients with periodontitis can therefore involve the following complementary treatment strategies:

- Patient education and motivation, including oral hygiene instruction; use of powered toothbrushes, antiseptics in rinses, toothpastes, and irrigation; and explanation of the rationale for any adjunctive treatments
- Reduction of the bacterial burden by high-quality SRP
- Site-specific antibacterial treatment with local delivery systems or systemic antimicrobial therapy in select cases
- Host response modulation by HMT
- Risk factor modification and risk reduction strategies
- Periodontal surgery with or without HMT

It is the responsibility of the dentist to customize the treatment plan for each individual patient by selecting and providing appropriate treatments, following discussion and informed decision making by the patient. Good communication and showing an interest in the patient's condition are essential to maximize compliance and modify risk factors. The best chance for clinical improvement may come from a combination of targeted treatment approaches for each patient (see Figure 49-4). In fact, Novak et al published very striking improvements in probing depth reductions and clinical attachment level gains in a 6-month, randomized, multicenter, examiner-blinded, placebo-controlled study, which showed that combination therapy of HMT (SDD) plus a locally delivered antimicrobial (doxycycline hyclate gel) and SRP provided optimal improvements in clinical parameters when compared to SRP alone in the treatment of moderate-to-severe periodontitis.[66]

Sub-Antimicrobial-Dose Doxycycline

As previously discussed, SDD is currently the only FDA-approved, systemically administered HMT indicated specifically in the treatment of periodontitis. SDD is used as an adjunct to SRP and must not be used as a stand-alone therapy (monotherapy). Because SDD, previously called "low-dose doxycycline" (LDD) and currently marketed as Periostat, is based on SDD, a member of the tetracycline family of compounds, the use of tetracyclines for the management of periodontal diseases must be put in perspective.

In regard to incorporation of a medical pharmacologic approach into the management of a disease in the dental practice setting, no class of drugs has made more of an impact on periodontal therapy than the tetracyclines. They have been used in conjunction with SRP, the "gold standard" of nonsurgical therapy, as well as with both resective and regenerative surgical procedures. The tetracyclines have been used locally and systemically as antimicrobial agents and more recently, systemically as a host modulation agent (SDD). The tetracyclines have been prescribed not only to address chronic periodontitis but also to manage specific and often more aggressive types of periodontitis. Most recently, the tetracyclines have been advocated for the management of patients with systemic diseases such as diabetes, rheumatoid arthritis, and rosacea (doxycycline [Oracea]); doxycycline has led to improvements in both the periodontal health of compromised diabetic patients and long-term markers of glycemic control (e.g., glycated hemoglobin).[40] As an adjunct to mechanical therapies, the goal of tetracycline therapy has been to enhance reattachment or even to stimulate new attachment of the supporting apparatus and osseous formation.

This section concentrates on the use of these pleiotropic compounds for modulation of the host response in the treatment of periodontitis.

Mechanisms of Action

In addition to its antibiotic properties, doxycycline (as well as the other members of the tetracycline family) has the ability to downregulate MMPs, a family of zinc-dependent enzymes that are capable of degrading extracellular matrix molecules, including collagen.[6,84] MMPs are secreted by the major cell types in the periodontal tissues (fibroblasts, keratinocytes, macrophages, PMNs, endothelial cells) and play a key role in periodontitis. Excessive quantities of MMPs are released in inflamed periodontal tissues, resulting in breakdown of the connective tissue matrix. The predominant MMPs in periodontitis, particularly MMP-8 and MMP-9, derive from PMNs[33] and are extremely effective in degrading type I collagen, the most abundant collagen type in gingiva and periodontal ligament.[57] Levels of PMN-type MMPs have been shown to increase with severity of periodontal disease and decrease after therapy.[26,33] The release of large quantities of MMPs in the periodontium leads to significant anatomic disruption and breakdown of the connective tissues, contributing to the clinical signs of periodontitis.

The rationale for using SDD as a HMT in the treatment of periodontitis is that doxycycline downregulates the activity of MMPs by a variety of synergistic mechanisms, including reductions in cytokine levels, and stimulates osteoblastic activity and new bone formation by upregulating collagen production (Figure 49-5).

Clinical Research Data on Distinct Patient Populations

Tetracyclines work well as host modulation agents because of their pleiotropic effects on multiple components of the host response (see Figure 49-3). The only enzyme (MMP) inhibitors that have been approved for clinical use and tested for the treatment of periodontitis are members of the tetracycline family of compounds. In early studies investigating the use of different commercially available tetracyclines, Golub et al[34] reported that the semisynthetic compound (e.g., doxycycline) was more effective than the parent compound tetracycline in reducing excessive collagenase activity in the GCF of chronic periodontitis patients. Because doxycycline was found to be a more effective inhibitor of collagenase than either minocycline or tetracycline[9,27] and because of its safety profile, pharmacokinetic properties, and ready systemic absorption, recent clinical trials have focused on this compound. In an effort to eliminate the side effects of long-term tetracycline therapy, especially the emergence of tetracycline-resistant organisms, SDD capsules were prepared and tested.[33] Each capsule contained 20 mg of doxycycline versus the commercially available 50 mg and 100 mg, antimicrobially effective, capsules or tablets. Multiple clinical studies using SDD have shown no difference in the composition or resistance level of the oral flora.[91,99] More recent studies also

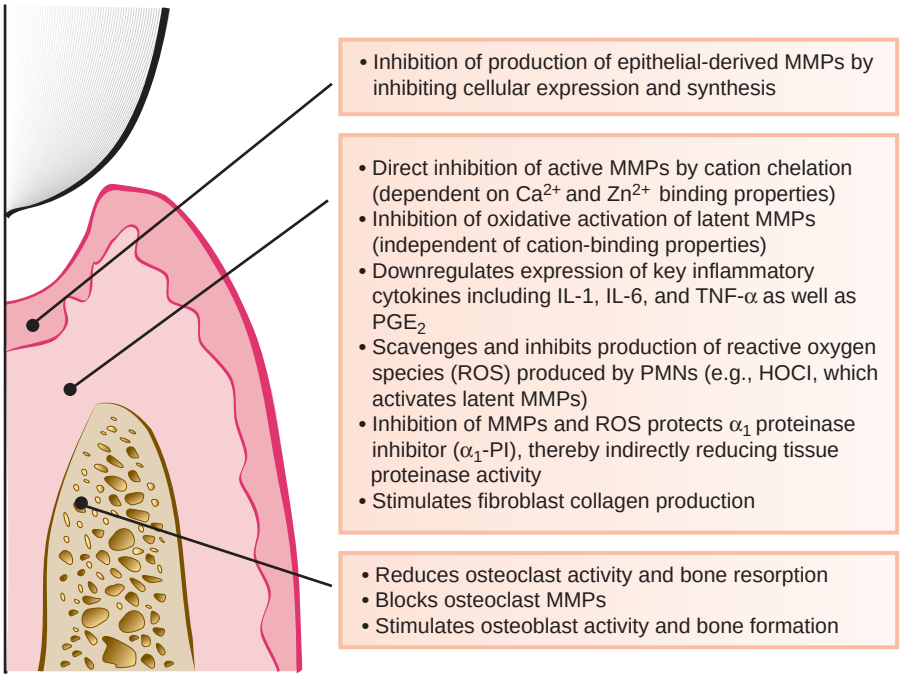

Figure 49-5 Schematic of periodontal pocket indicating the pleiotropic mechanisms by which doxycycline inhibits connective tissue breakdown. Downregulation of destructive events occurring in the periodontal tissues by doxycycline results from modulation of a variety of different proinflammatory pathways. *(From Golub LM, Lee HM, Ryan ME, et al:* Adv Dent Res *12:12, 1998.)*

demonstrate no appreciable differences in either fecal or vaginal microflora samples.[97] In addition, these studies have shown no overgrowth of opportunistic pathogens, such as *Candida,* in the oral cavity, gastrointestinal system, or genitourinary system.

With regard to MMP inhibition, Golub et al[26] reported that a 2-week regimen of SDD reduced collagenase in GCF and in the adjacent gingival tissues surgically excised for therapeutic purposes. Subsequent studies using SDD therapy adjunctive to routine scaling and prophylaxis indicated continued reductions in the excessive levels of collagenase in the GCF after 1 month of treatment. After cessation of SDD administration, however, there was a rapid rebound of collagenase activity to placebo levels, suggesting that a 1-month treatment regimen with this host modulation agent was insufficient to produce a long-term benefit.[3] In contrast, during the same study, a 3-month regimen produced a prolonged drug effect without a rebound in collagenase levels to baseline during the no-treatment phase of the study. The mean levels of GCF collagenase were significantly reduced (47.3% from baseline levels) in the SDD group versus the placebo group, who received scaling and prophylaxis alone (29.1% reduction from baseline levels). Accompanying these reductions in collagenase levels were gains in the relative attachment levels in the SDD group.[3,32] Continuous drug therapy over several months appears to be necessary for maintaining collagenase levels near normal over prolonged periods. However, it is reasonable to speculate that levels of these MMPs will eventually increase again in the more susceptible patients, and those individuals having the most risk factors and the greatest microbial challenge will require more frequent HMT than other patients.

General Patient Populations. Data from clinical trials of SDD are summarized in Table 49-1. In addition, a series of double-blind, placebo-controlled studies of 3, 6, and 9 months' duration all showed clinical efficacy based on reductions in probing depth and gains in clinical attachment as well as biochemical efficacy, based on the inhibition of collagenase activity and protection of serum α_1-antitrypsin (a naturally occurring protective mediator) from collagenase attack in the periodontal pocket.[14,27,52] Golub et al[29] showed that a 2-month regimen of SDD significantly decreased both the level of bone-type collagen breakdown products (carboxy terminal telopeptide of type 1 collagen [ICTP]; carboxy terminal peptide, a pyridinoline-containing cross-linked peptide of type 1 collagen) and MMP-8 and MMP-13 enzyme levels (neutrophil and bone-type collagenase) in chronic periodontitis subjects (Figure 49-6).

The Phase III, 9-month, randomized, double-blind, placebo-controlled trial conducted at five dental centers demonstrated clinical efficacy and safety of SDD versus placebo as an adjunct to SRP. The benefits of HMT as an adjunct to mechanical therapy were again seen, with statistically significant reductions in probing depths and gains in clinical attachment levels, as well as the prevention of disease progression.[12] When SDD administration was discontinued after 9 months of continuous therapy, the incremental improvements demonstrated in the SDD group were maintained for at least 3 months. There was no rebound effect in either the pocket depth reductions or the clinical attachment level gains; in fact, there appeared to be slight continued improvement in both these clinical parameters, presumably because of the enhanced clinical status of the patients who had benefited from adjunctive SDD, and possibly also because of the known persistence or substantivity of doxycycline in the bone and soft tissue of the periodontium. The clinical relevance of such findings confirms the utility of an MMP inhibitor in the management of chronic periodontitis.

High-Risk Patients: Smokers. The harmful effects of cigarette smoking and the reduced response to periodontal treatment in smokers compared with nonsmokers are well established.[51] A recent meta-analysis of randomized clinical trials of SDD used as an adjunct to SRP revealed a benefit when using SDD in smokers with periodontitis[65,76] (see Table 49-1). A hierarchic treatment response was observed such that nonsmokers who received SDD

TABLE 49-1 Summary of Data Reported in Clinical Trials of Sub-Antimicrobial-Dose Doxycycline (SDD)[78]

			MEAN CAL CHANGE (mm)		MEAN PD REDUCTION (mm)		% SITES WITH CAL GAIN‡		% SITES WITH PD REDUCTION‡	
Study (Year)	**Duration**	**Study Groups *(N)***	**4-6 mm Pockets**	**7+ mm Pockets**	**4-6 mm Pockets**	**7+ mm Pockets**	**≥2 mm**	**≥3 mm**	**≥2 mm**	**≥3 mm**
Caton et al (2000)[12]	Study: 9 months (drug: 9 months)	SRP + SDD (90)	1.03*	1.55*	0.95†	1.68†	46	22	47*	22*
		SRP + placebo (93)	0.86	1.17	0.69	1.20	38	16	35	13
Novak et al (2002)[67]	Study: 9 months (drug: 6 months)	SRP + SDD (10)	1.00	1.78	1.20	3.02	29	15	48	26
		SRP + placebo (10)	0.56	1.24	0.97	1.42	21	11	21	6
Emingil et al (2004)[19]	Study: 12 months (drug: 3 months)	SRP + SDD (10)	0.21 (all sites)	1.59* (all sites)						
		SRP + placebo (10)	0.05 (all sites)	1.32 (all sites)						
Preshaw et al (2004)[77]	Study: 9 months (drug: 9 months)	SRP + SDD (107)	1.27†	2.09*	1.29†	2.31†	58*	33†	62†	37†
		SRP + placebo (102)	0.94	1.60	0.96	1.77	44	20	45	21
Lee et al (2004)[53]	Study: 9 months (drug: 9 months)	SRP + SDD (240)	1.56*(all sites)	1.63* (all sites)						
		SRP + placebo (17)	0.80 (all sites)	1.19 (all sites)						
Choi et al (2004)[13]	Study: 4 months (drug: 4 months)	SRP + SDD (15)	2.2* (test sites)	1.6* (test sites)						
		SRP + placebo (17)	0.6 (test sites)	1.1 (test sites)						
Gurkan et al (2005)[43]	Study: 6 months (drug: 3 months)	SRP + SDD (13)	1.12	2.15	1.80	3.38				
		SRP + placebo (13)	0.78	1.76	1.46	2.57				
Preshaw et al (2005)¶[76]	Study: 9 months (drug:9 months)	SRP + SDD# (116)	1.23*	1.89†	1.22†	2.16*	59†	33†	63§	37
		SRP + placebo# (135)	0.96	1.43	0.88	1.53	43	19	44	18
		SRP + SDD## (81)	1.03	1.71	1.01	1.80	44	21	45†	20
		SRP + placebo## (60)	0.85	1.58	0.80	1.62	37	15	31	13
Mohammad et al (2005)[63]	Study: 9 months (drug: 9 months)	SRP + SDD (12)	2.14§	3.18*	1.57§	3.22§				
		SRP + placebo (12)	0.02	0.25	0.63	0.98				
Górska and Nedzi-Góra (2006)[37]	Study: 3 months (drug: 3 months)	SRP + SDD (33)	0.33* (all sites)	0.29* (all sites)						
		SRP + placebo (33)	0.04 (all sites)	0.08 (all sites)						
Needleman et al (2007)[65]	Study: 6 months (drug: 3 months)	SRP + SDD## (18)	0.65 (all sites)	1.40 (all sites)						
		SRP + placebo## (16)	0.40 (all sites)	0.98 (all sites)						

*$p < 0.05$ compared with placebo.

†$p < 0.01$ compared with placebo.

‡Percentage of sites with CAL gain and PD reduction ≥2 mm and ≥3 mm calculated for all sites that had 6+ mm probing depths at baseline.

§$p < 0.001$ compared with placebo.

¶Same study population as Preshaw et al (2004),[77] stratified by smoking status: *#*, nonsmokers, *##*, smokers.

N, Number of subjects; *SRP*, scaling and root planing; *CAL*, clinical attachment level, CAL change can be positive (CAL gain) or negative (CAL loss); *PD*, probing depth.

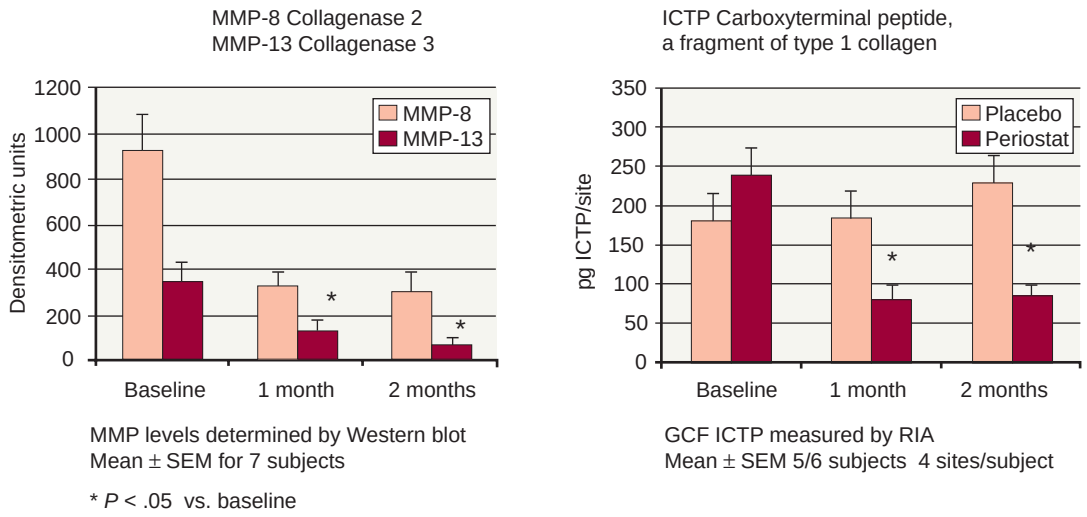

Figure 49-6 Effect of sub-antimicrobial-dose doxycycline (SDD) on gingival crevicular fluid (GCF) collagenase (MMP-8, MMP-13) and ICTP. A 2-month regimen of SDD significantly decreased levels of matrix metalloproteinases (MMP-8 and MMP-13, neutrophil and bone-type collagenases, respectively) and ICTP compared with placebo in GCF samples of adult periodontitis patients. Decreased levels of GCF bone-type collagen breakdown products (ICTP, pyridinoline-containing cross-linked peptide of type 1 collagen) in the SDD group versus the placebo group provides biochemical evidence of a reduction in bone resorption. *RIA,* Radioimmunoassay. *(From Golub LM, Lee HM, Greenwald RA, et al:* Inflamm Res *46:310, 1997.)*

demonstrated the best clinical improvements and smokers who received placebo had the poorest treatment response. The responses of the smokers who received SDD and the nonsmokers who received placebo were intermediate to the two extremes and were broadly identical. This suggests that even patients traditionally considered resistant to periodontal treatment (i.e., smokers) can benefit from SDD, with a treatment response similar to that expected when treating a nonsmoker by scaling and root planing alone.

Special Patient Populations. More recent Phase IV (i.e., post-licensing) clinical studies have revealed success using SDD in particular populations of susceptible individuals. Much interest has focused on genetic susceptibility to periodontal disease, particularly whether a specific variation in the genes that regulate the cytokine IL-1 confers increased susceptibility to disease. This polymorphism is known as the *periodontitis-associated genotype* (PAG), the presence of which can be characterized using a commercially available screening test, the PST genetic susceptibility test. Investigation of patients who possess this gene polymorphism has been driven by the assumption that local phenotypic differences exist in chronic periodontitis associated with this genotype (e.g., that PAG-positive patients produce more IL-1 cytokines for a given bacterial challenge, resulting in increased tissue damage and more extensive periodontal disease). However, few studies exist of the impact of cytokine gene polymorphism on tissue IL-1 cytokine levels in periodontal disease to support this, although IL-1β levels in shallow periodontal pockets have been reported to be higher in patients with the genotype than those without.[21] The studies that have investigated associations between PAG and periodontal disease status have thus far generated conflicting data (as reviewed by Taylor et al).[90] A reasonable assumption currently is that there are genetic associations between polymorphisms in the IL-1 gene cluster and periodontal disease but that unambiguous results are not yet apparent because of the heterogeneity of the disease and/or the variable design of the reported studies. Cullinan et al concluded that IL-1 genotype is a contributory but nonessential risk factor for periodontal disease progression.[15]

A 5-month preliminary investigation by Ryan et al[85] was designed to evaluate the impact of treatment on IL-1β and MMP levels in PST-positive (PAG) patients who presented with elevated levels of these biochemical markers in their GCF. These patients were initially treated with SRP, resulting in no change in the levels of these biochemical markers after 1 month. Al-Shammari et al[2] reported similar findings, with no changes in GCF levels of IL-1β and ICTP before and after SRP in patients who had not been genotyped. When the genotype-positive patients received SDD and these biochemical markers were monitored at 2 and 4 months, a significant decrease (50% to 61%) in the IL-1β and MMP-9 levels was noted after treatment with SDD. Correspondingly, gains in clinical attachment and reduced probing depths were also observed. The study concluded that SDD may provide PST-positive patients with a therapeutic strategy that specifically addresses their exaggerated host response.

Another recent study was conducted in susceptible patients with severe generalized periodontitis using host modulation (SDD) as an adjunct to repeated subgingival debridement.[67] Seventy percent of the patients who completed this 9-month double-blind, placebo-controlled study were smokers. SDD as an adjunct to mechanical therapy versus mechanical therapy alone resulted in significantly greater mean probing depth reductions in pockets of 7 mm or greater at baseline as early as 1 month after therapy (2.52 versus 1.25 mm, respectively). These improvements in the SDD group compared with the group receiving mechanical therapy only were maintained during the 5.25 months of therapy (2.85 versus 1.48 mm, respectively) and even at 3 months after stopping drug therapy (3.02 versus 1.41 mm), demonstrating that no rebound effect occurred. Because of the beneficial effects of HMT in susceptible patients, multicenter studies are using SDD in other susceptible populations, including diabetic, osteoporotic, and institutionalized geriatric patients, as well as smokers.

Since periodontitis is associated with many systemic diseases (e.g., osteoporosis, diabetes, and cardiovascular disease [CVD]), researchers have investigated the effect of SDD on these systemic conditions. Payne et al[72] conducted a 2-year randomized, double-blind, placebo-controlled trial in osteopenic women at two dental

centers demonstrating that SDD can effectively reduce the levels of localized and systemic inflammatory mediators in osteopenic patients in addition to improving on the clinical measurements of periodontitis[30]; SDD significantly reduced the progression of periodontal attachment loss[81] and the severity of gingival inflammation and alveolar bone loss in postmenopausal osteopenic women.[72] Golub et al[30] reported that collagenase activity in the GCF of these osteopenic women was significantly reduced by SDD treatment. ICTP showed a similar pattern of change during SDD treatment with GCF collagenase activity and ICTP levels positively correlated at all time periods ($P < 0.001$). MMP-8 accounted for approximately 80% of total collagenase in the GCF, with much lower levels of MMP-1 and -13. SDD dramatically reduced the elevated MMP-8 levels by 60%. This 2-year study also demonstrated that long-term continuous use of SDD did not produce antibiotic side effects,[98] confirming what had been reported previously in studies of continuous use of up to 12 months. Previously reported studies had demonstrated a relationship between serum high-sensitivity C-reactive protein (hsCRP) concentration and biochemical bone turnover markers in healthy pre- and postmenopausal women.[50] These findings suggested that low-grade systemic inflammation may be a common linking factor between the development of atherosclerosis and an increased bone turnover rate. A recently published study by Payne et al[69] demonstrated that the 2-year SDD regimen described above in postmenopausal women significantly reduced serum inflammatory biomarkers (hs-CRP and MMP-9) and, among women more than 5 years post-menopausal, increased the high-density lipoprotein (HDL) cholesterol level. These preliminary findings suggest that SDD may play a role in managing the care of patients at risk for developing coronary artery disease. Other studies have shown that SDD reduces systemic inflammatory biomarkers in CVD patients[8] and SDD decreases glycosylated hemoglobin (HbA_{1c}) assay in patients who are taking normally prescribed hypoglycemic agents.[20] The impact of SDD therapy on periodontitis may be amplified by the concurrent use of other HMTS used to manage other inflammatory diseases. Additional studies are being conducted to investigate the impact of combined HMT use not only on periodontal disease but on other chronic inflammatory conditions.

Suggested Uses and Other Considerations

Until relatively recently, treatment options for periodontal disease have focused solely on reducing the bacterial challenge by nonsurgical therapy, surgery, and systemic or local antimicrobial therapy. The development of SDD as an HMT, driven by research into the pathogenesis of periodontal disease, is a great example of how translational research can lead to new treatments. By better understanding the biochemical processes that are important in periodontal disease, a pharmacologic principle (doxycycline downregulates MMP activity) has been used in the development of a new drug treatment. Data presented from research studies show the clinical benefits of adjunctive SDD, and the science behind SDD has been transferred into clinical practice. In other words, dentists now have the opportunity to use SDD for patient care, with the aim being to enhance the treatment response to conventional therapy.

Candidate Patients. When deciding whether to use SDD as an adjunct to SRP, first consider the patient's motivation toward periodontal care, the medical history, and the patient's willingness to take a systemic drug treatment. SDD is contraindicated in any patient with a history of allergy or hypersensitivity to tetracyclines. It should not be given to pregnant or lactating women or children younger than 12 years old (because of the potential for discoloration of the developing dentition). Doxycycline may reduce the efficacy of oral contraceptives; therefore alternative forms of birth control should be discussed, if necessary. There is a risk of increased sensitivity to sunlight (manifested by an exaggerated sunburn) seen with higher doses of doxycycline, although this has not been reported in the clinical trials using the sub-antimicrobial dose.

The rationale for using SDD must be clearly explained to the patient. By discussing the etiology of periodontal disease, the available treatment options, and the anticipated outcomes, patients become more interested in their periodontal management, are more likely to comply with treatment, and take more responsibility for managing their disease. Therefore the anticipated compliance and likely commitment to treatment must also be gauged when considering SDD therapy. Patients who show little enthusiasm for complying with the treatment plan or with oral hygiene practices are less likely to be good candidates for systemic drug therapy.

Treatable Periodontal Conditions. SDD is indicated in the management of chronic periodontitis, and studies to date have focused on chronic and aggressive forms of periodontitis.[12,19,67,77] SDD should not be used in conditions such as gingivitis and periodontal abscess or when an antibiotic is indicated. SDD can be used in patients with aggressive periodontitis who are being treated nonsurgically. Furthermore, emerging studies have supported efficacy of SDD as an adjunct to periodontal surgery.[22] SDD may also be of benefit in cases that are refractory to treatment, as well as in patients with risk factors such as smoking, diabetes, osteoporosis/osteopenia, genetic susceptibility, and in whom the treatment response might be limited.

Side Effects. Doxycycline at antibiotic doses (≥100 mg) is associated with adverse effects, including photosensitivity, hypersensitivity reactions, nausea, vomiting, and esophageal irritation. However, in the clinical trials of SDD (20-mg dose), it was reported that the drug was well tolerated, and the profile of unwanted effects was virtually identical in the SDD and placebo groups.[12,19,67,77] The types of adverse events did not differ significantly between treatment groups, and the typical side effects of the tetracycline class were not observed indicating that the appearance of adverse events is dose related.[12,77] Furthermore, there was no evidence of adverse events that could be attributed to antimicrobial effects of treatment and no evidence of developing antibiotic resistance of the microflora after 2 years of continuous use.[12,91,92,98,99] Therefore the drug appears to be well tolerated, with a very low incidence of adverse effects.

Sequencing Prescription with Periodontal Treatment. SDD is indicated as an adjunct to mechanical periodontal therapy and should not be used as a stand-alone or monotherapy. SDD should be prescribed to coincide with the first round of SRP and is prescribed for 3 months, up to a maximum of 9 to 24 months of continuous dosing depending on the patient risk. Modification of any risk factors, such as smoking, nutrition, stress, contributing medications, faulty restorations, poor oral hygiene, and poor diabetic control, should also be addressed at this time. A patient's refusal or inability to modify contributing risk factors is an important consideration for treatment planning and evaluation of therapeutic responses.

After initial periodontal treatment, the patient is enrolled into an intensive periodontal maintenance program. This involves

regular monitoring of probing depths, reinforcement of oral hygiene, and remotivation of the patient, with further SRP to disrupt the plaque biofilm and remove re-forming calculus deposits. The 3-month prescription of SDD fits in well with the typical maintenance recall interval of 3 months, which in turn is based on the duration reported for recolonization of treated periodontal pockets.[55]

Thus SDD therapy is commenced at the start of initial periodontal therapy and continues for 3 months until the first reevaluation or maintenance appointment. At maintenance appointments, the need for further prescription of SDD can be assessed. For patients demonstrating a good treatment response with significant reductions in probing depths, further SDD may not be necessary. Periodontal maintenance care must continue, with an emphasis on plaque control, monitoring, and prophylaxis. In other patients, the treatment response after completion of initial therapy may be less favorable. Sites with persisting or progressing pockets may require additional instrumentation, and the prescription of SDD may be extended for an additional 3 months. SDD may be combined with the use of locally applied antimicrobials and surgical procedures. Remember that periodontitis is a chronic disease, and the treatment (whether SDD is used or not) is long term. The patient must be regularly reevaluated to determine disease stability or progression and the need for additional active therapy.

Therefore patients may cycle between phases of "active" treatment (SRP + SDD) and long-term periodontal maintenance. The success of the maintenance phase of treatment will be affected by many factors, including the following:

- Compliance with the maintenance regimen.
- Compliance with oral hygiene instruction.
- Presence of risk factors, such as smoking, poorly controlled diabetes, or stress.
- Extent (i.e., number) and severity (i.e., depth) of residual deep pockets.

Maintenance therapy is more likely to be successful in patients with good compliance, good oral hygiene, minimal or no systemic risk factors, and minimal residual deep pocketing. The patient who enters the maintenance program may have periodontal stability for months or years. However, plaque control may deteriorate, the patient may develop or acquire new risk factors, and disease progression (i.e., further loss of attachment) may become apparent, indicating that a further course of treatment is required. A further course of SRP will then be undertaken together with adjunctive SDD to restore periodontal stability.

Combining with Periodontal Surgery or Local Delivery Systems. Most clinical research to date has focused on using SDD as an adjunct to nonsurgical periodontal treatment. However, emerging data in which SDD was used as an adjunct to access flap surgery in 24 patients revealed better probing depth reductions in surgically treated sites greater than 6 mm compared with surgically treated sites in patients given placebo.[22] Furthermore, the SDD group demonstrated greater reductions in ICTP (carboxy-terminal peptide, a breakdown product of collagen) than the placebo group, indicating that collagenolytic activity was reduced in the patients taking SDD.

SDD treatment can also be combined with the local delivery of antibiotics into the periodontal pocket through sustained-delivery systems. The two treatment approaches target different aspects of the pathogenic process: Local delivery systems deliver antimicrobial concentrations of an antibacterial agent directly into the site of the pocket, whereas SDD is a systemic host response modulator. Thus combining these two complementary treatment strategies is another example of how antibacterial therapy (SRP + local antibiotics) can be combined with HMT (SDD) to maximize the clinical benefit for patients. Preliminary results from a 6-month, 180-patient clinical trial designed to evaluate the safety and efficacy of SDD combined with a locally applied antimicrobial (doxycycline hyclate [Atridox]) and SRP versus SRP alone demonstrated that patients receiving the combination of treatments experienced more than a 2-mm improvement in mean attachment gains and probing depth reductions ($P < 0.0001$) compared with SRP alone.[66]

Monitoring Benefits of Therapy. To improve the ability of dentists to make appropriate treatment decisions for patients undergoing periodontal therapy, it would be extremely useful if they had access to the types of diagnostic tests available to their medical colleagues. Such tests might be used, for example, to distinguish between active and inactive lesions. Studies have shown that SRP alone, although effective for improving clinical parameters such as probing depths, may not be sufficient to reduce excessive levels of many underlying destructive mediators, particularly in more susceptible patients. It would be valuable therefore if it were possible to monitor the levels of such inflammatory mediators as treatment progresses. SDD results in downregulation of MMP activity in inflamed periodontal tissues.[26,29] Therefore, in theory, MMP levels could be monitored before, during, and after SRP plus SDD treatment. Published data support a concomitant reduction in MMP levels in GCF[13,19] and improvements in clinical parameters when combining SDD and SRP.[19] Although chair-side tests for MMPs have been developed,[56] they are not in widespread use because of concerns about their specificity or sensitivity.

In the absence of new chair-side tests or a centralized diagnostic facility for monitoring the inflammatory status of the tissues, dentists must rely on clinical periodontal monitoring to assess the outcomes of treatment. In addition to the reductions in probing depths and gains in attachment that may be observed after SRP plus SDD, the quality of the periodontal tissues also tends to improve after treatment with SDD. More sensitive radiographic techniques, assessments of bone density, and bone height changes used solely in clinical trials in the past may be possible in clinical practice in the future. Until such diagnostic techniques are made widely available, however, clinicians must rely on clinical judgment to determine the most appropriate course of therapy.

Conclusion

Periodontal pathogens and destructive host responses are involved in the initiation and progression of periodontitis. Therefore the successful long-term management of this disease may require a treatment strategy that integrates therapies that address both etiologic components. Evidence for the role of MMPs, cytokines, and other mediators in the pathogenesis of periodontal disease distinguishes them as viable targets for a chemotherapeutic approach. The introduction of novel, adjunctive therapies such as host modulation to enhance the efficacy of existing mechanical procedures can contribute favorably to an integrated approach for the long-term, clinical management of periodontitis.

HMTs are an emerging treatment concept in the management of periodontitis. The use of HMT as an adjunct may be particularly useful in susceptible, high-risk patients in whom a prolonged and excessive host response to the presence of bacteria promotes the activity of MMPs and osteoclasts. SDD is the only systemically administered HMT currently approved and indicated as an adjunct to SRP for treating periodontitis. Clinical trials have demonstrated

a clear treatment benefit when using SDD versus SRP alone. SDD should be used as part of a comprehensive treatment strategy that includes antibacterial treatments (SRP, plaque control, oral hygiene instruction, local antimicrobials, and periodontal surgery), host response modulation (SDD), and assessment and management of periodontal risk factors. In the future, a range of HMTs targeting different aspects of the destructive cascade of breakdown events in the periodontal tissues are likely to be developed as adjunctive treatments for periodontitis. The further development of these agents will permit dentists to treat specific aspects of the underlying biochemical basis for periodontal disease. The goal is to maximize and make more predictable the treatment response by reducing inflammation and inhibiting destructive processes in the tissues, which will result in enhanced periodontal stability after conventional periodontal treatments such as SRP and surgery. The dentist is now in the exciting position to be able to combine established treatment strategies with new systemic and local drug treatments for this common, chronic disease.

The findings discussed with regard to the use of HMT to better manage chronic periodontal disease may have applications to other chronic systemic diseases such as arthritis, diabetes, osteoporosis, and cardiovascular disease. In addition, studies using locally applied antimicrobials as part of an intensive periodontal therapy (IPT) regimen have shown very promising results. Future studies may demonstrate that in addition to our current standard therapies, IPT with adjunctive antibiotics and/or host modulation for the management of periodontal disease may have profound positive effects on the overall health status of high-risk patients. The proper management of local infection and inflammation (periodontitis) will have a significant impact on the general overall health of the population.

Suggested Readings

Caton JG, Ciancio SG, Blieden TM, et al: Treatment with subantimicrobial dose doxycycline improves the efficacy of scaling and root planing in patients with adult periodontitis. *J Periodontol* 71:521, 2000.

Genco RJ: Current view of risk factors for periodontal diseases. *J Periodontol* 67:1041, 1996.

Golub LM, Ciancio S, Ramamurthy NS, et al: Low-dose doxycycline therapy: effect on gingival and crevicular fluid collagenase activity in humans. *J Periodontal Res* 25:321, 1990.

Mariotti A: The extracellular matrix of the periodontium: dynamic and interactive tissues. *Periodontol 2000* 3:39, 1993.

Novak MJ, Dawson DR 3rd, Magnusson I, et al: Combining host modulation and topical antimicrobial therapy in the management of moderate to severe periodontitis: a randomized multicenter trial. *J Periodontol* 79(1):33, 2008.

Payne JB, Golub LM, Stoner JA, et al: The effect of subantimicrobial-dose-doxycycline periodontal therapy on serum biomarkers of systemic inflammation: a randomized, double-masked, placebo-controlled clinical trial. *J Am Dent Assoc* 142(3):262, 2011.

Preshaw PM: Host response modulation in periodontics. *Periodontol 2000* 48:92, 2008.

Ryan ME, Ramamurthy NS, Golub LM: Matrix metalloproteinases and their inhibition in periodontal treatment. *Curr Opin Periodontol* 3:85, 1996.

Walker C, Preshaw PM, Novak J, et al: Long-term treatment with subantimicrobial dose doxycycline has no antibacterial effect on intestinal flora. *J Clin Periodontol* 32:1163, 2005.

Williams RC: Periodontal disease. *N Engl J Med* 322(6):373, 1990.

References

References for this chapter are found on the companion website www.expertconsult.com.

References

1. Ah MK, Johnson GK, Kaldahl WB, et al: The effect of smoking on the response to periodontal therapy. *J Clin Periodontol* 21:91, 1994.
2. Al-Shammari KF, Giannobile WV, Aldredge WA, et al: Effect of non-surgical periodontal therapy on C-telopeptide pyridinoline cross-links (ICTP) and interleukin-1 levels. *J Periodontol* 72:1045, 2001.
3. Ashley RA: Clinical trials of a matrix metalloproteinase inhibitor in human periodontal disease. SDD Clinical Research Team. *Ann NY Acad Sci* 878:335, 1999.
4. Beck JD, Offenbacher S, Williams R, et al: Periodontitis: a risk factor for coronary heart disease? *Ann Periodontol* 3:127, 1998.
5. Bezerra MM, de Lima V, Alencar VB, et al: Selective cyclooxygenase-2 inhibition prevents alveolar bone loss in experimental periodontitis in rats. *J Periodontol* 71:1009, 2000.
6. Birkedal-Hansen H: Role of matrix metalloproteinases in human periodontal diseases. *J Periodontol* 64:474, 1993.
7. Bhatavadekar NB, Williams RC: New directions in host modulation for the management of periodontal disease. *J Clin Periodontol* 36(2):124, 2009.
8. Brown DL, Desai KK, Vakili BA, et al: Clinical and biochemical results of the metalloproteinase inhibition with subantimicrobial doses of doxycycline to prevent acute coronary syndromes (MIDAS) pilot trial. *Arterioscler Thromb Vasc Biol* 24(4):733, 2004.
9. Burns FR, Stack MS, Gray RD, et al: Inhibition of purified collagenase from alkali-burned rabbit corneas. *Invest Ophthalmol Vis Sci* 30:1569, 1989.
10. Carranza FA, editor: *Clinical periodontology*, ed 8, Philadelphia, 1996, Saunders.
11. Carter G, Goss AN, Doecke C: Bisphosphonates and avascular necrosis of the jaw: a possible association. *Med J Aust* 182(8):413, 2005.
12. Caton JG, Ciancio SG, Blieden TM, et al: Treatment with subantimicrobial dose doxycycline improves the efficacy of scaling and root planing in patients with adult periodontitis. *J Periodontol* 71:521, 2000.
13. Choi DH, Moon IS, Choi BK, et al: Effects of sub-antimicrobial dose doxycycline therapy on crevicular fluid MMP-8, and gingival tissue MMP-9, TIMP-1 and IL-6 levels in chronic periodontitis. *J Periodontal Res* 39:20, 2004.
14. Crout RJ, Lee HM, Schroeder K, et al: The "cyclic" regimen of low-dose doxycycline for adult periodontitis: a preliminary study. *J Periodontol* 67:506, 1996.
15. Cullinan MP, Westerman B, Hamlet SM, et al: A longitudinal study of interleukin-1 gene polymorphisms and periodontal disease in a general adult population. *J Clin Periodontol* 28:1137, 2001.
16. Dawson D, Steffen M, Ebersole J, et al: Effects of dietary fish oil as adjunct to oral hygiene. *J Dent Res* 89A:2010. (abstract 1268).
17. Elkhouli AM: The efficacy of host response modulation therapy (omega-3 plus low-dose aspirin) as an adjunctive treatment of chronic periodontitis (clinical and biochemical study). *J Periodontal Res* 46(2):261, 2011.
18. El-Shinnawi UM, El-Tantawy SI: The effect of alendronate sodium on alveolar bone loss in periodontitis (clinical trial). *J Int Acad Periodontol* 5:5, 2003.
19. Emingil G, Atilla G, Sorsa T, et al: The effect of adjunctive low-dose doxycycline therapy on clinical parameters and gingival crevicular fluid matrix metalloproteinase-8 levels in chronic periodontitis. *J Periodontol* 75:106, 2004.
20. Engebretson SP, Hey-Hadavi J, Celenti R, et al: Low-dose doxycycline treatment reduces glycosylated hemoglobin in patients with type 2 diabetes: a randomized controlled trial. *J Dent Res* 82(special issue), 2003. (abstract 1445).
21. Engebretson SP, Lamster IB, Herrera-Abreu M, et al: The influence of interleukin gene polymorphism on expression of interleukin-1beta and tumor necrosis factor-alpha in periodontal tissue and gingival crevicular fluid. *J Periodontol* 70:567, 1999.
22. Gapski R, Barr JL, Sarment DP, et al: Effect of systemic matrix metalloproteinase inhibition on periodontal wound repair: a proof of concept trial. *J Periodontol* 75:441, 2004.
23. Genco RJ: Current view of risk factors for periodontal diseases. *J Periodontol* 67:1041, 1996.
24. Genco RJ: Host responses in periodontal diseases: current concepts. *J Periodontol* 63:338, 1992.
25. Genco RJ, Offenbacher S, Beck J, et al: Cardiovascular disease and oral infections. In Rose LF, editor: *Periodontal medicine*, Ontario, 1999, BC Decker.
26. Golub LM, Ciancio S, Ramamurthy NS, et al: Low-dose doxycycline therapy: effect on gingival and crevicular fluid collagenase activity in humans. *J Periodontal Res* 25:321, 1990.
27. Golub LM, Evans RT, McNamara TF, et al: A non-antimicrobial tetracycline inhibits gingival matrix metalloproteinases and bone loss in Porphyromonas gingivalis-induced periodontitis in rats. *Ann NY Acad Sci* 732:96, 1994.
28. Golub LM, Greenwald RA, Thompson RW: Antibiotic use and risk of myocardial infarction. *JAMA* 282:1999, 1997.
29. Golub LM, Lee HM, Greenwald RA, et al: A matrix metalloproteinase inhibitor reduces bone-type collagen degradation fragments and specific collagenases in gingival crevicular fluid during adult periodontitis. *Inflamm Res* 46:310, 1997.
30. Golub LM, Lee HM, Stoner JA, et al: Subantimicrobial-dose doxycycline modulates gingival crevicular fluid biomarkers of periodontitis in postmenopausal osteopenic women. *J Periodontol* 79(8):1409, 2008.
31. Golub LM, Lee HM, Zhang Y, et al: New collagenase (MMP) inhibitors for periodontitis and other diseases. *J Dent Res* 89A, 2010. (abstract 1182).
32. Golub LM, McNamara TF, Ryan ME, et al: Adjunctive treatment with subantimicrobial doses of doxycycline: effects on gingival fluid collagenase activity and attachment loss in adult periodontitis. *J Clin Periodontol* 28:146, 2001.
33. Golub LM, Sorsa T, Lee HM, et al: Doxycycline inhibits neutrophil (PMN)-type matrix metalloproteinases in human adult periodontitis gingiva. *J Clin Periodontol* 22:100, 1995.
34. Golub LM, Wolff M, Lee HM, et al: Further evidence that tetracyclines inhibit collagenase activity in human crevicular fluid and from other mammalian sources. *J Periodont Res* 20:12, 1985.
35. Golub LM, Suomalainen K, Sorsa T: Host modulation with tetracyclines and their chemically modified analogues. *Curr Opin Dent* 2:80, 1992.
36. Goodson JM, Dewhirst FE, Brunetti A: Prostaglandin E_2 levels and human periodontal disease. *Prostaglandins* 6:81, 1974.
37. Górska R, Nedzi-Góra M: The effects of the initial treatment phase and of adjunctive low-dose doxycycline therapy on clinical parameters and MMP-8, MMP-9, and TIMP-1 levels in the saliva and peripheral blood of patients with chronic periodontitis. *Arch Immunol Ther Exp (Warsz)* 54(6):419, 2006.
38. Grenier D, Plamondon P, Sorsa T, et al: Inhibition of proteolytic, serpinolytic, and progelatinase-b activation activities of periodontopathogens by doxycycline and the non-antimicrobial chemically modified tetracycline derivatives. *J Periodontol* 73:79, 2002.
39. Grossi SG, Genco RJ: Periodontal disease and diabetes mellitus: a two-way relationship. *Ann Periodontol* 3:51, 1998.
40. Grossi SG, Skrepcinski FB, DeCaro T, et al: Treatment of periodontal disease in diabetics reduces glycated hemoglobin. *J Periodontol* 68:713, 1997.
41. Grossi SG, Zambon JJ, Ho AW, et al: Assessment of risk for periodontal disease. I. Risk indicators for attachment loss. *J Periodontol* 65:260, 1994.
42. Gu Y, Lee HM, Prestwich G, et al: Therapeutic potential of a novel semi-synthetic-sulfated-polysaccharide to suppress inflammatory mediators. *J Dent Res* 92A, 2013 (abstract 1435).
43. Gürkan A, Cinarcik S, Hüseyinov A: Adjunctive subantimicrobial dose doxycycline: effect on clinical parameters and gingival crevicular fluid transforming growth factor-beta levels in severe, generalized chronic periodontitis. *J Clin Periodontol* 32(3):244, 2005.
44. Hasturk H, Kantarci A, Goguet-Surmenian E, et al: Resolvin E1 regulates inflammation at the cellular and tissue level and restores tissue homeostasis in vivo. *J Immunol* 179(10):7021, 2007.

45. Holzhausen M, Rossa C, Jr, Marcantonio E, Jr, et al: Effect of selective cyclooxygenase-2 inhibition on the development of ligature-induced periodontitis in rats. *J Periodontol* 73:1030, 2002.
46. Howell TH, Jeffcoat MK, Goldhaber P, et al: Inhibition of alveolar bone loss in beagles with the NSAID naproxen. *J Periodontal Res* 26:498, 1991.
47. Howell TH, Williams RC: Non-steroidal anti-inflammatory drugs as inhibitors of periodontal disease progression. *Crit Rev Oral Biol Med* 4:177, 1993.
48. Islam MM, Franco CD, Courtman DW, et al: A nonantibiotic chemically modified tetracycline (CMT-3) inhibits intimal thickening. *Am J Pathol* 163:1557, 2003.
49. Jeffcoat MK, Reddy MS, Haigh S, et al: A comparison of topical ketorolac, systemic flurbiprofen, and placebo for the inhibition of bone loss in adult periodontitis. *J Periodontol* 66:329, 1995.
50. Kim BJ, Yu YM, Kim EN, et al: Relationship between serum hsCRP concentration and biochemical bone turnover markers in healthy pre- and postmenopausal women. *Clin Endocrinol (Oxf)* 67(1):152, 2007.
51. Kinane DF, Chestnutt IG: Smoking and periodontal disease. *Crit Rev Oral Biol Med* 11:356, 2000.
52. Lee HM, Golub LM, Chan D, et al: α_1-Proteinase inhibitor in gingival crevicular fluid of humans with adult periodontitis: serpinolytic inhibition by doxycycline. *J Periodontal Res* 32:9, 1997.
53. Lee JY, Lee YM, Shin SY, et al: Effect of subantimicrobial dose doxycycline as an effective adjunct to scaling and root planing. *J Periodontol* 75(11):1500, 2004.
54. Lokeshwar BL, Escatel E, Zhu B: Cytotoxic activity and inhibition of tumor cell invasion by derivatives of a chemically modified tetracycline CMT-3 (COL-3). *Curr Med Chem* 8:271, 2001.
55. Magnusson I, Lindhe J, Yoneyama T, et al: Recolonization of a subgingival microbiota following scaling in deep pockets. *J Clin Periodontol* 11:193, 1984.
56. Mantyla P, Stenman M, Kinane DF, et al: Gingival crevicular fluid collagenase-2 (MMP-8) test stick for chair-side monitoring of periodontitis. *J Periodontal Res* 38:436, 2003.
57. Mariotti A: The extracellular matrix of the periodontium: dynamic and interactive tissues. *Periodontol 2000* 3:39, 1993.
58. Maynard J: Eras in periodontics: periodontal disease management: a conference for the dental team, Boston, 1993, American Academy of Periodontology.
59. Mealey B: Diabetes and periodontal diseases. *J Periodontol* 71:664, 2000.
60. Mealy B: Diabetes mellitus. In Rose LF, editor: *Periodontal medicine*, Ontario, 1999, BC Decker.
61. Meier CR, Derby LE, Jick SS, et al: Antibiotics and risk of subsequent first-time acute myocardial infarction. *JAMA* 281:427, 1999.
62. Mercado FB, Marshall RI, Bartold PM: Inter-relationships between rheumatoid arthritis and periodontal disease: a review. *J Clin Periodontol* 30:761, 2003.
63. Mohammad AR, Preshaw PM, Bradshaw MH, et al: Adjunctive subantimicrobial dose doxycycline in the management of institutionalised geriatric patients with chronic periodontitis. *Gerodontology* 22(1):37, 2005.
64. Nakaya H, Osawa G, Iwasaki N, et al: Effects of bisphosphonate on matrix metalloproteinase enzymes in human periodontal ligament cells. *J Periodontol* 71:1158, 2000.
65. Needleman I, Suvan J, Gilthorpe MS, et al: A randomized-controlled trial of low-dose doxycycline for periodontitis in smokers. *J Clin Periodontol* 34(4):325, 2007.
66. Novak MJ, Dawson DR 3rd, Magnusson I, et al: Combining host modulation and topical antimicrobial therapy in the management of moderate to severe periodontitis: a randomized multicenter trial. *J Periodontol* 79(1):33, 2008.
67. Novak MJ, Johns LP, Miller RC, et al: Adjunctive benefits of subantimicrobial dose doxycycline in the management of severe, generalized, chronic periodontitis. *J Periodontol* 73:762, 2002.
68. Offenbacher S: Periodontal diseases: pathogenesis. *Ann Periodontol* 1:821, 1996.
69. Offenbacher S, Heasman PA, Collins JG: Modulation of host PGE2 secretion as a determinant of periodontal disease expression. *J Periodontol* 64:432, 1993.
70. Page RC: Milestones in periodontal research and the remaining critical issues. *J Periodontal Res* 34:331, 1999.
71. Page RC, Kornman KS: The pathogenesis of human periodontitis: an introduction. *Periodontol 2000* 14:9, 1997.
72. Payne JB, Stoner JA, Nummikoski PV, et al: Subantimicrobial dose doxycycline effects on alveolar bone loss in post-menopausal women. *J Clin Periodontol* 34(9):776, 2007.
73. Payne JB, Golub LM, Stoner JA, et al: The effect of subantimicrobial-dose-doxycycline periodontal therapy on serum biomarkers of systemic inflammation: a randomized, double-masked, placebo-controlled clinical trial. *J Am Dent Assoc* 142(3):262, 2011.
74. Pirila E, Ramamurthy N, Maisi P, et al: Wound healing in ovariectomized rats: effects of chemically modified tetracycline (CMT-8) and estrogen on matrix metalloproteinases -8, -13 and type I collagen expression. *Curr Med Chem* 8:281, 2001.
75. Preber H, Bergstrom J: Effect of cigarette smoking on periodontal healing following surgical therapy. *J Clin Periodontol* 17:324, 1990.
76. Preshaw PM, Hefti AF, Bradshaw MH: Adjunctive subantimicrobial dose doxycycline in smokers and non-smokers with chronic periodontitis. *J Clin Periodontol* 32:610, 2005.
77. Preshaw PM, Hefti AF, Novak MJ, et al: Subantimicrobial dose doxycycline enhances the efficacy of scaling and root planing in chronic periodontitis: a multi-center trial. *J Periodontol* 75:1068, 2004.
78. Preshaw PM: Host response modulation in periodontics. *Periodontol 2000* 48:92, 2008.
79. Preshaw PM, Novak MJ, Mellonig J, et al: Modified-release subantimicrobial dose doxycycline enhances scaling and root planing in subjects with periodontal disease. *J Periodontol* 79(3):440, 2008.
80. Reddy MS, Weatherford TW, Smith CA, et al: Alendronate treatment of naturally-occurring periodontitis in beagle dogs. *J Periodontol* 66:211, 1995.
81. Reinhardt RA, Stoner JA, Golub LM, et al: Efficacy of subantimicrobial dose doxycycline in post-menopausal women: clinical outcomes. *J Clin Periodontol* 34(9):768, 2007.
82. Rocha M, Nava LE, Vazquez de la Torre C, et al: Clinical and radiological improvement of periodontal disease in patients with type 2 diabetes mellitus treated with alendronate: a randomized, placebo-controlled trial. *J Periodontol* 72:204, 2001.
83. Ryan ME: Host response in diabetes-associated periodontitis: effects of tetracycline analogues, Stony Brook, 1998, State University of New York.
84. Ryan ME, Ramamurthy NS, Golub LM: Matrix metalloproteinases and their inhibition in periodontal treatment. *Curr Opin Periodontol* 3:85, 1996.
85. Ryan ME, Lee HM, Bookbinder MK, et al: Treatment of genetically susceptible patients with a subantimicrobial dose of doxycycline. *J Dent Res* 79:608, 2000. (abstract 3719).
86. Salvi GE, Lawrence HP, Offenbacher S, et al: Influence of risk factors on the pathogenesis of periodontitis. *Periodontol 2000* 14:173, 1997.
87. Sasaki T, Ohyori N, Debari K, et al: Effects of chemically modified tetracycline, CMT-8, on bone loss and osteoclast structure and function in osteoporotic states. *Ann NY Acad Sci* 878:347, 1999.
88. Shoji K, Horiuchi H, Shinoda H: Inhibitory effects of a bisphosphonate (risedronate) on experimental periodontitis in rats. *J Periodont Res* 30:277, 1995.
89. Stoltenberg JL, Osborn JB, Pihlstrom BL, et al: Association between cigarette smoking, bacterial pathogens and periodontal status. *J Periodontol* 64:1225, 1993.
90. Taylor JJ, Preshaw PM, Donaldson PT: Cytokine gene polymorphism and immunoregulation in periodontal disease. *Periodontol 2000* 35:158, 2004.
91. Thomas J, Walker C, Bradshaw M: Long-term use of subantimicrobial dose doxycycline does not lead to changes in antimicrobial susceptibility. *J Periodontol* 71:1472, 2000.
92. Thomas JG, Metheny RJ, Karakiozis JM, et al: Long-term subantimicrobial doxycycline (Periostat) as adjunctive management in

adult periodontitis: effects on subgingival bacterial population dynamics. *Adv Dent Res* 12:32, 1998.
93. US Department of Health and Human Services (DHHS): Oral health in America: a Report of the Surgeon General, Executive Summary, Rockville, MD, 2000, DHHS, NIDCR, National Institutes of Health.
94. Van Dyke TE: The management of inflammation in periodontal disease. *J Periodontol* 79(8 Suppl):1601, 2008.
95. Vardar S, Baylas H, Huseyinov A: Effects of selective cyclooxygenase-2 inhibition on gingival tissue levels of prostaglandin E_2 and prostaglandin F_{2a} and clinical parameters of chronic periodontitis. *J Periodontol* 74:57, 2003.
96. Vilcek J, Feldmann M: Historical review: cytokines as therapeutics and targets of therapeutics. *Trends Pharmacol Sci* 25:201, 2004.
97. Walker C, Preshaw PM, Novak J, et al: Long-term treatment with subantimicrobial dose doxycycline has no antibacterial effect on intestinal flora. *J Clin Periodontol* 32:1163, 2005.
98. Walker C, Puumala S, Golub LM, et al: Subantimicrobial dose doxycycline effects on osteopenic bone loss: microbiologic results. *J Periodontol* 78(8):1590, 2007.
99. Walker C, Thomas J, Nango S, et al: Long-term treatment with subantimicrobial dose doxycycline exerts no antibacterial effect on the subgingival microflora associated with adult periodontitis. *J Periodontol* 71:1465, 2000.
100. Weinreb M, Quartuccio H, Seedor JG, et al: Histomorphometrical analysis of the effects of the bisphosphonate alendronate on bone loss caused by experimental periodontitis in monkeys. *J Periodontal Res* 29:35, 1994.
101. Williams RC: Periodontal disease. *N Engl J Med* 322(6):373, 1990.
102. Williams RC, Jeffcoat MK, Howell TH, et al: Altering the progression of human alveolar bone loss with the non-steroidal anti-inflammatory drug flurbiprofen. *J Periodontol* 60:485, 1989.
103. Williams RC, Jeffcoat MK, Howell TH, et al: Indomethacin or flurbiprofen treatment of periodontitis in beagles: comparison of effect on bone loss. *J Periodontal Res* 22:403, 1987.
104. Williams RC, Jeffcoat MK, Howell TH, et al: Three year trial of flurbiprofen treatment in humans: post-treatment period. *J Dent Res* 70:468, 1991. (abstract 1617).
105. Wouters FR, Salonen LE, Frithiof L, et al: Significance of some variables on interproximal alveolar bone height based on cross-sectional epidemiological data. *J Clin Periodontol* 20:199, 1993.

CHAPTER 50

Occlusal Evaluation and Therapy

Michael J. McDevitt

CHAPTER OUTLINE

Pathogenesis
Evidence-Based Decision Making
Terminology
Occlusal Function and Dysfunction
Parafunction
Clinical Examination
Occlusal Therapy
Conclusion

Among the numerous local and systemic factors with the potential to influence the progression of periodontitis, the patient's occlusion remains a variable that requires an exacting diagnosis. All of the disciplines of dentistry include the comprehensive analysis of occlusal relationships as being essential to the determination of appropriate care. The functional demands of the occlusion may fall well within or substantially exceed the tolerances and the adaptability of the patient's periodontium and his or her entire masticatory system. The full range of knowledge and skill needed to analyze all aspects of occlusal anatomy and function is beyond the scope of this text. Rather, this chapter presents practical guidelines for the assessment and management of the occlusion specific to a patient's unique susceptibility to periodontitis.

Pathogenesis

Our understanding of the host-driven inflammatory response of each patient to a pathogenic bacterial biofilm is growing exponentially.[37] Each individual's susceptibility appears to be so specific that the patient is actually his or her only reference with regard to the interpretation of possible contributing factors to the progressive loss of supporting bone. In addition, we can see that destructive events may be episodic, and they are clearly site specific. Our diagnostic responsibility includes the careful measurement of periodontal structures in the entire circumference of each tooth, accurate documentation, and timely reassessment. Periodontal deterioration that occurs rapidly or that is excessive for a person's age should prompt the clinician to investigate any variable that may amplify that patient's periodontitis. If a local factor such as an occlusal relationship can influence the course of the disease, then its analysis must be as precise as any other aspect of the periodontal examination.

Evidence-Based Decision Making

In a perfect world, all of our diagnostic and therapeutic decisions would reflect evidence from multiple prospective clinical trials that have been subject to systematic review. Prospective human investigations of occlusal trauma are considered unethical, so periodontics has conscientiously struggled to reach discipline-wide consensus regarding the interaction of a patient's occlusion with his or her periodontal status.[14] To be clinically applicable, the investigation's methodology must parallel the clinical diagnosis and treatment of an individual patient with periodontitis.[16] Historically, data management and statistical credibility and methodology within retrospective studies limited the ability of dedicated researchers to interpret the role of occlusion in an individual's periodontitis experience.[17,36,39] The grouping of data points, especially in large study populations, departs from the site specificity that periodontal diagnosis requires. If occlusal trauma is affecting a tooth, the effect on the periodontium is site specific for only that tooth. Treatment for a patient with periodontitis would never be based on an average of diagnostic references but rather on their unique susceptibility, anatomy, occlusion, and history.

In 2001, Nunn and Harrell[32] reported the retrospective findings of a group of patients with periodontitis in which the analysis was based on the measurement of the loss of attachment of each individual tooth and the presence or absence of occlusal interferences. This study and a similar investigation[4] confirmed that trauma from occlusion amplified the loss of attachment. Harrell and Nunn[15] also reported that eliminating occlusal interferences had a positive influence on the outcome of treatment when trauma from occlusion was found to be a contributing local factor. The positive influence of occlusal adjustment on the outcome of both surgical and nonsurgical periodontal therapies had also been reported by Burgett.[6] Evidence now appears to support the possibility that trauma from occlusion has the capability to amplify damage to an inflamed periodontium.

Interest in the occlusion within the discipline of periodontics appears to be increasing, especially with the rapid growth of the replacement of missing teeth with implants. Despite some conflicting evidence in the literature, common ground for consensus exists. There is general agreement that occlusal force has an effect on the periodontium (see Chapter 15) and that susceptibility to periodontitis is unique to each patient. Occlusal forces present themselves across a broad spectrum. No or minimal occlusal contact on a tooth results in disuse atrophy of the periodontium, which may result in the instability of that tooth. Harmonious occlusal force on a tooth stimulates the physiologic arrangement of its periodontal attachment fibers and its osseous architecture and encourages its stability. Forces that exceed the tolerance of the periodontium result in resorption of the bone and disruption of the attachment.[19,29,31] In the healthy person, the periodontium around teeth that are subject to excessive occlusal force experiences adaptation and repair or remodeling with no loss of attachment, which often occurs with orthodontics. For the patient who is losing bone as a result of periodontitis, coupling the ongoing inflammatory disease with excessive occlusal force may result in the amplification of

destruction and damage to the periodontium of affected teeth.[32] If this conclusion is valid, then the clinician has the responsibility to correlate the precise analysis of the periodontal status of each tooth with its occlusal responsibilities and its possible occlusal excesses.

Terminology

The following is a list of key descriptive terms that are used in this chapter, along with their common synonyms:

Maximum intercuspation: The position of the mandible when there is maximal interdigitation and occlusal contact between the maxillary and mandibular teeth; also called *centric occlusion* and *intercuspal position.*

Centric relation: The position of the mandible when both condyle–disc assemblies are in their most superior positions in their respective glenoid fossae and against the slope of the articular eminences of each respective temporal bone.

Initial contact in centric relation: The first occlusal contact in the centric relation closure arc.

Excursive movement: Any movement of the mandible away from maximum intercuspation.

Lateral excursion: Movement of the mandible laterally to the right or to the left from maximum intercuspation.

Working side: The side of either dental arch that corresponds with the side of mandible moving away from the midline during a lateral excursion.

Nonworking side: The side of either arch that corresponds with the side of the mandible moving toward the midline during a lateral excursion; also called the *balancing side.*

Protrusion: Movement of the mandible anteriorly from maximum intercuspation.

Retrusion: Movement of the mandible posteriorly relative to a more anterior position.

Guidance: The pattern of opposing tooth contact during excursive movements of the mandible.

Disclusion: The separation of certain teeth caused by the guidance provided by other teeth during an excursion. When anterior guidance provides for separation of posterior teeth during an excursion, posterior disclusion is achieved.

Interference: Any occlusal contact in the centric relation closure arc or in any excursion that prevents the remaining occlusal surfaces from achieving stable contact or from functioning harmoniously or that encourages masticatory system disharmony; also called an *occlusal discrepancy.*

Occlusal Function and Dysfunction

Excellent sources for a comprehensive understanding of dental anatomy and function include texts by Wheeler,[3] McNeill,[27] and Dawson.[9,10] The determination of whether trauma from occlusion is occurring is made on the basis of the conclusion that the composite of all occlusal forces on a specific tooth exceeds the tolerance or adaptability of its periodontium. The identification of masticatory system disharmonies begins with an appreciation of physiologic norms; this allows the clinician to recognize dysfunctional relationships, which may influence the accuracy of the diagnosis.[10,31,33]

Centric relation is a term that is used to describe the position of both condyles when they are fully seated in the fossae of their respective temporomandibular joints (TMJs). Rotation of the mandible around an axis through both condyles is called the *centric relation closure arc* (see Chapter 20). This is strictly a skeletal relationship until tooth contact occurs. Maximum intercuspation occurs when opposing teeth make contact, with optimal interdigitation, at the most stable endpoint of mandibular closure. Stability is enhanced by the simultaneous bilateral contact of multiple posterior teeth with occlusal forces in the long axis of most posterior teeth. If the initial tooth contact in the centric relation arc of closure occurs simultaneously with maximum intercuspation, then the teeth do not displace the condyles. Conversely, if the teeth are firm and any contact occurs before maximum intercuspation, then incline relationships of opposing occlusal surfaces will guide the mandible into intercuspal position, thereby requiring one or both condyles to become dislocated from their fossa.[10,32] If the teeth are mobile and contact first in the centric relation closure arc, then *they may move away from opposing teeth rather than cause condylar displacement.*

Cusp–fossa or cusp–marginal ridge relationships of the posterior teeth provide resistance to vertical loading and functional stability for the patient's dentition. When occlusal forces load teeth in their long axis, the periodontium is the most resistant and supportive.[9,10] The anterior teeth can be stable with little occlusal loading in centric occlusion if they are favorably influenced by the oral musculature. If the anterior teeth are in contact in maximum intercuspation, they are coupled. Movement of the mandible from centric occlusion is called an *excursion.* Movement forward is called a *protrusive excursion,* and movement to either side is called a *lateral excursion.* If the mandible can move posteriorly, it is called *retrusion.* There is evidence that the contact of posterior teeth in excursions can overload those teeth, which results in negative dental, periodontal, muscular, and TMJ consequences.[1,7,10,33,44,45,46] The ideal relationship may be a light coupling of the anterior teeth in centric occlusion with immediate separation (also called *disclusion*) of all posterior teeth in all excursions.[45] During a lateral excursion, posterior teeth that make contact on the same side as the direction of mandibular movement are described as having a working contact. Posterior teeth that make contact on the side opposite the direction of the lateral excursion are described as having a nonworking contact. Although nonworking contacts are classically associated with more potential negative consequences,[46] the analysis of working contacts and the function of anterior teeth are critically important. Contacts that are disruptive to mandibular movement or stressful to individual teeth are called *occlusal interferences* or *discrepancies.* Our ability to analyze the occlusion to identify contacts that may amplify a patient's periodontitis, thereby affecting certain teeth, is strategic to the making of the correct diagnosis.

Inflammation disrupts the integrity of the attachment apparatus, which results in less resistance to force from opposing teeth. When bone loss has occurred, less root surface area is supported,[2,18] and there are fewer sensory fibers in the periodontal ligament, which limits the protective muscle modulation of the occlusal forces.[38] The clinician must differentiate among inflammation-caused intolerance to occlusal forces, normal forces on teeth with reduced periodontal support, excessive occlusal forces, and well-tolerated forces on teeth affected by periodontitis.

Parafunction

Bruxism may cause occlusal forces on teeth that are susceptible to periodontitis to be increased in intensity or frequency, thereby magnifying the potential amplification of damage.[8,22,23,42] Daytime occlusal parafunction is commonly limited to clenching of the teeth during incidents that require a person's focused effort or mental concentration. Nighttime bruxing of the teeth can take the form of grinding the teeth during various excursions or clenching of the teeth. Sleep bruxism is probably an extension of the rhythmic masticatory muscle activity that is also observed in nonbruxers. Why nuclei in the brain stem allow for bruxing to occur in some

individuals while others are spared is unclear.[8,22,23] Bruxing is associated with the greater frequency and persistence of TMJ dysfunction, orofacial pain, and possibly periodontal attachment loss.[42] The sensory input of teeth that are subject to bruxism is probably dampened, which may interfere with both diagnosis and treatment.[35] There seems to be limited influence on bruxing tendencies from occlusal interferences.[24] Selective serotonin reuptake inhibitors such as Prozac have been reported to encourage bruxism.[13]

Evidence is emerging that sleep-disordered breathing may influence or be associated with inflammatory diseases, even periodontitis.[11,5,20] Although a causal relationship between obstructive sleep apnea and sleep bruxism has not been firmly established, the data and observations that have been reported support a definite association.[34,40,41] A patient with periodontitis with clinical evidence of occlusal trauma may be experiencing the consequences of sleep-disordered breathing. Chapter 28 of this text provides an overview of sleep-disordered breathing; it is a recommended reference for the dentist who is seeking to develop skill in the recognition of possible oral signs of sleep-disordered breathing to complement his or her diagnostic skills involving the evaluation of a patient's occlusion. If an occlusal appliance is being considered to address the periodontal implications of excessive occlusal force experienced by a periodontitis-susceptible patient, compliance may be problematic for a patient with sleep-disordered breathing, because the appliance may contribute to airway obstruction.[12]

Clinical Examination

Before clinical evaluation, a conversation with the patient can be very helpful for acquiring a more complete diagnosis. With minimal symptoms, a patient may not associate loose teeth or significant dental wear with TMJ dysfunction or orofacial pain with occlusal function or parafunction. The list of questions given in Chapter 20 and inquiries specific to the condition of the patient's teeth can help the clinician to open the lines of communication and set the tone for patient education during the clinical examination. The comprehensive evaluation of occlusal anatomy and relationships is accomplished via the analysis of many factors in the clinical setting and on mounted diagnostic casts.

The clinical evaluation of the occlusion is sequenced to support the patient's learning. It should always include a clinical assessment of masticatory system function and the identification of any disharmony.

Temporomandibular Disorders Screening Evaluation

The complete assessment of the masticatory system and the identification of temporomandibular disorders are carefully described in Chapter 20 and should be part of a patient's initial comprehensive examination. The temporomandibular disorder screening clinical evaluation then becomes part of each subsequent examination. The patient's range of motion is observed, maximal opening and both lateral and protrusive excursions are measured, and any deviation from the midline during opening and closing is defined. Light finger pressure applied over each TMJ can detect deflection of the tissue while the patient opens and closes the mouth, which is suggestive of condyle–disc discoordination. Tenderness on palpation may indicate TMJ capsulitis. Listening to the joint with a stethoscope or a Doppler instrument during opening and closing may detect sounds that are consistent with uncoordinated condyle–disc relationships, arthritic changes, and other diagnostic sounds.[10] Palpation of the muscles of mastication and the related head and neck musculature may reveal muscle tension or spasm related to compensation for occlusal or TMJ disharmonies.[10,33] Load testing of the TMJ is described in Chapter 20. Any significant discovery that is revealed during the screening examination summarized in Box 50-1 should lead the clinician to complete the comprehensive evaluation.

Testing for the Mobility of Teeth

There are two basic methods to assess the firmness or looseness of a tooth. Classically, a dental instrument is used to exert pressure in the facial or lingual direction, and the dentist places his or her finger on the opposite side of the tooth to both feel and see movement if it occurs, as described in Chapter 30. Recording a numeric value for the degree of mobility with a range of 0 to 3 allows the clinician to track changes that may occur in response to therapy. The other method is to test for the movement of teeth that are subject to pressure that the patient generates. Fremitus, vibration, or micromovement of a tooth can be felt when patients tap their teeth together. When the patient mimics clenching the teeth and then attempts to move the mandible in excursions, tooth movement can be observed. The patient placing a finger where the clinician felt tooth movement helps the patient to appreciate the looseness of his or her teeth (Figure 50-1). If the mobility of the teeth exceeds

BOX 50-1 Temporomandibular Disorder Screening Evaluation

1. Maximal interincisal opening (range, 40 to 50 mm)
2. Opening/closing pathway
3. Range of lateral and protrusive excursions (≥7 mm to 9 mm)
4. Auscultation for temporomandibular joint sounds
5. Palpation for temporomandibular joint tenderness or tissue displacement
6. Palpation for muscle tenderness
7. Load testing of the patient's temporomandibular joints

Figure 50-1 **A,** Tactile and visual testing for mobility with a dental instrument by the dentist. **B,** Tactile and visual testing for mobility with the patient clenching and beginning right lateral excursion by the dentist. **C,** Patient feeling movement of her tooth when lateral excursion is attempted while the teeth are clenched.

what is expected on the basis of the loss of support or the level of inflammation observed, then trauma from occlusion is included in the diagnosis. The assimilation of all of the occlusal and periodontal diagnostic references may also lead the clinician to conclude that, even without mobility, there may be evidence of the amplification of periodontal damage as a result of unfavorable occlusal forces.

Centric Relation Assessment

Bimanual manipulation of the mandible in the axis of rotation of the condyles in their respective glenoid fossae has become a standard method of assessing centric relation.[3,9,10,33] This method is illustrated in Figure 50-2, and it involves gentle guidance rather than the forced positioning of the mandible. This technique is essential to load testing of the TMJs, and it is effective for generating centric relation records for mounting diagnostic casts. Telling the patient that he or she will feel modest lifting pressure on the inferior borders of the mandible and light depressing force in the mental region often allows for relatively free and comfortable hinging of the mandible.[9,10] If the hinging is uncomfortable or not repeatable, then muscle deprogramming (see Chapter 20) may be beneficial. Other methods for guiding the condyles toward a seated position (e.g., leaf gauges, anterior bite stops) can also be effective.[10] Asking the patient to identify the first tooth to touch in the centric relation arc of closure may indicate that interferences to closure into maximum intercuspation exist. Asking the patient to close further may demonstrate a slide from centric relation to centric occlusion, because teeth are firm enough to dislocate one or both condyles.[33] Drying the occlusal surfaces, positioning marking paper, and then guiding the patient to the initial contact in centric relation will allow for the marking of occlusal contact points, thereby identifying any interference. Asking the patient to then close into maximum intercuspation will mark the points or surfaces that contact during the slide. An early occlusal contact in centric relation before closure to centric occlusion is obtained that does not cause a slide may indicate the early contact that occurs on teeth that are mobile enough to move, thus allowing maximal intercuspation to be gained without condylar accommodation (Figure 50-3). The confirmation of permissive intercuspation is a product of marking the teeth clinically and comparing those marks with the ones on mounted diagnostic casts, which demonstrates that mobile teeth can move out of the way to allow others to contact.

Figure 50-2 Bimanual manipulation to hinge the mandible in centric relation and to load test the temporomandibular joints.

Evaluation of Excursions

Marking of the teeth in all excursions will reveal the pathways of contact of opposing occlusal or incisal surfaces during function, and it may also identify interferences to harmonious function.[3,10,27] The movement of any teeth during marking may lessen the intensity of the marks and the assessed severity of the forces experienced by the affected teeth. Vectors of force and the steepness of the opposing inclines are studied to determine if force is excessive. Interpreting those contacts on a tooth-by-tooth basis can suggest or deny occlusal trauma as a contributing factor to the loss of attachment of each affected tooth. When patients are engaged in the evaluation of their occlusion, they can be given suggestions to observe certain habits, such as clenching their teeth during the day or sleeping with pressure on their mandible. As they contribute to their own diagnosis, patients become better prepared to make informed choices about their treatment options.

Articulated Diagnostic Casts

When the maxillary diagnostic cast is mounted on an articulator with a facebow transfer technique, the occlusal surfaces become oriented to the axis of rotation of the patient's condyles. The centric relation transfer record orients the mandibular teeth to the maxillary teeth in centric relation.[9,10] Study of the accurately mounted diagnostic casts may reveal occlusal discrepancies between initial contact in the centric relation closure arc and maximum intercuspation and occlusal disharmonies in excursions. Mobile teeth may produce a mark on a solid model but little or no mark in that patient's mouth during clinical assessment. The accuracy of the

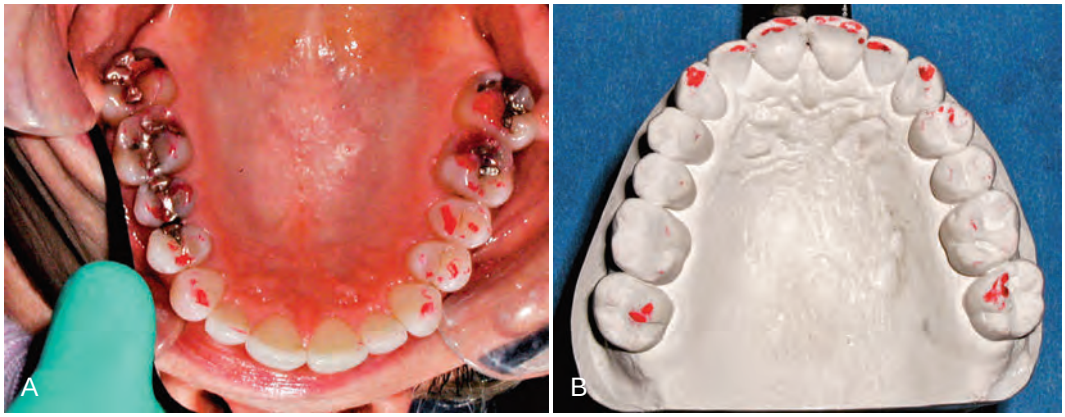

Figure 50-3 **A,** Teeth marked clinically in maximum intercuspation and in excursions while clenching. **B,** Teeth marked in centric relation and maximum intercuspation on a diagnostic cast mounted in centric relation. Marks only on the second molars indicate that they were mobile and that they moved to permit the contact of other teeth.

observations made on the models should be confirmed clinically to whatever degree possible.

Occlusal Therapy

Effective nonsurgical therapy usually reduces the inflammation within the periodontium and results in some healing of attachment,[30] which often results in mobile teeth becoming more stable. If the clinician concludes that inflammation has been optimally controlled and that occlusal forces on individual teeth still exceed the tolerance of their periodontium, then the basis for intervention is established. The harmonious function of both TMJs and their associated muscles is required for occlusal stability. When there is sufficient evidence of excessive occlusal forces on the patient's teeth or when masticatory system disharmony exists and the patient desires a more stable occlusion, then an occlusal appliance is prescribed.

A review of the TMJ anatomy presented in Chapter 20 will be helpful for a better understanding of the therapy.

Occlusal Appliance Therapy

A well-designed and accurately fitted appliance can benefit masticatory system function while encouraging loose teeth in both arches to tighten as the supporting periodontium heals. The bilateral simultaneous contact of all opposing posterior teeth in centric relation, shallow anterior guidance, and the immediate disclusion of all posterior teeth in every excursion are essential elements of both maxillary and mandibular occlusal appliances (Figures 50-4 and 50-5). Teeth that are opposing an appliance should be loaded as close as possible to their long axis. Maxillary appliances engage a portion of the hard palate, which provides for the substantial bracing of teeth and resistance to vertical and lateral forces. A horseshoe-shaped maxillary appliance relies on other, possibly compromised teeth to attempt to protect the most mobile teeth. Soft or partial coverage appliances are contraindicated for long-term protection and stabilization.[30] The protective role of occlusal appliances was discussed in the 8-year study by McGuire.[26] Occlusal appliances are not expected to cure bruxism,[25] but they are often prescribed for patients with habitual parafunction as a compensating or protective intervention to limit masticatory system disharmony, damage to the teeth, and the overstressing of implants.[21]

Occlusal Adjustment

As teeth tighten from the consistent use of the appliance, occlusal interferences may become more evident, and greater discrepancy between the initial dental contact and maximum intercuspation may be observed. Interferences with harmonious excursive movement of the mandible may also become more obvious. When the clinician confirms that the interferences correlate with a greater than expected loss of attachment, then direct intervention with the patient's occlusion is considered. With the patient's full understanding and consent, occlusal adjustment or the selective reshaping of the occluding surfaces of the teeth can reduce the magnitude of occlusal interferences or direct the forces to be more compatible with the long axes of the affected teeth. The clinical analysis of the occlusion should be combined with a detailed analysis of diagnostic casts mounted in centric relation on an adjustable articulator. Accurately mounted duplicate models can be used to accomplish a trial occlusal adjustment to determine safety and efficacy for a patient.[10,27] Scheduling patients so that they leave their appliances on overnight and in place until they are seated in the dental chair allows for the assessment of their teeth at maximum firmness, when interferences are most readily identifiable. Teeth will usually progressively tighten with continued compliance with the appliance and repeated careful occlusal adjustment. Other methods that can be employed to alter occlusal relationships include orthodontics and restorative dentistry. The provisional restoration of teeth is another method of improving occlusal contacts and stability, and it often simplifies the process of occlusal adjustment and final restoration.

Occlusal Stability for Restorative Dentistry

A stable occlusion is considered a prerequisite for any restorative therapy (Box 50-2). Implants to replace the teeth of a partially dentate patient add to the occlusal considerations. The osseointegration of implants eliminates micromovement, which may allow teeth to accommodate occlusal forces. The extent and timing of occlusal loading and the guidance requirement for each tooth and for each implant must be carefully harmonized (see Chapters 66 and 76). This is especially critical if any of the teeth are mobile or if the patient bruxes to any significant degree.[43] If bruxism is suspected or if the functional forces are considered to be excessive, then the occlusal appliance as described may be a valuable application.[21,28]

BOX 50-2 Requirements for Occlusal Stability

1. Forces on individual teeth that do not exceed the support and resistance of that tooth's periodontium and that are vertically oriented to the long axis of each tooth as much as possible
2. Even, simultaneous contact of all posterior teeth in the centric relation closure arc or in maximum intercuspation, with minimal difference between the two
3. Little or no contact of the anterior teeth in centric occlusion, although such contact readily available to provide guidance in any excursion and to produce posterior disclusion
4. Harmonious excursive movement of the mandible within the patient's envelope of function with complete absence of occlusal interference

Figure 50-4 **A,** An occlusal appliance fabricated on accurately mounted diagnostic casts. **B,** The entire dental and palatal surface has been carefully relined clinically to promote an optimal stabilizing influence on any mobile teeth. **C,** Bilateral simultaneous contact of the cuspids and all posterior teeth in centric relation, fabricated to enhance axial loading of opposing mandibular teeth. **D,** Smooth, relatively flat anterior guidance with immediate and sustained disclusion of all posterior teeth in protrusion. **E,** Smooth, relatively flat anterior guidance with immediate and sustained disclusion of all posterior teeth in right lateral excursions. **F,** Extreme left lateral excursion with smooth, harmonious transitions across the anterior teeth to maintain the disclusion of all posterior teeth. **G,** Marks created by the opposing dentition that demonstrate bilateral simultaneous contact in centric relation and the immediate disclusion of the opposing posterior teeth in all excursions.

Figure 50-5 A mandibular occlusal appliance fabricated after surgery to provide a stabilizing influence for the incisors in particular and to demonstrate occlusal attributes similar to those of the maxillary appliance.

Conclusion

Confirmation of the appropriateness of occlusal therapy is the product of the thorough and complete evaluation of both the patient's occlusion and his or her masticatory system. The sequence of occlusal treatment begins with anti-inflammatory therapy and progresses through reversible appliance therapy before any of the irreversible options are considered. This provides the clinician with the most careful approach to assessing and treating the occlusion of a patient with periodontitis.

Suggested Readings

Bernhardt O, Gesch D, Look JO, et al: The influence of dynamic interferences on probing depth and attachment level: results of the Study of Health in Pomerania (SHIP). *J Periodontol* 77:506, 2006.

Burgett F, Ramfjord S, Nissle R, et al: A randomized trial of occlusal adjustment in the treatment of periodontitis patients. *J Clin Periodontol* 19:381, 1992.

Dawson PE: *Evaluation, diagnosis, and treatment of occlusal problems*, ed 2, St Louis, 1989, Mosby.

Gher ME: Non-surgical pocket therapy: dental occlusion. *Ann Periodontol* 1:567, 1996.

Harrell SK, Nunn ME: The effect of occlusal discrepancies on treated and untreated periodontitis. II. Relationship of occlusal treatment to the progression of periodontal disease. *J Periodontol* 72:495, 2001.

Harrel SK, Nunn ME, Hallmon WW, et al: Is there an association between occlusion and periodontal destruction? *J Am Dent Assoc* 137:1380, 2006.

Lavigne GJ, Khoury S, Abe S, et al: Bruxism physiology and pathology: an overview for clinicians. *J Oral Rehabil* 35:476, 2008.

Nunn M, Harrell SK: The effect of occlusal discrepancies on treated and untreated periodontitis, part I: relationship of initial occlusal discrepancies to initial clinical parameters. *J Periodontol* 72:485, 2001.

Simmons JH, Prehn RS: Airway protection: the missing link between nocturnal bruxism and obstructive sleep apnea. *Sleep* 32:A218, 2009.

Youdelis RA, Mann WV, Jr: The prevalence and possible role of nonworking contacts in periodontal disease. *Periodontics* 3:219, 1965.

References

References for this chapter are found on the companion website www.expertconsult.com.

References

1. Al-Hadi LA: Prevalence of temporomandibular disorders in relation to some occlusal parameters. *J Prosthet Dent* 70:345, 1993.
2. Alkan A, Keskiner I, Arici S, et al: The effect of periodontitis on biting abilities. *J Periodontol* 77:1442, 2006.
3. Ash MM, Nelson SJ: *Wheeler's dental anatomy, physiology and occlusion*, ed 8, St Louis, 2003, Saunders.
4. Bernhardt O, Gesch D, Look JO, et al: The influence of dynamic interferences on probing depth and attachment level: results of the Study of Health in Pomerania (SHIP). *J Periodontol* 77:506, 2006.
5. Budhiraja R, Budhiraja P, Quan SF: Sleep disordered breathing and cardiovascular disorders. *Respir Care* 55:1322, 2010.
6. Burgett F, Ramfjord S, Nissle R, et al: A randomized trial of occlusal adjustment in the treatment of periodontitis patients. *J Clin Periodontol* 19:381, 1992.
7. Christensen GJ: Abnormal occlusal conditions: a forgotten part of dentistry. *J Am Dent Assoc* 126:1667, 1995.
8. Clark GT, Ram S: Four oral motor disorders: bruxism, dystonia, dyskinesia and drug-induced dystonic extrapyramidal reactions. *Dent Clin North Am* 51:225, 2007.
9. Dawson PE: *Evaluation, diagnosis, and treatment of occlusal problems*, ed 2, St Louis, 1989, Mosby.
10. Dawson PE: *Functional occlusion from TMJ to smile design*, St Louis, 2007, Mosby.
11. Edwards BA, O'Driscoll DM, Ali A, et al: Aging and sleep physiology and pathophysiology. *Semin Respir Crit Care Med* 31:618, 2010.
12. Gagnon Y, Mayer P, Morrison F, et al: Aggravation of respiratory disturbances by the use of an occlusal splint in apneic patients: a pilot study. *Int J Prosthodont* 17:447, 2004.
13. Gerber PE, Lynd LD: Selective serotonin reuptake inhibitor induced movement disorders. *Ann Pharmacother* 32:692, 1998.
14. Gher ME: Non-surgical pocket therapy: dental occlusion. *Ann Periodontol* 1:567, 1996.
15. Harrell SK, Nunn ME: The effect of occlusal discrepancies on treated and untreated periodontitis, part II: relationship of occlusal treatment to the progression of periodontal disease. *J Periodontol* 72:495, 2001.
16. Harrel SK, Nunn ME, Hallmon WW, et al: Is there an association between occlusion and periodontal destruction? *J Am Dent Assoc* 137:1380, 2006.
17. Jin L, Cao C: Clinical diagnosis of trauma from occlusion and its relation with severity of periodontitis. *J Clin Periodontol* 19:92, 1992.
18. Johansson AS, Svensson KG, Trulsson M: Impaired masticatory behavior in subjects with reduced periodontal tissue support.
19. Kaku M, Uoshima K, Yamashita Y, et al: Investigation of periodontal ligament reaction upon excessive occlusal load–osteopontin induction among periodontal ligament cells. *J Periodontal Res* 40:59, 2005.
20. Gunaratnam K, Taylor B, Curtis B, et al: Obstructive sleep apnoea and periodontitis: a novel association? *Sleep Breath* 13:233, 2009.
21. Kreiner M, Betancor E, Clark GT: Occlusal stabilization appliances evidence of their efficacy. *J Am Dent Assoc* 132:770, 2001.
22. Lavigne GJ, Kato T, Koltra A, et al: Neurobiological mechanisms involved in sleep bruxism. *Crit Rev Oral Biol Med* 14:30, 2003.
23. Lavigne GJ, Khoury S, Abe S, et al: Bruxism physiology and pathology: an overview for clinicians. *J Oral Rehabil* 35:476, 2008.
24. Lobbezoo F, Naeije M: Bruxism is regulated centrally not peripherally. *J Oral Rehabil* 28:1085, 2001.
25. Macedo CR, Silva AB, Machado MA, et al: Occlusal splints for treating sleep bruxism (tooth grinding). *Cochrane Database Syst Rev* (17):CD005514, 2007.
26. McGuire MK, Nunn ME: Prognosis versus actual outcome II: The effectiveness of clinical parameters in developing an accurate prognosis. *J Periodontol* 67:658, 1996.
27. McNeill C: *Science and practice of occlusion*, Carol Stream, IL, 1997, Quintessence.
28. Misch CE: The effect of bruxism on treatment planning for implants. *Dent Today* 21:76, 2002.
29. Motohira H, Hayshi J, Tatsumi J, et al: Hypoxia and reoxygenation augment bone-resorbing factor production from human periodontal ligament cells. *J Periodontol* 78:1803, 2007.
30. Narita N, Funato M, Ishii T, et al: Effects of jaw clenching while wearing an occlusal splint on awareness of tiredness, bite force and EEG power spectrum. *J Prosthodont Res* 53:120, 2009.
31. Newman MG, Takei HH, Klokkevold PR, et al: *Carranza's clinical periodontology*, ed 10, St Louis, 2006, Saunders.
32. Nunn M, Harrell SK: The effect of occlusal discrepancies on treated and untreated periodontitis, part I: relationship of initial occlusal discrepancies to initial clinical parameters. *J Periodontol* 72:485, 2001.
33. Okeson JP: *Management of temporomandibular joint disorders and occlusion*, ed 4, St Louis, 1998, Mosby.
34. Oksenberg A, Arons E: Sleep bruxism related to obstructive sleep apnea: the effect of continuous positive airway pressure. *Sleep Med* 3:513, 2002.
35. Ono Y, Suganuma T, Shinya A, et al: Effects of sleep bruxism on periodontal sensation and tooth displacement in the molar region. *Cranio* 26:282, 2008.
36. Pihlstrom B, Anderson K, Aeppli D, et al: Association between signs of trauma from occlusion and periodontitis. *J Periodontol* 57:1, 1986.
37. Proceedings of the 2008 workshop on inflammation and periodontal diseases: a reappraisal. *J Periodontol* 79:1501, 2008.
38. Rosenbaum RS: The possible effect of periodontal disease on occlusal function. *Curr Opin Periodontol* 163, 1993.
39. Shefter GJ, McFall WT, Jr: Occlusal relations and periodontal status in human adults. *J Periodontol* 55:386, 1984.
40. Simmons JH, Prehn RS: Airway protection: the missing link between nocturnal bruxism and obstructive sleep apnea. *Sleep* 32:A218, 2009.
41. Simmons JH, Prehn RS: Bruxism as a compensatory mechanism for a collapsing airway. *Sleep* 31:A199, 2008.
42. Tokiwa O, Park BK, Takezawa Y, et al: Relationship of tooth grinding pattern during sleep bruxism and dental status. *Cranio* 26:287, 2008.
43. Tosun T, Karabuda C, Cuhadaroglu C: Evaluation of sleep bruxism by polysomnographic analysis in patients with dental implants. *Int J Oral Maxillofac Implants* 18:286, 2003.
44. Watanabe EK, Yatani H, Kuboki T, et al: The relationship between signs and symptoms of temporomandibular disorders and bilateral occlusal contact patterns in lateral excursions. *J Oral Rehabil* 25:409, 1998.
45. Williamson EH, Ludquist DO: Anterior guidance: its effect on electromyographic activity of the temporal and masseter muscles. *J Prosthet Dent* 49:816, 1983.
46. Youdelis RA, Mann WV, Jr: The prevalence and possible role of nonworking contacts in periodontal disease. *Periodontics* 3:219, 1965.

CHAPTER 51

Adjunctive Role of Orthodontic Therapy

Vincent G. Kokich

CHAPTER OUTLINE

Benefits of Orthodontic Therapy
Preorthodontic Osseous Surgery *(e-only)*
Orthodontic Treatment of Osseous Defects *(e-only)*
Orthodontic Treatment of Gingival Discrepancies *(e-only)*
Conclusion

For discussions of preorthodontic osseous surgery, orthodontic treatment of osseous defects, and the orthodontic treatment of gingival discrepancies, please go to the companion website at www.expertconsult.com.

Orthodontic tooth movement may be a substantial benefit to the adult periorestorative patient. Many adults who seek routine restorative dentistry have problems with tooth malposition that compromise their ability to clean and maintain their dentitions. If these individuals also are susceptible to periodontal disease, tooth malposition may be an exacerbating factor that could cause premature loss of specific teeth.

Orthodontic appliances have become smaller, less noticeable, and easier to maintain during orthodontic therapy. Many adults are taking advantage of the opportunity to have their teeth aligned to improve the esthetics of their smiles. If these individuals also have underlying gingival or osseous periodontal defects, these defects often can be improved during orthodontic therapy if the orthodontist is aware of the situation and designs the appropriate tooth movement. In addition, implants have become a major part of the treatment plan for many adults with missing teeth. If adjacent teeth have drifted into edentulous spaces, orthodontic therapy is often helpful to provide the ideal amount of space for implants and subsequent restorations.

This chapter shows the ways in which adjunctive orthodontic therapy can enhance the periodontal health and restorability of teeth.

Benefits of Orthodontic Therapy

Orthodontic therapy can provide several benefits to the adult periodontal patient. The following six factors should be considered:

1. Aligning crowded or malposed maxillary or mandibular anterior teeth permits adult patients better access to clean all surfaces of their teeth adequately. This could be a tremendous advantage for patients who are susceptible to periodontal bone loss or do not have the dexterity to maintain their oral hygiene.
2. Vertical orthodontic tooth repositioning can improve certain types of osseous defects in periodontal patients. Often, the tooth movement eliminates the need for resective osseous surgery.
3. Orthodontic treatment can improve the esthetic relationship of the maxillary gingival margin levels before restorative dentistry. Aligning the gingival margins orthodontically avoids gingival recontouring, which could require bone removal and exposure of the roots of the teeth.
4. Orthodontic therapy also benefits the patient with a severe fracture of a maxillary anterior tooth that requires forced eruption to permit adequate restoration of the root. Erupting the root allows the crown preparation to have sufficient resistance form and retention for the final restoration.
5. Orthodontic treatment allows open gingival embrasures to be corrected to regain lost papilla. If these open gingival embrasures are located in the maxillary anterior region, they can be unesthetic. In most patients, these areas can be corrected with a combination of orthodontic root movement, tooth reshaping, and restoration.
6. Orthodontic treatment could improve adjacent tooth position before implant placement or tooth replacement. This is especially true for the patient who has been missing teeth for several years and has drifting and tipping of the adjacent dentition.

Conclusion

There are many benefits to integrating orthodontics and periodontics in the management of adult patients with underlying periodontal defects. The key to treating these patients is communication and proper diagnosis before orthodontic therapy, as well as continued dialog during orthodontic treatment. Not all periodontal problems are treated in the same way. This chapter provides a framework for the integration of orthodontics to solve periodontal problems.

Suggested Readings

Brown IA: The effect of orthodontic therapy on certain types of periodontal defects. I. Clinical findings. *J Periodontol* 44:742, 1973.

Preorthodontic Osseous Surgery

The extent of the osseous surgery depends on the type of defect (e.g., crater, hemiseptal defect, three-wall defect, or furcation lesion). The prudent clinician knows which defects can be improved with orthodontic treatment and which defects require preorthodontic, periodontal, or surgical intervention.

Osseous Craters

An osseous crater is an interproximal, two-wall defect that does not improve with orthodontic treatment. Some shallow craters (4- to 5-mm pocket) may be maintainable nonsurgically during orthodontic treatment. However, if surgical correction is necessary, this type of osseous lesion can easily be eliminated by reshaping the defect[12,15] and reducing the pocket depth (Figure 51-1) (see Chapter 60). This in turn enhances the ability to maintain these interproximal areas during orthodontic treatment. The need for surgery is based on the patient's response to initial root planing, the patient's periodontal resistance, the location of the defect, and the predictability of maintaining defects nonsurgically while the patient is wearing orthodontic appliances.

Three-Wall Intrabony Defects

Three-wall defects are amenable to pocket reduction with regenerative periodontal therapy.[1] Bone grafts using either autogenous bone from the surgical site or allografts along with the use of resorbable membranes have been successful in filling three-wall defects.[14] If the result of periodontal therapy is stable 3 to 6 months after periodontal surgery (Figure 51-2), orthodontic treatment may be initiated.

Orthodontic Treatment of Osseous Defects

Hemiseptal Defects

Hemiseptal defects are one- or two-wall osseous defects that often are found around mesially tipped teeth (Figure 51-3) or teeth that have supererupted (Figure 51-4). Usually, these defects can be eliminated with the appropriate orthodontic treatment. In the case of the tipped tooth, uprighting[2,5] and eruption of the tooth levels the bony defect. If the tooth is supererupted, intrusion and leveling of the adjacent cementoenamel junctions can help level the osseous defect.

It is imperative that periodontal inflammation be controlled before orthodontic treatment. This usually can be achieved with initial debridement and rarely requires any preorthodontic surgery. After the completion of orthodontic treatment, these teeth should be stabilized for at least 6 months and reassessed periodontally. Often, the pocket has been reduced or eliminated, and no further periodontal treatment is needed. It would be injudicious to perform preorthodontic osseous corrective surgery in such lesions if orthodontics is part of the overall treatment plan.

In the periodontally healthy patient, orthodontic brackets are positioned on the posterior teeth relative to the marginal ridges and cusps. However, some adult patients may have marginal ridge discrepancies caused by uneven tooth eruption. When marginal ridge discrepancies are encountered, the decision as to where to place the bracket or band is not determined by the anatomy of the tooth. In these patients, it is important to assess these teeth radiographically to determine the interproximal bone level.

Figure 51-1 This patient had a 6-mm probing defect distal to the maxillary right first molar **(A).** When this area was flapped **(B),** a cratering defect was apparent. Osseous surgery was used to alter the bony architecture on the buccal and lingual surfaces to eliminate the defect **(C** and **D).** After 6 weeks, the probing pocket defect had been reduced to 3 mm and orthodontic appliances were placed on the teeth **(E).** By eliminating the crater before orthodontic therapy, the patient could maintain the area during and after orthodontic treatment **(F).**

Figure 51-2 This patient had a significant periodontal pocket **(A)** distal to the mandibular right first molar. Periapical radiograph **(B)** confirmed the osseous defect. A flap was elevated **(C),** revealing a deep, three-wall osseous defect. Freeze-dried bone **(D)** was placed in the defect. Six months after the bone graft, orthodontic treatment was initiated **(E).** The final periapical radiograph shows that the preorthodontic bone graft helped regenerate bone and eliminate the defect distal to the molar **(F).**

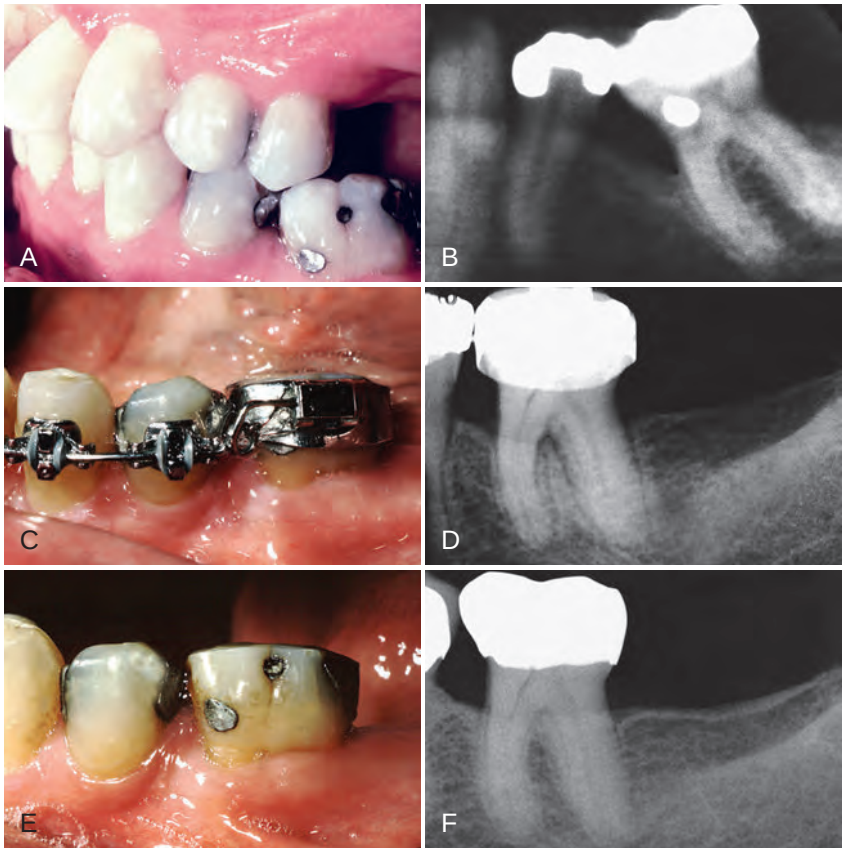

Figure 51-3 This patient was missing the mandibular left second premolar, and the first molar had tipped mesially **(A)**. Pretreatment periapical radiograph **(B)** revealed a significant hemiseptal osseous defect on the mesial side of the molar. To eliminate the defect, the molar was erupted, and the occlusal surface was equilibrated **(C).** The eruption was stopped when the bone defect was leveled **(D).** The posttreatment intraoral photograph **(E)** and periapical radiograph **(F)** show that the periodontal health had been improved by correcting the hemiseptal defect orthodontically.

Figure 51-4 This patient showed overeruption of the maxillary right first molar and a marginal ridge defect between the second premolar and first molar **(A).** Pretreatment periapical radiograph **(B)** showed that the interproximal bone was flat. To avoid creating a hemiseptal defect, the occlusal surface of the first molar was equilibrated **(C** and **D),** and the malocclusion was corrected orthodontically **(E** and **F).**

If the bone level is oriented in the same direction as the marginal ridge discrepancy, leveling the marginal ridges will level the bone. However, if the bone level is flat between adjacent teeth (see Figure 51-4) and the marginal ridges are at significantly different levels, correction of the marginal ridge discrepancy orthodontically produces a hemiseptal defect in the bone. This could cause a periodontal pocket between the two teeth.

If the bone is flat and a marginal ridge discrepancy is present, the orthodontist should not level the marginal ridges orthodontically. In these situations, it may be necessary to equilibrate the crown of the tooth (see Figure 51-4). For some patients, the latter technique may require endodontic therapy and restoration of the tooth because of the required amount of reduction of the length of the crown. This approach is acceptable if the treatment results in a more favorable bone contour between the teeth.

Some patients have a discrepancy between both the marginal ridges and the bony levels between two teeth. However, these discrepancies may not be of equal magnitude; orthodontic leveling of the bone may still leave a discrepancy in the marginal ridges (Figure 51-5). In these patients, the crowns of the teeth should not be used as a guide for completing orthodontic therapy. The bone should be leveled orthodontically, and any remaining discrepancies between the marginal ridges should be equilibrated. This method produces the best occlusal result and improves the patient's periodontal health.

During orthodontic treatment, when teeth are being extruded to level hemiseptal defects, the patient should be monitored regularly. Initially, the hemiseptal defect has a greater sulcular depth and is more difficult for the patient to clean. As the defect is ameliorated through tooth extrusion, interproximal cleaning becomes easier. The patient should be recalled every 2 to 3 months during the leveling process to control inflammation in the interproximal region.

Advanced Horizontal Bone Loss

After orthodontic treatment has been planned, one of the most important factors that determine the outcome of orthodontic therapy is the location of the bands and brackets on the teeth. In a periodontally healthy individual, the position of the brackets is usually determined by the anatomy of the crowns of the teeth. Anterior brackets should be positioned relative to the incisal edges. Posterior bands or brackets are positioned relative to the marginal ridges. If the incisal edges and marginal ridges are at the correct level, the cementoenamel junction (CEJ) will also be at the same level. This relationship creates a flat, bony contour between the teeth. However, if a patient has underlying periodontal problems and significant alveolar bone loss around certain teeth, using the anatomy of the crown to determine bracket placement is not appropriate (Figure 51-6).

In a patient with advanced horizontal bone loss, the bone level may have receded several millimeters from the CEJ. As this occurs, the crown-to-root ratio becomes less favorable. By aligning the crowns of the teeth, the clinician may perpetuate tooth mobility by maintaining an unfavorable crown-to-root ratio. In addition, by aligning the crowns of the teeth and disregarding the bone level, significant bone discrepancies occur between healthy and periodontally diseased roots. This could require periodontal surgery to ameliorate the discrepancies.

Many of these problems can be corrected by using the bone level as a guide to position the brackets on the teeth (see Figure 51-6). In these situations, the crowns of the teeth may require considerable equilibration. If the tooth is vital, the equilibration should be performed gradually to allow the pulp to form secondary dentin and insulate the tooth during the equilibration process. The goal of equilibration and creative bracket placement is to provide a more favorable bony architecture, as well as a more favorable

Figure 51-5 Before orthodontic treatment, this patient had significant mesial tipping of the maxillary right first and second molars, causing marginal ridge discrepancies **(A).** The tipping produced root proximity between the molars **(B).** To eliminate the root proximity, the brackets were placed perpendicular to the long axis of the teeth **(C).** This method of bracket placement facilitated root alignment and elimination of the root proximity, as well as leveling of the marginal ridge discrepancies **(D** to **F).**

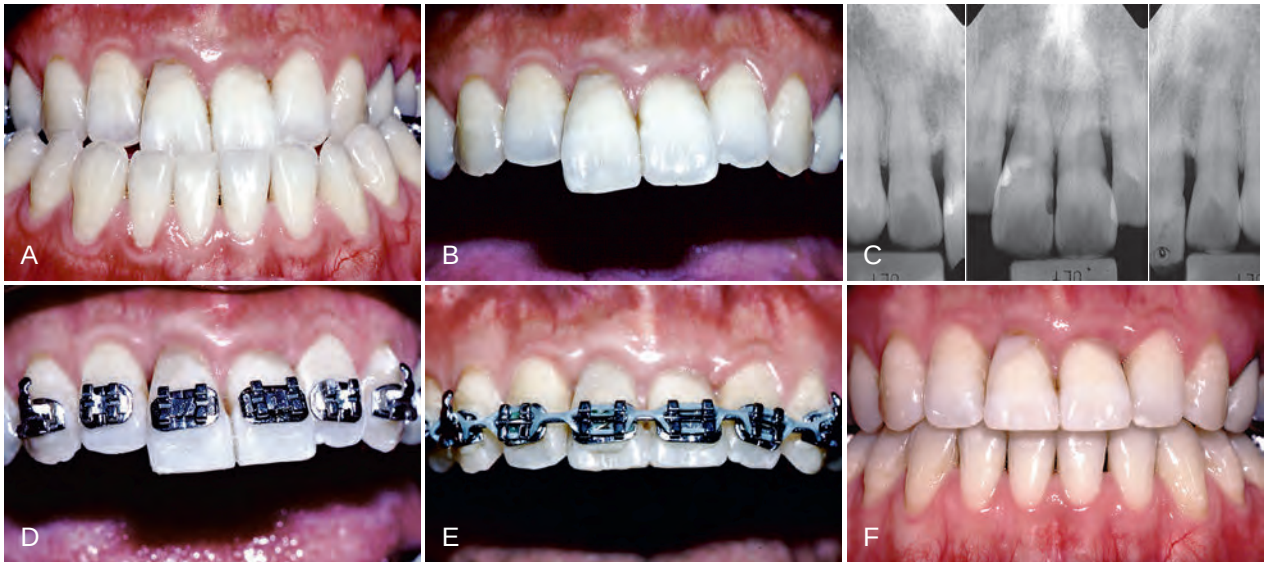

Figure 51-6 Before orthodontic treatment, this patient had a significant class III malocclusion **(A).** The maxillary central incisors had over-erupted **(B)** relative to the occlusal plane. Pretreatment periapical radiograph **(C)** showed that significant horizontal bone loss had occurred. To avoid creating a vertical periodontal defect by intruding the central incisors, the brackets were placed to maintain the bone height **(D).** The incisal edges of the centrals were equilibrated **(E),** and the orthodontic treatment was completed without intruding the incisors **(F).**

crown-to-root ratio. In some of these patients, the periodontal defects that were apparent initially may not require periodontal surgery after orthodontic treatment.

Furcation Defects

Furcation defects can be classified as *incipient* (class I), *moderate* (class II), or *advanced* (class III). These lesions require special attention in the patient undergoing orthodontic treatment. Often, the molars require bands with tubes and other attachments that impede the patient's access to the buccal furcation for home care and instrumentation at the time of recall.

Furcation lesions require special consideration because they are the most difficult lesions to maintain and can worsen during orthodontic therapy. These patients need to be maintained on a 2- to 3-month recall schedule. Detailed instrumentation of these furcations helps minimize further periodontal breakdown.

If a patient with a class III furcation defect will be undergoing orthodontic treatment, a possible method for treating the furcation is to eliminate it by hemisecting the crown and root of the tooth (Figure 51-7). However, this procedure requires endodontic, periodontal, and restorative treatment. If the patient will be undergoing orthodontic treatment, it is advisable to perform the orthodontic treatment first. This is especially true if the roots of the teeth will not be moved apart. In these patients the molar to be hemisected remains intact during orthodontics. This patient would require 2- or 3-month recall visits to ensure that the furcation defect does not lose bone during orthodontic treatment. Keeping the tooth intact during the orthodontic therapy simplifies the concentration of tooth movement for the orthodontist. After orthodontic treatment, endodontic therapy is required (followed by periodontal surgery) to divide the tooth.

In some patients requiring hemisection of a mandibular molar with a class III furcation, pushing the roots apart during orthodontic treatment may be advantageous (Figure 51-8). If the hemisected molar will be used as an abutment for a bridge after orthodontics, moving the roots apart orthodontically permits a favorable restoration and splinting across the adjacent edentulous spaces. In these patients, hemisection, endodontic therapy, and periodontal surgery must be completed before the start of orthodontic treatment. After completion of these procedures, bands or brackets can be placed on the root fragments and coil springs used to separate the roots. The amount of separation is determined by the size of the adjacent edentulous spaces and the occlusion in the opposing arch. About 7 or 8 mm may be created between the roots of the hemisected molar. This process eliminates the original furcation problem and allows the patient to clean the area with greater efficiency.

In some molars with class III furcation defects, the tooth may have short roots, advanced bone loss, fused roots, or other problems that prevent hemisection and crowning of the remaining roots. In these patients, extracting the root with a furcation defect and placing an implant may be more advisable[11] (Figure 51-9). If this type of plan has been adopted, the timing of the extraction and placement of the implant can occur at any time relative to the orthodontic treatment. In some patients, the implant can be used as an anchor to facilitate prerestorative orthodontic treatment.

The implant must remain embedded in bone for 4 to 6 months after placement before it can be loaded as an orthodontic anchor. It must be placed precisely so that it not only provides an anchor for tooth movement but also may be used as an eventual abutment for a crown or fixed bridge. If the implant will not be used as an anchor for orthodontic movement, it may be placed after the orthodontic treatment has been completed. Considerations regarding timing are determined by the restorative treatment plan.

Root Proximity

When roots of posterior teeth are close together, the ability to maintain periodontal health and accessibility for restoration of adjacent teeth may be compromised.[4] However, for the patient undergoing orthodontic therapy, the roots can be moved apart and bone will form between the adjacent roots (see Figure 51-5). This opens the embrasure beneath the tooth contact, provides additional bone support, and enhances the patient's access to the interproximal region for hygiene. This approach generally improves the periodontal health of this area.

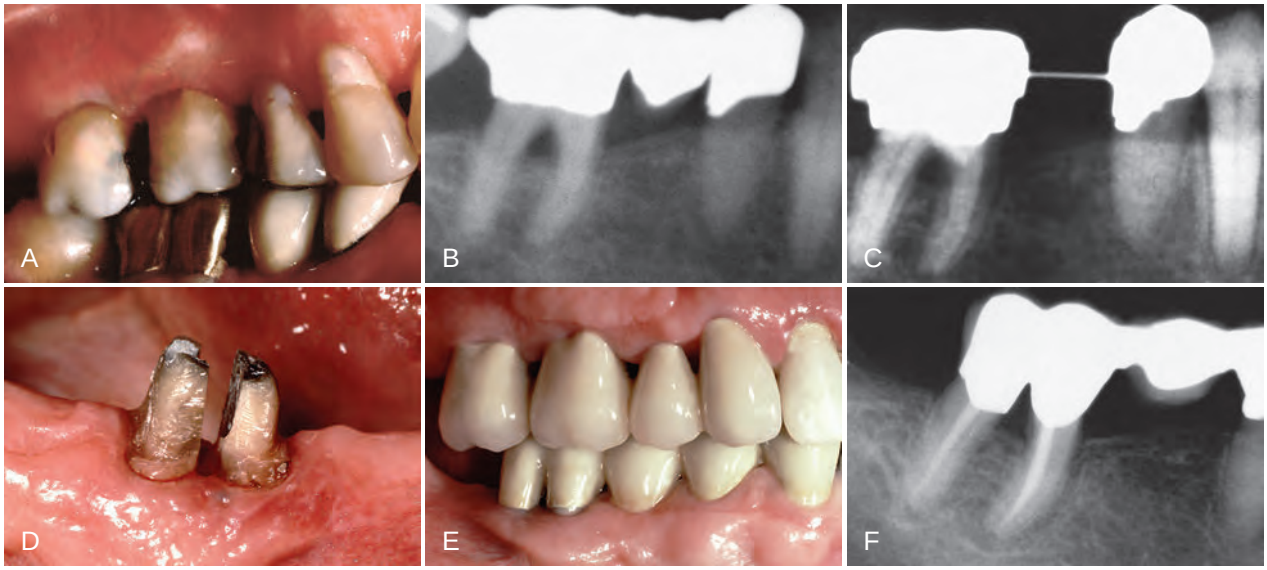

Figure 51-7 This patient had a class III furcation defect before orthodontic treatment **(A** and **B).** Orthodontic treatment was performed **(C)**, and the furcation defect was maintained by the periodontist on 2-month recalls until after orthodontic treatment. After appliance removal, the tooth was hemisected **(D),** and the roots were restored and splinted together **(E).** The final periapical radiograph **(F)** shows that the furcation defect has been eliminated by hemisecting and restoring the two root fragments.

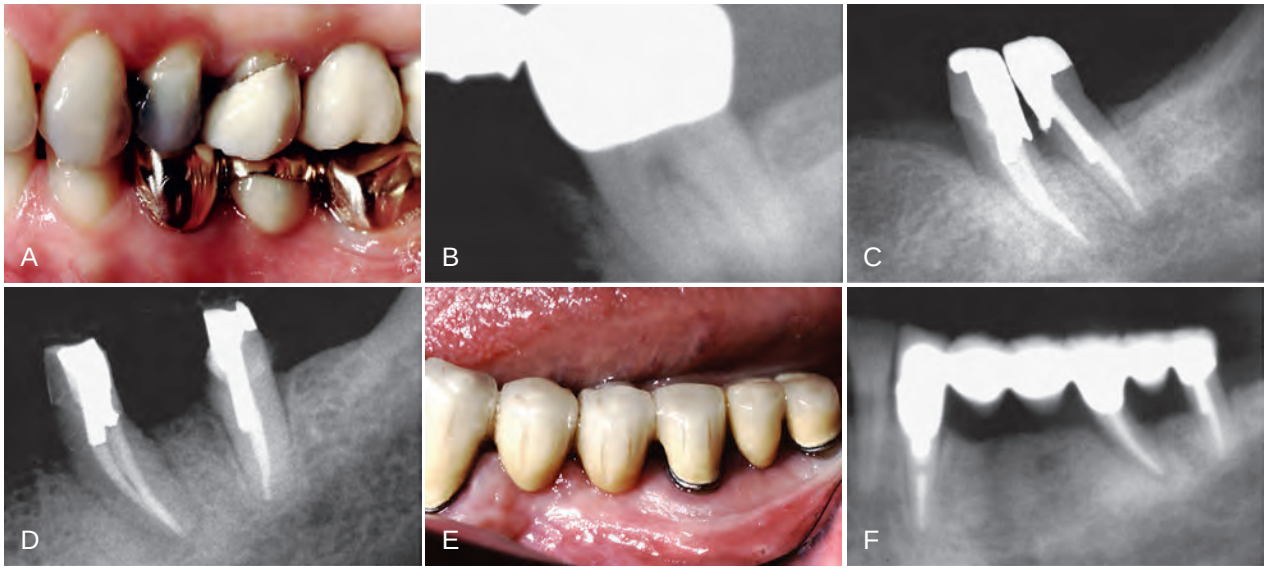

Figure 51-8 Before orthodontic treatment, this patient had a class III furcation defect in the mandibular left second molar **(A** and **B).** Because the patient had an edentulous space mesial to the molar, the tooth was hemisected **(C),** and the root fragments were separated orthodontically **(D).** After orthodontic treatment, the root fragments were used as abutments to stabilize a multiunit posterior bridge **(E** and **F).**

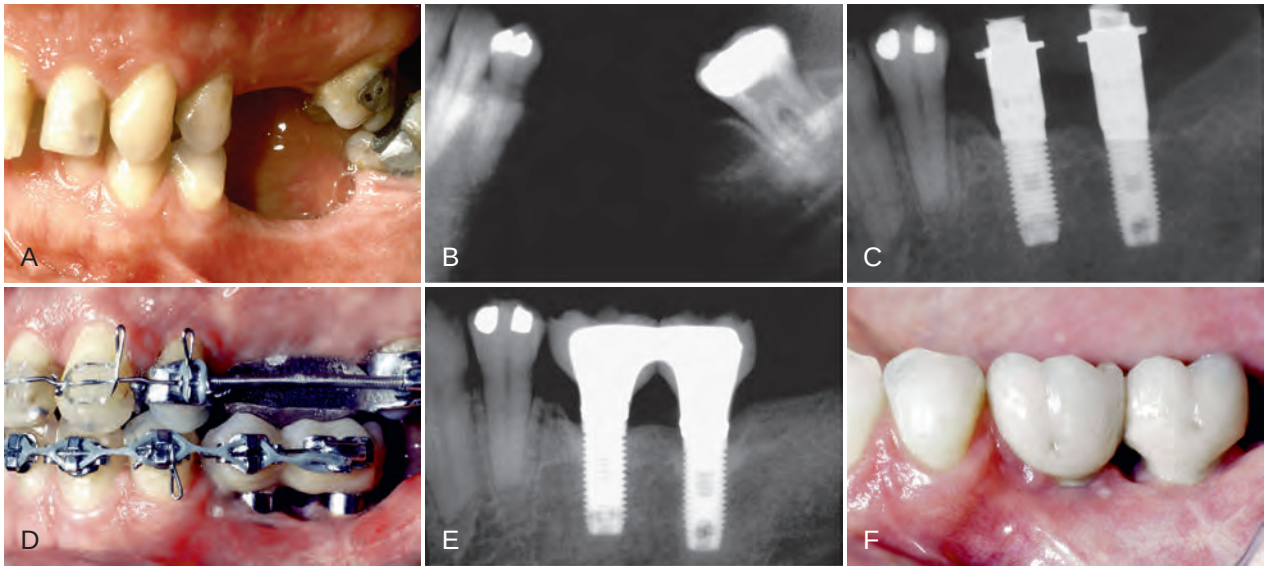

Figure 51-9 This patient was missing several teeth in the mandibular left posterior quadrant **(A).** The mandibular left third molar had a class III furcation defect and short roots **(B).** The third molar was extracted, and two implants were placed in the mandibular left posterior quadrant **(C).** The implants were used as anchors to facilitate orthodontic treatment **(D)** and help reestablish the left posterior occlusion **(E** and **F).**

If orthodontic treatment will be used to move roots apart, this plan must be known before bracket placement. It is advantageous to place the brackets so that the orthodontic movement to separate the roots will begin with the initial archwires (see Figure 51-5). Therefore brackets must be placed obliquely to facilitate this process. Radiographs are needed to monitor the progress of orthodontic root separation. In general, 2 to 3 mm of root separation provides adequate bone and embrasure space to improve periodontal health. During this time, the patient should be maintained to ensure that a favorable bone response occurs as the roots are moved apart. In addition, these patients need occasional occlusal adjustment to recontour the crown because the roots are moving apart. As this occurs, the crowns may develop an unusual occlusal contact with the opposing arch. This should be equilibrated to improve the occlusion.

Fractured Teeth and Forced Eruption

Occasionally, children and adolescents may fall and injure their anterior teeth. If the injuries are minor and result in small fractures of enamel, these can be restored with light-cured composite or porcelain veneers. In some patients, however, the fracture may extend beneath the level of the gingival margin and terminate at the level of the alveolar ridge (Figure 51-10); restoration of the fractured crown is impossible because the tooth preparation would extend to the level of the bone. This overextension of the crown margin could result in an invasion of the biologic width of the tooth

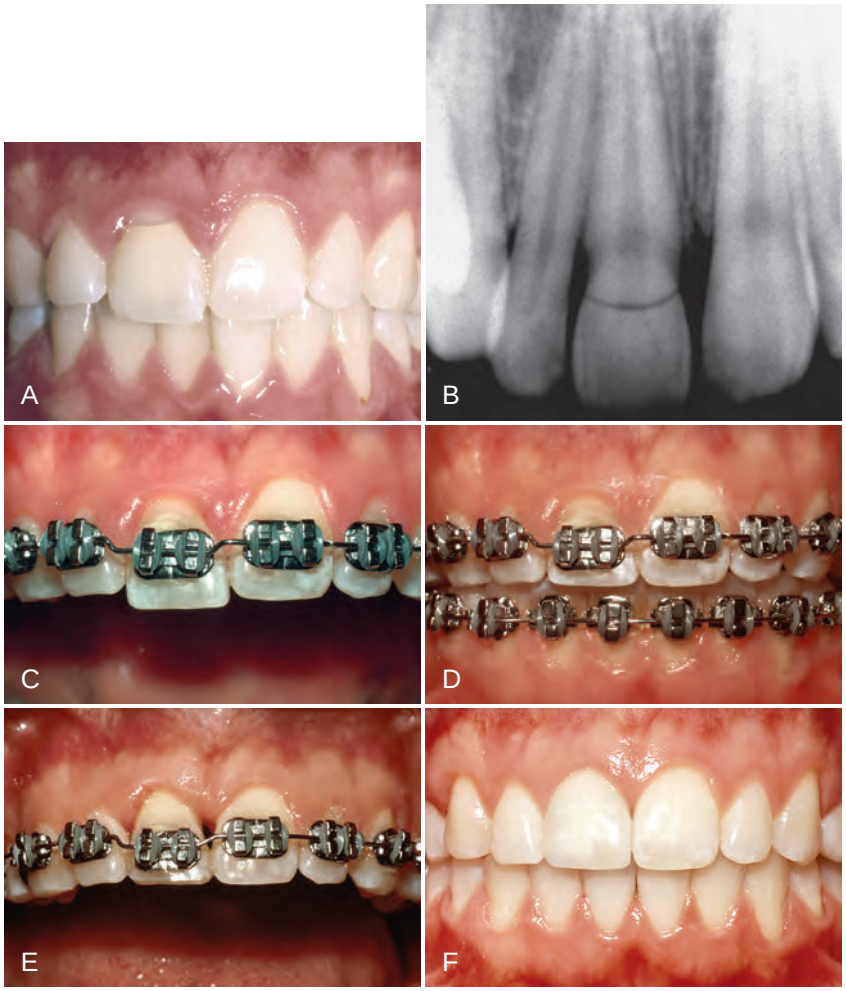

Figure 51-10 This patient had a severe fracture of the maxillary right central incisor **(A)** that extended apical to the level of the alveolar crest on the lingual side **(B).** To restore the tooth adequately and avoid impinging on the periodontium, the fractured root was extruded 4 mm **(C).** As the tooth erupted, the gingival margin followed the tooth **(D).** Gingival surgery was required to lengthen the crown of the central incisor **(E),** so that the final restoration had sufficient ferrule for resistance and retention and the appropriate gingival margin relationship with the adjacent central incisor **(F).**

and cause persistent inflammation of the marginal gingiva. It may be beneficial in such cases to erupt the fractured root out of the bone and move the fracture margin coronally so that it can be properly restored.[10] However, if the fracture extends too far apically, it may be better to extract the tooth and replace it with an implant or bridge. The following six criteria are used to determine whether the tooth should be forcibly erupted or extracted:

1. *Root length.* Is the root long enough so that a one-to-one crown-to-root ratio is preserved after the root has been erupted? To answer this question, the clinician must know how far to erupt the root. If a tooth fracture extends to the level of the bone, it must be erupted 4 mm. The first 2.5 mm moves the fracture margin far enough away from the bone to prevent a biologic width problem. The other 1.5 mm provides the proper amount of ferrule for adequate resistance form of the crown preparation. Therefore, if the root is fractured to the bone level and must be erupted 4 mm, the periapical radiograph must be evaluated (see Figure 51-10, *B*) and 4 mm subtracted from the end of the fractured tooth root. The length of the residual root should be compared with the length of the eventual crown on this tooth. The root-to-crown ratio should be about 1 : 1. If the root-to-crown ratio is less than this amount, there may be too little root remaining in the bone for stability. In the latter situation, it may be prudent to extract the root and place a bridge or implant.
2. *Root form.* The shape of the root should be broad and nontapering rather than thin and tapered. A thin, tapered root provides a narrower cervical region after the tooth has been erupted 4 mm. This could compromise the esthetic appearance of the final restoration. The internal root form is also important. If the root canal is wide, the distance between the external root surface and root canal filling will be narrow. In these patients, the walls of the crown preparation are thin, which could result in early fracture of the restored root. The root canal should not be more than one-third of the overall width of the root. In this way, the root could still provide adequate strength for the final restoration.
3. *Level of the fracture.* If the entire crown is fractured 2 to 3 mm apical to the level of the alveolar bone, it is difficult, if not impossible, to attach to the root to erupt it.
4. *Relative importance of the tooth.* If the patient is 70 years of age and both adjacent teeth have prosthetic crowns, it would be more prudent to construct a fixed bridge. However, if the patient is 15 years of age and the adjacent teeth are unrestored, forced eruption would be much more conservative and appropriate.
5. *Esthetics.* If the patient has a high lip line and displays 2 to 3 mm of gingiva when smiling, any type of restoration in this area will be more obvious. Keeping the patient's own tooth would be much more esthetic than any type of implant or prosthetic replacement.

6. *Endodontic/periodontal prognosis.* If the tooth has a significant periodontal defect, it may not be possible to retain the root. In addition, if the tooth root has a vertical fracture, the prognosis would be poor, and extraction of the tooth would be the proper course of therapy.

If all these factors are favorable, forced eruption of the fractured root is indicated. The orthodontic mechanics necessary to erupt the tooth can vary from elastic traction to orthodontic banding and bracketing. If a large portion of the tooth is still present, orthodontic bracketing is necessary. If the entire crown has fractured, leaving only the root, elastic traction from a bonded bar may be possible. The root may be erupted rapidly or slowly. If the movement is performed rapidly, the alveolar bone will be left behind temporarily, and a circumferential fiberotomy may be performed to prevent bone from following the erupted root. However, if the root is erupted slowly, the bone follows the tooth. In this situation, the erupted root requires crown lengthening to expose the correct amount of tooth to create the proper ferrule, resistance form, and retention for the final restoration.

After the tooth root has been erupted, it must be stabilized to prevent it from intruding back into the alveolus. The reason for *reintrusion* is the orientation of the principal fibers of the periodontium. During forced eruption, the periodontal fibers become oriented obliquely and stretched as the root moves coronally. These fibers eventually reorient themselves after about 6 months. Before this occurs, the root can reintrude significantly. Therefore, if this type of treatment is performed, an adequate period of stabilization is necessary to avoid significant relapse and reintrusion of the root.

As the root erupts, the gingiva moves coronally with the tooth. As a result, the clinical crown length becomes shorter after extrusion (see Figure 51-10). In addition, the gingival margin may be positioned more incisally than the adjacent teeth. In these patients, gingival surgery is necessary to create ideal gingival margin heights. The type of surgery varies, depending on whether bone removal is necessary. If bone has followed the root during eruption, a flap is elevated, and the appropriate amount of bone is removed to match the bone height of the adjacent teeth. If the bone level is flat between adjacent teeth, a simple excisional gingivectomy corrects the gingival margin discrepancy.

After gingival surgery, an open gingival embrasure may exist between the erupted root and adjacent teeth (see Figure 51-10). The space occurs because the narrower root portion of the erupted tooth has been moved into the oral cavity. This space may be closed in two ways: (1) overcontouring of the replacement restoration and (2) reshaping of the crown of the tooth and movement of the root to close the space. The second method often helps improve the overall shape of the final crown on the restored tooth.

Hopeless Teeth Maintained for Orthodontic Anchorage

Patients with advanced periodontal disease may have specific teeth diagnosed as hopeless, which would be extracted before orthodontic therapy (Figure 51-11). However, these teeth can be useful for orthodontic anchorage if the periodontal inflammation can be controlled. In moderate-to-advanced cases, some periodontal surgery may be indicated around a hopeless tooth. Flaps are reflected for debridement of the roots to control inflammation around the hopeless tooth during the orthodontic process. The important factor is to maintain the health of the bone around the adjacent teeth. Periodontal recall is imperative during the process.

After orthodontic treatment, there is a 6-month period of stabilization before reevaluating the periodontal status. Occasionally,

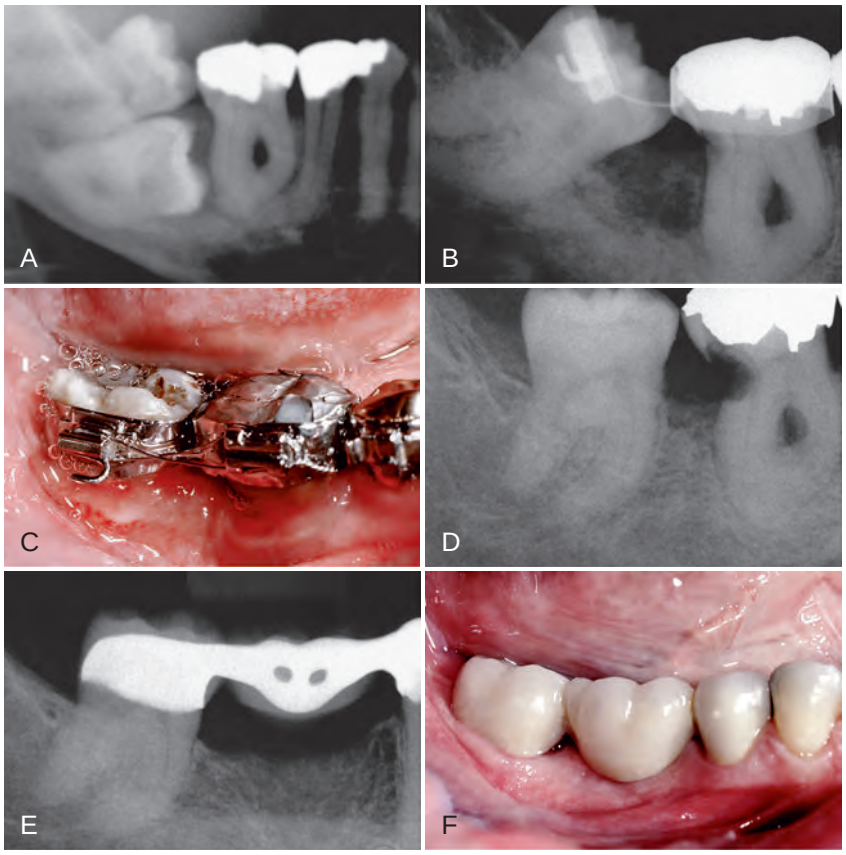

Figure 51-11 This patient had an impacted mandibular right second molar **(A).** The mandibular right first molar was periodontally hopeless because of an advanced class III furcation defect. The impacted second molar was extracted, but the first molar was maintained as an anchor to help upright the third molar orthodontically **(B** to **D).** After orthodontic uprighting of the third molar, the first molar was extracted and a bridge was placed to restore the edentulous space **(E** and **F).**

the hopeless tooth may be so improved after orthodontic treatment that it is retained. In most cases, however, the hopeless tooth requires extraction, especially if other restorations are planned in the segment. Again, these decisions require reevaluation by the clinician.

Orthodontic Treatment of Gingival Discrepancies

Uneven Gingival Margins

The relationship of the gingival margins of the six maxillary anterior teeth plays an important role in the esthetic appearance of the crowns. The following four factors contribute to ideal gingival form:

1. The gingival margins of the two central incisors should be at the same level.
2. The gingival margins of the central incisors should be positioned more apically than the lateral incisors and at the same level as the canines.[13]
3. The contour of the labial gingival margins should mimic the CEJs of the teeth.
4. A papilla should exist between each tooth, and the height of the tip of the papilla is usually halfway between the incisal edge and the labial gingival height of contour over the center of each anterior tooth. Therefore the gingival papilla occupies half of the interproximal contact, and the adjacent teeth form the other half of the contact.

However, some patients may have gingival margin discrepancies between adjacent teeth (Figure 51-12). These discrepancies may be caused by abrasion of the incisal edges or delayed migration of the gingival margins. When gingival margin discrepancies are present, the proper solution for the problem must be determined: orthodontic movement to reposition the gingival margins or surgical correction of gingival margin discrepancies.

To make the correct decision, it is necessary to evaluate four criteria. First, the relationship between the gingival margin of the maxillary central incisors and the patient's lip line should be assessed when the patient smiles. If a gingival margin discrepancy is present, but the discrepancy is not exposed, it does not require correction.

If a gingival margin discrepancy is apparent, the second step is to evaluate the labial sulcular depth over the two central incisors. If the shorter tooth has a deeper sulcus, excisional gingivectomy may be appropriate to move the gingival margin of the shorter tooth apically. However, if the sulcular depths of the short and long incisors are equivalent, gingival surgery does not correct the problem.

The third step is to evaluate the relationship between the shortest central incisor and the adjacent lateral incisors. If the shortest central incisor is still *longer* than the lateral incisors, the other possibility is to extrude the longer central incisor and equilibrate the incisal edge. This moves the gingival margin coronally and eliminates the gingival margin discrepancy. However, if the shortest central incisor is *shorter* than the lateral incisors, this technique would produce an unesthetic relationship between the gingival margins of the central and lateral incisors.

The fourth step is to determine whether the incisal edges have been abraded. This is best accomplished by evaluating the teeth from an incisal perspective. If one incisal edge is thicker labiolingually than the adjacent tooth, this may indicate that it has been abraded and the tooth has overerupted. In such cases, the best method of correcting the gingival margin discrepancy is to intrude the short central incisor (see Figure 51-12). This method moves the

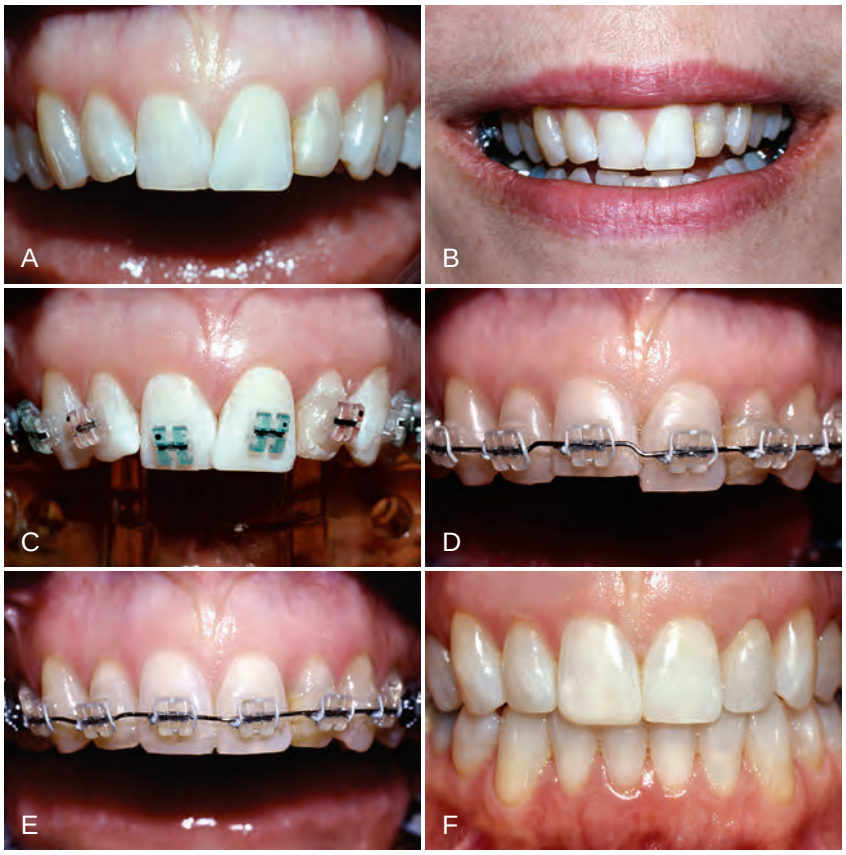

Figure 51-12 This patient had a protrusive bruxing habit that had resulted in abrasion and overeruption of the maxillary right central incisor **(A).** The objective was to level the gingival margins during orthodontic therapy. Although gingival surgery was a possibility, the labial sulcular depth of the maxillary right central incisor was only 1 mm, and the cementoenamel junction was located at the bottom of the sulcus. Therefore the best solution involved positioning the orthodontic brackets to facilitate intrusion of the right central incisor **(B** to **D).** This permitted the restorative dentist to restore the portion of the tooth that the patient had abraded **(E),** resulting in the correct gingival margin levels and crown lengths at the end of treatment **(F).**

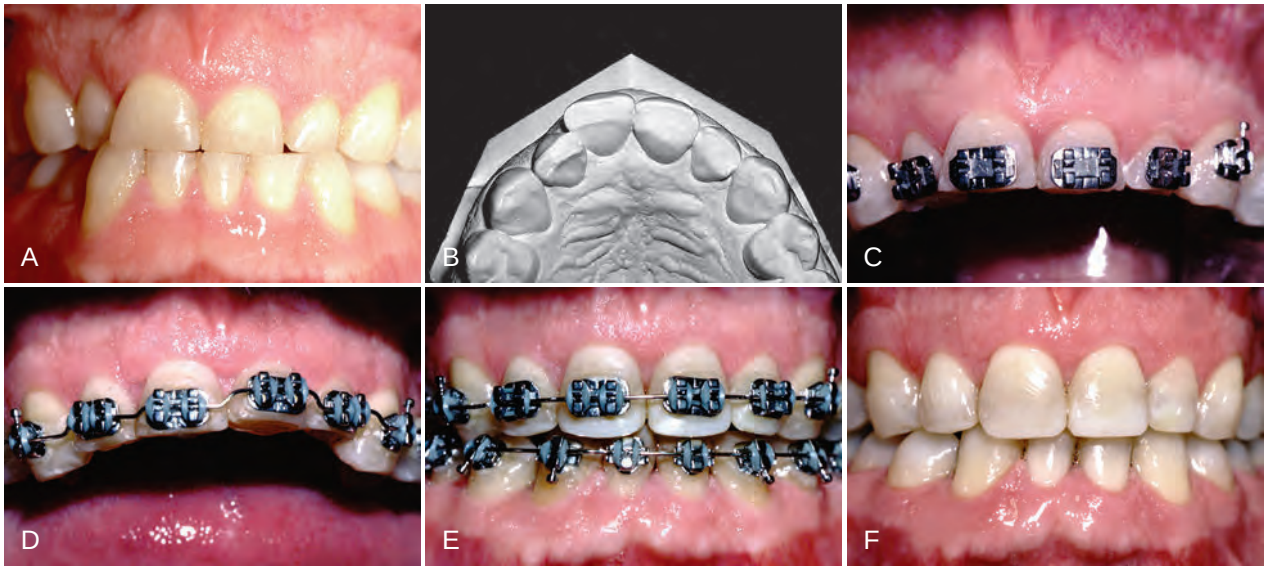

Figure 51-13 This patient had a protrusive bruxing habit that had caused severe abrasion of the maxillary anterior teeth, resulting in the loss of over half of the crown length of the incisors **(A** and **B).** Two possible options existed for gaining crown length to restore the incisors. One possibility was an apically positioned flap with osseous recontouring, which would expose the roots of the teeth. The less destructive option was to intrude the four incisors orthodontically, level the gingival margins **(C** and **D),** and allow the dentist to restore the abraded incisal edges **(E** and **F).** The orthodontic option was clearly successful and desirable in this patient.

gingival margin apically and permits restoration of the incisal edges.[3,6-9] The intrusion should be accomplished at least 6 months before appliance removal. This allows reorientation of the principal fibers of the periodontium and avoids reextrusion of the central incisor(s) after appliance removal.

Significant Abrasion and Overeruption

Occasionally, patients have destructive dental habits, such as a protrusive bruxing habit, that can result in significant wear of the maxillary and mandibular incisors and compensatory overeruption of these teeth (Figure 51-13). The restoration of these abraded teeth is often impossible because of the lack of crown length to achieve adequate retention and resistance form for the crown preparations. Two options are available. One option is extensive crown lengthening by elevating a flap, removing sufficient bone, and apically positioning the flap to expose adequate tooth length for crown preparation. However, this type of procedure is contraindicated in the patient with short, tapered roots because it could adversely affect the final root-to-crown ratio and potentially open gingival embrasures between the anterior teeth.

The other option for improving the restorability of these short abraded teeth is to intrude the teeth orthodontically and move the gingival margins apically (see Figure 51-13). It is possible to intrude up to four maxillary incisors by using the posterior teeth as anchorage during the intrusion process. This process is accomplished by placing the orthodontic brackets as close to the incisal edges of the maxillary incisors as possible. The brackets are placed in their normal position on the canines and remaining posterior teeth. The patient's posterior occlusion resists the eruption of the posterior teeth, and the incisors gradually intrude and move the gingival margins and the crowns apically. This creates the restorative space necessary to restore the incisal edges of these teeth temporarily and then eventually place the final crowns.

When abraded teeth are significantly intruded, it is necessary to hold these teeth for at least 6 months in the intruded position with orthodontic brackets or archwires (or both), or some type of bonded retainer. The principal fibers of the periodontium must accommodate to the new intruded position, a process that could take a minimum of 6 months in most adult patients. Orthodontic intrusion of severely abraded and overerupted teeth is usually a distinct advantage over periodontal crown lengthening, unless the patient has extremely long and broad roots or has had extensive horizontal periodontal bone loss.

Open Gingival Embrasures

The presence of a papilla between the maxillary central incisors is a key esthetic factor in any individual. Occasionally, adults have open gingival embrasures or lack gingival papillae between their central incisors. These unesthetic areas are often difficult to resolve with periodontal therapy. However, orthodontic treatment can correct many of these open gingival embrasures. This open space is usually caused by (1) tooth shape, (2) root angulation, or (3) periodontal bone loss.[9]

The interproximal contact between the maxillary central incisors consists of two parts: the tooth contact and the papilla. The papilla/contact ratio is 1 : 1. Half the space is occupied by papilla, and half is formed by the tooth contact. If the patient has an open embrasure, the first aspect that must be evaluated is whether the problem is caused by the papilla or the tooth contact. If the papilla is the problem, the cause is usually a lack of bone support because of an underlying periodontal problem.

In some situations, a deficient papilla can be improved with orthodontic treatment. By closing open contacts, the interproximal gingiva can be squeezed and moved incisally. This type of movement may help create a more esthetic papilla between two teeth despite alveolar bone loss. Another possibility is to erupt adjacent teeth when the interproximal bone level is positioned apically.

Most open embrasures between the central incisors are caused by problems with tooth contact. The first step in the diagnosis of this problem is to evaluate a periapical radiograph of the central incisors. If the root angulation is divergent, the brackets should be repositioned so that the root position can be corrected (Figure 51-14). In these patients the incisal edges may be uneven and require restoration with either composite or porcelain restorations.

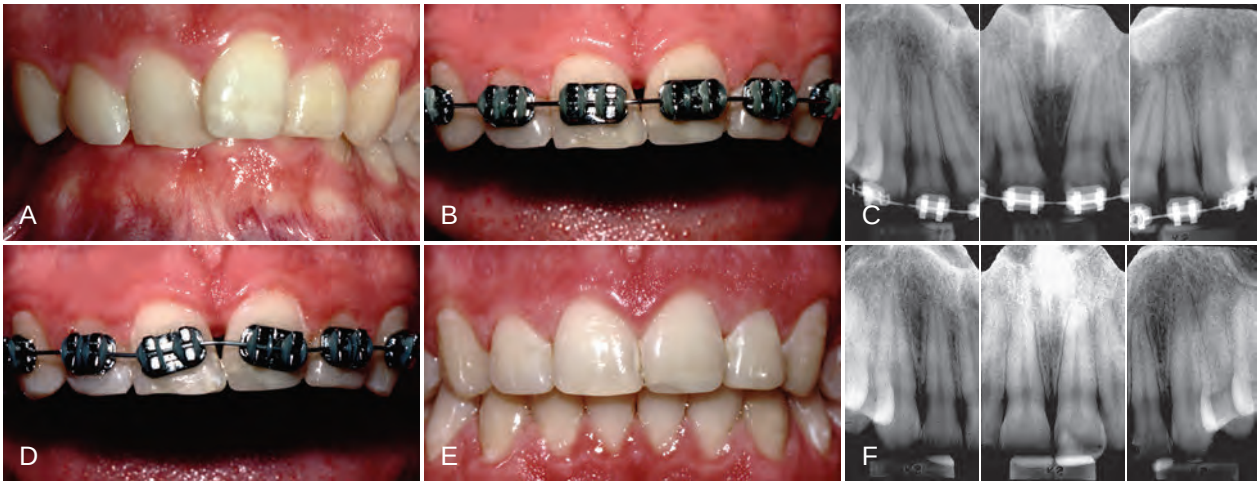

Figure 51-14 This patient initially had overlapped maxillary central incisors **(A),** and after initial orthodontic alignment of the teeth, an open gingival embrasure appeared between the centrals **(B).** Radiograph showed that the open embrasure was caused by divergence of the central incisor roots **(C).** To correct the problem, the central incisor brackets were repositioned **(D),** and the roots were moved together. This required restoration of the incisal edges after orthodontic therapy **(E)** because these teeth had worn unevenly before therapy. As the roots were paralleled **(F),** the tooth contact moved gingivally and the papilla moved incisally, resulting in the elimination of the open gingival embrasure.

Figure 51-15 This patient initially had triangular-shaped central incisors **(A** and **B),** which produced an open gingival embrasure after orthodontic alignment **(C).** Because the roots of the central incisors were parallel with one another, the appropriate solution for the open gingival embrasure was to recontour the mesial surfaces of the central incisors **(D).** As the diastema was closed **(E),** the tooth contact moved gingivally and the papilla moved incisally, resulting in the elimination of the open gingival embrasure **(F).**

If the periapical radiograph shows that the roots are in their correct relationship, the open gingival embrasure is caused by a triangular tooth shape (Figure 51-15).

If the shape of the tooth is the problem, two solutions are possible: (1) restore the open gingival embrasure or (2) reshape the tooth by flattening the incisal contact and closing the space (see Figure 51-15). This second option results in lengthening of the contact until it meets the papilla. In addition, if the embrasure space is large, closing the space squeezes the papilla between the central incisors. This helps create a 1 : 1 ratio between the contact and papilla and restores uniformity to the heights between the midline and adjacent papillae.

Ingber J: Forced eruption. Part I. A method of treating isolated one and two wall infrabony osseous defects: rationale and case report. *J Periodontol* 45:199, 1974.

Kokich V: Anterior dental esthetics: an orthodontic perspective. I. Crown length. *J Esthet Dent* 5:19, 1993.

Kokich V: Enhancing restorative, esthetic and periodontal results with orthodontic therapy. In Schluger S, Youdelis R, Page R, et al, editors: *Periodontal therapy*, Philadelphia, 1990, Lea & Febiger.

Kokich V: Esthetics and vertical tooth position: the orthodontic possibilities. *Compend Contin Educ Dent* 18:1225, 1997.

Kokich V, Nappen D, Shapiro P: Gingival contour and clinical crown length: their effects on the esthetic appearance of maxillary anterior teeth. *Am J Orthod* 86:89, 1984.

References

References for this chapter are found on the companion website www.expertconsult.com.

References

1. Becker W, Becker BE: Treatment of mandibular 3-wall intrabony defects by flap debridement and expanded polytetrafluoroethylene barrier membranes: long-term evaluation of 32 treated patients. *J Periodontol* 64:1138, 1993.
2. Brown IA: The effect of orthodontic therapy on certain types of periodontal defects. I. Clinical findings. *J Periodontol* 44:742, 1973.
3. Chiche G, Kokich V, Caudill R: Diagnosis and treatment planning of esthetic problems. In Pinault A, Chiche G, editors: *Esthetics in fixed prosthodontics*, Chicago, 1994, Quintessence.
4. Gould MS, Picton DC: The relation between irregularities of the teeth and periodontal disease. *Br Dent J* 121:21, 1966.
5. Ingber J: Forced eruption. Part I. A method of treating isolated one and two wall infrabony osseous defects: rationale and case report. *J Periodontol* 45:199, 1974.
6. Kokich V: Enhancing restorative, esthetic and periodontal results with orthodontic therapy. In Schluger S, Youdelis R, Page R, et al, editors: *Periodontal therapy*, Philadelphia, 1990, Lea & Febiger.
7. Kokich V: Anterior dental esthetics: an orthodontic perspective. I. Crown length. *J Esthet Dent* 5:19, 1993.
8. Kokich V: Esthetics: the orthodontic-periodontic-restorative connection. *Semin Orthod* 2:21, 1996.
9. Kokich V: Esthetics and vertical tooth position: the orthodontic possibilities. *Compend Contin Educ Dent* 18:1225, 1997.
10. Kokich V, Nappen D, Shapiro P: Gingival contour and clinical crown length: their effects on the esthetic appearance of maxillary anterior teeth. *Am J Orthod* 86:89, 1984.
11. Kramer GM: Surgical alternatives in regenerative therapy of the periodontium. *Int J Periodont Restor Dent* 12:11, 1992.
12. Ochsenbein C, Ross S: A re-evaluation of osseous surgery. *Dent Clin North Am* 13:87, 1969.
13. Rufenacht C: Structural esthetic rules. In Rufenacht C, editor: *Fundamental of esthetics*, Chicago, 1990, Quintessence.
14. Schallhorn R, McClain P: Combined osseous composite grafting, root conditioning and guided tissue regeneration. *Int J Periodont Restor Dent* 8:9, 1988.
15. Schluger S: Osseous resection: a basic principle in periodontal surgery. *Oral Surg* 2:316, 1949.

Pathologic Tooth Migration: A Case Report*

Charbel Bou Serhal and Birgit Pelsmaekers

CHAPTER OUTLINE

Case Report
Treatment
Results and Discussion

Pathologic tooth migration (PTM) is a common complication of moderate-to-severe periodontitis.[1,2] The prevalence of PTM among periodontal patients has been reported to range from 30.03% to 55.8%. It occurs most frequently in the anterior region, but posterior teeth can also be affected. There are many types of pathologic tooth migration: diastema, extrusion, rotation, facial flaring, and drifting into edentulous spaces. Some of the important factors are poor periodontal support as the result of periodontal disease and the eventual loss of teeth, which changes the forces exerted on the remaining dentition. Later, if the missing teeth are not replaced, especially the first molars, the maxillary incisors are forced labially and laterally, which leads to the extrusion of the anterior teeth and the resulting diastema. Teeth mobility increases, and the second and third molars tilt mesially, which results in a reduced vertical dimension. This can also lead to an anterior overbite, and the mandibular incisors occlude near or on the palatal gingival margin of the maxillary anterior dentition.

PTM is caused by several factors, and one or more teeth can be involved. The treatment of most cases may require a multidisciplinary approach. In addition to periodontal therapy, orthodontic tooth movement can be beneficial. Replacing missing teeth with implants can stabilize the occlusion and reduce the trauma on the anterior dentition

Case Report

The following is a case that involves the multidisciplinary approach. A 56-year-old female patient was referred for periodontal treatment. The general dentist had diagnosed periodontal involvement with deep pocket formation and increased tooth mobility. He was willing to place a bridge to replace the missing teeth #29 and 30 and asked an assessment of the prognosis of tooth #31.

The patient's complaints were as follows:

- A reduced ability to bite because of increased tooth mobility in the maxillary anterior area
- Bleeding during toothbrushing
- Increased sensitivity to cold

*This case report on the rehabilitation of a periodontally compromised patient combining periodontal, orthodontic, and implant therapy is provided to demonstrate different approaches to managing challenging cases. The editors and authors of associated chapters do not endorse treatments, procedures, products, or conclusions made by the authors of the case reports.

Medical History

The patient has no reported medical problems. She does not use medications or drugs and is a nonsmoker.

Dental History

The patient visited the dentist once a year for routine recall therapy. The most recent oral prophylaxis was performed 10 days before the first periodontal visit. The oral hygiene regimen included toothbrushing with a manual toothbrush, once a day. The patient was not using any other hygiene instruments or mouthwashes. She had a negative history of previous periodontal or orthodontic treatment.

Oral Examination

Her overall oral hygiene status was poor with abundant bacterial plaque present, especially around the distal and lingual surfaces. There were no visible supragingival calculus deposits because the patient had a dental appointment a few days earlier. However, subgingival calculus was present throughout. The patient did not present any pathologic lesions and was not aware of oral malodor.

There were numerous restorations on the maxillary arch, but no areas of abrasions or erosions presented. The majority of the teeth were sensitive to thermal changes.

There were symptoms of PTM in the anterior region (Supplement A Figure 51-1). Diastemas were present between the maxillary incisors, as well as the mandibular dentition. The patient confirmed that in the past the position of her anterior teeth was normal and that her teeth "were all touching." The maxillary and mandibular incisors displayed extrusion, rotation, and facial flaring. There was a pronounced anterior overbite.

In the posterior region, several teeth had been missing for many years. The most prominent missing teeth were the mandibular first molars. Only teeth #5 and 13 were replaced. The patient was able to function bilaterally even though the first molars were missing.

Periodontal Assessment

To assess the extent of the periodontal disease, a full periodontal examination was accomplished. The examination included pocket probing and evaluation of gingival recession and tooth mobility. Supplement A Figure 51-2 indicates the extensive periodontal involvement of the maxillary arch. Periodontal pockets that involved the interdental and lingual areas ranged from 4 to 6 mm. The majority of the anterior teeth presented recession that

Supplement A Figure 51-1 Different views of the oral cavity and the teeth. Note the different signs of pathologic tooth migration in the anterior region: diastemas, extrusion, tooth rotation, and flaring. **A**, Facial view. Note diastema between teeth #8 and #9. **B**, Lips retracted to display diastema. **C**, Palatal view of maxillary arch. **D**, Incisal view of mandibular arch. **E**, Right lateral view. Note overbite. **F**, Left lateral view.

measured 2 mm. Increased mobility was noted for most teeth, especially tooth #31. Most of the furcations were class I.

Radiographic Survey

The panoramic radiograph (Supplement A Figure 51-3) presented generalized horizontal bone loss. Tooth #31 presented mesial angular bone defect and early furcation involvement. Several areas presented subgingival calculus.

Casts

A diagnostic model was indicated to evaluate the occlusal problem of the anterior area (Supplement A Figure 51-4). A diagnostic model can help to better assess the occlusion, tooth malposition, and inclination and to visualize the entire dentition and jaw.

Diagnosis

The generalized bone loss and periodontal pockets are due to chronic periodontitis. The poor oral hygiene and the lack of maintenance therapy has been a major contribution to the periodontal involvement.

The failure to replace the missing teeth, especially the mandibular first molars, has also created an occlusal problem. Only one crown was used to replace both teeth #5 and #4 (Supplement A Figure 51-1, *C*), seriously reducing the occlusal surface in width. There were few stable occlusal contacts for many years. On the right side, only tooth #31 had occlusal contact, while only teeth #21 and #20 were contacting on the left side. Other occlusal contacts were sliding contacts, which are considered unstable.

The combination of chronic periodontitis and trauma from occlusion resulted in the pathologic migration in the anterior region. The reduced occlusal support caused by the missing mandibular first molars played an important role in the prognosis.

Determination of Prognosis

The prognosis of each tooth was determined individually, taking into account the patient's age, disease severity, plaque control compliance, and cooperation, as well as the periodontal and occlusal factors.

In addition to tooth #31, all teeth displaying PTM were considered to be susceptible to further periodontal breakdown in the future with inadequate treatment. The prognosis of these teeth was determined as poor. The prognosis of the remaining teeth was considered fair because of the reduced influence of trauma from occlusion.

The orthodontist was asked to assess the possibility of orthodontic treatment in the anterior region to restore a normal occlusal plane and thus reestablish the contacts.

Treatment Plan

The patient received detailed explanation about periodontitis and the etiologic factors. She was initially surprised but became aware of the severity of the problem and the negative effects of this disease in the future.

The initial therapy was the treatment of the periodontal disease to reduce the inflammation. It was also realized that neglecting the occlusal problem would not help improve the prognosis of these teeth. The orthodontist concurred on the need for orthodontic therapy in the anterior region. The patient also insisted on saving teeth #1 and #16 despite the supereruption.

The following treatment plan was proposed after considering the patient's complaints, wishes, and social situation:

- Initial periodontal therapy of scaling and root planing
- Plaque control and patient education
- Evaluation of the periodontal status after the nonsurgical phase of therapy
- Surgical phase of therapy, if indicated
- Orthodontic therapy
- Implant therapy to replace missing teeth #19 and #30
- Restorative phase
- Periodontal maintenance phase

Treatment

Periodontal Therapy

The nonsurgical phase of therapy consisted of scaling and root planing combined with the use of chlorhexidine rinses twice a day

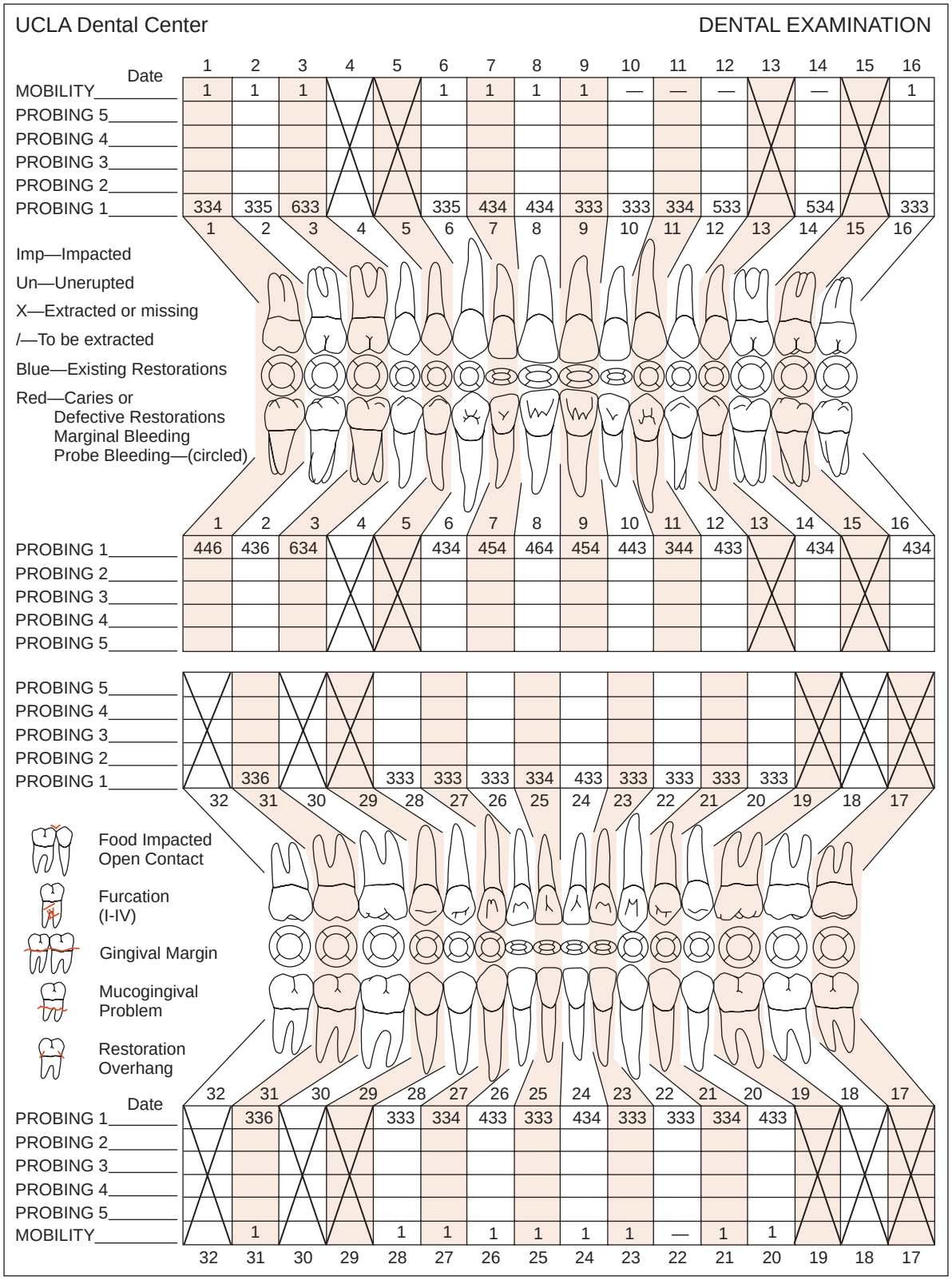

Supplement A Figure 51-2 The periodontal chart at the initial periodontal examination.

for 4 weeks. The patient's compliance was excellent after the initial 4 weeks of therapy. The patient was instructed to brush at least twice a day, using a manual toothbrush in combination with interdental brushes and dental floss.

The patient was seen 3 months later for reevaluation, plaque control, and professional prophylaxis.

Reevaluation

The results of the nonsurgical phase were evaluated 6 months after the start of the initial therapy and resulted in a new periodontal status (Supplement A Figure 51-5). The patient's motivation remained stable and consistent during the entire 6-month period.

Supplement A Figure 51-3 A panoramic radiograph displaying detailed information of the dentition and the jaw bone.

Supplement A Figure 51-4 A diagnostic model allows visualizing and analyzing the dentition from different views. **A**, Anterior view. Note the diastema and overbite. **B**, Right lateral view. **C**, Left lateral view.

There was significant generalized reduction of pocket depth. The remaining periodontal pockets around teeth #1, #2, and #11 did not display bleeding on probing, as well as the other remaining sites. This favorable response to the nonsurgical phase permitted the initiation of orthodontic therapy.

Orthodontic Therapy

The orthodontic treatment plan was to correct the overbite, intrude the maxillary anterior teeth, and move these teeth back to their previous position. They will also be splinted from canine to canine. Full-arch fixed orthodontic appliances were placed in both the maxillary and the mandibular arches (Supplement A Figure 51-6). The total duration of the orthodontic therapy was 1 year and 3 months. Only light orthodontic forces were applied.

During the orthodontic therapy phase, the patient was seen every 3 months for periodontal evaluation by the periodontist. This was essential to maintain periodontal health, to monitor progress, and to diagnose any periodontal changes caused by orthodontic tooth movement. The orthodontist also reinforced oral hygiene at each orthodontic visit.

After the removal of the appliances, an orthodontic retention wire was placed from canine to canine in the maxilla and from tooth #21 to tooth #28 in the mandible (see Supplement A Figure 51-7, *D*).

Implant Therapy

Two implants were placed 4 months after the start of the orthodontic therapy to replace teeth #19 and #30. It was possible to start the implant therapy at this stage because the orthodontist had confirmed that teeth #20 and #28 would not be displaced. There was also a possibility of using the implants for orthodontic anchorage at a later stage if needed.

Restorative Phase

After removal of the orthodontic appliances, the dentist initiated the final restorations on the implants. The addition of two crowns at the first molar sites was very important to stabilize the occlusion. Consequently, tooth #31was stabilized mesially (Supplement A Figure 51-7).

A panoramic radiograph was taken to determine the effect of the treatment on the jaw bone and the roots (Supplement A Figure 51-8).

Periodontal Maintenance

The periodontal maintenance consisted of 3-month recall visits that included hygiene control, probing, and prophylaxis. Regular maintenance care is essential in cases that use combined therapy to assure case stability.

One year after the termination of orthodontic treatment, a new periodontal recording and panoramic radiographs were obtained (Supplement A Figure 51-9 and Supplement A Figure 51-10) to evaluate the periodontal status. The result of these examinations presented a stable and healthy periodontal status.

Results and Discussion

The final result was considered satisfactory not only for the clinician but also for the patient (see Supplement A Video 51-1: Rehab of Periodontally Compromised Patient). The patient was especially pleased with the esthetic outcome. The main goal of periodontal therapy was the preservation of the dentition and treatment of

UCLA Dental Center — DENTAL EXAMINATION

Date	1	2	3	4	5	6	7	8	9	10	11	12	13	14	15	16
MOBILITY	1	1	1			1	1	1	1	1	—	—		—		—
PROBING 5																
PROBING 4																
PROBING 3																
PROBING 2																
PROBING 1	323	324	323			223	223	323	323	323	222	322		323		323

Imp—Impacted

Un—Unerupted

X—Extracted or missing

/—To be extracted

Blue—Existing Restorations

Red—Caries or
Defective Restorations
Marginal Bleeding
Probe Bleeding—(circled)

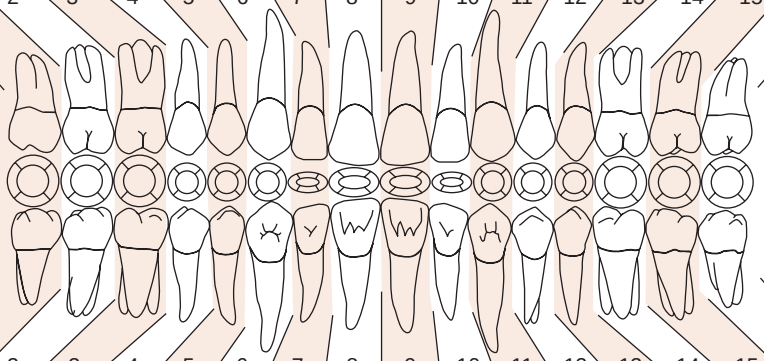

	1	2	3	4	5	6	7	8	9	10	11	12	13	14	15	16
PROBING 1	334	334	333			323	333	333	333	323	336	334		333		333
PROBING 2																
PROBING 3																
PROBING 4																
PROBING 5																

	32	31	30	29	28	27	26	25	24	23	22	21	20	19	18	17
PROBING 5																
PROBING 4																
PROBING 3																
PROBING 2																
PROBING 1		223			223	333	322	222	222	233	232	222	222			

Food Impacted
Open Contact

Furcation
(I-IV)

Gingival Margin

Mucogingival
Problem

Restoration
Overhang

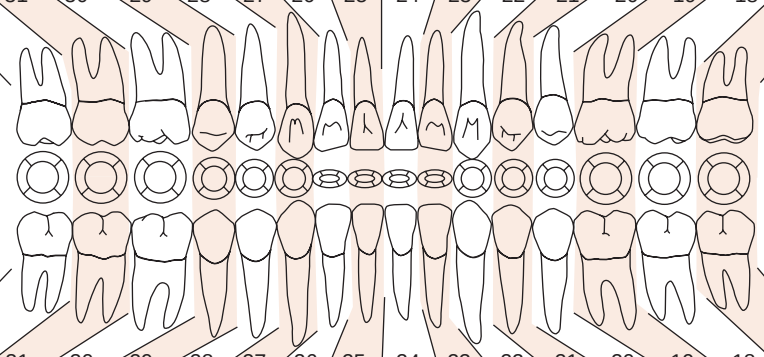

Date	32	31	30	29	28	27	26	25	24	23	22	21	20	19	18	17
PROBING 1		333			223	222	223	223	223	333	322	323	333			
PROBING 2																
PROBING 3																
PROBING 4																
PROBING 5																
MOBILITY		1			—	—	1	1	1	—	—	—	—			

Supplement A Figure 51-5 A new chart obtained 6 months after the initial therapy reveals an important reduction in probing pocket depth. Changes in the recessions in the anterior region were noted.

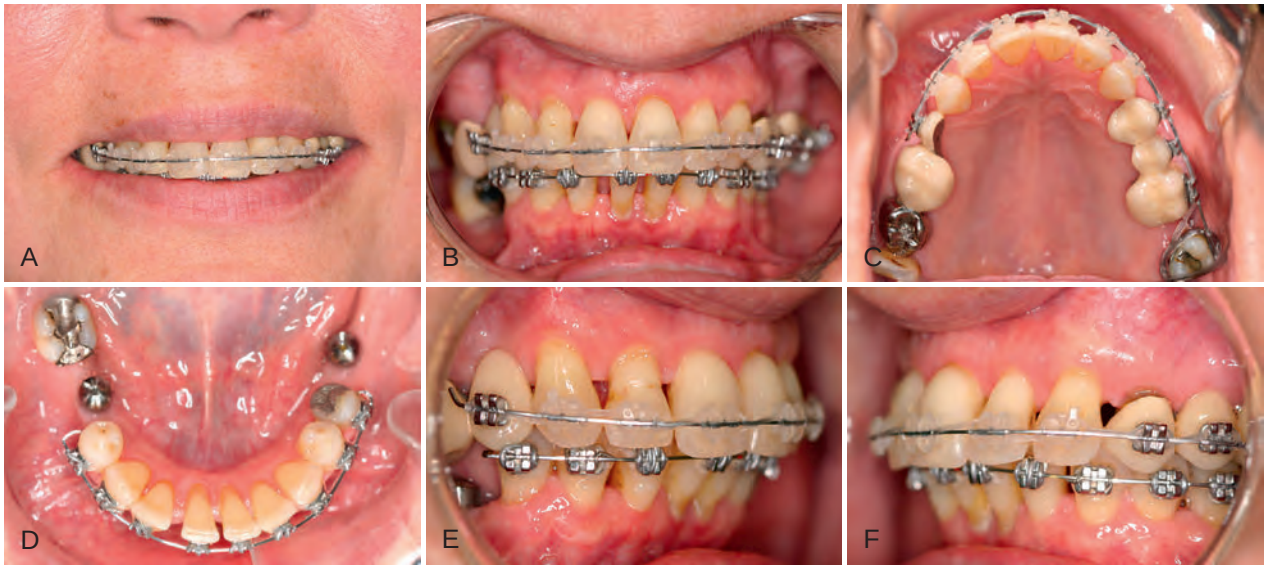

Supplement A Figure 51-6 Different views of the orthodontic appliance and implants placed in the mandibular and maxillary arches. Implants were placed at sites 19 and 30 a few months after the orthodontic treatment.

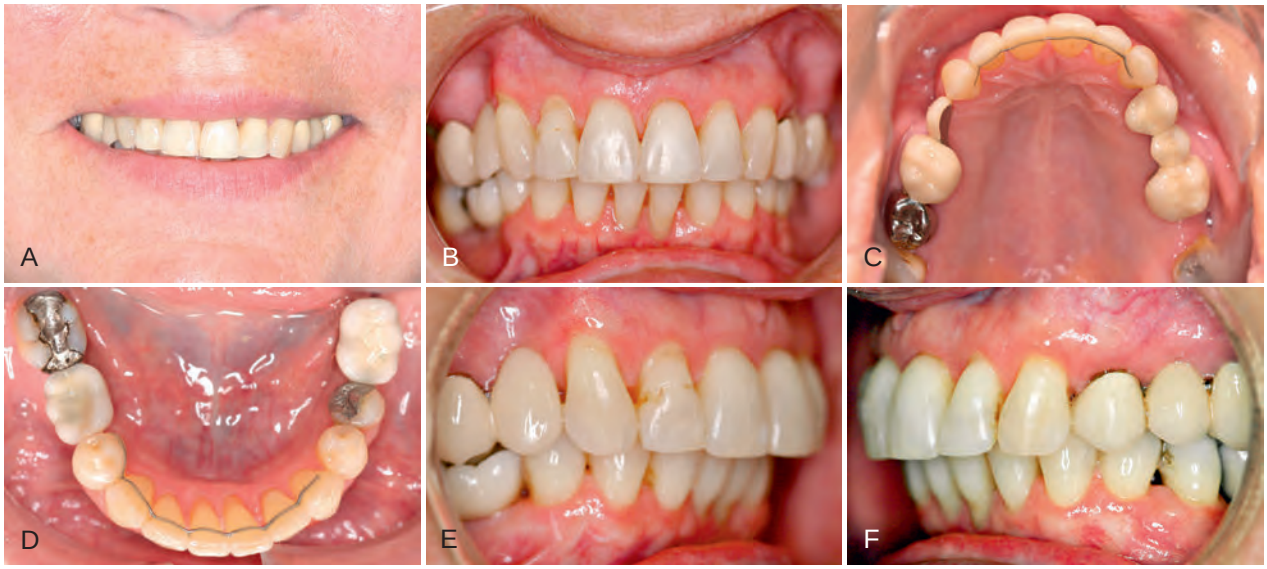

Supplement A Figure 51-7 Different views after completion of the orthodontic and restorative therapy. **A**, The diastemas were closed, and the maxillary incisors were intruded, significantly improving the esthetic appearance. **B**, Note the resolution of most of the recessions, especially at teeth #8 and #9. **C** and **D**, A normal curve could be obtained after aligning all teeth from canine to canine. **E** and **F**, The overbite, the facial flaring, and rotation of some teeth were either reduced or resolved.

Supplement A Figure 51-8 The panoramic radiograph confirmed no further bone loss. Teeth #1 and #16 slightly continued to erupt. Because of the intrusion of the maxillary incisors, apical root resorption was noted.

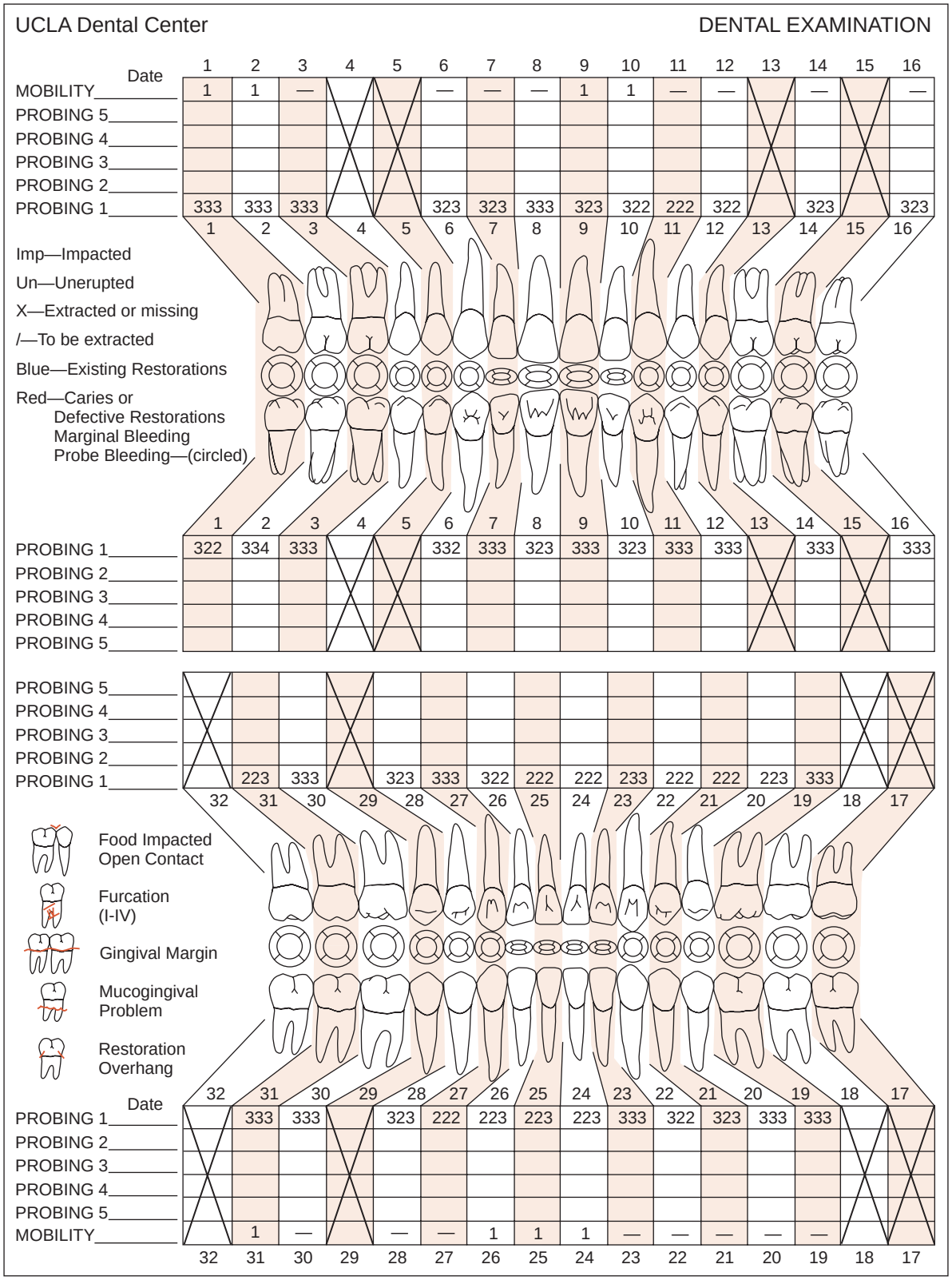

Supplement A Figure 51-9 Chart reveals a healthy periodontium. Despite the remaining angular defect at the mesial side of tooth #31, the probing pocket depth was 3 mm.

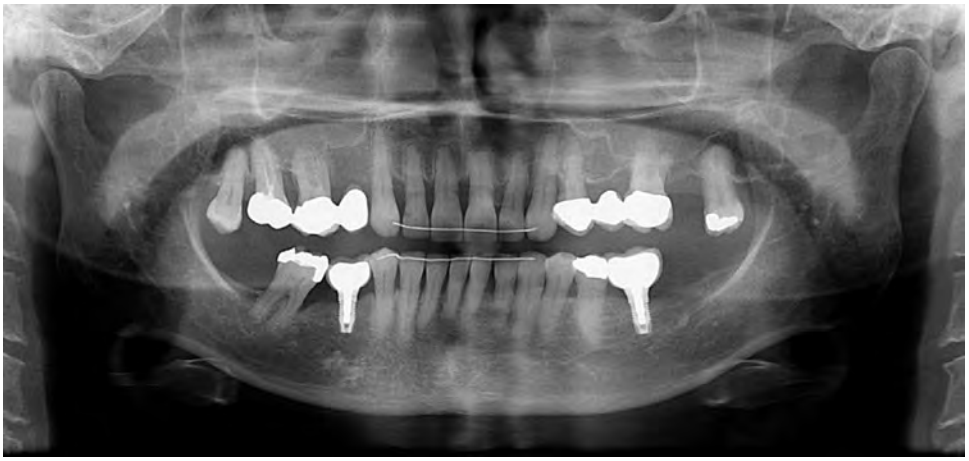

Supplement A Figure 51-10 A panoramic radiograph was taken 1 year after the end of the orthodontic treatment. The bone level remained stable. The apical root resorption in the anterior maxilla did not increase.

periodontal disease. This was achieved without surgical therapy. The cooperation of the patient played an important role in the outcome of treatment. The patient reported a significant improvement in mastication compared to her situation before the treatment. Sensitivity to thermal changes remained unchanged.

Supplement A Video 51-1: A slide presentation showing the results of the rehabilitation.

Periodontal therapy alone was not sufficient for the preservation of her dentition in the anterior region. The excessive PTM in this area could not be neglected. To improve the long-term stability of the dentition, both periodontal and orthodontic therapy was necessary. The facially flared teeth could be successfully aligned into a better position, which allowed for the splinting of the anterior dentition. Replacing the missing mandibular first molars was necessary to assure occlusal stability. Moreover, the periodontal maintenance during the orthodontic treatment was necessary to avoid any further bone loss.

Besides improving the prognosis of the anterior teeth, an esthetic improvement was noted at the gingival level. The recessions on the buccal side of the maxillary incisors were reduced significantly, and in some areas, it was completely eliminated. The closure of the diastema between teeth #8 and #9 allowed for the regeneration of the interdental papillae.

References

1. Brunsvold MA: Pathologic tooth migration. *J Periodontol* 76:859–866, 2005.
2. Towfighi PP, Brunsvold MA, Storey AT, et al: Pathologic migration of anterior teeth in patients with moderate to severe periodontitis. *J Periodontol* 68:967–972, 1997.

CHAPTER 52

Breath Malodor

Marc Quirynen, Isabelle Laleman, Jesica Dadamio, Sophie De Geest, Betty Vandekerckhove, and Wim Teughels

CHAPTER OUTLINE

Semantics and Classification
Epidemiology
Etiology
Fundamentals of Malodor Detection
Diagnosis of Malodor *(e-only)*
Treatment of Oral Malodor
Conclusion

For online-only content on extraoral causes of breath malodor and the portable volatile sulfur monitor as well as expanded discussions on epidemiology and etiology of malodor, fundamentals of malodor detection, diagnosis of malodor including organoleptic rating and gas chromatography, and chlorhexidine use in treating malodor, please go to the companion website www.expertconsult.com. Some figures and tables may be out of numeric order in this printed chapter.

Semantics and Classification

Breath odor can be defined as the subjective perception after smelling someone's breath. It can be pleasant, unpleasant, or even disturbing, if not repulsive. If unpleasant, the terms *breath malodor, halitosis, bad breath,* or *fetor ex ore* can be applied. These terms, however, are not synonymous with *oral malodor*. This term is restricted to halitosis with an origin in the oral cavity.

There are three main categories of halitosis: genuine halitosis, pseudo-halitosis, and halitophobia. *Genuine halitosis* is the term that is used when the breath malodor really exists and can be diagnosed organoleptically or by measurement of the responsible compounds. A distinction should be made between physiologic and a pathologic halitosis (Figure 52-1). The transient disturbing odor caused by food intake (e.g., garlic, onions, and certain spices), smoking, or medication (e.g., metronidazole) do not reveal a health problem and are common examples of physiologic halitosis. The same is true for "morning" bad breath, as habitually experienced on awakening. This malodor is caused by a decreased salivary flow and increased putrefaction during the night and spontaneously disappears after breakfast or after oral hygiene measures. A persistent breath malodor, by definition, does reflect some pathology (pathologic halitosis). The causes of this will be discussed later in the chapter. When an obvious breath malodor cannot be perceived, but the patient is convinced that he or she suffers from it, this is called *pseudo-halitosis.* If the patient still believes that there is bad breath after treatment of genuine halitosis or diagnosis of pseudo-halitosis, one considers halitophobia, which is a recognized psychiatric condition.[157]

Epidemiology

Breath malodor is a common complaint among the general population. It has a significant socioeconomic impact but unfortunately has been neglected until recently by scientists and clinicians, and is still hardly covered in the medical curricula. Halitosis can lead to personal discomfort and social embarrassment, and is still one of the biggest taboos of society. Almost $1 billion a year is spent in the United States on deodorant-type mouth (oral) rinses, mints, and related over-the-counter products to manage bad breath.[66] It would be preferable to spend this money on a proper diagnosis and etiologic care instead of short-term and even inefficient masking attempts.

Etiology

In the vast majority, breath malodor originates from the oral cavity. Gingivitis, periodontitis, and especially tongue coating are the predominant causative factors.[24,89,90,158,159]

In general, one can identify two pathways for bad breath. The first one involves an increase of certain metabolites in the blood circulation (e.g., due to a systemic disease), which will escape via the alveoli of the lungs during breathing (blood-breath exchange) and it is commonly referred as "extraoral halitosis." The second pathway (intraoral halitosis) involves an increase of either the bacterial load or the amount of substrate for these bacteria at one of the lining surfaces of the oropharyngeal cavity, the respiratory tract, or the esophagus. All types of infections, ulcerations, or tumors at one of the previously mentioned areas can thus lead to bad breath. Studies also suggest that oral malodor is associated with the total bacterial load of anaerobic bacteria in both saliva and tongue coating.[98] The most commonly involved bacteria are *Porphyromonas gingivalis, Prevotella intermedia/nigrescens, Aggregatibacter actinomycetemcomitans* (previously *Actinobacillus actinomycetemcomitans*), *Campylobacter rectus, Fusobacterium nucleatum, Peptostreptococcus micros, Tannerella forsythia, Eubacterium* spp, and spirochetes. A study conducted by Niles and Gaffar made clear that these gram-negative species in particular cause an unpleasant smell by the production of sulfur compounds.[80] However, because of the large species diversity found in patients with halitosis, it can be suggested that breath malodor is the result of complex interactions between several bacterial species. A recent study indicates that some gram-positive microorganisms, such as *Streptococcus salivarius,* also contribute to oral malodor production by deglycosylating salivary glycoproteins, thus exposing their protein core to further degradation by gram-negative microorganisms.[130]

There are few studies that document the prevalence of oral malodor. Moreover, the studies that exist used different methodologies ranging from self-reported breath malodor to more objective assessments such as the measurement of the volatile sulfur compounds (VSCs). Because self-reported halitosis correlates weakly with objective measurements and tends to overestimate the problem, data should be interpreted carefully.

The incidence of halitosis remains poorly documented in most countries. Large-scale studies have been performed for the Japanese,[72] Swedish,[126] and Chinese[65] populations. Smaller investigations in Brazilian,[77] Polish,[50] and Israeli[57,114] habitants have also been reported.

Despite the different approach of each study, if a VSC level of 75 ppb (limit for social acceptance)[159] is used as a threshold for halitosis, the prevalence reported in the different populations can be calculated as 23% (late-morning group) and 20% for the Japanese and Chinese studies, respectively. In line with this, prevalences of 27.5% and 29.8% for the Chinese and the Israeli groups, respectively, can be calculated when an organoleptic score of at least 2 is considered as being representative for halitosis. With the same criterion, the calculated prevalence varied between 11.0% and 29.7% for the different age groups in the Polish population. In conclusion, independent of the method used to assess oral malodor and independent of the study population, the results point out that about one in four subjects suffer from persistent bad breath.

From large-scale inventories in multidisciplinary outpatient clinics for breath odor,[23,24,99] no gender predominance seems to exist for bad breath, although other studies indicate a higher prevalence in women.[74,116] It has also been observed that women seek treatment more often than men.[72] Age can range from 5 years to more than 80 years. No association was found between increased age and oral malodor.[23,24] Most of the patients had been complaining about breath malodor for several years before seeking proper advice (recent report of the department involving 2000 patients).[99]

A recent large-scale study including 2000 patients with halitosis complaints showed that for those where bad breath could be objectively detected, the cause of it was mostly found within the oral cavity (90%). Tongue coating (51%), gingivitis/periodontitis (13%), or a combination (22%) accounted for the majority of the cases.[99] Because a large part of the population has a tongue coating or gingivitis/periodontitis, there is a risk that an intraoral condition is too easily considered as the cause while more important pathologies are overlooked. Indeed, for a minority of patients (4% in the same recent study), extraoral causes could be identified, including ear-nose-throat (ENT) pathologies, systemic diseases (e.g., diabetes), metabolic or hormonal changes, hepatic or renal insufficiency, bronchial and pulmonary diseases, or gastroenterologic pathologies.[24,79,94,145]

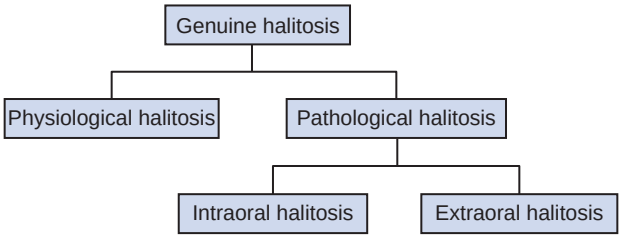

Figure 52-1 Genuine halitosis: classification.

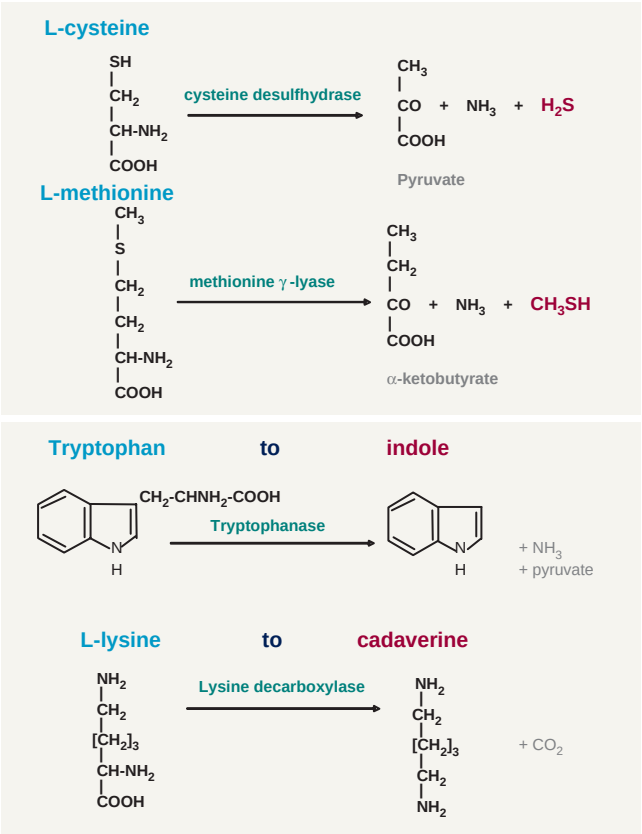

Figure 52-2 Proteolytic degradation by oral microorganisms of four amino acids (two containing sulfur and two not containing sulfur) to malodorous compounds.

Recently, the presence of *Solobacterium moorei*, a gram-positive bacterium, has also been linked to oral malodor.[45,44,53]

For oral malodor, the unpleasant smell of the breath mainly originates from volatile sulphur compounds (VSCs), especially hydrogen sulfide (H_2S), methylmercaptan (CH_3SH), and (less significantly) dimethyl sulfide [$(CH_3)_2S$], as first discovered by Tonzetich.[138] However, in certain conditions (e.g., when the saliva dries out on the mucosal surfaces), other compounds in mouth air may also play a role such as diamines (e.g., putrescine, cadaverine), indole, skatole, and volatile organic acids like butyric or propionic acid.[39] Most of these compounds result from the proteolytic degradation by oral microorganisms of peptides present in saliva (sulfur-containing or non–sulfur-containing amino acids) (Figure 52-2), shed epithelium, food debris, gingival crevicular fluid (GCF), interdental plaque, postnasal drip, and blood. In particular, gram-negative, anaerobic bacteria possess such proteolytic activity.

For the extraoral causes of halitosis, other compounds besides the VSCs may be involved. Bad-smelling metabolites can be formed/absorbed at any place in the body (e.g., the liver, the gut) and transported by the bloodstream to the lungs. Exhalation of these volatiles in the alveolar air then causes halitosis, at least when the concentrations of the bad-smelling metabolites are sufficiently high. The crevicular fluid reflects the circulating molecules in the blood and can thus also play a relevant role but due to the small amount probably not a very dominant one. The extraoral causes are much more difficult to detect, although they can sometimes be recognized by a typical odor. Uncontrolled diabetes mellitus can be associated with a sweet odor of ketones, liver disease can be revealed by a sulfur odor, and kidney failure can be characterized by a fishy odor because of the presence of dimethylamine and trimethylamine.[94]

In a special patient category, subjects imagine they have breath malodor; this is called *imaginary breath odor* or *halitophobia*.[86] The latter has been associated with obsessive-compulsive disorders and hypochondria. Well-established personality disorder questionnaires (e.g., Symptom Checklist 90) allow the clinician to assess the patient's tendency for illusional breath malodor.[25,26,28] The presence of a psychologist or psychiatrist at the malodor consultation can be especially helpful for such patients. Because of the complexity of this pathology, a malodor consultation is thus preferably multidisciplinary, combining the knowledge of a periodontologist or dentist, an ENT specialist, an internist (if necessary), and a psychologist or psychiatrist. In a recent study of 2000 patients, 16% were diagnosed with pseudo-halitosis or halitophobia.[99]

Intraoral Causes

Tongue and Tongue Coating. The dorsal tongue mucosa, with an area of 25 cm^2, shows a very irregular surface topography.[16,122] The posterior part exhibits a number of oval cryptolymphatic units, which roughen the surface of this area. The anterior part is even rougher because of the high number of papillae: the filiform papillae with a core of 0.5 mm in length, a central crater and uplifted borders; the fungiform papillae, 0.5 to 0.8 mm in length; the foliate papillae, located at the edge of the tongue, separated by deep folds; and the vallate papillae, 1 mm in height and 2 to 3 mm in diameter. These innumerable depressions in the tongue surface are ideal niches for bacterial adhesion and growth, sheltered from cleaning actions.[22,158] Moreover, desquamated cells and food remnants also remain trapped in these retention sites and consequently can be putrefied by the bacteria.[5] A fissurated tongue (deep fissures on dorsum, also called *scrotal tongue* or *lingua plicata*) and a hairy tongue (lingua villosa) have an even rougher surface (Figure 52-3).

The accumulation of food remnants intermingled with exfoliated cells and bacteria forms a coating on the tongue dorsum. The latter cannot be easily removed because of the retention offered by the irregular surface of the tongue dorsum (see Figure 52-3). As such, the two factors essential for putrefaction are united. Several investigators have identified the dorsal posterior surface of the tongue as the primary source of breath malodor.[5,15,22,111] Indeed, high correlations have been reported between tongue coating and odor formation.[5,18,72,158]

Both in healthy individuals and periodontitis patients with or without complaints of oral halitosis, a significant positive correlation was found between the presence or amount of tongue coating and levels of VSCs[72,100] and/or organoleptic scores of the mouth odor.[22] In a group of 2000 patients visiting a multidisciplinary halitosis clinic,[99,150] significant correlations were found between the organoleptic scores and tongue coating ($R = 0.52$; $p < 0.001$). In another study,[84] it was also observed that the amount of tongue

Figure 52-3 Different clinical pictures of heavily coated tongues.

coating was significantly greater in the halitosis-positive group compared to the halitosis-negative group.

Morita and Wang[74] found that the volume of tongue coating and the percentile of sites with bleeding on probing, were significantly associated with oral malodor.[74] In 1992, Yaegaki and Sanada[158,159] demonstrated that, even in patients with periodontal disease, 60% of the VSCs were produced from the tongue surface.[158,159]

Recent research showed that the strongest determinant for the presence of tongue coating is suboptimal oral hygiene. Other influencing factors were: periodontal status, presence of a denture, smoking, and dietary habits.[149]

Periodontal Infections. A relationship between periodontitis and oral malodor has been shown. However, not all patients with gingivitis and/or periodontitis complain about bad breath, and there is some disagreement in the literature as to what extent oral malodor and periodontal disease are related.[5,112,127] Bacteria associated with gingivitis and periodontitis are indeed able to produce VSCs.[55,78,80,89,90,138]

Several studies have shown that the VSC levels in the mouth correlate positively with the depth of periodontal pockets (the deeper the pocket, the more bacteria, particularly anaerobic species) and that the amount of VSCs in breath increases with the number, depth, and bleeding tendency of the periodontal pockets.[15,88,99,159] It is important to realize that VSCs aggravate the periodontitis process by, for example, increasing the permeability of the pocket and mucosal epithelium and therefore exposing the underlying connective tissues of the periodontium to bacterial metabolites. Moreover, methylmercaptan enhances interstitial collagenase production, interleukin-1 (IL-1) production by mononuclear cells, and cathepsin B production, thus further mediating connective tissue breakdown.[63,104] It was also shown that human gingival fibroblasts developed an affected cytoskeleton when exposed to methylmercaptan.[7,104] The same gas alters cell proliferation and migration. VSCs are also known to impede wound healing. Thus, when periodontal surgery is planned, especially the insertion of implants, clinicians should recognize this pathologic role of VSCs.

Some studies, however, have shown that when the presence of tongue coating is taken into account, the correlation between periodontitis and oral malodor is much lower, indicating that tongue coating remains a key factor for halitosis. The prevalence of tongue coating is six times higher in patients with periodontitis, and the same bacterial species associated with periodontal disease can also be found in large numbers on the dorsum of the tongue, particularly when tongue coating is present.[158] The reported association between periodontitis and oral malodor may thus primarily be due to the effects of periodontal disease on tongue coating. And may explain why other articles did not find a correlation.[5,127]

Other relevant malodorous pathologic manifestations of the periodontium are pericoronitis (the soft tissue "cap" being retentive for microorganisms and debris), major recurrent oral ulcerations, herpetic gingivitis, and necrotizing gingivitis/periodontitis. Microbiologic observations indicate that ulcers infected with gram-negative anaerobes (i.e., *Prevotella* and *Porphyromonas* species) are significantly more malodorous than noninfected ulcers.[6]

Dental Pathologies. Possible causes within the dentition are deep carious lesions with food impaction and putrefaction, extraction wounds filled with a blood clot, and purulent discharge leading to important putrefaction. The same applies to interdental food impaction in large interdental areas and crowding of teeth favor food entrapment and accumulation of debris. Acrylic dentures, especially when kept continuously in the mouth at night or not regularly cleaned, can also produce a typical smell. The denture surface facing the gingiva is porous and retentive for bacteria, yeasts, and debris, which are compounds needed for putrefaction.

Dry Mouth. Saliva has an important cleaning function in the oral cavity. Patients with xerostomia often present with large amounts of plaque on teeth and an extensive tongue coating. The increased microbial load and the escape of VSCs when saliva is drying up explain the strong breath malodor.[55] Several studies link stress with VSC levels, but it is not clear whether this can simply be explained by a reduction of salivary flow.[61,96] Other causes of xerostomia are medication,[73] alcohol abuse,[34] Sjögren syndrome (a common autoimmune rheumatic disease),[68] and diabetes.[151]

Fundamentals of Malodor Detection

The breath of a person contains up to 150 different molecules.[94,92,142,143,144] The characteristics of the expired molecules determine whether we can smell them or not. Some gases can cause a striking odor at very low concentrations, whereas others need to be present in much higher quantities. The perception of the molecules depends on the following factors[40]:

1. The odor itself *(olfactory response)* can be pleasant, unpleasant, or even repulsive.
2. Each particular molecule has its specific concentration before it can be detected *(threshold concentration)*.
3. The *odor power* is the extent of concentration that is necessary to increase the odor score with one unit.
4. The *volatility* of the compound: Malodorous molecules only express themselves when they become volatile.
5. The *substantivity:* The capacity of the molecule to stay present and thus to remain the cause of smell.

Table 52-1 provides an overview of these essential characteristics for the key malodorous compounds, clearly highlighting large

Extraoral Causes

Ear-Nose-Throat. During chronic or purulent tonsillitis, the deep crypts of the tonsils accumulate debris and bacteria, especially periopathogens, resulting in putrefaction. In the crypts, even calculus (e.g., subgingivally) can be formed (tonsilloliths or tonsil stones). Other examples include acute pharyngitis (viral or bacterial) and postnasal drip. The latter is a rather common condition, which is perceived by patients as a liquid flow in the throat, originating from the nasal cavity.[111] It is often associated with chronic sinusitis or regurgitation esophagitis, in which the acidic content of the stomach reaches the nasopharynx and causes mucositis. Ozena (caused by *Klebsiella ozaenae*) is a rare atrophic condition of the nasal mucosa, with the appearance of crusts that causes a very strong breath malodor. Finally, a foreign body in a nasal or sinus cavity can cause local irritation, ulceration, and subsequent putrefaction (e.g., children and mentally handicapped persons tend to put objects such as peas or wet paper in the nose).

Bronchi and Lungs. Pulmonary causes include chronic bronchitis, bronchiectasis (infection of standing mucus secretion in cystic dilations through walls of bronchioles), pneumonia, pulmonary abscesses, bronchial carcinoma, and carcinoma of the lung.[67,69] The relevance of an early diagnosis is evident.

Gastrointestinal Tract. In contrast to the common public opinion, even among medical physicians, gastrointestinal pathologies are rarely responsible for bad breath.[83,137] The following pathologies might be responsible for less than 1% of malodor cases:

- A Zenker diverticulum (a hernia in the esophageal wall, allowing accumulation of food and debris and thus putrefaction) can cause a significant breath odor because it is not separated from the oral cavity by any sphincter.[17]
- A gastric diaphragmatic hernia (the fundus of the stomach protrudes through the diaphragm with relative sphincter insufficiency, allowing gases to escape or contents to flow back in the esophagus) can cause reflux of the gastric contents up to the oropharynx. This is sometimes combined with ructus, in which air from the stomach suddenly regurgitates.
- Regurgitation esophagitis (ulceration of the mucosal lining of the esophagus by acidic stomach contents flowing back because of an improper function of the sphincter).[54]
- Intestinal gas production: Some gases (e.g., dimethyl sulfide) are absorbed but not metabolized by the intestinal endothelium and thus transported by the blood. These gases can then be exhaled through the lungs.[132]

There is some disagreement in the literature whether *Helicobacter pylori* infection is associated with halitosis.[52,75] In a recent paper, *H. pylori* was shown to produce hydrogen sulfide and methylmercaptan, which suggests that this microorganism can contribute to the development of halitosis.[64] Tangerman et al[137] found no association between halitosis and *H. pylori* infection.[137]

Liver. Patients with various degrees of hepatocellular failure and/or portosystemic shunting of blood may acquire a sweet, musty, or even slightly fecal aroma of the breath, termed *fetor hepaticus,* which has been mainly attributed to the accumulation of dimethyl sulfide.[10,135,143] Moreover, if the metabolizing function of the liver fails, the concentration of certain metabolites, normally processed in the liver, will increase and they will enter the systemic circulation again and will be exhaled.[18,141]

Kidney. Kidney insufficiency, primarily caused by chronic glomerulonephritis, will lead to an increase of the amines dimethylamine and trimethylamine, which causes a typical fishy odor of the breath.[125]

Systemic Metabolic Disorders. Uncontrolled diabetes mellitus results in the accumulation of ketones, which have a sweet smell, like the odor of rotten apples. Insulin resistance leads to an increase of triglycerides and free fatty acids and ketones (such as acetone, acetoacetate, and hydroxybutyrate) are formed during lipolysis.[131]

Trimethylaminuria. Trimethylaminuria is a hereditary metabolic disorder that leads to a typical fishy odor of the breath, urine, sweat, and other bodily secretions. Trimethylaminuria is an enzymatic defect that prevents the transformation of trimethylamine to trimethylaminoxide, resulting in abnormal amounts of this molecule. The prevalence is unknown but approaches 1% in the United Kingdom.[71]

Hormonal Causes. At certain moments during the menstrual cycle, a typical breath odor can develop; partners are often well aware of this odor. Evidence also indicates that VSC levels in the expired air are increased twofold to fourfold around the day of ovulation and in the perimenstrual period. Increases in VSCs are smaller in midfollicular phases.[94]

In a study by Kleinberg and Codipilly, aqueous solutions of oral odoriferous volatiles were placed on the skin of the back of the hand.[55] Afterwards, odor scores were given (organoleptic score, cfr. supra). The results are shown in Table 52-2. All metabolites caused an explicit odor, which decreased in intensity over time. Some molecules disappeared very fast (e.g., hydrogen sulfide and methylmercaptan), whereas others produced a bad smell for a longer period of time (e.g., indole and skatole, for 10 minutes and longer).

The olfactory response, rated by an organoleptic scale, follows an exponential curve when correlated with the concentration of different gases. In other words, when the concentrations of the molecules were compared to their organoleptic outcome, an optimal fit was only obtained when the concentrations of the gases were transformed to log values. The latter implies that all types of breath "measurements" (gas chromatography [GC], portable breath analyzers [e.g., Halimeter]) require log transformation to be comparable with organoleptic scores.[40]

TABLE 52-2 Odor Scores at the Back of the Hand

	Start	1 minute	3 minutes	10 minutes
Hydrogen sulfide	3	1	0	0
Methylmercaptan	3	1	0	0
Acetic acid	3	4	0	0
Propionic acid	3	4	0	0
Butyric acid	4	4	2	2
Valeric acid	4	4	3	2
Indole	4	4	4	2
Skatole	4	4	4	2
Putrescine	4	4	3	1
Cadaverine	4	4	2	1

To obtain a reliable result, both the judge and patient need to take a number of restrictions into account. Two days before the measurements they have to avoid the intake of spicy food, garlic, and onions. The use of any fragrance, shampoo, body lotion, tooth paste, or mouthrinse; smoking; and the consumption of alcohol or coffee are prohibited 12 hours before the organoleptic assessment is made. The patient should also not eat or drink on the morning of the organoleptic evaluation. The judge should not wear rubber gloves. Assessments should be repeated because breath odor can fluctuate from day to day. The patient should be encouraged to bring a confidant to the consultations who can identify whether the perceived odor is the one previously noticed. Some of these guidelines are not only crucial for the organoleptic evaluation, but also for a correct interpretation of the results obtained with certain breath analyzers (see later).

TABLE 52-1 Odor Threshold and Odor Power of Key Malodorous

	ODOR THRESHOLDS		ODOR POWER	VOLATILITY (HENRY'S CONSTANTS)
Compounds	Greenman (mol/dm^{-3})	Devos (mol/dm^{-3})	Greenman (× increase to "up" score 1 unit)	Volatility (K_{cc}) in H_2O at 20° C
Butyrate	2.3×10^{-10}	2.4×10^{-10}	10-fold	3.9×10^{4}
Isovalerate	1.8×10^{-11}	2.5×10^{-11}	42-fold	2.5×10^{4}
Skatole	7.2×10^{-13}	1.0×10^{-12}	8-fold	4.1×10^{5}
Trimethylamine	1.8×10^{-11}	1.5×10^{-11}	96-fold (low affinity)	2.0×10^{2}
Putrescine	9.1×10^{-10}	1.0×10^{-9}	27-fold	4.1×10^{1}
CH_3SCH_3	5.9×10^{-8}	5.0×10^{-8}	10-fold	1.7×10^{1}
H_2S	6.4×10^{-10}	5.0×10^{-10}	4.8-fold	$\approx 1.7 \times 10^{1}$
CH_3SH	1.0×10^{-11}	1.0×10^{-11}	7.2-fold	$\approx 1.7 \times 10^{1}$

Greenman J, Duffield J, Spencer P, et al: *J Dent Res* 83:81, 2004.

†Devos M, Patte F, Roualt J, et al: *Standardized human olfactory thresholds,* Oxford, 1990, IRL Press at Oxford University Press.

CH_3SH, Methylmercaptan; *CH_3SCH_3,* dimethylsulfide; *H2S,* hydrogen sulfide; *K_{cc},* unit for Henry's Law constant.

interproduct variations. The odor power is the strongest for hydrogen sulfide and methylmercaptan; if the concentration of these products increases fivefold to tenfold, the odor will receive a higher organoleptic rating. For some other compounds, increases of 25 to 100 times are needed to reach a similar effect. Skatole and methylmercaptan are detected at the lowest concentrations (low threshold). The three sulfur molecules have the lowest volatility (i.e., will escape the liquid phase first).[40]

Diagnosis of Malodor

Anamnesis

Each consultation should start with a thorough questioning about the breath malodor, eating habits, and medical and dental history. This can be done with a questionnaire that the patient fills out in the waiting room and/or orally at the beginning of the consultation, depending on the preferences of the examiner and the practical possibilities. To start with, the patient should be asked about the frequency of the halitosis (e.g. constantly, every day), the time of appearance during the day (e.g. after meals can indicate a stomach hernia), when the problem first appeared and whether others have identified the problem (to exclude imaginary breath odor). Also the medical history has to be recorded, with an emphasis on medication, and systemic diseases of the lungs, liver, kidneys, stomach, and pancreas. Concerning the ENT history, attention should be paid to the presence of nasal obstruction, mouth breathing, postnasal drip, allergy, tonsillitis, dysphagia, and previous ENT encounters. The dental history includes questions assessing the frequency of dental visits, the use of mouth rinses, the presence and maintenance of a dental prosthesis, and the frequency and the instruments used for tooth brushing, interdental cleaning, and tongue brushing and scraping. Finally, the patient is asked about his smoking, drinking, and dietary habits.

Clinical and Laboratory Examination

Self-Examination. Smelling one's own breath by expiring in the hands kept in front of the mouth is not relevant because the nose gets used to the odor and the smell of the skin and soaps used for handwashing may interfere. Moreover, studies have shown that self-assessment of oral malodor is notoriously unreliable and one should be careful with the information obtained from the patient.[27] Conversely, it can be worthwhile to involve the patient in monitoring the results of therapy, when an intraoral cause has been identified. For example, this can motivate the patient to continue the oral hygiene instructions. The following self-testing can be used:

- Smelling a metallic or nonodorous plastic spoon after scraping the back of the tongue
- Smelling a toothpick after introducing it in an interdental area
- Smelling saliva spit in a small cup or spoon (especially when allowed to dry for a few seconds so that putrefaction odors can escape from the liquid)
- Licking the wrist and allowing it to dry (reflects the saliva contribution to malodor)

Oropharyngeal Examination. The oropharyngeal examination includes inspection of deep carious lesions, interdental food impaction, wounds, bleeding of the gums, periodontal pockets, tongue coating, dry mouth, and the tonsils and pharynx (for tonsillitis and pharyngitis).

The tongue coating can be scored with regard to the thickness and surface. Several methods have been proposed for the thickness, Gross and coworkers (1975)[43] proposed an index, ranging from 0 (= no coating) to 3 (= severe coating). Miyazaki[72] (Figure 52-4, *A*) assessed the tongue-coating status according to the area: score 0 = none visible, score 1 = less than one-third of the tongue dorsum covered, score 2 = less than two-thirds, and score 3 = more than two-thirds.

Winkel and coworkers[155] considered both the extension and the thickness of the tongue coating. The dorsum of the tongue is divided into six areas, that is, three in the posterior and three in the anterior part of the tongue (see Figure 52-4, *B*). The tongue coating in each sextant is scored as 0 = no coating, 1 = light coating, and 2 = severe coating. Score 1 is given when the pink color underneath the coating is still visible; when this is not the case a score 2 is given.

Attention should be paid to the morphology of the tongue. For example, it should be noted if the tongue looks normal or rough or has a deep sulcus or large papillae vallatae.[155]

Organoleptic Rating. Even though devices are available, the organoleptic assessment by a judge is still the gold standard in the examination of breath malodor. It is the easiest and most often used method because it gives a reflection of the everyday situation when halitosis is noticed. Moreover, the human nose can smell 10,000

The judge smells a series of different air samples (Figure 52-5), as follows:

1. *Breath odor:* The subject expires through the mouth while the judge smells both at the beginning (rather oral) and at the end (rather extraoral) of the expiration. The first part of the breath is derived from the mouth and dead-space air of the upper airways and nasopharynx, whereas the last part is alveolar air from the lungs.
2. *Nasal breath odor:* The subject expires through the nose, keeping the mouth closed. When the nasal expiration is malodorous, yet the air expired through the mouth is not, a nasal/paranasal cause can be suspected.
3. *Oral cavity odor:* The subject opens the mouth and refrains from breathing while the judge places his or her nose close to the mouth opening (smelling the air while the patient counts from 1 to 20 reveals the same but favors oral malodor because drying of the palatal and tongue mucosa will occur, which promotes the expression of VSCs thus far soluble in the salivary coating).
4. *Saliva:* The patient is asked to lick his or her wrist. After drying, the judge gives a score.
5. *Tongue coating:* The judge smells a tongue scraping. This is also presented to the patient or the confidant to evaluate whether this smell is similar to the experienced malodor.

Although the organoleptic assessment is still the gold standard for diagnosis of halitosis, the method also has some important drawbacks. The assessment can, for example, be influenced by several aspects such as the position of the head, hunger, and the experience of the judge. Odor judges are also supposed to rest their noses for several minutes between the tests to avoid habituation. The most important disadvantage of the method, however, is that it clearly has a degree of subjectivity. Researchers are trying to improve the reliability and reproducibility of the organoleptic method.[41] When using a panel of odor judges instead of one judge, the reliability is already considered to increase.[157] Furthermore, the agreement among judges may be improved by standardization of the sense of smell using an odor solution kit for measuring the olfactory response.[163] Training is also considered to reduce the odor judges' errors.[76]

Portable Volatile Sulfur Monitor. The portable volatile sulfur monitor (Halimeter, Interscan, Chatsworth, CA) is an electronic device that detects the presence of volatile sulfur compounds such as hydrogen sulfide and methylmercaptan in breath. The instrument cannot discriminate among the different sulfur compounds. The sensitivity for methylmercaptan is five times lower than for hydrogen sulfide, and the device is almost insensitive to dimethyl sulfide.[31] Moreover, ethanol and other compounds can disturb the measurements.

The mouth air is aspirated by inserting a drinking straw fixed on the flexible tube of the instrument (Figure 52-6). The straw is kept inside the mouth, preferably above the posterior part of the tongue dorsum, not touching the oral mucosa nor the tongue, while the subject keeps the mouth slightly open and breathes through the nose. The sulfur meter uses a voltametric sensor that generates a signal when exposed to sulfur-containing gases. Using a recorder or specific software, a graphic presentation can be obtained, called a *haligram* (Figure 52-7), that gives the response in function of the time. The monitor needs regular calibration and replacement of the sensor biannually.

The Halimeter is easy to use as a chairside test and is relatively inexpensive. Patients are usually less embarrassed, and the absence of odor in case of halitophobia can be more convincingly proven than by an organoleptic assessment. Several studies have shown good correlations between the organoleptic measurement and the Halimeter.[115,118] An important drawback of the device is that it detects only sulfur compounds and thus is only useful for intraoral causes of halitosis. The absence of VSCs does not prove that no breath odor is present.

A wide range of threshold limits for halitosis has been proposed. Yaegaki and Sanade[158] recommended a value of 75 ppb as the limit for social acceptance, whereas the Halimeter's manufacturer proposes 150 ppb. Following this recommendation, the sensitivity and specificity of the device toward the organoleptic score has been calculated to be 63% and 98%, respectively. Previous studies from our group showed that a reduction in this threshold to 120 ppb improves the sensitivity of the device without detriment of their specificity.[150] In patients with oral malodor, VSCs concentrations easily reach 300 to 400 ppb.

Elaborate gas chromatography is only available in specialized centers but is especially useful for identifying nonoral causes.[49,91,132,141] It is expensive and needs trained personnel.

A small, portable "gas chromatograph" (OralChroma,™ FIS Inc, Japan) has been introduced, which makes this technique available for periodontal clinics (Figure 52-9). Sample collection occurs by use of a disposable syringe, which has to be inserted for two-thirds in the oral cavity of the patient. Patients have to close their mouth for 30 seconds before sample collection and afterwards the sample is injected into the gas chromatograph.

The analysis starts automatically. There is a software packet available, OralChroma™ Data Manager, which collects the data from the OralChroma™ and graphically displays the sensor responses on a computer screen. After 8 minutes, the process is completed, and the concentration of the three gases will be displayed in either ng/10 mL or ppb (nmol/mol) (Figure 52-10). The accompanying software packet gives a clear overview of the VSC measurement, but sometimes these graphics are not correct because of a wrong assignment of the place of the VSCs in the chromatogram. The latter can be corrected by analyzing the chromatograph.[136,137]

The OralChroma has the capacity to measure the concentration of the three key sulfur compounds (hydrogen sulfide, methylmercaptan, and dimethyl sulfide) separately. This can be helpful for a differential diagnosis. A high concentration of methylmercaptan compared to hydrogen sulfide indicates for example periodontitis.[159] If only hydrogen sulfide is increased, there might be a problem with oral hygiene. Dimethyl sulfide can be present in case of some extraoral causes.[135] Just like the Halimeter, the OralChroma cannot detect other than sulfur compounds and some intraoral and extraoral causes can thus be overlooked. The apparatus needs calibration and the sensor and column need to be replaced every 2 years.[150] Because of software limitations, the use of the device as standalone unit is not recommended. Visual inspection of the chromatogram is necessary to avoid erroneous results.

Figure 52-5 **A,** Organoleptic assessment of the expired air. **B,** preferably, two calibrated experts will compare their scores at testing. **C,** Patient is asked to lick her wrist. **D,** After allowing the wrist to dry, the clinicians organoleptically assess it to evaluate the volatiles originating from the saliva and anterior part of the tongue. **E,** Inspection of the posterior part of the tongue and pharynx can reveal coating, ulcerations, or inflammation. **F,** A sample of the coating is taken from the back of the tongue, which is pulled with a gauze pad. **G,** Clinician smells the air expired by the nose.

Figure 52-6 The Halimeter, a portable sulfide monitor.

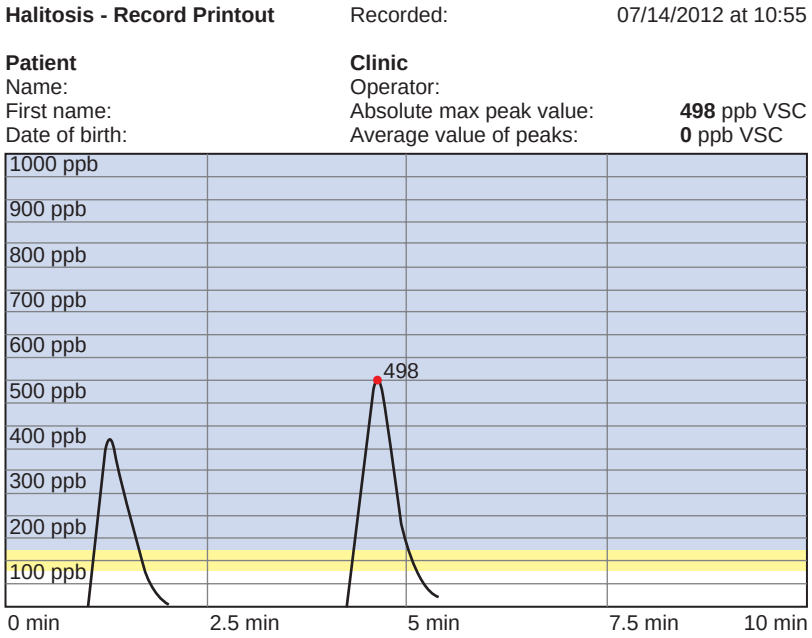

Figure 52-7 Haligram.

Figure 52-9 Portable gas chromatograph (GC). A small amount of the breath sample, aspirated with a plastic syringe, is injected into the input port of the GC. The computer displays the detection and amount of the three important VSCs (in ppb) within 8 minutes.

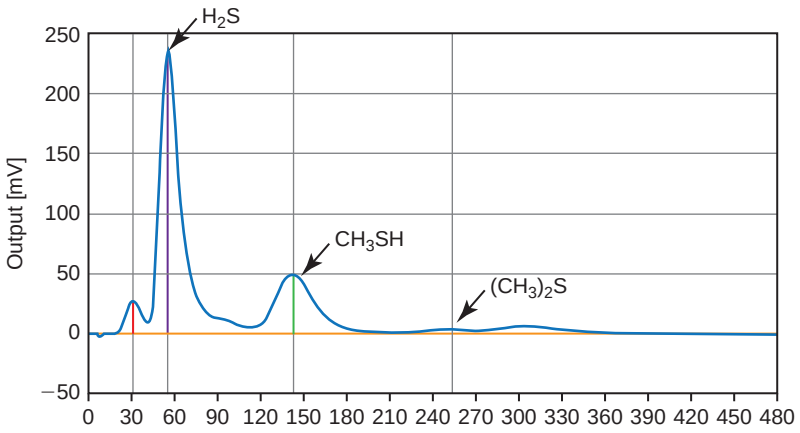

Figure 52-10 Graphic from the OralChroma. The first peak indicates the level of hydrogen sulphide, the second of methylmercaptan, and the third of dimethyl sulphide.

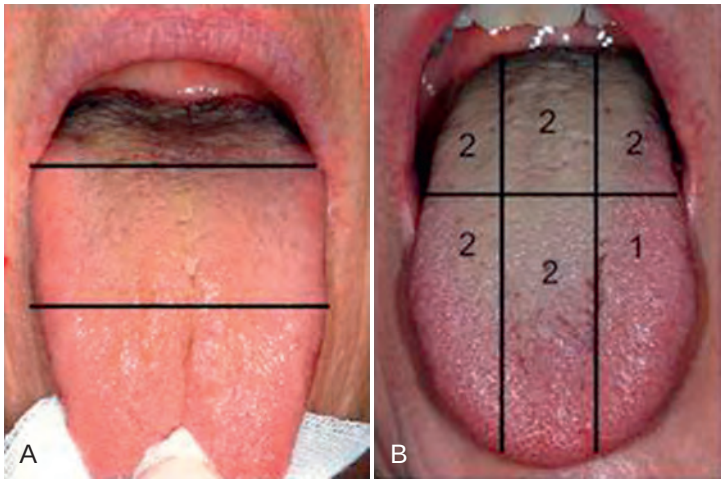

Figure 52-4 **A,** Miyazaki tongue coating index. Score 0 = none visible, score 1 = less than one-third of the tongue dorsum covered, score 2 = less than two-thirds, and score 3 = more than two-thirds; here score 2 applies since less than two-thirds of the tongue dorsum is covered. **B,** Winkel tongue coating index. Divide the dorsum of the tongue is into six areas, i.e., three in the posterior and three in the anterior part of the tongue. The tongue coating in each sextant is scored as 0 = no coating, 1 = light coating, and 2 = severe coating.

different odors.[46] In an organoleptic evaluation, a trained and preferably calibrated "judge" sniffs the expired air and assesses whether it is unpleasant by using an intensity rating.[117] Scoring is normally done according to the intensity scale of Rosenberg, where 0 represents absence of odor, 1 is given for barely noticeable odor, 2 for slight malodor, 3 for moderate malodor, 4 for strong malodor, and 5 for severe malodor.[117] In this six-point system, 0 indicates a concentration of odorant below a threshold, 1 to 4 are increasing occupancy of receptor binding sites, and 5 is assumed to be close to saturation.[40,41]

Before acting as a judge, clinicians must ensure they do not have *anosmia* (lost or impaired smelling capacity). A significant fraction of the adult population has partial loss of smelling acuity. After age 60, a decline of smelling acuity is common. Candidate odor judges should test their capacity to smell and recognize different odors (qualitative assessment), as well as their capacity to detect odors at low concentrations (quantitative assessment).[26] The first aspect can be checked by using for example a commercially available test (Smell Identification Test, Sensonic) that establishes a response curve based on the capacity to recognize and discriminate among smells. After scratching an odorous surface in a booklet, several options of smells are proposed. If a subject lacks the capacity to recognize certain odors, it will reveal a partial anosmia. The second aspect is tested by sniffing a series of dilutions of substances such as isovaleric acid, phenethyl alcohol, thiophene, and pyridine, which are inexpensive organic components. These are presented to the candidate judge as dilutions, in one-log dilution steps, from 1 to 10^{-19}. Concentrations of the odorous substances are presented in ascending order until the subject detects the substance, then in descending order until the person no longer detects it. This is the "psychophysical staircase method" for determination of the threshold level. The threshold corresponds to the average between ascending and descending levels. Clinicians can thus find out if their smelling threshold level is acceptable. Abnormalities in the capacity to judge or perceive odors can be caused by a viral infection of the nasal cavities, a concussion, and smoking. Whereas an infection can have a transient effect on olfactory performance, a concussion and smoking have permanent effects.

Gas Chromatography. A gas chromatograph can analyze air, saliva, or crevicular fluid (Figure 52-8). About 100 compounds have been isolated from the headspace of saliva and tongue coating, from ketones to alkanes, and sulfur-containing compounds to phenyl compounds.[14] In the expired air of a person, approximately 150 compounds can be found.[92,142,143,144] The most important advantage of the technique is that when coupled with mass spectrometry, it can detect virtually any compound when using adequate materials and conditions. Moreover, it has a very high sensitivity and specificity.

Figure 52-8 Gas chromatography machinery, including thermal desorber *(TD)* to release molecules trapped in special collectors); gas chromatograph *(GC)* for separation of molecules; and mass spectrometer *(MS)* for identification of molecules.

Dark-Field or Phase-Contrast Microscopy. Oral malodor is typically associated with a higher incidence of motile organisms and spirochetes, so shifts in these proportions allow monitoring of therapeutic progress. Another advantage of direct microscopy is that the patient becomes aware of bacteria being present in plaque, tongue coating, and saliva. Too often, patients confuse plaque with food remnants.

Saliva Incubation Test. The analysis of the headspace above incubated saliva by gas chromatography reveals VSCs and other compounds such as *indole, skatole,* lactic acid, *methylamine, diphenylamine, cadaverine,* putrescine, urea, ammonia, *dodecanol,* and *tetradecanol.* By adding some proteins, such as lysine or cysteine, the production of respectively cadaverine or hydrogen sulfide is dramatically increased. Organoleptic evaluation (or assessment of the VSCs) of the saliva headspace offers promising perspectives for monitoring treatment results.[101] It is a

less invasive test, especially for the patient, than smelling breath in front of the oral cavity.

Electronic Nose. Electronic noses identify the specific components of an odor and analyze its chemical makeup. They consist of a mechanism for chemical detection, such as an array of electronic sensors, and a mechanism for pattern recognition. They are smaller, less expensive, and easier to use than, for example, gas chromatography, but can only be developed for specific applications if the important metabolites are already known. An artificial nose that has the same capacities as the human nose would be ideal. Currently, although significant improvements still need to be made, the first trials thus far have been promising.[134]

Chair-Side Test. A salivary chair-side test may be an alternative tool for the general practitioner for diagnosing halitosis. Currently, several tests based on the detection of bacteria or metabolites involved in the process of oral malodor, are commercially available. All these tests have reported acceptable correlation with the organoleptic ratings and some of them even with the VSC level.[60,129,50] The BANA test is based on the ability of some bacterial species to hydrolyze a synthetic trypsin substrate (N-benzoyl-DL-arginine-2-naphthylamine).[60] In this way the test can detect three specific bacteria: *P. gingivalis*, *Bacteroides forsythus*, and *Treponema denticola* related to periodontal disease. As already mentioned, periodontitis is not the most common cause of oral malodor,[111] as not all patients with periodontitis suffer from bad breath.

The β-galactosidase tests quantify, by means of chromogenic substrates, bacterial enzymes involved in the initial degradation of oral mucin. β-galactosidase is one of the main responsible enzymes for the removal of carbohydrate side-chains, a limiting step of the proteolysis of glycoproteins.[129] It has been demonstrated that the presence of the enzyme accounts for the presence of oral malodor independently of the VSC level.[128] The *ninhydrin* method is a colorimetric test to determine amino acids and low-molecular-weight amines. These compounds are, as VSC, final products of bacterial proteolysis.[50]

Recently, a new colorimetric test offered the possibility of assessing amines in saliva by means of a simple color scale.[20] In a first clinical study the test appeared to be able to distinguish between volunteers with and without malodor. Besides the correlation of the test results with the organoleptic rating, the independent contribution to the odor of the amines in saliva, has been demonstrated.[21]

Treatment of Oral Malodor

The treatment of oral malodor (thus with an intraoral origin) should preferably be cause-related. Because oral malodor is caused by the metabolic degradation of available proteins to malodorous gases by certain oral microorganisms, the following general treatment strategies can be applied:

- Masking the malodor
- Mechanical reduction of intraoral nutrients (substrates) and microorganisms
- Chemical reduction of oral microbial load
- Rendering malodorous gases nonvolatile

Treatment should be centered on reducing the bacterial load and micronutrients by effective mechanical oral hygiene procedures, including tongue scraping. Periodontal disease should be treated and controlled, and as an auxiliary aid, oral rinses containing chlorhexidine (CHX) and other ingredients may further reduce the oral malodor. If breath malodor persists after these approaches, other sources of the malodor, such as the tonsils, lung disease, gastrointestinal disease, and metabolic abnormalities (e.g., diabetes) should be investigated.

Masking the Malodor

Treatments with rinses, mouth sprays, and lozenges containing volatiles with a pleasant odor have only a short-term effect.[106,107] Typical examples are the mint-containing lozenges and the aroma present in rinses without antibacterial components.[19]

Another pathway is to increase the solubility of malodorous compounds in the saliva by increasing the secretion of saliva; a larger volume allows the retention of larger volumes of soluble VSCs.[56] The latter can also be achieved by ensuring a proper liquid intake or by using a chewing gum; chewing triggers the periodontal-parotid reflex, at least when the lower (pre)molars are still present.

Mechanical Reduction of Intraoral Nutrients and Microorganisms

Because of the extensive accumulation of bacteria on the dorsum of the tongue, tongue cleaning should be emphasized.[12,119,158] Previous investigations demonstrated that tongue cleaning reduces both the amount of coating (and thus bacterial nutrients), as well as the number of bacteria and thereby improves oral malodor effectively.[22,37,38,43,103] Other reports indicated that the reduction of the microbial load on the tongue after cleaning is negligible and that the malodor reduction probably results from the reduction of the bacterial nutrients.[70,98]

Cleaning of the tongue can be carried out with a normal toothbrush, but preferably with a tongue scraper if a coating is established.[85,87] Tongue cleaning using a tongue scraper reduces the halitosis levels 75% after 1 week.[87] This should be gentle cleaning to prevent soft tissue damage. It is best to clean as far backward as possible; the posterior portion of the tongue has the most coating.[116] Tongue cleaning should be repeated until almost no coating material can be removed.[13] Gagging reflexes often are elicited, especially when using brushes[98]; practice helps to prevent this.[11] It can also be helpful to pull the tongue out with a gauze pad. Tongue cleaning has the additional benefit of improving taste sensation.[98,156]

Interdental cleaning and toothbrushing are essential mechanical means of dental plaque control. Both remove residual food particles and organisms that cause putrefaction. Clinical studies have shown that the mechanical action of toothbrushing alone has no appreciable influence on the concentration of VSCs.[133] In a short-term study, Tonzetich showed a short-term effect in bad breath after brushing with a sodium monofluorophosphate (MFP) toothpaste. However, the effect was half of what was observed when combined with tongue brushing (73% and 30% reduction in VSCs, respectively).[139]

When chronic oral malodor arises as consequence of the presence of periodontitis, professional periodontal therapy is needed.[5,15,88,159] A one-stage, full-mouth disinfection, combining scaling and root planing with the application of chlorhexidine, reduced the organoleptic malodor levels up to 90%.[100] In a recent study of the same authors, initial periodontal therapy had only a weak impact on the VSC levels, except when combined with a mouthrinse containing chlorhexidine.[101]

Chewing gum may control bad breath temporarily because it can stimulate salivary flow.[106] The salivary flow itself also has a mechanical cleaning capability. Not surprisingly, therefore, subjects with extremely low salivary flow rate have higher VSC ratings and tongue coating scores than those with normal saliva production.[58] Waler[152] showed that chewing a gum without any active ingredient can reduce halitosis modestly.

Chemical Reduction of Oral Microbial Load

Together with toothbrushing, mouth rinsing has become a common oral hygiene practice.[35] Formulations have been modified to carry antimicrobial and oxidizing agents with impact in the process of oral malodor formation. The active ingredients usually include antimicrobial agents such as chlorhexidine, cetylpyridinium chloride (CPC), essential oils, chlorine dioxide, triclosan (TCN), amine fluoride and stannous fluoride, hydrogen peroxide, and baking soda. Some of these agents have only a temporary effect on the total number of microorganisms in the oral cavity.

Chlorhexidine. Chlorhexidine is considered the most effective antiplaque and antigingivitis agent.[1-4,51] Its antibacterial action can be explained by disruption of the bacterial cell membrane by the chlorhexidine molecules, increasing its permeability and resulting in cell lysis and death.[51,62] Because of its strong antibacterial effects and superior substantivity in the oral cavity, chlorhexidine rinsing provides significant reduction in VSC levels and organoleptic ratings.[9,113,115,147,161]

Unfortunately, as mentioned in some trials, chlorhexidine at a concentration of 0.2% or greater also has some disadvantages, such as the increased tooth and tongue staining, bad taste, and some temporary reduction in taste sensation.[29]

Essential Oils. Previous studies evaluated the short-term effect (3 hours) of a Listerine rinse (which contains essential oils) compared with a placebo rinse.[93] Listerine was found to be only moderately effective against oral malodor (±25% reduction vs. 10% for placebo of VSCs after 30 minutes) and caused a sustained reduction in the levels of odorigenic bacteria. Similar VSC reductions were found after rinsing for 4 days.[9]

Chlorine Dioxide. Chlorine dioxide (ClO_2) is a powerful oxidizing agent that can eliminate bad breath by oxidation of hydrogen sulfide, methylmercaptan, and the amino acids, methionine, and cysteine. Studies demonstrated that a single use of a ClO_2-containing oral rinse slightly reduces mouth odor.[32,33]

Two-Phase Oil-Water Rinse. Rosenberg et al[113] designed a two-phase oil-water rinse containing CPC. The efficacy of oil-water-CPC formulations is thought to result from the adhesion of a high proportion of oral microorganisms to the oil droplets, which is further enhanced by the CPC. A twice-daily rinse with this product (before bedtime and in the morning) showed reductions in both VSC levels and organoleptic ratings. These reductions were superior to Listerine and significantly superior to a placebo.[59,113]

Triclosan. Triclosan, a broad-spectrum antibacterial agent, has been found to be effective against most oral bacteria and has a good compatibility with other compounds used for oral home care. A pilot study demonstrated that an experimental mouth rinse containing 0.15% triclosan and 0.84% zinc produced a stronger and more prolonged reduction in mouth odor than a Listerine rinse.[105] The anti-VSC effect of triclosan, however, seems strongly dependent on the solubilizing agents.[160] Flavoring oils or anionic detergents and copolymers are added to increase the oral retention and decrease the rate of release in toothpastes formulations containing triclosan. The effect of these formulations in oral malodor has been illustrated in several studies.[48,82,81,123,124] Significant reduction of the breath scores were observed after a single use as well as after a week (28% and >50%, respectively), with a similar effect on the VSC levels (57% reduction after 1 week use of the paste).

Aminefluoride/Stannous Fluoride. The association of aminefluoride with stannous fluoride (AmF/SnF_2) resulted in encouraging reductions of morning breath odor, even when oral hygiene was insufficient.[97] Recently, new evidence supporting the use of this AmF/SnF_2 rinse became available. The formulation showed not only short-term but also long-term effect on malodor indicators in patients with obvious malodor.[19]

Stannous fluoride also has shown to be effective in the management of oral malodor as component of a dentifrice reducing both organoleptic scores (OLS) and VSC levels.[36] A superior short-term and overnight benefit of a stannous-containing dentifrice versus a control dentifrice on morning bad breath has been recently demonstrated in a meta-analysis.[30]

Hydrogen Peroxide. Suarez et al[133] reported that rinsing with 3% hydrogen peroxide (H_2O_2) produced impressive reductions (±90%) in sulfur gases that persisted for 8 hours.

Oxidizing Lozenges. Greenstein et al[42] reported that sucking a lozenge with oxidizing properties reduces tongue dorsum malodor for 3 hours. This antimalodor effect may be caused by the activity of dehydroascorbic acid, which is generated by peroxide-mediated oxidation of ascorbate present in the lozenges.

Baking Soda. Baking soda dentifrices have been shown to confer a significant odor-reducing benefit for time periods up to 3 hours.[8,80] The mechanisms by which baking soda produces its inhibition of oral malodor is related to its bactericidal effects.[95]

Conversion of Volatile Sulfur Compounds

Metal Salt Solutions. Metal ions with affinity for sulfur are efficient in capturing the sulfur-containing gases. Zinc is an ion with two positive charges (Zn^{++}), which will bind to the twice–negatively loaded sulfur radicals, and thus can reduce the expression of the VSCs. The same applies for other metal ions such as stannous, mercury, and copper. Clinically, the VSC inhibitory effect was CuCl2 > SnF2 > ZnCl2. In vitro, the inhibitory effect was $HgCl_2 = CuCl_2 = CdCl_2 > ZnCl_2 > SnF_2 > SnCl_2 > PbCl_2$.[162]

Compared with other metal ions, Zn^{++} is relatively nontoxic and noncumulative and gives no visible discoloration. Thus, Zn^{++} has been one of the most-studied ingredients for the control of oral malodor.[152,162] Schmidt and Tarbet[121] already reported that a rinse containing zinc chloride was remarkably more effective than a saline rinse (or no treatment) in reducing the levels of both VSCs (±80% reduction) and organoleptic scores (±40% reduction) for 3 hours.

As mentioned, Halita, a rinse containing 0.05% chlorhexidine, 0.05% CPC, and 0.14% zinc lactate, has been even more efficient than a 0.2% chlorhexidine formulation in reducing the VSC levels and organoleptic ratings.[102,147] The special effect of Halita may result from the VSC conversion ability of zinc, besides its antimicrobial action. The combination Zn^{++} and chlorhexidine seems to act synergistically.[161]

Similar observations have been reported for a CHX-free mouthrinse. The addition of zinc ions to a basic formulation containing amino fluoride and stannous fluoride caused a short- and long-term reduction of oral malodor indicators in volunteers with morning bad breath[153,154] as well as in volunteers with obvious halitosis.[19]

In a study by Hoshi and van Steenberghe,[47] a zinc citrate/triclosan toothpaste applied to the tongue dorsum appeared to control morning breath malodor for 4 hours. If the flavor oil was removed, however, the antimalodor efficacy of the active ingredients decreased. Another clinical study reported an up to 41%

Rosenberg et al[115] showed that a 0.2% chlorhexidine regimen produced a 43% reduction in VSC values and >50% reduction in organoleptic mouth odor ratings. De Boever and Loesche[22] reported that a 1-week rinsing with 0.12% chlorhexidine gluconate, in combination with tooth and tongue brushing, significantly reduced VSC levels, mouth odor, and tongue odor by 73%, 69%, and 78%, respectively. Morning halitosis was reduced up to 90%.[147] Halita (Dentaid, Spain), a solution (0.05% chlorhexidine, 0.05% CPC, 0.14% zinc lactate, no alcohol), has been even more efficient than chlorhexidine alone, suggesting that the other compounds are also important.[109,108,147] This is explained by a synergistic effect between chlorhexidine and CPC on one hand and by the Zn^{++} on the other hand (see following discussion). The latter was confirmed in a recent randomized controlled trial (RCT) where amine fluoride/stannous fluoride solution showed improved outcomes when zinc was added.[19]

reduction in VSC levels after 7 days' use of a dentifrice containing triclosan and a copolymer, but the benefit compared with a placebo was relatively small (17% reduction).[82] Similar reductions were also found in two other more recent studies.[48,81]

Chewing gum can be formulated with antibacterial agents, such as fluoride or chlorhexidine, thus helping reduce oral malodor through both mechanical and chemical approaches. Tsunoda et al[140] investigated the beneficial effect of chewing gum containing tea extracts for its deodorizing mechanism. *Epigallocatechin* (EGCg) is the main deodorizing agent among the tea catechins. The chemical reaction between EGCg and CH_3SH results in a nonvolatile product. Waler[152] compared different concentrations of zinc in a chewing gum and found that a 2-mg Zn^{++} acetate–containing chewing gum that remained in the mouth for 5 minutes resulted in an immediate reduction in the VSC levels of up to 45%, but the long-term effect was not mentioned.

Conclusion

Breath malodor has important socioeconomic consequences and can reveal important diseases. A proper diagnosis and determination of the etiology allow initiation of the proper etiologic treatment. Although tongue coating and (less frequently) periodontitis and gingivitis are by far the most common causes of malodor, a clinician cannot take the risk of overlooking other, more challenging diseases. This can be done by a multidisciplinary consultation or, if this is not feasible, a trial therapy to deal quickly with intraoral causes (e.g., the full-mouth one-stage disinfection, including the use of the proper mouthrinses, tongue scrapers, and toothpastes). For more detailed information, the reader is encouraged to consult van Steenberghe[146] and recent review papers.[110,120,148]

Suggested Reading

Loesche WJ, Kazor C: Microbiology and treatment of halitosis. *Periodontol 2000* 28:256–279, 2002.

Quirynen M, Dadamio J, Van den Velde S, et al: Characteristics of 2000 patients who visited a halitosis clinic. *J Clin Periodontol* 36(11):970–975, 2009.

Rosenberg M, Sterer N: *Breath odors: origin, diagnosis, and management*, Berlin, 2011, Springer.

Sanz M, Roldán S, Herrera D: Fundamentals of breath malodour. *J Contemp Dent Pract* 2(4):1–17, 2001.

Scully C, Greenman J: Halitology (breath odour: aetiopathogenesis and management). *Oral Dis* 18(4):333–345, 2012.

Seemann R, Bizhang M, Djamchidi C, et al: The proportion of pseudohalitosis patients in a multidisciplinary breath malodour consultation. *Int Dent J* 56(2):77–81, 2006.

van Steenberghe D, Rosenberg M: *Bad breath: a multidisciplinary approach*, Leuven, 1996, University Press.

Van Tornout M, Dadamio J, Coucke W, et al: Tongue coating: related factors. *J Clin Periodontol* 40(2):180–185, 2013.

References

References for this chapter are found on the companion website www.expertconsult.com.

References

1. Addy M, Moran JM: Clinical indications for the use of chemical adjuncts to plaque control: chlorhexidine formulations. *Periodontol 2000* 15:52, 1997.
2. Addy M, Renton-Harper P: The role of antiseptics in secondary prevention. In Lang NP, Karring T, editors: *Proceedings of the second European workshop in periodontology*, London, 1997, Quintessence.
3. Addy M, Moran J, Wade W: Chemical plaque control in the prevention of gingivitis and periodontitis. In Lang NP, Karring T, editors: *Proceedings of the first European workshop in periodontology*, London, 1994, Quintessence.
4. Bollen CM, Quirynen M: Microbiological response to mechanical treatment in combination with adjunctive therapy: a review of the literature. *J Periodontol* 67:1143, 1996.
5. Bosy A, Kulkarni GV, Rosenberg M, et al: Relationship of oral malodor to periodontitis: evidence of independence in discrete subpopulations. *J Periodontol* 65:37, 1994.
6. Bowler PG, Davies BJ, Jones SA: Microbial involvement in chronic wound malodour. *J Wound Care* 8:216, 1999.
7. Brunette DM, Ouyang Y, Glass-Brudzinski J, et al: Effects of methylmercaptan on human gingival fibroblast shape, cytoskeleton and protein synthesis and the inhibition of its effect by Zn^{++}. In van Steenberghe D, Rosenberg M, editors: *Bad breath: a multidisciplinary approach*, Leuven, Belgium, 1996, Leuven University Press.
8. Brunette DM, Proskin HM, Nelson BJ: The effects of dentifrice systems on oral malodor. *J Clin Dent* 9:76, 1998.
9. Carvalho MD, Tabchoury CM, Cury JA, et al: Impact of mouthrinses on morning bad breath in healthy subjects. *J Clin Periodontol* 31(2):85, 2004.
10. Chen S, Zieve L, Mahadevan V: Mercaptans and dimethyl sulfide in the breath of patients with cirrhosis of the liver: effect of feeding methionine. *J Lab Clin Med* 75:628, 1970.
11. Christensen GJ: Why clean your tongue? *J Am Dent Assoc* 129:1605, 1998.
12. Cicek Y, Orbak R, Tezel A, et al: Effect of tongue brushing on oral malodor in adolescents. *Pediatr Int* 45:719, 2003.
13. Clark GT, Nachnani S, Messadi DV: Detecting and treating oral and nonoral malodors. *J Calif Dent Assoc* 25:133, 1997.
14. Claus D, Geypens B, Rutgeers P, et al: Where gastroenterology and periodontology meet: determination of oral volatile organic compounds using closed-loop trapping and high-resolution gas chromatography-ion trap detection. In van Steenberghe D, Rosenberg M, editors: *Bad breath: a multidisciplinary approach*, Leuven, Belgium, 1996, Leuven University Press.
15. Coil J, Tonzetich J: Characterization of volatile sulfur compounds production at individual gingival crevicular sites in humans. *J Clin Dent* 3:97, 1992.
16. Collins LM, Dawes C: The surface area of the adult human mouth and thickness of the salivary film covering the teeth and oral mucosa. *J Dent Res* 66:1300, 1987.
17. Crescenzo DG, Trastek VF, Allen MS, et al: Zenker's diverticulum in the elderly: is operation justified? *Ann Thorac Surg* 66:347, 1998.
18. Dadamio J, Van den Velde S, Laleman W, et al: Breath biomarkers of liver cirrhosis. *J Chromatogr B Analyt Technol Biomed Life Sci* 905:17, 2012.
19. Dadamio J, Van Tornout M, Teughels W, et al: Efficacy of different mouthrinse formulations in reducing oral malodour: a randomized clinical trial. *J Clin Periodontol* 40(5):505, 2013.
20. Dadamio J, Van Tornout M, Van den Velde S, et al: A novel and visual test for oral malodour: first observations. *J Breath Res* 5(4):046003, 2011.
21. Dadamio J, Van Tornout M, Vancauwenberghe F, et al: Clinical utility of a novel colorimetric chair side test for oral malodour. *J Clin Periodontol* 39(7):645, 2012.
22. De Boever EH, Loesche WJ: Assessing the contribution of anaerobic microflora of the tongue to oral malodor. *J Am Dent Assoc* 126:1384, 1995.
23. Delanghe G, Ghyselen J, Bollen C, et al: An inventory of patients' response to treatment at a multidisciplinary breath odor clinic. *Quintessence Int* 30(5):307, 1997.
24. Delanghe G, Ghyselen J, van Steenberghe D, et al: Multidisciplinary breath-odour clinic. *Lancet* 350:187, 1997.
25. Derogatis LR, Lipman RS, Covi L: SCL-90: an outpatient psychiatric rating scale—preliminary report. *Psychopharmacol Bull* 9:13, 1973.
26. Doty RL, Shaman P, Dann M: Development of the University of Pennsylvania Smell Identification Test: a standardized microencapsulated test of olfactory function. *Physiol Behav* 32:489, 1984.
27. Eli I, Baht R, Koriat H, et al: Self-perception of breath odor. *J Am Dent Assoc* 132:621, 2001.
28. Eli I, Baht R, Kozlovsky A, et al: The complaint of oral malodor: possible psychopathological aspects. *Psychosom Med* 58:156, 1996.
29. Fedorowicz Z, Aljufairi H, Nasser M, et al: Mouthrinses for the treatment of halitosis. *Cochrane Database Syst Rev* 8(4):CD006701, 2008.
30. Feng X, Chen X, Cheng R, et al: Breath malodor reduction with use of a stannous-containing sodium fluoride dentifrice: a meta-analysis of four randomized and controlled clinical trials. *Am J Dent* 23:27B, 2010.
31. Furne J, Majerus G, Lenton P, et al: Comparison of volatile sulfur compound concentrations measured with a sulfide detector vs. gas chromatography. *J Dent Res* 81(2):140, 2002.
32. Frascella J, Gilbert R, Fernandez P: Odor reduction potential of a chlorine dioxide mouthrinse. *J Clin Dent* 9:39, 1998.
33. Frascella J, Gilbert RD, Fernandez P, et al: Efficacy of a chlorine dioxide–containing mouthrinse in oral malodor. *Compend Contin Educ Dent* 21:241, 2000.
34. Friedlander AH, Marder SR, Pisegna JR, et al: Alcohol abuse and dependence: psychopathology, medical management and dental implications. *J Am Dent Assoc* 134:731, 2003.
35. Gagari E, Kabani S: Adverse effects of mouthwash use: a review. *Oral Surg Oral Med Oral Pathol Oral Radiol Endod* 80:432, 1995.
36. Gerlach RW, Hyde JD, Poore CL, et al: Breath effects of three marketed dentifrices: a comparative study evaluating single and cumulative use. *J Clin Dent* 9:83, 1998.
37. Gilmore EL, Bhaskar SN: Effect of tongue brushing on bacteria and plaque formed in vitro. *J Periodontol* 43:418, 1972.
38. Gilmore EL, Gross A, Whitley R: Effect of tongue brushing on plaque bacteria. *Oral Surg Oral Med Oral Pathol* 36:201, 1973.
39. Goldberg S, Kozlovsky A, Gordon D, et al: Cadaverine as a putative component of oral malodor. *J Dent Res* 73:1168, 1994.
40. Greenman J, Duffield J, Spencer P, et al: Study on the organoleptic intensity scale for measuring oral malodor. *J Dent Res* 83:81, 2004.
41. Greenman J, El Maaytah M, Duffield J, et al: Assessing the relationship between concentrations of malodor compounds and odor scores from judges. *J Am Dent Assoc* 136:749, 2005.
42. Greenstein RB, Goldberg S, Marku-Cohen S, et al: Reduction of oral malodor by oxidizing lozenges. *J Periodontol* 68:1176, 1997.
43. Gross A, Barnes GP, Lyon TC: Effects of tongue brushing on tongue coating and dental plaque scores. *J Dent Res* 54:1236, 1975.
44. Haraszthy VI, Gerber D, Clark B, et al: Characterization and prevalence of Solobacterium moorei associated with oral halitosis. *J Breath Res* 2:017002, 2008.
45. Haraszthy VI, Zambon JJ, Sreenivasan PK, et al: Identification of oral bacterial species associated with halitosis. *J Am Dent Assoc* 138:1113, 2007.
46. Hatt H: Molecular and cellular basis of human olfaction. *Chem Biodivers* 1:1857, 2004.
47. Hoshi K, van Steenberghe D: The effect of tongue brushing or toothpaste application on oral malodour reduction. In van Steenberghe D, Rosenberg M, editors: *Bad breath: a multidisciplinary approach*, Leuven, Belgium, 1996, Leuven University Press.
48. Hu D, Zhang YP, Petrone M, et al: Clinical effectiveness of a triclosan/copolymer/sodium-fluoride dentifrice in controlling oral malodor: a three-week clinical trial. *Compend Contin Educ Dent* 24(9):34, 2003.
49. Hunter CM, Niles HP, Lenton PA, et al: Breath-odor evaluation by detection of volatile sulfur compounds: correlation with organoleptic odor ratings. *Compend Contin Educ Dent* 24:25, 2003.

50. Iwanicka-Grzegorek K, Lipkowska E, Kepa J, et al: Comparison of ninhydrin method of detecting amine compounds with other methods of halitosis detection. *Oral Dis* 11(Suppl 1):37, 2005.
51. Jones CG: Chlorhexidine: is it still the gold standard? *Periodontol 2000* 15:55, 1997.
52. Katsinelos P, Tziomalos K, Chatzimavroudis G, et al: Eradication therapy in Helicobacter pylori-positive patients with halitosis: long-term outcome. *Med Princ Pract* 16:119, 2007.
53. Kazor CE, Mitchell PM, Lee AM, et al: Diversity of bacterial populations on the tongue dorsa of patients with halitosis and healthy patients. *J Clin Microbiol* 41:558, 2003.
54. Kislig K, Wilder-Smith CH, Bornstein MM, et al: Halitosis and tongue coating in patients with erosive gastroesophageal reflux disease versus nonerosive gastroesophageal reflux disease. *Clin Oral Investig* 17(1):159, 2013.
55. Kleinberg I, Codipilly M: The biological basis of oral malodor formation. In Rosenberg M, editor: *Bad breath: research perspectives*, Tel Aviv, 1995, Ramot.
56. Kleinberg I, Wolff MS, Codipilly DM: Role of saliva in oral dryness, oral feel and oral malodour. *Int Dent J* 52(Suppl 3):236, 2002.
57. Knaan T, Cohen D, Rosenberg M: Predicting bad breath in the non-complaining population. *Oral Dis* 11:105–106, 2005. (abstract).
58. Koshimune S, Awano S, Gohara K, et al: Low salivary flow and volatile sulfur compounds in mouth air. *Oral Surg Oral Med Oral Pathol Oral Radiol Endod* 96:38, 2003.
59. Kozlovsky A, Goldberg S, Natour I, et al: Efficacy of a 2-phase oil: water mouthrinse in controlling oral malodor, gingivitis, and plaque. *J Periodontol* 67:577, 1996.
60. Kozlovsky A, Gordon D, Gelernter I, et al: Correlation between the BANA test and oral malodor parameters. *J Dent Res* 73(5):1036, 1994.
61. Kurihara E, Marcondes FK: Oral concentration of volatile sulphur compounds in stressed rats. *Stress* 5:295, 2002.
62. Kuyyakanond T, Quesnel LB: The mechanism of action of chlorhexidine. *FEMS Microbiol Lett* 79:211, 1992.
63. Lancero H, Niu J, Johnson PW: Exposure of periodontal ligament cells to methylmercaptan reduces intracellular pH and inhibits cell migration. *J Dent Res* 75:1994, 1996.
64. Lee H, Kho HS, Chung JW, et al: Volatile sulfur compounds produced by *Helicobacter pylori*. *J Clin Gastroenterol* 40:421, 2006.
65. Liu XN, Shinada K, Chen XC, et al: Oral malodor-related parameters in the Chinese general population. *J Clin Periodontol* 33(1):31, 2006.
66. Loesche WJ: The effects of antimicrobial mouthrinses on oral malodor and their status relative to US Food and Drug Administration regulations. *Quintessence Int* 30:311, 1999.
67. Lorber B: "Bad breath": presenting manifestation of anaerobic pulmonary infection. *Am Rev Respir Dis* 112:875, 1975.
68. Mathews SA, Kurien BT, Scofield RH: Oral manifestations of Sjögren's syndrome. *J Dent Res* 87:308, 2007.
69. McGregor IA, Watson JD, Sweeney G, et al: Tinidazole in smelly oropharyngeal tumours. *Lancet* 1:110, 1982.
70. Menon MV, Coykendall AL: Effect of tongue scraping. *J Dent Res* 73:1492, 1994.
71. Mitchell SC, Smith RL: Trimethylaminuria: the fish malodor syndrome. *Drug Metab Dispos* 29:517, 2001.
72. Miyazaki H, Sakao S, Katoh Y, et al: Correlation between volatile sulphur compounds and certain oral health measurements in the general population. *J Periodontol* 66:679, 1995.
73. Moore PA, Guggenheimer J: Medication-induced hyposalivation: etiology, diagnosis, and treatment. *Compend Contin Educ Dent* 29:50, 2008.
74. Morita M, Wang HL: Relationship between sulcular sulfide level and oral malodor in subjects with periodontal disease. *J Periodontol* 72:79, 2001.
75. Moshkowitz M, Horowitz N, Leshno M, et al: Halitosis and gastroesophageal reflux disease: a possible association. *Oral Dis* 13:581, 2007.
76. Nachnani S, Majerus G, Lenton P, et al: Effect of training on odor judges scoring intensity. *Oral Dis* 11:40, 2005.
77. Nadanovsky P, Carvalho LBM, Ponce de Leon A: Oral malodour and its association with age and sex in a general population in Brazil. *Oral Dis* 13(1):105, 2007.
78. Nakano Y, Yoshimura M, Koga T: Correlation between oral malodor and periodontal bacteria. *Microbes Infect* 4:679, 2002.
79. Newman MG: The role of periodontitis in oral malodor: clinical perspectives. In van Steenberghe D, Rosenberg M, editors: *Bad breath: a multidisciplinary approach*, Leuven, Belgium, 1996, Leuven University Press.
80. Niles HP, Gaffar A: Advances in mouth odor research. In Rosenberg M, editor: *Bad breath: research perspectives*, Tel Aviv, 1995, Ramot.
81. Niles HP, Hunter C, Vazquez J, et al: The clinical comparison of a triclosan/copolymer/fluoride dentifrice vs a breath-freshening dentifrice in reducing breath odor overnight: a crossover study. *Oral Dis* 11(1):54, 2005.
82. Niles HP, Vazquez J, Rustogi KN, et al: The clinical effectiveness of a dentifrice containing triclosan and a copolymer for providing long-term control of breath odor measured chromatographically. *J Clin Dent* 10:135, 1999.
83. Norfleet RG: Helicobacter halitosis. *J Clin Gastroenterol* 16:274, 1993.
84. Oho T, Yoshida Y, Shimazaki Y, et al: Characteristics of patients complaining of halitosis and the usefulness of gas chromatography for diagnosing halitosis. *Oral Surg Oral Med Oral Pathol Oral Radiol Endod* 91(5):531, 2001.
85. Outhouse TL, Al-Alawi R, Fedorowicz Z, et al: Tongue scraping for treating halitosis. *Cochrane Database Syst Rev* 19(2):CD005519, 2006.
86. Oxtoby A, Field EA: Delusional symptoms in dental patients: a report of four cases. *Br Dent J* 176:140, 1994.
87. Pedrazzi V, Sato S, de Mattos Mda G, et al: Tongue-cleaning methods: a comparative clinical trial employing a toothbrush and a tongue scraper. *J Periodontol* 75(7):1009, 2006.
88. Persson S: Hydrogen sulfide and methylmercaptan in periodontal pockets. *Oral Microbiol Immunol* 7:378, 1992.
89. Persson S, Claesson R, Carlsson J: The capacity of subgingival microbiotas to produce volatile sulfur compounds in human serum. *Oral Microbiol Immunol* 4:169, 1989.
90. Persson S, Edlund MB, Claesson R, et al: The formation of hydrogen sulfide and methylmercaptan by oral bacteria. *Oral Microbiol Immunol* 5:195, 1990.
91. Phillips M, Cataneo RN, Cheema T, et al: Increased breath biomarkers of oxidative stress in diabetes mellitus. *Clin Chim Acta* 344:189, 2004.
92. Phillips M, Herrera J, Krishnan S, et al: Variation in volatile organic compounds in the breath of normal humans. *J Chromatogr B Biomed Sci Appl* 729:75, 1999.
93. Pitts G, Brogdon C, Hu L, et al: Mechanism of action of an antiseptic, anti-odor mouthwash. *J Dent Res* 62:738, 1983.
94. Preti G, Lawley HJ, Hormann CA: Non-oral and oral aspects of oral malodor. In Rosenberg M, editor: *Bad breath: research perspectives*, Tel Aviv, 1995, Ramot.
95. Putt MS, Milleman KR, Ghassemi A, et al: Enhancement of plaque removal efficacy by tooth brushing with baking soda dentifrices: results of five clinical studies. *J Clin Dent* 19:111, 2008.
96. Queiroz CS, Hayacibara MF, Tabchoury CP, et al: Relationship between stressful situations, salivary flow rate and oral volatile sulfur-containing compounds. *Eur J Oral Sci* 110:337, 2002.
97. Quirynen M, Avontroodt P, Soers C, et al: The efficacy of amine fluoride/stannous fluoride in the suppression of morning breath odour. *J Clin Periodontol* 29:944, 2002.
98. Quirynen M, Avontroodt P, Soers C, et al: Impact of tongue cleansers on microbial load and taste. *J Clin Periodontol* 31:506, 2004.
99. Quirynen M, Dadamio J, Van den Velde S, et al: Characteristics of 2000 patients who visited a halitosis clinic. *J Clin Periodontol* 36(11):970, 2009.
100. Quirynen M, Mongardini C, van Steenberghe D: The effect of a 1-stage full-mouth disinfection on oral malodor and microbial

colonization of the tongue in periodontitis: a pilot study. *J Periodontol* 69:374, 1998.
101. Quirynen M, Zhao H, Soers C, et al: The impact of periodontal therapy and the adjunctive effect of antiseptics on breath odor-related outcome variables: a double-blind randomized study. *J Periodontol* 76(5):705, 2005.
102. Quirynen M, Zhao H, van Steenberghe D: Review of the treatment strategies for oral malodour. *Clin Oral Invest* 6:1, 2002.
103. Ralph WJ: Oral hygiene—why neglect the tongue? *Aust Dent J* 33:224, 1988.
104. Ratkay LG, Tonzetich J, Waterfield JD: The effect of methylmercaptan on the enzymatic and immunological activity leading to periodontal tissue destruction. In van Steenberghe D, Rosenberg M, editors: *Bad breath: a multidisciplinary approach*, Leuven, Belgium, 1996, Leuven University Press.
105. Raven S, Matheson JR, Huntington E, et al: The efficacy of combined zinc and triclosan system in the prevention of oral malodour. In van Steenberghe D, Rosenberg M, editors: *Bad breath: a multidisciplinary approach*, Leuven, Belgium, 1996, Leuven University Press.
106. Reingewirtz Y, Girault O, Reingewirtz N, et al: Mechanical effects and volatile sulfur compound–reducing effects of chewing gums: comparison between test and base gums and a control group. *Quintessence Int* 30:319, 1999.
107. Replogle WH, Beebe DK: Halitosis. *Am Fam Physician* 53:1215, 1996.
108. Roldán S, Herrera D, Santa-Cruz I, et al: Comparative effects of different chlorhexidine mouth-rinse formulations on volatile sulphur compounds and salivary bacterial counts. *J Clin Periodontol* 31(12): 1128, 2004.
109. Roldan S, Herrera D, Sanz M: Clinical and microbiological efficiency efficacy of an antimicrobial mouthrinse on oral halitosis. *J Clin Periodontol* 27:24, 2000.
110. Roldan S, Herrera D, Sanz M: Biofilms and the tongue: therapeutical approaches for the control of halitosis. *Clin Oral Invest* 7:189, 2003.
111. Rosenberg M: Clinical assessment of bad breath: current concepts. *J Am Dent Assoc* 127:475, 1996.
112. Rosenberg M: Bad breath and periodontal disease: how related are they? *J Clin Periodontol* 33:29, 2006.
113. Rosenberg M, Gelernter I, Barki M, et al: Day-long reduction of oral malodor by a two-phase oil: water mouthrinse as compared to chlorhexidine and placebo rinses. *J Periodontol* 63:39, 1992.
114. Rosenberg M, Knaan T, Cohen D: Association among bad breath, body mass index, and alcohol intake. *J Dent Res* 86(10):997–1000, 2007.
115. Rosenberg M, Kulkarni GV, Bosy A, et al: Reproducibility and sensitivity of oral malodor measurements with a portable sulphide monitor. *J Dent Res* 70:1436, 1991.
116. Rosenberg M, Leib E: Experiences of an Israeli malodor clinic. In Rosenberg M, editor: *Bad breath: research perspectives*, Tel Aviv, 1995, Ramot.
117. Rosenberg M, McCulloch CA: Measurement of oral malodor: current methods and future prospects. *J Periodontol* 63:776, 1992.
118. Rosenberg M, Septon I, Eli I, et al: Halitosis measurement by an industrial sulphide monitor. *J Periodontol* 62:487, 1991.
119. Rowley EJ, Schuchman LC, Tishk MN, et al: Tongue brushing versus tongue scraping. *Clin Prev Dent* 9:13, 1987.
120. Sanz M, Roldan S, Herrera D: Fundamentals of breath malodour. *J Contemp Dent Pract* 2:1, 2001.
121. Schmidt NF, Tarbet WJ: The effect of oral rinses on organoleptic mouth odor ratings and levels of volatile sulfur compounds. *Oral Surg Oral Med Oral Pathol* 45(6):876, 1978.
122. Schroeder HE: Oral mucosa. In Schroeder HE, editor: *Oral structural biology*, New York, 1991, Thieme Medical.
123. Sharma NC, Galustians HJ, Qaquish J, et al: The clinical effectiveness of a dentifrice containing triclosan and a copolymer for controlling breath odor measured organoleptically twelve hours after toothbrushing. *J Clin Dent* 10:131, 1999.
124. Sharma NC, Galustians HJ, Qaquish J, et al: Clinical effectiveness of a dentifrice containing triclosan and a copolymer for controlling breath odor. *Am J Dent* 20:79, 2007.
125. Simenhoff ML, Burke JF, Saukkonen JJ, et al: Biochemical profile or uremic breath. *N Engl J Med* 297:132, 1977.
126. Söder B, Johansson B, Söder PO: The relation between foetor ex ore, oral hygiene and periodontal disease. *Swed Dent J* 24(3):73, 2000.
127. Stamou E, Kozlovsky A, Rosenberg M: Association between oral malodour and periodontal disease-related parameters in a population of 71 Israelis. *Oral Dis* 11:72, 2005.
128. Sterer N, Greenstein RB, Rosenberg M: Beta-galactosidase activity in saliva is associated with oral malodor. *J Dent Res* 81(3):182–185, 2002.
129. Sterer N, Rosenberg M: Effect of deglycosylation of salivary glycoproteins on oral malodour production. *Int Dent J* 52(Suppl 3):229, 2002.
130. Sterer N, Rosenberg M: *Streptococcus salivarius* promotes mucin putrefaction and malodor production by *Porphyromonas gingivalis*. *J Dent Res* 85:910, 2006.
131. Stewart RD, Boettner EA: Expired-air acetone in diabetes mellitus. *N Engl J Med* 270:1035, 1964.
132. Suarez F, Springfield J, Furne J, et al: Differentiation of mouth versus gut as site of origin of odoriferous breath gases after garlic ingestion. *Am J Physiol* 276:G425, 1999.
133. Suarez FL, Furne JK, Springfield J, et al: Morning breath odor: influence of treatments on sulfur gases. *J Dent Res* 79:1773, 2000.
134. Tanaka M, Anguri H, Nonaka A, et al: Clinical assessment of oral malodor by the electronic nose system. *J Dent Res* 83:317, 2004.
135. Tangerman A, Meuwesearends MT, Jansen JBMJ: Cause and composition of foetor hepaticus. *Lancet* 343:483, 1994.
136. Tangerman A, Winkel EG: The portable gas chromatograph OralChroma™: a method of choice to detect oral and extra-oral halitosis. *J Breath Res* 2(1):017010, 2008.
137. Tangerman A, Winkel EG, de Laat L, et al: Halitosis and Helicobacter pylori infection. *J Breath Res* 6(1):017102, 2012.
138. Tonzetich J: Production and origin of oral malodor: a review of mechanisms and methods of analysis. *J Periodontol* 48:13, 1977.
139. Tonzetich J, Ng SK: Reduction of malodor by oral cleansing procedures. *Oral Surg Oral Med Oral Pathol* 42:172, 1976.
140. Tsunoda M, Yamada S, Yasuda H: Deodorizing mechanism of epigallocatechin and chewing gum containing tea extracts. In van Steenberghe D, Rosenberg M, editors: *Bad breath: a multidisciplinary approach*, Leuven, Belgium, 1996, Leuven University Press.
141. Van den Velde S, Nevens F, Van hee P, et al: GC-MS analysis of breath odor compounds in liver patients. *J Chromatogr B Analyt Technol Biomed Life Sci* 875(2):344, 2008.
142. Van den Velde S, Quirynen M, Van hee P, et al: Differences between alveolar air and mouth air. *Anal Chem* 79:3425, 2007.
143. Van den Velde S, Quirynen M, Van hee P, et al: Halitosis associated volatiles in breath of healthy subjects. *J Chromatogr B Analyt Technol Biomed Life Sci* 853:54, 2007.
144. Van den Velde S, van Steenberghe D, Van Hee P, et al: Detection of odorous compounds in breath. *J Dent Res* 88(3):285, 2009.
145. van Steenberghe D: Breath malodor. *Curr Opin Periodontol* 4:137, 1997.
146. van Steenberghe D, editor: *Breath malodor: a step-by-step approach*, Copenhagen, 2004, Quintessence.
147. van Steenberghe D, Avontroodt P, Peeters W, et al: Effect of different mouthrinses on morning breath. *J Periodontol* 72:1183, 2001.
148. van Steenberghe D, Quirynen M: Breath malodor. In Lindhe J, Karring T, Lang NP, editors: *Clinical periodontology and implant dentistry*, Oxford, 2003, Blackwell.
149. Van Tornout M, Dadamio J, Coucke W, et al: Tongue coating: related factors. *J Clin Periodontol* 40(2):180, 2013.
150. Vandekerckhove B, Van den Velde S, De Smit M, et al: Clinical reliability of non-organoleptic oral malodour measurements. *J Clin Periodontol* 36(11):964, 2009.
151. Vernillo AT: Dental considerations for the treatment of patients with diabetes mellitus. *J Am Dent Assoc* 134:24S, 2003.
152. Waler SM: The effect of zinc-containing chewing gum on volatile sulfur-containing compounds in the oral cavity. *Acta Odontol Scand* 55:198, 1997.

153. Wigger-Alberti W, Gysen K, Axmann EM, et al: Efficacy of a new mouthrinse formulation on the reduction of oral malodour in vivo. A randomized, double-blind, placebo-controlled, 3 week clinical study. *J Breath Res* 4(1):017102, 2010.
154. Wilhelm D, Gysen K, Himmelmann A, et al: Short-term effect of a new mouthrinse formulation on oral malodour after single use in vivo: a comparative, randomized, single-blind, parallel-group clinical study. *J Breath Res* 4(3):036002, 2010.
155. Winkel EG, Roldán S, Van Winkelhoff AJ, et al: Clinical effects of a new mouthrinse containing chlorhexidine, cetylpyridinium chloride and zinc-lactate on oral halitosis. A dual-center, double-blind placebo-controlled study. *J Clin Periodontol* 30(4):300, 2003.
156. Winkler S, Garg AK, Mekayarajjananonth T, et al: Depressed taste and smell in geriatric patients. *J Am Dent Assoc* 130:1759, 1999.
157. Yaegaki K, Coil J: Examination classification and treatment of halitosis; clinical perspectives. *J Can Dent Assoc* 66:257, 2000.
158. Yaegaki K, Sanada K: Biochemical and clinical factors influencing oral malodor in periodontal patients. *J Periodontol* 63:783, 1992.
159. Yaegaki K, Sanada K: Volatile sulfur compounds in mouth air from clinically healthy subjects and patients with periodontal disease. *J Periodontal Res* 27:233, 1992.
160. Young A, Jonski G, Rolla G: A study of triclosan and its solubilizers as inhibitors of oral malodour. *J Clin Periodontol* 12:1078, 2002.
161. Young A, Jonski G, Rolla G: Inhibition of orally produced volatile sulfur compounds by zinc, chlorhexidine or cetylpyridinium chloride: effect of concentration. *Eur J Oral Sci* 5:400, 2003.
162. Young A, Jonski G, Rolla G, et al: Effects of metal salts on the oral production of volatile sulfur-containing compounds (VSC). *J Clin Periodontol* 28:776, 2001.
163. Zusho H, Asaka H, Okamoto H: Diagnosis of olfactory disturbance. *Auris Nasus Larynx* 8:19, 1981.

CHAPTER 53

Phase II Periodontal Therapy

Fermin A. Carranza and Henry H. Takei

CHAPTER OUTLINE

Objectives of the Surgical Phase
Pocket Elimination versus Pocket Maintenance
Reevaluation after Phase I Therapy
Critical Zones in Pocket Surgery
Indications for Periodontal Surgery
Methods of Pocket Therapy

Although in a strict sense, all instrumental therapy can be considered surgical, this chapter refers only to those techniques that include the intentional severing or incising of gingival tissue* with the following purposes:

- Controlling or eliminating periodontal disease
- Correcting anatomic conditions that may favor periodontal disease, impair esthetics, or impede placement of the correct prosthetic appliances
- Placing implants to replace lost teeth and improving the environment for their placement and function

Objectives of the Surgical Phase

The surgical phase of periodontal therapy has the following main objectives:

1. Improvement of the prognosis of teeth and their replacements
2. Improvement of esthetics

The surgical phase consists of techniques performed for pocket therapy and for the correction of related morphologic problems, namely, mucogingival defects. In many cases, procedures are combined so that one surgical intervention fulfills both objectives.

The purpose of surgical pocket therapy is to eliminate the pathologic changes in the pocket walls; to create a stable, easily maintainable state; and if possible, to promote periodontal regeneration. To fulfill these objectives, surgical techniques (1) increase accessibility to the root surface, making it possible to remove all irritants; (2) reduce or eliminate pocket depth, making it possible for the patient to maintain the root surfaces free of plaque; and (3) reshape soft and hard tissues to attain a harmonious topography. Pocket reduction surgery seeks to reduce pocket depth by either resective or regenerative means or often by a combination of both methods (Box 53-1). Chapters 59 to 61 describe the different techniques used for these purposes.

The second objective of the surgical phase of periodontal therapy is the correction of anatomic morphologic defects that may favor plaque accumulation and pocket recurrence or impair esthetics. It is important to understand that these procedures are not directed to treat disease but aim to alter the gingival and mucosal tissues to correct defects that may predispose to disease. They are performed on noninflamed tissues and in the absence of periodontal pockets. Three types of techniques fall into this category, as follows (see Box 53-1):

- *Plastic surgery techniques* are used to create or widen the attached gingiva by placing grafts of various types.
- *Esthetic surgery techniques* are used to cover denuded roots and to recreate lost papillae.
- *Preprosthetic techniques* are used to adapt the periodontal and neighboring tissues to receive prosthetic replacements; these include crown lengthening, ridge augmentation, and vestibular deepening.

The plastic and esthetic surgery techniques are presented in Chapter 63 and the preprosthetic techniques in Chapter 66.

In addition, periodontal surgical techniques for the placement of dental implants are available. These involve not only the implant placement techniques but also a variety of surgical procedures to adapt the neighboring tissues, such as the sinus floor or the mandibular nerve canal, for subsequent placement of the implant (see Box 53-1). These methods are discussed in Chapters 75 and 77.

Surgical Pocket Therapy

Surgical pocket therapy can be directed toward (1) access surgery to ensure the removal of irritants from the tooth surface or (2) elimination or reduction of the depth of the periodontal pocket.

The effectiveness of periodontal therapy is predicated on success in completely eliminating calculus, plaque, and diseased cementum from the tooth surface. Numerous investigations have shown that the difficulty of this task increases as the pocket becomes deeper.[2,5] The presence of irregularities on the root surface also increase the difficulty of the procedure. As the pocket becomes deeper, the surface to be scaled increases, more irregularities appear on the root surface, and accessibility is impaired.[11,15] The presence of furcations will also create insurmountable problems for scaling the root surface[4] (see Chapter 62).

These problems can be reduced by resecting or displacing the soft tissue wall of the pocket, thereby increasing the visibility and accessibility of the root surface.[3] The flap approach and the gingivectomy technique attain this result.

The need to eliminate or reduce the depth of the pocket is another important consideration. Pocket elimination consists of reducing the depth of periodontal pockets to that of a physiologic sulcus to enable cleansing by the patient. By proper case selection,

*Scaling and root planing are not included because these procedures are not used intentionally to act on the gingival tissue.

BOX 53-1 Periodontal Surgery

Pocket Reduction Surgery

Resective (gingivectomy, apically displaced flap, and undisplaced flap with or without osseous resection)

Regenerative (flaps with grafts, membranes, etc.)

Correction of Anatomic/Morphologic Defects

Plastic surgery techniques to widen attached gingiva (free gingival grafts, other techniques, etc.)

Esthetic surgery (root coverage, recreation of gingival papillae)

Preprosthetic techniques (crown lengthening, ridge augmentation, and vestibular deepening)

Placement of dental implants, including techniques for site development for implants (guided bone regeneration, sinus grafts)

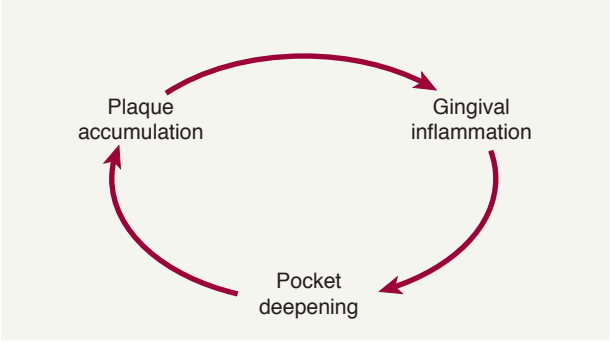

Figure 53-1 Accumulation of plaque leads to gingival inflammation and pocket deepening, which in turn increases the area of plaque accumulation.

both resective techniques and regenerative techniques can be used to accomplish this goal. The presence of a pocket produces areas that are impossible for the patient to keep clean, which establishes the vicious cycle depicted in Figure 53-1.

Results of Pocket Therapy

A periodontal pocket can be in an active state or a period of inactivity or quiescence. In an active pocket, underlying bone is being lost (Figure 53-2, *top left*). It often can be diagnosed clinically by bleeding, either spontaneously or on probing. After Phase I therapy, the inflammatory changes in the pocket wall subside, rendering the pocket inactive and reducing its depth (Figure 53-2, *top center*). The extent of this reduction depends on the depth before treatment and the degree to which the depth is the result of the edematous and inflammatory component of the pocket wall.

Whether the pocket remains inactive depends on the depth, the individual characteristics of the plaque components, and the host response. Recurrence of the initial activity is likely.

Inactive pockets can sometimes heal with a long junctional epithelium (Figure 53-2, *top right*). However, this condition also may be unstable, and the chance of recurrence and re-formation of the original pocket is always present because the epithelial union to the tooth is weak. However, one study in monkeys has shown that the long junctional epithelial union may be as resistant to plaque infection as a normal connective tissue attachment.[9]

Studies have shown that inactive pockets can be maintained for long periods with little loss of attachment by means of frequent scaling and root-planing procedures.[6,10,12] A more reliable and stable result is obtained, however, by transforming the pocket into a healthy sulcus. The bottom of the healthy sulcus can be located

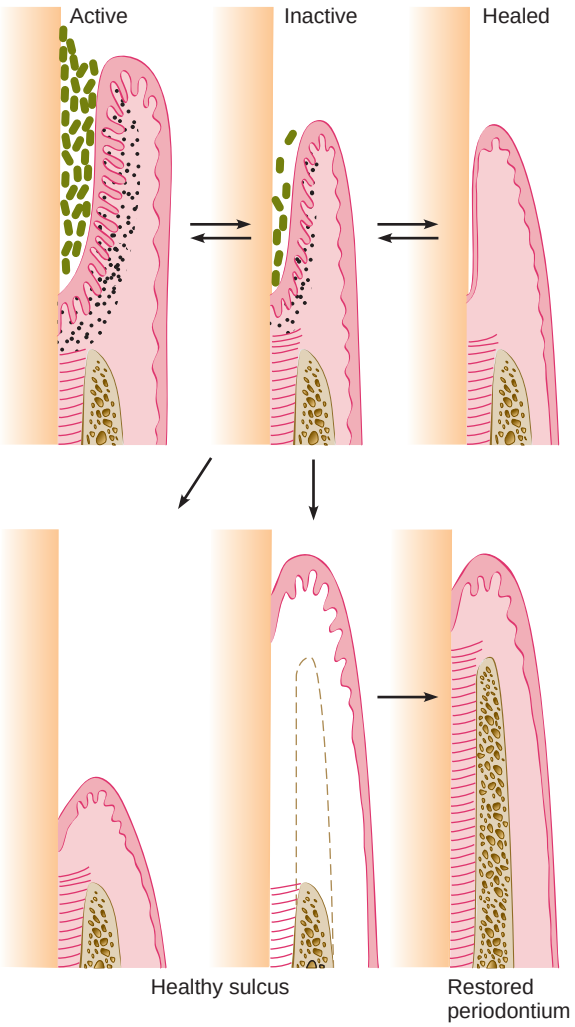

Figure 53-2 Possible results of pocket therapy. An active pocket can become inactive and heal by means of a long junctional epithelium. Surgical pocket therapy can result in a healthy sulcus, with or without gain of attachment. Improved gingival attachment promotes restoration of bone height, with re-formation of periodontal ligament fibers and layers of cementum.

either where the bottom of the pocket was localized or coronal to it. In the first case, there is no gain of attachment (Figure 53-2, *bottom left*), and the area of the root that was previously the tooth wall of the pocket becomes exposed. This does not mean that the periodontal treatment has caused recession but rather that it has uncovered the recession previously induced by the disease.

The healthy sulcus can also be located coronal to the bottom of the preexisting pocket (Figure 53-2, *bottom center* and *right*). This is conducive to a restored marginal periodontium; the result is a sulcus of normal depth with gain of attachment. The creation of a healthy sulcus and a restored periodontium entails a total restoration of the status that existed before periodontal disease began, which is the ideal result of treatment.

Pocket Elimination versus Pocket Maintenance

Pocket elimination (depth reduction to gingival sulcus levels) has traditionally been considered one of the main goals of periodontal therapy. It was considered vital because of the need to improve accessibility to root surfaces for the therapist during treatment and

for the patient after healing. The prevalent opinion is the presence of deep pockets after therapy represents a greater risk of disease progression than shallow sites. Individual probing depths are not good predictors of future clinical attachment loss. The absence of deep pockets in treated patients, conversely, is an excellent predictor of a stable periodontium.[5]

Longitudinal studies of different therapeutic modalities over the last 30 years have given conflicting results,[7,16] probably because of inherent problems created by the "split-mouth" design. In general, after surgical therapy, pockets that rebound to a shallow or moderate depth can be maintained in a healthy state and without radiographic evidence of advancing bone loss by maintenance visits consisting of scaling and root planing, with oral hygiene reinforcement performed at regular intervals of 3 months or less. In these patients, the residual pocket can be examined with a thin periodontal probe, but no pain, exudate, or bleeding results. This appears to indicate that no plaque has formed on the subgingival root surfaces.

These findings do not alter the indications for periodontal surgery because the results are based on surgical exposure of the root surfaces for thorough elimination of irritants. However, these findings emphasize the importance of the maintenance phase and the close monitoring of both level of attachment and pocket depth, together with the other clinical variables (bleeding, exudation, or tooth mobility). *The transformation of the initial deep, active pocket into a shallower, inactive, maintainable pocket requires some form of definitive pocket therapy and constant supervision thereafter.*

Pocket depth is an extremely useful and widely employed clinical determination, but it must be evaluated together with level of attachment and the presence of bleeding, exudation, and pain. The most important variable for evaluating whether a pocket (or deep sulcus) is progressive is the *level of attachment,* which is measured in millimeters from the cementoenamel junction. The apical displacement of the level of attachment places the tooth in jeopardy, not the increase in pocket depth, which may be caused by coronal displacement of the gingival margin.

Pocket depth remains an important clinical variable that contributes to decisions about treatment selection. Lindhe et al[8] compared the effect of root planing alone and with a modified Widman flap on the resultant level of attachment and in relation to initial pocket depth. They reported that scaling and root-planing procedures induce loss of attachment if performed in pockets shallower than 2.9 mm, whereas gain of attachment occurs in deeper pockets. The modified Widman flap induces loss of attachment if done in pockets shallower than 4.2 mm but results in a greater gain of attachment than root planing in pockets deeper than 4.2 mm. The loss is a true loss of connective tissue attachment, whereas the gain can be considered a false gain because of reduced penetrability of connective tissues apical to the bottom of the pocket after treatment.[9,17]

Furthermore, probing depths established after active therapy and healing (approximately 6 months after treatment) can be maintained unchanged or reduced even further during a maintenance period involving careful prophylaxis once every 3 months.[8]

Ramfjord[12] and Rosling[13] and their colleagues showed that, regardless of the surgical technique used for pocket therapy, a certain pocket depth recurs. *Therefore maintenance of this depth without any further loss of attachment becomes the goal.*

Reevaluation after Phase I Therapy

Longitudinal studies have noted that all patients should be treated initially with scaling and root planing and that a final decision on the need for periodontal surgery should be made only after a thorough evaluation of the effects of Phase I therapy.[5] The assessment is generally made no less than 1 to 3 months and sometimes as much as 9 months after the completion of Phase I therapy.[1] This reevaluation of the periodontal condition should include reprobing the entire mouth. The presence of calculus, root caries, defective restorations, and signs of persistent inflammation should also be evaluated.

Critical Zones in Pocket Surgery

Criteria for the selection of one of the different surgical techniques for pocket therapy are based on clinical findings in the soft tissue pocket wall, tooth surface, underlying bone, and attached gingiva.

Zone 1: Soft Tissue Pocket Wall

The clinician should determine the morphologic features, thickness, and topography of the soft tissue pocket wall and persistence of inflammatory changes in the wall.

Zone 2: Tooth Surface

The clinician should identify the presence of deposits and alterations on the cementum surface and determine the accessibility of the root surface to instrumentation. Phase I therapy should have solved many, if not all, of the problems on the tooth surface. Evaluation of the results of Phase I therapy should determine the need for further therapy and the method to be used.

Zone 3: Underlying Bone

The clinician should establish the shape and height of the alveolar bone next to the pocket wall through careful probing and clinical and radiographic examinations. Bony craters, horizontal or angular bone losses, and other bone deformities are important criteria in selection of the treatment technique.

Zone 4: Attached Gingiva

The clinician should consider the presence or absence of an adequate band of attached gingiva when selecting the pocket treatment method. Diagnostic techniques for mucogingival problems are described in Chapter 63. An inadequate attached gingiva may be caused by a high frenum attachment, marked gingival recession, or a deep pocket that reaches the level of the mucogingival junction. All these possible conditions should be explored and their influence on pocket therapy determined.

Indications for Periodontal Surgery

The following findings may indicate the need for a surgical phase of therapy:

1. Areas with irregular bony contours, deep craters, and other defects usually require surgical approach.
2. Pockets on teeth in which a complete removal of root irritants is not considered clinically possible may call for surgery. This occurs frequently in molar and premolar areas.
3. In cases of furcation involvement of grade II or III, a surgical approach ensures the removal of irritants; any necessary root resection or hemisection also requires surgical intervention.
4. Intrabony pockets on distal areas of last molars, frequently complicated by mucogingival problems, are usually unresponsive to nonsurgical methods.
5. Persistent inflammation in areas with moderate to deep pockets may require a surgical approach. In areas with shallow pockets or normal sulci, persistent inflammation may point to the presence of a mucogingival problem that needs a surgical solution.

Methods of Pocket Therapy

The methods for pocket therapy can be classified under the following three main headings:

1. **New attachment techniques** offer the ideal result because they eliminate pocket depth by reuniting the gingiva to the tooth at a position coronal to the bottom of the preexisting pocket. New attachment is usually associated with filling in of bone and regeneration of periodontal ligament and cementum.
2. **Removal of the pocket wall** is the most common method. The wall of the pocket consists of soft tissue and may also include bone in the case of intrabony pockets. It can be removed by the following:
   - *Retraction or shrinkage,* in which scaling and root-planing procedures resolve the inflammatory process, and the gingiva therefore shrinks, reducing the pocket depth.
   - *Surgical removal* performed by the gingivectomy technique or by means of an undisplaced flap.
   - *Apical displacement* with an apically displaced flap.
3. **Removal of the tooth side of the pocket,** which is accomplished by tooth extraction or by partial tooth extraction (hemisection or root resection).

The techniques, what they accomplish, and the factors governing their selection are presented in Chapters 59 to 62.

Criteria for Method Selection

Scientific criteria to establish the indications for each technique are difficult to determine. Longitudinal studies following a significant number of cases over a number of years, standardizing multiple factors and many variables, would be needed. Clinical experience, however, has suggested the criteria for selecting the method to treat the pocket. The selection of a technique for treatment of a particular periodontal lesion is based on the following considerations:

1. Characteristics of the pocket: depth, relation to bone, and configuration.
2. Accessibility to instrumentation, including presence of furcation involvements.
3. Existence of mucogingival problems.
4. Response to Phase I therapy.
5. Patient cooperation, including ability to perform effective oral hygiene. Smokers must be willing to stop their habit.
6. Age and general health of the patient.
7. Overall diagnosis of the case: various types of gingival enlargement and types of periodontitis (e.g., chronic marginal periodontitis, localized aggressive periodontitis, generalized aggressive periodontitis).
8. Esthetic considerations.
9. Previous periodontal treatments.

Each of these variables are analyzed in relation to the pocket therapy techniques available, and a specific technique is selected. Of the many techniques, the one that would most successfully solve the problems with the fewest undesirable effects should be chosen. *Clinicians who adhere to one technique to solve all problems do not use to the advantage of the patient the wide repertoire of techniques at their disposal.*

Approaches to Specific Pocket Problems

Therapy for Gingival Pockets. Two factors are taken into consideration: (1) the character of the pocket wall and (2) the accessibility of the pocket. The pocket wall can be either edematous or fibrotic. *Edematous* tissue shrinks after the elimination of local factors, thereby reducing or totally eliminating pocket depth. Therefore scaling and root planing are the technique of choice in these cases.

Pockets with a *fibrotic* wall are not appreciably reduced in depth after scaling and root planing; therefore they are eliminated surgically. Until recently, gingivectomy was the only technique available; it solves the problem successfully, but in cases of marked gingival enlargement (e.g., severe phenytoin enlargement), it may leave a large wound that goes through a painful and prolonged healing process. In these patients, a modified flap technique can adequately solve the problem with fewer postoperative problems (see Chapter 58).

Therapy for Slight Periodontitis. In slight or incipient periodontitis, a small amount of bone loss has occurred, and pockets are shallow to moderate. In these patients, the conservative approach with good oral hygiene will generally suffice to control the disease. Incipient periodontitis that recurs in previously treated sites may require a thorough analysis of the causes for the recurrence. Occasionally, a surgical approach may be required to correct the problem.

Therapy for Moderate-to-Severe Periodontitis in Anterior Sector. The anterior teeth are important esthetically; therefore the technique that causes the least amount of visual root exposure should be considered. However, the importance of esthetics may be different for different patients, and nonelimination of the pocket may place the tooth in jeopardy. The final decision may have to be a compromise between health and esthetics, not attaining ideal results in either respect.

Anterior teeth offer two main advantages to a conservative approach: (1) they are all single rooted and easily accessible and (2) patient compliance and thoroughness in plaque control are easier to attain. *Therefore scaling and root planing are the technique of choice for the anterior teeth.*

Sometimes, however, a surgical technique may be necessary because of the need for improved accessibility for root planing or regenerative surgery of osseous defects. The papilla preservation flap can be used for both purposes and also offers a better postoperative result, with less recession and reduced soft tissue crater formation interproximally.[14] *The papilla preservation flap is the first choice when a surgical approach is needed.*

When the teeth are too close interproximally, the papilla preservation technique may not be feasible, and a technique that splits the papilla must be used. The *sulcular incision flap* offers good esthetic results and is the next choice.

When esthetics are not the primary consideration, the *modified Widman flap* can be chosen. This technique uses an internal bevel incision about 1 to 2 mm from the gingival margin without thinning the flap and may result in some minor recession.

Infrequently, bone contouring may be needed despite the resultant root exposure. The technique of choice is the *apically displaced flap with bone contouring*.

Therapy for Moderate-to-Severe Periodontitis in Posterior Area. Treatment for premolars and molars usually poses no esthetic problem but frequently involves difficult accessibility. Bone defects occur more often in the posterior than the anterior sector, and root morphologic features, particularly in relation to furcations, may offer insurmountable problems for instrumentation in a close field. Therefore surgery is frequently indicated in the posterior region.

The purpose of surgery in the posterior area is either enhanced accessibility or the need for definitive pocket reduction requiring

osseous surgery. Accessibility can be obtained by either the undisplaced or the apically displaced flap.

Most patients with moderate to severe periodontitis have developed osseous defects that require some degree of osseous remodeling or reconstructive procedures. When osseous defects amenable to reconstruction are present, the *papilla preservation flap is the technique of choice* because it better protects the interproximal areas where defects are frequently present. *Second and third choices are the sulcular flap and the modified Widman flap,* maintaining as much of the papilla as possible.

When osseous defects with no possibility of reconstruction are present, such as interdental craters, the technique of choice is the flap with osseous contouring.

Surgical Techniques for Correction of Morphologic Defects. The objectives and rationale for the techniques performed to correct morphologic defects (mucogingival, esthetic, and preprosthetic) are given in Chapter 63.

Surgical Techniques for Implant Placement and Related Problems. The objectives and rationale for these techniques are described in Chapter 75.

References

References for this chapter are found on the companion website www.expertconsult.com.

References

1. Badersten A, Nilveus R, Egelberg J: Effect of nonsurgical periodontal therapy. II. Severely advanced periodontitis. *J Clin Periodontol* 11:63, 1984.
2. Bower RC: Furcation morphology relative to periodontal treatment: furcation root surface anatomy. *J Periodontol* 50:366, 1979.
3. Caffesse RG, Sweeney PL, Smith BA: Scaling and root planing with and without periodontal flap surgery. *J Clin Periodontol* 11:205, 1986.
4. Gher ME, Vernino AR: Root morphology: clinical significance in pathogenesis and treatment of periodontal disease. *J Am Dent Assoc* 101:627, 1980.
5. Greensteifl G: Contemporary interpretation of probing depth assessment: diagnostic and therapeutic implications: a literature review. *J Periodontol* 68:1194, 1997.
6. Hill RW, Ramfjord SP, Morrison GC, et al: Four types of periodontal treatment compared over two years. *J Periodontol* 52:655, 1981.
7. Kaldahl WB, Kalkwarf KL, Patil KD: A review of longitudinal studies that compared periodontal therapies. *J Periodontol* 64:243, 1993.
8. Lindhe J, Socransky SS, Nyman S, et al: Critical probing depths in periodontal therapy. *J Clin Periodontol* 9:323, 1982.
9. Magnusson I, Runstad L, Nyman S, et al: A long junctional epithelium: a locus minoris resistentiae in plaque infection. *J Clin Periodontol* 10:333, 1983.
10. Pihlstrom BL, Ortiz Campos C, McHugh RB: A randomized four-year study of periodontal therapy. *J Periodontol* 52:227, 1981.
11. Rabbani GM, Ash MM, Caffesse RG: The effectiveness of subgingival scaling and root planing in calculus removal. *J Periodontol* 52:119, 1981.
12. Ramfjord SP, Knowles JW, Nissle RR, et al: Results following three modalities of periodontal therapy. *J Periodontol* 12:522, 1975.
13. Rosling B, Nyman S, Lindhe J, et al: The healing potential of the periodontal tissues following different techniques of periodontal surgery in plaque-free dentitions: a 2-year clinical study. *J Clin Periodontol* 3:233, 1976.
14. Takei HH, Han TJ, Carranza FA, Jr, et al: Flap technique for periodontal bone implants: the papilla preservation technique. *J Periodontol* 56:204, 1985.
15. Waerhaug J: Healing of the dentoepithelial junction following subgingival plaque control. II. As observed on extracted teeth. *J Periodontol* 40:119, 1978.
16. Weeks PR: Pros and cons of periodontal pocket elimination procedures. *J West Soc Periodontol* 28:4, 1980.
17. Westfelt E, Bragd L, Socransky SS, et al: Improved periodontal conditions following therapy. *J Clin Periodontol* 12:283, 1985.

CHAPTER 54

Periodontal and Periimplant Surgical Anatomy

Fermin A. Carranza and Perry R. Klokkevold

CHAPTER OUTLINE

Mandible
Maxilla
Exostoses
Muscles
Anatomic Spaces

A sound knowledge of the anatomy of the periodontium and the surrounding hard and soft structures is essential to determine the scope and possibilities of periodontal and implant surgical procedures and to minimize their risks. The spatial relationship of bones, muscles, blood vessels, and nerves as well as the anatomic spaces located in the vicinity of the periodontal or implant surgical field are particularly important. Only those features of periodontal and implant surgery relevance are mentioned in this chapter; the reader is referred to books about oral anatomy for a more comprehensive description of these structures.[4,6]

Mandible

The mandible is a horseshoe-shaped bone connected to the skull by the temporomandibular joints. It presents several landmarks of great surgical importance for both periodontal and implant surgical procedures.

The *mandibular canal,* which is occupied by the inferior alveolar nerve and vessels, begins at the mandibular foramen on the medial surface of the mandibular ramus and curves downward and forward until it becomes horizontal below the apices of the molars (Figure 54-1). The distance from the canal to the apices of the molars is shorter in the third molar area and increases as it goes forward. A small percentage (1%) of mandibular canals bifurcate in the body of the mandible, thereby resulting in two canals and two mental foramen.[5,10] In the premolar area, the mandibular canal divides in two branches, with one exiting the mandible and the other continuing anteriorly: the *incisive canal,* which continues horizontally to the midline, and the *mental canal,* which turns upward and opens in the mental foramen.

The *mental foramen,* from which the mental nerve and vessels emerge, is located on the buccal surface of the mandible below the apices of the premolars, sometimes closer to the second premolar and usually halfway between the lower border of the mandible and the alveolar margin (Figure 54-2). It is often but not always visible on conventional radiographs. The opening of the mental foramen, which may be oval or round in shape, typically faces upward and distally, with its posterosuperior border slanting gradually to the bone surface. An "anterior loop" of the mental foramen has been described, with the use of cadaver dissection, as a reverse turn and looping back of the mental nerve before its exit out of the mental foramen; its length ranges from 0.5 to 5.0 mm.[10] More recent evaluation of the anterior loop of the mental nerve involving the use of cone beam scans and cadaveric dissection reported this loop extension to range from 0.0 to 9.0 mm.[22,23] The anterior loop of the mental nerve has a high prevalence (88%), symmetric occurrence, and a mean length of 4.13 ± 1.08 mm.[18] As it emerges, the *mental nerve* divides into three branches. One branch of the nerve turns forward and downward to supply the skin of the chin. The other two branches course anteriorly and upward to supply the skin and mucous membrane of the lower lip and the mucosa of the labial alveolar surface.

Surgical trauma (e.g., pressure, manipulation, postsurgical swelling) to the mental nerve can produce paresthesia of the lip, which recovers slowly. Partial or complete cutting of the nerve can result in permanent paresthesia, dysesthesia, or both. Familiarity with the location and appearance of the mental nerve reduces the likelihood of injury (Figure 54-3).

In partially or totally edentulous jaws, the disappearance of the alveolar portion of the mandible brings the mandibular canal and mental foramen closer to the superior border (Figures 54-4 and 54-5). When these patients are evaluated for the placement of implants, the distance between the canal and the superior surface of the bone as well as the location of the mental foramen must be carefully determined to avoid surgical injury to the nerve (see Chapter 73).

The anterior extension of the inferior alveolar nerve or incisive nerve has been measured with the use of conventional radiographs, computed tomography (CT) scans, cadaver dissections, and cone beam scans.[3,10,22,23] This nerve, which is less evident on conventional radiographs and often unnoticed, extends beyond the anterior loop of the mental foramen in a horizontal direction toward the midline. The length of the incisive canal has been reported to be up to 21.45 mm from the mesial aspect of the mental foramen and to terminate just 4 mm from the midline.[3]

The *lingual nerve,* along with the inferior alveolar nerve, is a branch of the posterior division of the mandibular nerve. It descends along the mandibular ramus medial to and in front of the inferior alveolar nerve. The lingual nerve lies close to the surface of the oral mucosa in the third molar area and goes deeper as it travels forward (Figure 54-6). It can be damaged during anesthetic injections and during oral surgery procedures (e.g., third molar extractions).[14] Less often, the lingual nerve may be injured when a

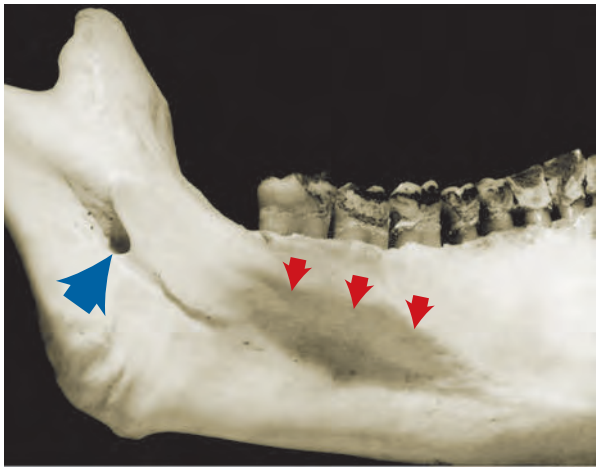

Figure 54-1 Mandible, lingual surface view. Note the lingual or mandibular foramen *(blue arrow),* where the inferior alveolar nerve enters the mandibular canal, and the mylohyoid ridge *(red arrows).*

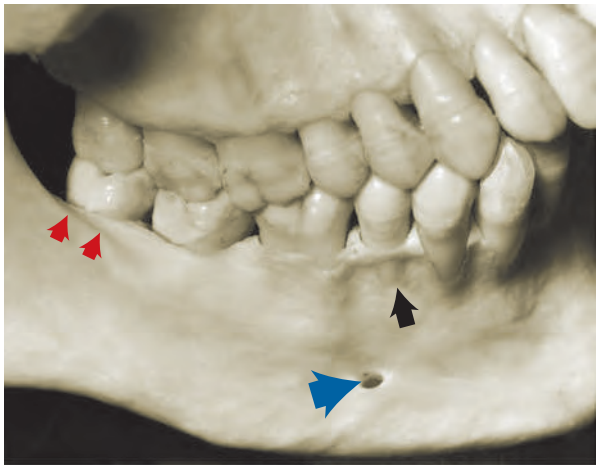

Figure 54-2 Mandible, facial surface view. Note the location of the mental foramen *(blue arrow),* which is slightly distal and apical to the apex of the second premolar, and the shelflike area in the region of the molars *(red arrows)* that is created by the external oblique ridge. Note also the fenestration that is present in the second premolar *(black arrow).*

periodontal partial-thickness flap is raised in the third molar region or when releasing incisions are made in the area.

The *alveolar process,* which provides the supporting bone to the teeth, has a narrower distal curvature than the body of the mandible (Figure 54-7), thus creating a flat surface in the posterior area between the teeth and the anterior border of the ramus. This results in the formation of the *external oblique ridge,* which runs downward and forward to the region of the second or first molar (Figure 54-8) to create a shelflike bony area. Resective osseous therapy may be difficult or impossible in this area because of the amount of bone that must be removed distally toward the ramus to achieve resection of a periodontal osseous defect on the distal aspect of the mandibular second or third molar.

Distal to the third molar, the external oblique ridge circumscribes the *retromolar triangle* (see Figure 54-8). This region is occupied by glandular and adipose tissue and covered by unattached, nonkeratinized mucosa. If sufficient space exists distal to the last molar, a band of attached gingiva may be present; only in such a case can a distal flap procedure be performed effectively.

The medial side of the body of the mandible is traversed obliquely by the *mylohyoid ridge,* which starts close to the alveolar margin in the third molar area and continues anteriorly in an apical direction, thereby increasing its distance from the osseous margin as it travels forward (Figure 54-9). The *mylohyoid muscle* inserts

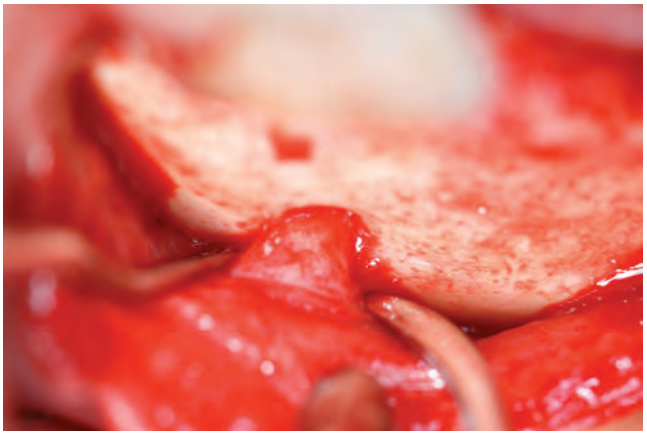

Figure 54-3 Mental nerve emerging from the foramen in the premolar area.

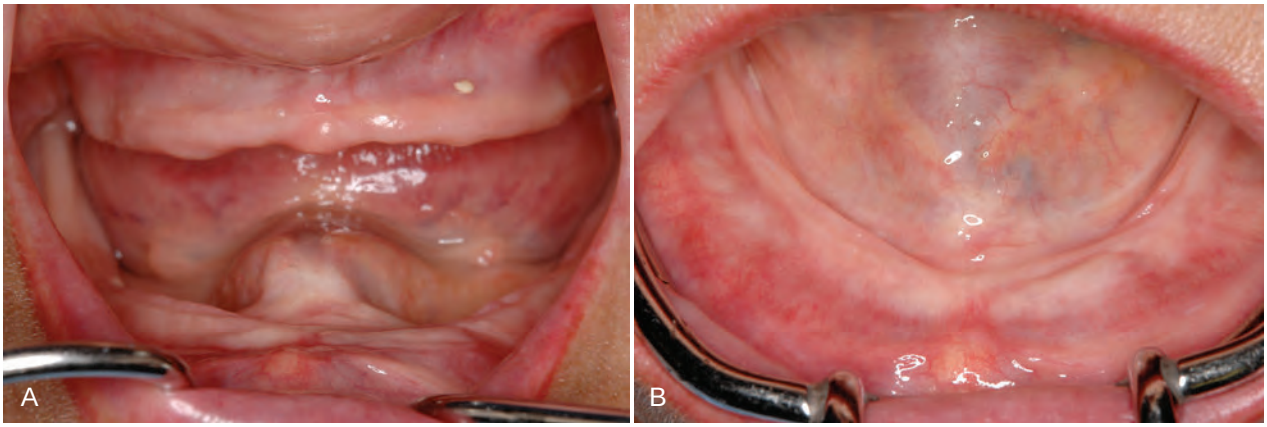

Figure 54-4 Loss of the alveolar ridge in an edentulous patient brings the mental foramen and the inferior alveolar nerve canal closer to the surface, which may lead to discomfort for the patient. **A,** Anterior view demonstrating a severe loss of vertical alveolar ridge height. **B,** Occlusal view of the same patient demonstrating a loss of vestibular depth with alveolar bone loss.

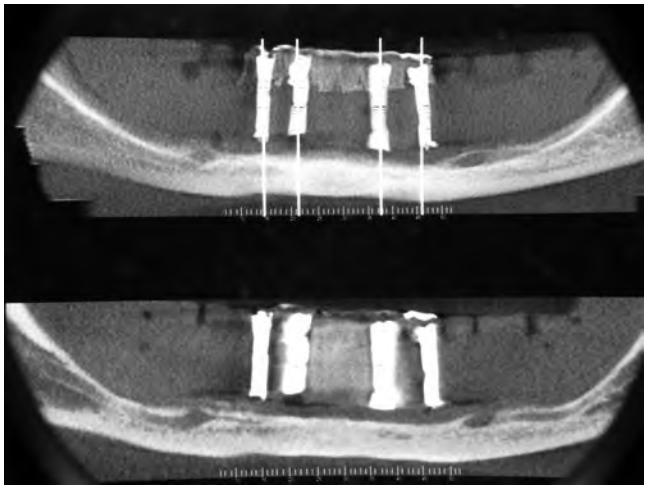

Figure 54-5 Panoramic radiograph of an edentulous patient with a loss of alveolar bone height. This results in the mental foramen exiting the jaw at the superior aspect of the remaining bone (ridge crest), which is the denture-bearing surface. Pressure from the complete removable denture over this area causes pain.

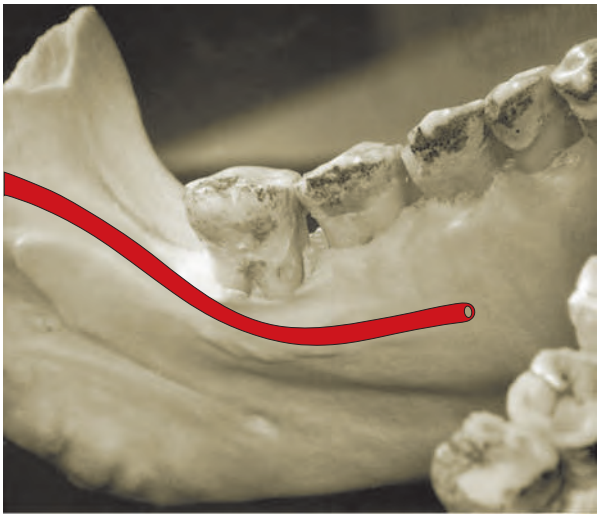

Figure 54-6 Lingual view of the mandible showing the pathway of the lingual nerve *(red),* which goes near the gingiva in the third molar area and then continues forward, going deeper and medially.

along this ridge and separates the *sublingual space,* which is located above or more anteriorly and superiorly, from the submandibular space, which is located below or more posteriorly and inferiorly.

Maxilla

The maxilla is a paired bone that is hollowed out by the maxillary sinus and the nasal cavity. The maxilla has the following four processes:

- The *alveolar process* contains the sockets for and supports the maxillary teeth.
- The *palatine process* extends horizontally from the alveolar process to meet its counterpart from the opposite maxilla at the midline intermaxillary suture, and it extends posteriorly with the horizontal plate of the palatine bone to form the hard palate.

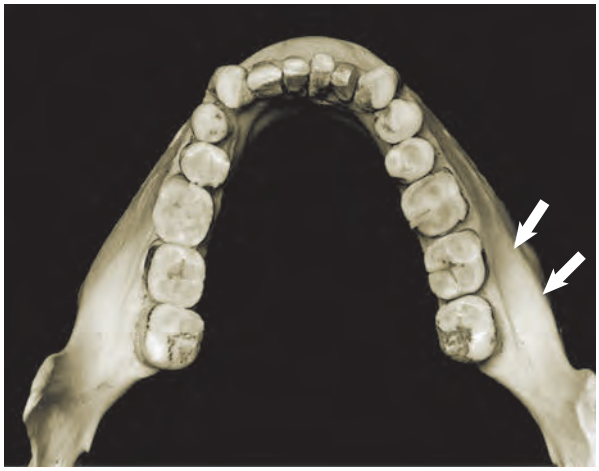

Figure 54-7 Occlusal view of the mandible. Note the shelf that is created in the facial molar areas by the external oblique ridge. *Arrows* show the attachment of the buccinator muscle.

Figure 54-8 Mandible; occlusal view of the ramus and molars. Note the retromolar triangle area distal to the third molar *(arrows).*

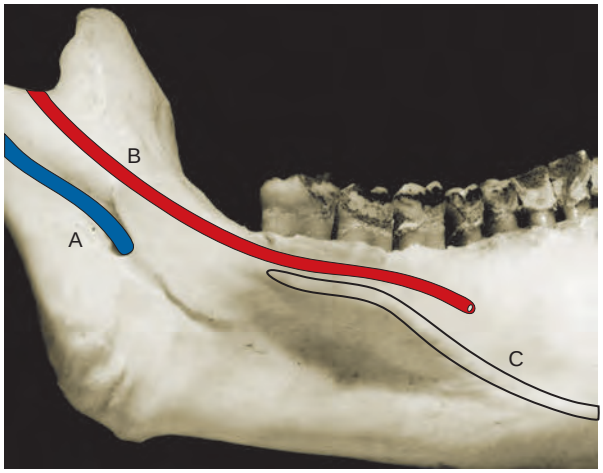

Figure 54-9 Lingual view of the mandible showing, *A,* the inferior alveolar nerve entering the mandibular canal, *B,* the lingual nerve traversing near the lingual surface of the third molar, and, *C,* the attachment of the mylohyoid muscle inferiorly.

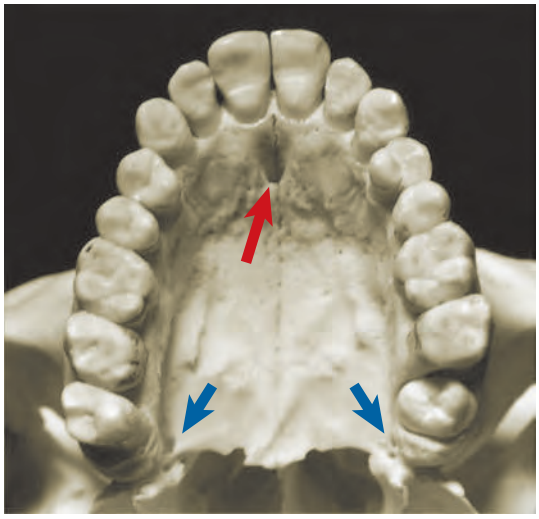

Figure 54-10 Occlusal view of the maxilla and the palatine bone. Note the opening of the incisive canal or the anterior palatine foramen *(red arrow)* and the greater palatine foramen *(blue arrows)*.

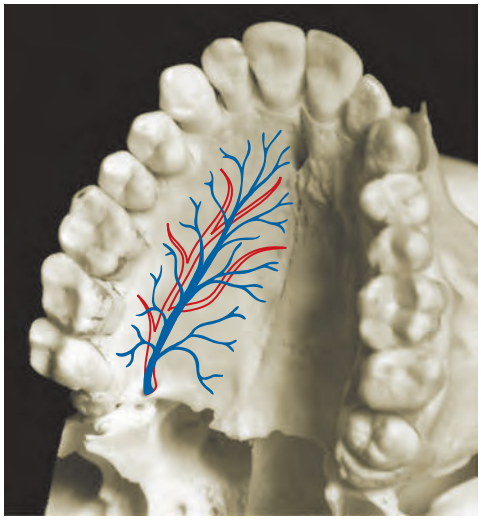

Figure 54-11 Occlusolateral view of the palate showing nerves *(red)* and vessels *(blue)* emerging from the greater palatine foramen and continuing anteriorly on the palate.

- The *zygomatic process* extends laterally from the area above the first molar and determines the depth of the vestibular fornix on the lateral aspect of the maxilla.
- The *frontal process* extends in an ascending direction and articulates with the frontal bone at the frontomaxillary suture.

The terminal branches of the nasopalatine nerve and vessels pass through the incisive canal, which opens in the midline anterior area of the palate (Figure 54-10). The mucosa overlying the incisive canal presents a slight protuberance called the *incisive papilla.* Vessels that emerge through the incisive canal are of small caliber, and their surgical interference is of little consequence.

The *greater palatine foramen* opens 3 to 4 mm anterior to the posterior border of the hard palate (Figure 54-11). The greater palatine nerve and vessels emerge through this foramen and run anteriorly in the submucosa of the palate, between the palatal and alveolar processes (Figure 54-12). Palatal flaps and donor sites for gingival grafts should be carefully performed and selected to avoid invading these areas, because profuse hemorrhage may ensue, particularly if vessels are damaged at the palatine foramen. Vertical incisions in the molar region should be avoided.

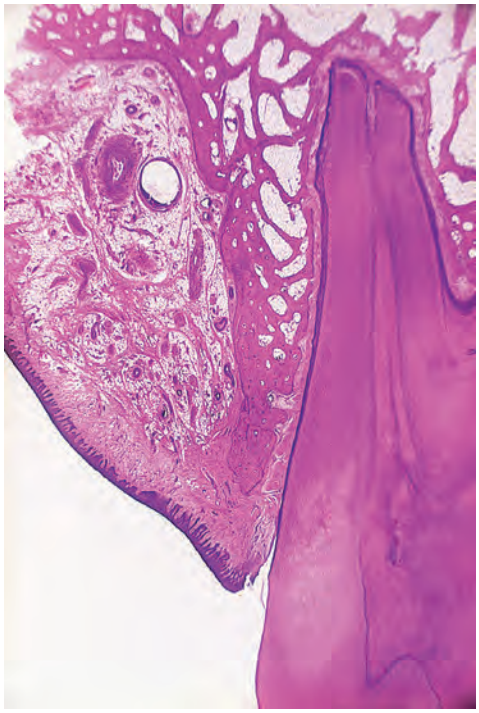

Figure 54-12 Histologic frontal section of a human palate at the level of the first molar showing the location of the vessels and the nerve surrounded by adipose and glandular tissue.

The mucous membrane that covers the hard palate is firmly attached to the underlying bone. The submucous layer of the palate posterior to the first molars contains the *palatal glands,* which are more compact in the soft palate and which extend anteriorly, thereby filling the gap between the mucosal connective tissue and the periosteum and protecting the underlying vessels and nerve (see Figure 54-22).

The area distal to the last molar, called the *maxillary tuberosity,* consists of the posteroinferior angle of the infratemporal surface of the maxilla. Medially it articulates with the pyramidal process of the palatine bone. It is covered by dense, fibrous connective tissue, and it contains the terminal branches of the middle and posterior palatine nerves. Excision of the area for distal flap surgery may reach medially to the tensor palati muscle. The tensor palati muscle comes from the greater wing of the sphenoid bone and ends in a tendon that forms the palatine aponeurosis, which expands, fanlike, to attach to the posterior border of the hard palate.

The body of the maxilla is occupied by the *maxillary sinus,* which is the largest of the paranasal sinuses. It is an air-filled cavity located in the posterior maxilla superior to the teeth. The lateral wall of the nasal cavity borders the sinus medially; it is bordered superiorly by the floor of the orbit and laterally by the lateral wall of the maxilla, the alveolar process, and the zygomatic arch (Figure 54-13). It is pyramidal in shape, with its apex in the zygomatic arch and its base at the lateral wall of the nasal cavity. The size of the maxillary sinus varies from one individual to another (depending on the individual and his or her age) and from very small and narrow to quite large and expansive.

The maxillary sinus is frequently subdivided (incompletely) into recesses by one or more septa. Maxillary sinus septa vary in size and location. Clinical and radiographic examinations suggest that septa are frequently present (≤39% of sinuses).[8,13,25] CT scans are the preferred method for detecting septa, because panoramic radiographs are not reliable (i.e., 26.5% false diagnosis of the

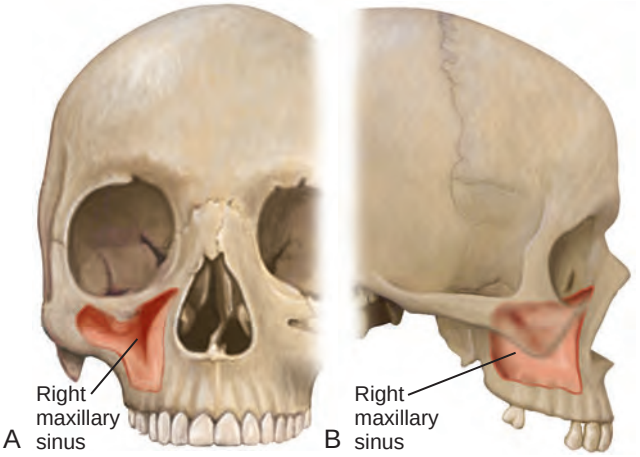

Figure 54-13 Location and anatomy of the maxillary sinus. **A,** Frontal view. **B,** Lateral view.

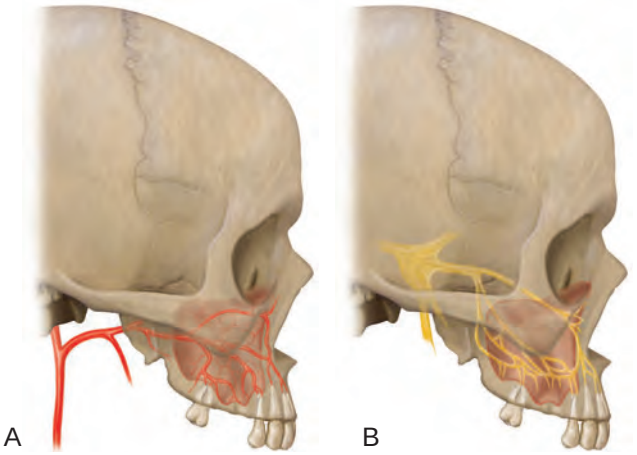

Figure 54-14 Blood supply and innervation of the maxillary sinus. **A,** Arterial blood supply. **B,** Innervation of the maxillary sinus.

presence or absence of septa).[13,15] Septa are found in the anterior (24%), middle (41%), and posterior (35%) aspects of the maxillary sinus, with the most common location being between the second premolar and the first molar.[12,25] The height of septa vary as well, ranging from 0 to 20.6 mm.[25] Only 0.5% of septa form a complete separation of the sinus spaces into separate chambers.[16]

The entire maxillary sinus is lined with a thin mucosal membrane called the *Schneiderian membrane.* This specialized structure of the respiratory mucous membrane, with its motile cilia and rich blood supply, is well adapted to purifying, moistening, and warming air to protect the lungs. The entrance to the maxillary sinus, through the orifice or maxillary duct, is located at the superior medial aspect of the cavity. The orifice is relatively small, measuring only 3 to 6 mm in length and diameter. An accessory opening is occasionally found inferior and posterior to the main opening. The maxillary sinus drains into the middle meatus of the nasal cavity through the maxillary duct, which passes secretions medially to the semilunar hiatus. Normal amounts of secretion are moved from the sinus by the spiral pattern of the beating cilia that surround the orifice. If the maxillary sinus becomes infected or chronically inflamed, swelling of the mucosa around the orifice impairs drainage. The floor of the maxillary sinus extends down below the level of the nasal cavity into the alveolar process.

The roots of the maxillary first and second molars are often close to the floor of the sinus. Less frequently, the roots of the premolars and third molars may protrude into the floor of the sinus. With increasing age, the maxillary sinus expands. It becomes more and more pneumatized down around the roots of the maxillary teeth, sometimes resulting in exposure of the roots through the bony floor into the sinus, with only the thin mucosal membrane covering the root surface. The ability to perform periodontal osseous surgery in the posterior maxilla may be limited when the sinuses are severely pneumatized.

Blood supply to the maxillary sinus arises from the superior alveolar (anterior, middle, and posterior) branches of the maxillary artery (Figure 54-14, *A*).[24] The maxillary artery, which is a large terminal branch of the external carotid artery, gives off many branches to supply the maxillary sinus, including the infraorbital artery, which travels superiorly and anteriorly and gives off the anterior superior alveolar artery.[9] Branches of the greater palatine artery contribute to a lesser extent. Venous blood drains via the pterygoid plexus. Much of the vasculature travels through channels in the bony walls of the maxillary sinus, with many branches anastomosing with the highly vascularized Schneiderian membrane. Innervation of the maxillary sinus is supplied by the superior alveolar (anterior, middle, and posterior) nerves and the branches of the maxillary nerve (Figure 54-14, *B*).

Knowledge of the arterial blood supply is particularly important when considering a lateral window approach to sinus floor elevation and bone augmentation. Solar and colleagues found an intraosseous branch of the posterior superior alveolar artery anastomosing with the infraorbital artery in 100% of their human cadaver specimens (134 sinuses, all males).[19] On average, the vessel was located 18.9 mm from the alveolar crest. By studying 50 CT scans from 625 patients (both males and females) who were undergoing sinus bone augmentation, Elian and colleagues found that the vessel was radiographically evident in 52.9% of sinuses.[7] The vessel was located an average of 16.4 mm from the alveolar crest, which is consistent with the previous study. Human cadaver dissection and CT scan evaluations of the vessels running through the lateral wall of the maxillary sinus have revealed that intraosseous vessels are present in the lower two thirds of the anterolateral wall in approximately 10.5% of cases (Figure 54-15).[9] In 57.1% of cases (about 6% of all sinuses), the vessel diameter ranged in size from 1 to 2.5 mm. The location of the artery in relation to the position of the lateral window for sinus augmentation presents a risk for bleeding complications in 10% to 20% of cases.[7,9]

The inferior wall of the maxillary sinus is frequently separated from the apices and roots of the maxillary posterior teeth by a thin, bony plate (Figure 54-16). In edentulous posterior areas, the maxillary sinus bony wall may be only a thin plate that is in intimate contact with the alveolar mucosa (Figure 54-17). Adequate determination of the extension of the maxillary sinus into the surgical site is important to avoid creating an oroantral communication, particularly in relation to osseous reduction in periodontal surgery or the placement of implants in edentulous areas. Determining the amount of available bone in the anterior area, below the floor of the nasal cavity, is also critical for the placement of implants (see Chapter 73).

Exostoses

Both the maxilla and the mandible may have exostoses or tori, which are considered to be within the normal range of anatomic variation. Sometimes these structures may hinder the removal of plaque by the patient and may have to be removed to improve the prognosis of neighboring teeth. Additional indications for the removal of exostoses include the inability to comfortably wear

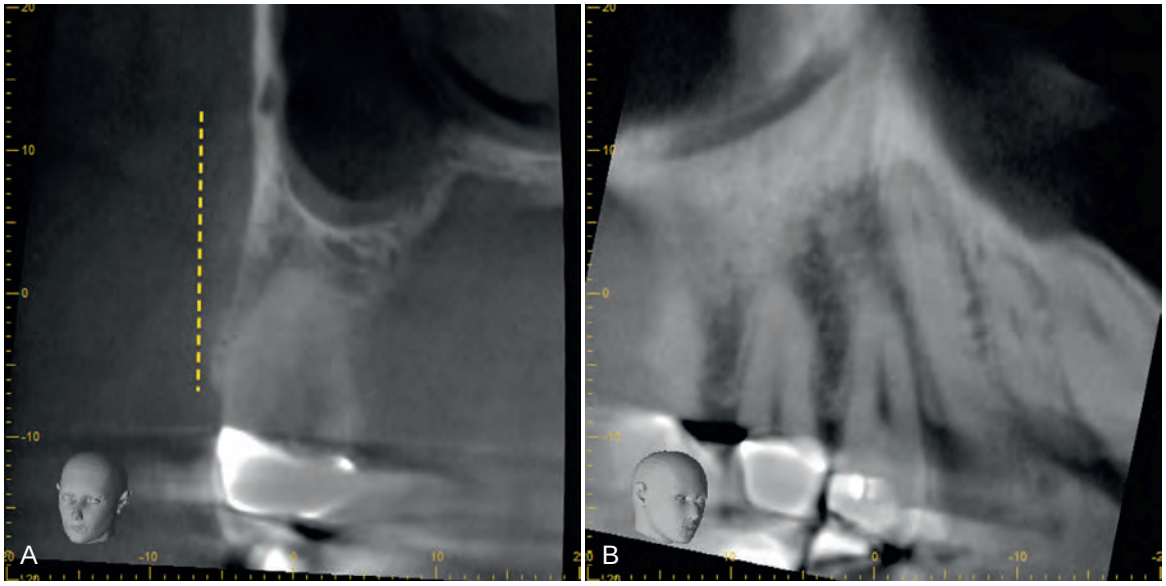

Figure 54-15 **A,** Cross-sectional image from a cone beam computed tomography scan of the maxillary sinus demonstrating the presence of an intraosseous vessel in the lateral wall approximately 20 mm from the alveolar crest. **B,** Sagittal section through the maxillary sinus in the same patient demonstrating an intraosseous vessel extending along the maxillary sinus. The diameter of the intraosseous canal is 2 mm.

Figure 54-16 Radiograph of the maxillary molars and premolars, with the maxillary sinus apparently near the apices.

Figure 54-17 Radiograph of an edentulous molar maxillary area demonstrating severe pneumatization of the maxillary sinus. There is only a thin layer of cortical bone separating the sinus from the oral cavity.

removable prostheses over these areas. The most common location of a mandibular torus is in the lingual area of the canines and the premolars, above the mylohyoid muscle (Figure 54-18). Mandibular tori can also be found on the buccal and labial surfaces of the mandibular teeth. Maxillary tori are usually located in the midline of the hard palate (Figure 54-19). Smaller tori may be seen over the palatal roots of the maxillary molars, in the area above the greater palatine foramen (see Figure 54-19), or on the buccal and labial surfaces of the maxillary teeth (Figure 54-20).

Muscles

Several muscles may be encountered when performing periodontal and implant flap surgery, particularly during mucogingival surgery and bone augmentation procedures. These are the mentalis, the incisivus labii inferioris, the depressor labii inferioris, the depressor anguli oris (triangularis), the incisivus labii superioris, and the buccinator muscles. Their bony attachments are shown in Figure 54-21. These muscles provide mobility to the lips and cheeks.

Anatomic Spaces

Several anatomic spaces or *compartments* are found close to the operative field of periodontal and implant surgery sites. These spaces contain loose connective tissue, but they can be easily distended by hemorrhage, inflammatory fluid, and infection.

Surgical invasion of these areas may result in dangerous hemorrhage (intraoperative) or infections (postoperative) and should be carefully avoided. Some of these spaces are briefly described in the following paragraphs. For more information, the reader is referred to other sources.[2,11,20,21]

The *canine fossa* contains varying amounts of connective tissue and fat. It is bounded superiorly by the quadratus labii superioris muscle, anteriorly by the orbicularis oris, and posteriorly by the buccinator. Infection of this area results in swelling of the upper lip, which obliterates the nasolabial fold, and of the upper and lower eyelids, which closes the eye.

The *buccal space* is located between the buccinator and the masseter muscles. Infection of this area results in swelling of the cheek that may extend to the temporal space or the submandibular space, with which the buccal space communicates.

The *mental* or *mentalis space* is located in the region of the mental symphysis, where the mental muscle, the depressor muscle of the lower lip, and the depressor muscle of the corner of the

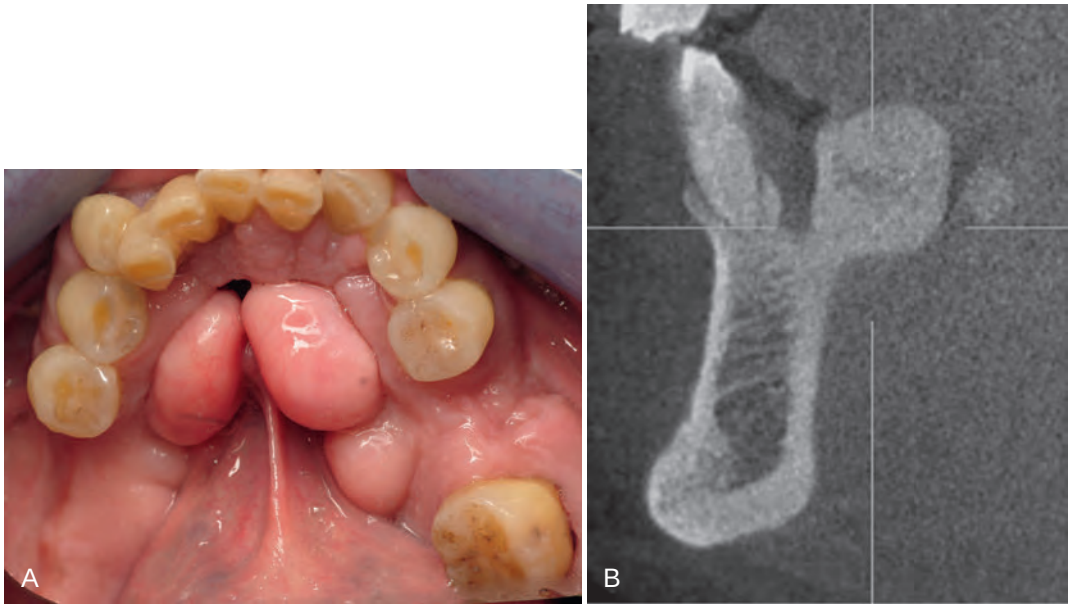

Figure 54-18 **A,** Clinical photograph of large mandibular tori on the lingual aspect of both the right and left mandible. **B,** Cross-sectional image of a mandibular torus in the premolar area in the same patient.

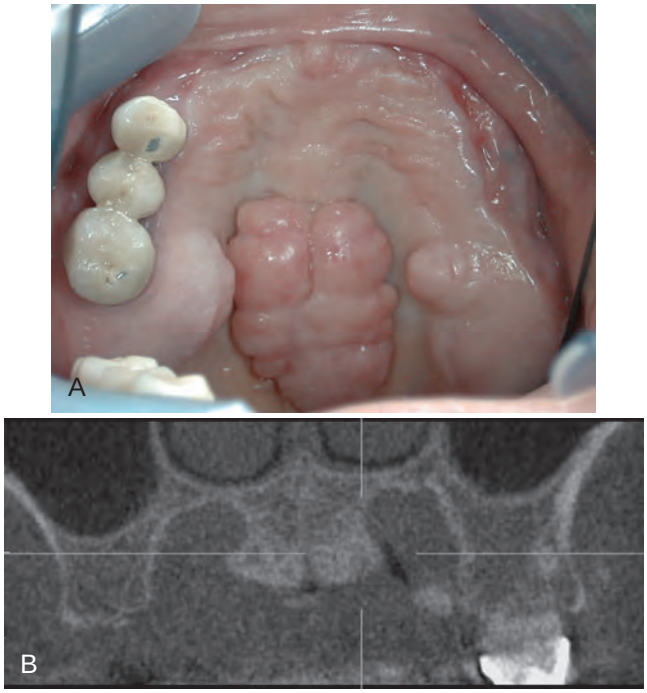

Figure 54-19 **A,** Clinical photograph of large palatal torus located in the midline of the palate. Notice the large tori on the palatal aspects of the maxillary alveolar ridge as well. **B,** Cross-sectional image of the maxillary midline torus in the same patient. Notice the torus located on the palatal aspect of the alveolar ridge as well.

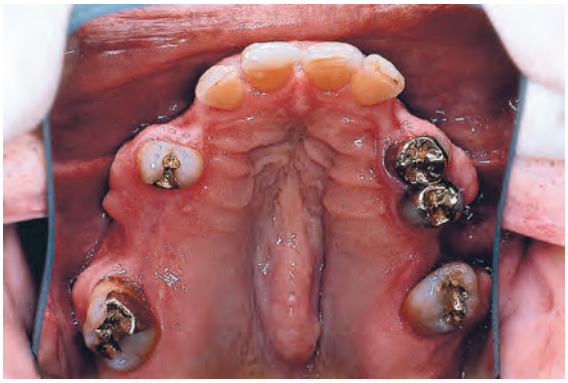

Figure 54-20 Clinical photograph of large buccal exostosis in the maxillary arch. There is also a large midline palatal torus.

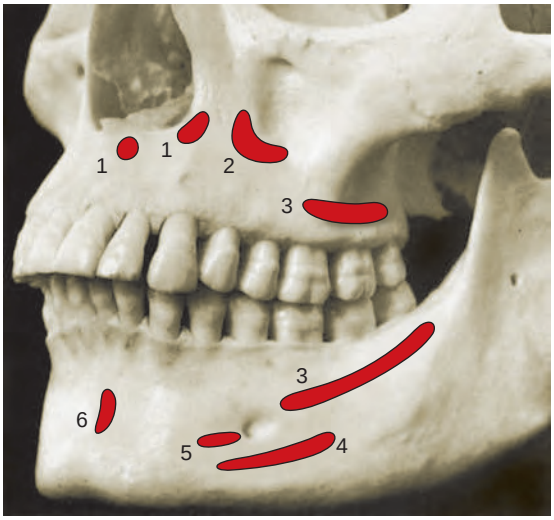

Figure 54-21 Muscle attachments that may be encountered in mucogingival surgery. *1,* Nasalis; *2,* levator anguli oris; *3,* buccinator; *4,* depressor anguli oris; *5,* depressor labii inferioris; *6,* mentalis.

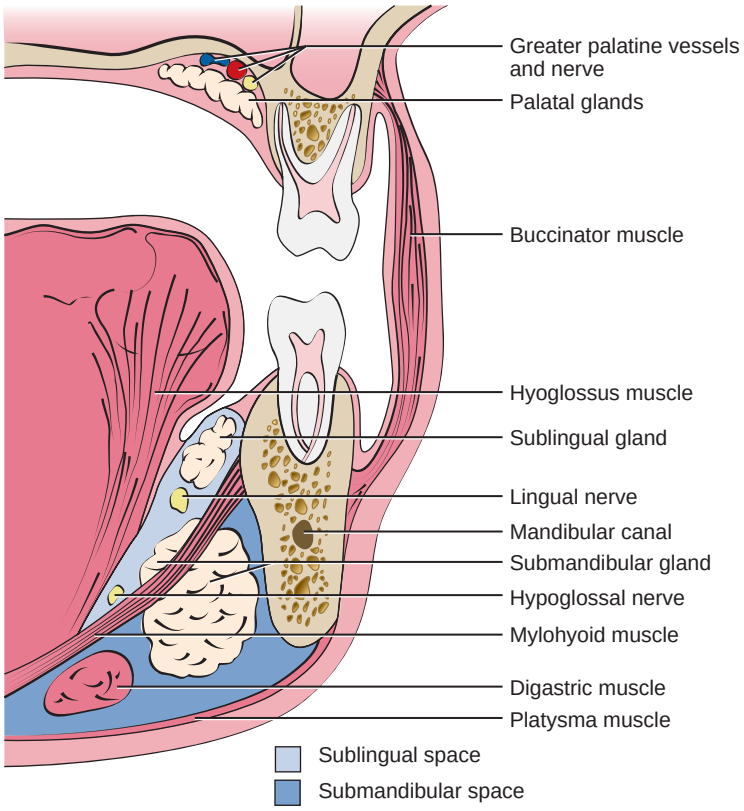

Figure 54-22 Diagram of a frontal section of the human head at the level of the first molars depicting the most important structures in relation to periodontal surgery. Note the location of the sublingual space, the submandibular space, and the greater palatine nerve and vessels.

mouth are attached. Infection of this area results in large swelling of the chin that extends downward.

The *masticator space* contains the masseter muscle, the pterygoid muscles, the tendon of insertion of the temporalis muscle, the mandibular ramus, and the posterior part of the body of the mandible. Infection of this area results in swelling of the face and severe trismus and pain. If the abscess occupies the deepest part of this compartment, facial swelling may not be obvious, but the patient may complain of pain and trismus. Patients may also have difficulty and discomfort when moving the tongue and swallowing.

The *sublingual space* is located below the oral mucosa in the anterior part of the floor of the mouth. It contains the sublingual gland and its excretory duct, the submandibular or Wharton's duct; it is traversed by the lingual nerve and vessels and by the hypoglossal nerve (Figure 54-22). Its boundaries are the geniohyoid and genioglossus muscles medially, the lingual surface of the mandible below, and the mylohyoid muscle laterally and anteriorly (Figure 54-23). Infection of this area raises the floor of the mouth and displaces the tongue, which results in pain and difficulty swallowing but little facial swelling.

The *submental space* is found between the mylohyoid muscle superiorly and the platysma inferiorly. It is bounded laterally by the mandible and posteriorly by the hyoid bone. It is traversed by the anterior belly of the digastric muscle. Infections of this area arise from the region of the mandibular anterior teeth and result in swelling of the submental region; infections become more dangerous as they proceed posteriorly.

The *submandibular space* is found external to the sublingual space, below the mylohyoid and hyoglossus muscles (see Figures 54-22 and 54-23). This space contains the submandibular gland, which extends partially above the mylohyoid muscle, thereby

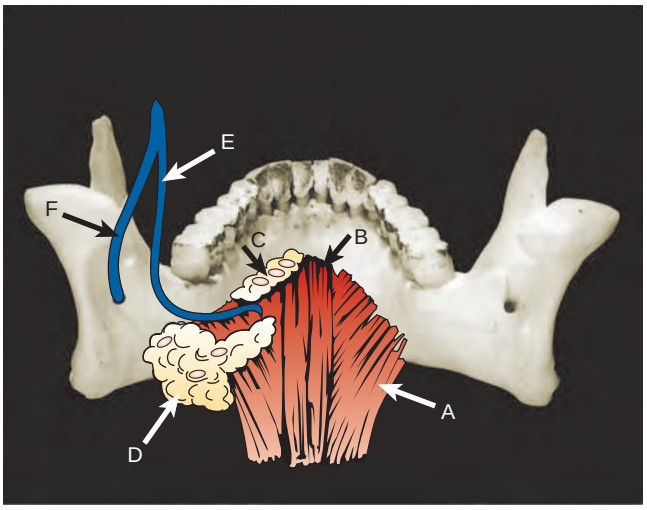

Figure 54-23 Posterior view of the mandible showing, *A,* the attachment of the mylohyoid muscles; *B,* the geniohyoid muscles; *C,* the sublingual gland; *D,* the submandibular gland, which extends below and also to some extent above the mylohyoid muscle; *E,* the sublingual nerve; and *F,* the inferior alveolar nerve.

communicating with the sublingual space and numerous lymph nodes. Infections of this area originate in the molar or premolar area and result in swelling that obliterates the submandibular line and in pain with swallowing. Ludwig's angina is a severe form of infection of the submandibular space that may extend to the sublingual and submental spaces. It results in the hardening of the floor of the mouth, and it may lead to asphyxiation from edema of the neck and glottis. Although the bacteriology of these infections has

not been completely determined, they are presumed to be mixed infections with an important anaerobic component.[1,17]

Suggested Readings

Clarke MA, Bueltmann KW: Anatomical considerations in periodontal surgery. *J Periodontol* 42:610, 1971.

Dixon AD: *Anatomy for students of dentistry*, ed 5, New York, 1986, Churchill Livingstone.

Dubrul EL: *Sicher and Dubrul's oral anatomy*, ed 8, St Louis, 1988, Ishiyaku Euroamerica.

References

References for this chapter are found on the companion website www.expertconsult.com.

References

1. Bartlett JG, Gorbach SL: Anaerobic infections of the head and neck. *Otolaryngol Clin North Am* 9:655–678, 1976.
2. Clarke MA, Bueltmann KW: Anatomical considerations in periodontal surgery. *J Periodontol* 42:610–625, 1971.
3. De Andrade E, Otomo-Corgel J, Pucher J, et al: The intraosseous course of the mandibular incisive nerve in the mandibular symphysis. *Int J Periodontics Restorative Dent* 21:591–597, 2001.
4. Dixon AD: *Anatomy for students of dentistry*, New York, 1986, Churchill Livingstone.
5. Driscoll CF: Bifid mandibular canal. *Oral Surg Oral Med Oral Pathol* 70:807, 1990.
6. DuBrul EL: *Sicher and DuBrul's oral anatomy*, St Louis, 1988, Ishiyaku EuroAmerica.
7. Elian N, Wallace S, Cho SC, et al: Distribution of the maxillary artery as it relates to sinus floor augmentation. *Int J Oral Maxillofac Implants* 20:784–787, 2005.
8. Ella B, Noble Rda C, Lauverjat Y, et al: Septa within the sinus: effect on elevation of the sinus floor. *Br J Oral Maxillofac Surg* 46:464–467, 2008.
9. Ella B, Sedarat C, Noble Rda C, et al: Vascular connections of the lateral wall of the sinus: surgical effect in sinus augmentation. *Int J Oral Maxillofac Implants* 23:1047–1052, 2008.
10. Greenstein G, Tarnow D: The mental foramen and nerve: clinical and anatomical factors related to dental implant placement: a literature review. *J Periodontol* 77:1933–1943, 2006.
11. Gregg JM: *Surgical anatomy*, St Louis, 1980, Mosby.
12. Jovanovic SA, Nevins M: Bone formation utilizing titanium-reinforced barrier membranes. *Int J Periodontics Restorative Dent* 15:56–69, 1995.
13. Kasabah S, Slezak R, Simunek A, et al: Evaluation of the accuracy of panoramic radiograph in the definition of maxillary sinus septa. *Acta Medica (Hradec Kralove)* 45:173–175, 2002.
14. Kiesselbach JE, Chamberlain JG: Clinical and anatomic observations on the relationship of the lingual nerve to the mandibular third molar region. *J Oral Maxillofac Surg* 42:565–567, 1984.
15. Krennmair G, Ulm C, Lugmayr H: Maxillary sinus septa: incidence, morphology and clinical implications. *J Craniomaxillofac Surg* 25:261–265, 1997.
16. Krennmair G, Ulm CW, Lugmayr H, et al: The incidence, location, and height of maxillary sinus septa in the edentulous and dentate maxilla. *J Oral Maxillofac Surg* 57:667–671, 1999. Discussion 671–662.
17. Mulligan MR: *Ear, nose, throat, and head and neck infections*, San Diego, 1989, Academic Press.
18. Neiva RF, Gapski R, Wang HL: Morphometric analysis of implant-related anatomy in Caucasian skulls. *J Periodontol* 75:1061–1067, 2004.
19. Solar P, Geyerhofer U, Traxler H, et al: Blood supply to the maxillary sinus relevant to sinus floor elevation procedures. *Clin Oral Implants Res* 10:34–44, 1999.
20. Spilka CJ: Pathways of dental infections. *J Oral Surg* 24:111–124, 1966.
21. Topazian RG, Goldberg MH, Hupp JR: *Oral and maxillofacial infections*, Philadelphia, 2002, W.B. Saunders.
22. Uchida Y, Noguchi N, Goto M, et al: Yosue T: Measurement of anterior loop length for the mandibular canal and diameter of the mandibular incisive canal to avoid nerve damage when installing endosseous implants in the interforaminal region: a second attempt introducing cone beam computed tomography. *J Oral Maxillofac Surg* 67:744–750, 2009.
23. Uchida Y, Yamashita Y, Goto M, et al: Measurement of anterior loop length for the mandibular canal and diameter of the mandibular incisive canal to avoid nerve damage when installing endosseous implants in the interforaminal region. *J Oral Maxillofac Surg* 65:1772–1779, 2007.
24. van den Bergh JP, ten Bruggenkate CM, Disch FJ, et al: Anatomical aspects of sinus floor elevations. *Clin Oral Implants Res* 11:256–265, 2000.
25. Velasquez-Plata D, Hovey LR, Peach CC, et al: Maxillary sinus septa: a 3-dimensional computerized tomographic scan analysis. *Int J Oral Maxillofac Implants* 17:854–860, 2002.

CHAPTER 55

General Principles of Periodontal Surgery

Perry R. Klokkevold, Henry H. Takei, and Fermin A. Carranza

CHAPTER OUTLINE

Outpatient Surgery
Hospital Periodontal Surgery *(e-only)*
Surgical Instruments
Conclusion

For online-only content on the treatment of root sensitivity and hospital periodontal surgery, please visit the companion website at www.expertconsult.com.

All surgical procedures must be carefully planned. The patient should be adequately prepared medically, psychologically, and practically for all aspects of the intervention. This chapter covers the preparation of the patient and the general considerations that are common to all periodontal surgical techniques. Complications that may occur during or after surgery are also discussed.

Surgical periodontal procedures are usually performed in the dental office. Hospital periodontal surgery is discussed later in this chapter, and this is followed by a review of common surgical instruments.

Outpatient Surgery

Patient Preparation

Reevaluation After Phase I Therapy. Almost every patient undergoes the so-called initial or preparatory phase of therapy, which basically consists of thorough scaling and root planing and the removing of all irritants responsible for the periodontal inflammation. These procedures do the following: (1) eliminate some lesions entirely; (2) render the tissues more firm and consistent, thereby allowing for a more accurate and delicate surgery; and (3) acquaint the patient with the office, the operator, and his or her assistants, thereby reducing the patient's apprehension and fear.

The reevaluation phase consists of reprobing and reexamining all of the pertinent findings that previously indicated the need for the surgical procedure. The persistence of these findings confirms the indication for surgery. The number of surgical procedures, the expected outcome, and the postoperative care necessary are all determined before therapy. These are discussed with the patient, and a final decision is made that incorporates any necessary adjustments to the original plan.

Premedication. For patients who are not medically compromised, the value of administering antibiotics routinely for periodontal surgery has not been clearly demonstrated.[29] However, some studies have reported reduced postoperative complications, including reduced pain and swelling, when antibiotics are given before periodontal surgery and continued for 4 to 7 days after surgery.[4,12,21,32]

The prophylactic use of antibiotics in patients who are otherwise healthy has been advocated for bone-grafting procedures and purported to enhance the chances of new attachment. Although the rationale for such use appears logical, no research evidence is available to support it. In any case, the risks inherent to the administration of antibiotics should be evaluated together with the potential benefits. Other presurgical medications include the administration of a nonsteroidal anti-inflammatory drug such as ibuprofen (e.g., Motrin) 1 hour before the procedure as well as the use of a mouthrinse with 0.12% chlorhexidine gluconate (Peridex, PerioGard).[38]

Precautions to be taken with medically compromised patients are discussed in Chapter 37.

Smoking. The deleterious effect of smoking on the healing of periodontal wounds has been amply documented[20,33,43] (see Chapter 10). Patients should be clearly informed of this fact and asked to quit smoking completely or to at least stop smoking for a minimum of 3 to 4 weeks after the procedure. For patients who are unwilling to follow this advice, an alternate treatment plan that does not include more sophisticated techniques (e.g., regenerative, mucogingival, aesthetic) should be considered.

Informed Consent. The patient should be informed at the initial visit about the diagnosis, prognosis, and different possible treatments his or her condition, with the expected results and all pros and cons of each approach discussed as well. At the time of surgery, the patient should again be informed, verbally and in writing, of the procedure to be performed, and he or she should indicate his or her agreement to undergo the procedure by signing the consent form.

Emergency Equipment

The operator, all assistants, and office personnel should be trained to handle all possible emergencies that may arise. Drugs and equipment for emergency use should be readily available at all times.

Treatment of Sensitive Roots

Root hypersensitivity is a relatively common problem in periodontal practice. It may occur spontaneously when the root becomes exposed as a result of gingival recession or pocket formation, or it may appear after scaling and root planing and surgical procedures. (See the article by Curro[10] for a literature review of this subject.) This type of sensitivity is manifested as pain that is induced by cold or hot temperature (more often cold), by citrus fruits or sweets, or by contact with a toothbrush or a dental instrument.

Root sensitivity occurs more frequently in the cervical area of the root, where the cementum is extremely thin. Scaling and root planing procedures remove this thin cementum, thereby inducing the hypersensitivity.

The transmission of stimuli from the surface of the dentin to the nerve endings located in the dental pulp or in the pulpal region of the dentin could result from the odontoblastic process or from a hydrodynamic mechanism (i.e., the displacement of dentinal fluid). The latter process seems more likely and would explain the importance of burnishing desensitizing agents to obturate the dentinal tubule. An important factor for reducing or eliminating hypersensitivity is adequate plaque control. However, hypersensitivity may prevent plaque control, and therefore a vicious cycle of escalating hypersensitivity and plaque accumulation may be created.

The patient should be informed about the possibility of root hypersensitivity before treatment is undertaken. The following information about how to cope with the problem should also be given to the patient:

1. Hypersensitivity appears as a result of the exposure of dentin, which is inevitable if calculus, plaque, and their products, which are buried in the root, are to be removed.
2. Hypersensitivity slowly disappears over a few weeks.
3. An important factor in reducing hypersensitivity is plaque control.
4. Desensitizing agents do not produce immediate relief and must be used for several days or even weeks to produce results.

Desensitizing Agents. A number of agents have been proposed to control root hypersensitivity. The clinical evaluation of the many agents proposed is difficult for the following reasons: (1) measuring and comparing pain among different persons is difficult; (2) hypersensitivity disappears by itself after a time; and (3) desensitizing agents usually take a few weeks to act.

Desensitizing agents can be applied by the patient at home or by the dentist or hygienist in the dental office. The most likely mechanism of action is the reduction of the diameter of the dentinal tubules to limit the displacement of fluid in them. According to Trowbridge and Silver,[44] this can be attained in the following ways: (1) by the formation of a smear layer produced by burnishing the exposed surface; (2) via the topical application of agents that form insoluble precipitates within the tubules; (3) with the impregnation of tubules with plastic resins; or (4) by sealing the tubules with plastic resins.

Agents Used by the Patient. The most common agents used by the patient for oral hygiene are dentifrices. Although many dentifrice products contain fluoride, additional active ingredients for desensitization are strontium chloride, potassium nitrate, and sodium citrate. The American Dental Association has approved the following dentifrices for desensitizing purposes: Sensodyne and Thermodent, which contain strontium chloride[7,9,36]; Crest Sensitivity Protection, Denquel, and Promise, which contain potassium nitrate[1,9]; and Protect, which contains sodium citrate. Fluoride rinsing solutions and gels can also be used after the usual plaque-control procedures.[42]

Patients should be aware that several factors must be considered during the treatment of tooth hypersensitivity, including the history and severity of the problem as well as the physical findings of the tooth or teeth involved. A proper diagnosis is required before any treatment can be initiated so that pathologic causes of pain (e.g., caries, cracked tooth, pulpitis) can be ruled out before attempting to treat hypersensitivity. Desensitizing agents act through the precipitation of crystalline salts on the dentin surface, which block dentinal tubules. Patients must be aware that their use will not prove to be effective unless they are used continuously for at least 2 weeks.

Agents Used in the Dental Office. Box 55-2 lists various office treatments for the desensitization of hypersensitive dentin. These products and treatments aim to decrease hypersensitivity by blocking dentinal tubules with either a crystalline salt precipitation or an applied coating (varnish or bonding agent) on the root surface.[44]

Several agents have been used to precipitate crystalline salts on the dentin surface in an attempt to occlude the dentinal tubules. *Fluoride solutions* and *pastes* historically have been the agents of choice. In addition to their anti-sensitivity properties, fluoride agents have the advantage of anticaries activity, which is particularly important for patients with a tendency to develop root caries. Certain agents, however, such as chlorhexidine, decrease the ability of fluoride to bind with calcium on the root surfaces.[1] Thus, it is important to advise patients not to rinse or eat for 1 hour after a desensitizing treatment. Currently, potassium oxalate (Protect) and ferric oxalate (Sensodyne Sealant) solutions are the preferred agents; special applicators have been developed for their use. These agents form insoluble calcium oxalate crystals that occlude the dentinal tubules.[27,30]

A newer method of treatment for hypersensitive dentin is the use of varnishes or bonding agents to occlude dentinal tubules. Newer restorative materials, such as glass-ionomer cements and the dentin bonding agents, are still under investigation, but when the tooth needs recontouring or when difficult cases do not respond

BOX 55-2 Office Treatments for Dentinal Hypersensitivity

Cavity varnishes
- Anti-inflammatory agents

Treatments that partially obturate dentinal tubules
- Burnishing of dentin
- Silver nitrate
- Zinc chloride–potassium ferrocyanide
- Formalin

Calcium compounds
- Calcium hydroxide
- Dibasic calcium phosphate

Fluoride compounds
- Sodium fluoride
- Stannous fluoride
- Iontophoresis
- Strontium chloride
- Potassium oxalate
- Restorative resins
- Dentin bonding agents

From Trowbridge HO, Silver DR: *Dent Clin North Am* 34:566, 1990.

to other treatments, the dentist may choose to use a restorative material. Resin primers alone could be promising, but the effects are not permanent, and investigations are ongoing.[14] Despite some success with decreasing dentin hypersensitivity, it is important to note that these "dental office" treatments have not been a predictable means of solving hypersensitivity, and the success that is achieved is often short lived. The crystalline salts and varnishes and the sealants can be washed away over time, and hypersensitivity may return. When this occurs, patients can have their sensitive root surfaces treated again.

Recently, attempts have been made to improve the success and longevity of these treatments with the use of lasers. Low-level laser "melting" of the dentin surface appears to seal dentinal tubules without damage to the pulp.[15,22] In a combined treatment modality, the neodymium:yttrium-aluminum-garnet laser has been used to congeal fluoride varnish on root surfaces. This in vitro study demonstrated that the laser-treated fluoride varnish resisted removal by electric toothbrushing, with 90% of tubules remaining blocked; in the control subjects (i.e., those who did not undergo laser treatment), the fluoride varnish was almost completely brushed away.[23] Despite these convincing preliminary results, more research is needed before laser treatment can be considered an effective and predictable means of desensitization (see Chapter 65).

Hospital Periodontal Surgery

Ordinarily, periodontal surgery is an office procedure that is performed in quadrants or sextants, usually at biweekly or longer intervals. Under certain circumstances, however, it is in the best interest of the patient to treat the mouth with only one surgery, with the patient in a hospital operating room and under general anesthesia.

Indications

Indications for hospital periodontal surgery include the optimal control and management of apprehension, convenience for individuals who cannot endure multiple visits to complete surgical treatment, and patient protection.

Patient Apprehension. Gentleness, understanding, and preoperative sedation usually suffice to calm the fears of most patients. For some patients, however, the prospect of a series of surgical procedures is sufficiently stressful to trigger disturbances that jeopardize their well-being and hamper treatment. Explaining that the treatment at the hospital will be performed painlessly and that it will be accomplished by a level of anesthesia that is neither practical nor safe for patients in a dental office is an important step in allaying patient fears. The thought of completing the necessary surgical procedures in one session rather than in repeated visits is an added comfort to many patients, because it eliminates the prospect of repeated anxiety in anticipation of each treatment.

Patient Convenience. With complete mouth surgery, there is less stress for the patient and less time involved in postoperative care. For patients whose occupation entails considerable contact with the public, surgery performed at biweekly intervals sometimes presents a significant problem. It means that, for several weeks, some area of the mouth will have undergone surgery and may be covered by a periodontal pack. With the complete mouth technique, the surgery is completed in one visit. Although the pack may cover the entire treated area, it is usually only retained for 1 week. Patients find this an acceptable alternative to several weeks of discomfort in different areas of the mouth and multiple dressing applications. For a variety of other reasons, patients may prefer to address their surgical needs in one session under optimal "operating room" conditions.

Patient Protection. Some patients have systemic conditions that are not severe enough to contraindicate elective surgery but that may require special precautions that are best provided in a hospital setting. This group includes (but is not limited to) patients with severe cardiovascular disease, abnormal bleeding tendencies, hyperthyroidism, or uncontrolled hypertension. Treating such a patient in a hospital operating room or an equivalent procedure room with an anesthesiologist present to monitor and manage the vitals signs and comfort level throughout the surgical procedure is the safest way to manage him or her.

The purpose of hospitalization is to protect patients by anticipating their special needs, not to perform periodontal surgery when it is contraindicated by the patient's general condition. For some patients, elective surgery is contraindicated, regardless of whether it is performed in the dental office or the hospital. When consultation with the patient's physician leads to this decision, palliative periodontal therapy in the form of scaling and root planing, if permissible, is the necessary compromise.

Patient Preparation

Premedication. Patients should be given a sedative the night before surgery. Benzodiazepines work well for most patients because they allow the patient to sleep well the night before surgery. If the patient is extremely nervous about the procedure, it is also helpful to advise him or her to take a benzodiazepine the morning of surgery. This ensures that the patient will be as rested and relaxed as possible before surgery.

Patients with systemic problems (e.g., history of rheumatic fever, cardiovascular problems) are premedicated as needed (see Chapter 37).

Anesthesia. Local or general anesthesia may be used.[26] Local anesthesia is the method of choice, except for especially apprehensive patients. It permits unhampered movement of the head, which is necessary for optimal visibility and accessibility to the various root surfaces. Local anesthesia is used in the same manner as for routine periodontal surgery.

When general anesthesia is indicated, it is administered by an anesthesiologist. It is important that the patient also receive local anesthesia, administered as for routine periodontal surgery, to ensure comfort for the patient and reduced bleeding during the procedure. The judicious use of local anesthetics to block regional nerves allows the level of sedation or general anesthesia to be lighter. Hence, the entire operation is performed with a wider margin of safety.

Positioning and Periodontal Dressing. Surgery in the operating room is typically performed on the operating table with the patient lying down and the table either positioned flat or with the head inclined up to 30 degrees. Some operating rooms are equipped with dental chairs that can be used either flat or at up to 30 degrees of inclination.

When general anesthesia is used, it is advisable to delay placing the periodontal dressing until the patient has recovered sufficiently to have a demonstrable cough reflex. Periodontal dressings placed before the end of general anesthesia can be displaced during the recovery period and pose serious risks of blocking the airway.

Postoperative Instructions

After a full recovery from general anesthesia, most patients can be discharged home with a responsible adult. The effects of general anesthesia and sedative agents make the patient drowsy for hours, and adult supervision at home is recommended for up to 24 hours after surgery. The typical postoperative instructions should be given to the responsible adult, and the patient should be scheduled for a postoperative visit in 1 week.

The most common emergency is syncope, which is a transient loss of consciousness caused by a reduction in cerebral blood flow. The most common causes of syncope are fear and anxiety. Syncope is usually preceded by a feeling of weakness, and then the patient develops pallor, sweating, coldness of the extremities, dizziness, and a slowing of the pulse. The patient should be placed in a supine position with the legs elevated; tight clothes should be loosened, and a wide-open airway should be ensured. The administration of oxygen is also useful. Unconsciousness may persists for a few minutes. A history of previous syncopal attacks during dental appointments should be explored before treatment is begun; if these are reported, extra efforts to relieve the patient's fear and anxiety should be made. The reader is referred to other texts for a complete analysis of this important topic.[3]

Measures to Prevent Transmission of Infection

The danger of transmitting infections to the dental team or other patients has become apparent in recent years, particularly with the threat of acquired immunodeficiency syndrome and hepatitis B virus infection. Universal precautions (e.g., protective attire) and barrier techniques are strongly recommended and often required by law. These include the use of disposable sterile gloves, surgical masks, and protective eyewear. All surfaces that may possibly be contaminated with blood or saliva and that cannot be sterilized (e.g., light handles, unit syringes) must be covered with aluminum foil or plastic wrap. Aerosol-producing devices (e.g., Cavitron) should not be used on patients with suspected infections, and their use should be kept to a minimum in all other patients. Special care should be taken when using and disposing of sharp items such as needles and scalpel blades.

Sedation and Anesthesia

Periodontal surgery should be painless for the patient. He or she should be assured of this at the outset and throughout the procedure. The most reliable means of providing painless surgery is the effective administration of local anesthesia. The area to be treated should be thoroughly anesthetized by means of regional block and local infiltration. Injections directly into the interdental papillae may also be helpful.

Apprehensive and neurotic patients require special management with anti-anxiety or sedative–hypnotic agents. Modalities for the administration of these agents include inhalation, oral, intramuscular, and intravenous routes. The specific agents and the modality of administration are based on the desired level of sedation, the anticipated length of the procedure, and the overall condition of the patient. Specifically, the patient's medical history and his or her physical and emotional statuses should be considered when selecting agents and techniques.

Perhaps the simplest, least invasive method to alleviate anxiety in the dental office is nitrous oxide and oxygen inhalation sedation. For many individuals, this is quite effective. Advantages include a quick onset of action, the ability to adjust the level of sedation throughout the procedure, a rapid recovery, and little or no concern for postoperative impairment of sensory or motor function. One disadvantage is that a small percentage of patients will not achieve the desired effect. This is especially true for the mentally impaired individual, because nitrous oxide and oxygen sedation requires some level of patient cooperation. Overall, inhalation sedation with nitrous oxide and oxygen is a safe, effective, and reliable means of reducing mild anxiety.

For individuals with mild to moderate anxiety, oral administration of a benzodiazepine can be effective to decrease anxiety and to produce a level of relaxation. The oral administration of a sedative agent can be more effective than inhalation anesthesia, because the level of sedation achieved may be more profound. Disadvantages of oral sedative administration include incomplete recovery, an inability to control the level of sedation, and a prolonged period of impaired sensory and motor skills. A variety of benzodiazepine agents are available for oral administration (see Chapter 36).

The intravenous administration of a benzodiazepine, either alone or in combination with other agents, can be used to achieve a greater level of sedation in individuals with moderate to severe levels of anxiety. Furthermore, the onset of action of intravenous sedation is almost immediate, and the level of sedation can be titrated on an individual basis to the desired effect. The recovery period depends on the half-life of the agent used and the amount given. The operator should receive formal training in the techniques of sedation; this often is required by law. A thorough understanding of the indications, contraindications, and risks of these agents is required.[3] The reader is referred to Chapter 36 and other texts for a more detailed discussion of conscious sedation modalities, agents, and techniques.[26]

Tissue Management

1. *Operate gently and carefully.* In addition to being most considerate to the patient, this is also the most effective way to operate. Tissue manipulation should be precise, deliberate, and gentle. Thoroughness is essential, but roughness must be avoided, because it produces excessive tissue injury, causes postoperative discomfort, and delays healing.
2. *Observe the patient at all times.* It is essential to pay careful attention to the patient's reactions. Facial expressions, pallor, and perspiration are distinct signs that may indicate that the patient is experiencing pain, anxiety, or fear. The physician's responsiveness to these signs can be the difference between success and failure.
3. *Be certain that the instruments are sharp.* Instruments must be sharp to be effective; successful treatment is not possible without sharp instruments. Dull instruments inflict unnecessary trauma as a result of poor cutting and excessive force applied to compensate for their ineffectiveness. A sterile sharpening stone should be available on the operating table at all times.

Scaling and Root Planing

Although scaling and root planing have been performed previously as part of Phase I therapy, all exposed root surfaces should be carefully explored and planed as needed as part of the surgical procedure. In particular, areas of difficult access (e.g., furcations, deep pockets) often have rough areas or even calculus that was undetected during the preparatory sessions. The assistant who is retracting the tissues and using the aspirator should also check for the presence of calculus and the smoothness of each surface from a different angle.

Hemostasis

Hemostasis is an important aspect of periodontal surgery, because good intraoperative control of bleeding permits an accurate visualization of the extent of disease, the pattern of bone destruction, and the anatomy and condition of the root surfaces. It provides the operator with a clear view of the surgical site, which is essential for wound debridement and scaling and root planing. In addition, good hemostasis also prevents the excessive loss of blood into the mouth, oropharynx, and stomach.

Periodontal surgery can produce profuse bleeding, especially during the initial incisions and flap reflection. After flap reflection

TABLE 55-1 Absorbable Hemostatic Agents

Generic (Brand)	Directions	Adverse Effects	Precautions
Absorbable gelatin sponge (Gelfoam)	May be cut into various sizes and applied to bleeding surfaces	May form nidus for infection or abscess	Should not be overpacked into extraction site or wound—may interfere with healing
Oxidized cellulose (Oxycel)	Most effective when applied to wound dry as opposed to moistened	May cause foreign-body reaction	Extremely friable and difficult to place; should not be used adjacent to bone—impairs bone regeneration; should not be used as a surface dressing—inhibits epithelialization
Oxidized regenerated cellulose (Surgicel Absorbable Hemostat)	May be cut to various shapes and positioned over bleeding sites; thick or excessive amounts should not be used	Encapsulation, cyst formation, and foreign-body reaction possible	Should not be placed in deep wounds—may physically interfere with wound healing and bone formation
Microfibrillar collagen hemostat (CollaCote, CollaTape, CollaPlug)	May be cut to shape and applied to bleeding surface	May potentiate abscess formation, hematoma, and wound dehiscence; possible allergic reaction or foreign-body reaction	May interfere with wound healing; placement in extraction sockets has been associated with increased pain
Thrombin (Thrombostat)	May be applied topically to bleeding surface	Allergic reaction can occur in patients with known sensitivity to bovine materials	Must not be injected into tissues or vasculature—can cause severe (and possibly fatal) clotting

and the removal of granulation tissue, bleeding disappears or is considerably reduced. Typically, the control of intraoperative bleeding can be managed with aspiration. Continuous suctioning of the surgical site with an aspirator is indispensable when performing periodontal surgery. The application of pressure to the surgical wound with moist gauze can be a helpful adjunct to control site-specific bleeding. Intraoperative bleeding that is not controlled with these simple methods may indicate a more serious problem and require additional control measures.

Excessive hemorrhaging after initial incisions and flap reflection may be caused by the laceration of venules, arterioles, or larger vessels. Fortunately, the laceration of medium or large vessels is rare, because incisions near highly vascular anatomic areas (e.g., the posterior mandible [the lingual and inferior alveolar arteries], the posterior mid-palatal regions [the greater palatine arteries]) are avoided by incision and flap procedures. Proper design of the flaps, which takes these areas into consideration, avoids accidents (see Chapter 53). However, even when all anatomic precautions are taken, it is possible to cause bleeding from medium or large vessels, because anatomic variations do occur and may result in inadvertent laceration. If a medium or large vessel is lacerated, a suture around the bleeding end may be necessary to control hemorrhage. Pressure should be applied through the tissue to determine the location that will stop blood flow in the severed vessel. A suture can then be passed through the tissue and tied to restrict blood flow. Excessive bleeding from a surgical wound may also result from incisions across a capillary plexus. Minor areas of persistent bleeding from capillaries can be stopped by applying cold pressure to the site with moist gauze (soaked in sterile ice water) for several minutes.

The use of a local anesthetic with a vasoconstrictor may also be useful for controlling minor bleeding from the periodontal flap. Both of these methods act through vasoconstriction, thereby reducing the flow of blood through incised small vessels and capillaries. This action is relatively short lived, and it should not be relied on for long-term hemostasis. It is important to avoid the use of vasoconstrictors to control bleeding before sending a patient home. If a more serious bleeding problem exists or if a firm blood clot is not established, bleeding is likely to recur when the vasoconstrictor has metabolized and the patient is no longer in the office.

For a slow constant blood flow and for oozing, hemostasis may be achieved with hemostatic agents. Absorbable gelatin sponge (Gelfoam), oxidized cellulose (Oxycel), oxidized regenerated cellulose (Surgicel Absorbable Hemostat), and microfibrillar collagen hemostat (CollaCote, CollaTape, CollaPlug) are useful hemostatic agents for the control of bleeding in capillaries, small blood vessels, and deep wounds (Table 55-1).

Absorbable gelatin sponge is a porous matrix prepared from pork skin that helps to stabilize a normal blood clot. The sponge can be cut to the desired dimensions and either sutured in place or positioned within the wound (e.g., an extraction socket). It is absorbed in 4 to 6 weeks.

Oxidized cellulose is a chemically modified form of surgical gauze that forms an artificial clot. The material is friable, and it can be difficult to keep in place. It is absorbed in 1 to 6 weeks.

Oxidized regenerated cellulose is prepared from cellulose via a reaction with alkali to form a chemically pure and more uniform structure than oxidized cellulose. The material is prepared in a cloth or thin gauze form that can be cut to the desired size and sutured or layered on the bleeding surface. It can be used as a surface dressing because it does not impair epithelialization, and it is bactericidal against many gram-negative and gram-positive microorganisms that are both aerobic and anaerobic. Caution should be used when wounds are infected or have an increased potential to becoming infected (e.g., immunocompromised patients), because the absorbable hemostatic agents can serve as a nidus for infection.

Thrombin is a drug that is capable of hastening the process of blood clotting. It is intended for topical use only, and it is applied as a liquid or powder. Thrombin should never be injected into tissues, because it can cause serious or even fatal intravascular coagulation. In addition, because thrombin is a bovine-derived material, caution should be used for any patient with a known allergic reaction to bovine products.

Finally, it is imperative to recognize that excessive bleeding may be caused by systemic disorders, including (but not limited

to) platelet deficiencies, coagulation defects, medications, and hypertension. As a precaution, all surgical patients should be asked about any current medications that may contribute to bleeding, any family history of bleeding disorders, and any hypertension. All patients, regardless of health history, should have their blood pressure evaluated before surgery, and anyone who is diagnosed with hypertension must be advised to see a physician before surgery. Patients with known or suspected bleeding deficiencies or disorders must be carefully evaluated before any surgical procedure. A consultation with the patient's physician is recommended, and laboratory tests should be performed to assess the risk of bleeding. It may be necessary to refer the patient to a hematologist for a comprehensive workup.

Periodontal Dressings (Periodontal Packs)

In most cases, after the surgical periodontal procedures are completed, the area is covered with a surgical pack. In general, dressings have no curative properties; they assist healing by protecting the tissue rather than providing "healing factors." The pack minimizes the likelihood of postoperative infection and hemorrhage, facilitates healing by preventing surface trauma during mastication, and protects the patient from pain induced by contact of the wound with food or with the tongue during mastication. (For a complete literature review on this subject, see the article by Sachs and colleagues.[37])

Zinc Oxide–Eugenol Packs. Packs that are based on the reaction of zinc oxide and eugenol include the Wondr Pak, which was developed by Ward[46] in 1923, and several other packs that use modified forms of Ward's original formula. The addition of accelerators such as zinc acetate gives the dressing a better working time.

Zinc oxide–eugenol dressings are supplied as a liquid and a powder that are mixed before use. Eugenol in this type of pack may induce an allergic reaction that produces reddening of the area and burning pain in some patients.

Noneugenol Packs. The reaction between a metallic oxide and fatty acids is the basis for the Coe-Pak, which is the most widely used dressing in the United States. This is supplied in two tubes, the contents of which are mixed immediately before use until a uniform color is obtained. One tube contains zinc oxide, an oil (for plasticity), a gum (for cohesiveness), and Lorothidol (a fungicide); the other tube contains liquid coconut fatty acids that have been thickened with colophony resin (or rosin) and chlorothymol (a bacteriostatic agent).[37,40] This dressing does not contain asbestos or eugenol, thereby avoiding the problems associated with these substances.

Other noneugenol packs include cyanoacrylates[6,19,24] and tissue conditioners (methacrylate gels).[2] However, these are not in common use.

Retention of Packs. Periodontal dressings are usually kept in place mechanically by interlocking in interdental spaces and joining the lingual and facial portions of the pack. In isolated teeth or when several teeth in an arch are missing, retention of the pack may be difficult. Numerous reinforcements and splints and stents for this purpose have been described.[17,18,47] The placement of dental floss tied loosely around the teeth enhances retention of the pack.

Antibacterial Properties of Packs. Improved healing and patient comfort with less odor and taste[6] have been obtained by incorporating antibiotics into the pack. Bacitracin,[5] oxytetracycline (Terramycin),[13] neomycin, and nitrofurazone have been tried, but all of these may produce hypersensitivity reactions. The emergence of resistant organisms and opportunistic infections has been reported.[35] The incorporation of tetracycline powder into the Coe-Pak is generally recommended, particularly when long and traumatic surgeries are performed.

Allergy. Contact allergies to eugenol and rosin have been reported.[34]

Preparation and Application of Dressing. Zinc oxide packs are mixed with eugenol or noneugenol liquids on a wax paper pad with a wooden tongue depressor. The powder is gradually incorporated with the liquid until a thick paste is formed.

The Coe-Pak is prepared by mixing equal lengths of paste from tubes that contain the accelerator and the base until the resulting paste is a uniform color (Figure 55-1, *A* to *C*). A capsule of tetracycline powder can be added at this time. The pack is then placed in a cup of water at room temperature (Figure 55-1, *D*). After 2 to

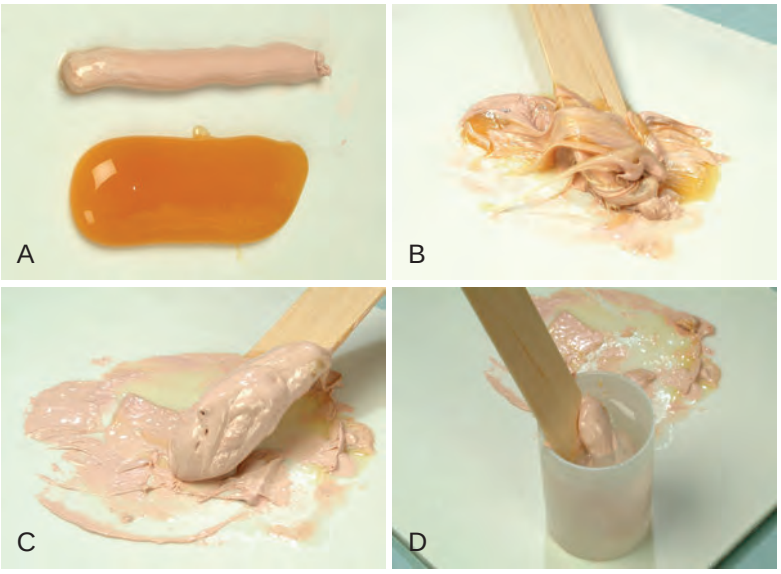

Figure 55-1 Preparing the surgical pack (Coe-Pak). **A,** Equal lengths of the two pastes are placed on a paper pad. **B,** The pastes are mixed with a wooden tongue depressor for 2 or 3 minutes until, **C,** the paste loses its tackiness. **D,** The mixed paste is placed in a paper cup of water at room temperature. With lubricated fingers, it is then rolled into cylinders and placed on the surgical wound.

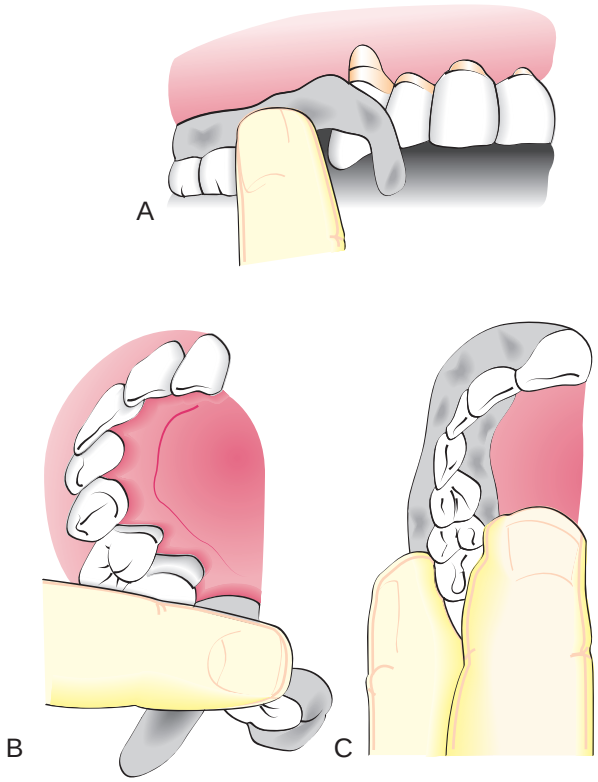

Figure 55-2 Inserting the periodontal pack. **A,** A strip of pack is hooked around the last molar and pressed into place anteriorly. **B,** The lingual pack is joined to the facial strip at the distal surface of the last molar and fitted into place anteriorly. **C,** Gentle pressure on the facial and lingual surfaces joins the pack interproximally.

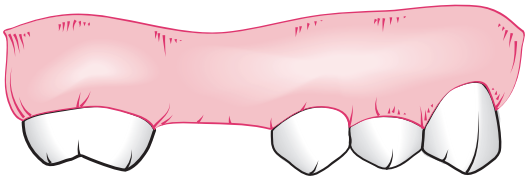

Figure 55-3 Continuous pack covers the edentulous space.

3 minutes, the paste loses its tackiness, and it can be handled and molded; it remains workable for 15 to 20 minutes. The working time can be shortened by adding a small amount of zinc oxide to the accelerator (pink paste) before spatulating.

The pack is then rolled into two strips that are approximately the length of the treated area. The end of one strip is bent into a hook shape and fitted around the distal surface of the last tooth to approach that tooth from the distal surface (Figure 55-2, *A*). The remainder of the strip is brought forward along the facial surface to the midline and gently pressed into place along the gingival margin and interproximally. The second strip is applied from the lingual surface. It is joined to the pack at the distal surface of the last tooth and then brought forward along the gingival margin to the midline (Figure 55-2, *B*). The strips are joined interproximally by applying gentle pressure on the facial and lingual surfaces of the pack (Figure 55-2, *C*). For isolated teeth separated by edentulous spaces, the pack should be made continuous from tooth to tooth to cover the edentulous areas (Figure 55-3).

When split flaps have been performed, the area should be covered with tinfoil to protect the sutures before the pack is placed.

Figure 55-4 Periodontal pack should not interfere with the occlusion.

The pack should cover the gingiva, but overextension onto uninvolved mucosa should be avoided. *Excess pack irritates the mucobuccal fold and the floor of the mouth, and it interferes with the tongue.* Overextension also jeopardizes the remainder of the pack, because the excess tends to break off and to take pack from the operated area with it. *Pack that interferes with the occlusion should be trimmed away before the patient is dismissed* (Figure 55-4). Failure to do this causes discomfort and jeopardizes retention of the pack.

The operator should ask the patient to move the tongue forcibly out and to each side, and the cheek and lips should be displaced in all directions to mold the pack while it is still soft. After the pack has set, it should be trimmed to eliminate all excess.

As a general rule, the pack is kept on for 1 week after surgery. This guideline is based on the usual timetable of healing and clinical experience. It is not a rigid requirement; the period may be extended, or the area may be repacked for an additional week.

Fragments of the surface of the pack may come off during the week, but this presents no problem. If a portion of the pack is lost from the operated area and the patient is uncomfortable, it is usually best to repack the area. The clinician should remove the remaining pack, wash the area with warm water, and apply a topical anesthetic before replacing the pack, which is then retained for 1 week. Again, the patient may develop pain from an overextended margin that irritates the vestibule, the floor of the mouth, or the tongue. The excess pack should be trimmed away, with care taken to ensure that the new margin is not rough, before the patient is dismissed.

Postoperative Instructions

After the pack is placed, printed instructions are given to the patient to be read before he or she leaves the chair (Box 55-1).

First Postoperative Week

When it is properly performed, periodontal surgery presents no serious postoperative problems. Patients should be told to rinse with 0.12% chlorhexidine gluconate (Peridex, PerioGard) immediately after the surgical procedure and twice daily thereafter until normal plaque control technique can be resumed.[30,38,45] The following complications may arise during the first postoperative week, although they are the exception rather than the rule:

1. *Persistent bleeding after surgery.* The pack is removed, the bleeding points are located, and the bleeding is stopped with pressure, electrosurgery, or electrocautery. After the bleeding is stopped, the area is repacked.
2. *Sensitivity to percussion.* Extension of inflammation into the periodontal ligament may cause sensitivity to percussion. The

BOX 55-1 Patient Instructions After Periodontal Surgery

Instructions for _____ (Patient's Name)

The following information about your gum operation has been prepared to answer questions that you may have about how to take care of your mouth. Please read the instructions carefully; our other patients have found them to be very helpful.

Although there will be little or no discomfort when the anesthesia wears off, you should take two acetaminophen (Tylenol) tablets every 6 hours for the first 24 hours. After that, take the same medication if you have any discomfort. Do not take aspirin, because this may increase bleeding.

We have placed a periodontal pack over your gums to protect them from irritation. The pack prevents pain, helps with healing, and enables you to carry on most of your usual activities in comfort. The pack will harden in a few hours, after which it can withstand most of the forces of chewing without breaking off. It may take a little while to become accustomed to it.

The pack should remain in place until it is removed in the office at your next appointment. If particles of the pack chip off during the week, do not be concerned as long as you do not have pain. If a piece of the pack breaks off and you are in pain or if a rough edge irritates your tongue or cheek, please call the office. The problem can be easily remedied by replacing the pack.

For the first 3 hours after the operation, avoid hot foods to permit the pack to harden. It is also convenient to avoid hot liquids during the first 24 hours. You can eat anything you can manage, but try to chew on the nonoperated side of your mouth. Semisolid or finely minced foods are suggested. Avoid citrus fruits and fruit juices, highly spiced foods, and alcoholic beverages; these will cause pain. Food supplements or vitamins are generally not necessary.

Do not smoke. The heat and smoke will irritate your gums, and the immunologic effects of nicotine will delay healing and prevent a completely successful outcome of the procedure that was performed. If possible, use this opportunity to give up smoking. In addition to all other well-known health risks, smokers have more gum disease than nonsmokers.

Do not brush over the pack. Brush and floss the areas of the mouth that are not covered by the pack as you normally would do. Use chlorhexidine (Peridex, PerioGard) oral rinses after brushing; a prescription for this rinse has been given to you.

During the first day, apply ice intermittently to your face over the operated area. It is also beneficial to suck on ice chips intermittently during the first 24 hours. These methods will keep tissues cool and reduce inflammation and swelling.

You may experience a slight feeling of weakness or chills during the first 24 hours. This should not be a cause for alarm, but it should be reported at your next visit. Follow your regular daily activities, but avoid excessive exertion of any type. Golf, tennis, skiing, bowling, swimming, and sunbathing should be postponed for a few days after the operation.

Swelling is not unusual, particularly in areas that required extensive surgical procedures. The swelling generally begins 1 to 2 days after the operation and subsides gradually after 3 or 4 days. If this occurs, apply moist heat over the operated area. If the swelling is painful or appears to become worse, please call the office.

Occasionally, blood may be seen in the saliva for the first 4 or 5 hours after the operation. This is not unusual, and it will correct itself. If there is considerable bleeding beyond this, take a piece of gauze, form it into the shape of the letter U, hold it with your thumb and index finger, apply it to both sides of the pack, and hold it there under pressure for 20 minutes. Do not remove it during this period to examine it. If the bleeding does not stop at the end of 20 minutes, please contact the office. Do not try to stop bleeding by rinsing the area with water.

After the pack is removed, the gums most likely will bleed more than they did before the operation. This is perfectly normal during the early stage of healing, and it will gradually subside. Do not stop cleaning because of it. If any other problems arise, please call the office.

patient should be questioned regarding the progress of the symptoms. Gradually diminishing severity is a favorable sign. The pack should be removed and the gingiva checked for localized areas of infection or irritation, which should be cleaned or incised to provide drainage. Particles of calculus that may have been overlooked should be removed. Relieving the occlusion is usually helpful. Sensitivity to percussion may also be caused by excess pack, which interferes with the occlusion. Removal of the excess usually corrects the condition.

3. *Swelling.* During the first 2 postoperative days, some patients may report a soft, painless swelling of the cheek in the surgical area. Lymph node enlargement may occur, and the temperature may be slightly elevated. The area of operation itself is usually symptom free. This type of involvement results from a localized inflammatory reaction to the procedure. It generally subsides by the fourth postoperative day, without necessitating the removal of the pack. If swelling persists, becomes worse, or is associated with increased pain, amoxicillin (500 mg) should be taken every 8 hours for 1 week, and the patient should also be instructed to apply moist heat intermittently over the area. The antibiotic should also be used as a prophylactic measure after the next procedure, starting before the surgical appointment.
4. *Feeling of weakness.* Occasionally, patients report having experienced a "washed-out," weakened feeling for about 24 hours after surgery. This represents a systemic reaction to a transient bacteremia induced by the procedure. This reaction is prevented by premedication with amoxicillin (500 mg) every 8 hours, beginning 24 hours before the next procedure and continuing for 5 days postoperatively.

Removal of Pack and Return Visit

When the patient returns after 1 week, the periodontal pack is taken off by inserting a surgical hoe along the margin and exerting gentle lateral pressure. Pieces of pack retained interproximally and particles adhering to the tooth surfaces are removed with scalers. Particles may be enmeshed in the cut surface and should be carefully picked off with fine cotton pliers. The entire area is rinsed with peroxide to remove superficial debris.

Findings at Pack Removal. The following are usual findings when the pack is removed:

- If a g*ingivectomy* has been performed, the cut surface is covered with a friable meshwork of new epithelium, which should not be disturbed. If calculus has not been completely removed, red,

beadlike protuberances of granulation tissue will persist. The granulation tissue must be removed with a curette to expose the calculus so that it can be removed and so the root can be planed. Removal of the granulation tissue without the removal of calculus is followed by recurrence.
- After a *flap operation*, the areas that correspond to the incisions are epithelialized, but they may bleed readily when touched; they should not be disturbed. Pockets should not be probed.
- The facial and lingual mucosa may be covered with a grayish-yellow or white granular layer of food debris that has seeped under the pack. This is easily removed with a moist cotton pellet. The root surfaces may be sensitive to a probe or to thermal changes, and the teeth may be stained.
- *Fragments of calculus delay healing.* Each root surface should be rechecked visually to be certain that no calculus is present. Sometimes the color of the calculus is similar to that of the root. The grooves on proximal root surfaces and the furcations are areas where calculus is likely to be overlooked.

Repacking. After the pack is removed, it is usually not necessary to replace it. However, repacking for an additional week is advised for the following types of patients: (1) those with a low pain threshold who are particularly uncomfortable when the pack is removed; (2) those with unusually extensive periodontal involvement; or (3) those who heal slowly. Clinical judgment helps when deciding whether to repack the area or leave the initial pack on for more than 1 week.

Tooth Mobility. Tooth mobility is increased immediately after surgery,[8] but it diminishes below the pretreatment level by the fourth week.[25]

Mouth Care Between Procedures

Care of the mouth by the patient between the treatment of the first and the final areas as well as after surgery is completed is extremely important.[48] These measures should begin after the pack is removed from the first surgery. The patient has been through a presurgical period of instructed plaque control and should be reinstructed at this time.

Vigorous brushing is not feasible during the first week after the pack is removed. However, the patient is informed that plaque and food accumulation impair healing, and he or she is advised to try to keep the area as clean as possible with the gentle use of soft toothbrushes and light water irrigation. Rinsing with a chlorhexidine mouthwash or applying such a rinse topically with cotton-tipped applicators is indicated for the first few postoperative weeks, particularly in advanced cases. Brushing is introduced when the healing of the tissues permits it; the vigor of the overall hygiene regimen is increased as healing progresses. Patients should be told that (1) more gingival bleeding will most likely occur than was present before the procedure; (2) that this bleeding is perfectly normal and that is will subside as healing progresses; and (3) that it should not deter them from following their oral hygiene regimen.

Management of Postoperative Pain

Periodontal surgery that follows the basic principles outlined here should produce only minor pain and discomfort.[41] One study of 304 consecutive periodontal surgical interventions revealed that 51.3% of the patients reported minimal or no postoperative pain, and only 4.6% reported severe pain. Of these, only 20.1% took five or more doses of analgesic.[11] The same study showed that mucogingival procedures result in six times more discomfort and that osseous surgery is three and a half times more uncomfortable than plastic gingival surgery. For the few patients who may have severe pain, its control then becomes an important part of patient management.[29]

A common source of postoperative pain is the overextension of the periodontal pack onto the soft tissue beyond the mucogingival junction or onto the frena. Overextended packs cause localized areas of edema that are usually noticed 1 to 2 days after surgery. The removal of excess pack is followed by resolution in about 24 hours. Extensive and excessively prolonged exposure and dryness of bone also induce severe pain. For most healthy patients, a preoperative dose of ibuprofen (600 mg to 800 mg) followed by one tablet every 8 hours for 24 to 48 hours is very effective for reducing discomfort after periodontal therapy. Patients are advised to continue taking ibuprofen or to change to acetaminophen thereafter, if needed. If pain persists, acetaminophen plus codeine (Tylenol #3) can be prescribed. Caution should be used when prescribing or dispensing ibuprofen to patients with hypertension controlled by medications, because it can interfere with the effectiveness of the medication. When severe postoperative pain is present, the patient should be seen at the office on an emergency basis. The area is anesthetized by infiltration or topically, the pack is removed, and the wound is examined. Postoperative pain related to infection is accompanied by localized lymphadenopathy and a slight elevation in temperature.[31] It should be treated with systemic antibiotics and analgesics.

Surgical Instruments

Periodontal surgery is accomplished with numerous instruments; Figure 55-5 shows a typical surgical cassette. Periodontal surgical instruments are classified as follows:
1. Excisional and incisional instruments
2. Surgical curettes and sickles
3. Periosteal elevators
4. Surgical chisels
5. Surgical files
6. Scissors
7. Hemostats and tissue forceps

Excisional and Incisional Instruments

Periodontal Knives (Gingivectomy Knives). The Kirkland knife is representative of the knives that are typically used for gingivectomy. These knives can be obtained as either double-ended or single-ended instruments. The entire periphery of these kidney-shaped knives is the cutting edge (Figure 55-6, *A*).

Interdental Knives. The Orban knife (nos. 1 and 2; Figure 55-6, *B*) and the Merrifield knife (nos. 1 through 4) are examples of knives that can be used for interdental areas. These spear-shaped knives have cutting edges on both sides of the blade, and they are designed with either double-ended or single-ended blades.

Surgical Blades. Scalpel blades of different shapes and sizes are used in periodontal surgery. The most common blades are nos. 12D, 15, and 15C (Figure 55-7). The no. 12D blade is a beak-shaped blade with cutting edges on both sides, which allow the operator to engage narrow, restricted areas with both pushing and pulling cutting motions. The no. 15 blade is used for thinning flaps and general purposes. The no. 15C blade, which is a narrower version of the no. 15 blade, is useful for making the initial, scalloping-type incision. The slim design of this blade allows for incising into the narrow interdental portion of the flap. All of these blades are discarded after one use.

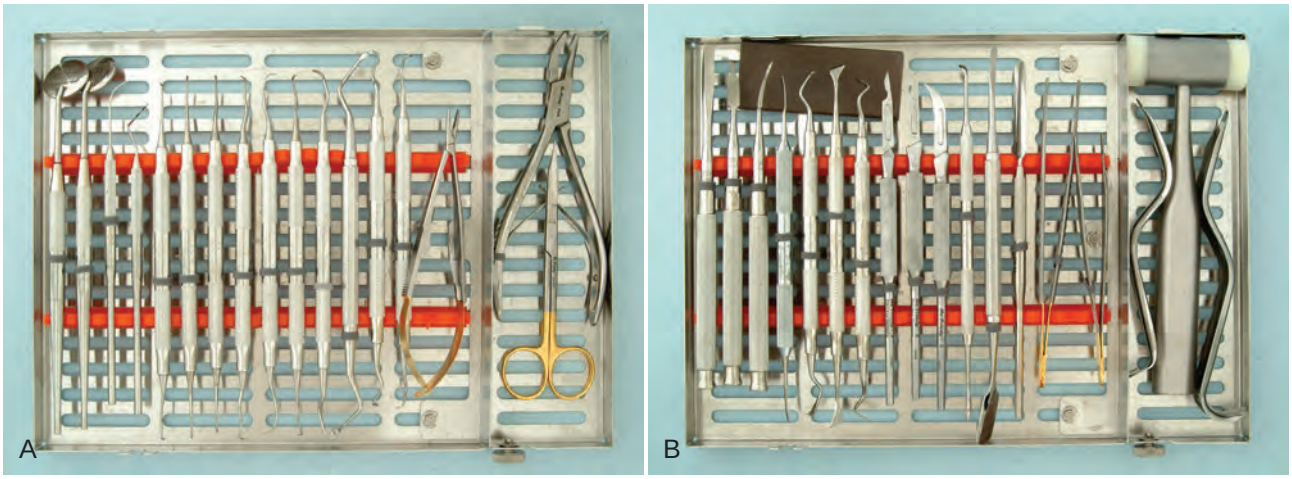

Figure 55-5 A typical series of periodontal surgical instruments, divided into two cassettes. **A,** *From left,* Mirrors, explorer, probe, series of curettes, needleholder, rongeurs, and scissors. **B,** *From left,* Series of chisels, Kirkland knife, Orban knife, scalpel handles with surgical blades (nos. 15C, 15, and 12D), periosteal elevators, spatula, tissue forceps, cheek retractors, mallet, and sharpening stone. *(**A,** Courtesy Hu-Friedy, Chicago, IL. **B,** Courtesy G. Hartzell & Son, Concord, CA.)*



Figure 55-6 Gingivectomy knives. **A,** Kirkland knife. **B,** Orban interdental knife.

Figure 55-7 Surgical blades. *Top to bottom,* Nos. 15, 12D, and 15C. These blades are disposable.

Electrosurgery (Radiosurgery) Techniques and Instrumentation. The terms *electrosurgery* and *radiosurgery*[39] are currently used to identify surgical techniques performed on soft tissue with the use of controlled, high-frequency electrical (radio) currents in the range of 1.5 to 7.5 million cycles per second (megahertz). There are three classes of active electrodes: single-wire electrodes for incising or excising; loop electrodes for planing tissue; and heavier, bulkier electrodes for coagulation procedures.[16,28]

The four basic types of electrosurgical techniques are electrosection, electrocoagulation, electrofulguration, and electrodesiccation.

Electrosection, which is also referred to as *electrotomy* or *acusection,* is used for incisions, excisions, and tissue planing. Incisions and excisions are performed with single-wire active electrodes that can be bent or adapted to accomplish any type of cutting procedure.

Electrocoagulation provides a wide range of coagulation and hemorrhage control by using the electrocoagulation current. Electrocoagulation can prevent bleeding or hemorrhage at the initial entry into soft tissue, but it cannot stop bleeding after blood is present. All forms of hemorrhage must be stopped first by some form of direct pressure (e.g., air, compress, hemostat). After bleeding has momentarily stopped, the final sealing of the capillaries or large vessels can be accomplished with a short application of the electrocoagulation current. The active electrodes that are used for coagulation are much bulkier than the fine tungsten wire used for electrosection. Electrosection and electrocoagulation are the procedures that are most often used in all areas of dentistry. The two monoterminal techniques, electrofulguration and electrodesiccation, are not in general use in dentistry.

The most important basic rule of electrosurgery is this: *always keep the tip moving*. The prolonged or repeated application of current to tissue induces heat accumulation and undesired tissue destruction, whereas interrupted application at intervals adequate for tissue cooling (5 to 10 seconds) reduces or eliminates heat buildup. Electrosurgery is not intended to destroy tissue; it is a controllable means of sculpturing or modifying oral soft tissue with little discomfort and hemorrhage for the patient.

The indications for electrosurgery in periodontal therapy and a description of wound healing after electrosurgery are presented in Chapter 56. Electrosurgery is contraindicated for patients who have incompatible or poorly shielded cardiac pacemakers.

Surgical Curettes and Sickles

Larger and heavier curettes and sickles are often needed during surgery for the removal of granulation tissue, fibrous interdental tissues, and tenacious subgingival deposits. The Prichard curette (Figure 55-8) and the Kirkland surgical instruments are heavy curettes, whereas the Ball scaler (nos. B2 and B3) is a popular heavy sickle. The wider, heavier blades of these instruments make them suitable for surgical procedures.

Figure 55-8 A Prichard surgical curette. The curettes that are used in surgery have wider blades than those that are used for conventional scaling and root planing.



Figure 55-9 Woodson periosteal elevator.

Figure 55-10 Back-action chisel.



Figure 55-11 Ochsenbein chisels are paired, with their cutting edges in opposite directions.

Periosteal Elevators

The periosteal elevators are needed to reflect and move the flap after the incision has been made for flap surgery. The Woodson and Prichard elevators are well-designed periosteal instruments (Figure 55-9).

Surgical Chisels

The back-action chisel is used with a pull motion Figure 55-10, whereas the straight chisel (e.g., Wedelstaedt, Ochsenbein [nos. 1 and 2]) is used with a push motion (Figure 55-11). The Ochsenbein chisel is a useful chisel with a semicircular indentation on both sides of the shank that allows the instrument to engage around the tooth and into the interdental area. The Rhodes chisel is another popular back-action chisel.

Figure 55-12 DeBakey tissue forceps.

Figure 55-13 Goldman–Fox scissors.

Tissue Forceps

The tissue forceps is used to hold the flap during suturing. It is also used to position and displace the flap after the flap has been reflected. The DeBakey forceps is an extremely efficient instrument (Figure 55-12).

Scissors and Nippers

Scissors and nippers are used in periodontal surgery to remove tabs of tissue during gingivectomy, to trim the margins of flaps, to enlarge incisions in periodontal abscesses, and to remove muscle attachments in mucogingival surgery. Many types are available, and individual preference determines the choice. The Goldman–Fox no. 16 scissors has a curved, beveled blade with serrations (Figure 55-13).

Needleholders

Needleholders are used to suture the flap at the desired position after the surgical procedure has been completed. In addition to the regular types of needleholders (Figure 55-14, *A*), the Castroviejo needleholder is used for delicate, precise techniques that require the quick and easy grasp and release of the suture (Figure 55-14, *B*).

Conclusion

The majority of periodontal surgeries can be carried out solely with the thorough application of local anesthesia, but clinicians have the obligation to ensure a patient-centered approach that includes oral,

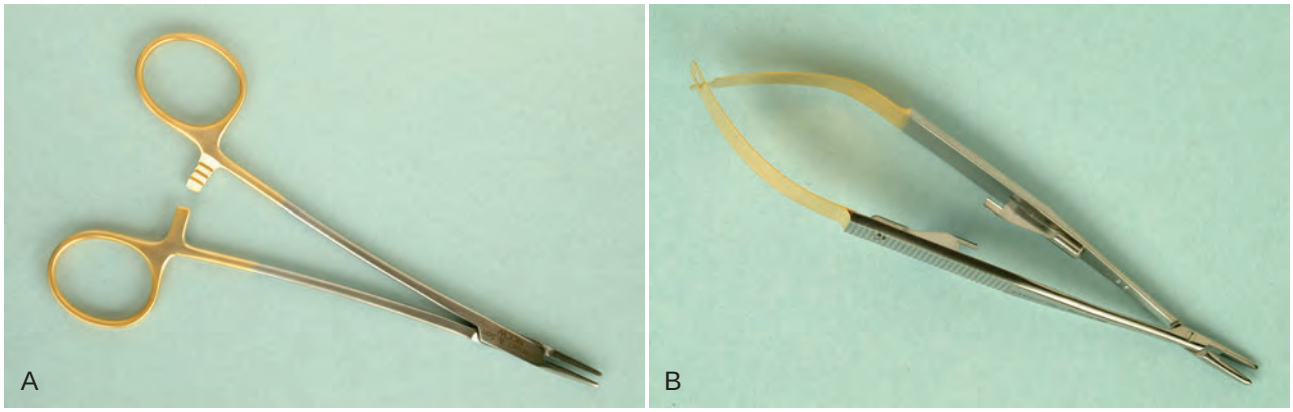

Figure 55-14 **A,** Conventional needleholder. **B,** Castroviejo needleholder.

intravenous, and inhalational sedation in their spectrum of available services to be used as needed.

The efficient, precise, and minimally traumatic management of tissues is the way to obtain the best clinical outcomes. All patients need oral analgesic support, and they should be given the necessary pain-relieving medications so that an effective level of analgesic is present during the immediate postsurgical period and thereafter as needed. The use of longer-acting local anesthesia agents (e.g., bupivacaine) and protective periodontal dressings also helps to reduce postsurgical pain.

During the immediate postsurgical weeks, plaque control and healing are enhanced by the use of antimicrobial mouthrinses such as chlorhexidine. Postsurgical root sensitivity is well controlled by ensuring that plaque control is optimal, and desensitizing agents will be needed only occasionally.

Suggested Readings

Curtis JW, Jr, McLain JB, Hutchinson RA: The incidence and severity of complications and pain following periodontal surgery. *J Periodontol* 56:597, 1985.

Douglas de Oliveira DW, Oliveira-Ferreira F, Flecha OD, et al: Is surgical root coverage effective for the treatment of cervical dentin hypersensitivity? A systematic review. *J Periodontol* 84:295, 2013.

Gangarosa LP, Sr: Current strategies for dentist-applied treatment in the management of hypersensitive dentine. *Arch Oral Biol* 39(suppl):101S, 1994.

Jones JK, Triplett RG: The relationship of cigarette smoking to impaired intraoral wound healing: a review of evidence and implications for patient care. *J Oral Maxillofac Surg* 50:237, 1992.

Pack PO, Haber J: The incidence of clinical infection after periodontal surgery: a retrospective study. *J Periodontol* 54:441, 1983.

Preber H, Bergstrom J: Effect of cigarette smoking on periodontal healing following surgical therapy. *J Clin Periodontol* 17:324, 1990.

Sachs HA, Farnoush A, Checchi L, et al: Current status of periodontal dressings. *J Periodontol* 55:689, 1984.

Sykes LM: Dentine hypersensitivity: a review of its aetiology, pathogenesis and management. *SADJ* 62:66, 2007.

Trowbridge HO, Silver DR: A review of current approaches to in-office management of tooth hypersensitivity. *Dent Clin North Am* 34:583, 1990.

Westfelt E, Nyman S, Socransky SS: Significance of frequency of professional cleaning for healing following periodontal surgery. *J Clin Periodontol* 10:148, 1983.

References

References for this chapter are found on the companion website www.expertconsult.com.

References

1. *ADA guide to dental therapeutics*, Chicago, 1998, American Dental Association.
2. Addy M, Douglas WH: A chlorhexidine-containing methacrylic gel as a periodontal dressing. *J Periodontol* 46:465, 1975.
3. Allen GD: *Dental anesthesia and analgesia (local and general)*, ed 3, Baltimore, 1984, Williams & Wilkins.
4. Ariaudo AA: The efficacy of antibiotics in periodontal surgery. *J Periodontol* 40:150, 1969.
5. Baer PN, Goldman HM, Scigliano J: Studies on a bacitracin periodontal dressing. *Oral Surg* 11:712, 1958.
6. Baer PN, Summer CF, III, Miller G: Periodontal dressings. *Dent Clin North Am* 13:181, 1969.
7. Blitzer B: A consideration of the possible causes of dental hypersensitivity: treatment by a strontium ion dentifrice. *Periodontics* 5:318, 1967.
8. Burch J, Conroy CW, Ferris RT: Tooth mobility following gingivectomy: a study of gingival support of the teeth. *Periodontics* 6:90, 1960.
9. Collins JF, Gingold J, Stanley H, et al: Reducing dentinal hypersensitivity with strontium chloride and potassium nitrate. *Gen Dent* 32:40, 1984.
10. Curro FA: Tooth hypersensitivity. *Dent Clin North Am* 34:403, 1990.
11. Curtis JW, Jr, McLain JB, Hutchinson RA: The incidence and severity of complications and pain following periodontal surgery. *J Periodontol* 56:597, 1985.
12. Dal Pra DJ, Strahan JD: A clinical evaluation of the benefits of a course of oral penicillin following periodontal surgery. *Aust Dent J* 17:219, 1972.
13. Fraleigh CM: An evaluation of topical Terramycin in postgingivectomy pack. *J Periodontol* 27:201, 1956.
14. Gangarosa LP, Sr: Current strategies for dentist-applied treatment in the management of hypersensitive dentine. *Arch Oral Biol* 39(Suppl):101S, 1994.
15. Gerschman JA, Ruben J, Gebart-Eaglemont J: Low-level laser therapy for dentinal tooth hypersensitivity. *Aust Dent J* 39:353, 1994.
16. Gnanasekhar JD, al-Duwairi YS: Electrosurgery in dentistry. *Quintessence Int* 29:649, 1998.
17. Hirschfeld AS, Wassermen BH: Retention of periodontal packs. *J Periodontol* 29:199, 1958.
18. Holmes CH: Periodontal pack on single tooth retained by acrylic splint. *J Am Dent Assoc* 64:831, 1962.
19. Javelet J, Torabinejad M, Danforth A: Isobutyl cyanoacrylate: a clinical and histological comparison with sutures in closing mucosal incisions in monkeys. *Oral Surg* 59:91, 1985.
20. Jones JK, Triplett RG: The relationship of cigarette smoking to impaired intraoral wound healing: a review of evidence and implications for patient care. *J Oral Maxillofac Surg* 50:237, 1992.
21. Kidd EA, Wade AB: Penicillin control of swelling and pain after periodontal osseous surgery. *J Clin Periodontol* 1:52, 1974.
22. Lan WH, Liu HC: Treatment of dentin hypersensitivity by Nd:YAG laser. *J Clin Laser Med Surg* 14:89, 1996.
23. Lan WH, Liu HC, Lin CP: The combined occluding effect of sodium fluoride varnish and Nd:YAG laser irradiation on human dentinal tubules. *J Endod* 25:424, 1999.
24. Levin MP, Cutright DE, Bhaskar SN: Cyanoacrylate as a periodontal dressing. *J Oral Med* 30:40, 1975.
25. Majewski I, Sponholz H: Ergebnisse nach parodonal therapeutischen massnahmen unter besonderer berucksichtigung der zahnbeweglichkeitssung mit dem makroperiodontometer nach muhlemann. *Zahnaerztl Rundsch* 75:57, 1966.
26. Malamed SF: *Sedation: a guide to patient management*, ed 3, St Louis, 1995, Mosby.
27. Miller JT, Shannon KL, Kilyore WG, et al: Use of water-free stannous fluoride–containing gel in the control of dental hypersensitivity. *J Periodontol* 40:490, 1969.
28. Moore DA: Electrosurgery in dentistry: past and present. *Gen Dent* 43:460, 1995.
29. Murphy NC, DeMarco TJ: Controlling pain in periodontal patients. *Dent Surv* 55:46, 1979.
30. Newman MG, Sanz M, Nachnani S, et al: Effect of 0.12% chlorhexidine on bacterial recolonization after periodontal surgery. *J Periodontol* 60:577, 1989.
31. Pack PO, Haber J: The incidence of clinical infection after periodontal surgery: a retrospective study. *J Periodontol* 54:441, 1983.
32. Pendrill K, Reddy J: The use of prophylactic penicillin in periodontal surgery. *J Periodontol* 51:44, 1980.
33. Preber H, Bergstrom J: Effect of cigarette smoking on periodontal healing following surgical therapy. *J Clin Periodontol* 17:324, 1990.
34. Romanow I: Allergic reactions to periodontal pack. *J Periodontol* 28:151, 1957.
35. Romanow I: Relationship of moniliasis to the presence of antibiotics in periodontal packs. *Periodontics* 2:298, 1964.
36. Ross MR: Hypersensitive teeth: effect of strontium chloride in a compatible dentifrice. *J Periodontol* 32:49, 1961.
37. Sachs HA, Fanroush A, Checchi L, et al: Current status of periodontal dressings. *J Periodontol* 55:689, 1984.
38. Sanz M, Newman MG, Anderson L, et al: Clinical enhancement of post-periodontal surgical therapy by 0.12 per cent chlorhexidine gluconate mouthrinse. *J Periodontol* 60:570, 1989.
39. Sherman JA: *Oral radiosurgery: an illustrated clinical guide*, ed 2, London, 1997, Martin Dunitz.
40. Smith DC: A materialistic look at periodontal packs. *Dent Pract Dent Rec* 20:273, 1970.
41. Strahan JD, Glenwright HD: Pain experience in periodontal surgery. *J Periodontal Res* 1:163, 1967.
42. Tarbet WJ, Silverman G, Stolman JW, et al: A clinical evaluation of a new treatment for dentinal hypersensitivity. *J Periodontol* 51:535, 1980.
43. Tonetti MS, Pini Prato G, Cortellini P: Effect of cigarette smoking on periodontal healing following GTR in infrabony pockets: a preliminary retrospective study. *J Clin Periodontol* 22:229, 1995.
44. Trowbridge HO, Silver DR: A review of current approaches to in-office management of tooth hypersensitivity. *Dent Clin North Am* 34:583, 1990.
45. Vaughan ME, Garnick JJ: The effect of 0.125 per cent chlorhexidine rinse on inflammation after periodontal surgery. *J Periodontol* 60:704, 1989.
46. Ward AW: Inharmonious cusp relation as a factor in periodontoclasia. *J Am Dent Assoc* 10:471, 1923.
47. Watts TA, Combe EC: Adhesion of periodontal dressings to enamel in vitro. *J Clin Periodontol* 7:62, 1980.
48. Westfelt E, Nyman S, Socransky SS: Significance of frequency of professional cleaning for healing following periodontal surgery. *J Clin Periodontol* 10:148, 1983.

CHAPTER 56

Gingival Surgical Techniques

Henry H. Takei, Fermin A. Carranza, and Kitetsu Shin

CHAPTER OUTLINE

Gingival Curettage
Gingivectomy
Gingivectomy by Electrosurgery *(e-only)*
Laser Gingivectomy *(e-only)*
Gingivectomy by Chemosurgery *(e-only)*
Conclusion

For online-only content on gingivectomy by electrosurgery, laser gingivectomy, and gingivectomy by chemosurgery, please visit the companion website at www.expertconsult.com.

Periodontal pocket reduction surgery limited to the gingival tissues only and not involving the underlying osseous structures, without the use of flap surgery, can be classified as *gingival curettage* and *gingivectomy.* The current understanding of disease etiology and therapy limits the use of both techniques, but their place in surgical therapy is essential.

Gingival Curettage

The word *curettage* is used in periodontics to mean the scraping of the gingival wall of a periodontal pocket to remove diseased soft tissue. *Scaling* refers to the removal of deposits from the root surface, whereas *planing* means smoothing the root to remove infected and necrotic tooth substance. Scaling and root planing may inadvertently include various degrees of curettage. However, they are different procedures with different rationales and indications. Both should be considered separate parts of periodontal treatment.

Curettage in periodontics has been defined as gingival and subgingival curettage (Figure 56-1). *Gingival curettage* consists of the removal of the inflamed soft tissue lateral to the pocket wall and the junctional epithelium. *Subgingival curettage* refers to the procedure that is performed apical to the junctional epithelium and that severs the connective tissue attachment down to the osseous crest.

It should also be understood that some degree of curettage is accomplished unintentionally during scaling and root planing and is referred to *inadvertent curettage.* This chapter refers to the intentional curettage performed during the same visit as scaling and root planing or as a separate procedure to reduce pocket depth by enhancing gingival shrinkage, new connective tissue attachment, or both.

Rationale

Curettage accomplishes the removal of the chronically inflamed granulation tissue that forms in the lateral wall of the periodontal pocket. This tissue, in addition to the usual components of granulation tissues (i.e., fibroblastic and angioblastic proliferation), contains areas of chronic inflammation, and it may also contain pieces of dislodged calculus and bacterial colonies. The latter may perpetuate the pathologic features of the tissue and hinder healing.

This inflamed granulation tissue is lined by epithelium, and deep strands of epithelium penetrate into the tissue. The presence of this epithelium is construed as a barrier to the attachment of new fibers in the area.

When the root is thoroughly planed, the major source of bacteria disappears, and the pathologic changes in the tissues adjacent to the pocket resolve with no need to eliminate the inflamed granulation tissue by curettage. The existing granulation tissue is slowly resorbed, and the bacteria present in the tissue without replenishment of their numbers from the plaque in the pocket are destroyed by the defense mechanisms of the host. *Therefore, the need for curettage to eliminate the inflamed granulation tissue appears to be questionable.* (This should not be confused with the elimination of granulation tissue during flap surgery. The reason for the latter is to remove the bleeding tissue that obstructs visualization and prevents the necessary examination of the root surface and the bone morphology. Thus, the removal of granulation tissue during surgery is accomplished for technical rather than biologic reasons.) It has been shown that scaling and root planing with additional curettage do not improve the condition of the periodontal tissues beyond the improvement that results from scaling and root planing alone.

Curettage may also eliminate all or most of the epithelium that lines the pocket wall and the underlying junctional epithelium. Curettage for this purpose is still valid, particularly when an attempt is made for new attachment, as occurs in intrabony pockets. However, opinions differ with regard to whether scaling and curettage consistently remove the pocket lining and the junctional epithelium. Some investigators report that scaling and root planing tear the epithelial lining of the pocket without removing either it or the junctional epithelium.[33] Others claim that both epithelial structures[6,7,32] and sometimes the underlying inflamed connective tissue[34] are removed by curettage. Some investigators have reported that the removal of the pocket lining and the junctional epithelium by curettage is not complete.[51,54,57]

Gingivectomy by Electrosurgery

Advantage and Disadvantages

Electrosurgery permits an adequate contouring of the tissue and controls hemorrhage.[15,17,39]

It cannot be used in patients who have incompatible or poorly shielded cardiac pacemakers. The treatment causes an unpleasant odor. If the electrosurgery point touches the bone, irreparable damage can be inflicted.[2,17,22,44] Furthermore, the heat generated by injudicious use can cause tissue damage and a loss of periodontal support when the electrode is used close to bone. When the electrode touches the root, areas of cementum can be burned.[60] *Therefore, the use of electrosurgery should be limited to superficial procedures such as the removal of gingival enlargements, gingivoplasty, the relocation of the frenum and muscle attachments, and the incision of periodontal abscesses and pericoronal flaps.* Extreme care should be used to avoid contacting the tooth surface. *Electrosurgery should not be used for procedures that involve proximity to the bone (e.g., flap operations) or for mucogingival surgery.*

Technique

The removal of gingival enlargements and gingivoplasty[39] is performed with a needle electrode supplemented by a small ovoid loop or diamond-shaped electrodes for festooning. A blended cutting and coagulating (fully rectified) current is used. During all reshaping procedures, the electrode is activated and moved in a concise "shaving" motion.

For the treatment of acute periodontal abscesses, the incision to establish drainage can be made with the needle electrode without exerting pressure. The incision remains open, because the edges are sealed by the current. After the acute symptoms subside, the regular procedure for the treatment of the periodontal abscess is followed (see Chapter 42).

For hemostasis, a ball electrode is used. Hemorrhage must first be controlled by direct pressure using air, a compress, or a hemostat; the surface is then lightly touched with a coagulating current. Electrosurgery is helpful for the control of isolated bleeding points. Bleeding areas located interproximally are reached with a thin, bar-shaped electrode.

Frenum and muscle attachments can be relocated to facilitate pocket elimination with the use of a loop electrode. For this purpose, the frenum or muscle is stretched and sectioned with the loop electrode and a coagulating current. For cases of acute pericoronitis, drainage may be obtained by incising the flap with a bent-needle electrode. A loop electrode is used to remove the flap after the acute symptoms subside.

Healing After Electrosurgery

Some investigators report no significant differences in gingival healing after resection by electrosurgery as compared with resection with periodontal knives.[14,31] Other researchers find delayed healing, a greater reduction in gingival height, and more bone injury after electrosurgery.[44] There appears to be little difference in the results obtained after shallow gingival resection with electrosurgery and those obtained with periodontal knives.[12] *However, when used for deep resections close to bone, electrosurgery can produce gingival recession, bone necrosis and sequestration, a loss of bone height, furcation exposure, and tooth mobility.* These problems do not occur with the use of periodontal knives.[2,17]

Laser Gingivectomy

The lasers that are most often used in dentistry are the carbon dioxide (CO_2) laser and the neodymium: yttrium-aluminum-garnet (Nd:YAG) laser, which have wavelengths of 10,600 nm and 1064 nm, respectively. They are both in the infrared range, so they must be combined with other types of visible lasers for the beam to be seen and aimed.

The CO_2 laser has been used for the excision of gingival growths,[3,42] although healing is delayed as compared with healing after conventional scalpel gingivectomy.[21,30,43] The use of a laser for oral surgery requires precautionary measures to avoid reflecting the beam on instrument surfaces, which could result in injury to neighboring tissues and to the eyes of the operator. (Chapter 65 includes additional information about laser therapy.)

Gingivectomy by Chemosurgery

Techniques to remove the gingiva with the use of chemicals such as 5% paraformaldehyde[38] or potassium hydroxide[29] have been described in the past, but they are not currently used. They are presented here to provide a historical perspective.

The chemical gingivectomy has the following disadvantages:

- The depth of action cannot be controlled; therefore, healthy attached tissue underlying the pocket may be injured.
- Gingival remodeling cannot be accomplished effectively.
- Epithelialization and reformation of the junctional epithelium and reestablishment of the alveolar crest fiber system occur more slowly in chemically treated gingival wounds than in those produced by a scalpel.[55]

The use of chemical methods therefore is not recommended.

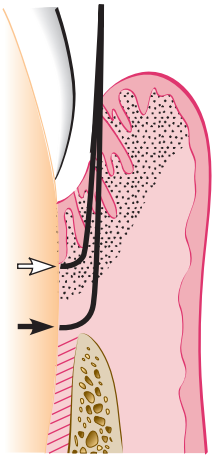

Figure 56-1 Extent of gingival curettage *(white arrow)* and subgingival curettage *(black arrow).*

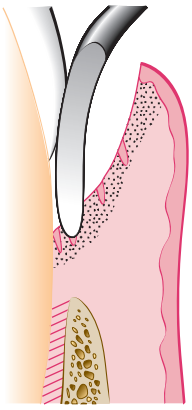

Figure 56-2 Gingival curettage performed with a horizontal stroke of the curette.

Curettage and Aesthetics. An awareness of aesthetics in periodontal therapy has become an integral part of care in the modern practice of periodontics. In the past, pocket elimination was the primary goal of therapy, and little regard was given to the aesthetic result. Rapid shrinkage of the gingival tissue was the goal to eliminate the pocket. Currently, aesthetics is a major consideration of therapy, especially in the maxillary anterior area (teeth #6 through #11), and every effort is made to minimize gingival tissue shrinkage and to preserve the interdental papilla.

Compromise therapy is feasible in the anterior maxilla. This therapy consists of thorough subgingival root planing while attempting to not detach the connective tissue attachment beneath the junctional epithelium. Gingival curettage should be avoided. The granulation tissue in the lateral wall of the pocket, in an environment that is free of plaque and calculus, becomes connective tissue, thereby minimizing gingival shrinkage. Thus, although complete pocket elimination is not accomplished, the inflammatory changes are reduced or eliminated, and the interdental papilla and the aesthetic appearance of the area are preserved.

There are many instances in which a surgical flap is necessary for access to the root surface for scaling and root planing. A surgical technique that has been specially designed to minimize gingival recession and preserve the interdental papilla is the *papilla preservation technique* (see Chapter 59).

Another important precaution is to avoid root planing apical to the base of the pocket to the osseous crest. The removal of the junctional epithelium and the disruption of the connective tissue attachment exposes the nondiseased portion of the cementum. Root planing and the removal of the nondiseased cementum may result in excessive shrinkage of the gingiva, which results in increased gingival recession.

Indications

Indications for curettage are very limited. It can be used after scaling and root planing for the following purposes:

1. Curettage can be performed as part of new attachment attempts in moderately deep intrabony pockets located in accessible areas in which a nonflap type of "closed" surgery is indicated.
2. Curettage can be attempted as a nondefinitive procedure to reduce inflammation when aggressive surgical techniques (e.g., flaps) are contraindicated in patients as a result of their age, systemic problems, psychologic problems, or other factors. It should be understood that, in these patients, the goal of pocket elimination is compromised, and their prognosis is impaired. The clinician should attempt this approach only when the indicated surgical techniques cannot be performed and both the clinician and the patient have a clear understanding of its limitations.
3. Curettage is also frequently performed on recall visits[45] as a method of maintenance treatment for areas of recurrent inflammation and pocket depth, especially where pocket reduction surgery has previously been performed. Careful probing should establish the extent of the required root planing and curettage.

Procedure

Basic Technique. Curettage does not eliminate the causes of inflammation (i.e., bacterial plaque and deposits). *Therefore, curettage should always be preceded by scaling and root planing,* which is the basic periodontal therapy procedure (see Chapter 46). The use of local infiltrative anesthesia for scaling and root planing is optional. However, gingival curettage will always require some type of local anesthesia.

The curette is selected so that the cutting edge is against the tissue (e.g., Gracey no. 13 or 14 for mesial surfaces, Gracey no. 11 or 12 for distal surfaces). Curettage can also be performed with a 4R-4L Columbia Universal curette. The instrument is inserted to engage the inner lining of the pocket wall, and it is then carried along the soft tissue, usually in a horizontal stroke (Figure 56-2). The pocket wall may be supported by gentle finger pressure on the external surface. The curette is then placed under the cut edge of the junctional epithelium to undermine it.

During subgingival curettage, the tissues attached between the bottom of the pocket and the alveolar crest are removed with a scooping motion of the curette to the tooth surface (Figure 56-3). The area is flushed to remove debris, and the tissue is partly adapted to the tooth by gentle finger pressure. In some cases, the suturing of separated papillae and the application of a periodontal pack may be indicated.

Other Techniques. Other techniques for gingival curettage include the excisional new attachment procedure, ultrasonic curettage, and the use of caustic drugs:

Excisional New Attachment Procedure. The excisional new attachment procedure has been developed and used by the US Naval Dental Corps.[40,62,63] It is a definitive subgingival curettage procedure that is performed with a knife. The excisional new attachment procedure technique is as follows:

1. After adequate anesthesia, make an internal bevel incision from the margin of the patient's free gingiva apically to a point below

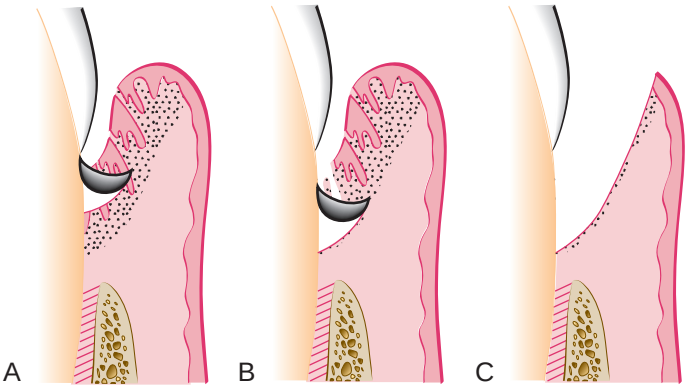

Figure 56-3 Subgingival curettage. **A,** Elimination of pocket lining. **B,** Elimination of junctional epithelium and granulation tissue. **C,** Procedure completed.

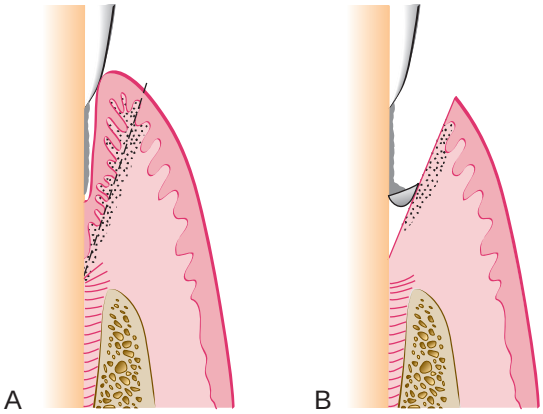

Figure 56-4 Excisional new attachment procedure. **A,** Internal bevel incision to a point below the bottom of the pocket. **B,** After the excision of tissue, scaling and root planing are performed.

the bottom of the pocket (Figure 56-4). Carry the incision interproximally on both the facial and the lingual side, and attempt to retain as much interproximal tissue as possible. The intention is to cut the inner portion of the soft-tissue wall of the pocket all around the tooth.

2. Remove the excised tissue with a curette, and carefully perform root planing on all exposed cementum to achieve a smooth, hard consistency. Preserve all connective tissue fibers that remain attached to the root surface.
3. Approximate the wound edges. If they do not meet passively, recontour the bone until good adaptation of the wound edges is achieved. Place sutures and a periodontal dressing.

Ultrasonic Curettage. The use of ultrasonic devices has been recommended for gingival curettage.[35] When applied to the gingiva of experimental animals, ultrasonic vibrations disrupt tissue continuity, lift off the epithelium, dismember collagen bundles, and alter the morphologic features of fibroblast nuclei.[20] Ultrasound is effective for debriding the epithelial lining of periodontal pockets. This results in a narrow band of necrotic tissue (microcauterization), which strips off the inner lining of the pocket.

The Morse scaler-shaped and rod-shaped ultrasonic instruments are used for this purpose. Some investigators found ultrasonic instruments to be as effective as manual instruments for curettage[35,50,64] and that such tools resulted in less inflammation and less removal of underlying connective tissue. The gingiva can be made more rigid for ultrasonic curettage by injecting anesthetic solution directly into it.[10]

Caustic Drugs. Since early in the development of periodontal procedures,[53,61] the use of caustic drugs has been recommended to induce a chemical curettage of the lateral wall of the pocket or even the selective elimination of the epithelium. Drugs such as sodium sulfide, alkaline sodium hypochlorite solution (Antiformin),[8,24,26] and phenol[4,9] have been proposed and then discarded after studies indicated their ineffectiveness.[5,18,26] The extent of tissue destruction with these drugs cannot be controlled, and they may increase rather than reduce the amount of tissue to be removed by enzymes and phagocytes.

Healing After Scaling and Curettage

Immediately after curettage, a blood clot fills the pocket area, which is totally or partially devoid of epithelial lining. Hemorrhage is also present in the tissues with dilated capillaries and abundant polymorphonuclear leukocytes, which appear on the wound surface. This is followed by a rapid proliferation of granulation tissue with a decrease in the number of small blood vessels as the tissue matures.

The restoration and epithelialization of the sulcus generally require 2 to 7 days,[27,34,37,57] and restoration of the junctional epithelium occurs in animals as early as 5 days after treatment. Immature collagen fibers appear within 21 days. Healthy gingival fibers that are inadvertently severed from the tooth and tears in the epithelium are repaired during the healing process.[33,46] Several investigators have reported that, in monkeys[11,62] and humans[58] treated by scaling and curettage, healing results in the formation of a long, thin junctional epithelium with no new connective-tissue attachment. In some cases, this long epithelium is interrupted by "windows" of connective-tissue attachment.[11]

Clinical Appearance After Scaling and Curettage

Immediately after scaling and curettage, the gingiva appears hemorrhagic and bright red. After 1 week, the gingiva appears reduced in height as a result of an apical shift in the position of the gingival margin. The gingiva is also darker red than normal, but it is much less red than it will have been on previous days. After 2 weeks and with proper oral hygiene, the normal color, consistency, surface texture, and contour of the gingiva are attained, and the gingival margin is well adapted to the tooth.

Gingivectomy

The word *gingivectomy* means "excision of the gingiva." By removing the pocket wall, gingivectomy provides visibility and accessibility for complete calculus removal and the thorough smoothing of the roots (Figure 56-5). This creates a favorable environment for gingival healing and restoration of a physiologic gingival contour.

The gingivectomy technique was widely performed in the past. Improved understanding of healing mechanisms and the development of more sophisticated flap methods have relegated the gingivectomy to a lesser role in the current repertoire of available techniques. However, it remains an effective form of treatment when indicated (see Figure 56-5).

Indications and Contraindications

The gingivectomy technique may be performed for the following indications[16]:

1. Elimination of suprabony pockets, regardless of their depth, if the pocket wall is fibrous and firm
2. Elimination of gingival enlargements
3. Elimination of suprabony periodontal abscesses

Figure 56-5 Results obtained by treating a suprabony pocket with gingivectomy. **A** and **B,** Preoperative facial and palatal views. **C,** Marking of the depth of the suprabony pocket. **D,** The bottoms of the pockets are indicated by pinpoint markings. **E,** A beveled palatal incision with an Orban knife. **F,** A facial beveled incision with a Bard–Parker no. 15 blade extends apical to the perforations made by the pocket marker. Note that the beveled incision can also be made with a Kirkland knife. **G,** The interdental incision and excision of the pocket wall with a Bard–Parker no. 12 blade. **H,** A completed gingivectomy. **I,** The surgical site covered with periodontal dressing. **J,** One week after healing. **K** and **L,** Results 22 months after the operation.

Contraindications to gingivectomy include the following:

1. The need for bone surgery or examination of the bone shape and morphology
2. Situations in which the bottom of the pocket is apical to the mucogingival junction
3. Aesthetic considerations, particularly in the anterior maxilla

The gingivectomy technique may be performed by means of scalpels, electrodes, lasers, or chemicals. All of these techniques are reviewed in this chapter, although the surgical method is the only technique that is recommended.

Surgical Gingivectomy

Step 1. The pockets on each surface are explored with a periodontal probe and marked with a pocket marker (Figure 56-5, *C* and *D*, Figure 56-6, and Figure 56-7). Each pocket is marked in several areas to outline its course on each surface.

Step 2. Periodontal knives (e.g., Kirkland knives) are used for incisions on the facial and lingual surfaces and on those distal to the terminal tooth in the arch. Orban periodontal knives are used for interdental incisions (Figure 56-5, *E, F,* and *G*). Bard–Parker

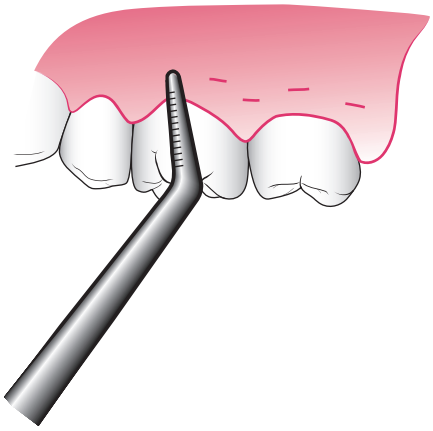

Figure 56-6 The pocket marker makes pinpoint perforations that indicate pocket depth.

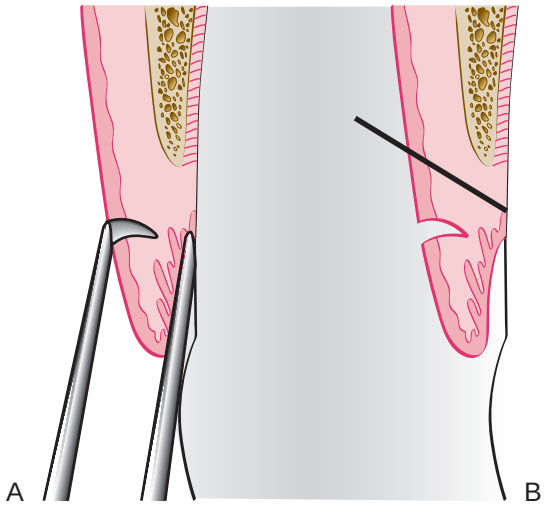

Figure 56-7 Marking the depth of a suprabony pocket. **A,** A pocket marker in position. **B,** The beveled incision extends apical to the perforation made by the pocket marker.

blades (nos. 12 and 15) as well as scissors are used as auxiliary instruments.

The incision is started apical to the points marking the course of the pockets,[48,56] and it is directed coronally to a point between the base of the pocket and the crest of the bone. It should be as close as possible to the bone without exposing it to remove the soft tissue coronal to the bone. Exposure of bone is undesirable. If this occurs, healing usually presents minimal complications if the area is adequately covered by the periodontal pack.

Either interrupted or continuous incisions may be used. The incision should be beveled at approximately 45 degrees to the tooth surface, and it should recreate the normal festooned pattern of the gingiva. Failure to bevel the incision will leave a broad, fibrous plateau that will take a longer time to develop a physiologic contour. During the interim, plaque and calculus may lead to the recurrence of pockets.

Step 3. Remove the excised pocket wall, clean the area, and closely examine the root surface. The most apical zone consists of a light, bandlike zone where the tissues were attached. Coronally, calculus remnants, root caries, or resorption may be found. Granulation tissue may be seen on the excised soft tissue (Figure 56-5, *G*).

Step 4. Carefully curette the granulation tissue and remove any remaining calculus and necrotic cementum to leave a smooth and clean surface.

Step 5. Cover the area with a surgical pack (Figure 56-5, *I*; see Chapter 55).

Gingivoplasty

Gingivoplasty is similar to gingivectomy, but its objective is different. Gingivectomy is performed to eliminate periodontal pockets, and it includes reshaping as part of the technique. Gingivoplasty is a reshaping of the gingiva to create physiologic gingival contours with the sole purpose of *recontouring the gingiva* in the absence of pockets.[19]

Gingival and periodontal disease often produces deformities in the gingiva that are conducive to the accumulation of plaque and food debris, which prolong and aggravate the disease process. Such deformities include the following: (1) gingival clefts and craters; (2) craterlike interdental papillae caused by acute necrotizing ulcerative gingivitis; and (3) gingival enlargements.

Gingivoplasty may be accomplished with a periodontal knife, a scalpel, rotary coarse diamond stones,[44] or electrodes.[13] The technique resembles that of the festooning of an artificial denture, which consists of tapering the gingival margin, creating a scalloped marginal outline, thinning the attached gingiva, creating vertical interdental grooves, and shaping the interdental papillae.

Healing After Surgical Gingivectomy

The *initial response* after gingivectomy is the formation of a protective surface blood clot. The underlying tissue becomes acutely inflamed with necrosis. The clot is then replaced by granulation tissue. In 24 hours, there is an increase in new connective tissue cells, which are mainly angioblasts beneath the surface layer of inflammation and necrotic tissue. By the third day, numerous young fibroblasts are located in the area.[47] The highly vascular granulation tissue grows coronally and creates a new free gingival margin and sulcus.[41] Capillaries derived from the blood vessels of the periodontal ligament migrate into the granulation tissue, and, within 2 weeks, they connect with the gingival vessels.[59]

After 12 to 24 hours, epithelial cells at the margins of the wound begin to migrate over the granulation tissue, thereby separating it from the contaminated surface layer of the clot. Epithelial activity at the margins reaches a peak after 24 to 36 hours.[13]

The new epithelial cells arise from the basal and deeper spinous layers of the epithelial wound edge and migrate over the wound over a fibrin layer that is later resorbed and replaced by a connective tissue bed.[25] The epithelial cells advance by a tumbling action, with the cells becoming fixed to the substrate by hemidesmosomes and a new basement lamina.[23,28]

After 5 to 14 days, surface epithelialization is generally complete (Figure 56-5, *J*). During the first 4 weeks after gingivectomy, keratinization is less than it was before surgery. Complete epithelial repair takes about 1 month.[52] Vasodilation and vascularity begin to decrease after the fourth day of healing, and they appear to be almost normal by the sixteenth day.[36] Complete repair of the connective tissue takes about 7 weeks.[52]

The flow of gingival fluid in humans is initially increased after gingivectomy, and it diminishes as healing progresses.[1,49] Maximal flow is reached after 1 week, which coincides with the time of maximal inflammation.

Although the tissue changes that occur during postgingivectomy healing are the same in all individuals, the time required for complete healing varies considerably, depending on the area of the incised surface and interference from local irritation and infection. In patients with physiologic gingival melanosis, the pigmentation is diminished in the healed gingiva.

Conclusion

The gingivectomy surgical technique has a long history of use in periodontal surgery. This technique has been attempted with the use of scalpels, electrosurgery, laser, and chemical cautery. Although this technique may have some use for the minimal reduction of redundant gingival tissue, many limiting factors must be considered. Current periodontal surgery must consider the following: (1) the conservation of keratinized gingiva; (2) minimal gingival tissue loss to maintain aesthetics; (3) adequate access to the osseous defects for definitive defect correction; and (4) minimal postsurgical discomfort and bleeding by attempting surgical procedures that will allow for primary closure. The gingivectomy surgical technique has limited use in current surgical therapy,

because it does not satisfy these considerations for periodontal therapy. The clinician must carefully evaluate each patient to address the proper application of this surgical procedure.

Suggested Readings

Engler WO, Ramfjord S, Hiniker JJ: Healing following simple gingivectomy: a tritiated thymidine radioautographic study. I. Epithelialization. *J Periodontol* 37:289, 1966.

Glickman I: The results obtained with the unembellished gingivectomy technique in a clinical study in humans. *J Periodontol* 27:247, 1956.

Lindhe J, Westfelt E, Nyman S, et al: Healing following surgical and nonsurgical treatment of periodontal disease. *J Clin Periodontol* 9:115, 1982.

Moskow BS: The response of the gingival sulcus to instrumentation: a histologic investigation. II. Gingival curettage. *J Periodontol* 35:112, 1964.

Ramfjord SP, Costich ER: Healing after exposure of the periosteum on the alveolar process. *J Periodontol* 38:199, 1968.

Ramfjord SP, Engler WD, Hiniker JJ: A radiographic study of healing following simple gingivectomy. II. The connective tissue. *J Periodontol* 37:179, 1966.

Stahl S, Witkin G, Cantor M, et al: Gingival healing. II. Clinical and histologic repair sequences following gingivectomy. *J Periodontol* 39:109, 1968.

References

References for this chapter are found on the companion website www.expertconsult.com.

References

1. Arnold R, Lunstad G, Bissada N, et al: Alterations in crevicular fluid flow during healing following gingival surgery. *J Periodontal Res* 1:303, 1966.
2. Azzi R, Kenney EB, Tsao TF, et al: The effect of electrosurgery upon alveolar bone. *J Periodontol* 54:96, 1983.
3. Barak S, Kaplan H: The CO_2 laser in the surgical excision of gingival hyperplasia caused by nifedipine. *J Clin Periodontol* 15:633, 1988.
4. Barkann A: A conservative technique for the eradication of a pyorrhea product. *J Am Dent Assoc* 26:61, 1939.
5. Beube FE: An experimental study of the use of sodium sulphide solution in treatment of periodontal pockets. *J Periodontol* 10:49, 1939.
6. Beube FE: Treatment methods for marginal gingivitis and periodontitis. *Texas Dent J* 71:427, 1953.
7. Blass JL, Lite T: Gingival healing following surgical curettage: a histopathologic study. *NY Dent J* 25:127, 1959.
8. Box KF: Periodontal disease and treatment. *J Ontario Dent Assoc* 29:194, 1952.
9. Bunting RW: The control and treatment of pyorrhea by subgingival surgery. *J Am Dent Assoc* 15:119, 1928.
10. Burman LR, Alderman LE, Ewen SJ: Clinical application of ultrasonic vibrations for supragingival calculus and stain removal. *J Dent Med* 13:156, 1958.
11. Caton JC, Zander HA: The attachment between tooth and gingival tissues after periodic root planing and soft tissue curettage. *J Periodontol* 50:462, 1979.
12. Eisenmann D, Malone WF, Kusek J: Electron microscopic evaluation of electrosurgery. *Oral Surg* 29:660, 1970.
13. Engler WO, Ramfjord S, Hiniker JJ: Healing following simple gingivectomy: a tritiated thymidine radioautographic study. I. Epithelialization. *J Periodontol* 37:289, 1966.
14. Fisher SE, Frame JW, Browne RM, et al: A comparative histological study of wound healing following CO_2 laser and conventional surgical excision of the buccal mucosa. *Arch Oral Biol* 28:287, 1983.
15. Flocken JE: Electrosurgical management of soft tissues and restoration dentistry. *Dent Clin North Am* 24:247, 1980.
16. Glickman I: The results obtained with the unembellished gingivectomy technique in a clinical study in humans. *J Periodontol* 27:247, 1956.
17. Glickman I, Imber LR: Comparison of gingival resection with electrosurgery and periodontal knives: biometric and histologic study. *J Periodontol* 41:242, 1970.
18. Glickman J, Patur B: Histologic study of the effect of Antiformin on the soft tissue wall of periodontal pockets in humans. *J Am Dent Assoc* 51:420, 1955.
19. Goldman HM: The development of physiologic gingival contours by gingivoplasty. *Oral Surg* 3:879, 1950.
20. Goldman HM: Histologic assay of healing following ultrasonic curettage versus hand-instrument curettage. *Oral Surg Oral Med Oral Pathol* 14:925, 1961.
21. Gottsegen R, Ammons WF, Jr: *Position paper: research in lasers in periodontics*, Chicago, 1992, American Academy of Periodontology.
22. Henning F: Healing of gingivectomy wounds in the rat: reestablishment of the epithelial seal. *J Periodontol* 39:265, 1968.
23. Henning F: Epithelial mitotic activity after gingivectomy: relationship to reattachment. *J Periodontal Res* 4:319, 1969.
24. Hunter HA: A study of tissues treated with Antiformin citric acid. *J Can Dent Assoc* 21:344, 1955.
25. Innes PB: An electron microscopic study of the regeneration of gingival epithelium following gingivectomy in the dog. *J Periodontal Res* 5:196, 1970.
26. Johnson RW, Waerhaug J: Effect of Antiformin on gingival tissue. *J Periodontol* 27:24, 1956.
27. Kon S, Novaes AB, Ruben MP, et al: Visualization of microvascularization of the healing periodontal wound. II. Curettage. *J Periodontol* 40:96, 1969.
28. Krawczyk WS: A pattern of epithelial cell migration during wound healing. *J Cell Biol* 49:247, 1971.
29. Löe H: Chemical gingivectomy: effect of potassium hydroxide on periodontal tissues. *Acta Odontol Scand* 19:517, 1961.
30. Loumanen M: A comparative study of healing of laser and scalpel incision wounds in rat oral mucosa. *Scand J Dent Res* 95:65, 1987.
31. Malone WF, Eisenmann D, Kusck J: Interceptive periodontics with electrosurgery. *J Prosthet Dent* 22:555, 1969.
32. Morris ML: The removal of the pocket and attachment epithelium in humans: a histological study. *J Periodontol* 25:7, 1954.
33. Moskow BS: The response of the gingival sulcus to instrumentation: a histologic investigation. I. The scaling procedure. *J Periodontol* 33:282, 1962.
34. Moskow BS: The response of the gingival sulcus to instrumentation: a histologic investigation. II. Gingival curettage. *J Periodontol* 35:112, 1964.
35. Nadler H: Removal of crevicular epithelium by ultrasonic curettes. *J Periodontol* 33:220, 1962.
36. Novaes AB, Kon S, Ruben MP, et al: Visualization of the microvascularization of the healing periodontal wound. III. Gingivectomy. *J Periodontol* 40:359, 1969.
37. O'Bannon JY: The gingival tissues before and after scaling the teeth. *J Periodontol* 35:69, 1964.
38. Orban B: New methods in periodontal treatment. *Bur* 42:116, 1942.
39. Oringer MJ: Electrosurgery for definitive conservative modern periodontal therapy. *Dent Clin North Am* 13:53, 1969.
40. *Periodontics syllabus: NAVED P5110*, 1975, US Naval Dental Corps, p 113.
41. Persson PA: The healing process in the marginal periodontium after gingivectomy with special regard to the regeneration of epithelium (an experimental study on dogs). *Odontol T* 67:593, 1959.
42. Pick RM, Pecaro BC, Silberman CJ: The laser gingivectomy: the use of CO_2 laser for the removal of phenytoin hyperplasia. *J Periodontol* 56:492, 1985.
43. Pogrel MA, Yen CK, Hanser LS: A comparison of carbon dioxide laser, liquid nitrogen cryosurgery and scalpel wound in healing. *Oral Surg Med Pathol* 69:269, 1990.
44. Pope JW, Gargiulo AW, Staffileno H, et al: Effects of electrosurgery on wound healing in dogs. *Periodontics* 6:30, 1968.
45. Ramfjord SP, Ash MM, Jr: *Periodontology and periodontics*, Philadelphia, 1979, Saunders.
46. Ramfjord SP, Kiester G: The gingival sulcus and the periodontal pocket immediately following scaling of the teeth. *J Periodontol* 25:167, 1954.
47. Ramfjord SP, Engler WD, Hiniker JJ: A radiographic study of healing following simple gingivectomy. II. The connective tissue. *J Periodontol* 37:179, 1966.
48. Ritchey B, Orban B: The periodontal pocket. *J Periodontol* 23:199, 1952.
49. Sandalli P, Wade AB: Alterations in crevicular fluid flow during healing following gingivectomy and flap procedures. *J Periodontal Res* 4:314, 1969.
50. Sanderson AD: Gingival curettage by hand and ultrasonic instruments: a histologic comparison. *J Periodontol* 37:279, 1966.
51. Sato M: Histopathological study of the healing process after surgical treatment for alveolar pyorrhea. *Bull Tokyo Dent College* 1:71, 1960.
52. Stanton G, Levy M, Stahl SS: Collagen restoration in healing human gingiva. *J Dent Res* 48:27, 1969.
53. Stewart H: Partial removal of cementum and decalcification of tooth in the treatment of pyorrhea alveolaris. *Dent Cosmos* 41:617, 1899.
54. Stone S, Ramfjord SP, Waldron J: Scaling and gingival curettage: a radioautographic study. *J Periodontol* 37:415, 1966.
55. Tonna E, Stahl SS: A polarized light microscopic study of rat periodontal ligament following surgical and chemical gingival trauma. *Helv Odontol Acta* 11:90, 1967.
56. Waerhaug J: Depth of incision in gingivectomy. *Oral Surg* 8:707, 1955.
57. Waerhaug J: Microscopic demonstration of tissue reaction incident to removal of subgingival calculus. *J Periodontol* 26:26, 1955.
58. Waerhaug J: Healing of the dentoepithelial junction following subgingival plaque control. I. As observed in human biopsy material. *J Periodontol* 49:1, 1978.

59. Watanabe Y, Suzuki S: An experimental study in capillary vascularization in the periodontal tissue following gingivectomy or flap operation. *J Dent Res* 42:758, 1963.
60. Wilhelmsen NR, Ramfjord SP, Blankenship JR: Effects of electrosurgery on the gingival attachment in rhesus monkeys. *J Periodontol* 47:160, 1976.
61. Younger WJ: Some of the latest phases in implantations and other procedures. *Dent Cosmos* 35:102, 1893.
62. Yukna RA: A clinical and histological study of healing following the excisional new attachment procedure in rhesus monkeys. *J Periodontol* 47:701, 1976.
63. Yukna RA, Bowers GM, Lawrence JJ, et al: A clinical study of healing in humans following the excisional new attachment procedure. *J Periodontol* 47:696, 1976.
64. Zach L, Cohen G: The histologic response to ultrasonic curettage. *J Dent Res* 40:751, 1961.

CHAPTER 57

The Periodontal Flap

Henry H. Takei, Fermin A. Carranza, and Jonathan H. Do

CHAPTER OUTLINE

Classification of Flaps
Flap Design
Incisions
Elevation of The Flap
Suturing Techniques *(e-only)*
Healing After Flap Surgery
Conclusion

For online-only content on suturing techniques, please visit the companion website at www.expertconsult.com.

A periodontal flap is a section of gingiva, mucosa, or both that is surgically separated from the underlying tissues to provide for the visibility of and access to the bone and root surface. The flap also allows the gingiva to be displaced to a different location in patients with mucogingival involvement.

Classification of Flaps

Periodontal flaps can be classified on the basis of the following:

- Bone exposure after flap reflection
- Placement of the flap after surgery
- Management of the papilla

For bone exposure after reflection, the flaps are classified as either full-thickness (mucoperiosteal) or partial-thickness (mucosal) flaps (Figure 57-1).

In a *full-thickness flap,* all of the soft tissue, including the periosteum, is reflected to expose the underlying bone. This complete exposure of and access to the underlying bone is indicated when resective osseous surgery is contemplated.

The *partial-thickness flap* includes only the epithelium and a layer of the underlying connective tissue. The bone remains covered by a layer of connective tissue that includes the periosteum. This type of flap is also called the *split-thickness flap.* The partial-thickness flap is indicated when the flap is to be positioned apically or when the operator does not want to expose bone.

Conflicting data surround the advisability of uncovering the bone when this is not actually needed. When bone is stripped of its periosteum, a loss of marginal bone occurs, and this loss is prevented when the periosteum is left on the bone.[4] Although this is usually not clinically significant,[7] the differences may be significant in some cases (Figure 57-2). The partial-thickness flap may be necessary when the crestal bone margin is thin and exposed with an apically placed flap or when dehiscences or fenestrations are present. The periosteum left on the bone may also be used for suturing the flap when it is displaced apically.

For flap placement after surgery, flaps are classified as either (1) *nondisplaced flaps,* when the flap is returned and sutured in its original position, or (2) *displaced flaps,* which are placed apically, coronally, or laterally to their original position. Both full-thickness and partial-thickness flaps can also be displaced. However, to do so, the attached gingiva must be totally separated from the underlying bone, thereby enabling the unattached portion of the gingiva to be movable. Palatal flaps cannot be displaced because of the absence of unattached gingiva.

Apically displaced flaps have the important advantage of preserving the outer portion of the pocket wall and transforming it into attached gingiva. Therefore, these flaps accomplish the double objective of eliminating the pocket and increasing the width of the attached gingiva.

For the management of the papilla, flaps can be conventional or papilla preservation flaps. With the *conventional flap,* the interdental papilla is split beneath the contact point of the two approximating teeth to allow for the reflection of the buccal and lingual flaps. The incision is usually scalloped to maintain gingival morphology and to retain as much papilla as possible. The conventional flap is used (1) when the interdental spaces are too narrow, thereby precluding the possibility of preserving the papilla, and (2) when the flap is to be displaced.

Conventional flaps include the modified Widman flap, the undisplaced flap, the apically displaced flap, and the flap for reconstructive procedures. These techniques are described in detail in Chapter 59.

The *papilla preservation flap* incorporates the entire papilla in one of the flaps by means of crevicular interdental incisions to sever the connective tissue attachment as well as a horizontal incision at the base of the papilla to leave it connected to one of the flaps.

Flap Design

The design of the flap is dictated by the surgical judgment of the operator, and it may depend on the objectives of the procedure. The necessary degree of access to the underlying bone and root surfaces and the final position of the flap must be considered when designing the flap. The flap design may also be dictated by the aesthetic concerns of the area of surgery. Preservation of good blood supply to the flap is another important consideration.

Two basic flap designs are used. Depending on how the interdental papilla is managed, flaps can either split the papilla (conventional flap) or preserve it (papilla preservation flap).

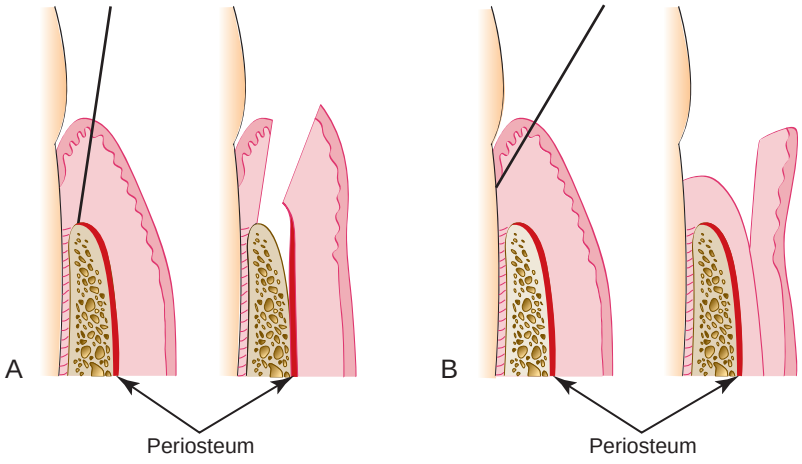

Figure 57-1 **A,** Diagram of the internal bevel incision (first incision) to reflect a full-thickness (mucoperiosteal) flap. Note that the incision ends on the bone to allow for the reflection of the entire flap. **B,** Diagram of the internal bevel incision to reflect a partial-thickness flap. Note that the incision ends on the root surface to preserve the periosteum on the bone.

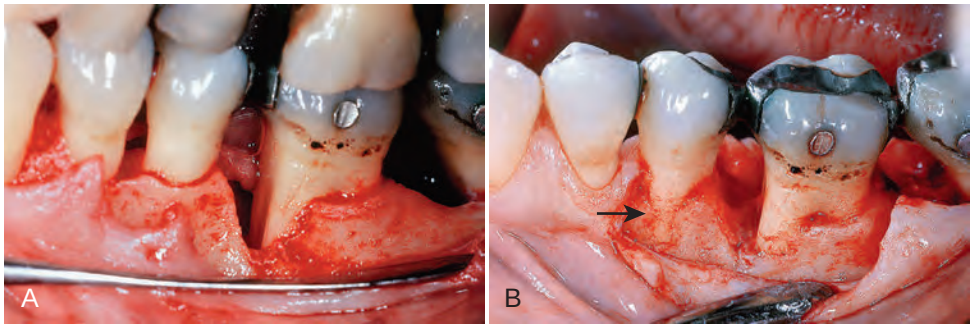

Figure 57-2 Loss of marginal bone as a result of uncovering the osseous crest. **A,** Mucoperiosteal flap elevated as part of a clinical study. **B,** Reentry performed 6 months later reveals a loss of marginal bone facial to the second premolar *(arrow)*. *(Courtesy Dr. Silvia Oreamuno, San Jose, Costa Rica.)*

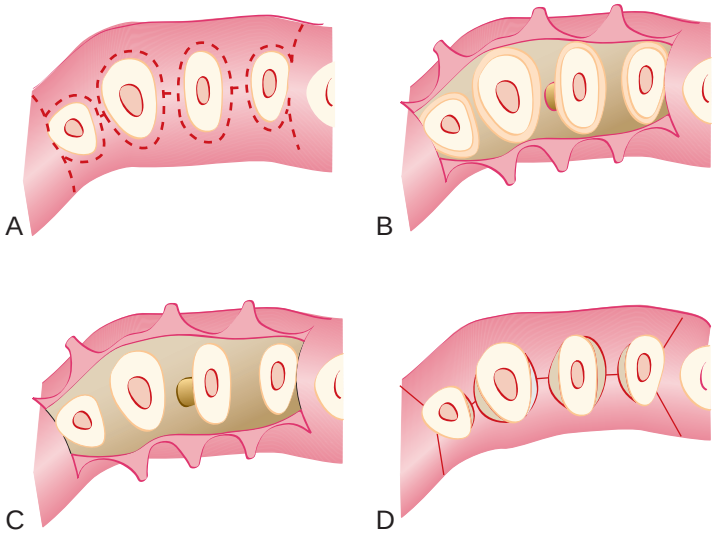

Figure 57-3 Flap design for a conventional or traditional flap technique. **A,** Design of incisions: internal bevel incision, splitting the papilla, and vertical incisions are drawn in interrupted lines. **B,** The flap has been elevated, and the wedge of tissue next to the tooth is still in place. **C,** All marginal tissue has been removed to expose the underlying bone (see the defect in one space). **D,** The tissue has been returned to its original position. The proximal areas are not totally covered.

For the conventional flap procedure, the incisions for the facial and the lingual or palatal flap reach the tip of the interdental papilla or its vicinity, thereby splitting the papilla into a facial half and a lingual or palatal half (Figures 57-3 and 57-4).

The entire surgical procedure should be planned in every detail before the procedure is initiated. This should include the type of flap, the exact location and type of incisions, the management of the underlying bone, and the final closure of the flap and sutures. Although some details may be modified during the actual performance of the procedure, detailed planning allows for a better clinical result.

Incisions

Periodontal flaps involve the use of horizontal (mesial–distal) and vertical (occlusal–apical) incisions.

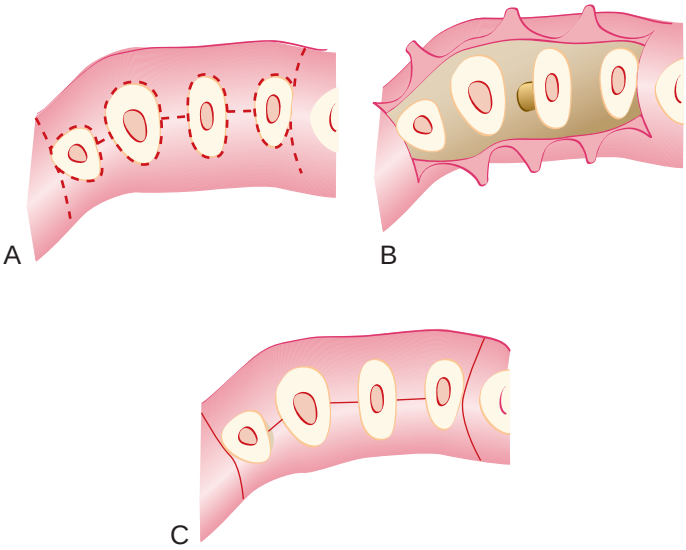

Figure 57-4 Flap design for a sulcular incision flap. **A,** Design of incisions: sulcular incisions and vertical incisions are depicted by interrupted lines. **B,** The flap has been elevated to expose the underlying bone (see the defect in one space). **C,** The tissue has been returned to its original position to cover the interdental spaces.

Horizontal Incisions

Horizontal incisions are directed along the margin of the gingiva in a mesial or distal direction. Two types of horizontal incisions have been recommended: the internal bevel incision,[6] which starts at a distance from the gingival margin and which is aimed at the bone crest, and the crevicular incision, which starts at the bottom of the pocket and which is directed to the bone margin. In addition, the interdental incision is performed after the flap is elevated to remove the interdental tissue.

The *internal bevel incision* is basic to most periodontal flap procedures. It is the incision from which the flap is reflected to expose the underlying bone and root. The internal bevel incision accomplishes three important objectives: (1) it removes the pocket lining; (2) it conserves the relatively uninvolved outer surface of the gingiva, which, if apically positioned, becomes attached gingiva; and (3) it produces a sharp, thin flap margin for adaptation to the bone–tooth junction. This incision has also been termed the *first incision,* because it is the initial incision for the reflection of a periodontal flap; it has also been called the *reverse bevel incision,* because its bevel is in reverse direction from that of the gingivectomy incision. The no. 15 or 15C surgical blade is used most often to make this incision. That portion of the gingiva left around the tooth contains the epithelium of the pocket lining and the adjacent granulomatous tissue. It is discarded after the crevicular (second) and interdental (third) incisions are performed (Figure 57-5).

The internal bevel incision starts from a designated area on the gingiva, and it is then directed to an area at or near the crest of the bone (Figure 57-6). The starting point on the gingiva is determined by whether the flap is apically displaced or not displaced (Figure 57-7).

The *crevicular incision,* which is also called the *second incision,* is made from the base of the pocket to the crest of the bone (Figure 57-8). This incision, together with the initial reverse bevel incision, forms a V-shaped wedge that ends at or near the crest of bone. This wedge of tissue contains most of the inflamed and granulomatous areas that constitute the lateral wall of the pocket as well as the junctional epithelium and the connective tissue fibers

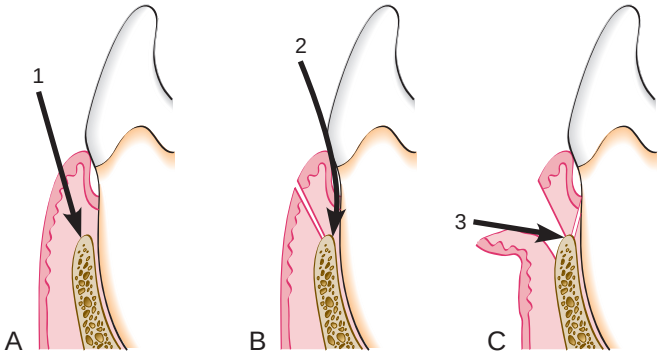

Figure 57-5 The three incisions necessary for flap surgery. **A,** First (internal bevel) incision; **B,** second (crevicular) incision; and **C,** third (interdental) incision.

Figure 57-6 Position of the knife to perform the internal bevel incision.

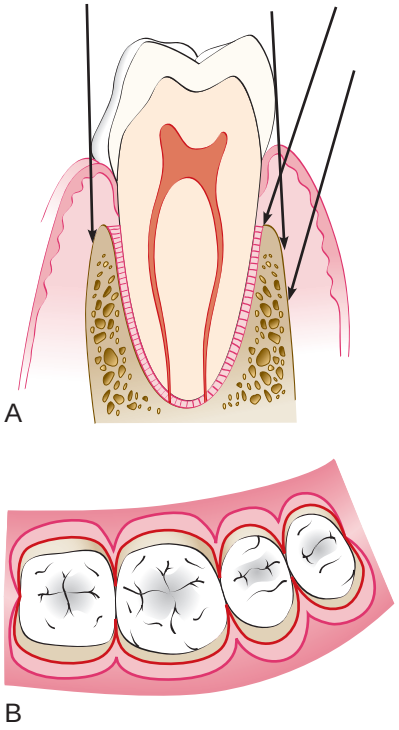

Figure 57-7 **A,** The internal bevel (first) incision can be made at varying locations and angles according to the different anatomic and pocket situations. **B,** Occlusal view of the different locations in which the internal bevel incision can be made. Note the scalloped shape of the incisions.

Figure 57-8 Position of the knife to perform the crevicular (second) incision.

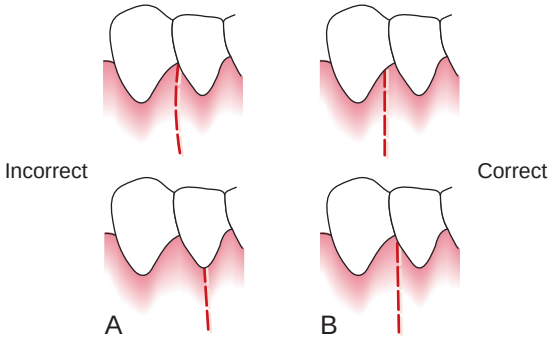

Figure 57-10 **A,** Incorrect and, **B,** correct locations of a vertical incision. This incision should be made at the line angles to prevent the splitting of a papilla or incising directly over a radicular surface.

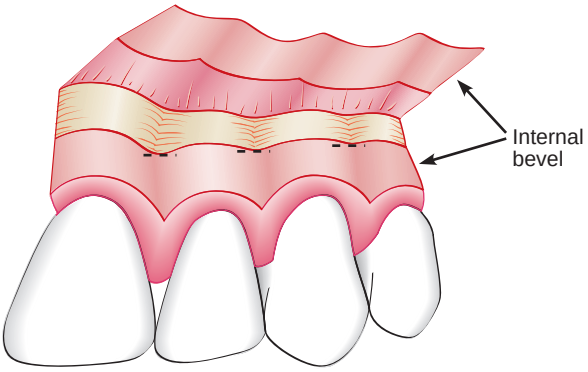

Figure 57-9 After the flap has been elevated, a wedge of tissue remains on the teeth and is attached by the base of the papillae. An interdental (third) incision along the horizontal lines seen in the interdental spaces will sever these connections.

Figure 57-11 Elevation of the flap with a periosteal elevator to obtain a full-thickness flap. Note the bone that is exposed with the full-thickness flap.

that still persist between the bottom of the pocket and the crest of the bone. The incision is carried around the entire tooth. The beak-shaped no. 12D blade is usually used for this incision.

A periosteal elevator is inserted into the initial internal bevel incision, and the flap is separated from the bone. The most apical end of the internal bevel incision is exposed and visible. With this access, the surgeon is able to make the *third incision,* which is also known as the *interdental incision,* to separate the collar of gingiva that is left around the tooth. The Orban knife is usually used for this incision. The incision is made not only around the facial and lingual radicular area but also interdentally, where it connects the facial and lingual segments to free the gingiva completely around the tooth (Figure 57-9; see Figure 57-5).

These three incisions allow for the removal of the gingiva around the tooth (i.e., the pocket epithelium and the adjacent granulomatous tissue). A curette or a large scaler (U15/30) can be used for this purpose. After the removal of the large pieces of tissue, the remaining connective tissue in the osseous lesion should be carefully curetted and removed so that the entire root and the bone surface adjacent to the teeth can be observed.

Flaps can be reflected with the use of only the horizontal incision if sufficient access can be obtained in this way and if apical, lateral, or coronal displacement of the flap is not anticipated. If vertical incisions are not made, the flap is called an *envelope flap.*

Vertical Incisions

Vertical or oblique releasing incisions can be used on one or both ends of the horizontal incision, depending on the design and purpose of the flap. Vertical incisions at both ends are necessary if the flap is to be apically displaced. Vertical incisions must extend beyond the mucogingival line to reach the alveolar mucosa; this allows for the release of the flap to be displaced (see Chapter 59).

In general, vertical incisions in the lingual and palatal areas are avoided. Facial vertical incisions should not be made in the center of an interdental papilla or over the radicular surface of a tooth. Incisions should be made at the line angles of a tooth either to include the papilla in the flap or to avoid it completely (Figure 57-10). The vertical incision should also be designed to avoid short flaps (mesiodistal) with long, apically directed incisions, because this could jeopardize the blood supply to the flap.

Several investigators proposed the *interdental denudation procedure,* which consists of horizontal, internal bevel, nonscalloped incisions to remove the gingival papillae and to denude the interdental space.[1,2,11,12] This technique completely eliminates the inflamed interdental tissue. Healing is by secondary intention and results in excellent gingival contour. It is contraindicated when bone grafts are used and the graft material placed interdentally will not be covered. It is also contraindicated in aesthetic areas such as the maxillary anterior segment, because the papilla will be lost.

Elevation of the Flap

When a full-thickness flap is desired, reflection of the flap is accomplished via blunt dissection. A periosteal elevator is used to separate the mucoperiosteum from the bone by moving it mesially, distally, and apically until the desired reflection is accomplished (Figure 57-11).

Sharp dissection is necessary to reflect a partial-thickness flap. A surgical scalpel (no. 15) is used (Figure 57-12).

Figure 57-12 Elevation of the flap with a Bard-Parker knife to obtain a split-thickness flap. Note that the bone is not exposed and that it is covered by periosteal tissue.

A combination of full-thickness and partial-thickness flaps may be indicated to obtain the advantages of both. The flap is started as a full-thickness procedure, and then a partial-thickness flap is made at the apical portion. In this way, the coronal portion of the bone—which may be subject to osseous remodeling—is exposed, whereas the remaining bone is protected by the periosteum. After the flap is reflected, the osseous shape and contour is examined, and the necessary osseous correction is accomplished. The root surface is than carefully root planed, and the flap is replaced and ready to be sutured.

Healing After Flap Surgery

Immediately after suturing (≤24 hours), a connection between the flap and the tooth or bone surface is established by a blood clot, which consists of a fibrin reticulum with many polymorphonuclear leukocytes, erythrocytes, debris of injured cells, and capillaries at the edge of the wound.[3] Bacteria and an exudate or transudate also result from tissue injury.

One to 3 days after flap surgery, the space between the flap and the tooth or bone is thinner. Epithelial cells migrate over the border of the flap, and they usually contact the tooth at this time. When the flap is closely adapted to the alveolar process, there is a minimal inflammatory response.[3]

One week after surgery, an epithelial attachment to the root has been established by means of hemidesmosomes and a basal lamina. The blood clot is replaced by granulation tissue derived from the gingival connective tissue, the bone marrow, and the periodontal ligament.

Two weeks after surgery, collagen fibers begin to appear parallel to the tooth surface.[3] Union of the flap to the tooth is still weak because of the presence of immature collagen fibers, although the clinical aspect may be almost normal.

One month after surgery, a fully epithelialized gingival crevice with a well-defined epithelial attachment is present. There is a beginning functional arrangement of the supracrestal fibers.

Full-thickness flaps, which denude the bone, result in a superficial bone necrosis after 1 to 3 days. Osteoclastic resorption follows and reaches a peak at 4 to 6 days and then declines thereafter.[13] This results in a loss of bone of about 1 mm^3; the bone loss is greater if the bone is thin.[14,15]

Osteoplasty (thinning of the buccal bone) with the use of diamond burs and included as part of the surgical technique results in areas of bone necrosis with a reduction in bone height, which is later remodeled by new bone formation. The final shape of the crest is determined more by osseous remodeling than by surgical reshaping.[8] Therefore, osseous surgery around the crestal areas must be carefully managed.

This may not be the case when osseous remodeling does not include excessive thinning of the radicular bone.[9] Bone repair reaches its peak after 3 to 4 weeks.[15]

A loss of bone occurs during the initial healing stages both in the radicular bone and in the interdental bone areas. However, in the interdental areas, which have cancellous bone, the subsequent repair stage results in total restitution without any loss of bone; in radicular bone (particularly if it is thin and unsupported by cancellous bone), bone repair results in the loss of marginal bone.[15]

Conclusion

Periodontal flap surgery is the most widely used surgical procedure to reduce the pocket depth. Periodontal flaps are designed to preserve gingival integrity and to gain access to root surfaces for residual calculus removal and to thoroughly remove granulation tissue so that bone defects can be visualized and treated. Gentle and efficient procedures result in optimum healing and minimal postoperative pain. When flaps need to be repositioned apically or, less often, coronally, then the flaps must sit passively at the appropriate level before suturing. To ensure this, buccal and lingual flaps need to be elevated beyond the mucogingival junction so that the elasticity of the mucosa allows for flap mobility. Sometimes it may be necessary to extend the flap elevation apically with a split incision approach to minimize the effect of the less elastic periosteum. Vertical incisions can aid in flap positioning by allowing the clinician to suture the flap at a different level to the adjacent untreated gingiva.

Palatal flaps are less mobile as a result of the absence of oral mucosa, so the apical position of the flap depends on how much marginal gingival tissue is discarded with the use of a reverse bevel incision. The more apical positioning desired, the more extensive is the reverse bevel cut. Palatal flaps are more difficult to position coronally than buccal or lingual flaps. Thus, if it is required to position flaps coronally or even at their original levels, then a sulcular incision is used. During osseous periodontal surgery, flaps are apically positioned to minimize postoperative pocket depth. During regenerative periodontal surgery, soft-tissue coverage of bony defects, graft materials, membranes, and biologic agents is important, so sulcular incisions and tight suturing techniques are crucial.

Suggested Readings

Ariaudo AA, Tyrell HA: Repositioning and increasing the zone of attached gingiva. *J Periodontol* 28:106, 1957.

Friedman N: Mucogingival surgery: the apically repositioned flap. *J Periodontol* 33:328, 1962.

Hoag PM, Wood DL, Donnenfeld OW, et al: Alveolar crest reduction following full and partial thickness flaps. *J Periodontol* 43:141, 1972.

Kaldahl WB, Kalkwarf KL, Patill KD, et al: Long-term evaluation of periodontal therapy: I. Response to 4 therapeutic modalities. *J Periodontol* 67:93, 1996.

Karring T, Cumming BR, Oliver RC, et al: The origin of granulation tissue and its impact on postoperative results of mucogingival surgery. *J Periodontol* 46:577, 1975.

Lobene RR, Glickman I: The response of alveolar bone to grinding with rotary stones. *J Periodontol* 34:105, 1963.

Staffileno H, Wentz FE, Orban BJ: Histologic study of healing of split thickness flap surgery in dogs. *J Periodontol* 33:56, 1962.

Wilderman MN, Pennel BM, King K, et al: Histogenesis of repair following osseous surgery. *J Periodontol* 41:551, 1970.

References

References for this chapter are found on the companion website www.expertconsult.com.

Suturing Techniques

After all of the necessary procedures are completed, the area is reexamined and cleansed, and the flap is placed in the desired position. The flap should remain in this position without tension. It is convenient to keep the flap in place with light pressure via the use of a piece of gauze to allow the blood clot to form.

The purpose of suturing is to maintain the flap in the desired position until healing has progressed to the point at which sutures are no longer needed.

There are many types of sutures, suture needles, and materials.[5,10] Suture materials may be either *nonresorbable* or *resorbable,* and they may be further categorized as *braided* or *monofilament* (Box 57-1). The resorbable sutures have gained popularity because they enhance patient comfort and eliminate suture removal appointments.

The monofilament type of suture alleviates the "wicking effect" of braided sutures that may allow bacteria from the oral cavity to be drawn through the suture to the deeper areas of the wound.

The braided silk suture was the most common nonresorbable suture used in the past because of its ease of use and low cost. The expanded polytetrafluoroethylene, synthetic, monofilament suture is an excellent nonresorbable suture that is widely used today.

The most common resorbable sutures used today are the plain and chromic gut sutures. Both are monofilaments, and both are processed from purified collagen of either sheep or cattle intestines. The chromic suture is a plain gut suture that has been processed with chromic salts to make it resistant to enzymatic resorption, thereby increasing the resorption time. The synthetic resorbable sutures are also often used.

Technique

The needle is held with the needle holder, and it should enter the tissues at right angles and be no less than 2 mm to 3 mm from the incision. The needle is then carried through the tissue, where it follows the needle's curvature. The knot should not be placed over the incision.

The periodontal flap is closed either with independent sutures or with continuous, independent sling sutures. The latter method eliminates the pulling of the buccal and lingual or palatal flaps together and instead uses the teeth as an anchor for the flaps. The flaps are less likely to buckle, and the forces on the flaps are better distributed.

BOX 57-1 Sutures for Periodontal Flaps

- Nonabsorbable (Nonresorbable)
  - Silk: braided
  - Nylon: monofilament (Ethilon)
  - ePTFE: monofilament (Gore-Tex)
  - Polyester: braided (Ethibond)
- Absorbable (Resorbable)
  - Surgical: gut
  - Plain gut: monofilament (30 days)
  - Chromic gut: monofilament (45 to 60 days)
- Synthetic
  - Polyglycolic: braided (16 to 20 days)
  - Vicryl (Ethicon)
  - Dexon (Davis & Geck)
  - Polyglycaprone: monofilament (90 to 120 days)
  - Monocryl (Ethicon)
  - Polyglyconate: monofilament (Maxon)

Sutures of any type that are placed in the interdental papillae should enter and exit the tissue at a point located below the imaginary line that forms the base of the triangle of the interdental papilla (Figure 57-13). The location of sutures for the closure of a palatal flap depends on the extent of flap elevation that has been performed. The flap is divided into four quadrants as depicted in Figure 57-14.

If the elevation of the flap is slight or moderate, the sutures can be placed in the quadrant closest to the teeth. If the flap elevation is substantial, the sutures should be placed in the central quadrants of the palate.

The clinician may or may not use periodontal dressings. When the flaps are not apically displaced, it is not necessary to use dressings other than those needed for patient comfort.

Ligation

Interdental Ligation. Two types of interdental ligation can be used: the direct loop suture (Figure 57-15) and the figure-eight suture (Figure 57-16). With the figure-eight suture, thread is placed between the two flaps. This suture is used when the flaps are not in close apposition as a result of apical flap position or nonscalloped incisions. This is simpler to perform than the direct ligation. The direct suture allows for a better closure of the interdental papilla. It should be performed when bone grafts are used or when close apposition of the scalloped incision is required.

Sling Ligation

The sling ligation can be used for a flap on one surface of a tooth that involves two interdental spaces (Figure 57-17).

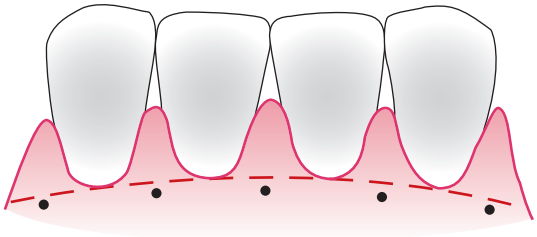

Figure 57-13 Placement of sutures in the interdental space below the base of an imaginary triangle in the papilla.

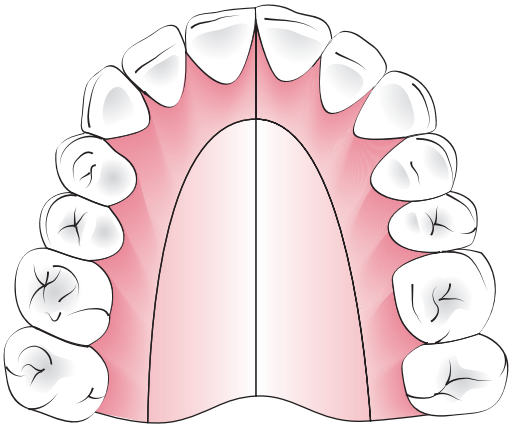

Figure 57-14 Placement of sutures to close a palatal flap. For slightly or moderately elevated flaps, the sutures are placed in the shaded areas. For the more substantial elevation of the flap, the sutures are placed in the central (unshaded) areas of the palate.

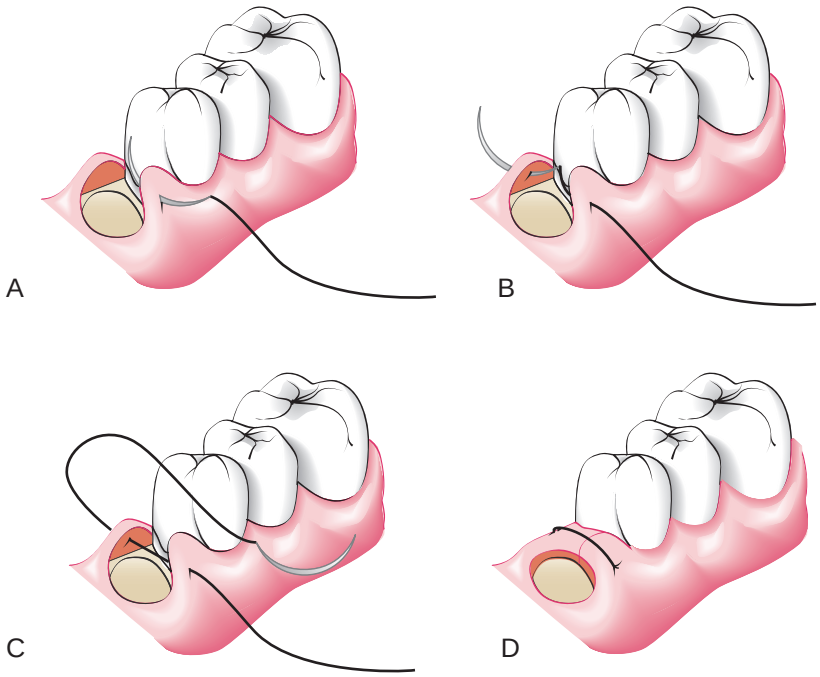

Figure 57-15 Simple loop suture is used to approximate the buccal and lingual flaps. **A,** The needle penetrates the outer surface of the first flap. **B,** The undersurface of the opposite flap is engaged, and, **C,** the suture is brought back to the initial side, where, **D,** the knot is tied.

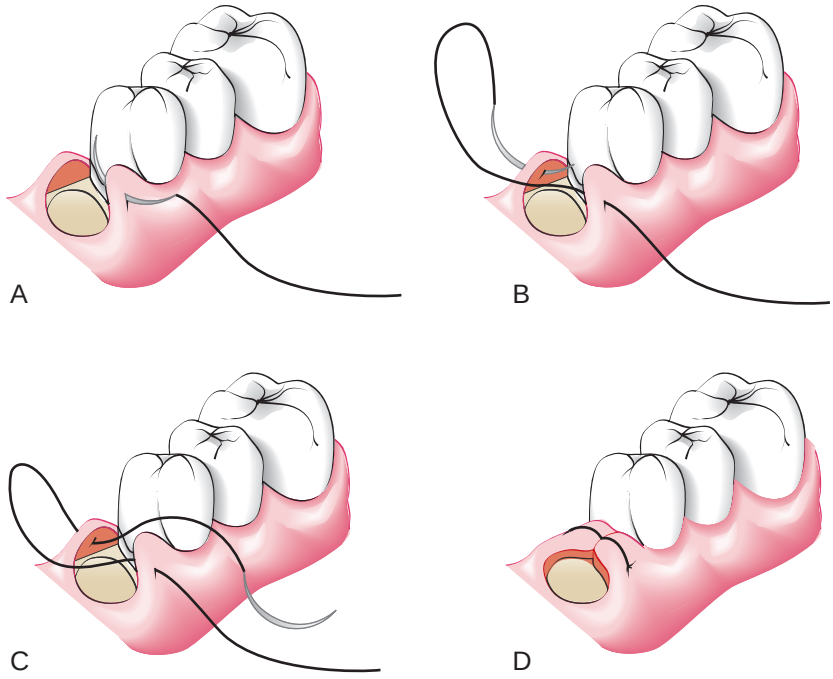

Figure 57-16 Interrupted figure-eight suture is used to approximate the buccal and lingual flaps. **A,** The needle penetrates the outer surface of the first flap and, **B,** the outer surface of the opposite flap. **C,** The suture is brought back to the first flap, and, **D,** the knot is tied.

Types of Sutures

Horizontal Mattress Suture. The horizontal mattress suture is often used for interproximal areas of diastemata or for wide interdental spaces to adapt the interproximal papilla properly against the bone. Two sutures are often necessary. The horizontal mattress suture can be incorporated with the continuous, independent sling sutures as shown in Figure 57-18.

The penetration of the needle is performed in such a way that the mesial and distal edges of the papilla lie snugly against the bone. The needle enters the outer surface of the gingiva and crosses the undersurface of the gingiva horizontally. The mattress sutures should not be close together at the midpoint of the base of the papilla. The needle reappears on the outer surface at the other base of the papilla and continues around the tooth with the sling sutures.

Continuous, Independent Sling Suture. A sling suture is used when both a facial flap and a lingual flap are used and when they involve many teeth. The continuous, independent sling suture is initiated on the facial papilla closest to the midline, because this is the easiest place to position the final knot (Figure 57-19). A

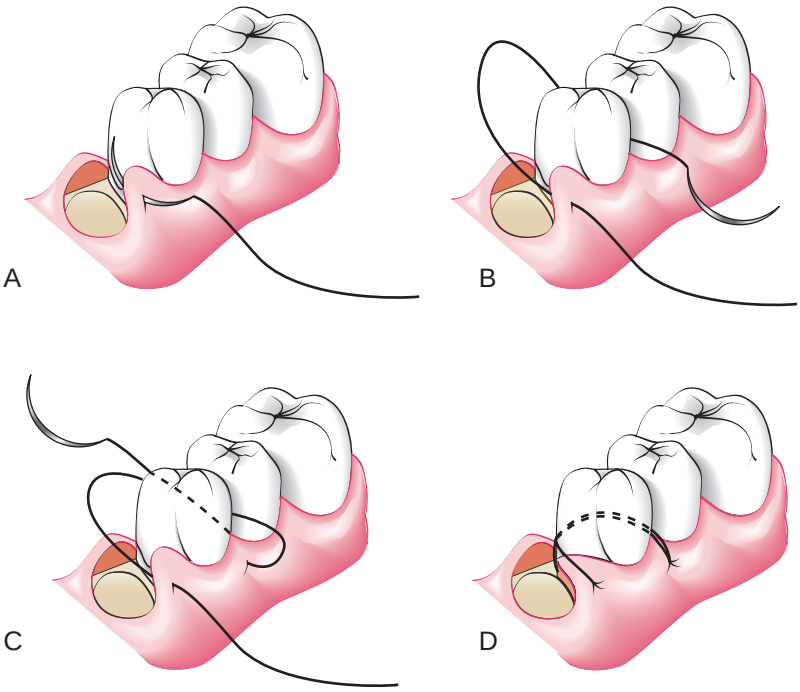

Figure 57-17 Single, interrupted sling suture is used to adapt the flap around the tooth. **A,** The needle engages the outer surface of the flap and, **B,** encircles the tooth. **C,** The outer surface of the same flap of the adjacent interdental area is engaged. **D,** The suture is returned to the initial site, and the knot is tied.

continuous sling suture is laced for each papilla on the facial surface. When the last tooth is reached, the suture is anchored around it to prevent any pulling of the facial sutures when the lingual flap is sutured around the teeth in a similar manner. The suture is again anchored around the last tooth before the final knot is tied.

This type of suture does not pull on the lingual flap when this flap is sutured. The facial and lingual flaps are completely independent of each other as a result of the anchoring around both the initial tooth and the final tooth. The flaps are tied to the teeth and not to each other because of the sling sutures.

Continuous, independent sling suturing is especially appropriate for the maxillary arch. This is true because the palatal gingiva is attached and fibrous, whereas the facial tissue is thinner and mobile.

Anchor Suture. The closing of a flap mesial or distal to a tooth, as in the mesial or distal wedge procedures, is best accomplished by the anchor suture. This suture closes the facial and lingual flaps and adapts them tightly against the tooth. The needle is placed at the line–angle area of the facial or lingual flap adjacent to the tooth, anchored around the tooth, passed beneath the opposite flap, and tied. The anchor suture can be repeated for each area that requires it (Figure 57-20).

Closed-Anchor Suture. Another technique to close a flap that is located in an edentulous area mesial or distal to a tooth consists of tying a direct suture that closes the proximal flap, carrying one of the threads around the tooth to anchor the tissue against the tooth, and then tying the two threads (Figure 57-21).

Periosteal Suture. The periosteal suture is used to hold the apically displaced partial-thickness flaps on the periosteum. There are two types of periosteal sutures: the holding suture and the closing suture. The holding suture is a horizontal mattress suture that is placed at the base of the displaced flap to secure it into the new position. Closing sutures are used to secure the flap edges to the periosteum. Both types of periosteal sutures are shown in Figure 57-22.

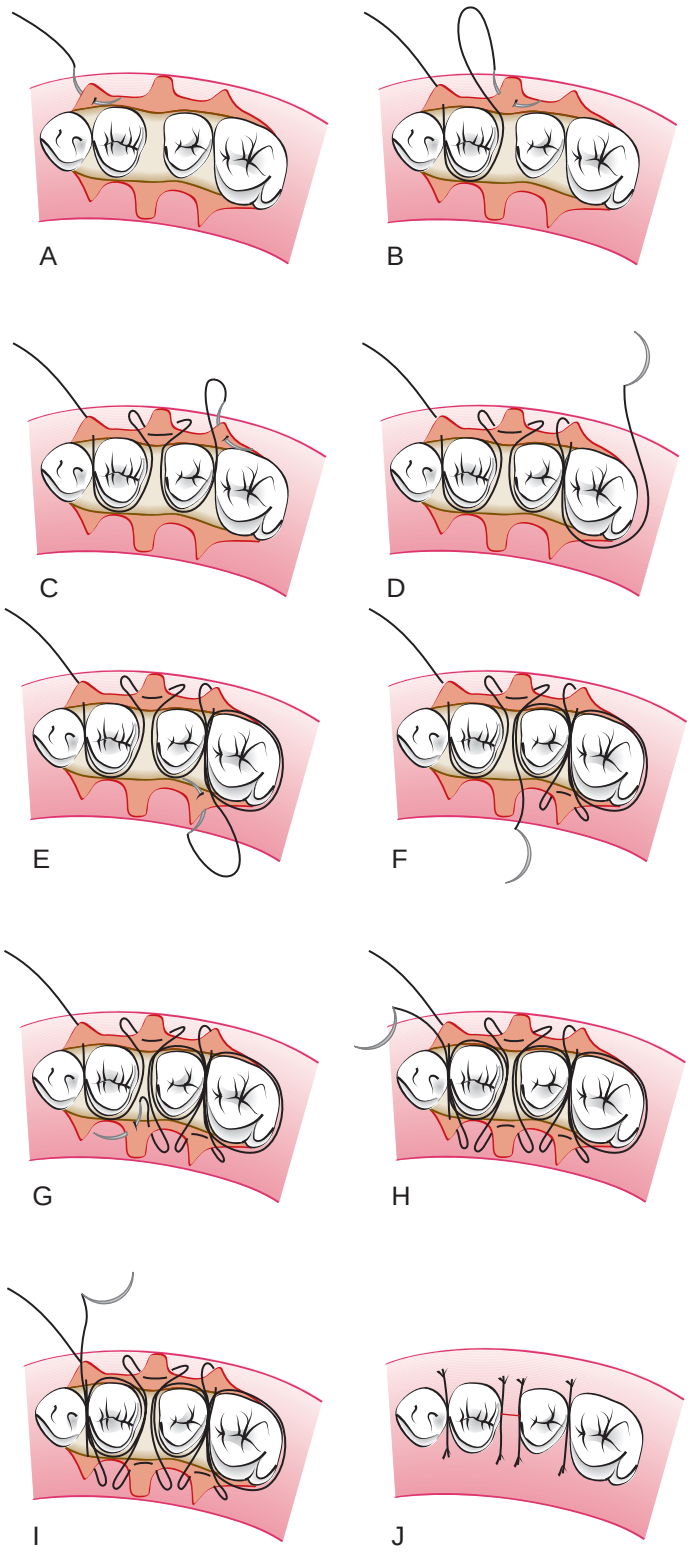

Figure 57-18 **A,** Continuous, independent sling suture with the use of a horizontal mattress suture around, **B,** diastemata or, **C,** wide interdental areas. This mattress suture is used on both the, **D,** buccal and, **E** and **F,** lingual surfaces. **G, H,** and **I,** Continuation of suture on the lingual surfaces. **J,** Completed suture.

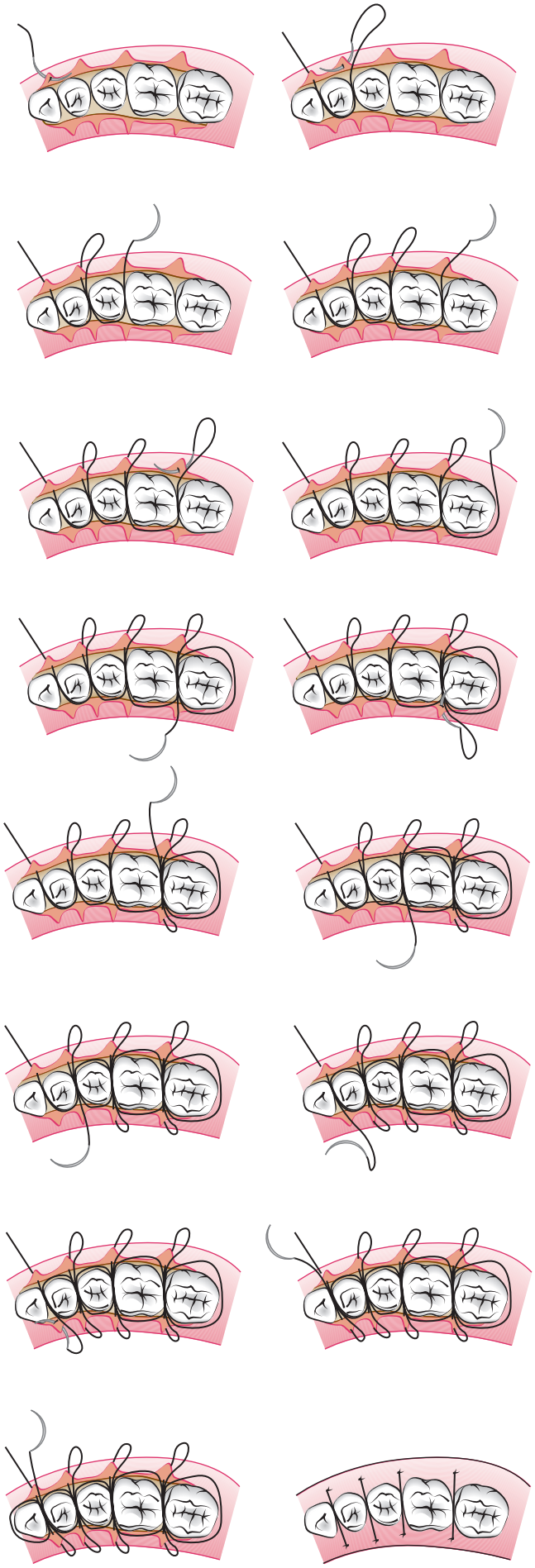

Figure 57-19 Continuous, independent sling suture is used to adapt the buccal and lingual flaps without tying the buccal flap to the lingual flap. The teeth are used to suspend each flap against the bone. It is important to anchor the suture on the two teeth at the beginning and end of the flap so that the suture will not pull the buccal flap to the lingual flap.

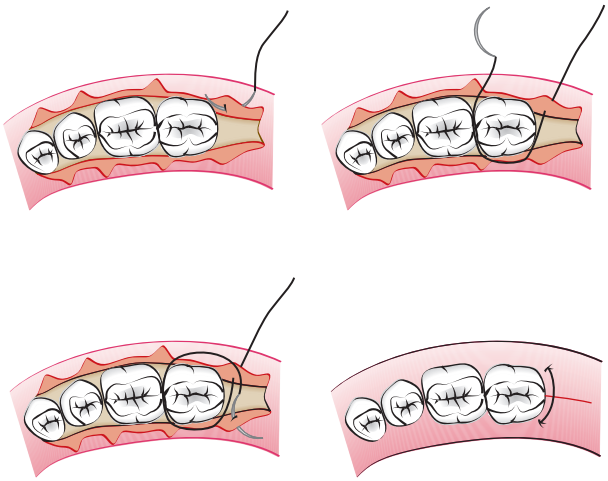

Figure 57-20 Distal wedge suture. This anchor suture is also used to close flaps that are mesial or distal to a lone standing tooth.

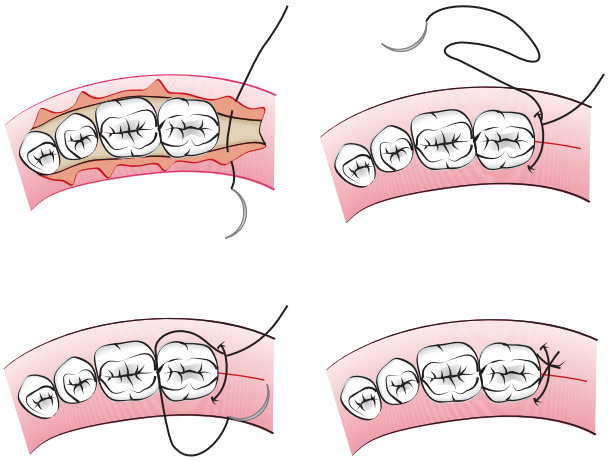

Figure 57-21 The closed-anchor suture, which is another technique that can be used to suture distal wedges.

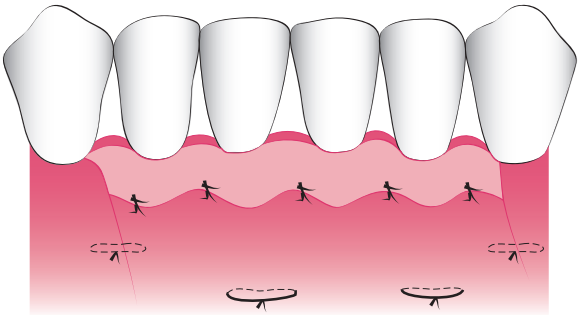

Figure 57-22 Periosteal sutures for an apically displaced flap. Holding sutures, which are shown at the bottom, are placed first. This is followed by the closing sutures, which are shown at the coronal edge of the flap.

References

1. Barkann L: A conservative surgical technique for the eradication of pyorrhea pockets. *J Am Dent Assoc* 26:61, 1939.
2. Beube FE: Interdental tissue resection; an experimental study of a surgical technique which aids in repair of the periodontal tissues to their original contour and function. *Oral Surg Oral Med Oral Pathol* 33:497, 1947.
3. Caffesse RG, Ramfjord SP, Nasjleti CE: Reverse bevel periodontal flaps in monkeys. *J Periodontol* 39:219, 1968.
4. Carranza FA, Jr, Carraro JJ: Effect of removal of periosteum on post-operative result of mucogingival surgery. *J Periodontol* 34:223, 1963.
5. Dahlberg WH: Incisions and suturing: some basic considerations about each in periodontal flap surgery. *Dent Clin North Am* 113:149, 1969.
6. Friedman N: Mucogingival surgery: the apically repositioned flap. *J Periodontol* 33:328, 1962.
7. Hoag PM, Wood DL, Donnenfeld OW, et al: Alveolar crest reduction following full and partial thickness flaps. *J Periodontol* 43:141, 1972.
8. Lobene RR, Glickman I: The response of alveolar bone to grinding with rotary stones. *J Periodontol* 34:105, 1963.
9. Matherson DG: An evaluation of healing following periodontal osseous surgery in monkeys. *Int J Periodontics Restorative Dent* 8:9, 1988.
10. Morris ML: Suturing techniques in periodontal surgery. *Periodontics* 3:84, 1965.
11. Prichard JF: Present state of the interdental denudation procedure. *J Periodontol* 48:566, 1977.
12. Ratcliff PA, Raust GT: Interproximal denudation: a conservative approach to osseous surgery. *Dent Clin North Am* 8:121, 1964.
13. Staffileno H, Wentz FE, Orban BJ: Histologic study of healing of split thickness flap surgery in dogs. *J Periodontol* 33:56, 1962.
14. Wilderman MN: Exposure of bone in periodontal surgery. *Dent Clin North Am* 8:23, 1964.
15. Wilderman MN, Pennel BM, King K, et al: Histogenesis of repair following osseous surgery. *J Periodontol* 41:551, 1970.

CHAPTER 58

Treatment of Gingival Enlargement

Paulo M. Camargo, Fermin A. Carranza, Flavia Q. Pirih, and Henry H. Takei

CHAPTER OUTLINE

Chronic Inflammatory Enlargement
Periodontal and Gingival Abscesses
Drug-Associated Gingival Enlargement
Leukemic Gingival Enlargement
Gingival Enlargement During Pregnancy
Gingival Enlargement During Puberty
Recurrence of Gingival Enlargement

The treatment of gingival enlargement is based on an understanding of the cause and underlying pathologic changes of this condition (see Chapter 16). Gingival enlargements are of special concern to the patient and the dentist because they pose problems that involve plaque control, function (including mastication, tooth eruption, and speech), and aesthetics. Because gingival enlargements differ with regard to cause, the treatment of each type is best considered individually.

Chronic Inflammatory Enlargement

Chronic inflammatory enlargements, which are soft and discolored and which are caused principally by edema and cellular infiltration, are treated by scaling and root planing, provided that the size of the enlargement does not interfere with the complete removal of deposits from the involved tooth surfaces.

When chronic inflammatory gingival enlargements include a significant fibrotic component that does not undergo shrinkage after scaling and root planing or are of such size that they obscure deposits on the tooth surfaces and interfere with access to them, surgical removal is the treatment of choice. Two techniques are available for this purpose: gingivectomy and the flap operation.

The selection of the appropriate technique depends on the size of the enlargement and the character of the tissue. When the enlarged gingiva remains soft and friable even after scaling and root planing, a gingivectomy is used to remove it, because a flap requires a firmer tissue so that the incisions and the other steps in the technique may be performed. However, if the gingivectomy incision removes all of the attached gingiva, thereby creating a mucogingival problem, then a flap operation is indicated.

Tumorlike inflammatory enlargements are treated by gingivectomy as follows. With the patient under local anesthesia, the tooth surfaces beneath the mass are scaled to remove calculus and other debris. The lesion is separated from the mucosa at its base with a no. 12 Bard-Parker blade. If the lesion extends interproximally, the interdental gingiva is included in the incision to ensure the exposure of irritating root deposits. After the lesion is removed, the involved root surfaces are scaled and planed, and the area is cleansed with warm water. A periodontal pack is applied and removed after a week, at which time the patient is instructed in plaque control.

For more information about the flap operation, see Chapters 57 and 59 and the following discussion of the flap technique for drug-induced enlargements.

Periodontal and Gingival Abscesses

The reader is referred to Chapter 42 for a complete discussion of abscess treatment.

Drug-Associated Gingival Enlargement

Gingival enlargement has been associated primarily with the administration of three different types of drugs: anticonvulsants, calcium channel blockers, and the immunosuppressant cyclosporine. Chapter 16 provides a comprehensive review of the clinical and microscopic features and the pathogenesis of gingival enlargement induced by these drugs. There is more limited evidence that other drugs may also induce gingival enlargement, albeit at a lower prevalence and with a lesser severity.[5]

The examination of cases of drug-induced gingival enlargement reveals the overgrown tissues to have two components: fibrotic, which are caused by the drug, and inflammatory, which are induced by bacterial plaque. Although the fibrotic and inflammatory components present in the enlarged gingiva are the result of distinct pathologic processes, they almost always are observed in combination. The role of bacterial plaque in the overall pathogenesis of drug-induced gingival enlargement is not clear. Some studies indicate that plaque is a prerequisite for gingival enlargement,[12] whereas others suggest that the presence of plaque is a consequence of its accumulation caused by the enlarged gingiva.

Treatment Options

The treatment of drug-induced gingival enlargement should be based on the medication being used and the clinical features of the case.

First, consideration should be given to the possibility of discontinuing the drug[10,13] or changing the medication. These possibilities should be examined with the patient's physician. Simple discontinuation of the offending drug is usually not practical, but its substitution with another medication may be an option. If any drug substitution is attempted, it is important to allow for a 6- to 12-month period to elapse between discontinuation of the offending drug and the possible resolution of gingival enlargement before a decision to implement surgical treatment is made.

Alternative medications to the anticonvulsant phenytoin include carbamazepine[8] and valproic acid, both of which have been reported to induce gingival enlargement to a lesser degree.

For patients who are taking nifedipine, which has a reported prevalence of gingival enlargement of up to 44%, other calcium channel blockers such as diltiazem or verapamil may be viable alternatives; their reported prevalences of inducing gingival enlargement are 20% and 4%, respectively.[4,11,18] In addition, consideration may be given to the use of another class of antihypertensive medications rather than calcium channel blockers, because none of these drugs are known to induce gingival enlargement.

Drug substitutions for cyclosporine are more limited. Tracolimus is another immunosuppressant that has been used with organ transplant recipients.[25] The incidence of gingival enlargement in patients receiving tacrolimus therapy is approximately 65% lower than that of individuals who are receiving cyclosporine.[2] Clinical trials have also shown that the substitution of cyclosporine with tacrolimus results in a significant decrease in the severity of gingival enlargement as compared with patients who are kept on cyclosporine therapy.[14,23,28] In another study,[16] the same drug substitution resulted in a strong decrease in or the complete resolution of gingival enlargement in more than 70% of the patients who initially presented with cyclosporine-induced gingival enlargement. Therefore, the dental practitioner should consult with the treating transplantation physician to investigate the possibility of a change in immunosuppressant therapy as one of the steps in the treatment of cyclosporine-induced gingival enlargement. Patients who take cyclosporine in combination with a calcium channel blocker tend to present an overall lower prevalence of and less severe gingival enlargement if the anti-hypertensive drug is amlodipine as compared with nifedipine.[15]

The administration of the antibiotic azithromycin has been shown to decrease the severity of gingival enlargement induced by the administration of cyclosporine. A 3-day course of systemic azithromycin significantly decreased gingival enlargement, and the effect was observed as early as 7 to 30 days after the initiation of antibiotic therapy.[27] The use of azithromycin to decrease cyclosporine-induced gingival enlargement resulted in significantly greater changes than those observed with an improvement in oral hygiene.[21] The topical administration of azithromycin in the form of a toothpaste also decreased the severity of cyclosporine-induced gingival enlargement.[2]

Second, the clinician should emphasize plaque control as the first step in the treatment of drug-induced gingival enlargement. Although the exact role played by bacterial plaque is not well understood, evidence suggests that good oral hygiene, chemotherapeutics,[24] and the frequent professional removal of plaque decrease the degree of gingival enlargement and improve overall gingival health.[10,12,26] The presence of drug-induced enlargement is associated with pseudopocket formation, frequently with abundant plaque accumulation, which may lead to the development of periodontitis; meticulous plaque control therefore helps to maintain attachment levels. In addition, adequate plaque control may help to prevent the recurrence of gingival enlargement in surgically treated cases.

Third, in some patients, gingival enlargement persists after careful consideration of the previous approaches. These patients may require surgery, which may involve either gingivectomy or the periodontal flap.

Figure 58-1 presents a decision tree that outlines the sequence of events and options for the treatment of drug-induced gingival enlargement.

Gingivectomy. Gingivectomy has the advantage of simplicity and quickness but presents the disadvantages of more postoperative discomfort and an increased chance of postoperative bleeding. It also sacrifices keratinized tissue and does not allow for osseous recontouring. The clinician's decision between the two surgical techniques available must consider the extension of the area to be operated, the presence of periodontitis and osseous defects, and the location of the base of the pockets in relation to the mucogingival junction.

In general, small areas (i.e., up to six teeth) of drug-induced gingival enlargement with no evidence of attachment loss (and therefore no anticipated need for osseous surgery) can be effectively treated with the gingivectomy technique. An important consideration is the amount of keratinized tissue present: remember that at least 3 mm in the apicocoronal direction should remain after the surgery is completed.

Chapter 56 describes the gingivectomy technique in detail. Figure 58-2 depicts the procedure diagrammatically, and Figure 58-3 illustrates a case of cyclosporine-induced gingival enlargement treated with the gingivectomy technique.

Gingivectomy or gingivoplasty can also be performed with electrosurgery or via a laser device[9] (see Chapter 56). There is some preliminary evidence that the recurrence of drug-induced gingival enlargement is slower in patients treated via laser as compared with conventional gingivectomy or flap surgery.[17]

Flap Technique. Larger areas of gingival enlargement (i.e., more than six teeth) or areas where attachment loss and osseous defects are present should be treated by the flap technique, as should any situation in which the gingivectomy technique may create a mucogingival problem.

The periodontal flap technique used for the treatment of gingival enlargements is a simple variation of the one used to treat periodontitis, which is described in Chapters 57 and 59. Figure 58-4 shows the basic steps in the technique, which can be described as follows:

1. After anesthetizing the area, sounding of the underlying alveolar bone is performed with a periodontal probe to determine the presence and extent of osseous defects.
2. With a no. 15 Bard-Parker blade, the initial scalloped internal bevel incision is made at least 3 mm coronal to the mucogingival junction and includes the creation of new interdental papillae.
3. The same blade is used to thin the gingival tissues in a buccolingual direction to the mucogingival junction. At this point, the blade establishes contact with the alveolar bone, and a full-thickness or split-thickness flap is elevated.
4. With the use of an Orban knife, the base of each papilla that connects the facial and the lingual incisions is incised.
5. The excised marginal and interdental tissues are removed with curettes.
6. Tissue tabs are removed, the roots are thoroughly scaled and planed, and the bone is recontoured as needed.
7. The flap is replaced and, if necessary, trimmed to reach the bone–tooth junction exactly. The flap is then sutured with an interrupted or a continuous mattress technique, and the area is covered with a periodontal dressing.

Sutures and pack are removed after 1 week, and the patient is instructed to start plaque control methods. Usually it is convenient for the patient to use chlorhexidine oral rinses once or twice daily for 2 to 4 weeks. Figure 58-5 shows a patient treated with the flap technique.

The recurrence of drug-induced gingival enlargement is a reality in surgically treated cases.[22] As stated previously, meticulous home care,[7,19] chlorhexidine gluconate rinses,[19] and professional cleanings can decrease the speed at which and the degree to

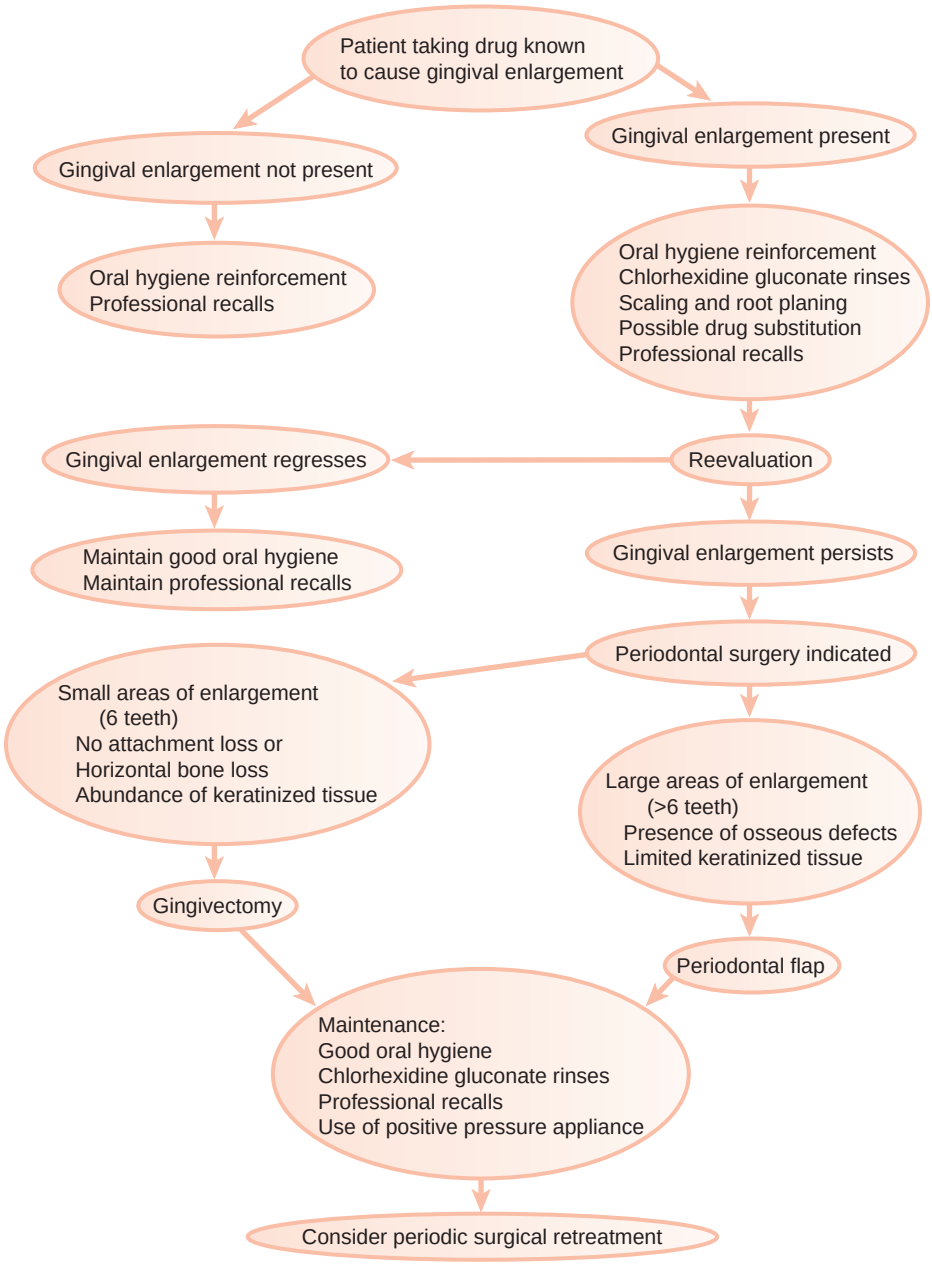

Figure 58-1 Decision tree for treatment of drug-induced gingival enlargements.

which recurrence occurs. A hard, natural rubber, fitted bite guard worn at night may help to control recurrence.[1,3]

Although the periodontal flap approach may be technically more difficult than the gingivectomy procedure, as indicated previously, the postsurgical healing of the flap technique presents less discomfort and alleviates hemorrhagic problems. The primary closure of the surgical site with the flap procedure is a great advantage over the secondary open wound that results from the gingivectomy technique. In addition, postsurgical home care can be instituted earlier with the periodontal flap.[6]

Recurrence may occur as early as 3 to 6 months after surgical treatment, but, in general, surgical results are maintained for at least 12 months. In one study, the 6-month postsurgical examination of the recurrence of cyclosporine-induced gingival enlargement after periodontal flap surgery or gingivectomy determined that the return of increased pocket depth was slower with the flap.[20] The recurrence of increased thickness of periodontal tissue, however, has not been objectively evaluated.

Leukemic Gingival Enlargement

Leukemic enlargement occurs with acute or subacute leukemia, and it is uncommon among patients in the chronic leukemic state. The medical care of leukemic patients is often complicated by gingival enlargement and superimposed painful acute necrotizing ulcerative gingivitis; this interferes with eating and creates toxic systemic reactions. The patient's bleeding and clotting times and platelet count should be checked, and the hematologist should be consulted before periodontal treatment is instituted (see Chapter 44).

The treatment of acute gingival involvement is described in Chapter 47. After acute symptoms subside, attention is directed to

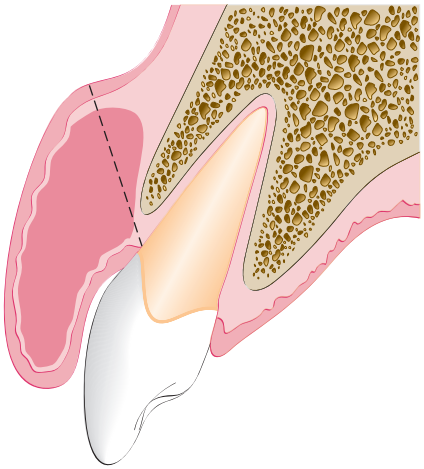

Figure 58-2 Gingivectomy technique as used to treat patients with drug-induced gingival enlargement. The dashed line represents the external bevel incision, and the *shaded area* corresponds to the tissue to be excised. The gingivectomy incision may not remove the entire hyperplastic tissue *(shaded area)*. This may leave a wide wound of exposed connective tissue.

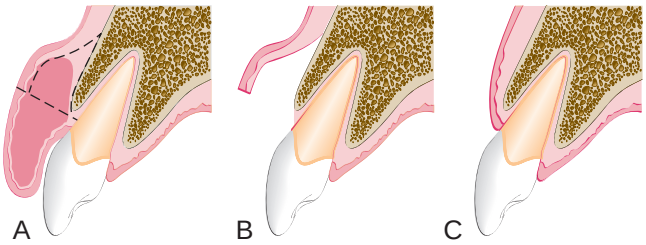

Figure 58-4 Diagram of periodontal flap treatment for drug-induced gingival enlargement. **A,** Initial reverse bevel incision followed by thinning of the enlarged gingival tissue; dotted lines represent incisions, and the shaded area represents the tissue portion to be excised. **B,** After flap elevation, enlarged portion of the gingival tissue is removed. **C,** The flap is placed on top of the alveolar bone and sutured.

Figure 58-3 Surgical treatment of cyclosporin-induced gingival enlargement with the use of the gingivectomy technique on a 16-year-old girl who had received a kidney allograft 2 years earlier. **A,** Enlarged gingival tissues and pseudopocket formation. No attachment loss or evidence of vertical bone loss existed. **B,** Initial external bevel incision performed with a Kirkland knife. **C,** Interproximal tissue release achieved with an Orban knife. **D** and **E,** Gingivoplasty performed with tissue nippers and a round diamond at high speed with abundant refrigeration. **F,** Aspect of the surgical wound at conclusion of the surgical procedure. **G,** Placement of non-eugenol periodontal dressing. **H,** The surgical area 3 months postoperatively. Note the successful elimination of the enlarged gingival tissue, the restoration of a physiologic gingival contour, and the maintenance of an adequate band of keratinized tissue.

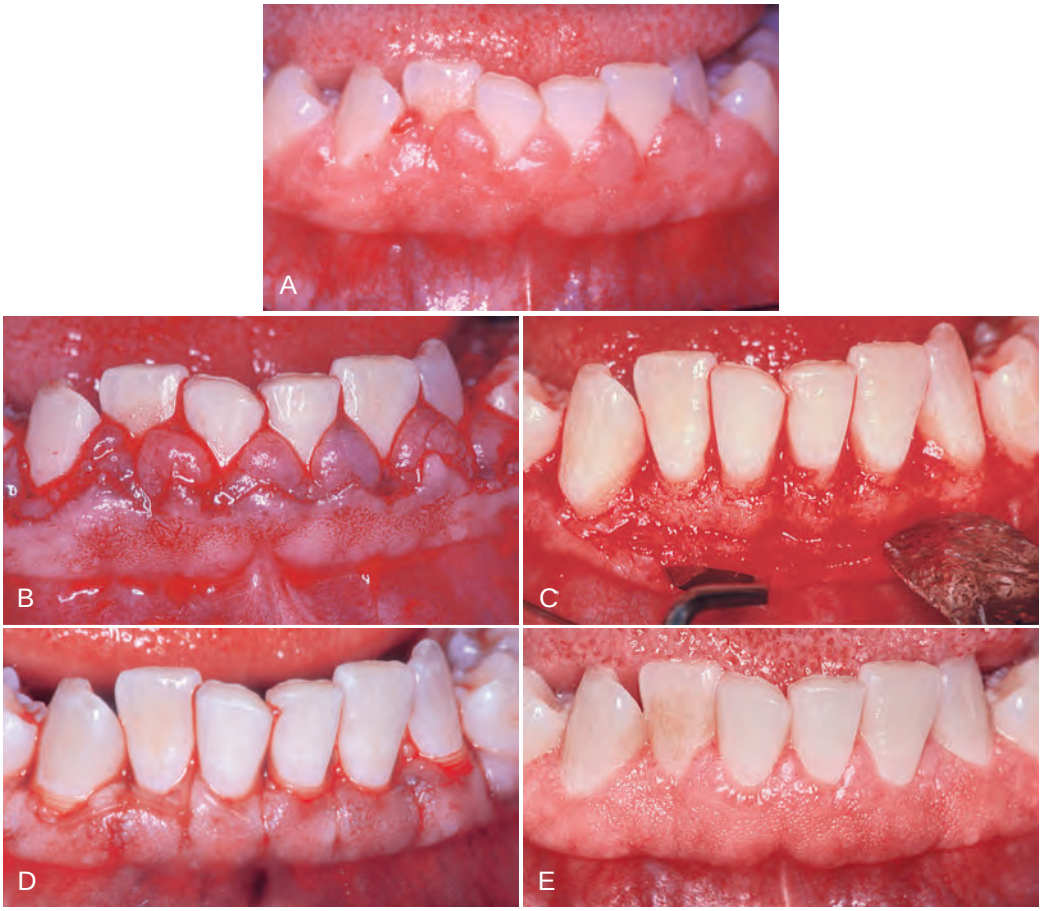

Figure 58-5 Treatment of combined cyclosporine and nifedipine–induced gingival enlargement with a periodontal flap on a 35-year-old female who had received a kidney allograft 3 years earlier. **A,** Presurgical clinical aspect of the lower anterior teeth, showing severe gingival enlargement. **B,** Initial scalloped reverse bevel incision, including maintenance of keratinized tissue and creation of surgical papillae. **C,** Elevation of a full-thickness flap and removal of the inner portion of the previously thinned gingival tissue. after scaling and root planing, osseous recontouring can be performed if necessary. **D,** The flap is positioned on top of the alveolar crest. **E,** Postsurgical aspect of the treated area at 12 months. Note the reduction of enlarged tissue volume and acceptable gingival health.

the correction of the gingival enlargement. The rationale is to remove the local irritating factors to control the inflammatory component of the enlargement.

The enlargement is treated by scaling and root planing, which are carried out in stages after the patient has received topical anesthesia. The initial treatment consists of gently removing all loose accumulations with cotton pellets, performing superficial scaling, and instructing the patient in oral hygiene for plaque control; this hygiene should include, at least initially, the daily use of chlorhexidine mouthwashes. Oral hygiene procedures are extremely important for these patients and should be performed by the nurse if necessary.

Progressively deeper scaling is carried out at subsequent visits. Treatments are confined to a small area of the mouth to facilitate the control of bleeding. Antibiotics are administered systemically the evening before and for 48 hours after each treatment to reduce the risk of infection.

Gingival Enlargement During Pregnancy

Treatment requires the elimination of all local irritants that may be responsible for precipitating the gingival changes that occur during pregnancy. The elimination of local irritants early in pregnancy is a preventive measure against gingival disease, which is preferable to the treatment of gingival enlargement after it occurs. Marginal and interdental gingival inflammation and enlargement are treated by scaling and curettage (see Chapters 51 and 62). The treatment of tumorlike gingival enlargements consists of surgical excision as well as the scaling and planing of the tooth surface. The enlargement recurs unless all irritants are removed. Food impaction is frequently an inciting factor.

Timing of Treatment and Indications

Gingival lesions during pregnancy should be treated as soon as they are detected, although not necessarily by surgical means. Scaling and root planing procedures and adequate oral hygiene measures may reduce the size of the enlargement. Gingival enlargements do shrink after pregnancy, but they usually do not disappear. After pregnancy, the entire mouth should be reevaluated, a full set of radiographs taken, and the necessary treatment undertaken.

Lesions should be removed surgically during pregnancy only if they interfere with mastication or produce an aesthetic disfigurement that the patient wants removed.

During pregnancy, the emphasis should be on (1) preventing gingival disease before it occurs and (2) treating existing gingival disease before it worsens. All patients should be seen as early as possible after becoming pregnant. Those without gingival disease

should be checked for potential sources of local irritation and should be instructed with regard to plaque-control procedures. Those with gingival disease should be treated promptly, before the conditioning effect of pregnancy on the gingiva becomes manifest. Chapter 43 presents the necessary precautions for the periodontal treatment of pregnant women.

Every pregnant patient should be scheduled for periodic dental visits. The importance of such visits for the prevention of serious periodontal disturbances should be stressed.

Gingival Enlargement During Puberty

Gingival enlargement during puberty is treated by performing scaling and curettage, removing all sources of irritation, and controlling plaque. Surgical removal may be required in severe cases. The main problem in these patients is recurrence, which is caused by poor oral hygiene.

Recurrence of Gingival Enlargement

Recurrence after treatment is the most common problem in the management of gingival enlargement. Residual local irritation and systemic or hereditary conditions that cause noninflammatory gingival hyperplasia are the responsible factors.

The recurrence of chronic inflammatory enlargement immediately after treatment indicates that all irritants have not been removed. Contributory local conditions (e.g., food impaction, overhanging margins of restorations) are often overlooked. If the enlargement recurs after healing is complete and normal contour is attained, inadequate plaque control by the patient is the most common cause.

Recurrence during the healing period is manifested as red, bead-like, granulomatous masses that bleed with slight provocation. This is a proliferative vascular inflammatory response to local irritation, which is usually a fragment of calculus on the root. The condition is corrected by removing the granulation tissue and scaling and planing the root surface.

Familial, hereditary, or idiopathic gingival enlargement recurs after surgical removal even if all local irritants have been removed. The enlargement can be maintained at minimal size by preventing secondary inflammatory involvement.

The use of escharotic drugs has been recommended in the past for the removal of gingival enlargements, but their use is currently not recommended. The destructive action of the drugs is difficult to control; injury to healthy tissue and root surfaces, delayed healing, and excessive postoperative pain are complications that can be avoided when the gingiva is removed with periodontal knives and scalpels or via electrosurgery.

Suggested Readings

Bondo-Guitton E, Bagheri H, Montastruc JL: Drug-induced gingival overgrowth: a study in the French Pharmacovigilance Database. *J Clin Periodontol* 29:513, 2012.

Camargo P, Melnick P, Pirih F, et al: Treatment of drug-induced gingival enlargement: aesthetic and functional considerations. *Periodontol 2000* 27:131, 2001.

Ciancio SG, Yaffe SJ, Catz CC: Gingival hyperplasia and diphenylhydantoin. *J Periodontol* 43:411, 1972.

Harel-Raviv M, Eckler M, Lalani K, et al: Nifedipine-induced gingival hyperplasia: a comprehensive review and analysis. *Oral Surg Oral Med Oral Pathol Oral Radiol Endod* 79:115, 1995.

López-Pintor RM, Hernández G, de Arriba L, et al: Amlodipine and nifedipine used with cyclosporine induce different effects on gingival enlargement. *Transplant Proc* 41:2351, 2009.

Margreiter R, Pohanka E, Sparacino V, et al: Open prospective multicenter study of conversion to tacrolimus therapy in renal transplant patients experiencing ciclosporin-related side-effects. *Transpl Int* 18:816, 2005.

Mavrogiannis M, Ellis JS, Seymour RA, et al: The efficacy of three different surgical techniques in the management of drug-induced gingival overgrowth. *J Clin Periodontol* 33:677, 2006.

Pilloni A, Camargo PM, Carere M, et al: Surgical treatment of cyclosporine A- and nifedipine-induced gingival enlargement. *J Periodontol* 69:791, 1998.

Rostaing L, Sánchez-Fructoso A, Franco A, et al: Conversion to tacrolimus once daily from ciclosporin in stable kidney transplant patients: a multicenter study. *Transpl Int* 25:391, 2012.

Walker RG, Cottrell S, Sharp K, et al: Conversion of cyclosporine to tacrolimus in stable renal allograft recipients: quantification of effects on the severity of gingival enlargement and hirsutism and patient-reported outcomes. *Nephrology (Carlton)* 12:607, 2007.

References

References for this chapter are found on the companion website www.expertconsult.com.

References

1. Zaiman R: The use of positive pressure mouthpiece as a new therapy for Dilantin gingival hyperplasia. *Chronicle* 131:244, 1968.
2. Argani H, Pourabbas R, Hassanzadeh D, et al: Treatment of cyclosporine-induced gingival overgrowth with azithromycin-containing toothpaste. *Exp Clin Transplant* 4:420, 2006.
3. Babcock JR: The successful use of a new therapy for Dilantin gingival hyperplasia. *Periodontics* 3:196, 1965.
4. Barclay S, Thomason JM, Idle JR, et al: The incidence and severity of nifedipine-induced gingival overgrowth. *J Clin Periodontol* 19:311, 1992.
5. Bondo-Guitton E, Bagheri H, Montastruc JL: Drug-induced gingival overgrowth: a study in the French Pharmacovigilance Database. *J Clin Periodontol* 29:513–518, 2012.
6. Camargo P, Melnick P, Pirih F, et al: Treatment of drug-induced gingival enlargement: aesthetic and functional considerations. *Periodontol 2000* 27:131, 2001.
7. Ciancio SG, Yaffe SJ, Catz CC: Gingival hyperplasia and diphenylhydantoin. *J Periodontol* 43:411, 1972.
8. Dahllöf G, Preber H, Eliasson S, et al: Periodontal condition of epileptic adults treated with phenytoin or carbamazepine. *Epilepsia* 34:960, 1993.
9. de Oliveira Guaré R, Costa SC, Baeder F, et al: Drug-induced gingival enlargement biofilm control and surgical therapy with gallium-aluminum-arsenide (GaAIAs) diode laser—a 2-year follow up. *Spec Care Dentist* 30:46, 2010.
10. Dongari A, O'Donnell HT, Langlais RP: Drug-induced gingival overgrowth. *Oral Surg Oral Med Oral Pathol* 76:543, 1993.
11. Fattore L, Stablein M, Bredfelt G, et al: Gingival hyperplasia: a side effect of nifedipine and diltiazem. *Spec Care Dentist* 11:107, 1991.
12. Hall WB: Dilantin hyperplasia: a preventable lesion. *J Periodontal Res* 4:36, 1969.
13. Harel-Raviv M, Eckler M, Lalani K, et al: Nifedipine-induced gingival hyperplasia: a comprehensive review and analysis. *Oral Surg Oral Med Oral Pathol Oral Radiol Endod* 79:115, 1995.
14. Hernandez G, Arriba L, Lucas M, et al: Reduction of severe gingival overgrowth in a kidney transplant patient by replacing cyclosporin A with tacrolimus. *J Periodontol* 71:1630, 2000.
15. López-Pintor RM, Hernández G, de Arriba L, et al: Amlodipine and nifedipine used with cyclosporine induce different effects on gingival enlargement. *Transplant Proceed* 41:2351, 2009.
16. Margreiter R, Pohanka E, Sparacino V, et al: Open prospective multicenter study of conversion to tacrolimus therapy in renal transplant patients experiencing ciclosporin-related side-effects. *Transpl Int* 18:816, 2005.
17. Mavrogiannis M, Ellis JS, Seymour RA, et al: The efficacy of three different surgical techniques in the management of drug-induced gingival overgrowth. *J Clin Periodontol* 33:677, 2006.
18. Nery EB, Edson RG, Lee KK, et al: Prevalence of nifedipine-induced gingival hyperplasia. *J Periodontol* 66:572, 1995.
19. Nishikawa S, Tada H, Hamasaki A, et al: Nifedipine-induced gingival hyperplasia: a clinical and in vitro study. *J Periodontol* 62:30, 1991.
20. Pilloni A, Camargo PM, Carere M, et al: Surgical treatment of cyclosporine A- and nifedipine-induced gingival enlargement. *J Periodontol* 69:791, 1998.
21. Ramalho VL, Ramalho HJ, Cipullo JP, et al: Comparison of azithromycin and oral hygiene program in the treatment of cyclosporine-induced gingival hyperplasia. *Ren Fail* 29:265, 2007.
22. Rees TD, Levine RA: Systemic drugs as a risk factor for periodontal disease initiation and progression. *Compendium* 16:20, 1995.
23. Rostaing L, Sánchez-Fructoso A, Franco A, et al: Conversion to tacrolimus once daily from ciclosporin in stable kidney transplant patients: a multicenter study. *Transpl Int* 25:391, 2012.
24. Saravia ME, Svirsky JA, Friedman R: Chlorhexidine as an oral hygiene adjunct for cyclosporine-induced gingival hyperplasia. *J Dent Child* 57:366, 1990.
25. Sekigucchi RT, Paixão CG, Saraiva L, et al: Incidence of tracolimus-induced gingival overgrowth in the absence of calcium-channel blockers: a short-term study. *J Clin Periodontol* 34:545, 2007.
26. Seymour RA, Jacobs DJ: Cyclosporin and the gingival tissues. *J Clin Periodontol* 19:1, 1992.
27. Tokgöz B, Sari HI, Yildiz O, et al: Effects of azithromycin on cyclosporine-induced gingival hyperplasia in renal transplant patients. *Transplant Proc* 36:2699, 2004.
28. Walker RG, Cottrell S, Sharp K, et al: Conversion of cyclosporine to tacrolimus in stable renal allograft recipients: quantification of effects on the severity of gingival enlargement and hirsutism and patient-reported outcomes. *Nephrology (Carlton)* 12:607, 2007.

CHAPTER 59

The Flap Technique for Pocket Therapy

Henry H. Takei, Fermin A. Carranza, and Kitetsu Shin

CHAPTER OUTLINE

Overview
Modified Widman Flap
Undisplaced Flap
Apically Displaced Flap
Flaps for Reconstructive Surgery
Distal Molar Surgery
Conclusion

Several techniques can be used for the treatment of periodontal pockets. The periodontal flap is one of the most frequently employed procedures, particularly for moderate and deep pockets in posterior areas (see Chapter 57).

Overview

Flaps are used for pocket therapy to accomplish the following:

1. Increase accessibility to root deposits for scaling and root planing
2. Eliminate or reduce pocket depth via resection of the pocket wall
3. Gain access for osseous resective surgery, if necessary
4. Expose the area for the performance of regenerative methods

To fulfill these purposes, several flap techniques are available and in current use.

Technique for Access and Pocket Depth Reduction or Elimination

The three different categories of flap techniques used in periodontal flap surgery are as follows: (1) the modified Widman flap; (2) the undisplaced flap; and (3) the apically displaced flap.

The modified Widman flap facilitates instrumentation for root therapy. It does not attempt to reduce the pocket depth, but it does eliminate the pocket lining. The original intent of the surgery was to access the root surface for scaling and root planing. The objectives for the other two flap procedures—the undisplaced flap and the apically displaced flap—include root surface access and the reduction or elimination of the pocket depth. The choice of which procedure to use depends on two important anatomic landmarks: the pocket depth and the location of the mucogingival junction. These landmarks establish the presence and width of the attached gingiva, which is the basis for the decision.

The *modified Widman flap* has been described for exposing the root surfaces for meticulous instrumentation and for the removal of the pocket lining.[6] Again, it is not intended to eliminate or reduce pocket depth, except for the reduction that occurs during healing as a result of tissue shrinkage.

The *undisplaced (unrepositioned) flap* improves accessibility for instrumentation, but it also removes the pocket wall, thereby reducing or eliminating the pocket. This is essentially an excisional procedure of the gingiva.

The *apically displaced flap* provides accessibility and eliminates the pocket, but it does the latter by apically positioning the soft-tissue wall of the pocket.[2] Therefore, it preserves or increases the width of the attached gingiva by transforming the previously unattached keratinized pocket wall into attached tissue. This increase in the width of the attached gingiva is based on the apical shift of the mucogingival junction, which may include the apical displacement of the muscle attachments. A study made before and 18 years after the use of apically displaced flaps failed to show a permanent relocation of the mucogingival junction.[1]

Incisions

All three flap techniques that were just discussed involve the use of the basic incisions described in Chapter 57: the internal bevel incision, the crevicular incision, and the interdental incision. However, there are important variations in the way these incisions are performed for the different types of flaps (Figures 59-1 and 59-2). The internal beveled incision for the modified Widman flap closely follows the scalloped outline of the dentition to minimize the loss of the attached keratinized gingiva. This incision is made 1 mm to 2 mm from the teeth. The gingival margin is removed, and the flap is reflected to gain access for root therapy.

The apically displaced flap technique is selected for cases that present a minimal amount of keratinized, attached gingiva. For this reason, the internal bevel incision should be made as close to the tooth as possible (i.e., 0.5 mm to 1.0 mm) (see Figure 59-1). There is no need to determine where the bottom of the pocket is in relation to the incision for the apically displaced flap as one would for the undisplaced flap. The flap is placed at the tooth–bone junction by apically displacing the flap. Its final position is not determined by the placement of the first incision.

For the undisplaced flap, the internal bevel incision is initiated at or near a point just coronal to where the bottom of the pocket is projected on the outer surface of the gingiva (see Figure 59-1). This incision can be accomplished only if sufficient attached gingiva remains apical to the incision. Therefore, the two anatomic landmarks—the pocket depth and the location of the mucogingival junction—must be considered to evaluate the amount of attached gingiva that will remain after the surgery has been completed. Because the pocket wall is not displaced apically, the initial incision should eliminate the pocket wall. Thus, an incision should not be made too close to the tooth, because it will not eliminate the pocket wall, and it may result in the re-creation of the soft-tissue pocket. If the tissue is too thick, the flap margin should be thinned with the initial incision. The proper placement of the flap margin

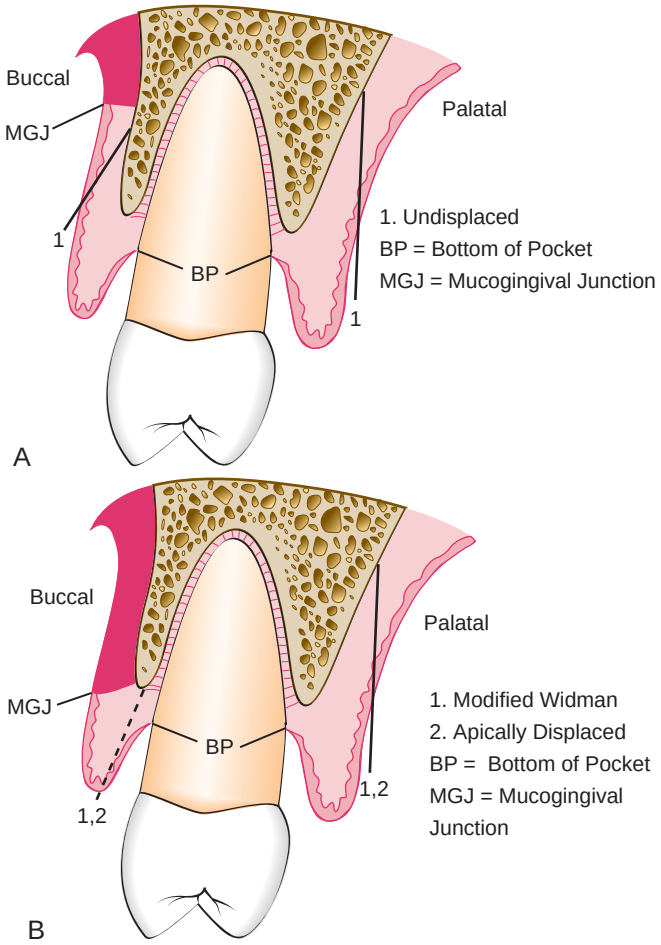

Figure 59-1 Locations of the internal bevel incisions for the different types of flaps.

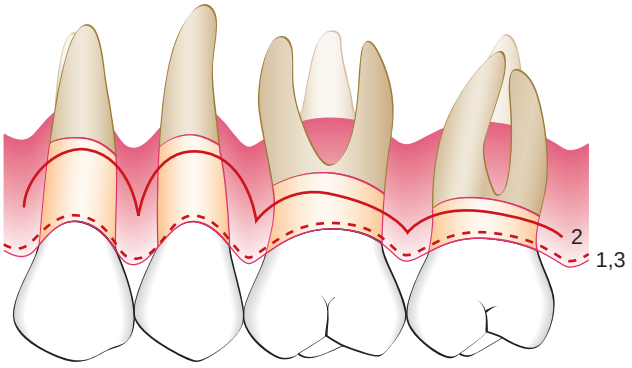

Figure 59-2 Scalloping required for the different types of flaps (see Figure 59-1).

at the tooth–bone junction during closure is important to prevent either recurrence of the pocket or the exposure of bone. The internal bevel incision should be scalloped into the interdental area to preserve the interdental papilla (see Figure 59-2). This will allow better coverage of the bone at both the radicular and interdental areas.

If the surgeon contemplates osseous surgery, the first incision should be placed in such a way to compensate for the removal of the bone tissue so that the flap can be placed at the tooth–bone junction.

Reconstructive Techniques

The techniques that are used to achieve reconstructive and regenerative objectives are the *papilla preservation flap*[8] and the *conventional flap,* which involve only crevicular or pocket incisions. This will allow the clinician to retain the maximum amount of gingival tissue, including the papilla, which is essential for graft or membrane coverage.

Modified Widman Flap

In 1965, Morris[4] revived a technique described early during the twentieth century in the periodontal literature; he called it the "unrepositioned mucoperiosteal flap." Essentially, the same procedure was presented in 1974 by Ramfjord and Nissle,[6] who called it the "modified Widman flap" (Figure 59-3). This technique offers the possibility of establishing an intimate postoperative adaptation of healthy collagenous connective tissue to tooth surfaces,[2,3,5,6] and it provides access for adequate instrumentation of the root surfaces and immediate closure of the area. The following steps outline the modified Widman flap technique.

Step 1: The initial incision is an internal bevel incision to the alveolar crest starting 0.5 mm to 1 mm away from the gingival margin (Figure 59-3, *C*). Scalloping follows the gingival margin. Care should be taken to insert the blade in such a way that the papilla is left with a thickness similar to that of the remaining facial flap. Vertical relaxing incisions are usually not needed.

Step 2: The gingiva is reflected with a periosteal elevator (Figure 59-3, *D*).

Step 3: A crevicular incision is made from the bottom of the pocket to the bone in such a way that it circumscribes the triangular wedge of tissue that contains the pocket lining.

Step 4: After the flap is reflected, a third incision is made in the interdental spaces coronal to the bone with a curette or an interproximal knife, and the gingival collar is removed (Figure 59-3, *E* and *F*).

Step 5: Tissue tags and granulation tissue are removed with a curette. The root surfaces are checked and then scaled and planed, if needed (Figure 59-3, *G* and *H*). Residual periodontal fibers attached to the tooth surface should not be disturbed.

Step 6: Bone architecture is not corrected unless it prevents good tissue adaptation to the necks of the teeth. Every effort is made to adapt the facial and lingual interproximal tissue adjacent to each other in such a way that no interproximal bone remains exposed at the time of suturing. The flaps may be thinned to allow for close adaptation of the gingiva around the entire circumference of the tooth and to each other interproximally.

Step 7: Continuous, independent sling sutures are placed in both the facial and palatal areas (Figure 59-3, *I* and *J*) and covered with a periodontal surgical pack.

Ramfjord and Nissle[6] performed an extensive longitudinal study that compared the Widman procedure (as modified by them) with the curettage technique and the pocket elimination methods, which include bone contouring when needed. The patients were assigned randomly to one of the techniques, and results were analyzed yearly for up to 7 years after therapy. The researchers reported similar results for each of the three methods tested. Pocket depth was initially similar for all methods, but it was maintained at shallower levels with the Widman flap; the attachment level remained higher with the Widman flap.

Figure 59-3 Modified Widman flap technique. **A,** Facial view before surgery. The probing of pockets revealed interproximal depths that ranged from 4 mm to 8 mm and facial and palatal depths of 2 mm to 5 mm. **B,** Radiographic survey of the area. Note the generalized horizontal bone loss. **C,** Facial internal bevel incision. **D,** Palatal incision. **E,** Elevation of the flap, which left a wedge of tissue still attached to its base. **F,** Removal of tissue. **G,** Tissue removed and ready for scaling and root planing. **H,** Scaling and root planing of exposed root surfaces. **I,** Continuous, independent sling suture of facial portion of surgery. **J,** Continuous, independent sling suture of palatal portion of surgery. **K,** Postsurgical result. *(Courtesy Dr. Kitetsu Shin, Saitama, Japan.)*

Undisplaced Flap

Currently, the undisplaced flap may be the most frequently performed type of periodontal surgery. It differs from the modified Widman flap in that the soft-tissue pocket wall is removed with the initial incision; thus, it may be considered an "internal bevel gingivectomy." The undisplaced flap and the gingivectomy are the two techniques that surgically remove the pocket wall. To perform this technique without creating a mucogingival problem, the clinician should determine that enough attached gingiva will remain after removal of the pocket wall. The following steps outline the undisplaced flap technique.

Step 1: The pockets are measured with the periodontal probe, and a bleeding point is produced on the outer surface of the gingiva to mark the pocket bottom.

Step 2: The initial or internal bevel incision is made (Figure 59-4) after scalloping the bleeding marks on the gingiva (Figure 59-5). The incision is usually carried to a point apical to the alveolar crest, depending on the thickness of the tissue. The thicker the tissue is, the more apical the ending point of the incision (see Figure 59-4). In addition, thinning of the flap should be performed with the initial incision, because it is easier to accomplish at this time than it is later with a loose, reflected flap that is difficult to manage. (The use of this technique in palatal areas is considered in the discussion that follows this list.)

Step 3: The second or crevicular incision is made from the bottom of the pocket to the bone to detach the connective tissue from the bone.

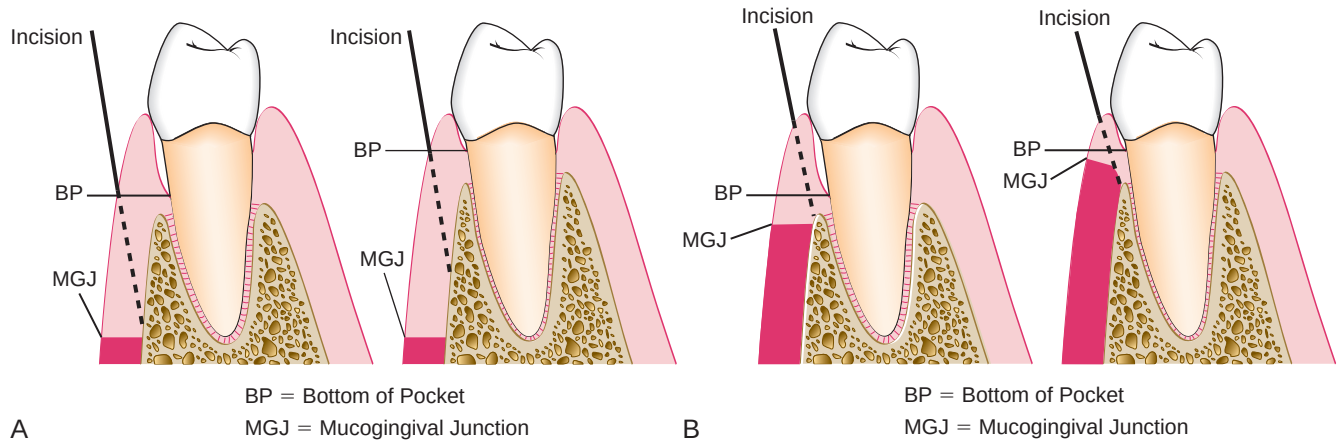

Figure 59-4 Diagram showing the location of two different areas where the internal bevel incision is made in an undisplaced flap. The incision is made at the level of the pocket to discard the tissue coronal to the pocket if there is sufficient remaining attached gingiva.

Figure 59-5 Undisplaced flap. **A** and **B,** Preoperative facial and palatal views. **C** and **D,** Internal bevel incisions in the facial and palatal aspects. Note the deeper scalloping palatally for the replaced flap. **E** and **F,** Flap elevated to show osseous defects. **G** and **H,** Osseous surgery has been performed. **I** and **J,** Flaps have been placed in their original sites and sutured. **K** and **L,** Postoperative results. *(Courtesy Dr. Paulo Camargo, University of California, Los Angeles.)*

Step 4: The flap is reflected with a periosteal elevator (blunt dissection) from the internal bevel incision. Usually there is no need for vertical incisions, because the flap is not displaced apically.

Step 5: The third or interdental incision is made with an interdental knife to separate the connective tissue from the bone.

Step 6: The triangular wedge of tissue created by the three incisions is removed with a curette.

Step 7: The area is debrided to remove all tissue tags and granulation tissue with the use of sharp curettes.

Step 8: After the necessary scaling and root planing, the flap edge should rest on the root–bone junction. If this is not the case as a result of the improper location of the initial incision or the unexpected need for osseous surgery, the edge of the flap is scalloped again and trimmed to allow the flap edge to end at the root–bone junction.

Step 9: A continuous sling suture is used to secure the facial and lingual or palatal flaps. This type of suture, which makes use of the tooth as an anchor, is advantageous to position and hold the flap edges at the root–bone junction. The area is covered with a periodontal pack.

Palatal Flap

The surgical approach to the palatal area differs from that used for other areas as a result of the character of the palatal tissue and the anatomy of the area. The palatal tissue is all attached, keratinized tissue and has none of the elastic properties associated with other gingival tissues. Therefore, the palatal tissue cannot be apically displaced, and a partial-thickness (split-thickness) flap cannot be accomplished.

The initial incision for the palatal flap should allow the flap, when sutured, to be precisely adapted at the root–bone junction. The flap cannot be moved apically or coronally to adapt to the root–bone junction, as can be done with the flaps in other areas. Therefore, the location of the initial incision is important for the final placement of the flap.

The palatal tissue may be thin or thick, and it may or may not have osseous defects. The palatal vault may be high or low. These anatomic variations may require changes in the location, angle, and design of the incision.

The initial incision for a flap varies with the anatomic situation. As shown in Figure 59-6, the initial incision may be the usual internal bevel incision, which will then be followed by crevicular and interdental incisions. If the tissue is thick, a horizontal gingivectomy incision may be made, and this may be followed by an internal bevel incision that starts at the edge of this incision and ends on the lateral surface of the underlying bone. The placement of the internal bevel incision must be done in such a way that the flap fits around the tooth without exposing the bone.

Before the flap is reflected to the final position for scaling and management of the osseous lesions, its thickness must be checked. Flaps should be thin to adapt to the underlying osseous tissue and provide a thin, knifelike gingival margin. Flaps—particularly palatal flaps—are often too thick; they may have a propensity to separate from the tooth, which may delay and complicate healing. It is best to thin the flaps before their complete reflection, because a free, mobile flap is difficult to hold for thinning (Figure 59-7). A sharp, thin papilla positioned properly around the interdental areas at the tooth–bone junction is essential to prevent the recurrence of soft-tissue pockets.

The purpose of the palatal flap should be considered before the incision is made. If the intent of the surgery is debridement, the internal bevel incision is planned so that the flap adapts at the root–bone junction when sutured. If osseous resection is necessary, the incision should be planned to compensate for the lowered level of the bone when the flap is closed. Probing and sounding of the osseous level and the depth of the intrabony pocket should be used to determine the position of the incision.

The apical portion of the scalloping should be narrower than the line–angle area, because the palatal root tapers apically. A

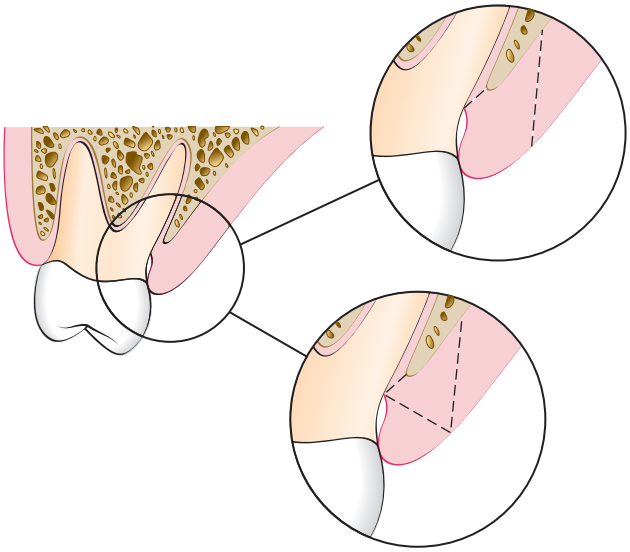

Figure 59-6 Examples of two methods for eliminating a palatal pocket. One incision is an internal bevel incision made at the area of the apical extent of the pocket. The other procedure involves a gingivectomy incision, which is followed by an internal bevel incision.

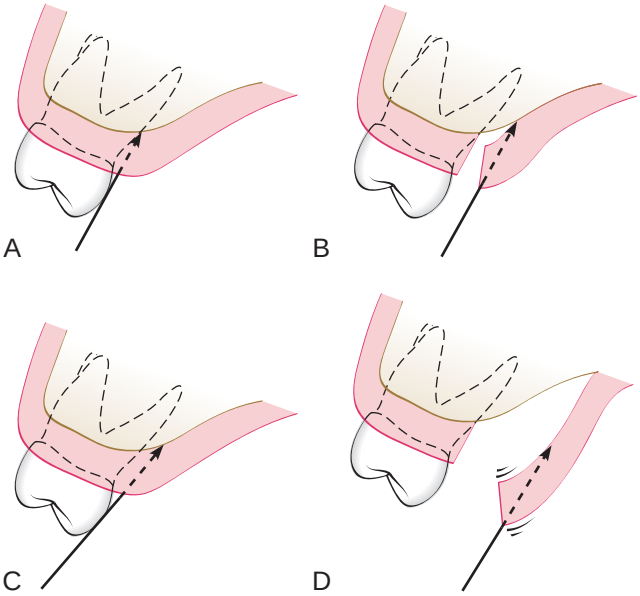

Figure 59-7 Diagrams that illustrate the angle of the internal bevel incision in the palate and the different ways to thin the flap. **A,** The usual angle and direction of the incision. **B,** Thinning of the flap after it has been slightly reflected with a second internal incision. **C,** Beveling and thinning of the flap with the initial incision if the position and contour of the tooth allow. **D,** The problem encountered when thinning the flap after it has been reflected. The flap is too loose and free for proper positioning and for the making of the incision.

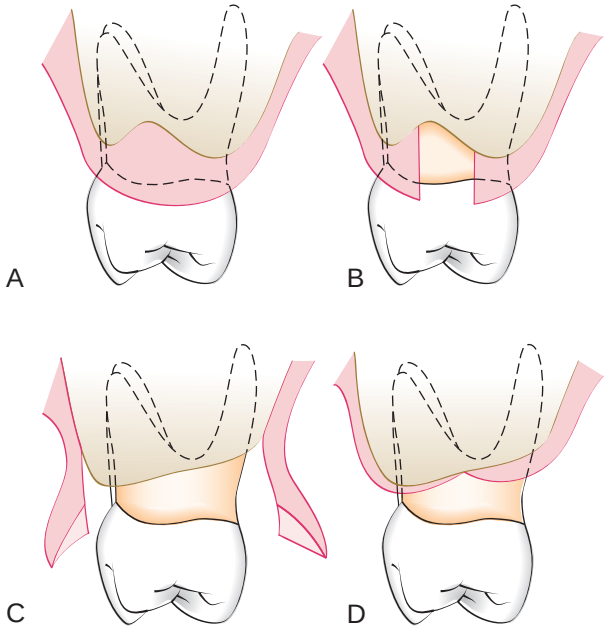

Figure 59-8 **A,** Distal view of incisions made to eliminate a pocket distal to the maxillary second molar. **B,** Two parallel incisions and the removal of the intervening tissue. **C,** Thinning of the flap and contouring of the bone. **D,** Approximation of the buccal and palatal flaps.

rounded scallop results in a palatal flap that does not fit snugly around the root. This procedure should be done before the complete reflection of the palatal flap, because a loose flap is difficult to grasp and stabilize for dissection.

It is sometimes necessary to thin the palatal flap after it has been reflected. This can be accomplished by holding the inner portion of the flap with a mosquito hemostat or Adson forceps as the inner connective tissue is carefully dissected away with a sharp no. 15 scalpel blade. Care must be taken to not perforate or overthin the flap. The edge of the flap should be thinner than the base; therefore, the blade should be angled toward the lateral surface of the palatal bone. The dissected inner connective tissue is removed with a hemostat. As with any flap, the triangular papilla portion should be thin enough to fit snugly against the bone and into the interdental area (Figure 59-8).

The principles for the use of vertical releasing incisions are similar to those for using other incisions. Care must be exercised so that the length of the incision is minimal to avoid the numerous vessels located in the palate.

Apically Displaced Flap

With some variants, the apically displaced flap technique can be used for pocket eradication, widening the zone of attached gingiva, or both. Depending on the purpose, the apically displaced flap can be a full-thickness (mucoperiosteal) flap or a split-thickness (mucosal) flap. The split-thickness flap requires more precision and time as well as a gingival tissue that is thick enough to split, but it can be more accurately positioned and sutured in an apical position with the use of a periosteal suturing technique, as follows.

Step 1: An internal bevel incision is made (Figure 59-9). To preserve as much of the keratinized and attached gingiva as possible, it should be no more than about 1 mm from the crest of the gingiva and directed to the crest of the bone (see Figure 59-1). The incision is made after the existing scalloping, and there is no need to mark the bottom of the pocket in the external gingival surface, because the incision is unrelated to pocket depth. It is also not necessary to accentuate the scallop interdentally, because the flap is displaced apically and not placed interdentally.

Step 2: Crevicular incisions are made, and this is followed by the initial elevation of the flap. Interdental incisions are then performed, and the wedge of tissue that contains the pocket wall is removed.

Step 3: Vertical incisions are made extending beyond the mucogingival junction. If the objective is a full-thickness flap, it is elevated by blunt dissection with a periosteal elevator. If a split-thickness flap is required, it is elevated via sharp dissection with the use of a Bard–Parker knife to split it. This leaves a layer of connective tissue, including the periosteum, on the bone.

Step 4: After the removal of all granulation tissue, scaling and root planing, and osseous surgery if needed, the flap is displaced apically. It is important that the vertical incisions—and therefore the flap elevation—reach past the mucogingival junction to provide adequate mobility to the flap for its apical displacement.

Step 5: If a full-thickness flap was created, a sling suture around the tooth prevents the flap from sliding to a position more apical than what is desired, and the periodontal dressing can avoid its movement in a coronal direction. A partial-thickness flap is sutured to the periosteum with the use of a direct loop suture or a combination of loop and anchor suture. A dry foil is placed over the flap before it is covered with the dressing to prevent the introduction of pack under the flap.

After 1 week, dressings and sutures are removed. The area is usually repacked for another week, after which the patient is instructed to use chlorhexidine mouthrinse or to apply chlorhexidine topically with cotton-tipped applicators for another 2 or 3 weeks.

Flaps for Reconstructive Surgery

In current reconstructive therapy, bone grafts, membranes, or a combination of these—with or without other agents—are used for a successful outcome (see Chapter 61). The flap design should therefore be set up so that the maximum amount of gingival tissue and papilla are retained to cover the material placed in the pocket.

Two flap designs are available for reconstructive surgery: the papilla preservation flap and the conventional flap with only crevicular incisions. *The flap design of choice is the papilla preservation flap,* which retains the entire papilla covering the lesion. However, to use this flap, there must be adequate interdental space to allow the intact papilla to be reflected with the facial or lingual/palatal flap. When the interdental space is very narrow, thereby making it impossible to perform a papilla preservation flap, a conventional flap with only crevicular incisions is made.

Papilla Preservation Flap

The technique for employing a papilla preservation flap (Figures 59-10 and 59-11) is as follows:

Step 1: A crevicular incision is made around each tooth, with no incisions across the interdental papilla.

Step 2: The preserved papilla can be incorporated into the facial or lingual/palatal flap, although it is most often integrated into the facial flap. In these cases, the lingual or palatal incision consists of a semilunar incision across the interdental papilla in its palatal or lingual aspect; this incision

Figure 59-9 An apically displaced flap. **A** and **B,** Facial and lingual preoperative views. **C** and **D,** The facial and lingual flaps have been elevated. **E** and **F,** After debridement of the areas. **G** and **H,** The sutures are in place. **I** and **J,** Healing after 1 week. **K,** Healing after 2 months. Note the preservation of attached gingiva displaced to a more apical position. *(Courtesy of Dr. Thomas Han, Los Angeles, CA.)*

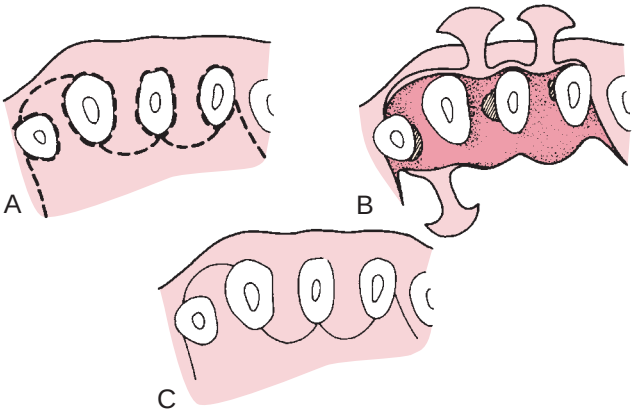

Figure 59-10 Flap design for a papilla preservation flap. **A,** Incisions for this type of flap are depicted by interrupted lines. The preserved papilla can be incorporated into the facial or the lingual–palatal flap. **B,** The reflected flap exposes the underlying bone. Several osseous defects are seen. **C,** The flap has been returned to its original position, where it covers all of the interdental spaces.

dips apically from the line angles of the tooth so that the papillary incision is at least 5 mm from the crest of the papilla.

Step 3: An Orban knife is then introduced into this incision to sever half to two thirds of the base of the interdental papilla. The papilla is then dissected from the lingual or palatal aspect and elevated intact with the facial flap.

Step 4: The flap is reflected without thinning the tissue.

Conventional Flap

The technique for employing a conventional flap for reconstructive surgery is as follows:

Step 1: With the use of a no. 12 blade, incise the tissue at the bottom of the pocket and to the crest of the bone to split the papilla below the contact point. Every effort should be made to retain as much tissue as possible to protect the area subsequently.

Step 2: Reflect the flap; keep it as thick as possible, and do not attempt to thin it as is done for resective surgery. The maintenance of a thick flap is necessary to prevent exposure of the graft or the membrane, which results from necrosis of the flap margins.

Distal Molar Surgery

The treatment of periodontal pockets on the distal surface of terminal molars is often complicated by the presence of bulbous fibrous tissue over the maxillary tuberosity or prominent retromolar pads in the mandible. Deep vertical defects are also often present in conjunction with the redundant fibrous tissue. Some of these osseous lesions may result from incomplete repair after the extraction of impacted third molars (Figure 59-12).

Figure 59-11 Papilla preservation flap. **A,** Facial view after sulcular incisions have been made. **B,** Straight-line incision in the palatal area about 3 mm from the gingival margins. This incision is then connected to the margins with vertical incisions at the mid part of each tooth. **C,** Papillae are reflected with the facial flap. **D,** Lingual view after the reflection of the flap. **E,** Lingual view after the flap is brought back to its original position. It is then sutured with independent sutures. **F,** Facial view after healing. **G,** Palatal view after healing. *(Courtesy of Dr. Thomas Han, Los Angeles, CA.)*

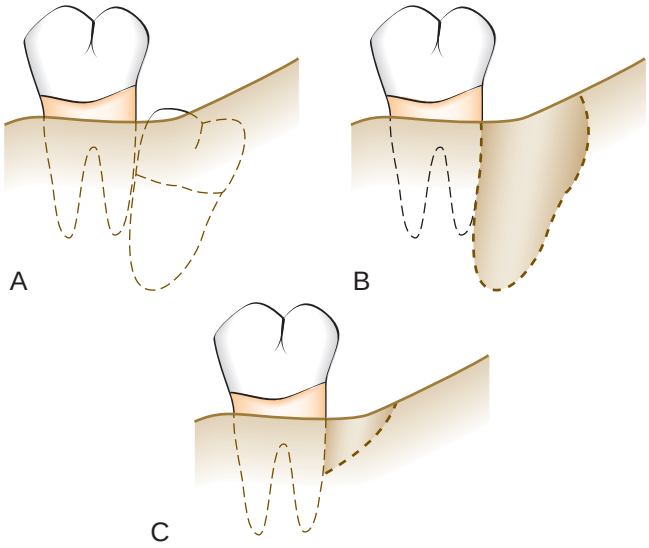

Figure 59-12 **A,** Impaction of a third molar distal to a second molar with little or no interdental bone between the two teeth. **B,** Removal of the third molar creates a pocket with little or no bone distal to the second molar. **C,** This often leads to a vertical osseous defect distal to the second molar.

The gingivectomy incision is the most direct approach to the treatment of distal pockets that have adequate attached gingiva and no osseous lesions. However, the flap approach is less traumatic postsurgically, because it produces a primary closure wound rather than the open secondary wound left by a gingivectomy incision. In addition, it results in attached gingiva. It also provides access for examination and, if needed, correction of the osseous defect. Procedures for this purpose were described by Robinson[7] and Braden[2] and modified by several other investigators. Some representative procedures are discussed in the following sections.

Maxillary Molars

The treatment of distal pockets on the maxillary arch is usually simpler than the treatment of a similar lesion on the mandibular arch, because the tuberosity presents a greater amount of fibrous attached gingiva than does the area of the retromolar pad. In addition, the anatomy of the tuberosity that extends distally is more adaptable to pocket elimination than is that of the mandibular molar arch, where the tissue extends coronally. However, the lack of a broad area of attached gingiva and the abruptly ascending tuberosity sometimes complicate therapy (Figure 59-13).

The following considerations determine the location of the incision for distal molar surgery: accessibility, amount of attached gingiva, pocket depth, and available distance from the distal aspect of the tooth to the end of the tuberosity or retromolar pad.

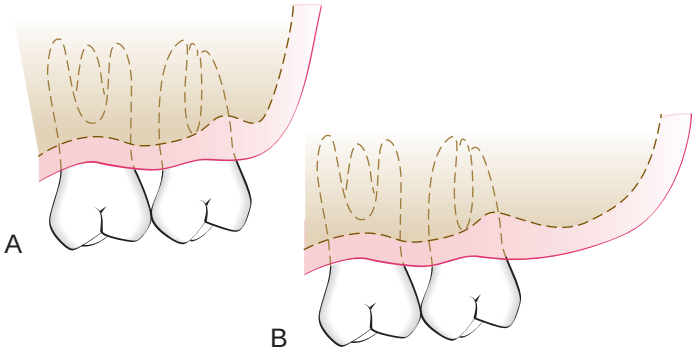

Figure 59-13 **A,** Removal of a pocket distal to the maxillary second molar may be difficult if there is minimal attached gingiva. If the bone ascends acutely apically, the removal of this bone may make the procedure easier. **B,** A long distal tuberosity with abundant attached gingiva is an ideal anatomic situation for distal pocket eradication.

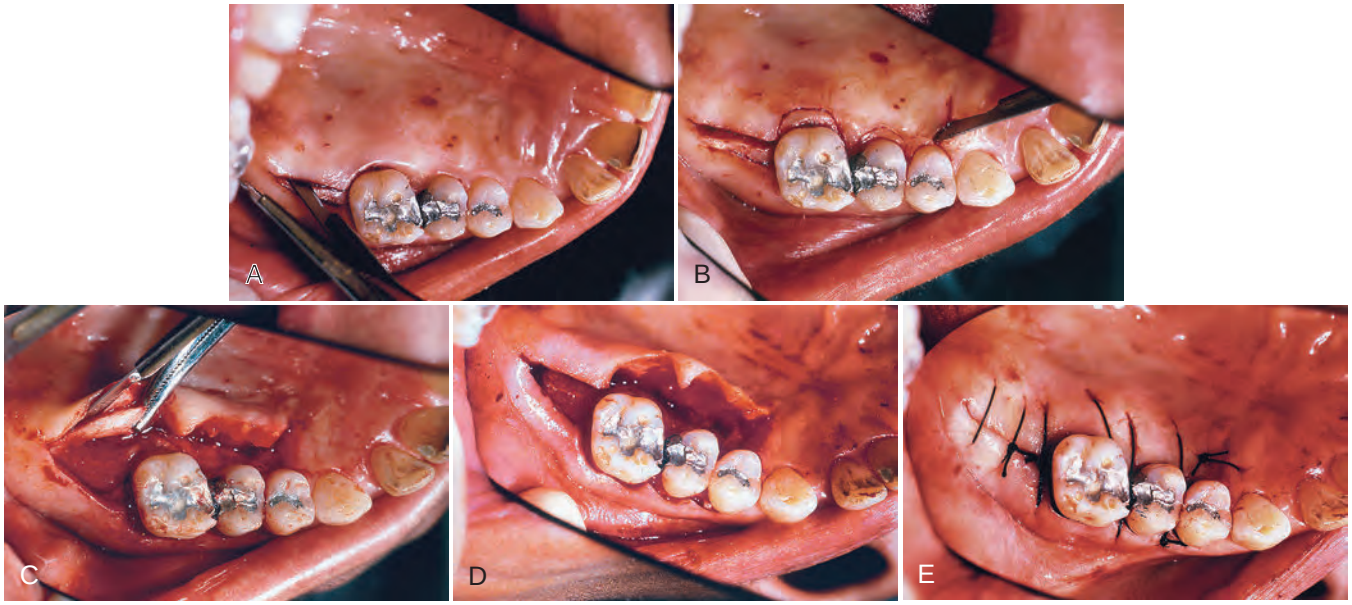

Figure 59-14 **A,** A distal pocket eradication procedure with the incision distal to the molar. **B,** A scalloped incision around the remaining teeth. **C,** The flap has been reflected and thinned around the distal incision. **D,** The flap in position before suturing. It should be closely approximated. **E,** The flap sutured both distally and over the remaining surgical area.

Technique. Two parallel incisions that begin at the distal portion of the tooth and extend to the mucogingival junction distal to the tuberosity or retromolar pad are made (Figure 59-14). The faciolingual distance between these two incisions depends on the depth of the pocket and the amount of fibrous tissue involved. The deeper the pocket, the greater is the distance between the two parallel incisions. It is important to note that, when the tissue between the two incisions is removed and the flaps are thinned, the two flap edges must approximate each other at a new apical position without overlapping.

When the depth of the pocket cannot be easily estimated, it is better to err on the conservative side to leave overlapping flaps rather than flaps that are too short and that result in the exposure of bone. When the two flaps overlap after the surgery is completed, they should be placed one over the other. The overlapping portion of one of them is grabbed with a hemostat, and a sharp knife or scissors is then used to cut the excess.

A transversal incision is made at the distal end of the two parallel incisions so that a long, rectangular piece of tissue can be removed. These incisions are usually interconnected with the incisions for the remainder of the surgery in the quadrant involved. The parallel distal incisions should be confined to the attached gingiva, because bleeding and flap management become problems when the incision is extended into the alveolar mucosa. If access is difficult—especially if the distance from the distal aspect of the tooth to the mucogingival junction is short—then a vertical incision can be made at the end of the parallel incisions.

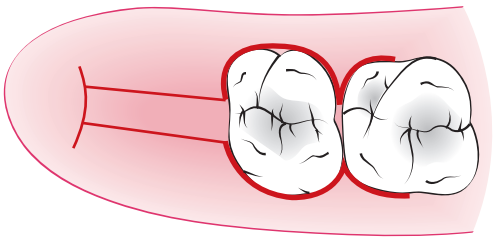

Figure 59-15 Typical incision design for a surgical procedure distal to the maxillary second molar.

When treating the tuberosity area, the two distal incisions are usually made at the midline of the tuberosity (Figure 59-15). In most cases, no attempt is made to undermine the underlying tissue at this time. These incisions are made straight down into the underlying bone, where access is difficult. A no. 12B blade is generally used. It is easier to dissect out the underlying redundant tissue when the flap is partially reflected. When the distal flaps are placed back on the bone, the two flap margins should closely approximate each other.

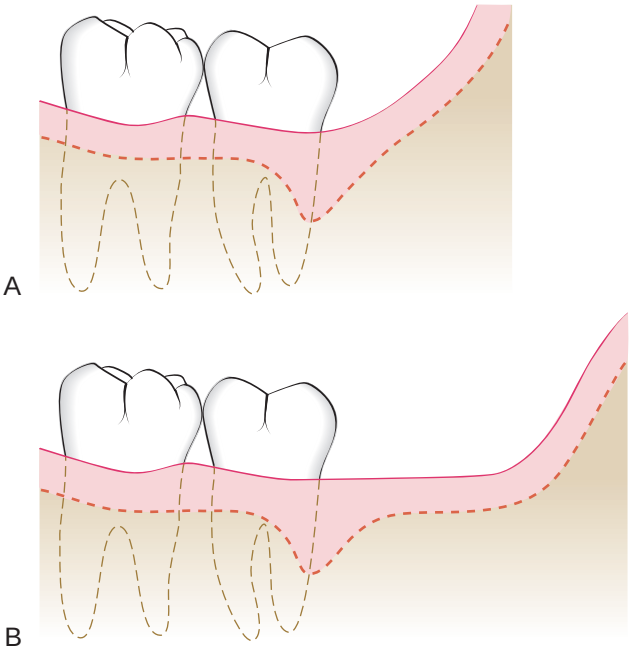

Figure 59-16 **A,** Pocket eradication distal to a mandibular second molar with minimal attached gingiva and a close ascending ramus is anatomically difficult. **B,** For surgical procedures distal to a mandibular second molar, abundant attached gingiva and distal space are ideal.

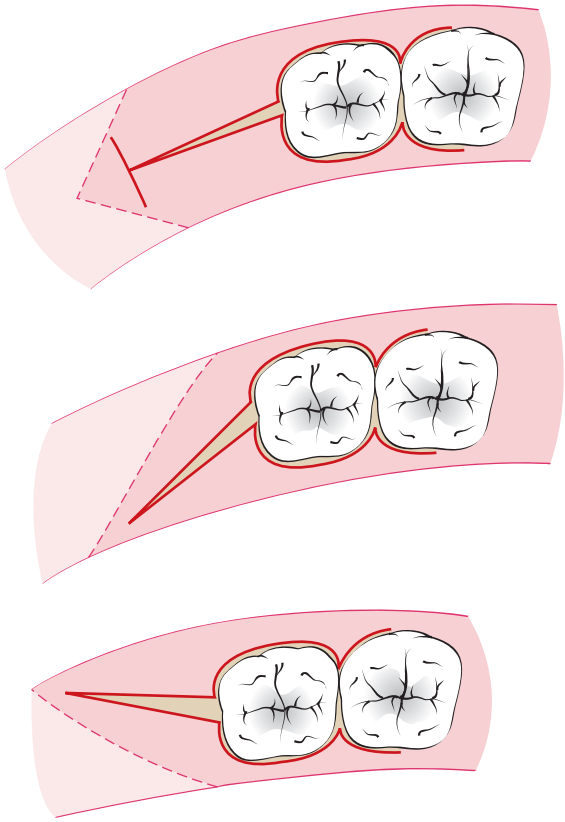

Figure 59-17 Incision designs for surgical procedures distal to the mandibular second molar. The incision should follow the areas of greatest attached gingiva and underlying bone.

Mandibular Molars

Incisions for the mandibular arch differ from those used for the tuberosity as a result of differences in the anatomy and histologic features of the areas. The retromolar pad area does not usually present as much fibrous attached gingiva. The keratinized gingiva, if present, may not be found directly distal to the molar. The greatest amount may be distolingual or distofacial, and it may not be over the bony crest. The ascending ramus of the mandible may also create a short, horizontal area distal to the terminal molar (Figure 59-16). The shorter this area, the more difficult it is to treat any deep distal lesion around the terminal molar.

The two incisions distal to the molar should follow the area with the greatest amount of attached gingiva (Figure 59-17). Therefore, the incisions could be directed distolingually or distofacially, depending on which area has more attached gingiva. Before the flap is completely reflected, it is thinned with a no. 15 blade. It is easier to thin the flap before it is completely free and mobile. After the reflection of the flap and the removal of the redundant fibrous tissue, any necessary osseous surgery is performed. The flaps are approximated similarly to those in the maxillary tuberosity area.

Conclusion

Periodontal flap procedures for pocket therapy include flaps that are created solely for access to root surfaces and bone margins, flaps for the precise processes of osseous surgery, and flaps for periodontal regeneration. All of these approaches have specific flap designs and step-by-step elements, and all of them include calculus removal and root planing as part of the essential treatment protocol. Flaps should allow for adequate access, and they should be reflected so that at least 3 mm of crestal bone is exposed. If the flaps are to be positioned apically, flap mobility is obtained by extending the facial and lingual flap elevation beyond the mucogingival junction, which enables the elasticity of the mucosa to be applied. Palatal flaps are much less mobile; thus, inverse bevel incisions are used to remove marginal gingival tissues so that, at the time of suturing, the flap margin is positioned apically, if so indicated.

Papilla preservation techniques with various modifications are applied to those areas in which gingival recession needs to be minimized. For some aesthetic locations, nonsurgical therapy may be more appropriate than flap surgery.

Adjacent edentulous areas are incorporated into the flap design with the use of wedge incisions that enable access to adjacent root surfaces for complete root planing and that allow clinicians to visualize and treat the associated bone defects. Postoperative plaque control is essential for successful outcomes. Clinicians should ensure that patients have demonstrated adequate oral hygiene during the presurgical phase, and they should emphasize that this must continue this after surgery.

Suggested Readings

Ainamo A, Bergenholtz A, Hugoson A, et al: Location of the mucogingival junction 18 years after apically repositioned flap surgery. *J Clin Periodontol* 19:49, 1992.

Braden BE: Deep distal pockets adjacent to terminal teeth. *Dent Clin North Am* 13:161, 1969.

Caton J, Nyman S: Histometric evaluation of periodontal surgery. I. The modified Widman flap procedure. *J Clin Periodontol* 7:212, 1980.

Matelski DE, Hurt WC: The corrective phase: the modified Widman flap. In Hurt WC, editor: *Periodontics in general practice*, Springfield, IL, 1976, Charles C Thomas.

Morris ML: The unrepositioned mucoperiosteal flap. *Periodontics* 3:147, 1965.

Olsen C, Ammons WF, van Belle G: A longitudinal study comparing apically repositioned flaps, with and without osseous surgery. *Int J Periodontics Restorative Dent* 5:10, 1985.

Ramfjord SP: Present status of the modified Widman flap procedure. *J Periodontol* 48:558, 1977.
Ramfjord SP, Nissle RR: The modified Widman flap. *J Periodontol* 45:601, 1974.
Robinson RE: The distal wedge operation. *Periodontics* 4:256, 1966.
Takei HH, Han TJ, Carranza FA, et al: Flap technique for periodontal bone implants: papilla preservation technique. *J Periodontol* 56:204, 1985.
Tavtigian R: The height of the facial radicular alveolar crest following apically positioned flap operation. *J Periodontol* 41:412, 1970.

References

References for this chapter are found on the companion website www.expertconsult.com.

References

1. Ainamo A, Bergenholtz A, Hugoson A, et al: Location of the mucogingival junction 18 years after apically repositioned flap surgery. *J Clin Periodontol* 19:49, 1992.
2. Braden BE: Deep distal pockets adjacent to terminal teeth. *Dent Clin North Am* 13:161, 1969.
3. Matelski DE, Hurt WC: The corrective phase: the modified Widman flap. In Hurt WC, editor: *Periodontics in general practice*, Springfield, IL, 1976, Charles C Thomas.
4. Morris ML: The unrepositioned mucoperiosteal flap. *Periodontics* 3:147, 1965.
5. Ramfjord SP: Present status of the modified Widman flap procedure. *J Periodontol* 48:558, 1977.
6. Ramfjord SP, Nissle RR: The modified Widman flap. *J Periodontol* 45:601, 1974.
7. Robinson RE: The distal wedge operation. *Periodontics* 4:256, 1966.
8. Takei HH, Han TJ, Carranza FA, et al: Flap technique for periodontal bone implants: papilla preservation technique. *J Periodontol* 56:204, 1985.

CHAPTER 60

Resective Osseous Surgery

Thomas N. Sims

CHAPTER OUTLINE

Selection of Treatment Technique
Rationale
Normal Alveolar Bone Morphology
Terminology
Factors in Selection of Resective Osseous Surgery
Examination and Treatment Planning
Methods of Resective Osseous Surgery
Osseous Resection Technique *(e-only)*
Flap Placement and Closure *(e-only)*
Postoperative Maintenance *(e-only)*
Specific Osseous Reshaping Situations *(e-only)*
Conclusion

For online-only content on osseous resection technique, flap placement and closure, postoperative maintenance, and specific osseous reshaping situations, please visit the companion website at www.expertconsult.com.

The damage resulting from periodontal disease manifests in variable destruction of the tooth-supporting bone. Generally, bony deformities are not uniform; they are not indicative of the alveolar housing of the tooth before the disease process and do not reflect the overlying gingival architecture. Bone loss has been classified as either "horizontal" or "vertical," but in fact, bone loss is most often a combination of horizontal and vertical loss. Horizontal bone loss generally results in a relative thickening of the marginal alveolar bone because bone tapers as it approaches its most coronal margin.

The effects of this thickening and the development of vertical defects leave the alveolar bone with countless combinations of bony shapes. If these various topographic changes are to be altered to provide a more physiologic bone pattern, a method for osseous recontouring must be followed.

Osseous surgery may be defined as the procedure by which changes in the alveolar bone can be accomplished to rid it of deformities induced by the periodontal disease process or other related factors such as exostosis and tooth supraeruption.

Osseous surgery can be either additive or subtractive in nature. *Additive osseous surgery* includes procedures directed at restoring the alveolar bone to its original level, whereas *subtractive osseous surgery* is designed to restore the form of preexisting alveolar bone to the level present at the time of surgery or slightly more apical to this level (Figure 60-1).

Additive osseous surgery brings about the ideal result of periodontal therapy; it implies regeneration of lost bone and reestablishment of the periodontal ligament, gingival fibers, and junctional epithelium at a more coronal level. This type of osseous surgery is discussed in Chapter 61.

Subtractive osseous surgery procedures provide an alternative to additive methods and should be used when additive procedures are not feasible. These subtractive procedures are discussed in this chapter.

Selection of Treatment Technique

The morphology of the osseous defect largely determines the treatment technique to be used. *One-wall angular defects* usually need to be recontoured surgically. *Three-wall defects,* particularly if they are narrow and deep, can be successfully treated with techniques that strive for new attachment and bone reconstruction. *Two-wall angular defects* can be treated with either method, depending on their depth, width, and general configuration. Therefore, except for one-wall defects and wide, shallow two-wall defects, and interdental craters, osseous defects are treated with the objective of obtaining optimal repair by natural healing processes.

Rationale

Osseous resective surgery necessitates following a series of strict guidelines for proper contouring of alveolar bone and subsequent management of the overlying gingival soft tissues. The specifics of these techniques are discussed later in this chapter. The techniques discussed here for osseous resective surgery have limited applicability in deep intrabony or hemiseptal defects, which could be treated with a different surgical approach (see Chapter 61). Osseous surgery provides the purest and surest method for reducing pockets with bony discrepancies that are not overly vertical and also remains one of the principal periodontal modalities because of its long-term success and predictability.

Osseous resective surgery is the most predictable pocket reduction technique.[10-12] However, more than any other surgical technique, osseous resective surgery is performed at the expense of bony tissue and attachment level.[1,2,8] Thus its value as a surgical approach is limited by the presence, quantity, and shape of the bony tissues and by the amount of attachment loss that is acceptable.

The major rationale for osseous resective surgery is based on the tenet that discrepancies in level and shapes of the bone and

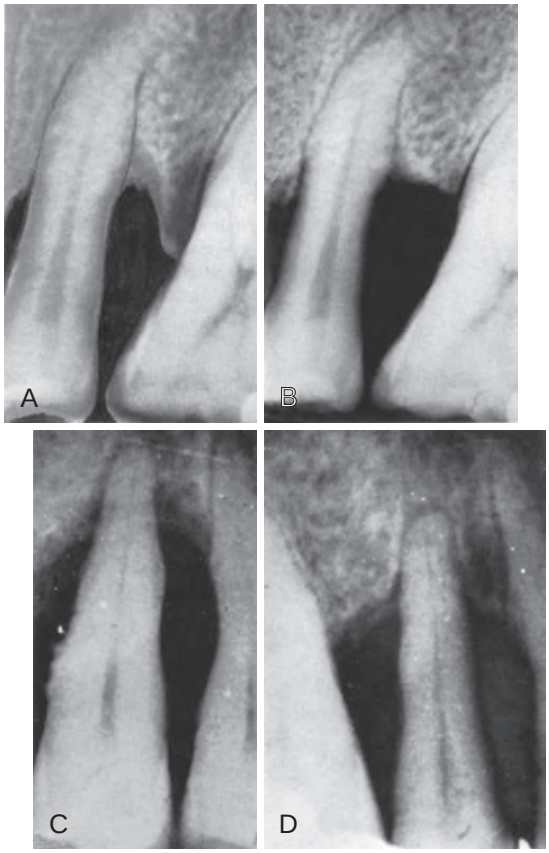

Figure 60-1 Additive and subtractive osseous surgery. A, Before, and, **B,** immediately after subtractive osseous surgery; the osseous wall of the two adjoining infrabony pockets has been removed. **C,** Before, and, **D,** 1 year after additive osseous surgery; the area has been flapped and thoroughly instrumented, resulting in reconstruction of the interdental and periapical bone. *(Courtesy Drs. E.A. Albano and B.O. Barletta, Buenos Aires, Argentina.)*

gingiva predispose patients to the recurrence of pocket depth post-surgically.[6] Although this concept is not universally accepted[3,5] and the procedure induces loss of radicular bone in the healing phase, recontouring of bone is the only logical treatment choice in some cases. The goal of osseous resective therapy is to reshape the marginal bone to resemble that of the alveolar process undamaged by periodontal disease. The technique is performed in combination with apically positioned flaps, and the procedure eliminates periodontal pocket depth and improves tissue contour to provide a more easily maintainable environment. The relative merits of pocket reduction procedures are discussed in Chapters 59 and 61; this chapter discusses the osseous resective technique and how and where it may be accomplished.

It is proposed that the conversion of the periodontal pocket to a shallow gingival sulcus enhances the patient's ability to remove plaque and oral debris from the dentition. Likewise, the ability of dental professionals to maintain the periodontium in a state free of gingivitis and periodontitis is more predictable in the presence of shallow sulci. The more effective the periodontal maintenance therapy, the greater is the longitudinal stability of the surgical result. The efficacy of osseous surgery therefore depends on its ability to affect pocket depth and to promote periodontal maintenance.[11,22,23] The merits of resection versus other treatment procedures are discussed in Chapter 61.

Figure 60-2 Photograph of a healthy bony periodontium in a skull. Although a slight amount of attachment may have been lost, this skull demonstrates the characteristics of normal form.

Normal Alveolar Bone Morphology

Knowledge of the morphology of the bony periodontium in a state of health is required to perform resective osseous surgery correctly (Figure 60-2). The characteristics of a normal bony form are as follows:

1. The interproximal bone is more coronal in position than the labial or lingual/palatal bone and pyramidal in form.
2. The form of the interdental bone is a function of the tooth form and the embrasure width. The more tapered the tooth, the more pyramidal is the bony form. The wider the embrasure, the more flattened is the interdental bone mesiodistally and buccolingually.
3. The position of the bony margin mimics the contours of the cementoenamel junction. The distance from the facial bony margin of the tooth to the interproximal bony crest is more flat in the posterior than the anterior areas. This "scalloping" of the bone on the facial surfaces and lingual/palatal surfaces is related to tooth and root form, as well as tooth position within the alveolus. Teeth with prominent roots or those displaced to the facial or lingual side may also have fenestrations or dehiscences (Figure 60-3). The molar teeth have less scalloping and a more flat profile than bicuspids and incisors.

Although these general observations apply to all patients, the bony architecture may vary from patient to patient in the extent of contour, configuration, and thickness. These variations may be both normal and healthy.

Terminology

Numerous terms have been developed to describe the topography of the alveolar housing, the procedure for its removal, and the resulting correction. These terms should be clearly defined.

Procedures used to correct osseous defects have been classified in two groups: osteoplasty and ostectomy.[7] *Osteoplasty* refers to reshaping the bone without removing tooth-supporting bone. *Ostectomy,* or *osteoectomy,* includes the removal of tooth-supporting bone. One or both of these procedures may be necessary to produce the desired result.

Terms that describe the bone form after reshaping can refer to morphologic features or to the thoroughness of the reshaping performed. Examples of morphologically descriptive terms include *negative, positive, flat,* and *ideal*. These terms all relate to a preconceived standard of ideal osseous form.

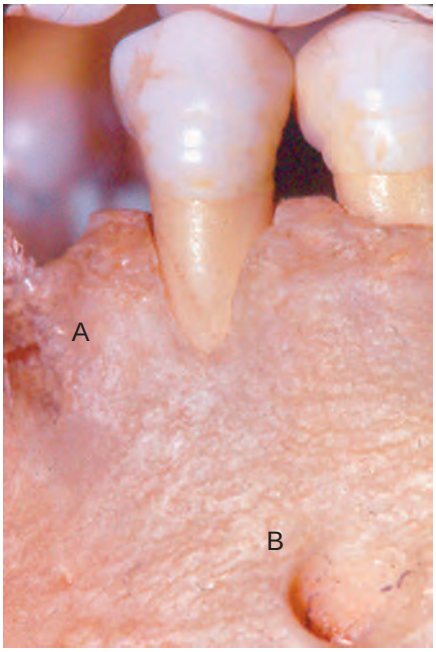

Figure 60-3 Effects of tooth position on facial bony contours. A, Bony fenestration. **B,** Bony dehiscence. These deformities can and should be detected by palpation, probing, and sounding before flap surgery.

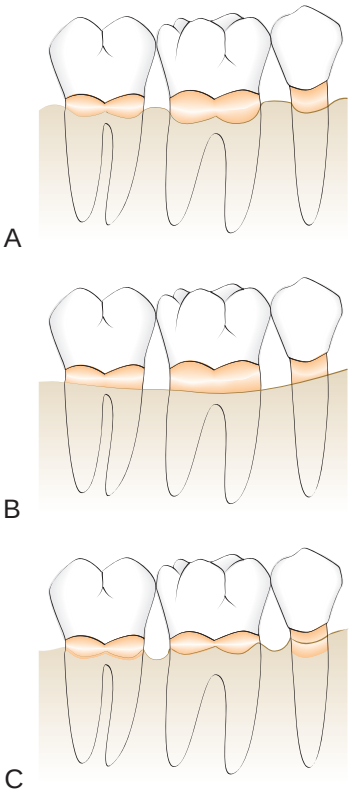

Figure 60-4 Diagram of types of bony architecture. A, Positive bony architecture. **B,** Flat bony architecture. **C,** Reversed, or negative, bony form.

Positive architecture and *negative architecture* refer to the relative position of interdental bone to radicular bone (Figure 60-4). The architecture is "positive" if the radicular bone is apical to the interdental bone. The bone has "negative" architecture if the interdental bone is more apical than the radicular bone. *Flat architecture* is the reduction of the interdental bone to the same height as the radicular bone.

Osseous form is considered to be "ideal" when the bone is consistently more coronal on the interproximal surfaces than on the facial and lingual surfaces. The ideal form of the marginal bone has similar interdental height, with gradual, curved slopes between interdental peaks (Figure 60-5).

Terms that relate to the thoroughness of the osseous reshaping techniques include "definitive" and "compromise." *Definitive osseous reshaping* implies that further osseous reshaping would not improve the overall result. *Compromise osseous reshaping* indicates a bone pattern that cannot be improved without significant osseous removal that would be detrimental to the overall result. References to compromise and definitive osseous architecture can be useful to the clinician, not as description of a morphologic feature, but as terms that express the expected therapeutic result.

Figure 60-5 Skull photograph of healthy periodontium. Note the shape of the alveolar bone housing. This bone is considered to have ideal form. It is more coronal in the interproximal areas, with a gradual slope around and away from the tooth.

Factors in Selection of Resective Osseous Surgery

The relationship between the depth and configuration of the bony lesion(s) to root morphology and the adjacent teeth determines the extent that bone and attachment is removed during resection. Bony lesions have been classified according to their configuration and number of bony walls.[9] The technique of ostectomy is best applied to patients with early to moderate bone loss (2 to 3 mm) with moderate-length root trunks[18] that have bony defects with one or two walls. These shallow-to-moderate bony defects can be effectively managed by osteoplasty and osteoectomy. Patients with advanced attachment loss and deep intrabony defects are not candidates for resection to produce a positive contour. To simulate a normal architectural form, so much bone would have to be removed that the survival of the teeth could be compromised.

Two-walled defects, or craters, occur at the expense of the interseptal bone. As a result, they have buccal and lingual/palatal walls that extend from one tooth to the adjacent tooth. The interdental loss of bone exposes the proximal aspects of both adjacent teeth. The buccal–lingual interproximal contour that results is opposite to the contour of the cementoenamel junction of the teeth (Figure 60-6, *A* and *B*). *Two-walled defects* (*craters*) *are the most common bony defects found in patients with periodontitis.*[14,20] If the

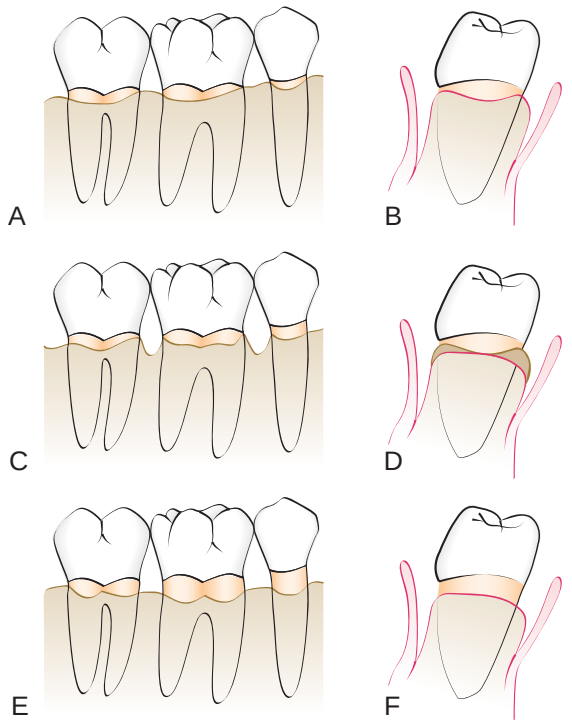

Figure 60-6 Effect of correction of craters. A and **B,** Diagram of facial and interproximal bony contours after flap reflection. Note the loss of some interproximal bone and cratering. **C** and **D,** Line angles; this is only osteoplasty and has resulted in a reversed architecture. **E** and **F,** Ostectomy on the facial and lingual bone and the removal of the residual widow's peaks to produce a positive bony architecture.

facial and lingual plates of this bone are resected, the resultant interproximal contour would become more flattened or ovate (Figure 60-6, *C* and *D*). However, confining resection only to ledges and the interproximal lesion results in a facial and lingual bone form in which the interproximal bone is located more apically than the bone on the facial or lingual aspects of the tooth. This resulting anatomic form is reversed, or negative, architecture[17,18,22] (Figure 60-6, *C* and *D*).

Although the production of a reversed architecture minimizes the amount of ostectomy that is performed, it is not without consequences.[5] Peaks of bone typically remain at the facial and lingual/palatal line angles of the teeth (*widow's peaks*). During healing, the soft tissue tends to bridge the embrasure from the most coronal height of the bone on one tooth to the most coronal heights on the adjacent teeth. The result is therefore the tendency to replicate the attachment contour on the tooth. The interproximal soft tissues invest these peaks of bone, which may subsequently resorb with a tendency to rebound without gain in attachment over time. Interproximal pocket depth can recur.[22,24]

Ostectomy to a positive architecture requires the removal of the line-angle inconsistencies (widow's peaks), as well as some of the facial, lingual, and palatal and interproximal bone. The result is a loss of some attachment on the facial and lingual root surfaces but a topography that more closely resembles normal bone form before disease (see Figure 60-6, *E* and *F*). Proponents of osseous resection to create a positive contour believe that this architecture, devoid of sharp angles and spines, is conducive to the formation of a more uniform and reduced soft-tissue dimension postoperatively.[17,21] The therapeutic result is less pocket depth and increased ease of periodontal maintenance by the patient, dental hygienist, or dentist.

The amount of attachment lost from the use of ostectomy varies with the depth and configuration of the treated osseous defects. Osseous resection applied to two-wall intrabony defects (craters), the most common osseous defects, results in attachment loss at the proximal line angles and the facial and lingual aspects of the affected teeth without affecting the base of the pocket. The extent of attachment loss during resection to a positive architecture has been measured. When the technique is properly applied to appropriate patients, the mean reduction in attachment circumferentially around the tooth has been determined to be 0.6 mm at six probing sites.[22] In practical terms, this means that the technique is best applied to interproximal lesions 1 to 3 mm deep in patients with moderate-to-long root trunks.[17] Patients with deep, multiwalled defects are not candidates for resective osseous surgery. They are better treated with regenerative therapies or by combining osteoplasty to reduce bony ledges and to facilitate flap closure with new attachment and regeneration procedures.

Examination and Treatment Planning

The potential for the use of resective osseous surgery is usually identified during a comprehensive periodontal examination. Suitable patients display the signs and symptoms of periodontitis (see Chapter 30). The gingiva may be inflamed, and deposits of plaque, calculus, and oral debris may be present. An increased flow of crevicular fluid may be detected, and bleeding on probing and exudation are often observed.

Periodontal probing and exploration are key aspects of the examination. Careful probing reveals the presence of (a) pocket depth greater than that of a normal gingival sulcus, (b) the location of the base of the pocket relative to the mucogingival junction and attachment level on adjacent teeth, (c) the number of bony walls, and (d) the presence of furcation defects. Transgingival probing, or sounding, under local anesthesia confirms the extent and configuration of the intrabony component of the pocket and of furcation defects.[6,16]

Routine dental radiographs do not identify the presence of periodontitis and do not accurately document the extent of bony defects. Radiographs cannot accurately document the number of bony walls and the presence or extent of bony lesions on the facial/buccal or lingual/palatal walls. Well-made radiographs provide useful information about the extent of interproximal bone loss, the presence of angular bone loss, caries, root trunk length, and root morphology. Films also facilitate the identification of other dental pathoses that require treatment. In addition, a radiographic survey serves as a means of evaluating the success of therapy and documenting the patient's longitudinal stability.[19]

Treatment planning should provide solutions for active periodontal diseases and correction of deformities that result from periodontitis. Planning should also facilitate the performance of other dental procedures included in a comprehensive dental treatment plan. The extent of periodontal involvement can vary significantly from tooth to tooth in the same patient. The response to therapy from patient to patient may also vary, as may the treatment objectives for the patients. Therefore a treatment plan may encompass a number of steps and combinations of procedures in the same surgical area.

After oral hygiene instruction, scaling and root planing, and other disease control procedures, the response of the patient to these treatment procedures is evaluated by reexamination and recording the changes in the periodontium. Because the extent of periodontal involvement can vary significantly from tooth to tooth in the same patient, the local response to therapy is also variable. The resolution of inflammation and decrease in edema and swelling

may have resulted in a return to normal depth and configuration of some pockets, and additional therapy beyond periodic maintenance may not be required.

The patient with moderate-to-advanced periodontitis and bony defects, although the overt signs of periodontitis may be reduced, may display a persistence of pocket depth bleeding on probing and suppuration. These signs may indicate the presence of residual plaque and calculus, attributable to the difficulty of achieving instrumentation in these deep pockets or the patient's inability or unwillingness to perform adequate oral hygiene in these sites. Patients with inadequate oral hygiene are not good candidates for periodontal surgery. If the supragingival plaque control is good and the residual pocket depths are 5 mm or more, patients with such areas may be candidates for periodontal surgery.[13]

Resective osseous surgery is also used to facilitate certain restorative and prosthetic dental procedures. Dental caries can be exposed for restoration; fractured roots of abutment teeth can be exposed for removal; and bony exostoses and ridge deformities can be altered in contour to improve the performance of removable or fixed prostheses (Figure 60-7). Severely decayed teeth or teeth with short anatomic crowns can be lengthened by resection or by a combination of orthodontic tooth extrusion and osseous resection. Such procedures allow the therapist to expose more tooth for restoration, prevent an invasion of the biologic width of attachment, and create a periodontal attachment of normal dimension.[8,15] Resection can also provide a means of producing optimal crown length for cosmetic purposes.

Methods of Resective Osseous Surgery

The reshaping process is fundamentally an attempt to gradualize the bone sufficiently to allow soft-tissue structures to follow the contour of the bone. The soft tissue predictably attaches to the bone within certain specific dimensions. The length and quality of connective tissue and junctional epithelium that reform in the surgical site depend on numerous factors, including the health of the tissue, condition and topography of the root surface, and proximity of the bone surrounding the tooth. Each of these factors must be controlled to the best of the clinician's ability to obtain the optimal result, making osseous resective surgery an extremely precise technique.

It is assumed in this chapter that the gingival tissue has been reflected by the apically positioned flap described in Chapter 57. Reshaping of the bone may necessitate selective changes in gingival height. These changes must be calculated and accounted for in the initial flap design. For this reason, it is important for the clinician to know about the underlying bone tissue before flap reflection. The clinician must gain as much indirect knowledge as possible from soft-tissue palpation, radiographic assessment, and transgingival probing (sounding).

Radiographic examination can reveal the existence of angular bone loss in the interdental spaces; these areas usually coincide with intrabony pockets. The radiograph does not show the number of bony walls of the defect or document with any accuracy the presence of angular cone defects on facial or lingual surfaces. Clinical examination and probing are used to determine the presence and depth of periodontal pockets on any surface of any tooth and can also provide a general sense of the bony topography, although intrabony pockets can go undetected by probing. Both clinical and radiographic examinations can indicate the presence of intrabony pockets when the clinician finds (a) angular bone loss, (b) irregular bone loss, or (c) pockets of irregular depth in adjacent areas of the same tooth or adjacent teeth.

The experienced clinician can use transgingival probing to predict many features of the underlying bony topography. The

Figure 60-7 Reduction of bony ledges and exposure of caries by osteoplasty. A, Buccal preoperative photograph showing two crowns, exostoses, and caries. **B,** Flap reflected to reveal caries on both molars at the restoration margins, interdental cratering, and a facial exostosis. **C,** After osseous surgery; the bulk of the bony removal was by osteoplasty, with minor ostectomy between the two molars. The caries is now exposed, and the crowns are lengthened for restoration. **D,** Postoperative photograph at 6 weeks. The plaque control is deficient, but the teeth should be readily restorable at this time. *(Courtesy Dr. Joseph Schwartz, Portland, OR.)*

information thus obtained can change the treatment plan. For example, an area that had been selected for osseous resective surgery may be found to have a narrow defect that was unnoticed in the initial probing and radiographic assessment and is ideal for augmentation procedures. Such findings can and do change the flap design, osseous procedure, and results expected from the surgical intervention. Transgingival probing is extremely useful just before flap reflection. It is necessary to anesthetize the tissue locally before inserting the probe. The probe should be "walked" along the tissue–tooth interface so that the operator can feel the bony topography. The probe may also be passed horizontally through the tissue to provide three-dimensional information regarding bony contours (i.e., thickness, height, and shape of the underlying base). It must be remembered, however, that this information is still "blind," and although it is undoubtedly better than probing alone, it has significant limitations. Nevertheless, this step is recommended immediately before the surgical intervention.

The situations that can be encountered after periodontal flap reflection vary greatly. When all soft tissue is removed around the teeth, there may be larger exostoses, ledges, troughs, craters, vertical defects, or combinations of these defects. Therefore each osseous situation presents uniquely challenging problems, especially if reshaping to the optimal level is contemplated.

Conclusion

Although osseous surgical techniques cannot be applied to every bony abnormality or topographic modification, it has been clearly demonstrated that properly used osseous surgery can eliminate and modify defects, as well as gradualize excessive bony ledges, irregular alveolar bone, early furcation involvement, excessive bony exostosis, and circumferential defects. When properly performed, resective osseous surgery achieves a physiologic architecture of marginal alveolar bone conducive to gingival flap adaptation with minimal probing depth. The advantages of this surgical modality include a predictable amount of pocket reduction that can enhance oral hygiene and periodic maintenance. It also preserves the width of the attached tissue while removing granulomatous tissue and providing access for debridement of the radicular surfaces. In addition, the osseous resection technique permits recontouring of bony abnormalities, including hemiseptal defects, tori, and ledges. Its substantial benefits include proper assessment for restorative procedures (e.g., crown lengthening) and assessment of restorative overhangs and tooth abnormalities (e.g., enamel projections, enamel pearls, perforations, fractures). Consequently, resective osseous surgery can be an important technique in the armamentarium necessary to provide a maintainable periodontium for periodontal patients.

Suggested Readings

Carnevale G, Kaldahl WB: Osseous Resective Surgery. *J Periodontol* 22:59–87, 2000.

Dibart S, Dibart J-P: *Practical Osseous Surgery in Periodontics and Implant Dentistry*, 2011, Wiley-Blackwell.

References

References for this chapter are found on the companion website www.expertconsult.com.

Osseous Resection Technique

Instrumentation

A number of hand and rotary instruments have been used for osseous resective surgery. Some excellent clinicians use only hand instruments and rongeurs, whereas others prefer a combination of hand and rotary instruments. Rotary instruments are useful for the osteoplastic steps outlined previously, whereas hand instruments provide the most precise and safe results with ostectomy procedures.

Recently piezoelectric surgical techniques, described in Chapter 80, have also been used with success for osseous surgical resective techniques[25,26] (Figure 60-8, *A*). Regardless of instrumentation used, care and precision are required for each step of the procedure to prevent excessive bone removal or root damage, both of which

Figure 60-8 Instruments often used in osseous surgery. A, Currently, the piezoelectric surgical instrument has been used successfully in osseous resective surgery. **B,** Rongeurs: Friedman *(top)* and 90-degree Blumenthal *(bottom)*. **C,** Carbide round burs. *Left to right,* Friction grip, surgical-length friction grip, and slow-speed handpiece. **D,** Diamond burs. **E,** Interproximal files: Schluger and Sugarman. **F,** Back-action chisels. **G,** Ochsenbein chisels.

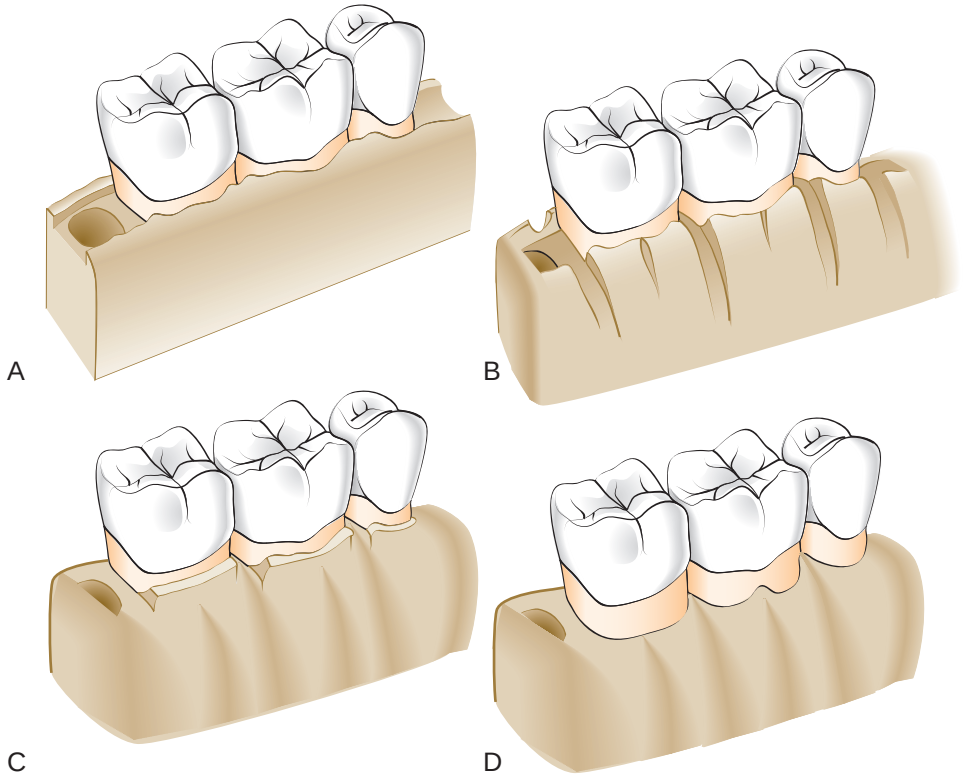

Figure 60-9 **A,** Drawing of bony topography in moderate periodontitis with interdental craters. **B,** Vertical grooving, the first step in correction by osseous reshaping. **C,** Radicular blending and flattening of interproximal bone. **D,** Gradualizing the marginal bone. Note the area of the furcation on the first molar where the bone is preserved.

are irreversible. Figure 60-8 illustrates some of the instruments commonly used for osseous resection techniques.

To address the many clinical situations, the following sequential steps are suggested for resective osseous surgery (Figure 60-9, *A* to *D*):

1. Vertical grooving
2. Radicular blending
3. Flattening interproximal bone
4. Gradualizing marginal bone

Not all steps are necessary in every case, but the sequencing of the steps in the order given is necessary to expedite the reshaping procedure, as well as to minimize the unnecessary removal of bone. Figure 60-10 illustrates bone reshaping in flap surgery for specific anatomic defects.

Vertical Grooving

Vertical grooving is designed to reduce the thickness of the alveolar housing and to provide relative prominence to the radicular aspects of the teeth (see Figure 60-9, *B*). It also provides continuity from the interproximal surface onto the radicular surface. It is the first step of the resective process because it can define the general thickness and subsequent form of the alveolar housing. This step is usually performed with rotary instruments, such as round carbide burs or diamonds. The advantages of vertical grooving are most apparent with thick bony margins, shallow crater formations, or other areas that require maximal osteoplasty and minimal ostectomy. Vertical grooving is contraindicated in areas with close roots or thin alveolar housing.

Radicular Blending

Radicular blending, the second step of the osseous reshaping technique, is an extension of vertical grooving (see Figure 60-9, *C*). Conceptually, it is an attempt to gradualize the bone over the entire radicular surface to provide the best results from vertical grooving. This provides a smooth, blended surface for good flap adaptation. The indications are the same as for vertical grooving (i.e., thick ledges of bone on the radicular surface, where selective surgical resection is desired). Naturally, this step is not necessary if vertical grooving is very minor or if the radicular bone is thin or fenestrated. Both vertical grooving and radicular blending are purely osteoplastic techniques that do not remove supporting bone. In most situations, these two procedures compose the bulk of resective osseous surgery. Classically, shallow crater formations, thick osseous ledges of bone on the radicular surfaces, and Class I and early Class II furcation involvements are treated almost entirely with these two steps.

Flattening Interproximal Bone

Flattening of the interdental bone requires the removal of very small amounts of supporting bone (Figure 60-11). It is indicated when interproximal bone levels vary horizontally. By definition, most of the indications for this step are one-walled interproximal defects or hemiseptal defects. The omission of flattening in such cases results in increased pocket depth on the most apical side of the bone loss. This step is typically not necessary with interproximal crater formations or flat interproximal defects. It is best used in defects that have a coronally placed, one-walled edge of a predominantly three-walled angular defect, and it can be helpful in obtaining good flap closure and improved healing in the three-walled defect. The limitation of this step, as with resective osseous surgical therapy in general, is in the treatment of advanced lesions. Large hemiseptal defects would require removal of inordinate amounts of bone to provide a flattened architecture, and the procedure would be too costly in terms of bony support.

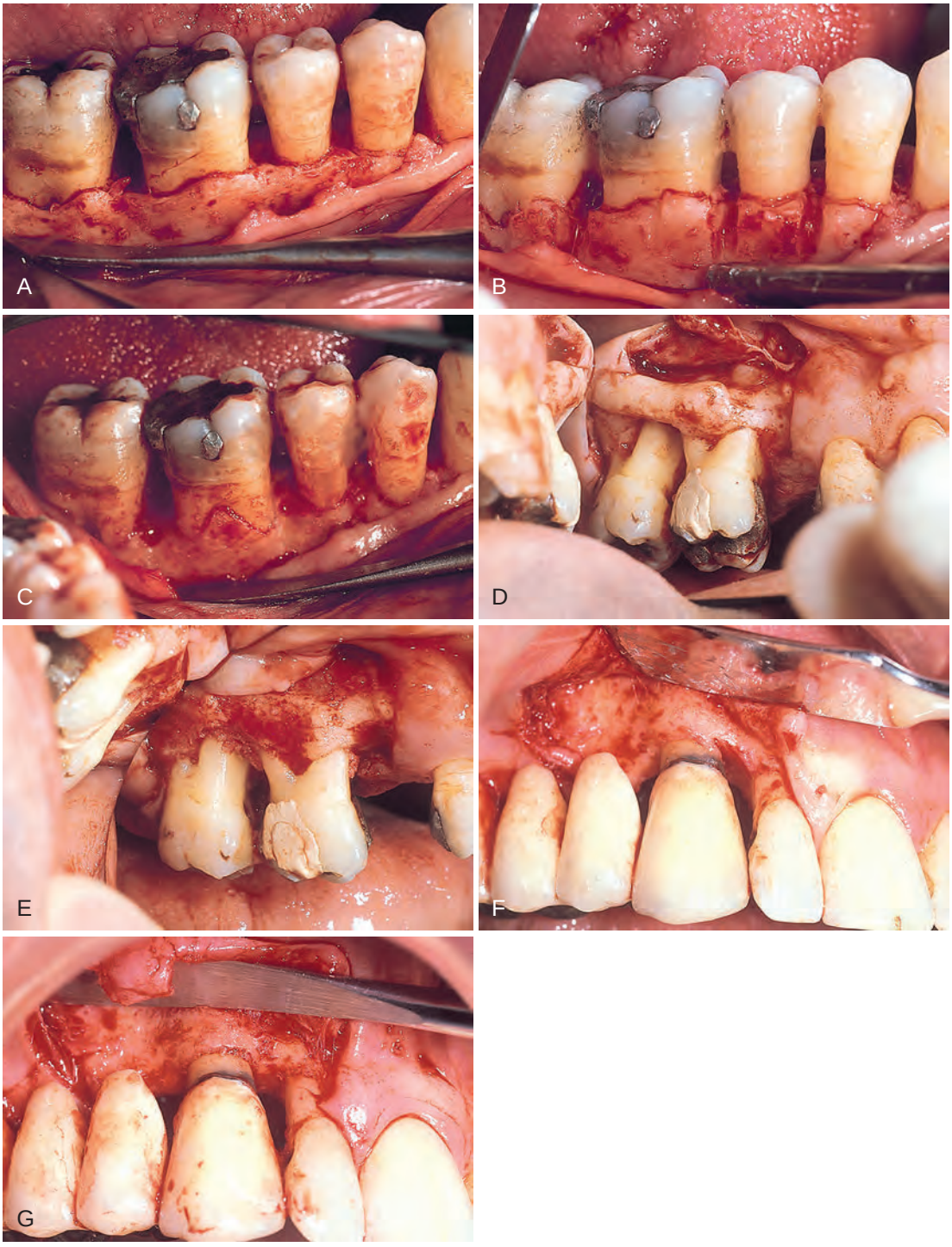

Figure 60-10 Bone contouring in flap surgery. A to **C,** Bone contouring in interdental craters. **D** and **E,** Bone contouring in exostoses. **F** and **G,** Bone contouring in one-wall vertical defect.

Compromised osseous architecture is the only logical solution (Figure 60-12).

Gradualizing Marginal Bone

The final step in the osseous resection technique is also an ostectomy process. Bone removal is minimal but necessary to provide a sound, regular base for the gingival tissue to follow. Failure to remove small bony discrepancies on the gingival line angles (widow's peaks) allows the tissue to rise to a higher level than the base of the bone loss in the interdental area (see Figure 60-9, *C* and *D*). This may make the process of selective recession and subsequent pocket reduction incomplete. This step of the procedure also requires gradualization and blending on the radicular surface (see Figures 60-10, *C,* and 60-11). The two ostectomy steps should be performed with great care so as not to produce nicks or grooves on the roots. When the radicular bone is thin, it is extremely easy to overdo this step, to the detriment of the entire surgical effort. For this reason, various hand instruments, such as chisels and curettes, are preferable to rotary instruments for gradualizing marginal bone.

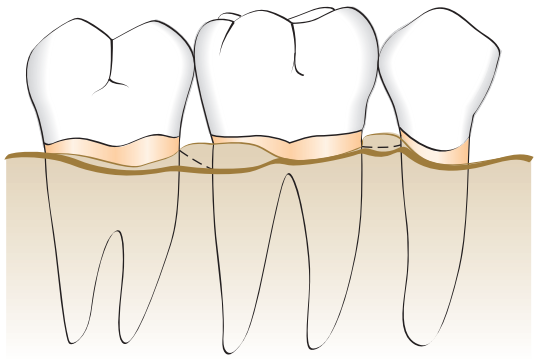

Figure 60-11 Diagrammatic representation of bone irregularities in periodontal disease. The thick line is the proposed correction of the defect. Note the flattening of the interproximal bone between the molars and the protection of the furcal bone on the first molar. Facial crest height is reduced in both interproximal areas to the depth of the defect.

Flap Placement and Closure

After performing resection, the clinician positions and sutures the flaps. Flaps may be replaced to their original position, to cover the new bony margin, or they may be apically positioned. Replacing the flap in areas that previously had deep pockets may result initially in greater postoperative pocket depth, although a selective recession may diminish the depth over time. Positioning the flap apically to expose marginal bone is one method of altering the width of the gingiva (denudation). However, such flap placement results in more postsurgical resorption of bone and patient discomfort than if the newly created bony margin were covered by the flap. Positioning the flap to cover the new margin minimizes postoperative complications and results in optimal postsurgical pocket depths (Figure 60-13).

Suturing may be accomplished using a variety of different suture materials and suture knots[4] (see Chapter 57). The sutures should be placed with minimal tension to coapt the flaps, prevent their separation, and maintain the position of the flaps. Sutures placed with excessive tension rapidly pull through the tissues.

Postoperative Maintenance

Sutures may be removed at various times after placement. Nonresorbable sutures such as silk are usually removed after 1 week of healing, although some of the newer synthetic materials may be left for up to 3 weeks or longer without adverse consequences. Resorbable sutures maintain wound approximation for varying periods of 1 to 3 weeks or more, depending on the type of suture material. At the suture removal appointment the periodontal dressing, if present, is removed, and the surgical site is gently cleansed of debris with a cotton pellet dampened with saline. Nonresorbable sutures are then cut and removed. If sutures of a resorbable material were used, the area should be inspected carefully to ensure that no suture fragments remain. Suture removal should be accomplished without dragging contaminated portions of the suture through the periodontal tissues. This may be accomplished by lightly compressing the soft tissue immediately adjacent to the suture. This exposes (extrudes) a portion of the suture that was previously under the gingival tissues and less likely to be contaminated by plaque. The suture is then cut at the gingival surface. Removal of the pressure from the site results in the cut surface being slightly submerged in the tissue. The sutures are then removed with cotton pliers by pulling the suture from its contaminated end.

After suture removal the surgical site is examined carefully, and any excessive granulation tissue is removed with a sharp curette. The patient is provided with postsurgical maintenance instructions and the instruments needed to maintain the surgical site in a plaque-free state. These instruments should not produce additional trauma to the healing tissues. Many therapists find the use of a plaque-suppressive agent such as chlorhexidine digluconate to be a valuable adjunct to postsurgical maintenance. A second postoperative visit is often performed at the second or third week, and the surgical site is lightly debrided for optimal results. Professional prophylaxis for complete plaque removal should be done every 2 weeks until healing is complete or the patient is maintaining appropriate levels of plaque control.

Healing should proceed uneventfully, with the attachment of the flap to the underlying bone completed in 14 to 21 days. Maturation and remodeling can continue for up to 6 months. It is usually advisable to wait at least 6 weeks after completion of healing of the last surgical area before beginning dental restorations. For those patients with a major cosmetic concern, it is wise to wait as long as possible to achieve a postoperative soft tissue position and a stable sulcus.

Specific Osseous Reshaping Situations

The osseous corrective procedure previously described is classically applied to shallow craters with heavy faciolingual ledges (Figure 60-14). The correction of other osseous defects is also possible; however, careful case selection for definitive osseous surgery is extremely important.

Correction of one-walled hemiseptal defects requires that the bone be reduced to the level of the most apical portion of the defect. Therefore, great care should be taken to select the appropriate case. If one-walled defects occur next to an edentulous space, the edentulous ridge is reduced to the level of the osseous defect (Figure 60-15).

Other situations that complicate osseous correction are exostoses (see Figure 60-10, *D* and *E*), malpositioned teeth, and supraerupted teeth. Following the four steps previously outlined best controls each of these situations. In most situations, the unique feature of the bony profile is well managed by prudently applying the same principles (see Figure 60-10). However, some situations require deviation from the definitive osseous reshaping technique; examples include dilacerated roots, root proximity, and furcations that would be compromised by osseous surgery.

In the absence of ledges or exostoses, the elimination of the bony lesion begins with reduction of the interdental walls of craters, the one-walled component of angular defects, and wells (moats) and grooving into sites of early involvement.[10] The walls of the crater may be reduced at the expense of the buccal, lingual, or both walls (Figure 60-16). The reduction should be made to remove the least amount of alveolar bone required to (a) produce a satisfactory form, (b) prevent the therapeutic invasion of furcations, and (c) blend the contours with the adjacent teeth. The selective reduction of bony defects by "ramping" the bone to the palatal or lingual to avoid involvement of the furcations has been advocated by Ochsenbein and Bohannan[18] and Tibbetts et al[23] (Figure 60-17).

In the presence of heavy ledges of bone, it is usually wise to do osteoplasty first to eliminate any exostoses or reduce the buccal/lingual bulk of the bone (Figure 60-18). It is common practice to incorporate a degree of vertical grooving during the reduction of bony ledges, because this facilitates the process of blending the radicular bone into the interproximal areas at the next step.

One-walled or hemiseptal defects usually require the removal of some bone from the tooth with the greatest coronal bony height.

Figure 60-12 Compromise osseous surgery. A and **B,** Preoperative views of the buccal and lingual surfaces. **C** and **D,** Preoperative and postoperative views of the buccal osseous recontouring of Class I buccal furcation defects, a moderate crater between the two molars, and a deep 1-2-3–walled defect at the mesial of the first involvements. **D,** Buccal aspects of these lesions were corrected with osteoplasty and a small amount of ostectomy. **E** and **F,** Preoperative and postoperative views of the lingual osseous management. In **E,** note the combination 1-2-3–walled defect between the second bicuspid and first molar, as well as the irregular pattern of bone loss with ledging. **F,** These defects were corrected by osteoplasty and ostectomy, except for the deep defect at the mesial surface of the molar. This area was resected until the residual defect was of two and three walls only and left to repair. **G** and **H,** Buccal and lingual 5-year postoperative views of tissue configuration. Note the residual soft-tissue defect between the bicuspid and first molar.

This removal of bone may result in a significant reduction in attachment on relatively unaffected adjacent teeth to eliminate the defect. However, if a tooth in the surgical field has one-walled defects on both its mesial and its distal surface and this is recognized during examination, the severely affected tooth may be extruded by orthodontic therapy during disease control treatment to minimize or eliminate the need for resection of bone from the adjacent teeth.

Figure 60-13 Ostectomy and osteoplasty to a positive contour with flap placement at the newly created bony crest for minimal pocket depth. A and **B,** Buccal and lingual preoperative views. **C** and **D,** Buccal preoperative view and postoperative correction. Osteoplasty and ostectomy were used to produce a positive contour. Note the osteoplasty into the buccal furcation of the first molar. This is about the extent of craters that can be corrected to a positive contour in teeth with moderate root trunk length. **E** and **F,** Lingual preoperative view and postoperative correction. Osteoplasty and ostectomy were done to produce a positive contour. Note the lingual ledge, which was reduced. Such ledges are common in this area. **G** and **H,** Buccal and lingual flaps sutured with continuous sling sutures to allow placement of the flaps to cover the bony margins. Ostectomy and osteoplasty performed to a positive contour, with flap placement at the newly created bony crest for minimal pocket depth. Ostectomy and osteoplasty to a positive contour with flap placement at the newly created bony crest for minimal pocket depth. **I** and **J,** Buccal and lingual postoperative views at 1 week. Soft-tissue thickness is minimal, and the interdental areas are granulating in over the positive bony form. Minimal pocket depth results from such management.

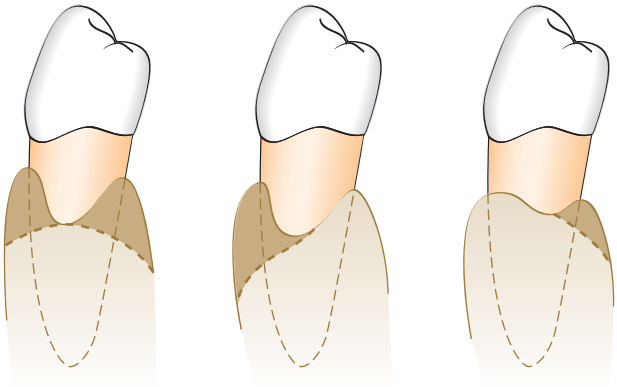

Figure 60-14 Interproximal craters. The shaded areas illustrate different techniques for the management of such defects. The technique that reduces the least amount of supporting bone is preferable.

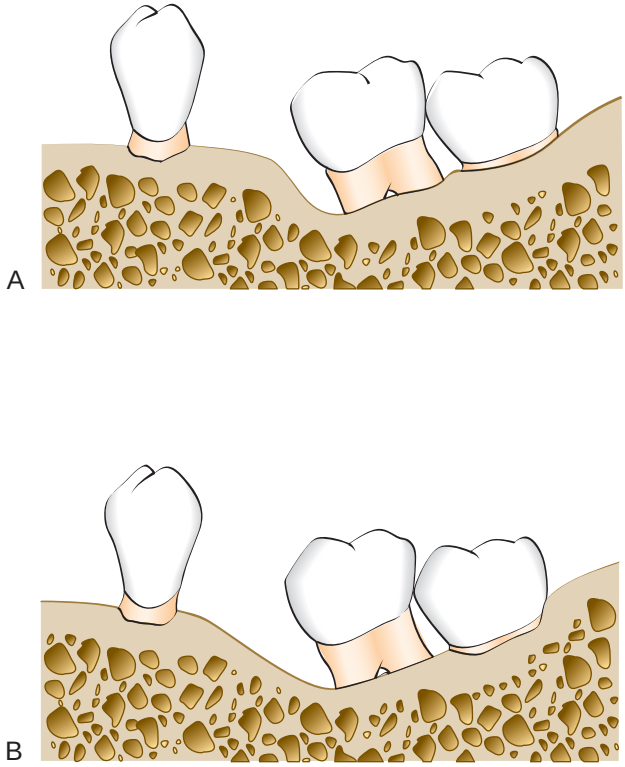

Figure 60-15 Reduction of a one-wall angular defect. A, Angular bone defect mesial to the tilted molar. **B,** Defect reduced by "ramping" angular bone.

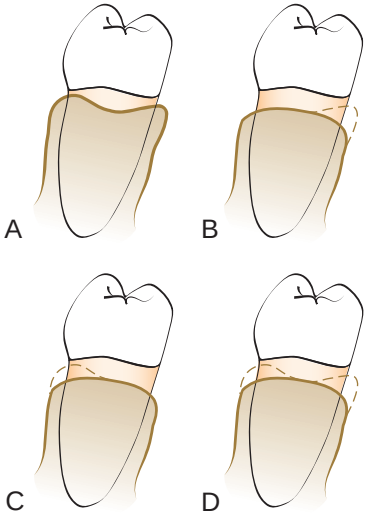

Figure 60-16 Diagram of crater-reduction patterns. A, Preoperative bony form after flap reflection. **B,** Reduction of craters to the lingual wall. **C,** Reduction of craters to the facial wall. **D,** Reduction of craters to both the buccal and the lingual wall.

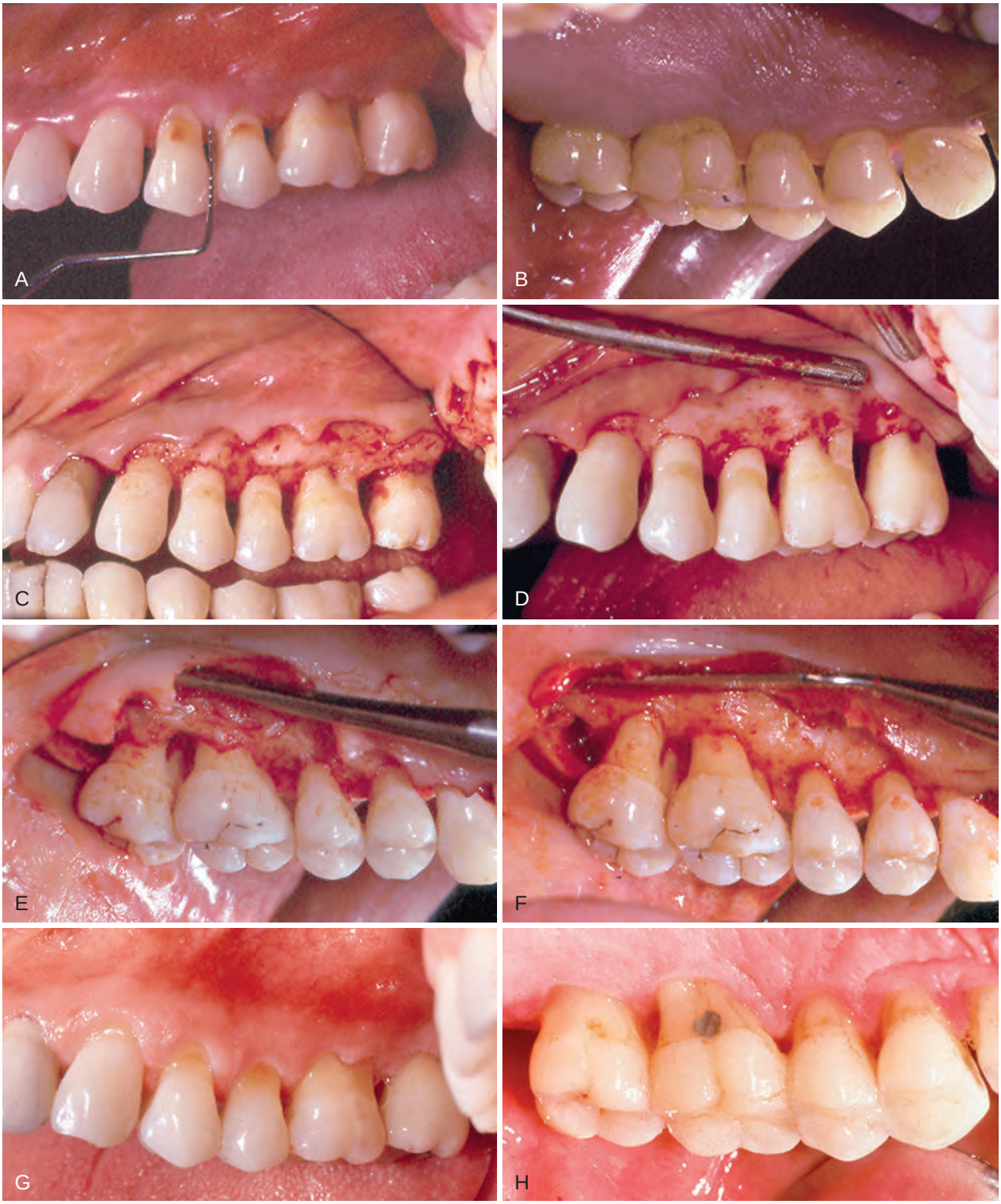

Figure 60-17 Correction of osseous defects largely to the palatal wall. A and **B,** Buccal and palatal preoperative views, 6 weeks after completion of scaling and root planing. **C** and **D,** Buccal preoperative and postoperative views. In **C,** note the ledging on the facial wall of molars and the one-wall defects on both molars. **D,** Postoperative view shows the elimination of these defects by osteoplasty on the ledges and ostectomy of the one-wall defects to produce a positive buccal architecture. **E** and **F,** Palatal preoperative and postoperative views. In **E,** note the pattern of bony loss, which is more severe on the palatal wall. In addition to the facial one-wall defects, there is an incipient furcation defect at the mesial wall of the first molar and a Class II furcation at the mesial wall of the second molar. **F,** Configuration of the defects was such that ostectomy was performed on the palatal roots of both molars to produce a compromise architecture. **G** and **H,** Ten-year postoperative views of the buccal and palatal areas showing the pattern of soft-tissue adaptation to the surgically produced bony form.

Figure 60-18 Reduction of bony ledges by osteoplasty before correction of interdental defects. A, Buccal preoperative view. **B,** Buccal flap reflection. Note the buccal ledge and the Class II buccal furcation. **C,** Buccal correction largely by osteoplasty with minor ostectomy over the root prominence to produce a positive architecture. **D,** Ten-year postoperative view of soft-tissue form. Minimal pocket depth is present.

References

1. Black GV: Surgical treatment of pockets. In Black AD, editor: *Special dental pathology*, ed 3, Chicago, 1917, Medico Dental.
2. Carranza FA, Carranza FA, Jr: The management of the alveolar bone in the treatment of the periodontal pocket. *J Periodontol* 27:29, 1956.
3. Caton J, Nyman S: Histometric evaluation of periodontal surgery. III. The effect of bone resection on the connective tissue attachment level. *J Periodontol* 52:405, 1981.
4. Dahlberg WH: Incisions and suturing: some basic considerations about each in periodontal surgery. *Dent Clin North Am* 13:149, 1969.
5. Donnenfeld OW, Hoag PM, Weissman DP: A clinical study of the effects of osteoplasty. *J Periodontol* 32:131, 1961.
6. Easley J: Methods of determining alveolar osseous form. *J Periodontol* 38:112, 1967.
7. Friedman N: Periodontal osseous surgery: osteoplasty and osteoectomy. *J Periodontol* 26:257, 1955.
8. Garguilo AW, Wentz FM, Orban B: Dimensions and relations of the dentogingival junction in humans. *J Periodontol* 32:261, 1961.
9. Goldman HM, Cohen DW: The infrabony pocket: classification and treatment. *J Periodontol* 29:272, 1958.
10. Kaldahl WB, Kalkwarf KL, Patil KD, et al: Evaluation of four modalities of periodontal therapy: mean probing depth, probing attachment level and recession changes. *J Periodontol* 59:783, 1988.
11. Kaldahl WB, Kalkwarf KL, Patil KD, et al: Long-term evaluation of periodontal therapy. I. Response to four therapeutic modalities. *J Periodontol* 67:93, 1996.
12. Knowles J, Burgett F, Nissle R, et al: Results of periodontal treatment related to pocket depth and attachment level: eight years. *J Periodontol* 50:225, 1979.
13. Lindhe J, Socransky S, Nyman S, et al: Critical probing depths in periodontal therapy. *J Clin Periodontol* 9:323, 1982.
14. Manson JD, Nicholson K: The distribution of bone defects in chronic periodontitis. *J Periodontol* 45:88, 1974.
15. Maynard JG, Wilson RD: Physiologic dimensions of the periodontium significant to the restorative dentist. *J Periodontol* 50:170, 1979.
16. Mealey BL, Beybayer MF, Butzin CA, et al: Use of furcal bone sounding to improve the accuracy of furcation diagnosis. *J Periodontol* 65:649, 1994.
17. Ochsenbein C: A primer for osseous surgery. *Int J Periodont Restor Dent* 6:9, 1986.
18. Ochsenbein C, Bohannan HM: The palatal approach to osseous surgery. II. Clinical application. *J Periodontol* 35:54, 1964.
19. Prichard JF: The roentgenographic depiction of periodontal disease. *Periodontics* 3(2):44–50, 1973.
20. Schluger S: Osseous resection: a basic principle in periodontal surgery. *Oral Surg Oral Med Oral Pathol* 2:316, 1949.
21. Schluger S, Yuodelis RA, Page RC, et al: *Resective periodontal surgery in pocket elimination. Periodontal diseases*, Philadelphia, 1990, Lea & Febiger.
22. Selipsky HS: Osseous surgery: how much need we compromise? *Dent Clin North Am* 20:79, 1976.
23. Tibbetts L, Ochsenbein C, Loughlin D: The lingual approach to osseous surgery. *J Periodontol* 20:61, 1976.
24. Townsend-Olsen C, Ammons WF, Van Belle C: A longitudinal study comparing apically repositioned flaps, with and without osseous surgery. *Int J Periodont Restor Dent* 5:11, 1985.
25. Vercellotti T, Nevins ML, Kim DM, et al: Osseous response following resective therapy with piezosurgery. *Int J Periodont Restor Dent* 25(6):543–549, 2005.
26. Vercellotti T, Pollack AS: A new bone surgery device: sinus grafting and periodontal surgery. *Compend Contin Educ Dent* 27(5):319–325, 2006.

CHAPTER 61

Periodontal Regeneration and Reconstructive Surgery

Richard T. Kao, Henry H. Takei, David L. Cochran, and Marc L. Nevins

CHAPTER OUTLINE

Assessment of Periodontal Wound Healing
Reconstructive Surgical Techniques
Factors That Influence Therapeutic Success
Future Directions for Periodontal Regeneration
Conclusion

For online only content on non—graft associated reconstructive procedures of historical interest as well as expanded discussions on assessment of periodontal wound healing, guided tissue regeneration, graft-associated reconstructive procedures of historical interest, factors that influence therapeutic success, and future directions for periodontal regeneration, go to the companion website www.expertconsult.com. Some figures may be out of numeric order in this printed chapter.

When the periodontium is damaged by inflammation or as a result of surgical treatment, the defect heals either through periodontal regeneration or repair.* In periodontal regeneration, healing occurs through the reconstitution of a new periodontium, which involves the formation of alveolar bone, functionally aligned periodontal ligament, and new cementum. Alternatively, repair due to healing by replacement with epithelial and/or connective tissue that matures into various nonfunctional types of scar tissue, is termed *new attachment*. Histologically, patterns of repair include long junctional epithelium, ankylosis, and/or new attachment (see Chapter 1). Although the stability of periodontal repair is not clear, the ideal goal of periodontal surgical therapy is periodontal regeneration.

This chapter summarizes our current understanding of therapy that results in periodontal regeneration and examines how regenerative approaches used for correcting intrabony defects have changed over the years.

Assessment of Periodontal Wound Healing

It is sometimes difficult in clinical and experimental situations to determine whether regeneration or new attachment has occurred and the extent to which it has occurred. Although there are various evidences of reconstruction, the *proof of principle* for the type of healing is determined by histological studies. Once defined, the evidence found subsequently by clinical, radiographic, and surgical reentry findings is implied.[35,37,166] All these methods have advantages and shortcomings that should be well understood and considered in individual cases and when critically evaluating the literature. A comparative analysis of regenerative approaches is detailed in Table 61-1.

*References 64,84,172,190,212,230.

Reconstructive Surgical Techniques

Reconstructive techniques can be subdivided into three major therapeutic approaches: non–bone graft–associated, graft-associated, and biological mediator–associated new attachment and regeneration. In clinical practice, it is common for clinicians to combine these various approaches.[84,104]

All recommended techniques include careful case selection and complete removal of all irritants on the root surface. Although this can be done in some cases as a closed procedure, in the great majority of cases, it should be done after exposure of the area with a flap.[6,7] Flap design and incisions should follow the description given in Chapter 59 for flaps used in reconstructive surgery. Trauma from occlusion, as well as other factors, may impair posttreatment healing of the supporting periodontal tissues, reducing the likelihood of new attachment. Occlusal adjustment, if needed, is therefore indicated.

Systemic antibiotics are generally used after reconstructive periodontal therapy, although definitive information on the advisability of this measure is still lacking. Case reports have shown extensive reconstruction of periodontal lesions after scaling, root planing, and curettage, with systemic and local treatment using penicillin or tetracycline, in combination with other forms of therapy.[32,192]

Non–Graft-Associated Reconstructive Procedures

The following sections discuss the rationale and techniques that must be considered for a successful outcome in achieving new attachment or periodontal bone regeneration in response to non–graft-associated reconstructive surgical therapy. Of these procedures, guided tissue regeneration (GTR) is the main procedure used in clinical practice. Recent evidences suggest that laser-assisted new attachment procedure (LANAP) may also result in new

Histological Methods

It is only through histological analysis can one define the nature of the reparative tissue (Figure 61-1). In periodontal reconstructive surgery, the goal is to achieve periodontal regeneration. Classically, experimental animal model systems[36,213] are used whereby reference notches are placed at the base of bony defects or at the apical extent of calculus deposits. Periodontal regeneration is considered to have occurred when the newly formed functionally aligned periodontium is coronal to the apical extent of the notches. Reparative tissue response dominated may include long junctional epithelium, connective tissue adhesion, and root resorption associated with ankylosis. It should be noted that the healing may be predominated by periodontal regeneration; there may be localized areas of repair.[233] Unfortunately, this approach cannot be used in human studies as it would be unethical to extract the treated tooth, especially when it responded positively to therapy. On rare circumstances, human histology is available if the tooth is to be extracted in conjunction with orthodontic or restorative therapy (Figure 61-2).

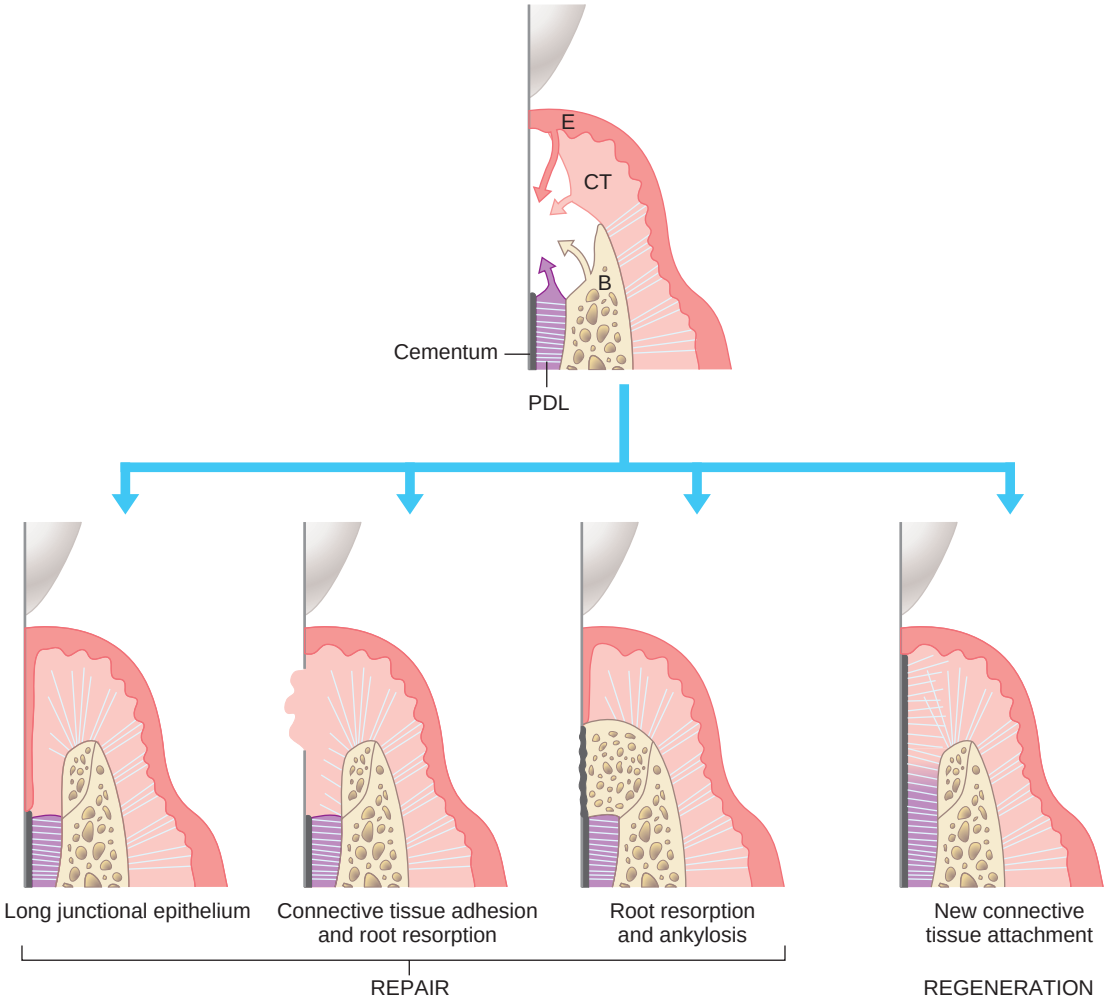

Figure 61-1 Possible healing patterns for a periodontal wound, which are dependent on the four possible cell types that predominate that wound site. The downgrowth of epithelial cells (E) results in a long junctional epithelium (JE). The proliferation of connective tissue (CT) may result in connective tissue adhesion ± root resorption. With the predominance of bone cells (B), there is root resorption and/or ankylosis. With the ingress of periodontal ligament (PDL) and perivascular cells from the bone, a regenerated periodontium develops. *(Courtesy of Rose L, et al, editor: Periodontics: medicine, surgery, and implants, St Louis, Elsevier Mosby, 2004.)*

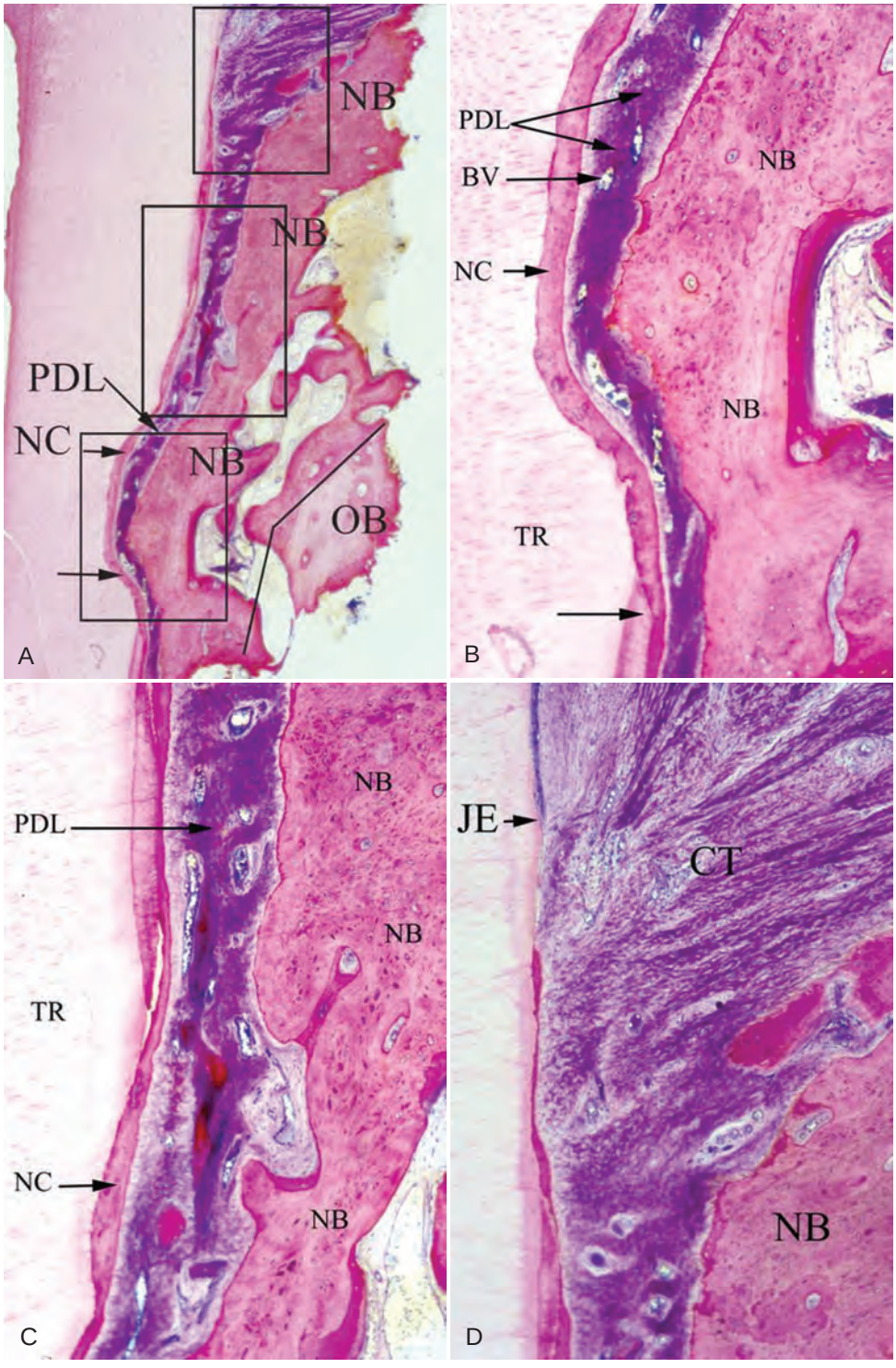

Figure 61-2 Photomicrographs of a clinical case of periodontal regeneration 9 months after the application of recombinant human platelet derived growth factor. Histological landmarks as evidence of regeneration should include: a low magnification view of the regenerated area (**A**); a detailed view of the notched root surface (**B**) and the newly regenerated periodontium coronal to this landmark (**C**); and the coronal aspect of the regenerated periodontium in relationship to the junctional epithelium (**D**). Abbreviations: PDL (periodontal ligament), NC (new cementum), NB (new bone), OB (old bone), TR (root trunk), BV (blood vessel), JE (junctional epithelium), and CT (connective tissue). *(Courtesy of Dr. S. Lynch Rose L, et al, editor: Periodontics: medicine, surgery, and implants, St Louis, Elsevier Mosby, 2004.)*

Clinical Methods

Clinical methods to evaluate periodontal reconstruction consist of comparisons between pretreatment and posttreatment pocket probings and determinations of clinical gingival findings. The probe can be used to determine pocket depth, attachment level, and bone level (Figure 61-3). Clinical determinations of attachment level are more useful than probing pocket depths because the latter may change as a result of displacement of the gingival margin (see Chapter 29).

Several studies have determined that the depth of penetration of a probe in a periodontal pocket varies according to the degree of inflammatory involvement of the tissues immediately beneath the bottom of the pocket (Figure 61-4). Therefore, even though the forces used may be standardized with pressure-sensitive probes, there is an inherent margin of error in this method that is difficult to overcome. Fowler et al[71] have calculated this error to be 1.2 mm, but it is even greater when furcations are probed.[189]

Bone probing performed with the patient under anesthesia is not subject to this error and has been found to be as accurate as bone height measurements made on surgical reentry.[93,240,311]

Measurements of the defect should be made before and after treatment from the same point within the defect and with the same angulation of the probe. This reproducibility of probe placement is difficult and may be facilitated in part by using a grooved stent to guide the introduction of the probe (Figure 61-5). Preoperative and postoperative comparability of probing measurements that do not use this standardized method may be open to question.

Radiographic Methods

Radiographic evaluation of periodontal regeneration allows assessment of the bone tissue adjacent to the tooth. This technique also requires carefully standardized techniques for reproducible positioning of the film and the tube.[216,249] Even with standardized techniques (see Chapter 31), the radiograph does not show the entire topography of the area before or after treatment. Furthermore, thin bone trabeculae may exist before treatment and go undetected radiographically because a certain minimal amount of mineralized tissue must be present to register on the radiograph. Several studies have demonstrated that radiographs, even those taken with standardized methods, are less reliable than clinical probing techniques.[154,299] A comparative study of pretreatment bone levels and posttherapy bone fill with 12-month reentry bone measurements showed that linear radiographic analysis significantly underestimates pretreatment bone loss and posttreatment bone fill.[300]

Studies with subtraction radiography have enhanced the usefulness of radiographic evaluation.[60,61,317] A comparative study of linear measurement, computer-assisted densitometric image analysis (CADIA), and a method combining the two reported that the linear-CADIA method offers the highest level of accuracy.[303]

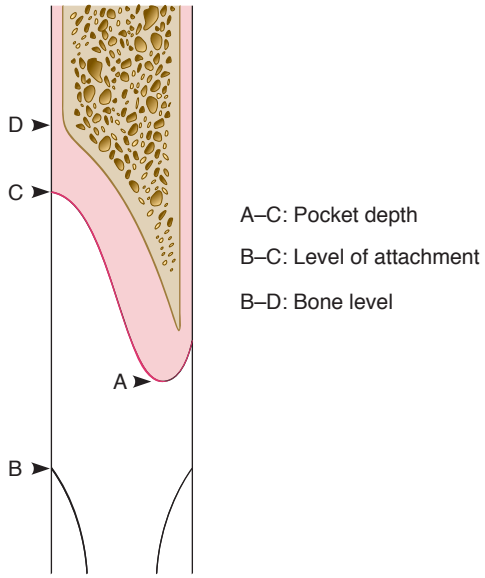

Figure 61-3 Different types of probings in an interdental space. Several studies have determined that the depth of penetration of a probe in a periodontal pocket varies according to the degree of inflammatory involvement of the tissues immediately beneath the bottom of the pocket (Figure 61-4). Therefore, even though the forces used may be standardized with pressure-sensitive probes, there is an inherent margin of error in this method that is difficult to overcome. Fowler et al[71] have calculated this error to be 1.2 mm, but it is even greater when furcations are probed.

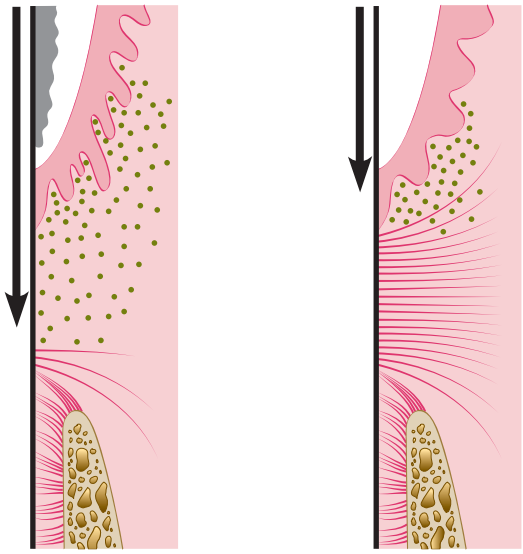

Figure 61-4 *Left,* Arrow pointing downward depicts penetration of a probe in an untreated periodontal pocket. The probe tip goes past the junctional epithelium and the inflamed tissue and is stopped by the first intact, attached collagen fibers. *Right,* After thorough scaling and root planing, the location of the bottom of the pocket has not changed, but the probe penetrates to only about one-third the length of the junctional epithelium (see Chapter 29). The reduction in probing depth may not reflect a change in attachment level.

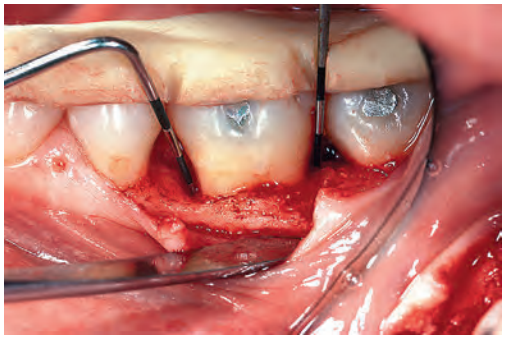

Figure 61-5 Grooved acrylic stent used in clinical research to standardize the direction of introduction of the probe.

Surgical Reentry

The surgical reentry of a treated defect after a period of healing can provide a good view of the state of the bone crest that can be compared with the view taken during the initial surgical intervention and can also be subject to measurements (Figure 61-6). Models from impressions of the bone taken at the initial surgery and later at reentry can be used to assess the results of therapy.

This method is very useful but has two shortcomings: It requires a frequently unnecessary second procedure, and it does not show the type of attachment that exists (i.e., new attachment or long junctional epithelium[35]) (Figure 61-7).

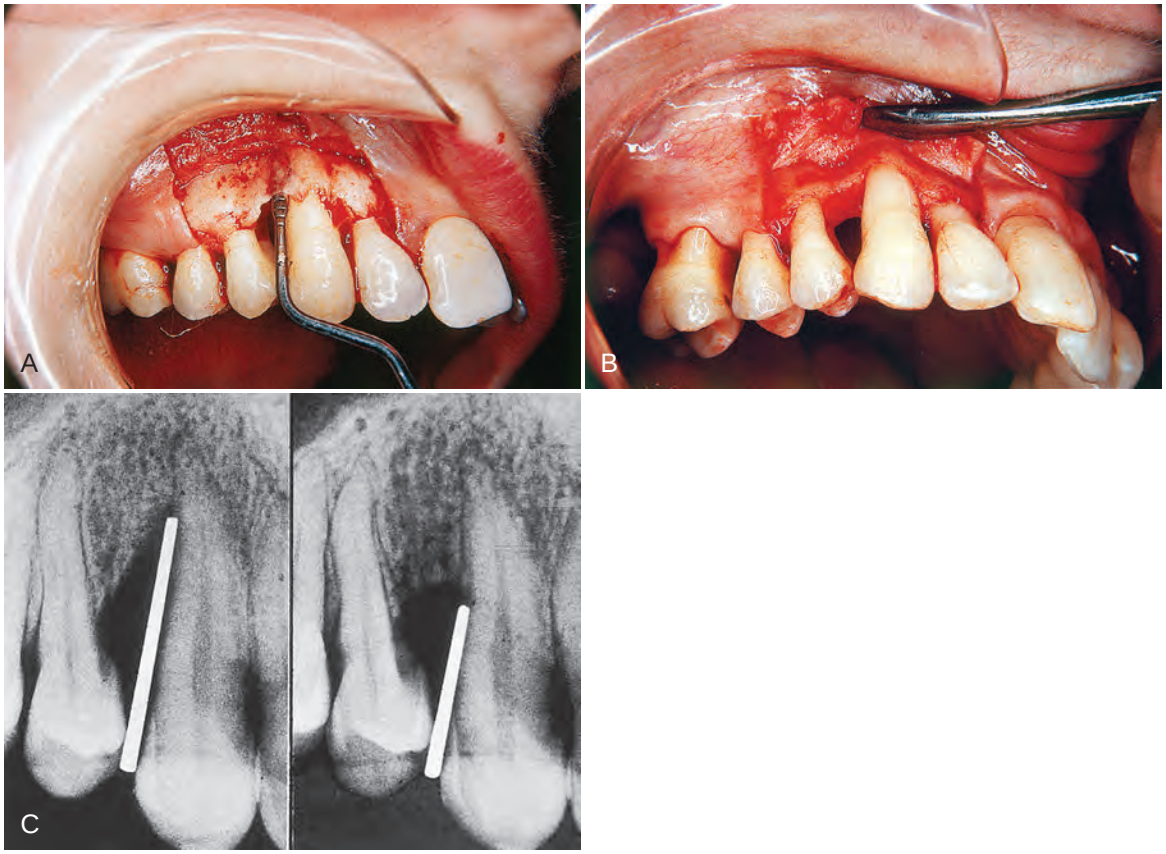

Figure 61-6 **A,** Deep three-wall vertical osseous defect with measuring probe inserted. **B,** Reentry surgery 9 months after treatment shows repaired bone defect. **C,** Radiographs before and after treatment showing fill of angular osseous defect; gutta percha points extend to base of pocket. *(From Glickman I: Clinical periodontology, ed 3, Philadelphia, 1964, Saunders.)*

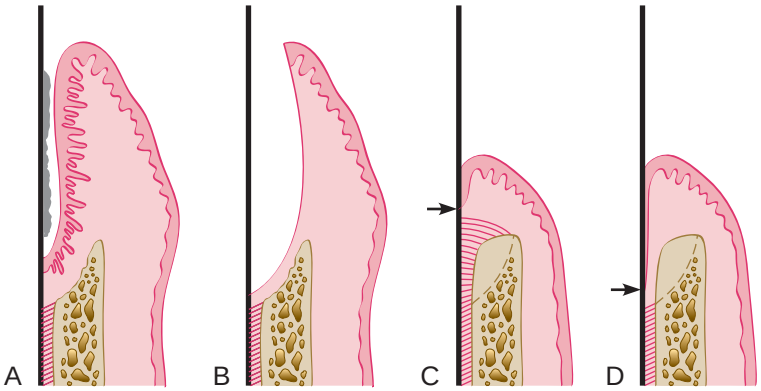

Figure 61-7 **A,** Periodontal pocket preoperatively. **B,** Periodontal pocket immediately after scaling, root planing, and curettage. **C,** New attachment. The arrow indicates the most apical part of the junctional epithelium. Note regeneration of bone and periodontal ligament. **D,** Healing by long junctional epithelium. Again, the arrow indicates the most apical part of the junctional epithelium. Note that the bone is new, but the periodontal ligament is not.

attachment and regeneration but further clinical trial are needed to test its efficacy and parameter for success. Additionally, there are several procedures such as (1) the removal of the junctional and pocket epithelium; (2) the prevention of their migration into the healing area after therapy; (3) clot stabilization, wound protection, and space creation; and (4) the biomodification of the root surfaces that are of historical interest. Although these procedures are not used individually as reconstructive approach, much of these strategies are currently incorporated as adjunct for reconstructive surgery.

Guided Tissue Regeneration. GTR is used for the prevention of epithelial migration along the cemental wall of the pocket and maintaining space for clot stabilization. Derived from the classic studies of Nyman, Lindhe, Karring, and Gottlow, this method is based on the assumption that periodontal ligament and perivascular cells have the potential for regeneration of the attachment apparatus of the tooth.* GTR consists of placing barriers of different types (membranes) to cover the bone and periodontal ligament, thus temporarily separating them from the gingival epithelium and connective tissue. Excluding the epithelium and the gingival connective tissue from the root surface during the postsurgical healing phase not only prevents epithelial migration into the wound but also favors repopulation of the area by cells from the periodontal ligament and the bone[38] (see also Chapter 1). It should be noted that in the United States, GTR is often performed with some type of bone graft as a scaffolding agent, so it is a combined therapy. In Europe and other parts of the world where regulatory and religious constraints makes human graft materials unavailable, so it is performed as a traditional GTR procedure and may be occasionally used in conjunction with a other graft materials as a combined therapy.

Initial animal experiments using Millipore filters and Teflon membranes resulted in regeneration of cementum and alveolar bone and a functional periodontal ligament.[32,34,38,129] Clinical case reports indicate that GTR results in a gain in attachment level.[17,18] Histologic studies in humans provided evidence of periodontal reconstruction in most cases, even with horizontal bone loss.[90,290,292]

The use of polytetrafluoroethylene (PTFE) membranes has been tested in controlled clinical studies in mandibular molar furcations and has shown statistically significant decreases in pocket depths and improvement in attachment levels after 6 months, but bone level measurements have been inconclusive.[158,225] A study on maxillary molar furcations did not result in significant gain in attachment or bone levels.[182]

With the regenerative success associated with the use of nonresorbable membrane, the advantage and disadvantage of this approach became apparent. Notably, problems such as membrane exposure, which resulted in no or limited regeneration and the need for a secondary procedure for surgical removal resulted in the development of biodegradable membranes.[274] Today in clinical practice, most GTR procedures use biodegradable membranes while the nonresorbable membranes are used for implant site development. Nevertheless, the historical research using nonresorbable membranes and the development of various types of biodegradable membranes is valuable.

Laser-Assisted New Attachment Procedure. The role of laser in periodontal therapy remains controversial (see Chapter 65). Nevertheless, the use of neodymium:yttrium-aluminum-garnet (Nd:YAG) to perform surgical LANAPs has been reported for the management of chronic periodontitis[138,186] and can potentially result in new attachment and periodontal regeneration (see Chapter 65).[201,334]

Many questions remain about LANAP that need to be clarified. The first is the exact mechanism and parameter by which healing by new attachment versus regeneration occur with LANAP therapy. Additionally, a blinded split mouth study to compare LANAP protocol to other existing periodontal therapies is in progress and needs to be completed. This along with other randomized controlled trials will be needed for meta-analysis to determine if LANAP is equivalent or superior to other conventional therapy. As with all periodontal therapy, the long-term stability of the regeneration need to be explored.

Graft Materials and Procedures

Numerous therapeutic grafting modalities for restoring periodontal osseous defects have been investigated. Periodontal reconstruction can be attained without the use of bone grafts in meticulously treated three-wall defects (intrabony defects) and in periodontal and endodontic abscesses.[32,116,137,230] New attachment is more likely to occur when the destructive process has occurred rapidly, such as after treatment of pockets complicated by acute periodontal abscesses and after treatment of acute necrotizing ulcerative lesions.[197] The use of graft materials at one time was to provide regenerative inductive effect but should be viewed primarily as providing a scaffold for healing.

The following classifications of bone graft material are important to note. Grafts are either categorized by their origins and function during healing. Categorization by origin include: (1) *autografts* are bone obtained from the same individual; (2) *allografts* are bone obtained from a different individual of the same species; and (3) *xenografts* are bone from a different species. Bone graft materials are also evaluated based on their osteogenic, osteoinductive, or osteoconductive potential. *Osteogenesis* refers to the formation or development of new bone by cells contained in the graft. *Osteoinduction* is a chemical process by which molecules contained in the graft (e.g., bone morphogenetic proteins) convert the neighboring cells into osteoblasts, which in turn form bone. *Osteoconduction* is a physical effect by which the matrix of the graft forms a scaffold that favors outside cells to penetrate the graft and form new bone.

Periodontal defects as sites for transplantation differ from osseous cavities surrounded by bony walls. Saliva and bacteria may easily penetrate along the root surface, and epithelial cells may proliferate into the defect, resulting in contamination and possible exfoliation of the grafts. Therefore the principles established to govern transplantation of bone or other materials into closed osseous cavities are not fully applicable to transplantation of bone into periodontal defects.[62]

Schallhorn[262] defined the considerations that govern the selection of a material as follows: biologic acceptability, predictability, clinical feasibility, minimal operative hazards, minimal postoperative sequelae, and patient acceptance. It is difficult to find a material with all these characteristics, and to date, there is no ideal material or technique.

Graft materials have been developed and tried in many forms. To familiarize the reader with various types of graft material, as defined by either the technique or the material used, a brief discussion of each is provided.

All grafting techniques require presurgical scaling, occlusal adjustment as needed, and exposure of the defect with a full-thickness flap. The flap technique best suited for grafting purposes is the *papilla preservation flap* because it provides complete

*References 52,89,90,183,208,209,292.

Nonresorbable Membranes. In classic animal and human studies demonstrating the efficacy of GTR, cellulose acetate filters were used. As this technique became more prevalent, the first commercial membrane was produced from expanded polytetrafluoroethylene (ePTFE). This membrane has all the properties necessary for GTR barriers in that it (1) is a cellular barrier; (2) is biocompatible; (3) provides space for the healing tissue; (4) permits tissue integration; and (5) is clinically manageable. Much of our current understanding of GTR is based on studies using ePTFE membranes. Although they are used less frequently now, they are still popular for guided bone regeneration and ridge preservation, so it is important to understand the clinical procedures for managing these membranes.

The clinical effectiveness of ePTFE membranes is dependent on technique. Preservation of the keratinized gingiva and a relatively thick overlying surgical flap are critical to avoid perforation of the flap by the membrane during healing. After the surgical area has been flapped, the defect is degranulated and the root surface scaled and root planed. The ePTFE membrane is trimmed to adapt to tooth configuration, secured by ePTFE sutures, and the flap repositioned. It is interesting to note that, although much of the emphasis in the literature is on adapting the membrane to the defect, no membrane can ever be perfectly adapted. Despite gaps, these membranes seem to work. After membrane placement, healing is allowed to proceed for 4 to 6 weeks. Barring any membrane exposure, a second surgery is performed to remove the membrane. During this removal, the healing tissue appears reddish and granulomatous. After membrane removal, the area should not be probed for 3 months. Radiographic evidence of bone fill is usually present after 6 months and should continue over the course of 1 year (Figure 61-8).

Clinical studies have shown that ePTFE membranes used in GTR procedures are more effective than surgical debridement in correcting intrabony defects.* In intrabony and furcation defects, there are gains in clinical attachment level (3 to 6 mm), improved bone levels (2.4 to 4.8 mm), and probing depth reductions (3.5 to 6 mm). Studies have demonstrated that these regenerative results can be maintained over the course of several years.[51,92,263,315]

The advent of titanium-reinforced ePTFE allowed for the formation of larger spaces, thus permitting correction of larger defects (Figure 61-9).[50] This resulted in significant clinical improvements using titanium-reinforced ePTFE compared to ePTFE.

To determine how regeneration can be enhanced with GTR technique, the prolonged retention of ePTFE membranes was evaluated.[196] After allowing the membrane to be retained for 4 months, surgical re-entry after 1 year determined that the mean bone fill of intrabony defects was 95%. This suggests that prolonged retention of a barrier membrane is desirable if no tissue perforation is present. This is consistent with many clinical reports of the improved bone quality associated with guided bone regeneration in implant site development.

The major problem with using non-resorbable membranes is that the membrane is exposed to the oral environment during healing. Upon exposure, the membrane is contaminated and colonized by oral microflora.[187,206,213,281] Several studies have shown that contamination of the surgical field can result in decreased formation of new attachment. If the membrane is exposed, the infection can be temporarily managed with topical application of chlorhexidine. This may minimize the infection and extend the time the membrane can be retained in place.

*References 18,44,47-49,51,94,105,141,168,263,289,300.

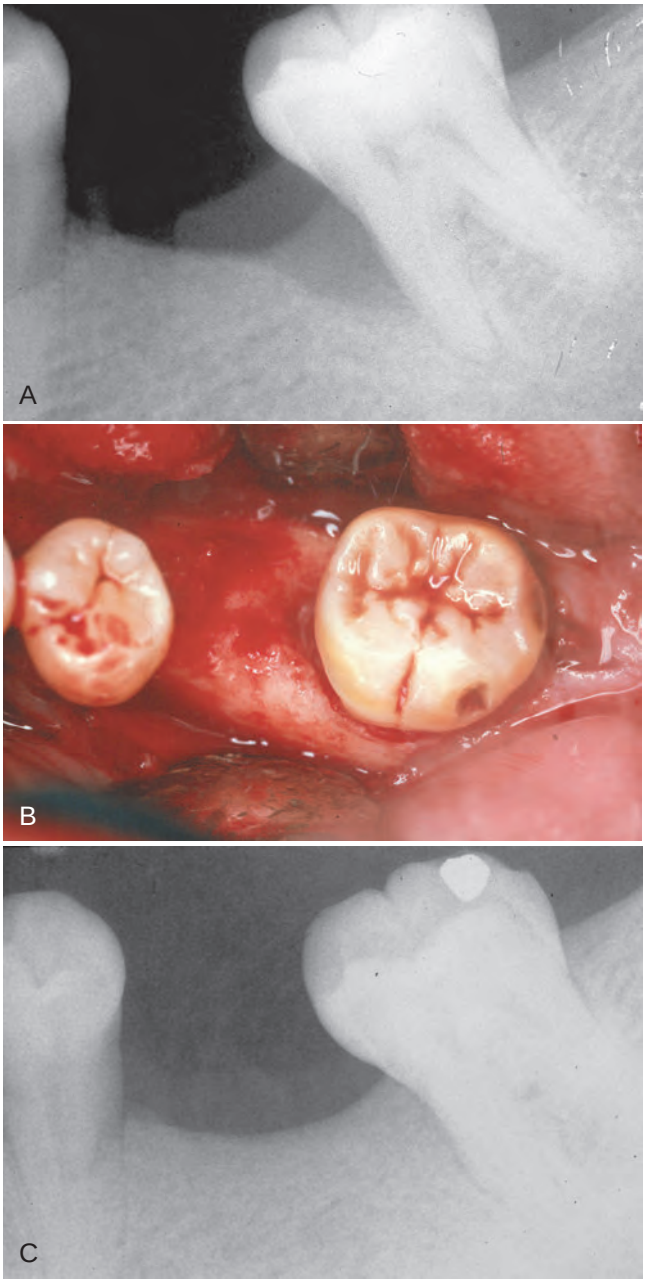

Figure 61-8 Radiographs of a guided tissue regeneration (GTR) case using a non-resorbable expanded polytetrafluoroethylene (ePTFE) membrane. The mesially inclined molar is associated with a three-walled intraosseous defect **(A, B)**. The defect was filled with demineralized freeze-dried bone allograft (DFDBA) and ePTFE was used. Membrane was exposed after 8 weeks and removed 2 weeks later. Radiographic "fill" was halfway after 6 months and maximum fill was present after 12 months **(C)** with minimal probing depth. *(Courtesy of Rose L, et al, editor: Periodontics: medicine, surgery, and implants, St Louis, Elsevier Mosby, 2004.)*

Biodegradable Membranes. Bioresorbable membranes have replaced the routine use of ePTFE membranes in guided tissue regeneration. There are basically three types of bioresorbable membranes: (1) polyglycoside synthetic polymers (i.e., polylactic acid, polylactate/polygalactate co-polymers), (2) collagen, and (3) calcium sulfate. Polyglycoside membranes degrade as the result of random nonenzymatic cleavage of the polymer, producing polylactide and polyglycolide, which are converted to lactic acid and

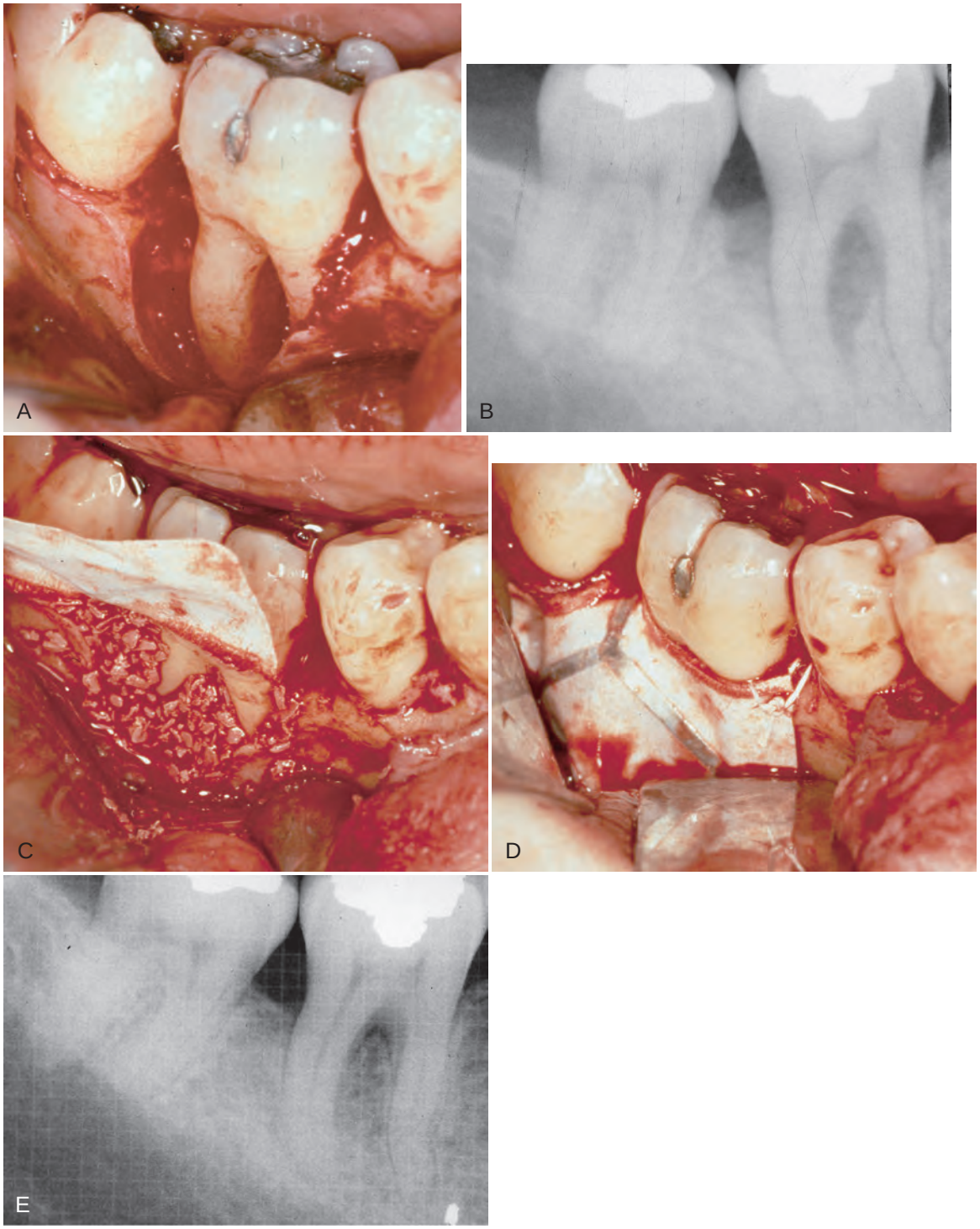

Figure 61-9 Clinical photographs and radiographs of a guided tissue regeneration case using expanded polytetrafluoroethylene (ePTFE) with titanium-reinforced membrane. The osseous defect was along the distal interproximal area wrapping buccally over the furcation **(A, B)**. To prevent the membrane from collapsing over the root surfaces, demineralized freeze-dried bone allograft (DFDBA) and adjusting the titanium membrane provide a larger space for regeneration **(C, D)**. One year afterward, the radiographic and clinical signs are consistent with achieving regeneration in this defect (**E**). *(Courtesy of Rose L, et al, editor: Periodontics: medicine, surgery, and implants, Elsevier Mosby, 2004.)*

pyruvate, respectively, and metabolized by the enzymes of the Krebs cycle. Porcine collagen membranes are degraded by collagenases and subsequently by gelatinases and peptidase. There has been a resurgence in the use of calcium sulfate as a regeneration material because it can be used as a pavable resorbable barrier when used in combination with bone or bone substitutes. The calcium sulfate is bioresorbed through a giant cell reaction. Several features make these bioresorbable membranes easier to manage clinically: (1) they are more tissue compatible than nonresorbable membranes; (2) the timing for resorption can be regulated by the amount of cross-linkage in the synthetic polymer and collagen membrane or the amount of heat-processed calcium sulfate chips

in calcium sulfate barrier; and (3) a second surgical procedure is not required to retrieve the nonresorbable membrane.

A recent GTR study compared the use of bioresorbable membranes (polylactate/polygalactate copolymer) versus ePTFE membranes, with surgical debridement as a control.[52] After 1 year, significant gains in clinical attachment level (CAL) were observed in all three groups. There was no difference in CAL gain between the two membrane groups, with both of them gaining 2 mm or more. In both membrane groups, 83% of the sites improved 4 mm or more, which was significantly better than the surgical debridement control group. These findings indicate GTR procedures are equally effective using resorbable and nonresorbable membranes. This finding has been confirmed by other investigators.[42,43,316]

A large multicenter clinical study reported the use of bioresorbable membranes in 203 consecutively treated intrabony defects.[66] After 1 year, investigators found that CAL improved by 79%, and 78% of the sites improved by 4 mm or more. An average of 3 mm of bone fill was measured radiographically. Compromised clinical results occurred in incidences in which membranes were exposed or patients had poor plaque control.

The search for resorbable membranes has included trials and tests with numerous materials and collagens from different species such as bovine, porcine, Cargile membrane derived from the cecum of an ox, polylactic acid, Vicryl (polyglactin 910), synthetic skin (Biobrane), and freeze-dried dura mater.* Clinical studies with a mixture of copolymers derived from polylactic acid and acetyl tributyl citrate resorbable membranes (Guidor membrane, no longer on the market) and a poly-D,L-lactide-co-glycolide (Resolut membrane, also no longer on the market) have shown significant gains in clinical attachment and bone fill.[43,68,198]

The potential of using autogenous periosteum as a membrane and also to stimulate periodontal regeneration has been explored in two controlled clinical studies, one of grade II furcation involvements in mandibular molars and another of interdental defects.[153,157] The periosteum was obtained from the patient's palate by means of a window flap. Both studies reported that autogenous periosteal grafts can be used in GTR and result in significant gains in clinical attachment and osseous defect fill.

Non–Graft-Associated Procedures of Historical Interest

Removal of Junctional and Pocket Epithelium. Since the earliest attempts at periodontal new attachment, the presence of junctional and pocket epithelium has been perceived as a barrier to successful therapy because its presence interferes with the direct apposition of connective tissue and cementum, thus limiting the height to which periodontal fibers can insert to the cementum.[86,131,156,212] Several methods have been recommended to remove the junctional and pocket epithelium. These include curettage, chemical agents, ultrasonics, lasers, and surgical techniques.

Curettage. Results of removal of the epithelium by means of curettage vary from complete removal to persistence of as much as 50%.[283] Though curettage is not a reliable procedure, occasional bone regeneration does occur (Figure 61-10). Ultrasonic methods, lasers, and rotary abrasive stones have also been used, but their effects cannot be controlled because of the clinician's lack of vision and tactile sense when using these methods.

Chemical Agents. Chemical agents have also been used to remove pocket epithelium, usually in conjunction with curettage.

*Vicryl, Johnson & Johnson Dental Care Division, New Brunswick, NJ; Biobrane, Smith & Nephew PLC, London, UK.

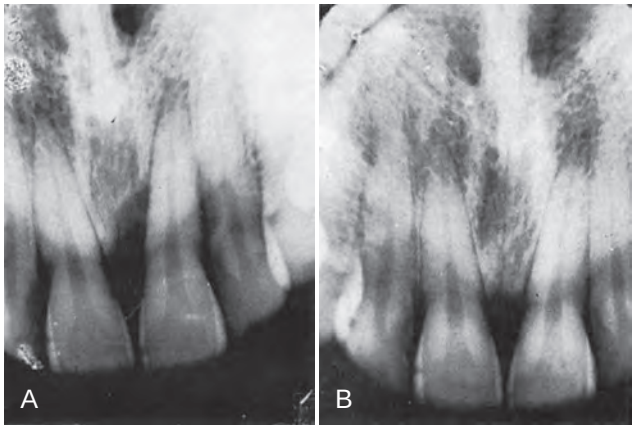

Figure 61-10 Bone regeneration after closed scaling, root planing, and curettage. Before **(A)** and after **(B)** radiographs are shown. This is a classic case from Dr. Fermin Carranza Sr. in 1954. *(From Carranza FA Sr: J Periodontol 25:272, 1954.)*

The drugs used most often have been sodium sulfide, phenol camphor, Antiformin, and sodium hypochlorite. However, the effect of these agents is not limited to the epithelium, and their depth of penetration cannot be controlled. These drugs are mentioned here for their historic interest.

Biomodification of Root Surface. Changes in the tooth surface wall of periodontal pockets (e.g., degenerated remnants of Sharpey's fibers, accumulation of bacteria and their products, disintegration of cementum and dentin) interfere with new attachment. Although these obstacles to new attachment can be eliminated by thorough root planing, the root surface of the pocket can be treated to improve its chances of accepting the new attachment of gingival tissues.

Several substances have been proposed for this purpose, including citric acid, fibronectin, and tetracycline.

Citric Acid. There has been a series of studies one of which applied citric acid to the roots to demineralize the surface, attempting to induce cementogenesis and attachment of collagen fibers.

The following actions of citric acid have been reported:

1. Accelerated healing and new cementum formation occur after surgical detachment of the gingival tissues and demineralization of the root surface by means of citric acid.[238]
2. Topically applied citric acid on periodontally diseased root surfaces has no effect on nonplaned roots, but after root planing, the acid produces a 4-µm-deep demineralized zone with exposed collagen fibers.[82]
3. Root-planed, non–citric acid treated roots are left with a surface smear layer of microcrystalline debris. Citric acid application not only removes the smear layer, exposing the dentinal tubules, but also makes the tubules appear wider and with funnel-shaped orifices.[224]
4. Citric acid has also been shown in vitro to eliminate endotoxins and bacteria from the diseased tooth surface.[55,70]
5. An early fibrin linkage to collagen fibers exposed by the citric acid treatment prevents the epithelium from migrating over treated roots.[223]

This technique using citric acid has been extensively investigated in animals and humans. Studies in dogs have shown encouraging results, especially for the treatment of furcation lesions, but the results in humans have been contradictory.*

*References 54,205,238,239,287,318,319.

The recommended citric acid technique is as follows:

1. Raise a mucoperiosteal flap and thoroughly instrument the root surface, removing calculus and underlying cementum.
2. Apply cotton pledgets soaked in a saturated solution of citric acid (pH of 1.0) for 2 to 5 minutes.
3. Remove pledgets, and irrigate root surface profusely with water.
4. Replace the flap and suture.

The use of citric acid has also been recommended in conjunction with coverage of denuded roots using free gingival grafts (see Chapter 63).

Fibronectin. Fibronectin is the glycoprotein that fibroblasts require to attach to root surfaces. The addition of fibronectin to the root surface may promote new attachment.[28,69,297] However, increasing fibronectin above plasma levels produces no obvious advantages. Adding fibronectin and citric acid to lesions treated with GTR in dogs did not improve the results.[29,284]

Tetracycline. In vitro treatment of the dentin surfaces with tetracycline increases binding of fibronectin, which in turn stimulates fibroblast attachment and growth while suppressing epithelial cell attachment and migration.[287,298] Tetracycline also removes an amorphous surface layer and exposes the dentin tubules. In vivo studies, however, have not shown favorable results.[318,319] A human study showed a trend for greater connective tissue attachment after tetracycline treatment of roots. Tetracycline gave better results when used alone than when combined with fibronectin.[3] Tetracycline has been used as an adjunctive procedure in preparation of the root in regenerative procedures and is recommended step for use with biologic mediators.

Surgical Techniques. Surgical techniques have been recommended to eliminate the pocket and junctional epithelium. The excisional new attachment procedure (ENAP) consists of an internal bevel incision performed with a surgical knife, followed by removal of the excised tissue.[328] No attempt is made to elevate a flap. After careful scaling and root planing, interproximal sutures are used to close the wound (see Chapter 56). This approach has been modified and is used in conjunction with the Nd:YAG laser in the previously described LANAP procedure.

Glickman[88] and Prichard[228] have advocated performing a *gingivectomy to the crest of the alveolar bone* and debriding the defect. Excellent results have been obtained with this technique in uncontrolled human studies.[16,230]

The modified Widman flap, as described by Ramfjord and Nissle,[234] is similar to the excisional new attachment procedure but is followed by elevation of a flap for better exposure of the area. The internal bevel incision eliminates the pocket epithelium (see Chapter 59).

Preventing or Impeding the Epithelial Migration. Elimination of the junctional and pocket epithelium may not be sufficient because the epithelium from the excised margin may rapidly proliferate to become interposed between the healing connective tissue and the cementum.

For experimental purposes, several investigators have analyzed in animals and humans the effect of excluding the epithelium by amputating the crown of the tooth and covering the root with the flap ("root submergence").[19,20,22,39] This experimental technique not only excludes the epithelium but also prevents microbial contamination of the wound during the reparative stages. Successful repair of osseous lesions in the submerged environment was reported, but obviously this method has little or no clinical application.

Two other methods have been proposed to prevent or impede the migration of the epithelium. One consists of the total removal of the interdental papilla covering the defect and its replacement with a free autogenous graft obtained from the palate.[63] During healing, the graft epithelium necroses and is slowly replaced by proliferating epithelium from the gingival surface. The graft simply delays the epithelium from proliferating into the healing area. This method has not been widely used.

The second approach is the use of *coronally displaced flaps,* which increase the distance between the epithelial wound edge and the healing area. This technique is particularly suitable for the treatment of mandibular molar furcations and has been used mostly in conjunction with citric acid treatment of the roots.[81,167] Periodontal regeneration after the use of this technique has been demonstrated histologically in humans.[276]

Clot Stabilization, Wound Protection, and Space Creation. Some investigators have attributed the successful results reported with graft materials, barrier membranes, and coronally displaced flaps to the fact that these techniques protect the wound and create a space for undisturbed and stable maturation of the clot[83,156,157] This hypothesis suggests that preservation of the root surface fibrin clot interface prevents apical migration of the gingival epithelium and allows for connective tissue attachment during the early wound-healing period.[83,213,223]

The importance of space creation for bone repair has long been recognized in orthopedic and maxillofacial surgery. Transference of this concept to periodontal therapy has been explored for treatment of periodontal and periimplant osseous defects and for root coverage. The space can be created by using a titanium-reinforced ePTFE membrane to prevent its collapse. For the study of reconstructive techniques, these membranes were placed over experimentally created supraalveolar bone defects in dogs, and considerable bone reconstruction was reported.[278] The following is a discussion of the guided tissue regeneration technique.

TABLE 61-1 Comparative Analysis of Regenerative Approaches

Graft Material	CAL Gain (mm)	Defect Fill (% or mm)	Histologic Assessment	Comments
Autologous				
Extraoral (iliac crest)	3.3-4.2[259] • 2.60 mm in 0-wall • 3.75 mm in 1-wall • 4.16 mm in 2-wall	—	33 of 39 defects showed evidence of regeneration[48]	Only evidence of regeneration in 0-wall and (2.5 mm) supracrestal regeneration.
Intraoral autologous	2.88-3.44 mm[34,73,75,117]	73%[51]	0.7 mm of regeneration[48,55]	Only one controlled study with 2.98 mm of bone gain vs. 0.66 mm with debridement.[51] No significant difference in one study.[54]
Allograft (vital)				
Human vital	3.6 mm mean[259] • 3.6 mm in 1-, 2-, and 3-wall • 2.1 mm in 0-wall	—	Evidence of regeneration[48]	Potential risk of disease transmission
Allograft (nonvital)				
FDBA	2.0 mm mean[174,179,256,276]	60%-68% of 1401 defects had >50% fill[61-64]	None available	Only controlled study using paired defects show no difference between FDBA vs. debridement.[65] No histological study of healing pattern.
Comparative Studies				
FDBA vs. FDBA + autologous graft	—	63%-67% had >50% fill 78%-80% had >50% fill[62]		The addition of autologous osseous coagulum enhances healing.
Allograft (non-vital)				
DFDBA vs. debridement	2.3-2.9 mm vs. 0.3-1.3 mm[177,217]	65% vs. 11%[72-74]	1.21mm of periodontal regeneration[70,71]	
Comparative Studies				
DFDBA vs. FDBA	1.7 vs. 2.4 mm[252]	59% vs. 66%[75]		
Ceramics				
HA vs. debridement	1.3-2.8 mm vs. 0.5-0.9 mm[171,329,330]	67% vs. 10%[91]	No new periodontal attachment, osteogenesis, or centogenesis[97]	
PHA vs. debridement	3.6 mm vs. 1.2 mm[139]	55%-60% vs. 23% had > 50% fill[92-94]	Bone formation in the implant pores and periphery. No new attachment. Pocket reduction by long JE.[104-106]	
TCP	2.3-2.7 mm[33,140,288]	24 mm vs. 9 mm[100] 58 mm vs. 22 mm[101] 67%[107]	Fibrous encapsulation followed by rapid resorption. No evidence of new attachment. Healing by long JE.[112]	
Calcium Carbonates				
NCS vs. debridement	2.3 mm vs. 0.7 mm	67% vs. 26%[121]		NCS is superior to debridement.
GTR				
ePTFE	2.0-5.3 mm[51,92,315]		0.5-1.7 mm of new attachment	
Resorbable barrier polyglactin-910 vs. ePTFE	4.0 mm vs. 3.5 mm[42,43]	77.5% vs. 70.7%[167,168]		

TABLE 61-1 Comparative Analysis of Regenerative Approaches—cont'd

Graft Material	CAL Gain (mm)	Defect Fill (% or mm)	Histologic Assessment	Comments
Comparative Studies				
ePTFE + DFDBA + citric acid root conditioning	4.7 mm[263]			Clinical series suggest improved results with DFDBA + citric acid root conditioning.
ePTFE vs. ePTFE + HA-collagen graft vs. HA-collagen graft vs. debridement	3.70 mm[141] 3.80 mm 2.60 mm 2.1 mm	1.50 mm[141] 1.55 mm 0.85 mm 0.60 mm		ePTFE membranes ± HA-collagen was better than HA-collagen or debridement.
EMDs				
EMD vs. placebo control or debridement	2.2 mm vs 1.7mm[113] 4.28 mm vs 2.65mm[78]	— 74.0% vs. 22.7%[196]	Histological analysis of 2 cases. Both cases had new cementum and attachment but only one had new bone.[191,192]	Suggests EMD can stimulate new attachment.
Comparative Studies				
EMD vs. GTR (evaluate after 24 and 48 months)	3.0 mm vs. 2.9mm[266] 2.9 vs. 3.1mm[226]	—		Both techniques improve CAL; comparable results and appear to be stable over 4 years.
EMD vs. DFDBA EMD + anorganic bone vs. EMD + fibrin glue	3.2 vs. 3.0 mm[98] 2.89 vs. 2.83mm[159]	—		Improved results over published debridement results but no difference between treatment modality.
rhPDGF + β-TCP				
rhPDGF+ β-TCP vs. placebo (pivotal trail 6-month data)	3.8 vs 3.3mm[203]	57% vs. 18% LBF: 2.6 mm vs. 0.9 mm		
rhPDGF + β-TCP vs. placebo (pivotal trail 36-month data)	4.3 vs. 3.2mm[204]	60.5% vs. 32.6% LBF 2.88 mm vs. 1.42 mm		Maximum regeneration seen with 0.3 mg/mL rhPDGF was at the 1-year mark and the results were stable.

CAL, clinical attachment level; *DFDBA*, Demineralized freeze-dried bone allograft; *EMD*, enamel matrix derivative; *ePTFE*, expanded polytetrafluoroethylene; *FDBA*, freeze-dried bone allograft; *GTR*, guided tissue regeneration; *HA*, hydroxyapatite; *JE*, junctional epithelium; *LBF*, linear bone fill; *NCS*, calcium carbonates; *PHA*, porous hydroxyapatite; *rhPDGF*, recombinant human platelet-derived growth factor; *TCP*, tricalcium phosphate.

coverage of the interdental area after suturing (see Chapter 57). The use of antibiotics after the procedure is generally recommended.

Autogenous Bone Grafts

Bone from Intraoral Sites. In 1923, Hegedüs[112] attempted to use bone grafts for the reconstruction of bone defects produced by periodontal disease. The method was revived by Nabers and O'Leary[198] in 1965, and numerous efforts have been made since that time to define its indications and technique.

Sources of bone include bone from healing extraction wounds, bone from edentulous ridges, bone trephined from within the jaw without damaging the roots, newly formed bone in wounds especially created for the purpose, bone removed from tuberosity, and the ramus and bone removed during osteoplasty and ostectomy.[34,103,116,117,246,327]

Osseous Coagulum. Robinson described a technique using a mixture of bone dust and blood that he termed "osseous coagulum."[246] The technique uses small particles ground from cortical bone. The advantage of the particle size is that it provides additional surface area for the interaction of cellular and vascular elements.

Sources of the graft material include the lingual ridge on the mandible, exostoses, edentulous ridges, the bone distal to a terminal tooth, bone removed by osteoplasty or ostectomy, and the lingual surface of the mandible or maxilla at least 5 mm from the roots. Bone is removed with a carbide bur #6 or #8 at speeds between 5000 and 30,000 rpm, placed in a sterile dappen dish and used to fill the defect (Figure 61-11). The obvious advantage of this technique is the ease of obtaining bone from an area already exposed during surgery. The disadvantages are its relatively low predictability and the inability to procure adequate material for large defects.[63] Although notable success has been reported by many individuals, studies documenting the efficacy of the technique are still inconclusive.[53,74,79,245]

Bone Blend. Some disadvantages of osseous coagulum derive from the inability to use aspiration during accumulation of the coagulum. Another problem is the unknown quantity and quality of the bone fragments in the collected material. To overcome these problems, the "bone blend technique" has been proposed.[56]

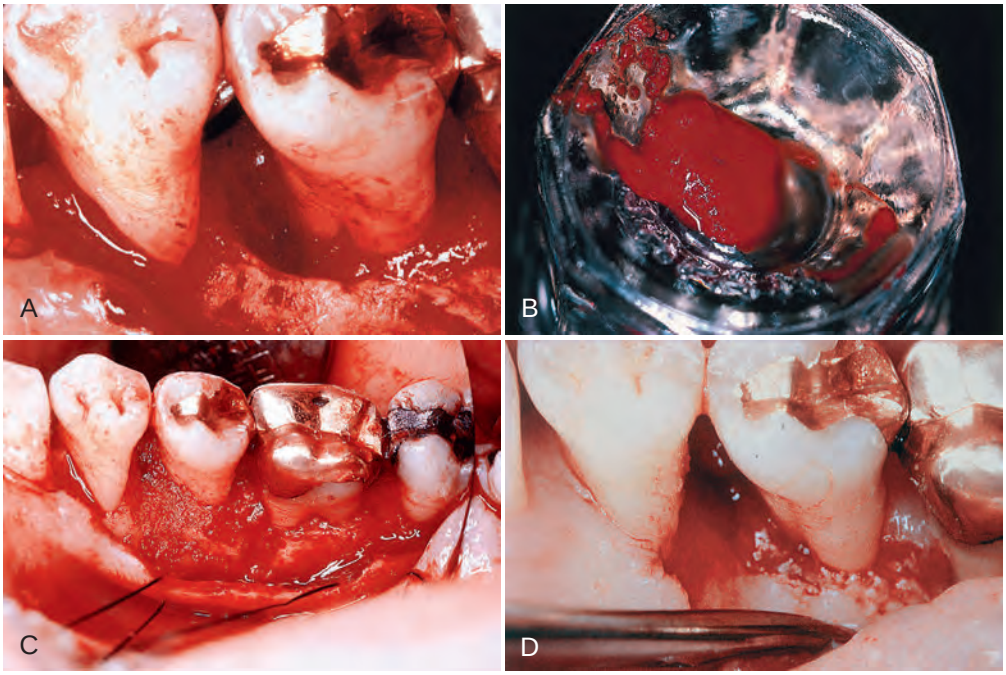

Figure 61-11 **A,** Osseous defect mesial to a second premolar. **B,** Graft material placed in dappen dish before transfer to the graft site. **C,** Material in place. **D,** Reentry 6 months later. *(Courtesy Dr. E. Earl Robinson.)*

The bone blend technique uses an autoclaved plastic capsule and pestle. Bone is removed from a predetermined site, triturated in the capsule to a workable, plasticlike mass, and packed into bony defects. Froum et al[73-75] found osseous coagulum–bone blend procedures to be at least as effective as iliac autografts and open curettage.

Cancellous Bone Marrow Transplants. Cancellous bone can be obtained from the maxillary tuberosity, edentulous areas, and healing sockets.[110] The maxillary tuberosity frequently contains abundant cancellous bone, particularly if the third molars are not present. After a ridge incision is made distally from the last molar, bone is removed with a curved rongeur. Care should be taken not to extend the incision too far distally to avoid entering the mucosal tissue of the pharyngeal area. Also, the location of the maxillary sinus must be analyzed on the radiograph to avoid entering or disturbing it.

Edentulous ridges can be approached with a flap, and cancellous bone and marrow are removed with curettes, back-action chisels, or trephine. Extraction sockets are allowed to heal for 8 to 12 weeks before reentering and removing the newly formed bone from the apical portion, which is used as the donor material.

Bone Swaging. The bone swaging technique requires an edentulous area adjacent to the defect, from which the bone is pushed into contact with the root surface without fracturing the bone at its base.[65,251] Bone swaging is technically difficult, and its usefulness is limited.

Bone from Extraoral Sites. In 1923, Hegedüs also pioneered the use of extraoral sites as a source of bone for grafting into periodontal osseous defects, using bone from the tibia. Schallhorn and Hiatt revived this approach in the 1960s using the iliac crest (see next discussion).

The use of fresh or preserved iliac cancellous marrow bone has been extensively investigated. This material has been used by orthopedic surgeons for years. Data from human and animal studies support its use, and the technique has proved successful in osseous defects with various numbers of walls. It has also been successful in furcations and even supracrestally to some extent.[10,26,58,259,260] However, because of numerous problems associated with its use, the technique is no longer in use.[260] Some of the problems were postoperative infection, bone exfoliation, sequestration, varying rates of healing, root resorption, and rapid recurrence of the defect (Figure 61-12). Other problems were increased patient expense and difficulty in procuring the donor material.[22,50,174,175]

Bone Allografts. Obtaining donor material for autograft purposes necessitates inflicting surgical trauma on another part of the patient's body. Obviously, it would be to the patient's and therapist's advantage if a suitable substitute could be used for grafting purposes that would offer similar potential for repair and not require the additional surgical removal of donor material from the patient. However, both allografts and xenografts are foreign to the patient and, therefore, have the potential to provoke an immune response. Attempts have been made to suppress the antigenic potential of allografts and xenografts by radiation, freezing, and chemical treatment.[25]

Bone allografts are commercially available from tissue banks. They are obtained from cortical bone within 12 hours of the death of the donor, defatted, cut in pieces, washed in absolute alcohol, and deep-frozen. The material may then be demineralized, and subsequently ground and sieved to a particle size of 250 to 750 µm and freeze-dried. Finally, it is vacuum-sealed in glass vials.

Numerous steps are also taken to eliminate viral infectivity. These include exclusion of donors from known high-risk groups and various tests on the cadaver tissues to exclude individuals with any type of infection or malignant disease. The material is then treated with chemical agents or strong acids to inactivate the virus, if still present. The risk of human immunodeficiency virus (HIV) infection has been calculated as 1 in 1 to 8 million and is therefore characterized as highly remote.[178]

Freeze-Dried Bone Allograft. Several clinical studies by Mellonig, Bowers, and coworkers reported bone fill exceeding 50% in 67% of the defects grafted with freeze-dried bone allograft (FDBA)

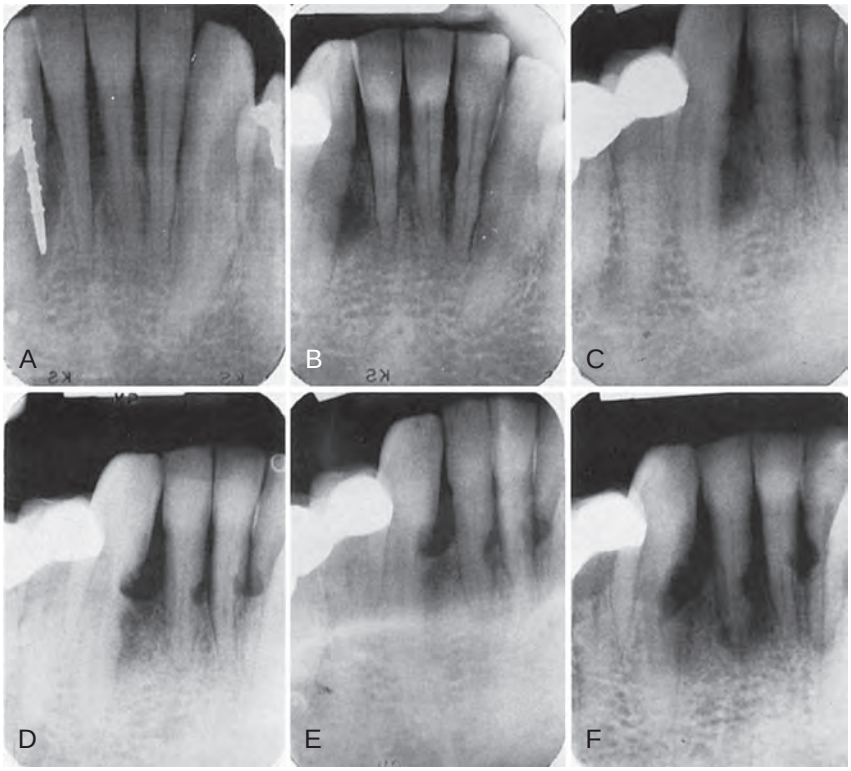

Figure 61-12 **A,** November 1973: Radiograph of a patient immediately before placement of a fresh iliac autograft. **B,** Two months later, bone repair is evident. Note the early radiolucent areas on the mesial aspect of the canine. **C,** After 7 months, "bone fill" is occurring, but obvious root resorption is present. **D,** April 1975: Root resorption is apparent on all grafted teeth. Note the obvious degree of fill of the original bone defects. **E,** February 1976: Further involvement. **F,** October 1977: Four years later, root resorption has progressed into the pulp of the lateral incisor, causing a periosteal-endosteal complication.

and in 78% of the defects grafted with FDBA plus autogenous bone.[174,198,256,276] FDBA, however, is considered an osteoconductive material, whereas demineralized FDBA (DFDBA) is considered an osteoinductive graft. Laboratory studies have found that DFDBA has a higher osteogenic potential than FDBA and is therefore preferred.[175,176,179]

Demineralized Freeze-Dried Bone Allograft. Experiments by Urist[307-310] have established the osteogenic potential of DFDBA. Demineralization in cold, diluted hydrochloric acid exposes the components of bone matrix, which are closely associated with collagen fibrils and have been termed *bone morphogenetic proteins* (BMPs).[41,309]

In 1975, Libin et al[161] reported three patients with 4 to 10 mm of bone regeneration in periodontal osseous defects. Subsequent clinical studies were made with cancellous DFDBA and cortical DFDBA.[217,231] The latter resulted in more desirable results (2.4 mm versus 1.38 mm of bone fill).

Bowers et al,[22] in a histologic study in humans, showed new attachment and periodontal regeneration in defects grafted with DFDBA. Mellonig et al[175,176,177] tested DFDBA against autogenous materials in the calvaria of guinea pigs and showed it to have similar osteogenic potential.

These studies provided strong evidence that DFDBA in periodontal defects results in significant probing depth reduction, attachment level gain, and osseous regeneration. The combination of DFDBA and GTR has also proved to be very successful[9,263]; however, limitations of the use of DFDBA include the possible, although remote, potential of disease transfer from the cadaver.

A bone-inductive protein isolated from the extracellular matrix of human bones, termed *osteogenin* or *BMP-3,* has been tested in human periodontal defects and seems to enhance osseous regeneration.[23] This bone inductive protein is discussed later in this chapter.

Xenografts. Bone products from other species have a long history of use in periodontal therapy. A few of these xenograft products are mentioned here for historic purposes but are no longer used today. It should be noted that bovine-derived bone (Bio-Oss) is used in combination with GTR for periodontal regeneration mainly in Europe. This material is also used in combination with autologous bone for ridge augmentation.

Calf bone (Boplant), treated by detergent extraction, sterilized, and freeze-dried, has been used for the treatment of osseous defects.[10,258] Kiel bone is calf or ox bone denatured with 20% hydrogen peroxide, dried with acetone, and sterilized with ethylene oxide. Anorganic bone is ox bone from which the organic material has been extracted by means of ethylenediamine; it is then sterilized by autoclaving.[173] These materials have been tried and discarded for various reasons.

Currently, an anorganic, bovine-derived bone marketed under the brand name Bio-Oss (Osteohealth) has been successfully used both for periodontal defects and in implant surgery. It is an osteoconductive, porous bone mineral matrix from bovine cancellous or cortical bone. The organic components of the bone are removed, but the trabecular architecture and porosity are retained.[30,172] The physical features permit clot stabilization and revascularization to allow for migration of osteoblasts, leading to osteogenesis. Bio-Oss is biocompatible with the adjacent tissues, eliciting no systemic immune response.

Several studies have reported successful bone regeneration and new attachment with Bio-Oss in periodontal defects,[30,180] as well as regeneration around implants and sinus grafting (see Chapter 77).

Periodontally, Bio-Oss has been used as a graft material covered with a resorbable membrane (Geistlich Bio-Gide®). The membrane prevents the migration of fibroblasts and connective tissues into the pores and between the granules of the graft. Histologic studies of this technique have shown significant osseous regeneration and cementum formation.

Yukna et al[332] have used Bio-Oss in combination with a cell-binding polypeptide (P-15) that is a synthetic analog of a 15–amino

acid sequence of type I collagen. marketed as PepGen P-15 (Dentsply/CeraMed); this combination seems to enhance the bone-regenerative results of the matrix alone in periodontal defects.

Graft-Associated Reconstructive Procedures of Historical Interest

In addition to bone graft materials, many nonbone graft materials have been used in an attempt to restore the periodontium. These include sclera, dura, cartilage, cementum, dentin, plaster of Paris, plastic materials, ceramics, and coral-derived materials.[27,159] None offers a reliable substitute to bone graft materials; some of these materials are briefly presented here to offer a complete picture of the many attempts that have been made to solve the critical problem of periodontal regeneration.

Tissue Engineering with Biologic Mediators

In wound healing, the natural healing process usually results in tissue scarring or repair. Using tissue engineering, the wound healing process is manipulated so that tissue regeneration occurs.[94] This manipulation usually involves one or more of the three key elements: the signaling molecules, scaffold or supporting matrices, and cells (Figure 61-13). The use of tissue engineering for periodontal regeneration and dental implant site preparation has recently been reviewed.[87,134,135]

Early clinical examples involving tissue engineering principles include the use of bone allografts and autologous platelet-rich plasma (PRP). Investigations indicated that the success rates with these materials were inconsistent. With the development of recombinant growth factors and morphogens, and the use of synthetic scaffolds, the level of success has improved. Once considered experimental in nature, tissue engineering is now clinically applicable with two commercially available tissue engineering systems for periodontal regeneration which involve the use of enamel matrix derivative (EMD) and platelet-derived growth factor-BB (PDGF-BB)-beta-tricalcium phosphate (β-TCP). The ability of BMP type I collagen sponge to enhance periodontal regeneration has been studied, but the mixed results and the concern for ankylosis have relegated this differentiation factor to be used primarily for implant site development. The development of a fourth promising system using basic fibroblast growth factor (FGF-2) is completing multicenter clinical trials.

Because tissue engineering approaches are likely to improve clinical results, clinicians need to understand the biology and clinical parameters and limitations of these techniques. In the following sections, each of the three key elements of tissue engineering and how they are applied to the spectrum of periodontal and other orofacial surgery procedures are reviewed.

Enamel Matrix Derivative for Periodontal Regeneration. EMD has been effective in the treatment of infrabony defects (Figure 61-14). The histological evidence of EMD-induced periodontal regeneration has been confirmed in a clinical case report.[113,114] A mandibular lateral incisor destined for orthodontic extraction was treated with acid etching and EMD. After 4 months, the tooth was extracted and examined histologically. Regenerated cementum covered 73% of the defect and regenerated alveolar bone covered 65%. This histological finding was later confirmed in other case reports,[267,333] whereas new connective tissue attachment was reported in another case series where EMD was used in combination with a bone-derived xenograft.[269]

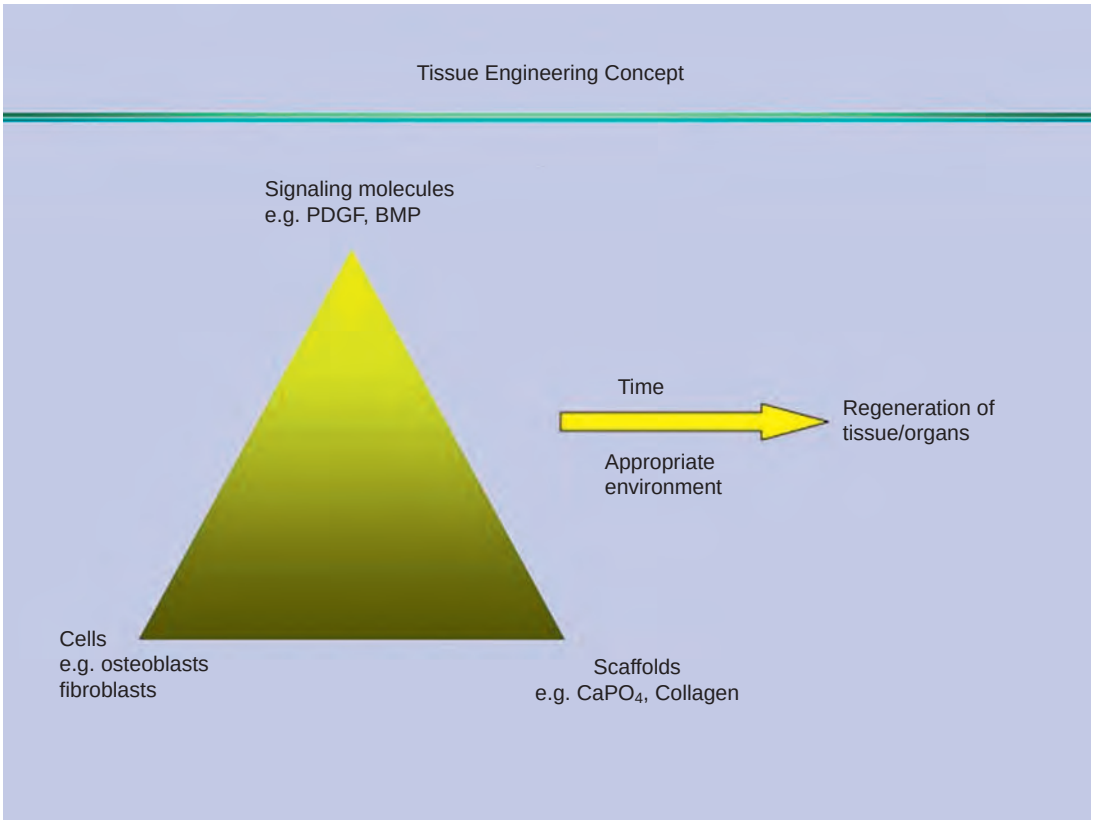

Figure 61-13 Tissue engineering is the manipulation of one or more of the three elements: signaling molecules, scaffolds, or cells. *(Courtesy Dr. Samuel Lynch.)*

Sclera. Sclera was originally used in periodontal procedures because it is a dense, fibrous connective tissue with poor vascularity and minimal cellularity.[149-151] This affords a low incidence of antigenicity and other untoward reactions.[131] In addition, sclera may provide a barrier to apical migration of the junctional epithelium and serve to protect the blood clot during the initial healing period.

Although some studies show that sclera is well accepted by the host and is sometimes invaded by host cells and capillaries and replaced by dense connective tissue, it does not appear to induce osteogenesis or cementogenesis.[68,191,215] The available scientific research does not warrant the use of sclera in periodontal therapy.

Cartilage. Cartilage has been used for studies in monkeys and treatment of periodontal defects in humans.[257,258] It can serve as a scaffold and when so used, new attachment was obtained in 60 of 70 case studies.[258] However, cartilage has received only limited evaluation and is not used today in periodontal therapy.

Plaster of Paris. Plaster of Paris (calcium sulfate) is biocompatible and porous, thereby allowing fluid exchange, which prevents flap necrosis. Plaster of Paris resorbs completely in 1 to 2 weeks. One study in surgically created three-wall defects in dogs showed significant regeneration of bone and cementum.[142] Plaster of Paris was found to be useful in one uncontrolled clinical study,[285] but other investigators have reported that it does not induce bone formation.[2,261] Its usefulness in human cases, however, has not been proved.

Plastic Materials. Hard tissue replacement (HTR) polymer is a nonresorbable, microporous, biocompatible composite of polymethylmethacrylate and polyhydroxyethylmethacrylate. A clinical 6-month study showed significant defect fill and improved attachment level. Histologically, this material is encapsulated by connective tissue fibers, with no evidence of new attachment.[291,331]

Calcium Phosphate Biomaterials. Several calcium phosphate biomaterials have been tested since the mid-1970s and are currently available for clinical use. Calcium phosphate biomaterials have excellent tissue compatibility and do not elicit any inflammation or foreign body response. These materials are osteoconductive, therefore, they act as a scaffold for blood clots to be retained to allow bone formation.

Two types of calcium phosphate ceramics have been used, as follows:

1. Hydroxyapatite (HA) has a calcium-to-phosphate ratio of 1.67, similar to that found in bone material. HA is generally nonbioresorbable.
2. Tricalcium phosphate (TCP), with a calcium-to-phosphate ratio of 1.5, is mineralogically B-whitlockite. TCP is at least partially bioresorbable.

Case reports and uncontrolled human studies have shown that calcium phosphate bioceramic materials are well tolerated and can result in clinical repair of periodontal lesions. Several controlled studies were conducted on the use of hydroxylapatite (Periograf) and Calcitite; clinical results were good, but histologically these materials appeared to be encapsulated by collagen.[76,171,232,288,329,330]

Bioactive Glass. Bioactive glass consists of sodium and calcium salts, phosphates, and silicon dioxide. For its dental applications, it is used in the form of irregular particles measuring 90 to 170 µm (PerioGlas, Block Drug, Jersey City, NJ) or 300 to 355 µm (BioGran, Ortho Vita, Malvern, PA). When this material comes into contact with tissue fluids, the surface of the particles becomes coated with hydroxy-carbonate apatite, incorporates organic ground proteins such as chondroitin sulfate and glycosaminoglycans, and attracts osteoblasts that rapidly form bone.[200]

Coral-Derived Materials. Two different coralline materials have been used in clinical periodontics: natural coral and coral-derived porous hydroxyapatite. Both are biocompatible, but whereas natural coral is resorbed slowly (several months), porous hydroxyapatite is not resorbed or takes years for resorption.

Clinical studies on these materials showed pocket reduction, attachment gain, and bone level gain.[33,118,139,140] Coral-derived materials have also been studied in conjunction with membranes, with good results.[156,293] Both materials have demonstrated microscopic cementum and bone formation, but their slow resorbability or lack of resorption has hindered clinical success in practice.

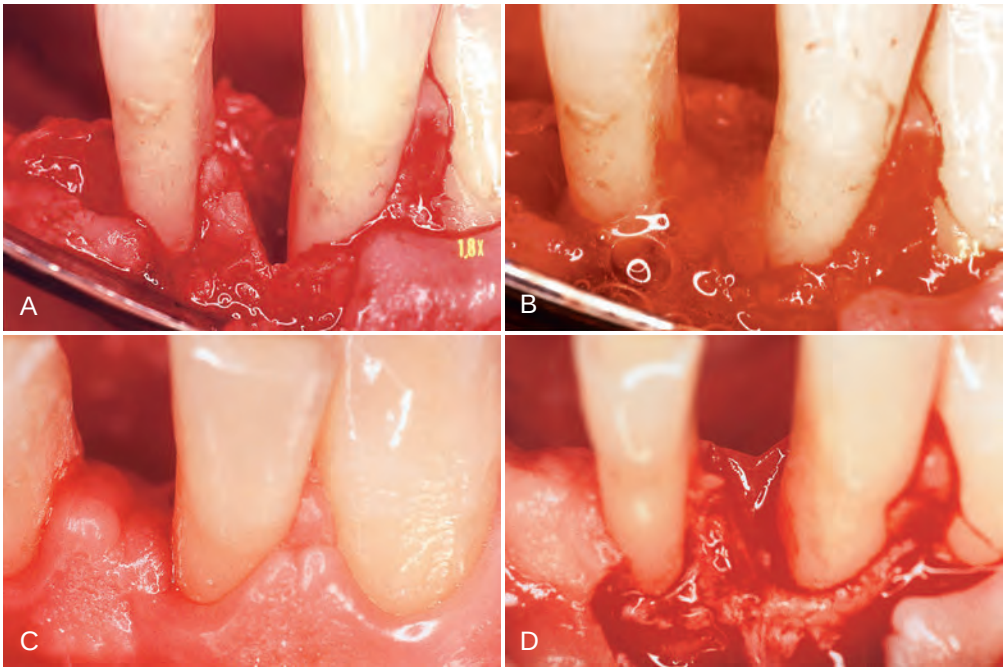

Figure 61-14 **A,** Deep vertical bone loss distal to lower left central incisor. **B,** Area flapped, root prepared, and defect filled with enamel matrix protein (Emdogain). **C,** Postoperative photo 6 months later. **D,** Reentry surgery showing extensive bone fill. *(Courtesy Dr. Marco Orsini, Aquila, Italy.)*

EMD has been shown to be safe for clinical use.[109,335] Evidence of clinical efficacy was first reported in a multicenter study consisting of 33 patients with at least two defects, which were treated in a split-mouth design. The experimental site was treated with acid etching and EMD while the control site was treated with a placebo.[114] Patients were examined at 8, 16, and 36 months after surgery. Increased bone fill of the osseous defect was observed over time for 25 of the 27 (93%) EMD-treated teeth, but no bone fill was detected in the controls. The mean radiographic bone fill was greater for the EMD-treated defects compared to the control sites treated with open flap debridement (2.7 mm versus 0.7 mm respectively). Statistically significant improvements were also observed for EMD-treated sites over control sites in mean pocket reduction (3.1 mm versus 2.3 mm respectively) and mean attachment level gain (2.2 mm versus 1.7 mm), respectively. These clinical findings have been supported by additional studies.* However, one randomized, double-masked, placebo-controlled clinical trial failed to show significant differences in clinical and radiographic measure between EMD and control.[250] Long-term stability of EMD regenerative therapy was reported in a case series that followed 106 EMD-treated defects in 90 patients.[111] The data suggest radiographic bone level, clinical attachment level gain, and reduced pocket depth reached near maximal response after 1 year and the results remained stable over 5 years. Other long-term studies have confirmed these findings.[236,270,272,273]

There have been several studies comparing the use of EMD alone or in conjunction with other regenerative approaches. When EMD treatment was compared to GTR using bioresorbable membranes, the clinical results were comparable and stable over as much as a 10-year period.[184,270,272,273,282] In a study comparing EMD, GTR, EMD+GTR to open flap debridgement, all three resulted in superior result to open flap surgery with no additional improvement when EMD was used in conjunction with GTR.[268] Others have confirmed this finding.[184,266,282]

*References 77,78,80,97,111,209,210,226,268,280,302,340,341.

The use of EMD in combination with other graft materials is controversial. When EMD is used in conjunction with autogenous bone, DFDBA, xenograft, and bioactive glass, additional improvements in clinical parameters were observed as compared to the use of either EMD or DFDBA alone.* However, others studies have failed to demonstrate clinical improvement when EMD was used in conjunction with TCP or bioactive glass.[21,126,160]

EMD remains a very intriguing biological mediator.[199] As we better understand the mechanism of action of the potpourri of proteins and growth factors, this may strengthen the biological rationale for clinical use of this material. The concern remains whether commercial batches of EMD will be consistent and provide comparable clinical results in all cases. Perhaps the message is that the achievement of maximum regenerative response will require a mixture of biological mediators. With further characterization of EMD, we may better develop a synergistic blend that will provide optimal result.

Recombinant Human Platelet-Derived Growth Factor for Periodontal Regeneration. PDGF is one of the earliest growth factors studied for its effect on wound healing because it is a potent mitogenic and chemotactic factor for mesenchymal cells in cell culture. Histological evidence of periodontal regeneration was first reported in experimental defects in beagle dog.[161,162] During the development of PDGF for clinical use, recombinant human platelet-derived growth factor (rhPDGF) was used in conjunction with allogenic bone to correct class II furcations and interproximal intrabony defects on hopeless teeth.[31,202] Histological evidence of periodontal regeneration was present with excellent furcation fill.

A human clinical trial was conducted using rhPDGF and recombinant human insulinlike growth factor 1 (rhIGF-1).[120] Using a split-mouth design, defects were treated with either a low dose (50 µg/mL) or high dose (150 µg/mL) of rhPDGF/rhIGF-1. After 9

*References 97,98,152,271,313,326.

months, the high-dose rhPDGF/rhIGF-1 induced 2.08 mm of new bone and 43.2% defect fill, compared to 0.75 mm vertical bone height and 18.5% bone fill in controls. Low-dose rhPDGF/rhIGF-1 results were statistically similar to the controls. Additionally, this study demonstrated that no adverse immunologic or clinical reaction resulted from use of these agents. A primate study examined the regenerative effects of PDGF/IGF-1 individually and in combination.[163] PDGF alone was found to be as effective as the PDGF/IGF-1 combination in producing new attachment after 3 months. No significant effect was found when IGF was used alone. This study suggests that IGF may not be important at the dose level tested.

Subsequently, the effectiveness of 0.3 mg/mL of rhPDGF + β-TCP (GEM21S, Osteohealth, Shirley, NY) to significantly improve attachment level gain, bone level, and bone volume compared to β-TCP alone was demonstrated after 6 months in a multicenter clinical trial.[203] A subset of these patients was followed for 24 months and a representative case series were reported to be stable with increases in radiographic bone fill compared to the end results after 6 months (Figure 61-15).[170] A review of these cases indicates the results were stable after 3 and 5 years.[136,204] Another case series suggests that rhPDGF with freeze-dried bone allograft can be combined to achieve excellent results in severe periodontal intrabony defects.[31]

rhPDGF in combination with a β-TCP carrier is now commercially available. These preliminary studies using rhPDGF-TCP suggest it is easy to use, requires no barrier membranes, and had results comparable or superior to other regenerative graft materials. The potential for using rhPDGF for regeneration of furcation defects and implant site preparation still needs to be evaluated. Additionally, there has been considerable clinical interest in combining rhPDGF-BB with other bone replacement grafts, particularly bone allografts and xenografts.

Combined Techniques

Periodontal new attachment and bone reconstruction has been a challenge for the clinicians throughout the history of periodontal therapy. To take advantage of the different bone graft materials and biologic mediators, clinicians have combined these graft materials along with the use of membranes in an attempt to find a predictable technique to regenerate bone.

Several clinicians have proposed a combination of the techniques previously described in an attempt to enhance their

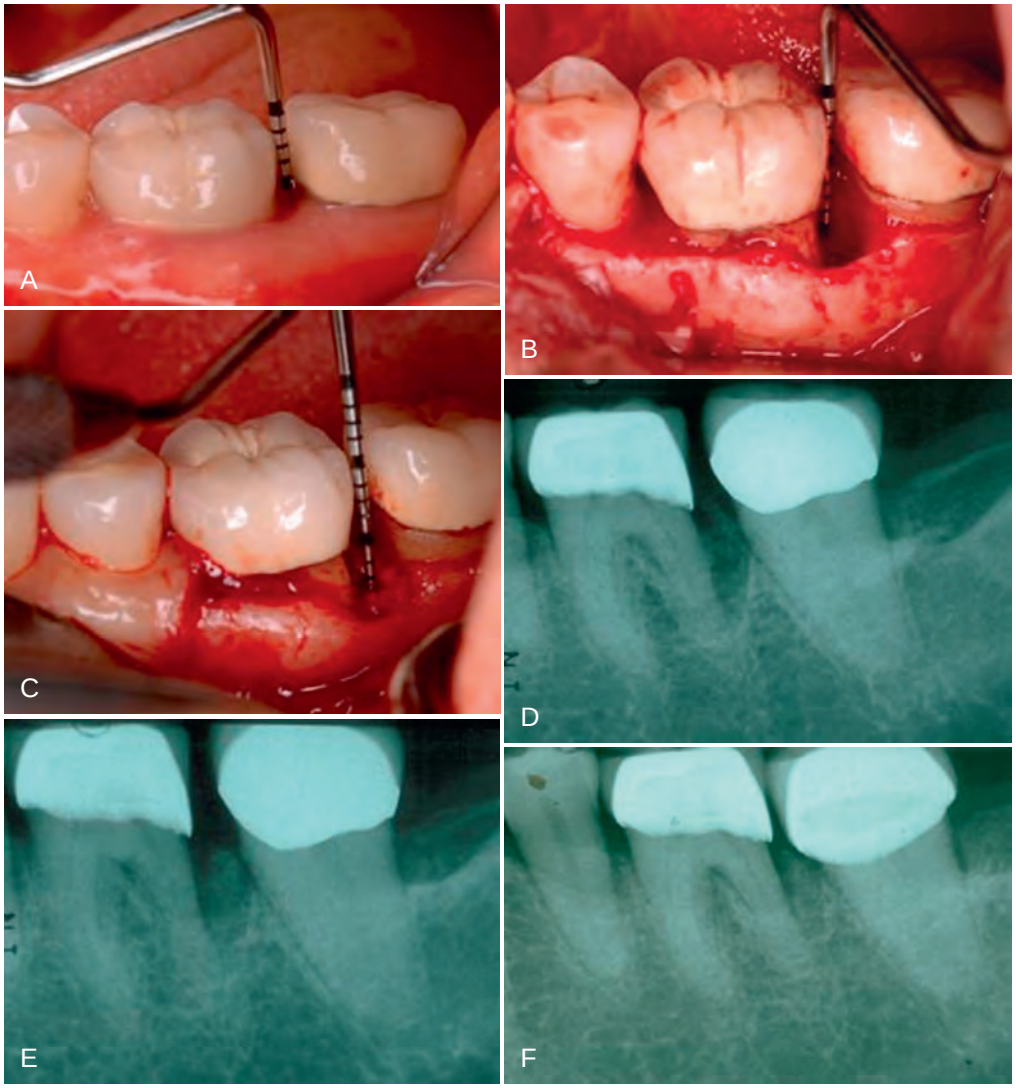

Figure 61-15 A sample case of a patient treated in the pivotal trial. **A–C,** The pretreatment situation at preop, surgical debridement, and postsurgical reentry. **C–E,** The radiographic appearance after 12, 24, and 60 months. Surgical reentry after 12 months indicates good bone fill of the circumferential intrabony defect **(C)**. The clinical pocket depth was 3 mm after 5 years and remained stable.

results.[9,104,156,173] A classic paper published by Schallhorn and McClain in 1988 described a combination technique using graft material, root conditioning with citric acid, and coverage with a nonresorbable membrane (the only available one at the time).[263] More recently, with the advent of osteopromotive agents, such as the enamel matrix derivative (Emdogain) and osteoconductive bovine-derived anorganic bone (Bio-Oss) graft materials, other combination techniques have been advocated.[159] The combined use of these products, along with autogenous bone with resorbable membrane coverage, has resulted in an increased percentage of cases with successful new attachment and periodontal reconstruction. Many of these combination techniques were reviewed in the previous sections of this chapter. Whereas the use of combination technique may be appealing, it is important for clinicians to remember that these added materials often escalate the cost of the procedure and should be balanced with the quality and the long-term stability of the clinical results.

Factors That Influence Therapeutic Success

Factors that adversely affect periodontal regeneration were reviewed at the 1996 World Workshop in Periodontics and 1997 Proceedings of the Second European Workshop on Periodontology.[212,230] A number of factors have been implicated or shown to adversely influence periodontal regenerative therapy. These include site selection for reconstructive therapy (Figure 61-16), patient selection with consideration for compliance and behavior habits such as smoking and surgical management.

Future Directions for Periodontal Regeneration

In wound healing, the natural healing process usually results in tissue scarring or repair. Using tissue engineering, the wound healing process is manipulated so that tissue regeneration occurs.[164] This manipulation usually involves one or more of the three key elements: the signaling molecules, scaffold or supporting matrices, and cells (see Figure 61-13). The cellular responses to these biologic mediators in vitro have been studied and are summarized in Table 61-2. Some of these biologic mediators are commercially available (recombinant human bone morphogenetic protein [rhBMP], rhPDGF, EMD).

Conclusion

Over the past three decades, the periodontal literature has been filled with numerous reports related to periodontal regeneration. This therapeutic goal, although ideal, is difficult to achieve. A variety of graft materials and regenerative strategies are now available, however, they all have limitations. The surgical procedure can be technically demanding, and when success is achieved, the maintenance of positive results is highly dependent on patients' oral hygiene habits and compliance with periodontal maintenance. Despite all these difficulties, periodontal regeneration is a clinical possibility that can be offered to patients. The clinician must carefully evaluate the various regenerative and reparative approaches and decide which technique may result in the best clinical outcome. With the advent of new regenerative approaches, such as biological modifiers like EMD and growth factors, we must critically evaluate how they may improve our ability to regenerate periodontal defects.

Treatment planning in periodontics also has changed dramatically in the past decade because of the acceptance of dental implants as a viable long-term option for replacing missing teeth. With the increased predictability of implants, the question arises as to when to treat severe periodontal defects with regenerative procedures and when to perform strategic extraction in preparation for implant placement. Sometimes the best management of a periodontal defect

TABLE 61-2 In Vitro Effects of Growth Factors on Periodontal Ligament Cells and Osteoblasts*

	PDGF	FGF-2	BMP	EMD	TGF-β	IGF-1 and IGF-2
PDL cells						
Cell proliferation	++	+++	++	++	–	+
Chemotaxis	++	+++	+	++	0	++
Collagen synthesis	+	–	+	+	+	+
Protein synthesis	+	+	+	+	+	+
Matrix gene expression	++	++/–	?	+	+	+
Cementoblasts						
Cell proliferation	+++	?	–	++	++	++
Chemotaxis	++	?	?	?	?	?
Collagen synthesis	+	?	++	++	+	+
Protein synthesis	+	?	++	++	+	+
Matrix gene expression	±	?	++	++/–	±	±
Osteoblasts						
Cell proliferation	++	+++	0	++	+++	++
Chemotaxis	+++	+++	+	++	+++	+
Collagen synthesis	0	++	0	+	+	+
Protein synthesis	0	+	ND	+	±	0
Matrix gene expression	±	++/–	++	++/–	++	++
Alkaline phosphatase synthesis	0	–	++	++	±	0

(–) Inhibition; (0) no effect; (+) effect; (?) unknown effect; *BMP*, bone morphogenetic protein; *EMD*, enamel matrix derivative; *FGF*, fibroblast growth factor; *IGF*, insulinlike growth factor; *PDGF*, platelet-derived growth factor; *PDL*, periodontal ligament; *TGF*-β, transforming growth factor β.

*Adapted and updated from Kao RT, Murakami S, Beirne OR: The use of biologic mediators and tissue engineering in dentistry. *Periodontol 2000* 20:127, 2009.

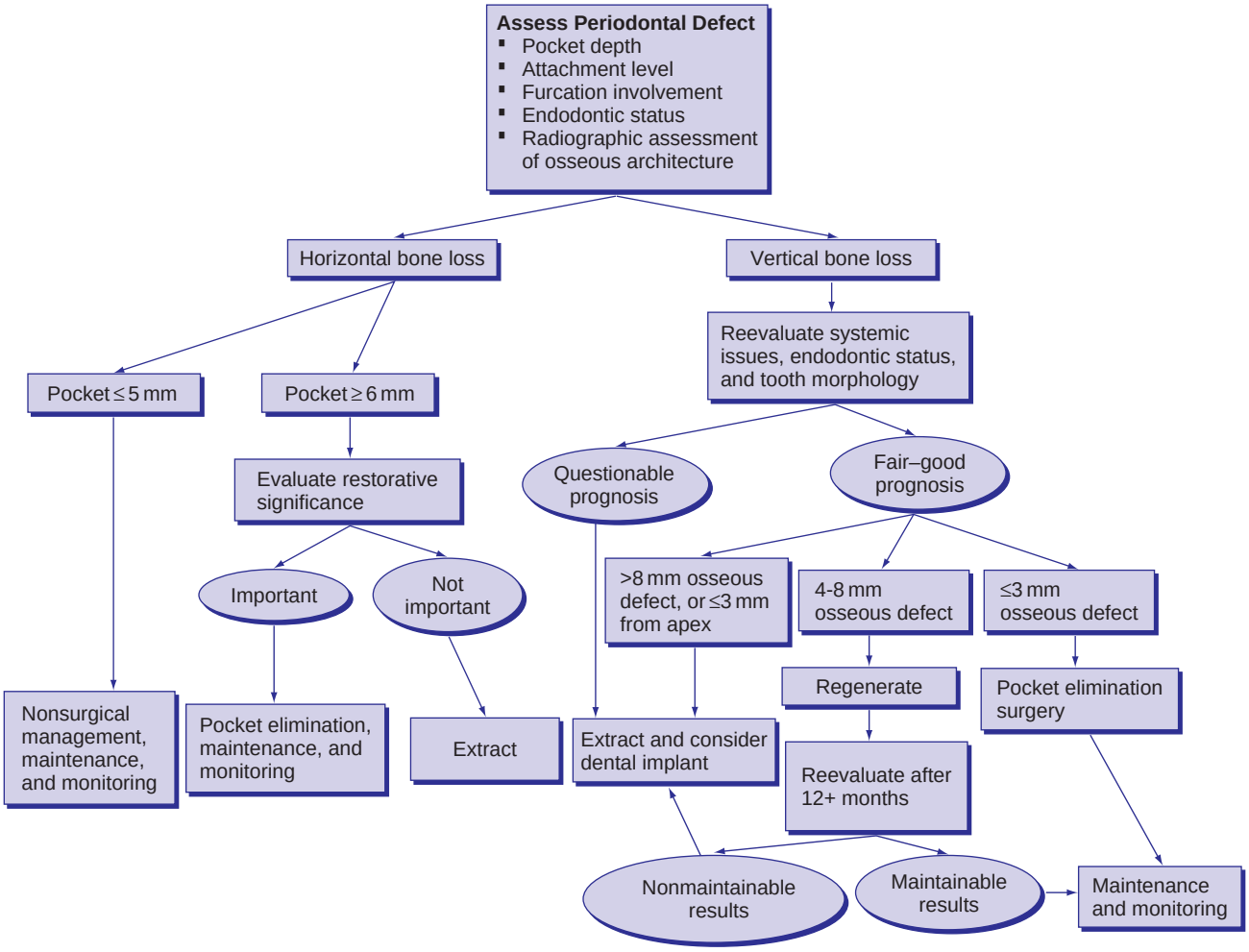

Figure 61-16 Clinical decision tree for the management of advanced periodontal defects. *(Courtesy of Rose L, et al, editor: Periodontics: medicine, surgery, and implants, St Louis, Elsevier Mosby, 2004.)*

Site Selection for Reconstructive Therapy

Therapeutic Selection. The selection of appropriate therapeutic approach is one that is based on accurate assessment of the periodontal defect, one's past clinical experience, and familiarity with the various regenerative and resective techniques. A clinical decision tree is provided to guide the clinician in deciding the appropriate situations (see Figure 61-16). As the new therapeutic approaches are developed, the clinical decision tree may need to be modified to accommodate for these advances.

Tooth and Defect Selection. Therapeutic success is influenced by the tooth's importance in the prosthetic rehabilitation, its endodontic status, and defect characteristics.

The critical question to be addressed is if the involved dentition is strategically important.[301] If not, the required expense and strategic extraction may avoid potential technical difficulty, postsurgical complications, and expenses. Strategic extraction may also improve access of better patient oral hygiene and compliance.[102]

Once a tooth is deemed essential, it is important to assess its endodontic status. If the tooth is endodontically healthy, regeneration may proceed. If not, then treatment of the endodontic component must be performed and resolution of the endodontic problem must be ascertained prior to the regenerative procedure.[124,125] Given the expense for endodontic treatment, periodontal regenerative procedures, crown buildup, and the crown, strategic extraction and possible replacement with a prosthesis or a dental implant should be seriously considered.

Characteristics of the defect, such as the overall defect depth, width, and walls, can influence clinical outcome in response to regenerative surgery.* Studies have consistently shown that the deeper defect is correlated with increased clinical attachment level and probing depth.[59,75] One is more likely to achieve improved regenerative results in narrow and circumferential, three- or two-walled configuration. Conversely, one- or zero-walled and wide defects are less amenable to regenerative procedures.[11,148,235,275] Barring early reports on the use of iliac and autologous grafts, current regenerative approaches have not been consistently successful in regenerating one- or zero-walled defects.

Patient Selection

Poor Plaque Control and Compliance. Classical studies on of poor plaque control and poor postoperative recall compliance have indicated that much of the therapeutic gain from periodontal surgery will deteriorate.[181,207,248,320,321] Similarly, the positive results from GTR regenerative procedure have been shown to deteriorate with poor compliance.[47-49] Progressive deterioration in these patients have been demonstrated to possess a higher incidence of infection with putative periodontal pathogens (*Porphyromonas*

*References 59,75,117,228,229,241,242.

gingivalis, Prevotella intermedia, and *Aggregatibacter actinomycetemcomitans*)[111,165] Areas that are difficult to maintain, such as furcation and root proximity situations, have also been shown to be difficult to be maintained. As a result, risk for deterioration is higher.[121,181,242,243] It is important to remember that the patient came in with behavioral and anatomical issues, which resulted in the periodontal defect. After therapy, the hardest challenge is to continue to motivate patients to be highly enthusiastic about oral hygiene and compliant with periodontal maintenance.

Smoking. Smoking is a behavioral challenge that the therapist must always assess if the patient is a smoker. Smoking not only promotes disease progression, but also results in adverse therapeutic outcomes.[95,96,100,132] It has been implicated as having a detrimental effect on periodontal wound healing following surgical procedures,[1,227] and to adversely influence periodontal regeneration.[301]

Bone Morphogenetic Proteins for Periodontal and Implant Site Regeneration

Bone morphogenetic proteins (BMPs) are a group of regulatory glycoproteins that are members of the transforming growth factor β (TGF-β) superfamily that function as differentiation factors. These proteins induce cellular differentiation of stem cells into chondroblastic and osteogenic cells. Much of the research interest has focused on BMP-2 (OP-2), BMP-3 (osteogenin), and BMP-7 (OP-1).[41] The amount of BMPs have been demonstrated to be present in FDBA and DFDBA, but the levels are so low that it is not biologically active. In fact, the amount of BMP is so low that it takes approximately 10 kg of bovine bone to yield only 2 μg of BMP.[264,265] It is only through recombinant DNA technology that BMP has been made available for clinical use.

Although early studies using crude preparations of BMP-2 and BMP-3 applied in surgically induced furcation defects appeared to stimulate periodontal regeneration,[244] recent study with rhBMP-2 indicates that periodontal regeneration was associated with areas of ankylosis.[279] Healing through ankylosis has been a concern, so most of the recent research using rhBMPs has involved correction of intrabony, supra-alveolar, furcation, and fenestration defects* and implant site preparation.‡

The Use of Recombinant Human Fibroblast Growth Factor 2 for Periodontal Regeneration

The potential use of recombinant human fibroblast growth factor 2 (rhFGF-2) for periodontal regeneration has been recently reviewed.[194,195] Preliminary beagle and nonhuman primate studies have demonstrated that topical application of FGF-2 into intraosseous defects in alveolar bones induces significant periodontal tissue regeneration.[296] Histological observation revealed new cementum with Sharpey's fibers, new functionally oriented periodontal ligament fibers, and new alveolar bone.[193] This suggests that topical application of FGF-2 may be efficacious in regeneration of human periodontal tissue that has been destroyed by periodontitis.

A recent randomized controlled, double-masked Phase II clinical trial at 13 Japanese dental facilities compared therapeutic response to varying doses of FGF-2 as compared to control.[146,147] Eighty patients with a two- or three-walled vertical bone defect 3 mm or more from the alveolar crest were randomly divided into four groups: Group A, placebo control; Group B, 0.03%-FGF-2; Group C, 0.1%-FGF-2; and Group D, 0.3%-FGF-2. The subjects underwent periodontal surgery during which 200 μL of the investigational drug or placebo carrier was applied to each test site. After 9 months, a significant increase ($P = 0.021$) in alveolar bone height was demonstrated by standardized radiographs between Group A (23.92%) and Group D (58.62%). No adverse effects were observed throughout this multicenter trial. This finding suggests that topical application of FGF-2 can be efficacious in regenerating periodontal tissue of patients with two- or three-walled intrabony defects. This has led to a subsequent larger clinical trial that has recently been completed and the results are forthcoming. These trials will provide crucial information regarding the safety and efficacy of using FGF-2 for periodontal regeneration.

Cell Therapy

Cell therapy has been recently employed in periodontal surgery. The most common application involves a cell expansion strategy in an ex vivo environment followed by transplantation back into the defect area. Reducing or eliminating gingival recession has been the objective of most of these studies. Reddy used the patient's own connective tissue to improve a cosmetic defect.[237] Unfortunately, the explanted material required a substantial volume of donor tissue and the advantage of this approach was not evident. Pini Prato et al[221,222] and Hou et al[119] reported on the use of harvested fibroblasts seeded onto a nonwoven three-dimensional hydroxyapatite-benzyl ester of hyaluronic acid matrix for gingival grafting. Although the grafts healed well, the increased width of attached gingiva varied. Momose et al[188] used a similar approach by seeding attached gingival tissue consisting of both epithelium and connective tissue from the retromolar pad onto a collagen/silicone bilayer membrane. After cell expansion, the graft was used as the donor tissue. This group reported that the graft composed of vascular endothelial growth factor (VEGF) and TGF-δ and TGF-β1 improved wound healing. Tissue-banked human fibroblasts cultured on a bioabsorbable polyglactin mesh were used by McGuire and Nunn for gingival grafting procedures.[169] The tissue-engineered fibroblast-polyglactin mesh graft had comparable clinical results with the exception of increased shrinkage compared to gingival autografts and decreased amount of keratinized tissue. When this graft was used in a subepithelial connective tissue graft procedure, the results were comparable to controls using a connective tissue autograft.[322] Recently, this fibroblast-polyglactin preparation has been shown to slightly enhance bone regeneration in experimental peri-implant dehiscence defects.[286,294] The convenience of having tissue-banked viable cell grafts suggests that cell therapy may potentially be feasible should the clinical results be superior and/or comparable to current surgical outcomes and if the economics are not prohibitive.

Although much of the work in cell therapy has focused on fibroblast explants, this approach has been successful with other cell types. Human oral mucosa consisting of epidermal and dermal components has also been engineered where it may be potentially used for intra-oral grafting.[123] In a case report, cultured gingival epithelial sheets were used to treat multiple quadrants in a patient with chronic desquamative gingivitis.[211] After grafting, decreased inflammatory cells, no epithelial-connective tissue separation, and gains in keratinized tissue were observed. In another study, regeneration was achieved when a cloned and well-characterized cementoblast cell culture, which exhibits phenotypic expression similar to cementum cells, was transplanted into a polylactide-co-glycolide acid (PLGA) carrier and placed in rodent bone defects.[338]

*References 85,122,144,279,304,323.
‡References 13,24,45,46,106,312,323.

This example suggests that a reasonable tissue-engineering approach would be to augment appropriate cells in conjunction with current commercial kits containing BMP-collagen or rhPDGF-BB-βTCP to further enhance regeneration.

In the field of craniofacial regeneration, this cell expansion approach has been used to tissue-engineer a human-shaped temporomandibular joint.[4,5,305] Mesenchymal stem cells were isolated from bone marrow and exposed to either chondrogenic- or osteogenic-supplemented culture medium. The resulting chondrocytes and osteoblasts were then implanted into a molded hydrogel in the shape of the human temporomandibular joint which were then implanted into immunodeficient mice for 12 weeks. Upon sacrifice, the resulting histological structure was consistent with the anatomy of a mandibular condyle.[4]

Although these reports are proof that tissue-engineering principles can be clinically applicable, the basic mechanisms and optimization of therapeutic application needs further study.

Gene Therapy

Although the use of growth and differentiation factors have changed periodontal and implant site regeneration, much of the mechanism for the mechanism of action is still not clear. Despite that fact, these factors have very short biological half-lives (minutes to a few hours). The carrier (i.e., collagen, FDBA, calcium sulfate) function to release these factors at different rate such that the release can be sustained over one to several weeks. Once released, these factors are subject to proteolytic breakdown and receptor-binding problems and are dependent on the stability of the carrier system. Interestingly, cells are triggered to differentiate and develop into cells that result in periodontal regeneration or bone formation even after the signaling molecules are no longer present.

Gene therapy can be used for extended local delivery of these factors.[67] Recently, gene transfer of PDGF into the cementoblast and other periodontal cell types was accomplished.[8,86,129] These studies of sustained PDGF production demonstrated increased cementum formation, ectopic biomineralization, and mineral neogenesis.[339] However, studies also suggest that sustained PDGF production may inhibit mineral formation by cementoblasts.[8] This suggests that gene transfer can provide a sustained level of growth factors, but may be detrimental toward the continuous progression associated with differentiation or wound healing.

The first successful evidence of periodontal tissue engineering employing gene therapy was demonstrated with BMP-7 transduced fibroblasts to stimulate repair of alveolar bone wounds and periodontal defects. Gene therapy studies using BMPs has also been performed. Fibroblasts[254] and oral keratinocytes[255] transduced with *BMP-7* gene resulted in increased bone formation and differentiation into osteoblasts.[40,128]

Gene therapy approaches have also been used to improve complimentary osteogenic signals, such as vectors transduced with PDGF,[86,129] bone sialoprotein,[101] BMP promoter,[72] or antagonist-like noggins.[130] These signals either synergistically improve or inhibit the expression of growth and differentiation factors, such the precise control of regulating the gene regulation is possible to mimic regeneration.

The use of gene delivery offers a new approach to delivering growth factors. The clinical application of this approach will be dependent on the safety and efficacy of using gene therapy.

Scaffold or Supporting Matrices

The use of scaffolding matrices to deliver growth factors to promote periodontal tissue regeneration has been an active area of research.[87,155] Supporting matrices for engineering bone and soft tissue have included processed bone allografts, synthetic and natural polymers, synthetic ceramics, bovine type I collagen, and calcium sulfate (commercially available scaffolds are found on Table 61-3). The major roles for the supporting matrices are to:

1. Provide physical support for the healing area so that there is no collapse of the surrounding tissue into the wound site. Examples of this would be bone allografts and synthetic ceramics such as tricalcium phosphate.
2. Serve as a barrier to selectively restrict cellular migration. This is best exemplified by principles of GTR and guided bone regeneration (GBR) where nonresorbable polytetrafluoroethylene and resorbable polylactate, polyglycolic acid, and calcium sulfate are used. The exclusive properties of cell barrier membranes have been reviewed[134,136,212] and will not be addressed here.
3. Serve as a scaffold for cellular migration and proliferation. Examples include the collagen matrix. Potentially, this scaffold can be further enhanced by selectively defining the types of cells permitted to attach to and proliferate on this matrix with the additions of adhesins and/or integrins.
4. Potentially serve as a time-release mechanism for signaling molecules.

Allogenic and Alloplastic Bone-Grafting Materials. The classic approach to orofacial regeneration in the past 30 years has been the use of bone grafts or substitutes to repair periodontal and maxillofacial defects. The literature contains several excellent reviews on the use of autografts, allografts, and alloplastic graft materials.[134,136,212]

For the past decade, mineralized and demineralized freeze-dried bone allografts (FDBA and DFDBA) were often the regeneration

TABLE 61-3 Commercially Available Scaffold Materials Potentially Available for Oral Tissue Engineering Application

Biomaterial	Commercial Name
Allografts	
Demineralized freeze-dried bone allograft (DFDBA)	Distributed under various name by tissue banks
Freeze-dried bone allograft (FDBA)	Distributed under various name by tissue banks
Xenografts	
Anorganic bovine bone	Bio-Oss, OsteoGraf, Pep-Gen P-15
Hydroxyapatite (HA)	
Alloplasts	
Tricalcium phosphate	Synthograft
Hydroxyapatite	Periograf, Osteogen, ProOsteone
Bioactive glass polymers	PerioGlas, BioGran
Hard-tissue replacement polymer	Bioplant
Coralline calcium carbonate	Biocoral
Polymers and Collagens	
Collagen	CollaPlug, CollaCote, Gelfoam, Helistat
Poly(lactide-co-polyglycolide)	
Methylcellulose	
Hyaluronic acid ester	HY
Chitosan	

material of choice. In addition to their availability and putative osteogenic potential, various clinical studies indicate that 2 to 3 mm of bone fill is possible with FDBA[173,179,256,257,276] and DFDBA.[106,252] However, other studies have questioned the osteogenic potential of bone allografts, suggesting that this may vary depending on the bone bank or batch,[264,265] processing procedures used, and donor characteristics.[127,277,336,337] Due to varying osteoinductive properties, which is not an area the U.S. Food Drug Administration (FDA) regulates, growth factors and morphogens with FDBA and DFDBA are not commercially available. However, off-label use of this combination is common both in orthopedic and oral-periodontal surgical procedures.

Alternatively, a variety of xenograft and alloplastic grafting materials is available as scaffolding agents for tissue engineering. Alloplastic bone grafts consist of ceramics, such as hydroxyapatite (HA), porous hydroxyapatite (PHA), β–tricalcium phosphate (β-TCP), and biocompatible composite polymers (such as HTR). Of these allografts, β-TCP is used in combination with rhPDGF-BB. In the development of rhPDGF-BB for clinical use, the biosynthetic β-TCP was used because it possessed defined and reproducible properties as required by the FDA. Allografts were not desirable because of varying osteogenic potential and properties.[264] Extensive animal and human studies demonstrated biocompatibility of the β-TCP with no reports of adverse reactions.[14,77] This material physically fills bone defects, provides a scaffold for new bone formation, and prevents soft tissue collapse into the wound site.[77] Clinically, β-TCP is osteoconductive and supports early healing. β-TCP resorbs at varying rates depending on the chemical structure, porosity, and particle size. Absorption, release, and bioactivity studies indicate that either β-TCP or calcium sulfate can be an effective carrier for PDGF-BB. Approximately 45% of the adsorbed PDGF-BB was released after 10 days.[11] In clinical studies with rhPDGF-BB, this material resorbs and is replaced with regenerated periodontium. Superficial granules at the soft tissue interface appear to resorb at a slower rate. Recently, the use of β-TCP coated with recombinant human growth/differentiation factor-5 was evaluated for its osteoinductive and osteoconductive properties in an experimental rat calvarial critical size defect.[219] Histomorphometric results suggest this proprietary coating of growth factor on β-TCP achieved superior bone regeneration compared to conventional materials. These latter two studies indicate that the absorption and release kinetics of signaling agents is an area that requires further elucidation if we are to achieve optimal regenerative response.

Collagen Carriers. Collagen is the main structural protein for tissue support. It also plays an essential role in wound healing by providing a biologic scaffold for cellular activities such as cell attachment, migration, and proliferation.[324,325] Collagen has been widely used in tissue engineering for seeding of mesenchymal stem cells[24,133] and incorporation of growth factors.[119,120] Because most collagens are derived from bovine dermal or skeletal tissue, concerns related to the purity, quality, immunogenicity, and potential for prion transmission have been raised.[115] Recent studies addressed these issues by further purifying bovine collagen and modifying the molecules to remove antigenic N- and C-terminal telopeptides.[119,253] Two variations of this collagen were produced to create an atelocollagen scaffold where both constructs were effective in supporting rhBMP-induced bone formation.

Calcium Sulfate. Calcium sulfate is one of the oldest bone graft materials. Early clinical and animal studies indicate calcium sulfate is biocompatible, degrades over time, is subsequently replaced with regenerated bone, and may be used in an infected area with no complications.[220] Recently, studies indicate that it also has barrier properties,[134,142,218] enhances angiogenesis,[295] and may be effective as a delivery vehicle for antibiotics as well as growth factors.[15,57,247] Rosenblum demonstrated that FGF was observed to be released at a rate directly proportional to the rate of calcium sulfate dissolution.[247] A secondary benefit of calcium sulfate dissolution is a local decrease in pH. An interesting study in the orthopedic literature reported that when an experimental sheep distal femoral cancellous defect was filled with calcium sulfate, increased immunostaining for BMP-2, BMP-7, TGF-β, and PDGF-BB was observed.[314] All of these growth factors have been demonstrated to stimulate bone formation and development. Calcium sulfate was found to be a suitable carrier for rhPDGF-BB with a longer release kinetic profile (~16 days) as compared to β-TCP.[14] Since both materials are resorbable, the current debate centers on whether a longer sustained release of rhPDGF-BB would be more advantageous to periodontal and bone regeneration.

Other Carriers. Bioresorbable polymers of PLGA and polyglycolic acid have been considered as scaffolding agents for tissue engineering due to their biodegradable and tissue compatibility properties. Although promising as a carrier for osteogenic factors in animals,[188,306] variable tissue responses have made clinical application of this material problematic. These tissue responses include inflammation, foreign body reaction, and local acid accumulation during polymer degradation.[143,145,153,185]

Substrate Modification to Enhance Cell Selection. Although still in the experimental phase, many investigations in orthopedics have focused on the cellular response to synthetic peptide-coated biomaterials.[107,108] When coated with various cell-binding peptide sequences of cell adhesins or integrins, the scaffold mimics the extracellular matrix components of bone. This type of scaffold contains specific surface peptides that selectively permit cell binding, osteoblastic phenotypic expression, and differentiation. These constructs can be used to direct the regenerative response. Current focus in this area has been on coating scaffolds with arginine-glycine-aspartic (RGD) and phyenylalanine-histidine-arginine-arginine-isoleucine-lysine-alanine (FHRRIKA) peptides selected from the cell-binding and putative heparin-binding domains of bone sialoprotein.[99,243] Additionally, these synthetic peptides can potentially be used to enhance osseointegration.[12,94] Although these products are still primarily in the in vitro research phase, bone regeneration has been reported in an experimental dog study.[214] In this study, deproteinized bone granules were coated with the 15 amino acid oligopeptides corresponding to the BMP cell receptor I and II binding domains. When this engineered graft material was used in the beagle alveolar three-wall defect model, enhanced new bone formation was found. This approach of directing tissue regeneration by selectively permitting the appropriate stem cells to colonize the wound site holds much potential, but requires further investigation to determine whether this approach be clinically applicable.

may be extraction in lieu of periodontal regeneration or when regenerative efforts have been unsuccessful. Extraction would minimize further bone loss and provide the maximum volume of bone at the future implant healing site. This paradigm shift has complicated our views about regeneration. With dental implants as a viable alternative, we need to redefine periodontal prognosis and consider strategic extraction more often. Conversely, heroic regenerative procedures would be contraindicated.

Periodontal regeneration continues to be one of the primary therapeutic approaches toward the management of periodontal defects. Although evidence suggests that present regenerative techniques can lead to periodontal regeneration, the use of GTR and biological modifiers can enhance these results. The crucial challenge for the clinician is to critically assess whether a periodontal defect can be corrected with a regenerative approach, or whether it would be better managed with osseous resection for the slight periodontal defect and with strategic extraction for the advanced diseased state. In this assessment, the clinician should attempt to differentiate between techniques that have been studied in depth and with acceptable results and those that are still experimental and promising. Research papers must be critically evaluated for adequacy of controls, selection of cases, methods of evaluation, and long-term postoperative results. In addition, the clinician should remember that we treat patients on the basis of "clinical" success and not "statistical" success. A resulting clinical attachment gain of half a millimeter may be a "statistical" success, but it is meaningless for the patients we treat and manage over the long term.

Suggested Readings

Alderman NE: Sterile plaster of Paris as an implant in the infrabony environment: a preliminary study. *J Periodontol* 40:11, 1969.

Alger FA, Solt CW, Vuddahanok S, et al: The histologic evaluation of new attachment in periodontally diseased human roots treated with tetracycline hydrochloride and fibronectin. *J Periodontol* 61:447, 1990.

Bowers GM, Chadroff B, Carnevale R, et al: Histologic evaluation of new attachment apparatus formation in humans. Part III. *J Periodontol* 60:683, 1989.

Camelo M, Nevins ML, Schenk RK, et al: Periodontal regeneration in human class II furcations using purified recombinant human platelet-derived growth factor-BB (rhPDGF-BB) with bone allograft. *Int J Periodontics Restorative Dent* 23:213–225, 2003.

Caton JC: Overview of clinical trials on periodontal regeneration. *Ann Periodontol* 2:215, 1987.

Giannobile WV, Hollister SJ, Ma PX: Future prospects for periodontal bioengineering using growth factors. *Clin Ad Periodontics* 1:88, 2011.

Kao RT, Murakami S, Beirne OR: The use of biologic mediators and tissue engineering in dentistry. *Periodontol 2000* 20:127, 2009.

Murphy KG, Gunsolley JC: Guided tissue regeneration for the treatment of periodontal intrabony and furcation defects. A systematic review. *Ann Periodontol* 8:266–302, 2003.

Needleman I, Tucker R, Giedrys-Leeper E, et al: Guided tissue regeneration for periodontal intrabony defects—a Cochrane Systematic Review. *Periodontol 2000* 37:106–123, 2005.

Nevins M, Camelo M, Nevins ML, et al: Periodontal regeneration in humans using recombinant human platelet-derived growth factor BB (rhPDGF-BB) and allogenic bone. *J Periodontol* 74:1282, 2003.

Nevins M, Giannobile WV, McGuire MK, et al: Platelet-derived growth factor stimulates bone fill and rate of attachment level gain: results of a large multicenter randomized controlled trial. *J Periodontol* 76:2205, 2005.

Nevins M, Kao RT, McGuire MK, et al: PDGF promotes periodontal regeneration in localized osseous defects: 36 month extension results from a randomized, controlled, double-masked clinical trial. *J Periodontol* 84:456, 2013.

Reynolds MA, Aichelmann-Reidy EM, Branch-Mays GL, et al: The efficacy of bone replacement grafts in the treatment of periodontal osseous defects. A systematic review. *Ann Periodontol* 8:227–265, 2003.

Schallhorn RG, McClain PK: Combined osseous composite grafting, root conditioning, and guided tissue regeneration. *Int J Periodont Restor Dent* 8:8, 1988.

Sculean A, Alessandri R, Miron R, et al: Enamel matrix proteins and periodontal wound healing and regeneration. *Clin Adv Periodontics* 1:101–117, 2011.

Susin C, Wikesjo UME: Regenerative periodontal therapy: 30 years of lessons learned and unlearned. *Periodontol 2000* 62:232–242, 2013.

References

References for this chapter are found on the companion website www.expertconsult.com.

References

1. Ah MKB, Johnson GK, Kaldahl WB, et al: The effects of smoking on the response to periodontal therapy. *J Clin Periodontol* 21:91, 1994.
2. Alderman NE: Sterile plaster of Paris as an implant in the infrabony environment: a preliminary study. *J Periodontol* 40:11, 1969.
3. Alger FA, Solt CW, Vuddahanok S, et al: The histologic evaluation of new attachment in periodontally diseased human roots treated with tetracycline hydrochloride and fibronectin. *J Periodontol* 61:447, 1990.
4. Alhadaq A, Mao JJ: Tissue engineered osteochondral constructs in the shape of an articular condyle. *J Bone Joint Surg Am* 87:936–944, 2005.
5. Alhadlaq A, Mao JJ: Tissue-engineered neogenesis of human-shaped mandibular condyle from rat mesenchymal stem cells. *J Dent Res* 82:951–956, 2003.
6. American Academy of Periodontology: *Glossary of periodontal terms*, ed 3, Chicago, 1992, American Academy of Periodontology.
7. American Dental Association, Council on Scientific Affairs: *Products designed to regenerate periodontal tissues: acceptance program guidelines*, Chicago, 1997.
8. Anusaksaathien O, Jin Q, Zhao M, et al: Effect of sustained gene delivery of platelet-derived growth factor or its antagonist (PDGF-1308) on tissue engineered cementum. *J Periodontol* 75:429, 2004.
9. Andereeg CR, Martin SJ, Gray JL, et al: Clinical evaluation of the use of decalcified freeze-dried bone allograft with guided tissue regeneration in the treatment of molar furcation invasions. *J Periodontol* 62:264, 1991.
10. Arrocha R, Wittwer J, Gargiulo A: Tissue response to heterogenous bone implantation in dogs. *J Periodontol* 39:162, 1968.
11. Axelsson P, Lindhe J, Nystrom B: On the prevention of carries and periodontal disease. Results of a 15-year-longitudinal study in adults. *J Clin Periodontol* 18:182, 1991.
12. Barber TA, Golledge SL, Castner DG, et al: Peptide-modified p(AAm-co-EG/AAc) IPNs grafted to titanium modulate osteoblast behavior in vitro. *J Biomed Mater Res* 64:38, 2003.
13. Barboza EP, Duarate ME, Geolas L, et al: Ridge augmentation following implantation of recombinant human bone morphogenetic protein-2 in the dog. *J Periodontol* 71:488, 2000.
14. Bateman J, Intini G, Margarone J, III, et al: Platelet-derived growth factor enhancement of two alloplastic matrices. *J Periodontol* 76:1833, 2005.
15. Beardmore AA, Brooks DE, Wenke JC, et al: Effectiveness of local antibiotic delivery with an osteoinductive and osteoconductive bone graft substitute. *J Bone Joint Surg Am* 87:107, 2005.
16. Becker W, Becker BE, Prichard JF, et al: Root isolation for new attachment procedures: a surgical and suturing method: three case reports. *J Periodontol* 58:819, 1987.
17. Becker W, Becker BE, Berg L, et al: Clinical and volumetric analysis of three-wall intrabony defects following open flap debridement. *J Periodontol* 57:277, 1986.
18. Becker W, Becker B, Berg L, et al: New attachment after treatment with root isolation procedures. Report for treated class II and class III furcations and vertical osseous defects. *Int J Periodontics Restorative Dent* 3:9, 1988.
19. Bjorn H: Experimental studies on reattachment. *Dent Pract* 11:351, 1961.
20. Bjorn H, Hollender L, Lindhe J: Tissue regeneration in patients with periodontal disease. *Odont Rev* 16:317, 1965.
21. Bokan I, Bill JS, Schlagenhauf U: Primary flap closure combined with Emdogain alone or Emdogain and Cerasorb in the treatment of intrabony defects. *J Clin Periodontol* 33:885, 2006.
22. Bowers GM, Chadroff B, Carnevale R, et al: Histologic evaluation of new attachment apparatus formation in humans. Part III. *J Periodontol* 60:683, 1989.
23. Bowers G, Felton F, Middleton F, et al: Histologic comparison of regeneration in human intrabony pockets when osteogenin is combined with demineralized freeze-dried bone allograft and with purified bovine collagen. *J Periodontol* 62:690, 1991.
24. Boyne PJ, Marx RE, Nevins M, et al: A feasibility study evaluating rhBMP-2/absorbable collagen sponge for maxillary sinus floor augmentation. *Int J Periodontics Restorative Dent* 17:11, 1997.
25. Buring K, Urist MR: Effects of ionizing radiation on the bone induction principle in the matrix of bone implants. *Clin Orthop* 55:225, 1967.
26. Burnette WE: Fate of the iliac crest graft. *J Periodontol* 43:88, 1972.
27. Busschopp J, De Boever J: Clinical and histological characteristics of lyophilized allogenic dura mater in periodontal bony defects in humans. *J Clin Periodontol* 10:399, 1983.
28. Caffesse RG, Smith BA, Nasjleti CE, et al: Cell proliferation after flap surgery, root conditioning and fibronectin application. *J Periodontol* 58:661, 1987.
29. Caffesse RG, Nasjleti CE, Anderson GB, et al: Periodontal healing following guided tissue regeneration with citric acid and fibronectin application. *J Periodontol* 62:21, 1991.
30. Carmelo M, Nevins M, Schenk R, et al: Clinical, radiographic and histologic evaluation of human periodontal defects treated with Bio-Oss and Bio-Guide. *Int J Periodont Restor Dent* 18:321, 1998.
31. Camelo M, Nevins ML, Schenk RK, et al: Periodontal regeneration in human class II furcations using purified recombinant human platelet-derived growth factor-BB (rhPDGF-BB) with bone allograft. *Int J Periodontics Restorative Dent* 23:213–225, 2003.
32. Carranza FA, Sr: A technic for reattachment. *J Periodontol* 25:272, 1954.
33. Carranza FA, Jr, Kenney EB, Lekovic V, et al: Histologic study of healing of human periodontal defects after placement of porous hydroxyapatite implants. *J Periodontol* 58:682, 1987.
34. Carraro JJ, Sznajder N, Alonso CA: Intraoral cancellous bone autografts in treatment of infrabony pockets. *J Clin Periodontol* 3:104, 1976.
35. Caton J, Zander H: Osseous repair of an infrabony pocket without new attachment of connective tissue. *J Clin Periodontol* 3:54, 1976.
36. Caton J, Nyman S, Zander H: Histometric evaluation of periodontal surgery: II. Connective tissue attachment levels after four regenerative procedures. *J Clin Periodontal* 7:224, 1980.
37. Caton JC: Overview of clinical trials on periodontal regeneration. *Ann Periodontol* 2:215, 1987.
38. Caton JG, DeFuria EL, Polson AM, et al: Periodontal regeneration via selective cell repopulation. *J Periodontol* 58:546, 1987.
39. Caton J, Wagener C, Polson A, et al: Guided tissue regeneration in interproximal defects in monkeys. *Int J Periodont Restor Dent* 12:267, 1992.
40. Cerny R, Slaby I, Hammarstrom L, et al: A novel gene expressed in a rat ameloblasts codes for proteins with cell binding domains. *J Bone Miner Res* 11:883, 1995.
41. Chen D, Zhao M, Mundy GR: Bone morphogenetic proteins. *Growth Factors* 22(4):233–241, 2004.
42. Christgau M, Schmalz G, Reich E, et al: Clinical and radiographical split-mouth study on resorbable GTR membranes. *J Clin Periodontol* 22:306, 1995.
43. Christgau M, Schmalz G, Wenzel A, et al: Periodontal regeneration of intrabony defects with resorbable and non-resorbable membranes: 30-month results. *J Clin Periodontol* 24:17, 1997.
44. Claffey N, Hahn R, Egelberg J: Effect of placement of occlusive membranes on root resorption and bone regeneration during healing of circumferential periodontal defects in dogs. *J Clin Periodontol* 14:371, 1989.
45. Cochran DL, Schenk R, Buser D, et al: Recombinant human bone morphogenetic protein-2 stimulation of bone formation around endosseous dental implants. *J Periodontol* 70:139, 1999.
46. Cochran DL, Jones AA, Lilly LC, et al: Evaluation of recombinant human bone morphogenetic protein-2 in oral applications including the use of endosseous implants: 3-year results of a pilot study in humans. *J Periodontol* 71:1241, 2000.

47. Cortellini P, Pini Prato G, Tonetti MS: Periodontal regeneration of human intrabony defects. I. Clinical measures. *J Periodontol* 64:254, 1993.
48. Cortellini P, Pini Prato G, Tonetti MS: Periodontal regeneration of human infrabony defects. II. Re-entry procedures and bone measures. *J Periodontol* 64:261, 1993.
49. Cortellini P, Pini Prato G: Tonatti M: Periodontal regeneration of human infrabony defects (v). Effect of oral hygiene on long-term stability. *J Clin Periodontol* 21:606, 1994.
50. Cortellini P, Pini Prato G, Tonetti MS: Peridontal regeneration of human intrabony defects with titanium reinforced membranes. A controlled clinical trial. *J Periodontol* 66:797, 1995.
51. Cortellini P, Pino Prato GP, Tonetti MS: Long-term stability of clinical attachment following guided tissue regeneration and conventional treatment. *J Clin Periodontol* 23:106, 1996.
52. Cortellini G, Tonetti MS: Focus on intrabony defects: guided tissue regeneration. *Periodontol 2000* 22:104, 2000.
53. Coverly L, Toto P, Gargiulo A: Osseous coagulum: a histologic evaluation. *J Periodontol* 46:596, 1975.
54. Crigger M, Bogle G, Nilvéus R, et al: Effect of topical citric acid application in the healing of experimental furcation defects in dogs. *J Periodontal Res* 13:538, 1978.
55. Daly CG: Antibacterial effect of citric acid treatment of periodontally diseased root surface in vitro. *J Clin Periodontol* 9:386, 1982.
56. Diem CR, Bowers GM, Moffitt WC: Bone blending: a technique for osseous implants. *J Periodontol* 43:295, 1972.
57. Doadrio JC, Acros D, Cabanas MV, et al: Calcium sulfate-based cements containing cephalexin. *Biomaterials* 25:2629, 2004.
58. Dragoo MR, Sullivan HC: A clinical and histological evaluation of autogenous iliac bone grafts in humans. Part I. Wound healing 2 to 8 months. *J Periodontol* 49:599, 1973.
59. Dragoo MR, Sullivan HC: A clinical and histologic evaluation of autogenous iliac bone grafts in humans. Part II. External root resorption. *J Periodontol* 44:614, 1973.
60. Eickholz P, Hausmann E: Evidence for healing of class II and III furcations after GTR therapy: digital subtraction and clinical measurements. *J Periodontol* 68:636, 1997.
61. Eickholz P, Hausmann E: Evidence for healing of interproximal intrabony defects after conventional and regenerative therapy: digital radiography and clinical measurements. *J Periodontal Res* 33:156, 1998.
62. Ellegaard B: Bone grafts in periodontal attachment procedures. *J Clin Periodontol* 3:5, 1976.
63. Ellegaard B, Karring T, Löe H: Retardation of epithelial migration in new attachment attempts in intrabony defects in monkeys. *J Clin Periodontol* 3:23, 1976.
64. European Academy of Periodontology: *Proceedings of the 2nd European Workshop on Periodontology*, Chicago, 1997, Quintessence.
65. Ewen SJ: Bone swaging. *J Periodontol* 36:57, 1965.
66. Falk H, Laurell L, Ravald N, et al: Guided tissue regeneration procedures of 203 consecutively treated intrabony defects using a bioabsorbable matrix barrier. Clinical and radiographic findings. *J Periodontol* 68:571, 1997.
67. Fang J, Zhu YY, Smiley E, et al: Stimulation of new bone formation by direct transfer of osteogenic plasmid genes. *Proc Natl Acad Sci U S A* 93:5753, 1996.
68. Feingold JP, Chasens AI, Doyle J, et al: Preserved scleral allografts on periodontal defects in man. II. Histologic evaluation. *J Periodontol* 48:4, 1977.
69. Fernyhough W, Page RC: Attachment, growth and synthesis of human gingival fibroblasts on demineralized or fibronectin-treated normal and diseased tooth roots. *J Periodontol* 54:133, 1983.
70. Fine DH, Morris ML, Tabak L, et al: Preliminary characterization of material eluted from the roots of periodontally diseased teeth. *J Periodontal Res* 15:10, 1980.
71. Fowler C, Garrett S, Crigger M, et al: Histologic probe position in treated and untreated human periodontal tissues. *J Clin Periodontol* 9:373, 1982.
72. Franceschi RT, Yang S, Rutherford RB, et al: Gene therapy approaches for bone regeneration. *Cells Tissues Organs* 176:95, 2004.
73. Froum SJ, Thaler R, Scoop IW, et al: Osseous autografts. I. Clinical responses to bone blend or hip marrow grafts. *J Periodontol* 46:515, 1975.
74. Froum SJ, Thaler R, Scoop IW, et al: Osseous autografts. II. Histologic responses to osseous coagulum-bone blend grafts. *J Periodontol* 46:656, 1975.
75. Froum SJ, Ortiz M, Witkin RT, et al: Osseous autografts. III. Comparison of osseous coagulum-bone blend implants with open curettage. *J Periodontol* 47:287, 1976.
76. Froum SJ, Kushner L, Scoop IW, et al: Human clinical and histologic responses to Durapatite implants in intraosseous lesions. *J Periodontol* 53:719, 1982.
77. Froum S, Stahl SS: Human intraosseous healing responses to the placement of tricalcium phosphate ceramic implants II. 13 to 18 months. *J Periodontal* 58:103, 1987.
78. Froum SJ, Weinberg MA, Roisenberg E, et al: A comparative study utilizing open flap debridement with and without enamel matrix derivative in the treatment of periodontal intrabony periodontal defects: a 12-month re-entry study. *J Periodontol* 72:25, 2001.
79. Froum S, Lemler J, Horowitz R, et al: The use of enamel matrix derivative in the treatment of periodontal osseous defects: a clinical decision tree based on biologic principles of regeneration. *Int J Periodont Restor Dent* 21:437, 2001.
80. Froum SJ, Weinberg MA, Rosenberg E, et al: A comparative utilizing open flap debridement with and without enamel matrix derivative in the treatment of periodontal intrabony defects: a 12-month re-entry study. *J Periodontol* 72:25, 2001.
81. Gantes BG, Garrett S: Coronally displaced flaps in reconstructive periodontal therapy. *Reconstr Periodont* 35:495, 1991.
82. Garrett S, Crigger M, Egelberg J: Effects of citric acid on diseased root surfaces. *J Periodontal Res* 13:155, 1978.
83. Garrett S: Early wound healing stability and its importance in periodontal regeneration. In Polson AM, editor: *Periodontal regeneration: current status and directions*, Chicago, 1994, Quintessence.
84. Garrett S: Periodontal regeneration around natural teeth. In Proceedings of the 1996 World Workshop in Periodontology. *Ann Periodontol* 7:621, 1996.
85. Giannobile WV, Ryan S, Shih MS, et al: Recombinant human osteogenic protein-1 (OP-1) promotes periodontal wound healing in class III furcation defects. *J Periodontol* 69:129, 1998.
86. Giannobile WV, Lee CS, Tomala MP, et al: Platelet-derived growth factor (PDGF) gene delivery for application in periodontal tissue engineering. *J Periodontol* 72:815, 2001.
87. Giannobile WV, Hollister SJ, Ma PX: Future prospects for periodontal bioengineering using growth factors. *Clin Adv Periodontics* 1:88, 2011.
88. Glickman I: *Clinical periodontology*, Philadelphia, 1953, Saunders.
89. Gottlow J, Nyman S, Lindhe J, et al: New attachment formation as a result of controlled tissue regeneration. *J Clin Periodontol* 11:494, 1984.
90. Gottlow J, Nyman S, Lindhe J, et al: New attachment formation in human periodontium by guided tissue regeneration. *J Clin Periodontol* 13:604, 1986.
91. Gottlow J, Nyman S, Lindhe J, et al: New attachment formation in the human periodontium by guided tissue regeneration. *J Clin Periodontol* 13:604, 1986.
92. Gottlow J, Nyman S, Karring T: Maintenance of new attachment gained through guided tissue regeneration. *J Clin Periodontol* 19:315, 1992.
93. Greenberg J, Laster L, Listgarten MA: Transgingival probing as a potential estimation of alveolar bone level. *J Periodontol* 47:514, 1976.
94. Gronowicz G, McCarthy MB: Response of human osteoblasts to implant materials: integrin-mediated adhesion. *J Orthop Res* 14:878, 1996.
95. Grossi SG, Zambon JJ, Ho AW: Assessment of risk for periodontal disease. I. Risk indicators for attachment loss. *J Periodontol* 65:260, 1994.

96. Grossi SG, Genco RJ, Machtei EE: Assessment of risk for periodontal disease. II. Risk indicators for alveolar bone loss. *J Periodontol* 66:23, 1995.
97. Guida L, Annunziata M, Belardo S, et al: Effect of autogenous cortical bone particulate in conjunction with enamel matrix derivative in the treatment of periodontal intraosseous defects. *J Periodontol* 78:231, 2007.
98. Gurinsky BS, Mills MP, Mellonig JT: Clinical evaluation of demineralized freeze-dried bone allograft and enamel matrix derivative versus enamel matrix derivative alone for the treatment of periodontal osseous defects in human. *J Periodontol* 75:1309, 2004.
99. Habers GM, Healy KE: The effect of ligand type and density on osteoblast adhesion, proliferation, and matrix mineralization. *J Biomed Mater Res* 15:855, 2005.
100. Habes J, Wattles J, Crowley M, et al: Evidence for cigarette smoking as a major risk factor for periodontitis. *J Periodontol* 64:16, 1993.
101. Hakki SS, Wang D, Franceschi R, et al: Bone sialoprotein gene transfer to periodontal ligament cells may not be sufficient to promote mineralization in vitro or in vivo. *J Periodontol* 77:1167, 2006.
102. Hall WB: Periodontal reasons to extract a tooth. In Hall WB, editor: *Decision making in periodontology*, St. Louis, 1998, Mosby.
103. Halliday DG: The grafting of newly formed autogenous bone in the treatment of osseous defects. *J Periodontol* 40:511, 1969.
104. Hancock EB: Regenerative procedures. In Nevins M, Becker W, Kornman K, editors: *Proceedings of the World Workshop in Clinical Periodontics*, Chicago, 1989, American Academy of Periodontology.
105. Haney JM, Nilvéus RE, McMillan PJ, et al: Periodontal repair in dogs: expanded polytetrafluoroethylene barrier membranes support wound stabilization and enhance bone regeneration. *J Periodontol* 64:883, 1993.
106. Hanisch O, Tatakis DN, Boskovic MM, et al: Bone formation and reosseointegration in peri-implantitis defects following surgical implantation of rhBMP-2. *Int J Oral Maxillafac Implants* 12:604, 1997.
107. Hardwick R, Hayes BK, Flynn C: Devices for dentoalveolar regeneration: an up-to-date literature review. *J Periodontol* 55:495, 1995.
108. Healy KE, Rezania A, Stile RA: Designing biomaterials to direct biological responses. *Ann NY Acad Sci* 18:24, 1999.
109. Heard RH, Mellonig JT, Brunsvold MA, et al: Clinical evaluation of wound healing following multiple exposures to enamel matrix protein derivative in the treatment of intrabony periodontal defects. *J Periodontol* 71:1715, 2000.
110. Hecker F: *Pyorrhea alveolaris*, St. Louis, 1913, Mosby.
111. Heden G: A case report study of 72 consecutive Emdogain-treated intrabony periodontal defects: Clinical and radiographic findings after 1 year. *Int J Periodontics Restorative Dent* 20:127, 2000.
112. Hegedüs Z: The rebuilding of the alveolar process by bone transplantation. *Dent Cosmos* 65:736, 1923.
113. Heijl L, Heden G, Svardstrom G, et al: Enamel matrix derivative (EMDOGAIN) in the treatment of intrabony periodontal defects. *J Clin Periodontol* 24:705, 1997.
114. Heijl L: Periodontal regeneration with enamel matrix derivative in one human experimental defect. A case report. *J Clin Periodontol* 24:693, 1997.
115. Herford AS, Boyne PJ, Williams RP: Clinical applications of rhBMP-2 in maxillofacial surgery. *J Calif Dent Assoc* 35:335, 2007.
116. Hiatt WH: Periodontal pocket elimination by combined endodontic-periodontic therapy. *J Periodontol* 1:153, 1963.
117. Hiatt WH, Schallhorn RG: Intraoral transplants of cancellous bone and marrow in periodontal lesions. *J Periodontol* 44:194, 1973.
118. Hippolyte MP, Fabre D, Peyrol S: Corail et regeneration tissulaire guidée: aspects histologiques. *J Parodontol* 10:279, 1991.
119. Hou L, Liu C, Liu B, et al: Tissue engineering bone formation in novel recombinant human bone morphogenic protein 2- atelocollagen composite scaffolds. *J Periodontol* 78:335, 2007.
120. Howell TH, Fiorellini J, Paquette DW, et al: A phase I/II trial to evaluate a combination of recombinant human platelet-derived growth factor-BB and recombinant human insulin-like growth factor-I in patients with periodontal disease. *J Periodontol* 68:1186, 1997.
121. Hugoson A, Ravald N, Fornell J, et al: Treatment of class II furcation involvement in humans with bioresorbable and non-resorbable guided tissue regeneration barriers. A randomized multi-center study. *J Periodontol* 66:624, 1995.
122. Ishikawa I, Kinashita A, Oda S: Regenerative therapy in periodontal disease. Histological observation after implantation of rhBMP-2 in surgically created periodontal defects in dogs. *Dent Jpn* 31:141, 1994.
123. Izumi K, Feinberg SE, Iida A, et al: Intraoral grafting of an ex vivo produced oral mucosa equivalent: a preliminary report. *Int J Oral Maxillofac Surg* 32:188, 2003.
124. Jansson L, Ehnevid H, Lindskog S, et al: Relationship between periapical and periodontal status. A clinical retrospective study. *J Clin Periodontol* 20:11, 1993.
125. Jansson LE, Ehnevid H, Blomlof L, et al: Endodontic pathogens in periodontal disease augmentation. *J Clin Periodontol* 22:598, 1995.
126. Jepsen S, Topoll H, Rengers H, et al: Clinical outcomes after treatment of intra-bony defects with an EMD/synthetic bone graft or EMD alone: a multicenter randomized-controlled clinical trial. *J Clin Periodontol* 35:420, 2008.
127. Jergessen HE, Chua J, Kao R, et al: Age effects on bone induction by demineralized bone powder. *Clin Orthop Relat Res* 268:253, 1991.
128. Jin Q, Anusaksathien O, Webb SA, et al: Engineering of tooth-supporting structures by delivery of PDGF gene therapy vectors. *Mol Ther* 9:519, 2004.
129. Jin QM, Anusaksathien O, Webb SA, et al: Gene therapy of bone morphogenetic protein for periodontal tissue engineering. *J Periodontol* 74:202, 2003.
130. Jin QM, Zhao M, Economides AN, et al: Noggin gene delivery inhibits cementoblast-induced mineralization. *Connect Tissue Res* 45:50, 2004.
131. Johnson W, Parkhill EM, Grindlay JH: Transplantation of homografts of sclera: experimental study. *Am J Ophthalmol* 54:1019, 1962.
132. Jones JK, Triplett RG: The relationship of cigarette smoking to impaired intraoral wound healing: a review of evidence and implications for patient care. *J Oral Maxillofac Surg* 50:237, 1992.
133. Juncosa-Melvin N, Boivin GP, Galloway MT, et al: Effects of cell-to-collagen ratio in mesenchymal stem cell-seeded implants on tendon repair. *Tissue Eng* 11:448, 2005.
134. Kao RT, Murakami S, Beirne OR: The use of biologic mediators and tissue engineering in dentistry. *Periodontol 2000* 20:127, 2009.
135. Kao RT: Periodontal regeneration and reconstructive surgery. In Rose LF, Mealey BL, Genco RJ, et al, editors: *Periodontics*, St. Louis, 2004, Elsevier Mosby.
136. Kao RT, Lynch SE: Stability of recombinant human platelet-derived growth factor-BB regenerated periodontal defects: sixty-month clinical and radiographic observations. *Clin Adv Periodontics* 1:132, 2011.
137. Kao ST, Scott DD: A review of bone substitutes. *Oral Maxillofac Surg Clin North Am* 19:513, 2007.
138. Karlsson MR, Diogo Lofgren CI, Jansson HM: The effect of laser therapy to nonsurgical periodontal treatment in subjects with chronic periodontitis: a systematic review. *J Periodontol* 79:2021, 2008.
139. Kenney EB, Lekovic V, Han T, et al: The use of a porous hydroxylapatite implant in periodontal defects. I. Clinical results after six months. *J Periodontol* 56:82, 1985.
140. Kenney EB, Lekovic V, Elbaz JJ, et al: The use of a porous hydroxylapatite implant in periodontal defects. II. Treatment of class II furcation lesions in lower molars. *J Periodontol* 59:67, 1988.
141. Kilic AR, Efeoglu E, Yilmaz S: Guided tissue regeneration in conjunction with hydroxyapatite-collagen grafts for intrabony defects. A clinical and radiological evaluation. *J Clin Periodontol* 24:372, 1997.
142. Kim CK, Kim HY, Chai JK, et al: Effect of a calcium sulfate implant with calcium sulfate barrier on periodontal healing in 3-wall intrabony defects in dogs. *J Periodontol* 69:982, 1998.
143. King GN: The importance of drug delivery to optimize the effects of bone morphogenetic protein during periodontal regeneration. *Curr Pharm Biotechnol* 2:131, 2001.

144. King GN, King N, Cruchley AT, et al: Recombinant human bone morphogenetic protein-2 promotes wound healing in rat periodontal fenestration defects. *J Dent Res* 1997:76:1460, 1997.
145. King GN, Cochran DL: Factors that modulate the effects of bone morphogenetic protein-induced periodontal regeneration: a critical review. *J Periodontol* 73:925, 2002.
146. Kitamura M, Nakashima K, Kowashi Y, et al: Periodontal tissue regeneration using fibroblast growth factor-2: randomized controlled phase II clinical trial. *PLoS ONE* 3:e2611, 2008.
147. Kitamuera M, Akamatsu M, Machigashira M, et al: FGF-2 stimulates periodontal regeneration: results of a multi-center randomized clinical trial. *J Dent Res* 90:35, 2011.
148. Klein F, Kim TS, Hassfeld S, et al: Radiographic defect depth and width for prognosis and description of periodontal healing of infrabony defects. *J Periodontol* 72:1639, 2001.
149. Klingsberg J: Preserved sclera in periodontal surgery. *J Periodontol* 43:634, 1972.
150. Klingsberg J: Scleral allografts in the repair of periodontal osseous defects. *NY State Dent J* 38:418, 1972.
151. Klingsberg J: Periodontal scleral grafts and combined grafts of sclera and bone: two-year appraisal. *J Periodontol* 45:262, 1974.
152. Kuru B, Yilmaz S, Argin K, et al: Enamel matrix derivative alone or in combination with a bioactive glass in wide intrabony defects. *Clin Oral Investig* 10:227, 2006.
153. Lam KH, Schakenraad JM, Esselbrugge H, et al: The effect of phagocytosis of poly (L-lactic acid) fragments on cellular morphology and viability. *J Biomed Mater Res* 27:1569, 1993.
154. Lang NP, Hill RW: Radiographs in periodontics. *J Clin Periodontol* 4:16, 1976.
155. Lee K, Silva EA, Mooney DJ: Growth factor delivery-based tissue engineering: general approaches and a review of recent developments. *J R Soc Interface* 8(55):153–170, 2011. doi: 10.1098/rsif.2010.0223. Epub August 18, 2010.
156. Lekovic V, Kenney EB, Carranza FA, Jr, et al: Treatment of class II furcation defects using porous hydroxyapatite in conjunction with a polytetrafluoroethylene membrane. *J Periodontol* 61:575, 1990.
157. Lekovic V, Kenney EB, Carranza FA, Jr, et al: The use of autogenous periosteal grafts as barriers for the treatment of grade II furcation involvements in lower molars. *J Periodontol* 62:775, 1991.
158. Lekovic V, Kenney EB, Kovacevic K, et al: Evaluation of guided tissue regeneration in class II furcation defects: a clinical study. *J Periodontol* 60:694, 1989.
159. Lekovic V, Camargo P, Weinlaender M, et al: A comparison between enamel matrix protein used alone or in combination with bovine porous bone mineral in the treatment of intrabony periodontal defects in humans. *J Periodontol* 71:1110, 2000.
160. Lekovic V, Camargo PM, Weinlaender M, et al: A comparison between enamel matrix proteins used alone or in combination with bovine porous bone mineral in the treatment of intrabony periodontal defects in human. *J Periodontol* 71:1110, 2000.
161. Libin BM, Ward HL, Fishman LL: Decalcified lyophilized bone allografts for use in human periodontal defects. *J Periodontol* 46:51, 1975.
162. Lynch SE, Williams RC, Polson AM, et al: A combination of platelet-derived and insulin-like growth factors enhanced periodontal regeneration. *J Clin Periodontol* 16:545, 1989.
163. Lynch SE, Ruiz de Castilla G, Williams RC, et al: The effects of short-term application of a combination of platelet-derived and insulin-like growth factors on periodontal wound healing. *J Periodontol* 62:458, 1991.
164. Lynch SE: Introduction to tissue engineering. In Lynch SE, Genco RJ, Marx RE, editors: *Tissue engineering: applications in maxillofacial surgery and periodontics*, Chicago, 1999, Quintessence.
165. Machtei EE, Cho MI, Dunford R, et al: Clinical, microbiological, and histological factors which influence the success of regenerative periodontal therapy. *J Periodontol* 65:154, 1994.
166. Machtei EE: Outcome variables for the study of periodontal regeneration. *Ann Periodontol* 2:229, 1997.
167. Martin M, Gantes B, Garrett S, et al: Treatment of periodontal furcation defects. I. Review of the literature and description of a regenerative surgical technique. *J Clin Periodontol* 15:227, 1988.
168. McClain PK, Schallhorn RG: Long-term assessment of combined osseous composite grafting, root conditioning, and guided tissue regeneration. *Int J Periodontics Restorative Dent* 13:9, 1993.
169. McGuire MK, Nunn ME: Evaluation of the safety and efficacy of periodontal applications of a living tissue-engineered human fibroblast-derived dermal substitute. I. Comparison to the gingival autograft: a randomized controlled pilot study. *J Periodontol* 76:867, 2005.
170. McGuire MK, Kao RT, Nevins M, et al: rhPDGF-BB promotes healing of periodontal defects: 24-month clinical and radiographic observations. *Int J Periodontics Restorative Dent* 26:223, 2006.
171. Meffert RM, Thomas JR, Hamilton KM, et al: Hydroxylapatite as an alloplastic graft in the treatment of human periodontal osseous defects. *J Periodontol* 56:63, 1985.
172. Melcher AH: On repair potential of periodontal tissues. *J Periodontol* 47:256, 1976.
173. Mellado JR, Salkin LM, Freedman AL, et al: A comparative study of ePTFE membranes with and without decalcified freeze-dried bone allografts for the regeneration of interproximal intraosseous defects. *J Periodontol* 66:751, 1995.
174. Mellonig JT, Bowers GM, Bright RW, et al: Clinical evaluation of freeze-dried bone allografts in periodontal osseous defects. *J Periodontol* 47:125, 1976.
175. Mellonig JT, Bowers GM, Bailey RC: Comparison of bone graft materials. Part I. New bone formation with autografts and allografts determined by strontium-85. *J Periodontol* 52:291, 1981.
176. Mellonig JT, Bowers GM, Bailey RC: Comparison of bone graft materials. Part II. New bone formation with autografts and allografts: a histological evaluation. *J Periodontol* 52:297, 1981.
177. Mellonig JT, Captain DC: Decalcified freeze-dried bone allograft as an implant material in human periodontal defects. *Int J Periodontics Restorative Dent* 4:41, 1984.
178. Mellonig JT, Prewett AB, Moyer MP: HIV inactivation in a bone allograft. *J Periodontol* 63:979, 1992.
179. Mellonig JT: Freeze-dried bone allografts in periodontal reconstructive surgery. *Dent Clin North Am* 35:505, 1991.
180. Mellonig JT: Human histologic evaluation of a bovine-derived bone xenograft in the treatment of periodontal osseous defects. *Int J Periodont Restor Dent* 20:19, 2000.
181. Mendoza AR, Newcomb GM: Compliance with supportive periodontal therapy. *J Periodontol* 62:731, 1991.
182. Metzler DG, Seamoons BC, Mellonig JT, et al: Clinical evaluation of guided tissue regeneration in the treatment of maxillary class II molar furcation invasions. *J Periodontol* 62:353, 1991.
183. Minabe M: A critical review of the biologic rationale for guided tissue regeneration. *J Periodontol* 62:171, 1991.
184. Minabe M, Kodama T, Kogou T, et al: A comparative study of combined treatment with a collagen membrane and enamel matrix proteins for the regeneration of intraosseous defects. *Int J Periodontics Restorative Dent* 22:595, 2002.
185. Miyamoto S, Takaoka K, Okada T, et al: Evaluation of polylactic acid homopolymers as a carrier for bone morphogenetic protein. *Clin Orthop Relat Res* (278):274–285, 1992.
186. Miyazaki A, Yamaguchi T, Nishikata J, et al: Effects of Nd:YAG and CO2 laser treatment and ultrasonic scaling on periodontal pockets of chronic periodontitis patients. *J Periodontol* 74:175, 2003.
187. Mombelli A, Lang NP, Nyman S: Isolation of periodontal species after guided tissue regeneration. *J Peridontol* 64:1171, 1993.
188. Momose M, Murata M, Kato Y, et al: Vascular endothelial growth factors and transforming growth factor-∂ and β are released from human cultured gingival epithelial sheets. *J Periodontol* 73:749, 2002.
189. Moriarty JD, Hutchens LH, Scheitler LE: Histological evaluation of periodontal probe penetration in untreated facial molar furcations. *J Periodontol* 16:21, 1989.

190. Morris ML: Reattachment of periodontal tissue: a critical study. *Oral Surg* 2:1194, 1949.
191. Moskow BS, Gold SI, Gottsegen R: Effects of scleral collagen upon the healing of experimental osseous wounds. *J Periodontol* 47:596, 1976.
192. Moskow BS, Tannenbaum P: Enhanced repair and regeneration of periodontal lesions in tetracycline-treated patients: case reports. *J Periodontol* 62:341, 1991.
193. Murakami S, Takayama S, Kitamura M, et al: Recombinant human basic fibroblast growth factor (bFGF) stimulates periodontal regeneration in class II furcation defects created in beagle dogs. *J Periodontal Res* 38:97, 2003.
194. Murakami S: Periodontal tissue regeneration by signaling molecule(s): what role does basic fibroblast growth factor (FGF-2) have in periodontal therapy? *Periodontol 2000* 56:188, 2011.
195. Murakami S, Yamada S, Nozaki T, et al: Fibroblast growth factor-2 stimulates periodontal tissue regeneration. *Clin Adv Periodontics* 1:95, 2011.
196. Murphy KG: Interproximal tissue maintenance in guided tissue regeneration procedures. Description of surgical technique and 1-year re-entry results. *Int J Periodontics Restorative Dent* 16:463, 1996.
197. Nabers JM, Meador HL, Nabers CL, et al: Chronology, an important factor in the repair of osseous defects. *Periodontics* 2:304, 1964.
198. Nabers CL, O'Leary TJ: Autogenous bone transplants in the treatment of osseous defects. *J Periodontol* 36:5, 1965.
199. Nagano T, Oida S, Suzuki S, et al: Porcine enamel protein fractions contain transforming growth factor-β1. *J Periodontol* 77:1688, 2006.
200. Nery EB, Lynch KL: Preliminary clinical studies of bioceramic in periodontal osseous defects. *J Periodontol* 49:523, 1978.
201. Nevins ML, Camelo M, Schupbach P, et al: Human clinical and histologic evaluation of laser-assisted new attachment procedure. *Int J Periodontics Restorative Dent* 32:497, 2012.
202. Nevins M, Camelo M, Nevins ML, et al: Periodontal regeneration in humans using recombinant human platelet-derived growth factor BB (rhPDGF-BB) and allogenic bone. *J Periodontol* 74:1282, 2003.
203. Nevins M, Giannobile WV, McGuire MK, et al: Platelet-derived growth factor stimulates bone fill and rate of attachment level gain: results of a large multicenter randomized controlled trial. *J Periodontol* 76:2205, 2005.
204. Nevins M, Kao RT, McGuire MK, et al: PDGF promotes periodontal regeneration in localized osseous defects: 36 month extension results from a randomized, controlled, double-masked clinical trial. *J Periodontol* 84:456, 2013.
205. Nilvéus R, Bogle G, Crigger M, et al: Effect of topical citric acid application in the healing of experimental furcation defects in dogs. 2. Healing after repeated surgery. *J Periodontal Res* 15:544, 1980.
206. Nowzari H, MacDonald ES, Flynn J, et al: The dynamics of microbial colonization of barrier membranes for guided tissue regeneration. *J Periodontol* 67:694, 1996.
207. Nyman S, Lindhe J, Rosling B: Periodontal surgery in plaque infected dentitions. *J Clin Periodontol* 4:240, 1977.
208. Nyman S, Gottlow J, Karring T, et al: The regenerative potential of the periodontal ligament: an experimental study in the monkey. *J Clin Periodontol* 9:257, 1982.
209. Nyman S, Lindhe J, Karring T, et al: New attachment following surgical treatment of human periodontal disease. *J Clin Periodontol* 9:290, 1982.
210. Okuda K, Momose M, Miyazaki A, et al: Enamel matrix derivative in the treatment of human intrabony osseous defects. *J Periodontol 2000* 71:1821, 2000.
211. Okuda K, Momose M, Murata M, et al: Treatment of chronic desquamative gingivitis using tissue-engineered human cultured gingival epithelial sheets: a case report. *Int J Periodontics Restorative Dent* 24:119, 2004.
212. Ouhayoun J-P: Bone grafts and biomaterials used as bone graft substitutes. In Lang NK, Karring T, Lindhe J, editors: *Proceedings of the 2nd European Workshop on Periodontology*, Chicago, 1997, Quintessence.
213. Page RC: Animal models in reconstructive periodontal therapy. *J Periodontol* 65:1142, 1994.
214. Park J, Lee J, Park Y, et al: Enhanced bone regeneration in beagle dogs with bovine bone mineral coated with a synthetic oligopeptide. *J Periodontol* 78:2150, 2007.
215. Passell MS, Bissada NF: Histomorphologic evaluation of scleral grafts in experimental bony defects. *J Periodontol* 46:629, 1975.
216. Patur B, Glickman I: Clinical and roentgenographic evaluation of the post-treatment healing of infrabony pockets. *J Periodontol* 33:164, 1962.
217. Pearson GE, Rosen S, Deporter DA: Preliminary observations on the usefulness of a decalcified freeze-dried cancellous bone allograft material in periodontal surgery. *J Periodontol* 52:55, 1981.
218. Pecora G, Andreana S, Margarone JE, et al: Bone regeneration with a calcium sulfate barrier. *Oral Surg Oral Med Oral Pathol Oral Radiol Endod* 84:424, 1997.
219. Pehling S, Pippig SD, Hellerbrand K, et al: Superior effect of MD05 beta-tricalcium phosphate coated with recombinant human growth/differentiation factor-5, compared to conventional bone substitutes in the rat calvarial defect model. *J Periodontol* 77:1582, 2006.
220. Peltier LF: The use of plaster of Paris to fill large defects in bone: a preliminary report. *Clin Orthop* 382:3, 2011.
221. Pini Prato GP, Rotundo R, Magnani C, et al: An autologous cell hyaluronic acid graft technique for gingival augmentation: a case series. *J Periodontol* 74:262, 2003.
222. Pini Prato GP, Rotundo R, Magnani C, et al: Tissue engineering technology for gingival augmentation procedures: a case report. *Int J Periodontics Restorative Dent* 20:552, 2000.
223. Polson AM, Proye MP: Fibrin linkage: a precursor for new attachment. *J Periodontol* 54:141, 1983.
224. Polson AM, Frederick GT, Ladenhein S, et al: The production of a root surface smear by instrumentation and its removal by citric acid. *J Periodontol* 55:443, 1984.
225. Pontoriero R, Lindhe J, Nyman S, et al: Guided tissue regeneration in degree II furcation-involved mandibular molars: a clinical study. *J Clin Periodontol* 15:247, 1988.
226. Pontoriero R, Wennstrom J, Lindhe J: The use of barrier membranes and enamel matrix proteins in the treatment of angular bone defects. A prospective controlled clinical study. *J Clin Periodontol* 26:833, 1999.
227. Preber H, Bergstrom J: Effect of cigarette smoking on periodontal healing following surgical therapy. *J Clin Periodontol* 17:324, 1990.
228. Prichard JF: The intrabony technique as a predictable procedure. *J Periodontol* 28:202, 1957.
229. Prichard J: A technique for treating infrabony pockets based on alveolar process morphology. *Dent Clin N Am* 1:85, 1960.
230. Proceedings of the 1996 World Workshop in Periodontology, Consensus Report: Periodontal regeneration around natural teeth. *Ann Periodontol* 7:667, 1996.
231. Quintero G, Mellonig JT, Gambill VM, et al: A six-month clinical evaluation of decalcified freeze-dried bone allografts in periodontal osseous defects. *J Periodontol* 53:726, 1982.
232. Rabalais ML, Yukna RA, Mayer ET: Evaluation of Durapatite ceramic as an alloplastic implant in periodontal osseous defects. *J Periodontol* 52:680, 1981.
233. Ramfjord SP: Experimental periodontal reattachment in rhesus monkeys. *J Periodontol* 22:67, 1951.
234. Ramfjord SP, Nissle RR: The modified Widman flap. *J Periodontol* 45:601, 1974.
235. Ramfjord S, Caffesse R, Morrison E, et al: 4 modalities of periodontal treatment compared over 5 years. *J Clin Periodontol* 14:445, 1987.
236. Rasperini G, Silvestri M, Ricci G: Long-term clinical observation of treatment of infrabony defects with enamel matrix derivative (Emdogain): surgical reentry. *Int J Periodontics Restorative Dent* 25:121, 2005.
237. Reddy MS: Achieving gingival esthetics. *J Am Dent Assoc* 134:295, 2003.

238. Register AA, Burdick FA: Accelerated reattachment with cementogenesis to dentin, demineralized in situ. II. Defect repair. *J Periodontol* 47:497, 1976.
239. Renvert S, Egelberg J: Healing after treatment of periodontal intraosseous defects. II. Effect of citric acid conditioning of the root surface. *J Clin Periodontol* 8:459, 1981.
240. Renvert S, Badersten A, Nilvéus R, et al: Healing after treatment of periodontal osseous defects. I. Comparative study of clinical methods. *J Clin Periodontol* 8:387, 1981.
241. Renvert S, Shallhorn RG, Egelberg J: Healing after treatment of periodontal intraosseous defects. III. Effect of osseous grafting and citric acid conditioning. *J Clin Periodontol* 12:441, 1985.
242. Reynolds MA, Aichelmann-Reidy ME, Branch-Mays GL, et al: The efficacy of bone replacement grafts in the treatment of periodontal osseous defects. A systematic review. *Ann Periodontol* 8:227, 2003.
243. Rezania A, Healy KE: Integrin subunits responsible for adhesion of human osteoblast-like cells to biomimetic peptide surfaces. *J Orthop Res* 17:615, 1999.
244. Ripamonti U, Heliotis M, van den Heever B, et al: Bone morphogenetic proteins induce periodontal regeneration in the baboon (*Papio ursinus*). *J Periodontal Res* 29:439, 1994.
245. Rivault AF, Toto PD, Levy S, et al: Autogenous bone grafts: osseous coagulum and osseous retrograde procedures in primates. *J Periodontol* 42:787, 1971.
246. Robinson RE: Osseous coagulum for bone induction. *J Periodontol* 40:503, 1969.
247. Rosenblum SF, Frenkel S, Ricci JR, et al: Diffusion of fibroblast growth factor from a plaster of Paris carrier. *J Appl Biomaterials* 4:67, 1993.
248. Rosling B, Nyman S, Lindhe J: The effects of systematic plaque control on bone regeneration in intrabony pockets. *J Clin Periodontol* 3:38, 1976.
249. Rosling B, Hollender L, Nyman S, et al: A radiographic method for assessing changes in alveolar bone height following periodontal therapy. *J Clin Periodontol* 2:211, 1975.
250. Rosing CK, Aass AM, Mavropoulos A: Gjermo P: Clinical and radiographic effects of enamel matrix derivative in the treatment of intrabony periodontal effects: a 12-month longitudinal placebo-controlled clinical trial in adult periodontitis patients. *J Periodontal* 76:129, 2005.
251. Ross SE, Malamed EH, Amsterdam M: The contiguous autogenous transplant: its rationale, indications and technique. *Periodontics* 4:246, 1966.
252. Rummelhart JM, Mellonig JT, Gray JL, et al: A comparison of freeze-dried bone allograft and demineralized freeze-dried bone allograft in human periodontal osseous defects. *J Periodontol* 60:655, 1989.
253. Rutherford RB, Ryan ME, Kennedy JE, et al: Platelet-derived growth factor and dexamethasone combined with a collagen matrix induce regeneration of the periodontium in monkeys. *J Clin Periodontol* 20:537, 1993.
254. Rutherford RB, Moalli M, Franceschi RT, et al: Bone morphogenetic protein transduced human fibroblasts convert to osteoblasts and form bone in vivo. *Tissue Eng* 8:441, 2002.
255. Rutherford RB, Racenis P, Fatherazi S, et al: Bone formation by BMA-7 transduced human gingival keratinocytes. *J Dent Res* 82:293, 2003.
256. Sanders JJ, Sepe WW, Bowers GM, et al: Clinical evaluation of freeze-dried bone allograft in periodontal osseous defects. Part III. Composite freeze-dried bone allografts with and without autogenous bone grafts. *J Periodontol* 54:1, 1983.
257. Schaffer EM: Cartilage transplants into periodontium of rhesus monkeys. *Oral Surg* 11:1233, 1956.
258. Schaffer EM: Cartilage grafts in human periodontal pockets. *J Periodontol* 29:176, 1958.
259. Schallhon RG, Hiatt WH: Human allografts of iliac cancellous bone and marrow in periodontal osseous defects. II. Clinical observations. *J Periodontol* 43:67, 1972.
260. Schallhorn RG: Postoperative problems associated with iliac transplants. *J Periodontol* 43:3, 1972.
261. Schallhorn RG: Osseous grafts in the treatment of periodontal osseous defects. In Stahl SS, editor: *Periodontal surgery: biologic basis and technique*, Springfield, IL, 1976, Charles C Thomas.
262. Schallhorn RG: Present status of osseous grafting procedures. *J Periodontol* 48:570, 1977.
263. Schallhorn RG, McClain PK: Combined osseous composite grafting, root conditioning, and guided tissue regeneration. *Int J Periodont Restor Dent* 8:8, 1988.
264. Schwartz Z, Mellonig JT, Carnes DL, et al: Ability of commercial demineralized freeze-dried bone allograft to induce new bone formation. *J Periodontol* 67:918, 1996.
265. Schwartz Z, Somers A, Mellonig JT, et al: Ability of commercial demineralized freeze-dried bone allograft to induce new bone formation is dependent on donor age but not gender. *J Periodontol* 69:470, 1998.
266. Sculean A, Donos N, Blaes A, et al: Comparison of enamel matrix proteins and bioabsorbable membranes in the treatment of intrabony periodontal defects. A split-mouth study. *J Periodontol* 70:255, 1999.
267. Sculean A, Chiantella GF, Windisch P, et al: Clinical and histologic evaluation of human intrabony defects treated with an enamel matrix derivative Emdogain. *Int J Periodontics Restorative Dent* 20:374, 2000.
268. Sculean A, Windisch P, Chiantella GC, et al: Treatment of intrabony defects with enamel matrix proteins and guided tissue regeneration. A prospective controlled clinical study. *J Clin Periodontol* 28:397, 2001.
269. Sculean A, Windisch P, Keglevich T: Clinical and histologic evaluation of human intrabony defects treated with an enamel matrix protein derived combined with bone-derived xenograft. *Int J Periodontics Restorative Dent* 23:47, 2003.
270. Sculean A, Donos N, Schwarz F, et al: Five-year results following treatment of intrabony defects with enamel matrix proteins and guided tissue regeneration. *J Clin Periodontol* 31:545, 2004.
271. Sculean A, Pietruska M, Schwarz F, et al: Healing of human intrabony defects following regenerative periodontal therapy with an enamel matrix protein derivative alone or combined with a bioactive glass. *J Clin Periodontol* 32:111, 2005.
272. Sculean A, Schwarz F, Miliauskaite A, et al: Treatment of intrabony defects with an enamel matrix protein derivative or bioabsorbable membrane: an 8-year follow-up split mouth study. *J Periodontol* 77:1879, 2006.
273. Sculean A, Kiss A, Miliauskaite A, et al: Ten-year results following treatment of intra-bony defects with enamel matrix proteins and guided tissue regeneration. *J Clin Periodontol* 35:817, 2008.
274. Selvig KA, Nilveus RE, Fitzmorris L, et al: Scanning electron microscopic observations of cell populations and bacterial contamination of membranes used for guided periodontal tissue regeneration in humans. *J Periodontol* 61:515, 1990.
275. Selvig KA, Kersten BG, Wikesjo UME: Surgical treatment of intrabony periodontal defects using expanded polytetrafluoroethylene barrier membranes: influence of defect configuration on healing response. *J Periodontol* 64:730, 1993.
276. Sepe W, Bowers G, Lawrence J, et al: Clinical evaluation of freeze-dried bone allograft in periodontal osseous defects. Part II. *J Periodontol* 49:9, 1978.
277. Shteyer A, Kaban L, Kao R: Effect of demineralized bone powder on osteoblast-like cells in culture. *Int J Oral Maxillofac Surg* 19:370, 1990.
278. Sigurdsson TJ, Hardwick R, Bogle GC, et al: Periodontal repair in dogs: space provision by reinforced ePTFE membranes enhances bone and cementum regeneration in large supraalveolar defects. *J Periodontol* 65:350, 1994.
279. Sigurdsson TJ, Lee MB, Kubota K, et al: Periodontal repair in dogs: recombinant human bone morphogenetic protein-2 significantly enhances periodontal regeneration. *J Periodontol* 66:131, 1995.
280. Silvestri M, Ricci G, Rasperini G, et al: Comparison of treatments of infrabony defects with enamel matrix derivative, guided tissue

regeneration with a nonresorbable membrane and Widman modified flap. A pilot study. *J Clin Periodontol* 27:603, 2000.
281. Simion M, Trisi P, Maglione M: Piettelli A: Bacterial penetration in vitro through GTAM membrane with and without topical chlorhexidine application. A light and scanning election microscopic study. *J Clin Periodontol* 22:321, 1995.
282. Sipos PM, Loos BG, Abbas F, et al: The combined use of enamel matrix proteins and a tetracycline-coated expanded polytetrafluoroethylene barrier membrane in the treatment of intra-osseous defects. *J Clin Periodontol* 32:765, 2005.
283. Smith BA, Echeverri M: The removal of pocket epithelium: a review. *J West Soc Periodontol* 32:45, 1984.
284. Smith BA, Smith JS, Caffesse RG, et al: Effect of citric acid and various concentrations of fibronectin on healing following periodontal flap surgery in dogs. *J Periodontol* 58:667, 1987.
285. Sottosanti J: Calcium phosphate: an aid to periodontal, implant and restorative therapy. *J Calif Dent Assoc* 20:45, 1992.
286. Sparks MS, Kerns DG, Wilson TG, et al: Bone regeneration around implants in the canine mandible with cultured fibroblasts in polyglactin mesh. *J Periodontol* 2007:78:1276, 2007.
287. Stahl SS, Froum SJ: Human clinical and histologic repair responses following the use of citric acid in periodontal therapy. *J Periodontol* 48:261, 1977.
288. Stahl SS, Froum SJ: Histological and clinical responses to porous hydroxylapatite implants in human periodontal defects three to twelve months post-implantation. *J Periodontol* 58:689, 1987.
289. Stahl SS, Froum S, Tarnow D: Human histologic responses to guided tissue regenerative techniques in intrabony lesions. Case reports on 9 sites. *J Clin Periodontol* 17:191, 1990.
290. Stahl SS, Froum SJ, Tarnow D: Human histologic responses to guided tissue regenerative techniques in intrabony lesions. *J Clin Periodontol* 17:191, 1990.
291. Stahl SS, Froum SJ, Tarnow D: Human clinical and histologic responses to the placement of HTR polymer particles in 11 intrabony lesions. *J Periodontol* 61:269, 1990.
292. Stahl SS, Froum SJ: Histologic healing responses in human vertical lesions following the use of osseous allografts and barrier membranes. *J Clin Periodontol* 18:149, 1991.
293. Stahl SS, Froum SJ: Human intrabony lesion response to debridement, porous hydroxylapatite implants and Teflon barrier membranes. *J Clin Periodontol* 18:605, 1991.
294. Sparks MS, Kerns DG, Wilson TG: Bone regeneration around implants in the canine mandible with cultured fibroblasts in polyglactin mesh. *J Periodontol* 78:1276, 2007.
295. Strocchi RO, Iezzi G, Scarano A, et al: Bone regeneration with calcium sulfate: evidence for increased angiogenesis in rabbits. *J Oral Implants* 28:43–48, 2002.
296. Takayama S, Murakami S, Shimabukuro Y, et al: Periodontal regeneration by FGF-2 (bFGF) in primate models. *J Dent Res* 80:2075, 2001.
297. Terranova VP, Martin GR: Molecular factors determining gingival tissue interaction with tooth structure. *J Periodontal Res* 17:530, 1982.
298. Terranova VP, Franzetti LC, Hic S, et al: A biochemical approach to periodontal regeneration: tetracycline treatment of dentin promotes fibroblast adhesion and growth. *J Periodontal Res* 21:330, 1986.
299. Theilade J: An evaluation of the reliability of radiographs in the measurement of bone loss in periodontal disease. *J Periodontol* 31:143, 1960.
300. Tonetti M, Pino Prato G, Cortellini P: Periodontal regeneration of human infrabony defects. IV. Determination of healing response. *J Periodontol* 64:934, 1993.
301. Tonetti MS, Pini Prato G, Cortellini P: Effect of cigarette smoking on periodontal healing following GTR in infrabony defects. A preliminary retrospective study. *J Clin Periodontol* 22:229, 1995.
302. Tonetti MS, Lang NP, Cortellini P, et al: Enamel matrix proteins in the regenerative therapy of deep intrabony defects. *J Clin Periodontol* 29:317, 2002.
303. Topback GA, Brunsvold MA, Nummikoski PV, et al: The accuracy of radiographic methods in assessing the outcome of periodontal regenerative therapy. *J Periodontol* 70:1479, 1999.
304. Toriumi DM, Kotler HS, Luxenberg DP, et al: Mandibular reconstruction with a recombinant bone-inducing factor. Functional, histologic and biochemical evaluation. *Arch Otolaryngol Head Neck Surg* 117:1101, 1991.
305. Troken A, Marion N, Hollister S, et al: Tissue engineering of the synovial joint: the role of cell density. *Proc Inst Mech Eng* 221:429, 2007.
306. Uludag H, D'Augusta D, Palmer R, et al: Characterization of rhBMP-2 pharmacokinetics implanted with biomaterial carriers in the rat ectopic model. *J Biomed Mater Res* 46:193, 1999.
307. Urist MR: Bone formation by autoinduction. *Science* 150:893, 1965.
308. Urist MR: Bone histogenesis and morphogenesis in implants of demineralized enamel and dentin. *Oral Surg* 29:38, 1971.
309. Urist MR, Strates BS: Bone morphogenetic protein. *J Dent Res* 50:1392, 1971.
310. Urist MR, Strates B: Bone formation in implants of partially and wholly demineralized bone matrix. *Clin Orthop* 71:271, 1990.
311. Ursell MJ: Relationships between alveolar bone levels measured at surgery, estimated by transgingival probing and clinical attachment level measurements. *J Clin Periodontol* 16:81, 1989.
312. Van den Bergh JP, ten Bruggenkate CM, Groeneveld HHJ, et al: Recombinant human bone morphogenetic protein-7 in maxillary sinus floor elevation surgery in 3 patients compared to autogenous bone grafts. *J Clin Periodontol* 27:627, 2000.
313. Velasquez-Plata D, Scheyer ET, Mellonig JT: Clinical comparison of an enamel matrix derivative used alone or in combination with a bovine-derived used alone or in combination with a bovine-derived xenograft for the treatment of intrabony defects: a comparative controlled clinical trial. *J Periodontol* 73:433, 2002.
314. Walsh WR, Morberg P, Yu Y, et al: Response of a calcium sulfate bone graft substitute in a confined cancellous defect. *Clin Orthop Relat Res* 406:228, 2003.
315. Weigel C, Brugger U, Hummerle CH, et al: Maintenance of new attachment 1 and 4 years following guided tissue regeneration (GTR). *J Clin Periodontol* 22:661, 1995.
316. Weltman R, Trojo PM, Morrison E, et al: Assessment of guided tissue regeneration procedures in intrabony defects with bioabsorbable and non-reabsorbable barriers. *J Periodontol* 68:582, 1997.
317. Wenzel A, Warrer K, Karring T: Digital subtraction radiography in assessing bone changes in periodontal defects following guided tissue regeneration. *J Clin Periodontol* 19:208, 1992.
318. Wikesjö UM, Nilvéus R: Periodontal repair in dogs: effects of wound stabilization in healing. *J Periodontol* 61:719, 1990.
319. Wikesjö UM, Claffey N, Christersson LA, et al: Repair of periodontal furcation defects in beagle dogs following reconstructive surgery including root surface demineralization with tetracycline hydrochloride and topical fibronectin application. *J Clin Periodontol* 15:73, 1988.
320. Wilson TF, Glover ME, Schoen J, et al: Compliance with maintenance therapy in a private periodontal practice. *J Periodontol* 55:468, 1984.
321. Wilson TG: Compliance: A review of the literature with possible applications to periodontics. *J Periodontal* 58:706, 1987.
322. Wilson TG, McGuire MK, Nunn ME: Evaluation of the safety and efficacy of periodontal applications of a living tissue-engineered human fibroblast-derived dermal substitute. II. Comparison to the subepithelial connective tissue graft: A randomized controlled feasibility study. *J Periodontol* 76:881, 2005.
323. Xiang W, Baolin L, Yan J: The effect of bone morphogenetic protein on osseointegration of titanium implants. *J Oral Maxillofac Surg* 51:647, 1993.
324. Xiao Y, Qian H, Young WG, et al: Tissue engineering for bone regeneration using differentiated alveolar bone cells in collagen scaffolds. *Tissue Eng* 9:1167, 2003.

325. Yang C, Hillas PF, Baez JA: The application of recombinant human collagen in tissue engineering. *Bio Drugs* 18:103, 2004.
326. Yilmaz S, Cakar G, Yildirim B, et al: Healing of two and three wall intrabony periodontal defects following treatment with an enamel matrix derivative combined with autogenous bone. *J Clin Periodontol* 37;37:544, 2010.
327. Younger WJ: Some of the latest phases in implantations and other operations. *Dent Cosmos* 25:102, 1893.
328. Yukna RA: A clinical and histological study of healing following the excisional new attachment procedure in rhesus monkeys. *J Periodontol* 47:701, 1976.
329. Yukna RA, Mayer ET, Brite DV: Longitudinal evaluation of Durapatite ceramic as an alloplastic implant in periodontal osseous defects after three years. *J Periodontol* 55:633, 1984.
330. Yukna RA, Cassingham RJ, Caudill RF, et al: Six month evaluation of calcite (hydroxyapatite ceramic) in periodontal osseous defects. *Int J Periodontics Restorative Dent* 3:35, 1986.
331. Yukna RA: HTR polymer graft in human periodontal osseous defects. I. 6-month clinical results. *J Periodontol* 61:633, 1990.
332. Yukna RA, Krauser JT, Callan DP, et al: Multi-center clinical comparison of combination anorganic bovine-derived hydroxyapatite matrix (ABM)/cell binding peptide (P-15) and ABM in human periodontal osseous defects: 6-month results. *J Periodontol* 71:1671, 2000.
333. Yukna RA, Mellonig JT: Histologic evaluation of periodontal healing in humans following regenerative therapy with enamel matrix derivative. *J Periodontol* 71:752, 2000.
334. Yukna RA, Carr RL, Evans GH: Histologic evaluation of an ND:YAG laser-assisted new attachment procedure in humans. *Int J Periodontics Restorative dentistry* 27:577, 2007.
335. Zetterstron O, Andersson C, Eriksson L, et al: Clinical safety of enamel matrix derivative (EMDOGAIN) in the treatment of periodontal defects. *J Clin Periodontol* 24:697, 1997.
336. Zhang M, Powers RM, Wolfinbarger L: A quantitative assessment of osteoinductivity of human demineralized bone matrix. *J Periodontol* 68:1076, 1997.
337. Zhang M, Powers RM, Wolfinbarger L: Effect(s) of the demineralization process on the osteoinductivity of demineralized bone matrix. *J Periodontol* 68:1085, 1997.
338. Zhao M, Jin Q, Berry JE, et al: Cementoblast delivery for periodontal tissue engineering. *J Periodontol* 75:154, 2004.
339. Zhu Z, Lee CS, Tejeda KM, et al: Gene transfer and expression of platelet-derived growth factors modulate periodontal cellular activity. *J Dent Res* 80:892, 2001.
340. Zucchelli G, Bernardi F, Montebugnoli L, et al: Enamel matrix proteins and guided tissue regeneration with titanium-reinforced expanded polytetrafluoroethylene membranes in the treatment of infrabony defects: a comparative controlled clinical trial. *J Periodontol* 73:3, 2002.
341. Zucchelli G, Amore C, Montebugnoli L, et al: Enamel matrix proteins and bovine porous bone mineral in the treatment of intrabony defects: a comparative controlled clinical trial. *J Clin Periodontol* 74:1725, 2003.

CHAPTER 62

Furcation: Involvement and Treatment

Thomas Sims and Henry H. Takei

CHAPTER OUTLINE

Etiologic Factors
Diagnosis and Classification of Furcation Defects
Local Anatomic Factors
Anatomy of The Bony Lesions
Indices of Furcation Involvement
Treatment
Nonsurgical Therapy
Surgical Therapy
Prognosis

For online-only content on root resection, hemisection, and root resection/hemisection procedure in the surgical therapy section, please visit the companion website at www.expertconsult.com. Some figures may be out of numeric order in this printed chapter. Editors Note: An animation (slide show) has been added as a supplement to the chapter by the Editors. This was produced by My Dental Hub as a patient education tool and covers the basic elements in a conceptual manner. It is not intended to be a procedural guide for dental professionals.

The progress of inflammatory periodontal disease, if unabated, ultimately results in attachment loss sufficient enough to affect the bifurcation or trifurcation of multirooted teeth. The furcation is an area of complex anatomic morphology[5,6,11] that may be difficult or impossible to debride by routine periodontal instrumentation.[29,36] Routine home care methods may not keep the furcation area free of plaque[17,23] (see Video 62-1: Bone Loss with Furcation).

The presence of furcation involvement is one clinical finding that can lead to a diagnosis of advanced periodontitis and potentially to a less-favorable prognosis for the affected tooth or teeth. Furcation involvement therefore presents both diagnostic and therapeutic dilemmas.

Etiologic Factors

The primary etiologic factor in the development of furcation defects is *bacterial plaque* and the inflammatory consequences that result from its long-term presence. The extent of attachment loss required to produce a furcation defect is variable and related to local anatomic factors (e.g., root trunk length, root morphology)[12,27] and local developmental anomalies (e.g., cervical enamel projections).[22,27] Local factors may affect the rate of plaque deposition or complicate the performance of oral hygiene procedures, thereby contributing to the development of periodontitis and attachment loss. Studies indicate that prevalence and severity of furcation involvement increase with age.[21,22,36] Dental caries and pulpal death may also affect a tooth with furcation involvement or even the area of the furcation. All of these factors should be considered during the diagnosis, treatment planning, and therapy of the patient with furcation defects.

Diagnosis and Classification of Furcation Defects

A thorough clinical examination is the key to diagnosis and treatment planning. Careful probing is required to determine the presence and extent of furcation involvement, the position of the attachment relative to the furca, and the extent and configuration of the furcation defect.[38] The Nabors probe may be helpful to enter and measure difficult to access furcal areas (Figure 62-1). Transgingival sounding may further define the anatomy of the furcation defect.[29] The goal of this examination is to identify and classify the extent of furcation involvement and to identify factors that may have contributed to the development of the furcation defect or that could affect treatment outcome. These factors include (a) the morphology of the affected tooth, (b) the position of the tooth relative to adjacent teeth, (c) the local anatomy of the alveolar bone, (d) the configuration of any bony defects, and (e) the presence and extent of other dental diseases (e.g., caries, pulpal necrosis).

The dimension of the furcation entrance is variable but usually quite small; 81% of furcations have an orifice of 1 mm or less, and 58% are 0.75 mm or less.[5,6] The clinician should consider these dimensions, and the local anatomy of the furcation area,[11-13] when selecting instruments for probing. A probe of small cross-sectional dimension is required if the clinician is to detect early furcation involvement.

Local Anatomic Factors

Clinical examination of the patient should allow the therapist to identify not only furcation defects but also many of the local anatomic factors that may affect the result of therapy (prognosis). Well-made dental radiographs, although not allowing a definitive classification of furcation involvement, provide additional information vital for treatment planning (Figure 62-2). Important local factors include anatomic features of the affected teeth, as described next.

Root Trunk Length

A key factor in both the development and the treatment of furcation involvement is the root trunk length. The distance from the cementoenamel junction to the entrance of the furcation can vary extensively. Teeth may have very short root trunks, moderate root trunk length, or roots that may be fused to a point near the apex (Figure

62-3). The combination of root trunk length with the number and configuration of the roots affects the ease and success of therapy. The shorter the root trunk, the less attachment needs to be lost before the furcation is involved. Once the furcation is exposed, teeth with short root trunks may be more accessible to maintenance procedures, and the short root trunks may facilitate some surgical procedures. Alternatively, teeth with unusually long root trunks or fused roots may not be appropriate candidates for treatment once the furcation has been affected.

Root Length

Root length is directly related to the quantity of attachment supporting the tooth. Teeth with long root trunks and short roots may have lost a majority of their support by the time that the furcation becomes affected.[13,20] Teeth with long roots and short-to-moderate root trunk length are more readily treated because sufficient attachment remains to meet functional demands.

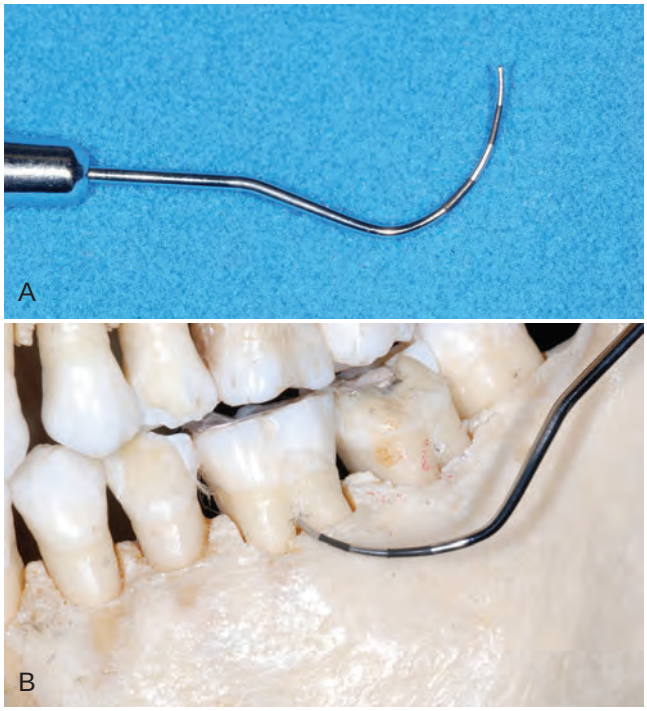

Figure 62-1 **A,** The Nabors probe is designed to probe into the furcation. **B,** The probe placed into a Class II furcation of a dried skull.

Root Form

The mesial root of most mandibular first and second molars and the mesiofacial root of the maxillary first molar are typically curved to the distal side in the apical third. In addition, the distal aspect of this root is usually heavily fluted. The curvature and fluting may increase the potential for root perforation during endodontic therapy or complicate post placement during restoration.[1,25] These anatomic features may also result in an increased incidence of vertical root fracture. The size of the mesial radicular pulp may result in removal of most of this portion of the tooth during preparation.

Interradicular Dimension

The degree of separation of the roots is also an important factor in treatment planning. Closely approximated or fused roots can preclude adequate instrumentation during scaling, root planing, and surgery. Teeth with widely separated roots present more treatment options and are more readily treated.

Anatomy of Furcation

The anatomy of the furcation is complex. The presence of bifurcational ridges, a concavity in the dome,[11] and possible accessory canals[16] complicates not only scaling, root planing, and surgical therapy,[28] but also periodontal maintenance. Odontoplasty to reduce or eliminate these ridges may be required during surgical therapy for an optimal result.

Cervical Enamel Projections

Cervical enamel projections (CEPs) are reported to occur on 8.6% to 28.6% of molars.[26,27,35] The prevalence is highest for mandibular and maxillary second molars. The extent of CEPs was classified by Masters and Hoskins[27] in 1964 (Box 62-1). Figure 62-4 provides an example of a grade III CEP. These projections can affect plaque removal, can complicate scaling and root planing, and may be a local factor in the development of gingivitis and periodontitis. CEPs should be removed to facilitate maintenance.

Anatomy of the Bony Lesions

Pattern of Attachment Loss

The form of the bony lesions associated with the furcation can vary significantly. Horizontal bone loss can expose the furcation as thin facial/lingual plates of bone that may be totally lost during resorption. Alternatively, areas with thickened bony ledges may persist and predispose to the development of furcations with deep vertical components. The pattern of bone loss on other surfaces of the

Figure 62-2 **Different degrees of furcation involvement in radiographs. A,** Grade I furcation on the mandibular first molar and a grade III furcation on the mandibular second molar. The root approximation on the second molar may be sufficient to impede accurate probing of this defect. **B,** Multiple furcation defects on a maxillary first molar. Grade I buccal furcation involvement and grade II mesiopalatal and distopalatal furcations are present. Deep developmental grooves on the maxillary second molar simulate furcation involvement in this molar with fused roots. **C,** Grades III and IV furcations on mandibular molars.

BOX 62-1 Classification of Cervical Enamel Projections

Grade I: The enamel projection extends from the cementoenamel junction of the tooth toward the furcation entrance.
Grade II: The enamel projection approaches the entrance to the furcation. It does not enter the furcation, and therefore no horizontal component is present.
Grade III: The enamel projection extends horizontally into the furcation.

From Masters DH, Hoskins SW: *J Periodontol* 35:49, 1964.

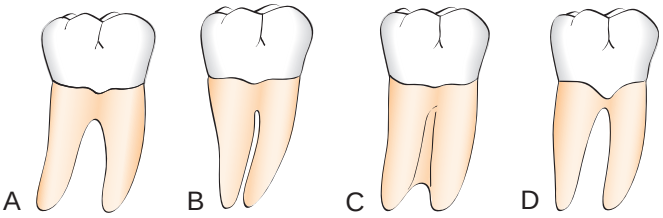

Figure 62-3 Different anatomic features that may be important in prognosis and treatment of furcation involvement. A, Widely separated roots. **B,** Roots are separated but close. **C,** Fused roots separated only in their apical portion. **D,** Presence of enamel projection that may be conducive to early furcation involvement.

Figure 62-4 Furcation involvement by grade III cervical enamel projections.

affected tooth and adjacent teeth must also be considered during treatment planning. The treatment response in deep, multiwalled bony defects is different from that in areas of horizontal bone loss. Complex multiwalled defects with deep, interradicular vertical components may be candidates for regenerative therapies. Alternatively, molars with advanced attachment loss on only one root may be treated by resective procedures.

Other Dental Findings

The dental and periodontal condition of the adjacent teeth must be considered during treatment planning for furcation involvement. The combination of furcation involvement and root approximation with an adjacent tooth represents the same problem that exists in furcations without adequate root separation. Such a finding may dictate the removal of the most severely affected tooth or the removal of a root or roots (Figure 62-5).

The presence of an adequate band of gingiva and a moderate to deep vestibule will facilitate the performance of a surgical procedure, if indicated.

Indices of Furcation Involvement

The extent and configuration of the furcation defect are factors in both diagnosis and treatment planning. This has led to the

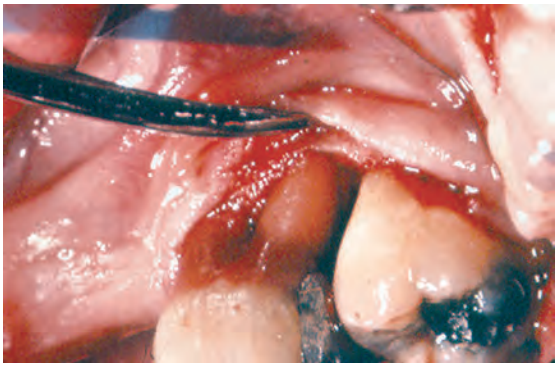

Figure 62-5 Advanced bone loss, furcation involvement, and root approximation. Note the buccal furcation, which communicates with the distal furcation of a maxillary first molar that also displays advanced attachment loss on the distal root and approximation with the mesial root of the maxillary second molar. The patient with such teeth may benefit from root resection of the distobuccal root of the first molar or extraction of the molar.

development of a number of indices to record furcation involvement. These indices are based on the horizontal measurement of attachment loss in the furcation,[14,17] on a combination of horizontal and vertical measurements,[37] or a combination of these findings with the localized configuration of the bony deformity.[10] Glickman[14] classified furcation involvement into four grades (Figure 62-6).

Grade I

A grade I furcation involvement is the incipient or early stage of furcation involvement (see Figure 62-6, *A*). The pocket is suprabony and primarily affects the soft tissues. Early bone loss may have occurred with an increase in probing depth, but radiographic changes are not usually found.

Grade II

A grade II furcation can affect one or more of the furcations of the same tooth. The furcation lesion is essentially a cul-de-sac (see Figure 62-6, *B*) with a definite horizontal component. If multiple defects are present, they do not communicate with each other because a portion of the alveolar bone remains attached to the tooth. The extent of the horizontal probing of the furcation determines whether the defect is early or advanced. Vertical bone loss may be present and represents a therapeutic complication. Radiographs may or may not depict the furcation involvement, particularly with maxillary molars because of the radiographic overlap of the roots. In some views, however, the presence of furcation "arrows" indicates possible furcation involvement (see Chapter 31).

Grade III

In grade III furcations, the bone is not attached to the dome of the furcation. In early grade III involvement, the opening may be filled with soft tissue and may not be visible. The clinician may not even be able to pass a periodontal probe completely through the furcation because of interference with the bifurcational ridges or facial/lingual bony margins. However, if the clinician adds the buccal and lingual probing dimensions and obtains a cumulative probing measurement that is equal to or greater than the buccal/lingual dimension of the tooth at the furcation orifice, the clinician must conclude that a grade III furcation exists (see Figure 62-6, *C*). Properly exposed and angled radiographs of early Class III furcations

Figure 62-6 Glickman's classification of furcation involvement. A, Grade I furcation involvement. Although a space is visible at the entrance to the furcation, no horizontal component of the furcation is evident on probing. **B,** Grade II furcation in a dried skull. Note both the horizontal and the vertical component of this cul-de-sac. **C,** Grade III furcations on maxillary molars. Probing confirms that the buccal furcation connects with the distal furcation of both these molars, yet the furcation is filled with soft tissue. **D,** Grade IV furcation. The soft tissues have receded sufficiently to allow direct vision into the furcation of this maxillary molar.

display the defect as a radiolucent area in the crotch of the tooth (see Chapter 31).

Grade IV

In grade IV furcations, the interdental bone is destroyed, and the soft tissues have receded apically so that the furcation opening is clinically visible. A tunnel therefore exists between the roots of such an affected tooth. Thus the periodontal probe passes readily from one aspect of the tooth to another (see Figure 62-6, *D*).

Other Classification Indices

Hamp et al[17] modified a three-stage classification system by attaching a millimeter measurement to separate the extent of horizontal involvement. Easley and Drennan[10] and Tarnow and Fletcher[37] have described classification systems that consider both horizontal and vertical attachment loss in classifying the extent of furcation involvement. The Tarnow and Fletcher article utilizes a subclassification that measures the probeable vertical depth from the roof of the furca apically. The subclasses being proposed are: A, B, and C. "A" indicates a probeable vertical depth of 1 to 3 mm, "B" indicates 4 to 6 mm, and "C" indicates 7 or more mm of probeable depth from the roof of the furca apically. Furcations would thus be classified as IA, IB, and IC; IIA, IIB, and IIC; and IIIA, IIIB, and IIIC.

Consideration of defect configuration and the vertical component of the defect provides additional information that is useful in planning therapy.

Treatment

The objectives of furcation therapy are to (a) facilitate maintenance, (b) prevent further attachment loss, and (c) obliterate the furcation defects as a periodontal maintenance problem. The selection of therapeutic mode varies with the class of furcation involvement, the extent and configuration of bone loss, and other anatomic factors.

Therapeutic Classes of Furcation Defects

Class I: Early Defects. Incipient or early furcation defects (Class I) are amenable to conservative periodontal therapy.[15] Because the pocket is suprabony and has not entered the furcation, oral hygiene, scaling, and root planing are effective.[16] Any thick overhanging margins of restorations, facial grooves, or CEPs should be eliminated by odontoplasty, recontouring, or replacement. The resolution of inflammation and subsequent repair of the periodontal ligament and bone are usually sufficient to restore periodontal health.

Class II. Once a horizontal component to the furcation has developed (Class II), therapy becomes more complicated. Shallow horizontal involvement without significant vertical bone loss usually responds favorably to localized flap procedures with odontoplasty, osteoplasty, and ostectomy. Isolated deep Class II furcations may respond to flap procedures with osteoplasty and odontoplasty (Figure 62-7). This reduces the dome of the furcation and alters gingival contours to facilitate the patient's plaque removal.

Classes II to IV: Advanced Defects. The development of a significant horizontal component to one or more furcations of a multirooted tooth (late Class II, Class III, or Class IV[13]) or the development of a deep vertical component to the furca poses additional problems. Nonsurgical treatment is usually ineffective because the ability to instrument the tooth surfaces adequately is compromised.[31,40] Periodontal surgery, endodontic therapy, and restoration of the tooth may be required to retain the tooth.

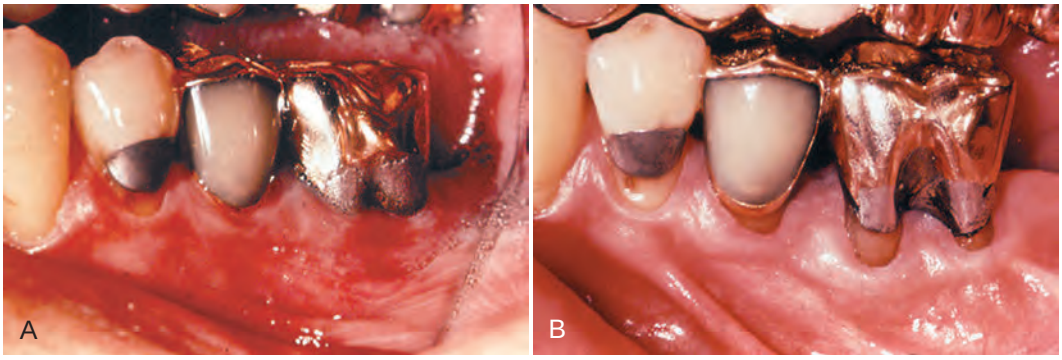

Figure 62-7 Treatment of a grade II furcation by osteoplasty and odontoplasty. A, This mandibular first molar has been treated endodontically and an area of caries in the furcation repaired. A Class II furcation is present. **B,** Results of flap debridement, osteoplasty, and severe odontoplasty 5 years postoperatively. Note the adaptation of the gingiva into the furcation area. *(Courtesy Dr. Ronald Rott, Sacramento, CA.)*

Nonsurgical Therapy

Oral Hygiene Procedures

Furcal management is difficult at best. Therapeutic modalities for the treatment and maintenance of furcations have long been a dilemma amongst periodontists and restorative dentists. Nonsurgical therapy is a very effective way of producing a satisfactory stable result. Ideal results with furcations are impossible to obtain. Once furcation breakdown has begun, there is always a somewhat compromised result clinically. Both surgical and nonsurgical therapies have been shown to work effectively over time. Nonsurgical therapy, a combination of oral hygiene instruction and scaling and root planing, has provided excellent results in some patients. The earlier the furcation is detected and treated the more likely a good long-term result can be obtained. Nonetheless, even advanced furcation lesions can have successful long-term treatment.[34] Several oral hygiene procedures have been used over time. All include access to the furcation. Obtaining access to the furcation requires a combination of the awareness of the furcation by the patient and an oral hygiene tool that facilitates that access. Many tools, including rubber tips; periodontal aids; toothbrushes, both specific and general; and other aids have been used over time for access to the patient (Figure 62-8).

Scaling and Root Planing

Nonsurgical maintenance by the clinician has also improved over time as instrumentation has improved. In recent decades, instruments beyond simple curettes have been used to instrument the furcation. The frustration of instrumentation of the furcation was illustrated beautifully by Bower in 1979 in his articles[5,6] showing that only 58% of furcations could be entered by typically using curettes (see Chapter 33). Subsequently, other instrumentation has evolved, including DeMarco curettes, diamond files, Quetin furcation curettes, and mini Five Gracey Curettes. See Chapter 46 for a detailed discussion on this subject.

Svärdström and Wennström[34] illustrated that in the long term, furcations could be maintained using nonaggressive techniques over a 10-year period in patients who were participants in consistent maintenance. Other studies also illustrate that maintenance therapy is useful for patients to facilitate furcation cleanliness. Chemotherapy has proven disappointing. Ribeiro et al[32] found that nonsurgical therapy can effectively treat Class II furcation involvements, but using povidone-iodine did not provide additional benefits to subgingival instrumentation.

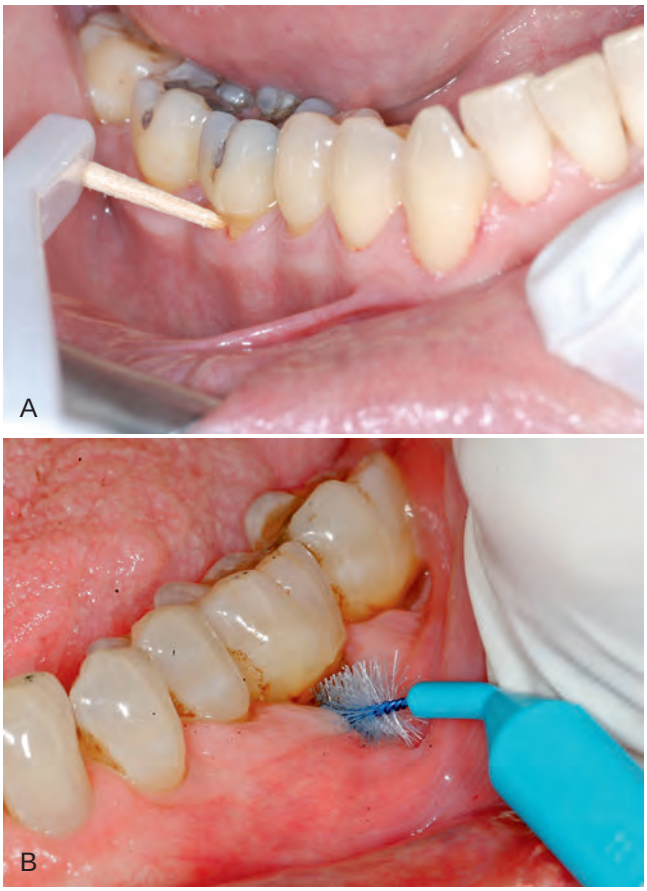

Figure 62-8 A, The utilization of a Perio-Aid into the furcation for plaque removal. **B,** Proxy brush is used for plaque removal into the furcation lesion. *(Courtesy Karen DeYoung, RDH, and Janet Shigekawa, RDH.)*

The area most critical in furcation management is maintaining a relatively plaque-free status to the furcation. Attaining access is a problem in this regard, but with the previously mentioned instruments and an effective nonsurgical approach, much can be accomplished. The most critical component of multirooted tooth maintenance is always the successful reduction or elimination of plaque retention areas from the furcation area; meticulous oral hygiene by the patient and an effective nonsurgical therapy can play a major role in attaining this goal.[21,33]

Surgical Therapy

Osseous Resection

Osseous surgical therapy can be divided into resective and regenerative therapy. This also applies to the furcation areas when surgical therapy is contemplated. For many years, osteoplasty and ostectomy have been used to make the furcation areas cleansable. In the advanced cases, techniques were used to open the furcation into a Class IV from a severe Class II or III case. This would allow easier hygiene into the furcation area for the patient. These techniques have limited usefulness today, but in the compromised individual in whom teeth cannot be extracted or in whom conservative therapy has failed, these surgical techniques have been used. The immediate goal with these surgical approaches is to create access for the patient to maintain good hygiene.

Regeneration

In furcal lesions, bone regeneration is often thought to be relatively futile. The periodontal literature has well-documented therapeutic efforts designed to induce new attachment and reconstruction on molars with furcation defects. Many surgical procedures using a variety of grafting materials have been tested on teeth with different classes of furcation involvement. Some investigators have reported clinical success,[24] whereas others have suggested that the use of these materials in Class II, III, or IV furcations offers little advantage compared with surgical controls.[3,9,30]

Furcation defects with deep two-walled or three-walled components may be suitable for reconstruction procedures. These vertical bony deformities respond favorably to a variety of surgical procedures, including debridement with or without membranes and bone grafts. Chapter 61 addresses therapies designed to induce new attachment or reattachment.

Tsao et al[39] have shown that the furcation defect is a graftable lesion. They found that lesions that were grafted had greater vertical fill than areas treated with open flap debridement alone. Bowers et al[7] have shown furcation bone grafting using various membranes can improve the clinical status of these lesions. Nonetheless, bone grafting remains an elusive goal with variable results in furcation lesions. Another area of interest has been barrier membrane technology. Analysis of published studies demonstrated a great variability in the clinical outcomes in mandibular grade II furcations treated with different types of nonbioabsorbable and bioabsorbable barrier membranes.

Although many barrier membrane studies show a slight clinical improvement after treatment in both maxillary and mandibular furcations, the results are generally inconsistent.

Extraction

The extraction of teeth with through-and-through furcation defects (Classes III and IV) and advanced attachment loss may be the most appropriate therapy for some patients. This is particularly true for individuals who cannot or will not perform adequate plaque control, who have a high level of caries activity, who will not commit to a suitable maintenance program, or who have socioeconomic factors that may preclude more complex therapies. Some patients are reluctant to accept periodontal surgery or even allow the removal of a tooth with advanced furcation involvement, even though the long-term prognosis is poor. The patient may elect to forego therapy, opt to treat the area with scaling and root planing or site-specific antibacterial therapies, and delay extraction until the tooth becomes symptomatic. Although additional attachment loss may occur, such teeth may survive a significant number of years.[21,33]

Dental Implants

The advent of osseointegrated dental implants as an alternative abutment source has had a major impact on the retention of teeth with advanced furcation problems. The high level of predictability of osseointegration may motivate the therapist and patient to consider removal of teeth with a guarded or poor prognosis and to seek an implant-supported prosthetic treatment plan. Therefore careful evaluation of the long-term periodontal, endodontic, and restorative prognosis must be considered before invasive surgical therapy is undertaken to save a tooth with an advanced furcated lesion (Figure 62-15).

Prognosis

For many years the presence of significant furcation involvement meant a hopeless long-term prognosis for the tooth. Clinical research, however, has indicated that furcation problems are not as severe a complication as originally suspected if one can prevent the development of caries in the furcation. Relatively simple periodontal therapy is sufficient to maintain these teeth in function for long periods.[21,33] Other investigators have defined the reasons for clinical failure of root-resected or hemisected teeth.[2,25] Their data indicate that recurrent periodontal disease is not a major cause of the failure of these teeth. Investigations of root-resected or hemisected teeth have shown that such teeth can function successfully for long periods.[2,8,25] The keys to long-term success appear to be (a) thorough diagnosis, (b) selection of patients with good oral hygiene, (c) excellence in nonsurgical therapy, and (d) careful surgical and restorative management.

Root Resection

Root resection may be indicated in multirooted teeth with grades II to IV furcation involvements. Root resection may be performed on vital teeth[19] or endodontically treated teeth. It is preferable, however, to have endodontic therapy completed before resection of a root(s).[18] If this is not possible, the pulp should be removed, the patency of the canals determined, and the pulp chamber medicated before resection. It is distressing for both patient and clinician to perform a vital root resection and subsequently have an unfavorable event occur, such as perforation, fracture of the root, or an inability to instrument the canal.

The indications and contraindications for root resection were well summarized by Bassaraba.[1] In general, teeth planned for root resection include the following:

1. Teeth that are critically important to the overall dental treatment plan.[4] Examples are teeth serving as abutments for fixed or removable restorations for which loss of the tooth would result in loss of the prosthesis and entail major prosthetic retreatment.
2. Teeth that have sufficient attachment remaining for function. Molars with advanced bone loss in the interproximal and interradicular zones, unless the lesions have three bony walls, are not candidates for root amputation.
3. Teeth for which a more predictable or cost-effective method of therapy is not available. Examples are teeth with furcation defects that have been treated successfully with endodontics but now present with a vertical root fracture, advanced bone loss, or caries on the root.
4. Teeth in patients with good oral hygiene and low activity for caries are suitable for root resection. Patients unable or unwilling to perform good oral hygiene and preventive measures are not suitable candidates for root resection or hemisection. Root-resected teeth require endodontic treatment[18] and usually cast restorations.

These therapies can represent a sizable financial investment by the patient in an effort to save the tooth. Alternative therapies and their impact on the overall treatment plan should always be considered and presented to the patient.

Which Root to Remove. A tooth with an isolated furcation defect in an otherwise intact dental segment may present few diagnostic problems. However, the existence of multiple furcation defects of varying severity combined with generalized advanced periodontitis can be a challenge to treatment planning. Careful diagnosis usually allows the therapist to determine the feasibility of root resection and the identification of which root to remove before surgery (Figure 62-9). Every attempt should be made to determine this prior to surgical exposure.

The following is a guide to determining which root should be removed in these cases:

1. Remove the root(s) that will eliminate the furcation and allow the production of a maintainable architecture on the remaining roots.
2. Remove the root with the greatest amount of bone and attachment loss. Sufficient periodontal attachment must remain after surgery for the tooth to withstand the functional demands placed on it such as bridge abutments and in bruxers. Teeth with uniform advanced horizontal bone loss are not suitable for root resection.
3. Remove the root that best contributes to the elimination of periodontal problems on adjacent teeth. For example, a maxillary first molar with a Class III buccal-to-distal furcation is adjacent to a maxillary second molar with a two-walled intrabony defect between the molars and an early Class II furcation on the mesial furcation of the second molar. There may or may not be local anatomic factors affecting the teeth. The removal of the distobuccal root of the first molar allows the elimination of the furcation and management of the two-wall intrabony lesion and also facilitates access for instrumentation and maintenance of the second molar.
4. Remove the root with the greatest number of anatomic problems such as severe curvature, developmental grooves, root flutings, or accessory and multiple root canals.
5. Remove the root that least complicates future periodontal maintenance.

Hemisection

Hemisection is the splitting of a two-rooted tooth into two separate portions. This process has been called bicuspidization or separation because it changes the molar into two separate roots. Hemisection is most likely to be performed on mandibular molars with buccal and lingual Class II or III furcation involvements. As with root resection, molars with advanced bone loss in the interproximal and interradicular zones are not good candidates for hemisection. After sectioning of the teeth, one or both roots can be retained. This decision is based on the extent and pattern of bony loss, root trunk and root length, ability to eliminate the osseous defect, and endodontic and restorative considerations. The anatomy of the mesial roots of mandibular molars often leads to their extraction and the retention of the distal root to facilitate both endodontic and restorative therapy.

The interradicular dimension between the two roots of a tooth to be hemisected is also important. Narrow interradicular zones can complicate the surgical procedure. The retention of both molar roots can complicate the restoration of the tooth, since it may be virtually impossible to finish margins or to provide an adequate embrasure between the two roots for effective oral hygiene and maintenance (Figure 62-10). Therefore, orthodontic separation of the roots is often required to allow restoration with adequate embrasure form (Figure 62-11). The result can be the need for multiple procedures and extensive interdisciplinary therapy. In these patients the availability of other treatment alternatives should be considered such as guided tissue/guided bone regeneration or replacement by osseointegrated dental implants.

Root Resection/Hemisection Procedure

The most common root resection involves the distobuccal root of the maxillary first molar,[2,26] as diagrammed in Figure 62-12. After appropriate local anesthesia, a full-thickness mucoperiosteal flap is elevated. Root resection or hemisection of teeth with advanced attachment loss usually requires opening both facial and lingual/palatal flaps (see Chapter 57). Typically, a root cannot be resected without elevating a flap. The flap should provide adequate access for visualization and instrumentation and minimize surgical trauma.

After debridement, resection of the root begins with the exposure of the furcation on the root to be removed (see Figure 62-12, *A*). The removal of a small amount of facial or palatal bone may be required to provide access for elevation and facilitate root removal (see Figure 62-12, *B*). A cut is then directed from just apical to the contact point of the tooth, through the tooth, and to the facial and distal orifices of the furcation (see Figure 62-12, *C*). This cut is made with a high-speed, surgical-length fissure or cross-cut fissure carbide bur. The placement of a curved periodontal probe into or through the furcation aids in orienting the angle of the resection. For hemisection, a vertically oriented cut is made

Figure 62-9 Resection of a root with advanced bone loss. A, Facial osseous contours. There is an early grade II furcation on the facial aspect of the mandibular first molar and a Class III furcation on the mandibular second molar. **B,** Resection of the mesial root. The mesial portion of the crown was retained to prevent mesial drift of the distal root during healing. The grade II furcations were treated by osteoplasty. **C,** Buccal flaps adapted and sutured. **D,** Lingual flaps adapted and sutured. **E,** Three-month postoperative view of the buccal aspect of this resection. New restorations were subsequently placed. **F,** Three-month postoperative view of the lingual aspect of this resection.

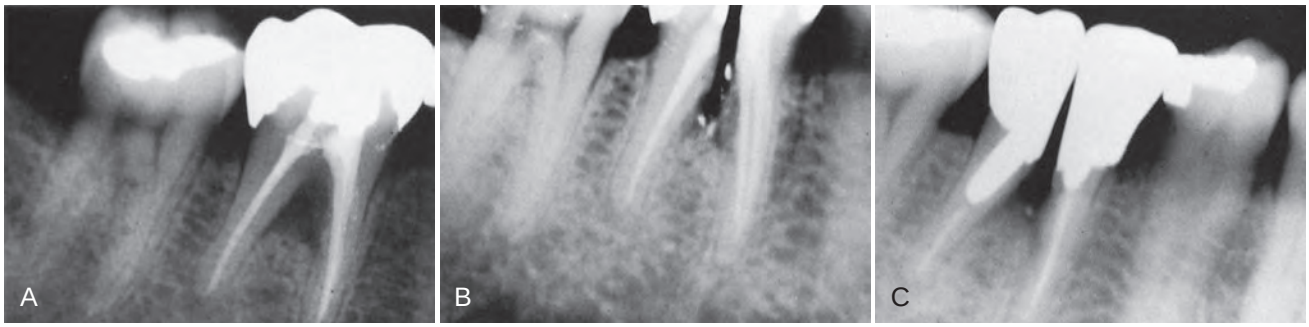

Figure 62-10 A, Grade III furcation lesion. **B,** Hemisection to divide the tooth into mesial and distal portions. **C,** Postoperative view of a hemisected mandibular with new crowns for both roots.

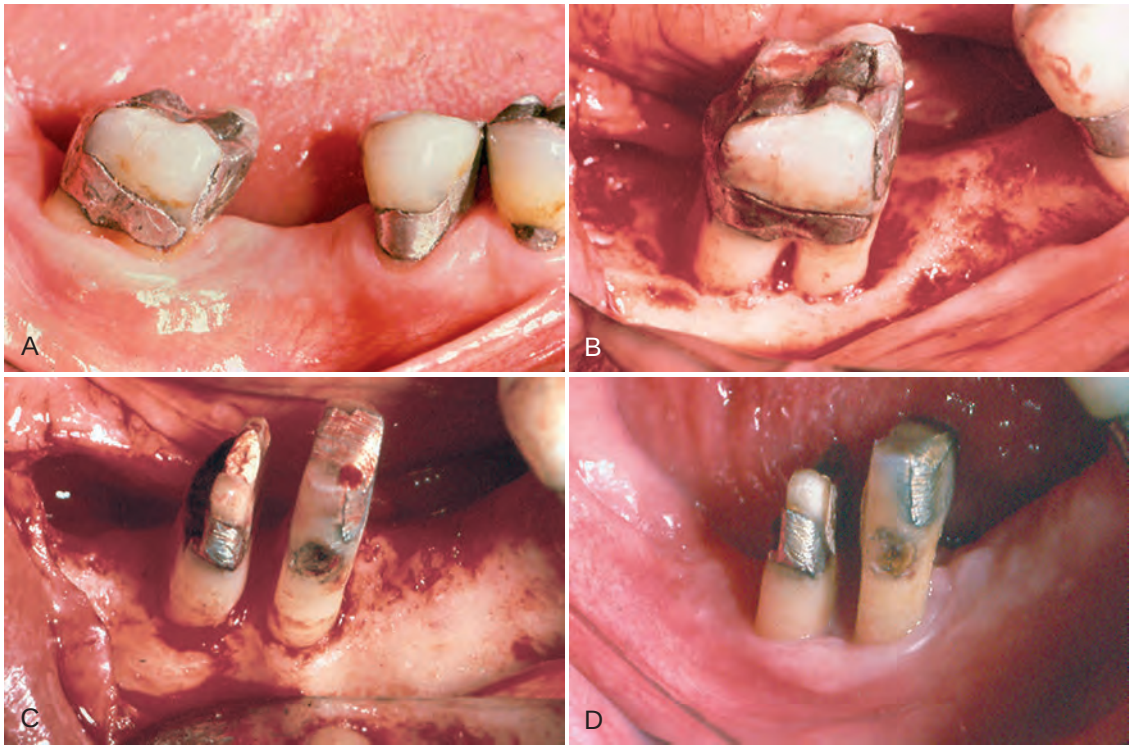

Figure 62-11 Hemisection and interradicular dimension. A, Buccal preoperative view of a mandibular right second molar with a deep grade II buccal furcation and root approximation. **B,** Buccal view of bony lesions with flaps. Note the mesial and distal one-wall bony defects. The lingual furcation was similarly affected. **C,** The molar has been hemisected and partially prepared for temporary crowns. Observe the minimal dimension between the two roots. **D,** Buccal view 3 weeks postoperatively. Because the embrasure space is minimal, these roots will be separated with orthodontic therapy to facilitate restoration. *(Courtesy Dr. Louis Cuccia, Roseville, CA.)*

faciolingually through the buccal and lingual developmental grooves of the tooth, through the pulp chamber, and through the furcation. If the sectioning cut passes through a metallic restoration, the metallic portion of the cut should be made before flap elevation. This prevents contamination of the surgical field with metallic particles.

If a vital root resection is to be performed, a more horizontal cut through the root is advisable (see Figure 62-12, *D*). An oblique cut exposes a large surface area of the radicular pulp and/or dental pulp chamber. This can lead to postoperative pain and can complicate endodontic therapy. A horizontal cut, although it may complicate root removal, has fewer postoperative complications. This root stump can be removed by odontoplasty after the completion of endodontic therapy or at the time of tooth preparation.

After sectioning, the root is elevated from its socket (see Figure 62-12, *E*). Care should be taken not to traumatize bone on the remaining roots or to damage an adjacent tooth. Removal of the root provides visibility to the furcation aspects of the remaining roots and simplifies the debridement of the furcation with hand, rotary, or ultrasonic instruments. If necessary, odontoplasty is performed to remove portions of the developmental ridges and prepare a furcation that is free of any deformity that would enhance plaque retention or adversely affect plaque removal (see Figure 62-12, *F*).

Patients with advanced periodontitis often have root resection performed in conjunction with other surgical procedures. Figure 68-13 provides an example of combining root resection and periodontal osseous surgery. The bony lesions that may be present on adjacent teeth are then treated using resective or regenerative therapies. After resection, the flaps are then approximated to cover any grafted tissues or slightly cover the bony margins around the tooth. Sutures are then placed to maintain the position of the flaps. The area may or may not be covered with a surgical dressing.

The removal of a root alters the distribution of occlusal forces on the remaining roots. Therefore, it is wise to evaluate the occlusion of teeth from which roots have been resected and, if necessary, adjust the occlusion. Centric holds should be maintained, but eccentric forces should be eliminated from the area over the root that was removed. Patients with advanced attachment loss may benefit from temporary stabilization of the resected tooth to prevent movement (Figure 62-14).

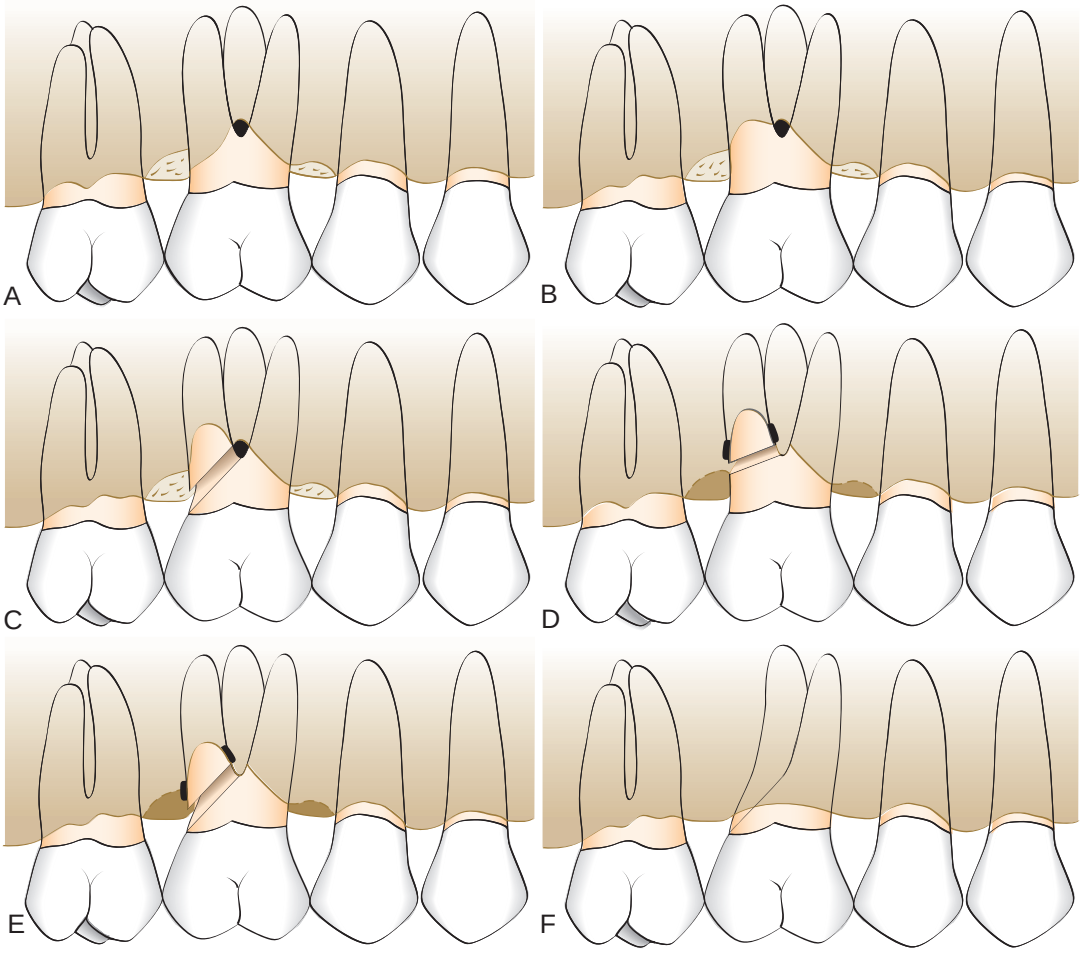

Figure 62-12 Diagrams of distobuccal root resection of maxillary first molar. A, Preoperative bony contours with grade II buccal furcation and a crater between the first and second molar. **B,** Removal of bone from the facial side of the distobuccal root and exposure of the furcation for instrumentation. **C,** Oblique section that separates the distal root from the mesial and palatal roots of the molar. **D,** More horizontal section that may be used on a vital root amputation because it exposes less of the pulp of the tooth. **E,** Areas of application of instruments to elevate the sectioned root. **F,** Final contours of the resection.

Figure 62-13 Hemisection combined with osseous surgery to treat furcation defects. A, Buccal preoperative view with provisional bridge. **B,** Lingual view with provisional bridge in place. **C,** Radiograph of bony defects. Note the deep mesial bony defect, largely of one wall, and the radiolucent area in the furcation of the first molar, indicating a grade II defect. **D,** Buccal view before osseous surgery. In addition to the furcation involvement, a root separation problem exists between the two roots of the first molar. Class II furcations are present on the second molar. **E,** Buccal view after osseous surgery. Mesial root hemisected and removed. The other defects were treated by osteoplasty and ostectomy. **F,** Lingual preoperative view. Note the heavy bony ledging at the lingual surface of these first and second molars. **G,** Lingual postoperative view. The mesial root has been resected, the bony ledging recontoured, and the grade II furcations treated by osteoplasty. **H,** Buccal view 10 years after treatment. **I,** Lingual view 10 years after treatment. *(Courtesy Dr. Louis Cuccia, Roseville, CA.)*

Figure 62-14 Mesial root resection in the presence of advanced bone loss. A and **B,** Buccal and lingual preoperative views. Note the soft-tissue contours that are predictive of the bony defects. **C,** Radiograph of extent of furcation involvement of the first and second molars. **D** and **E,** Buccal preoperative and postoperative views. The mesial root of the second molar was resected and the interproximal craters treated by osteoplasty and minor ostectomy. **F** and **G,** Lingual preresection and postresection views. The heavy ledges and horizontal bone loss on the lingual surface were managed by osteoplasty. **H** and **I,** Buccal and lingual views 6 weeks postoperatively. A temporary wire splint has been bonded to the molars to prevent tipping of the distal root of the mandibular second molar. *(Courtesy Dr. Louis Cucci, Roseville, CA.)*

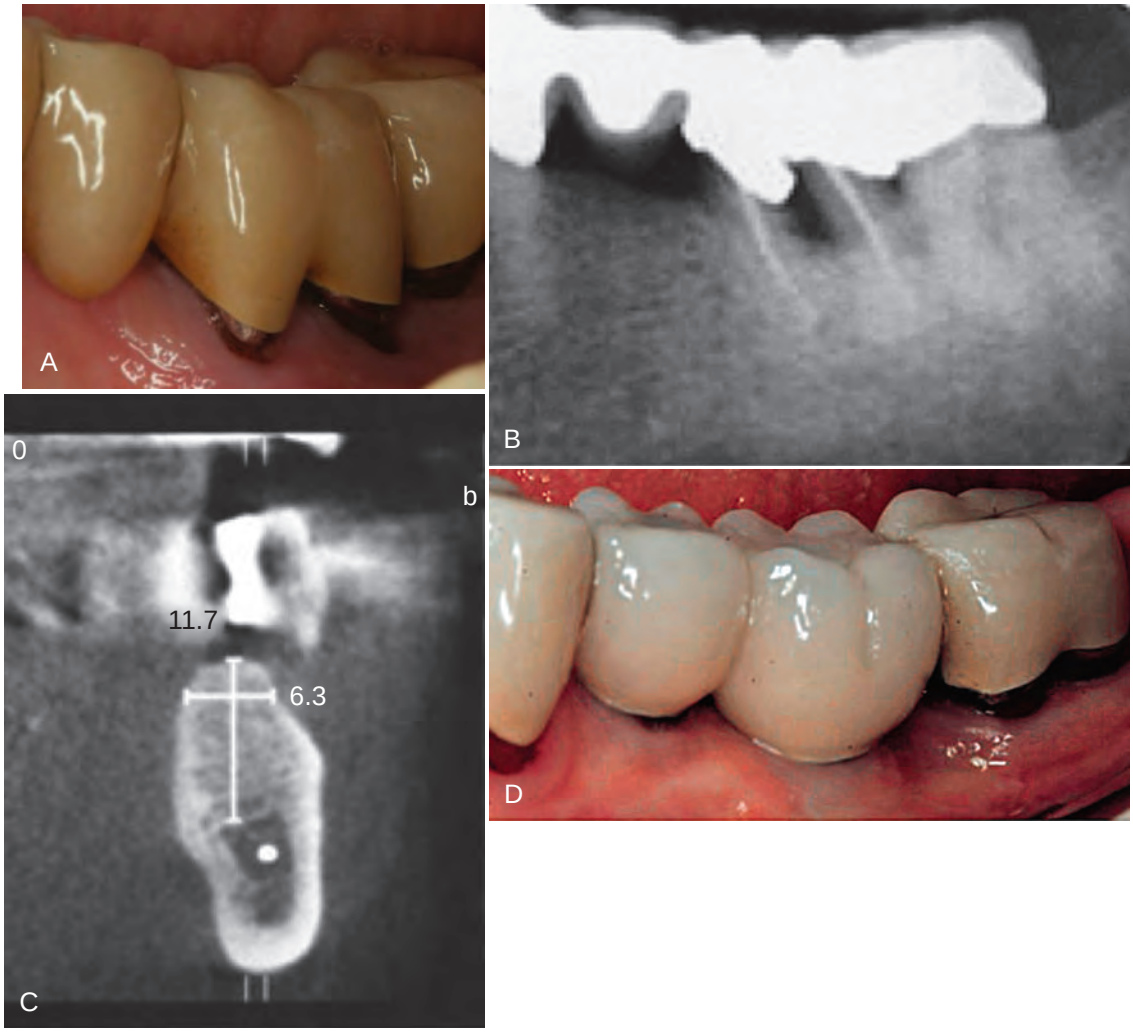

Figure 62-15 **A,** Clinical picture of a Class III furcation involvement. **B,** Radiographic appearance is far more grave than the clinical appearance. **C,** After the tooth is removed, a computed tomography (CT) radiograph is taken to plan treatment for implant replacement. **D,** The implant restored. *(Courtesy Dr. Sarvenaz Angha, Los Angeles.)*

Suggested Readings

DeSanctis M, Murphy KG: The role of resective periodontal surgery in the treatment of furcation defects. *J Periodontol* 22:154–168, 2000.

Newell DH: The diagnosis and treatment of molar furcation invasions. *Dent Clin North Am* 42(2):301–337, 1998.

References

References for this chapter are found on the companion website www.expertconsult.com.

References

1. Bassaraba N: Root amputation and tooth hemisection. *Dent Clin North Am* 13:121, 1969.
2. Basten CH, Ammons WF, Persson R: Long-term evaluation of root resected molars: a retrospective study. *Int J Periodont Restor Dent* 16(3):207, 1996.
3. Becker W, Becker BE, Berg L, et al: New attachment after treatment with root isolation procedures: report for treated class III and class II furcations and vertical osseous defects. *Int J Periodont Restor Dent* 8(3):9, 1988.
4. Black GV: The American system of dentistry, Philadelphia, 1886, Lea Brothers.
5. Bower RC: Furcation morphology relative to periodontal treatment: furcation root surface anatomy. *J Periodontol* 50:366, 1979.
6. Bower RC: Furcation morphology relative to periodontal treatment: furcation entrance architecture. *J Periodontol* 50:23, 1979.
7. Bowers GM, Schallhorn RG, McClain PK, et al: Factors influencing the outcome of regenerative therapy in mandibular class II furcations: part I. *J Periodontol* 74(9):1255–1268, 2003.
8. Carnevale G, DiFebo G, Toyelli MP, et al: A retrospective analysis of the periodontal-prosthodontic treatment of molars with interradicular lesions. *Int J Periodont Restor Dent* 11:188, 1991.
9. Demolon IA, Person GR, Ammons WF, et al: Effects of antibiotic treatment on clinical conditions with guided tissue regeneration: one-year results. *J Periodontol* 65:713, 1994.
10. Easley JR, Drennan GA: Morphological classification of the furca. *J Can Dent Assoc* 35:104, 1969.
11. Everett F, Jump E, Holder T, et al: The intermediate bifurcational ridge: a study of the morphology of the bifurcation of the lower molar. *J Dent Res* 37:162, 1958.
12. Gher ME, Vernino AR: Root morphology: clinical significance in pathogenesis and treatment of periodontal disease. *J Am Dent Assoc* 101:627, 1980.
13. Gher ME, Jr, Dunlap RW: Linear variation of the root surface area of the maxillary first molar. *J Periodontol* 56:39, 1985.
14. Glickman I: *Clinical periodontology*, Philadelphia, 1953, Saunders.
15. Goldman HM: Therapy of the incipient bifurcation involvement. *J Periodontol* 29:112, 1958.
16. Gutmann JL: Prevalence, location and patency of accessory canals in the furcation region of permanent molars. *J Periodontol* 49:21, 1978.
17. Hamp SE, Nyman S, Lindhe J: Periodontal treatment of multirooted teeth. Results after 5 years. *J Clin Periodontol* 2:126, 1975.
18. Harrington GW: The perio-endo question: differential diagnosis. *Dent Clin North Am* 23:673, 1979.
19. Haskell EW, Stanley HR: A review of vital root resection. *Int J Periodont Restor Dent* 2(6):29, 1982.
20. Hermann DW, Gher ME, Jr, Dumlap RM, et al: The potential attachment area of the maxillary first molar. *J Periodontol* 54:431, 1983.
21. Hirschfeld L, Wasserman B: A long-term survey of tooth loss in 600 treated periodontal patients. *J Periodontol* 49:225, 1978.
22. Hou GL, Tasai CC: Relationship between periodontal furcation involvement and molar cervical enamel projection. *J Periodontol* 58:715, 1978.
23. Kalkwarf K, Kaldahl W, Patil K, et al: Evaluation of furcation region response to periodontal therapy. *J Periodontol* 59:794, 1988.
24. Kenney EB, Lekovic V, Elbaz JJ, et al: The use of porous hydroxylapatite implants in periodontal defects. II. Treatment of class II furcation lesions in lower molars. *J Periodontol* 59:67, 1988.
25. Langer B, Stein SD, Wagenberg B: An evaluation of root resections: a ten-year study. *J Periodontol* 52:719, 1981.
26. Larato DC: Some anatomical factors related to furcation involvement. *J Periodontol* 46:608, 1975.
27. Masters DH, Hoskins SW: Projection of cervical enamel into molar furcations. *J Periodontol* 35:49, 1964.
28. Matia JB, Bissada NF, Maybury JE, et al: Efficiency of scaling of the molar furcation area with and without surgical access. *Int J Periodont Restor Dent* 6(6):25, 1986.
29. Mealy BL, Beybayer MF, Butzin CA, et al: Use of furcal bone sounding to improve accuracy of furcation diagnosis. *J Periodontol* 65:649, 1994.
30. Metzler DG, Seamons BC, Mellonig JT, et al: Clinical evaluation of guided tissue regeneration in the treatment of maxillary class II molar furcation. *J Periodontol* 62:353, 1991.
31. Parashis AO, Anognou-Vareltzides A, Demetrious N: Calculus removal from multirooted teeth with and without surgical access. I. Efficacy on external and furcation surfaces in relation to probing depth. *J Clin Periodontol* 20:63, 1993.
32. Ribeiro EDP, Bittencourt S, Ambrosano GMB, et al: Povidone-iodine used as an adjunct to non-surgical treatment of furcation involvements. *J Periodontol* 77(2):211–217, 2006.
33. Ross I, Thompson RH: A long-term study of root retention of maxillary molars with furcation involvement. *J Periodontol* 49:238, 1978.
34. Svärdström G, Wennström J: Periodontal treatment decisions for molars: an analysis of influencing factors and long-term outcome. *J Periodontol* 71(4):579–585, 2000.
35. Tal H: Furcal bony defects in dry mandibles. I. Biometric study. *J Periodontol* 53:360, 1982.
36. Tal H, Lemmer J: Furcal defects in dry mandibles. II. Severity of furcal defects. *J Periodontol* 53:364, 1982.
37. Tarnow D, Fletcher P: Classification of the vertical component of furcation involvement. *J Periodontol* 55:283, 1984.
38. Tibbetts LF: Use of diagnostic probes for detection of periodontal disease. *J Am Dent Assoc* 78:549, 1969.
39. Tsao Y, Neiva R, Al-Shammari K, et al: Factors influencing treatment outcomes in mandibular class II furcation defects. *J Periodontol* 77(4):641–646, 2006.
40. Wylam JM, Mealey B, Mills MP, et al: The clinical effectiveness of open versus closed scaling and root planing on multi-rooted teeth. *J Periodontol* 64:1023, 1993.

CHAPTER 63

Periodontal Plastic and Esthetic Surgery

Henry H. Takei, E. Todd Scheyer, Robert R. Azzi, Edward P. Allen, and Thomas J. Han

CHAPTER OUTLINE

Terminology
Objectives
Etiology of Marginal Tissue Recession
Factors That Affect Surgical Outcome
Techniques to Increase Attached Gingiva *(e-only)*
Techniques to Deepen the Vestibule *(e-only)*
Techniques to Remove the Frenum *(e-only)*
Techniques to Improve Esthetics *(e-only)*
Tissue Engineering *(e-only)*
Criteria for Selection of Techniques
Conclusion

For online only content on techniques to increase attached gingiva, techniques to deepen the vestibule, techniques to remove the frenum, techniques to improve esthetics, and tissue engineering, go to the companion website www.expertconsult.com. Some figures may be out of numeric order in this printed chapter. Editors Note: An animation (slide show) has been added as a supplement to the chapter by the Editors. This was produced by My Dental Hub as a patient education tool and covers the basic elements in a conceptual manner. It is not intended to be a procedural guide for dental professionals.

Terminology

The term *mucogingival surgery* was initially introduced in the literature by Friedman[38] to describe surgical procedures for the correction of relationships between the gingiva and the oral mucous membrane with reference to three specific problem areas: attached gingiva, shallow vestibules, and a frenum interfering with the marginal gingiva. With the advancement of periodontal surgical techniques, the scope of nonpocket surgical procedures has increased, now encompassing a multitude of areas that were not addressed in the past. Recognizing this, the 1996 World Workshop in Clinical Periodontics renamed mucogingival surgery as "periodontal plastic surgery,"[4] a term originally proposed by Miller in 1993 and broadened to include the following areas[3,4]:

- Periodontal-prosthetic corrections
- Crown lengthening
- Ridge augmentation
- Esthetic surgical corrections
- Coverage of the denuded root surface
- Reconstruction of papillae
- Esthetic surgical correction around implants
- Surgical exposure of unerupted teeth for orthodontics

Periodontal plastic surgery is defined as the surgical procedures performed to correct or eliminate anatomic, developmental, or traumatic deformities of the gingiva or alveolar mucosa.[3,4] Mucogingival therapy is a broader term that includes nonsurgical procedures such as papilla reconstruction by means of orthodontic or restorative therapy. Periodontal plastic surgery includes only the surgical procedures of mucogingival therapy (see Video 63-1: Periodontal Plastic and Esthetic Surgery).

This chapter discusses the periodontal plastic surgical techniques included in the traditional definition of mucogingival surgery: (1) widening of attached gingiva (2) deepening of shallow vestibules, and (3) resection of the aberrant frena. In addition, esthetic surgical therapy around the natural dentition and tissue engineering (biologic mediator) are included in this chapter. Other aspects of periodontal plastic surgery, such as periodontal-prosthetic surgery, esthetic surgery around implants, and surgical exposure of teeth for orthodontic therapy, are covered in Chapters 51, 66, and 78.

Objectives

The five objectives of periodontal plastic surgery addressed in this chapter are as follows:

1. Problems associated with attached gingiva
2. Problems associated with a shallow vestibule
3. Problems associated with an aberrant frenum
4. Esthetic surgical therapy
5. Tissue engineering

Problems Associated with Attached Gingiva

The ultimate goal of mucogingival surgical procedures is the creation or widening of attached gingiva around teeth and implants.[4] The width of the attached gingiva varies in different individuals and on different teeth of the same individual (see Chapter 2). Attached gingiva is not synonymous with "keratinized gingiva" because the latter also includes the free gingival margin.

The width of the attached gingiva is determined by subtracting the depth of the sulcus or pocket from the distance between the crest of the gingival margin and the mucogingival junction.

The original rationale for mucogingival surgery was predicated on the assumption that a minimal width of attached gingiva was required to maintain optimal gingival health. However, several studies have challenged the view that a wide, attached gingiva is more protective against the accumulation of plaque than a narrow or a nonexistent zone. No minimum width of attached gingiva has

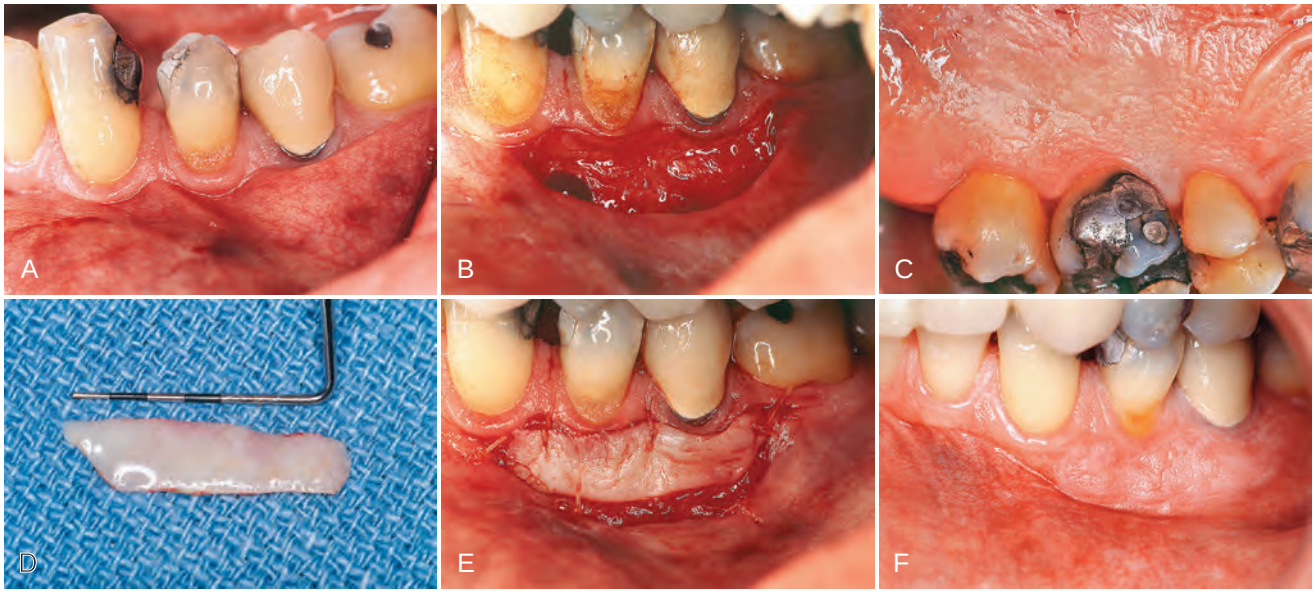

Figure 63-3 Free gingival graft. **A,** Before treatment; minimal keratinized gingiva. **B,** Recipient site prepared for free gingival graft. **C,** Palate will be donor site. **D,** Free graft. **E,** Graft transferred to recipient site. **F,** At 6 months, showing widened zone of attached gingiva. *(Courtesy Dr. Perry Klokkevold, Los Angeles.)*

Techniques to Increase Attached Gingiva

To simplify and better understand the techniques and the result of the surgery, the following classifications are presented:

- *Gingival augmentation apical to the area of recession.* A graft, either pedicle or free, is placed on a recipient bed apical to the recessed gingival margin. No attempt is made to cover the denuded root surface where there is gingival and bone recession.
- *Gingival augmentation coronal to the recession (root coverage).* A graft (either pedicle or free) is placed covering the denuded root surface. Both the apical and the coronal widening of attached gingiva enhance oral hygiene procedures, but only the latter can correct an esthetic problem. For preprosthetic purposes, the combination of widening keratinized gingiva apical and coronal to the recession would satisfy this objective. Consideration of the objectives as apical, coronal, or both provides a better understanding of the techniques required to achieve the goals.

Widening of the keratinized attached gingiva (apical or coronal to the area of recession) can be accomplished by numerous techniques, such as the free gingival autograft, free connective tissue autograft, and lateral pedicle flap, which can be used for either objective.

Gingival Augmentation Apical to Recession

Techniques for gingival augmentation apical to the area of recession include free gingival autograft, free connective tissue autograft,[10] and the apically positioned flap.

Free Gingival Autografts. Free gingival grafts are used to create a widened zone of attached gingiva. They were initially described by Bjorn[12] in 1963 and have been extensively investigated since that time (Figure 63-3).[13]

The Classic Technique. *Step 1: Prepare the recipient site.* The purpose of this step is to prepare a firm connective tissue bed to receive the graft. The recipient site can be prepared by incising at the existing mucogingival junction with a #15 blade to the desired depth, blending the incision on both ends with the existing mucogingival line. Periosteum should be left covering the bone.

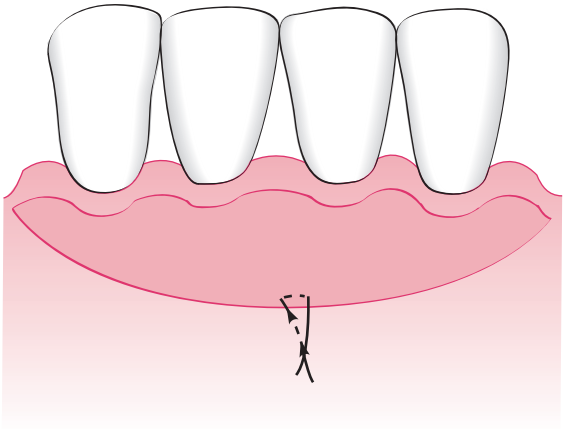

Figure 63-4 Diagram of graft bed suture.

Another technique consists of outlining the recipient site with two vertical incisions from the incised gingival margin into the alveolar mucosa. Extend the incisions to approximately twice the desired width of the attached gingiva, allowing for 50% contraction of the graft when healing is complete. The amount of contraction depends on the extent to which the recipient site penetrates the muscle attachments. The deeper the recipient site, the greater is the tendency for the muscles to elevate the graft and reduce the final width of the attached gingiva. The periosteum along the apical border of the graft is sometimes penetrated in an effort to prevent postoperative narrowing of the attached gingiva.

The #15 blade is used to incise along the gingival margin to separate a flap consisting of epithelium and underlying connective tissue without disturbing the periosteum. Extend the flap to the depth of the vertical incisions. Suture the flap where the apical portion of the free graft will be located. Three to four independent gut sutures are placed. The needle is first passed as a superficial mattress suture perpendicular to the incision and then on the periosteum parallel to the incision (Figure 63-4).

An aluminum foil template of the recipient site can be made to be used as a pattern for the graft.

Grafts can also be placed directly on bone tissue. For this technique, the flap should be separated by blunt dissection with a periosteal elevator. The advantages of this variant are less postoperative mobility of the graft, less swelling, better hemostasis,[32] and 1.5 to 2 times less shrinkage.[52,53] However, there is a healing lag period that is observed for the first 2 weeks.[21,22,36]

Step 2: Obtain the graft from the donor site. The classic or conventional free gingival graft technique consists of transferring a piece of keratinized gingiva approximately the size of the recipient site. To avoid the large wound that this procedure sometimes leaves in the donor site, some alternative methods have been proposed. The original technique is described first, followed by several of the most common variants.

For the classic technique, a partial-thickness graft is used. The palate is the usual site from which the donor tissue is removed. The graft should consist of epithelium and a thin layer of underlying connective tissue. Place the template over the donor site, and make a shallow incision around it with a #15 blade. Insert the blade to the desired thickness at one edge of the graft. Elevate the edge and hold it with tissue forceps. Continue to separate the graft with the blade, lifting it gently as separation progresses to provide visibility. Placing sutures at the margins of the graft helps control it during separation and transfer and simplifies placement and suturing to the recipient site.[10]

Proper thickness is important for survival of the graft. It should be thin enough to permit diffusion of fluid from the recipient site, which is essential in the immediate posttransplant period. A graft that is too thin may necrose and expose the recipient site.[75,82] If the graft is too thick, its peripheral layer is jeopardized because of the excessive tissue that separates it from new circulation and nutrients. Thick grafts may also create a deeper wound at the donor site, with the possibility of injuring major palatal arteries.[112] The ideal thickness of a graft is between 1.0 and 1.5 mm.[75,82] After the graft is separated, remove the loose tissue tags from the undersurface. Thin the edge to avoid bulbous marginal and interdental contours. Special precautions must be taken with grafts from the palate.

The submucosa in the posterior region is thick and fatty and should be trimmed so that it will not interfere with vascularization. Grafts tend to reestablish their original epithelial structure, so mucous glands may occur in grafts obtained from the palate.

A thick graft can be thinned by holding it between two wet wooden tongue depressors and slicing it longitudinally with a sharp #15 blade.

Step 3: Transfer and immobilize the graft. Remove the sponge from the recipient site; reapply it with pressure if necessary until bleeding is stopped. Remove the excess clot. A thick clot interferes with vascularization of the graft.[76]

Position the graft and adapt it firmly to the recipient site. A space between the graft and the underlying tissue (dead space) impairs vascularization and jeopardizes the graft. Suture the graft at the lateral borders and to the periosteum to secure it in position. The graft must be immobilized. Any movement interferes with healing. Avoid excessive tension, which can distort the graft from the underlying surface. Every precaution should be taken to avoid trauma to the graft. Tissue forceps should be used delicately and a minimum number of sutures used to avoid unnecessary tissue perforation.

Step 4: Protect the donor site. Cover the donor site with a periodontal pack for 1 week, and repeat if necessary. Retention of the pack on the donor site can be a problem. If facial attached gingiva was used, the pack may be retained by locking it through the interproximal spaces onto the lingual surface. If there are no open interdental spaces, the pack can be covered by a plastic stent wired to the teeth. A modified Hawley retainer is useful to cover the pack on the palate and over edentulous ridges.

Variant Techniques. The free gingival graft technique is a predictable procedure, but the donor site (palate) is left with an open wound that must heal by secondary intention. The following variant techniques attempt to minimize the donor site wound by removing the donor tissue in a different configuration and altering the shape to maximize coverage over the recipient site. These techniques are (1) the accordion technique, (2) the strip technique, and (3) the combination epithelial-connective tissue strip technique. All are modifications of the free gingival grafts.

The accordion technique, described by Rateitschak et al,[88] attains expansion of the graft by alternate incisions in opposite sides of the graft. This technique increases the donor graft tissue by changing the configuration of the tissue.

The strip technique, developed by Han et al,[48] consists of obtaining two or three strips of gingival donor tissue about 3 to 5 mm wide and long enough to cover the entire length of the recipient site (Figure 63-5). These strips are placed side by side to form one donor tissue and sutured on the recipient site. The area is then covered with aluminum foil and surgical dressing.

The advantages of this technique are the rapid healing of the donor site. The epithelial migration of the close wound edges (3 to 5 mm) allows rapid epithelialization of the open wound. The donor site usually does not require suturing and heals uneventfully in 1 to 2 weeks.

In some cases, a combination technique can be performed where a deep strip graft is taken from the palate and is split into both an epithelial-connective tissue strip and a pure connective strip. The tissue is obtained as follows: Remove a strip of tissue from the palate about 3 to 4 mm thick, place it between two wet tongue depressors, and split it longitudinally with a sharp #15 blade. Both will be used as free grafts. The superficial portion consists of epithelium and connective tissue, and the deeper portion consists only of connective tissue. These donor tissues are placed on the recipient site as in the strip technique. The minimal donor site wound obtained by two donor tissues from one site is the advantage of this technique.

Alternative Donor Tissue. Another technique to minimize the use of the palate as a donor site is the use of acellular dermal matrix (ADM) as a substitute for palatal donor tissue. The use of the palate as a donor site for gingival augmentation has numerous disadvantages, for not only are the patients fearful of palatal surgery from where the donor tissue is procured but, there is also a limitation on the amount of tissue that can be removed. Currently, there are numerous clinicians who advocate the use of ADM as a substitute for palatal donor tissue. (See Tissue Engineering for more information regarding ADM.) This product is commercially available under the name *AlloDerm* and is derived from donated human skin.[1] Commercial preparation of this tissue includes a multistep proprietary process that removes both the epidermis and the cells that can lead to tissue rejection and graft failure without damaging the matrix. The remaining ADM consists of a nondenatured three-dimensional arrangement of intact collagen fibers, ground substance, and vascular channels.[29] Randomized, controlled clinical trials have demonstrated outcomes with ADM equivalent to palatal donor tissue in treatment of gingival recession.[1,29,40,79,81,103] Equivalent root coverage has been shown in four trials.[1,79,81,103] Equivalent increase in marginal tissue thickness has been demonstrated at 6 and 12 months postoperatively, both by clinical assessment and by histometric analysis.[1,29,81] Equivalent attachment to the root surface

Figure 63-5 Free gingival graft: strip technique. **A** to **D,** Mucosal tissue around implants. **E** and **F,** Recipient site prepared. **G,** Donor site with strips of free graft removed. **H,** Donor strips of free graft. **I** and **J,** Strips placed side by side on recipient site. **K,** Donor area 1 week after graft removal. **L,** Healing of recipient site after 3 months. Note good keratinized, attached gingiva. *(Courtesy Dr. T. Han and Dr. P. Klokkevold, Los Angeles.)*

has been found by histologic evaluation of human block sections at 6 months postoperatively.[29]

In addition to avoiding palatal donor surgery, ADM offers the advantage of availability of unlimited donor tissue for treatment of multiple teeth in a single surgical appointment.

Surgical Techniques. Two surgical techniques are suggested for use of ADM in treating gingival recession. Each is a coronally positioned pouch method. The first is the alternate papilla tunnel (APT) method and the second is the papilla retention pouch (PRP) method (Figure 63-6, *A–G*).

In the APT method, an incision is made in a papilla adjacent to a tooth with recession while the adjacent papilla is tunneled. The next papilla is incised, and the following papilla tunneled. Intrasulcular incisions are made facial to each tooth and interproximally at each tunneled papilla. The papilla in the anatomic midline is always tunneled to reduce tension and retraction of the recipient pouch. At each incised papilla, a V-incision (or inverted V in the mandibular arch) is made to form a new surgical papilla tip approximately 3 mm from the anatomic papilla tip. The portion of the anatomic papilla coronal to the surgical papilla is denuded to expose a vascular recipient bed for the surgical papilla when coronally advanced. The initial dissection is performed with a microperiosteal elevator, extending apically past the mucogingival junction and laterally under the facial aspect of the tunneled papillae. The tunneling process is facilitated by the access provided at the incised papillae. The tunneled papillae are lifted from the interdental crest by blunt reflection with a curette. Following blunt reflection, supraperiosteal sharp dissection is used to deepen and mobilize the recipient pouch.

On completion of the recipient site preparation, the length of graft needed is measured and trimmed so that the graft will extend 3 mm past the last tooth with recession at each end of the prepared site. The vertical dimension of the graft should be 6 to 8 mm. The rehydrated and trimmed allograft is then placed into the surgical pouch, with the basement membrane surface facing outward, and secured coronally with 6-0 sling sutures. The graft should be well

Figure 63-6 **A,** Preoperative view. **B,** Intrasulcular incision. **C,** AlloDerm on the surface before insertion into the pouch. **D,** AlloDerm sutured within the pouch. **E,** Pouch coronally positioned and sutured. **F,** Postoperative view after 1 month. **G,** Postoperative view after 1 year.

adapted to the root surface, extending to but not coronal to the CEJ and to the apical margin, but not over the papillary recipient beds. The pouch is then coronally advanced to completely cover the allograft and secured with 6-0 or 7-0 sling sutures.

The APT method combines the advantages of surgical access at the incised papillae with retraction resistance and wound stability at the tunneled papillae.

In the PRP method, all papillae are tunneled. Initially, intrasulcular incisions are made facial and proximal to all teeth to be treated plus an additional tooth at each end. Next, full-thickness elevation of the margin is initiated with a microperiosteal elevator extending apically past the mucogingival junction and laterally under the facial aspect of the papillae. The pouch is extended apically and mobilized by supraperiosteal sharp dissection, and the papillae are lifted from the interdental crest as in the APT method. The allograft is rehydrated, measured, and trimmed. Placement of the allograft within the pouch may be accomplished by drawing it in with a suture or placing it through the sulcus with a curette so that it is aligned within the pouch over the exposed roots.

The unique feature of this method is the suturing of the allograft with a subgingival continuous subgingival double-back sling suture. Starting at the anterior end of the graft, the needle of a 6-0 suture is passed from the lingual side through the mesial embrasure and captured on the facial side. The allograft is engaged at the mesial line angle of the tooth, the needle is passed back through the mesial embrasure to the lingual side, around the lingual aspect toward the distal, through the distal embrasure back to the facial and crosses under the papilla to engage the allograft at the mesial line angle of the next tooth. This process continues until the needle has engaged the graft at the mesial line angle of the most distal tooth. At this point, the needle is passed through the mesial embrasure, around the lingual aspect, back to the facial through the distal embrasure, and the graft is engaged at the distal line angle. The needle is then passed back through the distal embrasure, around the lingual aspect, through the mesial embrasure to the facial, and under the papilla to engage the allograft at the distal line angle of the adjacent tooth. This process continues until passing through the distal embrasure of the initial tooth in which the suture is tied with the knot on the lingual side. The entire suture resides subgingivally and draws the graft and the pouch coronally. The PRP procedure is completed by coronally advancing the pouch over the allograft with a series of interrupted 6-0 or 7-0 sling sutures.

Advantages of the PRP method include enhanced retraction resistance, graft containment, and wound stability.

Postoperative care is similar for both methods and includes the following:

1. Systemic antibiotics for 10 days.
2. Chlorhexidine mouthrinse for 2 to 3 weeks.
3. Pain medication as needed.
4. Inactivity for 24 hours.
5. Ice applied to face for 24 hours.
6. Cold liquids for first three meals.
7. No mastication or toothbrushing at surgical site for 2 to 3 weeks.
8. Remove surface sutures at 2 to 4 weeks.
9. Remove subgingival graft suture at 2 months.

Developed over 15 years ago, ADM is a safe and effective biomaterial for use as a substitute for palatal connective tissue in root coverage grafting. There have been no reports of any disease transmission in medical or dental applications over this time period. ADM has proven equivalence to palatal connective tissue for root coverage procedures in randomized controlled clinical trials. It produces a thicker marginal tissue and a higher percentage of root coverage than a coronally advanced flap alone.[116] It provides advantages over palatal connective tissue in that it does not require a second surgical site to obtain donor tissue and provides an unlimited amount of tissue to treat multiple teeth in one appointment. The use of AlloDerm under a coronally advanced flap extends the application of the most esthetic procedure in root coverage. Further discussion regarding ADM and other techniques to avoid palatal donor site morbidity involve the use of biologic mediators, which is presented later in this chapter

Healing of the Graft. The success of the graft depends on survival of the connective tissue. Sloughing of the epithelium occurs in most cases, but the extent to which the connective tissue withstands the transfer to the new location determines the fate of the graft. Fibrous organization of the interface between the graft and the recipient bed occurs within 2 to several days.[95]

The graft is initially maintained by a diffusion of fluid from the host bed, adjacent gingiva, and alveolar mucosa.[42] The fluid is a transudate from the host vessels and provides nutrition and hydration essential for the initial survival of the transplanted tissues. During the first day, the connective tissue becomes edematous and disorganized and undergoes degeneration and lysis of some of its elements. As healing progresses, the edema is resolved, and degenerated connective tissue is replaced by new granulation tissue.

Revascularization of the graft starts by the second[6] or third[44] day. Capillaries from the recipient bed proliferate into the graft to form a network of new capillaries and anastomose with preexisting vessels.[54]

Many of the graft vessels degenerate and are replaced by new ones, and some of these participate in the new circulation. The central section of the surface is the last to vascularize, but this is complete by the tenth day.

The epithelium undergoes degeneration and sloughing, with complete necrosis occurring in some areas.[20,80] It is replaced by new epithelium from the borders of the recipient site. A thin layer of new epithelium is present by the fourth day, with rete pegs developing by the seventh day. Heterotopically placed grafts maintain their structure (keratinized epithelium), even after the grafted epithelium has become necrotic and has been replaced by neighboring areas of nonkeratinized epithelium, which suggests that a genetic predetermination of the specific character of the oral mucosa exists that depends on stimuli originating in the connective tissue.[55] This is the basis for the technique that uses grafts composed only of connective tissue obtained from areas in which it is covered by keratinized epithelium.[17,30,36]

As seen microscopically, healing of a graft of intermediate thickness (0.75 mm) is complete by 10.5 weeks; thicker grafts (1.75 mm) may require 16 weeks or longer.[43] The gross appearance of the graft reflects the tissue changes within it. At transplantation, the graft vessels are empty and the graft is pale. The pallor changes to an ischemic grayish white during the first 2 days until vascularization begins and a pink color appears. The plasmatic circulation accumulates and causes softening and swelling of the graft, which are reduced when the edema is removed from the recipient site by the new blood vessels. Loss of epithelium leaves the graft smooth and shiny. New epithelium creates a thin, gray, veil-like surface that develops normal features as the epithelium matures.

Functional integration of the graft occurs by the seventeenth day, but the graft is morphologically distinguishable from the surrounding tissue for months. The graft eventually blends with adjacent tissues, but sometimes, although pink, firm, and healthy, it is somewhat bulbous. This usually presents no problem, but if the graft traps plaque or is esthetically unacceptable, thinning of the graft may be necessary. Thinning the surface of the grafted tissue

does reduce the bulbous condition because the surface epithelium tends to proliferate again. The graft should be thinned by making the necessary incisions to elevate it from the periosteum, removing tissue from its undersurface, and suturing it back in place.

Accomplishments. Free gingival grafts effectively widen the attached gingiva. Several biometric studies have analyzed the width of the attached gingiva after the placement of a free gingival graft.[19,49,52] After 24 weeks, grafts placed on denuded bone shrink 25%, whereas grafts placed on periosteum shrink 50%.[62] The greatest amount of shrinkage occurs within the first 6 weeks.

The placement of a gingival graft does not "improve" the status of the gingiva.[34,35,108] Therefore the indication for a free gingival graft should be based on the presence of progressive gingival recession and inflammation. When recession continues to progress after a few months with good plaque control, a graft can be placed to prevent further recession and loss of attached gingiva.

Other materials have been used to replace gingival tissue in gingival extension procedures. Attempts with lyophilized dura mater,[93] and sclera have not been satisfactory. The use of irradiated free gingival allograft showed satisfactory results,[91] but further research is necessary before it can be considered for clinical use.

Free autogenous gingival grafts have been found to be useful for covering nonpathologic dehiscences and fenestrations. Nonpathologic refers to openings of the bone through the tooth surface not previously exposed to the oral environment and found in the course of flap surgery.[33]

The use of free gingival autografts to cover denuded roots is described in the Gingival Augmentation Coronal to Recession section.

Free Connective Tissue Autografts. The connective tissue autograft technique was originally described by Edel[36] and is based on the fact that the connective tissue carries the genetic message for the overlying epithelium to become keratinized. Therefore only connective tissue from beneath a keratinized zone can be used as a graft (Figure 63-7).

The advantage of this technique is that the donor tissue is obtained from the undersurface of the palatal flap, which is sutured back in primary closure; therefore healing is by first intention. The patient has less discomfort postoperatively at the donor site.

Another advantage of the free connective tissue autograft is that improved esthetics can be achieved because of a better color match of the grafted tissue to the adjacent areas.

Apically Displaced Flap. This technique uses the apically positioned flap, either partial thickness or full thickness, to increase the zone of keratinized gingiva. Chapter 59 provides a step-by-step description of the surgical technique for apically displaced flaps, and Figure 63-8 illustrates the procedure.

Accomplishments. The apically displaced flap technique increases the width of the keratinized gingiva but cannot predictably deepen the vestibule with attached gingiva. Adequate vestibular depth must be present before the surgery to allow apical positioning of the flap. The edge of the flap may be located in three positions in relation to the bone, as follows:

1. *Slightly coronal to the crest of the bone.* This location attempts to preserve the attachment of supracrestal fibers; it may also result in thick gingival margins and interdental papillae with deep sulci and may create the risk of recurrent pockets.
2. *At the level of the crest* (Figure 63-8, *C*). This results in a satisfactory gingival contour, provided that the flap is adequately thinned.
3. *Two millimeters short of the crest* (Figure 63-8, *D*). This position produces the most desirable gingival contour and the same posttreatment level of gingival attachment as obtained by placing the flap at the crest of the bone.[39] New tissue covers the crest of the bone to produce a firm, tapered gingival margin.

Placing the flap short of the crest increases the risk of a slight reduction in bone height,[28] but the advantage of a well-formed gingival margin compensates for this.

Other Techniques. The "vestibular extension technique," originally described by Edlan and Mejchar,[37] produced statistically significant widening of attached nonkeratinized tissue. This increase in width in the mandibular area reportedly persisted in patients observed for up to 5 years.[37,92,110] Currently, this technique is of historic interest only.

The fenestration operation was designed to widen the zone of attached gingiva with a minimum loss of bone height.[89,90] It has also been called the periosteal separation technique.[26] It uses a partial-thickness flap, except in a rectangular area at the base of the operative field, where the periosteum is removed, exposing the bone. This is the area of fenestration. Its purpose is to create a scar that is firmly bound to the bone.[23] It prevents soft tissue separation from the bone and postsurgical narrowing of the attached zone. Results obtained with this technique are not as predictable as with the free gingival graft; therefore it is not widely performed except for small isolated areas.

Gingival Augmentation Coronal to Recession (Root Coverage)

Understanding the different stages and conditions of gingival recession is necessary for predictable root coverage. Several classifications of denuded roots have been proposed. In the 1960s, Sullivan and Atkins[100] classified gingival recession into four anatomic categories: (1) shallow-narrow, (2) shallow-wide, (3) deep-narrow, and (4) deep-wide.

This early classification helped categorize the lesion but did not enable the clinician to predict the outcome of therapy. The predictability of root coverage can be enhanced by the presurgical examination and the correlation of the recession by using the classification proposed by Miller,[73] as follows (Figure 63-9):

Class I. Marginal tissue recession does not extend to the mucogingival junction. There is no loss of bone or soft tissue in the interdental area. This type of recession can be narrow or wide.

Class II. Marginal tissue recession extends to or beyond the mucogingival junction. There is no loss of bone or soft tissue in the interdental area. This type of recession can be subclassified into wide and narrow.

Class III. Marginal tissue recession extends to or beyond the mucogingival junction. There is bone and soft tissue loss interdentally or malpositioning of the tooth.

Class IV. Marginal tissue recession extends to or beyond the mucogingival junction. There is severe bone and soft tissue loss interdentally or severe tooth malposition.

In general, the prognoses for Classes I and II are good to excellent; whereas for Class III, only partial coverage can be expected. Class IV has a very poor prognosis with current techniques.

The following is a list of techniques used for gingival augmentation coronal to the recession (root coverage):

1. Free gingival autograft
2. Free connective tissue autograft

Figure 63-7 Free connective tissue graft. **A,** Lack of keratinized, attached gingiva buccal to central incisor. **B,** Vertical incisions to prepare recipient site. **C,** Recipient site prepared. **D,** Palate from which connective tissue will be removed for donor tissue. **E,** Removal of connective tissue. **F,** Donor site sutured. **G,** Connective tissue for graft. **H,** Free connective tissue placed at donor site. **I,** Postoperative healing at 10 days. **J,** Final healing at 3 months. Note wide, keratinized, attached gingiva. *(Courtesy Dr. M. Orisini, Italy.)*

3. Pedicle autografts
   - Laterally (horizontally) positioned pedicle flap
   - Coronally positioned flap; includes semilunar pedicle (Tarnow)
4. Subepithelial connective tissue graft (Langer)
5. Guided tissue regeneration (GTR)
6. Pouch and tunnel technique (coronally advanced tunnel technique)

Some of the techniques used for widening the attached gingiva apical to the area of recession can also be used for root coverage. Both the free gingival and the connective tissue autograft used for apical widening can be used for coronal augmentation by incorporating some modifications. In using the free grafts for root coverage, the recipient bed surrounding the denuded root surface must be extended wider to allow for better blood supply to the donor free graft. This is necessary because a portion of the donor tissue overlies the root surface, which does not have blood supply.

Free Gingival Autograft. Successful and predictable root coverage has been reported using free gingival autografts.[72,74]

The Classic Technique. Miller[74] applied the classic free gingival autograft described previously with a few modifications.

Step 1: Root planing. Root planing is performed with the application of saturated citric acid for 5 minutes on the root surface. The application of this acid has not been validated by some studies,[41] but numerous clinicians practice this technique.

Step 2: Prepare the recipient site. Make a horizontal incision in the interdental papillae at right angles to create a margin against which the graft may have a butt joint with the incision. Vertical incisions are made at the proximal line angles of adjacent teeth and the retracted tissue is excised. Maintain an intact periosteum in the apical area.

Steps 3 and 4. Refer to the step-by-step technique described for the classic gingival graft earlier in this chapter. This

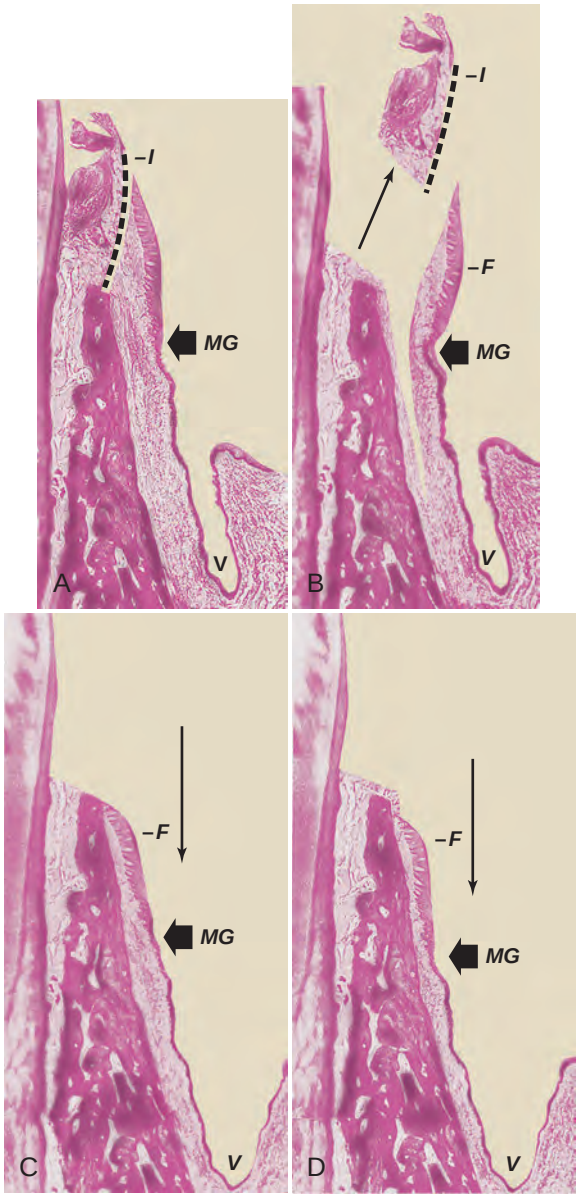

Figure 63-8 Apically displaced partial-thickness flap. **A,** Internal bevel incision *(I)* separates inner wall of periodontal pocket. *MG,* Mucogingival junction; *V,* vestibular fornix. **B,** Partial-thickness flap *(F)* separated, leaving periosteum and a layer of connective tissue on the bone. The inner wall of the periodontal pocket *(I)* is removed, and the tooth is scaled and planed. **C,** Partial-thickness flap *(F)* displaced apically, with edge of the flap at crest of the bone. Note that the vestibular fornix is also moved apically. **D,** Partial-thickness flap *(F)* displaced apically, with edge of the flap several millimeters below crest of the bone.

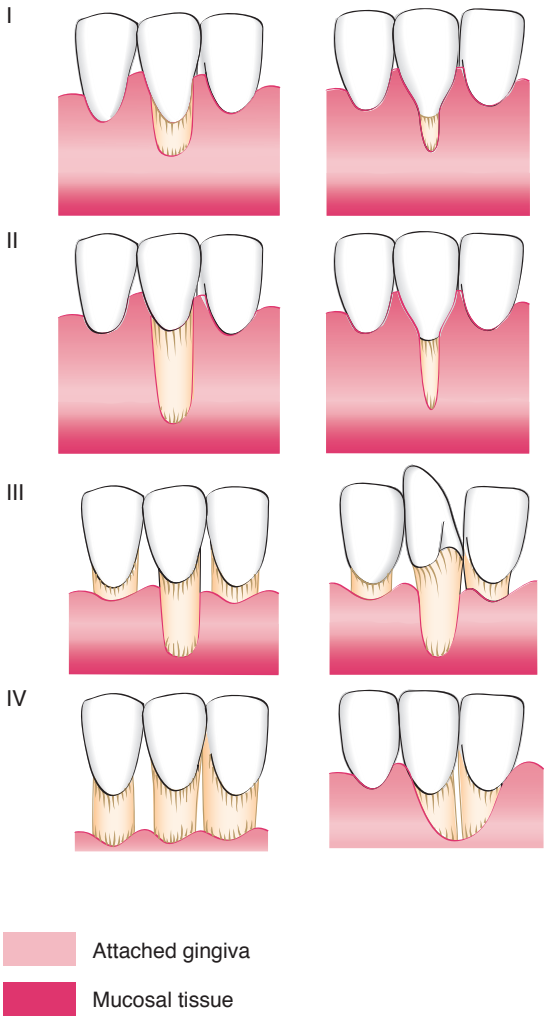

Figure 63-9 P. D. Miller's classification of denuded roots.

technique results in predictable coverage of the denuded root surface but may present esthetic color discrepancies with the adjacent gingiva because of a lighter color.

Free Connective Tissue Autograft.

The free connective tissue technique was described by Levine in 1991.[58] The difference between this technique and the free gingival autograft is that the donor tissue is connective tissue (see Figure 63-7).

The following is a step-by-step surgical description of the free connective tissue autograft technique:

Step 1: Divergent vertical incisions. Divergent vertical incisions are made at the line angles of the tooth to be covered, creating a partial-thickness flap to at least 5 mm apical to the receded area.

Step 2: Suturing. Suture the apical mucosal border to the periosteum using a gut suture.

Step 3: Scaling and root planing. Thoroughly scale and root plane, which also reduces any prominence on the root surface.

Step 4: Obtain the graft. From the palate, obtain a connective tissue graft. The donor site is sutured after the graft is removed.

Step 5: Transfer the graft. Transfer the graft to the recipient site, and suture it to the periosteum with a gut suture. Good stability of the graft must be attained with adequate sutures.

Step 6: Cover the graft. Cover the grafted site with dry aluminum foil and periodontal dressing.

Pedicle Autograft.

Laterally (Horizontally) Displaced Pedicle Flap. The displaced pedicle flap technique, originally described by Grupe and Warren in 1956,[45] was the standard technique for many years and is still indicated in some cases. The laterally positioned flap can be used to cover isolated, denuded root surfaces that have adequate donor tissue laterally. The vestibular depth must also be present (Figures 63-10 and 63-11).

The following is a step-by-step surgical description:

Step 1: Prepare the recipient site. Epithelium is removed around the denuded root surface. The exposed connective tissue will be the recipient site for the laterally displaced flap. The root surface will be thoroughly scaled and root planed (Figure 63-11, *B*).

Step 2: Prepare the flap. The periodontium of the donor site should have a satisfactory width of attached gingiva and minimal loss of bone, without dehiscence or fenestration. A full-thickness or partial-thickness flap may be used, but the latter is preferable because it offers the advantage of rapid healing at the donor site and reduces the risk of loss of facial bone height. This is especially important if the bone is thin or a dehiscence or fenestration is suspected. However, if the gingiva is thin, even a partial-thickness flap may not be sufficient for flap survival (Figure 63-11, *C*).

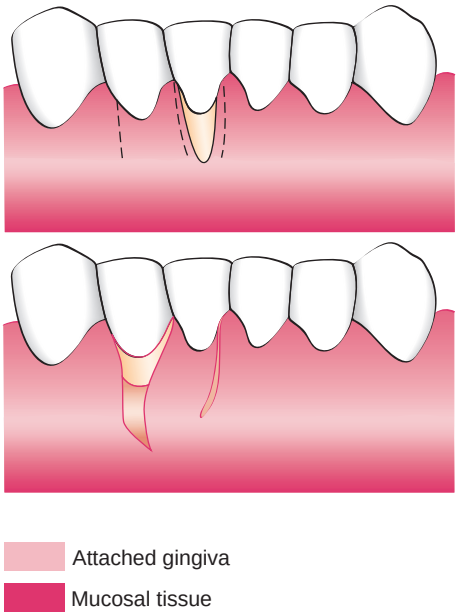

Figure 63-10 Laterally displaced flap for coverage of denuded root. *Top,* Incisions removing the gingival margin around the exposed root and outlining the flap. *Bottom,* After the gingiva around the exposed root is removed, the flap is separated, transferred, and sutured.

With a #15 blade, make a vertical incision from the gingival margin to outline a flap adjacent to the recipient site. Incise to the periosteum, and extend the incision into the oral mucosa to the level of the base of the recipient site. The flap should be sufficiently wider than the recipient site to cover the root and provide a broad margin for attachment to the connective tissue border around the root. The interdental papilla at the distal end of the flap, or a major portion of it, should be included to secure the flap in the interproximal space between the donor and the recipient teeth.

Make a vertical incision along the gingival margin and interdental papilla, and separate a flap consisting of epithelium and a thin layer of connective tissue, leaving the periosteum on the bone.

A releasing incision is sometimes needed to avoid tension on the base of the flap, which can impair the blood supply when the flap is moved. To do this, make a short oblique incision into the alveolar mucosa at the distal corner of the flap, in the direction of the recipient site.

Step 3: Transfer the flap. Slide the flap laterally onto the adjacent root, making sure that it lies flat and firm without excess tension on the base. Fix the flap to the adjacent gingiva and alveolar mucosa with interrupted sutures (Figure 63-11, *D*). A suspensory suture may be made around the involved tooth to prevent the flap from slipping apically.

Step 4: Protect the flap and donor site. Cover the operative field with aluminum foil and a soft periodontal dressing, extending it interdentally and onto the lingual surface to secure it. Remove the dressing and sutures after 1 week.

Variant Techniques. There are many variations in the incisions for the laterally displaced flap. A common alternative is the use of converging oblique incisions over the recipient site and a vertical or oblique incision at the distal end of the donor site so that the transposed flap is slightly wider at its base. In another modification,

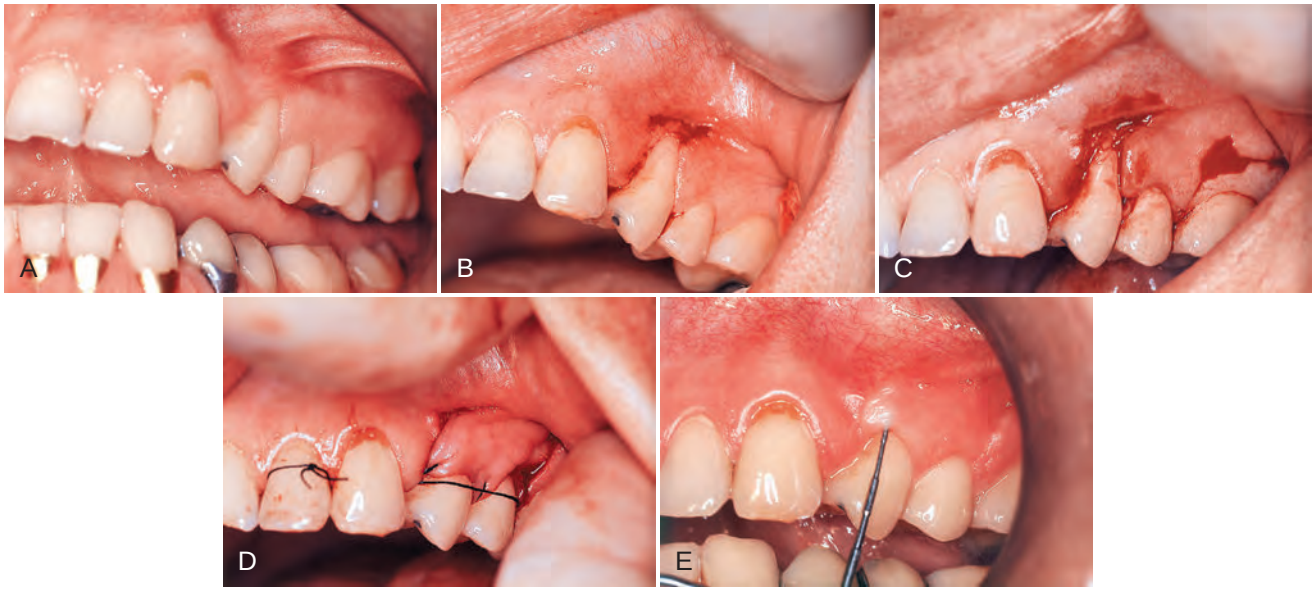

Figure 63-11 Laterally displaced flap. **A,** Preoperative view, maxillary bicuspid. **B,** Recipient site is prepared by exposing the connective tissue around the recession. **C,** Incisions are made at the donor site in preparation of moving the tissue laterally. **D,** Pedicle flap is sutured in position. **E,** Postoperative result at 1 year. *(Courtesy Dr. E.B. Kenney, Los Angeles.)*

the marginal attachment at the donor site is preserved to reduce the likelihood of recession and marginal bone resorption, but this requires a donor site with a wider zone of attached gingiva.

Sliding partial-thickness grafts from neighboring edentulous areas (pedicle grafts)[44] can be used to restore attached gingiva on teeth adjacent to edentulous spaces with denuded roots and a small, vestibular fornix, often complicated by tension from a frenum. The "double-papilla flap" attempts to cover roots denuded by isolated gingival defects with a flap formed by joining the contiguous halves of the adjacent interdental papillae.[25,50] Results with this technique are unpredictable because blood supply is impaired by suturing the two flaps over the root surface.

Accomplishments of Pedicle Autograft. Coverage of the exposed root surface with the sliding-flap technique has been reported to be 60%,[42] 61%, and 72%.[88] Histologic studies in animals have reported 50% coverage.[24,114]

The extent to which the flap establishes a new attachment to the root with the formation of new cementum and the embedding of new connective tissue fibers has not been established. New attachment on artificially denuded roots in experimental animals[114] and in some clinical studies of humans has been reported,[99,101] but it does not occur consistently enough to be predictable.

In the donor site, there is uneventful repair and restoration of gingival health and contours, with some loss of radicular bone (0.5 mm) and recession (1.5 mm) reported with full-thickness flaps.

Coronally Displaced Flap. The purpose of the coronally displaced flap procedure is to create a split-thickness flap in the area apical to the denuded root and position it coronally to cover the root. Two techniques are available for this purpose.

First Technique

Step 1. With two vertical incisions, delineate the flap. These incisions should go beyond the mucogingival junction. Make an internal bevel incision from the gingival margin to the bottom of the pocket to eliminate the diseased pocket wall. Elevate a mucoperiosteal flap using careful sharp dissection.

Step 2. Scale and plane the root surface.

Step 3. Return the flap and suture it at a level coronal to the pretreatment position. Cover the area with a periodontal dressing, which is removed along with the sutures after 1 week. The periodontal dressing is replaced for an additional week if it is necessary.

Variations to First Technique. Results with the coronally displaced flap technique are often unfavorable[46] because of insufficient keratinized gingiva apical to the recession. To overcome this problem and to increase the chances of success, a gingival augmentation procedure with a free autogenous graft can be performed before the coronally positioned graft, as described earlier in this chapter. This creates several millimeters of attached keratinized gingiva apical to the denuded root (Figure 63-12).

Two months after this surgery, a second-stage procedure is performed, coronally positioning the flap that includes the free autogenous graft. The use of citric acid with a pH 1.0 for conditioning the root surface has been suggested.[51,59]

A significant degree of reduction in recession treated by this double-step procedure was reported after 2 years by Bernimoulin et al[11] and confirmed by others.[18,61,62]

Second Technique. Tarnow has described the semilunar coronally repositioned flap to cover isolated denuded root surfaces[104] (Figure 63-13).

Step 1. A semilunar incision is made following the curvature of the receded gingival margin and ending about 2 to 3 mm short of the tip of the papillae. This location is very important because the flap derives its blood supply from the papillary areas. The incision may need to reach the alveolar mucosa if the attached gingiva is narrow.

Step 2. Perform a split-thickness dissection coronally from the incision, and connect it to an intrasulcular incision.

Step 3. The tissue will collapse coronally, covering the denuded root. It is then held in its new position for a few minutes with a moist gauze. Many cases do not require either sutures or periodontal dressing. This technique is simple and

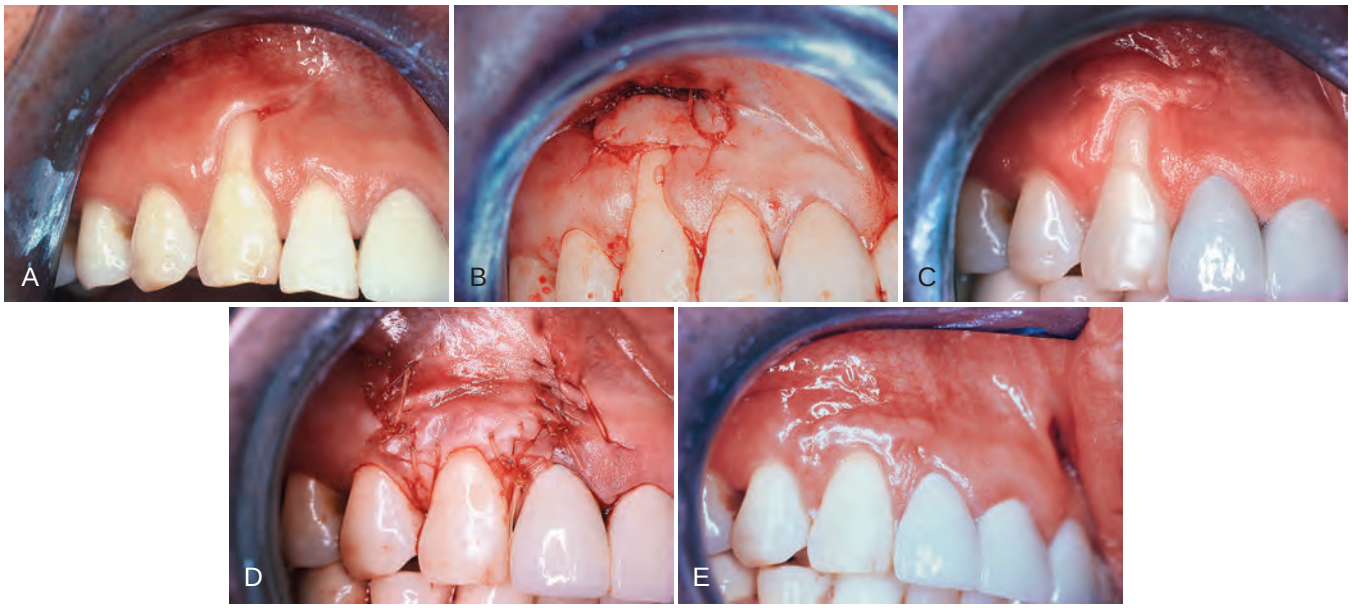

Figure 63-12 Coronally displaced flap. **A,** Preoperative view. Note the recession and the lack of attached gingiva. **B,** After placement of a free gingival graft. **C,** Three months after placement of the graft. **D,** Flap, including the graft, positioned coronally and sutured. **E,** Six months later. Note the root coverage and the presence of attached gingiva. Compare with **A.** *(Courtesy Dr. T.J. Han, Los Angeles.)*

Figure 63-13 Semilunar coronally positioned flap. **A,** Slight recession in facial of the upper left canine. **B,** After thorough scaling and root planing of the area, a semilunar incision is made and the tissue separated from the underlying bone. The flap collapses, covering the recession. **C,** Appearance after 7 weeks. Note coverage of the previous root denudation. *(Courtesy Dr. J.J. Elbaz, Beverly Hills, California.)*

predictably provides 2 to 3 mm of root coverage. It can be performed on several adjoining teeth. This technique is indicated where the recession is not extensive (3 mm) and the facial gingival biotype is thick. It is successful for the maxilla, particularly in covering roots left exposed by the gingival margin receding from a recently placed crown margin. It is not recommended for the mandibular dentition.

Subepithelial Connective Tissue Graft (Langer). The subepithelial connective tissue procedure is indicated for larger and multiple defects with good vestibular depth and gingival thickness to allow a split-thickness flap to be elevated. Adjacent to the denuded root surface, the donor connective tissue is sandwiched between the split flap (Figures 63-14 and 63-15). This technique was described by Langer and Langer in 1985.[57] Similar approaches had been previously reported by Perez-Fernandez[84] and Raetzke[87] (see Video 63-2: Root Coverage Graft).

The following is the step-by-step surgical description:

Step 1. Raise a partial-thickness flap with a horizontal incision 2 mm away from the tip of the papilla and two vertical incisions 1 to 2 mm away from the gingival margin of the adjoining teeth. These incisions should extend at least one tooth wider mesiodistally than the area of gingival recession. Extend the flap to the mucobuccal fold.

Step 2. Thoroughly plane the root, reducing its convexity.

Step 3. Obtain a connective tissue graft from the palate by means of a horizontal incision 5 to 6 mm from the gingival margin of molars and premolars. The palatal wound is sutured in a primary closure.

Step 4. Place the connective tissue on the denuded root(s). Suture it with resorbable sutures to the periosteum.

Step 5. Cover the graft with the outer portion of the partial-thickness flap and suture it interdentally.

Step 6. Cover the area with dry foil and surgical dressing. After 7 days, the dressing and sutures are removed. The esthetic results are favorable with this technique since the donor tissue is connective tissue (Figure 63-15, *E*). The donor site heals by primary intention, with considerably less discomfort than after a free gingival graft.

A variant of the subepithelial connective tissue graft, called a *subpedicle (bilaminar) connective tissue graft,* was described by Nelson in 1987.[77] This technique uses a pedicle over the connective tissue that covers the denuded root surface. Therefore the blood supply is increased over the donor tissue and the gingival margin is thickened for better marginal stability.

Guided Tissue Regeneration Technique for Root Coverage. Pini-Prato et al[85] described a technique based on the principle of GTR (see Chapter 61). Theoretically, GTR should result in reconstruction of the attachment apparatus, along with coverage of the denuded root surface (Figure 63-16).

The following is a step-by-step description of the surgery:

Step 1. A full-thickness flap is reflected to the mucogingival junction, continuing as a partial-thickness flap 8 mm apical to the mucogingival junction.

Step 2. A membrane is placed over the denuded root surface and the adjacent tissue. It is trimmed and adapted to the root surface and covers at least 2 mm of marginal periosteum.

Step 3. A suture is passed through the portion of the membrane that will cover the bone. This suture is knotted on the exterior and tied to bend the membrane, creating a space between the root and the membrane. This space allows for the growth of tissue beneath the membrane.

Step 4. The flap is then positioned coronally and sutured. Four weeks later, a small envelope flap is performed, and the membrane is carefully removed. The flap is then again positioned coronally, to protect the growing tissue, and sutured. One week later these sutures are removed.

Tinti and Vincenzi[107] used titanium-reinforced membranes to create space beneath the membrane. Resorbable membranes have also been used to achieve root coverage. The inability to create space between the resorbable membrane and the denuded root, because of its softness, may present a problem, even though not needing a second surgery is an advantage.

Clinical studies comparing this technique with the coronally displaced flap have shown that the GTR technique is better when the recession is greater than 4.98 mm apicocoronally.[85] Histologically, one case reported 3.66 mm of new connective tissue

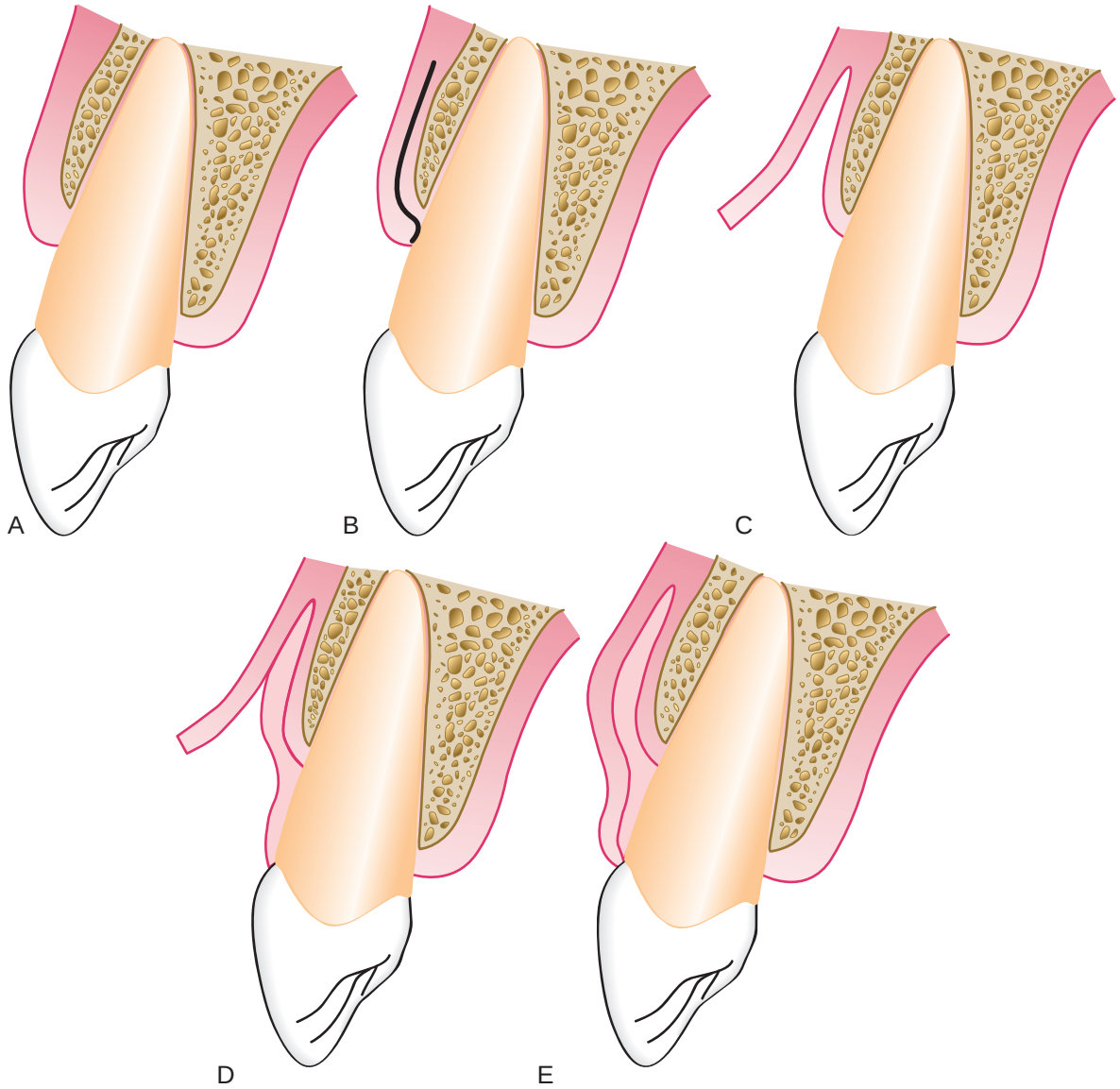

Figure 63-14 Subepithelial connective tissue graft for root coverage. **A** to **E,** Sagittal views. **A,** Preoperative view of facial recession on maxillary central incisor. **B,** Split-thickness incision for recipient site. **C,** Split-thickness flap reflected. **D,** Connective tissue placed over denuded root surface. Note that apical portion of the donor tissue is placed between the split-thickness flaps. **E,** Recipient flap is closed. Subepithelial connective tissue graft for root coverage.

attachment associated with 2.48 mm of new cementum and 1.84 mm of bone growth.[27]

Pouch and Tunnel Technique (Coronally Advanced Tunnel Technique). To minimize incisions and the reflection of flaps and to provide abundant blood supply to the donor tissue, the placement of the subepithelial donor connective tissue into pouches beneath papillary tunnels allows for intimate contact of donor tissue to the recipient site.[118] The positioning of the graft in the pouch and through the tunnel and the coronal placement of the recessed gingival margins completely covers the donor tissue. Therefore the esthetic result is excellent. The technique is especially effective for the anterior maxillary area in which vestibular depth is adequate and there is good gingival thickness (Figure 63-17).

One of the advantages to this technique is the thickening of the gingival margin after healing. The thicker gingival margin is stable to allow for the possibility of "creeping reattachment" of the margin. The use of small, contoured blades enables the surgeon to incise and split the gingival tissues to create the recipient pouches and tunnels (Figure 63-18). The work by Azzi et al[8] in this area of surgery has contributed to a better understanding of the technique and outcome of this procedure. This surgery is also referred to as the *coronally advanced tunnel technique.*

Following is a step-by-step description of the surgical procedure as outlined by Azzi (see Figure 63-17):

Step 1. Preparation of the patient includes plaque control instruction and careful scaling and root planing several weeks before the surgical procedure. The patient is instructed to rinse for 3.0 seconds with chlorhexidine gluconate solution 0.12%.

Step 2. After adequate anesthesia of the region, the surgical procedure, as follows, is performed.

Step 3. Composite material stops are placed at the contact points (temporary) to prevent the collapse of the suspended sutures into the interproximal spaces before the surgery.

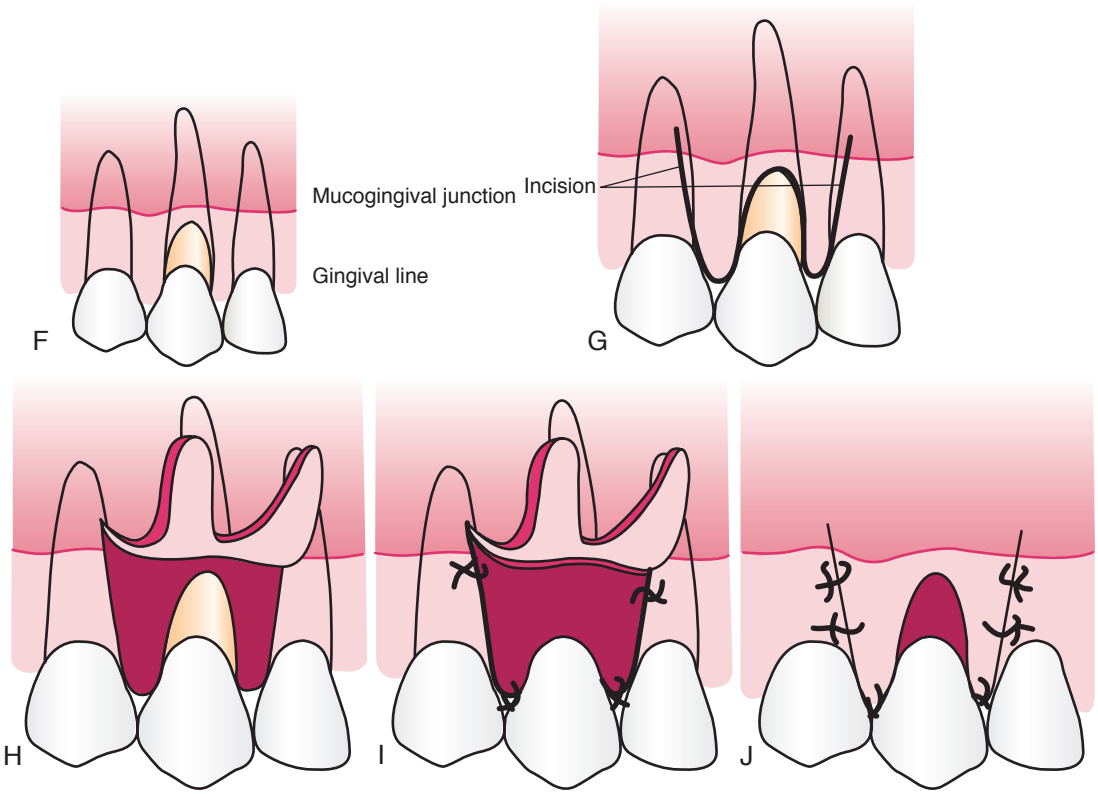

Figure 63-14, cont'd **F,** Gingival recession. **G,** Vertical incisions to prepare recipient site. **H,** Split-thickness flap reflected. **I,** Connective tissue sutured over denuded root surface. **J,** Split-thickness flap sutured over donor connective tissue.

Step 4. Root planing of the exposed root surfaces is performed using Gracey curettes.

Step 5. Initial sulcular incisions are made using 15c and 12d blades. Small, contoured blades (see Figure 69-17) and mini curettes are used to create the recipient pouches and tunnels.

Step 6. On the buccal aspect, an intrasulcular incision is made around the necks of the teeth. The incision is extended to one adjacent tooth both mesially and distally using a 15c blade. This incision maintains the full height and thickness of the gingival component and enables access beneath the buccal gingiva with Gracey curettes. The cutting edge is directed toward the bone to dissect the connective tissue beyond the mucogingival line and free the buccal flap from its insertions to the bone around each tooth.

Step 7. Muscle fibers and any remaining collagen fibers on the inner aspect of the flap, which prevent the buccal gingiva from being moved coronally, are cut using Gracey curettes.

Step 8. The papillae are kept intact and undermined to maintain their integrity and carefully released from the underlying bone, which allows the coronal positioning of the papillae.

Step 9. An envelope, full-thickness pouch, and tunnel are created and extended apically beyond the mucogingival line by blunt dissection for the insertion of the free connective tissue graft through the intrasulcular incision. Saline-moistened gauze is placed over the recipient site.

Step 10. The size of the pouch, which includes the area of the denuded root surface, is measured so that an equivalent size donor connective tissue can be procured from the tuberosity.

Step 11. A second surgical site is created to obtain a connective tissue graft of adequate size and shape to be placed at the recipient site. The connective tissue harvested from the tuberosity area is contoured to fit into the recipient tunnel and pouch.

Step 12. A mattress suture placed at one end of the graft is helpful in guiding the graft through the sulcus and beneath each interdental papilla. The border of the tissue is gently pushed into the pouch and tunnel using tissue forceps and a packing instrument. The graft is pushed from the adjacent tooth on one side of the surgical area to the adjacent tooth on the other side.

Step 13. A mattress suture placed on one end of the graft will help maintain the graft in position while the buccal tissue covers the connective tissue graft. This connective tissue graft is anchored to the inner aspect of the buccal flap in the interdental papilla area. A vertical mattress suture is used to hold the connective tissue in position beneath the gingiva. The connective tissue graft is completely submerged beneath the buccal flap and the papillae.

Step 14. The entire gingivopapillary complex (buccal gingiva with the underlying connective tissue graft, and papillae) is coronally positioned using a horizontal mattress suture anchored at the incisal edge of the contact area. The contact areas are splinted presurgically using a composite material.

Step 15. Other holding sutures may be placed through the overlying gingival tissue and donor tissue to the underlying periosteum to secure and stabilize the donor tissue and the overlying gingiva in a coronal position.

The area is not covered with periodontal dressing.

The patient is instructed to rinse daily with chlorhexidine gluconate and to avoid touching the sutures during oral hygiene procedures.

Antibiotics can be administered (amoxicillin 500 mg three times a day) if deemed necessary.

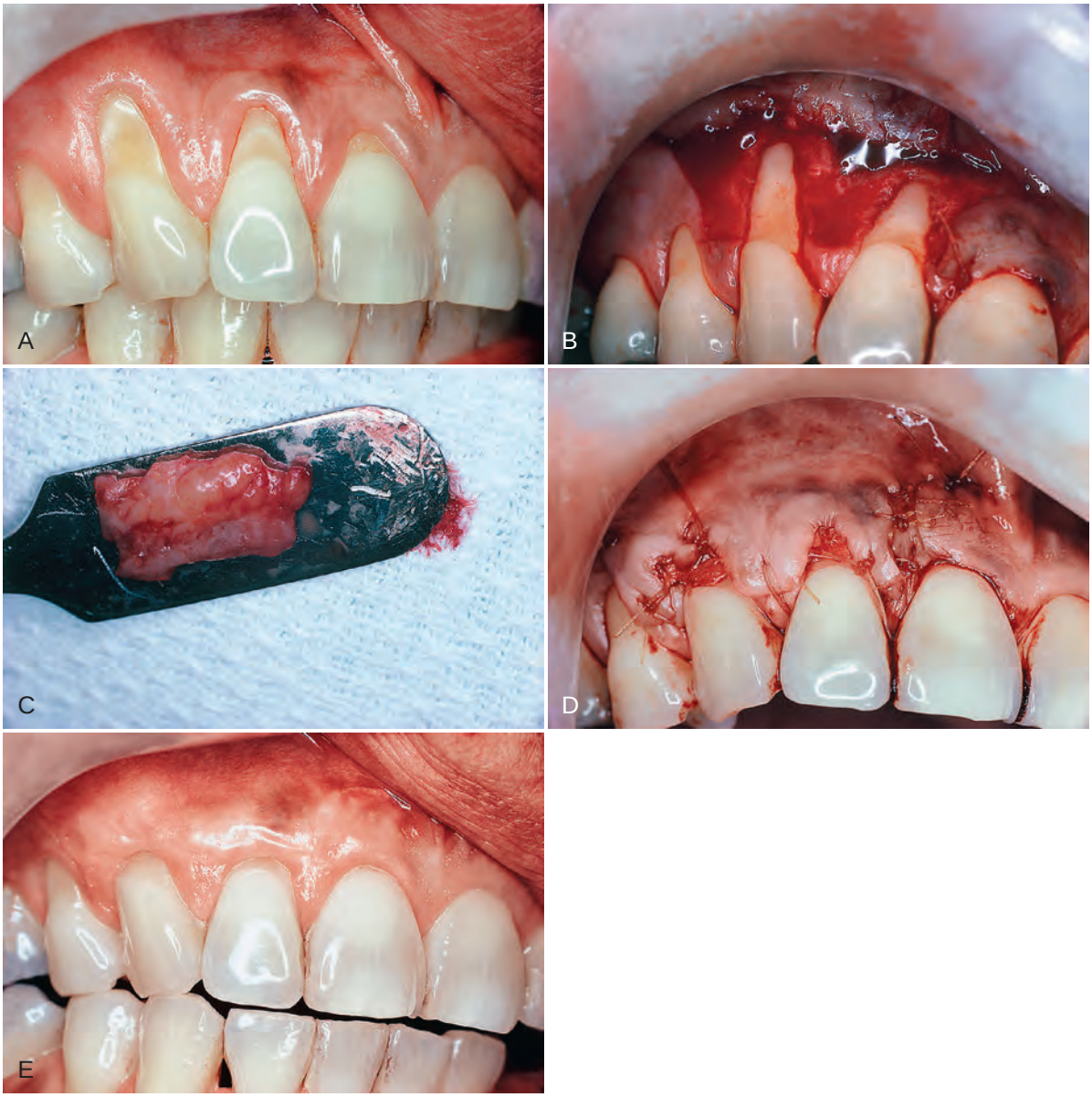

Figure 63-15 Langer technique for root coverage. **A,** Preoperative view. Note the recession on teeth #6 to #8. **B,** Split-thickness flap elevated on teeth #6 and #7. Note that the interdental papillae are not included in the flap, nor is the gingival margin area of tooth #8, which was treated by means of a coronally displaced flap. **C,** Connective tissue from palate. **D,** graft placed under the flap and covering receded areas approximately to the cementoenamel junction. Sutures in place. **E,** Roots covered after complete healing. Note the thickness of the tissue in the area covered and excellent color. *(Courtesy Dr. T.J. Han, Los Angeles.)*

Techniques to Deepen the Vestibule

The presence of adequate vestibular depth is important for both oral hygiene and retention of prosthetic appliances. Numerous surgical techniques have been proposed to accomplish the objective of deepening the vestibule. The classic clinical studies in the early 1960s by Bohannan[14,15,16] indicated that deepening of the vestibule by non–free-graft procedures were not successful when evaluated years later. Predictable deepening of the vestibule can only be accomplished by the use of free autogenous graft techniques and their variants, as covered in this chapter. The important clinical aspect in deepening the vestibule is the proper preparation of the recipient site. The recipient site must be covered by immobile periosteal tissue. If there is a lack of periosteal connective tissue, the donor tissue may be placed over bone. The donor tissue may be either free gingival or connective tissue, but it must be placed over a nonmobile recipient site.

Techniques to Remove the Frenum

A frenum is a fold of mucous membrane, usually with enclosed muscle fibers, that attaches the lips and cheeks to the alveolar mucosa and/or gingiva and underlying periosteum. A frenum becomes a problem if the attachment is too close to the marginal gingiva. This anatomic situation may be a genetic condition of the individual or the result of recession of the gingival margin reaching the area of the frenum. Tension on the frenum may pull the gingival margin away from the tooth. This condition may be conducive to plaque accumulation and inhibit proper placement of the toothbrush at the gingival margin. These hygiene problems are most often encountered in the mandibular anterior areas. The maxillary

Figure 63-16 Guided tissue regeneration technique for root coverage. **A,** Marked recession of maxillary left cuspid. **B,** Vertical incisions made and membrane placed over recession. **C,** Flap sutured over the membrane. **D,** Postoperative result. Note complete coverage of recession. *(Courtesy Dr. Zoran Aleksic, Belgrade, Serbia.)*

anterior vestibule is deep and the frenum is usually located in the midline between the two central incisors. The aberrant frenum located between the maxillary central incisors may present an esthetic problem in a patient with a high lip line.

Frenectomy and Frenotomy

Frenectomy and frenotomy refer to surgical procedures that differ in degree. Frenectomy is complete removal of the frenum, including its attachment to underlying bone, and may be required in the correction of an abnormal diastema between the maxillary central incisors. Frenotomy is the relocation of the frenum, usually in a more apical position.

Frenectomy and frenotomy can be performed in conjunction with other periodontal treatment procedures, such as during a free gingival graft procedure to deepen the vestibule in the mandibular anterior area, but most often they are accomplished as a separate surgical procedure. Frenal problems occur most often on the facial surface between the maxillary and mandibular central incisors and in the canine and premolar areas[113] (see Figure 63-1, *D*). They occur less often on the lingual surface of the mandible.

Procedure

If the vestibule is deep, the procedure is confined to the frenum. It is often necessary to deepen the vestibule to provide space for the repositioned frenum. This is accomplished as follows (Figure 63-19):

Step 1. After anesthetizing the area, engage the frenum with a hemostat inserted to the depth of the vestibule.

Step 2. Incise along the upper surface of the hemostat, extending beyond the tip.

Step 3. Make a similar incision along the undersurface of the hemostat.

Step 4. Remove the triangular resected portion of the frenum with the hemostat. This exposes the underlying fibrous attachment to the bone.

Step 5. Make a horizontal incision, separating the fibers, and bluntly dissect to the bone.

Step 6. If necessary, extend the incisions laterally and suture the labial mucosa to the apical periosteum. A gingival graft or connective tissue graft is placed over the wound.

Step 7. Clean the surgical field with gauze sponges until bleeding stops.

Step 8. Cover the area with dry aluminum foil and apply the periodontal dressing.

Step 9. Remove the dressing after 2 weeks and redress if necessary. One month is usually required for the formation of an intact mucosa with the frenum attached in its new position.

Techniques to Improve Esthetics

The maxillary anterior area in a patient with a high lip line presents a visible area in which patients are concerned with the esthetic appearance of the gingival tissues. This area is addressed as the "esthetic zone," which requires special consideration in restorative, periodontal, and implant therapy. The symmetry of the facial gingival margin from canine to canine is altered with the recession of the gingival margin, the loss of the interdental papilla, or if there is excessive amount of gingival tissue creating a "gummy smile." The therapy to correct these gingival conditions is discussed under the following topics:

Figure 63-17 Pouch and tunnel technique for root coverage. **A,** Preoperative view. Note gingival recession. **B,** Sulcular incision is made from the mesial to the facial line angles. **C,** A tunnel is made through the papilla using a blunt incision. **D,** A connective tissue graft is taken from the palate. **E,** The connective tissue is placed through the papillary tunnel and apically beneath the pouch. **F,** The facial gingival margin covers the connective tissue using horizontal mattress sutures interdentally. **G,** Postoperative view. Note complete root coverage and thickened gingival margin at 3 months. *(Courtesy Dr. Robert R. Azzi, Paris.)*



Figure 63-18 Small, contoured blades used for periodontal plastic surgery.

1. Root coverage
2. Papilla reconstruction
3. Therapy to correct excessive gingival display

Root Coverage (Gingival Augmentation Coronal to the Recession)

The surgical correction of root coverage is discussed in detail in the section on gingival augmentation coronal to the recession.

Papilla Reconstruction

As previously indicated in this chapter, the loss of the interdental papilla is a major esthetic problem for many patients. It is often referred to as the "black triangle or hole." (Figure 63-20). The reconstruction of the lost or reduced interdental papilla is the most difficult and unpredictable problem in esthetic periodontal therapy. The interdental papilla is gingival tissue supported and created by two adjacent teeth in contact and the underlying bone beneath this

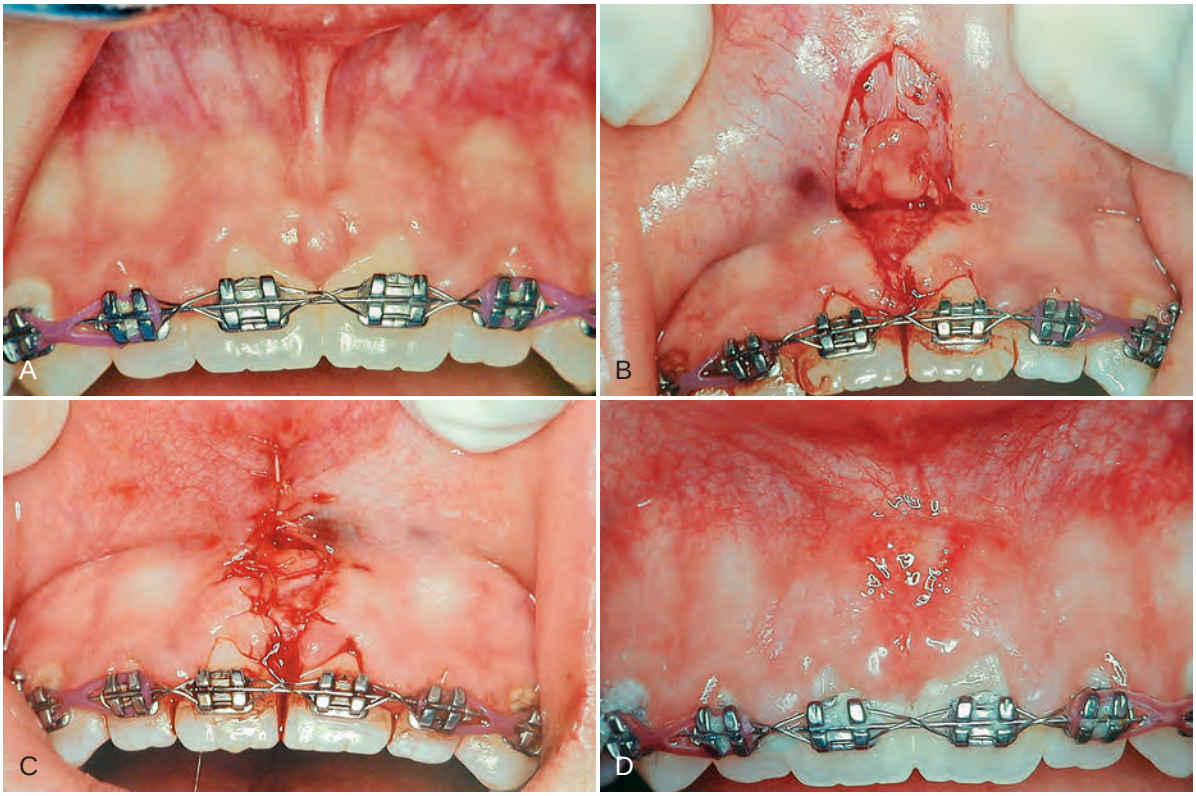

Figure 63-19 Removal of the frenum. **A,** Preoperative view of frenum between the two maxillary central incisors. **B,** Removal of the frenum from both the lip and gingiva. **C,** Site is sutured after it is placed over the wound. **D,** Postoperative view at 2 weeks. *(Courtesy Dr. J.J. Elbaz, Beverly Hills, California.)*

Figure 63-20 The loss of the interdental papilla and the esthetic problem. The black triangle or hole.

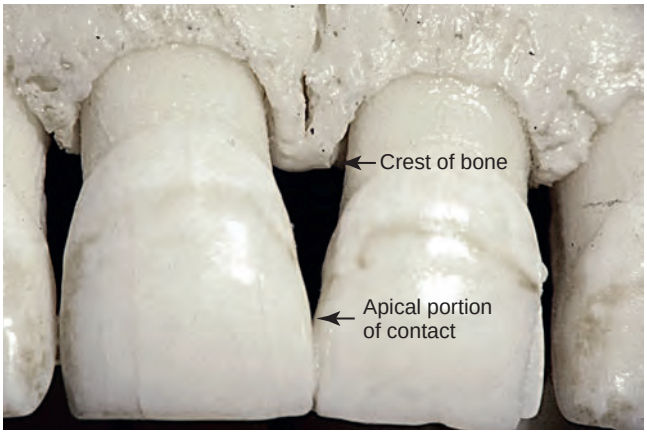

Figure 63-21 The distance from the crest of the interdental bone to the apical portion of the contact, which determines the absence or presence of the papilla as indicated by Tarnow et al.

tissue.[102] The loss of this bone as the result of periodontal disease or the loss of the contact alters the support of the interdental tissue, which can lead to the loss or the reduced height of the papilla. Tarnow[105] in his study of this area stated the distance from the crest of the interdental bone to the apical portion of the contact above this bone determines whether the interdental papilla is absent or present. (Figure 63-21). Therefore the predictable reconstruction of the papilla is determined not only by the augmentation of the gingival tissue but also by the presence or absence of the underlying bone and the contact of the two adjacent teeth. Orthodontics and restorative therapy also play an important role in the loss and reconstruction of the papilla since they can determine the location of the contact position in the dentition. We have also learned from experience that grafting bone or gingiva of minimal size to a small recipient site is unpredictable because of the lack of blood supply from the recipient site to the donor tissue. Therefore bone grafting or free gingival grafting of interdental areas to reconstruct the papilla is not a predictable procedure. There have been numerous case reports of different techniques to augment gingival tissue into the interdental area. All of these techniques must be based on the principle of adequate blood supply to the donor tissue. Of the many gingival grafting procedures used in periodontal therapy, the technique that offers the best blood supply to the donor tissue is the pedicle graft because it maintains a connection between the donor tissue and the origin of the graft. The pouch and tunnel surgical procedure also creates the ideal blood supply for the recipient site to accept the donor tissue. Han et al[47] reported a technique using a

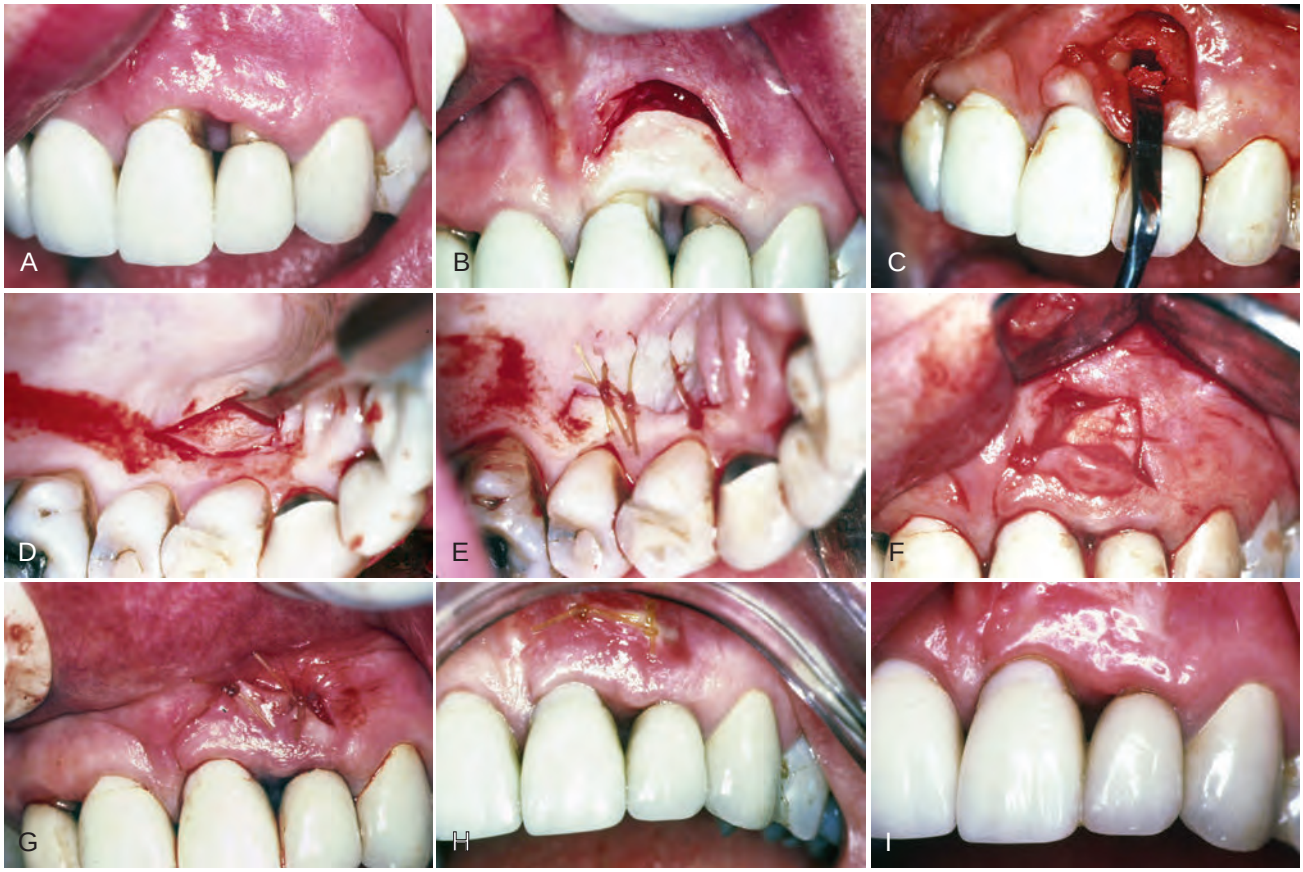

Figure 63-22 The semilunar surgical pouch and the connective tissue graft to reconstruct the interdental papilla. *(Courtesy Dr. T.J. Han, University of California, Los Angeles.)*

semilunar pedicle graft and pouch to gain papillary height, but without bone support this technique was able to only reduce the interdental space (Figure 63-22). Azzi et al[5-9] has also reported successful results with numerous cases using different surgical techniques to regain the lost papilla. All of these cases employ different grafting techniques, using not only connective tissue and bone but also a surgical flap design applying the principle of the pouch and tunnel to maximize the blood supply to the grafted tissue. The case in Figure 63-23 incorporates several of the concepts indicated earlier for papilla reconstruction. These concepts are (1) semilunar pedicle design, (2) both connective tissue and bone grafting into the interdental area, and (3) the use of restorative dentistry to place the apical portion of the contact closer to the crestal bone.[7]

The future of papilla reconstruction will involve techniques developed by tissue engineering using biologic mediators. In a study reported by McGuire and Scheyer,[68] autologous fibroblasts were injected into the interdental papilla to atraumatically augment the deficient interdental papilla. Further discussion of this topic is presented in the "Soft Tissue Regeneration" section of this chapter. The exciting field of tissue engineering will allow the clinician to use minimally invasive procedures to reconstruct the lost papilla.

Therapy to Correct Excessive Gingival Display

Excessive gingival display, commonly called a "gummy smile," represents an esthetic concern for many patients. This appearance may be caused by a skeletal problem called *vertical maxillary excess,* by dentoalveolar extrusion, or by incomplete exposure of the anatomic crown, often referred to as *altered passive eruption.* It may be associated with a short upper lip or excessive lip translation. There may be a combination of causative factors requiring more than one treatment option.

Even in patients with excessive gingival display, the primary esthetic feature is the appearance of the teeth. If the cause of the "gummy" appearance is incomplete exposure of the anatomic crown, the teeth will appear short and unattractive. This appearance is often noticed in adolescent patients during orthodontic treatment. It has been found that if there is a need for esthetic crown lengthening before orthodontic therapy, there will still be a need after orthodontic therapy and likely still a need 5 years later.[56] Although patients may complain of the gummy exposure, the real esthetic issue is the altered tooth form. Surgical crown lengthening addresses both concerns, but its focus should be the exposure of a properly proportioned tooth.

Ideally, the width/length ratio of a maxillary central incisor clinical crown should fall between 0.78 and 0.85.[60,96] Thus a central incisor with a width of 8.5 mm should have a length between 10 and 11 mm. The length of the maxillary canine is equal to or slightly less than the central incisor, and its gingival margin should be aligned with the central incisor gingival margin. The gingival margin of the lateral incisor is usually about 1.0 mm coronal to the margins of the adjacent teeth, although in patients with a high lip line, it is generally more pleasing to have the lateral incisor gingival margin equal to the central incisors and canines.[2]

Surgical Techniques (Figure 63-24, A–G). Exposure of the full anatomic crown is necessary to achieve a smile with minimal gingival exposure. Measurements before surgery should include clinical crown width and length, anatomic crown length, and height of keratinized tissue.

Surgical crown lengthening may be accomplished by soft tissue excision alone or by flap surgery with or without osseous surgery. The determinates for choice of surgical procedure are (1) the need to leave a minimum of 3.0 mm of keratinized marginal tissue and (2) the possible need for osseous surgery. If excision of soft tissue for full anatomic crown exposure would leave at least 3.0 mm of keratinized marginal tissue and there is no need for osseous surgery, soft tissue excision alone is the treatment of choice. If less than 3.0 mm of keratinized marginal tissue would remain after the necessary excision, an apically positioned flap would be required.

Osseous Surgery. Soft tissue level is determined by thickness and level of the underlying alveolar bone. A thick bone margin or an alveolar crest at or near the CEJ causes the overlying gingiva to cover more of the anatomic crown than that seen where the alveolar crest is of normal thickness and positioned 2 mm apical to the CEJ. The facial soft tissue margin is located approximately 3 mm coronal to the osseous crest, allowing 2 mm for biologic attachment and 1 mm for sulcus depth.[41] Failure to adjust bone form and level to account for these dimensions leads to rebound of surgically reduced soft tissue to reform this biologic width.[83,86]

Precise osseous surgery is best accomplished after elevation of a full-thickness mucoperiosteal flap that provides good visibility and access for three-dimensional ostectomy and osteoplasty. In esthetic crown lengthening, only a facial flap is raised to prevent loss of papillary fill. Initial gross osteoplasty is accomplished with

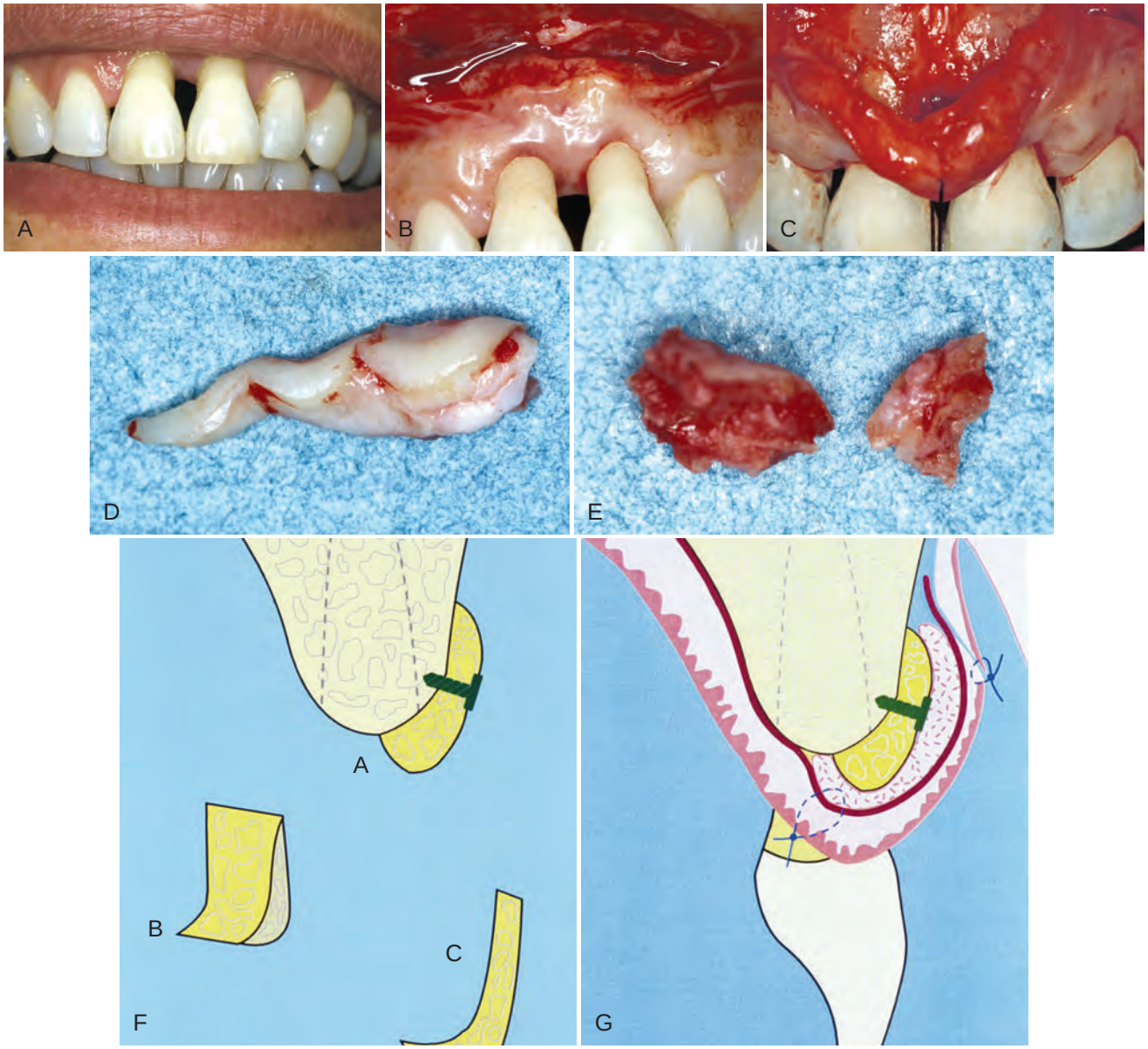

Figure 63-23 **A,** Preoperative view. Note the loss of the interdental papilla and the extensive recession of the facial marginal gingiva. **B,** Intrasulcular incision is made around the neck of the right lateral incisor and central incisors. A horizontal incision starting at the mucogingival junction, extending into the alveolar mucosa and apically up to the labial fold, is performed to elevate a split-thickness flap. **C,** Mucogingival flap is elevated coronally and secured with a horizontal mattress suture anchored to the interdental contact point of the central incisors, exposing the interdental bone. **D,** Connective tissue removed from the tuberosity to be placed over the bone graft in the interdental area. **E,** Bone graft removed from the tuberosity, which will be grafted in the interdental area. **F,** Diagram of the bone fixed to the alveolar crest using a titanium screw. *A,* Saddle-shaped graft fits over the interdental bone crest. *B,* Internal view of the osseous graft. *C,* Profile view of the osseous graft. **G,** Diagram of the flap returned and sutured over the grafted materials to obtain complete closure.

Continued

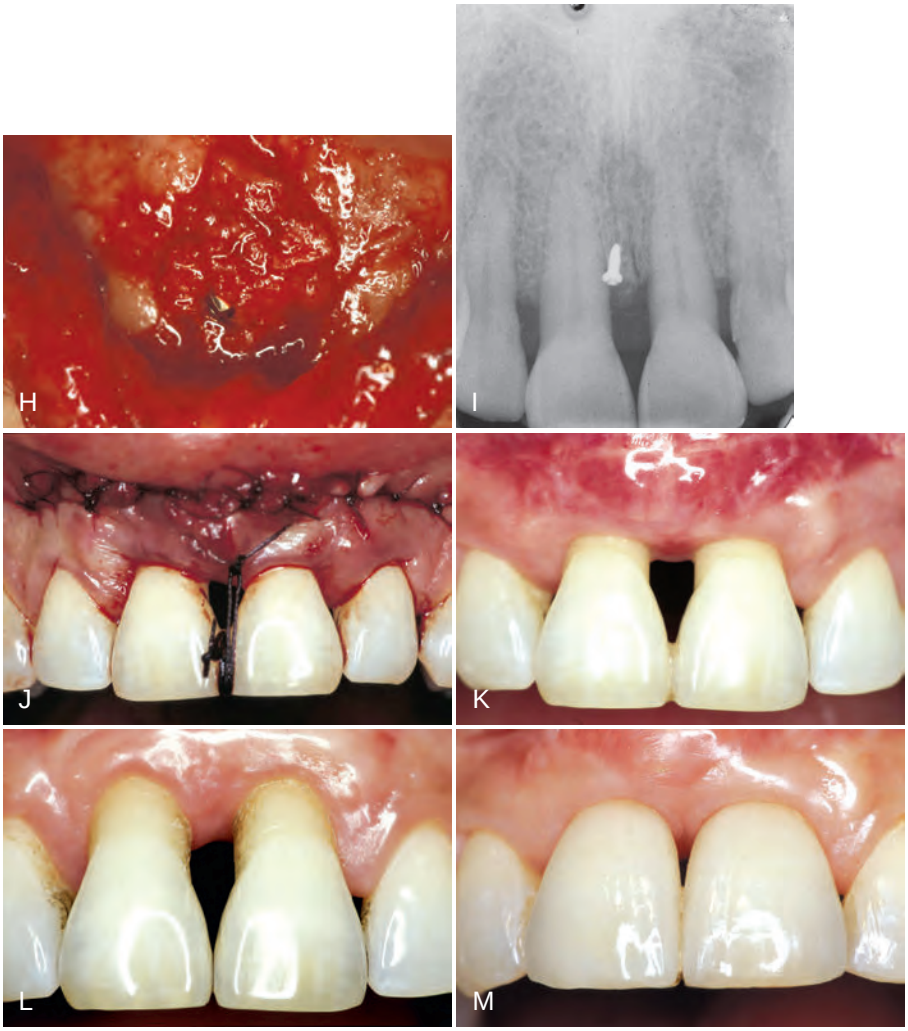

Figure 63-23, cont'd **H,** Crushed cancellous bone is packed around the grafted bone in the shape of the reconstructed interdental bone. **I,** A radiograph indicating the titanium screw that is used to hold the grafted bone in place. **J,** Coronal positioning of the entire gingivopapillary unit by the use of a horizontal mattress suture anchored over the splinted incisal portion of the contact. The mucosal portion of the flap is approximated to the gingivopapillary edge of the flap and sutured using 4.0 sutures. **K,** Three-month postoperative healing. Normal anatomy and shape with complete root coverage on the right lateral incisor, partial root coverage on the central incisors, and reconstruction of the interdental papilla. **L,** Preoperative view. Compare with the reconstructed papilla. **M,** One-year postoperative view with two porcelain veneers bonded on the central incisors. The contact is placed apically to help reduce the interdental space. *(Courtesy Dr R. Azzi, Paris.)*

a round bur to reduce excessive bone thickness, followed by alteration of the crestal level with hand chisels and curettes. It is important to reduce the osseous crest so that the new position parallels the CEJ at each tooth both facially and proximally. However, the height of the interdental crest is not reduced in esthetic crown lengthening. If full exposure of the anatomic crown is desired, the alveolar crest should be reduced to a position 3 mm apical to the CEJ. Excessive bone thickness interdentally is reduced with a round bur to produce a slight prominence of the roots relative to the alveolar ridge. Care should be exercised to maintain adequate bone thickness over the root surfaces. Creation of an ideal osseous form leads to predictable and stable soft tissue position and ideal crown exposure.

Flap closure is accomplished with interrupted 7-0 sutures. Postoperative instructions are focused on plaque control to prevent soft tissue rebound.

Figure 63-24, *A–G* demonstrates a clinical case of esthetic crown lengthening to correct the "gummy appearance" in the maxillary anterior esthetic zone.

Tissue Engineering

Tissue engineering in periodontics and all of dentistry holds the future of wound repair and will continue to evolve into a valuable treatment variable that the clinician can influence and upregulate. It is important, however, to understand our limitations when it comes to influencing the complex wound healing scenario. The role of inflammation, existing cytokines, growth factors, extracellular matrices, and collagen synthesis must be considered when evaluating tissue-engineering methods. Furthermore, having the correct factor at the appropriate time, at an effective concentration, and for the proper duration are issues that need further investigation and clinical validation. Just as we strive to understand the host role in the pathogenesis of periodontal disease, we must also take into consideration the host influence, both positive and negative, on wound healing after regenerative procedures.

Tissue engineering and the use of biologic mediators in periodontal plastic surgery has become a reality in recent years as the result of research and the demand for noninvasive surgical

Figure 63-24 **A,** Excessive gingival display and short clinical crowns. **B,** Short clinical crowns and thick periodontium. **C,** Excision of marginal gingiva to expose full anatomic crown. **D,** Full-thickness flap elevation revealing thick alveolar bone with irregular crest. **E,** Ostectomy and osteoplasty completed. **F,** Flap repositioned and sutured with interrupted sling sutures. **G,** Three weeks postoperative view. **H,** Two months postoperative view. *(Courtesy Dr. Edward P. Allen, Dallas, TX.)*

procedures by both the patients and clinicians. Current periodontal plastic surgery is based on the use of the palatal site for donor tissue (subepithelial connective tissue graft), which entails a second surgical wound. Many patients are fearful of this donor wound and resist the surgery needed to correct a mucogingival problem. For these patients who desire to avoid the palatal donor site, morbidity associated with the subepithelial connective tissue graft (SECTG), and free gingival graft (FGG), tissue-engineering methods are an excellent alternative. Periodontal therapy has been involved with tissue engineering for decades, beginning with GTR, a form of passive tissue engineering that excluded certain cell types and created an engineered wound left to heal with the appropriate cell types (see Chapter 61). The following is a summary of the materials that have been used for procedures based on tissue engineering and is divided into passive and active categories to recognize the role the cells play in tissue engineering.

Passive Engineering

1. Therapies based on GTR-based therapies; barrier membranes
2. Biologically based acellular dermal matrix (ADM)

Active Engineering

1. Enamel matrix derivative (EMD)
2. Growth factors: Recombinant human platelet-derived growth factor-BB (rhPDGF-BB) + beta-tricalcium phosphate (β-TCP) + collagen wound dressing
3. Cell therapy
   - Autologous fibroblast: Isolagen
   - Bilayered cell therapy (BLCT): Celltx
   - Human fibroblast-derived dermal substitute (HFDDS): Dermagraft

GTR (see Chapter 61) and ADM are both considered passive cell manipulation in which the cells themselves are not biologic mediators. Barrier membranes and ADM offer wonderful solutions with an unlimited source and positive outcomes in the literatures as a GTR technology or tissue replacement graft, respectively.[1,103,106,111] Barrier membranes allow certain cell types to proliferate but do not offer an active component. ADM used in periodontal plastic surgery holds no active component to influence wound healing and is also considered a component in passive engineering. Therefore, in both GTR and ADM, the cells themselves are not actively participating in the cellular changes. In active tissue engineering, the cells are biologically active in the regeneration process. A large body of literature provides clinical and histological evidence of periodontal regeneration from biologically active materials for the intrabony lesion.[64,78,94,109] This evidence can be used to support the exploration of these active materials for application in mucogingival surgery. Randomized controlled clinical trials and human histologic evidence are needed to claim true regeneration and efficacy using new technologies. The remainder of this chapter concentrates on the novel approaches using active tissue engineering for periodontal mucogingival applications. The following is a discussion of five active tissue engineering products.

In 2003, McGuire and Nunn[65,63] published results of a single-center randomized controlled clinical trial comparing a coronally advanced flap with EMD to SECTG. The results showed no statistical difference in the percentage of root coverage between test and control. It was concluded that within the limitations of this single-center trial that EMD with a coronally advanced flap is a valid alternative to the subepithelial connective tissue (Figure 63-25).

In 2006, McGuire and Scheyer published a case series using a growth factor–mediated procedure, including rhPDGF, β-TCP, and a collagen wound dressing to obtain root coverage comparable to SECTG, which led to a controlled clinical trial. This randomized controlled clinical trial used the growth factor–mediated procedure to obtain clinical and histologic evidence of root coverage and regeneration when compared to the SECTG was published.[67,71,69] These studies provided "proof of principle" that in four of four human histology block sections, true periodontal regeneration (alveolar bone, periodontal ligament, and new cementum) was possible with rhPDGF + β-TCP + a collagen wound dressing. Histologic evidence of root coverage verifies that this tissue-engineering method offers true periodontal regeneration, which is not expected with the SECTG (Figure 63-26, *A–O*).

The reconstruction of the open interproximal space remains one of the greatest challenges in esthetic periodontal therapy. In a landmark study by McGuire and Scheyer (2007),[68] autologous fibroblasts were injected into the interdental papilla in a method to atraumatically augment the deficient gingival papilla. Although this method has not been thoroughly validated, treatment outcomes reduced open interproximal spaces and improved esthetics in the maxillary (Figure 63-27). No long-term evidence exists for tissue stability with this method, but this pilot study shows promise for an innovative study design for a tissue-engineering application in dentistry. For example, this technology allows for the concept of "banking" autologous fibroblasts for future use or research.

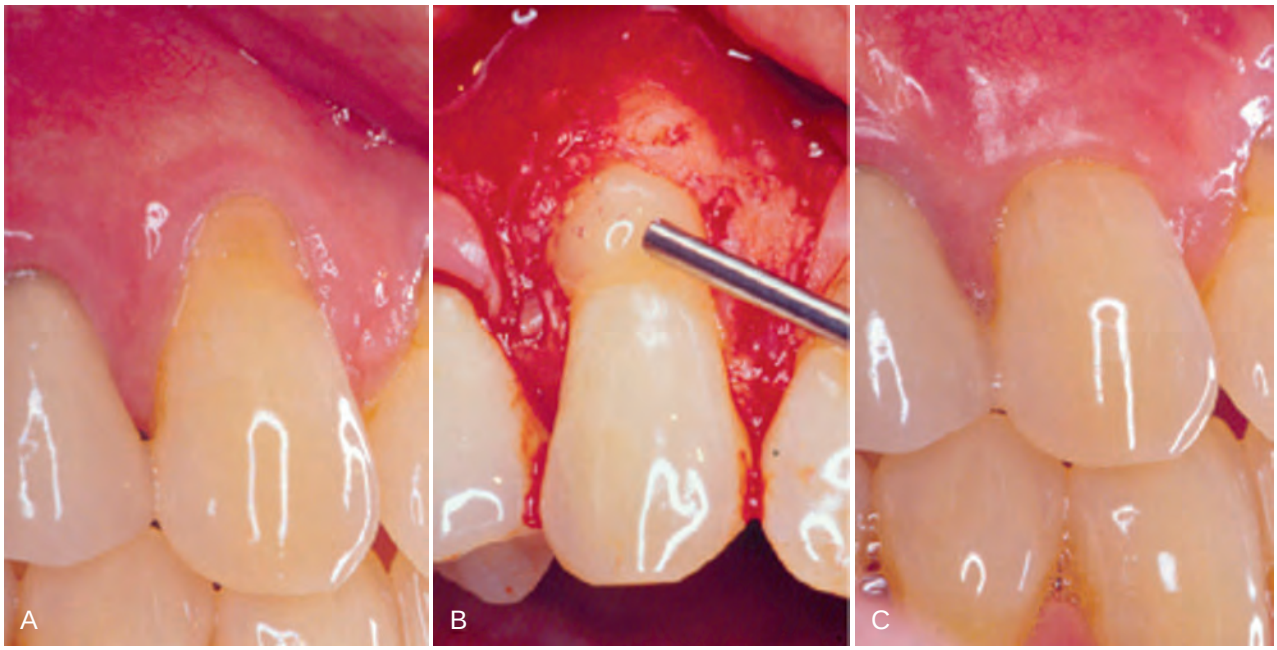

Figure 63-25 **A,** Pretreatment recession defect of 3 mm to be treated with enamel matrix derivative (EMD). **B,** Application of EMD to the root surface before coronally advancing the flap with 5-0 plain gut sutures. **C,** A 1-year follow-up with 100% root coverage and increased keratinized gingiva. *(Courtesy Dr. Michael K. McGuire.)*

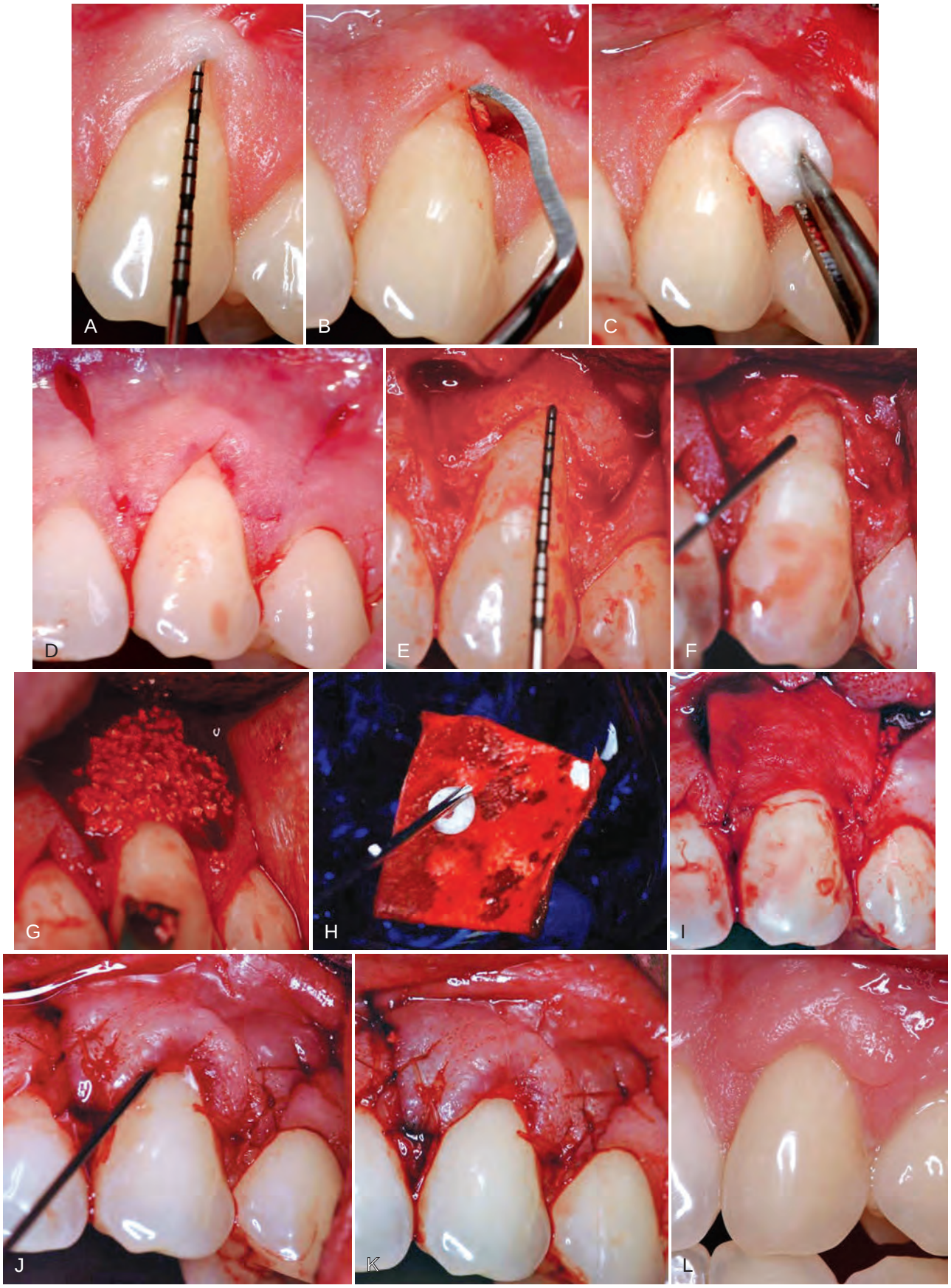

Figure 63-26 **A,** A study test tooth with preoperative 3 mm of recession and probing depth of 1 mm. This tooth will be treated with recombinant human platelet-derived growth factor-BB (rhPDGF-BB) + beta-tricalcium phosphate (β-TCP) + collagen wound dressing. **B,** Root surface preparations with a chisel. **C,** Root surface preparation with ethylenediaminetetraacetic acid (EDTA). **D,** Horizontal and vertical beveled incisions. **E,** Alveolar bone crest 6.5 mm from cement-enamel junction. **F,** Root surface exposed to rhPDGF. **G,** rhPDGF saturated β-TCP placed over the root surface. **H,** Collagen wound dressing saturated with rhPDGF. **I,** Collagen dressing sutured with resorbable 6-0 plain gut sutures to the papillary connective tissue bed. **J,** Remaining rhPDGF is expressed over the closed wound. **K,** Vertical incisions closed with 5-0 chromic gut sutures. **L,** Four-week postoperative photograph.

Continued

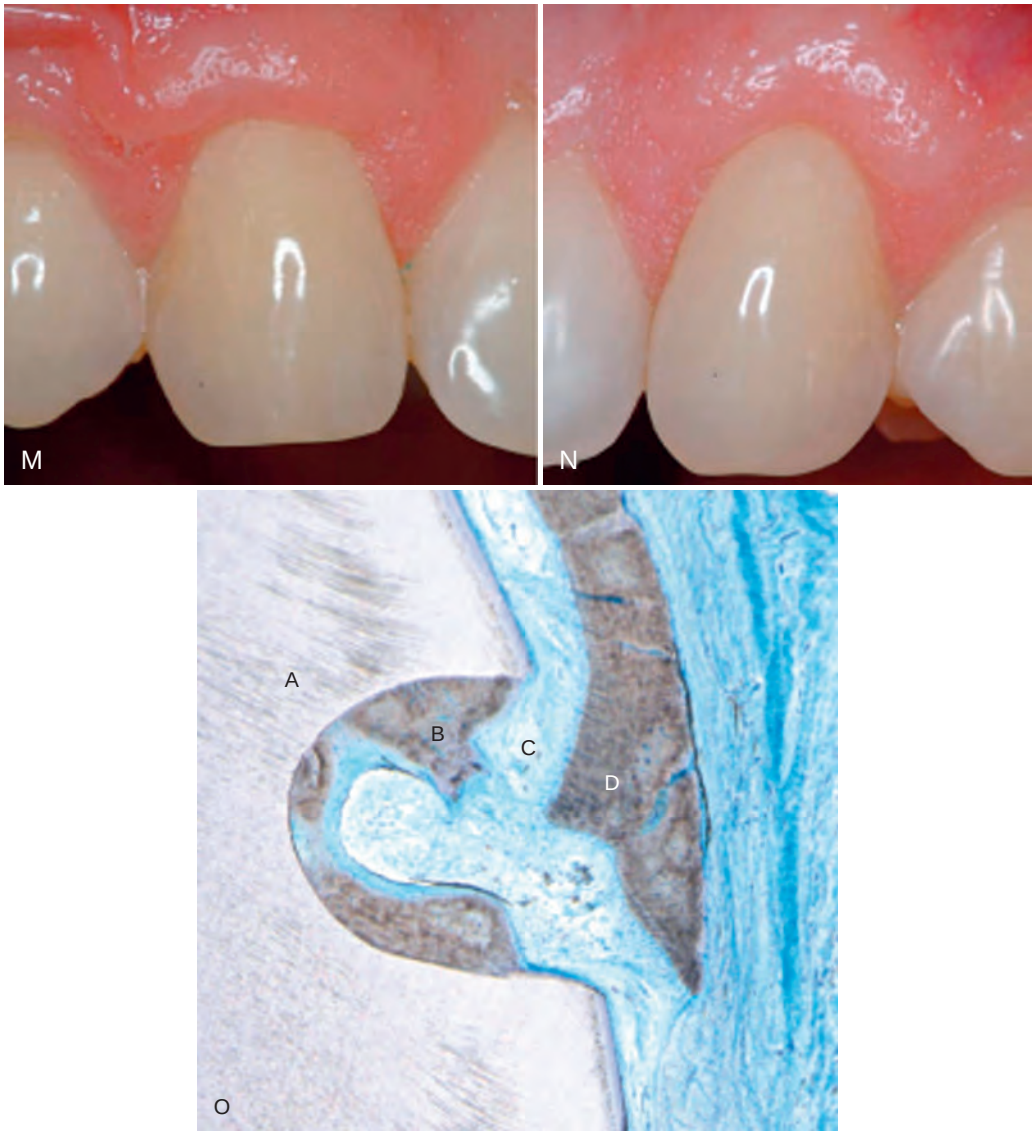

Figure 63-26, cont'd **M,** Six-month postoperative view of control tooth #6 treated with subepithelial connective tissue graft (SECTG). **N,** Six-month postoperative view without tissueplasty. **O.** *a*, Tooth root with histologic reference notch made at the pregrafted alveolar crest. *b*, New cementum. *c*, Periodontal ligament. *d*, New bone.

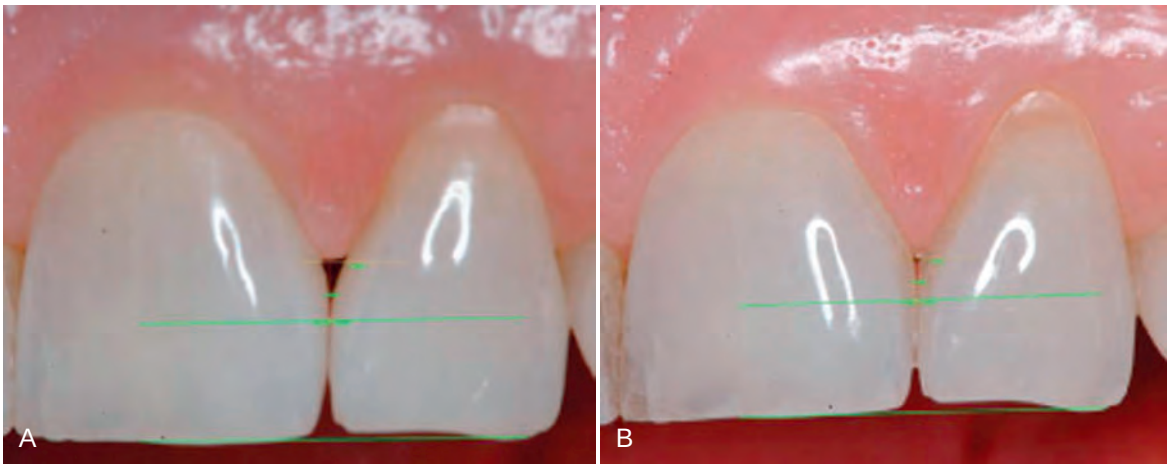

Figure 63-27 **A,** Preoperative view of open interproximal space. **B,** Four months after three injections into the papilla with the patient's own expanded and concentrated fibroblast. Note the improved papillary form. Also note green horizontal lines used for image analysis. *(From McGuire MK, Scheyer ET: J Periodontal 78:4-17, 2007.)*

In 2008, McGuire and Scheyer[70] published a pilot study comparing a tissue-engineered bilayered cell therapy (BLCT) (Apligraf, Organogenesis, Inc, Canton, MA) to FGG with promising enough results to warrant a multicentered controlled clinical trial (Figure 63-28). From the pilot study, there is evidence of de novo formation of attached and keratinized gingiva with the placement of a live cell therapy device without donor site surgery. In this randomized controlled clinical trial, the test material was capable of generating up to 2.72 mm of keratinized gingiva, and in more than 75% of the subjects, greater than 2 mm of keratinized tissue was developed after a 6-month follow-up visit. This pilot study supports further research of the BLCT to produce de novo keratinized gingiva without the use of a traditional autograft. More data are being analyzed that will allow for the commercial use of this material.

In 2005, McGuire and Nunn[66] published a pilot study evaluating the safety and efficacy of a living tissue-engineered HFDDS (Dermagraft, Advanced Tissue Science, La Jolla, CA) compared to a gingival autograft. Although the autograft produced a greater band of keratinized tissue, the test group represented the first attempt to use an "off-the-shelf" tissue-engineered material capable of generating attached and keratinized gingiva.[115]

Figure 63-28 **A,** Preoperative control site to be treated with free gingival graft. **B,** Preoperative view of test site to be treated with bilayered cell therapy (BLCT). **C,** Preoperative control site stained with Schiller's iodine to better delineate the mucogingival junction. **D,** Test site stained with Schiller's iodine. **E,** Immediate postoperative view of free gingival graft.

Continued

Figure 63-28, cont'd **F,** Partial-thickness graft-bed preparation at the test site. **G,** Stabilization of bilayered cell therapy (BLCT) with 5-0 plain gut sutures. **H,** A fourth layer of BLCT is secured to the papilla to serve as an active wound dressing. **I,** One-week postoperative view of test site. **J,** Six-month postoperative view of control site. **K,** Six-month postoperative view of test site. **L,** Control site stained with Schiller's iodine. **M,** Test site stained with Schiller's iodine. Note de novo formation of attached and keratinized gingiva.

In the quest for new technologies to reduce trauma during surgery, further research is needed to investigate treatment methods such as ADM and biologic factors, as well as materials that could carry growth factors to the surgical site and maintain their action. At some point, recombinant growth factors could eliminate both the need for donor sites and the use of exogenous materials inserted into the human body. Future research should focus on obtaining additional evidence when using growth factors and live-cell technology during periodontal therapy to eliminate donor site morbidity.

been established as a standard necessary for gingival health. People who practice good, atraumatic oral hygiene may maintain excellent gingival health with almost no attached gingiva.

However, those individuals whose oral hygiene practices are less than optimal can be helped by the presence of keratinized gingiva and vestibular depth. Vestibular depth provides space for easier placement of the toothbrush and prevents brushing on mucosal tissue. To improve esthetics, the objective is the coverage of the denuded root surface. The maxillary anterior area, especially the facial aspect of the canine, often presents extensive gingival recession. In such cases, the covering of the denuded root surface not only widens the zone of attached gingiva but also creates an improved esthetic result. This recession and the resultant denuded root surface have a special esthetic concerns for individuals with a high smile line. A wider zone of attached gingiva is also needed around teeth that serve as abutments for fixed or removable partial dentures, as well as in the ridge areas bearing a denture. Teeth with subgingival restorations and narrow zones of keratinized gingiva have higher gingival inflammation scores than teeth with similar restorations and wide zones of attached gingiva.[96,97] Therefore, in such cases, techniques for widening the attached gingiva are considered preprosthetic periodontal surgical procedures. Chapter 66 discusses this subject in detail.

Widening the attached gingiva accomplishes the following four objectives:

1. Enhances plaque removal around the gingival margin.
2. Improves esthetics.
3. Reduces inflammation around restored teeth.
4. Gingival margin binds better around teeth and implants with attached gingiva.

Problems Associated with Shallow Vestibule

Another objective of periodontal plastic surgery is the creation of vestibular depth when it is lacking. Gingival recession displaces the gingival margin apically, thus reducing vestibular depth, which is measured from the gingival margin to the bottom of the vestibule. As indicated previously, with minimal vestibular depth, proper hygiene procedures are jeopardized. The sulcular brushing technique requires the placement of the toothbrush at the gingival margin, which may not be possible with reduced vestibular depth.

Minimal attached gingiva with adequate vestibular depth may not require surgical correction if proper atraumatic hygiene is practiced with a soft brush. Minimal amounts of keratinized attached gingiva with no vestibular depth benefit from mucogingival correction. Adequate vestibular depth is also necessary for the proper placement of removable prostheses.

Problems Associated with Aberrant Frenum

Still another important objective of periodontal plastic surgery is to correct frenal or muscle attachments that may extend coronal to the mucogingival junction. If adequate keratinized, attached gingiva is present coronal to the frenum, it may not be necessary to remove the frenum. A frenum that encroaches on the margin of the gingiva may interfere with plaque removal, and the tension on the frenum may tend to open the sulcus. In such cases, surgical removal of the frenum is indicated.

Esthetic Surgical Therapy

As indicated earlier, the recession of the facial, gingival margin will alter the proper gingival symmetry and result in an esthetic problem. The presence of the interdental papilla is also important to satisfy the esthetic goals of the patient. A missing papilla creates a space that many address as a "black hole." The regeneration of the lost or reduced papilla is one of the most difficult goals in esthetic periodontal plastic surgery. Another area of concern is the patient who presents an excessive amount of gingiva in the visible area. This condition is often addressed as a "gummy smile" and may be corrected surgically by crown lengthening. The correction of these anatomic defects has become an important part of periodontal plastic surgery.

Tissue Engineering

The future of periodontal plastic surgery will encompass the use of tissue-engineered products at the recipient site to reduce the donor site morbidity. Currently, there are numerous studies, both clinically and in the laboratories, to allow the clinician to use this minimally invasive approach to periodontal plastic surgery.

Etiology of Marginal Tissue Recession

The most common cause of gingival recession and the loss of attached gingiva is abrasive and traumatic toothbrushing habits. The bone and soft tissue anatomy of the buccal, radicular surface of the dentition is usually thin, especially around the anterior area. Teeth positioned buccally may have an even thinner bone and gingiva. In many instances, such areas may have a complete absence of bone beneath the thin overlying gingival tissue. Such defect in the bone is called a *dehiscence.* This anatomic status combined with external trauma from overzealous brushing can lead to the loss of gingival tissue. Recession of the gingival tissue and bone exposes the cemental surface of the root, which results in abrasion and "ditching" of the cemental surface apical to the cementoenamel junction (CEJ). The cementum is softer than enamel and will be destroyed before the enamel surface of the crown.

Another cause for gingival recession is periodontal disease and chronic marginal inflammation. The loss of attachment caused by the inflammation is followed by the loss of bone and gingiva. Advanced periodontal involvement in areas of minimal attached gingiva results in the base of the pocket extending close to, or apical to, the mucogingival junction. Periodontal therapy of these areas also results in gingival recession caused by the loss of gingiva and bone.

Frenal and muscle attachments that encroach on the marginal gingiva can distend the gingival sulcus, which creates an environment for plaque accumulation. This condition increases the rate periodontal recession and will contribute to the recurrence of the recession even after treatment (Figure 63-1). These problems are more common on facial surfaces, but may also occur on the lingual surface.[11]

Orthodontic tooth movement through a thin buccal osseous plate may lead to a dehiscence beneath a thin gingiva. This also can lead to the recession of the gingiva[46,117] (Figure 63-2).

Factors That Affect Surgical Outcome

Irregularity of Teeth

Abnormal tooth alignment is an important cause of gingival deformities that require corrective surgery and also an important factor in determining the outcome of treatment. The location of the gingival margin, width of the attached gingiva, and alveolar bone height and thickness are all affected by tooth alignment. On teeth that are tilted or rotated labially, the labial bony plate is thinner and located farther apically than on the adjacent teeth; therefore the gingiva is recessed so that the root is exposed.[117] On the lingual surface of such teeth, the gingiva is bulbous, and the bone margins are closer to the CEJ. The level of gingival attachment on root

Figure 63-1 High frenum attachments. **A,** Frenum between maxillary central incisors. **B,** Frenum attached to facial surface of maxillary lateral incisors. **C,** Frenum attached to facial surface of mandibular incisor. **D,** Frenum attached to facial surface of an incisor.

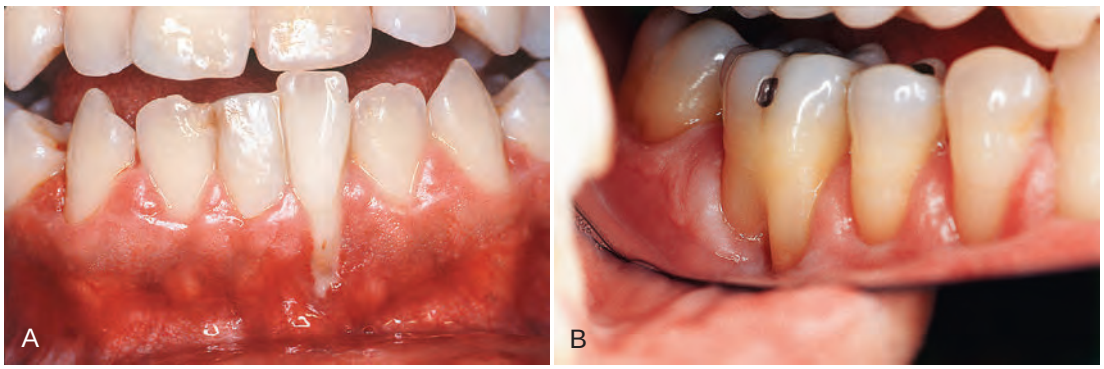

Figure 63-2 **A,** Gingival recession and extreme inflammation around a lower central incisor. **B,** Advanced recession of mesial root of a first lower molar.

surfaces and the width of the attached gingiva after mucogingival surgery are affected as much by tooth alignment as by variations in treatment procedures.

Orthodontic correction is indicated when mucogingival surgery is performed on malposed teeth in an attempt to widen the attached gingiva or to restore the gingiva over denuded roots. If orthodontic treatment is not feasible, the prominent tooth should be reduced to within the borders of the alveolar bone, with special care taken to avoid pulp injury.

Roots covered with thin bony plates present a hazard in mucogingival surgery. Even the most protective type of flap, a partial-thickness flap, creates the risk of bone resorption on the periosteal surface.[49] Resorption in amounts that ordinarily are not significant may cause loss of bone height when the bone plate is thin or tapered at the crest.

Mucogingival Line (Junction)

Normally, the mucogingival line in the incisor and canine areas is located approximately 3 mm apical to the crest of the alveolar bone on the radicular surfaces and 5 mm interdentally.[98] In periodontal disease and on malposed disease free teeth, the bone margin is located farther apically and may extend beyond the mucogingival line. The distance between the mucogingival line and the CEJ before and after periodontal surgery is not necessarily constant. After inflammation is eliminated, the tissue tends to contract and draw the mucogingival line in the direction of the crown.[31]

Criteria for Selection of Techniques

Different techniques are presented for solving mucogingival problems outlined in this chapter. The proper selection of the numerous techniques must be based on the predictability of success, which in turn is based on the criteria described next.

Criteria for selection of mucogingival techniques are as follows:

1. Surgical site free of plaque, calculus, and inflammation
2. Adequate blood supply to the donor tissue
3. Anatomy of the recipient and donor sites
4. Stability of the grafted tissue to the recipient site
5. Minimal trauma to the surgical site

Surgical Site Free of Plaque, Calculus, and Inflammation

Periodontal plastic surgical procedures should be undertaken in a plaque-free and inflammation-free environment to enable the clinician to manage gingival tissue that is firm. Meticulous, precise incisions and flap reflection cannot be achieved when the tissue is inflamed and edematous. Thorough scaling and root planing, as well as meticulous plaque removal by the patient, must be accomplished before any surgical procedure.

Adequate Blood Supply

To obtain the maximum amount of blood supply to the donor tissue, gingival augmentation apical to the area of recession provides a better blood supply than coronal augmentation, since the recipient site is entirely periosteal tissue. Root coverage procedures present a portion of the recipient site (denuded root surface) without blood supply. Therefore, if esthetics is not a factor, gingival augmentation apical to the recession may be more predictable. A pedicle-displaced flap has a better blood supply than a free graft, with the base of the flap intact. In root coverage, therefore, if the anatomy is favorable, the pedicle flap or any of its variants may be the best procedure.

The subepithelial connective tissue graft (Langer) and the pouch and tunnel techniques use a split flap with the connective tissue sandwiched between the flaps. This flap design maximizes the blood supply to the donor tissue. If large areas require root coverage, these sandwich-type recipient sites provide the best flap design for blood supply.

Anatomy of the Recipient and Donor Sites

The presence or absence of vestibular depth is an important anatomic criterion at the recipient site for gingival augmentation. If gingival augmentation is indicated apical to the area of recession, there must be adequate vestibular depth apical to the recessed gingival margin to provide space for either a free or a pedicle graft. If a vestibule is necessary, only a free graft can accomplish this objective apical to the recession.

Mucogingival techniques, such as free gingival grafts and free connective tissue grafts, can be used to create vestibular depth and widen the zone of attached gingiva. Other techniques require vestibular depth to be present before the surgery, including pedicle grafts (lateral and coronal), subepithelial connective tissue graft (Langer), and pouch and tunnel procedures.

The availability of donor tissue is another anatomic factor that must be considered. Pedicle displacement of tissue necessitates the presence of an adjacent donor site that presents gingival thickness and width. Palatal tissue thickness is also necessary for the connective tissue donor autograft. Gingival thickness is required at the recipient site for techniques using split-thickness, sandwich-type flap or the pouch and tunnel techniques.

Stability of the Grafted Tissue to the Recipient Site

Good communication of the blood vessels from the grafted donor tissue to the recipient site requires a stable environment. This necessitates sutures that stabilize the donor tissue firmly against the recipient site. The least amount of sutures and maximum stability should be achieved.

Minimal Trauma to the Surgical Site

As with all surgical procedures, periodontal plastic surgery is based on the meticulous, delicate, and precise management of the oral tissues. Unnecessary tissue trauma caused by poor incisions, flap perforations, tears, or traumatic and excessive placement of sutures can lead to tissue necrosis. The selection of proper instruments, needles, and sutures is mandatory to minimize tissue trauma; sharp contoured blades (see Figure 63-18), smaller-diameter needles, and resorbable monofilament sutures all are important factors in achieving atraumatic surgery.

Conclusion

As defined in this chapter, periodontal plastic surgery refers to soft tissue relationships and manipulations. In all of these procedures, blood supply is the most significant concern and must be the underlying issue for all decisions regarding the individual surgical procedure. A major complicating factor is the avascular root surface, and many modifications to existing techniques are used to overcome this. Diffusion of fluids is short term and of limited benefit as tissue size increases. Thus the formation of a circulation through anastomosis and angiogenesis is crucial to the survival of these therapeutic procedures. The formation of vascularity is based on growth molecules, such as vascular endothelial growth factor (VEGF), and cellular migration, proliferation, and differentiation. As tissue-engineering techniques improve, the success and predictability of mucogingival surgery should dramatically increase. Undoubtedly, however, all advancements will have adequate circulation and blood supply as their basis.

New techniques are constantly being developed and are slowly being incorporated into periodontal practice. The practitioner should be aware that, at times, new methods are published without adequate clinical research to ensure the predictability of the results and the extent to which the techniques may benefit the patient. Critical analysis of newly presented techniques should guide our constant evolution toward better clinical methods.

Suggested Readings

American Academy of Periodontology: *American Academy of Periodontology: glossary of periodontal terms*, ed 3, Chicago, 1992, American Academy of Periodontology.

Azzi R, Takei H, Etienne D, et al: Root coverage and papilla reconstruction using autogenous osseous and connective tissue grafts. *Int J Perio Rest Dent* 2:141–147, 2001.

Becker BE, Becker W: Use of connective tissue autografts for treatment of mucogingival problems. *Int J Periodont Restor Dent* 6:89, 1986.

Carranza FA, Jr, Carraro JJ: Mucogingival techniques in periodontal surgery. *J Periodontol* 41:294, 1970.

Cortellini P, Clauser C, Pini-Prato GP: Histologic assessment of new attachment following the treatment of a human buccal recession by means of a guided tissue regeneration procedure. *J Periodontol* 64:387, 1993.

Hawley CE, Staffileno H: Clinical evaluation of free gingival grafts in periodontal surgery. *J Periodontol* 41:105, 1970.

Langer B, Langer L: Subepithelial connective tissue graft technique for root coverage. *J Periodontol* 56:715, 1985.

McGuire MK, Nunn ME: Evaluation of human recession defects treated with coronally advanced flaps and either enamel matrix derivative or connective tissue. I. Comparison of clinical parameters. *J Periodontol* 74:1110–1125, 2003.

McGuire MK, Scheyer ET, Schupbach P: Growth factor-mediated treatment of recession defects: a randomized controlled trial and histologic and microcomputed tomography examination. *J Periodontol* 80:550–564, 2009.

Miller PD, Jr: A classification of marginal tissue recession. *Int J Periodont Restor Dent* 5:9, 1985.

References

References for this chapter are found on the companion website www.expertconsult.com.

References

1. Aichelmann-Reidy ME, Yukna RA, Evans GH, et al: Clinical evaluation of acellular allograft dermis for the treatment of human gingival recession. *J Periodontal* 72(8):998–1005, 2001.
2. Allen EP: Surgical crown lengthening for function and esthetics. *Dent Clin North Am* 37:163–179, 1993.
3. American Academy of Periodontology: *Proceedings of the World Workshop in Clinical Periodontics July 23-27*, Chicago, 1989, American Academy of Periodontology.
4. American Academy of Periodontology: Proceedings of the 1996 World Workshop in Periodontics, Lansdowne, Virginia, July 13-17. *Ann Periodontol* 1(1):1–947, 1996.
5. Azzi R, Carranza F, Etienne D: Surgical reconstruction of the interdental papilla. *Int J Perio Rest Dent* 18:467–473, 1998.
6. Azzi R, Etienne D, Sauvan J, et al: Root coverage and papilla reconstruction in class IV recession. A case report. *Int J Perio Rest Dent* 19:449–455, 1999.
7. Azzi R, Takei H, Etienne D, et al: Root coverage and papilla reconstruction using autogenous osseous and connective tissue grafts. *Int J Perio Rest Dent* 2:141–147, 2001.
8. Azzi R, Etienne D, Takei H, et al: Surgical thickening of the existing gingiva and reconstruction of interdental papilla around implant supported restorations. *Int J Perio Rest Dent* 22:71–77, 2002.
9. Azzi R, Etienne D, Schweitz B: Restorative dentistry and papilla reconstruction in reduced periodontium. *Clin Res Report* 1:27–34, 2004.
10. Becker NG: A free gingival graft utilizing a presuturing technique. *Periodontics* 5:194, 1967.
11. Bernimoulin JP, Loscher B, Muhlemann HR: Coronally repositioned periodontal flap. *J Clin Periodontol* 2:1, 1975.
12. Bjorn H: Free transplantation of gingiva propia. *Sveriges Tandlak T* 22:684, 1963.
13. Brackett RC, Gargiulo AW: Free gingival grafts in humans. *J Periodontol* 41:581, 1970.
14. Bohannan H: Studies in the alteration of vestibular depth. I. Complete denudation. *J Periodontol* 33:120, 1962.
15. Bohannan H: Studies in the alteration of vestibular depth. II. Periosteum retention. *J Periodontol* 33:120, 1962.
16. Bohannan H: Studies in the alteration of vestibular depth. III. Vestibular incision. *J Periodontol* 34:208, 1963.
17. Broome WC, Taggart EJ, Jr: Free autogenous connective tissue grafting. *J Periodontol* 47:580, 1976.
18. Caffesse RG, Guinard E: Treatment of localized gingival recessions. II. Coronally repositioned flap with a free gingival graft. *J Periodontol* 49:358, 1978.
19. Caffesse RG, Albano E, Plot C: Injertos gingivalis libres en perros: analisis biometrico. *Rev Asoc Odontol Argent* 60:517, 1972.
20. Caffesse RG, Carraro JJ, Carranza FA, Jr: Injertos givgivales libres en perros: estudio clinico e histologico. *Rev Asoc Odontol Argent* 60:465, 1972.
21. Caffesse RG, Burgett FG, Nasjleti CE, et al: Healing of free gingival grafts with and without periosteum. Part I. Histologic evaluation. *J Peridontol* 50:586, 1979.
22. Caffesse RG, Nasjleti CE, Burgett FG, et al: Healing of free gingival grafts with and without periosteum. II. Radioautographic evaluation. *J Periodontol* 50:595, 1979.
23. Carranza FA, Jr, Carraro JJ, Dotto CA, et al: Effect of periosteal fenestration in gingival extension operations. *J Periodontol* 37:335, 1966.
24. Chacker FM, Cohen DW: Regeneration of gingival tissues in nonhuman primates. *J Dent Res* 39:743, 1960.
25. Cohen DW, Ross SE: The double papillae repositioned flap in periodontal therapy. *J Periodontol* 39:65, 1968.
26. Corn H: Periosteal separation: its clinical significance. *J Periodontol* 33:140, 1962.
27. Cortellini P, Clauser C, Pini-Prato GP: Histologic assessment of new attachment following the treatment of a human buccal recession by means of a guided tissue regeneration procedure. *J Periodontol* 64:387, 1993.
28. Costich ER, Ramfjord SP: Healing after partial denudation of the alveolar process. *J Periodontol* 39:127, 1968.
29. Cummings LC, Kaldhal WB, Allen EP: Histologic evaluation of autogenous connective tissue and acellular dermal matrix grafts in humans. *J Periodontol* 76:178, 2005.
30. Donn BJ, Jr: The free connective tissue autograft: a clinical and histologic wound healing study in humans. *J Periodontol* 49:253, 1978.
31. Donnenfeld OW, Glickman I: A biometric study of the effects of gingivectomy. *J Periodontol* 37:447, 1966.
32. Donnenfeld OW, Marks R, Glickman I: The apically repositioned flap: a clinical study. *J Periodontol* 35:381, 1964.
33. Dordick B, Coslet JG, Seibert JS: Clinical evaluation of free autogenous gingival grafts placed on alveolar bone. II. Coverage of nonpathologic dehiscences and fenestrations. *J Periodontol* 47:568, 1976.
34. Dorfman HS, Kennedy JE, Bird WC: Longitudinal evaluation of free autogenous gingival grafts: a four-year report. *J Periodontol* 1:185, 1974.
35. Dorfman HS, Kennedy JE, Bird WC: Longitudinal evaluation of free autogenous gingival grafts. *J Clin Periodontol* 7:316, 1980.
36. Edel A: Clinical evaluation of free connective tissue grafts used to increase the width of keratinized gingiva. *J Clin Periodontol* 1:185, 1974.
37. Edlan A, Mejchar B: Plastic surgery of the vestibulum in periodontal therapy. *Int Dent J* 13:593, 1963.
38. Friedman N: Mucogingival surgery. *Texas Dent J* 75:358, 1957.
39. Friedman N, Levine HL: Mucogingival surgery: current status. *J Periodontol* 35:5, 1964.
40. Gapski R, Parks CA, Wang HL: Acellular dermal matrix for mucogingival surgery: a meta-analysis. *J Periodontol* 76(11):1814–1822, 2005.
41. Gargiulo AW, Wentz FM, Orban B: Dimensions and relations of the dentogingival junction in humans. *J Periodontol* 32:261–267, 1961.
42. Gargiulo AW, Arrocha R: Histo-clinical evaluation of free gingival grafts. *Periodontics* 5:285, 1967.
43. Gordon HP, Sullivan HC, Atkins JH: Free autogenous gingival grafts. Part II. Supplemental findings: histology of the graft site. *Periodontics* 6:130, 1968.
44. Grupe HE: Modified technique for the sliding flap operation. *J Periodontol* 37:491, 1966.
45. Grupe HE, Warren RF, Jr: Repair of gingival defects by a sliding flap operation. *J Periodontol* 27:92, 1956.
46. Hall WB: *Pure mucogingival problems: etiology, treatment and prevention*, Chicago, 1984, Quintessence.
47. Han TJ, Takei HH: Progress in gingival papilla reconstruction. *Periodontol 2000* 11:65, 1996.
48. Han TJ, Takei HH, Carranza FA, Jr: The strip gingival autograft technique. *Int J Periodont Restor Dent* 13:181, 1993.
49. Hangorsky V, Bissada NF: Clinical assessment of free gingival graft effectiveness on the maintenance of periodontal health. *J Periodontol* 51:274, 1980.
50. Harvey PM: Management of advanced periodontitis. Part I. Preliminary report of a method of surgical reconstruction. *NZ Dent J* 61:180, 1965.
51. Ibbott CG, Oles RD, Laverty WH: Effects of citric acid treatment on autogenous free graft coverage of localized recession. *J Periodontol* 56:662, 1985.
52. James WC, McFall WT, Jr: Placement of free gingival grafts on denuded alveolar bone. Part I. Clinical evaluations. *J Periodontol* 49:283, 1978.
53. James WC, McFall WT, Jr, Burkes EJ: Placement of free gingival grafts on denuded alveolar bone. II. Microscopic observations. *J Periodontol* 49:291, 1978.
54. Janson WA, Ruben MP, Kraamer GM, et al: Development of the blood supply to split-thickness free gingival autografts. *J Periodontol* 40:707, 1969.

55. Karring T, Ostergaard E, Löe H: Conservation of tissue specificity after heterotopic transplantation of gingiva and alveolar mucosa. *J Periodontal Res* 6:282, 1971.
56. Konikoff BM, Johnson DC, Schenkein HA, et al: Clinical crown length of the maxillary anterior teeth preorthodontics and post-orthodontics. *J Periodontol* 21:645–653, 2007.
57. Langer B, Langer L: Subepithelial connective tissue graft technique for root coverage. *J Periodontol* 56:715, 1985.
58. Levine RA: Covering denuded root surface with the subepithelial connective tissue graft. *Compend Contin Educ Dent* 12:568, 1991.
59. Liu WWJ, Solt CW: A surgical procedure for the treatment of localized gingival recession in conjunction with root surface citric acid conditioning. *J Periodontol* 51:505, 1980.
60. Magne P, Gallucci GO, Belser UC: Anatomic crown width/length ratios of unworn and worn maxillary teeth in white subjects. *J Prosthet Dent* 89:453–461, 2003.
61. Matter J: Free gingival graft and coronally repositioned flap: a 2-year follow-up report. *J Clin Periodontol* 6:437, 1979.
62. Matter J, Cimasoni G: Creeping attachment after free gingival grafts. *J Periodontol* 47:574, 1976.
63. McGuire MK, Cochran DL, Nunn ME: Evaluation of human recession defects treated with coronally advanced flaps and either enamel matrix derivative or connective tissue. II. Histological evaluation. *J Periodontol* 74:1126–1135, 2003.
64. McGuire MK, Kao RT, Nevins M, et al: rhPDGF-BB promotes healing of periodontal defects: 24-month clinical and radiographic observations. *Int J Periodontics Restorative Dent* 26:223–231, 2006.
65. McGuire MK, Nunn ME: Evaluation of human recession defects treated with coronally advanced flaps and either enamel matrix derivative or connective tissue. I. Comparison of clinical parameters. *J Periodontol* 74:1110–1125, 2003.
66. McGuire Mk, Nunn ME: Evaluation of the safety and efficacy of periodontal applications of a living tissue engineered human fibroblast-derived dermal substitute. I. Comparison to the gingival autograft: a randomized, controlled pilot study. *J Periodontol* 76:867–880, 2005.
67. McGuire MK, Scheyer ET: Comparison of recombinant human platelet-derived growth factor—BB plus beta tricalcium phosphate and a collagen membrane to subepithelial connective grafting for the treatment of recession defects. A case series. *Int J Periodontics Restorative Dent* 26:127–133, 2006.
68. McGuire MK, Scheyer ET: A randomized double blind placebo-controlled study to determine the safety and efficacy of cultured and expanded autologous fibroblast injection for the treatment of interdental papillary insufficiency associated with the papilla priming procedure. *J Periodont* 78:4–17, 2007.
69. McGuire MK, Scheyer ET, Nevins M, et al: Evaluation of human recession defects treated with coronally advanced flaps and either purified recombinant human platelet-derived growth factor –ββ (rhPDGF) with beta tricalcium phosphate (β-TCP) or connective tissue: a histological and micro-CT examination. *Int J Perio Rest Dent* 29:7–21, 2009.
70. McGuire MK, Scheyer ET, Nunn ME, et al: A pilot study to evaluate a tissue-engineered bilayered cell therapy as an alternative to tissue from the palate. *J Periodontol* 79:1847–1856, 2008.
71. McGuire MK, Scheyer ET, Schupbach P: Growth factor-mediated treatment of recession defects: a randomized controlled trial and histologic and microcomputed tomography examination. *J Periodontol* 80:550–564, 2009.
72. Miller PD, Jr: Root coverage using a free soft tissue autograft following citric acid application. Part I. Technique. *Int J Periodont Restor Dent* 2:65, 1982.
73. Miller PD, Jr: A classification of marginal tissue recession. *Int J Periodont Restor Dent* 5:9, 1985.
74. Miller PD, Jr: Root coverage using a free soft tissue autograft following citric acid application. III. A successful and predictable procedure in areas of deep wide recession. *Int J Periodont Restor Dent* 5:15, 1985.
75. Mormann W, Schaer F, Firestone AC: The relationship between success of free gingival grafts and transplant thickness. *J Periodontol* 52:74, 1981.
76. Nabers J: Free gingival grafts. *Periodontics* 4:243, 1966.
77. Nelson SW: The subpedicle connective tissue graft: a bilaminar reconstructive procedure for the coverage of denuded root surfaces. *J Periodontol* 58:95, 1987.
78. Nevins M, Giannobile WV, McGuire MK, et al: Platelet-derived growth factor stimulates bone fill and rate of attachment level gain: Results of a large multi-center, randomized controlled trial. *J Periodontol* 76:2205–2215, 2005.
79. Novaes AB, Grisi DC, Molina GO: Comparative 6-month clinical study of a subepithelial connective tissue graft and acellular dermal matrix graft for the treatment of gingival recession. *J Periodontol* 72(11):1477–1484, 2001.
80. Oliver RC, Löe H, Karring T: Microscopic evaluation of the healing and revascularization of free gingival grafts. *J Periodontol* 3:84, 1968.
81. Paolantonio M, Dolci M, Esposito P, et al: Subpedicle acellular dermal matrix graft and autogenous connective tissue graft in the treatment of gingival recession: a comparative 1-year study. *J Periodontol* 73(11):1299–1307, 2002.
82. Pennel BM, Tabor JC, King KO, et al: Free masticatory mucosa graft. *J Periodontol* 40:162, 1969.
83. Perez JR, Smukler H, Nunn M: Clinical evaluation of the supraosseous gingivae before and after crown lengthening. *J Periodontol* 21:1023–1030, 2007.
84. Perez-Fernandez A: Injerto submucoso libre de encia: una nueva perspectiva. *Bol Inform Dent* 42:63, 1982.
85. Pini-Prato G, Tinti C, Vincenzi G, et al: Guided tissue regeneration versus mucogingival surgery in the treatment of human buccal gingival recession. *J Periodontol* 63:919, 1992.
86. Pontoriero R, Carnevale G: Surgical crown lengthening: a 12-month clinical wound healing study. *J Periodontol* 72:841–848, 2001.
87. Raetzke PB: Covering localized areas of root exposure employing the "envelope" technique. *J Periodontol* 56:397, 1985.
88. Rateitschak KH, Rateitschak EM, Wolff HF, et al: *Color atlas of periodontology*, New York, 1985, Thieme.
89. Robinson RE: Periosteal fenestration in mucogingival surgery. *J West Soc Periodontol* 9:107, 1961.
90. Rosenberg MM: Vestibular alterations in periodontics. *J Periodontol* 31:231, 1960.
91. Rubenstein HS, Ruben MP, Levy C, et al: Evidence for successful acceptance of irradiated free gingival allografts in dogs. *J Periodontol* 46:195, 1975.
92. Schmid MO: The subperiosteal vestibule extension: literature review, rationale and technique. *J West Soc Periodontol* 24:89, 1976.
93. Schoo WH, Copes L: Use of palatal mucosa and lyophilized dura mater to create attached gingiva. *J Clin Periodontol* 3:166, 1976.
94. Sculean A, Donos N, Blaes A, et al: Comparison of enamel matrix proteins and bioresorbable membranes in the treatment of intrabony periodontal defects. A split-mouth study. *J Periodontol* 70:255–262, 1999.
95. Staffileno H, Levy S, Gargiulo A: Histologic study of cellular mobilization and repair following a periosteal retention operation via split thickness mucogingival flap surgery. *J Periodontol* 40:311, 1969.
96. Sterrett JD, Oliver T, Robinson F, et al: Width/length ratios of normal clinical crowns of the maxillary anterior dentition in man. *J Clin Periodontol* 26:153–157, 1999.
97. Stetler KJ, Bissada NF: Significance of the width of keratinized gingiva on the periodontal status of teeth with submarginal restorations. *J Periodontol* 58:696, 1987.
98. Strahan JD: The relation of the mucogingival junction to the alveolar bone margin. *Dent Pract Dent Rec* 14:72, 1963.
99. Sugarman EF: A clinical and histological study of the attachment of grafted tissue to bone and teeth. *J Periodontol* 40:381, 1969.
100. Sullivan HC, Atkins JC: Free autogenous gingival grafts. III. Utilization of grafts in the treatment of gingival recession. *Periodontics* 6:152, 1968.

101. Sullivan HC, Carman D, Dinner D: Histological evaluation of the laterally positioned flap. *IADR Abstr* 467:169, 1971.
102. Takei HH: The interdental space. *Dent Clin North Am* 24:169, 1980.
103. Tal H, Moses O, Zohar R, et al: Root coverage of advanced gingival recession: a comparative study between acellular dermal matrix allograft and subepithelial connective tissue grafts. *J Periodontol* 73(12):1405–1411, 2002.
104. Tarnow DP: Semilunar coronally repositioned flap. *J Clin Periodontol* 13:182, 1986.
105. Tarnow DP, Magner AW, Fletcher P: The effects of the distance from the contact point to the crest of bone on the presence or absence of the interproximal dental papilla. *J Periodontol* 63:995, 1992.
106. Tatakis DN, Trombelli L: Gingival recession treatment: Guided tissue regeneration with bioabsorbable membrane versus connective tissue graft. *J Periodontol* 71:299–307, 2000.
107. Tinti C, Vincenzi GP: Expanded polytetrafluoroethylene titanium-reinforced membranes for regeneration of muco-gingival recession defects: a 12-case report. *J Periodontol* 65:1088, 1994.
108. Trey E, Bernimoulin JP: Influence of free gingival grafts on the health of the marginal gingiva. *J Clin Periodontol* 7:381, 1980.
109. Velasquez-Plata D, Scheyer ET, Mellonig JT: Clinical comparison of an enamel matrix derivative used alone or in combination with a bovine-derived xenograft for the treatment of periodontal osseous defects in humans. *J Periodontol* 73:433–440, 2002.
110. Wade AB: Vestibular deepening by the technique of Edlan and Meejchar. *J Periodontal Res* 4:300, 1969.
111. Wang HL, Bunyaratavej P, Labadie M, et al: Comparison of two clinical techniques for treatment of gingival recession. *J Periodontol* 72:1301–1311, 2001.
112. Ward VJ: A clinical assessment of the use of the free gingival graft for correcting localized recession associated with frenal pull. *J Periodontol* 45:78, 1974.
113. Whinston GJ: Frenotomy and mucobuccal fold resection used in periodontal therapy. *NY Dent J* 22:495, 1956.
114. Wilderman MN, Wentz FM: Repair of a dentogingival defect with a pedicle flap. *J Periodontol* 36:218, 1965.
115. Wilson TG, Nunn ME, McGuire MK: Evaluation of the safety and efficacy of periodontal applications of a living tissue engineered human fibroblast-derived dermal substitute. Part II. Comparison to the subepithelial connective tissue graft. A randomized, controlled pilot study. *J Periodontol* 76:881–888, 2005.
116. Woodyard JG, Greenwell H, Hill M, et al: The clinical effect of acellular dermal matrix on gingival thickness and root coverage compared to coronally positioned flap alone. *J Periodontol* 75(1):44–56, 2004.
117. Woofter C: The prevalence and etiology of gingival recession. *Periodont Abstr* 17:45, 1969.
118. Zabalegui I, Sicua A, Cambra J, et al: Treatment of multiple adjacent gingival recessions with the tunnel subepithelial connective tissue graft: a clinical report. *Int J Periodont Restor Dent* 19:199, 1999.

CHAPTER 64

Periodontal Microsurgery

*Dennis A. Shanelec, Leonard S. Tibbetts, Adriana McGregor, and J. David Cross**

CHAPTER OUTLINE

Philosophy of Periodontal Microsurgery
Advantages of Microsurgery
Magnification Systems
Microsurgical Sutures
Esthetic Periodontal Microsurgery *(e-only)*
Microsurgical Knots *(e-only)*
Conclusion

For online-only content on esthetic periodontal microsurgery and microsurgical knots, please visit the companion website at www.expertconsult.com.

Microsurgery is defined as surgery performed under magnification of 10× or more which is only possible using a surgical microscope.[5] The hallmarks of microsurgery are increased visual acuity and improved manual dexterity.[17] When visibility is increased 10-fold, motor movement precision is increased from 1 mm to 10 μm.[3] This is the approximate size of an epithelial cell.[12] Large incisions for visibility are therefore not necessary. Small surgical instruments are used to advantage in the reduced surgical field (Figure 64-1). This minimally invasive philosophy results in less injury, diminished morbidity, and rapid healing.[9,12] Central to this approach are sharp microsurgical blades to create incisions at a virtual cellular level (Figure 64-2). These incisions are closed with meticulous apposition to eliminate wound edge gaps and dislocations, allowing healing by primary intention to begin within hours of microsurgical closure. This circumvents the need for an extensive secondary mitotic stage of wound healing to bridge wound gaps and fill surgical voids.

Philosophy of Periodontal Microsurgery

Microsurgery is a philosophy that embraces three core values. The first is enhanced motor skill for better surgical performance. This is accomplished through improved visual acuity and the use of a precise hand grip to increase accuracy and reduce tremor (Figure 64-3). The second is minimal tissue trauma, which is accomplished through smaller incisions and reduced surgical fields (Figure 64-4). The third value is primary passive wound closure.[18] This is accomplished by microsuturing to eliminate gaps and dead spaces at the wound edge (Figure 64-5).

Advanced periodontics has an increasing need for clinical procedures that require intricate surgical skills. Regenerative procedures, periodontal plastic surgery, and dental implants are but a few of the surgical procedures that demand clinical performance that frequently challenge the skills of periodontal surgeons beyond the range of possibility with ordinary vision. Microsurgery establishes a minimal invasive surgical approach to periodontics exemplified by fewer vertical incisions and smaller surgical sites. Every field of microsurgery has noted the extent to which reduced incision size and less retraction directly relates to reduced postoperative morbidity and rapid healing[2] (Figure 64-6).

In addition to the use of magnification and reliance on atraumatic technique, microsurgery requires specially constructed instruments designed specifically to minimize trauma. An important characteristic of microsurgical instruments is their ability to create clean incisions that prepare wounds for healing by primary intention. Microsurgical incisions are established at a 90-degree angle to the surface using ophthalmic microsurgical scalpels (Figure 64-7). Microscopy permits easy identification of ragged wound edges for trimming and freshening. For primary wound closure, microsutures in the range of 6-0 to 9-0 are needed to approximate the wound edges accurately (Figure 64-8). Microsurgical wound apposition minimizes gaps or voids at the wound edges and encourages rapid healing with less postoperative inflammation and less pain. Figures 64-9 and 64-10 illustrate periodontal surgery cases using microsurgical techniques.

Advantages of Microsurgery

Periodontal microsurgery raises the treatment bar in many ways. Surgical decision making is enhanced because the quality and quantity of visual data reaching the cerebral cortex is increased by a square of the magnification level. Ergonomic and body posture advantages also occur when using the surgical microscope[1] (Figure 64-11). Issues, such as neuromuscular fatigue and occupational skeletal pathology, are reduced. Sitting comfort, good body posture, arm support, and controlled breathing are inherent to proper microscope use. Motor skills are enhanced through instruments designed for a precision grip of the hand. Titanium instruments are used for strength and lightness and are made with round handles to permit precise rotation (Figure 64-12). This reduces hand fatigue and tremor for precise surgical movement. Ergonomic benefit may be one of the most significant aspects of microscope use in periodontics.

Text continued on p. 637

*The following doctors contributed to this chapter: Bryan S. Pearson, Scott O. Kissel, Leslie Broline, and Robert Henshaw.

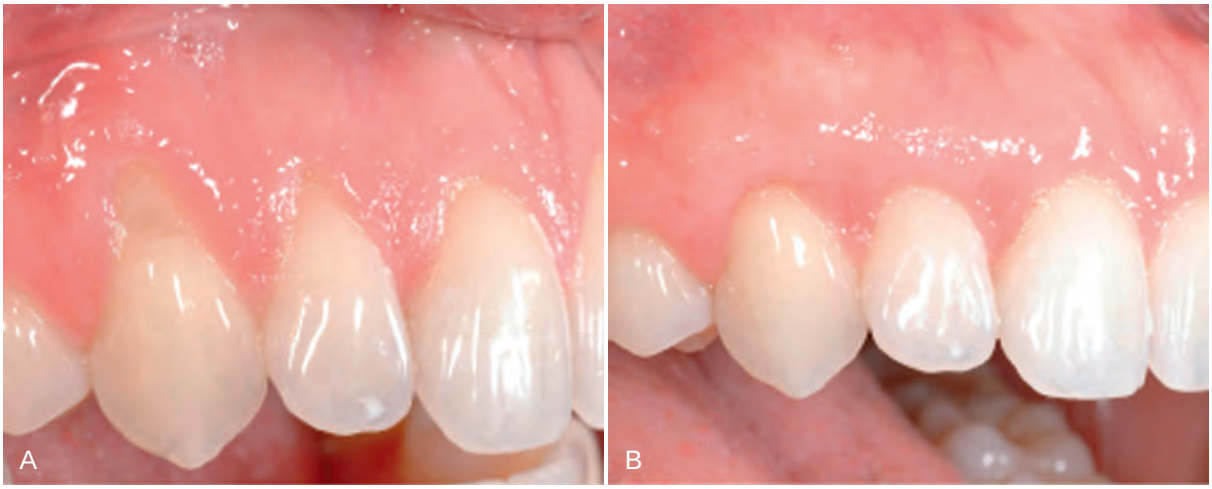

Figure 64-31 Preoperative (A) and postoperative (B) views of recession area treated microsurgically with connective tissue graft.

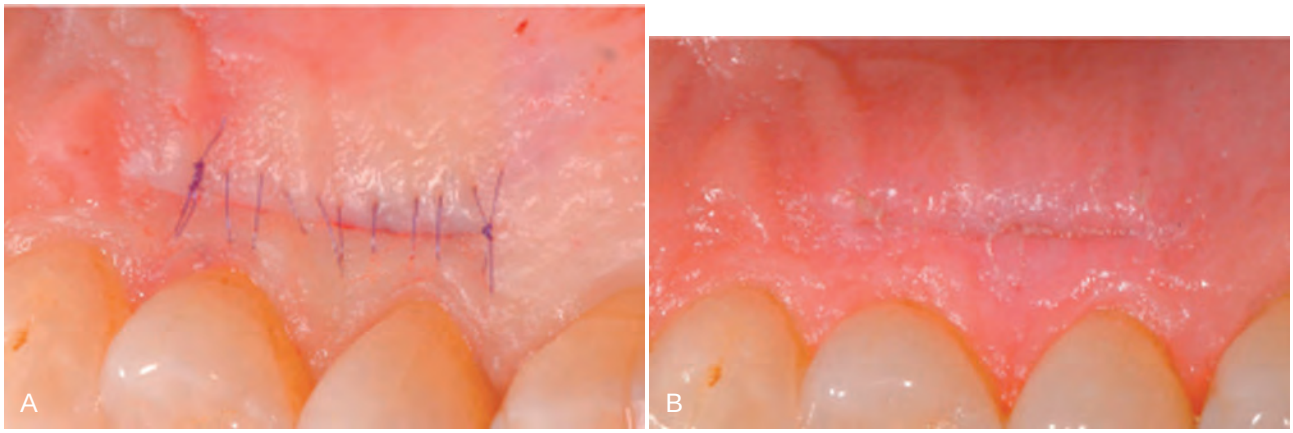

Figure 64-32 A, Microsuturing of palatal donor site after harvesting connective tissue graft (CTG). **B,** One-week postoperative healing of donor site.

Esthetic Periodontal Microsurgery

Esthetic periodontal microsurgery to reconstruct gingival tissue over denuded roots is routine and predictable using subepithelial connective tissue grafting (Figure 64-31). The color match, esthetic appearance, and lack of scarring of these grafts are ideal. Microsurgical closure of the palatal donor site allows healing by primary intention without a painful period of open granulation (Figure 64-32). This greatly reduces postoperative pain.

To achieve optimal wound healing, three basic microsurgical principles are needed: (a) precision tailoring, (b) delicate tissue manipulation, and (c) passive primary wound closure.[8]

Precise Tailoring

An important feature of microsurgery is the ability to create clean incisions. Design of incisions has significant impact on how the wound edges fit together. A fundamental principle of microsurgery is making incisions perpendicular to the tissue surface, creating "butt joint" edges that easily approximate for wound edge stability and maintain blood supply patency (Figure 64-33).

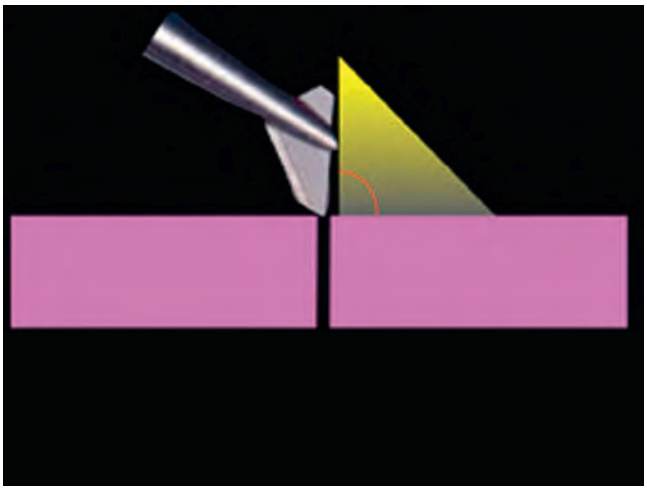

Figure 64-33 Cross-sectional representation of microsurgical blade making an incision line at 90 degrees of tissue surface.

Delicate Tissue Manipulation

The microsurgical philosophy is based on minimal invasiveness and minimal trauma. This premise extends to the manipulation gingival tissues during surgery.[10] Gentle handling is necessary to

reduce cellular injury and subsequent necrosis and inflammation. It is also necessary to maintain tissue hydration and color to maximize healing.[7]

Passive Primary Wound Closure

After precision tailoring and gentle tissue manipulation, the final and critical element of microsurgery is achieving passive primary wound closure. There is a specific geometry of the suturing required, with the following six well-defined components[13]:

1. Angle of entry and angle of exit. The needle should penetrate the tissue at a 90-degree angle, perpendicular to the tissue surface. Passing the needle at an oblique angle causes tearing when the knot is tied (Figure 64-34).
2. Bite size. Proper bite size is between 1 and 1.5 times the tissue thickness. Too small a bite size can tear the wound edges. Too large a bite size can cause underriding or overriding of wound edges (Figure 64-35). Both outcomes result in impaired healing and unsightly scarring (Figure 64-36).
3. Direction of passage. Once the needle has penetrated one edge of the wound, it must exit the opposing side of the wound with a direction of passage perpendicular to the incision line. This directs the suture force vectors at 90 degrees and prevents lateral dislocation at the wound edge (Figure 64-37).
4. Tension. Suturing should be accomplished with minimal tension. Gentle passage of the suture, in a perpendicular direction of passage, sets the stage for a microsurgical knot that does not cause tissue strangulation through ligation. Good suturing, however, will never save poor tailoring (Figure 64-38).
5. Symmetry. The distance between the bite sizes on either side of the wound edge should be the symmetrical as should the distance between sutures (Figure 64-39).
6. Frequency. Smaller suture material and smaller bite size makes it necessary to place more microsutures at frequent intervals along the wound edge. This supports wound closure and avoids stress breakage of sutures or tissue tearing (Figure 64-40).

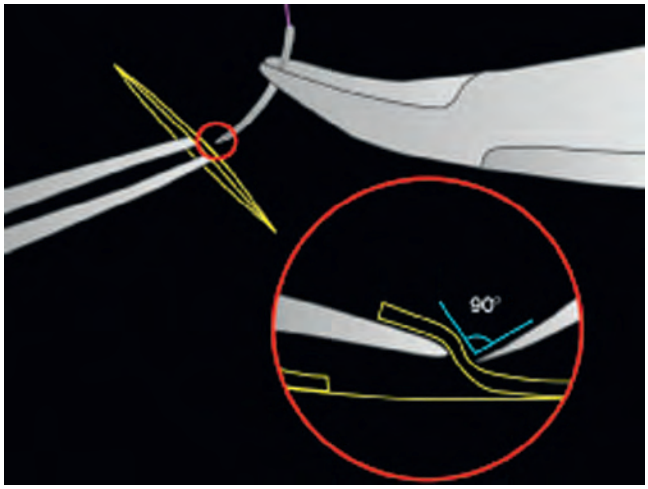

Figure 64-34 Suture needle penetrating the gingival at 90-degree angle of entry by elevating and supporting the soft tissue with microsurgical tissue forceps.

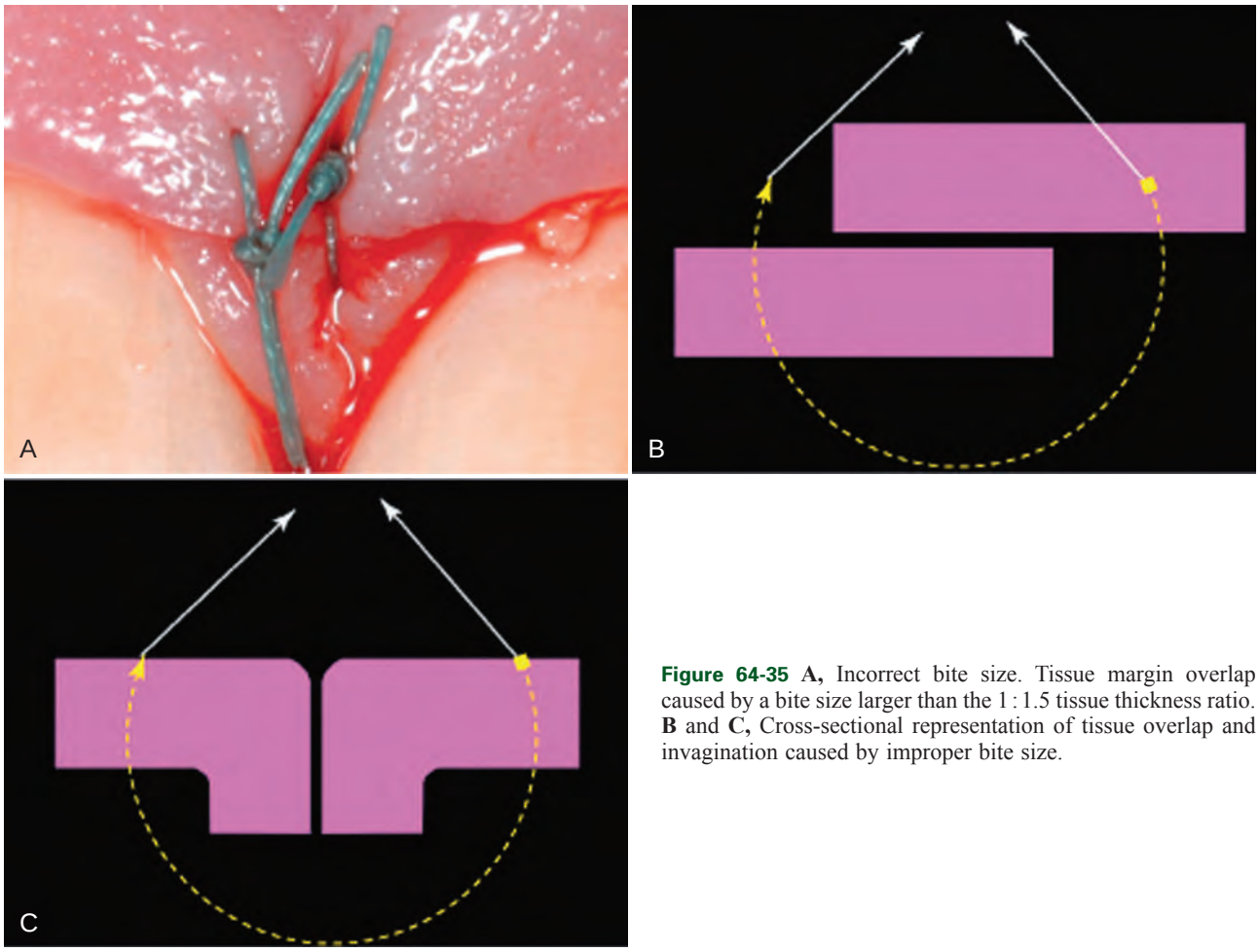

Figure 64-35 A, Incorrect bite size. Tissue margin overlap caused by a bite size larger than the 1 : 1.5 tissue thickness ratio. **B** and **C,** Cross-sectional representation of tissue overlap and invagination caused by improper bite size.

Figure 64-36 Unesthetic healing of incision caused by tissue margin invagination during suturing.

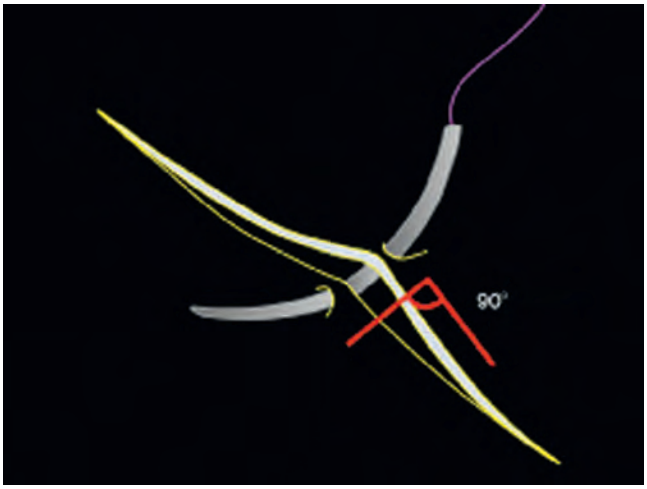

Figure 64-37 Direction of passage. Needle penetrating and exiting tissue perpendicular to the incision line.

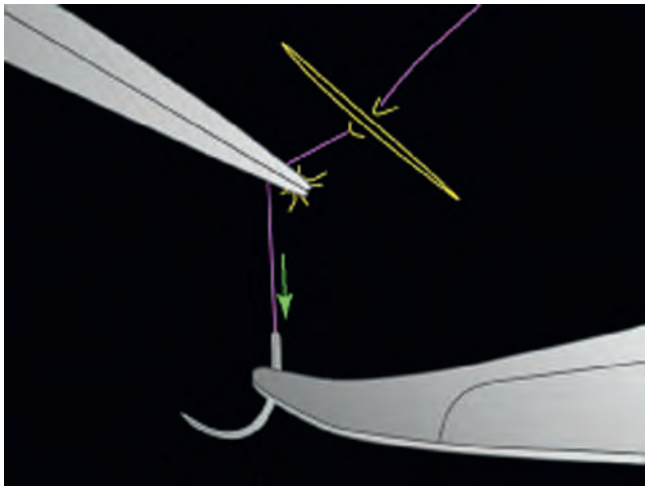

Figure 64-38 Using tissue forceps to guide the perpendicular direction of the suture tread breaks the surface tension while pulling the exiting needle away from the incision, thus avoiding tissue tearing.

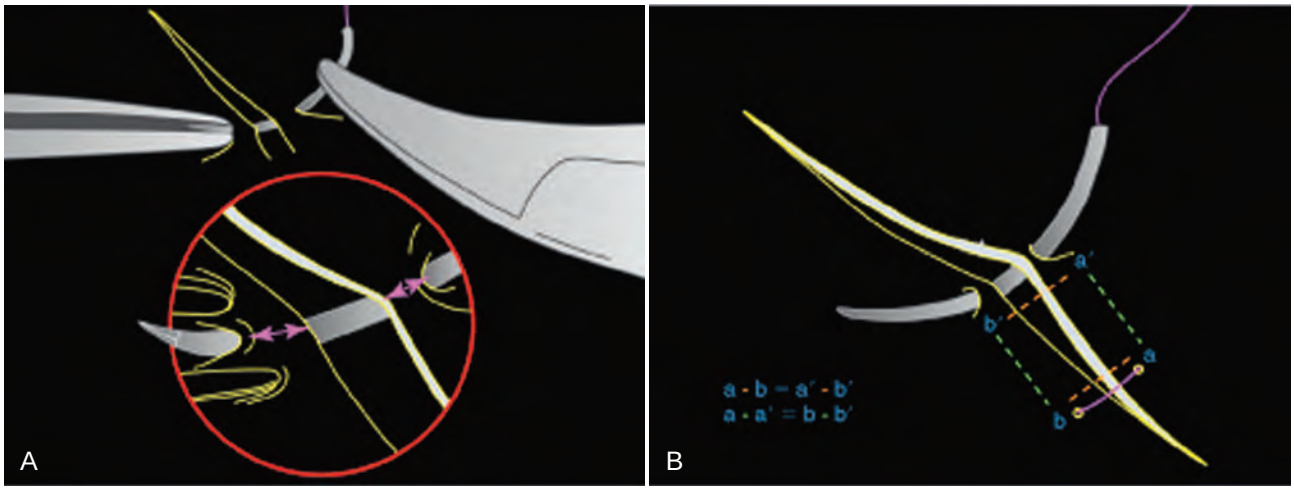

Figure 64-39 A, Symmetry of distance between entrance and exit points of the needle across and incision line. **B,** Symmetry of bite size and distance between suture #1 *(a-b)* and suture #2 *(a′-b′)*.

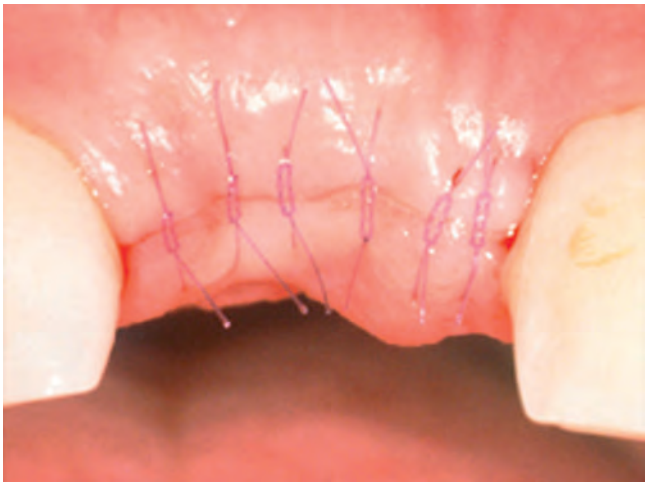

Figure 64-40 **Excellent tissue approximation and coadaptation as results from properly following the principles of the geometry of suturing.**

Microsurgical Knots

Two basic knots are employed in microsurgery. The square knot, or reef knot, is composed of two single loops thrown in opposite directions. The reef knot has more internal stability than any other knot. For this reason, it has been employed for centuries in nautical applications. It lies flat when tied well and is ideal for passive wound closure. As postsurgical edema occurs, the reef knot opens sightly then becomes self-locking. It maintains wound edge support without ligation caused by excessive tension (Figure 64-41). If, in tying a knot, both loops are thrown in opposite directions, it becomes the granny knot and unties easily. The English surgeon's knot is composed of two double loops thrown in opposite directions. The first double throw is less likely to loosen when performing the second throw, making it is easier to control tissue apposition. The English surgeon's knot requires, however, a larger bite size. Both knots are tied with instruments.

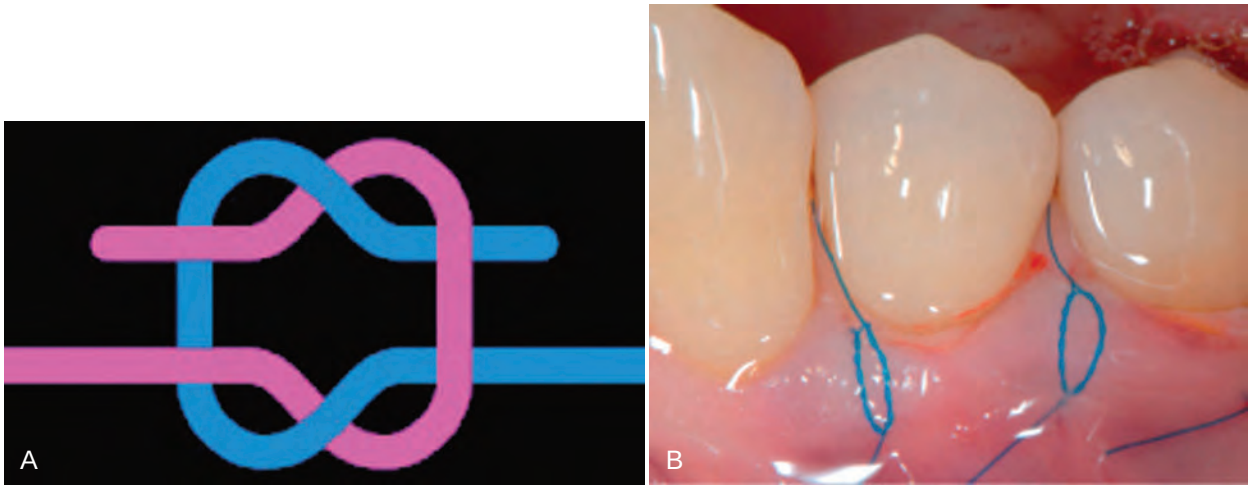

Figure 64-41 **English surgeon's knot has a hollow center that allows for tissue expansion without producing tissue ligation during the edema healing phase.**

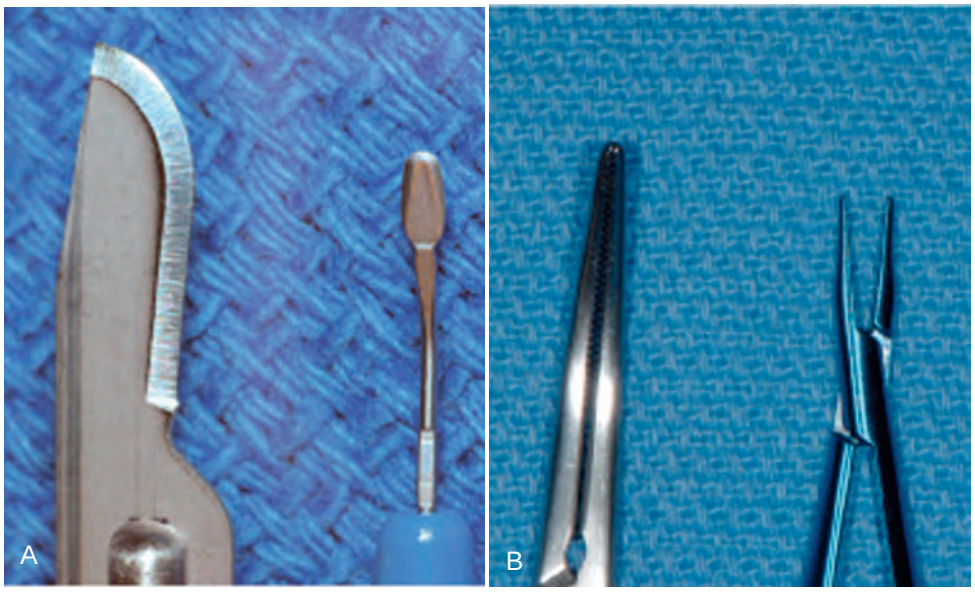

Figure 64-1 Side-by-side dimensional comparison of commonly used conventional versus microsurgical instruments. A, No. 15 blade versus ophthalmic blade. **B,** Working tip of conventional needleholder versus McGregor microsuturing forceps.

Figure 64-2 Scanning electron microscopy (SEM) comparison of incisions made with a #15 blade *(upper left image)* and an ophthalmic microsurgical "feather" blade *(upper right and lower right images).* The *red circle* in the upper right image shows the area magnified in the lower right image. The *green circle* shows the disruption of only one epithelial cell. *(SEM photographs courtesy Masana Susuki, DDS, Tokyo, Japan.)*

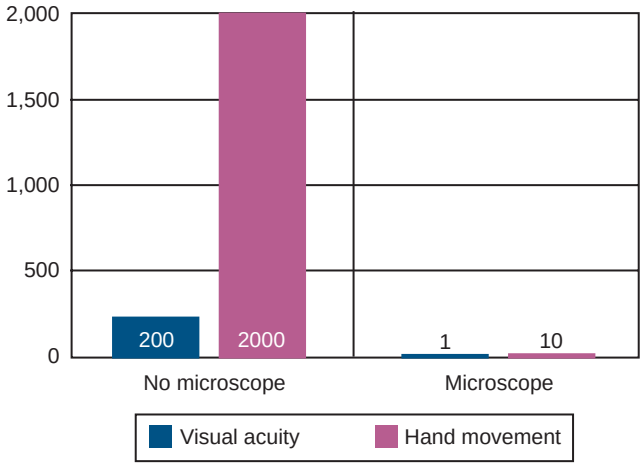

Figure 64-3 Chart showing the correlation between enhanced visual acuity through magnification and dramatic reduction in minimal hand movement.[16]

Figure 64-4 Microsurgical connective tissue graft. Minimal tissue trauma during incisions, surgical manipulation, and suturing is accomplished after microsurgical principles.

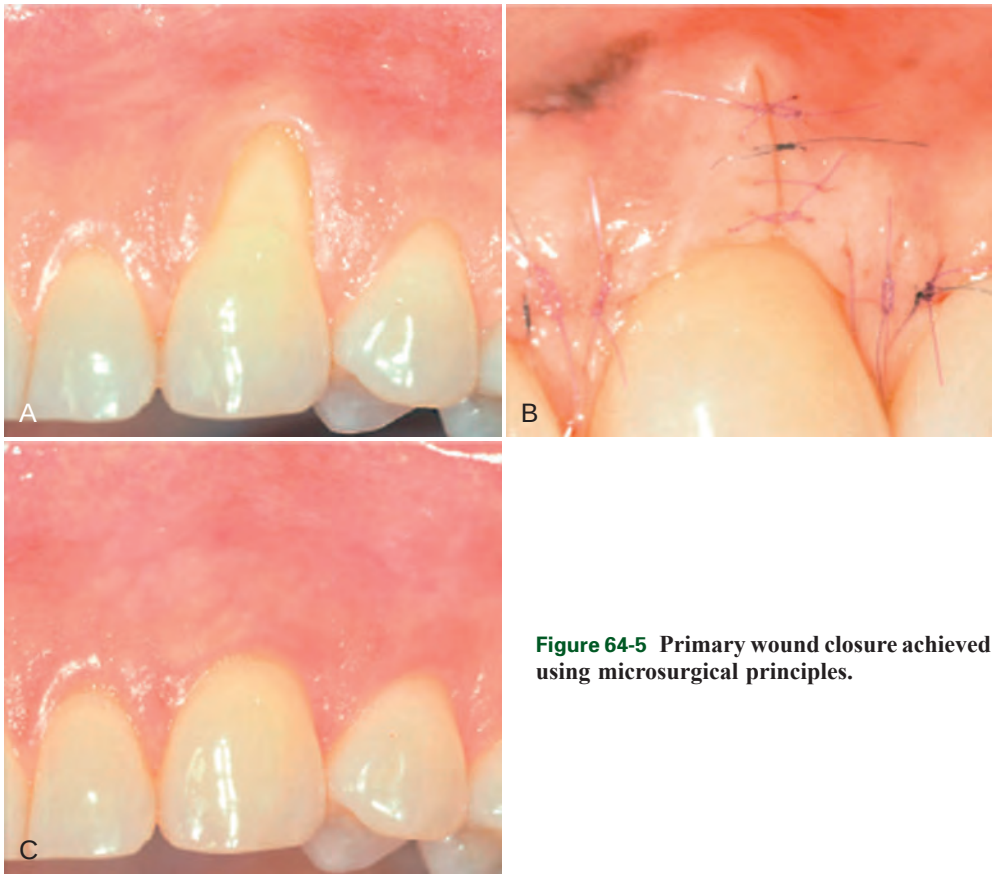

Figure 64-5 **Primary wound closure achieved using microsurgical principles.**

Figure 64-6 Before **(A)**, during **(B)**, and 8 weeks after healing **(C)** of microsurgical connective tissue graft.

Figure 64-7 **Castroviejo microsurgical scalpel.**



Figure 64-8 **Microsurgical suturing.**

Figure 64-9 **Microsurgical extraction. A,** Before surgery. **B,** Microsurgical view. **C,** One week after surgery.

Figure 64-10 **Papilla reconstruction. A,** Before surgery. **B,** Microsurgical view. **C,** After surgery.

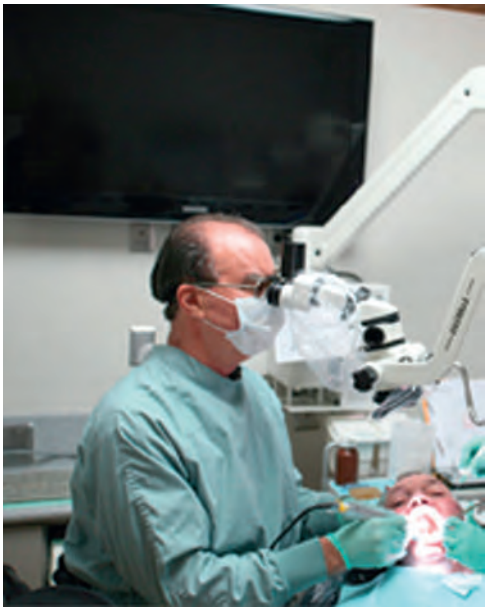

Figure 64-11 **Muscle strain and potential career-ending injuries can be prevented through a more ergonomic position facilitated by the proper use of a microscope.**

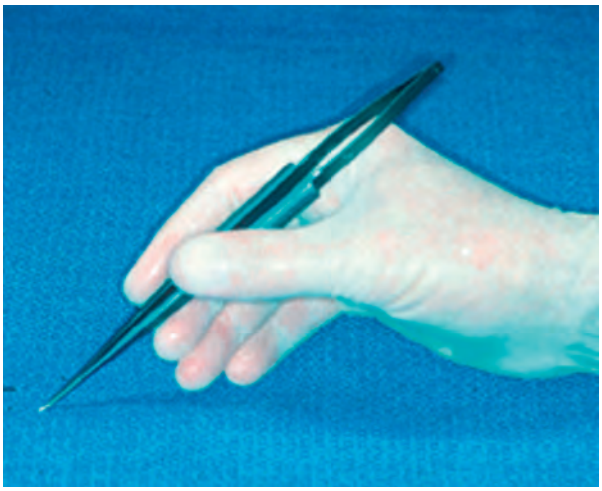

Figure 64-12 **Rounded, titanium microsurgical instruments, ideally 9 mm in diameter, reduce muscle fatigue and facilitate precise, rotational hand movements.**

An important aspect of periodontal microsurgery is technical improvement in surgical performance. Higher skill levels have been shown in many surgical disciplines and can be fully appreciated when a surgeon tries his or her hand under the microscope. Viewing surgery under the microscope impresses a surgeon with the coarseness of conventional surgical manipulation (Figure 64-13). What appears to the unaided eye as gentle surgery is revealed, under the microscope, as gross crushing and tearing of delicate tissues. Periodontics has long advocated atraumatic surgery, but the limits of normal vision have made this goal unattainable.

Proprioceptive guidance is of little value at the microsurgical level. Visual guidance is used for midcourse correction of scalpels and instruments to achieve the finest level of skill and dexterity.[4,9] Incisions can be accurately mapped, flaps elevated with minimal damage, and wounds closed accurately without tension (Figure 64-14). Periodontal microsurgery is a natural progression from conventional surgical principles to a surgical ethic in which the surgical microscope is employed for the most accurate and atraumatic handling of tissue (Figure 64-15).

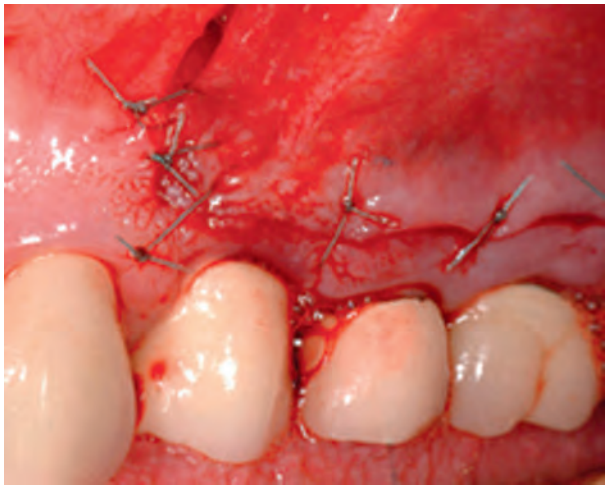

Figure 64-13 **The coarseness of conventional periodontal surgery is readily apparent under microscopic magnification.**

Figure 64-14 **Tension-free wound closure is one of the goals of a microsurgical approach.**

The end-point appearance of microsurgery is superior to that of conventional surgery. The difference is self-evident and often startling (Figures 64-16 to 64-18). As much as judgment and knowledge play a role in surgery, in the end, surgery is a craft. Surgeons appreciate this, especially when microsurgery raises their work to levels of artistic expression. Personal gratification in performing better surgery leads to acceptance of periodontal microsurgery by surgeons motivated to improve the quality of their work.

Another very important advantage of microsurgery is in the area of root preparation. The importance of root debridement is recognized universally as an essential component of periodontal therapy.[10,17] Research in clinical dentistry has shown that microscope-enhanced vision more readily accomplishes the long-established clinical goals of endodontic and restorative dentistry. In periodontics, studies demonstrated that root debridement performed without magnification was incomplete. When debrided roots were examined with the aid of a microscope, substantial deposits remained. Even in the absence of clinical studies, it may

be inferred that microscope-enhanced vision in periodontics permits more definitive root debridement.

The primary goals of periodontal surgery include visual access to the root surface for plaque and calculus removal and for removing pathologically altered tooth structure. Magnification greatly improves the surgeon's ability to create a clean, smooth root surface (Figure 64-19). The root surface represents one opposing edge of the periodontal wound. Root planing is therefore analogous to establishing a clean soft-tissue incision. Magnification permits preparation of both hard and soft tissue wound surfaces so that they may be joined together according to the accepted microsurgical principle of butt-joint wound approximation. This encourages primary wound healing and enhanced periodontal reconstruction. Wound-healing studies show epithelial anastomosis of microsurgically joined surgical wounds in animals within 48 hours.[4,16]

With training, the average periodontal microsurgeon can consistently produce better-crafted work than the most talented conventional surgeon (Figure 64-20).

Figure 64-15 Atraumatic microsurgical tissue manipulation during a microsurgical crown-lengthening procedure.

Magnification Systems

A variety of simple and complex magnification systems is available to dentists, ranging from simple loupes to prism telescopic loupes and surgical microscopes. Each magnification system has its specific advantages and limitations. Although magnification improves the accuracy of clinical and diagnostic skills, it requires an understanding of optical principles that govern all magnification systems. The assumption that "more magnification is better" must always be weighed against the decrease in field of view and depth of focus that can occur as magnification increases, which is a problem more common with dental loupes than operating microscopes.

Magnifying Loupes

Dental loupes are the most common system of optical magnification used in periodontics. *Loupes* are fundamentally dual monocular telescopes with side-by-side lenses convergent to focus on the operative field. The magnified image formed has stereoscopic

Figure 64-16 **A,** Suppurating gingival fenestration. **B,** After careful root planing, a connective tissue graft (CTG) was carefully sutured under the envelope flap. **C,** Three weeks' postoperative healing. **D,** One-year postoperative follow-up.

Figure 64-17 Microsurgical correction of macrosurgical unsatisfactory outcome. A, Improper placement caused unesthetic result. **B,** Microsurgical grafting procedure. **C,** Final surgical result after fabrication of new crowns.

Figure 64-18 Microsurgical crown-lengthening procedure. A, Altered passive eruption covering teeth crowns. **B,** Immediate microsurgical postoperative result. **C,** Three weeks' postoperative healing.

properties by virtue of their convergence. A convergent lens optical system is called a *Keplerian optical system.*

Although dental loupes are widely used, they have disadvantages compared with the microscope. The clinician's eyes must converge to view the operative field. This can result in eyestrain, fatigue, and even pathologic vision changes, especially after prolonged use.

Three types of Keplerian loupes are typically used in periodontics: simple or single-element loupes, compound loupes, and prism telescopic loupes. Each type may differ widely in optical sophistication and individual design.

Figure 64-19 Magnified root planing.

Simple Loupes. Simple loupes consist of a pair of single meniscus lenses (Figure 64-21). Simple loupes are primitive magnifiers with limited capabilities. Each lens is limited to only two refracting surfaces. Their magnification can only increase by increasing lens diameter and thickness. Size and weight constraints make simple loupes impractical for magnification beyond 1.5×. Another disadvantage of simple loupes is that they are greatly affected by spherical and chromatic aberration. This distorts the image shape and color of objects being viewed.

Compound Loupes. Compound loupes use multielement lenses with intervening air spaces to gain additional refracting surfaces (Figure 64-22). This allows increased magnification with more favorable working distance and depth of field. Magnification of compound loupes can be increased by lengthening the distance between lenses, thereby avoiding excessive size and weight.

In addition to offering improved optical performance, compound lenses can be *achromatic,* which is an optical feature that clinicians should always choose when selecting magnifying loupes. Achromatic lenses consist of two glass lenses joined together with clear resin. The specific density of each lens counteracts the chromatic aberration of its paired lens to produce a color-correct image.

Figure 64-20 Procedure accessibility enhanced through microsurgery. A, Connective tissue graft (CTG) on maxillary molar. **B,** Before surgery. **C,** During surgery. **D,** Seven weeks postoperatively.

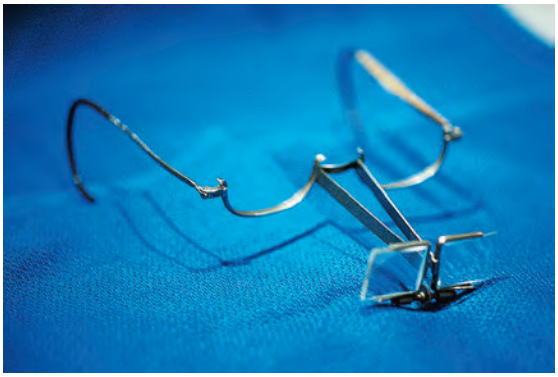

Figure 64-21 Simple loupes.

Figure 64-22 Compound loupes.

Figure 64-23 Eyeglass-mounted prism loupes.

However, multielement compound loupes become optically inefficient at magnifications above 3×.

Prism Telescopic Loupes. The most advanced loupe optical magnification currently available is the prism telescopic loupe. Such loupes employ Schmidt or "rooftop" prisms to lengthen the light path through a series of switchback mirrors between the lenses. This arrangement folds the light so that the barrel of the loupes can be shortened. Prism loupes produce better magnification, wider depths of field, longer working distances, and larger fields of view than other types of loupes. The barrels of prism loupes are short enough to be mounted on either eyeglass frames (Figure 64-23) or headbands. However, increased weight of prism telescopic loupes with magnification above 4× makes headband mounting more comfortable and stable than eyeglass frame mounting. Recent innovations in prism telescopic loupes include coaxial fiberoptic lighting incorporated in the lens elements to improve illumination (Figure 64-24).

Figure 64-24 Coaxial lighted prism loupes.

Magnification Range of Surgical Loupes. Dental loupes provide a limited range of magnification, 1.5× to 6×. Loupes delivering magnification of less than 3× are usually inadequate for the visual acuity necessary for clinical periodontics. Surgical loupes providing magnification of more than 4× are impractical because of their small field of view, shallow depth of focus, and excessive weight. Excessively heavy loupes can make it difficult to maintain a stable visual field.

For some periodontal procedures, prism telescopic loupes with magnification of 4× provide an adequate combination of magnification, field of view, and depth of focus. However, the surgical microscope offers much higher magnification and superior optics compared with any of the loupe optical systems mentioned. For some periodontal procedures, prism telescopic loupes with magnification of 4× provide an adequate combination of magnification, field of view, and depth of focus. However, the surgical microscope offers much higher magnification and superior optics compared with any of the loupe optical systems mentioned.

The Surgical Microscope

The surgical microscope offers greater versatility than dental loupes, by providing a range of magnification with superior optical performance. A surgical microscope can last an entire career, making its long-term expense practical. Proficient use of the microscope requires training and practice. Surgical microscopes designed for dentistry employ Galilean optics, which have binocular eyepieces joined by offset prisms, to establish a parallel optical axis and permit stereoscopic vision without eye convergence or eyestrain. An additional binocular eyepiece can aid the microsurgical assistant (Figure 64-25).

Surgical microscopes have coated achromatic lenses and high optical resolution, as well as a rotating magnification element that allows the microsurgeon to easily change magnification to a value appropriate for the surgical task at hand (Figure 64-26). Because the optical elements of surgical microscopes are more advanced than those in loupes, depth-of-focus and field-of-view characteristics are greatly enhanced. Surgical microscopes have objective lenses with various working distances. A useful range in dentistry is 250 to 350 mm. For practical use, a surgical microscope must have both maneuverability and stability. Mountings are available for the ceiling, wall, or floor. Adjustable inclining eyepieces enhance postural flexibility for various procedures (Figure 64-27). This maneuverability provides visual access to every area of the

Figure 64-25 Accessory binocular module allows the assistant to better support the operator during the procedure.

Figure 64-26 Rotating magnification element with field of view ranging from full mouth to approximately 3 cm when using a 250-mm objective lens.

Figure 64-27 The inclinable adjustable eyepieces have a wide range of motion.

mouth and is an important factor in choosing to use a surgical microscope.

Illumination of the microsurgical field is also an important consideration. Dentists are accustomed to working with lateral illumination from side-mounted dental lights or headlamps. Fiber-optic coaxial illumination is a major advantage because it focuses light parallel to the microscope's optical axis, which eliminates shadows. Surgeons can visualize the deepest reaches of the oral cavity, including subgingival pockets and angular bony defects. Definitive visualization of root surface to detect deposits and irregularities is possible. Surgeons can view anatomy to make clinical decisions based on accurate assessment of pathology rather than blind, educated guesses.

Documentation is important for patient and professional education and for dental–legal reasons. The surgical operating microscope is an ideal platform for documenting periodontal pathology and clinical procedures. Digital images can be captured using a beam splitter and camera attachment. A foot-control switch permits a surgeon to record, as the procedure unfolds, without interrupting surgery. These images represent the surgical field exactly as the surgeon sees it, as opposed to a camera view over the surgeon's shoulder. High-definition video cameras capture both still and



Figure 64-28 High-definition (HD) video and still capture camera mounts conveniently fit into the microscope and can be viewed in real time on an HD monitor. *(From Optronics Microcast HD Studio, Optronics Medical Grade HD Microimaging Systems, Goleta, CA.)*

video images simultaneously to permit documentation of periodontal procedures for educational purposes (Figure 64-28).

Microsurgical Sutures

To achieve ideal microsurgical wound closure, a surgeon depends on how the incisions were planned and executed, how the surgery was performed, and the suturing technique. Selection of proper suture needles and materials is essential for successful microsurgical wound closure. The choice of suture and needle size is critical for atraumatic tissue passage. Suture material must maintain wound closure until healing is sufficiently advanced to withstand functional stress.

Sutures are classified according to structure as monofilament or braided, according to surface as coated or uncoated, and according to biologic properties as absorbable or nonabsorbable.[2] The suture of choice in microsurgery is a monofilament suture material such as polypropylene or polydioxanone. These materials are bacteriostatic and noninflammatory, hold a knot extremely well, and are easily removed. The purpose of sutures is to provide initial wound support. They are chosen to appropriate wounds based on the fragility of the tissue. The smallest suture capable of supporting the wound produces the least tissue trauma and the least interruption of the blood supply.

In periodontal microsurgery the suture size ranges from 6-0 (diameter of a human hair) to 9-0 (Figure 64-29). The size and shape of the needle used is essential for the atraumatic passage of the suture. The needle diameter is ideally slightly larger than the suture size. Sutures used in microsurgery are swaged, making the needle and the suture continuous[1] (Figure 64-30). Penetration and passage of the needle depends on the angle of entry of needle point. Cutting needles pass through gingival tissue easily but can tear tissue. Tapered needles are less traumatic and less likely to tear tissue.

An important component to needle design is the chord distance (see Figure 64-30). The chord of a needle is the length of a line drawn between the cutting point and the swaged end.[1] The radius of a needle is the arc of its circumference. A one-half round needle has an arc of 180 degrees. The chord determines the ease in passing a suture between adjacent teeth. The arc determines the bite size and angle of entry taken by the needle. These needle dimensions are important when selecting sutures for periodontal microsurgery.[4]

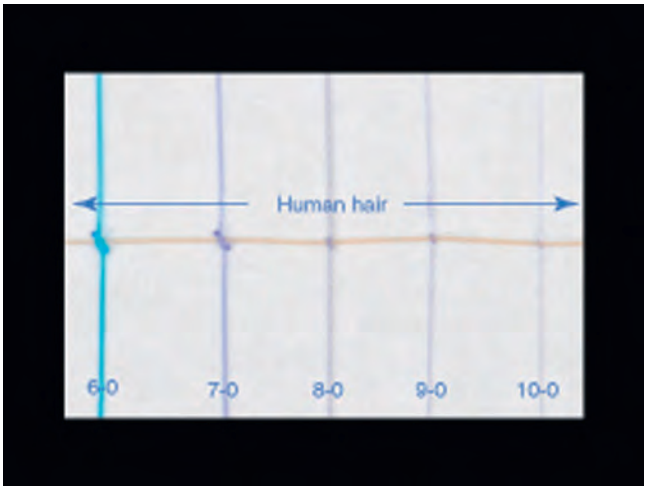

Figure 64-29 Size comparison of microsutures in relation to the dimension of a human hair.

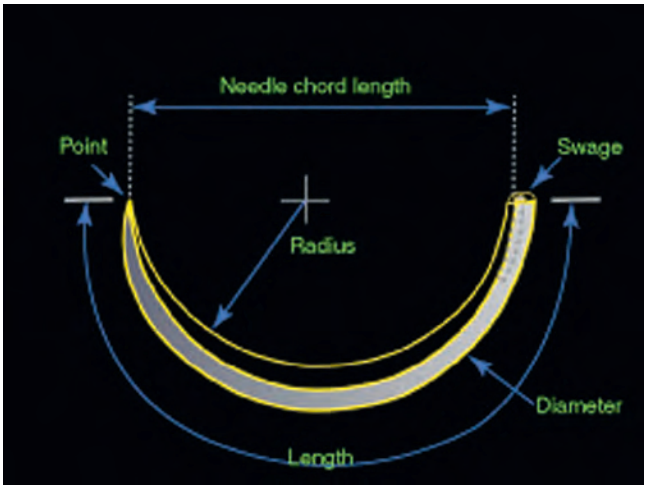

Figure 64-30 Anatomy of a needle. Microsutures are hand-inserted into the laser-drilled swaged end of the needle, forming a seamless, contiguous unit.

Conclusion

As medicine and dentistry continue the pursuit of minimally invasive treatment, periodontal microsurgery and its principles will emerge as the methodology to meet both professional and public demand.[14] The microscope provides a tremendous platform from which the microsurgical clinician can gather and observe detailed and precise amounts of information for the diagnosis and treatment of patients with skill and accuracy.[6] Microsurgery leads to improved esthetics, rapid healing, reduced morbidity, and enhanced patient acceptance.[3,15,16]

Suggested Readings

Barraquer JI: The history of microsurgery in ocular surgery. *J Microsurg* 1:288, 1980.

Hoerenz P: Optical principles, illumination systems and support systems. *J Microsurg* 1:367, 1980.

Shanelec D: Current trends in soft tissue grafting. *J Calif Dent Assoc* 19:57, 1991.

Shanelec D: Optical principles of dental loupes. *J Calif Dent Assoc* 20:25, 1992.

Shanelec D, Tibbetts L: An overview of periodontal microsurgery. *Curr Sci* 2:187, 1994.

References

References for this chapter are found on the companion website www.expertconsult.com.

References

1. Acland R: *Practice manual for microvascular surgery*, St. Louis, 1989, Mosby.
2. Banowsky LH: Basic microvascular techniques and principles. *Urology* 23:495–503, 1985.
3. Bunke H: *The manual of microvascular surgery*, San Francisco, 1975, Ralph K. Davies Medical Center Microsurgical Unit.
4. Chang T: *Principles, techniques and applications in microsurgery*, Hackensack, NJ, 1986, World Scientific.
5. Daniel RK: Through the looking glass: a history of microsurgery. *N Engl J Med* 300:1251–1258, 1979.
6. Leknius C, Geissberger M: The effect of magnification on the performance of fixed prosthodontic procedures. *J Calif Dent Assoc* 23(12):66–70, 1995.
7. McGregor M: *Scientific session*, 2008, Society of Microscope Enhanced Dentistry.
8. Olszewski W: *Handbook of microsurgery*, Boca Raton, FL, 1984, CRC Press.
9. Pecora G, et al: Operating microscope in endodontic surgery. *Oral Surg Oral Med Oral Pathol* 75:751–759, 1993.
10. Riediger D, Ehrenfeld M: *Microsurgical tissue transplantation*, Stuttgart, 1989, Quintessence.
11. Serafin D: Microsurgery: past, present and future. *Plast Reconstr Surg* 66:781, 1980.
12. Shanelec D, Tibbetts LS: Periodontal microsurgery. *Periodontal Insights*, Thieme, 1994.
13. Shanelec DA, Watson N: *The geometry of suturing*, 1995, Microsurgery Training Institute Workshop.
14. Shanelec D, Tibbetts LS: Periodontal microsurgery: Continuing Education Course, American Academy of Periodontology Seventy-Eighth Annual Meeting, Orlando, FL, 1992.
15. Tibbetts LS, Shanelec D: Current status of periodontal microsurgery. *Periodontol 2000* 2:88–92, 1996.
16. Shanelec DA: Periodontal microsurgery. *Esthet Restor Dent* 15(7):402–407, 2003.
17. Society of Microsurgical Specialists: Training curriculum position paper, 1999.
18. Urbaniak J: *Microsurgical skills development*, Chicago, 1985, American Academy of Orthopaedic Surgeons.

CHAPTER 65

Recent Advances in Surgical Therapy: Lasers in Periodontal Therapy

Richard T. Kao and Bobby Butler

CHAPTER OUTLINE

Physics of Lasers and Their Biological Interactions
Advantages and Disadvantages of Laser Therapy
Laser Use in Periodontal Procedures
Lasers in the Surgical Management of Periodontitis and Perilmplantitis *(e-only)*
Conclusion

For online only content on Nd:YAG, Er:YAG and diode lasers, photodynamic therapy, and lasers in the surgical management of periodontitis and periimplantitis as well as expanded discussions on physics of lasers and their biological interactions and periodontal esthetic applications and functional crown lengthening, go to the companion website www.expertconsult.com. Some figures may be out of numeric order in this printed chapter.

Many new technologies are being proposed for periodontal procedures. Most technologies, including the laser, are meant to replace curettes, scalpels, and other instruments used in traditional periodontal therapy. Lasers are currently available for clinical use to incise soft and hard tissues. In periodontics, lasers have potential application in three areas: (1) surgical procedures such as gingivectomy and osseous crown lengthening, (2) scaling and root planning, and (3) the management of pathological changes resulting from periodontal disease. However, many questions are still being asked and research is needed regarding the use of lasers even in these areas.

In deciding if a new technology, such as laser, should be incorporated into clinical practice, studies are required to demonstrate equivalence or superiority in clinical trials. The usual goals of clinical studies are to determine if a new product, therapy, or technique is superior or equivalent to an established therapy or a placebo. Superiority is usually defined as greater than 20% of the effect of the established treatment. If the new treatment is no greater than or less than 20% of the effect of the established treatment, then the two groups are considered equivalent. Despite the fact that two treatment modalities are equivalent, there may be other advantages such as safety, cost, or ease of use that may warrant the utilization of the new technology.[29] The sample size required to statistically test superiority versus equivalence is generally much larger than what has been used in clinical trials for implementation of lasers. Additionally, the limited number of longitudinal clinical trials and cohort studies for each type of laser (i.e., carbon dioxide [CO_2], neodymium:yttrium-aluminum-garnet [Nd:YAG], erbium:yttrium-aluminum-garnet [Er:YAG], GaAS [diode]) makes implementation of this new technology for periodontal application difficult. Recently, meta-analysis of the available reports has been used in an attempt to define if laser could provide additional benefits.[83-86] Despite the large number of reports, the lack of well-designed parallel randomized clinical trials on which meta-analyses are based are minimal. As such, the conclusions should be interpreted with caution. Nevertheless, this chapter discusses the current literature and some of the clinical applications of laser for periodontal therapy.

Physics of Lasers and Their Biological Interactions

Laser is an acronym for *l*ight *a*mplification by *s*timulated *e*mission of *r*adiation and functions by transmitting light energy to tissues. It is a collimated, focused monochromatic ray of light. The energy beam reacts with a target material by being absorbed, reflected, or scattered. A target tissue absorbs the light. If it is well absorbed, the energy virtually explodes the cell (and extracellular matrix) in a process called *ablation*.[66] The efficiency of ablation is related to the wavelength and the affinity of the target tissue. If the wavelength is not well absorbed, there is scattering and a thermal reaction occurs with carbonization, charring, and melting. The clinician must understand how this energy is affecting the target tissue and the adjacent tissues as well.

Lasers are named in relationship to the active element(s) that when stimulated, generate the energy beam. The range of lasers used in dentistry consist of CO_2, Nd:YAG, HO:YAG, Er:YAG, Er, CT:YSGG, Nd:YAP, GaAs (diode) and argon lasers with the wavelengths delivered as either a continuous, pulsed (gated), or running pulse waveform.[15] Reported periodontal applications for these lasers include soft tissue incision and ablation; subgingival curettage, scaling of root surfaces, bacterial elimination, osteoplasty, and ostectomy. Because of the varying absorption spectrum for each tissue type, each laser has its unique wavelength spectrum. In understanding the use of lasers, considerations that each type of wavelength, which the laser functions with, will have its own set of characteristics (Figure 65-1).

Lasers were first used in the 1960s for dental applications.[28,46,52,67,86] They were initially used for removing hard tissue

The affinity of the wavelength for the target tissue is critical. The wavelengths of the diode (655 to 980 nm) and Nd : YAG (1064 nm) are well absorbed by pigment. They are better suited for soft tissue resective procedures than for hard tissue procedures. The CO_2 laser has a very long wavelength (10,600 nm) with an affinity for water. The CO_2 laser should only be used with soft tissue procedures. It is interesting that the CO_2, diode, and Nd : YAG lasers have very different wavelengths, but none have a favorable wavelength for hydroxyapatite.

The wavelengths of erbium : YAG (Er : YAG) (2790 nm) and erbium, chromium : yttrium (Er,Cr : YSGG) (2780 nm) lasers have a positive affinity for both water and hydroxyapatite. The specificity for hydroxyapatite also allows cutting hard tissues such as bone, dentin, or enamel.[6-10] The selection of the type of laser is ultimately based on the amount of energy transmitted to that tissue during a procedure.

Photothermal energy is measured in watts (W = joules/second). There are other factors to consider besides the amount of watts being delivered. The amount of energy delivered to the target can be altered if it is continuous, gated, and/or pulsed. A continuous laser transmits more energy than a pulsed laser to the target tissues. Hertz (Hz) is the cycle/second of a pulsed laser. It is imperative when comparing techniques and the type of laser that watts, hertz, and total time in contact with surgical sites be evaluated. The benefits of using a laser can be compromised if the energy is excessive. Care must be taken to avoid the transmission of excessive thermal energy to the tissues adjacent to the target because it can result in cellular damage. In a study with the Nd : YAG laser, wound healing was compared to that of a scalpel used for soft tissue incisions. Two different energy levels were used. Healing with the laser was excellent with a setting of 1.75 W, 20 Hz. When the energy was increased to 3 W, 20 Hz, the healing was delayed. The scalpel was better compared to the laser at this higher energy setting.[69] This study demonstrated that it is not only the type of laser that is used but also the energy level and total quantity that is delivered to the tissue that make a difference. Different energy levels and quantity may have different effects. The secondary message from this study that it is inappropriate to have the result of one study compared to another unless the same type of laser and energy setting and quantity is being used. The literature shows a wide range of approaches for laser application.

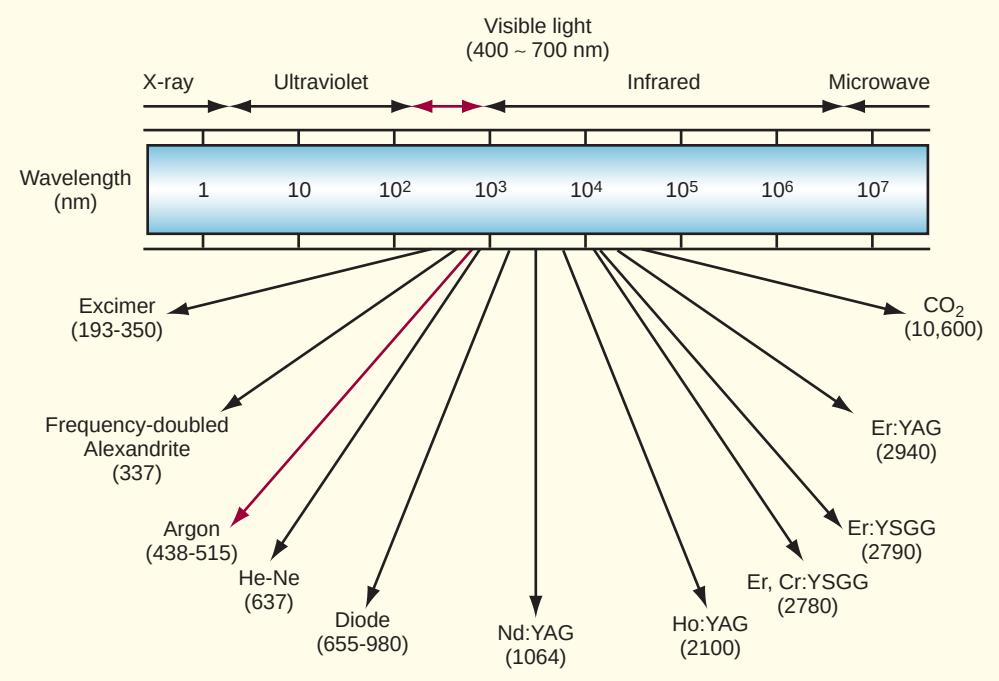

Figure 65-1 Laser wavelengths.

TABLE 65-1 Types of Lasers Currently Used in Dentistry

Laser Medium	Wavelength (nm)	Dental Uses
Argon	488-514	Tooth bleaching and advanced curing lights
Carbon dioxide (CO_2)	10,600	Gingivectomy/gingivoplasty, second-stage implant exposure, periodontal curettage (advocated but not evidence based)
Diode	655-980	Gingivectomy/gingivoplasty, oral medicine uses (aphthous ulcer therapy, biopsies, dentinal desensitizing), second-stage implant exposure, periodontal curettage (advocated but not evidence based)
Neodymium : yttrium-aluminum-garnet (Nd : YAG)	1064	Gingivectomy/gingivoplasty, oral medicine uses (aphthous ulcer therapy, biopsies, dentinal desensitizing), second-stage implant exposure, periodontal curettage (advocated but not evidence based)
Erbium : YAG (Er : YAG)	2940	Gingivectomy/gingivoplasty, oral medicine uses (aphthous ulcer therapy, biopsies, dentinal desensitizing), second-stage implant exposure, periodontal curettage (advocated but not evidence based), hard tissue cutting (dentin and osseous)
Erbium, chromium : yttrium (Er,Cr : YSGG)	2780	Gingivectomy/gingivoplasty, oral medicine uses (aphthous ulcer therapy, biopsies, dentinal desensitizing), second-stage implant exposure, periodontal curettage (advocated but not evidence based), hard tissue cutting (dentin and osseous)

and caries but offered little benefit over standard rotary instruments. Recent advances in new wavelengths, delivery units, and power maximums have refocused the use of lasers on both the soft and/or hard tissues (Table 65-1).[24,44] When applied to the various periodontal tissues such as the gingiva, periodontal ligament, cementum, dentin, and bone, the biological interactions will be unique for that wavelength. Gingiva, dentin, enamel, and bone are all composite structures of inorganic and organic elements. Gingiva is comprised of fibrous connective tissue, extracellular matrix components (including melanin pigmentation), and 70% water. Bone is comprised of 67% inorganic minerals (calcium hydroxyapatite) and 33% organic elements (collagen, noncollagenous proteins, and water). Other factors to consider are the textures and the densities of these structures. An example is the varying percentages of mineralized structures, blood vessels, and fluid found with cortical and cancellous bone. With the differences in tissue makeup, the laser energy beam will encounter many fluctuations in absorption and scattering, regardless of the wavelength. So when considering clinical application, it is important to appreciate not only what can be accomplished clinically but also the type of laser being used.

Advantages and Disadvantages of Laser Therapy

There are many advantages to using laser therapy, including better visualization of cutting, patient acceptance, and the detoxification of a wound. Other advantages are less invasive surgery to gain access and minimal wound contraction and scarring.[4,34,48] Many of these concepts of laser therapy are positive, although others still require research.[35] There are clearly many favorable applications for lasers in periodontal therapy but further studies are necessary as to which procedures laser therapy can be best applied.

While there are advantages, conversely, lasers can also generate excessive temperature changes in hard tissues as reported from the studies by Eriksson and Albrektsson.[24] The exposure of bone to temperatures ≥47° C (116.6° F) can induce cellular damage and osseous resorption. Extreme temperature levels of ≥60° C (140° F) result in tissue necrosis.[44]

Overexposure of laser energy has been the basis for reports of tissue damage and destruction of the periodontium. As such, it has been the basis for malpractice suits. Misuse of new technologies can result in "cutting-edge" clinicians finding their early experiences resulting in disastrous results (Figure 65-2). To avoid these negative results, knowledge of the laser mechanics and technique are essential to avoid causing damage to the adjacent tissues. Once mastery of the information has been achieved, it is critical to identify the desired laser application(s) and the fashion in which it will be used. In reviewing this chapter, you will find that most laser applications are at best equivalent. With the significant investment for lasers, it behooves the clinician to be clear as to the additional benefits that justifies this type of expense.

Laser Use in Periodontal Procedures

Currently, lasers are used in periodontal therapy for (1) surgical procedures such as gingivectomy and osseous crown lengthening, (2) nonsurgical therapy, and (3) the surgical management of pathological changes resulting from periodontal disease.

Periodontal Esthetic Applications and Functional Crown Lengthening

Several types of laser wavelengths have been reported to be effective for soft tissue procedures.[4,48,49] Appropriate use of laser for procedures such as frenectomy, gingivectomy/gingivoplasty, recontouring of drug-induced gingival overgrowth, short crowns associated with altered/delayed passive eruption, and management of mucosal tissue/pericoronitis situations distal of mandibular second molars have been well documented. Some of the positive aspects of laser therapy are good visibility during the surgical procedure as a result of coagulation, hemostasis, and minimal tissue damage adjacent to the laser wound are also advantages. Additionally, laser therapy can potentially offer extreme precision and may be easier than using a scalpel.

Esthetic applications for gingivectomy and gingivoplasty procedures allow delicate tissue shaping. The laser is effective for the removal of pigmentation from the gingival tissues, which can significantly improve the esthetics of highly pigmented areas. The CO_2, diode, and Nd:YAG lasers have been used for depigmentation.[3,53]

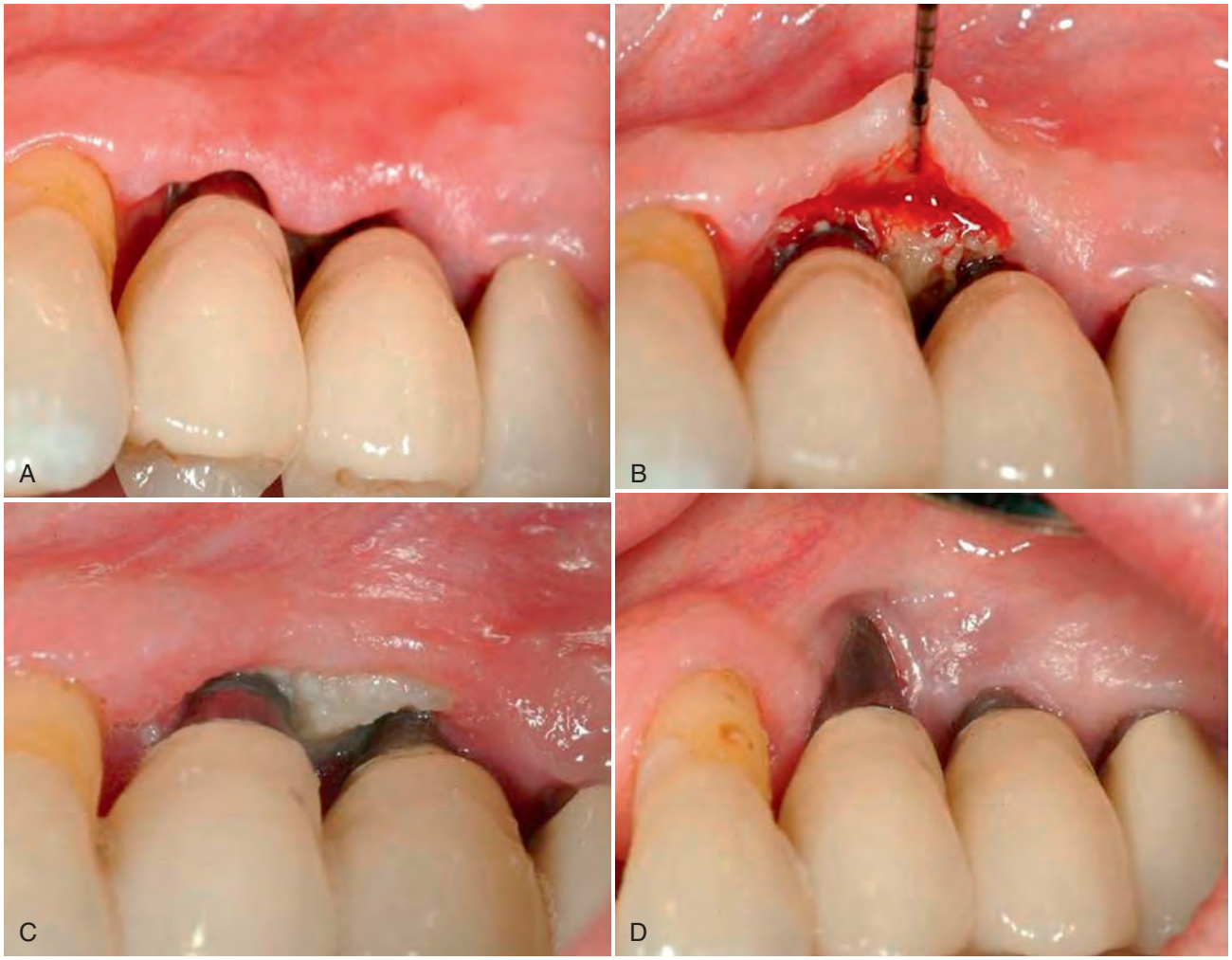

Figure 65-2 Interproximal soft tissue cratering with underlying bone necrosis around two dental implants following laser treatment of periimplantitis using inappropriate energy density and duration of exposure. Photos in sequence: **A, B,** One month post laser treatment. **C,** Sequestration of necrotic interproximal and facial bone at 2 months posttreatment. **D,** Healing at 3 months posttreatment. *(Courtesy of Dr. Charles Cobb, University of Missouri, Kansas City.)*

Some clinicians advocate the use of lasers for crown-lengthening procedures. Whereas crown lengthening involving only soft tissue can be effectively be performed with a wide variety of lasers, lasers may be somewhat advantageous for hemostatic control during tissue removal. For functional crown lengthening involving osseous contouring, the use of laser is controversial. (See Chapter 60 for a discussion of crown-lengthening surgery.) The Er:YAG and Er,Cr:YSGG lasers have been advocated as one approach for clinical crown lengthening without gingival flap reflection.[25,26,38,88,94-97] The Er,Cr:YSGG laser can safely cut bone without burning or altering the calcium-to-phosphate ratio of the irradiated bone.[38,95] This approach has been described in case technique reports and case series, but there are no controlled longitudinal or cohort studies supporting the use of lasers for clinical crown lengthening using the closed-flap technique.

Nonsurgical Laser Periodontal Therapy

Two of the purported benefits of using laser-mediated periodontal therapy are for subgingival curettage and significantly decreasing subgingival pathogenic bacteria.[80] In the clinical situation, periodontal pathogenic bacteria exist in a protective biofilm in a periodontal pocket. In vitro laboratory analysis of laser bactericidal properties is not clinically relevant in that these bacteria do not exist as a suspension or monolayer. The protective nature of the biofilm and the disruption of this biofilm result in renewal microbial colonization of this micro niche. In addressing these issues for each laser type, one needs to ask the following questions:

1. Do the in vivo studies indicate reduction in pathogenic bacteria as compared to conventional scaling and root planing?
2. Are the microbial changes sustained or does microbial colonization reinitiate?
3. Are there any differences in clinical parameters following laser-mediated versus conventional scaling and root planing? When evaluating nonsurgical periodontal therapy, gain in clinical attachment level (CAL) represents the gold standard. Pocket depth (PD) and levels of subgingival microbes are important because they correlate with changes in CAL.[14,71]
4. Are there changes in root surface in vitro conditions?

In evaluating laser (i.e., Nd:YAG, Er:YAG, and diode lasers) used for nonsurgical periodontal therapy, these questions need to be addressed. Three recent reviews on the effect of laser therapy as an adjunct of nonsurgical periodontal treatment in patients with chronic periodontitis have been published.[36,80,86]

Conclusion

The literature has numerous positive findings for the use of lasers in the management of periodontal and peri-implant disease. The quality of the literature is largely dominated by case reports and series. The problem is that there are limited well-designed random clinical trials and with the various laser types, no one laser has been well researched as to the exact parameter for use. Therefore laser use for the treatment of periodontal disease presents numerous unknowns.

As in all professions, technology is constantly advancing with new research to provide the clinician with better equipment, drugs, and techniques to improve the therapy rendered to patients. Lasers in periodontics may become an integral part of periodontal therapy, but at the present time, further research as to the parameters for clinical efficacy and biological basis for laser therapy are required. Clinician considering incorporating laser therapy should be familiar with what is known, the appropriate parameter for use, and receive adequate training to master the laser of interest.

Suggested Readings

Cobb CM: Lasers in periodontics: a review of the literature. *J Periodontol* 77(4):545–564, 2006.

de Paula Eduardo C, De Freitas PM, Esteves-Oliveira M, et al: Laser phototherapy in the treatment of periodontal disease. A review. *Lasers Med Sci* 25:781–792, 2010.

Harris DM, Gregg RH, McCarthy DK, et al: Laser-assisted new attachment procedure in private practice. *Gen Dent* 52:396–403, 2004.

Nevins ML, Camelo M, Schubach P, et al: Human clinical and histologic evaluation of laser-assisted new attachment procedure. *Int J Periodontics Restorative Dent* 32:497, 2012.

Schwarz F, Jepsen S, Herten M, et al: Influence of different treatment approaches on non-submerged and submerged healing of ligature induced periimplantitis lesions: an experimental study in dogs. *J Clin Periodontol* 33:584–595, 2006.

Sgolastra F, Petrucci A, Gatto R, et al: Efficacy of Er:YAG laser in the treatment of chronic periodontitis: systematic review and meta-analysis. *Lasers Med Sci* 27:661–673, 2012.

Sgolastra F, Severino M, Petrucci A, et al: Effectiveness of diode laser as adjunctive treatment to scaling root planning in the treatment of chronic periodontitis: a meta-analysis. *Lasers Med Sci* 28(5):1393–1402, 2013. doi: 10.10007/s10103-102-1181-5. [Epub August 16, 2012].

Sgolastra F, Severino M, Petrucci A, et al: Nd:YAG laser as an adjunctive treatment to nonsurgical periodontal therapy: a meta-analysis. *Lasers Med Sci* 2013. doi: 10.1007/s10103-013-1293-6. [Epub March 10, 2013].

Tilt LV: Effectiveness of LANAP over time as measure by tooth loss. *Gen Dent* 60:143–146, 2012.

Yukna RA, Carr RL, Evans GH: Histologic evaluation of an Nd:YAG laser-assisted new attachment procedure in humans. *Int J Periodontics Restorative Dent* 27(6):577–587, 2007.

References

References for this chapter are found on the companion website www.expertconsult.com.

Figure 65-3 Crown-lengthening procedure performed using closed approach with a laser. **A,** Periodontal sounding after the initial gingivectomy, which indicated the need for osseous contouring to achieve biological width.. **B,** The osseous contouring was done intrasulcularly. Sounding confirms 3 mm from gingival to osseous crest. Final small fragments of bone are checked and removed with a small chisel. **C,** Final surgical photograph shows minimal bleeding with no need for sutures. A frenectomy was also completed at the time of surgery. **D,** Smile at 3 months postsurgery. *(Case courtesy of Dr. Bobby Butler, Seattle, WA.)*

Decision making for the use of lasers in crown lengthening in an open or closed approach is based on osseous biotypes.[39] In the closed approach, the Er,Cr:YSGG or Er:YAG laser can be used only in the medium gingival biotype cases in which the width of the osseous crest is approximately 1 mm in thickness and may be limited to situations where only 1 to 2 mm of osseous removal is required. In this technique, sounding is indicated after the external gingivectomy to determine the thickness of the osseous biotype and to determine the amount of bone removal that is required. The laser tip is placed in contact with the bone, and the laser is fired for 1 to 2 seconds. The tip is moved slowly around the tooth until the biologic width is achieved. The osseous removal is verified by sounding, and detailing is performed with a small chisel (Figure 65-3). This technique can be surgically conservative and result in symmetric gingival levels in the esthetic zone.[4,43,48]

Case selection based on osseous biotypes is critical for the success of this closed approach for crown lengthening. In a thick biotype, the laser creates a "trough" or an intrabony defect. Since inadequate bone removal was performed, the soft tissue will often rebound within a few weeks. With the thick osseous biotype, the open-flap approach is indicated so appropriate osseous contouring can be performed. With thin osseous or gingival biotypes, laser should absolutely be avoided. Given the thin gingival and osseous structure with the thin biotype, laser use presents a high risk of overheating the tissue and the unpredictable healing response can result in poor or disastrous clinical outcomes.

Further issues of concern include: (1) Is there sufficient tactile sense to permit adequate osseous contouring with properly defined osseous anatomical dimension required for crown lengthening? (2) Is there any root surface damage?[15] Given these concerns and the possible retreatment because of tissue rebound or poor tissue healing suggest that this is not a superior or equivalent technique as compared to traditional functional crown lengthening that requires osseous contouring.

Neodymium:Yttrium-Aluminum-GarnetLaser. Presently, there are a limited number of clinical trials using the Nd:YAG laser for treatment of chronic periodontitis. A recent meta-analysis was conducted to investigate whether the use of Nd:YAG laser adjunctive to scaling root planing (S/Rp) could provide additional benefits compared to S/Rp alone in patients with chronic periodontitis.[85] Of the 438 articles available, only 3 articles met inclusion criteria. The conclusion was that the use of Nd:YAG as an adjunct to S/Rp could potentially provide additional benefits.

Although meta-analysis provides stringent criteria, some studies in the literature merit review. These studies provide conflicting results. Three studies reported little to no difference in PD reduction when comparing laser-treated sites to control sites (S/Rp only),[23,31,50] while two studies reported S/Rp sites had better resolution.[62,65] In this same series, reduction of the pathogenic bacteria is similarly conflicting. Three studies reported no difference,[31,55,86] one reported S/Rp to be more effective,[66] and two reported significant decrease in laser-treated sites of *Tannerella forsythia*, *Treponema denticola*, *Porphyromonas gingivalis*, and *Prevotella intermedia*.[7,54] These studies also reported the recolonization process to proceed similarly.[7,31] In vitro studies using the Nd:YAG at low power setting or those used in clinical situations reported

calculus ablation without resulting in cementum or dentinal changes.[91,93] But if the energy is increased beyond those clinically used, there is a linear increase in root surface alterations that included craters, charring, and melting and resolidification of the mineral phase.[1,92]

Erbium:Yttrium-Aluminum-Garnet Laser. Clinical trials with Er:YAG laser in the treatment of chronic periodontitis have provided more consistent results because, in part, they have come from the same group of investigators.[74-78,82] The Er:YAG laser possesses characteristics most suitable for the nonsurgical treatment of chronic periodonitis.[22,42,72] Although most of these studies concluded laser treatment to be superior in PD reduction, the results were statistically significant (ranging from no difference to 0.4 mm), but may be of little clinical relevance.[5,6,20,41,76-77] Microbial studies reported no significant differences between treatments.[20,75,76] In vitro studies indicate that Er:YAG laser can effectively achieve bacterial ablation at energy levels that do not result in heat-associated damages to the root surface.[56,72] Despite these encouraging reports, a meta-analysis of 1,282 potentially relevant titles and abstracts found only 5 randomized controlled trials included in the analysis.[83] Our conclusion was that there is no evidence of effectiveness over conventional S/Rp due to heterogeneity of the techniques, risks for bias, and methodical shortcomings. This conclusion of equivalence should be interpreted with caution since the number of well-designed randomized clinical trials was limited.

Diode Laser. Diode laser are used in two clinical fashions. The first is used as an adjunct initial therapy to reduce the gingival inflammatory response. This is called low-level laser therapy (LLLT). Limited studies indicate that LLLT had no impact on inflammatory response (as indicated by bleeding on probing and neovascularization) and plaque accumulation.[45,54] Contrary to these findings, LLLT has been demonstrated to be an effective adjunct to nonsurgical and supportive periodontal therapy.[35,47,57] The second use of diode therapy is an adjunct to S/Rp. Studies of diode use in the treatment of chronic periodontitis reported no or minimal changes in PDs[64,96] and little to no effect on bacterial levels.[51,64,96] This finding of equivalence has been recently confirmed by a meta-analysis study that found the use of diode laser as adjunctive therapy to S/Rp did not achieve additional improvement in clinical parameters.[84] Root alteration study reported little to no damage on the root surface at a power output of <1 W, whereas high-power selections produced varying level of carbonization and heat-induced surface cracking.[40] Due the affordability of diode laser, this is often purchased by clinicians for restorative tissue management. Unfortunately, misuse can often result in inappropriate energy density and duration resulting in tissue necrosis (Figure 65-4).

Photodynamic Therapy. The use of lasers for photodynamic therapy has recently been reviewed.[17,61,89] This therapy uses a photosensitizer (a nontoxic dye), which specifically targets microorganisms and is activated by low-level laser light. Photosensitizer activation can be achieved by various light sources including argon, Nd:YAG, and diode lasers. The introduction of a photosensitizer can greatly increase the bacteriocidal ability of a laser.[9,10,11,16,65,87] This is supported by an in vitro study using methylene blue with a diode laser to destroy black-pigmented bacteria (*P. gingivalis* and *P. intermedia*)[87]; 99% to 100% of bacteria were eliminated. Disrupting the biofilm may also be effective using the photodynamic therapy.[68] Anecdotally, lasers can be used to target pigments (i.e., Nd:YAG) and have the potential to target pigmented *P. gingivalis*. To date, there are seven studies available on the use of photodynamic therapy (PDT) as adjunct to S/Rp. Six of these studies reported significant clinical and microbiological improvements in the PDT + S/Rp as compared to S/Rp alone.[2,8-12,96] One study found the results to be comparable.[17] More clinical trials are required prior to clinical implementation.

Lasers in the Surgical Management of Periodontitis and Perilmplantitis

The role of laser therapy in the surgical management of periodontitis and periimplantitis remains controversial. At the center of this controversy is the apparent potential for the Nd:YAG laser to result in new attachment and regeneration when used with the LANAP protocol (see Chapter 61).[53,98] The patented LANAP procedure

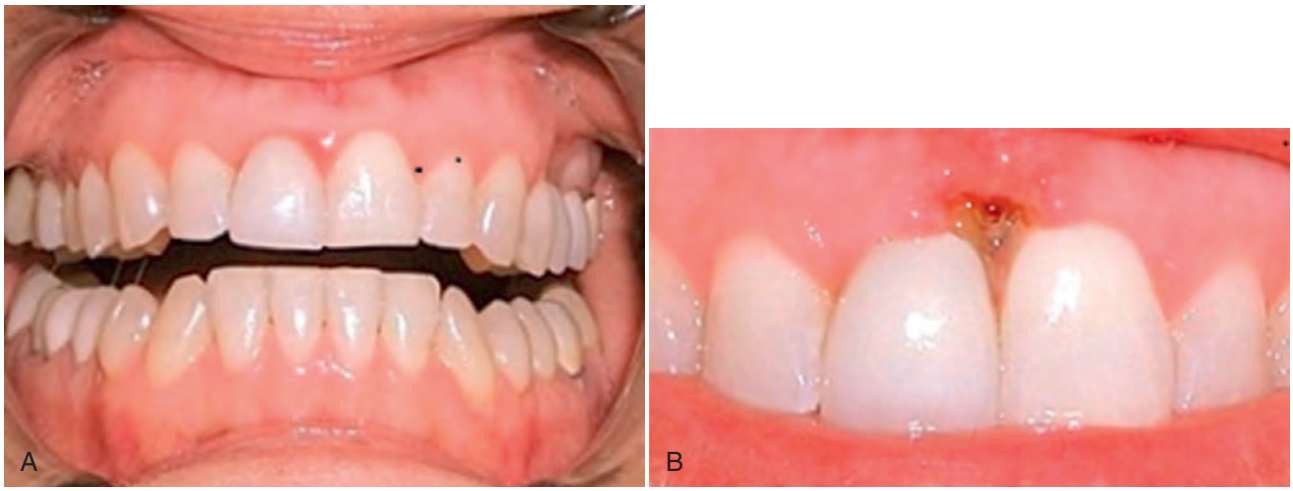

Figure 65-4 This is a case where the patient had a diastema. This was closed restoratively and the restorations violated the biological width. The bleeding and gingival inflammation was misdiagnosed and an 810 mm diode laser was used to "curettage" the gingiva. **A,** Patient present early postoperatively with tissue highly inflamed and symptomatic complaints of pain (7 days postoperatively). **B,** Necrotic interproximal and facial bone is present at 14 days posttreatment. *(Courtesy of Dr. Charles Cobb, University of Missouri, Kansas City.)*

consist of a first pass with a Nd:YAG laser at a setting of 4.0 W and energy density of 1965 mJ/mm^2, 100-µs pulse duration, and 20 Hz applied. The first pass de-epithelializes the sulcular epithelium, the underlying connective tissue is spared, and purportedly kills pigmented bacteria. The teeth are then scaled and root planed with piezo ultrasonic instrumentation. A second pass was performed with similar output but with a 650-µs pulse duration and 20 Hz. The second pass creates a blood clot and if kept stable, it acts as the foundation for periodontal wound healing (Figures 65-5 and 65-6).

Since the initial description of LANAP,[33] most evidence was based on case reports. Recent publications suggest that this

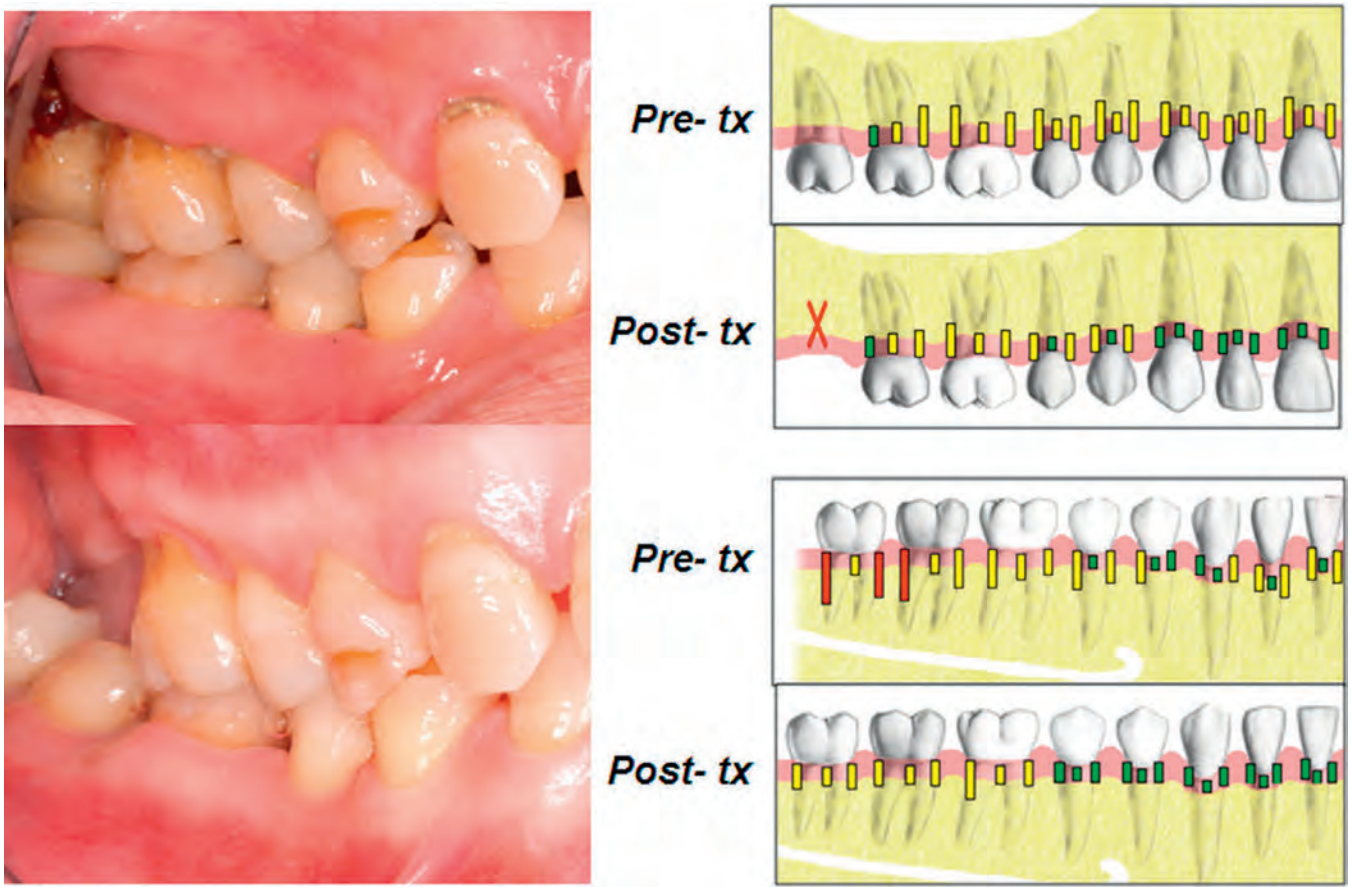

Figure 65-5 A case treated with LANAP procedure whereby good resolution was obtained and results can be maintained with conventional periodontal supportive therapy. Resolution was comparable with conventional flap osseous surgery.

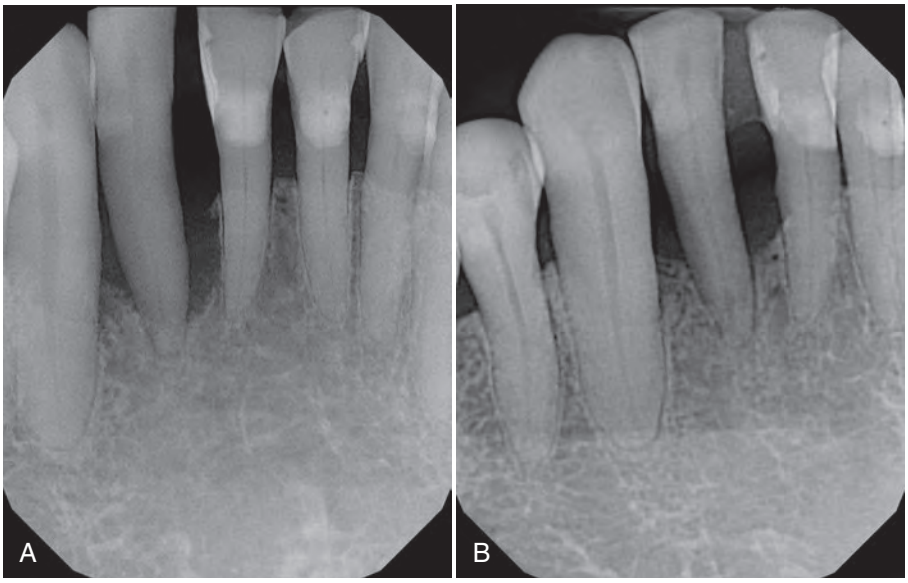

Figure 65-6 This lower anterior case was treated with LANAP, occlusal adjustment and splinting. **A,** Radiograph at pretreatment. **B**, Radiograph at 7 months posttreatment. *(Case courtesy of Dr. Braden Seamon, Kailua, HI.)*

protocol may have merits. This is based on two histological studies that report LANAP can result in the formation of new attachment and periodontal regeneration (detailed in Chapter 61).[53,98] More recently, the effectiveness of LANAP was examined in the treatment of 107 consecutive patients presenting with moderate-to-advanced chronic periodontitis.[92] The main criterion for determining treatment success over time was measured by tooth loss. Tooth loss per patient treated by LANAP was 0.43 teeth over the average of 6.2 years posttreatment. Although a direct comparison with classic studies is not possible due the shorter time frame for posttreatment evaluation, the trend suggest LANAP compares favorably with conventional surgical treatment modalities and may be a less invasive treatment alternative.

There are limited studies on the surgical management of chronic periodontitis with other laser types. Given the positive histological evidence of new attachment and regeneration associated with LANAP performed with the Nd:YAG, the question remains: Can Er:YAG or the Er,Cr:YSGG laser can reproduce similar results? The advantage is that there is less risk associated with this wavelenth.[38,62,94,95] Putative periodontal regeneration of a maxillary intrabony defect based on radiographs following Er,Cr:YSGG treatment has been recently reported.[58] The difficulty is that periodontal regeneration requires histological evidence of new PDL, cementum, and bone formation. Since this has not been demonstrated with this wavelength, one can only state that that finding is suggestive of radiographic fill of the intrabony defects that is consistent with possible periodontal regeneration. In a split-mouth design, the use of ER,Cr:YSGG laser versus open-flap debridement was compared. The laser-assisted pocket therapy was found to provide similar CAL gains with similar reduction in pocket depth, GI, and sulcular bleeding index.[30] These findings were similar to the findings that compared a split-mouth design with three closed approaches, which included S/Rp, diode laser curettage with S/Rp, and laser-assisted curettage with S/Rp and laser sealing, versus an open approach of papilla reflection with S/Rp and flap closure.[99] In comparing these open and closed protocols, all treatments resulted in a reduction in PD and bleeding on probing. Consistent with the previous study, closed protocols all resulted in less gingival recession. These authors concluded that if esthetics is a concern, laser curettage is a viable option. Since this is an issue of concern in the maxillary anterior region, the caveat is the clinician must be appropriately trained and familiar with the laser being used. There are clinical instances where mismanagement with laser resulted in irreversible hard and soft tissue damage (see Figures 65-2 and 65-4).

There is increased interest in the use of laser to manage peri-implantitis. This is due to anecdotal reports of cession and reversal of radiographic changes associated with bone damages surrounding periimplantitis cases (Figure 65-7). This clinical phenomenology, although interesting, is not a consistent finding and there is no clear biological basis for when and why this phenomenology happens. In the Sixth European Workshop on Periodontology, the surgical treatment of periimplantitis recognized the use of Er:YAG for implant surface decontamination.[13] In a dog study, surface decontamination of experimental periimplantitis was compared with closed- and open-approach debridement using Er:YAG laser and an ultrasonic scaler with a fifth group using curettes with local metronidazole gel application.[79] This group found both open-flap approaches (Er:YAG and ultrasonic scaling) resulted in higher clinical attachment gain with the laser therapy having a higher degree of reosseointegration (44.8%) as compared to ultrasonic and plastic curette/metronidazole gel debridement (8.7 and 14.8%, respectively). Similar but more modest results were found with the use of CO_2 laser.[18,19] Further in vitro investigation defined the optimal Er:YAG laser parameters for debridement of implant surfaces without damaging the implant surface.[90] Although the experimental findings of Er:YAG are encouraging, the use of this laser in two clinical trials found the healing response to be similar to control and the clinical improvements were limited.[59,81] This suggests the long-term stability of clinical outcomes may be influenced by factors other than the method used for surface debridement and decontamination. In a case report, a soft laser was successfully used to decontaminate the implant surface before regenerating the defect with autogenous bone and the use of an expanded polytetrafluoroethylene (ePTFE) membrane, but this approach has not been further investigated.[32] Finally, a laser-photodynamic approach for the management periimplantitis has been attempted. Although there was significant decrease in *Aggregatibacter actinomycetemcomitans*, *P. gingivalis*, and *P. intermedia*, complete elimination was not achieved.[21]

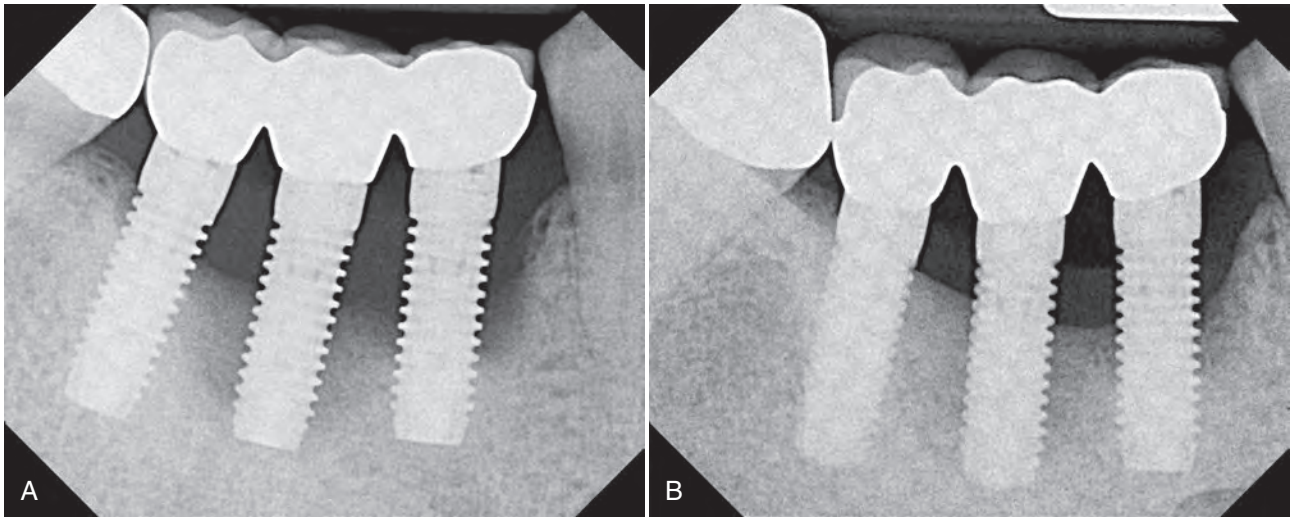

Figure 65-7 Management of periimplantitis with LANAP. Radiographic bone loss with increasing probing depth and tissue inflammation was present at pre-treatment. After 11 months post-LANAP treatment, there is increased radiopacity suggestive of remineralization in addition to decreased probing depth and tissue inflammation. *(Case courtesy of Dr. Braden Seamon, Kailua, Hawaii.)*

The biological basis of periodontal regeneration, new attachment, and reversal of periimplantitis by laser is being elucidated. Crevicular fluid analysis of patients and osteoblasts in cell culture treated with laser therapy demonstrate increase in the levels of cytokines associated with tissue regeneration including platelet-derived growth factor (PDGF), basic fibroblast growth factor (bFGF),[70,73] insulinlike growth factor 1 (IGF-1),[73] and bone morphogenic protein 2 (BMP-2).[37] These growth and differentiation factors are associated with tissue healing and regeneration. Conversely, proinflammatory cytokines associated with inflammation and tissue destruction such as interleukin-1-β, tumor necrosis factor (TNF)-α, and metalloproteinases decreased.[27,60,63,70] The combination of increase in reparative associated growth and differentiation factors and the decrease in proinflammatory cytokines suggest the biological mediators induced by lasers are of a profile that encourages tissue repair and regeneration. Although these studies provide early clues for possible biological basis, further elaborations are needed.

References

1. Aoki A, Sasaki KM, Watanabe H, et al: Lasers in nonsurgical periodontal therapy. *Periodontol 2000* 36:59–97, 2004.
2. Andersen R, Lebel N, Hammond D, et al: Treatment of periodontal disease by photodisinfection compared to scaling and root planing. *J Clin Dent* 18:34–38, 2007.
3. Atsawasuwan P, Greethong K, Nimmanon V: Treatment of gingival hyperpigmentation for esthetic purposes by Nd:YAG laser: report of 4 cases. *J Periodontol* 71:315–321, 2000.
4. Bader H: Use of lasers in periodontics. *Dent Clin North Am* 44:779–792, 2000.
5. Badran Z, Boutigny H, Struillou X, et al: Clinical outcomes after nonsurgical periodontal therapy with an Er:YAG laser device: a randomized controlled pilot study. *Photomed Laser Surg* 30:347–353, 2012.
6. Beaumont RH, O'Leary TJ, Kafrawy AH: Relative resistance of long junctional epithelial adhesions and connective tissue attachments to plaque-induced inflammation. *J Periodontol* 55:213–223, 1984.
7. Ben Hatit Y, Blum R, Severin C, et al: The effects of a pulsed Nd:YAG laser on subgingival bacterial flora and on cementum: an in vivo study. *J Clin Laser Med Surg* 14:137–143, 1996.
8. Braun A, Dehn C, Krause F, et al: Short-term clinical effects of adjunctive antimicrobial photodynamic therapy in periodontal treatment: a randomized clinical trial. *J Clin Periodontol* 35:877–884, 2008.
9. Cappuyns I, Cionca N, Wick P, et al: Treatment of residual pockets with photodynamic therapy, diode laser, or deep scaling. A randomized, split-mouth controlled clinical trial. *Lasers Med Sci* 27:979–986, 2012.
10. Chan Y, Lai CH: Bactericidal effects of different laser wavelengths on periodontopathic germs in photodynamic therapy. *Lasers Med Sci* 18(1):51–55, 2003.
11. Chandros P, Nikolidakis D, Christodoulides N, et al: Photodynamic therapy as adjunct to non-surgical periodontal treatment in patients on periodontal maintenance: a randomized controlled clinical trial. *Lasers Med Sci* 24:681–688, 2009.
12. Christodoulides N, Nikolidakis D, Chondros P, et al: Photodynamic therapy as an adjunct to non-surgical periodontal treatment: A randomized controlled clinical trial. *J Periodontol* 79:1638–1644, 2008.
13. Claffey N, Clarke E, Polyzois I, et al: Surgical treatment of periimplantitis. *J Clin Periodontol* 35:316–332, 2008.
14. Cobb CM: Non-surgical pocket therapy: mechanical. *Ann Periodontol* 1:443–490, 1995.
15. Cobb CM: Lasers in periodontics: a review of the literature. *J Periodontol* 77(4):545–564, 2006.
16. De Oliveira RR, Schwartz-Fliho HO, Novaes AB, Jr, et al: Antimicrobial photodynamic therapy in the non-surgical treatment of aggressive periodontitis: a preliminary randomized controlled clinical study. *J Periodontol* 78:965–973, 2007.
17. de Paula Eduardo C, De Freitas PM, Esteves-Oliveira M, et al: Laser phototherapy in the treatment of periodontal disease. A review. *Lasers Med Sci* 25:781–792, 2010.
18. Deppe H, Horch H, Henke J, et al: Peri-implant care of ailing implants with carbon dioxide laser. *Int J Oral Maxillofac Implants* 16:659–667, 2001.
19. Deppe H, Horch H, Neff A: Conventional versus CO2 laser-assisted treatment of peri-implant defects with the concomitant use of pure-phase beta-tricalcium phosphate: a 5-year clinical report. *Int Oral Maxillofac Implants* 22:79–86, 2007.
20. Derdilopoulou FV, Nonhoff J, Neumann K, et al: Microbiological findings after periodontal therapy using curettes, Er:YAG laser, sonic and ultrasonic scalers. *J Clin Periodontol* 343:588–598, 2007.
21. Dorbudak O, Haas R, Berhart T, et al: Lethal photosensitization for decontamination of implant surfaces in the treatment of periimplantitis. *Clin Oral Impl Res* 12:104–108, 2001.
22. Eberhard J, Ehlers H, Falk W, et al: Efficacy of subgingival calculus removal with Er:YAG compared to mechanical debridement: an in situ study. *J Clin Periodontol* 30:511–518, 2003.
23. El Yazami H, Azehoui N, Ahariz M, et al: Periodontal evaluation of an Nd:YAP laser combined with scaling and root planing for nonsurgical periodontal treatment. A clinical evaluation. *J Oral Laser Appl* 4: 97–102, 2004.
24. Eriksson RA, Albrektsson T: Temperature threshold levels for heat induced bone tissue injury: a vital microscopic study in the rabbit. *J Prosthet Dent* 50:101–107, 1983.
25. Flax HD: Radz GM: Closed-flap laser-assisted esthetic dentistry using Er:YSGG technology. *Compend Contin Educ Dent* 25(8):622, 626, 628–630, 2004.
26. Flax H: Maximizing esthetic transformations using a closed flap ER, Cr:YSGG modality. *Compend Contin Educ Dent* 26:174–176, 2005.
27. Giannopoulou C, Cappuyns I, Cancela J, et al: Effect of photodynamic therapy, diode laser, and deep scaling on cytokine and acute-phase protein levels in gingival crevicular fluid of residual periodontal pockets. *J Periodontol* 83:1018–1027, 2012.
28. Goldman L, Hornby P, Meyer R, et al: Impact of the laser on dental caries. *Nature* 203:417, 1964.
29. Gunsolley JC, Elswick RK, Davenport JM: Equivalence and superiority testing in regeneration clinical trials. *J Periodontol* 69:521–527, 1998.
30. Gupta M, Lamba AK, Verma M, et al: Comparison of periodontal open flap debridement versus close debridement with Er,Cr:YSFF laser. *Aust Dent J* 58(1):41–49, 2013.
31. Gutknecht N, Radufi P, Franzen R, et al: Reduction of specific microorganisms in periodontal pockets with the aid of an Nd:YAG laser: an in vivo study. *J Oral Laser Appl* 2:175–180, 1996.
32. Haas R, Baron M, Dortbudak O, et al: Lethal photosensitization, autogenous bone, and e-PTFE membrane for the treatment of periimplantitis: preliminary results. *Int J Oral Maxillofac Implants* 15:374–382, 2000.
33. Harris DM, Gregg RH, McCarthy DK, et al: Laser-assisted new attachment procedure in private practice. *Gen Dent* 52:396–403, 2004.
34. Hendrick DA, Meyers A: Wound healing after laser surgery. *Otolaryngol Clin North Am* 28(5):969–986, 1995.
35. Igic M, Kesic L, Lekovic V, et al: Chronic gingivitis: the prevalence of periodontopathogens and therapy efficiency. *Eur J Clin Microbiol Infect Dis* 31:1911–1915, 2012.
36. Karlsson MR, Diogo Löfgren CI, Jansson HM: The effect of laser therapy as an adjunct to non-surgical periodontal treatment in subjects with chronic periodontitis: a systematic review. *J Periodontol* 79(11):2021–2028, 2008.
37. Kim IS, Cho TH, Kim K, et al: High power-pulsed Nd:YAG laser as a new stimulus to induce BMP-2 expression in n MC3T3-E1 osteoblasts. *Lasers Surg Med* 42:510–518, 2010.
38. Kimura Y, Yu DG, Fujita A: Effects of erbium, chromium:YSGG laser irradiation on canine mandibular bone. *J Periodontol* 72(9):1178–1182, 2001.
39. Kois JC: Altering gingival levels: the restorative connection. Part I: biologic variables. *J Esthet Dent* 6:3–9, 1994.
40. Kreisler M, Christoffers AB: Willenshausen B, d'Hoedt B: Effect of diode laser irradiation on root surfaces in vitro. *J Clin Laser Med Surg* 20:63–69, 2002.
41. Krohn-Dale I, Boo OE, Enersen M, et al: Er:YAG laser in the treatment of periodontal sites with recurring chronic inflammation: a 12-month randomized, controlled clinical trial. *J Clin Periodontol* 39:745–752, 2012.
42. Lopes BM, Marcantonio RA, Thompson GM, et al: Short-term clinical and immunologic effects of scaling and root planing with Er:YAG laser in chronic periodontitis. *J Periodontol* 79(7):1158–1167, 2008.
43. Lowe RA: Clinical use of the Er,Cr:YSGG laser for osseous crown lengthening: redefining the standard of care. *Pract Proced Aesthet Dent* 18(4):S2–S9, 2006.
44. Luk K, Tam L, Hubert M: Effect of light energy on peroxide tooth bleaching. *J Am Dent Assoc* 135:194–201, 2004.
45. Magnusson I, Runstad L, Nyman S, et al: A long junctional epithelium: a locus minoris resistentiae in plaque infection? *J Clin Periodontol* 10:333–340, 1983.
46. Maiman TH: Stimulated optical radiation in ruby. *Nature* 187:493–494, 1960.
47. Makhlouf M, Dahaba MM, Tuner J, et al: Effect of adjunctive low level laser therapy (LLLT) on nonsurgical treatment of chronic periodontitis. *Photomed Laser Surg* 30:10–16, 2012.

48. Midda M: The use of lasers in periodontology. *Curr Opin Dent* 2:104–108, 1992.
49. Miyazaki A, Yamaguchi T, Nishikata J, et al: Effects of Nd:YAG and CO2 laser treatment and ultrasonic scaling on periodontal pockets of chronic periodontitis patients. *J Periodontol* 74:175–180, 2003.
50. Morlock BJ, Pippin DJ, Cobb CM, et al: The effect of Nd:YAG laser exposure on root surfaces when used as an adjunct to root planning: an in vitro study. *J Periodontol* 63:637–641, 1992.
51. Moritz A, Schoop U, Goharkhay K, et al: Treatment of periodontal pockets with a diode laser. *Lasers Surg Med* 22:302–311, 1998.
52. Nakamura Y, Hossain M, Hirayama K, et al: A clinical study on the removal of gingival melanin pigmentation with the CO_2 laser. *Lasers Surg Med* 25:140–147, 1999.
53. Nevins ML, Camelo M, Schubach P, et al: Human clinical and histologic evaluation of laser-assisted new attachment procedure. *Int J Periodontics Restorative Dent* 32:497, 2012.
54. Noguchi T, Sanaoka A, Fukuda M, et al: Combined effects of Nd:YAG laser irradiation with local antibiotic applications into periodontal pockets. *J Int Acad Periodontol* 7:8–15, 2005.
55. Neil ME, Mellonig JT: Clinical effects of the Nd:YAG laser for combination periodontitis therapy. *Pract Periodontics Aesth Dent* 9:1–5, 1997.
56. Noori ZT, Fekrazad R, Eslami B, et al: Comparing the effects of root surfaced scaling with ultrasound instruments and Er,Cr:YSGG laser. *Lasers Med Sci* 23:283–287, 2008.
57. Pejcic A, Zivkovic V: Histological examination of gingiva treated with low-level laser in periodontal therapy. *J Oral Laser Applications* 7:1–7, 2007.
58. Perio DN: Periodontal bone regeneration and the Er,Cr:YSGG laser: a case report. *Open Dent J* 7:16–19, 2013.
59. Persson GR, Roos-Jansaker AM, Lindahl C, et al: Microbiological results after non-surgical erbium-doped:yttrium, aluminum, and garnet laser or air-abrasive treatment of periimplantitis: a randomized clinical trial. *J Periodontol* 82:1267–1278, 2011.
60. Pesevska S, Nakova M, Gjorgoski I, et al: Effect of laser on TNF-alpha expression in inflamed human gingival tissue. *Lasers Med Sci* 27:377–781, 2012.
61. Pfitzner A, Sigusch BW, Albrecht V, et al: Killing of periodontopathogenic bacteria by photodynamic therapy. *J Periodontol* 75:1343–1349, 2004.
62. Pontoriero R, Carnevale G: Surgical crown lengthening: a 12-month clinical wound healing study. *J Periodontol* 72(7):841–848, 2001.
63. Qadri T, Miranda L, Tuner J, et al: The short-term effects of low-level lasers as an adjunct therapy in the treatment of periodontal inflammation. *J Clin Periodontol* 32:714–719, 2005.
64. Qadri T, Poddani P, Javed F, et al: A short-term evaluation of Nd:YAG lasers as an adjunct to scaling and root planing in the treatment of periodontal inflammation. *J Periodontol* 81:1161–1166, 2010.
65. Qin YL, Luan XL, Bi LJ, et al: Comparison of toluidine blue-mediated photodynamic therapy and conventional scaling treatment for periodontitis in rats. *J Periodontal Res* 43(2):162–167, 2008.
66. Radvar M, MacFarlane TW, MacKenzie D, et al: An evaluation of the Nd:YAG laser in periodontal pocket therapy. *Br Dent J* 180:57–62, 1996.
67. Rechmann P: Dental laser research: selective ablation of caries, calculus, and microbial plaque: from the idea to the first in vivo investigation. *Dent Clin North Am* 48:10077–11104, 2004.
68. Robertson CA, Evans DH, Abrahamse H: Photodynamic therapy (PDT): a short review on cellular mechanisms and cancer research applications for PDT. *J Photochem Photobiol B* 96(1):1–8, 2009.
69. Romanos GE, Pelekanos S, Strub JR: A comparative histologic study of wound healing following Nd:YAG laser with different energy parameters and conventional surgical incision in rat skin. *J Clin Laser Med Surg* 13:11–16, 1995.
70. Safavi SM, Kazemi B, Esmaeili M, et al: Effects of low-level He-Ne laser irradiation on the gene expression of IL-1 beta, TNF-alpha, IFN-gamma, TGF-beta, bFGF and PDGF in rat's gingiva. *Lasers Med Sci* 23:331–335, 2008.
71. Sanz M, Teugheis W: Innovations in non-surgical periodontal therapy: consensus report of the Sixth European Workshop on Periodontology. *J Clin Periodontol* 35(Suppl 8):3–7, 2008.
72. Sasaki KM, Aoki A, Ichinose S, et al: Ultrastructural analysis of bone tissue irradiated by Er:YAG laser. *Lasers Surg Med* 31:322–332, 2002.
73. Saygun I, Karacay S, Serdar M, et al: Effects of laser irradiation on the release of basic fibroblast growth factor (bFGF), insulin-like growth factor-1 (IGF-1), and receptor of IGF-1 (IGFBP3) from gingival fibroblasts. *Lasers Med Sci* 23:211–215, 2008.
74. Schwarz F, Sculean A, Berakdar M, et al: Periodontal treatment with an Er:YAG laser compared to scaling and root planing. A controlled clinical study. *J Periodontol* 72:361–367, 2001.
75. Schwarz F, Sculean A, Berakdar M, et al: Clinical evaluation of an Er:YAG laser combined with scaling and root planing for non-surgical periodontal treatment. A controlled, prospective clinical study. *J Clin Periodontol* 30:26–34, 2003.
76. Schwarz F, Sculean A, Berakdar M, et al: Periodontal treatment with an Er:YAG laser or scaling and root planing. A 2-year follow-up split mouth study. *J Periodontol* 74:590–596, 2003.
77. Schwarz F, Sculean A, Berakdar M, et al: Periodontal treatment with an Er:YAG laser compared to ultrasonic instrumentation: a pilot study. *J Periodontol* 75:966–973, 2004.
78. Schwarz F, Sculean A, Berakdar M, et al: Clinical evaluation of an Er:YAG laser in combination with an enamel matrix protein derivative for the treatment of intrabony periodontal defects: a pilot study. *J Clin Periodontol* 30:975–981, 2003.
79. Schwarz F, Jepsen S, Herten M, et al: Influence of different treatment approaches on non-submerged and submerged healing of ligature induced periimplantitis lesions: an experimental study in dogs. *J Clin Periodontol* 33:584–595, 2006.
80. Schwarz F, Aoki A, Becker J, et al: Laser application in non-surgical periodontal therapy: A systematic review. *J Clin Periodontol* 35(Suppl 8):24–44, 2008.
81. Schwarz F, John G, Mainusch S, et al: Combined surgical therapy of periimplantitis evaluating two methods of surface debridement and decontamination. A two-year clinical follow up report. *J Clin Periodontol* 39:789–797, 2012.
82. Sculean A, Schwarz F, Berakdar M, et al: Healing of intrabony defects following surgical treatment with or without an Er:YAG laser. *J Clin Periodontol* 31:604–608, 2004.
83. Sgolastra F, Petrucci A, Gatto R, et al: Efficacy of Er:YAG laser in the treatment of chronic periodontitis: Systematic review and meta-analysis. *Lasers Med Sci* 27:661–673, 2012.
84. Sgolastra F, Severino M, Petrucci A, et al: Effectiveness of diode laser as adjunctive treatment to scaling root planning in the treatment of chronic periodontitis: a meta-analysis. *Lasers Med Sci* 28(5):1393–1402, 2012. doi: 10.10007/s10103-102-1181-5. [Epub August 16, 2012].
85. Sgolastra F, Severino M, Petrucci A, et al: Nd:YAG laser as an adjunctive treatment to nonsurgical periodontal therapy: a meta-analysis. *Lasers Med Sci* 2013. doi: 10.1007/s10103-013-1293-6. [Epub March 10, 2013].
86. Slot DE, Kranendonk AA, Paraskevas S, et al: The effect of a pulsed Nd:YAG laser in non-surgical periodontal therapy. *J Periodontol* 80:1041–1056, 2009.
87. Soukos NS, Mulholland SE, Socransky SS, et al: Photodestruction of human dental plaque bacteria: enhancement of the photodynamic effect by photomechanical waves in an oral biofilm model. *Lasers Surg Med* 33(3):161–168, 2003.
88. Stübinger S, Landes C, Seitz O, et al: Er:YAG laser osteotomy for intraoral bone grafting procedures: a case series with a fiber-optic delivery system. *J Periodontol* 78(12):2389–2394, 2007.
89. Takasaki AA, Aoki A, Mizautani K, et al: Application of antimicrobial photodynamic therapy in periodontal and peri-implant diseases. *Periodontol 2000* 51:109–140, 2009.
90. Taniguchi Y, Aoki A, Mizutani K, et al: Optimal ER:YAG laser irradiation parameters for debridement of microstructured fixture surfaces of titanium dental implants. *Lasers Med Sci* 28(4):1057–1068, 2012. doi: 10.1007/s10103-012-1171-7. [Epub August 11, 2012].

91. Thomas D, Rapley J, Cobb C, et al: Effects of the Nd:YAG laser and combined treatment on in vitro fibroblast attachment to root surfaces. *J Clin Periodontol* 21:38–44, 1994.
92. Tilt LV: Effectiveness of LANAP over time as measure by tooth loss. *Gen Dent* 60:143–146, 2012.
93. Trylovich DJ, Cobb CM, Pippin DJ, et al: The effects of the Nd:YAG laser on in vitro fibroblast attachment to endotoxin-treated root surfaces. *J Periodontol* 63:626–632, 1992.
94. Wang X, Ishizaki NT, Suzuki N, et al: Morphological changes of bovine mandibular bone irradiated by Er, Cr:YSGG laser: an in vitro study. *J Clin Laser Med Surg* 20(5):245–250, 2002.
95. Wang X, Zhang C, Matsumoto K: In vivo study of the healing processes that occur in the jaws of rabbits following perforation by an Er,Cr:YSGG laser. *Lasers Med Sci* 20(1):21–27, 2005.
96. Yilmaz S, Kuru B, Kuru L, et al: Effect of gallium arsenide diode laser on human periodontal disease: A microbiological and clinical study. *Lasers Surg Med* 30:60–66, 2002.
97. Yoshino T, Aoki A, Oda S, et al: Long-term histologic analysis of bone tissue alteration and healing following Er:YAG laser irradiation compared to electrosurgery. *J Periodontol* 80(1):82–92, 2009.
98. Yukna RA, Carr RL, Evans GH: Histologic evaluation of an Nd:YAG laser-assisted new attachment procedure in humans. *Int J Periodontics Restorative Dent* 27(6):577–587, 2007.
99. Zingale J, Harpenau L, Chambers D, et al: Effectiveness of root planing with diode laser curettage for the treatment of periodontitis. *J Calif Dent Assoc* 40:786–793, 2012.

CHAPTER 66

Preparation of the Periodontium for Restorative Dentistry

Philip R. Melnick

CHAPTER OUTLINE

Rationale for Therapy
Sequence of Treatment
Control of Active Disease
Preprosthetic Surgery *(e-only)*

For online only content on preprosthetic surgery, please visit the companion website at www.expertconsult.com. Some figures and boxes may be out of numeric order in this printed chapter. Editors Note: An animation (slide show) has been added as a supplement to the chapter by the Editors. This was produced by My Dental Hub as a patient education tool and covers the basic elements in a conceptual manner. It is not intended to be a procedural guide for dental professionals.

Periodontal health is the "sine qua non," a prerequisite, of successful comprehensive dentistry.[23] To achieve the long-term therapeutic targets of comfort, good function, treatment predictability, longevity, and ease of restorative and maintenance care, active periodontal infection must be treated and controlled before the initiation of restorative, esthetic, and implant dentistry. In addition, the residual effects of periodontal disease or anatomic aberrations inconsistent with realizing and maintaining long-term stability must be addressed. More recently, this phase of treatment includes techniques performed in anticipation of esthetic or implant dentistry, such as clinical crown lengthening, covering denuded roots, alveolar ridge retention or augmentation, and implant site development (see Video 66-1: Effects of Single Tooth Loss).

Rationale for Therapy

The many reasons for establishing periodontal health before performing restorative dentistry include the following[45]:

1. Periodontal treatment is undertaken to ensure the establishment of stable gingival margins before tooth preparation. Noninflamed, healthy tissues are less likely to change (e.g., shrink) as a result of subgingival restorative treatment or postrestoration periodontal care.[26,27] In addition, tissues that do not bleed during restorative manipulation allow for a more predictable restorative and esthetic result.[20,21]
2. Certain periodontal procedures are designed to provide for adequate tooth length for retention, access for tooth preparation, impression making, tooth preparation, and finishing of restorative margins in anticipation of restorative dentistry.[20,41] Failure to complete these procedures before restorative care can add to the complexity of treatment and introduce unnecessary risk of failure.[20]
3. Periodontal therapy should antecede restorative care because the resolution of inflammation may result in the repositioning of teeth[40] or in soft tissue and mucosal changes. Failure to anticipate these changes may interfere with prosthetic designs planned or constructed before periodontal treatment.
4. Traumatic forces placed on teeth with ongoing periodontitis may increase tooth mobility, discomfort, and possibly the rate of attachment loss.[8] Restorations constructed on teeth free of periodontal inflammation, synchronous with a functionally appropriate occlusion, are more compatible with long-term periodontal stability and comfort (see Chapters 15 and 50).
5. Quality, quantity, and topography of the periodontium may play important roles as structural defense factors in maintaining periodontal health. Orthodontic tooth movement and restorations completed without the benefit of periodontal treatment designed for this purpose may be subject to negative changes that complicate construction and future maintenance.[47]
6. Successful esthetic and implant procedures may be difficult or impossible without the specialized periodontal procedures developed for this purpose.

Sequence of Treatment

Treatment sequencing should be based on logical and evidenced-based methodologies, taking into account not only the disease state encountered but also the psychologic and esthetic concerns of the patient. Because periodontal and restorative therapy is situational and specific to each patient, a plan must be adaptable to change depending on the variables encountered during the course of treatment. For example, teeth initially determined to be salvageable may be judged "hopeless," thus altering the established treatment scheme.

Generally, the preparation of the periodontium for restorative dentistry can be divided into two phases: (1) control of periodontal

Figure 66-1 Root planing has resolved the gingival inflammation of this patient.

BOX 66-1 Sequence of Treatment in Preparing Periodontium for Restorative Dentistry

Control of Active Disease
- Emergency treatment
- Extraction of hopeless teeth
- Oral hygiene instructions
- Scaling and root planing
- Reevaluation
- Periodontal surgery
- Adjunctive orthodontic therapy

Preprosthetic Surgery
- Management of mucogingival problems
- Preservation of ridge morphology after tooth extraction
- Crown-lengthening procedures
- Alveolar ridge reconstruction

inflammation with nonsurgical and surgical approaches and (2) preprosthetic periodontal surgery (Box 66-1).

Control of Active Disease

Periodontal therapy is intended to control active disease (see Chapters 42 to 49). In addition to the removal of root surface accretions that are primary etiologic agents, secondary local factors, such as plaque-retentive overhanging margins and untreated caries, must be addressed.[13,18]

Emergency Treatment

Emergency treatment is undertaken to alleviate symptoms and stabilize acute infection. This includes endodontic as well as periodontal conditions (see Chapters 42 and 43).

Extraction of Hopeless Teeth

Extraction of hopeless teeth is followed by provisionalization with fixed or removable prosthetics. Retention of hopeless teeth without periodontal treatment may result in bone loss on adjacent teeth.[30] Restorative margins are refined and provisional restorations refitted after the completion of active periodontal therapy.

Oral Hygiene Measures

Oral hygiene measures, when properly applied, have been shown to reduce plaque scores and gingival inflammation[28,44] (see Chapter 45). However, in patients with deep periodontal pockets (>5 mm), plaque control measures alone are insufficient in resolving subgingival infection and inflammation.[5,28]

Scaling and Root Planing

Scaling and root planing combined with oral hygiene measures have been demonstrated to significantly reduce gingival inflammation and the rate of progression of periodontitis[3,4,29] (see Chapter 45). This applies even to patients with deep periodontal pockets[5,14] (Figure 66-1).

Figure 66-2 **A,** Before treatment. **B,** After 4 weeks, oral hygiene instructions and scaling and root planing have improved this patient's periodontal status. However, inflammation associated with pockets deeper than 5 mm suggests a need for periodontal surgery.

Reevaluation

After 4 weeks the gingival tissues are evaluated to determine oral hygiene adequacy, soft tissue response, and pocket depth (see Chapter 44). This permits sufficient time for healing, reduction in inflammation and pocket depths, and gain in clinical attachment levels. In deeper pockets (>5 mm); however, plaque and calculus removal is often incomplete,[42,46] with risk of future breakdown[7] (Figure 66-2). As a result, periodontal surgery to access the root surfaces for instrumentation and to reduce periodontal pocket depths must be considered before restorative care may proceed.

Periodontal Surgery

Periodontal surgery may be required for some patients (see Chapters 64 and 65). This should be undertaken with future restorative and implant dentistry in mind. Some procedures are intended to treat active disease successfully,[11,34] and some are aimed at the preparation of the mouth for restorative or prosthetic care.[47]

Adjunctive Orthodontic Therapy

Orthodontic treatment has been shown to be a useful adjunctive to periodontal therapy[6,16,17,22] (see Chapter 51). It should be undertaken only after active periodontal disease has been controlled. If nonsurgical treatment is sufficient, definitive periodontal pocket therapy may be postponed until after the completion of orthodontic tooth movement. This allows for the advantage of the positive bone changes that orthodontic therapy can provide. However, deep pockets and furcation invasions may require surgical access for root instrumentation in advance of orthodontic tooth movement. Failure to control active periodontitis can result in acute exacerbations and bone loss during tooth movement.[9] As long as they are periodontally healthy, teeth with preexisting bone loss may be moved orthodontically without incurring additional attachment loss.[36,37]

Soft tissue–grafting procedures are often indicated in anticipation of orthodontic therapy to increase the dimension of attached tissue.[47]

Conclusion

As described in this and other sections of this textbook, the therapeutic goals of patient comfort, function, esthetics, predictability, longevity, and ease of restorative and maintenance care are attainable only by a carefully constructed interdisciplinary approach, with accurate diagnosis and comprehensive treatment planning serving as cornerstones. The complex interaction between periodontal therapy and successful restorative dentistry only serves to underscore this premise.

Suggested Readings

Camargo PM, Melnick PR, Camargo LM: Clinical crown lengthening in the esthetic zone. *J Calif Dent Assoc* 35(7):487–498, 2007.

Fradeani M: *Esthetic rehabilitation in fixed prosthodontics, volume 2: prosthetic treatment: a systematic approach to esthetic, biologic, and functional integration*, Chicago, 2004, Quintessence.

Gracis S, Fradeani M, Celletti R, et al: Biological integration of aesthetic restorations: factors influencing appearance and long-term success. *Periodontol 2000* 27:29–44, 2001.

Kois JC: The restorative-periodontal interface: biological parameters. *Periodontol 2000* 11:29, 1996.

Kois JC: Clinical techniques in prosthodontics: relationship of the periodontium to impression procedures. *Compend Contin Educ Dent* 21:684, 2000.

Kokich VG: Esthetics: the orthodontic-periodontic restorative connection. *Semin Orthodont* 2:21, 1996.

Melnick PR, Camargo PM: Alveolar bone reservation following tooth extraction in the esthetic zone. In Fugazzotto P, editor: *Implant and regenerative therapy in dentistry: a guide to decision making*, Hoboken, 2009, Wiley-Blackwell.

References

References for this chapter are found on the companion website www.expertconsult.com.

Preprosthetic Surgery

Management of Mucogingival Problems

Periodontal plastic surgical procedures may be undertaken for a variety of reasons. The most common techniques include those that increase gingival dimensions and achieve root coverage. These procedures are often indicated before restoration for prosthetic reasons (Figure 66-3) and in conjunction with orthodontic tooth movement. Root coverage procedures may also be undertaken for purposes of comfort and esthetics (Figure 66-4).

At least 2 months of healing is recommended after soft tissue grafting procedures before initiating restorative dentistry[47] (see Chapter 63).

Preservation of Ridge Morphology after Tooth Extraction

Alveolar ridge resorption is a common consequence of tooth loss.[1,2] Ridge preservation procedures have been shown to be useful in anticipation of the future placement of a dental implant or pontic, as well as in cases where unaided healing would result in an unesthetic deformity[15,24,25,31,33] (Figure 66-5).

Crown-Lengthening Procedures

Surgical crown-lengthening procedures are performed to provide retention form to allow for proper tooth preparation, impression procedures,[21] and placement of restorative margins (Figure 66-6)[21] and to adjust gingival levels for esthetics.[32,43] It is important that

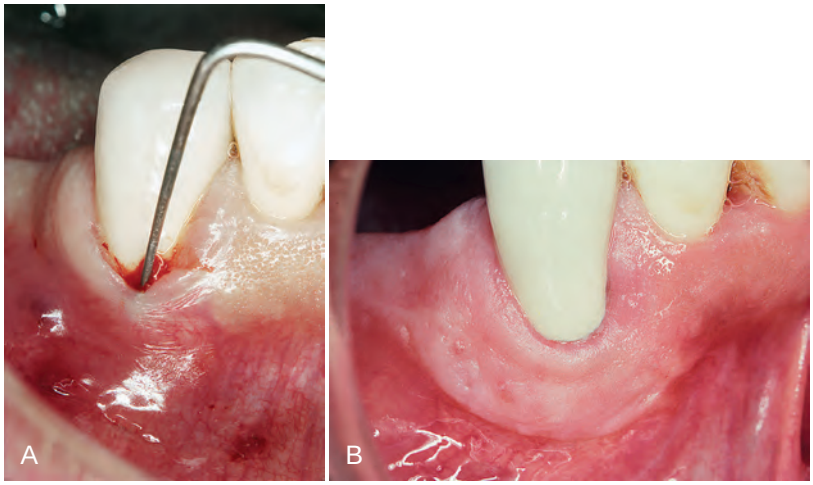

Figure 66-3 In preparation for a removable partial denture, this canine has received a gingival graft to increase attached gingiva and deepen the vestibule. **A,** Before therapy. Note minimal attached gingiva. **B,** After therapy, there is abundant attached gingiva and vestibular depth.

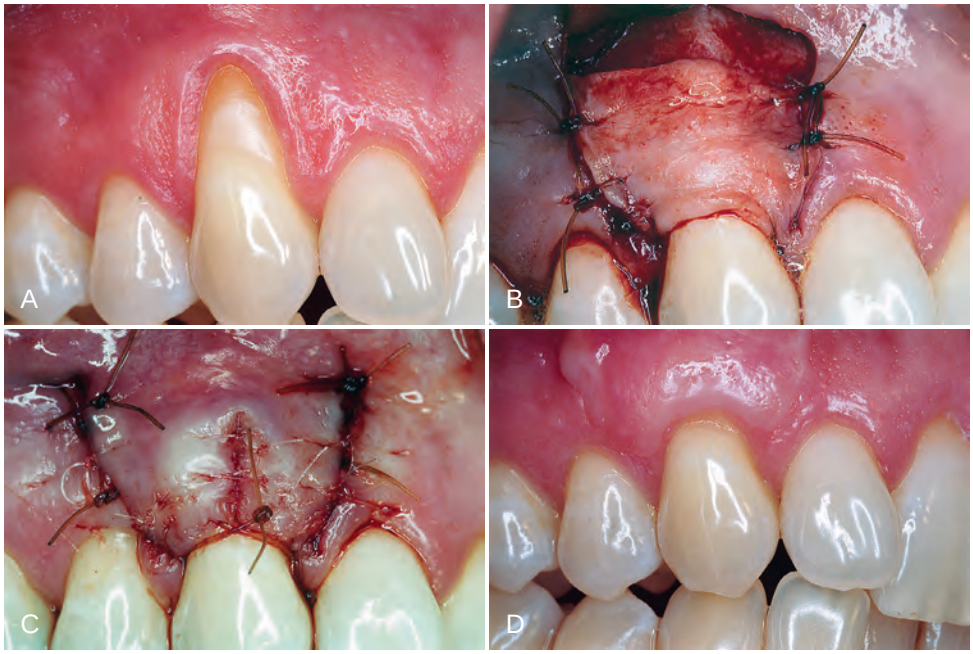

Figure 66-4 Connective tissue graft placed under a double-papilla flap has been used to provide root coverage for a maxillary right canine. **A,** Maxillary canine before therapy. **B,** Connective tissue graft placed over denuded root surface. **C,** Papilla placed over connective tissue. **D,** Final result.

Figure 66-5 **A,** The maxillary right lateral incisor has failed endodontically, with a fistulous tract noted exiting from the attached gingiva. **B,** The tooth is atraumatically removed and the socket debrided while maintaining the surrounding anatomic integrity. **C,** In an effort to reduce ridge collapse, the socket is grafted with a combination of deproteinized bovine bone and calcium sulfate. **D,** Provisional fixed partial denture is placed, with an ovate pontic extending 2 mm into the socket and supporting the surrounding tissues. **E** and **F,** After 8 weeks, the socket has healed, preserving the gingival and papillary architecture, in preparation for an esthetic final prosthesis. **G,** Final restoration.

crown-lengthening surgery is done in such a manner that the biologic width is preserved. The *biologic width* is defined as the physiologic dimension of the junctional epithelium and connective tissue attachment (see Chapter 67). This measurement has been found to be relatively constant at approximately 2 mm (±30%).[10] The healthy gingival sulcus has shown an average depth of 0.69 mm (Figure 66-7).[19] It has been theorized that infringement on the biologic width by the placement of a restoration within its zone may result in gingival inflammation,[19] pocket formation, and alveolar bone loss[35] (Figure 66-8). Consequently, it is recommended that there be at least 3.0 mm between the gingival margin and bone crest.[12,38,39,41] This allows for adequate biologic width when the restoration is placed 0.5 mm within the gingival sulcus[39,41] (Figure 66-9).

Surgical crown lengthening may include the removal of soft tissue or both soft tissue and alveolar bone. Reduction of soft tissue alone is indicated if there is adequate attached gingiva and more than 3 mm of tissue coronal to the bone crest (Figure 66-10). This may be accomplished by either gingivectomy or flap technique (see Chapters 65 and 66). Inadequate attached gingiva and less than 3 mm of soft tissue require a flap procedure and bone recontouring (Figure 66-11). In the case of caries or tooth fracture, to ensure margin placement on sound tooth structure and retention form, the surgery should provide at least 4 mm from the apical extent of the caries or fracture to the bone crest (Figure 66-12).

With the advent of predictable implant dentistry, it is important to weigh carefully the value of crown lengthening for restorative ease as opposed to tooth removal and replacement with a dental implant (Box 66-2).

Alveolar Ridge Reconstruction

Patients are frequently seen after tooth loss and alveolar ridge resorption have occurred (see Chapter 72). To provide for adequate anatomic dimensions for the construction of an esthetic pontic (see Chapter 67 or the placement of dental implants (see Chapter 72), alveolar ridge reconstruction is undertaken. In the case of esthetic pontic construction, small defects may be treated with soft tissue ridge augmentation (Figure 66-13). For larger defects and in those sites receiving dental implants, hard tissue modalities are used (Figure 66-14).

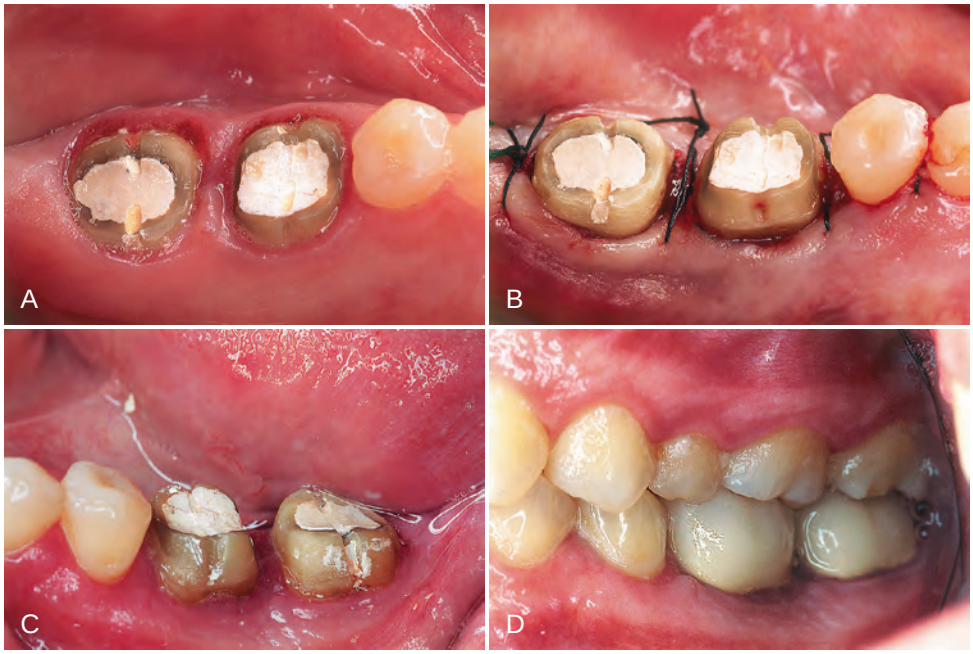

Figure 66-6 Surgical crown lengthening has provided these otherwise unrestorable mandibular molars with improved retention and restorative access for successful restorations. **A,** Before crown lengthening. **B,** Crown-lengthening surgery completed. Note increased clinical crown. **C,** Buccal view after surgery. **D,** Final restorations.

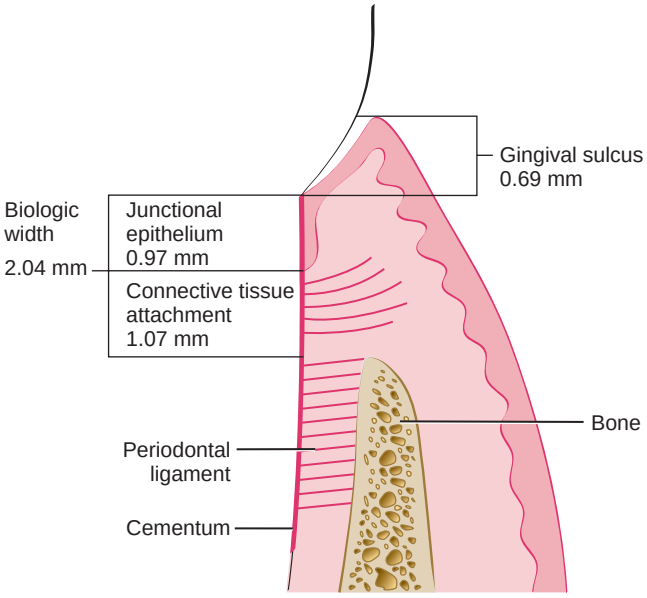

Figure 66-7 The biologic width has been estimated to be about 2 mm. Efforts should be made to preserve its integrity.

Figure 66-8 Although gingival inflammation around crowns may have a variety of causes, infringement of biologic width must be considered.

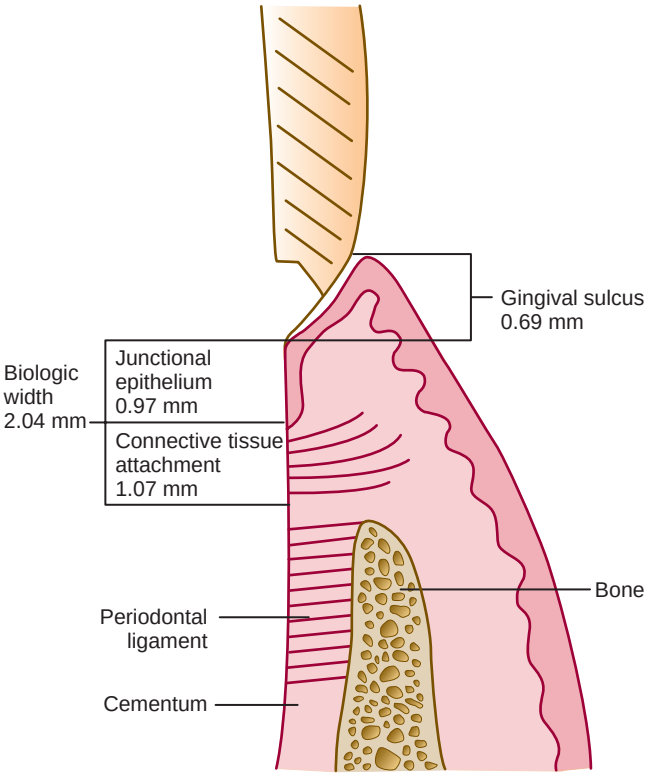

Figure 66-9 Placement of the restorative margin 0.5 mm into the sulcus allows for the maintenance of the biologic width.

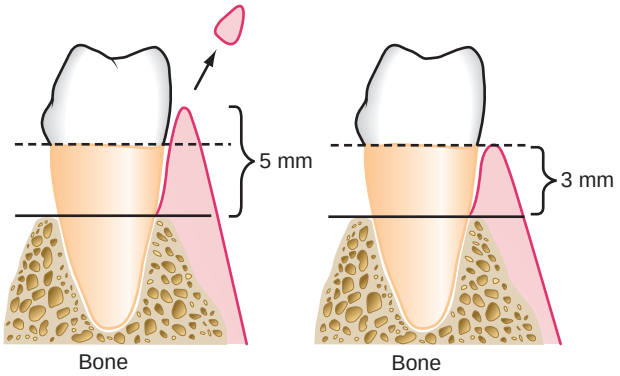

Figure 66-10 Greater than 3 mm of soft tissue between the bone and gingival margin, with adequate attached gingiva, allows crown lengthening by gingivectomy.

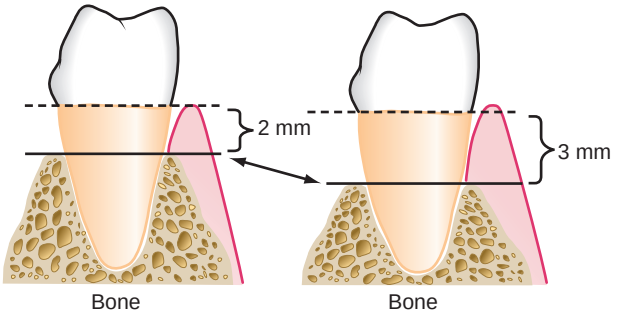

Figure 66-11 With less than 3 mm of soft tissue between the bone and gingival margin, or less-than-adequate attached gingiva, a flap procedure and osseous recontouring are required for crown lengthening.

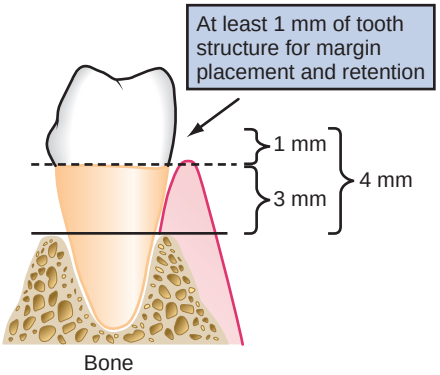

Figure 66-12 In the case of caries or fracture, at least 1 mm of sound tooth structure should be provided above the gingival margin for proper restoration.

BOX 66-2 Surgical Crown Lengthening

Indications

Subgingival caries or fracture.
Inadequate clinical crown length for retention.
Unequal or unesthetic gingival heights.

Contraindications

Surgery would create an unesthetic outcome.
Deep caries or fracture would require excessive bone removal on contiguous teeth.
The tooth is a poor restorative risk.

Figure 66-13 **A,** Loss of the maxillary left central incisor has resulted in an unesthetic alveolar ridge defect. **B** to **E,** An incision is made at ridge crest, a pouch is created, and a soft tissue graft harvested from the palate is placed into the pouch. **F** to **H,** A removable appliance with an ovate pontic is placed in light contact with the grafted site. Swelling around the pontic apex results in a tissue concavity from which the more natural-appearing final restoration emerges.

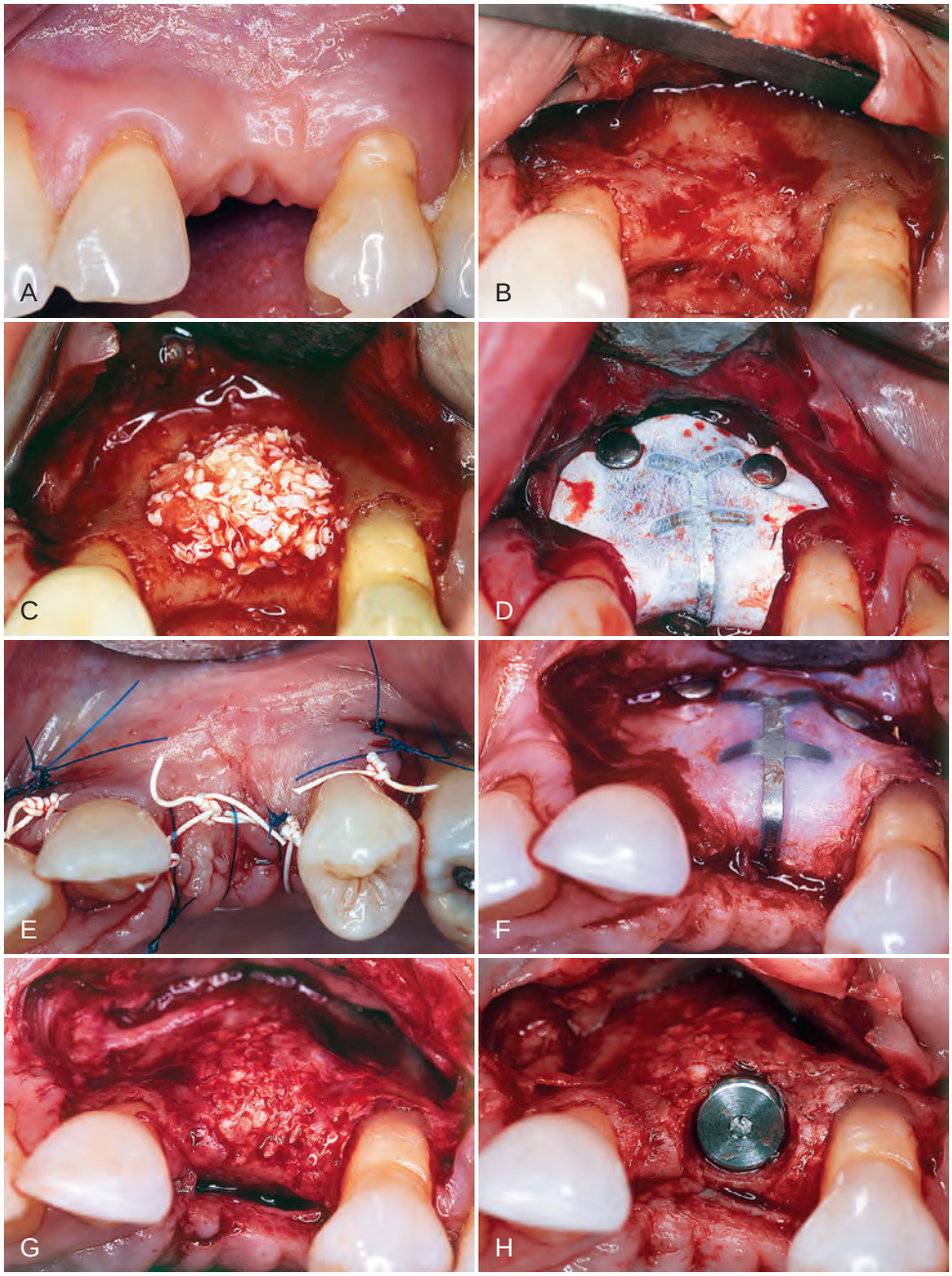

Figure 66-14 Postextraction ridge defect is grafted with a combination of autogenous and deproteinized bovine bone and contained by nonresorbable barrier membrane. After 8 months, the site is reopened and the membrane removed. A comparison of **B** and **G** shows significant reconstitution of hard tissue, in this case used for the installation of a dental implant. **A,** Edentulous ridge before surgery. **B,** Flap reflection to visualize defect. **C,** Graft material placed over resorbed ridge. **D,** Nonresorbable titanium-reinforced membrane placed over graft material. **E,** Graft site sutured. **F,** Surgical site reopened 8 months after surgery. **G,** New bone over ridge. **H,** Implant placed into augmented ridge.

References

1. Abrams H, Kopczyk RA, Kaplan AL: Incidence of anterior ridge deformities in partially edentulous patients. *J Prosthet Dent* 57:191, 1987.
2. Amler MH, Johnson PL, Salman I: Histological and histochemical investigation of human alveolar socket healing in undisturbed extraction wounds. *J Am Dent Assoc* 61:32, 1960.
3. Axelsson P, Lindhe J: Effect of controlled oral hygiene procedures on caries and periodontal disease in adults. *J Clin Periodontol* 5:133, 1978.
4. Axelsson P, Lindhe J: The significance of maintenance care in the treatment of periodontal disease. *J Clin Periodontol* 8:281, 1981.
5. Badersten A, Nilvens R, Egelberg J: Effect of nonsurgical periodontal therapy. II. Severely advanced periodontitis. *J Clin Periodontol* 11:63, 1984.
6. Brown SI: The effect of orthodontic therapy on certain types of periodontal defects. I. Clinical findings. *J Periodontol* 44:742, 1973.
7. Claffey N, Egelberg J: Clinical indicators of probing attachment loss following initial periodontal treatment in advanced periodontitis patients. *J Clin Periodontol* 22:690, 1995.
8. Ericsson I, Lindhe J: The effect of longstanding jiggling on experimental marginal periodontitis in the beagle dog. *J Clin Periodontol* 9:497, 1982.
9. Folio J, Rams TE, Keyes PH: Orthodontic therapy in patients with juvenile periodontitis: clinical and microbiological effects. *Am J Orthodont* 87:421, 1985.
10. Gargiulo AW: Dimensions and relations of the dentogingival junction in humans. *J Periodontol* 32:261, 1961.
11. Garret S: Periodontal regeneration around natural teeth. *Ann Periodontol* 1:621, 1996.
12. Herrero F, Scott JB, Maropis PS, et al: Clinical comparison of desired versus actual amount of surgical crown lengthening. *J Periodontol* 66:568, 1995.
13. Highfield JE, Powell RN: Effects of removal of posterior overhanging metallic margins of restoration upon the periodontal tissues. *J Clin Periodontol* 5:169, 1978.
14. Hirschfeld L, Wasserman B: A long-term survey of tooth loss in 600 treated periodontal patients. *J Periodontol* 5:225, 1978.
15. Iasella JM, Greenwell H, Miller RL, et al: Ridge preservation with freeze-dried bone allograft and a collagen membrane compared to extraction alone for implant site development: a clinical and histologic study in humans. *J Periodontol* 74:990, 2003.
16. Ingber JS: Forced eruption. Part I. A method of treating isolated one and two wall infrabony osseous defects: rationale and case report. *J Periodontol* 45:199, 1974.
17. Ingber JS: Forced eruption. Part II. A method of treating non-restorable teeth: periodontal and restorative considerations. *J Periodontol* 47:203, 1976.
18. Jeffcoat MK, Howell TH: Alveolar bone destruction due to overhanging amalgam in periodontal disease. *J Periodontol* 51:599, 1980.
19. Kois JC: The gingiva is red around my crowns. *Dent Economics* 100, 1993.
20. Kois JC: The restorative-periodontal interface: biological parameters. *Periodontol 2000* 11:29, 1996.
21. Kois JC: Clinical techniques in prosthodontics: relationship of the periodontium to impression procedures. *Compend Contin Educ Dent* 21:684, 2000.
22. Kokich VG: Esthetics: the orthodontic-periodontic restorative connection. *Semin Orthodont* 2:21, 1996.
23. Kramer JM, Nevins M: *Int J Periodont Restor Dent* 1:4, 1981. (editorial).
24. Lekovic V, Camargo PM, Klokkevold PR, et al: Alterations of the position of the marginal soft tissue following periodontal surgery. *J Clin Periodontol* 7:525, 1980.
25. Lekovic V, Kenney EB, Weinlaender M, et al: A bone regenerative approach to alveolar ridge maintenance following tooth extraction: report of 10 cases. *J Periodontol* 68:563, 1997.
26. Lindhe J, Nyman S: Alterations of the position of the marginal soft tissue following periodontal surgery. *J Clin Periodontol* 7:525, 1980.
27. Lindhe J, Westfelt E, Nyman S, et al: Healing following surgical/non-surgical treatment of periodontal disease: a clinical study. *J Clin Periodontol* 9:115, 1982.
28. Listgarten MA, Lindhe J, Hellden L: Effect of tetracycline and/or scaling on human periodontal disease: clinical, micro-biological and histological observations. *J Clin Periodontol* 5:246, 1978.
29. Lövdal A, Arno A, Schei O, et al: Combined effect of subgingival scaling and controlled oral hygiene on the incidence of gingivitis. *Acta Odontol Scand* 19:537, 1961.
30. Machtei E, Zubrey YI, Ben Yahuda A, et al: Proximal bone loss adjacent to periodontally "hopeless" teeth with and without extraction. *J Periodontol* 60:512, 1989.
31. Melnick PR, Camargo PM: Preservation of alveolar ridge dimensions and interproximal papillae through periodontal procedures: long-term results. *Contemp Esthet Restor Pract* 2:2004.
32. Minsk L: Clinical techniques in periodontics: esthetic crown lengthening. *Compend Contin Educ Dent* 22:562, 2001.
33. Nedic M: Preservation of alveolar bone in extraction sockets using bioabsorbable membranes. *J Periodontol* 69:1044, 1998.
34. Palcanis KG: Surgical pocket therapy. *Ann Periodontol* 1:589, 1996.
35. Parma-Benfenati S, Fugazzotto PA, Ruben MP: The effect of restorative margins on the postsurgical development and nature of the periodontium. Part I. *Int J Periodont Restor Dent* 6:31, 1985.
36. Polson AM, Reed BE: Long-term effects of orthodontic treatment on crestal bone levels. *J Periodontol* 55:28, 1984.
37. Polson AM, Caton J, Polson A, et al: Periodontal response to tooth movement into intrabony defects. *J Periodontol* 55:197, 1984.
38. Pontoriero R, Carnevale G: Surgical crown lengthening: a 12-month clinical wound healing study. *J Periodontol* 72:841, 2001.
39. Rosenberg ES, Cho SC, Garber DA: Crown lengthening revisited. *Compend Contin Educ Dent* 20:527, 1999.
40. Sato S, Ujiie H, Ito K: Spontaneous correction of pathologic tooth migration and reduced infrabony pockets following nonsurgical periodontal therapy: a case report. *Int J Periodont Restor Dent* 24:456, 2004.
41. Smukler H, Chaibi M: Periodontal and dental considerations in clinical crown extension: a rational basis for treatment. *Int J Periodont Restor Dent* 17:465, 1997.
42. Stambaugh RV, Dragoo M, Smith DM, et al: The limits of subgingival scaling. *Int J Periodont Restor Dent* 1:31, 1981.
43. Studer S, Zellweger U, Schärer P: The aesthetic guidelines of the mucogingival complex for fixed prosthodontics. *Pract Periodontics Aesthetic Dent* 4:333, 1996.
44. Tagge DL, O'Leary TJ, El-Kafrawy AH: The clinical and histological response of periodontal pockets to root planing and oral hygiene. *J Periodontol* 46:527, 1975.
45. Takei HH, Azzi RR, Han TJ: Preparation of the periodontium for restorative dentistry. In Newman MG, Takei HH, Carranza FA, editors: *Carranza's clinical periodontology*, ed 9, Philadelphia, 2002, Saunders.
46. Waerhaug J: The furcation problem: etiology, pathogenesis, diagnosis, therapy and prognosis. *J Clin Periodontol* 7:73, 1980.
47. Wennström JL: Mucogingival therapy. In Proceedings of the 1996 World Workshop in Periodontics. Lansdowne, Virginia, July 13-17. *Ann Periodontol* 1:671, 1996.

CHAPTER 67

Restorative Interrelationships

Frank M. Spear and Joseph P. Cooney

CHAPTER OUTLINE

Biologic Considerations
Esthetic Tissue Management
Occlusal Considerations in Restorative Therapy
Special Restorative Considerations *(e-only)*

For expanded discussions on margin placement and biologic width and esthetic tissue management as well as online-only content on special restorative considerations, please visit the companion website at www.expertconsult.com. Some figures may be out of numeric order in this printed chapter. Editors Note: An animation (slide show) has been added as a supplement to the chapter by the Editors. This was produced by My Dental Hub as a patient education tool and covers the basic elements in a conceptual manner. It is not intended to be a procedural guide for dental professionals.

The relationship between periodontal health and the restoration of teeth is intimate and inseparable. For restorations to survive long term, the periodontium must remain healthy so that the teeth are maintained. For the periodontium to remain healthy, restorations must be critically managed in several areas so that they are in harmony with their surrounding periodontal tissues. To maintain or enhance the patient's esthetic appearance, the tooth–tissue interface must present a healthy natural appearance, with gingival tissues framing the restored teeth in a harmonious manner. This chapter reviews the key areas of restorative management necessary to optimize periodontal health, with a focus on the esthetics and function of restorations.

Biologic Considerations

Margin Placement and Biologic Width

One of the most important aspects of understanding the periodontal–restorative relationship is the location of the restorative margin to the adjacent gingival tissue. Restorative clinicians must understand the role of biologic width in preserving healthy gingival tissues and controlling the gingival form around restorations. They must also apply this information in the positioning of restoration margins, especially in the esthetic zone, where a primary treatment goal is to mask the junction of the margin with the tooth.

A clinician is presented with three options for margin placement: supragingival, equigingival (even with the tissue), and subgingival.[69] The *supragingival margin* has the least impact on the periodontium. Classically, this margin location has been applied in unesthetic areas because of the marked contrast in color and opacity of traditional restorative materials against the tooth. With the advent of more translucent restorative materials, adhesive dentistry, and resin cements, the ability to place supragingival margins in esthetic areas is now a reality (Figures 67-1 and 67-2). Therefore, whenever possible, these restorations should be chosen not only for their esthetic advantages but also for their favorable periodontal impact.

The use of *equigingival margins* traditionally was not desirable because they were thought to retain more plaque than supragingival or subgingival margins and therefore result in greater gingival inflammation. There was also the concern that any minor gingival recession would create an unsightly margin display. These concerns are not valid today not only because the restoration margins can be esthetically blended with the tooth, but also because restorations can be finished easily to provide a smooth, polished interface at the gingival margin. From a periodontal viewpoint, both supragingival and equigingival margins are well tolerated.

The greatest biologic risk occurs when placing *subgingival margins*.[42] These margins are not as accessible as supragingival or equigingival margins for finishing procedures. In addition, if the margin is placed too far below the gingival tissue crest, it violates the gingival attachment apparatus.

As described in Chapter 1, the dimension of space that the healthy gingival tissues occupy between the base of the sulcus and the underlying alveolar bone is comprised of the junctional epithelial attachment and the connective tissue attachment. The combined attachment width is now identified as the *biologic width.* Most authors credit Gargiulo, Wentz, and Orban's 1961 study[18] on cadavers with the initial research establishing the dimensions of space required by the gingival tissues. They found that, in the average human, the connective tissue attachment occupies 1.07 mm of space above the crest of the alveolar bone and that the junctional epithelial attachment below the base of the gingival sulcus occupies another 0.97 mm of space above the connective tissue attachment. The combination of these two measurements, averaging approximately 1 mm each, constitutes the biologic width (Figure 67-3). Clinically, this information is applied to diagnose biologic width violations when the restoration margin is placed 2 mm or less away from the alveolar bone and the gingival tissues are inflamed with no other etiologic factors evident.

Restorative considerations frequently dictate the placement of restoration margins beneath the gingival tissue crest. Restorations may need to be extended gingivally (a) to create adequate

Figure 67-6 The left central incisor was fractured in an accident 12 months ago and restored at that time. The patient is unhappy with the appearance of the tissue surrounding the restoration (see Figures 67-7, 67-8, and 67-9).

Correcting Biologic Width Violations

Biologic width violations can be corrected either by surgically removing bone away from proximity to the restoration margin or by orthodontically extruding the tooth and thus moving the margin away from the bone. Surgery is the more rapid of the two treatment options.[57] It is also preferred if the resulting crown lengthening creates a more pleasing tooth length. Indications and contraindications for surgical crown lengthening are presented in Chapter 66 and illustrated with clinical examples. In these situations, the bone should be moved away from the margin by the measured distance of the ideal biologic width for that patient, with an additional 0.5 mm of bone removed as a safety zone.

There is a potential risk of gingival recession after removal of bone.[7] If interproximal bone is removed, there is a high likelihood of papillary recession and the creation of an unesthetic triangle of space below the interproximal contacts. If the biologic width violation is on the interproximal side, or if the violation is across the facial surface and the gingival tissue level is correct, orthodontic extrusion is indicated[27] (Figures 67-6 to 67-9). The extrusion can be performed in two ways. By applying low orthodontic extrusion force, the tooth will erupt slowly, bringing the alveolar bone and gingival tissue with it. The tooth is extruded until the bone level has been carried coronal to the ideal level by the amount that needs to be removed surgically to correct the attachment violation. The tooth is stabilized in this new position and then is treated with surgery to correct the bone and gingival tissue levels. Another option is to perform rapid orthodontic extrusion where the tooth is erupted to the desired amount over several weeks.[32] During this period, a supracrestal fiberotomy is performed circumferentially around the tooth weekly in an effort to prevent the tissue and bone from following the tooth. The tooth is then stabilized for at least 12 weeks to confirm the position of the tissue and bone, and any coronal creep can be corrected surgically.

Clinical Procedures in Margin Placement

The first step in using sulcus depth as a guide in margin placement is to manage gingival health. Once the tissue is healthy, the following three rules can be used to place intracrevicular margins:

Rule 1: If the sulcus probes 1.5 mm or less, place the restoration margin 0.5 mm below the gingival tissue crest. This is especially important on the facial aspect and will prevent a biologic width violation in a patient who is at high risk in that regard.

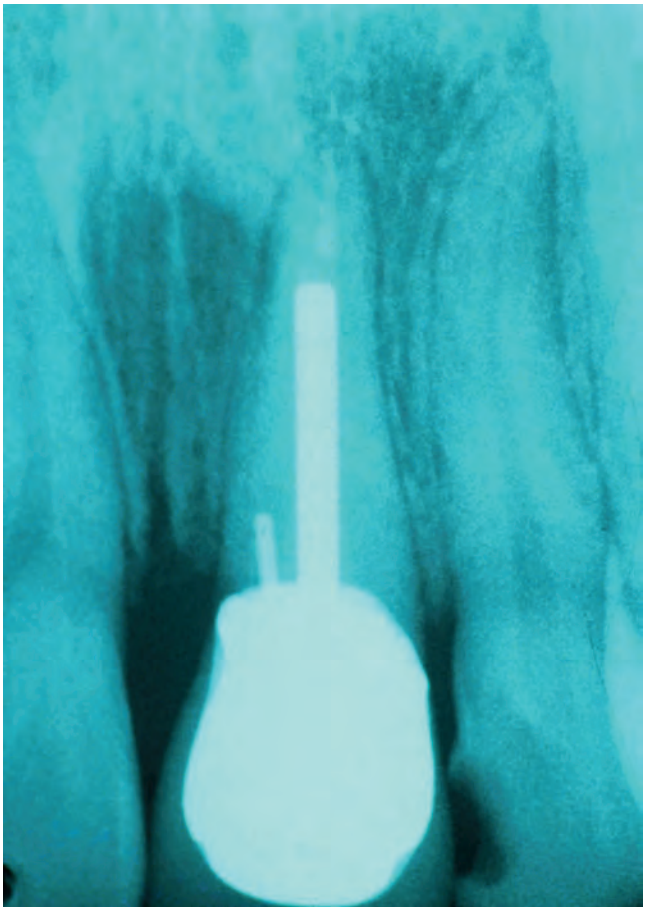

Figure 67-7 Radiograph reveals a biologic width violation on the mesial surface interproximally. Removal of interproximal bone would create an esthetic deformity. This patient is better treated with orthodontic extrusion (see Figures 67-6 and 67-8).

Figure 67-8 After orthodontic eruption. The tooth has been erupted 3 mm to move the bone and gingiva coronally 3 mm on the left central incisor. It is now possible to reposition the bone surgically to the correct level and position the gingiva to the correct level, reestablishing normal biologic width.

Rule 2: If the sulcus probes more than 1.5 mm, place the margin half the depth of the sulcus below the tissue crest. This places the margin far enough below tissue, so that it will still be covered if the patient is at higher risk of recession.

Rule 3: If a sulcus greater than 2 mm is found, especially on the facial aspect of the tooth, evaluate to see if a gingivectomy

Figure 67-9 One-year recall photograph after orthodontic extrusion, osseous surgery, and placement of a new restoration for patient in Figure 67-6. Note the excellent tissue health after the reestablishment of biologic width.

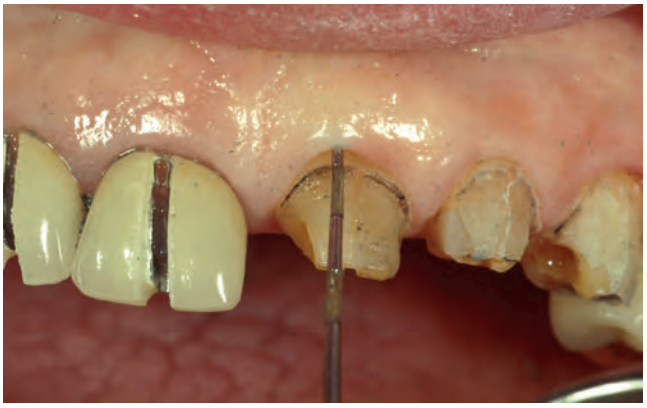

Figure 67-11 Depth from the attachment to the level of the preparation margin is greater than 3 mm. This patient in Figure 67-10 had an altered eruption pattern and a sulcus depth of more than 3 mm when these restorations were placed.

Figure 67-10 A 78-year-old woman presents with the maxillary anterior restorations placed 6 months earlier. She is unhappy with the exposed margins and notes that the margins were covered the day the restorations were placed (see Figures 67-11 to 67-14).

Figure 67-12 Two options were available to manage treatment appropriately: (a) place the original margins to half the depth of the sulcus, in which case the recession that occurred would not have exposed them, or (b) perform a gingivectomy, creating a 1- to 1.5-mm sulcus. The second option was chosen when the restorations were redone. The margins were then placed 0.5 mm below the tissue after the gingivectomy (see Figures 67-11 and 67-13).

could be performed to lengthen the teeth and create a 1.5-mm sulcus. Then the patient can be treated using Rule 1.

The rationale for Rule 3 is that deep margin placement is more difficult and the stability of the free gingival margin is less predictable when a deep sulcus exists. Reducing the sulcus depth creates a more predictable situation in which to place an intracrevicular margin. The clinician cannot be sure that the tissue will remain at the corrected level, however, because some gingival rebound can occur after gingivectomy. However, sulcular depth reduction ensures that the restorative margins will not be exposed and visible in the patient's mouth (Figures 67-10 to 67-14).

The placement of supragingival or equigingival margins is simple because it requires no tissue manipulation. With regard to overall tooth preparation, the amount reduced incisally or occlusally, facially, lingually, and interproximally is dictated by the choice of restorative materials. Before extending subgingivally, the preparation should be completed to the free gingival margin facially and interproximally. This allows the margin of the tooth preparation to be used as a reference for subgingival extension once the tissue is retracted (Figure 67-15).

Figure 67-13 At 6 weeks after the gingivectomy and preparation of the teeth. Note the tissue level and that the tissue is rebounding coronally over the margins. This is a common finding when a pure gingivectomy is done.

Figure 67-14 Four-year recall photograph after placement of the final restorations for patient in Figure 67-10. Note the tissue level has been maintained, with a sulcus depth of 2 mm on the facial surface.

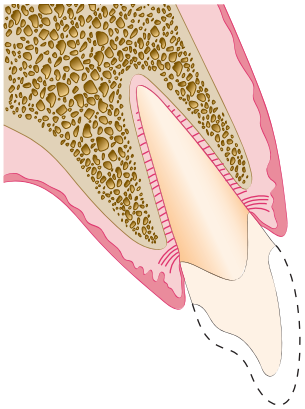

Figure 67-15 To provide a reference position for margin placement after tissue retraction, the margin of the tooth preparation is initially established level with the free gingival margin.

Tissue Retraction

Once the supragingival portion of the preparation is completed, it is necessary to extend below the tissue.[6,23] The preparation margin must now be extended to the appropriate depth in the sulcus, applying the guidelines presented previously. In this process the tissue must be protected from abrasion, which will cause hemorrhage and can adversely affect the stability of the tissue level around the tooth. Access to the margin is also required for the final impression, with a clean, fluid-controlled environment. Tissue management is achieved with gingival retraction cords using the appropriate size to achieve the displacement required. Thin, fragile gingival tissues and shallow sulcus situations usually dictate that smaller diameter cords be chosen to achieve the desired tissue displacement.

For a Rule 1 margin (sulcus depth 1.5 mm or less), the cord should be placed so that the top of the cord is located in the sulcus at the level in which the final margin is to be established, which will be 0.5 mm below the previously prepared margin (Figure 67-16). On the interproximal aspects of the tooth, the cord is usually 1.0 to 1.5 mm below the tissue height because the interproximal sulcus is often 2.5 to 3.0 mm in depth. With this initial cord in place, the preparation is extended to the top of the cord, with the bur angled to the tooth so that it does not abrade the tissue (Figure 67-17). This process protects the tissue, creates the correct axial reduction, and establishes the margin at the desired subgingival level. To create space and allow access for a final impression, it is now necessary to pack a second retraction cord. The second cord is pushed so that it displaces the first cord apically and sits between the margin and the tissue (Figure 67-18). For the final impression, only the top cord is removed, leaving the margins

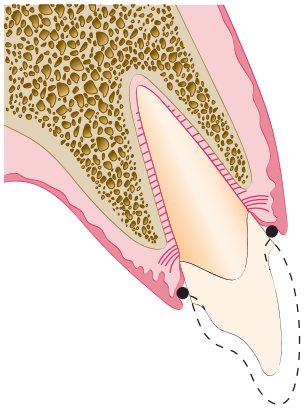

Figure 67-16 Second step in margin placement is to place a single layer of deflection cord below the previously prepared margin to the desired final margin level. Here, a single cord has been placed 0.5 mm below the previously prepared margin.

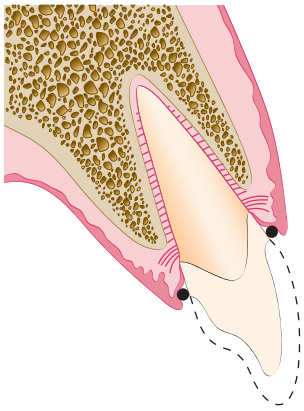

Figure 67-17 Margin of the preparation is now extended apically to the top of the retraction cord; this represents the correct placement of the margin below the previously nonreflected, free gingival margin.

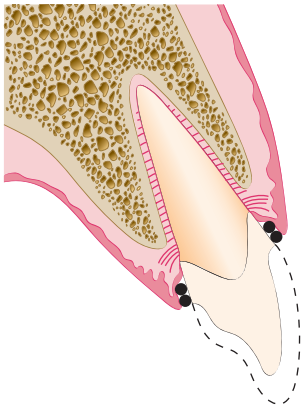

Figure 67-18 To provide space for impression material, a second impression cord is now placed on top of the first deflection cord. This impression cord is placed so that it is between the margin of the preparation and the gingiva to create adequate space for impression material after removal of the cord.

visible and accessible to be recorded with the impression material (Figure 67-19). The initial cord remains in place in the sulcus until the provisional restoration is completed.

As an alternative to additional retraction cords, electrosurgery can be used to remove any overlying tissue in the retraction process. A fine-wire electrode tip is held parallel to the tooth and against the margin in the sulcus and moved through the overhanging tissue, opening up the margin and the retraction cord to visual access (Figures 67-20 to 67-23). The electrosurgery tip sits on top of the retraction cord in place in the sulcus. This controls the vertical position of the tip and results in the removal of the least tissue needed for access.

For Rule 2 situations in which the sulcus is deeper, two larger-diameter cords are used to deflect the tissue before extending the margin apically (Figures 67-24 to 67-26). The top of the second cord is placed to identify the final margin location at the correct distance below the previously prepared margin, which was at the gingival tissue crest level. The margin is lowered to the top of the second cord (Figure 67-27), then a third cord is placed in preparation for the impression (Figures 67-28 and 67-29). In the patient

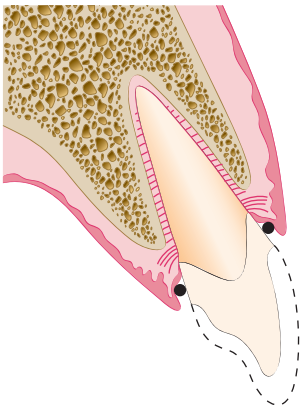

Figure 67-19 Ideal situation after removal of impression cord. The deflection cord is still in place maintaining the open sulcus but has been displaced apically another 0.5 mm by the placement of the impression cord, exposing tooth structure apical to the margin so that it can be captured in the impression.

Figure 67-20 Deflection cord and impression cord are in place. The soft tissue is falling over the margins of the preparation. In this situation, if the impression cord were removed, the impression would not capture the margins in the areas in which the tissue is overhanging.

Figure 67-21 Overhanging tissue has been removed and space created for the impression material with electrosurgery. Note that the deflection cord and the impression cord are still in place. The impression cord is now visible completely around the tooth, allowing easy access for the impression material to the margin after removal of the impression cord.

Figure 67-22 Using electrosurgery, the fine-wire electrode tip is held parallel to the tooth preparation and rests on the cord as the tip is moved around the tooth.

Figure 67-23 After removal of the impression cord, an adequate space is created for the impression material, with no soft tissue overhanging the margins to trap or tear the impression material. Note the first cord, or deflection cord, is still in place.

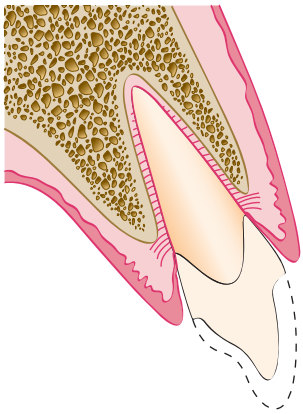

Figure 67-24 First step in margin placement for the patient with altered eruption or a deep sulcus is to prepare to the existing free gingival margin, as in the "Rule 1" patient (see text).

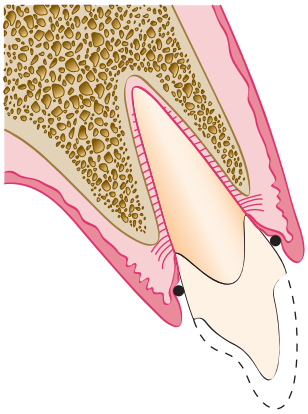

Figure 67-25 Second step for the patient with altered eruption is to place the deflection cord. Note that the placement of a single deflection cord does not provide adequate deflection of the tissue to allow the margin to be carried below tissue without abrading the gingiva with the bur.

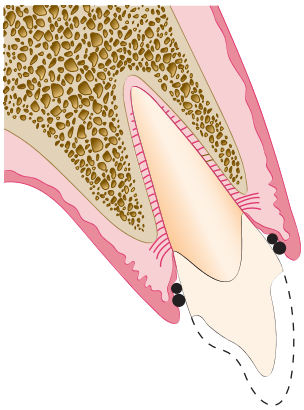

Figure 67-26 Third step for the patient with altered eruption and a deep sulcus is to place a second, larger-diameter deflection cord on top of the first deflection cord. Combined, these two cords allow adequate deflection to open up the sulcus so that the margin can be carried below tissue without abrading the gingiva.

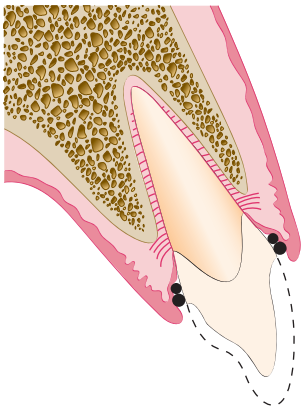

Figure 67-27 Preparation is now extended to the top of the second deflection cord, finalizing margin location.

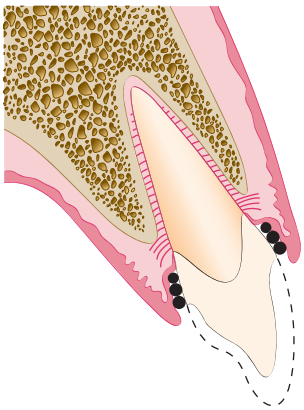

Figure 67-28 After extension of the margin to the top of the deflection cord, a third layer of cord is applied that will act as the impression cord. This impression cord should be placed so that it fits between the free gingival margin and the margin of the preparation. Its placement will also apically displace the two previously positioned deflection cords.

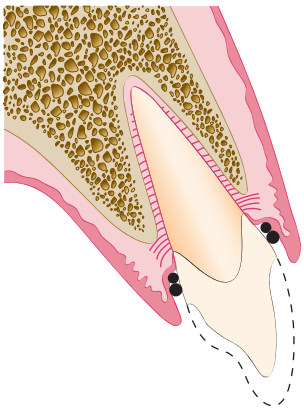

Figure 67-29 Removal of the impression cord creates an adequate space for the impression material to capture the margin and 0.5 mm of tooth structure below the margin in which the impression cord had displaced the first two cords.

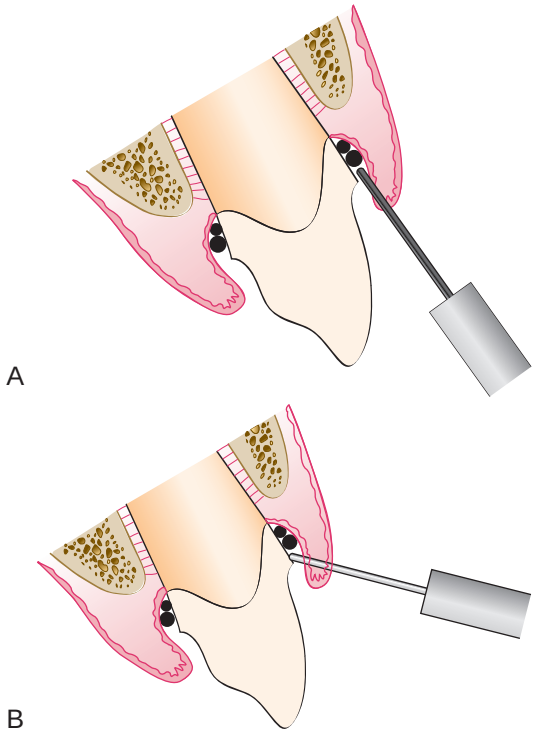

Figure 67-30 If it is necessary to use electrosurgery, either in the normal or altered-eruption patient, the correct inclination of the electrosurgery tip is important. A, Electrosurgery tip being held parallel to the preparation and resting on the previously placed retraction cord. This removes a minimal amount of tissue, and the presence of the retraction cord protects the attachment from the electrosurgery. **B,** Incorrect inclination of electrosurgery tip. The tip is leaning away from the preparation. This inclination results in excess tissue removal.

with a deep sulcus in which the margin may be 1.5 to 2.0 mm below the tissue crest, electrosurgery is often required to remove overhanging tissue. To avoid altering the gingival tissue height, it is important to hold the electrosurgery tip parallel to the preparation (Figure 67-30).

Figure 67-1 With the advent of adhesive dentistry and ultra-thin ceramic veneers, it now is possible to prepare restorations equigingival without visible margins. The preparations for six porcelain veneers with the margins placed at the level of tissue are shown.

Figure 67-2 The completed veneers from Figure 67-1. Note the invisible gingival finish line, even though the margin has not been carried below tissue.

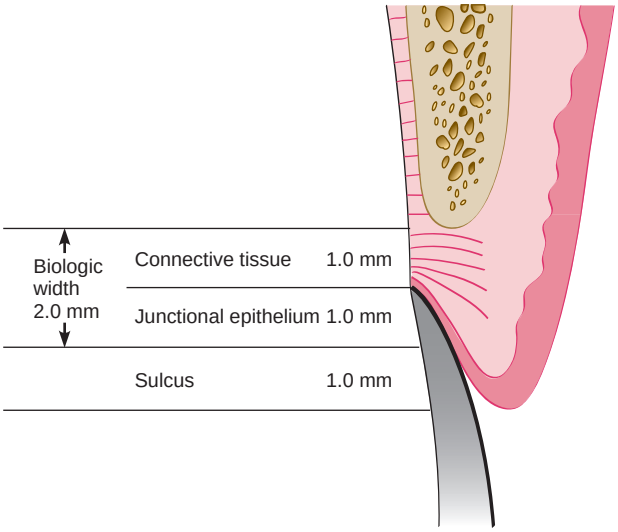

Figure 67-3 Average human biologic width: Connective tissue attachment 1 mm in height; junctional epithelial attachment 1 mm in height; sulcus depth of approximately 1 mm. The combined connective tissue attachment and junctional epithelial attachment, or biologic width, equals 2 mm.

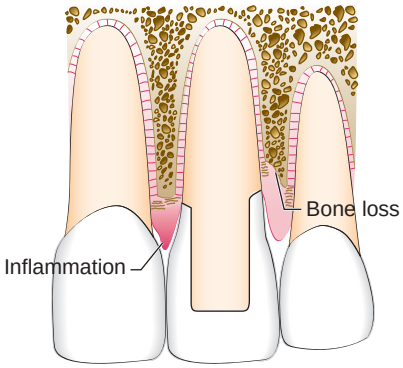

Figure 67-4 Ramifications of a biologic width violation if a restorative margin is placed within the zone of the attachment. On the mesial surface of the left central incisor, bone has not been lost, but gingival inflammation occurs. On the distal surface of the left central incisor, bone loss has occurred, and a normal biologic width has been reestablished.

resistance and retentive form in the preparation, (b) to make significant contour alterations because of caries or other tooth deficiencies, or (c) to mask the tooth–restoration interface by locating it subgingivally. When the restoration margin is placed too far below the gingival tissue crest, it impinges on the gingival attachment apparatus and create a violation of biologic width.[49] Two different responses can be observed from the involved gingival tissues (Figure 67-4).

One possibility is that bone loss of an unpredictable nature and gingival tissue recession occurs as the body attempts to recreate room between the alveolar bone and the margin to allow space for tissue reattachment. This is more likely to occur in areas in which the alveolar bone surrounding the tooth is very thin in width. Trauma from restorative procedures can play a major role in causing this fragile tissue to recede. Other factors that may impact the likelihood of recession include (a) whether the gingiva is thick and fibrotic or thin and fragile and (b) whether the periodontium is highly scalloped or flat in its gingival form. It has been found that highly scalloped, thin gingiva is more prone to recession than a flat periodontium with thick fibrous tissue.[47]

The more common finding with deep margin placement is that the bone level appears to remain unchanged, but gingival inflammation develops and persists. To restore gingival tissue health, it is necessary to establish space clinically between the alveolar bone and the margin. This can be accomplished either by surgery to alter the bone level or by orthodontic extrusion to move the restoration margin farther away from the bone level.

Biologic Width Evaluation

Radiographic interpretation can identify interproximal violations of biologic width. However, with the more common locations on the mesiofacial and distofacial line angles of teeth, radiographs are not diagnostic because of tooth superimposition. If a patient experiences tissue discomfort when the restoration margin levels are being assessed with a periodontal probe, it is a good indication that the margin extends into the attachment and that a biologic width violation has occurred.

A more positive assessment can be made clinically by measuring the distance between the bone and the restoration margin using a sterile periodontal probe. The probe is pushed through the anesthetized attachment tissues from the sulcus to the underlying bone. If this distance is less than 2 mm at one or more locations, a diagnosis of biologic width violation can be confirmed. This assessment

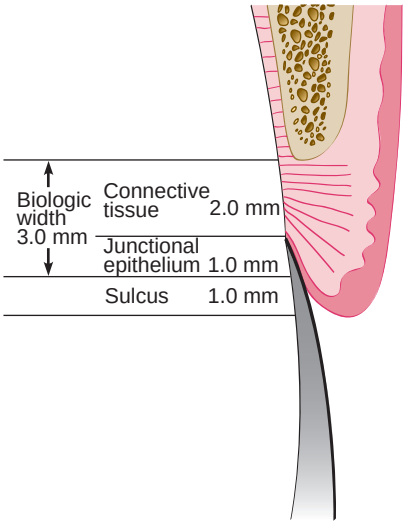

Figure 67-5 Possible variations exist in biologic width. Connective tissue attachments and junctional epithelial attachments may be variable. In this example, the connective tissue attachment is 2 mm in height, the junctional epithelial attachment 1 mm in height, and the sulcus depth 1 mm, for a combined total tissue height above bone of 4 mm. However, the biologic width is 3 mm. This is just one variation that can occur from the average depicted in Figure 67-3.

is completed circumferentially around the tooth to evaluate the extent of the problem. However, biologic width violations can occur in some patients in whom the margins are located more than 2 mm above the alveolar bone level.[22] In 1994, Vacek et al[70] also investigated the biologic width phenomenon. Although their average width finding of 2 mm was the same as that previously presented by Gargiulo et al,[18] they also reported a range of different biologic widths that were patient specific. They reported biologic widths as narrow as 0.75 mm in some individuals, whereas others had biologic widths as tall as 4.3 mm (Figure 67-5).

This information dictates that specific biologic width assessment should be performed for each patient to determine if the patient needs additional biologic width, in excess of 2 mm, for restorations to be in harmony with the gingival tissues. The biologic, or attachment, width can be identified for the individual patient by probing to the bone level (referred to as "sounding to bone") and subtracting the sulcus depth from the resulting measurement. This measurement must be done on teeth with healthy gingival tissues and should be repeated on more than one tooth to ensure an accurate assessment. The technique allows the variations in sulcus depths found in individual patients to be assessed and factored into the diagnostic evaluation. The information obtained is then used for definitive diagnosis of biologic width violations, the extent of correction needed, and the parameters for placement of future restorations.

Margin Placement Guidelines

When determining where to place restorative margins relative to the periodontal attachment, it is recommended that the patient's existing sulcular depth be used as a guideline in assessing the biologic width requirement for that patient. The base of the sulcus can be viewed as the top of the attachment, and therefore the clinician accounts for variations in attachment height by ensuring that the margin is placed in the sulcus and not in the attachment.[4,36,37,56] The variations in sulcular probing depth are then used to predict how deep the margin can safely be placed below the gingival crest. With shallow probing depths (1.0 to 1.5 mm), extending the preparation more than 0.5 mm subgingivally risks violating the attachment. This assumes that the periodontal probe will penetrate into the junctional epithelial attachment in healthy gingiva an average of 0.5 mm. With shallow probing depths, future recession is unlikely because the free gingival margin is located close to the top of the attachment. Deeper sulcular probing depths provide more freedom in locating restoration margins farther below the gingival crest. In most circumstances, however, the deeper the gingival sulcus, the greater is the risk of gingival recession.

Provisional Restorations

Three critical areas must be effectively managed to produce a favorable biologic response to provisional restorations.[3,74] The marginal fit, crown contour, and surface finish of the interim restorations must be appropriate to maintain the health and position of the gingival tissues during the interval until the final restorations are delivered. Provisional restorations that are poorly adapted at the margins, that are overcontoured or undercontoured, and that have rough or porous surfaces can cause inflammation, overgrowth, or recession of gingival tissues. The outcome can be unpredictable, and unfavorable changes in the tissue architecture can compromise the success of the final restoration.

Marginal Fit

Marginal fit has clearly been implicated in producing an inflammatory response in the periodontium. It has been shown that the level of gingival inflammation can increase corresponding with the level of marginal opening.[15] Margins that are significantly open (several tenths of a millimeter) are capable of harboring large numbers of bacteria and may be responsible for the inflammatory response seen. However, the quality of marginal finish and the margin location relative to the attachment are much more critical to the periodontium than the difference between a 20-µm fit and a 100-µm fit.[42,46,59]

Crown Contour

Restoration contour has been described as extremely important to the maintenance of periodontal health.[26,75] Ideal contour provides access for hygiene, has the fullness to create the desired gingival form, and has a pleasing visual tooth contour in esthetic areas. Evidence from human and animal studies clearly demonstrates a relationship between overcontouring and gingival inflammation, whereas undercontouring produces no adverse periodontal effect.[48,51] The most frequent cause of overcontoured restorations is inadequate tooth preparation by the dentist, which forces the technician to produce a bulky restoration to provide room for the restorative material. In areas of the mouth in which esthetic considerations are not critical, a flatter contour is always acceptable.

Subgingival Debris

Leaving debris below the tissue during restorative procedures can create an adverse periodontal response. The cause can be retraction cord, impression material, provisional material, or either temporary or permanent cement.[55] The diagnosis of debris as the cause of gingival inflammation can be confirmed by examining the sulcus surrounding the restoration with an explorer, removing any foreign bodies, and then monitoring the tissue response. It may be necessary to provide tissue anesthesia for patient comfort during the procedure.

Hypersensitivity to Dental Materials

Inflammatory gingival responses have been reported related to the use of nonprecious alloys in dental restorations.[52] Typically, the

responses have occurred to alloys containing nickel, although the frequency of these occurrences is controversial.[50] Hypersensitivity responses to precious alloys are extremely rare, and these alloys provide an easy solution to the problems encountered with the nonprecious alloys. More importantly, tissues respond more to the differences in surface roughness of the material rather than to the composition of the material.[1,66] The rougher the surface of the restoration subgingivally, the greater are the plaque accumulation and gingival inflammation. In clinical research, porcelain, highly polished gold, and highly polished resin all show similar plaque accumulation. Regardless of the restorative material selected, a smooth surface is essential on all materials subgingivally.

Esthetic Tissue Management

Managing Interproximal Embrasures

Current restorative and periodontal therapy must consider a good esthetic result, especially in the maxillary anterior "esthetic zone." As discussed in Chapter 63, the interproximal papilla is a very important part in creating this esthetic result. The interproximal embrasure created by restorations and the form of the interdental papilla have a unique and intimate relationship.[61,62] The ideal interproximal embrasure should house the gingival papilla without impinging on it and should also extend the interproximal tooth contact to the top of the papilla so that no excess space exists to trap food and to be esthetically displeasing.

Papillary height is established by the level of the bone, the biologic width, and the form of the gingival embrasure. Changes in the shape of the embrasure can impact the height and form of the papilla. The tip of the papilla behaves differently than the free gingival margin on the facial aspect of the tooth. Whereas the free gingival margin averages 3 mm above the underlying facial bone, the tip of the papilla averages 4.5 to 5.0 mm above the interproximal bone (Figure 67-31). This means that if the papilla is farther above the bone than the facial tissue but has the same biologic width, the interproximal area will have a sulcus 1.0 to 1.5 mm deeper than that found on the facial surface.

Van der Veldon[72] completely removed healthy papillae to the bone level and found that they routinely regenerated 4.0 to 4.5 mm of total tissue above bone, with an average sulcus depth of 2.0 to 2.5 mm. The height above bone that the papilla strives to maintain was indirectly confirmed by Tarnow et al,[67] who studied the relationship of the papilla between the interproximal contact and the underlying bone. When the gingival level of the interproximal tooth contacts measured 5 mm or less to the alveolar bone, the papilla always filled the space. When the contact was 6 mm from bone, only 56% of the papillae could fill the space. Finally, when the contact was 7 mm from bone, only 37% of the papillae could fill the spaces.

Knowing that there is individual variability to the required biologic width, this information relative to the papilla is applied by locating the lowest point of the interproximal contact in relation to the top of the epithelial attachment. The ideal contact should be 2 to 3 mm coronal to the attachment, which coincides with the depth of the average interproximal sulcus. As in assessing the facial tissues for margin location, this technique requires that the tissue is healthy to allow accurate probing. If the sulcus measures greater than 3 mm, there is some risk of papillary recession with restorative procedures.

The clinician most frequently confronts a normal or shallow sulcus with a papilla that appears too short rather than a tall papilla with a deep sulcus. Management of this situation is best approached by viewing the papilla as a balloon of a certain volume that sits on the attachment. This balloon of tissue has a form and height dictated by the gingival embrasure of the teeth. With an embrasure that is too wide, the balloon flattens out, assumes a blunted shape, and has a shallow sulcus (Figure 67-32).

If the embrasure is the ideal width, the papilla assumes a pointed form, has a sulcus of 2.5 to 3.0 mm, and is healthy. If the embrasure is too narrow, the papilla may grow out to the facial and lingual, form a col, and become inflamed. This information is applied when evaluating an individual papilla with an open embrasure. The papilla in question is compared to the adjacent papillae. If the papillae are all on the same level, and if the other areas do not have open embrasures, the problem is one of gingival embrasure form. If the papilla in the area of concern is apical to the adjacent papillae, however, the clinician should evaluate the interproximal bone levels. If the bone under that papilla is apical to the adjacent bone levels, the problem is caused by bone loss. If the bone is at the same level, the open embrasure is caused by the embrasure form of the teeth and not a periodontal problem with the papilla.

Pontic Design

Classically, there are four options to consider in evaluating pontic design: sanitary, ridge-lap, modified ridge-lap, and ovate designs (Figure 67-37). Regardless of design, the pontic should provide an

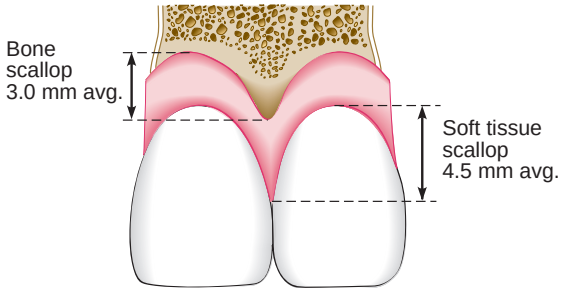

Figure 67-31 Comparison of the behavior of the interproximal papilla relative to bone and the free gingival margin relative to bone in the average human. There is a 3-mm scallop from the facial bone to the interproximal bone. However, on average, a 4.5- to 5.0-mm gingival scallop exists between the facial tissue height and the interproximal papilla height. This extra scallop of 1.5 to 2.0 mm of gingiva compared with bone is the result of the extra soft-tissue height above the attachment interproximally.

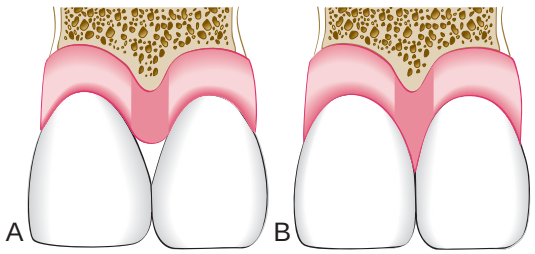

Figure 67-32 Relationship between gingival embrasure volume and papillary form. A, gingival embrasure of the teeth is excessively large as the result of a tapered tooth form. Because of the large embrasure form, the volume of tissue sitting on top of the attachment is not molded to the shape of a normal papilla but rather has a blunted form and a shallower sulcus. **B,** Ideal tooth form in which the same volume of tissue sits on top of the attachment as in **A.** Because of the more closed embrasure form from the teeth in **B,** however, the papilla completely fills the embrasure and has a deeper sulcus, averaging 2.5 to 3.0 mm. Note that the ideal contact position is 3 mm coronal to the attachment.

Correcting Open Gingival Embrasures Restoratively

There are two causes of open gingival embrasures: (a) the papilla is inadequate in height because of bone loss or (b) the interproximal contact is located too high coronally. If a high contact has been diagnosed as the cause of the problem, there are two potential reasons. If the root angulation of the teeth diverges, the interproximal contact is moved coronally, resulting in the open embrasure. However, if the roots are parallel, the papilla form is normal, and an open embrasure exists, then the problem is probably related to tooth shape, specifically an excessively tapered form. Restorative dentistry can correct this problem by moving the contact point to the tip of the papilla. To accomplish this, the margins of the restoration must be carried subgingivally 1.0 to 1.5 mm, and the emergence profile of the restoration is designed to move the contact point toward the papilla while blending the contour into the tooth below the tissue (Figure 67-33). This can be accomplished easily with direct bonded restorations because the soft tissue can clearly be seen (Figures 67-34 to 67-36). For indirect restorations, the desired restoration contours and embrasure form should be established in the provisional restorations, and the gingival tissues are allowed to adapt for 4 to 6 weeks before the tissue contour information is relayed to the laboratory for use in the final restorations.

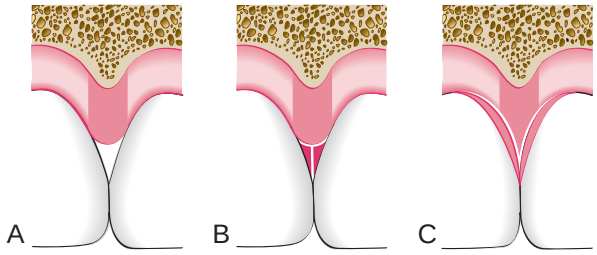

Figure 67-33 Methods of altering gingival embrasure form. A, Typical open gingival embrasure caused by excessively tapered tooth form. **B,** Common method employed by restorative dentists to correct the embrasure, in which material is added supragingivally. This closes the embrasure by moving the contact to the tip of the papilla but results in overhangs that cannot be cleaned using dental floss. Removing these overhangs restoratively reopens the embrasure. **C,** Correct method of closing the gingival embrasure, in which the margins of the restoration are carried 1.0 to 1.5 mm below the tip of the papilla. Note that this does not encroach on the attachment because the average interproximal sulcus probes 2.5 to 3.0 mm. This allows easy cleaning because of the convex profile. It also reshapes the papilla to a more pleasing profile esthetically.

Figure 67-34 This patient has parallel roots, has recently completed orthodontic therapy, and is unhappy with the open gingival embrasure between her central incisors. An evaluation of papillary height reveals that all are at an equal level. This can only mean that the open embrasure is the result of an overly tapered tooth form (see Figures 67-35 and 67-36).

Managing Gingival Embrasure Form for Patients with Gingival Recession

Management of the gingival embrasure form for patients who have experienced gingival recession varies, depending on whether the treatment is in the anterior or posterior regions of the mouth.[30] In esthetic areas, it is necessary to carry the interproximal contacts apically toward the papilla to eliminate the presence of large, open embrasures. With multiple-unit restorations, it is also possible with tissue-colored ceramics to bake porcelain papillae directly on the restoration. In the posterior areas where the interroot widths are significantly greater, it is often impossible to carry the proximal contacts to contact the tissue without creating large overhangs on the restorations. In these situations, the contact should be moved far enough apically to minimize any large food traps while still leaving an embrasure of a convenient size to be accessed with an interdental brush for hygiene. It should be noted that developing excessively long interproximal contacts, whether on anterior or posterior teeth, always creates rectangular, somewhat unesthetic, tooth forms.

Figure 67-35 One method of correctly altering tooth form of patient in Figure 67-34. A metal matrix band has been shaped to the desired tooth form and placed 1.0 to 1.5 mm below the tip of the papilla. Restorative material then was added to the tooth against the matrix band, forming the new mesial surface of the left central incisor.

Figure 67-36 One-year recall photograph after restoring the mesial surfaces of the right and left central incisors, moving the proximal contact to the tip of the papilla and extending the restorations 1.0 to 1.5 mm below the papilla, blending them into the tooth and making an easily cleaned area (see Figures 67-34 and 67-35).

Ridge Modification Procedures for Ideal Pontic Contours

When the ridge is being surgically modified, it is important to know the thickness of soft tissue above the bone. This measurement is obtained by probing to the bone through the anesthetized tissue. If the tissue is removed to less than 2 mm in thickness, significant rebound in ridge height may occur. If it is necessary to reduce the tissue height to less than 2 mm above the bone to create the desired pontic form, some bone will need to be removed to achieve the desired result.

It is important when considering an ovate pontic to realize that certain soft-tissue ridge parameters must exist to optimize the ovate pontic form. First, the ridge height needs to match the ideal height of the interproximal papillae where interproximal embrasures are planned, either between pontics or next to abutment teeth. Second, the gingival margin height must also be at the ideal level, or the pontic will appear too long. Third, the ridge tissue must be facial to the ideal cervical facial form of the pontic so that the pontic can emerge from the tissue. If any of these three areas is inadequate, some form of ridge augmentation is needed to produce a ridge that can have an adequate receptor site created (Figure 67-40). Any ridge augmentation procedures should be completed before, or in conjunction with, fabricating an ovate pontic. When constructing the final restorations, the contours of the developed ovate pontic receptor site can be conveyed to the laboratory by capturing a soft-tissue impression 4 to 6 weeks after the site has been created.

The ovate pontic can serve another important periodontal function by maintaining the interdental papilla next to abutment teeth after extraction.[61] When a tooth is removed, the gingival embrasure form is lost. The normal response of the papilla to this loss of embrasure form is to recede 1.5 to 2.0 mm, which corresponds to the additional soft tissue that exists above bone on the interproximal versus the facial aspect. However, this recession can be prevented. By inserting the correct pontic form 2.5 mm into the extraction site the day the tooth is removed, the gingival embrasure form and papilla can be maintained. At 4 weeks, the 2.5-mm extension can be reduced to a 1.0- to 1.5-mm extension to facilitate hygiene. This procedure can maintain the papilla next to the abutment teeth as long as the bone on the abutment tooth is at a normal level (Figures 67-41 to 67-48).

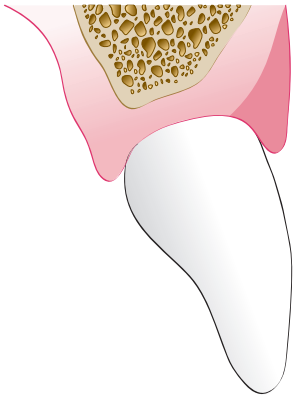

Figure 67-40 Ridge considerations when an ovate pontic is desired. For an ovate pontic to be properly created, the soft-tissue ridge must be labial to the desired cervical portion of the pontic. When the pontic is facial to the ridge, it is not possible to create what appears to be a "free gingival margin" correctly. The shaded area represents the necessary amount of tissue that would be augmented to produce an ideal ovate pontic in this particular site.

The "full ridge-lap pontic" is an outdated design that straddles the convexity of the ridge buccolingually and creates an undersurface that is entirely concave and cannot be cleaned. It is not recommended for use in any situations. However, a *modified ridge-lap pontic* can be an acceptable design if inadequate ridge exists to create an ovate pontic. With the modified ridge-lap design, the pontic follows the convexity of the ridge on the facial aspect but stops on the lingual crest of the ridge without extending down the lingual side of the ridge. Although the facial aspect of the undersurface has a concave shape, the more open lingual form allows adequate access for oral hygiene.

Figure 67-41 Patient who will have the right central incisor extracted because of periodontal disease. The patient is choosing to have a fixed partial denture rather than an implant as the method of replacement. An ovate pontic will be used to maintain the papillary form after the removal of this central incisor (see Figures 67-42 to 67-48).

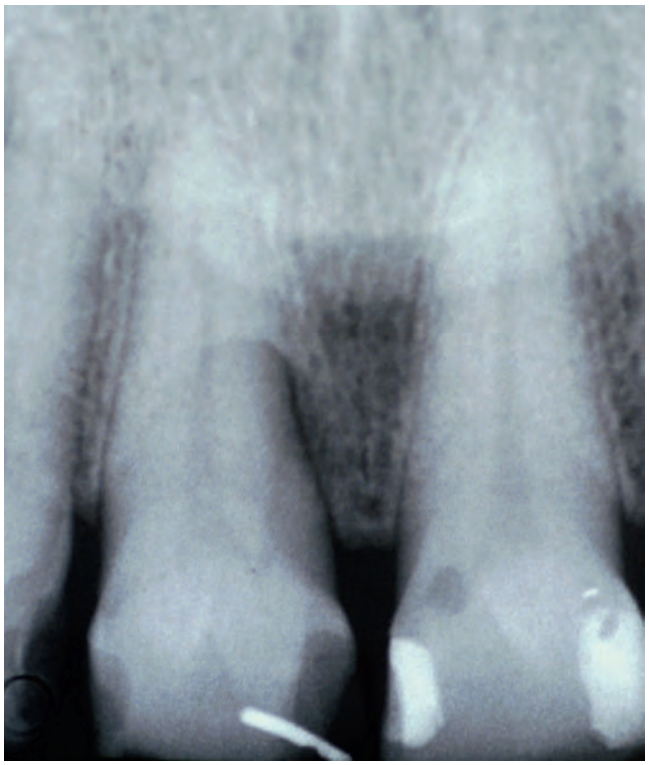

Figure 67-42 Note radiographic appearance of a palatal well caused by a deep palatal groove on this right central incisor of patient in Figure 67-41. Two attempted periodontal surgeries have failed to correct this, and it still probes 10 mm with suppuration.

Figure 67-43 Because the patient in Figure 67-41 desired to alter the esthetics of her remaining anterior teeth, all the anterior teeth were prepared before removal of the right central incisor.

Figure 67-44 The key to maintenance of the interproximal papilla is that the ovate pontic extend 2.5 mm into the extraction site on the day of extraction. This will maintain gingival embrasure form and therefore maintain interproximal papillary height.

Figure 67-45 Note that when the provisional restoration is seated on the day of the extraction, 2.5 mm of the pontic extends upward into the extraction socket. Also note the open gingival embrasures present to allow space for the papillae to rebound coronally.

Figure 67-46 Nine months after placement of the provisional restoration. (At 4 weeks after placement, the pontic was shortened to extend 1.5 mm into the extraction site to facilitate oral hygiene.) Note maintenance of papillary form and free gingival margin height, predictable in this patient because she has excellent interproximal and facial bone.

Figure 67-47 Ovate pontic site after removal of the provisional restoration and before final impressions. Note that the papillary form has been maintained because of the ovate pontic maintaining gingival embrasure volume.

Figure 67-48 Two-year recall photograph of the final fixed prosthesis of patient in Figure 67-41. Note how the final ovate pontic also has maintained papillary form.

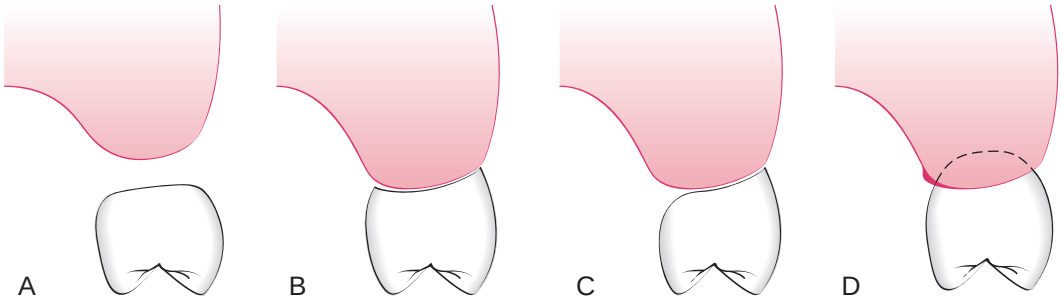

Figure 67-37 Four options to designing the shape of a pontic. A, Sanitary pontic. tissue surface of the pontic is 3 mm from the underlying ridge. **B,** Ridge-lap pontic. Tissue surface of the pontic straddles the ridge in saddlelike fashion. The entire tissue surface of the ridge-lap pontic is convex and very difficult to clean. **C,** Modified ridge-lap pontic. Tissue surface on the facial is concave, following the ridge. However, the lingual saddle has been removed to allow access for oral hygiene. **D,** Ovate pontic. The pontic form fits into a receptor site within the ridge. This allows the tissue surface of the pontic to be convex and also optimizes esthetics.

occlusal surface that stabilizes the opposing teeth, allows for normal mastication, and does not overload the abutment teeth. The restorative material for all four designs can be glazed porcelain, polished gold, or polished resin. The biologic response of the tissue in contact with the restoration is no different in regard to of the material chosen, as long as it has a smooth surface finish.[25,53,63]

The key differences between the four pontic designs relate to the esthetics and access for hygiene procedures. The primary method for cleaning the undersurface of pontics is to draw dental floss mesiodistally along the undersurface. The shape of this undersurface determines the ease with which plaque and food debris can be removed in the process. The sanitary and ovate pontics have convex undersurfaces, which makes them easiest to clean. The ridge-lap and modified ridge-lap designs have concave surfaces, which are more difficult to access with the dental floss. Although the sanitary pontic design provides the easiest access for hygiene procedures, it is rarely used because of its unesthetic form and a variable acceptance of the open contour by patients.

The ovate pontic is the ideal pontic form.[61] It is created by forming a receptor site in the edentulous ridge with a diamond bur or by electrosurgery. The site is shaped to create either a flat or a concave contour so that when the pontic is created to adapt to the site, it will have a flat or convex outline. The depth of the receptor site depends on the esthetic requirements of the pontic. In highly esthetic areas such as the maxillary anterior region, it is necessary to create a receptor area that is 1.0 to 1.5 mm below the tissue on the facial aspect. This creates the appearance of a free gingival margin and produces optimal esthetics (Figure 67-38). This site can then be tapered to the height of the palatal tissue to facilitate hygiene access from the palatal side. In the posterior areas, a deep receptor site can complicate hygiene access. In these situations, the ideal site has the facial portion of the pontic at the same level as the ridge, and then the site is created as a straight line to the lingual side of the pontic. This removes the convexity of the ridge and produces a flat, easily cleanable tissue surface on the pontic (Figure 67-39).

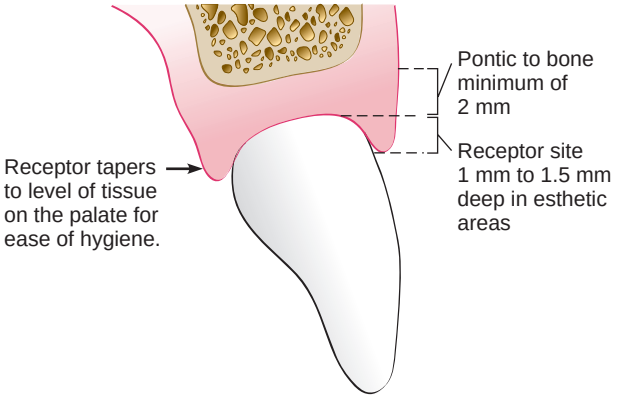

Figure 67-38 Ideal shape and form of an ovate pontic in the esthetic area. The receptor site has been created 1.0 to 1.5 mm apical to the free gingival margin on the facial aspect. This creates the illusion of the pontic erupting from the tissue. On the palatal side, the pontic is tapered so that the receptor site is not extended below tissue; this allows easier access for oral hygiene. Note that when the receptor site is created, the bone must be a minimum of 2 mm from the most apical portion of the pontic.

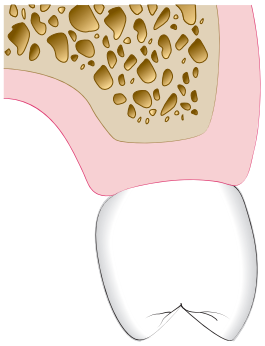

Figure 67-39 Option for creating an ovate pontic receptor site in less esthetic areas of the mouth. Rather than creating the receptor site so that the pontic extends into the ridge, it is possible to create a flattened receptor site in which the pontic sits flush with the ridge. This facilitates oral hygiene.

Occlusal Considerations in Restorative Therapy

The biology of occlusion and related clinical evaluation procedures are presented in detail in Chapter 49. The importance of occlusal trauma as a factor in periodontal disease and its role in orofacial pain have been deemphasized in numerous papers (see references 8, 14, 34, 35, 44, 45, 54, 65, and 71). However, the role that occlusion plays in restorative dentistry has been reemphasized. The increased use of dental implants and nonmetallic cosmetic restorations has resulted in greater concern over force management. These restorations are more sensitive to occlusal trauma, with subsequent structural failure, than are traditional restorations on teeth. Consequently, for the restorative dentist wanting a high degree of predictability in the final result, understanding occlusion is critical. The

clinician must know how to create an occlusion, with the following guidelines as a goal:

1. There should be even, simultaneous contacts on all teeth during centric closure. This distributes the force of closure over all the teeth instead of the few teeth that may touch first.
2. When the mandible moves from centric closure, some form of canine or anterior guidance is desirable, with no posterior tooth contacts. This combination of anterior guidance and posterior disclusion reduces the ability of the elevator muscles to contract and distributes the force of the movement onto the anterior teeth, which receive less force because of the Class III lever system being applied in this situation. It has been shown that, as a result of the Class III lever action, the anterior teeth receive approximately one-ninth the force of a second molar.[24,60]
3. The anterior guidance needs to be in harmony with the patient's neuromuscular envelope of function. Harmony of this relationship is demonstrated by a lack of fremitus and mobility on the anterior teeth, by the ability of the patient to speak clearly and comfortably, and by the patient's general sense of comfort with the overbite, overjet, and guidance created during chewing and when holding the head upright.
4. The occlusion should be created at a vertical dimension that is stable for the patient. It is generally accepted that the patient's existing vertical dimension is at equilibrium between the eruptive forces of the teeth and the repetitive contracted length of the elevator muscles. It has been demonstrated that vertical dimension can be altered with no sense of pain from muscles and joints.[8,10,21,29] However, if this alteration lengthens the pterygomasseteric sling beyond its ability to adapt, the patient will not maintain the vertical change and will close the occlusal vertical dimension back down by intruding the teeth.[11,33,39-41]
5. When managing a pathologic occlusion or when restoring a complete occlusion, the clinician needs to work with a repeatable condylar reference position. Centric relation, defined as the most superior condylar position, provides such a starting point.[20] Centric relation has been shown to be reproducible over multiple appointments, allowing the clinician to create the occlusion indirectly on an articulator and return it to the same reference position in the mouth.[13,38,43,73] It is the only position that has been shown to shut off lateral pterygoid muscle contraction.[19] Because it is a border position, any mandibular movement will result in the condyle moving inferiorly. Therefore, centric relation is the only position from which an interference-free occlusion can be created.

To manage the occlusion as previously described, the clinician must be able to make accurate casts, use a facebow, and create centric relation records so that the information can be transferred to a suitable articulator. Although the details of these procedures are beyond the scope of this chapter, they are a routine part of any restorative treatment plan and must be mastered for the clinician to achieve predictable, long-term restorative success. The reader is referred to Chapter 50 for a more comprehensive overview of occlusal evaluation and therapy.

Suggested Readings

Chiche GJ, Pinault A: *Esthetics of anterior fixed prosthodontics*, Chicago, 1994, Quintessence.

Felton DA, Kanoy Be, Bayne SC, et al: Effect of in vivo crown margin discrepancies on periodontal health. *J Prosthet Dent* 65:357, 1991.

Günay H, Seeger A, Tschernitschek H, et al: Placement of the preparation line and periodontal health: a prospective 2-year clinical study. *Int J Periodont Restor Dent* 20:173, 2000.

Kois JC, Spear FM: Periodontal prosthesis: creating successful restorations. *J Am Dent Assoc* 123:108, 1992.

Rufenache CR: Fundamentals of esthetics, Chicago, 1990, Quintessence.

Spear FM: Maintenance of the interdental papilla following anterior tooth removal. *Pract Periodontics Aesthet Dent* 11:21, 1999.

Studer S, Zellweger U, Scharer P: The esthetic guidelines of the mucogingival complex for fixed prosthodontics. *Pract Periodontics Aesthet Dent* 8:333, 1996.

Tarnow DP, Magner AW, Fletcher P: The effects of the distance from the contact point to the crest of bone on the presence or absence of the interproximal dental papilla. *J Periodontol* 63:995, 1992.

Vacek JS, Gher ME, Assad DA, et al: The dimensions of the human dentogingival junction. *Int J Periodont Restor Dent* 14:155, 1994.

Van der Veldon U: Regeneration of the interdental soft tissue following denudation procedures. *J Clin Periodontol* 9:455, 1982.

References

References for this chapter are found on the companion website www.expertconsult.com.

Special Restorative Considerations

Root-Resected Teeth

Although the availability of implant therapy has greatly reduced the frequency with which root-amputated teeth are saved, restoration of root-resected teeth is still a viable mode of treatment. Diagnosis and management of multirooted teeth with furcation involvement including the rationale for root resection is presented in detail in Chapter 62. Structural challenges are created in restoring these teeth because of the amount of tooth structure lost in the resection process (Figure 67-49). Conservative tooth preparation will maintain as much of the remaining tooth as possible, but the resulting supragingival or minimally prepared subgingival finish lines will require additional metal display in the final restoration. A cast post and core may be indicated to create an adequate foundation for the final restoration. Because the remaining roots are often very thin mesiodistally, it is difficult to cement premade posts and have adequate bulk to place a foundation core on the mesial and distal surfaces of the post. This problem is avoided with the one-piece cast post and core restoration.

Another area of concern when restoring root-resected teeth is the development of appropriate contours for hygiene access. The primary concern is to avoid any excessively heavy convexities of contour that would prevent access (Figures 67-50 and 67-51). Facially and lingually, the contours should be essentially a straight line from the margin coronally, while interproximally, the contour emerges from the margin as a straight line or is slightly convex as it slopes up to the contact point. The interproximal areas of root-amputated and hemisected teeth often present with surface concavities on the root trunk, and these areas cannot be adequately cleaned with floss because it will bridge across the concavity. The gingival embrasure form created in the restoration must be fluted into these areas so that the surfaces can be accessed with an interdental brush.

Esthetics is usually not a major concern unless the tooth in question is a maxillary molar with a mesiobuccal root amputation and the patient has a broad smile. The solution is to create an artificial mesiobuccal root with normal crown contour coronal to it and a furcation made of restorative material that is easily cleanable with an interdental brush.

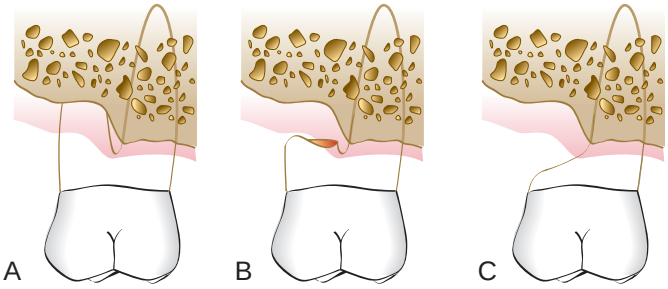

Figure 67-49 **A,** Maxillary molar with a Class III furcation and bone loss surrounding the distal buccal root. **B,** Contour created when the distal buccal root is removed, but the coronal contour has not yet been reshaped. Note the overhang, which can trap food and plaque and create gingival inflammation. **C,** Correct contour after the restoration or reshaping of the tooth. Note this illustration is only of the facial portion of the tooth. The palatal portion of the crown and the palatal root do not appear. Note how the contour has been altered to allow easy access for an interdental brush to the gingival tissue and the tooth in the area in which the root was removed.

Splinting

Splinting therapy may be applied with bonded external appliances, intracoronal appliances, or indirect cast restorations to connect multiple teeth, with the goal of improving tooth stability. Unstable teeth may be caused by a lack of periodontal support from bone loss, a lack of support from tooth loss, or the need to splint abutment teeth to support pontics. Indications for splinting are: (a) mobility of teeth that is increasing or that impairs patient comfort, (b) migration of teeth, and (c) prosthetics in which multiple abutments are necessary.

Before considering splinting, the clinician must identify the etiology of the instability.[2] Excessive occlusal forces from parafunction or deflective tooth contacts are frequent causes of excessive mobility. Whenever the occlusion is the cause, occlusal therapy is always performed first. The mobility is then evaluated over time to determine if it resolves before splinting is considered. In addition, any inflammation of the periodontal supporting apparatus must be controlled before making a decision on splinting because inflammation can produce mobility in the presence of normal occlusal forces and normal periodontal support. When the teeth are

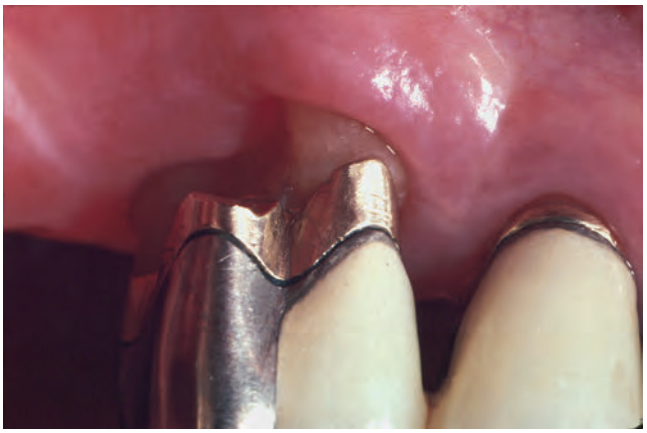

Figure 67-50 **Photograph taken 6 weeks after the removal of the distal buccal root on this maxillary first molar.** Note that the crown contour has not yet been altered. Also note the presence of a large overhang that easily traps debris.

Figure 67-51 **Correct modification of the crown form seen in Figure 67-50.** The roof of the furcation of the remaining distal buccal root has been completely removed and the crown re-formed to allow easy access to the remaining roots and soft tissue.

splinted, all the teeth in the splint share the occlusal load to some extent.[16] The rigidity of the splint and the number of teeth used determine how the forces are distributed.

The most common indication to splint mobile teeth is to improve patient comfort and to provide better control of the occlusion. If the anterior teeth are mobile. Adequate crown length on the teeth being splinted is critical so that the interproximal connectors do not impinge on the interdental papilla. Also, adequate space must exist between the connector and the papilla for access with dental floss anteriorly and with an interproximal brush on posterior teeth.

Anterior Esthetic Surgery

The importance of gingiva in relation to anterior esthetics has been well documented.[9,28,58,64] Various methods for altering gingival levels have been described, including gingivectomy, apically positioned flaps with osseous recontouring, and the use of orthodontic therapy to position the gingival tissue level apically or coronally by intruding or extruding the teeth[5,12,32,68] (see Video 67-1: Smile Design Principles).

Whenever an alteration in gingival levels is contemplated, the expected outcome must be communicated to the patient to determine if the planned surgery is acceptable. Computer imaging can be used to provide the patient with a visual plan for the final esthetic result.[17] However, the imaging process does not allow the dentist or patient to include the dynamics of lip movement in the evaluation of the proposed changes. Computer imaging provides enough information to depict the final outcome accurately when the planned surgery will alter the gingiva on one or two teeth while leaving the gingival levels of adjacent teeth in their existing position.

However, when the surgery will involve many or all of the anterior teeth and will result in moving gingiva several millimeters, to the extent that a flap will be raised and bony levels altered, an additional guide is desirable before surgery. Constructing these guides directly on a stone cast is the easiest and least time-consuming method. Before constructing the guide, treatment planning is completed on the patient to determine the desired incisal edge position and the desired gingival level of the tissues. This will establish the amount of tooth display at rest and at full smile. The information is transferred to a stone cast of the patient's teeth, and the desired shape of the gingival margins for each tooth is drawn on the cast. The existing incisal edge position of each tooth is used as a reference in establishing the desired gingival level. A composite or acrylic resin veneer is then constructed on the cast, extending gingivally to the desired tissue position. The veneer guide can also be extended incisally to the desired incisal edge position so that this information can also be included in the veneer. The veneer is trimmed, polished, and tried in the patient's mouth.

When the patient approves the gingival levels established with the guide, the desired gingival correction can be completed using the veneer guide as a surgical template. In addition to locating the initial incisions at the correct level, the guide can also be employed after flap reflection to aid in the bony recontouring to ensure adequate biologic width and sulcus depth at the new gingival position. The surgeon replaces the flap at closure to the gingival level established with the guide. Employing an esthetic template in this manner optimizes the predictability of the surgical therapy and establishes the ideal tissue framework to complete the esthetic restorations (Figures 67-52 to 67-59).

Figure 67-52 This patient is unhappy with the appearance of her maxillary teeth and the discrepancies of tissue height and tooth form (see Figures 67-53 to 67-59).

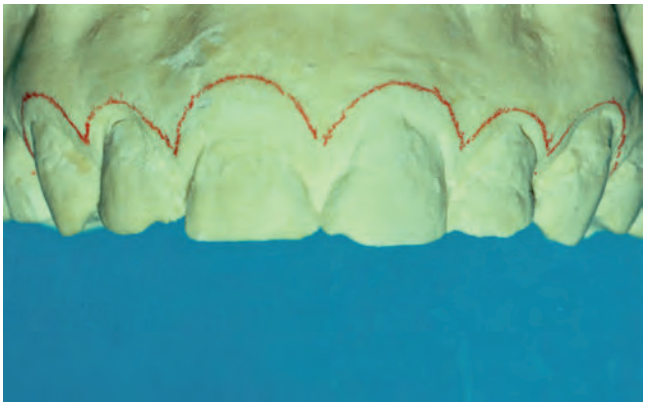

Figure 67-53 To create a surgical guide for patient in Figure 67-52, a stone cast is modified by drawing the desired soft-tissue profile with a red wax pencil.

Figure 67-54 Composite-resin surgical guide is fabricated on this stone cast, extending to the line drawn. This guide can be taken to the mouth for try-in and verification by the patient (see Figure 67-52).

Figure 67-55 Photograph taken the day the surgical guide was tried-in. This patient in Figure 67-52 approved the new length of the maxillary anterior teeth and the form created by altering the soft-tissue profile.

Figure 67-56 By placing the surgical guide during the surgery, it is possible to recognize where the bone needs to be placed. The surgical guide represents the desired final free gingival margin position and can be used as a reference for osseous recontouring. This patient had an average biologic width of 2 mm (see Figure 67-52). Allowing an additional 1 mm for sulcus depth, the desired distance between the bone and the free gingival margin will be 3 mm. With this knowledge, the periodontist can use the guide and remove bone until it is 3 mm from the position of the guide on each tooth.

Figure 67-57 Surgical guide is also useful during suturing. Because the guide represents the desired free gingival margin position, it is possible to suture to the level of the guide, knowing that the surgery has now recreated biologic width and a 1-mm sulcus. This shortens the amount of time necessary for healing and eliminates the need to wait for tissue rebound before restorative dentistry.

Figure 67-58 Soft-tissue profile as seen the day of surgery with the guide removed. Note that in this patient, the interproximal papillae were not changed because the interproximal papillary form and height were deemed acceptable (see Figures 67-52 to 67-57).

Figure 67-59 Photograph taken 4 years after placement of the final restoration of patient in Figure 67-52. Note the excellent soft-tissue health and the attainment of the desired free gingival margin and papillary form.

References

1. Adamczyk E, Speichowics E: Plaque accumulation on crowns made of various materials. *Int J Prosthodont* 3:285, 1990.
2. Amsterdam M: Periodontal prosthesis: twenty-five years in retrospect. *Alpha Omegan* 67:30, 1974.
3. Amsterdam M, Fox L: Provisional splinting: principles and techniques. *Dent Clin North Am* 4:73, 1959.
4. Armitage GC, Svanberg GK, Löe H: Microscopic evaluation of clinical measurements of connective tissue attachment levels. *J Clin Periodontol* 4:173, 1977.
5. Becker W, Ochsenbein C, Becker B: Crown lengthening: the periodontal-restorative connection. *Compend Contin Educ Dent* 19:239, 1998.
6. Benson BW, Bomberg TJ, Hatch RA, et al: Tissue displacement in fixed prosthodontics. *J Prosthet Dent* 55:175, 1986.
7. Bragger U, Laachenauer D, Lang NP: Surgical lengthening of the clinical crown. *J Clin Periodontol* 19:58, 1992.
8. Carlsson GE, Ingerval B, Kocak G: Effect of increasing vertical dimension on the masticatory system in subjects with natural teeth. *J Prosthet Dent* 41:284, 1979.
9. Chiche GJ, Pinault A: *Esthetics of anterior fixed prosthodontics*, Chicago, 1994, Quintessence.
10. Christensen J: Effect of occlusion-raising procedures on the chewing system. *Dent Pract Dent Rec* 20:233, 1970.
11. Dahl BL, Krogstad O: Long-term observations of an increased occlusal face height obtained by a combined orthodontic/prosthetic approach. *J Oral Rehabil* 12:173, 1985.
12. Dolt A, Robbins J: Altered passive eruption: an etiology of short clinical crowns. *Quintessence Int* 28:363, 1997.
13. Downs DH: An investigation into condylar position with leaf gauge and bimanual manipulation. *J Gnathol* 7:75, 1988.
14. Ericsson I, Lindhe J: Effect of longstanding jiggling on experimental periodontitis in the beagle dog. *J Clin Periodontol* 9:497, 1982.
15. Felton DA, Kanoy Be, Bayne SC, et al: Effect of in vivo crown margin discrepancies on periodontal health. *J Prosthet Dent* 65:357, 1991.
16. Foucher RR, Bryant RA: Bilateral fixed splints. *Int J Periodont Restor Dent* 5:9, 1983.
17. Ganz CH, Brisman SA, Tauro V: *Computer video imaging: computerization, communication, and creation*, Lombard, Ill., 1989, QDT Yearbook, p 64.
18. Gargiulo AW, Wentz FM, Orban B: Dimension and relations of the dentogingival junction in humans. *J Periodontol* 32:262, 1961.
19. Gibb CH, Mahan PE, Wilkenson TM, et al: EMG activity of the superior belly of the lateral pterygoid muscle in relation to other jaw muscles. *J Prosthet Dent* 51:691, 1984.
20. *The glossary of prosthodontic terms*, ed 8, St Louis, 2005, Elsevier/Mosby.
21. Gross MD, Ormianer Z: A preliminary study on the effect of occlusal vertical dimension increases on mandibular postural rest position. *Int J Prosthodont* 7:216, 1994.
22. Günay H, Seeger A, Tschernitschek H, et al: Placement of the preparation line and periodontal health: a prospective 2-year clinical study. *Int J Periodont Restor Dent* 20:173, 2000.
23. Hansen PA, Tira DE, Barlow J: Current methods of finish line exposure by practicing prosthodontists. *J Prosthodont* 8:163, 1999.
24. Hatcher DC, Faulkner MG, Hay A: Development of mechanical and mathematic models to study temporomandibular joint loading. *J Prosthet Dent* 55:377, 1986.
25. Henry PJ, Johnson JF, Mitchell DF: Tissue changes beneath fixed partial dentures. *J Prosthet Dent* 16:937, 1966.
26. Hochman N, Yaffe A, Ehrlich J: Crown contour variation in gingival health. *Compend Contin Educ Dent* 4:360, 1983.
27. Ingber JS: Forced eruption. II. A method of treating nonrestorable teeth: periodontal and restorative considerations. *J Periodontol* 47:203, 1995.
28. Kay HB: Esthetic considerations in the definitive periodontal prosthetic management of the maxillary anterior segment. *Int J Periodont Restor Dent* 2(3):44, 1982.
29. Kohno S, Bando E: Die funcktionelle anpassung der kaumuskulatur bei starker beisshenbung [Functional adaptation of masticatory muscles as a result of large increases in the vertical dimension]. *Dtsch Zahnarztl Z* 38:759, 1983.
30. Kois JC, Spear FM: Periodontal prosthesis: creating successful restorations. *J Am Dent Assoc* 123:108, 1992.
31. Kozlovsky A, Tal H, Lieberman M: Forced eruption combined with gingival fiberotomy: a technique for clinical crown lengthening. *J Clin Periodontol* 18:330, 1991.
32. Lie T: Periodontal surgery for the maxillary anterior area. *Int J Periodontics Restorative Dent* 12(1):73, 1992.
33. Lindauer SJ, Gay T, Rendell J: Effect of jaw opening on masticatory muscles: EMG-force characteristics. *J Dent Res* 72:51, 1993.
34. Lindhe J, Ericsson I: The influence of trauma from occlusion on progression of experimental periodontitis in dogs. *J Clin Periodontol* 53:562, 1982.
35. Lindhe J, Svanberg G: Influence of trauma from occlusion on progression of experimental periodontitis in the beagle dog. *J Clin Periodontol* 1:3, 1974.
36. Listgarten MA: Periodontal probing: what does it mean? *J Clin Periodontol* 7:165, 1980.
37. Listgarten MA, Mao R, Robinson PJ: Periodontal probing and the relationship of the probe tip to periodontal tissues. *J Periodontol* 47:511, 1976.
38. Long JH: Locating centric relation with a leaf gauge. *J Prosthet Dent* 29:608, 1973.
39. MacKenna BR, Türker KS: Jaw separation and maximum incising force. *J Prosthet Dent* 49:726, 1983.
40. Manns A, Mirallees R, Guerrs F: The changes in electrical activity of the postural muscles of the mandible upon varying the vertical dimension. *J Prosthet Dent* 45:438, 1981.
41. Manns A, Spreng M: EMG amplitude and frequency at different muscular elongations under constant masticatory force or EMG activity. *Acta Physiol Lat Am* 27:259, 1977.
42. Marcum JS: The effect of crown margin depth upon gingival tissue. *J Prosthet Dent* 17:479, 1967.
43. McKee JR: Comparing condylar position respectability for standardized versus nonstandardized methods of achieving centric relation. *J Prosthet Dent* 77:280, 1997.
44. Meitner S: Co-destructive factors of marginal periodontitis and repetitive mechanical injury. *J Dent Res* 54:78, 1975.
45. National Institutes of Health Technology: Management of temporomandibular disorders, Assessment conference statement, 1996. *Oral Surg Oral Med Oral Pathol Oral Radiol Endod* 83:177, 1997.
46. Newcomb GJ: The relationship between the location of subgingival crown margins and gingival inflammation. *J Periodontol* 45:151, 1974.
47. Olsson M, Lindhe S: Periodontol characteristics in individuals with varying forms of the upper central incisors. *J Clin Periodontol* 18:78, 1991.
48. Parkinson CF: Excessive crown contours facilitate endemic plaque niches. *J Prosthet Dent* 35:424, 1976.
49. Parma-Benfenati S, Fugazzoto PA, Ruben MP: The effect of restorative margins on the postsurgical development and nature of the periodontium. Part I. *Int J Periodont Restor Dent* 6:31, 1985.
50. Pelton L: Nickel sensibility in the general population. *Contact Dermatitis* 5:27, 1979.
51. Perel ML: Axial crown contours. *J Prosthet Dent* 25:642, 1971.
52. Pierce LH, Goodkind RJ: A status report of possible risks in base metal alloys and their components. *J Prosthet Dent* 62:234, 1989.
53. Podshadley AG: Gingival response to pontics. *J Prosthet Dent* 19:51, 1968.
54. Polson AM, Meitner SW, Zander HA: Trauma and progression of marginal periodontitis in squirrel monkeys. III. Adaptation of interproximal alveolar bone to repetitive injury. *J Periodontal Res* 11:279, 1976.
55. Price C, Whitehead FJH: Impression material as foreign bodies. *Br Dent J* 133:9, 1972.
56. Robinson PJ, Vitek RM: The relationship between gingival inflammation and the probe resistance. *J Periodontal Res* 14:239, 1975.

57. Rosenburg ES, Garber DA, Evian CL: Tooth lengthening procedures. *Compend Contin Educ Dent* 1:161, 1980.
58. Rufenache CR: *Fundamentals of esthetics*, Chicago, 1990, Quintessence.
59. Sillness J: Treated with dental bridges. III. The relationship between the location of the crown margin and the periodontal condition. *J Periodontal Res* 5:225, 1970.
60. Smith DM, McLachlan KR, McCall WD, Jr: A numerical model of temporomandibular joint loading. *J Dent Res* 65:1046, 1986.
61. Spear FM: Maintenance of the interdental papilla following anterior tooth removal. *Pract Periodontics Aesthet Dent* 11:21, 1999.
62. Spear FM, Mathews DM, Kokich VG: Interdisciplinary treatment: integrating orthodontics with periodontics, endodontics, and restorative dentistry. *Semin Orthod* 3(1):1997.
63. Stein RS: Pontic-residual ridge relationship: a research report. *J Prosthet Dent* 16:251, 1966.
64. Studer S, Zellweger U, Scharer P: The esthetic guidelines of the mucogingival complex for fixed prosthodontics. *Pract Periodontics Aesthet Dent* 8:333, 1996.
65. Suvinen T, Hanes K, Gerchman J, et al: Psychophysical subtypes of temporomandibular disorders. *J Orofac Pain* 11:200, 1997.
66. Swartz ML, Phillips RW: Comparison of bacterial accumulations on rough and smooth surfaces. *J Periodontol* 28:304, 1957.
67. Tarnow DP, Magner AW, Fletcher P: The effects of the distance from the contact point to the crest of bone on the presence or absence of the interproximal dental papilla. *J Periodontol* 63:995, 1992.
68. Townsend CL: Resective surgery: an esthetic application. *Quintessence Int* 24:535, 1993.
69. Tylman SD: *Theory and practice of crown and bridge prosthodontics*, ed 5, St Louis, 1965, Mosby.
70. Vacek JS, Gher ME, Assad DA, et al: The dimensions of the human dentogingival junction. *Int J Periodont Restor Dent* 14:155, 1994.
71. Vallon D: Studies of occlusion adjustment therapy in patients with craniomandibular disorders. *Swed Dent J Suppl* 124:1–65, 1997.
72. Van der Veldon U: Regeneration of the interdental soft tissue following denudation procedures. *J Clin Periodontol* 9:455, 1982.
73. Wood DP, Elliott RW: Reproducibility of the centric relation bite registration technique. *Angle Orthod* 64:211, 1994.
74. Yuodelis RA, Faucher R: Provisional restorations: an integrated approach to periodontics and restorative dentistry. *Dent Clin North Am* 24:285, 1980.
75. Yuodelis RA, Weaver JD, Sapko S: Facial and lingual contours of artificial complete crowns and their effect on the periodontium. *J Prosthet Dent* 29:61, 1973.

CHAPTER 68

Multidisciplinary Approach to Dental and Periodontal Problems

Dennis P. Tarnow and Mitchell J. Bloom

CHAPTER OUTLINE

Educational Trends Toward Multidisciplinary Specialist Education in Implant Treatment
The Future

Traditionally, periodontal treatment has been delivered using an interdisciplinary model of therapy, with general dentists and specialists providing their respective aspects of care to the same patient per a comprehensive plan of therapy (Figures 68-1 to 68-22). This system has worked well because the patient benefits from the best mix of talent from a "team" of dentists. For periodontal aspects of such care to be most effective, it is critical that the primary provider, often the general practitioner, have a thorough understanding of the signs, symptoms, risk factors, and pathophysiology of disease processes and their related local and systemic risk factors. Additionally, they must also possess a thorough understanding of the available treatment options and their related indications, contraindications, benefits, and liabilities to effectively formulate a proper treatment plan. The dentist then decides whether he or she has the requisite knowledge, expertise, and experience to meet the patient's needs or whether to refer the patient to a specialist for care at a more advanced level. Conversely, when a single provider (general dentist or specialist) delivers all aspects of the patient's care, rather than a team of dentists, it is best described as *multidisciplinary treatment* as opposed to the term *interdisciplinary treatment.*

Many of the early innovators in the field of implant dentistry were general practitioners. Subsequently, their early accomplishments were built on by the predictable outcomes achieved using the surgical and prosthetic tenets put forth by Dr. P.I. Brånemark. His namesake implant design allowed the clinician to achieve predictable treatment outcomes through rigid case selection, strict surgical protocols, specialized armamentarium, and a narrow range of treatment options. The initial offering of training in the Brånemark method was limited to specialist prosthodontists and oral surgeons. The former group being limited to providing only the restorative aspect of care and the latter group the surgical phase of therapy. However, as implant dentistry continued to evolve, periodontists become increasingly more active in the field, ultimately sharing the same role and stature as that of their oral surgeon colleagues in this arena. The same was true for general practitioners with respect to their prosthodontist colleagues as it relates to the delivery of implant restorative care.

The range of indications for the use of dental implants grew beyond the mandibular full arch case type to include partial edentulism, single teeth, and even orthodontic and maxillofacial applications. Regenerative techniques were developed to address hard and soft-tissue deficiencies for many patients that were previously deemed unsuitable candidates for dental implant therapy. Autogenous intraoral block grafting, guided bone regeneration, maxillary sinus grafting, transposition of the inferior alveolar nerve, ridge splitting, and distraction osteogenesis are just a few and have emerged as solutions to increase access for patients to implant therapy in less-than-optimal sites.

Early implant designs and materials were subject to limitations and even prone to problems. Those with machined surfaces suffered from a significantly higher failure rate in sites with poor quality bone, whereas those with rough surfaces, coupled with other design flaws, were prone to late failures resulting from inflammatory periimplant disease or prosthetic complications. With all of these variables in play and emerging so rapidly during the formative years, implant dentistry was relegated largely to the specialty care arena. Through innovative implant designs, advances in material science, opportunities for simplified surgical techniques, and systematic treatment strategies confirmed via studies that examined success and risk factors, predictable outcomes have become readily achievable. The widespread emergence and acceptance of implant dentistry in its contemporary iteration leads us to where we are today and where we are poised to go.

It is suggested that in addition to learning all of the standard periodontal procedures of the past, the contemporary periodontist should also be able to *restore* simple implant cases such as those located outside of the esthetic zone (Figures 68-23 to 68-32). It will continue to be the case that the periodontist will be trained to manage hard and soft tissues and perform all of the latest periodontal plastic surgical procedures for preserving and reconstructing pleasing gingival architecture in the esthetic zone to the highest level of sophistication and complexity. However, as the definition of what is deemed a successful outcome continues to evolve and the bar for the definition is raised, the surgeon must remain acutely aware of the restorative aspects of care and abreast of related advances. In other words, it is not enough for the future periodontist to limit care to the treatment of periodontal disease alone.

Surgical specialists (i.e., periodontists) who are trained according to a multidisciplinary approach will provide even greater benefit to their patients from this evolved philosophy. For the implant surgeon to provide optimal outcomes in implant dentistry,

Text continued on p. 666

Figure 68-1 Complex interdisciplinary implant care scenario. Extraoral preoperative condition. Esthetic compromise is evident in this challenging treatment scenario in which there is significant gingival display.

Figure 68-2 Intraoral preoperative condition. A concave soft-tissue profile that contributes to a dark shadow and esthetic compromise is evident bilaterally *(arrows)*.

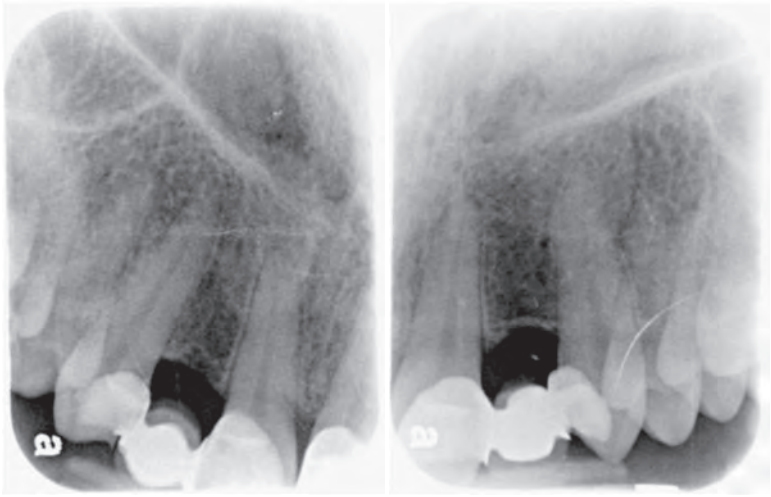

Figure 68-3 Preoperative radiographs. The roots of adjacent teeth do not converge to interfere with proper orientation of the positions of the planned dental implants. However, there is limited space between the adjacent tooth roots.

Figure 68-4 Intraoral preoperative. Soft-tissue contours as seen with the existing restorations removed.

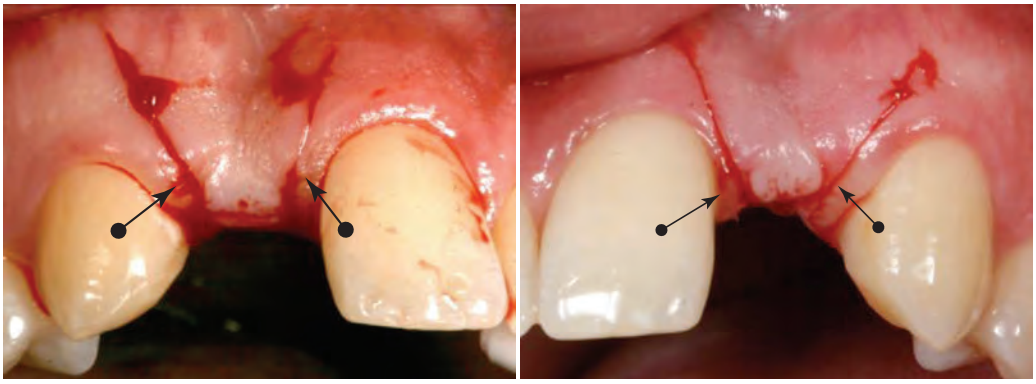

Figure 68-5 Implant surgery. Initial incisions using a papilla-sparing technique to minimize disturbing the healthy supracrestal attachment on the surfaces of the adjacent teeth.

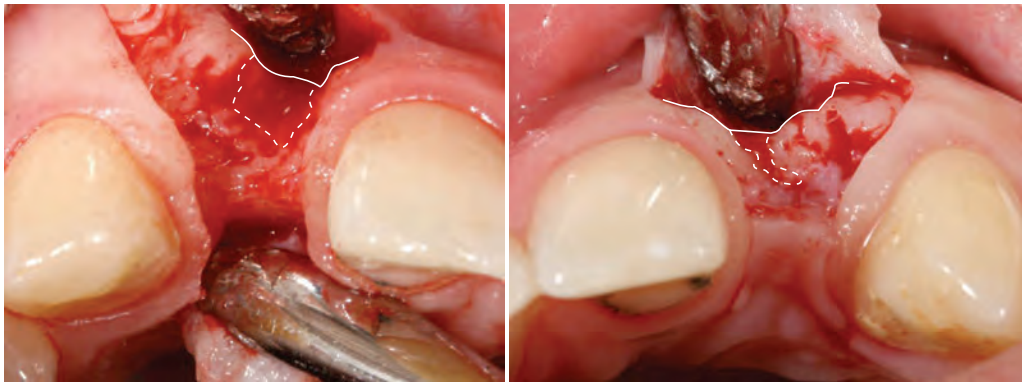

Figure 68-6 Edentulous right and left treatment areas both showing concave bony defects labially.

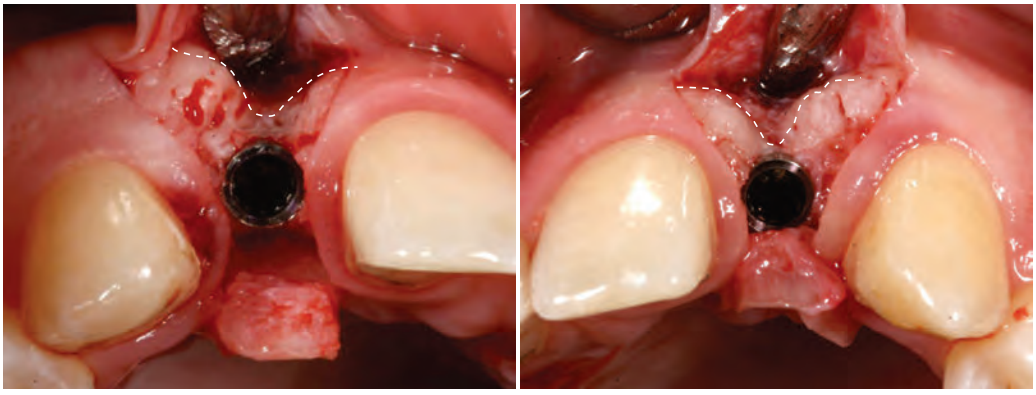

Figure 68-7 Implants placed in a prosthetically guided orientation to palatal of buccal depression.

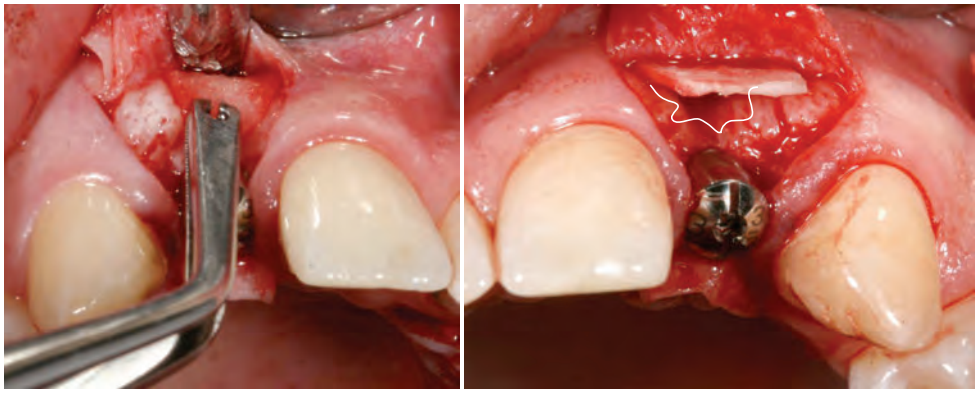

Figure 68-8 Correction of bony defect using guided bone regeneration technique. Resorbable barrier membranes are shown above after being trimmed to a suitable shape and fitted in place.

Figure 68-9 A particulate bone graft material is placed and shaped to fill the bony depression under the previously fitted membrane.

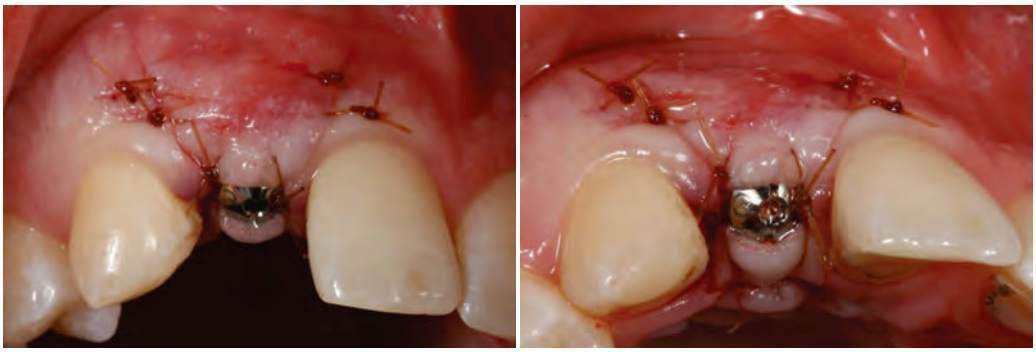

Figure 68-10 Implant healing abutments, which act to facilitate coronal and labial positioning of the soft-tissue flap, were previously placed. This will work in conjunction with the augmentation procedure to correct for the preoperative soft-tissue concavity.

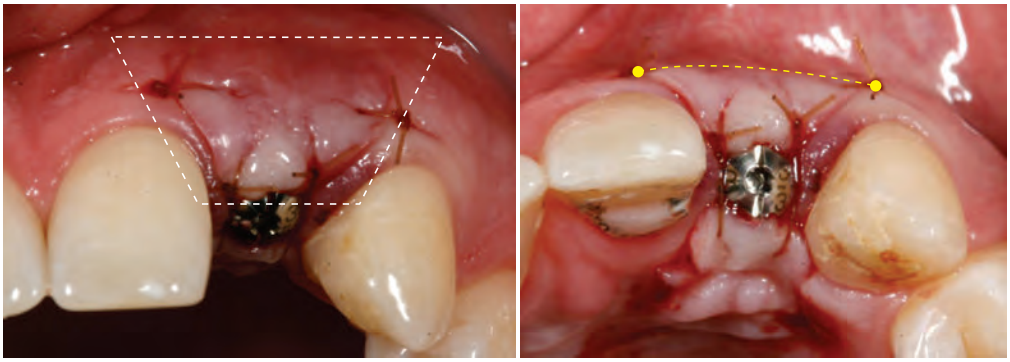

Figure 68-11 Convex ridge shape after augmentation is shown after completion of the surgical procedure.

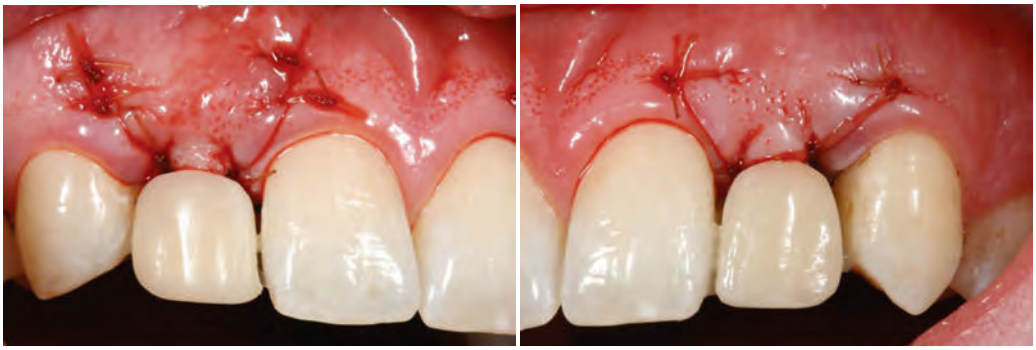

Figure 68-12 The gingival third of the provisional restoration has been reduced so it does not impinge on the surgical site. The vertical position of the soft-tissue height on completion of the surgery is favorable as compared to that of the adjacent natural teeth.

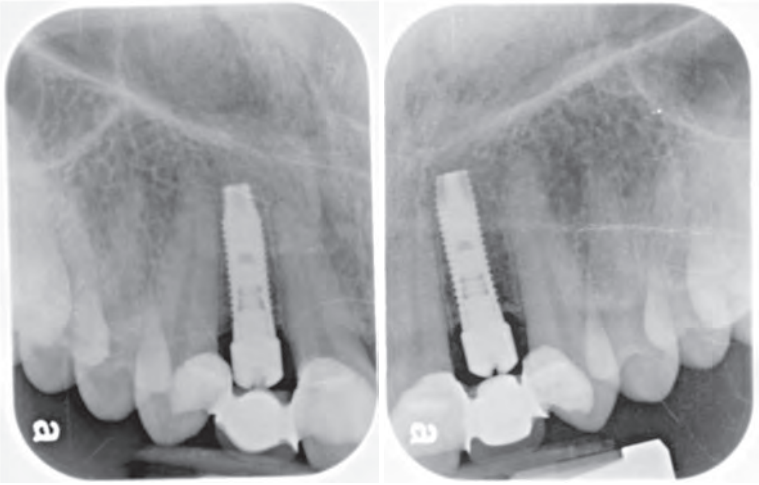

Figure 68-13 Radiograph shows the dental implants in position. Given the amount of available space between the adjacent tooth roots, a narrow-diameter implant was selected as part of the treatment plan to yield a biologically and prosthetically favorable result.

Figure 68-14 One week after surgery, the soft tissue is healing well. Note the favorable soft-tissue response where the papillae were not disturbed using a conservative incision design.

Figure 68-15 Three months after surgery, the soft tissues have healed favorably with maintenance of the free gingival margin position situated to yield a prosthetic clinical crown of appropriate length.

Figure 68-16 Screw-retained single provisional crowns inserted and connected to the dental implants to begin nonsurgical sculpting of the periimplant soft tissue.

Figure 68-17 The periimplant soft tissue is sculpted three-dimensionally to represent the cross-section of the natural tooth being replaced to create a more natural appearance in the final restoration than possible with prefabricated round healing abutments.

Figure 68-18 Periimplant soft tissue after nonsurgical sculpting. Notice the early stages of the papillae reforming in the spaces between the natural teeth and dental implants.

Figure 68-19 Custom abutments in place on the dental implants. Gold-plating of the custom abutments was done to impart a hue in the periimplant sulcus and soft tissue to optimize the esthetic outcome.

Figure 68-20 The final crowns are seen here on the date of insertion. The crown contours dictate the gingival contours.

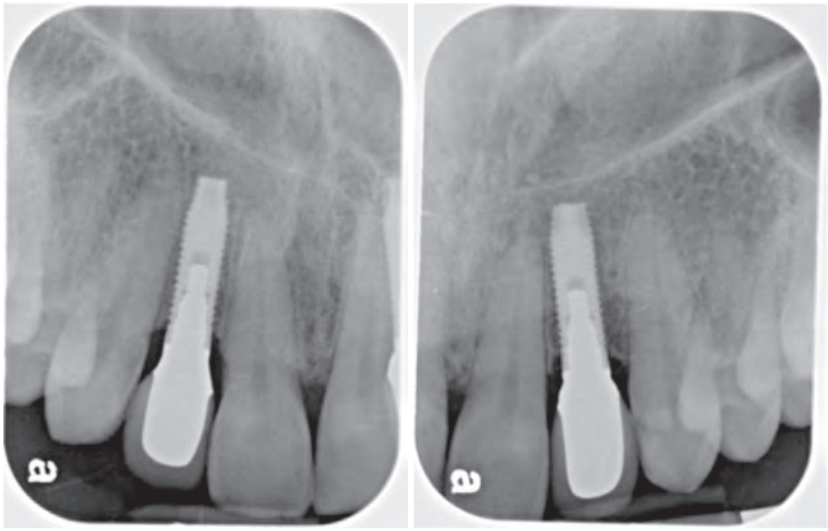

Figure 68-21 **Note the customized emergence profile of the prosthetic components on the dental implants.**

Figure 68-22 **The final esthetic outcome from both an intraoral and extraoral perspective.**

Figure 68-23 **Multidisciplinary simple implant care scenario: favorable soft-tissue parameters combined with a low smile line.** Preoperative view of the maxillary right first premolar. With the exception of a small degree of gingival recession, all other aspects of the surrounding periodontium are intact.

Figure 68-24 A fracture extending in a mesiodistal orientation is evident on the occlusal surface of the maxillary first premolar.

Figure 68-25 Healed ridge 3 months after tooth extraction. Note the wide zone of keratinized tissue present and favorable maintenance of the height of the adjacent interdental papillae.

Figure 68-26 The healed ridge demonstrates favorable buccolingual dimension and soft-tissue quality. Based on preoperative clinical and radiographic evaluation, placement of a dental implant in an uncomplicated fashion can be expected.

Figure 68-27 Surgical access for placement of the dental implant using a horizontal incision that extends intrasulcularly to the nearest buccal and palatal line angles of the adjacent teeth.

Figure 68-28 The endosseous implant properly positioned to facilitate an optimal prosthetic outcome in the final restoration.

Figure 68-29 After a period of healing during which the implant was submerged, stage II surgery to expose it was accomplished. In this scenario, a fixed provisional restoration was secured to the implant to serve as a matrix and begin sculpting the resultant soft-tissue profile in lieu of using a conventional nonanatomic round healing abutment. Note the position of the flap margin on the prosthetic crown. It is located occlusal to the expected cemento-enamel junction (CEJ) location to compensate for expected soft-tissue healing and remodeling and yield a favorable esthetic outcome.

Figure 68-30 The healed periimplant sulcus demonstrates the three-dimensionally generated result achieved using a provisional crown for soft-tissue sculpting. Note the recreation of the interdental papilla, the result of a favorable relationship between the interproximal bone height on the adjacent teeth and reestablishment of contact areas between the natural teeth and the provisional restoration.

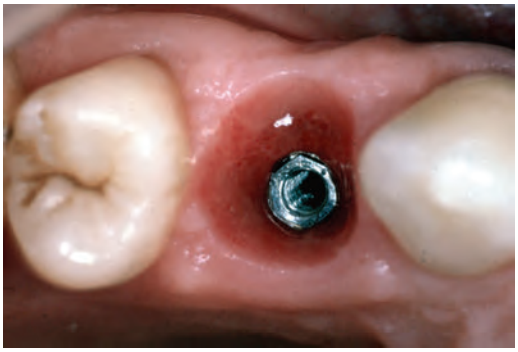

Figure 68-31 Occlusal view of the anatomic periimplant sulcus formed by the contours of the provisional restoration subgingivally.

Figure 68-32 Final implant-supported restoration in place.

even if their role is limited solely to the surgical aspect of care, they must have a thorough understanding of the realities and intricacies related to the fabrication and delivery of the planned prosthesis. Without such insight, achieving this on a predictable basis will continue to remain elusive. This "restorative" knowledge and experience will help them to place implants in optimal orientation in all three spatial dimensions and to avoid such common errors as excessive implant angulation through greater understanding of the resultant restorative challenges. Another benefit is that the prosthetically well-versed surgical specialist will be positioned to educate and guide their restorative colleagues with whom they work through the nonsurgical aspects of care. This will enhance the relationship between restorative and surgical colleagues by becoming a source of knowledge with respect to the restorative phase of implant therapy and ultimately raise the level of care available and provided to patients.

Educational Trends Toward Multidisciplinary Specialist Education in Implant Treatment

For the multidisciplinary model of practice to be able to deliver care at the level presently available using an interdisciplinary approach, the provider (general practitioner or specialist) would need to have been more comprehensively trained with a broader scope and depth of expertise than typical contemporary norms deliver.

The surgical aspect of implant dentistry has risen to center stage within many contemporary postgraduate specialty and continuing education programs. Continuing education programs span the gamut, with some being limited to didactic teaching with laboratory simulation and others take the form of clinical fellowship-style programs that encompass a clinical patient care component spanning one or more years in duration. As such, some general practitioners and prosthodontists who have sought out advanced postgraduate training might add some additional aspects of surgical care (commensurate with the scope and level of their respective training) to the range of services they personally provide. Conversely, members of the surgical specialties (e.g., periodontists and oral surgeons) would have received training to a level that would enable them to recommend, guide, and if necessary, provide a range of restorative treatments. Indeed, rigidly defined accreditation standards for some postgraduate specialties have already been revised and reflect this trend toward encouraging multidisciplinary training. Traditionally, nonsurgical restorative training programs have included basic implant surgical training into their curricula. Advanced education specialty programs in prosthodontics, among others, now include an increased allocation of time in their didactic and clinical curricula in the area of diagnosis, as well as training to the level of competency with respect to simple single-tooth implant scenarios in healed ridges of favorable dimension and in sites outside the esthetic zone.

In the United States, postgraduate periodontology training programs have been driven by the Accreditation Standards for Advanced Specialty Education Programs in Periodontics, which is regulated by the American Dental Association's Council on Dental Education (CODA). These requirements are based in part on input from the American Academy of Periodontology, whose major emphasis is on ensuring competency as a periodontal specialist. Multidisciplinary training and education represents a new era of training for periodontists that is beginning to emerge.

The Future

In the future, it will not be the accepted norm for all surgery to be done by a periodontist or oral surgeon nor will it likely be the accepted norm for all restorative work to be done by a general dentist or prosthodontist. Instead, simple cases that require surgery and restoration will probably be performed entirely by either a well-trained general dentist or a specialist. In fact, many periodontists have already begun working with their restorative colleagues by making the final impression or index of the implant at the time of surgery and forwarding it to them. In such scenarios, the restorative dentist may now only need to insert the final restoration when it comes back from the laboratory, thus expediting treatment and enhancing the experience for both the patient and doctor. As with most trends over time, it is conceivable that simple implant cases might be treated in a multidisciplinary fashion, whereas an interdisciplinary approach is more likely to be associated with advanced treatment scenarios.

The periodontists of the future will be multidisciplinary in the way they provide patient care. They will continue to provide all of the specialty services that "classically" trained periodontists have done for decades, but they will also be well suited to better support their restorative colleagues.

CHAPTER 69

Supportive Periodontal Treatment

Robert L. Merin

CHAPTER OUTLINE

Rationale for Supportive Periodontal Treatment
Maintenance Program
Classification of Posttreatment Patients
Referral of Patients to the Periodontist
Tests for Disease Activity
Maintenance for Dental Implant Patients

Preservation of the periodontal health of the treated patient requires as positive a program as that required for the elimination of periodontal disease. After Phase I therapy is completed, patients are placed on a schedule of periodic recall visits for maintenance care to prevent recurrence of the disease (Figures 69-1 and 69-2).

Transfer of the patient from active treatment status to a maintenance program is a definitive step in total patient care that requires time and effort on the part of the dentist and staff. Patients must understand the purpose of the maintenance program, and the dentist must emphasize that preservation of the teeth depends on maintenance therapy. Patients who are not maintained in a supervised recall program subsequent to active treatment show obvious signs of recurrent periodontitis (e.g., increased pocket depth, bone loss, or tooth loss).[7,10,16,17,21,41] The more often patients present for recommended supportive periodontal treatment (SPT), the less likely they are to lose teeth.[21,39,41,44,61,69] One study found that treated patients who do not return for regular recall are at 5.6 times greater risk for tooth loss than compliant patients.[17] Another study showed that patients with inadequate SPT after successful regenerative therapy have a 50-fold increase in risk of probing attachment loss compared with those who have regular recall visits.[20]

Motivational techniques and reinforcement of the importance of the maintenance phase of treatment should be considered before performing definitive periodontal surgery.[10] Studies show that few patients display complete compliance with recommended maintenance schedules[1,43,38,39,42,43,67,69] (Figure 69-3). *It is meaningless simply to inform patients that they are to return for periodic recall visits without clearly explaining the significance of these visits and describing what is expected of patients between visits.*

The maintenance phase of periodontal treatment starts immediately after the completion of Phase I therapy (see Figures 69-1 and 69-2). While the patient is in the maintenance phase, the necessary surgical and restorative procedures are performed. This ensures that all areas of the mouth retain the degree of health attained after Phase I therapy.

Rationale for Supportive Periodontal Treatment

Studies show that even with appropriate periodontal therapy, some progression of disease is possible.[29,32,45,53,60,66] One likely explanation for the recurrence of periodontal disease is *incomplete subgingival plaque removal*.[64,66] If subgingival plaque is left behind during scaling, it regrows within the pocket. The regrowth of subgingival plaque is a slow process compared with that of supragingival plaque. During this period (perhaps months), the subgingival plaque may not induce inflammatory reactions that can be discerned at the gingival margin. The clinical diagnosis may be further confused by the introduction of adequate supragingival plaque control because the inflammatory reactions caused by the plaque in the soft-tissue wall of the pocket are not likely to be manifested clinically as gingivitis. Thus inadequate subgingival plaque control can lead to continued loss of attachment, even without the presence of clinical gingival inflammation.

Bacteria are present in the gingival tissues in chronic and aggressive periodontitis cases.[14,18,24,48] Eradication of intragingival microorganisms may be necessary for a stable periodontal result.[24] Scaling, root planing, and even flap surgery may not eliminate intragingival bacteria in some areas.[14] These bacteria may recolonize the pocket and cause recurrent disease.

Bacteria associated with periodontitis can be transmitted between spouses and other family members.[2,62] Patients who appear to be successfully treated can become infected or reinfected with potential pathogens. This is especially likely in patients with remaining pockets.

Another possible explanation for the recurrence of periodontal disease is the microscopic nature of the dentogingival unit healing after periodontal treatment. Histologic studies have shown that after periodontal procedures, tissues usually do not heal by formation of new connective tissue attachment to root surfaces,[15,56,57] but result in a long junctional epithelium. It has been speculated that this type of dentogingival unit may be weaker and that inflammation may rapidly separate the long junctional epithelium from the tooth. Thus treated periodontal patients may be predisposed to recurrent pocket formation if maintenance care is not optimal.

Subgingival scaling alters the microflora of periodontal pockets.[40,47,54] In one study, a single session of scaling and root planing in patients with chronic periodontitis resulted in significant changes in subgingival microflora.[40] Reported alterations included a decrease in the proportion of motile rods for 1 week, a marked elevation in the proportion of coccoid cells for 21 days, and a marked reduction in the proportion of spirochetes for 7 weeks.

Although pocket debridement suppresses components of the subgingival microflora associated with periodontitis, periodontal pathogens may return to baseline levels within days or months.[4,53]

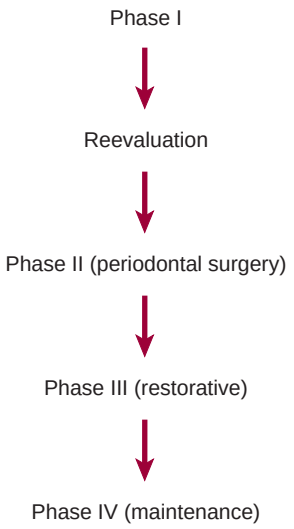

Figure 69-1 Incorrect sequence of periodontal treatment phases. Maintenance phase should be started immediately after the reevaluation of Phase I therapy.

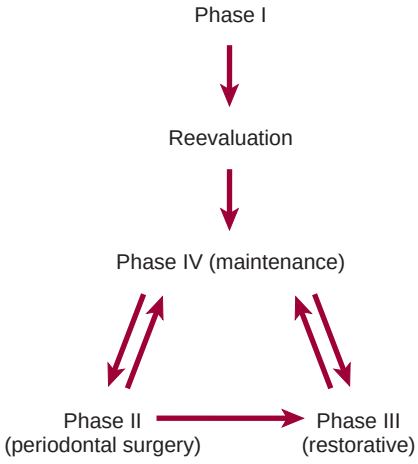

Figure 69-2 Correct sequence of periodontal treatment phases.

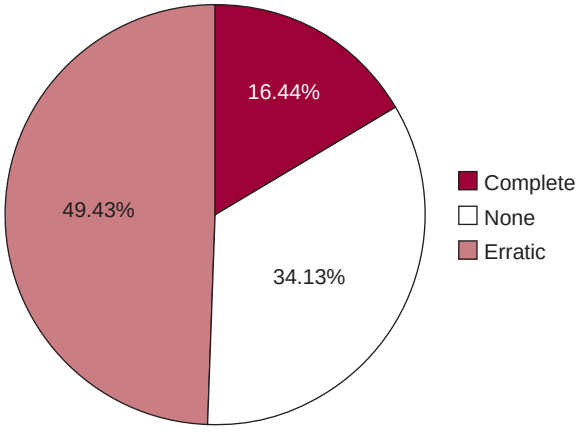

Figure 69-3 Compliance with maintenance therapy in 961 patients studied for 1 to 8 years. *(Modified from Wilson TG Jr, Glover ME, Schoen J, et al:* J Periodontol *55:468, 1984.)*

The return of pathogens to pretreatment levels generally occurs in approximately 9 to 11 weeks but can vary dramatically among patients.[4]

Both the mechanical debridement performed by the therapist and the motivational environment provided by the appointment seem to be necessary for good maintenance results. Patients tend to reduce their oral hygiene efforts between appointments.[5,69] Knowing that their hygiene will be evaluated motivates them to perform better oral hygiene in anticipation of the appointment.

In one study the proportion of spirochetes obtained in baseline samples of subgingival flora was highly correlated with clinical periodontal deterioration over 1 year.[35] However, subsequent reports in the same longitudinal study concluded that the arbitrary assignment of treated periodontitis patients to 3-month maintenance intervals appears to be as effective in preventing recurrences of periodontitis as assignment of recall intervals based on microscopic monitoring of the subgingival flora.[34,35] Microscopic monitoring was found not to be a reliable predictor of future periodontal destruction in patients on 3-month recall programs, presumably because of the alteration of subgingival flora produced by subgingival instrumentation.

In conclusion, *there is a sound scientific basis for recall maintenance because subgingival scaling alters the pocket microflora for variable but relatively long periods.*

Maintenance Program

Periodic recall visits form the foundation of a meaningful long-term prevention program. The interval between visits is initially set at 3 months but may be varied according to the patient's needs.

Periodontal care at each recall visit comprises three parts (Box 69-1). The first part involves examination and evaluation of the

BOX 69-1 Maintenance Recall Procedures

Part I: Examination
(Approximate time: 14 minutes)
Patient greeting
Medical history changes
Oral pathologic examination
Oral hygiene status
Gingival changes
Pocket depth changes
Mobility changes
Occlusal changes
Dental caries
Restorative, prosthetic, and implant status

Part II: Treatment
(Approximate time: 36 minutes)
Oral hygiene reinforcement
Scaling
Polishing
Chemical irrigation or site-specific antimicrobial placement

Part III: Report, Cleanup, and Scheduling
(Approximate time: 10 minutes)
Write report in chart.
Discuss report with patient.
Clean and disinfect operatory.
Schedule next recall visit.
Schedule further periodontal treatment.
Schedule or refer for restorative or prosthetic treatment.

patient's current oral health. The second part includes the necessary maintenance treatment and oral hygiene reinforcement. The third part involves scheduling the patient for the next recall appointment, additional periodontal treatment, or restorative dental procedures. The time required for a recall visit for patients with multiple teeth in both arches is approximately 1 hour,[49] which includes time for greeting the patient, setting up, and cleaning up.

Examination and Evaluation

The recall examination is similar to the initial evaluation of the patient (see Chapter 29). However, because the patient is not new to the office, the dentist primarily looks for changes that have occurred since the last evaluation. Analysis of the current oral hygiene status of the patient is essential. Updating of changes in the medical history and evaluation of restorations, caries, prostheses, occlusion, tooth mobility, gingival status, and periodontal and periimplant probing depths are important parts of the recall appointment. The oral mucosa should be carefully inspected for pathologic conditions (Figures 69-4 to 69-9).

Radiographic examination must be individualized,[27] depending on the initial severity of the case and the findings at the recall visit (Table 69-1). These are compared with findings on previous radiographs to check the bone height and look for repair of osseous defects, signs of trauma from occlusion, periapical pathologic changes, and caries.

Checking of Plaque Control

To assess the effectiveness of their plaque control, patients should perform their hygiene regimen immediately before the recall appointment. Plaque control must be reviewed and corrected until the patient demonstrates the necessary proficiency, even if additional instruction sessions are required. Patients instructed in plaque control have less plaque and gingivitis than uninstructed patients,[7,58,59] and the amount of supragingival plaque affects the number of subgingival anaerobic organisms.[15,55]

Figure 69-4 **A,** Hyperplastic gingivitis related to crown margins and plaque accumulation in a 27-year-old woman. **B,** Four months after treatment, there is significant improvement. However, some inflammation around crown margins still exists, which cannot be resolved without replacing the crowns.

Treatment

The required scaling and root planing are performed, followed by an oral prophylaxis (see Chapter 46). Care must be taken not to instrument normal sites with shallow sulci (1 to 3 mm deep) because studies have shown that repeated subgingival scaling and root planing in initially normal periodontal sites result in significant loss of attachment.[33] Irrigation with antimicrobial agents or placement of site-specific antimicrobial devices is performed in maintenance patients with remaining pockets.[4,30,36]

Recurrence of Periodontal Disease

Occasionally, lesions may recur, which often can be traced to inadequate plaque control on the part of the patient or failure to comply with recommended SPT schedules. It should be understood, however, that it is the dentist's responsibility to teach, motivate, and control the patient's oral hygiene technique, and the patient's failure is the dentist's failure. Surgery should not be undertaken unless the patient has shown proficiency and willingness to cooperate by adequately performing his or her part of therapy.[10,60,68]

Other causes for recurrence include the following:

1. Inadequate or insufficient treatment that has failed to remove all the potential factors favoring plaque accumulation (see Figure 69-4). Incomplete calculus removal in areas of difficult access is a common source of problems.
2. Inadequate restorations placed after the periodontal treatment was completed.
3. Failure of the patient to return for periodic checkups (see Figure 69-6). This may be a result of the patient's conscious or unconscious decision not to continue treatment or the failure of the dentist and staff to emphasize the need for periodic examinations.
4. Presence of some systemic diseases that may affect host resistance to previously acceptable levels of plaque.

A failing case can be recognized by the following:

1. Recurring inflammation revealed by gingival changes and bleeding of the sulcus on probing.
2. Increasing depth of sulci, leading to the recurrence of pocket formation.
3. Gradual increases in bone loss, as determined by radiographs.
4. Gradual increases in tooth mobility, as ascertained by clinical examination.

Cases that do not respond to adequate therapy or recur for unknown reasons are referred to as aggressive periodontitis (see Chapters 25 and 40).

The decision to retreat a periodontal patient should not be made at the preventive maintenance appointment but should be postponed for 1 to 2 weeks.[16] Often the mouth looks much better at that time because of the resolution of edema and the resulting improved tone of the gingiva. Table 69-2 summarizes the symptoms of recurrence of periodontal disease and their probable causes.

Classification of Posttreatment Patients

The first year after periodontal therapy is important in terms of indoctrinating the patient in a recall pattern and reinforcing oral hygiene techniques. In addition, it may take several months to evaluate accurately the results of some periodontal surgical procedures. Consequently, some areas may have to be retreated because

Text continued on p. 674

Figure 69-5 **A,** Patient was 38 years old when these original radiographs were taken and was treated with a combination of surgical and nonsurgical therapy. This individual is a classic class C maintenance patient. **B,** Pretreatment photograph. Note the inflammation and heavy calculus deposits. **C,** Photograph taken 10 years after treatment. **D,** Radiographs taken 5 years after treatment. **E,** Radiographs taken 10 years after treatment. The radiographic appearance is as good as can be expected in such a severe case. Teeth #15 and #17 were extracted 8 years after treatment.

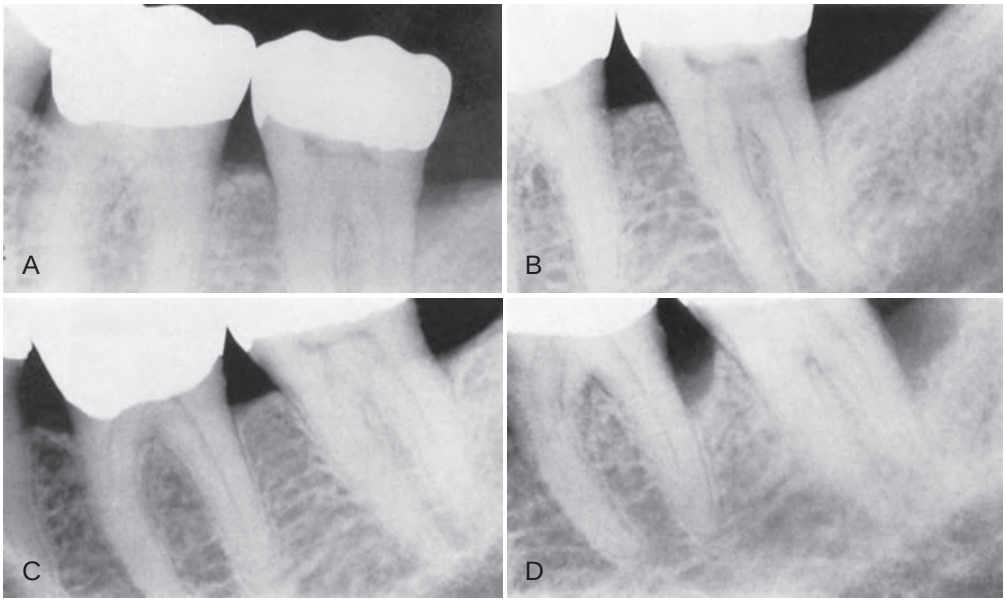

Figure 69-6 This series of radiographs clearly shows the importance of maintenance therapy. A, Original radiograph of a 58-year-old male. Note the deep distal bone loss on tooth #18 and the moderate distal lesion of tooth #19. Surgical treatment included osseous grafting. **B,** Radiograph 14 months after surgical therapy. The patient had recall maintenance performed every 3 to 4 months. **C,** Appearance 3 years after surgery, with regular recalls every 3 to 4 months. **D,** Appearance after 2 years without recalls (7 years after surgery). Note the progression of the disease on the distal surfaces of teeth #18 and #19.

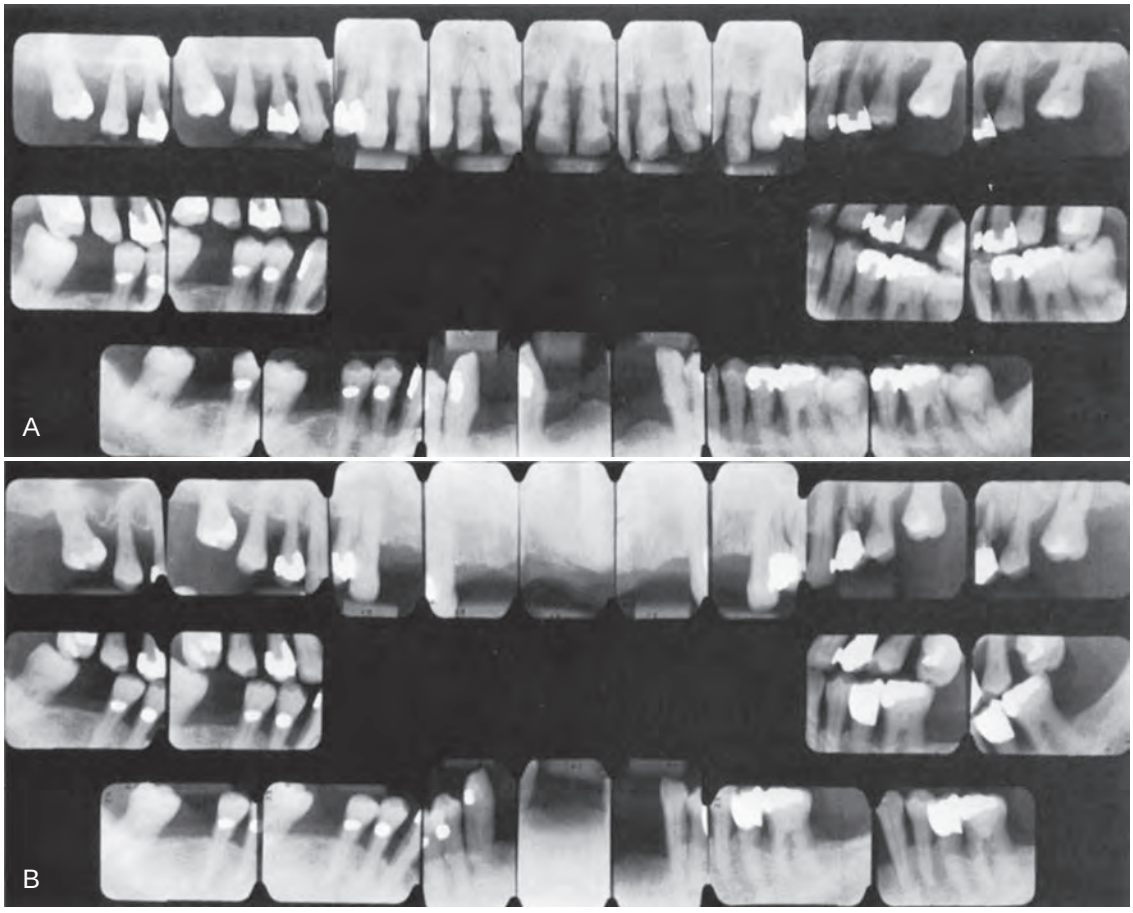

Figure 69-7 Advanced cases sometimes do better than expected when the patient complies with maintenance therapy. A, Initial radiographs showing a very advanced case. The maxillary arch had extractions and nonsurgical treatment. A plastic partial denture was placed and was expected to grow into a full denture within a few years. The mandibular arch was treated with periodontal surgery, and a permanent, metal and plastic, removable partial denture was placed. **B,** Radiographs taken 8 years later. The patient performed good oral hygiene and had 3-month recalls. Teeth #12 and #15 required extraction.

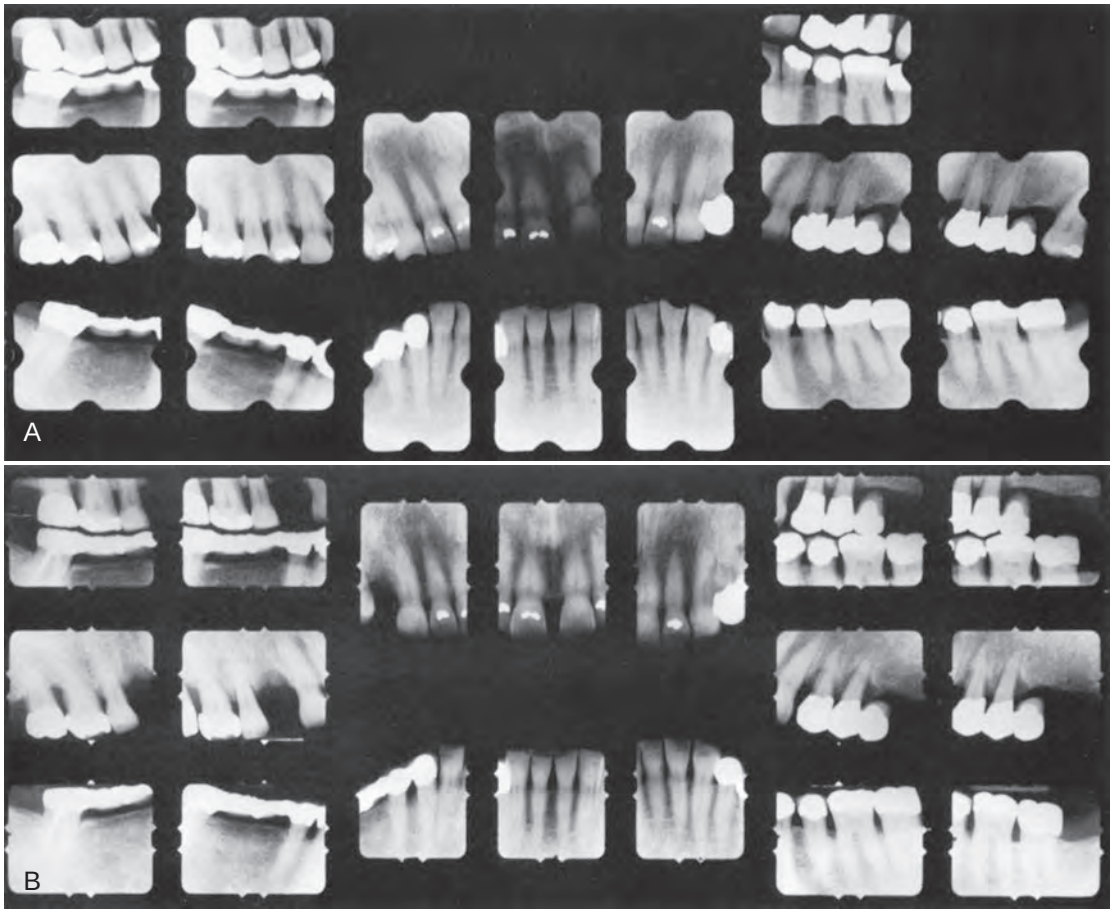

Figure 69-8 **A,** Initial radiographs. The patient was advised to have localized areas of periodontal surgery and periodontal recall every 3 months. However, the patient did not comply and only had dental cleanings once or twice yearly. **B,** Radiographs 4 years later. Note the loss of teeth #5 and #15 and the increased bone loss of several premolars and molars.

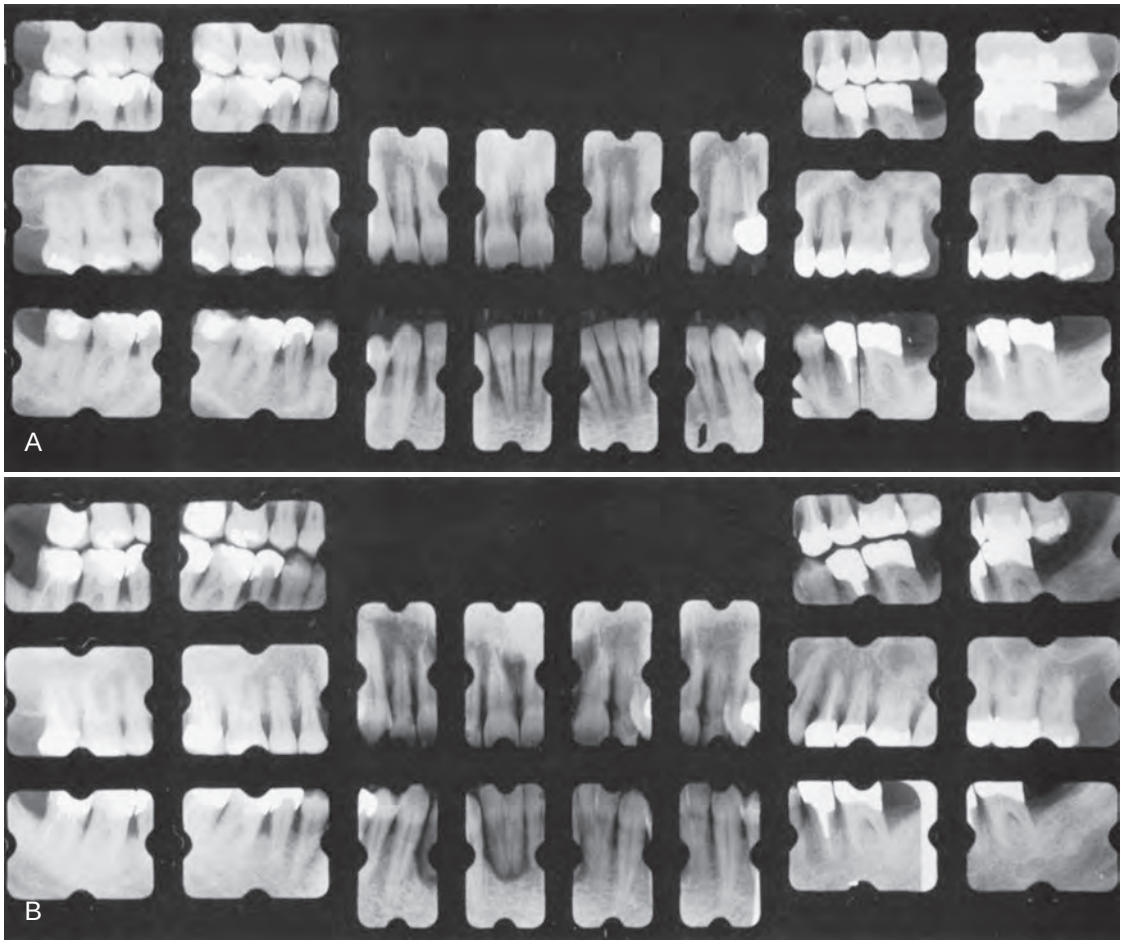

Figure 69-9 **A,** Initial radiographs. The patient was advised to have localized areas of periodontal surgery and periodontal recall every 3 months. However, the patient did not comply and had no treatment other than emergency care and occasional dental cleanings. **B,** Radiographs 7 years later. Note the advanced bone loss and caries on many teeth.

TABLE 69-1 Radiographic Examination of Recall Patients for Supportive Periodontal Treatment*

Patient Condition/Situation	Type of Examination
Clinical caries or high-risk factors for caries.	Posterior bite-wing examination at 6- to 18-month intervals.
No clinical caries and no high-risk factors for caries.	Posterior bite-wing examination at 24- to 36-month intervals.
Periodontal disease not under good control.	Periapical and/or vertical bite-wing radiographs of problem areas every 12 to 24 months.
History of periodontal treatment with disease under good control.	Bite-wing examination every 24 to 36 months.
Root form dental implants.	Periapical or vertical bite-wing radiographs after prosthetic placement and at 12 and 24 months, Then every 24 to 36 months unless clinical problems arise.
Transfer of periodontal or implant maintenance patients.	Full-mouth series if a current set is not available. If full-mouth series has been taken within 24 months, radiographs of implants and periodontal problem areas should be taken.

*Adapted from Guide to Patient Selection and Limiting Radiation Exposure. American Dental Association website. http://ada.org/2760/aspx. Accessed May 24, 2013.

Radiographs should be taken when they are likely to affect diagnosis and patient treatment. The recommendations in this table are subject to clinical judgment and may not apply to every patient.

TABLE 69-2 Symptoms and Causes of Recurrence of Disease

Symptom	Possible Causes
Increased mobility	Increased inflammation Poor oral hygiene Subgingival calculus Inadequate restorations Deteriorating or poorly designed prostheses Systemic disease modifying host response to plaque
Recession	Toothbrush abrasion Inadequate keratinized gingiva Frenum pull Orthodontic therapy
Increased mobility with no change in pocket depth and no radiographic change	Occlusal trauma caused by lateral occlusal interference, bruxism, high restoration Poorly designed or worn-out prosthesis Poor crown-to-root ratio
Increased pocket depth with no radiographic change	Poor oral hygiene Infrequent recall visits Subgingival calculus Poorly fitting partial denture Mesial inclination into edentulous space Failure of new attachment surgery Cracked teeth Grooves in teeth New periodontal disease Gingival overgrowth caused by medication
Increased pocket depth with increased radiographic bone loss	Poor oral hygiene Subgingival calculus Infrequent recall visits Inadequate or deteriorating restorations Poorly designed prostheses Inadequate surgery Systemic disease modifying host response to plaque Cracked teeth Grooves in teeth New periodontal disease

the results may not be optimal. Furthermore, the first-year patient often has etiologic factors that may have been overlooked and may be more amenable to treatment at this early stage. *For these reasons, the recall interval for first-year patients should not be longer than 3 months.*

The patients who are on a periodontal recall schedule are a varied group. Table 69-3 lists several categories of maintenance patients and a suggested recall interval for each. Patients can improve or may relapse to a different classification, with a reduction in or exacerbation of periodontal disease. When one dental arch is more involved than the other, the patient's periodontal disease is classified by the arch with the worse condition.

In summary, maintenance care is a critical phase of therapy. The long-term preservation of the dentition is closely associated with the frequency and quality of recall maintenance.

Referral of Patients to the Periodontist

Many periodontal patients can be well managed by the general dentist as more people retain their teeth throughout their lifetime and as the proportion of older people in the population increases, more teeth will be at risk of periodontal disease. Considerable research shows possible links between periodontal disease and systemic diseases, such as heart disease, stroke, and diabetes, and adverse pregnancy outcomes. Therefore the prevalence of patients requiring SPT is likely to increase in the future.

This expected increase in the number of periodontal patients will necessitate a greater understanding of periodontal problems and an increased level of expertise for the solution of such problems on the part of the general practitioner of dentistry. General dentists must know when comanagement with a periodontist is indicated. Specialists are needed to treat particularly difficult periodontal cases, patients with systemic health problems, dental implant patients, and those with a complex prosthetic construction that requires reliable results.

The question of where to draw the line between the cases to be treated in the general dental office and those to be referred to a specialist varies for different practitioners and patients, and the American Academy of Periodontology has issued guidelines to help the general practitioner decide when comanagement with a periodontist is indicated.[5] The diagnosis indicates the type of periodontal treatment required. If periodontal destruction necessitates surgery on the distal surfaces of second molars, extensive osseous surgery, or complex regenerative procedures, the patient is usually best treated by a specialist. On the other hand, patients who require localized gingivectomy or flap curettage usually can be treated by the general dentist.

TABLE 69-3 Recall Intervals for Various Classes of Recall Patients

Merin Classification	Characteristics	Recall Interval
First year	First-year patient: routine therapy and uneventful healing. First-year patient: difficult case with complicated prosthesis, furcation involvement, poor crown-to-root ratios, or questionable patient cooperation.	3 months 1-2 months
Class A	Excellent results well maintained for 1 year or more. Patient displays good oral hygiene, minimal calculus, no occlusal problems, no complicated prostheses, no remaining pockets, and no teeth with less than 50% of alveolar bone remaining.	6 months to 1 year
Class B	Generally good results maintained reasonably well for 1 year or more, but patient displays some of the following factors: 1. Inconsistent or poor oral hygiene 2. Heavy calculus formation 3. Systemic disease that predisposes to periodontal breakdown 4. Some remaining pockets 5. Occlusal problems 6. Complicated prostheses 7. Ongoing orthodontic therapy 8. Recurrent dental caries 9. Some teeth with less than 50% of alveolar bone support 10. Smoking 11. Positive family history or genetic test 12. More than 20% of pockets bleed on probing	3-4 months (decide on recall interval based on number and severity of negative factors)
Class C	Generally poor results after periodontal therapy and/or several negative factors from the following list: 1. Inconsistent or poor oral hygiene 2. Heavy calculus formation 3. Systemic disease that predisposes to periodontal breakdown 4. Many remaining pockets 5. Occlusal problems 6. Complicated prostheses 7. Recurrent dental caries 8. Periodontal surgery indicated but not performed for medical, psychologic, or financial reasons 9. Many teeth with less than 50% of alveolar bone support 10. Condition too far advanced to be improved by periodontal surgery 11. Smoking 12. Positive family history or genetic test 13. More than 20% of pockets bleed on probing	1-3 months (decide on recall interval based on number and severity of negative factors; consider retreating some areas or extracting severely involved teeth)

It is immediately obvious that some patients should be referred to a specialist, whereas most patients clearly have problems that can be treated by a general dentist. For a third group of patients, however, it will be difficult to decide whether treatment by a specialist is required. Any patient who does not clearly belong in the second of these categories should be considered a candidate for referral to a specialist.[5]

The decision to have the general practitioner treat a patient's periodontal problem should be guided by a consideration of the degree of risk that the patient will lose a tooth or teeth for periodontally related reasons or the risk of the periodontal disease contributing to their general health problems.

The most important factors in the decision are the extent and location of the periodontal deterioration. Teeth with pockets of 5 mm or more, as measured from the cementoenamel junction, may have a prognosis of rapid decline. The location of the periodontal deterioration is also an important factor in determining the risk of tooth loss. Teeth with furcation lesions may be at risk even when more than 50% of bone support remains. Therefore patients with strategically important teeth that fall into these categories are usually best treated by specialists.

An important question remains: *Should the maintenance phase of therapy be performed by the general practitioner or the specialist?* This should be determined by the amount of periodontal deterioration present. Class A recall patients should be maintained by the general dentist, whereas Class C patients should be maintained by the specialist (see Table 69-3). Class B patients can alternate recall visits between the general practitioner and the specialist (Figure 69-10). The suggested rule is that the *patient's disease should dictate whether the general practitioner or the specialist should perform the maintenance therapy.*

Tests for Disease Activity

Periodontal patients, even though they have received effective periodontal therapy, are at risk of disease recurrence for the rest of their lives.[29,30] In addition, many pockets in furcation areas may not have been eliminated by surgery. The best way of determining areas that are losing attachment is to use a well-organized charting system.[4]

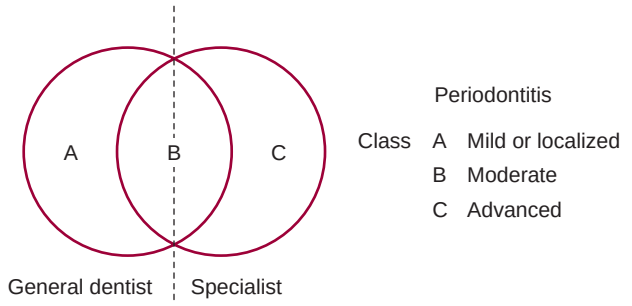

Figure 69-10 Scheme for determining which practitioner should perform periodontal maintenance in patients with different degrees of periodontitis.

Some computerized systems allow easy retrieval and comparison of past findings.

Comparison of sequential probing measurements gives the most accurate indication of the rate of loss of attachment. A number of other clinical and laboratory variables have been correlated with disease activity.

No accurate method of predicting disease activity exists, and clinicians rely on the information provided by combining probing, bleeding on probing, and sequential attachment measurements.[32,34,65] Patients whose disease is clearly refractory are candidates for bacterial culturing and antibiotic therapy in conjunction with additional mechanical therapy.

New methods will undoubtedly be developed in the future to help predict disease activity.[4] The clinician must be able to interpret whether a test may be useful in determining disease activity and future loss of attachment.[11] Tests should be adopted only when they are based on research that includes a critical analysis of the sensitivity, specificity, disease incidence, and predictive value of the proposed test.

Maintenance for Dental Implant Patients

According to the AAP report, periimplant diseases present in two forms—periimplant mucositis and periimplantitis.[3] Periimplant mucositis is defined as a disease in which the presence of inflammation is confined to the soft tissues surrounding a dental implant with no signs of loss of supporting bone beyond biologic bone remodeling. Periimplantitis is defined as a process around an implant that includes both soft-tissue inflammation and progressive bone loss beyond biologic bone remodeling. A systemic review showed a frequency of periimplant mucositis of 30.7% of implants, and a frequency of periimplantitis of 9.6% of implants.[6] Patients with periodontitis-associated tooth loss are at significantly increased risk of developing periimplantitis.[3,13,19,22,50,51]

The overall periodontal condition in partially edentulous implant patients can influence the clinical condition around implants.[12,52] The microflora of implants in partially edentulous patients differs from that in edentulous patients.[9] The implant microflora is similar to tooth microflora in the partially edentulous mouth. Periodontal and implant maintenance are linked because maintenance of a tooth microflora consistent with periodontal health is necessary to maintain implant microflora consistent with periimplant health.[8,63] Because periimplantitis is difficult to treat,[3,28] it is extremely important to treat periodontal disease before implant placement and to provide good supportive therapy with implant patients[6,13,19,22]

In general, procedures for maintenance of patients with implants are similar to those for patients with natural teeth,[4,25,31,37] with the following three differences:

1. Special instrumentation that will not scratch the implants is used for calculus removal on the implants.
2. Acidic fluoride prophylactic agents are avoided.
3. Nonabrasive prophy pastes are used.

During the phase after uncovering the implants, patients must use ultrasoft brushes, chemotherapeutic rinses, tartar control pastes, irrigation devices, and yarnlike materials to keep the implants and natural teeth clean. Patients often are reluctant to touch the implants but must be encouraged to keep the areas clean.

Special instruments should be used on the implants during recall appointments.[26,37] Metal hand instruments and ultrasonic and sonic tips should be avoided because they can alter the titanium surface.[26] Only plastic instruments or specially designed gold-plated curettes should be used for calculus removal because the implant surfaces can be easily scratched. The rubber cup with flour of pumice, tin oxide, or special implant-polishing pastes should be used on abutment surfaces with light, intermittent pressure.[46]

Although daily use of topically applied antimicrobials is advised, acidic fluoride agents should not be used because they cause surface damage to titanium abutments.[39,46]

When prosthetics must be unscrewed and removed for maintenance, it is best done in the office responsible for placing the prosthetics. Each time the prosthetic appliances are reattached, a slight change in the occlusion occurs. Time must be allowed for occlusal corrections.

Suggested Readings

American Academy of Periodontology: Position paper: periodontal maintenance. *J Periodontol* 74:1395, 2003.

American Academy of Periodontology: Peri-implant mucositis and peri-implantitis: a current understanding of their diagnoses and clinical implications. *J Periodontol* 84:436, 2013.

Becker W, Becker BE, Berg LE: Periodontal treatment without maintenance: a retrospective study in 44 patients. *J Periodontol* 155:505, 1984.

Costa FO, Lages EJ, Cota LO, et al: Tooth loss in individuals under periodontal maintenance therapy: 5-year prospective study. *J Periodontal Res* 49:121, 2014.

Hirschfeld L, Wasserman B: A long-term survey of tooth loss in 600 treated periodontal patients. *J Periodontol* 49:225, 1978.

Lang NP, Joss A, Orsanic T, et al: Bleeding on probing. *J Clin Periodontol* 13:590, 1986.

Lindhe J, Nyman S, Karring T: Scaling and root planing in shallow pockets. *J Clin Periodontol* 9:415, 1982.

Wilson TG, Jr, Glover ME, Malik AK, et al: Tooth loss in maintenance patients in a private periodontal practice. *J Periodontol* 58:231, 1987.

Wilson V: An insight into peri-implantitis: a systematic literature review. *Prim Dent J* 2:69, 2013.

References

References for this chapter are found on the companion website www.expertconsult.com.

References

1. Ainamo J, Ainamo A: Risk assessment of recurrence of disease during supportive periodontal care. *J Clin Periodontol* 23:232, 1996.
2. Alaluusua S, Asikainen S, Lai CH: Intrafamilial transmission of *Actinobacillus actinomycetemcomitans*. *J Periodontol* 62:207, 1991.
3. American Academy of Periodontology: Peri-implant mucositis and peri-implantitis: a current understanding of their diagnoses and clinical implications. *J Periodontol* 84:436–443, 2013.
4. American Academy of Periodontology: Position paper: Periodontal maintenance. *J Periodontol* 74:1395, 2003.
5. American Academy of Periodontology: Academy Report: Guidelines for the management of patients with periodontal diseases. *J Periodontol* 77:1608, 2006.
6. Atieh MA, Alsabeeha NH, Gaffion CM, Jr, et al: The frequency of peri-implant diseases: A systematic review and meta-analysis. *J Periodontol* 84:1586, 2013.
7. Axelson P, Lindhe J: The significance of maintenance care in the treatment of periodontal disease. *J Clin Periodontol* 8:281, 1981.
8. Bauman GR, Mills M, Rapley JW, et al: Plaque-induced inflammation around implants. *Int J Oral Maxillofac Implants* 7:330, 1992.
9. Bauman GR, Rapley JW, Hallmon WW, et al: The peri-implant sulcus. *Int J Oral Maxillofac Implants* 8:273, 1993.
10. Becker W, Becker BE, Berg LE: Periodontal treatment without maintenance: a retrospective study in 44 patients. *J Periodontol* 155:505, 1984.
11. Bennett WI: Screening for bowel cancer. *Harvard Med School Health Lett* 11:6, 1986.
12. Bragger U, Burgin WB, Hammerle CH, et al: Associations between clinical parameters assessed around implants and teeth. *Clin Oral Implants Res* 8:412, 1997.
13. Carcuac O, Jansson L: Peri-implantitis in a specialist clinic of periodontology. Clinical features and risk indicators. *Swed Dent J* 34:53–61, 2010.
14. Carranza FA, Jr, Saglie FR, Newman MG, et al: Scanning and transmission electron microscope study of tissue invading microorganisms in localized juvenile periodontitis. *J Periodontol* 54:598, 1983.
15. Caton JG, Zander HA: The attachment between tooth and gingival tissues after periodic root planing and soft tissue curettage. *J Periodontol* 50:462, 1979.
16. Chace R: Retreatment in periodontal practice. *J Periodontol* 48:410, 1977.
17. Checchi L, Montevecchi M, Gatto MR, et al: Retrospective study of tooth loss in 92 periodontal patients. *J Clin Periodontol* 29:651, 2002.
18. Christersson LA, Albini B, Zambon JJ, et al: Tissue localization of *Actinobacillus actinomycetemcomitans* in human periodontitis. I. Light, immunofluorescence and electron microscopic studies. *J Periodontol* 58:529, 1987.
19. Cho-Yan Lee J, Mattheos N, Nixon KC, et al: Residual periodontal pockets are a risk indicator for peri-implantitis in patients treated for periodontitis. *Clin Oral Implants Res* 23:325–333, 2012.
20. Cortellimi P, Pini-Prato G, Torretti M: Periodontal regeneration of human infrabony defects. V. Effects of oral hygiene on long-term stability. *J Clin Periodontol* 21:606, 1994.
21. Costa FO, Lages EJ, Cota LO, et al: Tooth loss in individuals under periodontal maintenance therapy: 5-year prospective study. *J Periodontal Res* 49:121, 2014.
22. Costa FO, Takenaka-Martinez S, Cota LO, et al: Peri-implant disease in sbujects with and without preventive maintenance: a 5-year follow-up. *J Clin Periodontol* 39:173–181, 2012.
23. Dahlen G, Lindhe J, Sato K, et al: The effect of supragingival plaque control on the subgingival microbiota in subjects with periodontal disease. *J Clin Periodontol* 19:802, 1992.
24. Egloff E, Saglie FR, Newman MG: Intragingival bacteria subsequent to scaling and root planing. *J Dent Res* 65:269, 1986. (abstract).
25. Eskow RN, Smith VS: Preventive periimplant protocol. *Compend Contin Educ Dent* 20:137, 1999.
26. Fox SC, Moriarty JD, Kusy RP: The effects of scaling a titanium implant surface with metal and plastic instruments: an in vitro study. *J Periodontol* 61:485, 1990.
27. Guide to Patient Selection and Limiting Radiation Exposure. American Dental Association website. http://ada.org/2760/aspx. Accessed May 24, 2013.
28. Grunder U, Hürzeler MB, Schüpbach P, et al: Treatment of ligature-induced peri-implantitis using guided tissue regeneration: a clinical and histologic study in the beagle dog. *Int J Oral Maxillofac Implants* 8:282, 1993.
29. Halazonetis TD, Smulow JB, Donnenfeld W, et al: Pocket formation 3 years after comprehensive periodontal therapy: a retrospective study. *J Periodontol* 56:515, 1985.
30. Hirschfeld L, Wasserman B: A long-term survey of tooth loss in 600 treated periodontal patients. *J Periodontol* 49:225, 1978.
31. Lang NP, Nyman SR: Supportive maintenance care for patients with implants and advanced restorative therapy. *Periodontol 2000* 4:119, 1994.
32. Lang NP, Joss A, Orsanic T, et al: Bleeding on probing. *J Clin Periodontol* 13:590, 1986.
33. Lindhe J, Nyman S, Karring T: Scaling and root planing in shallow pockets. *J Clin Periodontol* 9:415, 1982.
34. Listgarten MA, Schifter CC, Sullivan P, et al: Failure of a microbiological assay to reliably predict disease recurrence in a treated periodontitis population receiving regularly scheduled prophylaxes. *J Clin Periodontol* 13:768, 1986.
35. Listgarten MA, Sullivan P, George C, et al: Comparative longitudinal study of 2 methods of scheduling maintenance visit: 4-year data. *J Clin Periodontol* 16:105, 1989.
36. Mazza JE, Newman MG, Sims TN: Clinical and antimicrobial effect of stannous fluoride on periodontitis. *J Clin Periodontol* 8:213, 1981.
37. McCollum J, O'Neal RB, Brennan WA, et al: The effect of titanium implant abutment surface irregularities on plaque accumulation in vivo. *J Periodontol* 63:802, 1992.
38. Mendoza AR, Newcomb GM, Nixon KC: Compliance with supportive periodontal therapy. *J Periodontol* 62:731, 1991.
39. Miyamoto T, Kumagai T, Lang MS, et al: Compliance as a prognostic indicator. II. Impact of patient's compliance to the individual tooth survival. *J Periodontol* 81:1280–1288, 2010.
40. Mousques T, Listgarten MA, Phillips RW: Effect of scaling and root planing on the composition of human subgingival microflora. *J Periodontal Res* 15:144, 1980.
41. Ng MC, Ong MM, Lim LP, et al: Tooth loss in compliant and non-compliant periodontally treated patients: 7 years after active periodontal therapy. *J Clin Periodontol* 38:499–508, 2011.
42. Novaes AB, Jr, Novaes AB: Compliance with supportive periodontal therapy. Part 1. Risk of non-compliance in the first 5-year period. *J Periodontol* 70:679, 1999.
43. Novaes AB, Jr, Novaes AB: Compliance with supportive periodontal therapy. Part II. *Braz Dent J* 12:47, 2001.
44. Oliver RC: Tooth loss with and without periodontal therapy. *Periodontal Abstr* 17:8, 1969.
45. Pertuiset JH, Saglie FR, Lofthus J, et al: Recurrent periodontal disease and bacterial presence in the gingiva. *J Periodontol* 58:553, 1987.
46. Probster L, Lin W: Juttemann H: Effect of fluoride prophylactic agents on titanium surfaces. *Int J Oral Maxillofac Implants* 7:390, 1992.
47. Rosenberg ES, Evian CI, Listgarten MA: The composition of the subgingival microbiota after periodontal therapy. *J Periodontol* 52:435, 1981.
48. Saglie FR, Newman MG, Carranza FA, Jr, et al: Immunohistochemical localization of *Actinobacillus actinomycetemcomitans* in sections of gingival tissue in localized juvenile periodontitis. *Acta Odontol Latinoam* 1:40, 1984.
49. Schallhorn RG, Snider LE: Periodontal maintenance therapy. *J Am Dent Assoc* 103:227, 1981.
50. Schou S, Holmstrup P, Worthington HV, et al: Outcome of implant therapy in patients with previous tooth loss due to periodontitis. *Clin Oral Implants Res* 2:104, 2006.

51. Schou S: Implant treatment in periodontitis-susceptible patients: a systematic review. *J Oral Rehabil* 1:9, 2008.
52. Serino G, Strom C: Peri-implantitis in partially edentulous patients: association with inadequate plaque control. *Clin Oral Implants Res* 20:169, 2009.
53. Shiloah J, Patters MR: Repopulation of periodontal pockets by microbial pathogens in the absence of supportive therapy. *J Periodontol* 67:130, 1996.
54. Slots J, Mashimo P, Levine MJ, et al: Periodontal therapy in humans. I. Microbiological and clinical effects of a single course of periodontal scaling and root planing, and of adjunctive tetracycline therapy. *J Periodontol* 50:495, 1979.
55. Smulow JB, Turesky SS, Hill RG: The effect of supragingival plaque removal on anaerobic bacteria in deep pockets. *J Am Dent Assoc* 107:737, 1983.
56. Stahl SS: Repair potential of the soft tissue-root interface. *J Periodontol* 48:545, 1977.
57. Stahl SS, Witkin GJ, Heller A, et al: Gingival healing. IV. The effects of home care on gingivectomy repair. *J Periodontol* 40:264, 1969.
58. Suomi JD, Greene JC, Vermillion JR, et al: The effect of controlled oral hygiene procedures on the progression of periodontal disease in adults: results after the third and final year. *J Periodontol* 42:152, 1971.
59. Suomi JD, West JD, Chang JJ, et al: The effect of controlled oral hygiene procedures on the progression of periodontal disease in adults: radiographic findings. *J Periodontol* 42:562, 1971.
60. Tonetti MA, Muller-Campanile V, Lang NP: Changes in the prevalence of residual pockets and tooth loss in treated periodontal patients during a supportive maintenance care program. *J Clin Periodontol* 25:1008, 1998.
61. Tsami A, Pepelassi E, Kodovazenitis G, et al: Parameters affecting tooth loss during periodontal maintenance in a Greek population. *J Am Dent Assoc* 140:1100–1107, 2009.
62. van Steenbergen TJ, Petit MD, van der Velden U, et al: Transmission of *Porphyromonas gingivalis* between spouses. *J Clin Periodontol* 20:340, 1993.
63. van Steenberghe D, Klinge B, Linden U, et al: Periodontal indices around natural and titanium abutments: a longitudinal multicenter study. *J Periodontol* 64:538, 1993.
64. Waerhaug J: Healing of the dentoepithelial junction following subgingival plaque control. *J Periodontol* 49:119, 1978.
65. Wilson TG: Maintaining periodontal treatment. *J Am Dent Assoc* 121:491, 1990.
66. Wilson TG, Kornman KS: Retreatment. *Periodontol 2000* 12:119, 1996.
67. Wilson TG, Jr: Compliance: a review of the literature. *J Periodontol* 58:706, 1987.
68. Wilson TG, Jr, Glover ME, Malik AK, et al: Tooth loss in maintenance patients in a private periodontal practice. *J Periodontol* 58:231, 1987.
69. Wilson TG, Jr, Glover ME, Schoen J, et al: Compliance with maintenance therapy in a private periodontal practice. *J Periodontol* 55:468, 1984.

CHAPTER 70

Results of Periodontal Treatment

Robert L. Merin

CHAPTER OUTLINE

Prevention and Treatment of Gingivitis
Prevention and Treatment of Loss of Attachment
Tooth Mortality
Conclusion

The prevalence of periodontal disease, the resulting high rate of tooth mortality, and the potential for multiple systemic health complications aggravated by chronic periodontitis raise an important question: Is periodontal treatment effective in preventing and controlling the chronic infection and progressive destruction of periodontal disease? Current concepts of evaluating healthcare require a scientific basis for treatment, referred to as **evidence-based therapy.** *Evidence is now overwhelming that periodontal therapy is effective in preventing periodontal disease, slowing the destruction of the periodontium, and reducing tooth loss.*

Prevention and Treatment of Gingivitis

For many years, the belief that good oral hygiene is necessary for the successful prevention and treatment of gingivitis has been widespread among periodontists. In addition, worldwide epidemiologic studies have confirmed a close relationship between the incidence of gingivitis and lack of oral hygiene.[8,9]

Löe and coworkers[20,38] provided conclusive evidence on the association between oral hygiene and gingivitis. After 9 to 21 days without performing oral hygiene measures, healthy dental students with previously excellent oral hygiene and healthy gingiva developed heavy accumulations of plaque and generalized mild gingivitis. When oral hygiene techniques were reinstituted, the plaque in most areas disappeared in 1 or 2 days, and gingival inflammation in these areas disappeared approximately 1 week after the plaque was removed. Thus gingivitis is reversible and can be resolved by daily, effective plaque removal.

A number of long-term studies have shown that gingival health can be maintained by a combination of effective oral hygiene maintenance and scaling procedures.*

A 3-year study was conducted on 1248 General Telephone workers in California to determine whether progression of gingival inflammation is reduced in an oral environment in which high levels of hygiene are maintained.[36,37] Experimental and control groups were computer matched based on periodontal and oral hygiene status, past caries experience, age, and gender. During the study period, several procedures were instituted to ensure that the oral hygiene status of the experimental group was maintained at a high level. Subjects were given a series of frequent oral prophylaxis treatments combined with oral hygiene instruction. Subjects in the control group received no attention from the study team except for annual examinations. They were advised to continue their usual daily practices and accustomed visits for professional care. After 3 years, the increase in plaque and debris in the control group was four times as great as that in the experimental group. Similarly, gingivitis scores were much higher in control subjects than in the matching experimental group. Therefore *chronic marginal gingivitis can be controlled with good oral hygiene and dental prophylaxis.*

*References 1, 2, 11, 13, 14, 15, 22, 24, 36, 37.

Prevention and Treatment of Loss of Attachment

Although periodontal therapy has been used for more than 100 years, it is only since the mid-1970s that a number of studies have been conducted to determine the effect of treatment on reducing the progressive loss of periodontal support for the natural dentition.

Prevention of Loss of Attachment

Löe et al[19,20] conducted a longitudinal investigation to study the natural development and progression of periodontal disease. The first study group, established in Oslo, Norway, in 1969, consisted of 565 healthy male nondental students and academicians between 17 and 40 years of age. Oslo was selected mainly because this city had an ongoing preschool, school, and postschool dental program offering systematic preventive, restorative, endodontic, orthodontic, and surgical therapy on an annual recall basis for all children and adolescents, complete with a documented attendance record, for the previous 40 years. Members of the study population had experienced maximum exposure to conventional dental care throughout their lives. A second study group, established in Sri Lanka in 1970, consisted of 480 male tea laborers between 15 and 40 years of age. They were healthy and well built by local standards, and their nutritional condition was clinically fair. The workers had never been exposed to any programs relative to the prevention or treatment of dental diseases. Toothbrushing was unknown, and dental caries was virtually nonexistent.

The results of this study are interesting. As the members of the Norwegian group approached 40 years of age, the mean individual loss of attachment was slightly above 1.5 mm and the mean annual rate of attachment loss was 0.08 mm for interproximal surfaces and

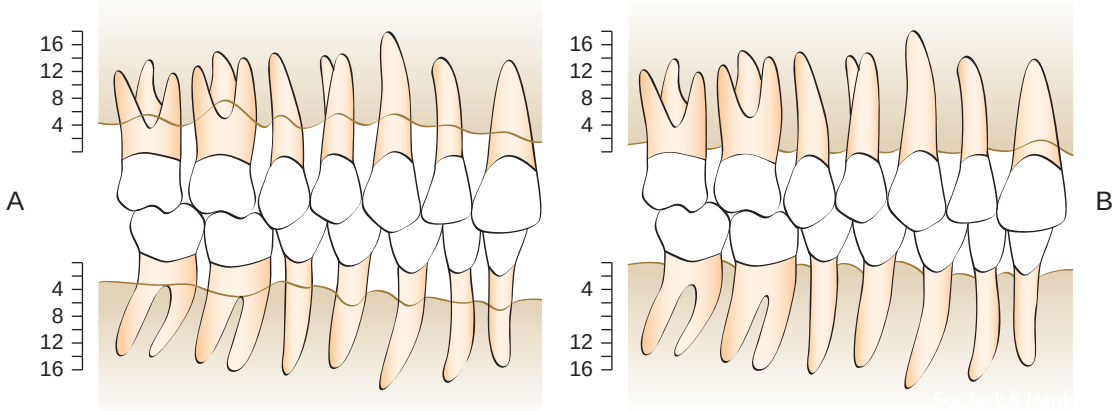

Figure 70-1 **A,** Mean periodontal support of teeth of Sri Lankan tea laborers at approximately 40 years of age. **B,** Mean periodontal support of teeth of Norwegian academicians at approximately 40 years of age. *(From Löe H, Anerud A, Boysen H, et al:* J Periodontol *49:607, 1978.)*

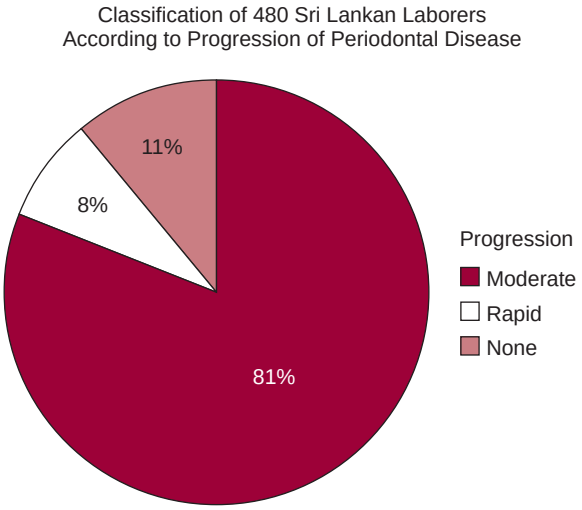

Figure 70-2 Progression of periodontal disease in an untreated population. *(Data from Löe H, Anerud A, Boysen H, et al:* J Clin Periodontol *13:431, 1986.)*

Mean Loss of Attachment at Various Ages (mm)

Age	Progression Group	
	Rapid	Moderate
35	9	4
45	13	7

Figure 70-3 Loss of attachment in untreated Sri Lankan laborers. *(Data from Löe H, Anerud A, Boysen H, et al:* J Clin Periodontol *13:431, 1986.)*

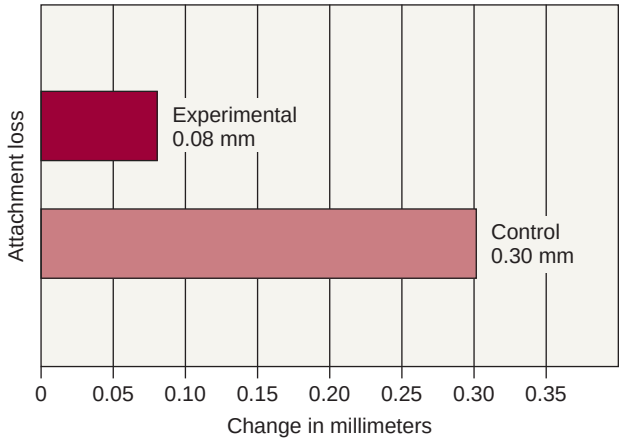

Figure 70-4 Change in mean attachment level from baseline to third-year examination for experimental and control groups. *(From Suomi JD, West JD, Chang JJ, et al:* J Periodontol *42:152, 1971.)*

0.10 mm for buccal surfaces. As the Sri Lankans approached 40 years of age, the mean individual loss of attachment was 4.50 mm, and the mean annual rate of progression of the lesion was 0.30 mm for interproximal surfaces and 0.20 mm for buccal surfaces. Figure 70-1 shows a graphic interpretation of the difference between the two groups. This study suggests that without interference, periodontal lesions progress continually and at a relatively even pace.

Further analysis of the Sri Lankan laborers showed that they were not all losing attachment at the same rate (Figures 70-2 and 70-3).[20] Virtually all gingival areas showed inflammation, but attachment loss varied tremendously. Based on interproximal loss of attachment and tooth mortality, three subpopulations were identified as individuals with "rapid progression" (RP) of periodontal disease (8%), individuals with "moderate progression" (MP) (81%), and individuals who exhibited "no progression" (NP) of periodontal disease beyond gingivitis (11%). At age 35, the mean loss of attachment in the RP group was 9 mm; in the MP group, 4 mm; and in the NP group, less than 1 mm. At the age of 45, the mean loss of attachment in the RP group was 13 mm and in the MP group, 7 mm. Therefore, under natural conditions and in the absence of therapy, 89% of the Sri Lankan laborers had severe periodontitis that progressed at much greater rates than in the Norwegian group.

In the previously discussed study of General Telephone workers in California, loss of attachment was measured clinically and alveolar bone loss measured radiographically.[36,37] After 3 years, the control group showed loss of attachment at a rate more than three times that of the matching experimental group during the same period (Figure 70-4). In addition, subjects who received frequent oral prophylaxis and were instructed in good oral hygiene practices showed less bone loss radiographically after 3 years than did control subjects. *It is clear that loss of attachment can be reduced by good oral hygiene and frequent dental prophylaxis.*

Treatment of Loss of Attachment

A longitudinal study of patients with moderate-to-advanced periodontal disease conducted at the University of Michigan showed

that the progression of periodontal disease can be stopped for 3 years postoperatively regardless of the modality of treatment.[29-32] With long-term observations, the average loss of attachment was only 0.3 mm over 7 years.[30] These results indicated a more favorable prognosis for treatment of advanced periodontal lesions than previously assumed.

Another study was conducted in 75 patients with advanced periodontal disease to determine the effect of plaque control and surgical pocket elimination on the establishment and maintenance of periodontal health.[16] This study showed that no further alveolar bone loss occurred during the 5-year observation period. The meticulous plaque control practiced by the patients in this study was considered a major factor in the excellent results produced. After 14 years, results for 61 of the initial 75 individuals were reported.[14] Repeated examinations demonstrated that treatment of advanced forms of periodontal disease resulted in clinically healthy periodontal conditions and that this state of health was maintained in most patients and sites during the 14-year period. A more detailed analysis of the data, however, revealed that a small number of sites in a few patients lost a substantial amount of attachment. Approximately 43 surfaces in 15 different patients were exposed to recurrent periodontal disease of significant magnitude. The frequency of sites that lost more than 2 mm of attachment during the 14 years of maintenance was 0.8% to 0.1% per year.

Neither of these studies used a control group because failing to treat advanced periodontal patients cannot be justified for ethical reasons. However, in a study in private practice, an effort was made to find and evaluate patients with diagnosed moderate-to-advanced periodontitis who had not followed through with recommended periodontal therapy.[3] Thirty patients ranging in age from 25 to 71 years were evaluated after periods ranging from 18 to 115 months. All of these untreated patients had progressive increases in pocket depth and radiographic evidence of progressive bone resorption.

In a study of the progression of periodontal disease in the absence of therapy, two different populations were monitored.[18] One group of 64 Swedish adults with mild-to-moderate periodontal disease and one group of 36 American adults with advanced destructive disease were monitored but not treated for 6 years and 1 year, respectively. During the course of 6 years, 11.6% of all sites in the Swedish population (1.9% per year) showed attachment loss of greater than 2 mm, and the corresponding figure for the American population was 3.2% per year. Thus the frequency of sites with disease progression was 20 to 30 times higher in untreated groups of patients than in the treated and well-maintained groups described in the preceding discussion.[18] *Thus treatment is effective in reducing loss of attachment.*

Tooth Mortality

The ultimate test for the effectiveness of periodontal treatment is whether the loss of teeth can be prevented. Sufficient studies from both private practice and research institutions are now available to document that loss of teeth is reduced or prevented by therapy.

The combined effect of subgingival scaling every 3 to 6 months and controlled oral hygiene was evaluated over a 5-year period in 1428 factory workers in Oslo.[22] Tooth loss was significantly reduced in all patients. This study showed that frequent subgingival scaling reduces tooth loss even when oral hygiene is "not good" (Table 70-1).

The previously mentioned longitudinal study conducted at the University of Michigan included 104 patients with a total of 2604 teeth.[29-32] After 1 to 7 years of treatment, 53 teeth were lost for various reasons (Table 70-2). Approximately 32 teeth were lost during the first and second years after initiation of treatment. The remaining 21 teeth were lost in a random pattern over the next 6 years. Therefore the loss of teeth caused by advanced periodontal disease after treatment was minimal (1.15%).

TABLE 70-1 Average Loss of Teeth during a 5-Year Period Compared with Normal Loss of Teeth in 1428 Men and Women Ages 20 through 59

	GRADE OF ORAL HYGIENE		
	Good	Fairly Good	Not Good
"Normal" loss of teeth*	1.1	1.4	1.8
Actual loss of teeth during 5-year period	0.4	0.6	0.9

From Lovdal A, Arno A, Schei O, et al: *Acta Odontol Scand* 19:537, 1961.

*Estimate based on data recorded at initiation of study period.

TABLE 70-2 Tooth Mortality after Treatment of Advanced Periodontitis in 104 Patients with 2604 Teeth Treated over a 10-Year Period

Teeth Lost*	Reason
2	Pulpal disease
3	Accidents
4	Prosthetic considerations
14	Various reasons; for example, one patient wanted a maxillary denture for cosmetic reasons
30	Periodontal
53	All reasons

Data from Ramfjord SP, Knowles JW, Nissle RR, et al: *J Periodontol* 44:66, 1973.

*2% of the teeth were lost during the study period. NOTE: United States health surveys conducted in the 1960s indicated that an average of 4.3 teeth were lost after age 35 in the general population.[9]

Another study was undertaken to test the effect of periodontal therapy in cases of advanced disease.[16-17] The subjects were 75 patients who had lost 50% or more of their periodontal support (Figure 70-5). Treatment consisted of oral hygiene measures, scaling procedures, extraction of untreatable teeth, periodontal surgery, and prosthetic therapy if indicated. After completion of periodontal treatment, no patient showed further loss of periodontal support for the next 5 years. No teeth were extracted in the 5-year posttreatment period. Patients in this study were selected because of their capacity to meet high requirements of plaque control after repeated instruction in oral hygiene techniques; this fact does not detract from the validity of the study but tends to show the etiologic importance of bacterial plaque. The results indicate that periodontal surgery coupled with a detailed plaque control program not only temporarily cures the disease but also reduces further progression of periodontal breakdown, even in patients with severely reduced periodontal support.

After 14 years, 61 of the original patients were still in the study.[17] Recurrence of destructive periodontal disease in isolated sites of the dentition resulted in loss of a certain number of teeth during the observation period (Figure 70-6). In the 6 to 10 years after active therapy, one tooth in each of three different patients was lost, and during the final observation period (11 to 14 years), three teeth in one patient, two teeth in each of three patients, and one tooth in each of four patients had to be extracted because of recurrent periodontal disease. In addition, three teeth in each of three different patients and one tooth in each of five patients were

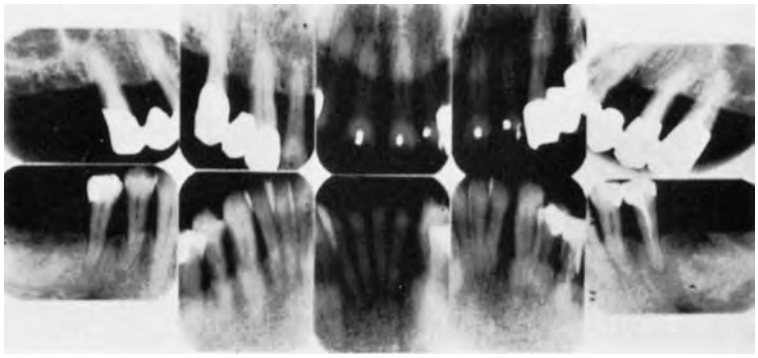

Figure 70-5 Radiographs taken 5 years after typical periodontal treatment. Note the advanced bone loss, despite the teeth retained in a healthy condition for the duration of the study. *(From Lindhe J, Nyman S:* J Clin Periodontol *2:67, 1975.)*

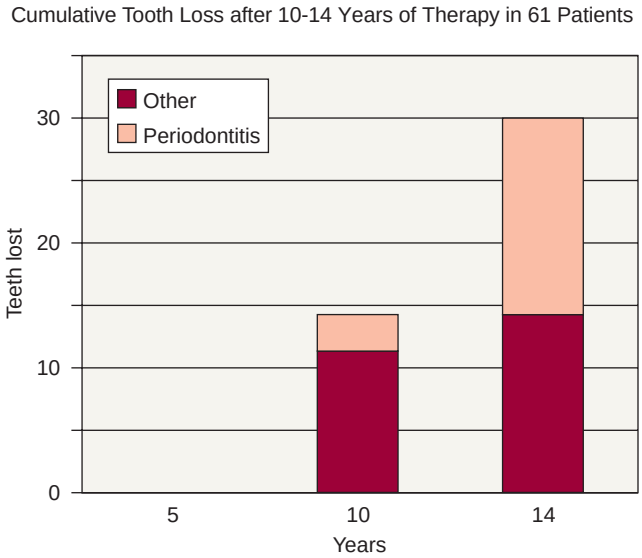

Figure 70-6 Tooth loss in treated patients with very advanced periodontal disease. *(Data from Lindhe J, Nyman S:* J Clin Periodontol *11:504, 1984.)*

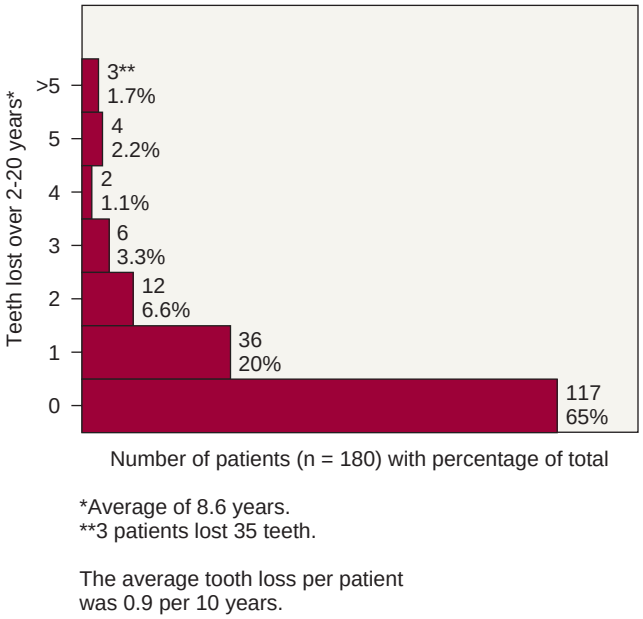

Figure 70-7 Tooth mortality. Average tooth loss per patient was 0.9 per 10 years. *(Modified from Ross IF, Thompson RH, Galdi M:* Parodontologie *25:125, 1971.)*

extracted because of the development of extensive caries, periapical lesions, or other endodontic complications. During the entire course of the study, the total loss was 30 teeth (for all reasons) of 1330 teeth. The tooth mortality rate was therefore 2.3%.

More recent university based studies on the treatment of moderate to severe periodontitis continue to show minimal tooth loss in patients who comply with periodontal maintenance therapy. [5,26]

Several studies in private practice have attempted to measure frequency of tooth loss after periodontal therapy. In one study, 180 patients who had been treated for chronic destructive periodontal disease were evaluated.[29-30] The average age of the patients before treatment was 43.7 years. A total of 141 teeth were lost. From the beginning of treatment to the time of the survey, the majority of patients lost no teeth (Figure 70-7). Three of 180 patients (1.7%) lost 35 teeth, approximately 25% of the teeth lost. Twelve additional patients lost 46 teeth, or 32.6% of the teeth lost. Many patients in the study had advanced alveolar bone loss, including extensive furcation involvements. However, only a relatively small number (141) of the teeth were lost in the study group of 180 patients between the beginning of periodontal treatment and the time of the study.

The teeth were lost for several reasons, including periodontal disease, caries, and other nonperiodontal causes. The length of time after treatment varied from 2 to 20 years, with an average of 8.6 years. Of considerable significance is the large number of teeth (81 teeth, or 57.5%) lost by a few patients (15 patients, or 8.4%). Even when this group is considered with the remaining 165 patients, the periodontal care helped to retain most teeth because the average tooth loss was slightly less than one tooth (0.9) over the 10 years after treatment.

In a follow-up study, the long-term results of periodontal therapy were evaluated after 15 to 34 years (average of 22.2 years).[4] The average tooth loss at this time was 1.6 teeth per 10 years. Patients were classified into three groups according to tooth loss. Approximately 62% had an average tooth loss of 0.45 per 10 years and were considered "well maintained"; 28% lost an average of 2.6 teeth per 10 years and were considered "downhill"; and 10% lost an average of 6.4 teeth per 10 years and were considered "extreme downhill" (Figure 70-8).

Another study included all patients in a practice who had been treated 5 or more years previously and had received regular preventive periodontal care since that time.[24] The 442 patients had an average of 10.1 years since treatment. Two-thirds of the patients were older than 40 years of age at the time of treatment. These patients had been seen every 4.6 months, on average, for their preventive periodontal care, which consisted of oral hygiene instruction and prophylaxis (Figures 70-9 and 70-10).

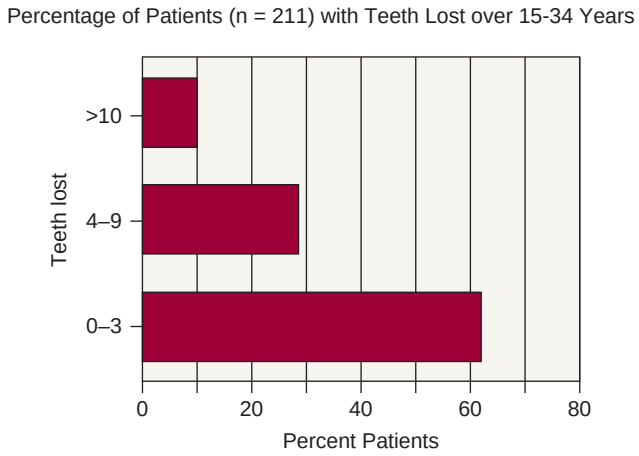

Figure 70-8 Tooth mortality 15 to 34 years after initiation of therapy (average of 22.2 years). Average tooth loss per patient was 1.6 teeth per 10 years. Compare with the same study population in Figure 70-7. As the treated population ages, the rate of bone loss appears to increase. *(Modified from Goldman MJ, Ross IF, Goteiner D:* J Periodontol *57:347, 1986.)*



Figure 70-9 Tooth mortality in 442 periodontal patients treated over 10 years. *(Courtesy Dr. R.C. Oliver, Rio Verde, AZ.)*

The total tooth loss resulting from periodontal disease was 178 of more than 11,000 teeth available for treatment. More important, 78% of the patients did not lose a single tooth after periodontal therapy, and 11% lost only one tooth. Considering that more than 600 teeth had furcation involvements at the time of the original treatment and that well over 1000 teeth had less than half the alveolar bone support remaining, the tooth loss was low. During the same average 10-year period after periodontal therapy, only 45 teeth were lost through caries or pulpal involvement. Even more surprising are the statistics over an average 10-year period for teeth with a less-than-optimal prognosis. Only 85 (14%) of a total of 601 teeth with furcation involvement were lost, and 117 (11%) of 1039 teeth with half or less of the bone remaining were lost. Of the 1043 teeth listed as having a "guarded prognosis" for any reason by the clinician performing the initial examination, only 126 (12%) were lost over this 10-year average period. The average tooth mortality rate was 0.72 tooth lost per patient per 10 years.

In a third study in private practice, 600 patients were followed for 15 to 53 years after periodontal therapy (Figures 70-11 and 70-12).[7] The majority (76.5%) had advanced periodontal disease at the start of treatment. There were 15,666 teeth present, for an average of 26 teeth per patient. During the follow-up period (average of 22 years), a total of 1312 teeth were lost from all causes. Of this number, 1110 were lost for periodontal reasons. The average tooth mortality rate per patient was 2.2 teeth; when this is converted to a 10-year rate, an average of one tooth was lost per 10 years in each patient. During this period of observation, 666

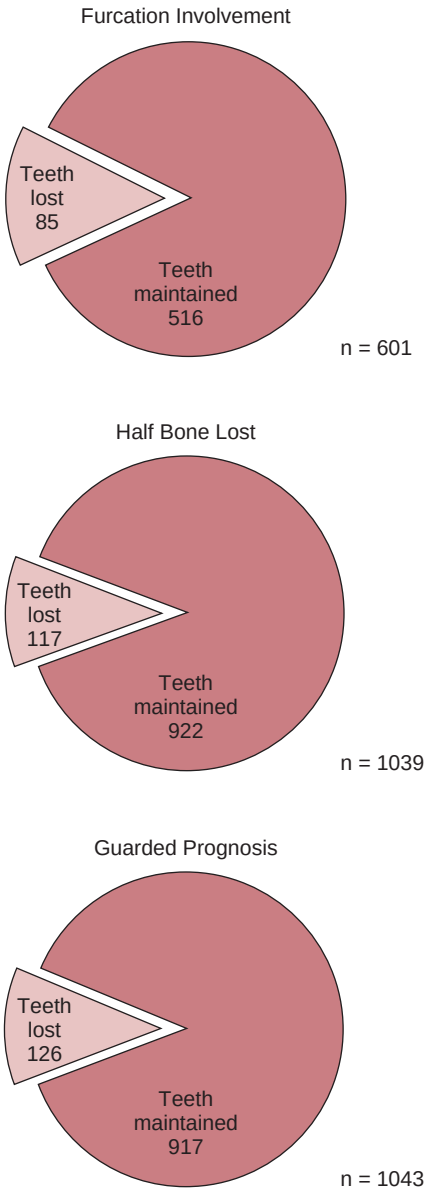

Figure 70-10 Loss of teeth with advanced periodontal disease over 10 years. *(Courtesy Dr. R.C. Oliver, Rio Verde, AZ.)*

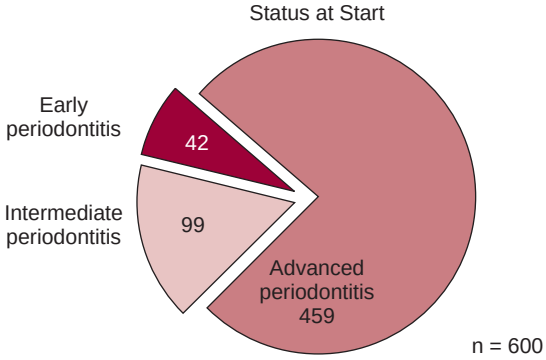

Figure 70-11 Status at the start of a study of 600 patients. *(Data from Hirschfeld L, Wasserman B:* J Periodontol *49:225, 1978.)*

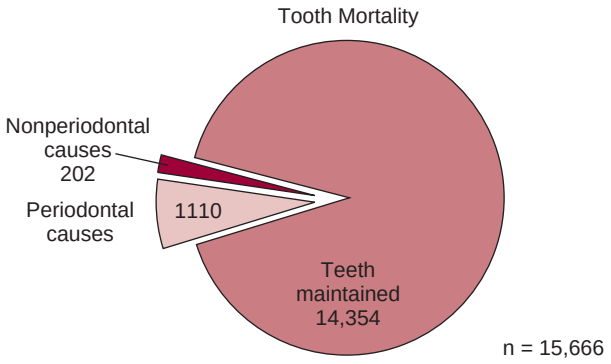

Figure 70-12 Loss of teeth in 600 patients over 15 to 53 years from nonperiodontal and periodontal causes. *(Data from Hirschfeld L, Wasserman B:* J Periodontol *49:225, 1978.)*

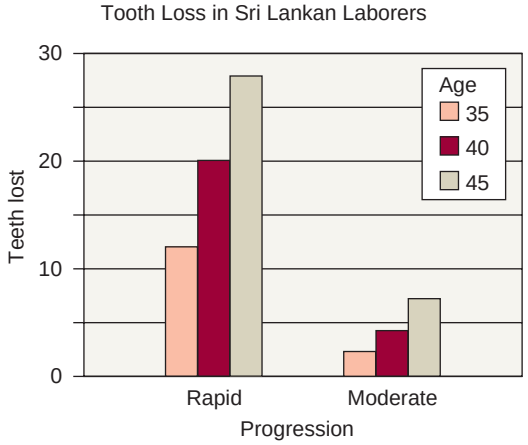

Figure 70-13 Tooth loss in a population with untreated periodontal disease. *(Data from Löe H, Anerud A, Boysen H, et al:* J Clin Periodontol *13:431, 1986.)*

teeth with a questionable prognosis were lost out of a total of 2141. This means that 31% of the teeth with a questionable prognosis were lost over 22 years of treatment. A total of 1464 teeth with furcation involvement were treated, and 31.6% were lost during the period of study. Approximately 83% of the patients lost fewer than three teeth over the 22-year average treatment period and were classified as "well maintained." The remaining 17% of the patients were divided into two groups: "downhill" (4 to 9 teeth lost) or "extreme downhill" (10 to 23 teeth lost). Thus 17% of the patients studied accounted for 69% of the teeth lost from periodontal causes. This study also showed that relatively few teeth are lost after periodontal therapy. In addition, relatively few of the teeth with guarded prognosis, including those with furcation involvement, are lost, and a small percentage of patients lose most of the teeth.

More recent private practice studies have also shown a relatively low rate of tooth loss in patients who are involved in a supportive periodontal maintenance program. One study showed that 0.9% of teeth were lost over 7.8 years while another showed 1.5% were lost over a 9.8-year period after active periodontal treatment.[4,6]

Three studies give insight into tooth mortality in untreated patients. The studies of Löe et al[22] in Sri Lankan laborers showed that after age 35, an average of 5 and 16 teeth were lost per 10 years in the "moderate progression" and "rapid progression" groups, respectively (Figure 70-13). In a previously discussed study in private practice,[3] an effort was made to find and evaluate patients with diagnosed moderate-to-advanced periodontitis who did not follow through with recommended periodontal therapy. Patients with untreated periodontal disease were losing teeth at a rate greater than 0.61 tooth per year (6.1 teeth per 10 years). A total of 83 teeth were lost in 30 patients, but the investigators excluded one patient who had lost 25 teeth. Including this patient would have increased the tooth loss in untreated patients to an even higher rate. In another study, reporting on patients with moderate-to-advanced periodontitis examined at the Department of Periodontology at the University of Kiel in Germany, Kocher et al[12] found a marked increase in tooth loss in the untreated patients compared with the treated patients when they were examined after 7 years.

When Tables 70-3 and 70-4 are compared, it is obvious that tooth mortality is much greater in untreated groups.

TABLE 70-3 Tooth Mortality in Treated Periodontitis Patients

Study	Average Number of Teeth Lost per 10 Years with Periodontal Treatment*
Hirschfeld and Wasserman[10]	1.0
Kocher et al[12]	1.6
McFall[23]	1.4
Oliver[28]	0.7
Ross et al[33]	0.9
Goldman et al[7]	1.6
McLeod et al[24]	1.5
Tsami et al[39] (nonsmokers)	1.7
Tsami et al[39] (smokers)	3.7
Ng et al[26] (compliant with maintenance)	0.8
Ng et al[26] (noncompliant with maintenance)	2.8

*Tooth mortality adjusted to 10 years by chapter author.

TABLE 70-4 Tooth Mortality in Untreated Periodontitis Patients

Study	Average Number of Teeth Lost per 10 Years without Periodontal Treatment*
Becker et al[3]	6
Kocher et al[12]	5
Löe et al[20] (moderate progression)	5
Löe et al[20] (rapid progression)	16

*Tooth mortality adjusted to 10 years by chapter author.

Conclusion

The prevalence of periodontal disease and the resulting high rate of tooth mortality have increased the need for effective treatment. Strong evidence now indicates that periodontal disease can contribute to numerous health problems, including pregnancy complications, heart disease, stroke, and diabetes.[25,26,27,34,35] Available treatment is effective in preventing periodontal disease and stopping the progression of bone destruction after periodontitis is present. In addition, overwhelming evidence suggests that periodontal therapy greatly reduces tooth mortality. Every dental practitioner should be familiar with the philosophy and techniques of periodontal therapy. Failure to diagnose and treat periodontal disease or to make periodontal treatment available to patients

causes unnecessary dental problems and tooth loss and places the patient at risk for systemic health problems.

Suggested Readings

Becker W, Berg L, Becker EB: Untreated periodontal disease: a longitudinal study. *J Periodontol* 50:234, 1979.

Chambrone L, Chambrone D, Lima LA, et al: Predictors of tooth loss during long-term periodontal maintenance: a systematic review of observational studies. *J Clin Periodontol* 37:675, 2010.

Costa FO, Lages EJ, et al: Tooth loss in individuals under periodontal maintenance therapy: 5 year prospective study. *J Periodontal Res* 49(1):121–128, 2014. doi: 10.1111/jre.12087. [Epub May 7, 2013].

Hirschfeld L, Wasserman B: A long-term survey of tooth loss in 600 treated periodontal patients. *J Periodontol* 49:225, 1978.

Löe H, Anerud A, Boysen H, et al: Natural history of periodontal disease in man. *J Clin Periodontol* 13:431, 1986.

Tsami A, Pepelassi E, et al: Parameters affecting tooth loss during periodontal maintenance in a Greek population. *J Am Dent Assoc* 140: 1100–1107, 2009.

References

References for this chapter are found on the companion website www.expertconsult.com.

References

1. Axelsson P, Lindhe J: Effect of controlled oral hygiene procedures on caries and periodontal disease in adults: results after 6 years. *J Clin Periodontol* 18:239, 1981.
2. Bay I, Moller IJ: The effect of a sodium monofluorophosphate dentifrice on the gingiva. *J Periodontal Res* 3:103, 1968.
3. Becker W, Berg L, Becker EB: Untreated periodontal disease: a longitudinal study. *J Periodontol* 50:234, 1979.
4. Carnevale G, Cairo F, Tonetti MS: Long-term effects of supportive therapy in periodontal patients treated with fibre retention osseous resective surger. II: tooth extractions during active and supportive therapy. *J Clin Periodontol* 34:342–348, 2007.
5. Costa FO, Lages EJ, et al: Tooth loss in individuals under periodontal maintenance therapy: 5 year prospective study. *J Periodontal Res* 49(1):121–128, 2014. doi: 10.1111/jre.12087. [Epub May 7, 2013].
6. Fardal O, Johannessen AC, Linden GJ: Tooth loss during maintenance following periodontal treatment in a periodontal practice in Norway. *J Clin Periodontol* 31:550–555, 2004.
7. Goldman MJ, Ross IF, Goteiner D: Effect of periodontal therapy on patients maintained for 15 years or longer. *J Periodontol* 57:347, 1986.
8. Greene JC: Periodontal disease in India: report of an epidemiological study. *J Dent Res* 39:302, 1960.
9. Greville TN: *United States life tables by dentulous or edentulous condition, 1971, and 1957–58, Pub No (HRA) 75-1338*, Washington, DC, 1974, US Department of Health, Education, and Welfare.
10. Hirschfeld L, Wasserman B: A long-term survey of tooth loss in 600 treated periodontal patients. *J Periodontol* 49:225, 1978.
11. Hoover DR, Lefkowitz W: Reduction of gingivitis by toothbrushing. *J Periodontol* 36:193, 1955.
12. Kocher T, Konig J, Dzierzon U, et al: Disease progression in periodontally treated and untreated patients: a retrospective study. *J Clin Periodontol* 27:866, 2000.
13. Konig J, Plagmann HC, Ruhling A, et al: Tooth loss and pocket probing depths in compliant periodontally treated patients: a retrospective analysis. *J Clin Periodontol* 29:1092, 2002.
14. Ladavalya MR, Harris R: A study of the gingival and periodontal conditions of a group of people in Chieng Mai province. *J Periodontol* 30:219, 1959.
15. Lightner LM, O'Leary JT, Drake RB, et al: Preventive periodontic treatment procedures: results over 46 months. *J Periodontol* 42:555, 1971.
16. Lindhe J, Nyman S: The effect of plaque control and surgical pocket elimination on the establishment and maintenance of periodontal health: a longitudinal study of periodontal therapy in cases of advanced disease. *J Clin Periodontol* 2:67, 1975.
17. Lindhe J, Nyman S: Long-term maintenance of patients treated for advanced periodontal disease. *J Clin Periodontol* 11:504, 1984.
18. Lindhe J, Haffajee AD, Socransky SS: Progression of periodontal disease in adult subjects in the absence of periodontal therapy. *J Clin Periodontol* 10:433, 1983.
19. Löe H, Theilade E, Jensen SB: Experimental gingivitis in man. *J Periodontol* 36:177, 1965.
20. Löe H, Anerud A, Boysen H, et al: The natural history of periodontal disease in man. *J Periodontol* 49:607, 1978.
21. Löe H, Anerud A, Boysen H, et al: Natural history of periodontal disease in man. *J Clin Periodontol* 13:431, 1986.
22. Lovdal A, Arno A, Schei O, et al: Combined effect of subgingival scaling and controlled oral hygiene on the incidence of gingivitis. *Acta Odontol Scand* 19:537, 1961.
23. McFall WT, Jr: Tooth loss with and without periodontal therapy. *Periodont Abstracts* 17:8, 1969.
24. McLeod DE, Lainson PA, Spivey JD: The effectiveness of periodontal treatment as measured by tooth loss. *J Am Dent Assoc* 128:316, 1997.
25. Meskin LH: Focal infection: back with a bang! *J Am Dent Assoc* 129:8, 1998.
26. Ng MC, Ong MM, et al: Tooth loss in compliant and non-compliant periodontally treated patients: 7 years after active periodontal therapy. *J Clin Periodontol* 38:499–508, 2011.
27. Offenbacher S, Lieff S, Beck JD: Periodontitis-associated pregnancy complications. *Pregnancy Neonat Med* 3:82, 1988.
28. Oliver RC: Personal communication, Rio Verde, AZ, 1977.
29. Ramfjord SP, Nissle RR: The modified Widman flap. *J Periodontol* 45:601, 1974.
30. Ramfjord SP, Knowles JW, Nissle RR, et al: Longitudinal study of periodontal therapy. *J Periodontol* 44:66, 1973.
31. Ramfjord SP, Knowles JW, Nissle RR, et al: Results following three modalities of periodontal therapy. *J Periodontol* 46:522, 1975.
32. Ramfjord SP, Nissle RR, Shick RA, et al: Subgingival curettage versus surgical elimination of periodontal pockets. *J Periodontol* 39:167, 1968.
33. Ross IF, Thompson RH, Galdi M: The results of treatment: a long-term study of one hundred and eighty patients. *Parodontologie* 25:125, 1971.
34. Slavkin HC: Does the mouth put the heart at risk? *J Am Dent Assoc* 130:109, 1999.
35. Stamm JW: Proceedings of the Sunstar-Chapel Hill Symposium 1997 on Periodontal Diseases and Human Health: new directions in periodontal medicine. *Ann Periodontol* 3:1, 1998.
36. Suomi JD, Greene JC, Vermillion JR, et al: The effect of controlled oral hygiene on the progression of periodontal disease in adults: results after the third and final year. *J Periodontol* 42:152, 1971.
37. Suomi JD, West JD, Chang JJ, et al: The effect of controlled oral hygiene procedures on the progression of periodontal disease in adults: radiographic findings. *J Periodontol* 42:152, 1971.
38. Theilade E, Wright WH, Jensen SB, et al: Experimental gingivitis in man. II, a longitudinal clinical and bacteriological investigation. *J Periodontal Res* 1:1, 1966.
39. Tsami A, Pepelassi E, et al: Parameters affecting tooth loss during periodontal maintenance in a Greek population. *J Am Dent Assoc* 140:1100–1107, 2009.

CHAPTER 71

Periimplant Anatomy, Biology, and Function

Joseph Fiorellini, Keisuke Wada, Panagiota Stathopoulou, and Perry R. Klokkevold

CHAPTER OUTLINE

Implant Geometry (Macrodesign)
Implant Surface Characteristics (Microdesign) *(e-only)*
Hard Tissue Interface
Soft Tissue Interface
Clinical Comparison of Teeth and Implants
Conclusion

For online-only content on endosseous implants, root form (cylindrical) implants, transmandibular implants, subperiosteal implants, and implant surface characteristics (microdesign), go to the companion website www.expertconsult.com. Some figures may be out of numeric order in this printed chapter.

Attempts to replace lost dentition by means of implanted materials can be traced back to the ancient Egyptians, who hammered shaped seashells directly into the jaws for the purpose of replacing teeth.[41] Over the last few centuries, a variety of materials have been implanted into jaws in an attempt replace missing teeth. The success of these early implants was extremely poor primarily because they never achieved a stable state of integration with the supporting tissues.[89] The typical outcome, regardless of material or design, was healing with a soft tissue layer interposed between the implant and bone (i.e., fibrous encapsulation). Consequently, implants became mobile, infected, and painful, which led to failure.

The history of modern implant dentistry began with the introduction of titanium implants.[41] In the 1950s, Per-Ingvar Brånemark, a Swedish professor of anatomy, had a serendipitous finding while studying blood circulation in bone that became a historical breakthrough in medicine. He discovered an intimate bone-to-implant apposition with titanium that offered sufficient strength to cope with load transfer. He called the phenomenon "osseointegration" and developed an implant system with a specific protocol to predictably achieve it. The implants were used to anchor prosthetic replacement teeth in the edentulous jaw,[30] and the first patient was successfully treated in 1965.[29,70] Subsequent clinical studies proved that commercially pure (CP) titanium implants, placed with a strict protocol, including an unloaded healing period, could predictably achieve osseointegration and retain a full-arch prosthesis in function with long-term success (15 years).[9] Since that time, millions of patients worldwide have had missing teeth replaced with implants based on this original concept. Over the years, implant systems with variations in design (geometric and surface characteristics) and modified protocols have been developed and used with equal or better long-term success.

Today, implant designs, surgical placement techniques, healing times, and restorative protocols continue to evolve with the goal of improving outcomes. It is important for clinicians to know periimplant anatomy, to understand the biology, and to appreciate the functional capacity of osseointegrated implants. This chapter reviews implant geometry and surface characteristics, as well as the anatomical and biological relationship of periimplant tissues.

Implant Geometry (Macrodesign)

Numerous implant systems with various geometric (macrodesign) designs have been developed and used before the current implant systems in use today. Previous implant designs included blade vents (narrow, flat shape; tapped into boney trough prepared with rotary burs),[67] press-fit cylindrical (bullet shape; pressed or tapped into prepared hole),[98] subperiosteal (custom-made framework; adapted to the surface of jawbone),[40] and transmandibular (long rods or posts; placed through the anterior mandible).[103] Some of these implant systems were initially stable and appeared to be successful over short-term periods (e.g., 5 years) but failed to remain stable, became symptomatic and/or loose, and failed over longer periods.[96,120] Lacking predictability, these implant systems are no longer used.

Since the time of the Brånemark studies, millions of patients have been treated worldwide using variations of these techniques with implants of different geometries and surface characteristics. Similar research including that of André Schroeder in Switzerland in the mid-1970s contributed to the success of endosseous dental implants. The serendipitous finding of Brånemark was that when a hole is prepared into bone without overheating or otherwise traumatizing the tissues, an inserted biocompatible implantable device would predictably achieve an intimate bone apposition, as long as micromovements at the interface were prevented during the early healing period. The history of the research endeavors in Sweden provides a better understanding of the relevant biologic parameters involved.[70]

The macroscopic configuration of implants has varied widely; the most common types are listed in Box 71-1. Currently, most endosseous implants have a cylindrical or tapered, screw-shaped/threaded design. The disastrous results with other implant configurations were largely responsible for the evolution toward the current popular designs.[14]

Endosseous Implants

Blade Implants. Blade implants were designed and developed by Linkow[67] and used clinically in 1960s and 1970s. Blade implants were inserted into the jawbone after mucoperiosteal flap elevation and preparation of a channel with a high-speed rotary bur. They were tapped into the narrow trench. One or several posts pierced through the mucoperiosteum after suturing of the flaps. After a few weeks of healing, a fixed prosthesis was fabricated by a classic method and cemented on top of it.

Because the high-speed drilling leads to extensive bone necrosis at the histologic level, fibrous scar tissue formation occurs. This allows downgrowth of the epithelium, which leads to marsupialization of the blade implants (Figure 71-1).[57] If a bacterial infection occurs, it can lead to an intractable periimplantitis with ample bone loss. More importantly, removal of such implants after complications implies sacrificing surrounding jawbone. Because of its retentive geometry, the blade implant cannot simply be extracted or removed by a trephine, as with a cylindrical or screw-shaped implant.

The interface between blade vent implant and bone was called *fibroosseous integration,* which was defined as tissue-to-implant contact: interposition of healthy dense collagen fibers at the interface between the implant and bone.[1] At that time, the fibrous tissue was thought to be the replacement of the periodontal ligament;[115] however, it was fibrous scar tissue following the bone necrosis initiated by high-speed drilling. This allows epithelial downgrowth around the post caused by the bacterial infection, which leads to encapsulation of blade implant with the fibrous scar tissue.

Most of the studies reported less than 50% success rate for 5-year duration with the complication of pocket formation exceeding 6 mm, followed by the significant alveolar bone loss around the implant.[36,106] It was also more complicated and invasive surgery to remove the failed implant, which was sacrificing significant surrounding jawbone. As a result of the poor long-term success, as well as the high complication rate, the use of blade vent implants has been significantly reduced. Removal of failed blade implants often requires significant cutting and bone removal despite being mobile.

Pins. Although seldom used at present, in the classic technique, three diverging pins were inserted either transgingivally or after reflection of mucoperiosteal flaps in holes drilled by spiral drills. At the point of convergence, the pins were interconnected with cement to ensure the proper stability because of their divergence. On top of this arrangement, a single tooth could be installed. In edentulous jaws, several of these pin triads could be used to interconnect with a fixed prosthesis.

As with blade implants, the bone necrosis during drilling leads to fibrous encapsulation, marsupialization, and loss of the implants because of infections. A positive aspect, however, is that when such implants must be removed, removing the connection at the place of convergence is sufficient to allow easy extraction of each individual pin. Thus bone loss from removal is minimal.

Disk Implants. Disk implants are rarely used at present. The concept developed by Scortecci is based on the lateral introduction into the jawbone of a pin with a disk on top.[100] Once introduced into the bone, the implant has strong retention against vertical extraction forces. Implants have been used with one, two, and even three disks. Unfortunately, as mentioned previously for blade implants, the cutting of the bone by means of high-speed drills leads to a fibrous scar tissue surrounding the implant, as revealed frequently by periimplant radiolucencies. Data on the clinical success of disk implants are mostly anecdotal.

Root Form (Cylindrical) Implants

The first implant in this category, designed and developed by Schroeder and colleagues between 1974 and 1985, was called *ITI* (International Team for Implantology) *hollow-cylinder, plasma-sprayed, one-stage implant*[98] (Figure 71-2). It was thought that the hollow geometry should provide large bone-to-implant contact and holes would favorable for the additional fixation of the implant. However, the survival rates were less favorable compared to the other system.[8] Thus this system was withdrawn from clinical use.

When discussing cylindrical implants, it is important to distinguish between hollow and full cylindrical implants. Straumann and coworkers introduced hollow cylinders in the mid-1970s with the ITI system.[107] The idea was that implant stability would benefit from the large bone-to-implant surface provided by means of the hollow geometry. It was also thought that the holes (vents) would favor the ingrowth of bone to offer additional fixation. The same



Figure 71-1 Blade implant shows a large radiolucency, indicating that the fibrous encapsulation has led to deep pocketing and subsequent bone loss. Neighboring teeth bear the load of the implant restoration.

Figure 71-2 International Team for Implantology (ITI) hollow cylinder implant. Note the hollow geometry, which should provide large bone-to-implant contact, and holes that theoretically should be favorable for the additional fixation of the implant.



Figure 71-3 The IMZ implants. The roughened surface of the fixture had an advantage of higher integration of bone. Conversely, the surface characteristic added to the high frequency of peri-implantitis in long-term use.

concept was used in the Core-Vent system developed by Niznick.[78] Although it was not clarified whether the cause was geometry or the associated surface characteristics (titanium plasma–sprayed surface, titanium alloy), survival statistics were disappointing for hollow cylinder implants.[111]

Solid cylindrical implants were used by Kirsch and became available under the name IMZ, referring to the *internal mobile shock absorber.*[63] The IMZ system, developed by Kirsch, prevailed in the market (Figure 71-3). The characteristic function of this system was the *internal mobile element* (IME) shock absorber, which was able to connect with the adjacent natural tooth. The system presented successful results in the short term, but long-term success rates were unacceptable (38% in 10 years), leading to the limited use of this implant design.[49] For this reason, this implant is rarely seen in the market.

Even when an intimate bone apposition is achieved, extraction forces on such cylindrical implants lead to strong shear forces at the bone-to-implant interface. Only the microscopic surface irregularities offer some mechanical retention by interdigitation of bone growing onto the implant surface. With a screw-based geometry, forces acting parallel to the long axis of the implants are dispersed in many directions.[102]

Transmandibular Implants

Transmandibular implants were developed to retain dentures in the edentulous lower jaw. They were indicated for use in the extremely resorbed edentulous mandible with a minimal alveolar ridge height less than 10 mm. The implant was inserted through a submandibular skin incision and required general anesthesia. Two models were available in the 1960s. The first, called the *staple-bone implant,* was developed by Small. It consisted of a splint adapted to the lower border of the mandible, to which it is fixed by stabilizing pins.[104] Two transmandibular screws were driven transgingivally into the mouth. The reported implant survival rate was 93% after 5 years and continued to exceed 90% after 15 years.[103,105] The other model, introduced by Bosker, has two metal splints, one below the lower border of the mandible and one intraorally to connect the four posts piercing through the soft tissues.[24] The Bosker implant seemed less reliable than the staple-bone implant, achieving only 70% survival after 5 years in the mandibular symphyseal area.[111] Both transmandibular implants presented with the gingival hyperplasia or infection with the incidence of 10% to 15% of all cases.[103] Despite the good long-term survival data reported (especially for the staple implant), the high incidence of complications and the necessity of using general anesthesia for implant placement, the transmandibular implant design is rarely used today.

Subperiosteal Implants

Subperiosteal implants are customized according to a plaster model derived from an impression of the exposed jawbone, before the surgery planned for implant insertion. The implant was designed with several posts, typically four or more for an edentulous jaw, which passed through the gingival tissues.[12]

Subperiosteal implants are designed to retain an overdenture, although fixed prostheses have also been cemented onto the posts. As a result of epithelial migration, the framework of subperiosteal implants usually becomes surrounded by fibrous connective tissue (scar), including the space between the implant and the bone surface. The marsupialization, as described earlier, often leads to infectious complications, which often necessitates removal of the implant. Furthermore, while being loaded by jaw function, jawbone resorption occurs rapidly, resulting in a lack of adaptation of the frame to the bone surface. As a result of this type of outcome, subperiosteal implants are now rarely used.

The subperiosteal implant was used in the treatment of atrophic mandibles. The implant is custom designed to fit the mandibular jaw bone using a plaster model obtained from an impression of the exposed mandible. It consisted of a cast metal framework with a subperiosteal component in contact with the bone and a transgingival component (posts), which were used to retain the dental prosthesis. The number of transgingival posts on the implants depend on the number of missing teeth, averaging four to six for the totally edentulous jaw. Several clinical studies reported poor survival rates of less than 50% for 5 to 10 years, with the frequent complication of gingival inflammation, involving tissue reaction around the post caused by the lack of soft tissue attachment to the metal post. These complications led to the development of sinus tract resorption of the cortical bone and exposure of framework.[79,121] As a result of this higher rate of failure, as well as the significant complications and surgical invasion, subperiosteal implants are rarely used.

The most common implant design being used today is the screw-shaped or threaded cylindrical implant (Figure 71-4, *A*). A threaded implant design is preferred because it engages bone well and is able to achieve good primary stabilization. Even systems that started with cylindrical press-fit (nonthreaded) designs progressively evolved to a threaded geometry. The (longitudinal) shape of implants may be parallel or tapered (Figure 71-4, *B*). Although a vast majority of all implants have been parallel walled, the use of a tapered implant design has recently been advocated because it requires less space in the apical region (i.e., better for placement between roots or in narrow anatomic areas with labial concavities). Tapered implants have also been advocated for use in extraction sockets (Figure 71-5).

Implant Surface Characteristics (Microdesign)

Implant surface characteristics (microtopography) have been shown to positively influence the healing process.[31,61,74,85] Accordingly, modification of implant surface characteristics has been a major area of research interest and development over the past 15 to 20 years. Modifications in surface energy, chemical composition, and surface topography are known to influence cellular activity and tissue responses leading to enhanced osteogenesis.[26,32,72,114] At the



Figure 71-4 **A,** Illustration of a parallel, threaded implant. **B,** Illustration of a tapered, threaded implant. *(Copyright 2012 BIOMET 3i, LLC. Used by permission, all rights reserved.)*

Figure 71-5 A tapered, threaded implant design is helpful to minimize apical bone fenestration in areas such as the anterior maxilla, as the result of the presence of labial concavities. Tapered implant designs are also advantageous for immediate implant placement into extraction sockets.

molecular level, modified implant surfaces increase adsorption of serum proteins, mineral ions, and cytokines, which subsequently promote cellular migration and attachment.[62,85,100] Implant surface characteristics can also aid in the retention of a fibrin clot, thus providing a migratory pathway for the differentiating osteogenic cells to reach the implant surface.[37,38,87] Today, implants are treated with a variety of technologies to modify surface characteristics (microscale or nanoscale) to enhance bone formation.

Additive Processes

The additive process modifies the microstructure/macrostructure and chemical nature of the implant surface by adding materials or chemicals to the existing surface. There are several methods used to

Figure 71-6 High magnification (acid fuchsin–toluidine blue; ×100) of hydroxyapatite-coated implant with intimate bone approximation. Parts of the hydroxyapatite coating are observed on the surface.

add materials and/or chemicals to the implant surface, such as inorganic mineral coatings, plasma spraying, biocoating with growth factors, fluoride, and particulates or cements containing calcium phosphates, sulfates, or carbonates. The addition of materials, such as hydroxyapatite (Figure 71-6), to the implant surface has been shown to enhance or accelerate the initial bone cells adaptation or proliferation.[42,43,53,118] In general, additive surface modifications

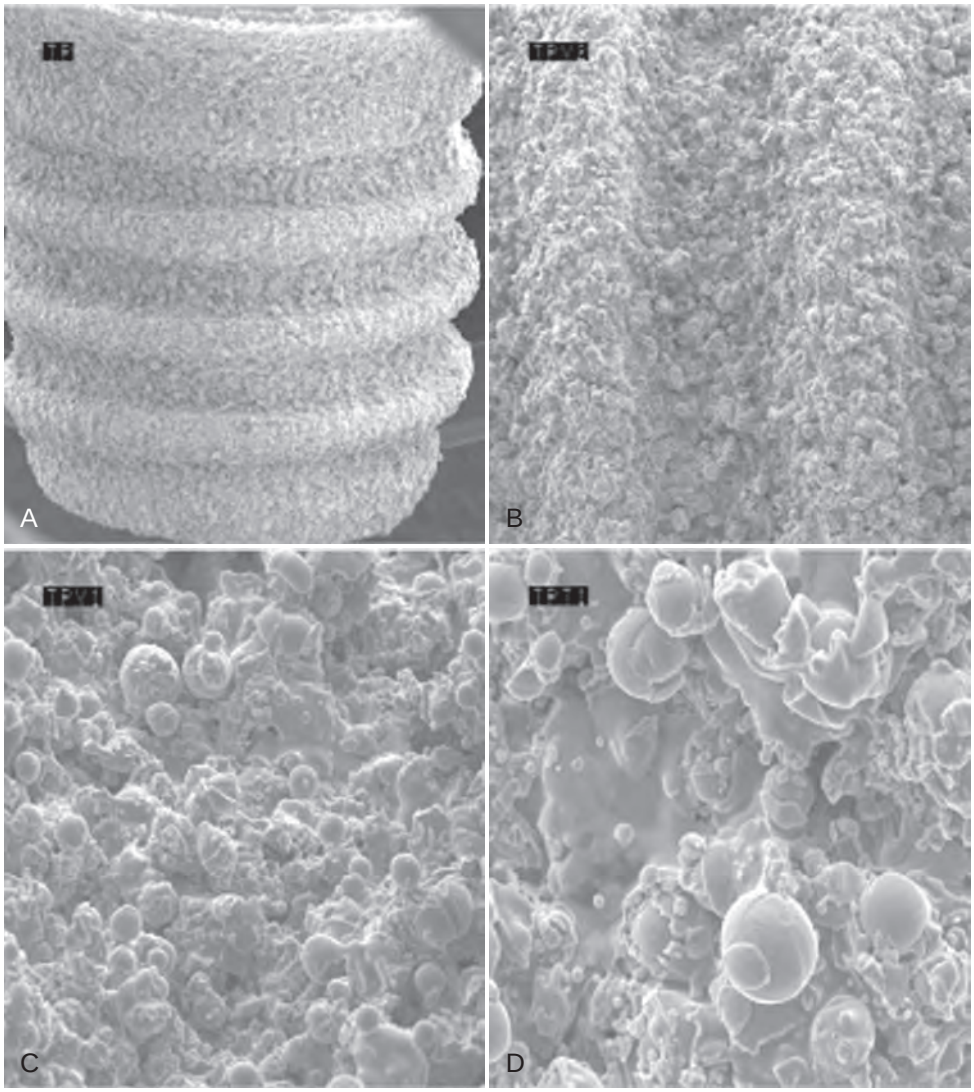

Figure 71-7 Scanning electron microscope (SEM) image of titanium plasma–sprayed surface implant with rough surface characteristics. **A,** Implant with titanium plasma–sprayed surface (×40). **B,** Notably complex macrotopography on titanium plasma–sprayed surface (×100). **C,** Titanium plasma–sprayed surface with 1- to 25-µm particles (×500). **D,** Titanium plasma–sprayed surface with 1- to 25-µm particles (×1000).

tend to increase the surface texture greater than subtractive surface modifications, which results in topographically "rougher" implant surfaces (Figure 71-7). Surface roughness can also be increased by oxidizing or adding an oxide layer (Figure 71-8).

Subtractive Processes

The subtractive process modifies the microstructure and chemical nature of the implant surface by removing or altering the existing surface. The roughness of implant surface can be modified by machining, acid etching, blasting, or a combination of these processes to enhance the amount or speed of osseointegration.[36,43,90] The changes are most notable at the microscopic level (Figures 71-9 and 71-10). Implant surfaces that are modified at the microscopic level with techniques such as acid-etching are thought to promote favorable cellular responses and increased bone formation in close proximity to the surface[16,55] (Figure 71-11).

Implant Surface Chemical Composition

There have been unsuccessful trials with oral implants made of carbon or hydroxyapatite. The lack of resistance, because of material properties, to occlusal forces led to frequent fractures. The so-called noble metals or alloys, however, do not resist corrosion

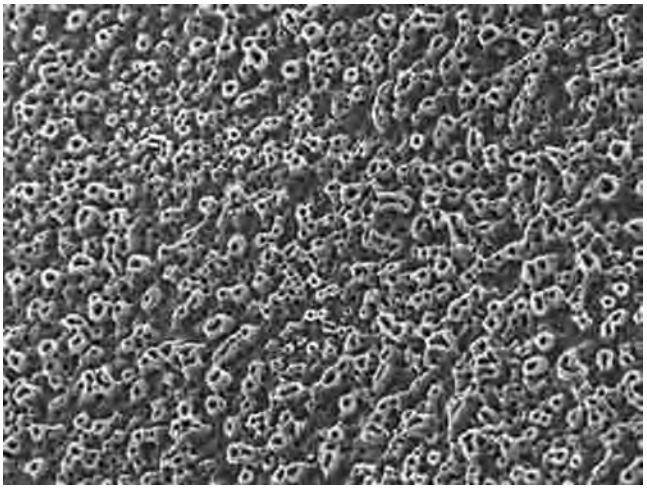

Figure 71-8 Roughened surfaces are achieved by plasma spraying, by acid etching, or as shown here by oxidizing (TiUnite surface). *(Courtesy Nobel Biocare Services AG, Zurich, Switzerland.)*



Figure 71-9 Scanning electron microscope (SEM) image of machined surface implant with characteristic grooved pattern. **A,** Implant with machined surface (×40). **B,** Grooved pattern apparent on machined surface (×100). **C,** Machined surface with distinct ridges and grooves (×500). **D,** Machined surface with distinct ridges and grooves (×1000). *(Courtesy Nobel Biocare Services AG, Zurich, Switzerland.)*

and have thus been abandoned. Today, the vast majority of oral implants are made of CP titanium or titanium alloys. The following discussion relates to titanium implants.

Titanium is a very reactive metal that oxidizes within nanoseconds when exposed to air. Because of this passive oxide layer, the titanium then becomes very resistant to corrosion in its CP form. Some alloys, such as titanium-aluminum 6%, vanadium 4% (Ti6Al4V), are known to provoke bone resorption as the result of leakage of some toxic components. The oxide layer of CP titanium reaches 10 nm of thickness. It grows over the years when facing a bioliquid. It consists mainly of titanium dioxide (TiO_2).

All titanium oxides have dielectric constants, which are higher than most other metal oxides. This factor may explain titanium's tendency to adsorb biomolecules, as seen during surgery when the blood creeps up the surface during implant insertion. The biomolecules normally appear as folded-up structures to hide their insoluble parts, while putting water-soluble radicals on their surface. Thus they will adhere to the TiO_2 surface after displacing the original water molecules sitting on its surface. Although initially attracted by weak van der Waals forces, the high dielectric constant of titanium oxides and the polarizability of the molecules after adsorption will lead to high bond strengths, which are considered irreversible when they surpass 30 kcal/mol.[59] In fact, because of its propensity for being covered by an uninterrupted oxide layer, which has ceramic-like properties similar to other metal oxides (e.g., aluminum oxides), titanium makes the coating of implants superfluous. This should be stressed because many authors hope for even better osseointegration potential with calcium phosphate (CaP)–coated surfaces and strongly advocate their use. To date, clinical results with CaP-coated implants have not been encouraging in a long-term perspective.[22]

Thus the overall view of potential advantages for different implant surface characteristics is complex, and only clinical observations can determine their validity. For good-quality bone, after 15 years of follow-up, clinical success rates of 99% have been reported for implants with a turned surface.[65] Enhanced implant surface characteristics are likely to be most beneficial for the more challenging situations, such as poor quality bone and early and immediate loading.

Implant Surface Free Energy and Micro-Roughness

When an implant is brought into contact with bodily tissues and fluids, in this case mostly bone, it faces a "bioliquid," an aqueous



Figure 71-10 Scanning electron microscope (SEM) image of acid-etched surface implant with typical microscopic peak-valley appearance. **A,** Implant with acid etched surface (×40). **B,** Microtextured surface alteration on acid-etched surface (×100). **C,** Acid-etched surface with micropits of 1 to 3 µm (×500). **D,** Acid-etched surface with micropits of 1 to 3 µm surrounded by larger areas with 6 to 10 µm peak-valley pits (×1000).

environment. Within milliseconds, water, ions, and small biomolecules are absorbed. One could imagine that this absorbed layer renders all surfaces equal. However, the large molecules and the cells that will subsequently adhere to this surface are influenced by the surface characteristics of this pellicle layer. The composition and structure of the initial layer are largely determined by the underlying surface.[93] Thus, the three-dimensional shape of the molecules will be modified during their adherence to this pellicle layer and will unveil different radicals, depending on this metamorphosis.

The surface free energy, often called *wettability,* is an important parameter for these interactions. It can be assessed through the shape of a standardized drop of liquid put on the clean implant surface. The angle of this drop toward the underlying surface reveals that the cohesive forces between liquid molecules are stronger than the adhesive forces between the liquid and the surface. Thus a ball-shaped drop would reveal a low surface free energy.

Surface topography at the cellular and molecular level means microscopic roughness. A surface roughness can be measured with a profilometer, a stylus that follows the surface and measures the peak-to-valley dimensions (expressed as Ra values) or the spacing between irregularities (expressed as Scx values). Wennerberg and Albrektsson[116] provide guidelines for topographic evaluation of implant surfaces.[116] No implant surface is smooth, although several reports have incorrectly referred to the "turned" (machined) implant surface as "smooth" (see Figure 71-9). Roughened implant surfaces speed up the bone apposition; as demonstrated in vitro, more prostaglandin E_2 (PGE_2) and transforming growth factor beta 1 (TGF-β_1) are produced on rough than on smooth surfaces.[62] Rough surfaces may show some disadvantages, such as increased ion leakage and increased adherence of macrophages and subsequent bone resorption.[73]

It was also reported that in vitro adsorption of fibronectin was higher on smooth than on rough, CP titanium surfaces.[44] Fibronectin is a glycoprotein quickly adhering on hard surfaces and known to determine subsequent cell adhesion.[81] Microtopography also influences the number and morphology of cell adhesion pseudopods and cell orientation.[52] Grooves in an implant surface will guide the cell migration along their direction. Bone growth can

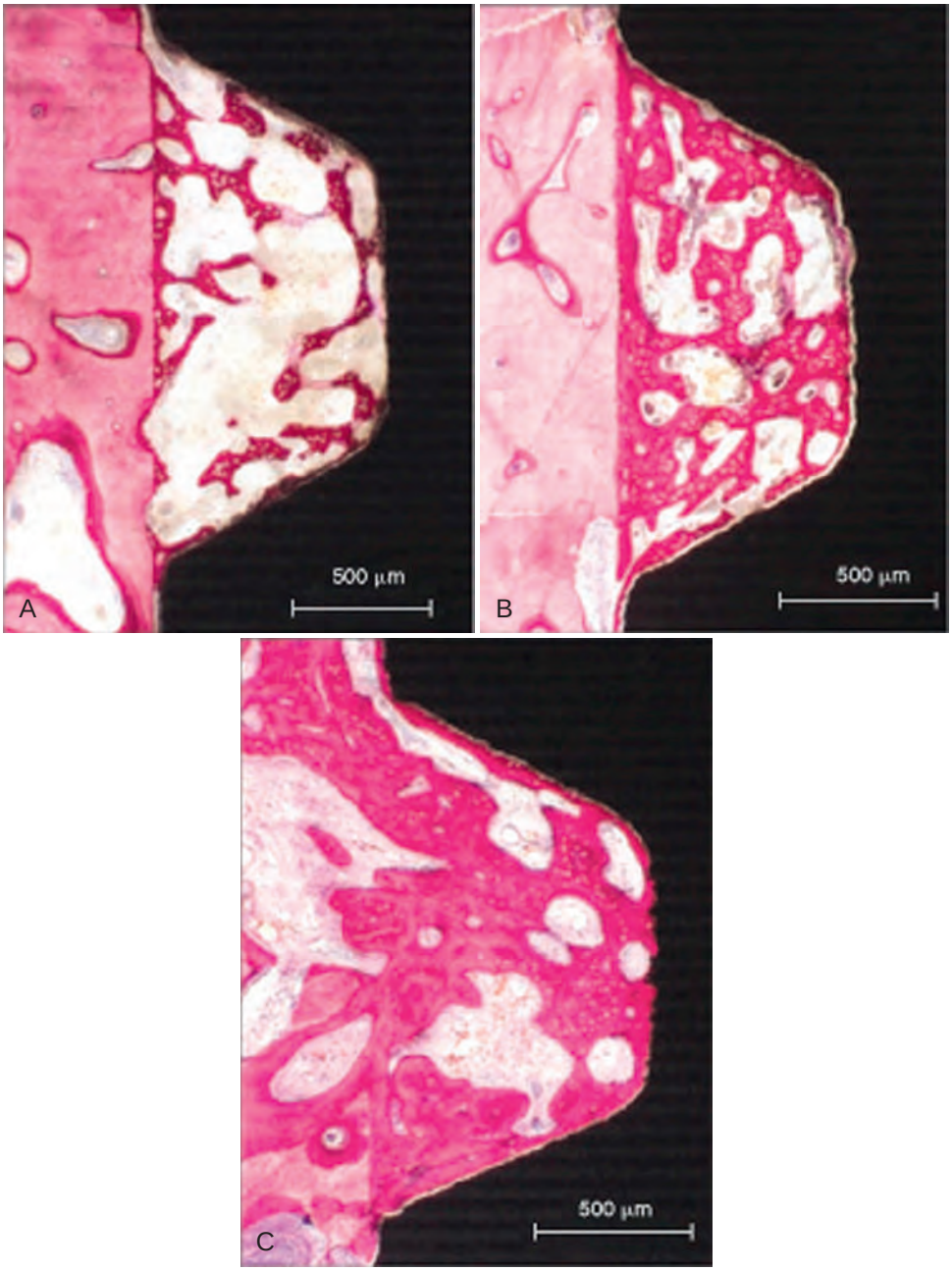

Figure 71-11 Histologic appearance of bone apposition. **A,** At 2 weeks, bone is deposited on the bony wall of the tissue chamber and on the implant surface. Both layers are connected by a scaffold of tiny trabeculae. Woven bone is characterized by the intense staining of the mineralized matrix and the numerous osteocytes located in large lacunae (undecalcified ground section, surface-stained with toluidine blue and basic fuchsin). **B,** At 4 weeks, the volume density of this scaffold has increased both by the formation of new trabeculae and by deposition of more mature, parallel-fibered bone onto the primary scaffold. Woven bone is mainly recognized by the numerous large osteocytic lacunae (bright). The gap between bone and implant surface is an artifact. **C,** At 8 weeks, growth and reinforcement result in a further increase in bone density and an almost perfect coating of the implant surface with bone. Remodeling has started, replacing the primary bone by secondary osteons (*arrows*).

enter altered microtopographic features such as pits and porosities with internal dimensions that are only a few microns.

Lack of load can also be detrimental and can lead to cortical bone resorption. This is well documented in orthopedics and is termed *stress shielding*.[54] This phenomenon has not been properly evaluated for oral implants in which marginal bone resorption is thought to be associated with chronic inflammation of the overlying soft tissues.

The use of finite element analysis (FEA) has become popular but lacks value by itself; invalid assumptions, such as the isotropic nature of the bone, must be used in the modeling. The deviation of FEA data from in vivo data has been well documented.[71] FEA data should be considered "descriptive" models that require confirmation by biologic data. However, as with photoelastic studies, FEA analyses do provide some insight on stress concentrations and their relation to implant geometry and the prosthetic superstructures.

Hard Tissue Interface

The primary goal of implant installation is to achieve and maintain a stable bone-to-implant connection (i.e., osseointegration).[27,29] Histologically, osseointegration is defined as the direct structural and functional connection between ordered, living bone and the surface of a load-bearing implant without intervening soft tissues (Figure 71-12).[28,30] Clinically, osseointegration is the asymptomatic rigid fixation of an alloplastic material (implant) in bone with the ability to withstand occlusal forces.[13,122] The hard tissue interface is a fundamental requirement for and an essential component of implant success.

Initial Bone Healing

The osseointegration process observed after implant insertion can be compared to bone fracture healing. Implant site osteotomy preparation (bone wounding) initiates a sequence of events, including an inflammatory reaction, bone resorption, release of growth factors, and attraction by chemotaxis of osteoprogenitor cells to the site. Differentiation of osteoprogenitor cells into osteoblasts leads to bone formation at the implant surface. Extracellular matrix proteins, such as osteocalcin, modulate apatite crystal growth.[119] Specific conditions, optimal for bone formation, must be maintained at the healing site to achieve osseointegration.

Immobility of the implant relative to the bone must be maintained for bone formation at the surface. A mild inflammatory response enhances the bone healing, but moderate inflammation or movement above a certain threshold is detrimental.[7] When micromovements at the interface exceed 150 µm, the movement will impair differentiation of osteoblasts and fibrous scar tissue will form between the bone and implant surface.[88] Therefore it is important to avoid excessive forces, such as occlusal loading, during the early healing period.

Bone tissue damage and debris created by the osteotomy site preparation must be cleared up by osteoclasts for normal bone healing. These multinuclear cells, originating from the blood, can resorb bone at a pace of 50 to 100 µm per day. There is a coupling between bone apposition and bone resorption (Figure 71-13). Preosteoblasts, derived from primary mesenchymal cells, depend on a favorable oxidation-reduction (redox) potential of the environment. Thus a proper vascular supply and oxygen tension are needed. If oxygen tension is poor, the primary stem cells may differentiate into fibroblasts, form scar tissue, and lead to implant failure (nonintegration).

If bone is overheated or crushed during preparation, it will become necrotic and may lead to nonmineralized (soft tissue) scar formation or be sequestered. The critical temperature for bone cells

BOX 71-1 Implant Geometry (Macrodesign)

1. Endosseous implants
   - Bladelike
   - Pins
   - Cylindrical (hollow and full)
   - Disklike
   - Screw shaped
   - Tapered and screw shaped
2. Subperiosteal framelike implants
3. Transmandibular implants

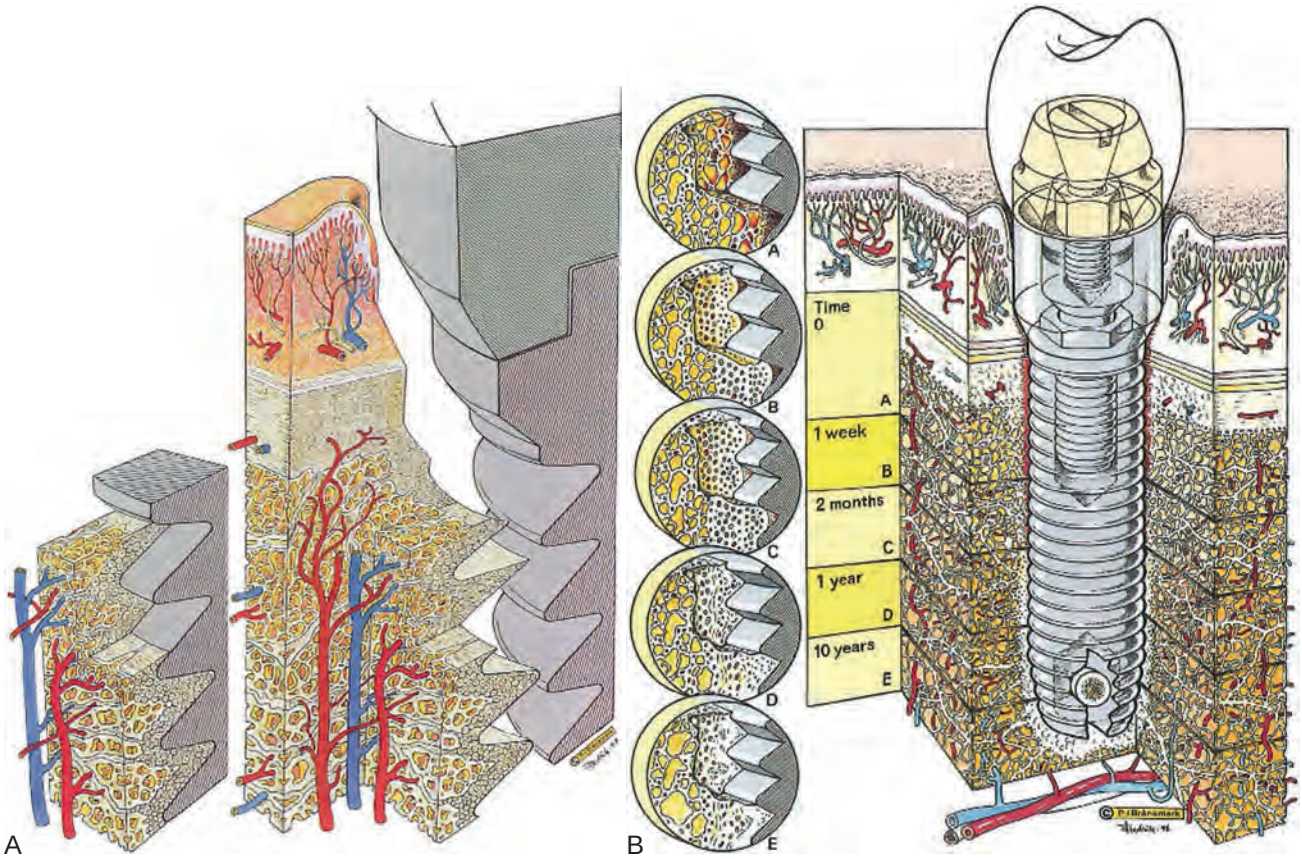

Figure 71-12 **A,** Three-dimensional diagram of the tissue and titanium interrelationship showing an overall view of the intact interfacial zone around the osseointegrated implant. **B,** Physiologic evolution of the biology of the interface over time.

that should not be exceeded is 47° C (116.6° F) at an exposure time of one minute.[7] Thus preparation of implant osteotomy sites require profuse irrigation (cooling) along with gentle, intermittent, moderate-speed drilling using sharp drills. Another complicating factor, well recognized from open wound fractures, is that microbial contamination jeopardizes the normal bone healing. Accordingly, strict aseptic techniques should be maintained.

New bone formation follows a specific sequence of events. Woven bone is quickly formed in the gap between the implant and the bone; it grows fast, up to 100 µm per day, and in all directions. Characterized by a random orientation of its collagen fibrils, high cellularity, and limited degree of mineralization, the biomechanical capacity of woven bone is poor (Figure 71-14, *A*). Thus any occlusal load should be well controlled or avoided in the early phase of healing. After several months, woven bone is progressively replaced by lamellar bone with organized, parallel layers of collagen fibrils and dense mineralization. Contrary to the fast-growing woven bone, lamellar bone formation occurs at a slow pace (only a few microns per day). Ultimately, after 18 months of healing, a steady state is reached where lamellar bone is continuously resorbed and replaced (Figure 71-14, *B*).[30] At the light microscopic level, an intimate bone-to-implant contact has been extensively reported (Figure 71-15).[94] Once the bone-to-implant interface has reached a steady state, it can maintain itself over decades, as ascertained by human histology from implants retrieved because of hardware fractures.[11]

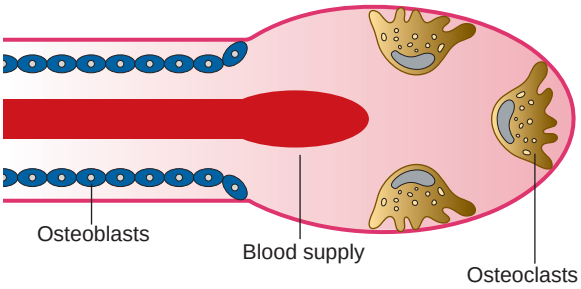

Figure 71-13 The basic multicellular unit is the basic remodeling process for bone renewal. Osteoclasts are imported by the vascular supply, and the resorption lacunae are soon filled by the lining osteoblasts.

Bone Remodeling and Function

Clinically, both primary and secondary stability of an implant are critical to success. Primary stability, achieved at the time of surgical placement, depends on the implant geometry (macrodesign), as well as the quality and quantity of bone available for implant anchorage at a specific site. Secondary stability, achieved over time with healing, depends on the implant surface (microdesign), as well as the quality and quantity of adjacent bone, which will determine the percentage of contacts between the implant and bone.[18,47,92,109] For example, areas such as the anterior mandible have dense cortical bone and provide rigid primary stabilization and good support throughout the healing process. Conversely, areas such as the posterior maxilla have thin cortical bone and large marrow spaces provide less primary stability. For this reason, the posterior maxilla has been associated with lower success rates compared to other sites with greater bone density and support.[17,58]

Once osseointegration is achieved, implants can resist and function under the forces of occlusion for many years. Longitudinal biomechanical assessments seem to indicate that during the first weeks after placement of one-stage implants, decreased rigidity is observed.[45] This may be indicative of bone resorption during the initial phase of healing. Subsequently, rigidity increases and continues to increase for years.[108] Thus, when a prosthesis is installed immediately (in 1 day) or early (in 1 to 2 weeks), care must be taken to control against overload. It is important to recognize that sites with limited primary stability or less bone-to-implant contact (e.g., posterior maxilla) will likely go through a period of even less bone support in the early stages of bone healing due to the initial phase of bone resorption.

Soft Tissue Interface

Not surprisingly, for two decades, research and clinical interest focused on the bone-to-implant interface of osseointegrated implants and the overlying soft tissues were largely ignored. Except for a few descriptive sentences, the classic handbook by Brånemark et al[30] presented no data or information about the soft tissue interface. This may be due in part to the fact that most patients were fully edentulous and the Brånemark system implants had turned

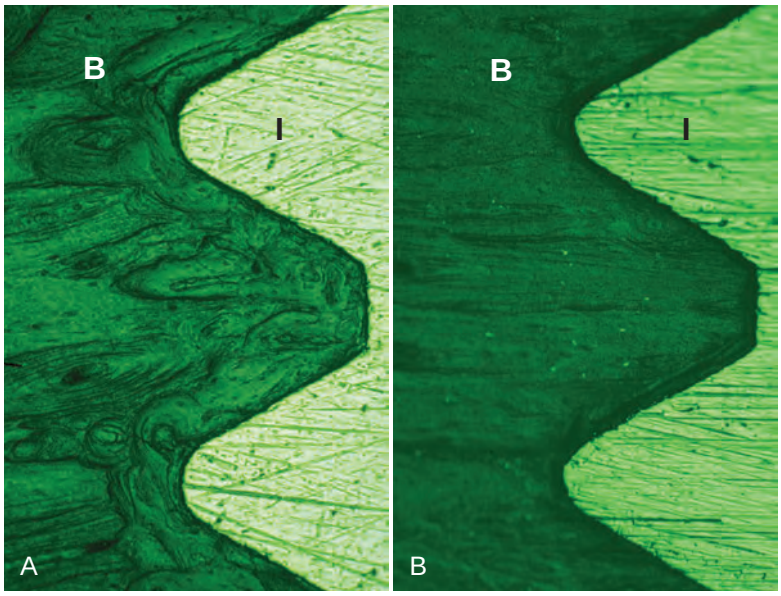

Figure 71-14 **A,** After initial healing, woven bone, as characterized by its irregular pattern, is laid down. **B,** After weeks or months, progressively a lamellar bone is laid down, with regular concentric lamellae. *B,* Bone; *I,* implant. *(Courtesy Professor T. Albrektsson, Gothenburg, Sweden.)*

(machined) surfaces, which are less likely to be associated with soft tissue inflammatory problems.[6] Today, there is greater interest in and appreciation for periimplant soft tissues and the soft tissue-to-implant interface as a function of esthetics and maintenance of a seal or barrier against microbial invasion.

Periimplant soft tissues are similar in appearance and structure to periodontal soft tissues (see Chapter 1). Clearly, both implants and teeth emerge through the soft tissues on the alveolar ridge. The soft tissues consist of connective tissue covered by epithelium. There is a gingival/mucosal sulcus, a long junctional epithelial attachment, and a zone of connective tissue above the supporting bone (Figure 71-16). Despite the apparent similarities in soft tissues around teeth and implants, the presence of a periodontal ligament around teeth and not around implants is an important, distinct difference. Whereas natural teeth have a periodontal ligament with connective tissue fibers suspending them in the alveolar bone, osseointegrated implants do not. There are no inserting collagen fibers anywhere along the interface of osseointegrated implants. Bone is in direct contact with the implant surface without intervening soft tissues.

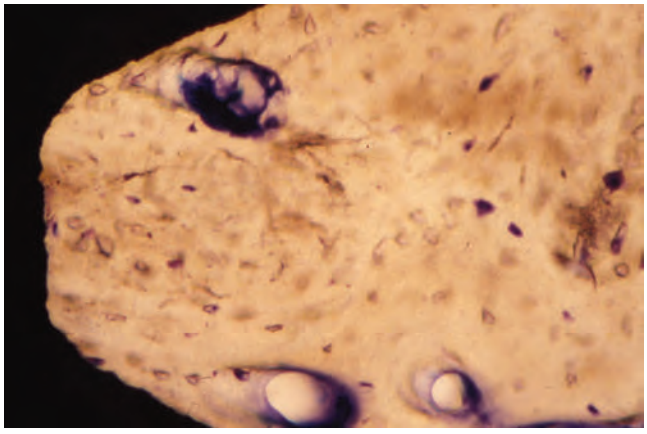

Figure 71-15 Once a steady state has been achieved at the bone-to-implant interface, an intimate contact can be observed, with some marrow spaces seen in between at the light microscopic level.

Clinically, the thickness of the periimplant soft tissues varies from 2 to several millimeters (Figure 71-17). An animal study determined the total height of the periimplant "biologic width" to be approximately 3 to 4 mm, where about 2 mm is the epithelial attachment and about 1 to 2 mm is the supracrestal connective tissue zone.[19] Consistent with this finding, a human histologic study determined the height of the periimplant "biologic width," consisting of an epithelial attachment and supracrestal connective tissue, to be about 4 to 4.5 mm[46] (Figure 71-18).

Epithelium

As in the natural dentition, the oral epithelium around implants is continuous with a sulcular epithelium that lines the inner surface

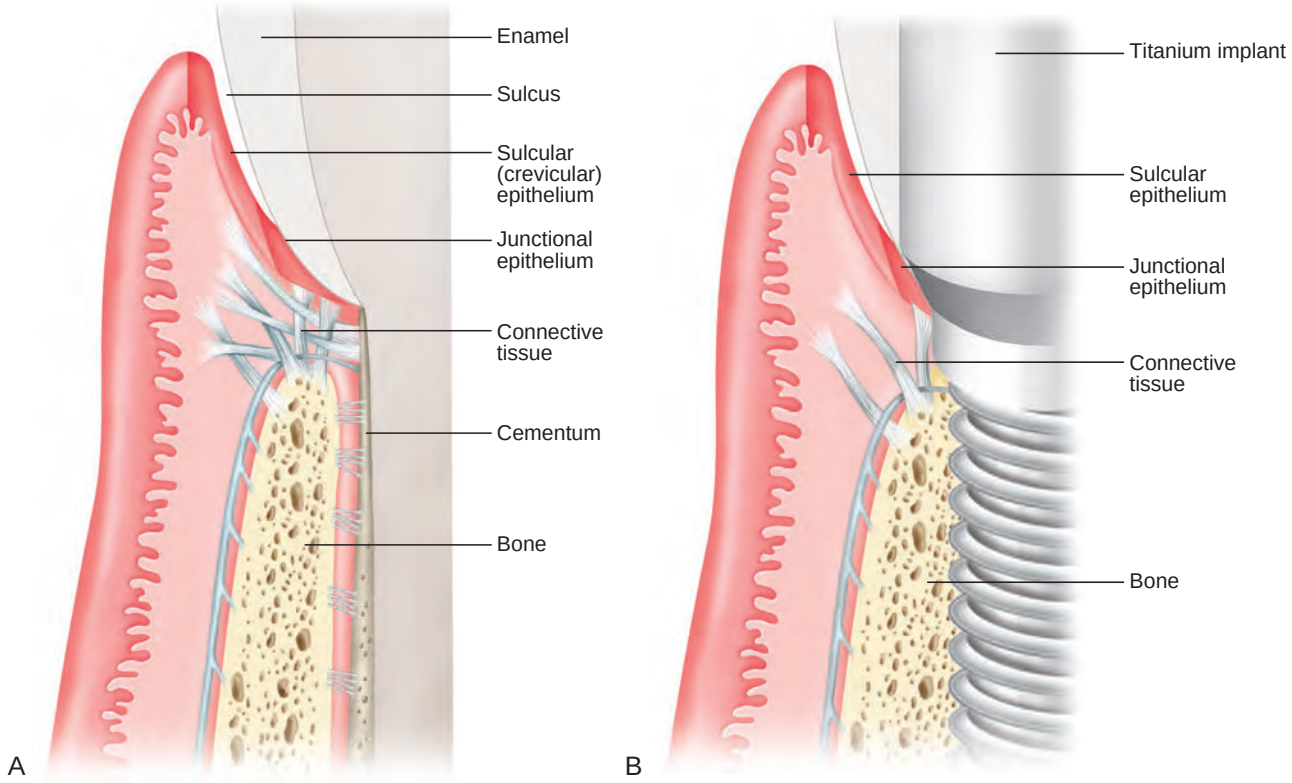

Figure 71-16 Schematic illustration of hard and soft tissue around a tooth and an implant. **A,** Hard and soft tissue anatomy around a natural tooth demonstrates bone support with a periodontal ligament, a connective tissue zone above the crest of bone with connective tissue fibers (Sharpey's) inserting into dentin, a long junctional epithelial attachment, a gingival sulcus lined with sulcular epithelium, and oral gingival epithelium (outer surface of gingiva). **B,** Hard and soft tissue anatomy around an implant demonstrates some similarities and some distinct differences. There is supporting bone in direct approximation to the implant surface without any intervening soft tissues (i.e., no periodontal ligament). A connective tissue zone is present above the level of bone with fibers running parallel to the implant surface and no inserting fibers. There is a long junctional epithelial attachment, a gingival/mucosal sulcus lined with sulcular epithelium and oral gingival/mucosal epithelium (outer surface of soft tissue). *(From Rose LF, Mealey BL:* Periodontics: medicine, surgery, and implants, *St. Louis, 2004, Mosby.)*

of the gingival sulcus; the apical part of the gingival sulcus is lined with long junctional epithelium.[69] Ultrastructural examination of the long junctional epithelial attachment adjacent to dental implants has demonstrated that epithelial cells attach with a basal lamina and hemidesmosomes[3,5,48,60,111] (Figure 71-19). Histologic studies indicate that these epithelial structures and the surrounding lamina propria cannot be distinguished from those structures around teeth.[33] In health, the dimension of the sulcular epithelium is about 0.5 mm,[91] and the dimension of the epithelial attachment is about 2 mm,[19] which is higher than that of the periodontal epithelial attachment.

The apical edge of the epithelial attachment is about 1.5 to 2.0 mm above the bone margin.[86] In healthy periimplant tissues, progressive epithelial downgrowth does not occur, indicating that factors other than inserted collagen fiber bundles (i.e., Sharpey's fibers in natural dentition) prevent it.

Figure 71-17 Clinical appearance of normal, healthy periimplant tissue with implant restoration removed. Soft tissue thickness varies from site-to-site, depending on quantity and quality of tissue, as well as the anatomy of the surrounding area (e.g., adjacent to natural teeth with healthy periodontal attachment versus adjacent to a space). Note that the intrasulcular tissue appears more erythematous as the result of the thin, nonkeratinized layer of epithelium overlying the connective tissue. *(Courtesy Dr. Stuart Froum, New York, NY.)*

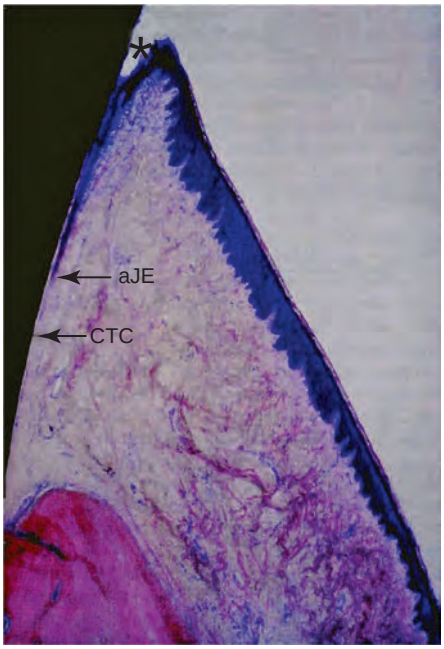

Figure 71-18 Buccolingual section (basic fuchsin stain; original magnification ×12.5; one-part SLA implant, 3 months unloaded) showing the gingiva and the most coronal part of alveolar bone. Rete peg formation is only apparent in the area of the keratinized oral gingival epithelium. The oral sulcular epithelium exhibits no keratinization. In the area of the most coronal point of the junctional epithelium (cJE), the soft tissues are slightly torn away (artifact) because of nondecalcified histologic processing. The most apical point of the junctional epithelium is indicated *(aJE)*. No rete peg formation is evident adjacent to the basal cell layer of the junctional epithelium (JE), all showing healthy and physiologic soft tissue structures. In addition, the area of connective tissue contact *(CTC)* adjacent to the machined titanium surface is marked. A slight round cell infiltrate in the connective tissue is indicating a mild inflammation. Note bone remodeling/new bone formation in the crestal bone region indicated by saturated, dark-red stained areas.

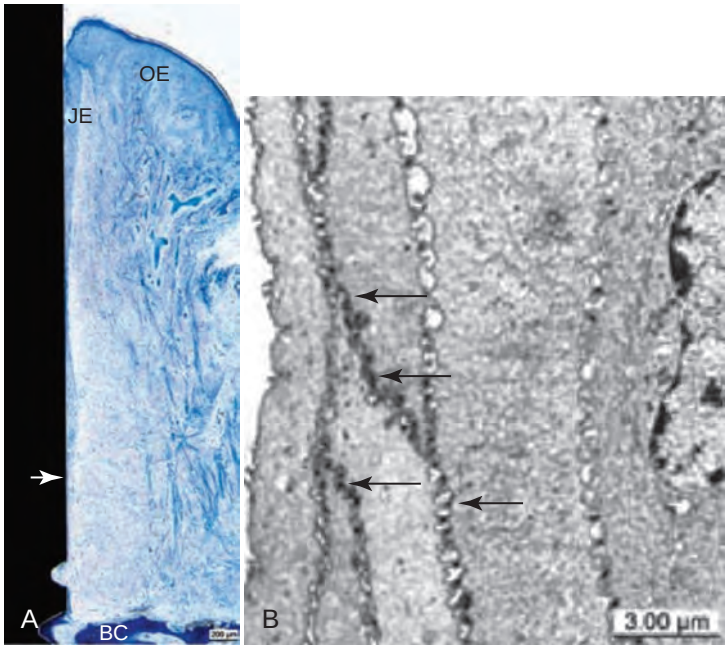

Figure 71-19 **A,** Overview of ground section showing periimplant tissues covered with keratinizing oral epithelium *(OE)*. Junctional epithelium *(JE)* is interposed between connective tissue and alveolar bone crest *(BC)*. Apical end of junctional epithelium *(arrow)*. Toluidine blue stain. (Bar = 200 µm.) **B,** Transmission electron microscopic view of sulcular epithelium showing tightly sealed intercellular spaces by numerous spot desmosomes *(arrows)*, contributing to low permeability of this portion of periimplant mucosa. Bar = 3 µm.[1]

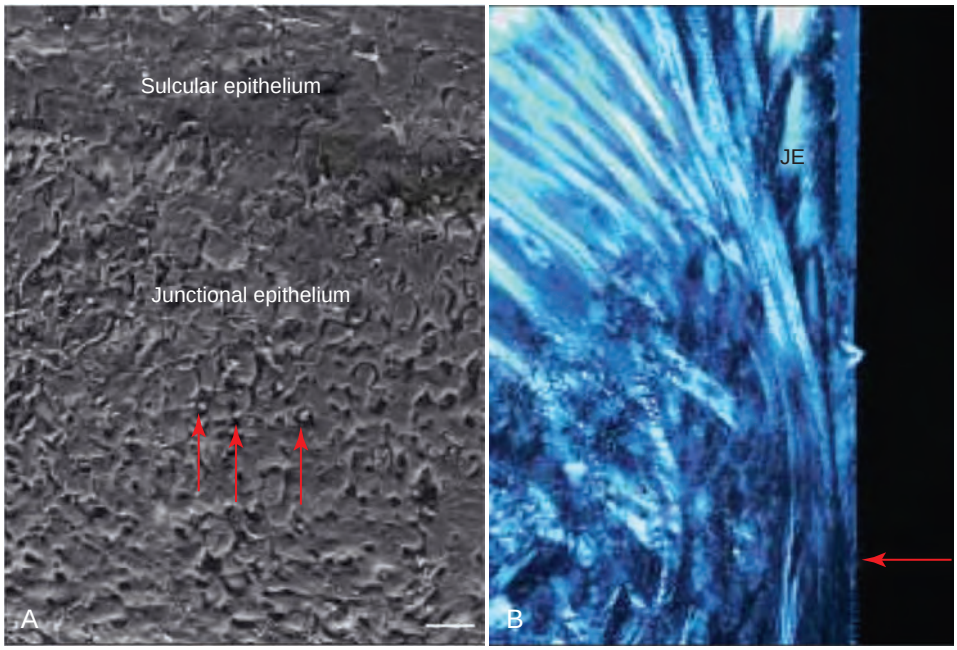

Figure 71-20 **A,** Scanning electron microscope (SEM) image of the junctional epithelium. Note the neutrophils located between the cells *(red arrows)*. Bar = 40 µm. **B,** Higher magnification of Figure 71-19 with polarized light showing the apical extent *(red arrow)* of the junctional epithelium *(JE)*. Note the dense collagen fibers running apicocoronal (i.e., parallel to the implant surface).

Connective Tissue

Periimplant connective tissue morphology closely resembles that of the natural dentition except that it lacks a periodontal ligament, cementum, and inserting fibers (Figure 71-20). No significant differences were found at the biochemical level between the periimplant and the periodontal soft tissues,[34] while the dimension of the periimplant connective tissue is 1 to 2 mm, which is higher than that of the periodontal connective tissue.[19,86]

The zone of supracrestal connective tissue has an important function in the maintenance of a stable soft tissue–implant interface and as a seal or barrier to the "outside" oral environment. The orientation of connective tissue fibers adjacent to an implant differs from that of periodontal connective tissue fibers. In the absence of cementum and inserting connective tissue fibers (i.e., as in a natural tooth), most periimplant connective tissue fibers run in a direction more or less parallel to the implant surface. Even when the fiber bundles are oriented perpendicularly, which occurs more often in the gingiva than in the mucosa surrounding implants, the bundles are never embedded in the implant surface.

The fiber bundles can also have a "cuff-like" circular orientation.[20] The role of these fibers remains unknown, but it appears that their presence helps to create a soft tissue "seal" around the implant. The adaptation of the connective tissue to an implant surface may also be affected by the mobility of the soft tissue around the implant. The connective tissue in direct contact with the implant surface is characterized by an absence of blood vessels and an abundance of fibroblasts interposed between collagen fibers.[66] Several animal and human studies have shown that the alignments of connective fibers were circular and horizontal around the implants* (Figure 71-21).

More recent studies have shown histologic evidence of connective tissue attachment perpendicular to the microgrooved implant surface on both animal and human studies.[75,76,77] This laser-microtextured grooves (Figure 71-22) have been shown to be able to stop the epithelial down growth and establish connective tissue insertion right at the most coronal part of the laser microgrooved area. (Figure 71-23). A prospective controlled clinical study showed that laser-grooved surface resulted in shallower probing depth and less periimplant crestal bone loss than that seen around implants with machined collars.[25,82]

This connective tissue interface has been examined by probing attachment level measurements in patients. Probing attachment levels were consistently found coronal to the alveolar crest in patients with periimplant tissue health, indicating the presence of a zone of direct connective tissue contact to the implant surface. This means that the probing depth measurement performed with a periodontal probe may be about 1.5 mm higher above the bone level in healthy tissues. At inflamed sites, the probe may penetrate to the bone with probing depth measurement reflecting the total soft tissue thickness above bone. In cases with inflammatory periimplant tissue disease, increasing probing depth and reduced attachment levels have been reported.[4,39,83,113]

Keratinized Tissue

Questions emerged decades ago, as it did for the natural dentition, about the need for keratinized tissue to surround implants. Prospective and cross-sectional studies, evaluating screw-shaped implants with a machined surface, suggest that the presence or absence of keratinized gingiva is not a prerequisite for long-term stability.[97] However, it has been suggested that implants surrounded by mucosa only (i.e., nonkeratinized) are more susceptible to periimplant problems. An animal study observed that ligature-induced periimplantitis occurs more frequently when alveolar mucosa surrounds the implant as compared to when keratinized mucosa surrounds the implant.[112]

Keratinized mucosa tends to be more firmly anchored by collagen fibers to the underlying periosteum than nonkeratinized mucosa, which has more elastic fibers and tends to be moveable relative to the underlying bone. In clinical studies evaluating

*References 2, 15, 35, 47, 50, 51, 95.

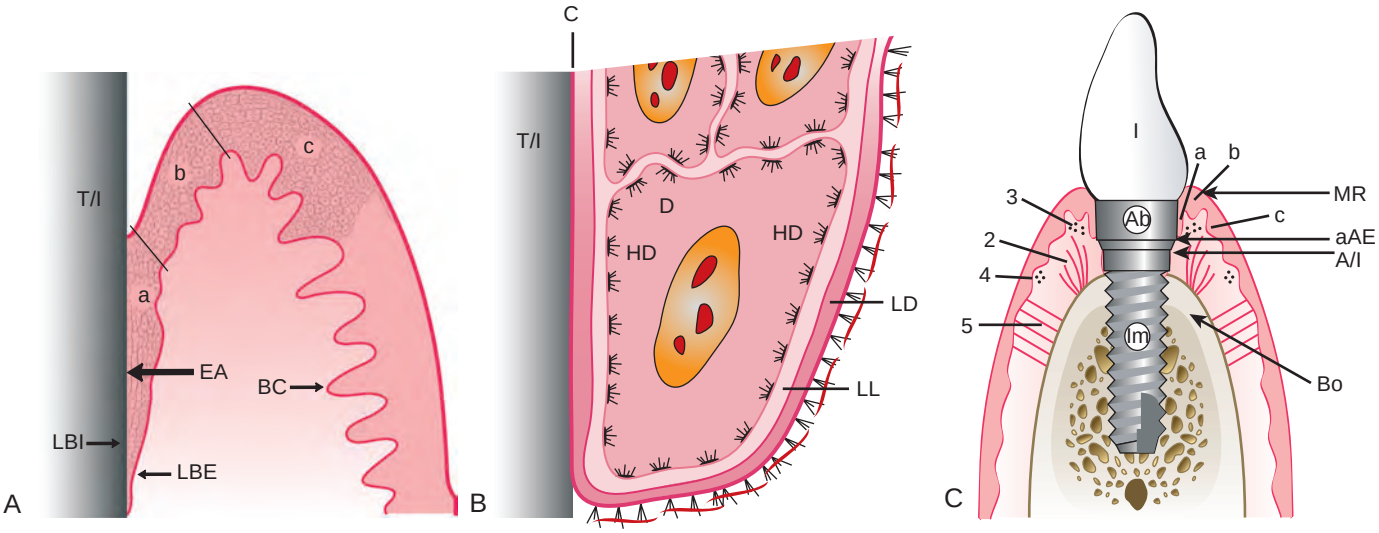

Figure 71-21 **A,** Histologic scheme of epithelial attachment *(EA)* (identical for tooth and implant). *T/I,* Titanium implant; *BC,* basal complex; *LBI,* lamina basalis interna; *LBE,* lamina basalis externa (only location where cell divisions occur); *a,* long junctional epithelial attachment zone; *b,* sulcular epithelial zone; *c,* oral epithelial zone. **B,** At electron microscopic level, basal complex at epithelial attachment (three most apical cells) and connection with stroma. *HD,* Hemidesmosomes; *D,* desmosome; *LL,* lamina lucida; *LD,* lamina densa; *C,* cuticle. **C,** Implant, abutment *(Ab)*, and crown within alveolar bone and soft tissues. *Im,* Endosseous part of implant; *MR,* margin of gingiva/alveolar mucosa; *Bo,* marginal bone level; *1,* implant crown; *2,* vertical alveolar-gingival connective tissue fibers; *3,* circular gingival connective tissue fibers; *4,* circular gingival connective tissue fibers; *5,* periosteal-gingival connective tissue fibers; *a*, junctional epithelium; *b,* sulcular epithelium; *c,* oral epithelium; *A/I,* abutment/implant junction; *aAE,* apical (point) of attached epithelium.



Figure 71-22 **A,** Laser-microtextured surface; **B,** machined collar, 500×. *(Botos et al:* Int J Oral Maxillofac Implants *26:492-498, 2011. With the permission of Dr. Spyros Botos.)*

intraoral implants, with or without periimplant keratinized mucosa, no clinically significant difference in implant success was reported.[64,117] However, when there is a lack of keratinized tissue, patients tend to complain about pain and discomfort while performing oral hygiene procedures or other functions in the area. The symptoms are alleviated by increasing the amount of keratinized (firmly bound) tissue around the implant(s) via soft tissue grafting (see Figure 63-5, *A-L*). Finally, although it may not be comparable to intraoral implants, mobility of soft tissues surrounding extraoral implants is associated with a higher incidence of implant failure.[10]

Vascular Supply and Inflammation

The vascular supply of the periimplant gingival or alveolar mucosa may be limited, as compared to periodontal gingiva, due to the lack of a periodontal ligament (Figure 71-24).[21] This is especially true in the tissue immediately adjacent to the implant surface. However, capillary loops in the connective tissue under the junctional and sulcular epithelium around implants appear to be anatomically similar to those found in the normal periodontium (Figure 71-25).[110]

Emerging knowledge indicates that the periimplant gingival or alveolar mucosa has the same morphology as the corresponding tissues around teeth. These soft tissues also react the same way to

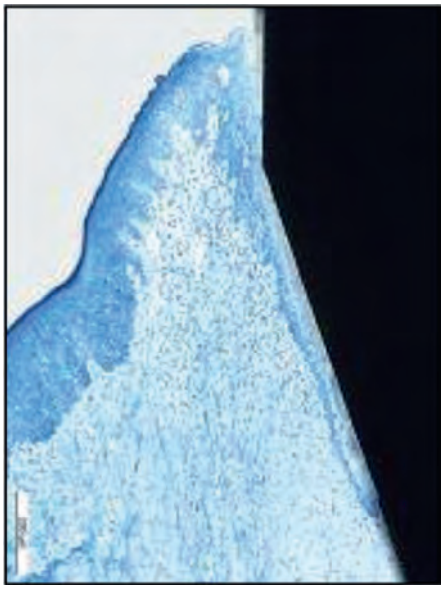

Figure 71-23 Laser-ablated surface: epithelial downgrowth was stopped right at the coronal-most microgrooved area *(arrow)*. Apical to the junctional epithelium, healthy connective tissue fibers attached perpendicularly to the laser-ablated channels. *(Courtesy Dr. Myron Nevins.)*

plaque accumulation. Studies investigating the histology (light microscopic and ultrastructural) of healthy and inflamed tissues surrounding implants in humans have indicated that the inflammatory response to plaque is similar to that observed in periodontal tissues.[91] Polymorphonuclear cells and mononuclear cells transmigrate normally through the periimplant sulcular epithelium (Figure 71-26).[91]

Clinical Comparison of Teeth and Implants

Although the soft tissue-to-implant (abutment) interface offers striking similarities with tissue surrounding the natural dentition, some differences should be considered. At the bone level, the lack of a periodontal ligament is the most striking difference. The following discussion elaborates on the clinical perspectives of these similarities and differences.

At the bone level, the absence of the periodontal ligament surrounding an implant has important clinical consequences. This means that no resilient connection exists between implants and supporting bone. Implants cannot intrude or migrate to compensate for the presence of a premature occlusal contact (as teeth can). Implants and the rigidly attached implant restorations do not move. Thus any occlusal disharmony will have repercussions at either the restoration-to-implant connection, the bone-to-implant interface, or both.

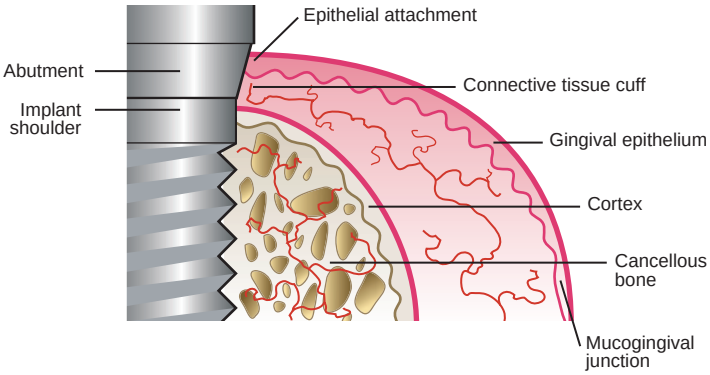

Figure 71-24 Schematic illustration of the blood supply in the connective tissue cuff surrounding the implant/abutment is scarcer than in the gingival complex around teeth because none originates from a periodontal ligament.

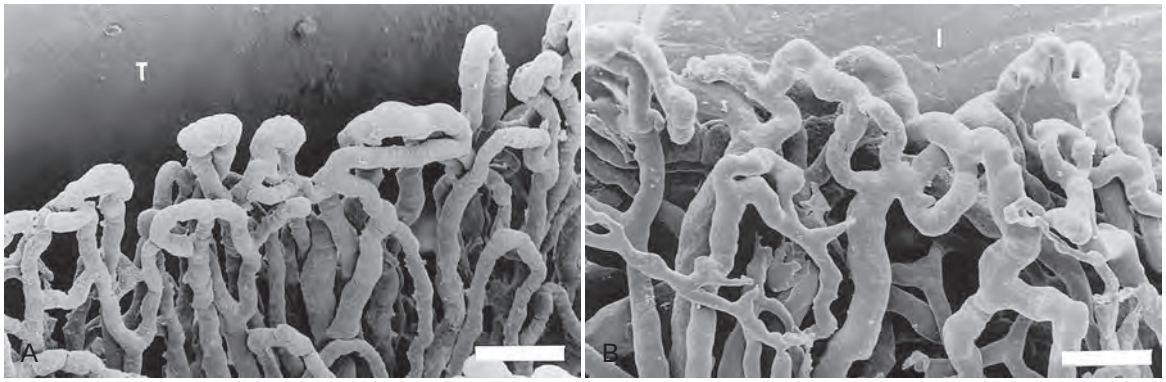

Figure 71-25 **A,** Microvascular topography surrounding a tooth. **B,** Microvascular topography surrounding an implant. Bar = 5 µm.[101] *(Courtesy Drs. N. Selliseth and K. Selvig, Bergen, Norway.)*

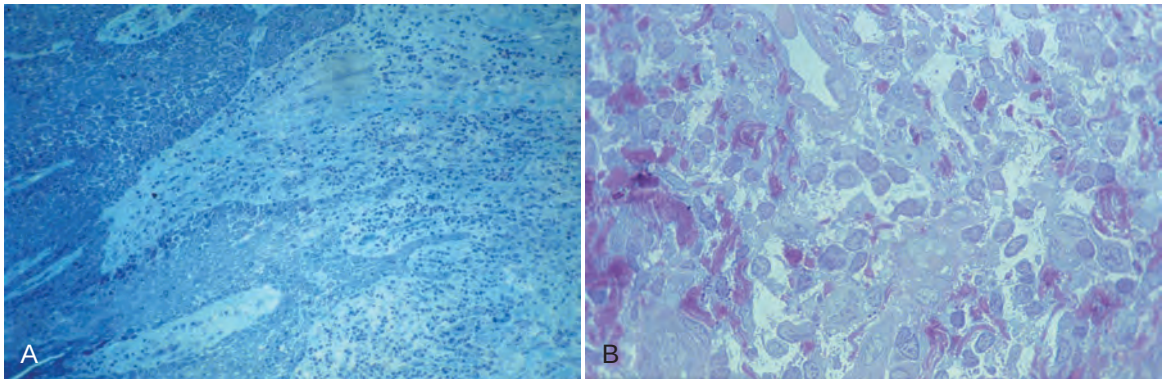

Figure 71-26 **A,** Histologic slide from healthy gingiva surrounding a well-functioning implant in human patient. No morphologic characteristics differentiate tissue around implant from that around teeth. **B,** When gingivitis occurs, a profuse migration of inflammatory cells through the pocket epithelium can be observed. *(Courtesy Professor Mariano Sanz, Madrid.)*

Proprioception in the natural dentition comes from the periodontal ligament. The absence of a periodontal ligament around implants reduces tactile sensitivity[56] and reflex function.[23] This can become even more challenging when osseointegrated, implant-supported, fixed prostheses are present in both jaws.

The lack of a periodontal ligament and inability of implants to move contraindicates their use in growing individuals. Natural teeth continue to erupt and migrate during growth while implants do not. Implants placed in individuals prior to the completion of growth can lead to occlusal disharmonies with implants.[80] Likewise, it may be problematic to place one or more implants in a location adjacent to teeth that are very mobile from the loss of periodontal support because as the teeth move in response to or away from the occlusal forces, the implant(s) will bear the entire load.

Overload, because of improper superstructure design, parafunctional habits, or excessive occlusal load, may cause microstrains and microfractures in the bone, which will lead to bone loss and a fibrous inflammatory tissue at the implant interface.[110]

Conclusion

Appreciating the osseointegration process is facilitated by a good knowledge and understanding of bone healing. Many factors can interfere with the predictable establishment of a permanent rigid connection between an implant surface and the surrounding bone that is able to sustain occlusal loads. The bone-to-implant interface and its rigidity are a predominant biomechanical aspect of coping with the time and intensity of loading. The soft tissue-to-implant interface also plays an important role in the long-term maintenance of a stable marginal bone levels around implants. Clinicians must familiarize themselves with the underlying molecular and cellular events to evaluate the future evolution of implant design and implant protocols, including surgical placement, restoration, and maintenance.

Suggested Readings

Abrahamsson I, Soldini C: Probe penetration in periodontal and peri-implant tissues. An experimental study in the beagle dog. *Clin Oral Implants Res* 17:601–605, 2006.

Botos S, Yousef H, Zweig B, et al: The effects of laser microtexturing of the dental implant collar on crestal bone levels and peri-implant health. *Int J Oral Maxillofac Implants* 26(3):492–498, 2011.

Buser D, Schenk RK, Steinemann S, et al: Influence of surface characteristics on bone integration of titanium implants. A histomorphometric study in miniature pigs. *J Biomed Mater Res* 25:889–902, 1991.

Davies JE: Mechanisms of endosseous integration. *Int J Prosthodont* 11:391–401, 1998.

Hermann JS, Buser D, Schenk RK, et al: Biologic width around titanium implants. A physiologically formed and stable dimension over time. *Clin Oral Implants Res* 11:1–11, 2000.

Nevins M, Nevins ML, Camelo M, et al: Human histologic evidence of a connective tissue attachment to a dental implant. *Int J Periodontics Restorative Dent* 28:111–121, 2008.

Nevins M, Kim DM, Jun SH, et al: Histologic evidence of a connective tissue attachment to laser microgrooved abutments: a canine study. *Int J Periodontics Restorative Dent* 30:245–255, 2010.

Nevins M, Camelo M, Nevins ML, et al: Connective tissue attachment to laser-microgrooved abutments: a human histologic case report. *Int J Periodontics Restorative Dent* 32:385–392, 2012.

Pecora GE, Ceccarelli R, Bonelli M, et al: Clinical evaluation of laser microtexturing for soft tissue and bone attachment to dental implants. *Implant Dent* 18:57–66, 2009.

Quirynen M, van Steenberghe D, Jacobs R, et al: The reliability of pocket probing around screw-type implants. *Clin Oral Implants Res* 2:186–192, 1991.

References

References for this chapter are found on the companion website www.expertconsult.com.

References

1. American Academy of Implant Dentistry: Glossary of implant terms. *J Oral Implantol* 12:284–294, 1986.
2. Abrahamsson I, Berglundh T, Moon IS, et al: Peri-implant tissues at submerged and non-submerged titanium implants. *J Clin Periodontol* 26:600–607, 1999.
3. Abrahamsson I, Berglundh T, Wennstrom J, et al: The peri-implant hard and soft tissues at different implant systems. A comparative study in the dog. *Clin Oral Implants Res* 7:212–219, 1996.
4. Abrahamsson I, Soldini C: Probe penetration in periodontal and peri-implant tissues. An experimental study in the beagle dog. *Clin Oral Implants Res* 17:601–605, 2006.
5. Abrahamsson I, Zitzmann NU, Berglundh T, et al: The mucosal attachment to titanium implants with different surface characteristics: an experimental study in dogs. *J Clin Periodontol* 29:448–455, 2002.
6. Adell R, Lekholm U, Rockler B, et al: Marginal tissue reactions at osseointegrated titanium fixtures (I). A 3-year longitudinal prospective study. *Int J Oral Maxillofac Surg* 15:39–52, 1986.
7. Albrektsson T: Bone tissue response. In Brånemark PI, Zarb G, Albrektsson T, editors: *Tissue-integrated prothesis: osseointegration in clinical dentistry*, Chicago, 1987, Quintessence.
8. Albrektsson T: The host-implant interface: biology. *Int J Prosthodont* 16(Suppl):29–30, discussion 47-51, 2003.
9. Albrektsson T, Brånemark PI, Hansson HA, et al: Osseointegrated titanium implants. Requirements for ensuring a long-lasting, direct bone-to-implant anchorage in man. *Acta Orthop Scand* 52:155–170, 1981.
10. Albrektsson T, Brånemark PI, Jacobsson M, et al: Present clinical applications of osseointegrated percutaneous implants. *Plast Reconstr Surg* 79:721–731, 1987.
11. Albrektsson T, Eriksson AR, Friberg B, et al: Histologic investigations on 33 retrieved Nobelpharma implants. *Clin Mater* 12:1–9, 1993.
12. Albrektsson T, Sennerby L: State of the art in oral implants. *J Clin Periodontol* 18:474–481, 1991.
13. Albrektsson T, Wennerberg A: The impact of oral implants—past and future, 1966-2042. *J Can Dent Assoc* 71:327, 2005.
14. Albrektsson T, Zarb G, Worthington P, et al: The long-term efficacy of currently used dental implants: a review and proposed criteria of success. *Int J Oral Maxillofac Implants* 1:11–25, 1986.
15. Arvidson K, Fartash B, Hilliges M, et al: Histological characteristics of peri-implant mucosa around Brånemark and single-crystal sapphire implants. *Clin Oral Implants Res* 7:1–10, 1996.
16. Arvidsson A, Sater BA, Wennerberg A: The role of functional parameters for topographical characterization of bone-anchored implants. *Clin Implant Dent Relat Res* 8:70–76, 2006.
17. Balshi TJ, Wolfinger GJ: Management of the posterior maxilla in the compromised patient: historical, current, and future perspectives. *Periodontol 2000* 33:67–81, 2003.
18. Barewal RM, Oates TW, Meredith N, et al: Resonance frequency measurement of implant stability in vivo on implants with a sand-blasted and acid-etched surface. *Int J Oral Maxillofac Implants* 18:641–651, 2003.
19. Berglundh T, Lindhe J: Dimension of the periimplant mucosa. Biological width revisited. *J Clin Periodontol* 23:971–973, 1996.
20. Berglundh T, Lindhe J, Ericsson I, et al: The soft tissue barrier at implants and teeth. *Clin Oral Implants Res* 2:81–90, 1991.
21. Berglundh T, Lindhe J, Jonsson K, et al: The topography of the vascular systems in the periodontal and peri-implant tissues in the dog. *J Clin Periodontol* 21:189–193, 1994.
22. Block MS, Kent JN: Long-term follow-up on hydroxylapatite-coated cylindrical dental implants: a comparison between developmental and recent periods. *J Oral Maxillofac Surg* 52:937–943, discussion 944, 1994.
23. Bonte B, van Steenberghe D: Masseteric post-stimulus EMG complex following mechanical stimulation of osseointegrated oral implants. *J Oral Rehabil* 18:221–229, 1991.
24. Bosker H, van Dijk L: The transmandibular implant: a 12-year follow-up study. *J Oral Maxillofac Surg* 47:442–450, 1989.
25. Botos S, Yousef H, Zweig B, et al: The effects of laser microtexturing of the dental implant collar on crestal bone levels and peri-implant health. *Int J Oral Maxillofac Implants* 26(3):492–498, 2011.
26. Boyan BD, Hummert TW, Dean DD, et al: Role of material surfaces in regulating bone and cartilage cell response. *Biomaterials* 17:137–146, 1996.
27. Brånemark PI: Osseointegration and its experimental background. *J Prosthet Dent* 50:399–410, 1983.
28. Brånemark PI: *The osseointegration book: from calvarium to calcaneus*, Berlin/Chicago, 2005, Quitessenz Verlag.
29. Brånemark PI, Adell R, Breine U, et al: Intra-osseous anchorage of dental prostheses. I. Experimental studies. *Scand J Plast Reconstr Surg* 3:81–100, 1969.
30. Brånemark PI, Zarb G, Albrektsson T: *Tissue-integrated prothesis: osseointegration in clinical dentistry*, Chicago, 1987, Quintessence.
31. Buser D, Broggini N, Wieland M, et al: Enhanced bone apposition to a chemically modified SLA titanium surface. *J Dent Res* 83:529–533, 2004.
32. Buser D, Schenk RK, Steinemann S, et al: Influence of surface characteristics on bone integration of titanium implants. A histomorphometric study in miniature pigs. *J Biomed Mater Res* 25:889–902, 1991.
33. Buser D, Weber HP, Donath K, et al: Soft tissue reactions to non-submerged unloaded titanium implants in beagle dogs. *J Periodontol* 63:225–235, 1992.
34. Chavrier C, Couble ML, Hartmann DJ: Qualitative study of collagenous and noncollagenous glycoproteins of the human healthy keratinized mucosa surrounding implants. *Clin Oral Implants Res* 5:117–124, 1994.
35. Cochran DL, Hermann JS, Schenk RK, et al: Biologic width around titanium implants. A histometric analysis of the implanto-gingival junction around unloaded and loaded nonsubmerged implants in the canine mandible. *J Periodontol* 68:186–198, 1997.
36. Cooper LF, Zhou Y, Takebe J, et al: Fluoride modification effects on osteoblast behavior and bone formation at TiO_2 grit-blasted c.p. titanium endosseous implants. *Biomaterials* 27:926–936, 2006.
37. Davies JE: Mechanisms of endosseous integration. *Int J Prosthodont* 11:391–401, 1998.
38. Davies JE: Understanding peri-implant endosseous healing. *J Dent Educ* 67:932–949, 2003.
39. DeAngelo SJ, Kumar PS, Beck FM, et al: Early soft tissue healing around one-stage dental implants: clinical and microbiologic parameters. *J Periodontol* 78:1878–1886, 2007.
40. Dahl G: Om Mojligheten for implantationi kaken ac metallskelette som bas dller retention for fasta eller avtagbara proteser. *Odont Tidskr* 1943.
41. Driskell TD: History of implants. *CDA J* 15:16–25, 1987.
42. Ellingsen JE, Johansson CB, Wennerberg A, et al: Improved retention and bone-to-implant contact with fluoride-modified titanium implants. *Int J Oral Maxillofac Implants* 19:659–666, 2004.
43. Ellingsen JE, Thomsen P, Lyngstadaas SP: Advances in dental implant materials and tissue regeneration. *Periodontol 2000* 41:136–156, 2006.
44. Francois P, Vaudaux P, Taborelli M, et al: Influence of surface treatments developed for oral implants on the physical and biological properties of titanium. (II) Adsorption isotherms and biological activity of immobilized fibronectin. *Clin Oral Implants Res* 8:217–225, 1997.
45. Friberg B, Sennerby L, Linden B, et al: Stability measurements of one-stage Brånemark implants during healing in mandibles. A clinical resonance frequency analysis study. *Int J Oral Maxillofac Surg* 28:266–272, 1999.
46. Glauser R, Schupbach P, Gottlow J, et al: Periimplant soft tissue barrier at experimental one-piece mini-implants with different surface topography in humans: a light-microscopic overview and histometric analysis. *Clin Implant Dent Relat Res* 7(Suppl 1):S44–S51, 2005.

47. Glauser R, Sennerby L, Meredith N, et al: Resonance frequency analysis of implants subjected to immediate or early functional occlusal loading. Successful vs. failing implants. *Clin Oral Implants Res* 15:428–434, 2004.
48. Gould TR, Westbury L, Brunette DM: Ultrastructural study of the attachment of human gingiva to titanium in vivo. *J Prosthet Dent* 52:418–420, 1984.
49. Haas R, Mensdorff-Pouilly N, Mailath G, et al: Survival of 1,920 IMZ implants followed for up to 100 months. *Int J Oral Maxillofac Implants* 11:581–588, 1996.
50. Hermann JS, Buser D, Schenk RK, et al: Biologic width around titanium implants. A physiologically formed and stable dimension over time. *Clin Oral Implants Res* 11:1–11, 2000.
51. Hermann JS, Buser D, Schenk RK, et al: Biologic Width around one- and two-piece titanium implants. *Clin Oral Implants Res* 12:559–571, 2001.
52. Hong HL, Brunette DM: Effect of cell shape on proteinase secretion by epithelial cells. *J Cell Sci* 87(Pt 2):259–267, 1987.
53. Huang YH, Xiropaidis AV, Sorensen RG, et al: Bone formation at titanium porous oxide (TiUnite) oral implants in type IV bone. *Clin Oral Implants Res* 16:105–111, 2005.
54. Huiskes R, Weinans H, Dalstra M: Adaptive bone remodeling and biomechanical design considerations for noncemented total hip arthroplasty. *Orthopedics* 12:1255–1267, 1989.
55. Ivanoff CJ, Widmark G, Johansson C, et al: Histologic evaluation of bone response to oxidized and turned titanium micro-implants in human jawbone. *Int J Oral Maxillofac Implants* 18:341–348, 2003.
56. Jacobs R, van Steenberghe D: Role of periodontal ligament receptors in the tactile function of teeth: a review. *J Periodontal Res* 29:153–167, 1994.
57. James RA: Peri-implant considerations. *Dent Clin North Am* 24:415–420, 1980.
58. Jemt T: Failures and complications in 391 consecutively inserted fixed prostheses supported by Brånemark implants in edentulous jaws: a study of treatment from the time of prosthesis placement to the first annual checkup. *Int J Oral Maxillofac Implants* 6:270–276, 1991.
59. Kasemo B: Biocompatibility of titanium implants: surface science aspects. *J Prosthet Dent* 49:832–837, 1983.
60. Kawahara H, Kawahara D, Mimura Y, et al: Morphologic studies on the biologic seal of titanium dental implants. Report II. In vivo study on the defending mechanism of epithelial adhesions/attachment against invasive factors. *Int J Oral Maxillofac Implants* 13:465–473, 1998.
61. Kieswetter K, Schwartz Z, Dean DD, et al: The role of implant surface characteristics in the healing of bone. *Crit Rev Oral Biol Med* 7:329–345, 1996.
62. Kieswetter K, Schwartz Z, Hummert TW, et al: Surface roughness modulates the local production of growth factors and cytokines by osteoblast-like MG-63 cells. *J Biomed Mater Res* 32:55–63, 1996.
63. Kirsch A: The two-phase implantation method using IMZ intramobile cylinder implants. *J Oral Implantol* 11:197–210, 1983.
64. Lekholm U, Ericsson I, Adell R, et al: The condition of the soft tissues at tooth and fixture abutments supporting fixed bridges. A microbiological and histological study. *J Clin Periodontol* 13:558–562, 1986.
65. Lindquist LW, Carlsson GE, Jemt T: A prospective 15-year follow-up study of mandibular fixed prostheses supported by osseointegrated implants. Clinical results and marginal bone loss. *Clin Oral Implants Res* 7:329–336, 1996.
66. Linkevicius T, Apse P: Biologic width around implants. An evidence-based review. *Stomatologija* 10:27–35, 2008.
67. Linkow LI: The endosseous blade vent. *Newsl Am Acad Implant Dent* 18:15–24, 1969.
68. Listgarten MA: Soft and hard tissue response to endosseous dental implants. *Anat Rec* 245:410–425, 1996.
69. Listgarten MA, Lang NP, Schroeder HE, et al: Periodontal tissues and their counterparts around endosseous implants [corrected and republished with original paging, article originally printed in Clin Oral Implants Res 1991 Jan-Mar;2(1):1-19]. *Clin Oral Implants Res* 2:1–19, 1991.
70. McClarence E: *Close to the edge: Brånemark and the development of osseointegration*, London, 2003, Quintessence.
71. Mellal A, Wiskott HW, Botsis J, et al: Stimulating effect of implant loading on surrounding bone. Comparison of three numerical models and validation by in vivo data. *Clin Oral Implants Res* 15:239–248, 2004.
72. Mendonca G, Mendonca DB, Aragao FJ, et al: Advancing dental implant surface technology—from micron- to nanotopography. *Biomaterials* 29:3822–3835, 2008.
73. Murray DW, Rae T, Rushton N: The influence of the surface energy and roughness of implants on bone resorption. *J Bone Joint Surg Br* 71:632–637, 1989.
74. Nanci A, Wuest JD, Peru L, et al: Chemical modification of titanium surfaces for covalent attachment of biological molecules. *J Biomed Mater Res* 40:324–335, 1998.
75. Nevins M, Nevins ML, Camelo M, et al: Human histologic evidence of a connective tissue attachment to a dental implant. *Int J Periodontics Restorative Dent* 28:111–121, 2008.
76. Nevins M, Kim DM, Jun SH, et al: Histologic evidence of a connective tissue attachment to laser microgrooved abutments: a canine study. *Int J Periodontics Restorative Dent* 30:245–255, 2010.
77. Nevins M, Camelo M, Nevins ML, et al: Connective tissue attachment to laser-microgrooved abutments: a human histologic case report. *Int J Periodontics Restorative Dent* 32:385–392, 2012.
78. Niznick GA: The Core-Vent implant system. *J Oral Implantol* 10:379–418, 1982.
79. Obwegeser HL: Experiences with subperiosteal implants. *Oral Surg Oral Med Oral Pathol* 12:777–786, 1959.
80. Op Heij DG, Opdebeeck H, van Steenberghe D, et al: Age as compromising factor for implant insertion. *Periodontol 2000* 33:172–184, 2003.
81. Pearson BS, Klebe RJ, Boyan BD, et al: Comments on the clinical application of fibronectin in dentistry. *J Dent Res* 67:515–517, 1988.
82. Pecora GE, Ceccarelli R, Bonelli M, et al: Clinical evaluation of laser microtexturing for soft tissue and bone attachment to dental implants. *Implant Dent* 18:57–66, 2009.
83. Pontes AE, Ribeiro FS, Iezzi G, et al: Biologic width changes around loaded implants inserted in different levels in relation to crestal bone: histometric evaluation in canine mandible. *Clin Oral Implants Res* 19:483–490, 2008.
84. Puleo DA, Nanci A: Understanding and controlling the bone-implant interface. *Biomaterials* 20:2311–2321, 1999.
85. Quirynen M, De Soete M, van Steenberghe D: Infectious risks for oral implants: a review of the literature. *Clin Oral Implants Res* 13:1–19, 2002.
86. Quirynen M, van Steenberghe D, Jacobs R, et al: The reliability of pocket probing around screw-type implants. *Clin Oral Implants Res* 2:186–192, 1991.
87. Raghavendra S, Wood MC, Taylor TD: Early wound healing around endosseous implants: a review of the literature. *Int J Oral Maxillofac Implants* 20:425–431, 2005.
88. Recum AF, Shannon CE, Cannon CE, et al: Surface roughness, porosity, and texture as modifiers of cellular adhesion. *Tissue Eng* 2:241–253, 1996.
89. Ring ME: A thousand years of dental implants: a definitive history—part 1. *Compend Contin Educ Dent* 16:1060, 1062, 1064 passim, 1995.
90. Ronold HJ, Lyngstadaas SP, Ellingsen JE: A study on the effect of dual blasting with TiO2 on titanium implant surfaces on functional attachment in bone. *J Biomed Mater Res A* 67:524–530, 2003.
91. Sanz M, Alandez J, Lazaro P, et al: Histo-pathologic characteristics of peri-implant soft tissues in Brånemark implants with 2 distinct clinical and radiological patterns. *Clin Oral Implants Res* 2:128–134, 1991.
92. Scarano A, Degidi M, Iezzi G, et al: Correlation between implant stability quotient and bone-implant contact: a retrospective histological and histomorphometrical study of seven titanium implants

retrieved from humans. *Clin Implant Dent Relat Res* 8:218–222, 2006.
93. Schakenraad JM, Busscher HJ, Wildevuur CR, et al: The influence of substratum surface free energy on growth and spreading of human fibroblasts in the presence and absence of serum proteins. *J Biomed Mater Res* 20:773–784, 1986.
94. Schenk RK, Buser D: Osseointegration: a reality. *Periodontol 2000* 17:22–35, 1998.
95. Schierano G, Ramieri G, Cortese M, et al: Organization of the connective tissue barrier around long-term loaded implant abutments in man. *Clin Oral Implants Res* 13:460–464, 2002.
96. Schnitman PA, Shulman LB: Recommendations of the consensus development conference on dental implants. *J Am Dent Assoc* 98:373–377, 1979.
97. Schou S, Holmstrup P, Hjorting-Hansen E, et al: Plaque-induced marginal tissue reactions of osseointegrated oral implants: a review of the literature. *Clin Oral Implants Res* 3:149–161, 1992.
98. Schroeder A, Pohler O, Sutter F: Tissue reaction to an implant of a titanium hollow cylinder with a titanium surface spray layer. *SSO Schweiz Monatsschr Zahnheilkd* 86:713–727, 1976.
99. Schwartz Z, Boyan BD: Underlying mechanisms at the bone-biomaterial interface. *J Cell Biochem* 56:340–347, 1994.
100. Scortecci G: Immediate function of cortically anchored disk-design implants without bone augmentation in moderately to severely resorbed completely edentulous maxillae. *J Oral Implantol* 25:70–79, 1999.
101. Selliseth NJ, Selvig KA: Microvascular adaptation to transmucosal implants. A scanning electron microscopic study in the rat. *Clin Oral Implants Res* 6:205–212, 1995.
102. Siegele D, Soltesz U: Numerical investigations of the influence of implant shape on stress distribution in the jaw bone. *Int J Oral Maxillofac Implants* 4:333–340, 1989.
103. Small IA, Chalmers J: Lyons memorial lecture: metal implants and the mandibular staple bone plate. *J Oral Surg* 33:571–585, 1975.
104. Small IA, Metz H, Kobernick S: The mandibular staple implant for the atrophic mandible. *J Biomed Mater Res* 8:365–371, 1974.
105. Small IA, Misiek D: A sixteen-year evaluation of the mandibular staple bone plate. *J Oral Maxillofac Surg* 44:60–66, 1986.
106. Smithloff M, Fritz ME: The use of blade implants in a selected population of partially edentulous adults. A five-year report. *J Periodontol* 47:19–24, 1976.
107. Sutter F, Schroeder A, Straumann F: Engineering and design aspects of the I.T.I. hollow-basket implants. *J Oral Implantol* 10:535–551, 1983.
108. Tricio J, Laohapand P, van Steenberghe D, et al: Mechanical state assessment of the implant-bone continuum: a better understanding of the Periotest method. *Int J Oral Maxillofac Implants* 10:43–49, 1995.
109. Trisi P, Lazzara R, Rao W, et al: Bone-implant contact and bone quality: evaluation of expected and actual bone contact on machined and osseotite implant surfaces. *Int J Periodontics Restorative Dent* 22:535–545, 2002.
110. Ueda M, Matsuki M, Jacobsson M, et al: Relationship between insertion torque and removal torque analyzed in fresh temporal bone. *Int J Oral Maxillofac Implants* 6:442–447, 1991.
111. Versteegh PA, van Beek GJ, Slagter AP, et al: Clinical evaluation of mandibular overdentures supported by multiple-bar fabrication: a follow-up study of two implant systems. *Int J Oral Maxillofac Implants* 10:595–603, 1995.
112. Warrer K, Buser D, Lang NP, et al: Plaque-induced peri-implantitis in the presence or absence of keratinized mucosa. An experimental study in monkeys. *Clin Oral Implants Res* 6:131–138, 1995.
113. Weber HP, Kim DM, Ng MW, et al: Peri-implant soft-tissue health surrounding cement- and screw-retained implant restorations: a multicenter, 3-year prospective study. *Clin Oral Implants Res* 17:375–379, 2006.
114. Webster TJ, Ejiofor JU: Increased osteoblast adhesion on nanophase metals: Ti, Ti6Al4V, and CoCrMo. *Biomaterials* 25:4731–4739, 2004.
115. Weiss CM: Tissue integration of dental endosseous implants: description and comparative analysis of the fibro-osseous integration and osseous integration systems. *J Oral Implantol* 12:169–214, 1986.
116. Wennerberg A, Albrektsson T: Suggested guidelines for the topographic evaluation of implant surfaces. *Int J Oral Maxillofac Implants* 15:331–344, 2000.
117. Wennstrom JL, Bengazi F, Lekholm U: The influence of the masticatory mucosa on the peri-implant soft tissue condition. *Clin Oral Implants Res* 5:1–8, 1994.
118. Wikesjo UM, Huang YH, Xiropaidis AV, et al: Bone formation at recombinant human bone morphogenetic protein-2-coated titanium implants in the posterior maxilla (type IV bone) in non-human primates. *J Clin Periodontol* 35:992–1000, 2008.
119. Xiao G, Cui Y, Ducy P, et al: Ascorbic acid-dependent activation of the osteocalcin promoter in MC3T3-E1 preosteoblasts: requirement for collagen matrix synthesis and the presence of an intact OSE2 sequence. *Mol Endocrinol* 11:1103–1113, 1997.
120. Yanase R: *Management of subperiosteal implant denture problems: International Symposium on Preprosthetic Surgery*, California, 1985, Palm Springs.
121. Yurkatas AA, The current state of implants in prosthodontics. *Newsletter AM Acad Implant Dent* 1967.
122. Zarb G, Albrektsson T: Osseointegration—a requiem for the periodontal ligament? *Int J Periodontics Restorative Dent* 14:251–262, 1991.

CHAPTER 72

Clinical Evaluation of the Implant Patient

Perry R. Klokkevold and David L. Cochran

CHAPTER OUTLINE

Case Types and Indications
Pretreatment Evaluation
Risk Factors and Contraindications
Posttreatment Evaluation
Conclusion

Editors Note: An animation (slide show) has been added as a supplement to the chapter by the Editors. This was produced by My Dental Hub as a patient education tool and covers the basic elements in a conceptual manner. It is not intended to be a procedural guide for dental professionals.

Endosseous dental implants and their retained prostheses have had great success over the past few decades following the landmark research and development of osseointegrated implants by Brånemark et al.[15-17] Initially, most prosthetic reconstructions with osseointegrated implants were limited to use in the edentulous patient, with many reports documenting excellent long-term success of implant-retained prostheses for edentulous patients.[1,2,25]

Following much success with implants in edentulous patients, the original implant treatment protocols were adapted for use in partially edentulous patients. Although some transitional problems were associated with the early use of dental implants in the partially edentulous patient, successes were achieved for this population as well. Subsequently, modifications in implant design, procedural techniques, and treatment planning greatly improved implant therapy for the partially edentulous patient. Currently, the long-term success of dental implants used to replace single and multiple missing teeth in the partially edentulous patient is very good[29,40,42,48,52] (see Chapter 84). Additionally, with the implementation of bone augmentation procedures, even patients with inadequate bone volume have a good opportunity to be successfully restored with implant-retained prostheses.[27,34,53] Virtually any patient with an edentulous space is a candidate for endosseous implants, and studies suggest that greater than 90% to 95% success rates can be expected in healthy patients with good bone and normal healing capacity.[24]

The ultimate goal of dental implant therapy is to satisfy the patient's desire to replace one or more missing teeth in an esthetic, secure, functional, and long-lasting manner. To achieve this goal, clinicians must accurately diagnose the current dentoalveolar condition, as well as the overall mental and physical well-being of the patient to determine whether implant therapy is possible or practical and perhaps most importantly, whether it is indicated for a particular patient. Local evaluation of potential jaw sites for implant placement (e.g., measuring available alveolar bone height, width, and spatial relationship) and prosthetic restorability are an essential part of determining whether an implant(s) is possible. However, determining whether the patient is a good candidate for implants is an equally important aspect of the evaluation process. This aspect of the patient evaluation includes identifying factors that might increase the risk of failure or complications, as well as determining whether the patient's expectations are reasonable.

This chapter presents an overview of the clinical aspects of dental implant therapy, including an assessment of possible risk factors and contraindications. It also provides guidelines for the pretreatment evaluation of potential implant patients and the posttreatment evaluation of patients with implants.

Case Types and Indications

Edentulous Patients

The patients who seem to benefit most from dental implants are those with fully edentulous arches. These patients can be effectively restored, both esthetically and functionally, with an implant-assisted removable prosthesis or an implant-supported fixed prosthesis.

The original design for the edentulous arch was a fixed-bone–anchored bridge that used five to six implants in the anterior area of the mandible or the maxilla to support a fixed, hybrid prosthesis. The design is a denture-like complete arch of teeth attached to a substructure (metal framework), which in turn is attached to the implants with cylindrical titanium abutments (Figure 72-1). The prosthesis is fabricated without flange extensions and does not rely on any soft tissue support. It is entirely implant supported (see Figure 75-13). Usually, the prosthesis includes bilateral distal cantilevers, which extend to replace posterior teeth (back to premolars or first molars).

Another implant-supported design used to restore an edentulous arch is the ceramic-metal fixed bridge (Figure 72-2). Some patients prefer this design because the ceramic restoration emerges directly from the gingival tissues in a manner similar to the appearance of natural teeth. Depending on the volume of existing bone, the jaw relationship, the amount of lip support, and phonetics, some

Figure 72-1 Clinical photograph of patient with a complete maxillary denture opposing a full-arch implant-supported fixed prosthesis in the mandibular arch.

patients may not be able to be rehabilitated with an implant-supported fixed prosthesis.

One limitation of both hybrid and ceramometal implant-supported fixed prostheses is that they provide very little lip support and thus may not be indicated for patients who have lost significant alveolar dimension. This is often more problematic for maxillary reconstructions because lip support is more critical in the upper arch. Furthermore, for some patients, the lack of a complete seal (i.e., spaces under the framework) allows air to escape during speech, thus creating phonetic problems.

Depending on the volume of existing bone, the jaw relationship, the amount of lip support, and phonetics, some patients may not be able to be rehabilitated with an implant-supported fixed prosthesis. For these patients, a removable, complete-denture type of prosthesis is a better choice because it provides a flange extension that can be adjusted and contoured to support the lip, and there are no spaces for unwanted air escape during speech. This type of prosthesis can be retained and stabilized by two or more implants placed in the anterior region of the maxilla or mandible. Methods used to secure the denture to the implants vary from separate attachments on each individual implant to clips or other attachments that connect to a bar, which splints the implants together (Figure 72-3). Advantages and disadvantages of these attachment designs are discussed in Chapter 76.

Although the stability of the implant-retained overdenture does not compare to the rigidly attached, implant-supported fixed prosthesis, the increased retention and stability over conventional complete dentures is an important advantage for denture wearers.[55] Additionally, implant-assisted and implant-supported prostheses are thought to protect alveolar bone from additional bone loss caused by long-term use of removable prostheses that are bearing directly on the alveolar ridges.

Partially Edentulous Patients

Multiple Teeth. Partially edentulous patients with multiple missing teeth represent another viable treatment population for osseointegrated implants, but the remaining natural dentition (occlusal schemes, periodontal health status, spatial relationships, and esthetics) introduces additional challenges for successful rehabilitation.[41] The juxtaposition of implants with natural teeth in the partially edentulous patient presents the clinician with challenges

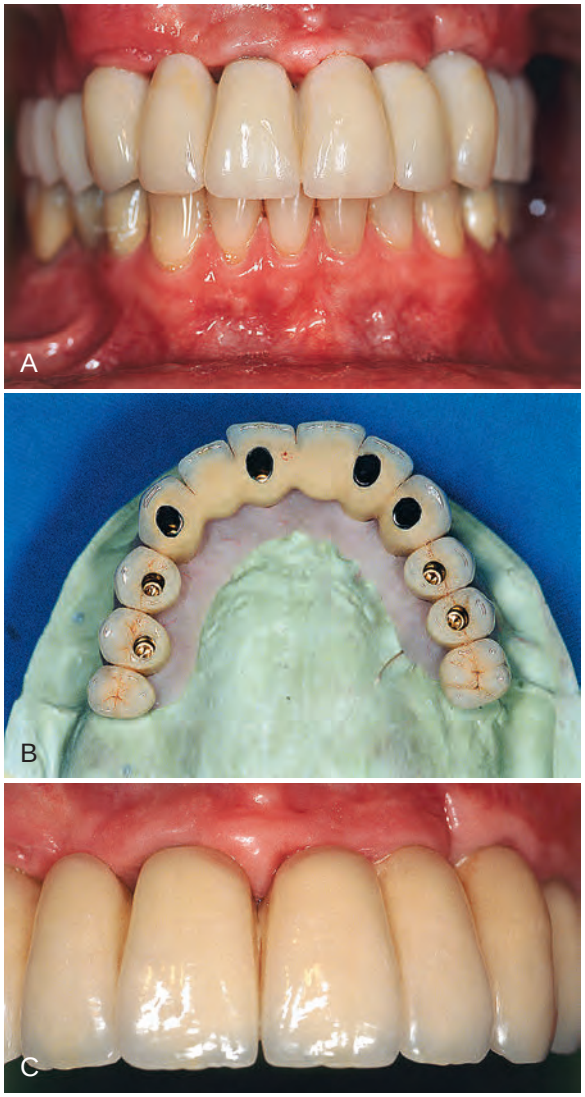

Figure 72-2 **A,** Clinical photograph of acrylic provisional fixed full-arch prosthesis in the maxilla. **B,** Clinical photograph of the final ceramometal restoration, anterior view. **C,** Occlusal view of final restoration on master cast. *(Courtesy Dr. Russell Nishimura, Westlake Village, CA.)*

not encountered with implants in the edentulous patient. As a result of distinct differences in the biology and function of implants compared with natural teeth, clinicians must educate themselves and use a prescribed approach to the evaluation and treatment planning of implants for partially edentulous patients (see Chapter 74). In general, endosseous dental implants can support a freestanding fixed partial denture. Adjacent natural teeth are not necessary for support, but their close proximity requires special attention and planning.[11] The major advantage of implant-supported restorations in partially edentulous patients is that they replace missing teeth without invasion or alteration of adjacent teeth. Preparation of natural teeth becomes unnecessary, and larger edentulous spans can be restored with implant-supported fixed bridges.[49] Moreover, patients who previously did not have a fixed option, such as those with Kennedy Class I and II partially edentulous situations, can be restored with an implant-supported fixed restoration (Figure 72-4).

Early attempts to use endosseous implants to replace missing teeth in the partially edentulous patient were a challenge partly because the implants and armamentarium were designed for the

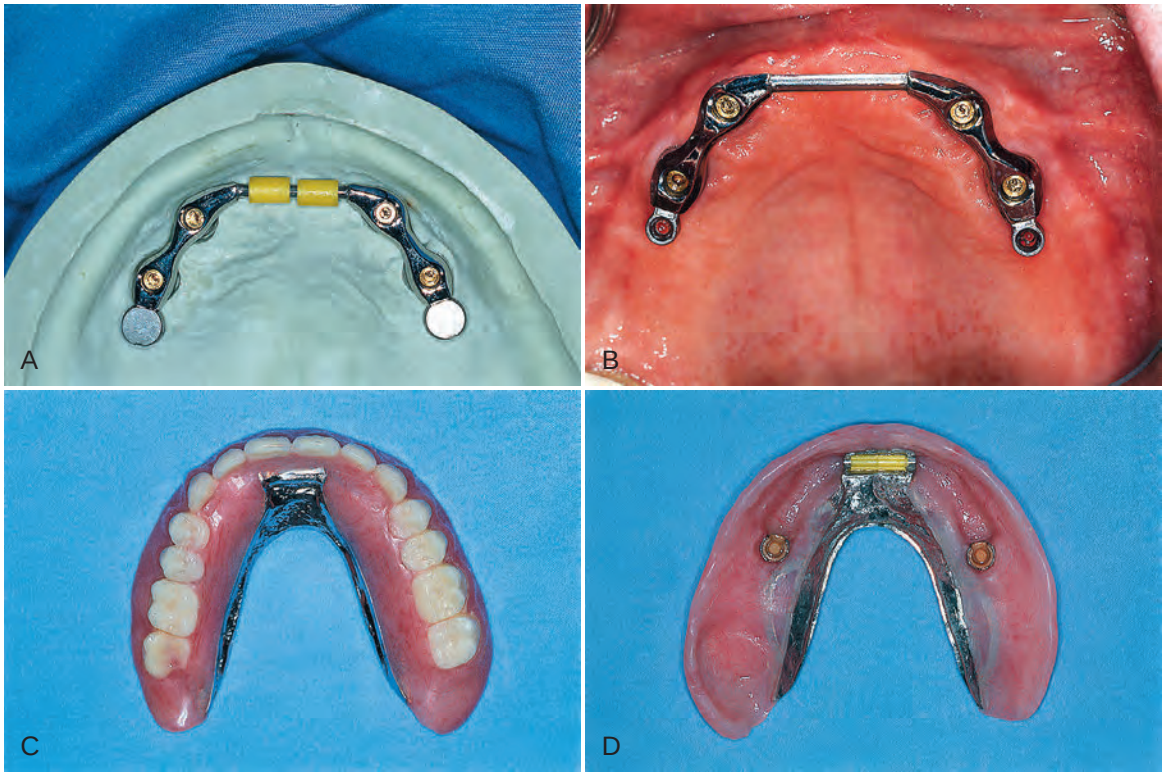

Figure 72-3 **A,** Laboratory view of maxillary overdenture bar attached to four implants with anterior clips and posterior extracoronal resilient attachments (ERAs). **B,** Clinical view of maxillary overdenture bar. **C,** Palateless maxillary complete overdenture. **D,** Tissue surface of same maxillary implant-assisted overdenture showing clips and ERAs. *(Courtesy Dr. John Beumer, UCLA Maxillofacial Prosthodontics, Los Angeles.)*

Figure 72-4 **A,** Clinical view of partially edentulous posterior mandible (Kennedy Class II distal extension). **B,** Occlusal view of same patient in **A** restored with implant-supported fixed restoration replacing teeth #18 and #19. Note that the dimensions of the crowns are smaller than typical mandibular molars (i.e., closer to bicuspid size). **C,** Buccal view of same restorations.

edentulous patient and did not have much flexibility for adaptation and use in the partially edentulous patient. Today, clinicians have many choices in terms of implant length, diameter, and abutment connection to choose for the optimal replacement of any missing tooth, large or small (Figure 72-5).

The primary challenge with partially edentulous cases is an underestimation of the importance of treatment planning for implant-retained restorations with an adequate number of implants to withstand occlusal loads. For example, one problem that required correction was the misconception that two implants could be used

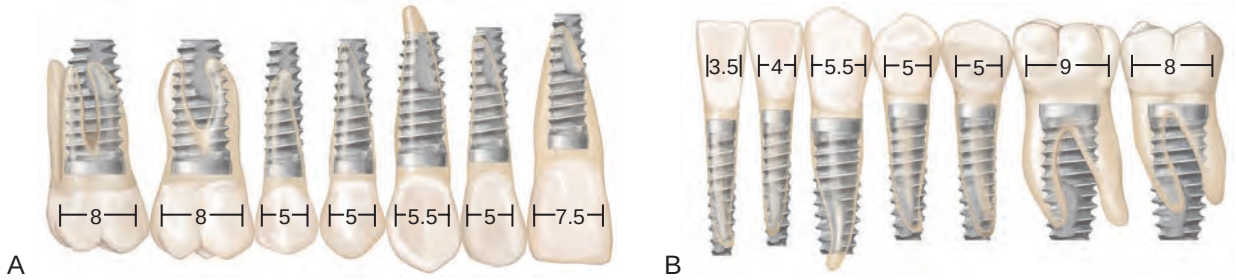

Figure 72-5 Diagram representing the use of wide-, narrow-, and standard-diameter implants for molars, mandibular incisors, and other teeth (different-sized implants superimposed over various teeth). **A,** Maxillary teeth. **B,** Mandibular teeth.

to support a long-span, multiunit fixed bridge in the posterior area. Multiunit fixed restorations in the posterior jaw are more likely to experience complications or failures (mechanical or biologic) when they are inadequately supported either in terms of the number of implants, quality of bone, or strength of the implant material (see Chapter 74). The use of implants of adequate width and length and better treatment planning (more implants used to support more restorative units), particularly in areas of poor-quality bone, has solved many of these problems.

Single Tooth. Patients with a missing single tooth (anterior or posterior) represent another type of patient who benefits greatly from the success and predictability of endosseous dental implants (see Video 72-1: Single Esthetic Implant Slide Show). Replacement of a single missing tooth with an implant-supported crown is a much more conservative approach than preparing two adjacent teeth for the fabrication of a tooth-supported fixed partial denture. It is no longer necessary to "cut" healthy or minimally restored adjacent teeth to replace a missing tooth with a nonremovable prosthetic replacement (Figure 72-6). Reported success rates for single-tooth implants are excellent.[23]

Replacement of an individual missing posterior tooth with an implant-supported restoration has been successful as well. The greatest challenges to overcome with the single-tooth implant restorations were screw loosening and implant or component fracture. Because of increased potential to generate forces in the posterior area, the implants, components, and screws often failed. Both these problems have been addressed with the use of wider-diameter implants and internal fixation of components (Figure 72-7). Wide-diameter implants often have a wider platform (restorative interface) that resists tipping forces and thus reduces screw loosening. The wide-diameter implant also provides greater strength and resistance to fracture as a result of increased wall thickness (the thickness of the implant between the inner screw thread and the outer screw thread). Implants with an internal connection are inherently more resistant to screw loosening and thus have an added advantage for single-tooth applications.

Esthetic Considerations. Anterior single-tooth implants present some of the same challenges as the single posterior tooth supported by an implant, but they also are an esthetic concern for patients. Some cases are more esthetically challenging than others because of the nature of each individual's smile and display of teeth. The prominence and occlusal relationship of existing teeth, the thickness and health of periodontal tissues, and the patient's own psychologic perception of esthetics all play a role in the esthetic challenge of the case. Cases with good bone volume, bone height, and tissue thickness can be predictable in terms of achieving satisfactory esthetic results (see Figure 72-6). However,

Figure 72-6 Single-tooth replacement. **A,** Implant in place. **B,** Metalloceramic crown.

achieving esthetic results for patients with less-than-ideal tissue qualities poses difficult challenges for the restorative and surgical team.[12] Replacing a single tooth with an implant-supported crown in a patient with a high smile line, compromised or thin periodontium, inadequate hard or soft tissues, and high expectations is probably one of the most difficult challenges in implant dentistry and should not be attempted by novice clinicians.

Pretreatment Evaluation

A comprehensive evaluation is indicated for any patient who is being considered for dental implant therapy. The evaluation should assess all aspects of the patient's current health status, including a review the patient's past medical history, medications, and medical treatments. Patients should be questioned about parafunctional

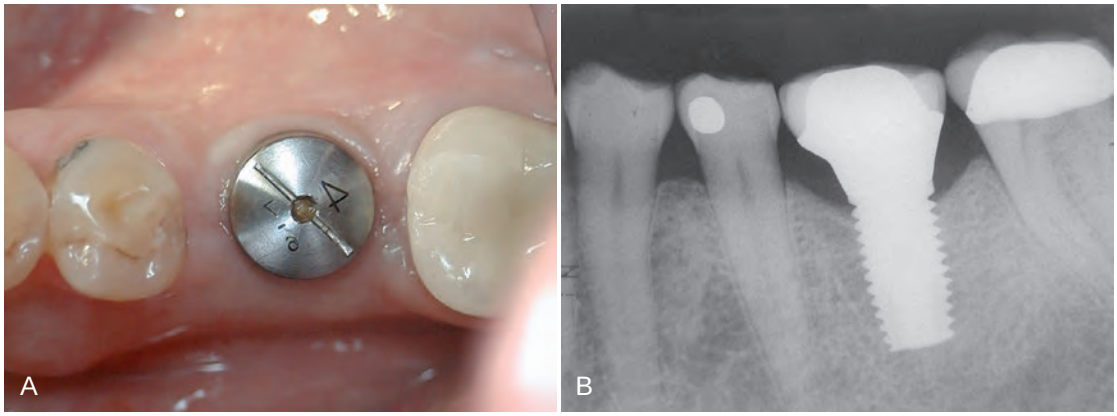

Figure 72-7 **A,** Occlusal view of healing abutment, which is attached to a wide-diameter implant used to replace a single missing molar. **B,** Radiograph of same patient depicted in **A,** showing the wide-diameter implant supporting the final restoration (molar replaced with a single-tooth implant-supported crown).

habits, such as clenching or grinding teeth, as well as any substance use or abuse, including tobacco, alcohol, and drugs. The assessment should also include an evaluation of the patient's motivations, level of understanding, compliance, and overall behavior. For most patients, this involves simply observing their demeanor and listening to their comments for an impression of their overall sensibility and coherence with other patient norms.

An intraoral and radiographic examination must be done to determine whether it is possible to place implant(s) in the desired location(s). Properly mounted diagnostic study models and intraoral clinical photographs are a useful part of the clinical examination and treatment-planning process to aid in assessment of spatial and occlusal relationships. Once the data collection is completed, the clinician will be able to determine whether implant therapy is possible, practical, and indicated for the patient.

Conducting an organized, systematic history and examination is essential to obtaining an accurate diagnosis and creating a treatment plan that is appropriate for the patient. Each treatment plan should be comprehensive and provide several treatment options for the patient, including periodontal and restorative therapies. Then, in consultation, the clinician can agree on the final treatment plan with the patient. Information gathered throughout the process will help the clinician's decision making and determination of whether a patient is a good candidate for dental implants. A thoughtful and well-executed evaluation can also reveal deficiencies and indicate what additional surgical procedures may be necessary to accomplish the desired goals of therapy (e.g., localized ridge augmentation, sinus bone augmentation). Each part of the pretreatment evaluation is briefly discussed here.

Chief Complaint

What is the problem or concern in the patient's own words? What is the patient's goal of treatment, and how realistic are the patient's expectations? The patient's chief concern, desires for treatment, and vision of the successful outcome must be taken into consideration. The patient will measure implant success according to personal criteria. The overall comfort and function of the implant restoration are often the most important factors, but satisfaction with the appearance of the final restoration will also influence the patient's perception of success. Furthermore, patient satisfaction may be influenced simply by the impact that the treatment has on the patient's perceived quality of life. Patients will evaluate for themselves whether the treatment helped them to eat better, look better, or feel better about themselves.

The clinician could consider an implant(s) and the retained prosthesis a success using standard criteria of symptom-free implant function, implant stability, and lack of periimplant infection or bone loss. At the same time, however, the patient who does not like the esthetic result or does not think the condition has improved could consider the treatment a failure. Therefore it is critical to inquire, as specifically as possible, about the patient's expectations before initiating implant therapy and to appreciate the patient's desires and values. With this goal in mind, it is often helpful and advisable to invite patients to bring their spouses or family members to the consultation and treatment-planning visits to add an independent "trusted" observer to the discussion of treatment options. Ultimately, it is the clinician's responsibility to determine if the patient has realistic expectations for the outcome of therapy and to educate the patient about realistic outcomes for each treatment option.

Medical History

A thorough medical history is required for any patient in need of dental treatment, regardless of whether implants are part of the plan. This history should be documented in writing by the patient's completion of a standard health history form and verbally through an interview with the treating clinician. The patient's health history should be reviewed for any condition that might put the patient at risk for adverse reactions or complications.

Patients must be in reasonably good health to undergo surgical therapy for the placement of dental implants. Any disorder that may impair the normal wound-healing process, especially as it relates to bone metabolism, should be carefully considered as a possible risk factor or contraindication to implant therapy (see later discussion).

A thorough physical examination is warranted if any questions arise about the health status of the patient.[15] Appropriate laboratory tests (e.g., coagulation tests for a patient receiving anticoagulant therapy) should be requested to evaluate further any conditions that may affect the patient's ability to undergo the planned surgical and restorative procedures safely and effectively. If any questions remain about the patient's health status, a medical clearance for surgery should be obtained from the patient's treating physician.

Dental History

A review of a patient's past dental experiences can be a valuable part of the overall evaluation. Does the patient report a history of recurrent or frequent abscesses, which may indicate a

susceptibility to infections or diabetes? Does the patient have many restorations? How compliant has the patient been with previous dental recommendations? What are the patient's current oral hygiene practices?

The individual's previous experiences with surgery and prosthetics should be discussed. If a patient reports numerous problems and difficulties with past dental care, including a history of dissatisfaction with past treatment, the patient may have similar difficulties with implant therapy. It is essential to identify past problems and to elucidate any contributing factors. The clinician must also assess the patient's dental knowledge and understanding of the proposed treatment, as well as the patient's attitude and motivation toward implants.

Intraoral Examination

The oral examination is performed to assess the current health and condition of existing teeth, as well as to evaluate the condition of the oral hard and soft tissues. It is imperative that no pathologic conditions are present in any of the hard or soft tissues in the maxillofacial region. All oral lesions, especially infections, should be diagnosed and appropriately treated before implant therapy. Additional criteria to consider include the patient's habits, level of oral hygiene, overall dental and periodontal health, occlusion, jaw relationship, temporomandibular joint condition, and ability to open wide.

After a thorough intraoral examination, the clinician can evaluate potential implant sites. All sites should be clinically evaluated to measure the available space in the bone for the placement of implants and in the dental space for prosthetic tooth replacement (Box 72-1). The mesial-distal and buccal-lingual dimensions of edentulous spaces can be approximated with a periodontal probe or other measuring instrument. The orientation or tilt of adjacent teeth and their roots should be noted as well. There may be enough space in the coronal area for the restoration but not enough space in the apical region for the implant if roots are directed into the area of interest (Figure 72-8). Conversely, there may be adequate space between roots, but the coronal aspects of the teeth may be too close for emergence and restoration of the implant. If either of these conditions is discovered, orthodontic tooth movement may be indicated. Ultimately, edentulous areas need to be precisely measured using diagnostic study models and imaging techniques to determine whether space is available and whether adequate bone volume exists to replace missing teeth with implants and implant restorations. Figure 72-9 diagrams the minimal space requirements for standard-, wide-, and narrow-diameter implants placed between natural teeth, and the minimal interocclusal space needed to restore implants.

BOX 72-1 How Much Space Is Required for Placement of One or More Implants?*

Alveolar Bone

Assuming an implant is 4 mm in diameter and 10 mm long, the minimal width of the jawbone needs to be 6 to 7 mm, and the minimal height should be 10 mm (minimum of 12 mm in the posterior mandible, where an additional margin of safety is required over the mandibular nerve). This dimension is desired to maintain at least 1.0 to 1.5 mm of bone around all surfaces of the implant after preparation and placement.

Interdental Space

Edentulous spaces need to be measured to determine whether enough space exists for the placement and restoration with one or more implant crowns. The minimal space requirements for the placement of one, two, or more implants are illustrated diagrammatically in Figure 72-9. The minimal mesial-distal space for an implant placed between two teeth is 7 mm. The minimal mesial-distal space required for the placement of two standard-diameter implants (4.0-mm diameter) between teeth is 14 mm. The required minimal dimensions for wide-diameter or narrow-diameter implants will increase or decrease incrementally according to the size of the implant. For example, the minimal space needed for the placement of an implant 6 mm in diameter is 9 mm (7 mm + 2 mm). Whenever the available space between teeth is greater than 7 mm and less than 14 mm, only one implant, such as placement of a wide-diameter implant, should be considered. The placement of a wide-diameter implant should be considered. Two narrow-diameter implants could be positioned in a space that is 12 mm. However, the smaller implant may be more vulnerable to implant fracture.

Interocclusal Space

The restoration consists of the abutment, the abutment screw, and the crown (it may also include a screw to secure the crown to the abutment if it is not cemented). This restorative "stack" is the total of all the components used to attach the crown to the implant. The dimensions of the restorative stack vary slightly depending on the type of abutment and the implant-restorative interface (i.e., internal or external connection). The minimum amount of interocclusal space required for the restorative "stack" on an external hex-type implant is 7 mm.

*All the minimal space requirements discussed here are generic averages. The actual space limitations for any particular implant system must be determined according to the manufacturer's specifications.

Diagnostic Study Models. Mounted study models are an excellent means of assessing potential sites for dental implants. Properly articulated models with diagnostic wax-up of the proposed restorations allow the clinician to evaluate the available space and to determine potential limitations of the planned treatment (Figure 72-10). This is particularly useful when multiple teeth are to be replaced with implants or when a malocclusion is present.

Hard Tissue Evaluation. The amount of available bone is the next criterion to evaluate. Wide variations in jaw anatomy are encountered, and it is therefore important to analyze the anatomy of the dentoalveolar region of interest both clinically and radiographically.

A visual examination can immediately identify deficient areas (Figure 72-11), whereas other areas that appear to have good ridge width will require further evaluation (Figure 72-12). Clinical examination of the jawbone consists of palpation to feel for anatomic defects and variations in the jaw anatomy, such as concavities and undercuts. If desired, it is possible with local anesthesia to probe through the soft tissue (intraoral bone mapping) to assess the thickness of the soft tissues and measure the bone dimensions at the proposed surgical site.

The spatial relationship of the bone must be evaluated in a three-dimensional view because the implant must be placed in the appropriate position relative to the prosthesis. It is possible that an adequate dimension of bone is available in the anticipated implant site (see Box 72-1), but that the bone and thus the implant placement might be located too lingual or too buccal for the desired prosthetic tooth replacement.[30] Bone augmentation procedures may be necessary to facilitate the placement of an implant in an acceptable prosthetic position despite the availability of an adequate

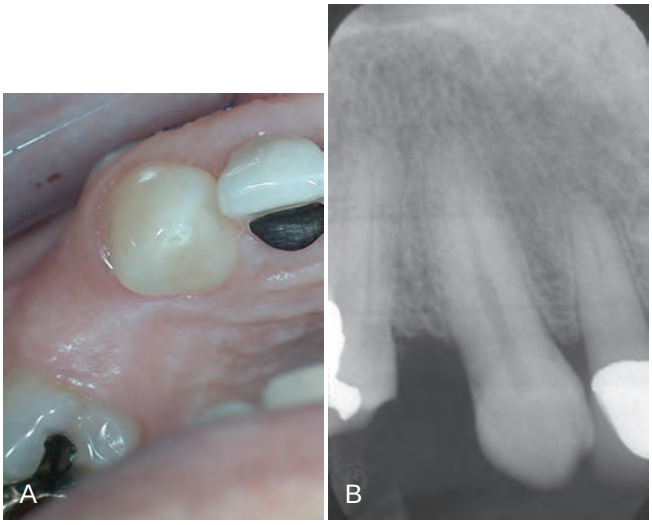

Figure 72-8 **A,** Clinical photograph of maxillary premolar space with apparently adequate space between the remaining teeth for an implant-supported crown. **B,** Radiograph clearly shows a lack of space between the roots of the adjacent teeth as a result of convergence into the space (same patient as in **A**).

quantity of bone (i.e., the bone is in the wrong location). Indications for the use of bone augmentation procedures are discussed in Chapter 76.

Radiographic Examination. Radiographic assessment of the quantity, quality, and location of available alveolar bone in potential implant sites ultimately determines whether a patient is a candidate for implants and if a particular implant site needs bone augmentation. Appropriate radiographic procedures, including periapical radiographs, panoramic projections, and cross-sectional imaging, can help identify vital structures such as the floor of the nasal cavity, maxillary sinus, mandibular canal, and mental foramen (see Chapter 73). In addition to the absolute dimensional measurement of the alveolar bone, it is important to determine whether the volume of bone radiographically (as well as clinically) is located in a position to allow for the proper position of the implant to facilitate restoration of the tooth/teeth in proper esthetic and functional relationship with the adjacent and opposing dentition. The best way to evaluate the relationship of available bone to the dentition is to image the patient with a diagnostically accurate guide using radiopaque markers that are positioned at the proposed prosthetic locations, ideally with appropriate restorative contours (see Figure 74-5).

Soft Tissue Evaluation. Evaluation of the quality, quantity, and location of soft tissue present in the anticipated implant site helps to anticipate the type of tissue that will surround the implant(s) after treatment is completed (keratinized vs. nonkeratinized mucosa). For some cases, depending on the clinician's view of keratinized tissue, evaluation may reveal a need for soft tissue augmentation (Box 72-2). Areas with minimal or no existing keratinized mucosa may be augmented with gingival or connective tissue grafts. Other soft tissue concerns, such as frenum attachments or pulls, should be thoroughly evaluated as well.

Risk Factors and Contraindications

Clearly, there are numerous indications for the use of endosseous dental implants to replace missing teeth. Most patients who are missing one or more teeth can benefit from the application of an implant-retained prosthesis provided they meet the requirements for surgical and prosthetic rehabilitation. Edentulous patients who are unable to function with complete dentures and who have adequate bone for the placement of dental implants can be especially good dental implant candidates. More and more partially edentulous patients are also being treated with dental implant restorations. Many patients, whether they are missing one, several, or all of their teeth, can be predictably restored with implant-retained prostheses.

In this era of high implant success and predictability and thus possible complacency, it is imperative for clinicians to recognize risk factors and contraindications to implant therapy so that problems can be minimized and patients can be accurately informed about risks. As such, the clinician must be knowledgeable in this area and inform patients about risk factors and contraindications before initiating treatment. Contraindications for the use of dental implants, although relatively few and often not well defined, do exist. Some conditions are probably best described as "risk factors" rather than "contraindications" to treatment because implants can be successful in almost all patients; implants may be less *predictable* in some situations, and this distinction should be recognized. Ultimately, it is the clinician's responsibility with the patient to make decisions as to when implant therapy is not indicated.

Table 72-1 lists some conditions and factors that are thought to increase the risk for implant failure or otherwise deem the patient a poor candidate for implant therapy. Some of these conditions are briefly discussed here.

Medical and Systemic Health–Related Issues

Although few absolute medical contraindications to implant therapy exist, some relative contraindications are important to consider. The clinician must consider medical and health-related conditions that affect bone metabolism or any aspect of the patient's capacity to heal normally.[10] This category includes conditions such as diabetes, osteoporosis, and immune compromise, medications, and medical treatments such as chemotherapy and irradiation.

Diabetes Mellitus. Diabetes is a metabolic disease that can have significant effects on the patient's ability to heal normally and resist infections. This is particularly true for patients whose diabetes is not well controlled. Poorly controlled diabetics often have impaired wound healing and a predisposition to infections, whereas diabetic patients whose disease is well controlled experience few, if any, problems (see Chapter 11).

There is concern about the success and predictability of implants in patients with diabetes. Several studies have reported moderate failure rates in patients with diabetes, with implant success ranging from 85.6% to 94.3%.[8,26,36,39] A prospective study demonstrated 2.2% early failures and 7.3% late failures in diabetic patients.[51] After 5 years, the overall success rate for this group of diabetic patients was 90%.[47] None of these studies was able to correlate gender, age, smoking, diabetes type, or level of diabetic control with implant failure. In a meta-analytical review of implant failures in patients who were not diabetics, the early implant failure rate was 3.2% and the late implant failure rate 5.2%.[22] The finding that patients with diabetes experience slightly more late failures may be related to less tissue integrity caused by reduced tissue turnover and impaired tissue perfusion. These results suggest that diabetes may be a risk factor for implants, particularly for late failures. However, the risk does not appear to be particularly high.

Bone Metabolic Disease. Osteoporosis is a skeletal condition characterized by decreased mineral density. The two main classifications are primary (three types) and secondary (multiple

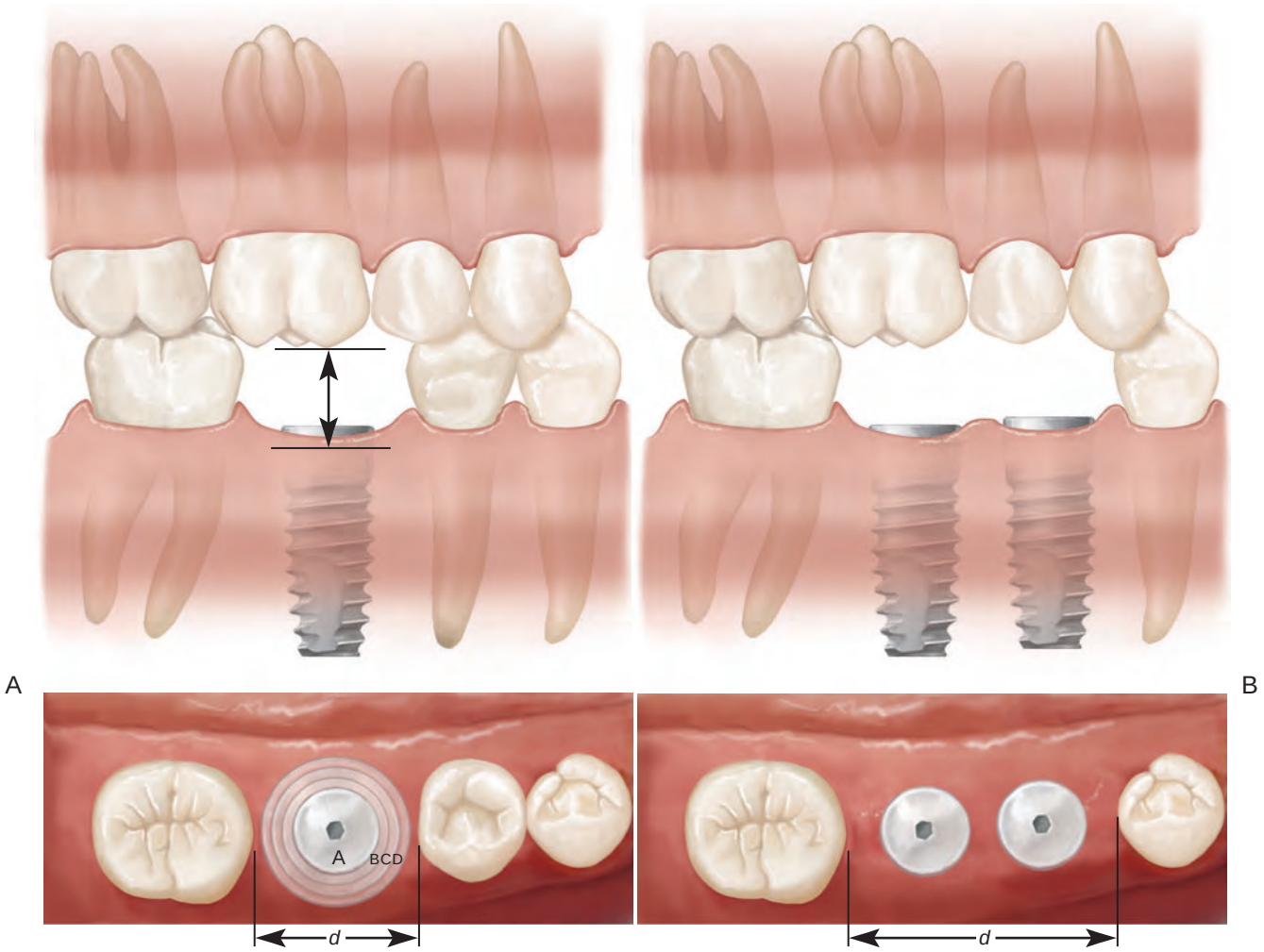

The minimum mesial-distal (*d*) required for a:
A. Narrow diameter implant (e.g., 3.25 mm) is 6 mm.
B. Standard diameter implant (e.g., 4.1 mm) is 7 mm.
C. Wide diameter implant (e.g., 5.0 mm) is 8 mm.
D. Wide diameter implant (e.g., 6.0 mm) is 9 mm.

The minimum mesial-distal (*d*) required for two standard diameter implants is 14 mm wide.

Figure 72-9 **A,** Minimum amount of mesial-distal space *(d)* required for placement of single-tooth implant between natural teeth: *A,* 6 mm for narrow-diameter implant (3.25 mm); *B,* 7 mm for standard-diameter implant (4.1 mm); *C* and *D,* 8 mm and 9 mm, respectively, for wide-diameter implants (5.0 mm and 6.0 mm). **B,** Minimum amount of mesial-distal space *(d)* required for placement of two standard-diameter (4.1 mm) implants between natural teeth is 14 mm. This allows approximately 2 mm between teeth/implants and between implant/implant. Minimum amount of space required between implant/restoration interface and opposing occlusal surfaces for restoration of an implant. This dimension will vary, depending on implant design and manufacturer component dimensions. The minimal dimension of 7 mm is based on an externally hexed implant and UCLA abutment.

types) osteoporosis. *Primary osteoporosis* has been attributed to menopausal changes (type I), age-related changes (type II), or idiopathic causes (type III). *Secondary osteoporosis* has been attributed to many different diseases and conditions, including diabetes, alcoholism, malnutrition, and smoking.[31]

All the various types of osteoporosis share the same fundamental problem of decreased bone mineral density, and the concern that this condition may impair the patient's ability to achieve and maintain implant osseointegration. The premise that implants will not perform as well in a patient with osteoporosis is reasonable given that osseointegration depends on bone formation adjacent to the implant surface and that success rates are highest in dense bone and lowest in poor-quality, loose trabecular bone. However, to date, there is no clear evidence to suggest that implants will not be successful in patients with osteoporosis, so the issue continues to be debated.[9,19] On the positive side, although the evidence is weak, case reports have demonstrated successful implant treatment in patients with osteoporosis.[30] Some investigators advocate the use of longer healing times for osseointegration to occur before loading the implants in patients with osteoporosis.[28] Conversely, in a retrospective analysis of 49 patients who received sinus bone augmentation, individuals (11 patients) with lower bone mass density had significantly lower implant success rates as compared to age- and sex-matched controls.[14] Other parameters evaluated in this study did not demonstrate any significant differences.

Interestingly, there is a trend in aging adults (men over 50 years and postmenopausal women) for bone mass to decrease progressively through bone demineralization at a rate of 1% to 2% per year and in some individuals as much as 5% to 8% per year throughout their later life.[21,35] If one considers this decline in bone

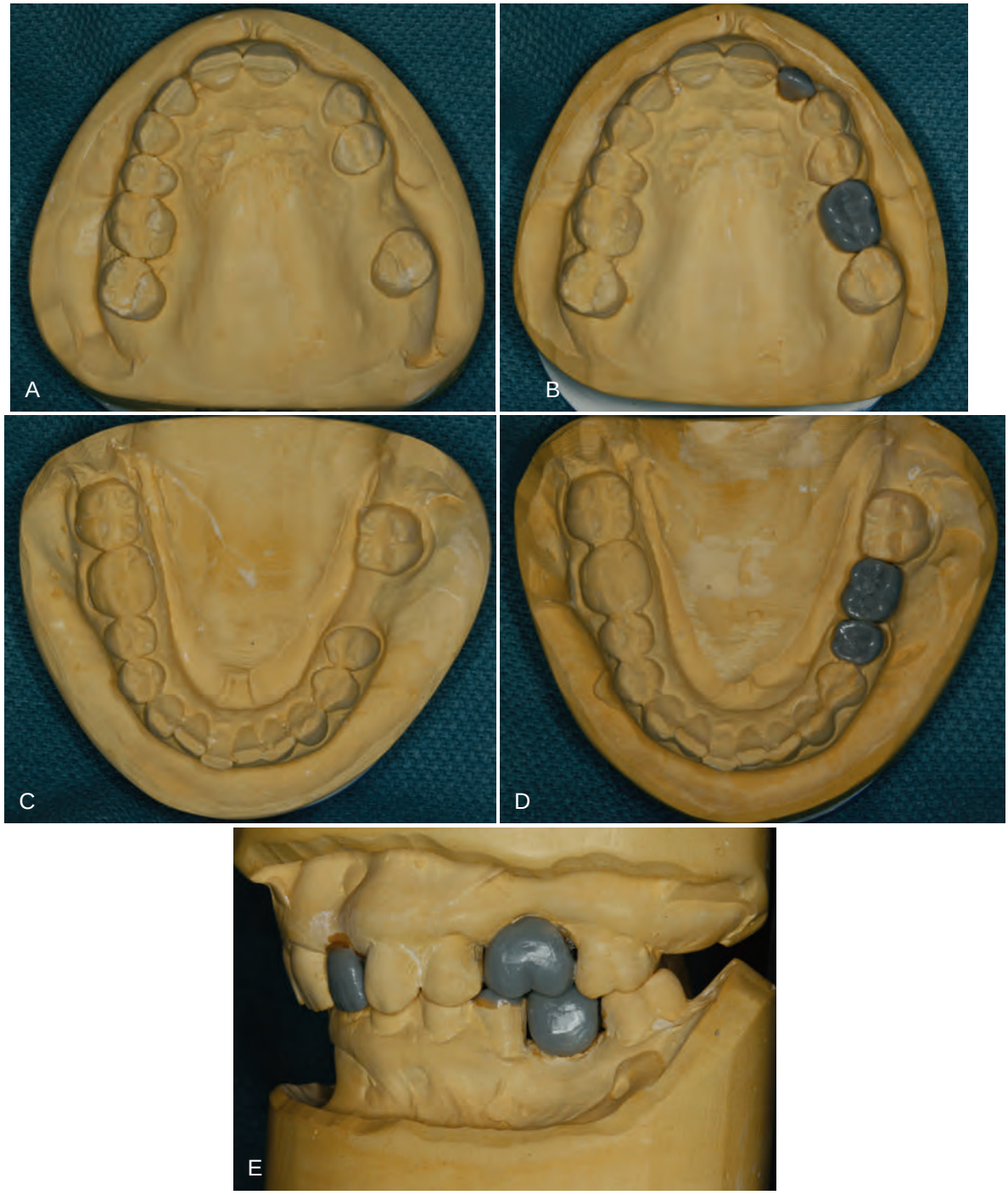

Figure 72-10 Photographs of a diagnostic models with proposed lateral incisor and first molar tooth replacement waxed-up to evaluate the amount of space and contours. **A,** Diagnostic cast of maxillary arch with missing left lateral incisor and left first molar. **B,** Diagnostic wax-up of lateral incisor and first molar in the maxillary arch. **C,** Diagnostic cast of mandibular arch with missing left first molar. **D,** Diagnostic wax-up of first molar. **E,** Articulated maxillary and mandibular diagnostic models with wax-up of lateral incisor and first molars to evaluate dimensions and contours. *(Courtesy Dr. Stacy Yu, University of California, Los Angeles).*

mass with aging along with a continually increasing life expectancy in the population, the number of individuals with osteopenia or osteoporosis will continue to increase, and the concern about this condition's influence on implant success will become increasingly more important for clinicians.

Medications. Some prescribed medications, including steroids and bisphosphonates, may be cause for concern relative to the potential implant patient. Corticosteroid therapy, whether used for hormone replacement, cancer treatment, immune suppression or other chronic condition may suppress the immune response, impair wound healing or compromise the normal adrenal response to stress. See the later section on immune compromise and immune suppression, as well as Chapters 11 and 37 for more information on the treatment of patients taking corticosteroids and bisphosphonate medications. Only a brief statement regarding the risk of bisphosphonate therapy is offered here. Readers are encouraged to review more detailed explanations in Chapters 11 and 37 and to

Figure 72-11 Clinical photographs of edentulous areas with obvious deficient areas of alveolar dimension noted on visual examination: **A,** anterior maxilla; **B,** posterior maxilla; **C,** anterior mandible; **D,** posterior mandible. These clinical images all represent buccal-lingual deficiencies in the alveolar dimensions.

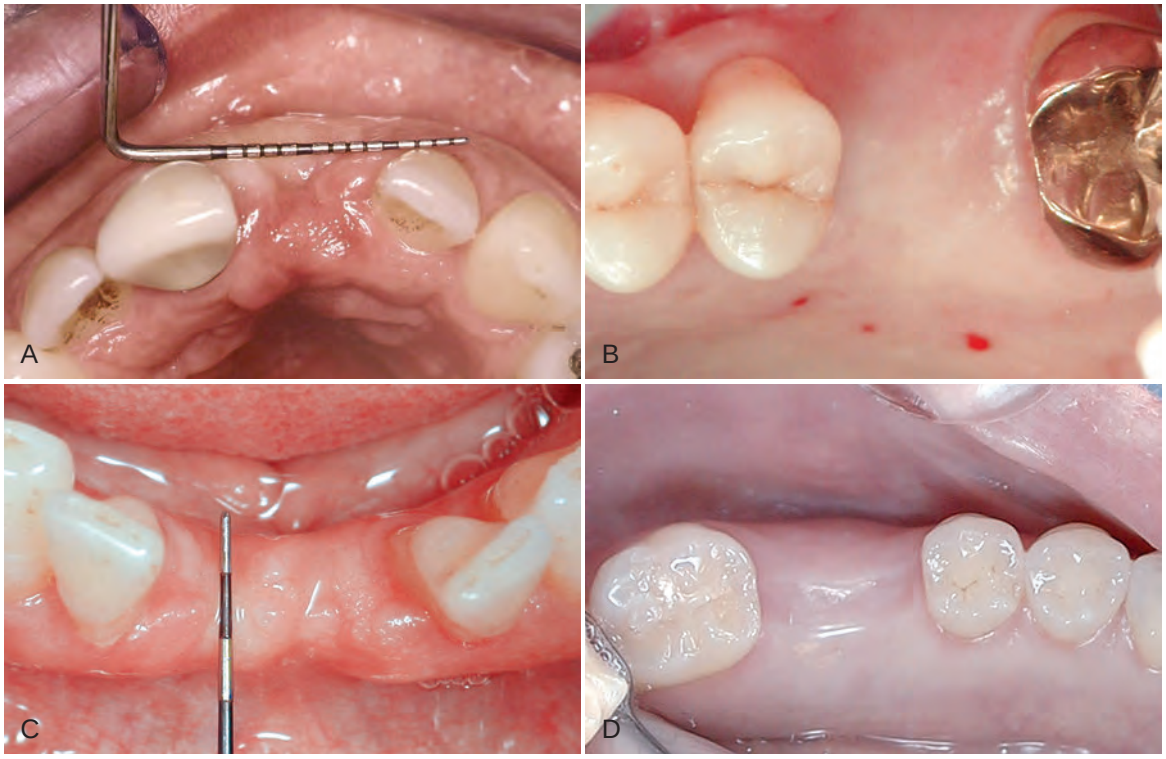

Figure 72-12 Clinical photographs of edentulous areas with apparent good alveolar dimension noted on visual examination: **A,** anterior maxilla; **B,** posterior maxilla; **C,** anterior mandible; **D,** posterior mandible. It is likely that these sites have adequate bone volume for implant placement. However, it is also possible to find alveolar deficiencies despite the appearance of wide ridges.

BOX 72-2 How Much Keratinized Tissue Is Required for Health and Maintenance of Implants?

Debate continues about whether it is necessary to have a zone of keratinized tissue surrounding implants. Despite strong opinions and beliefs about the need for keratinized mucosa around implants versus this mucosa being unnecessary, neither argument has been proved.

Some studies have concluded that, in the presence of good oral hygiene, a lack of keratinized tissue does not impair the health or function of implants.[54] Others strongly believe that keratinized mucosa has better functional and esthetic results for implant restorations. Keratinized mucosa is typically thicker and denser than alveolar mucosa (nonkeratinized). It forms a strong seal around the implant with a cuff of circular (parallel) fibers around the implant, abutment, or restoration that is resistant to retracting with mastication forces and oral hygiene procedures. Implants with coated surfaces (i.e., hydroxyapatite [H] or titanium plasma spray [TPS] coating) demonstrate greater periimplant bone loss and failures in the absence of keratinized mucosa.[13,38]

consult online information, as well as other resources to get updated information about this important subject as more is learned and recommendations are developed.

Although there is heightened awareness and great concern about risk of bisphosphonate-related osteonecrosis of the jaw (BRONJ), the causal relationship and pathogenesis of the problem has not been defined. A review of available literature offers information that will help to guide clinicians in their decision making, but it is far from definitive. The prevalence and incidence remains uncertain. In general, the risk of BRONJ is between 1 in 10,000 and 1 in 100,000 but may increase to 1 in 300 after an oral surgical procedure. The great majority of BRONJ cases will likely remain in the intravenous population. Cofactors, such as smoking, steroid use, anemia, hypoxemia, diabetes, infection, and immune deficiency, have not been firmly established but may be important.[45] Rarely does BRONJ in the oral bisphosphonate patient appear to progress beyond stage 2, and many cases reverse with discontinuation of oral medication. Procedures reported to have contributed to the development of BRONJ include extractions, periodontal surgery, root canal treatment, and dental implant surgery.[46] Dental implant therapy, as well as other surgical procedures, should be avoided in individuals who have been treated with intravenous (IV) bisphosphonate therapy and carefully considered with caution in patients treated with oral bisphosphonate therapy, particularly those with a history of more than 3 years of use.[3]

Immune Compromise and Immune Suppression. Individuals undergoing chemotherapy or taking medications that impair healing potential (e.g., steroids) are probably not good candidates for implant therapy because of the effects these agents have on normal healing. This is especially true for cancer chemotherapy. A lowered resistance to infection may also be problematic for these patients. Past history of chemotherapy or immunosuppressive therapy may not be problematic if the patient has recovered from the side effects of treatment.

Patients with an immunocompromising disease, such as human immunodeficiency virus (HIV) infection or acquired immunodeficiency syndrome (AIDS), are not good candidates for implants when their immune system is seriously impaired. Patients with very low or undetectable viral loads and normal (T cell counts) immune function may be candidates for implant therapy (see Chapter 26).

TABLE 72-1 Risk Factors and Contraindications for Implant Therapy

	Risk Factor	Contraindication
Medical and Systemic Health–Related Issues		
Diabetes (poorly controlled)	??—Possibly	Relative
Bone metabolic disease (e.g., osteoporosis)	??—Probably	Relative
Radiation therapy (head and neck)	Yes	Relative/Absolute
Bisphosphonate therapy (intravenous)	??—Probably	Relative/Absolute
Bisphosphonate therapy (oral)	??—Possibly	Relative
Immunosuppressive medication	??—Probably	Relative
Immunocompromising disease (e.g., HIV, AIDS)	??—Possibly	Relative
Psychologic and Mental Conditions		
Psychiatric syndromes (e.g., schizophrenia, paranoia)	No	Absolute
Mental instability (e.g., neurotic, hysteric)	No	Absolute
Mentally impaired; uncooperative	No	Absolute
Irrational fears; phobias	No	Absolute
Unrealistic expectations	No	Absolute
Habits and Behavioral Considerations		
Smoking; tobacco use	Yes	Relative
Parafunctional habits	Yes	Relative
Substance abuse (e.g., alcohol, drugs)	??—Possibly	Absolute
Intraoral Examination Findings		
Atrophic maxilla	Yes	Relative
Current infection (e.g., endodontic)	Yes	Relative
Periodontal disease	??—Possibly	Relative

HIV, Human immunodeficiency virus; *AIDS,* acquired immunodeficiency syndrome.

Radiation Therapy. Patients with a history of radiation treatment to the head and neck region may not heal well after surgery. Soft tissue dehiscence may follow surgical manipulation, which may lead to osteoradionecrosis (ORN), a serious condition of nonhealing exposure and infection of bone. This is especially problematic for patients who have received radiation dosages greater than 60 Gy. Surgical procedures, or any procedure that may initiate a wound, are generally avoided in patients with a history of radiation therapy. If deemed necessary, surgical procedures can be done in conjunction with hyperbaric oxygen (HBO) therapy to reduce the risk of ORN.

Several studies have documented poor success rates for implants in patients with a history of radiation therapy.[32,33,44] In a literature review, Sennerby and Roos[50] found irradiation to be associated with high failure rates, as did Esposito et al[24] in their review. Beumer et al[12] reported success rates as low as 60.4% in the irradiated maxilla. Granstrom et al[32] reported a significant improvement in survival rates for implants in patients treated with HBO. However, in a systematic review, Coulthard et al[18] concluded that the evidence is lacking to support the clinical effectiveness of HBO in irradiated patients receiving implants. The application of

implants in patients with a history of irradiation, with or without the use of HBO, is not resolved and continues to be debated. Clearly, irradiation is a risk factor for implant success and may be a contraindication.

Psychologic and Mental Conditions

In general, any type of psychologic abnormality can be considered a contraindication to dental implant treatment because of the patient's uncooperativeness, lack of understanding, or behavioral problems. Physiologically, there is no reason to suspect that implants could not become osseointegrated in these patients. However, the patient's ability to tolerate the number and type of treatment appointments required for implant placement, restoration, and maintenance could be problematic. All psychologic conditions have the potential to be absolute contraindications to implant treatment depending on the severity of the condition. The exception might be individuals who demonstrate good cooperative behavior with only mild psychologic or mental impairment. The clinician should take great care before accepting a mentally or psychologically impaired individual for treatment with implants.

Habits and Behavioral Considerations

Patients have a variety of habits and behaviors that may increase the risk of failure for dental implants. Smoking, clenching or grinding of teeth, and drug or alcohol abuse are among the most well-known habits that should be identified because of the increased risk for implant failure or complications.

Smoking and Tobacco Use. Moderate to heavy smoking has been documented to result in higher rates of early implant failure and adversely affect the long-term prognosis of dental implant restorations.[6,20,43] This is particularly true for implants placed in poor quality bone such as the posterior maxilla.[39] The mechanisms of action responsible for higher implant failures associated with smoking are not understood. Plausible explanations include the effect of smoking on white blood cells, vasoconstriction, wound healing, and osteoporosis.[4,37] Smoking is a known risk factor for osteoporosis and thus may adversely affect implant success through its effect on bone metabolism. Smoking cessation may improve the success rate of implants.[5] In a meta-analytical review, Bain et al[7] found that implants with an altered surface microtopography (Biomet 3i, Osseotite®; dual acid-etched surface) seemed to significantly lessen the adverse effects of smoking on implant success.

Parafunctional Habits. Parafunctional habits, such as clenching or grinding of teeth (consciously or unconsciously), has been associated with an increased rate of implant failure (e.g., failure to integrate, loss of integration, implant fracture). Repeated lateral forces (i.e., parafunctional habits) applied to implants can be detrimental to the osseointegration process, especially during the early healing period. Patients with known parafunctional habits should be advised of an increased risk of complications or failures as a result of their clenching or grinding. Many consider bruxism to be a contraindication to implant treatment, especially in the case of a short-span, fixed partial denture or a single-tooth implant. If implants are planned for a patient with parafunctional habits, protective measures should be employed, such as creating a narrow occlusal table with flat cusp angles, protected occlusion, and the regular use of occlusal guards (see Chapter 74).

Substance Abuse. Drug and alcohol abuse should be considered a contraindication for implant therapy for reasons similar to the psychologic problems discussed earlier. Patients with drug or alcohol addictions can be irresponsible and noncompliant with treatment recommendations. Depending on the severity and duration of an individual's addiction, some patients may be malnourished or may even have impaired organ function and therefore may not be good surgical candidates because of poor healing capacity. All elective treatments, including implant therapy, should be refused until addictions are treated and controlled.

Posttreatment Evaluation

Periodic posttreatment examination of implants, the retained prosthesis, and the condition of the surrounding periimplant tissue is an important part of successful treatment. Aberrations and complications can often be treated if discovered early, but many problems will go unnoticed by the patient. Thus periodic examination is essential to discovering problems early and to intervene and prevent problems from getting worse. Several parameters are available to evaluate the condition of the prosthesis, the stability of the implant(s), and the health of surrounding periimplant tissues after implant integration and prosthetic restoration. Intraoral radiographs should be taken at the time of placement (baseline), at the time of abutment connection (confirm seating and serve as another baseline), at the time of final restoration delivery (loading), and subsequently to monitor marginal or periimplant bone changes. Periapical radiographs have excellent resolution and provide adequate details for evaluating bone support around implants if taken at a perpendicular direction.

The long-term success of dental implants is dependent on the health and stability of supporting periimplant tissues. Good oral hygiene and regular professional care are essential to maintaining periimplant health and the importance of good oral hygiene should be stressed as early as possible. Patients should be taught to maintain good oral hygiene. Their performance should be monitored and reinforced at each visit.

See Chapter 83, Supportive Implant Treatment, for a detailed description of important clinical and radiographic monitoring methods as well as oral hygiene and implant maintenance protocols.

Conclusion

Dental clinicians can now predictably replace missing teeth with endosseous dental implants. Most patients, whether missing a single tooth, several teeth, or all their teeth, can be candidates for dental implant therapy. However, many factors influence the outcome; the clinician must consider the quantity, quality, and location of available bone; the patient's mental and physical health; as well as risk factors and contraindications. Patients should be advised about risk factors and provided treatment options both with and without dental implants. Periodic evaluation, good oral hygiene, and regular maintenance are important aspects of care for the long-term success and the prevention of complications with dental implants.

Suggested Readings

Baxter JC, Fattore L: Osteoporosis and osseointegration of implants. *J Prosthodont* 2:120–125, 1993.

Beikler T, Flemmig TF: Implants in the medically compromised patient. *Crit Rev Oral Biol Med* 14:305–316, 2003.

DeBruyn H, Collaert B: The effect of smoking on early implant failure. *Clin Oral Implants Res* 5:260, 1994.

Esposito M, Hirsch JM, Lekholm U, et al: Biological factors contributing to failures of osseointegrated oral implants. (I). Success criteria and epidemiology. *Eur J Oral Sci* 106:527–551, 1998.

Esposito M, Hirsch JM, Lekholm U, et al: Biological factors contributing to failures of osseointegrated oral implants. (II). Etiopathogenesis. *Eur J Oral Sci* 106:721–764, 1998.

Fiorellini JP, Chen PK, Nevins M, et al: A retrospective study of dental implants in diabetic patients. *Int J Periodontics Restorative Dent* 20:366–373, 2000.

Klokkevold PR, Han TJ: How do smoking, diabetes, and periodontitis affect outcomes of implant treatment? *Int J Oral Maxillofac Implants* 22(Suppl):173–202, 2007.

Marx RE, Sawatari Y, Fortin M, et al: Bisphosphonate-induced exposed bone (osteonecrosis/osteopetrosis) of the jaws: risk factors, recognition, prevention, and treatment. *J Oral Maxillofac Surg* 63:1567–1575, 2005.

Pjetursson BE, Tan K, Lang NP, et al: A systematic review of the survival and complication rates of fixed partial dentures (FPDs) after an observation period of at least 5 years. *Clin Oral Implants Res* 15:667–676, 2004.

Wennstrom JL, Bengazi F, Lekholm U: The influence of the masticatory mucosa on the peri-implant soft tissue condition. *Clin Oral Implants Res* 5:1–8, 1994.

References

References for this chapter are found on the companion website www.expertconsult.com.

References

1. Adell R, Eriksson B, Lekholm U, et al: Long-term follow-up study of osseointegrated implants in the treatment of totally edentulous jaws. *Int J Oral Maxillofac Implants* 5:347–359, 1990.
2. Adell R, Lekholm U, Rockler B, et al: A 15-year study of osseointegrated implants in the treatment of the edentulous jaw. *Int J Oral Surg* 10:387–416, 1981.
3. Assael LA: Oral bisphosphonates as a cause of bisphosphonate-related osteonecrosis of the jaws: clinical findings, assessment of risks, and preventive strategies. *J Oral Maxillofac Surg* 67:35–43, 2009.
4. Baig MR, Rajan M: Effects of smoking on the outcome of implant treatment: a literature review. *Indian J Dent Res* 18:190–195, 2007.
5. Bain CA: Smoking and implant failure: benefits of a smoking cessation protocol. *Int J Oral Maxillofac Implants* 11:756–759, 1996.
6. Bain CA, Moy PK: The association between the failure of dental implants and cigarette smoking. *Int J Oral Maxillofac Implants* 8:609–615, 1993.
7. Bain CA, Weng D, Meltzer A, et al: A meta-analysis evaluating the risk for implant failure in patients who smoke. *Compend Contin Educ Dent* 23:695–699, 702, 704 passim, quiz 708, 2002.
8. Balshi TJ, Wolfinger GJ: Dental implants in the diabetic patient: a retrospective study. *Implant Dent* 8:355–359, 1999.
9. Baxter JC, Fattore L: Osteoporosis and osseointegration of implants. *J Prosthodont* 2:120–125, 1993.
10. Beikler T, Flemmig TF: Implants in the medically compromised patient. *Crit Rev Oral Biol Med* 14:305–316, 2003.
11. Belser UC, Buser D, Hess D, et al: Aesthetic implant restorations in partially edentulous patients—a critical appraisal. *Periodontol 2000* 17:132–150, 1998.
12. Beumer J, 3rd, Roumanas E, Nishimura R: Advances in osseointegrated implants for dental and facial rehabilitation following major head and neck surgery. *Semin Surg Oncol* 11:200–207, 1995.
13. Block MS, Gardiner D, Kent JN, et al: Hydroxyapatite-coated cylindrical implants in the posterior mandible: 10-year observations. *Int J Oral Maxillofac Implants* 11:626–633, 1996.
14. Blomqvist JE, Alberius P, Isaksson S, et al: Factors in implant integration failure after bone grafting: an osteometric and endocrinologic matched analysis. *Int J Oral Maxillofac Surg* 25:63–68, 1996.
15. Brånemark P, Zarb GA, Albrektsson T: *Tissue-integrated prostheses*, Chicago, 1985, Quintessence.
16. Brånemark PI: Osseointegration and its experimental background. *J Prosthet Dent* 50:399–410, 1983.
17. Brånemark PI, Adell R, Breine U, et al: Intra-osseous anchorage of dental prostheses. I. Experimental studies. *Scand J Plast Reconstr Surg* 3:81–100, 1969.
18. Coulthard P, Esposito M, Worthington HV, et al: Therapeutic use of hyperbaric oxygen for irradiated dental implant patients: a systematic review. *J Dent Educ* 67:64–68, 2003.
19. Dao TT, Anderson JD, Zarb GA: Is osteoporosis a risk factor for osseointegration of dental implants? *Int J Oral Maxillofac Implants* 8:137–144, 1993.
20. DeBruyn H, Collaert B: The effect of smoking on early implant failure. *Clin Oral Implants Res* 5:260, 1994.
21. Elders PJ, Netelenbos JC, Lips P, et al: Accelerated vertebral bone loss in relation to the menopause: a cross-sectional study on lumbar bone density in 286 women of 46 to 55 years of age. *Bone Miner* 5:11–19, 1988.
22. Esposito M, Hirsch JM, Lekholm U, et al: Failure patterns of four osseointegrated oral implant systems. *J Mater Sci Mater Med* 8:843–847, 1997.
23. Esposito M, Hirsch JM, Lekholm U, et al: Biological factors contributing to failures of osseointegrated oral implants. (I). Success criteria and epidemiology. *Eur J Oral Sci* 106:527–551, 1998.
24. Esposito M, Hirsch JM, Lekholm U, et al: Biological factors contributing to failures of osseointegrated oral implants. (II). Etiopathogenesis. *Eur J Oral Sci* 106:721–764, 1998.
25. Ferrigno N, Laureti M, Fanali S, et al: A long-term follow-up study of non-submerged ITI implants in the treatment of totally edentulous jaws. Part I: Ten-year life table analysis of a prospective multicenter study with 1286 implants. *Clin Oral Implants Res* 13:260–273, 2002.
26. Fiorellini JP, Chen PK, Nevins M, et al: A retrospective study of dental implants in diabetic patients. *Int J Periodontics Restorative Dent* 20:366–373, 2000.
27. Fiorellini JP, Nevins ML: Localized ridge augmentation/preservation. A systematic review. *Ann Periodontol* 8:321–327, 2003.
28. Friberg B, Ekestubbe A, Mellstrom D, et al: Brånemark implants and osteoporosis: a clinical exploratory study. *Clin Implant Dent Relat Res* 3:50–56, 2001.
29. Fugazzotto PA, Gulbransen HJ, Wheeler SL, et al: The use of IMZ osseointegrated implants in partially and completely edentulous patients: success and failure rates of 2,023 implant cylinders up to 60+ months in function. *Int J Oral Maxillofac Implants* 8:617–621, 1993.
30. Fujimoto T, Niimi A, Nakai H, et al: Osseointegrated implants in a patient with osteoporosis: a case report. *Int J Oral Maxillofac Implants* 11:539–542, 1996.
31. Glaser DL, Kaplan FS: Osteoporosis. Definition and clinical presentation. *Spine* 22:12S–16S, 1997.
32. Granstrom G, Tjellstrom A, Brånemark PI: Osseointegrated implants in irradiated bone: a case-controlled study using adjunctive hyperbaric oxygen therapy. *J Oral Maxillofac Surg* 57:493–499, 1999.
33. Granstrom G, Tjellstrom A, Brånemark PI, et al: Bone-anchored reconstruction of the irradiated head and neck cancer patient. *Otolaryngol Head Neck Surg* 108:334–343, 1993.
34. Hammerle CH, Jung RE, Feloutzis A: A systematic review of the survival of implants in bone sites augmented with barrier membranes (guided bone regeneration) in partially edentulous patients. *J Clin Periodontol* 29(Suppl 3):226–231, discussion 232-223, 2002.
35. Hildebolt CF: Osteoporosis and oral bone loss. *Dentomaxillofac Radiol* 26:3–15, 1997.
36. Kapur KK, Garrett NR, Hamada MO, et al: A randomized clinical trial comparing the efficacy of mandibular implant-supported overdentures and conventional dentures in diabetic patients. Part I: methodology and clinical outcomes. *J Prosthet Dent* 79:555–569, 1998.
37. Kenney EB, Kraal JH, Saxe SR, et al: The effect of cigarette smoke on human oral polymorphonuclear leukocytes. *J Periodontal Res* 12:227–234, 1977.
38. Kirsch A, Ackermann KL: The IMZ osteointegrated implant system. *Dent Clin North Am* 33:733, 1989.
39. Klokkevold PR, Han TJ: How do smoking, diabetes, and periodontitis affect outcomes of implant treatment? *Int J Oral Maxillofac Implants* 22(Suppl):173–202, 2007.
40. Lekholm U, Gunne J, Henry P, et al: Survival of the Brånemark implant in partially edentulous jaws: a 10-year prospective multicenter study. *Int J Oral Maxillofac Implants* 14:639–645, 1999.
41. Lekholm U, Van Steenberghe D, Herrmann I, et al: Osseointegrated implants in the treatment of partially endentulous jaws: a prospective 5-year multicenter study. *Int J Oral Maxillofac Implants* 9:627, 1994.
42. Lindh T, Gunne J, Tillberg A, et al: A meta-analysis of implants in partial edentulism. *Clin Oral Implants Res* 9:80–90, 1998.
43. Lindquist LW, Carlsson GE, Jemt T: Association between marginal bone loss around osseointegrated mandibular implants and smoking habits: a 10-year follow-up study. *J Dent Res* 76:1667–1674, 1997.
44. Lindquist LW, Rockler B, Carlsson GE: Bone resorption around fixtures in edentulous patients treated with mandibular fixed tissue-integrated prostheses. *J Prosthet Dent* 59:59–63, 1988.
45. Marx RE: *Oral & intravenous bisphosphonate-induced osteonecrosis of the jaws: history, etiology, prevention, and treatment*, Chicago, 2007, Quintessence.
46. Marx RE, Sawatari Y, Fortin M, et al: Bisphosphonate-induced exposed bone (osteonecrosis/osteopetrosis) of the jaws: risk factors, recognition, prevention, and treatment. *J Oral Maxillofac Surg* 63:1567–1575, 2005.
47. Olson JW, Shernoff AF, Tarlow JL, et al: Dental endosseous implant assessments in a type 2 diabetic population: a prospective study. *Int J Oral Maxillofac Implants* 15:811–818, 2000.
48. Pjetursson BE, Tan K, Lang NP, et al: A systematic review of the survival and complication rates of fixed partial dentures (FPDs) after

an observation period of at least 5 years. *Clin Oral Implants Res* 15:667–676, 2004.
49. Pylant T, Triplett RG, Key MC, et al: A retrospective evaluation of endosseous titanium implants in the partially edentulous patient. *Int J Oral Maxillofac Implants* 7:195–202, 1992.
50. Sennerby L, Roos J: Surgical determinants of clinical success of osseointegrated oral implants: a review of the literature. *Int J Prosthodont* 11:408–420, 1998.
51. Shernoff AF, Colwell JA, Bingham SF: Implants for type II diabetic patients: interim report. VA Implants in Diabetes Study Group. *Implant Dent* 3:183–185, 1994.
52. Sullivan DY, Sherwood RL, Porter SS: Long-term performance of Osseotite implants: a 6-year clinical follow-up. *Compend Contin Educ Dent* 22:326–328, 330, 332–334, 2001.
53. Wallace SS, Froum SJ: Effect of maxillary sinus augmentation on the survival of endosseous dental implants. A systematic review. *Ann Periodontol* 8:328–343, 2003.
54. Wennstrom JL, Bengazi F, Lekholm U: The influence of the masticatory mucosa on the peri-implant soft tissue condition. *Clin Oral Implants Res* 5:1–8, 1994.
55. Zitzmann NU, Marinello CP: Treatment plan for restoring the edentulous maxilla with implant-supported restorations: removable overdenture versus fixed partial denture design. *J Prosthet Dent* 82:188–196, 1999.

CHAPTER 73

Diagnostic Imaging for the Implant Patient

Sotirios Tetradis, Sanjay Mallya, and Perry R. Klokkevold

CHAPTER OUTLINE

Standard Projections
Cross-Sectional Imaging
Interactive "Simulation" Software Programs
Patient Evaluation
Clinical Selection of Diagnostic Imaging
Conclusion

Several radiographic imaging options are available for diagnosis and treatment planning of patients receiving dental implants.[2,17,18] Options range from standard projections routinely available in the dental office to more complex radiographic techniques typically available only in radiology centers. Standard projections include intraoral (periapical, occlusal) and extraoral (panoramic, lateral cephalometric) radiographs. More complex imaging techniques include cone-beam computed tomography (CBCT) and multislice computed tomography (MSCT). The CBCT and MSCT image data files can be reformatted and viewed on a personal computer using simulation software, making the diagnosis and treatment-planning process interactive and visually more meaningful. Often, combinations of various modalities are used because no single modality can provide all information pertinent to the radiographic evaluation of the implant patient. Familiarity with the benefits and limitations of various techniques and awareness of the specific clinical questions that need to be answered should guide the decision-making process and selection of radiographic examinations for individual patients.

Multiple factors influence the selection of radiographic technique(s) for a particular case, including cost, availability, radiation exposure, and case type. The decision is a balance between these factors and the desire to minimize risk of complications to the patient. Accurately identifying vital anatomic structures and being able to perform implant placement surgery without injury to these structures are critical to treatment success. Diagnostic imaging techniques must always be interpreted in conjunction with a good clinical examination.

This chapter discusses common imaging techniques used for evaluation of the implant patient. Indications for each technique are outlined, along with the advantages and limitations of each technique.

Standard Projections

Standard diagnostic imaging modalities include periapical, panoramic, lateral cephalometric, and occlusal radiographs. Table 73-1 summarizes the advantages and disadvantages of each modality.

Periapical Radiographs

Periapical radiographs offer great advantages to evaluate the implant patient.[19,20] They provide an overall assessment of the quantity and quality of the edentulous alveolar ridge and the adjacent teeth. They are easy to obtain in the dental office, are inexpensive, and deliver low radiation to the patient (Table 73-2). Dentists are familiar with the depicted anatomy and possible pathology. Because these direct-exposure projections do not use intensifying screens, intraoral radiographs offer the highest detail and spatial resolution of all radiographic modalities (Figure 73-1). Thus, intraoral radiographs are the projection of choice when subtle pathology, such as a retained root tip, needs to be detected and evaluated.

The most significant disadvantage of periapical radiographs is their susceptibility to unpredictable magnification of anatomic structures, which does not allow reliable measurements.[15] Foreshortening or elongation can be minimized by the use of paralleling technique. However, distortion is particularly accentuated in edentulous areas, where missing teeth and resorption of the alveolus necessitate receptor placement at significant angulation in relation to the long axis of the teeth and alveolar bone. Additionally, periapical radiographs are two-dimensional representations of three-dimensional objects and do not provide any information of the buccal–lingual dimension of the alveolar ridge. Structures that are distinctly separated in the buccal–lingual dimension appear to be overlapping. Also, the periapical image is limited by the size of film or sensor being used. Often, it is not possible to image the entire height of the remaining alveolar ridge, and when extensive mesial–distal areas need to be evaluated, multiple periapical radiographs are required.

In summary, periapical radiographs are useful screening images that offer a detailed view of a small area of the alveolar arch. Limitations that must be considered include the possibility of distortion and the two-dimensional representation of anatomic structures.

Occlusal Radiographs

Occlusal radiographs are intraoral projections that offer easy, economic, low-dose, and high-resolution images covering a larger area than periapical projections.[20] Depending on receptor placement and the angulation of the x-ray tube, occlusal radiographs can provide an image of the mandibular width or can depict an extended area of the edentulous ridge. Occlusal radiographs have the same limitations of distortion and overlapping anatomy as periapical radiographs.

In summary, occlusal radiographic projections are good screening images that can provide an overview of the mandibular width

TABLE 73-1 Advantages and Disadvantages of the Various Radiographic Projections

Modality	Advantages	Disadvantages
Periapical and occlusal radiography	High resolution and detail, easy acquisition, low exposure, inexpensive	Unpredictable magnification, small imaged area, 2D representation of anatomy
Panoramic radiography	Easy to acquire, images whole ridge, low exposure, inexpensive	Unpredictable magnification, unequal magnification in vertical and horizontal dimensions, 2D representation of anatomy, not detailed
Lateral cephalometric radiography	Easy to acquire, predictable magnification, low exposure, inexpensive	Limited use in area of midline, 2D representation of anatomy
Multislice computed tomography	3D representation, predictable magnification, sufficient detail, digital format, images whole arch	Requires special equipment, expensive, high-exposure dose
Cone-beam computed tomography	3D representation, predictable magnification, sufficient detail, digital format, images whole arch, low dose	Requires special equipment, expensive

2D, Two-dimensional; *3D,* three-dimensional.

TABLE 73-2 Radiation Dose (Effective Dose in μSv) Received from Common Projections During Evaluation of the Implant Patient Data*

Modality	Effective Dose (μSv)
Full-mouth x-ray (FMX) series	35-388
Panoramic	9-26
Conventional tomography	26-187
CT of the head	2000
Large field-of-view CBCT	
NewTom 3G	30-68
i-CAT: next generation portrait mode	74-83
Kodak 9500, 20 cm × 18 cm	93-260
Galileos Comfort, 15 cm × 15 cm	70-128
Scanora 3D, 14.5 cm × 13.5 cm	68
CB Mercuray, 20 cm diameter	569-1073
Medium field-of-view CBCT	
Accuitomo 170, 10 cm × 5 cm	54
iCat next generation, 16 cm × 6 cm	45
iCat, classic, 16 cm × 8 cm	34-77
NewTom 3G, 10 cm diameter	57
Kodak 9500, 15 cm × 8 cm	76-166
Prexion, 8 cm × 8 cm, low dose	189
Prexion, 8 cm × 8 cm, high dose	389
Promax 3D, low dose	28
Promax 3D, high dose	122-652
Small field-of-view CBCT	
Accuitomo 3DX, 4 cm × 4 cm	13-44
Kodak 9000, 5 cm × 3.7 cm	19-40
Pax Uni-3D	44

CT, Computed tomography; *CBCT,* cone-beam computed tomography.

*Reviewed by Ludlow JB, Davies-Ludlow LE, White SC: Patient risk related to common dental radiographic examinations: The impact of 2007 International Commission on Radiological Protection recommendations regarding dose calculation, *J Am Dent Assoc* 139:1237, 2008; Ludlow JB, Ivanonic M: Comparative dosimetry of dental CBCT devices and 64-slice CT for oral and maxillofacial radiology, *Oral Surg Oral Med Oral Pathol Oral Radiol Endod* 106:106, 2008; and White SC, Mallya SM. Update on the biological effects of ionizing radiation, relative dose factors and radiation hygiene. *Aust Dent J* 57(Suppl 1):2, 2012.

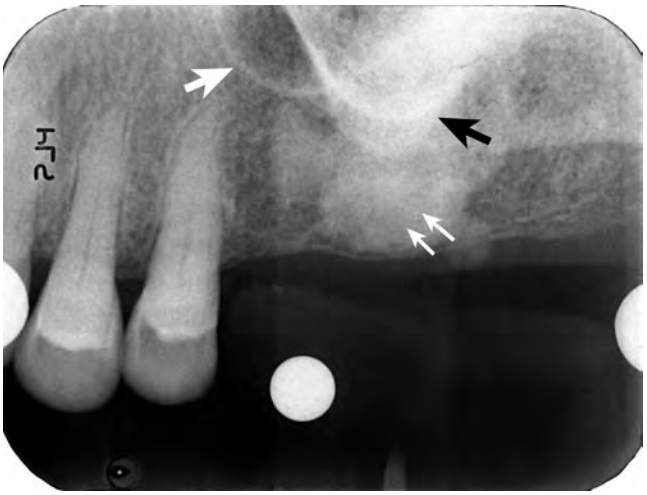

Figure 73-1 The periapical radiograph offers a high-resolution, detailed image of the edentulous area. Healing of the extraction socket with dense bone (socket sclerosis) can be seen *(small white arrows).* Some anatomic structures, such as the maxillary sinus *(large white arrow)* and the zygomatic process of the maxilla *(black arrow),* can also be visualized.

or can visualize larger areas of alveolar ridge compared with periapical radiographic projections.

Panoramic Radiographs

Panoramic radiographs are often used in the evaluation of the implant patient because they offer several advantages over other modalities.[16] Panoramic radiographs deliver low radiation (see Table 73-2) to provide a broad picture of both arches and thus allow assessment of extensive edentulous areas, angulation of existing teeth and occlusal plane, and important anatomy in implant treatment planning such as the maxillary sinus, nasal cavity, mental foramen, and mandibular canal (Figure 73-2). Panoramic units are widely available and easy to operate, and dentists are familiar with the anatomy and pathology depicted by the images. Similar to intraoral projections, panoramic images are two-dimensional and thus do not offer diagnostic information for the buccal–lingual width of the alveolar arch.

Figure 73-2 Panoramic radiograph. Both jaws are visualized on the same image. An overall assessment of superoinferior and mesial-distal dimensions of the alveolar ridge can be formulated. Tooth and root positions relative to planned implant sites can be evaluated. Important anatomic structures, such as the maxillary sinus and mandibular canal, can be identified.

Panoramic images appear intuitively familiar. However, they combine characteristic physical and radiographic principles that make them distinct from other intraoral and extraoral radiographs. Although outside the scope of this chapter, familiarity with the principles underlying panoramic radiography is central in understanding, and thus compensating for, the limitations and constraints of the images. The reader is referred to other textbooks for detailed discussion of this topic.[7,10] Briefly, the existence of ghost shadows, unpredictable horizontal and vertical magnification, distortion of structures outside the focal trough, projection geometry generated by the negative vertical angulation of the x-ray beam, and propensity to patient-positioning errors do not allow consistently detailed and accurate measurements to be generated. As a result, panoramic radiographs do not provide the highly detailed images that are generated by intraoral radiographs.

Measurement distortion is more prevalent and varies across the radiographic image. On average, panoramic radiographs are 25% magnifications of actual size. Implant manufacturers often provide transparency sheets with implant size outlines of 25% magnification. However, it is important to appreciate that the 25% magnification is an estimate. The actual magnification may range from 10% to 30% in different areas within the same image, and depends greatly on patient positioning during panoramic radiography. For this reason, precise measurements on panoramic projections are not possible. Nonetheless, panoramic radiographs offer an overall view of the maxilla and mandible that can be used to estimate bone measurements and evaluate the approximate relationships between teeth and other anatomic structures. More precise diagnostic imaging should be used to measure proximity of critical anatomic structures, such as the maxillary sinus or the mandibular canal, to proposed implant positions.

In summary, panoramic projections are useful screening images of the jaws for approximations and relative spatial relationships. However, because of magnification and distortion errors, panoramic radiographs should not be used for detailed measurements of proposed implant sites.

Lateral Cephalometric Radiographs

Lateral cephalometric radiographs are occasionally used to evaluate potential implant patients.[17] These projections provide useful information for the cortical thickness, height, and width of the alveolar ridge at the midline, as well as the skeletal relationship between maxilla and mandible and facial profile. Lateral cephalometric radiographs are low in cost, readily available, and easy to interpret, and have a predictable magnification of the depicted structures. However, their use for the implant patient is limited to structures at the midline, with minimal usefulness for other areas of the jaws.

In summary, lateral cephalometric radiographs have a limited use in implant treatment planning.

Cross-Sectional Imaging

Cross-sectional diagnostic imaging modalities include MSCT and CBCT. Conventional tomography also provides cross-sectional images with predictable magnification and has been used in the assessment of the implant patient. However, with the introduction and expansion of CBCT imaging, conventional tomography is becoming progressively infrequent and is not described in this chapter.

Multislice Computed Tomography

CT scanning is widely used in the evaluation of the implant patient.[3,6] The detailed physics behind image acquisition during CT scanning are beyond the scope of this chapter.[4] In general, a fan-beam of x-rays and an array of detectors rotate around the patient to generate axial slices of the area of interest (Figure 73-3, *A*). Multiple overlapping axial slices are obtained by several revolutions of the x-ray beam until the whole area of interest is covered. These slices are then used to generate, with the help of a computer and sophisticated algorithms, a digital volume of the imaged object. CT's advantage during evaluation of the implant patient is the construction of this three-dimensional digital map of the jaws. Specialized software can be used to generate appropriate views that best depict the dimensions of the jaws and the location of important anatomic structures.

Typical dental views reconstructed from a CT scan include axial (see Figure 73-3, *B*), panoramic (see Figure 73-3, *C*), and cross-sectional (see Figure 73-3, *D*) views of the jaws. Appropriate axial slices through the alveolar ridge of interest are selected as scout views. The curvature of the maxillary or mandibular ridge is then drawn on the axial slices, and panoramic images along the drawn line are created. Finally, cross-sectional slices, every 1 to 2 mm and perpendicular to the drawn curvature, are created. In addition to these flat, two-dimensional views, complex, three-dimensional images with surface rendering can also be generated from the CT data (see Figure 73-3, *E*). These images can provide useful information about the alveolar ridge defects that are easy to comprehend. Images can be printed on photographic paper or transparent film or can be displayed on the computer screen.

CT scans offer several advantages for evaluation of the implant patient. True cross sections offer a precise and detailed evaluation of the height and width of the alveolar ridge. The images can be adjusted and printed without magnification, facilitating measurements directly on the prints or films with standard rulers (i.e., not magnified). Vertical and horizontal rulers adjacent to each section allow the clinician to check for magnification and make direct measurements. The digital format allows for image enhancement tools, rapid communication between the radiologist and the surgeon, and generation of multiple copies of the images. Various anatomic structures can be visualized and analyzed at all three coordinate axes, so that their superoinferior, anteroposterior, and buccolingual location can be identified with precision. The process of CT scanning images the entire arch (usually one arch per scan), so several edentulous areas can be visualized with a single examination. The bone and soft-tissue contrast and resolution are excellent for the diagnostic task.

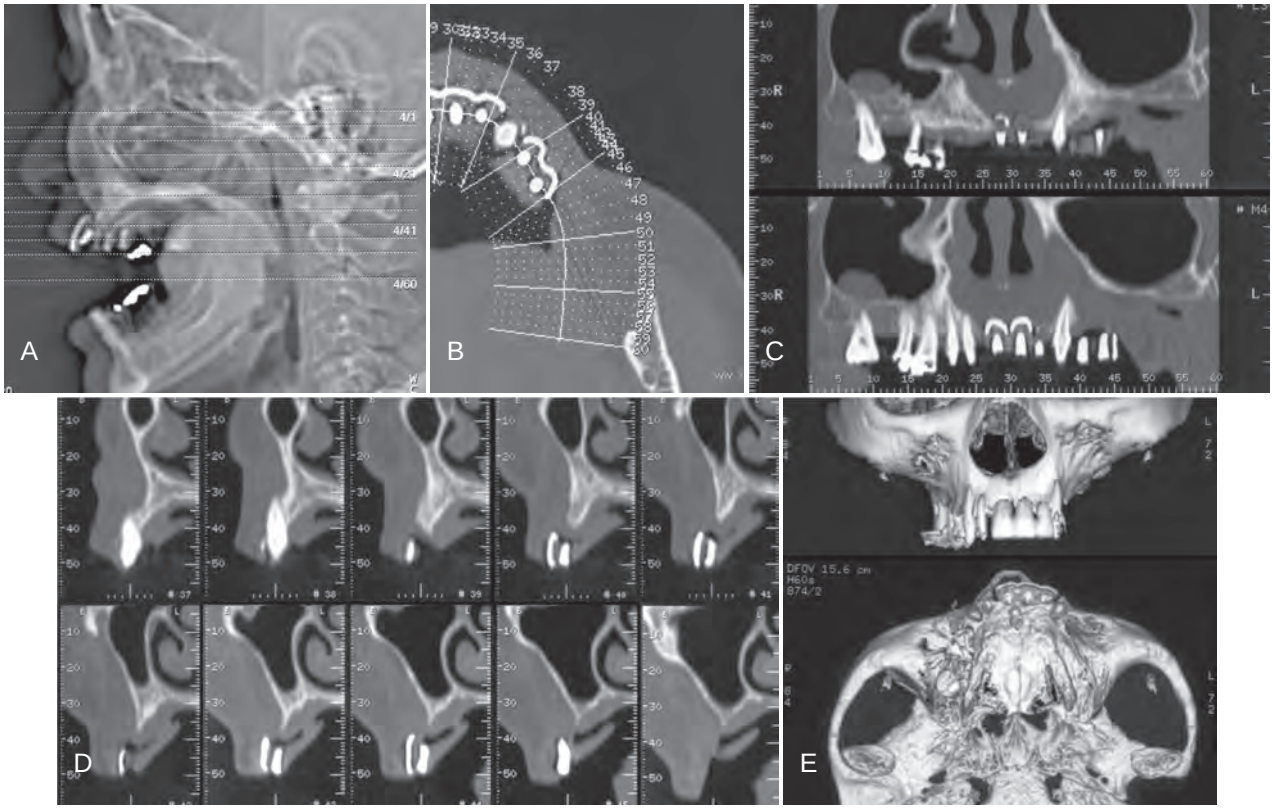

Figure 73-3 Computed tomography (CT) examination for evaluation of edentulous maxilla before implant placement. A, Scout view of the patient's head; axial sections through the area of interest are indicated. **B,** Axial slice through the markers is used to display the orientation of the panoramic and cross-sectional images through the alveolar ridge. **C,** Panoramic views through the alveolar ridge demonstrate the relation of the markers to adjacent teeth. **D,** Cross-sectional slices through the area of the markers reveal the height and buccolingual dimension of the alveolar ridge, as well as the relation of the markers to the ridge. **E,** Three-dimensional reconstructions provide an overall impression of the bone contours and shape of the alveolar ridge.

CT scanning requires specialized equipment and setting. Radiologists and technicians need to be knowledgeable of the anatomy, anatomic variants, and pathology of the jaws, as well as considerations pertinent to implant treatment planning, so that optimal views will be provided. A CT scan delivers much higher radiation dose to the patient than the other modalities used during implant treatment planning[13] (see Table 73-2). Because a CT scan images the whole arch, radiation is delivered to the entire imaged area, regardless of how many or few sites are actually needed. Metallic restorations can cause ring artifacts that impair the diagnostic quality of the images. This is particularly challenging in patients with heavily restored dentition. In general, the cost of CT is significantly higher than that of conventional tomography or the other standard intraoral and extraoral projections.

In summary, CT scanning offers many advantages during implant treatment planning, including accurate cross-sectional imaging and three-dimensional visualization of anatomic structures. High dose to the patient and ring artifacts caused by metallic restorations are concerns that should be considered.

Cone-Beam Computed Tomography

CBCT is a newer imaging modality that offers significant advantages for the evaluation of implant patients.[5,14] CBCT was introduced to dentistry in the late 1990s,[1,12] and currently several CBCT units are commercially available for imaging of the craniofacial complex. The x-ray source and the detector are diametrically positioned and make a 180- to 360-degree rotation around the patient's head within the gantry. The shape of the x-ray beam is that of a cone. Thus, at the end of a single complete rotation, 180 to 500 images of the region of interest are generated. The computer uses these images to generate a digital, three-dimensional map of the face. Once this map is generated, multiplanar reconstructions, as well as axial, coronal, sagittal, or oblique sections of various thicknesses, can be reconstructed from the data.

An important feature of the various CBCT units is the field of view (FOV) describing the extent of the imaged volume. CBCT units can be distinguished in large-FOV (greater than 15 cm), medium FOV (5 to 15 cm) and limited-FOV systems (less than 5 cm). Figure 73-4 depicts schematically the anatomic area covered by large, medium, and limited FOV scans. In general, large FOV units image a more extensive anatomic area, deliver a higher radiation exposure to the patient, and produce lower resolution images (Figure 73-5). Conversely, limited FOV units image a small area of the face, delivering less radiation and producing a higher resolution image (Figure 73-6).

CBCT offers the same advantages and disadvantages as CT. However, the two modalities have basic differences that result from the different physical principles used during image acquisition. CT scan offers a greater *contrast resolution,* or the ability to distinguish two objects with small density differences. CBCT scans have a limited capacity to separate muscle from fat or connective tissue compared with CT scans. Fortunately, contrast resolution is not a significant concern in implant evaluation. Because bone has a much higher density than surrounding soft tissues, both CBCT and CT can clearly depict bone shape and architecture. One of the most significant advantages of CBCT scanning versus CT scanning is

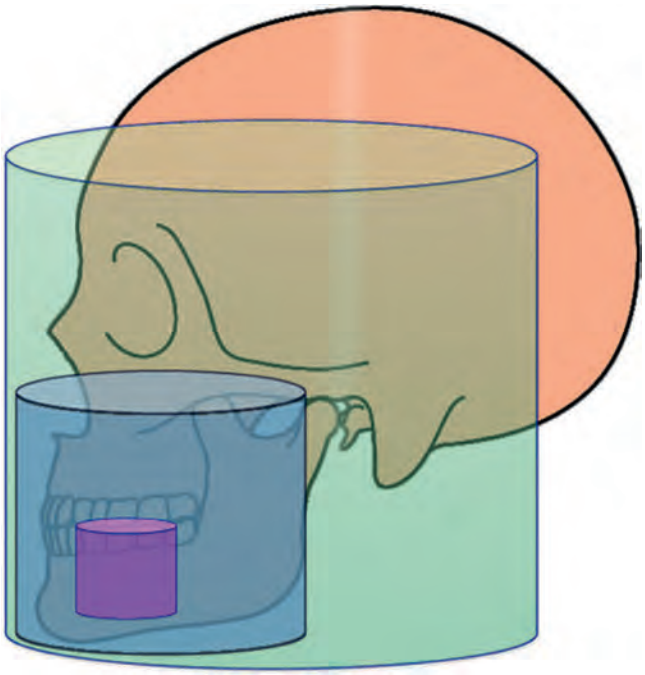

Figure 73-4 Schematic diagram of the anatomic area imaged with large *(green),* medium *(blue),* and limited *(magenta)* field of view cone-beam computed tomography.

the reduced amount of radiation dose delivered to the patient[9,21,22] (see Table 73-2).

In summary, CBCT scanning is a valuable imaging modality for three-dimensional and cross-sectional evaluation of the implant patient. It has similar advantages and disadvantages as CT scanning. The most significant difference is that CBCT imaging delivers much less radiation exposure to the patient.

Interactive "Simulation" Software Programs

Implant treatment planning can be greatly enhanced by the use of specialized software. In addition to measuring the quantity and quality of bone in potential implant sites, these programs use CT or CBCT scan data to simulate placement of implant and restorations. Using a database of commercially available implant images, the length, width, angulation, and position of implants can be "simulated" in the desired positions and evaluated relative to other structures in three-dimensions. In cases of alveolar ridge deficiency or defects or when sinus bone augmentation is indicated, the additional bone volume needed can be evaluated and quantified. The restoration of the implants can also be simulated and the distribution of mechanical forces onto the implant and adjacent bone predicted.

Software programs specialized in implant treatment planning, such as SIM/Plant (Materialise/Columbia Scientific, Glen Burnie, MD), can reformat CBCT or CT scan data. The clinician can use the reformatted images on a personal computer in an interactive manner to identify anatomic structures, simulate implant placement positions and better appreciate relationships between planned implant positions and teeth or anatomic structures (Figure 73-7). InVivo5 planning software (Anatomage, San Jose, CA) acquires data directly from CBCT or CT scan DICOM (Digital Imaging and Communications in Medicine) files without the need for reformatting. The clinician can evaluate the case on a personal computer in an interactive manner to identify anatomic structures, simulate implant placement positions and better appreciate relationships between planned implant positions and teeth or anatomic structures. Once implant positions are confirmed, a computer generated surgical guide is produced to facilitate the surgical placement of implants in the planned positions (Figure 73-8).

Patient Evaluation

Evaluation of the implant patient should be disciplined and objective. Specific questions that can affect implant placement and outcome should be considered and examined carefully and explicitly. The advantages and disadvantages of various radiographic projections should be considered and radiographic modalities chosen based on necessary information for the particular patient. The objectives for any radiographic evaluation, regardless of imaging technique used, should include an evaluation to (a) exclude pathology, (b) identify anatomic structures, and (c) measure the quantity, quality, and location of available bone.

Exclude Pathology

Healthy bone is prerequisite for successful osseointegration and long-term implant success. The first step in the radiographic evaluation of the implant site is to establish the health of the alveolar bone and other tissues imaged within a particular projection. Local and systemic diseases that affect bone homeostasis can preclude, modify, or alter placement of implants. Retained root fragments, residual periodontal disease, cysts, and tumors should be identified and resolved before implant placement. Systemic diseases, such as osteoporosis and hyperparathyroidism, alter bone metabolism and might affect implant osseointegration. Areas of poor bone quality should be identified and if indicated, adjustments to the treatment plan incorporated. Maxillary sinusitis, polyps, or other sinus pathology should be diagnosed and treated when implants are considered in the posterior maxilla, especially if sinus bone augmentation procedures are planned (Figure 73-9).

Identify Anatomic Structures

Several important anatomic structures are found close to desired areas of implant placement in the maxilla and mandible (Box 73-1). Familiarity with the radiographic appearance of these structures is important during treatment planning and implant placement. Their exact localization is central to prevent unwanted complication and unnecessary morbidity. Important anatomic structures in the maxilla include the floor and anterior wall of the maxillary sinus, incisive foramen, floor and lateral wall of the nasal cavity, and canine fossa. Important anatomic structures in the mandible that should be recognized include the mandibular canal, anterior loop of the mandibular canal, mental foramen, anterior extension of the canal, and submandibular fossa. The existence of anatomic variants, such as incomplete healing of an extraction site, sinus loculation, division of mandibular canal (Figure 73-10), or absence of a well-defined corticated canal, should also be recognized. See Chapter 55 for important periodontal and implant surgical anatomy.

Assess Bone Quantity, Quality, and Volume

The primary goal of diagnostic imaging for potential implant patients is to evaluate the available bone volume for implant placement in desired anatomic locations. The clinician wants to estimate and verify exact adequate height, width, and density to the recipient bone while avoiding damage to critical anatomic structures. Failure to assess accurately the location of important anatomic structures can lead to unnecessary complications. For example, inadvertent penetration and damage to the inferior alveolar nerve can result in

Text continued on p. 717

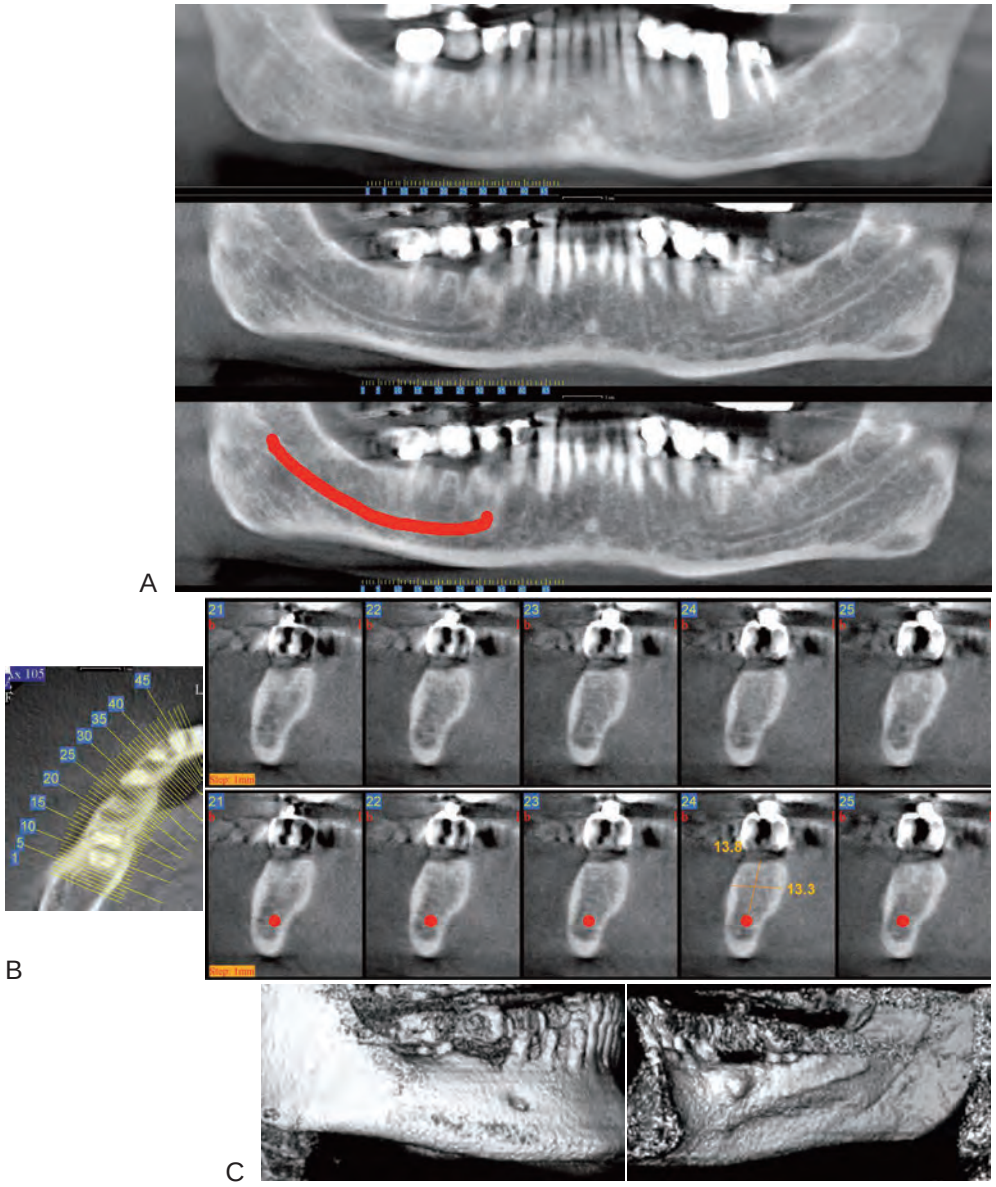

Figure 73-5 Cone-beam computed tomography images for the evaluation of the edentulous space at the area of missing tooth #30 before implant placement using a large field-of-view unit (NewTom 3G, Verona, Italy distributed by AFP Imaging, Elmsford, NY). Note the tooth-shaped marker used. **A,** Series of "panoramic" reconstructions through the alveolar ridge reveals the relationship of the marker to the adjacent teeth. The top "panoramic" view is 12 mm thick so as to depict most of the extent of the alveolar ridge and adjacent teeth. The middle "panoramic" image is 1 mm thick through the area of the mandibular canal. Note that adjacent teeth are out of the plane of the section and thus not depicted on the image. The bottom "panoramic" view is the same as the middle one, but the position of the mandibular canal has been depicted by the *red line*. **B,** Scout axial view and series of cross sections through the area of the marker. The bottom row shows the same axial slices as the top row. However, the position of the *red line* drawn on the panoramic view is also depicted to help localization of the mandibular canal. The height and width of the alveolar ridge have been measured in a selected section. **C,** Three-dimensional reconstructions provide an overall impression of the bone contours and shape of the alveolar ridge. Note the small exostosis on the lingual surface of the alveolar ridge.

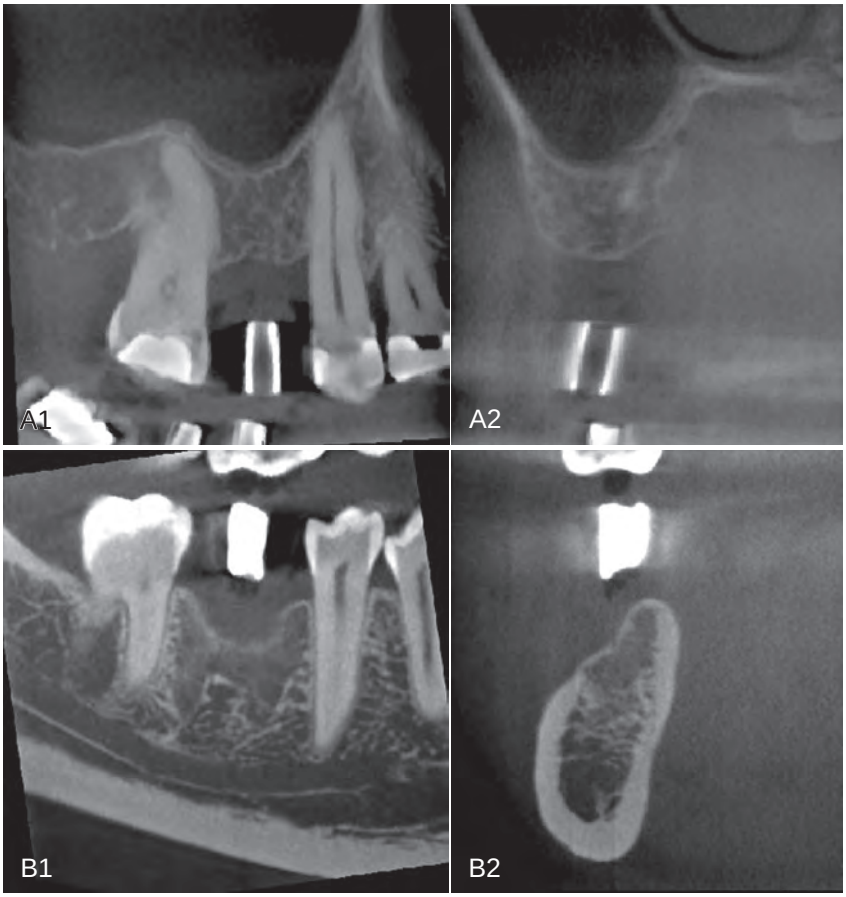

Figure 73-6 Cone-beam computed tomography images for the evaluation of the edentulous space at the area of missing tooth #4 **(A)** and missing tooth #30 **(B)** using a limited field of view scan (3D Accuitomo, J. Morita Corporation, Suita City, Osaka, Japan, distributed by J. Morita USA, Inc., Irvine, CA). Sagittal and cross-sectional slices are shown. Although the anatomic area imaged is limited, the resolution of the images are high. **A,** Implant site #4 (maxillary right second premolar) in anterior–posterior and buccolingual cross-sectional views. **B,** Implant site #30 (mandibular right first molar) in anterior–posterior and buccolingual cross-sectional views.

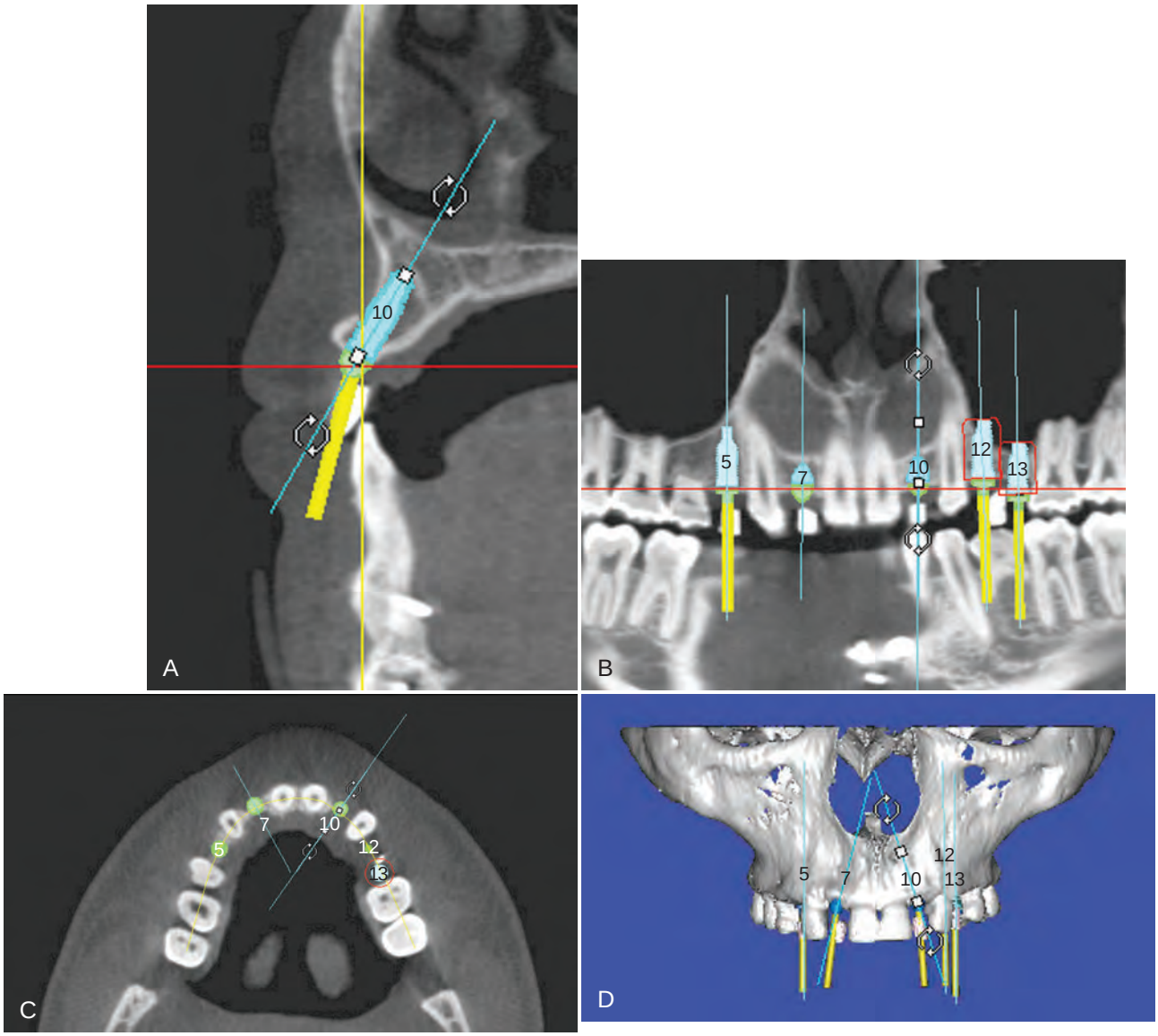

Figure 73-7 SIM/Plant images. The SIM/Plant software program allows clinicians to measure bone height, width, density, and volume on a personal computer. Scan data are reformatted for interactive evaluation and manipulation. Implant positions can be simulated on the patient's scan data before surgery, allowing the surgeon to anticipate areas of deficiency.

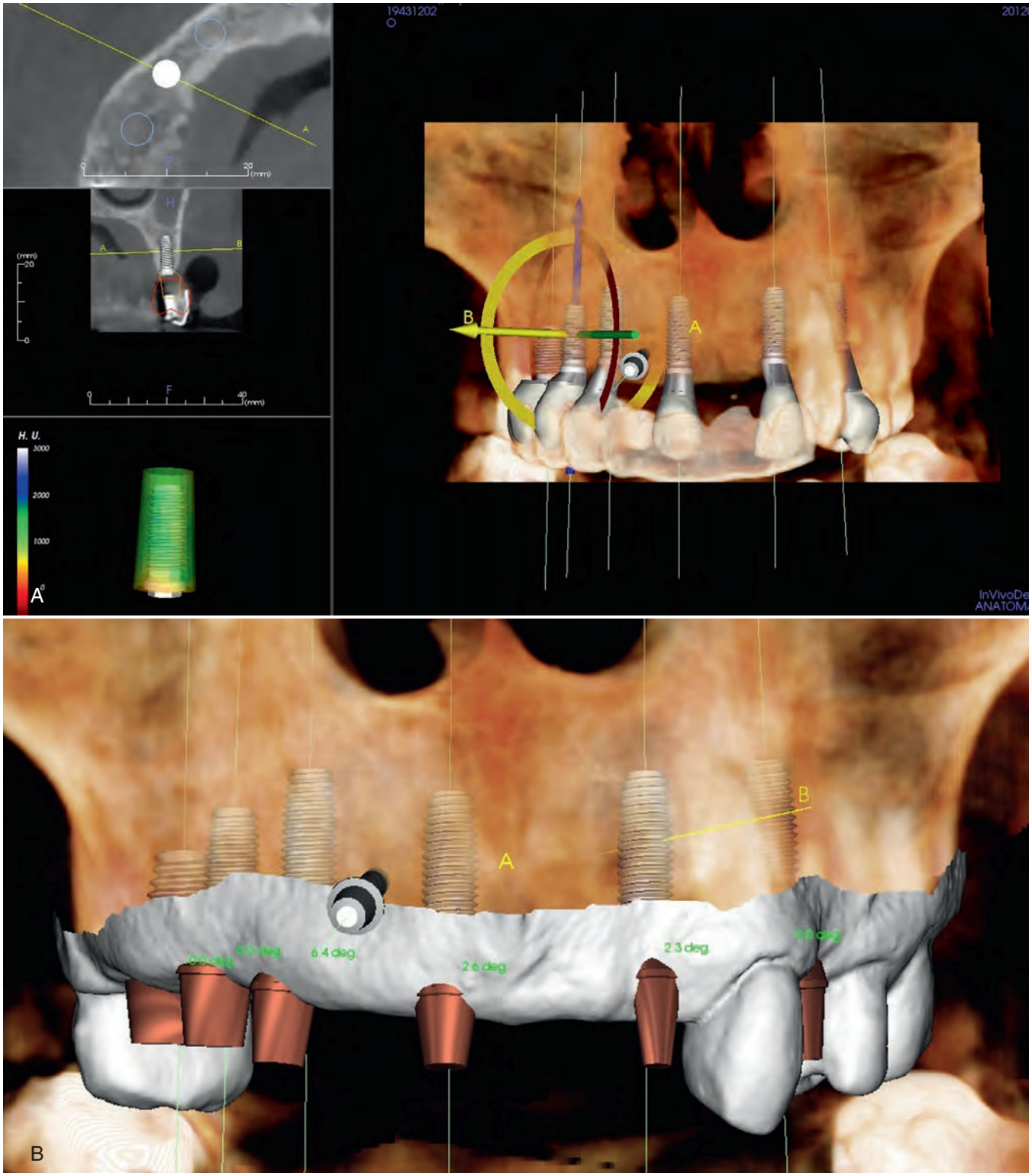

Figure 73-8 InVivo5 simulation images. The InVivo5 software program allows clinicians to plan implant treatment and simulate virtual implant positions directly from DICOM scan data on a personal computer. **A,** Cross-section and axial images with 3D simulation of implant positions. **B** and **C,** Model mockup for computer generated surgical guide.

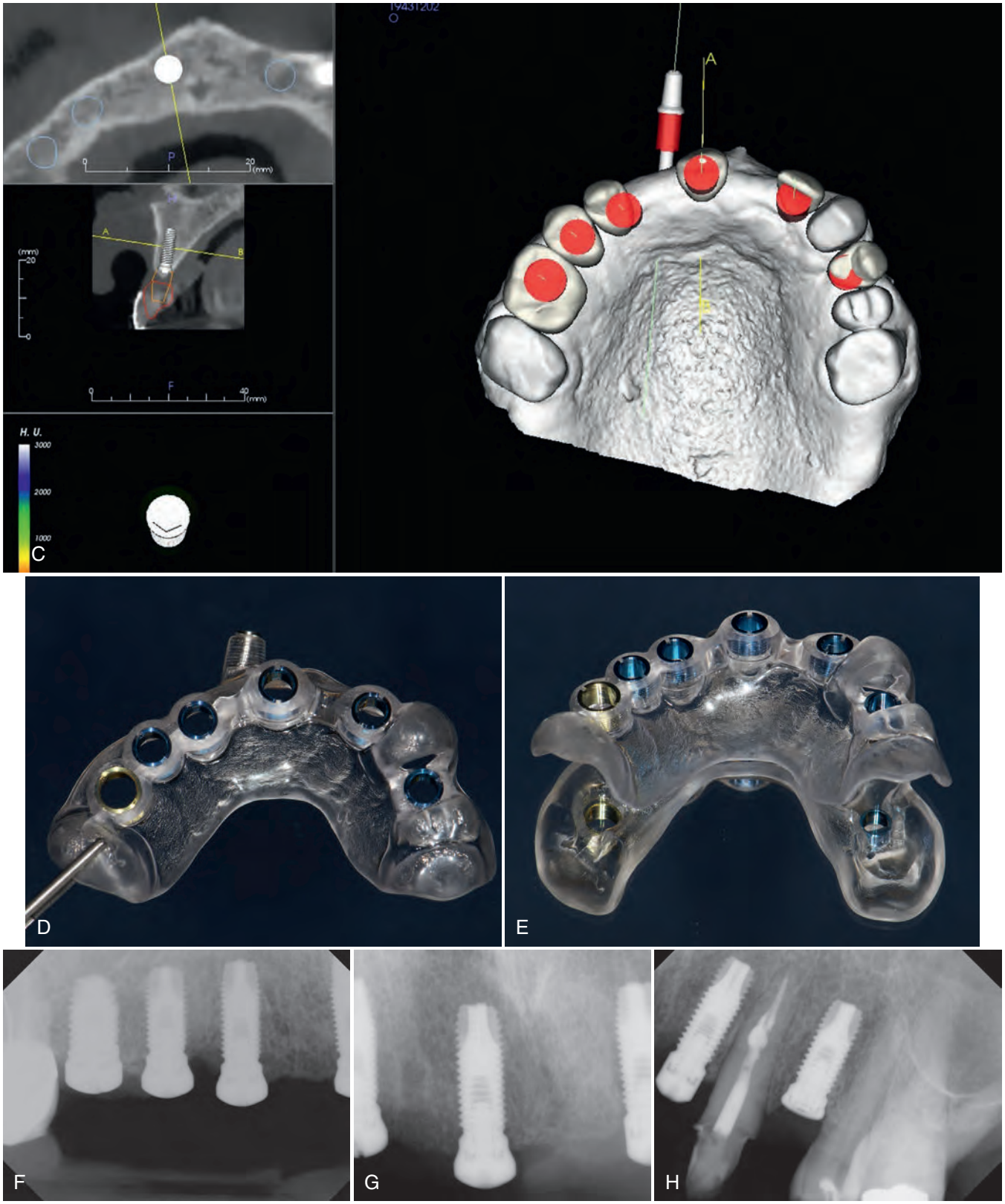

Figure 73-8, cont'd **D** and **E,** Surgical guide that was created from simulated plan. **F-H,** Periapical radiographs demonstrating accurate position and alignment of implants that were placed using computer generated surgical guide.

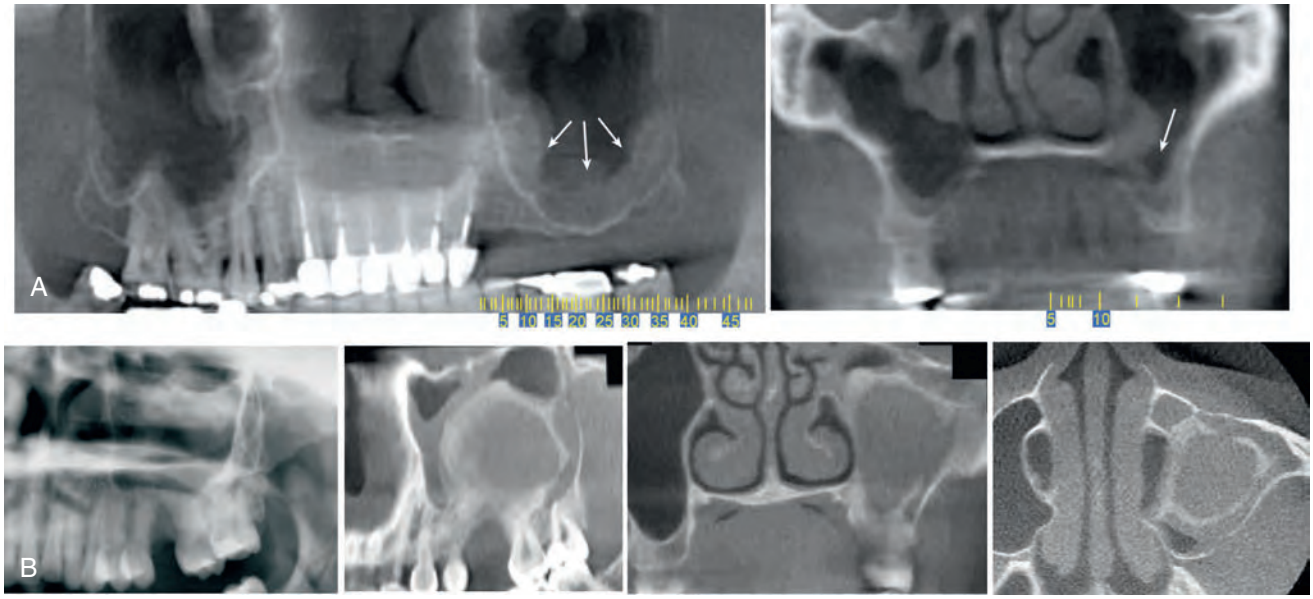

Figure 73-9 Cone-beam computed tomography examination of the posterior left maxilla. Top row **(A)** shows reconstructed "panoramic" and coronal sections of the alveolar ridge. Note the thickened mucoperiosteal lining of the floor of the left maxillary sinus *(white arrow)*. The patient has chronic maxillary sinusitis. Bottom row **(B)** shows conventional panoramic, reconstructed "panoramic," coronal and axial sections of the alveolar ridge at the area of missing first maxillary molar. A large radiolucent lesion at the edentulous alveolar ridge elevates the floor of the maxillary sinus and occupies most of the sinus. Biopsy revealed a keratocystic odontogenic tumor that was an incidental finding in this asymptomatic patient.

BOX 73-1 Anatomic Structures Pertinent to Treatment Planning of the Implant Patient

Maxilla	Mandible
Maxillary sinus (floor and anterior wall)	Mandibular canal
Nasal cavity (floor and lateral wall)	Anterior loop of the mandibular canal
Incisive foramen	Anterior extension of the mandibular canal
Canine fossa	Mental foramen
Canalis sinuosus	Submandibular fossa
	Retromolar canal
	Lingual inclination of the alveolar ridge

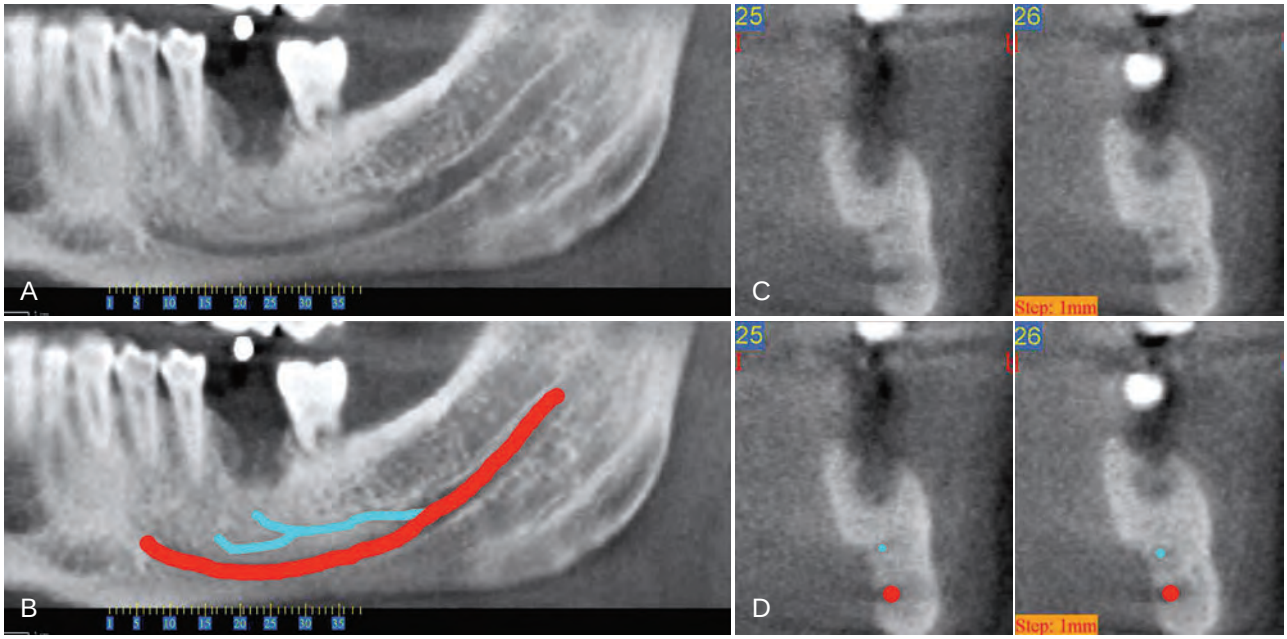

Figure 73-10 Cone-beam computed tomography examination of the area of missing tooth #19 before implant placement. A, Panoramic view of the area of interest depicts an accessory mandibular canal. **B,** Same panoramic view with the accessory mandibular canal colored blue and the main canal red. **C,** Cross-sectional views through the area of missing tooth #19. **D,** Same cross-sectional images depicting the blue and red markings. Note that the position of the markings coincides with the position of the accessory and main mandibular canals (compare **C** and **D**).

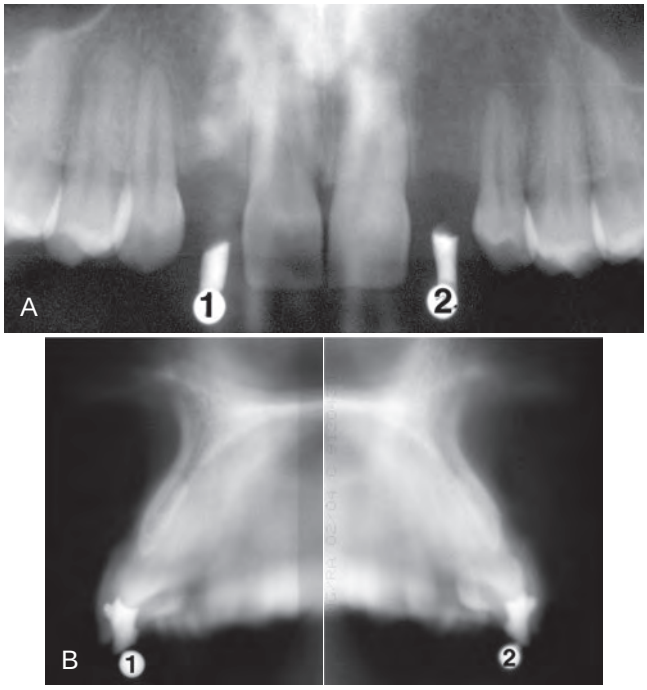

Figure 73-11 Radiographic evaluation of a patient with congenitally missing maxillary lateral incisors before implant placement. A, Panoramic radiograph reveals sufficient height and mesial-lateral width of the alveolar ridge. **B,** Cross-sectional conventional tomography of the edentulous areas reveals a narrow (<4 mm) buccal–lingual width of the alveolar ridge that needs to be addressed by modifications in the treatment planning, such as bone augmentation.

serious immediate-term (profuse bleeding), short-term, and long-term (nerve paresthesia/anesthesia) complications. The height and width of the alveolar bone should be accurately detailed. Depending on the technique, diagnostic imaging can estimate or measure the coronal–apical height, the buccal–lingual width, and the mesial–distal spacing available for implants that will be placed in proximity to teeth or relative to other planned implants.

This task can be simple in cases with good bone quality and sufficient bone volume in the desired implant location(s). However, in cases with moderate-severe bone resorption, alveolar defects, or recent extraction sites, obtaining a clear and accurate diagnostic image can be more challenging. The diagnostic imaging may reveal inadequate bone volume for the proposed implant(s) and indicate a need for bone augmentation or depending on the severity of the deficiency, preclude the patient from the possibility of implant therapy (Figure 73-11). When ridge augmentation is deemed necessary, radiographic evaluation prior and postsurgery informs treatment planning and ensures grafting integrity and quality (Figure 73-12).

In addition to the amount, the quality of the available bone should also be evaluated. A uniform, continuous cortical outline and a lacy, well-defined trabecular core reflect the normal bone homeostasis necessary for appropriate bone response around the implant. Thin or discontinuous cortex, sparse trabeculation, large marrow spaces, and altered trabecular architecture should be noted because they might predict poor implant stabilization and less desirable response of the bone. Poor bone quality may necessitate modifications of the treatment planning, such as waiting longer for healing (osseointegration) to maximize bone-to-implant contact before loading.

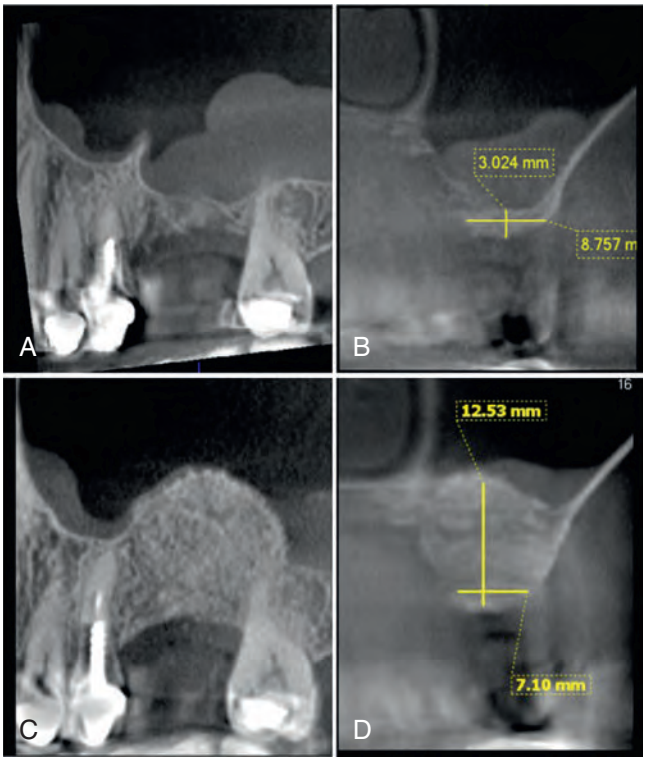

Figure 73-12 Radiographic evaluation of a patient with missing left maxillary second premolar and first molar. Initial cone-beam computed tomography (CBCT) reveals an atrophic alveolar ridge **(A)** with inadequate height for implant placement **(B).** Also note the thickened mucoperiosteum at the floor of the maxillary sinus. CBCT after sinus grafting for ridge augmentation shows uniformly opaque grafting area blending with alveolar trabeculation and a smooth sinus floor elevation **(C),** which provides adequate dimensions for implant placement **(D).**

Evaluate Relation of Alveolar Ridge with Existing Teeth and Desired Implant Position

Accurate placement (spatial position and angulation relative to adjacent teeth and occlusal plane) will greatly affect the restorative success and long-term prognosis of the implant (see Chapter 74). A significant variable during the preimplant evaluation is the relation of the desired implant position relative to the existing teeth, alveolar crest, and occlusal plane. Angled or custom abutments can accommodate slight variations in implant position and implant inclination. However, more significant deviations should be avoided.

Prolonged tooth loss is usually associated with atrophy of the alveolar ridge and in the case of the maxilla, with pneumatization of the sinus floor toward the alveolar crest. Traumatic extractions can compromise the buccal or lingual cortex and alter the shape and buccolingual ridge dimension. Anatomic variants, such as lingual inclination of the alveolus or narrow ridges, should be considered during treatment planning of the implant patient (Figure 73-13).

An important part of diagnostic imaging must include an evaluation of the available bone relative to the "prosthetically driven" implant position. This aspect of the patient evaluation is best accomplished with diagnostic models, wax-up of planned tooth replacement, and radiographic markers in the desired tooth positions during imaging. Steel balls, brass tubes, and gutta-percha have all been used to establish the proposed tooth positions relative

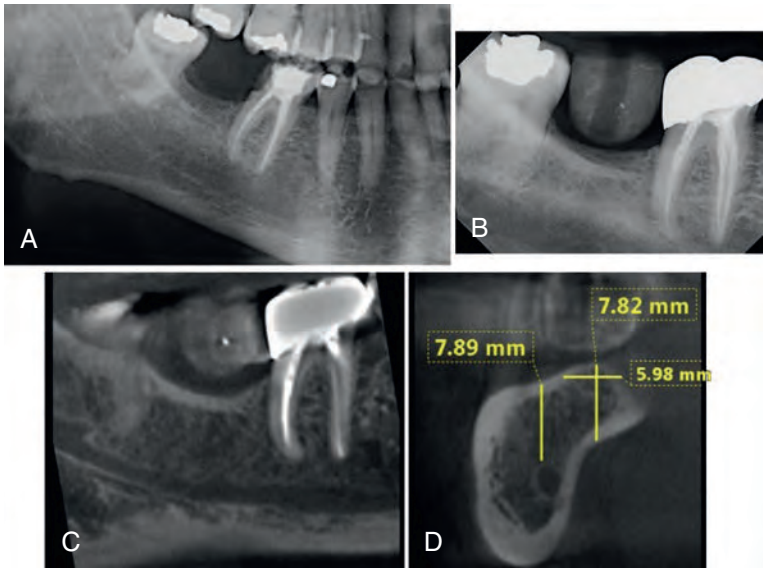

Figure 73-13 Radiographic evaluation of a patient with edentulous posterior left mandible before implant placement. Panoramic **(A)** and periapical **(B)** radiographs demonstrate sufficient height of the alveolar ridge with little or no resorption. Cone-beam computed tomography sections (**C** and **D**) reveal significant lingual inclination of the alveolar ridge with lingual concavity that is not depicted on conventional radiographs.

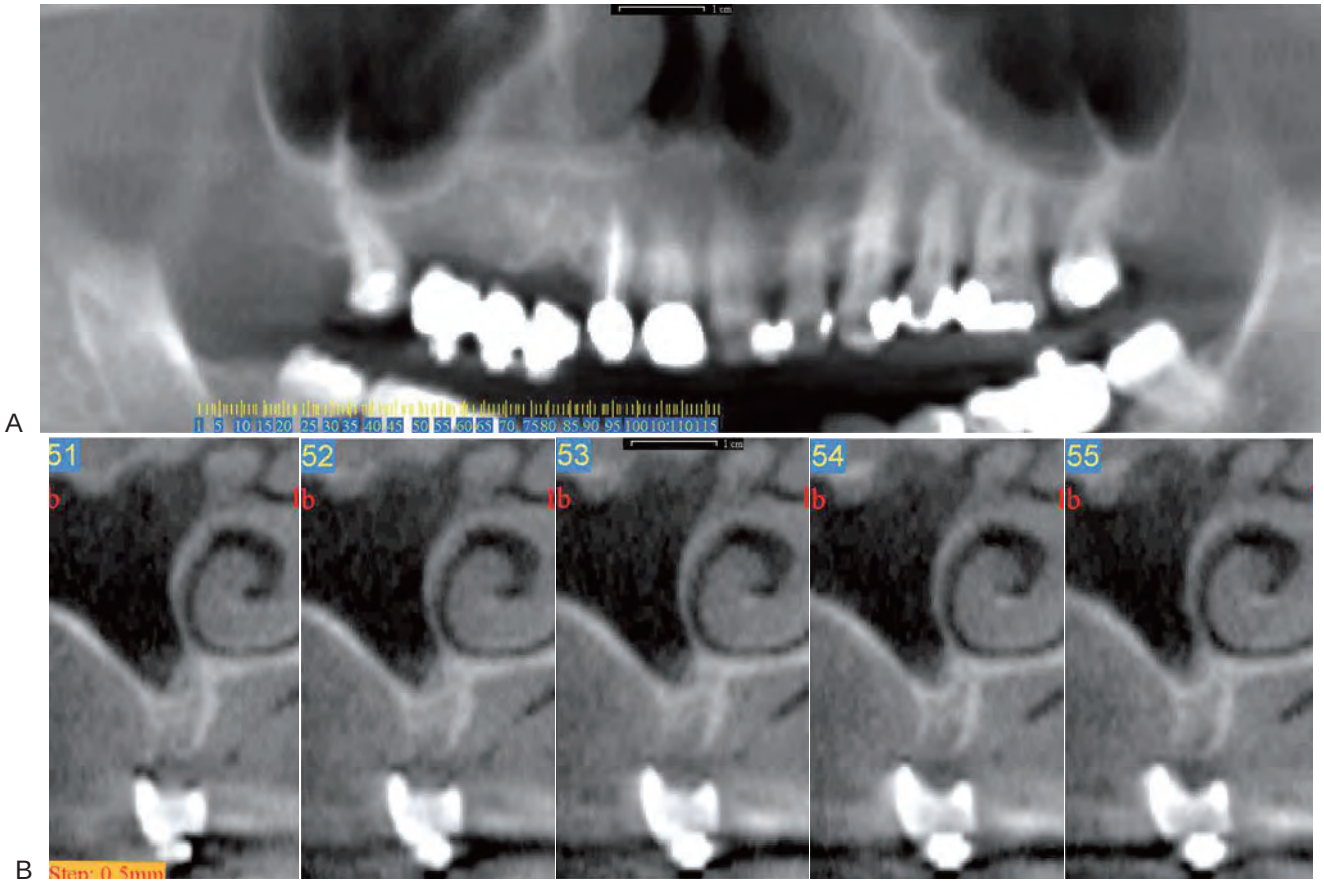

Figure 73-14 **A,** Panoramic view of partially edentulous maxilla with tooth shaped markers in areas of missing teeth (potential implant sites). **B,** Cross-sectional views from a cone-beam computed tomography examination before implant placement in the right maxilla. Appropriately sized and shaped tooth markers placed in the prosthetically desired locations of the planned restorations for the missing teeth help evaluate the existing alveolar ridge relative to the prospective tooth positions and contours.

to the existing alveolar bone. The use of these nonanatomic markers is helpful for evaluating bone height and width in specific anatomic locations. However, they do not accurately represent the tooth contours and do not allow the clinician to estimate variations in implant position and angulation relative to the position and emergence of the planned tooth replacement. Therefore, it is more desirable and beneficial to use radiopaque "tooth-shaped" markers so that the existing alveolar bone can be evaluated relative to the entire tooth position/contours (Figure 73-14; see also Figure 73-5). This is particularly important for anterior, esthetic implant cases.

Patients should always be imaged with radiographic guides (markers).

Clinical Selection of Diagnostic Imaging

Radiography is an important diagnostic tool for the evaluation of the implant patient. However, radiographic imaging alone is insufficient. It is important to correlate diagnostic information with a good clinical examination. Conversely, a clinical examination is insufficient to provide the information needed to plan implant treatment for a patient without some radiographic imaging.

Clinical Examination

Before taking any radiographs, a complete clinical examination of the implant patient is required. This should include the etiology and duration of tooth loss, any history of traumatic extraction, and a review of records and radiographs, if available. Clinical assessment of the edentulous area, covering mucosa, adjacent and opposing teeth, and occlusal plane should be performed. Temporomandibular function, mandibular maximal opening, and protrusive and lateral movements should be evaluated (see Chapter 74).

Screening Radiographs

At this point, an overall assessment of the health of the jaws should be performed. Periapical radiographs provide a high-resolution image of the alveolus and the surrounding structures, including adjacent teeth. For extended edentulous areas, panoramic, lateral cephalometric, and occlusal radiographs can be used to estimate bone height and width. Any pathology of the bone at the prospective implant site, as well as of the surrounding structures, should be identified and treated as indicated.

Fabrication of Radiographic and Surgical Guides

Once the health of the soft and hard tissues is established, casts should be taken and detailed analysis performed. The clinician should decide on the number of implants and their desired location. Next, a radiographic guide should be fabricated, usually with clear acrylic. The position of the desired implants is indicated by the use of radiopaque objects such as metallic balls, cylinders, or rods; gutta-percha; or composite resin. If CT imaging might be performed, the use of metallic markers should be avoided. The design of such a guide greatly enhances the diagnostic information provided by the radiographs because it correlates the radiographic anatomy with the exact position of the proposed implant location.

Cross-Sectional Tomography

Some type of cross-sectional imaging, such as conventional tomography, CT, or CBCT, should be performed before implant placement in any site of the jaws.[17] The potential morbidity of a compromised anatomic structure and the poor performance and potential failure of a misplaced implant, combined with the wide availability of tomographic facilities, favor the use of cross-sectional imaging in most cases of implant treatment planning. It is crucial that the cross sections are perpendicular to the curvature of the mandible and parallel to the planned implant. Improper patient positioning can lead to an overestimation of the height and width of the available bone. If the surgeon believes that sections were performed at the wrong angulation, new images should be requested. This might necessitate reexposure of the patient.

Intraoperative and Postoperative Radiographic Assessment

Various radiographic modalities can provide valuable information during implant placement. Because of the ease of acquisition and high resolution, periapical radiographs are most commonly used. Intraoperative radiographs can be taken during surgery to evaluate proximity to important anatomic structures. Sequential periapical radiographs guide the clinician to visualize changes in direction and depth of the drilling procedure and parallelism to adjacent teeth and other implants (Figure 73-15). Digital radiographs are particularly advantageous during intraoperative assessment of implant placement; images appear on the screen almost instantaneously and can be manipulated to extract the most pertinent diagnostic information (see Chapter 31).

Implant osseointegration, and the level of periimplant alveolar bone are major determinants of implant prognosis. Panoramic and periapical radiographs offer a fast, easy, and low-radiation depiction of the implant and surrounding tissues and aid in assessment of implant success. To obtain an accurate assessment of periimplant bone height, the x-ray beam should be directed perpendicular to the implant. In the case of threaded implants, the implant threads should be distinguishable and not overlapping (Figure 73-16, *A*).

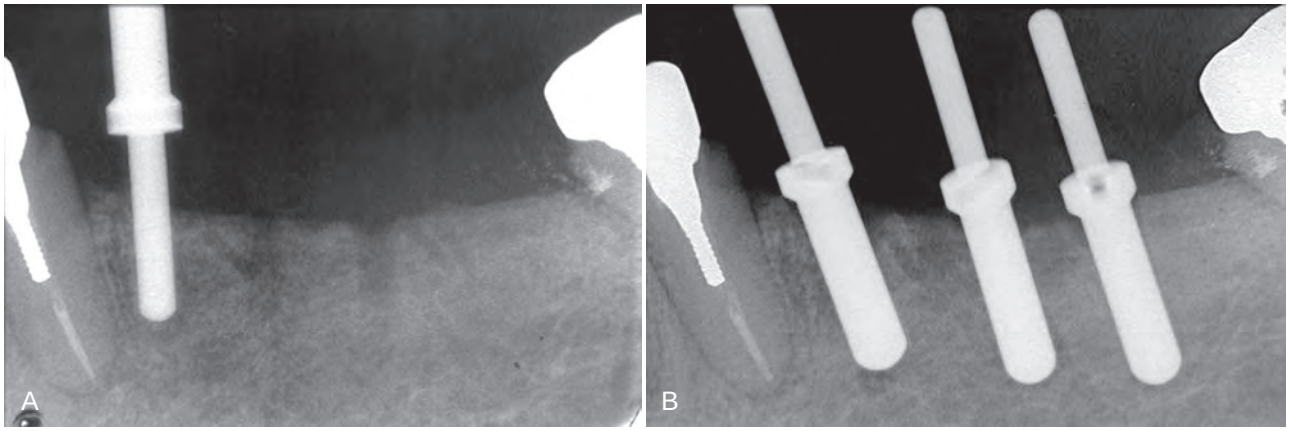

Figure 73-15 Intraoperative periapical radiographs are valuable in assessing the proximity of adjacent teeth. A, The 2-mm guide pin is used to determine direction of the osteotomy site and its proximity to the adjacent root. **B,** After angle correction, the osteotomy sites are completed to length with the final drill. Here the 3-mm guide pins confirm the correct angulation and spacing of the final osteotomy site preparation before implant placement.

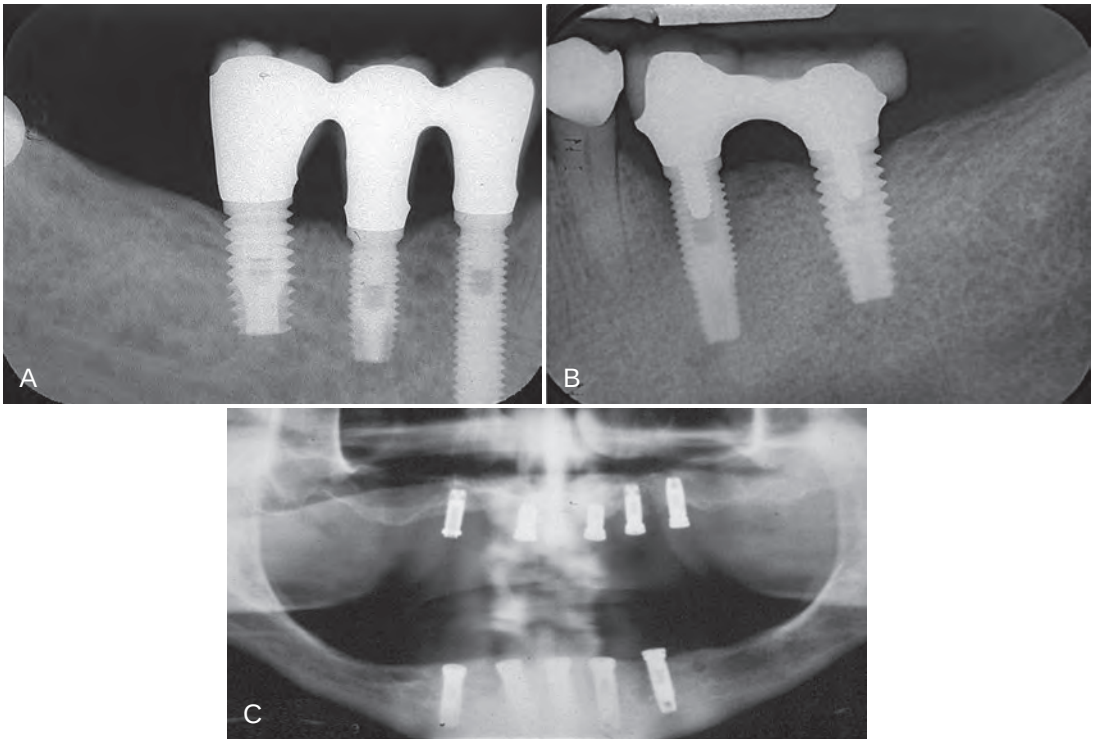

Figure 73-16 Radiographic follow-up after implant placement in three different patients. A, Periapical radiograph of three implants in the posterior right mandible. "Normal" bone remodeling around anterior two implants and slight horizontal bone loss/remodeling around the molar/posterior implant is present. **B,** Periapical radiograph of two implants in the left posterior mandible. Severe bone loss (50% of implant length) is seen around anterior implant, while mild bone loss/bone remodeling is observed around posterior implant. A moderate buccal cantilever in the restoration likely contributed to an adverse occlusal load and the resultant bone loss observed in this case. **C,** Panoramic radiograph of maxillary and mandibular implants in an edentulous patient prior to implant loading. The mandibular implants do not show signs of bone loss and appear to be osseointegrated. All maxillary show signs of moderate-to-severe periimplant bone loss and the success of osseointegration is questionable.

A 1.2-mm marginal bone loss during the first year after implant placement and 0.1 mm per year afterwards are expected; however, further bone loss is considered abnormal.[2] Pathologic bone loss could be localized along the full extend of the implant (periimplant bone loss), or around the crestal part of the implant ("saucerization"), and could reflect poor osseointegration, periimplantitis and/or unfavorable stress distribution (see Figure 73-16, *B* and *C*).

In select cases, when poor implant placement (Figure 73-17) or compromise of vital anatomic structures (Figure 73-18) are suspected, advanced imaging (CBCT, CT, or conventional tomography) provides a three-dimensional evaluation of the oral structures in relation to the implants. Such information can be very important for proper assessment and treatment planning. The treating dentist should recognize relevant signs and symptoms and order appropriate imaging as soon after implant placement as possible. Implant removal, if necessary, would be less complicated before advanced osseointegration.

Conclusion

Many radiographic projections are available for the evaluation of implant placement, each with advantages and disadvantages. The clinician must follow sequential steps in patient evaluation, and radiography is an essential diagnostic tool for implant design and successful treatment of the implant patient. Selection of appropriate radiographic modalities will provide the maximum diagnostic information, help avoid unwanted complications, and maximize treatment outcomes while delivering "as low as reasonably achievable" radiation dose to the patient.[11]

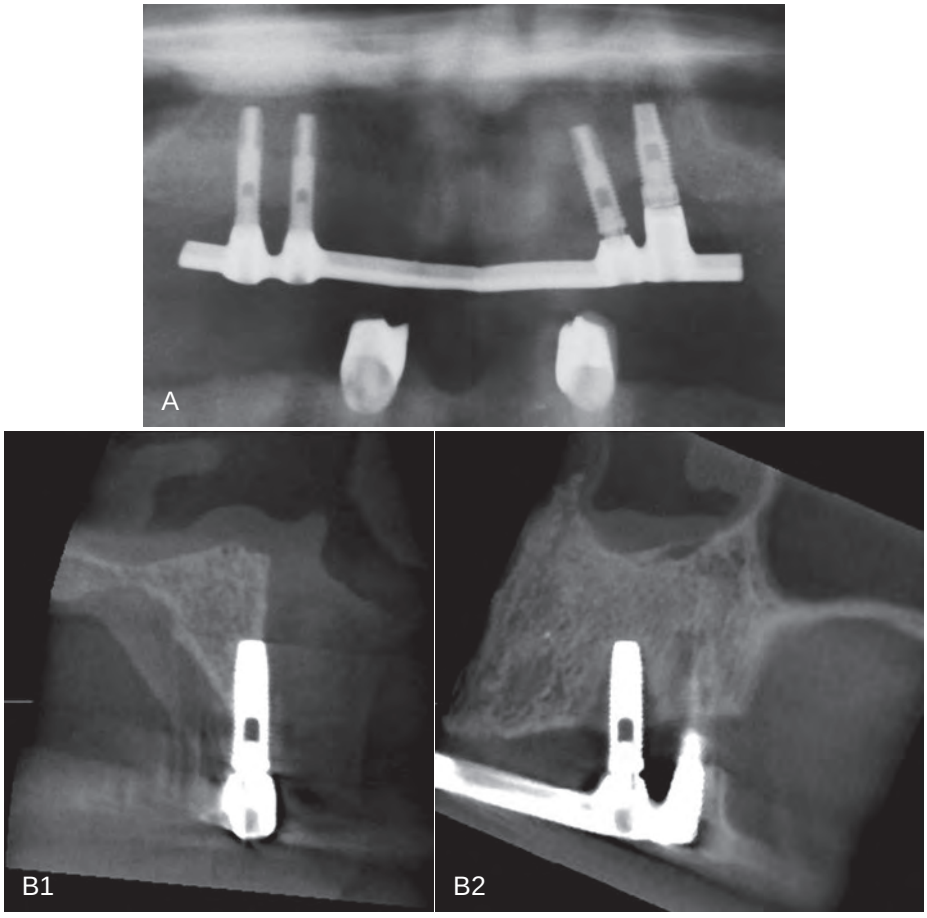

Figure 73-17 Radiographic follow-up after implant placement. A, Panoramic radiograph suggests mild-to-moderate bone loss around the neck of all implants. This is especially true for the implants in the left maxilla. These implants appear to be angled and the distal implant is positioned more apical. The overdenture bar is not completely seated on the left implants. Note superimposed overlapping anatomic structures in this panoramic radiograph impair the ability to clearly visualize and assess bone loss around implants. **B,** Cross-sectional **(B1)** and sagittal cone-beam computed tomography **(B2)** images of the anterior implant in the left maxilla. Poor implant placement beyond the buccal cortex of the alveolar ridge (cross section) and periimplant bone loss (sagittal) are revealed.

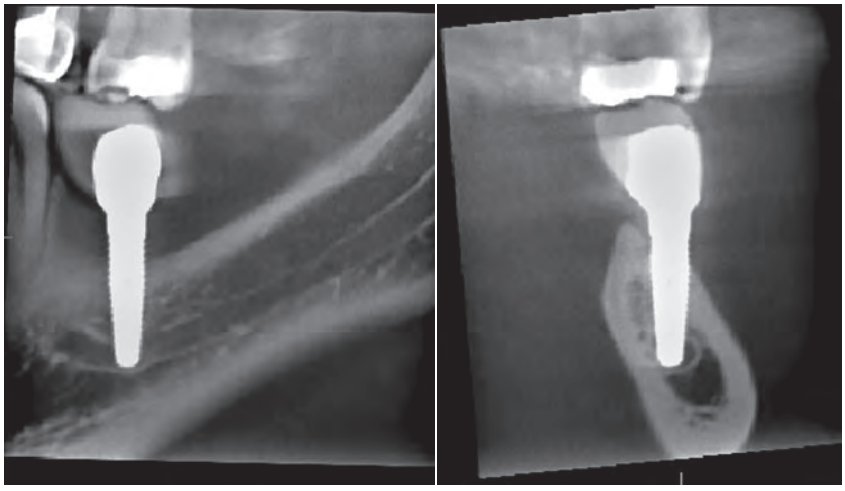

Figure 73-18 Cone-beam computed tomography sagittal and cross-sectional images clearly demonstrate penetration of the implant into the mandibular canal.

Suggested Reading

Angelopoulos C, Aghaloo T: Imaging technology in implant diagnosis. *Dent Clin North Am* 55(1):141–158, 2011.

Benson BW, Shetty V: Dental Implants. In White SC, Pharoah MJ, editors: *Oral radiology: principles and interpretation*, ed 6, St. Louis, 2009, Mosby.

Hatcher DC, Dial C, Mayorga C: Cone beam CT for pre-surgical assessment of implant sites. *J Calif Dent Assoc* 31:824, 2003.

Tyndall DA, Price JB, Tetradis S, et al: Position statement of the American Academy of Oral and Maxillofacial Radiology on selection criteria for the use of radiology in dental implantology with emphasis on cone beam computed tomography. *Oral Surg Oral Med Oral Pathol Oral Radiol* 113(6):817, 2012.

White SC, Mallya SM: Update on the biological effects of ionizing radiation, relative dose factors and radiation hygiene. *Aust Dent J* 57(Suppl 1):2, 2012.

References

References for this chapter are found on the companion website www.expertconsult.com.

References

1. Arai Y, Tammisalo E, Iwai K, et al: Development of compact computed tomographic apparatus for dental use. *Dentomaxillofac Radiol* 28:245, 1999.
2. Benson BW, Shetty V: Dental Implants. In White SC, Pharoah MJ, editors: *Oral radiology: principles and interpretation*, ed 6, St. Louis, 2009, Mosby.
3. Cavalcanti MG, Yang J, Ruprecht A, et al: Validation of spiral computed tomography for dental implants. *Dentomaxillofac Radiol* 27:329, 1998.
4. Bushberg JT, Seibert JA, Leiholdt E, et al: *The essential physics of medical imaging*, ed 3, Philadelphia, 2011, Lippincott Williams and Wilkins.
5. Hatcher DC, Dial C, Mayorga C: Cone beam CT for pre-surgical assessment of implant sites. *J Calif Dent Assoc* 31:824, 2003.
6. Kraut RA: Utilization of 3D/dental software for precise implant site selection: clinical reports. *Implant Dent* 1:134, 1992.
7. Langland OE, Langlais RP, Preece JW: *Panoramic and special imaging techniques. Principles of dental imaging*, ed 2, Baltimore, 2002, Lippincott Williams & Wilkins.
8. Ludlow JB, Davies-Ludlow LE, White SC: Patient risk related to common dental radiographic examinations: The impact of 2007 International Commission on Radiological Protection recommendations regarding dose calculation. *J Am Dent Assoc* 139:1237, 2008.
9. Ludlow JB, Ivanonic M: Comparative dosimetry of dental CBCT devices and 64-slice CT for oral and maxillofacial radiology. *Oral Surg Oral Med Oral Pathol Oral Radiol Endod* 106:106, 2008.
10. Mallya SM, Lurie AG: Panoramic imaging. In White SC, Pharoah MJ, editors: *Oral radiology: principles and interpretation*, ed 7, St. Louis, 2013, Mosby.
11. Michel R, Zimmerman TL: Basic radiation protection considerations in dental practice. *Health Phys* 77:S81, 1999.
12. Mozzo P, Procacci C, Tacconi A, et al: A new volumetric CT machine for dental imaging based on the cone-beam technique: preliminary results. *Eur Radiol* 8:1558, 1998.
13. Scaf G, Lurie AG, Mosier KM, et al: Dosimetry and cost of imaging osseointegrated implants with film-based and computed tomography. *Oral Surg Oral Med Oral Pathol Oral Radiol Endod* 83:41, 1997.
14. Schulze D, Heiland M, Blake F, et al: Evaluation of quality of reformatted images from two cone-beam computed tomographic systems. *J Craniomaxillofac Surg* 33:19, 2005.
15. Sewerin IP: Errors in radiographic assessment of marginal bone height around osseointegrated implants. *Scand J Dent Res* 98:428, 1990.
16. Truhlar RS, Morris HF, Ochi S: A review of panoramic radiography and its potential use in implant dentistry. *Implant Dent* 2:122, 1993.
17. Tyndall DA, Brooks SL: Selection criteria for dental implant site imaging: a position paper of the American Academy of Oral and Maxillofacial Radiology. *Oral Surg Oral Med Oral Pathol Oral Radiol Endod* 89:630, 2000.
18. Tyndall DA, Price JB, Tetradis S, et al: Position statement of the American Academy of Oral and Maxillofacial Radiology on selection criteria for the use of radiology in dental implantology with emphasis on cone beam computed tomography. *Oral Surg Oral Med Oral Pathol Oral Radiol* 113(6):817, 2012.
19. Whaites E: *Periapical radiography. Essentials of dental radiography and radiology*, ed 3, London, 2002, Churchill Livingstone.
20. White SC, Pharoah MJ: *Intraoral radiographic examinations. Oral radiology: principles and interpretation*, ed 6, St. Louis, 2009, Mosby.
21. White SC, Pharoah MJ: *Radiation Safety and Protection. Oral radiology: principles and interpretation*, ed 6, St. Louis, 2009, Mosby.
22. White SC, Mallya SM: Update on the biological effects of ionizing radiation, relative dose factors and radiation hygiene. *Aust Dent J* 57(Suppl 1):2, 2012.

CHAPTER 74

Biomechanics, Prosthetic Considerations, and Treatment Planning

Evelyn Chung, Ting-Ling Chang, and Perry R. Klokkevold

CHAPTER OUTLINE

Biomechanical Considerations
Treatment Planning With Dental Implants
Strategies to Avoid Implant Overload
Conclusion

For online-only content on the edentulous maxilla and edentulous mandible in the section on treatment planning with dental implants, please visit the companion website at www.expertconsult.com. Some figures may be out of numeric order in this printed chapter.

Clinical research has demonstrated excellent long-term success rates for implant-supported restorations in fully and partially edentulous patients. The replacement of missing teeth with an implant-retained prosthesis restores function and esthetics, improves confidence and self-esteem, and enhances quality of life. However, it is important to recognize that implant success is achieved by following certain principles. Proper treatment planning is essential for predictability and success. One of the most critical factors in planning is the control and distribution of stress for preservation of the "biologic" connection between the implants and bone as well as the prevention of "mechanical" breakage of implants and restorative components. The quantity and quality of bone available to support implants play an important role in stress distribution,[2] maintenance of bone apposition, and support under functional loading.

This chapter discusses important biomechanical considerations and treatment-planning guidelines for the use of dental implants in fully edentulous, partially edentulous, and single-tooth cases. Considerations for occlusal designs, cantilevers, and connecting implants to teeth are addressed as well.

Biomechanical Considerations

Osseointegrated dental implants provide a predictable means of replacing missing teeth and restoring dental function. A thorough understanding of implant biomechanics is essential if implant-retained restorations are to be employed predictably. The load-bearing capacity of implants supporting the restoration must be greater than the anticipated loads during function. If applied loads exceed load-bearing capacity, it may lead to mechanical and/or biologic failure. In the case of *mechanical failure,* screws that secure the restoration may bend, loosen, or fracture. The most devastating type of mechanical failure is fracture of the implant. In the case of *biologic failure,* a resorptive–remodeling response of the bone around the implant(s) is provoked, leading to progressive bone loss.[13,25] If bone loss around the implant progresses until the implant is no longer supported, osseointegration may be lost resulting in implant failure.

The function and support of implant-retained restorations is quite different from tooth-retained restorations. Teeth are suspended within the supporting alveolar bone by a periodontal ligament, which allows slight physiologic "movement" of teeth in function. If forces are excessive, teeth have the capacity to adjust or move in response to the applied forces. In the absence of inflammatory periodontal disease, teeth will adapt to these forces without appreciable bone loss. Orthodontic movement of teeth through alveolar bone is the ultimate example of the capacity of teeth to adapt to excessive applied forces. As orthodontic forces move a tooth, bone resorbs in response to pressure and forms in response to tension applied by the "attached" periodontal ligament fibers. *Osseointegrated* dental implants, by definition, are in direct contact with the alveolar bone without intervening soft tissues; there is no periodontal ligament and should movement occur, it would indicate a loss of osseointegration (e.g., fibrous encapsulation).[12] Because excessive forces are destructive, it is crucial to have a good understanding of the biomechanical properties and the limitations of dental implants to ensure proper treatment planning that will sustain the anticipated occlusal forces.

Load-Bearing Capacity

The load-bearing capacity of implants is influenced by several factors, including the number and size of implants, the angulation and arrangement of implant positions, and the quality of the bone-to-implant interface (Box 74-1).

The number of implants used will influence the load-bearing capacity. In the 1980s and early 1990s, many posterior quadrants of the maxilla were restored with one or two implants, and in some patients, two implants were used to support restorations with three or four dental units. In many cases, a distinct pattern of bone loss

BOX 74-1 Implant Biomechanics

Load-Bearing Capacity

Implant
- Number
- Length
- Angulation

Quality of bone-implant interference

Anticipated Load (Affected By)

Occlusal factors
Cusp angles
Width of occlusal table
Guidance type
- Anterior guidance
- Group function

Cantilever Forces

Connection to natural dentition
Size of occlusal table
- Buccolingual dimension
- Mesiodistal dimension

Cantilevered extensions

Parafunctional Habits

Chronic bruxism
Clenching habit
Grinding habit

BOX 74-2 Finite Element Analysis

Finite element analysis (FEA) is a computerized investigative method that uses a mathematic model to assess stress in various objects and their surroundings when subjected to forces. It is useful in generating a hypothesis and testing basic biomechanical mechanisms but cannot be relied on for definitive answers. Only hard clinical evidence is undisputed and any assumption or predictions that are made by FEA needs to be validated clinically.

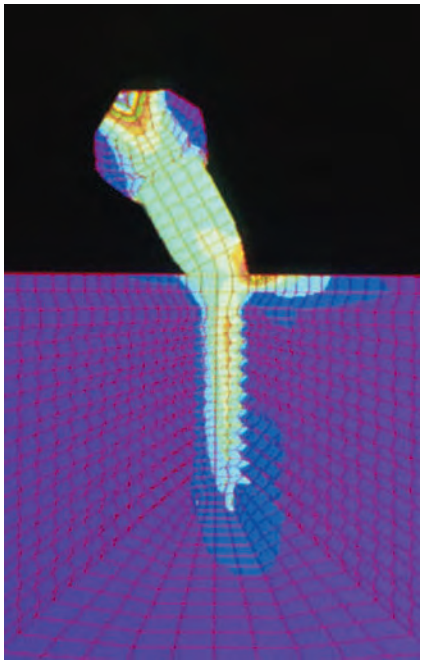

Figure 74-1 Nonaxial loads result in load magnification. Using FEA, Cho and coworkers demonstrated that nonaxial loads concentrated stresses around the neck of the implant. *(Courtesy Dr. In Ho Cho.)*

was observed soon after loading that led to bone loss and failure of the implants (see Figure 82-16). Additional implants significantly improved the biomechanics of these implant-supported fixed partial dentures.

Historically, the use of longer (>7 mm) implants has been advocated as the result of reported higher rates of failure for shorter (≤7 mm) implants.[24,27,38,51] Logic suggests that biomechanical stress around "short" implants leads to greater bone loss relative to the implant length and a higher rate of implant failure. However, Pierrisnard et al[47] showed that the maximum implant stress somewhat increased with implant length and bicortical anchorage. They also stated that the low anchorage stiffness of shorter implants might reduce the mechanical stress to the implant because of the flexibility of the bone. Using the finite element analysis (FEA), Pierrisnard and colleagues[46] showed that greater implant length did not positively affect transfer of stresses to the implant but that increasing implant diameter did reduce the intensity of stress along the length of the implant. Other studies also observed that wider rather than longer implants registered lower stress values to the whole system, suggesting that the use of short, wide implants could increase the load-bearing capacity of implants and implant prostheses[7,26,45] (Box 74-2). In a recent systematic review of the literature, Atieh et al concluded that the survival of short (≤8.5 mm) implants used in the posterior partially edentulous jaw is high and not related to implant surface, design or width.[4]

Angulation and Arrangement

The angulation and arrangement of implants used to retain and support a prosthesis influence the load-bearing capacity of the system (i.e., implants, components, prosthesis, and supporting bone). In the 1980s, conventional dogma stated that once an implant became "osseointegrated," it did not matter whether occlusal loads were applied axially. However, as more clinical follow-up and animal research data became available, the adverse effect of nonaxial loads on implants became increasingly more apparent. The angulation of implants in relation to the plane of occlusion and the direction of the occlusal load is an important factor in optimizing the transfer of occlusal forces to implants and surrounding bone. Axial loads are tolerated well. Minor discrepancies in angulation are probably not clinically significant, but if loads are applied at an angle of 20 degrees or more to the long axis of the implant, load magnification can result, provoking a resorptive remodeling response of the adjacent bone. This concept is supported by numerous FEA studies, which clearly demonstrate that nonaxial forces significantly increase the stress concentration to the cortical bone around the neck of the implant (Figure 74-1).[3,14,42,56] Nonaxial loads lead to implant overload through load magnification at the bone-to-implant interface, which, in turn, precipitates a resorptive remodeling response of the bone around the neck of the implants.

When excessive loads persist, bone loss continues and may progress to implant failure. Brunski et al[13] proposed that excessive occlusal loads lead to microdamage (fractures, cracks, delamination) of the bone adjacent to the implant, which provokes a resorptive remodeling response. The bone remodeling at the implant surface results in less bone density adjacent to the implant, especially around the coronal aspect of the implant. This bone has poor capacity for repair that is the result in part to the absence of a periodontal ligament fiber attachment (i.e., no bone-forming tension exists). Thus a vicious cycle ensues in which continued excessive loading leads to more microdamage and progressive bone loss until the implant fails (Box 74-3).

Short-span, linear implant configurations in the posterior segments are particularly prone to bone loss when loads are not applied axially. Bone loss in posterior areas can be more damaging because implants in these areas are often primarily supported by the cortical bone around the most coronal aspect of the implant. In

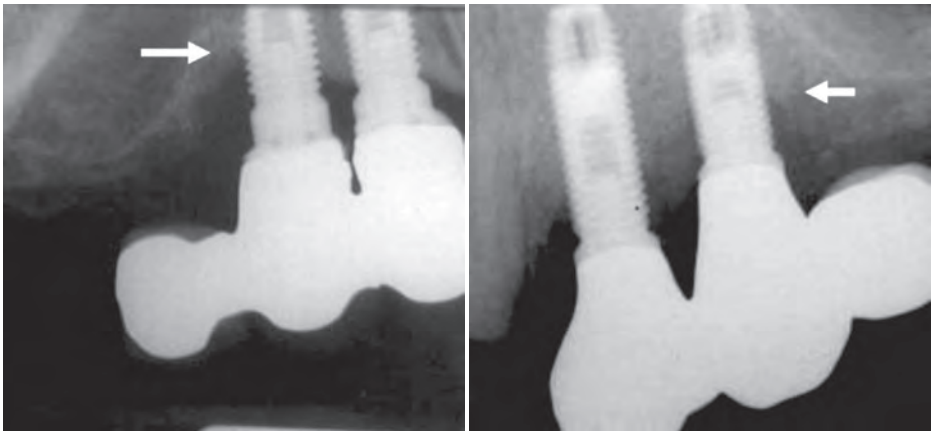

Figure 74-2 Cantilevers in posterior quadrants of partially edentulous patients should be avoided. These radiographs demonstrate two cases of bone loss *(arrows)* around the neck of short implants (closest to the cantilever) in which load magnification occurs.

BOX 74-3 Implant Overload and Bone Resorption: Proposed Mechanisms of Implant Failure

- Excessive occlusal loads
- Load resulting in microdamage: fractures, cracks, and delaminations
- Resorption–remodeling response of bone
- Loss of bone at the bone-to-implant interface as a result of remodeling
- Vicious cycle of continued loading, additional microdamage, and bone loss progressing to implant failure

the posterior maxilla, the cortical bone can be very thin, and unless the implant is positioned to engage the superior cortical bone (floor of maxillary sinus), the apical aspect of the implant is usually poorly supported by loose trabecular bone. The load-bearing capacity is poor, and nonaxial loads can lead to failure.

Before the widespread use of bone augmentation procedures in the posterior maxilla (i.e., sinus augmentation), many implants were positioned with excessive buccal angulations or were restored with buccal and/or distal cantilevers. Implant-supported restorations with a cantilevered pontic transfer nonaxial occlusal forces to the adjacent implant and surrounding bone resulting in bone loss. This load magnification causes bone loss around the neck of the implant closest to the cantilever (Figure 74-2). Excessive distal angulations, which creates nonaxial loading is another recognized problem that leads to bone loss. These implants often exhibit signs of overload (i.e., progressive and irreversible bone loss around neck of implant) when nonaxial occlusal loads are applied to the prosthesis (Figure 74-3).

The *bone appositional index* (percentage of bone-to-implant contact) may be the most important factor to consider when evaluating the load-bearing capacity of any given implant(s). Less bone density and lower bone-to-implant contact provide less support and resistance to occlusal loading. As an example, consider the bone support of implants in the posterior maxilla; the bone quality is particularly poor as compared with the anterior mandible. The trabecular bone is less dense and the cortical bone layer is thin in the posterior maxilla. As a result, the bone appositional index in the posterior maxilla is significantly less than what can be achieved in the anterior mandible, where the trabecular bone is typically dense with a thick cortical bone layer. The bone appositional index for implants in the posterior maxilla typically ranges from 30% to 60%, whereas the bone appositional index for implants placed in the anterior mandible typically ranges from 65% to 90% (Figure 74-4).

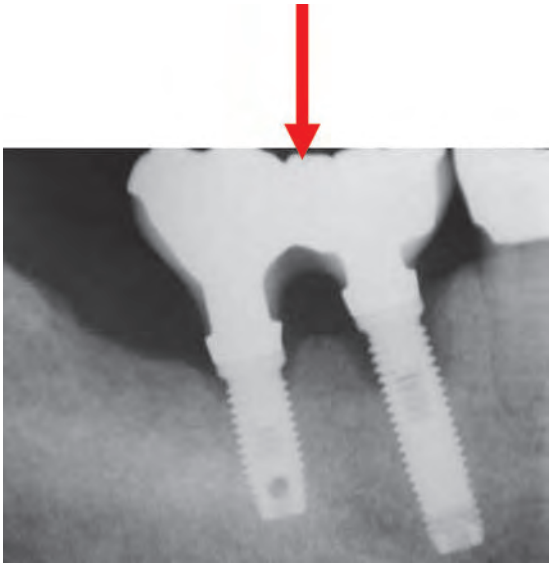

Figure 74-3 Because of the curve of Spee and the distal angulation of these implants (posterior mandible), the occlusal loads *(arrow)* are nonaxial. The nonaxial loading results in implant overload and bone loss around the neck of both implants.

Technologic advances in surface modification (as compared to the original machined Brånemark surface) may enhance bone apposition and support for implants placed in poor quality/quantity bone, thereby gaining anchorage and improving the biomechanics.[5,32,33,54] These "rougher" implant surfaces appear to have a significant effect on bone anchorage.[32,33,43] Surfaces with an altered microtopography achieve higher bone appositional indices than the machined surfaces and appear to facilitate the biologic processes of bone formation through greater deposition of bone onto the surface of the implant. In addition, bone deposited on the surface of acid-etched implants appears to be harder and denser and may be more resistant to resorptive remodeling.[52]

A lack of bone height limits the amount of available bone for placement of implants and reduces the potential for bone-to-implant contact. In the posterior mandible the inferior alveolar nerve and vessels travel through the body of the mandible until

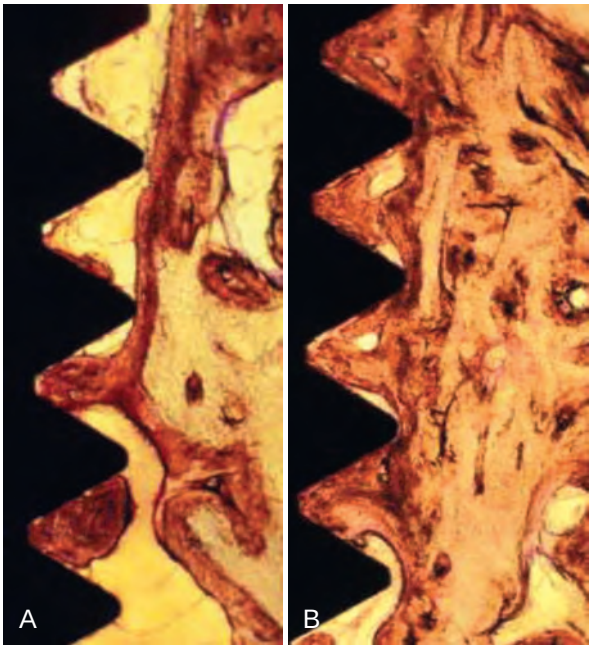

Figure 74-4 Bone quality influences the load-bearing capacity. In these histologic images obtained with light microscopy, note the difference in bone appositional index achieved in sparse "poor-quality" bone **(A),** often found in the posterior maxilla, versus dense bone **(B),** typical of the anterior mandible.

exiting the mental foramen in the premolar region (see Chapter 54). The height of bone available for placement of implants in the posterior mandible is determined by the location of the neurovascular bundle and the resorption of the alveolar ridge. Lateral nerve repositioning is possible but has a moderately high morbidity rate. In the posterior maxilla, pneumatization of the maxillary sinus combined with loss of alveolar bone results in a decreased total height of available bone in the posterior maxilla, which limits the length of implants that can be used. Sinus floor elevation and bone augmentation procedures have enabled clinicians to increase the height of bone available in the posterior maxilla, allowing for the placement of longer implants with improved success (see Chapter 77). Vertical ridge augmentation is challenging and less predictable for all sites.

Treatment Planning With Dental Implants

The success of implant-retained restorations is measured not only by successful osseointegration but also by the lack of problems associated them in function over time. Implant complications and failures have taught clinicians that the "engineering" of implant support for prosthetic appliances is an essential part of treatment planning and the key to success for implant-retained restorations (see Chapter 82 for a description of implant complications and failures).

Partially Edentulous Patients

Prosthetic options for patients who are partially edentulous (missing one to several teeth) include a conventional removable partial denture, a fixed partial denture (tooth-borne), or an implant-supported prosthesis.

Multiple-Tooth Sites. Unilateral, implant-supported fixed partial dentures are predictable when they are supported by an adequate number of implants with good quality bone surrounding them. However, anatomic limitations can prevent ideal placement of implants and/or may require the use of shorter implants in posterior sextants. The lowest success rates for implants have consistently been reported for short-span (segmental) restorations in the posterior maxilla.[28] In the posterior maxilla, the maxillary sinus limits the lengths used, and in the mandible, the inferior alveolar nerve limits the lengths of the implants used. The bone-implant interface for osseointegrated implants in the posterior maxilla is compromised because the poor bone quality. Anchorage for an implant placed in this region may be improved by engaging the cortical bone of the floor of the sinus. Because many patients possess insufficient bone in the posterior maxilla to receive an implant of suitable length, bone augmentation of the alveolar ridge or maxillary sinus has been suggested.[44,53] Vertical augmentation of the alveolar ridge has not been predictable, but the "sinus lift and graft procedure" appears predictable and has achieved wide acceptance[29,55] (see Chapter 77).

It is imperative to "engineer" the treatment of unilateral, posterior segments with an implant used to support each missing tooth that will be restored. If space and available bone permits, it is desirable to use a minimum of three implants to replace three missing posterior teeth in the maxilla. The same rule (one implant for every missing tooth being restored) applies to replacing teeth with implants in the posterior mandible as well. However, greater bone density (i.e., thickness of cortical bone) provides better support in the posterior mandible and sometimes permits the use of fewer implants. A three-unit bridge supported by two implants in the posterior mandible is widely accepted. However, the decision to restore three missing teeth supported by two implants should always be made with consideration for the quantity and quality of bone available to support the implants (i.e., effective load-bearing capacity of the implants).

Single-Tooth Sites. Implants have been used successfully to replace missing single teeth despite the fact that the loading limit of a single implant remains unknown. Single-tooth implant restorations have replaced the traditional three-unit bridge and gained acceptance and patient satisfaction.

Standard-diameter implants have been used to restore single-tooth defects in the posterior quadrants of the maxilla and mandible with mixed results. Solitary implants restoring maxillary molars have had unpredictable results, whereas single implants used to restore mandibular molars have had a better prognosis. In the 1980s, clinicians attempted to restore mandibular first molar sites with conventional implants 3.75 or 4.0 mm in diameter. Unfortunately, the results were quite disappointing. Occlusal overload led to bone loss and, in some cases, fractured implants, especially for the 3.75-mm diameter implant.[18]

The most common problem observed, particularly when external hex-headed implants were used, was loosening of the screw retaining the restoration. This problem results because the diameter of the head of the implant is much smaller than the size of the occlusal surface. The buccolingual width of the crown can be minimized by narrowing the dimension of the restoration, but there is less control over the mesiodistal dimension because contacts need to be established and the space is most often filled. Consequently, a mesiodistal cantilever, albeit small, is created. Tipping of the restoration during function eventually leads to stretching and loosening of the screw that secures the crown to the implant fixture. If hex-headed implants are used, the use of wide-diameter implants greatly diminishes the screw-loosening complication (Figure 74-13).

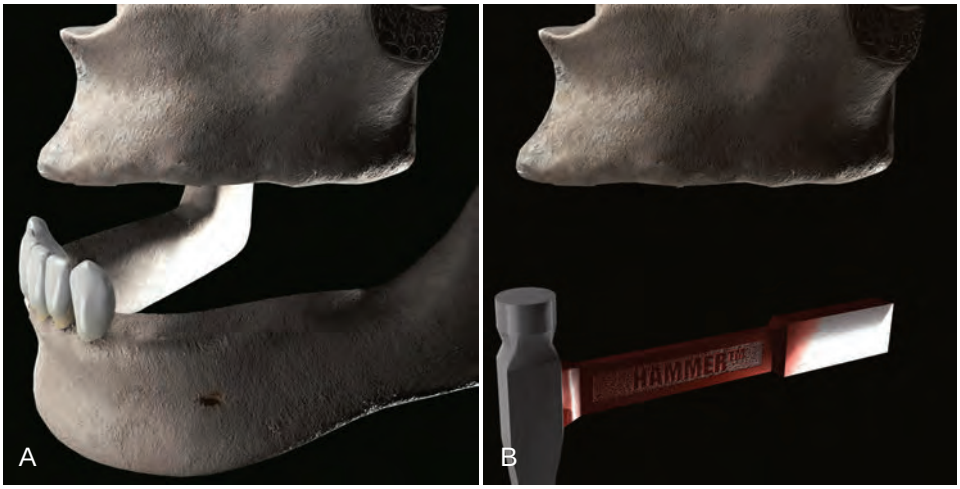

Figure 74-5 The hammer-and-anvil effect is a useful analogy for the clinician to keep in mind, evoking the combination syndrome, when treatment planning an edentulous maxilla opposing a partially dentate mandible. **A,** Illustration of an edentulous maxilla opposing a mandible that is missing posterior teeth. The lack of posterior occlusion leads to overclosure of the mandible and results in increased forces being applied to the anterior maxilla by the mandibular anterior natural dentition. **B,** Illustration of the hammer-and-anvil effect of combination syndrome.

Edentulous Maxilla

Prosthetic options for the patient with an edentulous maxilla include a conventional complete denture, an implant-assisted denture, an implant-supported removable prosthesis or an implant-supported fixed prosthesis. For many patients, a conventional complete denture does not provide the comfort and quality of life that they desire. An implant-assisted or implant-supported prosthesis can provide stability, retention, comfort and restore confidence to the patient, especially in patients with one or more of the following conditions:

1. Poor ridge form with a marginally stable conventional maxillary denture. Two or four implants provide greater stability and security of a maxillary denture in function when the maxillary ridge is severely resorbed and lacks resistance to lateral forces.
2. Lack of posterior support with an intact mandibular anterior dentition. Implants in the maxilla can offset the potentially destructive effects on the premaxillary region when a mandible with natural anterior teeth and missing posterior teeth opposes an edentulous maxilla. In this situation, the lack of posterior support leads to a condition often referred to as combination syndrome in which overclosure of the anterior teeth causes a "hammer-and-anvil" type of destruction of the edentulous anterior maxilla (Figure 74-5).
3. Palatal coverage is not tolerated. Some patients prefer a palateless denture, which may enhance their sensations of taste and texture or may simply provide a psychologic advantage. Some patients prefer a palateless denture because the proximity of the denture with the soft palate induces a gag reflex. Patients with large palatal tori (see Figure 54-19) can also benefit from a palateless maxillary denture. Minimum of four implants with adequate anterior–posterior (AP) spread allows the fabrication of an implant-assisted overdenture without palatal coverage.

The design of a maxillary implant-retained prosthesis is greatly influenced by the anatomy of the maxilla. Most notably, the maxillary sinus limits the height of bone available for implant placement in the posterior region. As a result, implant placement is confined to the anterior region, and the AP spread that can be achieved is often limited (Figure 74-6). If the AP spread is inadequate to provide support, a full-palatal-coverage overlay denture is recommended.

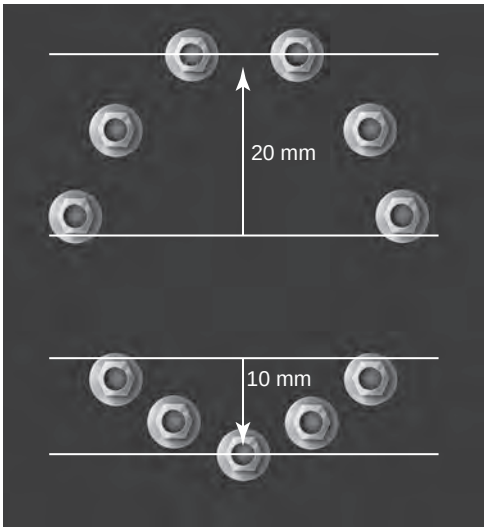

Figure 74-6 Diagram demonstrating the anterior–posterior implant spread. It is defined as the distance from the middle of the most anterior implant to the distal edge of the most posterior implant.

Most patients are best served with an implant-assisted overlay denture. Lower cost, improved hygiene access, and predictable speech articulation are additional benefits that favor the use of an overlay denture in the edentulous maxilla over an implant-supported fixed prosthesis. The four-implant–assisted, palateless overlay denture ideally addresses the needs of most patients (Figure 74-7). Many patients who are edentulous in the maxilla have lost a significant amount of structure in the premaxillary region resulting in a lack of support for the upper lip. An implant-assisted maxillary overdenture is preferred over an implant-supported fixed prosthesis because the labial flange can provide the needed lip support. The usual resorption pattern of the alveolus places the gingival margin of a fixed restoration too far superiorly, too far palatally, or both.

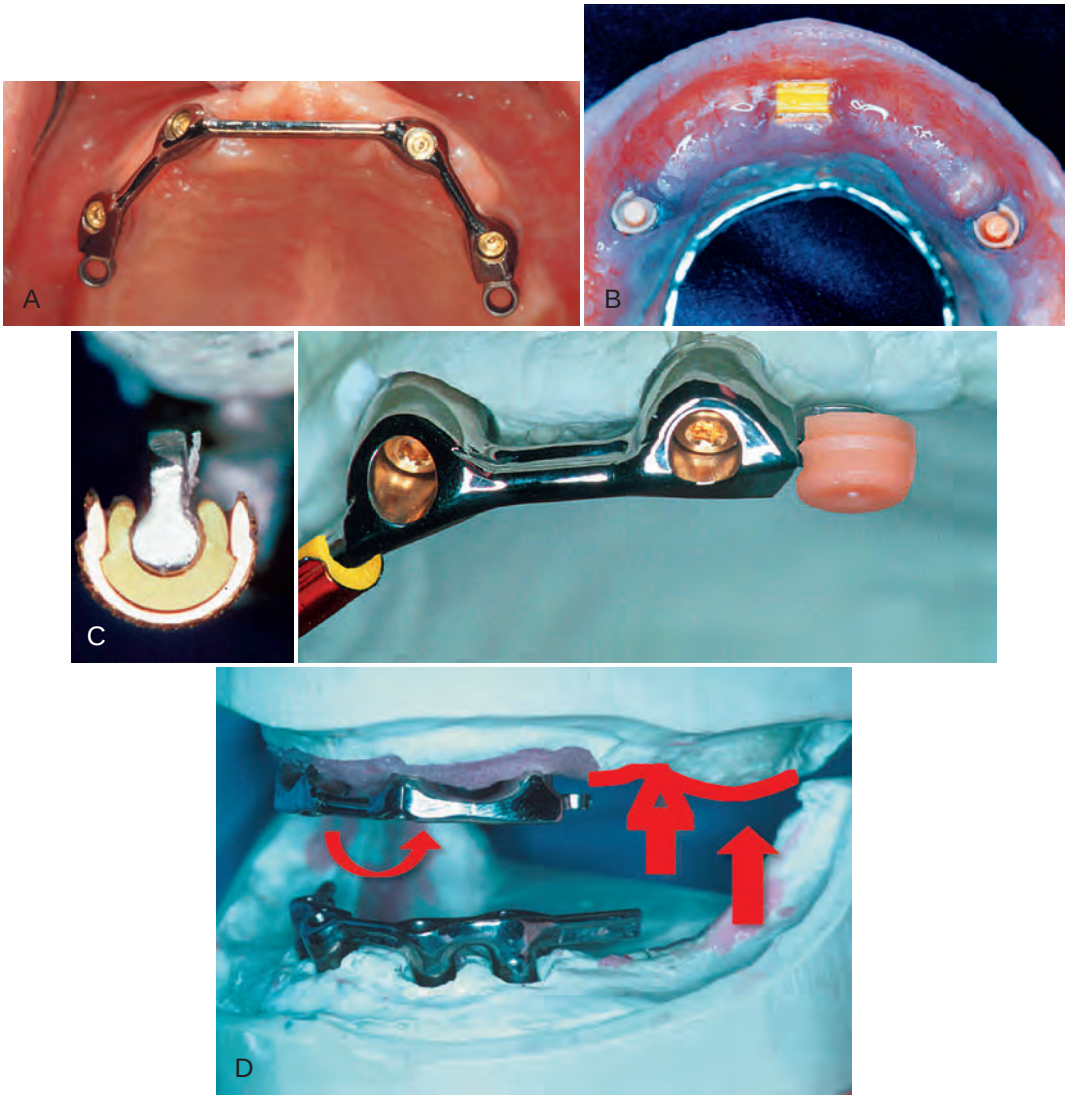

Figure 74-7 Implant-assisted overlay denture. A, Clinical photograph of four-implant bar in the maxilla designed to retain a palateless overlay denture. **B,** Photograph of clip and attachment design of palateless overlay denture. Anterior Hader clip attaches to anterior bar, and posterior extracoronal resilient attachments (ERAs) attach to female connectors at posterior ends of the bar. **C,** Cross-section of Hader bar clip attached to anterior bar *(inset)*. View of overdenture bar with Hader clip *(left)* and ERA *(right)* attached. These plastic components will be embedded in the overdenture as in **(B). D,** Axis of rotation and function of resilient attachment. When posterior occlusal forces *(solid vertical arrow)* are applied, the denture rotates around the bar clip anteriorly *(curved arrow),* and resilient attachment *(arrow)* allows the denture to be compressed to primary denture-support areas posteriorly *(open arrow).*

Even if the patient has a low enough smile line to hide the appearance of long crowns and deficient soft tissue height (Figure 74-8), a lack of lip support just beneath the nose can be unsightly with fixed prostheses.

For those patients who prefer an implant-supported fixed prosthesis (and don't require additional lip support), six or more implants arranged in an appropriate arc of curvature with at least 2 cm of AP spread are required (see Figure 74-6). In this situation, the fixed prosthesis can be fabricated with distal extension cantilevers up to half the AP spread provided it does not exceed 10 mm.

Edentulous Mandible

Similar to the edentulous maxilla, prosthetic options for patients with an edentulous mandible include a conventional complete denture, an implant-assisted denture or an implant-supported prosthesis. A mandibular complete denture is more problematic for patients than a maxillary complete denture, especially for patients with a severely resorbed (atrophic) mandibular ridge. The lack of stability and retention makes it very challenging for patients to control the denture. The addition of implants offers unprecedented control (i.e., stability and retention) for a complete removable prosthesis.

Implant-assisted overlay dentures are designed so that most of the masticatory load is borne by the primary denture-support areas (i.e., retromolar pad, buccal shelf). A common practice is to place two implants in the anterior mandible with a connecting bar. One or two clips retain the denture to the bar (Figure 74-9). When occlusal forces are applied, the denture rotates around the bar (anterior axis of rotation) and depresses slightly in the posterior aspect, directing the forces to the primary denture-bearing areas (Figure 74-10). The implants provide stability and retention while bearing minimal stress from occlusal loads. Individual attachments secured to each implant can also offer a simple prosthetic alternative (Figure 74-11) to the bar and clip design. However, it is more

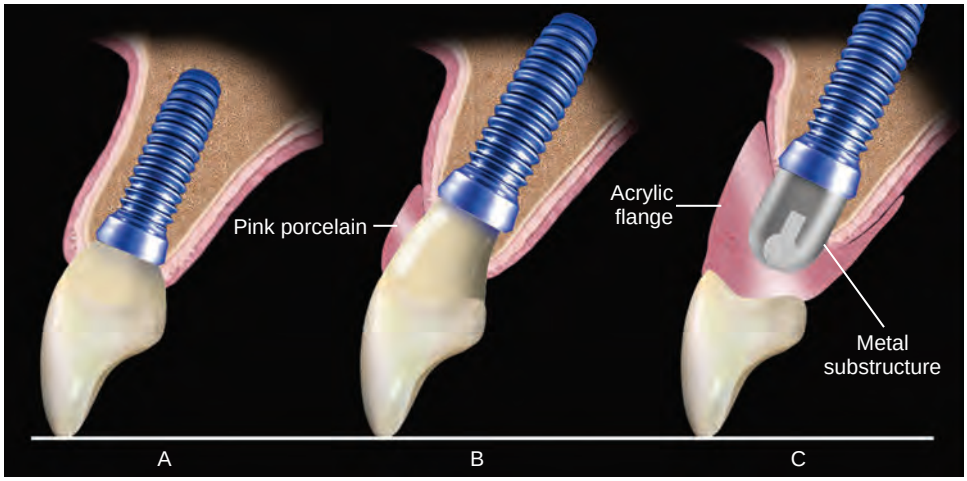

Figure 74-8 Three different scenarios of bone level dictating three different fixed restorations. Note that the incisal edge of all three restorations is at the same level, where ideally it should be, according to esthetics and phonetics. **A,** Bone resorption is minimal and no need to replace any soft tissue. A conventional implant-supported fixed partial denture is planned. **B,** Bone resorption is moderate, mainly vertical, and there is a need to replace soft-tissue loss. To avoid the unesthetic look of a long porcelain restoration, the laboratory technician is asked to add some facial pink porcelain to mimic the lost soft tissue and reduce visually the length of the fixed partial denture giving the restoration a more acceptable look. **C,** Bone resorption is severe and it is vertical and horizontal. The soft tissue has followed, and there is a lack of support of the maxillary lip. The fixed restoration has to restore esthetics and function and of course the support of the lip; a fixed-removable (hybrid) prosthesis with a metal substructure and a buccal acrylic flange is the restoration planned in this case.

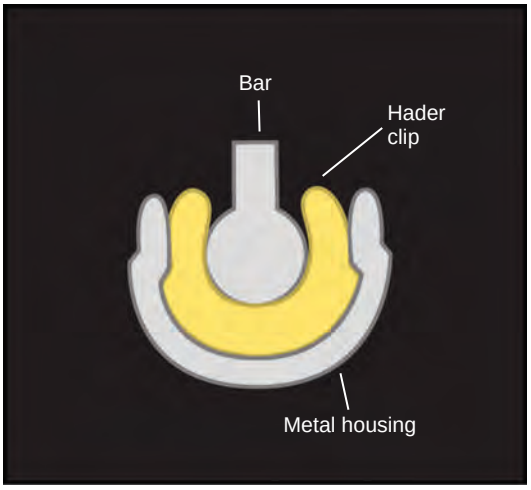

Figure 74-9 Cross-section of a Hader bar with clip. Note that the minimal height of the Hader bar is 2.5 mm and about 1.2 mm for the plastic clip and the metal housing. We should also allow room for acrylic for the retention of these components.

critical for implants with individual attachments to be parallel to one another to facilitate a proper path of insertion and to minimize stress during prosthetic seating and function.

For those patients who prefer an implant-supported fixed prosthesis, four, five, or six implants arranged in an appropriate arc of curvature with at least 1 cm of AP spread are required (see Figure 74-6). In this situation, the fixed prosthesis can be fabricated with distal extension cantilevers up to twice the AP spread (Figure 74-12).

Many patients prefer a fixed option for psychologic reasons, but the difference in mastication efficiency provided by a fixed versus removable prosthesis does not appear to be significant.[31] Evidence suggests that such fixed restorations tend to stop resorption of the body of the posterior mandible and in some cases enable regeneration of the bone in this region.[34]

Regardless of whether implants will retain or support the prosthesis, every attempt should be made to position posterior implants with the long axis directed toward the opposing stamp cusp and aligned perpendicular to the occlusal plane. Then, occlusal forces can be directed down the long axis of the implant, which is tolerated better than nonaxial forces. A recent concept is to restore atrophied maxillary and mandibular ridges in edentulous patients with both axially inclined and distally inclined implants placed in areas with bone (e.g., the anterior region) to increase AP spread and used to support a full-arch prosthesis, thus avoiding the need for extensive bone augmentation in posterior segments. Early studies have reported success with initial stability and integration with immediate loading.[16,17,30,36] This technique involves the placement of two dental implants in the anterior region of the edentulous jaws in the axial direction and then placement of two implants, one on each side with a 45-degree distal inclination to avoid the maxillary sinuses in the maxilla or mental foramen in the mandible. This technique is appealing to patients because it can decrease the treatment time and obviate the need for extensive bone augmentation. However, long-term results are lacking and further research is required to better understand and assess the risks and benefits of this technique.

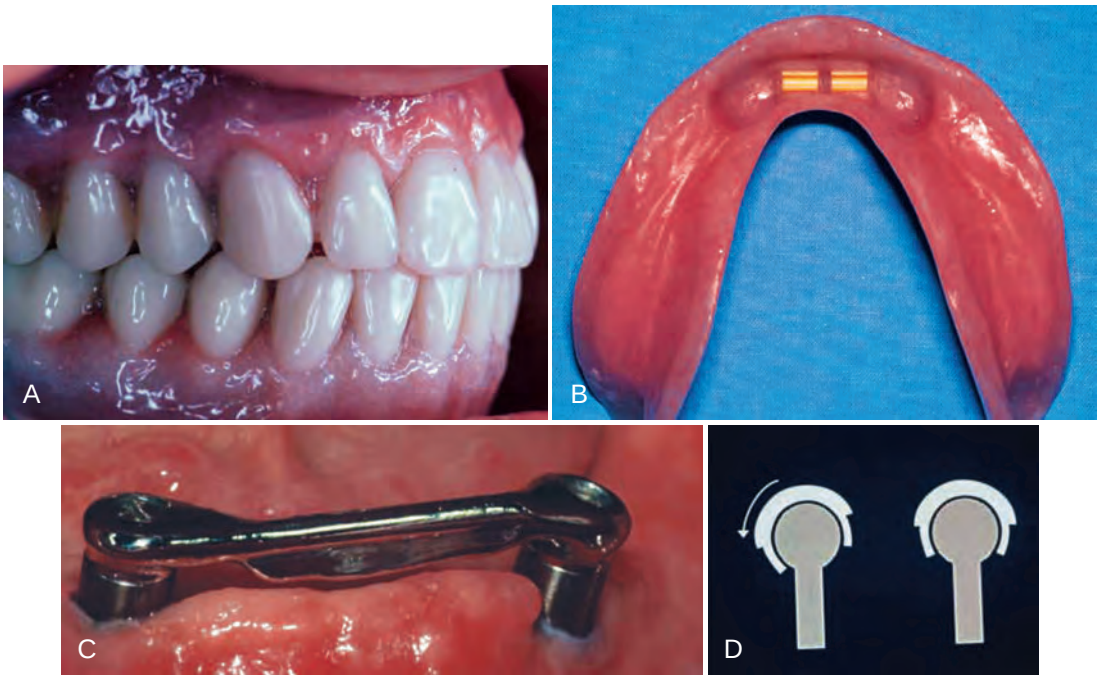

Figure 74-10 Implant-assisted overlay denture. A, Clinical view of overdenture in occlusion. **B,** Photograph of mandibular overlay denture (tissue-bearing surface) designed for an implant bar attached to two implants in the anterior mandible. Two Hader clips are embedded in the anterior acrylic. **C,** Clinical view of bar attached to two implants in the anterior mandible. **D,** Illustration demonstrating how axis of rotation allows denture to rotate around the bar. When the patient applies occlusal force posteriorly, the overlay denture rotates around the bar, and the load is absorbed by primary denture-bearing surfaces posteriorly.

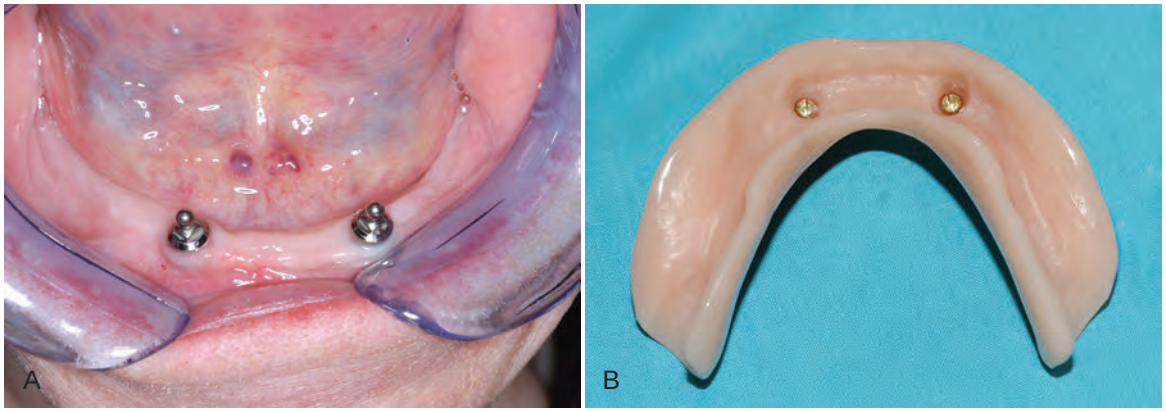

Figure 74-11 Individual attachments can be used on each implant to assist in retention of the mandibular overdenture. A, Clinical view of anterior mandible with individual ball attachments on two implants. **B,** Tissue-bearing surface of mandibular overdenture showing individual female attachments embedded in the denture. *(Courtesy Dr. Sal Esposito, Beachwood, OH.)*

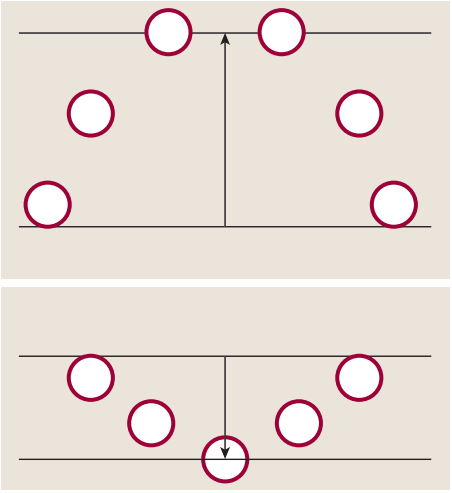

Anterior-posterior spread is the distance from the center of the most anterior implant(s) to the distal surface of the most posterior implants.

The AP spread required for an implant-supported prosthesis is:

✓ Maxilla = 2 cm
6+ implants

✓ Mandible = 1 cm
4+ implants

A

B

Figure 74-12 Cantilever length relative to AP spread of implant distribution. A, Clinical view of an implant-supported restoration replacing mandibular teeth. Notice that the restoration is supported by five implants in the anterior and has cantilever extensions in the posterior segments. **B,** Study model view of similar mandibular implant-supported restoration with posterior cantilever extensions. Cantilever length, in the edentulous mandible, should not exceed twice the AP spread.

The larger platform reduces the potential for tipping forces to stretch or break the screw. The use of implants with internal connections has been shown to be less susceptible to screw loosening than implants with an external connection. Implant systems with internal connections have been introduced to lower or eliminate the mechanical complications such as abutment screw loosening or even fatigue fracture. A systematic review by Gracis et al concluded loosening of abutment screws was the most frequently occurring technical complication.[19] The type of connection seems to have an influence on the incidence of the screw loosening: more loose screws were reported for externally connected implant systems for both types of materials. To minimize the screw loosening incidence of both external and internal connection abutment/reconstructions, it is highly recommended to tighten the retention screws at the recommended torque level.

If the first molar is lost and suitable abutments are present, a conventional three-unit, fixed partial denture is still a viable option, especially if the adjacent teeth already have large restorations or preexisting crowns. However, if adjacent teeth have small or no restorations, it is more conservative and preferable to replace the missing single tooth with an implant. This restoration is cost-effective and predictable. In distal extension areas when restoring a single molar tooth, two conventionally sized implants may be placed (with appropriate spacing) to improve biomechanical support and dramatically decrease or eliminate rotational forces.[6,8,49] (Figure 74-14).

Single implants can be used with a high rate of success in the anterior and premolar areas. The bone-implant interface achieved in this area is good, and the size of the occlusal surface is generally small. Although similar considerations exist regarding screw loosening for single-implant restorations in the anterior and premolar regions, these concerns are less significant because of a more anterior position (lesser forces generated). Typically, there is better bone quantity and quality compared with more posterior sites.

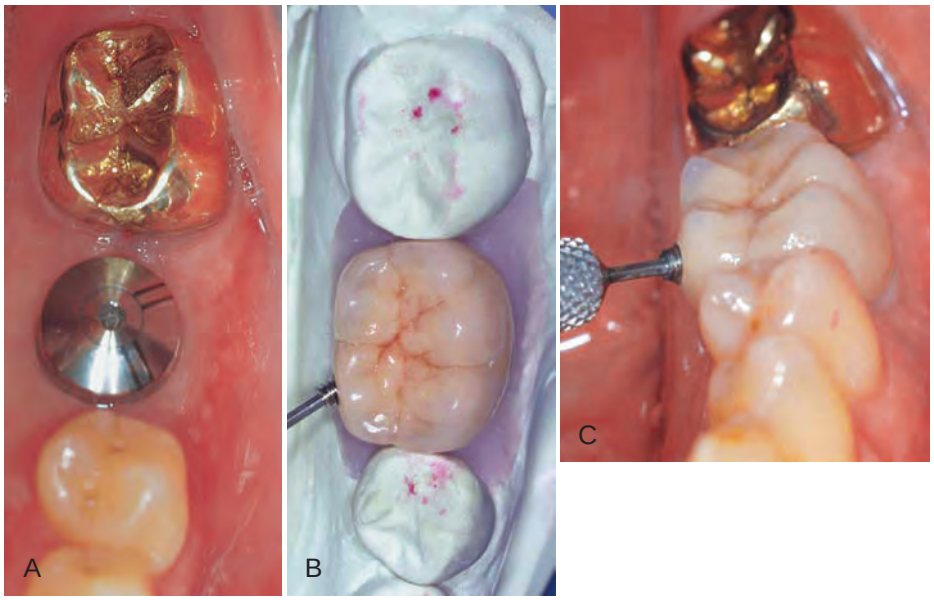

Figure 74-13 Single-tooth restoration in the posterior mandible supported by a wide-diameter implant. A, Clinical photograph of healing abutment on wide-diameter implant. **B,** Photograph of laboratory model with single molar. **C,** Clinical photograph of molar crown supported by wide-diameter implant. The use of wide-diameter (external hex) implants eliminates the problem of screw loosening for single-tooth, posterior, implant-supported crowns. *Note:* This crown is secured to the abutment via a lingual set screw (small hex driver seen attaching set screw).

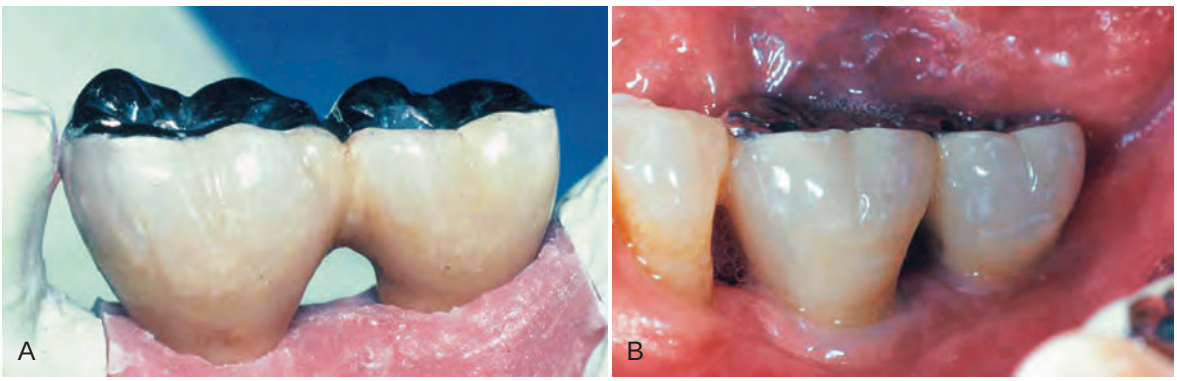

Figure 74-14 Guidelines for restoring posterior quadrants. Embrasures should be large enough for access with a proxy brush. The occlusal table must be narrow, cusp angles flattened, and proper emergence profiles developed. Anterior guidance should be restored with the natural dentition whenever possible. Laboratory model **(A)** and clinical photograph **(B)** of two-unit, fixed partial denture supported by two implants in the posterior mandible demonstrate these qualities.

Strategies to Avoid Implant Overload

Multiunit implant restorations should be splinted to maximize implant support by distributing the occlusal loads, and emergence profiles should be developed with open embrasure spaces to facilitate oral hygiene (see Figure 72-9).

Implants should be of adequate number, size and position to sustain the anticipated occlusal loads. Implants with smaller diameters have a lesser capacity to support bending forces than do implants with larger diameters. Implants with a minimum of 4 mm diameter should be used in areas expected to sustain greater occlusal loads (i.e., the posterior regions). Wider-diameter implants can be used when adequate bone and space exists (see Figure 73-9). Thus, when the residual ridge and site permits, wide diameter implants should be used for molar replacement. Wide diameter implants should be avoided in anterior sites because of less bone width and the risk of bone loss, especially along the labial-buccal surface. Standard diameter (4-mm) implants may be best for premolar and anterior tooth replacement because they approximate the size of these teeth and will provide a better emergence profile.

Occlusal Design

Occlusal design for implant-supported prostheses is an essential and integral determinant of overall treatment planning.[37,48] The risk of implant overload can be minimized by limiting the width of the occlusal table of the implant-supported fixed partial denture, flattening the cusp angles, avoiding the use of cantilevered restorations, and restoring the anterior guidance (ideally natural tooth). Box 74-4 lists strategies to avoid implant overload.

The intensity and the vector of the force depend on several variables including the amount of bone contact (osseointegration), the quality and the quantity of the supporting bone and the implant surface characteristics. Regardless of the direction or the amount of this force, it always leads to micromotion at the bone–implant interface, which translates stress to the adjacent bone. Splinting implant crowns together and placing longer and wider implants, as well as enhanced implant surface features, increase the bone-to-implant contact, or *bone appositional index,* and reduce stress forces, thereby increasing the load-bearing capacity of the implant(s).

Cantilevers

The use of cantilevered implant-supported restorations (i.e., unilateral, linear configurations) in posterior quadrants of the mandible or maxilla is strongly discouraged and should be avoided. Cantilever extensions result in load magnification that can cause overloading of the implant next to the cantilever extension, which in turn may lead to progressive bone loss and implant failure (see Figure 74-3).

BOX 74-4 Strategies to Avoid Implant Overload

- Place implants perpendicular to the occlusal plane
- Place implants in tooth positions
- Use an implant for each unit being replaced
- Avoid the use of cantilevers in linear configurations
- Avoid connecting implants to teeth
- If connecting implants to teeth, use a rigid attachment
- Control occlusal factors such as cusp angles and width of occlusal table
- Restore anterior guidance if possible

Connecting Implants to Teeth

In general, it is advisable to keep implant-supported restorations separate from natural teeth because implants and teeth function differently and connecting them can lead to complications such as screw loosening and intrusion of natural dentition.[15,50] Teeth have the capacity to move under functional occlusal loads while implants do not. Connecting implants to teeth may create a cantilever effect on the implant.[11,35,39,40] Furthermore, designing the restoration so that it is independent of the natural dentition simplifies the restoration and biomechanics.

In contrast to this widely accepted view, a recent critical review of the literature suggests that these concerns may have been overstated.[20] Some situations may warrant connection of implants to teeth. Several authors have shown (animal and human research) that success is possible when specific guidelines are followed.[1,9,10,21,23,41] Specifically, if implants are to be connected to the natural dentition, it should be done in a rigid manner, either with screw-retained attachments or with copings secured by permanent cement. Tooth preparation should allow good retention, teeth should be periodontally healthy and stable, and the occlusal scheme should be good. Gulbransen[22] showed that if implants are connected to the natural dentition with a rigid system of attachment, the implant failure and complication rates were dramatically reduced. It appears that the intrusion problem (and other complications) is increased when implants and natural teeth are connected with "nonrigid" and "semirigid" attachments. In addition, the well-documented phenomenon of intrusion of the natural tooth abutment associated with the use of semiprecision attachments is prevented.[21]

Conclusion

The importance of biomechanics and the limitations of implant systems were initially underestimated. It was believed that multiunit fixed bridges could be supported by as few as two implants, as it was done with the natural dentition. Over the years, clinical experience and research underscored the importance of biomechanics in the success and predictability of implant-retained prostheses. The rigid nature of implant-retained restorations and the lack of forgiveness in these systems require proper treatment planning and a good understanding of the biomechanics of implant prostheses. The principles of biomechanics must be factored into the planning at the beginning of any implant treatment to achieve long-term, predictable success.

When clinicians follow a strategy that avoids implant overload and place an adequate number of implants in optimal positions, abutment selection is simplified and proper emergence profiles can be developed. There should always be sufficient space in interproximal areas for hygienic access and tissue health. The clinician will also have better control over occlusal loads by idealizing the occlusal anatomy with narrowed occlusal table and flattened cusp angles.

Suggested Readings

Brånemark PI, Hansson BO, Adell R, et al: Osseointegrated implants in the treatment of the edentulous jaw. Experience from a 10-year period. *Scand J Plast Reconstr Surg Suppl* 16:1–132, 1977.

Brunski JB, Puleo DA, Nanci A: Biomaterials and biomechanics of oral and maxillofacial implants: current status and future developments. *Int J Oral Maxillofac Implants* 15:15–46, 2000.

Eckert SE, Meraw SJ, Cal E, et al: Analysis of incidence and associated factors with fractured implants: a retrospective study. *Int J Oral Maxillofac Implants* 15:662–667, 2000.

Hagi D, Deporter DA, Pilliar RM, et al: A targeted review of study outcomes with short (< or = 7 mm) endosseous dental implants placed in partially edentulous patients. *J Periodontol* 75:798–804, 2004.

Iplikcioglu H, Akca K: Comparative evaluation of the effect of diameter, length and number of implants supporting three-unit fixed partial prostheses on stress distribution in the bone. *J Dent* 30:41–46, 2002.

Lang NP, Pjetursson BE, Tan K, et al: A systematic review of the survival and complication rates of fixed partial dentures (FPDs) after an observation period of at least 5 years. II. Combined tooth–implant-supported FPDs. *Clin Oral Implants Res* 15:643–653, 2004.

Sahin S, Cehreli MC, Yalin E: The influence of functional forces on the biomechanics of implant-supported prosthesis–a review. *J Dent* 30(7–8):271–282, 2002.

References

References for this chapter are found on the companion website www.expertconsult.com.

References

1. Akagawa Y, Hosokawa R, Sato Y, et al: Comparison between free-standing and tooth-connected partially stabilized zirconia implants after two years' function in monkeys: a clinical and histologic study. *J Prosthet Dent* 80:551–558, 1998.
2. Akca K, Fanuscu MI, Caputo AA: Effect of compromised cortical bone on implant load distribution. *J Prosthodont* 17:616–620, 2008.
3. Akca K, Iplikcioglu H: Evaluation of the effect of the residual bone angulation on implant-supported fixed prosthesis in mandibular posterior edentulism. Part II: 3-D finite element stress analysis. *Implant Dent* 10:238–245, 2001.
4. Atieh MA, Zadeh H, Stanford CM, et al: Survival of short dental implants for treatment of posterior partial edentulism: a systematic review. *Int J Oral Maxillofac Implants* 27(6):1323–1331, 2012.
5. Avila G, Misch K, Galindo-Moreno P, et al: Implant surface treatment using biomimetic agents. *Implant Dent* 18:17–26, 2009.
6. Balshi TJ, Hernandez RD, Ptyszlak MC, et al: A comparative study of one implant versus two replacing a single molar. *Int J Oral Maxillofac Implants* 11:372–378, 1996.
7. Baggi L, Cappelloni I, Di Girolamo M, et al: The influence of implant diameter and length on stress distribution of osseointegrated implants related to crestal bone geometry: a three-dimensional finite element analysis. *J Prosthet Dent* 100:422–431, 2008.
8. Bahat O, Handelsman M: Use of wide implants and two implants in the posterior jaw: a clinical report. *Int J Oral Maxillofac Implants* 11:379–386, 1996.
9. Biancu S, Ericsson I, Lindhe J: The periodontal ligament of teeth connected to osseointegrated implants. An experimental study in the beagle dog. *J Clin Periodontol* 22:362–370, 1995.
10. Block MS, Lirette D, Gardiner D, et al: Prospective evaluation of implants connected to teeth. *Int J Oral Maxillofac Implants* 17:473–487, 2002.
11. Bragger U, Aeschlimann S, Burgin W, et al: Biological and technical complications and failures with fixed partial dentures (FPD) on implants and teeth after four to five years of function. *Clin Oral Implants Res* 12:26–34, 2001.
12. Brånemark PI, Hansson BO, Adell R, et al: Osseointegrated implants in the treatment of the edentulous jaw. Experience from a 10-year period. *Scand J Plast Reconstr Surg Suppl* 16:1–132, 1977.
13. Brunski JB, Puleo DA, Nanci A: Biomaterials and biomechanics of oral and maxillofacial implants: current status and future developments. *Int J Oral Maxillofac Implants* 15:15–46, 2000.
14. Canay S, Hersek N, Akpinar I, et al: Comparison of stress distribution around vertical and angled implants with finite-element analysis. *Quintessence Int* 27:591–598, 1996.
15. Chee WW, Mordohai N: Tooth-to-implant connection: a systematic review of the literature and a case report utilizing a new connection design. *Clin Implant Dent Relat Res* 12(2):122–133, 2010.
16. Crespi R, Vinci R, Capparé P, et al: A clinical study of edentulous patients rehabilitated according to the "all on four" immediate function protocol. *Int J Oral Maxillofac Implants* 27(2):428–434, 2012.
17. Dierens M, Collaert B, Deschepper E, et al: Patient-centered outcome of immediately loaded implants in the rehabilitation of fully edentulous jaws. *Clin Oral Implants Res* 20(10):1070–1077, 2009.
18. Eckert SE, Meraw SJ, Cal E, et al: Analysis of incidence and associated factors with fractured implants: a retrospective study. *Int J Oral Maxillofac Implants* 15:662–667, 2000.
19. Gracis S, Michalakis K, Vigolo P, et al: Internal versus external connections for abutments/reconstructions: a systematic review. *Clin Oral Implants Res* 23(6):202–216, 2012.
20. Greenstein G, Cavallaro J, Smith R, et al: Connecting teeth to implants: a critical review of the literature and presentation of practical guidelines. *Compend Contin Educ Dent* 30:440–453, 2009.
21. Gross M, Laufer BZ: Splinting osseointegrated implants and natural teeth in rehabilitation of partially edentulous patients. Part I: laboratory and clinical studies. *J Oral Rehabil* 24:863–870, 1997.
22. Gulbransen H: Unpublished data. In: *Unpublished data* 1995.
23. Gunne J, Astrand P, Lindh T, et al: Tooth-implant and implant supported fixed partial dentures: a 10-year report. *Int J Prosthodont* 12:216–221, 1999.
24. Hagi D, Deporter DA, Pilliar RM, et al: A targeted review of study outcomes with short (< or = 7 mm) endosseous dental implants placed in partially edentulous patients. *J Periodontol* 75:798–804, 2004.
25. Hoshaw S, Brunski J, Cochran C: Mechanical loading of Brånemark implants affects interfacial bone modeling and remodeling. *Int J Oral Maxillofac Implants* 9:345, 1994.
26. Iplikcioglu H, Akca K: Comparative evaluation of the effect of diameter, length and number of implants supporting three-unit fixed partial prostheses on stress distribution in the bone. *J Dent* 30:41–46, 2002.
27. Jemt T, Hager P: Early complete failures of fixed implant-supported prostheses in the edentulous maxilla: a 3-year analysis of 17 consecutive cluster failure patients. *Clin Implant Dent Relat Res* 8:77–86, 2006.
28. Jemt T, Lekholm U, Adell R: Osseointegrated implants in the treatment of partially edentulous patients: a preliminary study on 876 consecutively placed fixtures. *Int J Oral Maxillofac Implants* 4:211–217, 1989.
29. Jensen OT, Shulman LB, Block MS, et al: Report of the Sinus Consensus Conference of 1996. *Int J Oral Maxillofac Implants* 13(Suppl):11–45, 1998.
30. Heschl A, Payer M, Platzer S, et al: Immediate rehabilitation of the edentulous mandible with screw type implants: results after up to 10 years of clinical function. *Clin Oral Implants Res* 23(10):1217–1223, 2012.
31. Kapur KK: Veterans Administration Cooperative Dental Implant Study–comparisons between fixed partial dentures supported by blade-vent implants and removable partial dentures. Part III: Comparisons of masticatory scores between two treatment modalities. *J Prosthet Dent* 65:272–283, 1991.
32. Kinni ME, Hokama SN, Caputo AA: Force transfer by osseointegration implant devices. *Int J Oral Maxillofac Implants* 2:1–14, 1987.
33. Klokkevold PR, Johnson P, Dadgostari S, et al: Early endosseous integration enhanced by dual acid etching of titanium: a torque removal study in the rabbit. *Clin Oral Implants Res* 12:350–357, 2001.
34. Klokkevold PR, Nishimura RD, Adachi M, et al: Osseointegration enhanced by chemical etching of the titanium surface. A torque removal study in the rabbit. *Clin Oral Implants Res* 8:442–447, 1997.
35. Lang NP, Pjetursson BE, Tan K, et al: A systematic review of the survival and complication rates of fixed partial dentures (FPDs) after an observation period of at least 5 years. II. Combined tooth–implant-supported FPDs. *Clin Oral Implants Res* 15:643–653, 2004.
36. Maló P, Rangert B, Nobre M: All-on-4 immediate-function concept with Brånemark System implants for completely edentulous maxillae: a 1-year retrospective clinical study. *Clin Implant Dent Relat Res* 7(Suppl 1):S88–S94, 2005.
37. Misch CE, Bidez MW: Implant-protected occlusion: a biomechanical rationale. *Compendium* 15:1330, 1332, 1334 passim; quiz 1344, 1994.
38. Naert I, Koutsikakis G, Duyck J, et al: Biologic outcome of implant-supported restorations in the treatment of partial edentulism. part I: a longitudinal clinical evaluation. *Clin Oral Implants Res* 13:381–389, 2002.
39. Naert IE, Duyck JA, Hosny MM, et al: Freestanding and tooth-implant connected prostheses in the treatment of partially edentulous patients Part II: An up to 15-years radiographic evaluation. *Clin Oral Implants Res* 12:245–251, 2001.
40. Naert IE, Duyck JA, Hosny MM, et al: Freestanding and tooth-implant connected prostheses in the treatment of partially edentulous patients. Part I: An up to 15-years clinical evaluation. *Clin Oral Implants Res* 12:237–244, 2001.
41. Nickenig HJ, Schafer C, Spiekermann H: Survival and complication rates of combined tooth-implant-supported fixed partial dentures. *Clin Oral Implants Res* 17:506–511, 2006.
42. O'Mahony A, Bowles Q, Woolsey G, et al: Stress distribution in the single-unit osseointegrated dental implant: finite element analyses of axial and off-axial loading. *Implant Dent* 9:207–218, 2000.
43. Ogawa T, Nishimura I: Different bone integration profiles of turned and acid-etched implants associated with modulated expression of

extracellular matrix genes. *Int J Oral Maxillofac Implants* 18:200–210, 2003.
44. Ogawa T, Ozawa S, Shih JH, et al: Biomechanical evaluation of osseous implants having different surface topographies in rats. *J Dent Res* 79:1857–1863, 2000.
45. Ormiaher A, Palti A, Demiralp B, et al: Implant-supported first molar restorations: correlation of finite element analysis with clinical outcomes. *Int J Oral Maxillofac Implants* 27(1):e1–e12, 2012.
46. Pierrisnard L, Augereau D, Barquins M: Analyse comparative par la method des elements finis des contraintes osseuses induites par des implants de geometrie variee. 2ieme partie: influence relative de la longueur et de l'orientation des implants. *Implants* 6:93–105, 2000.
47. Pierrisnard L, Renouard F, Renault P, et al: Influence of implant length and bicortical anchorage on implant stress distribution. *Clin Implant Dent Relat Res* 5:254–262, 2003.
48. Rangert B, Sennerby L, Meredith N, et al: Design, maintenance and biomechanical considerations in implant placement. *Dent Update* 24:416–420, 1997.
49. Sahin S, Cehreli MC, Yalin E: The influence of functional forces on the biomechanics of implant-supported prosthesis—a review. *J Dent* 30(7–8):271–282, 2002.
50. Sheets CG, Earthman JC: Tooth intrusion in implant-assisted prostheses. *Clin Oral Implants Res* 12(3):245–251, 2001.
51. Snauwaert K, Duyck J, van Steenberghe D, et al: Time dependent failure rate and marginal bone loss of implant supported prostheses: a 15-year follow-up study. *Clin Oral Investig* 4:13–20, 2000.
52. Takeuchi K, Saruwatari L, Nakamura HK, et al: Enhanced intrinsic biomechanical properties of osteoblastic mineralized tissue on roughened titanium surface. *J Biomed Mater Res A* 72:296–305, 2005.
53. Tolman DE: Reconstructive procedures with endosseous implants in grafted bone: a review of the literature. *Int J Oral Maxillofac Implants* 10:275–294, 1995.
54. Trisi P, Lazzara R, Rao W, et al: Bone-implant contact and bone quality: evaluation of expected and actual bone contact on machined and Osseotite implant surfaces. *Int J Periodontics Restorative Dent* 22:535–545, 2002.
55. Wallace SS, Froum SJ: Effect of maxillary sinus augmentation on the survival of endosseous dental implants. A systematic review. *Ann Periodontol* 8:328–343, 2003.
56. Watanabe F, Hata Y, Komatsu S, et al: Finite element analysis of the influence of implant inclination, loading position, and load direction on stress distribution. *Odontology* 91:31–36, 2003.

CHAPTER 75

Basic Implant Surgical Procedures

Perry R. Klokkevold

CHAPTER OUTLINE

General Principles of Implant Surgery
Two-Stage "Submerged" Implant Placement
One-Stage "Nonsubmerged" Implant Placement
Conclusion

Editors Note: A video has been added as a supplement to the chapter by the Editors. This was produced by My Dental Hub as a general education tool and covers the basic elements in a conceptual manner. It is not intended to be a procedural guide for dental professionals.

The surgical procedures for the placement of nearly all endosseous dental implants currently used are based on the original work of Professor Per-Ingvar Brånemark and colleagues in Sweden in the 1960s and 1970s.[4,5] Their landmark research evaluated the biologic, physiologic, and mechanical aspects of the titanium screw-shaped implant, subsequently known commercially as the Nobelpharma "Brånemark" implant system and currently manufactured by Nobel Biocare. The original Brånemark implant was a parallel-walled, cylindrically shaped, threaded implant with an external hex connection and a machined surface. In the last few decades many different designs of root form implants have been developed, modified, and studied. The same fundamental principles of atraumatic, precise implant site preparation applies to all implant systems. Briefly, this includes a gentle surgical technique and progressive, incremental preparation of the bone for a precise fit of the implant at the time of placement.

This chapter outlines the basic surgical procedures for the placement of endosseous dental implants using either one-stage or two-stage protocols. The principles described here are intentionally generic and designed to serve as guidelines and to be applicable to most of the common implant systems (see Video 75-1: Single Tooth Implant). Each implant system is designed with specific armamentarium and recommendations for use (e.g., drilling speeds) and it is advisable to follow the detailed protocols provided by the manufacturer.

General Principles of Implant Surgery

Patient Preparation

Most implant surgical procedures can be done in the office using local anesthesia. Conscious sedation (oral or intravenous) may be indicated (see Chapter 36) for some patients. The risks and benefits of implant surgery specific to the patient's situation and needs should be thoroughly explained prior to surgery. A written, informed consent should be obtained for the procedure.

Implant Site Preparation

Some basic principles must be followed to achieve osseointegration with a high degree of predictability[3,4,7] (Box 75-1). The surgical site should be kept aseptic, and the patient should be appropriately prepared and draped for an intraoral surgical procedure. Prerinsing with chlorhexidine gluconate for 1 to 2 minutes immediately before the procedure will aid in reducing the bacterial load present around the surgical site. Every effort should be made to maintain a sterile surgical field and to avoid contamination of the implant surface. Implant sites should be prepared using gentle, atraumatic surgical techniques with an effort to avoid overheating the bone.

When these clinical guidelines are followed, successful osseointegration occurs predictably for submerged[4] and nonsubmerged[11] dental implants. Well-controlled studies of patients with good plaque control and appropriate occlusal forces have demonstrated that root form, endosseous dental implants show little change in bone height around the implant over years of function.[1] After initial bone remodeling in the first year (1.0 to 1.5 mm of resorption described as "normal remodeling around an externally hexed implant"),[1] the bone level around healthy functioning implants remains stable for many years. The average annual crestal bone loss after the first year in function is expected to be 0.1 mm or less. Hence, implants offer a predictable solution for tooth replacement.

Regardless of the surgical approach, the implant must be placed in healthy bone with good primary stability to achieve osseointegration, and an atraumatic technique must be followed to avoid damage to bone. Drilling of the bone without adequate cooling generates excessive heat, which injures bone and increases the risk of failure.[12] The anatomic features of bone quality (dense compact versus loose trabecular) at the recipient site influence the interface between bone and implant.[9] Compact bone offers a much greater surface area for bone-to-implant contact than cancellous bone. Areas of the jaw exhibiting thin layers of cortical bone and large cancellous spaces, such as the posterior maxilla, have lower success

BOX 75-1 Basic Principles of Implant Therapy to Achieve Osseointegration

1. Implants must be sterile and made of a biocompatible material (e.g., titanium).
2. Implant site preparation should be performed under sterile conditions.
3. Implant site preparation should be completed with an atraumatic surgical technique that avoids overheating of the bone during preparation of the recipient site.
4. Implants should be placed with good initial stability.
5. Implants should be allowed to heal without loading or micromovement (i.e., undisturbed healing period to allow for osseointegration) for 2 to 4 or 4 to 6 months, depending on the bone density, bone maturation, and implant stability.

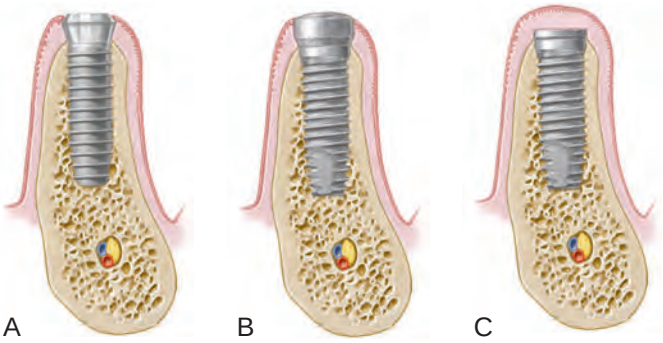

Figure 75-1 One-stage implant versus two-stage implant surgeries. A, One-stage surgery with the implant designed so that the coronal portion of the implant extends through the gingiva. **B,** One-stage surgery with implant designed to be used for two-stage surgery. A healing abutment is connected to the implant during the first-stage surgery. **C,** In the two-stage surgery, top of the implant is completely submerged under gingiva.

rates than areas of dense bone.[9] The best results are achieved when the bone-to-implant contact is intimate at the time of implant placement.

One-Stage Versus Two-Stage Implant Placement Surgery

Currently, most threaded endosseous implants can be placed using either a one-stage (nonsubmerged) or a two-stage (submerged) protocol. In the one-stage approach, the implant or the abutment emerges through the mucoperiosteum/gingival tissue at the time of implant placement, whereas in the two-stage approach, the top of the implant and cover screw are completely covered with the flap closure (Figure 75-1). Implants are allowed to heal, without loading or micromovement, for a period of time to allow for osseointegration. In two-stage implant surgery, the implant must be surgically exposed following a healing period. Some implants are specifically designed with the coronal portion of the implant positioned above the crest of bone and extending through the gingival tissues at the time of placement in a one-stage protocol (Figure 75-1, *A*). Other implant systems are designed to be placed at the level of bone, require a healing abutment to be attached to the implant at the time of placement to be used in a one-stage approach[8] (Figure 75-1, *B*).

A one-stage surgical approach simplifies the procedure because a second-stage exposure surgery is not necessary. The two-stage, submerged approach is advantageous for situations that require simultaneous bone augmentation procedures at the time of implant placement because membranes can be submerged, which will minimize postoperative exposure. Mucogingival tissues can be augmented if desired at the second-stage surgery in a two-stage protocol or as part of the one-stage protocol. Fundamental differences in flap management for these two surgical techniques are described separately.

Two-Stage "Submerged" Implant Placement

In the two-stage implant surgical approach, the first-stage or implant placement surgery ends by suturing the soft tissues together over the implant cover screw so that it remains submerged and isolated from the oral cavity. In areas with dense cortical bone and good initial implant support, the implants are left to heal undisturbed for a period of 2 to 4 months, whereas in areas of loose trabecular bone, grafted sites, and sites with lesser implant stability, implants may be allowed to heal for periods of 4 to 6 months or more. Longer healing periods are indicated for implants in sites with less bone support. During healing, osteoblasts migrate to the surface and form bone adjacent to the implant (osseointegration).[6] Shorter healing periods are indicated for implants placed in good quality (dense) bone and for implants with an altered surface microtopography (e.g., acid etched, blasted, or etched and blasted). Readers are referred to online material and other resources for more information about implant surface microtopography.

In the second-stage (exposure) surgery, the implant is uncovered and a healing abutment is connected to allow emergence of the abutment through the soft tissues. Once healed, the restorative dentist then proceeds with the prosthodontic aspects of the implant therapy (impressions and fabrication of prosthesis).

The following paragraphs describe the steps for osteotomy preparation and the first-stage implant placement surgery of the two-stage protocol. Figures 75-2 and 75-3 illustrate the procedures via diagrams, and Figure 75-4 depicts the procedures with clinical photographs.

Flap Design, Incisions, and Elevation

Flap management for implant surgery varies slightly, depending on the location and objective of the planned surgery. There are different incision/flap designs but the most common is the crestal flap design. The incision is made along the crest of the ridge, bisecting the existing zone of keratinized mucosa (see Figures 75-2, *A,* and 75-4, *B*).

A remote incision with a layered suturing technique may be used to minimize the incidence of bone graft exposure when extensive bone augmentation is planned. The crestal incision, however, is preferred in most cases, because closure is easier to manage and typically results in less bleeding, less edema, and faster healing.[10]

A full-thickness flap is raised (buccal and lingual) up to or slightly beyond the level of the mucogingival junction, exposing the alveolar ridge of the implant surgical sites (see Figures 75-2, *B,* and 75-4, *C*). Elevated flaps may be sutured to the buccal mucosa or the opposing teeth to keep the surgical site open during the surgery. The bone at the implant site(s) must be thoroughly debrided of all granulation tissue.

For a "knife-edge" alveolar process with sufficient alveolar bone height and distance from vital structures (e.g., inferior alveolar nerve), a large round bur is used to recontour or flatten the bone to provide a wider, level surface for the implant site preparation (see Figure 75-2, *B*). However, if the vertical height of the alveolar bone is limited (e.g., <10 mm), the knife-edge alveolar bone height

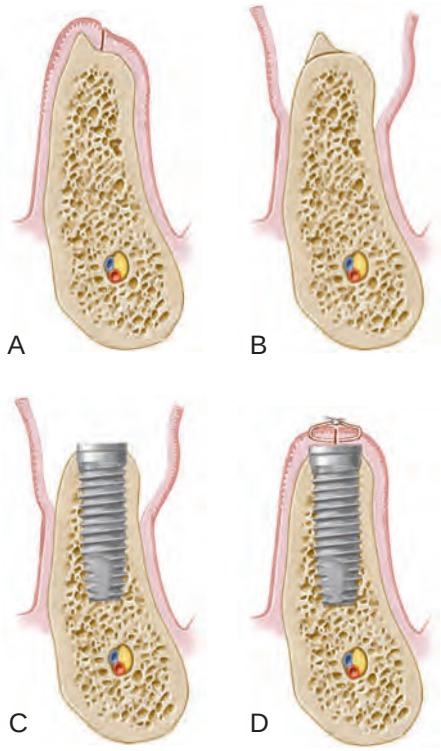

Figure 75-2 Tissue management for a two-stage implant placement. A, Crestal incision made along the crest of the ridge, bisecting the existing zone of keratinized mucosa. **B,** Full-thickness flap is raised buccally and lingually to the level of the mucogingival junction. A narrow, sharp ridge can be surgically reduced/contoured to provide a reasonably flat bed for the implant. **C,** Implant is placed in the prepared osteotomy site. **D,** Tissue approximation to achieve primary flap closure without tension.

should be preserved. Bone augmentation procedures can be used to increase the ridge width while preserving alveolar bone height (see Chapter 76).

Implant Site Preparation

Once the flaps are reflected and the bone is prepared (i.e., all granulation tissue removed and knife-edge ridges flattened), the implant osteotomy site can be prepared. A series of drills are used to prepare the osteotomy site precisely and incrementally for an implant (Figure 75-5). A surgical guide or stent is inserted, checked for proper positioning, and used throughout the procedure to direct the proper implant placement (see Figure 75-4, *E*).

Round Bur. A small round bur (or spiral drill) is used to make the initial penetration into bone for the implant site(s). The surgical guide is removed, and the initial marks are checked for their appropriate buccal-lingual and mesial-distal location, as well as the positions relative to each other and adjacent teeth (see Figure 72-9). Slight modifications may be necessary to adjust spatial relationships and to avoid minor ridge defects. Any changes should be compared to the prosthetically driven surgical guide positions. Each marked site is then prepared to a depth of 1 to 2 mm with a round drill, breaking through the cortical bone and creating a starting point for the 2-mm twist drill (see Figure 75-3, *A*).

The 2-mm Twist Drill. A small twist drill, usually 2 mm in diameter and marked to indicate various lengths (i.e., corresponding to the implant sizes), is used next to establish the depth and align the long axis of the implant recipient site (see Figure 75-3, *B*). This drill may be externally or internally irrigated. In either case, the twist drill is used at a speed of approximately 800 to 1500 rpm, with copious irrigation to prevent overheating of the bone. Additionally, drills should be intermittently and repeatedly "pumped" or pulled out of the osteotomy site while drilling to expose them to the water coolant and to facilitate clearing bone debris from the cutting surfaces. In other words, clinicians should pump the drill (up and down) intermittently and avoid using a constant "push" of the drill in the apical direction only.

When multiple implants are being placed next to one another, a guide pin should be placed in the prepared sites to check alignment, parallelism, and proper prosthetic spacing throughout the preparation process (see Figure 75-3, *C*). The relationship to neighboring vital structures (e.g., nerve and tooth roots) can be determined by taking a periapical radiograph with a guide pin(s) or radiographic marker(s) in the osteotomy site(s) (see Figure 73-15). Implants should be positioned with approximately 3 mm between one another to ensure sufficient space for interimplant bone and soft-tissue health and to facilitate oral hygiene procedures. Therefore, the initial marks should be separated by at least 7 mm (center to center) for 4 mm standard-diameter implants. Incrementally more space is needed for wide-diameter implants (see Figure 72-9).

The 2-mm twist drill is used to establish the final depth of the osteotomy site corresponding to the length of each planned implant. The clinician should also evaluate the bone quality (density) with this drill while preparing the osteotomy to assess the need for modification of subsequent drills used (Box 75-2). If the vertical height of the bone was reduced during the initial ridge preparation, this must be taken into account when preparing the site for a predetermined implant length. For example, if it appears that the implant will be too close to a vital structure, such as the inferior alveolar nerve canal, the depth of the implant osteotomy site and length of the implant may need to be reduced.

The next step is to use a series of drills to incrementally increase the width of the osteotomy site to accommodate the planned implant diameter. The styles, shapes, and final diameter of the drills will differ slightly among different implant systems, but their general purpose is to prepare a recipient site with a precise diameter (and depth) for the selected implant without unduly traumatizing the surrounding bone. It is important to use copious irrigation and a "pumping" action for all drilling.

Pilot Drill. Following the 2-mm twist drill, a pilot drill with a noncutting 2-mm–diameter "guide" at the apical end and a cutting 3-mm–diameter (wider) midsection is used to enlarge the osteotomy site at the coronal end, thus facilitating the insertion of the subsequent drill in the sequence (see Figure 75-3, *D*).

The 3-mm Twist Drill. The final drill in the osteotomy site preparation for a standard-diameter (4.0 mm) implant is the 3-mm twist drill. It is the last drill used to widen the site along the entire depth of the osteotomy from the previous diameter (2 mm) to final diameter (3 mm). This final drill in the sequence finishes preparing the osteotomy site and consequently is the step that dictates whether the implant will be stable or not (see Figure 75-3, *E*). It is critically important that the final diameter drilling be accomplished with a steady hand, without wobbling or changing direction so that the site is not overprepared. Finally, depending on bone density, the diameter of this final drill may be slightly increased or decreased to enhance implant support (see Box 75-2).

Countersink Drill (Optional). When it is desirable to place the cover screw at or slightly below the crestal bone, countersink drilling is used to shape or flare the crestal aspect of the osteotomy

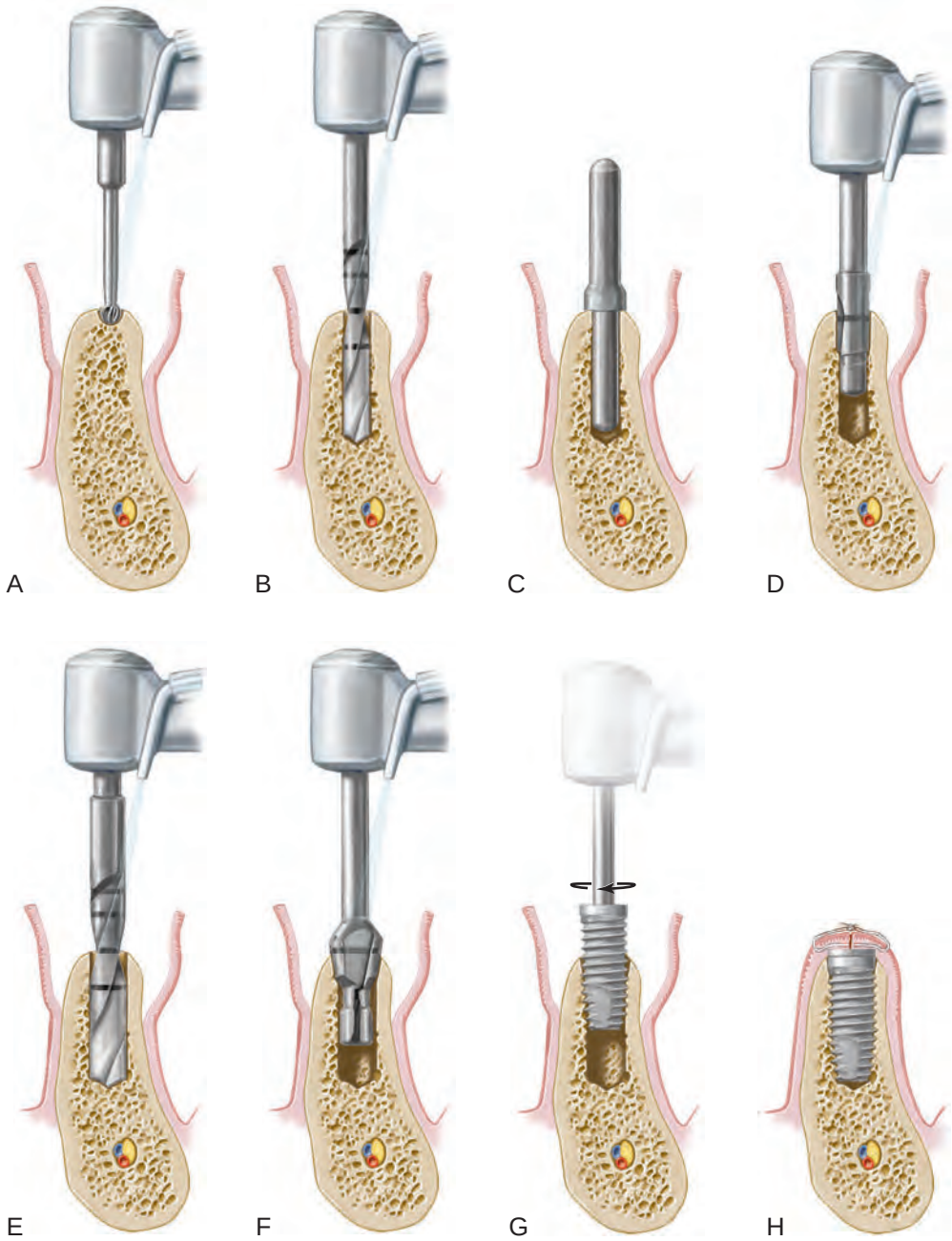

Figure 75-3 Implant site preparation (osteotomy) for a 4.0-mm diameter, 10-mm length screw-type, threaded (external hex) implant in a subcrestal position. A, Initial marking or preparation of the implant site with a round bur. **B,** Use of a 2-mm twist drill to establish depth and align the implant. **C,** Guide pin is placed in the osteotomy site to confirm position and angulation. **D,** Pilot drill is used to increase the diameter of the coronal aspect of the osteotomy site. **E,** Final drill used is the 3-mm twist drill to finish preparation of the osteotomy site. **F,** Countersink drill is used to widen the entrance of the recipient site and allow for the subcrestal placement of the implant collar and cover screw. *Note:* An optional tap (not shown) can be used following this step to create screw threads in areas of dense bone. **G,** Implant is inserted into the prepared osteotomy site with a handpiece or handheld driver. *Note:* In systems that use an implant mount, it would be removed prior to placement of the cover screw. **H,** Cover screw is placed and soft tissues are closed and sutured.

site allowing the coronal flare of the implant head and cover screw to fit within the osteotomy site (see Figure 75-3, *F*). As with all drills in the sequence, copious irrigation and gentle surgical techniques are used.

Bone Tap (Optional). As the final step in preparing the osteotomy site in dense cortical bone, a tapping procedure may be necessary (not shown). With self-tapping implants being almost universal, there is less need for a tapping procedure in most sites. However, in dense cortical bone or when placing longer implants into moderately dense bone, it is prudent to tap the bone (create threads in the osteotomy site) before implant placement to facilitate implant insertion and to reduce the risk of implant binding (see Figure 75-3, *G*).

Clinical Comment: When faced with a very soft, poor-quality bone (e.g., loose trabecular bone in the posterior maxilla), tapping is not necessary or recommended (see Box 75-2). It is better to allow the threaded implant to "cut" its own path into the osteotomy site.

Bone tapping and implant insertion are both done at very slow speeds (e.g., 20 to 40 rpm). All other drills in the sequence are used at higher speeds (800 to 1500 rpm).

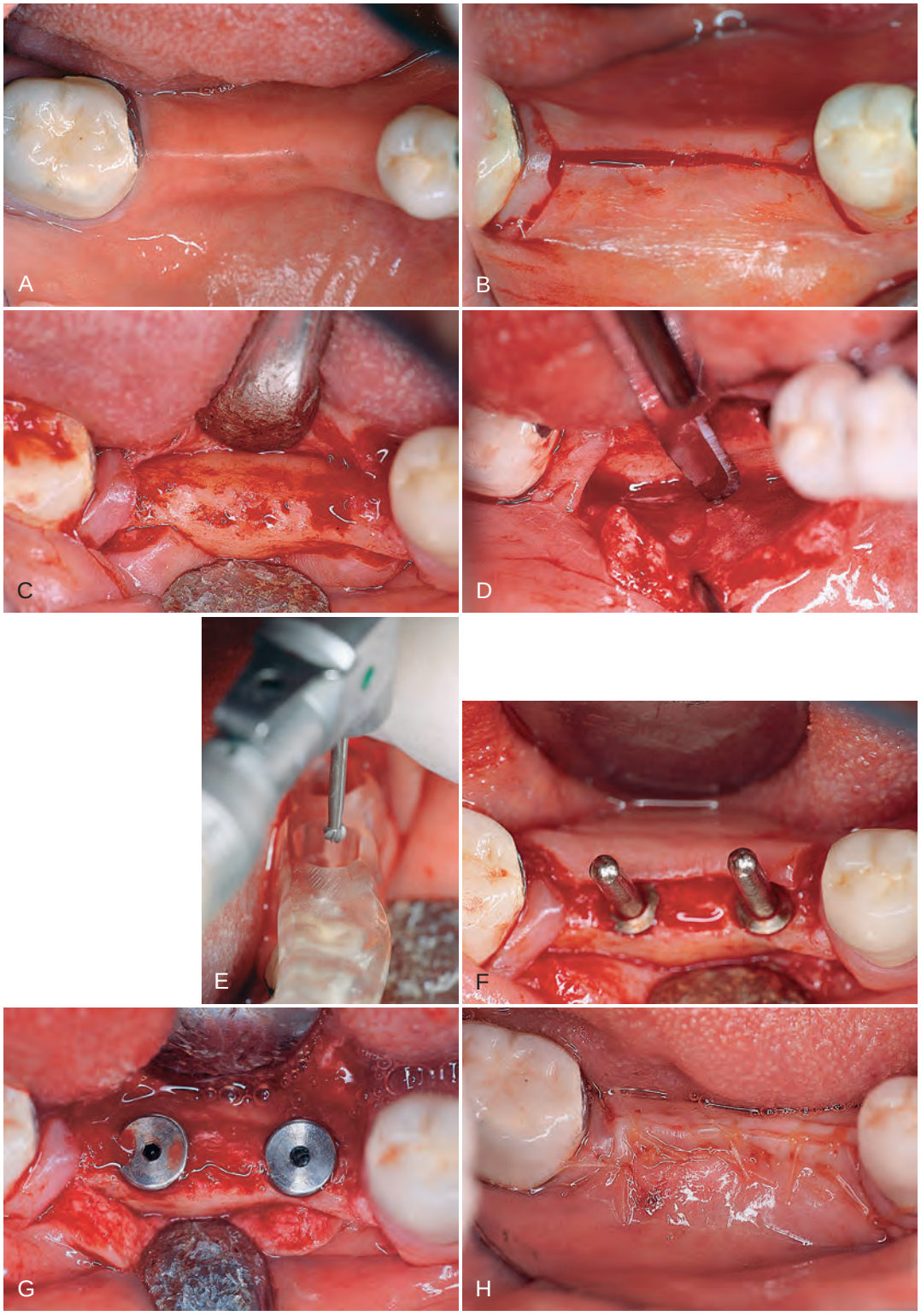

Figure 75-4 Clinical view of stage one implant placement surgery. A, Partial edentulous ridge; presurgical and prosthodontic treatment has been completed. **B,** Mesial sulcular and distal vertical incisions are connected by a crestal incision. Notice that bands of gingival collars remain adjacent to the distal molar tooth. **C,** Minimal flap reflection is used to expose the alveolar bone. Sometimes a ridge modification is necessary to provide a flap recipient bed. **D,** Buccal flap is partially dissected at the apical portion to provide a flap extension. This is a critical step to ensure a tension-free closure of the flap after implant placement. **E,** It is important to use the surgical stent to determine the mesial-distal and buccal-lingual dimensions and proper angulation of the implant placement. **F,** Frequent use of the guide pins ensures parallelism of the implant placement. **G,** After placement of two Nobelpharma implants, the cover screws are placed. The cover screws should be flush with the rest of the ridge to minimize the chance of exposure. This is especially important if the patient will wear a partial denture during the healing phase. **H,** Suturing completed. Both regular interrupted and inverted mattress sutures are used intermittently to ensure tension-free, tight closure of the flaps.



Figure 75-5 Sequence of drills used for standard-diameter (4.0-mm) implant site osteotomy preparation: round, 2-mm twist, pilot, 3-mm twist, and countersink. Bone tap (not shown here) is an optional drill that is sometimes used in dense bone before implant placement.

BOX 75-2 Clinical Advice to Enhance Precision of Final Implant Site Preparation

Clinical Situation 1

If the final drill hits the bottom of the recipient site before reaching the desired depth, the added hand pressure necessary to achieve the proper depth often causes wobbling and funneling of the recipient site. This is especially true with "cannon" drills (used for cylindrical implants). To minimize this effect, a smaller-diameter drill should be used to prepare the site slightly deeper (e.g., 0.5 mm or less). This narrower drill allows the desired depth to be reached without affecting the side walls and facilitates a more precise osteotomy preparation with the final drill.

Clinical Situation 2

If the final drill is inserted at an inaccurate angle, the result is funneling of the coronal portion of the implant site. To minimize this potential problem, when drilling multiple implant sites, the operator should always keep a direction indicator in an adjacent site. For single-implant sites, the adjacent teeth and surgical guide should serve as direction indicators. When dealing with dense bone, a precise recipient site can be achieved more predictably if there is minimal diameter change from drill to drill. For example, switching from 3.0 to 5.0 mm is much less precise than proceeding from 3.0 to 3.3 to 4.2 to 5.0 mm.

Clinical Situation 3

If the bone is "soft" (e.g., loose trabecular bone), it may be advantageous to underprepare the osteotomy site. A slightly underprepared site can be accomplished by using the final drill to a shallower depth than the previous drill (e.g., half the depth of the osteotomy site). This avoids removing too much bone and increases the implant stability or tightness at the time of placement. Another method to achieve an underprepared site is to use a drill with a slightly smaller diameter as the final drill in the preparation (e.g., a 2.75-mm drill as the final drill rather than a 3.0 mm or a 3.25 mm as the final drill for a 4.0-mm implant).

It is important to create a recipient site that is very accurate in size and angulation. In partially edentulous cases, limited jaw opening or proximity to adjacent teeth may prevent appropriate positioning of the drills in posterior edentulous areas. In fact, implant therapy may be contraindicated in some patients because of a lack of interocclusal clearance, lack of interdental space, or a lack of access for the instrumentation. Therefore, a combination of longer drills and shorter drills, with or without extensions, may be necessary. Anticipating these needs before surgery facilitates the procedure and improves the results.

Implant Placement. Implants are inserted with a handpiece rotating at slow speeds (e.g., 25 rpm) or by hand with a wrench. Insertion of the implant must follow the same path or line as the osteotomy site. When multiple implants are being placed, it is helpful to use guide pins in the other sites to have a visual guide for the path of insertion.

Flap Closure and Suturing

Once the implants are inserted and the cover screws secured (see Figure 75-4, *G*), the surgical sites should be thoroughly irrigated with sterile saline to remove debris and clean the wound. Proper closure of the flap over the implant(s) is essential. One of the most important aspects of flap management is achieving good approximation and primary closure of the tissues in a tension free manner (see Figure 75-3, *H*). This is achieved by incising the periosteum (innermost layer of full-thickness flap), which is nonelastic. Once the periosteum is released, the flap becomes very elastic and is able to be stretched over the implant(s) without tension. One suturing technique that consistently provides the desired result is a combination of alternating horizontal mattress and interrupted sutures (see Figure 75-4, *H*). Horizontal mattress sutures evert the wound edges and approximate the inner, connective tissue surfaces of the flap to facilitate closure and wound healing. Interrupted sutures help to bring the wound edges together, counterbalancing the eversion caused by the horizontal mattress sutures.

The clinician should choose an appropriate suture for the given patient and procedure. For patient management, it is sometimes simpler to use a resorbable suture that does not require removal during the postoperative visit (e.g., 4-0 chromic gut suture). However, when moderate-to-severe postoperative swelling is anticipated, a nonresorbable suture is recommended to maintain a longer closure period (e.g., 4-0 monofilament suture). These sutures require removal at a postoperative visit.

Postoperative Care

Simple implant surgery in a healthy patient usually does not require antibiotic therapy. However, antibiotics (e.g., amoxicillin, 500 mg three times a day [tid]) can be prescribed if the surgery is extensive, or if the patient is medically compromised. Postoperative swelling is likely after flap surgery. This is particularly true when the periosteum has been incised (released). As a preventive measure, patients should apply cold packs over the first 24 to 48 hours. Chlorhexidine gluconate oral rinses can be prescribed to facilitate plaque control, especially in the days after surgery when oral hygiene is typically poorer. Adequate pain medication should be prescribed (e.g., ibuprofen, 600 to 800 mg tid).

Patients should be instructed to maintain a relatively soft diet after surgery. Then, as healing progresses, they can gradually return to a normal diet. Patients should also refrain from tobacco and alcohol use after surgery. Provisional restorations, whether fixed or removable, should be checked and adjusted to minimize trauma to the surgical area.

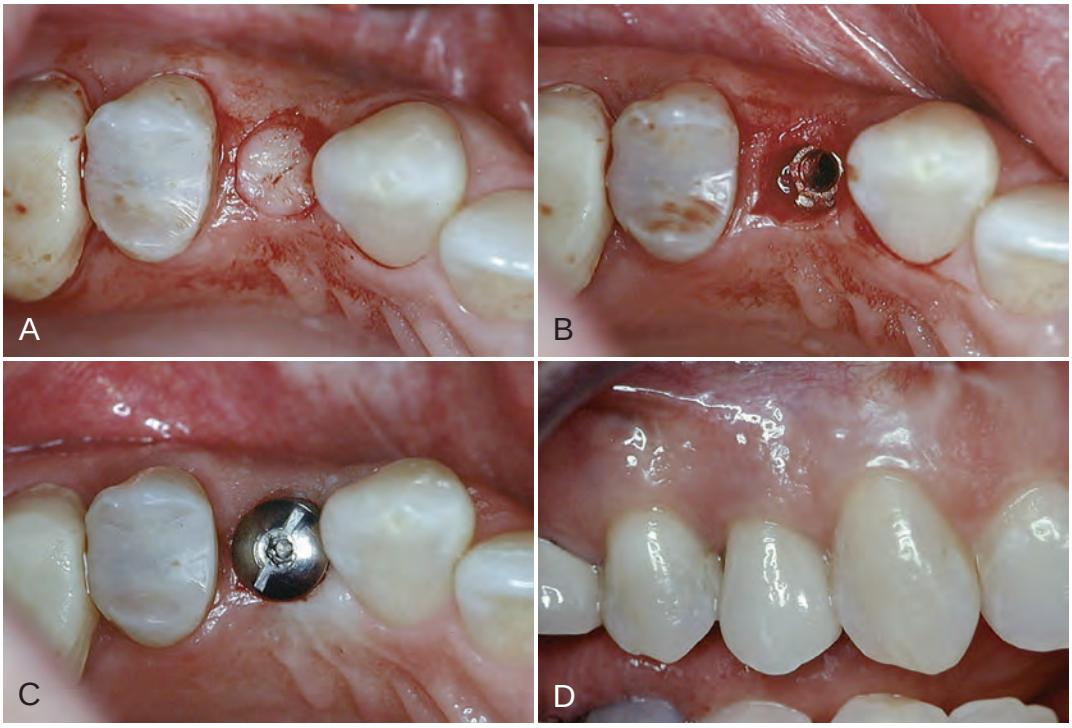

Figure 75-6 Clinical view of second-stage implant exposure surgery in a case with adequate keratinized tissue. A, Simple circular "punch" incision used to expose implant when sufficient keratinized tissue is present around the implant(s). **B,** Implant exposed. **C,** Healing abutment attached. **D,** Final restoration in place, achieving an esthetic result with a good zone of keratinized tissue.

BOX 75-3 Objectives of Second-Stage Implant Surgery

1. To expose the submerged implant without damaging the surrounding bone.
2. To control the thickness of the soft tissue surrounding the implant.
3. To preserve or create attached keratinized tissue around the implant.
4. To facilitate oral hygiene.
5. To ensure proper abutment seating.
6. To preserve soft-tissue esthetics.

Second-Stage Exposure Surgery

For implants placed using a two-stage "submerged" protocol, a second-stage exposure surgery is necessary. Box 75-3 lists the objectives for second-stage implant exposure surgery. The need for a zone of keratinized tissue surrounding implants is desirable, as one long-term study indicated that the presence of keratinized tissue is strongly correlated with soft- and hard-tissue health.[2]

Simple Circular "Punch" or Crestal Incision. In areas with sufficient zones of keratinized tissue, the gingiva covering the head of the implant can be exposed with a circular or "punch" incision (Figure 75-6). Alternatively, a crestal incision through the middle of the keratinized tissue and full-thickness flap reflection can be used to expose implants.

Partial-Thickness Repositioned Flap. If a minimal zone of keratinized tissue exists at the implant site, a partial-thickness flap technique can be used to fulfill the objective of the second-stage surgery (exposing the implant) while increasing the width of keratinized tissue. The initial incision is made within the zone of keratinized tissue so that it becomes the outer edge of the reflected split-thickness flap. Vertical releasing incisions are used on both the mesial and the distal end of the flap (Figure 75-7, *A* and *B*). A partial-thickness flap is then raised in such a manner that a nonmobile, firm periosteum remains attached to the underlying bone. The flap, containing a narrow band of keratinized tissue, is then repositioned to the facial side of the emerging head of the implant and sutured to the periosteum with a fine needle and resorbable suture such as a 5-0 gut suture (Figure 75-8). If the initial amount of keratinized tissue is less than 2 mm, the flap may be started at the labial edge of the keratinized tissue allowing that zone to remain on the lingual aspect of the implant. A partial-thickness flap is apically displaced and sutured to the periosteum without exposing the alveolar bone (Figure 75-7, *C*). A free gingival graft may be harvested from the palate and sutured to the periosteum on the labial surface of the implants to increase the zone of keratinized tissue (not shown).

After the flap is repositioned and secured with periosteal sutures, the excess tissue coronal to the cover screw is excised, usually with a surgical blade (see Figure 75-8, *B*). However, if removal of this tissue would jeopardize the amount of remaining keratinized tissue around the lingual aspect of the implant(s), a similar partial-thickness flap can be elevated and repositioned on the lingual side as well. Extra care must be taken when creating a split-thickness flap on the lingual surface of mandibular sites because the tissue is often very thin. Alternatively, a full-thickness lingual flap will be safer and will serve a similar purpose of preserving keratinized tissue on the lingual surface of the implant(s).

When the excess tissue over the cover screw is removed or displaced, the outline of the cover screw is visible. A sharp blade is used to eliminate all tissues coronal to the cover screw (see Figure 75-7, *D*). The cover screw is then removed, the head of the implant is thoroughly cleaned of any soft- or hard-tissue overgrowth, and the healing abutments or standard abutments are placed on the implant (see Figure 75-7, *E* and *F*). The fit of the healing abutments to the implants can often be visually evaluated. However, if it is not possible to visualize clearly the intimate

Figure 75-7 Clinical view of second-stage implant exposure surgery in a case with inadequate keratinized tissue. A, Two endosseous implants were placed 4 months previously and are ready to be exposed. Note the narrow band of keratinized tissue. **B,** Two vertical incisions are connected by crestal incision. If facial keratinized tissue is insufficient, it is necessary to locate the crestal incision more lingually so that there is at least 2 to 3 mm of keratinized band. **C,** Buccal partial-thickness flap is sutured to the periosteum apical to the emerging implants. **D,** Gingival tissue coronal to the cover screws is excised using the gingivectomy technique. **E,** Cover screws are removed, and heads of the implants are cleared. **F,** Abutments are placed. Visual inspection ensures intimate contact between the abutments and the implants. **G,** Healing at 2 to 3 weeks after second-stage surgery. **H,** Four months after the final restoration. Note the healthy band of keratinized attached gingiva around the implants.

connection between the implant and the abutment, an intraoral periapical x-ray film should be taken to confirm complete seating. Bone may need to be removed around the top of the implant to get the abutment to seat properly. Readers are referred to online material for a discussion of bone profiling.

Postoperative Care. Once the implant is exposed and soft tissues are sutured, it is important to remind the patient of the need for good oral hygiene around the implant and adjacent teeth. Care should be taken during oral hygiene procedures to avoid dislodging any repositioned or grafted soft tissues. Direct pressure or movement directed toward the soft tissue from a provisional prosthesis can delay healing and should be avoided. Tissues should be monitored regularly and the provisional prosthesis should be adjusted as needed. Impressions for the final prosthesis fabrication can begin about 2 to 6 weeks after implant exposure surgery, depending on healing and maturation of soft tissues. Figure 75-7, *G* and *H*, shows the postoperative results in a clinical case after 2 to 3 weeks and 4 months, respectively.

One-Stage "Nonsubmerged" Implant Placement

In the one-stage implant surgical approach, a second implant exposure surgery is not needed because the implant is exposed (per gingival) from the time of implant placement (Figure 75-9). In the standard (classic) implant protocol, the implants are left unloaded and undisturbed for a period similar to that for implants placed in the two-stage approach (i.e., in areas with dense cortical bone and good initial implant support, the implants are left to heal undisturbed for a period of 2 to 4 months, whereas in areas of loose trabecular bone, grafted sites, and/or minimal implant support, they may be allowed to heal for periods of 4 to 6 months or more).

In the one-stage surgical approach, the implant or the healing abutment protrudes approximately 2 to 3 mm from the bone crest, and the flaps are adapted around the implant/abutment. As with the second-stage surgical procedures described, the soft tissues may be thinned, repositioned, or augmented at the implant placement surgery to increase the zone of keratinized tissue surrounding the implant(s).

Flap Design, Incisions, and Elevation

The flap design for the one-stage surgical approach is always a crestal incision bisecting the existing keratinized tissue (see Figure 75-9). Vertical incisions may be needed at one or both ends to facilitate access to the bone or osteotomy site. Tissues can be thinned in posterior areas if desired but are generally not thinned in anterior esthetic areas. Full-thickness flaps are elevated facially and lingually.

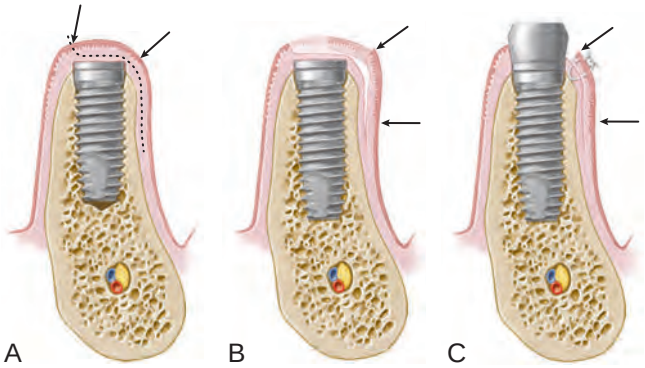

Figure 75-8 Illustration depicting the use of a split-thickness flap that is repositioned to the labial surface in order to preserve and increase the amount of keratinized tissue. A, Partial-thickness flap is created from the lingual aspect of the crest toward the labial surface in order to preserve the keratinized tissue on the crest (over the implant). *Note:* This tissue might be excised in a simple implant exposure. **B,** The split-thickness flap is repositioned to the labial surface. **C,** The flap is sutured to the periosteum at a more apical position preserving the amount of keratinized tissue *(arrows)*. Finally, the remaining connective tissue over the cover screw **(B)** is excised with a sharp blade to expose the implant. Care should be taken to avoid removing keratinized tissue from the lingual aspect of the implant.

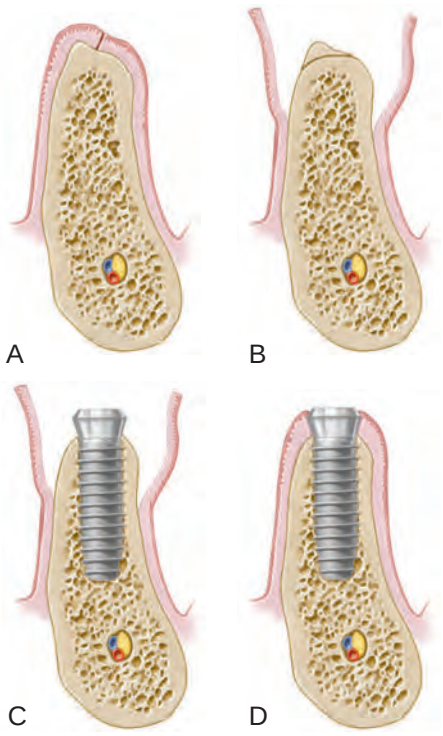

Figure 75-9 Tissue management for a one-stage implant placement. A, Crestal incision made along the crest of the ridge, bisecting the existing zone of keratinized mucosa. **B,** Full-thickness flap is raised buccally and lingually to the level of the mucogingival junction. A narrow, sharp ridge can be surgically reduced or contoured to provide a reasonably flat bed for the implant. **C,** Implant is placed in the prepared osteotomy site. **D,** Tissues are adapted around the neck of the implant to achieve flap closure with the implant protruding through the soft tissues.

Implant Site Preparation

Implant site preparation for the one-stage approach is identical in principle to the two-stage implant surgical approach. The primary difference is that the coronal aspect of the implant or the healing abutment (two-stage implant) is placed approximately 2 to 3 mm above the bone crest and the soft tissues are approximated around the implant/implant abutment.

Flap Closure and Suturing

The keratinized edges of the flap are sutured with single interrupted sutures around the implant. Depending on the clinician's preference, the wound may be sutured with resorbable or nonresorbable sutures. When keratinized tissue is abundant, scalloping around the implant(s) provides better flap adaptation.

Postoperative Care

The postoperative care for one-stage surgical approach is similar to that for the two-stage surgical approach except that the cover screw or healing abutment is exposed to the oral cavity. Patients are advised to avoid chewing in the area of the implant(s). Prosthetic appliances should not be used if direct chewing forces can be transmitted to the implant, particularly in the early healing period (first 4 to 8 weeks). When removable prosthetic appliances are used, they should be adequately relieved and a soft-tissue liner should be applied.

Conclusion

It is essential to understand and follow basic guidelines to predictably achieve osseointegration. Fundamental protocols must be followed for implant placement (stage one) and implant exposure surgery (stage two). These fundamentals apply to all implant systems.

Suggested Readings

De Bruyn H, Koole S, Mattheos N, et al: A survey on undergraduate implant dentistry education in Europe. *Eur J Dent Educ* 13(Suppl 1):3–9, 2009.

Klokkevold PR: Implant education in the dental curriculum. *J Calif Dent Assoc* 29(11):747–755, 2001.

Mattheos N, Albrektsson T, Buser D, et al: Teaching and assessment of implant dentistry in undergraduate and postgraduate education: a European consensus. *Eur J Dent Educ* 13(Suppl 1):11–17, 2009.

Petropoulos VC, Arbree NS, Tarnow D, et al: Teaching implant dentistry in the predoctoral curriculum: a report from the ADEA Implant Workshop's survey of deans. *J Dent Educ* 70(5):580–588, 2006.

References

References for this chapter are found on the companion website www.expertconsult.com.

References

1. Adell R, Lekholm U, Rockler B, et al: A 15-year study of osseointegrated implants in the treatment of the edentulous jaw. *Int J Oral Surg* 10:387–416, 1981.
2. Block MS, Kent JN: Factors associated with soft- and hard-tissue compromise of endosseous implants. *J Oral Maxillofac Surg* 48:1153–1160, 1990.
3. Brånemark P, Zarb GA, Albrektsson T: *Tissue-integrated prostheses*, Chicago, 1985, Quintessence.
4. Brånemark PI, Adell R, Breine U, et al: Intra-osseous anchorage of dental prostheses. I. Experimental studies. *Scand J Plast Reconstr Surg* 3:81–100, 1969.
5. Brånemark PI, Hansson BO, Adell R, et al: Osseointegrated implants in the treatment of the edentulous jaw. Experience from a 10-year period. *Scand J Plast Reconstr Surg Suppl* 16:1–132, 1977.
6. Brånemark PI, Zarb G, Albrektsson T: *Tissue-integrated prothesis*, Chicago, 1987, Quintessence.
7. Brunski JB: Biomechanics of oral implants: future research directions. *J Dent Educ* 52:775–787, 1988.
8. Buser D, Weber HP, Bragger U: The treatment of partially edentulous patients with ITI hollow-screw implants: presurgical evaluation and surgical procedures. *Int J Oral Maxillofac Implants* 5:165–175, 1990.
9. Jaffin RA, Berman CL: The excessive loss of Brånemark fixtures in type IV bone: a 5-year analysis. *J Periodontol* 62:2–4, 1991.
10. Scharf DR, Tarnow DP: The effect of crestal versus mucobuccal incisions on the success rate of implant osseointegration. *Int J Oral Maxillofac Implants* 8:187–190, 1993.
11. Schroeder A, van der Zypen E, Stich H, et al: The reactions of bone, connective tissue, and epithelium to endosteal implants with titanium-sprayed surfaces. *J Maxillofac Surg* 9:15–25, 1981.
12. Watanabe F, Tawada Y, Komatsu S, et al: Heat distribution in bone during preparation of implant sites: heat analysis by real-time thermography. *Int J Oral Maxillofac Implants* 7:212–219, 1992.

CHAPTER 76

Localized Bone Augmentation and Implant Site Development

Perry R. Klokkevold

CHAPTER OUTLINE

Guided Bone Regeneration *(e-only)*
Localized Ridge Augmentation
Alveolar Ridge Preservation/Management of Extractions
Conclusion

For online-only content on guided bone regeneration, please visit the companion website at www.expertconsult.com. Some figures may be out of numeric order in this printed chapter.

One of the most critical aspects of creating an esthetic implant restoration is surgical placement of the implant in a "prosthetically driven" position to restore the tooth in a natural position and to emulate the natural emergence of the tooth from the soft tissues. Implants placed without regard for prosthetic position often lead to dental restorations that are functionally and esthetically compromised, and patients are left with a less-than-optimal reconstruction. Placement of dental implant(s) in an esthetically and functionally optimal position requires reconstruction of deficient alveolar ridges (or preservation of ridges when teeth are to be extracted).

Periodontal bone loss, gingival recession, tooth loss, and long-term use of removable appliances typically result in alveolar defects that prevent the placement of implants in an optimal prosthetic position. It also leads to soft-tissue deficiencies that are unacceptable. Fortunately, continuous innovations in surgical techniques and advances in the biologic understanding of bone-regenerative techniques have led to advanced implant procedures and an increased predictability in the reconstruction of alveolar ridge defects.[27,38]

Standard implant placement surgery, as described in Chapter 75, is based on adequate bone volume and quality in the desired implant location. The time-tested standard protocol allows for adequate remodeling and maturation of bone, with healing periods of 3 to 6 months. Recent implant procedures often challenge these original conventions by placing implants in areas with inadequate bone volume, simultaneous with bone augmentation, and restoring or loading implants after shorter healing periods. This chapter presents an overview of surgical bone augmentation procedures used to correct or to prevent alveolar ridge deficiencies for the optimal placement of dental implants.

For a discussion of guided bone regeneration, please visit the companion website at www.expertconsult.com.

Localized Ridge Augmentation

Patients often present for implant planning after tooth loss and alveolar ridge resorption. In these cases, the clinician is obligated to perform augmentation procedures to reconstruct lost bone and place implants in a prosthetically driven position.

Surgical reconstructive procedures for the preparation and placement of dental implants have become more numerous and complex. Depending on the size and morphology of the defect, various augmentation procedures can be used. These procedures have been categorized according to the deficient dimension: horizontal or vertical. Methods used to augment horizontal, as well as vertical, bone deficiencies include particulate bone grafts and monocortical block grafts. Barrier membranes can be used with bone grafts to reconstruct all types of alveolar bone defects. See Chapter 77 for a review of procedures used to achieve vertical augmentation. All the proven principles of GBR and flap management must be followed to achieve good results. These include an adequate blood supply; maintaining a stable, protected space for bone growth; and achieving tension-free flap wound closure.

Flap Management

Soft-tissue management is a critical aspect of bone augmentation procedures. Incisions, reflection, and manipulation should be designed to optimize blood supply and wound closure. The design and management of mucoperiosteal flaps must consider the increased dimensions of the ridge after augmentation as well as esthetics and approximation of the wound margins. The surgical procedure must be executed with the utmost of care in order to preserve the vascularity of the flap and to minimize tissue injury.[1]

Several flap techniques maintain a "submerged" position of bone grafts and barrier membranes during the entire healing process, including a remote or displaced incision.[9,25] The advantage of a remote incision is that the wound opening is positioned away from the graft. A conventional crestal incision can be used, even in large supracrestal defects, as long as a periosteal releasing incision and coronal advancement of the flap achieve a tension-free closure.[30] Most reports suggest removing sutures approximately 10 to 14 days after surgery. It is also suggested that no prosthesis be

Guided Bone Regeneration

Much of what can be achieved with implant surgery and specifically with bone augmentation procedures is directly related to the achievements and understanding of guided bone regeneration (GBR). Historically, augmentation or "regeneration" of alveolar bone that was lost following tooth removal, or from alveolar bone resorption or traumatic injury, presented a significant challenge for clinicians. Allowed to heal without the intervention of regenerative procedures, extraction site defects (especially those lacking a self-supporting bone structure) heal with fibrous connective tissue or scar formation and often did not fill completely with bone. The surrounding soft tissues collapsed into the bone defect, leaving an alveolar ridge deficiency with respect to the natural tooth position and jaw shape. Over time, the alveolar ridge continued to resorb, especially when removable prosthetic appliances are used.

Periodontal studies during the last several decades have led to new techniques and a new treatment approach referred to as guided tissue regeneration (GTR). Briefly, this concept is based on the principle that specific cells contribute to the formation of specific tissues. Exclusion of the faster-growing epithelium and connective tissue from a periodontal wound for a minimum of 6 to 8 weeks allows the slower-growing tissues to occupy the space adjacent to the tooth. Osteoblasts, cementoblasts, and periodontal ligament cells are then afforded the opportunity to regenerate a new periodontal attachment (defined by new bone and new connective tissue fibers inserted into newly formed cementum) on the previously diseased root surface. Chapter 61 includes a discussion on the concepts of GTR as related to periodontal regeneration.

The same basic principle of GTR has been applied to alveolar bone defects to regenerate new bone.[13] Using a canine model, Schenk et al[47] demonstrated with histology that bone regeneration in membrane-protected defects healed in a sequence of steps that simulated bone formation after tooth extraction. They found that after blood clot formation, bone regeneration was initiated by the formation of woven bone initially along new blood vasculature at the periphery of the defect. The new vascular supply emanated from the existing bone bed (recipient site). Cortical perforations surgically created in the recipient site are thought to enhance the blood supply and cellular access to the bone grafted area. The woven bone, which is formed quickly with a disorganized, immature structure, was subsequently replaced by lamellar bone with an organized, mature structure. Over time, bone remodeling continued with new, secondary osteons being formed.

This concept employed the same principles of specific tissue exclusion but was not associated with teeth. Rather, it was bone that was being isolated from the surrounding soft tissues. Thus the term applied to this technique was GBR. Because the objective of GBR is to regenerate a single tissue, namely bone, it is theoretically easier to accomplish than GTR, which strives to regenerate multiple tissues simultaneously in a complex relationship.

Interestingly, long before the current concepts of GBR were introduced, Murray and coworkers[40] demonstrated that when a cavity with a source of osteoblasts and a blood supply was isolated from adjacent soft tissues, it could fill with bone, whereas if the space were not protected, it would fill with fibrous connective tissue. In addition to this observation, they suggested that a bone graft placed in the space might interfere with bone formation because the graft would need to be resorbed before bone could occupy the space.

Bone is a unique tissue that has the capacity to regenerate itself completely. Because of its rigid calcified structure, however, bone has specific requirements that must be respected to achieve regeneration. Because the calcified structure of bone is not conducive to perfusion, new bone formation is critically dependent on establishing an adequate blood supply through the ingrowth of new vasculature while maintaining rigid fixation or stabilization for bone formation. Any movement of the segments of bone relative to one another (even micromotion) during healing results in disruption of the blood supply and a change in the type of tissue formed in the site from mineralized bone to fibrous connective tissue. Table 76-1 lists the biologic requirements for bone regeneration and the associated component of GBR surgical procedures needed to accomplish bone regeneration.

TABLE 76-1 Biologic Requirements for Bone Regeneration

Requirement	Surgical Procedure
Blood supply	Cortical perforations
Stabilization	Fixation screws, membrane tacks
Osteoblasts	Autogenous bone (graft or recipient site)
Confined space	Barrier membrane
Space maintenance	Tenting screws, bone graft materials
Wound coverage	Flap management, tension-free suturing

Barrier Membranes

Barrier membranes are biologically inert materials that serve to protect the blood clot and prevent soft-tissue cells (epithelium and connective tissue) from migrating into the bone defect, allowing osteogenic cells to be established. Membranes have been manufactured from biocompatible materials that are either nonresorbable and resorbable. The ideal properties of a barrier membrane are (a) biocompatibility, (b) space maintenance, (c) cell occlusiveness, (d) good handling properties, and (e) resorbability or ease of removal (nonresorbable). Advantages and disadvantages of the resorbable versus nonresorbable membranes are outlined next.

Nonresorbable Barrier Membranes. Various nonresorbable materials have been used as barrier membranes, including latex and Teflon. Teflon, an expanded polytetrafluoroethylene membrane (ePTFE, Gore-Tex Periodontal and Bone Regenerative Membranes, Gore and Associates, Flagstaff, AZ), has been used extensively as a barrier membrane in both GTR and GBR procedures. A variety of shapes and sizes have been designed to be custom-fit around teeth and osseous defects. These barrier membranes are nonresorbable and thus require a subsequent surgical procedure to remove them. The advantage of a nonresorbable barrier membrane is its ability to maintain separation of tissues over an extended time. Unless the barrier is exposed, it can remain in place for several months to years. Typically, GBR membranes are removed after 6 to 12 months.

The disadvantage of a nonresorbable barrier membrane is that if it becomes exposed, it will not heal (i.e., wound will remain open) spontaneously and may become progressively more exposed. Exposed membranes become contaminated with oral bacteria, which may lead to infection of the site and result in bone loss. Therefore exposed membranes must be removed. Contamination or early removal may also result in less bone regeneration.

Space can be maintained under a barrier membrane with bone graft material or tenting screws, thereby facilitating the regeneration of increased bone volume. Stiffer or titanium-reinforced (TR) membranes (Gore and Associates, Flagstaff, AZ) with space-maintaining capabilities can regenerate bone without the need for bone grafts or tenting apparatus.[36,47] Stiffer membranes are able to promote significant amounts of new bone and maintain sufficient

space without the addition of supportive devices. Ridge augmentation can be enhanced with a TR membrane in conjunction with implant placement in localized bone defects.[24]

Resorbable Barrier Membranes. The use of resorbable membranes continues to attract widespread interest primarily because it eliminates the need for an additional surgery to be removed. Copolymers of polylactide and polyglycolide have been used to construct biodegradable membranes. Today, collagen-based resorbable barrier membranes are used extensively. The primary advantage of a resorbable membrane is the elimination of surgical reentry for membrane removal. In the case of a subsequent implant placement procedure (or exposure surgery), this may not be a significant advantage. The other advantage is that resorbable membranes are less likely to become exposed and are less problematic if they do become exposed.

A possible disadvantage is that many resorbable membranes degrade before bone formation is completed, and the degradation process may produce varying degrees of inflammation.[61] Recent developments include cross-linking of collagen to increase resistance to biodegradation and thus increase longevity of the barrier function.[17] Fortunately, the mild inflammatory reaction caused by bioresorbable membranes does not seem to interfere with osteogenesis. Another disadvantage is that resorbable barrier membranes are quite pliable. The lack of stiffness often results in collapse of the membrane into the defect area.[46] Thus resorbable membranes are best suited for situations that allow the graft material or hardware (tenting screws, plates) or the adjacent alveolar bone to maintain the desired dimensions.

Human histology has demonstrated that resorbable barrier membranes support the growth of new bone when used in GBR procedures for horizontal, vertical, sinus, and extraction socket defects.[18,20,37] They have also been shown to reduce bone resorption when used over a monocortical bone block to augment horizontally deficient ridges.[58] Geurs et al[20] demonstrated that a bioabsorbable barrier membrane, used in a GBR procedure along with an allograft, was able to facilitate new bone formation. At present, it can be stated that biodegradable membranes have the potential to support bone formation if they are supported by bone graft material to resist collapse and if they are long-lasting enough to maintain their barrier function for extended periods in small to moderate bone defects.[28,29]

Bone Graft Materials

Unlike other tissues, bone has the unique capacity to completely regenerate itself. The major limiting factors are maintenance of space and structure for bone formation. Bone graft materials have been used to facilitate bone formation within a given space by occupying that space and allowing the subsequent bone growth (and graft replacement) to take place on the structure. The biologic mechanisms that support the use of bone graft materials are osteoconduction, osteoinduction, and osteogenesis.

Osteoconduction is the formation of bone by osteoblasts from the margins of the defect on the bone graft material. Materials that are osteoconductive serve as a scaffold for bone growth. They neither inhibit nor induce bone formation. They simply allow the normal formation of bone by osteoblasts into the grafted defect along the surface of the graft material. Osteoconductive bone graft materials facilitate bone formation by bridging the gap between the existing bone and a distant location that otherwise would not be occupied by bone.

Osteoinduction involves new bone formation through stimulation of osteoprogenitors from the defect (or from the vasculature) to differentiate into osteoblasts and begin forming new bone. This induction of the bone-forming process by cells that would otherwise remain inactive occurs through cell mediators that "turn on" these bone-forming cells. The most widely studied of these mediators is the family of bone morphogenic proteins (BMPs). See Chapter 77 for a review of BMP use in bone augmentation.

TABLE 76-2 Biologic Properties of Various Bone Graft Materials

Source	Osteoconductive	Osteoinductive	Osteogenic
Alloplast	Yes	No	No
Xenograft	Yes	No	No
Allograft	Yes	Yes/No?	No
Autograft	Yes	Yes	Yes

Osteogenesis occurs when living osteoblasts are part of the bone graft, as in autogenous bone transplantation. Given an adequate blood supply and cellular viability, these transplanted osteoblasts form new centers of ossification within the graft. Thus, in addition to the bone formation from osteoblasts that already exist in the defect, osteoblasts added as part of the bone graft also form ossification centers and contribute to the total capacity for bone formation.

Numerous bone graft materials have been used to aid in the reconstruction of bone defects. These range from allografts (derived from the same species) to xenografts (derived from a different species) and alloplast or synthetic graft materials. At a minimum, bone graft materials should be osteoconductive. Bone graft materials that are also osteoinductive are believed to be more advantageous than those that are only osteoconductive. Table 76-2 lists the properties of different classes of bone graft materials.

Demineralized freeze-dried bone allograft (DFDBA) is thought to have osteoinductive effects because viable BMPs within the donor tissue matrix are exposed by the decalcification process.[57] In contrast to this view, more recent reports suggest that bone augmentation with DFDBA is not osteoinductive because it does not contain the BMPs necessary to induce bone formation.[4,8] Schwartz et al[48] reported that variations in the amount of bone formation induced by BMPs in DFDBA may be related to the source (i.e., donor tissue) of the bone and the techniques used to process it. In addition to processing variations, it has been demonstrated that young donor bone results in significantly greater quantities of BMPs retained in the bone allograft matrix compared with older donor bone.[49] Therefore the source of donor bone can greatly influence its osteoinductive capacity.

Bone graft materials help maintain space under a barrier membrane to facilitate the formation of bone within a confined space. Perhaps more importantly, bone graft materials should facilitate neovascularization and the migration of osteoprogenitors. Because the size of the bone graft particles determines the resultant space available (between particles) for osseous formation, particle size has been carefully selected according to this concept. The typical size of bone graft particles ranges from 100 to 1000 µm, which is conducive to neovascularization and the ingrowth of bone. Bone forms in cones called osteons with a central blood supply. The dimension of these cones (100-µm radius) is determined by the distance that the central vasculature supply can provide nutrients to cells at the edges of the osteon.

Autogenous Bone

Compared with other bone graft materials, autogenous bone is thought to be the best bone graft material because, in addition to

being osteoconductive, it is osteoinductive and osteogenic. Furthermore, barring contamination, there is no risk of rejection or adverse reaction to the autogenous graft material. Intraoral sources of autogenous bone include edentulous spaces, maxillary tuberosity, mandibular ramus, mandibular symphysis, and extraction sites. Bone harvested from a recent extraction site (e.g., approximately 6 to 12 weeks healing) may have the advantage of increased osteogenic activity compared with other sites, which are more static and undergoing little or no osteogenesis. The maxillary tuberosity provides a more cellular source of autogenous bone compared with other sites. However, the trabecular nature of this site provides a lesser quantity of mineralized matrix, and the resultant total volume of bone available for grafting is often inadequate. For greater amounts of bone, it is more desirable to harvest bone from the mandibular ramus or symphysis. This bone, which is typically more cortical, can be harvested and used as a monocortical block graft or it can be ground or shaved into small fragments and used as a particulate graft.

Although the mandibular ramus and symphysis offer good sources of bone for grafting, clinicians are sometimes reluctant to harvest bone from these sites because of an increased risk of morbidity from the surgical procedure. Risks of surgery in the mandibular symphysis region include postoperative bleeding, bruising, wound dehiscence, damage to lower incisors, disfigurement, and injury to nerves. Nerve injury may be the most significant concern because it can be a long-term (possibly permanent), annoying alteration in sensation of the lower lip, chin, anterior teeth, and gingiva for the patient. A more serious risk is the alteration of facial appearance, particularly when the facial muscles are completely elevated from the bone beyond the inferior border of the mandible. A condition referred to as "witch's chin" can occur when the facial muscles and overlying skin of the chin fall, causing a disfiguring sag of facial tissues after surgery.

A retrospective analysis of 48 chin graft–harvesting procedures, suggests that maintaining a 5-mm margin of safety between graft harvest sites and vital structures (e.g., lower incisors, the inferior border of the chin, and the mental foramen) will minimize postoperative complications.[21] In the 48 procedures, postoperative sequelae included bruising of the lower face (48/48), bruising of the upper neck (6/48), and paresthesia of the lower lip and incisors (6/48). No patient experienced facial disfigurement or muscle prolapse (chin droop). Three of the six patients with paresthesia experienced transient symptoms and recovered completely within 2 months, whereas symptoms persisted longer than 6 months in the other three patients. Not surprisingly, the larger harvest defects (trephined six-ring sites) resulted in a higher incidence of paresthesia, which was longer lasting than that of the smaller defects (trephined four-ring sites). Harvesting bone in a custom-shaped "block" did not result in paresthesia, presumably because these harvest sites were smaller than the four-ring and six-ring trephine-harvested sites.

Observation of the following basic principles can minimize the risk of postoperative morbidity:

1. Carefully evaluate the harvest site for potential risks. A critical radiographic evaluation before surgery can identify individuals with inferior alveolar nerve branches that extend anterior beyond the mental foramen.
2. Use extreme care in making incisions laterally toward the mental nerve, and dissect the area with blunt instruments to locate the foramen.
3. Do not elevate and reflect muscle attachments beyond the inferior border of the mandible.
4. Limit bone cuts to an area at least 5 mm away from the tooth apices, the inferior border of the mandible, and the mental foramen. Do not extend cuts or harvest bone deeper than 6 mm, and do not include both labial and lingual cortical plates.
5. Suture the wound in layers (muscle and overlying mucosa separately) to prevent postoperative wound separation.

When harvesting autogenous bone, regardless of site or method used, it is important to use techniques that prevent overheating and maintain viability of the bone cells. Exceeding 47° C (116.6° F) is known to cause bone necrosis.[16] Thus the use of drills, trephines, or saws to cut bone should always be done with profuse irrigation to keep instruments and bone cooled. Precision of osseous cuts can be facilitated with new technologies such as piezoelectric bone surgery (see Chapter 80).

inserted for 2 to 3 weeks after surgery to avoid pressure over the wound during the early healing phase.

General concepts for flap management associated with ridge augmentation include the following:

1. It is desirable to make incisions remote relative to the placement of barrier membranes (e.g., vertical releasing incisions at least one tooth away from the site to be grafted). In the anterior maxilla, keeping vertical incisions remote is also an esthetic advantage.
2. Full mucoperiosteal flap elevation at least 5 mm beyond the edge of the bone defect is desirable.
3. The use of vertical incisions, although often required for surgical access, should be minimized.
4. Use of a periosteal releasing incision to give the flap elasticity and permit tension-free suturing is essential. This permits complete closure without stress on the wound margins.
5. Removable appliance should not be inserted over the wound for 2 weeks or more to avoid postoperative trauma to the surgical site.
6. Wound closure should incorporate a combination of mattress sutures to approximate connective tissues and interrupted sutures to adapt wound edges.

Horizontal Bone Augmentation

A deficiency in the horizontal dimension of bone may be minimal, such as a dehiscence or fenestration of an implant surface, or it may be more significant, such that the implant would have more than one axial surface exposed while having some bone along the entire vertical length. Dehiscence defects can usually be managed during implant placement because most of the implant is covered and stabilized by native bone. If the horizontal deficiency is large and the implant placement would result in significant exposure (i.e., implant body is significantly outside the alveolar bone), it may be better to reconstruct the bone first, in a staged approach, with a subsequent surgery for implant placement.

Although reconstruction of deficient ridges with bone grafts alone (i.e., without barrier membrane) has proved to be effective, variable resorption of the grafted bone has been reported. Preliminary results in a 1- to 3-year study using autografts harvested from the maxillary tuberosity showed an increased ridge width, but resorption of 50% of the graft volume was also noted.[55] Buser et al[9] investigated the lateral ridge augmentation procedure using an autograft from the retromolar or symphysis area covered by a membrane in 40 consecutively treated patients and noted no clinical signs of resorption of the block graft. The researchers emphasized a remote incision technique, perforation of the cortex, stable placement of corticocancellous autografts, precise adaptation and stabilization (with miniscrews) of the ePTFE membranes, and a tension-free primary soft tissue closure. After 7 to 13 months, the sites were reopened for membrane removal and implant placement. Of the 40 patients, 38 exhibited excellent ridge augmentation, whereas 2 sites showed some soft tissue encapsulation of the grafted bone.

Nevins and Mellonig[42] and Doblin et al[14] reported an increased amount of new bone using freeze-dried bone allografts (FDBAs) with membranes, even in the presence of membrane exposure. The biopsies showed viable bone cells and visible osteocytes in lacunae, and a 9-month specimen showed no remaining allograft material.

On the other hand, there are some contradictory results using DFDBA and membrane combinations.[2,7,8] In a human study, seven paired extraction sockets were grafted with either DFDBA or autologous bone. Sites were reentered and biopsied after 3 to 13 months to evaluate bone formation. Histologic specimens revealed dead particles of DFDBA with no evidence of bone formation on the surface and no evidence of osteoclastic resorption. Conversely, the autogenous sites revealed vascular channels with woven and lamellar bone. Some nonvital, cortical bone chips were observed with osteoclastic resorption.

Figure 76-1 shows an example of the lack of bone formation around DFDBA particles used in a ridge augmentation procedure after more than 20 months of healing under a nonresorbable ePTFE barrier membrane.

Particulate Bone Graft. Advantages of particulate bone grafts (or bone chips) are that the smaller pieces of bone demonstrate more rapid ingrowth of blood vessels (revascularization), larger osteoconduction surface, more exposure of osteoinductive growth factors, and easier biologic remodeling compared with a bone block for reconstruction of large defects. However, particulate grafts often lack a rigid, supportive structure and are much more easily displaced than block grafts.

Autologous particulated bone grafts can be harvested from any edentulous jaw site, either in smaller "particle" or in a larger "block" of bone. If the bone has been harvested in a block, a bone mill is necessary to "particulate" the bone and prepare it for transplantation into the bone defect (Figure 76-2).

Particulate grafts are indicated (a) in defects with multiple osseous walls that will contain the graft or (b) in dehiscence or fenestration defects when implants are placed during the bone augmentation procedure. If a bone defect does not have sufficient osseous walls to contain the graft, the barrier membrane (placed in contact with the native bone) should be secured along the periphery with tacks, screws, or sutures. This bone graft and secured barrier membrane combination becomes an environment that is stable and supports new bone formation. Figure 76-3 depicts the use of a barrier membrane in combination with a particulate bone graft to treat a mandibular horizontal defect.

Monocortical Block Graft. Horizontal alveolar deficiencies that might be challenging to reconstruct with particulate grafts can easily be reconstructed with a monocortical block bone graft. The technique uses a cortical block of bone harvested from a remote site and used to increase the width of bone. The block graft taken from an intraoral (e.g., mandibular symphysis or ramus) or extraoral (e.g., iliac crest or tibia) site is fixated to the prepared recipient site with screws. The overlying soft tissues can be separated from the bone graft with a barrier membrane or simply covered with the mucoperiosteal flap. Fixation hardware (screws and plates) should be removed after an adequate period of healing (approximately 6 months). The disadvantage of this technique is the biologic limitation of revascularizing large bone blocks. It therefore is crucial to have sufficient osteogenic cells in the residual surface of the surrounding bone and to limit this technique to horizontal augmentation and only minimal vertical defects.

Figure 76-4 shows the use of a monocortical block graft to reconstruct a horizontal deficiency in the posterior right mandible. The patient presented with a loss of the buccal cortical plate of bone after a traumatic extraction of endodontically treated tooth #29. The surgical extraction also resulted in a nonrestorable cut into the mesial root of tooth #30. Recommended treatment included extraction of tooth #30, monocortical block graft reconstruction of the buccal defect at site #29, and bone augmentation of the extraction socket #30. The procedure for this case follows.

Procedure. After local anesthesia, an incision was made in keratinized tissue along the crest and around the molar tooth (#30) with a vertical releasing incision mesial to the first bicuspid (#28). A

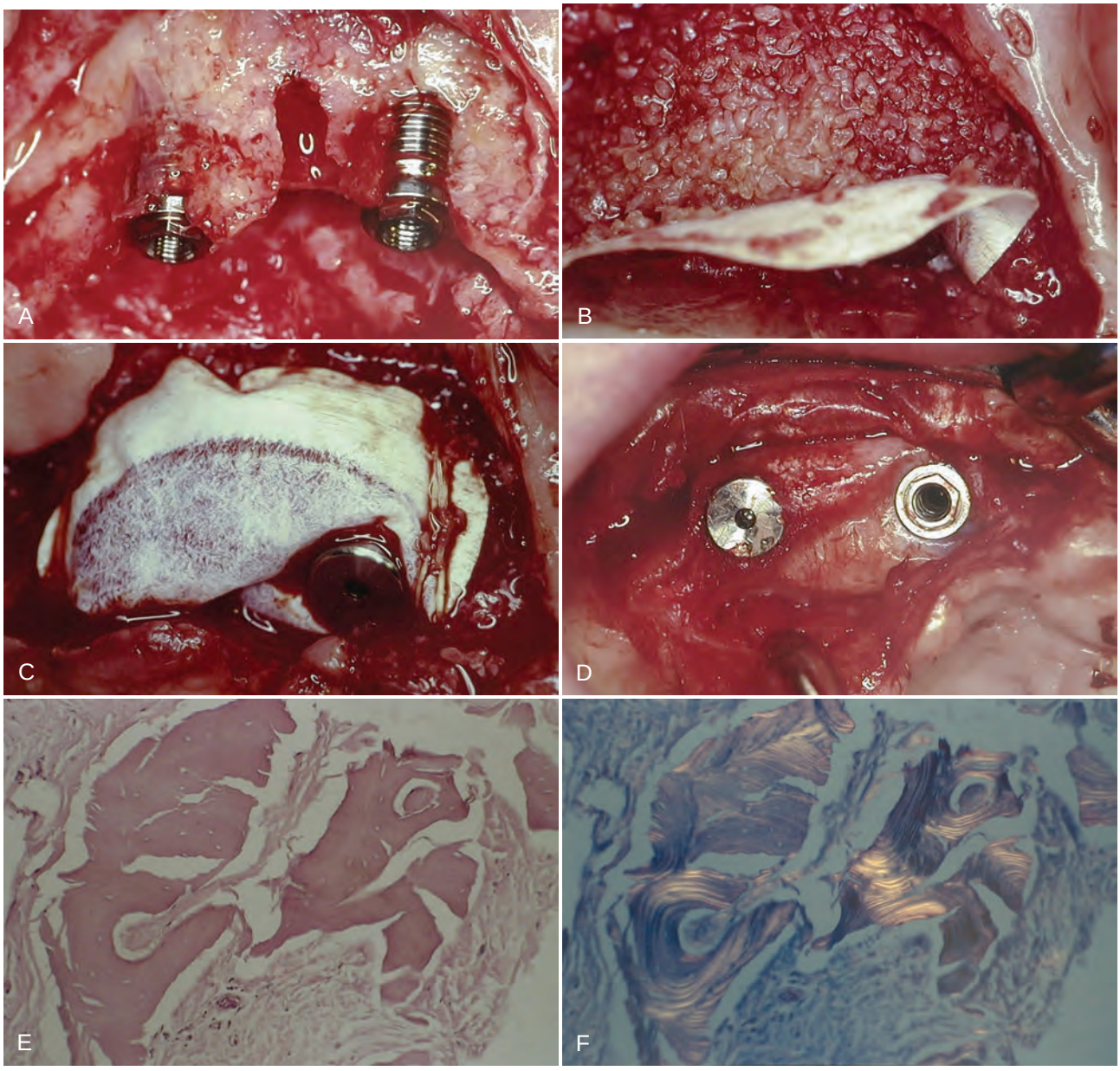

Figure 76-1 **A,** Clinical view of maxillary alveolar ridge after removal of a failed implant (center defect) and placement of two implants in the bone adjacent to this sites. **B,** The narrow ridge was grafted with decalcified freeze-dried bone allograft (DFDBA) particulate bone graft material. The graft material was completely covered by a nonresorbable, expanded polytetrafluoroethylene (ePTFE) barrier membrane. **C,** The ePTFE barrier membrane was secured with the cover screw of one implant and sutures that were secured to the periosteum. **D,** Clinical view of DFDBA-augmented ridge after more than 20 months healing under a nonresorbable ePTFE barrier membrane. The membrane remained submerged throughout the entire healing period. **E,** Hematoxylin-eosin (H&E) light microscopic view of specimen harvested from the DFDBA-augmented ridge. Note there are no bone cells (osteoblasts, osteoclasts, or osteocytes), no bone formation, and no osteoclastic resorption of DFDBA particles. There is no evidence of inflammation. Fibroblasts and connective tissue surround the "dead" DFDBA particles. **F,** Polarized light microscopic view of the same specimen **(E)** harvested from the DFDBA-augmented ridge. Note the appearance of lamellar layers demonstrating the presence of the DFDBA particles.



Figure 76-2 **A,** R. Quetin bone mill (assembled). **B,** R. Quetin bone mill (disassembled). **C,** Ground bone observed in blades of bone mill. **D,** Autogenous block bone ground into evenly sized particulate bone with bone mill suitable for bone grafting.

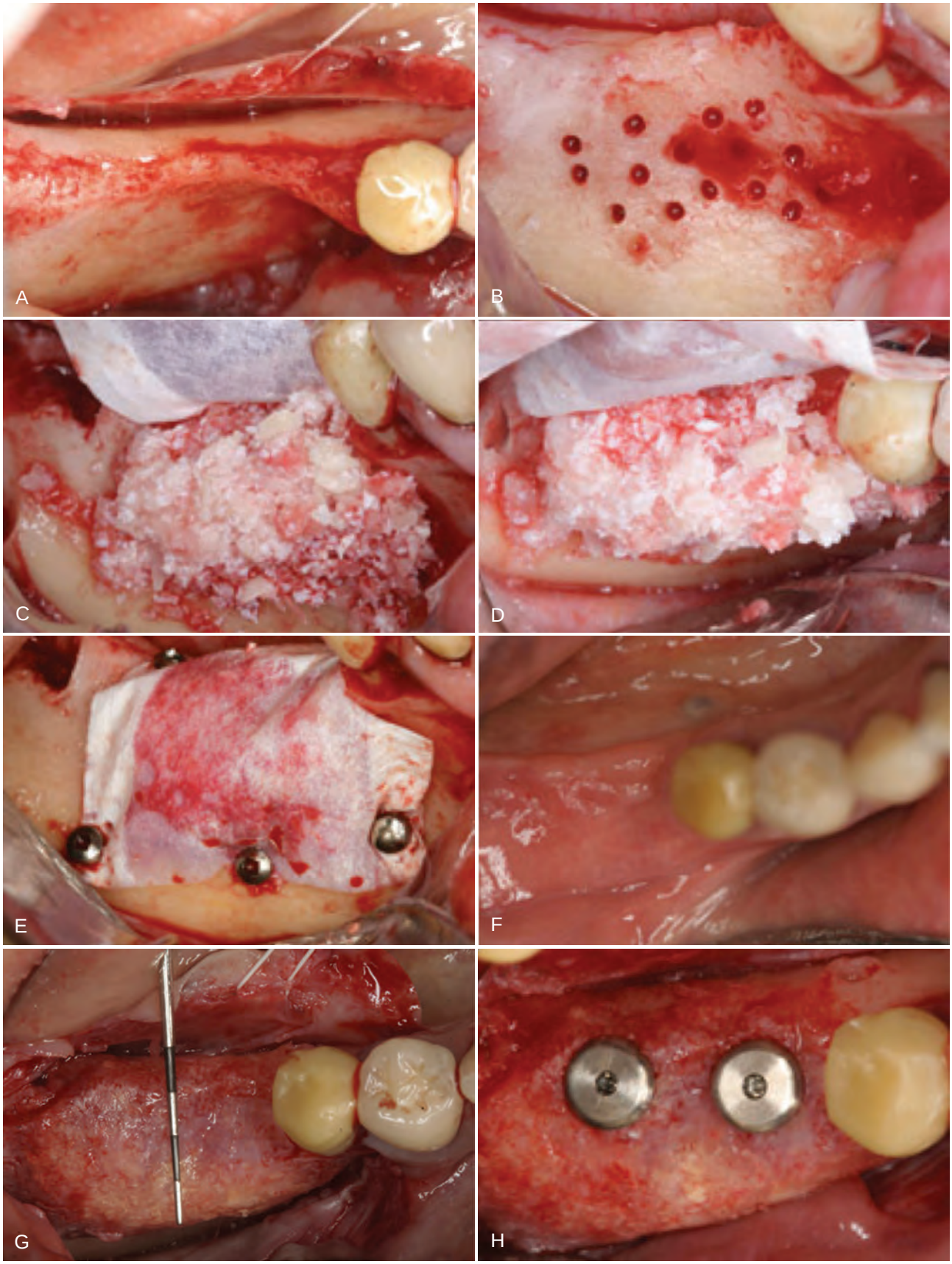

Figure 76-3 Horizontal bone augmentation with expanded polytetrafluoroethylene (ePTFE) barrier membrane. Bone graft consists of a mixture of autogenous particles harvested from the alveolar ridge and Bio-Oss (Osteohealth Company, Luipold Pharmaceuticals, Inc., Shirley, NY). **A,** Partially edentulous posterior mandible with narrow buccolingual dimensions. **B,** Cortical perforations made in buccal bone with small round bur to enhance blood supply to grafted area. **C,** Placement of ePTFE barrier membrane and mixture of autogenous and Bio-Oss particulate bone graft. **D,** View of **C** from occlusal perspective to visualize horizontal augmentation. **E,** Barrier membrane secured to native bone with fixation screws. **F,** Clinical photograph of healed site prior to membrane removal. Soft-tissue closure maintained throughout healing without membrane exposure. **G,** Clinical photograph of healed ridge after membrane removal. Dimensions of alveolar ridge are significantly wider as demonstrated with periodontal probe. **H,** Two standard-diameter implants placed in "prosthetically driven" ideal position. Notice there are no implant exposures. *(Images courtesy Dr. Istvan A. Urban, Budapest, Hungary.)*

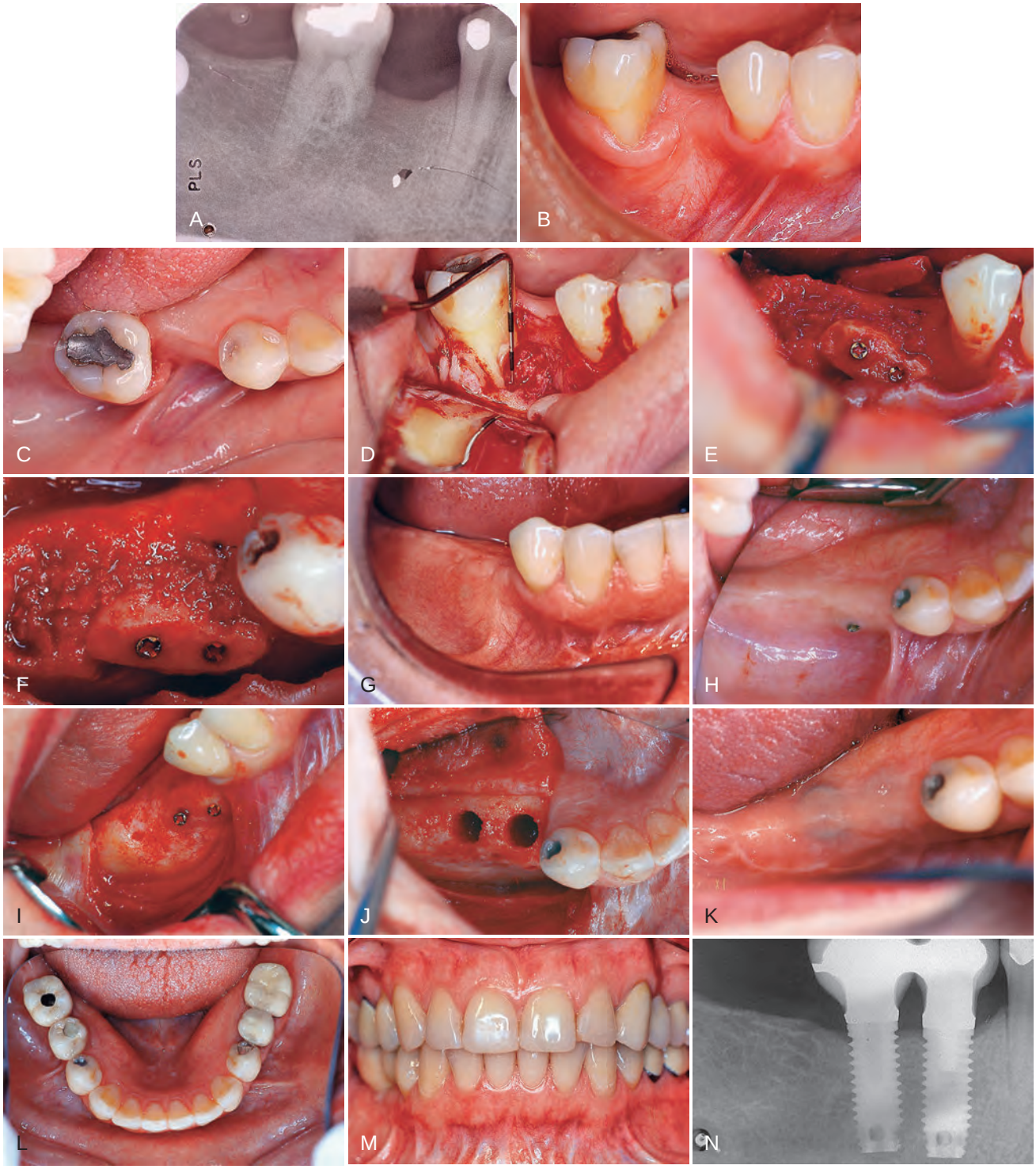

Figure 76-4 Use of a monocortical block graft to reconstruct a horizontal deficiency in the posterior right mandible. A, Periapical radiograph shows missing tooth #29 and damaged (i.e., cut) mesial root #30. **B** and **C,** Labial and occlusal views, respectively, of site reveal deficient alveolar ridge on buccal side of #29. **D,** Full-thickness flap reflection reveals the extent of missing bone in the buccal aspect of site #29, as well as the periodontal defect and damaged mesial root #30. **E** and **F,** Autogenous monocortical bone block graft secured to native alveolar bone with fixation screws. **G,** Good tissue healing after block graft, with evidence of a widened alveolar ridge. **H,** After 6 months of healing, posterior fixation screw is observed protruding through the mucosa. **I,** Full-thickness flap reveals that bone resorption has resulted in exposure of part of the fixation screw. **J,** Osteotomy prepared for wide-diameter implants, taking care to avoid making the labial bone "graft" too thin. **K,** Complete closure and good healing of wound after implant placement. **L** and **M,** Clinical photographs of completed restorations. **N,** Final radiograph shows good restoration contours on wide-diameter implants.

full-thickness flap was elevated to expose the alveolar bone (see Figure 76-4, *D*). All soft tissues were thoroughly removed from the recipient site before bone grafting. After simple forceps delivery of tooth #30, the defect to be grafted was measured to determine the size of block graft to harvest from the mandibular symphysis. Several bleeding points were created using a small round bur.

The autogenous monocortical block graft was harvested from the mandibular symphysis. It was cut to an appropriate size and mortised to intimately fit the recipient defect site. Once properly positioned, the graft was fixated with two fixation screws (Leibinger, Kalamazoo, MI) that passed through the graft and into the existing native alveolar bone. A periosteal releasing incision was used to sever the periosteum from anterior to posterior and facilitate coronal advancement of the mucogingival flap.

After 6 months of healing, a full-thickness mucoperiosteal flap was elevated to expose the alveolar bone sites #29 and 30. Mild resorption of the monocortical block graft is evident. Notice that the position of the head of the fixation screws (especially the posterior screw) is more protruded than the grafted bone as a consequence of bone remodeling and resorption (see Figure 76-4, *H* and *I*).

The fixation screws are removed, and the sites are prepared in the usual manner for the placement of two screw-type, wide-diameter implants (Implant Innovations, Palm Beach Gardens, FL). Care is taken to avoid preparing the grafted site too wide or too far labially because the grafted bone may be vulnerable to fracture or additional resorption (see Figure 76-4, *J*).

Simultaneous Implant Placement

Large alveolar bone defects need to be augmented before implant placement and require a healing period of 6 months or longer. In selected cases, it is possible to perform a bone augmentation procedure simultaneously with the implant placement. It is essential to achieve good implant stability in the existing native bone so that endosseous integration can occur.

A very predictable osseous defect to manage with simultaneous implant placement is the implant dehiscence or fenestration defect. *Fenestration* defects are exposures of the implant's axial surface that do not include the coronal aspect of the implant (Figure 76-5). *Dehiscence* defects expose a part of the axial surface, including the coronal aspect of the implant, while maintaining sufficient bone volume around all remaining implant surfaces (Figure 76-6). In a dehiscence defect the implant remains within the confines of the existing bone.

Fenestration and dehiscence defects have been managed with barrier membranes or simply with flap closure. Bone grafts have also been used. The only controlled comparison studies between membrane treatment and periosteal flap coverage of exposed implant surfaces in humans demonstrated that the membrane treatment was far superior with regard to bone fill.[11] Another controlled study in humans showed better results in the membrane groups; four of six sites (67%) treated with a membrane resulted in 95% to 100% elimination of the dehiscence and total coverage of the threads. In the control sites, only 2 of 6 sites (33%) showed moderate-to-complete bone fill.[43] All other clinical studies are in the form of case reports.[38] Figure 76-7, *M,* demonstrates coverage of an implant dehiscence using a barrier membrane. Admittedly, without a biopsy, it cannot be determined whether the tissue covering the implant is bone or firm connective tissue.[22,26]

A 1-year multicenter study evaluating 55 Brånemark implants (i.e., machined-surface, external hex) with bone dehiscence in 45 patients, treated by ePTFE membrane alone, demonstrated an average bone fill of 82%.[12] The average initial defect height was 4.7 mm. The 1-year follow-up of these implants demonstrated a favorable response to loading. Of the 55 implants, a total of 6 failed, corresponding to a cumulative survival rate of 84.7% in the maxilla and 95.0% in the mandible, which is similar to previously published results for this implant design.

A clinical report on the use of TR membranes demonstrated the biologic potential to fill a large protected space in four patients.[24] Bone dehiscence at implant sites ranged from 5 to 12 mm (mean: 8.2 mm). They were covered with a TR membrane alone (no graft). Reentry after 7 to 8 months of submerged healing found complete bone coverage over all implants. Radiographic evaluation demonstrated the implants functioning with normal crestal bone support after 1 year.

No clinical comparisons are available in the literature evaluating the placement of bone grafts with or without barrier membranes

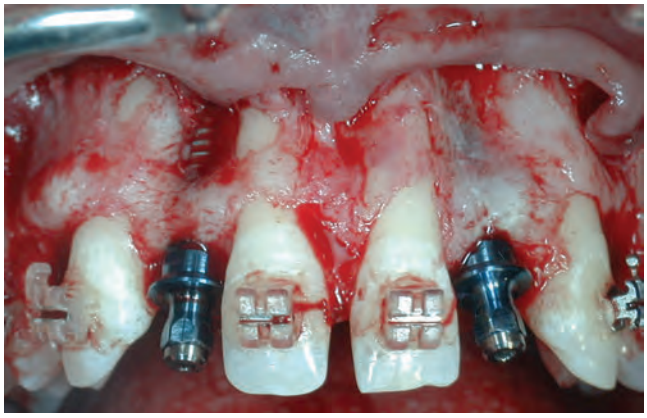

Figure 76-5 Fenestration defect observed in very thin maxillary anterior sites. Implants placed in the maxillary lateral incisor positions demonstrating fenestration defects caused by the concavities in the apical area. Notice that the natural teeth (centrals and cuspids) also demonstrate fenestrations. Bone will grow across this type of defect in a very predictable manner because the implants are stable; the defect is small and surrounded by bone.

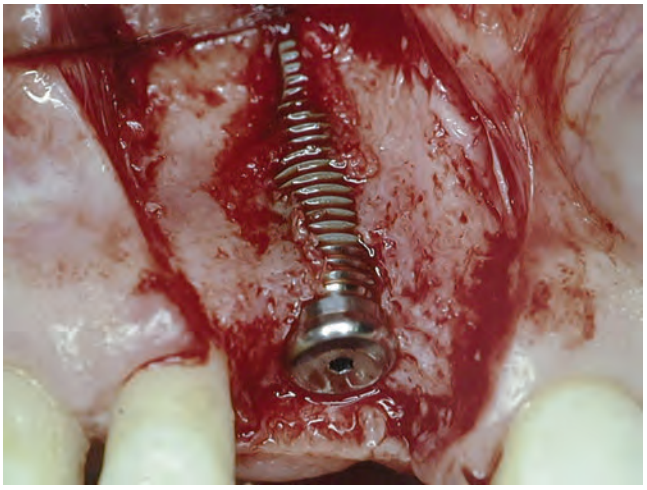

Figure 76-6 Dehiscence defect observed during placement of an implant in the maxillary central incisor position. Note that the implant is completely surrounded by existing native bone except for the facial surface, which is exposed. Bone will grow across this type of defect in a very predictable manner because the implant is stable and the exposed surface is relatively flat with bone on all surfaces.

on implant dehiscence defects. Most evidence supports the use of graft materials in conjunction with membrane treatment, especially the use of FDBA in conjunction with GBR. In a study with 40 patients, 110 implants were placed in conjunction with barrier membranes and FDBA; a success rate of 96.8% was achieved with complete bone fill (defined as >90% fill of dehiscence).[45] This study reported a membrane exposure rate of 29%, but noted little adverse effect on the bone regeneration.

With respect to ridge preservation, Becker et al[6] reported the effect of barrier membranes and autogenous bone grafts on the preservation of ridge width around implants. They evaluated the ridge width around 76 implants in 61 patients from a case series database. Three groups were compared, including 34 implants treated with GBR (barrier membranes), 27 implants treated with autogenous bone grafts, and 15 implants placed without the need for ridge preservation/augmentation procedures (control group). The results revealed that implant sites treated with barrier membranes and autogenous bone grafts lost an average of 0.1 mm and 0.8 mm, respectively, more than the no augmentation group.

Another study evaluated the possibility of regenerating bone around implants placed in extraction sockets.[30] Bone augmentation was achieved with human DFDBA particles mixed with tetracycline packed around the exposed implant surfaces. Implants and graft material were covered with ePTFE barrier membranes

Figure 76-7 Use of staged (A to H) and delayed (I to O) implant placement after extraction of two maxillary lateral incisors in one individual. A, Preoperative photograph of tooth #7 with gingival recession and marginal inflammation. **B,** Atraumatic extraction or tooth #7 without tissue incision or tissue elevation. Palpation reveals no facial bone present at the time of extraction. **C,** Decalcified freeze-dried bone allograft condensed into extraction site. **D,** Expanded polytetrafluoroethylene (ePTFE) barrier membrane positioned over graft and held in place with sutures. **E,** Six months after the extraction/graft, the implant is placed. Notice the implant is completely covered with bone. **F,** Final restoration. **G,** Preoperative photograph of tooth #10 with exposed gingival margin. **H,** Atraumatic extraction of tooth #10 without tissue incision or tissue elevation. Palpation reveals no facial bone present, and dehiscence is expected.

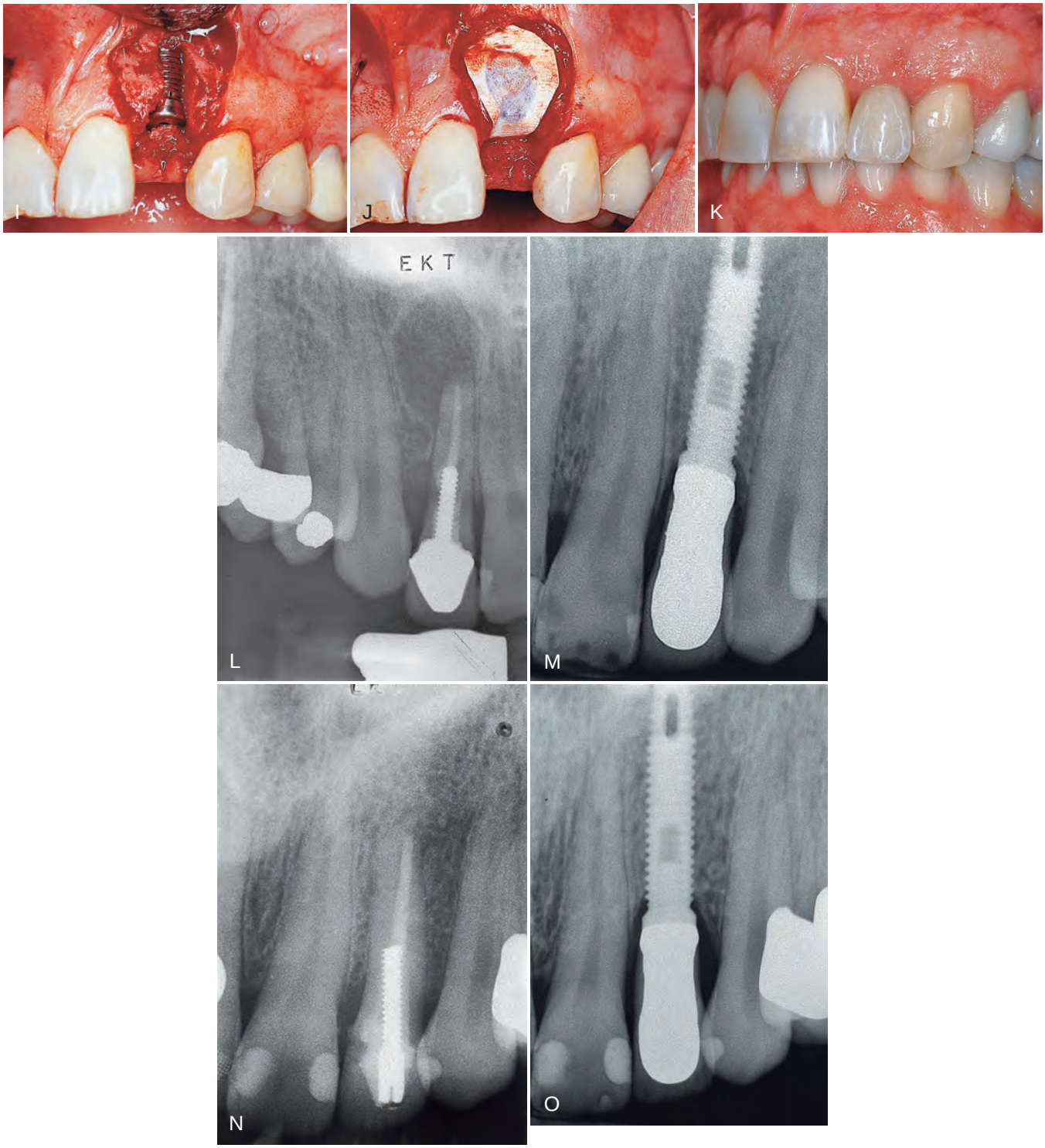

Figure 76-7, cont'd **I,** Two months after extraction, the implant is placed with dehiscence defect. **J,** Guided bone regeneration accomplished with ePTFE barrier membrane positioned over the dehiscence. **K,** Final restoration. **L,** Periapical radiograph of tooth #7 with a large radiolucent lesion around the apex and periodontal bone loss along the distal interproximal area. **M,** Final radiograph of delayed implant placement. **N,** Periapical radiograph of tooth #10.O, Final radiograph. *(Figures **A, B, C, F, G, J, M, N,** and **O** from Klokkevold PR, Han TJ, Camargo PM.: Aesthetic management of extractions for implant site development: delayed versus staged implant placement.* Pract Periodontics Aesthet Dent *11:603, 1999.)*

with complete flap closure for 4 to 6 months. The results demonstrated complete bone regeneration in all cases except when barrier membranes were prematurely exposed and removed. One-year posttreatment histologic evaluation of regenerated bone revealed remnants of the DFDBA graft particles in direct contact with vital bone tissue (woven and lamellar bone). Osteoblasts were observed and appeared to be actively engaged in bone formation adjacent to graft particles. Figure 76-7, *L* and *M*, demonstrates a simultaneous GBR and implant placement in a dehiscence defect.

Complications

Bone augmentation procedures used to increase the bone volume in deficient alveolar ridges have been successful and have enabled the placement of implants into prosthetically driven positions.[51] Unfortunately, these augmentation procedures carry an increased risk of morbidity and can require secondary surgeries to correct problems resulting from the procedure.[60] The subsequent corrective surgeries required to correct problems add surgical time and complexity to the implant therapy.

Surgical complications are reported for a variety of bone reconstructive techniques.[15] A review assessed the number and types of complications associated with bone reconstructive procedures for endosseous implants.[56] The review of literature (1976-1994) included 2315 implants in 733 autogenous block, particulate, and various other bone graft materials. Complications reported included bleeding, postoperative infection, bone fracture, nerve dysfunction, perforation of the mucosa, loss of a portion of the bone graft, pain, decubital ulcers, sinusitis, and wound dehiscence. Wound dehiscence seemed to have the most deleterious effect on implant survival. This finding emphasizes the importance of flap management.

Typical findings include less bone fill with early exposure and membrane removal versus retaining the membrane without exposure for 6 to 8 months.[25,53] Buccolingual ridge deficiencies were treated in a prospective study involving 19 patients using ePTFE membranes and miniscrews as fixation and tenting devices.[32] The group of defects, which healed uneventfully, yielded on reentry a 90% to 100% bone regeneration compared with the maximal volume of the space defined by the membrane placement. In the exposed-membrane group, the percentage of regenerated bone ranged from 0% to 62%. When a late membrane removal was performed (3 to 5 months postsurgically), the regeneration varied between 42% and 62%. The authors concluded that the length of membrane healing and size of the defect played a significant role in the amount of new bone formation.[32]

Other authors have reported successful bone fill in situations in which the membranes had to be removed because of an early exposure.[42,52] A significantly greater fill of the osseous defects at the grafted sites was noted. The authors concluded that the regeneration of bone around the implants appeared most dependent on the anatomy of the bony defect at the time of implant placement.

Although the effect or amount of regenerated bone with regard to membrane exposure is somewhat contradictory, the goal should be to keep the membranes covered during the healing period so that the risk of infection and soft tissue and esthetic problems can be minimized or eliminated. Again, the importance of flap management for ridge augmentation procedures should be stressed. See Chapter 82 for more information and details regarding surgical complications and failures.

Alveolar Ridge Preservation/Management of Extractions

Because tooth extraction (or tooth loss) often results in alveolar ridge resorption or collapse, preservation of bone volume at the time of extraction is a desirable goal. Most bone loss after extraction occurs in the first 6 to 24 months.[10] Therefore, when clinicians are afforded the opportunity to intervene at the time of extraction, preservation of alveolar bone should be initiated. A conservative approach to the management of extraction sites can eliminate or significantly reduce the necessity of advanced bone augmentation procedures.

When extracting a tooth and preparing for implant placement, alveolar bone resorption should be prevented. Experimental animal studies show that the use of a barrier membrane enhances the predictability of bone fill in the extraction site and therefore maintains original bone volume when compared with mucoperiosteal flap coverage alone.[7] Clinical studies also demonstrate the benefits of a regenerative approach to tooth extraction.[34,35,41] These authors found that a nonresorbable barrier membrane results in minimal resorption of alveolar ridge size and shape.

Although earlier studies have proposed the concept of treating extraction sites without flap closure (i.e., an exposed membrane used to cover the graft), more recent studies conclude that complete wound closure over the physical barrier might be associated with greater bone fill.[5,53] The decision about whether to advance a flap to achieve wound closure must be weighed against the soft-tissue changes that will be created and may need to be corrected (i.e., mucogingival junction discrepancies and esthetic problems).

The timing of implant placement relative to the time of extraction has been widely debated. Depending on the quantity, quality, and support of existing bone, as well as the preferences of the clinician and patient, the placement of implants after tooth extraction can be immediate, delayed, or staged. By definition, *immediate* implant placement occurs at the time of extraction. Delayed implant placement is performed approximately 2 months after extraction to allow for soft tissue healing. *Staged* implant placement allows for substantial bone healing within the extraction site, which typically requires 4 to 6 months or longer.

Tooth extraction is managed with an atraumatic surgical technique that uses a narrow, flat instrument (e.g., Periotome, Hu-Friedy, Chicago) directed apically into the sulcus to sever the periodontal ligament and slightly expand the adjacent periodontal tissues. The tooth is elevated and removed with forceps using a gentle, rotational movement. Chapter 80 describes new techniques for atraumatic extraction. Buccolingual forces are avoided to prevent damaging the integrity of the labial bone. No incisions are made, and care is taken to avoid soft-tissue reflection. In this manner, soft tissues maintain their structural anatomy, and the periosteum (blood supply to the bone) remains intact. If the tooth has multiple roots, curved roots, or other anatomic features that make removal difficult, it may be necessary to cut the tooth using a high-speed rotary drill or other cutting device and remove it in smaller pieces. It is important to cut only tooth structure and avoid cutting (overheating) bone when using high-speed rotary drills. The bone within the extraction site is completely debrided of soft tissue with surgical curettes. After debridement, the extraction site is thoroughly irrigated with sterile saline. Finally, the clinician can evaluate the bone level and socket anatomy to determine whether to bone-graft the site and when to place the implant (immediate, delayed, or staged placement).

Delayed Implant Placement

Delayed implant placement shares some advantages of immediate implant placement, including extraction site preservation, and offers additional advantages. Unlike immediate implant placement, which is deficient of soft tissue for coverage, the delayed-implant placement technique allows time for soft-tissue healing to close the wound.[23] The delayed-placement technique still reduces the length of treatment by several months because it is not necessary to wait for complete bone healing. Furthermore, because bone formation is active within the first few months after tooth extraction, the delayed technique may facilitate more osteogenesis adjacent to the implant.

The primary advantage of delayed implant placement is that by allowing for soft-tissue healing and closure of the extraction site, mucogingival flap advancement is not necessary. This alleviates the need for additional surgeries to correct mucogingival discrepancies. Delayed implant placement also allows time for resolution of infections that may have been present within the extraction site.

As with immediate implant placement, similar limitations of bone support and implant stability exist for delayed placement. The normal osseous healing that occurs within the first 2 months does not significantly affect the anatomy of the alveolar bone. Therefore limitations in bone support after 2 months of healing are similar to those that exist at the time of extraction.

Staged Implant Placement

Staged implant placement allows adequate time for osseous healing. This may be complete osseous healing of an extraction site without a bone graft (if circumferential bone support is good) or with a bone graft. Staged implant placement, by definition, allows for complete hard and soft-tissue healing and permits the placement of implants into healed bone sites with adequate coverage by hard and soft tissues.[51] This eliminates the necessity of mucogingival flap advancement, allows for the resolution of preexisting infections, and prevents soft-tissue invasion. Furthermore, by using an extended healing period, the grafted bone also has the opportunity to become vascularized. Bone grafts performed simultaneously with implant placement do not share this advantage.

The primary disadvantage of staged implant placement is the length of time required for bone healing.

Delayed Versus Staged Technique

Delayed and staged techniques for implant placement are demonstrated here in one individual using two extraction sites with similar bone morphologies in the anterior maxilla (see Figure 76-7). Both techniques facilitate the esthetic placement of implants into prosthetically driven positions. Delayed and staged approaches maintain alveolar bone volume, reduce the need for advanced bone augmentation, and eliminate the need for subsequent mucogingival surgery. The timing and management of delayed versus staged implant placement is described in the next section.

To decide which implant placement method to use, the quantity and location of bone surrounding the tooth should be assessed. Once the patient has been anesthetized, a periodontal probe can be used to "sound" for the level of bone support through the soft tissue. Using this method, the bone levels surrounding the tooth can be mapped. Bone support that surrounds the extraction site can also be evaluated and confirmed after tooth removal by palpation, probing, and direct (internal) visualization.

If the tooth to be extracted has sufficient bone support on all surfaces, the extraction site can be expected to fill with bone without additional augmentation procedures, except when the labial bone is very thin. A simple extraction followed by a healing period of 4 to 6 months could be sufficient for complete osseous healing. Subsequently, an implant could be placed in the usual manner without the need for bone augmentation. Conversely, if little or no bone exists on the labial surface, it should be anticipated that the site would require bone augmentation to facilitate placement of the implant. In this case, bone grafting at the time of extraction can be used to maintain the alveolar ridge dimensions occupied by the tooth.

Immediate Implant Placement

The primary advantage of immediate implant placement is the reduction of the healing time, which translates to an earlier restorative time (i.e., shorter time to completion for the patient).[33,39,50,59] Because the implant is placed at the time of extraction, the bone-to-implant healing begins immediately with extraction site healing. Another advantage is that the normal bone healing, which generally occurs within the extraction site, takes effect around the implant. This bone-forming activity may enhance the bone-to-implant contact compared with an implant placed in a less osteogenically active site.

Possible disadvantages of immediate implant placement include the need for subsequent mucogingival surgeries to correct tissues moved by repositioned flaps and the need for bone grafting to fill extraction site defects around the implant. If inadequate bone exists to stabilize the implant, immediate implant placement is not recommended.

When a two-stage implant is placed at the time of tooth extraction, the mucogingival flap is advanced, with releasing incisions, to cover the implant completely (exception: one-stage implants). It may also be necessary to graft bone into the extraction site in areas that do not contact the implant to avoid soft-tissue invasion around the implant.[50] A 1-year study of 49 immediate extraction site implants treated by a membrane alone demonstrated a 93.6% bone fill. After 1 year (postloading), the implant success rate was 93.9%.[5]

Although some have advocated submerging implants placed in extraction sockets with flap advancement,[23] others have demonstrated success with a nonsubmerged approach. Implants may be placed in extraction sockets along with bone augmentation without flap advancement using a one-stage implant placement approach. Clinical studies evaluating the outcome of bone augmentation around implants placed in extraction sockets reveal good bone fill.[31] The placement of 21 transmucosal implants in immediate extraction sites treated with a barrier membrane were tested for the implant success rate and the percentage of bone fill. Of 21 transmucosal implants, 20 yielded complete bone fill and coverage of the entire plasma-coated implant surface.

A clinical report on the use of resorbable collagen membranes around extraction site implants demonstrated a variable degree of bone fill in nine patients.[44] More clinical review of the use of resorbable membranes for GBR is required because evidence is insufficient to evaluate the predictability.

In a study of 30 patients, the use of autografts alone in 54 extraction sites was highly effective for simultaneously placed implants completely within the envelope of bone.[3] The study showed that extraction sites, including those with a buccal dehiscence, could be treated with autografts alone. However, because ungrafted sites were not included, the absolute need to graft small defects adjacent to implants was not ascertained by this study. In another study, implants placed in extraction sockets were tested for their potential to regenerate bone with allograft alone, a membrane alone, and a combination treatment.[19] Reentry confirmed 100% thread coverage in all but one implant in the "no-wall" group treated with DFDBA alone. A clinical study of five patients evaluated different treatment modalities for extraction site implants together with bone graft combinations.[54] This small study supported the concept that "non–space-making defects" are best treated with a combination of barrier membrane and an autograft or allograft as compared to treatment with a nonreinforced membrane alone (without a graft).

Immediate placement of an implant into the extraction socket in a one-stage approach along with immediate provisionalization is perhaps the best way to manage the hard and soft tissues following extraction (Figure 76-8). The immediate placement of a provisional restoration is the best way to support the soft tissues (papilla and marginal gingiva) following tooth extraction.

Figure 76-8 Immediate implant placement after extraction of a maxillary first premolar. A, Preoperative clinical photograph of tooth #12, which fractured and was deemed nonrestorable. **B,** Periapical radiograph of tooth #12. It is root canal–treated and has a full-coverage porcelain-fused-to-metal crown. **C,** Atraumatic extraction of tooth #12 without incisions or tissue elevation. **D,** Extracted tooth. **E,** Palpation and examination with probe reveals intact bony walls around the extraction socket. The facial bone wall is observed to be about 2 mm below the facial gingival margin. **F,** The palatal aspect of the extraction socket is prepared, and a tapered implant is placed to emerge through the central fossa. Autogenous bone chips (harvested from the maxillary tuberosity) are condensed into the labial aspect of the extraction socket to support the facial bone and soft tissue contours. **G,** An immediate provisional restoration is fabricated (indirectly in the laboratory) and delivered at the time of implant placement. The palatal cusp is not replaced in this provisional to avoid function and the occlusion is checked for light centric contacts only. **H,** Facial view of provisional restoration at the time of delivery. Notice how the interdental papilla and facial gingival margin is well supported by the contours of the provisional restoration. **I,** Final restoration at time of delivery (approximately 4 months after implant placement). **J,** Final radiograph of definitive restoration.

Conclusion

Localized bone augmentation procedures allow clinicians to reconstruct horizontal alveolar ridge deficiencies and replace missing teeth with dental implants in a prosthetically driven position with natural appearance and function. In many cases, implants can be placed simultaneously with the augmentation procedure. In cases of advanced bone resorption, ridge augmentation before implant placement may be a better choice. Bone augmentation procedures can also be used to preserve alveolar dimensions following tooth extraction. If adequate bone exists to stabilize an implant, these procedures may be combined. The predictable outcome of these procedures depends on several biologic principles that must be followed. Diagnosis, treatment planning, careful execution of the surgical treatment, postoperative follow-up, and appropriate implant loading are all important factors in achieving success.

Suggested Readings

Bahat O, Handelsman M: Periodontal reconstructive flaps–classification and surgical considerations. *Int J Periodontics Restorative Dent* 11:480–487, 1991.

Becker W, Becker BE, Caffesse R: A comparison of demineralized freeze-dried bone and autologous bone to induce bone formation in human extraction sockets. *J Periodontol* 65:1128–1133, 1994.

Becker W, Becker BE, Polizzi G: Autogenous bone grafting of bone defects adjacent to implants placed into immediate extraction sockets in patients: a prospective study. *Int J Oral Maxillofac Implants* 9:398, 1994.

Becker W, Dahlin C, Becker BE, et al: The use of e-PTFE barrier membranes for bone promotion around titanium implants placed into extraction sockets: a prospective multicenter study. *Int J Oral Maxillofac Implants* 9:31–40, 1994.

Becker W, Hujoel P, Becker BE: Effect of barrier membranes and autologous bone grafts on ridge width preservation around implants. *Clin Implant Dent Relat Res* 4:143–149, 2002.

Becker W, Schenk R, Higuchi K, et al: Variations in bone regeneration adjacent to implants augmented with barrier membranes alone or with demineralized freeze-dried bone or autologous grafts: a study in dogs. *Int J Oral Maxillofac Implants* 10:143–154, 1995.

Buser D, Dula K, Hirt HP, et al: Lateral ridge augmentation using autografts and barrier membranes: a clinical study with 40 partially edentulous patients. *J Oral Maxillofac Surg* 54:420–432, discussion 432-423, 1996.

Klokkevold PR, Han TJ, Camargo PM: Aesthetic management of extractions for implant site development: delayed versus staged implant placement. *Pract Periodontics Aesthet Dent* 11:603–610, quiz 612, 1999.

Mellonig JT, Nevins M: Guided bone regeneration of bone defects associated with implants: an evidence-based outcome assessment. *Int J Periodontics Restorative Dent* 15:168–185, 1995.

Simion M, Dahlin C, Trisi P, et al: Qualitative and quantitative comparative study on different filling materials used in bone tissue regeneration: a controlled clinical study. *Int J Periodontics Restorative Dent* 14:198–215, 1994.

References

References for this chapter are found on the companion website www.expertconsult.com.

References

1. Bahat O, Handelsman M: Periodontal reconstructive flaps–classification and surgical considerations. *Int J Periodontics Restorative Dent* 11:480–487, 1991.
2. Becker W, Becker BE, Caffesse R: A comparison of demineralized freeze-dried bone and autologous bone to induce bone formation in human extraction sockets. *J Periodontol* 65:1128–1133, 1994.
3. Becker W, Becker BE, Polizzi G: Autogenous bone grafting of bone defects adjacent to implants placed into immediate extraction sockets in patients: a prospective study. *Int J Oral Maxillofac Implants* 9:398, 1994.
4. Becker W, Clokie C, Sennerby L, et al: Histologic findings after implantation and evaluation of different grafting materials and titanium micro screws into extraction sockets: case reports. *J Periodontol* 69:414–421, 1998.
5. Becker W, Dahlin C, Becker BE, et al: The use of e-PTFE barrier membranes for bone promotion around titanium implants placed into extraction sockets: a prospective multicenter study. *Int J Oral Maxillofac Implants* 9:31–40, 1994.
6. Becker W, Hujoel P, Becker BE: Effect of barrier membranes and autologous bone grafts on ridge width preservation around implants. *Clin Implant Dent Relat Res* 4:143–149, 2002.
7. Becker W, Schenk R, Higuchi K, et al: Variations in bone regeneration adjacent to implants augmented with barrier membranes alone or with demineralized freeze-dried bone or autologous grafts: a study in dogs. *Int J Oral Maxillofac Implants* 10:143–154, 1995.
8. Becker W, Urist MR, Tucker LM, et al: Human demineralized freeze-dried bone: inadequate induced bone formation in athymic mice. A preliminary report. *J Periodontol* 66:822–828, 1995.
9. Buser D, Dula K, Hirt HP, et al: Lateral ridge augmentation using autografts and barrier membranes: a clinical study with 40 partially edentulous patients. *J Oral Maxillofac Surg* 54:420–432, discussion 432-423, 1996.
10. Carlsson GE, Persson G: Morphologic changes of the mandible after extraction and wearing of dentures. A longitudinal, clinical, and x-ray cephalometric study covering 5 years. *Odontol Revy* 18:27–54, 1967.
11. Dahlin C, Andersson L, Linde A: Bone augmentation at fenestrated implants by an osteopromotive membrane technique. A controlled clinical study. *Clin Oral Implants Res* 2:159–165, 1991.
12. Dahlin C, Lekholm U, Becker W, et al: Treatment of fenestration and dehiscence bone defects around oral implants using the guided tissue regeneration technique: a prospective multicenter study. *Int J Oral Maxillofac Implants* 10:312–318, 1995.
13. Dahlin C, Linde A, Gottlow J, et al: Healing of bone defects by guided tissue regeneration. *Plast Reconstr Surg* 81:672–676, 1988.
14. Doblin JM, Salkin LM, Mellado JR, et al: A histologic evaluation of localized ridge augmentation utilizing DFDBA in combination with e-PTFE membranes and stainless steel bone pins in humans. *Int J Periodontics Restorative Dent* 16:120–129, 1996.
15. Donovan MG, Dickerson NC, Hanson LJ, et al: Maxillary and mandibular reconstruction using calvarial bone grafts and Branemark implants: a preliminary report. *J Oral Maxillofac Surg* 52:588–594, 1994.
16. Eriksson AR, Albrektsson T: Temperature threshold levels for heat-induced bone tissue injury: a vital-microscopic study in the rabbit. *J Prosthet Dent* 50:101–107, 1983.
17. Friedmann A, Strietzel FP, Maretzki B, et al: Histological assessment of augmented jaw bone utilizing a new collagen barrier membrane compared to a standard barrier membrane to protect a granular bone substitute material. *Clin Oral Implants Res* 13:587–594, 2002.
18. Fugazzotto PA: GBR using bovine bone matrix and resorbable and nonresorbable membranes. Part 1: histologic results. *Int J Periodontics Restorative Dent* 23:361–369, 2003.
19. Gelb DA: Immediate implant surgery: three-year retrospective evaluation of 50 consecutive cases. *Int J Oral Maxillofac Implants* 8:388–399, 1993.
20. Geurs NC, Korostoff JM, Vassilopoulos PJ, et al: Clinical and histologic assessment of lateral alveolar ridge augmentation using a synthetic long-term bioabsorbable membrane and an allograft. *J Periodontol* 79:1133–1140, 2008.
21. Hunt D, Jovanovic S: Autogenous bone harvesting: a clinical graft technique for particulate and amniocortical bone blocks. *Int J Periodontics Restorative Dent* 19:165, 1999.
22. Jensen OT, Greer RO, Jr, Johnson L, et al: Vertical guided bone-graft augmentation in a new canine mandibular model. *Int J Oral Maxillofac Implants* 10:335–344, 1995.
23. Jovanovic SA, Buser D: *Guided bone regeneration in dehiscence defects and delayed extraction sockets*, Chicago, 1994, Quintessence.
24. Jovanovic SA, Nevins M: Bone formation utilizing titanium-reinforced barrier membranes. *Int J Periodontics Restorative Dent* 15:56, 1995.
25. Jovanovic SA, Spiekermann H, Richter EJ: Bone regeneration around titanium dental implants in dehisced defect sites: a clinical study. *Int J Oral Maxillofac Implants* 7:233–245, 1992.
26. Klokkevold PR, Han TJ, Camargo PM: Aesthetic management of extractions for implant site development: delayed versus staged implant placement. *Pract Periodontics Aesthet Dent* 11:603–610, quiz 612, 1999.
27. Klokkevold PR, Newman MG: Current status of dental implants: a periodontal perspective. *Int J Oral Maxillofac Implants* 15:56–65, 2000.
28. Kostopoulos L, Karring T: Augmentation of the rat mandible using guided tissue regeneration. *Clin Oral Implants Res* 5:75–82, 1994.
29. Kostopoulos L, Karring T: Guided bone regeneration in mandibular defects in rats using a bioresorbable polymer. *Clin Oral Implants Res* 5:66–74, 1994.
30. Landsberg CJ, Grosskopf A, Weinreb M: Clinical and biological observations of demineralized freeze-dried bone allografts in augmentation procedures around dental implants. *Int J Oral Maxillofac Implants* 9:586, 1994.
31. Lang NP, Bragger U, Hammerle CH, et al: Immediate transmucosal implants using the principle of guided tissue regeneration. I. Rationale, clinical procedures and 30-month results. *Clin Oral Implants Res* 5:154–163, 1994.
32. Lang NP, Hammerle CH, Bragger U, et al: Guided tissue regeneration in jawbone defects prior to implant placement. *Clin Oral Implants Res* 5:92–97, 1994.
33. Lazzara RJ: Immediate implant placement into extraction sites: surgical and restorative advantages. *Int J Periodontics Restorative Dent* 9:332–343, 1989.
34. Lekovic V, Camargo PM, Klokkevold PR, et al: Preservation of alveolar bone in extraction sockets using bioabsorbable membranes. *J Periodontol* 69:1044–1049, 1998.
35. Lekovic V, Kenney EB, Weinlaender M, et al: A bone regenerative approach to alveolar ridge maintenance following tooth extraction. Report of 10 cases. *J Periodontol* 68:563–570, 1997.
36. Linde A, Thoren C, Dahlin C, et al: Creation of new bone by an osteopromotive membrane technique: an experimental study in rats. *J Oral Maxillofac Surg* 51:892–897, 1993.
37. Llambes F, Silvestre FJ, Caffesse R: Vertical guided bone regeneration with bioabsorbable barriers. *J Periodontol* 78:2036–2042, 2007.
38. Mellonig JT, Nevins M: Guided bone regeneration of bone defects associated with implants: an evidence-based outcome assessment. *Int J Periodontics Restorative Dent* 15:168–185, 1995.
39. Missika P, Abbou M, Rahal B: Osseous regeneration in immediate postextraction implant placement: a literature review and clinical evaluation. *Pract Periodontics Aesthet Dent* 9:165–175, quiz 176, 1997.
40. Murray G, Holden R, Roschlau W: Experimental and clinical study of new growth of bone in a cavity. *Am J Surg* 93:385, 1957.
41. Nemcovsky CE, Serfaty V: Alveolar ridge preservation following extraction of maxillary anterior teeth. Report on 23 consecutive cases. *J Periodontol* 67:390–395, 1996.
42. Nevins M, Mellonig JT: The advantages of localized ridge augmentation prior to implant placement: a staged event. *Int J Periodontics Restorative Dent* 14:96–111, 1994.
43. Palmer RM, Floyd PD, Palmer PJ, et al: Healing of implant dehiscence defects with and without expanded polytetrafluoroethylene

membranes: a controlled clinical and histological study. *Clin Oral Implants Res* 5:98–104, 1994.
44. Parodi R, Santarelli G, Carusi G: Application of slow-resorbing collagen membrane to periodontal and peri-implant guided tissue regeneration. *Int J Periodontics Restorative Dent* 16:174–185, 1996.
45. Rominger JW, Triplett RG: The use of guided tissue regeneration to improve implant osseointegration. *J Oral Maxillofac Surg* 52:106–112, discussion 112-103, 1994.
46. Sandberg E, Dahlin C, Linde A: Bone regeneration by the osteopromotion technique using bioabsorbable membranes: an experimental study in rats. *J Oral Maxillofac Surg* 51:1106–1114, 1993.
47. Schenk RK, Buser D, Hardwick WR, et al: Healing pattern of bone regeneration in membrane-protected defects: a histologic study in the canine mandible. *Int J Oral Maxillofac Implants* 9:13–29, 1994.
48. Schwartz Z, Mellonig JT, Carnes DL, Jr, et al: Ability of commercial demineralized freeze-dried bone allograft to induce new bone formation. *J Periodontol* 67:918–926, 1996.
49. Schwartz Z, Somers A, Mellonig JT, et al: Ability of commercial demineralized freeze-dried bone allograft to induce new bone formation is dependent on donor age but not gender. *J Periodontol* 69:470–478, 1998.
50. Schwartz-Arad D, Chaushu G: Placement of implants into fresh extraction sites: 4 to 7 years retrospective evaluation of 95 immediate implants. *J Periodontol* 68:1110–1116, 1997.
51. Shanaman RH: The use of guided tissue regeneration to facilitate ideal prosthetic placement of implants. *Int J Periodontics Restorative Dent* 12:256–265, 1992.
52. Shanaman RH: A retrospective study of 237 sites treated consecutively with guided tissue regeneration. *Int J Periodontics Restorative Dent* 14:292–301, 1994.
53. Simion M, Baldoni M, Rossi P, et al: A comparative study of the effectiveness of e-PTFE membranes with and without early exposure during the healing period. *Int J Periodontics Restorative Dent* 14:166–180, 1994.
54. Simion M, Dahlin C, Trisi P, et al: Qualitative and quantitative comparative study on different filling materials used in bone tissue regeneration: a controlled clinical study. *Int J Periodontics Restorative Dent* 14:198–215, 1994.
55. ten Bruggenkate CM, Kraaijenhagen HA, van der Kwast WA, et al: Autogenous maxillary bone grafts in conjunction with placement of I.T.I. endosseous implants. A preliminary report. *Int J Oral Maxillofac Surg* 21:81–84, 1992.
56. Tolman DE: Reconstructive procedures with endosseous implants in grafted bone: a review of the literature. *Int J Oral Maxillofac Implants* 10:275–294, 1995.
57. Urist MR: Bone: formation by autoinduction. *Science* 150:893–899, 1965.
58. von Arx T, Buser D: Horizontal ridge augmentation using autogenous block grafts and the guided bone regeneration technique with collagen membranes: a clinical study with 42 patients. *Clin Oral Implants Res* 17:359–366, 2006.
59. Wilson TG, Jr, Schenk R, Buser D, et al: Implants placed in immediate extraction sites: a report of histologic and histometric analyses of human biopsies. *Int J Oral Maxillofac Implants* 13:333–341, 1998.
60. Yildirim M, Hanisch O, Spiekermann H: Simultaneous hard and soft tissue augmentation for implant-supported single-tooth restorations. *Pract Periodontics Aesthet Dent* 9:1023–1031, quiz 1032, 1997.
61. Zellin G, Gritli-Linde A, Linde A: Healing of mandibular defects with different biodegradable and non-biodegradable membranes: an experimental study in rats. *Biomaterials* 16:601–609, 1995.

CHAPTER 77

Advanced Implant Surgical Procedures

Istvan A. Urban, Perry R. Klokkevold, and David L. Cochran

CHAPTER OUTLINE

Maxillary Sinus Elevation and Bone Augmentation
Supracrestal/Vertical Bone Augmentation
Growth Factors In Bone Augmentation
Conclusion

The high predictability of endosseous dental implants has led to routine use and an expectation for success. However, the ultimate success for any patient or any particular implant relies on several factors, the most important of which is the *availability of bone.* The loss of teeth, whether caused by disease or trauma, can result in severe deficiency of the alveolar bone. Horizontal bone deficiencies are managed quite predictably with localized bone augmentation procedures (see Chapter 76). However, vertical bone deficiencies are much more challenging. The edentulous posterior maxilla is challenging as the result of a general lack of bone volume and the omnipresent poor bone quality of the area; that is, posterior maxillary bone often consists of a thin cortical shell filled with sparse trabecular bone. Edentulous sites, in any anatomic location, that have suffered significant vertical alveolar bone loss are especially challenging to reconstruct.

This chapter reviews advanced surgical procedures used to treat the most challenging type of bone loss, which is *a deficiency in vertical bone height.* Maxillary sinus elevation and bone augmentation, vertical bone augmentation, and distraction osteogenesis are reviewed. The role of growth factors in bone augmentation procedures is also discussed.

Maxillary Sinus Elevation and Bone Augmentation

Rehabilitation of the edentulous posterior maxilla with endosseous dental implants often represents a clinical challenge because of insufficient bone volume resulting from *pneumatization* of the maxillary sinus and resorption or loss of alveolar crestal bone. Before the utilization of bone augmentation procedures, patients with missing teeth and deficient bone in the posterior maxilla could only be rehabilitated with removable prostheses, short implants, or cantilevered restorations (i.e., supported by adjacent teeth or implants). Historically, the failure rate for implants in the posterior maxilla has been significantly higher than failure rates for implants in all other anatomic locations.[17] Consequently, procedures such as the maxillary sinus elevation and bone augmentation are needed to increase the amount of vertical bone height in the posterior maxilla for the placement of implants (see Video 77-1: Crestal Window Technique with Immediate Implant Placement).

In 1980, Boyne and James[4] first described a procedure to graft the maxillary sinus floor with autogenous marrow and bone for placing an implant (blade type). Access to the maxillary sinus was gained through a "Caldwell-Luc" procedure (i.e., an opening into the maxillary sinus created at the anterior–superior aspect). Since then several other techniques have been described, including variations on the lateral window osteotomy and a variety of techniques to lift the sinus floor from a crestal approach.

Various bone graft materials have been used to augment the maxillary sinus. The 1996 Consensus Conference on Maxillary Sinus Bone Grafting reviewed available data and concluded that allografts, alloplasts, and xenografts, alone or in combination with autogenous bone, can be effective as bone substitute graft materials for sinus bone augmentation.[18] More importantly, it was concluded that the sinus graft procedure with implant placement is a highly predictable and effective therapeutic modality for the rehabilitation of the posterior maxilla. Sinus floor elevation with bone augmentation of the maxillary sinus is now a well-accepted procedure used to increase bone volume in the posterior maxilla. Numerous reports have validated the safety and efficacy of this procedure.[7,10,12,42] Implant success rates are equal to or better than that of implants placed in nongrafted maxillary bone (i.e., areas of the posterior maxilla with adequate height of existing native bone).[42] Thus bone augmentation of the maxillary sinus is a viable option for the vertically deficient posterior maxilla in which the interocclusal dimension is normal or only moderately increased.

Indications and Contraindications

As with any therapeutic procedure, treatment success depends on appropriate patient selection, careful evaluation of the anatomy, identification and management of any pathology, sound surgical procedures, and appropriate postsurgical management. The primary indication for maxillary sinus elevation and bone augmentation, specific for the placement of endosseous dental implants, is an alveolar bone height in the posterior maxilla that is deficient (e.g., less than 7 mm of existing vertical bone height). Other factors that must be considered include the health of the patient, the condition of the remaining dentition, and the likelihood of a beneficial outcome. A thorough evaluation of the patient and the judgment of the clinician ultimately determine whether the procedure is indicated for any particular individual.

Contraindications to maxillary sinus elevation and bone augmentation are similar to contraindications for other surgical procedures, with the added consideration of the maxillary sinus (Box 77-1). Patients must be in good general health and free of diseases

BOX 77-1 Contraindications for Maxillary Sinus Elevation and Bone Augmentation

Local Factors
Tumors or pathologic growth in the sinus
Maxillary sinus infection
Severe chronic sinusitis
Surgical scar/deformity of sinus cavity
Dental infection involving or in proximity to sinus
Severe allergic rhinitis/sinusitis
Chronic topical steroid use

Systemic Factors
Radiation therapy involving the maxillary sinus
Metabolic disease (e.g., uncontrolled diabetes mellitus)
Excessive tobacco use
Drug/alcohol abuse
Psychological/mental impairment

that affect the maxilla or maxillary sinus. Local factors that are considered contraindications to maxillary sinus elevation and bone augmentation include the presence of tumors, maxillary sinus infection, severe chronic sinusitis, scar or deformity of the sinus cavity from previous surgery, dental infection, severe allergic rhinitis, and chronic use of topical steroids. Systemic contraindications to treatment include radiation therapy, uncontrolled metabolic disease (e.g., diabetes), excessive tobacco use, drug or alcohol abuse, and psychologic or mental impairment.

Surgical Procedures for Sinus Elevation

The goal of sinus elevation and bone augmentation is to lift the schneiderian membrane from the floor of the sinus, raising it up into the sinus cavity to create a new, more superiorly located sinus floor with a space between it and the deficient alveolar ridge. The newly created space can then be filled with bone (or a suitable bone substitute material) to increase the total vertical height of bone in the posterior maxilla for the placement of endosseous implants.

The maxillary sinus bone augmentation procedure was first described in the 1960s by Boyne (unpublished oral presentations to United States Navy Dental postgraduates, 1965-1968) and originally used as a preprosthetic surgical procedure for patients with large tuberosities and pneumatized sinuses.[3] To reduce the size of the tuberosity without creating an oral-antral defect, bone was grafted into the sinus cavity to increase the volume of bone within the maxillary tuberosity. After a period of healing, the tuberosity was able to be reduced surgically from the alveolar ridge crest. As stated earlier, Boyne and James[4] were the first to describe the use of the maxillary sinus bone-grafting procedure for placement of an implant (blade type) to retain a prosthesis. Greater use and further development of this procedure evolved along with the success of endosseous dental implants and the desire to replace missing posterior maxillary teeth with implant-retained restorations.

The techniques used for sinus elevation and bone augmentation are primarily differentiated by the anatomic location of the osteotomy used to gain access to the maxillary sinus. Specifically, four different anatomic locations have been described: (a) the superior lateral wall, or "Caldwell-Luc," opening, which is located just anterior to the zygomatic arch; (b) the middle lateral wall opening, which is located midway between the alveolar ridge and the zygomatic arch; (c) the inferior lateral wall opening, which is located at the level of the alveolar ridge; and (d) the crestal osteotomy approach, which is an opening through the alveolar bone crest superiorly toward the floor of the sinus. At present, the most common procedures used for sinus elevation and bone augmentation are the lateral wall antrostomy (middle or inferior approach) and the crestal approach osteotomy.

Presurgical Evaluation of Maxillary Sinus. Presurgical evaluation of the maxillary sinus is primarily accomplished using radiographic examination techniques (Figure 77-1). Several observations about the anatomy can be made with a periapical or panoramic projection, but the internal anatomy is more accurately assessed with a three-dimensional scan, such as computed tomography (CT) or cone-beam CT (CBCT) scan. The maxillary sinus should be evaluated for any pathology, masses, or the presence of septa. If three-dimensional scans are available, the lateral wall should also be evaluated for the presence of medium or large intraosseous vascular channels (see Figure 54-15). Medium- to large-sized vessels occasionally traverse the lateral wall of the maxillary sinus, and identifying them is helpful in avoiding a bleeding problem during surgery (see Chapter 54).[25]

Simultaneous Implant Placement. Simultaneous implant placement is possible with sinus elevation and bone augmentation procedures as long as the implant can be stabilized in the desired location with the existing native bone (Figure 77-2).

It has been suggested that a minimum of 5 mm of existing native bone in the alveolar crest is required for simultaneous implant placement. However, some clinicians claim that it is possible to place implants simultaneously with as little as 1 mm of remaining bone.[23,48] The most important factor in determining whether implant(s) can be placed at the time of sinus bone augmentation is the ability to achieve implant stability in the existing bone rather than any measure of bone height. Factors that influence implant stability include bone height, bone quality, precision of osteotomy preparation, and the surgeon's skill and experience. If inadequate native bone exists to place implants at the time of the bone augmentation procedure, they can be placed at a subsequent surgery after an appropriate healing period (Figure 77-3).

Bone Graft Materials. *Autogenous bone* is often considered the "gold standard" for bone augmentation because of its osteoconductive, osteoinductive, and osteogenic properties.[4] However, harvesting autogenous bone from intraoral or extraoral locations creates a second surgical site with additional morbidity. Numerous studies have demonstrated clinical success using many variations of bone graft materials and combinations.[18,42]

Several recent clinical studies and reports have attempted to evaluate the maxillary sinus augmentation procedures using a variety of bone-grafting materials, including autogenous bone from the iliac crest or oral cavity and bone substitutes such as freeze-dried demineralized bone, resorbable and nonresorbable hydroxyapatite, and xenografts. However, only a few studies have critically evaluated the long-term clinical outcome of this procedure, and most have used a small study population. Short- to long-term clinical studies of dental implants placed into grafted sinuses demonstrate an equivalent or higher survival rate as compared to implants placed in native maxillary bone (i.e., without the need of sinus augmentation).[18,42] The results of these studies support the clinical predictability of maxillary sinus augmentation procedures for the rehabilitation of the edentulous posterior maxilla with implant-supported prostheses (Figure 77-4).

The use of bone-substitute graft materials can reduce the morbidity introduced by a second surgical site while maintaining equally good implant success rates.[18] Anorganic bovine bone-derived mineral (ABBM; ABBM has also been referred to in the

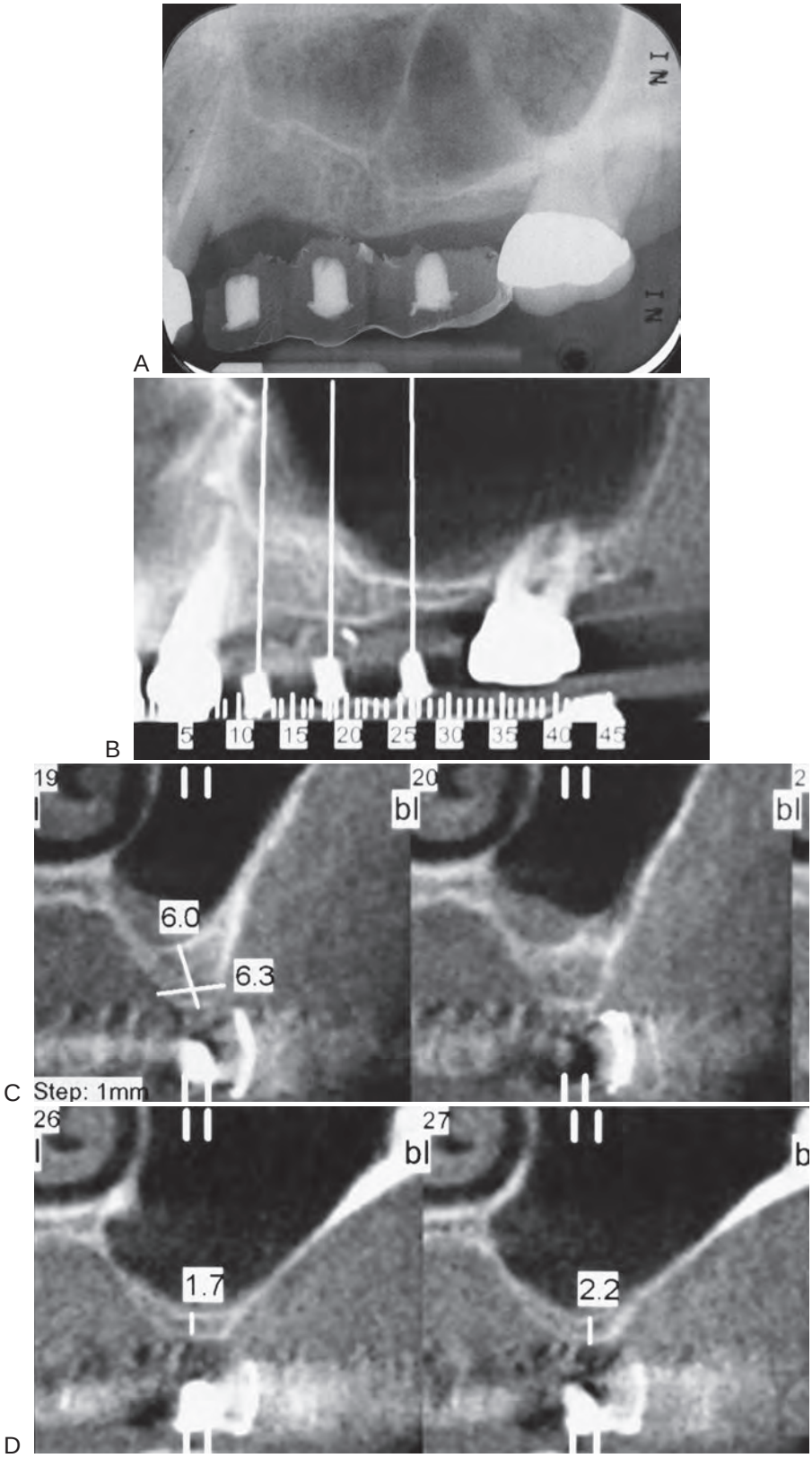

Figure 77-1 Presurgical evaluation of the maxillary sinus. A, Periapical radiograph. **B,** Panoramic projection from cone-beam scan. Note the presence of maxillary septa in the premolar region. **C,** Cross-sectional image in premolar region showing about 6 mm of bone height and presence of maxillary septa. **D,** Cross-sectional image in molar region showing about 2 mm of bone height.

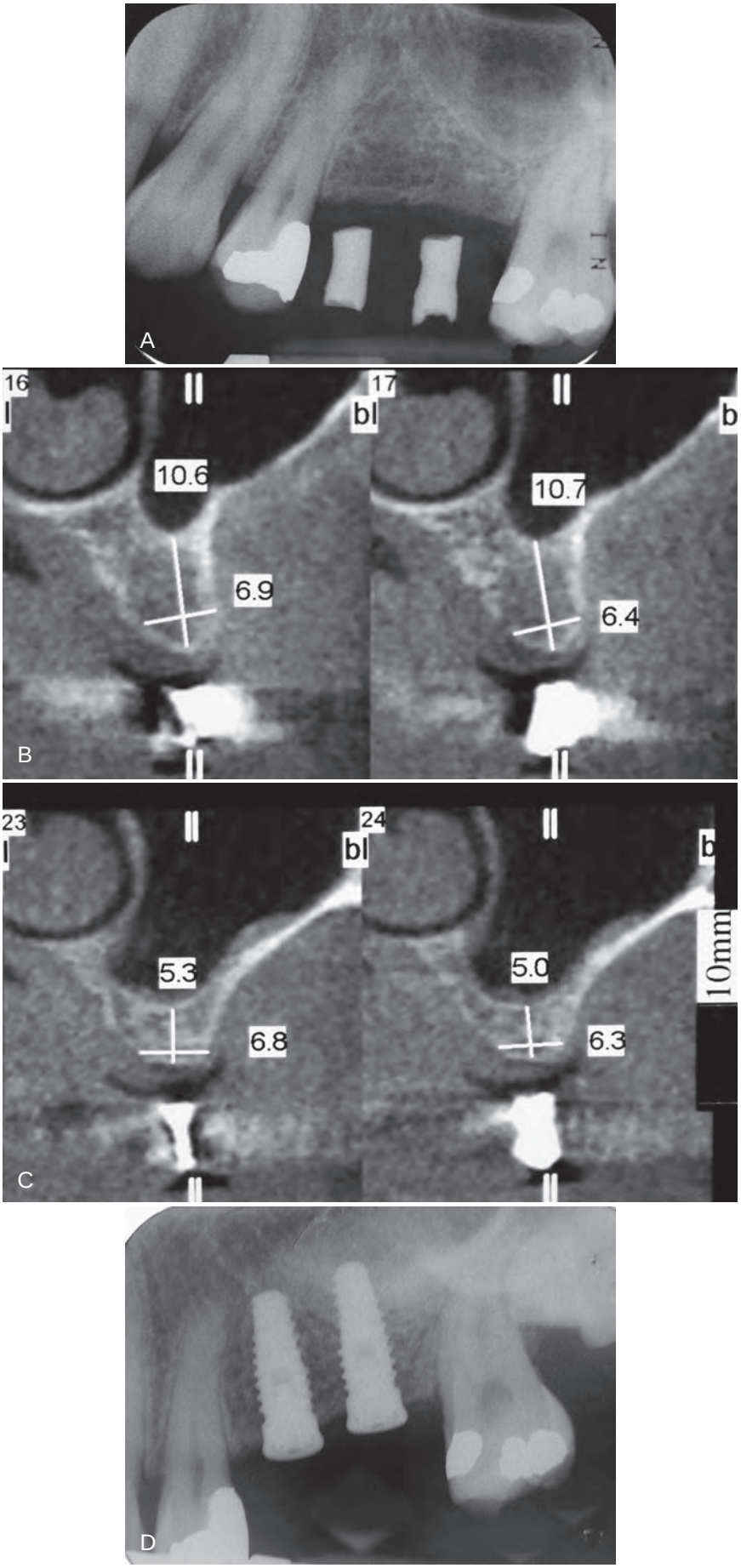

Figure 77-2 Simultaneous implant placement with maxillary sinus elevation and bone augmentation procedure. A, Preoperative periapical radiograph. **B,** Preoperative, cross-sectional image in premolar region demonstrating 10.6 mm of vertical bone height. **C,** Preoperative, cross-sectional image in molar region demonstrating 5.3 mm of vertical bone height. **D,** Postsurgical radiograph of graft and implants in place.

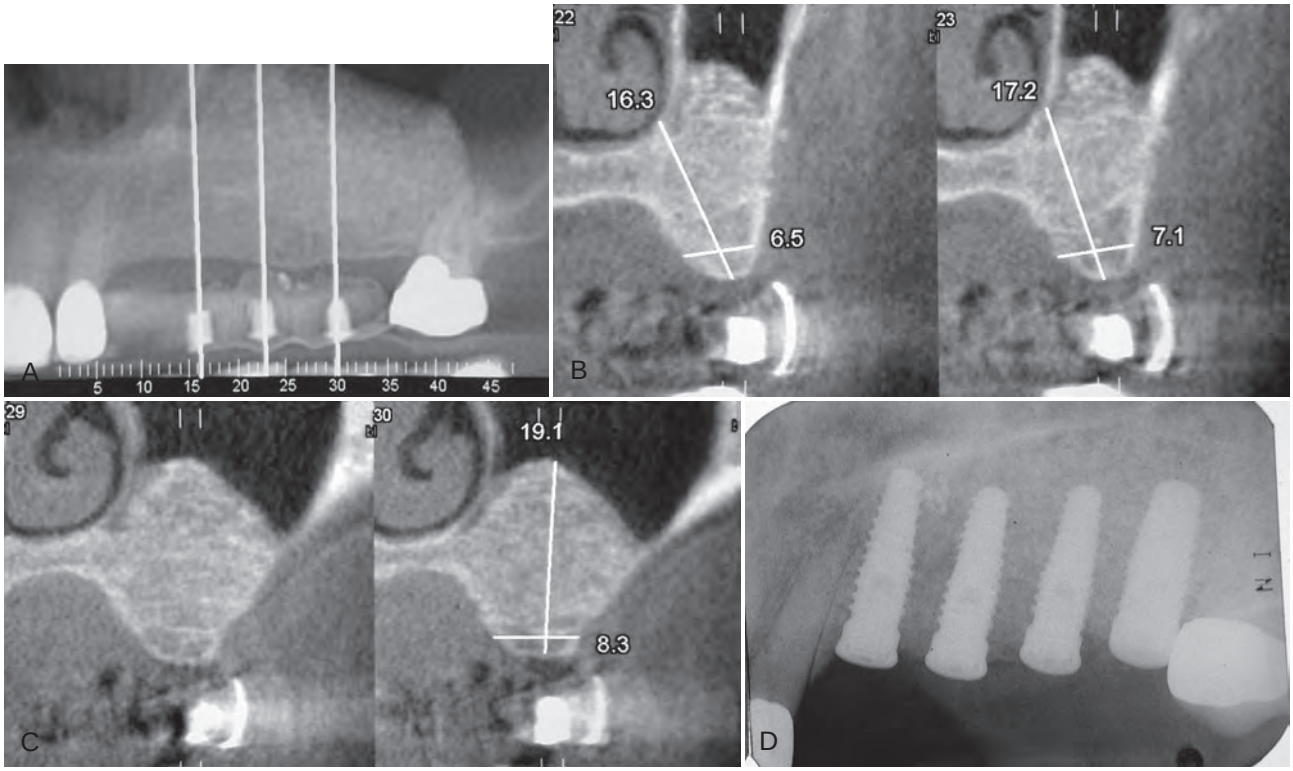

Figure 77-3 Staged implant placement after sinus elevation and bone augmentation procedure. Same patient as in Figure 77-1. See preoperative radiograph and preoperative cross-sectional images. **A,** Postsurgical panoramic view of bone-augmented maxillary sinus. The maxillary left cuspid has been extracted because of a vertical fracture. **B,** Postsurgical cross-sectional image in premolar region demonstrating more than 17-mm vertical bone height. **C,** Postsurgical cross-sectional image in molar region demonstrating 19.1-mm vertical bone height. **D,** Postsurgical radiograph of implants placed in the previously grafted maxillary sinus (and cuspid site).

literature as *deproteinized bovine bone mineral, deproteinized anorganic bovine bone,* and *anorganic bovine bone*) has also been used successfully for sinus augmentation.[46] This graft material has demonstrated good dimensional stability and high implant survival rates.[10] These materials form an osteoconductive scaffold for bone growth but do not have any osteoinductive properties. A possible exception is demineralized freeze-dried bone allograft (DFDBA). This material has demonstrated osteoinductive potential but has not proved to be particularly advantageous in the maxillary sinus bone augmentation.[18,45] In fact, the bone volume gained with the use of DFDBA is less than that achieved with mineralized graft materials as a result of moderate postoperative shrinkage of DFDBA-grafted bone.

Crestal Osteotomy Technique. In cases with moderate bone height (e.g., 7 to 9 mm) that require limited sinus bone augmentation, a crestal approach to elevation may be desirable. The osteotome technique is a procedure that uses osteotomes (Figure 77-5) to compress bone (internally from the alveolar crest upward) against the floor of the sinus, ultimately leading to a controlled "inward fracture" of the sinus floor bone and the schneiderian membrane, which should remain intact above the inward-fractured bone.

The osteotome sinus floor elevation technique was described by Summers.[35,36] It is considered to be a "conservative" approach to sinus elevation, but it is also a "blind" technique because it does not allow the operator to visualize the schneiderian membrane during the osteotomy. For this reason, it is a technique-sensitive procedure as well (i.e., the operator must "feel" the bone fracture and the membrane elevation). Verification of success can only be observed with radiographs and visualization of the bone graft material in the sinus cavity.

Procedure. An osteotomy site is prepared with a series of drills (e.g., initial drills used for implant site preparation) to a depth that is approximately 1 to 2 mm from the floor of the maxillary sinus. Osteotomes are used to increase compressive forces gradually against the floor of the sinus by adding incremental quantities of graft material until the floor of the sinus fractures inward (Figure 77-6). After the controlled inward fracture of the maxillary sinus floor, bone graft materials continue to be slowly introduced, through the osteotomy site and into the maxillary sinus, which continues to elevate the membrane and thus allows a vertical expansion of the bone height in a localized area of the maxillary sinus. Once the sinus membrane is elevated with bone graft material to the desired height, the implant osteotomy can be completed, with a final drill used to finish preparation of the site, and an implant can be inserted. Multiple individual sites can be elevated and prepared simultaneously through separate osteotomy sites.

Published reports of this technique have demonstrated increased bone height from 2 to 7 mm (average: 3.8 mm).[39] Thus the crestal approach is a useful technique for increasing the vertical height of bone up to approximately 4 mm. If more vertical bone height is needed, the lateral wall osteotomy approach may be more advantageous. In addition to the usual precautions and contraindications for sinus elevation and bone augmentation procedures, the osteotome technique may be contraindicated for sinuses that have an acutely sloped floor or septa in the location of the planned osteotomy. An acutely sloped sinus floor will tend to deflect the osteotome in an undesirable direction rather than allowing the osteotome to penetrate into the sinus space, and the presence of septa makes

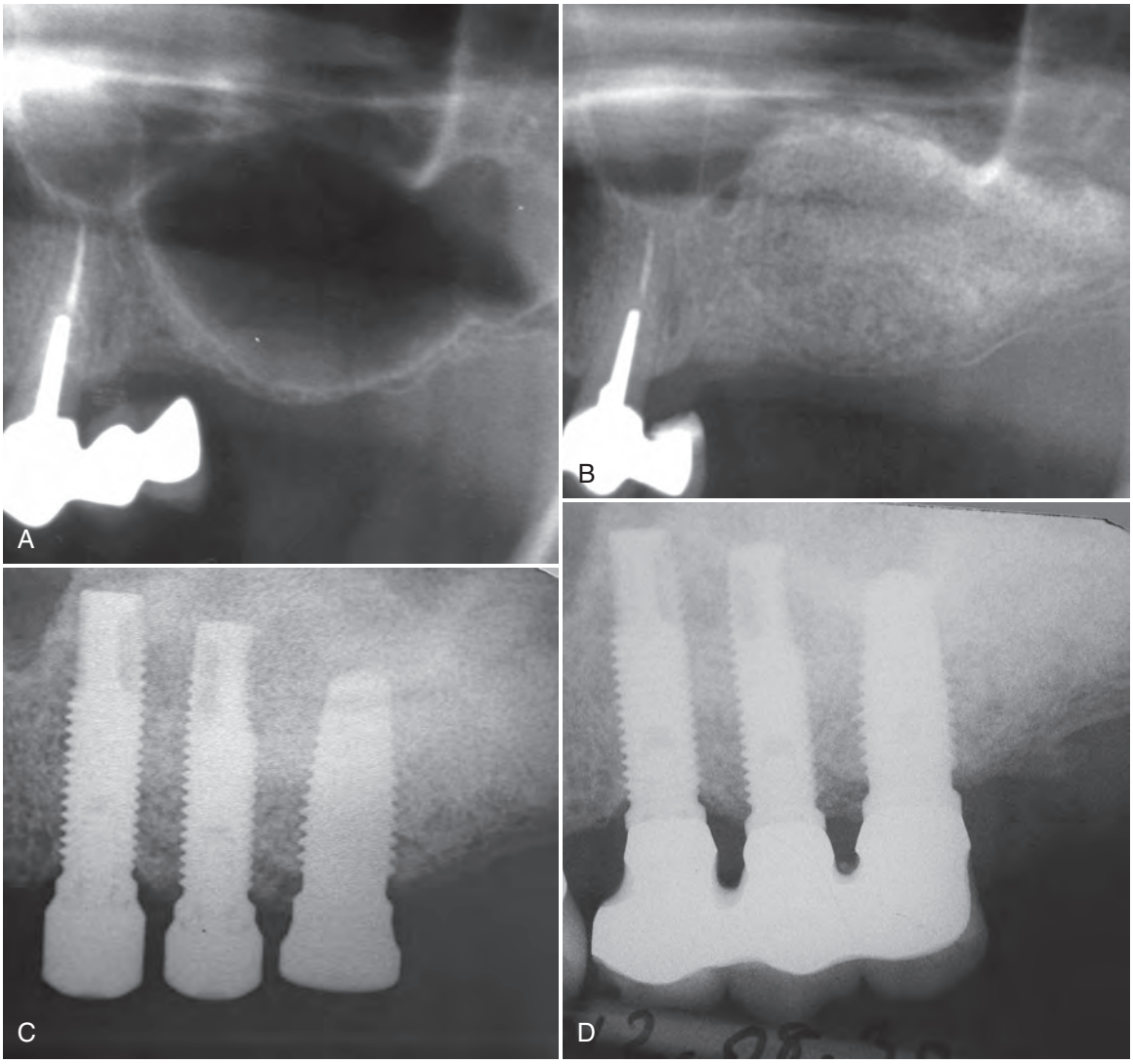

Figure 77-4 Long-term follow-up of patient presenting with minimal residual crestal bone height. A, Preoperative radiograph demonstrates minimal residual crestal bone height. **B,** Postoperative radiograph demonstrates sinus graft healing after 6 months. **C,** Abutment connection of implants after 6 months of submerged healing. The three distal implants were placed into augmented bone. **D,** Periapical radiograph demonstrates stability of crestal bone around implants at 10 years loading. *(From Urban IA, Lozada JL. A prospective study of implants placed in augmented sinuses with minimal and moderate residual crestal bone: results after 1 to 5 years.* Int J Oral Maxillofac Implants. *25(6):1203-12, 2010.)*

it virtually impossible to fracture the sinus floor inward. Box 77-2 provides additional precautions and clinician comments on using the osteotome technique. Several new instruments and techniques have emerged that improve the ability to create a crestal approach osteotomy while avoiding trauma or injury to the schneiderian membrane. These instruments/techniques vary from drill systems to piezoelectric bone surgery. See Chapter 80 for a description of piezoelectric bone surgery.

Lateral Window Technique. The lateral window technique is probably the most effective and efficient way to access the maxillary sinus and elevate the sinus floor. In this procedure, an opening into the maxillary sinus is created to elevate the schneiderian membrane and to place bone graft in the space immediately above the existing alveolar bone. The osteotomy can be prepared with a high-speed round diamond or a piezoelectric bone surgery device (see Chapter 81). Some clinicians prefer to cut the lateral window (outline cut through to the membrane) and use the impacted bony wall as the superior wall of the space created for bone grafting (Figure 77-7, *A* to *C*), and others prefer to eliminate the bony window entirely by reducing it to a paper-thin layer, which is easily removed (Figure 77-7, *D* to *F*). With the former technique, it is important to create a window that is small enough, relative to the mediolateral width of the maxillary sinus, to allow the "window" to be pushed completely into the sinus cavity. If the window cannot be inserted completely, it must be carefully separated from the membrane and removed. The bone removed from the lateral window osteotomy can be harvested and incorporated into the bone graft.

Elevation of the schneiderian membrane is accomplished with hand instruments that are inserted along the internal aspect of the bony walls of the sinus (Figure 77-8).

Great care is taken to avoid perforation of the membrane. Small instruments, such as the De Marco curette, are introduced along the inferior, anterior, posterior, and superior aspects of the prepared antrostomy window, gradually inserting further along the bone until the membrane begins to separate and lift away from the bone. Subsequently, larger instruments, such as the Gracey 13/14 curette, are gently introduced along the bone to continue lifting the membrane to the desired levels (height, width, and depth). Instruments

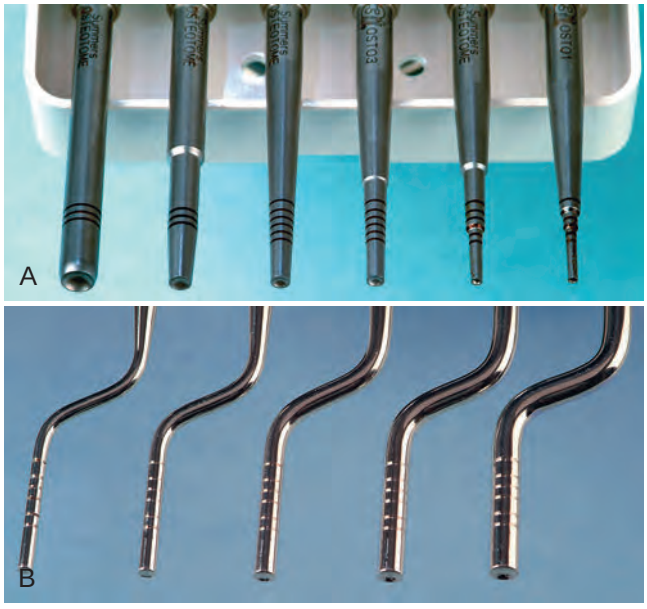

Figure 77-5 Osteotome instruments. A, Straight osteotomes. **B,** Offset osteotomes.

must always be kept in contact with the bone surface while elevating the schneiderian membrane to avoid perforation. Regardless of whether implants are being placed simultaneously or not, it is useful to estimate the dimensions of the augmentation needed by inserting a surgical guide with holes or markers indicating the ideal location for planned implants. Once elevated, the space can be grafted with bone (autogenous, bone substitute, or a combination). If implants are being simultaneously placed, the implant osteotomy sites should be prepared, and implants placed after the medial, anterior, and posterior aspects are filled with bone, thereby supporting the schneiderian membrane up and away from the drills and implants. After implant placement, the remaining lateral aspect is packed with bone graft. Finally, the antrostomy and bone graft is covered with a barrier membrane (e.g., resorbable membrane) and the flap is sutured.

Risks and Complications

The maxillary sinus elevation and bone augmentation procedure is technique sensitive, requiring meticulous surgical skills. Risks and complications of the procedure include tearing or perforation of the schneiderian membrane, intraoperative/postoperative bleeding, postoperative infection, and loss of bone graft or implants (see Chapter 82).

The reported incidence of perforation or tearing of the schneiderian membrane varies greatly (up to 60%) and depends largely on the anatomy of the sinus and the skill and experience of the operator.[20,24,30] The presence of septa in the maxillary sinus increases the likelihood of membrane perforation.

Positioning of the sinus window within 2 to 4 mm from the anterior and inferior borders of the sinus makes it easier to get direct access to the bony walls. This may lessen the amount of membrane perforation during the elevation of the sinus membrane.

If the perforation is small, it can often be managed with a resorbable barrier membrane placed over the opening, followed by careful packing of the bone augmentation material. If a perforation or tear is extensive (see Figure 82-18, *A* online), it may be necessary to abort the procedure, close the wound, and attempt it again at a later date.

Infections have been reported in a small but significant number of cases (up to 10%) after maxillary sinus elevation and bone augmentation procedures.[30,43] Prevention of infection is crucial for bone augmentation procedures. Surgery should always be performed using sterile technique. Patients should use a presurgical antimicrobial mouth rinse (e.g., chlorhexidine), and postoperative antibiotics should be prescribed. The signs and symptoms of sinus graft infection as well as a detailed protocol for its treatment was described in a recent clinical study.[43]

Opening a window through the lateral wall is accomplished by completely cutting through the bone of the lateral wall up to the schneiderian membrane. The membrane is highly vascularized and may bleed significantly.[1,25] However, a more serious bleeding problem can arise if an intraosseous artery is severed in the process. Bone wax and topical hemostatic agents must be available to manage such an urgent surgical complication. If a medium-to-large vascular channel is identified (with CT or CBCT scan) presurgically, it can usually be avoided.

Supracrestal/Vertical Bone Augmentation

Supracrestal or vertical bone augmentation presents one of the greatest challenges of bone regeneration in implant dentistry. This is primarily a result of the difficulty of the surgical procedure and its potential complications. Since vertical augmentation can be a very challenging procedure with a relatively high rate of complications, it is necessary to justify this particular treatment for each patient. The rate of complications associated with vertical bone augmentation procedures, including membrane exposure and/or postoperative infection, is reported to range from 2.78% to 17%.[33,34,38,41] Alternative treatment options, albeit with limited outcomes, need to be considered. For example, regenerating a vertically deficient defect may not be necessary if (a) implants can be placed in adjacent sites, (b) short implants can be used, or (c) pink ceramic can be used to create an illusion of "normal" soft-tissue anatomy.

Historical attempts to vertically increase alveolar bone height using modalities such as onlay bone grafting have failed. More recent treatment modalities developed for vertical bone growth include distraction osteogenesis and vertical guided bone regeneration (GBR). The techniques and evidence of success are presented.

Guided Bone Regeneration and Augmentation

The surgical technique of GBR for supracrestal regeneration was described in the 1990s.[36] Both animal and human studies demonstrated successful vertical bone augmentation with histologic evidence.[19,34] The available evidence describing and supporting the use of supracrestal GBR is limited. Some studies have evaluated the effect of space creation by a membrane alone, whereas others have used an autogenous bone graft to maintain space under the membrane. Animal (dog) studies demonstrated the ability to gain about 2.7 mm (0.4 to 4.0 mm) of vertical bone height around simultaneously placed implants.[19] In one clinical study, 5 patients were treated with a supracrestal exposure of 3 to 7 mm (average: 4.67 mm) and showed a clinical bone gain of 0.5 to 4 mm (average: 2.97 mm) after 9 months.[34] These studies suggest that supracrestal bone formation up to 3 mm is predictable using the GBR technique with a membrane–blood clot combination.

Simion et al[34] and Jovanovic et al[19] used a titanium-reinforced (TR) membrane for vertical bone regeneration around dental implants without the placement of supportive bone substrates. Instead, the space was filled with a blood clot facilitated by perforating the cortical bone surface or by injecting the space with

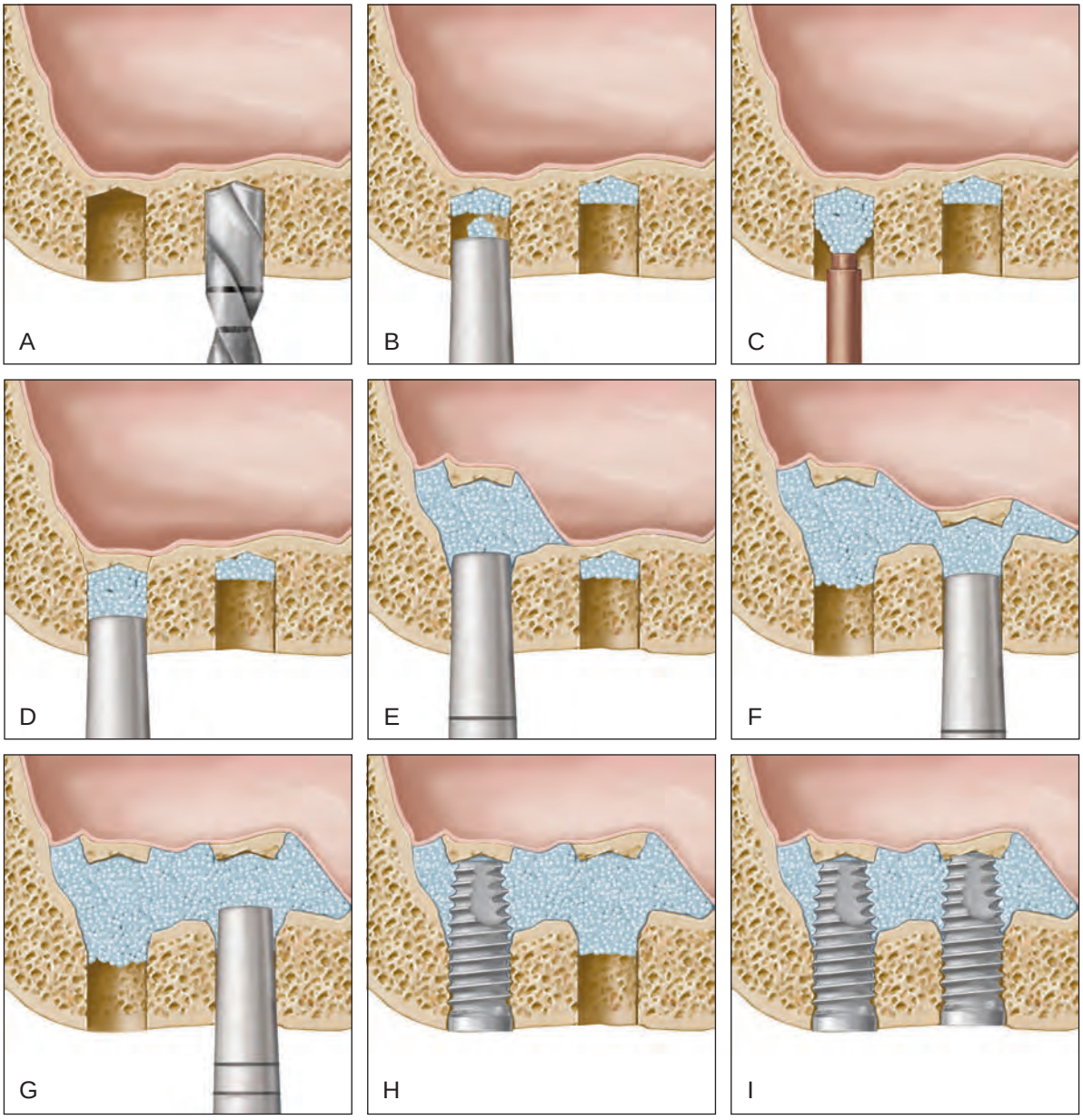

Figure 77-6 Illustration of the osteotome sinus floor elevation (OSFE) technique. A, Osteotomy prepared with drills to a depth that is near the maxillary sinus floor. **B,** Graft material introduced into osteotomy and condensed with osteotome. **C,** Additional bone graft material is added to the osteotomy. **D,** Bone graft continues to be condensed by osteotomes. **E,** This process is continued until floor of sinus is "fractured" up internally and the floor is lifted with the bone graft material. **F,** Continuation of process shown in E for second site. **G,** Bone graft material continues to be added gradually to both sites with osteotome condensation to elevate the schneiderian membrane away from the bone (maxillary sinus walls) until sufficient height and volume are created for the placement of implants. **H,** The coronal aspect of the osteotomy is carefully prepared for the placement of implants (instrumentation not shown) and the implant is placed. **I,** Final view of two implants placed in the grafted maxillary sinus using the OSFE technique.

venous blood. Supracrestal bone regeneration achieved was 3.3 mm and 1.82 mm in these studies, respectively.[19,34] Recent studies showed that supracrestal bone formation is more predictable using a bone graft filler material placed under the TR membrane. Therefore, at present, advanced surgical GBR augmentation for vertical bone gain should be achieved with a nonresorbable TR membrane that is supported by a bone graft (Figure 77-9).

The long-term results of vertical GBR after 1 to 5 years of prosthetic loading were examined in a retrospective multicenter study evaluating 123 implants.[32] Three treatment modalities (nonresorbable regenerative membranes in combination with blood clot only, DFDBA, and autogenous bone chips) were studied, and the results from this investigation revealed that vertical bone regeneration greater than 4 mm could only be achieved with the use of autogenous bone chips. These authors reported an overall success rate of 97.5%, leading them to conclude that vertically augmented bone using GBR techniques supports implant placement in a fashion similar to native, nonregenerated bone.

Urban et al[41] used TR membranes with autogenous particulated bone for vertical bone augmentation before implant placement. The study included 35 patients with 36 vertical bone defects. Eighty-two implants were placed in a staged approach and a resorbable collagen membrane (Bio-Gide Resorbable Bilayer Membrane, Osteohealth, Shirley, NY) was placed over the newly formed

BOX 77-2 Clinician Comments on Use of Osteotome Technique

Clinical Perspective 1

The osteotome procedure involves repeated tapping of osteotomes with a mallet to create the necessary pressure to fracture the floor of the maxillary sinus. This tapping can be bothersome to some individuals, especially those patients who are not sedated for the procedure. The tapping procedure tends to be more bothersome for patients with dense cortical bone than for those with loose trabecular bone. In fact, a specific postoperative complication, called *benign paroxysmal positional vertigo* (BPPV), has been associated with the osteotome sinus elevation technique. During the osteotomy preparation and sinus floor elevation, the trauma induced by percussion of the osteotome with the surgical hammer, along with hyperextension of the neck during the operation, can displace otoliths in the inner ear and induce BPPV (see Chapter 82).

Clinical Perspective 2

The osteotome technique requires that the osteotome be properly aligned in the direction of the long axis of the planned implant. Thus patients must be able to open wide enough to allow a direct insertion of the osteotome into the osteotomy site. Offset osteotomes are available that can facilitate the correct angulation (see Figure 77-4, *B*).

crestal bone at the implant placement surgery to protect the graft from early resorption after removal of the expanded polytetrafluoroethylene (ePTFE) membrane. Implants were followed from 1 to 6 years after prosthetic loading.

Treatment groups included single and multiple tooth sites, as well as vertical defects in the posterior maxilla. Vertical bone augmentation of the posterior maxillary ridge was done simultaneously with sinus bone augmentation (Figure 77-10). At membrane removal, the mean vertical bone augmentation was 5.5 mm (±2.29 mm). The mean combined crestal remodeling was 1.01 mm (±0.57 mm) at 12 months, which remained stable through the 6-year follow-up period. There were no statistically significant differences between the treatment groups in mean marginal bone remodeling. The overall implant survival rate was 100% with a cumulative success rate of 94.7%.

The efficacy of a 1:1 mixture of ABBM and autogenous particulated bone graft using ePTFE membranes was evaluated histologically and histomorphometrically in 8 patients (10 ridge defects).[31] After a healing period of 6 to 9 months, a mean vertical gain of 3.15 mm (SD ±1.12 mm) was achieved. In a recent clinical and histologic study evaluating the same graft material and using dense PTFE membranes in 19 patients, an average bone gain of 5.45 mm (SD 1.93) was achieved.[44] In both studies histologic evaluation showed that ABBM was connected with a dense network of newly formed bone of varying degrees of maturation. However, long-term results are not available to confirm the predictability of the procedure or implant success. More long-term studies are needed.

Distraction Osteogenesis

Distraction osteogenesis is a surgical technique that has been developed to increase vertical bone height in the deficient jaw site and contrasts with the more conventional method of bone grafting with or without membranes. Under the proper circumstances, most cells in bone can differentiate into osteogenic (or chondrogenic) cells needed for repair. Ilizarov popularized the concept of distraction osteogenesis in the 1980s by developing a protocol for "cutting" long bones and "stretching" them during the healing process.[14-16]

Based on experimental and clinical studies over 35 years, distraction osteogenesis can provide a surgeon with the ability to treat small bones in the hands and feet using external fixation devices. Recently, new intraoral devices for vertical bone growth of the alveolar process have been developed and successfully applied in preparation for the placement of dental implants. Other important advantages of distraction osteogenesis are that it may avoid the need for a second surgical site to harvest bone, and the newly created bone has native bone at the crest, which is thought to withstand forces better than regenerated bone.

One of the most significant disadvantages of the distraction osteogenesis procedure for intraoral application is the unidirectional limitation of current devices. The application of distraction osteogenesis for vertical bone growth has shown good predictability. However, limitations have been encountered in achieving horizontal bone growth with this method. Secondary bone grafting is frequently needed following vertical distraction osteogenesis, especially for the extremely resorbed (narrow) ridges. Consequently, distraction osteogenesis cannot be expected to solve vertical ridge defects without the use of additional augmentation procedures.

Growth Factors in Bone Augmentation

Current research is exploring the use of various growth factors to induce bone formation.[5,6] These bone-inductive mediators are powerful modifiers of the healing process. Incorporation of osteoinductive mediators into bone graft material or other carriers can be applied to sites in conjunction with conventional bone augmentation procedures to enhance the outcome.

Most of the clinical techniques available to try and stimulate new bone growth at such sites use some type of bone replacement graft, including autograft, allograft, xenograft, or alloplast. These bone graft materials have both advantages and limitations. Consequently, attempts have been made to improve bone grafting by either using growth factors alone or growth factors combined with a bone replacement graft.[2,28,29] The rationale is that bone formation can be further enhanced when a growth factor is used to stimulate osteoblast precursor or osteoblast cells and hence to push the bone formation/bone resorption balance in favor of bone formation.[27]

Bone Morphogenetic Proteins

Perhaps the most studied of all the osteoinductive growth factors are the bone morphogenetic proteins (BMPs), which belong to the transforming growth factor beta (TGF-β) superfamily. Of this family, *recombinant human bone morphogenetic protein-2* (rhBMP-2) has shown significant signs of bone-enhancing potential.

One commercial bone growth factor product has been approved by the Food and Drug Administration (FDA) for use in the oral cavity to stimulate bone formation. As was noted in the use of growth factors for periodontal regeneration, the growth factor protein must be combined with a carrier to have activity and be used clinically. The commercially available bone growth product contains rhBMP-2 combined with a bovine type I collagen sponge. This product has been cleared for oral cavity use in both sinus lift augmentation therapy and for ridge augmentation in maxillary anterior extraction sites with bone loss.[5,6,11,13,40]

The BMPs are a group of related proteins that are found in the body and are important for skeletal development.[8,9,49] Each of the proteins has relatively specific functions, and BMP-2 has been shown to have some of the strongest bone-producing activity.

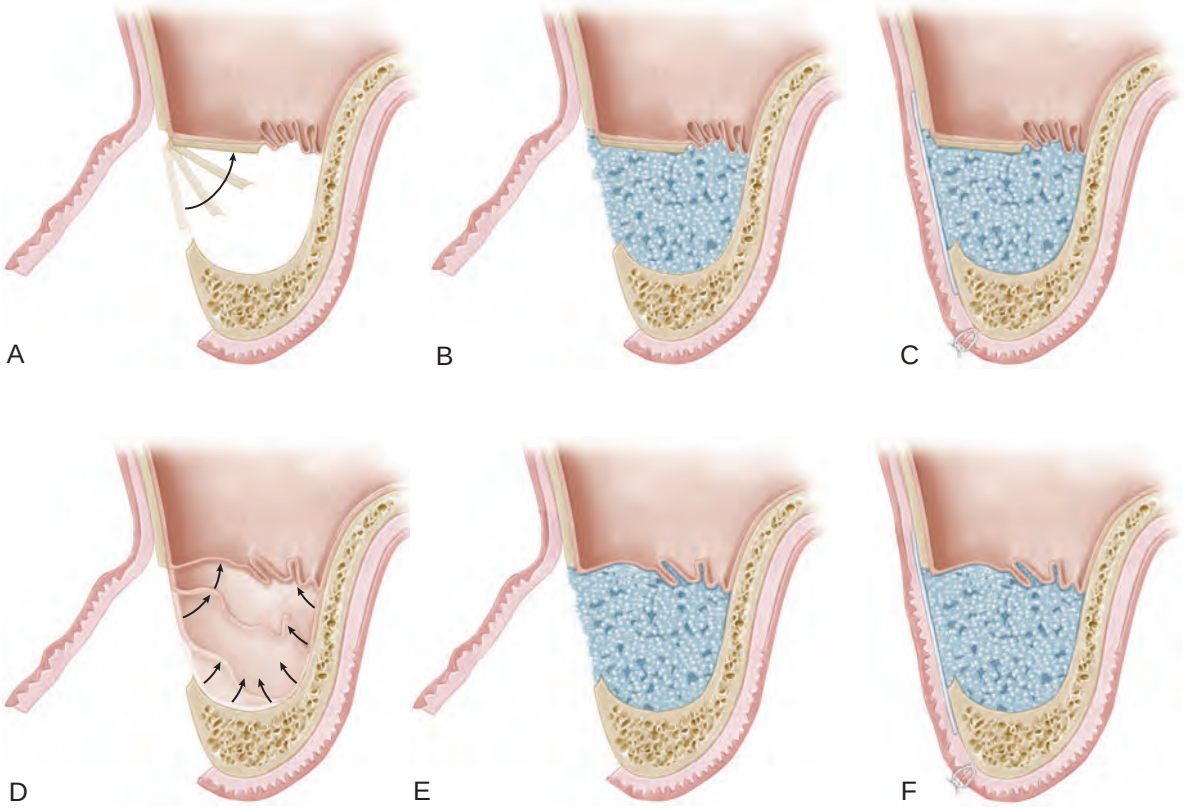

Figure 77-7 Illustrations showing two techniques for the lateral window procedure to access the maxillary sinus for bone augmentation. The first technique (**A** to **C**) preserves the bone of the lateral window elevating it up into the sinus cavity to create a new sinus floor. The second technique (**D** to **F**) completely removes the lateral window as part of the preparation. **A,** Lateral window is cut at the periphery of the access window, leaving the lateral bony wall in the center of the window intact. The bony window is then pushed inward to become the new, elevated sinus floor/superior wall of the grafted maxillary sinus space. **B,** Bone graft material is packed into the newly created space. **C,** A barrier membrane is placed over the lateral window and bone graft material. The full-thickness flap is sutured over the barrier membrane. **D,** Lateral window is removed entirely during the preparation of the osteotomy. The schneiderian membrane is elevated inward and upward to become the superior containment of the grafted maxillary sinus space without a superior bony wall. **E,** Bone graft material is packed into the newly created space. **F,** A barrier membrane is placed over the lateral window and bone graft material. The full-thickness flap is sutured over the barrier membrane.

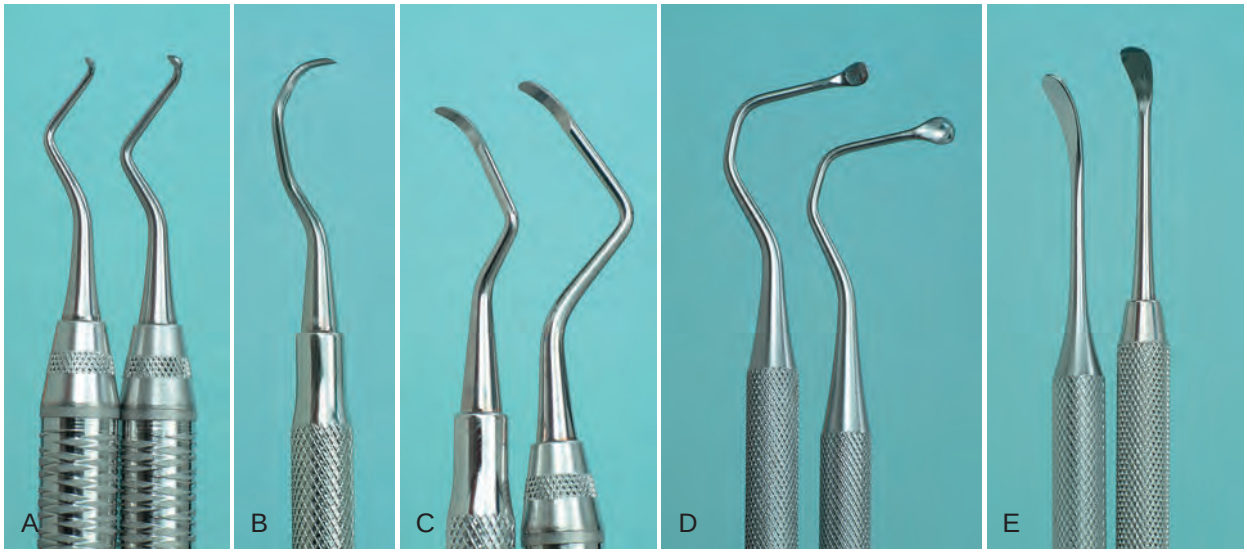

Figure 77-8 Instruments used to elevate the schneiderian membrane through lateral window antrostomy. A, De Marco curettes. **B,** Gracey 13/14 curette. **C,** Universal curettes. **D,** Large spoon curettes. **E,** Medium-size curved membrane elevators.

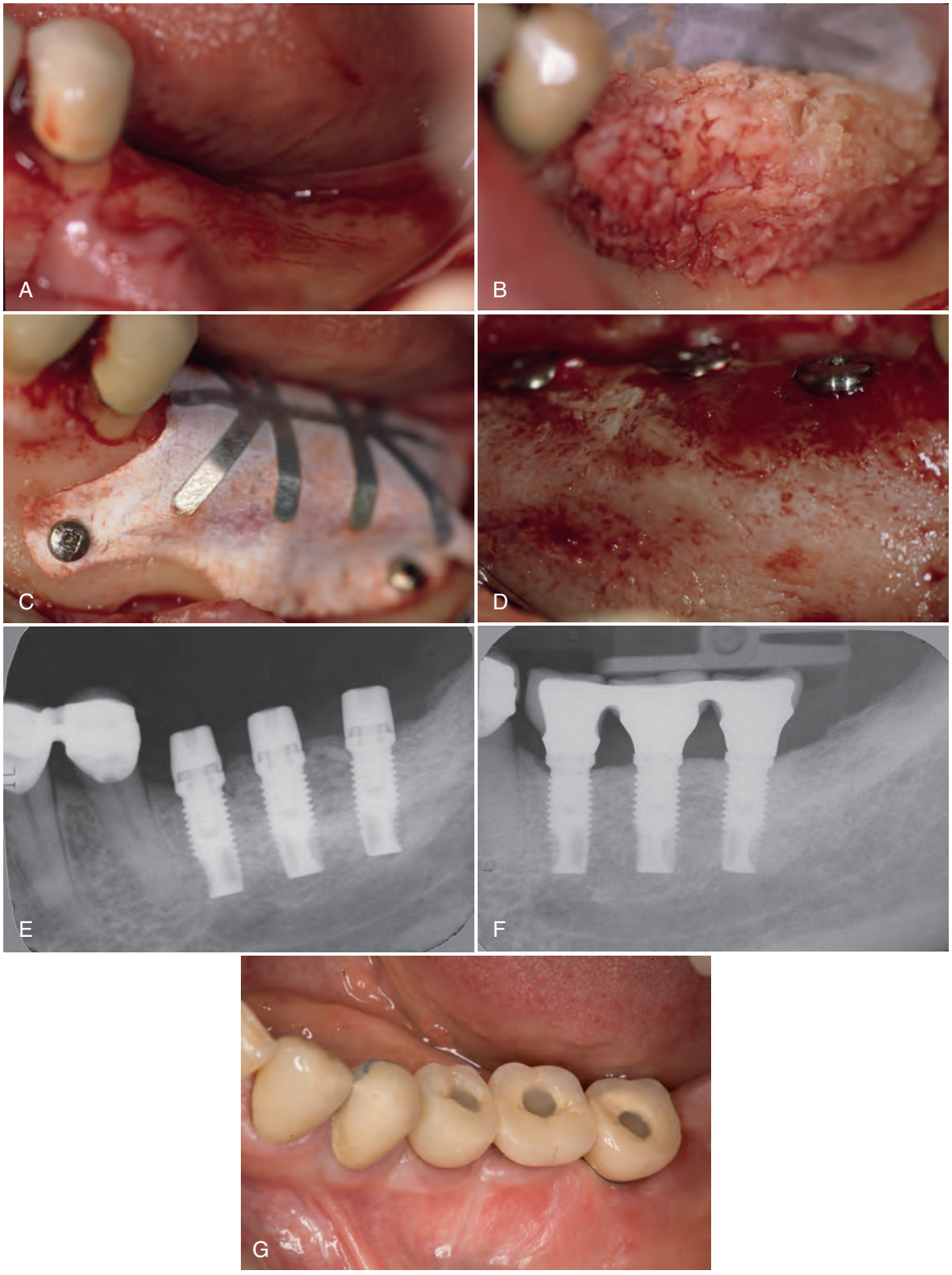

Figure 77-9 Representative case of a posterior mandibular vertical ridge augmentation. A, Atrophic posterior mandibular area. **B,** Particulated chin bone graft is placed on the ridge. Cortical bone was perforated and guided tissue regeneration membrane/titanium-reinforced (GTRM-TR) membrane was secured on the lingual side before applying bone graft. **C,** GTRM-TR membrane is secured over the graft with titanium pins. **D,** Three implants are in place in the newly formed posterior mandibular ridge. Note the well-integrated bone graft. **E,** Periapical radiograph at abutment connection. **F,** Periapical radiograph at 8-year follow-up with implants in function. **G,** Clinical picture demonstrates healthy periimplant mucosa. *(From Urban IA, Jovanovic SA, Lozada JL: Vertical ridge augmentation using guided bone regeneration (GBR) in three clinical scenarios prior to implant placement: a retrospective study of 35 patients 12 to 72 months after loading.* Int J Oral Maxillofac Implants *24(3):502-10, 2009.)*

BMP-7 (also called *osteogenic protein-1* [OP-1]) and BMP-3 (also known as *osteogenin*) have also been shown to stimulate bone formation. The BMPs were originally isolated from bovine bone by Marshall Urist.[45] As a growth factor, the BMPs induce the differentiation of mesenchymal stem cells to become bone-producing osteoblast cells. Thus, unlike proliferation factors that increase the number of cells, the BMPs are differentiation factors that stimulate cells to produce bone tissue. Many carriers have been tested with the BMPs, but the binding and release kinetics using bovine type I collagen have proved to be the most useful clinically. BMP binds tightly to the collagen within minutes and has been shown to be released over time for 2 to 3 weeks at the defect site. The extended release kinetics likely allow the undifferentiated mesenchymal cells migrating into the wound site over time to be exposed to the growth factor. These BMPs have been extensively studied and have been shown to stimulate bone formation in many animal models and in humans under a variety of conditions and indications.[47] In fact, the same product approved for use in the oral cavity had previously been approved by the FDA for use in single-level spine fusion procedures and in open tibial fractures in humans.

The BMPs have specific receptors on the surfaces of cells.[26,37,50] Binding of the BMP causes dimerization of the receptor proteins, which in turn stimulates a cascade of events intracellularly involving a set of proteins called *SMADs*. The end result of the intracellular cascade is the activation of genetic activity and bone cell differentiation.

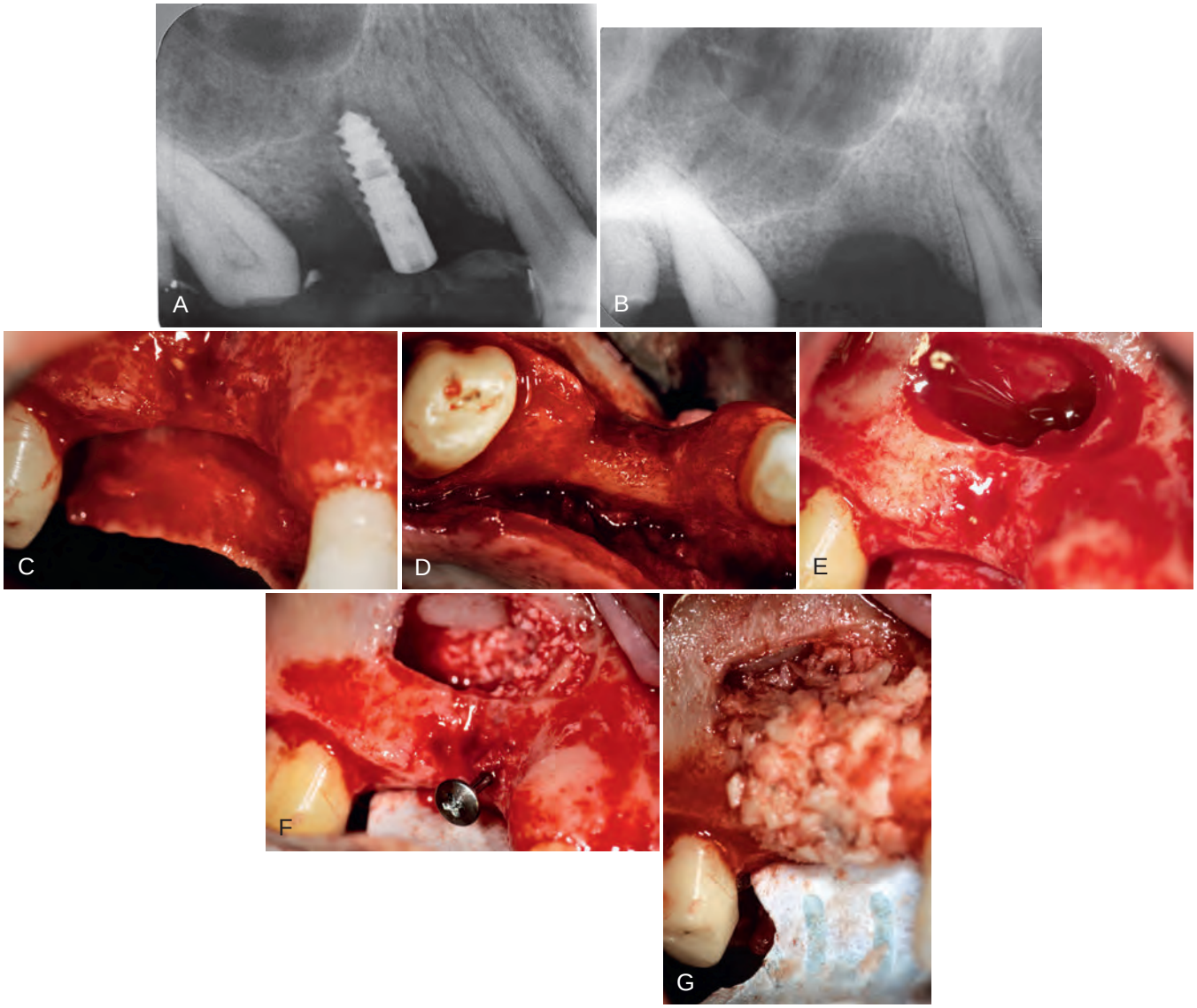

Figure 77-10 Simultaneous vertical ridge and sinus bone augmentation. Representative case requiring posterior maxillary vertical and sinus augmentation. **A,** Failing implant and severe periimplant bone defect on the right maxillary premolar area. **B,** Radiograph 3 months after implant removal demonstrates vertical deficiency and sinus proximity. **C** and **D,** Remote full-thickness flap is elevated exposing the facial bone of the posterior maxillary region. Buccal and occlusal views of esthetically and functionally demanding vertical defect. **E,** The lateral window of the sinus is outlined and fractured inward. The schneiderian membrane is carefully elevated until the correct vertical height is reached. **F** and **G,** Anorganic bovine-derived bone mineral (ABBM) and autogenous bone was applied and packed to the subantral space of the elevated sinus. Guided tissue regeneration membrane/titanium-reinforced (GTRM-TR) membrane was fixated on the palatal bone and a titanium tenting screw is placed protruding to the desired vertical position. Autogenous particulated bone was applied to the vertical defect.

Continued

Figure 77-10, cont'd **H** and **I,** Buccal and occlusal views of GTRM-TR membrane secured over the graft with titanium pins. **J,** After 9 months of uneventful healing, the GTRM-TR membrane has maintained its position. **K** and **L,** Buccal and occlusal views of the regenerated alveolar bone crest. **M,** The final reconstruction demonstrates a functional and esthetic outcome. **N,** Stable crestal bone around the implants after 10 years of loading.

The preclinical results of using rhBMP-2 in animals with critical-sized defects have reported rapid new bone formation. The inductive capacity of rhBMP-2 was demonstrated by impregnating a polymer carrier and placing the substrate in critical-sized rat mandibular defects with or without a barrier membrane.[21] The study evaluated 12- and 24-day healing times and showed a bony union of the defects for rhBMP-treated sites. The control sites were not closed at the same intervals.

The clinical results of using rhBMP-2 and collagen in patients are remarkable considering that only one bone differentiation agent is being delivered to the bone site and it is only delivered at the time of the surgical procedure. Relatively high doses of the protein are often used in some sites however, possibly as the result of the need to release effective doses at later times. Future research directions will likely focus on more targeted delivery of the bone growth factor at specified times during the wound healing process.

The use of growth factors for bone augmentation has the potential to completely eliminate the need of bone harvesting and any bone filler materials, and preliminary results are encouraging. However, the clinician must recognize that there is limited clinical information available on these new modalities, and no information on resorption of the regenerated bone, implant survival, or bone remodeling around implants. Further documentation from long-term, randomized, controlled clinical studies are necessary.

Autologous Platelet Concentration

In recent years, a new approach to enhance the vitality of bone grafts has been introduced by using platelet concentrate or platelet-rich plasma (PRP).[22] PRP is an autologous source of platelet-derived growth factors and transforming growth factors that is obtained by sequestering and concentrating platelets by centrifugation. The patient's own blood is withdrawn and separated into platelet-rich and platelet-poor components. The PRP is the important content, containing a high-level mixture of platelets and a concentration of growth factors. This PRP mixture is added to the autologous bone graft and has been shown to increase the quality of and reduce the time needed for bone regeneration. Clinical and experimental studies are scarce but suggest that this technique holds promise for large bone defects and bone defects with low osteogenic potential. Extrapolation to the possible effect of PRP on other bone-filler materials cannot be made at this time.

Conclusion

Bone augmentation and advanced implant surgery procedures allow clinicians to reconstruct vertical alveolar bone deficiencies and replace missing teeth with endosseous dental implants. As stated in Chapter 77, the predictable outcome of these procedures depends on several biologic principles that must be followed. Diagnosis, treatment planning, careful execution of the surgical treatment,

postoperative follow-up, and appropriate implant loading are all important factors in achieving success. Sinus elevation and bone augmentation has become a widely used and predictable procedure to augment the deficient posterior maxilla (i.e., pneumatized maxillary sinus). Reconstruction of vertically deficient ridges remains a significant challenge despite the reported progress and success of new techniques.

Suggested Readings

Boyne PJ, Lilly LC, Marx RE, et al: De novo bone induction by recombinant human bone morphogenetic protein-2 (rhBMP-2) in maxillary sinus floor augmentation. *J Oral Maxillofac Surg* 63:1693–1707, 2005.

Cochran DL, Wozney JM: Biological mediators for periodontal regeneration. *Periodontol 2000* 19:40–58, 1999.

Del Fabbro M, Testori T, Francetti L, et al: Systematic review of survival rates for implants placed in the grafted maxillary sinus. *Int J Periodontics Restorative Dent* 24:565, 2004.

Geurs NC, Wang IC, Shulman LB, et al: Retrospective radiographic analysis of sinus graft and implant placement procedures from the Academy of Osseointegration Consensus Conference on Sinus Grafts. *Int J Periodontics Restorative Dent* 21:517–523, 2001.

Ilizarov GA: Clinical application of the tension-stress effect for limb lengthening. *Clin Orthop Relat Res* 250:8–26, 1990.

Jensen OT, Shulman LB, Block MS, et al: Report of the Sinus Consensus Conference of 1996. *Int J Oral Maxillofac Implants* 13(Suppl):11–45, 1998.

Rosano G, Taschieri S, Gaudy JF, et al: Maxillary sinus vascular anatomy and its relation to sinus lift surgery. *Clin Oral Implants Res* 22:711–715, 2011.

Simion M, Fontana F, Rasperini G, et al: Vertical ridge augmentation by expanded-polytetrafluoroethylene membrane and a combination of intraoral autogenous bone graft and deproteinized anorganic bovine bone (Bio Oss). *Clin Oral Implants Res* 18:620–629, 2007.

Summers RB: A new concept in maxillary implant surgery: the osteotome technique. *Compendium* 15:152, 154–156, 158 passim; quiz 162, 1994.

Urban IA, Lozada JL: Implants placed in augmented sinuses with minimal and moderate residual crestal bone: Results after 1 to 5 years. *Int J Oral Maxillofac Implants* 25:1203–1212, 2010.

References

References for this chapter are found on the companion website www.expertconsult.com.

References

1. Barone A, Santini S, Sbordone L, et al: A clinical study of the outcomes and complications associated with maxillary sinus augmentation. *Int J Oral Maxillofac Implants* 21:81–85, 2006.
2. Boyan BD, Weesner TC, Lohmann CH, et al: Porcine fetal enamel matrix derivative enhances bone formation induced by demineralized freeze dried bone allograft in vivo. *J Periodontol* 71:1278–1286, 2000.
3. Boyne PJ: History of maxillary sinus grafting. In Jensen Ole T, editor: *The sinus bone graft*, 2nd ed, Hanover Park, IL, 2006, Quintessence Publishing Co. Inc, pp 3–12.
4. Boyne PJ, James RA: Grafting of the maxillary sinus floor with autogenous marrow and bone. *J Oral Surg* 38:613–616, 1980.
5. Boyne PJ, Lilly LC, Marx RE, et al: De novo bone induction by recombinant human bone morphogenetic protein-2 (rhBMP-2) in maxillary sinus floor augmentation. *J Oral Maxillofac Surg* 63:1693–1707, 2005.
6. Boyne PJ, Marx RE, Nevins M, et al: A feasibility study evaluating rhBMP-2/absorbable collagen sponge for maxillary sinus floor augmentation. *Int J Periodontics Restorative Dent* 17:11–25, 1997.
7. Bruschi GB, Scipioni A, Calesini G, et al: Localized management of sinus floor with simultaneous implant placement: a clinical report. *Int J Oral Maxillofac Implants* 13:219–226, 1998.
8. Chen D, Zhao M, Mundy GR: Bone morphogenetic proteins. *Growth Factors* 22:233–241, 2004.
9. Cochran DL, Wozney JM: Biological mediators for periodontal regeneration. *Periodontol 2000* 19:40–58, 1999.
10. Del Fabbro M, Testori T, Francetti L, et al: Systematic review of survival rates for implants placed in the grafted maxillary sinus. *Int J Periodontics Restorative Dent* 24:565, 2004.
11. Fiorellini JP, Howell TH, Cochran D, et al: Randomized study evaluating recombinant human bone morphogenetic protein-2 for extraction socket augmentation. *J Periodontol* 76:605–613, 2005.
12. Geurs NC, Wang IC, Shulman LB, et al: Retrospective radiographic analysis of sinus graft and implant placement procedures from the Academy of Osseointegration Consensus Conference on Sinus Grafts. *Int J Periodontics Restorative Dent* 21:517–523, 2001.
13. Howell TH, Fiorellini J, Jones A, et al: A feasibility study evaluating rhBMP-2/absorbable collagen sponge device for local alveolar ridge preservation or augmentation. *Int J Periodontics Restorative Dent* 17:124–139, 1997.
14. Ilizarov GA: The tension-stress effect on the genesis and growth of tissues: Part II. The influence of the rate and frequency of distraction. *Clin Orthop Relat Res* 239:263–285, 1989.
15. Ilizarov GA: The tension-stress effect on the genesis and growth of tissues. Part I. The influence of stability of fixation and soft-tissue preservation. *Clin Orthop Relat Res* 238:249–281, 1989.
16. Ilizarov GA: Clinical application of the tension-stress effect for limb lengthening. *Clin Orthop Relat Res* 250:8–26, 1990.
17. Jaffin RA, Berman CL: The excessive loss of Branemark fixtures in type IV bone: a 5-year analysis. *J Periodontol* 62:2–4, 1991.
18. Jensen OT, Shulman LB, Block MS, et al: Report of the Sinus Consensus Conference of 1996. *Int J Oral Maxillofac Implants* 13(Suppl):11–45, 1998.
19. Jovanovic SA, Schenk RK, Orsini M, et al: Supracrestal bone formation around dental implants: an experimental dog study. *Int J Oral Maxillofac Implants* 10:23–31, 1995.
20. Levin L, Herzberg R, Dolev E, et al: Smoking and complications of onlay bone grafts and sinus lift operations. *Int J Oral Maxillofac Implants* 19:369–373, 2004.
21. Linde A, Hedner E: Recombinant bone morphogenetic protein-2 enhances bone healing, guided by osteopromotive e-PTFE membranes: an experimental study in rats. *Calcif Tissue Int* 56:549–553, 1995.
22. Marx RE, Carlson ER, Eichstaedt RM, et al: Platelet-rich plasma: growth factor enhancement for bone grafts. *Oral Surg Oral Med Oral Pathol Oral Radiol Endod* 85:638–646, 1998.
23. Peleg M, Mazor Z, Chaushu G, et al: Sinus floor augmentation with simultaneous implant placement in the severely atrophic maxilla. *J Periodontol* 69:1397–1403, 1998.
24. Raghoebar GM, Batenburg RH, Timmenga NM, et al: Morbidity and complications of bone grafting of the floor of the maxillary sinus for the placement of endosseous implants. *Mund Kiefer Gesichtschir* 3(Suppl 1):S65–S69, 1999.
25. Rosano G, Taschieri S, Gaudy JF, et al: Maxillary sinus vascular anatomy and its relation to sinus lift surgery. *Clin Oral Implants Res* 22:711–715, 2011.
26. Rosen V: BMP and BMP inhibitors in bone. *Ann N Y Acad Sci* 1068:19–25, 2006.
27. Schwartz Z, Carnes DL, Jr, Pulliam R, et al: Porcine fetal enamel matrix derivative stimulates proliferation but not differentiation of preosteoblastic 2T9 cells, inhibits proliferation and stimulates differentiation of osteoblast-like MG63 cells, and increases proliferation and differentiation of normal human osteoblast NHOst cells. *J Periodontol* 71:1287–1296, 2000.
28. Schwartz Z, Mellonig JT, Carnes DL, Jr, et al: Ability of commercial demineralized freeze-dried bone allograft to induce new bone formation. *J Periodontol* 67:918–926, 1996.
29. Schwartz Z, Somers A, Mellonig JT, et al: Addition of human recombinant bone morphogenetic protein-2 to inactive commercial human demineralized freeze-dried bone allograft makes an effective composite bone inductive implant material. *J Periodontol* 69:1337–1345, 1998.
30. Schwartz-Arad D, Herzberg R, Dolev E: The prevalence of surgical complications of the sinus graft procedure and their impact on implant survival. *J Periodontol* 75:511–516, 2004.
31. Simion M, Fontana F, Rasperini G, et al: Vertical ridge augmentation by expanded-polytetrafluoroethylene membrane and a combination of intraoral autogenous bone graft and deproteinized anorganic bovine bone (Bio Oss). *Clin Oral Implants Res* 18:620–629, 2007.
32. Simion M, Jovanovic SA, Tinti C, et al: Long-term evaluation of osseointegrated implants inserted at the time or after vertical ridge augmentation. A retrospective study on 123 implants with 1-5 year follow-up. *Clin Oral Implants Res* 12:35–45, 2001.
33. Simion M, Jovanovic SA, Trisi P, et al: Vertical ridge augmentation around dental implants using a membrane technique and autogenous bone or allografts in humans. *Int J Periodontics Restorative Dent* 18:8–23, 1998.
34. Simion M, Trisi P, Piattelli A: Vertical ridge augmentation using a membrane technique associated with osseointegrated implants. *Int J Periodontics Restorative Dent* 14:496–511, 1994.
35. Summers RB: A new concept in maxillary implant surgery: the osteotome technique. *Compendium* 15:152, 154–156, 158 passim; quiz 162, 1994.
36. Summers RB: Sinus floor elevation with osteotomes. *J Esthet Dent* 10:164–171, 1998.
37. ten Dijke P: Bone morphogenetic protein signal transduction in bone. *Curr Med Res Opin* 22(Suppl 1):S7–S11, 2006.
38. Tinti C, Parma-Benfenati S: Vertical ridge augmentation: surgical protocol and retrospective evaluation of 48 consecutively inserted implants. *Int J Periodontics Restorative Dent* 18:434–443, 1998.
39. Toffler M: Osteotome-mediated sinus floor elevation: a clinical report. *Int J Oral Maxillofac Implants* 19:266–273, 2004.
40. Triplett RG, Nevins M, Marx RE, et al: Pivotal, randomized, parallel evaluation of recombinant human bone morphogenetic protein-2/absorbable collagen sponge and autogenous bone graft for maxillary sinus floor augmentation. *J Oral Maxillofac Surg* 67:1947–1960, 2009.
41. Urban IA, Jovanovic SA, Lozada JL: Vertical ridge augmentation using guided bone regeneration (GBR) in three clinical scenarios prior to implant placement: a retrospective study of 35 patients 12 to 72 months after loading. *Int J Oral Maxillofac Implants* 24:502–510, 2009.
42. Urban IA, Lozada JL: Implants placed in augmented sinuses with minimal and moderate residual crestal bone: Results after 1 to 5 years. *Int J Oral Maxillofac Implants* 25:1203–1212, 2010.
43. Urban IA, Nagursky H, Church C, et al: Incidence, diagnosis and tyreatment of sinus graft infection, An infrequent complication after sinus floor elevation: A clinical study. *Int J Oral Maxillofac Implants* 27(2):449–457, 2012.

44. Urban IA, Lozada JL, Jovanovic SA, et al: Vertical ridge augmentation with titanium-reinforced, dense-PTFE membranes and a combination of particulated autogenous bone and anorganic bovine bone-derived mineral: a prospective case series in 19 patients. *Int J Oral Maxillofac Implants* 29(1):185–193, 2014.
45. Urist MR: Bone: formation by autoinduction. *Science* 150:893–899, 1965.
46. Valentini P, Abensur DJ: Maxillary sinus grafting with anorganic bovine bone: a clinical report of long-term results. *Int J Oral Maxillofac Implants* 18:556–560, 2003.
47. Wikesjo UM, Huang YH, Polimeni G, et al: Bone morphogenetic proteins: a realistic alternative to bone grafting for alveolar reconstruction. *Oral Maxillofac Surg Clin North Am* 19:535–551, vi–vii, 2007.
48. Winter A, Pollack AS, Odrich RB: Placement of implants in the severly atrophic posterior maxilla using localized management of the sinus floor: a preliminary study. *Int J Oral Maxillofac Implants* 17:687, 2002.
49. Wozney JM: The bone morphogenetic protein family: multifunctional cellular regulators in the embryo and adult. *Eur J Oral Sci* 106(Suppl 1):160–166, 1998.
50. Wu X, Shi W, Cao X: Multiplicity of BMP signaling in skeletal development. *Ann N Y Acad Sci* 1116:29–49, 2007.

CHAPTER 78

Esthetic Management of Difficult Cases (Minimally Invasive Approach)

Thomas J. Han, Kwang-Bum Park, and Perry R. Klokkevold

CHAPTER OUTLINE

Surgical Strategy for Predictable Esthetics
Immediate Implant Placement for Predictability and Esthetics
Surgical Management of Difficult Cases (Minimally Invasive Approach)
Conclusion

For expanded content on surgical strategy for predictable esthetics, as well as two additional case presentations for the surgical management of difficult cases, please visit the companion website at www.expertconsult.com. Some figures may be out of numeric order in this printed chapter.

In recent years, implant dentistry has been increasingly influenced by esthetic considerations. In addition to successful osseointegration, harmonious soft and hard tissues must surround the implant restorations so that they look natural and healthy. A major challenge in implant dentistry is that, in many instances, dental implants need to be placed in an esthetic zone in which there is extensive alveolar bone deficiency from tooth loss, dentoalveolar infection, or other pathology (Figure 78-1, *A* to *C*). Gingival morphology follows the shape of the underlying bone, and it is difficult to build esthetically acceptable gingiva in areas with deficient supporting bone. Furthermore, using conventional surgical approaches to accomplish the goal in a patient-friendly manner with minimal trauma and clinical predictability is an extremely demanding task.

Treatment planning in a complex implant case today is often confusing because there are many different surgical and restorative approaches to solve the same problem. Many times these procedures seem to conflict. When considering the surgical placement of implants, clinicians must consider the approach (conventional two-stage approach versus a one-stage approach) and the timing of implant placement (immediate versus delayed or staged placement). For bone augmentation procedures, there is the more conventional approach of augmenting the ridge first and placing the implant(s) after healing, or the simultaneous implant placement with bone augmentation approach in which bone grafting is done at same time as implant placement. All of these approaches can provide a successful outcome if patient selection is appropriate and techniques are performed properly.[9,22,24,32] However, depending on the situation, some of these techniques are more advantageous than others in achieving esthetic results with better predictably and less patient discomfort.

It is easy for a clinician to "dogmatically" choose one approach, usually choosing the one that the clinician feels most comfortable with, and to treat all patients with the same approach. However, with heightened expectations of esthetics pushing the art and science of dentistry, it is necessary more than ever for clinicians to fully understand all the available options of treatment and decide appropriately which, where, when, and how to use these options for each patient.

An important recent clinical development in dental implant surgery is the concept of "minimally invasive" approaches to treatment. Specifically, there is a new drive toward minimally invasive implant placement. With advances in technologies, materials, and biologic sciences in dentistry, this approach to implant surgery is becoming more popular among clinicians and will most likely dominate the way dental implants will be placed in the near future.

Minimally invasive surgery in implant dentistry implies a surgical approach that minimizes the extent and number of surgeries while providing esthetics, predictability, and longevity with minimal surgical morbidity and discomfort to patients. The surgical approach most often required to achieve these goals for anterior implant therapy involves immediate implant placement, one-stage surgical approach, with or without flap, and simultaneous bone grafting. Furthermore, these surgical techniques need to be guided by a consistent surgical strategy that provides predictable esthetic results in implant dentistry. A minimally invasive approach to implant therapy in posterior sextants in which esthetics is not a major concern can be predictably achieved with the use of short wide implants.[2,15,16,27]

This chapter introduces surgical strategies that enhance the esthetic predictability in implant dentistry. The minimally invasive surgical approach to manage difficult esthetic and anatomically deficient cases is discussed with examples. The one-stage, immediate implant placement technique, which is the foundation of a patient-friendly approach to esthetic implant dentistry, is presented in detail. The thought processes involved in case selection, their scientific rationale, and proper techniques of soft and hard tissue management are described with cases.

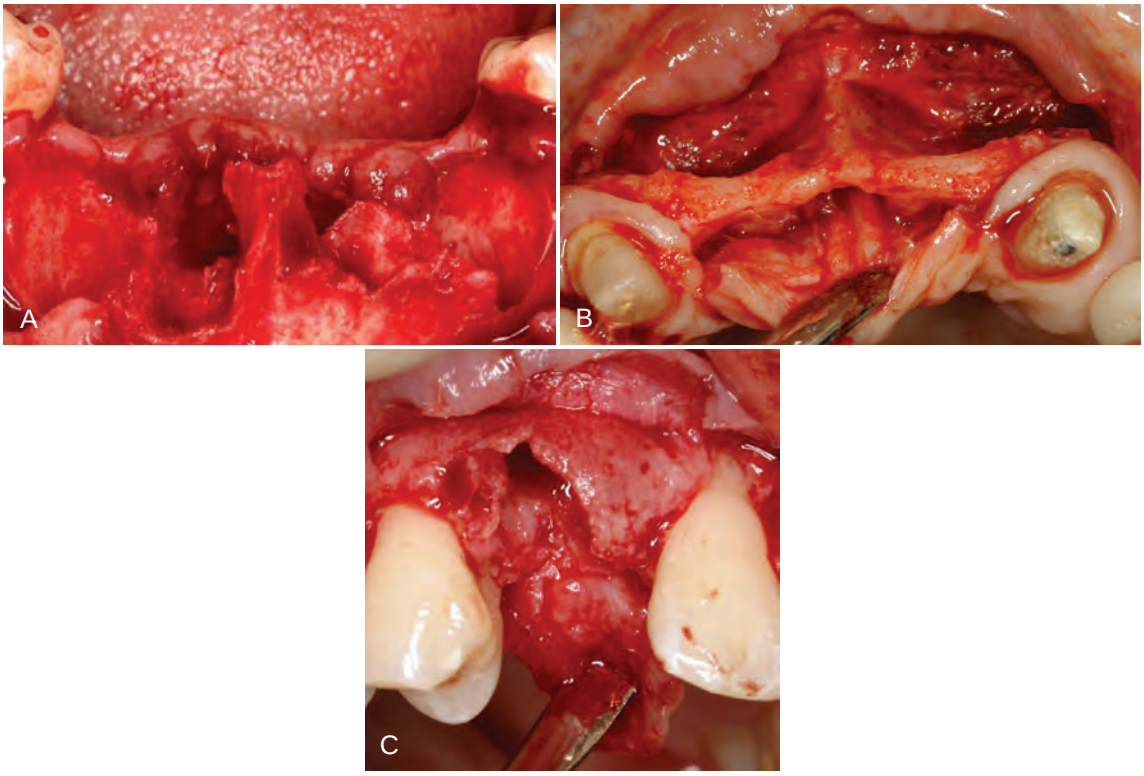

Figure 78-1 Implant sites in the anterior, esthetic zone with extensive bone loss. A, Anterior mandibular site showing extensive bone loss following extraction of hopelessly infected mandibular incisors. **B,** Extremely narrow (labial-palatal) ridge width in the anterior maxilla that was missing centrals and laterals for many years. **C,** Moderate bone loss associated with the extraction socket of a maxillary cuspid.

Surgical Strategy for Predictable Esthetics

Observation of and adherence to the following surgical strategies enhance predictability and outcomes for esthetic dental implant surgeries with minimal discomfort to patients:

1. Determine the level of surgical esthetic goal to be achieved.
2. Visualize the final outcome.
3. Preserve existing tissues important for esthetics.
4. Always overbuild bone and soft tissue in augmentation surgeries.

Immediate Implant Placement for Predictability and Esthetics

Immediate implant placement in a one-stage approach, in which a healing abutment or provisional restoration is attached to the implant and remains exposed, provides more predictable preservation of the interproximal periimplant gingival tissue with less patient discomfort and treatment time.[21,22] This approach to implant placement is the foundation of a minimally invasive approach to esthetic implant dentistry. However, as with any surgical technique, it takes learning and practice to perform it properly. The criteria and techniques for proper immediate implant placement have previously been established and reported with successful long-term outcomes.[18,32]

One of the more difficult aspects of immediate implant placement is positioning the implant with sufficient primary stability in an extraction socket, often without elevating a flap. The alveolar architecture in relation to the angle of the implant to be inserted; the presence or absence of a bone concavity apical to the extracted tooth; the amount of existing bone apical and palatal to the extraction socket, which can provide primary stability for the immediate implant; and the quality of the bone and soft tissues of the ridge should all be thoroughly evaluated clinically and radiographically before surgery.[18,32] Many clinicians perform successful immediate implant placement without the aid of a three-dimensional scans (e.g., computed tomography [CT] or cone-beam CT [CBCT]). However, if the tooth involved is long and large or if there is an alveolar concavity or other anatomic variations, the use of a CT/CBCT scan is advised.

A major disadvantage of placing implants immediately in the changing alveolar bone of an extraction socket is that it may result in progressive recession of the gingival labial margin over the implant restoration.[4,17] Therefore, when placing an immediate implant with one-stage surgical approach in an esthetic zone, a prudent strategy would be to improve the quality and quantity of labial gingival tissue, which seems to be vital for the stability of the labial gingival margin involving immediate implants.[19,31] One of the most effective ways to keep the implanted socket from collapsing and improve the labial gingival biotype is to simultaneously fill the labial socket void with particulate bone and augment the labial gingival tissue with soft tissue.[3,23,26,30,32]

An effective bone and gingival tissue augmentation technique used with flapless immediate implant placement in a one-stage approach is the bone and crescent-shaped free gingival grafting technique.[18] In this technique, the space between the inner surface of the labial bony wall and the labial surface of the implant is filled with slow-resorbing mineralized, freeze-dried particulate bone allograft or particulate xenograft to help preserve the horizontal dimension of the ridge (Figure 78-5, *A*). Then, a crescent-shaped soft-tissue graft is harvested from the ipsilateral palate (Figure 78-5, *B*) and transplanted into the labial recipient site coronal to the particulate bone graft (Figure 78-5, *C*). To provide/maintain the blood supply to the donor tissue, it is important that the outer surface of the crescent graft fits with an intimate contact with the bleeding lamina propria of the labial gingiva. Proper suturing ensures good proximity and prevents the graft from being displaced coronally out of the recipient site (Figure 78-5, *D*).

Figure 78-2 Ideal surgical esthetic goal. Clinical photograph of an implant-supported crown replacing maxillary right cuspid in a 20-year-old female with a high smile line. Soft tissues are full and contours appear natural.

Figure 78-4 Compromised surgical esthetic goal. Severe ridge deficiency resulted in long implant-supported fixed restoration and difficult oral hygiene access. Notice the pink porcelain used to mask the increased length of the crowns. Soft tissues are obviously compromised and completely lack any semblance of normal.

Figure 78-3 Acceptable surgical esthetic goal. Clinical photograph of implant-supported crowns replacing multiple missing maxillary anterior teeth in a 63-year-old female with a low smile line. Soft tissues are nearly full and contours appear fairly normal but not ideal.

Determine the Level of Surgical Esthetic Goal

In dental implant therapy, it is important to determine from the onset the level of surgical esthetic goal. To determine the treatment needs, it is important to assess the patient's esthetic expectations and to consider their age, medical condition, time constraints, and finances as well as the status of existing soft and hard tissue. The ability and experience of the clinician must also be factored into the determination.

The surgical esthetic goal can be ideal, acceptable, or compromised. An ideal surgical esthetic goal (Figure 78-2) implies an ideal, complete surgical reproduction of periimplant tissue around an implant restoration. An acceptable surgical esthetic goal (Figure 78-3) implies that the esthetics of the final implant restoration and the periimplant tissue is not ideal, but both the patient and the clinician accept it. Also, the hygiene and the long-term health of the restoration is not compromised. A compromised surgical esthetic goal (Figure 78-4) implies that the esthetic, hygiene, and long-term health of the implant is far below what is acceptable in today's clinical standard.

In general, more surgeries are required to achieve esthetic results that are close to ideal. The treatment time is usually much longer, and the cost is much higher. There is more surgical morbidity for the patient, and the ideal esthetic outcome remains elusive and often is not achieved.

Because of the logistic consequences of this decision, the level of the esthetic goal should be determined at the beginning of treatment so that the patient is well informed about treatment costs and time requirements. Many clinicians feel it is overtreatment to attempt ideal esthetics for all patients.

Visualize the Final Outcome

Once the level of the esthetic goal is determined, the next step is to visualize the final outcome. Determination of the vertical position of the implant, quantity and quality of the soft and hard tissue augmentation needed, components of the alveolar tissue that need to be preserved in surgery, and what surgical approach is most appropriate for the patient cannot be accomplished without first visualizing the final esthetics of the implant restoration(s) involved. In simple cases, the visualization can be done mentally or with the aid of computer graphic simulation. In more complex cases, a diagnostic wax-up may be necessary.[38]

Preserve Existing Tissues Important for Esthetics

Once what needs to be accomplished surgically is decided through visualization of the esthetics of the final restorations, the next step is determining what aspects of the soft and hard tissues need to be preserved for a predictable esthetic result. For example, if the initial vertical position of the interdental papilla is esthetically compatible with the image of the final restorations, it is prudent to preserve them rather than needing to rebuild them after they are lost. Knowing what needs to be preserved will help assist in choosing an appropriate surgical approach.

Always Overbuild Bone and Soft Tissue in Augmentation Surgeries

Many studies have shown that there is rapid labial and vertical bone loss after extractions,[3,26,30] and immediate implant placement does not stop the resorption process.[10,12,35] Furthermore, it has been demonstrated that soft and hard tissues grafted in augmentation procedures to enhance esthetics undergo extensive shrinkage within 3 to 6 months.[1,36] Therefore the deficient ridge needs to be overbuilt by approximately 30% to 40% at the time of surgery to be esthetically sufficient after the expected primary and secondary tissue shrinkage.

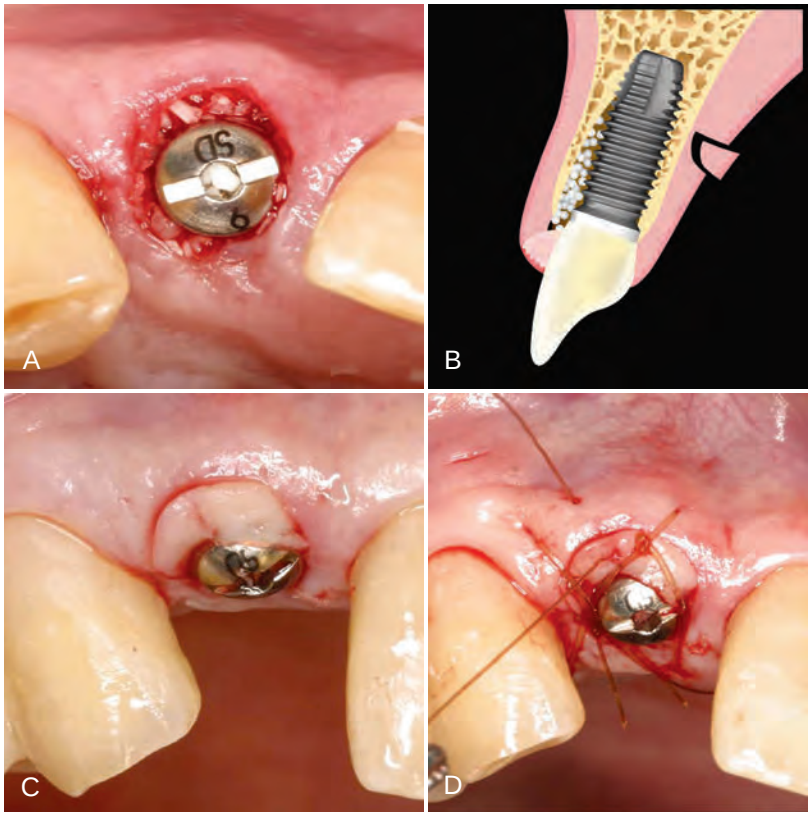

Figure 78-5 **A,** Bone graft material is lightly packed into the extraction socket gap between the labial wall and the implant surface. **B,** Diagram of crescent-shaped, free gingival graft tissue being harvested from the palate. **C,** Clinical photograph of crescent-shaped, free gingival graft tissue positioned over the bone graft to fit snuggly in the gap between the gingival wall and the implant surface. **D,** Crescent-shaped, free gingival graft is sutured in place using 5-0 gut sutures. The sutures pass through the gingival graft toward the labial gingival margin and are tied. Then, without cutting the ends, the suture is passed over the graft and tied to the palatal gingival tissue. Three sutures are needed to keep the graft in position.

The advantage of this approach to gingival augmentation is simplicity and minimal surgical morbidity. In addition to providing a sealed protection for the bone graft, it prevents resorption of the sensitive labial crestal bone. Preparation of the recipient site involves no surgical manipulation other than deepithelialization as described. Gingival walls are completely intact with a full blood supply. The donor site wound is small (approximately 3 mm depth × 3 mm height at the widest point) with intact epithelium around the wound, which epithelializes within a week and causes minimal discomfort for the patient. Because each donor tissue graft is small, multiple grafts can be harvested from a single palate, so that multiple immediate implants can be augmented at same time. Furthermore, this gingival augmentation technique frequently improves an unfavorable initial gingival margin because the grafted gingival margin is always coronal to the existing gingival margin. This minimizes a need for other time-consuming techniques, such as orthodontic extrusion, or a delayed approach to implant placement when the initial gingival margin is not esthetic or ideal, as recommended by many authors.[5,33]

The risk-to-benefit ratio of the crescent grafting technique is favorable enough that if the graft does not survive, or if more than expected horizontal resorption of the ridge occurs, traditional techniques (e.g., subepithelial connective tissue graft) can be performed to augment the results. This is usually possible without refabrication of the implant restoration because the vertical height of the interdental papilla is sufficiently preserved with immediate implant placement in a one-stage approach.

Surgical Management of Difficult Cases (Minimally Invasive Approach)

The cause of the failure to satisfy the esthetic needs of a patient frequently starts with an inadequate examination of the soft and hard tissues surrounding the surgical site and the natural dentition. This can result in an incorrect diagnosis, which leads to incorrect treatment plan. The wrong treatment plan combined with selection of inappropriate surgical approaches or techniques can result in a disastrous esthetic outcome and unnecessary patient suffering. The first two case presentations describe the examination and thought processes involved in determining the diagnosis and treatment planning of complex anterior cases with extensive alveolar bone loss. The proper application of the surgical strategies and the minimally invasive techniques, previously described, are illustrated. The final case presentation illustrates the minimally invasive approach to posterior implant therapy with the use of short wide implants, in which esthetics is not the major concern.[2,15,16,27]

Components of Esthetic Examination

The patient's chief complaint, esthetic zone, tooth positions, gingival form, osseous crest position, biotype, tooth shape, horizontal and vertical ridge deficiency, and occlusal status all play an important role in deriving an accurate esthetic treatment plan for the patient. Therefore developing the necessary skill and knowledge to examine and recognize problems of these components is an essential first step to clinical success.

Case Presentation 1

The first case presented is a simultaneous bone and soft-tissue augmentation with multiple maxillary anterior immediate implants placed in a one-stage, flapless approach.

Patient Dental History and Chief Complaint. The patient is a 70-year-old female with severe mobility and discomfort of the maxillary four incisors. Except for a generalized feeling of weakness, she is healthy and does not have any medical contraindications for dental treatment. She presented with a desire to replace her maxillary incisors with dental implants, but she is very concerned about the physical discomfort she may experience from the implant surgery. She does not want to wear a removable pros-

thesis at all, not even for a short time. She is content with her present dental esthetics.

Examination and Diagnosis. The maxillary incisors exhibit moderate-to-severe periodontitis with 4- to 7-mm periodontal probing depths. They exhibit severe (2+) mobility with fremitus. The periodontal and restorative prognosis of these teeth is poor. She has an excessive overbite with evidence of moderate mandibular incisor wear, indicating possible parafunctional habits. Her incisors are slightly elongated, but the dentogingival symmetry is acceptable (Figure 78-6, *A*). The shape of the incisors is slightly triangular with sufficient interdental papilla volume and height. Interproximal gingival tissue is not swollen or edematous. Her gingival biotype appears to be on the thin side with slight marginal inflammation, and the position of the labial gingival margins is already high (i.e., maximal apical position). Any further recession will be unaesthetic.

Radiographic evaluation demonstrates moderate-to-severe vertical and horizontal periodontal bone loss. The osseous crest position, in relation to the gingival margins, appears too apical to provide adequate gingival support (see Figure 78-6, *B*). The restorative and periodontal status of the canines is healthy.

Treatment Objectives. Considering her age, reasonable esthetic expectation, concern for surgical morbidity, and a lack of willingness to wear a removable provisional prosthesis, the treatment objective for this patient would be to use a surgical approach that minimizes the extent and number of surgical procedures while providing predictability, longevity, and acceptable esthetics. Recommending orthodontic extrusion or multiple surgeries to achieve ideal esthetics on this patient would be considered an excessive treatment plan and would not provide any additional value or benefits for her.

Treatment Options. Considerations for extracting four maxillary incisors include the need to remove sound porcelain-fused-to-metal crowns from the canines to replace them as part of a 6-unit fixed prosthesis. This option has questionable long-term functional and esthetic prognosis. Her dentition exhibits evidence of excessive overbite and parafunctional habit, which may have contributed to the alveolar bone loss of the incisors in the first place. The convex shape of the ridge and the lack of osseous support most likely result in substantial horizontal and vertical resorption of the edentulous ridge under the pontics of the fixed bridge, even with extraction socket grafting and ovate provisionalization. This will compromise the long-term esthetics.

Even if this patient can tolerate the temporary removable partial denture, which she said she could not, this option poses a considerable esthetic challenge. The ridge surrounding the extraction sockets will rapidly lose vertical and horizontal dimensional soon after the extractions.[3] The loss of vertical height in the interproximal gingival areas creates an esthetic problem that is very difficult to correct. It often requires multiple surgeries that have a high incidence of surgical morbidity and rarely achieves the desired ideal esthetic result. This is especially true in a case like this in which there is extensive periodontal vertical and horizontal bone loss. The anticipated vertical ridge collapse after the extraction is substantial, even with bone grafting of the extraction sockets. More importantly, the need for multiple surgeries to achieve "acceptable" esthetic results for this patient may be too traumatic for her.

Extracting four maxillary incisors, immediately placing two implants, and replacing the teeth with a 4-unit provisional fixed partial denture supported by two implants is an acceptable but risky treatment option. Immediate provisionalization of the two immediately placed implants, with her occlusion and suspected parafunctional habit, carries the risk of early excessive loading and implant failure. Additionally, it will be challenging to maintain the vertical and horizontal ridge dimensions in the edentulous area under the pontics. Most likely it will require additional soft-tissue augmentation procedure(s) to achieve "acceptable" esthetics in the pontic area (i.e., missing central incisor area).

Extracting four maxillary incisors, immediately placing four implants in the sockets, and replacing the missing teeth with a 4-unit provisional fixed partial denture supported by four implants is another acceptable option. Splinting four provisionals together should provide sufficient resistance and protection to the implants from early excessive loading. Some clinicians do not recommend placing implants next to each other in the lateral and central incisor positions because they are often positioned too close and it is very difficult to create or maintain an interdental papilla that emulates an interdental papilla between an implant and a tooth or between two natural teeth.[39] However, the more recent use of implants with a platform-switching design may change the spatial requirements for achieving an interdental papilla between implants. The bone between implants appears to be better protected, and as a result, the vertical height of the interproximal tissue may be better preserved.[8,25] If procedures are carried out properly, this option can provide a long-term functional and esthetic result, with minimal discomfort to the patient.

1. Extract four maxillary incisors and replace them with a conventional (6-unit) fixed prosthesis supported by the canines.
2. Extract four maxillary incisors and wait for healing of the sockets and ridge while temporarily replacing the missing teeth with a removable partial denture. Plan to place two or four implants after 3 to 6 months of healing using either a one- or two-stage approach.
3. Extract four maxillary incisors, immediately place two implants in the lateral positions and replace the missing teeth with a 4-unit provisional fixed partial denture supported by two implants.
4. Extract four maxillary incisors, immediately place four implants in the sockets and replace the missing teeth with a 4-unit provisional fixed partial denture supported by four implants.

Surgical Strategy for Predictable Esthetics. Because of the patient's age and reasonable expectation, the level of the esthetic goal determined for this patient is not ideal but is acceptable. This level of esthetics can be predictably achieved in a minimally invasive, patient-friendly manner. By mentally visualizing the surgical and prosthetic goal, an acceptable esthetic outcome can be achieved for this patient if the existing heights of the interproximal gingival tissues can be maintained. Additionally, if the existing biotype and the level of the labial gingival margin can be overbuilt with hard and soft-tissue augmentation, the final esthetic outcome is enhanced. If this can be accomplished with simultaneous implant placement, it minimizes the number of surgeries required. In this case, especially as the patient appears to have parafunctional habits, it is desirable to place more implants and use them to support the immediate provisionalization.

Considering all of these treatment options, the treatment that is most compatible with this patient's surgical strategy for predictability, acceptable esthetics, and long-term results is treatment option 4, extraction of the incisors followed by immediate placement of four implants with an immediate provisional restoration supported by the implants.

Figure 78-6 **A,** Clinical photograph of periodontally compromised maxillary anterior teeth with long clinical crowns. The presenting esthetic status is not ideal. However, the dentogingival symmetry is fair as the gingival margin is approximately the same for all incisors (cuspids, laterals, and centrals). **B,** Periapical radiographs of the maxillary anterior teeth reveal moderate to severe horizontal periodontal bone loss with vertical intrabony defects. **C,** Simple, atraumatic extraction of the maxillary incisors reveals sockets with unsupported interdental tissues. Note that there are no incisions or flap reflection, which has preserved the blood supply and integrity of the interdental soft tissues. **D,** Guide pins placed in prepared implant sites reveal good position within the extraction sockets achieving good primary stability from the palatal aspect of the socket. **E,** Implants with temporary abutments and crescent shaped, free gingival grafts (not yet sutured). **F,** Implant provisional abutments are prepared and provisional restorations are fabricated using conventional methods. **G,** One-year postloading results show nearly complete preservation of the interproximal papilla height and improved labial gingival biotype. Labial gingival margins are substantially coronal in position as compared to the initial levels. **H,** The final restorations have a more normal length offering the patient a much more youthful smile. Preexisting moderate to severe attrition is noted on the incisal edges of the mandibular anterior teeth. **I,** Periapical radiographs at 1 year of the implants with final restorations reveal good preservation of interproximal bone height with minimal saucerization. The platform-switched implant restorations likely contribute to the preservation of bone.

Treatment Plan and Rationale. Four maxillary incisors are to be extracted, and four implants placed immediately in a one-stage approach with simultaneous bone and soft-tissue grafting. The bone and crescent-shaped free-gingival grafting technique is used to overbuild labial gingival biotype.[18] A tapered implant with platform-switching design is to be used. The tapered design has shown to promote primary stability in sockets, and the platform-switching design better maintains the interimplant bone.[8,25] An immediate provisional restoration without centric contacts is attached to the implants.

Treatment Sequence. In complex treatment involving dental implants, the treatment plan must be sequenced and coordinated between the restorative dentist and the surgeon before starting the treatment. This is especially true when immediate provisionalization is planned. This will enhance success and help make the treatment more patient friendly.

Surgical Procedure. Once the patient is anesthetized, the incisors are extracted atraumatically, ensuring that gingival tissues, especially the interdental papilla are not damaged (see Figure 78-6, *C*). The sockets are prepared to receive implants by removing the sulcular epithelium, and by completely and thoroughly removing all granulation tissue. Immediately placed implants must have complete primary stability at the time of placement. Proper vertical position, buccolingual position, and mesiodistal position, as well as buccolingual angulation, are all critical factors for a successful outcome. Implants in anterior sockets are prepared and placed toward the palate (see Figure 78-6, *D*) to ensure sufficient labial bone thickness for labial margin stability.[9] Once the provisional healing abutments are accurately seated (may require bone profiler), the labial void of the sockets are grafted with particulate bone and a crescent-shaped free gingival tissue graft is harvested and placed over the graft (see Figure 78-6, *E*) as described previously and in the literature.[18] Using this technique, all four teeth can be augmented in one surgery with minimal discomfort to the patient. Once the soft-tissue crescent grafts are secured with sutures, the provisional abutments are prepared for provisional crowns. The provisional crowns (splinted) are fabricated using conventional methods (see Figure 78-6, *F*). Contours of the provisional crowns may need to be modified as the healing and remodeling occurs. Impression taking for the final restoration is relatively easy because the provisional abutments placed at the time of surgery and modified during healing nicely shape the tissues for an optimal prosthetic emergence profile.

Results. The 1-year result shows nearly complete preservation of the interproximal papilla height, an improved labial biotype with labial gingival margins that are substantially coronal to the original gingival margin level (see Figure 78-6, *G*). The final result is crowns with a more normal incisor length and a more youthful smile (see Figure 78-6, *H*). There is some gingival irregularity noted, which appears to be a result of the soft-tissue grafting. These areas could easily be smoothed with gingivoplasty, but the patient refused. Radiographs reveal preservation of interproximal bone with minimal saucerization around the implants with a platform-switch design (see Figure 78-6, *I*).

After the surgical strategies described and using minimally invasive surgical techniques, this 70-year-old patient received immediate implant-supported replacement of severely compromised maxillary incisors with an acceptable (or better) esthetic result and minimal treatment discomfort. With one surgery, including the extractions, she was provided with a fixed implant restoration on four implants. In the same surgery, the bone and soft tissue was augmented while preserving the interdental papilla. She experienced very little postoperative pain and was pleased with her new, more youthful-looking smile. The treatment time was only 6 months from extraction to final restoration. She was never without teeth and never wore a removable prosthesis. The improvement of the labial gingival margin was achieved without orthodontic extrusion or multiple surgeries.

Conclusion

The clinical science in dentistry has evolved to where placement of dental implants and restoring them requires sufficient knowledge in several disciplines of dentistry. In addition to mastering surgical objectives and techniques, periodontists must be able to evaluate and accurately diagnose (and treat or refer) a wide range of related "restorative" issues including but not limited to esthetics, occlusion, temporomandibular joint function, vertical dimension, and dental–skeletal relationships. These "other" aspects of diagnosis are essential for the development of an appropriate treatment plan, which is necessary for a successful outcome in esthetic implant dentistry.

In addition, with heightened expectations of esthetics pushing the art and science of dentistry, it is necessary more than ever for clinicians to fully understand all the available treatment options and to be able to appropriately determine which option to choose, when to use certain techniques, and how to apply them for each patient scenario.

The minimally invasive approach and techniques presented in this chapter are not the only ways to manage difficult esthetic cases, and some may consider them controversial. Certainly, these techniques require learning and practice to make them effective in each clinician's hands. However, they present a sound approach to what is possible in hard- and soft-tissue management for esthetic implant surgery and provide effective strategies and techniques for solving many difficult esthetic cases in a patient-friendly manner.

Suggested Readings

Chen ST, Darby IB, Reynolds EC, et al: Immediate implant placement postextraction without flap elevation. *J Periodontol* 80:163–172, 2009.

Grunder U: Stability of the mucosal topography around single-tooth implants and adjacent teeth: 1-year results. *Int J Periodontics Restorative Dent* 20:11–17, 2000.

Han TJ, Jeong CW: Bone and crescent shaped free gingival grafting for anterior immediate implant placement: Technique and Case Report. *J Implant Adv Clin Dent* 1(5):23–33, 2009.

Kan JY, Rungcharassaeng K, Lozada J: Immediate placement and provisionalization of maxillary anterior single implants: 1-year prospective study. *Int J Oral Maxillofac Implants* 18:31–39, 2003.

Lazzara RJ, Porter SS: Platform switching: a new concept in implant dentistry for controlling postrestorative crestal bone levels. *Int J Periodontics Restorative Dent* 26:9–17, 2006.

Park KB, Ryu KH: *Super wide diameter implants. The rescue system (from 6.0 mm to 8.0 mm in diameter)*, Seoul, Korea, 2008, Narae Publishing, Inc.

Park KB, Ryu KH: *The short implant (5 mm and 6 mm in length)*, Seoul, Korea, 2007, Narae Publishing, Inc.

References

References for this chapter are found on the companion website www.expertconsult.com.

Case Presentation

Case presentation 2 is a simultaneous extensive bone augmentation with multiple mandibular anterior immediate implants placed in a one-stage approach with labial flap reflection.

Dental History and Chief Complaint. The patient is a 41-year-old female with severe periodontal and endodontic infection affecting her mandibular anterior teeth. She is experiencing pain, halitosis, and a bad taste in her mouth. She is healthy and does not present with any medical contraindications for dental treatment. She is frustrated by her current dental condition because she recently replaced the crowns on the involved teeth. She understands the hopeless condition and would like to replace the teeth with dental implants, but she is apprehensive about the surgical procedure(s) and concerned the procedures will interfere with her busy schedule. She prefers a fixed provisional during the healing period if possible.

Examination and Diagnosis. The patient's mandibular incisors exhibit severe periodontal and endodontic infections with periodontal pockets extending to the apex on several of her teeth. Porcelain-fused-to-metal crowns with overhanging margins are splinted together. The gingival tissue is swollen, erythematous, and heavy exudation is expressed from the gingival margins with palpation (Figure 78-7, *A*). She has a difficult time brushing because of the pain from the infection. Radiographic evaluation reveals severe generalized vertical and horizontal periodontal bone loss around

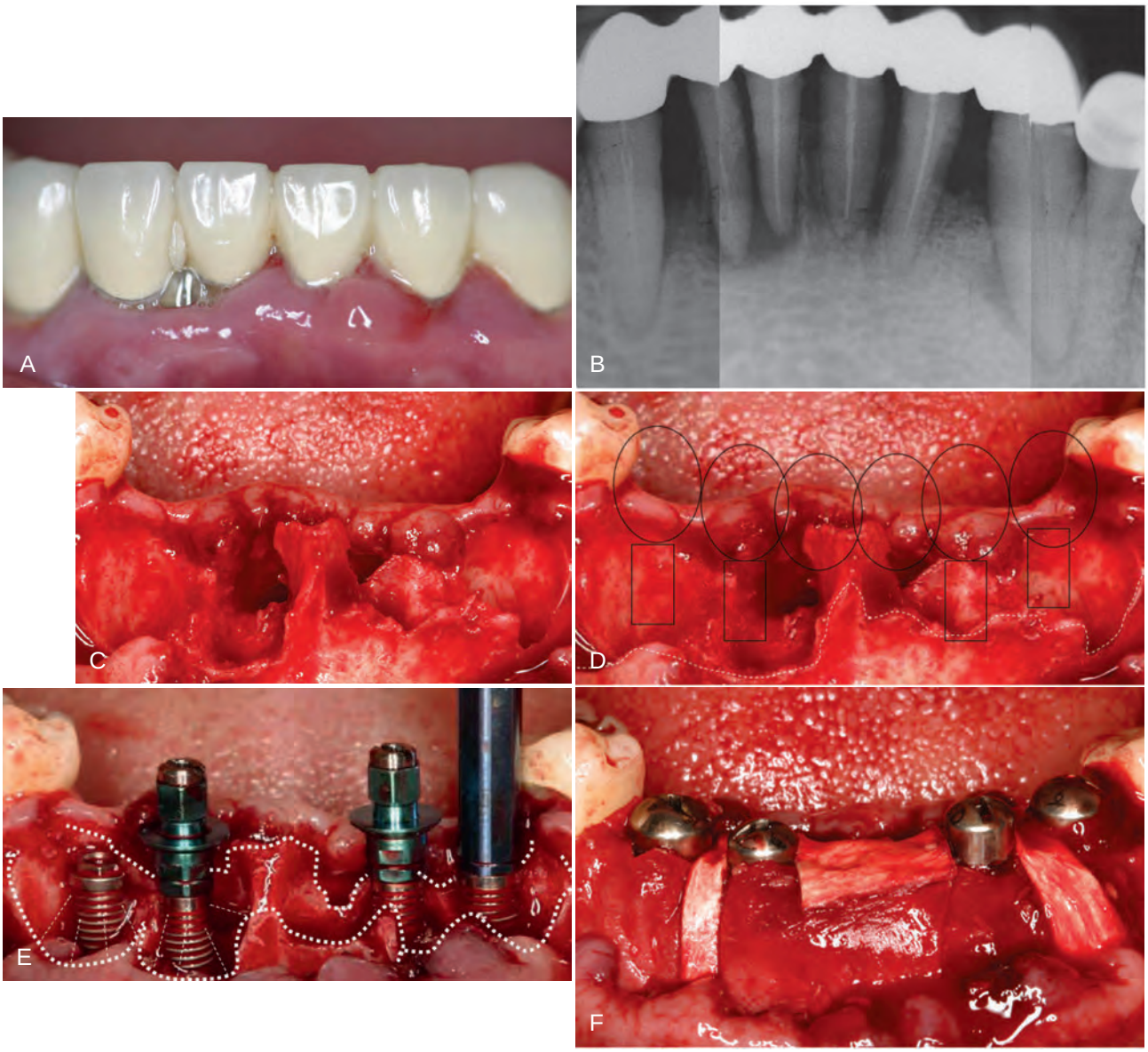

Figure 78-7 **A,** Splinted porcelain-fused-to-metal crowns with overhanging margins on mandibular incisors that are infected. The gingival tissues are swollen with moderate to severe inflammation. **B,** Radiograph reveals severe generalized vertical and horizontal bone loss from periodontal and endodontic infections. **C,** Alveolar bone shows extensive destruction from periodontal and endodontic infections. **D,** With a surgical stent, the proposed implant sites are visualized and the surrounding bone is evaluated. **E,** Visualizing how the adjacent bone topography (socket walls) will contribute to bone formation around the implants, it is evident that even without grafting, most of the implant surface will become integrated with bone. **F,** Layers of resorbable collagen membrane cover the bone graft material.

Continued

Figure 78-7, cont'd **G,** Full-thickness periosteal flaps are released, adapted around the healing abutments and sutured. **H,** Three months after surgery, the provisional restoration shows healing gingival tissues with sufficient ridge height and volume. **I,** Four-year results show acceptable esthetic implant restorations in a stable ridge with a wide zone of keratinized, attached gingiva. **J,** Periapical radiographs at 4 years demonstrate good bone regeneration and maintenance with osseointegration of all implants.

the incisors with endodontic involvement. Existing endodontic treatment showed inadequate obturation and apical seal (Figure 78-7, *B*). These mandibular incisors have poor periodontal and endodontic prognosis. The remaining dentition is stable. She is not overtly concerned with esthetics, but desperately wants relief from pain, halitosis, and the bad taste in her mouth.

Treatment Objectives. The immediate focus for this patient is to make her comfortable by eliminating the source of infection as soon as possible. However, considering her esthetic requirements, concern for surgical morbidity, and preference for a fixed provisional, an important treatment objective for this patient would be to identify a surgical approach that minimizes the extent and number of surgeries while providing predictability, longevity, and acceptable esthetics. Getting into a situation in which multiple extensive surgeries are necessary to achieve acceptable esthetics would be difficult for both the clinician and the patient.

Treatment Options

1. Extracting six mandibular incisors and replacing missing teeth with a removable provisional prosthesis immediately addresses the patient's chief complaints, but because of the anticipated severe ridge collapse after the extractions, this approach will most likely result in a situation in which multiple extensive surgeries will be necessary to achieve acceptable esthetics.

   It is common to expect a loss of vertical height ranging from 5 to 10 mm after extraction of multiple mandibular incisors with severe bone loss. Surgical procedures used in an attempt to regain the vertical height of the ridge for acceptable esthetics in this region carry substantial risk and morbidity. Once the ridge collapses, any vertical ridge augmentation procedure requires extensive labial flap releasing to close over the grafting material and membrane. These large flaps often dehisce from the tension caused by the lower lip muscle movements and require more time to heal by secondary intention with potentially compromised outcome.

   Even when flap closure is maintained, extensive labial flap releasing frequently results, obliterates the vestibular space, and creates mucogingival problems, which may require additional surgery to correct. The ridge augmentation procedure can be done on an incremental basis to minimize surgical complications, but the patient is subjected to multiple surgeries and prolonged treatment time. Distraction osteogenesis is an option to gain back the lost ridge height, but there are other problems associated with this approach, and it also requires multiple patient visits with extended use of a removable provisional prosthesis.[11,20] However, the biggest disadvantage to this direction of treatment is that whichever ridge augmentation procedure is used to reconstruct the ridge, it is extremely difficult to gain back the vertical ridge height that was lost. The final esthetic result is usually disappointing.
2. Extracting six mandibular incisors and augmenting the ridge/sockets with particulate bone graft using a labial flap approach to completely remove granulation tissues and expose healthy alveolar bone is better than the first but still requires considerable labial flap releasing to close over the grafting material and barrier membrane.

There is risk of flap dehiscence during healing for the reason mentioned previously. Because of the postoperative swelling and ridge dimensional changes, maintaining the flap closure under a removable provisional prosthesis is difficult. Complete bone regeneration will take 6 to 10 months, depending on the type of bone grafting material used, and the total treatment time will be prolonged. Most often, multiple surgeries are required with several provisional modifications to obtain the desired esthetics. However, the biggest disadvantage of this treatment option is the inability to predictably reconstruct the lost vertical ridge height. The final esthetic result is typically disappointing, especially considering the enormous time and effort invested in treatment.

3. Extracting six mandibular incisors, immediately placing four implants, augmenting the alveolar defects with particulate bone graft and resorbable membranes, and replacing the missing teeth with a 6-unit provisional fixed partial denture supported by four implants is the third option. (*Note:* It is preferable to place implants in a one-stage approach and to restore them with a provisional restoration, but the decision depends on the relationship of the implants to the surrounding bone.)

   If implants are placed immediately using a two-stage approach (i.e., flap release with primary closure), there will be similar surgical risks and esthetic limitations as described for treatment option 2. However, this option has some advantages over treatment option 2. The implants placed at the time of extractions will function as tent poles to support the bone graft materials and membrane and will be osseointegrated and able to support a fixed provisional restoration in approximately 6 months. This will minimize the required time that the patient will have to endure a removable provisional prosthesis. If the implant–bone relationship is favorable enough to place the implants in a one-stage approach (i.e., the implant will be positioned in an intraosseous location or within the bony envelope and not supracrestal or outside the bony envelope), the surgical risks and morbidity will be less and an immediate fixed provisional restoration can be delivered at the time of the surgery. This treatment option more predictably preserves the vertical height of the ridge, and avoids the likelihood of severe ridge collapse following extractions. Only this treatment option offers a reasonable possibility of providing an esthetic implant restoration; it is accomplished with a minimal number of surgeries and less surgical risk.

Surgical Strategy for Predictable Esthetics. Because of the patient's reasonable expectation, the level of the esthetic goal selected for this patient is not an ideal level but an acceptable level. This level of esthetics can be predictably achieved in a minimally invasive, patient-friendly manner. Mentally visualizing the final result with clinical and radiographic data, an acceptable esthetic outcome can be achieved for this patient if the existing heights of the lingual and interproximal bone can be preserved with grafting. If the implants can be placed immediately, they will assist in preserving the alveolar bone height by acting as tent poles to support the grafting material and membrane. The ridge will be overbuilt in anticipation of augmentation tissue/material shrinkage. If the implant-bone relationship is favorable, a one-stage approach can be used and an immediate fixed provisional restoration can be delivered at the time of surgery.

Considering all of these treatment options, the treatment that is most compatible with this patient's surgical strategy for predictability, acceptable esthetics, and long-term results is treatment option 3, extraction of the mandibular incisors, immediate placement of implants (provided the implant–bone relationship is favorable), bone augmentation with particulate bone graft and barrier membrane, and immediate fixed provisional restoration supported by the implants. Again, provided the implant–bone relationship is favorable).

Treatment Plan and Rationale. To decrease the infectious process, alleviate symptoms, and improve tissue quality, initial therapy consisted of patient education, oral hygiene instructions with an ultrasoft toothbrush, chlorhexidine rinses, and 1 week of antibiotic therapy (e.g., Augmentin 500 mg, by mouth [PO], every 8 hours [q8h] × 7 days). Six mandibular incisors will be extracted using a labial full-thickness flap reflection to ensure complete removal of the granulation tissue and to visualize the bony architecture. If the implant–bone relationship is favorable for bone regeneration around the restoratively determined implant positions (canines and laterals), implants are immediately placed in a one-stage approach with simultaneous bone augmentation, which allows immediate provisionalization of these implants. Because the bone in the anterior mandible is dense, sufficient primary stability for immediate provisionalization can be easily achieved. If the bone architecture is unfavorable for a one-stage approach, the implants are placed in a two-stage approach with simultaneous bone grafting, barrier membrane, and primary flap closure. If a one-stage implant placement is achieved, the implant position is recorded (i.e., indexed) at the time of surgery for the purpose of laboratory provisional fabrication, and the provisionals are delivered within 1 to 2 weeks after surgery. The bulk of the surgical swelling should have subsided at that time. An Essex provisional is delivered at the time of surgery for temporary esthetic replacement of the missing teeth. The patient is in provisional restoration for 6 months to ensure implant integration and periimplant tissue stabilization. A final restoration can be fabricated and delivered at that time.

Treatment Sequence. Impressions are taken at the initial oral hygiene appointment and used to fabricate a surgical guide and an Essex provisional restoration.

During the surgical appointment, the anterior mandibular teeth are extracted, and the surgical treatments are carried out as outlined in the treatment plan. The Essex provisional is delivered, and patient is dismissed. If all goes as planned and implants are immediately placed in a one-stage approach, the fixed provisionals are delivered in 1 to 2 weeks. The fixed provisional restoration is replaced with the final restoration in approximately 6 months.

Surgical Procedure. Once the patient is anesthetized, the incisors are extracted with minimal damage to the delicate gingiva. The interdental papilla are severed at the crest, and a full-thickness labial flap is reflected. The flap is designed with divergent vertical incisions at the mesial line angles of the first premolars to facilitate surgical access and wound closure. A lingual full-thickness flap is reflected just enough to expose the crest of the lingual bony wall. Granulation tissue is thoroughly debrided to prepare the bone for implant placement and bone augmentation (see Figure 78-7, *C*).

The initial impression of the extensive bony destruction observed after complete debridement suggests that immediate implant placement may not be possible and certainly immediate implant placement in a one-stage approach is doubtful. However, when the surgical guide is put in position, the bony architecture surrounding the proposed implant sites indicates a favorable implant–bone relationship (see Figure 78-7, *D*) and a good potential for bone regeneration around the immediately placed implants, even in a one-stage approach. Mentally visualizing the final result

again with the bone exposed confirms that an acceptable esthetic result can be achieved for this patient because the existing heights of the lingual and interproximal bone can be preserved with immediate implant placement and bone augmentation.

It has been documented in the literature and confirmed with clinical cases that if implant(s) are placed within the bony envelope of the ridge (i.e., in an intraosseous relationship with the surrounding bone), the bone regeneration potential around immediately placed implant(s) is favorable even when there is a labial dehiscence.[40] Furthermore, when the implant head is positioned at or below the crest of bone in an intraosseous relationship to the surrounding bone and bone grafts are used with barrier membranes, bone will predictably fill to the top of the implant and integrate with the implant surface.[34]

Therefore the four implants are placed according to these principles, in the sites determined by the surgical guide. The apical-coronal position of the implant is partially dictated by the adjacent level of the bony wall, but care is taken to avoid placing them more than 4 mm below the anticipated labial gingival margin of the final restorations. The implants are placed as far lingual as reasonably possible to maximize the distance from the implant to the labial envelope of the residual ridge to enhance the likelihood of achieving an intraosseous relationship with the surrounding bone. Imagining how the adjacent bone topography (socket walls) contributes to bone formation around the implants, it is evident that even without grafting, most of the implant surfaces will become integrated with bone (see Figure 78-7, *E*). Once a favorable potential for bone regeneration around the implants was ascertained, the decision to proceed with a one-stage implant placement approach was confirmed. Long implants (15 mm length) were placed to ensure sufficient primary stabilization that, when splinted together, would be capable of withstanding occlusal loads. A rapid setting registration material was used to register the implant position for provisional fabrication. Healing abutments (5 mm tall) were lightly secured to the implants for the initial postoperative healing phase.

For more complete bone regeneration around the implants and to overbuild the ridge dimensions, the site was augmented with particulated autogenous graft and mineralized allograft. A thin layer of particulated autogenous bone harvested from the ramus area was placed directly on the implant surfaces to enhance integration, and the allograft was layered to overbuild the ridge. Because only a small piece of the ramus bone was harvested, the donor surgical site was minimized and postoperative discomfort was minor. The grafted material was covered with two layers of resorbable collagen membrane (Bio-Gide, Osteohealth, Shirley, NY) to isolate and protect the graft material (see Figure 78-7, *F*). The labial flap periosteum was adequately released to minimize flap tension during closure and healing. The flaps were adapted around the healing abutments and sutured with interrupted 4-0 chromic gut sutures (see Figure 78-7, *G*). The mucogingival junction and the vestibular depth was not appreciably altered because it was not necessary to advance the flap significantly. The Essex provisional was delivered to the patient, making sure that the apical edges did not cut the sutures or impinge on the wound during the postoperative healing and probable swelling. The patient was dismissed with postoperative instructions.

Ten days after the surgery and after the postoperative swelling has mostly subsided, the lightly secured healing abutments were removed. The laboratory-fabricated provisionals were carefully placed; making sure to avoid tissue impingement. Provisional bridges should be sectioned before placing and rejoined after the placement on the implants. The joined contacts should be strong enough to avoid being separated during mastication. The patient should be seen on a monthly basis to enforce good oral hygiene and to evaluate tissue healing and provisional stability (see Figure 78-7, *H*). The provisional restoration is replaced with a final restoration in approximately 6 months.

Results. The 4-year result demonstrates an acceptable esthetic implant restoration in a stable ridge with sufficient vertical height and horizontal volume. There is a wide zone of keratinized, attached gingiva (see Figure 78-7, *I*). Periapical radiograph (4 years) indicates bone regeneration and maintenance at the top of the implants. All implants are stable and appear to be osseointegrated (see Figure 78-7, *J*).

By following the surgical strategies described and using minimally invasive techniques, this 41-year-old patient was provided with esthetic dental implant restoration with a minimal number of surgeries and treatment time. Her immediate complaints were addressed without the need for multiple extensive surgeries. She did experience some postoperative pain and swelling, but her entire treatment required only one surgery and the total treatment time was only 6 months from extractions to the final restoration. She was provided immediately with an Essex provisional restoration, which was replaced with a laboratory-fabricated fixed provisional restoration attached to the implants 10 days after surgery. She was comfortable throughout the duration of the treatment.

This surgery may appear very extensive and at first impression not minimally invasive. However, any treatment option other than this approach would most likely require multiple, more extensive surgeries with higher surgical morbidity and much longer treatment time. More critically, because it is difficult to reconstruct vertical ridge height after it is lost, the biggest disadvantage of the other treatment options is that the final esthetic result is more often than not disappointing. Therefore, even with the extensive bone loss observed in this case, immediate implant placement in a one-stage approach with simultaneous bone augmentation and immediate provisionalization is considered by many to be a minimally invasive and patient-friendly approach to providing esthetic dental implant therapy.

Case Presentation 3

Case presentation 3 illustrates the use of short wide-diameter implants to treat a severely resorbed mandibular posterior ridge.

Dental History and Chief Complaint. The patient is a 65-year-old female with a severely resorbed mandibular posterior ridge. She is frustrated with her partial denture and wants dental implants to give her better "chewing" ability. She does not present any medical contraindication for dental treatment, but she is anxious about extensive dental surgeries. The esthetic outcome is not a concern for her.

Examination and Diagnosis. The patient's posterior ridge of the mandible shows extensive vertical ridge resorption with a narrow band of keratinized gingiva at the crest. The ridge height is near the floor of the mouth, with frenum and muscle pull on the buccal side (Figure 78-8, *A*). The radiographic vertical height of the ridge measured from the crest to the mandibular canal is approximately 7 mm (Figure 78-8, *B*). Clinical examination shows what appears to be a narrow ridge, but the horizontal width of the ridge measured at the bony crest with a caliper is approximately 8 mm. A three-dimensional scan (e.g., CT or CBCT) can confirm this finding. The typical anatomy of mandibular and maxillary posterior segments after severe vertical resorption cases often has sufficient ridge width for implant placement.

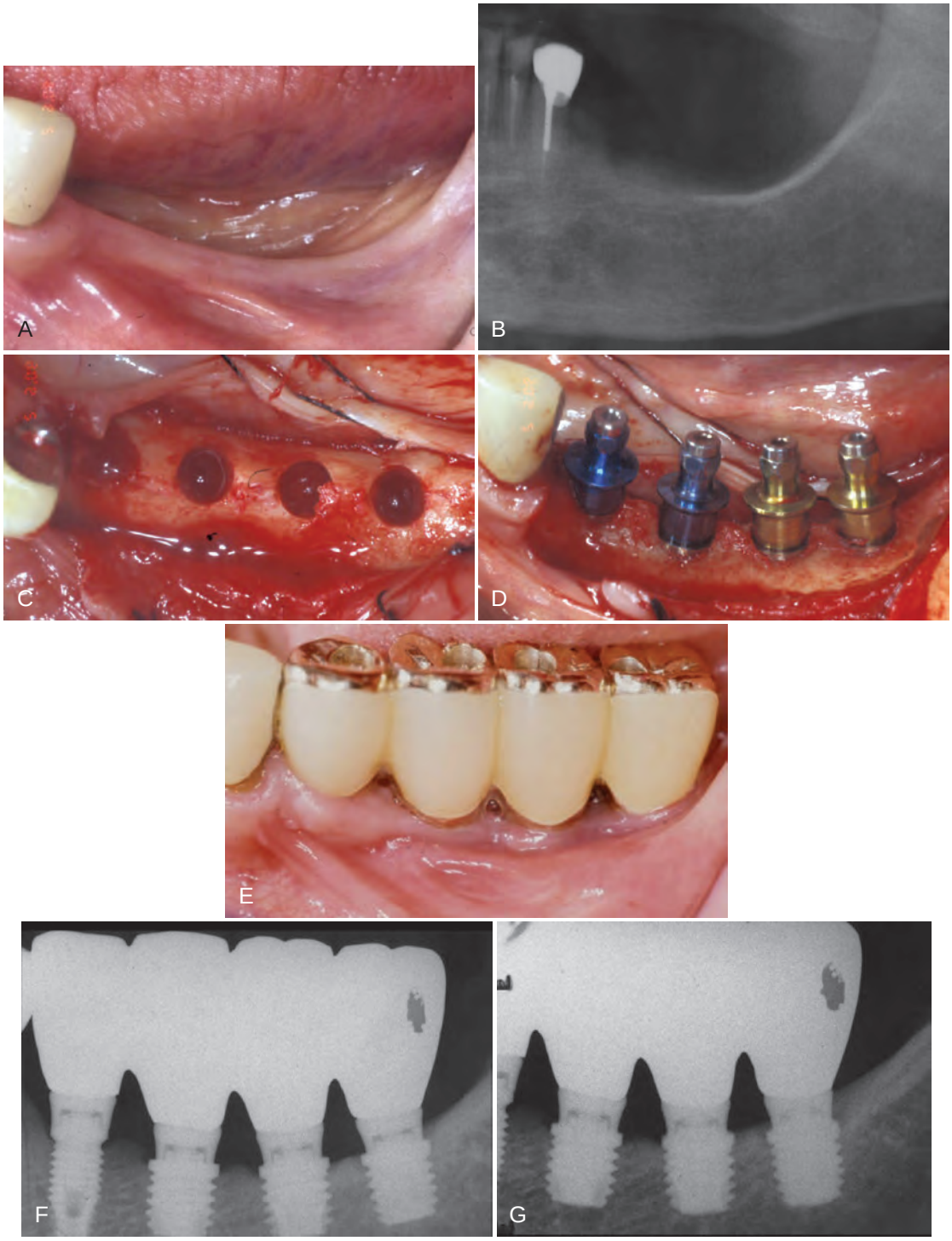

Figure 78-8 **A,** Severely resorbed ridge in the posterior mandible in a 65-year-old female. Examination reveals a narrow band of keratinized, attached gingiva at the ridge crest. **B,** Panoramic radiograph of patient in **(A)** showing a limited vertical height of bone above the inferior alveolar nerve of approximately 7 mm. **C,** Clinical view of prepared implant osteotomy sites in the posterior mandible. Despite the severe vertical ridge resorption, most of the time there is sufficient ridge width in posterior sites to accommodate wide-diameter implants. **D,** One 4-mm–diameter short (7-mm) implant and three 5-mm–diameter short (5-mm) implants were placed with good initial stability. The bone width was adequate, and there were no implant thread exposures. **E,** The final implant restorations were fabricated with gold occlusal surfaces and splinted together. Adequate interproximal spaces were created for oral hygiene access. **F,** Periapical radiograph (13 months postloading) reveals stable crestal bone height despite the long crown-to-implant ratio. **G,** Another follow-up periapical radiograph (30 months postloading) reveals continued stability of the crestal bone height. Platform-switched abutment/restorations, adequate biomechanical support, and careful occlusal design contributes to bone preservation and maintenance.

Treatment Objectives. Considering her concerns about surgical morbidity, the treatment objective would be to identify a surgical approach that minimizes the extent and number of surgeries while providing predictability and longevity. Attempting to reconstruct the vertical height of the deficient posterior ridge with multiple extensive surgeries would be difficult for both the clinician and the patient.

Treatment Options

1. Distraction osteogenesis can provide sufficient vertical height for normal implant placement, but it most likely requires multiple surgeries, may be associated with high surgical morbidity, and certainly increases treatment time.[11,20] Furthermore, performing this procedure in a severely resorbed posterior mandible area is challenging, technique-sensitive, and skill-dependent.
2. Interpositional bone augmentation can provide sufficient vertical height for normal implant placement, but as with the distraction osteogenesis approach, it requires multiple surgeries, longer treatment time, and high surgical morbidity of both the donor and recipient sites. Performing this procedure in a severely resorbed posterior mandibular area is challenging, technique-sensitive, and skill-dependent.[13] Furthermore, the ridge height initially gained using interpositional grafts has been shown to decrease during healing, and often, the resulting ridge is insufficient to place implants with longer lengths.
3. Vertical ridge augmentation with autogenous monocortical bone block can provide vertical ridge height gain, but as with the other two options, there is increased surgical morbidly of both the donor and recipient sites.[28,29] It will require multiple surgeries and longer treatment time. This surgical approach often requires extensive reshaping of the recipient site to maximize bone contact between it and the donor bone. Even in the cases in which the graft has survived, there is substantial vertical height loss as the result of postsurgical resorption. As with the other two options, the final ridge height is often insufficient to place implants with longer lengths.
4. Vertical ridge augmentation with particulate bone and membrane (see Chapter 77) has provided vertical height gains up to several millimeters, but depending on the type of bone graft used, it can increase treatment time substantially.[6,7,37] If autogenous bone graft is used, there will be increased postoperative surgical morbidity as the result of the donor site wound. Maintaining the flap closure over the grafted ridge and membrane is difficult, and clinicians have experienced increased surgical complications. It is a technique-sensitive and skill-dependent procedure. Furthermore, the vertically augmented bone can be unstable, and the resulting ridge is often insufficient to place implants with longer lengths.
5. Vertical augmentation using bone morphogenetic proteins (BMPs) and space-maintaining membrane or titanium mesh has the advantage of limiting or eliminating the need for donor sites to harvest autogenous bone. However, many clinically important questions related to the predictability of augmentation with biologic mediators such as BMPs remain unanswered. As with other vertical augmentation procedures, the surgical challenge of maintaining flap closure over the grafted ridge and membrane or titanium mesh is difficult. The commercially available biologic mediator such as BMP is expensive, and the surgical procedure is a technique-sensitive and skill-dependent procedure.
6. Implant placement with mandibular nerve repositioning can provide the opportunity for placement of longer implants by repositioning the inferior alveolar nerve, but there is an increased surgical morbidity and complications associated with it.[14] Also, it is a technique-sensitive and skill-dependent procedure.
7. Placing multiple, short wide-diameter implants. Since examination of the alveolar dimensions reveals an 8-mm horizontal width and a 7-mm vertical height, it is possible to plan for the placement of four short wide-diameter implants. To increase the biomechanical stability, the restorations are splinted together. Since bone dehiscence is not anticipated, these implants can be placed using either a one-stage or two-stage approach, depending on the clinician's preference. A one-stage approach would further reduce the number of required surgeries and treatment time. Preparation of precise osteotomy sites is important for short implants to ensure good stability. A mild-to-moderate amount (e.g., two threads) of bone loss around short implants is more significant than the same amount of bone loss around longer implants because it results in a greater percentage of lost support relative to the implant length.

Treatment Plan and Rationale. Because there is an 8-mm horizontal width and only a 7-mm vertical ridge height at the three distal implant sites, three 5-mm–diameter × 5-mm–long implants are placed. A 4-mm–diameter × 7-mm–long implants are placed in the most anterior site because the ridge is narrower (≈6 mm) and taller (≈9 mm). These implants will be placed in a two-stage approach to accommodate the clinician's preference, but with precise surgery, they could be placed in a one-stage approach. This surgery does not require special skills, and if the restorative treatment plan is properly executed, the use of short implants will provide predictability and longevity.[2,15,16,27]

Treatment Sequence. No special treatment sequencing is necessary. This procedure is facilitated, like all implant surgeries, by using a surgical stent and following a proper restorative treatment plan.

Surgical Procedure. Once the patient is anesthetized, a crestal incision is made, bisecting the existing band of crestal keratinized tissue. Buccal and lingual full-thickness flaps are reflected to clearly visualize the full width of the ridge. Sutures can be used to keep the flaps away from the surgical site. Properly spaced osteotomy sites are prepared to accommodate one 4-mm–diameter and three 5-mm–diameter implants (see Figure 78-8, *C*). Implants are placed with very good primary stability and no bone dehiscence(s) (see Figure 78-8, *D*). The flaps are closed with a combination of mattress and interrupted sutures. The exposure of the implants and the fabrication of the restorations are done 3 months after the implant placement. Because the esthetic is not the major concern for the patient, the clinician elected to use gold metal occlusal surfaced implant restorations (see Figure 78-8, *E*). The restorations have a platform-switching configuration to enhance crestal bone preservation, and they are splinted together with sufficient embrasure for proper oral hygiene.

Results. A periapical radiograph, taken 13 months after loading, shows a stable crestal bone level despite the long crown-to-implant ratio of the restorations (see Figure 78-8, *F*). The implant abutments have platform-switching design, which has been shown to preserve crestal bone. A periapical radiograph, taken 30 months after loading, shows long-term crestal bone stability without further bone loss around the short wide-diameter implants (see Figure 78-8, *G*).

This patient was provided with a very functional stable implant restoration in just 3 months using short wide-diameter implants. The other possible treatment options for this patient would have required multiple surgeries and would have increased the risk of surgical morbidities and complications. Treatment time would have been much longer and the results may have fallen short of the treatment goal. This case offers a sound example of how patients with extensive vertical bone loss in posterior regions can be treated using short wide-diameter implants with a minimally invasive, patient-friendly surgical approach, without sacrificing predictability and longevity.

References

1. Allen EP, Gainza CS, Farthing GG, et al: Improved technique for localized ridge augmentation. A report of 21 cases. *J Periodontol* 56:195–199, 1985.
2. Anitua E, Orive G, Aguirre JJ, et al: Five-year clinical evaluation of short dental implants placed in posterior areas: a retrospective study. *J Periodontol* 79:42–48, 2008.
3. Araujo MG, Sukekava F, Wennstrom JL, et al: Ridge alterations following implant placement in fresh extraction sockets: an experimental study in the dog. *J Clin Periodontol* 32:645–652, 2005.
4. Bengazi F, Wennstrom JL, Lekholm U: Recession of the soft tissue margin at oral implants. A 2-year longitudinal prospective study. *Clin Oral Implants Res* 7:303–310, 1996.
5. Buser D, Bornstein MM, Weber HP, et al: Early implant placement with simultaneous guided bone regeneration following single-tooth extraction in the esthetic zone: a cross-sectional, retrospective study in 45 subjects with a 2- to 4-year follow-up. *J Periodontol* 79:1773–1781, 2008.
6. Buser D, Bragger U, Lang NP, et al: Regeneration and enlargement of jaw bone using guided tissue regeneration. *Clin Oral Implants Res* 1:22–32, 1990.
7. Buser D, Dula K, Belser UC, et al: Localized ridge augmentation using guided bone regeneration. II. Surgical procedure in the mandible. *Int J Periodontics Restorative Dent* 15:10–29, 1995.
8. Cappiello M, Luongo R, Di Iorio D, et al: Evaluation of peri-implant bone loss around platform-switched implants. *Int J Periodontics Restorative Dent* 28:347–355, 2008.
9. Chen ST, Darby IB, Reynolds EC, et al: Immediate implant placement postextraction without flap elevation. *J Periodontol* 80:163–172, 2009.
10. Chiapasco M: Early and immediate restoration and loading of implants in completely edentulous patients. *Int J Oral Maxillofac Implants* 19(Suppl):76–91, 2004.
11. Chiapasco M, Consolo U, Bianchi A, et al: Alveolar distraction osteogenesis for the correction of vertically deficient edentulous ridges: a multicenter prospective study on humans. *Int J Oral Maxillofac Implants* 19:399–407, 2004.
12. Covani U, Cornelini R, Barone A: Bucco-lingual bone remodeling around implants placed into immediate extraction sockets: a case series. *J Periodontol* 74:268–273, 2003.
13. Felice P, Checci V, Pistilli R, et al: Bone augmentation versus 5-mm dental implants in posterior atrophic jaw. Four-month post-loading results from a randomized controlled clinical trial. *Eur J Oral Implantol* 2:267–281, 2009.
14. Friberg B, Ivanoff CJ, Lekholm U: Inferior alveolar nerve transposition in combination with Branemark implant treatment. *Int J Periodontics Restorative Dent* 12:440–449, 1992.
15. Fugazzotto PA: Shorter implants in clinical practice: rationale and treatment results. *Int J Oral Maxillofac Implants* 23:487–496, 2008.
16. Grant BT, Pancko FX, Kraut RA: Outcomes of placing short dental implants in the posterior mandible: a retrospective study of 124 cases. *J Oral Maxillofac Surg* 67:713–717, 2009.
17. Grunder U: Stability of the mucosal topography around single-tooth implants and adjacent teeth: 1-year results. *Int J Periodontics Restorative Dent* 20:11–17, 2000.
18. Han TJ, Jeong CW: Bone and crescent shaped free gingival grafting for anterior immediate implant placement: Technique and Case Report. *J Implant Adv Clin Dent* 1(5):23–33, 2009.
19. Hermann F, Lerner H, Palti A: Factors influencing the preservation of the periimplant marginal bone. *Implant Dent* 16:165–175, 2007.
20. Jensen OT, Cockrell R, Kuhike L, et al: Anterior maxillary alveolar distraction osteogenesis: a prospective 5-year clinical study. *Int J Oral Maxillofac Implants* 17:52–68, 2002.
21. Kan JY, Rungcharassaeng K: Site development for anterior single implant esthetics: the dentulous site. *Compend Contin Educ Dent* 22:221–226, 228, 230–221; quiz 232, 2001.
22. Kan JY, Rungcharassaeng K, Lozada J: Immediate placement and provisionalization of maxillary anterior single implants: 1-year prospective study. *Int J Oral Maxillofac Implants* 18:31–39, 2003.
23. Kan JY, Rungcharassaeng K, Lozada JL: Bilaminar subepithelial connective tissue grafts for immediate implant placement and provisionalization in the esthetic zone. *J Calif Dent Assoc* 33:865–871, 2005.
24. Klokkevold PR, Han TJ, Camargo PM: Aesthetic management of extractions for implant site development: delayed versus staged implant placement. *Pract Periodontics Aesthet Dent* 11:603–610, quiz 612, 1999.
25. Lazzara RJ, Porter SS: Platform switching: a new concept in implant dentistry for controlling postrestorative crestal bone levels. *Int J Periodontics Restorative Dent* 26:9–17, 2006.
26. Lekovic V, Kenney EB, Weinlaender M, et al: A bone regenerative approach to alveolar ridge maintenance following tooth extraction. Report of 10 cases. *J Periodontol* 68:563–570, 1997.
27. Malo P, de Araujo Nobre M, Rangert B: Short implants placed one-stage in maxillae and mandibles: a retrospective clinical study with 1 to 9 years of follow-up. *Clin Implant Dent Relat Res* 9:15–21, 2007.
28. Misch CM: Ridge augmentation using mandibular ramus bone grafts for the placement of dental implants: presentation of a technique. *Pract Periodontics Aesthet Dent* 8:127–135, quiz 138, 1996.
29. Misch CM, Misch CE, Resnik RR, et al: Reconstruction of maxillary alveolar defects with mandibular symphysis grafts for dental implants: a preliminary procedural report. *Int J Oral Maxillofac Implants* 7:360–366, 1992.
30. Nevins M, Camelo M, De Paoli S, et al: A study of the fate of the buccal wall of extraction sockets of teeth with prominent roots. *Int J Periodontics Restorative Dent* 26:19–29, 2006.
31. Nozawa T, Enomoto H, Tsurumaki S, et al: Biologic height-width ratio of the buccal supra-implant mucosa. *Eur J Esthet Dent* 1:208–214, 2006.
32. Park KB, Han TJ, Kenney EB: Immediate implant placement with immediate provisional crown placement: Three case reports. *Pract Periodontics Aesthet Dent* 14:147–154, 2002.
33. Salama H, Salama M: The role of orthodontic extrusive remodeling in the enhancement of soft and hard tissue profiles prior to implant placement: a systematic approach to the management of extraction site defects. *Int J Periodontics Restorative Dent* 13:312–333, 1993.
34. Schou S, Holmstrup P, Skovgaard LT, et al: Autogenous bone graft and ePTFE membrane in the treatment of peri-implantitis. II. Stereologic and histologic observations in cynomolgus monkeys. *Clin Oral Implants Res* 14:404–411, 2003.
35. Schropp L, Wenzel A, Kostopoulos L, et al: Bone healing and soft tissue contour changes following single-tooth extraction: a clinical and radiographic 12-month prospective study. *Int J Periodontics Restorative Dent* 23:313–323, 2003.
36. Seibert JS: Treatment of moderate localized alveolar ridge defects. Preventive and reconstructive concepts in therapy. *Dent Clin North Am* 37:265–280, 1993.
37. Simion M, Trisi P, Piattelli A: Vertical ridge augmentation using a membrane technique associated with osseointegrated implants. *Int J Periodontics Restorative Dent* 14:496–511, 1994.
38. Spear FM, Kokich VG, Mathews DP: Interdisciplinary management of anterior dental esthetics. *J Am Dent Assoc* 137:160–169, 2006.
39. Tarnow DP, Cho SC, Wallace SS: The effect of inter-implant distance on the height of inter-implant bone crest. *J Periodontol* 71:546–549, 2000.
40. Tinti C, Parma-Benfenati S: Clinical classification of bone defects concerning the placement of dental implants. *Int J Periodontics Restorative Dent* 23:147–155, 2003.

CHAPTER 79

Technologic Advances in Implant Surgery: Dental Implant Microsurgery—Immediate Placement

Dennis Shanelec and Leonard S. Tibbetts

CHAPTER OUTLINE

Implant Microsurgery
Conclusion

The success of dental implants in extraction sites combined with immediate provisionals for newly placed dental implants has brought a convergence in restorative and surgical practice for treatment planning of dental implants. This convergence reaches its summit in the approach to failing teeth in the maxillary esthetic zone. For anatomic reasons, maxillary anterior teeth are at high risk for traumatic injury[13,14] (Figure 79-1). Traumatized teeth frequently receive endodontic treatment that may be followed by horizontal or vertical root fracture.[1,2,15] Dentistry's historic answer to tooth loss has been the fixed bridge. Tooth preparation necessary for a fixed bridge often results in significant reduction of tooth structure.[22] Inherent esthetic limitations of fixed bridges include loss of gingival papillae and resorption of the buccal alveolar plate. For these reasons, dental implants are a preferred choice for tooth replacement in the maxillary esthetic zone.

Implant Microsurgery

Microsurgery is associated with enhanced soft-tissue procedures and fine suturing. This is part of the scope of implant microsurgery but additional benefits include dental implant drilling precision. The ability to discern minute dimensional differences permits implant osteotomy preparations centered exactly between reference points such as adjacent teeth, adjacent implants, or buccal and lingual ridge anatomy. More profoundly, the microscope allows immediate detection of subtle changes in drill position so appropriate feedback corrections can be applied to the handpiece. Enhanced angular perception is also important. The drill's angular position can be oriented relative to small landmarks such as the implant platform surface level or the angle of adjacent implant healing caps. This permits optimal parallel positioning and depth of adjacent implants. The implant drill angle can also be accurately oriented to root surface angulation using just 3 to 4 mm of root anatomy exposed between the cementoenamel junction and the osseous crest. These reference points are simply not visible without a microscope. The detection of subtle angulation reference points and changes in drill position permit feedback correction, which is important for osteotomy preparation in extraction sockets. The microscope-enhanced accuracy of osteotomy microsurgery permits socket implant placement in an ideal position followed by an esthetic implant-supported provisional (Figure 79-2). As a flapless procedure, this is accomplished with minimal patient morbidity.[22]

Microsurgical Tooth Extraction

Tooth extraction has been traumatic for centuries. Conventional tooth extraction may require mucogingival flaps and bone removal, resulting in compromised esthetics. Employing a microscope with minimally invasive principles reduces trauma and results in predictable esthetic outcomes.[6] Instrument selection influences the trauma of tooth removal. Periotome luxation or leveraged mechanical extraction employing tapped root anchorage systems can carefully separate a tooth from its surrounding ligament and lift it vertically from the socket. This limits injury to papillae and preserves natural gingival anatomy (Figure 79-3). Subtle nuances in luxation direction can be microscopically detected for root removal in a proper anatomic path of extraction. Increased visibility under the microscope permits most extractions without mucogingival flaps. Greater visibility also permits atraumatic sectioning of ankylosed roots to leave alveolar bone and soft tissue uninjured. Apical granulomatous lesions can be completely debrided with full visibility. Such minimally invasive microsurgical techniques translate into reduced patient morbidity with enhanced healing.

Implant Drilling in the Extraction Site

Microsurgical implant drilling in the extraction socket is unique. Under the microscope, a socket appears as large as a room with its apex and walls clearly visible. A different set of skills is required for socket drilling. For placement of maxillary anterior implants, the most favorable bone lies to the palatal (Figure 79-4). Drilling therefore must be done at an angle to the palatal socket wall. Twist drills innately track toward the direction of less dense bone and into the open socket. Drilling sockets under a microscope utilizes visual feedback to constantly redirect the drill to the correct position and angulation. This avoids the common mistake of an implant being placed too far toward the buccal. With the magnification and lighting a microscope provides, implants can be placed in the palatal socket wall with good initial stability and ideal esthetic position. Microscope-enhanced dimensional and angular perceptions allow adjustments to correct drilling speed. Too little or too much drill pressure or excessive drill speed causes frictional heat. This adversely affects implant osteointegration. Detecting micromovement of the advancing drill ensures that proper pressure and rotational speed are applied to varying bone densities encountered in the socket. The angular velocity at the cutting edge of a 4-mm

Figure 79-1 **X-ray of typical fractured central incisor.**

Figure 79-2 **Flapless dental implant microsurgery.**

Figure 79-3 **A,** Periotome extraction of lateral incisor. **B,** Noninvasive extraction of lateral incisor.

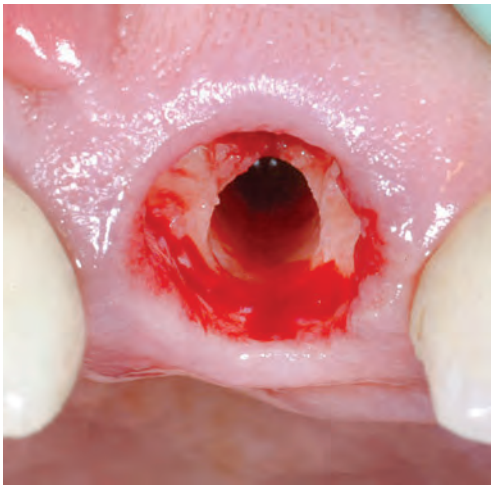

Figure 79-4 **Palatal wall socket osteotomy.**

drill is several times faster than the velocity at the cutting edge of a 2-mm drill. For this reason, pressure and rotation of larger diameter drills must be decreased to compensate for their faster cutting speed. Enhanced visual feedback for speed and pressure correction is accomplished through directly viewing the advancing drill under the microscope.

Bone Grafting

The osteotomy in an extraction socket is prepared in the palatal wall. This placement results in a gap between the implant and the buccal socket wall. To avoid displacing a particulate graft, the provisional is finished before a socket bone graft is placed. The socket is filled with xenograft to within a millimeter of its crest. Xenograft is selected to reduce remodeling resorption of the buccal bone. Filtered bone from the osteotomy preparation is rinsed with 3% tetracycline solution then condensed on the top of the xenograft. Finally, it is covered with a layer of microfibrillar collagen to contain the graft.

Buccal Gingival Grafting

Recession on the buccal gingival margin around anterior implants placed in extraction sockets has been well documented.[11,17] Multiple factors, such as the periodontal biotype, presence or absence of the buccal cortical plate, surgical trauma, implant position, and the emergence profile of both the provisional and final restorations, are associated with such recession.[9,12,16,18-20] A subepithelial connective tissue graft is therefore harvested from the palate and transferred into a split-thickness envelope incision on the buccal of the implant. A connective tissue graft is done to maintain or augment gingival height and thickness that may have been lost as the result of injury (Figure 79-5). Even gingival tissue at a normal height can be expected to recede as much as 1.5 mm unless gingival grafting is performed. Placing a subepithelial connective tissue graft concurrent with implant placement insures stability of the postoperative gingival level.[7,21]

Immediate Provisional Fabrication

To preserve natural esthetics and provide support for gingival anatomy, an implant provisional must emerge from the surrounding gingival tissue exactly like the extracted tooth.[4,23] The surgical microscope gives dentists the visibility necessary to fabricate ideal anatomy for implant provisional crowns (Figure 79-6). Subgingival provisional contours created under the microscope provide tissue support and well-finished margins. The provisional crown on the implant serves a number of functions, as follows:

1. It provides optimal esthetics and function.
2. It minimizes tissue collapse by supporting the gingival tissue.
3. It obturates the surgical extraction socket to contain particulate and soft-tissue grafts.

Creating an implant provisional crown begins before the tooth is removed.[8] A clear silicone impression captures the dentogingival junction and its proximal tooth contours (Figure 79-7). Tooth color-matching is done and a light-cured flowable composite resin duplicate of the tooth is created using the impression (Figure 79-8). The duplicate crown is trimmed to the exact location of the dentogingival junction then hollowed to create a shell crown. It is fitted to a screw-retained titanium provisional abutment that is opaque for a color match (Figure 79-9). Great attention is paid to the incisal edge position of the shell crown before luting it to the abutment with flowable composite resin. Screw access for removal of the provisional is accomplished by drilling through the incisal one-third of the provisional crown.

The luted abutment and crown are removed and placed on a laboratory handle to facilitate shaping and polishing (see Figures 79-12 and 79-13). Each provisional crown has a uniquely shaped subgingival emergence profile that duplicates the original tooth. Voids and rough edges are eliminated, and the provisional is carefully shaped under the microscope to provide gingival support (Figure 79-10). Shaping the provisional is accomplished with a 12-fluted finishing bur, glass nail file, and a prophylaxis cup with pumice. Attention to detail is critical. As a final step, the provisional crown is glazed and thoroughly cured. Light curing the

Figure 79-5 Facial connective tissue graft.

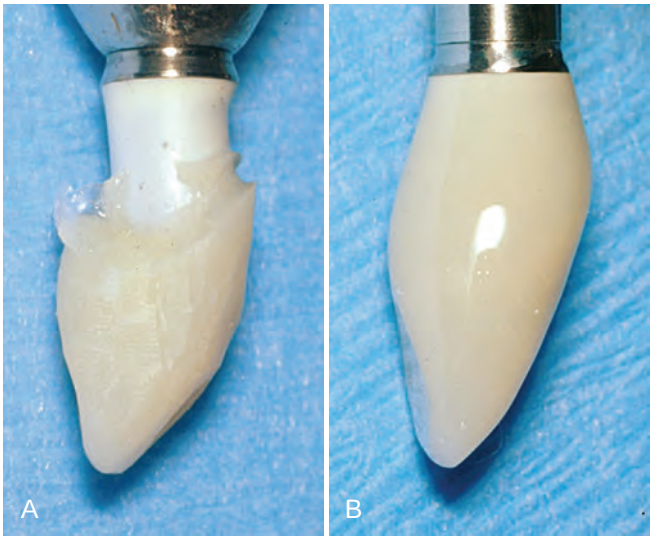

Figure 79-6 A, Screw-retained provisional before finishing. **B,** Screw-retained provisional after finishing.

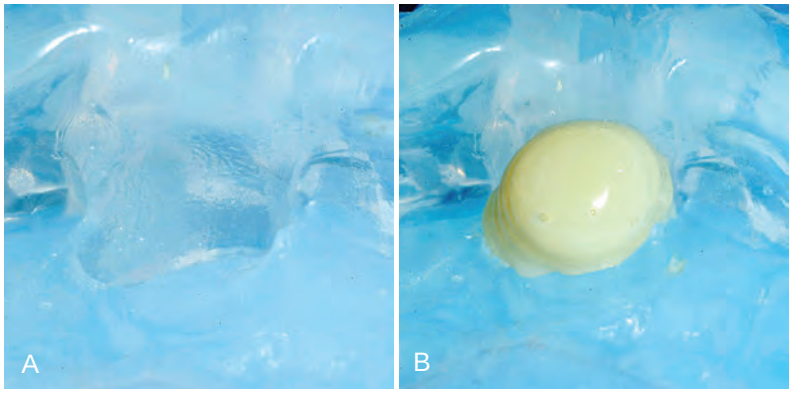

Figure 79-7 A, Clear silicone impression of failing tooth crown. **B,** Clear silicone impression filled with composite.

composite ensures that no free monomer is present to irritate soft tissue or bone. The machined titanium provisional abutment ensures good marginal fit and reduces the possibility for the loosening.

Immediate Implant Occlusion

Early loading bone trauma is minimized in multiple immediate implant provisional cases by splinting. Early loading bone trauma in single implant cases is reduced by lessening occlusal forces. Symmetric and light mesial and distal proximal contacts are established and the provisional is taken out of centric and lateral occlusal contact using 1-mm green occlusal indicator wax. This technique allows patients to leave the dental office with a nonloaded esthetic provisional tooth securely anchored to the implant (Figure 79-11).

Figure 79-8 **Shell composite crown created from impression.**

Custom Impression Transfer Coping

A custom impression transfer coping is necessary to preserve and communicate gingival supporting contours to the ceramicist. The chairside-created provisional anatomy must be precisely reproduced for the dental laboratory via the custom impression transfer coping.[5,10] To make the custom transfer coping, an impression of the gingival third of the provisional crown is made with an implant analog attached (Figure 79-12). This registers the implant platform orientation and preserves the provisional anatomy. The crown is removed, and a standard impression coping is attached to the implant analog. Acrylic powder is filled into the gap between the impression coping and the clear silicone impression. Monomer liquid is then infused into the powder to create a hard acrylic copy of provisional anatomy.[3,5] Using a 25-gauge needle to apply monomer to the powder from the base up minimizes inclusion of air bubbles in the custom transfer coping. For orientation, a mark is initially applied to the labial of the provisional impression. It is transferred to the custom transfer coping to provide orientation for the restorative dentist during final impressions (Figure 79-13). This technique allows precise communication from the surgeon to the restorative dentist to the ceramicist of the anatomy required for a final restoration that esthetically supports gingival tissue.

Final Implant Restoration

Final impressions are taken, using the custom impression transfer coping. Computer-assisted scanning and machining creates a zirconia abutment and zirconia coping for an all-ceramic crown

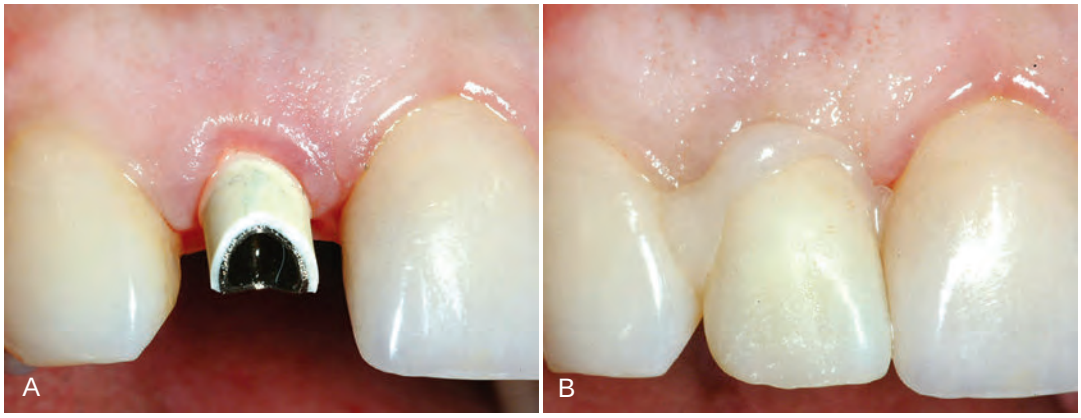

Figure 79-9 **A,** Opaque titanium temporary abutment. **B,** Composite crown luted to opaque titanium temporary abutment.

Figure 79-10 **Provisional supporting gingival tissue.**

Figure 79-11 **Provisional 1 week after implant microsurgery.**

(Figure 79-14). Zirconia has the benefit of tissue biocompatibility and light translucency. The sequence described ensures a final implant abutment and crown that exactly matches both the provisional emergence profile and the original tooth shape. Working as a team, surgeon, restorative dentist, and laboratory technician can create a final restoration in harmony with preserved gingival architecture (Figure 79-15).

Conclusion

Some of the advantages of microsurgery for extraction and implant placement have been described with an emphasis on tissue management and the ability to enhance visualization of details, which translates into better results. This microsurgery protocol advances dentistry from an era of traumatic tooth extraction to one of seamless immediate tooth replacement using implant microsurgery.



Figure 79-12 **Clear silicon impression of provisional.**

Figure 79-13 **Custom impression transfer coping reproducing emergence profile.**

Figure 79-14 **A,** Before microsurgery. **B,** Immediately after microsurgery. **C,** Provisional 8 weeks after microsurgery.

Figure 79-15 **A,** Before microsurgery. **B,** Immediately after microsurgery. **C,** Final restoration.

Suggested Readings

Attard N, Barzilay I: A modified impression technique for accurate registration of peri-implant soft tissues. *J Can Dent Assoc* 69:80–83, 2003.

Breeding LC, Dixon DL: Transfer of gingival contours to a master cast. *J Prosthet Dent* 75:341–343, 1996.

Covani U, Barone A, Cornelini R, et al: Soft tissue healing around implants placed immediately after tooth extraction without incision: a clinical report. *Int J Oral Maxillofac Implants* 19:549–553, 2004.

Hinds KF: Custom impression coping for an exact registration of the healed tissue in the esthetic implant restoration. *Int J Periodontics Restorative Dent* 17:584–591, 1997.

Kan JY, Rungcharassaeng K, Lozada JL: Bilaminar subepithelial connective tissue grafts for immediate implant placement and provisionalization in the esthetic zone. *J Calif Dent Assoc* 33:865–871, 2005.

O'Sullivan D, Sennerby L, Meredith N: Influence of implant taper on the primary and secondary stability of osseointegrated titanium implants. *Clin Oral Implants Res* 15:474–480, 2004.

Saadoun AP: Immediate implant placement and temporization in extraction and healing sites. *Compend Contin Educ Dent* 23:309–312, 314–306, 318 passim; quiz 326, 2002.

Shanelec DA: Anterior esthetic implants: microsurgical placement in extraction sockets with immediate provisionals. *J Calif Dent Assoc* 33:233–240, 2005.

Small BW: Achieving and maintaining periodontal health and esthetics following the extraction of a central incisor. *Gen Dent* 51:396–398, 2003.

Touati B, Guez G, Saadoun A: Aesthetic soft tissue integration and optimized emergence profile: provisionalization and customized impression coping. *Pract Periodontics Aesthet Dent* 11:305–314, quiz 316, 1999.

References

References for this chapter are found on the companion website www.expertconsult.com.

References

1. Al-Jundi SH: Dental emergencies presenting to a dental teaching hospital due to complications from traumatic dental injuries. *Dent Traumatol* 18:181–185, 2002.
2. Andreasen FM: Transient root resorption after dental trauma: the clinician's dilemma. *J Esthet Restor Dent* 15:80–92, 2003.
3. Attard N, Barzilay I: A modified impression technique for accurate registration of peri-implant soft tissues. *J Can Dent Assoc* 69:80–83, 2003.
4. Breeding LC, Dixon DL: Transfer of gingival contours to a master cast. *J Prosthet Dent* 75:341–343, 1996.
5. Buskin R, Salinas TJ: Transferring emergence profile created from the provisional to the definitive restoration. *Pract Periodontics Aesthet Dent* 10:1171–1179, quiz 1180, 1998.
6. Covani U, Barone A, Cornelini R, et al: Soft tissue healing around implants placed immediately after tooth extraction without incision: a clinical report. *Int J Oral Maxillofac Implants* 19:549–553, 2004.
7. Covani U, Marconcini S, Galassini G, et al: Connective tissue graft used as a biologic barrier to cover an immediate implant. *J Periodontol* 78:1644–1649, 2007.
8. Davarpanah M, Martinez H, Celletti R, et al: Three-stage approach to aesthetic implant restoration: emergence profile concept. *Pract Proced Aesthet Dent* 13:761–767, quiz 768, 721–762, 2001.
9. Hartman GA, Cochran DL: Initial implant position determines the magnitude of crestal bone remodeling. *J Periodontol* 75:572–577, 2004.
10. Hinds KF: Custom impression coping for an exact registration of the healed tissue in the esthetic implant restoration. *Int J Periodontics Restorative Dent* 17:584–591, 1997.
11. Kan JY, Rungcharassaeng K, Lozada JL: Bilaminar subepithelial connective tissue grafts for immediate implant placement and provisionalization in the esthetic zone. *J Calif Dent Assoc* 33:865–871, 2005.
12. King KO: Implant abutment emergence profile: key to esthetics. *J Oral Implantol* 22:27–30, 1996.
13. Lalloo R: Risk factors for major injuries to the face and teeth. *Dent Traumatol* 19:12–14, 2003.
14. Majorana A, Pasini S, Bardellini E, et al: Clinical and epidemiological study of traumatic root fractures. *Dent Traumatol* 18:77–80, 2002.
15. Nicopoulou-Karayianni K, Bragger U, Lang NP: Patterns of periodontal destruction associated with incomplete root fractures. *Dentomaxillofac Radiol* 26:321–326, 1997.
16. O'Sullivan D, Sennerby L, Meredith N: Influence of implant taper on the primary and secondary stability of osseointegrated titanium implants. *Clin Oral Implants Res* 15:474–480, 2004.
17. Rompen E, Raepsaet N, Domken O, et al: Soft tissue stability at the facial aspect of gingivally converging abutments in the esthetic zone: a pilot clinical study. *J Prosthet Dent* 97:S119–S125, 2007.
18. Saadoun AP: Immediate implant placement and temporization in extraction and healing sites. *Compend Contin Educ Dent* 23:309–312, 314–306, 318 passim; quiz 326, 2002.
19. Saadoun AP, LeGall M: Implant positioning for periodontal, functional, and aesthetic results. *Pract Periodontics Aesthet Dent* 4:43–54, 1992.
20. Saadoun AP, Touati B: Soft tissue recession around implants: is it still unavoidable? Part I. *Pract Proced Aesthet Dent* 19:55–62, quiz 64, 2007.
21. Shanelec DA: Anterior esthetic implants: microsurgical placement in extraction sockets with immediate provisionals. *J Calif Dent Assoc* 33:233–240, 2005.
22. Small BW: Achieving and maintaining periodontal health and esthetics following the extraction of a central incisor. *Gen Dent* 51:396–398, 2003.
23. Touati B, Guez G, Saadoun A: Aesthetic soft tissue integration and optimized emergence profile: provisionalization and customized impression coping. *Pract Periodontics Aesthet Dent* 11:305–314, quiz 316, 1999.

CHAPTER 80

Technologic Advances in Implant Surgery: Piezoelectric Bone Surgery

Tomaso Vercellotti and Perry R. Klokkevold

CHAPTER OUTLINE

Clinical Characteristics of Ultrasonic Cutting
Clinical Applications
Advanced Clinical Applications *(e-only)*
Conclusion

For online-only content on advanced clinical applications including sinus lift, ridge expansion, and bone harvesting, please visit the companion website at www.expertconsult.com.

Ultrasound has been used for many years in periodontics to remove tartar, debride root surfaces, and to degranulate periodontal defects. In the last decade a novel family of ultrasonic-powered devices has been developed that is revolutionizing maxillofacial bone surgery.

A new surgical technique, known as *piezosurgery,* was invented by Vercellotti and developed by Mectron Medical Technology. The piezosurgery device (Figure 80-1) consists of a piezoelectric ultrasonic transducer powered by an ultrasonic generator, capable of driving a range of specially designed cutting inserts (Figure 80-2).[17,22] Box 80-1 describes the main cutting properties of piezosurgery by Mectron, and Box 80-2 describes piezosurgery inserts. Piezoelectric bone surgery techniques have been developed for clinical applications in dentistry and are becoming state of the art for a variety of procedures.[18-20,22,28,29] Recently, Piezosurgery Medical expanded development of clinical applications to other fields of medicine. The extraordinary cutting properties of piezoelectric bone surgery have been introduced and applied in maxillofacial surgery, cranial and spinal neurosurgery, and hand-foot surgery.[3-13]

The most compelling characteristics of piezoelectric bone surgery are low surgical trauma, exceptional control during surgery, and a fast healing response of tissues. Clinical studies demonstrate that the specificity of operation and the techniques employed with piezoelectric bone surgery make it possible to advantageously exploit differences in hard- and soft-tissue anatomy.[3,23,25,26] This not only increases treatment effectiveness but it also improves postoperative recovery and healing. Experimental studies on animals have shown faster tissue healing when compared to traditional cutting instruments.[3]

Ideally, surgical trauma should be minimized to obtain the optimal healing, which depends on gentle management of soft and hard tissues. Surgery, by definition, alters normal physiology by interrupting the vascular supply of tissues. The degree of surgical invasiveness is extremely important for the quality of tissue healing and may effect whether wounds heal by repair or regeneration. Indeed, when surgical trauma is kept to a minimum it generates enough stimulation to favor healing mechanisms that lead to regeneration. On the other hand, surgical techniques that are more traumatic often lead to greater inflammatory responses with slow healing that may lead to repair and scarring rather than regeneration. For this reason, it is desirable to choose the least-traumatic surgical instruments and techniques for any surgical procedure. Piezoelectric bone surgery was conceived and developed precisely to overcome the limits of traditional bone-cutting instruments and to achieve the most effective treatment with the least morbidity.

From a mechanical standpoint, the effect of burs or twist drills on bone is characterized by lamellar fracturing in areas adjacent to the cut surface and the deposition of large bone fragments and debris in the endosteal spaces. This finding is thought to be, at least in part, responsible for the inflammatory process that takes place in the immediate postsurgical wound healing and for the delay of osteogenesis observed in these wounds. On the other hand, the micromechanical cutting action of piezoelectric bone surgery results in micronization of the cut bone and does not cause lamellar fracturing in adjacent bone, which may favor exposure and release of bone morphogenetic proteins and be responsible for the early onset of osteogenesis at these sites (see below). Furthermore, there may be a diminished inflammatory response since there is little or no need to remove damaged bone and surgical debris as compared to conventional rotary drilled sites.

Clinical Characteristics of Ultrasonic Cutting

The primary clinical characteristics of the piezosurgery cutting action include microprecision, selective cutting, maximum visibility, and excellent healing.

Microprecision

Piezosurgery cuts mineralized tissues with microprecision. The cut is made by mechanical microvibrations at a linear range of

Advanced Clinical Applications

Sinus Lift

Procedures used to lift the floor of the maxillary sinus for bone augmentation make it possible to use dental implants to replace teeth in the atrophied posterior maxilla. Approaches to sinus lift techniques typically involve the use of a lateral window or crestal osteotomy. The lateral window approach enables the surgeon to visually see and monitor the integrity of the sinus membrane at each step in the process. The crestal osteotomy approach is a blind technique because it is not possible to visually observe the schneiderian membrane during preparation (i.e., the orifice is limited in size if being used for implant placement). In some cases, when the crestal window is slightly larger (e.g., when simultaneous implant placement is not anticipated), the schneiderian membrane can be observed during the lift procedure (Figure 80-7).

The lateral window approach entails the opening of a bony window through the lateral wall of the maxillary sinus cavity (see Chapter 78). This window is generally prepared in the premolar to first molar area. The traditional technique using a high-speed rotary bur to remove bone runs a high risk of damaging the schneiderian membrane, which often results in membrane perforation (approximately 14% to 56% incidence).[1,15,16]

In 2000, a new technique was developed that entails cutting an antrostomy (lateral window) using piezosurgery. This technique has greatly reduced the risk of membrane perforation (approximately 5% to 7%).[21,24,27,30,33] In a series of 100 consecutive cases, Wallace et al[33] reported the perforation rate was reduced from the average of 30% with rotary instrumentation to only 7% with piezosurgery. The authors stated that all incidences of membrane perforation occurred during hand instrumentation and were not caused by the piezosurgery inserts. The use of piezosurgery for lateral window osteotomy has greatly reduced the incidence of membrane perforation even in cases of particularly difficult anatomy with thin schneiderian membranes.

The surgical technique entails a lateral window osteotomy that traces the frame of the bony window, which is then removed (Figure 80-8, *A* and *B*). Separation of the membrane from the inner wall is made using an inverted cone insert that detaches the membrane around the perimeter of the bony window (Figure 80-8, *C*). This reduces membrane tension facilitating further separation and lifting with piezoelectric or manual instruments (Figure 80-8, *D* to *F*). Once completely elevated, bone augmentation material is inserted and packed and the bony window is closed with a collagen membrane (Figure 80-8, *G*).

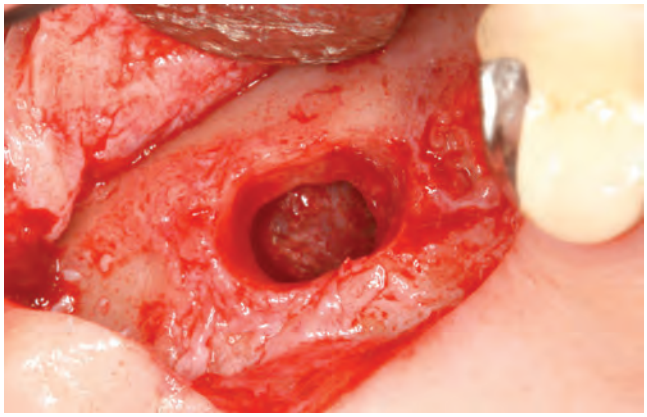

Figure 80-7 Schneiderian membrane observed through the crestal osteotomy prepared for sinus lift with piezosurgery inserts. Notice the membrane is exposed through the crestal bone and elevated without perforation.

Piezosurgery simplifies the sinus lift technique and increases predictability with its selective cutting action, which enables surgeons to maintain membrane integrity. This has resulted in a considerable reduction in patient morbidity in maxillary sinus surgery.

Ridge Expansion

Horizontal alveolar ridge expansion is an extremely useful technique for increasing bone width and simultaneously placing implants in narrow ridges. The great advantage is that both augmentation and implant placement are accomplished in one surgical procedure. A possible disadvantage is that crestal bone loss may be greater in cases that begin with very narrow ridges.

Clinical and radiographic evaluation of the size, shape, and morphologic characteristics of the alveolar bone in the ridge is necessary to determine whether to use a ridge expansion or a traditional bone augmentation technique (Figure 80-9, *A*). In brief, it can be said that this technique exploits bone elasticity so it is necessary to know the bone anatomy of each implant site. In particular, the morphology of the crestal bone and the thickness of the buccal cortical and lingual cortical plates in relation to the amount of cancellous bone present in the ridge greatly influences the ease and ability to prepare an osteotomy and to expand the ridge. The technique requires preservation of periosteum integrity while elevating mucogingival flaps enough for access to create the appropriate osteotomy. Piezosurgery is an indispensable tool used to create a horizontal osteotomy through the alveolar bone crest caused by its precise (narrow) cutting action. In some cases (e.g., areas of dense bone with little elasticity), it may also be necessary to make one or two vertical cuts in the alveolar bone to allow ridge expansion. The horizontal osteotomy is expanded in subsequent steps using piezoelectric inserts for implant site preparation together with screw-type or fan-type expanders for increasing the diameter or section, respectively.

Expanding a narrow ridge by the entire width (diameter) of the planned implant(s) may be challenging because of the density of cortical bone and limited elasticity. The need to expand or displace the buccal cortical bone can be reduced (i.e., less than the implant diameter) with rigorous application of DISP to the lingual cortical bone (i.e., preferential preparation of the lingual side), which is generally thicker than the buccal cortical. This is difficult to do with traditional twist drills because they cannot limit cutting to one side and tend to get displaced by areas of dense bone into areas of loose or missing bone (i.e., twist drills are deflected away from dense cortical bone). In fact, attempting to prepare the site (between separated cortical plates) with traditional drills can fracture the weaker, inelastic buccal cortical bone, making simultaneous implant placement impossible.

Piezoelectric bone surgery has radically simplified the ridge expansion technique in the horizontal osteotomy phase, which can be performed with micrometric precision, and in the site preparation phase, which exploits the different degree of cortical resistance compared to cancellous bone (Figure 80-9, *B* to *F*).[17,31]

Bone Harvesting

The bone harvesting technique using piezosurgery is effective for harvesting bone fragments and for removing blocks of monocortical-cancellous bone.

Particulate Bone Chip Harvesting Technique. Particulate bone chips are harvested using special osteoplasty inserts

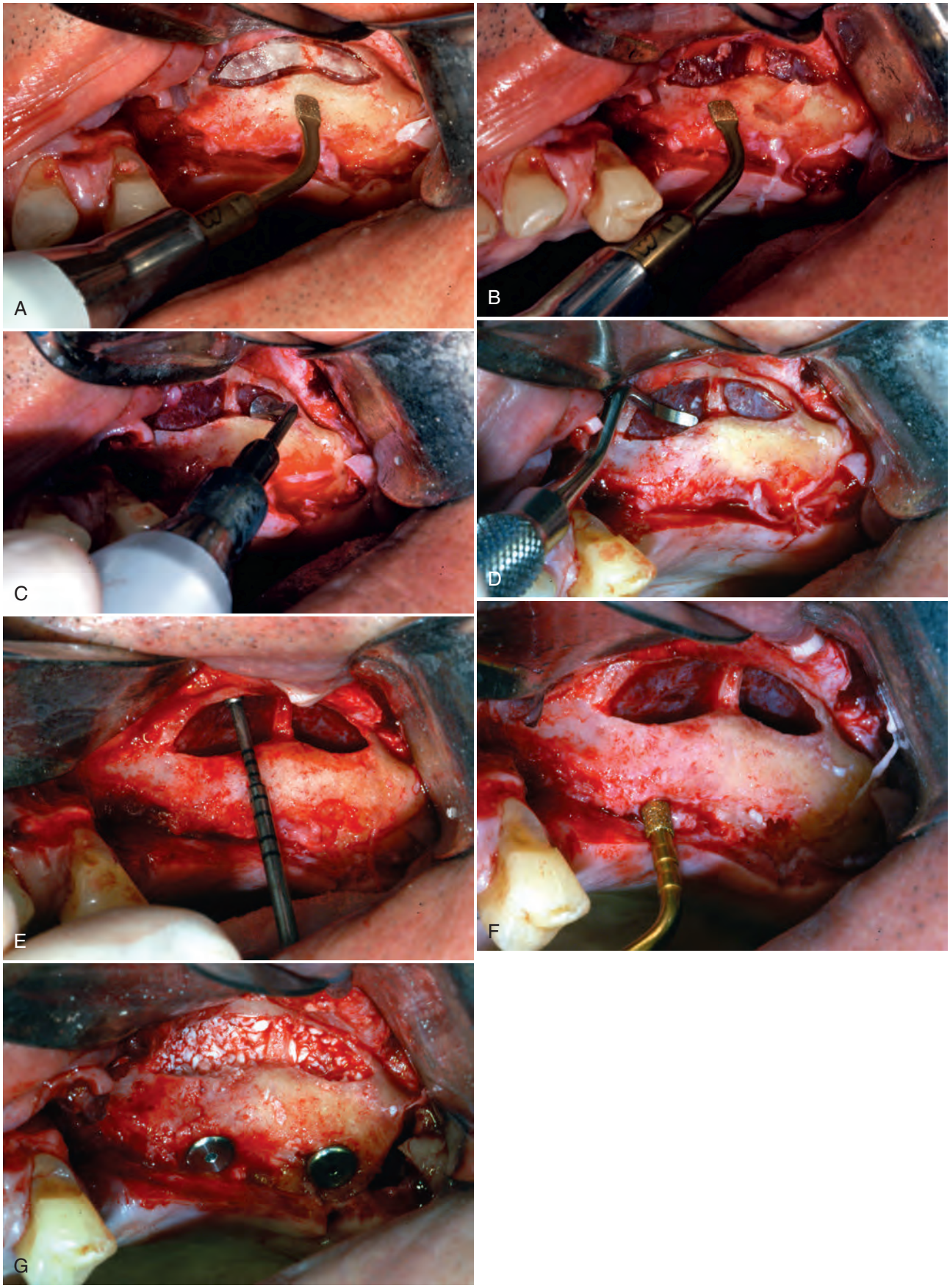

Figure 80-8 Sinus bone augmentation using a lateral window approach. A, Lateral window osteotomy outline created using a piezosurgery diamond-coated scalpel (OT1). **B,** Complete bony wall removal to expose the schneiderian membrane. Notice the membrane is completely intact without damage or perforations. **C,** Initial membrane separation from the edges of the lateral window using a noncutting piezosurgery insert (EL1). **D,** Membrane elevation with a manual instrument. **E,** Schneiderian membrane completely elevated. Ball probe used to evaluate adequate height of sinus lift. **F,** Implant site is prepared with piezosurgery inserts after sinus membrane elevation for simultaneous bone augmentation and implant placement. **G,** Bone augmentation material is inserted and packed to fill prepared sinus cavity.

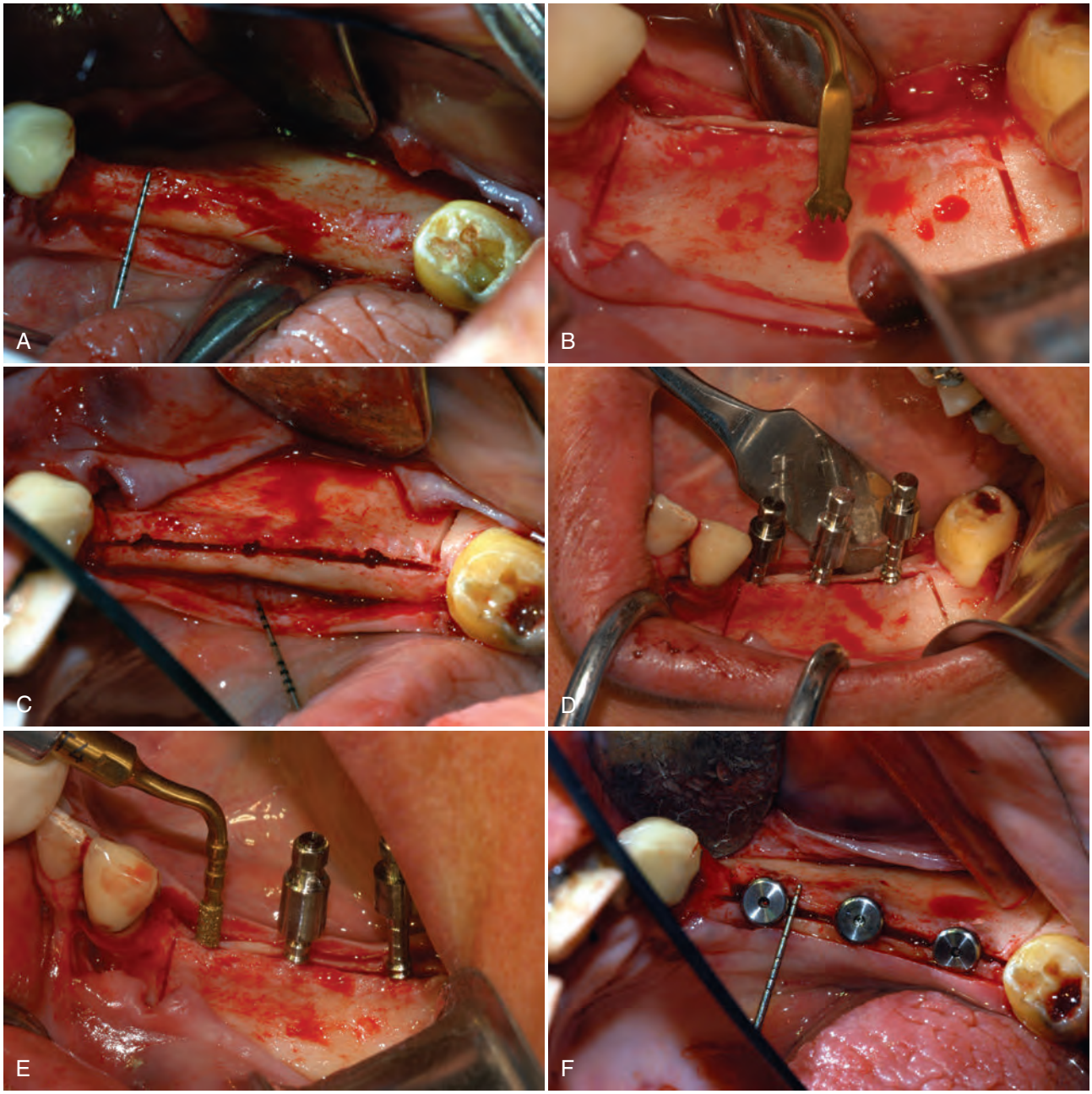

Figure 80-9 Ridge expansion. A, Evaluation of narrow (3-mm wide) posterior mandibular ridge with a periodontal probe. **B,** Horizontal and vertical osteotomies prepared with narrow (0.35 mm) piezosurgery insert (OT7S). **C,** Initial implant site preparation started with piezosurgery insert IM1. **D,** Screw expanders used to separate bone segments and begin expanding alveolar ridge. **E,** Differential implant site preparation (DISP) using piezosurgery insert OT4. **F,** Mandibular ridge expanded, implant sites prepared, and three implants simultaneously placed. Periodontal probe demonstrates final ridge width.

to scrape the bone surface. The flow of the irrigation fluid should be reduced to prevent particles from being dispersed after harvesting. The end of the aspirator tip should be kept away from the collecting particles or placed in the opposite direction of the insert movement.

There are two piezosurgery inserts used for performing this bone chip harvesting technique. Osteoplasty insert 1 (OP1) is the most effective because it is large and quickly harvests bone fragments. However, the size and surgical movement requires donor sites with ample surface area. It is generally used in bone grafting techniques for implant surgery. Osteoplasty insert 3 (OP3) is smaller and tends to harvest smaller bone fragments in any anatomic situation. It can be used in any site to collect bone for any bone grafting technique, but is best used in limited areas to harvest smaller quantities of bone for periodontal osseous defects.

Clinical Note. It is advantageous to use OP1/OP3 inserts to collect bone (for grafting defects) while performing other procedures (e.g., in maxillary sinus lift surgery while removing bone from the lateral window osteotomy or in periodontal surgery while recontouring bone with osteoplasty/ostectomy).

Block Harvesting Technique. Choosing an appropriate donor site and selecting the best instruments and technique for

harvesting block bone are important decisions in the success of bone augmentation with monocortical bone block grafts. Harvesting block bone with piezosurgery is extremely simple, precise and fast.

The most common donor sites for harvesting monocortical-cancellous block bone are the mandibular ramus and symphysis (chin). The surgical operation with piezosurgery offers considerable precision and operating sensitivity during surgery so that the operator is able to easily recognize differences in cortical and cancellous bone allowing him/her to preserve the integrity of important structures.

Harvesting a monocortical-cancellous bone block from the mandibular ramus is generally preferable to the symphysis region because of the reduced level of morbidity. Evaluation of presurgical three-dimensional (3D) scan images facilitates measurements and determines how much bone can be harvested with respect to the position of the inferior alveolar nerve canal, the position of molar roots, and the width of the mandible in the ramus area. Osteotomies performed with piezosurgery allow an extremely precise, clean, and smooth vertical cut through bone with excellent visibility.[2] The result is that a cortical block can be removed with a portion of spongy bone and its surface is extremely regular compared to blocks harvested from the chin.

This technique is very predictable because it facilitates harvesting the maximum amount of bone with respect to the donor site. By comparison, bone blocks harvested using traditional rotary cutting instruments reduce the width of the cortical bone by at least 1 mm circumferentially around the entire graft. Furthermore, traditional cutting instruments are unable to effectively cut the internal cancellous bone. The result is that the block is detached by using scalpels or chisels to break it away, which makes the width irregular. Subsequently, it becomes necessary to further reduce the block width.

Figure 80-1 Piezosurgery device by Mectron Medical Technology.

approximately 80 µm and a frequency of 30,000 times a second. A sound wave is overmodulated on this base frequency, which generates a hammering action with very little heat because the mechanical energy necessary to produce the microvibrations is very low. This action, along with the water spray, facilitates removal of bone debris.

Piezoelectric osteotomies are easy to create, but it is important to recognize that the technique and instrument handling are different than the technique using a traditional handpiece with rotary instruments. The piezosurgery insert is applied to the bone with a relatively light stroke similar to the smooth precision used to draw a picture. Heavy pressure or force is not required. Indeed, the pressure applied by the surgeon to the piezosurgery handpiece is much lower than the pressure typically applied to a rotary or oscillating type handpiece, which uses mechanical macrovibrations for cutting. This characteristic provides maximum control during surgery and makes this technique unique especially in areas with delicate anatomy.

Selective Cutting

Piezosurgery ultrasonic microvibrations are low frequency and selective for cutting mineralized tissue only. These microvibrations are physically unable to cut soft tissue. Clearly, the most significant demonstrated benefit of piezosurgery selective cutting is the ability to preserve the integrity of soft tissues, such as the alveolar nerve, the infraorbital nerve, the maxillary sinus membrane, and the dura mater, while effectively cutting the mineralized tissue (bone) in close proximity to these tissues.

Maximum Visibility

Piezosurgery creates a surgical field that is blood free during cutting because of its cavitation effect. Cavitation is a physical phenomenon that, from a clinical standpoint, happens with the nebulization of the saline solution. The slight hydropneumatic pressure applied by piezosurgery temporarily stops bleeding from both hard and soft tissues. It is important for the liquid pump to be flowing properly and for the cutting action to be intermittent to maintain optimal surface microcirculation, especially for long surgical procedures. Tissue perfusion resumes shortly after cutting (and cavitation action) is stopped.

Excellent Healing

Clinical studies comparing use of piezoelectric bone surgery with traditional rotary instruments for third molar extractions[14] and periodontal surgery[25] have reported better recovery and fewer postoperative symptoms in those treated with piezosurgery. Postoperative healing after piezoelectric bone surgery is characterized by minimal swelling and little bleeding and postoperative morbidity is lower compared to traditional techniques.[24] Gingival tissue is typically light in color when compared to the appearance of autogenous gel of platelet-rich plasma.

Clinical Applications

There are many important clinical applications of piezoelectric bone surgery in dentistry. In fact, nearly all techniques previously performed with burs, twist drills, chisels, or oscillating saws have the potential to be performed with piezosurgery. For 10 consecutive years the author (TV) has used piezosurgery on a daily basis for oral, periodontal, and implant surgical procedures, enabling him to develop techniques and protocols for each. Readers are referred to online materials and other publications for detailed descriptions and step-by-step instructions on these piezosurgery protocols. A brief overview of basic clinical applications using piezoelectric surgery is described here.

Periodontal Surgery

The use of piezosurgery in periodontal surgery simplifies and improves handling of soft and hard tissues.[30] In resective periodontal surgery, for example, after raising the primary flap with a traditional technique, using a scaler-shaped insert (PS2) (Figure 80-3, *A*) or an insert in the shape of a rounded scalpel (OP3) makes it easier to detach the secondary flap and remove inflammatory granulation tissue. This phase has little bleeding as the result of the cavitation of the saline solution (coolant). With the right inserts and power mode, the ultrasound device facilitates effective scaling, debridement, and root planing (Figure 80-3, *B* and *C*). In particular, debridement with a special diamond-coated insert enables thorough cleaning even for interproximal bone defects (Figure 80-3, *D*). The mechanical action of ultrasonic microvibrations, together with cavitation of the irrigation fluid (pH neutral; isotonic saline solution) eliminates bacteria, toxins, dead cells, and debris, which creates a clean physiology for healing. Healing is improved by applying ultrasound to produce micropits at the base of the defect to activate cellular response of healing mechanisms. Autogenous bone-grafting material consists of bone chips that are collected during the piezoelectric osteoplasty operation for recontouring bone irregularities (Figure 80-3, *E*). The result is that this technology reduces the invasiveness of traditional surgery by making surgery faster and by ensuring thorough cleaning of the periodontium. It also favors tissue healing by using bone removed in the osteoplasty procedure to graft osseous defects.

Piezosurgery in periodontal surgery redefines the guidelines that mark the border between resective treatment and regenerative treatment. Indeed, the choice between a resective technique and a regenerative technique generally depends on the depth of the bone defect, whether it is higher or lower than 3.5 mm.

The ability to work on the bone defect with magnifying systems makes it possible to exploit the benefits of piezosurgery microprecision in preparing the recipient site and stabilizing micrografts (Figure 80-3, *F* to *H*).

Crown Lengthening

Clinical crown lengthening is the most common periodontal surgical (ostectomy) operation performed in otherwise healthy

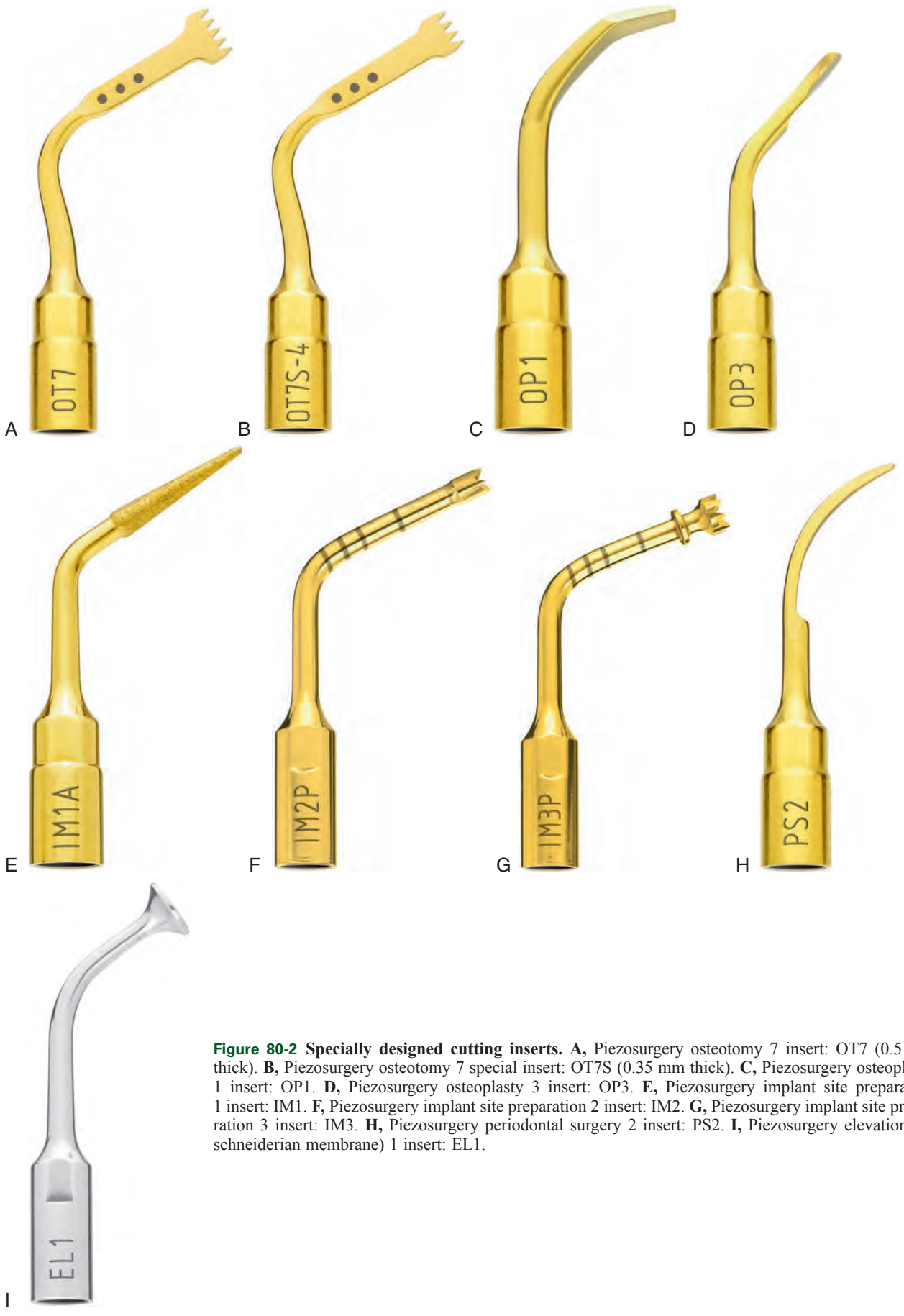

Figure 80-2 Specially designed cutting inserts. A, Piezosurgery osteotomy 7 insert: OT7 (0.5 mm thick). **B,** Piezosurgery osteotomy 7 special insert: OT7S (0.35 mm thick). **C,** Piezosurgery osteoplasty 1 insert: OP1. **D,** Piezosurgery osteoplasty 3 insert: OP3. **E,** Piezosurgery implant site preparation 1 insert: IM1. **F,** Piezosurgery implant site preparation 2 insert: IM2. **G,** Piezosurgery implant site preparation 3 insert: IM3. **H,** Piezosurgery periodontal surgery 2 insert: PS2. **I,** Piezosurgery elevation (of schneiderian membrane) 1 insert: EL1.

BOX 80-1 Description and Cutting Properties of Piezosurgery by Mectron

Piezosurgery is an electronic device that generates ultrasonic microvibrations at variable frequency. Its technology is unique in the world (U.S. Patent 6,695,047B2) for the characteristic vibrations generated in parallel and variable frequency modulation for precise cutting of bone with different degrees of density.

The unit has a display that allows the operator to select either the BONE or ROOT operating modes. The BONE cutting mode is used to cut bone with selections that are specific to bone type or density. The ROOT mode is used to shape, debride, and smooth root surfaces (both external: periodontal and internal: endodontic).

Bone Operating Mode

Cortical Bone

The basic low ultrasonic frequency (30 kHz) is overmodulated by sound waves for cutting and removing small cortical bone fragments.

Spongy Bone

The basic low ultrasonic frequency is overmodulated by sound waves that are slower than those for cortical bone, which is better for cutting and removing cancellous bone fragments.

Root Operating Mode

Periodontal Surgery

The low ultrasonic frequency without overmodulation is set at an ideal power level for scaling, debridement, and root planing.

Endodontic Surgery

The ultrasonic frequency is set at an ideal power level for retrocanal and intracanal debridement after root canal treatment.

BOX 80-2 Description of Piezosurgery Inserts

The mechanical action of bone cutting takes place thanks to the linear microvibrations of inserts with a variable range from 20 to 80 μm, depending on efficiency. Piezosurgery inserts are classified based on their functional and clinical characteristics.

Functional Classification

Sharp: These inserts have sharp ends for osteotomy and osteoplasty. They are made of nitride titanium steel and they are gold in color.

Smoothing: These nitride titanium inserts are diamond coated and gold in color. Their different granulometry produces a smoothening action that is generally used to complete the cut near soft tissue.

Blunt: These steel color inserts are characterized by rounded ends and are generally used to refine the cut in contact with soft tissue.

The inserts described in the functional classification as sharp, smoothing, and blunt have clinical classification codes that relate to their specific use.

Clinical Classification

OT: The identification code for inserts used to perform osteotomy is *OT* followed by a number.

OP: The identification code for inserts used to perform osteoplasty is *OP* followed by a number.

EX: The identification code for inserts used to perform extraction is *EX* followed by a number.

IM: The identification code for inserts used to perform implant site preparation is *IM* followed by a number.

periodontal conditions. The indication for this procedure is usually associated with a need or desire to expose more tooth structure because of short clinical crowns and/or loss of clinical tooth structure. In general, the goal is to reposition the periodontal bone and soft tissues to a more apical position with appropriate biologic dimensions and minimal periodontal inflammation.

The clinical crown lengthening technique entails performing a periradicular ostectomy of a few millimeters, which allows repositioning of the periodontal flap in a more apical position. The positive result obtained is that the health of the treated part is preserved even though the normal gingival morphology is altered. Clinical application must include esthetic assessment, as well as an assessment on the position and health of the adjacent periodontium.

The traditional surgical technique entails raising a full-thickness flap, performing the ostectomy with manual instruments, osteoplasty with a bur for crest bone architecture recontouring, periradicular bone removal, root planing, and, finally, replacing the flap in an apical position.

The ostectomy is simple to perform using piezosurgery in direct contact with the root surface because control of the instrument during surgery is precise, even in very difficult proximity cases (piezosurgery OP3 insert). The root planing phase can be performed very effectively using blunt ultrasonic inserts (piezosurgery PP1 insert).

Saline solution cavitation reduces bleeding during surgery and facilitates debridement of the surgical area. This effect is likely responsible for the excellent soft-tissue healing result, which is always characterized by a light color and without edema.

A histologic study conducted by Harvard University showed a better healing response for bone and root cementum in teeth that were crown lengthened using piezosurgery as compared to teeth that were crown lengthened with traditional rotary instruments.[26] Concerning the latter, the tungsten carbide bur is more favorable than the diamond-coated bur for the bone healing process.

The crown lengthening technique performed with piezosurgery using appropriate inserts makes it possible to effectively reduce bone while preserving root surface integrity.

Tooth Extraction Techniques

Today, tooth extraction is often the first step in the preparation for implant placement. Maintaining the integrity of the alveolar bone walls is an essential part of this process. Consequently, whether an implant is being placed at the time of extraction or not, the selection of instruments and techniques that minimize trauma to socket walls is critical.

Anatomic differences greatly influence the difficulty of extraction and the challenge of maintaining alveolar bone walls. A new bone classification system has been developed that makes it easier to choose the best surgical tooth extraction technique for different anatomic situations (Table 80-1).[28] The aim is always to preserve the integrity of the alveolar walls and the morphology of soft tissue. This classification divides anatomy into four types depending on the anatomic characteristics of periodontal biotype and anatomy/pathology of the periodontal ligament. Classifying anatomy into type 1, 2, 3, or 4 simplifies the diagnosis and the subsequent surgical decision. Each type corresponds to a different anatomic issue, which requires a specific extraction technique and determines the most effective surgical instruments.

Figure 80-3 Clinical case demonstrating the use of piezoelectric bone surgery for periodontal surgery. A, Ultrasonic scaling using piezosurgery PS2 insert. **B,** Root surface debridement using piezosurgery diamond-coated OP5 insert. **C,** Ultrasonic root planing using piezosurgery blunt insert: PP1. **D,** Interproximal infrabony defect with probe. **E,** Autogenous bone chip–harvesting technique using piezosurgery osteoplasty insert: OP3. **F,** Autogenous bone grafting technique. **G,** Collagen membrane stabilizing microbone grafting. **H,** Flap repositioned and sutured.

Type 1 anatomy describes a normal periodontal biotype and a normal periodontal ligament (i.e., no pathology). This anatomic condition poses little surgical difficulty. A traditional extraction technique using manual instruments is sufficient.

Type 2 anatomy describes a thin periodontal biotype with a normal periodontal ligament. The surgical difficulty for tooth removal is minimal. However, preserving the integrity of the thin alveolar walls makes the extraction more complex. In this situation, the normal displacement operation runs the risk of creating a dehiscence from fracturing the thin buccal cortical plate. To avoid this risk, a root fractioning technique that makes it possible to obtain root mobility inside the alveolus to eliminate the risk of damaging the thin labial and crestal bone is recommended.

Type 3 anatomy describes a normal periodontal biotype with an ankylotic periodontal ligament. The surgical difficulty for tooth removal is high because it is not possible to obtain the mobility necessary for displacement. The traditional technique uses a periradicular osteotomy with burs. This is possible without much consequence for mandibular third molars but results in serious damage to the alveolar walls of all the other teeth. The recommended technique creates the space necessary for extraction by operating only on the root surface through a root-plasty maneuver. The tooth is removed from the socket by cutting the root surface without touching the alveolar bone. This technique is easy to perform with excellent control using specific piezosurgery inserts.

TABLE 80-1 Root Extraction Surgical Classification by Tomaso Vercellotti

Anatomy	Periodontal Biotype	Alveolar Ligament	Surgery Difficulty	Technique
Type 1	Normal	Normal	Easy	Standard
Type 2	Thin	Normal	Medium	Advanced*
Type 3	Normal	Ankylotic	Complex	Advanced†
Type 4	Thin	Ankylotic	Severe	Advanced‡

*Advanced technique involves cutting root into fractions, internal luxation, and removal.

†Advanced technique involves root-plasty to reduce size, internal luxation, and removal.

‡Advanced technique involves root-plasty, cutting root into buccal slice fractions, internal luxation, and removal.

Type 4 anatomy describes a thin periodontal biotype and an ankylotic periodontal ligament, which is a combination of the challenging aspects of type 2 and type 3 anatomy. The surgical difficulty for tooth removal is the highest. In the anterior maxilla, where esthetics are important, a root-sectioning technique that divides the root into segments with a mesial–distal cut is recommended. This allows the separate pieces (e.g., buccal and palatal) to be removed internal to the socket with minimal force applied to the socket walls.

Simplified Tooth Extraction. In addition to the techniques described, there is a simplified version to assist most extraction operations. This technique consists of cutting the root surface with a thin, cone-shaped diamond-coated insert that cuts the outer circumference of the tooth in manner similar to a crown preparation (Figure 80-4). This operation, performed under magnification, enables preservation of the alveolar bone, which is important for the placement of dental implants. The reader is referred to other publications for more information and details on this technique.

Implant Site Preparation

Special piezosurgery inserts developed for bone perforation have enabled the development of a new technique for ultrasonic implant site preparation (UISP). Extensive experience gained over 5 years using the technique to prepare more than 1500 implant sites has culminated in the development of a protocol with significant clinical advantages.

The first advantage of UISP is related to the cutting characteristics of piezosurgery, which facilitate differential preparation of the cortical and cancellous bone. A surgical bone classification system was developed that simplifies the diagnosis and surgical decision-making process by exploiting differences in bone anatomy (Figure 80-5). The differential implant site preparation (DISP) technique can be used within the initial osteotomy site to correct the implant axis by selectively directing the cutting action in the desired direction.[22] DISP can also be used in combination with twist drills to facilitate preservation of alveolar crestal bone while achieving maximum primary stability.[32]

The second advantage of UISP is the fast clinical healing of both soft and hard tissue. Animal research demonstrates that new bone formation (neo-osteogenesis) is active at implant sites prepared with piezoelectric bone surgery earlier than at sites prepared

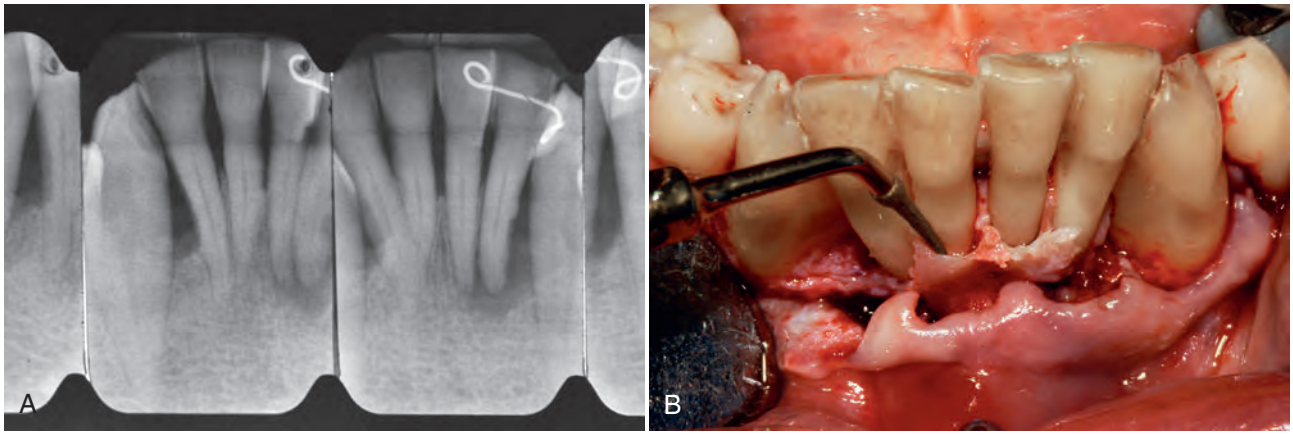

Figure 80-4 Case demonstrating use of piezoelectric bone surgery for tooth extraction. A, Radiograph of mandibular incisors with severe periodontal bone loss that are to be extracted because of a hopeless prognosis. **B,** The piezosurgery insert operates only on the root surface without cutting, damaging, or overheating the surrounding bony walls of the extraction socket.

Continued

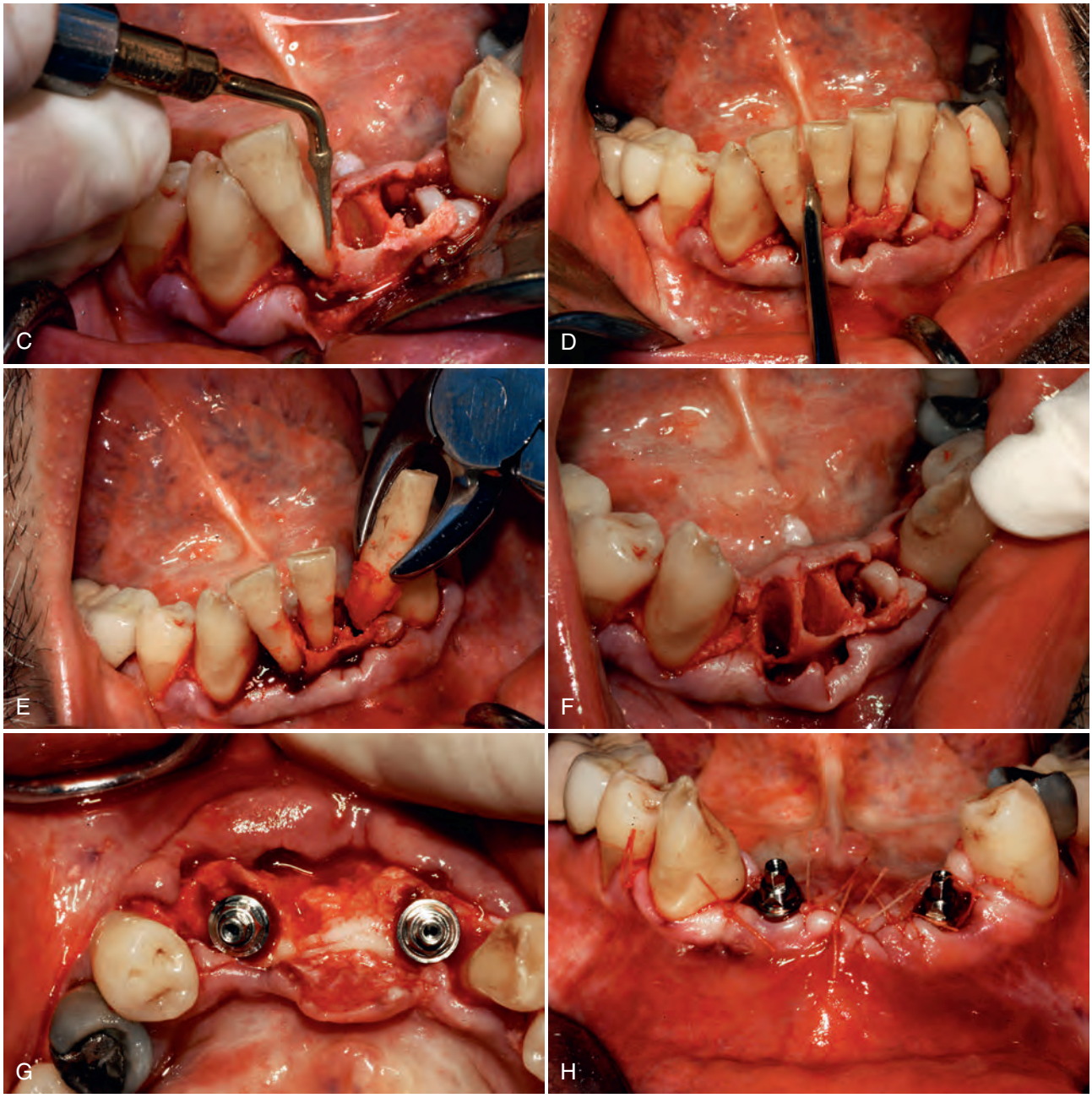

Figure 80-4, cont'd **C,** The piezosurgery insert is directed at cutting the root surface only (root-plasty) without cutting, damaging, or overheating the surrounding bony walls of the extraction socket in this simplified extraction technique. **D**, Mobility is obtained with an elevator in a mesial–distal direction. **E,** Teeth are extracted with forceps after displacement. **F,** Notice the preservation of the alveolar bone. The narrow socket walls are completely intact after this root-plasty extraction technique. **G,** Implant placement and particulate bone grafting of extraction socket defects. **H,** Flap closure and suturing.

with traditional techniques.[3] A histomorphometric study on minipigs showed more bone formation and a greater density of periimplant osteoblasts at implant sites prepared with piezosurgery as compared to sites prepared with twist drills.[3]

The improved healing response observed at piezoelectric bone surgery–treated sites (compared to sites prepared with traditional drills) may be explained by differences in the level of bone morphogenetic proteins (BMPs), growth factors, and cytokines. In an animal study comparing the biomolecular profile of sites prepared with piezoelectric bone surgery or rotary drills, BMP-4 increased earlier at implant sites prepared with piezoelectric bone surgery.[3] As compared to drilled sites, the levels of BMP-4 at piezoelectric bone surgery–treated sites were 18.5 times higher at 7 days, 15 times higher at 14 days, and 2 times lower at 56 days. The peak levels of BMP-4 were observed at 14 days for piezoelectric bone surgery–treated sites. The level of BMP-4 at drilled sites did not reach the same level of BMP-4 achieved at piezoelectric bone surgery–treated sites until day 56. There was also a greater increase in the level of transforming growth factor β_2 (TGF-β_2) cytokine at implant sites prepared with piezoelectric bone surgery techniques. As compared to drilled sites, the levels of TGF-β_2 at piezoelectric bone surgery treated sites were 3.5 times higher at 7 days, 19 times higher at 14 days, and diminished below baseline at 56 days. The level of TGF-β_2 at drilled sites never exceeded baseline levels.



Figure 80-5 Surgical bone classification by Tomaso and Giuseppe Vercellotti. A, Cortical crestal thickness in millimeters. **B,** Radiographic cancellous bone classification.

Proinflammatory cytokine tumor necrosis factor α, proinflammatory and bone-resorbing cytokine interleukin-1β (IL-1β), and antiinflammatory cytokine IL-10 were also measured. In general, the expression of these proinflammatory cytokines was higher in the early experimental phases of drilled sites only, which also showed more inflammatory cells. The piezoelectric bone surgery–treated sites showed a higher expression of the proinflammatory and bone-resorbing cytokine IL-1β at 56 days. This latter finding might be indicative of bone remodeling at day 56 in piezoelectric bone surgery treated sites (IL-1β is involved in osteoclast differentiation).

It is assumed that the micronization of the bone reduces cut trauma while saline solution cavitation produces debridement of the osteotomy surfaces with exposure and preservation of a high number of BMPs and growth factors. These proteins are capable of increasing the mitosis of stromal stem cells and osteoblasts.

The surgical technique entails an osteotomy preparation using a series of piezosurgery insert. The preparation is initiated with the narrow, pointed IM1 insert (Figure 80-6, *A*). Parallel pins are used throughout the procedure to check alignment (Figure 80-6, *B*). The 2-mm–diameter IM2 insert is used to further prepare the osteotomy

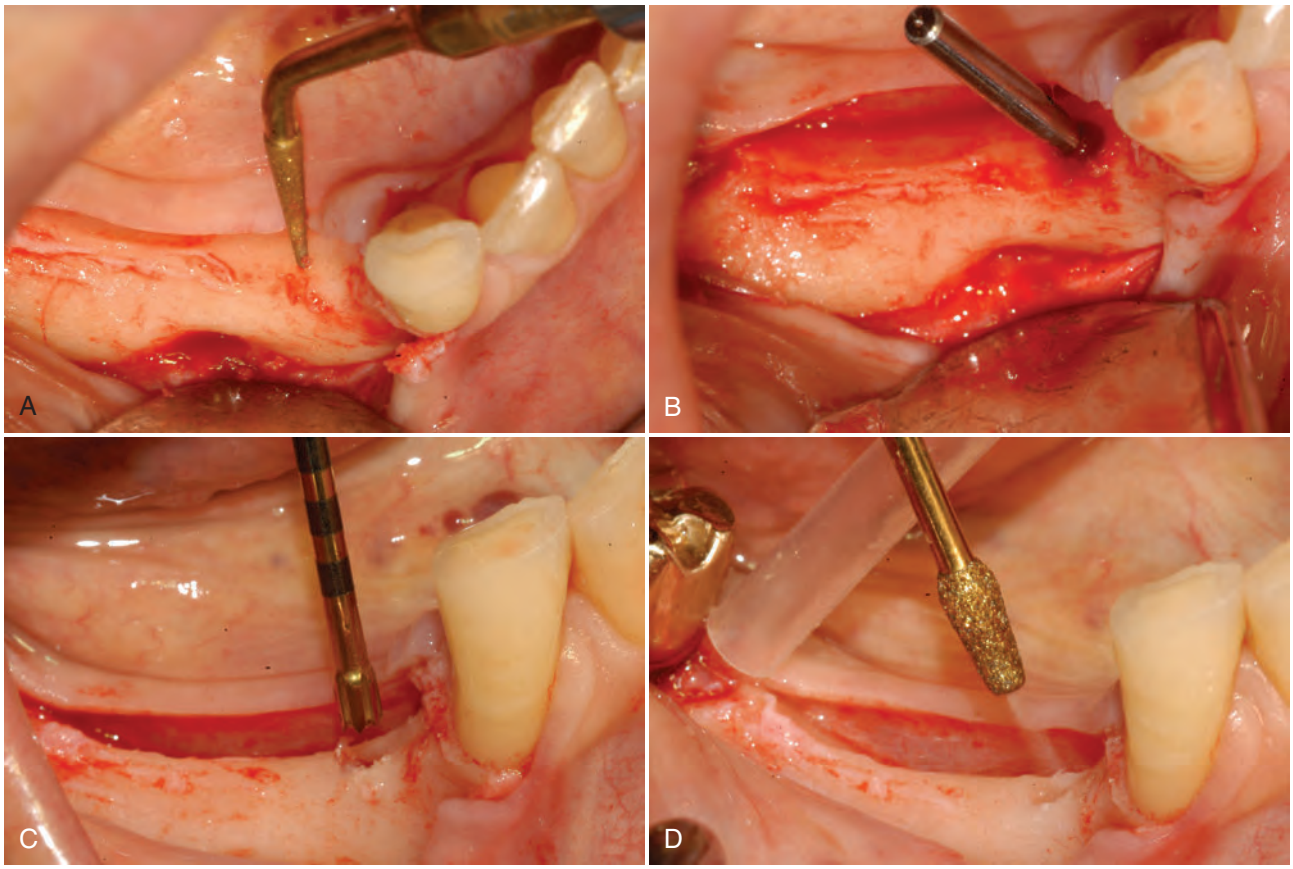

Figure 80-6 Implant site preparation and placement. A, Piezosurgery insert (IM1) used to start the implant site preparation. **B,** Parallel pin in place to check the direction of osteotomy. **C,** Piezosurgery 2-mm–diameter insert (IM2) for pilot osteotomy. **D,** Piezosurgery insert for cortical preparation (pilot 2/3).

Continued

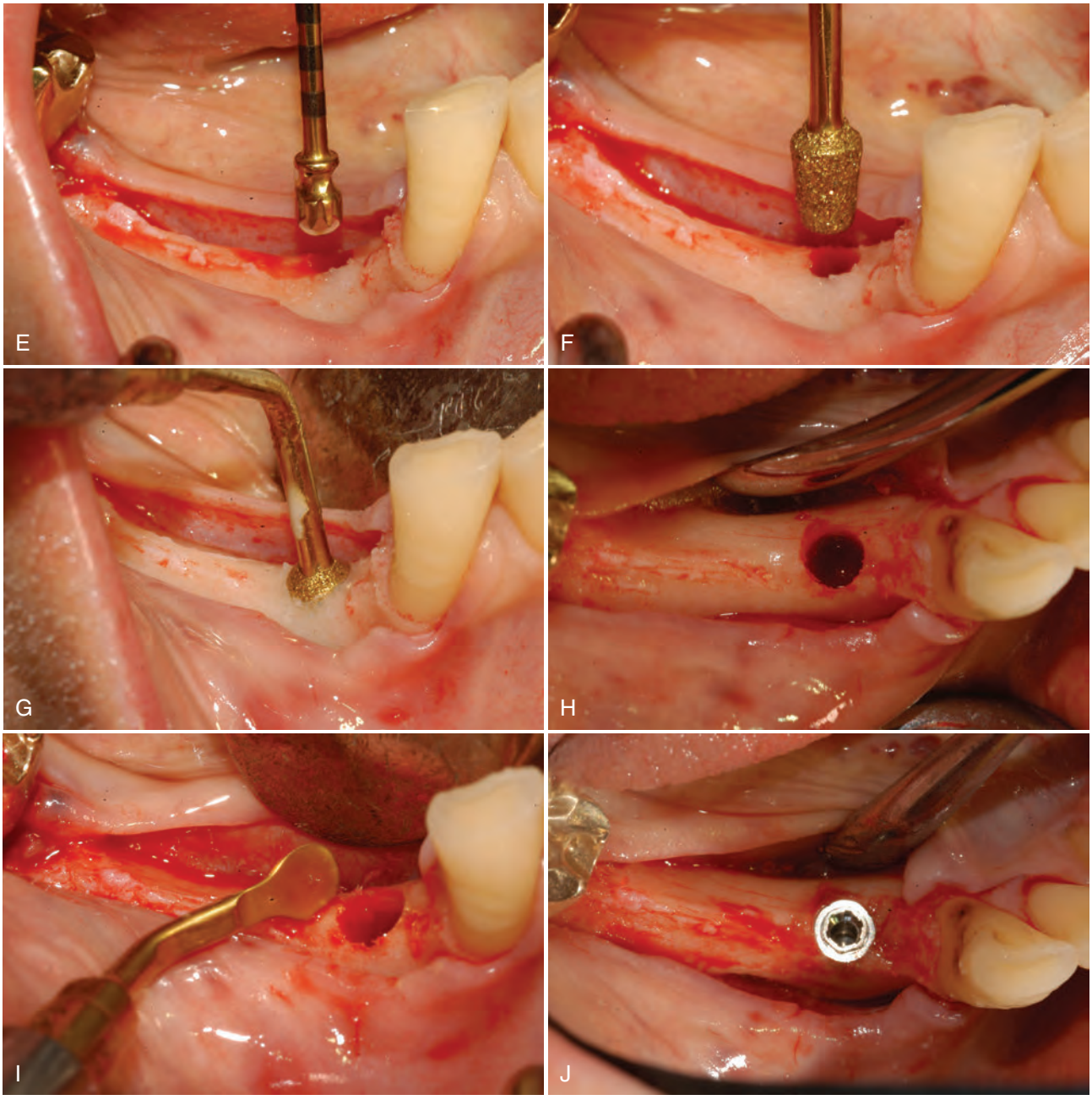

Figure 80-6, cont'd **E,** Cancellous bone preparation with piezosurgery insert IM3. **F,** Piezosurgery diamond-coated insert (IM4) for final cortical bone preparation. **G,** Piezosurgery pilot insert 3/4 in action. **H,** Occlusal view of completed implant site preparation. **I,** Osteoplasty of crestal bone in the periimplant area using piezosurgery insert OP3. **J,** Occlusal view of well-placed implant despite the narrow ridge.

(Figure 80-6, *C*). The coronal aspect of the preparation is widened with the pilot 2/3 insert (Figure 80-6, *D*), and the osteotomy is finished with the IM3 insert (Figure 80-6, *E*). Final cortical preparation is accomplished with the IM4 insert (Figure 80-6, *F*). After pilot 3/4 insert (Figure 80-6, *G*), the implant osteotomy is completed (Figure 80-6, *H*). If desired, before implant placement, osteoplasty of the crestal bone is possible with the OP3 insert (Figure 80-6, *I*). Final occlusal view of implant placed in a narrow ridge (Figure 80-6, *J*).

Conclusion

Piezosurgery is a new surgical technique for bone surgery with many clinical applications in dentistry. The extraordinary cutting properties and applications of piezoelectric bone surgery were described. The most compelling characteristics of piezoelectric bone surgery are low surgical trauma, exceptional precision, and fast healing response. As a result, piezosurgery has the ability to increase treatment effectiveness while improving postoperative recovery and healing.

Although a great deal of scientific research focuses on new products for tissue engineering and bone regeneration, the importance of minimal surgical trauma for optimal bone healing and regeneration should not be overlooked. A new appreciation for the effectiveness of piezosurgery has the potential to redefine the concept of minimally invasive surgery in osteotomy and osteoplasty procedures.

Suggested Readings

Preti G, Martinasso G, Peirone B, et al: Cytokines and growth factors involved in the osseointegration of oral titanium implants positioned using piezoelectric bone surgery versus a drill technique: a pilot study in minipigs. *J Periodontol* 78(4):716, 2007.

Schaeren S, Jaquiéry C, Heberer M, et al: Assessment of nerve damage using a novel ultrasonic device for bone cutting. *J Oral Maxillofac Surg* 66:593, 2008.

Vercellotti T: Piezoelectric surgery in implantology: a case report—a new piezoelectric ridge expansion technique. *Int J Periodontics Restorative Dent* 20(4):359, 2000.

Vercellotti T: Technological characteristics and clinical indications of piezoelectric bone surgery. *Minerva Stomatol* 53(5):207, 2004.

Vercellotti T: *Essentials in piezosurgery. Clinical advantages in dentistry*, Hanover Park, IL, 2009, Quintessence.

Vercellotti T, Crovace A, Palermo A, et al: The piezoelectric osteotomy in orthopedics: clinical and histological evaluations (pilot study in animals). *Medit J Surg Med* 9:89, 2001.

Vercellotti T, De Paoli S, Nevins M: The piezoelectric bony window osteotomy and sinus membrane elevation: introduction of a new technique for simplification of the sinus augmentation procedure. *Int J Periodontics Restorative Dent* 21(6):561, 2001.

Vercellotti T, Nevins ML, Kim DM, et al: Osseous response following resective therapy with a piezosurgery. *Int J Periodontics Restorative Dent* 25(6):543, 2005.

Wallace SS, Froum SJ: Effect of maxillary sinus augmentation on the survival of endosseous dental implants. A systematic review. *Ann Periodontol* 8:328, 2003.

References

References for this chapter are found on the companion website www.expertconsult.com.

References

1. Boyne PJ, James RA: Grafting of the maxillary sinus floor with autogenous marrow and bone. *J Oral Surg* 38:613–616, 1980.
2. Happe A: Use of a piezoelectric surgical device to harvest bone grafts from the mandibular ramus: report of 40 cases. *Int J Periodontics Restorative Dent* 27:241–249, 2007.
3. Preti G, Martinasso G, Peirone B, et al: Cytokines and growth factors involved in the osseointegration of oral titanium implants positioned using piezoelectric bone surgery versus a drill technique: a pilot study in minipigs. *J Periodontol* 78:716–722, 2007.
4. Robiony M, Polini F, Costa F, et al: Endoscopically assisted intraoral vertical ramus osteotomy and piezoelectric surgery in mandibular prognathism. *J Oral Maxillofac Surg* 65:2119–2124, 2007.
5. Robiony M, Polini F, Costa F, et al: Ultrasound piezoelectric vibrations to perform osteotomies in rhinoplasty. *J Oral Maxillofac Surg* 65:1035–1038, 2007.
6. Robiony M, Polini F, Costa F, et al: Piezoelectric bone cutting in multipiece maxillary osteotomies. *J Oral Maxillofac Surg* 62:759–761, 2004.
7. Robiony M, Toro C, Costa F, et al: Piezosurgery: a new method for osteotomies in rhinoplasty. *J Craniofac Surg* 18:1098–1100, 2007.
8. Salami A, Dellepiane M, Mora F, et al: Piezosurgery in the cochleostomy through multiple middle ear approaches. *Int J Pediatr Otorhinolaryngol* 72:653–657, 2008.
9. Salami A, Dellepiane M, Mora R: A novel approach to facial nerve decompression: use of Piezosurgery. *Acta Otolaryngol* 128:530–533, 2008.
10. Salami A, Dellepiane M, Salzano FA, et al: Piezosurgery in the excision of middle-ear tumors: effects on mineralized and non-mineralized tissues. *Med Sci Monit* 13:PI25–PI29, 2007.
11. Salami A, Mora R, Dellepiane M: Piezosurgery in the exeresis of glomus tympanicum tumours. *Eur Arch Otorhinolaryngol* 265:1035–1038, 2008.
12. Salami A, Vercellotti T, Mora R, et al: Piezoelectric bone surgery in otologic surgery. *Otolaryngol Head Neck Surg* 136:484–485, 2007.
13. Schaeren S, Jaquiery C, Heberer M, et al: Assessment of nerve damage using a novel ultrasonic device for bone cutting. *J Oral Maxillofac Surg* 66:593–596, 2008.
14. Sortino F, Pedulla E, Masoli V: The piezoelectric and rotatory osteotomy technique in impacted third molar surgery: comparison of postoperative recovery. *J Oral Maxillofac Surg* 66:2444–2448, 2008.
15. Tatum O: *Maxillary sinus grafting for endosseous implants*. In Lectur, Alabama Implant Study Group, Annual Meeting. Birmingham, AL, 1997.
16. Tordjman S, Boioli LT, Fayd N: Apport de la Piezochirurgie dans la surelevation du plancher sinusien, Departement de Parodontologie de l'UFR de Stomatologie et Chirurgie Maxillo-Faciale. Universite de Paris VI-Paris. *Revue Implantologie* 17–25, 2006.
17. Vercellotti T: Piezoelectric surgery in implantology: a case report–a new piezoelectric ridge expansion technique. *Int J Periodontics Restorative Dent* 20:358–365, 2000.
18. Vercellotti T: La chirurgia ossea piezoelettrica, II. *Dentista Moderno* 5:21, 2003.
19. Vercellotti T: Technological characteristics and clinical indications of piezoelectric bone surgery. *Minerva Stomatol* 53:207–214, 2004.
20. Vercellotti T: Caracteristicas tecnologicas e indicaciones clinicas de la cirugia osea piezoelectrica. *Revista Mundo Dental* 53:207, 2005.
21. Vercellotti T: La Chirurgia piezoelecttrica. Edizioni Acme, Gorizia La Chirurgia del Seno Mascellare e le alternative terapeutiche, 2005.
22. Vercellotti T: *Essentials in Piezosurgery*, Hanover Park, IL, 2009, Quintessence.
23. Vercellotti T, Crovace A, Palermo A, et al: The piezoelectric and rotatory osteotomy technique in impacted third molar surgery: comparison of postoperative recovery. *Medit J Surg* 9:89, 2001.
24. Vercellotti T, De Paoli S, Nevins M: The piezoelectric bony window osteotomy and sinus membrane elevation: introduction of a new technique for simplification of the sinus augmentation procedure. *Int J Periodontics Restorative Dent* 21:561–567, 2001.
25. Vercellotti T, Majzoub Z, Trisi P, et al: Histologic evaluation of bone response to piezoelectric, surgical saw and drill osteotomies in the rabbit calvaria. *Int J Oral Maxillofac Implants* (submitted).
26. Vercellotti T, Nevins ML, Kim DM, et al: Osseous response following resective therapy with piezosurgery. *Int J Periodontics Restorative Dent* 25:543–549, 2005.
27. Vercellotti T, Nevins M, Jensen Ole T: *Piezoelectric bone surgery*, ed 2, Chicago, 2006, Quintessence, p 273,
28. Vercellotti T, Obermair G: Introduction to piezosurgery. *Dent Implant Parodont* 7:270, 2003.
29. Vercellotti T, Obermair G: Inroduzione alla chirurgia piezoelettrica. *Implant Dent* 2:78, 2005.
30. Vercellotti T, Pollack AS: A new bone surgery device: sinus grafting and periodontal surgery. *Compend Contin Educ Dent* 27:319–325, 2006.
31. Vercellotti T, Russo C, Gianotti S: A new piezoelectric ridge expansion technique in the lower arch—a case report (online article). *World Dentistry* 2000. <http://www.world-dent.com/2001/05/articles/vercellotit.xml>. Accessed April 2014.
32. Wallace SS, Froum SJ: Effect of maxillary sinus augmentation on the survival of endosseous dental implants. A systematic review. *Ann Periodontol* 8:328–343, 2003.
33. Wallace SS, Mazor Z, Froum SJ, et al: Schneiderian membrane perforation rate during sinus elevation using piezosurgery: clinical results of 100 consecutive cases. *Int J Periodontics Restorative Dent* 27:413–419, 2007.

CHAPTER 81

Technologic Advances in Implant Surgery: Computer-Assisted Implant Surgery

Daniel H. Etienne, Raymond R. Derycke, and Perry R. Klokkevold

CHAPTER OUTLINE

Computer-Assisted Implant Surgery
Conclusion

Implant surgical procedures have more or less remained the same since the introduction of osseointegrated dental implants. Briefly, implant placement surgery involves the use of a full-thickness flap elevation and a sequential series of drills with increasing diameters under profuse irrigation to create a precise osteotomy site in the bone for the placement of a dental implant (see Chapter 75). The site is prepared, and the implant positioned to avoid important anatomic structures, such as the inferior alveolar nerve, sinus cavities, and teeth, and to optimally support and emulate the planned prosthetic tooth replacement(s). Proper implant position is important for optimal function and esthetics.

Clinicians determine implant positions based on presurgical diagnostic imaging, study models, and the use of a diagnostic wax-up of the planned tooth replacement(s). The actual or final position of the implant(s) results from the surgeon's interpretation of diagnostic information and his or her ability to translate that information to the patient at surgery. Most often, the surgical "guide" between the diagnostic information and the patient is an acrylic stent, fabricated by a laboratory technician that may or may not have precise guide channels for implant positioning. Consequently, inaccuracies in the stent fabrication and movement of the stent during surgery, as well as variations in the use of the stent during surgery, can lead to imprecise implant positioning.

Recent advances in implant surgical technology include the following:

- Computer-imaging software used preoperatively to "simulate" the implant position(s) into a virtual patient, that is, a three-dimensional (3D) computer image of the patient's jaw created from the computed tomography (CT) scan data.[24]
- Computer-generated surgical guides with drill sleeves based on the presurgical "virtual" implant positioning are used to more accurately place implants in the "planned" locations.[11,14,18]
- Computer-assisted implant surgery (CAIS) uses simultaneous tracking and "guidance" of the implant instrumentation to accurately follow the planned treatment during surgery.[6]

  The actual trend is to use two different approaches:
- CT based images where the correlation with the patient anatomy is done with radiomarkers.
- Novel real time ultrasound or contact probe 3D mapping, which captures positional data at the time of patient positioning. There is no need for image matching or fusion.

Computer-Assisted Implant Surgery

CAIS is the most sophisticated and perhaps the most promising of these technologies because it has the greatest potential to reduce surgical time, minimize surgical invasiveness, and result in a more precise translation of implant planning to the actual surgical procedure.[23] CAIS immediate mapping has the advantage of an immediate chairside procedure, which can be performed without CT scan images. Understandably, CAIS is also the technique that requires the greatest amount of preparation and coordination of the patient, image data, and surgical instrumentation. This chapter provides a conceptual overview of the techniques and terminology used in CAIS.

Uses and Requirements

Computerized navigation surgery evolved from early applications in neurosurgical procedures and continues to evolve today with applications in many surgical specialties.[17,19] Clearly, the advantage of using a computer to assist surgery is the precision that it offers. There is also a real-time safety control obtained with multiple imaging sources facilitating a minimally invasive approach to surgical procedures. As in medicine, 3D imaging is used in dentistry to facilitate presurgical planning and to guide the surgical placement of dental implants. This allows precise positioning while avoiding injury to nearby important anatomic structures. Several different approaches to computers have been used in dental implant surgery, from simple imaging software to visualize the implant positions in a 3D virtual patient to more complex, simultaneous image monitoring and instrument navigation used to perform surgery.[6]

The use of CAIS requires precise and continuous coordination of the patient, the image data, and the surgical instrumentation. Therefore CAIS requires an accurate alignment (identification and registration) of the patient with the patient's image data (contact probe or ultrasound 3D mapping CT scan data) and a system of tracking the precise movements of the surgical instrumentation (e.g., handpiece, drills) in relation to the actual patient. A variety of systems have been developed to acquire and register image data and to coordinate and track movements. These methods are described in the following sections.

Sequence of Steps

The clinical sequence of steps required for conventional CAIS is as follows:

1. *Data acquisition*. The patient is scanned for image data acquisition (e.g., CT scan) with fiducial (artificial) radiographic markers (e.g., stent with markers or intentionally placed pins or screws into jaw) or anatomic (natural) markers such as teeth or bony landmarks. If fiducial markers are placed in a stent, the patient must have it in place when scanned.
2. *Identification*. The anatomic or fiducial markers will be identified with a probe tracked by the system. If markers were incorporated into a radiographic stent, the stent will again be placed in the mouth and the markers identified by hand with a probe tracked by the stereovision system.
3. *Registration*. After identification of the predetermined markers, the software will indicate the best localization or "match" on the arch between the image data and the patient. If registration is not validated, matching can be improved with additional points. An invalidated registration may be caused by an improper initialization or CT scan data.
4. *Navigation*. Ultimately, the operator will be able to visualize surgical instrument navigation (movement). The drilling instruments will be guided to a target point of impact with a 3D spatial orientation.
5. *Accuracy*. Sustained accuracy procedures are critical during surgery and should prove reliability in regard to the system's overall accuracy. This sustained accuracy procedure will be done through contact of the drill on the handpiece with selected teeth, by visualization of markers, which can be viewed by the stereovision system, or repositioning of the radiomarker stent.
6. *Feedback*. Variations from the ideal position can be restricted by the software through inactivation of the drill (stop-and-go action) or by an audible or visual cue.

The clinical sequence of steps required for **CAIS** immediate mapping is as follows[8]:

1. *Preparation for 3D mapping data acquisition*. A removable attachment (bracket or similar device) is stuck on a nonmobile tooth to support infrared markers for a 3D real-time tracking of the patient position. If no teeth are available, a mini implant can be placed to hold a bracket. Any other tool with its *tracking device will be localized, in real time, with the patient position*. These tools and patient position will generate data in the same referral time and 3D space.
2. *Chairside 3D mapping data acquisition.*
   a. Anatomical 3D contouring with a contact probe or a similar device. Tracking cameras are scanning in an infrared light environment, while reflecting markers (rigid body) are connected to a contra angle through a rigid mount. The contact probe can be a regular drill and its tip will draw lines to contour teeth surfaces or a bone socket in case of extraction. Because a 3D mapping is recorded at the same time as the patient is positioned, the inaccuracy is limited to the maximum deviation (0.3 mm) of the camera's tracking systems.
   b. 3D Ultrasound bone and root contour acquisition. An ultrasound probe depth provides a bone surface mapping, point by point, with a maximum deviation of 0.2 mm for 10 mm of soft-tissue thickness. With this technology of 3D bone and soft-tissue mapping there is no need to match images.
3. *Navigation*. Can be performed immediately after chairside acquisition.
4. *Accuracy.* Sustained accuracy procedures are easily performed in a 3D mapping real-time system by a contact on a tooth or a bone surface. In case of discrepancy the system can be reset rapidly to provide a real time safety.

Data Acquisition

CAIS CT-Based Technology. CT scans and the more-recent cone-beam CT (CBCT) scans are widely used for 3D patient imaging (see Chapter 73). Factors that must be considered when deciding to use a CT scan include radiation exposure, limitations in accuracy, and the possibility of diffracted images as a result of metallic restorations. The evolution of scanner technology (spiral CT scan, CBCT scan) has made it possible to reduce the radiation dose to the level of a conventional panoramic radiograph while maintaining adequate diagnostic quality for preoperative implant planning.[9]

Similar to implant planning using conventional diagnostic methods, radiographically identifiable markers are important for CAIS. However, unlike conventional planning, in which orientation and simulation of implant positions are related to the planned prosthetic crown positions, CAIS markers must relate the image data to the actual patient anatomy. In other words, the position of the surgical instrumentation (and ultimately the implant) must be related to the scan image data of the patient's jaw morphology. Thus it is critically important to scan the patient with markers that are identified in the scan and correlated to the patient at surgery. Markers can be anatomic markers, such as teeth or specific bony landmarks, or artificial markers (fiducial), such as small tacks or screws that are secured in the bone.

CAIS Immediate Mapping. Chairside real-time synchronization between 3D images (contact probe and ultrasound) and patient position allows a real-time accuracy and, in case of mismatch, the ability to perform a new chairside 3D acquisition at any time during the procedure. This accuracy depends on a rigid body tracking system with a maximum deviation around 0.3 mm without artifacts or deviations that can occur with CT scan or CBCT. An ultrasound surface mapping[4] will not provide internal structure images, except root contours and the sinus floor. However, the distance from the alveolar crest to the nerve canal can be evaluated on 2D X-ray, transferred precisely to the extracted 2D image from a 3D mapping image. If needed 3D X-ray images can be superimposed on the ultrasound or probe mapping.[8,22]

Identification and Registration

After scan acquisition, the 3D image data of the patient's jaw(s) are interpreted by software as anatomic geometric elements. As previously stated, a sufficient number of markers (anatomic or fiducial) must be identified in the patient's mouth to correlate the image data with the patient anatomy. Several devices have been used to capture the actual patient anatomy for registration with the scan data, including a touch pointer and an ultrasound probe. The touch pointer allows the operator to touch specific anatomic points (or fiducial markers) while a tracking device "sees" the instrument and records each point of reference. This device is fairly accurate, but if the clinician is not careful, there is a tendency to define points that are not in contact to a real surface, thus creating a false mapping. The ultrasound probe has a lower accuracy than the touch pointer but has the advantage of being able to capture continuous data of bone morphology through the mucosa or gingiva. Echo quality is subject to variations with the type of penetrated tissue.

Matching between the geometry of the image data with the patient anatomy is called *registration*. Five registration methods are

used to compare anatomic points of the preoperative image data and the intraoperative patient anatomy: (a) point-based, (b) line-based or curve-based, (c) surface-based, (d) volume-based, and (e) projective methods. Point-based and line-based methods are described here to illustrate the requirements for an adequate registration.

In the point-based method, a few particular points are identified in the preoperative image data and the patient anatomy. These can be natural (anatomic points) or artificial (fiducial) markers. In either case, points must be well defined and stable so that they can be precisely measured. The operator can manually click, with a tracking device, on the point in the patient corresponding to the image point. After several points are matched, the computer calculates a transformation equation that minimizes the mean distance between matched points to complete the registration. Three nonaligned points are necessary to obtain a nonambiguous result. The registration accuracy can be predicted, depending on the distribution of points (e.g., an equilateral tripod will give more accurate results than three colinear points).[10,16]

The most intuitive algorithm may be the Hough transformation, in which the most simple geometric invariant, the distances between points, are computed, compared, and used to find a triangle in the preoperative set of points and a triangle in the intraoperative set of points that shares similar edge lengths. The triangle points are then registered using the best-fit algorithm. Once a first estimate of the transformation has been computed, the clinician can apply the transformation to the intraoperative points. An average accuracy is around 0.5 to 1 mm.

Line-based or curve-based methods are derived from point-based methods but require a few lines or curves to be measured and identified. Artificial lines can be extracted from the CT scan image data and measured intraoperatively by the operator with the tracking device. All lines and surfaces measured on image planning (after segmentation of anatomic structure of the jawbone in the CT scan), and the points taken on the patient anatomy by the tracking device are known as a set of points. These sets may be dense or sparse; a segmented bone surface may have hundreds or thousands of points. However, it is not practical to measure hundreds of points.

When the segmented surface is dense, one can assume that almost all points measured with the tracking device will be identified as points of the segmented surface. Thus, algorithms developed for the point-based registration, based on identification of matching between the preoperative and the intraoperative data, can be easily adapted. However, the number of possible errors in the identification process increases dramatically in line-based or curve-based methods.

Navigation and Positional Tracking

Numerous commercial products exist for navigation or positional tracking, but few meet the *computer-aided surgery* (CAS) requirements in terms of accuracy[5,26] (approximately 1 mm in 1 m^3), reliability, and clinical usability. The "real-time" navigational technology is based on the global positioning system technology.[20] Some of the technologies used in medical CAS to track movement include mechanical, magnetic, and optical tracking systems.

Mechanical tracking systems use a six-axis coding robot with a passive arm. The system is very reliable and highly accurate but has limitations when more than one instrument or patient marker needs to be located. Thus mechanical tracking is less desirable for CAIS, which requires the use of several different instruments and multiple markers.

Magnetic tracking systems use a magnetic source and a field receiver. The system loses accuracy in the presence of magnetic field interference. Relative inaccuracies result from changes in the magnetic field, which may be caused by any metallic mass that may be present, such as a drill motor (with or without activation).[2,3] Thus the obligatory presence of drill motors in the operatory during implant surgery makes magnetic trackers impractical for CAIS.

Optical tracking systems are recognized for their dependability and accuracy. Positioning is made by intersecting the vision plane between two or three cameras to locate markers with stereovision. A passive system absorbs and processes ambient light, whereas an active system interprets reflected light.

Active markers with infrared light–emitting diodes (IREDs) have been widely used with superb accuracy but are sensitive to reflections and interference with the line of sight between the IRED markers and the cameras.[12,15] Although variations in optical localizers are adequate for medical applications,[1,7] they need to be improved for use in dental implant surgery. This is particularly problematic with the typical seating arrangement of surgeon and assistant (i.e., the direct line of sight to the cameras may be interrupted by the operators). A stereovision with natural-light cameras is a less expensive alternative compared with IREDs. However, natural-light systems are more sensitive to surrounding light, background, and the shape of markers. In comparison, infrared cameras are less sensitive to these light variations.

With optical tracking devices, the surrounding light in the operatory is important, and a headset light is preferred with a camera sensitive to natural light. Patient motion will be tracked efficiently if the marker is stable during surgery. In case of loose teeth or unstable markers, cortical bone screws should be used.

External Viewer, Augmented Reality, and 3D Projection Screens

Once registration between the data and the actual patient has been established, the instrumentation can be coordinated with the system and observed by the surgeon/operator (Figures 81-1 and 81-2). Instrument movement relative to the image data (and through registration to the patient) may be viewed on an external monitor,



Figure 81-1 Global setup for surgical navigation. The basic setup for a navigation system consists of stereovision cameras with several tools. The contra-angle probe, the ultrasound probe and the patient jig need to have markers, which are tracked by the cameras. The occlusal stent, with markers in the standard process and without markers in ultrasound registration, used during computed tomography scan acquisition will be recognized in its three dimensions for prosthetic planning.

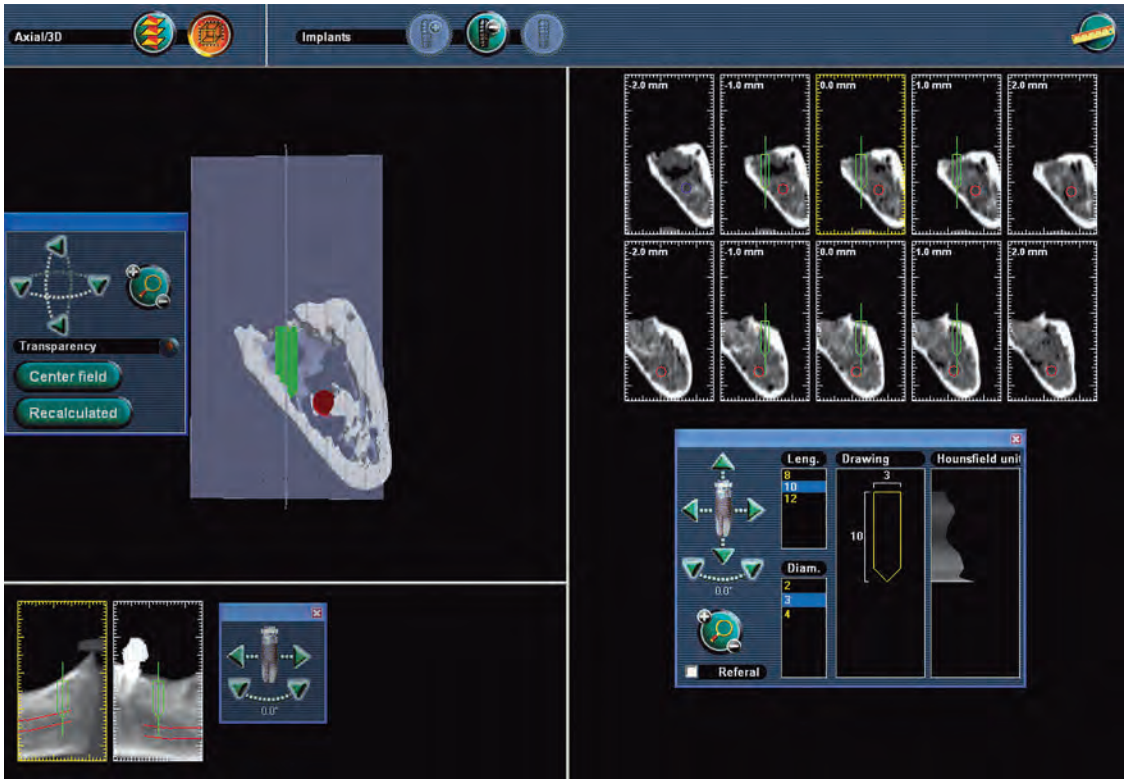

Figure 81-2 Images of computer screen and surgeon's view of computer-aided implant surgery navigation simulated with dry mandible. During navigation, the surgeon concentrates on visual cues seen on the eye viewer.

visually projected in the surgeon's field of vision (resulting in a superimposed visual image seen over the surgical field) using a head-mounted projection system or projected on a 3D projection screen (Figure 81-3).[25] In this manner, the image on the external monitor (see Figure 81-2), the surgical field, or the 3D projection screen (Figures 81-4 and 81-5) will guide the surgeon to perform the planned procedure.

Side viewers display target data in two dimensions and require the surgeon to look away from the surgical field. However, see-through viewers display target data transparently in the surgeon's field of view and allow the operator to observe the surgical field continuously. An augmented-reality viewer[13] allows the surgeon to see target data in three dimensions, superimposed over the surgical site through projected images in both eyes.[27] The augmented-reality method allows the operator to adapt to the system more naturally and therefore more rapidly, but there do not appear to be advantages over the use of a two-dimensional (2D) side-viewer devices in terms of accuracy.[21] Both systems allow simultaneous viewing of virtual information of the implant (axis and target) and a real vision of the surgical site. Augmented-reality devices are very sensitive to calibration before surgery and require care and monitoring intraoperatively to prevent misalignment during the surgery. The relative stability of a headset is critical to maintaining accuracy.

Alternatively, 3D projection screens provide a "real 3D vision" viewed on a specialized monitor (see Figure 81-3) without the need for viewers (i.e., operator glasses).

Two types of 3D projection screens are available, as follows:

1. The multiplane device has a screen that provides three simulated real-time planes. The object is projected in the screen with a back-field simulated projection. A plane within the screen surface and the forward plane are at a maximum focus of 10 to

Figure 81-3 Dental implant real-time navigation system with infrared stereovision cameras and a three-dimensional monitor display showing the reconstruction of a computed tomography scanned mandible.

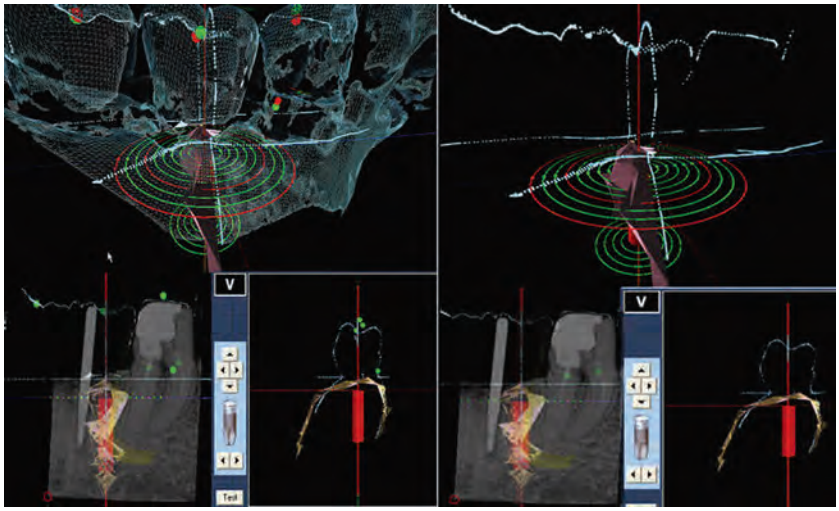

Figure 81-4 Conventional x-ray and ultrasound acquisition for alveolar bone topography (in *light brown, lower left*) combined with an optical scan image showing crown and alveolar bone morphology (*dark green*). The implant position is shown in *red*. This two-dimensional view is obtained without a computed tomography scan.

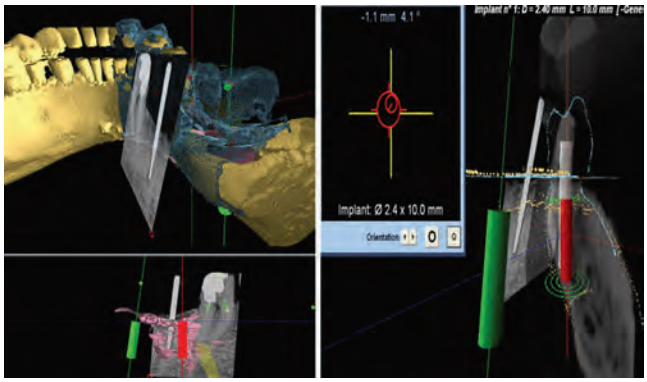

Figure 81-5 Screen views available during surgery. *Upper left,* Simulated implants in green and red. The computed tomography (CT) scan reconstruction of the mandible and teeth is observed in yellow. Surface mapping of bone and crown morphology (*dark green/blue*) obtained from ultrasound or optical scanner. The computer compares the data from the three-dimensional (3D) topography to the two-dimensional (2D) x-ray. *Lower left,* The 2D x-ray is matched to a 3D topography of the patient "matrix" with the simulated implant positions in *green* and *red. Upper right,* The target and position of the drill/implant are observed. *Lower right,* Real-time navigation with a combination of superimposed images from a 2D x-ray, optical scanner, CT scan, and 3D ultrasound.

20 cm. This device provides a 3D view that is extremely dependent on the shape.

2. A new generation device uses nanolenses on each pixel of screen resolution. It provides a natural light-splitting effect similar to the effect of a natural eye separating the three basic colors. Consequently, it is perceived as a natural view. A lateral displacement of the operator's head provides 8 to 12 simulated views, which together create a natural "volume" effect. No adaptation time is required and viewing is intuitive.

This 3D projection screen technology cannot provide a true holographic 3D view because of the eye's plane of focus on a flat screen, but it does provide a 3D "real volumetric view." The actual 3D projected screen technology does not provide enough high-quality texture, but it is overviewed with simple shape symbols (e.g., cross, circle). Another difficulty is introduced by the nonlinear depth scale of the screen, which is perceived by the operator's brain as nonlogical and induces a decrease in intuitive hand localization. In addition to this improvement in 3D vision, a 3D sequence of images can be modified for specific applications such as navigation. For example, a 3D sequence of 8 views can be modified to facilitate the observation of a projected view of the object at 90 degrees with a minimal head side shift of only 5 degrees. These real-time, 3D front and side views provide intuitive 3D data views in spite of the 2D parameters used to visualize them.

Advantages and Disadvantages

Benefits and advantages of CAIS include:

1. CAIS 3D mapping provides real time matching position with the patient.
2. CAIS 3D mapping provides chairside accurate 3D bone surface, which will allow an immediate surgical procedure in most cases.
3. Security features can stop the rotary instrument in proximity to important structures.
4. Simulation can be visualized before surgery. A real 3D simulation with a 3D projected screen can be visualized before and during surgery.
5. Implant position can be planned before surgery.
6. Real-time information is provided to the surgeon.
7. Inexperienced surgeons will improve their skill with training.
8. Experienced surgeons can treat more challenging cases with greater comfort and confidence.
9. Surgical time is reduced using a surgical guide.
10. Noninvasive surgery is possible; some cases may be performed with minimal or no flap reflection.

Limitations and disadvantages of CAIS include:

1. Initial cost of the system.
2. Increased installation time for surgery.
3. Training time is mandatory.
4. Accuracy depends on the various components of the system.
5. Inaccurate data (e.g., CT scan, displaced markers) can lead to difficulties in registration.
6. Three anatomic or fiducial markers must be visible.

Conclusion

CAS involves the use of digitalized 3D data obtained by the use of cone-beam computer-generated radiographs, markers placed in a surgical stent, and a computer-directed guidance system used during implant placement. This new technology is being developed to enhance accuracy of implant placement and to reduce angulation and alignment errors. At present, these systems require extensive training, and the intraoperative surgical guidance methodology is being improved. The use of CAIS with simultaneous tracking and

"guidance" of the implant instrumentation facilitates the precise surgical placement of implants with "real-time" visual assessment of anatomic structures. The system is complex, and several steps must be coordinated for CAIS to be accurate and useful. The ultrasound 3D mapping allows a real time accurate bone surface image to be captured. Newer generation systems are becoming more intuitive with 3D-projected vision with improved software interface for the operator.

Suggested Readings

Brief J, Edinger D, Hassfeld S, et al: Accuracy of image-guided implantology. *Clin Oral Implants Res* 16:495–501, 2005.

Derycke R, Tracol JJ, Mongeot M, et al: La chirurgie Implantaire mini-invasive: un nouvel environnement clinique et de communication. *Clinic* 2012. 6-19 November Special Issue.

Fitzpatrick JM, West JB, Maurer CR, Jr: Predicting error in rigid-body point-based registration. *IEEE Trans Med Imaging* 17:694–702, 1998.

Fortin T, Coudert JL, Champleboux G, et al: Computer-assisted dental implant surgery using computed tomography. *J Image Guid Surg* 1:53–58, 1995.

Kai J, Shiomi H, Sasama T, et al: Optical high-precision three-dimensional position measurement system suitable for head motion tracking in frameless stereotactic radiosurgery. *Comput Aided Surg* 3:257–263, 1998.

Kawachi H, Kawachi Y, Ikeda C, et al: Oral and maxillofacial surgery with computer-assisted navigation system. *Bull Tokyo Dent Coll* 51:35–39, 2010.

Klein M, Abrams M: Computer-guided surgery utilizing a computer-milled surgical template. *Pract Proced Aesthet Dent* 13:165–169, quiz 170, 2001.

Malamas E, Petrakis E, Zervakis M, et al: A survey of industrial vision systems: applications and tools. *Image Vis Comput* 21:171–188, 2003.

Pennec X, Thirion JP: A framework for uncertainty and validation of 3D registration methods based on points and frames. *Int J Comput Vis* 25:203, 1997.

References

References for this chapter are found on the companion website www.expertconsult.com.

References

1. Armangue X, Salvi J: Overall view regarding fundamental matrix estimation. *Image Vis Comput* 1:205, 2003.
2. Birkfellner W, Watzinger F, Wanschitz F, et al: Systematic distortions in magnetic position digitizers. *Med Phys* 25:2242–2248, 1998.
3. Birkfellner W, Watzinger F, Wanschitz F, et al: Calibration of tracking systems in a surgical environment. *IEEE Trans Med Imaging* 17:737–742, 1998.
4. Brendel B, Winter S, Rick A, et al: Registration of 3D CT and ultrasound datasets of the spine using bone structures. *Comput Aided Surg* 7:146–155, 2002.
5. Brief J, Edinger D, Hassfeld S, et al: Accuracy of image-guided implantology. *Clin Oral Implants Res* 16:495–501, 2005.
6. Casap N, Tarazi E, Wexler A, et al: Intraoperative computerized navigation for flapless implant surgery and immediate loading in the edentulous mandible. *Int J Oral Maxillofac Implants* 20:92–98, 2005.
7. Chassat F, Lavallée S: Experimental protocols of accuracy evaluation of 6-D localizers for computer-integrated surgery: Application to four optical localizers. Lecture notes in Computer Science. *Medical Image Computing and Computer-Assisted Intervention- MICCAI'98* 1496: 277–284, 1998.
8. Derycke R, Tracol JJ, Mongeot M, et al: La chirurgie Implantaire mini-invasive: un nouvel environnement clinique et de communication. *Clinic* 2012. 6-19 November Special Issue.
9. Diederichs CG, Engelke WG, Richter B, et al: Must radiation dose for CT of the maxilla and mandible be higher than that for conventional panoramic radiography? *AJNR Am J Neuroradiol* 17:1758–1760, 1996.
10. Fitzpatrick JM, West JB, Maurer CR, Jr: Predicting error in rigid-body point-based registration. *IEEE Trans Med Imaging* 17:694–702, 1998.
11. Fortin T, Coudert JL, Champleboux G, et al: Computer-assisted dental implant surgery using computed tomography. *J Image Guid Surg* 1:53–58, 1995.
12. Kai J, Shiomi H, Sasama T, et al: Optical high-precision three-dimensional position measurement system suitable for head motion tracking in frameless stereotactic radiosurgery. *Comput Aided Surg* 3:257–263, 1998.
13. Kawachi H, Kawachi Y, Ikeda C, et al: Oral and maxillofacial surgery with computer-assisted navigation system. *Bull Tokyo Dent Coll* 51: 35–39, 2010.
14. Klein M, Abrams M: Computer-guided surgery utilizing a computer-milled surgical template. *Pract Proced Aesthet Dent* 13:165–169, quiz 170, 2001.
15. Malamas E, Petrakis E, et al: A survey of industrial vision systems: applications and tools. *Image Vis Comput* 21:171, 2003.
16. Pennec X, Thirion JP: A framework for uncertainty and validation of 3D registration methods based on points and frames. *Int J Comput Vis* 25:203, 1997.
17. Roberts DW, Strohbehn JW, Hatch JF, et al: A frameless stereotaxic integration of computerized tomographic imaging and the operating microscope. *J Neurosurg* 65:545–549, 1986.
18. Sarment DP, Al-Shammari K, Kazor CE: Stereolithographic surgical templates for placement of dental implants in complex cases. *Int J Periodontics Restorative Dent* 23:287–295, 2003.
19. Satava RM: Emerging technologies for surgery in the 21st century. *Arch Surg* 134:1197–1202, 1999.
20. Siessegger M, Schneider BT, Mischkowski RA, et al: Use of an image-guided navigation system in dental implant surgery in anatomically complex operation sites. *J Craniomaxillofac Surg* 29:276–281, 2001.
21. Tian X, Ling KV, Ng WS: Magnetic tracker calibration for an augmented reality system for therapy. *Proc Inst Mech Eng [H]* 215:51–59, 2001.
22. Verma SN, Schow SR, Stone BH, et al: Applications of surgical navigational systems for craniofacial bone-anchored implant placement. *Int J Oral Maxillofac Implants* 25:582–588, 2010.
23. Verstreken K, Van Cleynenbreugel J, Marchal G, et al: Computer-assisted planning of oral implant surgery: a three-dimensional approach. *Int J Oral Maxillofac Implants* 11:806–810, 1996.
24. Verstreken K, Van Cleynenbreugel J, Martens K, et al: An image-guided planning system for endosseous oral implants. *IEEE Trans Med Imaging* 17:842–852, 1998.
25. Wanschitz F, Birkfellner W, Figl M, et al: Computer-enhanced stereoscopic vision in a head-mounted display for oral implant surgery. *Clin Oral Implants Res* 13:610–616, 2002.
26. Widmann G, Stoffner R, Schullian P, et al: Comparison of the accuracy of invasive and noninvasive registration methods for image-guided oral implant surgery. *Int J Oral Maxillofac Implants* 25:491–498, 2010.
27. Zamorano LJ, Nolte L, Kadi AM, et al: Interactive intraoperative localization using an infrared-based system. *Neurol Res* 15:290–298, 1993.

CHAPTER 82

Implant-Related Complications and Failures

Stuart J. Froum, Perry R. Klokkevold, Sang Choon Cho, and Scott H. Froum

CHAPTER OUTLINE

Definition of Implant Survival and Implant Success
Types and Prevalence of Implant Complications
Different Types of Dental Implants
Surgical Complications
Biologic Complications
Complications Related to Augmentation Procedures *(e-only)*
Complications Related to Placement and Loading Protocols *(e-only)*
Prosthetic or Mechanical Complications
Esthetic and Phonetic Complications
Conclusion

For online-only content on complications related to augmentation procedures and complications related to placement and loading protocols, please visit the companion website www.expertconsult.com. Some figures may be out of numeric order in this printed chapter.

Patients have experienced much success with endosseous dental implants.[2,96] Yet, despite the long-term predictability and success of implants, complications do occur in a percentage of cases.[3,27] Some complications are relatively minor and easy to correct, but others are more significant, resulting in loss of implants, failure of prostheses, and occasionally in severe loss of tissues in the area of implant failure. Complications may be surgical, biologic, mechanical, or esthetic.

Biologic complications are those that involve the periimplant supporting hard and soft tissues. Changes in the periimplant soft tissues may be minor, such as inflammation and proliferation, or more significant, involving progressive bone loss. The ultimate biologic complication is implant loss or failure, which may also result in soft and hard-tissue defects. Biologic loss of implants may be caused by a lack of osseointegration in the early stages before restoration or by a loss of osseointegration as a result of bone loss after the restoration is installed and functioning.

Surgical complications are those problems or adverse outcomes that result from surgery, including procedures used for implant placement, implant exposure, and augmentation procedures. One of the more prevalent types of implant complications are those arising from implant malposition or those arising from an implant being placed in a nonideal position. Malpositioned implants, which usually are the result of poor presurgical treatment planning and/or surgical technique, can lead to an array of implant problems ranging in severity from minor to major. These complications include compromised esthetic and/or prosthetic results, soft-tissue and bone dehiscences, impingement on anatomic structures, and possibly implant failure. Unfortunately, the extent of the problems that arise from implant malposition are often not recognized until the time of implant restoration or years after insertion.

Prosthetic or mechanical complications and failures typically occur in the form of material failure such as abutment and prosthetic screw loosening or fractures. The patient can recover from many of these mechanical problems if they are minor and recognized early. However, some complications, such as implant fractures, are not salvageable.

Esthetic complications arise when patient expectations are not met. Patient satisfaction with the esthetic outcome of the implant prosthesis will vary from patient to patient, depending on several factors. The risk for esthetic complications is increased for patients with high esthetic expectations and less-than-optimal patient-related factors (e.g., high smile line, thin gingival tissues, or inadequate bone quantity and quality).

This chapter reviews several of the more common implant-related complications. A summary of findings from the literature is presented to offer some insight into the prevalence of various types of implant-related complications. Implant failure, surgical complications related to site development, and different implant placement protocols are discussed as well.

Definition of Implant Survival and Implant Success

Implant success (or failure) is reported in many ways. Case reports, case series, retrospective studies, controlled studies, and prospective studies all report levels of success and failure as related to the population being evaluated. Each type of report or study has recognized limitations. However, recognizing the tremendous variation in the way individual investigators measure and interpret success may be more important. At times, outcomes are measured simply by the presence or absence of the implant(s) at the time of the last examination, which is only a measure of implant survival and should not be confused with implant success. In contrast to this simplified assessment, some investigators use detailed criteria to measure implant success and failure, with variations of successful outcomes separated and defined by additional criteria.

Complications Related to Augmentation Procedures

A common problem encountered in implant dentistry is insufficient bone quantity to allow implant placement according to standard procedures. Deficiencies in alveolar bone result from developmental defects, periodontal disease, tooth loss, and trauma.[9,30,137] For most cases with alveolar ridge resorption, bone regenerative procedures are required to correct the defects before or simultaneous with implant placement. The success of bone augmentation procedures has been assessed by experienced clinicians in several workshops.[4,35,58,72,73] One systematic review of literature (the 2003 Workshop on Contemporary Science in Clinical Periodontics) found that survival rates of dental implants in augmented bone achieved a high level of predictability and showed that these rates were similar to implants placed in natural bone.[58] However, a more-recent systematic review of the literature (the 2008 Consensus Report of the Sixth European Workshop on Periodontology) concluded that bone augmentation procedures can fail and that implants placed in these areas do not enjoy the high long-term survival rates of dental implants placed in pristine sites.[154] The consensus emphasized that research is needed to answer questions concerning (1) long-term performance of dental implants placed in augmented bone, (2) the clinical performance of dental implants placed in augmented or pristine sites, and (3) the clinical benefits of bone augmentation with respect to alternative treatments.

The procedures most often used to regenerate bone include autogenous bone harvesting and grafting, guided bone regeneration, and sinus bone augmentation (see Chapters 76 and 77 for detailed descriptions of these procedures). The following is a brief review of the most common complications related to these three augmentation procedures.

Autogenous Bone Harvesting and Grafting

Autogenous bone from a histologic and biologic point of view has been considered the gold standard for osseous reconstruction. Bone block grafts of autogenous bone from extraoral and intraoral sources have been documented as a predictable procedure for reconstruction of defective or atrophic alveolar ridges.[106] Complications can occur either at the donor or recipient sites. The most common extraoral donor sites include the ilium and tibia. Complications related to extraoral donor sites are beyond the scope of this chapter. The most common intraoral donor sites include the mandibular symphysis, mandibular ramus, and maxillary tuberosity. Although each donor area has specific associated complications, the most common complications of intraoral autogenous harvesting and grafting concern those from the mandibular symphysis.

The ramus donor site is associated with a much lower incidence of complications compared to the symphysis area.[71,105] Potential complications associated with surgical harvesting of bone from the ramus include damage to the inferior alveolar nerve and trismus after surgery. Damage to the buccal nerve, although rare, has been reported as well. Surgical harvesting of bone from the mandibular symphysis region are associated with a higher incidence of altered neurosensory disturbances to the mandibular anterior teeth and soft tissues of the chin area. The incidence of mental nerve paresthesia after symphysis grafts has been reported to be as high as 43%.[122] Many of these paresthesias are temporary.

In addition, fracture of the mandible has been reported after bone graft harvesting from the symphysis.[37] Many of these complications can be avoided by proper surgical technique, good planning, and an experienced operator.

Recipient site complications include wound dehiscence, flap necrosis, graft exposure, graft contamination, infection, and problems with bone graft incorporation and resorption. Proper flap reflection, intimate fixation of the graft, and flap coverage without tension can avoid many of the potential postsurgical complications. Bone graft material including barrier membranes should be immobilized (fixated if possible). Provisional restorations should be adjusted to prevent pressure over grafted areas. Block grafts, as well as other augmentation procedures, require experience in handling hard and soft tissue, as well as a clinician who is prepared to recognize and treat complications should they arise.

Guided Bone Regeneration

Guided bone regeneration (GBR) is a procedure that uses a barrier membrane to isolate an area for bone growth. The technique has been well documented for horizontal (and limited vertical) ridge augmentation[25,38,85] (see Chapter 76). The most common complication associated with GBR is premature exposure of the barrier membrane and necrosis of the overlying flap (Figure 82-17). Exposure rates of expandable polytetrafluoroethylene (ePTFE) membranes during various GBR procedures range from 41% when the technique was first introduced in the early 1990s for horizontal ridge augmentation[25] to 12.5% when surgical techniques improved and clinicians became more familiar with handling the material.[141] Once exposed to the oral environment, the membrane becomes colonized with bacteria within 3 to 4 weeks and the potential for bone regeneration under the membrane is limited to an area that is at least 2 to 3 mm from the contaminated surface.[18,142] Topical application of chlorhexidine to the exposed membrane has been advocated as a method of reducing the amount of bacteria, but it does not solve the problem and removal of the exposed membrane is necessary.

Other complications associated with GBR procedures include soft tissue or bone graft infection, failure to regenerate adequate bone volume and mucogingival problems, including loss of keratinized tissue and decrease in the vestibule.[25] Most of these complications are related to insufficient soft-tissue healing after tooth extraction, inadequate flap design, movement of the membrane and/or graft caused by transmucosal loading and improper provisionalization, flap suturing under tension, poor surgical technique, contamination of the membrane or surgical site, compromise of the vascular supply and flap advancement for graft coverage that reduces the keratinized tissue, and vestibular depth. To prevent complications associated with GBR procedures, proper surgical technique should be employed.

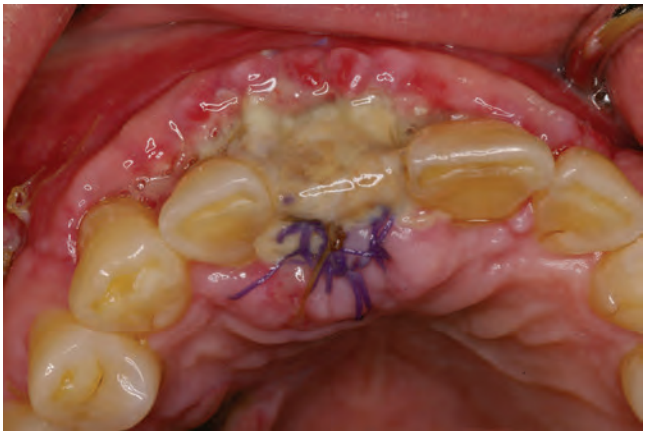

Figure 82-17 Clinical view of flap necrosis over area treated with guided bone regenerative procedure.

Sinus Bone Augmentation

Lateral Window Sinus Lift. The lateral window sinus lift and bone augmentation procedure has been well documented and reviewed in three published systematic reviews.[4,43,156] Although survival rates of implants placed in sinus-grafted areas has been shown to be high (95%), there are intraoperative and postoperative complications associated with this procedure. The most common intraoperative complications include bleeding and perforation of the schneiderian membrane. Bleeding usually occurs when the vascular supply to the lateral wall of the sinus is severed or damaged.[49] In most cases, if the patient does not have an underlying bleeding problem and is not taking anticoagulants, the bleeding is usually minor and relatively easy to control with local measures. Perforation of the schneiderian membrane, as reported in the literature, has an incidence that varies from 11%[160] to 56%[88] with most clinicians reporting an incidence of approximately 20% to 30%. Minor membrane perforations can be treated by reflection of the membrane that folds on itself, whereas medium-to-large membrane perforations require the use of an absorbable membrane placed over the perforation to "patch" the opening (Figure 82-18). Very large membrane tears may be too big to repair and require aborting the procedure. Careful surgical technique and the use of newer instruments (e.g., piezoelectric surgery) have been shown to significantly reduce this complication[157] (see Chapter 80).

The most common, although infrequent, postsurgical complication associated with sinus bone augmentation is infection.[15,88,106] The incidence of infection has been reported to vary from 2% to 5.6%. Careful surgical techniques, adherence to sterility, and the judicious use of antibiotics can minimize the risk of postoperative infections. Some infections resolve with antibiotic treatment alone, whereas others require surgical debridement of the infected area. Consultation or referral to a specialist may be indicated for persistent infections.

Crestal (Osteotome) Sinus Lift. Another method of sinus elevation and bone augmentation involves the use of osteotomes. This technique is indicated when there is enough native bone to stabilize the implant and a minimal need for sinus floor elevation. Bone is added through the crestal osteotomy by means of osteotomes and a mallet, the floor of the sinus is fractured, and the schneiderian membrane lifted by the bone graft (see Chapter 77). This method is thought to be a relatively less invasive technique of great utility in certain patients. However, it has been associated with the complication of benign paroxysmal positional vertigo (BPPV),[119] which has been described as a consequence of working the implant bed with osteotomes. During the osteotomy preparation and sinus floor elevation using the osteotome technique, the trauma induced by percussion with the surgical hammer, along with hyperextension of the neck during the operation, can displace otoliths in the inner ear and induce BPPV. It has been reported that 1.25% of the patients treated suffered vertigo when trying to sit up immediately after surgery and were diagnosed with BPPV. Because implant treatment is increasingly being carried out on older patients, and because of the widespread use of bone expansion technique with osteotomes, the incidence of BPPV can be expected to increase.[120] In suspected cases of BPPV, the patient should be informed about the condition and then referred to an otoneurologic specialist to determine which semicircular canal is affected and to carry out the appropriate otolithic reinstatement maneuver.

To prevent this complication, care should be taken when using the osteotome technique. The application of manual force instead of hammer percussion and the use of a surgical fraise in combination with osteotomes can minimize the trauma to the craniofacial area, especially in older patients. Many alternative techniques for a crestal approach to sinus elevation and bone augmentation have been developed including the use of inflatable balloon techniques, selective drill systems, and piezoelectric surgical instruments that cut bone while leaving the schneiderian membrane intact (see

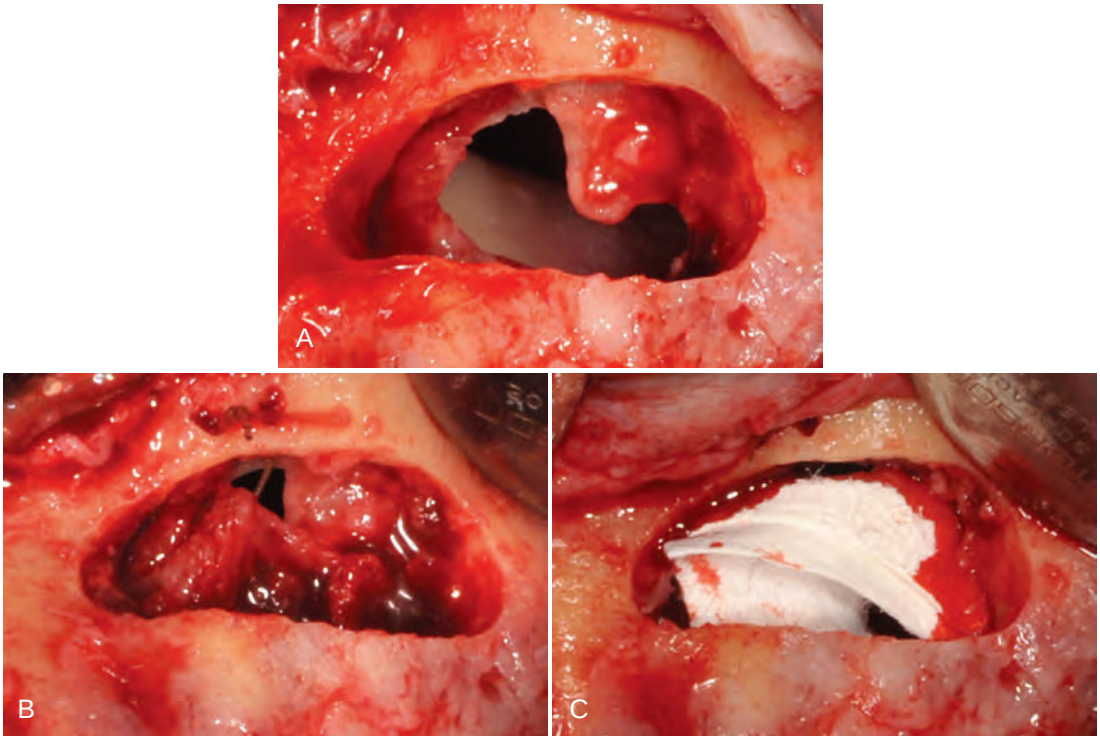

Figure 82-18 **A,** Large perforation of the schneiderian membrane during a sinus elevation procedure. **B,** Attempts to close or reduce the size of the perforation with resorbable sutures. **C,** Use of resorbable barrier membranes to cover the perforation.

Chapters 77 and 80). These newer methods should be considered to avoid BPPV.

Complications Related to Placement and Loading Protocols

The traditional implant placement protocol required a healed edentulous ridge into which implants were placed and allowed to osseointegrate for a period of 3 to 6 months without occlusal loading (see Chapter 75). In contrast to these early standards, some current protocols advocate dramatically different approaches, including (1) implant placement immediately after tooth extraction, (2) implant loading immediately after placement, and (3) flapless implant placement surgery. Each of these approaches has distinct advantages but are also accompanied by specific risks of complications. The most common complications associated with these newer, developing protocols are discussed in this section.

Immediate Implant Placement

Immediate implant placement (IIP) is a protocol that places an implant in an extraction socket immediately after tooth removal and socket debridement. This procedure was originally described by Schulte et al[138] and Lazzara[95] and has been reported to have similar implant survival rates as implants placed into healed ridges[33,101] with long-term survival rates of approximately 94%.[155] The advantages of this protocol include fewer surgical procedures (and decreased morbidity), decreased time of treatment, decreased cost, and decreased soft-tissue healing time by avoiding flap reflection and advancement.[139] However, as with any surgical protocol, complications are possible and there are specific complications associated with IIP. These include implant failure, poor implant position, bone loss, recession of the periimplant marginal soft tissues, and compromised esthetic outcomes.

After tooth extraction, there may be a compromised socket as the result of pathology (periodontal, endodontal, or fracture) of the hopeless tooth. Proper implant position may be difficult to establish when the socket walls are missing or deficient. For example, the implant osteotomy for extracted maxillary anterior teeth should be made on the lingual incline of the lingual wall of the socket. Quite often the burs will "slip" buccally causing the osteotomy to be made too far to the buccal or at an undesired angulation. Careful use of a surgical stent, round bur, sharp initial bur, and side cutting burs can avoid slipping and improve the accuracy of implant site preparation (see Chapter 79). Although success rates of implants placed with an IIP are excellent, failure to attain primary stability in native bone apical or lateral to the socket may increase failure rates. Inability or lack of thorough debridement of an infected or compromised (e.g., tooth with an apicoectomy) socket may also increase the risks of failure.[97] Buccal plate resorption and gingival margin recession postimplant placement may expose the implant surface following integration of the implant (see Figures 82-5 and 82-11). This may, in turn, compromise the esthetic results or necessitate hard- and soft-tissue augmentation procedures to improve the esthetic outcome.[88] A recent published case series documented this problem for IIP postextraction without flap elevation.[57] The risk of the previously mentioned complications may be decreased with proper case selection, proper procedures, and experience in using this protocol. Until clinicians have the knowledge and experience to use an IIP protocol, they should avoid using it in the esthetic zone.

Immediate Loading after Implant Placement

Brånemark established the concept and predictability of the osseointegrated dental implant based on a requirement for an unloaded healing period of 3 to 6 months.[24] This original protocol purported that premature loading would cause micromotion of the dental implant leading to fibrous encapsulation and implant failure. However, several studies in the dental literature have shown that immediately loaded dental implants can have success rates similar to that of conventionally loaded dental implants.* Whether restoring a single tooth or a complete dentition, there are many advantages to early or immediate loading. It is critical to recognize that these advantages may come with increased risks for complications and failures. The most significant complications are failure to achieve primary stability and implant failure.

Studies have shown that using longer and wider implants can provide increased success rates when immediately loading the dental implant.[135,136] In addition, when placing multiple implants in an edentulous area, the implants should be placed in a fashion that maximizes the anterior to posterior spread leading to a greater distribution of forces over a wider area and a reduction in cantilever forces. Studies have suggested that implants placed around the arch lead to what is known as *cross-arch stabilization*, which can decrease the individual force and motion experienced by any individual implant.[129,148] For the fully edentulous case a minimum of four to six implants of adequate size, good stability, and properly spaced throughout the ridge is recommended to improve success with immediate load case.[40] Mandibular cases may require fewer implants than maxillary cases because of greater bone density, especially in the interforaminal region. If the opposing arch is restored with a removable prosthesis, fewer implants may be needed to immediately support a restoration because of a decreased opposing occlusal force.

Other contributing factors associated with increased failure rates of immediately loaded implants include implant surface and implant design. Lower success rates with immediately loaded implants have been reported with smooth (i.e., turned/machined) surface implants, especially in cases of single tooth immediately loaded restorations.[77,128,134] Studies have also suggested that the macrodesign features of an implant (e.g., threaded versus cylindrical) can affect initial stability and success rates in immediately loaded cases.[32,87] Two studies have concluded that patient bruxism, clenching, and the posterior maxilla may reduce the likelihood of implant success under an immediate loading protocol.[19,63]

Complications of immediately loaded implants can also arise from a poorly constructed or inserted restoration despite all things going well with the surgical placement. Extreme care must be taken to achieve a passive fit of restoration and to eliminate nonworking or balancing contacts on the restoration. In addition, in full arch cases that were immediately loaded, the restoration must be designed to withstand direct occlusal force. This can be accomplished via a rigid connection and splinting the implants together in cross-arch fashion. Loosening or unseating of the provisional restoration usually indicates mismanagement of occlusal forces and be an early predictor of failure.

Immediately loading dental implants is a technique that offers many advantages but can also increase the incidence of complications and failure. This technique should only be performed by an experienced operator that is prepared and informed. Controlling micromotion postloading is tantamount to success. Meticulous case selection, which incorporates cross-arch stabilization, controlling occlusal overload, minimizing cantilevers, and increasing the anterior-posterior distribution of implant placement, can significantly increase the success rates of loading dental implants immediately after placement.

*References 1, 11, 34, 42, 54, 62, 83, 104, 152.

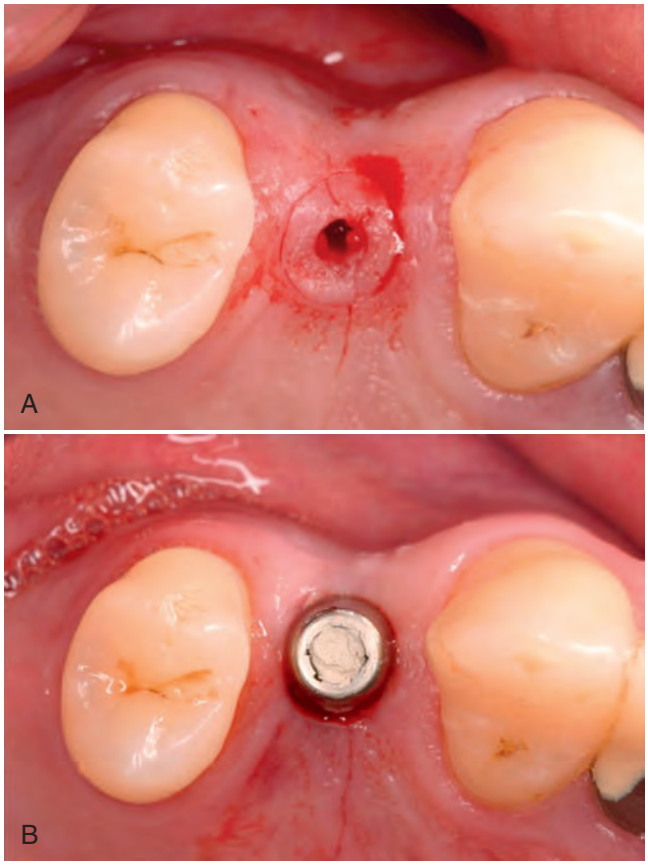

Figure 82-19 **A,** Removal of small circular section of tissue prior to osteotomy. **B,** Dental implant in place.

Implant Placement Using a Flapless Approach

Flapless implant surgery is the placement of a dental implant without elevation of the epithelium, connective tissue, and periosteum covering the alveolar bone. It is performed by either drilling through the soft tissue with twist drills or by first removing a small circular section of the soft tissue (Figure 82-19, *A*) and preparing the osteotomy, and placing the implant (Figure 82-19, *B*) without reflecting a full-thickness flap.[5]

Flapless surgery has been shown to be successful and has many advantages because it is minimally invasive.[28,29] The benefits of flapless surgery include a decrease in associated surgical morbidity, including postoperative pain, ecchymosis, and swelling, as well as a reduction in surgical time and intraoperative bleeding.[119] Studies show that when a full-thickness mucoperiosteal flap is raised, there is loss of bone volume,[64] while a flapless approach results in less bone resorption.

The lack of operator visualization of the alveolus when preparing osteotomies and placing implants may increase the potential for complications. The most common problems associated with flapless surgery are the loss of keratinized tissue when excising the crestal "circle" of soft tissue and improper positioning of the dental implant within the bone resulting from a lack direct vision. Improper positioning may result in a dehiscence/fenestration defect (Figure 82-20) or damage to adjacent vital structures.

An anatomically correct computer-generated surgical guide fabricated from a three-dimensional CT or CBCT scan is recommended when performing flapless surgery to reduce potential implant malposition complications. There are several systems (i.e., Nobelguide, Materialize SurgiGuide) that can generate a precise surgical guide with metal sleeves of exact dimension that can direct the implant into proper position (Figure 82-21). These guides are usually used in fully edentulous arches and have fixation screws that keep them in place. When using a flapless approach, before initiating the osteotomy, the operator should sound the soft tissue with a periodontal probe to ascertain the tissue thickness and account for this dimension when determining the final position of the implant platform in the apical–coronal dimension (Figure 82-22).

A common complication is placement of the implants apical to the crestal bone because it is difficult, even with a punch, to visualize the alveolar bony crest in relation to the platform of the implant. If this occurs, it is difficult to fully seat the abutment. Therefore, the relationship between implant and abutment connection must be verified by periapical radiographs. If bone prevents abutment seating, the implant must be backed out until it is at the crest or the bone must be removed with a profile drill. If a fenestration occurs when placing the dental implant, full flap reflection is required, and GBR procedures should be performed to augment the bone and cover the fenestration.

Although flapless implant surgery has many beneficial features, it is a technique-sensitive procedure that requires surgical experience, an accurate surgical guide, and knowledge of the anatomy surrounding the planned implant site.

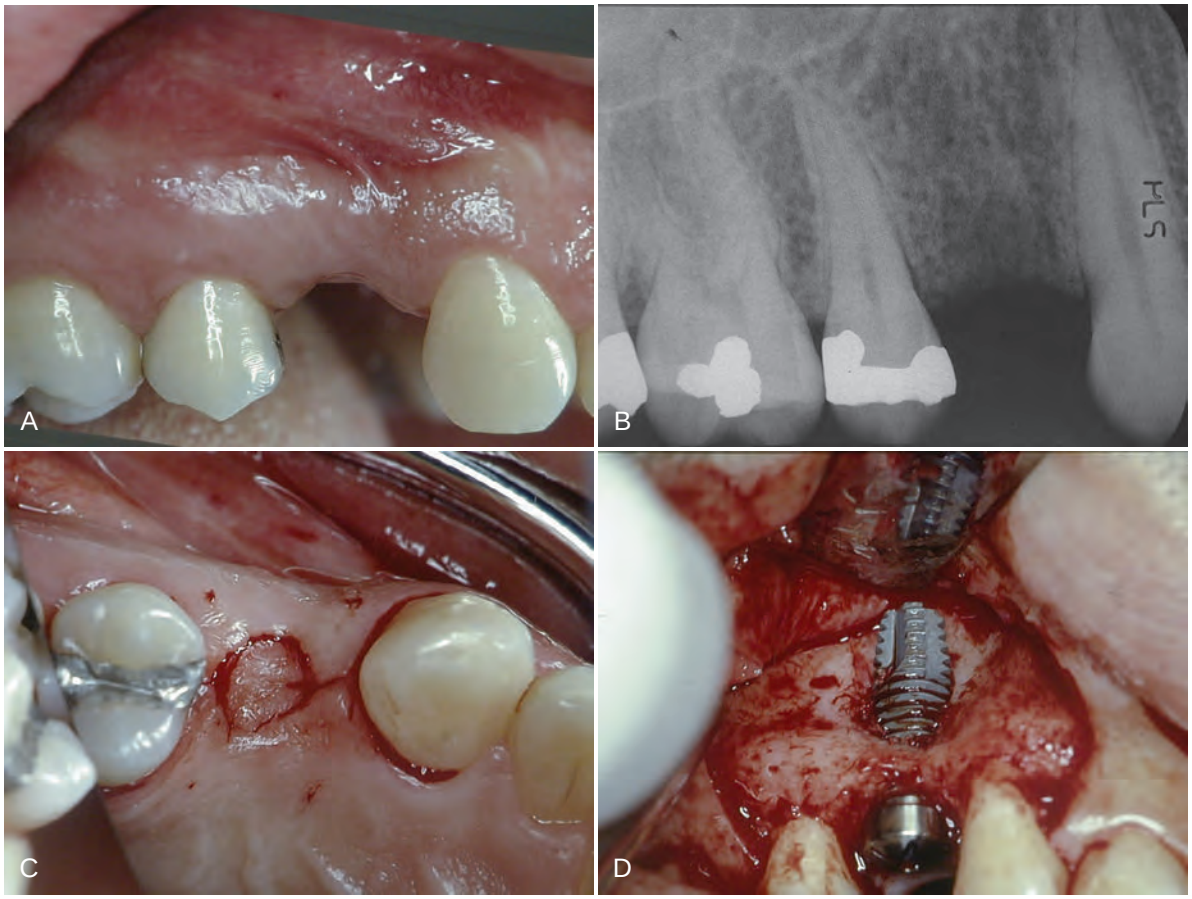

Figure 82-20 **A,** Preoperative clinical view of missing single tooth #5. There appears to be good alveolar ridge shape with adequate keratinized gingiva. **B,** Radiograph showing good bone height and mesial-distal space available for single tooth implant. **C,** Occlusal view of circular "punch" incision used to access bone and prepare implant osteotomy. **D,** Full flap reflection (after noticing suspicious protrusion in labial vestibule) revealed implant protruding out of alveolar bone on buccal surface.

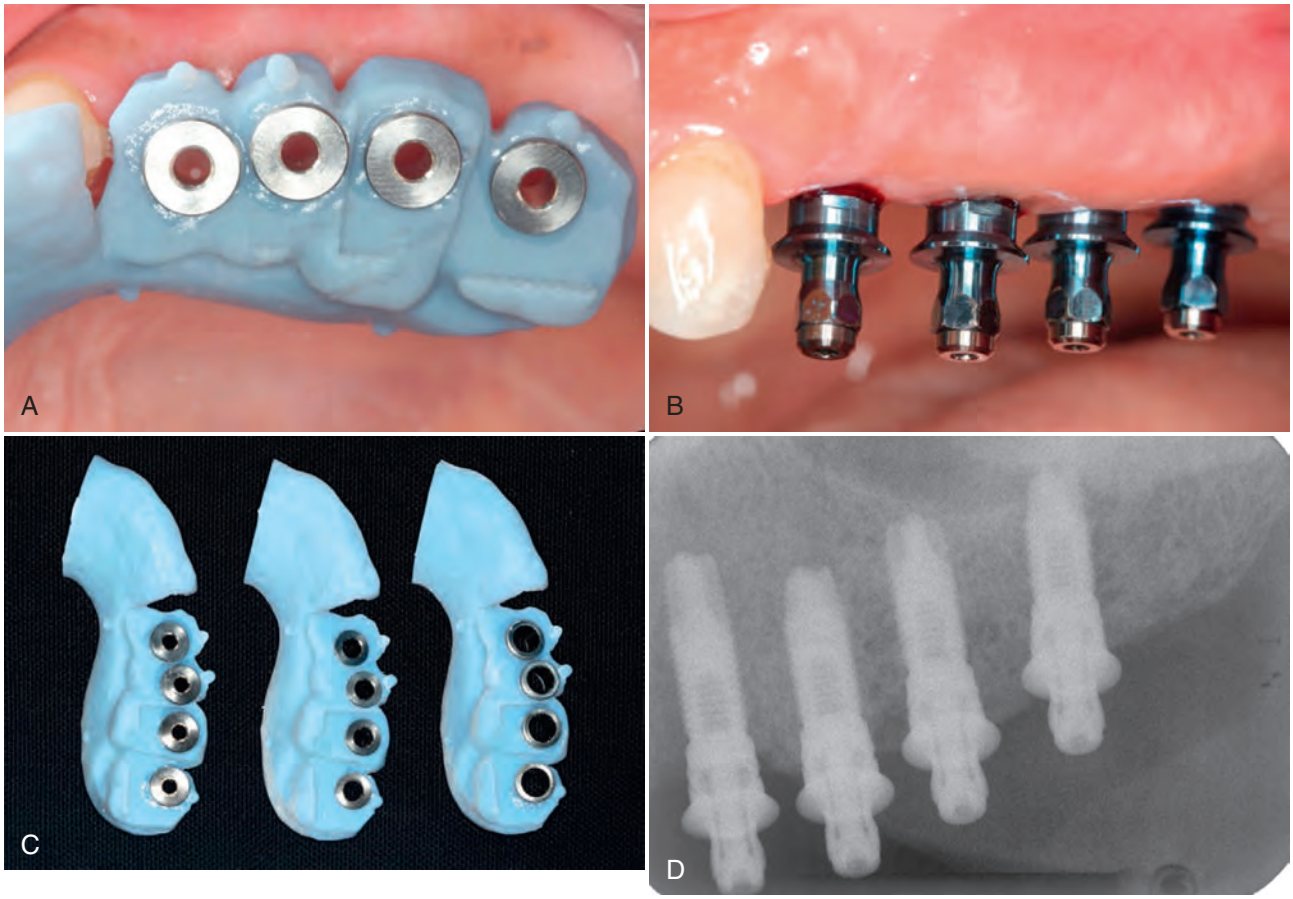

Figure 82-21 **A,** Clinical view of computer-generated surgical guide showing metal drill sleeves in the position of planned implants. **B,** Clinical view (buccal) of implant mounts emerging from gingival showing accurate placement of four implants in the posterior maxilla using the computer-generated surgical guide. **C,** Photo of three surgical guides with increasing sleeve diameter that are used in the sequence of implant site preparation. **D,** Radiographic view of four implants placed in the planned position using the computer-generated surgical guide.

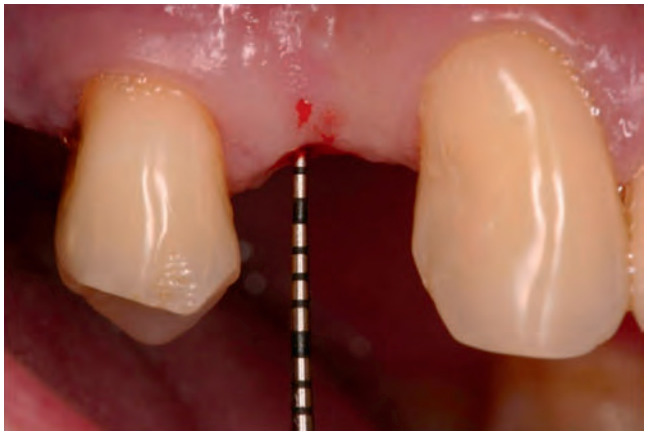

Figure 82-22 Use of a periodontal probe to sound the bone and measure the soft-tissue thickness over the bone in the proposed implant site.

Implant survival is simply defined as any implant that remains in place at the time of evaluation, regardless of any untoward signs, symptoms, or history of problems. Clearly, there is a difference between implants that are present and functioning under an implant-retained restoration and implants that are present but not connected to any restoration and not providing support or function. These implants are sometimes referred to as "sleepers" and should not be considered successful merely because they are present and remain osseointegrated. Rather, sleeper implants should be included in the discussion as "surviving" but counted as "failures" because they failed to fulfill the originally intended treatment.

Implant success, conversely, is defined not only by the presence of the implant but also by criteria evaluating the condition and function of the implant at the time of examination. Criteria for implant success and failure have been defined over the years, but not all investigators use them. In the classic definition, Albrektsson et al[6] defined implant success as an implant with no pain, no mobility, no radiolucent periimplant areas, and no more than 0.2 mm of bone loss annually following the first year of loading. Roos-Jansaker et al[130] added to this definition by defining a successful implant as one that lost no more than 1 mm of bone during the first year in function. Sometimes these criteria are used as proposed, whereas at other times, they are used by investigators with modifications and new criteria. Consequently, it is inherently difficult to make comparisons between studies and often impossible to make absolute conclusions about any aspect of implant success or failure based on one or a few studies.

If one considers "success" using a strict definition as the outcome without any adverse effects or problems, then "implant success" should be defined as any implant-retained restoration in which (1) the original treatment plan is performed as intended without complications, (2) all implants that were placed remain stable and functioning without problems, (3) periimplant hard and soft tissues are healthy, and (4) both the patient and the treating clinician(s) are pleased with the results. When these strict criteria are used, implant success (i.e., absence of complications) is projected to be only about 61% after 5 years for implant-supported fixed partial dentures (FPDs) and 50% after 10 years for combined tooth/implant FPDs.[94]

An additional criteria of implant success that is often unreported but must be considered is the "esthetic" success or patient satisfaction with the outcome. There have been a number proposed methods to evaluate esthetic results. A restorative index was proposed by Jensen et al[80] to appraise the esthetics of the final restoration. The index uses a scale from 1 to 10 with 1 being an extremely poor result and 10 being a superlative esthetic result. The index, based on both subjective and objective criteria, evaluates the size and shape of the implant restoration in comparison to the equivalent contralateral tooth, blending into the arch, as well as the presence of the papillae, gingival form, color, and other factors considered essential in determining an esthetic result. The pink esthetic score (PES) is an index proposed by Furhauser et al[61] that considers seven soft-tissue parameters, including an evaluation of the color, contour, and texture of the surrounding soft tissues (papilla and facial mucosa). Each parameter is given a score of 0, 1, or 2, which allows the best score of 14 to determine the highest level of esthetics. Other indices were proposed for single-tooth implant restorations in the esthetic zone.[21,102] The most recent, proposed by Belser et al,[21] combines a modified PES index with a white esthetic score (WES) focusing on the visible part of the implant restoration scoring five parameters from general tooth form to hue, value, surface texture, and translucency. The maximum possible WES score is 10. These indices are aimed at quantifying the esthetic result, which could then present an objective method of judging "implant esthetic success."

Types and Prevalence of Implant Complications

The prevalence of implant-related complications has been reported in several reviews. However, until recently, a systematic review of the incidence of biological and technical complications in studies of at least 5 years revealed that biological complications were considered in only 40% to 60% and technical complications in only 60% to 80% of the studies. One of the few conclusions of this review indicated that the incidence of technical complications related to implant components and suprastructures was higher in overdentures than in fixed restorations.[22] In a systematic review of reports on the survival and complication rates of implant-supported FPDs, Pjetursson et al[94] found that the most common technical complication was fracture of veneers (13.2% after 5 years), followed by loss of the screw access hole restoration (8.2% after 5 years), abutment/occlusal screw loosening (5.8% after 5 years), and abutment/occlusal screw fracture (1.5% after 5 years; 2.5% after 10 years). Fracture of implants occurred infrequently (0.4% after 5 years; 1.8% after 10 years). A retrospective evaluation of 4937 implants by Eckert et al[48] found that implant fractures occur more frequently in partially edentulous restorations (1.5%) than in restorations of completely edentulous arches (0.2%), and all observed implant fractures occurred with commercially pure 3.75-mm diameter threaded implants.

In a literature review that included all types of implant-retained prostheses, Goodacre et al[66] found that the most common technical complications were loosening of the overdenture retentive mechanism (33%), resin veneer fracture with FPDs (22%), overdentures needing to be relined (19%), and overdenture clip/attachment fracture (16%). Their review, with the inclusion of edentulous patients having overdentures, seemed to indicate a significantly higher percentage of complications than Pjetursson's systematic review[121] of patients with implant-supported FPDs. Goodacre et al[65] found it impossible to calculate an overall prosthesis complication rate because most studies included in their review did not report on several of the complication categories.

The most common complication reported for single crowns was abutment or prosthesis screw loosening. Abutment screw loosening varied dramatically from one study to another, ranging from 2% to 45%.[66] The highest rate of abutment screw loosening was associated with single crowns, followed by overdentures. The rate of prosthesis screw loosening was similar, ranging from 1% to 38% in various studies. A higher frequency was reported for single crowns in the posterior areas (premolar and molar) than in the anterior region.

Implant fracture is an uncommon but significant complication. Goodacre et al[65] reported a 1.5% incidence in their literature review. The incidence of implant fracture was higher in FPDs supported by only two implants. Consistent with this finding, Rangert et al[125] reported that most fractured implants occurred in single- and double-implant–supported restorations. They also indicated that most of these fractures were in posterior partially edentulous segments, in which the generated occlusal forces can be greater, as opposed to anterior segments (Figure 82-1).

In a systematic review of prospective longitudinal studies (minimum of 5 years) reporting both biologic and technical complications associated with implant therapy (all restoration types included), Berglundh et al[22] found that the incidence of technical complications was consistent with Pjetursson's findings, with implant fracture occurring in less than 1% (0.08% to 0.74%) of

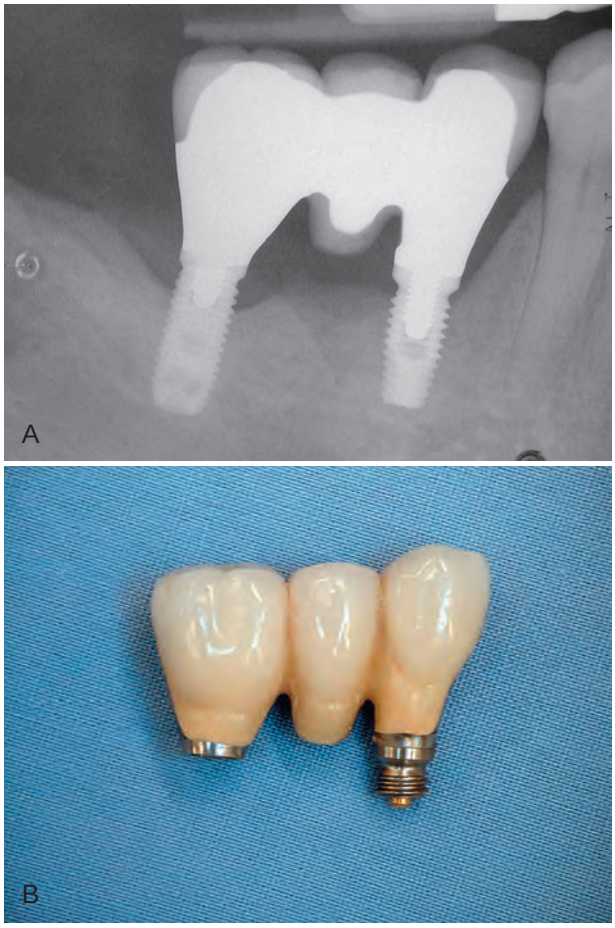

Figure 82-1 **A,** Radiograph of a three-unit, posterior, fixed partial denture (FPD) supported by two standard-diameter, screw-shaped threaded implants. Notice long crown height, relatively short implant length, and bone loss around posterior implant. **B,** Photograph of the ultimate implant-supported restoration failure. The anterior implant fractured between the second and third threads, which resulted in loss of the restoration.

cases. Interestingly, consistent with the findings in Goodacre's review, technical complications were higher for implants used in overdenture therapy than implants supporting fixed prostheses.

In Pjetursson's systematic review[94] of survival and complication rates for implant-supported FPDs, biologic complications, such as periimplantitis and soft-tissue lesions, occurred in 8.6% of implant-supported FPDs after 5 years. However, in a more recent literature review of the prevalence of periimplant diseases, Zitzmann and Berglundh[161] reported that although cross-sectional studies are rare, data from the only two studies available showed that periimplant mucositis occurred in 80% of the subjects and 50% of implant sites. Periimplantitis, conversely, was identified in 28% and 56% or more of subjects and in 12% and 43% of implant sites in the two studies that followed subjects with implants in function at least 5 years. A critical review of the literature by Esposito et al[56] included 73 publications reporting early and late failures of Brånemark implants; biologically related implant failures were relatively low at 7.7%. The treatments involved all anatomic areas and all types of prosthetic design. The authors concluded that the predictability of implant treatment was especially good for partially edentulous patients compared with totally edentulous patients, with failures in the latter population being twice as high. Also, the incidence of implant failure was three times higher for the edentulous maxilla than for the edentulous mandible, whereas failure rates for the partially edentulous maxilla were similar to those for the partially edentulous mandible.

Risk factors, such as smoking, diabetes, and periodontal disease, may contribute to implant failure and complications. Several studies with numerous implants and years of follow-up have concluded that smoking is a definite risk factor for implant survival.[12,44,45,50,111] A systematic review of the effect of risk factors on implant outcomes concluded that smoking has an adverse effect on implant survival and success, with the effects being more pronounced in areas of loose trabecular bone (i.e., posterior maxilla).[90] The review suggested that type 2 diabetes may have an adverse effect on implant survival rates but did not have enough studies to permit a definitive conclusion.[90] Finally, the same review also concluded that while patients with a history of treated periodontitis did not show any decrease in implant survival, they did experience more biologic implant complications and lower success rates.[90]

Different Types of Dental Implants

When analyzing the data concerning prevalence of implant complications (i.e., failure, fracture, periimplantitis) in the published systematic reviews, the reader should be cognizant of the fact that many of the studies reviewed for these complications reported on implants with previous designs (i.e., machined surfaces and external connections). Currently, nearly all implant systems feature surfaces with an altered microtopography (rough) and many have internal connections. As a result, the prevalence and type of complications associated with these newer implant designs may be different.

Many modifications have been developed to try to improve the long-term success rates of implants. More than 1300 types of dental implants are now available with different materials, shapes, sizes, lengths, and surface characteristics or coatings. There is limited evidence to show that implants with relatively smooth surfaces (i.e., machined) are less prone to bone loss from chronic infection (periimplantitis) than implants with rougher surfaces. Conversely, implants with a turned (smoother) surface might be at greater risk to fail early than implants with roughened surfaces since the bone-to-implant contact is comparatively less. To date, there is no evidence showing that any particular type of dental implant has superior long-term success.[53]

Different implant designs and surfaces must be studied in prospective human trials over long periods of time. At present, this data is not available, and the clinician should be aware that the data we currently have, even on rates of implant failure, may not reflect the outcome for implants being used today. Moreover, new implant surfaces and designs are continually being introduced with even less data available on potential complications.*

Surgical Complications

As with any surgical procedure, there are risks involved with implant surgery. Proper precautions must be taken to prevent the risk of injury resulting from surgical procedures, including but not limited to (1) a thorough review of the patient's past medical history, (2) a comprehensive clinical and radiographic examination, and (3) good surgical techniques. Surgical complications include perilous bleeding, damage to adjacent teeth, injury to nerves, and iatrogenic jaw fracture. Postoperative complications include bleeding, hematoma, and infection. They may be minor, transient, and easily managed or more serious and require postoperative treatment.

*References 8, 10, 36, 47, 117, 118, 145, 149, 162.

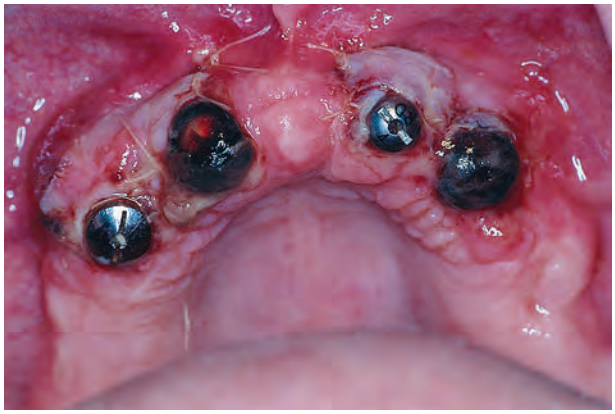

Figure 82-2 Clinical photograph of postoperative bleeding around healing abutments after second-stage implant exposure surgery.

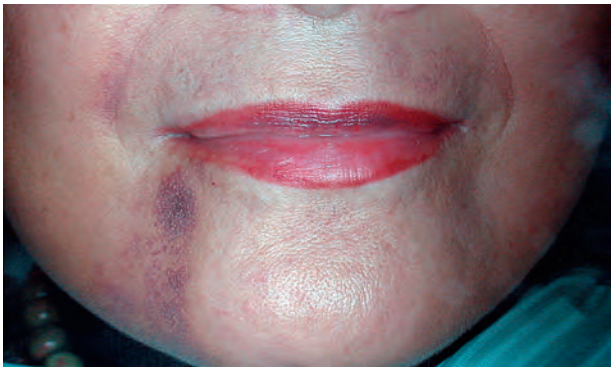

Figure 82-3 Clinical photograph of postoperative (extraoral) bruising indicative of subdermal bleeding into connective tissues spaces. This is a normal expectation that resolves within 7 to 14 days.

Hemorrhage and Hematoma

Bleeding during surgery is expected and usually easily controlled. However, if a sizable vessel is incised or otherwise injured during surgery, the hemorrhage can be difficult to control. Smaller vessels will naturally constrict or retract to slow the hemorrhage. If bleeding continues, it may be necessary to apply pressure or to suture the hemorrhaging vessel. This can be especially difficult if there is a vascular injury to an artery that is inaccessible such as in the floor of the mouth or posterior maxilla. Serious bleeding from an inaccessible vessel can be life threatening, not by exsanguination but rather as a result of airway obstruction. This is most problematic when the point of bleeding is inaccessible and internal (within the connective tissues and soft-tissue spaces).

Postoperative bleeding is an equally important problem to manage (Figure 82-2). Patients should be given postoperative instructions on normal expectations for bleeding and how to prevent and manage minor bleeding. Historically, standard practice has recommended that they should be advised, with their physician's approval, to discontinue or reduce medications that increase bleeding tendency 7 to 10 days before surgery. However, recent evidence suggests that this may not be necessary and may increase the risk of hematologic or cardiovascular problems[81,82,111,132] (see Chapter 37). Dental healthcare providers should consult with medical healthcare providers regarding the best management for each individual patient. Furthermore, dental healthcare providers and patients should always include the treating medical practitioner in the management decisions if postoperative bleeding is excessive or persistent. Submucosal or subdermal hemorrhage into the connective tissues and soft-tissue spaces can result in hematoma formation. Postoperative bruising is a typical example of minor submucosal or subdermal bleeding into the connective tissues (Figure 82-3). Bruising and small hematomas typically resolve without special treatment or consequence. However, larger hematomas or those that occur in medically compromised individuals are susceptible to infection as a result of the noncirculating blood that sits in the space. Thus it is prudent to prescribe antibiotics for patients who develop a noticeably large hematoma.

Although the incidence of a life-threatening hemorrhage from implant surgery is extremely low, the seriousness of the problem warrants the attention of everyone who participates in this type of surgery. Potentially fatal complications have been reported for implant surgical procedures in the mandible (especially the anterior region).* Massive internal bleeding in the highly vascular region of the floor of the mouth can result from instrumentation or implants that perforate the lingual cortical plate and sever or injure the arteries running along the lingual surface. Depending on the severity and location of the injury, bleeding may be apparent immediately or only after some delay. In either case, the progressively increasing hematoma dissects and expands to displace the tongue and soft tissues of the floor of the mouth, ultimately leading to upper airway obstruction. Emergency treatment includes airway management (primary importance) and surgical intervention to isolate and stop the bleeding. Clinicians must be aware of this risk and must be prepared to act quickly. It is important to recognize that bleeding, although considered a complication at the time of surgery, may be a serious complication in the hours and days after surgery.[41]

Neurosensory Disturbances

One of the more problematic surgical complications is an injury to nerves. Neurosensory alterations caused by damage to a nerve may be temporary or permanent. Neuropathy can be caused by a drilling injury (cut, tear, or puncture of the nerve) or by implant compression or damage to the nerve (Figure 82-4; also see Figure 73-18). In either case, the injury produces neuroma formation, and two patterns of clinical neuropathy may follow. *Hypoesthesia* is a neuropathy defined by impaired sensory function that is sometimes associated with phantom pain. *Hyperesthesia* is a neuropathy defined by the presence of pain phenomena with minimal or no sensory impairment.[68] Some neuropathies will resolve, whereas other will persist. The type of neuropathy is not indicative of the potential for recovery.

It is likely that neurosensory disturbances occur more frequently after implant surgery than currently reported in the literature for several reasons. First, many of these changes are transient in nature, and most patients recover completely or at least recover to a level that is below a threshold of annoyance or daily perception. Second, wide variation exists in the postoperative evaluation of patients by clinicians. Some clinicians do not examine or inquire about postsurgical neurosensory disturbances at all, thus allowing this complication to go unnoticed. Likewise, some patients may think that the altered sensation is part of the expected "side effect" of surgery and may never acknowledge or comment on its presence, especially if the disturbance is minor. Therefore it is likely that minor neuropathies exist but go unrecognized and unreported.

Neurosensory disturbances reported in the literature are most prevalent and significant when they are more serious and occur more frequently, such as those associated with lateral transposition

*References 17, 39, 41, 59, 76, 114, 115, 151.

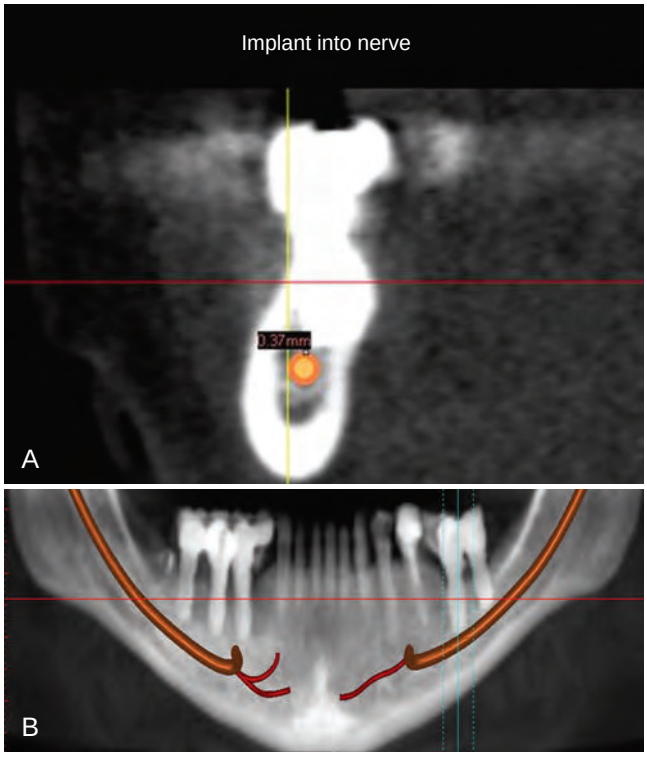

Figure 82-4 **A,** Cross-sectional image from computed tomography (CT) scan showing implant impinging on inferior alveolar nerve canal. **B,** Panoramic image of CT scan showing implant in lower left first molar area impinging on inferior alveolar nerve canal. Nerve is marked by tracing with software.

of the mandibular nerve.[79,86] This relatively uncommon procedure is used to reposition the nerve and allow longer implants to be placed in the atrophic posterior mandible. Lateral nerve transposition procedures are associated with almost 100% incidence of neurosensory dysfunction immediately after surgery. More than 50% of these neurosensory changes are permanent (ranging from 30% to 80%).[86] Several articles have been written on the treatment of neurosensory disturbances.[7,107,126]

Implant Malposition

Many of the aforementioned complications that arise during implant surgery can be attributed to the dental implant being placed in an undesired or unintended position. Malpositioning of dental implants is usually the result of poor treatment planning before the implant surgery, lack of surgical skill by the implant surgeon, and/or poor communication between implant surgeon and restorative dentist. Optimal implant esthetics and the avoidance of positional complications can be achieved by placing the implant in a prosthetically driven manner.[103,116] In other words, the implant should be placed with reference to the three dimensions dictated by the position of the final restoration and not by the availability of bone. The angulation is another important determinant (fourth dimension) of implant position that will affect outcome esthetics. The ideal implant position entails an accurate preparation, insertion, and placement of the implant into the alveolus in a proper three-dimensional geometry according to apicocoronal, mesiodistal, and buccolingual parameters, as well as implant angulation relative to the final prosthetic restoration and gingival margins.[91,133] (see Chapter 75).

Apicocoronally, the implant should be placed so the dental implant platform is 2 to 3 mm apical to the gingival margin of the anticipated restoration.[26] The actual implant position varies slightly from one implant system to another, depending on abutment design and space requirements. If the implant platform is placed too coronal, there will not be sufficient room to develop a natural-looking emergence profile and the tooth may have a squarish, unesthetic contour. If the platform is placed at or above the level of the gingival margin, a metal collar or implant exposure can occur yielding an unesthetic result (Figure 82-5). Conversely, if the implant platform is placed too apically, a long transmucosal abutment will be necessary to restore the implant. This can lead to a deep pocket and difficult hygiene access for the patient and clinician.

Figure 82-5 Clinical photograph of gingival recession around a maxillary anterior implant (left central incisor) resulting in exposure of the crown margin, the implant collar, and several threads of the implant.

Figure 82-6 Radiograph of two mandibular anterior implants placed too close together (no proximal space) resulting in implants that will be impossible to restore.

Mesiodistal implants should be placed at a distance of 1.5 to 2 mm from a natural tooth and 2 to 3 mm from an adjacent implant to maintain an adequate biologic dimension.[70] Similar to natural teeth, violation of biologic width around an implant can lead to bone loss.[75] Implants that are placed too close to each other (Figure 82-6) or natural teeth can be difficult to restore. Impression copings

and impression-taking techniques must be modified. Improperly spaced implants invariably lead to chronic inflammation and peri-implantitis.[51,153] Conversely, implants placed with excessive distance from an adjacent tooth or implant may require prosthetic compensation in the form of mesial or distal cantilevers, which may predispose the implant to biologic (e.g., bone loss) and mechanical (e.g., screw loosening,[66] screw fracture,[150] or implant fracture[125]) complications, as well as difficulties with hygiene.[153]

Ideally, implants should be placed, buccolingually so there is at least 2 mm of bone circumferentially around the implant.[144] Implant exposure through the lingual or buccal cortex can predispose an individual to abscess and/or suppuration.[35] Implants that are placed too far palatally/lingually require prosthetic compensation in the form of a buccal ridge lap, which may be difficult for the patient to clean and could lead to tissue inflammation.[20]

To obtain ideal esthetics, to avoid potential esthetic complications, and to correct bodily placement of the dental implant, the implant must be correctly angulated on insertion. In most anterior cases, it is desirable to have the implant long axis directed so it is emerging toward the cingulum. In the posterior region, the implant axis should be directed toward the central fossa or the stamp cusp of the opposing tooth. Implants that are placed with mild-to-moderate misangulations can often be corrected prosthetically with implant abutments. Minor misangulations (up to 15 or 20 degrees) can be corrected by with prefabricated stock-angled abutments; moderate misangulations (20 to 35 degrees) can usually be managed with customized UCLA-type abutments; extreme errors in implant angulations (more than 35 degrees) may deem an implant unrestorable and require it to be left submerged (i.e., sleeper) or to be removed (Figure 82-7).

The ultimate complication of malposed implant(s) is implant or instrument invasion into vital structures. The most common violation of neighboring anatomy is the placement of the dental implant into the adjacent tooth root. Surgical procedures used to prepare osteotomy sites and place implants adjacent to teeth can injure the teeth either by directly cutting into the tooth structure or by damaging nearby supporting tissues and nerves. Instrumentation (e.g., drills) directed at or near the adjacent tooth may cause injury to the periodontal ligament, tooth structure, and nerve of the tooth. Depending on the extent of the injury, the tooth may require endodontic therapy or extraction. On insertion, dental implants will follow the trajectory of the osteotomy prepared by the surgical drills. Care must be taken when preparing the osteotomy to stay true to the planned path of insertion. Guidepin location radiographs taken during implant surgery can greatly reduce the potential for damaging adjacent teeth (see Figure 73-15). Radiographic analysis before implant surgery should include detection of curved, convergent, and/or dilacerated root structures of adjacent teeth that can limit implant placement.

Particular care must be taken when placing implants in the mandible so as to not encroach on the inferior alveolar canal or the mental foramen (see Chapter 54) for a description of this anatomy. Encroachment on the mandibular canal or mental foramen during osteotomy or implant placement via direct contact or mechanical compression of bone can result in injury to nerves and blood vessels. Paresthesia, hypoesthesia, hyperesthesia, dysesthesia, or anesthesia of the lower lip, skin, mucosa, and teeth may result, as well as arterial or venous bleeding.[67] The incidence of sensory disturbances after mandibular implant placement has been reported to range from 0% to 17.5%.[16]

In the maxilla, care must be taken to avoid dental implant perforation into the maxillary sinus or nasal cavity. Displacement of the entire dental implant into the maxillary sinus cavity may require a Caldwell-Luc procedure for retrieval. See the online section on

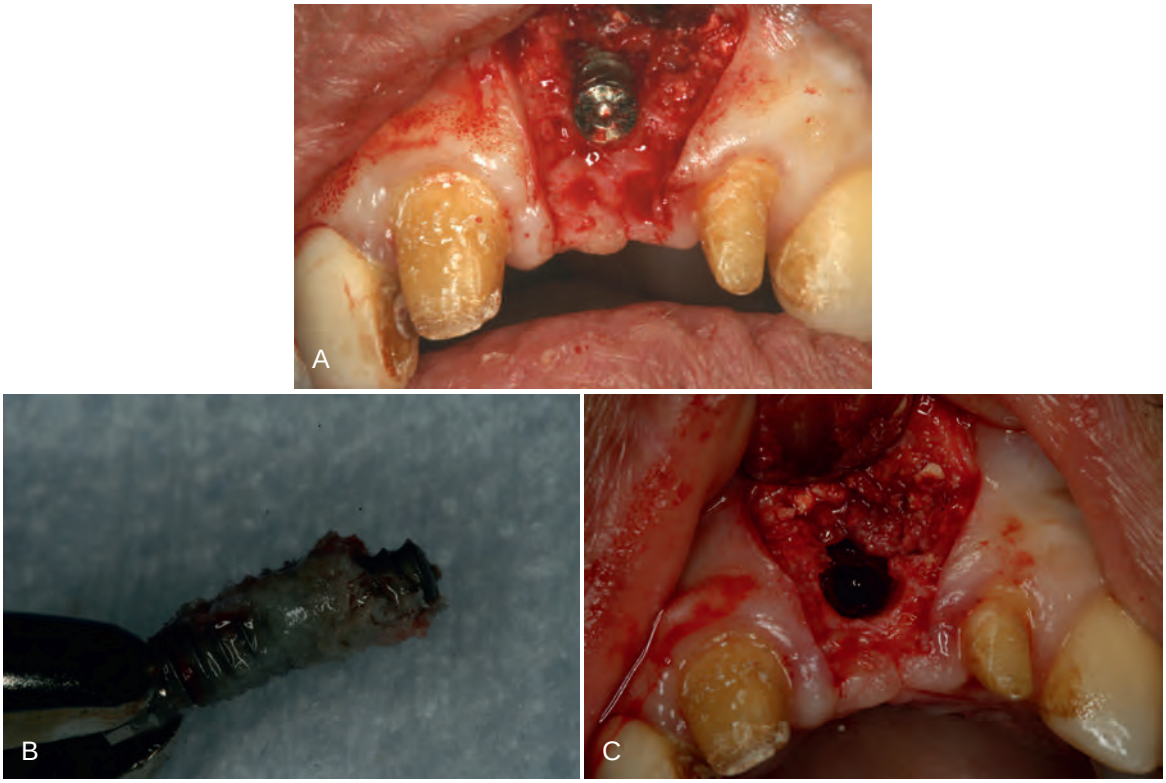

Figure 82-7 Clinical photograph of maxillary anterior implant (left central incisor) placed with an extreme facial angulation resulting in an implant that emerges through the gingiva at a level that is more apical than the adjacent natural tooth gingival margins. **A,** Surgical exposure of malpositioned implant. **B,** Surgically removed implant. **C,** Alveolar defect resulting from surgical removal of malpositioned implant.

sinus augmentation for further information about complications related to the maxillary sinus.

The risks of surgery are always present, but the complications can be minimized with an understanding of the etiologies and with proper diagnosis and treatment planning. Three-dimensional imaging (e.g., computed tomography [CT] and cone-beam CT [CBCT] scans) provides the surgeon with useful presurgical information for proper diagnosis and treatment planning (see Chapter 73). Careful surgical exposure for direct visualization and identification of the mental nerve may be indicated as well. Once identified, it is recommended to establish a "zone of safety" and to keep instrumentation and implants a safe margin away from the nerve (e.g., ≥2 mm).[67]

Biologic Complications

Biologic complications involve pathology of the surrounding periimplant hard and soft tissues. Frequently, soft-tissue problems are an inflammatory response to bacterial accumulation. The cause of bacterial accumulation around implants is key to understanding the problem. For example, bacteria may accumulate at the junction of an ill-fitting implant-abutment or abutment-crown connection. Some of the highly textured, macroscopically rough implant surfaces (e.g., titanium plasma-sprayed [TPS] or hydroxyapatite [HA] coated) may also perpetuate the accumulation of bacteria on the implant surface.

Inflammation and Proliferation

Inflammation in the periimplant soft tissues has been found to be similar to the inflammatory response in gingival and other periodontal tissues. Not surprisingly, the clinical appearance is similar as well. Inflamed periimplant tissues demonstrate the same erythema, edema, and swelling seen around teeth. Occasionally, however, the reaction of periimplant soft tissues to bacterial accumulation is profound, almost unusual, with a dramatic inflammatory proliferation (Figure 82-8). This type of lesion is somewhat characteristic around implants and is indicative of either a loose-fitting implant to abutment connection or trapped excess cement that remains buried within the soft-tissue space or "pocket." The precipitating local factor ultimately becomes infected with bacterial pathogens, leading to mucosal hypertrophy or proliferation and possible abscess formation (Figure 82-9). Correction of the precipitating factors (e.g., loose connection, retained cement) may effectively resolve the lesion. Another type of lesion resulting from a loose abutment connection is the fistula (Figure 82-10). Again, correcting the etiologic factor can quickly resolve the fistula.

Dehiscence and Recession

Dehiscence or recession of the periimplant soft tissues occurs when support for those tissues is lacking or has been lost. Recession is a common finding after implant restoration and should be

Figure 82-8 Inflammatory proliferation caused by a loose-fitting connection between the abutment and the implant. *(Courtesy Dr. John Beumer, UCLA Maxillofacial Prosthetics, Los Angeles, CA.)*

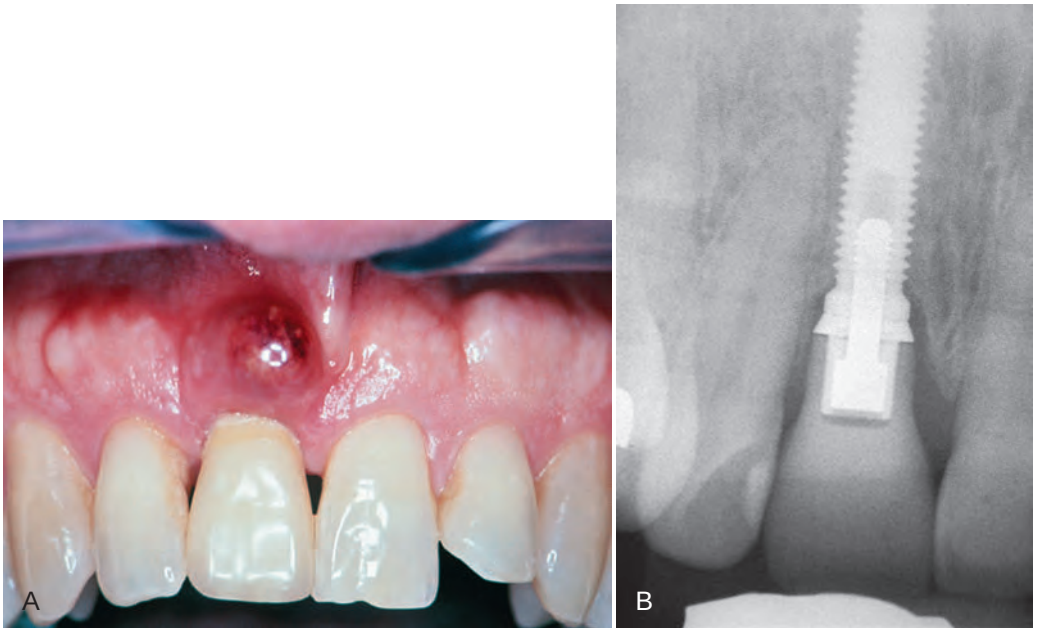

Figure 82-9 **A,** Clinical photograph of abscess caused by excess cement trapped within the soft tissues. **B,** Radiograph of implant with cemented crown (same patient as in **A**). Notice the subgingival depth of the crown-abutment (cement line) junction, which is below the level of the adjacent interproximal bone and therefore impossible to adequately access with explorer to remove excess cement. *(Courtesy Dr. John Beumer, UCLA Maxillofacial Prosthetics, Los Angeles, CA.)*

anticipated especially when soft tissues are thin and not well supported (Figure 82-11). Improper implant positioning also predisposes periimplant tissues to recession. As noted earlier, placement or angulation of the implant too far to the buccal causes the buccal plate to resorb and has been shown to result in greater recession.[143] Another factor to consider is the thickness of the buccal plate of bone. Spray et al[144] recommended this thickness to be 2 mm or greater to support the buccal soft tissue. If this thickness is not present, presurgical or simultaneous site development using guided bone regeneration is indicated. Recession is a problem that is particularly disconcerting in anterior esthetic areas. Patients with a high smile line or high esthetic demands consider such recession a failure (Figure 82-12).

The anatomy and soft-tissue support around implants is different than that around teeth. Specifically, periodontal tissues have the distinct advantage of soft-tissue support from circumferential and transseptal connective tissue fibers that insert into the cementum at a level that is more coronal than the supporting bone. In the absence of inflammation, these fibers support periodontal soft tissues far above the level of crestal bone. As a result, gingival margins and interdental papillae are supported and maintained around teeth even when the periodontal tissues are very thin. Periimplant soft tissues, however, are entirely dependent on the surrounding bone for support. Soft-tissue thickness accounts for some soft-tissue height, but there are no supracrestal inserting connective tissue fibers to aid in the soft-tissue support around an implant. Therefore soft-tissue height around implants typically does not exceed about 3 to 4 mm, and bone loss around implants often leads to recession.

Figure 82-10 Fistula caused by loose implant-abutment connection (maxillary left lateral incisor).

Periimplantitis and Bone Loss

Periimplantitis is defined as an inflammatory process affecting the tissues around an osseointegrated implant in function, resulting in loss of supporting bone.[108] The prevalence of periimplantitis has been reported to be controversial depending on the criteria used to define the amount of marginal bone loss necessary to be present, together with evidence of soft-tissue inflammation to determine the existence of the disease.[89] Reports of prevalence of periimplantitis have varied from approximately 7% to 37% of implants in various studies.[92,131] Recently, a proposed classification for early, moderate, and advanced periimplantitis based on degree of bone loss was presented in an attempt to improve communication when describing prevalence and treatment.[60] To diagnose a compromised implant site, soft-tissue measurements using manual or automated probes have been suggested. Although some reports state that probing is contraindicated, careful monitoring of probing depth over time seems useful in detecting changes of the periimplant tissue.[38,124,146,147] Standardized radiographic techniques, with or without computerized analysis, have been well documented and found to be useful in evaluating periimplant bone levels.[3,23,27,84,124] Together with periodic evaluation of tissue appearance, probing depth changes, and radiographic assessment as the best means of detecting changes in

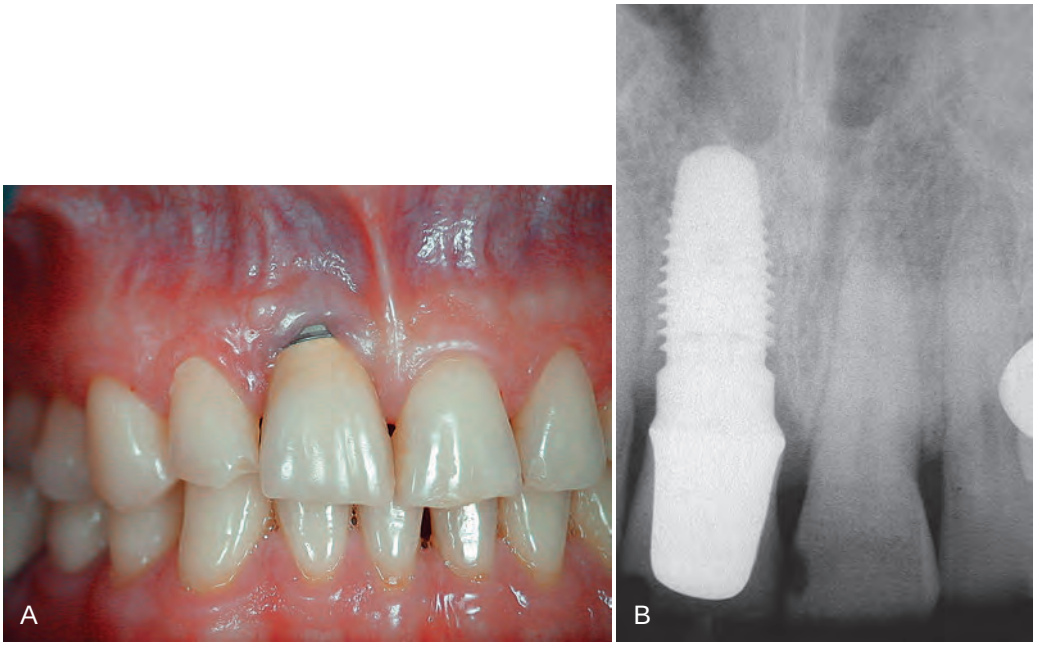

Figure 82-11 **A,** Clinical photograph of single-tooth implant crown (maxillary right central) with moderate recession that occurred 1 year after delivery of final restoration. Recession, in this case, most likely occurred because the labial bone around this wide-diameter implant was very thin or nonexistent. **B,** Radiograph of wide-diameter (6 mm) implant supporting maxillary central incisor crown (same patient as in **A**).

Figure 82-12 Poor esthetics resulting from gingival recession and exposure of crown margins, implant collars, and threads of several maxillary and mandibular implants supporting full-arch fixed partial dentures (FPDs). Notice the thin labial tissues and erythema (especially around mandibular implant sites).

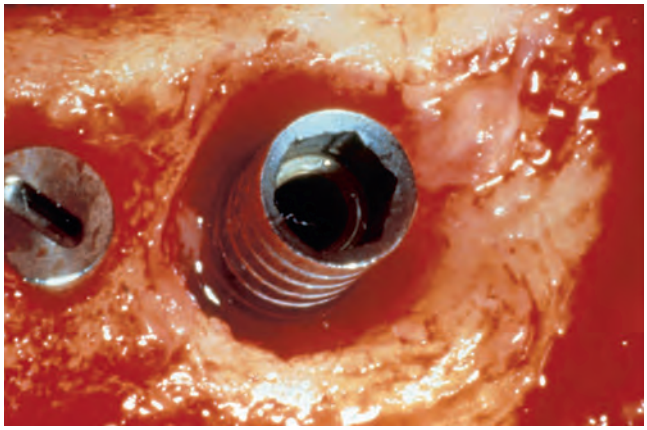

Figure 82-13 Moderately advanced bone loss around an implant with the typical circumferential trough type of boney defect. *(From Garg AK:* Implant dentistry: a practical approach, *ed 2, Mosby, St. Louis, 2010.)*

bone support. Clinicians should monitor the surrounding tissues for signs of periimplant disease by monitoring changes in probing depth and radiographic evidence of bone destruction, suppuration, calculus buildup, swelling, color changes, and bleeding.[109,113] Periimplantitis may be perpetuated by bacterial infection that has contaminated a rough (e.g., TPS, HA-coated) implant surface and by excessive biomechanical forces.[158,159] A classic trough-type defect is typically associated with periimplantitis (Figure 82-13). In cases with severely reduced bone support extending into the apical half of the implant (Figure 82-14) or in cases demonstrating mobility, implant removal should be considered.[6,112] The number and distribution of implants and the occlusal relationships influence the biomechanical forces applied to implants[123,127] (see Chapter 74). A recent review by Lindhe and Meyle from the Consensus Report of the Sixth European Workshop on Periodontology concluded that risk indicators for periimplantitis included (1) poor oral hygiene, (2) a history of periodontitis, (3) diabetes, (4) cigarette smoking, (5) alcohol consumption, and (6) implant surface.[98] Most of these risk factors (1 to 4) have been recognized and reported in the literature.[90] The report suggests that although data for the latter two risk factors (5 and 6) are limited, they appear to be relevant to periimplantitis.[98] Another risk factor that has been proposed

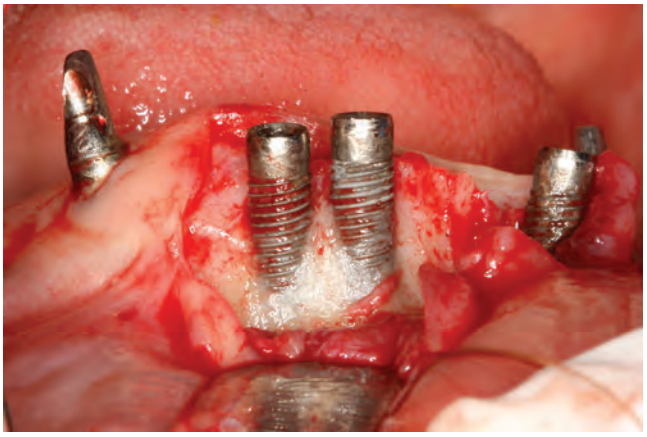

Figure 82-14 Severe horizontal and vertical bone loss around several mandibular implants.

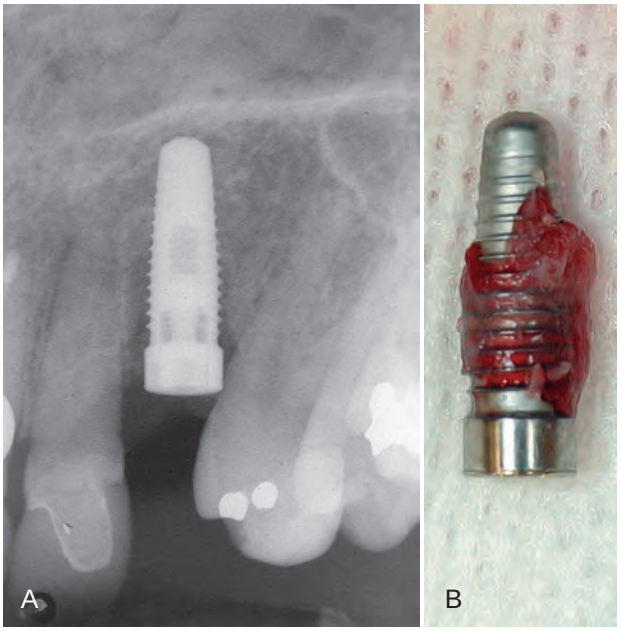

Figure 82-15 **A,** Radiograph of early failed implant caused by lack of osseointegration. In addition to the crestal bone loss, notice the radiolucency along the sides of the implant. **B,** Photograph of the failed (nonintegrated) implant (shown in **A**) that was easily removed along with surrounding connective tissue.

involves gene polymorphism related to an individual's genotype.[31,93] More research is needed to study the relationship of this potential risk factor to the development of periimplantitis.

Implant Loss or Failure

Implant loss or failure is generally considered relative to the time of placement or restoration. Early implant failures occur before implant restoration. Late implant failures occur after the implant has been restored. When an implant fails before restoration, it probably did not achieve osseointegration, or the integration was weak or jeopardized by infection, movement, or impaired wound healing (Figure 82-15). Late implant failures occur after prosthesis installation for a variety of reasons, including infection and implant overload (Figure 82-16). In a review of the literature to evaluate biologic causes for implant failure, Esposito et al[55] found that infections, impaired healing, and overload were the most important

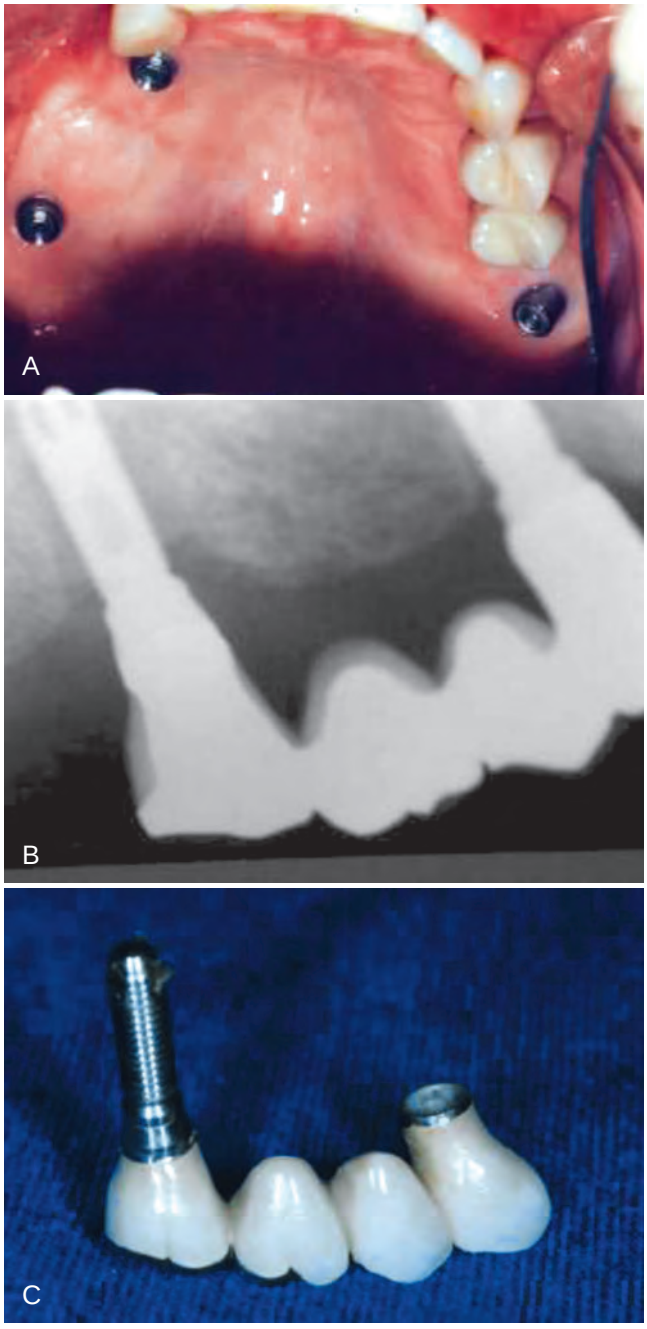

Figure 82-16 Four-unit fixed partial denture (FPD) in the posterior maxilla supported by only two implants. **A,** Clinical photograph of implant abutments in the posterior maxilla. **B,** Radiograph taken 30 months after restoration. Note the bone loss around the distal implant. **C,** Failed distal implant attached to failed prosthesis. The biologic failure of one (posterior) implant resulted in a long-span cantilever extension from the other (anterior) implant that ultimately led to its mechanical failure (i.e., abutment screw fracture). *(Courtesy Dr. John Beumer, UCLA Maxillofacial Prosthetics, Los Angeles, CA.)*

contributing factors. Two systematic reviews of the literature concluded that a single dose of preoperative antibiotic therapy may decrease the failure rate of dental implants.[52,140]

The risk of implant failure varies among patients and patterns of loss tend to cluster within subjects. A second attempt at dental implant placement should be approached cautiously when attempting to place the implant in the same site as the one that previously failed. Oftentimes, it is challenging to achieve adequate diameter, length, and stability of replacement implants due to the residual defect created by removal of the failed implant. In 2007, Grossmann and Levin reported an overall survival rate of 71% for dental implants that were placed in sites of previously failed single implants. In that study all of the original implants failed during the early healing phase (mean 2.3 to 3.2 months post-placement).[69] In a similar study in 2008, Machtei reported an overall survival rate of 83.5% for the second attempt of dental implants. They concluded that replacing failed implants resulted in implants with a lower survival rate compared with implants placed in pristine sites. A factor that could not be associated with conventional implant or patient-related implant failures. They suggested a possible site-specific negative effect that might be associated with this phenomenon.[99]

In 2011, Machtei reported a lower survival rate of 60% for the third reimplanted sites.[100] This outcome represents a further diminished prognosis compared with implants in original sites in or even following the first re-do.[46] Their findings demonstrated that the replacement of a failed implant presents a challenge in achieving osseointegration in a healed bone site and may result in a decline in the survival rate.

Prosthetic or Mechanical Complications

Prosthetic or mechanical complications occur when the strength of materials is no longer able to resist the forces that are being applied. As materials fatigue, they begin to stretch and bend; ultimately, depending on the applied forces, they will fracture. Material failures, in turn, lead to prosthetic complications such as loose, broken, and failed restorations.

Screw Loosening and Fracture

Screw loosening has been reported to occur quite frequently in screw-retained FPDs. Screw-retained single crowns attached to externally hexed implants (i.e., those with narrow- or standard-diameter restorative interface connection surfaces) are particularly prone to this type of mechanical complication. Studies have reported screw loosening in 6% to 49% of cases at the first annual checkup.[78,110] Screw loosening was a more prevalent problem with earlier designs. For example, abutment screws were previously made with titanium, which did not offer the clamping forces of current materials. Newer abutment designs and improved abutment screws allow for an increased clamping force to be achieved without excessive torque levels, which has helped to reduce the rate of screw loosening.

Abutment or prosthesis screw loosening is often corrected by retightening the screws. Over time, however, if screws continue to be stretched, they become fatigued and eventually fracture. This problem is evident in the patient with a loose single crown. However, in the patient with a prosthesis retained by multiple implants, the ability to detect a loose screw is greatly diminished and the problem may go unnoticed until additional screws stretch, fatigue, and fracture. In either case, the biomechanical support (and resistance) for the restoration must be evaluated and if possible, changed to prevent recurrence of the problem.

Implant Fracture

The ultimate mechanical failure is implant fracture because it results in loss of the implant and possibly the prosthesis (Figure 82-23). Furthermore, removal of a fractured implant creates a large osseous defect. Factors such as fatigue of implant materials (Figure 82-24) and weakness in prosthetic design or dimension are the usual causes of implant fractures.[3,14] Balshi[14] listed three categories

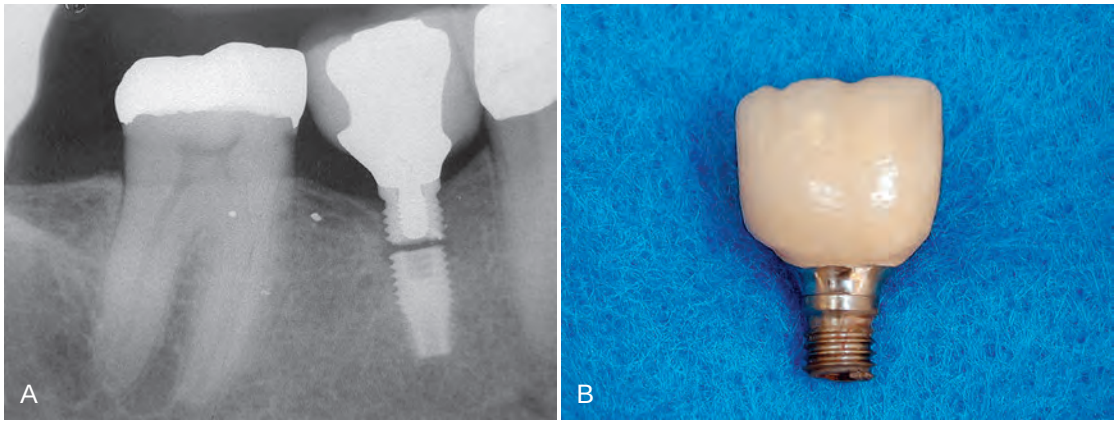

Figure 82-23 **A,** Radiograph of fractured implant (standard diameter) used to support a molar-sized single crown in the posterior mandible. **B,** Crown and coronal portion of implant (same as that shown in **A**) that fractured between the third and fourth threads.

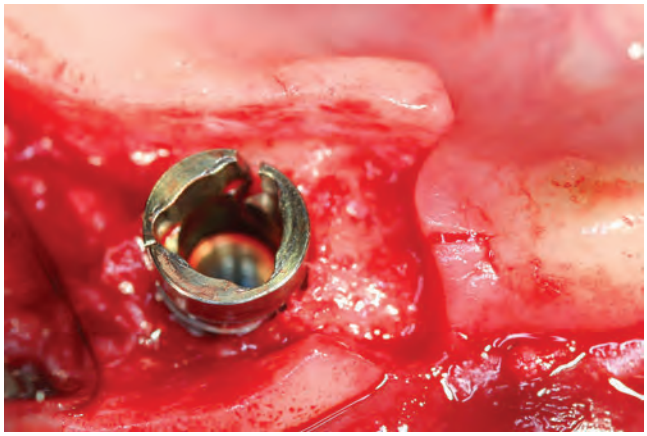

Figure 82-24 Implant fractured at internal connection collar resulting from fatigue. This collar fracture was caused by rotational forces applied to the implant at the time of placement into dense bone. The fracture was likely the result of a combination of material weakness and density of the prepared site.

Figure 82-25 Fractured porcelain from incisal edges of implant-supported fixed partial denture (FPD).

of causes that may explain implant fractures: (1) design and material, (2) nonpassive fit of the prosthetic framework, and (3) physiologic or biomechanical overload. Patients with bruxism seem to be at higher risk for such events and therefore need to be screened, informed, and managed accordingly.[13,14] These patients should be fitted with occlusal guards in conjunction with placement of the final prostheses.

Fracture of Restorative Materials

Fracture or failure of materials used for implant-retained restorations can be a significant problem. This is particularly true for veneers (acrylic, composite, or ceramic) that are attached to superstructures (Figure 82-25).

Esthetic and Phonetic Complications

Esthetic Complications

The challenge of modern implant dentistry is achieving an esthetic, as well as a functional, implant restoration. Harmonious tooth shape, size, and ideal soft-tissue contours are key factors for successful esthetic outcomes.[91]

Esthetic complications arise when patient expectations are not met. Patient satisfaction with the esthetic outcome of the implant prosthesis vary from patient to patient, depending on a number of factors. As mentioned earlier, the risk for esthetic complications is increased for patients with high esthetic expectations and less-than-optimal patient-related factors (e.g., high smile line, thin periodontal soft tissues, or inadequate bone quantity and quality). In addition to the actual appearance of the final restoration, individual perceptions and desires determine the acceptance of the results. Esthetic complications result from poor implant position and deficiencies in the existing anatomy of the edentulous sites that were reconstructed with implants. An important prerequisite for achieving optimal gingival tissue contour is sufficient periimplant bone to support the soft tissues. Hard-tissue defects can be treated by a variety of bone augmentation procedures.

Implant placement in the esthetic zone requires precise three-dimensional tissue reconstruction and ideal implant placement.[70,133] This reconstructive procedure enables the restorative dentist to develop a natural emergence profile of the implant crown. If the amount of available bone does not allow for ideal implant placement and if the implant is positioned too apical, buccal, or in the proximal space, an unesthetic prosthetic profile will be developed (Figure 82-26).

If crown contours and dimensions are not ideal or if gingival harmony around the implant restoration is unesthetic, the patient may consider the implants or restorations as complications because the outcome does not represent a natural appearance (Figure 82-27). Gingiva-colored materials used to replace lost gingival anatomy can offer an alternative to surgical augmentation in patients undergoing implant therapy (Figure 82-28). These restorations provide numerous advantages over conventional restorations,

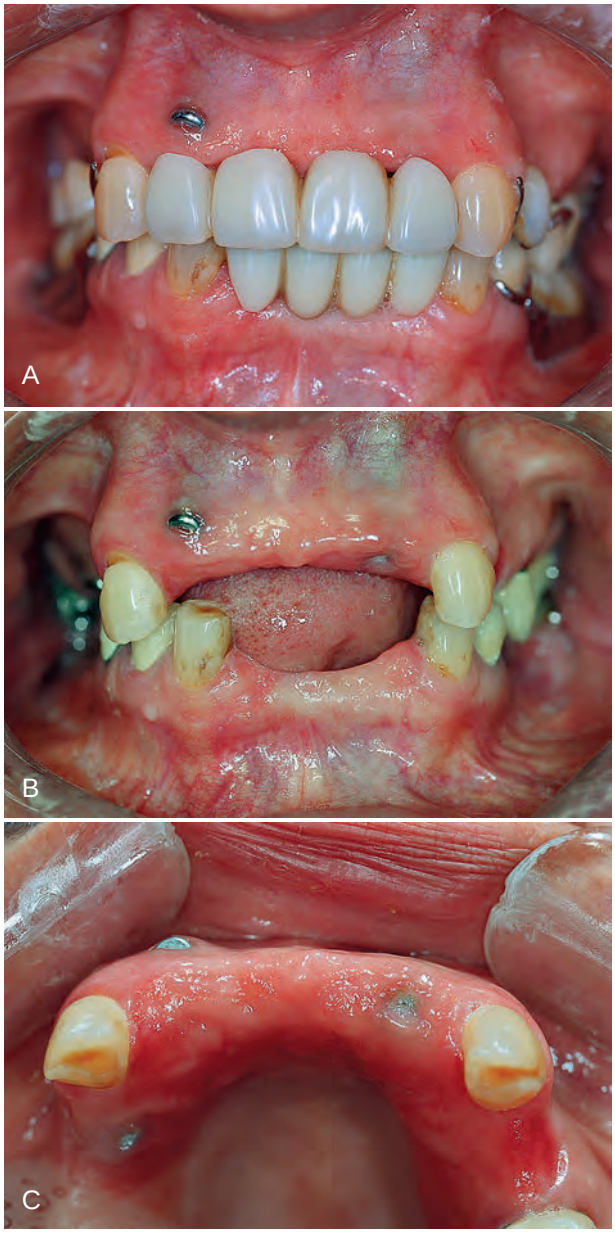

Figure 82-26 Poor implant position makes it impossible to restore with an esthetic, "natural appearing" restoration. **A,** Anterior view with removable partial dentures inserted. **B,** Anterior view without removable partial dentures. Notice the high level of implant cover screw/head exposure (maxillary right lateral incisor) that is significantly apical to the level of the adjacent natural tooth (cuspid) gingival margin. **C,** Occlusal view of same patient. Again, notice the labial projection of same implant (maxillary right lateral incision), as well as the palatal position of the implant in premolar area. Any attempt to restore the anterior implants would not be esthetically acceptable.

including improved lip support, masking of interproximal spaces, and restoration of gingival symmetry in selected cases.[74]

If the patient is truly dissatisfied with the esthetic result and there is a problem with the position of the implants that can be corrected (i.e., the patient's expectations are reasonable), the implants could be removed; the case could be reevaluated and possibly retreated. However, the clinician should consider prosthetic solutions before implant removal. Use of angulated abutments, superstructures, and gingiva-colored materials may result in an

Figure 82-27 High gingival margin on single-tooth implant crown in the maxillary lateral incisor position. Notice the discrepancy between gingival margin levels of the implant and the adjacent natural teeth.

Figure 82-28 Pink porcelain used on implant-supported fixed restoration to mask the high gingival margin and long implant crowns resulting from an uncorrected alveolar ridge defect.

acceptable esthetic result, thus avoiding multiple surgeries necessary to rebuild hard and soft tissue if an integrated implant is removed.

Careful patient evaluation and treatment planning along with a solid understanding and appreciation for the predictability and limitations of implant procedures will minimize esthetic complications. Patients with a high smile line, high esthetic demands, thin periodontium, or lack of hard- and soft-tissue support in the anterior esthetic region are some of the most difficult cases to treat and should only be treated after extensive planning by experienced clinicians.

Phonetic Problems

Implant prostheses that are fabricated with unusual palatal contours (e.g., restricted or narrow palatal space) or that have spaces under and around the superstructure can create phonetic problems for the patient. This is particularly problematic when full-arch, implant-supported, fixed restorations are fabricated for patients who have a severely atrophied maxilla. These patients are probably best served with an implant-assisted maxillary overdenture because the design facilitates replacement of missing alveolar structure and avoids creating spaces that allow air to escape during speech.

Conclusion

Although implants offer a highly predictable treatment option for the replacement of single and multiple missing teeth, there are a

variety of potential complications that may be surgical, biologic, mechanical, prosthetic, or esthetic. Careful diagnosis and treatment planning, along with the use of diagnostic imaging, surgical guides, meticulous techniques, and adherence to proven principles can prevent many of the problems discussed in this chapter. A thorough understanding of anatomy, biology, and wound healing can reduce the incidence of complications. However, there is no substitute for training, knowledge, and clinical experience for preventing, recognizing, and successfully managing complications. This chapter is a start. The clinician who places and/or restores implants must be aware of techniques and procedures for early intervention should a complication arise.

Suggested Readings

Berglundh T, Persson L, Klinge B: A systematic review of the incidence of biological and technical complications in implant dentistry reported in prospective longitudinal studies of at least 5 years. *J Clin Periodontol* 29(Suppl 3):197–212, discussion 232–233, 2002.

Del Fabbro M, Testori T, Francetti L, et al: Systematic review of survival rates for immediately loaded dental implants. *Int J Periodontics Restorative Dent* 26:249–263, 2006.

den Hartog L, Slater JJ, Vissink A, et al: Treatment outcome of immediate, early and conventional single-tooth implants in the aesthetic zone: a systematic review to survival, bone level, soft-tissue, aesthetics and patient satisfaction. *J Clin Periodontol* 35:1073–1086, 2008.

Esposito M, Hirsch J, Lekholm U, et al: Differential diagnosis and treatment strategies for biologic complications and failing oral implants: a review of the literature. *Int J Oral Maxillofac Implants* 14:473–490, 1999.

Goodacre CJ, Bernal G, Rungcharassaeng K, et al: Clinical complications with implants and implant prostheses. *J Prosthet Dent* 90:121–132, 2003.

Lang NP, Pjetursson BE, Tan K, et al: A systematic review of the survival and complication rates of fixed partial dentures (FPDs) after an observation period of at least 5 years. II. Combined tooth–implant-supported FPDs. *Clin Oral Implants Res* 15:643–653, 2004.

Pjetursson BE, Tan K, Lang NP, et al: A systematic review of the survival and complication rates of fixed partial dentures (FPDs) after an observation period of at least 5 years. *Clin Oral Implants Res* 15:667–676, 2004.

Roos-Jansaker AM, Lindahl C, Renvert H, et al: Nine to fourteen-year follow-up of implant treatment. Part II: presence of peri-implant lesions. *J Clin Periodontol* 33:290–295, 2006.

References

References for this chapter are found on the companion website www.expertconsult.com.

References

1. Achilli A, Tura F, Euwe E: Immediate/early function with tapered implants supporting maxillary and mandibular posterior fixed partial dentures: preliminary results of a prospective multicenter study. *J Prosthetic Dent* 97:S52–S58, 2007.
2. Adell R, Eriksson B, Lekholm U, et al: Long-term follow-up study of osseointegrated implants in the treatment of totally edentulous jaws. *Int J Oral Maxillofac Implants* 5:347–359, 1990.
3. Adell R, Lekholm U, Rockler B, et al: A 15-year study of osseointegrated implants in the treatment of the edentulous jaw. *Int J Oral Surg* 10:387–416, 1981.
4. Aghaloo TL, Moy PK: Which hard tissue augmentation techniques are the most successful in furnishing bony support for implant placement? *Int J Oral Maxillofac Implants* 22(Suppl):49–70, 2007.
5. al-Ansari BH, Morris RR: Placement of dental implants without flap surgery: a clinical report. *Int J Oral Maxillofac Implants* 13:861–865, 1998.
6. Albrektsson T, Zarb G, Worthington P, et al: The long-term efficacy of currently used dental implants: a review and proposed criteria of success. *Int J Oral Maxillofac Implants* 1:11–25, 1986.
7. Alhassani AL, AlGhamdi AST: Inferior alveolar nerve injury in implant dentistry: diagnosis, causes, prevention, and management. *J Oral Implantol* 36:401–407, 2010.
8. Andersson P, Verrochi D, Pagliant L, et al: Immediate/early loading of Neoss implants. Preliminary results from an ongoing study. *App Osseointe Res* 6:27–30, 2008.
9. Araujo M, Linder E, Lindhe J: Effect of a xenograft on early bone formation in extraction sockets: an experimental study in dog. *Clin Oral Implants Res* 20:1–6, 2009.
10. Astrand P, Engquist B, Dahlgren S, et al: Astra Tech and Brånemark System implants: a prospective 5-year comparative study. Results after one year. *Clin Implant Dent Related Res* 1:17–26, 1999.
11. Attard NJ, Zarb GA: Immediate and early implant loading protocols: a literature review of clinical studies. *J Prosthet Dent* 94:242–258, 2005.
12. Bain CA, Moy PK: The association between the failure of dental implants and cigarette smoking. *Int J Oral Maxillofac Implants* 8:609–615, 1993.
13. Balshi TJ: Preventing and resolving complications with osseointegrated implants. *Dent Clin North Am* 33:821–868, 1989.
14. Balshi TJ: An analysis and management of fractured implants: a clinical report. *Int J Oral Maxillofac Implants* 11:660–666, 1996.
15. Barone A, Santini S, Sbordone L, et al: A clinical study of the outcomes and complications associated with maxillary sinus augmentation. *Inter J Oral Maxillofac Implants* 21:81–85, 2006.
16. Bartling R, Freeman K, Kraut RA: The incidence of altered sensation of the mental nerve after mandibular implant placement. *J Oral Maxillofac Surg* 57:1408–1412, 1999.
17. Bavitz JB, Harn SD, Homze EJ: Arterial supply to the floor of the mouth and lingual gingiva. *Oral Sur Oral Med Oral Pathol* 77:232–235, 1994.
18. Becker W, Dahlin C, Becker BE, et al: The use of e-PTFE barrier membranes for bone promotion around titanium implants placed into extraction sockets: a prospective multicenter study. *Int J Oral Maxillofac Implants* 9:31–40, 1994.
19. Becktor JP, Eckert SE, Isaksson S, et al: The influence of mandibular dentition on implant failures in bone-grafted edentulous maxillae. *Int J Oral Maxillofac Implants* 17:69–77, 2002.
20. Belser UC, Buser D, Hess D, et al: Aesthetic implant restorations in partially edentulous patients—a critical appraisal. *Periodontol 2000* 17:132–150, 1998.
21. Belser UC, Grutter L, Vailati F, et al: Outcome evaluation of early placed maxillary anterior single-tooth implants using objective esthetic criteria: a cross-sectional, retrospective study in 45 patients with a 2- to 4-year follow-up using pink and white esthetic scores. *J Periodontol* 80:140–151, 2009.
22. Berglundh T, Persson L, Klinge B: A systematic review of the incidence of biological and technical complications in implant dentistry reported in prospective longitudinal studies of at least 5 years. *J Clin Periodontol* 29(Suppl 3):197–212, discussion 232–233, 2002.
23. Bragger U, Burgin W, Fourmoussis I, et al: Image processing for the evaluation of dental implants. *Dentomaxillofac Radiol* 21:208–212, 1992.
24. Brånemark PI: Osseointegration and its experimental background. *J Prosthet Dent* 50:399–410, 1983.
25. Buser D, Bragger U, Lang NP, et al: Regeneration and enlargement of jaw bone using guided tissue regeneration. *Clin Oral Implants Res* 1:22–32, 1990.
26. Buser D, Martin W, Belser UC: Optimizing esthetics for implant restorations in the anterior maxilla: anatomic and surgical considerations. *Int J Oral Maxillofac Implants* 19(Suppl):43–61, 2004.
27. Buser D, Weber HP, Bragger U, et al: Tissue integration of one-stage ITI implants: 3-year results of a longitudinal study with hollow-cylinder and hollow-screw implants. *Int J Oral Maxillofac Implants* 6:405–412, 1991.
28. Campelo LD, Camara JR: Flapless implant surgery: a 10-year clinical retrospective analysis. *Int J Oral Maxillofac Implants* 17:271–276, 2002.
29. Cannizzaro G, Leone M, Consolo U, et al: Immediate functional loading of implants placed with flapless surgery versus conventional implants in partially edentulous patients: a 3-year randomized controlled clinical trial. *Int J Oral Maxillofac Implants* 23:867–875, 2008.
30. Cardaropoli D, Cardaropoli G: Preservation of the postextraction alveolar ridge: a clinical and histologic study. *Int J Periodontics Restorative Dent* 28:469–477, 2008.
31. Casado PL, Villas-Boas R, de Mello W, et al: Peri-implant disease and chronic periodontitis: is interleukin-6 gene promoter polymorphism the common risk factor in a Brazilian population? *Int J Oral Maxillofac Implants* 28:35–43, 2013.
32. Chaushu G, Chaushu S, Tzohar A, et al: Immediate loading of single-tooth implants: immediate versus non-immediate implantation. A clinical report. *Int J Oral Maxillofac Implants* 16:267–272, 2001.
33. Chen ST, Wilson TG, Jr, Hammerle CH: Immediate or early placement of implants following tooth extraction: review of biologic basis, clinical procedures, and outcomes. *Int J Oral Maxillofac Implants* 19(Suppl):12–25, 2004.
34. Chiapasco M: Early and immediate restoration and loading of implants in completely edentulous patients. *Int J Oral Maxillofac Implants* 19(Suppl):76–91, 2004.
35. Chiapasco M, Zaniboni M, Boisco M: Augmentation procedures for the rehabilitation of deficient edentulous ridges with oral implants. *Clin Oral Implants Res* 17(Suppl 2):136–159, 2006.
36. Cooper L, Felton DA, Kugelberg CF, et al: A multicenter 12-month evaluation of single-tooth implants restored 3 weeks after 1-stage surgery. *Int J Oral Maxillofac Implants* 16:182–192, 2001.
37. Cordaro L, Rossini C, Mijiritsky E: Fracture and displacement of lingual cortical plate of mandibular symphysis following bone harvesting: case report. *Implant Denti* 13:202–206, 2004.
38. Dahlin C, Sennerby L, Lekholm U, et al: Generation of new bone around titanium implants using a membrane technique: an experimental study in rabbits. *Int J Oral Maxillofac Implants* 4:19–25, 1989.
39. Darriba MA, Mendonca-Caridad JJ: Profuse bleeding and life-threatening airway obstruction after placement of mandibular dental implants. *J Oral Maxillofac Surg* 55:1328–1330, 1997.
40. Degidi M, Piattelli A: Immediate functional and non-functional loading of dental implants: a 2- to 60-month follow-up study of 646 titanium implants. *J Periodontol* 74:225–241, 2003.
41. Del Castillo-Pardo de Vera JL, Lopez-Arcas Calleja JM, Burgueno-Garcia M: Hematoma of the floor of the mouth and airway obstruction during mandibular dental implant placement: a case report. *Oral Maxillofac Surg* 12:223–226, 2008.
42. Del Fabbro M, Testori T, Francetti L, et al: Systematic review of survival rates for immediately loaded dental implants. *Int J Periodontics Restorative Dent* 26:249–263, 2006.
43. Del Fabbro M, Testori T, Francetti L, et al: Systematic review of survival rates for implants placed in the grafted maxillary sinus. *Int J Periodontics Restorative Dent* 24:565, 2004.

44. DeLuca S, Habsha E, Zarb GA: The effect of smoking on osseointegrated dental implants. Part I: implant survival. *Int J Prosthodontics* 19:491–498, 2006.
45. DeLuca S, Zarb G: The effect of smoking on osseointegrated dental implants. Part II: peri-implant bone loss. *Int J Prosthodontics* 19:560–566, 2006.
46. den Hartog L, Slater JJ, Vissink A, et al: Treatment outcome of immediate, early and conventional single-tooth implants in the aesthetic zone: a systematic review to survival, bone level, soft-tissue, aesthetics and patient satisfaction. *J Clin Periodontol* 35:1073–1086, 2008.
47. Doring K, Eisenmann E, Stiller M: Functional and esthetic considerations for single-tooth Ankylos implant-crowns: 8 years of clinical performance. *J Oral Implantol* 30:198–209, 2004.
48. Eckert SE, Meraw SJ, Cal E, et al: Analysis of incidence and associated factors with fractured implants: a retrospective study. *Int J Oral Maxillofac Implants* 15:662–667, 2000.
49. Elian N, Wallace S, Cho SC, et al: Distribution of the maxillary artery as it relates to sinus floor augmentation. *Int J Oral Maxillofac Implants* 20:784–787, 2005.
50. Ellegaard B, Baelum V, Kolsen-Petersen J: Non-grafted sinus implants in periodontally compromised patients: a time-to-event analysis. *Clin Oral Implants Res* 17:156–164, 2006.
51. Esposito M, Ekestubbe A, Grondahl K: Radiological evaluation of marginal bone loss at tooth surfaces facing single Branemark implants. *Clin Oral Implants Res* 4:151–157, 1993.
52. Esposito M, Grusovin MG, Talati M, et al: Do preoperative antibiotics prevent dental implant complications? *Cochrane Database Syst Rev* 3:109–110, 2008.
53. Esposito M, Grusovin MG, Maghaireh H, et al: Interventions for replacing missing teeth: management of soft tissues for dental implants. *Cochrane Database Syst Rev* (3):CD006697, 2007.
54. Esposito M, Grusovin MG, Willings M, et al: The effectiveness of immediate, early, and conventional loading of dental implants: a Cochrane systematic review of randomized controlled clinical trials. *Int J Oral Maxillofac Implants* 22:893–904, 2007.
55. Esposito M, Hirsch J, Lekholm U, et al: Differential diagnosis and treatment strategies for biologic complications and failing oral implants: a review of the literature. *Int J Oral Maxillofac Implants* 14:473–490, 1999.
56. Esposito M, Hirsch JM, Lekholm U, et al: Biological factors contributing to failures of osseointegrated oral implants. (II). Etiopathogenesis. *Eur J Oral Sci* 106:721–764, 1998.
57. Evans CD, Chen ST: Esthetic outcomes of immediate implant placements. *Clin Oral Implants Res* 19:73–80, 2008.
58. Fiorellini JP, Nevins ML: Localized ridge augmentation/preservation. A systematic review. *Ann Periodontol* 8:321–327, 2003.
59. Flanagan D: Important arterial supply of the mandible, control of an arterial hemorrhage, and report of a hemorrhagic incident. *J Oral Implantol* 29:165–173, 2003.
60. Froum SJ, Rosen PS: A proposed classification for peri-implantitis. *Int J Periodontics Restorative Dent* 32:533–540, 2012.
61. Furhauser R, Florescu D, Benesch T, et al: Evaluation of soft tissue around single-tooth implant crowns: the pink esthetic score. *Clin Oral Implants Res* 16:639–644, 2005.
62. Ganeles J, Wismeijer D: Early and immediately restored and loaded dental implants for single-tooth and partial-arch applications. *Int J Oral Maxillofac Implants* 19(Suppl):92–102, 2004.
63. Glauser R, Ree A, Lundgren A, et al: Immediate occlusal loading of Branemark implants applied in various jawbone regions: a prospective, 1-year clinical study. *Clin Implants Oral Res* 3:204–213, 2001.
64. Gomez-Roman G: Influence of flap design on peri-implant interproximal crestal bone loss around single-tooth implants. *Int J Oral Maxillofac Implants* 16:61–67, 2001.
65. Goodacre CJ, Bernal G, Rungcharassaeng K, et al: Clinical complications with implants and implant prostheses. *J Prosthet Dent* 90:121–132, 2003.
66. Goodacre CJ, Kan JY, Rungcharassaeng K: Clinical complications of osseointegrated implants. *J Prosthet Dent* 81:537–552, 1999.
67. Greenstein G, Tarnow D: The mental foramen and nerve: clinical and anatomical factors related to dental implant placement: a literature review. *J Periodontol* 77:1933–1943, 2006.
68. Gregg JM: Neuropathic complications of mandibular implant surgery: review and case presentations. *Ann R Australas Coll Dent Surg* 15:176–180, 2000.
69. Grossmann Y, Levin L: Success and survival of single dental implants placed in sites of previously failed implants. *J Periodontol* 78:1670–1674, 2007.
70. Grunder U, Gracis S, Capelli M: Influence of the 3-D bone-to-implant relationship on esthetics. *Int J Periodontics Restorative Dent* 25:113–119, 2005.
71. Hallman M, Hedin M, Sennerby L, et al: A prospective 1-year clinical and radiographic study of implants placed after maxillary sinus floor augmentation with bovine hydroxyapatite and autogenous bone. *J Oral Maxillofac Surg* 60:277–284, discussion 285–286, 2002.
72. Hammerle CH, Jung RE, Feloutzis A: A systematic review of the survival of implants in bone sites augmented with barrier membranes (guided bone regeneration) in partially edentulous patients. *J Clin Periodontol* 29(Suppl 3):226–231, discussion 232–233, 2002.
73. Hammerle CH, van Steenberghe D: The first EAO Consensus Conference 16–19 February 2006, Pfaffikon, Switzerland. *Clin Oral Implants Res* 17(Suppl 2):1, 2006.
74. Hannon SM, Colvin CJ, Zurek DJ: Selective use of gingival-toned ceramics: case reports. *Quintessence Int* 25:233–238, 1994.
75. Hermann JS, Cochran DL, Nummikoski PV, et al: Crestal bone changes around titanium implants. A radiographic evaluation of unloaded nonsubmerged and submerged implants in the canine mandible. *J Periodontol* 68:1117–1130, 1997.
76. Isaacson T: Sublingual hematoma formation during immediate placement of mandibular endosseous implants. *J Am Dent Assoc* 30:202, 2004.
77. Jaffin RA, Kumar A, Berman CL: Immediate loading of dental implants in the completely edentulous maxilla: a clinical report. *Int J Oral Maxillofac Implants* 19:721–730, 2004.
78. Jemt T: Fixed implant-supported prostheses in the edentulous maxilla. A five-year follow-up report. *Clin Oral Implants Res* 5:142–147, 1994.
79. Jensen J, Reiche-Fischel O, Sindet-Pedersen S: Nerve transposition and implant placement in the atrophic posterior mandibular alveolar ridge. *J Oral Maxillofac Surg* 52:662–668, discussion 669–670, 1994.
80. Jensen OT, Cockrell R, Kuhike L, et al: Anterior maxillary alveolar distraction osteogenesis: a prospective 5-year clinical study. *Int J Oral Maxillofac Implants* 17:52–68, 2002.
81. Jeske AH, Suchko GD: Lack of a scientific basis for routine discontinuation of oral anticoagulation therapy before dental treatment. *J Am Dent Assoc* 134:1492–1497, 2003.
82. Jimenez Y, Poveda R, Gavalda C, et al: An update on the management of anticoagulated patients programmed for dental extractions and surgery. *Med Oral Patol Oral Cir Bucal* 13:E176–E179, 2008.
83. Jokstad A, Carr AB: What is the effect on outcomes of time-to-loading of a fixed or removable prosthesis placed on implant(s). *Int J Oral Maxillofac Implants* 22(Suppl):19–48, 2007.
84. Jovanovic SA: *Plaque-induced periimplant bone loss in mongrel dogs: a clinical, microbial, radiographic, and histological study*, Master's thesis, Los Angeles, 1994, UCLA.
85. Jovanovic SA, Spiekermann H, Richter EJ: Bone regeneration around titanium dental implants in dehisced defect sites: a clinical study. *Int J Oral Maxillofac Implants* 7:233–245, 1992.
86. Kan JY, Lozada JL, Goodacre CJ, et al: Endosseous implant placement in conjunction with inferior alveolar nerve transposition: an evaluation of neurosensory disturbance. *Int J Oral Maxillofac Implants* 12:463–471, 1997.
87. Kan JY, Rungcharassaeng K, Lozada J: Immediate placement and provisionalization of maxillary anterior single implants: 1-year prospective study. *Int J Oral Maxillofac Implants* 18:31–39, 2003.
88. Kasabah S, Krug J, Simunek A, et al: Can we predict maxillary sinus mucosa perforation? *Acta Medica (Hradec Kralove)/Universitas Carolina, Facultas Medica Hradec Kralove* 46:19–23, 2003.

89. Klinge B: Peri-implant marginal bone loss: an academic controversy or a clinical challenge? *Eur J Oral Implantol* 5(Suppl):S13–S19, 2012.
90. Klokkevold PR, Han TJ: How do smoking, diabetes, and periodontitis affect outcomes of implant treatment? *Int J Oral Maxillofac Implants* 22(Suppl):173–202, 2007.
91. Kois JC: Predictable single tooth peri-implant esthetics: five diagnostic keys. *Compend Contin Educ Dent* 22:199–206, quiz 208, 2001.
92. Koldsland OC, Scheie A, Aass AM: Prevalence of peri-implantitis related to severity of the disease with different degrees of bone loss. *J Periodontol* 81:231–238, 2010.
93. Laine ML, Leonhardt A, Roos-Jansaker AM, et al: IL-1RN gene polymorphism is associated with peri-implantitis. *Clin Oral Impl Res* 17:380–385, 2006.
94. Lang NP, Pjetursson BE, Tan K, et al: A systematic review of the survival and complication rates of fixed partial dentures (FPDs) after an observation period of at least 5 years. II. Combined tooth–implant-supported FPDs. *Clin Oral Implants Res* 15:643–653, 2004.
95. Lazzara RJ: Immediate implant placement into extraction sites: surgical and restorative advantages. *Int J Periodontics Restorative Dent* 9:332–343, 1989.
96. Lekholm U, Gunne J, Henry P, et al: Survival of the Branemark implant in partially edentulous jaws: a 10-year prospective multicenter study. *Int J Oral Maxillofac Implants* 14:639–645, 1999.
97. Lindeboom JA, Tjiook Y, Kroon FH: Immediate placement of implants in periapical infected sites: a prospective randomized study in 50 patients. *Oral Surg Oral Med Oral Pathol Oral Radiol Endod* 101:705–710, 2006.
98. Lindhe J, Meyle J: Peri-implant diseases: Consensus Report of the Sixth European Workshop on Periodontology. *J Clin Periodontol* 35:282–285, 2008.
99. Machtei EE, Mahler D, Oettinger Barak O, et al: Dental implants placed in previously failed sites: survival rate and factors affecting the outcome. *Clinical Oral Implants Res* 19(3):259–264, 2008.
100. Machtei EE, Horwitz J, Mahler D, et al: Third attempt to place implants in sites where previous surgeries have failed. *J Clin Periodontol* 38:195–198, 2011.
101. Mayfield L: *Immediate delayed and late submerged and transmucosal implants*, Berlin, 1999, Quintessence.
102. Meijer HJ, Stellingsma K, Meijndert L, et al: A new index for rating aesthetics of implant-supported single crowns and adjacent soft tissues—the Implant Crown Aesthetic Index. *Clin Oral Implants Res* 16:645–649, 2005.
103. Meitner SW, Tallents RH: Surgical templates for prosthetically guided implant placement. *J Prosthetic Dent* 92:569–574, 2004.
104. Meyer U, Joos U, Mythili J, et al: Ultrastructural characterization of the implant/bone interface of immediately loaded dental implants. *Biomaterials* 25:1959–1967, 2004.
105. Misch CE: Maxillary sinus augmentation for endosteal implants: organized alternative treatment plans. *Int J Oral Implantol* 4:49–58, 1987.
106. Misch CE: *Contemporary Implant Dentistry*, St. Louis, 2008, Mosby.
107. Misch CE, Resnik R: Mandibular nerve neurosensory impairment after dental implant surgery: management and protocol. *Implant Dent* 19:378–386, 2010.
108. Mombelli A, Lang NP: The diagnosis and treatment of peri-implantitis. *Periodontol 2000* 17:63–76, 1998.
109. Mombelli A, Marxer M, Gaberthuel T, et al: The microbiota of osseointegrated implants in patients with a history of periodontal disease. *J Clin Periodontol* 22:124–130, 1995.
110. Mombelli A, van Oosten MA, Schurch E, Jr, et al: The microbiota associated with successful or failing osseointegrated titanium implants. *Oral Microbiol Immunol* 2:145–151, 1987.
111. Moy PK, Medina D, Shetty V, et al: Dental implant failure rates and associated risk factors. *Int J Oral Maxillofac Implants* 20:569–577, 2005.
112. Nakou M, Mikx FH, Oosterwaal PJ, et al: Early microbial colonization of permucosal implants in edentulous patients. *J Dent Res* 66:1654–1657, 1987.
113. Nevins M, Mellonig JT: Enhancement of the damaged edentulous ridge to receive dental implants: a combination of allograft and the GORE-TEX membrane. *Int J Periodontics Restorative Dent* 12:96–111, 1992.
114. Niamtu J, 3rd: Near-fatal airway obstruction after routine implant placement. *Oral Surg Oral Med Oral Pathol Oral Radiol Endod* 92:597–600, 2001.
115. Panula K, Oikarinen K: Severe hemorrhage after implant surgery. *Oral Surg Oral Med Oral Pathol Oral Radiol Endod* 87:2, 1999.
116. Parel SM: Aesthetics and osseointegration. *Dent Today* 9:50–51, 1990.
117. Payne AG, Tawse-Smith A, Thompson WM, et al: Early functional loading of unsplinted roughened surface implants with mandibular overdentures 2 weeks after surgery. *Clin Implant Dent Relat Res* 5:143–153, 2003.
118. Payne AG, Tawse-Smith A, Thomson WM, et al: One-stage surgery and early loading of three implants for maxillary overdentures: a 1-year report. *Clin Implant Dent Relat Res* 6:61–74, 2004.
119. Penarrocha M, Perez H, Garcia A, et al: Benign paroxysmal positional vertigo as a complication of osteotome expansion of the maxillary alveolar ridge. *J Oral Maxillofac Surg* 59:106–107, 2001.
120. Penarrocha-Diago M, Rambla-Ferrer J, Perez V, et al: Benign paroxysmal vertigo secondary to placement of maxillary implants using the alveolar expansion technique with osteotomes: a study of 4 cases. *Int J Oral Maxillofac Implants* 23:129–132, 2008.
121. Pjetursson BE, Tan K, Lang NP, et al: A systematic review of the survival and complication rates of fixed partial dentures (FPDs) after an observation period of at least 5 years. *Clin Oral Implants Res* 15:667–676, 2004.
122. Raghoebar GM, Louwerse C, Kalk WW, et al: Morbidity of chin bone harvesting. *Clin Oral Implants Res* 12:503–507, 2001.
123. Rams TE, Link CC, Jr: Microbiology of failing dental implants in humans: electron microscopic observations. *J Oral Implantol* 11:93–100, 1983.
124. Rangert B, Jemt T, Jorneus L: Forces and moments on Branemark implants. *Int J Oral Maxillofac Implants* 4:241–247, 1989.
125. Rangert B, Krogh PH, Langer B, et al: Bending overload and implant fracture: a retrospective clinical analysis. *Int J Oral Maxillofac Implants* 10:326–334, 1995.
126. Renton T, Yilmaz Z: Managing iatrogenic trigeminal nerve injury: a case series and review of the literature. *Int J Oral Maxillofac Surg* 41:629–637, 2012.
127. Richter EJ, Jansen V, Spiekerann H, et al: Langzeitergebnisse von IMZ-und TPS-Implantaten im interforaminalen Bereich des zahnlosen Unterkierfers. *Dtsch Zahnarztl Z* 47:449, 1992.
128. Rocci A, Martignoni M, Gottlow J: Immediate loading of Branemark System TiUnite and machined-surface implants in the posterior mandible: a randomized open-ended clinical trial. *Clin Implant Dent Relat Res* 5(Suppl 1):57–63, 2003.
129. Romanos GE, Nentwig GH: Immediate loading using cross-arch fixed restorations in heavy smokers: nine consecutive case reports for edentulous arches. *Int J Oral Maxillofac Implants* 23:513–519, 2008.
130. Roos J, Sennerby L, Lekholm U, et al: A qualitative and quantitative method for evaluating implant success: a 5-year retrospective analysis of the Branemark implant. *Int J Oral Maxillofac Implants* 12:504–514, 1997.
131. Roos-Jansaker AM, Lindahl C, Renvert H, et al: Nine- to fourteen-year follow-up of implant treatment. Part II: presence of peri-implant lesions. *J Clin Periodontol* 33:290–295, 2006.
132. Sacco R, Sacco M, Carpenedo M, et al: Oral surgery in patients on oral anticoagulant therapy: a randomized comparison of different intensity targets. *Oral Surg Oral Med Oral Pathol Oral Radiol Endod* 104:e18–e21, 2007.
133. Salama H, Salama MA, Li TF, et al: Treatment planning 2000: an esthetically oriented revision of the original implant protocol. *J Esthetic Dent* 9:55–67, 1997.
134. Schincaglia GP, Marzola R, Scapoli C, et al: Immediate loading of dental implants supporting fixed partial dentures in the posterior mandible: a randomized controlled split-mouth study–machined versus

titanium oxide implant surface. *Int J Oral Maxillofac Implants* 22:35–46, 2007.
135. Schnitman PA, Wohrle PS, Rubenstein JE: Immediate fixed interim prostheses supported by two-stage threaded implants: methodology and results. *J Oral Implantol* 16:96–105, 1990.
136. Schnitman PA, Wohrle PS, Rubenstein JE, et al: Ten-year results for Branemark implants immediately loaded with fixed prostheses at implant placement. *Int J Oral Maxillofac Implants* 12:495–503, 1997.
137. Schropp L, Wenzel A, Kostopoulos L, et al: Bone healing and soft tissue contour changes following single-tooth extraction: a clinical and radiographic 12-month prospective study. *Int J Periodontics Restorative Dent* 23:313–323, 2003.
138. Schulte W, Kleineikenscheidt H, Lindner K, et al: The Tubingen immediate implant in clinical studies. *Dtsch Zahnarztl Z* 33:348–359, 1978.
139. Schwartz-Arad D, Chaushu G: Immediate implant placement: a procedure without incisions. *J Periodontol* 69:743–750, 1998.
140. Sharaf B, Jandali-Rifai M, Susarla SM, et al: Do perioperative antibiotics decrease implant failure? *J Oral Maxillofac Surg* 69:2345–2350, 2011.
141. Simion M, Fontana F, Rasperini G, et al: Long-term evaluation of osseointegrated implants placed in sites augmented with sinus floor elevation associated with vertical ridge augmentation: a retrospective study of 38 consecutive implants with 1- to 7-year follow-up. *Int J Periodontics Restorative Dent* 24:208–221, 2004.
142. Simion M, Trisi P, Maglione M, et al: A preliminary report on a method for studying the permeability of expanded polytetrafluoroethylene membrane to bacteria in vitro: a scanning electron microscopic and histological study. *J Periodontol* 65:755–761, 1994.
143. Small PN, Tarnow DP, Cho SC: Gingival recession around wide-diameter versus standard-diameter implants: a 3- to 5-year longitudinal prospective study. *Pract Proced Aesthet Dent* 13:143–146, 2001.
144. Spray JR, Black CG, Morris HF, et al: The influence of bone thickness on facial marginal bone response: stage 1 placement through stage 2 uncovering. *Ann Periodontol Am Acad Periodontol* 5:119–128, 2000.
145. Stach RM, Kohles SS: A meta-analysis examining the clinical survivability of machined-surfaced and Osseotite implants in poor-quality bone. *Implant Dent* 12:87–96, 2003.
146. Strub J: *Langzeitprognose von enossalen oralen Implantaten unter spezieller Berucksichtigung von periimplantaren, materialkundlichen und okklusalen Gesichtspunkten*, Berlin, 1986, Verlag Quintessenz.
147. Strub JR, Gaberthuel TW, Grunder U: The role of attached gingiva in the health of peri-implant tissue in dogs. 1. Clinical findings. *Int J Periodontics Restorative Dent* 11:317–333, 1991.
148. Tarnow DP, Emtiaz S, Classi A: Immediate loading of threaded implants at stage 1 surgery in edentulous arches: ten consecutive case reports with 1- to 5-year data. *Int J Oral Maxillofac Implants* 12:319–324, 1997.
149. Tawse-Smith A, Payne AG, Kumara R, et al: Early loading of unsplinted implants supporting mandibular overdentures using a one-stage operative procedure with two different implant systems: a 2-year report. *Clin Implant Dent Relat Res* 4:33–42, 2002.
150. Taylor TD, Agar JR: Twenty years of progress in implant prosthodontics. *J Prosthetic Dent* 88:89–95, 2002.
151. ten Bruggenkate CM, Krekeler G, Kraaijenhagen HA, et al: Hemorrhage of the floor of the mouth resulting from lingual perforation during implant placement: a clinical report. *Int J Oral Maxillofac Implants* 8:329–334, 1993.
152. Testori T, Galli F, Capelli M, et al: Immediate nonocclusal versus early loading of dental implants in partially edentulous patients: 1-year results from a multicenter, randomized controlled clinical trial. *Int J Oral Maxillofac Implants* 22:815–822, 2007.
153. Tolman DE, Laney WR: Tissue-integrated prosthesis complications. *Int J Oral Maxillofac Implants* 7:477–484, 1992.
154. Tonetti MS, Hammerle CH: Advances in bone augmentation to enable dental implant placement: Consensus Report of the Sixth European Workshop on Periodontology. *J Clin Periodontol* 35:168–172, 2008.
155. Wagenberg B, Froum SJ: A retrospective study of 1925 consecutively placed immediate implants from 1988 to 2004. *Int J Oral Maxillofac Implants* 21:71–80, 2006.
156. Wallace SS, Froum SJ: Effect of maxillary sinus augmentation on the survival of endosseous dental implants. A systematic review. *Ann Periodontol* 8:328–343, 2003.
157. Wallace SS, Mazor Z, Froum SJ, et al: Schneiderian membrane perforation rate during sinus elevation using piezosurgery: clinical results of 100 consecutive cases. *Int J Periodontics Restorative Dent* 27:413–419, 2007.
158. Zablotsky MH, Diedrich DL, Meffert RM: Detoxification of endotoxin-contaminated titanium and hydroxyapatite-coated surfaces utilizing various chemotherapeutic and mechanical modalities. *Implant Dent* 1:154–158, 1992.
159. Zablotsky MH, Diedrich D, Meffert R, et al: The ability of various chemotherapeutic agents to detoxify the endotoxin infected HA-coated implant surface. *Int J Oral Maxillofac Implants* 8:45, 1991.
160. Zijderveld SA, van den Bergh JP, Schulten EA, et al: Anatomical and surgical findings and complications in 100 consecutive maxillary sinus floor elevation procedures. *J Oral Maxillofac Surg* 66:1426–1438, 2008.
161. Zitzmann NU, Berglundh T: Definition and prevalence of peri-implant diseases. *J Clin Periodontol* 35:286–291, 2008.
162. Zustein T, Billistrom C: A retrospective follow-up of 50 consecutive patients treated with Neoss implants with or without an adjunctive GBR-procedure. *App Osseoint Res* 6:27–30, 2008.

CHAPTER 83

Supportive Implant Treatment

Jonathan H. Do and Perry R. Klokkevold

CHAPTER OUTLINE

Rationale for Supportive Implant Treatment
Examination of Implant(s)
Assessment of Periimplant Health
Implant Maintenance
Treatment of Periimplant Disease
Referral to a Periodontist

Dental implant therapy does not end with the final prosthetic restoration of the implant. Predictability and long-term success of a dental implant and its restoration require sound treatment planning, precise surgical and restorative execution, and impeccable long-term maintenance, which is contingent on patient compliance with home care and professional supportive implant treatment. Periimplant maintenance begins as the implant becomes exposed to the oral cavity and continues at regular intervals during the life of the implant. The recall interval is determined by the patient's oral hygiene and susceptibility to plaque-induced inflammatory diseases. Initially, for the first year after treatment, recall maintenance visits should be scheduled at 3-month intervals and then adjusted to suit the patient's individual needs. Some patients (those who have good oral hygiene, minimal deposits, and disease resistance) will require infrequent professional hygiene maintenance, whereas others (those who have poor oral hygiene, heavy deposits, and disease susceptibility) will require more frequent follow-up care.

Rationale for Supportive Implant Treatment

Although dental implants are not vulnerable to dental caries, they are still susceptible to mechanical complications and periimplant plaque-induced inflammatory tissue changes. A 10-year retrospective study[48] of 397 fixed-implant reconstructions in 300 patients observed a mechanical complication rate of 24.7%. The most frequent complication was ceramic chipping (20.31%) followed by occlusal screw loosening (2.57%) and loss of retention (2.06%). Although relatively infrequent, occlusal screw loosening can result in a subgingival gap at the implant-abutment junction that retains plaque and stimulates an inflammatory reaction in both the soft and hard tissue.

Biologically, periimplant plaque accumulation due to inadequate or lack of access for oral hygiene can result in periimplant mucositis and periimplantitis. Periimplant mucositis is characterized by inflammation confined to the soft tissue and is reported to affect up to 80% of patients with dental implants.[25] Periimplantitis is characterized by periimplant inflammation with progressive crestal bone loss beyond the initial remodeling. The prevalence of periimplantitis in patients ranges from 11.2% to 53%.[17,20,27,37,38,39,40] Poor oral hygiene, residual cement, current or history of periodontitis, cigarette smoking, and diabetes mellitus are risk factors for periimplant diseases.[1,9]

The relationship between periimplant mucositis and periimplantitis is similar to that of gingivitis and periodontitis. Although periimplant mucositis does not necessarily progress to periimplantitis, it is likely the precursor to periimplantitis.[1] The inflammatory response in periimplant disease appears to be similar to that in periodontal disease.[41] However, severity and rate of disease progression appear to be more pronounced around implants. This, perhaps, is due to the absence of a "self-limiting" process, observed in periodontitis, around implants that separates the inflammatory cell infiltrate from the bone.[6] Experimental models demonstrated that periimplant mucositis is reversible at the biomarker level (matrix metalloproteinase 8 [MMP-8] and interleukin-1β [IL-1β]).[41] A review of the literature[36] reported that periimplant mucositis can be effectively treated with nonsurgical mechanical therapy, while such modalities tend to be ineffective against periimplantitis. Furthermore, results of surgical treatment for periimplantitis are not predictable. For these reasons, the prevention, early detection, and early treatment of periimplant diseases are critical. Periodic and well-regimented supportive implant treatment is essential to the long-term success of dental implant therapy.

Examination of Implant(s)

The supportive implant treatment appointment should include: an inquiry of any new concerns, problems, or pain; review of changes in the patient's medical and oral status; evaluation and reinforcement of oral hygiene; examination and evaluation of soft and hard tissue health; evaluation of implants and the associated implant restorations' stability and integrity; professional supportive treatment. Finally, assessment should be made to determine the appropriate recall interval and plan for the next visit.

Examination begins with visual inspection for: plaque and calculus accumulation; signs of inflammation and swelling; periimplant soft tissue quality, color, consistency, and contour; and aberrations in the implant prostheses. Periimplant soft tissue can be digitally palpated to detect edema, tenderness, exudation, or suppuration. Periimplant probing can be used to assess the condition and level of soft and hard tissues surrounding implants. When indicated, radiographic images can be obtained to help verify the level of the periimplant crestal bone. Determination of implant stability (mobility) and percussion testing can help verify implant osseointegration. Figure 83-1.

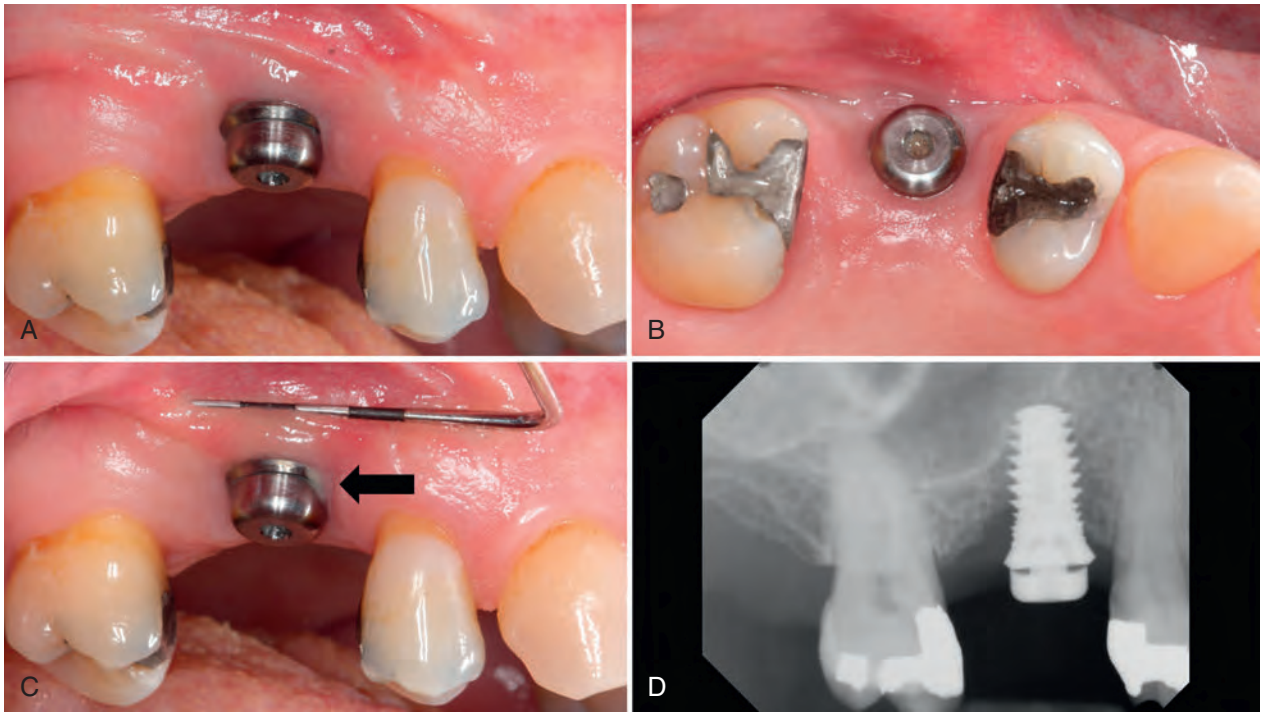

Figure 83-1 Periimplantitis. **A and B,** Minimal plaque accumulation. Periimplant mucosa exhibits minimal erythema and edema. Note: buccal placement of implant in **B. C,** Manipulation of tissue indicates lack of buccal keratinized attached gingiva and exudation from periimplant sulcus (*arrow*). **D,** Periapical radiograph shows periimplant bone loss to the apex of the implant.

Periimplant Probing

Probing of implants can be done with light force (0.25 N) using a traditional steel probe without adverse effects to the periimplant mucosa.[15] Implant probing should be recorded at the time of final restoration delivery as the baseline measurement and at least annually thereafter.[25]

Clinicians should use caution when evaluating periimplant probing because these measures cannot be interpreted the same as probing depths around teeth. While periodontal probing around natural teeth is very useful to assess the health of periodontal tissues, the sulcus or pocket depth, and the level of attachment, probing around implants may not provide comparable results.[7] Due to distinct differences in the tissues that surround and support teeth compared to those that surround and support implants, the probe inserts and penetrates differently. Around teeth, the periodontal probe is resisted by the health of the periodontal tissues and, perhaps most importantly, by the insertion of supracrestal connective tissue fibers into the cementum of the root surface. These fibers, unique to teeth, are the primary source of resistance to the probe.[3] There is no equivalent fiber attachment around implants. Connective tissue fibers around implants generally run parallel to the implant or restorative surface and do not have perpendicular or inserting fibers (see Chapter 71). The primary source of resistance to the probe around an implant will differ depending on the conditions surrounding the implant.[12,24] At noninflamed sites, the most coronal aspect of connective tissue adhesion to the implant will resist the probe. At inflamed sites, the probe tip consistently penetrates farther into the connective tissue until less inflamed connective tissue is encountered, which is often close to or at the level of bone.

The value of periimplant probing is different than periodontal probing and offers very limited information by comparison. Probing around implants can measure the level of the mucosal margin relative to a fixed position on the implant or restoration and can also measure the depth of tissue around the implant. The periimplant probing depth is often a measure of the thickness of the surrounding connective tissues and correlates most consistently with the level of surrounding bone. However, periimplant probing is affected by several conditions, including the size of the probe, the force and direction of insertion, the health and resistance of periimplant tissues, the level of bone support, and the features of the implant, abutment, and prosthesis design (Figure 83-2). A comparison[45] of probing pocket depth of implants with periimplantitis before and after the removal of the prosthetic restorations reported similar probing depths in only 37% of sites. In 39% of sites, the difference was ±1 mm, in 15% of sites, it was ±2 mm, and in 9% of sites, it was ±3 mm. In other words, probing measurements can be an accurate measure of soft tissue thickness around an implant (i.e., periimplant soft tissue above the bone level), but in many cases or sites, the inability to properly angle and direct the probe alongside of the implant may lead to inaccurate assessment of soft tissue thickness. In these situations, the clinician must appreciate

Figure 83-2 Buccal probing of implant impeded by implant restoration.

the limitations and know that other clinical parameters and radiographs are required to help evaluate periimplant condition. Furthermore, probing around implants is likely to be more variable than around teeth; studies have shown that a change in probing force around implants results in more dramatic changes than a similar change in probing force around teeth.[29] The probing depth around implants presumed to be "healthy" (and without bleeding) has been documented to be about 3 mm around all surfaces.[2,8] The absence of bleeding on probing around teeth has been established as an indicator of health and a predictor of periodontal stability.[21] Studies comparing bleeding on probing around teeth and implants in the same patient have reported that bleeding around implants occurs more frequently. The presence of bleeding on probing at implant sites may indicate inflammation in the periimplant mucosa. However, the ability to use bleeding on probing as an indicator of assessing diseased versus healthy sites around implants has not been established. Due to the potential for false-positive bleeding (i.e., provoked-bleeding) with probing, the use of marginal bleeding, which is a more sensitive indicator of inflammation and is less likely to elicit false-positive bleeding, has been proposed to assess periimplant inflammation.[50] Marginal bleeding can be evaluated by running a probe circumferentially along the coronal portion in the implant sulcus. Overall, the value of periimplant probing is in monitoring changes in the probing pocket depth over time rather than the initial value as some implants may be placed apically for esthetics.[1]

Microbial Testing

Studies in animals and humans have demonstrated the development of periimplant mucosal inflammation in response to the accumulation of bacterial plaque.[5,33,41,51] Microbiologic studies suggest that greater probing depths or "pockets" around implants harbor higher levels of pathogenic microorganisms.[30,35,43] Studies have also documented similarities in the microbial composition of plaque in healthy periodontal sites compared to healthy periimplant sites.[31] Likewise, evidence indicates that the microbiota of diseased periodontal pockets harbor the same periodontal pathogenic microorganisms as those observed in inflamed periimplant sites (periimplantitis).[31,43] However, there is no evidence to prove that periodontal pathogens cause periimplant disease, and the pathogenesis of inflammatory disease around implants has not been defined.[10] A recent report[1] now generally accepts the belief that periimplant disease, like periodontal disease, occurs primarily as a result of an overwhelming bacterial insult and subsequent host response. Furthermore, human biopsies indicate that periimplantitis and periodontitis exhibit similar histologic features including an inflammatory cell infiltrate in the connective tissue dominated by B-lymphocytes and plasma cells as well as upregulation of inflammatory biomarkers. No convincing evidence indicates that laboratory tests for the identification of suspected periodontal pathogens are of any use in the evaluation of implants.[14] The usefulness of microbial testing may be limited to the evaluation of periimplant sites that are showing signs of infection and bone loss, so the clinician can prescribe appropriate antibiotics.

Stability Measures

The assessment of implant stability (or mobility) is an important measure for determining whether osseointegration is being maintained. Important as it is, however, this measure has extremely low sensitivity but high specificity. That is, an implant may exhibit significant bone loss and remain stable; stability measure in this case has a low sensitivity for the detection of any bone loss. Conversely, if any implant mobility is detected, it is likely that the implant is not surrounded by bone; mobility is highly specific for the detection of implant failure or lack of osseointegration. Mobility must be differentiated between loss of implant osseointegration and loose implant restoration.

There is great interest in evaluating the stability of the bone-to-implant contact in a noninvasive manner. Two noninvasive techniques that have been used for evaluating implant stability are impact resistance (e.g., Periotest) and resonance frequency analysis (RFA). Originally designed to evaluate tooth mobility quantitatively, the Periotest (Gulden, Bensheim, Germany) is a noninvasive, electronic device that provides an objective measurement of the reaction of the periodontium to a defined impact load applied to the tooth crown. The Periotest value depends to some extent on tooth mobility but mainly on the dampening characteristics of the periodontium. Despite the dependence on the periodontium, the Periotest has been used to evaluate implant stability as well. However, unlike teeth, the movement of implants and the surrounding bone is minuscule, and therefore the Periotest values fall within a much smaller range compared to the range found with teeth. Detection of horizontal mobility may be a significant advantage for the use of the Periotest because it is much more sensitive to horizontal movement than similar detection by other means, such as manual assessment.[14] Another noninvasive method used to measure the stability of implants is with RFA.[28] This method uses a transducer that is attached to the implant or abutment. A steady-state signal is applied to the implant through the transducer, and a response is measured. The RFA value is a function of the stiffness of the implant in the surrounding tissues. The stiffness is influenced by the implant, the interface between the implant and bone and soft tissues, as well as the surrounding bone itself. Additionally, the height of the implant or abutment above the bone will influence the RFA value. Unlike the Periotest, however, the RFA is not dependent on movement in only one direction. Thus the absolute RFA values vary from one implant design to another and from one site to another, but there is high consistency for any one implant or location. The value of RFA is most appreciated with repeated measures of the same implant over time because it is very sensitive to changes in the bone-implant interface. Small changes in tissue support can be detected using RFA. An increase in RFA value indicates increased implant stability, whereas a decrease indicates loss of stability. However, this is a relative measure and it has not been determined whether RFA is capable of detecting impending failure before the implant actually fails. Currently, much interest and research have focused on the use of noninvasive methods to evaluate implant stability. Mobility remains the cardinal sign of implant failure, and detecting mobility is therefore an important parameter.

Implant Percussion

Tapping of an implant healing abutment or restoration with an instrument will produce a sound that can help determine implant osseointegration. A solid resonating sound and the absence of pain usually indicate implant osseointegration. A dull sound may indicate the implant is fibrous encapsulated; radiographic and other clinical findings are needed for diagnosis. See online for a video demonstration of percussion testing, which distinguishes the difference between an osseointegrated implant and a failed implant.

Radiographic Examination

Perpendicular intraoral periapical radiographs should be taken at implant placement, at abutment connection and at final restoration delivery for baseline documentation of bone levels, and annually[11] thereafter to monitor marginal or periimplant bone changes. In the

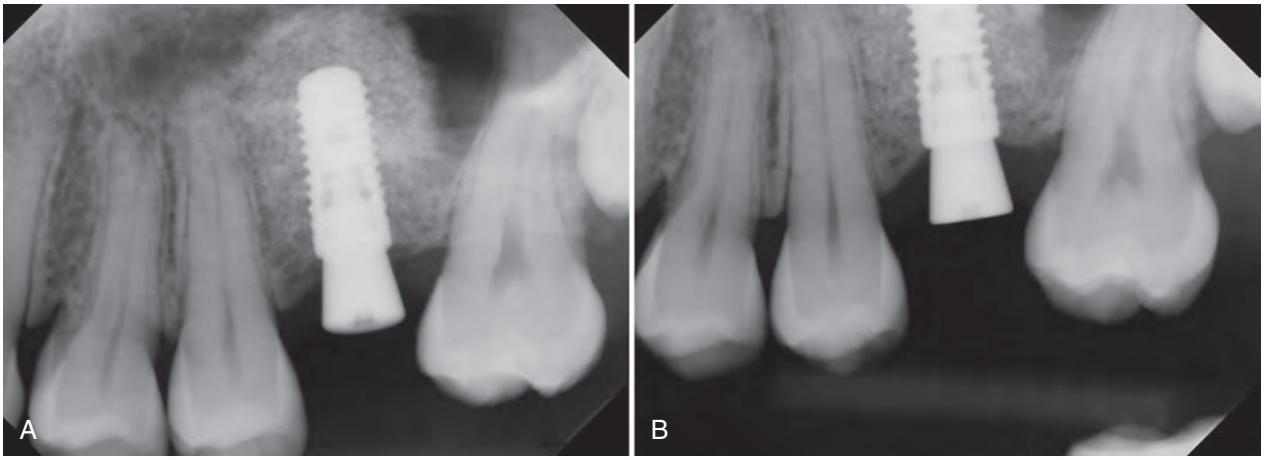

Figure 83-3 **A,** Periapical radiograph capturing the whole implant. **B,** A second perpendicular periapical is necessary to assess crestal bone level. Note: platform-switching at implant-abutment junction.

presence of periimplant inflammation, a periapical radiograph is indicated for periimplant bone evaluation and disease diagnosis. Periapical radiographs have excellent resolution and, when taken perpendicular to an implant, can provide valuable details of the implant-abutment junction, mesial and distal crestal bone level relative to the implant platform, and bone to implant interface along the length of the implant (Figure 83-3). The limitation of periapical radiographs is that they are difficult to standardize, and great variability is inherent in the acquisition process. However, periapical radiographs are relatively simple, inexpensive, and readily available in the dental office. It is diagnostically important to obtain images that clearly show implant threads (i.e. not blurred by nonperpendicular angulation) and the restorative-implant abutment connection.

The objective of the radiographic examination is to measure the height of bone adjacent to the implant(s) and to evaluate the presence and quality of bone along the length of the implant, as well as to detect any periimplant radiolucencies. Although the predictive value of assessing implant stability with radiographs is low, films do offer a reasonable method to measure changes in bone levels.[46] The predictive value of detecting implant failure or loss of stability is good when radiolucent lesions are discovered with periapical radiographs. Radiographic identification of unstable implants is reliable when performed as part of annual examinations and when examining patients on a routine, long-term basis.[19]

The radiographic examination remains one of the primary tools for detection of failed or failing implants in routine clinical evaluation, even though it is not as accurate as mobility tests. In one study designed to evaluate the accuracy and precision of radiographic diagnosis of mobility, the probability of predicting implant mobility in a population with a low prevalence of implant failures was found to be low.[46] Other studies, however, have demonstrated much higher predictive value for radiographic diagnosis of implant mobility.[18,19] The authors concluded that the most important factors for making an accurate radiographic diagnosis are the quality of the radiograph and the experience of the clinician.[19,46]

Assessment of Periimplant Health

Evaluation of Plaque (Biofilm) Control

Impeccable plaque control or removal of biofilm is crucial to periimplant tissue health. Poor plaque control is associated with periimplant diseases with an odds ratio of 14.3.[25] It is advantageous to evaluate plaque control prior to any tissue manipulation. The amount and location of plaque and calculus accumulation should be assessed visually. Poor plaque control is typically associated with plaque and calculus retention, and erythematous and edematous gingival tissue. When plaque control is inadequate, the patient should be asked to demonstrate his or her oral hygiene routine in front of a mirror so that the clinician can evaluate the patient's oral hygiene techniques. If the patient fails to remove plaque in any areas, the patient's attention should be directed to the location of the plaque. An instrument can be used to remove the plaque under the attention of the patient so that he or she can see its color and consistency. At this time, oral hygiene instruction should be demonstrated and reinforced.

Evaluation of Periimplant Health and Disease

Periimplant mucosal health is characterized by pink, firm, and well-adapted gingival tissue. Periimplant disease is associated with clinical erythema, edema, and loss of tissue tightness around the implant. Periimplant mucosa can be nonkeratinized unattached (see Figure 83-1, *C*) or keratinized attached (Figure 83-4, *C*). In the presence of keratinized attached mucosa, a gingival seal or gingival cuff is established around the implant.[4] The gingival cuff has the potential to protect the underlying bone and reduce subgingival plaque formation. Due to the mobile nature of oral mucosa, the protective function of nonkeratinized unattached periimplant mucosa may not be as effective. However, the presence of keratinized attached gingiva, which can facilitate oral hygiene, is not a requisite for periimplant health if plaque is well controlled.[44,49] Nonetheless, sites deficient in keratinized attached tissue typically exhibit vertical and/or horizontal ridge deficiencies, shallow vestibular depths, and long or bulky restorations. All of these factors can impede oral hygiene access and contribute to plaque accumulation and periimplant inflammation.

In the presence of periimplant inflammation, the periimplant tissue must be palpated for tenderness and suppuration, the implant must be probed, and periapical radiographs must be obtained and compared to baseline radiographs to determine periimplant bone loss. The presence of suppuration often indicates periimplantitis.[25] Radiographic crestal bone loss beyond the implant baseline level at the time of final prosthesis delivery in conjunction with bleeding on probing is characteristic of periimplantitis[22]; due to potential measurement errors, a threshold of detectable bone loss of 1.0 to 1.5 mm is recommended for diagnosis of periimplantitis.[42] In the absence of a baseline radiograph, a vertical distance of 2 mm from the expected marginal bone level following the initial crestal bone

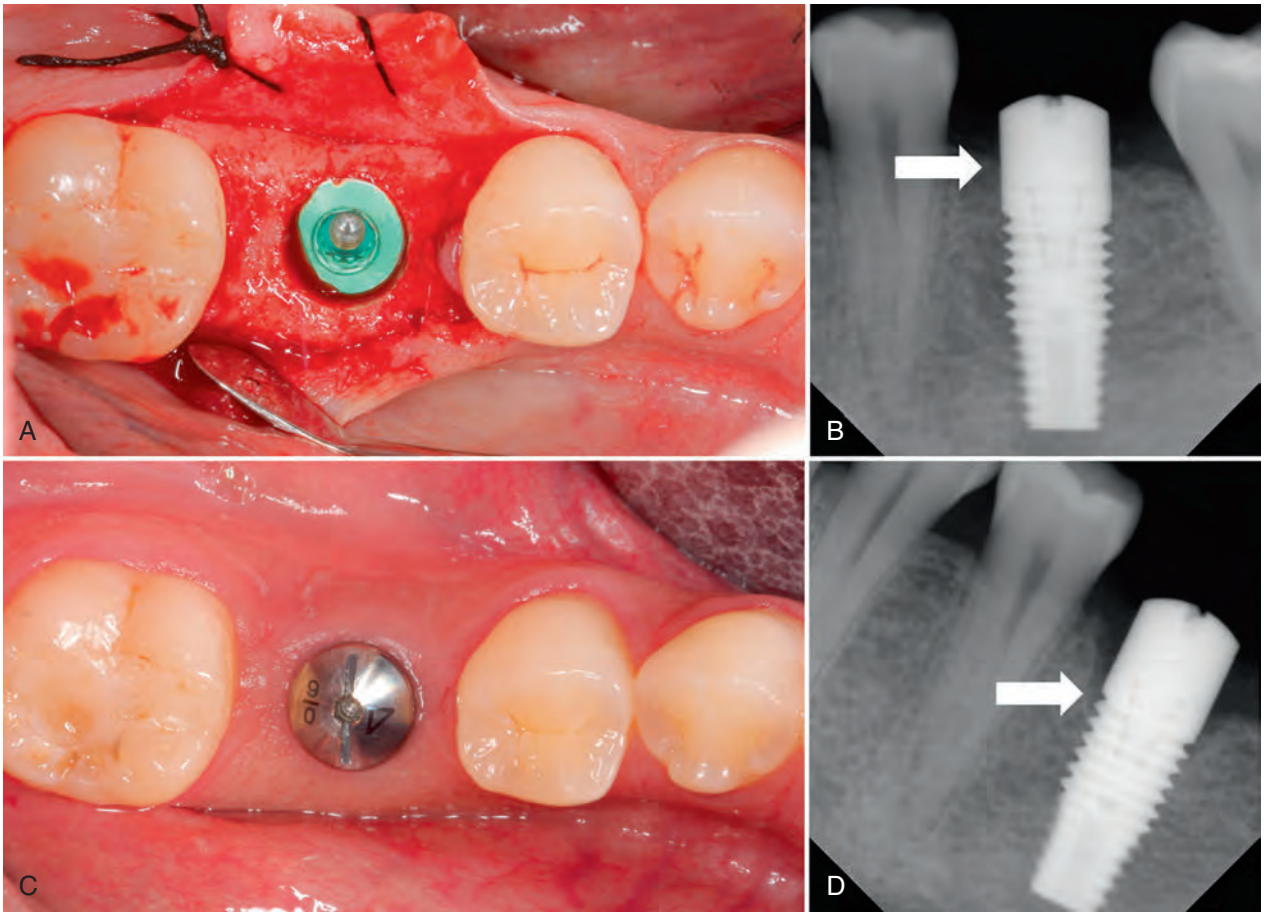

Figure 83-4 **A,** Subcrestal placement of implant with adequate buccal and lingual bone thickness. **B,** Periapical radiograph at time of implant placement. Implant at 5-month osseointegration check exhibiting adequate periimplant keratinized attached tissue **(C),** and crestal bone remodeling to the first thread **(D).** Arrows indicate mesial crestal bone level.

remodeling is recommended as the threshold for diagnosing periimplantitis.[42] The amount of initial marginal bone remodeling can vary depending on the design of the implant-abutment junction. Platform-switched implants (Figure 83-5, *C;* see Figure 83-3), in which the abutment is internally offset relative to the implant fixture at the implant-abutment junction, may exhibit less crestal bone remodeling than non–platform-switched implants (see Figure 83-4), in which the abutment is flush or even with the implant fixture at the implant-abutment junction.

Evaluation of Implant Osseointegration

Implant osseointegration must be determined prior to the fabrication and delivery of the final implant prosthesis. Implant osseointegration can only be definitively determined histologically, which would require the implant and the surrounding bone to be removed. Thus a combination of radiographic and clinical parameters are used to make an assessment implant osseointegration or to rule out lack of osseointegration. These include absence of periimplant inflammation and pain to palpation and percussion, presence of a solid resonating sound to percussion, complete radiographic bone to implant contact along the implant surface (i.e. absence of radiolucencies along the bone-implant interface), and implant stability.

Evaluation of Implant Restorations

Implant superstructures, frameworks, and restorations should be fabricated to accommodate and facilitate oral hygiene (e.g., embrasure spaces should be made to allow the passage of a proxy brush) (see Figure 83-4). Occlusal schemes of implant restorations should provide adequate posterior support, maximize axial loading, and minimize incline contacts, nonaxial loading and interferences in excursive movements. During delivery, radiographs perpendicular to the implant should be obtained for baseline documentation and to verify complete seating of the restorations. Following delivery, cement-retained implant restorations should be thoroughly evaluated for residual excess cement, which must be removed. During follow-up visits, implant restorations should be carefully examined for heavy contacts, fractures, loose screws, and in removable prostheses, worn-out retentive components (i.e., Hader clips and locator attachment inserts). Occlusion should be adjusted accordingly to prevent implant overload and fractures of implant parts. Loose abutment and set screws must be evaluated, possibly replaced and properly torqued down. Worn-out retentive components must be replaced periodically to ensure proper retention, stability, and function of the removable prostheses. Occlusal wear of teeth and fit of tissue-borne surfaces of implant-tissue borne prostheses should be assessed and corrected as indicated. In patients with oral parafunctions and heavy occlusal forces, occlusal guards are recommended to protect implants and restorations.

Implant Maintenance

Methods for Patient Oral Hygiene

The importance of good oral hygiene should be stressed even before implants are placed, and periimplant oral hygiene for plaque

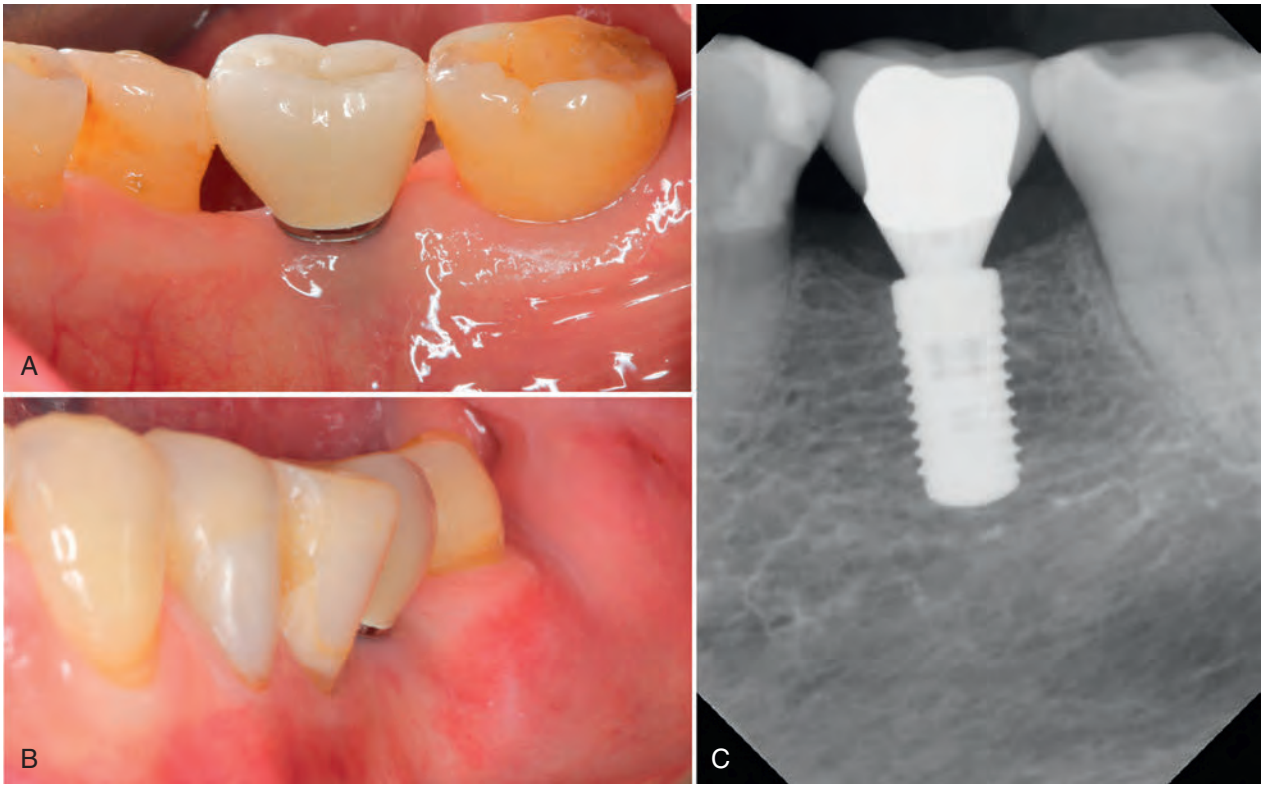

Figure 83-5 Restoration designed with adequate hygiene access. **A,** Lingual view. **B,** Mesial view of buccal contour. **C,** Periapical radiograph showing gradual transition from implant fixture to restoration. Note: platform-switching at implant-abutment junction.

control should begin as early as possible once the implant is exposed to the oral cavity. A cotton tip, cotton gauze, or soft toothbrush can be used to gently remove plaque from healing abutments or provisional restorations during the early postoperative phase of healing. Prior to implant osseointegration, the use of powered toothbrushes should be avoided. Once implant osseointegration has been achieved and verified, brushing with dentifrice can help remove deposits and increase smoothness of exposed implant and restoration surfaces.[32] Other dental hygiene aids, such as dental floss, rubber tip, and interdental brushes, may also be employed (Figure 83-6). Oral hygiene should emphasize the removal of plaque and deposits along the gingival margin. Evidence on the use of powered oral irrigator around implants is limited. One study reported subgingival irrigation of 0.06% chlorhexidine gluconate with a Waterpik® (Water Pik, Inc., Fort Collins, CO, USA) to be more effective at reducing plaque and gingival inflammation and produced less stains than rinsing with 0.12% chlorhexidine gluconate once a day.[16]

Methods for Professional Recall Maintenance

Professional maintenance consists of the removal of dental plaque and calculus from implant components exposed to the oral environment.[26] Like root surfaces, the transmucosal surfaces of implants should be smooth to minimize plaque accumulation and to facilitate oral hygiene practices.[23] As such, at sites with excellent plaque control and periimplant health, the need for professional instrumentation is minimal and should be limited to prevent iatrogenic damage to implant components that can contribute to plaque and calculus accumulation. In the presence of plaque, calculus, and tenacious deposits, care should be taken to minimize damage to transmucosal implant surfaces. However, priority should be placed on the complete removal of implant surface deposits.

All metal instruments, including metal curettes and scalers, and (ultra)sonic scalers, increase surface roughness of polished titanium.[26] As such, the use of plastic, Teflon-coated, and carbon and gold-coated curettes, and nonmetal ultrasonic tips have been advocated to protect the titanium implant surface and the titanium abutment from contamination by other metals, and to reduce the likelihood of scratching the surface. Unfortunately, the large size and flexibility of nonmetal curettes may not allow effective plaque and calculus removal,[34] and Teflon and gold-coated curettes cannot be sharpened. Most current implant prostheses are made with gold alloys or ceramic materials, which are usually identical to the materials used in restorations for the natural dentition. Furthermore, the location of the connection between these restorative materials and the implant is typically below the mucosa and often near the crest of bone; most calculus removal will be above this level. Thus the fear of contaminating the titanium implant is unwarranted. The gold alloy or ceramic surfaces can be debrided with most scalers and curettes (plastic, gold coated, stainless steel) without damaging the surface. Rubber cups and polishing paste can be used to remove plaque or biofilm and to enhance surface smoothness of machined and polished surfaces. Magnetostrictive and piezoelectric ultrasonic instruments with metal tips (e.g., Cavitron) should be used with caution because of irregularities that can easily be created in the surface.

Treatment of Periimplant Diseases

The goals of periimplant disease treatment are elimination of all periimplant infectious and inflammatory processes, prevention of disease progression, and preservation and restoration of function and esthetics. Treatment begins with patient education in the etiology, disease process, and prevention of periimplant diseases, and oral hygiene instruction. Although bacteria are the main etiologic

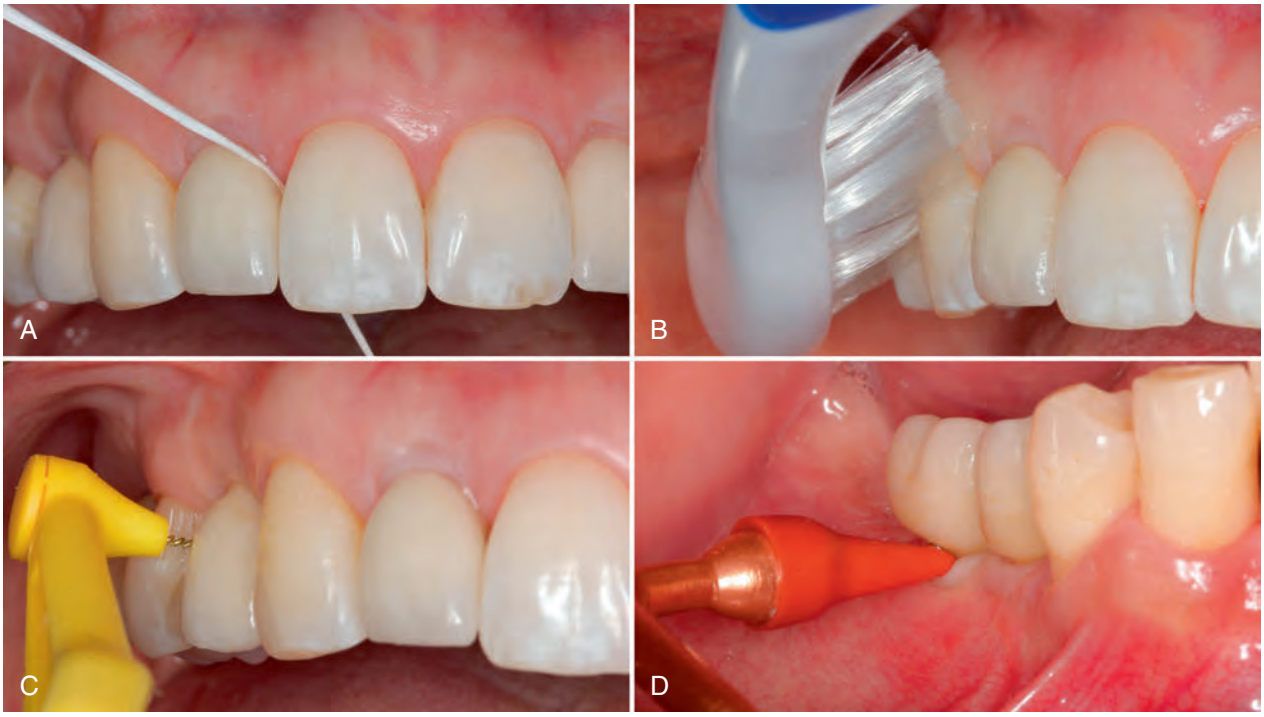

Figure 83-6 Methods for patient oral hygiene. **A,** Flossing. **B,** Bass method of brushing with extra-soft toothbrush. **C,** Interproximal brushing. **D,** Removal of plaque with a rubber tip. Note: hygiene is targeted at the removal of plaque along the gingival margin.

factor, systemic (e.g., smoking, poorly controlled diabetes) and local factors (e.g., residual excess cements, poorly designed restorations that inhibit hygiene access) should be identified and modified.

Periimplant Mucositis

Periimplant mucositis can be effectively treated with nonsurgical mechanical therapy.[36] Treatment requires complete removal of supramucosal and submucosal plaque, calculus, and deposits using curettes, ultrasonic scalers, and polishing cups and prophy paste. The use of adjunctive antimicrobials (e.g., chlorhexidine irrigation and mouth rinse) to mechanical debridement can enhance treatment outcome.[36]

Periimplantitis

The treatment of periimplantitis includes nonsurgical and surgical interventions, both of which may be combined with the adjunctive use of antimicrobials. Nonsurgical interventions consist of antimicrobial rinse and irrigation, local antibiotics, ultrasonic debridement, mechanical debridement with air-abrasive devices, and laser therapy. Surgical treatment includes full-thickness flap elevation for access followed by degranulation, surface debridement by laser or mechanical instruments, surface decontamination with laser or antimicrobials, and bone augmentation. Based on two systematic reviews,[13,47] currently available scientific data is insufficient to suggest which treatment intervention of periimplantitis is most effective and to allow any specific recommendations for the use of locally or systematically administered antibiotic. Implant surface decontamination/disinfection remains challenging especially for implants with roughened surfaces. For some treatment modalities, recurrence of periimplantitis appears to be high (up to 100%) after 1 or more years of treatment and retreatment may be necessary. Surgical access appears to be necessary to arrest periimplant bone loss. Surgical treatment may result in gingival recession and compromised esthetics. At sites with high esthetic demands, definitive treatment of periimplantitis may include the removal of the implant, grafting of the site and placement of another implant.

Referral of Patients to the Periodontist

The guidelines described in this chapter will allow many implant patients to be maintained very well by their primary dental care provider (i.e. general dentists). Referral to a periodontist should be considered if periimplantitis or periimplant mucositis is diagnosed and not resolved with improved oral hygiene and professional maintenance care. Early referral is advantageous to stop progression and limit extent of bone loss.

Suggested Readings

Academy Report: Peri-implant mucositis and peri-implantitis: a current understanding of their diagnoses and clinical implications. *J Periodontol* 84(4):436–443, 2013. doi: 10.1902/jop.2013.134001.

De Bruyn H, Vandeweghe S, Ruyffelaert C, et al: Radiographic evaluation of modern oral implants with emphasis on crestal bone level and relevance to peri-implant health. *Periodontol 2000* 62(1):256–270, 2013. doi: 10.1111/prd.12004.

Esposito M, Grusovin MG, Worthington HV: Interventions for replacing missing teeth: treatment of peri-implantitis. *Cochrane Database Syst Rev* (1):CD004970, 2012. doi: 10.1002/14651858.CD004970.pub5.

Lang NP, Berglundh T: Working Group 4 of Seventh European Workshop on Periodontology: Periimplant diseases: where are we now? Consensus of the Seventh European Workshop on Periodontology. *J Clin Periodontol* 38(Suppl 11):178–181, 2011. doi: 10.1111/j.1600-051X.2010.01674.x.

Lindhe J, Meyle J: Group D of European Workshop on Periodontology. Peri-implant diseases: Consensus Report of the Sixth European Workshop on Periodontology. *J Clin Periodontol* 35(Suppl 8):282–285, 2008. doi: 10.1111/j.1600-051X.2008.01283.x.

Louropoulou A, Slot DE, Van der Weijden FA: Titanium surface alterations following the use of different mechanical instruments: a systematic review. *Clin Oral Implants Res* 23(6):643–658, 2012. doi: 10.1111/j.1600-0501.2011.02208.x.

Salvi GE, Aglietta M, Eick S, et al: Reversibility of experimental peri-implant mucositis compared with experimental gingivitis in humans. *Clin Oral Implants Res* 23(2):182–190, 2012. doi: 10.1111/j.1600-0501.2011.02220.x. [Epub 2011].

Serino G, Turri A, Lang NP: Probing at implants with peri-implantitis and its relation to clinical peri-implant bone loss. *Clin Oral Implants Res* 24(1):91–95, 2013.

van Winkelhoff AJ: Antibiotics in the treatment of peri-implantitis. *Eur J Oral Implantol* 5(Suppl):S43–S50, 2012.

References

References for this chapter are found on the companion website www.expertconsult.com.

References

1. Academy Report: Peri-implant mucositis and peri-implantitis: a current understanding of their diagnoses and clinical implications. *J Periodontol* 2013 84(4):436–443, 2013. doi: 10.1902/jop.2013.134001.
2. Adell R, Lekholm U, Rockler B, et al: A 15-year study of osseointegrated implants in the treatment of the edentulous jaw. *Int J Oral Surg* 10(6):387–416, 1981.
3. Armitage GC, Svanberg GK, Löe H: Microscopic evaluation of clinical measurements of connective tissue attachment levels. *J Clin Periodontol* 4(3):173–190, 1977.
4. Berglundh T, Lindhe J, Ericsson I, et al: The soft tissue barrier at implants and teeth. *Clin Oral Implants Res* 2(2):81–90, 1991.
5. Berglundh T, Lindhe J, Marinello C, et al: Soft tissue reaction to de novo plaque formation on implants and teeth. An experimental study in the dog. *Clin Oral Implants Res* 3(1):1–8, 1992.
6. Berglundh T, Zitzmann NU, Donati M: Are peri-implantitis lesions different from periodontitis lesions? *J Clin Periodontol* 38(Suppl 11):188–202, 2011. doi: 10.1111/j.1600-051X.2010.01672.x.
7. Brägger U, Bürgin WB, Hämmerle CH, et al: Associations between clinical parameters assessed around implants and teeth. *Clin Oral Implants Res* 8(5):412–421, 1997.
8. Buser D, Weber HP, Brägger U: The treatment of partially edentulous patients with ITI hollow-screw implants: presurgical evaluation and surgical procedures. *Int J Oral Maxillofac Implants* 5(2):165–175, 1990.
9. Carcuac O, Jansson L: Peri-implantitis in a specialist clinic of periodontology. Clinical features and risk indicators. *Swed Dent J* 34(2):53–61, 2010.
10. Cooper L, Moriarty J: Prosthodontic and periodontal considerations for implant-supported dental restorations. *Curr Opin Periodontol* 4:119–126, 1997.
11. De Bruyn H, Vandeweghe S, Ruyffelaert C, et al: Radiographic evaluation of modern oral implants with emphasis on crestal bone level and relevance to peri-implant health. *Periodontol 2000* 62(1):256–270, 2013. doi: 10.1111/prd.12004.
12. Ericsson I, Lindhe J: Probing depth at implants and teeth. An experimental study in the dog. *J Clin Periodontol* 20(9):623–627, 1993.
13. Esposito M, Grusovin MG, Worthington HV: Interventions for replacing missing teeth: treatment of peri-implantitis. *Cochrane Database Syst Rev* (1):CD004970, 2012. doi: 10.1002/14651858.CD004970.pub5.
14. Esposito M, Hirsch JM, Lekholm U, et al: Biological factors contributing to failures of osseointegrated oral implants. (II). Etiopathogenesis. *Eur J Oral Sci* 106(3):721–764, 1998.
15. Etter TH, Håkanson I, Lang NP, et al: Healing after standardized clinical probing of the periimplant soft tissue seal: a histomorphometric study in dogs. *Clin Oral Implants Res* 13(6):571–580, 2002.
16. Felo A, Shibly O, Ciancio SG, et al: Effects of subgingival chlorhexidine irrigation on peri-implant maintenance. *Am J Dent* 10(2):107–110, 1997.
17. Fransson C, Lekholm U, Jemt T, et al: Prevalence of subjects with progressive bone loss at implants. *Clin Oral Implants Res* 16(4):440–446, 2005.
18. Friberg B, Jemt T, Lekholm U: Early failures in 4,641 consecutively placed Brånemark dental implants: a study from stage 1 surgery to the connection of completed prostheses. *Int J Oral Maxillofac Implants* 6(2):142–146, 1991.
19. Gröndahl K, Lekholm U: The predictive value of radiographic diagnosis of implant instability. *Int J Oral Maxillofac Implants* 12(1):59–64, 1997.
20. Koldsland OC, Scheie AA, Aass AM: Prevalence of peri-implantitis related to severity of the disease with different degrees of bone loss. *J Periodontol* 2010 81(2):231–238, 2010. doi: 10.1902/jop.2009.090269.
21. Lang NP, Adler R, Joss A, et al: Absence of bleeding on probing. An indicator of periodontal stability. *J Clin Periodontol* 17(10):714–721, 1990.
22. Lang NP, Berglundh T: Working Group 4 of Seventh European Workshop on Periodontology. Periimplant diseases: where are we now? Consensus of the Seventh European Workshop on Periodontology. *J Clin Periodontol* 38(Suppl 11):178–181, 2011. doi: 10.1111/j.1600-051X.2010.01674.x.
23. Lang NP, Nyman SR: Supportive maintenance care for patients with implants and advanced restorative therapy. *Periodontol 2000* 4:119–126, 1994.
24. Lang NP, Wetzel AC, Stich H, et al: Histologic probe penetration in healthy and inflamed peri-implant tissues. *Clin Oral Implants Res* 5(4):191–201, 1994.
25. Lindhe J, Meyle J: Group D of European Workshop on Periodontology. Peri-implant diseases: Consensus Report of the Sixth European Workshop on Periodontology. *J Clin Periodontol* 35(Suppl 8):282–285, 2008. doi: 10.1111/j.1600-051X.2008.01283.x.
26. Louropoulou A, Slot DE, Van der Weijden FA: Titanium surface alterations following the use of different mechanical instruments: a systematic review. *Clin Oral Implants Res* 23(6):643–658, 2012. doi: 10.1111/j.1600-0501.2011.02208.x. [Epub 2011].
27. Marrone A, Lasserre J, Bercy P, et al: Prevalence and risk factors for peri-implant disease in Belgian adults. *Clin Oral Implants Res* 24(8):934–940, 2013. doi: 10.1111/j.1600-0501.2012.02476.x. [Epub May 3, 2012].
28. Meredith N, Alleyne D, Cawley P: Quantitative determination of the stability of the implant-tissue interface using resonance frequency analysis. *Clin Oral Implants Res* 7(3):261–267, 1996.
29. Mombelli A, Mühle T, Brägger U, et al: Comparison of periodontal and peri-implant probing by depth-force pattern analysis. *Clin Oral Implants Res* 8(6):448–454, 1997.
30. Mombelli A, van Oosten MA, Schurch E, Jr, et al: The microbiota associated with successful or failing osseointegrated titanium implants. *Oral Microbiol Immunol* 2(4):145–151, 1987.
31. Mombelli A: Microbiology and antimicrobial therapy of peri-implantitis. *Periodontol 2000* 28:177–189, 2002.
32. Park JB, Kim N, Ko Y: Effects of ultrasonic scaler tips and toothbrush on titanium disc surfaces evaluated with confocal microscopy. *J Craniofac Surg* 23(5):1552–1558, 2012. doi: 10.1097/SCS.0b013e31825e3ba6.
33. Pontoriero R, Tonelli MP, Carnevale G, et al: Experimentally induced peri-implant mucositis. A clinical study in humans. *Clin Oral Implants Res* 5(4):254–259, 1994.
34. Ramaglia L, di Lauro AE, Morgese F, et al: Profilometric and standard error of the mean analysis of rough implant surfaces treated with different instrumentations. *Implant Dent* 15(1):77–82, 2006.
35. Rams TE, Link CC, Jr: Microbiology of failing dental implants in humans: electron microscopic observations. *J Oral Implantol* 11(1):93–100, 1983.
36. Renvert S, Roos-Jansåker AM, Claffey N: Non-surgical treatment of peri-implant mucositis and peri-implantitis: a literature review. *J Clin Periodontol* 35(8 Suppl):305–315, 2008. doi: 10.1111/j.1600-051X.2008.01276.x.
37. Renvert S, Roos-Jansåker AM, Lindahl C, et al: Infection at titanium implants with or without a clinical diagnosis of inflammation. *Clin Oral Implants Res* 18(4):509–516, 2007. [Epub 2007].
38. Rinke S, Ohl S, Ziebolz D, et al: Prevalence of periimplant disease in partially edentulous patients: a practice-based cross-sectional study. *Clin Oral Implants Res* 22(8):826–833, 2011. doi: 10.1111/j.1600-0501.2010.02061.x. [Epub December 28, 2010].
39. Roccuzzo M, De Angelis N, Bonino L, et al: Ten-year results of a three-arm prospective cohort study on implants in periodontally compromised patients. Part 1: implant loss and radiographic bone loss. *Clin Oral Implants Res* 21(5):490–496, 2011. doi: 10.1111/j.1600-0501.2009.01886.x. [Epub 2010].
40. Heitz-Mayfield LJ: Peri-implant diseases: diagnosis and risk indicators. *J Clin Periodontol* 35(8 Suppl):292–304, 2008. doi: 10.1111/j.1600-051X.2008.01275.x.
41. Roos-Jansåker AM, Lindahl C, Renvert H, et al: Nine- to fourteen-year follow-up of implant treatment. Part II: presence of peri-implant lesions. *J Clin Periodontol* 33(4):290–295, 2006.
42. Salvi GE, Aglietta M, Eick S, et al: Reversibility of experimental peri-implant mucositis compared with experimental gingivitis in humans. *Clin Oral Implants Res* 23(2):182–190, 2012. doi: 10.1111/j.1600-0501.2011.02220.x. [Epub August 2, 2011].

43. Sanz M, Chapple IL: Working Group 4 of the VIII European Workshop on Periodontology: Clinical research on peri-implant diseases: consensus report of Working Group 4. *J Clin Periodontol* 39(Suppl 12):202–206, 2012. doi: 10.1111/j.1600-051X.2011.01837.x.
44. Sanz M, Newman MG, Nachnani S, et al: Characterization of the subgingival microbial flora around endosteal sapphire dental implants in partially edentulous patients. *Int J Oral Maxillofac Implants* 5(3):247–253, 1990.
45. Schou S, Holmstrup P, Hjørting-Hansen E, et al: Plaque-induced marginal tissue reactions of osseointegrated oral implants: a review of the literature. *Clin Oral Implants Res* 3(4):149–161, 1992.
46. Serino G, Turri A, Lang NP: Probing at implants with peri-implantitis and its relation to clinical peri-implant bone loss. *Clin Oral Implants Res* 24(1):91–95, 2013.
47. Sundén S, Gröndahl K, Gröndahl HG: Accuracy and precision in the radiographic diagnosis of clinical instability in Brånemark dental implants. *Clin Oral Implants Res* 6(4):220–226, 1995.
48. van Winkelhoff AJ: Antibiotics in the treatment of peri-implantitis. *Eur J Oral Implantol* 5(Suppl):S43–S50, 2012.
49. Wittneben JG, Buser D, Salvi GE, et al: Complication and failure rates with implant-supported fixed dental prostheses and single crowns: a 10-year retrospective study. *Clin Implant Dent Relat Res* 2013. doi: 10.1111/cid.12066. [Epub ahead of print].
50. Yeung SC: Biological basis for soft tissue management in implant dentistry. *Aust Dent J* 53(Suppl 1):S39–S42, 2008. doi: 10.1111/j.1834-7819.2008.00040.x.
51. Zeza B, Pilloni A: Peri-implant mucositis treatments in humans: a systematic review. *Ann Stomatol (Roma)* 3(3–4):83–89, 2012. [Epub January 14, 2012].
52. Zitzmann NU, Berglundh T, Marinello CP, et al: Experimental peri-implant mucositis in man. *J Clin Periodontol* 28(6):517–523, 2001.

CHAPTER 84

Results of Implant Treatment

Perry R. Klokkevold

CHAPTER OUTLINE

Defining Implant Outcomes
Factors That Influence Implant Outcomes
Esthetic Results and Patient Satisfaction
Conclusion

The landmark Göteborg study, as well as the replica study at the University of Toronto, set the stage for success and predictability expectations of root-form dental implants. The study, conducted over a 15-year period at the University of Göteborg, Sweden, by P. I. Brånemark and coworkers, began in 1965 and concluded in 1980. The results, reported in several articles, defined the concept of osseointegration, described protocols for success, and shared clinical experiences. Perhaps the most significant article from the study, published in 1981, was a paper on osseointegrated implants in the treatment of the edentulous jaw.[2] Briefly, the Göteborg study included 2768 root-form implants placed into 410 edentulous jaws in 371 consecutive patients. The data were most often reported in subsets according to the three study phases (initial, developmental, and routine). Those cases treated in the routine period with standardized procedures and an observation time of 5 to 9 years were thought to reflect the potential of the method and were the basis of data reported in that historic publication. This subset consisted of 895 implants placed in 130 jaws. Implant survival was 81% in the maxilla and 91% in mandible. Prosthesis survival (continuous stability) was 89% in the maxilla and 100% in the mandible. The replica study, conducted at the University of Toronto, demonstrated that comparable results could be predictably achieved using the same implant design and treatment protocols.[5,73-75] Together, these studies demonstrated that implant survival of 81% or more and prosthesis survival of 89% or more could be expected in the edentulous patient.

In the decades since the landmark discovery of osseointegration and the documentation of its clinical effectiveness, clinicians have experienced tremendous success replacing missing teeth with endosseous, root-form dental implants in partially edentulous, as well as edentulous, patients.[1,46] Yet, despite the high level of success and long-term predictability, achieving success all the time, in every patient, and in each situation is not absolute (100%). Complications and implant failures do occur.[2,12] Some implants fail to achieve osseointegration, some achieve osseointegration only to lose bone progressively over time leading to failure, and other implants rapidly lose bone and fail in a short time. Just as important, some implants may achieve and maintain osseointegration but fail because they do not meet the patient's or clinician's esthetic expectations.

The reporting of implant success varies widely in the literature, which makes defining an absolute implant success rate impractical. This chapter considers implant treatment results in light of the factors that influence implant survival and success. The intent is to outline important aspects that need to be considered in evaluating implant outcomes and to offer the reader guidelines for understanding published results.

Defining Implant Outcomes

Implant outcomes are reported in a variety of ways in the literature. Various levels of implant success and failure are described in case reports, case series, retrospective studies, controlled studies, and prospective studies. The type of study and method of reporting is decided by the authors and often influenced by the information (data) collected and the study objectives. Each type of study or report has recognized limitations, but because of the tremendous variation that exists in the way individual investigators measure, interpret, and report implant outcomes, differences in the results from one study to another may not be obvious. Some implant outcomes are reported simply as the presence or absence of the implant(s) at the time of the last examination, regardless of whether the implant was in function, suffered from bone loss, or had other problems. This type of assessment is a measure of implant *survival* and should not be confused with implant *success*. In contrast to such an overly simplified assessment, some investigators report implant outcomes using very specific criteria to determine implant *success*.

Implant success is defined by specific criteria used to evaluate the condition and function of the implant. Criteria for implant success have been proposed in the literature but not used consistently. The problem is that a universally accepted definition of implant success has not been established. In the classic definition, Albrektsson et al[3] defined implant success as an implant with no pain, no mobility, no radiolucent periimplant areas, and less than 0.2 mm of bone loss annually after the first year of loading.[3] Bone loss in the first year was recognized but it was not defined or quantified as part of the success criteria until later in a separate definition by Roos.[57] The real challenge in comparing reported data from study to study is that authors use different criteria of success in their work. As a result, it is difficult or impossible to make comparisons between studies and drawing conclusions about implant success or failure from data reported in different studies is tenuous.

It is important to recognize that success rates are dramatically affected by variations in the criteria used to define them. In strict

terms, if one considers "implant success" to be the outcome without any adverse effects or problems, then the treatment would be performed as planned, implants would remain stable and functioning without problems, periimplant tissues would be stable and healthy, and both the patient and the treating clinician(s) would be pleased with the outcome (Figure 84-1). If such strict criteria are used, implant success rates would be undoubtedly lower than those determined using less stringent criteria. Table 84-1 illustrates the powerful effect that small changes in success criteria have on the reported success rates. The data demonstrates that simply changing the

Figure 84-1 Clinical example of implant success. A single implant was placed in the mandible to replace the lower second premolar (as planned). The implant integrated and was successfully restored in function. Both the patient and clinician(s) are pleased with the outcome. **A,** Clinical photograph of dentition in occlusion (from left side). **B,** Close-up clinical photograph of dentition in occlusion. Mandibular second premolar is an implant supported crown. **C,** Occlusal view of implant supported crown in the second premolar position. Notice that the replacement of the mandibular second premolar with an implant is a conservative treatment, obviating the need to prepare adjacent teeth. **D,** Periapical radiograph of the posterior mandibular teeth and implant in the second premolar position. Bone support is good and bone loss is minimal and consistent with expectations for this implant design.

TABLE 84-1 Effect of Slight Modifications in Implant Success Criteria on Implant Success Rate Outcomes*

	PPD ≤5 mm No BOP BL <0.2 mm/year (%)	PPD ≤6 mm No BOP BL <0.2 mm/year (%)	PPD ≤5 mm No BOP (%)	PPD ≤6 mm No BOP (%)	Implant Survival (%)
Group A (history of periodontitis)	52.4	62	71.4	81	90.5
Group B (periodontal health)	79.1	81.3	94.5	96.7	96.5

Based on data from Karoussis IK, Salvi GE, Heitz-Mayfield LJ, et al: *Clin Oral Implant Res* 14:329-339, 2003.

PPD, Probing pocket depth; *BOP,* bleeding on probing; *BL,* bone loss.

*The initial success criteria at 10 years were set at PPD ≤5 mm, no BOP, and BL <0.2 mm annually. The implant success rates for group A (patients with a history of periodontitis) and group B (patients with periodontal health) using this initial criteria is listed in the first column. Notice how dramatically the success rates change when the criteria used to define success are modified to include PPD ≤6 mm (second column). The next two columns show the success rates for each group using PPD ≤5 mm and PPD ≤6 mm when the criteria are modified to omit bone loss as a determinant. The last column shows the implant survival rate for each group, which clearly demonstrates that survival rate is different than success rate.

Figure 84-2 Panoramic radiograph of an individual with an implant placed in the position of a missing maxillary right central incisor. The implant appears to be placed in a nonrestorable position. It is osseointegrated and could technically be counted as a "surviving" implant but must be considered a failure because it does not meet the intended goal and has not been restored into function.

criteria of success to include probing pocket depth (PPD) ≤5 mm to ≤6 mm changed the implant success rates from 52.4% to 62% and from 79.1% to 81.3% in patients with and without a history of periodontitis, respectively.[40] It also shows that implant survival (last column) is quite different than implant success.

"Implant survival," conversely, is simply defined as any implant that remains in place at the time of evaluation, regardless of any untoward signs, symptoms, or history of problems. Clearly, there is a difference between implants that are present, healthy, and functioning under an implant-retained restoration, implants that are present but suffering from periimplant bone loss, or implants that are present but not connected to any restoration and not functioning (Figure 84-2). Implants that are osseointegrated but not restored into function are referred to as "sleepers" and should not be considered successful merely because they are present and osseointegrated. To reiterate, implant survival and implant success are distinctly different outcome measures. As an example, consider the dramatic difference between survival and success rate for implants reported in a systematic review (21 studies included) of implants supporting fixed partial dentures; the reported 5-year implant survival rate was 95.4%, whereas the 5-year patient success rate,* defined as free of any complications, was only 61.3%.[55] In a 10-year retrospective study of 397 fixed implant reconstructions in 300 patients, the observed mechanical complication rate was 24.7%. The most frequent complication was ceramic chipping (20.31%) followed by occlusal screw loosening (2.57%) and loss of retention (2.06%).[72] Although relatively infrequent, occlusal screw loosening can result in a subgingival gap at the implant-abutment junction that retains plaque and stimulates an inflammatory reaction in both the soft and hard tissue leading to bone loss around the implant. These implants could be considered *surviving* but would fail to meet optimal *success* criteria.

Defining implant results in absolute terms is difficult and confusing. Implant survival, which is almost always reported in studies, may actually overestimate implant outcomes. Implant success, however, which is less often reported, could be a better measure of actual implant outcomes if specific success criteria were universally defined, accepted, and used. Currently, implant success is difficult or impossible to compare across studies because of differences in evaluation criteria used by investigators. Implant success in a single study (or series of studies that use the same success criteria) is meaningful only in the context of that study (or series). At present, the usefulness of implant success rates from multiple different studies is limited. Implant survival is important but is only an indicator of surviving implants and does not reveal whether implants are functioning or whether any problems were associated with them over time.

*Individual implant success rates were not reported or estimated.

Factors That Influence Implant Outcomes

Many factors influence implant outcomes, including available bone, implant design, placement and loading protocols, and host-related factors. Some of the factors thought to affect implant outcomes are briefly discussed here.

Anatomic Location

Osseointegration depends on the availability of an adequate quantity and quality of bone at the implant site(s). Areas with abundant bone volume in the desired location will be better than areas with deficient bone volume. Likewise, areas with good bone density provide more predictable outcomes than areas with poor bone density. The bone classification system described by Lekholm and Zarb[47] was intended to define bone sites that would have different levels of bone support for implants and that would likely impact survival and success. The quality of bone support is greatly influenced by the anatomic location, thus implant outcomes are sometimes categorized according to anatomic location. Extreme examples are the anterior mandible and the posterior maxilla. The anterior mandible typically consists of dense cortical bone, which offers great support and high bone-to-implant contact, whereas the posterior maxilla is often limited in volume because of alveolar resorption and sinus pneumatization and typically consists of a loose, trabecular structure and a thin cortical bone shell.

Implants placed in the posterior maxilla are less well supported compared to implants placed in the anterior mandible. Jaffin and Berman[34] demonstrated the significance of bone quality on implant survival in a report of 1054 Brånemark implants. Ninety percent of these implants were placed in type I, II, and III bone with only 3% failures. However, of the 10% that were placed in type IV bone, 35% failed.[34] Excluding those placed in the mandible, 23/52 implants placed in type IV bone in the maxilla failed for a dismal 56% survival rate (44% failed). They concluded that bone quality stood out as the single greatest determinant of implant loss.

Anatomic location appears to have a significant effect on implant outcomes. This is particularly true for the posterior maxilla. It should be recognized that the implants used in this study were machined surface implants and that current implants with altered microtopography are expected to perform better in the posterior maxilla. Not surprisingly, when all 1054 implants are considered together, the combined implant survival rate (93.9%) in this study falls within (or slightly higher than) the range of reported survival rates of implants in the Göteborg study (with similar implants).

Implant Design

One of the many factors thought to influence implant outcomes is implant design. Today, there are hundreds of companies that manufacture and market dental implants worldwide and the number continues to grow. Implant dimensions, geometries, and surface characteristics vary tremendously and continue to evolve as innovation and research findings pave the way to changes that are thought to improve outcomes. Very few of these implant designs

have been studied and rely on being clinically similar to the other researched and approved implant designs without studies or documentation to support their effectiveness. Thus, in most cases, it is impossible to appreciate the effect of particular implant design features on implant outcomes. Nonetheless, these new, different implant designs are being used and outcomes are being reported in studies that evaluate other aspects of treatment (i.e., not specific to the implant design) only to make comparisons and assessments more confusing and difficult.

Those studies that have documented the success of dental implants based on implant design characteristics have shaped some of the tenets for current implant standards, selection, and use. For example, many clinicians adhere to the premise that longer implants are better, threaded implants are better, rough-surfaced implants are better, and so on. Over time, as changes in design and utilization evolved, some beliefs have been disproved, and continued advances and research will also refute other firmly held beliefs.

What are the best implant design characteristics? Is there an implant design that performs better than the rest? Actually, it is nearly impossible to determine which implant design characteristics are important because there are many variables to consider and implants are successful most of the time. Given the generally high success, it seems that subtle differences in implant design are probably not significant for the majority of patients and situations.[22,26] However, in compromised patients, inadequate sites, or challenging circumstances, certain implant designs may perform better than others. A prime example is the effect of implant surface characteristics. Implants with an altered surface microtopography (i.e., acid-etched, blasted) have been shown to enhance the bone-to-implant interface[42,43] and are thought to improve implant outcomes, especially in compromised sites.[66,67] Lower success rates have been associated with smooth surface (i.e., machined) implants.[35,56,60] Implant length is another consideration. Implant length is a factor that has long been held as important for success (i.e., longer is better), and many studies have supported this dogma,[61,62] but recent studies are challenging it.[29]

Placement and Loading Protocols

The traditional implant placement protocol required a healed edentulous ridge into which implants were placed and allowed to osseointegrate for a period of time without occlusal loading (see Chapter 75). The nonloading period after implant placement was empirically determined to be 3 to 4 months in the mandible and 6 months in the maxilla.[10] A strongly held belief at the time was that early loading would lead to higher failure rates.[11] In contrast to these early standards, some current protocols advocate dramatically different approaches, including implant placement immediately after tooth extraction and implant occlusal loading immediately or shortly after placement. Each of these approaches has distinct advantages, but they are also accompanied by challenges that have the potential to adversely affect implant outcomes.

Immediate Implant Placement. The immediate implant placement protocol describes the procedure in which an implant is placed in an extraction socket after tooth removal and socket debridement. This procedure, originally described by Schulte et al[64] and later by Lazzara,[45] has been reported with survival rates equivalent to that of implants placed into healed ridges.[14,49] The advantages of immediate placement include decreased surgery, cost, and healing time.[65] Immediate implant placement introduces additional risks of complications, including poor implant position, compromised esthetic outcome, and implant failure (see Chapter 82). Despite the increased risks, high long-term (1- to 16-year) survival rates of 96% have been reported for implants immediately placed into extraction sockets.[69]

Immediate Occlusal Loading. Brånemark established the concept of the osseointegrated dental implant as a predictable modality of treatment for the edentulous patient based on the empirically based requirement that the implant remain submerged and unloaded for a healing period of 3 to 6 months.[10] This original protocol, requiring the implant to remain stress free, was based on the concern that premature loading would cause micromotion of the dental implant leading to fibrous encapsulation and implant failure. However, studies have shown this assumption to be incorrect, demonstrating that immediately loaded implants can achieve success rates (>90%) similar to conventionally loaded dental implants.[15,18,27,31,38] The long-term predictability of immediately loaded implants requires strict surgical and prosthodontic protocols.[7]

Bone Augmentation

A common problem encountered in implant dentistry is insufficient bone quantity to allow implant placement. Deficiencies in alveolar bone result from developmental defects, periodontal disease, tooth loss, and trauma.[6,13,63] For most cases with alveolar ridge resorption, bone regenerative procedures are required to correct the defects before or simultaneous with implant placement (see Chapters 76 and 77). The obvious question is whether implants placed in sites that are reconstructed with bone augmentation procedures will achieve the same survival and success rates as implants placed in native bone sites.

The results of implants and bone augmentation procedures reported in the literature have been assessed by expert clinicians in several workshops.[16,28,32,33] One systematic review of literature (2003 Workshop on Contemporary Science in Clinical Periodontics), including 13 studies (guided bone regeneration) with 1741 patients and 5 studies (distraction osteogenesis) with 92 patients, found that survival rates of dental implants in augmented bone achieved a high level of predictability that was similar to implants placed in natural (ungrafted) bone.[28] A more recent systematic review of the literature (the 2008 Consensus Report of the Sixth European Workshop on Periodontology) pointed out that the bone augmentation procedures can fail and that implants placed in these areas do not enjoy the high long-term survival rates of dental implants placed in pristine sites.[68] The 2003 systematic review did not include an assessment of whether bone augmentation procedures failed, rather it intentionally focused on implants placed in sites that were successfully treated with bone augmentation. More research is needed to determine the long-term performance of dental implants placed in augmented bone and the clinical benefits of bone augmentation with respect to alternative treatments (i.e., the use of short implants).

Risk Factors

In general, most patients enjoy a similar rate of survival and success with dental implants. It is only a small percentage of patients who experience implant failure. In addition to factors previously discussed, host-related factors may adversely affect healing, osseointegration, and maintenance of dental implants. Smoking, diabetes, and periodontitis have been identified as "risk factors" that may adversely affect implant outcomes. In a systematic review of the literature, Klokkevold and Han[41] evaluated the influence of smoking, diabetes, and periodontal disease on implant outcomes and found that smoking has an adverse effect on implant survival and success, with the effects being more pronounced in

areas of loose trabecular bone (i.e., the posterior maxilla). The review also suggested that type 2 diabetes may have an adverse effect on implant survival rates, but the limited number of included studies did not permit a definitive conclusion.[41] Finally, their review also concluded that although patients with a history of treated periodontitis did not show any decrease in implant survival, they did experience more implant complications and lower success rates, especially when these implants were followed over longer time periods (10+ years).[41]

Smoking. Above all other risk factors, smoking has been shown to have a significant negative impact on implant survival and success. In a study of 2194 implants, Bain and Moy reported a significantly greater rate of failure in smokers (11.28%) compared to nonsmokers (4.76%).[8] De Bruyn and Colleart reported an early failure rate of 9% in smokers compared to 1% in nonsmokers.[17] Two other studies, one of 10 years[23] and the other with follow-up ranging from 6 months to 21 years,[53] concluded that smoking was a definite risk factor for implant survival.[19,20]

Diabetes. The role of diabetes mellitus as a risk factor for implant outcomes is less clear. Although it is expected that a metabolic disease such as diabetes would have an adverse effect on bone healing[70] and tissue support for implants, the research has not definitively determined that diabetes has a negative impact on implant survival or success.[4] Moy and coworkers[53] reported a significantly lower patient* success rate (68.7%) for patients with diabetes compared to the patient success rate (85.1%) for the entire study population (1140 patients with 4680 implants). However, this low success rate (high failure rate) may be an overestimate of the actual implant failure rate for patients with diabetes because it counts the number of patients with implant failures regardless of how many implants they had (i.e., implants that may have been successfully inserted and maintained in these patients are not counted). The number of patients with diabetes included in the study was 48/1140 or 4.2% of the total. Of these, 15 patients experienced implant failure(s). Conversely, in a systematic review of the literature (33 studies), Javed and Romanos found that patients with good metabolic control (glycosylated hemoglobin [HbA_{1c}] in normal range) achieve similar success with osseointegrated implants as patients without diabetes.[36] Dowell and coworkers[21] also found similar success for implants placed in patients with controlled diabetes.

Periodontitis. There are a limited number of studies available to assess the prognosis of implant treatment in patients with a history of periodontitis.[39] Most of these studies suggest that implants are equally successful in patients with a past history of chronic periodontitis. Short-term studies demonstrate 90% to 100% implant survival in patients with a history of chronic periodontitis.[50,52] Long-term studies report 90% to 97% implant survival rates for patients with a history of chronic periodontitis.[40,48,58,71] Short-term implant survival rates for patients treated for aggressive periodontitis are 95% to 100%.[50,51] One long-term study reported an 88.8% implant survival over 5 years for patients treated for aggressive periodontitis.[52] Implant survival in patients with a history of periodontitis appears to be highly predictable. However, the lack of long-term studies to support implant survival in patients treated for aggressive periodontitis leaves the prognosis in these patients open to question.[39]

*Individual implant survival or implant success rates were not reported.

Long-term studies evaluating implant treatment in periodontally compromised patients suggest that they may experience more periimplant problems.[40] When these patients are followed for extended periods of time, there appear to be more complications (i.e., periimplantitis) associated with implants compared to periodontally healthy patients. In a 10-year prospective study of patients with or without a history of chronic periodontitis, biologic complications (i.e., periimplantitis) were higher for those with a history of chronic periodontitis (28.6%) compared to those with periodontal health (5.8%).[40] This controlled study by Karoussis and coworkers[40] found a statistically significant difference in mean periimplant bone loss between patients with a history of chronic periodontitis and periodontally healthy patients. These periimplant problems may be attributed to a continuous increase in the percentage of implants exhibiting probing pocket depths 4 mm and deeper over time.[24]

Esthetic Results and Patient Satisfaction

The ultimate test for implant outcomes is achieving natural appearing, as well as optimally functioning, implant-supported tooth replacements. Proper tooth dimensions, contours, and ideal soft-tissue support are key factors for successful esthetic outcomes.[44] If crown form, dimension, and shape and gingival harmony around the implants are not ideal, the patient may consider the implant restoration unacceptable because the result does not represent a natural dental profile (Figure 84-3). For some patients, such as those with severe alveolar deficiency, an ideal esthetic outcome may be impossible because reconstructive surgical procedures are complex, require extensive time, and remain unpredictable. For others, a "less than ideal" esthetic outcome may be perfectly acceptable (see Chapter 78).

Esthetic problems and patient dissatisfaction happen when results are inferior to what were expected. Patient satisfaction with the esthetic outcome of the implant prosthesis varies from patient to patient, depending on a number of factors. The risk for esthetic failure is increased for patients with high esthetic expectations. The risk is also higher when patients present with patient-related risk factors such as a high smile line, thin periodontal soft tissues, and compromised bone support. Patient perceptions and desires greatly

Figure 84-3 Clinical photograph of maxillary anterior fixed restoration supported by two malpositioned implants in the central incisor positions. The patient is dissatisfied with the esthetic outcome. The left implant is positioned between the central and lateral incisor and angled toward the facial surface at a level above the gingival margin. A tooth-colored material was used to mask the exposed framework in the gingival area.

TABLE 84-2 Patient Satisfaction with Implant Treatment*

Implant Experience	Highly Satisfied or Satisfied (%)
Function/chewing	97
Phonetics	96
Esthetics	97
Oral hygiene ease	93
Complete fulfillment	92
Do treatment again	94
Recommend to friend or relative	89
Reasonable/justified cost	87

Based on data from Pjetursson BE, Karoussis I, Burgin W, et al: *Clin Oral Implants Res* 16:185-193, 2005.

*This table lists the percentage of patients subjectively responding with highly satisfied or satisfied to survey questions about their implant experience. More than 90% responded favorably and felt that implant treatment was positive.

influence and determine how well an individual patient accepts the implant outcome.

Although infrequently reported, the "esthetic success" and "patient satisfaction" of implant therapy needs to be included when considering the results of implant therapy. There have been a number of proposed methods to evaluate esthetic results, yet the reporting of esthetic parameters in the scientific literature is scarce.[9] There is a restorative index that appraises the "white" esthetics of the final restoration,[37] a soft-tissue or "pink" esthetic score that considers soft-tissue parameters,[30] and an esthetic index that uses a combination of pink and white esthetic scores focusing on the visible part of the implant restoration.[8] These indices are aimed at quantifying the esthetic result, which could then present an objective method of judging "implant esthetic success."

In a survey of patient satisfaction, more than 90% were completely satisfied both in terms of function and esthetics.[54] The study consisted of a questionnaire given to 104 patients 5 to 15 years (mean = 10.2 years) after implant placement to assess their subjective perception of implant treatment. Of these patients, 48% were treated with single implant crowns and 52% were treated with fixed partial dentures. The survival rate for all implants was 93%. A great majority of patients had favorable responses to the questions regarding function, esthetics, hygiene, and cost. Table 84-2 lists the percentage of patients responding with highly satisfied or satisfied to each category. Comparing chewing comfort for teeth or implants, 72.1% perceived no difference, 17.3% felt more secure chewing on teeth, and 7.7% felt more secure chewing on implants.

In another survey study, patient satisfaction with implant-supported prostheses in totally edentulous jaws was evaluated.[59] Patient experience with an implant-supported prosthesis was over a period of 10 years. Most of the 135 patients (97%) reported overall satisfaction with treatment. Chewing satisfaction was reported as good or very good by all but one patient (99.3%). Improved lifestyle and greater self-confidence in public was reported by 75% and 82% of patients, respectively.

A systematic review of the literature including all randomized controlled trials published in English or French up to April 2007 comparing mandibular conventional dentures and implant overdentures in adult edentulous patients identified eight publications for meta-analysis.[25] The study reported that patients were more satisfied with implant overdentures when compared with conventional mandibular dentures. However, there was a lack of evidence to show a patient's perception on the impact of mandibular implant overdentures on general health.

Conclusion

The utilization of dental implants to replace missing teeth is highly predictable, advantageous, and beneficial for patients. Because of variations in implant design, study protocols, and populations studied, results are difficult to compare and an absolute definition of implant success is elusive. The results of implant treatment are reported using a wide range of criteria from simply being present (survival) to being in function without complications (success). It is challenging to compare the results of one study to another because of the number of variables that continue to change. Clinical research suggests that certain risk factors may decrease success rates for some patients. Understanding what is being reported in the literature will help readers to appreciate implant treatment results.

Suggested Readings

Adell R, Eriksson B, Lekholm U, et al: Long-term follow-up study of osseointegrated implants in the treatment of totally edentulous jaws. *Int J Oral Maxillofac Implants* 5:347–359, 1990.

Albrektsson T, Zarb G, Worthington P, et al: The long-term efficacy of currently used dental implants: a review and proposed criteria of success. *Int J Oral Maxillofac Implants* 1:11–25, 1986.

Anner R, Grossmann Y, Anner Y, et al: Smoking, diabetes mellitus, periodontitis, and supportive periodontal treatment as factors associated with dental implant survival: a long-term retrospective evaluation of patients followed for up to 10 years. *Implant Dent* 19:57–64, 2010.

Fiorellini JP, Nevins ML: Localized ridge augmentation/preservation. A systematic review. *Ann Periodontol* 8:321–327, 2003.

Karoussis IK, Kotsovilis S, Fourmousis I: A comprehensive and critical review of dental implant prognosis in periodontally compromised partially edentulous patients. *Clin Oral Implants Res* 18:669–679, 2007.

Karoussis IK, Salvi GE, Heitz-Mayfield LJ, et al: Long-term implant prognosis in patients with and without a history of chronic periodontitis: a 10-year prospective cohort study of the ITI Dental Implant System. *Clin Oral Implants Res* 14:329–339, 2003.

Klokkevold PR, Han TJ: How do smoking, diabetes, and periodontitis affect outcomes of implant treatment? *Int J Oral Maxillofac Implants* 22(Suppl):173–202, 2007.

Mengel R, Schroder T, Flores-de-Jacoby L: Osseointegrated implants in patients treated for generalized chronic periodontitis and generalized aggressive periodontitis: 3- and 5-year results of a prospective long-term study. *J Periodontol* 72:977–989, 2001.

Pjetursson BE, Karoussis I, Burgin W, et al: Patients' satisfaction following implant therapy. A 10-year prospective cohort study. *Clin Oral Implants Res* 16:185–193, 2005.

Roos J, Sennerby L, Lekholm U, et al: A qualitative and quantitative method for evaluating implant success: a 5-year retrospective analysis of the Brånemark implant. *Int J Oral Maxillofac Implants* 12:504–514, 1997.

Wittneben JG, Buser D, Salvi GE, et al: Complication and failure rates with implant-supported fixed dental prostheses and single crowns: a 10-year retrospective study. *Clin Implant Dent Relat Res* 2013. doi: 10.1111/cid.12066. [Epub ahead of print].

References

References for this chapter are found on the companion website www.expertconsult.com.

References

1. Adell R, Eriksson B, Lekholm U, et al: Long-term follow-up study of osseointegrated implants in the treatment of totally edentulous jaws. *Int J Oral Maxillofac Implants* 5:347–359, 1990.
2. Adell R, Lekholm U, Rockler B, et al: A 15-year study of osseointegrated implants in the treatment of the edentulous jaw. *Int J Oral Surg* 10:387–416, 1981.
3. Albrektsson T, Zarb G, Worthington P, et al: The long-term efficacy of currently used dental implants: a review and proposed criteria of success. *Int J Oral Maxillofac Implants* 1:11–25, 1986.
4. Anner R, Grossmann Y, Anner Y, et al: Smoking, diabetes mellitus, periodontitis, and supportive periodontal treatment as factors associated with dental implant survival: a long-term retrospective evaluation of patients followed for up to 10 years. *Implant Dent* 19:57–64, 2010.
5. Apse P, Zarb GA, Schmitt A, et al: The longitudinal effectiveness of osseointegrated dental implants. The Toronto Study: peri-implant mucosal response. *Int J Periodontics Restorative Dent* 11:94–111, 1991.
6. Araujo M, Linder E, Lindhe J: Effect of a xenograft on early bone formation in extraction sockets: an experimental study in dog. *Clin Oral Implants Res* 20:1–6, 2009.
7. Attard NJ, Zarb GA: Immediate and early implant loading protocols: a literature review of clinical studies. *J Prosthet Dent* 94:242–258, 2005.
8. Belser UC, Grutter L, Vailati F, et al: Outcome evaluation of early placed maxillary anterior single-tooth implants using objective esthetic criteria: a cross-sectional, retrospective study in 45 patients with a 2- to 4-year follow-up using pink and white esthetic scores. *J Periodontol* 80:140–151, 2009.
9. Belser UC, Schmid B, Higginbottom F, et al: Outcome analysis of implant restorations located in the anterior maxilla: a review of the recent literature. *Int J Oral Maxillofac Implants* 19(Suppl):30–42, 2004.
10. Brånemark PI: Osseointegration and its experimental background. *J Prosthet Dent* 50:399–410, 1983.
11. Brånemark PI, Hansson BO, Adell R, et al: Osseointegrated implants in the treatment of the edentulous jaw. Experience from a 10-year period. *Scand J Plast Reconstr Surg Suppl* 16:1–132, 1977.
12. Buser D, Weber HP, Bragger U, et al: Tissue integration of one-stage ITI implants: 3-year results of a longitudinal study with hollow-cylinder and hollow-screw implants. *Int J Oral Maxillofac Implants* 6:405–412, 1991.
13. Cardaropoli D, Cardaropoli G: Preservation of the postextraction alveolar ridge: a clinical and histologic study. *Int J Periodontics Restorative Dent* 28:469–477, 2008.
14. Chen ST, Wilson TG, Jr: Hammerle, CH: Immediate or early placement of implants following tooth extraction: review of biologic basis, clinical procedures, and outcomes. *Int J Oral Maxillofac Implants* 19(Suppl):12–25, 2004.
15. Chiapasco M: Early and immediate restoration and loading of implants in completely edentulous patients. *Int J Oral Maxillofac Implants* 19(Suppl):76–91, 2004.
16. Chiapasco M, Zaniboni M, Boisco M: Augmentation procedures for the rehabilitation of deficient edentulous ridges with oral implants. *Clin Oral Implants Res* 17(Suppl 2):136–159, 2006.
17. De Bruyn H, Collaert B: The effect of smoking on early implant failure. *Clin Oral Implants Res* 5:260–264, 1994.
18. Del Fabbro M, Testori T, Francetti L, et al: Systematic review of survival rates for immediately loaded dental implants. *Int J Periodontics Restorative Dent* 26:249–263, 2006.
19. DeLuca S, Habsha E, Zarb GA: The effect of smoking on osseointegrated dental implants. Part I: implant survival. *Int J Prosthodont* 19:491–498, 2006.
20. DeLuca S, Zarb G: The effect of smoking on osseointegrated dental implants. Part II: peri-implant bone loss. *Int J Prosthodont* 19:560–566, 2006.
21. Dowell S, Oates TW, Robinson M: Implant success in people with type 2 diabetes mellitus with varying glycemic control: a pilot study. *J Am Dent Assoc* 138:355–361, quiz 397–358, 2007.
22. Eckert SE, Choi YG, Sanchez AR, et al: Comparison of dental implant systems: quality of clinical evidence and prediction of 5-year survival. *Int J Oral Maxillofac Implants* 20:406–415, 2005.
23. Ellegaard B, Baelum V, Kolsen-Petersen J: Non-grafted sinus implants in periodontally compromised patients: a time-to-event analysis. *Clin Oral Implants Res* 17:156–164, 2006.
24. Ellegaard B, Kolsen-Petersen J, Baelum V: Implant therapy involving maxillary sinus lift in periodontally compromised patients. *Clin Oral Implants Res* 8:305–315, 1997.
25. Emami E, Heydecke G, Rompre PH, et al: Impact of implant support for mandibular dentures on satisfaction, oral and general health-related quality of life: a meta-analysis of randomized-controlled trials. *Clin Oral Implants Res* 20:533–544, 2009.
26. Esposito M, Grusovin MG, Coulthard P, et al: A 5-year follow-up comparative analysis of the efficacy of various osseointegrated dental implant systems: a systematic review of randomized controlled clinical trials. *Int J Oral Maxillofac Implants* 20:557–568, 2005.
27. Esposito M, Grusovin MG, Willings M, et al: The effectiveness of immediate, early, and conventional loading of dental implants: a Cochrane systematic review of randomized controlled clinical trials. *Int J Oral Maxillofac Implants* 22:893–904, 2007.
28. Fiorellini JP, Nevins ML: Localized ridge augmentation/preservation. A systematic review. *Ann Periodontol* 8:321–327, 2003.
29. Fugazzotto PA, Beagle JR, Ganeles J, et al: Success and failure rates of 9 mm or shorter implants in the replacement of missing maxillary molars when restored with individual crowns: preliminary results 0 to 84 months in function. A retrospective study. *J Periodontol* 75:327–332, 2004.
30. Furhauser R, Florescu D, Benesch T, et al: Evaluation of soft tissue around single-tooth implant crowns: the pink esthetic score. *Clin Oral Implants Res* 16:639–644, 2005.
31. Ganeles J, Wismeijer D: Early and immediately restored and loaded dental implants for single-tooth and partial-arch applications. *Int J Oral Maxillofac Implants* 19(Suppl):92–102, 2004.
32. Hammerle CH, Jung RE, Feloutzis A: A systematic review of the survival of implants in bone sites augmented with barrier membranes (guided bone regeneration) in partially edentulous patients. *J Clin Periodontol* 29(Suppl 3):226–231, discussion 232–233, 2002.
33. Hammerle CH, van Steenberghe D: The first EAO Consensus Conference 16-19 February 2006, Pfaffikon, Switzerland. *Clin Oral Implants Res* 17(Suppl 2):1, 2006.
34. Jaffin RA, Berman CL: The excessive loss of Brånemark fixtures in type IV bone: a 5-year analysis. *J Periodontol* 62:2–4, 1991.
35. Jaffin RA, Kumar A, Berman CL: Immediate loading of dental implants in the completely edentulous maxilla: a clinical report. *Int J Oral Maxillofac Implants* 19:721–730, 2004.
36. Javed F, Romanos GE: Impact of diabetes mellitus and glycemic control on the osseointegration of dental implants: a systematic literature review. *J Periodontol* 80:1719–1730, 2009.
37. Jensen OT, Cockrell R, Kuhike L, et al: Anterior maxillary alveolar distraction osteogenesis: a prospective 5-year clinical study. *Int J Oral Maxillofac Implants* 17:52–68, 2002.
38. Jokstad A, Carr AB: What is the effect on outcomes of time-to-loading of a fixed or removable prosthesis placed on implant(s). *Int J Oral Maxillofac Implants* 22(Suppl):19–48, 2007.
39. Karoussis IK, Kotsovilis S, Fourmousis I: A comprehensive and critical review of dental implant prognosis in periodontally compromised partially edentulous patients. *Clin Oral Implants Res* 18:669–679, 2007.
40. Karoussis IK, Salvi GE, Heitz-Mayfield LJ, et al: Long-term implant prognosis in patients with and without a history of chronic periodontitis: a 10-year prospective cohort study of the ITI Dental Implant System. *Clin Oral Implants Res* 14:329–339, 2003.
41. Klokkevold PR, Han TJ: How do smoking, diabetes, and periodontitis affect outcomes of implant treatment? *Int J Oral Maxillofac Implants* 22(Suppl):173–202, 2007.
42. Klokkevold PR, Johnson P, Dadgostari S, et al: Early endosseous integration enhanced by dual acid etching of titanium: a torque removal study in the rabbit. *Clin Oral Implants Res* 12:350–357, 2001.

43. Klokkevold PR, Nishimura RD, Adachi M, et al: Osseointegration enhanced by chemical etching of the titanium surface. A torque removal study in the rabbit. *Clin Oral Implants Res* 8:442–447, 1997.
44. Kois JC: Predictable single tooth peri-implant esthetics: five diagnostic keys. *Compend Contin Educ Dent* 22:199–206, quiz 208, 2001.
45. Lazzara RJ: Immediate implant placement into extraction sites: surgical and restorative advantages. *Int J Periodontics Restorative Dent* 9:332–343, 1989.
46. Lekholm U, Gunne J, Henry P, et al: Survival of the Brånemark implant in partially edentulous jaws: a 10-year prospective multicenter study. *Int J Oral Maxillofac Implants* 14:639–645, 1999.
47. Lekholm U, Zarb G: Patient selection and preparation. In Brånemark PI, Zarb G, Albrektsson T, editors: *Tissue-integrated prosthesis: osseointegration in clinical dentistry*, Chicago, 1987, Quintessence.
48. Leonhardt A, Grondahl K, Bergstrom C, et al: Long-term follow-up of osseointegrated titanium implants using clinical, radiographic and microbiological parameters. *Clin Oral Implants Res* 13:127–132, 2002.
49. Mayfield L: *Immediate delayed and late submerged and transmucosal implants*, Berlin, 1999, Quintessence.
50. Mengel R, Flores-de-Jacoby L: Implants in patients treated for generalized aggressive and chronic periodontitis: a 3-year prospective longitudinal study. *J Periodontol* 76:534–543, 2005.
51. Mengel R, Flores-de-Jacoby L: Implants in regenerated bone in patients treated for generalized aggressive periodontitis: a prospective longitudinal study. *Int J Periodontics Restorative Dent* 25:331–341, 2005.
52. Mengel R, Schroder T, Flores-de-Jacoby L: Osseointegrated implants in patients treated for generalized chronic periodontitis and generalized aggressive periodontitis: 3- and 5-year results of a prospective long-term study. *J Periodontol* 72:977–989, 2001.
53. Moy PK, Medina D, Shetty V, et al: Dental implant failure rates and associated risk factors. *Int J Oral Maxillofac Implants* 20:569–577, 2005.
54. Pjetursson BE, Karoussis I, Burgin W, et al: Patients' satisfaction following implant therapy. A 10-year prospective cohort study. *Clin Oral Implants Res* 16:185–193, 2005.
55. Pjetursson BE, Tan K, Lang NP, et al: A systematic review of the survival and complication rates of fixed partial dentures (FPDs) after an observation period of at least 5 years. *Clin Oral Implants Res* 15:625–642, 2004.
56. Rocci A, Martignoni M, Gottlow J: Immediate loading of Brånemark System TiUnite and machined-surface implants in the posterior mandible: a randomized open-ended clinical trial. *Clin Implant Dent Relat Res* 5(Suppl 1):57–63, 2003.
57. Roos J, Sennerby L, Lekholm U, et al: A qualitative and quantitative method for evaluating implant success: a 5-year retrospective analysis of the Brånemark implant. *Int J Oral Maxillofac Implants* 12:504–514, 1997.
58. Rosenberg ES, Cho SC, Elian N, et al: A comparison of characteristics of implant failure and survival in periodontally compromised and periodontally healthy patients: a clinical report. *Int J Oral Maxillofac Implants* 19:873–879, 2004.
59. Sandberg G, Stenberg T, Wikblad K: Ten years of patients' experiences with fixed implant-supported prostheses. *J Dent Hyg* 74:308–316, 2000.
60. Schincaglia GP, Marzola R, Scapoli C, et al: Immediate loading of dental implants supporting fixed partial dentures in the posterior mandible: a randomized controlled split-mouth study–machined versus titanium oxide implant surface. *Int J Oral Maxillofac Implants* 22:35–46, 2007.
61. Schnitman PA, Wohrle PS, Rubenstein JE: Immediate fixed interim prostheses supported by two-stage threaded implants: methodology and results. *J Oral Implantol* 16:96–105, 1990.
62. Schnitman PA, Wohrle PS, Rubenstein JE, et al: Ten-year results for Brånemark implants immediately loaded with fixed prostheses at implant placement. *Int J Oral Maxillofac Implants* 12:495–503, 1997.
63. Schropp L, Wenzel A, Kostopoulos L, et al: Bone healing and soft tissue contour changes following single-tooth extraction: a clinical and radiographic 12-month prospective study. *Int J Periodontics Restorative Dent* 23:313–323, 2003.
64. Schulte W, Kleineikenscheidt H, Lindner K, et al: The Tubingen immediate implant in clinical studies. *Dtsch Zahnarztl Z* 33:348–359, 1978.
65. Schwartz-Arad D, Chaushu G: Immediate implant placement: a procedure without incisions. *J Periodontol* 69:743–750, 1998.
66. Stach RM, Kohles SS: A meta-analysis examining the clinical survivability of machined-surfaced and Osseotite implants in poor-quality bone. *Implant Dent* 12:87–96, 2003.
67. Sullivan DY, Sherwood RL, Porter SS: Long-term performance of Osseotite implants: a 6-year clinical follow-up. *Compend Contin Educ Dent* 22:326–328, 2001.
68. Tonetti MS, Hammerle CH: Advances in bone augmentation to enable dental implant placement: Consensus Report of the Sixth European Workshop on Periodontology. *J Clin Periodontol* 35:168–172, 2008.
69. Wagenberg B, Froum SJ: A retrospective study of 1925 consecutively placed immediate implants from 1988 to 2004. *Int J Oral Maxillofac Implants* 21:71–80, 2006.
70. Wang F, Song YL, Li DH, et al: Type 2 diabetes mellitus impairs bone healing of dental implants in GK rats. *Diabetes Res Clin Pract* 2010.
71. Wennstrom JL, Ekestubbe A, Grondahl K, et al: Oral rehabilitation with implant-supported fixed partial dentures in periodontitis-susceptible subjects. A 5-year prospective study. *J Clin Periodontol* 31:713–724, 2004.
72. Wittneben JG, Buser D, Salvi GE, et al: Complication and failure rates with implant-supported fixed dental prostheses and single crowns: a 10-year retrospective study. *Clin Implant Dent Relat Res* 2013. doi: 10.1111/cid.12066. [Epub ahead of print].
73. Zarb GA, Schmitt A: The longitudinal clinical effectiveness of osseointegrated dental implants: the Toronto study. Part I: surgical results. *J Prosthet Dent* 63:451–457, 1990.
74. Zarb GA, Schmitt A: The longitudinal clinical effectiveness of osseointegrated dental implants: the Toronto Study. Part II: the prosthetic results. *J Prosthet Dent* 64:53–61, 1990.
75. Zarb GA, Schmitt A: Osseointegration and the edentulous predicament. The 10-year-old Toronto study. *Br Dent J* 170:439–444, 1991.

CHAPTER 85

Atlas of Periodontal Diseases

M. Cenk Haytac and Onur Ozcelik

This final chapter presents additional illustrations to the chapters in Parts 2 and 3, Sections 1 and 2, and Chapter 27. The presentation of cases follows the Classification of Periodontal Diseases and Conditions developed in the 1999 International Workshop for the Classification of Periodontal Diseases organized by the American Academy of Periodontology (see Chapter 4).

All figures are from the Archives of the Department of Periodontology, School of Dentistry, Cukurova University, Adana, Turkey (Box 85-1).

BOX 85-1 Gingival Diseases

Dental Plaque-Induced Gingival Diseases

I. Gingivitis associated with dental plaque only
  A. Without local contributing factors
  B. With local contributing factors (Figures 85-1 to 85-32)
II. Gingival diseases modified by systemic factors
  A. Associated with endocrine system
    1. Puberty-associated gingivitis (Figure 85-33)
    2. Menstrual cycle–associated gingivitis (Figure 85-34)
    3. Pregnancy-associated gingivitis (Figures 85-35 to 85-37)
      a. Gingivitis
      b. Pyogenic granuloma
    4. Diabetes mellitus–associated gingivitis
  B. Associated with blood dyscrasias
    1. Leukemia-associated gingivitis (Figures 85-38 to 85-40)
    2. Other (Figures 85-41 to 85-46)
III. Gingival diseases modified by medications
  A. Drug-induced gingival diseases
    1. Drug-influenced gingival enlargements (Figures 85-47 to 85-51)
    2. Drug-influenced gingivitis
      a. Oral contraceptive–associated gingivitis
      b. Other
IV. Gingival diseases modified by malnutrition
  A. Ascorbic acid deficiency gingivitis
  B. Other

Non–Plaque-Induced Gingival Lesions

I. Gingival diseases of specific bacterial origin
  A. *Neisseria gonorrhoeae*
  B. *Treponema pallidum*
  C. *Streptococcus* species (Figure 85-52)
  D. Other
II. Gingival diseases of viral origin
  A. Herpesvirus infections (Figure 85-53)
    1. Primary herpetic gingivostomatitis
    2. Recurrent oral herpes
    3. Varicella zoster
  B. Other (Figure 85-54)
III. Gingival diseases of fungal origin
  A. Candida species infections: generalized gingival candidiasis (Figure 85-55 and 85-56)
  B. Linear gingival erythema
  C. Histoplasmosis
  D. Other (Figures 85-57 and 85-58)
IV. Gingival lesions of genetic origin
  A. Hereditary gingival fibromatosis (Figures 85-59 to 85-61)
  B. Other
V. Gingival manifestations of systemic condition
  A. Mucocutaneous lesions
    1. Lichen planus (Figures 85-62 to 85-65)
    2. Pemphigoid
    3. Pemphigus vulgaris (Figure 85-66)
    4. Erythema multiforme
    5. Lupus erythematosus
    6. Drug induced
    7. Other (Figures 85-67 to 85-73)
  B. Allergic reactions
    1. Dental restorative materials
      a. Mercury
      b. Nickel
      c. Acrylic
      d. other

Continued

BOX 85-1 Gingival Diseases—cont'd

2. Reactions attributable to:
   a. Toothpastes or dentifrices
   b. Mouth rinses or mouthwashes
   c. Chewing gum additives
   d. Foods and additives (Figure 85-74)
3. Other

VI. Traumatic lesions (factitious, iatrogenic, or accidental) (Figures 85-75 to 85-92)
   A. Chemical injury
   B. Physical injury
   C. Thermal injury

VII. Foreign body reactions

VIII. Not otherwise specified
   A. Cysts and tumors (Figures 85-93 to 85-102)

Chronic Periodontitis (Figures 85-103 to 85-108)

I. Localized
II. Generalized
III. Chronic periodontitis modified by systemic disorders
   A. Diabetes mellitus (Figures 85-109 to 85-113)

Aggressive Periodontitis (Figures 85-114 to 85-119)

I. Localized
II. Generalized

Periodontitis as a Manifestation of Systemic Diseases

I. Hematologic disorders
   A. Acquired neutropenia
   B. Leukemias (Figures 85-120 to 85-122)
   C. Other
II. Genetic disorders
   A. Familial and cyclic neutropenia (Figure 85-123)
   B. Down syndrome
   C. Leukocyte adhesion deficiency syndromes (Figures 85-124 and 85-125)
   D. Papillon-Lefèvre syndrome (Figure 85-126 and 85-127)
   E. Chediak-Higashi syndrome
   F. Histiocytosis syndromes
   G. Glycogen storage disease
   H. Infantile genetic agranulocytosis
   I. Cohen syndrome
   J. Ehlers-Danlos syndrome (types 4 and 8)
   K. Hypophosphatasia (Figure 85-128)
   L. Other
III. Not otherwise specified

Necrotizing Periodontal Diseases

I. Necrotizing ulcerative gingivitis (NUG) (Figures 85-129 to 85-131)
II. Necrotizing ulcerative periodontitis (NUP) (Figure 85-132)
III. Bisphosphonate-related osteonecrosis (Figures 85-133 and 85-134)

Abscesses of the Periodontium

I. Gingival abscess
II. Periodontal abscess (Figures 85-135 to 85-137)
III. Pericoronal abscess (Figure 85-138)

Periodontitis Associated with Endodontic Lesions

I. Endodontic-periodontal lesions (Figures 85-139 and 85-140)
II. Periodontal-endodontic lesions
III. Combined lesions

Developmental or Acquired Deformities and Conditions

I. Localized tooth related factors
II. Mucogingival deformities around teeth
III. Mucogingival deformities on edentulous ridges
IV. Occlusal trauma

Plaque-Induced Gingival Diseases

Clinical Features of Gingivitis

Bleeding

Color Changes

Consistency

Surface Texture

Position

Contour

Figure 85-1 Healthy gingiva in a 17-year-old female. Note the demarcation (mucogingival line) (*arrows*) between the attached gingiva and the darker alveolar mucosa.

Figure 85-2 Prominent stippling of healthy gingiva in a 21-year-old male.

Figure 85-3 Bright red color and loss of stippling of gingiva in a 21-year-old female with gingivitis.

Figure 85-4 Bleeding on probing in a 24-year-old male with gingivitis and inflammatory enlargement.

Figure 85-5 Plaque accumulation and red color of gingiva in a 17-year-old female with gingivitis.

Figure 85-6 Bluish-red color of gingival in a 46-year-old male with advanced chronic periodontitis.

Melanin Pigmentation

Figure 85-7 Melanin pigmentation causing esthetic problems in a 21-year-old female and 6 months after treatment with CO_2 laser.

Figure 85-8 Diffuse melanin pigmentation causing esthetic considerations in a 34-year-old female and 2 months after treatment by conventional gingivectomy.

Figure 85-9 Localized melanin pigmentation in a 26-year-old female and 1 month after treatment with CO_2 laser.

Figure 85-10 Diffuse localized melanin pigmentation in a 33-year-old female and 1 month after CO_2 laser treatment.

Etiology of Periodontal Diseases

I. Microbial Dental Plaque

II. Calculus

III. One-Sided chewing

IV. Malocclusion

V. Mouth-Breathing

Figure 85-11 Severe plaque accumulation and gingivitis in a 13-year-old boy with neglected hygiene.

Figure 85-12 Extensive plaque formation in a 46-year-old male with chronic periodontitis. Note the darker shade of gingiva in areas with subgingival calculus.

Figure 85-13 Extreme plaque formation and periodontitis in a 52-year-old female with prolonged neglect of oral hygiene procedures.

Figure 85-14 Plaque formation caused by habitual one-sided chewing in a 9-year-old boy. The patient had avoided chewing on the right side because of the mobility of deciduous teeth.

Figure 85-15 Extensive plaque accumulation and severe inflammation in a 35-year-old male smoker.

Figure 85-16 Advanced plaque and calculus formation around implants of a 72-year-old woman.

Figure 85-17 Plaque and calculus formation around the implants of a 55-year-old man.

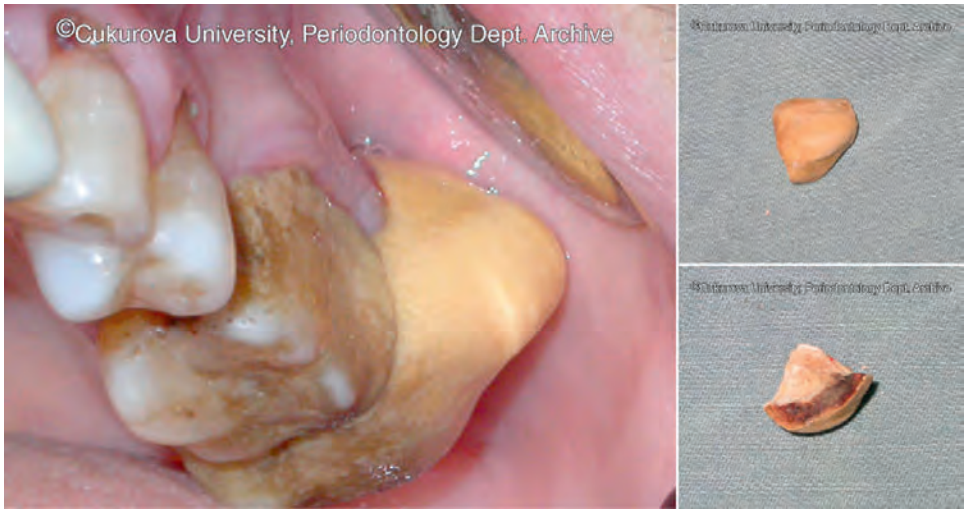

Figure 85-18 Calculus formation on teeth #26 and #27 where the parotid gland duct (Stensen's duct) opens in a 47-year-old male. These teeth, in addition, had lost their functional antagonists. Note that calculus had also covered the occlusal surfaces.

Figure 85-19 Calculus formation on upper molars, adjacent to Stensen's duct in a 44-year-old male. Note the divergence of the roots of first molar.

Figure 85-20 Anterior open-bite malocclusion and the loss of functional antagonist teeth had caused extensive calculus formation on the left maxillary teeth in this 35-year-old female.

Figure 85-21 Bridge-like formations of calculus due to malocclusion, loss of antagonist tooth, tilting of the remaining teeth and avoidance of chewing on the affected site in a 49-year-old female.

Figure 85-22 Extensive calculus formation adjacent to Stensen's duct in a 53-year-old male.

Figure 85-23 Extensive bridge-like calculus formation on the lingual surfaces of lower anterior teeth where Wharton's and Bartholin's ducts empty in a 36-year-old male.

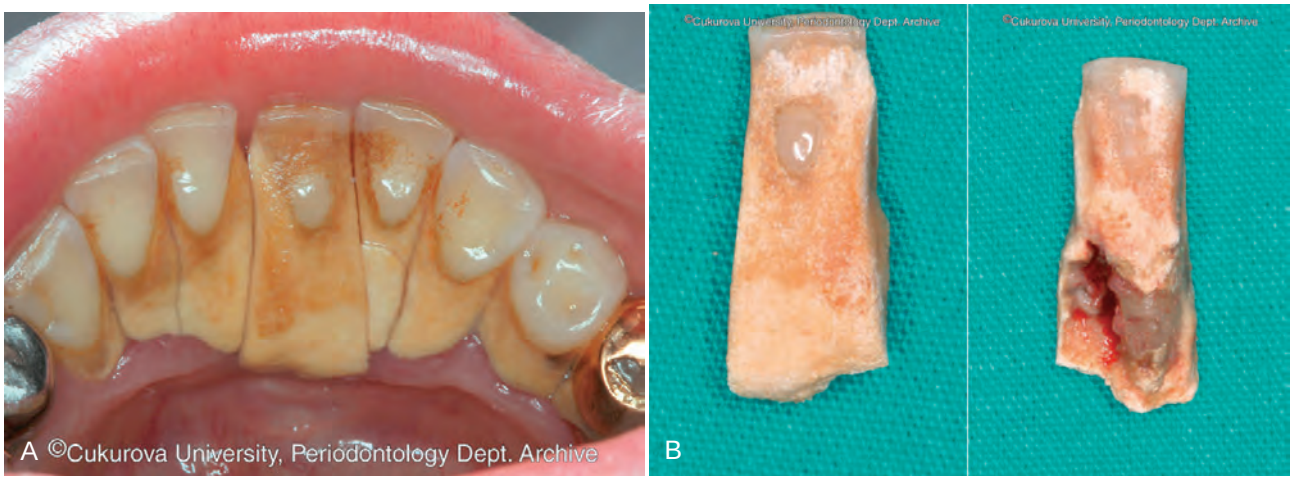

Figure 85-24 **A,** Extensive bridge-like calculus formation on the lingual surfaces of lower anterior teeth where Wharton's and Bartholin's duct empty in a 42-year-old female. **B,** Same patient seen in **A** after the extraction of left central incisor. Note that calculus has covered almost all surfaces of the tooth.

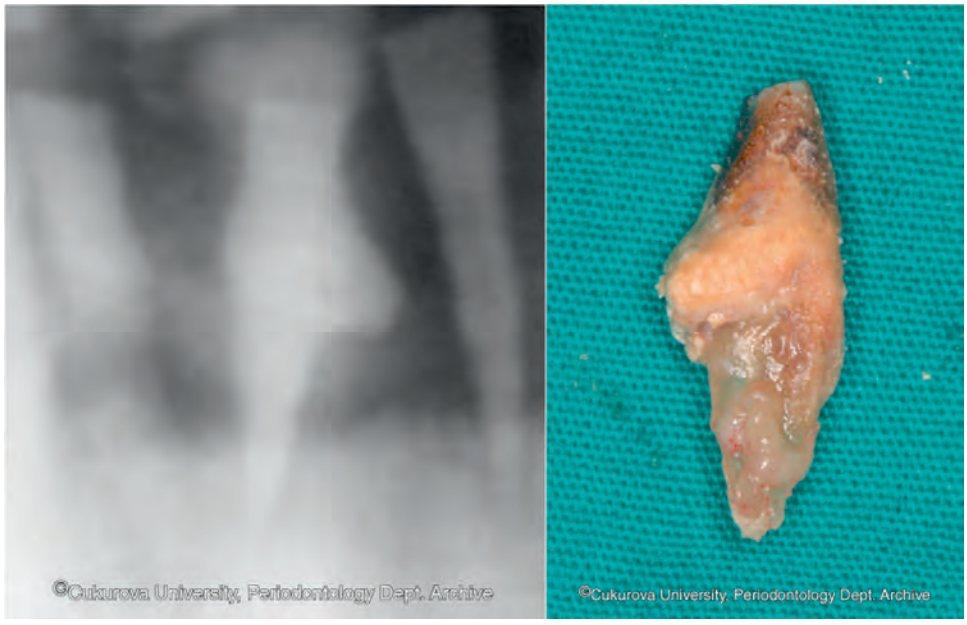

Figure 85-25 Radiograph showing radiopaque projection of extensive calculus and its appearance after extraction in a 62-year-old male.

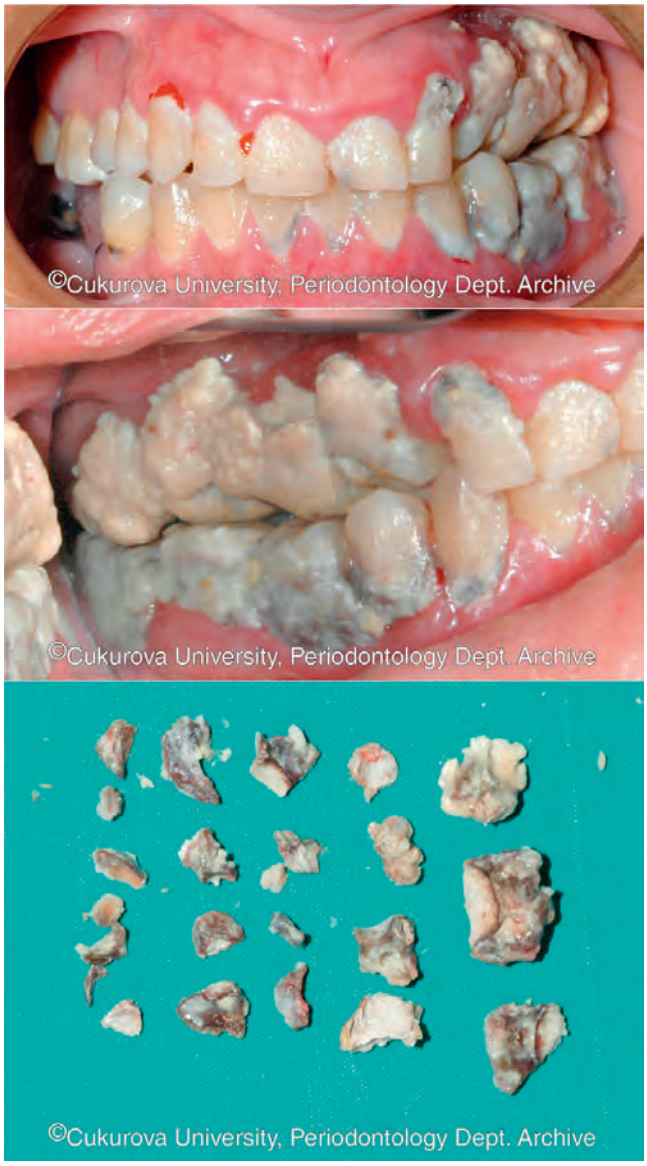

Figure 85-26 Extreme plaque and calculus formation caused by habitual one-sided chewing in a 35-year-old female. The patient had avoided chewing on the left side for 10 years.

Figure 85-27 Extensive plaque and calculus formation associated with the crowding of teeth in a 21-year-old female.

Figure 85-28 Periodontal destruction associated with Class III malocclusion in a 35-year-old male.

Figure 85-29 Extensive calculus formation in a 9-year-old child with open-bite and hygiene neglect.

Figure 85-30 Plaque formation and gingival inflammation with crowding and supernumerary teeth in a 14-year-old male.

Figure 85-31 Gingival inflammation and enlargement associated with chronic habitual mouth-breathing in a 16-year-old male. Note the clear demarcation of affected gingiva.

Figure 85-32 Extensive plaque and calculus formation in a 27-year-old female. Same patient after 2 months of receiving initial debridement and oral hygiene instruction. Note that although the patient still has hygiene problems, the inflammation, redness, and contour of gingiva is greatly reduced.

Gingival Diseases Modified by Systemic Factors

Endocrine System

Sex Hormones

Figure 85-33 Puberty gingivitis in a 14-year-old girl associated with poor hygiene, crowding of teeth, and mouth breathing. Note the gingival hyperplasia confined to the anterior regions.

Figure 85-34 Periodic localized color changes of gingiva around maxillary anterior teeth associated with menstruation in a 29-year-old female.

Figure 85-35 Localized gingival enlargement in a 24-year-old female who is at the seventh month of pregnancy. The lesion was first noticed in the fourth month by the patient.

Figure 85-36 Severe gingival enlargement in an 8-month-pregnant 29-year-old.

Figure 85-37 Gingival enlargement in a 32-year-old female at the seventh **(A)**, eighth **(B)**, and ninth **(C)** month of pregnancy and 1 month after delivery **(D)**. Note the progression of the dimensions and the increase of the vascularization of the lesion. Extraoral view of the lesion interfering with occlusion and esthetics **(E)**.

Gingival Diseases Associated with Blood Dyscrasias

Leukemia

Figure 85-38 Gingival hyperplasia and spontaneous bleeding in a 6-year-old boy with newly diagnosed acute myelogenous leukemia. The view of the patient after one course of chemotherapy and periodontal treatment.

Figure 85-39 Enlargement of the gingiva and floor of the mouth in an 8-year-old boy with acute myelogenous leukemia.

Figure 85-40 Severe gingival inflammation, hyperplasia and poor hygiene in a 46-year-old male with chronic myelogenous leukemia.

Anemia

Figure 85-41 Pale gingiva and apparent vascular structures in a 22-year-old female with iron deficiency anemia.

Figure 85-42 Severe malocclusion and gingival recession in an 18-year-old-male with thalassemia.

Figure 85-43 Skeletal disturbance of the thumb and severe gingival inflammation with spontaneous bleeding in a 12-year-old male with Fanconi anemia.

Figure 85-44 Localized bleeding in the tissue in a 24-year-old female with Glanzmann thrombasthenia.

Figure 85-45 Plaque accumulation and spontaneous bleeding in a 28-year-old hemophilia-A patient who neglected oral hygiene procedures due to severe bleeding.

Figure 85-46 Spontaneous bleeding and clot formation in a 22-year-old male with von Willebrand disease.

Drug-Induced Gingival Diseases

Figure 85-47 Gingival enlargement associated with phenytoin use in a 20-year-old epilepsy patient.

Figure 85-48 Amlodipine-associated gingival enlargement in a 47-year-old male with hypertension.

Figure 85-49 Gingival enlargement in a 44-year-old male receiving cyclosporine after kidney transplant.

Figure 85-50 Cyclosporine-associated gingival enlargement. Note that clinical crowns are covered and the enlargement reaches up to occlusal plane. **A,** Intraoperative view of the enlargement. **B,** The view of the patient after 6 **(C)** and 12 months **(D)**. *(From Haytac MC, et al:* Quintessence Int *38(1):e54-59, January 2007.)*

Figure 85-51 Gingival thickening and hyperplasia in a 25-year-old male bodybuilder who had been using steroid injections for 3 years.

Non–Plaque-Induced Gingival Lesions

Streptococcus Species

Figure 85-52 Lesions on the lip and gingiva in a 7-year-old child with acute streptococcal gingivostomatitis.

Herpes Virus Infections

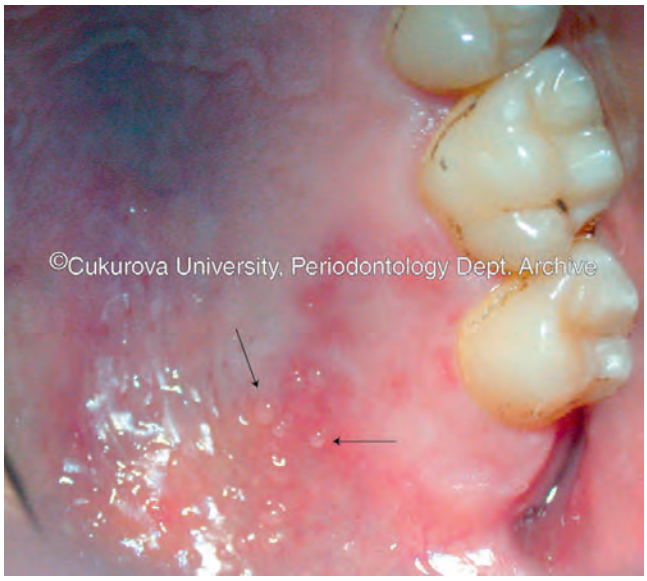

Figure 85-53 Ruptured and unruptured herpetic vesicles in a patient with herpetic gingivostomatitis in a 19-year-old male.

Figure 85-54 Recurrent aphthous ulcers in a 27-year-old female.

Figure 85-55 Severe mucositis on the gingiva, cheek, palatal mucosa, and tongue of a 7-year-old boy with acute myelogenous leukemia after remission-induction chemotherapy. These lesions are very prone to candidal infections.

Figure 85-56 Candidal infection of the oral cavity after chemotherapy in a 3-year-old boy with acute myelogenous leukemia.

Figure 85-57 Mucormycosis causing soft and hard tissue destruction in a 9-year-old acute myelogenous leukemia patient.

Figure 85-58 **A,** Rapid gingival and alveolar bone destruction caused by mucormycosis infection in a 14-year-old boy with acute myelogenous leukemia. The lesions started on the third day of chemotherapy and the breakdown occurred within 1 week. **B,** The histologic analysis with Gomori methenamine silver staining showing fungal hyphae. *(Courtesy Dr. M. Cem Dogan and Dr. M. Cenk Haytac.)*

Gingival Lesions of Genetic Origin

Hereditary Gingival Fibromatosis

Figure 85-59 Hereditary gingival fibromatosis in a family. The intraoral view of the father in 2000 **(A)**, 2003 **(B)**, and 2005 **(C)**.

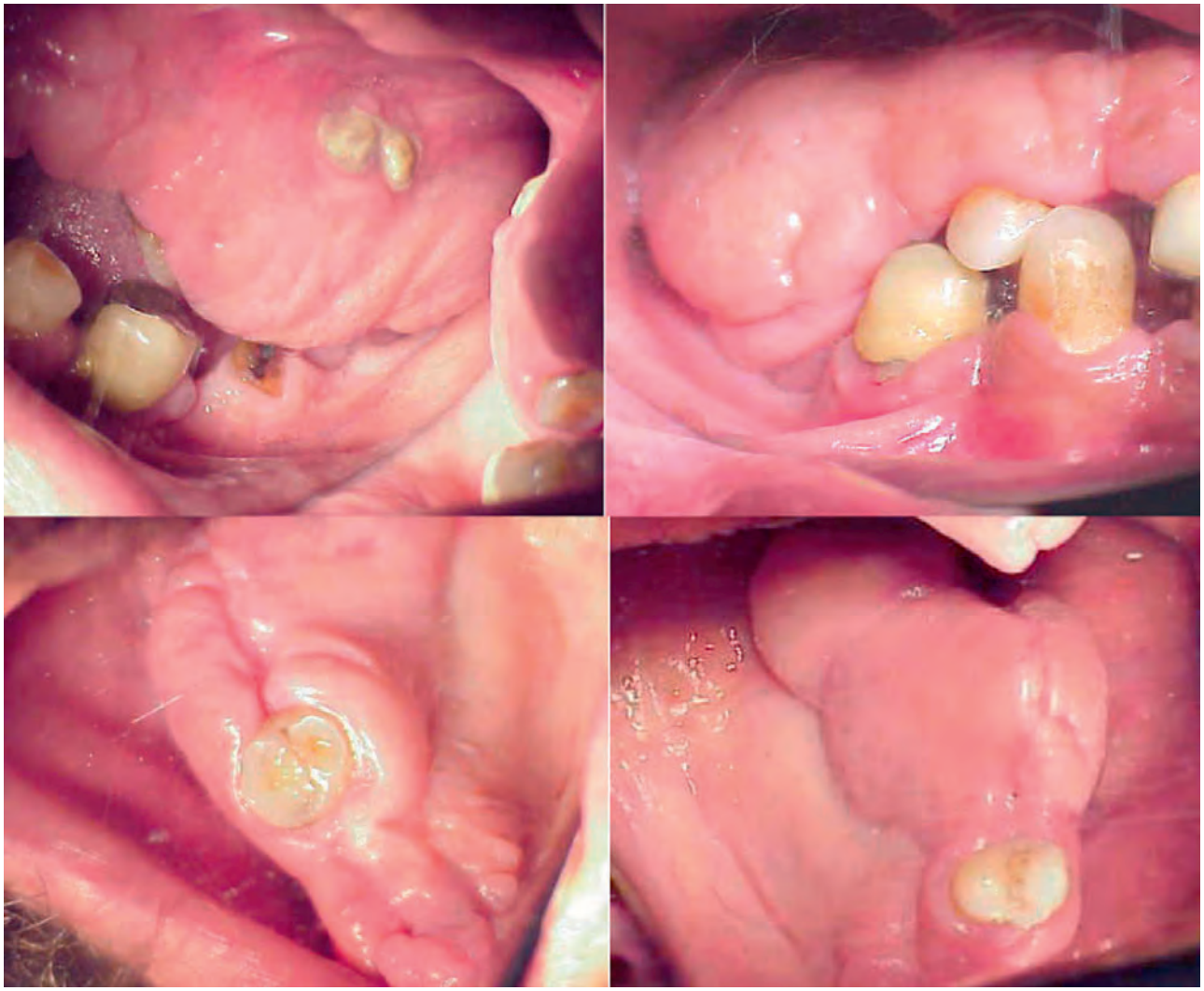

Figure 85-60 Hereditary gingival fibromatosis in a family. The view of the father in 2000. Note the severe enlargement of the tuberosities contacting mandibular ridges and the root fragments in the overgrown tissue.

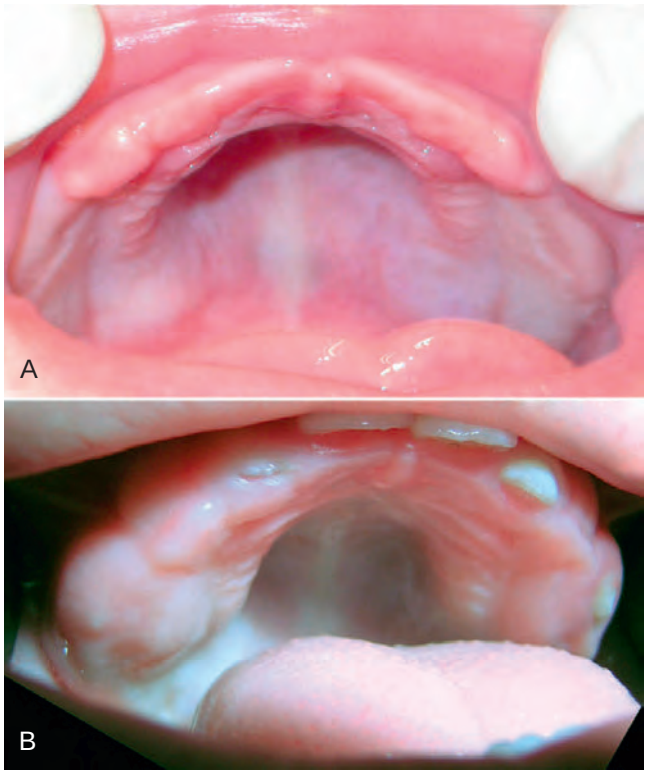

Figure 85-61 Hereditary gingival fibromatosis in a family. The intraoral view of the younger son when he was 10 days **(A)** and 2 years **(B)** old. *(From Haytac MC, Ozcelik O:* Oral Surg Oral Med Oral Pathol Oral Radiol Endodontol *103(4):521-527, April 2006.)*

Figure 85-63 Reticular lichen planus in a 63-year-old female who was referred with a complaint of burning sensation in her mouth.

Gingival Manifestations of Systemic Conditions

Mucocutaneous Lesions

Figure 85-62 Severe desquamation and positive Nikolsky sign in a 56-year-old female with lichen planus. The desquamation leaves the connective tissue exposed and painful to stimulant agents.

Figure 85-64 Desquamation and spontaneous bleeding in a 62-year-old female with erosive lichen planus. The patient is extremely sensitive to temperature changes and foods.

Figure 85-65 Atrophic lichen planus causing exposed connective tissue in a 62-year-old male.

Figure 85-66 Pemphigus vulgaris characterized by desquamation, pain, and bleeding in a 56-year-old female. The suprabasal and subepithelial separation of cells can be detected in the histologic analysis.

Other Systemic Diseases

Figure 85-67 The developmental deformities of the fingers and limited mouth opening in an 18-year-old male with scleroderma. Insufficient attached gingival width complicates oral hygiene procedures, and advanced gingival recession is noted on lower central incisor.

Figure 85-68 Gingival enlargement in a 9-year-old boy with juvenile hyaline fibromatosis.

Figure 85-69 Atopic dermatitis characterized by pruritic lesions on the extremities and lips in a 22-year-old female. Note the inadequate vestibular depth and gingival recession.

Figure 85-70 Fibrous dysplasia characterized by unilateral fibroosseous expansion of the bones in a 17-year-old female. Note the facial asymmetry, advanced malocclusion, migration of teeth starting from the midline, and gingival enlargement in accordance with the expansion of the underlying bones. The radiograph shows unilateral increases of the dimensions of mandible and maxilla.

Figure 85-71 Sturge-Weber syndrome characterized by unilateral cavernous hemangiomas on the face and neck in a 35-year-old male. Note the unilateral soft and easily bleeding gingival enlargement with high vascularization on the affected site.

Figure 85-72 Rothmund-Thomson syndrome characterized by photosensitivity and hypopigmentation and hyperpigmentation on the skin in a 16-year-old female. Note the decreased keratinization and spontaneous bleeding of the gingiva. Histologic analysis showing the discontinuity of the basement membrane. *(From Haytac MC, et al:* Oral Surg Oral Med Oral Pathol Oral Radiol Endodontol *94(4):479-484, October 2002.)*

Figure 85-73 Recurrent major aphthous lesions on the cheek and lip mucosa, tongue and alveolar mucosa in a 42-year-old male with Behçet disease.

Allergies

Figure 85-74 Oral challenge test for the diagnosis of allergic reaction of gingiva to apple in a 48-year-old female. Note the formation of blisters, desquamation, and subepithelial bleeding. *(From Haytac MC, Ozcelik O:* Oral Surg Oral Med Oral Pathol Oral Radiol Endodontol *101(3):317-321, March 2006.)*

Traumatic Lesions (Factitious, Iatrogenic, and Accidental)

Figure 85-75 Inadequate margins, design and shape of restoration violating biologic width, which had subsequently caused severe gingival inflammation in a 32-year-old female.

Figure 85-76 Overhanging margins and injury of the self-curing acrylic used for restoration in a 49-year-old female.

Figure 85-77 Extensive calculus formation and ill-fitting restoration on the lower anterior teeth of a 51-year-old male. Note the trauma of the deposits on the sublingual soft tissue after the restoration is removed.

Figure 85-78 Extensive calculus formation under the restoration on the lower anterior teeth of a 44-year-old male. Note the trauma of the calculus on the sublingual soft tissue after removal.

Figure 85-79 Subgingival margin locations and lack of interproximal embrasures of the crowns causing gingival inflammation in a 29-year-old male.

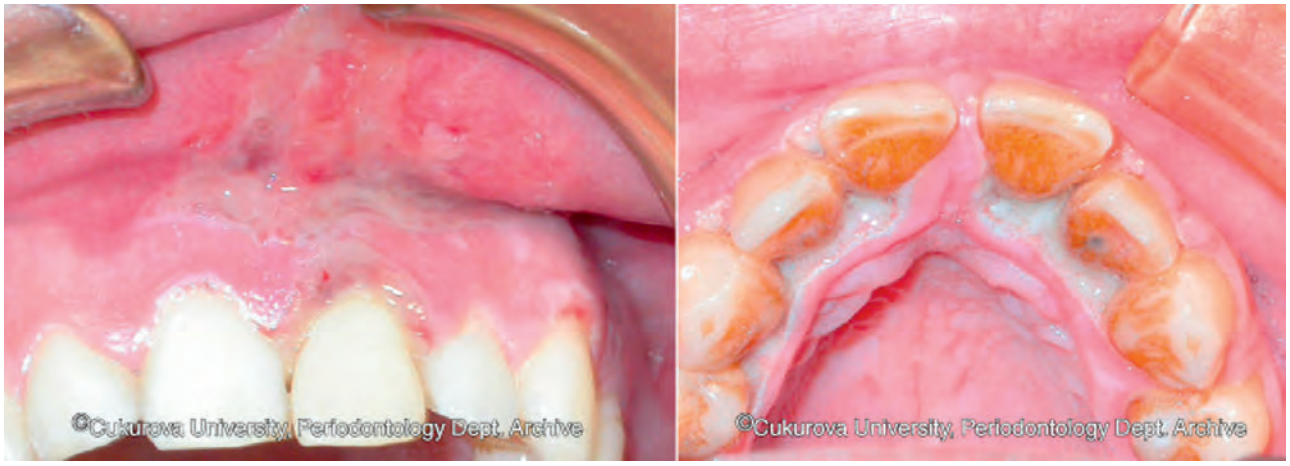

Figure 85-80 Misuse of ferric sulfate during gingival retraction causing burns and desquamation in a 30-year-old male.

Figure 85-81 Iatrogenic use of a bonding agent for the treatment of dentinal hypersensitivity causing gingival recession in a 32-year-old female.

Figure 85-82 Trauma and inflammation of the soft tissues caused by the brackets in a 14-year-old orthodontic patient.

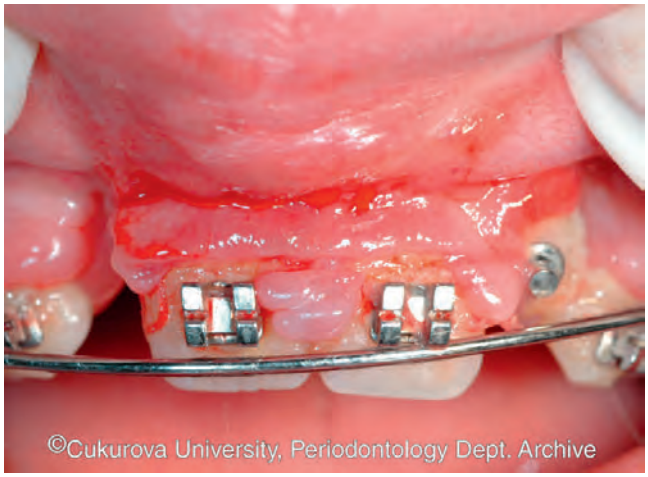

Figure 85-83 Gingival trauma from the ligature wire in a 12-year-old female.

Figure 85-84 Gingival recession associated with vigorous tooth-brushing 48-year-old male.

Figure 85-85 Gingival desquamation after rinsing with cologne in a 21-year-old female.

Figure 85-86 Hyperkeratosis associated with smokeless tobacco use in a 42-year-old male.

Figure 85-87 Desquamation associated with toothbrushing with soap in a 55-year-old male.

Figure 85-88 Trauma and desquamation after placing plant seeds on gingiva for toothache in a 41-year-old male.

Figure 85-89 Gingival recession associated with habitual scratching the gingiva with nail in a 26-year-old female.

Figure 85-90 Gingival recession associated with habitual cleansing with tissue in a 42-year-old female.

Figure 85-91 Desquamation and burn after rinsing with raki (a Turkish drink with 40% to 50% alcohol content) in a 50-year-old male.

Figure 85-92 Traumatic lesion after placing fresh garlic onto the aching third molar in a 26-year-old male.

Cysts and Tumors

Figure 85-93 Fibroma of firm and nodular character in a 45-year-old male.

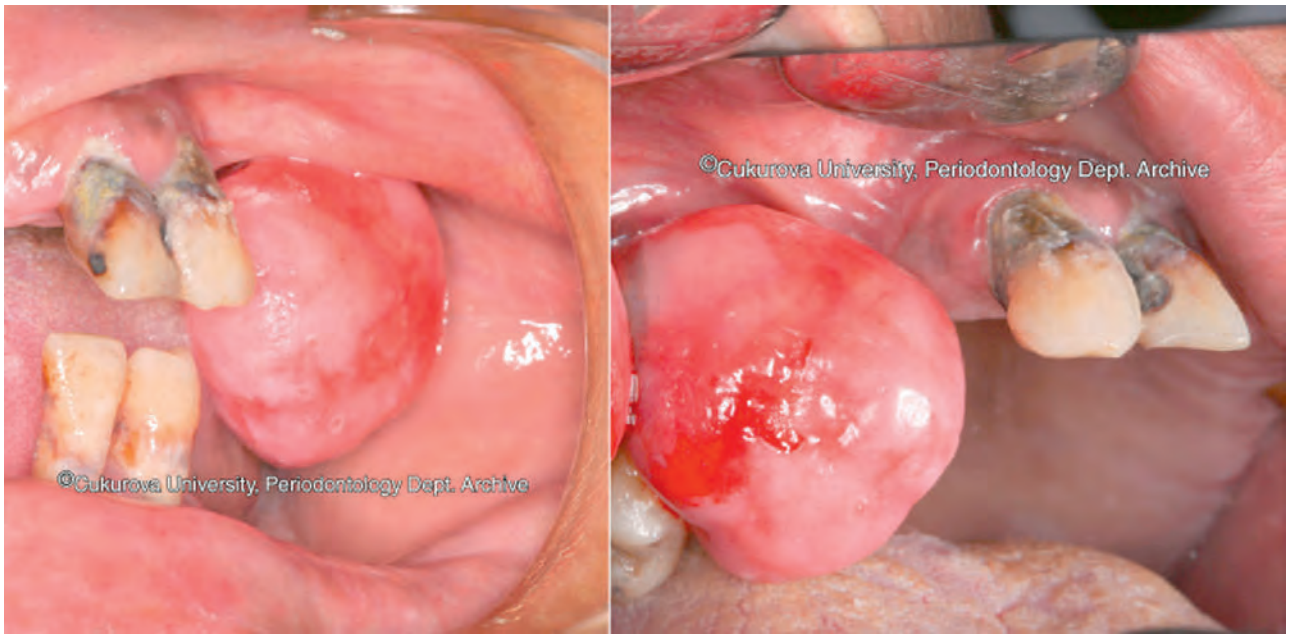

Figure 85-94 Fibroma in a 56-year-old male. *(Courtesy Dr. Burcu Cam and Dr. Onur Ozcelik.)*

Figure 85-95 Papilloma in a 27-year-old female.

Figure 85-96 Papilloma on the palatal tissue in a 42-year-old female.

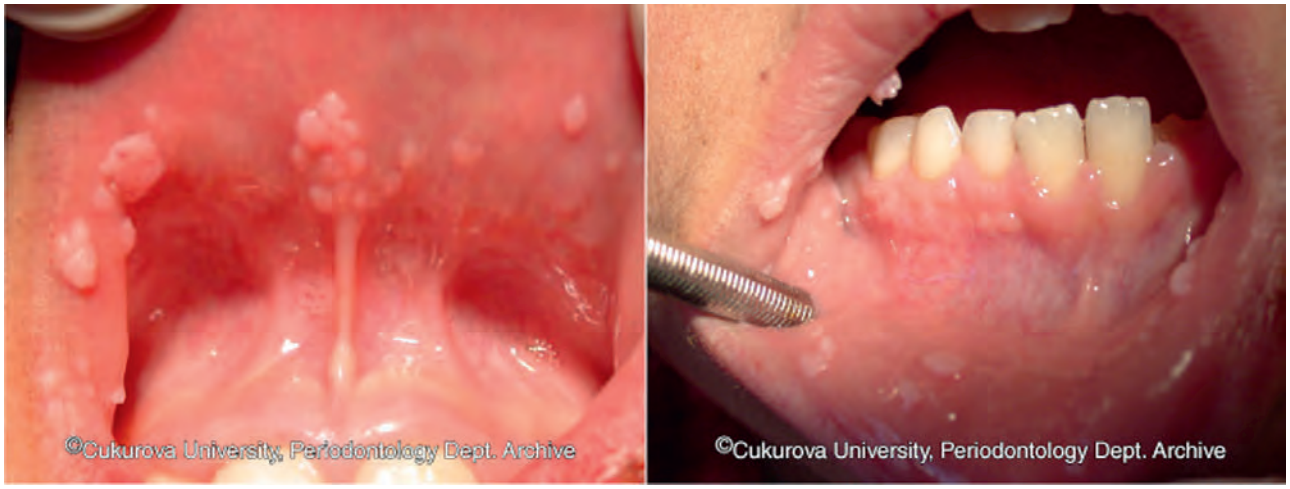

Figure 85-97 Severe generalized human papillomavirus-associated warts in a 7-year-old child.

Figure 85-98 Peripheral giant cell granuloma in a 31-year-old female.

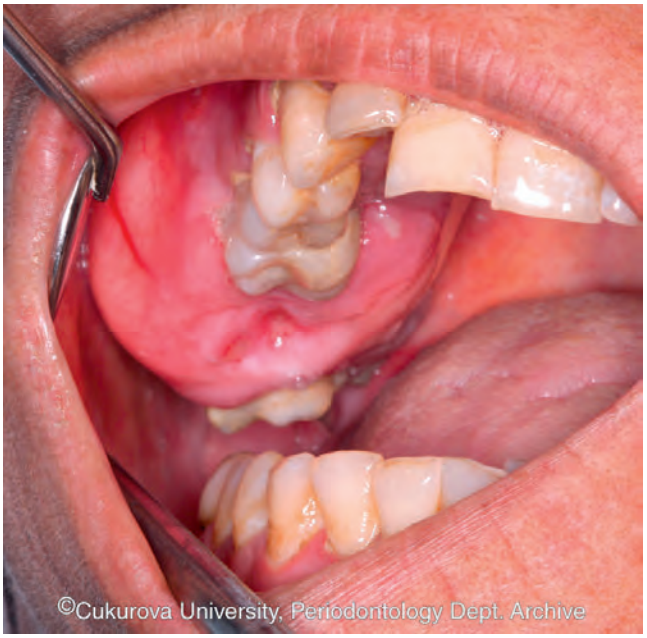

Figure 85-99 Ameloblastoma in a 54-year-old female.

Figure 85-100 Ameloblastoma in a 49-year-old patient.

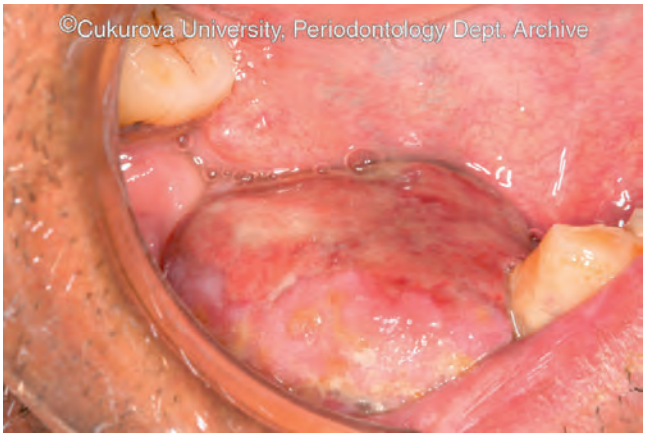

Figure 85-101 Squamous cell carcinoma in a 62-year-old patient.

Figure 85-102 Malignant melanoma in a 52-year-old female.

Chronic Periodontitis

Figure 85-103 Plaque and calculus causing chronic periodontitis in a 42-year-old man without any systemic diseases. Note the generalized radiographic bone loss.

Figure 85-104 Gingival recession, mobility, migration, and extrusion of teeth due to alveolar bone loss in a 48-year-old man with chronic periodontitis.

Figure 85-105 Advanced chronic periodontitis in a 54-year-old man with hygiene neglect and smoking as contributing factors.

Figure 85-106 Generalized bone loss in a 38-year-old female with moderate chronic periodontitis.

Figure 85-107 Generalized bone loss in a 45-year-old male smoker with advanced chronic periodontitis.

Figure 85-108 Cone-beam computed tomography view **(A)** showing generalized bone loss in a 39-year-old male with advanced chronic periodontitis. The clinical view of the patient before and 4 months after **(B)** initial periodontal therapy and extraction of mandibular incisors (*below*). Note the closure of diastema between maxillary central incisors after therapy.

Chronic Periodontitis Modified by Systemic Factors

Diabetes Mellitus

Figure 85-109 Severe gingival inflammation and periodontal abscess in a 26-year-old female with type 1 diabetes mellitus. Note the extrusion of maxillary left central incisor caused by alveolar bone loss.

Figure 85-110 Severe inflammation, pus formation, and periodontal breakdown in a 34-year-old male with uncontrolled type 1 diabetes mellitus.

Figure 85-111 A 14-year-old female was referred with a complaint of tooth mobility. She had spontaneous loss of teeth #11, #31, #41, and #46 in the past 2 years. The patient had advanced bone loss despite minimal amount of bacterial plaque with degree 3 mobility in many teeth. She was diagnosed as having type 1 diabetes mellitus upon consultation.

Figure 85-112 Alveolar bone loss and severe inflammation with spontaneous bleeding, pus formation, and abscess in a 56-year-old male with type 2 diabetes mellitus, who has been using external insulin for 12 years.

Figure 85-113 A 28-year-old female with uncontrolled type 1 diabetes mellitus was referred with complaints of rapid mobility of teeth, severe pain, and spontaneous pus and several abscesses formation. Her fasting glucose level was 486 mg/dL on the day of referral. Although the lesions resembled abscess of periodontal origin **(A)**, the pocket depths and the attachment levels were within normal levels. The computed tomography findings **(B)** and the consultation with the infection department, confirmed the diagnosis of osteomyelitis. The view of the patient after 1 week of blood glucose level control in the intensive care unit and hyperbaric oxygen therapy **(C)**. Although the lesions healed uneventfully, severe malocclusion was evident at the 1-year follow-up **(D)** examination.

Aggressive Periodontitis

Figure 85-114 Aggressive periodontitis in a 3-year-old boy without any systemic diseases. Note the severe alveolar bone destruction of deciduous molar teeth.

Figure 85-115 Extrusion of left central incisor in a 21-year-old male with localized aggressive periodontitis. Note the severe breakdown of alveolar bone on the incisor and mandibular first molar.

Figure 85-116 Advanced bone loss in an 18-year-old male with aggressive periodontitis.

Figure 85-117 Intrabony defects in a 24-year-old woman with aggressive periodontitis.

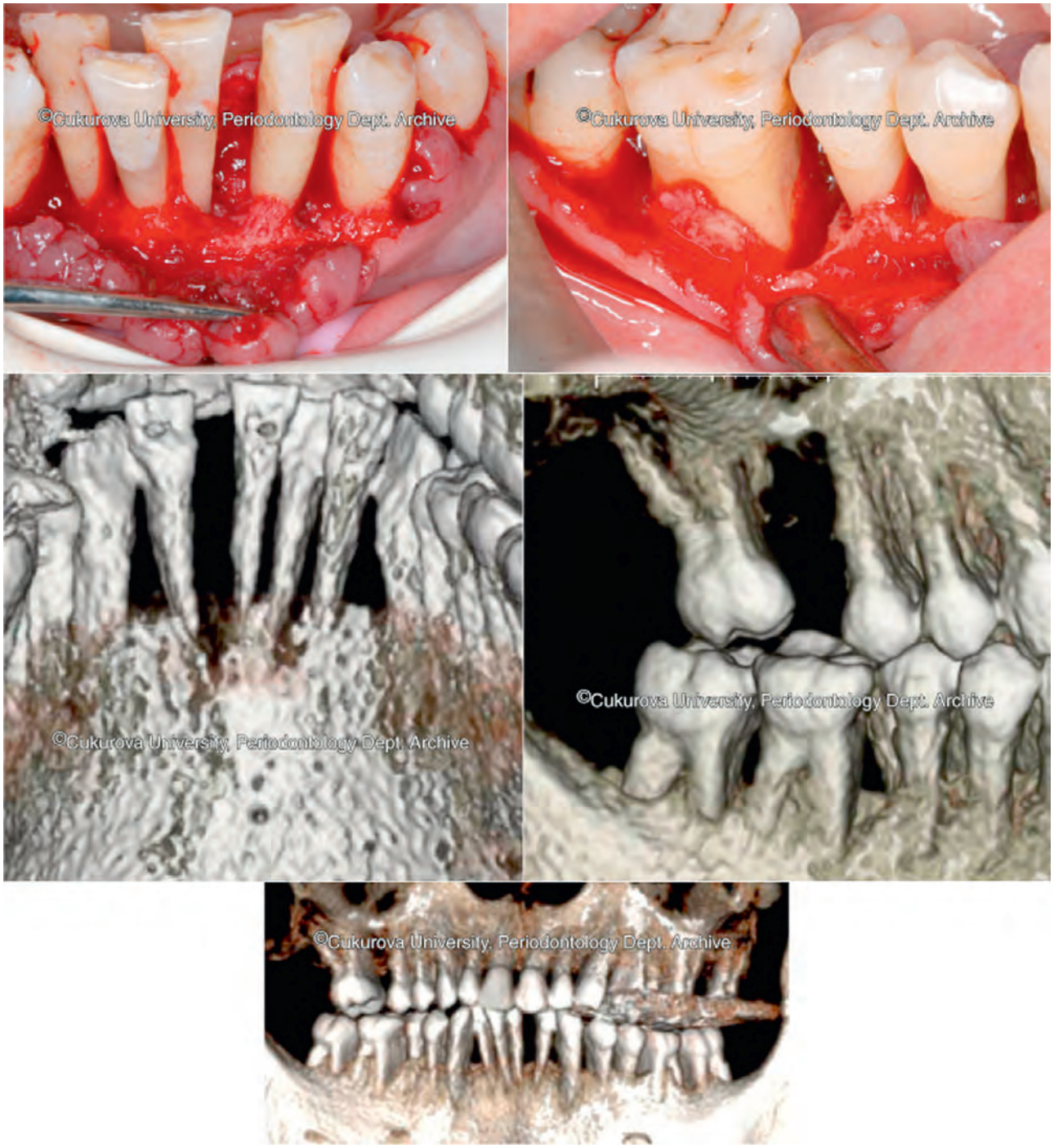

Figure 85-118 Clinical and cone-beam computed tomography view of advanced alveolar bone resorption around incisors and first molar in a 24-year-old male with aggressive periodontitis.

Figure 85-119 Clinical and radiographic views of a 27-year-old male with generalized aggressive periodontitis at the initial visit **(A)** and at the 5-year follow-up examination after therapy **(B)**. Note the cone-beam computed tomography views of advanced alveolar bone resorption around incisors **(C, D, and F)**, premolars **(E)**, and first molar **(G)**.

Periodontitis as a Manifestation of Systemic Diseases

Leukemias

Figure 85-120 A 12-year-old girl was referred with complaints of rapid swelling on the face **(A)** and gingiva **(B)** and spontaneous bleeding **(C)**. The patient also had persistent fever and general malaise for 2 weeks. Radiographic analysis revealed alveolar bone loss and separation of the roots of maxillary right lateral and canine **(D)**. The consultation with the hematology department and the histologic analysis of the lesion confirmed the diagnosis of granulocytic sarcoma (proceeder of acute myelogenous leukemia [AML]). Histologically, infiltration of atypic myeloid cells into the gingival tissues was evident **(E)** (H&E ×100). The lesion regressed significantly after two courses of chemotherapy **(F)**. *(From Antmen B, et al:* J Periodontol *74:1514-1519, October 2003.)*

Figure 85-121 A 14-year-old boy was referred with complaints of rapid mobility of teeth, gingival swelling, persistent fever, and joint pain. Clinical examination revealed gingival hyperplasia in accordance with the expansion of jaw bones and third-degree mobility in many teeth despite minimal bacterial plaque **(A)**. Radiographically, there was severe bone loss, abnormal trabeculation, and radiolucent areas around roots, which was more prominent on the molar teeth **(B)**. The bone marrow aspiration biopsy revealed cytoplasmic vacuolization of lymphoblasts, which is specific for acute lymphoblastic leukemia type L3 **(C)** (May-Grünwald Giemsa ×100). *(From Haytac, et al:* J Periodontol *74(4):547-551, April 2003.)*

Figure 85-122 Alveolar bone destruction and gingival enlargement around teeth #41, #42, and #43 in a 15-year-old boy with acute lymphocytic leukemia.

Genetic Disorders

Figure 85-123 A 16-year-old female who had been receiving treatment for neutropenia for 8 years was referred for gingival inflammation. Severe malocclusion and gingival inflammation, spontaneous bleeding, deep periodontal pockets up to 15 mm and advanced radiographic alveolar bone was observed.

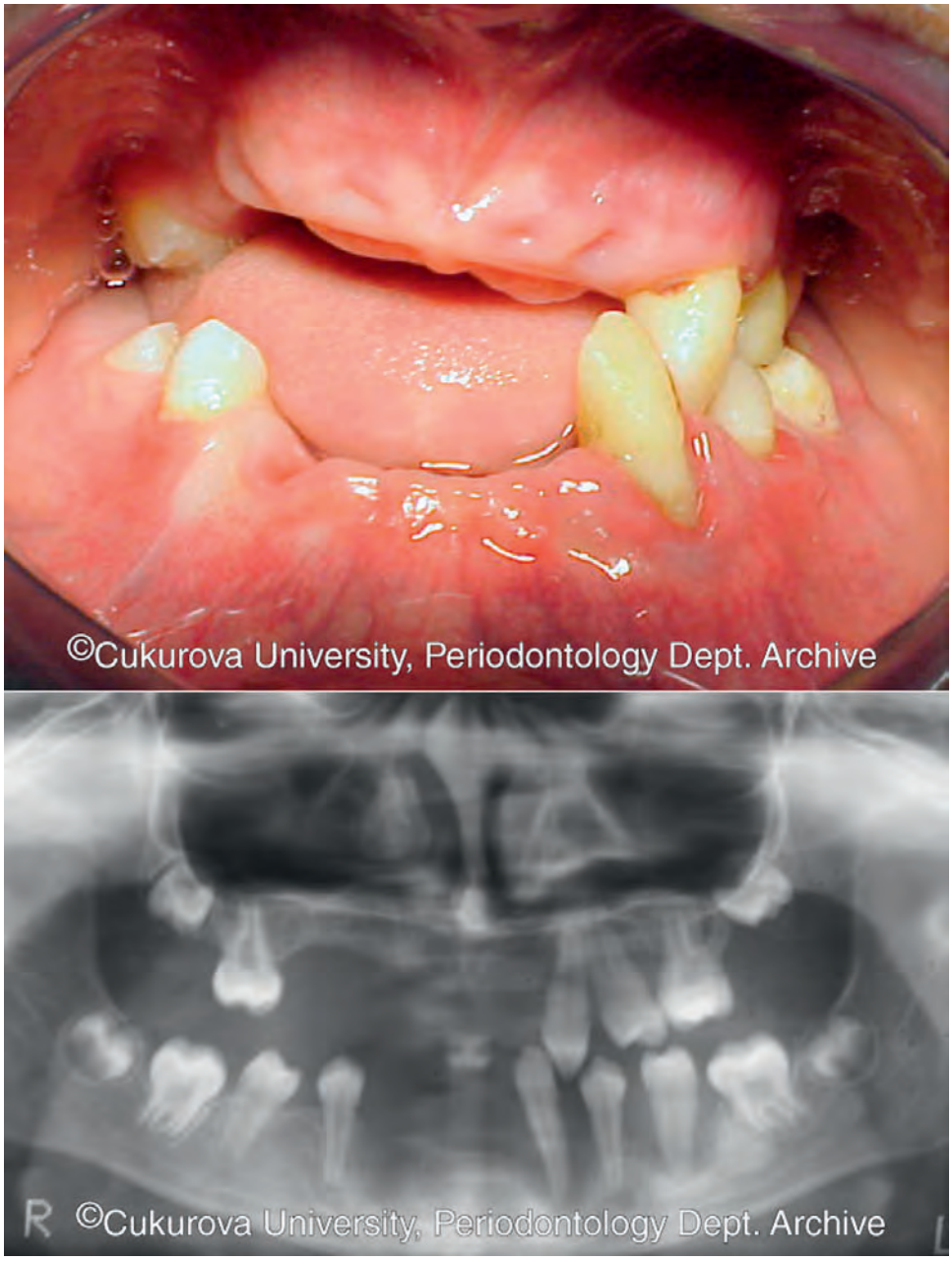

Figure 85-124 An 11-year-old girl with leukocyte adhesion deficiency was referred to the periodontology department. She had recurrent skin, ear, upper respiratory tract, and lung infections since childhood and was diagnosed having leukocyte adhesion deficiency (LAD) 4 years ago. She had one kidney surgically removed due to infection. Intraorally, the patient had severe periodontal breakdown with spontaneous loss of many teeth and advanced bone loss, deep pockets up to 15 mm, and mobility for the remaining teeth. The patient's elder sister, who was 14 years old, also had LAD and diagnosed at the same period. The elder sister's periodontal status is shown in Figure 85-125.

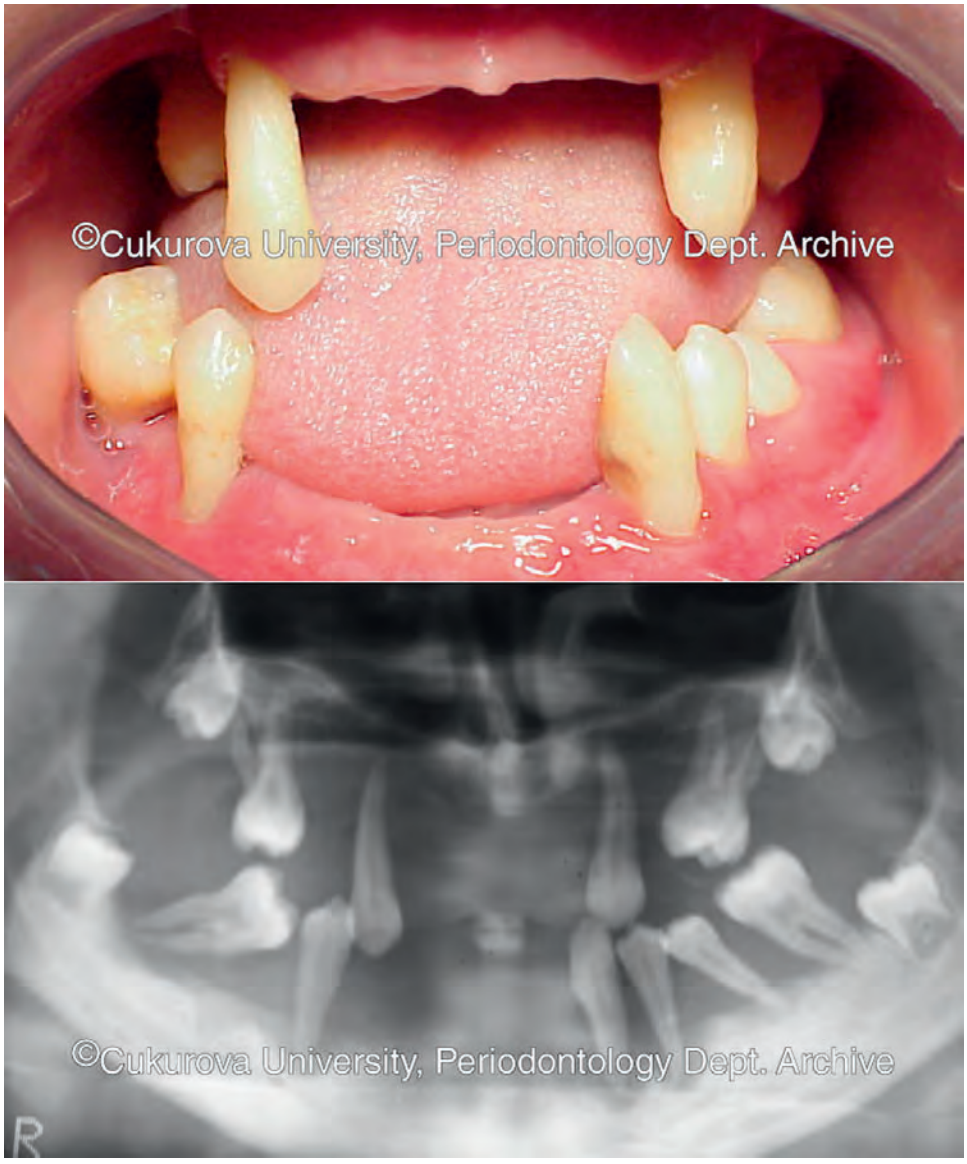

Figure 85-125 Leukocyte adhesion deficiency in a 14-year-old girl.

Figure 85-126 Hyperkeratosis of the palms, loss of anterior teeth, gingival recession, and extensive radiographic alveolar bone loss of deciduous teeth in a 3-year-old boy with Papillon-Lefèvre syndrome.

Figure 85-127 Hyperkeratosis of the palms and soles of a 12-year-old girl with Papillon-Lefèvre syndrome. The patient had spontaneous loss of many teeth and deep pockets ranging from 4 to 12 mm on the remaining teeth. Note the severe alveolar bone destruction in the panoramic radiograph.

Figure 85-128 Skeletal deformities and gingival inflammation in a 14-year-old girl with hypophosphatasia.

Necrotizing Periodontal Diseases

Figure 85-129 Typical "punched-out" appearance of gingiva in necrotizing ulcerative gingivitis (NUG) of a 25-year-old man.

Figure 85-130 Necrotizing ulcerative gingivitis (NUG) lesion before and after the removal of pseudomembrane in a 27-year-old female.

Figure 85-131 Crater-like lesion and pseudomembrane formation on the palatal gingival in a 31-year-old man with necrotizing ulcerative gingivitis (NUG).

Figure 85-132 Severe necrotizing ulcerative gingivitis (NUG) and necrotizing ulcerative periodontitis (NUP) infection causing extreme pain in a 22-year-old female on the first, third, and seventh day of referral. Note the rapid soft tissue destruction exposing the alveolar bone.

Bisphosphonates

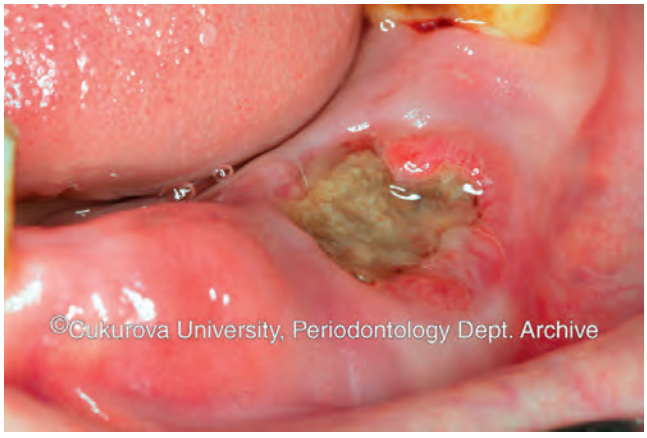

Figure 85-133 Zoledronic acid–related osteonecrosis in a 54-year-old female who had been using the drug intravenously for breast cancer. The lesion had occurred after 1 month after the extraction of tooth #36.

Figure 85-134 Rapid gingival and bone necrosis 1 month (*top left*), 2 months, and 7 months after scaling and root planing in a 52-year-old female receiving intravenous (IV) zoledronic acid after breast cancer treatment.

Abscesses of Periodontium

Figure 85-135 Periodontal abscess of left central incisor in a 21-year-old female with aggressive periodontitis.

Figure 85-136 Periodontal abscess of maxillary first molar in a 35-year-old male with chronic periodontitis.

Figure 85-137 Periodontal abscess in a 39-year-old female before and after treatment.

Figure 85-138 Pericoronitis around partially erupted mandibular third molar in a 19-year-old female.

Endodontic-Periodontal Lesions

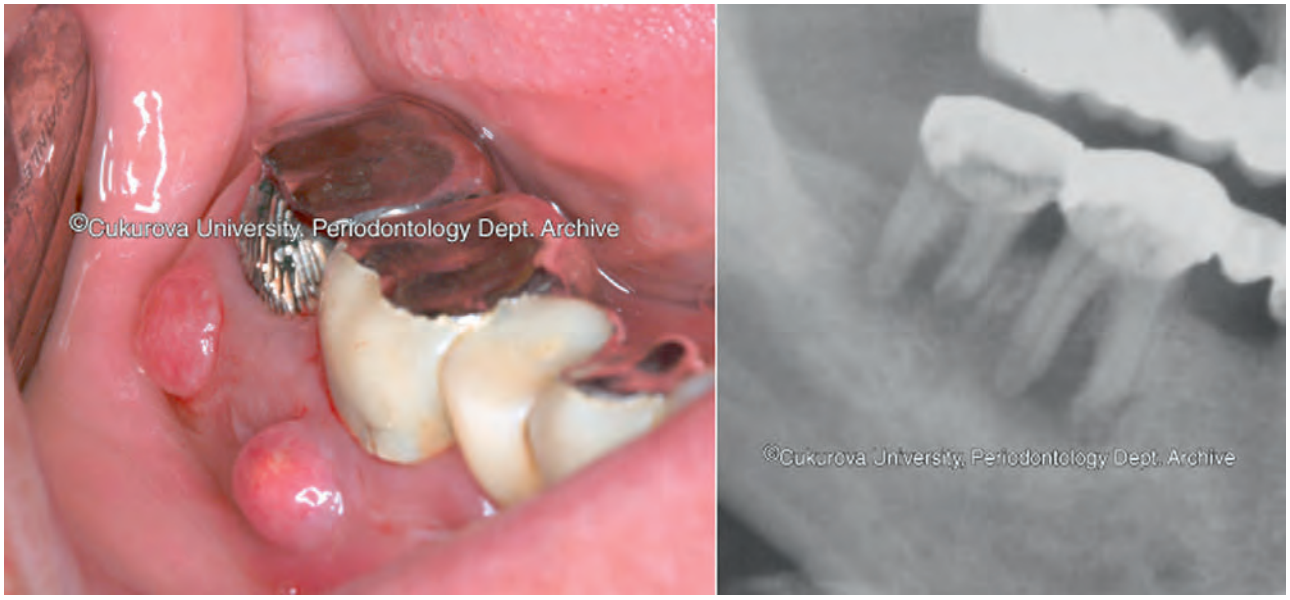

Figure 85-139 Endodontic-periodontal lesion in a 36-year-old male.

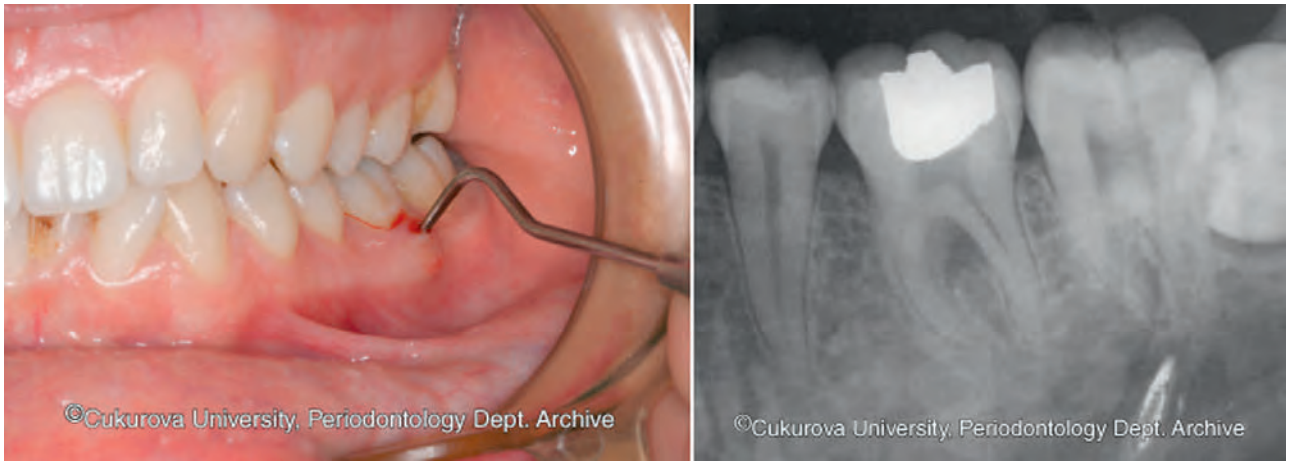

Figure 85-140 Endodontic-periodontal lesion in an 18-year-old female.

Suggested Readings

Armitage GC: Development of a classification system for periodontal diseases and conditions. *Ann Periodontol* 4:1, 1999.

Flemmig TF: Periodontitis. *Ann Periodontol* 4:32, 1999.

Holmstrup P: Non-plaque-induced gingival lesions. *Ann Periodontol* 4:20, 1999.

Kinane DF: Periodontitis modified by systemic factors. *Ann Periodontol* 4:54, 1999.

Mariotti A: Dental plaque-induced gingival diseases. *Ann Periodontol* 4:7, 1999.

Tonetti MS, Mombelli A: Early-onset periodontitis. *Ann Periodontol* 4:39, 1999.

CHAPTER 86

Introduction to Evidence-Based Decision Making

Jane L. Forrest, Syrene A. Miller, Greg W. Miller, and Michael G. Newman

CHAPTER OUTLINE

Background and Definition
Principles of Evidence-Based Decision Making
Evidence-Based Decision-Making Process and Skills
Conclusion

Each day, dental care professionals make decisions about clinical care. It is important that these decisions incorporate the best available scientific evidence to maximize the potential for successful patient care outcomes. It is also important for readers of this book to have the background and skills necessary to evaluate information they read and hear about. These evaluative skills are as important as learning facts and clinical procedures. **The ability to find, discriminate, evaluate, and use information is the most important skill that can be learned as a professional.** Becoming excellent at this skill will provide a rewarding and fulfilling professional career.

Background and Definition

Using evidence from the medical literature to answer questions, direct clinical action, and guide practice was pioneered at McMaster University, Ontario, Canada, in the 1980s. As clinical research and the publication of findings increased, so did the need to use the medical literature to guide practice. The traditional clinical problem-solving model based on individual experience or the use of information gained by consulting authorities (colleagues or textbooks) gave way to a new methodology for practice and restructured the way in which more effective clinical problem solving should be conducted. This new methodology was termed *evidence-based medicine* (EBM).[12] EBM is defined as "the integration of the best research evidence with our clinical expertise and our patient's unique values and circumstances."[31]

The use of evidence to help guide clinical decisions is not new. However, the following aspects of EBM are new:

- The methods of generating high-quality evidence, such as randomized controlled trials and other well-designed methods.
- The statistical tools for synthesizing and analyzing the evidence (systematic reviews and meta-analysis).
- The ways for accessing the evidence (electronic databases) and applying it (evidence-based decision making and practice guidelines).[9,10]

These changes have evolved along with the understanding of what constitutes the evidence and how to minimize sources of bias, quantify the magnitude of benefits and risks, and incorporate patient values.[13] "In other words, evidence-based practice is not just a new term for an old concept and as a result of advances, practitioners need (1) more efficient and effective online searching skills to find relevant evidence and (2) critical appraisal skills to rapidly evaluate and sort out what is valid and useful and what is not."[27]

Evidence-based decision making (EBDM) is the formalized process and structure for learning and using the skills for identifying, searching for, and interpreting the results of the best scientific evidence, which is considered in conjunction with the clinician's experience and judgment, the patient's preferences and values, and the clinical and patient circumstances when making patient-care decisions. Translating the EBDM process into action is based on the abilities and skills identified in Box 86-1.[31]

Principles of Evidence-Based Decision Making

The use of current best evidence does not replace clinical expertise or input from the patient but rather provides another dimension to the decision-making process,[11,16,19] which is also placed in context with the patient's clinical circumstances (Figure 86-1). It is this decision-making process that we refer to as "evidence-based decision making" and is not unique to medicine or any specific health discipline; it represents a concise way of referring to the application of evidence to clinical decision making.

EBDM focuses on solving clinical problems and involves two fundamental principles, as follows[13]:

1. Evidence alone is never sufficient to make a clinical decision.
2. Hierarchies of quality and applicability of evidence exist to guide clinical decision making.

EBDM is a structured process that incorporates a formal set of rules for interpreting the results of clinical research and places a lower value on authority or custom. In contrast to EBDM, traditional decision making relies more on intuition, unsystematic clinical experience, and pathophysiologic rationale.[13]

Evidence-Based Dentistry

Since the 1990s, the evidence-based movement has continued to advance and is widely accepted among the healthcare professions, with some refining the definition to make it more specific to their area of healthcare. The American Dental Association (ADA) has defined evidence-based dentistry (EBD) as "an approach to oral health care that requires the judicious integration of systematic assessments of clinically relevant scientific evidence, relating to

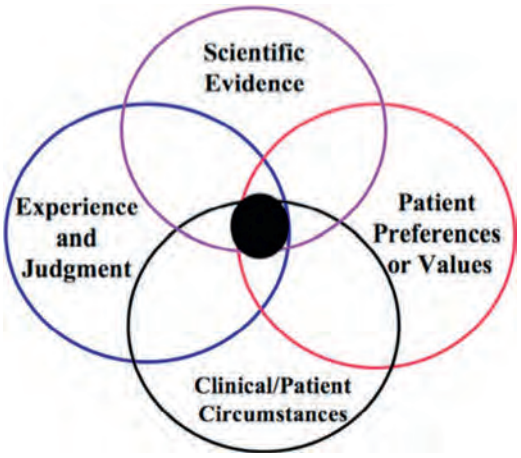

Figure 86-1 Evidence-based decision making. *(Copyright: Jane L. Forrest, reprinted with permission.)*

BOX 86-1 Skills and Abilities Needed to Apply an Evidence-Based Decision-Making Process[31]

1. Convert information needs and problems into clinical questions so that they can be answered.
2. Conduct a computerized search with maximum efficiency for finding the best external evidence with which to answer the question.
3. Critically appraise the evidence for its validity and usefulness (clinical applicability).
4. Apply the results of the appraisal, or evidence, in clinical practice.
5. Evaluate the process and your performance.

the patient's oral and medical condition and history, with the dentist's clinical expertise and the patient's treatment needs and preferences."[4] They also have established the ADA Center for Evidence-Based Dentistry™ (www.ebd.ada.org) to facilitate the integration of EBD into clinical practice.

The ADA's definition is now incorporated in the Accreditation Standards for Dental Education Programs.[3] Dental schools are expected to develop specific core competencies that focus on the need for graduates to become critical thinkers, problem solvers, and consumers of current research findings to enable them to become lifelong learners. The accreditation standards require learning EBDM skills so that graduates are competent in being able to find, evaluate, and incorporate current evidence into their decision making.[3]

Evidence-Based Decision-Making Process and Skills

The growth of evidence-based practice has been made possible through the development of online scientific databases such as MEDLINE (PubMed) and web-based software, along with the use of computers and mobile devices, for example, smart phones, that enable users to quickly access relevant clinical evidence from almost anywhere. This combination of *technology* and *good evidence* allows healthcare professionals to apply the benefits from clinical research to patient care.[29] EBDM recognizes that clinicians can never be completely current with all conditions, medications, materials, or available products, and it provides a mechanism for assimilating current research findings into everyday practice to answer questions and to stay current with innovations in dentistry.

Translating the EBDM process into action is based on the abilities and skills identified in Box 86-1.[31] This is illustrated clearly in a real patient case scenario that is introduced in Box 86-2 and used throughout the chapter.

Asking Good Questions: The PICO Process

Converting information needs and problems into clinical questions is a difficult skill to learn, but it is fundamental to evidence-based practice. The EBDM process almost always begins with a patient question or problem. A "well-built" question should include four parts that identify the patient problem or population *(P)*, intervention *(I)*, comparison *(C)*, and outcome(s) *(O)*, referred to as PICO.[31] Once these four components are clearly and succinctly identified, the following format can be used to structure the question:

"For a patient with _____ (P), will _____ (I) as compared to _____ (C) increase/decrease/provide better/in doing _____ (O)?"

The formality of using PICO to frame the question serves two key purposes, as follows:

1. PICO forces the clinician to focus on what he or she and the patient believe to be the most important single issue and outcome.
2. PICO facilitates the next step in the process, the computerized search, by identifying key terms that will be used in the search.[31]

The conversion of information needs into a clinical question is demonstrated using the case scenario from Box 86-2. Two separate PICO questions were written as follows:

1. For a patient with replanted avulsed and luxated teeth (P), will early pulp extirpation (10 to 14 days) (I) as compared to late pulp extirpation (past 14 days) (C) increase the likelihood of successful tooth integration and functional periodontal healing, and decrease the likelihood of resorption and ankylosis (O)?
2. For a patient with replanted avulsed and luxated teeth (P), will short-term splinting (7 to 14 days) (I) as compared to long-term splinting (2 to 4 weeks) (C) increase the likelihood of successful tooth integration and functional periodontal healing, and decrease the development of resorption and ankylosis (O)?

PICO directs the clinician to clearly identify the problem, the results, and the outcomes related to the specific care provided to that patient. This in turn helps identify the search terms that should be used to conduct an efficient search. It also allows identification of the type of evidence and information required to solve the problem, as well as considerations for measuring the effectiveness of the intervention and the application of the EBDM process. Thus EBDM supports continuous quality improvements through measuring outcomes of care and self-reflection.

Prior to conducting a computerized search, it is important to have an understanding of the types of research study methodologies and the appropriate methodology that relates to different types of clinical questions. The methodology, in turn, relates to the levels of evidence. Table 86-1 shows these relationships.

Becoming a Competent Consumer of the Evidence

Evidence typically comes from studies related to questions about treatment and prevention, diagnosis, etiology and harm, and prognosis of disease, as well as from questions about the quality and economics of care. Evidence is considered the synthesis of all valid

BOX 86-2 Case Scenario—Clinical Application of Evidence-Based Decision Making

The clinician received a call from the parents of a 13-year-old female patient who had been struck in the face with a softball. She was being examined by paramedics in a town 30 minutes north of the dental office. The paramedics cleared the patient of any head or neck injury and other medical issues and informed the dentist that dental trauma was her primary injury. The dentist and his assistant met the parents and the patient at the office 45 minutes following the dental trauma. The patient's teeth remained in her mouth following the incident. Figure 86-2 shows the initial examination of the patient. The patient and her parent's preference was to "do anything to keep the teeth." After the site was cleaned and irrigated, it was apparent that there was complete avulsion of the maxillary right central incisor from the socket and lateral luxation of the maxillary left central and lateral incisors. In addition, there was alveolar bone fracture partially encasing the roots of the maxillary left central and lateral incisors (Figure 86-3.) The clinician replanted the teeth and reapproximated the gingival tissue with sutures (Figure 86-4). A stable and accurate Ribbond® and flowable composite splint was placed (Figure 86-5) and a radiograph was taken (Figure 86-6).

Radiographic Examination

The radiograph shows reimplantation of maxillary central incisors and left lateral incisor in correct socket location and confirmed proper reapproximation of the alveolar bone that was fractured with maxillary left central and lateral incisors. The stent also is apparent in this radiograph showing the splinting of the displaced teeth.

Due to the difficulty of splint placement and not wanting to risk displacing the teeth or breaking the splint prematurely, the clinician was hesitant to proceed with endodontic treatment until he had access to dependable information. The dentist had two questions regarding the treatment of the patient. He needed to determine the optimal timing of the pulp extirpation and splinting that would result in the best outcome and prognosis for healing. Figure 86-7 diagrams the decision making pathway from phone call to resolution.[24]

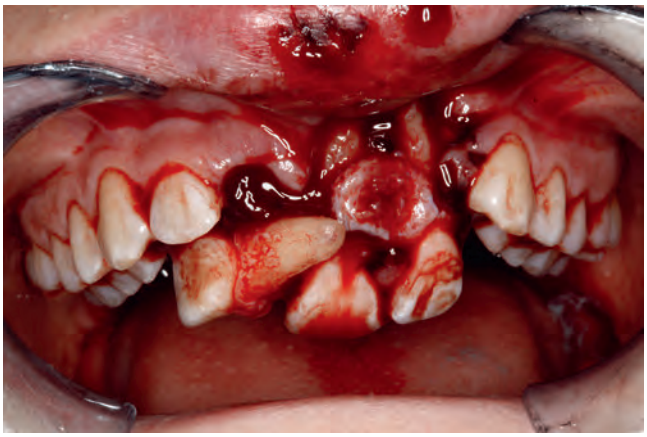

Figure 86-3 Trauma site following irrigation. *(Copyright: Greg W. Miller, DDS, reprinted with permission.)*

Figure 86-4 Replantation of avulsed and luxated teeth. *(Copyright: Greg W. Miller, DDS, reprinted with permission.)*

Figure 86-2 Initial examination of the patient. *(Copyright: Greg W. Miller, DDS, reprinted with permission.)*

Figure 86-5 Replanted and splinted teeth. *(Copyright: Greg W. Miller, DDS, reprinted with permission.)*

Figure 86-6 Radiograph after placement of the splint. *(Copyright: Greg W. Miller, DDS, reprinted with permission.)*

research that answers a specific question, which in most cases, distinguishes it from a single research study.[15] Once synthesized, evidence can help inform decisions about whether a method of diagnosis or a treatment is effective relative to other methods of diagnoses or to other treatments and under what circumstances. The challenge in using EBDM arises when there is only one research study available on a particular topic. In these cases, individuals should be cautious in relying on the study because it can be contradicted by another study and it may only test efficacy and not effectiveness. This underscores the importance of staying current with the scientific literature, because the body of evidence evolves over time as more research is conducted. Another challenge in using EBDM occurs when the limited research available is weak in quality or poorly conducted. In these cases, one may rely more heavily on clinical experience and patient preferences and values than the scientific evidence (see Figure 86-1).

Sources of Evidence. The two types of evidence-based sources are primary and secondary, as follows:

- *Primary sources* are original research studies and publications that have not been filtered or synthesized, such as a randomized controlled trial (RCT) or a cohort study.
- *Secondary sources* are synthesized studies and publications of the already conducted primary research. These include clinical practice guidelines (CPGs), systematic reviews (SRs), meta-analyses (MAs), and evidence-based article reviews and protocols. This terminology is often confusing

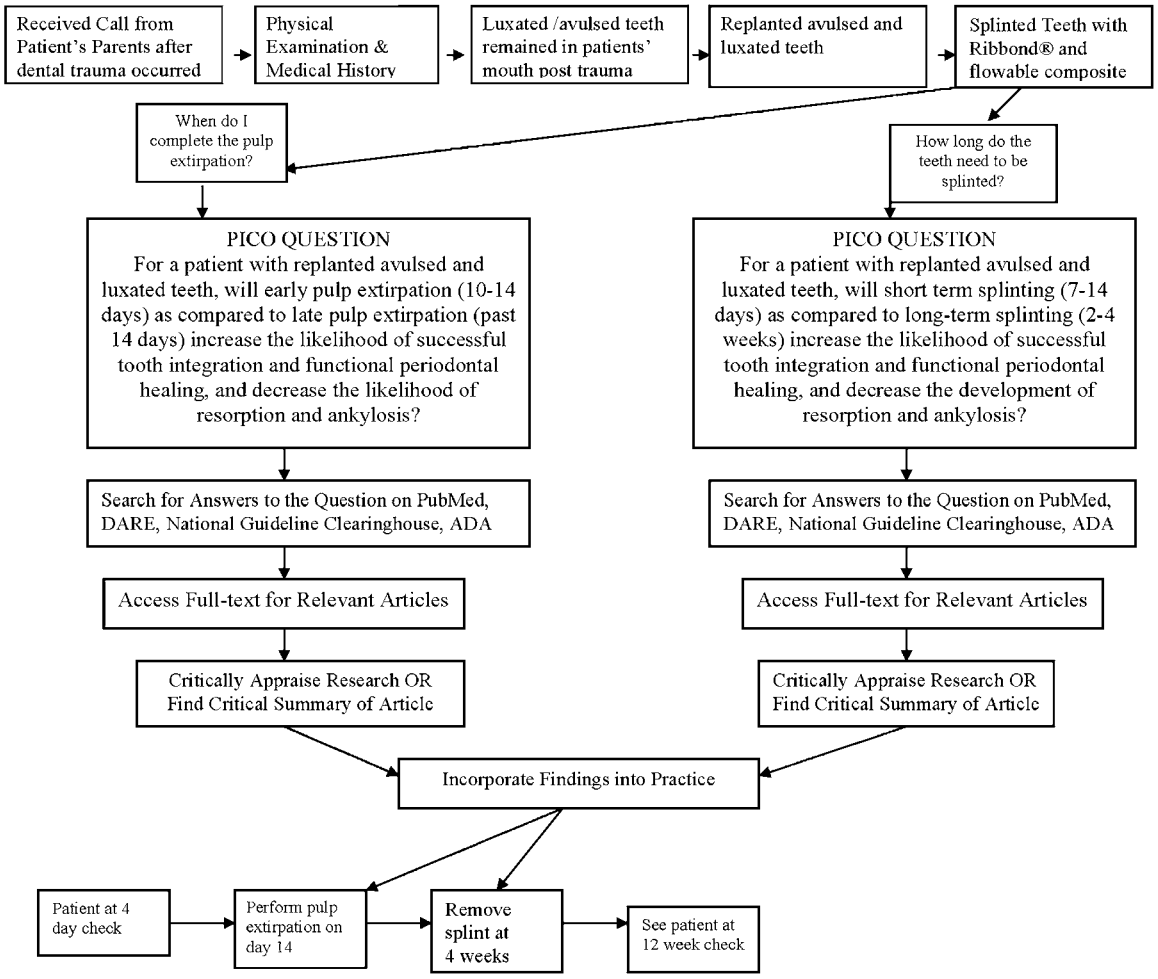

Figure 86-7 Decision-making pathway from phone call to resolution. *(Copyright: Greg W. Miller, DDS, reprinted with permission.)*

TABLE 86-1 Type of Question Related to Type of Methodology and Levels of Evidence

Type of Question	Methodology of Choice[23]	Question Focus[23]
Therapy, prevention	Meta-analyses (MA) or systematic review (SR) of randomized controlled trials (RCTs) SR of cohort studies	Study effect of therapy or test on real patients; allows for comparison between intervention and control groups; largest volume of evidence-based literature.
Diagnosis	MA or SR of controlled trials (prospective cohort study) *Controlled trial* (Prospective: compare tests with a reference or "gold standard" test.)	Measures reliability of a particular diagnostic measure for a disease against the "gold standard" diagnostic measure for the same disease.
Etiology, causation, harm	MA or SR of cohort studies *Cohort study* (Prospective data collection with formal control group)	Compares a group exposed to a particular agent with an unexposed group; important for understanding prevention and control of disease.
Prognosis	MA or SR of inception cohort studies *Inception cohort study* (All have disease but free of the outcome of interest.) *Retrospective cohort*	Follows progression of a group with a particular disease and compares with a group without the disease.

to individuals new to the EBDM approach because, although SRs are **secondary** sources of evidence, they are considered a higher level of evidence than a **primary** source, such as an individual RCT.

Both primary and secondary sources can be found by conducting a search using such biomedical databases as MEDLINE (PubMed), EMBASE, and Database of Abstracts of Review of Effectiveness (DARE). Other sources of secondary evidence, such as CPGs, clinical recommendations, parameters of care, position papers, or academy statements related to dental practice can be found on the websites of professional organizations, such as the

- American Academy of Pediatric Dentistry: Definitions, Oral Health Policies and Clinical Guidelines (http://www.aapd.org/policies/).[1]
- American Academy of Periodontology (AAP): AAP Clinical and Scientific Papers (http://www.perio.org/resources-products/posppr2.html).[2]
- American Dental Association, Center for Evidence-Based Dentistry website (http://ebd.ada.org) provides links to SRs and critical summaries; clinical recommendations on fluorides, sealants, oral cancer screening along with chairside guides on many of these topics; and links to a variety of external resources, including PubMed and Cochrane.
- American Heart Association (AHA): Prevention of Bacterial Endocarditis, Recommendations by the American Heart Association[5] (http://circ.ahajournals.org/cgi/content/full/96/1/358).
- Centers for Disease Control and Prevention: Guidelines and Recommendations (http://www.cdc.gov/OralHealth/guidelines.htm).
- Cochrane Collaboration: The Cochrane Collaboration is an international, independent, not-for-profit organization comprised of more than 28,000 contributors from more than 100 countries dedicated to producing SRs as a reliable and relevant source of evidence about the effects of healthcare for making informed decisions. Their work is recognized as the gold standard for SRs.[7] The Cochrane Oral Health Group is but 1 of 52 groups. All Cochrane Review groups have an obligation to update the review every 2 to 4 years to account for new evidence (http://www.cochrane.org; Oral Health Group, http://ohg.cochrane.org).

Ideally, we want to be able to quickly access new research that is valid, easy to read, and has been preappraised, as there is in the two evidence-based dentistry journals, *Evidence-Based Dentistry* (http://www.nature.com/ebd/index.html) and the *Journal of Evidence-Based Dental Practice* (http://www.jebdp.com). Each journal specifically publishes one- to two-page summaries of SRs or original research articles with expert commentary including the clinical application. Also, many of the general dentistry and specialty journals are publishing CPGs, SRs, and MAs that support the care provided in clinical practice. However, when secondary sources are not available, it is necessary to review the primary literature.

Levels of Evidence. As previously mentioned, one principle of EBDM is that hierarchies of evidence exist to guide decision making. At the top of the hierarchy for therapy are CPGs (Figure 86-8). These are systematically developed statements to assist clinicians and patients about appropriate healthcare for specific clinical circumstances.[8] CPGs should be based on the best available scientific evidence typically from MAs and SRs, which put together all that is known about a topic in an objective manner. The level and quality of the evidence are then analyzed by a panel of experts who formulate the CPGs. Thus, guidelines are intended to translate the research into practical application.

Guidelines also will change over time as the evidence evolves, underscoring the importance of keeping current with the scientific literature. One example of this is the change in the American Heart Association guidelines for the prevention of infective endocarditis related to the need for premedication before dental and dental hygiene procedures.[32] Prior to the 2007 guidelines, the last update was in 1997, and prior to then, there were eight updates to the primary regimens for dental procedures since the original guideline was first published in 1955. In the 2007 update, the rationale for revising the 1997 document was provided, notably that the prior guidelines were largely based on expert opinion and a few case-controlled studies. With more research conducted, there now was the ability to synthesize those findings to provide a more objective body of evidence on which to base recommendations.[32]

If a CPG does not exist, there are other sources of preappraised evidence (critical summaries, critically appraised topics [CATs], SRs, MAs, or reviews of individual research studies) available to help stay current. MAs and SRs have strict protocols to reduce bias and the synthesis of research from more than one study. These reviews provide a summary of multiple research studies that have investigated the same specific question. SRs use explicit criteria

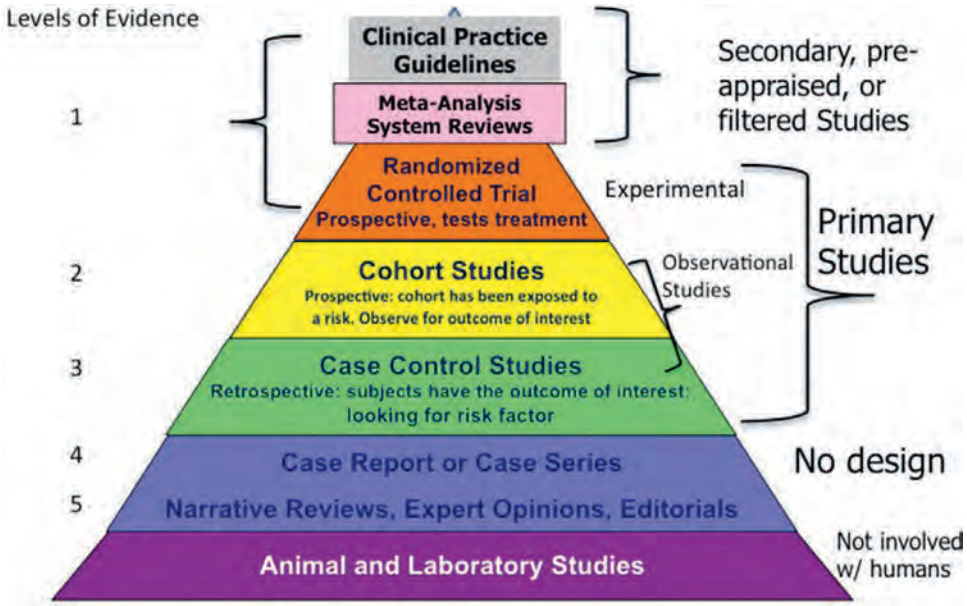

Figure 86-8 Hierarchy of research and levels of clinical evidence. *(Image © 2012 JL Forrest, SA Miller: National Center for Dental Hygiene Research & Practice.)*

for retrieval, assessment, and synthesis of evidence from individual RCTs and other well-controlled methods. SRs facilitate decision making by providing a clear summary of the current state of the existing evidence on a specific topic. SRs provide a way of managing large quantities of information,[25] making it easier to keep current with new research.

MA is a statistical process used when the data from the individual studies in the SR can be combined into one analysis. When data from these studies are pooled, the sample size and power usually increase. As a result, the combined effect can increase the precision of estimates of treatment effects and exposure risks.[25]

SRs and MAs are followed respectively by individual RCT studies, cohort studies, case-control studies, and then studies not involving human subjects.[28] In the absence of scientific evidence, the consensus opinion of experts in appropriate fields of research and clinical practice is used (see Figure 86-8). This hierarchy of evidence is based on the concept of causation and the need to control bias.[21,23] Although each level may contribute to the total body of knowledge, "not all levels are equally useful for making patient care decisions."[23] In progressing up the pyramid, the number of studies and, correspondingly, the amount of available literature decreases, while at the same time their relevance to answering clinical questions increases.

Evidence is judged on its rigor of methodology, and the level of evidence is directly related to the type of question asked, such as those derived from issues of therapy or prevention, diagnosis, etiology, and prognosis (see Table 86-1). For example, the highest level of evidence associated with questions about therapy or prevention will be from CPGs based on MAs and/or SRs of RCT studies. However, the highest level of evidence associated with questions about prognosis will be from CPGs based on MAs and/or SRs of inception cohort studies.[28] Because the two case scenario questions are related to prognosis, the highest level of evidence for them is a CPG based on MAs and/or SRs of inception cohort studies. If no CPG is found, then the next highest level would be a critical summary of an MA or SR of cohort studies. In the event that a critical summary is not found, MAs or SRs of cohort studies followed by individual cohort studies provide the next highest levels of evidence.

Knowing what constitutes the highest levels of evidence and knowing how to apply evidence-based filters are necessary skills in order to search the literature with maximum efficiency.[23] By using filters, one can refine the search to limit the citations to publication types such as practice guidelines, MAs, SRs, RCTs, and clinical trials, the highest levels of evidence.

Searching for and Acquiring the Evidence

PubMed is designed to provide access to both primary and secondary research from the biomedical literature. PubMed provides free access to MEDLINE, the National Library of Medicine's premier bibliographic database covering the fields of medicine, nursing, dentistry, veterinary medicine, the healthcare system, and the preclinical sciences. MEDLINE contains bibliographic citations and author abstracts from more than 5200 biomedical journals published in the United States and 80 other countries. The database contains more than 22 million citations dating back to 1966, and it adds more than 520,000 new citations each year.[26]

It is often helpful to identify the appropriate terminology when searching PubMed. This is done by using the Medical Subject Heading (MeSH) database. It provides the definition of terms and illustrates how the terms are indexed in MEDLINE. The PICO terms from the question can be typed into the MeSH database to maximize searching efficiency. For example, by typing "avulsed tooth" into the MeSH database, a term from the case scenario, it is learned that the MeSH term is "tooth avulsion." It is defined as partial or complete displacement of a tooth from its alveolar support. It is commonly the result of trauma. It also is learned that "tooth luxation" links to the MeSH term "tooth avulsion." This informs the searcher that "tooth avulsion" is the best term to use for the search because it encompasses both avulsed and luxated teeth.[22]

Using PubMed's Clinical Queries feature, one can quickly pinpoint a set of citations that will potentially provide an answer to the question being posed. Although online databases provide quicker access to the literature, knowing how databases filter information and having an understanding of how to use search terms and database features allows a more efficient search to be conducted.

Because two focused clinical (PICO) questions were generated from the clinical case, two separate searches were conducted, one

TABLE 86-2 Search Terms for Each PICO Question

PICO Question 1 Search Terms		PICO Question 2 Search Terms
Tooth avulsion (MeSH)[22] OR Tooth replantation (MeSH)[22]	**P**	Tooth avulsion (MeSH)[22] OR Tooth replantation (MeSH)[22]
Pulp extirpation OR root canal therapy (MeSH)[22]	**I**	Splints (MeSH)[22]
(Same intervention as above, however, timing is the real comparison so that is the factor in the final article selection.)	**C**	(Same intervention as above, however, timing is the real comparison so that is the factor in the final article selection.)
Tooth integration OR functional periodontal healing OR root resorption (MeSH)[22] OR tooth ankylosis (MeSH)[22]	**O** These terms were used as inclusion criteria and were not used when searching PubMed because only a few number of systematic reviews and guidelines were found just using the P, I, C terms.	Tooth integration OR functional periodontal healing OR root resorption (MeSH)[22] OR tooth ankylosis (MeSH)[22]

for each PICO question. In addition to PubMed, several other databases were used to find high levels of evidence. These included the Database of Abstracts of Reviews of Effects (http://www.crd.york.ac.uk), the National Guideline Clearinghouse (http://www.guideline.gov), the ADA Center for Evidence-Based Dentistry website (http://ebd.ada.org), the American Academy of Pediatric Dentistry website (www.aapd.org), and the American Association of Endodontists (www.aae.org), resulting in several relevant references.

When searching for evidence, the PICO question guides the search[4,6] (Table 86-2). By using key terms identified in the PICO question and combining them using the Boolean operators "OR" and "AND," relevant articles can be narrowed to a manageable number.

The first search used the terms "(tooth avulsion OR tooth replantation) AND (pulp extirpation OR root canal therapy)." This resulted in 590 papers. Studies were limited to practice guidelines, MAs, and SRs using each of these three filters separately so that each of these types of studies could be identified. The findings included four practice guidelines including those of the American Association of Endodontists and the International Association of Dental Traumatology, one critical summary of an SR, and, one SR. The second search used the terms "(tooth avulsion OR tooth replantation) AND splints." This resulted in 340 papers. Again, studies were limited to practice guidelines, MAs, and SRs using the filter for each publication type separately. Relevant results included four practice guidelines from the International Association of Dental Traumatology and Pediatric Dentistry, one MA, and one SR. Figure 86-7 provides a detailed review of the decision-making steps in this case and the outcomes.[24]

The articles that were selected as relevant research included each aspect of the PICO question. Inclusion criteria included the following: The patient population studied had to have replanted avulsed or luxated teeth; the research studied the intervention for each of the two PICO questions, pulp extirpation and splint duration respectively; and measured at least one of the outcomes of tooth integration, functional periodontal healing, or the levels of resorption or ankylosis. To reduce the requirement of critical appraisal, the search also looked for critical summaries of the SRs that were found.

Appraising the Evidence

After identifying the evidence gathered to answer a question, it is important to have the skills to understand the evidence found. In all cases, it is necessary to review the evidence, whether it is a CPG, MA, SR, or an original study, to determine if the methods were conducted rigorously and appropriately. International evidence-based groups have made this easier by developing appraisal forms and checklists that guide the user through a structured series of "YES/NO" questions to determine the validity of the individual study or SR. Table 86-3 provides the names and websites of three different guides that can be used for critical analysis.

TABLE 86-3 Examples of Critical Analysis Guides

Guide	Purpose
CONSORT (Consolidated Standards of Reporting Trials) statement[3] http://www.consort-statement.org/	To improve the reporting and review of RCTs.
PRISMA (Preferred Reporting Items for Systematic Reviews and Meta-analyses) http://www.prisma-statement.org/	To improve the reporting and review of SRs.
CASP (Critical Appraisal Skills Program)[9] http://www.casp-uk.net/	To review RCTs, SRs, and several other types of studies.

RCTs, Randomized controlled trials; *SRs*, systematic reviews.

Common Ways Used to Report Results. Once the results are determined to be valid, the next step is to determine if the results, potential benefits (or harms), are important. Straus and colleagues[31] identified the clinically useful measures for each type of study. For example, in determining the magnitude of therapy results, we would expect articles to report the control event rate (CER), the experimental event rate (EER), the absolute and relative risk reduction (ARR or RRR), and numbers needed to treat (NNT). NNT provides the number of patients (e.g., surfaces, periodontal pockets) who would need to be treated with the experimental treatment or intervention to achieve one additional patient (surfaces, periodontal pockets) who has a favorable response. Another way of assessing evidence is presented in Chapter 87, which introduces 12 tools that may be useful in assessing causality in clinical sciences.

In appraising the evidence found for the case scenario, the first research study retrieved that answered the first PICO question was a well-conducted SR published in *Dental Traumatology* in 2009.[17]

Results indicated there was an association between pulp extirpations performed after 14 days following replantation and the development of inflammatory resorption. A corresponding critical summary also was found.[30] This evidence was consistent with the 2007 clinical guidelines from the International Association of Dental Traumatology for pulp extirpation within 10 to 14 days of replantation.[14]

The Practice Guideline on the Management of Acute Dental Trauma from the American Academy of Pediatric Dentistry answered the second PICO question. It recommended a "flexible splint for 1 week" for avulsed teeth. However, for lateral luxation, an additional 2 to 4 weeks may be needed when there is breakdown of marginal bone.[1] In addition, a recent well-conducted SR about splinting duration reported inconclusive evidence of an association between short-term splinting and an increased likelihood of functional periodontal healing, acceptable healing, or decreased development of replacement resorption.[18] The study found no evidence to contraindicate the current guidelines and suggests that the likelihood of successful periodontal healing after replantation is unaffected by splinting duration. Although this SR excluded studies of luxated teeth, this SR is still applicable to the patient. It concluded that dentists should continue to use the currently recommended splinting periods when replanting avulsed permanent teeth, pending future research to the contrary.[18] Consistent with previous reviews, another SR on splinting luxated, avulsed, and root-fractured teeth reported that "the types of splint and the fixation period are generally not significant variables when related to healing outcomes."[20] These two SRs were appraised using the Critical Appraisal Skills Program (CASP) form for appraising reviews (see Table 86-3).

Applying the Evidence: Evidence-Based Dentistry in Action

Throughout this chapter, the EBDM process has illustrated the application of evidence in clinical decision-making. The clinician used the EBDM process to answer two clinical questions. There were several relevant resources that were incorporated into the decision-making process and the treatment of the patient. The clinician performed pulp extirpations on the avulsed and luxated teeth within the recommended time period of 10 to 14 days (Figure 86-9). Healing at 2 weeks posttrauma is seen in Figure 86-10. The clinician also removed the splint within the recommended time frame for luxated teeth of 2 to 4 weeks. The evidence, in combination with clinical experience helped provide care for this patient that resulted in the best possible prognosis given the extent of the patient's dental trauma. It also allowed the patient to keep her own teeth, which incorporated the patient preferences aspect of the EBDM process. Figure 86-11 shows the patient at 4 weeks posttrauma; Figure 86-12 shows the patient at 12 weeks; and Figure 86-13 shows the patient 2 years posttrauma.

Evaluating the Outcomes

The final steps in the EBDM process are to evaluate the effectiveness of the intervention and clinical outcomes and to determine how effectively the EBDM process was applied. For example, one question to ask in evaluating the effectiveness of the intervention is, "Did the selected intervention or treatment achieve the desired result?" In this specific case, the answer is yes.

EBDM is a valuable tool that guides practice decisions to achieve optimal results. In the case of tooth avulsion, the key PICO questions were established to identify research that studied the outcomes of reducing the risk of root resorption and tooth ankylosis and increase periodontal healing. In using the EBDM process, providers can be confident that they have the most current and

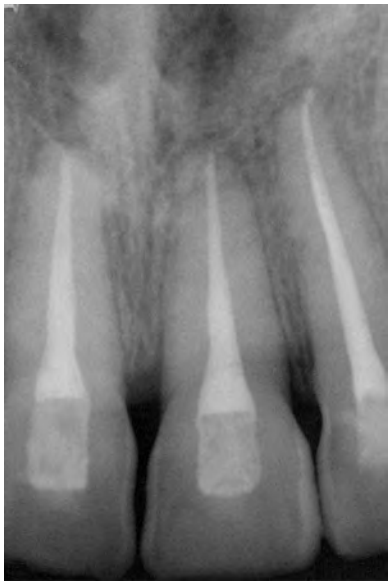

Figure 86-9 Periapical radiograph following pulp extirpations. *(Copyright: Greg W. Miller, DDS, reprinted with permission.)*

Figure 86-10 Healing at 2 weeks posttrauma. *(Copyright: Greg W. Miller, DDS, reprinted with permission.)*

Figure 86-11 Healing at 4 weeks posttrauma. *(Copyright: Greg W. Miller, DDS, reprinted with permission.)*

Figure 86-12 Healing at 12 weeks posttrauma. *(Copyright: Greg W. Miller, DDS, reprinted with permission.)*

Figure 86-13 Patient 2 years posttrauma. *(Copyright: Greg W. Miller, DDS, reprinted with permission.)*

relevant evidence available on which to base treatment decisions in order to provide the best treatment to improve the possibility of a successful outcome.

Using an EBDM approach requires understanding new concepts and developing new skills. In addition to evaluating patient care outcomes, another aspect of evaluation is in using the EBDM process. Questions that parallel each step in the EBDM process can be asked in evaluating self-performance. For example, "How well was the search conducted to find appropriate and relevant evidence to answer the question?" As with most learning, time and practice are essential to mastering new techniques.

Conclusion

An EBDM approach closes the gap between clinical research and the realities of practice by providing dental practitioners with the skills to find, efficiently filter, interpret, and apply research findings so that what is known is reflected in the care provided. This approach assists clinicians in keeping current with conditions that a patient may have by providing a mechanism for addressing gaps in knowledge to provide the best care possible.

As EBDM becomes standard practice, individuals must be knowledgeable about what constitutes the evidence and how it is reported. Understanding evidence-based methodology and distinctions between different types of articles, allows the clinician to judge better the validity and relevance of reported findings. To assist practitioners with this endeavor, SRs and MAs are being conducted to answer specific clinical questions and to support the development of CPGs. Journals devoted to evidence-based practice are being published to alert readers about important advances in a concise and user-friendly manner. By integrating good science with clinical judgment and patient preferences, clinicians enhance their decision-making ability and maximize the potential for successful patient care outcomes.

Suggested Readings

Free online courses: Found under Electives under the Continuing Education section of Dentalcare.com.

EBDM: Intro and formulating good clinical questions, course 311. <http://www.dentalcare.com/en-US/conteduc/index.jspx>.

Searching the literature using PubMed, course 340. <http://www.dentalcare.com/en-US/conteduc/index.jspx>.

DiCenso A, Bayley L, Haynes RB: Accessing pre-appraised evidence: fine-tuning the 5S model into a 6S model. *ACP Journal Club* 151:JC3-2–JC3-3, 2009.

Forrest JL, Miller SA: Translating evidence-based decision making into practice: EBDM concepts and finding the evidence. *J Evid Based Dent Pract* 9(2):59–72, 2009.

Forrest JL, Overman P: Keeping current: a commitment to patient care excellence through evidence based practice. *J Dent Hyg* 87(Suppl 1): 33–40, 2013.

Greenhalgh T: How to read a paper. Statistics for the non-statistician. Part I: different types of data need different statistical tests. *BMJ* 315(7104):364–366, 1997. <http://bmj.com/cgi/content/full/315/7104/364>.

Greenhalgh T: How to read a paper. Statistics for the non-statistician. II: "significant" relations and their pitfalls. *BMJ* 315(7105):422–425, 1997. <http://bmj.com/cgi/content/full/315/7105/422>.

Guide to research methods, the evidence pyramid and research designs. <http://library.downstate.edu/EBM2/2100.htm>.

Miller SA, Forrest JL: Translating evidence-based decision making into practice: appraising and applying the evidence. *J Evid Based Dent Pract* 9(4):164–182, 2009.

Miller SA, Miller G: User of evidence-based decision-making in private practice for emergency treatment of dental trauma: EB case report. *J Evid Based Dent Pract* 10:135–146, 2010.

References

1. American Academy on Pediatric Dentistry Council on Clinical Affairs: Guideline on management of acute dental trauma. *Pediatr Dent* 30(7 Suppl):175–183, 2008–2009.
2. American Academy of Periodontology (AAP): Index of AAP guidelines, position papers, statements and parameters of care. <http://www.perio.org/resources-products/posppr2.html>. Accessed April 4, 2013.
3. American Dental Association (ADA): *Commission on Dental Accreditation: Accreditation standards for dental education programs*, Chicago, 2010, ADA. <http://www.ada.org/sections/educationAndCareers/pdfs/predoc_2013.pdf>. Accessed April 1, 2013.
4. American Dental Association (ADA): ADA policy on evidence-based dentistry. professional issues and research, ADA guidelines, positions and statements. <http://www.ada.org/1754.aspx>. Accessed April 4, 2013.
5. American Heart Association (AHA): Prevention of bacterial endocarditis, recommendations by the American Heart Association. See also Dajani AS, Taubert KA, Wilson W, et al: *Prevention of bacterial endocarditis,* Circulation 96:358, 1997. <http://circ.ahajournals.org/cgi/content/full/96/1/358>. Accessed April 4, 2013.
6. Bader J, Ismail A: Survey of systematic reviews in dentistry. *J Am Dent Assoc* 135:464, 2004.
7. Cochrane Collaboration: About us. <http://www.cochrane.org/about-us> and the Cochrane Oral Health Group, <http://ohg.cochrane.org>. Accessed April 4, 2013.
8. Committee on Quality of Health Care in America IOM: *Crossing the quality chasm: a new health system for the 21st century*, Washington, DC, 2000, National Academy of Sciences.
9. Davidoff F: In the teeth of the evidence: the curious case of evidence-based medicine. *Mt Sinai J Med* 66:75, 1999.

10. Davidoff F, Case K, Fried P, et al: Evidence-based medicine: why all the fuss? *Ann Intern Med* 122:727, 1995.
11. Eisenberg J: *Statement of health care quality before the House Subcommittee on Health and the Environment*, Washington, DC, 1997, Agency for Health Care Policy and Research Archive.
12. Evidence-Based Medicine Working Group: Evidence-based medicine: a new approach to teaching the practice of medicine. *JAMA* 268:2420, 1992.
13. Evidence-Based Medicine Working Group: *Users' guides to the medical literature: a manual for EB clinical practice*, ed 2, Chicago, 2008, American Medical Association.
14. Flores MT, Andersson L, Andreasen JO, et al; International Association of Dental Traumatology: Guidelines for the management of traumatic dental injuries. <http://www.iadt-dentaltrauma.org>. Accessed April 4, 2013.
15. Greenhalgh T: Is my practice evidence-based?" Should be answered in qualitative, as well as quantitative terms. *BMJ* 313:957, 1996.
16. Haynes R: Some problems in applying evidence in clinical practice. *Ann NY Acad Sci* 703:210, 1999.
17. Hinckfuss SE, Messer LB: An evidence-based assessment of the clinical guidelines for replanted avulsed teeth. Part I: timing of pulp extirpation. *Dent Traumatol* 25(1):32–42, 2009.
18. Hinckfuss SE, Messer LB: Splinting duration and periodontal outcomes for replanted avulsed teeth: a systematic review. *Dent Traumatol* 25(2):150–157, 2009.
19. Institute of Medicine: *Dental education at the crossroads: challenges and change*, Washington, DC, 1995, National Academy Press.
20. Kahler B, Heithersay GS: An evidence-based appraisal of splinting luxated, avulsed and root-fractured teeth. *Dent Traumatol* 24(1):2–10, 2008.
21. Long A, Harrison S: The balance of evidence: evidence-based decision making. *Health Serv J* 6(Suppl):1, 1995.
22. MeSH Database. PubMed (website): <http://www.ncbi.nlm.nih.gov/mesh>. Accessed April 1, 2013.
23. McKibbon A, Eady A, Marks S: *PDQ: evidence-based principles and practice*, Hamilton, Ontario, 1999, BC Decker.
24. Miller SA, Miller G: User of evidence-based decision-making in private practice for emergency treatment of dental trauma: EB case report. *J Evid Based Dent Pract* 10:135–146, 2010.
25. Mulrow C: Rationale for systematic reviews. *BMJ* 309:597, 1994.
26. National Library of Medicine: Fact sheet, what's the difference between MEDLINE® and PubMed®? <http://www.nlm.nih.gov/pubs/factsheets/dif_med_pub.html>. Accessed June 9, 2009.
27. Palmer J, Lusher A, Snowball R: Searching for the evidence. *Genitourinary Med* 73:70, 1997.
28. Phillips B, Ball C, Sackett DL, et al: Levels of evidence and grades of recommendations. Centre for Evidence-Based Medicine, 2001; updated March 2009. <http://www.cebm.net/?o=1025>. Accessed April 4, 2013.
29. Rosenberg W, Donald A: Evidence based medicine: an approach to clinical problem-solving. *BMJ* 310:1122, 1995.
30. Stewart C: Timing of pulp extirpation for replanted avulsed teeth. *Evid Based Dent* 10(3):72, 2009.
31. Straus SE, Glasziou P, Richardson WS, et al: *Evidence-based medicine: how to practice and teach it*, ed 4, London, 2011, Churchill Livingstone Elsevier.
32. Wilson W, Taubert KA, Gewitz M, et al: Prevention of infective endocarditis, guidelines from the American Heart Association: a guideline from the American Heart Association Rheumatic Fever, Endocarditis, and Kawasaki Disease Committee, Council on Cardiovascular Disease in the Young, and the Council on Clinical Cardiology, Council on Cardiovascular Surgery and Anesthesia, and the Quality of Care and Outcomes Research Interdisciplinary Working Group. <http://circ.ahajournals.org/content/116/15/1736.full.pdf+html?sid=ada268bd-1f10-4496-bae4-b91806aaf341>. Accessed April 4, 2013.

CHAPTER 87

Assessing Evidence

Philippe P. Hujoel

CHAPTER OUTLINE

Twelve Tools for Assessing Evidence
Conclusion

Between 1950 and 2013, 1995 scientific articles were published that have the terms "periodontal diseases" and "antibacterial agents" as Medical Subject Headings. Which of these articles provides information that is clinically relevant? Are those articles that are clinically relevant selected and accurately summarized in educational courses, textbooks, or systematic reviews? Relying on authority to ensure that this happened can be dangerous.

Einstein purportedly said that "his own major scientific talent was his ability to look at an enormous number of experiments and journal articles, select the very few that were both correct and important, ignore the rest, and build a theory on the right ones."[7] Most evidence-based clinicians aspire toward the same goal when evaluating clinical evidence. In this search for good evidence, a "baloney detection kit"[69] can be helpful to separate salesmanship from science and suggestive hints from unequivocal evidence. This chapter introduces 12 tools that might be useful in assessing causality in clinical sciences.

Twelve Tools for Assessing Evidence

Be Skeptical

Of all machines ours is the most complicated and inexplicable.

—Thomas Jefferson

By 1990 it was concluded that "available data thus strongly support the hypothesis that dietary carotenoids reduce the risk of lung cancer."[80] Beta carotene (β-carotene) was hypothesized to interfere passively with oxidative damage to deoxyribonucleic acid (DNA) and lipoproteins,[40] and these beliefs in part translated into $210 million sales of β-carotene in 1997 in the United States. Was this convincing evidence or should it be evaluated skeptically? Two large randomized controlled trials (RCTs) were initiated and both were stopped prematurely because β-carotene increased lung cancer risk, cardiovascular disease risk, and overall mortality risk.[1,59] In 2005, the primary investigator of one of the trials reported that "beta-carotene should be regulated as a human carcinogen."[58]

Evidence on how to cure, manage, or prevent chronic diseases is notoriously contradictory, inconsistent, and unreliable. Mark Twain reminded people to be careful when reading health books because one may die of a misprint.[68] Powerful forces conspire to deliver a preponderance of misleading results:

1. Identifying a successful treatment for chronic diseases can be challenging. It has been estimated that less than 0.1% of all investigated treatments are effective. Because the odds for identifying successful interventions for chronic diseases are so small, most so-called effective treatments identified in small clinical trials turn out to be noneffective or even harmful when evaluated in rigorously conducted pivotal trials.
2. Chronic diseases can be complex and include both environmental and genetic causes. The "obvious" causes of disease, such as radiation, tobacco, and sugars, are often ignored, while more profitable etiologic hypotheses are explored ad nauseam. As a result of such biased epidemiologic research, incomplete and mistaken understandings of chronic disease etiology can lead to a cascade of wrong turns in the exploration of possible diagnosis, prognosis, and treatment.
3. Poor scientific methodology is a common problem permeating most of the evidence that surrounds us. Popular press headlines tell it all: "Lies, damned lies and medical statistics,"[66] "Undermined by an error of significance: a widespread misconception among scientists casts doubt on the reliability of a huge amount of research,"[51] and "Sloppy stats shame science."[40,70]

Finally, the possibility needs to be considered that no "Zauberkugeln" or magic bullets exist against certain noxious aspects of the civilized lifestyles. Vitamin A was supposed to be the magic antidote for smoking and fluoride for sugar. The extent to which antidotes worked varied from highly effective to harmful.

These factors may all be at play in periodontics suggesting that skepticism is required in the evaluation of periodontal evidence. First, the large number of "effective" periodontal treatments may be a telltale sign of a challenging chronic disease. Before 1917, there were hundreds of pneumonia treatments, none of which worked. Before the advent of antibiotics in the 1940s, the wealth of available tuberculosis treatments was misleading in the sense that none really worked. The current "therapeutic wealth" for periodontal diseases may well mean poverty—an indication of the absence of truly effective treatments—and a suggestion we are dealing with a challenging chronic disease. Second, many no longer regard periodontal diseases as the simple, plaque-related diseases they were thought to be in the mid-twentieth century, but rather as complex diseases. Complex diseases are challenging to diagnose, treat, and investigate. Third, the scientific quality of periodontal studies has been rated as low.[5,6] Major landmark trials were analyzed using wrong statistics,[39] most randomized studies were not properly randomized,[53] and the primary drivers of the

periodontitis epidemic may have been misunderstood because of the definition of periodontal diseases as an infectious diseases without properly controlled epidemiologic studies.[34,38] The chances that periodontal research somehow managed to escape the scientific challenges and hurdles that were present in research in other chronic diseases appears slim.

Don't Trust Biologic Plausibility

Born but to die, and reasoning but to err.

—Alexander Pope

If an irregular heartbeat increases mortality risk and if encainide can turn an irregular heartbeat into a normal heartbeat, then encainide should improve survival.[14] If high serum lipid levels increase myocardial infarction risk and if clofibrate can successfully decrease lipid levels, clofibrate should improve survival.[64] If *Streptococcus mutans* causes dental decay, and if chlorhexidine can eradicate *S. mutans,* then chlorhexidine can wipe out dental decay. Such "causal chain thinking" (A causes B, B causes C, therefore A causes C) is common and dangerous. These examples of treatment rationales, although seemingly reasonable and biologically plausible, turned out not to help or to harm patients. Causal chain thinking is sometimes referred to as "deductive inference," "deductive reasoning," or a "logical system."

In mathematics, "once the Greeks had developed the deductive method, they were correct in what they did, correct for all time."[64] In medicine or dentistry, decisions based on deductive reasoning have not been "correct for all time" and are certainly not universal. Because of an incomplete understanding of biology, the use of deductive reasoning for clinical decisions may be dangerous. Deductive reasoning largely failed for thousands of years to lead to medical breakthroughs. In evidence-based medicine, evidence that is based on deductive inference is classified as level 5, which is the lowest level of evidence available.

Unfortunately, much of our knowledge on how to prevent, manage, and treat chronic periodontitis depends largely on deductive reasoning. Small, short-term changes in pocket depth or attachment levels have been assumed to translate into tangible, long-term patient benefits, but minimal evidence to support this deductive inference leap is available. In one small study without statistical hypothesis testing, dental plaque was related to the transition from an unnatural inflammation-free condition referred to as "Aarhus superhealthy gingiva" to experimental gingivitis[47] (which is different from clinical gingivitis). Such studies do not offer proof that dental plaque bacteria cause destructive periodontal disease. It is even unclear if experimental gingivitis and plaque are correlated at a site-specific level above and beyond what would be expected by chance alone. One subsequent study at the same university, using a similar population, and using a similar experimental design, failed to identify an association between plaque and gingivitis.[20] Evidence that personal plaque control affects the most common forms of periodontal diseases is still weak[35] and largely based on "biologic plausibility" arguments. A move toward a higher level of evidence (higher than biologic plausibility) is needed to put periodontics on a firmer scientific footing.

What Level of Controlled Evidence Is Available?

Development of Western science is based on two great achievements: the invention of a formal logical system (in Euclidean geometry) by the Greek philosophers, and the discovery of the possibility to find out causal relationships by systematic experiment (during the Renaissance).

—Albert Einstein

Rational thought requires reliance on either deductive reasoning (biologic plausibility) or on systematic experiments (sometimes referred to as inductive reasoning). Galileo is typically credited with the start of systematic experimentation in physics. Puzzlingly, it took until the latter half of the twentieth century before systematic experiments became part of clinical thinking. Three systematic experiments are now routine in clinical research: the case-control study, the cohort study, and the RCT. In the following brief descriptions of these three systematic experimental designs, the term *exposure* refers to a suspected etiologic factor or an intervention, such as a treatment or a diagnostic test, and the term *endpoint* refers to the outcome of disease, quality-of-life measures, or any type of condition that may be of interest in clinical studies.

1. *RCT.* Individuals or clusters of individuals are randomly assigned to different exposures and monitored longitudinally for the endpoint of interest. An association between the exposure and the endpoint is present when frequency of the endpoint occurrence differs between the exposure groups. The RCT is the "gold standard" design in clinical research. In evidence-based medicine, RCTs, when properly executed, are referred to as level 1 evidence and the highest (best) level of evidence available.
2. *Cohort study.* Exposed individuals are compared to nonexposed individuals and monitored longitudinally for the occurrence of the primary endpoint of interest. An association between the exposure and endpoint is present when the frequency of endpoint occurrences differs between exposed and nonexposed individuals. A cohort study is often considered the optimal study design in nonexperimental clinical research (i.e., for those study designs where randomization may not be feasible). In evidence-based medicine, cohort studies, when properly executed, are referred to as level 2 evidence.
3. *Case-control study.* Cases (individuals with the endpoint of interest) are compared with controls (individuals without the endpoint of interest) with respect to the prevalence of the exposure. If the prevalence of exposure differs between cases and controls, an association between the exposure and the endpoint is present. In a case-control study, it is challenging to select cases and controls in an unbiased manner and to obtain reliable information on possible causes of disease that occurred in the past. The case-control study is the most challenging study design to use for obtaining reliable evidence. As a result, in evidence-based medicine, case-control studies, when properly executed, are the lowest level of evidence.

All three study designs permit us to study the association between the exposure and the endpoint. This association can be represented schematically as follows:

$$\text{Exposure} \rightarrow \text{Endpoint}$$

An important challenge in the assessment of controlled evidence is determining whether the association identified (→) is causal. Criteria used to assess causality include factors such as the assessment of temporality, the presence of a pretrial hypothesis, and the size or strength of the reported association. Unlike deductive reasoning, in which associations are either true or false, such absolute truths cannot be achieved with systematic experiments. Conclusions based on controlled study designs are always surrounded with a degree of uncertainty, a frustrating limitation to real-world clinicians who have to make yes/no decisions.

Did the Cause Precede the Effect?

You can't change the laws of physics, Captain.

—"Scotty" in *Star Trek*

In 2001, a study published in the *British Medical Journal* suggested that retroactive prayer shortened hospital stay in patients with bloodstream infection.[45] The only problem was that patients were already dismissed from the hospital when the nonspecified prayer to the nonspecified deity was made. To most scientists, findings in which the effect (shorter hospital stay) precedes the cause (the prayer) are impossible, and this provides an unequivocal example of a violation of correct temporality; the effect preceded the hypothesized cause. In chronic disease research, it is often challenging to disentangle temporality, and fundamental questions regarding temporality often remain disputed. For example, in Alzheimer research the amyloid in the senile plaques in the brain is often considered to be the cause of Alzheimer disease, but some researchers suggested that amyloid may be the result rather than the cause of Alzheimer disease and that the amyloid may be protective.[44] Vigorous investigation of temporality is a key aspect in scientific investigation.

Temporality is the only criterion that needs to be satisfied for claiming causality; the cause needs to precede the effect. In periodontal research, many studies relating plaque or specific infections to periodontal diseases suffer from unclear temporality. Are observed microbial profiles the result or the cause of periodontitis? There are no cohort studies in adults that have established that an infectious cause precedes the onset of chronic periodontitis.[38] Unequivocal establishment of temporality is an essential element of causality and can be difficult to establish for chronic diseases, including the epidemiology of periodontal diseases.

No Betting on the Horse After the Race Is Over

Predictions are difficult, especially about the future.

—Niels Bohr

An acquired immunodeficiency syndrome (AIDS) researcher at an international AIDS conference was jeered when she claimed that AIDS therapy provided a significant benefit for a subgroup of trial participants.[57] A study published in the *New England Journal of Medicine*[48] was taken as a textbook example of poor science[24] when it claimed that coffee drinking was responsible for more than 50% of the pancreatic cancers in the United States. Results of a large collaborative study demonstrating that aspirin use after myocardial infarction increased mortality risk in patients born under Gemini or Libra provided a comical example of an important scientific principle: data-generated ideas are unreliable.

An essential characteristic of science is that hypotheses or ideas predict observations, not that hypotheses or ideas can be fitted to observations. This essential characteristic of scientific enterprise—prediction—is often lost in medical and dental research when poorly defined prestudy hypotheses result in convoluted data-generated ideas or hypotheses that fit the observed data. It has been reported that even for well-organized studies with carefully written protocols, investigators often do not remember which hypotheses were defined in advance, which hypotheses were data derived, which hypotheses were "a priori" considered plausible, and which were unlikely.[82] A wealth of data-generated ideas can be created by exploring patient subgroups, exposures, and endpoints, as shown by the following:

1. Modifying study sample definition. A commonly observed post-trial modification of a hypothesis is to evaluate improper or proper subgroups of the original study sample. Improper subgroups are based on patient characteristics that may have been influenced by the exposure. For example, one may evaluate tumor size only in those patients who survived or pocket depths only in those teeth that were not lost during the maintenance. Results of improper subgroup analyses are almost always meaningless when establishing causality. Proper subgroups are based on patient characteristics that cannot be influenced by the exposure, such as gender, race, or patient's age. A review of trials in the area of cardiovascular disease suggested that even the results of proper-subgroup analyses turn out to be misleading in a majority of cases.[82] In the human immunodeficiency virus (HIV) area, one proper subgroup analysis (based on racial characteristics) drew an investor lawsuit on the basis that company officials "deceived" investors with a "fraudulent scheme."[17]
2. Modifying exposure definition. After or during the conduct of a study, the exposure definition can be changed, or the number of exposures under study can be modified. In a controversial trial on the use of antibiotics for middle ear infections, the placebo treatment was replaced with a boutique antibiotic, causing a potentially misleading perception about the antibiotics' effectiveness.[18,22,49] In another example of "betting on the horse after the race was over," a negative finding for cigarette smoking (the primary exposure) as a cause for pancreatic cancer led reportedly to the data-generated hypothesis that coffee drinking increased pancreatic cancer risk.[18] When this study was repeated in the same hospital, using the same protocol, but now with the pretrial hypothesis to evaluate coffee drinking, the results of the prior study could not be duplicated.
3. Modifying endpoint definition. Almost all pivotal trials specify one primary endpoint in the pretrial hypothesis. In periodontal research the absence of a specific pretrial defined endpoint is common and permits effortless changing of the endpoint definition. The typical periodontal trial has six endpoints and does not specify which endpoint is primary, and it is not always clear what is a good or a bad outcome.[36] Similarly, the definition of adverse pregnancy outcomes is flexible and susceptible to post-hoc manipulations to squeeze out statistical significance. Statistical trickery to reach desired conclusions under such circumstances may be child's play.

Deviating from the pretrial hypothesis is often compared to data torturing.[52] Detecting the presence of data torturing in a published article is often challenging; just as the talented torturer leaves no scars on the victim's body, the talented data torturer leaves no marks on the published study. Opportunistic data torturing refers to exploring data without the goal of "proving" a particular point of view. Opportunistic data torturing is an essential aspect of scientific activity and hypothesis generation. Procrustean data torturing refers to exploring data with the goal of proving a particular point of view. Just as the Greek mortal Procrustes fitted guests perfectly to his guest bed either through bodily stretching or through chopping of the legs to ensure correspondence between body height and bed length, so can data be fitted to the pretrial hypothesis by Procrustean means.

What Is a Clinically Relevant Pretrial Hypothesis?

When alendronate was shown to lower fracture rates (a tangible benefit),[19] it became the leading worldwide treatment for postmenopausal osteoporosis, and its use is expected to continue to grow.[8] When a randomized trial showed that simvastatin saved lives of patients with prior heart disease (a tangible benefit),[19] sales increased by 80% in the first 9 months after the study's publication. A pivotal trial on hormone replacement therapy turned thriving drug sales into a major decline.[27] A pivotal trial found a routine eye surgery to be harmful, prompting the National Institutes of Health to send a clinical trial alert to 25,000 ophthalmologists and neurologists.[3]

Clinically relevant questions are designed to have an impact on clinical practice and trials on clinically relevant questions can succeed in exactly doing that; dramatically changing clinical practice. Usually, clinically relevant questions share four important characteristics of the pretrial hypothesis: (a) a clinically relevant endpoint (referred to as the Outcome in the PICO question), (b) relevant exposure comparisons (referred to as the Intervention and the Control in the PICO question, (c) a study sample representative of real-world clinical patients (should be representative of the Patient defined in the PICO question), and (d) small error rates.

Clinically Relevant Endpoint. An endpoint is a measurement related to a disease process or a condition and used to assess the exposure effect. Two different types of endpoints are recognized. True endpoints are tangible outcomes that directly measure how a patient feels, functions, or survives[46]; examples include tooth loss, death, and pain. Surrogate endpoints are intangible outcomes used as a substitute for true endpoints[74]; examples include blood pressure and probing depths of periodontal pockets. Treatment effects on surrogates do not necessarily translate into real clinical benefit (Table 87-1). Use of surrogate endpoints has led to widespread use of deadly medications, and it has been suggested that such disasters should prompt policy changes in drug approval.[63] Most major causes of human disease (e.g., cigarette smoking) were identified through studies using true endpoints. A first requirement for a clinically relevant study is the pretrial specification of a true endpoint.

Common and Relevant Comparisons. The more prevalent a studied exposure, the more relevant is the clinical question. A clinically relevant comparison implies the absence of comparator bias, which is defined as the presence of contrived or unethical control groups. Providing the control subjects with less than the standard dose of the standard treatment or providing a control therapy that avoids the real clinical questions are examples of clinically irrelevant research. Similarly, the presence of a placebo group can be critical given the large beneficial effects that can be obtained by proper interaction in medical settings. For instance, the absence of placebo controls in fluoride varnish trials for primary teeth raises serious doubts whether fluoride varnish has an effect above and beyond what would be observed with just a placebo. In case-control or cohort studies the measurement and characterization of exposures (e.g., mercury, fluoride, chewing tobacco) can be difficult and imprecise, making answers to the questions almost unavoidably imprecise. Moreover, a conclusion regarding the safety or efficacy of one particular type of treatment such as dental implant of a particular brand does not necessarily translate into safety or efficacy of another brand of a dental implant.[33] There are many "me-too" drugs and "me-too" devices that claim safety and effectiveness, but where hard evidence remains missing.

Representative Study Sample. The larger the discrepancy between the typical subjects enrolled in clinical studies and the patient you seek to treat, the more questionable the applicability of the study's conclusions becomes. When cholesterol-lowering

TABLE 87-1 Examples of Potentially Misleading Surrogates*

Disease/ Conditions	Experimental Treatment	Control Treatment	Effect on Surrogate Endpoint	Effect on True Endpoint	Misleading Conclusion	Reference
AIDS	Immediate zidovudine	Delayed zidovudine	Significant increase of 30-35 CD4 cells/mm^3.	No change in incidence of AIDS, AIDS-related complex, or survival.	False-positive	80
Osteoporosis	Fluoride	Placebo	Significant increase of 16% in bone mineral density of lumbar spine.	Nonvertebral fracture rates increased by 85%.	False-positive	
Lung cancer	ZD1839 (Iressa)	Placebo	Dramatic tumor shrinkage in 10% of patients.	No effect.	False-positive	82
Aphthous ulcers	Thalidomide	Placebo	Although thalidomide expected to decrease TNF-α production, significant increase of 4.4 pg/mL in TNF-α production occurred, suggesting harm.	Pain diminished and ability to eat improved.	False-negative	32
Edentulism dentures	Implant-supported	Conventional dentures	No impact on chewing cycles.	Improved oral health–related quality of life	False-negative	5
Prostate cancer	Radical prostatectomy	Watchful waiting	Substantial elimination of tumor mass.	No effect on overall mortality risk.	False-positive	78
Advanced colorectal cancer	5-FU + LV	5-FU	23% of patients had 50% or greater reduction in tumor volume.	No effect on overall survival.	False-positive	40
Periodontitis	Surgery	Scaling	Mean pocket depth reduced by 0.5 mm.	Effect on tooth loss or quality of life unknown.	?	

AIDS, Acquired immunodeficiency syndrome; *5-FU,* 5-fluorouracil; *LV,* leucovorin; *TNF,* tumor necrosis factor.

*For some examples, the experimental treatment led to improvements in surrogate endpoints while the true endpoint was either unaffected or worsened (a false-positive conclusion). For other examples, the experimental treatment had no impact or worsened the surrogate endpoint while the true endpoint improved (a false-negative conclusion).

drugs provided a small benefit in middle-age men with abnormally high cholesterol levels, it was concluded that those benefits "could and should be extended" to other age groups and women with "more modest elevations" of cholesterol levels.[46] Findings on blood lipids and heart disease derived mostly from Polish immigrants in the Framingham Study were generalized to a much more diverse population. An antidepressant, which was approved for use in adults, was widely prescribed for children with unexpected, serious consequences.[2]

Ideally, clinical trials should use simple entry criteria in which the enrolled patients reflect as closely as possible your real-world clinical practice situation.[28] Legislation has been enacted to reach this goal. In 1993, U.S. policy ensured the recruitment of women and minority groups in clinical trials.[11] A U.S. policy for the inclusion of children in clinical studies was then set into law in 1998. Experiments with long lists of inclusion and exclusion criteria can be expensive recipes for failure because they can lead to study subjects which are unrepresentative of most real-world clinical patients.

Small Type I and Type II Error Rates. The type I error rate is the likelihood of concluding there is an effect, when in truth there is no effect. The type I error rate is set by the investigator, and common values are 1% or 5%. The type II error rate is the likelihood of concluding there is no effect, when in truth there is an effect. The type II error rate is typically set by the investigator at 10% or 20%. The complement of the type II error rate (i.e., 1 – type II error rate) is referred to as the power of the study. The likelihood for a false-positive or false-negative result depends, in addition to the types I and II error rates, on the likelihood of finding an effect that is not under the investigator's control. For chronic diseases, in which the likelihood for identifying effective treatments or true causes is low, the false-positive rate can be high even when the type I error rate is low.[33] Clinically relevant studies require small type I and type II error rates to minimize false-positive and false-negative conclusions.

Size Does Matter

Chronic hepatitis B infection increased the chances for liver cancer by more than 23,000%.[8] Proximity to electromagnetic radiation increased the chance for leukemia in children by 49%.[79] Periodontitis in populations with smokers increased the chance for coronary heart disease by 12%.[37] No one doubts the causality of the association between chronic hepatitis B infection and liver cancer, but the role of periodontitis in coronary heart disease or electromagnetic radiation in childhood leukemia remain controversial. Why? To a large extent, the size of the association drives the interpretation of causality.

The larger an association, the less likely it is caused by bias, and the more likely it is causal. One simple way to calculate the size of the association is to calculate an odds ratio. The odds for an event is the probability that an event happens divided by the probability that an event does not happen. An odds ratio is a ratio of odds. To calculate an odds ratio, a two-by-two (2 × 2) table is constructed in which the outcome is cross-tabulated with the exposure (Table 87-2). Odds ratios can be calculated for data from RCTs, cohort studies, and case-control studies.

The odds ratio is the ratio of the cross-products (ad/bc). The odds ratio associated with penciclovir use for lesion healing is (376 × 757)/(526 × 878) = 0.62 (Table 87-3). The odds ratio associated with chronic periodontitis for a fatal myocardial infarction is (2 × 1241)/(8 × 257) = 1.21 (Table 87-4). The 95% confidence interval can be approximated by exp[ln(odds ratio) ±1.96 $\sqrt{(1/a + 1/b + 1/c + 1/d)}$]. The 95% confidence intervals of the odds ratio for lesion healing and fatal myocardial infarction are, respectively, exp(–0.48 ±1.96 $\sqrt{0.007}$), or 0.52 to 0.73, and exp(0.18 ±1.96 $\sqrt{0.63}$), or 0.25 to 5.72.

The size of the odds ratio ranges between 0 and infinity. An odds ratio of 1 indicates the absence of an association, and if the two-by-two table is set up with the reference cell (poor outcome-exposure of interest) in the left-hand side of the top data row, an odds ratio larger than 1 means a harmful effect (e.g., periodontitis increases the odds for a fatal myocardial infarction by 20%), and an odds ratio smaller than 1 means a protective effect (e.g., penciclovir decreases the odds for failed lesion healing by day 6 by 38%).

The confidence interval is the range of numbers between the upper confidence limit and the lower confidence limit. The confidence interval contains the true odds ratio with a certain predetermined probability (e.g., 95%). In a properly executed randomized trial, a conclusion of causality is typically made if the 95% confidence interval does not include the possibility of "no association" (e.g., odds ratio = 1). For example, because the 95% confidence interval for the odds ratio associated with penciclovir use is 0.52 to 0.73 and does not include 1, the effect can be referred to as "statistically significant." For the chronic periodontitis–myocardial infarction example, the 95% confidence interval ranges from 0.25 to 5.72, includes 1, and is therefore referred to as "statistically insignificant."

TABLE 87-2 Two-by-Two Table Cross-Classifying Exposure and Endpoint*

		ENDPOINT	
		Failure	Success
Exposure	Experimental	A	B
	Control	C	D

*Note that the top left cell, by convention, tallies the number of failures for the experimental group.

TABLE 87-3 Two-by-Two Table on Association between Penciclovir and Oral Lesion Healing

		ENDPOINT	
		No Lesion Healing by Day 6	Lesion Healing by Day 6
Exposure	1% Penciclovir	376	878
	Placebo	526	757

TABLE 87-4 Two-by-Two Table on Association between Chronic Periodontitis and Fatal Myocardial Infarction (MI)

		ENDPOINT	
		Fatal MI	No Fatal MI
Exposure	Chronic periodontitis (CP)	2	257
	No gingivitis or CP	8	1241

In epidemiology, where there is no randomization of individuals to exposures, the interpretation of a confidence interval is challenging because no probabilistic basis (in the form of randomization) exists for making causal inference. A pessimist will claim that because no randomization was present, no statistical interpretations are allowed.[29] The emphasis should be on visual display of the identified associations and on sensitivity analyses where the results are interpreted under "what if" assumptions. An optimist will argue that the absence of randomization does not preclude the making of statistical inferences, and that one always starts from the assumption that "assignments were random" (even when they were not).[83]

When individuals are randomly assigned to exposures, very small associations (i.e., associations very close to 1, such as 1.1) can reliably be identified. When individuals are not randomly assigned to exposures, as is the case in cohort studies and cases-control studies, the size of the reported association (e.g., the odds ratio) becomes key in the interpretation of the findings. Because of the inherent biases in epidemiologic research, small odds ratios cannot be reliably identified. But what is small? Leading epidemiologists provide some guidelines on how to interpret the size of an association with respect to possible causality. Richard Doll, one of the founders of epidemiology, said, "No single epidemiological study is persuasive by itself unless the lower limit of its 95% confidence level falls above a threefold (200%) increased risk." Dimitrios Trichopoulos, past chairperson of epidemiology at Harvard University, opts "for a fourfold (300%) increase at the lower limit (of the 95% confidence interval)." Marcia Angell, former editor of the *New England Journal of Medicine,* reported: "As a general rule of thumb we are looking for an odds ratio of 3 or more (≥200% increased odds) [before accepting a paper for publication]." Robert Temple, Director of the Food and Drug Administration, stated: "My basic rule is if the odds ratio isn't at least 3 or 4 (a 200% or 300% increased risk), forget it."[73] These opinions provide some guidelines on what size of odds ratio to look for when determining causality.

Is There a Better Alternative Explanation

No amount of experimentation can ever prove me right; a single experiment can prove me wrong.

—Albert Einstein

When you have eliminated the impossible, whatever remains, however improbable, must be the truth.

—Sir Conan Doyle

Dozens of epidemiologic studies appeared to support the hypothesis that β-carotene intake lowered lung cancer risk. However, RCTs provided unequivocal evidence to the contrary. What went wrong? Different explanations that worked as well or better may have been inadequately explored. Possibly, smoking was not adequately considered as an alternative explanation and led to a misunderstanding on the health effects of β-carotene.[25,72] Similarly, a systematic review of epidemiologic studies appeared to support the hypothesis that chronic periodontitis caused low birth weight.[81] In contrast, however, a systematic review of RCTs suggested that the periodontitis–low birth weight theory may be dead.[78] Why was epidemiology misleading? Again, different explanations may have been inadequately explored. There may have been more efforts toward proving associations by ignoring common causal factors rather than disproving associations. The highest goal of a scientist is the attempt to refute, disprove, and vigorously explore factors and alternative hypotheses that may "explain away" the observed association.[13] Not vigorously exploring smoking and nutrition as potential confounders in periodontics may have led to a significant waste of clinical research resources.

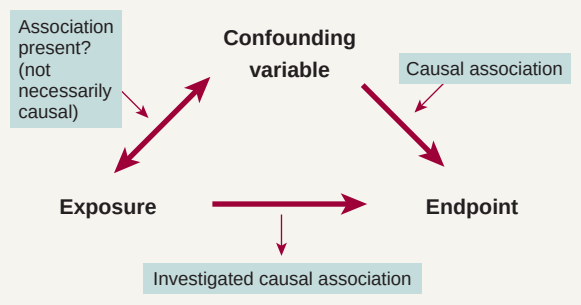

Figure 87-1 Schematic representation of the two necessary criteria for a variable to induce spurious associations (i.e., to be a confounding variable). The confounding variable has to be (a) associated with the exposure and (b) causally linked to the outcome. When both criteria are satisfied, confounding is said to be present.

For a factor to explain away an observed association, two criteria need to be fulfilled. First, the factor must be related to the exposure, but not necessarily in causal way. Second, the factor must be causally related to the outcome and must not be in the causal pathway. If both criteria are satisfied, the factor is referred to as a confounder, and confounding is said to be present. For example, smoking satisfied the criteria for a confounder in the β-carotene–lung cancer association because (a) cigarette smokers consumed less β-carotene than nonsmokers and (b) smoking caused lung cancer. Confounding is often represented schematically (Figure 87-1).

In randomized studies, confounding is not an issue because randomization typically balances known and unknown confounders across the compared groups with a high degree of certainty. In epidemiologic studies, in which no randomization is present, three questions related to confounding need to be considered in the assessment of the causality, as addressed next.

First, were all important confounders identified? Complex diseases have multiple risk factors, which may act as confounders in the reported association. The multiple confounders need to be included in the statistical analyses. An association unadjusted for any potential confounders is sometimes referred to as the crude association. When this crude association is adjusted for potential confounders, it is referred to as an adjusted association. Typically, crude associations are adjusted for multiple confounders, and both crude and adjusted odds ratios are presented.

Second, how accurately were confounders measured? Some potential confounders, such as age, gender, and race, can be measured relatively accurately. Other potential confounders, such as smoking or lifestyle, are notoriously more difficult to measure. A discrepancy between what is measured and what is the truth will result in the incomplete removal of bias and lead to spurious associations. The remaining bias is sometimes referred to as residual confounding. Residual confounding is common in epidemiology and is one of the reasons why case-control and cohort studies are less effective research tools than randomized trials in identifying small effects. For instance, an accurate summary of smoking history over a person's lifetime may be impossible.

Third, was the statistical modeling of the confounders appropriate? Any misspecification of the functional relationships causes bias. For example, assuming a linear relationship between a confounder and an endpoint, while in truth the relationship is quadratic, will cause bias.

Evaluating the impact of confounding can be a challenge. The goal of an epidemiologist is to come up with the best possible defense why an identified association is spurious. All possible efforts should be spent identifying known confounders, obtaining accurate measurements on the confounders, and exploring different analytic approaches to refute the observed association. Smoking, a potential confounder in many studies, has been found to be such a strong confounder that several leading epidemiologist have suggested that restriction to never-smokers is required to eliminate the potential for residual confounding by smoking.[61] Control for confounding is the major methodologic challenge in epidemiology, and randomization is the only tool available to eliminate confounding reliably.

Was the Study Properly Randomized?

Attempts by physicians to circumvent randomization are not isolated events; they're part of an endemic problem stemming from ignorance.[57]

Randomization can be a counterintuitive process because it (a) creates heterogeneity, (b) takes control over treatment assignment away from the physician, and (c) leads to apparently illogical situations in which patients randomly assigned to a treatment, but refusing it, still are analyzed as if they received the treatment. Although randomization was a radical innovation introduced for agriculture, some have suggested that is doubtful whether it would have ever been widely introduced into medicine (and subsequently dentistry) was it not for a confluence of factors surrounding the end of World War II in Great Britain. Because of the revolutionary nature of randomization, fundamental misunderstandings of this process remained prevalent until recently. About one third of the clinical trials published in elite medical journals apparently did not ensure that patients are assigned to different treatments by chance.[57] The majority of reported periodontal trials failed to convince reviewers that (a) the studies were properly randomized, (b) randomization was concealed, or (c) randomized patients were accounted for.[53] Tampering with the delicate process of randomization can quickly, using the words of Ronald Fisher, a statistician and geneticist, turn an "experiment into an experience."

Several studies have shown how an inadequate randomization process will bias study findings. In one review study, the ability to reject patients from the study after random treatment assignment tripled the likelihood of finding significant results and doubled the likelihood that confounders were unequally distributed among the compared groups.[44] Trials where clinicians can break the randomization code reported treatment effects that averaged 30% larger than effects in trials where the randomization could not be broken.[15] The common desire to eliminate noncompliant patients can similarly lead to biases, as shown by the following two examples. First, in one cardiovascular disease trial, patients compliant to a placebo pill had a 10% reduction in mortality risk compared with patients noncompliant to the placebo.[64] Second, in a caries trial, adolescents compliant to a placebo varnish had on average 2.2 fewer new caries lesions than adolescents noncompliant to a placebo varnish.[26] Such findings suggest that factors related to compliance and unrelated to the treatments under investigation have a powerful influence on the outcome measured. Deleting such noncompliant patients may lead to biases.

Proper randomization ideally includes the following elements. First, subjects are enrolled into a study before randomization: important baseline disease characteristics are recorded and provided to an independent person or organization. This step ensures that baseline information is available for every patient who will be randomized. Without this step, randomized patients can be "lost," leading to biases. Subsequently, an independent person or organization randomly assigns subjects to treatments and informs the clinician regarding the treatment assignment. This randomization process needs to be auditable, making pseudorandom processes such as coin tosses unacceptable. The concealment of the randomization process ensures that clinicians cannot crack the code and that they will enroll only those patients they think are suited for the treatment that will be assigned. Finally, the outcome in the subject is evaluated regardless of follow-up time or compliance and according to the treatment assigned, not the treatment received. Imputation is used in sensitivity analyses to determine the extent that subjects with missing information can bias the conclusions. The whole process of randomization is complex and often deviated from leading to unreliable results.

When to Rely on Nonrandomized Evidence?

Randomize the first patient.

—Thomas Chalmers[57]

To tell the truth, all of the discussion today about the patient's informed consent still strikes me as absolute rubbish.

—Sir Bradford Hill

Scores of epidemiologic studies reported evidence that hormone replacement therapy provided benefits to postmenopausal women. Despite this "strong" evidence from "leading" researchers, and despite the opposition on ethical grounds to initiate a placebo-controlled trial, the Women's Health Initiative trial was initiated. The "miracle" of hormone replacement therapy was shown to lead to increased breast cancer risk, dementia, myocardial infarction, and stroke. This example illustrates the need for randomized studies and for questioning well-established and widely accepted beliefs based on numerous epidemiologic studies. Nonetheless, the initiation of randomized trials can become difficult because of ethical considerations and unaffordably large sample sizes.

Ethical principles dictate that proposed interventions do more good than harm, that the populations in whom the study will be conducted will benefit from the findings, that informed consent is obtained from enrolled subjects, and that a genuine uncertainty exists with respect to treatment efficacy. The interpretation of these ethical principles is largely determined by culture and era. Ethical principles also play an important role in determining which clinical questions are sufficiently important to warrant the conduct of a RCT.

Sample size considerations may prevent the conduct of RCTs. The smaller the rate at which endpoints occur in an RCT, the larger the required sample size will be. For rare events, such as bacterial endocarditis subsequent to a dental procedure or HIV conversion after exposure to an HIV-contaminated dental needle, RCTs may never be possible because the required sample sizes are in the 100,000s or millions of subjects.

In addition to both ethical and practical reasons, there can be powerful political issues surrounding the decision to initiate clinical trials. It has been pointed out that specialist are unlikely to support clinical trials that evaluate their main source of income.[62] This observation for medical specialties may hold for periodontics. Although a professional organization claims that periodontal disease is a major cause of tooth loss, there is still no evidence that standard periodontal therapy is effective at reducing tooth loss. Unequivocal evidence requires the conduct of rigorously designed

and executed RCTs. The absence of RCT evidence for important and answerable clinical questions can be frustrating to those who seek reliable evidence-based practice guidelines.

Did the Investigators Take into Account the Placebo/Nocebo Effects?

> *I never knew any advantage from electricity in (the treatment of) palsies that was permanent. And how far the apparent temporary advantage might arise from the exercise in the patient's journey, and coming daily to my house, or from the spirits given by the hope of success, enabling them to exert more strength in moving their limbs, I will not pretend to say.*
>
> **—Benjamin Franklin**[77]

Sham or mock surgeries have been used to evaluate whether implanting human fetal tissue in the brain decreases symptoms of Parkinson disease, whether surgical lavage and debridement decreases pain in arthritic knee joints,[54] whether mammary artery ligation improves heart disease outcomes,[16] and whether alveolar trephination relieves the pain of acute apical periodontitis.[31,56]

What motivates clinical investigators to subject patients to surgical risks, and yet knowingly provide no hypothesized benefits to these patients? A partial answer to this question lies in a phenomenon known as placebo or nocebo effects: the beneficial or harmful effects patients may experience by participating in a study, by patient–physician interaction, by the patient's anticipation for improvement, or by the patient's desire to please the physician. One group of researchers suspects that the placebo or nocebo effect may be related to the balance of the parasympathetic and sympathetic nervous system, which could explain both placebo and nocebo effects.[43] Without mock surgeries it would be impossible to tell whether the improvements observed in clinical trials are caused by the placebo effects associated with the surgical procedures or by the hypothesized active ingredient of the surgery itself.

Two studies have quantified the placebo effect. In the first study, the magnitude of the placebo effect was estimated by evaluating patient responses to ineffective treatments.[65] Five treatments were identified as ineffective if the treatment had been abandoned by the medical profession and if at least one controlled study confirmed its ineffectiveness. With these ineffective treatments, good to excellent treatment responses were observed in 45% to 90% of the patients, a powerful placebo effect indeed. In the second study, placebo interventions (pharmacologic placebo, physical or psychologic intervention) were compared to true "no-treatment" interventions.[32] A significant placebo effect was observed for pain, the condition that was evaluated in the largest number of trials and that had the largest number of evaluated participants. In dentistry, sound systematic reviews may provide some ability to evaluate placebo effects. One systematic review of 133 studies reported that the fluoride effect on caries was significantly larger when a no-treatment control group was used versus a placebo control group.[50] One possible interpretation for these differences is a placebo effect: the placebo lowered caries rates possible through reequilibrating of parasympathetic and sympathetic nervous activity, which may influence factors such as improved saliva flow. Other explanations, such as the scientific quality of the studies, may, of course, also be responsible for such observed differences, especially for pain. Overall, sufficient evidence is available to suggest that placebo effects can be real and measurable, and that the magnitude of the placebo effect may depend on the treatment under study and the type of outcome evaluated.

Was There Protection Against Conflict of Interest?

Can one trust clinical recommendations regarding a novel, noninvasive cardiac bypass surgery by a physician who has a $100 million stake in the procedure he is recommending? Is it possible that financial stakes are preventing physicians from disclosing a 10-fold increased mortality risk? Can one trust guidelines establishing sharply lowered lipid levels knowing that eight of the nine panel experts have financial connections to the manufacturers of lipid-lowering drugs? Is it possible that panelists are picked for ideology?[9] The answers to these questions are not straightforward and in general are discussed under the heading of "conflicts of interest."

Conflict of interest has been defined as "a set of conditions in which professional judgment concerning a primary interest (such as patient's welfare or validity of research) tends to be unduly influenced by a secondary interest."[4,10,12,21,55,67,75] A common secondary interest is financial but can include others, such as religious or scientific beliefs, ideologic or political beliefs, or academic interests (e.g., promotion). Some examples of how conflicts of interests can bias evidence are now given:

1. Evidence can be suppressed by lawsuits. For example, a company initiated a multimillion-dollar legal action[17] against the investigator who reported that their HIV vaccine was ineffective.[41] Companies can suppress submitted scientific articles that they perceived as incorrect.
2. Negative evidence can disappear into a "black hole."[30] One can expect that 2 of 40 trials on an ineffective treatment will provide positive results by chance if the experiments are run with a type I error rate of 5%. If the 38 negative trial reports go into a file drawer, and if the two positive reports lead to drug approval and are published in leading journals, a misleading perception of the drug's effectiveness will be given to the practicing community. Although a Food and Drug Administration (FDA) official indicated that such situations have never happened,[23] reports on nondisclosed negative trials on an antidepressant drug suggests the contrary.[76] Although registries of clinical trials should succeed at eliminating the problem of disappearing trial results, and although many leading journals request a priori trial registration as a prerequisite for publishing, the problem of disappearing trial results remains with us today.
3. Conflicts of interest can lead to distortion of study designs and analyses to provide the desired results. Such distortions can range from data fabrication and data falsification to design and analysis "tweaks" such as contrived control groups, unplanned subgroup analyses, and only showing that time point in the analysis where the differences favor the investigated drug.
4. Conflicts of interests related to loss of patents or orphan drugs can shunt available research resources to the conduct of clinical trials that are not necessarily in the best interest of public health.[58]

The potential for conflict of interest appears to be ever increasing. The prevalence of industry-funded trials is increasing, and more and more universities hold stock in start-up companies that support clinical trials within that institution. Such connections can be viewed with a skeptical eye–It has been confirmed over-and-over again that industry-sponsored studies are more likely to have pro-industry conclusions as non–industry-sponsored studies.[10]

Protection against potential conflict of interest is an important aspect of clinical research. Mandatory registration of clinical trials helps. The appointment of independent data and safety monitoring

boards for trial monitoring provide protection against biases. Policy regulations established by journals, academic institutions, and governments can further decrease the impact of perceived conflicts of interests. For instance, all the work that has been done toward establishing a registry of RCTs helps in decreasing biases.[42,71]

Conflict-of-interest issues may be just as prevalent in dental research as in other medical areas dealing with chronic disease. In 2002, an article published in a leading dental journal ended up on the cover of *The New York Times*.[60] In part, the reason was a perceived conflict of interest; the article did not disclose that funding for the study came from an advertising company. Disclosure of conflict of interest is often poorly enforced, and some dental journals do not have regulations in place to reveal potential conflicts of interest of authors. Such situations (a) make it challenging for clinicians to recognize the potential for conflicts of interest, (b) may reduce trust in dental journals, and (c) may affect the scientific integrity of dental research.

Conclusion

Lessons learned from other chronic disease areas do apply to the evaluation of evidence in the periodontal disease research arena. Randomization or confounding are as important in periodontal research as they are in cancer research. Work remains to be done to integrate evidence-based thinking into clinical practice. The most challenging task may be to lessen the excessive reliance on biologic plausibility in determining both research priorities and patient management and to transition to clinical thinking that is based on controlled clinical observations, rather than biologic plausibility. Although the 12 discussed tools for assessing evidence do not cover all necessary tools, or maybe even the most important tools, it is hoped that they provide a useful starting point for the further exploration of the issues and principles involved in the conduct of systematic experiments in periodontal disease research.

References

1. The ATBC Cancer Prevention Study Group: The alpha-tocopherol, beta-carotene lung cancer prevention study: design, methods, participant characteristics, and compliance. The ATBC Cancer Prevention Study Group. *Ann Epidemiol* 4(1):1–10, 1994.
2. Abbott A: British panel bans use of antidepressant to treat children. *Nature* 423(6942):792, 2003.
3. Altman LK: Health officials urge halt to routine eye operation. *New York Times* February 22, 1995; Health.
4. Angell M: Is academic medicine for sale? *N Engl J Med* 342(20):1516–1518, 2000.
5. Antczak AA, Tang J, Chalmers TC: Quality assessment of randomized control trials in dental research. I. Methods. *J Periodontal Res* 21(4): 305–314, 1986.
6. Antczak AA, Tang J, Chalmers TC: Quality assessment of randomized control trials in dental research. II. Results: periodontal research. *J Periodontal Res* 21(4):315–321, 1986.
7. Barry JM: *The Great Influenza. The Epic Story of the Deadliest Plague in History*, New York, 2004, Viking.
8. Beasley RP, Hwang LY, Lin CC, et al: Hepatocellular carcinoma and hepatitis B virus. A prospective study of 22 707 men in Taiwan. *Lancet* 2(8256):1129–1133, 1981.
9. Begley S: Now, Science Panelists are picked for ideology rather than expertise. *Wall St J* December 6, 2002; Science Journal: B1.
10. Bekelman JE, Li Y, Gross CP: Scope and impact of financial conflicts of interest in biomedical research: a systematic review. *JAMA* 289(4): 454–465, 2003.
11. Bennett J-C: Inclusion of women in clinical trials—policies for population subgroups [see comments]. *N Engl J Med* 329(4):288–292, 1993.
12. Bodenheimer T: Uneasy alliance—clinical investigators and the pharmaceutical industry. *N Engl J Med* 342(20):1539–1544, 2000.
13. Buck C: Popper's philosophy for epidemiologists. *Int J Epidemiol* 4:159–168, 1975.
14. The Cardiac Arrhythmia Suppression Trial (CAST) investigators: Preliminary report: effect of encainide and flecainide on mortality in randomized trial of arrhythmia suppression after myocardial infarction. *N Engl J Med* 321:406–412, 1989.
15. Chalmers T, Celano P, Sacks H, et al: Bias in treatment assignment in controlled clinical trials. *N Engl J Med* 309(22):1358–1361, 1983.
16. Cobb LA, Thomans GI, Dillard DH: An evaluation of internal mammary artery ligation by a double-blind technique. *N Engl J Med* 260:1115–1118, 1959.
17. Cohen J: Clinical research. AIDS vaccine results draw investor lawsuits. *Science* 299(5615):1965, 2003.
18. Crossen C: The treatment. A medical research pays for challenging drug-industry funding. *Wall St J* A1–A6 C4, 2001..
19. Cummings SR, Black DM, Thompson DE, et al: Effect of alendronate on risk of fracture in women with low bone density but without vertebral fractures: results from the Fracture Intervention Trial. *JAMA* 280(24):2077–2082, 1998.
20. Danielsen B, Manji F, Nagelkerke N, et al: Transition dynamics in experimental gingivitis in humans. *J Periodontal Res* 24:254–260, 1989.
21. DeAngelis CD: Conflict of interest and the public trust. *JAMA* 284(17):2237–2238, 2000.
22. Del Mar C, Glasziou P, Hayem M: Are antibiotics indicated as initial treatment for children with acute otitis media? A meta-analysis. *BMJ* 314(7093):1526–1529, 1997.
23. Ehrlich R: *Can a sugar pill kill you. 8 preposterous propositions*, Princeton, NJ, 2003, Princeton University Press.
24. Feinstein AR: Scientific standards in epidemiologic studies of the menace of daily life. *Science* 242(4883):1257–1263, 1988.
25. Feskanich D, Ziegler RG, Michaud DS, et al: Prospective study of fruit and vegetable consumption and risk of lung cancer among men and women. *J Natl Cancer Inst* 92(22):1812–1823, 2000.
26. Forgie AH, Paterson M, Pine CM, et al: A randomised controlled trial of the caries-preventive efficacy of a chlorhexidine-containing varnish in high-caries-risk adolescents. *Caries Res* 34(5):432–439, 2000.
27. Fuhrmans V: HRT worries give headaches to drug makers. *Wall St J* October 25, 2002, Marketplace: B1.
28. Gray R, Clarke M, Collins R, et al: Making randomised trials larger: a simple solution? *Eur J Surg Oncol* 21(2):137–139, 1995.
29. Greenland S: Randomization, statistics, and causal inference. *Epidemiology* 1(6):421–429, 1990.
30. Hensley S, Abboud L: Medical Research has "Black Hole". *Wall St J* B3, June 4, 2004.
31. Houck V, Reader A, Beck M, et al: Effect of trephination on postoperative pain and swelling in symptomatic necrotic teeth. *Oral Surg Oral Med Oral Pathol Oral Radiol Endod* 90(4):507–513, 2000.
32. Hrobjartsson A, Gotzsche PC: Is the placebo powerless? An analysis of clinical trials comparing placebo with no treatment. *N Engl J Med* 344(21):1594–1602, 2001.
33. Hujoel P, Becker W, Becker B: Monitoring failure rates of commercial implant brands; substantial equivalence in question? *Clin Oral Implants Res* 2012.
34. Hujoel P, Zina LG, Cunha-Cruz J, et al: Historical perspectives on theories of periodontal disease etiology. *Periodontol 2000* 58(1):153–160, 2012.
35. Hujoel PP, Cunha-Cruz J, Loesche WJ, et al: Personal oral hygiene and chronic periodontitis: a systematic review. *Periodontol 2000* 37:29–34, 2005.
36. Hujoel PP, DeRouen TA: A survey of endpoint characteristics in periodontal clinical trials published 1988-1992, and implications for future studies. *J Clin Periodontol* 22(5):397–407, 1995.
37. Hujoel PP, Drangsholt MT, Spiekerman C, et al: Periodontal disease and risk of coronary heart disease. *JAMA* 285(1):40–41, 2001.
38. Hujoel PP, Guimarães LZ, Cunha-Cruza J, et al: Specific infections and the etiology of destructive periodontal disease: a systematic review. *Eur J Oral Sci* 121(1):2–6, 2013.

39. Hujoel PP, Moulton LH: Evaluation of test statistics in split-mouth clinical trials. *J Periodontal Res* 23(6):378–380, 1988.
40. Jha P, Flather M, Lonn E, et al: The antioxidant vitamins and cardiovascular disease. A critical review of epidemiologic and clinical trial data. *Ann Intern Med* 123(11):860–872, 1995.
41. Kahn JO, Cherng DW, Mayer K, et al: Evaluation of HIV-1 immunogen, an immunologic modifier, administered to patients infected with HIV having 300 to 549 × 10(6)/L CD4 cell counts: A randomized controlled trial. *JAMA* 284(17):2193–2202, 2000.
42. Kennedy D: The old file-drawer problem. *Science* 305(5683):451, 2004.
43. Kok BE, Coffey KA, Cohn MA, et al: How positive emotions build physical health: perceived social connections account for the upward spiral between positive emotions and vagal tone. *Psychol Sci* 24(7):1123–1132, 2013.
44. Lee HG, Casadesus G, Zhu X, et al: Perspectives on the Amyloid-beta Cascade Hypothesis. *J Alzheimers Dis* 6(2):137–145, 2004.
45. Leibovici L: Effects of remote, retroactive intercessory prayer on outcomes in patients with bloodstream infection: randomised controlled trial. *BMJ* 323(7327):1450–1451, 2001.
46. The Lipid Research Clinics Coronary Primary Prevention Trial results. I. Reduction in incidence of coronary heart disease. *JAMA* 251(3):351–364, 1984.
47. Löe H, Theilade E, Jensen SB: Experimental Gingivitis in Man. *J Periodontol* 36:177–187, 1965.
48. MacMahon B, Yen S, Trichopoulos D, et al: Coffee and cancer of the pancreas. *N Engl J Med* 304(11):630–633, 1981.
49. Mandel EM, Rockette HE, Bluestone CD, et al: Efficacy of amoxicillin with and without decongestant-antihistamine for otitis media with effusion in children. Results of a double-blind, randomized trial. *N Engl J Med* 316(8):432–437, 1987.
50. Marinho VC, Higgins JP, Logan S, et al: Topical fluoride (toothpastes, mouthrinses, gels or varnishes) for preventing dental caries in children and adolescents. *Cochrane Database Syst Rev* (4):CD002782, 2003.
51. Matthews R: Statistics -Undermined by an error of significance. *Financ Times* 9, Friday July 9 2004.
52. Mills JL: Data torturing. *N Engl J Med* 329(16):1196–1199, 1993.
53. Montenegro R, Needleman I, Moles D, et al: Quality of RCTs in periodontology—a systematic review. *J Dent Res* 81(12):866–870, 2002.
54. Moseley JB, O'Malley K, Petersen NJ, et al: A controlled trial of arthroscopic surgery for osteoarthritis of the knee. *N Engl J Med* 347(2):81–88, 2002.
55. Moses H, 3rd, Martin JB: Academic relationships with industry: a new model for biomedical research. *JAMA* 285(7):933–935, 2001.
56. Nist E, Reader A, Beck M: Effect of apical trephination on postoperative pain and swelling in symptomatic necrotic teeth. *J Endod* 27(6):415–420, 2001.
57. Nowak R: Problems in clinical trials go far beyond misconduct. *Science* 264(5165):1538–1541, 1994.
58. Omenn GS: Human lung cancer chemoprevention strategies: Parker B. Francis lecture. *Chest* 125(5 Suppl):123S–127S, 2004.
59. Omenn GS, Goodman GE, Thornquist MD, et al: Effects of a combination of beta carotene and vitamin A on lung cancer and cardiovascular disease. *N Engl J Med* 334(18):1150–1155, 1996.
60. Petersen M, Madison Ave: Has Growing Role In the Business of Drug Research. *New York Times* August 20, 2002.
61. Peto J: Cancer epidemiology in the last century and the next decade. *Nature* 411(6835):390–395, 2001.
62. Prasad V, Cifu A, Ioannidis JP: Reversals of established medical practices: evidence to abandon ship. *JAMA* 307(1):37–38, 2012.
63. Psaty BM, Weiss NS, Furberg CD, et al: Surrogate end points, health outcomes, and the drug-approval process for the treatment of risk factors for cardiovascular disease. *JAMA* 282(8):786–790, 1999.
64. Report of the Committee of Principal Investigators: WHO cooperative trial on primary prevention of ischaemic heart disease with clofibrate to lower serum cholesterol: final mortality follow-up. *Lancet* 2(8043):600–604, 1984.
65. Roberts AH, Kewman DG, Mercier L, et al: The power of nonspecific effects in healing: Implications for psychosocial and biological treatments. *Clin Psychol Rev* 13(5):375–391, 1993.
66. Ross PE: Lies, damned lies and medical statistics. *Forbes* (August):130–135, 1995.
67. Rothman KJ: Journal policies on conflict of interest [letter]. *Science* 261(5129):1661, 1993.
68. Ryan M: *Who Really Said? The book that tests your "quote" I.Q*, Hong-Kong, 1967, Great Quotations Publishing Company.
69. Sagan C: *The Demon-Haunted World*, New York, 1996, Ballantine Books.
70. Sloppy stats shame science. *The Economist* 2004.
71. Steinbrook R: Public registration of clinical trials. *N Engl J Med* 351(4):315–317, 2004.
72. Stram DO, Huberman M, Wu AH: Is residual confounding a reasonable explanation for the apparent protective effects of beta-carotene found in epidemiologic studies of lung cancer in smokers? *Am J Epidemiol* 155(7):622–628, 2002.
73. Taubes G: Epidemiology faces its limits. *Science* 269(5221):164–169, 1995.
74. Temple RJ: A regulatory authority's opinion about surrogate endpoints. In Nimmo WS, Tucker GT, editors: *Clinical Measurement in Drug Evaluation*, New York, 1995, Wiley.
75. Thompson DF: Understanding financial conflicts of interest. *N Engl J Med* 329(8):573–576, 1993.
76. Turner EH, Matthews AM, Linardatos E, et al: Selective publication of antidepressant trials and its influence on apparent efficacy. *N Engl J Med* 358(3):252–260, 2008.
77. Van Doren C: *Benjamin Franklin*, New York, 1938, The Viking Press.
78. Vettore MV, Lamarca Gde A, Leao AT, et al: Periodontal infection and adverse pregnancy outcomes: a systematic review of epidemiological studies. *Cad Saude Publica* 22(10):2041–2053, 2006.
79. Washburn EP, Orza MJ, Berlin JA, et al: Residential proximity to electricity transmission and distribution equipment and risk of childhood leukemia, childhood lymphoma, and childhood nervous system tumors: systematic review, evaluation, and meta-analysis. *Cancer Causes Control* 5(4):299–309, 1994.
80. Willett WC, Vitamin A: and lung cancer. *Nutr Rev* 48(5):201–211, 1990.
81. Xiong X, Buekens P, Fraser WD, et al: Periodontal disease and adverse pregnancy outcomes: a systematic review. *BJOG* 113(2):135–143, 2006.
82. Yusuf S, Wittes J, Probstfield J, et al: Analyses and interpretation of treatment effects in subgroups of patients in randomized controlled trials. *JAMA* 266(1):93–98, 1991.
83. Zeger SL: RE: "Statistical reasoning in epidemiology" The author replies. *Epidemiology* 135(10):1187, 1992.

CHAPTER 88

Electronic Dental Records and Decision Support Systems

Thankam P. Thyvalikakath, Corey Stein, and Titus Schleyer

CHAPTER OUTLINE

Functionalities and Components Available in Electronic Dental Records
Electronic Dental Record Use in Dental Practices
Future of Electronic Dental Records and Decision Support Systems In Dentistry

Dental practices are using electronic dental records (EDRs) for patient care to a significant and rapidly rising degree.[14] While early on, computers primarily automated administrative and financial functions, they now increasingly support clinical patient documentation, digital radiographs, intraoral oral photos, and oral disease risk assessments. This shift in EDR use is generating vast amounts of patient data that could provide significant benefits to clinicians and researchers. Until now, clinicians have been able to track only individual patient outcomes through paper-based records. At the same time, researchers typically spend considerable time transcribing data from paper into electronic form to analyze data.

Digitization of patient data creates opportunities to dissect and analyze data in ways not possible before. Clinicians are able to track their patients' treatment progress and risks for various diseases at the individual, group, and practice level. Analyzing electronic data can generate new knowledge in real time. In this chapter, we discuss the current functions available in EDRs; EDR use by dental practices in the United States, Europe, and other countries; commonly used EDRs in the United States and Europe; and the drawbacks and advantages of using EDRs in practice. Finally, we describe the decision support systems available in dentistry, focused specifically on periodontal disease, and close with a discussion of the future of EDRs.

Functionalities and Components Available in Electronic Dental Records

An EDR typically includes components such as patient registration, medical and medication history, extraoral and intraoral exam, hard and soft tissue charting, treatment planning, patient education, visit documentation, imaging, and scheduling. In this section, we review selected examples of these functions.

Patient Registration

The data captured in patient registration include the patient's name, gender, birth date, identification numbers, such as Social Security and driver's license numbers, and address and contact information. Typically, offices with more than one clinician assign a provider. That makes it easy to list all patients for a particular provider.

Registration also includes an unobtrusive, but important data field, which is the chart number whereby a patient chart number is assigned automatically as soon as this record is saved. This chart number is the identifier that links all parts of the electronic record for a particular patient together; it is a unique, internal identifier with which all information items of one patient are "stamped."

Another feature of an EDR is that most information on the registration screen is stored in separate fields, called "structured data." Structured data fields can be summarized and analyzed on their own or in combination, enabling some of the powerful reporting and analysis functions found in EDRs.

Periodontal Chart

The sample periodontal chart shown in Figure 88-1 shows not only the pocket depth and clinical attachment loss, it also a graphical presentation of the periodontal changes over time. This presentation is difficult to achieve using paper-based periodontal charts.

Electronic Dental Record Use in Dental Practices

Over the last 20 years, the use of EDRs in dental practices has risen significantly worldwide, and especially in the United States.[13,26] Early on, dental practices used computerized systems primarily for administrative functions, such as patient accounting and billing (94%), insurance processing (90.9%), and patient scheduling (83%).[6] Only 37% of dental practices reported using a computer to maintain patient records at that time. Studies on EDR use in the England, Wales, and Sweden reported similar figures.[28,26,19]

More recent studies have pointed to a marked increase in EDR use for clinical documentation.[14,13,6] In 2010, U.S. dental practices used EDRs to acquire and store radiographs (68%), intraoral photos and videos (67%), examination forms (54%), progress notes (54%), and dental charting (50%).[6] Most practices maintained a hybrid system of patient records with some information spread across paper and the EDR. As opposed to 2% in 2006, in 2012 about 15% of practices maintained completely paperless records.[14]

Figures 88-2, 88-3, and 88-4 illustrate how clinical information is stored in U.S. solo and group practices, as well as in

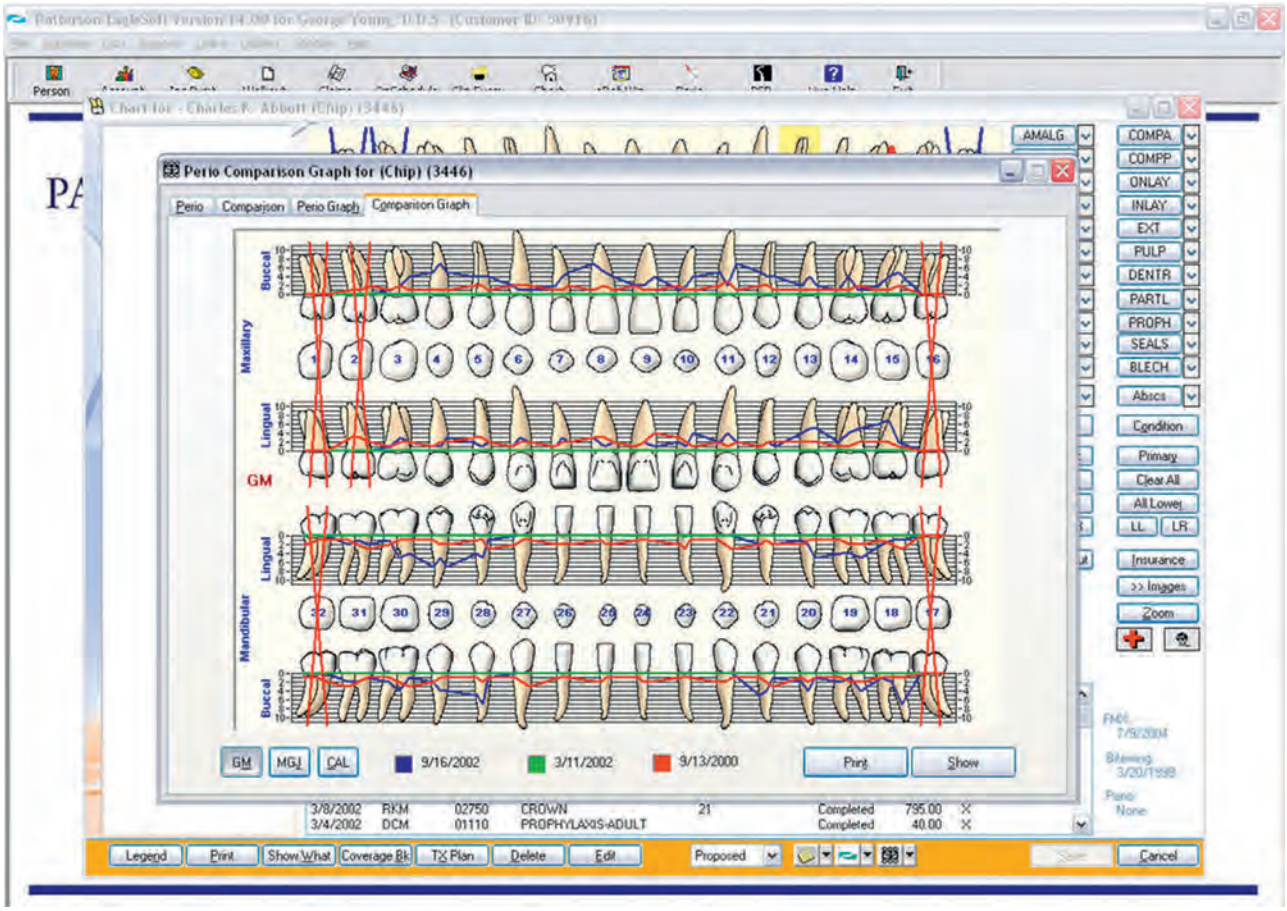

Figure 88-1 Screenshot of the periodontal chart in EagleSoft. *(Courtesy of Patterson Technology.)*

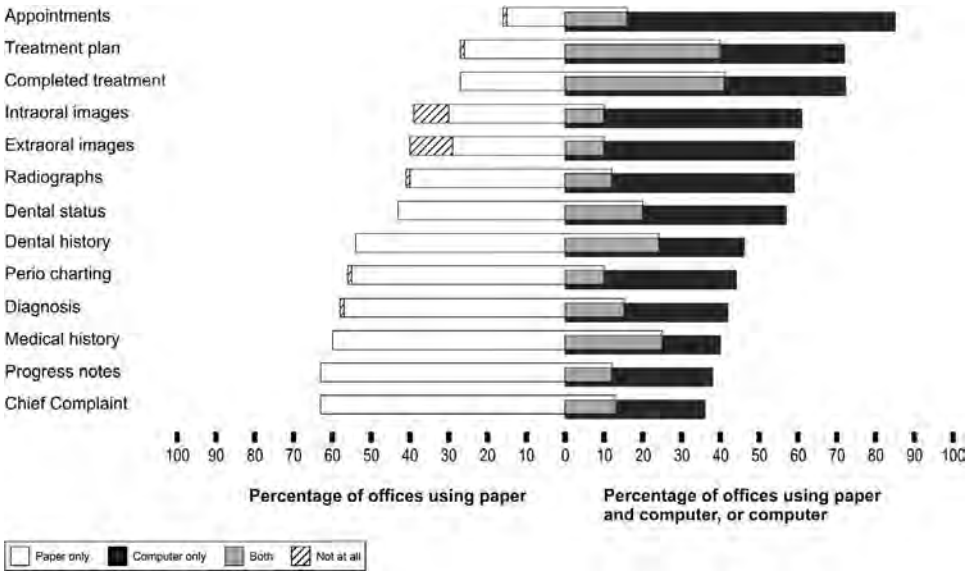

Figure 88-2 Types of major clinical information stored on paper, a computer, or both by U.S. solo practices. *(Reprinted with permission from Schleyer T, Song M, Gilbert G, et al: Electronic dental record use and clinical information management patterns among practitioner-investigators in The Dental Practice-Based Research Network,* J Am Dent Assoc *144(1):49-58, 2013.)*

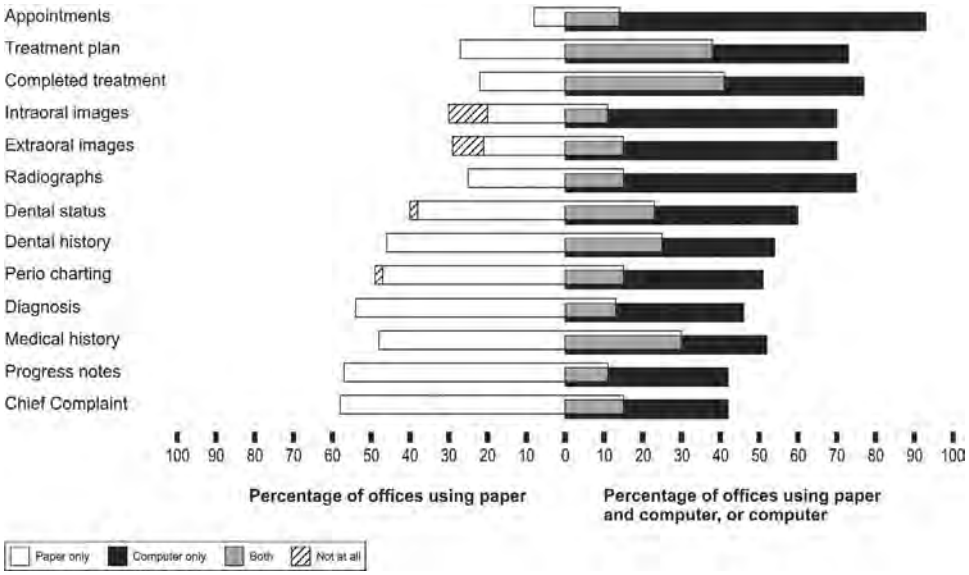

Figure 88-3 Types of major clinical information stored on paper, a computer, or both by U.S. group practices. *(Reprinted with permission from Schleyer T, Song M, Gilbert G, et al. Electronic dental record use and clinical information management patterns among practitioner-investigators in The Dental Practice-Based Research Network,* J Am Dent Assoc *144(1):49-58, 2013.)*

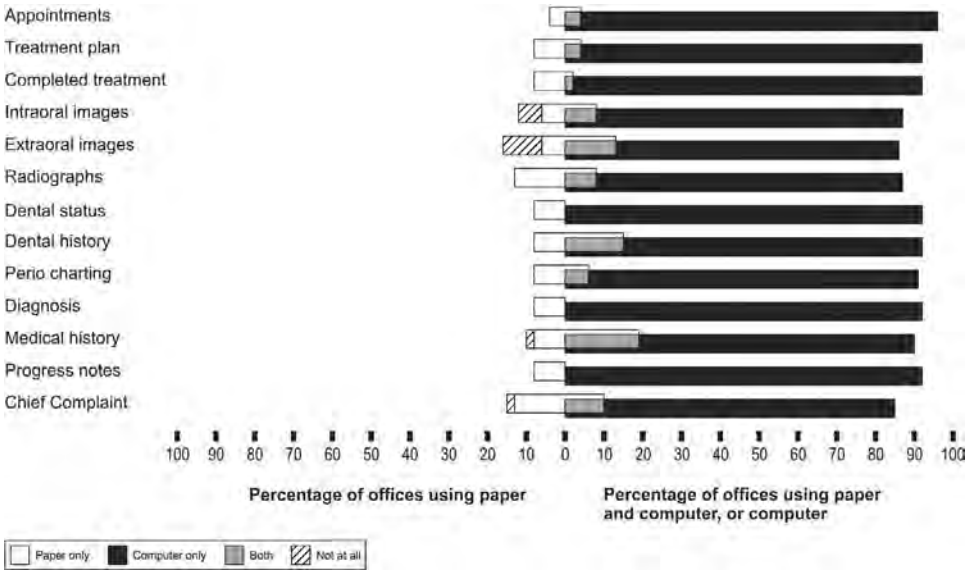

Figure 88-4 Types of major clinical information stored on paper, a computer, or both by Scandinavian group. *(Reprinted with permission from Schleyer T, Song M, Gilbert G, et al. Electronic dental record use and clinical information management patterns among practitioner-investigators in The Dental Practice-Based Research Network,* J Am Dent Assoc *144(1):49-58, 2013.)*

Scandinavian group dental practices.[14] These figures clearly show that more dental practices in Scandinavian countries stored clinical information on the computer than in the United States. Meanwhile, nearly all dental schools in the United States and Europe use (primarily commercial) EDR systems in some capacity.[15,7] However, very few studies exist on how these systems are used in academic settings.

Commonly Used Electronic Dental Records

Four systems currently hold about 75% of the market in EDRs in the United States. They are Dentrix Dental Systems (Henry Schein; 37%), EagleSoft (Patterson Dental; 18%), and SoftDent and PracticeWorks (Carestream; 20%).[14,13,6] About 100 other companies, most of them fairly small, develop and market EDR systems in the United States. Notable among them are the Windows-based MOGO, and Curve Dental and Dental Symphony, both web-based. While no general reports on EDRs commonly used in Europe exist, Al Dente (Nordenta, Horning, Denmark), Dental Suite (Plandent, Helsinki), and Opus (Planmeca, Helsinki) appear to dominate in Scandinavian countries.

Barriers to Using Electronic Dental Records

In spite of the rapid adoption of EDR, several barriers exist to using EDR effectively for patient care. They include limited functionality, suboptimal usability and a steep learning curve, insufficient operational reliability, and cost and infection control issues.

Limited Functionality for Communication and Collaboration. Dental personnel collaborate extensively during patient care.[9] However, existing EDRs provide limited support

for collaboration and communication among dental team members. In addition, breakdowns related to technology interrupt the workflow, cause rework, and increase the number of steps in work processes.

Suboptimal Usability and Steep Learning Curve. Several studies have reported poor usability of existing EDRs.* Two examples of usability problems are the separation of patient information across multiple screens, and the frequent mismatch between system design and task flow. As a result, users have to shift their attention from patients to EDRs to navigate through the information and to avoid making mistakes. Users believed they spent a longer time interacting with EDRs than with paper records, resulting in less face time with their patients.

Insufficient Reliability of Electronic Dental Records and Infection Control Issues. System crashes during patient care that lead to loss of patient data and time[13,15] are an example of insufficient operational reliability of EDRs. Infection control issues are primarily due to the fact that the keyboard and mouse are the primary mechanisms for interacting with a computer. Many practices use auxiliary personnel as remote controls for the EDR. While this workaround is effective, it reduces efficiency and increases the chance of errors.

Challenges to Realizing the Full Potential of Electronic Dental Records

Standards for Information Content of Electronic Dental Records. As expressed by the adage "dentists and patients forget, but good records remember," complete and comprehensive patient records are essential to support effective decision making and outcomes research.[27] Currently, no standards exist on what clinical information dental records should or must contain. As more and more dentists adopt EDRs to deliver patient care,[14] it is essential that we address the question of what patient information should be documented and how it should be structured.[25] During the last three decades, state, national, and international dental organizations have produced many guidelines and/or standards for essential components of the dental record. Common information categories recommended include personal and demographic information, reason for visit, dental history, medical history, clinical examination information, diagnosis, treatment plan, and informed consent information. However, these recommendations are very general and dental records vary significantly in the degree to which they meet them.[13] Currently, major work is being pursued toward developing a standard information model for EDRs.[25,4]

Data Representation and Interoperability. Dentistry lacks a standard terminology for documenting and describing dental findings and diagnosis. The World Health Organization's International Classification of Disease coding system or ICD is limited with regard to oral and dental diagnoses. Several terminologies, such as SNODENT[24] and the EZcodes,[20] are being developed and evaluated as standard diagnostic codes for dentistry. However standard terminologies alone will not solve the problem of data representation and interoperability. We need to consider how dental data in their totality can be represented on the computer so they can be easily stored, exchanged, and analyzed. Patient records typically consist of free text; numbers; standardized codes; and radiographic, histological, and clinical images. While structured data can be represented and analyzed unambiguously, that is not true for free text data and images. Concepts in dental records must be represented to facilitate semantic interoperability and exchange of information across different systems. Ontologies are a powerful way to create computer-based representations that fulfill that goal.[12]

*References 13, 28, 15, 7, 3, 16

Benefits of Using Electronic Dental Records

In spite of barriers and challenges to using EDR for patient care, tremendous opportunities exist for using EDRs to improve patient care. As mentioned in the introduction, EDRs can provide significant benefits for clinicians and researchers. Using EDRs, clinicians are able to track their patients' treatment progress and risks for various diseases. Other benefits include timely access to patient records, access to patient records regardless of geographic location, simultaneous access to patient records by multiple users, the ability to generate best evidence from patient data and built-in decision support systems to reduce errors such as medication errors and drug-drug interactions. For researchers, digitization of patient data creates opportunities to dissect and analyze data in ways that have not been possible before.[22] Reuse of electronic patient data for dental research is in a nascent stage, but provides a significant opportunity to help build a "learning healthcare system." Advantages of using EDR data for research include the ability to conduct studies of significant statistical power due to large sample sizes, obtain well-matched controls, ascertain important potential confounders, identify patients with rare diseases, save study time, collect data in real time, and generate systematic data documentation. We discuss a few of these benefits below.

Reusing Electronic Dental Records Data for Research Purposes. EDR data can be a strong alternative or be synergistic to traditional research methods. They can be used for many types of studies, including epidemiology, outcomes, and comparative effectiveness.[22] Using EDRs for research allows the study of patient populations instead of the research study populations, thus generating study results that are applicable to real-world clinical settings and patients. However, using electronic patient data for research is significantly more common in medicine than in dentistry.[22] Limitations, such as the poor quality of clinical data, lack of standards for clinical findings and diagnoses, and lack of interoperability of EDRs, hamper our ability to synthesize patient data for research in dentistry. More work is needed toward reusing clinical data to generate knowledge that impacts research and clinical care.

Clinical Decision Support Systems

Clinical decision support systems (CDSSs) are "information systems that improve clinical decision-making."[1] They are designed to provide relevant and current evidence to clinicians to improve patient care and reduce errors in practice. CDSSs systems analyze patient characteristics against a computerized knowledge base and generate patient-specific recommendations. Required patient data are either entered by clinicians and/or patients, or retrieved from the electronic health record. Patient-specific recommendations are delivered to clinicians through the electronic health records, email communications, text messages, or through printouts placed in the patient charts. As Garg et al found, many CDSSs demonstrably improve practitioner performance.[1]

Decision Support System Types. Both the theoretical foundations and the applications of decision support have been extensively studied in medicine.[23] Research on medical decision support has included studies on human diagnostic problem solving, the development of several types of algorithms to encode decision-support processes (e.g., rule-based systems, Bayesian belief

systems, and neural networks) and the evaluation of their performance in the clinics. These systems could be of two types: the open-loop system or the closed-loop system. Open-loop systems provide recommendations but do not take action of their own. For example, alerts and reminders are part of open-loop systems. Closed-loop systems take action on their own without the clinicians' intervention. During the last three decades, dentistry also saw the development of many decision support systems,[2] but their use is not common. These systems addressed topics such as dental emergencies and trauma, radiographic interpretation of lesions, analysis of cephalograms in orthodontics, pulpal diagnosis, and design of partial denture in restorative dentistry.

Risk-Based Decision Support Systems for Periodontal Disease. In periodontology, risk-based decision support systems are the most common type of CDSSs. The PreViser Risk Calculator (PRC) (PreViser Corp., Mount Vernon, WA) developed by Page et al,[17] UniFe developed by Trombelli et al, and DentoRisk (DentoSystem Scandinavia AB, Stockholm, Sweden) developed by Lindskog et al are examples of risk assessment tools for periodontal disease. The PRC is a web-based tool developed based on the scientific evidence of the importance of risk factors for periodontal disease. The tool calculates the patient's disease score and risk score based on a mathematical algorithm that assigns relative weights to eleven factors: patient age, smoking history, diagnosis of diabetes, history of periodontal surgery, bleeding on probing, pocket depth, furcation involvement, subgingival restorations, root calculus, vertical bone defects, and radiographic bone loss. The disease score ranges from 0 (no disease) to 100 (severe periodontitis), and the risk score from 1 (lowest) to 5 (highest).

Barriers to the Adoption of Clinical Decision Support Systems. There are several reasons for the slow implementation of CDSSs: standalone systems that are not integrated with the clinicians' workflow, lack of formal evaluation, challenges in developing standards for representing data, lack of studies on the clinicians' decision-making process, and the clinicians' skepticism on the value of CDSSs for patient care. Investigators emphasize the need for vigorous studies to integrate decision support systems into the clinicians' clinical workflow to improve patient care.[2,18,10,11]

Factors That Improve the Adoption of Clinical Decision Support Systems. Several important lessons on the implementation of CDSSs are available from the extensive literature in medical informatics. In syntheses of research on decision support, Bates et al[5] and Kawamato et al[8] identified several factors that facilitate the adoption of decision support systems by practitioners. They include delivering decision support to the individual making the decision at the time the decision is made; fitting the system into the user's workflow; focusing on usability for the clinician; and not requiring additional data entry unless absolutely necessary. It is also important to evaluate the impact of these systems during the early phases of development and keep their knowledge bases up to date.

To summarize, CDSSs have the potential to improve clinical care and patient outcomes by delivering the best evidence to the clinician at the point of care. However, most systems are developed in isolation with limited impact on patient care. It is important that these systems are implemented in electronic patient records to achieve improvements in patient care. Finally, more studies are needed to learn how best to influence clinician behavior through these systems.

Future of Electronic Dental Records and Decision Support Systems in Dentistry

Adoption of EDRs has the potential not just to support clinical care, but also to advance research and improve patient outcomes. In addition, EDRs offer the opportunity to move from a reparative to a preventive approach to treating oral diseases. Many dental diseases, including periodontal disease, are currently being managed using a reparative model, under which dentists and hygienists concentrate on the clinically obvious that requires immediate intervention, focusing less attention on preventing future disease.[17,21] Using this model, the treatment is essentially the same for all patients with identical clinical presentation. EDRs with integrated decision support systems can help with identifying patients at high risk, as well as with providing individualized recommendations. Despite emerging evidence of the validity and clinical utility of these systems on treatment in dentistry and, specifically, periodontology, little evidence suggests that these approaches are adopted broadly in general practice.[11] Leveraging the full functionalities of these systems will require significant work as well as trained informatics personnel. Dental informatics is an interdisciplinary field that applies computer and information science knowledge and methods to improve information management during clinical care, research and dental education. Until now, the challenge for dentistry was to transition from paper to EDRs in a very basic fashion. Often, EDRs were designed as close or exact replicas of paper records.

Going forward, this approach will be insufficient. Dentistry now faces the challenge of making sense of electronic data collected, facilitating clinical care and research, and improving outcomes. It is important that trained dental informaticians, clinicians, educators, and researchers collaborate to accomplish this goal. Dentistry, just as other healthcare disciplines, is an information-intensive domain. The future success of dentistry depends on how we best use information technology to make sense of data and improve patient care. Informatics holds the key to that success.

Suggested Readings

Bates D, Kuperman G, Wang S, et al: Ten commandments for effective clinical decision support: making the practice of evidence-based medicine a reality. *JAMA* 10(6):523–530, 2003.

Mendonca E: Clinical decision support systems: perspectives in dentistry. *J Dent Educ* 68(6):589–597, 2004.

Page R, Krall E, Martin J, et al: Validity and accuracy of a risk calculator in predicting periodontal disease. *J Am Dent Assoc* 133(5):569–576, 2002.

Schleyer T, Thyvalikakath T, Spallek H, et al: Clinical computing in general dentistry. *J Am Med Inform Assoc* 13:344–352, 2006.

Thyvalikakath T, Schleyer T, Monaco V: Heuristic evaluation of clinical functions in four practice management systems: a pilot study. *J Am Dent Assoc* 138(2):209–218, 2007.

White S: Decision-support systems in dentistry. *J Dent Educ* 60(1):47–63, 1996.

References

1. Acharya A, Hernandez P, Thyvalikakath T, et al: Bottom-up development of a taxonomy of information items for patient records in general dentistry. *Int J Med Inform Dec* 82(12):1171–1182, 2013.
2. Acharya A, Mital D, Schleyer T: Electronic dental record information model. *Int J Med Eng Inform* 1(4):418–434, 2009.
3. Bates D, Kuperman G, Wang S, et al: Ten commandments for effective clinical decision support: making the practice of evidence-based medicine a reality. *JAMA* 10(6):523–530, 2003.
4. Dobrev A, Peng K, Jones T: *The socio-economic impact of the regional integrated EHR and ePrescribing system in Kronoberg, Sweden*, EHR Impact, Bonn, 2009, European Commission, DG INFSO & Media.

5. Douglass C: Risk assessment and management of periodontal disease. *J Am Dent Assoc* 137:27–32, 2006.
6. Garg AX, Adhikari NK, McDonald H, Rosas-Arellano MP, et al: Effects of computerized clinical decision support systems on practitioner performance and patient outcomes: a systematic review. *JAMA* 293(10):1223–1238, 2005.
7. Goldberg L, Ceusters W, Eisner J, et al: *The significance of SNODENT: connecting medical informatics and bio-informatics: proceedings of MIE2005—the XIXth International Congress of the European Federation for Medical Informatics*, vol 116/2005, Leiden, 2005, IOS Press.
8. Hill H, Stewart D, Ash J: Health information technology systems profoundly impact users: a case study in a dental school. *J Dent Educ* 74(4):434–445, 2010.
9. Irwin J, Torres-Urquidy MH, Schleyer T, et al: A preliminary model of work during initial examination and treatment planning appointments. *Br Dent J* 206:1–9, 2009.
10. John JH, Thomas D, Richards D: Questionnaire survey on the use of computerisation in dental practices across the Thames Valley region. *Br Dent J* 195:585–590, 2003.
11. Kalenderian E, Ramoni R, White J, et al: The development of a dental diagnostic terminology. *J Dent Educ* 75(1):68–76, 2010.
12. Kawamoto K, Houlihan C, Balas E, et al: Improving clinical practice using clinical decision support systems: a systematic review of trials to identify features critical to success. *BMJ* 330(7494):765, 2005. [Epub March 14, 2005].
13. Kye W, Davidson R, Martin J, et al: Current status of periodontal risk assessment. *J Evid Based Dent Pract* 12(3 Suppl):2–11, 2012.
14. Loeb P, McGibony R, Yeung P: *Health information technology in California dental practices: survey findings*, Oakland, 2010, California Healthcare Foundation.
15. Mendonca E: Clinical decision support systems: perspectives in dentistry. *J Dent Educ* 68(6):589–597, 2004.
16. Miller R: Medical diagnostic decision support systems—past, present, and future: a threaded bibliography and brief commentary. *J Am Inform Assoc* 1(1):8–27, 1994.
17. Oberbreckling P: The components of quality dental records. *Dent Econ* 41:410–414, 1993.
18. Page R, Krall E, Martin J, et al: Validity and accuracy of a risk calculator in predicting periodontal disease. *J Am Dent Assoc* 133(5):569–576, 2002.
19. Schleyer T, Song M, Gilbert G, et al: Electronic dental record use and clinical information management patterns among practitioner-investigators in the Dental Practice-Based Research Network. *J Am Dent Assoc* 144(1):49–58, 2013.
20. Schleyer T, Spallek H, Bartling W, et al: The technologically well-equipped dental office. *J Am Dent Assoc* 134(1):30–41, 2003.
21. Schleyer T, Thyvalikakath T, Spallek H, et al: Clinical computing in general dentistry. *J Am Med Inform Assoc* 13:344–352, 2006.
22. Smith BGL, Ruttenberg A, Glick M: Ontology and the future of dental research informatics. *J Am Dent Assoc* 141(10):1173–1175, 2010.
23. Song M, Liu K, Abromitis R, et al: Reusing electronic patient data for dental clinical research: a review of current status. *J Dent* 41(12):1148, 2013. doi: 10.1016/j.dent.2013.04.006. [Epub April 18, 2013].
24. Thyvalikakath T, Schleyer T, Monaco V: Heuristic evaluation of clinical functions in four practice management systems: a pilot study. *J Am Dent Assoc* 138(2):209–218, 2007.
25. Thyvalikakath T, Thambuganipalle H, Monaco V, et al: Comparative study of heuristic evaluation and usability testing methods. *Stud Health Technol Inform* 143:322, 2009.
26. Wagner I, Ireland R, Eaton K: Digital clinical records and practice administration in primary dental care. *Br Dent J* 204(7):387–395, 2008.
27. Walji M, Taylor D, Langabeer J, et al: Factors influencing implementation and outcomes of a dental electronic patient record system. *J Dent Educ* 73(5):589–600, 2009.
28. White S: Decision-support systems in dentistry. *J Dent Educ* 60(1):47–63, 1996.

CHAPTER 89

Locally Delivered, Controlled-Release Antimicrobials

Richard D. Finkelman and Alan M. Polson

CHAPTER OUTLINE

Background and Objectives
Drug Development and Registration
Clinical Use
Currently Available Agents (Non-U.S.)
Conclusion

Background and Objectives

Chronic periodontitis is a bacterial infection. The focus of almost all nonsurgical periodontal therapy, including mechanical therapy such as scaling and root planing (SRP), is directed to combat that infection. With regard to chemical antibacterial therapies, a number of treatment strategies have been considered including systemic delivery, oral rinses or toothpastes, and irrigating devices. As a potential treatment strategy for chronic periodontitis, none of these therapies ultimately seemed to have resulted in a significant clinical benefit to reduce signs of periodontitis. Within the past two decades, however, a new strategy has emerged. A number of controlled-release delivery systems have been developed to deliver antimicrobials directly into the periodontal pocket and to maintain effective concentrations of drug for an extended period of time. These agents have been studied extensively and have been shown to be safe and effective for the treatment of chronic adult periodontitis, in some cases as monotherapy, and in other cases when administered adjunctively with SRP. Although monotherapy has been studied, the general consensus of the professional community is that the best use may be in the adjunctive setting.

It is well accepted that evidence-based practice, providing dental treatment based on research evidence, leads to the most optimal care for the greatest number of patients.[66,67] A considerable set of data exists with respect to locally delivered, controlled-release antimicrobials, perhaps the most robust dataset that currently exists for any periodontal therapy. The focus of this chapter is to consider the available clinical data that support the use of these agents for the treatment of chronic periodontitis and to provide an evidence-based guidance for their use. For this discussion, locally delivered, controlled-release antimicrobials are considered as a drug class rather than individually. Since appropriate comparative trials have not been performed, there are insufficient data on which to base any comparison of agents or to consider differential indications for use. The indications for use for each product can only be based on the indications as described in the respective full prescribing information. Additionally, some commentary is provided regarding these agents and available research for potentially new indications that have not yet been evaluated by the U.S. Food and Drug Administration (FDA; Box 89-1).

Currently Available Agents (U.S.)

Three locally delivered, controlled-release antimicrobial products are currently available for dental use in the United States (Table 89-1), a chlorhexidine-containing chip (PerioChip), a doxycycline gel (Atridox), and minocycline microspheres (Arestin). A fourth product, an ethylene/vinyl acetate copolymer fiber containing the antibiotic tetracycline (Actisite; 12.7 mg per 9-inch filament), was the first product introduced into the U.S. market in the early 1990s and was the prototypic system. The tetracycline fiber is no longer commercially available in the United States, and its clinical use will not be further considered. The fiber is included in this chapter, however, because data generated from clinical studies of the product are pertinent for a discussion of the general effects of locally delivered, controlled-release antimicrobials.

Chlorhexidine Chip. The chlorhexidine chip is a small chip ($4.0 \times 5.0 \times 0.35$ mm) that contains 2.5 mg of the active ingredient chlorhexidine gluconate in a resorbable, biodegradable matrix of hydrolyzed gelatin, cross-linked with glutaraldehyde, packaged in individual foil containers (Figure 89-1, *A*). It is indicated as an adjunct to SRP procedures for the reduction of pocket depth (PD) in patients with adult periodontitis and may be used as part of a periodontal maintenance program, which includes good oral hygiene and SRP.[80] After placement in the pocket, the chip has been reported to release chlorhexidine into the gingival crevicular fluid (GCF) over 7 to 10 days.[96] Chlorhexidine is active against a broad range of microbes, disrupting the cell membrane and causing precipitation of the cytoplasm, resulting in cell death. No adverse alterations within the oral microbial flora or overgrowth of opportunistic microorganisms have been observed.[80] The chip is biodegradable and does not require removal, but dental floss should be avoided for 10 days to avoid dislodging the chip. The chip is stored at 20° to 25° C (68° to 77° F), with excursions permitted to 15° to 30°C (59° to 86°F). The chlorhexidine chip is placed into the pocket directly from the foil container using a forceps (Figure 89-1, *B*).

Copyright © 2015, 2012, 2006 by Saunders, an imprint of Elsevier Inc.

BOX 89-1 Clinical Insights

- Adjunctive therapy makes scaling and root planing (SRP) more effective.
- Because most pockets are quiescent, mean changes are modest when all pockets are included.
- Significantly more patients show large pocket depth (PD) reductions with adjunctive therapy.
- Clinical responses are evident only after time and with clinical pocket measurements.
- The greatest clinical benefit is likely to result when adjunctive agents are routinely included as part of SRP procedures and in a long-term periodontal maintenance program.

TABLE 89-1 Locally Delivered Controlled-Release Antimicrobials Developed for Dental Use in the United States

Product	Antimicrobial Agent
Actisite*	Tetracycline
PerioChip	Chlorhexidine
Arestin	Minocycline
Atridox	Doxycycline

*No longer commercially available in the United States.

Doxycycline Gel. The doxycycline gel is a subgingival controlled-release delivery product composed of a two-syringe mixing system (Figure 89-2, *A*). Syringe A contains 450 mg of a bioabsorbable polymeric formulation of 36.7% poly(D,L,-lactide) dissolved in 63.3% *N*-methyl-2-pyrrolidone. Syringe B contains 50 mg of doxycycline hyclate, equivalent to 42.5 mg doxycycline. The two syringes are stored at 2° to 30° C (36° to 86° F). When mixed, the constituted product is a viscous liquid of 500 mg, which contains 50 mg (10%) doxycycline hyclate. The doxycycline gel is indicated for the treatment of chronic adult periodontitis for a gain in clinical attachment, reduction in probing depth, and reduction of bleeding on probing.[8] Doxycycline, a broad-spectrum semisynthetic tetracycline, is bacteriostatic, inhibiting bacterial protein biosynthesis by interfering with transfer RNA (tRNA) and messenger RNA (mRNA) at the ribosome. No overgrowth of opportunistic organisms was observed following use of the doxycycline gel.[8] The gel has been reported to release doxycycline within the GCF over 7 days.[103] The doxycycline gel is biodegradable and does not require removal. If not used immediately, the mixed contents in syringe A may be stored at room temperature for a maximum of 3 days within an airtight container. The doxycycline gel is used by injecting the mixed contents of the two syringes directly into the pocket (Figure 89-2, *B*). The pocket contents are then covered with either a periodontal dressing or a cyanoacrylate dental adhesive.

Minocycline Microspheres. The minocycline microspheres product is a subgingival controlled-release delivery system

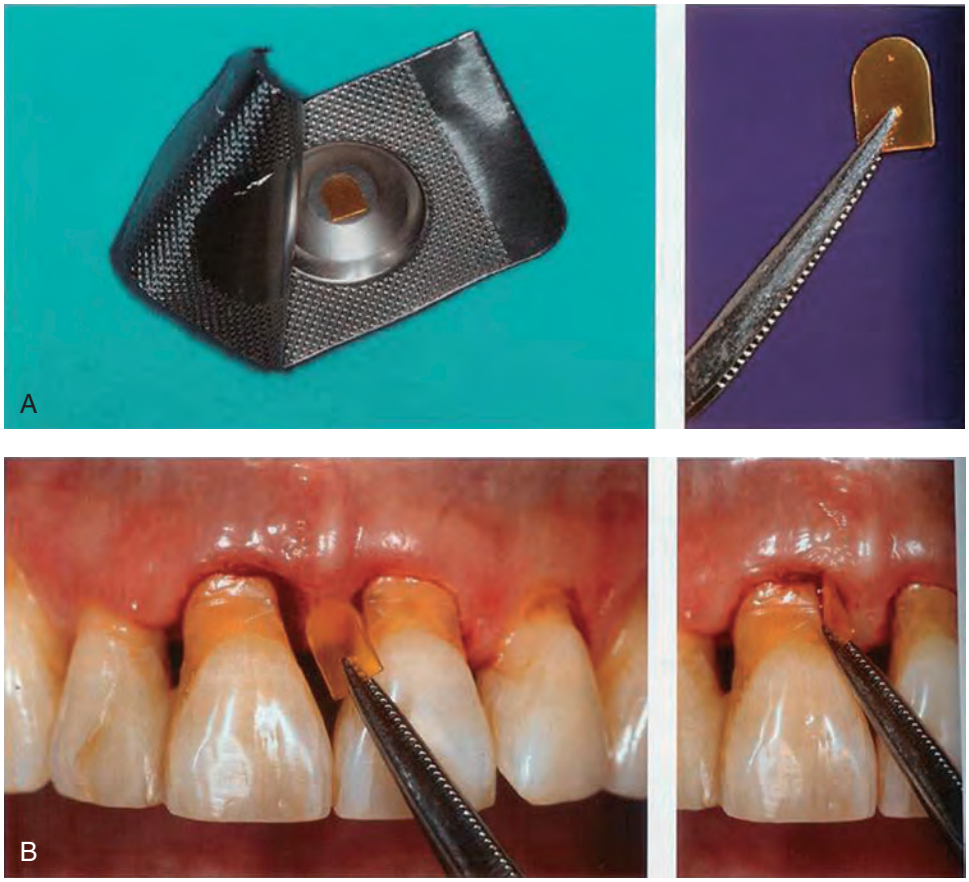

Figure 89-1 Chlorhexidine gluconate chip (PerioChip). **A,** *Left panel,* The chip is packaged in a foil packet. *Right panel,* The chip is removed from the foil container with a suitable forceps. **B,** *Left panel,* The chip is inserted into the pocket, curved end first. *Right panel*. After insertion, the chip is pressed apically to the base of the pocket. *(Reprinted from Wolf HF, Hassell TM:* Color atlas of dental hygiene: periodontology, *ed 1, Stuttgart, Germany, 2006, Thieme, with permission.)*

Copyright © 2015, 2012, 2006 by Saunders, an imprint of Elsevier Inc.

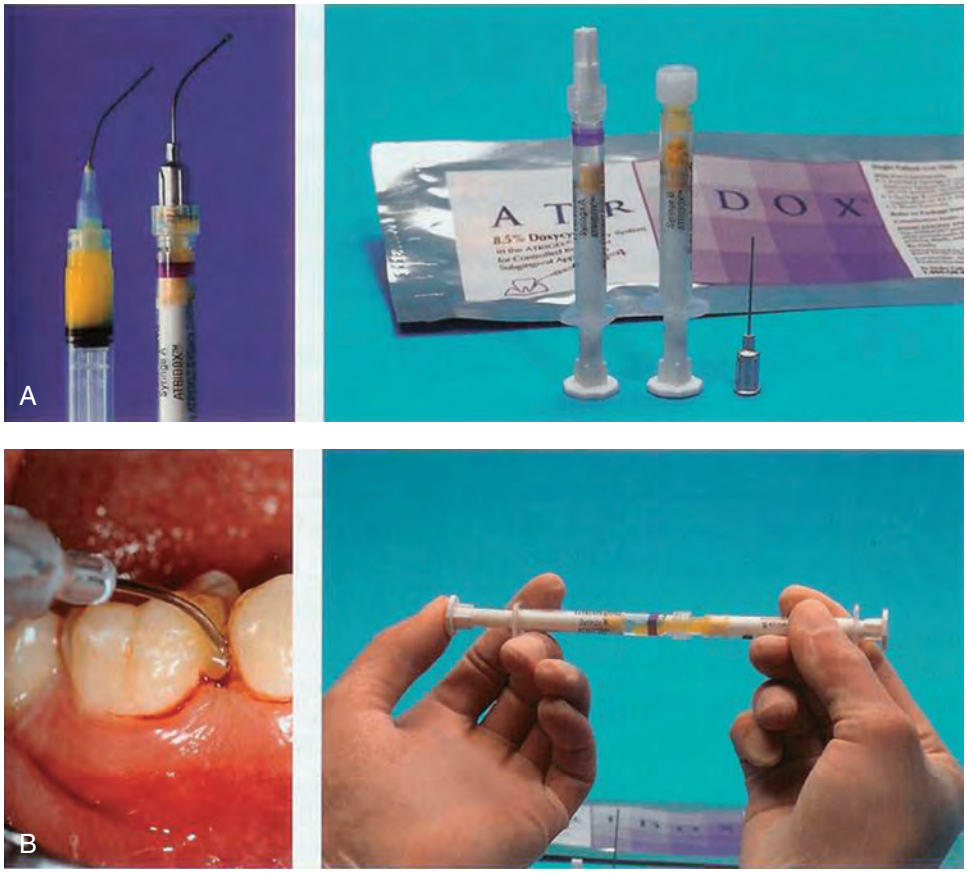

Figure 89-2 Doxycycline hyclate gel (Atridox). **A,** *Right panel,* Doxycycline gel is packaged as a two-syringe mixing system. *Left panel,* After mixing the gel, a cannula is attached for injection. **B,** *Right panel,* The two syringes are coupled, and the liquid contents of syringe A are injected into the powder within syringe B; the contents are mixed within the two syringes for 100 cycles (one cycle per second) and then left within syringe A. *Left panel,* The mixed solution is injected into the pocket through the cannula attached to syringe A until the pocket is completely filled. The pocket contents are covered with either a periodontal dressing or a cyanoacrylate dental adhesive. *(Reprinted from Wolf HF, Hassell TM:* Color atlas of dental hygiene: periodontology*, ed 1, Stuttgart, Germany, 2006, Thieme, with permission.)*

Figure 89-3 Minocycline hydrochloride microspheres (Arestin). *Left panel,* Minocycline microspheres are packaged into unit-dose cartridges. *Right panel,* Microspheres are used by injecting the cartridge contents directly with a syringe into the periodontal pocket. *(Reprinted from Wolf HF, Hassell TM:* Color atlas of dental hygiene: periodontology*, ed 1, Stuttgart, Germany, 2006, Thieme, with permission.)*

containing the antibiotic minocycline hydrochloride incorporated into a bioresorbable poly(glycolide-co-D,L-lactide) polymer in unit-dose cartridges (Figure 89-3). Each cartridge delivers minocycline hydrochloride equivalent to 1 mg of minocycline free base. The minocycline microspheres are indicated as an adjunct to SRP for reduction of PD in patients with adult periodontitis and as part of a periodontal maintenance program, which includes good oral hygiene and SRP.[6] Minocycline belongs to the tetracycline class of antibiotics and has a broad spectrum of activity. Its bacteriostatic, antimicrobial activity results from the inhibition of protein biosynthesis. No overgrowth of opportunistic microorganisms was noted during clinical studies. No changes in the presence of minocycline-resistant bacteria, *Candida albicans* or *Staphylococcus aureus*, in the gastrointestinal tract were detected at the end of a 56-day study, although there was a slight increase in the numbers of minocycline-resistant bacteria in periodontal pocket plaque samples after 9 months.[6] The clinical significance of the changes is unknown. Patients should avoid hard or sticky foods at the treated teeth for 1 week and interproximal cleaning devices for about 10 days. The minocycline microspheres formulation is biodegradable and does

Copyright © 2015, 2012, 2006 by Saunders, an imprint of Elsevier Inc.

not require removal. The cartridges are stored at 20° to 25° C (68° to 77° F), with excursions permitted to 15° to 30° C (59° to 86° F). Excessive heat should be avoided. The minocycline microspheres are used by injecting the contents of a unit-dose cartridge into the pocket. Neither a periodontal dressing nor an adhesive are needed.

For complete details for the use of locally delivered, controlled-release antimicrobial products, including a discussion of the safety profiles, the reader is referred to the full prescribing information for each product.[6,8,80]

Rationale for Local Delivery and Controlled-Release

Chronic adult periodontitis is a multifactorial disease (Figure 89-4). The first requirement is a susceptible host, largely due to genetics and not modifiable. Another nonmodifiable risk factor is age. Other components of disease risk, which may be modifiable, include pathogenic oral plaque microorganisms and behavioral or environmental factors such as tobacco use. Mediating the pathogenesis are host-derived elements including immune and inflammatory responses that may impact soft and hard tissue metabolism and feed back upon the pathogenic flora. From the most basic perspective, however, periodontal diseases are bacterial infections; the requirement for bacteria to initiate the periodontal lesion is well recognized. Also well recognized are that (1) the antibacterial effect of SRP or other mechanical therapy generally is due to either a reduction of the bacterial load or an alteration of the composition of the bacterial flora at the periodontal site; and (2) the antibacterial effect of mechanical treatment alone is incomplete. Thus a good rationale exists to try to augment chemically the antibacterial effect of mechanical therapy. Multiple strategies have been used to try to deliver antimicrobial agents to the periodontal pocket at effective doses to impact the bacterial microflora including systemic administration or local administration via local irrigation of fluid formulations or placement of various gels or ointments. None of these strategies have proven to be as effective as controlled-release.

One of the drawbacks of antimicrobials delivered to the pocket but not in controlled-release formulations results from the dynamics of the GCF. The GCF fills the periodontal pocket space, but there is a copious flow of GCF out of the pocket that continuously moves GCF contents to the oral cavity.[29,35] Additionally, the flow rate may be markedly enhanced in the presence of inflammation. Thus, antimicrobials delivered to the pocket are quickly washed out of the pocket by the GCF, rapidly reducing the concentration of drug locally to subantimicrobial levels (Figures 89-5 and 89-6). Drug concentrations within the GCF may even need to be elevated above usual antimicrobial levels because microorganisms within the pocket may exist within a protective biofilm structure in the periodontal ecosystem[19,99] (for reviews, see Palmer[75] or Kuboniwa and Lamont[58]). Bacterial biofilms may be highly resistant to penetration by fluids,[26] providing further evidence for the critical need for high GCF concentrations of active antimicrobial, concentrations only achievable with suitable locally delivered controlled-release agents (see Pharmacokinetics, below) but not possible with locally delivered antimicrobials not in controlled-release formulations or via systemic routes. Additionally, Drisko[24] has suggested that the high concentrations of antimicrobial in the GCF as a result of local delivery may help to reach infected sites within the root or tissue.

With regard to systemically delivered antimicrobials, drug concentrations within the GCF are orders of magnitude less than those achievable with controlled-release local delivery and cannot

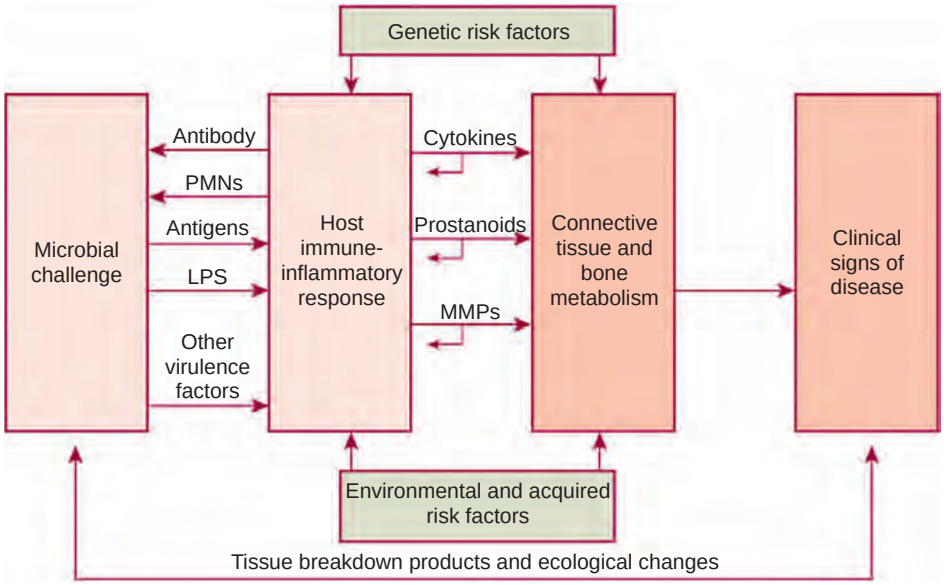

Figure 89-4 Schematic representation of the pathogenesis of periodontal diseases and possible avenues for prevention or treatment. Reading left to right: Pathogenic microorganisms, via a number of virulence factors including antigens or lipopolysaccharides (LPS), stimulate a host immuno-inflammatory response. Immune elements including polymorphonuclear leukocytes (PMNLs) and antibodies may be active to inhibit the offending microorganisms, while various cytokines, prostanoids or enzymes may act to affect connective tissue and bone metabolism, ultimately resulting in the clinical signs of periodontitis initiation and progression. Genetic factors or environmental/acquired factors may separately impact disease risk. Potential avenues for intervention include scaling and root planing and/or antimicrobial agents to inhibit pocket microorganisms (impacting the microbial challenge), non-steroidal (or other) anti-inflammatory agents to inhibit cytokines and/or prostanoids (impacting the host immuno-inflammatory response), anti-resorptive agents (e.g., bisphosphonates) to inhibit osteoclastic bone resorption and/or host-modulation therapy (e.g., low-dose oral doxycycline) to inhibit matrix-metalloproteinase (MMP) activity (impacting connective tissue and bone metabolism). *(Modified from Page RC, Kornman KS: Periodontal 2000 14:9-11, 1997.)*

Copyright © 2015, 2012, 2006 by Saunders, an imprint of Elsevier Inc.

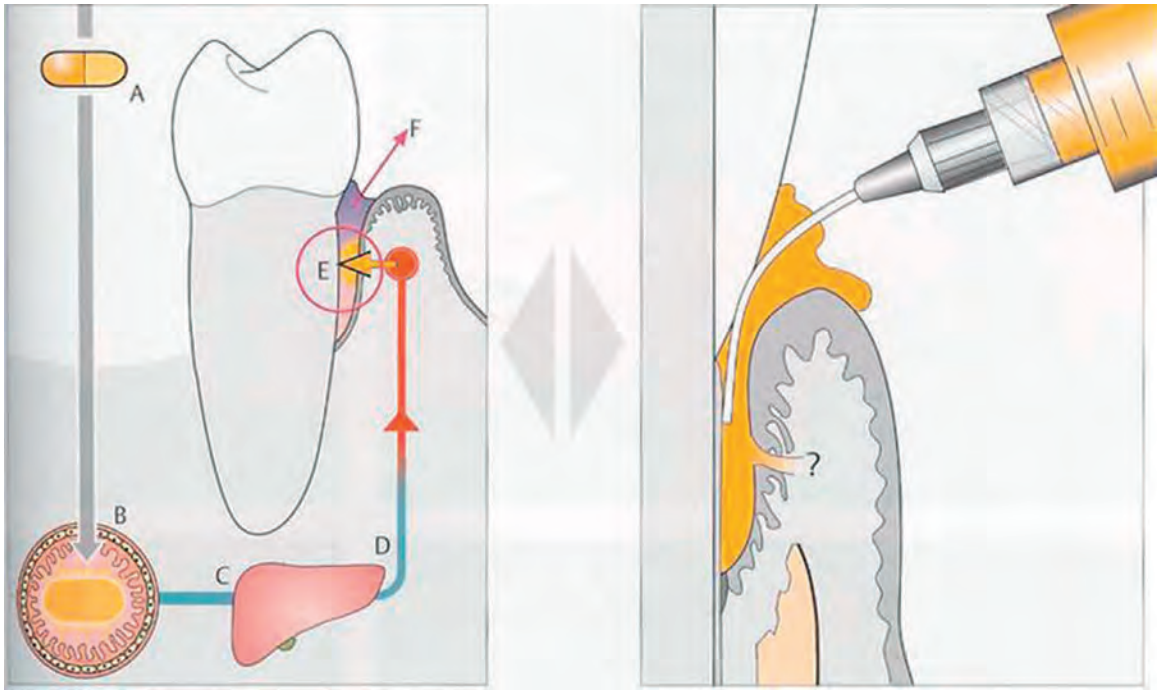

Figure 89-5 Schematic representation of the inability to achieve therapeutically sufficient concentrations within the periodontal pocket for sufficient lengths of time with antimicrobials delivered either systemically or locally but not in controlled-release formulations. *Left panel*. Orally administered drug **(A)** is absorbed in the gastrointestinal tract **(B)**, transported by the portal pathway to the liver **(C)** and enters the circulatory system **(D)**, from where drug exits the vasculature into the periodontal pocket **(E)**. Drug is quickly eliminated from the pocket into the oral cavity by the copious flow of gingival crevicular fluid (GCF) **(F)**. Locally administered drugs not in controlled-release formulations suffer from the same limitation. *Right panel,* Locally delivered, controlled-release antimicrobial is administered into the periodontal pocket where it remains until it degrades, continuously releasing drug into the GCF over time [?], antimicrobial drug perhaps may be active against plaque bacteria that may have invaded the surrounding periodontal tissues. *(Reprinted from Wolf HF, Hassell TM:* Color atlas of dental hygiene: periodontology*, ed 1, Stuttgart, Germany, 2006, Thieme, with permission.)*

provide an equivalent, alternative therapy.[92,103] Drug that is transferred from the plasma compartment to the GCF within the periodontal pocket is quickly washed away by the GCF flow (see Figure 89-5). It was previously thought that systemically delivered tetracyclines markedly concentrated drug within the GCF compared with plasma,[33,79] but this hypothesis was not supported by later studies.[92,103] A number of authors have suggested that systemic therapies, rather than locally delivered agents, should be considered when there are multiple pocket sites, both for convenience and to save costs,[4,34,88] but it seems clear that if high concentrations of an antimicrobial drug are desired within the periodontal pocket, systemic delivery is not the appropriate therapy, regardless of the number of pocket sites. Other potential benefits of locally delivered, controlled-release antimicrobials may include decreased systemic, off-target effects or a decreased risk for promoting microbial resistance.

Pharmacokinetics

The pharmacokinetic principles of controlled-release local delivery are illustrated in Figure 89-6. Drug delivered locally to the periodontal pocket but not in a controlled-release formulation (e.g., via irrigation) is washed out of the pocket by the GCF flow, quickly reducing the concentration of drug within the GCF.[29] Locally delivered, controlled-release antimicrobials have been designed to maintain high and clinically relevant concentrations of drug within the GCF for extended periods of time. The pharmacokinetics of the chlorhexidine chip, the doxycycline gel, and minocycline microspheres have been studied in clinical trials.

Controlled-release agents maintain clinically effective intrapocket concentrations of antimicrobial for an extended period of time.

Chlorhexidine Chip. The release profile of the chlorhexidine chip was evaluated in a single-center, 10-day clinical trial in 19 patients with chronic adult periodontitis.[96] Each patient received a single chip administered into each of four pocket sites, and concentrations of chlorhexidine were determined in GCF, plasma, and urine at various times post dosing. Peak GCF concentrations were achieved 2 hours postdose (2007 ± 422 μg/mL), with GCF concentrations maintained between approximately 1300 and 1900 μg/mL to 4 days postdose. Mean chlorhexidine concentrations then steadily decreased to 57 ± 13 μg/mL at 9 days. Chlorhexidine was below detectable limits in plasma and urine at all time points. For perspective, Wilson et al[108] reported that chlorhexidine, at a concentration of 125 μg/mL, killed 99.9% of cultivable bacteria from plaque samples from patients with chronic periodontitis within 15 minutes.

Doxycycline Gel. The release profile of the doxycycline gel was evaluated in a single-center, 28-day clinical trial in 32 patients with adult periodontitis and compared with oral doxycycline.[103] All patients assigned to receive local delivery had doxycycline gel administered to all pocket sites with probing depth 5 mm or more that bled on probing; drug was retained after placement either with a noneugenol (NE) periodontal dressing ($n = 13$) or 2-octyl cyanoacrylate (2-O; $n = 13$). Mean GCF concentrations peaked at 2 hours

Copyright © 2015, 2012, 2006 by Saunders, an imprint of Elsevier Inc.

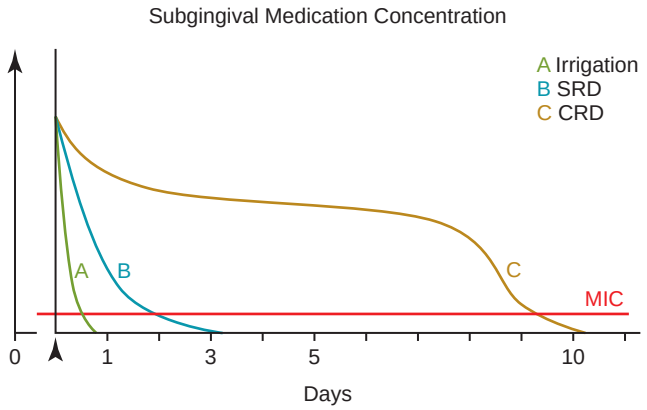

Figure 89-6 Schematic representation of the release profile of locally delivered, antimicrobials via irrigation, sustained-release or controlled-release. Drug concentration within the gingival crevicular fluid (GCF) is diminished rapidly following irrigation **(A)**. Drug concentration may be extended for several days with drug administered in a modified, sustained-release formulation **(B)**. Drug concentration in GCF may be maintained at therapeutically relevant concentrations for up to 10 days with controlled-release formulations **(C)**. Area under the curve but above the MIC line represents drug concentration within the gingival crevicular fluid greater than MIC values. Note: The MIC for subgingival plaque bacteria may be substantially greater than typically reported bacterial MIC values because of the potentially protective effect of a subgingival biofilm formation (see text). *CRD*, Controlled-release delivery; *MIC*, minimum inhibitory concentration; *SRD*, sustained-release delivery; ⮝, administration of locally delivered agent. *(Adapted from Wolf HF, Hassell TM:* Color atlas of dental hygiene: periodontology*, ed 1, Stuttgart, Germany, 2006, Thieme, with permission.)*

after dosing (1473 ± 328 µg/mL, NE; 1986 ± 445 µg/mL, 2-O). At day 7, mean concentrations were 309 ± 127 µg/mL (NE) and 148 ± 49 µg/mL (2-O). Mean salivary concentrations peaked at 2 hours (4.05 ± 1.24 µg/mL, NE; 8.78 ± 1.48 µg/mL, 2-O) and were ≤ 2 µg/mL at 24 hours. Serum concentrations following local administration remained ≤ 0.1 µg/mL. With regard to oral doxycycline (200 mg on day 0, then 100 mg/day for 7 days; $n = 6$), GCF concentrations peaked at 12 hours postdose (2.53 ± 1.56 µg/mL), and serum concentrations ranged from 0.91 to 2.26 µg/mL for the 8 days of data collection. Salivary concentrations never exceeded 0.11 µg/mL.

Minocycline Microspheres. The release profile of minocycline microspheres was studied in 18 patients with moderate to advanced chronic periodontitis.[6,7] Minocycline microspheres (mean dose: 46.2 mg; 25 to 112 unit doses) were administered to eligible periodontal pocket sites 5 mm or more in probing depth (minimum of 30 sites on at least eight teeth; 1 mg per treatment site) following SRP. Serum and saliva samples were collected predose and at various times postdose to 14 days. Mean dose-normalized saliva area under the curve and maximal concentration (C_{max}) were approximately 125 and 1000 times that of serum parameters, respectively. In saliva minocycline, C_{max} was 254.0 ± 139.3 mg/mL at 0.75 ± 0.56 hours postdose with a half-life of 44.7 ± 19.2 hours.[7] In serum mean minocycline concentrations peaked at 4.8 ± 1.8 hours postdose (C_{max}: 216.4 ± 122.9 µg/mL) and were undetectable by 7 days. Minocycline concentrations in saliva and GCF were sufficient (defined as >1 µg/mL) to kill bacteria associated with periodontal disease in vitro.[7] These concentrations were evident up to 14 days without significant systemic exposure.[7]

Drug Development and Registration

An investigational drug is typically studied in many clinical trials before it can be approved for clinical use; locally delivered, controlled-release antimicrobials are no exception. These products have been rigorously studied in multiple trials to confirm their safety and efficacy for the indication of chronic adult periodontitis. This section includes a detailed discussion of the effectiveness of locally delivered, controlled-release antimicrobials as evidenced by trial data. A more detailed discussion of drug development and registration, including information regarding the phases of drug development, the evaluation of safety and efficacy, informed consent and trial design and information specifically relevant to periodontal studies, is provided in Chapter 90.

Locally Delivered, Controlled-Release Antimicrobials: Magnitude of the Effect

To consider results of clinical trials of locally delivered, controlled-release antimicrobials, a literature search for published trials was conducted in Ovid MEDLINE® from 1990 to 2012 using the search terms (1) chlorhexidine, minocycline, doxycycline, or tetracycline; (2) clinical trial, delayed action preparations/tetracycline/drug delivery systems/periodontal diseases/periodontitis/minocycline/local delivery, double-blind methods/placebo, parallel group, local drug delivery or pharmaceutical preparations/drug delivery systems/polymers/delayed-action preparations/drug carriers; and (3) periodontitis/chronic periodontitis, gingivitis/periodontal diseases/dental scaling/periodontal attachment loss/alveolar bone loss/periodontal pocket, planing, gingival crevicular fluid, periodontal index, periodontal treatment, or dental plaque. A total of 1216 articles were identified; of these, 186 were reviewed as potentially relevant. Overviews of results of reviewed trials of the doxycycline gel, minocycline microspheres, or the chlorhexidine chip used adjunctively or as monotherapy are presented in Tables 89-2, 89-3, and 89-4.

Although somewhat arbitrary, trials have been organized into three tables based on the number of patients per treatment group, $n \geq 60$ (Table 89-2), $n = 20$ to 59 (see Table 89-3), or $n \leq 19$ (see Table 89-4). This separation was an attempt to group trials based on size and, hence, approximately on robustness for ease of consideration. A review of these trials shows a wide range of designs. Many suffer from design features that, as described in Chapter 90, lessen the robustness of the data, including relatively small sample sizes, lack of blinding, or split-mouth design.

Results of trials with n's per group ≥ 60 and largely with Phase III-like designs are presented in Table 89-2. As noted previously, regulatory decisions are generally based on the clinical results of these types of trials, and these are generally the outcomes on which treatment decisions should be based. As can be seen in Table 89-2, the results of published trials with treatment period endpoints and with antimicrobial agent administered as per the registration trials and the full prescribing information consistently show that outcomes obtained with SRP that includes the adjunctive use of a locally delivered, controlled-release antimicrobial are significantly improved compared with mechanical therapy alone. Mean differences of probing depth reductions from baseline in trials of adjunctive locally delivered, controlled-release antimicrobials in comparison with SRP alone range from approximately 0.20 mm to approximately 0.70 mm. Clinical benefits that potentially could be

Text continued on p. e115

Copyright © 2015, 2012, 2006 by Saunders, an imprint of Elsevier Inc.

TABLE 89-2 Clinical Trials of Locally Delivered, Controlled-Release Antimicrobials ($N \geq 60$ per treatment group)

DRUG	STUDY DESIGN	INCLUSION CRITERIA	TREATMENT GROUPS	TREATMENT	STUDY DURATION	PD OUTCOMES (MEAN)			PD REDUCTION ≥2.0 MM FROM BASELINE	AL OUTCOMES (MEAN)		
						Absolute Reduction from Baseline (mm)	Absolute Reduction Difference between Groups (mm)	Percent Change between Groups	Percent	Absolute Gain from Baseline (mm)	Absolute Gain Difference between Groups (mm)	Percent Change between Groups
DOX[91]	Randomized, multicenter (10 ctrs), parallel-group, single-blind, monotherapy	Mod-sev periodontitis in ≥2 quads. Each quad had ≥4 pocket sites with PD ≥5 mm with BOP. Two sites had to be ≥ 7 mm.	DOX (1) Nonsmokers $N = 52$ (2) Former smokers $N = 65$ (3) current smokers $N = 60$ SRP (1) Nonsmokers $N = 48$ (2) Former smokers $N = 72$ (3) current smokers $N = 61$	All pts received OH. SRP pts rec'd SRP in the 2 treated quads, repeated at 4 mo (SRP until hard & smooth; local anesthesia PRN; no time restraints). DOX & veh at baseline and 4 mo applied to all qualifying pockets	9 mo	DOX (1) 1.12 ± 0.11 (2) 1.33 ± 0.09 (3) 1.21 ± 0.10 SRP (1) 1.43 ± 0.11 (2) 1.05 ± 0.09 (3) 1.02 ± 0.10	(1) 0.31 $P < 0.04$ (2) 0.28, $P < 0.03$ (3) 0.19 $P =$ ns	(1) 27% (2) 27% (3) 18%	NR	DOX (1) 0.69 ± 0.12 (2) 0.88 ± 0.11 (3) 0.83 ± 0.11 SRP (1) 1.00 ± 0.12 (2) 0.60 ± 0.10 (3) 0.76 ± 0.11	(1) 0.31, $P =$ ns (2) 0.28, $P < 0.05$ (3) 0.07 $P =$ ns	(1) 45% (2) 47% (3) 9%
DOX[13]	Randomized, multicenter (3 ctrs), parallel-group, single-blind, adjunctive	≥15 natural teeth, ≥4 w PD ≥ 5 mm, previously treated for moderate/ advanced chronic periodontitis, recall programs for SPT ≥ 1 y	(1) SPT alone, $N = 65$ (2) SPT + DOX, $N = 63$	SRP at baseline, no time limit, anesthesia if requested. In group (2), DOX in all sites w PD, PD ≥5 mm. 0.1% chlorhexidine rinse for 1 mo. Returned to clinic for SPT q 6 mo. At 1 & 2 y, DOX in sites w PD ≥5 mm	3 y	(1) 1.1 (2) 1.2 [at 3 mo: (1) 0.7; (2) 0.9]	0.1, $P =$ ns [at 3 mo, 0.2, $P < 0.001$]	9.1% [at 3 mo, 28.6%]	NR	(1) 0.7 (2) 0.9 [at 3 mo: (1) 0.5; (2) 0.8]	0.2, $P =$ ns [at 3 mo, 0.3, $P < 0.01$]	28.6% [at 3 mo, 60%]

TET[25]	Randomized, multicenter (3 ctrs), split-mouth, single-blind, adjunctive and monotherapy	≥1 site in each of 4 quads with PD ≥5 mm with BOP	(1) SRP alone (2) TET alone (3) TET alone administered twice, 10 d apart (4) SRP + TET *N* = 122	Supragingival scaling 2 wk before baseline. SRP w anesthesia for 5 min/tooth. Scaling at 10 d to remove any residual calc.	12 mo, maintenance period	Sites <7 mm: 1.01–1.15 mm. Sites ≥7 mm: 1.63–2.39 mm	0.17–0.29 mm. Some significant differences between groups at some time points, but not considered clinically significant	NR	NR	Sites <7 mm: 0.98–1.14 mm Sites ≥7 mm: 0.89–1.51 mm	NR. No significant differences between groups	NR
TET[68]	Multicenter (7 private practices) randomized, split-mouth, single-blind, adjunctive	Maintenance pts receiving regular SPT in private practice. Two nonadjacent sites in separate quadrants w PD 5–8 mm + BOP.	(1) SRP alone (2) SRP + TET fiber *N* = 113	Full-mouth SRP (no more SRP info). TET placed in test teeth.	6 mo	(SD 6 mo) (1) 1.08 ± 0.121 (2) 1.81 ± 0.12	0.73 mm *P* < 0.01	68%	NR	(1) 1.08 ± 0.145 (2) 1.56 ± 0.145	0.48 *P* < 0.05	26%
TET[30]	Multicenter (5 ctrs), randomized, split-mouth, single-blind, monotherapy	4 nonadjacent teeth w PD 6–10 mm w BOP	*N* = 113 (1) TET (2) plc (3) SRP (4) No tx	Prebaseline prophy; SRP for each tooth ≥5 min, local anesthesia. 10 d, fiber removal.	60 d	(1) 1.05 ± 0.1 (2) 0.63 ± 0.1 (3) 0.74 ± 0.1 (4) 0.45 ± 0.09	1 vs 2: 0.42, *P* = 0.0001 1 vs 4: 0.6, *P* = 0.0001 1 vs 3: 0.31, *P* = 0.0002 2 vs 4: 0.18, *P* = 0.2003 2 vs 3: 0.11, *P* = 0.8711 3 vs 4: 0.29, *P* = 0.1496	1 vs 2: 67% 1 vs 4: 133% 1 vs 3: 42% 2 vs 4: 15% 2 vs 3: 17% 3 vs 4: 64%	NR	(1) 0.66 ± 0.13 (2) 0.49 ± 0.12 (3) 0.41 ± 0.12 (4) 0.37 ± 0.12	1 vs 2: 0.17, *P* = 0.0456 1 vs 4: 0.29, 0.0150 1 vs 3: 0.25, *P* = 0.0111 2 vs 4: 0.12, 0.6606 2 vs 3: 0.08, *P* = 0.5795 3 vs 4: 0.04, *P* = 0.9072	1 vs 2: 35% 1 vs 4: 78% 1 vs 3: 61% 2 vs 4: 32% 2 vs 3: 20% 3 vs 4: 11%
MIN[107]	Parallel-group; double-blind; adjunctive therapy; multicenter (18 ctrs)	ADA Type III (mod) or Type IV (sev) periodontitis. ≥4 teeth w PD 6–9 mm w BOP	(1) SRP alone, *N* = 250; (2) SRP + vehicle, *N* = 249; (3) SRP + MIN, *N* = 249; All sites ≥5 mm received study drug or vehicle at baseline, 3 & 6 mo	Full-mouth SRP at baseline; No limits: time or local anesthesia	9 mo	9 mo: (1) 1.08 (0.04) mm (2) 1.00 (0.04) (3) 1.32 (0.04)	1 vs 2: 0.08, *P* = ns 1 vs 3: 0.24, *P* < 0.001 2 vs 3: 0.32, *P* < 0.001	22% greater reduction vs SRP alone 32% greater reduction vs SRP + vehicle (both *p* < 0.001)	(1) 32.87%; (2) 28.98%; (3) 40.02%* *Diff from other 2 groups *p* < 0.001	NR	NA	NA

Continued

TABLE 89-2 Clinical Trials of Locally Delivered, Controlled-Release Antimicrobials (N ≥ 60 per treatment group)—cont'd

DRUG	STUDY DESIGN	INCLUSION CRITERIA	TREATMENT GROUPS	TREATMENT	STUDY DURATION	PD OUTCOMES (MEAN)			PD REDUCTION ≥2.0 MM FROM BASELINE	AL OUTCOMES (MEAN)		
						Absolute Reduction from Baseline (mm)	Absolute Reduction Difference between Groups (mm)	Percent Change between Groups	Percent	Absolute Gain from Baseline (mm)	Absolute Gain Difference between Groups (mm)	Percent Change between Groups
CHX[76]	Split-mouth; single-blind; adjunctive therapy; multicenter (4 ctrs)	Two sites per pt; PD ≥5 mm; BOP	(1) SRP alone (1 site); (2) SRP + CHX chip (1 site) $N = 116$	Two 2-h sessions within 48 h; w local anesthesia; full-mouth subgingival prophy at 3 mo	6 mo	Est from figure 3 mo (1) 1.2 (2) 1.5 6 mo (1) 1.0 (2) 1.5	0.30 mm ($p < 0.01$) at 3 mo; 0.55 mm ($p < 0.001$) at 6 mo vs SRP alone	113% increase vs SRP alone ($p < 0.01$) at 6 mo	NR	Est from figure 3 mo (1) 0.6 (2) 0.9 6 mo (1) 0.5 (2) 1.1	0.28 mm at 3 mo; 0.64 mm at 6 mo vs SRP alone	128.6% vs SRP alone
CHX[97]	Randomized, single-blind, multicenter (3 ctrs), adjunctive therapy, split-mouth	≥1 pocket, PD 5–8 mm, w BOP, in each max quadrant	(1) SRP alone; $N = 118$ pts; 485 pockets (2) SRP + CHX chip $N = 118$ pts; 474 pockets	Full mouth SRP (tx time limited to 1 h). At 3 mo, full mouth supragingival prophy per clin need. CHX inserted if PD 5–8 mm	6 mo	(1) 0.70 ± 0.056 (2) 1.16 ± 0.058	0.46 $p \leq 0.0001$	65.7%	(1) 21.3% ± 2.0 (2) 35.4% ± 2.1 both $p \leq 0.0001$	(1) 0.31 ± 0.06 (2) 0.47 ± 0.06	0.16 $P < 0.05$	51.6%
CHX[49]	2 Multicenter, randomized, double-blind, parallel-group, adjunctive therapy (5 ctrs each)	≥10 teeth, ≥4 teeth w PD ≥5 mm, BOP. Stratified by smoking status	Group 1 pts (active chip) SRP + CHX chip (Tx 1). SRP alone, $N = 225$ Group 2 pts (plcb chip) SRP + plcb (Tx 2); SRP alone (Tx 3). $N = 222$	Supragingival prophy for 1 h. SRP for 1 h for all teeth. Chips in test sites at baseline, at 3 & 6 mo if PD still ≥5 mm. Exit prophy at 9 mo	9 mo	(1) 0.95 ± 0.05 (2) 0.69 ± 0.05 (3) 0.65 ± 0.05	1–3 0.26 ± 0.08, $P = 0.00056$ 1–2 0.30 ± 0.07 $P = 0.00001$	46% greater reduction vs SRP alone ($p = 0.00001$) 38% greater reduction vs SRP + vehicle ($p = 0.00056$)	139% increase vs SRP alone ($p < 0.0001$) 48% increase vs SRP + vehicle ($p = 0.039$)	(1) 0.75 ± 0.06 (2) 0.55 ± 0.06 (3) 0.58 ± 0.06	1–3 0.16 ± 0.08 $P = 0.05$ 1–2 0.20 ± 0.068 $P = 0.012$	29% gain vs SRP alone; 34% gain vs SRP + vehicle
DOX[27] Study 1	Randomized, multicenter (10 ctrs), parallel-group, single-blind, monotherapy	Mod-sev periodontitis in ≥2 quads. Each quad had ≥4 pocket sites with PD ≥5 mm with BOP. Two sites had to be ≥7 mm.	(1) DOX, $N = 95$; (2) Veh $N = 94$ (3) OH $N = 95$ (4) SRP $N = 99$	All pts received OH. SRP pts rec'd SRP in the 2 treated quads, repeated at 4 mo (SRP until hard & smooth; local anesthesia PRN; no time restraints). DOX & veh at baseline and 4 mo applied to all qualifying pockets	9 mo	(1) 1.1 ± 0.1 (2) 0.8 ± 0.1 (3) 0.5 ± 0.1 (4) 0.9 ± 0.1	1 vs 2, 0.3, $p = 0.001$; 1 vs 3, 0.6, $p < 0.001$; 1 vs 4, 0.2, $p = 0.050$	1 vs 2: 37.5% 1 vs 3: 120% 1 vs 4: 22.2%	NR	(1) 0.8 ± 0.1 (2) 0.1 ± 0.1 (3) 0.3 ± 0.1 (4) 0.7 ± 0.1	1 vs 2, 0.7, $p < 0.001$ 1 vs 3, 0.5, $p = 0.001$ 1 vs 4, 0.1, $p = 0.294$	1 vs 2: 700% 1 vs 3: 166% 1 vs 4: 14.3%

DOX[27] Study 2	Randomized, multicenter (10 ctrs), parallel-group, single-blind, monotherapy	Mod-sev periodontitis in ≥2 quads. Each quad had ≥4 pocket sites with PD ≥ 5 mm with BOP. Two sites had to be ≥7 mm.	(1) DOX, *N* = 95; (2) Veh *N* = 94 (3) OH *N* = 95 (4) SRP *N* = 99	All pts received OH. SRP pts rec'd SRP in the 2 treated quads, repeated at 4 mo (SRP until hard & smooth; local anesthesia PRN; no time restraints). DOX & Veh at baseline and 4 mo applied to all qualifying pockets	9 mo	(1) 1.3 ± 0.1 (2) 1.0 ± 0.1 (3) 0.9 ± 0.1 (4) 1.3 ± 0.1	1 vs 2, 0.3, *p* = 0.001; 1 vs 3, 0.4, *p* < 0.001; 1 vs 4, 0.0, *p* = 0.765	1 vs 2: 30% 1 vs 3: 44.4% 1 vs 4: 0%	NR	(1) 0.8 ± 0.1 (2) 0.5 ± 0.1 (3) 0.5 ± 0.1 (4) 0.9 ± 0.1	1 vs 2, 0.3, *p* = 0.002 1 vs 3, 0.3, *p* = 0.012 1 vs 4, 0.1, *p* = 0.665	1 vs 2: 60% 1 vs 3: 60% 1 vs 4: 12.5%
CHX[98]	Open-label, 8 private dental offices, Phase IV	≥30 y age; pockets w PD ≥5 mm; no perio sx or SRP by periodontist within 2 y of entrance	SRP group Non-SRP group (already on active RPMT) *N* = 835 enrolled; 595 completed at 24 mo	SRP (SRP group only) 1 mo before baseline. RPMT q 3 mo. All sites receiving CHX chip at baseline got CHX q 3 mo if PD ≥5 mm	2 y	12 mo, 4.98 ± 1.01 24 mo, 4.77 ± 1.05	NA	NA	≥1 site 12 mo, 42.88 24 mo, 51.26 ≥2 sites 12 mo, 17.93 24 mo, 23.19			
MIN[31,12]	Multicenter, single-blind, randomized, parallel-group, Phase IV	30-65 y age; ≥16 teeth; 5 sites w PD ≥5 mm in 5 nonadjacent interproximal spaces (excluding distal of terminal teeth; no perio tx or antibiotics within 3 mo	(1) SRP alone, *N* = 65 (2) SRP + MIN, *N* = 62	Full-mouth SRP in ≤2 visits ≤10 d apart w hand, ultrasonic instruments, & local anesthesia permitted. MIN administered for group 2 to sites w PD ≥5 mm	30 d	(1) 1.01 (2) 1.38	0.37 *P* = 0.00004	37%	(1) 31.2% (2) 46.6%	(1) 0.80 (2) 1.16	0.36 *P* = 0.00004	45%

AL, attachment level; *BOP*, Bleeding on probing; *calc*, calculus; *CHX*, chlorhexidine chip; *cln*, clinical; *ctr*, center; *d*, day(s); *DOX*, doxycycline hyclate gel; *est*, estimated; *h*, hour; *info*, information; *MIN*, minocycline microspheres; *mo*, month(s); *mod*, moderate; *NR*, not reported; *NA*, not applicable; *OH*, oral hygiene; *perio*, periodontal; *plcb*, placebo; *PD*, probing depth; *prophy*, prophylaxis; *pt*, patient; *quad*, quadrant; *rec'd*, received; *RPMT*, routine perio maintenance therapy; *sev*, severe; *SPT*, supportive periodontal therapy; *SRP*, scaling and root planing; *sx*, surgery; *tx*, treatment; *veh*, vehicle; *vs*, versus; *w*, with; *wk*, week; *y*, year.

TABLE 89-3 Clinical Trials of Locally Delivered, Controlled-Release Antimicrobials ($N = 20$-59 per treatment group)

DRUG	STUDY DESIGN	INCLUSION CRITERIA	TREATMENT GROUPS	TREATMENT	STUDY DURATION	PD OUTCOMES (MEAN)			PD REDUCTION ≥2.0 MM FROM BASELINE	AL OUTCOMES (MEAN)		
						Absolute Reduction from Baseline (mm)	Absolute Reduction Difference between Groups (mm)	Percent Change between Groups	Percent	Absolute Gain from Baseline (mm)	Absolute Gain Difference between Groups (mm)	Percent Change between Groups
TET, MIN, MET[57]	Randomized, single-blind, parallel-group, single-center, adjunctive	≥4 nonadjacent teeth w PD ≥5 mm w BOP or suppuration	(1) SRP alone. $N = 20$ (2) SRP + MIN. $N = 21$ (3) SRP + TET. $N = 19$ (4) SRP + MET. $N = 19$	Full mouth SRP w local anesthesia (target teeth for ~5 min) MIN or MET applied at baseline and 2 & 4 wk. TET fiber placed for 10 d.	6 mo after last tx	(1) 1.711 ± 0.188 (2) 1.102 ± 0.159 (3) 1.380 ± 0.166 (4) 0.929 ± 0.196	1 vs 2. 0.609 1 vs 3. 0.331 1 vs 4. 0.782 2 vs 3. 0.278 2 vs 4. 0.173 3 vs 4. 0.451 1 vs 3, $P = 0.008$; All others = ns	1 vs 2. 55.3% 1 vs 3. 24.0% 1 vs 4. 84.2% 2 vs 3. 25.2% 2 vs 4. 18.6% 3 vs 4. 48.5%	NR	(1) 0.537 ± 0.143 (2) 0.573 ± 0.109 (3) 0.687± 0.138 (4) 0.541 ± 0.214	1 vs 2. 0.036 1 vs 3. 0.15 1 vs 4. 0.004 2 vs 3. 0.114 2 vs 4. 0.032 3 vs 4. 0.146 All differences: ns	1 vs 2. 6.7% 1 vs 3. 27.9% 1 vs 4. 7.4% 2 vs 3. 5.6% 2 vs 4. 5.9% 3 vs 4. 27.0%
DOX, SAN[82]	Randomized, double-blind parallel-group, multicenter, monotherapy	≥2 quads w ≥4 pockets w PD ≥5 mm w BOP (≥2 ≥7 mm)	(1) SAN $N = 54$ (2) DOX $N = 56$ (3) veh $N = 53$	Gel placed at baseline and at 4 mo	9 mo	(1) 1.1 ± 0.1 (2) 1.8 ± 0.1 (3) 1.2 ± 0.1	1 vs 2 0.7. $P < 0.001$ 1 vs 3 0.1. $P = 0.6$ 2 vs 3 0.6. $P < 0.001$	1 vs 2. 63.6% 1 vs 3. 9% 2 vs 3. 50%	NR	(1) 0.5 ± 0.1 (2) 1.0 ± 0.1 (3) 0.6 ± 0.1	1 vs 2. 0.5 $P = 0.0062$ 1 vs 3. 0.1 $P = 0.002$ 2 vs 3 0.4 $P = 0.029$	1 vs 2. 100% 1 vs 3. 20% 2 vs 3. 67%
DOX[106]	Randomized, single-blind, parallel-group, multicenter, adjunctive	≥8 perio sites with PD ≥5 mm, stratified by smoking status	Smokers (1) SRP $N = 20$ (2) SRP + DOX $N = 22$ Nonsmokers (3) SRP $N = 32$ (4) SRP + DOX $N = 29$	At baseline, single episode of full-mouth supra- and subging debridement w ultrasonic. Test sites then rec'd DOX gel	3 mo	(95% CI) (1) 1.09 (0.25) (2) 1.35 (0.3) (3) 1.48 (0.25) (4) 1.62 (0.2) CI (only) est. from figure *P* value for effect of treatment = 0.019 *P* for effect of smoking = 0.001 *P* for effect of baseline PD = 0.000	1 vs 2: 0.26 1 vs 3: 0.39 1 vs 4: 0.53 2 vs 3: 0.13 2 vs 4: 0.27 3 vs 4: 0.14	1 vs 2: 23.9% 1 vs 3: 35.8% 1 vs 4: 48.6% 2 vs 3: 9.6% 2 vs 4: 20.0% 3 vs 4: 9.5%	NR	(95% CI) (1) 0.46 (0.25) (2) 0.84 (0.25) (3) 0.75 (0.2) (4) 0.90 (0.25) CI (only) est from figure *P* value for effect of treatment 0.024 *P* value for effect of baseline PD = 0.007	1 vs 2: 0.38 1 vs 3: 0.29 1 vs 4: 0.44 2 vs 3: 0.09 2 vs 4: 0.06 3 vs 4: 0.14	1 vs 2: 82.6% 1 vs 3: 63.0% 1 vs 4: 95.7% 2 vs 3: 12.0% 2 vs 4: 7.1% 3 vs 4: 18.7%

CHX[41]	Split-mouth, single-blind, controlled, randomized, single-center, adjunctive	Chronic periodontitis, ≥10 uncrowned teeth, ≥1 pocket per quad with PD ≥5 mm w BOP; nonsurgical phase of tx completed ≥ 3 mo prior to baseline. 80% power to detect a 0.5-mm difference	(1) SRP + CHX chip (2) SRP alone $N = 26$. Chips placed at baseline, no further CHX placed regardless of pocket depth	Supraging ultrasonic scaling & prophy of all teeth; all target sites root planed for max 5 min per tooth.	6 mo	(1) 0.78 ± 0.12 (2) 0.45 ± 0.13	0.33 $P = 0.06$	73.3%	NR	(1) 0.43 ± 0.01 (2) 0.15 ± 0.09	0.28 $P = 0.048$	186%
CHX[89]	Randomized, parallel-group, single-blind, single-center	Chronic periodontitis, SRP 3 mo prior to baseline, at least 1 site w PD 5–8 mm & BOP	(1) SRP alone $N = 21$ completed (2) SRP + CHX chip $N = 21$ completed ($N = 56$ total started)	SRP at baseline, w local anesthesia, until smooth & clean. CHX for (2)	6 mo	6 mo (1) 2.2 (2) 2.8	0.6 $P =$ ns	27.3%	(1) 75.9% (2) 85.2% $P =$ ns	6 mo (1) 2.1 (2) 2.2	0.1 $P =$ ns	4.8%
DOX[59]	Parallel-group; single-center, blind; adjunctive therapy; number of centers not reported	≥4 sites w PD ≥5 mm & BOP; ≥10 cigarettes/d for ≥5 y; anterior teeth only	(1) SRP + DOX gel $N = 22$ (completed) (2) SRP + saline irrigation $N = 21$ (completed)	SRP at baseline & 12 mo; until roots considered smooth and clean	24 mo	(1) 12 mo 1.63 ± 1.09 24 mo 2.29 ± 1.14 (2) 12 mo 1.76 ± 0.63 24 mo 2.19 ± 0.76	12 mo 0.13 24 mo 0.10 $P =$ ns between group	12 mo, 8.0% 24 mo, 4.6%	(sites) (1) 65% (2) 46.5% $P = 0.01$	(1) 12 mo 1.31 ± 0.95 24 mo 1.58 ± 0.73* (2) 12 mo 0.99 ± 0.85 24 mo 0.70 ± 0.94	12 mo 0.32 24 mo 0.88* *$p < 0.05$ between groups	12 mo 24.4% 24 mo 125.7%
CHX[61]	Parallel-group; single center; double-blind	≥2 teeth w PD 5–9 mm; BOP at ≥1 tooth; bone loss on radiograph	(1) SRP + CHX chip, $N = 30$; (2) SRP + flurbiprofen chip, $N = 30$	Full-mouth SRP 2 wk prior to chip placement (reinsertion of chip at 1, 2, 3, 5, & 7 wk)	2 mo	(1) 2.08 ± 0.13; $p < 0.0001$ from baseline; (2) 2.27 ± 0.15; $p < 0.0001$ from baseline	0.19, $p =$ ns	9.1%	(1) 72% (2) 73$	(1) 1.66, $p < 0.0001$ from baseline; (2) 1.95, $p < 0.0001$ from baseline	0.29, $p =$ ns	17.5%

Continued

TABLE 89-3 Clinical Trials of Locally Delivered, Controlled-Release Antimicrobials ($N = 20\text{-}59$ per treatment group)—cont'd

DRUG	STUDY DESIGN	INCLUSION CRITERIA	TREATMENT GROUPS	TREATMENT	STUDY DURATION	PD OUTCOMES (MEAN)			PD REDUCTION ≥2.0 MM FROM BASELINE	AL OUTCOMES (MEAN)		
						Absolute Reduction from Baseline (mm)	Absolute Reduction Difference between Groups (mm)	Percent Change between Groups	Percent	Absolute Gain from Baseline (mm)	Absolute Gain Difference between Groups (mm)	Percent Change between Groups
CHX[17]	Randomized, split-mouth, single-blind; single-center	2 nonmolar sites, PD ≥5 mm w BOP & AL loss ≥2 mm; ≤1 mm horizontal mobility	(1) SRP alone (2) SRP + CHX chips $N = 28$ enrolled. Power analysis: 80% power at $\alpha = 0.05$, n needed = 26 to show a moderate effect	Full-mouth SRP w ultrasonic, hand instruments, no local anesthesia, no time limit. Periodontal supportive treatment at 3, 6, 9 mo. CHX chip at 3 & 6 mo if PD ≥5 mm	9 mo	(1) 1.1 (2) 1.2	0.1, $p = \text{ns}$	9.1%	NR	(1) 0.7 (2) 1.1	0.4, $p \leq 0.05$	57%

AL, attachment level; *BOP*, Bleeding on probing; *calc*, calculus; *CHX*, chlorhexidine chip; *CI*, confidence interval; *d*, day(s); *DOX*, doxycycline hyclate gel; *est*, estimated; *max*, maximum; *MET*, metronidazole; *MIN*, minocycline microspheres; *mo*, month(s); *NR*, not reported; *ns*, not significant; *PD*, probing depth; *perio*, periodontal; *prophy*, prophylaxis; *quad*, quadrant; *rec'd*, received; *SAN*, sanguinarium chloride; *SRP*, scaling and root planing; *subging*, subgingival; *supraging*, supragingival; *TET*, tetracycline; *tx*, treatment; *veh*, vehicle; *vs*, versus; *w*, with; *wk*, week; *y*, year.

TABLE 89-4 Clinical Trials of Locally Delivered, Controlled-Release Antimicrobials ($N \leq 19$ per treatment group)

DRUG	STUDY DESIGN	INCLUSION CRITERIA	TREATMENT GROUPS	TREATMENT	STUDY DURATION	PD OUTCOMES (MEAN)			PD REDUCTION ≥ 2.0 MM FROM BASELINE	AL OUTCOMES (MEAN)		
						Absolute Reduction from Baseline (mm)	Absolute Reduction Difference between Groups (mm)	Percent Change between Groups	Percent	Absolute Gain from Baseline (mm)	Absolute Gain Difference between Groups (mm)	Percent Change between Groups
CHX[53]	Randomized, double-blind, parallel-group, single-center, adjunctive	≥12 teeth w PD ≥5 mm w BOP	(1) SRP + placebo chip. $N = 12$ (2) SRP + CHX. $N = 12$	2 supraging scaling at d 7 & 14. CHX or placebo placed (max 2 chips/tooth if >1 site/tooth w PD ≥5 mm. At d 24, SRP on test teeth & on teeth w PD >3 mm w BOP in 1 app't for 1 h. New chip placed per randomization	6 mo	Estimated from figure only. (1) 1.1 (2) 1.2	Estimated from figure only. 0.1 $P =$ ns	9.1% (est)	NR	(1) 0.79 (2) 1.17	0.37 $P =$ ns	46.8%
CHX[65]	Randomized, single-blind, parallel-group, single-center, adjunctive	≥15 natural teeth, ≥2 sites w PD ≥5 mm, radiographic bone loss	(1) SRP alone. $N = 17$ (2) SRP + CHX. $N = 17$	Supraging scaling ≥2 wk before study. SRP at baseline (methods NR). Group 2, CHX at baseline & at 3 mo if PD ≥5 mm	6 mo	(1) 2.35 (2) 3.82	1.47 $P < 0.05$	62.6%	NR	(1) 1.64 (2) 2.82	1.18 $P < 0.05$	72.0%
MIN[28]	Randomized, single-blind, parallel-group, single-center, adjunctive, & monotherapy	≥ 2 sites on different teeth w PD ≥7 mm in 1 quad w culture of ≥ 1 of *Porphyromonas gingivalis*, *Prevotella intermedia*, or *Aggregatibacter actinomycetemcomitans*. Exclusion if ≥Class II mobility or hopeless bone loss	(1) No tx. $N = 10$ (2) SRP alone. $N = 6$ (3) SRP + MIN. $N = 11$ (4) MIN only. $N = 12$	SRP (methods NR) in study quad. MIN at baseline only	6 mo	Estimated from figure only. (1) 0.75 (2) 0.85 (3) 1.12 (4) 0.95	Estimated from figure only. 1 vs 2. 0.10 1 vs 3. 0.37 1 vs 4. 0.20 2 vs 3. 0.27 2 vs 4. 0.10 3 vs 4. 0.17 All ns. 3 different from 1 & 2 at 3 mo $P <$ 0.05	1 vs 2: 13.3% 1 vs 3: 49.3% 1 vs 4: 26.7% 2 vs 3: 31.8% 2 vs 4: 11.8% 3 vs 4: 15.2% (estimated)	(1) 7.2 vs 8.3% (2) NR (3) 21.2–27.0% (4) NR 1–3, $P<0.02$	Estimated from figure only. (1) 0.09 (2) 0.58 (3) 0.38 (4) 0.11	Estimated from figure only. 1 vs 2. 0.49 1 vs 3. 0.29 1 vs 4. 0.02 2 vs 3. 0.20 2 vs 4. 0.47 3 vs 4. 0.27 2 different from 1 & 4, $P < 0.05$	1 vs 2: 544% 1 vs 3: 322% 1 vs 4: 22.2% 2 vs 3: 34.55 2 vs 4: 81.0% 3 vs 4: 71.0%

Continued

TABLE 89-4 Clinical Trials of Locally Delivered, Controlled-Release Antimicrobials ($N \leq 19$ per treatment group)—cont'd

DRUG	STUDY DESIGN	INCLUSION CRITERIA	TREATMENT GROUPS	TREATMENT	STUDY DURATION	PD OUTCOMES (MEAN)			PD REDUCTION ≥ 2.0 MM FROM BASELINE	AL OUTCOMES (MEAN)		
						Absolute Reduction from Baseline (mm)	Absolute Reduction Difference between Groups (mm)	Percent Change between Groups	Percent	Absolute Gain from Baseline (mm)	Absolute Gain Difference between Groups (mm)	Percent Change between Groups
TET, MIN, MET[51]	Randomized, single-blind, parallel-group, single-center, adjunctive	≥4 nonadjacent teeth w PD ≥5 mm w BOP or suppuration	(1) SRP alone. $N = 13$ (2) SRP + MIN. $N = 14$ (3) SRP + TET. $N = 13$ (4) SRP + MET. $N = 14$	Full-mouth SRP w local anesthesia (target teeth for ~5 min) MIN or MET applied at baseline and 2 & 4 wk. TET fiber placed for 10 d.	6 wk after last treatment	(1) 0.60 ± 0.14 (2) 0.87 ± 0.13 (3) 1.35 ± 0.17 (4) 0.95 ± 0.16	1 vs 2: 0.27 1 vs 3: 0.75 1 vs 4: 0.35 2 vs 3: 0.48 2 vs 4: 0.08 3 vs 4: 0.40 Significantly different between 1 & 3. All others = ns	1 vs 2: 45% 1 vs 3: 125% 1 vs 4: 58.3% 2 vs 3: 55.2% 2 vs 4: 9.2% 3 vs 4: 29.6%	NR	(1) 0.26 ± 0.11 (2) 0.45 ± 0.14 (3) 0.75 ± 0.12 (4) 0.57 ± 0.15	1 vs 2: 0.19 1 vs 3: 0.49 1 vs 4: 0.21 2 vs 3: 0.30 2 vs 4: 0.12 3 vs 4: 0.18 No significant differences between groups	1 vs 2: 73.1% 1 vs 3: 188.4% 1 vs 4: 80.8% 2 vs 3: 66.7% 2 vs 4: 26.7% 3 vs 4: 24%
DOX[85]	Randomized, controlled, single-blind, parallel-group; single-center, adjunctive	Mod to adv periodontitis. ≥20 teeth. ≥10 w PD ≥5 mm w BOP. No subging instrumentation within 12 mo of baseline	(1) Ultrasonic + DOX gel $N = 19$ (2) ultrasonic $N = 14$	Full-mouth ultrasonic debridement 3 mo before baseline. Baseline exam. Reinstrumentation w ultrasonic (no time limit). Local analgesia if requested. Supraging plaque control at 1 & 3 mo	9 mo	(95% CI) (1) 1.0 (0.9–1.3) (2) 1.1 (0.8–1.4)	0.1 P = ns	10%	9 mo (1) 36 (29–43) (2) 36 (28–44) P = ns	(95% CI) (1) 0.8 (0.5–1.0) (2) 0.9 (0.5–1.3)	0.1 P = ns	12.5%
TET[105]	Single-center, split-mouth	≥20 teeth. In each quad, 2–3 interprox sites w PD ≥6 mm & BOP	(1) untreated (2) TET alone (3) SRP alone (4) SRP + TET $N = 10$	Prior to screening: OHI, supraging calc removal, polishing. Tx 1 at baseline: Subging SRP. Tx 2 at 10 d: SRP again for groups 3 & 4. TET again for 2 & 4. 0.2% CHX rinse. Q 2 wk, OHI & supraging, cleaning.	62 d	(1) −0.02 ± 0.39 (2) 1.98 ± 0.86 (3) 1.78 ± 0.75 (4) 2.15 ± 1.31	1 vs 2: 1.96 1 vs 3: 1.76 1 vs 4: 2.13 2 vs 3: 0.20 2 vs 4: 0.17 3 vs 4: 0.27 P 1 vs 2: 0.00002 1 vs 3: 0.0001 1 vs 4 0.00001 2 vs 3 0.62 2 vs 4 1.0 3 vs 4 0.37	1 vs 2: 9800% 1 vs 3: 8800% 1 vs 4: 10650% 2 vs 3: 11.2% 2 vs 4: 8.6% 3 vs 4: 15.9%	NR	NR	NA	NA

CHX[43]	Split-mouth, single-center; single-blind	1 tooth per treatment group, PD 6–7 mm	(1) SRP + CHX chip; (2) SRP alone; $N = 13$	SRP w anesthesia for ≥10 min per tooth	1 mo	NR*	NA	NA	NR	NR	NA	NA
CHX[20]	Split-mouth; single-center; single-blind	≥4 teeth w PD 4–5 mm & BOP. No furcations, third molars or incisors	(1) SRP + TET fiber. (2) SRP alone $N = 19$	SRP w anesthesia. Time NR. Fiber placed, then cyanoacrylate adhesive. CHX rinse for 10 days. Maintenance scaling at 3, 6, & 9 months.	12 mo	(1) 6 mo, 2.24; 12 mo, 2.06 (2) 6 mo, 1.48; 12 mo, 1.21	6 mo, 0.76 ($p = 0.0006$); 12 mo, 0.85 ($p = 0.0004$)	6 mo, 51.4%; 12 mo, 70.2%	NR	(1) 6 mo, 2.05; 12 mo, 1.76 (2) 6 mo, 1.16; 12 mo, 0.53	6 mo, 0.89 ($p = 0.0035$); 12 mo, 1.23 ($p = 0.00025$)	6 mo, 76.7%; 12 mo, 232.1%
CHX, MET[93]	Parallel-group; single-center; single-blind	≥2 teeth w PD ≥5 mm & BOP	(1) CHX chip, $N = 15$; (2) DOX gel, $N = 16$ (3) MET gel, $N = 16$	SRP 2–4 mo prior to baseline. Drug placed at baseline.	4 mo	(1) 0.27 ± 0.10; $p = 0.21$ from baseline; (2) 0.33 ± 0.08, $p = 0.001$ from baseline (3) 0.25 ± 0.10 $p = 0.018$ from baseline	1 vs 2: 0.06 1 vs 3: 0.02 2 vs 3: 0.08	1 vs 2: 22.2% 1 vs 3: 7.4% 2 vs 3: 24.2%	(1) 6% (2) 5% (3) 10%	(1) 0.16 ± 0.12 (2) 0.33 ± 0.08 (3) 0.03 ± 0.10	1 vs 2: 0.17 1 vs 3: 0.13 2 vs 3: 0.30	1 vs 2: 106% 1 vs 3: 433% 2 vs 3: 1000%
CHX[1]	Randomized, single-blind, parallel-group design. Number of centers not reported.	≥4 pockets, PD ≥5 mm, BOP	(1) SRP alone $N = 9$ (2) SRP + CHX chip, $N = 10$	SRP at baseline w local anesthesia. At 3 & 6 mo, all sites w PD ≥5 mm received subgingival retreatment. Test group received a new CHX chip. Full-mouth supragingival prophylaxis monthly for both groups until the end of the study	9 mo	(1) 2.8 (2) 3.0	0.2, $p =$ ns	7.1%	NR	(1) 1.0 ± 0.4 (2) 0.6 ± 0.7	0.4 $P = 0.07$, ns	57.1%

Continued

TABLE 89-4 Clinical Trials of Locally Delivered, Controlled-Release Antimicrobials ($N \leq 19$ per treatment group)—cont'd

DRUG	STUDY DESIGN	INCLUSION CRITERIA	TREATMENT GROUPS	TREATMENT	STUDY DURATION	PD OUTCOMES (MEAN)			PD REDUCTION ≥ 2.0 MM FROM BASELINE	AL OUTCOMES (MEAN)		
						Absolute Reduction from Baseline (mm)	Absolute Reduction Difference between Groups (mm)	Percent Change between Groups	Percent	Absolute Gain from Baseline (mm)	Absolute Gain Difference between Groups (mm)	Percent Change between Groups
MIN[18]	Double-blind, randomized, single-center, adjunctive therapy	Nontreated chronic periodontitis, nonsmoker, 2 sites (no molars) from each pt w PD ≥6 mm (no furcation involvement	(1) SRP + MIN, $N = 13$ (2) SRP + veh, $N = 13$	Local anesthesia, then full-mouth SRP (supraging & subging) + MIN or veh at baseline and again at 90, 180, & 270 days	24 mo	(1) 12 mo, 3.58; 24 mo, 2.27 (2) 12 mo, 2.53; 24 mo, 1.8	12 mo, 1.05, p = ns; 24 mo, 0.47, p = ns	12 mo, 41.5% 24 mo, 26.1%	NR	NR	NA	NA
TET[36]	Nonrandomized, single-center, adjunctive, and monotherapy	Periodontal maintenance w ≥1 site w PD ≥4.0 mm & BOP	(1) TET alone, $N = 16$ (2) SRP + TET, $N = 6$	SRP w local anesthesia, 5 min/tooth. TET fiber placed	6 mo	(1) 1.5 ± 0.38 (2) 1.3 ± 0.51	0.2 ± 0.64 P = ns	15%	NR	NR	NA	NA
TET[16]	Single-center, single-blind, randomized, adjunctive, split-mouth	Mod to adv perio disease; ≥2 sites in each quad w PD 5 mm + BOP	(1) SRP alone (2) SRP + TET $N = 17$	SRP, then TET for group 2 target teeth	7 wk	(1) 1.04 ± 0.148 (2) 1.45 ± 0.14	0.41 P = 0.047	39%	NR	(1) 0.75 ± 0.158 (2) 0.95 ± 0.132	0.2	P = ns
MIN[110]	Single-center, single-blind, randomized, adjunctive, split-mouth	Mod to sev chronic periodontitis; 2 pairs of adjacent teeth on opposite sides of mouth w adjacent interproximal sites of PD 6–9 mm, smooth surfaces only w ≥3 mm attachment loss; no antibiotics for 3 mo or perio tx for 6 mo	(1) SRP alone (adjacent to MIN site) (2) SRP alone (opposite side from MIN site) (3) SRP + MIN $N = 15$	Full-mouth SRP w sonic/ ultrasonic or hand instruments w local anesthesia as needed, then MIN administration	6 mo	(1) 5.2 ± 1.7 (2) 5.2 ± 1.2 (3) 4.3 ± 1.4 All different from baseline, $p < 0.01$	(1) vs (2) 0.0 (1) vs (3) 0.9 (2) vs (3) 0.9 All p = ns	(1) vs (2) 0% (1) vs (3) 21% (2) vs (3) 21%	(1) 40% (2) 53% (3) 73%	(1) 1.3 ± 1.3 (2) 1.4 ± 1.4 (3) 2.1 ± 1.5	(1) vs (2) 0.1 (1) vs (3) 0.8 (2) vs (3) 0.7	(1) vs (2) 7.7% (1) vs (3) 61.5% (2) vs (3) 50%

*Report of no microbiological difference between two groups at 1 mo.

AL, attachment level; *app't*, appointment; *BOP*, Bleeding on probing; *calc*, calculus; *CHX*, chlorhexidine chip; *d*, day(s); *DOX*, doxycycline hyclate gel; *est*, estimated; *h*, hour; *max*, maximum; *MET*, metronidazole; *MIN*, minocycline microspheres; *mo*, month(s); *mod*, moderate; *NR*, not reported; *NS*, not significant; *OHI*, oral hygiene instructions; *PD*, probing depth; *perio*, periodontal; *pt*, patient; *q*, every; *quad*, quadrant; *sev*, severe; *SRP*, scaling and root planing; *subging*, subgingival; *supraging*, supragingival; *TET*, tetracycline; *tx*, treatment; *veh*, vehicle; *vs*, versus; *w*, with; *wk*, week; *y*, year.

realized as a result of these changes are discussed later in this chapter. The important consideration is that the changes were significant; trials met their primary objectives. Trials designed to consider monotherapy have shown an outcome with local delivery that is at least equivalent to SRP.

Results from smaller trials are presented in Tables 89-3 and 89-4. Accordingly, results from these trials are mixed. Some have shown an increased benefit with adjunctive therapy compared with SRP alone, while others have shown no such increase. It is evident that many these trials suffer from design features that are less robust than those in Table 89-2 and cannot provide conclusions that can support treatment decisions. These trials mostly have to be considered hypotheses-generating. In contrast, many of the trials reported in Table 89-2 can be considered as hypothesis-testing and have reached conclusive outcomes that both supported regulatory approvals and can support treatment decision making; the results from these trials were that clinical outcomes following SRP plus the adjunctive use of a locally delivered, controlled-release antimicrobial were significantly enhanced compared with SRP alone.[40]

Statistical Versus Clinical Significance

Multiple clinical trials have consistently shown in at least six multicentered, randomized, Phase III-style trials[49,68,76,97,107] that SRP plus adjunctive treatment resulted in a significantly greater probing depth reduction from baseline compared with SRP alone. Probing depth is thought to be a clinically meaningful endpoint for periodontitis trials,[78,81] an appropriate outcome measure of inflammation,[54,78] and predictive of further disease progression,[87] although the progression of periodontitis may be most meaningfully measured by loss of attachment or alveolar bone.[3,23,73,86,90] It is clear that the improvement in probing depth reduction with SRP plus adjunctive therapy versus SRP alone is statistically significant; the more relevant question may be whether the difference is clinically significant and meaningful for patient benefit.

The mean differences in clinical trials between the probing depth reduction from baseline between treated (SRP plus adjunctive agent) and control (SRP plus placebo or SRP alone) groups were reported as tenths of a millimeter (approximately 0.2 to 0.7 mm).[49,68,76,97,107] The changes numerically seem small and of little clinical significance, but they need to be viewed from several perspectives. For example, it is commonly believed that only a low percentage of periodontitis sites are "active" at any point in time, that is, actively evidencing tissue breakdown, and that most sites are relatively stable and "inactive."[32,39,73,95] Because most sites may be stable at most times, unless a trial is enriched for "active" sites, it seems likely that there would not be much difference between treated and control in most patients. Many of the data points used to define a mean difference may be small or near zero (i.e., no difference versus control).

Additionally, clinical trials for FDA registration are typically performed using an intent-to-treat analysis. The data from all entered patients are included in the analysis regardless of whether they complete the trial; thus, the anticipated small mean changes may be even further diluted by data recorded prior to the planned endpoint. The expected small mean outcomes highlight the importance of the statistical analyses. Adjunctive locally delivered, controlled-release antimicrobials have consistently shown this statistical benefit in multiple, well-designed, Phase III-style clinical trials, for example, improving mean probing depth reduction across all tested sites entered, including those patients with incomplete treatment, in a number of trials from about 22% to about 68% compared with control (see Table 89-2), a magnitude of change that indeed seems clinically significant. A significant mean percentage change versus control implies that the response curve is significantly shifted toward increased benefit for the population under study. The efficacy of local adjuncts was subsequently supported at the 2003 Workshop on Contemporary Science in Clinical Periodontics, which also concluded that the clinical result obtained following SRP that includes the adjunctive use of a locally delivered, controlled-release antimicrobial is significantly enhanced in comparison with that following SRP alone.[40]

Perhaps the most compelling evidence to support clinical significance comes from the consideration of large changes. A mean probing depth reduction 2 mm or more from baseline is commonly considered evidence of clinical significance.[49,84,107] Adjunctive locally delivered, controlled-release antimicrobials resulted in a significantly greater percentage of patients or sites with a probing depth reduction 2 mm or more in comparison with SRP alone in these same adequate and well-controlled trials (see Table 89-2). This level of reduction may ultimately translate into a clinical outcome of fewer lost teeth, but this hypothesis remains to be tested in clinical trials with tooth mortality as the primary objective rather than surrogate endpoints.[47] Thus, available data support that adjunctive therapy is not only statistically significant but clinically significant as well. The clinical significance of the adjunctive benefit was also acknowledged at a symposium to consider locally delivered chemotherapeutic agents in periodontal therapy sponsored by the Periodontal Research Group at the 1998 Annual Meeting of the American Association for Dental Research (AADR).[55]

Significantly more patients showed PD reductions 2 mm or more following SRP plus adjunctive therapy versus SRP alone.

To consider the results from another perspective, surgery is a common treatment for patients with chronic adult periodontitis, but the mean differences in probing depth reduction between sites treated surgically versus sites treated with SRP alone have also been reported in the neighborhood of several tenths of a millimeter.[44,74] Thus, the mean difference in probing depth reduction as a result of SRP plus adjunctive therapy versus SRP alone is similar to the mean difference of probing depth reduction as a result of surgical procedures versus SRP. It follows that a consideration of the clinical significance of adjunctive therapy parallels a consideration of the clinical significance of periodontal surgery. The 1996 World Workshop in Periodontics concluded that "[o]utcomes [following both surgical and nonsurgical therapy] after several years are generally similar."[109] As was stated at a symposium to consider the clinical significance of locally delivered antimicrobials at the 2001 Annual Meeting of the AADR, "[t]he case is stronger for local delivery than for surgery."[56] A discussion regarding the potential use of locally delivered, controlled-release antimicrobials in the surgical setting is presented in Chapter 90.

An example from the medical literature further illustrates the value of examining percentage changes rather than only concentrating on absolute changes. Osteoporosis is a substantial public health concern, and the morbidity and mortality that result from osteoporotic fractures are substantial. Bisphosphonates have long been a mainstay of pharmacological treatment for osteoporosis. Boonan and coworkers[14] reported that the rate of new morphometric vertebral fracture was 1.6% with zoledronic acid treatment versus 4.9% with placebo over 24 months. Although the absolute percentage of fractures was low, the percentage change represented a 67% risk reduction as a result of therapy (relative risk, 0.33; 95% confidence interval 0.16–0.70, $P = 0.002$).

In summary, currently available data support that adjunctive therapy is not only statistically significant but clinically significant

Copyright © 2015, 2012, 2006 by Saunders, an imprint of Elsevier Inc.

as well. When used routinely, practitioners can expect an enhanced mean clinical result. Additional clinical trials are necessary to expand our knowledge regarding further potential indications for locally delivered, controlled-release antimicrobials.

Current data support that adjunctive therapy is clinically significant as well as statistically significant.

Clinical Use

Costs and Outcomes

Locally delivered, controlled-release antimicrobials, as with any drug product, entail costs. Adjunctive therapy with these products adds cost to the patient in addition to that of SRP, depending on fees charged by the practice for such therapy. Concerns about the costs and the cost-effectiveness of these locally delivered agents have proven to be a deterrent to routine clinical use. Thus it is appropriate to include some discussion about costs in order to be able to consider the incorporation of adjunctive therapy into clinical practice, although a thorough cost-effectiveness analysis is beyond the scope of this chapter. A discussion of costs, of course, cannot be separated from a consideration of outcomes as well.

To consider any economic evaluation of adjunctive therapy, the relevant issues are the additional costs associated with treatment versus the additional benefits obtained. All therapies entail costs, and very few therapies may actually result in a cost savings. The question then translates to a consideration of the value of the incremental benefit obtained. A true analysis of the additional benefit obtained by adjunctive periodontal therapy in relation to the additional costs is challenging and not easily addressed.

There have been few reports regarding the cost-effectiveness of locally delivered, controlled-release antimicrobials. In a clinical trial of more than 450 patients to study costs associated with the chlorhexidine chip, adjunctive therapy increased total treatment costs by approximately 50% but reduced the likelihood for surgical treatment by about 50% in comparison with patients treated with standard care.[46] There was a sufficient reduction in other dental treatment to offset about half of the acquisition costs of the chip. The result was consistent with a previously published modeled assessment.[22] After 12 months, the examining periodontists recommended similar further amounts of surgery for both groups.[46] No information was available, however, regarding any further disease progression or tooth mortality or whether patients received any further surgical care. Additionally, no information was available for these patients regarding any differential outcomes with either follow-up surgical care or continued nonsurgical maintenance with SRP and adjunctive therapy.

A cost-effectiveness comparison of three locally delivered, controlled-release antimicrobial agents was performed by Niederman et al[69] based on a review of published data. The measures used in the analysis included a number needed to treat (the number of teeth or sites treated to produce one site with a probing depth reduction ≥2 mm) and total costs of treatment. The analysis concluded with a cost-effectiveness in the order of tetracycline fibers > chlorhexidine chips > minocycline microspheres. The use of a number needed to treat analysis has been reviewed[63]; the key message is the inappropriateness of this method for a comparison of different therapies assessed in dissimilar populations over different times, perhaps with different baselines of disease or with different comparators.

What might be the outcomes if locally delivered, controlled-release antimicrobials were included in a long-term periodontal maintenance program? The Phase III pivotal trials have provided evidence for the safety and efficacy of these agents to improve clinical signs of periodontitis (e.g., probing depth, attachment level) over the length of the trials (e.g., 6 to 9 months). Longer term clinical trials, including studies of minocycline microspheres, doxycycline gel, and chlorhexidine chip, have provided evidence for the safety and efficacy of locally delivered, controlled-release antimicrobials for periodontal maintenance.* The data are suggestive of a benefit to improve tooth retention, but long-term adequate and well-controlled clinical trials are needed to provide conclusive data that adjunctive therapy reduces tooth mortality. Other potential outcomes could include an increase in nonsurgical periodontal therapy, with a corresponding reduction in surgical therapy. In a meta-analysis of the effects of adjunctive therapy of chlorhexidine, metronidazole, minocycline, or tetracycline with SRP, Bonito et al[15] concluded that benefit in favor of adjunctive therapy with respect to changes in clinical attachment was significant for all antimicrobials assessed. Examples of clinical outcomes are shown in Figures 89-7 and 89-8, including data as examples of additional microbiological effects of adjunctive, locally delivered, controlled-release antimicrobials versus SRP alone.[31] For details regarding the microbiology of periodontal diseases, see Chapter 8.

Little information is available regarding the effect of adjunctive therapy on alveolar bone levels. In a subset of patients from the chlorhexidine chip Phase III clinical trials,[49] some SRP-alone patients evidenced reduced alveolar bone over 9 months as measured by subtraction radiography, but no patient treated adjunctively showed any radiographic evidence of bone loss.[50] Similarly in another small study of periodontitis patients treated adjunctively with another formulation of a chlorhexidine chip (PerioCol-CG, see Chapter 90), Grover et al[38] reported that, although most sites showed no changes in alveolar bone height, 5% of SRP-alone sites showed bone loss and 21% of sites showed a bone gain. In contrast, 47% of SRP plus chlorhexidine chip sites showed bone gain, while no site evidenced a loss of alveolar bone.

Additionally, with respect to the possible impact of adjunctive therapy on the resorption of bone associated with periodontitis, treatment with SRP plus adjunctive minocycline microspheres resulted in a significant reduction of markers associated with bone resorption (pyridinoline cross-linked carboxy terminal telopeptide of type I collagen [ICTP] and interleukin 1-beta [IL-1β]) in the GCF of sites with probing depth 5 mm or more compared with SRP alone at 1 month.[71] GCF levels of ICTP and IL-1β were significantly increased in periodontitis patients versus healthy controls.[71] SRP plus chlorhexidine chip was reported to reduce levels of matrix metalloproteinase-8 activity[9] and prostaglandin E_2 (PGE_2)[65] in GCF compared with SRP alone. Adequate and well-controlled clinical trials are needed to test the hypothesis that adjunctive, locally delivered controlled-release antimicrobials may reduce alveolar bone loss.

A consideration of the incremental costs of adjunctive therapy also requires the estimation of the cost-effectiveness of SRP alone versus no treatment. The data reported by Antczak-Bouckoms and Weinstein,[5] perhaps the first cost-effectiveness analysis of periodontal therapy, support that all treatment entails cost but that the addition of antimicrobials may provide for an incremental benefit with an additional incremental cost. Just as the true benefit of SRP generally seems to derive from continued maintenance treatment and repeated instrumentation for life, it seems likely that the true benefits of locally delivered, controlled-release antimicrobials will derive from their routine incorporation as adjuncts to SRP procedures and as part of a periodontal maintenance program as indicated.

*References 13, 18, 21, 41, 62, 64, 89, 93, 98, 101, 102.

Copyright © 2015, 2012, 2006 by Saunders, an imprint of Elsevier Inc.

Figure 89-7 Clinical use of locally delivered, controlled-release antimicrobials. The patient was a 75-year-old black female who presented with chronic adult periodontitis. A pocket site of 5-mm probing depth was associated with the mesiobuccal of tooth #21; the site presented with signs of inflammation, including bleeding on probing and discomfort. Scaling and root planing (SRP) was performed at the site with the placement of minocycline microspheres as an adjunctive therapy. Figures present clinical and radiographic conditions prior to treatment and clinical photographs both during and following administration: **A,** Baseline—clinical; **B,** Baseline—radiographic; **C,** Syringe next to site, ready for administration; **D,** Syringe in pocket site for administration; **E,** Immediately after application, postoperative instructions were given; **F,** One week postapplication, substantial clinical improvement was noted; **G,** Two weeks postapplication, with maintained clinical status; **H,** Four weeks postapplication, maintained clinical status—patient reported lack of bleeding during oral home care, in contrast to pretreatment condition (probing to determine probing depth was not performed to allow for continued postoperative healing). Note: Although posttreatment site changes can be monitored clinically (e.g., resolution of inflammation; changes in probing depth), there is a general inability to determine any additional adjunctive benefit clinically. Expected additional benefits from adjunctive treatment can be assessed only with adequate and well-controlled clinical trials. *(Courtesy Dr. Hector L. Sarmiento, Department of Periodontics, University of Pennsylvania, Philadelphia, PA, and Department of Periodontics, University of Pennsylvania, Philadelphia, PA.)*

Copyright © 2015, 2012, 2006 by Saunders, an imprint of Elsevier Inc.

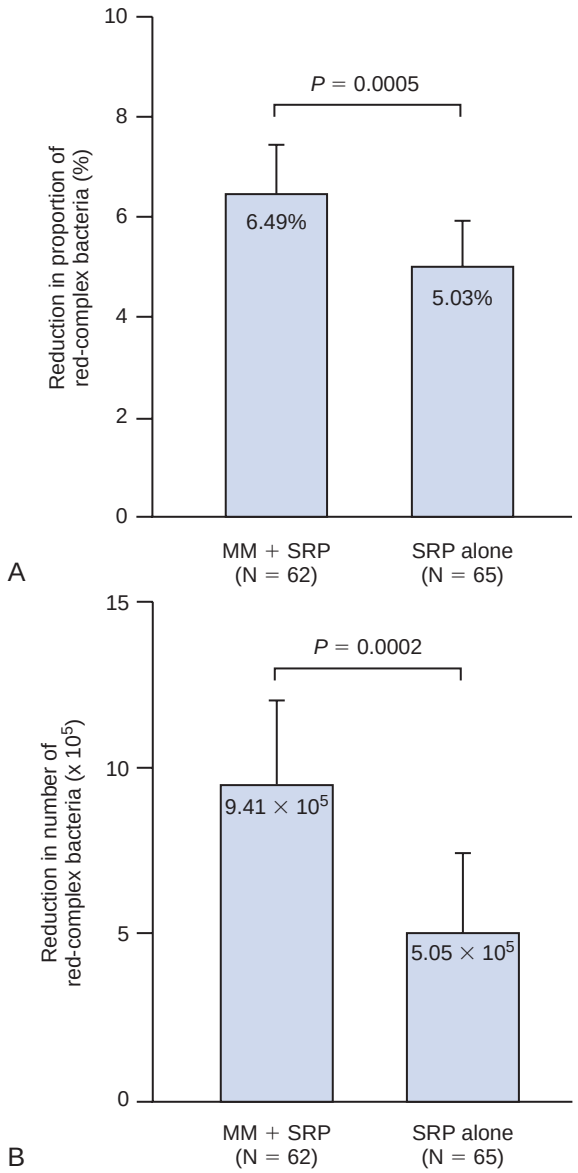

Figure 89-8 Microbiological effects following the adjunctive administration of minocycline microspheres (MM).[31] **A,** Mean percent reduction in the proportion of red-complex bacteria (RCB) (sum of *Porphyromonas gingivalis*, *Tannerella forsythia*, and *Treponema denticola*) from baseline to day 30. Brackets represent standard error (0.88% and 1.00% for the MM + scaling and root planing [SRP] and SRP alone groups, respectively). **B,** Mean reduction in the number of RCB (sum of *P. gingivalis*, *T. forsythia*, and *T. denticola*) from baseline to day 30. Brackets represent SE (both 2.43×10^5). *(Reprinted from Goodson JM et al:* J Periodontol *78:1568, 2007, with permission from the American Academy of Periodontology.)*

For a more detailed review of the cost-effectiveness of locally delivered, controlled-release antimicrobials in periodontal therapy, the reader is referred to Heasman and coworkers.[42] The authors emphasized, however, the need for long-term studies to assess effects on tooth mortality or other patient-reported outcomes.

Tobacco Smoking

Smoking is a well-known risk factor for the development or progression of periodontitis and may limit the effectiveness of periodontal therapy.[11,48,52,83] The adjunctive use of locally delivered, controlled-release antimicrobials may enhance the efficacy of SRP in smokers. In a 3-month trial, SRP plus adjunctive doxycycline gel resulted in significantly greater probing depth reduction and clinical attachment gain versus SRP alone approximately equally in both smokers and nonsmokers.[106] This result was consistent with subset analyses of current smokers, former smokers, and nonsmokers from two 9-month, multicenter trials of the doxycycline gel[91] and of smokers versus nonsmokers (minocycline microspheres).[107] Subset analyses of minocycline microspheres showed that results for smokers were consistent with overall trial results.[72,77] Consistent results were seen as well in a later clinical trial of minocycline microspheres.[37] Additional periodontal microbiological alterations suggested as beneficial changes in adjunctively treated sites compared with SRP alone have also been reported for both doxycycline gel and minocycline microspheres (Figure 89-9).[37,60,94] A 2-year trial of the doxycycline gel with a small number of patients provided further supportive evidence of clinical efficacy.[59] Finally, in a pilot trial to test the use of adjunctive minocycline microspheres in a surgical setting, clinical improvement was seen similarly both in smokers and nonsmokers.[45] Thus, adjunctive therapy may both lessen the adverse impact of smoking on the periodontium and improve treatment outcomes in patients who smoke. A recent systematic review regarding the doxycycline gel and minocycline microspheres has noted, however, that available data are insufficient to conclude that adjunctive therapy significantly enhances SRP specifically in smokers and suggests that additional clinical trials (i.e., adequate and well-controlled trials) are necessary to assess outcomes in smokers.[2]

Potential New Indications

Additional dental indications for locally delivered controlled-release antimicrobials can be considered, although these indications have not been evaluated by the FDA. Additional indications could include, for example, combination adjunctive therapy, adjuncts with surgical therapy or periimplantitis. Some preliminary data regarding these potential indications are available, and a more detailed discussion of these data is provided in Chapter 90.

Currently Available Agents (Non-U.S.)

Following approval by the FDA of locally delivered, controlled-release antimicrobials for clinical use in the United States, a number of products have been approved for use in various other countries outside of the United States. In general, these products use antimicrobial agents that have already been discussed above with respect to U.S. products. A further discussion of these non-U.S. products is provided in Chapter 90.

Conclusion

The evidence is strong that adjunctive, locally delivered, controlled-release antimicrobials make SRP significantly more effective with a known safety profile; SRP without adjunctive treatment in appropriately eligible sites (i.e., probing depth ≥5.0 mm) may be less than maximally effective. It is not appropriate to determine therapy based solely on clinical judgment. The practitioner should evaluate the evidence and suggest a treatment that has the greatest probability for success and patient benefit based on current data. Spielman and Wolff[100] have commented on the unfortunate tendency for many dentists to base treatment on personal experience and not on reported evidence; they highlight that optimal care is evidence based. As an example of the suboptimal care that can result from the lack of incorporation of the best available evidence into clinical practice, O'Donnell and colleagues[70] recently reported on the underutilization of pit-and-fissure sealants in dental practice despite

Copyright © 2015, 2012, 2006 by Saunders, an imprint of Elsevier Inc.

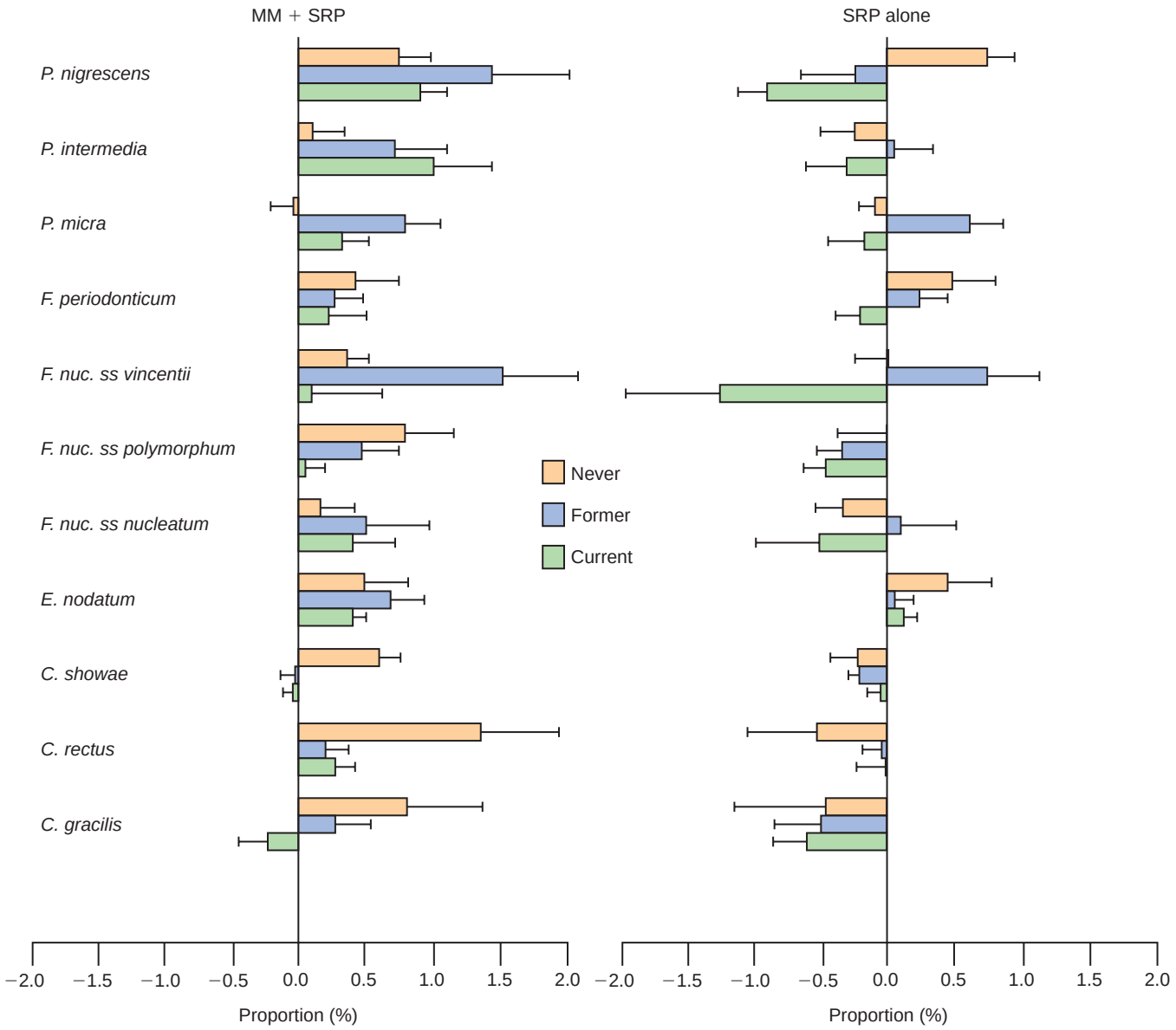

Figure 89-9 Microbiological effects following the adjunctive administration of minocycline microspheres in smokers and nonsmokers.[37] Changes in proportion of orange complex bacteria (OCB) following therapy. Positive changes represent antibacterial effects as reductions in proportions. Negative changes represent proportional increases or proliferation of bacterial groups. *F. nuc.*, *Fusobacterium nucleatum*. *(Reprinted from Grossi SG et al:* J Periodontol *78:1741, 2007, with permission from the American Academy of Periodontology.)*

published American Dental Association (ADA) recommendations.[10] Available data support that adjunctive use of locally delivered, controlled-release antimicrobials provides a significant additional mean clinical benefit.

SRP procedures have previously been considered the nonsurgical standard of care.[4,15] The evidence supports that adjunctive locally delivered, controlled-release antimicrobials make SRP more effective[40] with a known safety profile. Based on currently available data, when these agents are used routinely as adjuncts to SRP as indicated either as part of initial periodontal treatment or maintenance therapy, clinicians can expect an enhanced result as measured by a significantly greater mean reduction in probing depth in comparison with SRP alone. SRP plus adjunctive therapy, used in a manner that is consistent with the approved full prescribing information, could potentially be considered a new standard for nonsurgical periodontal therapy for the management of chronic adult periodontitis. Additionally, a number of pilot trials have suggested additional potential indications for adjunctive locally delivered, controlled-release antimicrobials. More research is necessary to test these additional hypotheses before further clinical comments can be made.

SRP plus adjunctive therapy could potentially be considered a new standard for nonsurgical periodontal therapy.

Key Points

- Locally delivered, controlled-release antimicrobials have been studied in multiple adequate and well-controlled clinical trials (Phase III).
- Phase III clinical trials are the gold standard for evidence-based clinical decision making. Evidence-based practice leads to the greatest clinical benefit for the greatest number of patients.
- Locally delivered, controlled-release agents maintain a clinically effective concentration of antimicrobial in the periodontal pocket for an extended period of time.

Copyright © 2015, 2012, 2006 by Saunders, an imprint of Elsevier Inc.

- When PD changes were assessed in clinical trials for all included periodontal pockets, mean changes were modest, since most pockets are quiescent at any point in time.
- The mean PD reduction observed after SRP that included adjunctive therapy was significantly greater than the mean PD reduction after SRP alone.
- Significantly more patients showed a large PD reduction (≥2 mm) following SRP that included adjunctive therapy compared with patients treated with SRP alone.
- SRP that includes adjunctive therapy is significantly more effective than SRP alone.
- The greatest clinical benefit of adjunctive therapy is likely to be realized when adjunctive therapy is routinely incorporated with SRP procedures and included as part of a long-term periodontal maintenance program.

Suggested Readings

Finkelman RD, Polson AM: Evidence-based considerations for the clinical use of locally delivered, controlled-release antimicrobials in periodontal therapy. *J Dent Hyg* 87:249–264, 2013.

Garrett S, Johnson L, Drisko CH, et al: Two multi-center studies evaluating locally delivered doxycycline hyclate, placebo control, oral hygiene, and scaling and root planing in the treatment of periodontitis. *J Periodontol* 70:490–503, 1999.

Hanes PJ, Purvis JP: Local anti-infective therapy: pharmacological agents. A systematic review. *Ann Periodontol* 8:79–98, 2003.

Heasman PA, Vernazza CR, Gaunt FL: Cost-effectiveness of adjunctive antimicrobials in the treatment of periodontitis. *Periodontol 2000* 55:217–230, 2011.

Jeffcoat MK, Bray KS, Ciancio SG, et al: Adjunctive use of a subgingival controlled-release chlorhexidine chip reduces probing depth and improves attachment level compared with scaling and root planing alone. *J Periodontol* 69:989–997, 1998.

Killoy WJ: Local delivery of antimicrobials: a new era in the treatment of adult periodontitis. *Comp Cont Educ Dent* 20(Suppl):13–18, 1999.

Mathieu MP, Milne C-P: *New drug development: a regulatory overview*, ed 8, 2008, Barnett International.

Newman MG, Kornman KS, Doherty FM: A 6-month multi-center evaluation of adjunctive tetracycline fiber therapy used in conjunction with scaling and root planing in maintenance patients: clinical results. *J Periodontol* 65:685–691, 1994.

Page RC: The microbiological case for adjunctive therapy for periodontitis. *J Int Acad Periodontol* 6(Suppl):143–149, 2004.

Van Dyke TE: The clinical significance of new therapies for the management of periodontal disease. *J Int Acad Periodontol* 7(Suppl):191–196, 2005.

Williams RC, Paquette DW, Offenbacher S, et al: Treatment of periodontitis by local administration of minocycline microspheres: a controlled trial. *J Periodontol* 72:1535–1544, 2001.

References

1. Aimetti M, Romano F, Torta I, et al: Debridement and local application of tetracycline-loaded fibres in the management of persistent periodontitis: results after 12 months. *J Clin Periodontol* 31:166–172, 2004.
2. Angaji M, Gelsky S, Nogueira-Filho G, et al: A systematic review of clinical efficacy of adjunctive antibiotics in the treatment of smokers with periodontitis. *J Periodontol* 81:1518–1528, 2010.
3. Anonymous: Acceptance Program Guidelines. Chemotherapeutic agents to slow or arrest periodontitis. Council on Scientific Affairs. American Dental Association. *J Periodontol* 69:1076–1080, 1998.
4. Anonymous: American Academy of Periodontology statement on local delivery of sustained or controlled release antimicrobials as adjunctive therapy in the treatment of periodontitis. *J Periodontol* 77:1458, 2006.
5. Antczak-Bouckoms AA, Weinstein MC: Cost-effectiveness analysis of periodontal disease control. *J Dent Res* 66:1630–1635, 1987.
6. Arestin [Package insert], Horsham, PA, 2012, OraPharma, Inc.. <http://www.accessdata.fda.gov/drugsatfda_docs/label/2012/050781s019lbl.pdf>. Accessed August 31, 2012.
7. Arestin (Minocycline Hydrochloride) Microspheres: Food and Drug Administration Review Documents, Clinical Pharmacology Biopharmaceutics Review(s): Application No. 50-781, approval date February 16, 2001. <http://www.accessdata.fda.gov/drugsatfda_docs/nda/2001/50781_Arestin_biopharmr.pdf>. Accessed September 13, 2012.
8. Atridox [Package insert], Fort Collins, CO, 2011, Tolmar Inc. <http://www.accessdata.fda.gov/drugsatfda_docs/label/2011/050751s015lbl.pdf>. Accessed August 31, 2012.
9. Azmak N, Atilla G, Luoto H, et al: The effect of subgingival controlled-release delivery of chlorhexidine chip on clinical parameters and matrix metalloproteinase-8 levels in gingival crevicular fluid. *J Periodontol* 73:608–615, 2002.
10. Beauchamp J, Caufield PW, Crall JJ, et al: American Dental Association Council on Scientific Affairs: Evidence-based clinical recommendations for the use of pit-and-fissure sealants: a report of the American Dental Association Council on Scientific Affairs. *J Am Dent Assoc* 139(3):257–268, 2008.
11. Bergstrom J: Cigarette smoking as risk factor in chronic periodontal disease. *Community Dent Oral Epidemiol* 17:245–247, 1989.
12. Bland PS, Goodson JM, Gunsolley JC, et al: Association of antimicrobial and clinical efficacy: Periodontitis therapy with minocycline microspheres. *J Int Acad Periodontol* 12:11–19, 2010.
13. Bogren A, Teles RP, Torresyap G, et al: Locally delivered doxycycline during supportive periodontal therapy: a 3-year study. *J Periodontol* 79:827–835, 2008.
14. Boonen S, Reginster J-Y, Kaufman J-M, et al: Fracture risk and zoledronic acid therapy in men with osteoporosis. *N Engl J Med* 367:1714–1723, 2012.
15. Bonito AJ, Lux L, Lohr KN: Impact of local adjuncts to scaling and root planing in periodontal disease therapy: a systematic review. *J Periodontol* 76:1227–1236, 2005. (erratum *J Periodontol* 77:326–327, 2006).
16. Cattabriga M, Pedrazzoli V, Cattabriga A, et al: Tetracycline fiber used alone or with scaling and root planing in periodontal maintenance patients: clinical results. *Quintessence Int* 27:395–400, 1996.
17. Carvalho J, Novak MJ, Mota LF: Evaluation of the effect of subgingival placement of chlorhexidine chips as an adjunct to scaling and root planning. *J Periodontol* 78:997–1001, 2007.
18. Cortelli JR, Querido SMR, Aquino DR, et al: Longitudinal clinical evaluation of adjunct minocycline in the treatment of chronic periodontitis. *J Periodontol* 77:161–166, 2006.
19. Costerton W, Veeh R, Shirtliff M, et al: The application of biofilm science to the study and control of chronic bacterial infections. *J Clin Invest* 112:1466–1477, 2003. (erratum *J Clin Invest* 117:278, 2007).
20. Daneshmand N, Jorgensen MG, Nowzari H, et al: Initial effect of controlled release chlorhexidine on subgingival microorganisms. *J Periodont Res* 37:375–379, 2002.
21. Dean JW, Branch-Mays GL, Hart TC, et al: Topically applied minocycline microspheres: why it works. *Comp Cont Educ Dent* 24:247–250, 252–257, 2003.
22. de Lissovoy G, Rentz AM, Dukes EM, et al: The cost-effectiveness of a new chlorhexidine delivery system in the treatment of adult periodontitis. *J Am Dent Assoc* 130:855–862, 1999.
23. DeRouen TA, Hujoel PP, Mancl LA: Statistical issues in periodontal research. *J Dent Res* 74:1731–1737, 1995.
24. Drisko CH: The use of locally-delivered doxycycline in the treatment of periodontitis. Clinical results. *J Clin Periodontol* 25:947–952, comments, 978–979, 1998.
25. Drisko CL, Cobb CM, Killoy WJ, et al: Evaluation of periodontal treatments using controlled-release tetracycline fibers: clinical response. *J Periodontol* 66:692–699, 1995.
26. Epstein AK, Pokroy B, Seminara A, et al: Bacterial biofilm shows persistent resistance to liquid wetting and gas penetration. *Proc Natl Acad Sci USA* 108:995–1000, 2011.
27. Garrett S, Johnson L, Drisko CH, et al: Two multi-center studies evaluating locally delivered doxycycline hyclate, placebo control,

Copyright © 2015, 2012, 2006 by Saunders, an imprint of Elsevier Inc.

oral hygiene, and scaling and root planing in the treatment of periodontitis. *J Periodontol* 70:490–503, 1999.
28. Gonzales JR, Harnack L, Schmitt-Corsitto G, et al: A novel approach to the use of subgingival controlled-release chlorhexidine delivery in chronic periodontitis: a randomized clinical trial. *J Periodontol* 82:1131–1139, 2011.
29. Goodson J: Pharmacokinetic principles controlling efficacy of oral therapy. *J Dent Res* 68:1625–1632, 1989.
30. Goodson JM, Cugini MA, Kent RL, et al: Multicenter evaluation of tetracycline fiber therapy: II. clinical response. *J Periodont Res* 26:371–379, 1991.
31. Goodson JM, Gunsolley JC, Grossi SG, et al: Minocycline HCl microspheres reduce red-complex bacteria in periodontal disease therapy. *J Periodontol* 78:1568–1579, 2007.
32. Goodson JM, Tanner ACR, Haffajee AD, et al: Patterns of progression and regression of advanced destructive periodontal disease. *J Clin Periodontol* 9:472–481, 1982.
33. Gordon JM, Walker CB, Murphy JC, et al: Tetracycline: levels achievable in gingival crevice fluid and in vitro effect on subgingival organisms. Part I. Concentrations in crevicular fluid after repeated doses. *J Periodontol* 52:609–612, 1981.
34. Greenstein G: Local drug delivery in the treatment of periodontal diseases: assessing the clinical significance of the results. *J Periodontol* 77:565–578, 2006.
35. Griffiths GS, Sterne JAC, Wilton JMA, et al: Associations between volume and flow rate of gingival crevicular fluid and clinical assessments of gingival inflammation in a population of British male adolescents. *J Clin Periodontol* 19:464–470, 1992.
36. Grisi DC, Salvador SL, Figueiredo LC, et al: Effect of a controlled-release chlorhexidine chip on clinical and microbiological parameters of periodontal syndrome. *J Clin Periodontol* 29:875–881, 2002.
37. Grossi SG, Goodson JM, Gunsolley JC, et al: Mechanical therapy with adjunctive minocycline microspheres reduces red-complex bacteria in smokers. *J Periodontol* 78:1741–1750, 2007.
38. Grover V, Kapoor A, Malhotra R, et al: To assess the effectiveness of a chlorhexidine chip in the treatment of chronic periodontitis: a clinical and radiographic study. *J Indian Soc Periodontol* 15:139–146, 2011.
39. Haffajee AD, Socransky SS, Goodson JM: Periodontal disease activity. *J Periodont Res* 17:521–522, 1982.
40. Hanes PJ, Purvis JP: Local anti-infective therapy: pharmacological agents. A systematic review. *Ann Periodontol* 8:79–98, 2003.
41. Heasman PA, Heasman L, Stacey F, et al: Local delivery of chlorhexidine gluconate (PerioChip) in periodontal maintenance patients. *J Clin Periodontol* 28:90–95, 2001.
42. Heasman PA, Vernazza CR, Gaunt FL: Cost-effectiveness of adjunctive antimicrobials in the treatment of periodontitis. *Periodontol 2000* 55:217–230, 2011.
43. Heijl L, Dahlen G, Sundin Y, et al: A 4-quadrant comparative study of periodontal treatment using tetracycline-containing drug delivery fibers and scaling. *J Clin Periodontol* 18:111–116, 1991.
44. Heitz-Mayfield LJA, Trombelli L, Heitz F, et al: A systematic review of the effect of surgical debridement vs. non-surgical debridement for the treatment of chronic periodontitis. *J Clin Periodontol* 29(Suppl 3):92–102, 2002.
45. Hellström M-K, McClain PK, Schallhorn RG, et al: Local minocycline as an adjunct to surgical therapy in moderate to severe, chronic periodontitis. *J Clin Periodontol* 35:525–531, 2008.
46. Henke CJ, Genco RJ, Killoy WJ, et al: An economic evaluation of a chlorhexidine chip for treating chronic periodontitis. The CHIP (Chlorhexidine in Periodontitis) study. *J Am Dent Assoc* 132:1557–1569, 2001. (erratum *J Am Dent Assoc* 132:1658, 2001).
47. Hujoel PP: Endpoints in periodontal trials: the need for an evidence-based research approach. *Periodontol 2000* 36:196–204, 2004.
48. Jansson LE, Hagstrom KE: Relationship between compliance and periodontal treatment outcome in smokers. *J Periodontol* 73:602–607, 2002.
49. Jeffcoat MK, Bray KS, Ciancio SG, et al: Adjunctive use of a subgingival controlled-release chlorhexidine chip reduces probing depth and improves attachment level compared with scaling and root planing alone. *J Periodontol* 69:989–997, 1998.
50. Jeffcoat MK, Palcanis KG, Weatherford TW, et al: Use of a biodegradable chlorhexidine chip in the treatment of adult periodontitis: clinical and radiographic findings. *J Periodontol* 71:256–262, 2000.
51. Jones AA, Kornman KS, Newbold DA, et al: Clinical and microbiological effects of controlled-release locally delivered minocycline in periodontitis. *J Periodontol* 65:1058–1066, 1994.
52. Kaldahl WB, Johnson GK, Patil KD, et al: Levels of cigarette consumption and response to periodontal therapy. *J Periodontol* 67:675–681, 1996.
53. Kasaj A, Chiriachide A, Willershausen B: The adjunctive use of a controlled-release chlorhexidine chip following treatment with a new ultrasonic device in supportive periodontal therapy: a prospective, controlled clinical trial. *Int J Dent Hyg* 5:225–231, 2007.
54. Khan S, Cabanilla LL: Periodontal probing depth measurement: a review. *Compend Contin Educ Dent* 30:12–14, 16, 18–21, 2009.
55. Killoy WJ: The use of locally-delivered chlorhexidine in the treatment of periodontitis. Clinical results. *J Clin Periodontol* 25:953–958, comments: 978–979, 1998.
56. Killoy WJ: The clinical significance of local chemotherapies. *J Clin Periodontol* 29(Suppl 2):22–29, 2002.
57. Kinane DF: Radvar M: A six-month comparison of three periodontal local antimicrobial therapies in persistent periodontal pockets. *J Periodontol* 70:1–7, 1999.
58. Kuboniwa M, Lamont RJ: Subgingival biofilm formation. *Periodontol 2000* 52:38–52, 2010.
59. Machion L, Andia DC, Lecio G, et al: Locally delivered doxycycline as an adjunctive therapy to scaling and root planing in the treatment of smokers: a 2-year follow-up. *J Periodontol* 77:606–613, 2006.
60. Machion L, Andia DC, Saito D, et al: Microbiological changes with the use of locally delivered doxycycline in the periodontal treatment of smokers. *J Periodontol* 75:1600–1604, 2004.
61. Machtei EE, Hirsh I, Falah M, et al: Multiple applications of flurbiprofen and chlorhexidine chips in patients with chronic periodontitis: a randomized, double blind, parallel, 2-arms clinical trial. *J Clin Periodontol* 38:1037–1043, 2011.
62. Martorelli de Lima AF, Cury CC, Palioto DB, et al: Therapy with adjunctive doxycycline local delivery in patients with type 1 diabetes mellitus and periodontitis. *J Clin Periodontol* 31:648–653, 2004.
63. McAlister FA: The "number needed to treat" turns 20—and continues to be used and misused. *CMAJ* 179:549–553, 2008.
64. Meinberg TA, Barnes CM, Dunning DG, et al: Comparison of conventional periodontal maintenance versus scaling and root planing with subgingival minocycline. *J Periodontol* 73:167–172, 2002.
65. Mızrak T, Güncü GN, Çağlayan F, et al: Effect of a controlled-release chlorhexidine chip on clinical and microbiological parameters and prostaglandin E2 levels in gingival crevicular fluid. *J Periodontol* 77:437–443, 2006.
66. Newman MG: Improved clinical decision making using the evidence-based approach. *Ann Periodontol* 1:i–ix, 1996.
67. Newman MG, Caton JG, Gunsolley JC: The use of the evidence-based approach in a periodontal therapy contemporary science workshop. *Ann Periodontol* 8:1–11, 2003.
68. Newman MG, Kornman KS, Doherty FM: A 6-month multi-center evaluation of adjunctive tetracycline fiber therapy used in conjunction with scaling and root planing in maintenance patients: clinical results. *J Periodontol* 65:685–691, 1994.
69. Niederman R, Abdelshehid G, Goodson JM: Periodontal therapy using local delivery of antimicrobial agents. *Dent Clin North Am* 46:665–677, 2002.
70. O'Donnell JA, Modesto A, Oakley M, et al: Sealants and dental caries. Insights into dentists' behaviors regarding implementation of clinical practice recommendations. *J Am Dent Assoc* 144:e24–e30, 2013.
71. Oringer RJ, Al-Shammari KF, Aldredge WA, et al: Effect of locally delivered minocycline microspheres on markers of bone resorption. *J Periodontol* 73:835–842, 2002.

Copyright © 2015, 2012, 2006 by Saunders, an imprint of Elsevier Inc.

72. Oringer RJ, Van Dyke TE, Lessem J: The challenge of treating periodontal patients who smoke—the efficacy of Arestin. *J Int Acad Periodontol* 4:89–94, 2002.
73. Page RC, DeRouen TA: Design issues specific to studies of periodontitis. *J Periodont Res* 27:395–404, 1992.
74. Palcanis KG: Surgical pocket therapy. *Ann Periodontol* 1:589–617, 1996.
75. Palmer RJ, Jr: Supragingival and subgingival plaque: paradigm of biofilms. *Comp Cont Educ Dent* 31:104–106, 108, 110, 112, 114, 116–118, 120, 122, 2010.
76. Paolantonio M, D'Angelo M, Grassi RF, et al: Clinical and microbiologic effects of subgingival controlled-release delivery of chlorhexidine chip in the treatment of periodontitis: a multicenter study. *J Periodontol* 79:271–282, 2008.
77. Paquette D, Oringer R, Lessem J, et al: Locally delivered minocycline microspheres for the treatment of periodontitis in smokers. *J Clin Periodontol* 30:787–794, 2003.
78. Paquette DW: Pocket depth reduction as an outcome measure of inflammation and soft tissue changes in periodontitis trials. *J Int Acad Periodontol* 7(Suppl):147–156, 2005.
79. Pascale D, Gordon J, Lamster I, et al: Concentration of doxycycline in human gingival fluid. *J Clin Periodontol* 13:841–844, 1986.
80. PerioChip [Package insert], Jerusalem, Israel, 2012, Dexcel® Pharma Technologies Ltd.. <http://www.accessdata.fda.gov/drugsatfda_docs/label/2012/020774s011lbl.pdf>. Accessed August 31, 2012.
81. Pihlstrom B: Issues in the evaluation of clinical trials of periodontitis: a clinical perspective. *J Periodont Res* 27(special issue):433–441, 1992.
82. Polson AM, Garrett S, Stoller NR, et al: Multi-center comparative evaluation of subgingivally delivered sanguinarine and doxycycline in the treatment of periodontitis. II. Clinical results. *J Periodontol* 68:119–126, 1997.
83. Preber H, Linder L, Bergstrom J: Periodontal healing and periopathogenic microflora in smokers and non-smokers. *J Clin Periodontol* 22:946–952, 1995.
84. Preshaw PM, Hefti AF, Novak MJ, et al: Subantimicrobial dose doxycycline enhances the efficacy of scaling and root planing in chronic periodontitis: a multicenter trial. *J Periodontol* 75:1068–1076, 2004.
85. Radvar M, Pourtaghi N, Kinane DF: Comparison of 3 periodontal local antibiotic therapies in persistent periodontal pockets. *J Periodontol* 67:860–865, 1996.
86. Reddy MS: Radiographic alveolar bone change as an outcome measure for therapies that inhibit bone loss or foster bone gain. *J Int Acad Periodontol* 7(Suppl):175–188, 2005.
87. Renvert S, Persson GR: A systematic review on the use of residual probing depth, bleeding on probing and furcation status following initial periodontal therapy to predict further attachment and tooth loss. *J Clin Periodontol* 29(Suppl 3):82–89, 2002.
88. Research, Science and Therapy Committee of the American Academy of Periodontology: The role of controlled drug delivery for periodontitis. *J Periodontol* 71:125–140, 2000.
89. Rodrigues IFG, Machion L, Casati MZ, et al: Clinical evaluation of the use of locally delivered chlorhexidine in periodontal maintenance therapy. *J Periodontol* 78:624–628, 2007.
90. Ryan ME: Clinical attachment level change as an outcome measure for therapies that slow the progression of periodontal disease. *J Int Acad Periodontol* 7(Suppl):162–171, 2005.
91. Ryder MI, Pons B, Adams D, et al: Effects of smoking on local delivery of controlled-release doxycycline as compared to scaling and root planing. *J Clin Periodontol* 26:683–691, 1999.
92. Sakellari D, Goodson JM, Socransky SS, et al: Concentration of 3 tetracyclines in plasma, gingival crevice fluid and saliva. *J Clin Periodontol* 27:53–60, 2000.
93. Salvi GE, Mombelli A, Mayfield L, et al: Local antimicrobial therapy after initial periodontal treatment. A randomized clinical trial comparing three biodegradable sustained release polymers. *J Clin Periodontol* 29:540–550, 2002.
94. Shaddox LM, Andia DC, Casati MZ, et al: Microbiologic changes following administration of locally delivered doxycycline in smokers: a 15-month follow-up. *J Periodontol* 78:2143–2149, 2007.
95. Socransky SS, Haffajee AD, Goodson JM, et al: New concepts of destructive periodontal disease. *J Clin Periodontol* 11:21–32, 1984.
96. Soskolne WA, Chajek T, Flashner M, et al: An in vivo study of the chlorhexidine release profile of the PerioChip in the gingival crevicular fluid, plasma and urine. *J Clin Periodontol* 25:1017–1021, 1998.
97. Soskolne WA, Heasman PA, Stabholz A, et al: Sustained local delivery of chlorhexidine in the treatment of periodontitis: a multi-center study. *J Periodontol* 68:32–38, 1997.
98. Soskolne WA, Proskin HM, Stabholz A: Probing depth changes following 2 years of periodontal maintenance therapy including adjunctive controlled release of chlorhexidine. *J Periodontol* 74:420–427, 2003.
99. Soukos NS, Mulholland SE, Socransky SS, et al: Photodestruction of human dental plaque bacteria: enhancement of the photodynamic effect by photomechanical waves in an oral biofilm model. *Lasers Surg Med* 33:161–168, 2003.
100. Spielman AI, Wolff MS: Overcoming barriers to implementing evidence-based dentistry. *J Dent Educ* 72:263–264, 2008. (letter to the editor).
101. Stabholz A, Shapira L, Mahler D, et al: Using the PerioChip in treating adult periodontitis: an interim report. *Comp Cont Educ Dent* 21:325–328, 330, 332, 2000.
102. Stabholz A, Soskolne WA, Friedman M, et al: The use of sustained release delivery of chlorhexidine for the maintenance of periodontal pockets: 2-year clinical trial. *J Periodontol* 62:429–433, 1991.
103. Stoller NH, Johnson LR, Trapnell S, et al: The pharmacokinetic profile of a biodegradable controlled-release delivery system containing doxycycline compared to systemically delivered doxycycline in gingival crevicular fluid, saliva, and serum. *J Periodontol* 69:1085–1091, 1998. (erratum *J Periodontol* 70:238, 1999).
104. Teughels W, Quirynen M, Jakubovics N: Periodontal microbiology. In Newman MG, Takei HH, Klokkevold PR, et al, editors: *Carranza's clinical periodontology*, ed 11, St Louis, 2012.
105. Tomasi C, Koutouzis T, Wennström JL: Locally delivered doxycycline as an adjunct to mechanical debridement at retreatment of periodontal pockets. *J Periodontol* 79:431–439, 2008.
106. Tomasi C, Wennström JL: Locally delivered doxycycline improves the healing following non-surgical periodontal therapy in smokers. *J Clin Periodontol* 31:589–595, 2004.
107. Williams RC, Paquette DW, Offenbacher S, et al: Treatment of periodontitis by local administration of minocycline microspheres: a controlled trial. *J Periodontol* 72:1535–1544, 2001.
108. Wilson M, Stanley A, Bansal G, et al: Effect of phenoxyethanol, chlorhexidine and their combination on subgingival plaque bacteria. *J Antimicrob Chemother* 25:921–929, 1990.
109. World Workshop in Periodontics: consensus report. Surgical pocket therapy. *Ann Periodontol* 1:618–620, 1996.
110. Yalcin F, Demirel K, Onan U: Evaluation of adjunctive tetracycline fiber therapy with scaling and root planing: short-term clinical results. *Periodont Clin Invest* 21:23–27, 1999.

Copyright © 2015, 2012, 2006 by Saunders, an imprint of Elsevier Inc.

CHAPTER 90

Locally Delivered, Controlled-Release Antimicrobials: Drug Development and Clinical Research

Richard D. Finkelman and Alan M. Polson

CHAPTER OUTLINE

Drug Development and Registration
Clinical Trial Evidence
Clinical Use
Currently Available Agents (Non-U.S.)
Considerations for Future Research

Drug Development and Registration

Phases of Drug Development

The typical investigational drug is studied in many clinical trials before an application can be submitted to the U.S. Food and Drug Administration (FDA) for clearance for commercial marketing in the United States (New Drug Application [NDA]). In the most general terms clinical trials prior to registration are often considered in three phases. Phase I trials are usually conducted in small numbers of healthy volunteers to determine preliminary safety and dosing. Phase II trials are typically conducted in larger numbers of patients to characterize preliminary safety in patients and further to determine dosing to be evaluated in later trials. Phase III includes large trials, often called pivotal or registration trials and usually multicenter, blinded, and randomized, in sufficiently large numbers of patients to provide conclusive evidence of safety and efficacy to support the submission of an NDA to the FDA for registration for marketed use. Following FDA registration, additional trials (Phase IV) may be performed to provide additional information about drug products including longer term safety and efficacy in a broader number of patients or in alternative practice settings. The general objectives of the phases of clinical research as described by the National Institutes of Health[86] are given in Table 90-1. These typical phases of drug development now seem less distinct as trials are more lately considered in either exploratory or confirmatory stages.[85] Additionally, specialized clinical pharmacology trials may be conducted at any phase in order to provide specific information such as, for example, pharmacokinetics or to address specific treatment conditions such as specific patient populations (e.g., geriatric or pediatric patients, patients with hepatic or renal impairment) or the effect of the drug on cardiac electrophysiology (e.g., QT phase prolongation). For an overview of the drug development process, the reader is referred to Tonkens[83] or Mathieu and Milne.[52] The FDA also offers a continuing education tutorial regarding human drug development and regulation, accessible at http://www.fda.gov/Training/ForHealthProfessionals/ucm209538.htm.

Investigational drugs are typically studied in many clinical trials prior to clearance for marketed use.

Evaluating Safety and Efficacy

To approve a drug for marketed use in the United States, the FDA requires conclusive evidence that a drug is safe and effective for its intended use. As a general rule, data from at least two pivotal Phase III trials are required for regulatory decisions, although in some circumstances, for example in the case of a life-threatening disease such as cancer, only one trial might be required (when it would be considered unethical to withhold an effective treatment from patients and conduct a second trial). The concern is that results of one trial may represent a chance occurrence and should thus be confirmed by a second trial. Earlier trials, that is, Phase I and II, cannot provide data on which to base regulatory or clinical decisions. The FDA notes that each of these pivotal trials must be "adequate and well-controlled" and describes common characteristics of study designs that are considered adequate and well-controlled (Table 90-2).[85] Specific comments about trial design, especially Phase III trials, and these characteristics are made later in this chapter.

Drugs must be shown to be safe and effective before they can be marketed.

Informed Consent and Legal Considerations

Concerns about malpractice litigation and the legal aspects of dentistry are realities of dental practice. Often at the core of malpractice issues is the concept of informed consent. It is appropriate to make some comment about how adjunctive therapy might fit into this legal framework.

Informed consent is the standard within all dental practice. Clinicians must treat all patients under the principles of informed consent, and all patients must provide their consent for all treatment. With respect to clinical research, the FDA [adapted from 21CFR 50.25(a)[84]] describes eight elements of informed consent (Table 90-3). These elements apply to clinical practice as well. Appropriate treatment that satisfies the principles of informed

TABLE 90-1 Phases of Clinical Research*

Phase I: Researchers test a new drug or treatment in a small group of people for the first time to evaluate its safety, determine a safe dosage range, and identify side effects.
Phase II: The drug or treatment is given to a larger group of people to see if it is effective and to evaluate further its safety.
Phase III: The drug or treatment is given to large groups of people to confirm its effectiveness, monitor side effects, compare it to commonly used treatments, and collect information that will allow the drug or treatment to be used safely.
Phase IV: Studies are done after the drug or treatment has been marketed to gather information on the drug's effect in various populations and any side effects associated with long-term use.

*From the National Institutes of Health.[86]

TABLE 90-2 Characteristics of Adequate and Well-Controlled (Phase III) Clinical Trial Designs*

1. Type I error rate control.
2. Clear statement of the objectives, proposed and actual.
3. Methods of analysis in the protocol, statistical analysis plan, and reports
4. Methods of adequate assurance of patient selections.
5. Patient assignments that minimize bias, group comparability.
6. Methods to minimize bias for all parties: patients, investigators, and data analysts.
7. Endpoints well defined, address the primary hypothesis.
8. Analysis of results allows for the interpretability of the effects of the study drug.

*Adapted from U.S. Food and Drug Administration (FDA) 21CFR314.126.[85]

TABLE 90-3 Elements of Informed Consent*

1. Description of planned treatment.
2. Description of reasonably foreseeable risks or discomforts.
3. Description of any reasonably expected benefits.
4. Disclosure of appropriate alternative treatment.
5. Description of procedures to maintain confidentiality.
6. Disclosure of associated costs or payments.
7. Answering all patient questions.
8. Disclosure that all treatment, or study participation, is voluntary.

*Adapted from U.S. Food and Drug Administration (FDA) 21CFR 50.25.[84]

consent generally includes treatment that is evidence-based, that is, supported by appropriate research data. Because locally delivered, controlled-release antimicrobials as adjuncts have been consistently shown in adequate and well-controlled clinical trials to enhance the efficacy of scaling and root planing (SRP) and provide an additional incremental benefit,[31] performing SRP but not at least offering an adjunctive agent seems to violate the principles of informed consent.

With respect to the issue of malpractice, undiagnosed or undertreated periodontitis are major sources of dental malpractice litigation.[93] Since SRP procedures are commonly considered the standard of care for nonsurgical periodontal therapy,[6,11] and available data support that adjunctive locally delivered, controlled-release antimicrobials enhance the efficacy of SRP,[31] then SRP plus adjunctive therapy could potentially be considered a new standard. Other authors have noted the clinical relevance of locally delivered, controlled-release antimicrobials.* SRP without adjunctive therapy could accordingly be considered less than maximally effective. Would it be plausible to consider a possible defense in a malpractice litigation of alleged improperly managed periodontitis if it were claimed that the patient had not been offered maximally effective therapy (i.e., SRP with an adjunctive agent)?

Clinical Trial Evidence

Trial Design Considerations

Regulatory decisions generally depend on the data produced by adequate and well-controlled Phase III clinical trials to provide evidence that a drug is safe and effective when used as intended. These trials are usually large and conducted in many investigational centers in order (1) to enroll a sufficient number of patients to give the proper statistical power; and (2) to complete the trial within a reasonable length of time. Multicentered trials are enormously expensive and are difficult to perform. Clinical trials must be designed appropriately to test the hypotheses of interest. Some important design features of trials that are considered adequate and well-controlled are listed in Table 90-2 and further discussed below.

Data from adequate and well-controlled clinical trials (e.g., Phase III) are required for regulatory decision making.

Trial I Error Rate Control. A type I error is the error that occurs when one rejects the null hypothesis when it is true (i.e., rejecting the null hypothesis that there is no effect of the treatment or drug in question and concluding that there is an effect). The probability of a type I error is the level of significance of the statistical test of the hypothesis and is denoted by *alpha*. This error contrasts to a type II error, when one rejects the alternative hypothesis (fails to reject the null hypothesis) when the alternative hypothesis is actually true. A clinical trial should be adequately designed so that the *alpha* level is set at $p \leq 0.05$.

Clear Statement of the Objectives, Proposed and Actual. The objectives of the trial, primary and secondary, must be clearly defined within the protocol at the start of the study. The stated objectives should be adequately considered to address the study hypotheses. Exploratory objectives may also be included in the trial protocol, but these objectives are typically considered as hypothesis-generating rather than hypothesis-testing. Analyses not predefined and generated during the course of the study or assessed at the end of the study are typically denoted as post hoc analyses and are usually not appropriate for regulatory evaluation or decision.

Methods of Analysis in the Protocol, Statistical Plan, and Reports. The statistical methods planned for the analysis of trial data should be prespecified in the trial protocol, perhaps expanded in a statistical analysis plan, ideally before the start of the trial but at least prior to the locking of study data. In this fashion, all methods are predefined and not subject to any bias as a result of the trial outcomes. Additionally any manuscripts or reports arising from the trial should adequately describe the analytical methods so that readers can appropriately consider and interpret the results of the trial.

*References 21, 41, 44, 73, 18, 40, 45, 63, 49, 35, 75, 17, 37, 42, 43, 51, 58, 62, 64, 65, 80, 82, 87, 88

Methods of Adequate Assurance of Patient Selections. The protocol should include methods to enter patients appropriately so that the study population is representative of the broader population in general, that the study outcomes can be generalized to a broader population of similar patients. Multicenter trials (versus single-center or a limited number of centers) increase the heterogeneity of the study population and make the study results more generalizable. There must be adequate procedures in place to ensure that patients are randomly included and not specifically selected potentially to skew study results.

Patient Assignments That Minimize Bias, Group Comparability. Patients should be randomly assigned to treatment groups so as to minimize the chances for any systematic differences between groups. Treatment groups should be as comparable as possible; in this manner, any differences in study outcomes between groups can confidently be ascribed to the study treatment. Treatment assignments should be sequential and generated via appropriate randomization schemes (usually computer-generated) to eliminate any potential for bias in treatment selection by investigators or sponsors. Should there be particular characteristics of interest (e.g., smoking status for periodontal trials), treatment assignments can be stratified to assure an equal distribution of those characteristics among all treatment groups.

A comment is needed about controls. Dental studies often use teeth randomized to different treatment assignments within the same patient (i.e., split-mouth designs), highlighting that patients serve as their own controls. This type of assignment should be discouraged, since the units of statistical analysis are no longer independent. With this intrapatient design, there are considerable concerns that treatment for one (or more) teeth (periodontal pockets) within one treatment group could affect the other treatment sites within the same patient or that treatments of all treatment groups could be affected by host factors, either equally or differentially. The parallel-group design is preferable so that the statistical unit is the patient, assuring that sites within treatment groups are completely independent and not subject to possible confounding by the other treatment group(s).

Methods to Minimize Bias for All Parties: Patients, Investigators, and Data Analysts. Pivotal trials are typically double-blinded (or triple-blinded) so that no study participants (e.g., patients, investigators or statistical analysts) are aware of treatment assignments. In this fashion no patients, investigators, study staff, or those who analyze the data can either consciously or inadvertently influence the study outcome.

Endpoints Well Defined and Addressing the Primary Hypothesis. The study protocol should clearly describe all of the endpoints that will be assessed and the methods of assessment. Pivotal trials may include many dozens of study sites; there is considerable risk for systematic differences among different investigators. Protocols must standardize study methods as much as possible among study sites so that all treatments and study procedures are performed in the same manner at all study centers and that all endpoints are assessed in the same manner as well. The endpoints chosen should be relevant to the study objectives.

A comment is needed about endpoints in periodontal trials. Current designs of clinical trials to assess periodontal outcomes are generally limited to the evaluation of surrogate endpoints (e.g., probing depth, attachment level) rather than direct and more clinically relevant endpoints such as tooth survival. An endpoint of tooth survival, although arguably more ideal, is not practical for a clinical trial that is to be conducted within a reasonable length of time or with a reasonable number of patients. Surrogate variables, however, are considered reasonable endpoints in periodontal clinical trials and relevant to tooth retention,[28,34] although the inherent weaknesses of surrogate outcome variables have been noted.[33] Additionally, there may be discordance among surrogate periodontal outcome endpoints,[53] further highlighting the need for long-term data from clinical trials with tooth mortality as the primary objective.

Analysis of Results Allows for the Interpretability of the Effects of the Study Drug. The statistical analysis should be conducted so that the study results can be interpreted confidently as caused by the study drug or treatment under investigation and not influenced by any systematic differences between treatment groups or biases of any of those who participated in any aspects of the study trial.

The basic objective of any clinical trial is to answer a particular research question. The worst result possible is to complete a trial but not to be able to interpret the outcome of the trial with confidence, essentially a nonresult that would require the repeat of the trial. The many elements of study design described above all contribute to the degree of confidence with which one can consider the outcome of the trial and the interpretation of the result.

The pivotal trials for the chlorhexidine chip[36] and the minocycline microspheres[91] provide examples of Phase III designs for the study of adjunctive, locally delivered, controlled-release antimicrobials for the treatment of periodontitis. Representative populations of patients with chronic adult periodontitis were enrolled into multicentered, double-blinded clinical trials and were randomly assigned to treatment groups. Target pocket sites received SRP at baseline with or without adjunctive drug as per the randomization. At 3 and 6 months, sites randomized to drug received additional drug only if probing depth remained 5 mm or more. Final study results showed a reduction of probing depth from baseline at 9 months as expected in all groups, but the treatment group (SRP + adjunctive therapy) showed a significantly greater reduction from baseline versus control (SRP alone or SRP + placebo). If the adjunctive therapy had no effect, probing depth at these sites would have trended back toward baseline as in the SRP alone (or SRP + placebo) sites; the observation that probing depth remained reduced clearly demonstrated that the drug was efficacious. It should be noted for the chlorhexidine chip trials[36] that baseline measurements were obtained following a supragingival scaling. Since a supragingival scaling might result in a mean probing depth reduction of approximately 0.3 to 0.4 mm,[22] interpretation of the absolute changes in probing depth as a result of treatment should include a consideration of this potential prebaseline change.

Also with respect to these trials, it has been hypothesized that trial results might have been different had control groups also received repeated treatment (i.e., repeated SRP).[5] If the control group had received repeated SRP, however, to maintain design balance the adjunctively treated group also would have had to receive repeated instrumentation. It cannot be assumed that results might have been different only for the control group. Additionally, locally delivered, controlled-release antimicrobials may be effective in the presence of calculus[38] or with reduced amounts of instrumentation.[90] Additional instrumentation also would have made data interpretation more difficult; multiple treatments at multiple times make it more difficult to separate treatment effects meaningfully. Further in support of the lack of an impact of additional instrumentation on the outcome, a similarly significant

difference was reported when both treatment arms received SRP at baseline and a supragingival prophylaxis at 3 months.[60]

A final comment regarding locally delivered, controlled-release antimicrobials is needed regarding the consideration of adjunctive therapy or monotherapy. As suggested in Chapter 89, the general consensus of the professional community is that the best use for these products may be in the adjunctive setting. There are considerable data, however, that support efficacy in the monotherapy setting (for example, see Garrett et al[25]), and Garrett et al[24] have suggested that monotherapy may be equally as effective as mechanical instrumentation for supportive periodontal maintenance. The authors cautioned, however, that further studies are needed to validate this treatment regimen and emphasized the importance of compliance including frequent supportive maintenance professional visits.

Clinical Use

Combination Adjunctive Therapy

With regard to the potential to treat patients with combination adjunctive therapy, multiple adjunctive therapies, local and systemic, currently are available with supportive data regarding their use. None of these adjunctive therapies are currently labeled to be used in combination. It seems likely, however, that at least some practitioners may already be providing combination adjunctive therapy off-label for their patients, even though appropriate data do not yet exist. Thus, it is appropriate to include some commentary regarding combination therapy.

Locally delivered, controlled-release antimicrobials have been shown to enhance the clinical efficacy of SRP. Similarly, adjunctive systemic therapy with low-dose (20 mg) doxycycline, given orally twice daily as a host-modulating agent (later reported as a once daily, modified-release formulation[69]), has also been shown to enhance the clinical efficacy of SRP[68,16,13] (see Reddy et al[70] or Ryan and Golub[76] for a review of matrix metalloproteinase modulation as a treatment strategy). An obvious question is whether a combination of local antimicrobial and host-modulating adjunctive therapies will result in a greater clinical benefit compared with either adjunctive agent used alone.

In a 6-month clinical trial, combination adjunctive therapies resulted in significantly greater improvements in probing depth and clinical attachment compared with SRP alone.[57] More sites showed a probing depth reduction 2.0 mm or more, and fewer sites had residual probing depth 5.0 mm or more.[57] A single case report from this trial has been published.[67] Because the appropriate control groups (SRP plus single adjunctive therapy) were not included in the trial, definitive conclusions regarding any increased benefit from combination versus single adjunctive therapy cannot be made. The potential for combined adjunctive therapy to enhance clinical benefit is promising and warrants additional research.

A final comment is needed regarding systemic adjunctive therapy with low-dose doxycycline. The focus of the present chapter is locally delivered, controlled-release antimicrobials—hence, the concentration on these agents. The data support the efficacy of these local antimicrobials,[31] supporting the conclusion that SRP plus adjunctive therapy could potentially be considered a new standard for nonsurgical periodontal therapy. As above, available data also support the adjunctive efficacy of low-dose oral doxycycline[69,68,16,13] to an extent that is numerically similar to that reported for locally delivered, controlled-release antimicrobials. Because appropriate comparative data are not available, comparisons of these therapies is not appropriate, and no conclusion can be reached regarding the most efficacious approach for adjunctive therapy, local or systemic with single agents, or combined as above.

Surgical Therapy

Pocket sites that do not seem to respond adequately to nonsurgical therapy and evidence residual probing depth with inflammation are often treated with follow-up surgical therapy. An interesting question is whether locally delivered, controlled-release antimicrobials could augment surgical results. This hypothesis was tested in a pilot study by Hellström and coworkers[32] with minocycline microspheres at all pocket sites 5 mm or more. Sixty patients with at least one nonmolar pocket site with probing depth 6 mm or more in each of two quadrants were treated with either (1) microspheres at baseline, then immediately following each of two surgical procedures at weeks 2 and 3 and again at week 5; or (2) standard surgical therapy. The mean probing depth was reduced in both treatment groups, but the reduction was significantly greater in the test group versus control at 25 weeks (2.51 ± 0.10 mm vs. 2.18 ± 0.10 mm, respectively; $p = 0.027$).

A specialized periodontal surgical procedure, regenerative surgery, has become a standard procedure within periodontal practice. In this regard it had been suggested verbally, as early as 1993 (Killoy WJ, personal communication, 2002), and in print in 1998,[40,45] that adjunctive locally delivered, controlled-release antimicrobials may improve outcomes following regenerative periodontal surgery. In a pilot clinical trial, the adjunctive use of the chlorhexidine chip with regenerative surgery resulted in more than a 100% greater mean improvement from baseline in bone height and mass 9 months after surgical treatment compared with SRP alone and surgery.[71] It is worth noting that both groups had also received prophylactic systemic antimicrobial treatment as well prior to surgery, but the addition of a locally administered antimicrobial still resulted in a significant benefit compared with control.

Other reports support the lack of efficacy of systemic antimicrobials,[54] and the benefit of locally delivered antimicrobials,[92] as adjunctive treatments in the regenerative setting. A microbiological rationale for the use of locally delivered antimicrobials in the regenerative setting was also supported by Sbordone et al[78] with regard to the tetracycline fiber. Aichelmann-Reidy and coworkers[3] have suggested that regenerative surgical procedures should include an adjunctive locally delivered, controlled-release antimicrobial agent in order to provide a more consistent clinical benefit.

These preliminary reports have suggested that the adjunctive use of locally delivered, controlled-release antimicrobials may improve clinical outcomes following periodontal surgery both in the regenerative and nonregenerative settings. These hypotheses remain to be tested in prospective, adequate, and well-controlled trials; none of the three available agents are currently approved to be used as an adjunct with surgery.

Periimplantitis

Similarly to periodontitis, periimplantitis is also an inflammatory disease process that is initiated by local microorganisms, affecting the tissues surrounding an implant; an opportunity exists to treat diseased implant sites chemically by targeting the local microflora. Thus there is a potential rationale for the use of locally delivered, controlled-release antimicrobials for the treatment of periimplantitis. Although the treatment of periimplantitis is an off-label use, it seems likely that some clinicians may have tried local delivery in this setting; thus some comments in this regard are in order.

Renvert and coworkers[72] studied 32 patients with at least one implant site with a probing depth 4 mm or more plus bleeding or

exudate on probing. Patients were treated with debridement followed by either minocycline microspheres (17 patients, 57 implants) or a chlorhexidine gel formulation (15 patients, 38 implants); treatments were repeated at 30 and 90 days. Follow-up examinations were performed at 10 days and 1, 3, 6, 9, and 12 months. There were significant reductions in probing depth versus chlorhexidine at 1, 3, and 6 months and marked reductions in indicator microorganisms in both treatment groups. The authors concluded that adjunctive minocycline microspheres may be of value to treat peri-implant lesions.

Buchter et al[12] studied 28 patients with a total of 48 peri-implant defects. Two to 18 weeks prior to baseline, patients had been treated for periimplantitis (including scaling with a plastic instrument). Patients then either continued to receive this treatment alone or with the additional adjunctive use of the doxycycline gel. At 18 weeks, the test group evidenced a significant reduction in mean probing depth and a significant gain in mean attachment levels compared with control.

The current labels for the available locally delivered, controlled-release antimicrobials do not include an indication for periimplantitis. The potential for local antimicrobial therapy as a treatment strategy to treat periimplantitis, however, is an exciting possibility, one that indeed warrants additional research. Phase III trials are needed to test the hypothesis that locally delivered, controlled-release antimicrobials are of clinical benefit as part of a treatment regimen to manage periimplantitis.

Adverse Effects and Cautions for Use

A complete listing of cautions for use and possible adverse effects as listed in the FDA labels is out of scope for this chapter. A general discussion of cautions for use and adverse reactions for the class of locally delivered, controlled-release antimicrobials as described in the U.S. labels on the FDA website (as of May 7, 2013) is provided in the following paragraphs. For complete details regarding the use of these products and the listed safety profiles, the reader is referred to the respective full prescribing information.[66,10,9]

FDA labels provide complete information for the proper use of locally delivered, controlled-release antimicrobials.

In general, clinicians are cautioned regarding (1) the potential for hypersensitivity reactions (not to be used in patients with a known sensitivity to any ingredient); (2) the potential for the overgrowth of nonsusceptible microorganisms, including fungi; (3) usage in pregnancy; (4) the potential for discoloration during tooth development (tetracyclines only); (5) use in an acutely abscessed periodontal pocket or in extremely severe periodontal defects with little remaining periodontium; or (6) the use of local mechanical oral hygiene procedures (e.g., toothbrushing, interdental cleaning devices) for approximately 7 to 10 days postadministration. These comments were class cautions and not necessarily associated with any specific product.

The most frequently reported adverse reactions reported in the clinical trials, without mention of causality, include such terms as headache, infection (including upper respiratory tract infection), flu syndrome, pain, tooth disorder and toothache, and a collection of various oral signs or symptoms. In the chlorhexidine chip label, toothache was the only adverse reaction that was significantly higher ($p = 0.042$) in the chip group when compared with placebo.[66]

Currently Available Agents (Non-U.S.)

As the locally delivered, controlled-release antimicrobials available in the United States were developed well before those available only in other countries, for convenience we have grouped a discussion of products that are available outside of the United States separately. In general these products use antimicrobial agents that have already been discussed above with respect to U.S. products.

Chlorhexidine-based or tetracycline-based locally delivered, controlled-release products are available in countries outside of the United States.

Chlorhexidine-Based Products

PerioCol-CG. This product is a small chip (4 × 5 × 0.25–0.32 mm; weight 10 mg) as a collagen matrix into which chlorhexidine gluconate (2.5 mg) is incorporated from a 20% chlorhexidine solution as its active ingredient. The chip is designed for insertion into the periodontal pocket and resorbs after 30 days, but its coronal edge degrades within 10 days.[8,15] It releases chlorhexidine in vitro at a rate of approximately 40% to 45% in the first 24 hours followed by a linear release for 7 to 8 days and has a shelf life of 2 years.[8,29]

Chlo-Site. This product is a xanthan gel, consisting of a saccharide polymer as a three-dimensional mesh containing 1.5% chlorhexidine in 0.5 mL of gel, which is injected into the periodontal pocket (Figure 90-1). The gel product is sterilized by gamma

Figure 90-1 Chlo-Site gel. *Left panel,* Packaging. *Right panel,* Insertion into the periodontal pocket. *(Reprinted from Gill, et al:* J Clin Exp Dent *3:e424-e429, 2011.)*

irradiation at 2.5 mega-rads and is individually packed for delivery in 0.25 mL prefilled syringes fitted with a blunt side-exit needle.[15,7,20] The gel contains two types of chlorhexidine, a slow-release chlorhexidine digluconate (0.5%) and a rapid release chlorhexidine dihydrochloride (1.0%).[7] The gel is retained within the pocket and is not easily dislodged by the gingival crevicular fluid (GCF) or saliva. The gel disappears from the pocket within 10 to 30 days and is reported to achieve a chlorhexidine concentration in GCF more than 100 µg/mL for an average of 6 to 9 days and maintain an effective concentration for at least 15 days.[15,30]

Tetracycline-Based Products

PerioCol-TC. As reported by the manufacturer[23] each PerioCol-TC vial contains fish type I collagen (approximately 25 mg) impregnated with approximately 2.0 mg tetracycline hydrochloride, sterilized by gamma radiation (Figure 90-2). PerioCol-TC releases tetracycline in vitro for 8 to 10 days. A periodontal dressing should be placed to avoid dislodging the fibers. PerioCol-TC is indicated for the treatment of adult periodontitis as an adjunct to SRP for pockets more than 5 mm in depth and can be administered every 3 months. The fibers are moistened with saline and placed into the periodontal pocket to the depth of the pocket base; they are biodegradable and do not have to be removed. PerioCol-TC is stored in a dry place between 5° C (41° F) and 25° C (77° F) and has a shelf life of 2 years with proper storage.

Figure 90-2 PerioCol-TC fibers packaged in an individual vial. *(Courtesy Eucare Pharmaceuticals (P) Ltd., Chennai, India http://www.eucare.in/dental-regeneration-concepts.html.)*

Periodontal Plus AB. This product is a bioresorbable tetracycline fiber, 25 mg pure fibrillar collagen evenly impregnated with approximately 2 mg tetracycline hydrochloride (Figure 90-3).[77] The fibers are packaged as a strip containing four individually packed and separable sterile product packs. The fiber biodegrades in the periodontal pocket within 7 days.[15] The fiber should be retained with a periodontal dressing or covered with a dental adhesive for 10 days.

Clinical Studies

Published clinical trials accessible online and in English are tabulated in Table 90-4. These studies were not included in the literature review described in Chapter 89. Studies are listed in descending order based on the number of enrolled patients. A wide range of designs is evident. Table 90-4 includes studies that reported effects on probing depth or attachment levels. In general the data reported for these products may be considered less robust in comparison with the data reported for the agents available within the United States as indicated in Chapter 89. A meta-analysis regarding the effect of local drug delivery for chronic periodontitis, which included four agents (chlorhexidine chip [PerioChip]), doxycycline gel (Atridox), minocycline microspheres (Arestin), and tetracycline fibers (Periodontal Plus AB), concluded that adjunctive local drug delivery appeared to provide additional probing depth reduction benefit compared with SRP alone.[39] Additional microbiological effects of these non-U.S. products with adjunctive therapy, which have been suggested as potentially providing additional clinical benefit compared with SRP alone, have been reported; examples are indicated.[1,79,2]

Considerations for Future Research

Future research regarding locally delivered treatment strategies for periodontitis, specifically targeting the periodontal pocket, could include, for example, the study of different treatment regimens

Figure 90-3 Periodontal Plus AB. *Left panel,* Packaging. *Right panel,* Insertion of fibers into the periodontal pocket. *(Reprinted from Gill, et al:* J Clin Exp Dent *3:e424-e429, 2011.)*

TABLE 90-4 Clinical Trials of Locally Delivered, Controlled-Release Antimicrobials (Non-U.S. Products)

DRUG	STUDY DESIGN	INCLUSION CRITERIA	TREATMENT GROUPS	TREATMENT	STUDY DURATION	PD OUTCOMES (MEAN)			PD REDUCTION ≥2.0 MM FROM BASELINE	AL OUTCOMES (MEAN)		
						Absolute Reduction from Baseline (mm)	Absolute Reduction Difference between Groups (mm)	Percent Change between Groups	Percent	Absolute Gain from Baseline (mm)	Absolute Gain difference Between Groups (mm)	Percent Change between Groups
CHL[61]	Randomized, multicenter, split-mouth, adjunctive	Moderate to advanced periodontitis, ≥10 teeth. 2 teeth w PD 5 mm & BOP in 2 opposite & contralateral quad; difference in PD ≤2 mm. No antimicrobial/ antiinflammatory tx within 3 mo; no perio tx within 6 mo.	(1) SRP alone (2) SRP + CHL $N = 98$	Full-mouth supragingival scaling 2 wk prior to baseline, at which full-mouth SRP w local anesthesia (2 visits 48 h apart, 2 h session each). SRP w Gracey curette 5 min per experimental site. CHL at test sites. At 3 mo a second supragingival prophylaxis per need	6 mo	(1) 4.0 (2) 4.7 Estimated from Figure 90-1	0.83 $P \leq 0.001$	18% Estimated from Figure 90-1	(1) 49.0 (2) 78.6 $P = 0.004$	(1) 5.5 (2) 6.2 Estimated from Figure 90-1	0.90 $P \leq 0.001$	13% Estimated from Figure 90-1
CHL[19]	Randomized, split-mouth, adjunctive	Periodontitis, PD 5 mm, opposing quads in same arch	(1) SRP + chlorhexidine gel (PlakOut) (2) SRP + CHL $N = 51$	Full-mouth one-stage disinfection. Chlorhexidine gel or CHL administration. 0.2% chlorhexidine mouthwash for 4 wk	4 wk	(1) NR (2) 3.65	(2) more favorable vs (1)	NR	NR	(2) more favorable vs (1)	NR	NR

Continued

TABLE 90-4 Clinical Trials of Locally Delivered, Controlled-Release Antimicrobials (Non-U.S. Products)—cont'd

DRUG	STUDY DESIGN	INCLUSION CRITERIA	TREATMENT GROUPS	TREATMENT	STUDY DURATION	PD OUTCOMES (MEAN)			PD REDUCTION ≥2.0 MM FROM BASELINE	AL OUTCOMES (MEAN)		
						Absolute Reduction from Baseline (mm)	Absolute Reduction Difference between Groups (mm)	Percent Change between Groups	Percent	Absolute Gain from Baseline (mm)	Absolute Gain difference Between Groups (mm)	Percent Change between Groups
CHL[89]	Randomized, single-center, split-mouth, adjunctive	Moderate to advanced chronic periodontitis, 30-65 y, ≥2 nonadjacent interproximal sites w 5-8 mm PD. No definitive perio tx or antibiotics in 6 mo. Nonsmokers	(1) SRP alone (2) SRP + CHL *N* = 46	Supra- & subgingival SRP. At 1 mo, CHL in selected sites, no floss or interdental aids for 10 d	3 mo	Baseline to 3 mo: (1) 1.22 ± 0.73 (2) 2.15 ± 0.92 Both *P* < 0.001 1 mo to 3 mo: (1) 0.35 ± 0.67 (2) 1.24 ± 0.82	Baseline to 3 mo: 0.93 ± 0.16 *P* = s 1-3 mo: 1.11 *P* < 0.001	Baseline to 3 mo: 76% 1-3 mo: 317%	NR	Baseline to 3 mo: (1) 0.89 ± 0.64 (2) 1.52 ± 0.72 Both *P* < 0.001 1 mo to 3 mo: (1) 0.22 ± 0.42 (2) 0.85 ± 0.63	1-3 mo: 0.63 *P* < 0.001	1-3 mo: 286%
PCOL-C[29]	Randomized, single-center, parallel-group, adjunctive	PD 5-8 mm in one or both sides of mouth	(1) SRP alone *N* = 20 (2) SRP + PCOL-C *N* = 20	Full-mouth supragingival scaling 1 wk prior to baseline. At baseline subgingival SRP with hand instruments, then chip placement for group 2. No flossing for 10 days at selected sites or any chemotherapeutic mouthrinses or oral irrigation devices	3 mo	(1) 0.42 ± 0.77 *P* = ns (2) 1.26 ± 1.19 *P* = 0.001	0.84 Significant	200%	NR	(1) 0.47 ± 1.26 *P* = ns (2) 1.58 ± 1.30 *P* = 0.001	1.11 Significant	236%

PCOL-C[8]	Randomized, single-center, parallel-group, adjunctive	Mild to moderate adult periodontitis, PD 5-8 mm	(1) SRP alone $N = 20$ (2) SRP + PCOL-C $N = 20$	1 wk before baseline, full mouth supragingival scaling. SRP w hand instruments; chip placed for group (2). No flossing for 10 d at selected & adjacent sites.	3 mo	(1) 0.42 ± 0.77 $P < 0.05$ (2) 1.26 ± 1.19 $P = 0.001$ (vs baseline)	0.84 $P =$ s	200	NR	(1) 0.47 ± 1.26 $P =$ ns (2) 1.16 ± 1.30 $P = 0.001$ (vs baseline)	0.69 $P =$ s	147
PPAB[77]	Randomized, single-center, split-mouth, adjunctive	2 nonadjacent teeth ≥1 tooth apart w PD ≥5 mm w BOP. No perio tx within 6 mo; no furcation involvement	(1) SRP + PPAB (2) SRP alone $N = 35$	SRP then adjunctive tx per randomization, cyanoacrylate adhesive at PPAB sites	3 mo	(1) 2.69 ± 0.71 (2) 1.57 ± 0.65 Both $P =$ 0.001 vs baseline	1.12 $P < 0.05$	71.3%	NR	(1) 1.89 ± 0.63 (2) 1.03 ± 0.51 Both $P =$ 0.001 vs baseline	0.86 $P <$ 0.001	83.5%
PPAB[59]	Single-center, split-mouth, adjunctive	Chronic periodontitis w PD of 5 mm in 2 quads	(1) SRP alone (2) SRP + PPAB $N = 30$	SRP then PPAB fibers. No brushing or flossing at treated areas, w chlorhexidine rinses twice daily	3 mo	(1) 3.28 (2) 3.93	0.65 $P =$ hs	16%	NR	NR	NR	NR
DOX; CHL[30]	Randomized, single-center, split-mouth, adjunctive	Moderately advanced chronic periodontitis. No perio sx within 24 mo. ≥3 teeth ≥1 tooth apart, PD 5-8 mm w BOP.	(1) SRP + DOX (2) SRP + CHL (3) SRP alone $N = 30$	Full-mouth supra- & subgingival SRP w ultrasonic & curettes. No OH at treated sites for 7 d	3 mo	(1) 2.75 ± 1.33 (2) 2.76 ± 1.25 (3) 1.73 ± 0.94 All $P =$ 0.001 vs baseline	1 vs 2: 0.04 $p = 0.46$ 1 vs 3: 1.00 $p = 0.001$ 2 vs 3: 1.04 $p = 0.02$	1 vs 2: 1.46% 1 vs 3: 57.8% greater reduction vs 3 2 vs 3: 60.1% greater reduction vs 3	(1) 83.3% (2) 83.3% (3) 66.7%	(1) 1.73 ± 0.90 (2) 2.03 ± 1.12 (3) 0.86 ± 0.68	1 vs 2: 0.30 $p = 0.54$ 1 vs 3: 0.87 $P = 0.001$ 2 vs 3: 1.17 $p = 0.02$	1 vs 2: 17.3% 1 vs 3: 101.2% 2 vs 3: 136.0%
PPAB; CHL[27]	Randomized, single-center, split-mouth, adjunctive	Generalized chronic moderate periodontitis. 2 sites w PD >5 mm in symmetric quads. No perio tx within 6 mo	(1) SRP + PPAB (2) SRP + CHL $N = 30$	SRP then adjunctive tx per randomization, perio dressing at PPAB sites for 10 d	3 mo	(1) 1.90 ± 0.55 (2) 1.45 ± 0.60 Both $P <$ 0.001 vs baseline	0.45 $P < 0.05$	31.0%	NR	(1) 1.62 ± 0.71 (2) 1.12 ± 0.50 Both $P <$ 0.001 vs baseline	0.50 $P < 0.05$	44.6%

Continued

TABLE 90-4 Clinical Trials of Locally Delivered, Controlled-Release Antimicrobials (Non-U.S. Products)—cont'd

DRUG	STUDY DESIGN	INCLUSION CRITERIA	TREATMENT GROUPS	TREATMENT	STUDY DURATION	PD OUTCOMES (MEAN)			PD REDUCTION ≥2.0 MM FROM BASELINE	AL OUTCOMES (MEAN)		
						Absolute Reduction from Baseline (mm)	Absolute Reduction Difference between Groups (mm)	Percent Change between Groups	Percent	Absolute Gain from Baseline (mm)	Absolute Gain difference Between Groups (mm)	Percent Change between Groups
PCOL-C[47]	Single-center, split-mouth, adjunctive	Chronic periodontitis, 2 posterior sites w PD ≥5 mm. No antibiotics or perio tx within 6 mo	(1) SRP alone (2) SRP + PCOL-C *N* = 20	Full-mouth supragingival scaling. Baseline: SRP, then PCOL-C at test sites. No interdental cleaning for 10 d. At 3 mo, supragingival scaling, then PCOL-C for group (2).	6 mo	(1) 2.8 ± 1.0 (2) 3.2 ± 0.6	0.4 *P* = 0.07	14%	NR	(1) 2.7 ± 1.0 (2) 3.2 ± 0.9	0.5 *P* = 0.05	19%
PPAB[55]	Single-center, split-mouth, adjunctive, randomized	Chronic generalized periodontitis w PD ≤5 mm, ≥2 sites w PD ≥5 mm in 1 quad.	(1) SRP alone (2) SRP + PPAB *N* = 20	SRP, PPAB in test sites, perio pack, removed after 10 d	3 mo	NR						
CHL[4]	Single-center, split-mouth, ± randomization NR	Moderate to severe chronic adult periodontitis. No antimicrobial tx for 6 mo; no perio tx prior to study.	(1) SRP (2) SRP + CHL 1 : 2 ratio, respectively *N* = 15	SRP, then 1 side received CHL application at baseline & at 3, 6, 9, & 12 mo.	12 mo	Improvement vs baseline in both groups. Change NR	Slight difference. Change NR	NR	NR	Improvement vs baseline in both groups. Change NR	Slight difference. Change NR	NR
COL, PPAB[81]	Single-center, split-mouth (all 3 tx per patient), adjunctive	Chronic generalized periodontitis, pocket sites w PD 5-8 mm + BOP in diff quads, no perio tx or antibiotics in 6 mo or antimicrobial rinses in 2 mo	(1) SRP + PCOL-C (15 sites) (2) SRP + PPAB (15 sites (3) SRP alone *N* = 14 (45 sites w PD 5-8 mm + BOP)	SRP, adjunctive agents placed, perio pack placed (removed after 7 d). No brushing/flossing on treated site or hard, sticky food for 7 d	3 mo	(1) 3.4 ± 1.0 (2) 2.8 ± 1.2 (3) 1.4 ± 0.8 All *P* < 0.01 vs baseline	(1) vs (2) 1.6 *P* = 0.007 (1) vs (3) 2.0 *P* < 0.001 (2) vs (3) 1.4 *P*: NR	(1) vs (2) 57% (1) vs (3) 143% (2) vs (3) 100%	NR	(1) 4.2 ± 1.2 (2) 3.3 ± 0.8 (3) 2.3 ± 1.0 All *P* < 0.01 vs baseline	(1) vs (2) 0.9 *P* = 0.046 (1) vs (3) 1.9 *P* = 0.001 (2) vs (3) 1.0 *P*: NR	(1) vs (2) 27% (1) vs (3) 58% (2) vs (3) 43%

CHL[48]	Single-center, split-mouth, randomized, triple-blind, adjunctive	≥4 teeth w PD 5-8 mm, no perio tx or antibiotics for 6 mo	*N* = 10 patients (30 teeth each, control & experimental) (1) SRP + CHL (2) SRP + placebo gel	Supragingival prophylaxis prior to baseline. SRP at baseline, then CHL or placebo gel placed subgingivally	6 mo	(1) 3.11 ± 0.47 (2) 2.44 ± 0.55 Both *p* < 0.00001 vs baseline	0.67 *P* < 0.0001	27%	NR	(1) 3.11 ± 0.65 (2) 2.44 ± 0.98 Both p < 0.001 vs baseline	0.67 *P* = 0.004	27%
CHL[74]	Split-mouth, randomized, adjunctive	Chronic periodontitis w PD >5 mm, light or nonsmokers (NSm). 188 teeth in opposing quads in same arch	(1) SRP + chlorhexidine gel (PlakOut) (2) SRP + CHL *N* = 8	Full-mouth one-stage disinfection. Chlorhexidine gel or CHL administration. 0.2% chlorhexidine mouthwash for 4 wk	4 wk	(1) 2.38 ± 1.77 *P* = 0.026 (2) 4.00 ± 2.45 *P* = 0.012	1.62 *P* = ns	68%	NR	(1) 1.50 ± 3.34 *P* = ns (2) 2.75 ± 2.76 *P* = 0.027	1.25 *P* = ns	83%
CHL[14]	Single-center, split-mouth, randomized, adjunctive	Chronic generalized periodontitis. Pockets with PD 5-7 mm in different quads and signs of bone loss	*N* = 6 patients [3 nonsmokers (NSm), 3 smokers (Sm)]. Groups randomized by pocket site (141 sites). (1) SRP alone (46 sites; 21 NSm, 25 Sm) (2) SRP + CHL (49 sites; 25 NSm, 24 Sm) (3) CHL alone (46 sites; 21 NSm, 25 Sm)	SRP details NR. Sites washed with distilled water & dried w paper points before CHL application	3 mo	NR	NR	NR	NR	(1) NSm, 2.4; Sm, 2.3 (2) NSm, 2.0; SM, 2.2 (3) NSm, 2.1; Sm, 2.0. *p* = hs for all from baseline	(1) vs (2) NSm, 0.4; Sm, 0.1 (1) vs (3) NSm, 0.3; Sm 0.3 (2) vs (3) NSm, 0.1; Sm, 0.2	(1) vs (2) NSm, 20%; Sm, 4.5% (1) vs (3) NSm, 14%; Sm 15% (2) vs (3) NSm, 5%; Sm, 10% All: *p* = ns

AL, attachment level; *BOP*, bleeding on probing; *CHL*, (Chlo-Site) xanthan chlorhexidine gel; *d*, day(s); *DOX*, doxycycline gel (Atridox); *h*, hour(s); *hs*, highly significant; *mo*, month(s); *min*, minutes; *N*, number of patients; *NR*, not reported; *ns*, not significant; *NSm*, nonsmokers; *OH*, oral hygiene; *PCOL-C*, (PerioCol-CG) chlorhexidine chip; *PD*, probing depth; *perio*, periodontal; *PPAB*, (Periodontal Plus AB) tetracycline fiber; *quad*, quadrant(s); *s*, significant; *Sm*, smokers; *sx*, surgery; *tx*, treatment; *vs*, versus; *w*, with; *wk*, week(s); *y*, year(s).

using currently available agents. For example, a Phase III clinical trial to study the more frequent administration of a chlorhexidine chip has been completed (ClinicalTrials.gov NCT01249846). Suggestions for other research regarding currently available locally delivered, controlled-release antimicrobials have been noted throughout this chapter.

Additionally, other classes of agents could be developed for local delivery into periodontal pockets such as growth factors or antiinflammatory agents. Indeed, a multicenter, randomized, clinical trial provided evidence that the delivery of a recombinant human platelet-derived growth factor-BB in combination with a beta-tricalcium phosphate (β-TCP) resulted in greater bone fill and attachment gain following treatment of advanced periodontal osseous defects in comparison with β-TCP as an active control.[56] This combination product has now been approved for marketed use.[26] With respect to other growth factors, a Phase II trial of fibroblast growth factor (FGF)-2 in a hydroxypropylcellulose vehicle has been published.[46] Phase II and III trials of recombinant human basic FGF (trafermin) have been completed (NCT00199290, NCT00734708, NCT00514657, NCT01015404). Another growth factor, sargramostim (granulocyte/macrophage colony-stimulating factor) has been studied in a Phase I trial (NCT00689143).

As an example of the local delivery of antiinflammatory agents, the nonsteroidal antiinflammatory drug (NSAID) flurbiprofen has been studied. A Phase II trial of a combination chip of chlorhexidine and flurbiprofen has been completed (NCT00425451), and a flurbiprofen chip has been compared to a chlorhexidine chip in another completed Phase II trial (NCT01040286).[50] Other NSAIDs or other agents may be studied as well. Additionally, an exciting alternative approach for local controlled-release delivery has recently been reported. Described in this report was the development of a controlled-release system for the steady delivery of a chemo-attractant for regulatory lymphocytes; local administration in preclinical canine and murine models led to reduced alveolar bone resorption and a reduction in clinical measures of inflammation.[28a] It should be anticipated that future research may make available new locally delivered treatment strategies for the treatment of periodontitis. Adequate and well-controlled clinical trials are necessary to establish safety and efficacy for all new agents or treatment regimens.

Key Points

- Drugs are typically studied in many clinical trials prior to clearance for marketed use.
- Drugs have to be shown to be safe and effective before they can be marketed.
- Data from adequate and well-controlled clinical trials (e.g., Phase III) are needed for regulatory decision-making.
- Locally delivered, controlled-release products for dental use based on chlorhexidine or tetracycline are available in countries outside of the United States.

References

1. Abrishami M, Iramloo B, Ansari G, et al: The effect of locally delivered xanthan-based CHLO-SITE gel with scaling and root planing in the treatment of chronic periodontitis: microbial findings. *Dent Res J* 5:47–52, 2008.
2. Abrishami M, Iramloo B, Eslami G, et al: Effect of locally delivered xanthan-based CHLO-SITE gel along with scaling and root planning on reduction of gingival pocket microbial counts. *J Islamic Dent Assoc* 20:199–206, 2008.
3. Aichelmann-Reidy ME, Reynolds MA: Predictability of clinical outcomes following regenerative therapy in intrabony defects. *J Periodontol* 79:387–393, 2008.
4. Al-Abdaly MM, El-Refai A-NM, Gouda UM, et al: Evaluation of topical application of CHLO-SITE (chlorhexidine gel) in management of chronic periodontitis. *Suez Canal Univ Med J* 11:35–40, 2008.
5. American Academy of Periodontology: Research, Science and Therapy Committee [of the American Academy of Periodontology]. Letter to the Editor. *J Periodontol* 71:1932–1933, 2000.
6. Anonymous: American Academy of Periodontology statement on local delivery of sustained or controlled release antimicrobials as adjunctive therapy in the treatment of periodontitis. *J Periodontol* 77:1458, 2006.
7. Anonymous: Trade News. Treatment for periodontal pockets. *British Dent J* 201:787, 2006.
8. Archana B, Kumar BS, Singh BV: To assess the effectiveness of a single subgingival application of chlorhexidine chip in the treatment of chronic periodontitis: a clinical study. *J Pharmaceutical Biomedical Sci* 20:1–7, 2012.
9. Arestin [Package insert]: OraPharma, Inc., Horsham, PA, July 2012. <http://www.accessdata.fda.gov/drugsatfda_docs/label/2012/050781s019lbl.pdf>. Accessed August 31, 2012.
10. Atridox [Package insert]: Tolmar Inc., Fort Collins, CO, February 2011. at: <http://www.accessdata.fda.gov/drugsatfda_docs/label/2011/050751s015lbl.pdf>. Accessed on 31 August 2012.
11. Bonito AJ, Lux L, Lohr KN: Impact of local adjuncts to scaling and root planing in periodontal disease therapy: a systematic review. *J Periodontol* 76:1227–1236, 2005. (erratum *J Periodontol* 77:326-327, 2006).
12. Buchter A, Meyer U, Kruse-Losler B, et al: Sustained release of doxycycline for the treatment of periimplantitis: randomised controlled trial. *Br J Oral Maxillofac Surg* 42:439–444, 2004.
13. Caton JG, Ciancio SG, Blieden TM, et al: Treatment with subantimicrobial dose doxycycline improves the efficacy of scaling and root planing in patients with adult periodontitis. *J Periodontol* 71:521–532, 2000.
14. Chandra C, Valavalkar N, Vandana KL: The comparative evaluation of xanthan gel with chlorhexidine (Chlo-Site) in smokers and non-smokers: a clinical and microbiological assessment. *J Indian Soc Periodontol* 15:221–227, 2011.
15. Chhina K, Bhatnagar R: Local drug delivery. *Ind J Dent Sci* 4:66–69, 2012.
16. Ciancio S, Ashley R: Safety and efficacy of sub-antimicrobial-dose doxycycline therapy in patients with adult periodontitis. *Adv Dent Res* 12:27–31, 1998.
17. Ciancio SG: Site specific delivery of antimicrobial agents for periodontal disease. *Gen Dent* 47:172–178, 181, 1999.
18. Dean JW, Branch-Mays GL, Hart TC, et al: Topically applied minocycline microspheres: why it works. *Compend Contin Educ Dent* 24:247–250, 252–257, 2003.
19. Dinca A, Stratul S-I, Mesaros M, et al: Periodontal non-surgical therapy with the chlorhexidine xanthan-based gel Chlo-Site: a randomized split-mouth study on 51 cases. *Int Poster J Dent Oral Med* 9:341, 2007. (poster).
20. Dodwad V, Vaish S, Mahajan A, et al: Local drug delivery in periodontics: a strategic intervention. *Int J Pharm Pharmaceut Sci* 4:30–34, 2012.
21. Drisko CH: The use of locally-delivered doxycycline in the treatment of periodontitis. Clinical results. *J Clin Periodontol* 25:947–952, comments: 978-979, 1998.
22. Drisko CL, Cobb CM, Killoy WJ, et al: Evaluation of periodontal treatments using controlled-release tetracycline fibers: clinical response. *J Periodontol* 66:692–699, 1995.
23. Eucare Pharmaceuticals, Chennai, India: PerioCol-TC, <http://www.eucareindia.com/PDF/Periocol-TC.pdf>. Accessed May 18, 2013.
24. Garrett S, Adams DF, Bogle G, et al: The effect of locally delivered controlled-release doxycycline or scaling and root planing on periodontal maintenance patients over 9 months. *J Periodontol* 71:22–30, 2000.
25. Garrett S, Johnson L, Drisko CH, et al: Two multi-center studies evaluating locally delivered doxycycline hyclate, placebo control, oral hygiene, and scaling and root planing in the treatment of periodontitis. *J Periodontol* 70:490–503, 1999.

26. GEM21S [Package insert]: Osteohealth Co. Division of Luitpold Pharmaceuticals Inc., Shirley, NY, June 2009. <http://www.osteohealth.com/GEM21S.aspx>. Accessed May 18, 2013.
27. Gill JS, Bharti V, Gupta H, et al: Non-surgical management of chronic periodontitis with two local drug delivery agents—a comparative study. *J Clin Exp Dent* 3:e424–e429, 2011.
28a. Glowacki AJ, Yoshizawa S, Jhunjhunwala S, et al: Prevention of inflammation-mediated bone loss in murine and canine periodontal disease via recruitment of regulatory lymphocytes. *Proc Natl Acad Sci USA* 110:18525–18530, 2013.
28. Greenstein G: The use of surrogate variables to reflect long-term tooth survivability. *J Periodontol* 76:1398–1402, 2005.
29. Grover V, Kapoor A, Malhotra R, et al: To assess the effectiveness of a chlorhexidine chip in the treatment of chronic periodontitis: a clinical and radiographic study. *J Indian Soc Periodontol* 15:139–146, 2011.
30. Gupta R, Pandit N, Aggarwal S, et al: Comparative evaluation of subgingivally delivered 10% doxycycline hyclate and xanthan-based chlorhexidine gels in the treatment of chronic periodontitis. *J Contemp Dent Pract* 9:25–32, 2008.
31. Hanes PJ, Purvis JP: Local anti-infective therapy: pharmacological agents. A systematic review. *Ann Periodontol* 8:79–98, 2003.
32. Hellström M-K, McClain PK, Schallhorn RG, et al: Local minocycline as an adjunct to surgical therapy in moderate to severe, chronic periodontitis. *J Clin Periodontol* 35:525–531, 2008.
33. Hujoel PP: Endpoints in periodontal trials: the need for an evidence-based research approach. *Periodontol 2000* 36:196–204, 2004.
34. Hujoel PP, Löe H, Anerud A, et al: The informativeness of attachment loss on tooth mortality. *J Periodontol* 70:44–48, 1999.
35. Hussein I, Ranka M, Gilbert A, et al: Locally delivered antimicrobials in the management of periodontitis: a critical review of the evidence for their use in practice. *Dent Update* 34:494–506, 2007.
36. Jeffcoat MK, Bray KS, Ciancio SG, et al: Adjunctive use of a subgingival controlled-release chlorhexidine chip reduces probing depth and improves attachment level compared with scaling and root planing alone. *J Periodontol* 69:989–997, 1998.
37. Johnson LR, Stoller NH: Rationale for the use of Atridox therapy for managing periodontal patients. *Compend Contin Educ Dent* 20(Suppl):19–25, 1999.
38. Johnson LR, Stoller NH, Polson A, et al: The effects of subgingival calculus on the clinical outcomes of locally-delivered controlled-release doxycycline compared to scaling and root planing. *J Clin Periodontol* 29:87–91, 2002.
39. Kalsi R, Vandana KL, Prakash S: Effect of local drug delivery in chronic periodontitis patients: a meta-analysis. *J Ind Soc Periodontol* 15:304–309, 2011.
40. Killoy WJ: Chemical treatment of periodontitis: local delivery of antimicrobials. *Int Dent J* 48(Suppl 1):305–315, 1998.
41. Killoy WJ: The use of locally-delivered chlorhexidine in the treatment of periodontitis. Clinical results. *J Clin Periodontol* 25:953–958, comments: 978-979, 1998.
42. Killoy WJ: Assessing the effectiveness of locally delivered chlorhexidine in the treatment of periodontitis. *J Am Dent Assoc* 130:567–570, 1999.
43. Killoy WJ: Local delivery of antimicrobials: a new era in the treatment of adult periodontitis. *Compend Contin Educ Dent* 20(Suppl):13–18, 1999.
44. Killoy WJ: The clinical significance of local chemotherapies. *J Clin Periodontol* 29(Suppl 2):22–29, 2002.
45. Killoy WJ, Polson AM: Controlled local delivery of antimicrobials in the treatment of periodontitis. *Dent Clin North Am* 42:263–283, 1998.
46. Kitamura M, Nakashima K, Kowashi Y, et al: Periodontal tissue regeneration using fibroblast growth factor-2: randomized controlled phase II clinical trial. *PLoS ONE* 3:e2611, 2008. doi: 10.1371/journal.pone.0002611.
47. Kondreddy K, Ambalavanan N, Ramakrishna T, et al: Effectiveness of a controlled release chlorhexidine chip (PerioCol-CG) as an adjunctive to scaling and root planing when compared to scaling and root planing alone in the treatment of chronic periodontitis: a comparative study. *J Ind Soc Periodontol* 16:553–557, 2012.
48. Kranti K, Seshan H, Zope S: Clinical evaluation of topical subgingival application of biodegradable xanthan based 1.5% chlorhexidine gel for treatment of periodontal pockets. *J Adv Dent Res* 1:47–54, 2010.
49. Krayer JW, Leite RS, Kirkwood KL: Non-surgical chemotherapeutic treatment strategies for the management of periodontal disease. *Dent Clin North Am* 54:13–33, 2010.
50. Machtei EE, Hirsh I, Falah M, et al: Multiple applications of flurbiprofen and chlorhexidine chips in patients with chronic periodontitis: a randomized, double blind, parallel, 2-arms clinical trial. *J Clin Periodontol* 38:1037–1043, 2011.
51. Magnusson I: Local delivery of antimicrobial agents for the treatment of periodontitis. *Compend Contin Educ Dent* 19:953–954, 956, 958, 960–964, 1998.
52. Mathieu MP, Milne C-P: *New drug development: a regulatory overview*, ed 8, 2008, Barnett International.
53. Michalowicz BS, Hodges JS, Pihlstrom BL: Is change in probing depth a reliable predictor of change in clinical attachment? *J Am Dental Assoc* 144:171–178, 2013.
54. Minabe M, Kodama T, Kogou T, et al: Clinical significance of antibiotic therapy in guided tissue regeneration with a resorbable membrane. *Periodontal Clin Investigations* 23:20–30, 2001.
55. Munir S, Kaur R: Evaluation of the effect of tetracycline HCL (Periodontal Plus AB) in conjunction with scaling and root planing on aspartate transaminase level in chronic periodontitis—A clinic-biochemical study. *J Adv Dent Res* 1:Oct-Dec, 2010. <http://www.ispcd.org/~cmsdev/userfiles/rishabh/tetracline.pdf>. Accessed May 22, 2013.
56. Nevins M, Giannobile WV, McGuire MK, et al: Platelet-derived growth factor stimulates bone fill and rate of attachment level gain: results of a large multicenter randomized controlled trial. *J Periodontol* 76:2205–2215, 2005.
57. Novak MJ, Dawson DR, III, Magnusson I, et al: Combining host modulation and topical antimicrobial therapy in the management of moderate to severe periodontitis: a randomized multicenter trial. *J Periodontol* 79:33–41, 2008.
58. Page RC: The microbiological case for adjunctive therapy for periodontitis. *J Int Acad Periodontol* 6(Suppl):143–149, 2004.
59. Panwar M, Gupta SH: Local drug delivery with tetracycline fiber: an alternative to surgical periodontal therapy. *Med J Armed Forces India* 244–246, 2009.
60. Paolantonio M, D'Angelo M, Grassi RF, et al: Clinical and microbiologic effects of subgingival controlled-release delivery of chlorhexidine chip in the treatment of periodontitis: a multicenter study. *J Periodontol* 79:271–282, 2008.
61. Paolantonio M, D'Ercole S, Pilloni A, et al: Clinical, microbiologic, and biochemical effects of subgingival administration of a xanthan-based chlorhexidine gel in the treatment of periodontitis: a randomized multicenter trial. *J Periodontol* 80:1479–1492, 2009.
62. Paquette DW: Minocycline microspheres: a complementary medical-mechanical model for the treatment of chronic periodontitis. *Compend Contin Educ Dent* 23(Suppl):15–21, 2002.
63. Paquette DW: Locally administered antimicrobials for the management of periodontal infections. *Dent Today* 28:97–98, 100–101, 2009.
64. Paquette DW, Hanlon A, Lessem J, et al: Clinical relevance of adjunctive minocycline microspheres in patients with chronic periodontitis: secondary analysis of a phase 3 trial. *J Periodontol* 75:531–536, 2004.
65. Pavia M, Nobile CGA, Angelillo IF: Meta-analysis of local tetracycline in treating chronic periodontitis. *J Periodontol* 74:916–932, 2003.
66. PerioChip [Package insert]: Dexcel® Pharma Technologies Ltd., Jerusalem, Israel, January 2012. <http://www.accessdata.fda.gov/drugsatfda_docs/label/2012/020774s011lbl.pdf>. Accessed August 31, 2012.
67. Polson AM, Sharkey D, Polson AP, et al: Use of systemic host modulation and a locally applied antimicrobial in periodontal disease. *J Appl Res Clin Dent* 2:1–9, 2005.
68. Preshaw PM, Hefti AF, Novak MJ, et al: Subantimicrobial dose doxycycline enhances the efficacy of scaling and root planing in chronic periodontitis: a multicenter trial. *J Periodontol* 75:1068–1076, 2004.

69. Preshaw PM, Novak MJ, Mellonig J, et al: Modified-release subantimicrobial dose doxycycline enhances scaling and root planing in subjects with periodontal disease. *J Periodontol* 79:440–452, 2008.
70. Reddy MS, Geurs NC, Gunsolley JC: Periodontal host modulation with antiproteinase, anti-inflammatory, and bone-sparing agents. A systematic review. *Ann Periodontol* 8:12–37, 2003.
71. Reddy MS, Jeffcoat MK, Geurs NC, et al: Efficacy of controlled-release subgingival chlorhexidine to enhance periodontal regeneration. *J Periodontol* 74:411–419, 2003.
72. Renvert S, Lessem J, Dahlen G, et al: Mechanical and repeated antimicrobial therapy using a local drug delivery system in the treatment of periimplantitis: a randomized clinical trial. *J Periodontol* 79:836–844, 2008.
73. Rodrigues IFG, Machion L, Casati MZ, et al: Clinical evaluation of the use of locally delivered chlorhexidine in periodontal maintenance therapy. *J Periodontol* 78:624–628, 2007.
74. Rusu D, Stratul S-I, Necker A, et al: Non-surgical periodontal therapy using a novel chlorhexidine-based xanthan-gel: a split-mouth study. *Int Poster J Dent Oral Med* 7:Poster 286, 2005.
75. Ryan ME: Nonsurgical approaches for the treatment of periodontal diseases. *Dent Clin North Am* 49:611–636, 2005.
76. Ryan ME, Golub LM: Modulation of matrix metalloproteinase activities in periodontitis as a treatment strategy. *Periodontol 2000* 24:226–238, 2000.
77. Sachdeva S, Agarwal V: Evaluation of commercially available biodegradable tetracycline fiber therapy in chronic periodontitis. *J Ind Soc Periodontol* 15:130–134, 2011.
78. Sbordone L, Barone A, Di Genio M, et al: Tetracycline fibres used to control bacterial infection during guided tissue regeneration (GTR). *Minerva Stomatol* 49:27–34, 2000.
79. Shetty S, Shakir QJA: The therapeutic evaluation of scaling and root planing alone and with tetracycline (Periodontal Plus AB) combination therapy, in patients with chronic [periodontitis]. A clinical & microbiological study, <http://www.dypdentaljournals.com/2007/Dr.%20Sarika%20Shetty%20-%20Perio.pdf>. Accessed February 3, 2014.
80. Soskolne WA: Subgingival delivery of therapeutic agents in the treatment of periodontal diseases. *Crit Rev Oral Biol Med* 8:164–174, 1997.
81. Srivastava R, Verma PK, Tandon P, et al: Chlorhexidine chip and tetracycline fibers as adjunct to scaling and root planing—A clinical study. *Braz J Oral Sci* 8:201–205, 2009.
82. Tonetti MS: Local delivery of tetracycline: from concept to clinical application. *J Clin Periodontol* 25:969–977, 1998.
83. Tonkens R: An overview of the drug development process. *Physician Exec* 31(3):48–52, 2005.
84. U.S. Food and Drug Administration, 21CFR50.25, Revised as of August 9, 2011, <www.fda.gov/RegulatoryInformation/Guidances/ucm126431.htm>. Accessed August 18, 2012.
85. U.S. Food and Drug Administration, 21CFR314.126, <http://www.fda.gov/downloads/Drugs/NewsEvents/UCM275448.pdf?utm_campaign=Google2&utm_source=fdaSearch&utm_medium=website&utm_term=Phase%20IIIstudydesigns&utm_content=3>. Accessed May 26, 2012.
86. U.S. National Library of Medicine, National Institutes of Health: FAQ Clinicaltrials.gov—clinical trial phases, at: <http://www.nlm.nih.gov/services/ctphases.html>. Accessed August 22, 2012.
87. Van Dyke TE: The clinical significance of new therapies for the management of periodontal disease. *J Int Acad Periodontol* 7(Suppl):191–196, 2005.
88. Van Dyke TE, Offenbacher S, Braswell L, et al: Enhancing the value of scaling and root-planing: Arestin clinical trial results. *J Int Acad Periodontol* 4:72–76, 2002.
89. Verma A, Sanghi S, Grover D, et al: Effect of insertion of xanthan-based chlorhexidine gel in the maintenance phase following the treatment of chronic periodontitis. *J Ind Soc Periodontol* 16:381–385, 2012.
90. Wennström JL, Newman HN, MacNeill SR, et al: Utilisation of locally delivered doxycycline in non-surgical treatment of chronic periodontitis. A comparative multi-centre trial of 2 treatment approaches. *J Clin Periodontol* 28:753–761, 2001.
91. Williams RC, Paquette DW, Offenbacher S, et al: Treatment of periodontitis by local administration of minocycline microspheres: a controlled trial. *J Periodontol* 72:1535–1544, 2001.
92. Yoshinari N, Tohya T, Kawase H, et al: Effect of repeated local minocycline administration on periodontal healing following guided tissue regeneration. *J Periodontol* 72:284–295, 2001.
93. Zinman E: Dental and legal considerations in periodontal therapy. *Periodontol 2000* 25:114–130, 2001.

INDEX

A
ABBM. *See* Anorganic bovine bone-derived mineral
Aberrant frenum, problems, 629
Abnormal mobility, 364
Abrasion, 363, **542.e10**
  example, 363f
Abrasive dentifrice, usage, 363, 488f
Abscesses
  classification, 460-463
  clinical photograph, 798f
  periodontal origin, **e52f**
Absorbable gelatin sponge, 568
  Gelfoam, 568
Absorbable hemostatic agents, 568t
Accessory binocular module, example, 642f
Accessory pulpal canals, presence, 299
Accessory root canals, prevalence, 470-472
Accidental damage, 49-50
Accidental traumatic lesions, **e40**
Accumulated glycation end-products (AGEs), 189
Acellular afibrillar cementum, 28
Acellular cementum (AC), 28f
  arrangement, 28
  formation, 28
Acellular extrinsic fiber cementum, composition, 28
Achromatic compound lenses, 640-641
Acoustic steaming, 507
Acquired coatings, 17
Acquired deformities/conditions, 46, **e10**
Acquired immunodeficiency syndrome (AIDS), 320-321
  advanced AIDS, periodontal health (appearance), 342f
  characterization, 335
  HAART, usage, 377
  health status, 343
  infection control measures, 343
  maintenance therapy, 343
  psychologic factors, 343
  therapy, goals, 343
Acquired pellicle, 144
Acrylic provisional fixed full-arch prosthesis, clinical photograph, 694f
Actinobacillus actinomycetemcomitans levels, elevation, 437
Actinomyces odontolyticus (colony morphology), 134f-135f
Actinomyces oris MG1 in vitro, coaggregation, 146f
Actinomyces viscosus
  branches, 134f-135f
  root surface caries microorganism, 284
Actinomyces odontolyticus (increase), 126
Active disease
  adjunctive orthodontic therapy, 651
  control, 650-651
  emergency treatment, 650
Active disease *(Continued)*
  hopeless teeth, extraction, 650
  oral hygiene measures, 650
  periodontal surgery, 651
  reevaluation, 650
  scaling and root planing (SRP), 650
Active markers, IREDs (usage), 788
Actonel, 357
Acusection, 573
Acute abscess, 463-464
  chronic abscess, differences, 461
Acute anginal attacks, nitroglycerin (usage), 422
Acute herpetic gingivostomatitis, 257f, 463-464
  treatment, 464f
Acute inflammation (initiation), neutrophils (impact), 89-90
Acute inflammatory enlargement, 233-234
Acute leukemia, periodontal ligament/alveolar bone (involvement), 192
Acute lymphoblastic leukemia, appearance, 260f
Acute lymphocytic leukemia, **e59f**
Acute myelocytic leukemia, 193f
  anterior view/palatal view, 194f
  leukemic gingival enlargement, appearance, 240f
Acute myelogenous leukemia
  gingiva/floor, enlargement, **e23f**
  gingival hyperplasia/spontaneous bleeding, **e23f**
  oral cavity, candidal infection, **e28f**
  remission-induction chemotherapy, usage, **e28f**
  soft/hard tissue destruction, mucormycosis (impact), **e28f**
Acute necrotizing ulcerative gingivitis (ANUG), 244, 460-463
  drugs, role, 462
  first visit, 460-461
  gingiva, contouring, 462
  local therapy, inadequacy, 463
  patient instructions, 461
  second visit, 461
  systemic disease, 463
  third visit, 461
  treatment, 462f
    considerations, 462
    gingiva, reshaping, 462f
Acute pericoronitis, 463
  treatment, 463
    requirement, 463f
Acute periodontal abscesses, 373f
  appearance, 373
Acute streptococcal gingivostomatitis, lip/gingiva lesions, **e26f**
Acute trauma, 300, 347
Adaptive immunity, 94-97
  innate immunity, differences, 94
Addison's disease, 228
Additive osseous surgery, 604
  impact, 605f
Adhesion capacity, differences (microscopic confirmation), 139f
Adhesive dentistry, 653f
Adhesive surface proteins, 167

Page numbers followed by "f" indicate figures, "t" indicate tables, and "b" indicate boxes.

For entries that have a boldface page reference, i.e., 179.e2, go to the Expert CONSULT website at www.expertconsult.com, and after registering, search for the term on the book website.

Adipose cells, 18
Adjacent teeth, roots (nonconvergence), 659f
Adjunctive orthodontic therapy, 651
Adjunctive therapeutic approaches, 526f
Adjunctive therapy
  combination adjunctive therapy, **e126**
  consideration, **e126**
  impact, **e116**
  SRP, differences, **e115**
Adolescents, mean alveolar bone loss per patient, 126
Adult blood pressure, classification, 421t
Adult gingiva
  appearance, 10f
  clinical appearance, 20f
  melanotic pigmentation, 20f
Adult oral sedative premedication, usage, 415b
Adult periodontitis, 258
Adult sedation, 412-414
Advanced alveolar bone resorption, clinical/cone-beam computed tomography, **e56f**
Advanced bone loss, 623f, 800f
  aggressive periodontitis, presence, **e54f**
  bacterial plaque, impact, **e50f**
  presence, mesial root resection, **626.e6f**
Advanced chronic periodontitis, **e12f**
  hygiene neglect/smoking, contributing factors, **e47f**
Advanced gingivitis, 223f
Advanced horizontal bone loss, **542.e3-542.e5**
Advanced periodontitis, pocket wall (bacterial penetration), 138f
Advanced radiographic alveolar bone, observation, **e60f**
Aerosol production, 509
After Five curette, 499f
  Gracey curette, comparison, 500f
  Mini Five curette, comparison, 500f
Afunctional atrophy, 38
Agammaglobulinemia, presence, 191f
Agar plates, periodontal/cariogenic species, 134f-135f
AGEs. *See* Accumulated glycation end-products
Aggregatibacter actinomycetemcomitans (Aa), 423, **55.e1**
  colonization, 324
  complement evasion, 168
  counts, 180-182
  etiologic agent, 391-392
  growth, 134f-135f
    inhibition, tetracyclines (usage), 517
  invasion, 82
  involvement, 258
  isolates, 151
  levels, elevation, 402
  LtxA production, 168
  periodontitis, association, 97
  prevalence, 322
  primary etiologic agent, 165
  role, decrease, 42
  strain JP2, 331
  translocation, 151-152
Aggressive periodontitis, 46, 53-55, 165-166, 258, 451-459, **e10**, **e53**
  advanced bone loss, **e54f**
  alveolar bone destruction, 295
  antibiotic therapy, 457t
  anti-infective therapy, considerations, 333
  antimicrobial therapy, 452-457
  appearance, 259f
  bacterial challenge, host response, 331-332
Aggressive periodontitis *(Continued)*
  case definition, 325-330
  chronic periodontitis, differences, 54-55
  classification, 324-325
  clinical characteristics, 324-325
  clinical presentation, assessment, 332-333
  cyclic neutropenia/agammaglobulinemia, presence, 191f
  dental implants, usage, 458
    clinical considerations, 458
  diagnosis, 332-333
  diagnostic criteria, 325t
  epidemiology, 325-331
  features, 324
  full-mouth disinfection, 457-458
  full-mouth radiographs, 454f-455f
  generalized form, 54, 258
  genetic features, assessment, 333
  genetics
    family studies, 332
    polymorphisms, 332
  GLT6D1, association, 112
  host defense, assessment, 333
  host modulation, 458
  host response, 332
  implant therapy, 333
  independent gene association reports, 111t
  intraoral clinical photographs, 454f-455f
  local delivery, 457
  localized aggressive periodontitis, 165
  localized form, 53
  microbial testing, 456-457
  microbiological burden, assessment, 333
  microbiology, 331
  oral rehabilitation, 333
  pathobiology, 331-332
  periodontal maintenance, 458-459
  periodontal therapy, 452
  postoperative radiographs, 457f
  prevalence, assessment, 330
  probing depths, 58f
  prognosis, 402, 451
  radiographic presentation, assessment, 333
  regenerative therapy, 452
  results, 453
  risk factors, 331-332
  subgroups, 324-325
  supportive periodontal therapy, considerations, 333
  surgical resective therapy, 452
  surgical therapy, considerations, 333
  susceptibility, environmental factors, 332
  systemic diseases, absence, **e53f**
  therapeutic considerations, 333
  therapeutic modalities, 451-458
  treatment, 451-452
    planning/restorative considerations, 458
    systemic tetracycline, usage, 457b
  understanding, 331
Agranulocytosis, 191, 431
  characterization, 246
AI-2 (strain-specific competence-stimulating peptides)
  functions, 150
  production/detection, 150
Air-powder polishing, 505-506
  devices, abrasive effects, 505
Airway status, 353f

For entries that have a boldface page reference, i.e., 179.e2, go to the Expert CONSULT website at www.expertconsult.com, and after registering, search for the term on the book website.

Albright's syndrome (polyostotic fibrous dysplasia), 228
Alendronate (bisphosphonate), 404
Alertness/sedation scale, observer assessment, 417t
Allergies, **e39**
  history, usage, 358
  outpatient surgery, 569
Allogenic bone graft, usage, 62f
Allogenic succession, 160
Allografts, 611
Alpha-defensins, 91
Alveolar bone, 37
  aging, impact, 42
  cancellous portion, 33
  CEJ (relationship), periapical radiographs (usage), 378
  destruction, **e59f**
    aggressive periodontitis, 295
    mucormycosis infection, impact, **e29f**
    panoramic radiograph, **e64f**
  development, 37
  height, 126
    loss, panoramic radiograph, 559f
    vertical increase, 756
  involvement, 192
  leukemic infiltrate, 193f
  loss, 372
    appearance, **e47f**
    external insulin, usage, **e51f**
  metabolism, periodontal ligament (impact), 42
  morphologic changes, 42
  morphology, 605
  remodeling, 36
  resorption, 88-89
    stimulation, slightly excessive pressure (impact), 301
  space, requirement, 698
  topography, x-ray/ultrasound acquisition, 790f
  variation, 294
  vertical bite-wing films, usage, 380f
Alveolar crest
  apical position, 286
  fibers
    coronal radiation, 24f
    oblique extension, 24
Alveolar dimension, 702f
Alveolar mucosa (AM), 21f
Alveolar process, 31-36, 558
  components, 31-32
  divisibility, 32
  knife-edge alveolar process, 731-732
  remodeling, 33
  sockets, presence, 559
Alveolar ridge
  defect, 63f
  evaluation, 717-719
  loss, 558f
    clinical images, 62f
  preservation/management, 746-747
Alveologingival fibers, 78
Amalgam
  overhang, radiograph, 121f
  retrofill, impact, 52f
Ameloblastic epithelium, reduction, 17
Ameloblastoma, appearance, **e45f**
American Academy of Oral Medicine (AAOM), reports, 435
American Academy of Orthopedic Surgeons (AAOS), reports, 435
American Academy of Pediatric Dentistry, **e76**
American Academy of Periodontology (AAP), **e76**
American Dental Association (ADA), **e76**
  Committee on Anesthesiology (2007 policy/guidelines), 412t
  conscious sedation policy statement/guidelines, 411-412
  reports, 435
  sedation usage/general anesthesia, 411-412
    guidelines, 412
American Heart Association (AHA), **e76**
American Society of Anesthesiologists (ASA), physical status classification system, 414t
Amine fluoride, 550
Aminefluoride, 550
Amino acids, proteolytic degradation, 545f
Aminobisphosphonate medications, therapeutic uses, 198t
Amino groups, reduction, 119
Amlodipine-associated gingival enlargement, **e25f**
Ammonia, production, 81-82
Amoxicillin, 518
Amoxicillin-clavulanate potassium, 518
Anaerobic-to-aerobic species, ratio, 167
Analgesia, levels, 406f
Anamnesis, 547
Anatomic area, schematic diagram, 710f
Anatomic crown/root, distinction, 22
Anatomic differences, impact, 779
Anatomic factors, 398-400
  impact, 392
Anatomic location, 815
  impact, 815
Anatomic morphologic defects, correction, 552
Anatomic/morphologic defects, correction, 553
Anatomic periimplant sulcus, occlusal view, 666f
Anatomic spaces, 562-565
Anatomic structures, identification, 710
Androgenic hormones, changes, 227
Anemia, **e23**
Anesthesia, 567
Anginal episode, 422-423
Angioplasty, 423
Angiotensin-converting enzyme (ACE) inhibitors, 423
Angular bone loss
  furcation, involvement, 381f
  mandibular molar location, 381f
Angular defects (bone), 296
Angulation, 724-726
  distal angulation, 725f
Animals, mitotic rate, **16.e1**
Ankyloblepharon, 268
Ankylosis, 31
  results, **31.e1**
Anorganic bovine bone-derived mineral (ABBM), 751-754
Anosmia, 548
Anoxemia, 220-221
ANRIL, 318
Anterior gingival tissues, initial view, 461f
Anterior open bite
  flared incisors, 125f
  malocclusion, **e15f**
Anterior sector, moderate-to-severe periodontitis (therapy), 555
Anterior teeth
  loss, **e63f**
  mobility, 351
  pathologic migration, 365f

For entries that have a boldface page reference, i.e., **179.e2**, go to the Expert CONSULT website at www.expertconsult.com, and after registering, search for the term on the book website.

Antibiotics
agents, 517
coverage, administration, 431
prophylactic regimens, 424
prophylaxis regimens, 424t
serial/combination antibiotic therapy, 519-521
systemic administration, 516-519
background/rationale, 516-517
tetracyclines, 517
therapy, selection (decision tree), 521f
usage, 516t
guidelines, 520-521
rationale, 478
Antibodies, 97
Anticoagulant medications, 430
Anticoagulant therapy, 432
clinical studies, 432
Anticonvulsants, 235
Antigen-presenting cells (APCs), 94-95
Antigen-specific immunity, 90
Anti-infective agent
chemotherapeutic agent, 515-516
definitions, 515-516
Anti-infective therapy, 313f-314f
Anti-inflammatory cytokines, 87-88
Antimicrobial agents
delivery, drawbacks, **e101-e102**
local delivery, 524
Antimicrobial peptides, defining, 91
Antimicrobial resistance, biofilm (relationship), 151
Antiplaque agents, usage, 449-450
Antiplatelet medications, 430-431
Antiplatelet therapy, 432
Aortocoronary bypass (cardiac bypass), 423
APCs. *See* Antigen-presenting cells
Aphthous lesions, recurrence, **e39f**
Aphthous ulcers, recurrence, **e27f**
Apical abscesses, drainage, 476
Apical diseases
classification, 472
initiation, factors, 472
Apical fibers, 24
Apically displaced flap, 593, 598
facial/lingual preoperative views, 599f
selection, 593
Apical third, tobacco stains, 121f
Apical vessels, branches, 38
Apicoectomy, impact, 52f
Aplastic anemia, appearance, 256f
Apneic episode, 351
Arbitrarily primed-polymerase chain reaction, 151
Arbitrary values, 74
Archaea, 157
Area-specific curettes, 497-502
curved blade, presence, 498-499
universal curettes, comparison, 499t
Aredia, 357
Arg-gingipains, 167
Arginyl-glycyl-aspartic acid sequences, **28.e1**
Armamentaria, representation, 172
Arrangement, 724-726
Arterial blood supply, 561f
importance, 561
Arterial oxygen tension (PaO_2) tissue oxygenation, 418t
Arterioles, 19
diagram, 19f
Articulated diagnostic casts, 538-539
Aspirin-induced chemical burn, biopsy, 129f
Association
analysis, 105-106
spurious associations, schematic representation, **e87f**
study, example, **110.e1t-110.e235t**
Atherosclerosis, 207-208
coronary angiogram, 422f
periodontal disease, relationship, 205-209
periodontal infection, influence, 208f
Atopic dermatitis, pruritus lesions, **e36f**
Atraumatic microsurgical tissue manipulation, 638f
Atrial pacing, inhibition, 509
Atrophic lesions, 265
Atrophic lichen planus, impact, **e33f**
Atrophic periodontal ligament, 38f
Atrophy, 22-23
afunctional atrophy, 38
disuse atrophy, 38
Attached gingiva, 10, 554
amount, 371-372
demarcation, 20
example, 372f
impact, 11f
interdental papillae, 11f
mean width, 10f
problems, 628-629
stippling, 21
variation, 252
width, 10
determination, example, 372f
Attached plaque, 284
Attachment
apparatus, development, 36-37
level
determination, 370
pocket depth, differences, 370
Attachment loss, 678f
bone loss, relationship, 283f
pattern, 622-623
prevention, 677-679
reduction, 679
treatment, 677-679
Attrition, 363
Atypical ulcers (nonspecific oral ulcerations), 339
Augmentation surgeries, **765.e1**
bone/soft tissue overbuilding, **765.e1**
Augmented-reality viewer, 789
Autogenic succession, 160
Autogenous bone grafts, 613-614
Autogenous monocortical block graft, harvesting, 743
Autografts, 611
iliac autograft, placement, 615f
Autoinducer 2, 150
Autologous platelet concentration, 762
Autologous PRP, usage, 616
Automated periodontal probes, example, 371f
Automatic cardioverter-defibrillators, 420
Automatic periodontal probing, 370
Avascular necrosis, 198
Avulsed teeth, replantation, **e74f**
Axis II mental disorders, 347
Azithromycin, administration, 588

For entries that have a boldface page reference, i.e., **179.e2**, go to the Expert CONSULT website at www.expertconsult.com, and after registering, search for the term on the book website.

B
Bacillary angiomatosis (BA) (epithelioid angiomatosis), 338
Back-action chisel, 574f
Background characteristic, 391-393
Bacteria-host interactions (modulation), oral streptococci (impact), 151
Bacterial accumulation areas, 282
Bacterial challenge
host response, 331-332
inflammatory response characteristics, 98f
Bacterial DNA, virulence factor, 82-83
Bacterial enzymes
impact, 149
virulence factor, 81-82
Bacterial pathogens, 188
identification, 158
Bacterial plaque, 42
impact, 76-77, 621
Bacterial resistance, development (risk), 517
Bacterial species, summary, 164t
Bacterial transmission/translocation, 151-152
Bacteroides intermedius, 437
Bacterium (bacteria)
adherence, 136
ability, 136
biofilm mode of living, 138-149
identification, molecular methods, 157-158
initial adhesions/attachment, 144
intraoral translocation, 151
pathogenic bacteria, 161-162
presence, 667
reservoir, subgingival environment, 204
scanning electron micrograph, 143f
secondary colonizers, 144-145
species, colonization, 132
survival, strategies, 136-137
Bacteroides gingivalis (injection), 68
Bad breath
control, chewing gum (usage), 549
pathways, 544
Baking soda, 550
Ball sickle scaler, 495-497
Bard-Parker knife, usage, 598
Barrier membranes, submerged position, 739-740
Bartholin's duct, **e16f**
Basal cell layer, 14f
Basal lamina, 13
fibrils, connection, 14
internal basal lamina, 15
Basement membrane, immunofluorescent-labeled antibodies, 50f
Basic life support (BSL), impact, 415
Bass method, 488f-489f
Bass technique, 488
B-cell activation, endpoint, 97
Behavioral considerations, 704
Behçet disease, **e39f**
Beneficial species, 162
Benign masses, 242
Benign mucous membrane pemphigoid, 50f
Benzodiazepine, intravenous administration, 567
Benzothiazine derivatives, 236
Beta-adrenergic receptor antagonists (β-blockers)
types, 422t
usage, 421-422
Bile pigments, 228
Biofilm
accumulation, 144-145
antimicrobial resistance, relationship, 151
bacteria
characteristics, 149-151
communication, 150
resistance, 139
control, evaluation, 808
development, impact, 316-317
heterogeneity, 139
mode of living, 138-149
Biological mediators
elicitation, 173t
expression, 170
Biologic complications, 792, 798-801
Biologic considerations, 652-655
Biologic depth, 366
Biologic failure, 723
Biologic mediators, usage, 616-618
Biologic plausibility, **e83**
Biologic pocket depth, 369f
Biologic width, 652-653
evaluation, 653-654
human biologic width, 653f
identification, 652
variations, 654f
violation, ramifications, 653f
violation, restoration design/shape (impact), **e40f**
Biomarkers, 101
Biomechanics. *See* Implants
angulation/arrangement, 724-726
considerations, 723-726
load-bearing capacity, 723-724
Biomedical databases, **e76**
Bio-Oss (Osteohealth), usage, 615
Birbeck granules, 12-13
Birth defects
cause, 443b
FDA drug classification system, 443b
Bisection-of-the-angle technique, long-cone paralleling (comparison), 379f
Bismuth gingivitis, appearance, 227f
Bisphosphonate-associated osteonecrosis of the jaw, 198
Bisphosphonate-induced osteonecrosis of the jaw (BIONJ), 198
Bisphosphonate-related osteonecrosis of the jaw (BRONJ), 59-60, 198, 431
American Association of Oral and Maxillofacial Surgeons definition, 59-60
development, 431-432, 703
lesions
asymptomatic characteristics, 60
occurrence, 199-200
lower premolar/molar, lingual aspect (bone exposure), 60f
Bisphosphonates (BPs), 59, 197-200, 431-432, 526, **e67**
bone-seeking agents, 526
chemical structure, 197f
discontinuance, 60
effects, 526
impact, 200
medications, usage, 197
therapy, C-terminal telopeptide laboratory risk assessment, 432t
Bite-wing radiographs
examples, 380f
schematic diagram, 380f

For entries that have a boldface page reference, i.e., **179.e2**, go to the Expert CONSULT website at www.expertconsult.com, and after registering, search for the term on the book website.

Biting, pain, 474f
Blast cells, release, 191
Bleeding, 192-194. *See also* Gingival bleeding
disorder (thrombocytopenia), 190f, 428
laboratory tests, 429t
gingivitis, clinical features, **e10**
measures (NHANES III), 70
persistence, 570
postoperative bleeding, clinical photograph, 795f
probing, impact, 70, 370
production, periodontal surgery (impact), 567-568
reduction, saline solution cavitation (impact), 779
Blisters, formation, **e39f**
Blood dyscrasias
gingival diseases, association, **e23**
gingival/periodontal disturbances, association, 190-191
Blood pressure (BP), increase, 421
Blood supply, 18-19
adequacy, 631
Blood vessels, presence, **18.e1**
Blood viscosity
factors, 206f
increase, 206-207
Blotter (Periopaper), usage, 215
Bonding agent, iatrogenic use, **e42f**
Bone
action radius, 291-292
allografts, 614-615
freeze-dried bone allograft, 614-615
usage, 616
angular defects, 296
appositional index, 725
architecture, correction (absence), 594
blend, 613-614
technique, 613
bulbous bone contours, 298
contour, conformation, 36f
deformities (osseous defects), 296
distribution, 32f
exposure, 582
faciolingual diameter, 378
formation
buttressing, 295
periodontal disease, 294
presence, 294
furcation involvement, 298-299
grafting, 771
height limits, absence, 725
inorganic matter/organic matrix, 32
marrow, 34
metabolic disease, 699-701
morphology, factors, 294-295
necrosis, **e68f**
new bone formation, 686
occlusal forces, transmission, 26-27
operating mode, 779
osteoclasis, mesial root surface, 34f
osteonectin, expression, **28.e1**
overbuilding, **765.e1**
pocket, relationship, 286
quality
assessment, 710-717
impact, 726f
quantity/volume, assessment, 710-717
regeneration, 626
Bone *(Continued)*
remodeling/function, 686
remodeling, regulation, **31.e1**
removal, osteoplasty/ostectomy (usage), 613
renewal, remodeling process (multicellular unit), 686f
resorption, 302, 725b
complexity, 33
reversed architecture, 298
appearance, 298f
sialoprotein, **28.e1**
sialoprotein, expression, **28.e1**
spatial relationship, 698-699
swaging, 614
tap, 733-735
tissue damage/debris, creation, 685
vascular supply, 39
vertical defects, 296
Bone augmentation, 750-756, 816
achievement, 744-745
case presentation, 758-762, 766-769
dental history/complaint, **769.e1**
examination/diagnosis, **769.e1-769.e2**
growth factors, 758-762
usage, 762
horizontal bone augmentation, 740-743
indications/contraindications, 750-751
maxillary sinus access, lateral window procedure, 759f
procedures, 725, 753f-754f
results, **769.e4**
supracrestal/vertical bone augmentation, 756-758
surgical procedure, **769.e3-769.e4**
surgical strategy, **769.e3**
treatment objectives, **769.e2**
treatment options, **769.e2-769.e3**
treatment sequence, **769.e3**
Bone destruction, 378-380
gingival inflammation, impact, 290-294
histopathology, 290b-291b
mechanisms, 293-294
occlusion, trauma (impact), 294
patterns, 295-299, 379-380
systemic disorders, impact, 294
Bone grafts
materials, 751-754
packing, 766f
submerged position, 739-740
Bone loss, 379
advanced bone loss, 623f
advanced horizontal bone loss, **542.e3-542.e5**
anterior/esthetic zone, implant sites, 752f
generalized horizontal bone loss, 381f
horizontal bone loss, 296
appearance, 296f
mandibular implants, impact, 800f
intraoral radiographs, 59f
periimplantitis, relationship, 799-800
rate, 292-293
severity, 285
tooth support, loss, 364
vertical bone loss, mandibular implants (impact), 800f
vertical movement, 295f
Bone morphogenetic proteins (BMPs), 527, 758-762
Bone-substitute graft materials, impact, 751-754
Bone-to-implant interface, 687f
Boniva, 357

For entries that have a boldface page reference, i.e., 179.e2, go to the Expert CONSULT website at www.expertconsult.com, and after registering, search for the term on the book website.

Bony architecture, types (diagram), 606f
Bony defect, correction, 661f
Bony depression, filling, 661f
Bony ledges (reduction), osteoplasty (usage), 608f
Bony lesions, anatomy, 622-623
Bony periodontium, photograph, 605f
Bony trabeculae, realignment, 38f
Breastfeeding, 443
  antibiotic/sedative-hypnotic administration, 445t
  local anesthetic/analgesic administration, 444t
Breath malodor
  dental pathologies, 546
  dry mouth, 546
  epidemiology, 544
  etiology, 544-546
  intraoral causes, 545-546
  pathways, 544
  periodontal infections, 546
  semantics/classification, 544
Breath odor, defining, 544
Bristle brushes, 505
British Society for Antimicrobial Chemotherapy (BSAC), reports, 435
BRONJ. *See* Bisphosphonate-related osteonecrosis of the jaw
Bruxism, 347, 355
Buccal alveolar plate, cervical portion (variations), 36f
Buccal depression, prosthetically guided orientation, 660f
Buccal epithelial cells, double labeling, 143f
Buccal exostosis, clinical photograph, 563f
Buccal gingival grafting, 772
Buccal lower premolar, bone (exposure), 60f
Buccal mucosa, intraoral habitats, 137t
Buccal space, location, 562
Bulbous bone contours, 298
Bullous lesions (vesicular lesions), 265
Bullous lichen planus, consideration, 271
Bullous pemphigoid, 267
  appearance, 267f
  histopathology, 267b
  immunofluorescence, 267
  oral lesions, 267
  steroid-sparing strategies, usage, 267
  treatment, 267
Bundle bone, 33
  teeth, physiologic mesial migration (association), 34f
Bundles, 20
Bupropion, usage, 181
Burns
  ferric sulfate, misuse (impact), **e41f**
  raki, usage, **e43f**
Butyrivibrio fibrisolvens (microbial lineage), 123

C
Cadaverine, 548-549
CAIS. *See* Computer-assisted implant surgery
Calcification, initiation, 119-120
  chemical inhibitors, 485
Calcium channel blockers, 236
Calculus, 116-121, 141, 255, **e13**
  advanced formation, **e15f**
  assessment, 366
  attachment, 118f
  bridge-like formations, malocclusion (impact), **e16f**
  cemental resorption area attachment, 119f
Calculus *(Continued)*
  composition, 117-118
    inorganic content, 117
    organic content, 117-118
  contours, 123-124
  delay healing, fragments, 572
  deposits, rarity/increase, 255
  etiologic significance, 120-121
  extensiveness, radiopaque projection, **e17f**
  iatrogenic factors, 121-124
  local factor, 398
  malocclusion, 124-125
  mineralization
    microorganisms, role, 120
    theories, 120
  non-decalcified specimen, 118f
  open contacts, 123-124
  predisposing factors, 121-131
  presence, 392
  prevalence, 116-117
  radiation therapy, 130-131
  removal, 481-482
    incompleteness, 286
  retained cement/periimplantitis, 122-123
  tooth surface attachment, 118
Calculus accumulation
  decline, 120
  rate, variation, 119-120
  reduction, 116-117
  visual inspection, 805
Calculus control toothpastes, 487-488
Calculus formation, 118-120
  debridement/oral hygiene instruction, **e20f**
  extensiveness, **e40f**
  one-side chewing, relationship, **e18f**
  open-bite neglect/hygiene neglect, **e19f**
  Stensen's duct, proximity, **e16f**
Caldwell-Luc procedure, 797-798
Calf bone (Boplant), usage, 615
Campylobacter rectus, 163
  proportion, 364
Cancellous bone
  destruction, 379
  marrow, transplants, 614
  presence, 33-34
  proportions, 32f
Cancer therapies, 431-435
Candida albicans
  infection, 48-49
  prevalence, 322
Candidate genes, 105
  approach, 106t
Candidiasis
  diagnosis, 336-337
    techniques, 337f
  limitation, 275
Canine fossa, 562
Canines
  mesial surface, calculus/bone loss, 306f
Canines, dehiscence, 37f
Cantilevers, 725f, 728
Carbon dioxide laser treatment, **e13f**
Carboxy terminal telopeptide of type 1 collagen (ICTP), 529
  levels, time period correlation, 531-532
Carcinoma, 242

For entries that have a boldface page reference, i.e., 179.e2, go to the Expert CONSULT website at www.expertconsult.com, and after registering, search for the term on the book website.

Cardiac bypass (aortocoronary bypass), 423
surgery, 420
Cardiac conditions, risk, 424b
Cardiac pacemakers, 423
presence, 420
Cardioselective beta blockers, 421-422
Cardiotonic agents, 423
Cardiovascular disease, 43, 420-425
serum CRP/fibrinogen levels, elevations (risk factors), 208-209
systemic inflammatory component, 208
Career-ending injuries, prevention, 637f
Caries, 401
exposure, osteoplasty (usage), 608f
Cariogenic species
growth, 134f-135f
intraoral habitats, 137t
solid surface restriction, 137-138
Carious lesions, management, 482
Case-control studies, 68, 72, 106-107, **e83**
periodontal case-control studies, examples, 72t
usage, 106t
Case management, treatment plan, 408
Castroviejo microsurgical scalpel, 636f
Castroviejo needleholder, 575f
Casts, 361
Cathepsin K, lysosomal cysteine protease (expression), 87
Cat, tooth (eruption), 25f
process, 16f
Causal web, impact, 73
Cause/effect, relationship, **e83-e84**
Causes, 72-74
component cause, 72-73
necessary cause, 72-73
noniatrogenic periodontitis, causes, 73f
sufficient cause, 72-73
Cavernous lesions, 386
CBCT. *See* Cone-beam computed tomography
CD4, expression, 95
CD4+ T-helper cell subsets, development, 92
CD8, expression, 95
CDKN2B antisense RNA (CDKN2BAS), 110
CDSSs. *See* Clinical decision support systems
Cell-cell adhesion, 144
Cell-cell signaling (facilitation), biofilm mode of growth (impact), 139
Cell-mediated delayed-type hypersensitivity, 58-59
Cell renewal cycle, 448f
Cells
intercellular matrix, 33
layers, **15.e1**
signaling pathways, 174
suprabasal/subepithelial separation, **e34f**
tissue engineering element, 616f
Cellular cementum
arrangement, 28
cementocytes, presence, 29f
formation, 28
Cellular elements, 18, 25
Cellular innate responses, activation, 92
Cellular intrinsic fiber cementum, 29
Cellular mixed stratified cementum, composition, 29
Cellular processes, hormonal regulation, 441-442
Cellular proliferation, estrogen regulation, 441
Cemental resorption area, calculus (attachment), 119f
Cemental tears, 63
appearance, 301f
Cementicles, 25
Cementoblasts, 25
Cementodentinal junction, 29
Cementoenamel junction (CEJ), 29, 370
catch, facilitation, 371
impact, 378
Cementoid, 37
Cement, retention, 122-123
Cementum, 28-31, 37
aging, impact, 42
attachment protein, role, **28.e1**
calculus, coverage, 284
caries, attention, 284
cellular resorption areas, 284
collagen fibers, 23f
decalcification/remineralization, 284
deposition, 29
exposure, 31
fiber, formation (clinical human histology), 31f
formation
importance, 30
initiation, 37
fusion, 31
organic matrix, 28
permeability, 29
protection/preservation, 475
regeneration, 30
repair, 30-31
requirements, 30
resorption, 30-31, 31f
cause, 30
microscopic appearance, 30
occlusal forces, association, 30f
surface, subgingival calculus, embedding, 119f
thickness, 29-30
abnormalities, 29
Cementum, pellicle (calculus attachment), 118f
Centers for Disease Control and Prevention (CDC), **e76**
Central apnea, 352
obstructive apnea, differences, 352f
Central giant cell granuloma, 241
Central incisors
open embrasures, **542.e10-542.e11**
roots, horizontal lines (appearance), 384f
triangular shape, impact, **542.e11f**
Central nervous system (CNS) depressants, increase, 439
Central sleep apnea (CSA), 352
Central upper incisor, crack, 147f
Central upper incisors, oral hygiene (absence), 148f
Centric relation, 345-346, 536
assessment, 538
bimanual manipulation, 538f
closure arc, 536
initial contact, 536
term, usage, 536
Cephalosporins, 518
clinical use, 518
pharmacology, 518
side effects, 518
Cerebral infarction, periodontal disease (role), 208-209
Cerebrovascular accident (CVA), 420-421
post-CVA patients, dental clinician treatment, 425
stroke, result, 425

For entries that have a boldface page reference, i.e., 179.e2, go to the Expert CONSULT website at www.expertconsult.com, and after registering, search for the term on the book website.

Cervical area, periodontal ligament (widening), 303f
Cervical enamel projections (CEPs), 63, 621-622
classification, 623b
extensions, 398-399
occurrence, 622
Cervical root resorption, 63
computed tomography scanning, 64f
Cetylpyridinium chloride (CPC), 550
CFTR gene, recessive mutations, 104
Chairside 3D mapping data acquisition, 787
Chair-side test, 549
Charge-coupled devices (CCDs), usage, 387
Cheek, aphthous lesions (recurrence), **e39f**
Chemical burn
aspiring-induced chemical burn, biopsy, 129f
aspirin, impact, 129f
Chemical irritation, 129
Chemokines, 87
Chemotaxis, 182-183
Chemotherapeutic agents, 515-516
usage, 449-450
Chemotherapy, 433
performing, 433
Chemotherapy-induced thrombocytopenia, 190f
Chewing gum
formulation, 551
impact, 549
Chewing, pain, 474f
Chewing tobacco (smokeless tobacco), 129-130
Childhood
diseases, oral mucosa, 259
gingival diseases, 255-257
periodontal diseases, 257-258
Children
acute lymphoblastic leukemia, appearance, 260f
aggressive periodontitis, 259f
chronic gingivitis, 255
congenital anomalies, 259
diabetes mellitus, 258
endocrine disorders, 258
hematologic disorders, 258-259
hormonal changes, 258
immune deficiencies, 258-259
leukocyte (neutrophil) disorders, 258-259
pediatric patient, therapeutic considerations, 259-260
systemic disease, gingival manifestation, 258-259
Chisel scalers, 494, 503, 503f
Chlorhexidine (CHX), 549-550
chip, **e98**, **e102**
release profile, **e102**
trial, **e125**
chlorhexidine-based products, **e127-e128**
dilutions, 514t
gluconate chip (PerioChip), **e99f**
placement, 522f
subgingival chlorhexidine, 522
Chlorhexidine, cationic bisbiguanide (usage), 449
Chlorine dioxide (ClO_2), 550
Chlo-Site, **e127-e128**
gel, **e127f**
Christmas disease (hemophilia B), 428-430
Chronic abscess
acute abscess, differences, 461
Chronic adult periodontitis, 258
Chronic cutaneous lupus erythematosus, 273-274
appearance, 273f
histopathology, 274b
Chronic desquamative gingivitis, 261
appearance, 262f
Chronic destructive periodontal diseases, progression modes (diagrammatic representation), 159f
Chronic diseases, 72-73
complexity, **e82**
initiation/progression, causal web, 73
risk-based diagnosis, 75
Chronic gingivitis, 224
appearance, 228f
marginal/interdental gingivae, appearance, 225f
Chronic gram-negative periodontal infections, impact, 211
Chronic inflammation, cycle (establishment), 88
Chronic inflammatory enlargement, 232-233, 587
clinical features, 232-233
etiology, 233
histopathology, 232b-233b
Chronic inflammatory gingival enlargement
anterior region, localization, 233f
appearance, 233f
fibrotic component, 587
occurrence, 232-233
survey section, 233f
Chronic leukemia, Gleevec (usage), 377
Chronic marginal gingivitis, 256f
Chronic myelogenous leukemia, gingival inflammation/hyperplasia, **e23f**
Chronic oral malodor, 549
Chronic periodontal abscess
appearance, 385f
presentation, 373
Chronic periodontal destruction, 52
Chronic periodontal disease, necrotizing ulcerative gingivitis (differentiation), 246t
Chronic periodontitis, 46, 52-54, 163-165, 342-343, **e10**, **e46**
adult periodontitis, 258
aggressive periodontitis, differences, 54-55
anti-infective therapy/periodontal reevaluation, 313f
asynchronous, multiple-burst model, 315-316
bacterial infection, **e98**
behavioral factors, 318
calculus, impact, **e46f**
characteristics, 309
chronic adult periodontitis, 258
clinical features, 309-316
clinical revelation, 309
continuous model, 315
diagnostic criteria, 325t
disease distribution, 309-314
disease progression, 314-316
disease risk factors, 316-318
disease severity, 314
environmental factors, 318
generalized chronic periodontitis, 309
generalized severe chronic periodontitis, 397f
genetic factors, 318
genome-wide association studies (GWAS), 318
immunologic factors, 318
independent gene association reports, 111t
local factors, 316-317
localized chronic periodontitis, 309
microbiological aspects, 316

For entries that have a boldface page reference, i.e., 179.e2, go to the Expert CONSULT website at www.expertconsult.com, and after registering, search for the term on the book website.

Chronic periodontitis *(Continued)*
microbiological examinations, 163
mild chronic periodontitis, 314
moderate chronic periodontitis, 314
modification, systemic condition (usage), 55-57
modification, systemic factors, **e49**
myocardial infarction (association), two-by-two table (usage), **e86t**
periodontal attachment, documentation, 315f
plaque
formation, excess, **e13f**
impact, **e46f**
presence, **e47f**
prevalence, 316
prognosis, 401-402
radiographic periodontal status, 312f
random/episodic-burst model, 315
severe periodontitis, 314
symptoms, 314
systemic factors, 317-318
treatment, systemic antibiotics (usage), 211
Chronic toothbrush trauma, 128-129
Chronic trauma, 300, 347
occlusion, impact, 300
Chronic ulcerative stomatitis, 271-272
appearance, 272f
diagnosis, 272
direct immunofluorescence, 272f
histopathology, 271b
immunofluorescence, 271-272
oral lesions, 271
treatment, 272
Cicatricial pemphigoid
differentiation, 269
mucous membrane pemphigoid, 268-269
treatment, 264f
Ciprofloxacin, 519
clinical use, 519
pharmacology, 519
side effects, 519
Circadian periodicity, 216
Circular fibers, 18, 78
Circular punch, 736
Class III furcation defect
orthodontic treatment, **542.e5**
preorthodontic treatment, **542.e5f-542.e6f**
Class III furcation involvement, clinical picture, 627f
Class III malocclusion, periodontal destruction, **e18f**
Cleansing instruments, 494, 505-506
Clearing technique, usage, 470-472
Clindamycin, 518-519
clinical use, 518
pharmacology, 518
side effects, 518-519
Clinical attachment level (CAL)
determination, 395
gain, 648
Clinical crown
apical third, tobacco stains, 121f
lengthening technique, 779
periodontally compromised maxillary anterior teeth, clinical photograph, 768f
Clinical decision support systems (CDSSs), **e95-e96**
adoption, barriers, **e96**
Clinical diagnosis
first visit, 357-362
laboratory aids, 374
patient, appraisal, 357
Clinical evidence, research/levels (hierarchy), **e77f**
Clinical examination, 719
Clinical indices, usage, 366
Clinical information, types, **e93f-e94f**
Clinical insights, **e99b**
Clinically relevant endpoint, **e85**
Clinically relevant pretrial hypothesis, **e84-e86**
Clinically relevant questions, design, **e85**
Clinically significant, term (usage), 375
Clinical practice guidelines (CPGs), **e75-e76**
absence, **e76-e77**
Clinical probing, 383-385
Clinical Queries (PubMed), usage, **e77**
Clinical research, phases, **e124t**
Clinical significance
Level 1, 376
Level 2, 376
Level 3, 377
Level 4, 377
levels, defining, 376-377
benefit, impact, 376t
statistical significance, differences, **e103-e115**
Clinical studies, **e128**
Clinical trials
bias, minimization, **e125**
patient assignments, impact, **e125**
design characteristics, **e124t**
design considerations, **e124-e126**
endpoints, **e125**
evidence, **e124-e126**
group comparability (minimization), patient assignments (impact), **e125**
initiation, political issues, **e88-e89**
mean differences, **e103**
objectives, **e125**
statement, **e124**
patient selection methods, **e125**
protocol/statistical plan/reports, analysis methods, **e124**
study drug effects (interpretability), results analysis (impact), **e125-e126**
Clinical use, **e126-e127**
adverse effects, **e127**
Clofibrate, usage, 377
Closed-loop systems, **e95-e96**
Clot formation, von Willebrand disease, **e25f**
Clot stabilization, 610-611
Coagulation
disorders, 428-431
inherited coagulation disorders, 429t
factors, 218
factor VIII
deficiency, 428-430
factors, 206-207
time, 428
Coatings, developmental origin, 17
Coaxial lighted prism loupes, 641f
Cochrane Collaboration, **e76**
Co-destruction, zone, 304
Coe-Pak, preparation, 569-570, 569f
Cohorts, definition, 72

For entries that have a boldface page reference, i.e., 179.e2, go to the Expert CONSULT website at www.expertconsult.com, and after registering, search for the term on the book website.

Cohort studies, 68, 72, **e83**
periodontal cohort studies, examples, 72t
Cohort study, **e75**
Col
interdental col, anatomic variations, 11f
intervening col, 11f
nonkeratinized stratified squamous epithelium (covering), 11f
CollaCote (CollaTape/CollaPlug), 568
Collagen, 17
areas, depletion, 80-81
biosynthesis, occurrence, 23
bundles, 23f
composition, 23
degradation, MMPs (relationship), 220
fibers, 23f
embedding, 23f, 284
sources, 28
fibrils, 23f
loss, mechanisms, 279
metabolism, alteration, 189
microfibrils, 23f
molecular configuration, 24
organic matrix, 32-33
synthesis, 23-24
Collagenase-1, 86
Collagenase, presence, 529
Colloidal protein, calculus/phosphate ion binding, 120
Combination adjunctive therapy, **e126**
Combination antibiotic therapy, 519-521
clinical use, 519-520
pharmacologic implications, 520-521
rationale, 519
Combined lesions, 62-63
Combined osseous defect, usage, 296
Compact bone, relative proportions, 32f
Comparisons, usage, **e85**
Competence-stimulating peptides, 150
Complementary treatment strategies, 527f
involvement, 528
Complex apnea, 352
Component cause, 72-73
Compound loupes, 640-641
example, 641f
Comprehensive periodontal management, host modulation (relationship), 527-528
Compromised surgical esthetic goal, 755f
Compromise osseous reshaping, 606
Compromise therapy, feasibility, 577
Computed tomography (CT)
scanning, requirement, 709
scans, advantages, 708
Computer-aided surgery (CAS), 788
Computer-assisted implant surgery (CAIS), 786-790
advantages/disadvantages, 790
augmented reality, 788-790
computer screen, images, 789f
CT-based technology, 787
data acquisition, 787
external viewer, 788-790
identification, 787-788
immediate mapping, 787
navigation, 787-788
positional tracking, 788
registration, 787-788
requirements, 786
Computer-assisted implant surgery (CAIS) *(Continued)*
screen views, 790f
side viewers, 789
steps, sequence, 787
surgeon view, 789f
3D projection screens, 788-790
uses, 786
Concave bony defects, 660f
Concave proximal tooth surfaces, cleaning, 492f
Conditioned gingival enlargement, appearance, 238f
Conditions, occurrence (measurement), 68-69
Condylar displacement, 536
Condyles, rotation, 346f
Cone-beam computed tomography (CBCT), 387, 706, 709-710
advantages/disadvantages, 709-710
images, usage, 711f-712f
view, **e48f**
Confidence interval, range, **e86**
Conflict of interest
definition, **e89**
impact, **e89**
issues, **e90**
protection, **e89-e90**, **e89-e90**
Confounders
measurement accuracy, **e87**
statistical modeling, usage, **e87**
Confounding, **e87**
impact, evaluation, **e88**
issue, absence, **e87**
Congenitally missing maxillary lateral incisors, radiographic evaluation, 717f
Congestive heart failure (CHF), 420-421, 423
Connective tissue, 689
breakdown, cytokine expression (impact), 226
cells, 25
cellular/extracellular components, 17
cuff, blood supply (schematic illustration), 691f
exposure
atrophic lichen planus, impact, **e33f**
desquamation, impact, **e32f**
fibers, types, 17
homeostasis, MMP role, 87
interface, examination, 689
Connective tissue graft (CTG), suturing, 638f
Conscious sedation, ADA policy statement/guidelines, 404
Consensus, classification, 435
Contact stomatitis, 275
Continuous tooth eruption, 22-23
Contours, 123-124
Contrast resolution, 709-710
Control event rate (CER), **e78**
Controlled evidence level, availability, **e83**
Controlled-release antimicrobial products
availability, **e98**
development, **e99t**
drug class consideration, **e98**
Controlled-release local delivery, pharmacokinetics, **e102**
Controlled-release rationale, **e101-e102**
Controls, examination, **e125**
Conventional flap, 582, 599
design, 583f
Conventional instruments, microsurgical instruments (side-by-side dimensional comparison), 633f
Convex ridge shape, augmentation, 661f
Coping, 195-196

For entries that have a boldface page reference, i.e., 179.e2, go to the Expert CONSULT website at www.expertconsult.com, and after registering, search for the term on the book website.

Cordless dental water jet, 512f
Corneocytes, formation, **11.e1**
Coronal cementum, 17
Coronal integrity, 476-477
Coronary angiogram, 422f
Coronary artery disease, risk factors, 205
Coronary heart disease (CHD)
  CHD-related events, presence/absence, 206
  patient education, 212
  periodontal disease, relationship, 205-209
  periodontal infection, influences, 203
  risk, 206
Corrosion (erosion), 362-363
Corticosteroids, 200-201, 432-433
Countersink, 735f
  drill, 732-733
CPC. *See* Cetylpyridinium chloride
Crater-like lesion, **e66f**
Craters, correction (effect), 607f
C-reactive protein (CRP)
  acute-phase proteins, 208
  inflammatory marker, 43
Crestal bone
  resorption, osteoclasts/Howship lacunae, 293f
  surface, inflammation extension, 293f
Crestal incision, 736
Crestal osteotomy technique, 754-755
Crevicular incision, 584-585
  initiation, 594, 598
  knife position, 585f
Crevicular washings, usage, 214
Critical analysis guides, examples, **e78t**
Critically appraised topics (CATs), **e76-e77**
Critical probing depth, 482-483
Crossbite, 365
Cross-sectional imaging, 708-710
Cross-sectional studies, 205
Cross-sectional tomography, 719
Crowns
  contours, 654
    problems, 802-803
  esthetic appearance, gingival margins (impact), **542.e9**
  formation, 36
  fracture, 64f
  gingival margin, relationship (diagram), 41f
  interproximal embrasures, absence, **e41f**
  lengthening, 777-779
  margin
    luting material, impact, 122f
    overextension, **542.e6-542.e7**
  proximal surfaces, 21
  recontouring, 482
Crown-to-root ratio, problems, 399f
Cryptococcus neoformans, 156
CSA. *See* Central sleep apnea
C-terminal telopeptide laboratory risk assessment, 432t
CTG. *See* Connective tissue graft
  Curettage. *See* Gingival curettage; Subgingival curettageaesthetics, relationship, 577
  clinical appearance, 578
  defining, 576
  impact, 576
  inadvertent curettage, 576
  instruments, 495-505
Curettes, 494, 497-502
  selection, 577
  shank, double turn, 498f
  types, 497f
Current illnesses, 358-361
Curve-based methods, 788
Curve Dental and Dental Symphony, **e94**
Curve of Spee, impact, 725f
Cushioning, occlusal forces (increase), 294
Cusp-fossa relationship, 536
Cusp-marginal ridge relationship, 536
Custom impression transfer coping, 773
  usage, 774f
Cuticle, term (usage), 17
Cuticular structures, 17
  classification, 17
Cutting inserts, 778f
CXCL8, 84, 88
Cyclic neutropenia, presence, 191f
Cyclin-dependent kinase inhibitor 2B antisense, 318
Cyclooxygenase-1 (COX-1), 83
  expression, 86
Cyclooxygenase-2 (COX-2), 83
  expression, 86
  inhibitors, usage, 526
Cyclosporine
  drug substitutions, 588
  potency, 235-236
  therapy, impact, 49f
Cyclosporine-associated gingival enlargement, 236f
  intraoperative view, **e26f**
  microscopic view, 236f
Cyclosporine-induced gingival enlargement, 236
  nifedipine-induced gingival enlargement, combination (treatment), 591f
Cyclosporine-induced gingival hyperplasia, appearance, 256f
Cyclosporin-induced gingival enlargement, surgical treatment, 590f
Cysts, **e44**
Cytokeratins, characteristic pattern (identification), **11.e1**
Cytokines, 83
  expression, impact, 226
  immunity, 83
  inflammation, 174-176
  interleukin-6 (IL-6), relationship, 86
  production, 83, 95
  profile, 175
  responses, signaling, 92
  upregulation, 92, 96f
Cytoplasmic organelle concentration, variation, **11.e1**
Cytoplasmic PRRs, representation, 172

D

Dark-field microscopy, 548
Data acquisition, 787
Database of Abstracts of Review of Effectiveness (DARE), **e76**
DDAVP. *See* Parenteral 1-deamino-8-D-arginine vasopressin
DeBakey tissue forceps, 574f
Debridement, 481
Deciduous molar teeth, alveolar bone destruction, **e53f**
Deciduous teeth
  mobility, impact, **e14f**
  radiographic alveolar bone loss, **e63f**

For entries that have a boldface page reference, i.e., 179.e2, go to the Expert CONSULT website at www.expertconsult.com, and after registering, search for the term on the book website.

Decision-making pathway, **e75f**
Decision support systems. *See* Clinical decision support systemsfuture, **e96**
types, **e95-e96**
Deep furcation invasions, location, 461f
Deep periodontal pocket
appearance, **e60f**
lateral wall, ulceration area, 283f
soft tissue wall, abscess, 286
Deep periodontal pocket, probing, 278f
Deep sedation, 414
Deep subgingival visualization, 505f
Defect type, determination, 395
Defense cells, 25
Definitive osseous reshaping, 606
Definitive trials, 72
Dehiscence, 36, 629
biologic complication, 798-799
defects
exposure, 743
management, 740, 743
observation, 743f
Delayed implant placement, 746-747
Delayed technique, staged technique (difference), 747
Demineralization areas, 284
Demineralized freeze-dried bone allograft (DFDBA), 615
Dendritic cells, 172
De novo plaque formation, 147-148, 147f
patient age, impact, 148
De novo subgingival plaque formation, 149
Dental anomalies, periodontium (effect), 478-479
Dental biofilm
activation, 171f
development, 316
Dental endoscope, 504-505
example, 504f
Dental floss, 489-491
holders, 490
impact, 490f
positioning, 490f
recommendations, 491
technique, 490-491
example, 490f
Dental habits, destructiveness, **542.e10**
Dental history, 358-361, 697-698
components, 358-361
Dental implants, 626
case types/indications, 693-696
custom abutments, 663f
interproximal soft tissue cratering, bone necrosis, 647f
patients, maintenance, 676
placement, surgical access, 665f
prosthetic components, emergence profile, 664f
radiograph, 662f
real-time navigation system, 789f
therapy, goal, 693
treatment planning, 726-727
types, 794
usage, 458
clinical considerations, 458
Dental loupes, usage, 640
Dental materials, impact, 654-655
Dental pain, identification, 347
Dental pathologies, 546
Dental plaque
bacterial proteolytic activity, 167
biofilm
accumulation, 144-145
structure, 141-144
causative factor, 73-74
classification, 141
composition, 141
gingivitis, association, 45, 401
host, reaction, 304f
microbial composition, change, 145
phosphatase, liberation, 120
primary colonizers, 145t
secondary colonizers, 145t
supragingival dental plaque formation, factors, 145-149
trichomonas, visualization, 157f
Dental plaque bacteria
interactions, 150-151
metabolism, 149
nutrients, origination, 149
Dental plaque-induced gingival disease, **e9**
prognosis, 401
Dental-plaque-induced gingival diseases, 45-47
Dental-plaque-induced gingivitis (chronic gingivitis), subgingival microbiota, 163
Dental practices, EDR (usage), **e92-e96**
Dental pulp
biologic effects, 475
occlusal forces, effects, 303
periodontal infection, biologic effects, 475
Dental restorations/appliances, 63
Dental stains, 121, 363
Dental tape, 505
Dental therapy, periodontal therapy (relationship), 409
Dental tissues, 243
Dental treatment, complications, 339
Dental use, locally delivered controlled-release antimicrobials development, **e99t**
Dental views, reconstruction, 708
Dental water jet, 512f
benefits, understanding, 510t
cordless dental water jet, 512f
Dentate state, 355
Dentin
cellular resorption areas, 284
protection/preservation, 475
resorption, 31f
Dentinal hypersensitivity (treatment), bonding agent (iatrogenic use), **e42f**
Dentinal tubules, bacteria (scanning electron micrograph), 143f
Dentinogenesis imperfecta, cause, 107-109
Dentition
panoramic radiograph, **e4f**
reconstruction, long-term goals, 404
variation, 148
visualization/analysis, diagnostic model, **e4f**
Dentoalveolar ablations, 363
Dentogingival area, leukocytes (usage), 216-217
Dentogingival fibers, 78
Dentogingival unit, 15
connective tissue component, 78
epithelial component, characteristics, 78b
Dentoperiosteal fibers, 78
DentoRisk, **e96**
Dentifrices, 487-488

For entries that have a boldface page reference, i.e., 179.e2, go to the Expert CONSULT website at www.expertconsult.com, and after registering, search for the term on the book website.

Dentrix Dental Systems, **e94**
Deoxyribonucleic acid (DNA)
  answers, 105-107
  band pattern, isolation, 152f
  exchange, 139
  intercellular exchange, 151
  variants, 106-107
  variation, inheritance, 101
Depression, 195-196
Depression, side effect, 422
Dermatitis herpetiformis, 273
  histopathology, 273b
  treatment, 273
Desmopressin, 428-430
Desquamation
  ferric sulfate misuse, impact, **e41f**
  formation, **e39f**
  raki, usage, **e10**
  severity, **e32f**
  soap toothbrushing, association, **e43f**
  spontaneous bleeding, combination, **e33f**
Desquamative gingivitis
  biopsy, 261-262
  chronic desquamative gingivitis, 261
  clinical examination, 261
  clinical history, 261
  clinical presentation
    conditions, 263t, 265t
    diseases, 262-275
  conditions, mimicry, 275-276
  diagnosis, 261-262
  diagnostic approach, 262f
  gingival erythematous candidiasis, 336f
  immunofluorescence, 262
  lichen planus, impact, 262-267
  management, 262
  microscopic examination, 262
  presentation, appearance, 266f
Destructive periodontal disease, risk-based diagnosis, 74-75
Developmental/acquired deformities/conditions, 63-66
Developmental deformities/conditions, 46, **e10**
Developmental gingival enlargement, appearance, 243f
Developmental grooves, 400
DFDBA. *See* Demineralized freeze-dried bone allograft
Diabetes
  biologic mechanisms, impact, 210
  control, laboratory evaluation, 426b
  endocrine disorders, 425-428
  glycemic control, periodontal infection (association), 211
  guidelines, 426-427
  infections, association, 187
  management, oral agents (usage), 427t
  periodontal condition, 188f
  periodontal disease risk factor, 391
  risk factor, 817
Diabetes mellitus, 186-189, 699, **e49**
  bacterial pathogens, 188
  collagen metabolism, alteration, 189
  complications, 210b
  diagnostic criteria, 426b
  oral manifestations, 187-188
  periodontal disease, relationship, 210-211
  polymorphonuclear leukocyte function, 188-189
Diabetes mellitus *(Continued)*
  role, 817
  Type 1 diabetes mellitus, 187
  Type 2 diabetes mellitus, 187
Diabetic ketoacidosis, 428
Diabetic periodontitis, 75
Diagnosis, 74-75
  challenge, 113
  definition, 74
  prognosis, relationship, 401-403
Diagnostic imaging, clinical selection, 719-720
Diagnostic study models, 698
Diamond-coated files, 504
Diamond files, 504f
Diastema, **e4f**
  closure, **e6f**
Diastolic blood pressure, 420
Differential implant site preparation (DISP), 781
Differentiation, 12
Diffuse gingivitis, 224
Diffuse localized melanin pigmentation, **e13f**
Diffuse melanin pigmentation, esthetic considerations, **e12f**
Digital Imaging and Communications in Medicine (DICOM), 710
  scan data, 714f-715f
Digital intraoral radiography, 386-387
Dihydropyridine derivatives, 236
Diphenylamine, 548-549
Diphtheria, necrotizing ulcerative gingivitis (differentiation), 247t
Direct-to-consumer models, 114
Direct vasodilators, 423
Discharge criteria, 417b
Disclusion, 536
Discoid lupus erythematosus (DLE), 273-274
Disease
  activity
    determination, 371
    measurement, 520
    tests, 675-676
  clinical signs, pathogenesis (linkage), 88-89
  health transition, 160-167
  occurrence
    comparison, 104
    genetic epidemiological examination, 104
  periodontitis, 107-109
  protection, AA genotype (usage), 106-107
  recurrence, symptoms/causes, 674t
  risk, biomarkers, 101
  risk factors, 316-318
Disease, definition, 74
Diseases, occurrence (measurement), 68-69
DISP. *See* Differential implant site preparation
Displaced flaps, 582
Distal angulation, 725f
Distal flap surgery, excision, 560
Distal molar surgery, 599-602
Distal pockets, treatment, 600
Distobuccal root resection, diagrams, **626.e4f**
Distraction osteogenesis, 758
Disuse atrophy, 38
Diuretics, 423
Dizygotic twins, disease occurrence (comparison), 104
DLE. *See* Discoid lupus erythematosus
Dodecanol, 548-549

For entries that have a boldface page reference, i.e., 179.e2, go to the Expert CONSULT website at www.expertconsult.com, and after registering, search for the term on the book website.

Dog
experimental occlusal trauma, 303f
jaw, lamina dura (foramina perforation), 26f
pigmented gingiva, melanocytes (presence), 13f
Dorsal tongue mucosa, irregular surface topography, 545
Dosing
incremental dosing, 413
supplemental dosing, 413
Double-ended curette, usage, 497f
Double-ended Gracey curettes, pairing, 498
Down syndrome (trisomy 21), 107-109
Doxycycline, 517
Atridox, usage, 522
comparative studies, 524
gel (Atridox), **e99**, **e102**
placement, 522f
hyclate gel (Atridox), **e100f**
low-dose doxycycline (LDD), 528
sub-antimicrobial-dose doxycycline, 526
subgingival doxycycline, 522-523
Draining sinus, orifice (nodular mass), 374f
Dramatic bone destruction, clinical picture/intraoral radiograph, 165f
Drills
countersink drill, 732-733
pilot drill, 732
sequence, 735f
3-mm twist drill, 732
2-mm twist drill, 732
Drug-associated gingival enlargement, 587-589
flap technique, 588-589
gingivectomy, 588
treatment options, 587-589
Drug-induced gingival diseases, **e25**
Drug-induced gingival enlargement, 234-236, 256
clinical features, 234-235
decision tree, 589f
gingivectomy technique, usage, 590f
histopathology, 235b
information, 234-235
occurrence, 234
recurrence, 588-589
Drug-induced hyperpigmentation, zidovudine use (impact), 339f
Drugs
clinical research, phases, **e99t**
development, **e103-e115**, **e123-e124**
phases, **e123**
eruptions, 275
registration, **e103-e115**, **e123-e124**
safety/efficacy, evaluation, **e123**
study drug effects (interpretability), results analysis (impact), **e125-e126**
Dry mouth, 354, 546
D series resolvins (RvD), 89

E
Early human gingivitis lesion, 222f
Early implant designs/materials, limitations, 658
Early-onset aggressive periodontitis, cause, 107-109
Early-onset diseases, aggressiveness, 51-52
Early-onset periodontitis, 165-166
EBDM. *See* Evidence-based decision making
EBM. *See* Evidence-based medicine
Ecchymosis, evidence, 190f
Ecological plaque hypothesis, 158
Ecologic plaque hypothesis, periodontal diseases (relationship), 158f
Edentulous arch, design, 693
Edentulous areas
periapical radiograph, high-resolution detailed image, 707f
Edentulous areas, clinical photographs, 702f
Edentulous edges, mucogingival deformities/conditions, 54
Edentulous maxilla, CT examination, 709f
Edentulous molar maxillary area, radiograph, 562f
Edentulous patients, 693-694
Edentulous posterior left mandible, radiographic evaluation, 718f
Edentulous ridges
defects, clinical image, 66f
mucogingival deformities/conditions, 63-66
Edentulous right/left treatment areas, 660f
Edentulous space
evaluation, CBCT images (usage), 711f
Edentulous space, continuous pack coverage, 570f
eDNA. *See* Extracellular DNA
Ehlers-Danlos syndrome, 107-109
Eikenella corrodens, 423, 440
ELAM-1. *See* Endothelial leukocyte adhesion molecule-1
Elastic connective tissue fiber, 17
Elastic ligature, usage, 127f
Elastics, usage, 126-127
Electrocoagulation, 573
Electronic dental records (EDRs)
communication/collaboration, limited functionality, **e94-e95**
data representation/interoperability, **e95**
functionalities/components, **e92**
future, **e96**
information content standards, **e95**
learning curve, steepness, **e95**
potential, realization (challenges), **e95**
reliability, insufficiency, **e95**
reuse, research purposes, **e95**
suboptimal usability, **e95**
usage, **e92-e96**, **e92**, **e94**
barriers, **e94-e95**
benefits, **e95**
Electronic nose, 549
Electronic periodontal probing, 370
Electrosection, 573
Electrosurgery (radiosurgery) techniques/instrumentation, 573
Electrotomy, 573
Elevation, 731-732, 737
EMBASE, **e76**
Embrasure spaces, variation, 491
EMD. *See* Enamel matrix derivative
Emergence profile (reproduction), custom impression transfer coping, 774f
Emergency equipment, 566-567
Enamel epithelium, reduction, 15-16
Enamel formation, completion, 17
Enamel matrix derivative (EMD)
safety, 617
usage, 616-617
Enamel matrix proteins, 527
Enamel surface, 407f
pellicle, calculus attachment, 118f
Endocrine disorders, 186-190, 258, 425-428
Endocrine system, **e20**
Endodontic disease, bacteria (role), 473
Endodontic infection, treatment (absence), 474
Endodontic lesions, periodontitis (association), 61-63, **e10**

For entries that have a boldface page reference, i.e., 179.e2, go to the Expert CONSULT website at www.expertconsult.com, and after registering, search for the term on the book website.

Endodontic-periodontal lesions, 61
appearance, **e71f**
Endodontic/periodontal prognosis, **542.e8**
Endodontic-periodontic lesions
endodontic/periodontal therapies, requirement, 477
independent endodontic-periodontic lesion, 478f
treatment considerations, 477-478
Endodontic-periodontic lesions, classification, 471f
Endodontic procedural complications, periodontium (effect), 478-479
Endosseous implant, positioning, 665f
Endosteum, 34-35
Endothelial leukocyte adhesion molecule-1 (ELAM-1), 207-208
Endotoxins, reservoir, 207
Endpoint
cross-classification, two-by-two table (usage), **e86t**
definition, modification, **e84**
End-tidal carbon dioxide, monitoring, 417
Enhanced visual acuity, correlation, 633f
Enlargements, 237-240
acute inflammatory enlargement, 233-234
chronic inflammatory enlargement, 232-233
conditioned enlargements, 237-239
drug-induced gingival enlargement, 234-236
false enlargement, 243
idiopathic gingival enlargement, 236-237
inflammatory enlargement, 232-234
marginal enlargement, 237
neoplastic enlargement, 240-243
pregnancy, association, 239
puberty, 238
tumorlike gingival enlargement, 237-238
vitamin C deficiency, 238-239
Entamoeba gingivalis, 156
Eosinophils, 18
Epidemiological studies
designs, 71-72
impact, 68
Epidemiologic studies, usage, **e87**
Epidemiology
evidence, emergence, 68
requirements, 68-71
Epidermal blisters, occurrence, 270
Epilepsy patient, gingival enlargement, **e25f**
Episodic-burst model, 315
Epitactic concept, 120
Epithelial adaptation, 406
periodontal treatment, impact, 407f
Epithelial attachment (EA)
apical edge, 688
histologic scheme, 690f
Epithelial cells
cell-to-cell junctions, 91
Fusobacterium nucleation invasion, 82f
stimulation, 91
tombstone appearance, 270b
Epithelial desquamation areas, 282
Epithelial downgrowth, 691f
Epithelial intercellular spaces, scanning electron micrograph, 136f
Epithelial rests, distribution, 25
Epithelial rests of Malassez, 25, 25f
Epithelial surface
scanning electron microscopic view, 15f
sloughing, clinical images, 50f
Epithelial tissues, 91
Epithelioid angiomatosis (bacillary angiomatosis), 338
Epithelium, 687-688
elimination, curettage (usage), 576
physical barrier, 88
Epstein Barr Virus (EBV), 165
impact, 337
ePTFE. *See* Expanded polytetrafluoroethylene
Epulis, 240
Erectile dysfunction (ED), periodontal disease (role), 209
Erosion (corrosion), 362-363
Erosive lesions (ulcerative lesions), 265
Erosive lichen planus
appearance, 265f
desquamation/spontaneous bleeding, **e33f**
desquamative gingivitis, presentation, 266f
Error rates, types, **e86**
Erupting tooth, junctional epithelium (formation), 16f
Eruption cyst, 252
appearance, 253f
Eruption gingivitis, 256
Erythema multiforme, 274-275
appearance, 275f
duration, 274
histopathology, 274b-275b
immunofluorescence, 275
oral lesions, 274-275
treatment, 275
Erythematous candidiasis (presence), 336
Escharotic drugs, 462
E-selectin, 79
E series resolvins (RvE), 89
Esophageal-type cytokeratins, **14.e1**
Essential hypertension (primary hypertension), occurrence, 420-421
Essential oils, 550
Essex provisional, delivery, **769.e4**
Esthetics, **542.e7**
complications, 792, 802-803
avoidance, 797
considerations, 696
diffuse melanin pigmentation, impact, **e12f**
examination, components, 766
implant placement, 751
outcome, intraoral/extraoral perspective, 664f
problems
gingival recession, impact, 800f
melanin pigmentation, impact, **e12f**
restoration (impossibility), implant position (impact), 803f
results, 817-818
success, 818
surgical strategy, 765, 767, **769.e3**
tissue preservation, **765.e1**
Esthetic surgery
techniques, 552
therapy, 629
Esthetic tissue management, 655-656
Esthetic zone, 655
implant placement, 802
Estrogen receptor (ESR1), 110
Ethical principles, impact, **e88**
Ethosuximide (Zarontin), 235
Ethotoin (Peganone), 235
Eubacterium nodatum, 161-163
Event, odds (probability), 69

For entries that have a boldface page reference, i.e., 179.e2, go to the Expert CONSULT website at www.expertconsult.com, and after registering, search for the term on the book website.

Evidence
acquisition, **e77-e78**
application, 817-818
appraisal, **e78-e79**
assessment, tools, **e82-e90**
consumer, becoming, **e73-e77**
evaluation, 204t
levels, **e76-e77**, **e76t**
search, **e77-e78**
suppression, **e89**
Evidence-based clinical practice, 203-204
Evidence-based decision making (EBDM), 535-536
background/definition, **e72**
clinical application, case scenario, **e74b**
diagram, **e73f**
pathway, **e75f**
principles, **e72-e73**
process, application skills/abilities, **e73b**
skills, **e73-e80**
tool, value, **e79-e80**
Evidence-based dentistry, **e72-e73**
usage, **e79**
Evidence-based medicine (EBM), **e72**
Evidence-based sources, types, **e75-e76**
Exacerbation period, 285
Excisional instruments, 572-573
Excisional new attachment procedure, 577-578
example, 578f
Excursion, 536
evaluation, 538
Excursive movement, 536
Exogenous cortisone, adverse effect, 200
Exophytic squamous cell carcinoma, 242
Exostoses, 294-295, 561-562, 613
buccal exostosis, clinical photograph, 563f
Expanded polytetrafluoroethylene (ePTFE)
membrane, removal, 757-758
Expanded polytetrafluoroethylene (ePTFE) barrier membrane, 741f
Experimental gingivitis, human biopsy sample, 220f-221f
Experimental occlusal trauma
dog, 303f
rats, 302f
Explorers, 494
types, 495f
insertion, 495f
viewing periodontal explorers, 505f
Exposure
cross-classification, two-by-two table (usage), **e86t**
definition, modification, **e84**
randomization, absence, **e87**
Extended-shank curettes, 499-500
External insulin, impact, **e51f**
External oblique ridge, 558
Extracellular DNA (eDNA), virulence factor, 82-83
Extracellular enzymes, 151
Extracted lower molar (distal root), subgingival calculus (dark-pigmented deposits), 141f
Extraction
alveolar ridge preservation/management, 746-747
site, implant drilling, 770-771
Extraoral bruising, clinical photograph, 795f
Extraoral halitosis, 544
Extraoral preoperative condition, 659f
Extraoral sites, bone (retrieval), 614
Eyeglass-mounted prism loupes, 641f
EZcodes, **e95**

F
Face
Sturge-Weber syndrome, unilateral cavernous hemangiomas, **e38f**
swelling, complaints, **e58f**
Facial asymmetry, **e37f**
Facial bone, lipping, 295f
Facial bony contours, tooth position (effects), 606f
Facial connective tissue graft, 772f
Facial gingival surface, gingival abscess, 233f
Facial interdental papillae, 11f
Facial lesions, radiograph, 382f
Facial pocket, gutta-percha points (placement), 386f
Factitious lesions, 275
Factitious traumatic lesions, **e40**
Fair prognosis, 394
False enlargement, 243
Familial aggregation, 106t
Favorable prognosis, 394
FDBA. *See* Freeze-dried bone allograft
Female reproductive cycle, 438f
Female sex hormones, 189-190
Femoral artery bypass, 423
Fenestration, 36
defects
exposure, 743
management, 743
observation, 743f
dehiscence, 37f
Ferric sulfate, misuse, **e41f**
Fetor ex ore (term), 362, 544
Fetor oris (term), 362
Fiber bundles, cuff-like circular orientation, 689
Fibers, 20
apical fibers, 24
circular fibers, 18
gingivodental fibers, 17
groups, diagram, 24f
horizontal fibers, 24
interradicular fibers, 24
oblique fibers, 24
principal fibers, 23
Sharpey fibers, 23
transseptal fibers, 18, 24f
Fibrils, 23f, 167
Fibroma, 240, **e44f**
appearance, **e10**
histopathology, 240b
Fibrosarcoma, 242
Fibrotic pocket walls, 282-283
Fibrous dysplasia, unilateral fibroosseous expansion, **e37f**
Field of view (FOV), 709
Filaggrin, **11.e1**
Files, 503
diamond-coated files, 504
File scalers, 494, 503f
Fimbriae, virulence factor, 82
Final crowns, 663f
Final implant site preparation, precision (enhancement), 735b
Fingers, developmental deformities, **e35f**

For entries that have a boldface page reference, i.e., 179.e2, go to the Expert CONSULT website at www.expertconsult.com, and after registering, search for the term on the book website.

Finite element analysis, 724b
First incision, 584
First lower molar, mesial root (recession), 630f
First molars
advanced alveolar bone resorption, clinical/cone-beam computed tomography, **e56f**
angular bone loss, furcation (involvement), 381f
furcation involvement, 384f
human head, frontal section (diagram), 564f
mesial surface, angular defect, 296f
radiographic evaluation, 717f
replacement failure, 306-307
First molar tooth replacement, diagnostic models (photographs), 701f
First premolar, canine/fenestration (dehiscence), 37f
Fistula, impact, 799f
Fistula tract, clinical images, 63f
Fixed-bone-anchored bridge, usage, 693
Fixed macrophages, 18
Fixed partial dentures (FPDs), 793
Flapless dental implant microsurgery, 771f
Flaps
apically displaced flap, 593
classification, 582
closure, 735, 738
maintenance, 758
design, 582-583, 583f, 731-732, 737
displaced flaps, 582
elevation, 585-586
Bard-Parker knife, usage, 586f
example, 585f
full-thickness flap, 582
internal bevel incisions, locations, 594f
management, 739-740
nondisplaced flaps, 582
operation, epithelialization, 572
partial-thickness flap, 582
partial-thickness repositioned flap, 736-737
scalloping, requirement, 594f
submerged position, 739-740
surgery
healing, 586
incisions, usage, 584f
usage, 593, 598-599
varices, incision, 597
Flap technique, 588-589
access technique, 593
incisions, 593-594
overview, 593-594
pocket depth reduction/elimination technique, 593
Florida Probe System, 370-371
example, 371f-372f
Floss. *See* Dental floss
Flossing, 811f
contraindication, 260
devices. *See* Powered flossing devices.
facilitation, 490
Fluorides, caries-preventive effect, 487
Fluoride, usage, 450
Focal infection theory, 203
problems, 203
proposal/defense, 204
Follicle-stimulating hormone (FSH), production, 438
Follicle, widening, 127f
Follicular phase, 438
Food
accumulation, 545
debris, 121
impaction, 123-124, 295
abnormalities, 124
Food and Drug Administration (FDA) registration, clinical trials, **e103-e115**
Forced eruption, **542.e6-542.e8**
Foreign body
gingivitis, 276
impaction, proliferative gingival overgrowth, 52f
reactions, 50
Formyl peptide receptor (FPR1), 110
Fosamax, 357
Four-unit FPDs, 801f
FPDs. *See* Fixed partial dentures
Fractionation, 130
Fractured central incisor, X-ray, 771f
Fractured implant, radiograph (usage), 802f
Fractured porcelain, 802f
Fractured root, extrusion, **542.e7f**
Fractured teeth, **542.e6-542.e8**
Fractures, 801
extension, mesiodistal orientation, 664f
level, **542.e7**
Fragmented sleep, hypnogram, 352f
Free gingival groove, 9
Free gingival margin, 655f
Freeze-dried bone allograft (FDBA), 614-615
demineralized FDBA, 615
usage, 740
Frontal process, 560
Full-arch FPDs, 800f
Full-course radiation treatment, 433
Full-mouth disinfection, 457-458
Full-mouth series, periapical/bite-wing radiographs, 380f
Full-thickness flap, 582, 586
internal bevel incision, diagram, 583f
raising, 731
Full-thickness periosteal flaps, release, **769.e1f-769.e2f**
Functional antagonist teeth, loss, **e15f**
Functional crown lengthening, lasers (usage), 647-648
Functional imbalance, 300
Functional occlusal relationships, 366
Furcation
advanced defects, 624
anatomy, 622
areas
access, 400
Nabers probe, usage, 495f
Class III furcation involvement, clinical picture, 627f
defects (treatment), hemisection/osseous surgery (usage), **626.e5f**
dental implants, 626
early defects, 624
entrance, narrowness, 401f
etiologic factors, 621
hemisection, **626.e1**
dimension, **626.e3f**
interradicular dimension, **626.e3f**
lesions, considerations, **542.e5**
nonaggressive techniques, usage, 625
nonsurgical therapy, 625
oral hygiene procedures, 625
Pero-Aid, utilization, 625f

For entries that have a boldface page reference, i.e., 179.e2, go to the Expert CONSULT website at www.expertconsult.com, and after registering, search for the term on the book website.

Furcation *(Continued)*
prognosis, 626
regeneration, impact, 626
root resection, **626.e1**
scaling and root planing (SRP), 625
surgical therapy, 626
treatment, 624
Furcation defects, **542.e5**
classification, **542.e5**
diagnosis/classification, 621
therapeutic classes, 624
two-walled/three-walled components, 626
Furcation involvement, 298-299, 383, 623f
degrees
appearance, 299f
radiographs, 622f
dental findings, 623
example, 381f
first molar, 384f
Glickman's classification, 624f
grade III cervical enamel projections, 623f
indication, triangular radiolucency (usage), 384f
indices, 623-624
mandibular first/second molars, 384f
possibility, 369
prognosis/treatment, anatomic features (impact), 623f
suggestion, 384f
Fusobacterium nucleation, **55.e1**
growth, 134f-135f
invasion, 82
levels, elevation, 437
prevalence, 322

G
Gamma-aminobutyric acid (GABA), 439
GAP. *See* Generalized aggressive periodontitis
Gas chromatography, 548
machinery, 548f
Gastroesophageal reflux disease (GERD), 355
susceptibility, 438-439
GBR. *See* Guided bone regeneration
GCF. *See* Gingival crevicular fluid
Gelatinase B, 80
GEM 21S, 527, 618
Gene association reports, 111t
Gene association tests, cases/*P* values, 110f
Gene-mapping strategy, 105
General anesthesia, 414
ADA guidelines, 412
ADA policy statement, 411-412
definition, 413f
patient preference, 412f
Generalized aggressive periodontitis (GAP), 165-166, 325, 331
appearance, 326f-327f
clinical/radiographic views, **e57f**
crown-to-root ratio, problems, 399f
diagnostic criteria, 325t
Generalized bone loss
advanced chronic periodontitis, **e48f**
chronic periodontitis, presence, **e47f**
Generalized calculus deposit, 255f
Generalized chronic periodontitis, 309
clinical features, 310f
Generalized diffuse gingivitis, 224
appearance, 225f
Generalized horizontal bone loss, 381f
Generalized human papilloma virus-associated warts, **e45f**
Generalized marginal gingivitis, 224
appearance, 225f
Generalized papillary gingivitis, appearance, 225f
Generalized periodontitis, host modulation (usage), 531
Generalized radiographic bone loss, **e46f**
Generalized severe chronic periodontitis, 397f
Genetic association study, case-control design, 107f
Genetic disorders, 195, **e60**
Genetic drift, 104
Genetic epidemiology, 102-104
Genetic factors, 397-398
importance, 161
Genetic heterogeneity, 104-105
Genetic methods, 102-107
Genetics
study, techniques, 106t
usage, 113-114
Genetic syndromes, periodontitis, 107-109
Genome-wide analyses, 106t
Genome-wide association studies (GWAS), 102
method, usage, 105-106
studies
failures, 113
susceptibility alleles, observation, 109
usefulness, 107
Genomic methods, 102-107
Genotype frequencies, 106-107
Genuine halitosis, 544
classification, 545f
Germany, periodontitis (prevalence), 316f
Gerontogene(s), 447
Getting long in the tooth, expression, 43
GG genotype, 113-114
Gingipains, 82, 167
Gingiva, 9-23
accidental damage, 49-50
advanced chronic periodontitis, **e12f**
allergic reaction, diagnosis (oral challenge test), **e39f**
allergic response, 51f
anatomic landmarks, 10f
apparent/actual positions, diagram, 230f
appearance (adult), 10f
appearance (child), 253f
assessment, 366
attached gingiva, 10
mean width, 10f
benign tumors, 240-242
biopsy, 22f
blood supply, 18-19, 19f
buccolingual section, 688f
calcified masses, 228
clinical appearance, 20f
clinical features, 9-10
microscopic features, correlation, 20-23
color, 20
changes, 227-228
consistency, 21
changes, 228-229
clinical/histopathologic changes, 229t
contour, 20-21
contouring, adjunctive procedure, 462
destruction, mucormycosis infection (impact), **e29f**
discoloration, metal particles (impact), 228f

For entries that have a boldface page reference, i.e., 179.e2, go to the Expert CONSULT website at www.expertconsult.com, and after registering, search for the term on the book website.

Gingiva *(Continued)*
female, **e10f**
histologic appearance, 77f
histologic slide, 692f
incipient gingivitis, 368f
interdental area, 9
interdental col, anatomic variations, 11f
interdental gingiva, 10
keratinization, decrease, **e38f**
keratinized gingiva, scanning electron micrograph, 13f
lesions, acute streptococcal gingivostomatitis (impact), **e26f**
leukoplakia, 242f
lymphatic drainage, 19
lymphatics, 18-19
malignant tumors, 242-243
marginal area, 9
medications, impact, 227
melanotic pigmentation, 20f
metallic pigmentation, 227-228
metastasis, 242-243
microscopic examination, 220
microscopic features, 10-19
clinical features, correlation, 20-23
mucositis, **e28f**
nerves, 18-19
opportunistic bacterial infection, 195f
papilloma, 241f
passive eruption, diagrammatic representation, 22f
pemphigus vulgaris, 270f
periodic localized color changes, **e21f**
peripheral circulation, 19f
pigmentation, apicoectomy/amalgam retrofill (impact), 52f
plaque accumulation, **e12f**
position, 22-23
changes, 229-230
positions, 229-230
recontouring, 580
red color, **e12f**
sarcoma, 242
shape, 21
shelflike contour, 21f
size, 20
spontaneous bleeding, decrease, **e38f**
squamous cell carcinoma, 242f
staining, periodic acid-Schiff histochemical method (usage), 14f
stippling
appearance, **e11f**
loss, **e11f**
surface texture, 21-22
surface texture, changes, 229
swelling, complaints, **e58f-e59f**
swollen/spongy gingiva, leukemia (primary medical diagnosis), 49f
toothache, plant seed placement, **e43f**
toothbrushing, impact, 229
traumatic lesions, 229
Gingival abscess, 233, 461
appearance, 233f
etiology, 233
histopathology, 233b
periodontal abscess, relationship, 374
Gingival bleeding
acute episodes, 226-227
chronic bleeding, 226-227
Gingival bleeding *(Continued)*
hemorrhagic disorders, 227
increase, 439
local factors, 226-227
probing
appearance, 226f
usage, 225-226
recurrent bleeding, 226-227
severity, factors, 226
spontaneous bleeding, 227
systemic changes, impact, 227
variation, 225
Gingival connective tissue, 17-19
aging, impact, 40-42
repair, 18
Gingival contour
changes, 230
irregularity, 222f
Gingival crevicular fluid (GCF), 78, 92
amount, 215
analysis, 216
cellular elements, 215
cellular/humoral activity, 216
chlorhexidine, release, **e98**
circadian periodicity, 216
clinical significance, 216
collagenase, presence, 529
collagenase, SDD (effect), 531f
components, analysis methodology, 215
composition, 215
drugs, usage, 216
electrolytes, presence, 215
flow, increase, 79, 94, 183
IL-18 levels, correlation, 84-85
measurement, electronic device (usage), 215f
mechanical stimulation, 216
metabolic/bacterial products, identification, 215
organic compounds, 215
periodontal therapy, 216
PGE_2 levels, 440-441
presence, 214
serum transudate, 119
sex hormones, 216
smoking, relationship, 216
total protein content, 215
Gingival curettage, 576-578
clinical appearance, scaling/curettage (usage), 578
extent, 577f
healing, scaling/curettage (usage), 578
indications, 577
procedure, 577-578
rationale, 576-577
techniques, 577-578
Gingival cyst, 241-242
histopathology, 242b
Gingival desquamation, cologne (impact), **e42f**
Gingival discrepancies, orthodontic treatment, **542.e9-542.e11**
Gingival diseases, 45-50, 47b, 339-343, 358b
atlas, **e9b-e10b**
bacterial origin, 47-48
dental-plaque-induced gingival diseases, 45-47
fungal origin, 47-49
genetic origin, 49
malnutrition, impact, 401

For entries that have a boldface page reference, i.e., 179.e2, go to the Expert CONSULT website at www.expertconsult.com, and after registering, search for the term on the book website.

Gingival diseases *(Continued)*
modification
malnutrition, impact, 47
medications, impact, 46-47
systemic factors, impact, 45-46
prognosis, 401
systemic factors, impact, **e20**
viral origin, 47-48
Gingival disturbances, blood dyscrasias (association), 190-191
Gingival embrasure volume, papillary form (relationship), 655f
Gingival enlargement, 232, 401
acute lymphocytic leukemia, **e59f**
bone augmentation, association, 243f
cyclosporine, usage, **e25f**
designation, 232
drug-associated gingival enlargement, 587-589
induction, phenytoin administration (usage), 235
inflammatory involvement, impact, 234f
juvenile hyaline fibromatosis, **e35f**
leukemia
clinical features, 239-240
impact, 239
microscopic view, 235f
mouth breather location, 233f
occurrence, 235
phenytoin therapy, impact, 234f
pregnancy, **e21f-e22f**
microscopic view, 238f
recurrence, 592
systemic diseases, impact, 239-240
types, classification, 232
Gingival enlargement, orthodontic appliance/oral hygiene (association), 126f
Gingival epithelium, 11-17
biology, 11
cell type, 12
characteristics, 78
components, 12
features, 12b
function, 12, 12b
keratinization, decrease, 40
oral aspect, 13f
renewal, 16-17
structural/metabolic characteristics, 14
thinning, 40
variations, 14f
Gingival erythematous candidiasis, 336f
Gingival fibers, 17-18
faciolingual section, 18f
Gingival fluid (sulcular fluid), 17
Gingival form, factors, **542.e9**
Gingival giant cell granuloma, 241f
Gingival hemorrhage, 192-194
Gingival hyperplasia, 232
acute myelogenous leukemia, association, **e23f**
Gingival index, 366
Gingival Index (GI), 70
Gingival inflammation, 50f
appearance, 362f
area, 291f
biologic width violation, impact, **e40f**
calculus, indirect contribution, 120
extension, impact, 290-294
Gingival inflammation *(Continued)*
histopathologic alterations, impact, 226
impact, 148, **e41f**
measures, 70
molar, appearance, 298f
orthodontic appliance/oral hygiene, association, 126f
pathways, 292f
plaque accumulation, impact, 553f
presence, 19f
resolution, 650f
signs, 141f
spontaneous bleeding, **e24f**
Gingival innervation, 19
Gingival lesions
genetic origin, 47, **e30**
lichen planus, 265-266
Gingival margin
attached tissues, distance, 369f
crown/root surface, relationship (diagram), 41f
discrepancy, **542.e9**
position, variation, 41f
unevenness, **542.e9-542.e10**
Gingival margin, scanning electron micrograph, 13f
Gingival massage, 493
Gingival mucous membrane pemphigoid, appearance, 268f
Gingival necrosis, **e68f**
Gingival overgrowth, 232
calcium channel blocker, usage (clinical images), 49f
proliferation, 52f
Gingival overgrowth, heart transplant/cyclosporine therapy (impact), 49f
Gingival pigmentation, causes, 227-228
Gingival plexus, neutrophil migration, 94
Gingival pockets, 277
therapy, 555
Gingival recession, 229-230, 739
appearance, 254f, **e63f**
atrophy, 22-23
causes, 629
clinical photograph, 796f
clinical significance, 230
degree, 372
habitual cleansing, **e43f**
inadequacy, **e36f**
increase, 229-230
nail scratching, **e43f**
root, prominence, 125f
self-inflicted trauma, impact, 128f
severity, 229
thalassemia, **e24f**
Gingival responses, etiology, 441b
Gingival retraction, ferric sulfate (misuse), **e41f**
Gingival sulcular depth, 252
Gingival sulcus, 9-10
development, 15-16
epithelial surface, scanning electron microscopic view, 15f
epon-embedded human biopsy specimen, 15f
filter strip, placement, 215f
formation, 16
keratinocytes, exfoliation, 13f
probing depth, 9-10
spontaneous bleeding, thrombocytopenia (impact), 192f
Gingival surgery, **542.e8**
Gingival thickening, steroid injections (usage), **e26f**
Gingival third, provisional restoration, 662f

For entries that have a boldface page reference, i.e., 179.e2, go to the Expert CONSULT website at www.expertconsult.com, and after registering, search for the term on the book website.

Gingival tissues
advanced histologic changes, 79
bacteria
impact, 110
presence, 82
early histologic changes, 79
edematous characteristics, 438
health, 77-78
histologic changes, 79
initial histologic changes, 79
scanning electron microscopic view, 20f
steady-state equilibrium, 78
Gingival trauma, 126
ligature wire, impact, **e42f**
Gingival tumors (neoplastic enlargement), 240-243
Gingival wall, microtopography, 282
Gingival width, insufficiency, **e35f**
Gingivectomy, 578-580, 588
incision, 600
indications/contraindications, 578-579
knives (periodontal knives), 572
examples, 573f
performing, 588
surgical gingivectomy, 579-580
technique, usage, 590f
usage, 579f
Gingivitis, **152.e1**
advanced gingivitis, 223f
advanced lesion, 80-81
advanced stage, 219
anatomic/histologic changes, 19
bacterial etiology, experimental proof, 146f
categorization, 219
chronic gingivitis, 224
clinical features, **e10**
evaluation, systematic approach, 224-225
clinical findings, 224-230
color changes, 227
course/duration, 224
dental plaque, association, 401
description, 224
development, observation, 78-79
diffuse gingivitis, 224
early human gingivitis lesion, 222f
early lesion, 79-80
early stage, 219
established lesion, 80
established stages, 219
establishment, 222f
experimental gingivitis, human biopsy sample, 220f-221f
histologic appearance, photomicrographs, 80f
histologic stages, features, 79b
histopathology, 78-81
HIV-associated gingivitis, 48-49
initial lesion, 79
initial stage, 219
marginal gingivitis, 224
occurrence, 224
papillary gingivitis, 224
plasma cell gingivitis, 239
pregnancy-associated gingivitis, 163
prevention, 677
progression, 223
recurrent gingivitis, 224
smoking, effects, 179
Gingivitis *(Continued)*
stages, 220t
treatment, 677
Gingivodental fibers, 17
diagram, 18f
Gingivoplasty, 580
performing, 588
Glanzmann thrombasthenia, impact, **e24f**
Gleevec, usage, 377
GLT6D1, aggressive periodontitis (association), 112
Glucometers, usage, 426-427
Glucose measurements, estimation, 426t
Glutathione S-transferase mu 1 (GSTM1), responsibility, 110
Glycemic control
improvement, periodontal treatment (association), 210-211
periodontal infection, association, 211
problem, chronic gram-negative periodontal infections (impact), 211
Glycemic control, periodontal therapy (impact), 210
Glycogen, intracellular accumulation, **14.e1**
Glycosylated hemoglobin (HbA1c)
assay, 426, 426b
values
comparison, 426t
graphic representation, 426f
Glycosyltransferase (GLT6D1) gene, 110
Gold alloy crown, 122f
Goldman-Fox scissors, 574f
Good prognosis, 394
Gracey curettes, 497-499, 500f
additions, 499
After Five curette, comparison, 500f
blades
acute turn, 498f
comparison, 501f
design, 499f
mini-bladed curettes, 500-501
set, reduction, 498f
shank availability, 499
universal curettes, differences, 498
Gracey Curvette blade, 501f
Grade I furcation involvement, 623
Grade II furcation involvement, 623
Grade III furcation involvement, 623-624
Grade III furcation lesion, **626.e2f**
Grade IV furcation involvement, 624
Graft-associated reconstructive procedures, 616
Grafted site, stability, 631
Grafts
allografts, 611
autogenous bone grafts, 613-614
autografts, 611
bone allografts, 614-615
materials/procedures, 611-616
microsurgical connective tissue graft, 634f
xenografts, 611, 615-616
Graft-*versus*-host disease
appearance, 276f
occurrence, 275
Gram-predominant species, 163
Granular layer, 14f
Granulation tissue, removal, 594
Granulocytopenia, 191
WBC count, reduction, 194
Granulomatous diseases, 240

For entries that have a boldface page reference, i.e., 179.e2, go to the Expert CONSULT website at www.expertconsult.com, and after registering, search for the term on the book website.

Greater palatine foramen, opening, 560
GroEL molecule, 95
Grooving, 500-501
Ground substance, 17, 25
Growth factors, 527
usage, 762
in vitro effects, 619t
G-specific granules, 12-13
Guarded prognosis, 681
Guidance, 536
Guided bone regeneration (GBR), 661f
augmentation, relationship, 756-758
Guided tissue regeneration (GTR), 611
biodegradable membranes, usage, 611
usage, 610-611
Guided tissue regeneration membrane/titanium-reinforced (GTRM-TR) membrane, 760f
Gum, chewing (impact), 549
Gut-associated lymphoid tissues, 173
Gutta-percha points, 166f
calibrated silver points, usage, 366
placement, 386f
GWAS. *See* Genome-wide association studies

H
Habits, considerations, 704
Haim-Munk syndrome, 107-109
Halitophobia, 545
Halitosis, 362
categories, 544
extraoral causes, 545
Handicap oral hygiene, accumulation, 123
Hard tissues
destruction, mucormycosis (impact), **e28f**
evaluation, 698-699
interface, 685-686
schematic illustration, 687f
Hard tissues, bacteria (adherence), 136
Hayflick's limit, 447
HbA1c. *See* Glycosylated hemoglobin
hBDs. *See* Human β-defensins
HBO. *See* Hyperbaric oxygen
Headache disorders (neurovascular disorders), 347
Headache pain, perception, 347
Head, squamous cell carcinomas, 433
Healing, 482
abutment, occlusal view, 697f
delay, 405
factors, 404-405
gingival changes, 462
hormones, impact, 405
impairment, food intake (impact), 405
improvement, debridement (usage), 405
lesions, 406
local factors, 404-405
new attachment, 406-407
periodontal therapy, relationship, 405-407
repair, 406
success/failure rates, 475
systemic factors, 405
Heart transplant, impact, 49f
Hematologic disorders, 190-195, 258-259
Hematologic laboratory values, monitoring, 431
Hematoma, 795
Hemidesmosomes, impact, 15
Hemisection, **626.e1**
dimension, **626.e3f**
procedure, **626.e1-626.e3**
usage, **626.e5f**
Hemiseptal defects, **542.e1-542.e3**
Hemophilia A
impact, 428-430
patient, plaque accumulation/spontaneous bleeding, **e24f**
Hemophilia B (Christmas disease), 428-430
Hemorrhage, 795
Hemorrhagic disorders, 428-431
Hemorrhaging, excess, 568
Hemostasis, 567-569
absorbable hemostatic agents, 568t
Hereditary gingival fibromatosis, 49, **e30**
intraoral view, **e30f**, **e32f**
tuberosities, enlargement, **e31f**
Heritability, calculation, 113
Herpes simplex virus type 1, electron micrographic picture, 153f
Herpesviruses, 153
recovery, 153t-154t
Herpetic gingivostomatitis, ruptured/unruptured herpetic vesicles, **e27f**
Herpetic lesions
abnormality, 340f
treatment, penciclovir (usage), 376
Herpetic whitlow, 464
Hertwig epithelial root sheath, role, 36-37
Heterogeneous nucleation, 120
Highly active antiretroviral therapy (HAART), 336
High-molecular-weight mucinous glycoproteins, 217-218
High-risk patients (smokers), 529-531
High-sensitivity C-reactive protein (hsCRP) concentration, biochemical bone turnover markets (relationship), 531-532
Histologic descriptions, 79
Histologic pocket depth, 369f
HLAs. *See* Human leukocyte antigens
Hoe scalers, 494, 502-503
design, 503f
usage, 503
Home irrigation, impact, 510
Home/self-applied irrigation, 509-510
Hopeless prognosis, 394
Hopeless teeth
extraction, 650
maintenance, **542.e8-542.e9**
Horizontal bone augmentation, 740-743
ePTFE barrier membrane, expansion, 741f
Horizontal bone loss, 296
appearance, 296f
mandibular implants, impact, 800f
Horizontal fibers, 24
Horizontal incisions, 584-585
Hormonal changes, 186-190, 258
Hormone-exaggerated marginal/papillary inflammation, 48f
Hormone replacement therapy, evidence, **e88**
Horny layer, 14f
Host cells, expression, 172t
Host-cell signaling (disruption), therapeutic strategies (impact), 177
Host-derived inflammatory mediators, 83-84
Host-driven inflammatory response, 535
Host immune response, deficiencies, 191
Host immunity, evasion strategies, 168

For entries that have a boldface page reference, i.e., 179.e2, go to the Expert CONSULT website at www.expertconsult.com, and after registering, search for the term on the book website.

Host modulation (HMT), 404
comprehensive periodontal management, relationship, 527-528
definition, 525
usage, 525
Host proteins (degradation), bacterial enzymes (impact), 149
Host response modulation, 528
Host susceptibility, 161
concept, 97-100
importance, recognition, 202
Host tissue cells, invasion, 163-165
Host-tissue-degrading activity, restriction, 167
Host vaginal epithelial cells, glucose supply, 136
Hough transformation, 788
Human β-defensins (hBDs), 88
expression, 91
Human biologic width, 653f
Human cytomegalovirus (hCMV), 165
Human DFDBA particles, mixture, 744-745
Human herpesvirus-8 (HHV-8), identification, 337
Human immunodeficiency virus (HIV), 320-321
health status, 343
herpetic lesions, abnormality, 340f
HIV-associated gingivitis, 48-49
HIV-infected patients, periodontal treatment, 342
identification, 335
infection
control measures, 343
oral/periodontal manifestations, 335-339
risk, 614
maintenance therapy, 343
psychologic factors, 343
therapy, goals, 343
Human leukocyte antigens (HLAs), 105
HLA-B, reports/findings, 110-111
Humans
disease/nondisease traits, 104
palate, histologic frontal section, 560f
papillomaviruses, grouping, 153
plaque sample, vertical section, 139f
teeth, extraction, scanning electron microscope view, 121f
trauma, occlusion (impact), 304
Huntington disease gene mutation, 104-105
Hydrogen peroxide, 550
Hydrogen sulfide, production, 81-82
Hydrokinetic activity zones, creation, 510
pulsation, impact, 512f
Hydropic degeneration, 14
Hydroxyapatite
bisphosphonate affinity, 198
crystals, alignment, 37
Hygiene
access, restoration, 810f
neglect, **e19f**
plaque accumulation/gingivitis, **e13f**
problems, example, 362f
Hyperbaric oxygen (HBO) therapy, 703
Hypercementosis, 29
cause, variation, **29.e1**
occurrence, **29.e1**
Hyperesthesia, 795
Hyperglycemia, 187
Hyperinflammatory trait, 98
Hyperkeratosis, 59f
Hypermobility, 483
Hyperplasia, 440f
steroid injections, usage, **e26f**
Hyperplastic candidiasis, 337f
Hyperplastic candidiasis, 336
Hyperresponsive monocyte/macrophage phenotype, cardiovascular/periodontal consequences, 209f
Hypersalivation, 354
Hypersensitivity, dental materials (impact), 654-655
Hypersomnolence, 352
Hypertension, 420-422
amlodipine-associated gingival enlargement, **e25f**
diagnosis, absence, 420
Hypertensive patients
dental treatment, 421
treatment, 421
Hypertrophic gingivitis, 232
Hypoesthesia, 795
Hypoglycemia, 427
occurrence, 428
signs/symptoms, 427b
Hypophosphatasia, **e65f**

I
Iatrogenic factors, 121-124
Iatrogenic traumatic lesions, **e40**
ICAM-1. *See* Intercellular adhesion molecule-1
ICTP. *See* Carboxy terminal telopeptide of type 1 collagen
Idiopathic gingival enlargement, 236-237
appearance, 237f
clinical features, 236-237
etiology, 237
histopathology, 237b
information, 236-237
Iliac autograft, placement, 615f
Imaginary breath odor, 545
Imaging modalities, 387
Immediate implant occlusion, 773
Immediate implant placement, 816
Immediate occlusal loading, 816
Immune compromise, 322, 703
Immune deficiencies, 190-195, 258-259
Immune-inflammatory responses, 182-183
Immune responses
aging, impact, 43
nutrition, modulator, 43
Immune suppression, 703
Immunoglobulin A (IgA) antibodies, 90-91
Immunoglobulin-producing plasma cells, recognition, 174
Immunosuppressants, 235-236
Immunosuppressed patient, opportunistic bacterial infection, 195f
Immunosuppression, 433
systemic disease, impact, 463
Immunosuppressive therapy, 200
Impacted mandibular right second molar, **542.e8f**
Impacted maxillary canine, radiograph, 127f
Impacted third molars, extraction, 127
Implacare implant instruments, 502f
Implantable cardioverter-defibrillators, 423
Implant-abutment connection, fistula, 799f
Implant dentistry, surgical aspect, 666
Implantitis, local delivery, 524
Implant placement, 660f, 735
congenitally missing maxillary lateral incisors, radiographic evaluation, 717f
dehiscence defect, observation, 743f

For entries that have a boldface page reference, i.e., 179.e2, go to the Expert CONSULT website at www.expertconsult.com, and after registering, search for the term on the book website.

Implant placement *(Continued)*
delayed implant placement, 746-747
delayed technique, staged technique (differences), 747
disadvantage, 765
edentulous posterior left mandible, radiographic evaluation, 718f
example, 783f-784f
immediate implant placement, 816
loading protocols, 816
maxillary first premolar, extraction, 748f
missing tooth, CBCT examination, 716f
one-stage nonsubmerged placement, 737-738
predictability, 765-766
radiographic follow-up, 720f-721f
simultaneous implant placement, 743-745
space, requirement, 698b
staged implant placement, 747
surgery
clinical view, 734f
differences, 731
surgical techniques, 556
timing, 746
two-stage approach, 762
Implants
advanced plaque/calculus formation, **e15f**
anatomic location, 815
biomechanics, 724b
buccal probing, 806f
buccolingual placement, 797
clinical comparison, 691-692
complications, types/prevalence, 793-794
curve of Spee, 725f
dental implants, 626
dentistry, minimally invasive surgery, 764
design, 815-816
characteristics, 816
examination, 362-366, 805-808
failure, 800-801
detection, radiographic examination (usage), 808
mechanisms, 725b
radiograph, 800f
report, 792
flap surgery, muscles, 562
fracture, 801-802
internal connection collar location, 802f
geometry, 684, 685b
healing, 665f
abutments, 661f
health/maintenance, 703b
immobility, 685
loss, 800-801
macrodesign, 684, 685b
macroscopic configuration, 684
maintenance, 809-810
malposition, 796-798
microsurgery, 770-774
occlusion, 773
osseointegration, evaluation, 809
outcomes
defining, 813-815
factors, 815-817
overload, 725b
avoidance, strategies, 728
panoramic radiograph, 815f
patient (treatment planning), anatomic structures (relationship), 716b
Implants *(Continued)*
penetration (demonstration), CBCT sagittal/cross-section images (usage), 721f
percussion, 807
periapical radiograph, 808f
plaque/calculus formation, **e15f**
plastic/titanium instruments, 502
position, alveolar ridge (relationship), 717-719
primary/secondary stability, 686
probing, 370
provisional crown, creation, 772
restoration, 773-774
evaluation, 809
occlusal schemes, 809
results, 815
stability measures, 807
subcrestal placement, 809f
surgery, 660f
patient preparation, 730
principles, 730-731
surgical complications, 792, 794-798
surgical procedures, sedation (rationale), 404
survival, definition, 792-793
teeth, connection, 728
therapy, **e4**
principles, 731b
risk factors/contraindications, 703t
short-term outcomes/long-term outcomes, smoking (impact), 184
traumatic occlusion, adverse effect, 123
treatment
multidisciplinary specialist education, trends, 666
patient satisfaction, 818t
usage, 727
views, **e6f**
Implant sites
osteotomy preparation, drills (sequence), 735f
preparation, 730-735, 738, 781-784
example, 783f-784f
osteotomy, 733f
precision, enhancement, 735b
Implant success
clinical example, 814f
criteria, modifications (impact), 814t
definition, 792-793, 813
rate, outcomes, 814t
report, 792
reporting, variation, 813
Implant-supported bridge, usage, 66f
Implant-supported crowns/veneers, posttreatment clinical image, 64f
Implant-supported fixed restoration, pink porcelain (usage), 803f
Implant-supported FPDs, 793
survival/complication rates, 794
Implant-support restoration, 666f
Inactive pockets, healing, 553
Inadvertent curettage, 576
Incidence rates, 69
time implication, 69
Incipient gingivitis, 368f
Incisional instruments, 572-573
Incisions, 583-585, 593-594, 731-732, 737
crevicular incision, 584-585
first incision, 584
horizontal incisions, 584-585

For entries that have a boldface page reference, i.e., 179.e2, go to the Expert CONSULT website at www.expertconsult.com, and after registering, search for the term on the book website.

Incisions *(Continued)*
interdental incision, 585
remote incision, layered suturing technique, 731
reverse bevel incision, 584
second incision, 584-585
SEM comparison, 633f
third incision, 585
vertical incisions, 585
Incisive nerve, anterior extension, 557
Inclinable adjustable eyepieces, motion example, 642f
Inconclusive, term (usage), 435
Incremental dosing, 413
Independent endodontic-periodontic lesions, 478f
Indiana University sickle scaler, 495-497
Individualized dentistry, pharmacogenetics (relationship), 113-114
Individualized plaque growth pattern, 147f
Individualized treatments, benefits, 114
Individual tooth prognosis
determination, 395
overall prognosis, differences, 395
Indole, 548-549
Infections
control issues, **e95**
elimination, 404
transmission, prevention (measures), 567
Infective endocarditis (IE), 420, 423-425
prevention (AHA publication), 423
risk
periodontal procedures, 424t
reduction, preventive measures, 424-425
Inferior alveolar nerve
anterior extension, 557
canal, CT scan, 796f
Inflammation
biologic complication, 798
cytokines, 174-176
impact, 83
extension, 364
mediators, 174-176
reduction, 511t
resolution, 89-90
absence, 483
severity, **e49f**
vascular supply, relationship, 690-691
Inflammatory disease, SDB (impact), 537
Inflammatory enlargement, 232-234
Inflammatory infiltrate, 291
Inflammatory mediators
expression (modulation), cell signaling events (impact), 176-177
function, 99
role, 84-88
serum levels, assessment, 209
Inflammatory process, 167
elimination, 404
Inflammatory proliferation, impact, 798f
Inflammatory reactions, WBC involvement, 190
Inflammatory responses
aging, impact, 43
characteristics, 98f
nutrition modulation, 43
Informed consent, 566
elements, **e124t**
legal considerations, **e123-e124**
Infrabony periodontal pocket, 81f
features, 288t
flap, raising, 288f
Infrared light-emitting diodes (IREDs), usage, 788
INFUSE, 527
Inherited coagulation disorders, 429t
Inherited genetic variation, impact, 114f
Inherited variation/risk, 107-113
Initial bone healing, 685-686
Initial periodontal examination, periodontal chart, **e3f**
Innate immune response, biologically active mediators (expression), 174
Innate immunity, 90-94, 170-171
Innate responses, cytokine production, 96f
Inorganic polyphosphate, usage, 450
Instrumentation
principles, 509
side-by-side dimensional comparisons, 633f
Insulin
classification, 428
insulin-dependent diabetes mellitus, 187
resistance (increase), chronic gram-negative periodontal infections (impact), 211
types, 428t
Intangible benefits
realization/perception, absence, 375
tangible benefits, differences, 375
Intangible treatment benefits, 375
Interactive simulation software programs, 710
Intercellular adhesion molecule-1 (ICAM-1), 79, 207-208
expression, increase, 84
upregulation, 92
Intercellular matrix, cells (relationship), 33
Interdental alveolar bone, arteriole penetration (diagram), 19f
Interdental bone, 378
appearance, 383f
crest
appearance, 379f
transseptal fibers, 24f
Interdental brushes, 491-492
Interdental cleaning, 549
aids, 489-492
recommendations, 491
Interdental cleaning devices, 491-492
technique, 492
Interdental col
absence, 11f
anatomic variations, 11f
mandibular anterior segment, 11f
mandibular posterior segment, 11f
Interdental craters, 369, 382
Interdental denudation procedure, 585
Interdental gingiva, 10
broadness, 252
col shape, 10
facial/lingual surfaces, tapering, 10
Interdental gingival papillae, shape (correlation), 21f
Interdental incision, 585
Interdental knives, 572
Interdental lesion, extension, 382f
Interdental mesial/distal lesions, 382f
Interdental papillae, 11f
absence, 11f
appearance, 21f
crest, 244

For entries that have a boldface page reference, i.e., 179.e2, go to the Expert CONSULT website at www.expertconsult.com, and after registering, search for the term on the book website.

Interdental papillae *(Continued)*
formation, attached gingiva (impact), 11f
localized gingival swelling, leukemic infiltration (impact), 192f
survey section, 245f
Interdental septum (interdental septa), 35, 35f
autopsy section, 293f
inflammation, 10f
Interdental space
microscopic view, 226f
space, requirement, 698
suprabony pockets, 288f
Interdisciplinary implant care scenario, 659f
Interdisciplinary treatment, 658
Interference, 536
Interferon gamma (IFN-γ), induction, 84-85
Interleukin-1 (IL-1), 42, 196
Interleukin-1α (IL-1α), 84
genetic variations, 114
Interleukin-1β (IL-1β), 84, 783, **e116**
Interleukin-1 beta (IL-1β), 440-441
Interleukin-1 family (L-1F) cytokines, 84-86
nomenclature, 85t
tissue expression, limitation, 85
Interleukin-1Ra, structural homology, 84
Interleukin-4 (IL-4), 42
Interleukin-6 (IL-6)
activities/importance, 86
cytokines, relationship, 86
Interleukin-10 (IL-10), 42
Interleukin-10 family of cytokines, 87-88
Interleukin-18 (IL-18), interaction, 84-85
Interleukin-33 (IL-33), stimulation, 85
Intermediate cementum, 29
Internal basal lamina, 15
Internal bevel incision, 584
angle, diagrams, 597f
diagram, 583f
knife position, 584f
locations, 594f
making, 584f
Interocclusal space, requirement, 698
Interproximal bone loss, extent, 607
Interproximal cleaning devices, 491f
Interproximal embrasures
management, 655
spaces, variation, 491f
Interproximal gingiva, overhanging amalgam margin (effects), 483f
Interproximal papilla, behavior (comparison), 655f
Interproximal soft tissue cratering, bone necrosis, 647f
Interproximal space, bone destruction, 242f
Interproximal spurs, depiction, 118f
Interradicular dimension, 622
example, **626.e3f**
Interradicular fibers, 24
Interseptal bone (flattening), bitewing radiograph, 253f
Intervening col, 11f
Intrabony defects
aggressive periodontitis, **e55f**
treatment, 611
Intrabony periodontal pockets, occurrence, 277
Intrabony pockets, radiographic/microscopic features, 287f
Intracapsular disorder, 347
Intraoperative assessment, 719-720
Intraoperative periapical radiographs, value, 719f
Intraoral aphthous stomatitis, AIDS (impact), 341f
Intraoral examination, 698-699
Intraoral habitats, 137t
Intraoral hard surfaces, 136
Intraoral herpetic vesicles, recurrence, 249f
Intraoral nutrients/microorganisms, mechanical reduction, 549
Intraoral pain disorders, 347
Intraoral preoperative, 660f
condition, 659f
Intraoral radiographic survey, 361
Intraoral series, requirement, 361
Intraoral sites, bone (usage), 613-614
Intravenous (IV) conscious sedation, consent form/explanation, 415f
Intravenous (IV) sedation, equipment/supplies, 416f
Invasion-associated genes, screen, 168
InVivo5 simulation images, 714f-715f
Involucrin, **11.e1**
Ion-exchange resin, 151
IREDs. *See* Infrared light-emitting diodes
Iron deficiency anemia, gingiva/vascular structures, **e23f**
Iron, deposition, 228
Irregular proximal tooth surfaces, cleaning, 492f
Irrigation
absence, example, 513f
action mechanism, 510-511
clinical outcomes, 511-512
safety, 511
Ischemic heart disease, 206, 422-423
acute/chronic pathways, 206f

J
Jaquette sickle scalers, 495-497
Jaw
bisphosphonate-related osteonecrosis, 59-60
bone, panoramic radiograph, **e4f**
closure, dentition, 365
cystic spaces, panoramic radiograph, 362f
pathologic process, 364
titanium implants, placement, **31.e1**
tooth in situ, 32f
visualization, 708f
Jet tip
example, 513f
usage, 511
Jiggling forces, 304
JP2 clone strains, occurrence, 331
Junctional epithelium, 15
attachment, 15
zone, 285
changes, detection, 219
characteristics, 78
degenerative changes, 279
epithelial structure, uniqueness, 77-78
extension, 279
formation, 16f
keratin polypeptides, **15.e1**
location, aging (effect), 40
permeability, 214-215
proliferation, 22
removal, 610-611
scanning electronic microscope (SEM) image, 689f
structure, self-renewal, 16
Juvenile hyaline fibromatosis, gingival enlargement, **e35f**

For entries that have a boldface page reference, i.e., 179.e2, go to the Expert CONSULT website at www.expertconsult.com, and after registering, search for the term on the book website.

K
Kaposi's sarcoma (KS), 337-338
bacillary angiomatosis, mimicry, 339f
histologic view, 338f
Kennedy Class II distal extension, 695f
Kennedy Class I/II partially edentulous situations, 694
Keplerian loupes, types, 640
Keplerian optical system, 638-640
Keratinization process, 12
Keratinized attached gingiva, reestablishment, 65f
Keratinized gingiva, absence, 65f
Keratinized gingival epithelium, 14f
Keratinized gingiva, scanning electron micrograph, 13f
Keratinized mucosa, 689-690
Keratinized tissue, 689-690
requirement, 703b
Keratinocytes
exfoliation, 13f
flattening, 13f
Keratinosomes, **11.e1**
Keratins
immunohistochemical expression, **14.e1**
polypeptides, **15.e1**
Keratolinin, **11.e1**
Keratotic lesions, 265
Keystone pathogen, 158-159
Kidney
failure, 421
transplant, cyclosporine usage (gingival enlargement), **e25f**
Kindler syndrome, 107-109
Kirkland knife, 573f
usage, 579-580
Knife-edge alveolar process, 731-732
Krause-type end bulbs, 19

L
Lacrimal glands, neutropenia, 107-109
Lactic acid, 548-549
Lactoperoxidase-thiocyanate system, 217
LAD. *See* Leukocyte adhesion deficiency; Linear immunoglobulin A disease
Lamina dura
foramina perforation, 26f
fuzziness/disruption, 382
prominence, 252
Lamina propria, 17
LANAP. *See* Laser-assisted new attachment procedure
Langer curettes, 501-502
Gracey-type shanks, combination, 502f
Langerhans cells, 12-13
LAP. *See* Localized aggressive periodontitis
Laser ablated surface, 691f
Laser-assisted new attachment procedure (LANAP), 611
impact, 610-611
Laser-microtextured surface, 690f
Lasers
biological interactions, 645-646
carbon dioxide laser treatment, **e13f**
energy, overexposure, 647
functional crown lengthening, 647-648
naming, 645
nonsurgical laser periodontal therapy, 648
periodontal esthetic applications, 647-648
physics, 645-646
therapy, advantages/disadvantages, 646-647
Lasers *(Continued)*
treatment, advocacy, 481
types, usage, 646t
wavelengths, 646f
effectiveness, 647
Lateral abscess (periodontal abscess), 233-234
Lateral cephalometric radiographs, 708
Lateral excursion, 536
Lateral incisor
diagnostic models, photographs, 701f
noninvasive extraction, 771f
periotome extraction, 771f
Lateral periodontal cyst, 286-289
Lateral window antrostomy, 759f
Lateral window technique, 755-756
LDD. *See* Low-dose doxycycline
Ledges, 298
Left central incisor
extrusion, localized aggressive periodontitis (impact), **e54f**
periodontal abscess, **e69f**
Left maxillary second premolar, radiographic evaluation, 717f
Lesions
advanced lesion, 80-81, 223
early lesion, 79-80, 220
established lesion, 80, 220-223
initial lesion, 79, 219-220
occlusal view, 382f
Leukemia, 191-195, 431, **e23**, **e58**
acute lymphoblastic leukemia, appearance, 260f
acute phases, 431
classification, 191
cutis, 192
existence, 195
primary medical diagnosis, gingival problems, 49f
ulcerations, 194f
Leukemic gingival enlargement, 589-591
acute myelocytic leukemia, appearance, 240f
indications, timing, 591-592
treatment, SRP usage, 591
Leukemic infiltrate, 193f
human histologic appearance, 193f
Leukemic infiltration, 192
impact, 192f
Leukemic patients
gingival (bacterial) infection, 194-195
periodontium, condition, 192-195
Leukocyte adhesion deficiency (LAD), 402
appearance, **e61f-e62f**
Leukocyte-bacteria interaction areas, 282
Leukocytes
adhesion deficiency, oral/radiographic appearance, 108f
attraction, 216
consideration, **18.e1**
disorders, 191, 258-259
emergence
areas, 282
scanning electron micrograph, 222f
scanning electron microscope view, 217f
foci, 94
infiltration, 279
traversal, scanning electron micrograph, 222f
usage, 216-217
Leukopenia, 192

For entries that have a boldface page reference, i.e., 179.e2, go to the Expert CONSULT website at www.expertconsult.com, and after registering, search for the term on the book website.

Leukoplakia, 241
gingiva, 242f
histopathology, 241b
Lichen planus
bullous lichen planus, consideration, 271
differential diagnosis, 266
direct immunofluorescence, 266f-267f
erosive lichen planus, appearance, 265f
erosive subtype, 264-265
gingival lesions, 265-266
immunopathology, 266
impact, 262-267
microscopic appearance, 266f
oral lesions, 264-265
oral lichen planus, histopathology, 266b
reticular lichen planus, **e32f**
treatment, 266-267
Ligature wire, impact, **e42f**
Light amplification by stimulated emission of radiation (laser), 645
Light conscious sedation, 425
Limited, term (usage), 435
Line-angle inconsistencies (widow's peak), removal, 607
Linear gingival erythema (LGE), 48-49, 339-341
AIDS, impact, 341f
appearance, 341f
corrective therapy, response problem, 340
diagnosis, difficulty, 340
precursor, 340
Linear immunoglobulin A disease (LAD) (linear immunoglobulin A dermatosis), 272-273
appearance, 272f
differential diagnosis, 272
immunofluorescence, 272
oral lesions, 272
treatment, 272-273
Line-based methods, 788
Lingual nerve, 557-558
Linkage analysis, 105
usage, 105, 106t
Lip
herpetic vesicles, recurrence, 249f
lesions, acute streptococcal gingivostomatitis (impact), **e26f**
mucosa, recurrence, **e39f**
Lipopolysaccharide (LPS), 204
neutralization, 90-91
virulence factor, 81
Lipoxins, 89
Lip paresthesia, surgical trauma (impact), 557
Listerine antiseptic, ADA approval, 450
Liver disease, impact, 430
Load-bearing capacity, 723-724
bone quality, impact, 726f
Load excess, persistence, 724
Loading protocols, 816
Load magnification, nonaxial loads (impact), 724f
Local anatomic factors, 621-622
Local anesthetic, usage, 568
Local delivery agents, 521-524
SDD, combination, 533
Local delivery rationale, **e101-e102**
Localized aggressive periodontitis (LAP), 165, 258, 325, 330-331, 385
abnormalities, 332
appearance, 328f-330f
bacteria, presence, 331
Localized aggressive periodontitis (LAP) *(Continued)*
bone destruction, 386f
characterization, 385
diagnostic criteria, 325t
left central incisor, extrusion, **e54f**
osseous lesion, progression (radiographs), 456f
scaling/root planing, 453
treatment, tetracyclines (usage), 517
Localized bleeding, Glanzmann thrombasthenia (impact), **e24f**
Localized chronic periodontitis, 309
Localized diffuse gingivitis, 224
Localized gingival anoxemia, 220-221
Localized gingival enlargement, appearance, 238f
Localized gingivitis, 224
Localized juvenile periodontitis (LJP), 165, 385
prevalence, 330-331
Localized juvenile spongiotic gingival hyperplasia, 257
appearance, 257f
Localized marginal gingivitis, 224
Localized papillary gingivitis, 224
Localized ridge augmentation, 739-746
complications, 746
simultaneous implant placement, 743-745
Localized tooth-related factors, 54, 63
Locally administered agents, 526-527
Locally delivered antimicrobials, release profile (schematic representation), **e102f**
Locally delivered controlled-release antimicrobials
availability, **e127-e128**
clinical trials, **e105t-e106t**, **e108t-e110t**, **e111t-e114t**, **e129t-e132t**
clinical use, **e115-e116**, **e117f**
cost-effectiveness, **e115**
costs/outcomes, **e115-e116**
development, **e99t**
drug development, **e123-e124**
phases, **e123**
drug registration, **e123-e124**
effect, magnitude, **e103**
safety/efficacy, evaluation, **e123**
Local therapy, 404
Long-cone paralleling technique, 378
bisection-of-the-angle techniques, comparison, 379f
Longitudinal studies
data, 205-206
usage, 203
Long-term goals, 408
Loupes
compound loupes, 640-641
dental loupes, usage, 640
Keplerian loupes, types, 640
magnifying loupes, 638-641
prism telescopic loupes, 641
simple loupes, 640
surgical loupes, magnification range, 641
usage, 638-640
Low-dose doxycycline (LDD), 528
systemic adjunctive therapy, **e118**
Lower anterior teeth
calculus formation, extensiveness, **e41f**
lingual surfaces, bridge-like calculus formation, **e16f-e17f**
restoration, **e40f**
Lower central incisor
advanced gingival recession, **e35f**
gingival recession/inflammation, 630f

For entries that have a boldface page reference, i.e., 179.e2, go to the Expert CONSULT website at www.expertconsult.com, and after registering, search for the term on the book website.

Lower first molar, mesial surface (one-wall vertical defect), 297f
Lower front teeth, clinical picture, 166f
Lower incisor
  thin labial bone, 295f
Lower incisor, root (prominence), 125f
Lower molars, horizontal section, 297f
Ludwig's angina, 564-565
Lupus erythematosus, 273-274
  oral cavity, 274f
  subacute cutaneous lupus erythematosus, 274
  systemic lupus erythematosus, 273
Luteinizing hormone (LH), production, 438
Luting material
  dissolution/disintegration, void (development), 122f
Luting material, impact, 122f
Luxated teeth, replantation, **e74f**
Lymphatics, 18-19, 39
Lymph nodes, examination, 362
Lymphocytic leukemia, 191
Lymphosarcoma, 242
Lymphotoxin-alpha (LTA), role, 110
Lys-gingipains, 167
Lysozyme, linkage cleaving, 217
Lys-Xaa peptide bonds, 167

M
Macrodesign, 684, 685b
Macrolides, 519
  clinical use, 519
  pharmacology, 519
Macrophage inflammatory protein-1α (MIP-1α), 87
Macrophage phenotype, 208
Macrophages, 172
Macrosurgical unsatisfactory outcome, microsurgical correction, 639f
Magnetic tracking systems, 788
Magnetostrictive tip, working sides, 508f
Magnetostrictive ultrasonic device, 508f
Magnification systems, 638-643
Magnifying loupes, 638-641
Maintenance program, 668-669
Maintenance recall procedures, 668b
Maintenance therapy
  importance, radiographs, 671f
  patient compliance, 671f
Maintenance therapy, compliance, 668f
Malignant melanoma, 242-243
  appearance, **e46f**
Mallampati classification, 414f
Malnutrition, impact, 401
Malocclusion, 124-125, 300, **e13**
  advanced malocclusion, **e37f**
  impact, **e16f**
  periodontal status, relationship, 254
  severity, **e60f**
  thalassemia, presence, **e24f**
  Malodor. *See* Breath malodoranamnesis, 547
  clinical/laboratory examination, 547-549
  detection, fundamentals, **546.e1**
  diagnosis, 547-549
  masking, 549
  organoleptic rating, 547-548
  oropharyngeal examination, 547
  self-examination, 547
  self-testing, 547
Malodorous compounds, solubility (increase), 549
Malposed implants, complication, 797
Malpositioned implant, surgical exposure, 797f
MAMPs. *See* Microbe-associated molecular patterns
Mandible, 557-559
  alveolar portion, disappearance, 557
  alveolar process, 31
  body, medial side, 558-559
  centric relation, bimanual manipulation, 538f
  facial surface view, 558f
  lingual aspect, 563f
  lingual surface view, 558f
  lingual view, 559f
  nutrient canals, 383f
  occlusal view, 559f
  posterior view, 564f
  ramus/molars, occlusal view, 559f
Mandibular advancement device (MAD), 354-355
Mandibular anterior implants, radiographs, 796f
Mandibular anterior teeth
  alignment, 542
  appearance, 368f
Mandibular arches, orthodontic appliance/implants (views), **e6f**
Mandibular basal bone, mineralization, 37
Mandibular canal, 557
  implant penetration (demonstration), CBCT sagittal/cross-sectional images (usage), 721f
Mandibular first molar
  bone destruction, 398f
  furcation involvement, 384f
  root concavities, 400f
Mandibular implants, bone loss, 800f
Mandibular incisors
  area, radiograph, 35f
  extraction, **769.e3**
  implants, diagram, 696f
  splinted porcelain-fused-to-metal crowns, overhanging margins (presence), **769.e1f-769.e2f**
Mandibular left posterior quadrant, teeth (absence), **542.e6f**
Mandibular left primary canine, gingival recession, 254f
Mandibular left second molar, class III furcation defect, **542.e6f**
Mandibular left second premolar, absence, **542.e2f**
Mandibular left third molar, class III furcation defect, **542.e6f**
Mandibular molars, 602
  angular bone loss, 381f
  mesiodistal section, 32f
Mandibular premolar, resting state (diagram), 26f
Mandibular repositioning devices (MRDs), 352-356
  characteristics, 355t
  dentate state, 355
  dentist, usage, 353-354
  periodontal condition, tooth mobility (relationship), 355
  suitability, determination, 354
  taxonomy, 354f
Mandibular ridges, tuberosity enlargement (contact), **e31f**
Mandibular right canine
  localized periodontal abscess, 463f
  plaque-associated gingival abscess, 464f
Mandibular right first molar
  periodontally hopeless condition, **542.e8f**
  periodontal pocket, **542.e2f**
Mandibular right second molar, impaction, **542.e8f**
Mandibular second molar
  furcation involvement, 384f
  pocket eradication, 602f

For entries that have a boldface page reference, i.e., 179.e2, go to the Expert CONSULT website at www.expertconsult.com, and after registering, search for the term on the book website.

Mandibular teeth, absence, 306f
Mandibular tori, clinical photograph, 563f
Manual instruments, advantages/disadvantages, 508b
Manual toothbrushes, 486f
Marginal alveolar bone, shape (change), 303f
Marginal bone (loss), osseous crest uncovering (impact), 583f
Marginal enlargement, 237
Marginal fit, 654
Marginal gingiva (MG), 9
  faciolingual section, 18f
  inflammation, 123f
  microscopic appearance, 192
  sloughing, ulcerative gingivitis, 61f
  stippling, absence, 21
Marginal gingivitis, 222f, 224
  contour, 222f
Marginal inflammation, 46f
Marginal periodontitis (occlusion), trauma (impact), 303-305
Marginal ridge
  defect, overeruption, **542.e3f**
  discrepancy, **542.e3**
Marginal supragingival plaque/gingivitis, 222f
Marginal tissue resection, etiology, 629
Margins
  inadequacy, **e40f**
  placement, 652-653
    guidelines, 654
Marrow spaces, resorption, 291
Masticator space, 564
Masticatory mucosa, 9
Masticatory system
  clinical examination, 348
  diagnostic decision making, 348-349
  discomfort, 347
  dysfunction/deterioration, 347
  evaluation, 348
  imaging, 348
  muscles/nerves, 345
  patient history/interview, 348
  questions, examples, 348b
Materia alba, 121, 141
Maternal immunoresponse, 441-442
Mathematic analyses, usage, 105
Matrix metalloproteinase-1 (MMP-1), 83-84
  secretion, 84
Matrix metalloproteinase-8 (MMP-8), 80, 83-84
Matrix metalloproteinase-9 (MMP-9), 80, 196
Matrix metalloproteinases (MMPs), 83-84, 86-87
  biologic activities, 87t
  classification, 84t
  collagen degradation, relationship, 220
  connective tissue homeostasis, 87
  inhibition, 529
  inhibitors, 528-529
  neutral proteases, 175-176
  osteoclast access, 87
Matrix, organic constituents, 140-141
Maxilla, 559-561
  acrylic provisional fixed full-arch prosthesis, clinical photograph, 694f
  body, 560
  occlusal view, 560f
  palatal surface, exposed bone (clinical photograph), 200f
Maxilla, alveolar process, 31
Maxillary anterior esthetic zone, 655
Maxillary anterior fixed restoration, clinical photograph, 817f
Maxillary anterior implant, clinical photograph, 797f
Maxillary anterior teeth
  abrasion, **542.e10f**
  alignment, 542
  gingiva, periodic localized color changes, **e21f**
  periodontally compromised maxillary anterior teeth, clinical photograph, 768f
Maxillary arches
  orthodontic appliance/implants, views, **e6f**
  restorations, **e1**
Maxillary canine
  region, localized gingival recession, 254
  self-inflicted trauma, impact, 128f
Maxillary canine, impaction (radiograph), 127f
Maxillary central incisor position, implant placement (dehiscence defect), 743f
Maxillary central incisors
  cervical root resorption, computed tomography scanning, 64f
  elastic ligature, usage, 127f
  interproximal contact, **542.e10**
  labial migration, 305f
  overlapping, **542.e11f**
Maxillary cuspid, radiograph, 386f
Maxillary denture, clinical photograph, 694f
Maxillary first molar
  distobuccal root resection, diagrams, **626.e4f**
  interproximal gingiva, overhanging amalgam margin (effects), 483f
  periodontal abscess, **e69f**
  roots
    concavities, 399f
    location, 561
  tilt/extrusion, 306f
Maxillary first premolar (extraction), implant placement (usage), 748f
Maxillary incisors
  labial push, 307f
  porcelain-fused-to-metal crowns, usage, 66f
Maxillary lateral incisors (extraction), staged/delayed implant placement (usage), 744f-745f
Maxillary left primary canine, gingival recession, 254f
Maxillary molars, 600-601
  buccal surfaces, supragingival calculus, 117f, 141f
  radiograph, 562f
  technique, 601
Maxillary overdenture bar, laboratory view, 695f
Maxillary premolar space, clinical photograph, 699f
Maxillary provisional acrylic partial denture, 124f
Maxillary right canine
  attached gingiva, fistula (observation), 462f
Maxillary right central incisor
  fracture severity, **542.e7f**
  overeruption, **542.e9f**
Maxillary right first molars
  mesial tipping, significance, **542.e4f**
  overeruption, **542.e3f**
  probing defect, **542.e1f**
Maxillary right second molars, mesial tipping (significance), **542.e4f**
Maxillary second molar
  distal surface, amalgam overhang (radiograph), 121f
  pocket removal, 601f
  roots, location, 561
  surgical procedure, incision design, 601f

For entries that have a boldface page reference, i.e., 179.e2, go to the Expert CONSULT website at www.expertconsult.com, and after registering, search for the term on the book website.

Maxillary second molar, mesial-palatal surface (inflammation), 48f
Maxillary sinus
access, lateral window procedure, 759f
blood supply, 561f
origin, 561
elevation, 750-756, 753f
contraindications, 750-751, 751b
indications, 750-751
inferior wall, 561
innervation, 561f
location/anatomy, 561f
presence, 560
presurgical evaluation, 752f
subdivision, 560-561
Maxillary tuberosity, 560
Maximum intercuspation, 536
teeth, clinical mark, 538f
Maximum recommended dose (MRD), 413
McCall festoons, 230
term, usage, 230
Mean alveolar bone loss per patient, 126
Mean attachment level, change, 678f
Measurement distortion, 708
Mechanical complications, 792, 801-802
Mechanical debridement, 668
Mechanical determinants, 160
Mechanical failure, 723
Mechanical tracking systems, 788
Mechanical treatment, antibacterial effect, **e101**
Mechanized instruments
usage, indications/precautions/contraindications, 512b
Mechanized instruments, advantages/disadvantages, 508b
Medical health-related issues, 699-704
Medical history, 357-358, 697
form (ADA), example, 359f-360f
references, 357-358
Medical Subject Heading (MeSH) database, usage, **e77**
Medications, 431-435, 701-703
prescription, 197-201
Meissner-type tactile corpuscles, 19
Melanin
physiologic pigmentation, 20
pigmentation, **e12**
downregulation, ascorbic acid (impact), 20
impact, **e12f**
Melanocytes, 12
Melanocytes, presence, 13f
Menses, 438-439
follicular phase, 438
luteal phase, 438
management, 439
periodontal manifestations, 438-439
Mental conditions, 704
Mental foramen, 557
Mentalis space, location, 562-564
Mental nerve, emergence, 558f
Mental space, location, 562-564
Mephenytoin (Mesantoin), 235
Merkel cells, 13
MeSH. *See* Medical Subject Heading
Mesial-distal space, minimum amount, 700f
Mesial impacted lower left third molar, panoramic radiograph, 127f
Mesial lesions, radiograph, 382f
Mesial root resection, advanced bone loss (impact), **626.e6f**
Mesiodistal implants, distance, 796-797
Mesioposterior surfaces, New Gracey curette design, 499f
Meta-analyses (MAs), **e75-e76**, **e77**
Metabolic interactions, schematic illustration, 150f
Metal fragments, biopsy, 52f
Metal hand instruments, 676
Metal instruments, 810
Metalloceramic crown, 696f
Metal prophylaxis angle, 505f
Metastasis, 242-243
Methodology, 814t
Methsuximide (Celontin), 235
Methylamine, 548-549
Metronidazole, 517-518
clinical use, 518
effectiveness, 518
efficacy, 518
pharmacology, 517-518
side effects, 518
subgingival metronidazole, 523
Mevalonate pathway, 199f
Microbe-associated molecular patterns (MAMPs), 81
engagement, 94-95
presence, 171f
PRR-mediated sensing, 170
response, 92
Microbial-associated molecular patterns (resident/nonresident cells), 173t
Microbial biofilm growth, occurrence, 485
Microbial flora, 322
Microbial growth, surfaces (growth), 139
Microbial homeostasis, 158
disruption, pathogens (impact), 158-159
Microbial-host interactions, study, 170
Microbial invasion, 82
Microbial plaque biofilm control, 485
Microbial testing, 807
Microbial tooth deposits, periodontal disease risk factor, 391-392
Microbial virulence factors, 81-83
Microbiologic plaque sampling, 520
Microbiota, establishment, 132
Microfibrillar collagen hemostat (CollaCote), 568
Microflora, intervention studies, 42
Micro Mini Five Gracey curettes, 500f
blade description, 500
Microorganisms, mechanical reduction, 549
Micropipettes, usage, 214
Microprecision, 776-777
Microsurgery. *See* Periodontal microsurgeryadvantages, 632-638
end-point appearance, 637
impact, 640f
Microsurgical approach, tension-free wound closure, 637f
Microsurgical connective tissue graft, 634f
healing, 635f
Microsurgical crown-lengthening procedure, 639f
atraumatic microsurgical tissue manipulation, 638f
Microsurgical extraction, 636f
Microsurgical field, illumination, 642
Microsurgical instruments, conventional instruments (side-by-side dimensional comparison), 633f
Microsurgical principles, usage, 635f
Microsurgical sutures, 643
Microsurgical suturing, 636f

For entries that have a boldface page reference, i.e., 179.e2, go to the Expert CONSULT website at www.expertconsult.com, and after registering, search for the term on the book website.

Microsurgical tooth extraction, 770
Microsutures
needle anatomy, 643f
size comparison, 643f
Microvasculature permeability (increase), progesterone (association), 438
Mild chronic periodontitis, 314
Mild sedation
equipment, requirement, 417t
patient pretreatment instructions, 415b
Millipore filters, usage, 611
Mineralized dental plaque, 118-119
Mini-bladed curettes, 500-501
Mini Five curette, 500f
After Five curette, comparison, 500f
Mini-Langer curettes, 501-502
Minimal hand movement, reduction, 633f
Minimally invasive approach, 766-769
Minimal sedation, 412-413
clinical guidelines, 414-418
preoperative preparation, 414
Minocycline, 517
hydrochloride microspheres (Atrestin), **e100f**
microspheres (Arestin), **e99-e101**
adjunctive administration, microbiological effects, **e118f**
placement, 523f
release profile, **e102**
Missing maxillary right central incisor, implant (panoramic radiograph), 815f
Missing teeth
CBCT examination, 716f
partially edentulous maxilla, panoramic view, 718f
Mixed apnea, 352
Mixed erythematous/pseudomembranous candidiasis, 336f
Mixed infection, periodontitis (consideration), 158
Miyazaki tongue coating index, 548f
MMPs. *See* Matrix metalloproteinases
Moat, radiograph, 123f
Mobility, type, 364
Moderate chronic periodontitis, 314
Moderate intravenous (IV) sedation, equipment/supplies, 416f
Moderate-length root trunks, 606
Moderate sedation, 413-414
clinical guidelines, 414-418
equipment, requirement, 417t
preoperative preparation, 414
record sample, 418f
Moderate-to-severe periodontitis
anterior sector, therapy, 555
posterior area, therapy, 555-556
Modified pen grasp, 512f
Modified Widman flap, 593
description, 593
selection, 555
technique, 595f
MOGO, usage, **e94**
Molars
bone, exposure, 60f
implants, diagram, 696f
maxillary area, radiograph, 562f
roots, boneless window, 36f
Molar-sized single crown, support, 802f
Monkey
faciolingual section, 11f
periodontium, vascular supply, 39f
Monoclonal antibodies, involvement, **18.e1**
Monocortical block graft, 740-743
procedure, 740-743
usage, 742f
Monocytic leukemia, 191
Mononuclear cells, identification, 216
Monozygotic twins, disease occurrence (comparison), 104
Montana Jack sickle scaler, 495-497
Morning sickness, 442
Morphologic defects (correction), surgical techniques (usage), 556
Morse scaler, 501
Morse scaler-shaped ultrasonic instruments, 578
Mortality, periodontal disease (relationship), 204-205
Mortality risk, increase, 75
Mouth
breather, gingival enlargement, 233f
breathing, 256-257, **e13**
gingival changes, 233
care, 572
hyperplastic candidiasis, 337f
rinsing, 550
MRDs. *See* Mandibular repositioning devices
Mucocutaneous lesions, **e32**
Mucogingival defect, recession (impact), 65f
Mucogingival deformities/conditions
edentulous edges, 54
teeth, 54
Mucogingival junction, 10
Mucogingival line (junction), 630
Mucogingival problems, 254
Mucogingival surgery
muscle attachments, 563f
rationale, 628-629
term, introduction, 628
Mucogingival techniques, selection (criteria), 630
Mucoperiosteal flaps, elevation, 433-434
Mucormycosis
impact, **e28f**
infection, impact, **e9**
Mucositis, 431
gingiva, **e28f**
Mucous membrane blisters, occurrence, 270
Mucous membrane pemphigoid (cicatricial pemphigoid), 268-269
appearance, 268f
differential diagnosis, 269
direct immunofluorescence, 269f
histopathology, 268b
immunofluorescence, 268-269
ocular lesions, 268
oral lesions, 268
treatment, 269
Multidisciplinary simple implant care scenario, 664f
Multidisciplinary specialist education, trends, 666
Multidisciplinary treatment, 658
Multinuclear osteoclast, presence, 31f
Multiple-burst model, 315-316
Multiple teeth, 694-696
Multiple-tooth sites, 726
Multi-rooted teeth, mobility, 364
Multislice computed tomography (MSCT), 706, 708-709
Muscles, 562
strain, prevention, 637f
Myelogenous, term (usage), 191

For entries that have a boldface page reference, i.e., 179.e2, go to the Expert CONSULT website at www.expertconsult.com, and after registering, search for the term on the book website.

Myeloperoxidase, 217
Mylohyoid muscle, 558-559
Mylohyoid ridge, 558-559
Myocardial infarction (MI), 203, 420
chronic periodontitis (association), two-by-two table (usage), **e86t**
ischemic heart disease category, 423
periodontal disease, role, 208-209

N
Nabers probe, usage, 495f
Nabors probe, design, 622f
N-acetyltransferase 2 (NAT2) genes, responsibility, 110
Narrow-diameter implants, 696f
Nasal cavities, viral infection, 548
National Institute of Dental Research probe, usage, 70
National tooth, cross-section, 663f
Natural killer cells, 172
NDA. *See* New Drug Application
Necessary cause, 72-73
Neck
squamous cell carcinomas, 433
Sturge-Weber syndrome, unilateral cavernous hemangiomas, **e38f**
Necrotizing gingivitis, lower front teeth (clinical picture), 166f
Necrotizing periodontal diseases, 46, 60-61, 166, **e10**, **e65-e67**
prognosis, 402-403
Necrotizing ulcerative gingivitis (NUG), 60-61, 244-249, 341
appearance, 245f
bacteria, role, 247
chronic desquamative gingivitis, differentiation, 246t
chronic periodontal disease, differentiation, 246t
clinical course, 244-245
clinical features, 244-245
communicability, 248-249
debilitating disease, 248
diagnosis, 245-247
differential diagnosis, 246-247
reassessment, 462-463
diphtheria, differentiation, 247t
epidemiology, 248
etiology, 247-248
extension, 320
extraoral/systemic signs/symptoms, 244
histopathology, 244b-245b
history, 244
host response, role, 247
incidence, increase, 341
infection, **e67f**
lesions
bacterial smear, 246f
bacteria, relationship, 245
pseudomembrane, removal, **e66f**
local predisposing factors, 247-248
nutritional deficiency, 248
occurrence, epidemic-like outbreaks, 249
oral signs, 244
oral symptoms, 244
prevalence, 248
primary herpetic gingivostomatitis, differentiation, 246t
psychosomatic factors, 248
punched-out appearance, **e65f**
smoking, relationship, 248
syphilis (secondary stage), differentiation, 247t
Necrotizing ulcerative gingivitis (NUG) *(Continued)*
systemic predisposing factors, 248
treatment, 460
metronidazole, usage, 247
Necrotizing ulcerative periodontitis (NUP), 61, 341-342, 459
appearance, 321f, 341f
clinical attachment, severity, 61f
clinical features, 320
early NUP, AIDS (presence), 342f
etiology, 321-322
HIV, absence, 342f
immunocompromised status, 322
infection, **e67f**
malnutrition, 322-323
microbial flora, 322
microscopic findings, 320
psychologic stress, 322
term, adoption, 320
therapy, 342
Necrotizing ulcerative stomatitis, 321, 336
Needle anatomy, 643f
Needleholders, 574
example, 575f
Negative architecture, 606
Negative evidence, **e89**
Neisseria gonorrhoeae (gonorrhea), 48
Neodymium:yttrium-aluminum-garnet (Nd:YAG), usage, 611
Neoplastic enlargement (gingival tumors), 240-243
Nerves, 18-19
Neurofibromatosis (von Recklinghausen's disease), 228
Neurogenic pain disorders, 347
Neurosensory disturbances, 795-796
occurrence, 795
prevalence/significance, 795-796
Neutral polysaccharides, presence (histochemical evidence), 15
Neutropenia, 191
treatment, **e60f**
types, 107-109
Neutrophils
collagenase, 80
collection, 183
deficiencies, 191
disorders, 258-259
function, 92-94
impairment, 57-58
impact, 89-90
infiltration, 79-80
migration, 94
Nevi curved posterior sickle scale, 495-497
New bone formation, 686
New Drug Application (NDA), **e123**
Next-generation DNA sequencing methods, 105
NHL. *See* Non-Hodgkin's lymphoma
Nickel allergy, gingival inflammation, 51f
Nicotine replacement therapy (NRT), 181
Nifedipine-induced gingival enlargement, cyclosporine-induced gingival enlargement combination (treatment), 591f
Nifedipine, usage, 236
Nikolsky sign, **e32f**
Ninhydrin method, 549
Nippers, 574
Nitrogen-containing bisphosphonates
potency, 198-199
usage, 431
Nitroglycerin lingual spray formulations, popularity, 423

For entries that have a boldface page reference, i.e., 179.e2, go to the Expert CONSULT website at www.expertconsult.com, and after registering, search for the term on the book website.

NNT. *See* Number needed to treat
Nocebo effects, **e89**
Nonaminobisphosphonate medications, therapeutic uses, 198t
Nondisplaced flaps, 582
Noneugenol packs, 569
Non-graft-associated reconstructive procedures, 610-611
Non-Hodgkin's lymphoma (NHL), 337-338
Noniatrogenic periodontitis, causes, 73f
Noninsulin-dependent diabetes mellitus, 187
Non-insulin-dependent diabetes mellitus, control (problems), 440f
Nonkeratinized gingival epithelium, 14f
Nonkeratinized stratified squamous epithelium, covering, 11f
Nonmalignant WBCs, 192
Non-plaque-induced gingival lesions, 47-50, 257, **e9-e10**, **e26-e28**
  appearance, 401
Nonrandomized evidence, reliance (reasons), **e88-e89**
Nonresident cells (microbial-associated molecular patterns), 173t
Nonselective beta-adrenergic receptor antagonists (β-blockers), 422t
Nonselective beta blockers, 421-422
Nonspecific conditioned enlargement (pyogenic granuloma), 239
Nonspecific oral ulcerations (atypical ulcers), 339
Nonspecific plaque hypothesis, 157
Nonsteroidal antiinflammatory drugs (NSAIDs), 404, 525-527
  impact, 430-431
Nonsurgical laser periodontal therapy, 648
Nonsurgical sculpting, periimplant soft tissue, 663f
Nonsyndromic aggressive/chronic periodontitis, 109-112
Nonsyndromic periodontitis, 109
Nonvital teeth, 401
Nonworking side, 536
Normative values, 74
Noxious products, virulence factors, 81-82
Nuclear factor-κB ligand, receptor activator, 89
Nucleotide-oligomerization domain (NOD) protein-like receptors, 172
Null hypothesis, 105
Number needed to treat (NNT), 375
Nutrient canals, 383f
Nutritional deficiencies, impact, 197
Nutritional determinant, 160
Nutrition, causative factors, 73
Nutrition, impact, 197

O
Oblique fibers, 24
Obliterative endarteritis, radiation treatment (impact), 130
Obstructed breathing, dental clinical signs/symptoms, 351
Obstructive apnea, central apnea (differences), 352f
Obstructive sleep apnea (OSA)
  communication, 354
  diagnosis, 352
  indications/contradictions, 354-355
  oral devices, 353
  otolaryngology/oromaxillofacial surgery, 352
  patient communication, 354
  prevalence, 352
  primary care physician communication, 354
  sleep disturbance, absence, 350
  take home message, 355b
  treatment options, 352-353
Occlusal adjustment, 539
Occlusal appliance therapy, 539
Occlusal design, 728
Occlusal disharmony, 300
Occlusal dystrophy, 300
Occlusal evaluation/therapy
  clinical examination, 537-539
  parafunction, 536-537
  pathogenesis, 535
  terminology, 536
Occlusal evaluation/therapy, requirement, 407
Occlusal forces, 300
  adaptive capacity, 300
  direction, stress patterns, 301f
  effects, 303
  impact, resistance, 26
  increase, tissue response stages, 301-303
  Stage I (injury), 301-302
  stage II (repair), 302
  Stage III (periodontium, adaptive remodeling), 302-303
Occlusal function/dysfunction, 536
Occlusal interferences/discrepancies, 536
Occlusal loading, 816
Occlusal radiographs, 706-707
Occlusal stability, 539
Occlusal surfaces
  calculus coverage, **e15f**
  contour, establishment, 123-124
Occlusal therapy, 539
Occlusal trauma, 54, 66, 300
Occlusal wear, discolored surfaces, 363f
Occlusion
  clinical evaluation, 537
  mutilation, examples, 307f
  periodontal pack interference, absence, 570f
  primary trauma, 300-301
  secondary trauma, 300-301
  trauma, 295
Occupational disease, possibility, 358
Occupational HIV infection, concerns, 69
Ochsenbein chisels, pairing, 574f
OCs. *See* Oral contraceptives
Odds
  probability, 69
  reporting, 69
Odds ratio
  cross-products ratio, **e86**
  size, range, **e86**
Odontoclasts, 25
Odor
  chair-side test, 549
  dark-field/phase-contrast microscopy, 548
  electronic noise, 549
  gas chromatography, usage, 548
  oral microbial load, chemical reduction, 550
  power, 546, 547t
  saliva incubation test, 548-549
  threshold, 547t
OHL. *See* Oral hairy leukoplakia
Older adults, periodontal diseases, 448
  antiplaque agents, 449-450
  chemotherapeutic agents, 449-450
  etiology, 448
  systemic disease, relationship, 448
Older adults, periodontal health (maintenance), 449-450
Olfactory response, 546
Oligogenic inheritance, 104-105

For entries that have a boldface page reference, i.e., 179.e2, go to the Expert CONSULT website at www.expertconsult.com, and after registering, search for the term on the book website.

One-sided chewing, **e13**
calculus formation, **e18f**
plaque formation, **e14f**, **e18f**
One-stage implant placement
surgery, two-stage implant placement surgery (differences), 731
tissue management, 738f
One-stage implant surgery, two-stage implant surgery (differences), 731f
One-stage nonsubmerged implant placement, 737-738
One-stage surgical approach, impact, 731
One-wall angular defects, 604
ONJ. *See* Osteonecrosis of the jaw
Online Mendelian Inheritance, 107-109
Opaque titanium temporary abutment, 773f
Open-bite neglect, **e19f**
Open-bite relationships, 365
Open contacts, 123-124
Open flap access surgery, usage, 184
Open gingival embrasures, **542.e10-542.e11**
existence, **542.e8**
orthodontic alignment, impact, **542.e11f**
Open growth system, 135-136
Open-loop systems, **e95-e96**
Open mouth posture, 256-257
OPG. *See* Osteoprotegerin
Opportunistic bacterial infection, 195f
Opportunistic data, **e84**
Optical tracking systems, 788
Oral appliance, 354-355
Oral candidiasis, 336-337
commonness, 431
Oral cavity
archaea, 157
candidal infection, acute myelogenous leukemia, **e28f**
colonization, 132, 133f
ecosystems, 136
examination, 362, 460
herpesviruses, recovery, 153t-154t
lupus erythematosus, 274f
melanin pigmentation, prominence, 20
microbial perspective, 135-138
nonbacterial inhabitants, 152-157
papillomaviruses, recovery, 155t
pemphigus vulgaris, 269f
picornaviruses, recovery, 155t
protozoa, presence, 156-157
retroviruses, recovery, 155t
views, **e2f**
viruses, 152-156
yeasts, presence, 156
Oral contraceptive-associated gingivitis, 401
Oral contraceptives (OCs), 445
management, 445
Oral device, characteristics, 354
Oral diseases, biofilm (importance), 141
Oral environment, cementum (exposure), 31
Oral (outer) epithelium, 14
Oral epithelium, intestinal mucosa (differences), 173
Oral examination, performing, 698
Oral hairy leukoplakia (OHL), 337
tongue, left lateral border, 338f
Oral halitosis, complaints (presence/absence), 545-546
Oral health, saliva (role), 217t
Oral hygiene
complication, **e35f**
impact, 650f
instruction, provision, 424
measures, 650
methods, 811f
Oral hygiene procedures, 625
neglect (prolongation), plaque formation/periodontitis, **e14f**
Oral hyperpigmentation, 338-339
incidence, increase, 338-339
Oral implants, introduction, 149
Oral irrigation, safety, 511
Oral jewelry
impact, 128f
trauma, 128
Oral lesions
bullous pemphigoid, 267
chronic ulcerative stomatitis, 271
erythema multiforme, 274-275
healing, penciclovir (association), **e86t**
linear immunoglobulin A disease (linear immunoglobulin A dermatosis), 272
pemphigus vulgaris, 270
Oral lesions, lichen planus, 264-265
Oral leukoplakia, 129f
histologic features, 130f
smokeless tobacco, impact, 130f
Oral lichen planus, lesions, 267
Oral malodor, 362
chronic oral malodor, 549
dark-field/phase-contrast microscopy, 548
treatment, 549-551
Oral microbial load
aminefluoride/stannous fluoride, 550
baking soda, 550
chemical reduction, 550
chlorhexidine, 550
chlorine dioxide, 550
essential oils, 550
hydrogen peroxide, 550
oxidizing lozenges, 550
triclosan, 550
two-phase oil-water rinse, 550
Oral mucosa, 9
facial/palatal surfaces, 21f
palpation, 373
Oral mucous membrane pemphigoid, microscopic features, 268f
Oral pathologies, 153
Oral pemphigus, direct immunofluorescence, 271f
Oral repigmentation, 20
Oral tumors, 153
Oral ulcerations, 431
Oral ulcers, 153
Oral viral diseases
clinical manifestations, 153-156
oral pathologies, 153
oral tumors, 153
oral ulcers, 153
periodontitis, 153-156
Oral yeast infections, etiologic agents, 156t
Orange complex, 173
Orban interdental knife, 573f
Organic constituents, 140-141
Organic matrix, 32-33
Organoleptic rating, 547-548

For entries that have a boldface page reference, i.e., 179.e2, go to the Expert CONSULT website at www.expertconsult.com, and after registering, search for the term on the book website.

Orofacial pain, 347-348
development, 351
differential diagnosis, 347b
Oropharyngeal examination, 547
Orthodontic anchorage, hopeless teeth (maintenance), **542.e8-542.e9**
Orthodontic appliances
gingival changes, 256
size, reduction, 542
views, **e6f**
Orthodontic correction, indication, 630
Orthodontic therapy
benefits, 542
periodontal complications, association, 125-127
Orthodontic tooth movement, 542
Orthodontic treatment, 126
open gingival embrasures, 542
Orthograde periodontitis, 470
Orthopedic instability, example, 346f
Orthopedic stability (maintenance), TMJ (impact), 346
OSA. *See* Obstructive sleep apnea
Osseointegrated dental implants, 723
Osseointegration
achievement, 686
implant therapy principles, 731b
landmark discovery, 813
Osseous coagulum, 613
Osseous craters, 296-298, **542.e1**
diagrammatic representation, 297f
Osseous crest, uncovering (impact), 583f
Osseous defects
bone deformities, 296
combined type, 297f
orthodontic treatment, **542.e1-542.e9**
Osseous lesions, 243, 456f
Osseous resection, 626
Osseous resective surgery, 604
division, 626
rationale, 604-605
terminology, 605-606
Osseous surgery
defining, 604
usage, **626.e5f**
Osseous topography, 35-36
Ostectomy, 605
requirements, 607
simplicity, 779
Osteoblasts, 25, 33
apoptosis (inhibition), transforming growth factor-β (impact), 87
growth factors, in vitro effects, 619t
Osteoclastic bone resorption, initiation, 80-81
Osteoclastogenesis, stimuli factors, 175f
Osteoclasts, 25
access, MMPs (importance), 87
Osteocytes, extension, 33
Osteoectomy, 605
Osteogenic protein-1 (OP-!), 758-761
Osteonecrosis of the jaw (ONJ), 197
Osteoplasty, 586, 605
usage, 608f
Osteoporosis, types, 700
Osteoprotegerin (OPG), 42
RANKL endogenous inhibitor, 176
receptor activator, 89
Osteoradionecrosis (ORN), 433
development, risk, 433-434
risk
evaluation, 131
increase, oral conditions (impact), 130-131
reduction, 703
Osteotome instruments, 756f
Osteotome sinus floor elevation (OSFE) technique, illustration, 757f
Osteotome technique, clinician comments, 758b
Osteotomy, 733f
Outcome-based study designs, 72
Outcomes, evaluation, **e79-e80**
Outer (oral) epithelium, 14
Outpatient surgery, 566-572
allergy, 569
anesthesia, 567
dressing, preparation/application, 569-570
emergency equipment, 566-567
excisional/incisional instruments, 572-573
first postoperative week, 570-571
hemostasis, 567-569
infection transmission, prevention measures, 567
informed consent, 566
mouth care, 572
noneugenol packs, 569
packs
antibacterial properties, 569
removal, 571-572
retention, 569
patient preparation, 566
periodontal dresses (periodontal packs), 569-570
postoperative instructions, 570
postoperative pain, management, 572
premedication, 566
repacking, 572
return visit, 571-572
scaling and root planing, 567
sedation, 567
surgical instruments, 572-574
surgical pack (Coe-Pak), preparation, 569f
tissue management, 567
tooth mobility, 572
zinc oxide-eugenol packs, 569
Ovate pontic
creation, 656
receptor site, creation option, 656f
shape/form, 656f
Overall prognosis, individual tooth prognosis (differences), 395
Overbite, **e4f**
Overcontoured crowns/restorations, plaque/handicap oral hygiene (accumulation), 123
Overeruption, **542.e10**
recession, presence, 41f
Overhanging amalgam margin, effects, 483f
Overhanging dental restorations, 230
Overhanging margins
frequency, 121
impact, **e40f**
Oxidized cellulose, 568
Oxycel, 568
Oxidized regenerated cellulose, 568
Oxidizing lozenges, 550
Oxytalan fibers, de novo development, 24

For entries that have a boldface page reference, i.e., 179.e2, go to the Expert CONSULT website at www.expertconsult.com, and after registering, search for the term on the book website.

P
PAAP. *See* Platelet-aggregation-associated protein
Packs
  antibacterial properties, 569
  removal, 571-572
    findings, 571-572
  retention, 569
PAG. *See* Periodontitis-associated genotype
Paget disease, **29.e1**
Palatal erythematous candidiasis, 336f
Palatal flap, 597-598
  initial incision, 597
  reflection, 127f
Palatal gingiva
  inflammation, 124f
  pseudomembrane formation, **e66f**
Palatal glands, 560
Palatal interdental papillae, 11f
Palatal pocket, elimination methods, 597f
Palatal pseudomembranous candidiasis, 336f
Palatal tissue
  papilloma, **e44f**
  thinness/thickness, 597
Palatal torus, clinical photograph, 563f
Palatal wall socket osteotomy, 771f
Palate
  denture stomatitis, 156f
  histologic frontal section, 560f
  mixed erythematous/pseudomembranous candidiasis, 336f
  occlusolateral view, 560f
  ulcerations, 194f
Palatine bone, occlusal view, 560f
Palatine process, extension, 559
Palatogingival groove, 400f
Palliative treatment, postirradiation follow-up, 434-435
Palms, hyperkeratosis, **e63f-e64f**
Panoramic images, familiarity, 708
Panoramic radiographs, 707-708
  example, 708f
PAP. *See* Positive airway pressure
Papilla
  management, 582
  presence, **542.e10**
  preservation flap, 582, 598-599
    design, 599f
    selection, 555, 598
    sulcular incisions, facial view, 600f
  preservation technique, 577
  reconstruction, 636f
Papillary form, gingival embrasure volume (relationship), 655f
Papillary gingiva, 123f
Papillary gingivitis, 224
Papillary height, establishment, 655
Papillary inflammation, 46f
Papillary layer, 17
Papilla-sparing technique, 660f
Papilloma, 240
  appearance, **e44f**
  histopathology, 240b
Papillomaviruses, recovery, 155t
Papillon-Lefèvre syndrome (PLS), 57, 107-109
  appearance, **e64f**
  hyperkeratosis, 59f
  oral/radiographic/dermatologic findings, 108f
  panoramic radiograph/clinical photographs, 58f
Parafunction, 536-537
Parakeratinized epithelia, 12
Parakeratinized gingival epithelium, 14f
Parakeratotic layer, 14f
Parenteral 1-deamino-8-D-arginine vasopressin (DDAVP), 428-430
PARL. *See* Periapical radiolucency
Parotid gland
  duct (Stensen's duct), opening, **e15f**
  saliva, flow, 116
PARs. *See* Protease-activated receptors
Partially edentulous maxilla, panoramic view, 718f
Partially edentulous patients, 694-696, 726-727
Partially edentulous patients, posterior quadrants (cantilevers), 725f
Partially edentulous posterior mandible, clinical view, 695f
Partially erupted mandibular third molar, **e70f**
Partial-thickness flap, 582
  vestibular deepening, 65f
Partial-thickness repositioned flap, 736-737
Partial thromboplastin time (PTT), 428
Particulate bone graft, 740
  material, placement/shape, 661f
Parvimonas micra (detail), 134f-135f
Passive eruption, 22
  steps, 22f
Pathogenesis
  definition, 76
  linkage, 88-89
Pathogenic bacteria, 161-162
  periodontal disease risk factor, 391-392
Pathogen recognition, 92
  systems, 90
Pathogens, prevalence, 162t
Pathologic granules, observation, 284
Pathologic mobility, 364
Pathologic tooth migration (PTM), 305-308
  case report, **e1-e2**
  casts, **e2**
  dental history, **e1**
  diagnosis, **e2**
  first molars, replacement failure, 306-307
  implant therapy, **e4**
  medical history, **e1**
  oral examination, **e1**
  orthodontic therapy, **e4**
    completion, views, **e6f**
  orthodontic treatment, panoramic radiograph, **e8f**
  panoramic radiograph, **e6f**
  pathogenesis, 305-308
  periodontal assessment, **e1-e2**
  periodontal maintenance, **e4**
  periodontal support, weakening, 306
  periodontal therapy, **e2-e3**
  prognosis, determination, **e2**
  radiographic survey, **e2**
  reevaluation, **e3-e4**
  restorative phase, **e4**
    completion, views, **e6f**
  results/discussion, **e4-e8**
  signs, differences, **e2f**
  teeth, forces (changes), 306-308
  treatment, **e2-e4**
    plan, **e2**
  unreplaced missing teeth, 306

For entries that have a boldface page reference, i.e., 179.e2, go to the Expert CONSULT website at www.expertconsult.com, and after registering, search for the term on the book website.

Patients
age, impact, 395
anatomic structures, identification, 710
appraisal, 357
assignments, impact, **e103-e115**
bone quantity/quality/volume, assessment, 710-717
clinical photographs, 362
complaints, 697
compliance/cooperation, 396
current illness, 358-361
data, digitization, **e92**
dental history, 358-361, 754-755
disease activity, determination, 371
evaluation, 710-719
gingival disease, prognosis, 401
implants, examination, 362-366
initial examination, **e74f**
review, 362
long-term follow-up, residual crestal bone height, 755f
lymph nodes, examination, 362
medical history, 357-358
oral cavity, examination, 362
oral examination, 362
oral hygiene, 362
methods, 809-810, 811f
oral malodor, 362
palpation, 373
pathology, exclusion, 710
periodontal abscesses, 373-374
periodontal referral, 811
periodontium, examination, 366-374
preparation, 730
registration, **e92**
satisfaction, 817-818
second visit, 362-374
selection methods, **e125**
suppuration, 373
teeth, examination, 362-366
treatment plan, explanation, 410
Pattern recognition receptors (PRRs)
activation, 92
armamentaria representation, 172
engagement, 94-95
expression, 92, 172t
PRR-signaling activation, 170
secretion, 172
PDGF-BB. *See* Platelet-derived growth factor-BB-beta-tricalcium phosphate
PDL. *See* Periodontal ligament
Pediatric patient, therapeutic considerations, 259-260
Pediatric sedation, 412
Pedigrees, patterns, 102-105
Pellicle
acquired pellicle, 144
formation, 144
layers, 144
microbiology, ecological relationship, 144
Pemphigoid, 267-269
bullous pemphigoid, 267
mucous membrane pemphigoid, 268-269
pemphigus, clinical resemblance, 271
Pemphigus vulgaris, 269-271
characterization, **e34f**
cutaneous lesion, 269f
differential diagnosis, 270-271
Pemphigus vulgaris *(Continued)*
gingiva, 270f
histopathology, 270b
immunofluorescence, 270
microscopic features, 270f
oral cavity, 269f
oral lesions, 270
treatment, 264f, 271
Penciclovir
oral lesion healing, association (two-by-two table), **e86t**
usage, 376
Penetrance, reduction, 104-105
Penicillins, 518
amoxicillin, 518
amoxicillin-clavulanate potassium, 518
clinical use, 518
pharmacology, 518
side effects, 518
Peptostreptococcus micros (proportion), 364
Percussion, sensitivity, 365, 570-571
Perfusion, India ink (usage), **18.e1**
Periapical abscess
cervical root resorption, computed tomography, 64f
periodontal abscess, relationship, 374
Periapical radiographs, 706
disadvantage, 706
examples, 380f
high-resolution detailed image, 707f
information, 378
long-cone paralleling technique, 378
schematic diagram, 380f
Periapical radiolucency (PARL), 470
Pericoronal abscess, 460-461
Pericoronitis, 251
appearance, 251f, **e70f**
clinical features, 251
complications, 251
Periimplantitis, 122-123, 167
site, moat (radiograph), 123f
Periimplantitis, 799-800, 811, **e126-e127**
example, 806f
Periimplant mucositis, 811
Periimplant mucositis, local delivery, 524
Periimplant mucositis, periimplantitis (differences), 805
Peri-implants
defects, **e118**
disease
evaluation, 808-809
treatment, 810-811
health
assessment, 808-809
evaluation, 808-809
inflammation, presence, 808-809
plaque accumulation, 805
probing, 806-807
value, 806-807
soft tissues, 687
Periimplant soft tissue
nonsurgical sculpting, 663f
three-dimensional sculpting, 663f
Periimplant sulcus, healing, 665f
Periimplant tissues
clinical appearance, 688f
ground section, 688f
PerioCol-CG, **e127**

For entries that have a boldface page reference, i.e., 179.e2, go to the Expert CONSULT website at www.expertconsult.com, and after registering, search for the term on the book website.

PerioCol-TC, **e128**
fibers, packaging, **e128f**
Periodontal abscesses, 286, 373-374, 383, 460-461
acute lesions, 166
clinical pictures, 166f
deep furcation invasions, location, 461f
diagnosis, 373
formation, occurrence, 286
gingival abscess, relationship, 374
lateral abscesses, 233-234
microscopic view, 288f
periapical abscess, relationship, 374
pre/posttreatment, **e70f**
pulpal abscesses
differences, 462
separation, 476
radiographic appearance, 385f
suppuration/drainage, **478.e1**
treatment
approaches, 463
upper right central incisor, 288f
Periodontal attachment
documentation, 311f
loss, 130
Periodontal bone loss, 739
bisphosphonates, impact, 200
differentiation, 379-380
Periodontal breakdown, **e49f**
Periodontal case-control studies, examples, 72t
Periodontal chart, **e92**
initial periodontal examination, **e3f**
screenshot, **e93f**
(UCLA), example, 367f-368f
Periodontal cohort studies, examples, 72t
Periodontal complications, orthodontic therapy (association), 125-127
Periodontal conditions
assessment, diagnostic tests (usage), 74
clinical measurement, 69-70
true/surrogate measures, 70
epidemiologic measures, obtaining, 70-71
measures, diversity, 71
periodontal diseases, differences, 74
tooth mobility, relationship, 355
treatment, systemic therapy (usage), 404
Periodontal continuum, anatomic considerations, 470-472
Periodontal cyst, asymptomatic characteristic, 289
Periodontal destruction
Class III malocclusion, **e18f**
examination, 70
periods, 293
radiographs, 125f
Periodontal diagnosis, 357
full-mouth intraoral radiographic series, usage, 361f
microbial tooth deposits, 391-392
Periodontal diagnostic test, translation, 74-75
Periodontal diseases, 339-343
abnormalities, 124
activity, 285
adaptive immunity, 174
activation, 174
age, impact, 392
anterior teeth, pathologic migration, 365f
bacteria groups/complexes, association, 171-172
bacteria, role, 473
Periodontal diseases *(Continued)*
bone destruction, 291, 378-380
patterns, 295-299
bone formation, 294
bone morphology, factors, 294-295
cause, 74
classification, 46b
clinical entity, uniqueness, 77
clinical management, goal, 449
clinical presentation, 176
complicating factors, 158-159
coronary heart disease/atherosclerosis, relationship, 205-209
cytokine networks, 96f
development, beneficial species (impact), 162
diabetes, impact, 391
diabetes mellitus, relationship, 210-211
diagnosis, 74-75
normative/arbitrary values, 74
risk-based reference values, 74-75
therapeutic reference values, 75
ecologic plaque hypothesis, relationship, 158f
epidemiologic measures, obtaining, 70-71
etiology, 160-161, **e13**
smoking, effects, 180-183, 182t
factors, 76
gender, impact, 392-393
genetic factors, 392
genetics
study, techniques, 106t
terms, 102t-103t
habits, 127-129
histopathology, 77-81
immunopathology, TNF/LTA roles, 110
inflammatory mediators, role, 84-88
innate immunity, 171-174
knowledge, evolution, 202
management, change, 180b
measures, diversity, 71
microbiologic specificity, 157-159
microbiology, 180-182
modifiable causative factors, 73-74
mortality, relationship, 204-205
nutrition, impact, 197
older adults, 448
pathogenesis
smoking, effects, 180-183, 182t
pathogenic bacteria, 391-392
periodontal conditions, differences, 74
prevalence/severity, smoking (effects), 179-180, 179t
prevention, 449-450
progression, 678f
aging, impact, 43
pathobiology, 174-177
T-Helper 1/T-Helper 2 concept, 97b
radiographic appearance, 380-386
recurrence, 669
risk-based decision support systems, **e96**
risk determinants/background characteristics, 392-393
risk elements, categories, 392b
risk factors, 391-392
role, 208-209
self-inflicted injuries, 127-129
socioeconomic status, 393
stress, 393
stroke, relationship, 209-210

For entries that have a boldface page reference, i.e., 179.e2, go to the Expert CONSULT website at www.expertconsult.com, and after registering, search for the term on the book website.

Periodontal diseases *(Continued)*
systemic antimicrobial agents, therapeutic uses, 520t
systemic health, relationship, 212
tobacco smoking, impact, 391
treatment
antibiotic regimens, 516t
antibiotics, usage, 516t
host-cell signaling, therapeutic strategies, 177
vigilance/tolerance, 171-173
Periodontal (gum) diseases, 68
Periodontal disturbances, blood dyscrasias (association), 190-191
Periodontal dressings (periodontal packs), 569-570
Periodontal dystrophies, 75
Periodontal-endodontic lesions, 62
Periodontal endoscopes, 494
Periodontal esthetic applications (lasers), 647-648
Periodontal exploration, importance, 607
Periodontal fibers, 23-25
Periodontal flaps
incisions, usage, 583
technique, usage, 588
treatment, diagram, 590f
Periodontal health, 162
subgingival samples, morphotypes, 160f
Periodontal health, maintenance, 449-450
Periodontal immunobiology, terms, 92t-93t
Periodontal Index, 71
Periodontal indices, recordation (absence), 260
Periodontal infection, 546
daily activity, 207
differential diagnosis, 475-477
effect, 206-208, 211f
organ systems/conditions, 203b
stroke, association, 209-210
Periodontal infection, host response, 170
Periodontal inflammation
concentrations, 174-175
probing bleeding, 70
Periodontal instruments
classification, 494-506
parts, 495f
Periodontal knives (gingivectomy knives), 572
usage, 579-580
Periodontal lesions, presence, 485
Periodontal ligament (PDL), 23-28, 37
aging, impact, 42
cells
growth factors, in vitro effects, 619t
proliferation, 42
types, 25
cementicles, 26f
defense cells, 25
fibers, 23f
formation, 31f
formative function, 27
functions, 26-28
involvement, 192
nutritional functions, 27-28
physical functions, 26-27
principal fibers, 24
radiolucent shadow, **29.e1**
radiopaque line, 378
remodeling function, 27
replacement, **31.e1**
role, importance, 42
Periodontal ligament (PDL) *(Continued)*
sensory functions, 27-28
sensory nerve fibers, 27-28
space width, 378, 385-386
tension/pressure, areas, 302f
thickness, 27t
vascular supply, 39f
vessels, 19
containment, 38-39
width, regulation, 28
Periodontally compromised maxillary anterior teeth, clinical photograph, 768f
Periodontal maintenance, determination, 676f
Periodontal measures
collection, 70
preference, 71
Periodontal medicine, clinical practice, 211-212
Periodontal microbiology, advances, 168-169
Periodontal microsurgery
advantages, 632-638
philosophy, 632
Periodontal origin, radiographic appearance, 477
Periodontal pack, insertion, 570f
Periodontal pain, identification, 347
Periodontal parameters, computerized diagram, 367f-368f
Periodontal pathogenesis
immune responses, 90-97
knowledge, evolution, 76
pathogenesis, 277-280
types, 277
Periodontal pathology, saliva (role), 218
Periodontal plastic/esthetic surgery
aberrant frenum, problems, 629
blood supply, adequacy, 631
donor sites, 631
esthetic surgical therapy, 629
magnification systems, 638-643
mucogingival line (junction), 630
objectives, 628-629
orthodontic correction, indication, 630
recipient
anatomy, 631
site, grafted tissue (stability), 631
shallow vestibule, problems (association), 629
surgical site
plaque/calculus/inflammation, absence, 631
trauma, 631
techniques, selection criteria, 630-631
terminology, 628
tissue engineering, 629
Periodontal plastic surgery, 628
Periodontal Plus AB, **e128f**
Periodontal pockets, 366-371
appearance, 368f, **542.e2f**
attachment level, differences, 370
bacterial invasion, 281
bacterial survival strategies, 136-137
base
lateral epithelium proliferation, 281f
low-power view, 279f
bleeding, probing (impact), 370
classification, 277
clinical features, 277
histopathologic features, correlation, 278t
concentrations, schematic representation, **e101f**

For entries that have a boldface page reference, i.e., 179.e2, go to the Expert CONSULT website at www.expertconsult.com, and after registering, search for the term on the book website.

Periodontal pockets *(Continued)*
conversion, 605
deepening, plaque accumulation (impact), 553f
deep periodontal pocket, probing, 278f
depth, determination, 371
detection, 366
elimination, outcomes, 406f
epithelium, transmission electron micrograph, 281f
granulation tissue, pressure, 308
healing lesions, 282-283
healing stages, regenerating cell sources, 406f
histopathology, 280-285
inactivity/activity periods, 285
infection, extension, 286
inflammation, lateral extension, 286
intraoral habitats, 137t
lateral wall, 280f
pleiotropic mechanisms, schematic, 529f
postprophylaxis periodontal abscess, 462f
probe
angulation, 370-371
timing, 370
walking, 369f
probing
force, 370
technique, 369
production, 277
pulp, changes, 285
reduction surgery, 553
signs/symptoms, 366
site specificity, 285
soft-tissue wall, 282
therapy, results, 553
types, 278f
Periodontal pocket wall
appearance, 283f
pathologic changes (elimination), surgical pocket therapy (purpose), 552
removal, 580
scanning electron frontal micrograph, 282f
scanning electron micrograph, 282f
scanning electron microscope view, 216f
Periodontal probes, 494
composition, 495f
exploration, 370f
types, 495f
Periodontal probing
importance, 607
limitations, 371f
types, 370
Periodontal procedures
antibiotic prophylaxis regimens, 424t
design, 649
lasers, usage, 647-648
Periodontal randomized controlled trials, examples, 72t
Periodontal reconstruction, 407
Periodontal reconstructive surgery, approaches (comparative analysis), 612t-613t
Periodontal reevaluation, 313f-314f
Periodontal regeneration
approaches, comparative analysis, 612t-613t
enamel matrix derivative, usage, 616-617
recombinant human platelet-derived growth factor, 617-618
Periodontal regenerative procedures, 452
Periodontal space (widening), trauma from occlusion (impact), 387f
Periodontal species, growth, 134f-135f
Periodontal statistics, interpretation, 71
Periodontal status
malocclusion, relationship, 254
United States, 71t
Periodontal support, weakening, 306
Periodontal surgery, 553b
coarseness, 637f
goals, 638
impact, 364
indications, 554
localized areas, radiographs, 672f-673f
muscles, relationship, 562
outpatient surgery, 566-572
patient instructions, 571b
piezoelectric bone surgery, usage (clinical case), 780f
piezosurgery, usage, 777
SDD, combination, 533
sedation, rationale, 404
Periodontal surgical instruments, series, 573f
Periodontal surgical (ostectomy) operation, 777-779
Periodontal therapy
accomplishments, 404
antibiotics, usage guidelines, 520-521
dental therapy, relationship, 409
effectiveness, 552
effects, 211f
healing, 405-407
impact, 210
maintenance phase (phase IV therapy), 409
maintenance therapy, 184
nonsurgical phase (phase I therapy), 409
nonsurgical therapy, 183
outcomes, stress (impact), 196
phases, 409b
response, smoking effects, 183-184, 183t
restorative care, relationship, 649
restorative phase (phase III therapy), 409
surgical phase (phase II therapy), 409
objectives, 552-553
surgical therapy/implants, 184
Periodontal tissues
abscess, 286
inflammatory/immune processes, 83
observational studies, 90
plaque-bacteria association, depiction, 140f
plaque-bacteria penetration, 92
pulpal infection, biologic effects, 472-474
Periodontal treatment
clinical results, 405f
design, 424-425
health status, 343
maintenance therapy, 343
outcomes, smoking cessation (effects), 184-185
intervention studies, 185
performing, 430
phases, sequence, 668f
planning, 449
procedures, 425
protocol, 343
radiographs, 680f
recommendations, 430
tissue response, 405f
usage, 649

For entries that have a boldface page reference, i.e., 179.e2, go to the Expert CONSULT website at www.expertconsult.com, and after registering, search for the term on the book website.

Periodontal width, comparison, 38t
Periodontal wound healing, assessment, 610
Periodontics
  occlusion, 535-536
  practice, 424
Periodontist, patient referral, 674-675
Periodontitis, 50-60, 53b-54b, 153-156
  advanced lesion, 80-81
  aggressive periodontitis, 46, 53-55
  association studies, failure, 109
  biologic systems, 99f
  cause, bacterial plaque (factor), 76-77
  chronic periodontitis, 46, 52-54
  clinical forms, microbial species (prevalence), 161t
  clinical manifestations, 51-52
  comparison, 104
  complementary treatment strategies, 527f
    involvement, 528
  consideration, 158
  developmental/acquired deformities/conditions, 54b
  early lesion, 79-80
  endodontic lesions, association, 61-63, **e10**
  established lesion, 80
  etiologic agents, 391-392
  forms, classification, 53t
  gingivitis, relationship, 290
  histologic appearance, 81f
  histologic stages, features, 79b
  histopathology, 78-81
  host susceptibility, systemic condition, 202-203
  impact, 54-59
  inherited variation/risk, 107-113
  initial lesion, 79
  localized tooth-related factors, 54
  management, advances (factors), 76
  manifestations, 54, 402, **e58**
  multicenter clinical trials, 523
  pathogens, prevalence, 162t
  pathology, 202-203
  patients, tooth mortality, 682t
  plaque accumulation, causal relationship, 391
  plaque-related aggressive moderate periodontitis, clinical image, 56f
  plaque-related moderate chronic periodontitis, clinical image, 55f
  plaque-related severe advanced chronic periodontitis, clinical image, 56f
  plaque-related severe aggressive periodontitis, clinical image, 57f
  plaque-related slight early chronic periodontitis, clinical image, 55f
  presence (identification), dental radiographs (usage), 607
  prevalence
    Germany, 316f
    United States, 316f-317f
  prognosis, 401-403
  radiographic changes, 383f
  risk factor, 817
  smoking
    effects, 179-180
    risk factor, 178-179
  systemic disease, manifestation, 46
  therapy, 555
  types, features, 358t
Periodontitis-associated genotype (PAG), 531
Periodontium
  abscesses, 61, 166, **e10**, **e69-e71**
  adaptive capacity, 300
  adaptive remodeling, 302-303
  aging, 447-448
    clinical changes, 448
    effects, 40-43
    functional changes, 448
    intrinsic changes, 447
    physiologic changes, 447-448
    stochastic changes, 447
  bleeding, 192-194
  damage, inflammation (impact), 610
  developmental issues, 254
  dysfunction/deterioration, 347
  effect, 478-479
  examination, 366-374
  external forces, 37-38
  health, chart (usage), **e7f**
  inflammatory responses, 81-88
  microbial virulence factors, 81-83
  oral ulceration/infection, 194-195
  periodontal changes, 252-254
  preparation, treatment sequence, 650b
  regeneration ability, 474
  sleep-related breathing disorders, 350
  treatment, aging (response), 43-44
Periodontopathogen-host interactions, 162
Periodontopathogenic species, intraoral habitats, 137t
Periodontopathogens
  presence, microbiological diagnostic tests, 159
  virulence factors, 167-168
Periodontosis, diagnosis, 75
Perioradicular bony lesions, primary periodontal defects, 475f
Perioscopic instrumentation, 505f
Perioscopy system
  components, 504-505
  dental endoscope, 504f
Periosteal elevators, 574
  insertion, 585
Periosteum, 34-35
  cellular events, 35
  components, 34
  inner layer, 34
  outer layer, 34
Peripheral blood, neutrophils (collection), 183
Peripheral giant cell granuloma, 240-241
  appearance, **e45f**
  histopathology, 241b
  microscopic survey, 241f
Periradicular abscesses, suppuration/drainage, 476
Periradicular diseases, classification, 473t
Perivascular connective tissue, changes (detection), 219
Permanent dentition, attached gingiva (mean width), 10f
Pero-Aid, utilization, 625f
Personalized treatment
  benefits, 114
  genetics, usage, 113-114
Person-time dimension, 69
PES. *See* Pink esthetic score
Petechiae, evidence, 190f
Peutz-Jeghers syndrome, 228
Peyer's patches, 173
Phagocytosis, 182-183

For entries that have a boldface page reference, i.e., 179.e2, go to the Expert CONSULT website at www.expertconsult.com, and after registering, search for the term on the book website.

Pharmacogenetics, individualized dentistry (relationship), 113-114
Phase-contrast microscopy, 548
Phase I periodontal therapy
elements, 480
procedures, sequence, 481-482
rationale, 480
reevaluation, 554, 566
results, 481f, 482
specialist treatment, referral decision, 482-483
treatment sessions, 480
Phase II periodontal therapy
method selection, criteria, 555
periodontal surgery, indications, 554
surgical phase objectives, 552-553
Phenylalkylamine derivatives, 236
Phenytoin (Dilantin), 235
administration, 235
medications, alternatives, 587
stimulation, 235
usage, gingival enlargement, **e25f**
Phenytoin gingival enlargement, 234f
Phenytoin-induced overgrowth, 234f
Phenytoin therapy, impact, 234f
Phonetic complications, 802-803
Photodynamic therapy, 482
Photostimulable phosphor (PSP) plates, usage, 387
Physical examination, 697
Physical status classification system (ASA), 414t
Physicochemical determinants, 160
Physiologic mesial migration, bundle bone (association), 34f
Physiologic pigmentation (melanin), 20
Physiologic recession, 22-23
PICO. *See* Population intervention comparison and outcome
Picornaviruses, 153
recovery, 155t
Piezoelectric bone surgery
characteristics, 776
clinical applications, 777-784
clinical case, 780f
example, 781f-782f
Piezoelectric tip, working sides, 509f
Piezoelectric ultrasonic device, 509f
Piezosurgery
cutting properties, 779b
description, 779b
device, example, 777f
inserts
description, 779b
usage, 781f-782f
osteotomy insert, 778f
usage, 777
Pigmented gingiva, melanocytes (presence), 13f
Pik Pocket tip
placement, 513f
usage, 513f
Pilot drill, 732
Pink esthetic score (PES), 793
Pink porcelain, usage, 803f
Placebo effects, **e89**
Planing, meaning, 576
Plaque
advanced formation, **e15f**
assessment, 366
attachment, 284
Plaque *(Continued)*
bacteria
leukocytes, attraction, 216
protease production, 82
composition, 126
control, 396
checking, 669
emphasis, 588
evaluation, 808
derivation, 163f
growth, topography (clinical illustration), 147f
hypothesis, 157-158
ecological plaque hypothesis, 158
nonspecific plaque hypothesis, 157
inorganic components, 141
local factor, 398
maturation, colonization (relationship), **144.e1**
microcolonies, 142f
presence, 119f
removal, proxy brush (usage), 625f
retention, 126
samples, phase-contrast micrographs, 160f
site specificity, 143-144
supragingival plaque, calcification, 119
unattached plaque zone, 284
Plaque accumulation, 123, 158f
excess, **e14f**
hemophilia-A patient, **e24f**
impact, 316-317, 553f
increases, 78
periodontitis, causal relationship, 391
visual inspection, 805
Plaque biofilm
chemical inhibitors, 485
control instruction, 481
reduction, 511t
removal, 481-482
in vivo generation, intraoral device (usage), 139f
Plaque formation
debridement/oral hygiene instruction, impact, **e20f**
excess, **e13f**
process, phases, 144
variables, 147-148
Plaque-induced gingival diseases, 255-257, **e10-e12**
calculus, 255
clinical features, 255
disease, microbiology, 255-256
localized tooth-related factors, 54, 63
medications, impact, 401
systemic factors, impact, 401
Plaque-induced gingivitis, appearance, 255f
Plaque-related aggressive moderate periodontitis, clinical image, 56f
Plaque-related aggressive severe periodontitis, clinical image, 57f
Plaque-related gingivitis, 46f
Plaque-related moderate chronic periodontitis, clinical image, 55f
Plaque-related severe advanced chronic periodontitis, clinical image, 56f
Plaque-related severe aggressive periodontitis, clinical image, 57f
Plaque-related slight early chronic periodontitis, clinical image, 55f
Plasma cells
gingivitis, 239-240
appearance, 239f, 275f
histopathology, 239b

For entries that have a boldface page reference, i.e., 179.e2, go to the Expert CONSULT website at www.expertconsult.com, and after registering, search for the term on the book website.

Plasma cells *(Continued)*
infiltrate, biopsy, 51f
predominance, 221
Plastic probe (Colorvue), 502f
Plastic surgery techniques, 552
Platelet-aggregation-associated protein (PAAP), expression, 207
Platelet-derived growth factor-BB (PDGF-BB)-beta-tricalcium phosphate (β-TCP), usage, 616
Platelet-rich plasma (PRP), usage, 616
Pleiotropic mechanisms, schematic, 529f
Plunger cusps, 123-124
PMS. *See* Premenstrual syndrome
Pneumonia, impact, 448
Pocket epithelium, removal, 610-611
Pocket marker, usage, 579f
Pocket reduction surgery, 553
Pockets. *See* Gingival pockets; Periodontal pocketsbone
alveolar bone, base (area), 285-286
relationship, 286
classification, 278f
contents, 283-284
depth
attachment loss/bone loss, relationship, 285
reduction/elimination technique, 593
usefulness, 554
detection, 366
diagram, 285f
elimination/maintenance, differences, 553-554
eradication, 602f
formation, 277
absence, 302
illustration, 278f
inactive pockets, healing, 553
inflammation, 291f
problems, approaches, 555-556
removal, 601f
surgery, critical zones, 554
therapy
methods, 555-556
results, 553
Pocket walls
bacterial penetration, 138f
scanning electron micrograph, 281f
ulcerated lateral pocket wall, view, 280f
Point-based method, 788
Polishing instruments, 494, 505-506
Polydipsia, 425
Polymerase chain reaction (PCR), 164t
Polymorphisms, 332
Polymorphonuclear cells, 172
Polymorphonuclear leukocyte (PMN), 219
aggregations, 320
deficiencies, 188-189
exit, 220
function, 188-189
Polyostotic fibrous dysplasia (Albright's syndrome), 228
Polyphagia, 425
Polysaccharide capsules, production, 168
Polytetrafluorethylene (PTFE) membranes, usage, 611
Polyuria, 425
Pontic design, 655-656
differences, 656
Pontic shape, design options, 656f
Population intervention comparison and outcome (PICO)
process, **e73**
question, search terms, **e78t**
Populations, patterns, 102-105
Porcelain fracture, 802f
Porcelain-fused-to-metal crowns
radiograph, 123f
usage, 66f
Porphyromonas gingivalis, 89-90, **55.e1**
adhesion capacity, differences (microscopic confirmation), 139f
counts, 180-182
details, 134f-135f
etiologic agent, 391-392
glycocalyx/polysaccharide capsule, 168f
growth, enhancement, 149
host cell infection, 91
levels, elevation, 402
molecules, antigen action, 97
prevalence, 322
reduction, 210
role, increase, 42
strains, polysaccharide capsule production, 168
virulence factors, 91t
Porphyromonas gingivalis, atypical form, 81
Positive airway pressure (PAP) therapy, 350
example, 353f
Positive architecture, 606
ostectomy, requirements, 607
Post-CVA patients, dental clinician treatment, 425
Posterior area, moderate-to-severe periodontitis (therapy), 555-556
Posterior left maxilla, CBCT examination, 716f
Posterior mandible
lingual surface, exposed bone (clinical photograph), 200f
resorbed ridge, **769.e5f**
single-tooth restoration, 727f
Posterior mandibular vertical ridge augmentation, example, 760f
Posterior maxilla, four-unit FPDs (presence), 801f
Posterior quadrants, restoration guidelines, 727f
Posterior right mandible (horizontal deficiency reconstruction), monocortical block graft (usage), 742f
Posterior segments, short-span linear implant configurations, 724-725
Posterior teeth
cusp-fossa//cusp-marginal ridge relationships, 536
Posterior teeth, replacement failure, 124
Postoperative assessment, 719-720
Postoperative bleeding, clinical photograph, 795f
Postoperative bruising, clinical photograph, 795f
Postoperative care, 735, 737-738
Postoperative microsurgery, 774f-775f
Postoperative pain, 572
management, 572
Posttrauma, **e80f**
healing, **e79f-e80f**
Posttreatment evaluation, 704
Posttreatment patients, classification, 669-674
Postural hypotension, 422
Power-driven instruments, clinical outcomes, 508
Powered flossing devices, 491f
availability, 491
Powered toothbrushes, 487
brushing, 489
positioning, 489f
recommendations, 487, 489

For entries that have a boldface page reference, i.e., 179.e2, go to the Expert CONSULT website at www.expertconsult.com, and after registering, search for the term on the book website.

Power instruments
efficiency, 507
tip designs, 507-508
type/benefit, 507-508
Power scales, action mechanisms, 507
Practice Guideline on the Management of Acute Dental Trauma from the American Academy of Pediatric Dentistry, **e79**
PracticeWorks, **e94**
Precementum, 37
Preeclampsia, 441
Pregnancy, 439-443
analgesic administration, 444t
antibiotic administration, 444t
breastfeeding, 443
clinical management, 442
dental radiographs, usage, 442
elective dental treatment, 442
enlargement, 237-238
epulis, 440
estrogen, elevation, 441b
gingival enlargement, **e22f**
histopathology, 238b, 591-592
microscopic view, 238f
gingivitis, 439
moderate form, 439f
severity, 440f
granulomas, 439
hormones, role, 440-441
local anesthetic administration, 444t
localized gingival enlargement, **e21f**
medications, usage, 443
oral manifestations, 442
periodontal manifestations, 439-440
plaque control, 442
pregnancy-associated gingivitis, 163
prenatal fluoride, usage, 442
progesterone, elevation, 441b
pyogenic granuloma, 440f
sedative-hypnotic drug administration, 444t
treatment, 442-443
algorithm, 443f
tumors, 440
Preirradiation treatment, 433
Premenstrual syndrome (PMS), 439
Premolar area, mental nerve (emergence), 558f
Premolars
apical area, experimental occlusal trauma (impact), 303f
radiograph, 562f
Prenatal fluoride, usage, 442
Preoperative microsurgery, 774f-775f
Preoperative physical evaluation, 414b
Preoperative radiographs, 659f
Preorthodontic osseous surgery, **542.e1**
Preprosthetic surgery, 650
Preprosthetic techniques, 552
Preterm, low-birth-weight (PLBW) infants, 440
Pretreatment evaluation, 696-699
Pretreatment periapical radiograph, **542.e1**, **542.e2f**
Pretreatment root resorption, panoramic radiograph, 126f
Prevalence
example, 69
sum, 69
PreViser Risk Calculator (PRC), **e96**
Prevotella intermedia
counts, 180-182
detail, 134f-135f
growth, 150f
prevalence, 322
Prevotella melaninogenica (increase), 126
Prevotella nigrescens, 161-162
Preweighed twisted threads, usage, 214
Prichard surgical curette, 574f
Prickle cell layer, 14f
Primary colonizers (dental plaque), 145t
Primary dentition, periodontium, 252
Primary endodontic infection, lateral canal-led periodontal defect, 471f
Primary herpetic gingivostomatitis, 249-251, 257
appearance, 249f
clinical features, 249-250
communicability, 250-251
diagnosis, 250
acyclovir suspension, prescription, 464
differential diagnosis, 250
extraoral/systemic signs/symptoms, 250
histopathology, 250b
history, 250
lip/gingiva/tongue, involvement, 250f
necrotizing ulcerative gingivitis, differentiation, 246t
oral signs, 249-250
oral symptoms, 250
Primary herpetic infection, 50f
Primary hypertension (essential hypertension), occurrence, 420-421
Primary osteoporosis, 699-700
Primary periodontal defects, impact, 475f
Primary pulpal infection, impact, 471f
Primary sources, **e75**
Primary tooth exfoliation, 254
Primary trauma from occlusion, 300-301
occurrence, 301
Primary wound closure, microsurgical principles (usage), 635f
Principal components, 113
Principal fibers, 23-24
remodeling, 24-25
Prism telescopic loupes, 641
Probe
angulation, 370-371
exploration. *See* Periodontal probe.
penetration, variation, 366-368
vertical insertion, 369f
walking, 369f
Probing. *See* Clinical probing; Periodontal probingbleeding, 70, **e11f**
critical probing depth, 482-483
depths, 58f
consideration, 483
improvement, combination adjunctive therapies (impact), **e126**
force, 370
pocket depth, reduction, **e5f**
standardization, absence, 371
standard, referral, 483f
technique, 369
Probing pocket depth (PPD), 813-815
Procedure accessibility (enhancement), microsurgery (usage), 640f

For entries that have a boldface page reference, i.e., **179.e2**, go to the Expert CONSULT website at www.expertconsult.com, and after registering, search for the term on the book website.

Progesterone
elevation, 441b
microvasculature permeability, association, 438
Prognosis
adverse effects, 395
aggressive periodontitis, 402
anatomic factors, 398-400
calculus, local factor, 398
caries, impact, 401
chronic periodontitis, 401-402
clinical factors, 395-396
definition, 394
dental plaque-induced gingival disease, 401
determination, factors, 395-401, 395b
diagnosis, relationship, 401-403
disease severity, impact, 395-396
environmental factors, 396-398
genetic factors, 397-398
local factors, 398-400
necrotizing periodontal diseases, 402-403
nonvital teeth, relationship, 401
patient age, impact, 395
patient compliance/cooperation, 396
periodontitis, 401-403
plaque (local factor), 398
plaque control, 396
prosthetic factors, 400-401
provisional prognosis, establishment, 394-395
reevaluation, 403
restorative factors, 400-401
risk, confusion, 394
root resorption, 401
scheme, 394
smoking, impact, 396
stress, 398
subgingival restorations, 398
systemic disease/condition, 396-397
systemic factors, 396-398
teeth, example, 397f
types, 394-395
Proinflammatory cytokine tumor necrosis factor α, 783
Pro-inflammatory mediators, impact, 318
Proliferation, biologic complication, 798-801
Proof of principle, 610
Prophy-Jet air-powder polishing device, 506f
Proprioceptive guidance, 637
Prostaglandin E_2 (PGE_2), 86
synthesis, elevation, 438
Prostaglandin-endoperoxide synthase (PTGS2), 110
Prostaglandins, 83
inhibition, NSAIDs (usage), 525-526
Prostanoids, 83
Prosthesis screw loosening, 801
Prosthetic complications, 792, 801-802
Prosthetic factors, 400-401
Prosthetic joint infections, prevention (antibiotic regimens), 435t
Prosthetic joint replacement, 435
Protease-activated receptors (PARs), 82
Proteases, production, 82, 168
Protectins, 89-90
Proteolytic enzymes, 217
Prothrombin time (PT), 428
Protozoa, 156-157
Protrusion, 536
Protrusive bruxing habit, appearance, **542.e9f-542.e10f**
Protrusive excursion, 536
Provisional
clear silicon impression, 774f
fabrication, 772-773
implant microsurgery, impact, 773f
restorations, 654
gingival third, 662f
Provisional prognosis, establishment, 394-395
Provisional supporting gingival tissue, 773f
Proximal contact relations, 363-364
Proximal restorations, overhanging margins (frequency), 121
Proximal tooth contact, absence, 11f
PRRs. *See* Pattern recognition receptors
Pseudomembrane
formation, **e66f**
removal, **e66f**
Pseudomembranous candidiasis (thrush), 336
Psychologic conditions, 704
Psychologic stress, 322
Psychophysical staircase method, 548
Psychosocial stress, 195-196
Psychosomatic disorders, 195-197
PTFE. *See* Polytetrafluorethylene
PTGS2. *See* Prostaglandin-endoperoxide synthase
PTM. *See* Pathologic tooth migration
Pubertal gingivitis, 256
Puberty, 437-438
enlargement, 238
histopathology, 238b
gingival enlargement, 238, 592
gingivitis, 256
impact, **e20f**
management, 437-438
Pulmonary parenchymal fibrous infiltrate, 59f
Pulpal abscesses
periodontal abscesses
differences, 462
separation, 476
Pulpal continuum, anatomic considerations, 470-472
Pulpal diseases
classification, 472, 472t
initiation, factors, 472
Pulpal infection
biologic effects, 472-474
differential diagnosis, 475-477
fungi/yeast, presence, 473
subjective symptoms, 476
Pulpal inflammation, extensiveness, 473
Pulpal irritation, primary periodontal defects, 475f
Pulpal origin, radiographic appearance, 477
Pulp extirpations, periapical image, **e79f**
Pulp tissue, infection (persistence), 470
Pulsating lavage, impact, 514f
Pulse oximeter reading, 418t
Pus formation, **e49f**, **e51f**
Putrescine, 548-549
Pyogenic granuloma
appearance, 240f
clinical/histologic images, 48f
nonspecific conditioned enlargement, 239
occurrence, 440
Pyridinoline cross-linked carboxy terminal telopeptide of type I collagen (ICTP), **e116**
Pyrophosphates, 487-488

For entries that have a boldface page reference, i.e., 179.e2, go to the Expert CONSULT website at www.expertconsult.com, and after registering, search for the term on the book website.

Pyrosequencing, 161
Ptyalism (sialorrhea), 442

Q
Quasi-experimental studies, meta-analyses, 520
Questionable prognosis, 394
Questions, type, **e76t**
Quétin furcation curettes, 503-504, 503f
Quiescence periods, 285
Quorum sensing, roles, 150

R
Radiation caries, clinical view, 434f
Radiation dose, 707t
Radiation therapy, 130-131, 433-435, 703-704
  cytotoxic effects, 130
Radiation treatment, impact, 130
Radiographic examination, 699, 807-808, **e74**
  objective, 808
Radiographic guides, fabrication, 719
Radiographic projections, advantages/disadvantages, 707t
Radiographic techniques, 378
  selection factors, 706
Radiographs
  interpretation, 477
  screening, 719
RAGEs. *See* Receptors for AGEs
Raki, usage, **e43f**
Ramus block graft, usage, 66f
Randomization, **e88**
  process, bias, **e88**
Randomized controlled trials (RCTs), 71-72, **e75**, **e83**
  meta-analyses, 520
  periodontal randomized controlled trials, examples, 72t
  prevention, sample size considerations, **e88**
  requirement, 376
Randomized studies, confounding (impact), **e87**
RANKL. *See* Receptor activator of nuclear factor-κB ligand
RANTES. *See* Regulated on activation, normal T-cell expressed and secreted
Rapidly progressive periodontitis, 165-166
Rapid progression (RP), 677-678
RAS. *See* Recurrent aphthous stomatitis
Rat
  alveolar bone, 33f
  experimental occlusal trauma, 302f
  occlusion, 303f
  periodontal ligament, vascular supply, 39f
Rat molar
  bundle bone, 34f
  occluso-horizontal forces, microscopic view, 27f
  section, alveolar crest fibers (coronal radiation), 24f
RCT. *See* Root canal therapy
Reactive oxygen species (ROS), 88
  action, 94
Real 3D vision, 789
Recall intervals, 675t
Recall maintenance, methods, 810
Recall patients
  recall intervals, 675t
  supportive periodontal treatment, radiographic examination, 673t
Receptor activator of nuclear factor-βB (RANK), 89
Receptor activator of nuclear factor-κB ligand (RANKL), 42, 172-173, 318
Receptors for AGEs (RAGEs), 189
  Recession. *See* Gingival recessionbiologic complication, 798-799
  changes, **e5f**
  degrees, appearance, 230f
  differences, 286f
  extensiveness, 59f
  presence, 41f
  smokeless tobacco, impact, 130f
Recombinant human insulinlike growth factor 1 (rhIGF-1), 617
  usage, 617-618
Recombinant human platelet-derived growth factor, 617-618
Reconstructive surgery, flaps (usage), 598-599
Reconstructive surgical techniques, 610-619
  case, sample, 618f
  combined techniques, 618-619
  therapeutic success, factors, 619
Recurrent aphthous stomatitis (RAS), 250
Recurrent gingivitis, 224
Red complex bacteria, 157-158
Reduced enamel epithelium (REE), 15-16
  degeneration, 16f
Reduced penetrance, 104-105
Refractory periodontitis (treatment), tetracyclines (usage), 517
Regenerated ridge, computed tomography image, 62f
Regenerating cells, sources, 406f
Regeneration, 406
  occurrence, 406
Regenerative approaches, comparative analysis, 612t-613t
Regenerative success, clinical photographs/periapical radiographs, 453f
Regenerative surgery, **e126**
Regulated on activation, normal T-cell expressed and secreted (RANTES), role, 87
Reintrusion, reason, **542.e8**
Relative risk, 106t
Remote incision, layered suturing technique, 731
Removable appliances, long-term use, 739
Replanted teeth, **e74f**
Replicative senescence, 447
Representative study sample, **e85-e86**
Resective osseous surgery
  methods, 608-609
  rationale, 604-605
  selection factors, 606-607
  treatment technique, selection, 604
  usage, 608
Resective periodontal surgery, 313f-314f
Resident cells (microbial-associated molecular patterns), 173t
Residual cement, local factor, 123
Residual crestal bone height, minimum, 755f
Resolvins, 89-90
Resonance frequency analysis (RFA), 807
Resorptive process, events (sequence), 33
Restorations
  defects, recontouring, 482
Restorations, margins, 121-122
Restorative dentistry
  occlusal stability, 539
  periodontium preparation, treatment sequence, 650b
  procedures, 124
  therapy, rationale, 649
  treatment, sequence, 649-650
Restorative factors, 400-401

For entries that have a boldface page reference, i.e., 179.e2, go to the Expert CONSULT website at www.expertconsult.com, and after registering, search for the term on the book website.

Restorative materials, 124
fracture, 802
Restorative therapy, occlusal considerations, 656-657
Results, reporting (usage), **e78-e79**
Reticular connective tissue fiber, 17
Reticular lichen planus, **e32f**
Reticulum cell sarcoma, 233
Retroactive prayer, impact, **e84**
Retrograde periodontitis, 470
periapical lesion, extension, 471f
Retromolar triangle, 558
Retroviruses
genera, 153
recovery, 155t
Retrusion, 536
Reversal phenomenon, 120
Reverse bevel incision, 584
Reversed architecture, 298
appearance, 298f
rhBMP-2, usage (preclinical results), 762
rhIGF-1. *See* Recombinant human insulinlike growth factor 1
Rhodotorula glutinis, 156
Ridge
augmentation, 740
deficiency, reconstruction, 740
healing, 665f
preservation, 744
Right central incisor, periodontal abscess (radiographic appearance), 385f
Right lateral incisor, vertical defects, 297f
Risk
contraindications, 699-704
determinant/background characteristic, 391-393
elements, categories, 392b
estimation, 69
factors, 391, 699-704, 816-817
impact, 794
first-degree relatives, 104-105
indicators, 391
predictors/markers, 391
probability, 69
prognosis, confusion, 394
Risk-based decision support systems, **e96**
Risk-based diagnosis, 74-75
Risk-based reference values, 74-75
Rod-shaped ultrasonic instruments, 578
Root canal therapy (RCT), 477
Roots
apical portion, movement, 26
approximation, 623f
cementum, tooth-associated cervical plaque (adherence), 142
chronic periodontal abscess, lateral aspect (radiolucent area), 385f
concavities, 399f
exposure, 399
mandibular first molars, 400f
dentin, formation, 36
development, Hertwig epithelial root sheath (role), 36-37
exposure, scanning electron micrograph, 31f
extraction surgical classification, 781t
form, 622, **542.e7**
fractures, 63, 63f
fragments, tuberosity enlargement (contact), **e31f**
length, 622, **542.e7-542.e8**
operating mode, 779
Roots *(Continued)*
planing, 576
curette, selection, 497f
difficulty, 483
magnification, 640f
resolution, 650f
scaling, usage, 399
proximity, **542.e5-542.e6**
determination, 35
result, 400
removal, decision, **626.e1**
resection, **626.e1**
advanced bone loss, impact, **626.e2f**
procedure, **626.e1-626.e3**
vital root resection, **626.e3**
resorption, 401
trauma-induced areas, 305
shape, 32f
subgingival adaptation, 496f
trunk length, 621-622
Root surfaces
biomodification, 610-611
debridement, 520
gingival margin, relationship, 41f
irregularities, smoothness (detection), 368f
walls, 284-285
ROS. *See* Reactive oxygen species
Rotating magnification element, example, 642f
Rothmund-Thomson syndrome, characterization, **e38f**
Round bur, 732
Rubber cups, 505
Rubber tips, 492
recommendations, 492
technique, 492
Ruptured herpetic vesicles, **e27f**

S
S100 calcium binding protein (S100A8), 110
Saccharomyces cerevisiae, 156
Saline solution cavitation, impact, 779
Saliva, 90-91, 136, 217-218
antibacterial factors, 217
constituents, 90t
enzymes, 217-218
high-molecular-weight mucinous glycoproteins, 217-218
impact, 148
incubation test, 548-549
intraoral habitats, 137t
leukocytes, 218
mineralization source, 119
proteolytic enzymes, 217
role, 217t
substitutes, 450
Salivary antibodies, 217
Salivary buffers, 218
Salivary composition, change, 445
Salivary glands
aplasia, 107-109
disorders, 339
Sample size considerations, impact, **e88**
Sarcoidosis, 58-59, 240
histopathology, 240b
prednisone treatment, 60f
pretreatment, 59f
Sarcoma, 242

For entries that have a boldface page reference, i.e., 179.e2, go to the Expert CONSULT website at www.expertconsult.com, and after registering, search for the term on the book website.

Scaffolds, tissue engineering element, 616f
Scaling
clinical appearance, 578
difficulty, 483
instruments, 495-505
types, 496f
reference, 576
Scaling and root planing (SRP), 527f, 650, **e98**
adjunctive therapy, differences, **e115**
antibacterial effect, **e101**
clinical efficacy, enhancement, **e126**
furcation, 625
outpatient surgery, 567
technique, usage, 555
Scalloping
apical portion, 597-598
requirement, 594f
Scanning electron micrograph (SEM) comparison, 633f
Schneiderian membrane, 561
elevation, 755, 759f
Schwartz Periotriever, 502
magnetic tip, 502f
tip designs, 502f
Scissors, 574
Scleroderma, **e35f**
Screw loosening, 802f
Screw-retained provisional, 772f
Screw-retained single provision crowns, insertion, 663f
SDB. *See* Sleep-disordered breathing
SDD. *See* Sub-antimicrobial-dose doxycycline
Secondary colonizers
dental plaque, 145t
interactions, 144
Secondary hypertension, 420-421
Secondary osteoporosis, 699-700
Secondary sources, **e75-e76**
Secondary trauma from occlusion, 300-301
occurrence, 301
Second incision, 584-585
Second premolar, osseous defect, 614f
Second-stage exposure surgery, 736-737
clinical view, 736f
Second-stage implant surgery, objectives, 736b
Secreted protein, acidic, rich in cysteine (SPARC), 33
Sedation, 567
adult sedation, 412-414
alertness/sedation scale, observer assessment, 417t
deep sedation, 414
definitions/levels, 412-418
depth, continuum, 413f
discharge criteria, 417b
documentation, 418
emergency preparedness, 419
failures, 418-419
administration route, 419t
general anesthesia, 414
incremental dosing, 413
intravenous conscious sedation, consent form/explanation, 415f
levels, 413f
maximum recommended dose (MRD), 413
mild sedation, protocol, 415b
minimal sedation, 412-413
moderate sedation, 413-414
monitoring, 415-418
Sedation *(Continued)*
patient preference, 412f
pediatric sedation, 412
personnel/equipment, 415
recovery/discharge, 418
supplemental dosing, 413
titration, 414
usage
ADA guideline, 412
ADA policy statement, 411-412
Segregation analysis, 104-105
usage, 106t
Selective beta-adrenergic receptor antagonists (β-blockers), 422t
Selective serotonin reuptake inhibitors (SSRIs), 439
Self-curing acrylic, overhanging margins/injury (impact), **e40f**
Self-inflicted gingival dehiscence (induction), fingernail (impact), 51f
Self-inflicted injury, psychiatric influence, 197
Semidestroyed connective tissue fibers, 285
Sequential probing measurements, comparison, 676
Serial antibiotic therapy, 519-521
clinical use, 519-520
pharmacologic implications, 520-521
rationale, 519
Serum CRP elevations, risk factor, 208-209
Serum C-terminal telopeptide fragment, laboratory blood test, 431-432
Seventh Report of the Joint National Committee on Prevention, Detection, Evaluation, and Treatment of High Blood Pressure (JNC-7) guidelines, 420
Severe periodontitis, 314
Sex hormones, **e20**
concentration, 441
impact, 216
Shallow-to-moderate bony defects, management, 606
Shallow vestibule, problems, 629
Sharpey fibers, 23, 28
deep penetration, 34f
presence, 33
Shell composite crown, creation, 773f
Shock absorption, 26
Short-term goals, 408
Sialorrhea (ptyalism), 442
Sickle scalers, 494-497
characteristics, 496f
sizes, variation, 496f
usage, 496f
Signaling molecules, tissue engineering element, 616f
Signaling systems, study, 92
Significance. *See* Clinical significance
Silver points, example, 369f
SIM/Plant images, 713f
Simple diseases, linkage analysis (usage), 105
Simple Keplerian loupes, 640
Simple loupes, 640
example, 641f
Simultaneous implant placement, 743-745, 751
maxillary sinus elevation/bone augmentation procedure, 753f
Single-element loupes, 640
Single-ended Gracey curettes, collection, 498
Single nucleotide polymorphisms (SNIPs), 105, 318
Single-rooted teeth, mobility, 364
Single-stranded filaments, fimbriae, 167
Single teeth, 696

For entries that have a boldface page reference, i.e., 179.e2, go to the Expert CONSULT website at www.expertconsult.com, and after registering, search for the term on the book website.

Single-tooth implant crown
clinical photograph, 799f
gingival margin, 803f
Single-tooth replacement, 696f
Single-tooth restoration, 727f
Single-tooth sites, 726-727
Sinus bone augmentation, vertical ridge (combination), 761f-762f
Sinus elevation, 754f
surgical procedures, 751-756
Site-specific designed insert, 509f
Site-specific periodontal data, 70
Site-specific tip, example, 513f
Site-time dimension, 69
Skatole, 548-549
Skeletal deformities, **e65f**
Skull
bone loss, appearance, 299f
bony periodontium, photograph, 605f
periodontium, photograph, 606f
SLE. *See* Systemic lupus erythematosus
Sleep
definition, 351
fragmented sleep, hypnogram, 352f
hypnogram, 351f
Sleep apnea
cause, 350
mainstay therapy, 350
Sleep bruxism, 351
development/increase, 351
Sleep-disordered breathing (SDB)
clinical signs/symptoms, 351
communication, 354
complementary therapies, 353f
dentist, role, 350
health status/systems, review, 351
impact, 537
oral devices, 353-356
oral signs, 537
predictor devices, 354
signs/symptoms, dental identification, 351
Sleep-related breathing disorders, 350
Slime city, life, 149-151
Sling sutures, placement, 594
Smokeless tobacco, 129-130
histologic features, 130f
hyperkeratosis, association, **e42f**
impact, 130f
nicotine uptake, 129-130
usage, vestibule (oral leukoplakia), 129f
Smokers
high-risk patients, 529-531
plaque accumulation/inflammation, **e14f**
Smoking
behavioral factor, 161
effects, 179-183, 179t, 183t, 566
epidemic, 178-179
harm, 178
immune-inflammatory responses, 182-183
impact, 396
maintenance therapy, 184
nonsurgical therapy, 183
NUG, relationship, 248
physiology, 183
quitting, patient assistance, 181b
Smoking *(Continued)*
risk factor, 817
periodontitis, 178-179
status, assessment (challenges), 179b
surgical therapy/implants, 184
tobacco use, relationship, 704
Smoking cessation
advice, barriers/stimulation, 182t
effects, 184-185
methods, 181b
SNIPs. *See* Single nucleotide polymorphisms
SNODENT, **e95**
Snoring
oral devices, 353
vibratory noise, 351
Snuff (smokeless tobacco), 129-130
Socioeconomic status (SES), impact, 393
Socket wall, 33-34
responsiveness, 37-38
SoftDent, **e94**
Soft palate
ecchymosis, evidence, 190f
petechiae, evidence, 190f
Soft plaque, hardening, 118-119
Soft tapered bristles, 513f
Soft tissue
augmentation, case presentation, 766-769
concave profile, 659f
contours, 660f
destruction, mucormycosis (impact), **e28f**
evaluation, 699
healing, 662f
interface, 686-691
overbuilding, **765.e1**
parameters, multidisciplinary simple implant care scenario, 664f
pocket wall, 554
procedures, lasers (usage), 647
schematic illustration, 687f
trauma/inflammation, **e42f**
Soft tissue, biopsy, 64f
Soft-tissue wall, 280b
Soles, hyperkeratosis, **e64f**
Solid-state detectors, usage, 387
Solobacterium moorei (presence), 545
Sonic instruments, 494, 504
considerations, 509
Specialized mucosa, 9
Splinted porcelain-fused-to-metal crowns, overhanging margins (presence), **769.e1f-769.e2f**
Splinted teeth, **e74f**
Splint placement, radiograph, **e75f**
Split-mouth design, 554
Split-thickness flap, usage, 738f
Spontaneous bleeding
acute myelogenous leukemia, association, **e23f**
desquamation, combination, **e33f**
gingival inflammation, **e24f**
hemophilia-A patient, **e24f**
von Willebrand disease, **e25f**
Spontaneous tooth cleaning, 148-149
SPT. *See* Supportive periodontal treatment
Spurious associations, induction (schematic representation), **e87f**
Squamous cell carcinoma, 242
appearance, **e45f**
gingiva, location, 242f

For entries that have a boldface page reference, i.e., 179.e2, go to the Expert CONSULT website at www.expertconsult.com, and after registering, search for the term on the book website.

Squirrel monkey, eruption (studies), **37.e1**
SR. *See* Systematic review
SRP. *See* Scaling and root planing
SSRIs. *See* Selective serotonin reuptake inhibitors
Stabident, 422
Stability measures, 807
Staged implant placement, 747, 754f
Stage I gingival inflammation (initial lesion), 219-220
Stage II gingival inflammation (early lesion), 220
Stage III gingival inflammation (established lesion), 220-223
Stage IV gingival inflammation (advanced lesion), 223
Standard-diameter implants, 696f
  usage, 726
Standard projections, 706-708
Stannous fluoride, 550
Statistical power estimates, 109f
Statistical significance, clinical significance (differences), **e103-e115**
Stensen's duct (parotid gland duct)
  calculus formation, **e16f**
  opening, **e15f**
  upper molars, calculus formation, **e15f**
Steroid hormones, increase, 149
Steroid-induced gingivitis, 448
Steroid-sparing strategies, usage, 267
Stillman's clefts, 230
Stippling, 229
  variation, 21
Stomatitis medicamentosa, 275
Stomatitis venemata, 275
Stratified squamous epithelium, representative cells (diagram), 11f
Streptococcal gingivostomatitis (rarity), 246
Streptococcus gordonii DL1, coaggregation, 146f
Streptococcus mutans (microbial lineage), 123
Streptococcus sanguinis (colony morphology), 134f-135f
Streptococcus species, **e26**
Stress, 195-197
  impact, 196, 398
Stress-induced immunosuppression, 196
Stroke
  patients, oral anticoagulants (usage), 425
  periodontal disease, relationship, 209-210
  periodontal infection, association, 209-210
  repetition, prevention, 425
Studies
  designs (distortion), conflicts of interest (impact), **e89**
  randomization, **e88**
  systematic review, **e89**
Study drug effects (interpretability), results analysis (impact), **e125-e126**
Study sample
  definition, modification, **e84**
  representative study sample, **e85-e86**
Sturge-Weber syndrome, unilateral cavernous hemangiomas, **e38f**
Subacute cutaneous lupus erythematosus, 274
  differential diagnosis, 274
  treatment, 274
Subacute leukemia, periodontal ligament/alveolar bone (involvement), 192
Sub-antimicrobial-dose doxycycline (SDD), 526
  action mechanism, 528
  active treatment, 533
  candidate patients, 532
  clinical research data, 528-532
Sub-antimicrobial-dose doxycycline (SDD) *(Continued)*
  clinical trials, data (summary), 530t
  effect, 531f
  general patient populations, 529-531
  high-risk patients (smokers), 529-531
  local delivery systems, combination, 533
  periodontal surgery, combination, 533
  Periostat, 526
  sequencing prescription, periodontal treatment (usage), 532-533
  side effects, 532
  special patient populations, 531-532
  therapy, benefits (monitoring), 533
  uses/considerations, 532-533
Sub-antimicrobial tetracycline (Periotstat), usage, 449-450
Subepithelial bleeding, formation, **e39f**
Subgingival area, roughness, 122
Subgingival biofilms, oxygen (scarcity), 151
Subgingival calculus, 116
  composition, 118
  dark-pigmented deposits, 141f
  deposits, 117f
    bitewing radiograph, 118f
  embedding, 119f
  location, 116
  pigmented deposits, 117f
  removal, double-ended curette (usage), 497f
  undersurface, 119f
Subgingival chlorhexidine, 522
Subgingival curettage, 460, 578f
Subgingival debris, 654
Subgingival dental plaque, nonpathogenic organisms (impact), 150
Subgingival doxycycline, 522-523
Subgingival margins, 654-655
  locations, **e41f**
Subgingival metronidazole, 523
Subgingival microbiota, composition (differences), 141
Subgingival minocycline, 523
Subgingival moxifloxacin, 524
Subgingival plaque
  biofilm, removal, 481-482
  composition, 143, 440-441
  formation, dynamics, 149
  location, 141
  spirochetes, phase-contrast microscopy, 61f
  vitality stain, 163f
Subgingival recolonization, primary source, 149
Subgingival restorations, 398
Subgingival scaling, 460
  curette, selection, 497f
Subinfection, result, 203
Subjects, bacterial transmission, 151
Sublingual space, location, 564
Submandibular space, location, 564-565
Submental space, location, 564
Subtractive osseous surgery, 604
  impact, 605f
Sufficient cause, 72-73
Sulcular epithelium, 14-15
  capillaries, arrangement, 19
  characteristics, 78
  importance, 15
  permeability, 214-215
Sulcular fluid (gingival fluid), 17, 214-216
  collection methods, 214

For entries that have a boldface page reference, i.e., 179.e2, go to the Expert CONSULT website at www.expertconsult.com, and after registering, search for the term on the book website.

Sulcular incision flap, usage, 555
Sulcus. *See* Gingival sulcusbleeding index, 366
paper strips, placement, 214
probe, penetration, 369f
Sulfhydryl groups, reduction, 119
Supernumerary teeth, plaque formation/gingival inflammation, **e20f**
Super-resistant bacteria, identification, 151
Supine hypotensive syndrome, occurrence, 442
Supplemental dosing, 413
Supporting structures, vascularization, 38-39
Supportive implant treatment, rationale, 805
Supportive periodontal care, 407
Supportive periodontal treatment (SPT), 667
examination/evaluation, 669
radiographic examination, 673t
Suppurating gingival fenestration, 638f
Suppuration, 373
Suprabony periodontal pockets
depth, marking, 580f
features, 288t
interdental papilla, 279f
interdental space, 288f
occurrence, 277
treatment, gingivectomy (usage), 579f
ulcerated suprabony periodontal pockets, interdental papilla, 283f
Supracrestal bone augmentation, 756-758
Supracrestal connective tissue zone, function, 689
Supragingival calculus, 116
depiction, 141f
deposits, 117f
location, 116
maxillary molars, 117f
removal, sickle scaler (usage), 496f
Supragingival dental plaque formation, factors, 145-149
Supragingival hard surfaces, 136
Supragingival margin, 652
Supragingival plaque
biofilm, removal, 481-482
calcification, 119
clinical picture, 141f
filamentous nature, 142f
intraoral habitats, 137t
location, 141
subgingival progression, 305
topography, 145-147
Supraperiosteal arterioles, 19
Surface irregularities, 147f
Surface modification, advances, 725
Surface scratches, gold alloy crown, 122f
Surgical blades, 572, 573f
Surgical bone classification, 783f
Surgical chisels, 574
Surgical complications, 792, 794-798
Surgical curettes/sickles, 573
Surgical esthetic goal, **765.e1f**
compromise, **765.e1f**
level, determination, **765.e1**
Surgical gingivectomy, 579-580
healing, 580
initial response, 580
Surgical guides
creation, 714f-715f
fabrication, 719
Surgical loupes, magnification range, 641
Surgical management, 766-769
examination/diagnosis, 767
treatment objectives, 767
treatment options, 767
treatment plan/rationale, 769
Surgical microscope, 641-643
coated achromatic lenses, 641-642
Surgical navigation, global setup, 788f
Surgical performance, improvement, 637
Surgical pocket therapy, 552-553
purpose, 552
Surgical specialists, training, 658-666
Surgical therapy, **e126**
nonsurgical therapy, combination, 670f
Surgical trauma
lip paresthesia, 557
minimization, 776
Surrogate endpoints, 70
misleading information, 70
Surrogates, problems, **e85t**
Survival bias, 71
Susceptible patient, defining, 424
Sutures
classification, 643
microsurgical sutures, 643
Suturing, 735, 738
Swelling, 571
Swollen/spongy gingiva, leukemia (primary medical diagnosis), 49f
Symblepharon, 268
Syncope, emergency, 567
Syndrome Z, 352
Syphilis (secondary stage), necrotizing ulcerative gingivitis (differentiation), 247t
Systematic review (SR), **e75-e76**, **e77**
usage, 204
Systemically administered agents, 525-526
Systemic antibiotics, usage, 520
Systemic antimicrobial agents
efficacy, absence, **e126**
therapeutic uses, 520t
Systemic conditions, 407
gingival manifestations, 47, 49, **e32-e39**
impact, 396-397
oral manifestations, 47
Systemic diseases
enlargements, association, 237-240
impact, 396-397
manifestation, periodontitis (impact), 54-59, 402, **e10**, **e58**
periodontal manifestations, 357
Systemic health, periodontal disease (relationship), 212
Systemic health-related issues, 699-704
Systemic infections, 206-207
Systemic lupus erythematosus (SLE), 273
appearance, 273f
Systemic tetracycline, usage, 457b
Systemic therapy, 404
Systolic BP, increase, 421

T
Tangible benefits
intangible benefits, differences, 375
treatment outcomes, 375

For entries that have a boldface page reference, i.e., **179.e2**, go to the Expert CONSULT website at www.expertconsult.com, and after registering, search for the term on the book website.

Tannerella forsythia, **55.e1**
etiologic agent, 391-392
Targeted oral hygiene, 481
Tartar control toothpastes, 487-488
T cells. *See* Thymic lymphocytes
Teeth
alveolar bone destruction, **e59f**
alveolar ridge, relationship (evaluation), 717-719
anatomic factors, 63
atrophic periodontal ligament, 38f
average loss, 679t
clinical comparison, 691-692
clinical indices, usage, 366
clinical marks, 538f
continuous tooth eruption, 22-23
crowding
calculus formation, **e18f**
gingival inflammation, **e20f**
plaque formation, **e18f**, **e20f**
crown, failure (silicone impression), 772f
cusps, dimpling, 351
cuticular structures, 17
deposits, differences, 142t
endodontic/periodontal prognosis, **542.e8**
eruption, 252
examination, 362-366
extraction, ridge (healing), 665f
facial surface, appearance, 225f
fracture, **542.e6-542.e8**
functional occlusal relationships, 366
gingival enlargement, **e59f**
gingiva, shelflike contour, 21f
hypersensitivity, 363
implants, connection, 728
irregularity, 629-630
irrigation, absence (example), 513f
lingual surfaces, dimpling, 351
location, 63
marginal gingiva, relationship, 21
mean periodontal support, 678f
microvascular topography, 691f
migration, **e37f**
missing tooth, CBCT examination, 716f
movement, 37
mucogingival deformities/conditions, 54, 63
orthodontic alignment, **542.e11f**
pain, acute trauma, 300
pathologic migration, 305-308, 365
periapical radiograph, 744f-745f
physiologic migration, 37
position
effects, 606f
shift, 307
preservation, 408-409
prognosis, 397f
differences, 395
proximal contact relations, 363-364
proximity (assessment), intraoperative periapical radiographs (usage), 719f
pulsating lavage, impact, 514f
relative importance, **542.e7**
removal, 408
retention, 408
Teeth *(Continued)*
root
eruption, **542.e8**
interradicular dimension, **626.e1**
resorption, development, 126f
shape, problem, **542.e11**
similarities/differences, illustration, 113f
spontaneous tooth cleaning, 148-149
support
loss (bone loss), 364
tensional theory, 26
surface
facet angle, importance, 363
hoe scaler design, 503f
total tooth loss, 681
trauma, 474f
views, **e2f**
vitality, 477
wall, surface morphology, 284-285
wasting disease, 362-363
Teething, 254
Teflon membranes, usage, 611
Telomere shortening, 447
Temporal bone, articular eminence (posterior slope), 346f
Temporality, **e84**
Temporomandibular disorders, 347
screening evaluation, 537, 537b
Temporomandibular joint (TMJ), 345
anterior view, 346f
cross-section, lateral view, 346f
disharmonies, 537
dysfunction, 355
symptoms, development, 351
internal derangement, 347
panoramic radiograph, 362f
Tension-free wound closure, 637f
Tenting screw, usage, 62f
Tetracyclines, 517
antibacterial doses, long-term use, 517
clinical use, 517
pharmacology, 517
tetracycline-based products, **e128**
tetracycline-containing fibers, 522
Tetradecanol, 548-549
TGF-β. *See* Transforming growth factor-β
Thalassemia, malocclusion/gingival recession, **e24f**
Therapeutic procedures, sequence, 409-410
Therapeutic reference values, 75
Thin maxillary anterior sites, fenestration defect, 743f
Third molars
impaction, 600f
extraction, 127
partially erupted mandibular third molar, **e70f**
traumatic lesion, garlic (placement), **e43f**
Third National Health and Nutrition Examination Survey (NHANES III), bleeding measures, 70
3D mapping data acquisition, 787
3D projection screens, 788-790
types, 789-790
3D real volumetric view, provision, 790
3-mm twist drill, 732
Three-unit FPDs, radiograph, 794f
Three-wall defects, 604
treatment, 611

For entries that have a boldface page reference, i.e., 179.e2, go to the Expert CONSULT website at www.expertconsult.com, and after registering, search for the term on the book website.

Three-wall intrabony defects, **542.e1**
Thrombin, 568
Thrombocytopenia (bleeding disorder), 190f
  chemotherapy-induced thrombocytopenia, 190f
  impact, 192f
Thrombogenesis, 207
Thrush, 336
Thumb, skeletal disturbance, **e24f**
Thymic lymphocytes (T cells), 95-97
  CD4 subsets, 95
  infiltration, 79-80
  Th17 cells, 95
  T-helper1/T-helper 2 concept, 97b
Tilted molar, mesial root, 38f
Tissue destruction, 489
  mechanisms, 281-282
  tissue-destruction-promoting factors, 167-168
Tissue engineering, 629
  biologic mediators, usage, 616-618
  manipulation, 616f
Tissue fluids, depletion, 26
Tissue forceps, 574
Tissue management, 567
  two-stage implant placement, 732f
Tissue plasminogen activator (t-PA), advantage, 376
Tissue preservation, **765.e1**
Tissue reevaluation, 482
Tissue response, stages, 301-303
Tissue tags, removal, 594
Tissue/titanium interrelationship, three-dimensional diagram, 685f
Titanium implants
  curettes, 503f
  introduction, 684
  placement, **31.e1**
Titanium microsurgical instruments, 637f
Titanium-reinforced (TR) membranes, **739.e1-739.e2**
Titanium temporary abutment, 773f
Titration, 414
  devices, 354
TNF. *See* Tumor necrosis factor
Tobacco
  smoke, components, 178
  smoking, **e116**
    causative factor, 73
    periodontal disease risk factor, 391
  stains, 121f
  use, smoking (relationship), 704
Tolerance mechanisms, 173
Toll-like receptors (TLRs), 81
  agonists, impact, 174
  discovery, 171-172
  engagement, 94-95
  knowledge, 90
  single-pass transmembrane proteins, 174
Tongue
  cleaning, 549
  coating, 545-546
    clinical pictures, 546f
    scores, 547
  crenulations (scalloped borders), 351
  dorsum, 136
  intraoral habitats, 137t
  left lateral border, oral hairy leukoplakia, 338f
  Miyazaki tongue coating index, 548f
Tongue *(Continued)*
  piercing, oral jewelry (impact), 128f
  pressure, pathologic migration (association), 307f
  thrusting, 124-125
    flared incisors, anterior open bite, 125f
Tonsils, 136
Tooth-associated cervical plaque, root cementum (adherence), 142
Toothbrush, 492
  design, 486-487
    options, 487f
  manual toothbrushes, 486f
  powered toothbrushes, 487
  recommendation, 486-487
  trauma, 128-129
  usage, impact, 129f
Toothbrushing
  abrasive dentifrice, usage, 363, 488f
  aggressiveness, abrasion (example), 363f
  impact, 229
  importance, 549
  methods, 488-489
  soap toothbrushing, desquamation (association), **e43f**
Tooth extraction, 408-409, 746
  example, 398f
  microsurgical tooth extraction, 770
  piezoelectric bone surgery, example, 781f-782f
  scanning electron microscope view, 121f
  simplification, 781
  site, implant drilling, 770-771
  techniques, 779-781
Tooth loss, 130, 739
  advanced periodontal disease, 680f-681f
  nonperiodontal/periodontal causes, 682f
  predictors, 184
  prolongation, 717
  rate, 69f
  untreated periodontal disease, 682f
Tooth mobility, 364, 400, 572
  causes, 400
  checking, example, 364f
  complaint, **e50f**, **e59f**
  increase, 305
  periodontal condition, relationship, 355
  stages, 364
  tactile/visual testing, 537f
  testing, 537-538
Tooth mortality
  average tooth loss, 680f
  periodontal treatment, 681f
  posttreatment, 679t
  therapy initiation, 681f
  untreated periodontitis patients, 682t
Tooth surface, 554
  calculus, attachment, 118, 119f
  free energy, clinical impact (photographs), 147f
  irregularities, 147f
  microbial populations, 139-140
  microorganism, adherence, 145f
  microroughness, 147
  pigmented deposits, 121
  plaque-bacteria association, depiction, 140f
  plaque, presence, 119f
  roughness, clinical impact (photographs), 147f
Traditional flap, design, 583f

For entries that have a boldface page reference, i.e., 179.e2, go to the Expert CONSULT website at www.expertconsult.com, and after registering, search for the term on the book website.

Transforming growth factor-β (TGF-β)
cytokine function, 88
superfamily, 758
Transforming growth factor-β (TGF-β), impact, 87
Transgingival probing, usage, 608-609
Transgingival sounding, impact, 621
Transseptal fibers, 18, 78
interproximal extension, 24
reformation, 292f
Transversal incision, 601
Trauma
elimination, 304
occlusion, impact, 38, 299-301
site, irrigation (usage), **e74f**
Trauma from occlusion, 364-365, 385-386
clinical/radiographic signs, 305
impact, 305
injury phase, 385
repair phase, 385
term, usage, 300
Traumatic forces, occurrence, 301f
Traumatic lesions, 49-50, 229
evolution, 304f
result, 386
reversibility, 303
types, **e40**
Traumatic occlusion, 300
Traumatism, 300
Treatment
benefit, obtaining (likelihood), 375-376
biologic mechanisms, understanding, 376
clinical relevance, determination, 376
clinical significance, assessment, 375
effect, size, 375-376
master plan, 408-409
plan, 408
explanation, 410
presentation, 410
planning, 764
success (determination), inherited genetic variation (impact), 114f
Treponema denticola (spirochete), culture difficulty, 134f-135f
Treponema microdentium (cultivated strains), 245
Treponema pallidum (syphilis), 48
Trial I error rate control, **e124**
Triangular wooden tips, popularity, 492f
Trichomonas tenax, 156
Triclosan (TCN), 550
True endpoints, 70
True holographic 3D view, provision, 790
Tuberosity area, treatment, 601
Tumorlike gingival enlargement, 237-238
Tumorlike inflammatory enlargements, 587
Tumor metastasis, 242-243
Tumor necrosis factor (TNF), 110
Tumor necrosis factor-α (TNF-α), 85-86
Tumors, **e44**
Twin studies, 106t
2-mm twist drill, 732
Two-dimensional (2D) side-viewer devices, usage, 789
Two-phase oil-water rinse, 550
Two-stage implant placement
surgery, one-stage implant placement surgery (differences), 731
tissue management, 732f
Two-stage implant surgery, one-stage implant surgery (differences), 731f
Two-stage submerged implant placement, 731-737
Two-wall angular defects, 604
Two-walled defects/craters, 606-607
Tx methods, 113-114
Type 1 anatomy, 781
Type 1 diabetes
abscess, presence, 190f
medical management, interindividual variability, 211
Type 1 diabetes mellitus, 187
gingival inflammation/periodontal abscess, impact, **e49f**
Type 2 anatomy, 781
Type 2 diabetes
longitudinal study, 210
long-term history, 189f
Pima Indians, 187-188
placebo-controlled study, 210
Type 2 diabetes mellitus, 187
alveolar bone loss/inflammation, **e51f**
Type 3 anatomy, 781
Type 4 anatomy, 781
Type I error rates, **e86**
Type II error rates, **e86**

U
U15/30 scaler, 495-497
ends, 496f
Ulcerated lateral pocket wall, view, 280f
Ulcerated suprabony periodontal pockets, interdental papilla, 283f
Ulcerative lesions (erosive lesions), 265
Ulcerative squamous cell carcinoma, 242
Ultrasonic cutting
clinical characteristics, 776-777
healing, 777
microprecision, 776-777
selective cutting, 777
visibility, 777
Ultrasonic implant site preparation (UISP), 781
advantages, 781-782
Ultrasonic insert, universal design, 509f
Ultrasonic instruments, 494, 504
considerations, 509
Ultrasonic scalers, 515
Ultrasonic tips, 676
Ultrasound, usage, 776
Ultra-thin ceramic veneers, 653f
Unattached plaque zone, 284
Uncontrolled type 1 diabetes mellitus
complaints, **e52f**
Uncontrolled type 1 diabetes mellitus, appearance, **e49f**
Undisplaced flap, 593, 595-598
internal bevel incision, initiation, 593-594, 596f
preoperative facial/palatal views, 596f
Unfavorable prognosis, 394
Unilateral fibroosseous expansion, **e37f**
United States
periodontal status, 71t
periodontitis, prevalence, 316f-317f
Universal curettes, 497
area-specific curettes, comparison, 499t
Gracey curettes, differences, 498
types, 498f
Unreplaced missing teeth, 306

For entries that have a boldface page reference, i.e., 179.e2, go to the Expert CONSULT website at www.expertconsult.com, and after registering, search for the term on the book website.

Unruptured herpetic vesicles, **e27f**
Upper molars, calculus formation, **e15f**
Upper premolar, circumferential vertical defect, 297f
Upper right central incisor, periodontal abscess, 288f
Upper second premolar/molars, facial aspect (exostosis), 295f
Urea, 548-549
Urinary tract infections (women), 136
Uvula, ulcerations, 341f
Uvulopalatopharyngoplasty, 352

V
Valproic acid (Depakene), 235
Vascular cell adhesion molecule-1 (VCAM-1), 207-208
Vascular supply, inflammation (relationship), 690-691
Vasoconstrictor, usage, 568
Veillonella parvula (anaerobic gram-negative small cocci), 134f-135f
Veneers
  ceramic veneers, 653f
  completion, 653f
Venous drainage, 39
Ventricular pacing, inhibition, 509
Vertical bite-wing films, usage, 380f
Vertical bone augmentation, 756-758
Vertical bone loss, 617f
  mandibular implants, impact, 800f
Vertical defects (bone), 296
Vertical incisions, 585
  avoidance, 585
  locations, 585f
Vertical ridge
  sinus bone augmentation, combination, 761f-762f
Vesicular lesions (bullous lesions), 265
Vestibular depth
  inadequacy, **e36f**
  reestablishment, 65f
Vestibular fornix, mucogingival ridge defect, 65f
Vestibule, oral leukoplakia, 129f
Veterans Affairs Dental Longitudinal Study, 205
Viewing periodontal explorers, 505f
Vincent's angina, 247
Viruses, presence, 152-156
Viscoelastic system theory, 26
Vitality. *See* Teeth
Vital root resection, **626.e3**
Vitamin C deficiency, enlargement, 238-239
  appearance, 239f
  histopathology, 239b
Vitamin D receptor (VDR), 110
Volatile sulfur compounds (VSCs), 545
  amount, increase, 546
  gas chromatography, usage, 548-549
  production, 546
von Recklinghausen's disease (neurofibromatosis), 228
von Willebrand disease, 428-430
  result, 430
  spontaneous bleeding/clot formation, **e25f**
von Willebrand factor antigen, increase, 206-207

W
Wasting, definition, 362
Weakness, feeling, 571
Wear and tear repair, 406
Wegener's granulomatosis, 240, 275-276
  appearance, 276f
  cause, 240
  histopathology, 240b
WES. *See* White esthetic score
Wharton's duct, **e16f**
White blood cells (WBCs)
  count, reduction, 194
  involvement, 190
White esthetic score (WES), 793
Wide-diameter implants, 696f
  case presentation, **769.e4-769.e7**
  dental history/complaints, **769.e4**
  examination/diagnosis, **769.e4**
  results, **769.e6-769.e7**
  surgical procedure, **769.e6**
  treatment objectives, **769.e6**
  treatment options, **769.e6**
  treatment plan/rationale, **769.e6**
  treatment sequence, **769.e6**
Widow's peak (line-angle inconsistencies), removal, 607
Women, urinary tract infections, 136
Wooden tips, 492
  popularity. *See* Triangular wooden tips.
  recommendations, 492
  technique, 492
Wooden toothpick, 492f
Woodson periosteal elevator, 574f
Working side, 536
Wound
  primary wound closure, microsurgical principles (usage), 635f
  protection, 610-611
Woven bone, characterization, 686f

X
Xenografts, 611, 615-616
Xerostomia, 339
  complaint, 442
  results, 130

Y
Yeasts, 156
  species, isolation, 156

Z
Zaleplon, precautions/drug interactions, **411.e1b**
Zauberkugeln, **e82**
Zinc oxide-eugenol packs, 569
Zoledronic acid-related osteonecrosis, **e67f**
Zometa, 357
Zonae occludens, **11.e1**
Zygomatic process, 560

For entries that have a boldface page reference, i.e., 179.e2, go to the Expert CONSULT website at www.expertconsult.com, and after registering, search for the term on the book website.