





FUNDAMENTALS OF FIXED PROSTHODONTICS

FOURTH EDITION

Herbert T. Shillingburg, Jr, DDS

David A. Sather, DDS

Edwin L. Wilson, Jr, DDS, MEd

Joseph R. Cain, DDS, MS

Donald L. Mitchell, DDS, MS

Luis J. Blanco, DMD, MS

James C. Kessler, DDS

Fundamentals of Fixed Prosthodontics
Fourth Edition



FUNDAMENTALS OF FIXED PROSTHODONTICS

FOURTH EDITION

Herbert T. Shillingburg, Jr, DDS

David Ross Boyd Professor Emeritus
Department of Fixed Prosthodontics
University of Oklahoma College of Dentistry
Oklahoma City, Oklahoma

with

David A. Sather, DDS

Edwin L. Wilson, Jr, DDS, MEd

Joseph R. Cain, DDS, MS

Donald L. Mitchell, DDS, MS

Luis J. Blanco, DMD, MS

James C. Kessler, DDS

Illustrations by

Suzan E. Stone



Quintessence Publishing Co, Inc

Chicago, Berlin, Tokyo, London, Paris, Milan, Barcelona,
Istanbul, Moscow, New Delhi, Prague, São Paulo, and Warsaw

Library of Congress Cataloging-in-Publication Data

Fundamentals of fixed prosthodontics / Herbert T. Shillingburg Jr. ... [et al.]. -- 4th ed.

p. ; cm.

Includes bibliographical references and index.

ISBN 978-0-86715-475-7

I. Shillingburg, Herbert T.

[DNLM: 1. Denture, Partial, Fixed. 2. Crowns. 3. Dental Prosthesis Design. 4. Prosthodontics--methods. WU 515]

617.6'9--dc23

2011041249

5 4 3 2 1



© 2012 Quintessence Publishing Co, Inc

All rights reserved. This book or any part thereof may not be reproduced, stored in a retrieval system, or transmitted in any form or by any means, electronic, mechanical, photocopying, or otherwise, without prior written permission of the publisher.

Quintessence Publishing Co, Inc
4350 Chandler Drive
Hanover Park, IL 60133
www.quintpub.com

Editor: Leah Huffman
Design: Ted Pereda
Production: Patrick Penney

Printed in the USA

Contents

Dedication	<i>vii</i>
Authors	<i>viii</i>
Preface	<i>ix</i>
Acknowledgments	<i>x</i>

1	An Introduction to Fixed Prosthodontics	1
2	Fundamentals of Occlusion	13
3	Articulators	27
4	Interocclusal Records	35
5	Articulation of Casts	45
6	Treatment Planning for Single-Tooth Restorations	71
7	Treatment Planning for the Replacement of Missing Teeth	81
8	Fixed Partial Denture and Implant Configurations	99
9	Principles of Tooth Preparations	131
10	Preparations for Full Coverage Crowns	149
11	Preparations for Partial Coverage Crowns	165
12	Preparations for Intracoronar Restorations	193
13	Preparations for Severely Debilitated Teeth	203
14	Preparations for Periodontally Weakened Teeth	229
15	Provisional Restorations	241
16	Fluid Control and Soft Tissue Management	269



17	Impressions	291
18	Working Casts and Dies	325
19	Wax Patterns	343
20	Investing and Casting	363
21	Cementation and Bonding	383
22	Esthetic Considerations	413
23	All-Ceramic Restorations	425
24	Metal-Ceramic Restorations	447
25	Pontics and Edentulous Ridges	471
26	Solder Joints and Other Connectors	493
27	Restoration of Osseointegrated Dental Implants	517
28	Single-Tooth Implant Restoration	531
29	Multiple-Tooth Implant Restoration	543

	Index	555
--	-------	-----

Dedication



In Memoriam
Constance Murphy Shillingburg
1938–2008

This book is dedicated to the loving memory of Constance Murphy Shillingburg. We met at the University of New Mexico at the beginning of her freshman year in 1956. We were married 4 years later, 1 week after she graduated. During my first 2 years in dental school, I made 13 trips, totaling over 22,000 miles, from Los Angeles to Albuquerque. She shared all of the triumphs and disappointments of my last 2 years in dental school. It was not my career; it was our career. She supported me in all that I did. She didn't question my leaving practice to start a career in academics or our moving from California to Oklahoma. We had three daughters along the way. Although she had three open-heart surgeries in her teens because of rheumatic fever and then two cancer

surgeries later in life, she was the most optimistic person I ever met.

She accompanied me on 29 trips outside the United States. At first she came along because she loved to travel, and I didn't enjoy the trips nearly as much without her. However, I very quickly learned that my hosts and audiences were enchanted by her. They enjoyed her as much or more than they did me, and she used what she learned on those trips in her teaching. She died 3 weeks after we celebrated our 48th wedding anniversary. There is a song on the most recent Glen Campbell album, *Ghost on the Canvas*, that sums it up perfectly: "There's no me...without you."

Authors



Luis J. Blanco, DMD, MS

Professor and Chair
Department of Fixed Prosthodontics
University of Oklahoma College of Dentistry
Oklahoma City, Oklahoma

Joseph R. Cain, DDS, MS

Professor Emeritus
Department of Removable Prosthodontics
University of Oklahoma College of Dentistry
Oklahoma City, Oklahoma

James C. Kessler, DDS

Director of Education
L. D. Pankey Institute
Key Biscayne, Florida

Donald L. Mitchell, DDS, MS

Professor Emeritus
Department of Oral Implantology
University of Oklahoma College of Dentistry
Oklahoma City, Oklahoma

David A. Sather, DDS

Associate Professor
Department of Fixed Prosthodontics
University of Oklahoma College of Dentistry
Oklahoma City, Oklahoma

Herbert T. Shillingburg, Jr, DDS

David Ross Boyd Professor Emeritus
Department of Fixed Prosthodontics
University of Oklahoma College of Dentistry
Oklahoma City, Oklahoma

Edwin L. Wilson, Jr, DDS, MEd

Professor Emeritus
Department of Occlusion
University of Oklahoma College of Dentistry
Oklahoma City, Oklahoma

Preface

Fixed prosthodontics is the art and science of restoring damaged teeth with cast metal, metal-ceramic, or all-ceramic restorations and of replacing missing teeth with fixed prostheses using metal-ceramic artificial teeth (pontics) or metal-ceramic crowns over implants. Successfully treating a patient by means of fixed prosthodontics requires a thoughtful combination of many aspects of dental treatment: patient education and the prevention of further dental disease, sound diagnosis, periodontal therapy, operative skills, occlusal considerations, and, sometimes, placement of removable complete or partial prostheses and endodontic treatment.

Restorations in this field of dentistry can be the finest service rendered for dental patients or the worst disservice perpetrated upon them. The path taken depends upon one's knowledge of sound biologic and mechanical principles, the growth of manipulative skills to implement the treatment plan, and the development of a critical eye and judgement for assessing detail.

As in all fields of the healing arts, there has been tremendous change in this area of dentistry in recent years. Improved materials, instruments, and techniques have made it possible for today's operator with average skills to provide a service whose quality is on a par with that provided only by the most gifted dentist of years gone by. This is possible, however, only if the dentist has a thorough background in the principles of restorative dentistry and an intimate knowledge of the techniques required.

This book was designed to serve as an introduction to the area of restorative dentistry dealing with fixed partial dentures and cast metal, metal-ceramic, and all-ceramic restorations. It should provide the background knowledge needed by the novice as well as serve as a refresher for the practitioner or graduate student.

To provide the needed background for formulating rational judgments in the clinical environment, there are chapters dealing with the fundamentals of treatment planning, occlusion, and tooth preparation. In addition, sections of other chapters are devoted to the fundamentals of the respective subjects. Specific techniques and instruments are discussed because dentists and dental technicians must deal with them in their daily work.

Alternative techniques are given when there are multiple techniques widely used in the profession. Frequently, however, only one technique is presented. Cognizance is given to the fact that there is usually more than one acceptable way of accomplishing a particular task. However, in the limited time available in the undergraduate dental curriculum, there is usually time for the mastery of only one basic technique for accomplishing each of the various types of treatment.

An attempt has been made to provide a sound working background in the various facets of fixed prosthodontic therapy. Current information has been added to cover the increased use of new cements, new packaging and dispensing equipment for the use of impression materials, and changes in the management of soft tissues for impression making. New articulators, facebows, and concepts of occlusion needed attention, along with precise ways of making removable dies. The usage of periodontally weakened teeth requires different designs for preparations of teeth with exposed root morphology or molars that have lost a root.

Different ways of handling edentulous ridges with defects have given the dentist better control of the functional and cosmetic outcome. No longer are metal or ceramics needed to somehow mask the loss of bone and soft tissue. The biggest change in the replacement of missing teeth, of course, is the widespread use of endosseous implants, which make it possible to replace teeth without damaging adjacent sound teeth.

The increased emphasis on cosmetic restorations has necessitated expanding the chapters on those types of restorations. The design of resin-bonded fixed partial dentures has been moved to the chapters on partial coverage restorations. There are some uses for that type of restoration, but the indications are far more limited than they were thought to be a few years ago.

Updated references document the rationale for using materials and techniques and familiarize the reader with the literature in the various aspects of fixed prosthodontics. If more background information on specific topics is desired, several books are recommended: For detailed treatment of dental materials, refer to Kenneth J. Anusavice's *Phillip's Science of Dental Materials, Eleventh Edition* (Saunders, 2003) or William J. O'Brien's *Dental Materials and Their Selection, Fourth Edition* (Quintessence, 2008). For an in-depth study of occlusion, see Jeffrey P. Okeson's *Management of Temporomandibular Disorders and Occlusion, Sixth Edition* (Mosby, 2007). The topic of tooth preparations is discussed in detail in *Fundamentals of Tooth Preparations* (Quintessence, 1987) by Herbert T. Shillingburg et al. For detailed coverage of occlusal morphology used in waxing restorations, consult the *Guide to Occlusal Waxing* (Quintessence, 1984) by Herbert T. Shillingburg et al. Books of particular interest in the area of ceramics include W. Patrick Naylor's *Introduction to Metal Ceramic Technology* (Quintessence, 2009) and Christoph Hämmerle et al's *Dental Ceramics: Essential Aspects for Clinical Practice* (Quintessence, 2009).

—Herbert T. Shillingburg, Jr, DDS

Acknowledgments



No book is the work of just its authors. It is difficult to say which ideas are our own and which are an amalgam of those with whom we have associated. Two fine restorative dentists had an important influence on this book: Dr Robert Dewhirst and Dr Donald Fisher have been mentors, colleagues, and, most importantly, friends. Their philosophies have been our guide for the last 40 years. Dr Manville G. Duncanson, Jr, Professor Emeritus of Dental Materials, and Dr Dean Johnson, Professor Emeritus of Removable Prosthodontics, both of the University of Oklahoma, were forthcoming through the years with their suggestions, criticism, and shared knowledge. Thanks are also due to Mr James Robinson of Whip-Mix Corporation for his help with materials and instruments in the chapters that deal with laboratory procedures. Appreciation is expressed to Dr Mike Fling for his input regarding tooth preparations for laminate veneers. Thank you to Mr

Lee Holmstead, Brasseler USA, for his assistance with the illustrations of the diamonds and carbide burs.

Illustrations have been done by several people through the years: Mr Robert Shackelford, Ms Laurel Kallenberger, Ms Jane Cripps, and Ms Judy Amico of the Graphics and Media Department of the University of Oklahoma Health Sciences Center. Artwork was also contributed by Drs Richard Jacobi and Herbert T. Shillingburg. This book would not have come to fruition without the illustrations provided by Ms Suzan Stone and the computer program, *Topaz Simplify*, suggested by Mr Alvin Flier, a friend from 40 years ago in Simi, California. A special thank you to the Rev John W. Price of Houston, Texas, for restoring my sense of mission in June 2008.

Thanks to you all.

An Introduction to Fixed Prosthodontics

1

The scope of fixed prosthodontics treatment can range from the restoration of a single tooth to the rehabilitation of the entire occlusion. Single teeth can be restored to full function, and improvement in esthetics can be achieved. Missing teeth can be replaced with fixed prostheses that will improve patient comfort and masticatory ability, maintain the health and integrity of the dental arches, and, in many instances, elevate the patient's self-image.

It is also possible, through the use of fixed restorations, to render an optimal occlusion that improves the orthopedic stability of the temporomandibular joints (TMJs). On the other hand, with improper treatment of the occlusion, it is possible to create disharmony and damage to the stomatognathic system.

Terminology

A *crown* is a cemented or permanently affixed extracoral restoration that covers, or veneers, the outer surface of the clinical crown. It should reproduce the morphology and contours of the damaged coronal portions of a tooth while performing its function. It should also protect the remaining tooth structure from further damage.

If it covers the entire clinical crown, the restoration is called a *full veneer*, *full coverage*, *complete*, or just a *full crown* (Fig 1-1). It may be fabricated entirely of a gold alloy or another untarnishable metal, a ceramic veneer fused to metal, an all-ceramic material, resin and metal, or resin only. If only portions of the clinical crown are veneered, the restoration is called a *partial coverage* or *partial veneer crown* (Fig 1-2).

Intracoronar restorations are those that fit within the anatomical contours of the clinical crown of a tooth. *Inlays* may be used as single-tooth restorations for Class II proximo-occlusal or Class V gingival lesions with minimal to moderate extensions. They may be made of gold alloy (Fig 1-3a), a ceramic material (Fig 1-3b), or processed resin. When modified with occlusal coverage, the intracoronar restoration is called an *onlay* and is useful for restoring more extensively

damaged posterior teeth needing wide *mesio-occlusodistal (MOD) restorations* (Fig 1-4).

Another type of cemented restoration that has gained considerable popularity in recent years is the all-ceramic *laminate veneer*, or *facial veneer* (Fig 1-5). It is used on anterior teeth that require improved esthetics but are otherwise sound. It consists of a thin layer of dental porcelain or cast ceramic that is bonded to the facial surface of the tooth with an appropriate resin.

The *fixed partial denture* is a prosthetic appliance that is permanently attached to remaining teeth or implants and replaces one or more missing teeth (Fig 1-6). In years past, this type of prosthesis was known as a *bridge*, a term that has fallen from favor^{1,2} and is no longer used.

A tooth or implant serving as an attachment for a fixed partial denture is called an *abutment*. The artificial tooth suspended from the abutments is a *pontic*. The pontic is connected to the fixed partial denture retainers, which are extracoronar restorations that are cemented to or otherwise attached to the abutment teeth or implants. Intracoronar restorations lack the necessary retention and resistance to be used as fixed partial denture retainers. The *connectors* between the pontic and the retainer may be rigid (ie, solder joints or cast connectors) or nonrigid (ie, precision attachments or stress breakers) if the abutments are teeth. As a rule, only rigid connectors are used with implant abutments.

Diagnosis

A thorough diagnosis of the patient's dental condition must first be made, considering both hard and soft tissues. This must be correlated with the individual's overall physical health and psychologic needs. Using the diagnostic information that has been gathered, it is then possible to formulate a treatment plan based on the patient's dental needs, mitigated to a variable degree by his or her medical, psychologic, and personal circumstances.

1 An Introduction to Fixed Prosthodontics

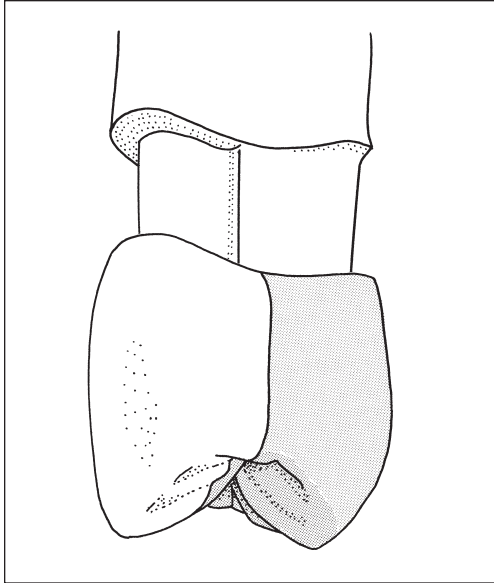


Fig 1-1 A full veneer, full coverage, or complete crown covers the entire clinical crown of a tooth. The example shown is a metal-ceramic crown.

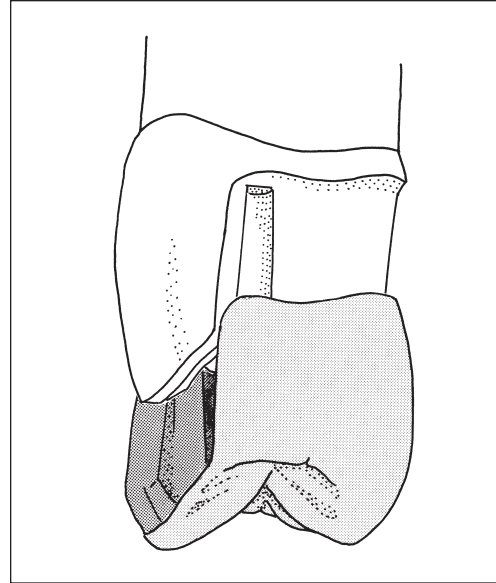


Fig 1-2 A partial veneer or partial coverage crown covers only portions of the clinical crown. The facial surface is usually left unveneered.

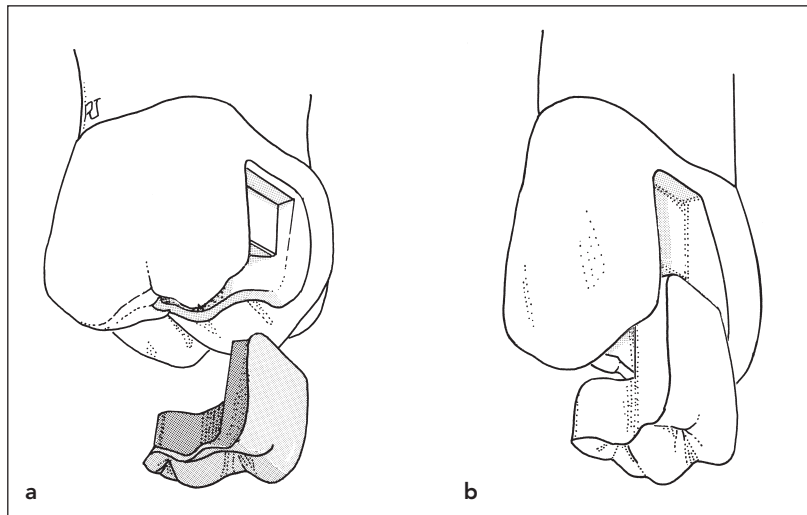


Fig 1-3 Inlays are intracoronal restorations with minimal to moderate extensions made of gold alloy (a) or a ceramic material (b).

There are five elements to a good diagnostic work-up in preparation for fixed prosthodontic treatment:

1. Health history
2. TMJ and occlusal evaluation
3. Intraoral examination
4. Diagnostic casts
5. Full-mouth radiographs

Health history

It is important that a good history be taken before the initiation of treatment to determine if any special precautions are necessary. Some elective treatments might be canceled or postponed because of the patient's physical or emotional health. It may be necessary to premedicate patients with certain conditions or to avoid medication for others.

It is not within the scope of this book to describe all the conditions that might influence patient treatment. However, there are some whose frequency or threat to the patient's

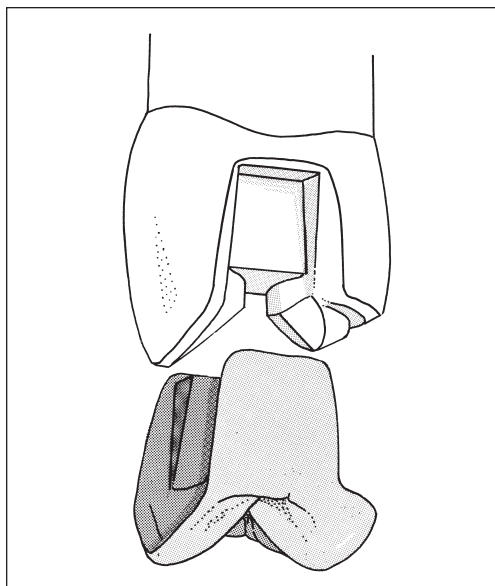


Fig 1-4 An onlay is an intracoronal restoration with an occlusal veneer.

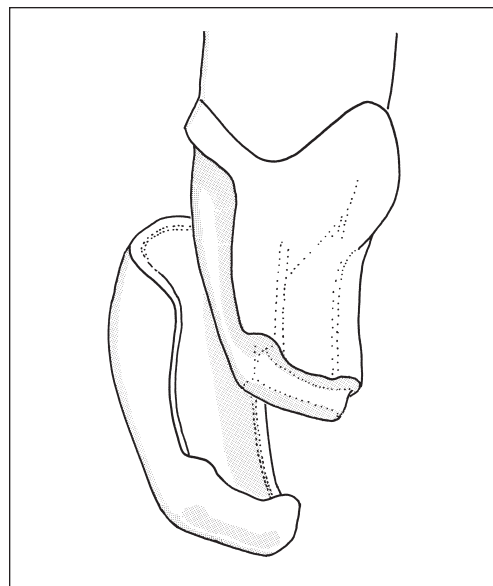


Fig 1-5 A laminate veneer is a thin layer of porcelain or cast ceramic that is bonded to the facial surface of a tooth with resin.

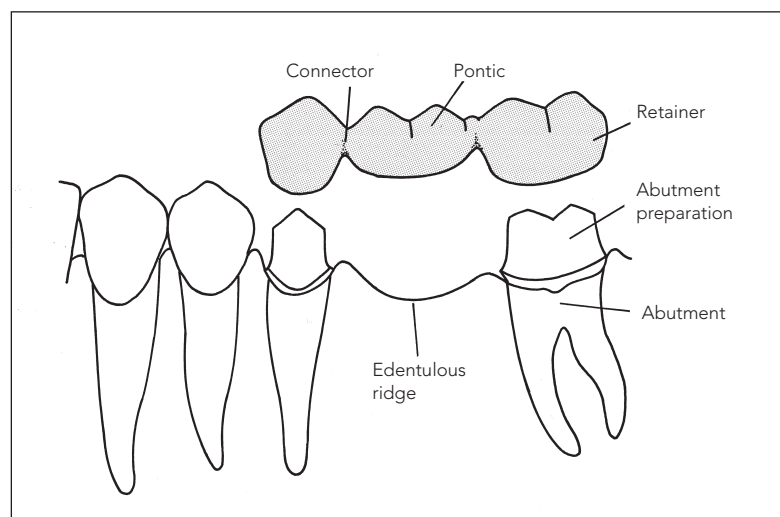


Fig 1-6 The components of a fixed partial denture.

or office staff's well-being is significant enough to merit discussion. A history of infectious diseases, such as serum hepatitis, tuberculosis, and human immunodeficiency virus (HIV)/AIDS, must be known so that protection can be provided for other patients as well as office personnel. There are numerous conditions of a noninfectious nature that also can be important to the patient's well-being.

Medications

The patient should be asked what medications, prescribed or over-the-counter, are currently being taken and for what purpose.³ It is important to be aware that an estimated 25%

of the population is taking some type of herbal product.⁴ All medications should be identified and their contraindications noted before proceeding with treatment. The patient should be questioned about current medications at each subsequent appointment to ensure that information on the patient's medication regimen is kept up to date.

Allergies

If a patient reports a previous reaction to a drug, it should be determined whether it was an allergic reaction or syncope resulting from anxiety in the dental chair. If there is any possibility of a true allergic reaction, a notation should be made

1 An Introduction to Fixed Prosthodontics

on a sticker prominently displayed in the patient's record so that the medication is not administered or prescribed. Local anesthetics and antibiotics are the most common allergenic drugs.

The patient might also report a reaction to a dental material. Impression materials and nickel-containing alloys are leading candidates in this area. It is imperative that the dentist not engage in any type of improvised allergy testing to corroborate the patient's recollection of previous problems. It is possible to initiate a life-threatening anaphylactic reaction by challenging the patient's immune system with an allergen to which he or she has been previously sensitized.

Cardiovascular disorders

Patients who present with a history of cardiovascular problems require special attention. Hypertension affects nearly 50 million Americans.⁵ Thirty percent of those with high blood pressure (HBP) are not aware of having the condition; only 59% of them are being treated for it; and only 34% have their blood pressure controlled to recommended levels.⁶ Based on these statistics, it is probable that dentists see numerous patients with undetected or uncontrolled HBP, who are prime candidates for disastrous cardiovascular events. Therefore, dentists should check blood pressure of all patients at the first appointment and at subsequent visits. No patient with uncontrolled hypertension should be treated until the blood pressure has been lowered.

The 7th Report of the Joint National Committee on Prevention, Detection, Evaluation, and Treatment of High Blood Pressure (JNC-7) has revised guidelines that simplify blood pressure classification.⁶ There are two categories of hypertension:

- Stage 1: systolic blood pressure (SBP) \geq 140–159 mm Hg or diastolic blood pressure (DBP) \geq 90–99 mm Hg
- Stage 2: SBP \geq 160 or DBP \geq 100

In this simplified classification, *prehypertension* describes SBP = 120–139 mm Hg or DBP = 80–89 mm Hg. This replaces the category called *high normal* (SBP = 130–139, DBP = 85–89 mm Hg).⁶ Risk of a stroke or heart attack doubles for each 20/10 mm Hg incremental blood pressure increase above 115/75 mm Hg.⁷ For most patients, treatment should be performed only if blood pressure is below 140/90 mm Hg,^{6,8} but in patients with diabetes or kidney disease, blood pressure should be lower than 130/80 mm Hg.^{9,10}

Epinephrine in local anesthetic is contraindicated for patients with severe cardiovascular disease but not for patients with mild-to-moderate forms of the disease if the number of carpules used is limited to two or three.⁶ The rationale is that lessening of pain will decrease the endogenous release of epinephrine, which could be 20 to 40 times greater if the patient becomes stressed by pain.¹¹ Retraction cord, however, does not provide any such potential benefit; therefore, cord containing epinephrine is contraindicated. Because of the availability of numerous alternatives for hemostasis and sul-

cus enlargement, the use of epinephrine-impregnated cords is not warranted.⁶

Patients on oral anticoagulant therapy are the most likely to experience hemorrhagic problems during dental treatment.¹² They may be taking anticoagulants for a variety of reasons: prosthetic heart valves, myocardial infarction (MI), stroke (cerebrovascular accident [CVA]), atrial fibrillation (AF), deep venous thrombosis (DVT), or unstable angina.¹³ The two most widely used coumarin derivatives are warfarin sodium (Coumadin [Bristol-Myers Squibb]) and bishydroxycoumarin (dicumarol), both of which are vitamin K antagonists.¹²

Anticoagulation level is measured by the international normalized ratio (INR). A patient whose blood coagulates normally would have an INR of 1.0.¹³ Increasing the anticoagulant effect increases the INR.¹² The INR range recommended by the American College of Chest Physicians¹⁴ and endorsed by the American Heart Association (AHA)¹⁵ is 2.0 to 3.0 in every situation mentioned previously, except for prosthetic heart valves, for which the INR range should be 2.5 to 3.5. The INR for artificial heart valves should not exceed 4.0.¹⁶

The patient's physician should be consulted to learn why the patient is on anticoagulants,¹² the most recent INR value,^{13,17} and when it was taken. Anticoagulant therapy is the responsibility of the physician, not the dentist. However, the physician may recommend stopping anticoagulant therapy 2 to 3 days prior to treatment, which is the traditional management of patients on anticoagulants, although the dental literature indicates that this may not be the optimal approach.¹⁸

An update of the recommendations by the AHA for prevention of infective endocarditis (IE) was issued in 2007.¹⁹ Guidelines were first published in 1955, and the most recent update before the present one was published in 1997. The current guideline greatly reduces the number of patients who should be premedicated, stating, "Only an extremely small number of cases of infective endocarditis (IE) might be prevented by antibiotic prophylaxis even if it were 100% effective."¹⁹

Antibiotic prophylaxis for dental procedures now is recommended only for patients with cardiac conditions with the greatest risk of adverse outcome from IE¹⁹:

- Prosthetic heart valve
- Previous IE
- Congenital heart disease (CHD)
- Unrepaired cyanotic CHD
- CHD repaired with a prosthetic material for 6 months after repair
- Repaired CHD with residual defect at or near the prosthetic patch that would interfere with endothelialization
- Cardiac transplants that develop valvulopathy

For patients with these conditions, prophylaxis is recommended for all dental procedures that involve the gingiva, the periapical region of the teeth, or perforation of oral mucosa.

The antibiotic regimen now recommended is a single 2-g oral dose of amoxicillin for adults who are not allergic to penicillin, 30 to 60 minutes before the procedure.¹⁹ There is no need to prescribe a follow-up dose after the procedure. If the patient is allergic to penicillin, 600 mg clindamycin or 500 mg azithromycin or clarithromycin may be substituted. If none of these is acceptable, consult the patient's physician or the guidelines article in the June 2007 issue of the *Journal of the American Dental Association*.¹⁹

Patients with valvular dysfunction from rheumatic heart disease (RHD),²⁰ mitral valve prolapse (MVP) with valvular regurgitation,²¹ systemic lupus erythematosus,²² and valvulopathy resulting from the diet medication fenfluramine-phentermine ("fen-phen")²³ were once indicated for antibiotic prophylaxis, but following the 2007 guidelines set by the AHA, they no longer require premedication.¹⁹ Most unrepaired congenital heart malformations still do require antibiotic prophylaxis.¹⁹ Patients with cardiac pacemakers do not require prophylaxis.¹⁹

With regard to artificial joints, the American Dental Association (ADA) states, "Antibiotic prophylaxis is not indicated for dental patients with pins, plates or screws, nor is it routinely indicated for most dental patients with total joint replacements. However, it is advisable to consider premedication in a small number of patients who may be at risk of experiencing hematogenous total joint infection."²⁴ For those patients not allergic to penicillin who do require premedication, 2 g amoxicillin taken orally 1 hour prior to the dental procedure is the antibiotic of choice. For variations of this regimen, the reader is referred to the advisory statement in the July 2003 issue of the *Journal of the American Dental Association*.²⁴

Patients who are on an antibiotic regimen prescribed to prevent the recurrence of rheumatic fever are not adequately premedicated to prevent IE.¹⁹ It is very possible that these patients will have developed strains of microorganisms that have some resistance to amoxicillin. If they require prophylactic antibiotic coverage, it would be wise to prescribe a different type than the one they are taking. Tetracyclines and sulfonamides are not recommended.

Epilepsy

Epilepsy is another patient condition of which the dentist should be aware. It does not contraindicate dentistry, but the dentist should know of its history in a patient so that appropriate measures can be taken without delay in the event of a seizure. Steps should also be taken to control anxiety in these patients. Long, fatiguing appointments should be avoided to minimize the possibility of precipitating a seizure.

Diabetes

More than 18 million Americans have diabetes, and another 41 million are "prediabetic."²⁵ Diabetic patients are predisposed to periodontal breakdown or abscess formation.^{26,27} Well-controlled diabetic patients should be able to report

Table 1-1 Correlation between HbA_{1c} and mean plasma glucose²⁹

HbA _{1c}	6	7	8
Mean plasma glucose (mg/dL)	126	154	183

their self-monitoring blood glucose (SMBG) from that morning. This value, which they obtain by placing a drop of their blood in a glucometer, is a measure of their capillary plasma glucose. Their *preprandial* (fasting) reading should be in the 90 to 130 mg/dL range. Their peak *postprandial* (after meals) reading should be 180 mg/dL.²⁸ A long-term measure of diabetic patients' glycemic control is their *glycosylated hemoglobin* (HbA_{1c}), a lab test that measures how much glucose is tied to red blood cells (Table 1-1). Its correlation with daily blood glucose numbers is 0.84.²⁹ It can be considered the average blood glucose level over the previous few months.³⁰

Those whose diabetes is poorly controlled will have elevated blood sugar, or *hyperglycemia*, and could be adversely affected by the stress of a dental appointment. *Hypoglycemia* (low blood sugar) can also cause problems. A controlled diabetic (on medication) who has missed a meal or has not eaten for several hours may become sweaty, light-headed, and disoriented. These patients usually carry some quick source of glucose, such as candy, which should be administered. Four ounces of a regular soft drink or fruit juice or several pieces of hard candy should help them recover quickly. Treatment should be halted for that appointment, and the patient should be monitored at the office until complete recovery can be confirmed. It would be wise to have a family member drive the patient home. Dental treatment for the diabetic patient should interfere as little as possible with the patient's dietary routine, and the patient's stress level should be reduced. Any questions about the patient's ability to cope with dental treatment and whether he or she is properly controlled should be referred to the patient's physician before proceeding.

Xerostomia

The prolonged presence of *xerostomia*, or dry mouth, is conducive to greater carious activity and is therefore extremely hostile to the margins of cast metal or ceramic restorations. Xerostomia can be caused by large doses of radiation in the oral region,³¹ lupus erythematosus,^{22,32} or Sjögren syndrome, an autoimmune disease.³³ Sjögren syndrome frequently is first noticed and diagnosed by a dentist because of the xerostomia.³⁴ It is frequently seen in conjunction with other autoimmune diseases, such as rheumatoid arthritis, lupus erythematosus, and scleroderma.³³

There are approximately 400 drugs capable of producing mild to severe xerostomia.^{3,35} Anticholinergics, anorectics, and antihypertensives may produce this effect. Antihistamines comprise the largest group of such drugs, and chronic

1 An Introduction to Fixed Prosthodontics

allergy sufferers who use them over a prolonged time may suffer from dry mouth.

Osteonecrosis

A relatively new problem that has arisen in relation to drug side effects and dental treatment is bisphosphonate-related osteonecrosis of the jaws (BRONJ). There is some controversy regarding the etiology and pervasiveness of this condition. Over the past 7 years, more than 4,000 cases have been reported to the Food and Drug Administration.³⁶ This family of drugs is administered intravenously (IV) to treat metastatic bone cancer, and the greatest risk of osteonecrosis occurs in these patients. Bisphosphonates are used more widely, but at lower dosage levels, as an oral preventive treatment for osteoporosis. The ratio of patients on oral bisphosphonate therapy who have developed osteonecrosis compared with those on the IV drug has varied from 10%³⁷ to as high as 83%.³⁸

Osteonecrosis was initially associated with oral surgery, but there have been reports of spontaneous occurrences without surgery at rates as high as 25%.^{39,40} Scully et al⁴¹ have stated that bisphosphonate therapy is a contraindication for dental endosseous implants, and at the present time, Marx et al³⁹ strongly discourage implant placement in patients taking bisphosphonates.

Current complaint and patient expectations

As part of the health history, the patient should be given an opportunity to describe the exact nature of the complaint that has brought him or her to the dental office for treatment. Attitudes about previous treatment and the dentists who have rendered it offer insight into the patient's level of dental awareness and the quality of care expected. This will help the dentist to determine how much education the patient will require and how amenable the patient will be to cooperating with a good home-care program. Moreover, an effort should be made to get an accurate description of the patient's expectations for the treatment results. Particular attention should be paid to the esthetic effect anticipated. A judgment must be made as to whether the patient's desires are compatible with sound restorative procedures. Possible conflicts in this area, as well as in the realm of personality, should be noted. The option of not providing care may need to be exercised with some patients.

TMJ and occlusal evaluation

Prior to the start of fixed prosthodontics procedures, the patient's occlusion and TMJs must be evaluated to determine if they are healthy enough to allow the fabrication of restorations. If the occlusion and TMJs are within normal limits, then treatment should be designed to maintain that relationship. However, if the occlusion or one or both TMJs are dysfunctional in some manner, further appraisal is necessary to de-

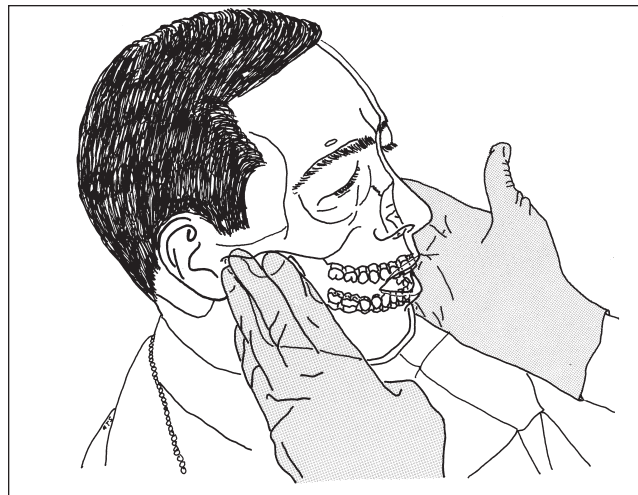


Fig 1-7 The joints are palpated as the patient opens and closes to detect signs of dysfunction.

termine whether the dysfunction can be improved prior to the placement of the restorations or if restorations should not be placed.

Does the patient suffer from frequent occasions of head, neck, or shoulder pain? If so, an attempt must be made to determine the origin of such pain. It may be *referred pain*, ie, it may not originate from the area where the pain is experienced.⁴² Many patients suffer from undiagnosed muscle and/or joint dysfunction of the head and neck region; such a history should be investigated further.

Next, an assessment of the TMJs themselves should be performed. Healthy TMJs function with no evidence of pain. Asymptomatic clicking or crepitation occurs in about one-third of the general population.⁴³ Limitation of movement on opening, closing, or moving laterally should be investigated further to determine the condition of the TMJs. Palpation of the joints as the patient opens and closes should reveal the existence of any signs of dysfunction (Fig 1-7). Many patients suffer from muscle pain as a result of parafunctional jaw activity related to stress. Habits such as clenching the teeth and manipulating the bite during the course of the daily routine may result in fatigue and muscle pain. The physical appearance and activities of the patient should be observed for signs of such habits. Many times they will have a square-jawed appearance, with masseter muscles that are overdeveloped from hyperactivity. They may even clench their teeth during the patient interview.

A brief palpation of the masseter (Fig 1-8), temporalis (Fig 1-9), medial pterygoid (Fig 1-10), trapezius (Fig 1-11), and sternocleidomastoid (Fig 1-12) muscles may reveal tenderness. The patient may demonstrate limited opening due to tightness of the masseter, temporalis, and/or medial pterygoid muscles. This can be noted by asking the patient to

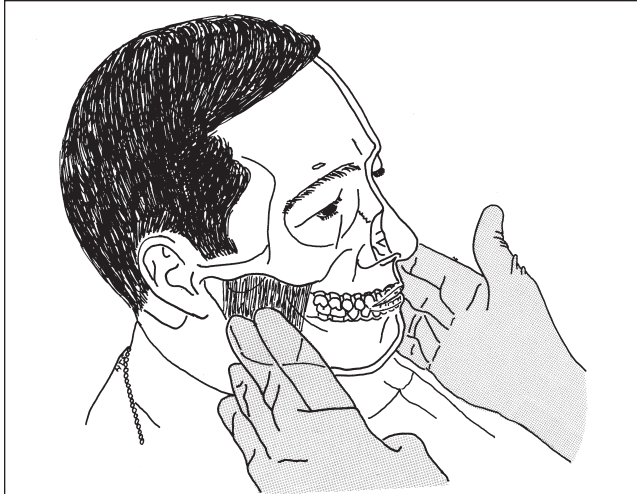

Fig 1-8 The masseter muscles are palpated extraorally by placing the fingers over the lateral surfaces of the rami of the mandible.



Fig 1-9 The fingers are placed over the patient's temples to feel the temporalis muscles.

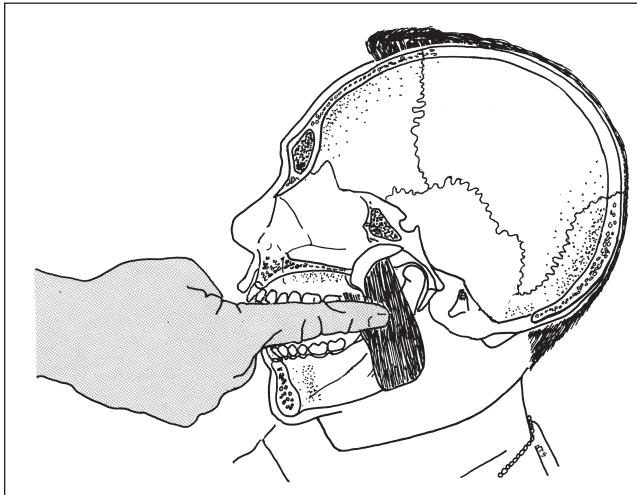


Fig 1-10 The index finger is used to touch the medial pterygoid muscle on the inner surface of the ramus.

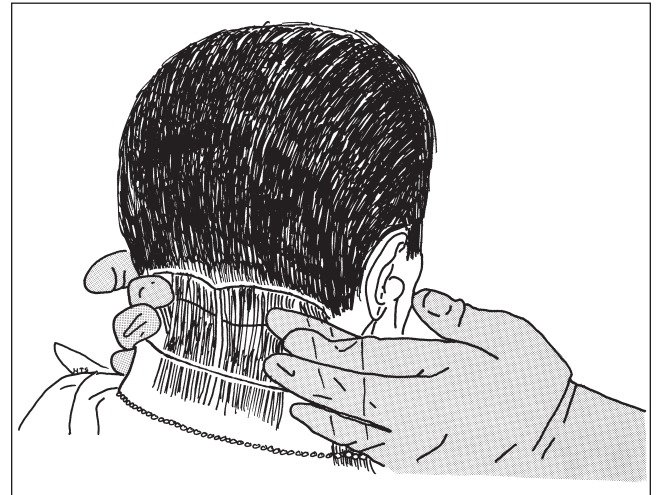


Fig 1-11 The trapezius muscle is felt at the base of the skull, high on the neck.

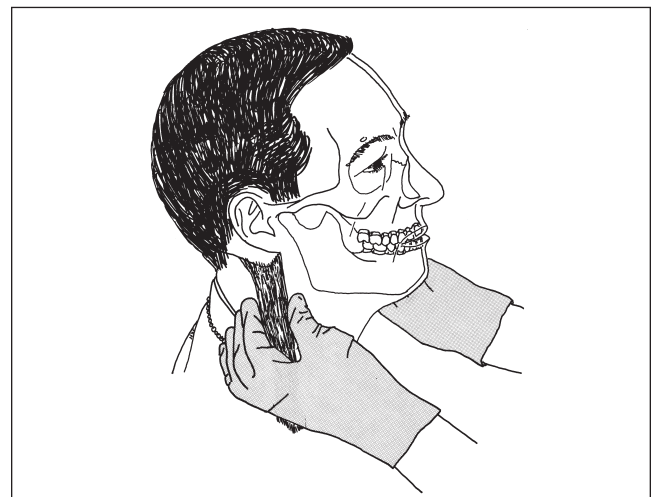


Fig 1-12 The sternocleidomastoid muscle is grasped between the thumb and forefingers on the side of the neck. The muscle can be accentuated by a slight turn of the patient's head.

1 An Introduction to Fixed Prosthodontics

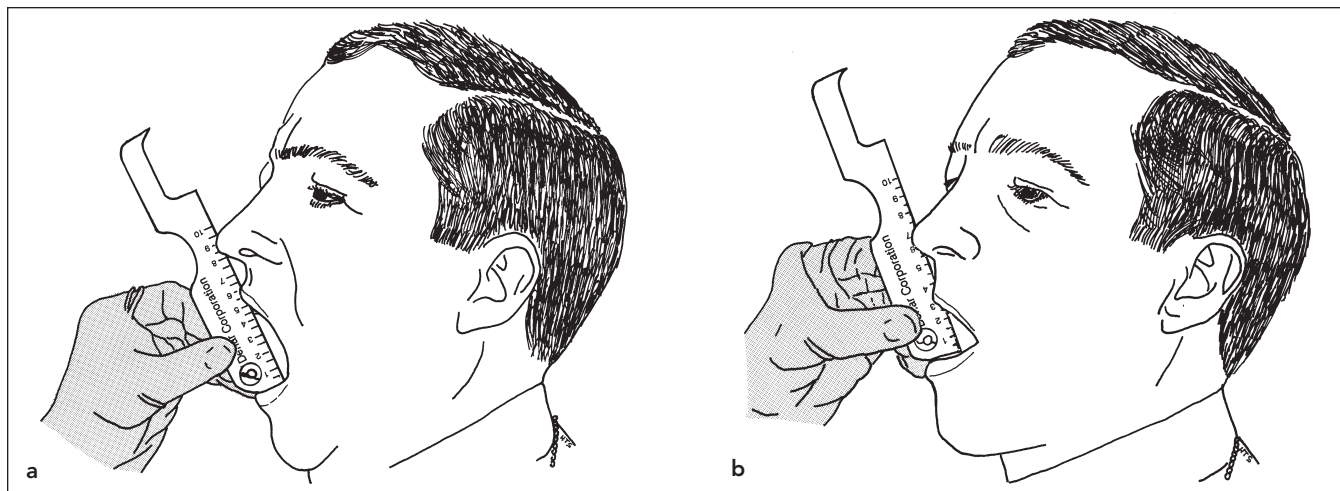


Fig 1-13 (a) The distance between the maxillary and mandibular incisors is measured when the patient is instructed to open "all the way." (b) If the patient can only open partially, or opens very slowly, the cause should be determined.




Fig 1-14 If opening is limited or painful, the patient should be instructed to use a finger to indicate the area that hurts.

open "all the way" (Fig 1-13). If it appears that the opening is limited or the movement is slowed, ask the patient to point to the area that hurts (Fig 1-14). If the patient touches a muscle area, as opposed to the TMJ, there is probably some dysfunction of the neuromuscular system. Patients experiencing a problem with one or both TMJs will most frequently point to the joint itself.

Evidence of pain or dysfunction in either the TMJs or the muscles associated with the head and neck region is an indication for further evaluation prior to starting any fixed prosthodontics procedures.

Intraoral examination

Check for a band of attached gingiva around all teeth, particularly those to be restored with crowns. Mandibular third molars frequently (30% to 60%) do not have attached gingiva around the distal segment. A prospective abutment that lacks the necessary attached tissue is a poor candidate to receive a crown. The probability of chronic inflammation occurring in response to any minute marginal irregularity in the crown is quite high.

The presence or absence of inflammation should be noted, along with gingival architecture and stippling. The existence of pockets should be entered in the record, and their location and depth should be charted. The presence and amount of tooth mobility should also be recorded, with special attention paid to any relationship with occlusal prematurities and to potential abutment teeth.

Edentulous ridges should be examined, and the relationship of spaces should be noted if there is more than one. What is the condition of prospective abutment teeth? The presence and location of caries should be noted. Is it localized or widespread? Are there large numbers of gingival lesions and decalcification areas? The amount and location of caries, coupled with an evaluation of plaque retention, can provide insight into the prognosis for the new restorations that will be placed. It will also help to determine the preparation designs to be used.

Previous restorations and prostheses should be examined carefully. This will make it possible to determine if they are suitable or if they need to be replaced. It will help to determine the prognosis for future work to be done.

Finally, an evaluation should be made of the occlusion itself. Are there large facets of wear? Are they localized or widespread? Are there any nonworking interferences? The amount of slide between the centric relation position and the maximal intercuspal position should be noted. Is the slide a straight one, or does the mandible deviate to one

side? The presence or absence of simultaneous contact on both sides of the mouth should be observed. The existence and amount of anterior guidance is also important. Restorations of anterior teeth must duplicate existing guidance or, in some patients, replace what has been lost through wear or trauma.

Diagnostic casts

Diagnostic casts are an integral part of the diagnostic procedures necessary to give the dentist as complete a perspective as possible regarding the patient's dental needs. To accomplish their intended goal, the casts must be accurate reproductions of the maxillary and mandibular arches, made from distortion-free alginate impressions. The casts should contain neither bubbles as a result of faulty pouring nor any positive nodules on the occlusal surfaces ensuing from air entrapment during the taking of the impression.

To derive maximum benefit from the diagnostic casts, they should be mounted on a semi-adjustable articulator. When they have been positioned with a facebow and the articulator adjustments have been set using lateral interocclusal records, a reasonably accurate simulation of jaw movements is possible. The articulator settings should be included in the patient's permanent record to facilitate resetting the instrument when restorations are fabricated for this patient at a future date. Finally, the mandibular cast should be set in a relationship determined by the patient's optimum condylar position (with the disc interposed) to better enable a critical occlusal analysis.

Articulated diagnostic casts can provide a great deal of information for diagnosing problems and arriving at a treatment plan. They allow an unobstructed view of the edentulous spaces and an accurate assessment of the span length as well as the occlusogingival dimension. The curvature of the arch in the edentulous region can be determined, which enables prediction of whether the pontic(s) will act as a lever arm on the abutment teeth.

The length of abutment teeth can be accurately gauged to determine which preparation designs will provide adequate retention and resistance. The true inclination of the abutment teeth also becomes evident; as a result, problems in a common path of insertion can be anticipated. Mesiodistal drifting, rotation, and faciolingual displacement of prospective abutment teeth can also be clearly seen.

A further analysis of the occlusion can be conducted using the diagnostic casts. The difference between the centric relation position and the intercuspal position should be noted. A thorough evaluation of wear facets—their numbers, size, and location—is possible when they are viewed on casts. Occlusal discrepancies can be evaluated, and the presence of centric relation prematurities or excursive interferences can be determined. The relationship of the anterior teeth and the anterior guidance can be viewed and analyzed. Discrepancies in the occlusal plane become very apparent on the articulated casts. Teeth that have supererupted into oppos-

ing edentulous spaces are easily spotted, and the amount of correction needed can be determined.

Situations calling for the use of pontics that are wider or narrower than the teeth that would normally occupy the edentulous space require a diagnostic wax-up. Changes in contour plus widening or narrowing of an abutment tooth can also be tried and evaluated on a duplicate of the original cast. This enables the dentist and the patient to see how a difficult treatment will look when finished. The diagnostic wax-up, done in ivory wax, allows the patient to see all of the compromises that will be necessary.

It is far better to discover that the projected result is unsatisfactory to the patient before treatment is begun. If the patient is satisfied and the work proceeds, the wax-up will help the dentist plan and execute the preparations and the provisional restorations.

Full-mouth radiographs

Radiographs, the final aspect of the diagnostic procedure, provide the dentist with information to help correlate all of the facts that have been collected in listening to the patient, examining the mouth, and evaluating the diagnostic casts. The radiographs should be examined carefully for signs of caries, both on unrestored proximal surfaces and recurring around previous restorations. The presence of periapical lesions, as well as the existence and quality of previous endodontic treatments, should be noted.

General alveolar bone levels, with particular emphasis on prospective abutment teeth, should be observed. The crown-root ratio of abutment teeth can be calculated. The length, configuration, and direction of those roots should also be examined. Any widening of the periodontal membrane should be correlated with occlusal prematurities or occlusal trauma. An evaluation can be made of the thickness of the cortical plate of bone around the teeth and of the trabeculation of the bone.

The presence of retained root tips or other pathologies in the edentulous areas should be recorded. On many radiographs, it is possible to trace the outline of the soft tissue in edentulous areas so that the thickness of the soft tissue overlying the ridge can be determined.

Protection Against Infectious Diseases

Protecting against cross-contamination of patients and preventing exposure of the office staff to infectious diseases have become major concerns in dentistry in recent years. In particular, patients should be queried about a past history of hepatitis B virus (HBV), hepatitis C virus (HCV), or HIV. Although AIDS has received greater publicity and generated near hysteria in the recent past, hepatitis is the major

1 An Introduction to Fixed Prosthodontics




Fig 1-15 Rubber gloves, a surgical mask, and eye protection are important for safeguarding dental office personnel.

infectious occupational hazard to health care professionals.⁴⁴ HCV is the most common chronic, blood-borne infection in the United States⁴⁵ and is transmitted primarily through contact with blood from an infected individual.⁴⁵ It has been estimated that 3.2 million Americans have been infected with HCV.⁴⁶

There is no evidence that these diseases are contracted through casual contact with an infected person. However, the nature of dental procedures does produce the risk of contact with blood and tissues. A safe, effective vaccine against HBV is available and is recommended by the Centers for Disease Control^{47–49} and the ADA Council on Dental Therapeutics⁵⁰ for all dental personnel who have contact with patients. There is no vaccine against HCV.

While special precautions should be taken when treating patients with a history of either disease, every patient should be treated as being potentially infectious. Rubber gloves, a surgical mask or full-length plastic face shield, protective eyeglasses (if a shield is not used), and a protective uniform are recommended for the dentist and all other office personnel who will be in contact with the patient during actual treatment (Fig 1-15).

Concern for these matters does not end at the door to the operatory. Any item contaminated with blood or saliva in the operatory, such as an impression, is just as contaminated when it is touched outside the operatory. The specifics of decontaminating impressions are covered in chapter 17.

In addition, steps must be taken in a receiving area of the laboratory to isolate and decontaminate items coming from the dental operatory.⁵⁰ An infection-control program should be established to protect laboratory personnel from infectious diseases, as well as to prevent cross-contamination that could affect a patient when an appliance returns from the laboratory to the operatory for insertion in the patient's mouth.⁵¹ There is more to dental laboratory work than manipulating inert gypsum, wax, resins, metal, and ceramics.

References

1. The Glossary of Prosthodontic Terms. *J Prosthet Dent* 2005;94:10–92.
2. American Dental Association. Current Dental Terminology (CDT 2007–2008). Eden Prairie, MN: Ingenix, 2006:47.
3. Ciancio SC. Medications' impact on oral health. *J Am Dent Assoc* 2004;135:1440–1448.
4. Bent S, Ko R. Commonly used herbal medications in the United States: A review. *Am J Med* 2004;116:478–485.
5. Hajjar J, Kotchen TA. Trends in prevalence, awareness, treatment, and control of hypertension in the United States, 1988–2000. *JAMA* 2003;290:199–206.
6. Herman WW, Konzelman JL Jr, Prisant LM; Joint National Committee on Prevention, Detection, Evaluation, and Treatment of High Blood Pressure. New national guidelines on hypertension: A summary for dentistry. *J Am Dent Assoc* 2004;135:576–584.
7. Lewington S, Clarke R, Qizilbash N, Peto R, Collins R, Prospective Studies Collaboration. Age-specific relevance of usual blood pressure to vascular mortality: A meta-analysis of individual data for one million adults in 61 prospective studies. *Lancet* 2002;360:1903–1913 [erratum 2003;361:1060].
8. Glick M. The new blood pressure guidelines—A digest. *J Am Dent Assoc* 2004;135:585–586.
9. Arauz-Pacheco C, Parrott MA, Raskin P; American Diabetes Association. Treatment of hypertension in adults with diabetes. *Diabetes Care* 2003;26(suppl 1):S80–S82.
10. National Kidney Foundation. K/DOQI clinical practice guidelines for chronic kidney disease: Evaluation, classification, and stratification. *Am J Kidney Dis* 2002;39(2 suppl 1):S1–S266.
11. Rose LF, Mealey B, Minsk L, Cohen DW. Oral care for patients with cardiovascular disease and stroke. *J Am Dent Assoc* 2002;133(suppl):37S–44S.
12. Herman WW, Konzelman JL, Sutley SH. Current perspectives on dental patients receiving coumarin anticoagulant therapy. *J Am Dent Assoc* 1997;128:327–335.
13. Jeske AH, Suchko GD; ADA Council on Scientific Affairs and Division of Science, Journal of the American Dental Association. Lack of a scientific basis for routine discontinuation of oral anticoagulant therapy before dental treatment. *J Am Dent Assoc* 2003;134:1492–1497 [erratum 2004;135:28].
14. Hirsh J, Dalen JE, Deykin D, Poller L. Oral anticoagulants: Mechanism of action, clinical effectiveness, and optimal therapeutic range. *Chest* 1992;102(4 suppl):312S–326S.
15. Hirsh J, Fuster V. Guide to anticoagulant therapy. Part 2: Oral anticoagulants. American Heart Association. *Circulation* 1994;89:1469–1480.
16. Cannegieter SC, Rosendaal MD, Briët E. Thromboembolic and bleeding complications in patients with mechanical heart valve prostheses. *Circulation* 1994;89:635–641.
17. Wahl MJ. Myths of dental surgery in patients receiving anticoagulant therapy. *J Am Dent Assoc* 2000;131:77–81.
18. Scully C, Wolff A. Oral surgery in patients on anticoagulant therapy. *Oral Surg Oral Med Oral Pathol Oral Radiol Endod* 2002;94:57–64.
19. Wilson W, Taubert KA, Gewitz M, et al. Prevention of infective endocarditis: Guidelines from the American Heart Association: A guideline from the American Heart Association Rheumatic Fever, Endocarditis and Kawasaki Disease Committee, Council on Cardiovascular Disease in the Young, and the Council on Clinical Cardiology, Council on Cardiovascular Surgery and Anesthesia, and the Quality of Care and Outcomes Research Interdisciplinary Working Group. *J Am Dent Assoc* 2007;138:739–760.
20. Tong DC, Rothwell BR. Antibiotic prophylaxis in dentistry: A review and practice recommendations. *J Am Dent Assoc* 2000;131:366–374.
21. Brackett SE. Infective endocarditis and mitral valve prolapse—The unsuspected risk. A case report. *Oral Surg Oral Med Oral Pathol* 1982;54:273–276.

22. Miller CS, Egan RM, Falace DA, Rayens MK, Moore CR. Prevalence of infective endocarditis in patients with systemic lupus erythematosus. *J Am Dent Assoc* 1999;130:387–392.
23. Lessard E, Glick M, Ahmed S, Saric M. The patient with a heart murmur: Evaluation, assessment and dental considerations. *J Am Dent Assoc* 2005;136:347–356.
24. American Dental Association, American Academy of Orthopedic Surgeons. Antibiotic prophylaxis for dental patients with total joint replacements. *J Am Dent Assoc* 2003;134:895–899.
25. Glick M. Diabetes: It is all about the numbers [editorial]. *J Am Dent Assoc* 2006;137:12,14.
26. Shlossman M, Knowler WC, Pettitt DJ, Genco RJ. Type 2 diabetes mellitus and periodontal disease. *J Am Dent Assoc* 1990;121:532–536.
27. Vernillo AT. Dental considerations for the treatment of patients with diabetes mellitus. *J Am Dent Assoc* 2003;134(special issue):24S–33S.
28. American Diabetes Association. Standards of medical care in diabetes—2007. *Diabetes Care* 2007;30(suppl 1):S4–S41.
29. Nathan DM, Kuenen J, Borg R, et al. Translating the A1C assay into estimated average glucose values. *Diabetes Care* 2008;31:1473–1478 [erratum 2009;32:207].
30. Kahn R, Fonseca V. Translating the A1C assay. *Diabetes Care* 2008;31:1704–1707.
31. Frank RM, Herdly J, Philipe E. Acquired dental defects and salivary gland lesions after irradiation for carcinoma. *J Am Dent Assoc* 1965;70:868–883.
32. Bertram U. Xerostomia. Clinical aspects, pathology and pathogenesis. *Acta Odontol Scand* 1967;25(suppl 49):1–126.
33. Daniels T, Silverman S, Michalski JP, Greenspan JS, Sylvester RA, Talal N. The oral component of Sjögren's syndrome. *Oral Surg Oral Med Oral Pathol* 1975;39:875–885.
34. Al-Hashimi I. The management of Sjögren's syndrome in dental practice. *J Am Dent Assoc* 2001;132:1409–1417.
35. Sreebny LM, Schwartz SS. A reference guide to drugs and dry mouths. *Gerodontology* 1986;5:75–99.
36. Guttenberg SA. Bisphosphonates and bone . . . What have we learned? [editorial] *Oral Surg Oral Med Oral Pathol Oral Radiol Endod* 2008;106:769–772.
37. Ruggiero SL, Fantasia J, Carlson E. Bisphosphonate-related osteonecrosis of the jaw: Background and guidelines for diagnosis, staging and management. *Oral Surg Oral Med Oral Pathol Oral Radiol Endod* 2006;102:433–441.
38. Hess LM, Jeter JM, Benham-Hutchins M, Alberts DS. Factors associated with osteonecrosis of the jaw among bisphosphonate users. *Am J Med* 2008;121:475–483.
39. Marx RE, Sawatari Y, Fortin M, Broumand V. Bisphosphonate-induced exposed bone (osteonecrosis/osteopetrosis) of the jaws: Risk factors, recognition, prevention, and treatment. *J Oral Maxillofac Surg* 2005;63:1567–1575.
40. Sedghizadeh PP, Stanley K, Caligiuri M, Hofkes S, Lowry B, Shuler CF. Oral bisphosphonate use and the prevalence of osteonecrosis of the jaw: An institutional inquiry. *J Am Dent Assoc* 2009;140:61–66.
41. Scully C, Madrid C, Bagan J. Dental endosseous implants in patients on bisphosphonate therapy. *Implant Dent* 2006;15:212–218.
42. Wright EF. Referred craniofacial pain patterns in patients with temporomandibular disorder. *J Am Dent Assoc* 2000;131:1307–1315 [erratum 2000;131:1553].
43. Tallents RH, Hatala M, Katzberg RW, Westesson PL. Temporomandibular joint sounds in asymptomatic volunteers. *J Prosthet Dent* 1993;69:298–304.
44. US Department of Labor, US Department of Health and Human Services. Joint Advisory Notice: Protection Against Occupational Exposure to Hepatitis B Virus (HBV) and Human Immunodeficiency Virus (HIV). Washington, DC: US Department of Labor, US Department of Health and Human Services, 1987.
45. Recommendations for prevention and control of hepatitis C virus (HCV) infection and HCV-related chronic diseases. Centers for Disease Control and Prevention. *MMWR Recomm Rep* 1998;47(RR-19):1–39.
46. Centers for Disease Control and Prevention. Viral Hepatitis. <http://www.cdc.gov/hepatitis/>. Accessed 10 Apr 2009.
47. Mast EE, Weinbaum CM, Fiore AE, et al. A comprehensive immunization strategy to eliminate transmission of hepatitis B virus infection in the United States: Recommendation of the Advisory Committee on Immunization Practices (ACIP). Part II: Immunization of adults. *MMWR Recomm Rep* 2006;55(RR-16):1–33 [erratum *MMWR Morb Mortal Wkly Rep* 2007;56:1114].
48. Centers for Disease Control. Hepatitis B virus vaccine safety: Report of an inter-agency group. *MMWR* 1982;31:465–467.
49. Centers for Disease Control. The safety of hepatitis B virus vaccine. *MMWR* 1983;32:134–136.
50. Infection control recommendations for the dental office and the dental laboratory. Council on Dental Materials, Instruments and Equipment. Council on Dental Practice. Council on Dental Therapeutics. *J Am Dent Assoc* 1988;116:241–248 [erratum 1988;116:614].
51. National Board for Certification of Dental Laboratories. Infection Control Requirements for Certified Dental Laboratories. Alexandria, VA: National Association of Dental Laboratories, 1986.

Fundamentals of Occlusion

2

Unfortunately, the occlusion is frequently overlooked or taken for granted in providing restorative dental treatment to patients. This may be due in part to the fact that the symptoms of occlusal disorders are often hidden from the practitioner untrained to recognize them or to appreciate their significance. Long-term successful restoration with cast metal or ceramic restorations is dependent on the maintenance of occlusal harmony.

While it is not possible to present the philosophies and techniques required to render extensive occlusal reconstruction in this limited space, it is essential that the reader develop an appreciation for the importance of occlusion. The perfection of skills required to provide sophisticated treatment of complex occlusal problems may take years to acquire. However, the minimum expectation of the competent practitioner is the ability to diagnose and treat simple occlusal disharmonies and to produce restorations that will not create iatrogenic occlusal or temporomandibular disorders.

Centric Relation

In restorative treatment, the goal is to create occlusal contacts in posterior teeth that stabilize the mandibular position instead of creating deflective contacts that may destabilize it. In restorative treatment, the occlusion should be in harmony with the optimum condylar position, *centric relation*, which is an anteriorly, superiorly braced position along the articular eminence of the glenoid fossa, with the articular disc interposed between the condyle and eminence.¹ This position is the most orthopedically stable position, and because it is a result of activated elevator muscles, it is also the most musculoskeletally stable position.²

This position of the condyles in the glenoid fossae has been discussed and debated for years. It is used in dentistry as a repeatable reference position for mounting casts in an articulator.^{3,4} The term attempts to define the optimum relative position between all of the anatomical components. Ideally, that condylar position is also coincident with maximal intercuspation of the teeth.^{4,5}

For the concept of centric relation to be meaningful, the basic anatomy of the temporomandibular joint (TMJ) must be understood (Fig 2-1). The bone of the glenoid fossa is thin at its most superior aspect and is not suited to be a stress-bearing area. However, the slope of the eminence in the anterior aspect of the fossa is composed of thick cortical bone that is capable of bearing stress.

The articular disc is biconcave, devoid of nerves and blood vessels in the central area, and tough—much like a piece of shoe leather. It has a few muscle fibers attached in the anterior aspect from the superior lateral pterygoid muscle. The disc is attached to the condyle on its medial and lateral aspects and should be interposed between the condyle and articular eminence during function. The condyle is not spherical but has an irregular, elliptical shape. This shape helps to distribute stress throughout the TMJ rather than concentrating it in a small area.

Many methods have been used to guide the mandible into an optimal position. Earlier concepts of centric relation involved the most posterior condylar position in the fossa. The condyle was sometimes forcefully manipulated into the rearmost, uppermost, and midmost (RUM) position within the glenoid fossa,^{4,6-8} using chin point guidance. However, when the condyle is retruded, it might not be seated on the central area of the articular disc; instead, it might be on the highly vascular and innervated retrodiscal tissues (the posterior attachment) posterior to the disc⁹ (Fig 2-2). This can occur if the inner horizontal portion of the temporomandibular ligament has been unduly traumatized so that it no longer supports the condyle in a more anterior, physiologic position. It is presently thought that rather than being a physiologic position, this is frequently an abnormal, forced position that could create unnecessary strain in the TMJ. In this circumstance, the disc is displaced anteriorly, and clicking of the joint is frequently observed as the patient opens and closes.

The more recent concept describes a physiologic position in terms of the musculoskeletal relationships of the structures¹⁰ (Fig 2-3). It is not a forced position; rather, the mandible is gently guided by the operator using the bilateral method¹¹ or by allowing natural muscle action to place the condyle in a physiologically unstrained position.¹²

2 Fundamentals of Occlusion

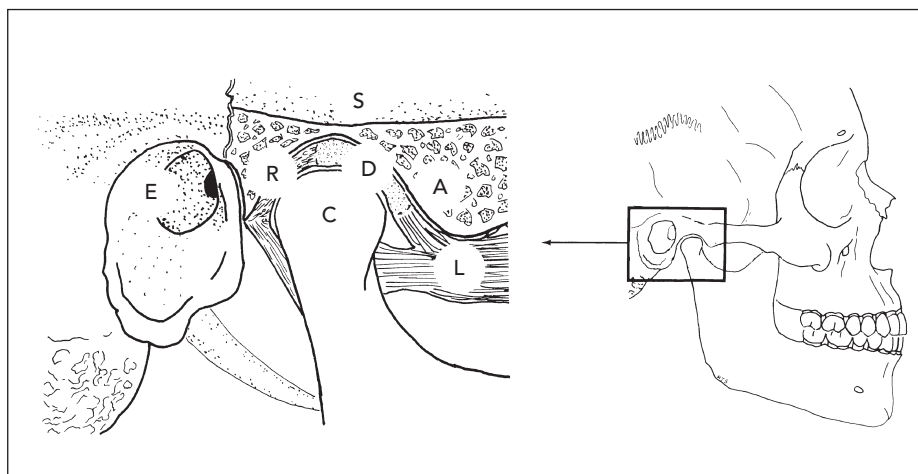


Fig 2-1 Some of the components of the TMJ. A, articular eminence; C, condyle; D, articular disc; E, external auditory meatus; L, superior and inferior lateral pterygoid muscles; R, retrodiscal tissue (posterior attachment); S, thin superior wall of the glenoid fossa.

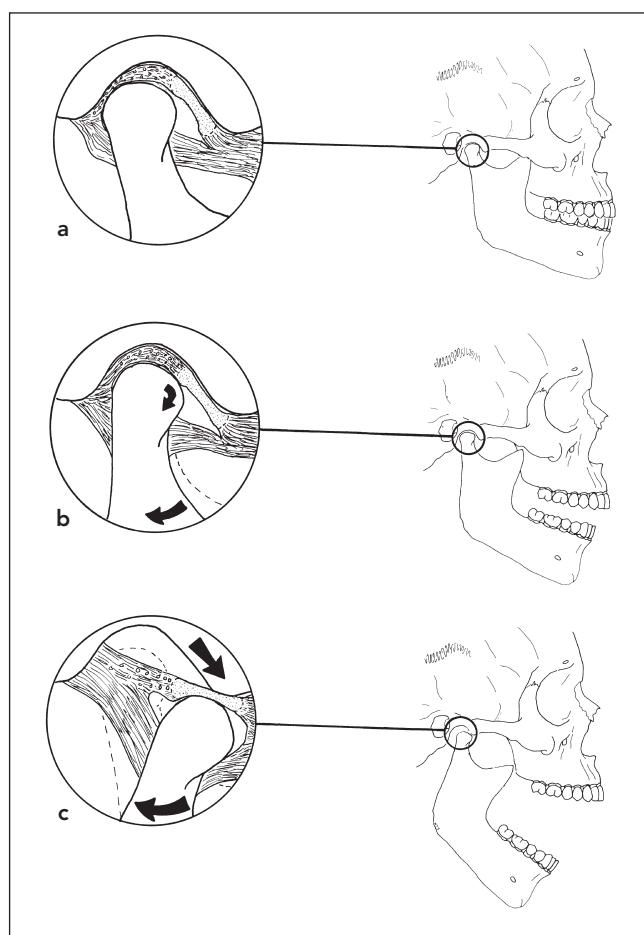


Fig 2-2 (a) In a dysfunctional joint with an internal derangement, the disc is displaced anterior to the condyle at the intercuspal position. (b) After initial rotational opening, the condyle is still posterior to the disc. (c) In translation of the mandible to maximum opening, the condyle recaptures the disc, clicking into position as it does.

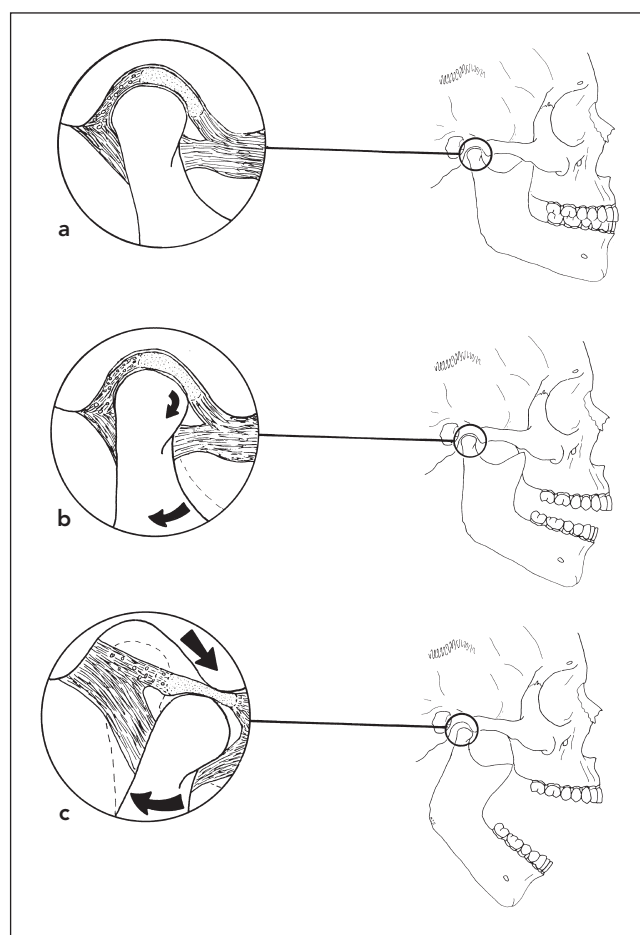


Fig 2-3 (a) In a healthy joint, the condyle is in a superoanterior position in the fossa with the articular disc interposed when the teeth are in maximal intercuspal position. (b) In the initial stage of opening, the condyle rotates in position, with the disc remaining stationary. (c) In maximum opening, the condyle translates forward, with the disc still interposed.

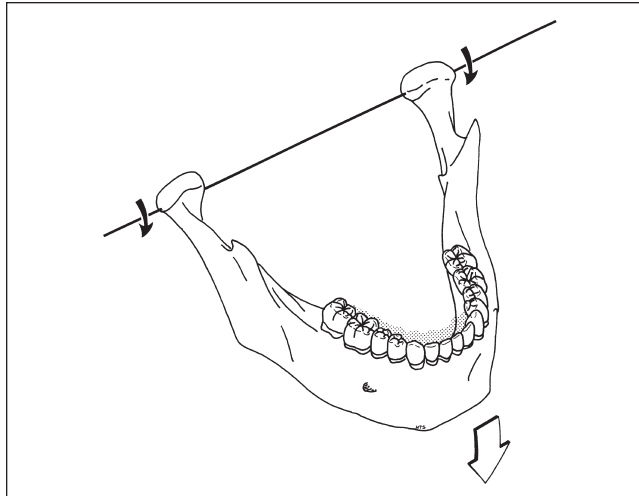


Fig 2-4 The mandible moves on a horizontal axis, as seen in a hinge axis opening.

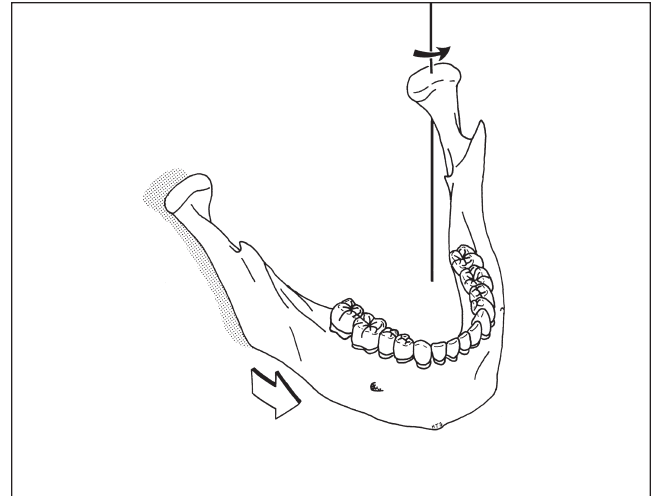


Fig 2-5 Mandibular movement occurs around a vertical axis during a lateral excursion.

Mandibular Movement

Mandibular movement can be broken down into a series of motions that occur around three axes:

1. **Horizontal axis** (Fig 2-4): This movement, in the sagittal plane, happens when the mandible in centric relation makes a purely rotational opening and closing border movement around the transverse horizontal axis, which extends through both condyles.
2. **Vertical axis** (Fig 2-5): This movement occurs in the horizontal plane when the mandible moves into a lateral excursion. The center for this rotation is a vertical axis extending through the rotating or working-side condyle.
3. **Sagittal axis** (Fig 2-6): When the mandible moves to one side, the condyle on the side opposite the direction of movement travels forward. As it does, it encounters the eminence of the glenoid fossa and moves downward simultaneously. When viewed in the frontal plane, this produces a downward arc on the side opposite the direction of movement, rotating around an anteroposterior (sagittal) axis passing through the other condyle.

Various mandibular movements are composed of motions occurring concurrently around one or more of the axes. The up-and-down motion of the mandible is a combination of two movements. A purely hinge movement occurs as the result of the condyles rotating in the lower compartments of the TMJs within a 10- to 13-degree arc, which creates a 20- to 25-mm separation of the anterior teeth (see Fig 2-3b). This phenomenon was the basis for the terminal hinge axis theory in the early 1920s by McCollum.³ Kohno verified the presence of a transverse horizontal axis, which he termed the *kinematic axis*.¹³ There is also some gliding movement in the upper compartment of the joint if the mandible drops

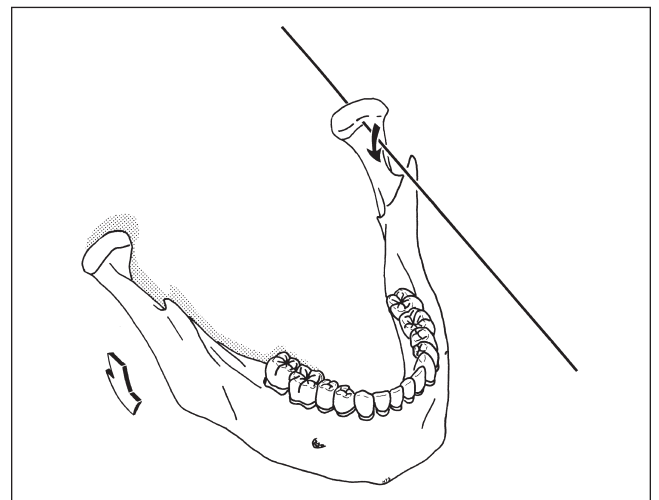


Fig 2-6 The mandible also rotates around a sagittal axis when one side drops down during a lateral excursion.

down farther (see Fig 2-3c). Then the axis of rotation shifts to the area of the mandibular foramen, as the condyles translate forward and downward while continuing to rotate.

When the mandible slides forward so that the maxillary and mandibular anterior teeth are in an end-to-end relationship, it is in a protrusive position. Ideally, the anterior segment of the mandible will travel a path guided by contacts between the anterior teeth, with complete disocclusion of the posterior teeth (Fig 2-7).

Mandibular movement to one side will place it in a working, or laterotrusive, relationship on that side and a nonworking, or mediotrusive, relationship on the opposite side; eg, if

2 Fundamentals of Occlusion

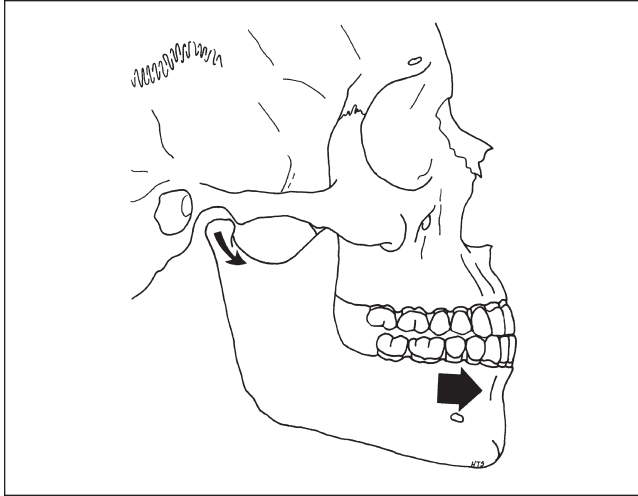


Fig 2-7 A protrusive movement occurs when the mandible moves forward.

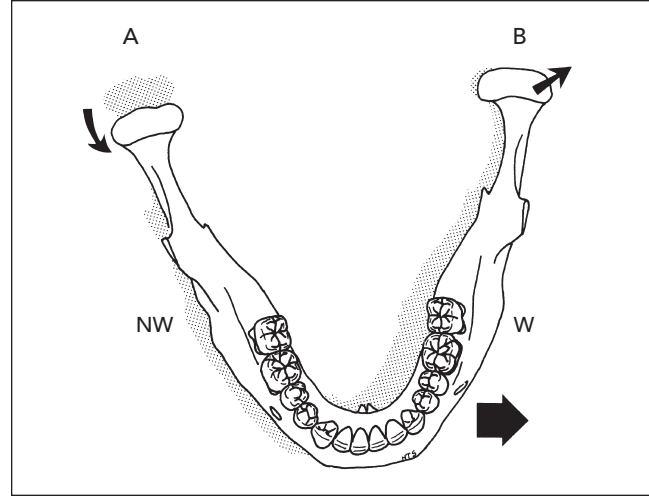


Fig 2-8 When the mandible moves into a left lateral excursion, the right condyle (A) moves forward and inward, while the left condyle (B) will shift slightly in a lateroposterior direction. In this example, the left side is the working side (W), and the right side is the nonworking side (NW).

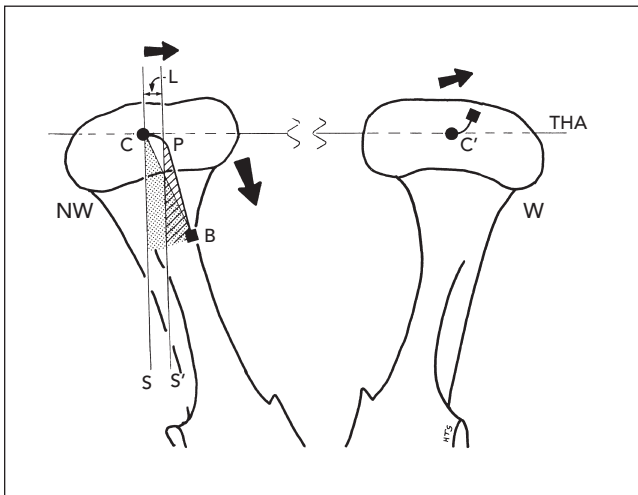


Fig 2-9 In the nonworking condyle (NW), the traditional Bennett angle (SCB) measures the angle from the sagittal plane to the endpoint of the movement of the condyle center. The Bennett angle used in articulators with an immediate lateral translation capability (S'PB) is measured from the sagittal plane after the immediate or early lateral translation (L) has occurred. The transverse horizontal axis (THA), or hinge axis of purely rotational movement, extends through both condyles. The working side condyle (W) slides laterally, or outward, in laterotrusion.

the mandible is moved to the left, the left side is the working side and the right side the nonworking side (Fig 2-8). In this type of movement, the condyle on the nonworking side will arc forward and medially (see A in Fig 2-8). Meanwhile, the condyle on the working side will shift laterally and usually slightly posteriorly (see B in Fig 2-8).

The bodily shift of the mandible in the direction of the working side was first described by Bennett.¹⁴ The angle formed in the horizontal plane between the pathway of the nonworking condyle, the mandibular lateral translation, and the sagittal plane is called the *Bennett angle* (Fig 2-9). The presence of an immediate or early lateral translation, or side shift, has been reported in 86% of the condyles studied.¹⁵ In addition to confirming the predominant presence of the early lateral translation, Lundeen and Wirth, using a mechan-

ical apparatus, showed its median dimension to be approximately 1.0 mm with a maximum of 3.0 mm.¹⁶ Hobo and Mochizuki, using an electronic measuring device, found a lower mean value of 0.4 mm for the immediate lateral translation, with a high of 2.6 mm.^{17,18}

Following the immediate lateral translation, there is a further gradual shifting of the mandible, or progressive lateral translation, which occurs at a rate proportional to the forward movement of the nonworking condyle.¹⁹ At one time, this was known as *progressive side shift* or *Bennett side shift*. Lundeen and Wirth found slight variation in the direction of the progressive lateral translation or Bennett angle, with a mean value of 7.5 degrees.¹⁶ Hobo and Mochizuki found a much greater variation, ranging from 1.5 to 36 degrees, with a mean value of 12.8 degrees.^{17,18}

Determinants of mandibular movement

The two condyles and the contacting teeth are analogous to the three legs of an inverted tripod suspended from the cranium. The determinants of the movements of that tripod are, posteriorly, the right and left TMJs; anteriorly, the teeth of the maxillary and mandibular arches; and overall, the neuromuscular system.²⁰

The dentist has no control over the posterior determinants, the TMJs; they are unchangeable. However, they influence the movements of the mandible, and of the teeth, by the paths that the condyles must travel when the mandible is moved by the muscles of mastication. The measurement and reproduction of those condylar movements is the basis for the use of articulators.

The anterior determinant, the teeth, provides guidance to the mandible in several ways. The posterior teeth provide the vertical stops for mandibular closure. They also guide the mandible into the position of maximal intercuspation, which may or may not correspond with the optimum position of the condyles in the glenoid fossae. The anterior teeth (canine to canine) help to guide the mandible in right and left lateral excursive movements and in protrusive movements. Anterior teeth are especially suited for guidance by virtue of:

- Canines having the longest, strongest roots in their respective arches
- The load being reduced by distance from the fulcrum (Class III lever)
- The proprioceptive threshold and concomitant reflexes reducing the load²¹⁻²³

Dentists have direct control over the tooth determinant by orthodontic movement of teeth; restoration of the anterior lingual or posterior occlusal surfaces; and equilibration, or selective grinding, of any teeth that are not in a harmonious relationship. Intercuspal position and anterior guidance can be altered, for better or for worse, by any of these means.

The closer a tooth is located to a determinant, the more it will be influenced by that determinant (Fig 2-10). A tooth located near the anterior region will be influenced greatly by anterior guidance and less by the TMJ. A tooth in the posterior region will be influenced partially by the joints and partially by anterior guidance.

The neuromuscular system, through proprioceptive nerve endings in the periodontium, muscles, and joints, monitors the position of the mandible and its paths of movement. Through reflex action, it will program the most physiologic paths of movement possible under the set of circumstances present. Dentists have indirect control over this determinant through procedures performed on the teeth, which may affect the response of the neuromuscular system.

One of the objectives of restorative dentistry is to place the teeth in harmony with the TMJs. This results in minimum stress on the teeth and joints, with only a minimum effort expended by the neuromuscular system to produce mandibu-

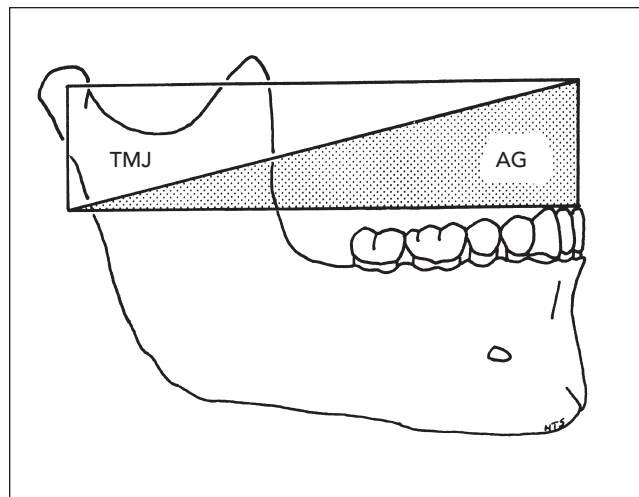


Fig 2-10 The farther anterior a tooth is located, the less the influence of the TMJ and the greater the influence of the anterior guidance (AG).

lar movements. When the teeth are not in harmony with the joints and the movements of the mandible, an interference is said to exist.

Occlusal interferences

Interferences are undesirable occlusal contacts that may produce mandibular deviation during closure to maximal intercuspation or may hinder smooth passage to and from the intercuspal position. There are four types of occlusal interferences:

1. Centric
2. Working
3. Nonworking
4. Protrusive

The *centric interference* is a premature contact that occurs when the mandible closes with the condyles in their optimum position in the glenoid fossae (Fig 2-11). It will cause deflection of the mandible in a posterior, anterior, and/or lateral direction.²⁴

A *working interference* may occur when there is contact between the maxillary and mandibular posterior teeth on the same side of the arches as the direction in which the mandible has moved (Fig 2-12). If that contact is heavy enough to disocclude anterior teeth, it is an interference.²⁵

A *nonworking interference* is an occlusal contact between maxillary and mandibular teeth on the side of the arches opposite the direction in which the mandible has moved in a lateral excursion (Fig 2-13). The nonworking interference is

2 Fundamentals of Occlusion

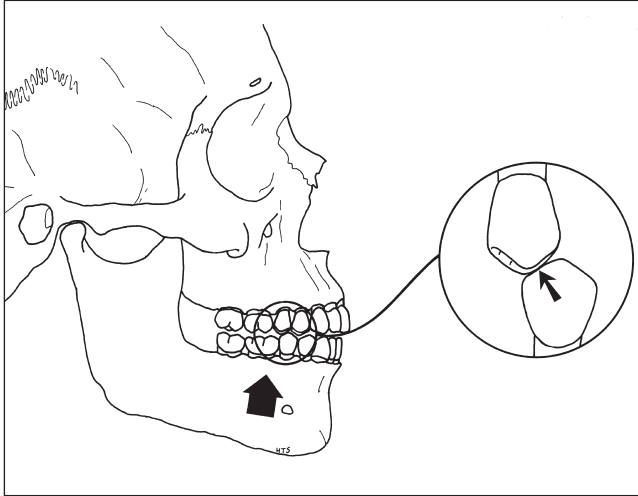


Fig 2-11 A centric occlusal interference often occurs during mandibular closure between maxillary mesial-facing cusp inclines and mandibular distal-facing inclines. As a result, the mandible is deflected anteriorly.

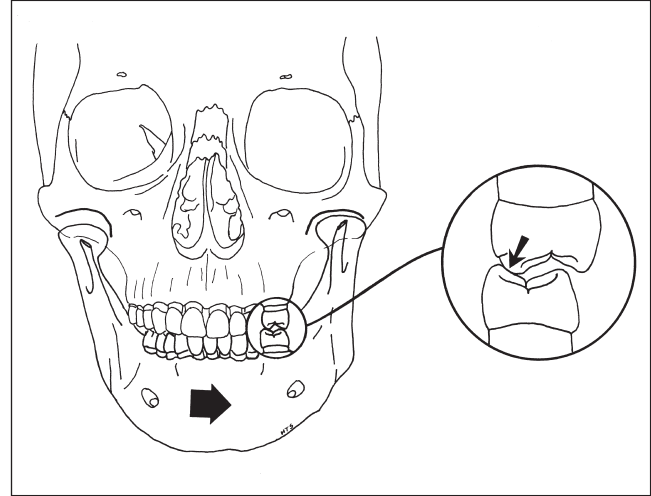


Fig 2-12 A working interference may occur between maxillary palatal-facing cusp inclines and mandibular facial-facing cusp inclines on the working side.

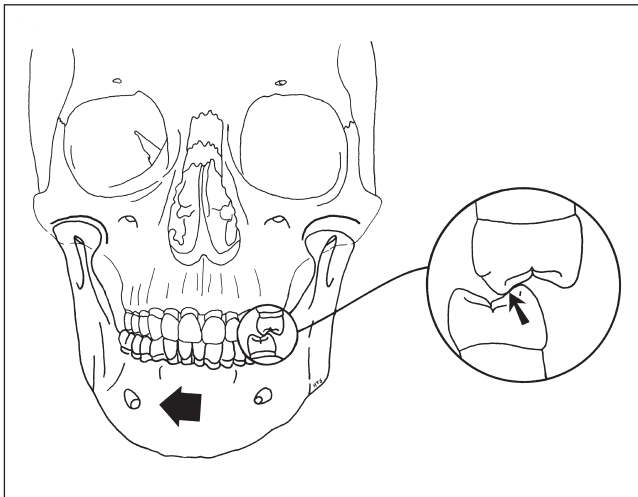


Fig 2-13 A nonworking interference results when there is contact between maxillary facial-facing cusp inclines and mandibular lingual-facing cusp inclines on the nonworking side.

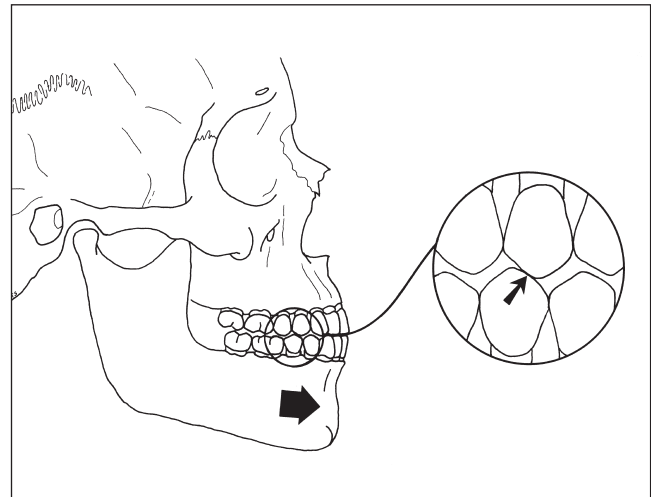


Fig 2-14 A protrusive interference occurs when distal-facing inclines of maxillary posterior teeth contact mesial-facing inclines of mandibular posterior teeth during a protrusive movement.

particularly destructive in nature.²⁶⁻²⁹ The potential for damaging the masticatory apparatus has been attributed to changes in the mandibular leverage, the placement of forces outside the long axes of the teeth, and disruption of normal muscle function.³⁰

A *protrusive interference* is a premature contact occurring between the mesial aspects of mandibular posterior teeth

and the distal aspects of maxillary posterior teeth (Fig 2-14). Because of the proximity of the teeth to the muscles and the oblique vector of the forces, contacts between opposing posterior teeth during protrusion are potentially destructive and interfere with the patient's ability to incise properly.

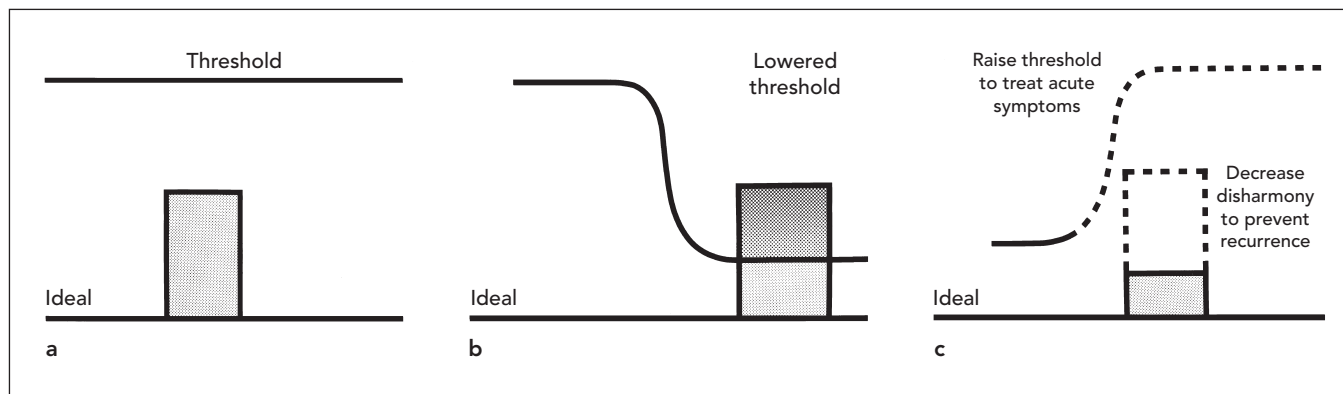


Fig 2-15 (a) There may be an occlusal disharmony (shaded bar) that is not ideal but is tolerated by the patient because it is below his or her threshold of perception and discomfort. (b) If the threshold is lowered, the disharmony that had been previously tolerated may produce symptoms in the patient. (c) Treatment is then rendered by first raising the patient's threshold and then decreasing or eliminating the disharmony.³³

Normal versus pathologic occlusion

In only slightly more than 10% of the population is there complete harmony between the teeth and the TMJs.³¹ This finding is based on a concept of centric relation in which the mandible is in the most retruded position. With the present concept of the condyles being in the most superoanterior position with the disc interposed, the results could be different. Nonetheless, in a majority of the population, the position of maximal intercuspation causes the mandible to be deflected away from its optimum position.

In the absence of symptoms, this can be considered physiologic, or normal. Therefore, in the normal occlusion there will be a reflex function of the neuromuscular system, producing mandibular movement that avoids premature contacts. This guides the mandible into a position of maximal intercuspation with the condyle in a less-than-optimal position. The result will be either some hypertonicity of nearby muscles or trauma to the TMJ, but it is usually well within most people's physiologic capacity to adapt and will not cause discomfort.

However, the patient's ability to adapt may be influenced by the effects of psychologic stress and emotional tension on the central nervous system.³² An increase in the patient's stress level will frequently increase parafunctional jaw activity such as clenching or bruxing, and a normal occlusion can become a pathologic one³³⁻³⁷ (Fig 2-15). Simple muscle hypertonicity may give way to muscle fatigue and pain, with chronic headaches and localized muscle tenderness, or TMJ dysfunction may occur. Pathologic occlusion can also manifest itself in the physical signs of trauma and destruction. Heavy facets of wear on occlusal surfaces, fractured cusps, and tooth mobility often are the result of occlusal disharmony. There is no evidence that occlusal trauma will produce a primary periodontal lesion. However, when occlusal trauma

is present, there will be more severe periodontal breakdown in response to local factors than there would be if only the local factors were present.³⁸

Habit patterns may develop in response to occlusal disharmony and emotional stress. Bruxism and clenching, the cyclic rubbing together of opposing occlusal surfaces, will produce even greater tooth destruction and muscle dysfunction.

When the acute discomfort of a patient with a pathologic occlusion has been relieved, changes that will prevent the recurrence of symptoms must be effected in the occlusal scheme. Care must also be taken when providing occlusal restorations for a patient without symptoms. The dentist must not produce an iatrogenic pathologic occlusion.

In the placement of restorations, the dentist must strive to produce an occlusion that is as nearly optimum as his or her skills and the patient's oral condition will permit. The optimum occlusion is one that requires minimal adaptation by the patient. The criteria for such an occlusion have been described by Okeson³⁹:

- In closure, the condyles are in the most superoanterior position against the discs on the posterior slopes of the eminences of the glenoid fossae. The posterior teeth are in solid and even contact, and the anterior teeth are in slightly lighter contact.
- Occlusal forces are along the long axes of the teeth.
- In lateral excursions of the mandible, working-side contacts (preferably on the canines) disocclude or separate the nonworking teeth instantly.
- In protrusive excursions, anterior tooth contacts will disocclude the posterior teeth.
- In an upright posture, posterior teeth contact more heavily than do anterior teeth.

2 Fundamentals of Occlusion

Organization of the Occlusion

The collective arrangement of the teeth in function is quite important and has been subjected to a great deal of analysis and discussion over the years. There are three recognized concepts that describe the manner in which teeth should and should not contact in the various functional and excursive positions of the mandible: (1) bilateral balanced occlusion, (2) unilateral balanced occlusion, and (3) mutually protected occlusion.

Bilateral balanced occlusion

Bilateral balanced occlusion is based on the work of von Spee⁴⁰ and Monson.⁴¹ It is a concept that is not used as frequently today as it has been in the past. It is largely a prosthodontics concept that dictates that a maximum number of teeth should contact in all excursive positions of the mandible. This is particularly useful in complete denture construction, in which contact on the nonworking side is important to prevent tipping of the denture.⁴¹ Subsequently, the concept was applied to natural teeth in complete occlusal rehabilitation. An attempt was made to reduce the load on individual teeth by sharing the stress among as many teeth as possible.⁴² It was soon discovered, however, that this was a very difficult type of arrangement to achieve. As a result of the multiple tooth contacts that occurred as the mandible moved through its various excursions, there was excessive frictional wear on the teeth.⁴³

Unilateral balanced occlusion

Unilateral balanced occlusion, which is also commonly known as *group function*, is a widely accepted and used method of tooth arrangement in restorative dental procedures today. This concept had its origin in the work of Schuyler⁴⁴ and others who began to observe the destructive nature of tooth contact on the nonworking side. They concluded that inasmuch as cross-arch balance was not necessary in natural teeth, it would be best to eliminate all tooth contact on the nonworking side.

Therefore, unilateral balanced occlusion calls for all teeth on the working side to be in contact during a lateral excursion. On the other hand, teeth on the nonworking side are contoured to be free of any contact. The group function of the teeth on the working side distributes the occlusal load. The absence of contact on the nonworking side prevents those teeth from being subjected to the destructive, obliquely directed forces found in nonworking interferences. It also saves the centric holding cusps (ie, the mandibular facial cusps and the maxillary palatal cusps) from excessive

wear. The obvious advantage is the maintenance of the occlusion.

The functionally generated path technique, originally described by Meyer,⁴⁵ is used for producing restorations in unilateral balanced occlusion. It has been adapted by Mann and Pankey for use in complete-mouth occlusal reconstruction.^{46,47}

Mutually protected occlusion

Mutually protected occlusion is also known as *canine-protected occlusion* or *organic occlusion*. It had its origin in the work of D'Amico,⁴⁸ Stuart,^{49,50} Stallard and Stuart,²⁷ and Lucia⁵¹ and the members of the Gnathological Society. They observed that in many mouths with a healthy periodontium and minimum wear, the teeth were arranged so that the overlap of the anterior teeth prevented the posterior teeth from making any contact on either the working or the nonworking side during mandibular excursions. This separation from occlusion was termed *disocclusion*. According to this concept of occlusion, the anterior teeth bear the entire load, and the posterior teeth are disoccluded in any excursive position of the mandible. The desired result is an absence of frictional wear.

The position of maximal intercuspation coincides with the optimal condylar position of the mandible. All posterior teeth are in contact with the forces being directed along their long axes. The anterior teeth either contact lightly or are very slightly out of contact (approximately 25 microns), relieving them of the obliquely directed forces that would be the result of anterior tooth contact. As a result of the anterior teeth protecting the posterior teeth in all mandibular excursions and the posterior teeth protecting the anterior teeth at the intercuspal position, this type of occlusion came to be known as a *mutually protected occlusion*. This arrangement of the occlusion is probably the most widely accepted because of its ease of fabrication and greater tolerance by patients.

However, to reconstruct a mouth with a mutually protected occlusion, it is necessary to have anterior teeth that are periodontally healthy. In the presence of anterior bone loss or missing canines, the mouth should probably be restored to group function (unilateral balance). The added support of the posterior teeth on the working side will distribute the load that the anterior teeth may not be able to bear. The use of a mutually protected occlusion is also dependent on the orthodontic relationship of the opposing arches. In either a Class II or a Class III malocclusion (Angle), the mandible cannot be guided by the anterior teeth. A mutually protected occlusion cannot be used in a situation of reverse occlusion, or crossbite, in which the maxillary and mandibular facial cusps interfere with each other in a working-side excursion.

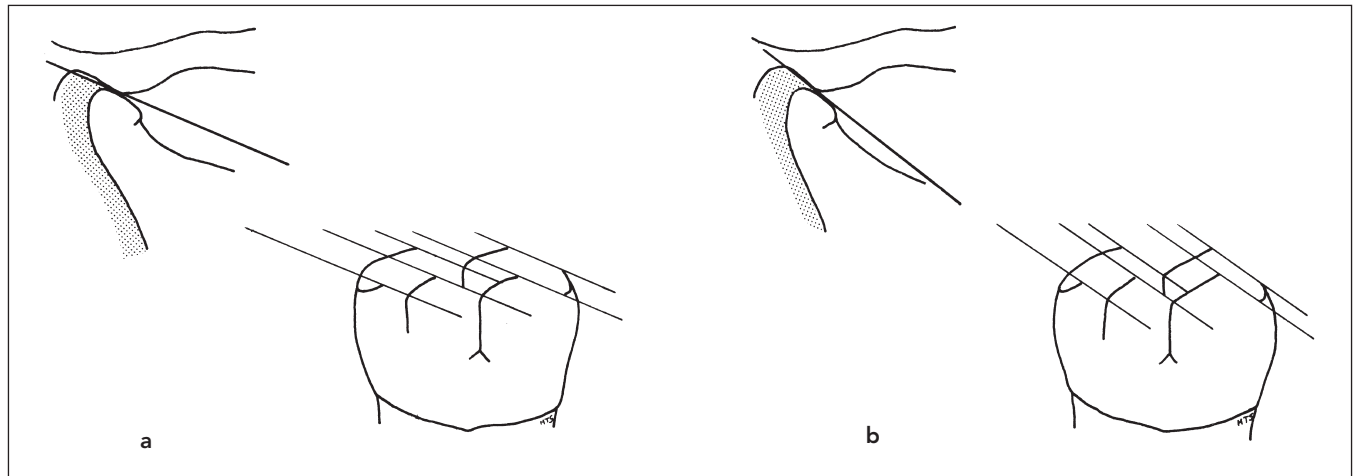


Fig 2-16 A shallow protrusive condylar inclination requires short cusps (a), while a steeper path permits the cusps to be longer (b).

Effects of Anatomical Determinants

The anatomical determinants of mandibular movement (ie, condylar and anterior guidance) have a strong influence on the occlusal surface morphology of the teeth being restored. There is a relationship between the numerous factors, such as immediate lateral translation, condylar inclination, and even disc flexibility, on the cusp height, cusp location, and groove direction that are acceptable in the restoration. It is beyond the scope of this text to discuss all of the nearly 50 rules that have been written on the subject of determinants⁵²; therefore, only those that have the greatest effect on morphology are considered.

Molar disocclusion

When subjects with normal occlusions perform repeated lateral mandibular movements, they will not trace the same path on electronic recordings, presumably because of the flexible nature of the articular disc. The measured deviation averages 0.2 mm in centric relation, 0.3 mm in working movements, and 0.8 mm in both protrusive and nonworking movements.⁵³ To avoid occlusal interferences and nonaxially directed forces on molars during eccentric mandibular movements, molar disocclusion must equal or surpass these observed deviations in mandibular movement.

Healthy natural occlusions exhibit clearances that will accommodate these aberrations. Measurements of disoc-

clusions from the mesiofacial cusp tips of mandibular first molars in asymptomatic test subjects with good occlusions showed separations averaging 0.5 mm in working, 1.0 mm in nonworking, and 1.1 mm in protrusive movements.⁵⁴ Therefore, one of the treatment goals in placing occlusal restorations should be to produce a posterior occlusion with buffer space that equals or surpasses the deviations resulting from natural variations found in the TMJ.

Condylar guidance

Chief among those aspects of condylar guidance that will have an impact on the occlusal surface of posterior teeth are the protrusive condylar path inclination and mandibular lateral translation.

The inclination of the condylar path during protrusive movement can vary from steep to shallow in different patients. It forms an average angle of 30.4 degrees with the horizontal reference plane (43 mm above the maxillary central incisor edge).^{17,18} If the protrusive inclination is steep, the cusp height may be longer. However, if the inclination is shallow, the cusp height must be shorter (Fig 2-16).

Immediate mandibular lateral translation is the lateral shift during initial lateral movement. If immediate lateral translation is great, then the cusp height must be shorter or the fossa width wider (Fig 2-17). With minimal immediate translation, the cusp height may be made longer or the fossa may be narrower.

Ridge and groove directions are affected by the condylar path, particularly the lateral translation. The effects are observed on the occlusal surface of a mandibular molar and

2 Fundamentals of Occlusion

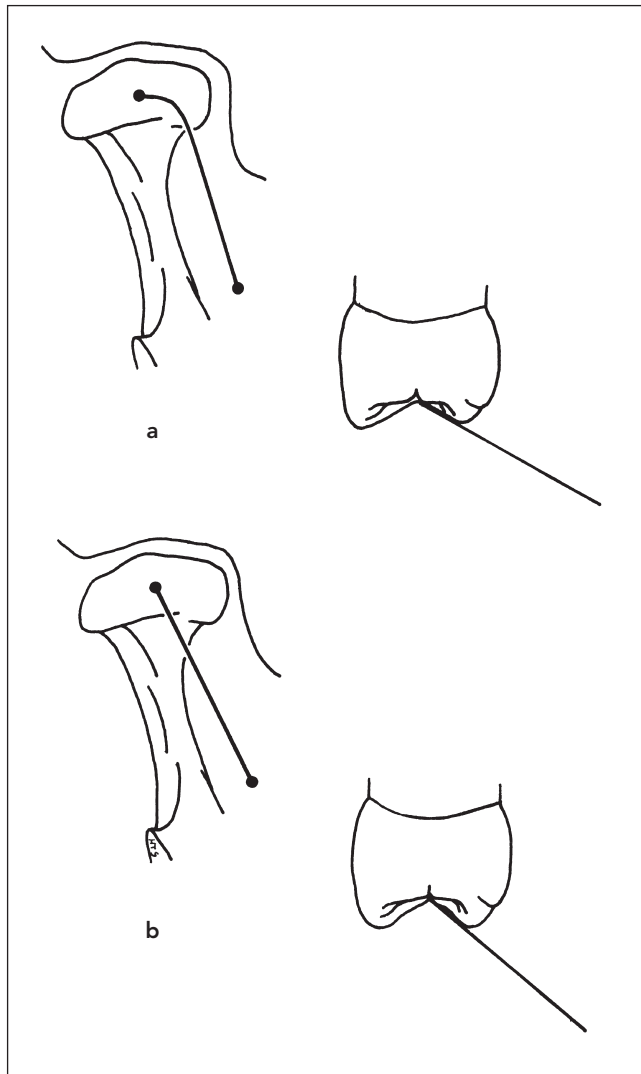


Fig 2-17 A pronounced immediate lateral translation requires that the cusps be short or the fossa wider (a), while a gradual lateral translation allows the cusps to be longer or the fossa narrower (b).

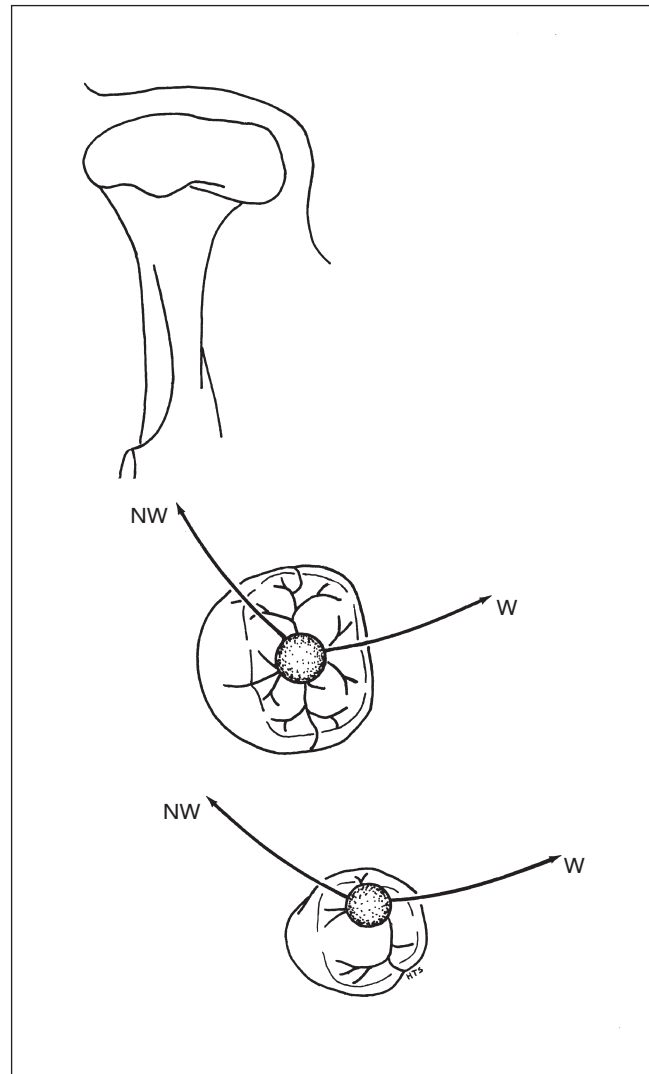


Fig 2-18 The angle between the working (W) and nonworking (NW) paths is greater on teeth located farther from the condyle.

premolar with the paths traced by the palatal cusps of the respective opposing maxillary teeth. The working path is traced on the mandibular tooth in a lingual direction, and the nonworking path is in a distofacial direction. The nearer the tooth is to the working-side condyle anteroposteriorly, the smaller the angle between the working and nonworking paths (Fig 2-18). The farther the tooth is located from the working-side condyle, the greater the angle between the working and nonworking condyles. When immediate lateral translation is increased, the angle also becomes more oblique.

Anterior guidance

During protrusive movement of the mandible, the incisal edges of mandibular anterior teeth move forward and downward along the palatal concavities of the maxillary anterior teeth. The track of the incisal edges from maximal intercuspation to edge-to-edge occlusion is termed the *protrusive incisal path*. The angle formed by the protrusive incisal path and the horizontal reference plane is the protrusive incisal path inclination, which ranges from 50 to 70 degrees.^{55,56} Although they are conventionally regarded as independent

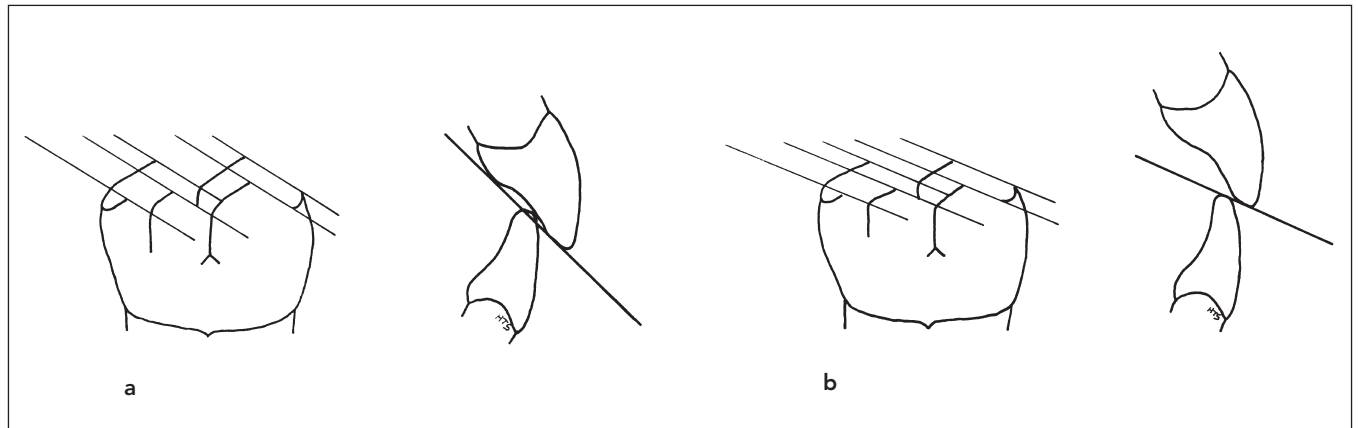


Fig 2-19 (a) A pronounced vertical overlap of the anterior teeth permits posterior teeth to have longer cusps. (b) A minimum anterior vertical overlap requires shorter cusps.

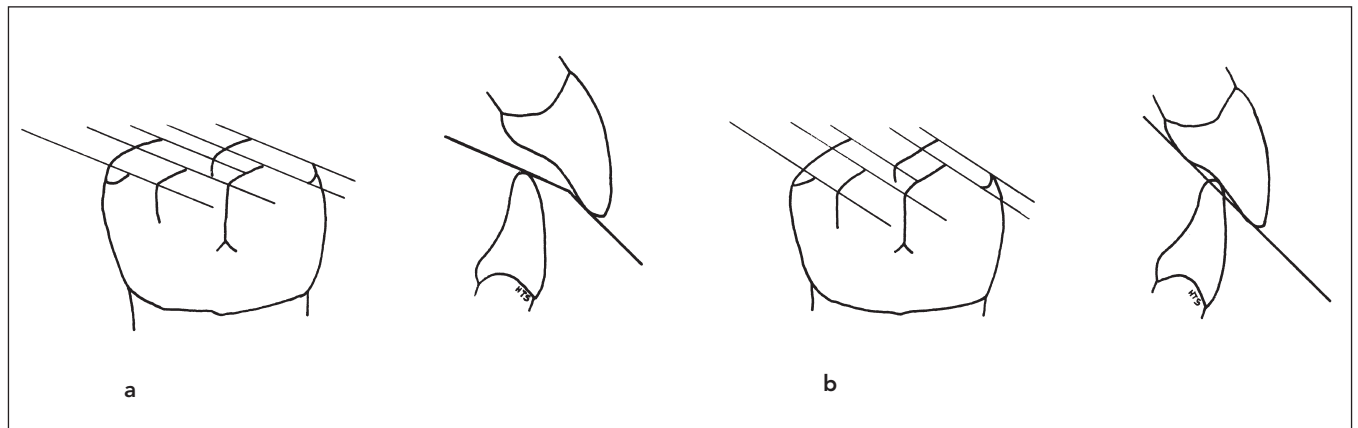


Fig 2-20 (a) A pronounced horizontal overlap of the anterior teeth requires short cusps on the posterior teeth. (b) A minimum anterior horizontal overlap permits the posterior cusps to be longer.

factors, there is evidence to suggest that condylar inclination and anterior guidance are linked, or dependent factors^{57,58} (Takayama H and Hobo S, unpublished data, 1989). In a healthy occlusion, the anterior guidance is approximately 5 to 10 degrees steeper than the condylar path in the sagittal plane. Therefore, when the mandible moves protrusively, the anterior teeth guide the mandible downward to create disocclusion, or separation, between the maxillary and mandibular posterior teeth. The same phenomenon should occur during lateral mandibular excursions.

The palatal surface of a maxillary anterior tooth has both a concave aspect and a convexity, or cingulum. The mandibular incisal edges should contact the maxillary palatal surfaces

at the transition from the concavity to the convexity in the centric relation position. The concavity represents a uniform shape in all subjects.⁵⁹

Anterior guidance, which is linked to the combination of vertical and horizontal overlap of the anterior teeth, can affect occlusal surface morphology of the posterior teeth. The greater the vertical overlap of the anterior teeth, the longer the posterior cusp height may be. When the vertical overlap is less, the posterior cusp height must be shorter (Fig 2-19). The greater the horizontal overlap of the anterior teeth, the shorter the cusp height must be. With a decreased horizontal overlap, the posterior cusp height may be longer (Fig 2-20).

2 Fundamentals of Occlusion

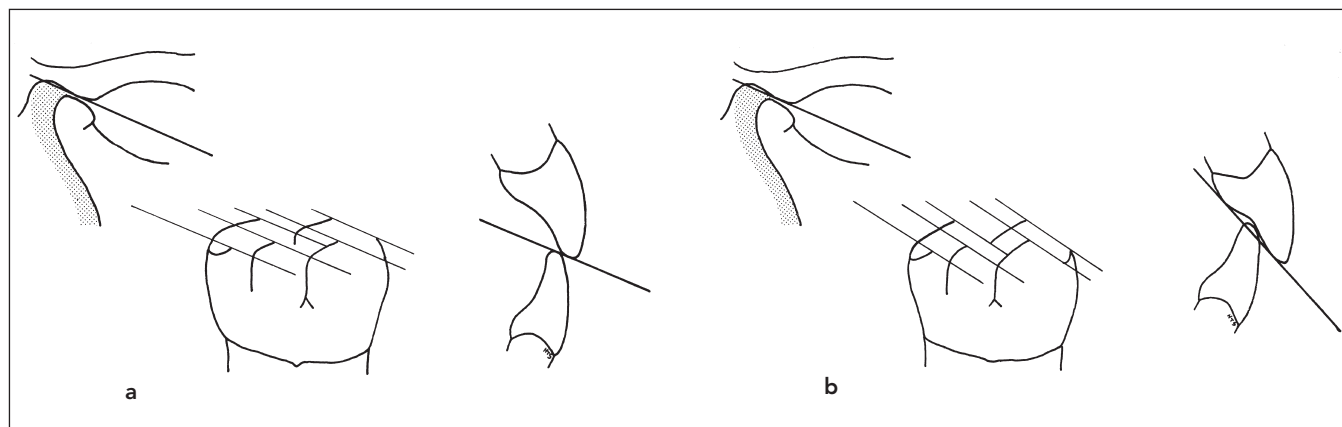


Fig 2-21 While a shallow protrusive path would require short cusps in the presence of minimal anterior guidance (a), the posterior cusps can be lengthened if the anterior guidance is increased (b).

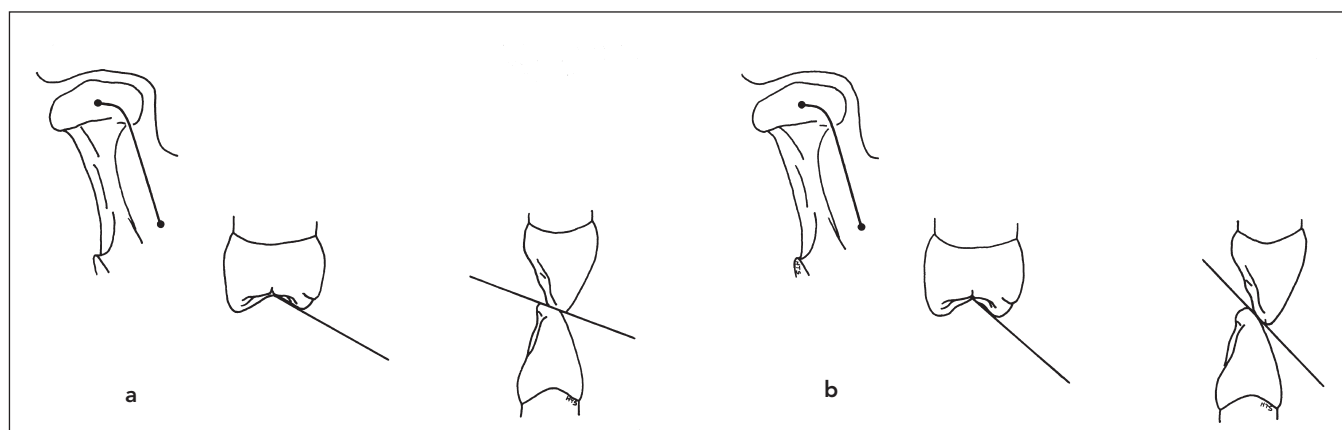


Fig 2-22 (a) A pronounced immediate lateral translation would dictate short cusps where there is little anterior guidance. (b) However, the cusps can be lengthened if the anterior guidance is increased.

By increasing anterior guidance to compensate for inadequate condylar guidance, it is possible to increase the cusp height. If the protrusive condylar inclination is shallow, requiring short posterior cusps, the cusps may be lengthened by making the anterior guidance steeper (Fig 2-21). In like

manner, increasing anterior guidance will permit the lengthening of cusps that would otherwise have to be shorter in the presence of a pronounced immediate lateral translation (Fig 2-22).

References

1. Nomenclature Committee of the Academy of Denture Prosthetics. Glossary of Prosthodontic Terms, ed 5. St Louis: Mosby, 1987:15.
2. Okeson JP. Management of Temporomandibular Disorders and Occlusion, ed 6. St Louis: Mosby, 2008:96.
3. McCollum BB, Stuart CE. Gnathology—A Research Report. South Pasadena, CA: Scientific Press, 1955:91–123.
4. Lucia VO. Modern Gnathological Concepts. St Louis: Mosby, 1961:15–22.
5. Dawson PE. Evaluation, Diagnosis, and Treatment of Occlusal Problems. St Louis: Mosby, 1974:293.
6. Kornfeld M. Mouth Rehabilitation: Clinical and Laboratory Procedures. St Louis: Mosby, 1967:34.
7. Bauer A, Gutowski A, Koehler HM. Gnathology: Introduction to Theory and Practice. Berlin: Quintessence, 1975:85–91.
8. Huffman R, Regenos J. Principles of Occlusion, ed 8. Columbus, OH: H & R Press, 1980:VA1–VB39.
9. Parsons MT, Boucher LJ. The bilaminar zone of the meniscus. J Dent Res 1966;45:59–61.
10. McNeill C. The optimum temporomandibular joint condyle position in clinical practice. Int J Periodontics Restorative Dent 1985;5(6):52–76.
11. Dawson PE. Evaluation, Diagnosis, and Treatment of Occlusal Problems. St Louis: Mosby, 1961:48–79.
12. Brill N, Lammie GA, Osborne J, Perry HT. Mandibular positions and mandibular movements. Br Dent J 1959;106:391–400.
13. Kohno S. Analyse der Kondylenbewegung in der Sagittalebene. Dtsch Zahnärztl Z 1974;27:739–743.
14. Bennett NG. A contribution to the study of the movements of the mandible. Proc Roy Soc Med 1908;1:79–95.
15. Aull AE. Condylar determinants of occlusal patterns. Part I. Statistical report on condylar path variations. J Prosthet Dent 1965;15:826–835.
16. Lundeen HC, Wirth CG. Condylar movement patterns engraved in plastic blocks. J Prosthet Dent 1973;30:866–875.
17. Hobo S, Mochizuki S. Study of mandibular movement by means of an electronic measuring system. Part I. J Jpn Prosthodont Soc 1982;26:619–634.
18. Hobo S, Mochizuki S. Study of mandibular movement by means of an electronic measuring system. Part II. J Jpn Prosthodont Soc 1982;26:635–653.
19. Nomenclature Committee of the Academy of Denture Prosthetics. Glossary of Prosthodontic Terms, ed 5. St Louis: Mosby, 1987:31.
20. Guichet NF. Occlusion. Anaheim, CA: Denar, 1970:13.
21. Manly RS, Pfaffmann C, Lathrop DD, Kayser J. Oral sensory thresholds of persons with natural and artificial dentitions. J Dent Res 1952;31:305.
22. Williamson EH, Lundquist DO. Anterior guidance: Its effect on electromyographic activity of the temporal and masseter muscles. J Prosthet Dent 1983;49:816–823.
23. Manns A, Chan C, Miralles R. Influence of group function and canine guidance on electromyographic activity of elevator muscles. J Prosthet Dent 1987;57:494–501.
24. Dawson PE. Temporomandibular joint pain-dysfunction problems can be solved. J Prosthet Dent 1973;29:100–112.
25. Dawson PE. Evaluation, Diagnosis, and Treatment of Occlusal Problems. St Louis: Mosby, 1961:299.
26. Ramfjord SP. Dysfunctional temporomandibular joint and muscle pain. J Prosthet Dent 1961;11:353–374.
27. Stallard H, Stuart CE. Eliminating tooth guidance in natural dentitions. J Prosthet Dent 1961;11:474–479.
28. Schuyler CH. Factors contributing to traumatic occlusion. J Prosthet Dent 1961;11:708–715.
29. Yuodelis RA, Mann WV Jr. The prevalence and possible role of nonworking contacts in periodontal disease. Periodontics 1965;3:219–223.
30. Whitsett LD, Shillingburg HT Jr, Duncanson MG Jr. The non-working interference. Your Okla Dent Assoc J 1974;65:5–7,11.
31. Posselt U. Studies in the mobility of the human mandible. Acta Odontol Scand 1952;10(suppl 10):1–109.
32. Ramfjord SP, Ash MM Jr. Occlusion, ed 2. Philadelphia: Saunders, 1971:104.
33. Schiffman EL, Friction JR, Haley D. The relationship of occlusion, parafunctional habits and recent life events to mandibular dysfunction in a non-patient population. J Oral Rehabil 1992;19:201–223.
34. Rugh JD, Solberg WK. Electromyographic studies of bruxist behavior before and during treatment. J Calif Dent Assoc 1975;3:56–59.
35. Solberg WK, Clark GT, Rugh JD. Nocturnal electromyographic evaluation of bruxism patients undergoing short term splint therapy. J Oral Rehabil 1975;2:215–223.
36. Clark GT, Beemsterboer PL, Solberg WK, Rugh JD. Nocturnal electromyographic evaluation of myofascial pain dysfunction in patients undergoing occlusal splint therapy. J Am Dent Assoc 1979;99:607–611.
37. Yemm R. Cause and effect of hyperactivity of the jaw muscles. In: Bryant P, Gale E, Rugh J (eds). Oral Motor Behavior: Impact on Oral Conditions and Dental Treatment, NIH Publication 79-1845. Bethesda, MD: National Institutes of Health, 1979.
38. Glickman I, Smulow JB. Alterations in the pathway of gingival inflammation into the underlying tissues induced by excessive occlusal forces. J Periodontol 1962;33:7–13.
39. Okeson JP. Management of Temporomandibular Disorders and Occlusion, ed 2. St Louis: Mosby, 1989:113.
40. von Spee FG. The gliding path of the mandible along the skull [in German]. Arch Anat Physiol 1890;16:285–294.
41. Monson GS. Impaired function as a result of a closed bite. J Am Dent Assoc 1921;8:833–839.
42. Schuyler CH. Fundamental principles in the correction of occlusal disharmony, natural and artificial. J Am Dent Assoc 1935;22:1193–1202.
43. Stuart CE, Stallard H. Principles involved in restoring occlusion to natural teeth. J Prosthet Dent 1960;10:304–313.
44. Schuyler CH. Factors of occlusion applicable to restorative dentistry. J Prosthet Dent 1953;3:772–782.
45. Meyer FS. Can the plain line articulator meet all the demands of balanced and functional occlusion in all restorative work? J Colo Dent Assoc 1938;17:6–16.
46. Mann AW, Pankey LD. Oral rehabilitation. Part I: Use of the P-M instrument in treatment planning and in restoring the lower posterior teeth. J Prosthet Dent 1960;10:135–150.
47. Pankey LD, Mann AW. Oral rehabilitation. Part II: Reconstruction of the upper teeth using a functionally generated path technique. J Prosthet Dent 1960;10:151–162.
48. D'Amico A. Functional occlusion of the natural teeth of man. J Prosthet Dent 1961;11:899–915.
49. Stuart CE. Good occlusion for natural teeth. J Prosthet Dent 1964;14:716–724.
50. Stuart CE. Why dental restorations should have cusps. J South Calif Dent Assoc 1959;27:198–200.
51. Lucia VO. The gnathological concept of articulation. Dent Clin North Am 1962;6:183–197.
52. Katz GT. The Determinants of Human Occlusion. Los Angeles: Marina Press, 1972:vi.
53. Oliva RA, Takayama H, Hobo S. Three-dimensional study of mandibular movement using an automatic electronic measuring system. J Gnathol 1986;5:115–182.
54. Hobo S, Takayama H. Pilot study—Analysis and measurement of the amount of disclusion during lateral movement. J Jpn Prosthodont Soc 1984;29:238–239.
55. Gysi A, Kohler L: Handbuch der Zahnheilkunde. Berlin & Vienna: Scheff, 1929:IV.
56. Gysi A. The problem of articulation. Dent Cosmos 1910;52:1–19, 148–169, 403–418.
57. Takayama H, Hobo S. The derivation of kinematic formulae for mandibular movement. Int J Prosthodont 1989;2:285–295.
58. Takayama H, Hobo S. Kinematic and experimental analyses of mandibular movement for clinical application. Prec Mach Incomp Life Supp Tech 1989;2:229–304.
59. Kubein-Meesenburg D, Naegerl H, Meyer G, Buecking W. Individual reconstruction of palatal concavities. J Prosthet Dent 1988;60:662–672.

Articulators

An *articulator* is a mechanical device that simulates the movements of the mandible (Fig 3-1). The principle employed in the use of articulators is the mechanical replication of the paths of movement of the posterior determinants, the temporomandibular joints (TMJs), and, in some cases, the anterior guidance. The instrument is then used in the fabrication of fixed and removable dental restorations that are in harmony with those movements. The articulator is a tool, and, as with all tools, its value to the dentist is determined by its appropriate use.

The outer limits of all excursive movements made by the mandible are referred to as *border movements*. All functional movements of the mandible are confined to the three-dimensional envelope of movement contained within these borders.¹ The border movements are of significance in discussing articulation because they are limited by ligaments. As such, they are highly repeatable and useful in setting the various adjustments on the mechanical fossae of an articulator. The more nearly the articulator duplicates the border movements, the more nearly it will simulate the posterior determinants of occlusion. As a result, the harmony between the fabricated restoration and the posterior determinants (ie, the TMJs) will be improved.

Articulators vary widely in the accuracy with which they reproduce the movements of the mandible. At the lower end of the scale is the nonadjustable articulator. It is usually a small instrument that is capable of only a hinge opening. The distance between the teeth and the axis of rotation on the small instrument is considerably shorter than it is in the skull, with a resultant loss of accuracy.

As the mandible moves up and down in the retruded position, the cusp tip of a mandibular tooth moves along an arc in a sagittal plane, with the center for that rotation located at the transverse horizontal axis (THA), which passes through the condyles (Fig 3-2). If the location of the axis of rotation relative to the cusp tip differs markedly from the patient to the articulator, the radius of the arc of closure of the cusp tip may be different, producing an error. Drastic differences between the radius of closure on the articulator and in the patient's mouth can affect the placement of morphologic features such as cusps, ridges, and grooves on the occlusal surface.

The casts mounted on a smaller articulator will have a much shorter radius of movement, and a tooth will travel a steeper arc during closure of the small articulator (Fig 3-3).

If the casts are mounted at an increased dimension of occlusion (ie, with a thick interocclusal record), the teeth will occlude in a different intercuspal position on the articulator than in the mouth.² A slight positive error resulting in a deflective occlusal contact could develop between the mesial incline of the maxillary teeth and the distal incline of the mandibular teeth.³

The mediolateral location of the centers of rotation (ie, the intercondylar distance) will change the radius of tooth movement, which in turn will affect the arc traveled by a tooth cusp in the horizontal plane during a lateral excursion of the mandible. On a small hinge articulator, the discrepancy between the arcs traveled by a cusp on the instrument and in the mouth can be sizable, particularly on the nonworking side (Fig 3-4). The result is an increased possibility of incorporating a nonworking occlusal interference into the restoration.

A *semi-adjustable articulator* is an instrument whose larger size allows a close approximation of the anatomical distance between the axis of rotation and the teeth. If casts are mounted with a facebow transfer using no more than an approximate THA, the radius of movement produced on the articulator will reproduce the tooth closure arc with relative accuracy, and any resulting error will be slight (Fig 3-5). Placing the casts a small distance closer to or farther from the condyles through the use of an approximate THA will produce an error of only a small magnitude during lateral excursions⁴ (Fig 3-6).

The semi-adjustable articulator reproduces the direction and endpoint but not the intermediate track of some condylar movements. As an example, the inclination of the condylar path is reproduced as a straight line on many articulators, when in fact it usually traverses a curved path. On many instruments, the lateral translation, or Bennett movement, is reproduced as a gradually deviating straight line, although several recently introduced semi-adjustable articulators do accommodate the immediate lateral translation.

Intercondylar distances are not totally adjustable on semi-adjustable articulators. They can be adjusted to small, medium, and large configurations, if at all. Restorations will require some intraoral adjustment, but it should be inconsequential if the restoration is fabricated carefully on accurately mounted casts. This type of articulator can be used for the fabrication of most single units and fixed partial dentures.

3 Articulators

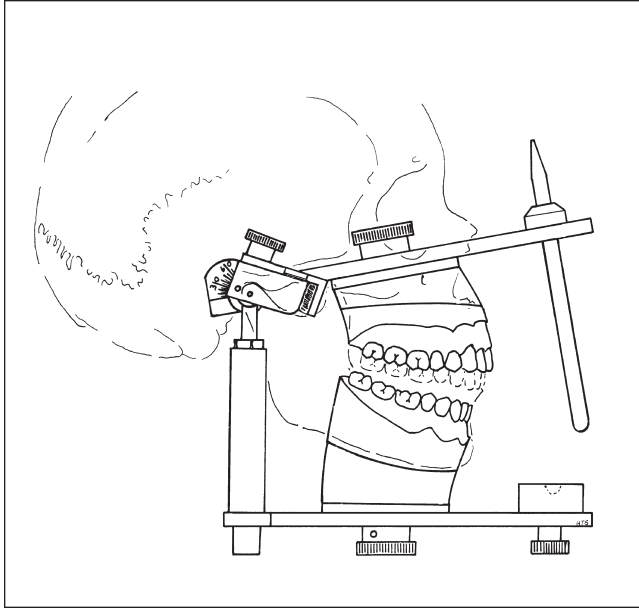


Fig 3-1 The articulator should simulate the movements of the mandible.

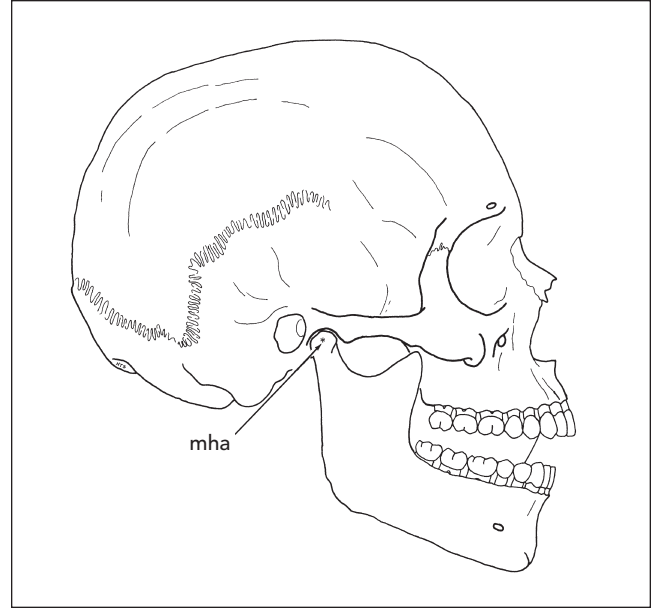


Fig 3-2 As the mandible closes around the hinge axis (mha), the cusp tip of each mandibular tooth moves along an arc. (Reprinted from Hobo et al² with permission.)

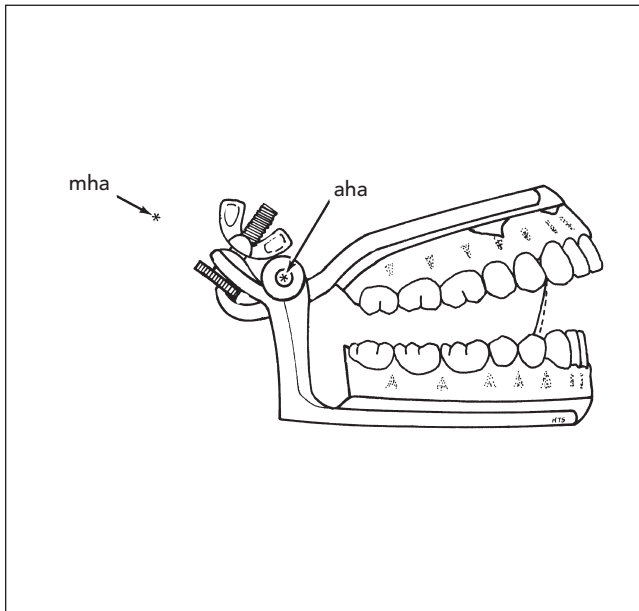


Fig 3-3 The large dissimilarity between the hinge axis of the small articulator (aha) and the hinge axis of the mandible (mha) will produce a large discrepancy between the arcs of closure of the articulator (dotted line) and of the mandible (solid line). (Reprinted from Hobo et al² with permission.)

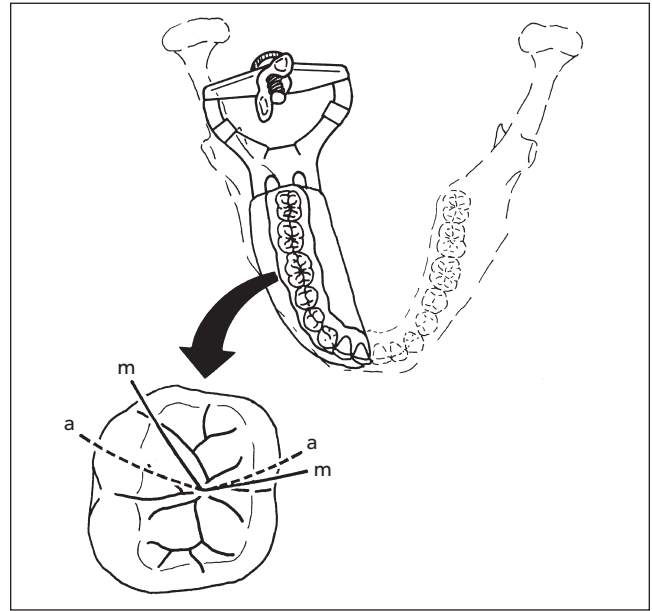


Fig 3-4 A major discrepancy exists between the nonworking cusp path on the small articulator (a) and that in the mouth (m). (Reprinted from Hobo et al² with permission.)

The most accurate instrument is the fully adjustable articulator. It is designed to reproduce the entire character of border movements, including immediate and progressive

lateral translation, and the curvature and direction of the condylar inclination. Intercondylar distance is completely adjustable. When a kinematically located hinge axis and an

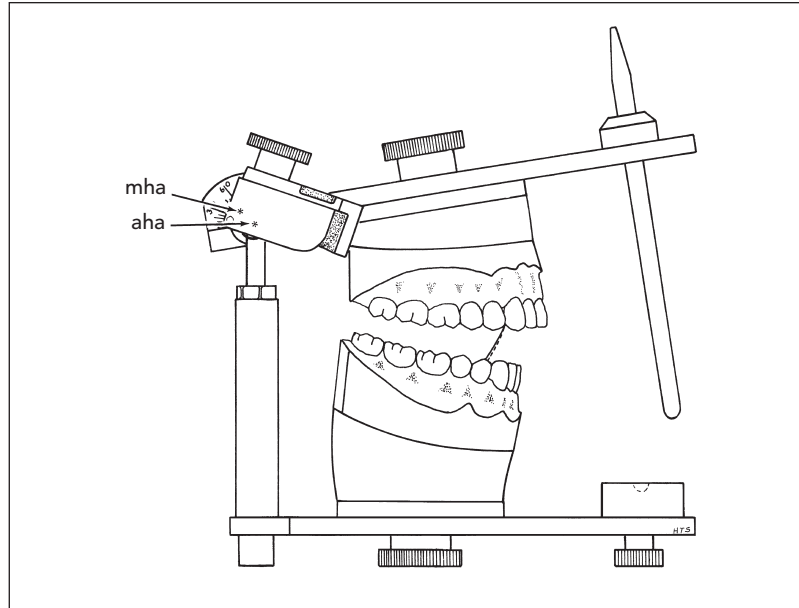


Fig 3-5 The dissimilarity between the hinge axis of the full-size semi-adjustable articulator (aha) and the mandibular hinge axis (mha) will cause a slight discrepancy between the arcs of closure of the articulator (*dotted line*) and of the mandible (*solid line*). (Reprinted from Hobo et al² with permission.)

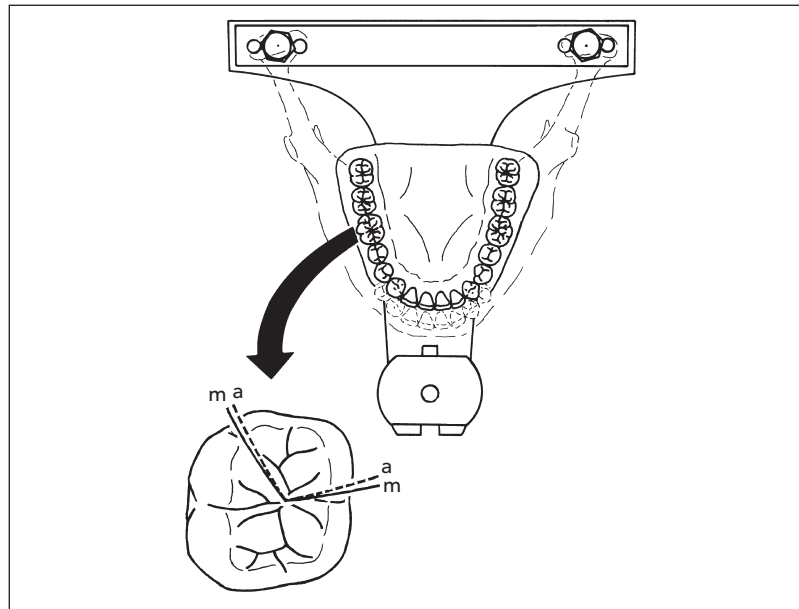


Fig 3-6 There is only a slight difference between cusp paths on a full-size articulator (a) and those in the mouth (m), even though the cast mounting exhibits a slight discrepancy. (Reprinted from Hobo et al² with permission.)

accurate recording of mandibular movement are employed, a highly accurate reproduction of the mandibular movement can be achieved.

This type of instrument is expensive. The techniques required for its use demand a high degree of skill and are time-

consuming to accomplish. For this reason, fully adjustable articulators are used primarily for extensive treatment requiring the reconstruction of an entire occlusion.

3 Articulators

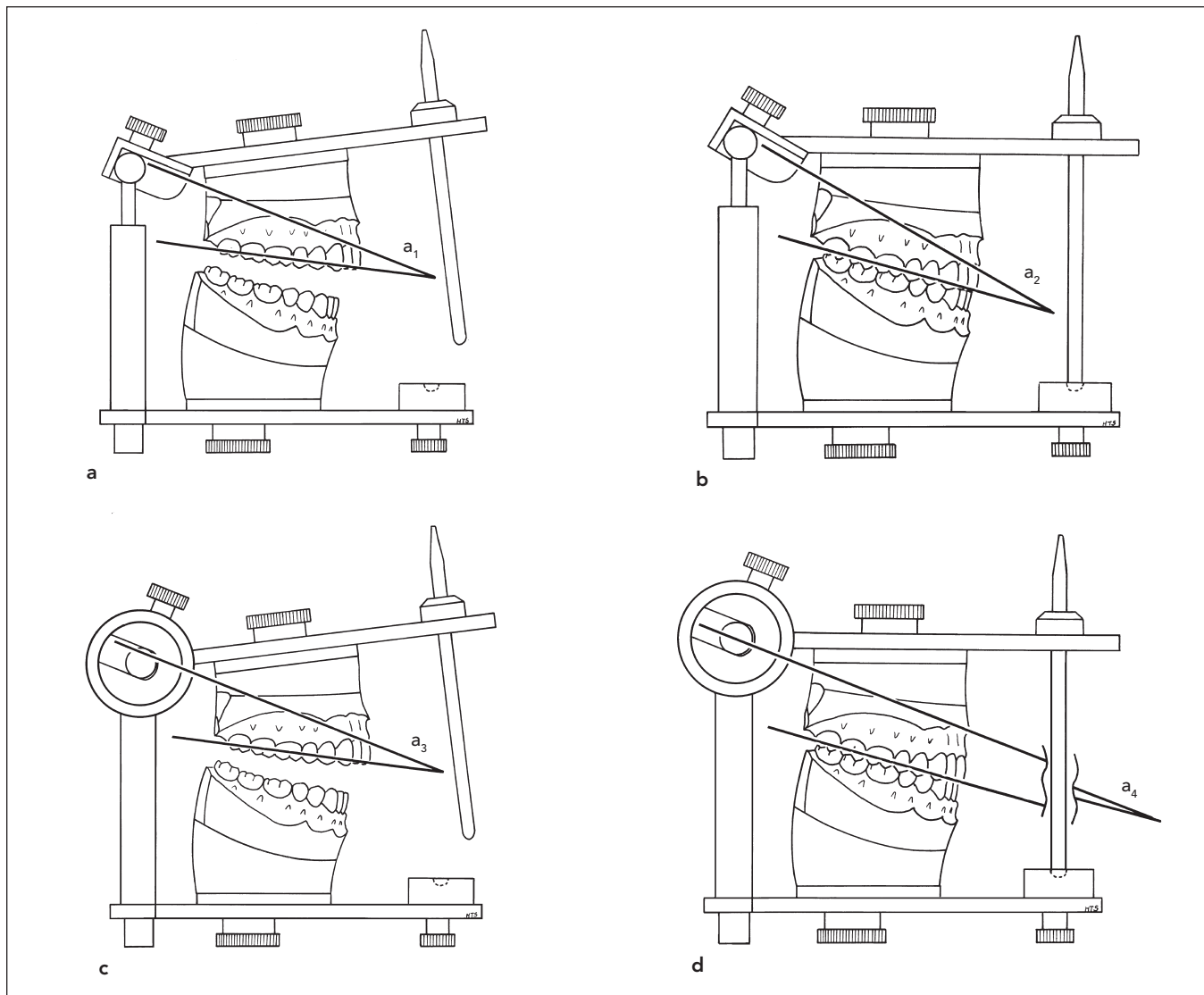


Fig 3-7 The angle between the condylar inclination and the occlusal plane of the maxillary teeth remains the same in an open (a) and a closed (b) arcon articulator ($a_1 = a_2$). However, the angle changes in an open (c) and a closed (d) nonarcon instrument ($a_3 \neq a_4$). For the amount of opening illustrated, there would be a difference of 8 degrees between the condylar inclination at an open position (where the articulator settings are adjusted) and the closed position at which the articulator is used.

Arcon and Nonarcon Articulators

There are two basic designs used in the fabrication of articulators: arcon and nonarcon. On an arcon articulator, the condylar elements are placed on the lower member of the articulator, just as the condyles are located on the mandible. The mechanical fossae are placed on the upper member of the articulator, simulating the position of the glenoid fossae in the skull. In the case of the nonarcon articulator, the condylar paths simulating the glenoid fossae are attached to the lower member of the instrument, while the condylar elements are placed on the upper portion of the articulator.

To set the condylar inclinations on a semi-adjustable instrument, wax wafers called *interocclusal records* are used to transfer the terminal positions of the condyles from the skull to the instrument (see chapter 4 for the technique). These wafers are 3.0 to 5.0 mm thick so that the teeth on the maxillary and mandibular casts are separated by that distance when the condylar inclinations are set.

When the wafers are removed from an arcon articulator and the teeth are closed together, the condylar inclination will remain the same. However, when the teeth are closed on a nonarcon articulator, the inclination changes, becoming less steep (Fig 3-7). Arcon articulators have become more widely used because of their accuracy and the ease with which they disassemble to facilitate the occlusal waxing required for cast gold restorations. However, this very

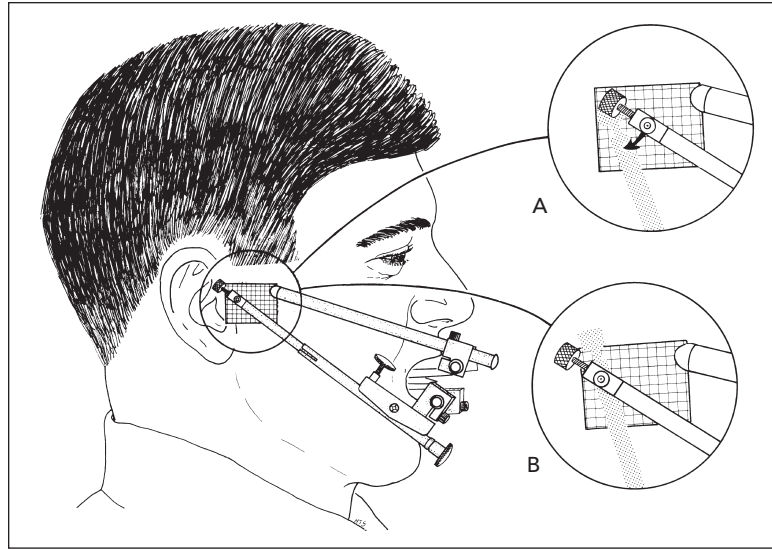


Fig 3-8 After the THA locator is placed, the patient is assisted in opening and closing on the THA. An arcing movement of the stylus on the side arm (A) indicates that it is not located over the THA. The side arm is adjusted so the stylus will rotate without moving during opening and closing (B). This indicates that it has been positioned over the THA.

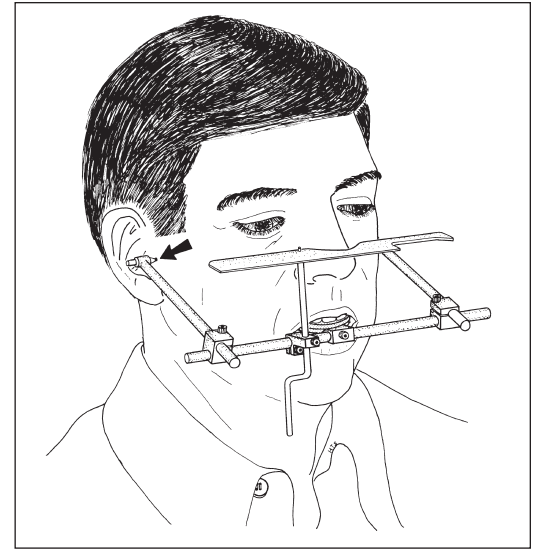


Fig 3-9 When a precision facebow transfer is made, both side arms are adjusted so that the stylus at the end of each arm is located over the THA (arrow). A third reference point, such as the plane indicator shown here, is used.

feature makes them unpopular for arranging denture teeth. The centric position is less easily maintained when the occlusion of all of the posterior teeth is being manipulated. Therefore, the nonarcon instrument has been more popular for the fabrication of dentures. Arcon articulators equipped with firm centric latches that prevent posterior separation will overcome many of these objections.

Tooth–Transverse Horizontal Axis Relationship

To achieve the highest possible degree of accuracy from an articulator, the casts mounted on it should be closing around an axis of rotation that is as close as possible to the THA (hinge) of the patient's mandible. This axis is an important reference because it is repeatable. It is necessary to transfer the relationship of the maxillary teeth, the THA, and a third reference point from the patient's skull to the articulating device. This is accomplished with a *facebow*, an instrument that records those spatial relationships and is then used for the attachment of the maxillary casts to the articulator.

The more precisely located the THA, the more accurate the transfer and the mounting of the casts will be. The most accurate way to determine the hinge axis is by the "trial and error" method developed by McCollum and Stuart in 1921.⁵ A device with horizontal arms extending to the region of the ears is fixed to the mandibular teeth. A grid is placed under the pin at the end of the arm, just anterior to the tragus of the

ear. The mandible is manipulated so that the condyles are in the optimum position in the mandibular fossae with the articular discs properly interposed, from which it is guided to open and close 10 mm. As it does, the pin will trace an arc (Fig 3-8). The arm is adjusted in small increments to move it up, down, forward, or back, until the pin simply rotates without tracing an arc. This is the location of the hinge axis, which is marked with ink on the patient's face.

The facebow is attached to the maxillary teeth, and the side arms are adjusted so that the pin at the free (posterior) end of each side arm will touch the hinge axis mark on its respective side of the face (Fig 3-9). A third reference point is selected on the face and recorded by adjusting a pointer on the facebow. The facebow is removed from the patient and transferred to the articulator. The reference pins on the facebow are placed over the axis of rotation on the articulator condyles. With the anterior reference device providing the vertical orientation of the facebow, it can then be used to accurately mount the maxillary cast on the articulator. This technique is most commonly used for facebow transfers to fully adjustable articulators.

A facebow that employs an approximate location of the hinge axis based on an anatomical average can also be used. This technique should provide enough accuracy for the restoration of most mouths, if the occlusal vertical dimension is not to be altered to any significant extent. An error of 5.0 mm in the location of the THA will produce a negligible antero-posterior mandibular displacement of approximately 0.2 mm when a 3.0-mm centric relation record is removed to close the articulator.⁴

3 Articulators

Table 3-1 Accuracy of arbitrary hinge axis points*

Measurements and landmarks for arbitrary hinge axis points	Arbitrary points within 6 mm of kinematic hinge axis points (%)	Investigator(s)
13 mm from posterior margin of tragus to canthus	98.0 92.1 58.3	Schallhorn ⁷ Beyron ⁸ Beck ⁹
13 mm in front of anterior margin of meatus	16.7 40.0	Beck ⁹ Lauritzen and Bodner ¹⁰
13 mm from foot of tragus to canthus	33.0	Teteruck and Lundeen ¹²
10 mm anterior to center of external auditory meatus and 7 mm below Frankfort plane	83.3	Beck ⁹
Ear axis	75.5	Teteruck and Lundeen ¹²

*Data from Whitsett et al.¹⁵




Fig 3-10 Three caliper-style facebows among those in use at the present time: (a) QuickMount (Whip Mix); (b) Denar Slidematic (Whip Mix); (c) Hanau Spring-Bow (Whip Mix).

There are numerous techniques used for arbitrarily locating the hinge axis to serve as the set of posterior reference points for a facebow.⁶⁻¹⁴ A comparison of the accuracy of arbitrary and kinematically located hinge axis points is shown in Table 3-1.

Facebows must have acceptable accuracy and be simple to apply or they will not be used routinely. Caliper-style ear

facebows possess a relatively high degree of accuracy, with 75% of the axes located by it falling within 6 mm of the true hinge axis.¹² There are several caliper-style facebows (Fig 3-10). They are designed to be self-centering so that little time is wasted in centering the bite fork and adjusting individual side arms. The technique for their use is described in chapter 4.

Fig 3-11 An air-activated pantograph for recording mandibular movements.

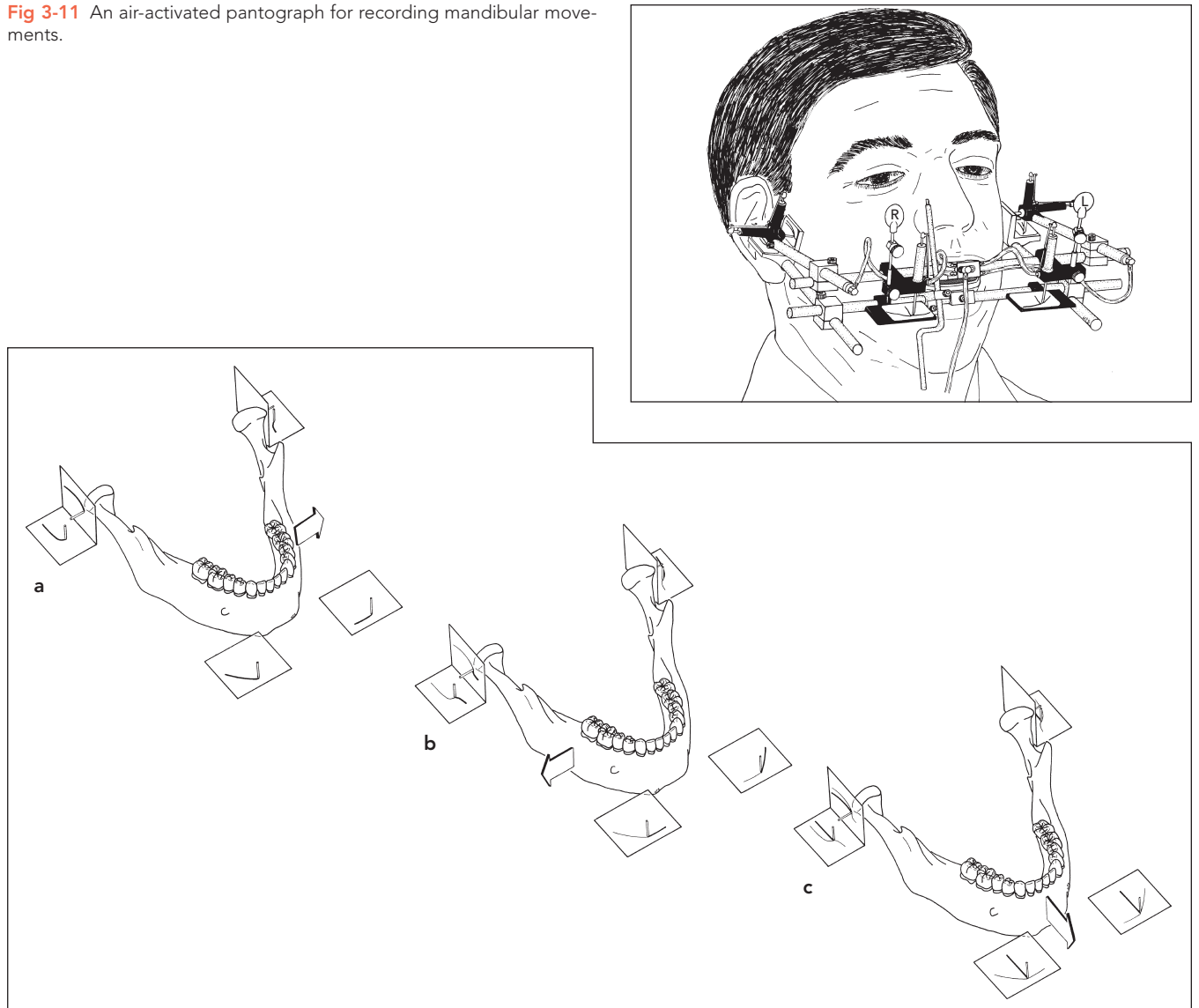


Fig 3-12 Tracings are shown for a pantograph in which all recording tables are attached to the mandible and all styli are attached to the maxilla. Styli are shown in their initial positions. (a) Left lateral excursion; (b) right lateral excursion; (c) protrusive excursion.

Registration of Condylar Movements

To faithfully simulate the condylar movement on an articulator, it is necessary to obtain a precise tracing of the paths followed by the condyle. This can be achieved most accurately by means of a pantographic recording, which will capture all of the characteristics of the mandibular border movement from its optimum position to its most forward and most lateral positions.

The pantograph consists of two facebows. One is affixed to the maxilla and the other to the mandible, using clutches that attach to the teeth in the respective arches. Recording

styli are attached to the one member, and small tables upon which the tracings are made are attached to the other member of the instrument, opposite the styli. There are both horizontal and vertical posterior tables attached in the vicinity of the hinge axis on each side of the pantograph. There are also two tables attached to the anterior member of the bow, one on either side of the midline (Fig 3-11).

The mandible goes through a series of right and left lateral, as well as protrusive, excursions. The styli on one facebow scribe on the recording tables the paths followed by the condyles in each movement (Fig 3-12). When the pantograph is attached to the articulator, various adjustments are made until the movements of the articulator will follow the same paths scribed on the tracings during mandibular excursions.

3 Articulators

The pantographic tracing can only be utilized to full advantage when used with a fully adjustable articulator. To adjust the settings of a semi-adjustable articulator, wax interocclusal records are used. The patient closes into a heat-softened wax wafer in a right lateral protrusive position and maintains that posture until the wax has hardened. The procedure is repeated with another wax wafer for a left lateral protrusive position. The wax wafers are then placed, first one and then the other, on the articulated casts. After the right lateral wafer is used to adjust the condylar inclination for the left condyle, the left lateral wafer is used to adjust the right condylar inclination. Complete details of the technique are described in chapter 4.

Advances in electronics and computers have brought about the introduction of new electronic pantographs that determine the condylar settings of the articulator. One type of electronic pantograph is similar to a traditional pantograph, with the styli and recording tables replaced by electronic senders and receivers. Another type utilizes a sender unit located at the end of a bite fork that is attached to the mandibular teeth. A receiver unit is suspended from a face-bow mechanism directly above it. With both types of instruments, as the patient moves the mandible through the border movements, information is recorded and displayed on a small computer. This information can then be used to adjust the condylar settings on a fully adjustable or semi-adjustable articulator.

References

1. Posselt U. Physiology of Occlusion and Rehabilitation, ed 2. Oxford: Blackwell Scientific, 1968:55.
2. Hobo S, Shillingburg HT Jr, Whitsett LD. Articulator selection for restorative dentistry. *J Prosthet Dent* 1976;36:35–43.
3. Hodge LC, Mahan PE. A study of mandibular movement from centric occlusion to maximum intercuspation. *J Prosthet Dent* 1967;18:19–30.
4. Weinberg LA. An evaluation of the face-bow mounting. *J Prosthet Dent* 1961;11:32–42.
5. McCollum BB, Stuart CE. Gnathology—A Research Report. South Pasadena, CA: Scientific Press, 1955:39.
6. Kornfeld M. Mouth Rehabilitation: Clinical and Laboratory Procedures, ed 2. St Louis: Mosby, 1974:48,336.
7. Schallhorn RG. A study of the arbitrary center and the kinematic center of rotation for face-bow mountings. *J Prosthet Dent* 1957;7:162–169.
8. Beyron H. Orienteringsproblem vid protetiska rekonstruktioner och bettstudier. *Sven Tandlak Tidskr* 1942;35:1–55.
9. Beck HO. A clinical evaluation of the arcon concept of articulation. *J Prosthet Dent* 1959;9:409–421.
10. Lauritzen AG, Bodner GH. Variations in location of arbitrary and true hinge axis points. *J Prosthet Dent* 1961;11:224–229.
11. Gysi A. The problem of articulation. *Dent Cosmos* 1910;52:1–19.
12. Teteruck WR, Lundeen HC. The accuracy of an ear face-bow. *J Prosthet Dent* 1966;16:1039–1046.
13. Bergstrom G. On the reproduction of dental articulation by means of articulators—A kinematic investigation. *Acta Odontol Scand Suppl* 1950;9(suppl 4):1–131.
14. Guichet NF. Procedures for Occlusal Treatment—A Teaching Atlas. Anaheim, CA: Denar, 1969:35.
15. Whitsett LD, Shillingburg HT Jr, Keenan MP. Modifications of a new semi-adjustable articulator for use with a caliper style ear face-bow. *J Calif Dent Assoc* 1977;5(4):32–38.

Interocclusal Records

After the maxillary cast has been accurately affixed to the articulator using a facebow, the mandibular cast must be oriented to the maxillary cast with equal exactitude to be able to diagnose the patient's occlusion.^{1,2} Centric relation records are used to replicate, on the articulator, the relationship between the maxillary and mandibular arches that exists when the condyles are in their most anterosuperior position in the glenoid fossae. Lateral interocclusal records are used to adjust the condylar guidance of the articulator. Then, it is possible to observe tooth relationships and identify deflective contacts and/or other occlusal discrepancies from the casts on the articulator. When this information has been gathered and assessed, a determination can be made as to what corrective measures, if any, will be performed on the occlusion.

A distinction must be made between mounting for diagnosis and mounting for treatment. The attachment of casts to an articulator for diagnosis will be done with the condyles in a centric relation position. When casts are articulated for restoration of a significant portion of the occlusion, it also may be done with the condyles in the centric relation position. However, the beginning operator usually restores only limited segments of the occlusion at one time. Mounting casts for restoration of only a small part of the occlusion generally is done with the teeth in a position of maximal intercuspation.

Centric Relation Record

To mount the mandibular cast on the articulator, it is necessary to record the relationship of the dental arches to each other. There are three techniques that are frequently used in locating the centric relation position: (1) chin point guidance, (2) bilateral manipulation, and (3) the unguided method. With a computer-assisted three-dimensional mandibular recording device, Hobo and Iwata³ analyzed condylar position achieved by the three methods. Chin point guidance puts the condyles in the most posterior and superior position, while the bilateral and unguided methods allow the muscles to guide the condyles into a physiologic anterosuperiorly braced position on the articular disc along the articular eminence.

The unguided method produces a physiologic "muscle position," but it can be difficult to achieve consistent results because of the patient's muscle activity. Muscle proprioception is minimized by separating the teeth with a leaf gauge composed of several 0.1-mm-thick plastic strips, which help to eliminate direct proprioceptor responses. While the patient occludes with light pressure, strips are added one at a time in the anterior region until the patient no longer feels any posterior tooth contact. This permits the muscles to act freely and allows the condyles to move into a physiologic position.^{4,5} Then the muscles will rotate the mandible anteriorly and superiorly.

Armamentarium

- Cotton rolls
- Green stick compound
- Polyvinyl siloxane registration material
- Impression material dispenser
- Laboratory knife with no. 25 blade
- 28-gauge green wax
- No. 10 red-inked silk ribbon

Technique

The most consistent, repeatable results can be accomplished using the technique of "bimanual manipulation" described by Dawson.^{6,7} The neuromuscular system monitors all sensory impulses from the teeth and jaws and programs occlusal contact to occur where the protective stimuli are minimal. This position, through repeated closures, becomes habitual and is maintained at the expense of normal muscle function.⁸ To enable the condyles to be placed in an unstrained position, the musculature must first be deprogrammed from its habitual closing pattern.

A simple means of doing this is to place a cotton roll between the anterior teeth and instruct the patient to "bite on your back teeth." It should be confirmed that there is no contact of the posterior teeth. If the cotton roll is placed as soon as the patient is seated, the operator and assistant can prepare the materials for the subsequent interocclusal record during the 5 minutes that the patient's jaws remain

4 Interocclusal Records

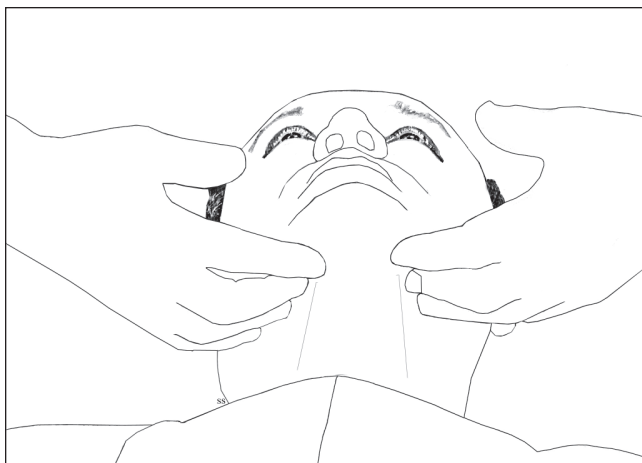

Fig 4-1 The fingers are placed along the inferior border of the mandible.

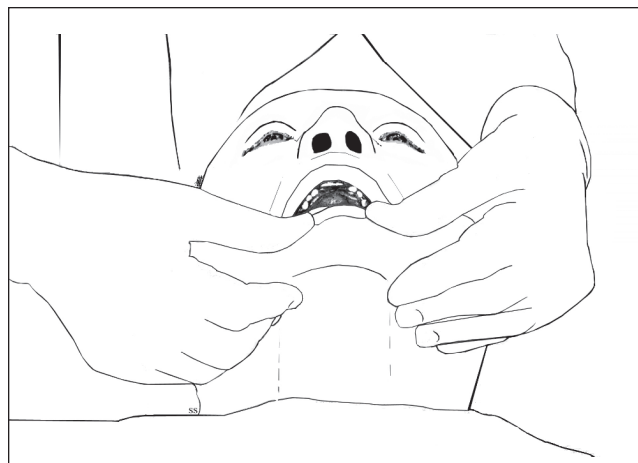


Fig 4-2 With the thumbs in position, the mandible is manipulated into a centric relation position.

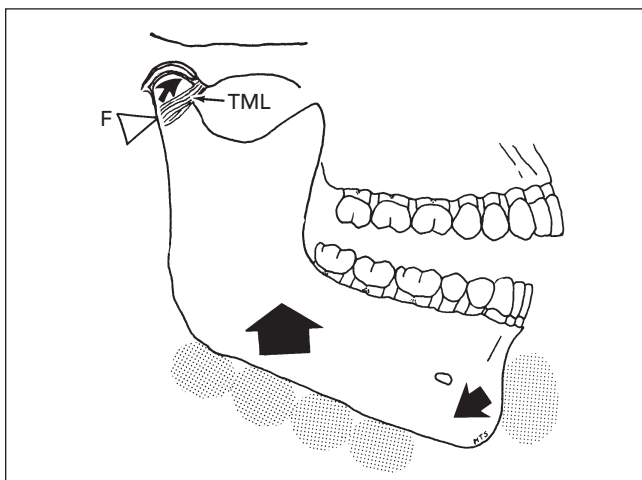


Fig 4-3 The temporomandibular ligament (TML) acts as the posterior limit and fulcrum (F). The downward force of the thumbs and upward force of the fingers help to seat the condyles in the postero-superior portion of the glenoid fossa. (Modified from Dawson⁷ with permission.)

closed. After this time, the “memory” of the position in which the teeth intercusate fully will likely have been lost, and the mandible can be manipulated more easily into its optimum position. As soon as the cotton roll has been removed, mandibular manipulation should be initiated. The patient should not be allowed to close the teeth together again, as this will permit the musculature to readapt to a tooth-guided closure.

The patient should be seated with the chair back approximately 45 degrees from the floor. The patient's head should be tilted back with the chin up so that the face is parallel with the floor. This position tends to keep the patient from protruding the mandible. The dentist should take a position behind the patient that will facilitate stabilization of the patient's head between the dentist's rib cage and forearm. The patient's head must not move while the mandible is being manipulated. All four fingers of each hand should be placed

on the lower border of the mandible, making sure that the fingertips are in direct contact with bone (Fig 4-1).

The thumbs should be placed lightly over the mandibular symphysis so that they touch each other at the midline. The patient is instructed to open approximately 35 mm and then asked to relax the jaw as the dentist closes it, guiding the mandible posteriorly into a terminal hinge relationship with a gentle motion (Fig 4-2). Observation of the patient's mandible will demonstrate that it shifts posteriorly with this gentle motion.

When the mandible has “dropped back,” firm pressure is applied to seat the condyles anterosuperiorly in the glenoid fossae (centric relation). An upward-lifting force is applied on the inferior border of the mandible by the fingers of each hand while a downward force is applied to the symphysis by the thumbs (Fig 4-3). With firm seating pressure, the dentist should once again open and close the mandible in small in-

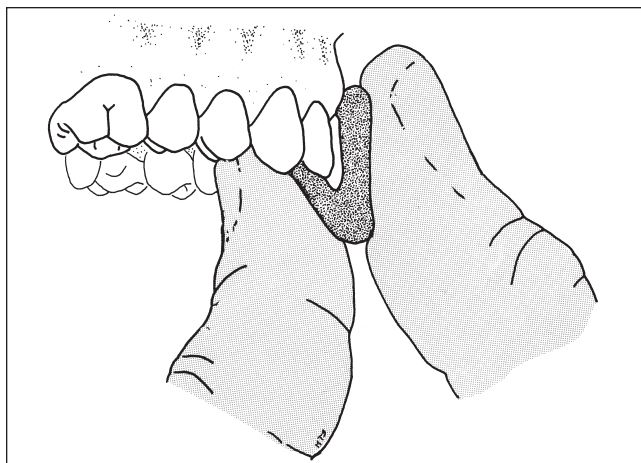


Fig 4-4 Green stick compound is molded to form the anterior programming device.

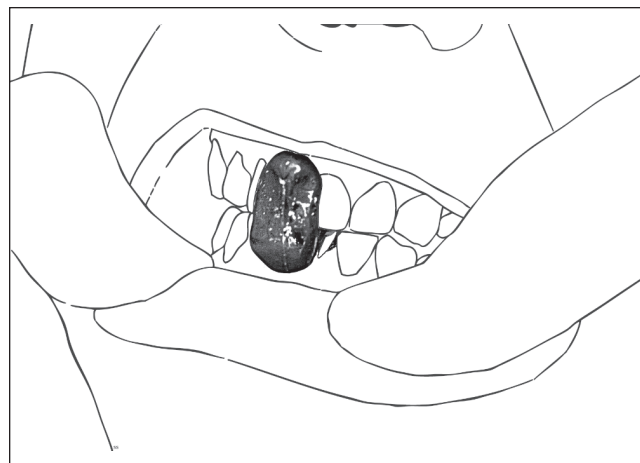


Fig 4-5 The patient is guided into centric relation to complete formation of the anterior programming device.

crements of 2.0 to 5.0 mm while gradually closing the mandible to the point of first tooth contact. The mandible should not be allowed to deviate from this arc while closing. This position of initial tooth contact with the mandible in the optimum position is the centric relation contact position (CRCP).

A piece of 28-gauge green wax is lightly adapted over both quadrants of the maxillary teeth, and the mandible is again manipulated into centric relation. At this position, the teeth are tapped together lightly until perforations are made in the wax at CRCP. The wax is removed and stored in a cup of cool water. This is used in the articulation of casts in chapter 5.

An anterior programming device, or *jig*, is made to establish a predetermined stop to vertical closure with the condyles in optimum position. The absence of deflecting incline tooth contact allows muscle function to be reprogrammed to eliminate the adaptive arc of closure. A 2.5-cm (1.0-inch) length of green stick compound is softened in hot tap water and bent into a J. The compound is placed over the midline between the two maxillary central incisors, with the short leg of the J on the facial surface, extending approximately halfway between the incisal edge and the gingiva. While the compound is still quite soft, it should be quickly adapted to the maxillary teeth using the following three-step procedure:

1. The facial portion of the compound should be firmly adapted into the labial embrasure with the thumb while the compound is thinned out to an approximate thickness of 2.0 mm.
2. Both thumbs should be placed on the facial and both index fingers on the lingual, with approximately 6.0 mm (1/4 inch) of space between the tips. The compound should be molded to the lingual surface by squeezing tightly (Fig 4-4).
3. While the finger posture and pressure in step 2 are maintained, the fingertips should be pushed closer together to form a spine of compound at approximately the mid-

line. (The entire process described should take no more than a few seconds, and the compound should still be soft enough to mold further as the patient's mandible is closed into it.)

While the compound is still soft, the mandibular positioning previously rehearsed should be repeated, guiding the patient into a centric relation position while arcing the mandible closed until the mandibular incisors have made an indentation in the compound and the posterior teeth are 1.0 mm out of contact (Fig 4-5). The compound is cooled, and the accuracy of the programming device is confirmed. There are two important points to be checked at this time:

1. The condyles are in the optimum position in their fossae, confirmed by lightly tapping the mandibular incisors into the compound. The patient should close precisely into the programming device with no deflection.
2. The patient must not be closed to the point of contact between the maxillary and mandibular teeth. The mandibular teeth should make contact only with the compound programming device and be no closer than 1.0 mm to the maxillary teeth at any location in the arch.

If the patient's posture is maintained with the chair back and the chin up, the face will be parallel with the floor, and a well-adapted compound programming device should stay firmly in place. If necessary, it can be held in place by the patient, using his or her index finger (Fig 4-6). It need not be removed until the centric relation registration has been completed.

With the programming device in the mouth, the twin-barrel cartridge of bite registration material (eg, Stat BR, Kerr; Regisil PB, Dentsply Caulk) should be placed in the impression material dispenser and a new tip locked on (Fig 4-7). The registration material is then mixed by expressing it from the dispenser with steady pressure on the trigger.

4 Interocclusal Records

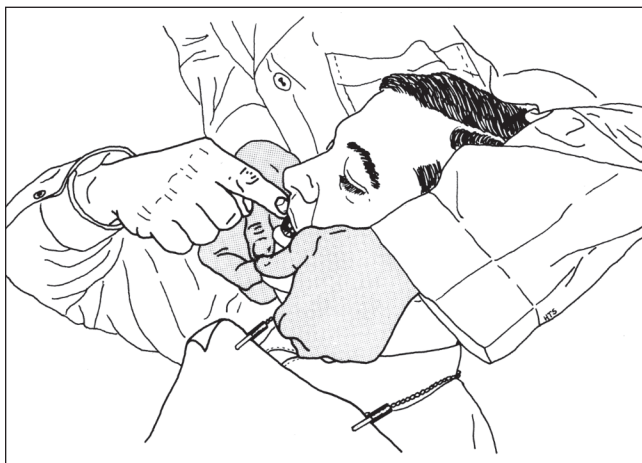


Fig 4-6 The patient holds the programming device in position while the operator manipulates the mandible.

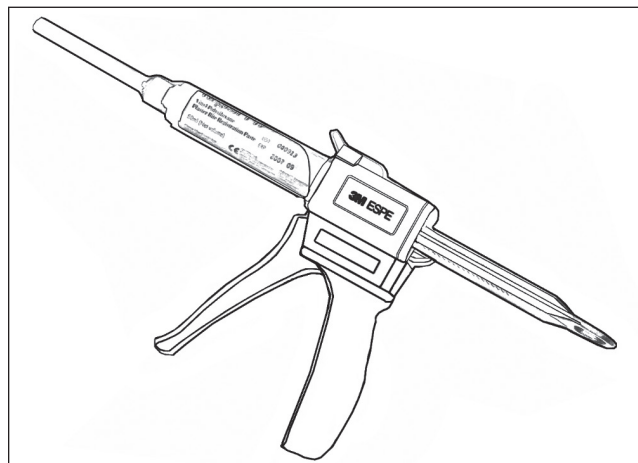


Fig 4-7 The cartridge of bite registration material is placed in the impression material dispenser with a new tip.

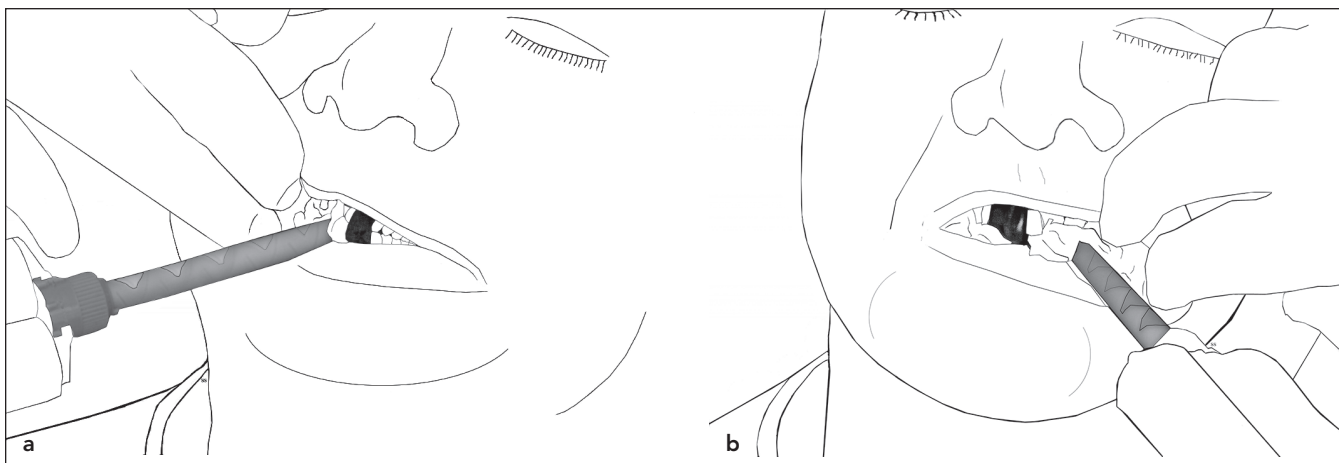


Fig 4-8 Registration material is injected between the teeth on the right (a) and left (b) sides.

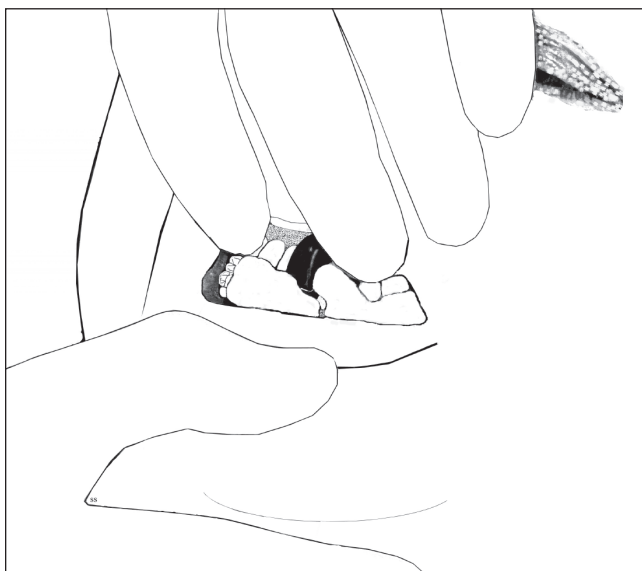


Fig 4-9 The patient is assisted in opening the mouth.

The registration material should be injected between the teeth on both sides of the arch and allowed to harden (Fig 4-8). When the registration material has set, the patient is assisted in opening the mouth (Fig 4-9). The bite registrations are removed from each side of the mouth (Fig 4-10) and rinsed with running water. The programming device is also removed at this time. A sharp laboratory knife is used to remove excess registration material that extends gingivally beyond the occlusal one-third of the tooth (Fig 4-11). Both the maxillary and mandibular sides of the registrations are trimmed, leaving only the cusp tips of the teeth. The registrations are then trimmed on the facial and lingual sides. The lingual aspect is trimmed, leaving the entire cusp tip indentation in place (Fig 4-12). The facial aspect is trimmed through the facial cusp tips (Fig 4-13). Trimming through the facial cusp tips allows complete seating of the registration to be visualized on the maxillary and mandibular casts (Fig 4-14). The registration is then rinsed with a hospital-grade disinfectant and placed in an unsealed sterilization bag until ready to be used.

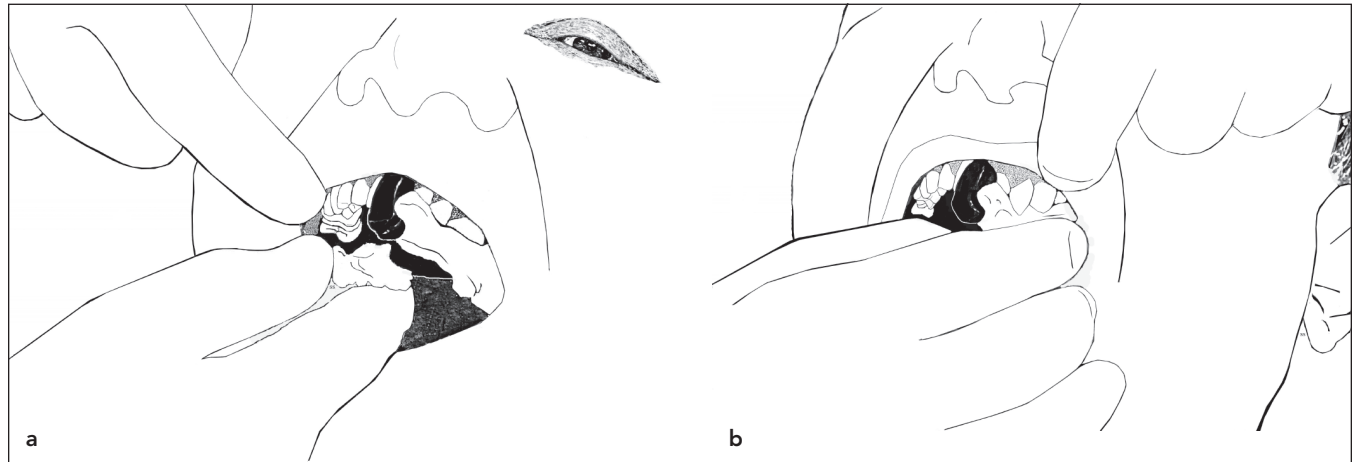


Fig 4-10 The registrations are removed from the right (a) and left (b) sides of the mouth.

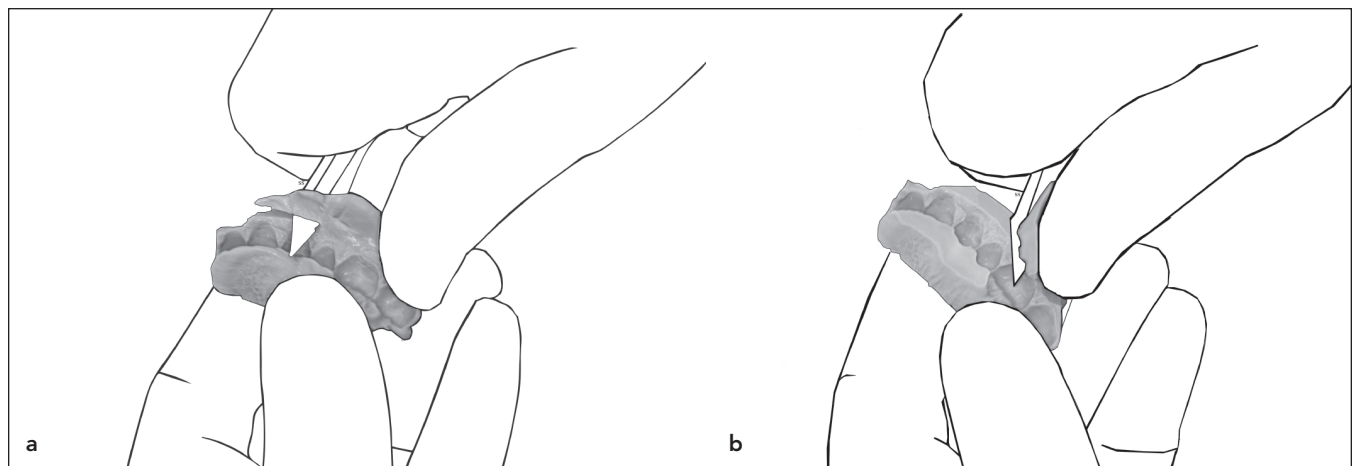


Fig 4-11 (a and b) Registration material extending gingival to the occlusal one-third of the teeth is removed.

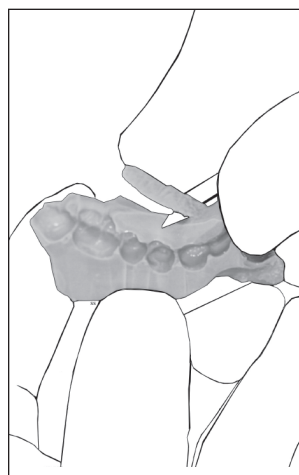


Fig 4-12 Registration material is removed from the lingual aspect of the registration.

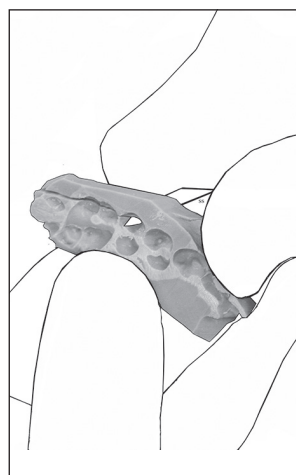


Fig 4-13 Registration material is removed from the facial aspect of the registration by cutting along a line through the facial cusp tips.

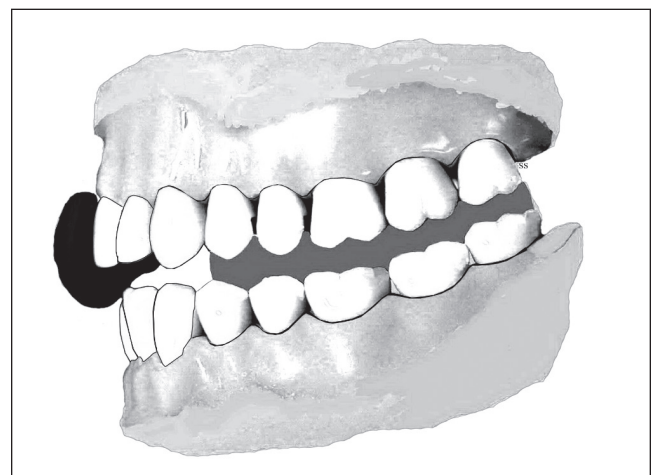


Fig 4-14 The registration is checked to determine if the teeth seat fully in the registration.

4 Interocclusal Records

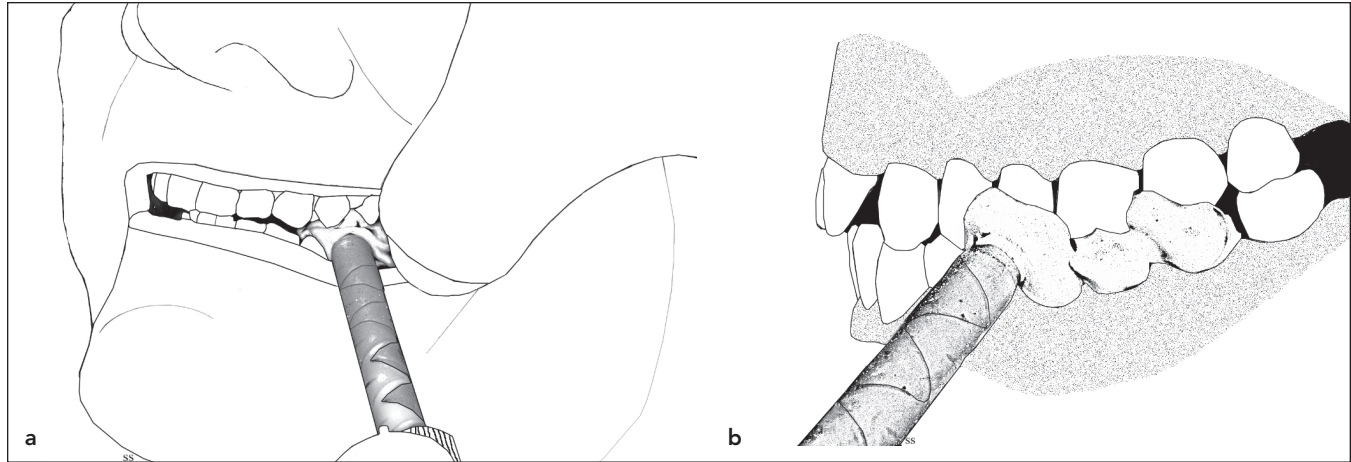


Fig 4-15 (a and b) Registration material is injected between the prepared teeth and the opposing arch.

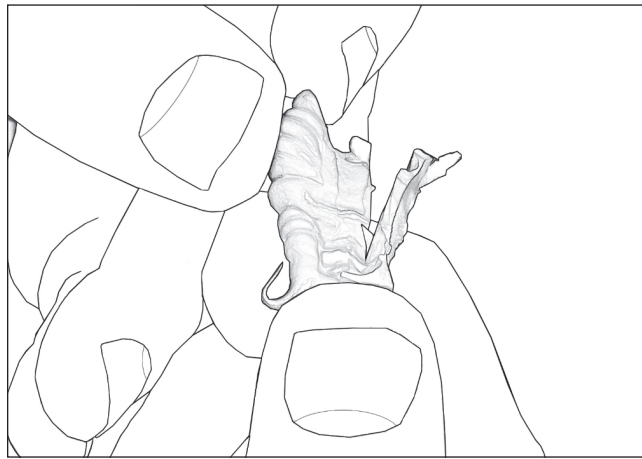


Fig 4-16 The excess material is removed from the facial and lingual aspects of the registration.

Maximal Intercuspal Record

Although diagnostic mountings are done with the condyles in a centric relation position, casts that are to be used for the fabrication of restorations for a small portion of the occlusion are attached to the articulator in a position of maximal intercuspation. Mounting them in a centric relation position could result in a restoration with a built-in interference.

Armamentarium

- Polyvinyl siloxane registration material
- Impression material dispenser
- Laboratory knife with no. 25 blade

Technique

The technique employed to index the intercuspal position for restoration fabrication produces an interocclusal record with the maxillary and mandibular teeth in full contact.

An impression gun is assembled in the same manner as when obtaining a centric relation record with registration material (see Fig 4-7). With the patient's mouth slightly open, material is injected between the prepared teeth and the opposing arch (Fig 4-15). The patient is instructed to close firmly until all posterior teeth are contacting normally. The dentist parts the lips and verifies that the patient has not closed in a protrusive or working relationship. The patient is instructed to keep the teeth together until asked to open. The record is left in place until the material has hardened. The bite registration is removed from the mouth and rinsed under running tap water. It should be inspected to ensure that all of the necessary teeth have been captured. A laboratory knife with a no. 25 blade is used to cut off all excess material on the facial and lingual sides of the prepared teeth (Fig 4-16). Any material that extends over the unprepared teeth adjacent to the preparations should be removed.

Excess thickness is removed from the upper and lower surfaces of the record (Fig 4-17). On the unprepared teeth opposing the preparation(s), enough material should be removed so that little more than the cusp tip indentations remain. Any material that reproduces edentulous ridges, gingival crevices, or the central fossae of the opposing occlusal

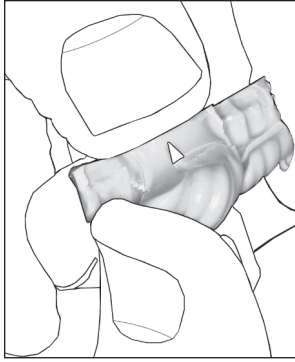


Fig 4-17 The excess thickness from the upper and lower surfaces of the record are removed.

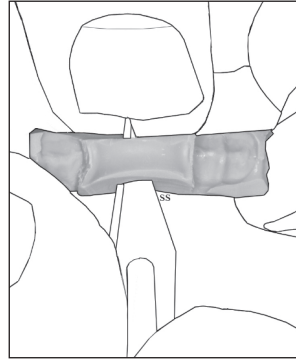


Fig 4-18 All material contacting soft tissue or the central fossae of the opposing occlusal surfaces is removed.

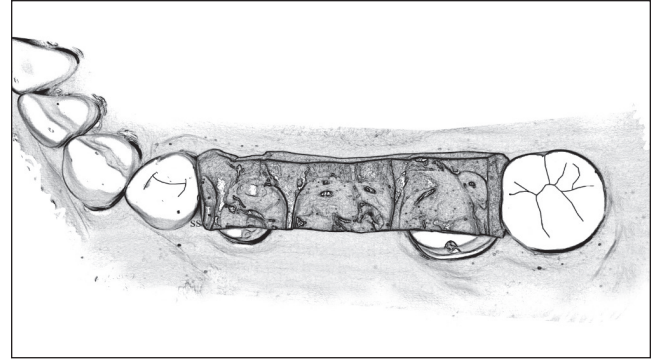


Fig 4-19 The registration is trimmed along the facial cusps to verify complete seating of the record.

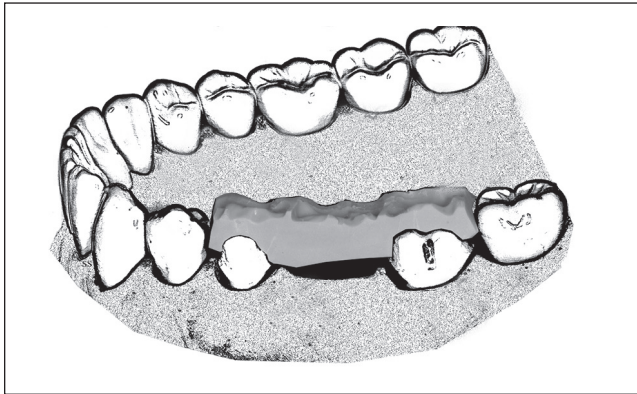


Fig 4-20 The record is placed on the mandibular cast, and complete seating is confirmed.

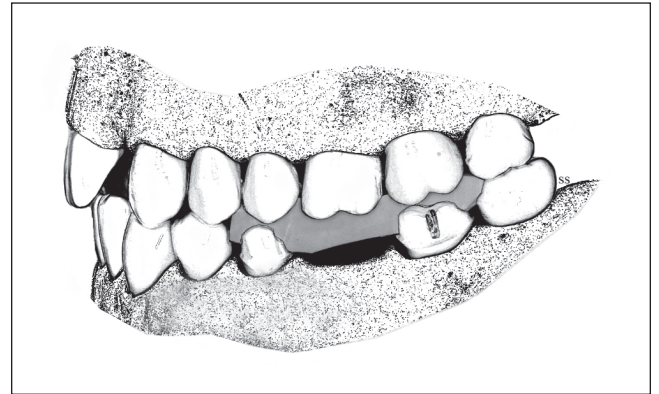


Fig 4-21 The maxillary cast is placed in the completed record and articulated with the mandibular cast.

surfaces is likely to produce incomplete seating of a cast with imperfections in those areas, so it is important to eliminate it (Fig 4-18). The overall thickness of the record should be approximately 4.0 mm, with an equal amount having been removed from its upper and lower aspects.

To verify seating of the casts into the record, its thickness along the facial cusps of the mandibular teeth is cut through completely using a laboratory knife with a no. 25 blade (Fig 4-19). The registration is then rinsed with a hospital-grade disinfectant before proceeding.

The record is set on the mandibular cast, and its complete seating is verified (Fig 4-20). The teeth of the maxillary cast are placed completely into the index while the teeth on the opposite side of the arch and those near the preparation(s) are articulated (Fig 4-21). The record is used to articulate the casts, and the mandibular cast is mounted on the articulator (Fig 4-22).

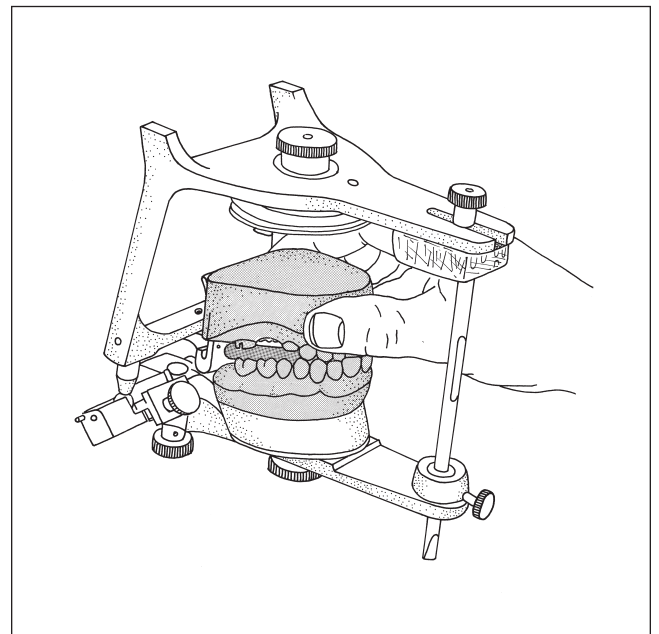


Fig 4-22 The mandibular cast is mounted on the articulator using the record.

4 Interocclusal Records

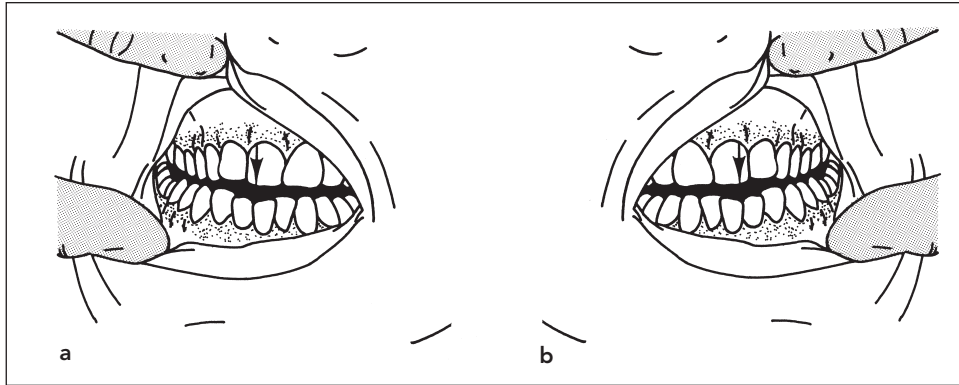


Fig 4-23 The patient is guided into working excursions on the right (a) and left (b) sides.

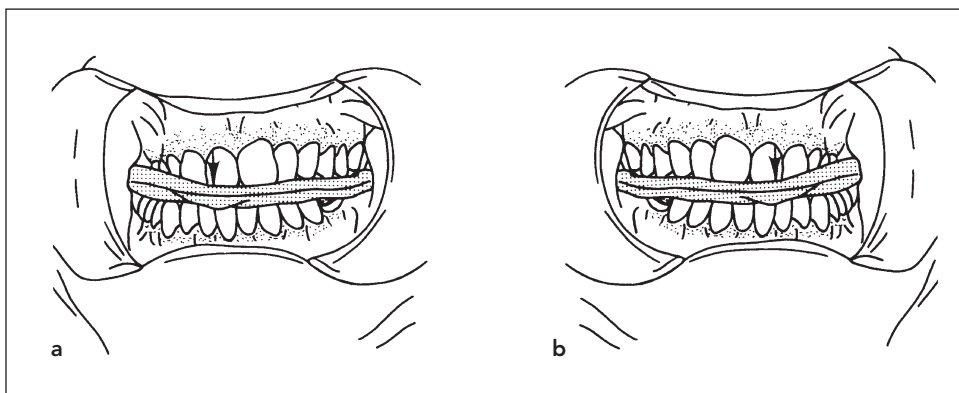


Fig 4-24 Right (a) and left (b) lateral interocclusal records are made in wax wafers.

Lateral Interocclusal Record

Lateral interocclusal records are made in the mouth for the purpose of capturing the position of the condyles in their respective fossae. These records are then used to set the condylar guides to approximate the anatomical limits of the temporomandibular joints (TMJs). This allows the maximum benefit from using an articulator, facilitating the fabrication of accurate restorations with minimal time required for intra-oral adjustment when the restoration is cemented.

Because the configuration of the TMJs has a strong determining influence on the movements of the mandible, the occlusal morphology of any restoration placed in the mouth must be in harmony with the movements of the mandible to prevent the initiation of occlusal disharmony and trauma. Cusp placement, cusp height, groove direction, and groove depth are all features ultimately affected by TMJ configuration.⁹

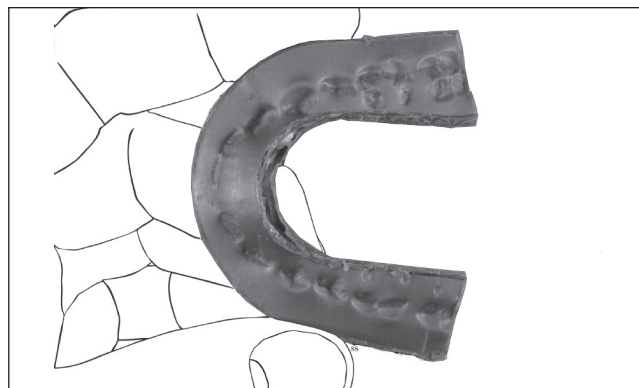
Armamentarium

- Laboratory knife with no. 25 blade
- Horseshoe wax wafers
- Plaster bowl

Technique

The patient is guided into a CRCP closure, and the position of the mandibular midline in relation to the maxillary teeth is visually noted. The points on the maxillary teeth that would be opposite the mandibular midline if the patient moves the mandible 5.0 mm in both a right and left lateral excursion are measured and marked with a pencil (Fig 4-23). With a hand on the patient's chin, the dentist asks the patient to open slightly. The dentist then guides the mandible approximately 5.0 mm to the right and closes it until the teeth lightly touch. The dentist explains that this procedure will

Fig 4-25 The lateral interocclusal record has been trimmed before use.



be repeated with some wax between the teeth and that the patient should bite down carefully until told to stop.

A slightly warmed wax wafer (Surgident Coprwax Bite Wafer, Heraeus Kulzer) is placed against the maxillary teeth approximately 4.0 mm to the right of center. Using one hand to support the wax, the dentist guides the mandible to the right. The closure practiced previously is repeated until the teeth make indentations in the wax approximately 1.0 mm deep (Fig 4-24). The wax wafer is cooled with compressed air, removed from the mouth, and placed in a plaster bowl of cold tap water. The steps are repeated with a second wax wafer on the left side. After the wax wafer has cooled, a sharp laboratory knife is used to carefully cut off any of the wax that extends distal to the marginal ridge of the most posterior mandibular tooth on both sides of the wafer (Fig 4-25). This ensures that the wax wafer will completely seat on the mandibular cast when the articulator condylar inclination is set. The bite registrations are then rinsed with a hospital-grade disinfectant and placed in an unsealed sterilization bag until ready to be used.

References

1. Lucia VO. Centric relation: Theory and practice. *J Prosthet Dent* 1960;10:849–856.
2. Lucia VO. A technique for recording centric relation. *J Prosthet Dent* 1964;14:492–505.
3. Hobo S, Iwata T. Reproducibility of mandibular centricity in three dimensions. *J Prosthet Dent* 1985;53:649–654.
4. Williamson EH, Steinke RM, Morse PK, Swift TR. Centric relation: A comparison of muscle-determined position and operator guidance. *Am J Orthod* 1980;77:133–145.
5. McHarris WH. Centric relation defined. *J Gnathol* 1986;5:5–21.
6. Dawson PE. Temporomandibular joint pain-dysfunction problems can be solved. *J Prosthet Dent* 1973;29:100–112.
7. Dawson PE. *Evaluation, Diagnosis, and Treatment of Occlusal Problems*. St Louis: Mosby, 1974:58.
8. Perry HT. Muscular changes associated with temporomandibular joint dysfunction. *J Am Dent Assoc* 1957;54:644–653.
9. Weinberg LA. Physiologic objective of reconstruction techniques. *J Prosthet Dent* 1960;10:711–724.

Articulation of Casts

5

To properly evaluate a patient's occlusion, it is mandatory that diagnostic casts be placed in an articulator in approximately the same relationship to the temporomandibular joints (TMJs) as that which exists in the patient.¹ A facebow registration is used to mount the maxillary cast on the articulator so that it is properly located both anteroposteriorly and mediolaterally.^{2,3} To be used enough to make a real contribution to the improvement of quality dentistry, a facebow and articulator that possess reasonable accuracy, are simple to assemble and use, and can be set up relatively quickly should be selected.

Information collected in an informal manufacturer's survey of the 67 North American dental schools indicated that 31 schools were using a Whip Mix articulator, 29 were using a Hanau (Whip Mix), 4 were using a Stratos (Ivoclar Vivadent), and 3 were using a Panadent. Models used varied among the schools, and some schools used one brand of articulator for one discipline and another brand for a different discipline. Each of the following sections on a facebow-articulator combination is meant to stand alone (ie, everything the reader needs to know about the use of a system is contained in that respective section). The one exception lies in the description of a mechanical anterior guide. Although similar devices are available for all three articulators, use of the mechanical anterior guide is described only for the Hanau articulator.

Whip Mix Facebow and Articulator

The technique for the QuickMount facebow with Quick Lock Toggle (Whip Mix) (Fig 5-1), an ear facebow that possesses the qualities previously described, is presented. Following that is the technique for the use of the Whip Mix 2200 series articulator, a semi-adjustable instrument. Casts mounted on one of these articulators can be transferred accurately to another instrument of the same type that has been set to the same parameters.⁴ There are many advantages to this feature, including the ability to send casts to the laboratory without sending the instrument.⁵

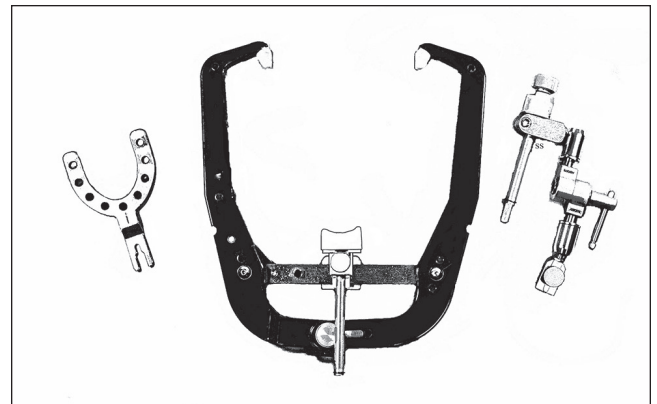


Fig 5-1 The components of a QuickMount facebow are (left to right) a bite fork, the facebow with the nasion relator, and the Quick Lock Toggle assembly.

Facebow armamentarium

- QuickMount facebow (with bite fork, nasion relator, and Quick Lock Toggle assembly)
- Whip Mix articulator
- Plaster bowl
- Spatula
- Laboratory knife with no. 25 blade
- Trimmed maxillary cast
- Horseshoe wax wafers
- Mounting stone (Whip Mix)

Facebow record technique

Two horseshoe wax wafers (Surgident Coprwax Bite Wafer, Heraeus Kulzer) are heated in warm tap water until they become soft and flexible. A wafer is adapted to each side of the bite fork so that it is uniformly covered (Fig 5-2). The wax-covered bite fork is placed against the maxillary teeth. The attachment portion of the fork is centered on the patient's midline. The bite fork is supported, and the patient is instructed to close lightly into the wax to obtain shallow

5 Articulation of Casts

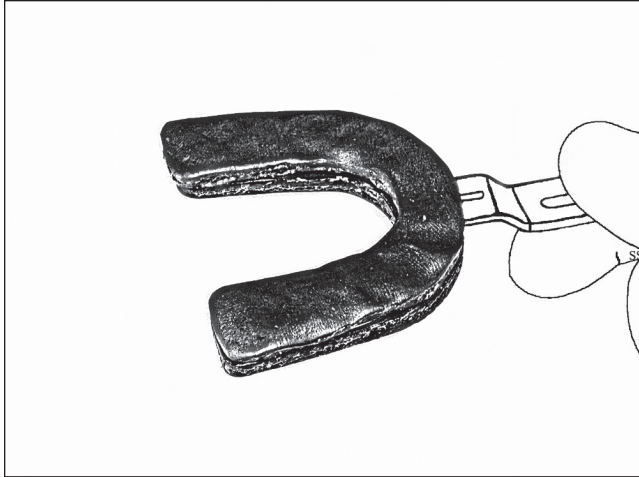


Fig 5-2 A wax wafer has been adapted to each side of the bite fork.

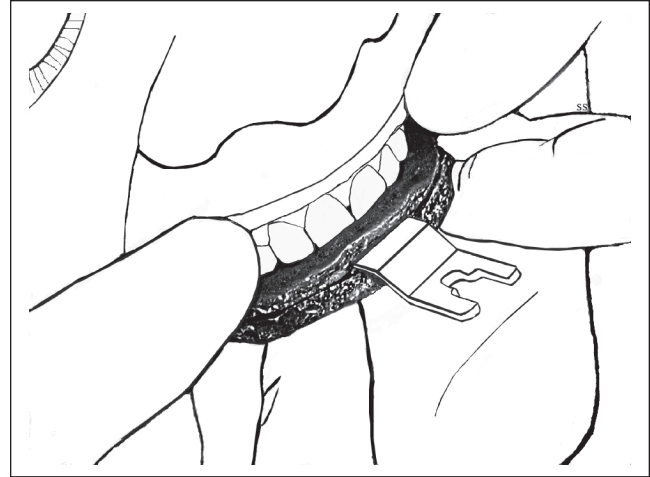


Fig 5-3 The bite fork is placed against the maxillary teeth and supported by the dentist as the patient closes lightly for a shallow impression of the cusp tips.

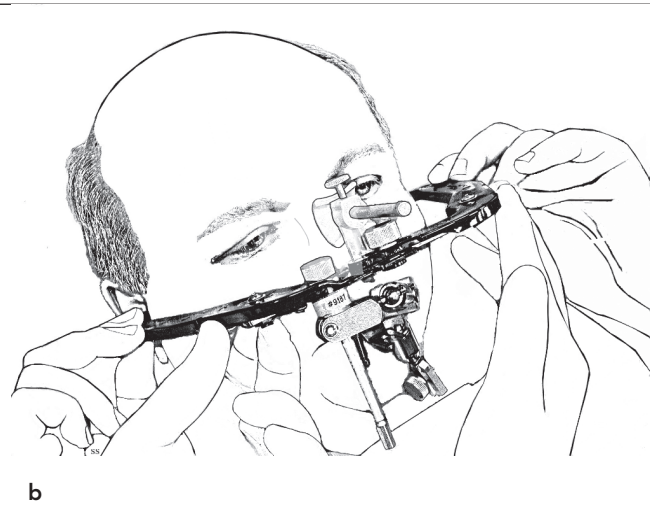
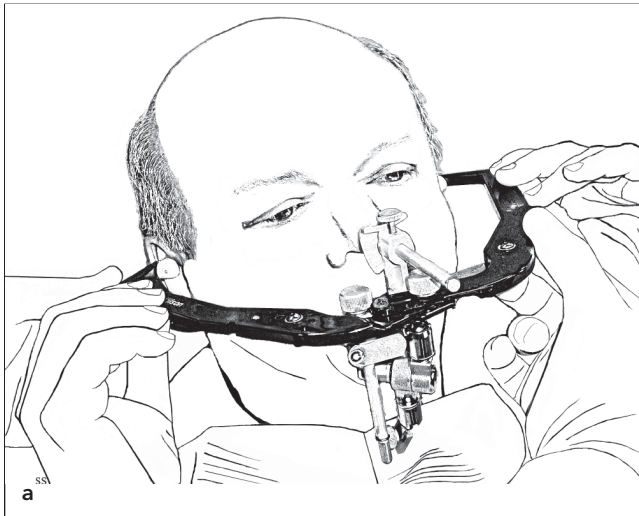


Fig 5-4 The patient guides the earpieces (a) as the dentist places them into the external auditory meati (b).

impressions of only the cusp tips (Fig 5-3). The wax is cooled, and the bite fork is removed from the mouth. Excess wax is trimmed away. Any areas where soft tissue was registered on the wax must be completely removed.

The maxillary cast is set in the bite fork registration to confirm that the cast seats firmly in the index with no rocking or instability. If the cast does not seat, first the occlusal surfaces of the cast are checked to make sure there are no nodules of stone. If there are none, then either the registration or the cast is distorted and should be remade.

The bite fork is placed back in the mouth, and the patient is instructed to close to hold it securely between the maxillary and mandibular arches. The patient is then asked to

grasp both arms of the facebow and guide the plastic earpieces into the external auditory meati, much as one would guide the earpieces of a stethoscope (Fig 5-4). The shaft of the nasion relator is extended while the facebow is adjusted up or down to center the plastic nosepiece on the patient's nasion, and the thumbscrew is tightened (Fig 5-5). Next, the thumbscrew is tightened on the top of the facebow (Fig 5-6).

The Quick Lock Toggle is slipped into the slot on the bite fork with the head of the thumbscrew facing downward, and the screw is tightened (Fig 5-7). The Quick Lock Toggle is stabilized, and the T screw is tightened (Fig 5-8). The facebow record is now complete (Fig 5-9).

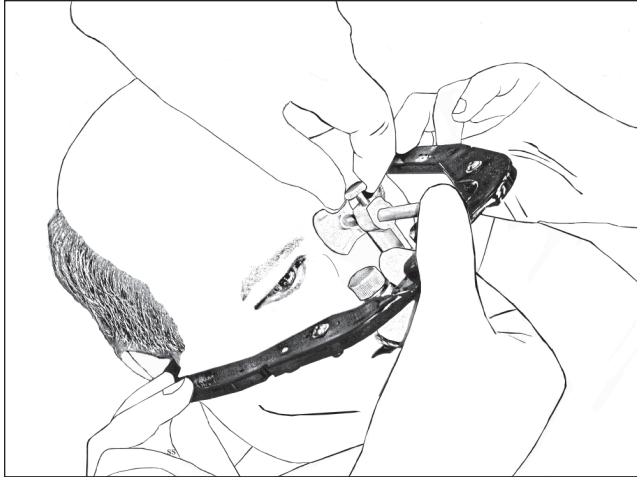


Fig 5-5 The shaft of the nasion relator is extended, and the thumbscrew is tightened.

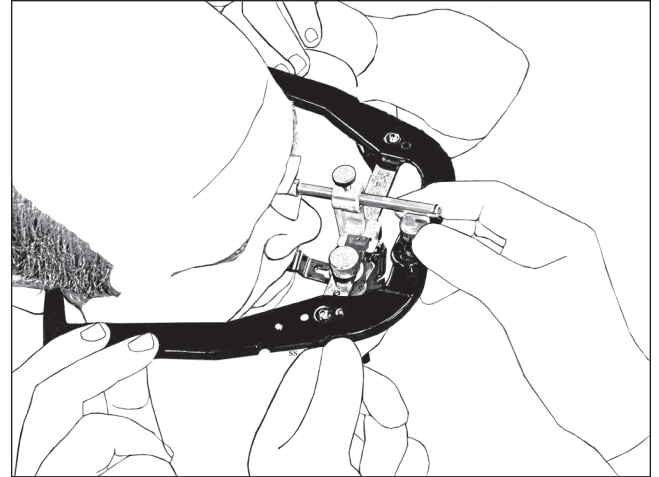


Fig 5-6 The thumbscrew on the top of the facebow is tightened.

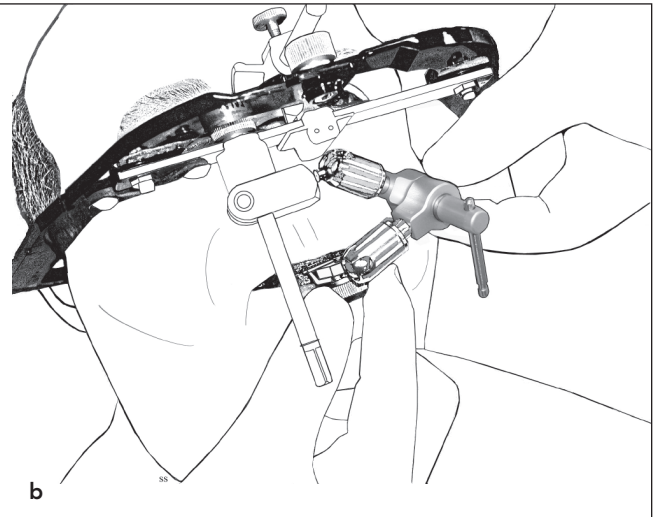
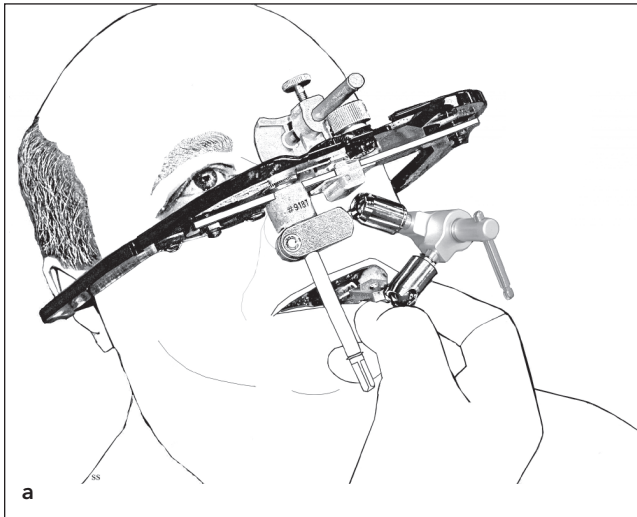


Fig 5-7 The Quick Lock Toggle is slipped into the slot on the bite fork (a), and the thumbscrew is tightened (b).

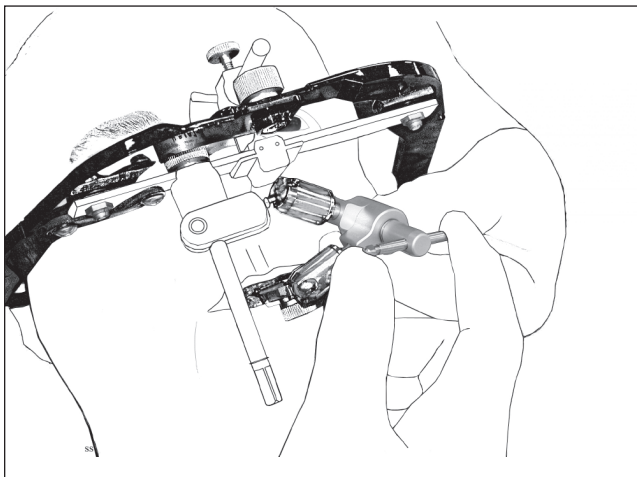


Fig 5-8 The Quick Lock Toggle is stabilized, and the T screw is tightened.

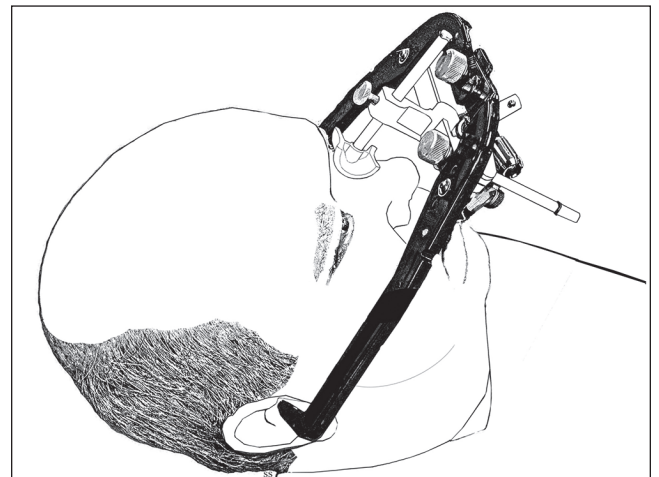


Fig 5-9 Completed facebow record.

5 Articulation of Casts

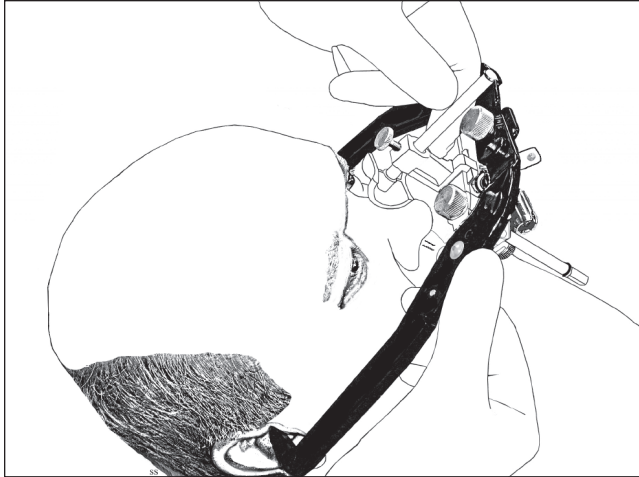

Fig 5-10 The thumbscrew is loosened, and the nasion relator is withdrawn.

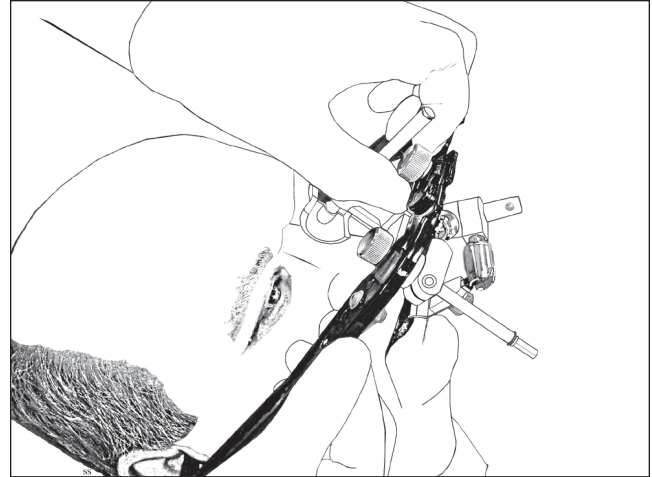


Fig 5-11 The thumbscrew on the top of the facebow is loosened.

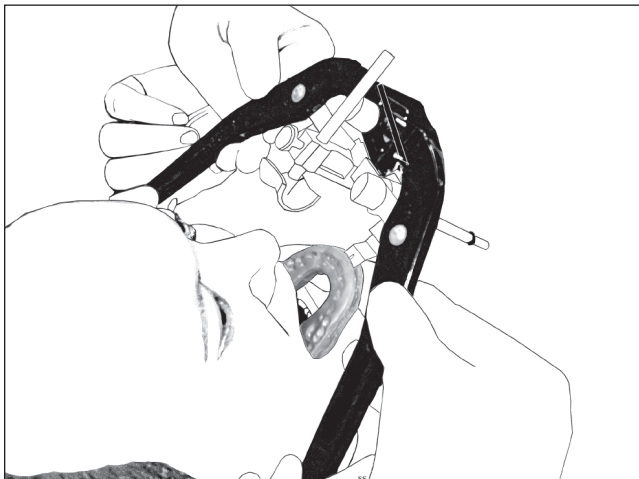


Fig 5-12 The patient is instructed to open, and the facebow record is removed.

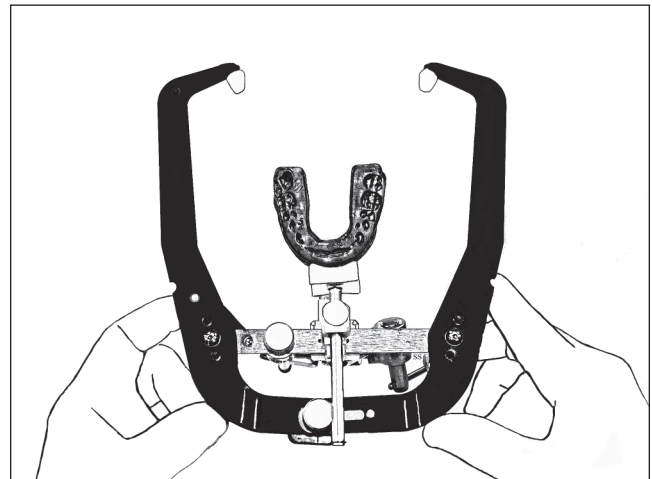


Fig 5-13 The space between the facebow and the bite fork is checked for uniformity.

The thumbscrew is loosened, and the plastic nasion relator is withdrawn (Fig 5-10). Then the thumbscrew on the top surface of the facebow is loosened by a quarter turn (Fig 5-11). As the patient slowly opens the mouth, the entire assembly is carefully removed from the head (Fig 5-12). The T screw is rechecked and securely tightened while the Quick Lock Toggle is stabilized. It is sometimes difficult to adequately tighten the T screw while the facebow is on the patient's head. It is confirmed that the bite fork is evenly

spaced inside the facebow (Fig 5-13). The transfer assembly is removed from the facebow, and the support bar is reinstalled (Fig 5-14). The bite fork is rinsed with running tap water, and the plastic earpieces, the facebow assembly, and the bite fork (Fig 5-15) are disinfected with a hospital-grade disinfectant. The transfer assembly and bite fork are stored in an unsealed sterilization bag until it is time to mount the maxillary cast (Fig 5-16).

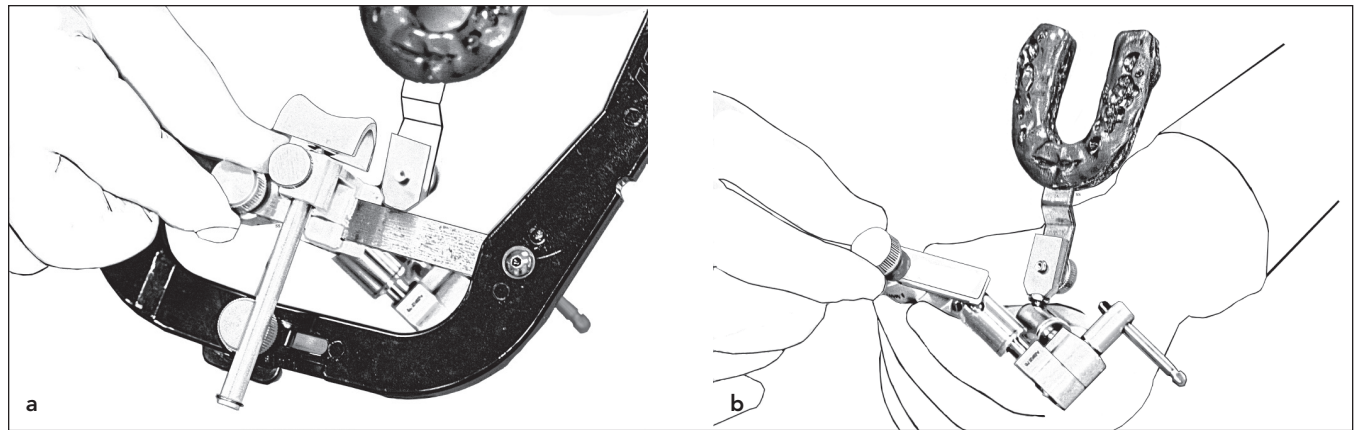


Fig 5-14 The transfer assembly is removed from the facebow (a), and the support bar is placed in position (b).

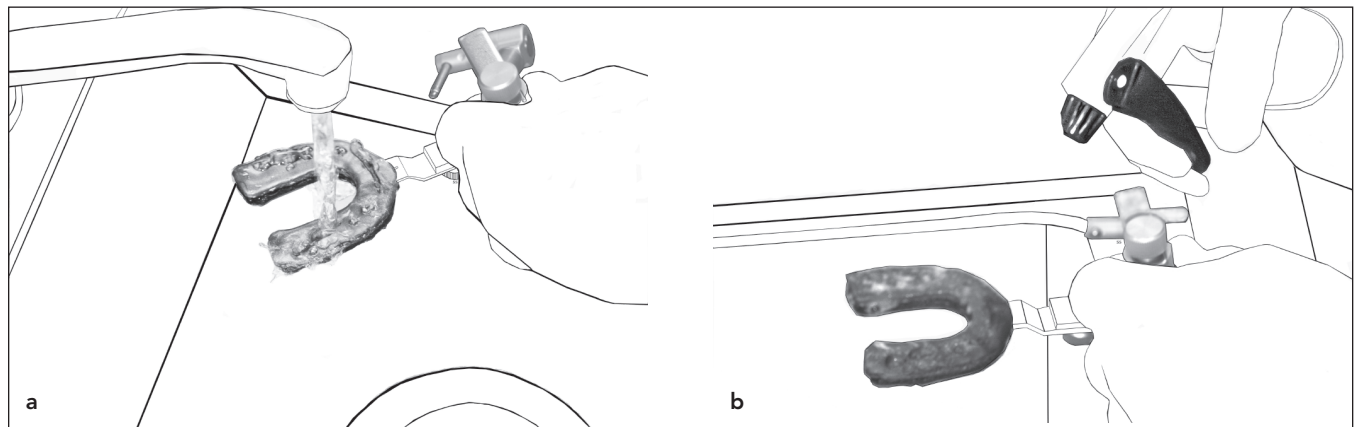


Fig 5-15 The bite fork is rinsed with running water (a) and sprayed with disinfectant (b).

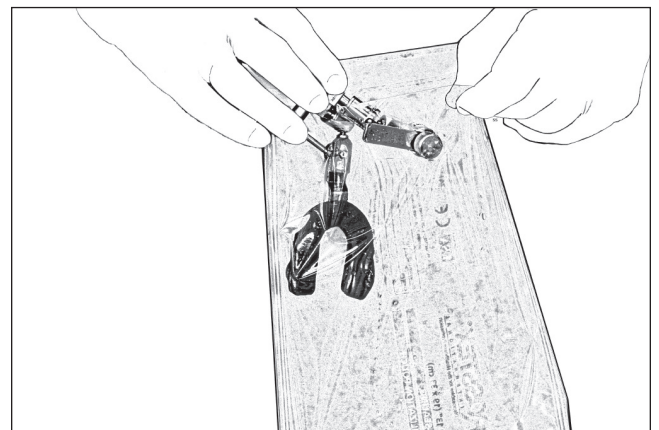


Fig 5-16 The transfer assembly and attached bite fork are stored in an open sterilization bag.

5 Articulation of Casts

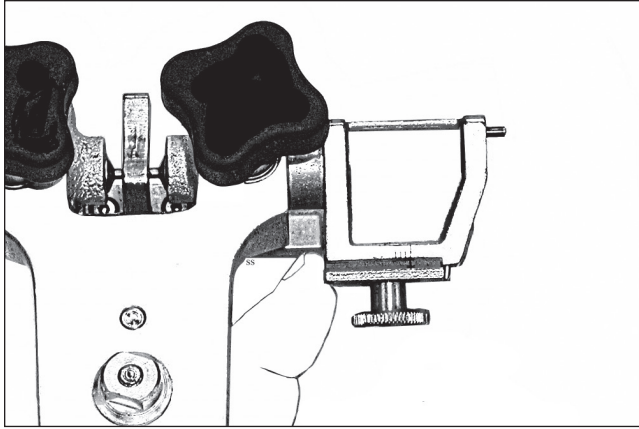


Fig 5-17 The immediate lateral translation guide is moved to zero on each condylar guide.

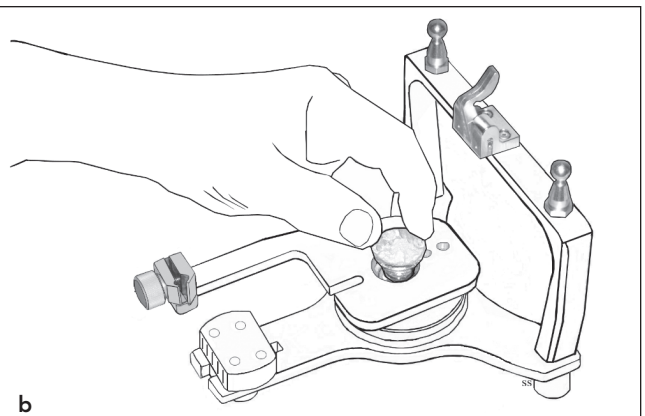
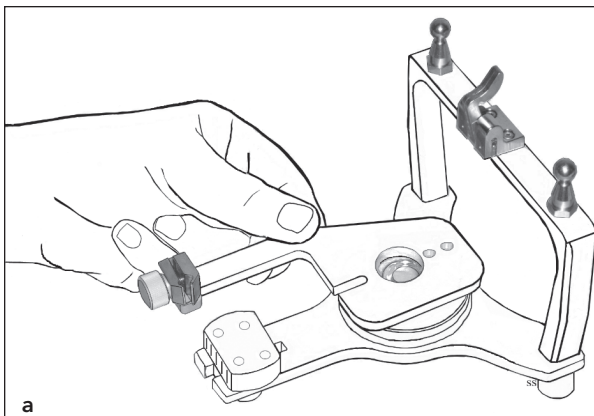


Fig 5-18 The transfer base is placed on the articulator (a) and stabilized with a metal mounting disk (b).

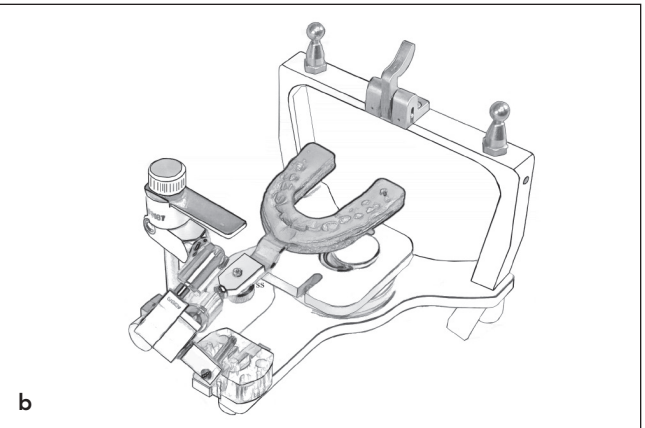
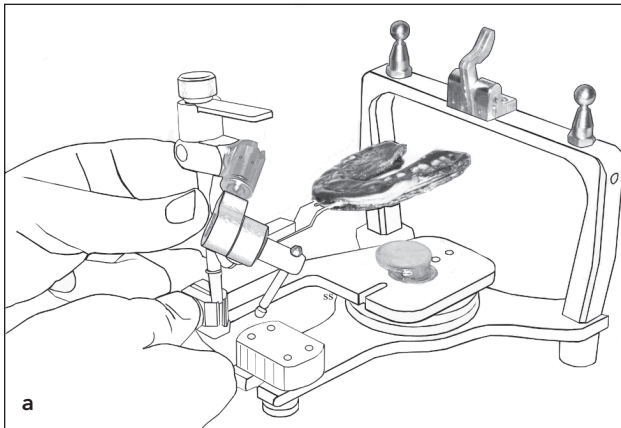


Fig 5-19 (a) The vertical shaft of the transfer assembly is placed in the transfer assembly. (b) After tightening the clamp screw.

Mounting the maxillary cast

The articulator is prepared to receive the cast. The upper and lower members of the articulator are separated. The immediate lateral translation guide on the front of each condylar guide is moved outward to a setting of zero (Fig 5-17). This will prevent any lateral movement during mounting of

the casts. A clean mounting plate is firmly secured to the upper member of the articulator. The incisal guide pin is removed. The transfer base is placed on the lower member of the articulator and secured by placing one of the metal mounting disks on the lower member magnet (Fig 5-18). The vertical rod of the transfer assembly is inserted into the transfer base, and the clamp screw is tightened (Fig 5-19).

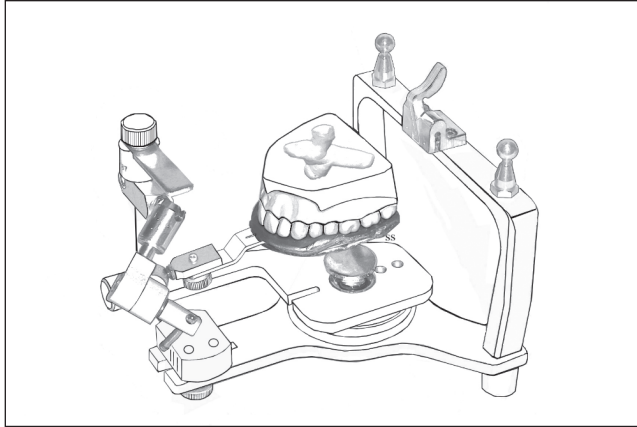


Fig 5-20 The maxillary cast is seated in the bite fork registration.

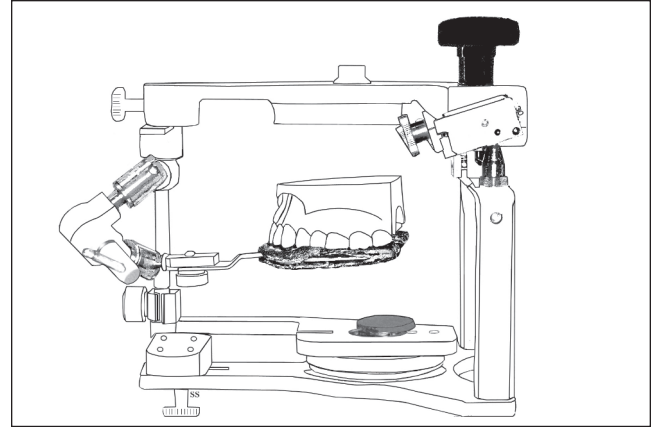


Fig 5-21 The space between the base of the maxillary cast and the upper member of the articulator is checked.

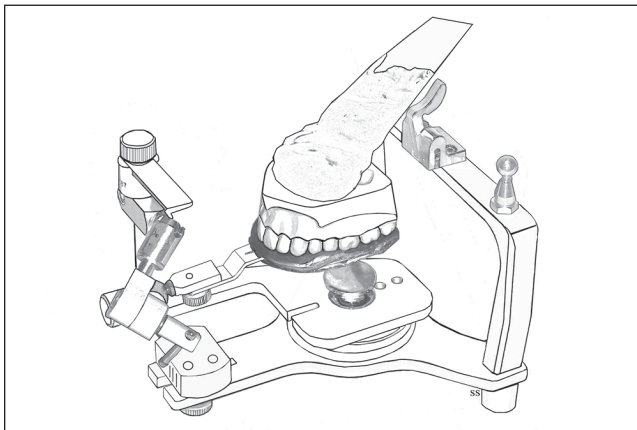


Fig 5-22 Mounting stone is applied to the base of the cast.

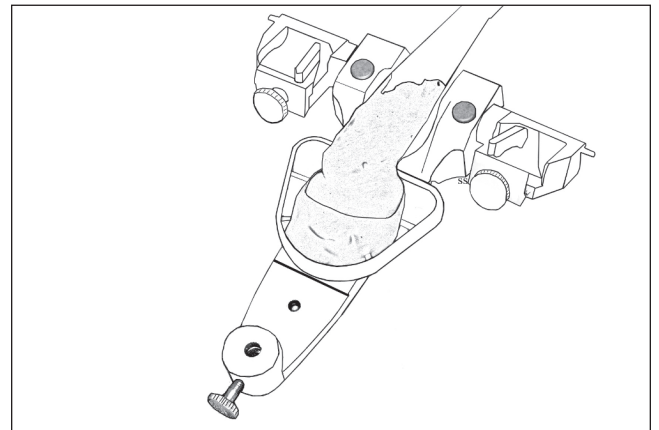


Fig 5-23 A small amount of mounting stone is applied to the mounting plate on the upper member.

The bottom of the maxillary cast is indexed, and then the cast is soaked, tooth side up, in a plaster bowl. There should not be enough water to cover the teeth. The cast is carefully seated into the bite fork registration (Fig 5-20). The upper member of the articulator is placed on the lower portion of the articulator so that the front of the upper frame rests on the transfer assembly support bar (Fig 5-21). This is done to ensure that the cast does not contact the mounting plate while the upper member is fully seated on the lower member of the articulator. At this time, the amount of mounting stone required to mount the cast to the upper mounting plate is estimated.

Mounting stone is mixed to a thick, creamy consistency. The upper frame of the articulator is lifted, and a golf ball-sized mound of stone is applied to the base of the cast (Fig

5-22). A small amount of mounting stone is applied to the mounting plate on the upper member also (Fig 5-23). Using one hand for support to prevent any movement of the facebow fork or cast, the upper member of the articulator is placed on the condyles, and the anterior portion is lowered until contact is made with the support bar (Fig 5-24). This will force the mounting plate into the soft mounting stone. The centric latch is engaged to ensure that the condyles are in the correct position and contact the posterior and superior walls of the condylar fossae (Fig 5-25).

The mounting stone should engage undercuts on the base of the cast and the mounting plate. If necessary, more mounting stone is added into these areas to ensure adequate retention for mounting. When the stone has completely set, the transfer base and transfer assembly are removed from

5 Articulation of Casts

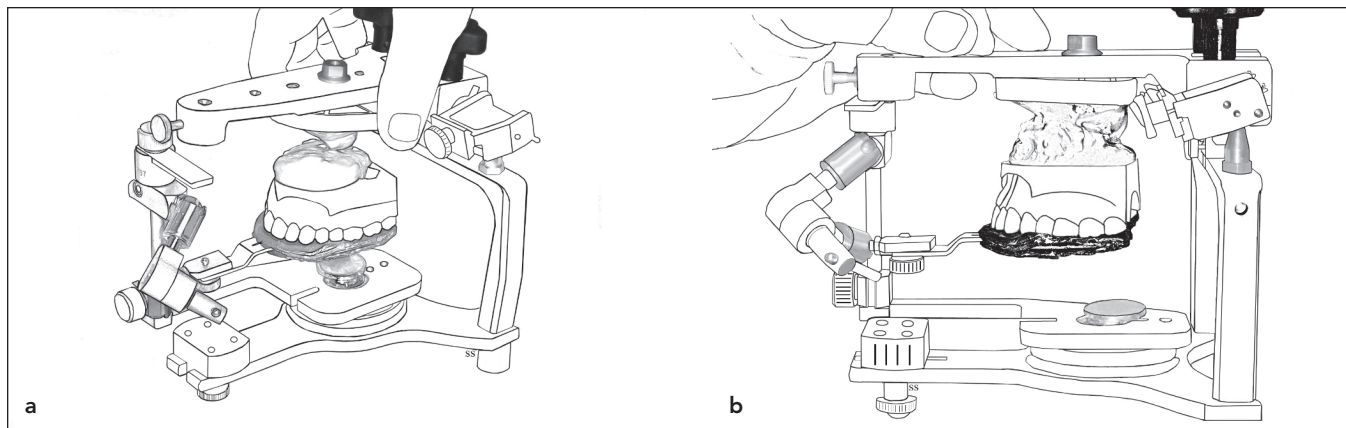


Fig 5-24 The upper member of the articulator is placed on the condyles (a) and lowered against the support bar (b).

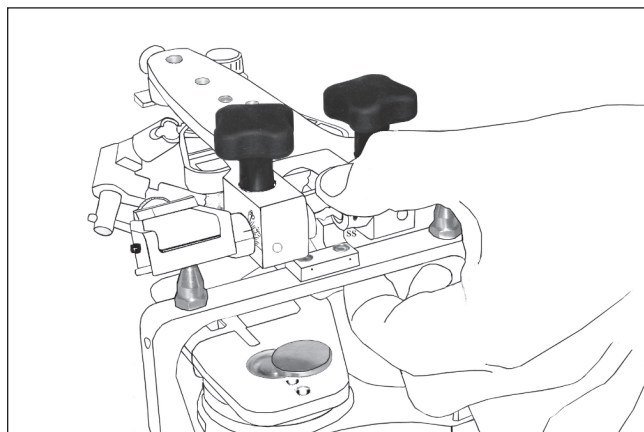


Fig 5-25 The centric latch is engaged to lock the upper member of the articulator in the correct position.

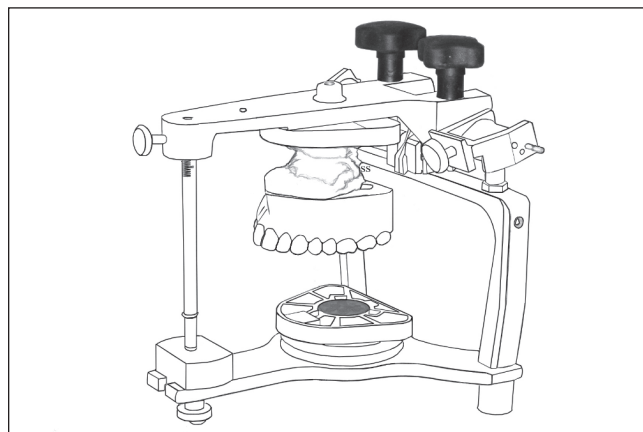


Fig 5-26 The maxillary cast has been mounted on the articulator with the transfer base and transfer assembly removed.

the articulator (Fig 5-26). Once the mounting of the maxillary cast is completed, the transfer assembly is separated from the bite fork. The transfer assembly is disinfected with a hospital-grade disinfectant and stored until the next use. All registration material is removed from the bite fork, which is then placed in a sealed sterilization bag and submitted for steam sterilization.

Mounting the mandibular cast

The incisal guide pin is replaced in the upper frame of the articulator with the rounded end down and set at a 2-mm opening. (The second mark above the circumferential line of the pin is aligned with the top edge of the bushing.) The centric latch is snapped closed at the rear center of the articulator (see Fig 5-25). The upper frame of the articulator

(with maxillary cast attached) is placed upside down on the laboratory bench with the incisal guide pin extending over the front edge of the bench. The centric relation interocclusal record is set on the maxillary cast. The teeth should seat completely into the depressions in the record.

The mandibular cast is now positioned in the interocclusal record, and it is confirmed that the teeth are fully seated. The maxillary and mandibular casts should not contact at any location. The mandibular cast is removed and soaked, tooth side up, in a plaster bowl for approximately 2 minutes. There should not be enough water in the bowl to cover the teeth.

After the cast has soaked, it is resealed into the record. Mounting stone is mixed to the consistency of thick cream, and a golf ball-sized mound of stone is placed on the bottom of the cast. A small portion of stone is applied to the mounting plate on the lower frame, and the lower frame is

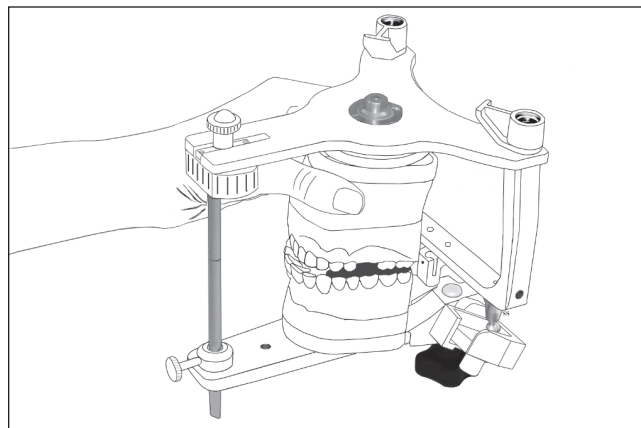


Fig 5-27 The mandibular cast is steadied by hand while the mounting stone sets.

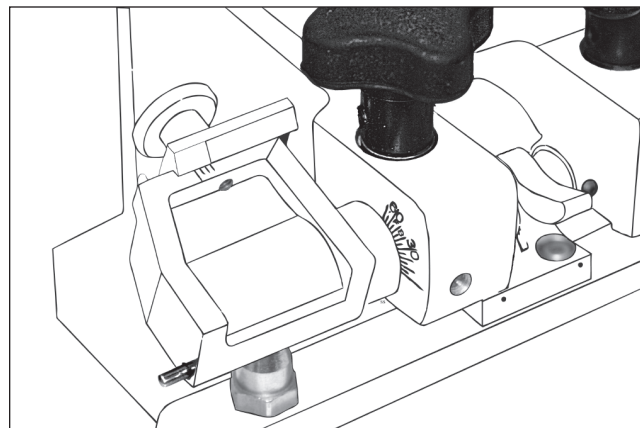


Fig 5-28 The condylar inclination is set at 0 degrees.

hinged down into the soft stone until contact is made between the incisal guide pin and the incisal guide block. The mandibular cast is held to steady it in the interocclusal record until the mounting stone has set (Fig 5-27). The centric latch is rechecked to be sure it has remained closed.

These features are checked:

- Each condylar element should be against the posterior and superior walls of its condylar guide.
- The maxillary and mandibular casts should be completely seated in the interocclusal record.
- The mounting stone should be engaged in the undercuts on both the base of the cast and on the mounting plate.

The mounting stone is allowed to set completely. Then the mounting accuracy is confirmed by opening the articulator, removing the interocclusal record, and raising the incisal guide pin 2.5 cm (1 inch). A 5-cm (2-inch) strip of no. 10 red-inked silk ribbon is placed between the posterior teeth on both sides, and the teeth are lightly tapped with the condyles retruded. This will leave red dots at centric relation position, as mentioned in chapter 4.

The pieces of 28-gauge green wax are removed from the storage cup and carefully placed over the maxillary cast. If the red dots show through the perforations in the wax, the accuracy of the mounting procedure has been confirmed. If they do not show through, the procedure should be rechecked and the error corrected.

Both casts are removed, with their respective mounting plates, from the articulator. More mounting stone is mixed, and all voids between the casts and mounting plates are filled. The mounting stone is smoothed over using a finger to give it a neat appearance. There must be no stone on the surface of the mounting plate that contacts the articulator frame. The neatness of the casts (or lack thereof) is interpreted by the technician and the patient as an indicator of how much the dentist cares about the work that he or she is doing.

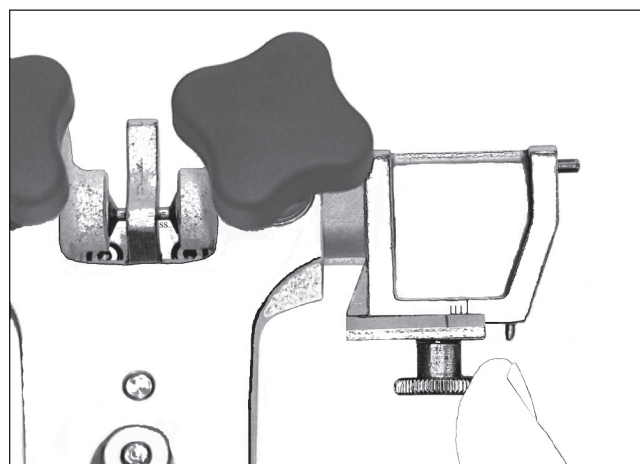


Fig 5-29 The lateral translation controls are set at maximum opening.

Setting condylar guidance

The medial pair of clamp thumbscrews on the top or backside of the upper frame of the articulator are loosened slightly. Both condylar guides are set at 0 degrees (Fig 5-28). The lateral translation clamp screws on the forward aspect of each condylar guide are loosened, and the immediate lateral translation controls are set at their most open position (Fig 5-29). The incisal guide pin is raised so that it will not touch the plastic incisal stop in any position.

The upper frame, with cast attached, is inverted, and the right lateral interocclusal record is seated on the teeth of the maxillary cast. The teeth should seat completely in the wax indentations. The upper frame is held in the left hand, and the right condylar element is placed in the right condylar guide. The teeth of the mandibular cast are gently positioned in the indentations of the wax record. They must be seated completely. The articulator is supported in this

5 Articulation of Casts

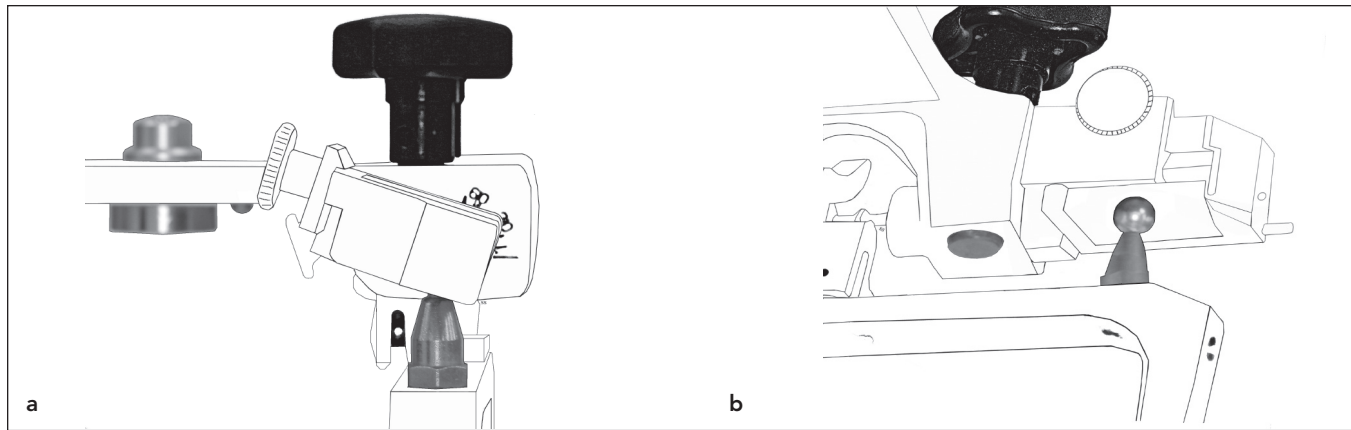


Fig 5-30 With the right lateral interocclusal record in place, the left condyle does not contact the superior wall (a) or the medial wall (b) of the guide.

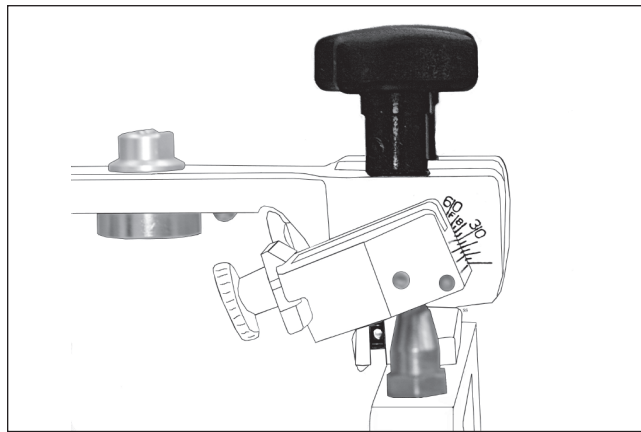


Fig 5-31 The condylar inclination is increased until the condyle contacts the superior wall of the guide.

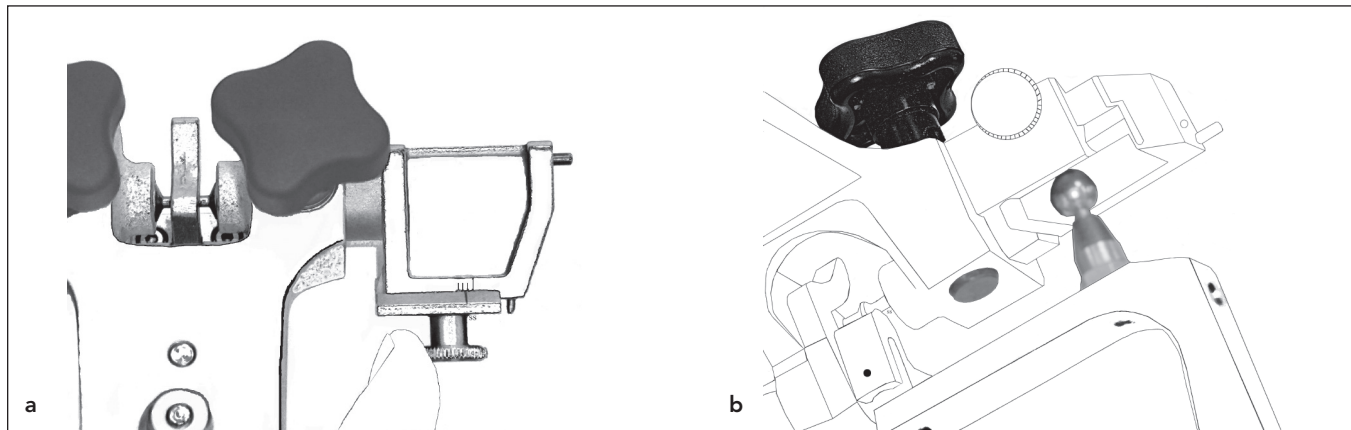


Fig 5-32 The medial wall of the guide is moved (a) until it contacts the condyle (b).

position with one hand on the right side. The left condylar element will have moved downward, forward, and inward. It is not touching the condylar guide at any point (Fig 5-30).

The inclination of the left guide is set by releasing its clamp screw. The guide is rotated inferiorly until the superior wall again touches the condylar element (Fig 5-31). The holding screw is tightened. Mandibular lateral translation is accommodated by releasing the lateral translation clamp

screw and sliding the lateral translation guide laterally until it touches the medial surface of the condylar element (Fig 5-32). The clamp screw is retightened. The right condylar guidance is set by using the record for the left lateral excursion and repeating these steps.

Once the lateral interocclusal records have been made for the diagnostic mounting and the articulator has been set, the data is recorded on the patient's information card. On

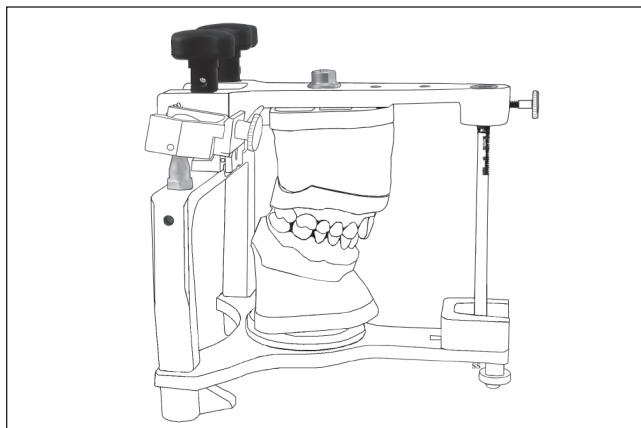


Fig 5-33 The guidance provided by anterior teeth can be recorded in acrylic resin in the dovetail incisal block.

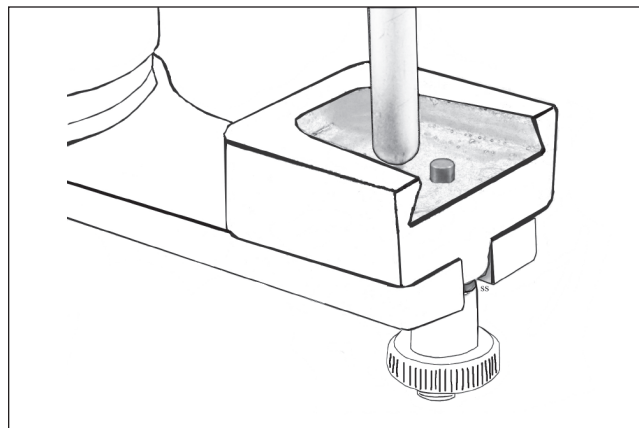
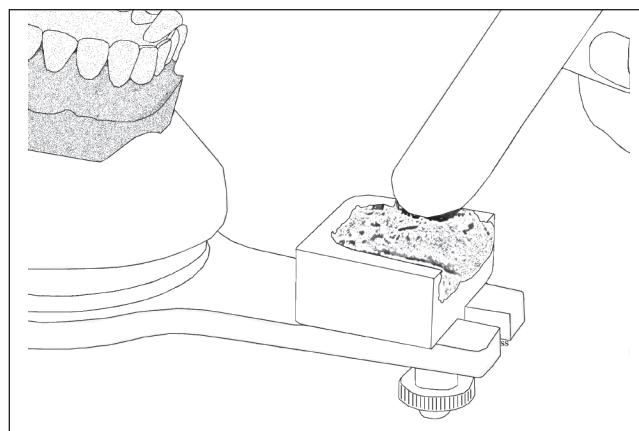


Fig 5-34 The incisal guide pin is 2 to 3 mm posterior to the tip of the retaining screw.

Fig 5-35 Tray resin is placed in the dovetail incisal block.



the patient's casts, the correct articulator settings for each side are marked. For example, a condylar inclination of 40 degrees and a lateral translation of 0.3 mm would be recorded as 40/0.3. When teeth are prepared at a future date and working casts are mounted on the articulator, it will not be necessary to make new lateral interocclusal records. The recorded information from the diagnostic mounting can be used to set the instrument.

Anterior guidance

The influence of the TMJ on the occlusal scheme has been noted. The use of lateral interocclusal records in the setting of the condylar guides enables transfer of some of the influence from the TMJ to the semi-adjustable articulator. The influence of the incisors and canines (ie, anterior guidance) on the occlusion during excursive movements must also be taken into account.^{6,7}

The guidance given to mandibular movements by the anterior teeth can be recorded using either acrylic resin or a light-cured material such as Triad (Dentsply) and made part of the setting of the articulator (Fig 5-33). Anterior guidance can, in effect, be transferred from the teeth to the incisal guide block

of the articulator. If crowns restoring the lingual contours of the anterior teeth are to be placed, it is extremely important that the anterior guidance be registered on the articulator. If this is not done, the lingual contours or length of the restorations produced may not provide anterior guidance.

The mounted casts are examined on the articulator to assess the anterior guidance. If there are nonworking interferences on the casts, they are removed to enable the articulator to move freely while maintaining contact between the anterior teeth. The anterior guidance is examined to determine its adequacy. If it is not adequate because of wear, fracture, or missing teeth, it is restored to an optimum form with inlay wax or denture teeth on the cast.

The acrylic incisal block is replaced on the articulator with the dovetail incisal block (Whip Mix). The block is positioned so that the incisal guide, with the round end down, is 2 to 3 mm posterior to the tip of the retaining screw (Fig 5-34). The round end of the incisal guide pin and the functioning surfaces of the anterior teeth are lubricated with petrolatum. The interior surface of the dovetail block is also coated. One-half scoop of tray acrylic resin is mixed in a paper cup. While it still flows freely, a small amount is placed in the interior of the block (Fig 5-35). The material is allowed to acquire some body before proceeding.

5 Articulation of Casts

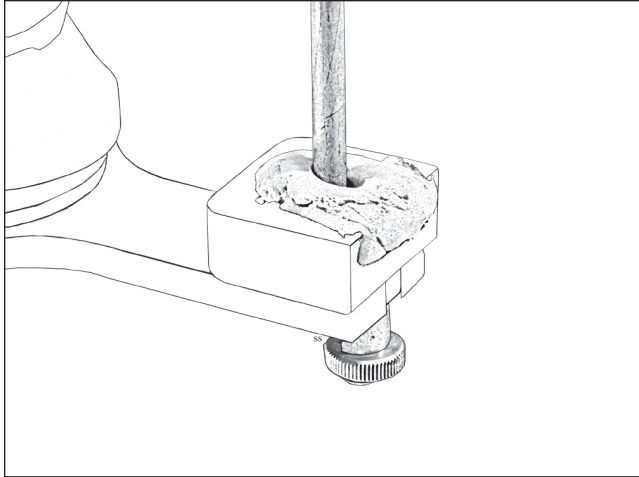


Fig 5-36 The guide pin is closed into the soft acrylic resin.

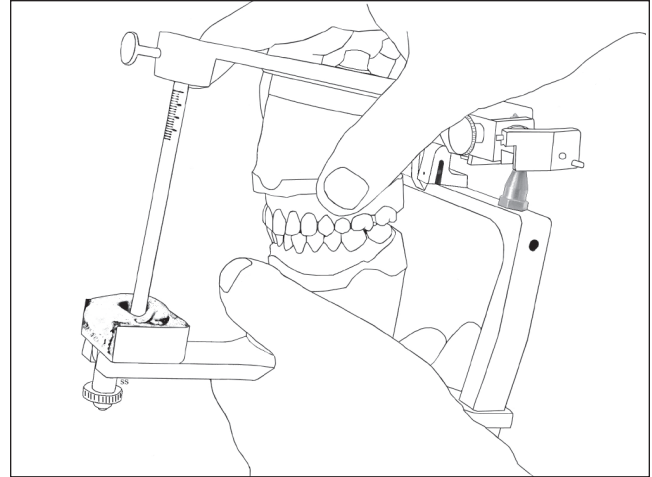


Fig 5-37 The articulator is moved through all excursions.

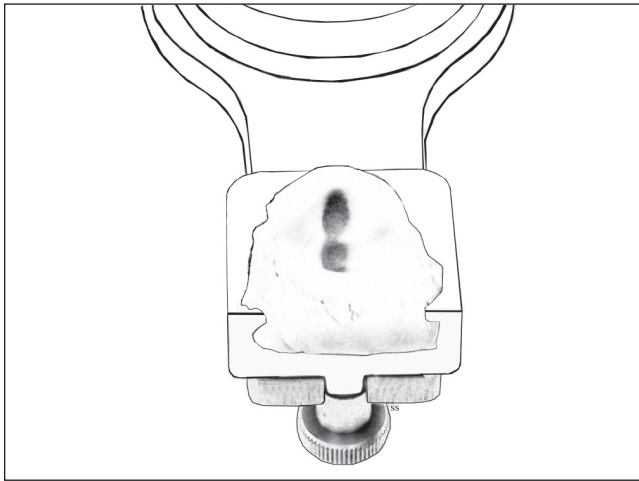


Fig 5-38 An anterior guidance record has been formed in the dovetail incisal block.

The articulator is closed into full occlusion so that the guide pin penetrates into the soft tray resin (Fig 5-36). The articulator is moved repeatedly through all the mandibular movements, making sure that the anterior teeth remain in contact at all times (Fig 5-37). The tip of the incisal guide pin molds the acrylic resin to conform to the various movements. Movement of the articulator through all the excursions continues until the tray resin has polymerized.

Excess resin is trimmed off after it has polymerized. The tip of the guide pin has acted as a stylus in forming a registration of the anterior guidance (Fig 5-38). It will now be possible to duplicate the influence of the anterior teeth on the movements of the casts, even if the anterior teeth are prepared and the incisal edges shortened.

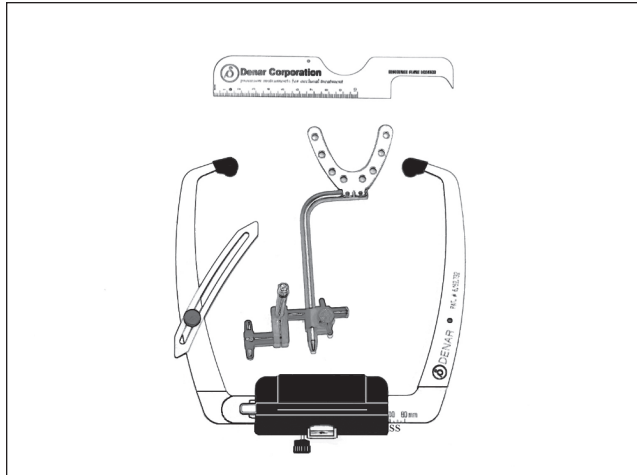


Fig 5-39 The components of a Slidematic facebow are (top to bottom) a reference plane indicator, the bite fork assembly, and the facebow with pointer.

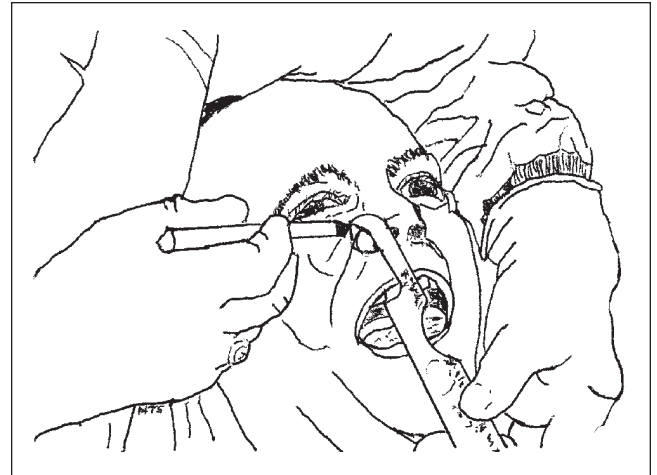


Fig 5-40 A reference point is marked 43 mm above the incisal edges of the maxillary teeth.

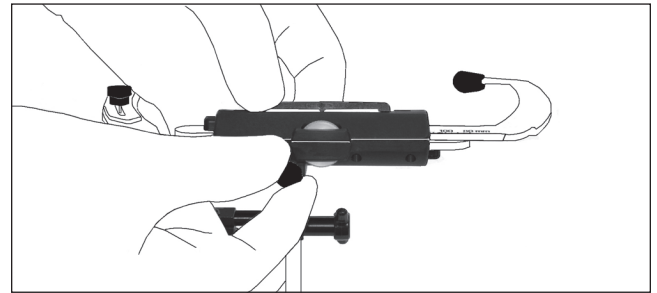


Fig 5-41 The thumbscrew is tightened to attach the bite fork assembly to the underside of the facebow.

Denar Facebow and Articulator

The Denar Slidematic facebow (Whip Mix) is another self-centering ear facebow that is easy to use (Fig 5-39). The technique for its use is described with the Denar Mark II articulator (Whip Mix), an arcon semi-adjustable articulator. This articulator also allows interchangeability of articulated casts with other Mark II articulators without a loss of accuracy.

Facebow armamentarium

- Denar Slidematic facebow (with bite fork, articulator index, reference pin, and reference plane indicator)
- Felt-tip marker
- Denar Mark II articulator
- Plaster bowl
- Spatula
- Laboratory knife with no. 25 blade
- Trimmed maxillary cast
- Horseshoe wax wafers
- Mounting stone (Whip Mix)

Facebow record technique

The reference plane indicator is used to measure a point 43 mm above the incisal edges of the maxillary incisors on the right side. This point is marked with a felt-tip marker (Fig 5-40). This will form the anterior, or third, reference point for the facebow transfer.

Two horseshoe wax wafers (Surgident Coprwxw Bite Wafer) are heated in warm tap water until they become soft and flexible. A wafer is adapted to each side of the bite fork so that it is uniformly covered. The wax-covered bite fork is placed between the teeth, with the bite fork shaft to the patient's right. The fork is centered by aligning the index ring on the fork with the patient's midline. The patient is instructed to bite lightly into the wax to produce shallow indentations of the cusp tips in the wax. The wax is cooled, and the bite fork is removed from the mouth. Any excess wax is trimmed off the bite fork.

The maxillary cast is tried in the wax record to ensure that it will seat without rocking. If the cast fails to seat, the occlusal surfaces of the cast are checked for nodules of stone. If none are evident, there is a distortion in the registration or the cast.

The reference pin is fastened to the underside of the facebow by tightening the thumbscrew (Fig 5-41). The clamp marked with a 2 should be on the patient's right (with the left side of the instrument viewed from the front).

5 Articulation of Casts

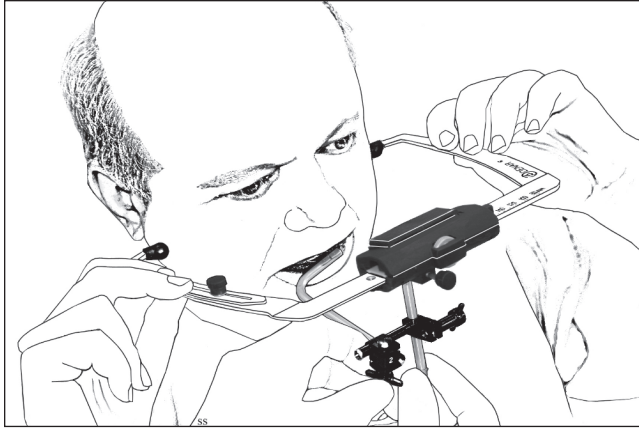

Fig 5-42 The dentist places the clamp over the bite fork shaft while the patient inserts the earpieces.

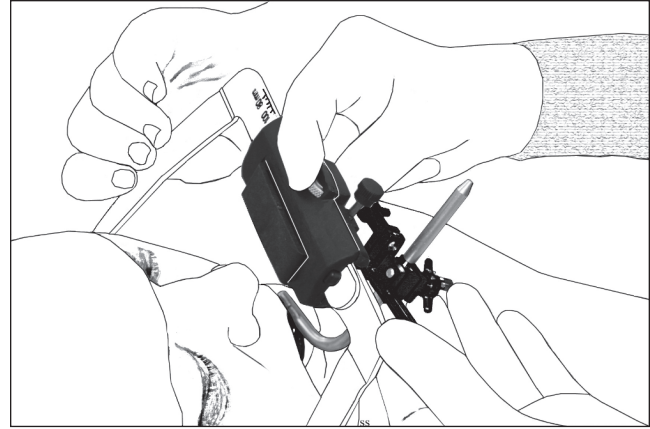


Fig 5-43 The thumbscrew on the front of the facebow is tightened.

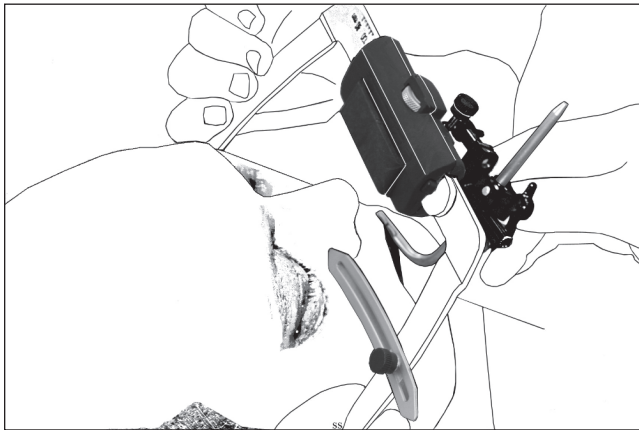


Fig 5-44 The reference pointer is aligned with the reference mark.

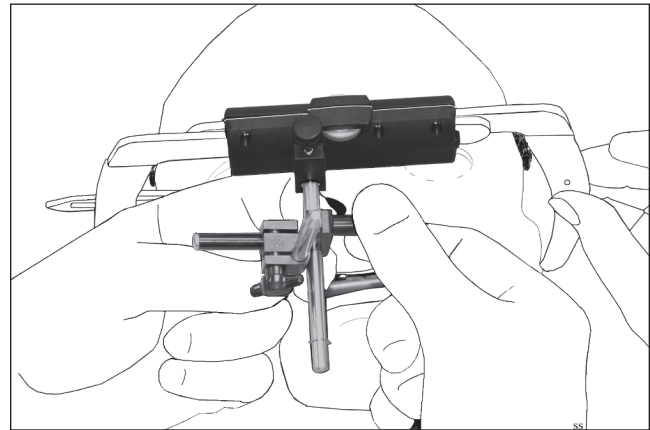


Fig 5-45 The clamps in the facebow assembly are tightened.

The bite fork is placed in the mouth, and the patient is instructed to hold it securely between the maxillary and mandibular teeth. The patient should grip both arms of the facebow to guide the plastic earpieces into the external auditory meati, in the same manner as one would place a stethoscope into the ears (Fig 5-42). While the patient is inserting the earpieces, the operator should slide the clamp marked with a 2 onto the shaft of the bite fork. The clamp should be positioned above the shaft. The single thumbscrew on the front of the facebow is tightened (Fig 5-43).

The anterior reference pointer is extended while the facebow is moved up or down. When the pointer is properly aligned with the anterior reference point, the thumbscrew is tightened (Fig 5-44). With the facebow still supported, the set screw on clamp 1 is tightened on the vertical reference

pin (Fig 5-45). Then clamp 2 is tightened on the horizontal reference pin. For added stability and peace of mind, the patient can continue to support the facebow by holding the side arms. The facebow should not be allowed to torque or tilt during the tightening procedure.

The thumbscrew on the front of the facebow is loosened by a quarter turn. As the patient opens the mouth, the assembly is removed from the head. The clamps are rechecked and tightened. The bite fork assembly is removed from the underside of the facebow by loosening the set screw on the clamp by a quarter turn. Only the bite fork assembly needs to be used for mounting the maxillary cast and should be disinfected at this time. The facebow, after being disinfected with a hospital-grade disinfectant, is ready for use on another patient.

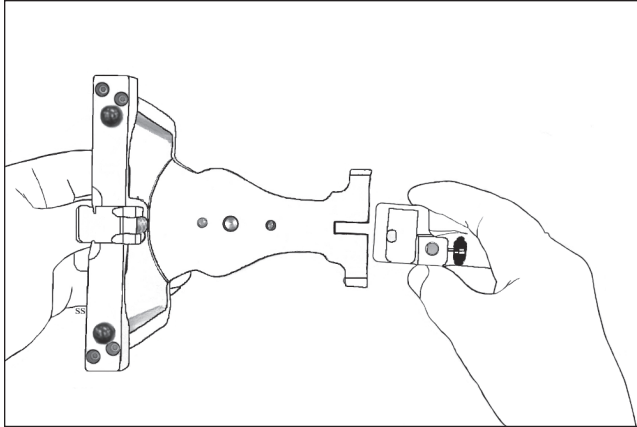


Fig 5-46 The articulator index is placed on the lower member of the articulator.

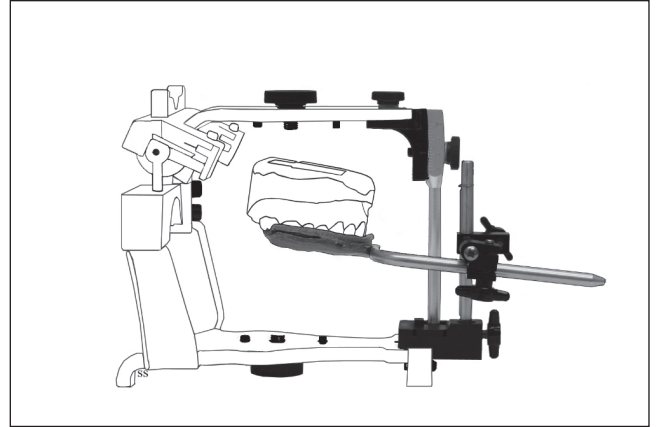


Fig 5-47 The maxillary cast in the bite fork is positioned by the articulator index.

Mounting the maxillary cast

The incisal guide block is removed from the articulator and replaced with the articulator index (Fig 5-46). The vertical reference pin of the bite fork assembly is inserted into the hole on the top of the articulator index. The reference pin has a flat side, which will match a flat side on the hole. The numbers 1 and 2 on the clamps of the bite fork assembly should be upright. The set screw at the front of the index is tightened.

Clean mounting plates are secured to the upper and lower members of the articulator. The articulator is assembled by placing the fossae over the condyles. The incisal pin is placed at the zero position. The long incisal pin for the dimpled guide block will rest in the recessed center of the index. The short pin used for flat guide blocks will contact the sliding metal piece in the middle of the index. The incisal pin with the adjustable foot sits on the posterior section of the index. The upper member of the articulator is removed and set on the top of the bench with the mounting plate up.

The maxillary cast is soaked, tooth side up, in a plaster bowl containing only enough water to wet the sides and bottom of the cast. The cast is seated into the wax registration on the bite fork (Fig 5-47). Mounting stone is mixed to the consistency of thick cream. A golf ball-sized mound of stone is applied to the base of the cast and the mounting plate. The articulator is assembled by placing the fossae over the condyles. The upper member of the articulator is closed into the soft mounting stone until the incisal guide pin contacts the appropriate spot on the articulator index. The centric latch is locked by pushing it into the down position.

The mounting stone will engage undercuts in the mounting plate and cast. Additional stone can be added if needed to secure the mounting. When the stone has set completely,

the transfer jig is removed from the articulator. The incisal guide block is replaced in the articulator. The transfer jig is then rinsed with a hospital-grade disinfectant and stored until ready to be used again. All registration material is removed from the bite fork, which is then placed in a sealed sterilization bag and submitted for steam sterilization.

Mounting the mandibular cast

The incisal pin is adjusted for a 2-mm opening to accommodate the thickness of the interocclusal record. The articulator with the attached maxillary cast is inverted, with care taken to ensure that the centric latch is engaged. The centric relation interocclusal wax record is placed on the maxillary cast. The teeth should seat completely into the record.

The mandibular cast is placed into the interocclusal record, with care taken to ensure that the teeth are fully seated. There should be no contact between the maxillary and mandibular casts. The mandibular cast is removed, and the bottom and sides of it are soaked in a partially filled bowl of water for about 2 minutes.

The soaked mandibular cast is resealed into the interocclusal wax record. Some mounting stone is mixed to a thick, creamy consistency, and a mound of it is placed on the inverted bottom of the cast. Some mounting stone is applied to the mounting plate on the lower member of the articulator, which is hinged down into the soft stone on the cast until the incisal guide pin makes firm contact with the incisal guide block. The mandibular cast is stabilized by hand to keep it securely in the interocclusal record until the mounting stone sets (Fig 5-48). Rubber bands or sticky wax can also be used, but they are more likely to slip and produce a mounting error.

5 Articulation of Casts

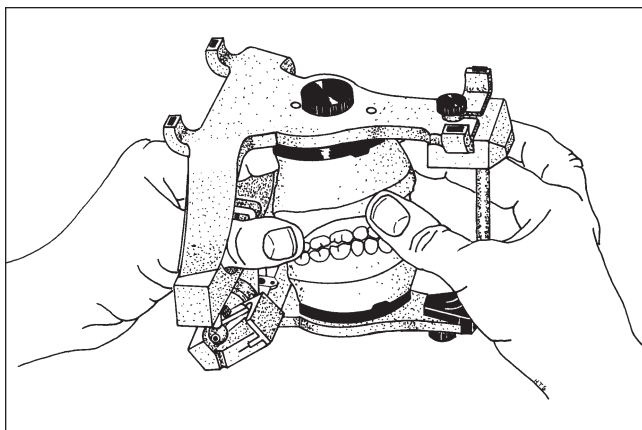


Fig 5-48 The cast is held in the interocclusal wax record until the mounting stone sets.

The casts and articulator are examined for the following:

- The condyle is located against the posterior and superior walls of the condylar guide.
- Both casts are completely seated in the interocclusal record.
- Mounting stone engages undercuts on both the base of the cast and the mounting plate.

When the mounting stone has set completely, the accuracy of the mounting is confirmed. The articulator is opened, the interocclusal record is removed, and the incisal guide pins are raised 1 inch. A 2-inch piece of no. 10 red-inked silk ribbon is placed between the posterior teeth on both sides. The teeth are tapped together lightly with the condyles against the posterior wall of the condylar guide, leaving red dots that represent the contacts at centric relation position, as described in chapter 4.

The pieces of 28-gauge green wax that have been stored in a cup are retrieved and lightly placed on the teeth of the maxillary cast. The accuracy of the mounting is confirmed if the red dots are visible through the perforations in the wax. If they are not visible, the procedure should be rechecked and the error corrected.

The casts and their mounting plates are removed from the articulator. Additional mounting stone is mixed to fill any voids between the casts and their mounting plates. The mounting stone is smoothed with a finger to give it a neat appearance. No stone should remain on the surface of the mounting plate that will contact the articulator frame. Both the dental technician and the patient form an impression of the dentist when they see these casts on the articulator, so it is important to make sure that it is a positive one.

Setting condylar guidance

A hex driver is used to loosen the set screw on the underside of each fossa, and the medial side wall is set to a 6-degree progressive lateral translation. The lock screw on each end of the posterior aspect of the upper crossbar of the articulator is released using a hex driver, and both condylar guides are set at 0 degrees. Then the set screw is loosened on the top of each fossa as far as possible to the medial. The incisal guide pin is lifted to prevent it from touching the plastic incisal stop in any position. The centric latch is released.

The right lateral interocclusal record is seated on the maxillary cast attached to the inverted upper member of the articulator. The teeth should seat completely in the wax indentations. The upper member of the articulator is held in the left hand, and the right condylar element is placed in the right condylar guide. The teeth of the mandibular cast are seated gently but completely into the indentations of the wax record.

One hand is used on the right side of the articulator to support it in this position. The left condylar element will have moved downward, forward, and inward. It should not be touching the condylar guide at any point (Fig 5-49).

The inclination of the right protrusive condylar path is increased by rotating the fossa until the superior wall makes contact with the condylar element (Fig 5-50a). The set screw on the back of the upper crossbar is tightened with a hex driver. The immediate lateral translation is set by moving the medial wall of the fossa outward or laterally until it contacts the medial surface of the condylar element (Fig 5-50b). The set screw is retightened. The wax interocclusal record for the left lateral excursion is used to set the right condylar guidance in the same manner.

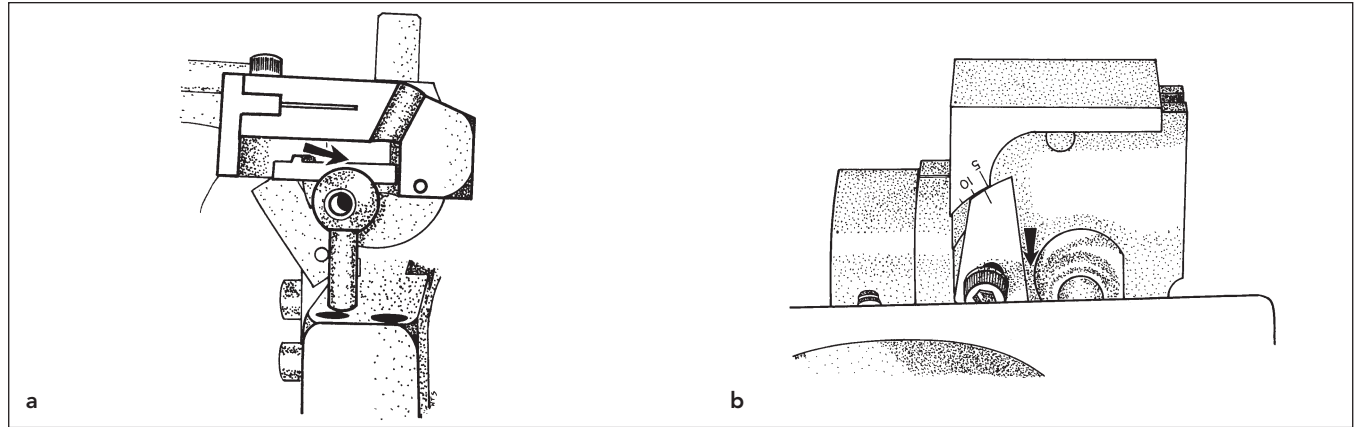


Fig 5-49 The right lateral interocclusal record causes the left condyle to move away from the superior wall (a) and the medial wall (b) of the guide.

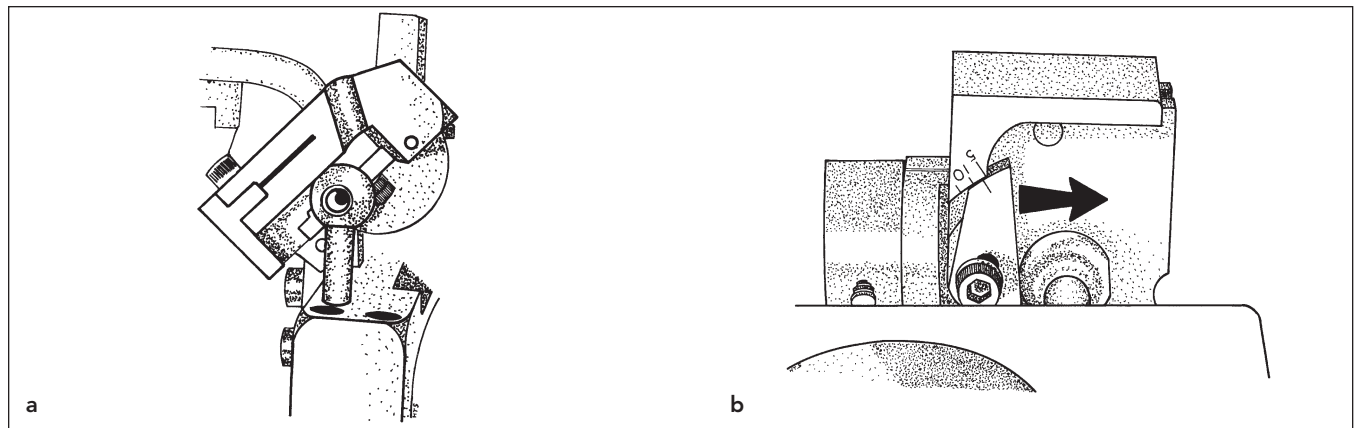


Fig 5-50 To adjust the condylar guide, the condylar inclination is increased until the superior wall contacts the condyle (a), and the medial wall is moved into contact with the condyle (b).

After the articulator is set, the data is recorded on the patient's information card. The articulator settings for each side are marked on the respective side of the patient's cast. For example, a condylar inclination of 35 degrees and an immediate lateral translation of 0.6 mm would be recorded as 35/0.6. When teeth are prepared at a future time, working casts can be mounted on the articulator without making new records. The instrument can be reset using the recorded information from the diagnostic mounting.

Anterior guidance

The mounted casts are examined on the articulator. Any nonworking interferences are removed from the casts so that the articulator can move freely while the anterior teeth remain in contact. If the guidance is inadequate for any reason, it is restored to an optimum configuration with a diagnostic wax-up.

The incisal guide pin is raised so that it will be at least 1 mm off the plastic incisal guide block in all excursions (Fig

5 Articulation of Casts

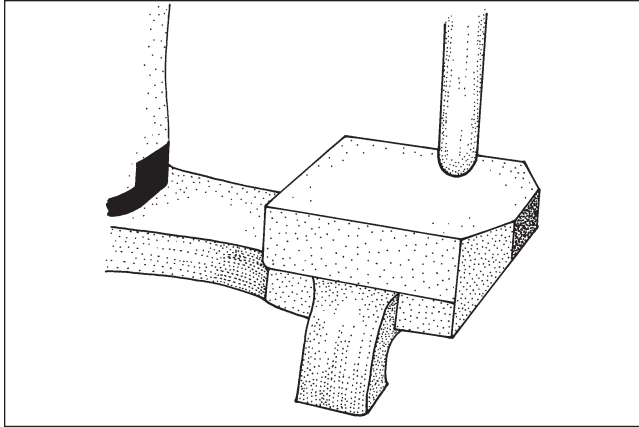


Fig 5-51 The incisal guide pin should not contact the guide block.

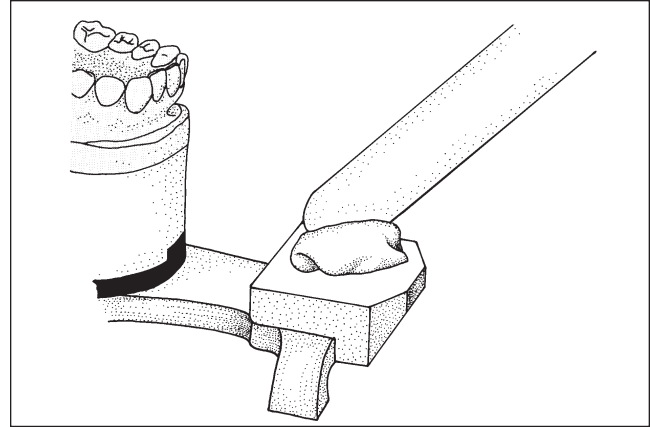


Fig 5-52 Acrylic resin is placed on the incisal guide.

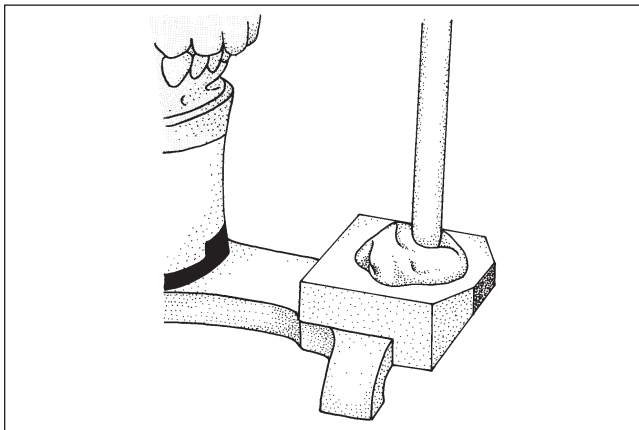


Fig 5-53 The guide pin is allowed to close into the soft resin.

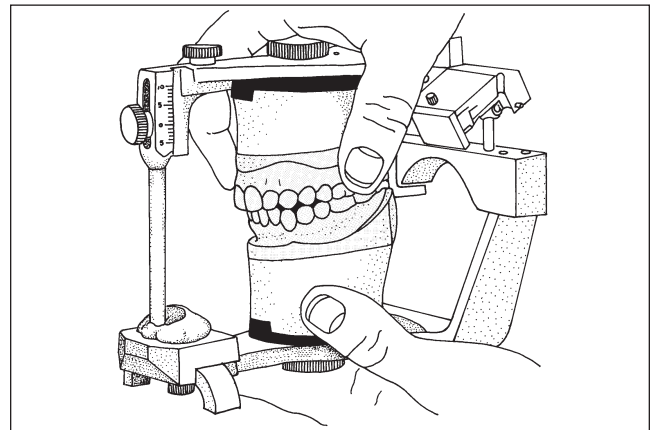


Fig 5-54 The articulator is moved through all excursions.

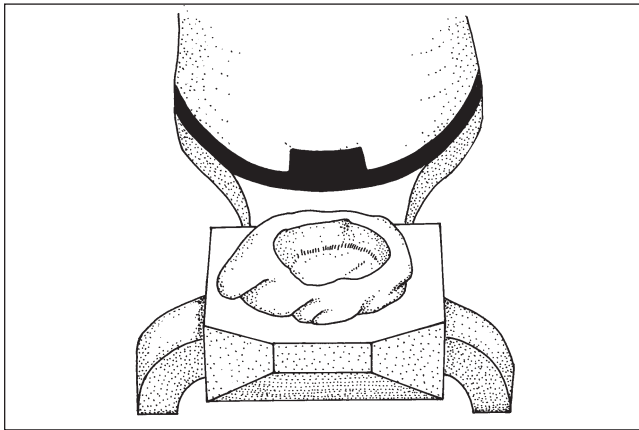


Fig 5-55 An anterior guidance record exists on the guide block.

5-51). Acrylic resin or a light-cured material (Triad) may be used. If a resin is used, the surface of the guide block is moistened with monomer. A half scoop of tray resin is mixed, and, while it is still free-flowing, a small amount is placed on the incisal guide. As the polymerizing resin becomes stiffer, more is added until there is about $\frac{1}{4}$ inch of it covering the guide block (Fig 5-52). The end of the incisal guide pin and all contacting surfaces of the anterior teeth are lubricated with petrolatum. The articulator is closed so that the teeth

occlude completely. The guide pin will penetrate the soft acrylic resin (Fig 5-53). The articulator is moved through all excursions repeatedly, keeping the teeth contacting at all times (Fig 5-54). The tip of the guide pin will mold the acrylic resin to record the pathway of the various movements. The movements are continued until the resin is completely polymerized. The excess is trimmed off. A record of the anterior guidance has been formed on the incisal table (Fig 5-55).

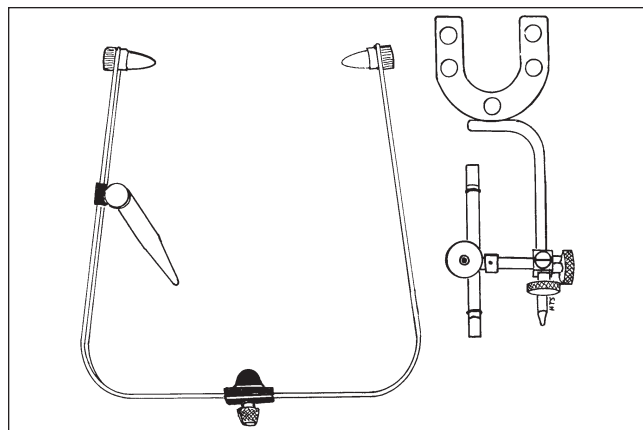


Fig 5-56 The components of a Spring-Bow are (left to right) the facebow with orbital pointer and the bite fork assembly.

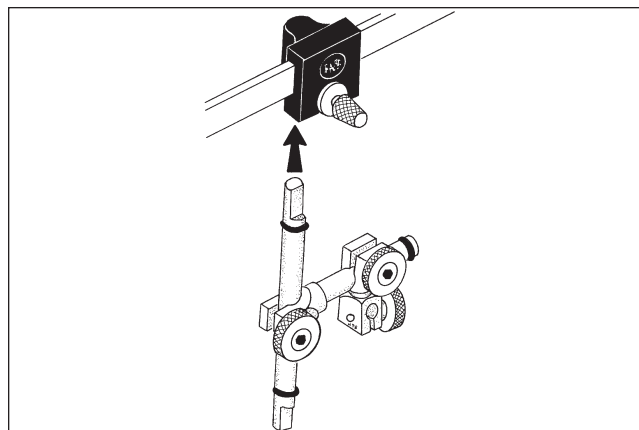


Fig 5-57 The vertical rod of the bite fork assembly is inserted into the bow socket. The flat side is in front, with the empty bite fork clamp to the right.

Hanau Facebow and Articulator

The Hanau Spring-Bow (Whip Mix) is an ear facebow that utilizes a one-piece spring-steel bow (Fig 5-56). It is simple in design and can be used either as a direct-mount or an indirect-mount device with the removable bite fork assembly and mounting platform.⁸ The technique for its use is described with the Hanau Series 184 Wide-Vue articulator (Whip Mix), an arcon semi-adjustable instrument.

Facebow armamentarium

- Spring-Bow (with bite fork assembly and mounting guide)
- Hanau Wide-Vue articulator
- Plaster bowl
- Spatula
- Laboratory knife with no. 25 blade
- Trimmed maxillary cast
- Pink baseplate wax
- Mounting stone

Facebow record technique

A sheet of baseplate wax is softened in hot water, and the bite fork is completely covered with it. The wax-covered bite

fork is positioned against the maxillary teeth, and the patient is instructed to close until the mandibular teeth contact the wax on the underside of the fork. The shaft of the bite fork will be to the left of the patient's midline.

The wax is cooled in the mouth with an air syringe. The fork is removed from the mouth and placed in a bowl of cold tap water to finish cooling. Excess wax and any areas imprinted by soft tissue are trimmed off. The maxillary cast is seated in the wax record to be sure that it is stable. If there is any rocking of the cast, the occlusal surfaces of the cast should be checked for nodules of stone. If there are none, either the cast or the record is distorted and must be remade.

If the bite fork assembly is separate from the facebow, the transfer (vertical) rod of the assembly is inserted into the bow socket on the underside of the black centerpiece on the front of the facebow. The flat surface on the rod must be in front when it is placed in the socket. The assembly should be on the right, with the knobs facing the front (Fig 5-57). The thumbscrew is tightened on the front of the centerpiece.

While the patient grips the bite fork between the maxillary and mandibular teeth, the loosened bite fork clamp is positioned 4 cm (1.5 inches) over the bite fork shaft. The facebow should be pointed upward during this action (Fig 5-58). The bow is opened by pulling outward on the arms and is swung down into position, with an earpiece placed gently into each external auditory meatus. The patient is instructed to adjust the earpieces to the most comfortable seated position (Fig 5-59).

5 Articulation of Casts

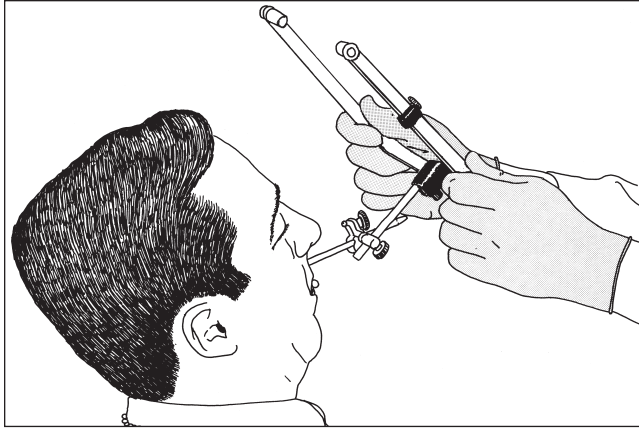


Fig 5-58 The bite fork clamp is slid onto the shaft.

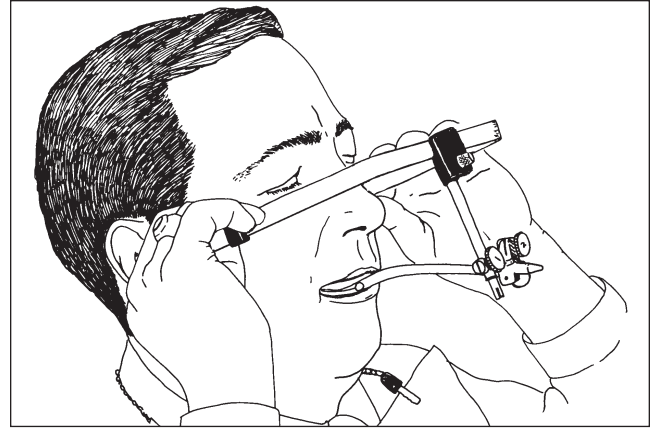


Fig 5-59 The patient should adjust the facebow for comfort. The earpieces should be checked to make sure they are still seated.

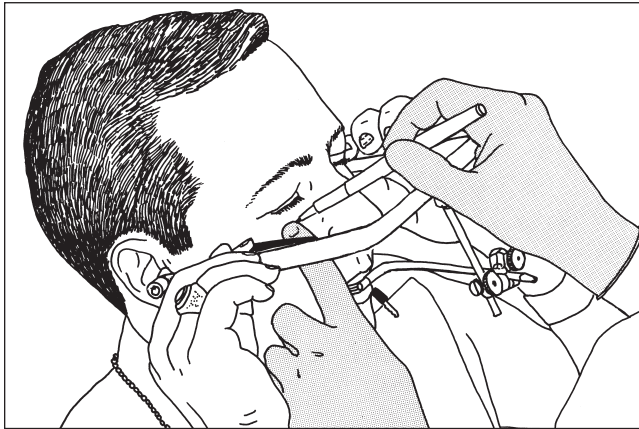


Fig 5-60 The infraorbital notch (orbitale) is located and marked.

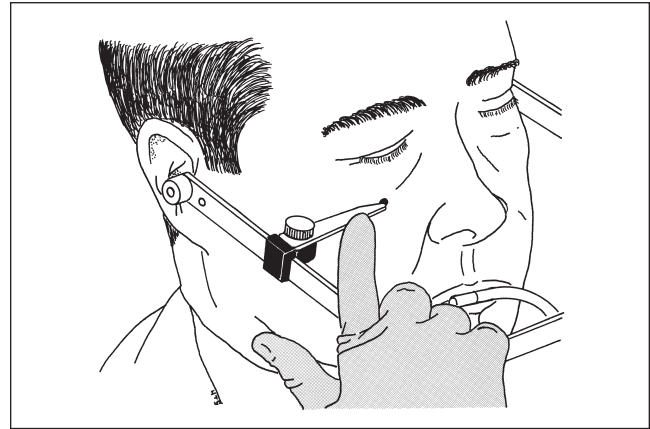


Fig 5-61 The pointer is rotated toward the reference mark.




Fig 5-62 The bow is secured with one hand while the other tightens the thumbscrews on the bite fork assembly.

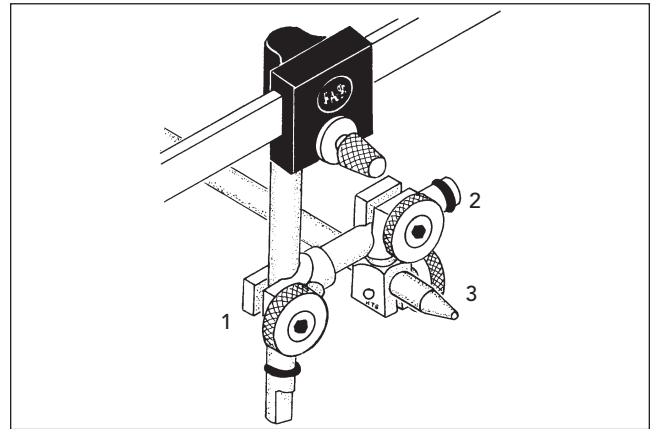


Fig 5-63 The thumbscrews are tightened in the order indicated (1-3).

The orbitale (infraorbital notch) is marked on the patient's face with a felt-tip marker to provide an anterior reference point (Fig 5-60). The thumbscrew that holds the orbital pointer is loosened and gently swung in toward the reference mark (Fig 5-61). The front of the facebow is elevated

along the transfer (vertical) rod of the bite fork assembly until the pointer is at the plane of the anterior reference point. The bow is grasped to resist torquing (Fig 5-62), and the three thumbscrews are tightened in order from left to right (Fig 5-63):

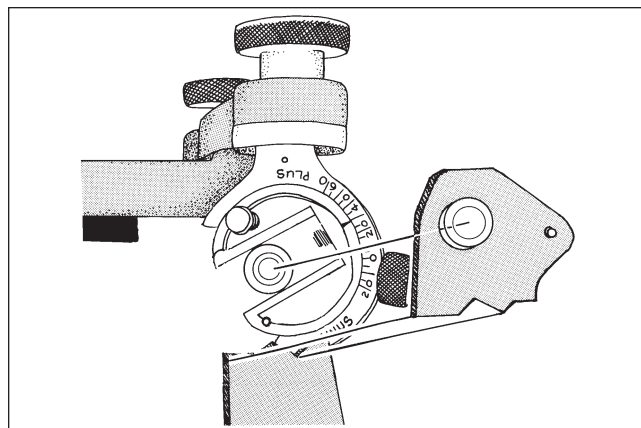


Fig 5-64 Before the facebow is attached, the condylar inclination is set at 30 degrees.

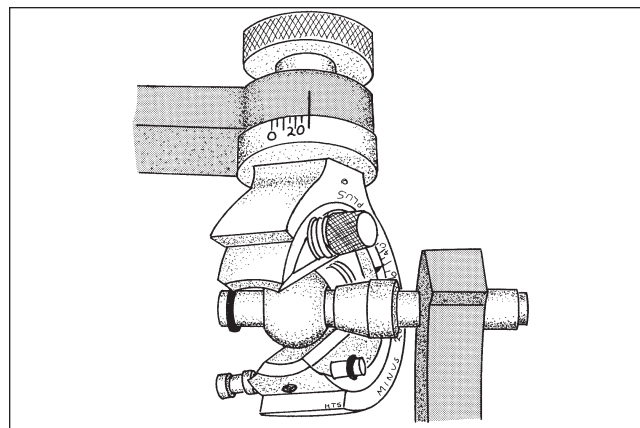


Fig 5-65 The Bennett angle ring is rotated to 30 degrees.

1. Transfer (vertical) rod/transverse (horizontal) rod
2. Transverse rod clamp (upper)
3. Bite fork clamp (lower)

They must be tight; an Allen wrench can be used to tighten them if necessary.

The reference pointer is rotated back over the right temple of the bow, and the thumbscrew is tightened enough to hold it there. While the patient opens, the ends of the bow are grasped, and the earpieces are removed from the auditory meati. It should be held firmly because the bow is made of spring steel and could snap back. The bow is slid away from the patient. The facebow, earpieces, and bite fork are disinfected with a hospital-grade disinfectant before continuing.

Mounting the maxillary cast

The articulator is prepared to accept the casts by setting the inclination of the enclosed condylar track mechanisms at 30 degrees on each side (Fig 5-64). The Bennett angle ring for the progressive mandibular lateral translation should be set at 30 degrees (Fig 5-65).

Petrolatum is used to lubricate the surfaces of the upper and lower members of the articulator around the threaded mounting studs. Then a clean mounting plate is firmly secured to the mounting stud on the upper member of the articulator. A mounting guide or platform is attached to the lower member of the articulator. The thumbscrew on the front of the facebow is loosened, and the bite fork assembly is removed. The vertical transfer rod of the assembly is placed into the hole at the front of the mounting guide and secured by tightening the screw. The cast support is adjusted to touch the underside of the wax on the bite fork (Fig 5-66).

The maxillary cast is soaked in a plaster bowl, but the teeth should not be covered with water. The maxillary cast is carefully seated into the imprints in the baseplate wax on the bite fork. The upper member of the articulator is raised, and a golf ball-sized mound of thick, creamy mounting stone is placed on the base of the cast. The upper member of the

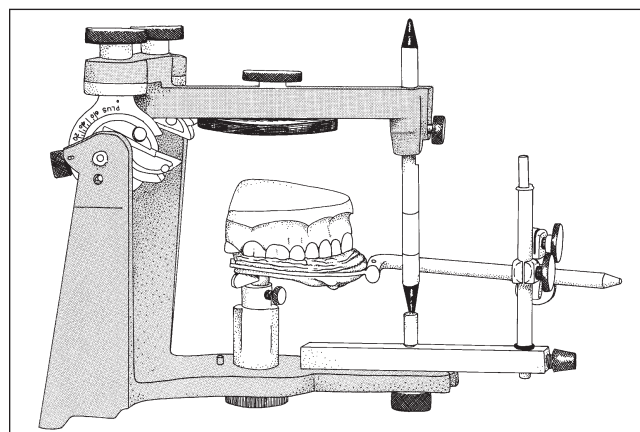


Fig 5-66 The maxillary cast is oriented to the articulator by the bite fork assembly in the mounting guide.

articulator is swung down until the incisal pin is resting on the mounting guide or the anterior table, depending on the type of guide used. Stone must be engaging the cutouts in the top of the mounting plate. More stone is added if necessary, and the top is smoothed off with a spatula. When the stone has set completely, the bite fork assembly and mounting guide are removed from the articulator. All registration material is removed from the bite fork, which is then placed in a sealed sterilization bag and submitted for steam sterilization. A clean mounting plate is attached to the lower member of the articulator.

Mounting the mandibular cast

The incisal guide pin is extended 1 to 2 mm to compensate for the thickness of the interocclusal wax record. The centric lock is tightened on each enclosed condylar track mechanism to ensure that the articulator is capable of only a hinge opening.

5 Articulation of Casts

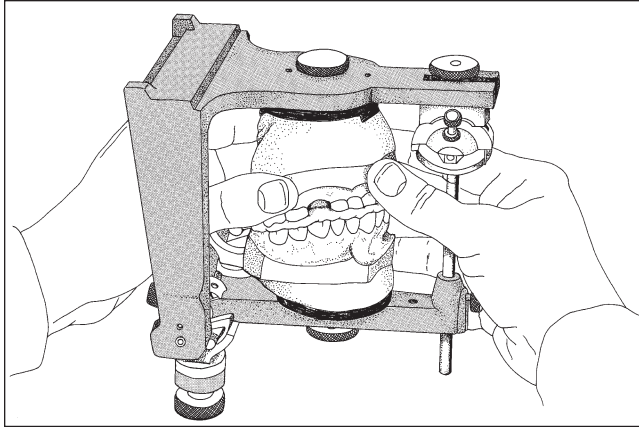


Fig 5-67 The mandibular cast is held steady in the wax record while the mounting stone sets.

The articulator is inverted on the bench, resting on the three thumb nuts protruding from the upper member of the articulator. The centric relation interocclusal wax record is placed on the teeth of the maxillary cast. The teeth must seat completely into the wax record.

The mandibular cast is placed into the interocclusal record, and complete seating is again confirmed. There should be no contact between the maxillary and mandibular casts. The mandibular cast is removed and soaked for about 2 minutes. To prevent any erosion of the teeth on the cast, they must not be covered by water. The soaked mandibular cast is re-seated into the record. The lower member of the articulator is swung up and back. A mound of thick, creamy mounting stone is placed on the bottom of the cast. Enough is applied to the mounting plate on the lower member to fill the cutout slots on either side of it. The lower member of the articulator is hinged back over into the soft mounting stone. The incisal guide pin should be resting firmly against the incisal guide table. A hand is used to steady the mandibular cast in the retruded position wax registration until the mounting stone has achieved an initial set (Fig 5-67).

The articulated casts are inspected for the following criteria:

- The condyle is in the retruded position in its condylar track mechanism.
- Both casts are seated completely in the interocclusal wax record.
- Mounting stone is securely attached to both casts and mounting plates.

After the mounting stone has achieved a final set, the accuracy of the mounting is corroborated. The articulator is opened, and the incisal guide pin is raised so that it will not touch the incisal table when the teeth are contacting. The interocclusal record is removed, and a 2-inch piece of no. 10 red-inked silk ribbon is placed between the posterior teeth

on both sides. The teeth are tapped together lightly, producing red marks on the teeth where they contact in the retruded position.

The pieces of 28-gauge green wax are retrieved and carefully positioned on the teeth of the maxillary cast. If the cast mounting is correct, the red marks on the teeth will be visible through the perforations in the wax. If they are not visible, the procedure should be rechecked step by step and the error corrected.

The mounting plates are unscrewed, and the casts are removed from the articulator. The plates and attached mounting stone are soaked in water. More mounting stone is added wherever it is needed to fill voids between the casts and the mounting plates. The additional stone is smoothed as it sets to give it a neat appearance. Care should be taken not to leave any stone on the surface of the mounting plate that will contact the articulator frame. It has been said that sloppy cast mountings are not an indication of a poor operator; they are absolute proof.

Setting condylar guidance

Wax lateral or protrusive interocclusal records are used for setting the condylar inclination of this instrument. Note that when lateral interocclusal records are employed, the left record is used for the right condylar inclination and the right record for the left condylar inclination. The thumb nut is loosened at the rear of each condylar track mechanism so that it can be easily rotated. At this time, however, the condylar inclination should be left at 30 degrees. The incisal guide pin should still be raised out of contact with the incisal table.

The right interocclusal record is seated on the teeth of the mandibular cast. The upper member of the articulator is gently lowered until the maxillary teeth engage the wax record. The left condylar guide is adjusted by changing the condylar inclination with the thumb nut located at the rear of the guide. The teeth on the right side of the cast will rock in and out of the record. If the condylar path is too shallow, the anterior teeth will be drawn out of the wax record (Fig 5-68a). When the path becomes too steep, the posterior teeth become unseated (Fig 5-68b). The correct condylar inclination has been determined when the cast is seated completely in the wax record (Fig 5-68c). The nut at the rear of the condylar guide is tightened.

The thumb nut on the top of each condylar guide of the articulator is loosened. The Bennett angle ring is slowly rotated outward (from 30 toward 0 degrees) until the flat side on the outer aspect of the condylar ball contacts the inner surface of the sleeve on the condylar shaft, forming brass-to-brass contact (Fig 5-69). This process is repeated on the right side.

If a protrusive interocclusal wax record is used to establish the condylar inclination, both condylar mechanisms are rotated simultaneously in the same manner described above for setting each condylar inclination separately. In this situation, the angle of mandibular lateral translation (L) is esti-

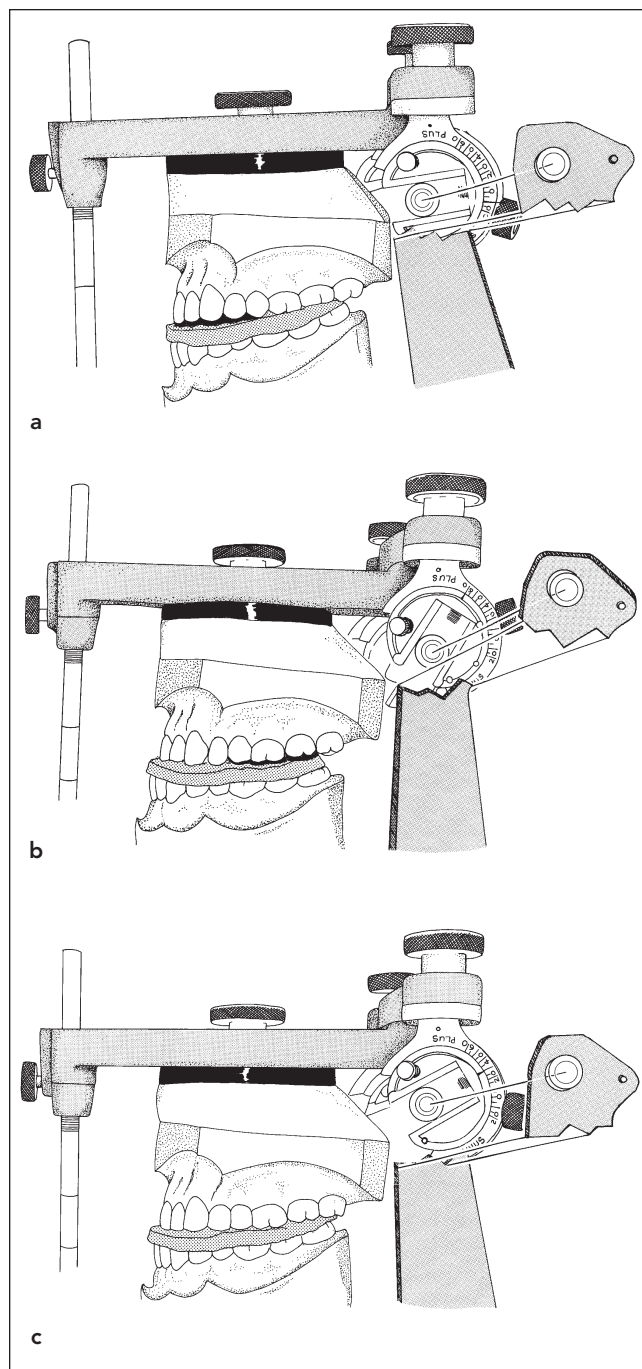


Fig 5-68 When using a protrusive interocclusal record to set the condylar guidance, the condylar inclination is rocked up and down. (a) When the angle is too shallow, the anterior teeth lift out of the record. (b) When the inclination is too steep, the posterior teeth lift out. (c) When the cast is completely seated, the inclination is correct.

mated by use of the *Hanau formula*: $L = H/8 + 12$, where H is the condylar protrusive inclination. Because a change in condylar inclination from 20 to 50 degrees would produce less than a 4-degree change in the Bennett angle by this calculation, placing the Bennett angle ring at an arbitrary 15-degree angle would produce minimal error.

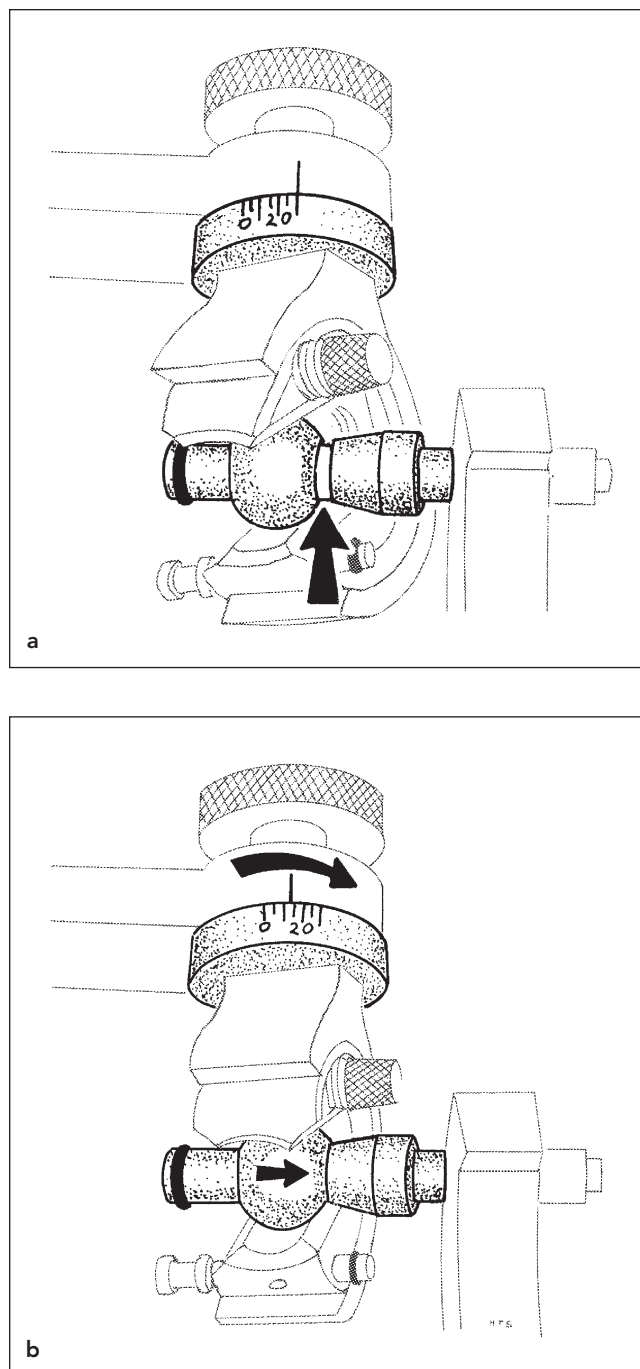


Fig 5-69 (a) With the casts seated in a lateral interocclusal record, there is a gap between the condyle and sleeve. (b) When the Bennett angle ring (and condylar track mechanism) are rotated, the condyle contacts the sleeve. The number on the scale is the angle of the lateral translation.

The condylar inclinations are entered in the patient's record. The amount of condylar inclination for each condyle is written on the corresponding side of the cast. When teeth are prepared at a future time, it will not be necessary to make new interocclusal records to adjust the articulator. The settings developed during the diagnostic mounting can be reused.

5 Articulation of Casts

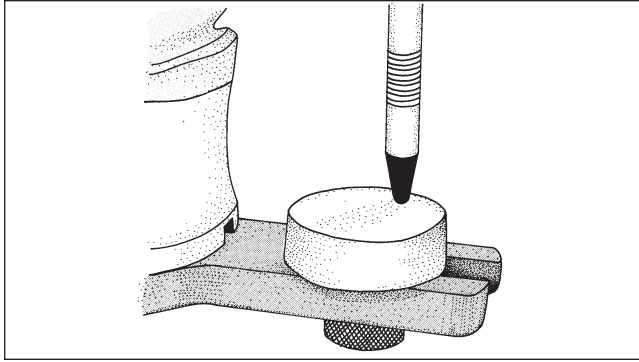


Fig 5-70 The incisal guide pin is raised 1.0 mm off the guide block.

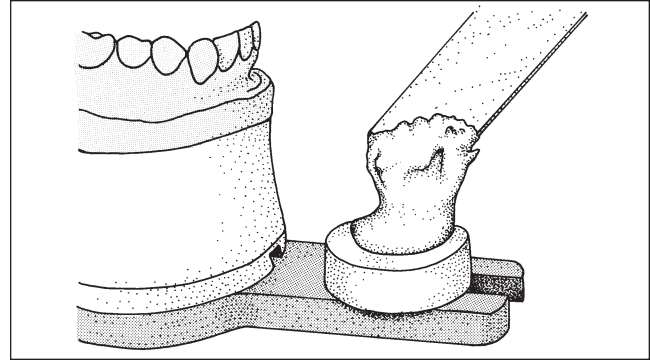


Fig 5-71 Tray resin is placed on the incisal block.

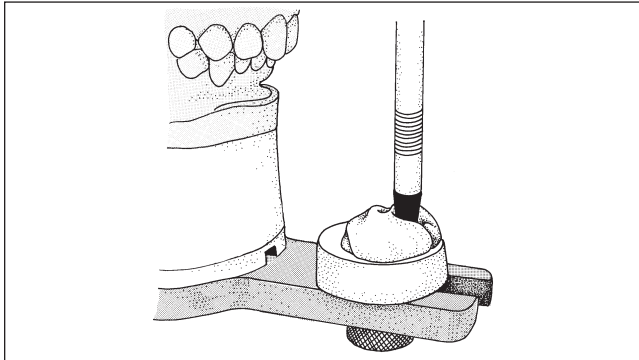


Fig 5-72 The guide pin is closed into the soft resin.

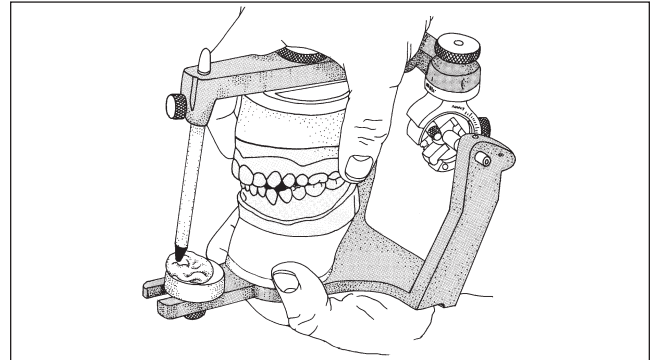


Fig 5-73 The casts are moved through all excursions.

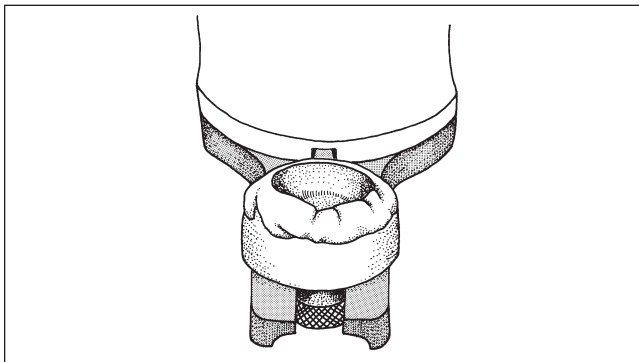


Fig 5-74 There is a custom anterior guidance record on the guide block.

Custom anterior guidance

A customized anterior guidance jig can be made for this articulator using a round-end incisal pin and a flat anterior table or an incisal cup. Acrylic resin or a light-cured material (Triad) is molded by the end of the incisal pin in the same manner that the anterior guidance is recorded for the other articulators. The mounted casts are examined on the articulator, and any nonworking interferences are removed. The articulator must be able to move freely with the anterior teeth in contact. If the guidance is inadequate, it is rebuilt to an optimum configuration with a diagnostic wax-up.

The incisal guide pin is raised at least 1 mm off the plastic incisal guide block in all excursions (Fig 5-70). The surface of the guide block is moistened with monomer. A half scoop of

tray resin is mixed, and, while it is still free-flowing, a small amount is placed on the incisal guide. As the polymerizing resin becomes stiffer, more is added until there is about 6 mm (¼ inch) of it covering the guide block (Fig 5-71). The tip of the incisal guide pin and the occluding surfaces of the anterior teeth are lubricated with petrolatum. The articulator is closed to complete contact between the casts. The guide pin should sink into the soft acrylic resin (Fig 5-72). The articulator is moved through all excursions repeatedly, keeping the anterior teeth touching at all times (Fig 5-73). The pathways of all the movements will be imprinted by the tip of the guide pin in the acrylic resin as a permanent record (Fig 5-74). Movement of the casts is continued until polymerization is complete. The excess is removed.

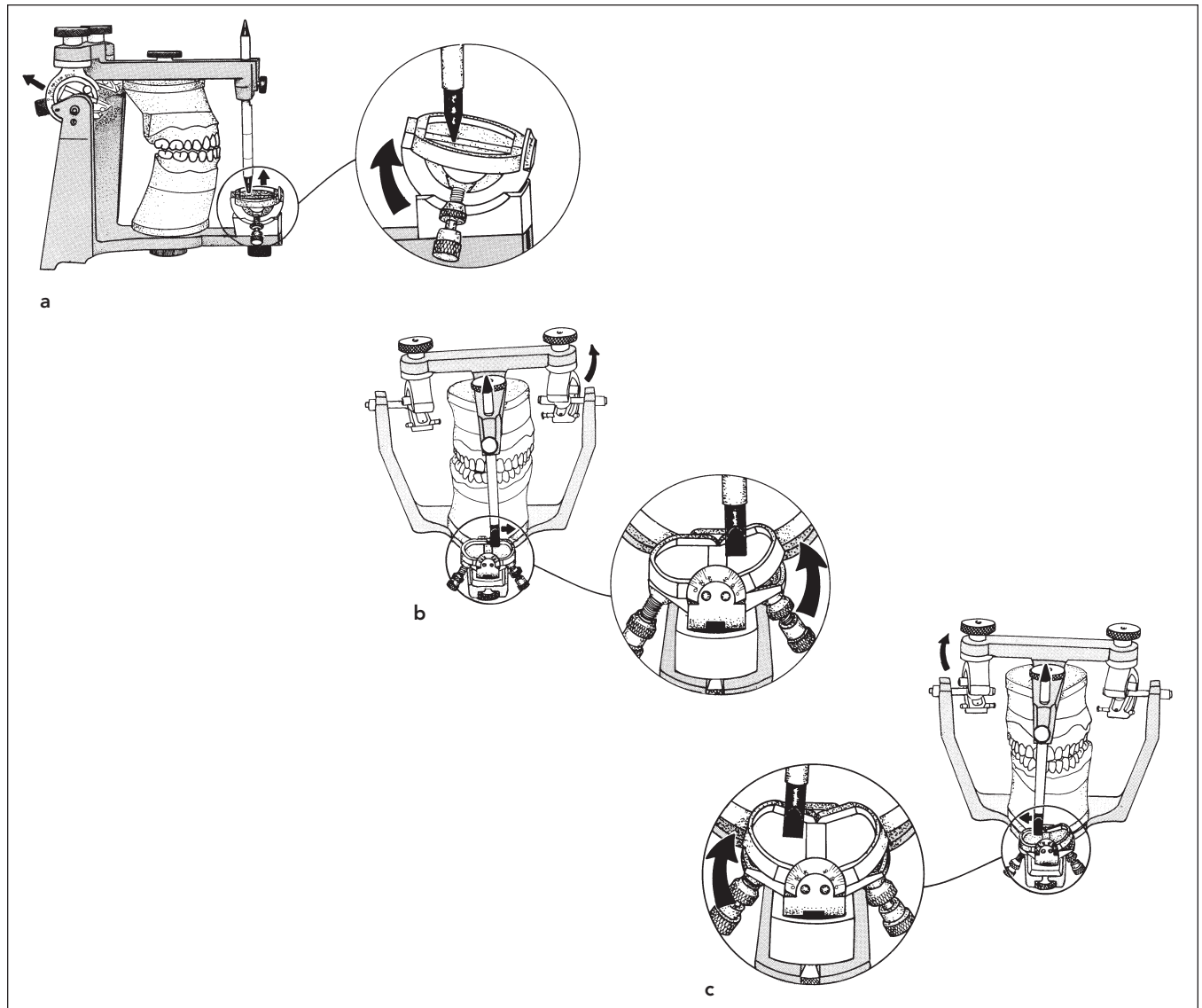


Fig 5-75 To set the mechanical incisal guide, the casts are moved into a protrusive relationship. (a) The angulation of the table is increased to contact the pin. (b) The casts are moved into a right lateral excursion, and the left wing of the incisal table is raised. (c) The casts are moved into a left lateral excursion, and the right wing of the table is lifted to complete the recording.

Mechanical anterior guidance

The guidance of mandibular movement imparted by the anterior teeth also can be recorded on this instrument with a mechanical incisal guide. The mounted casts are examined. Any interferences that prevent the anterior teeth from remaining in contact in all excursions are removed from the casts. Any inadequacies in the guidance are restored by building up an optimum configuration in a diagnostic wax-up.

The lock nut under the incisal table at the front end of the lower member of the articulator is loosened. The incisal pin should be in contact with the incisal table.

The casts are protected from undue abrasion by lubrication of the contacting surfaces with petrolatum. The upper

member of the articulator is gently moved back to bring the maxillary and mandibular teeth into an end-to-end position. The incisal pin will be lifted off the incisal table. The incisal guide is rotated to raise it posteriorly until it makes contact with the pin (Fig 5-75a). The lock nut is tightened to maintain this inclination of the table.

The casts are moved into a right lateral excursion. The pin will move to the left side and will again be lifted off the table. The small thumb nut under the left side of the table is loosened, and the elevating screw is used to raise the left wing of the table into contact with the corner of the guide pin (Fig 5-75b). The process is repeated by moving the casts into a left lateral excursion. The right wing of the incisal table is raised to contact the pin (Fig 5-75c).

5 Articulation of Casts

References

1. Pruden WH. The role of study casts in diagnosis and treatment planning. *J Prosthet Dent* 1960;10:707–710.
2. Hickey JC, Lundeen HC, Bohannon HM. A new articulator for use in teaching and general dentistry. *J Prosthet Dent* 1967;18:425–437.
3. Teteruck WR, Lundeen HC. The accuracy of an ear face-bow. *J Prosthet Dent* 1966;16:1039–1046.
4. Cowan RD, Sanchez RA, Chappell RP, Glaros AG, Hayden WJ. Verifying the reliability of interchanging casts with semiadjustable articulators. *Int J Prosthodont* 1991;4:258–264.
5. Sokolow SM. Interchangeable quick-mounted study models. *J Clin Orthod* 1986;20:779–781.
6. Weinberg LA. Physiologic objective of reconstruction techniques. *J Prosthet Dent* 1960;10:711–724.
7. Schuyler CH. The function and importance of incisal guidance in oral rehabilitation. *J Prosthet Dent* 1963;13:1011–1030.
8. Strohaber RA, Ryan JR. New face-bow simplifies use and dental laboratory cooperation. *J Prosthet Dent* 1988;60:638–641.

Treatment Planning for Single-Tooth Restorations

6

Using cast metal, ceramic, and metal-ceramic restorations, large areas of missing coronal tooth structure can be replaced while the remainder is preserved and protected. Function can be restored, and where required, a pleasing esthetic effect can be achieved. The successful use of these restorations is based on thoughtful treatment planning, which is manifested by choosing a restorative material and design that are suited to the needs of the patient. In a time when production and efficiency are heavily stressed, it should be restated that the needs of the patient take precedence over the convenience of the dentist.

In what circumstances should cemented restorations made from cast metal or ceramic be used instead of amalgam or composite resin restorations? The selection of the material and design of the restoration is based on several factors.

The first factor is *destruction of tooth structure*. If the amount of destruction previously suffered by the tooth to be restored is such that the remaining tooth structure must gain strength and protection from the restoration, cast metal or ceramic is indicated over amalgam or composite resin.

Esthetics is another important factor. If the tooth to be restored with a cemented restoration is in a highly visible area, or if the patient is highly discriminating, the esthetic effect of the restoration must be considered. Sometimes a partial coverage restoration will serve this function. Where full coverage is required in such an area, the use of ceramic in some form is indicated. Metal-ceramic crowns can be used for single-unit anterior or posterior crowns, as well as for fixed partial denture retainers. All-ceramic crowns are most commonly used on incisors, although they can be used on posterior teeth when an adequate amount of tooth structure has been removed and the patient is willing to accept the possibility of more frequent replacement.

Plaque control also plays a role. The use of a cemented restoration demands the institution and maintenance of a good plaque-control program to increase the chances for success of the restoration. Many teeth are seemingly prime candidates for cast metal or ceramic restorations, based solely on the amount of tooth destruction that has previ-

ously occurred. However, when these teeth are evaluated from the standpoint of the oral environment, they may, in fact, be poor candidates for cemented restorations. If extensive plaque, decalcification, and caries are present in a mouth, the use of crowns of any kind should be carefully weighed. The design of a restoration should take into account those factors that will enable the patient to maintain adequate hygiene to make the restoration successful. The patient must be motivated to follow a regimen of brushing, flossing, and dietary regulation to control or eliminate the disease process responsible for destruction of tooth structure. It may be desirable to use pin-retained amalgam provisional restorations to save the teeth until the conditions responsible for the tooth destruction can be controlled. This will give the patient the time necessary to learn and demonstrate good oral self-care. It will also permit the dentist and staff to reinforce the skills required of the patient and to evaluate the patient's willingness and ability to cooperate. If these measures prove successful, cast metal, ceramic, or metal-ceramic restorations can be fabricated. Because these restorations are used to repair the damage caused by caries and do nothing to cure the condition responsible for the caries, they should not be used if the oral environment has not been brought under control.

A fourth factor is *financial considerations*. Finances influence all treatment plans because someone must pay for the treatment. That may be a government agency, a branch of the military, an insurance company, and/or the patient. If the patient is to pay, the dentist should provide good advice and then allow the patient to make the choice. A conscientious dentist must walk a fine ethical line. On the one hand, a dentist should not preempt the choice by selecting a less-than-optimum restoration just because he or she thinks that the patient cannot afford the optimum treatment. On the other hand, a dentist should be sensitive enough to the individual patient's situation to offer a sound alternative to the optimum treatment plan and not apply pressure.

A final factor is *retention*. Full coverage crowns are unquestionably the most retentive^{1,2} (Fig 6-1). However, maxi-

6 Treatment Planning for Single-Tooth Restorations

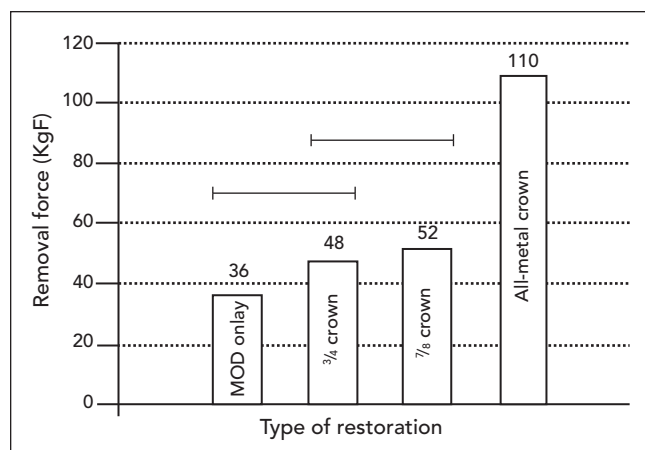


Fig 6-1 A comparison of resistance to removal forces for four types of crowns ($P = .05$).^{1,2} MOD, mesio-occlusodistal.

mum retention is not nearly as important for single-tooth restorations as it is for fixed partial denture retainers. It does become a special concern for short teeth and removable partial denture abutments.

Twelve restoration types are presented in the following pages to provide a frame of reference for making a decision whether to use a “plastic” restoration or a cemented restoration. The plastic restoration is inserted as a soft (ie, plastic) mass into the cavity preparation, where it will harden and be retained by mechanical undercuts or adhesion. The cemented restoration, made of cast metal, metal-ceramic, or all-ceramic material, is fabricated outside of the operatory and is luted or bonded to the patient’s tooth at a subsequent appointment. One type can be better suited for a particular application than the other, or in some cases either may be suitable.

Intracoronar Restorations

When sufficient coronal tooth structure exists to retain and protect a restoration under the anticipated stresses of mastication, an intracoronar restoration can be employed. In this circumstance, the crown of the tooth and the restoration itself are dependent on the strength of the remaining tooth structure to provide structural integrity.

Glass ionomer

Small lesions where extensions can be kept minimal and where preparation retention will be minimal can be restored with glass ionomer. It is useful for restoring Class V lesions caused by erosion or abrasion (Fig 6-2). It also can be employed for incipient lesions on the proximal surfaces of posterior teeth by use of a so-called tunnel preparation, which leaves the marginal ridge intact (Fig 6-3).

Glass ionomer has found a niche in the restoration of root caries in geriatric and periodontal patients (Fig 6-4). An occlusal approach may be precluded by the presence of an otherwise acceptable crown, or a conventional restoration at such an apical level might require the destruction of an unacceptable amount of tooth structure. In addition, handpiece access may be too restricted to create the needed retention for a small amalgam restoration.

Glass ionomer also can be placed rapidly enough to serve as an interim treatment restoration to assist in the control of rampant caries (Fig 6-5). This is further enhanced by the release of fluoride by the material.

Composite resin

This material can be used for minor to moderate lesions in esthetically critical areas (Fig 6-6). While it can be used in the restoration of incisal angles assisted by acid etching, a tooth that has received a Class IV resin restoration ultimately will require a crown.

Composite resin has been used in the restoration of posterior teeth with mixed results. Sufficient abrasion resistance to prevent occlusal wear has been a problem. Also, unless the resin is carefully applied in small increments, polymerization shrinkage will lead to leakage and ultimately to failure. Its use probably should be restricted to small occlusal and mesio-occlusal restorations on first premolars.

An innovative approach to the prevention of root caries at the margins of restorations that extend from enamel to cementum is the application of a slurry of unfilled resin and sodium fluoride combined with laser energy.³ This approach resulted in a significantly increased resistance to acid and mechanical destruction. In another study, topical fluoride in combination with laser energy provided resistance to enamel caries.⁴

A technique devised to combat the problems of shrinkage and leakage is the fabrication of a composite resin inlay (Fig 6-7). This can be accomplished in the dental office, using a fast-setting gypsum cast, or in a dental laboratory. The resultant bench-polymerized inlay will have greater hardness, and the thin layer of resin used for affixing it to tooth structure will be less susceptible to significant shrinkage at the margin than a restoration that is bulk cured in situ.

Simple amalgam

The simple amalgam, without pins or other means of auxiliary retention, for decades has been the standard one- to three-surface restoration for minor- to moderate-sized lesions in esthetically noncritical areas (Fig 6-8). It has received a good amount of negative attention in the media, and some segments of the profession use this as an excuse to replace otherwise acceptable amalgam restorations with composite resin. The American Dental Association’s Statement on Dental Amalgam states that amalgam is a valuable, viable, and safe choice for dental patients.⁵ A European Commission’s

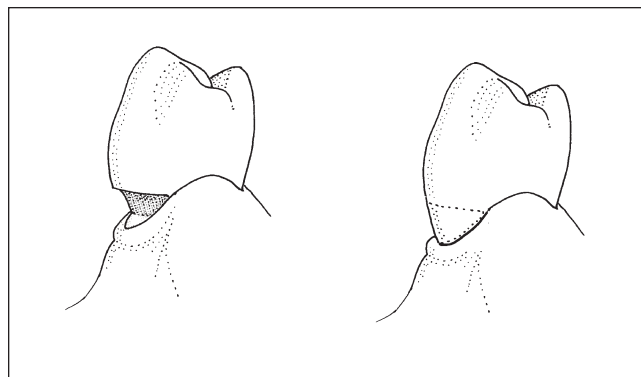


Fig 6-2 Glass ionomer can be used to restore gingival abrasion or erosion.

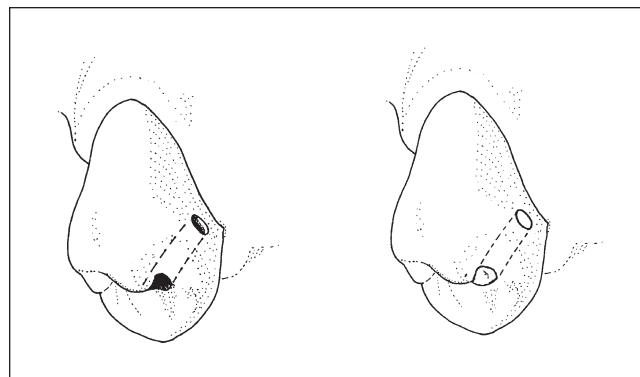


Fig 6-3 Tunnel preparation and glass ionomer can be used to restore an incipient lesion on the proximal surface of a posterior tooth.

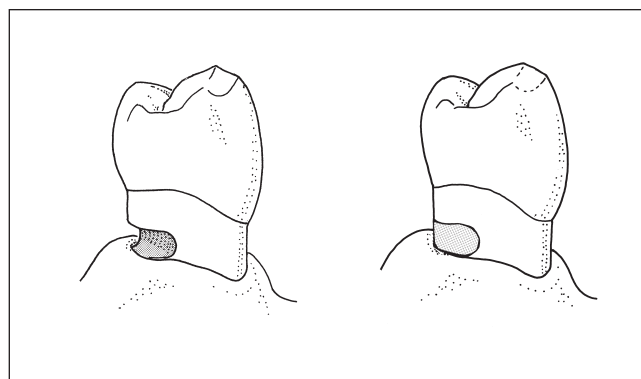


Fig 6-4 Root caries restored with glass ionomer.

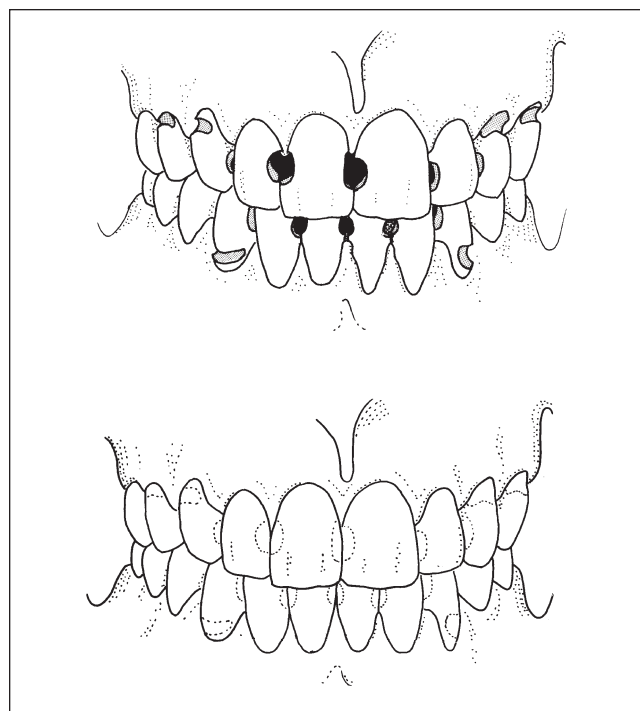


Fig 6-5 Rampant caries can be brought under control with glass ionomer.

Scientific Committee also concluded that amalgams are effective and safe.⁶ They further state that there is no clinical justification for removing satisfactory amalgams except for allergic reactions. Nor is the mere presence of a defective margin alone enough to require replacement.⁷ Approximately 71 million or more simple amalgam restorations are placed annually.⁸ They are best used where more than half of the coronal dentin is intact.

Tooth preparation size for incipient lesions has diminished in recent years as the popularity of the concept of "extension for prevention" has waned. This move toward less destructive preparations has been augmented by the development of smaller instruments and stronger amalgams. Nonetheless,

even a minimal preparation for an amalgam restoration significantly weakens the structural integrity of the tooth.⁹

Complex amalgam

Amalgam augmented by pins or other auxiliary means of retention can be used to restore teeth with moderate to severe lesions in which less than half of the coronal dentin remains (Fig 6-9). Amalgam used in this manner can be employed as a definitive restoration when a crown is contraindicated because of limited finances or poor oral hygiene. It can be used in the restoration of teeth with missing cusps or endodon-

6 Treatment Planning for Single-Tooth Restorations

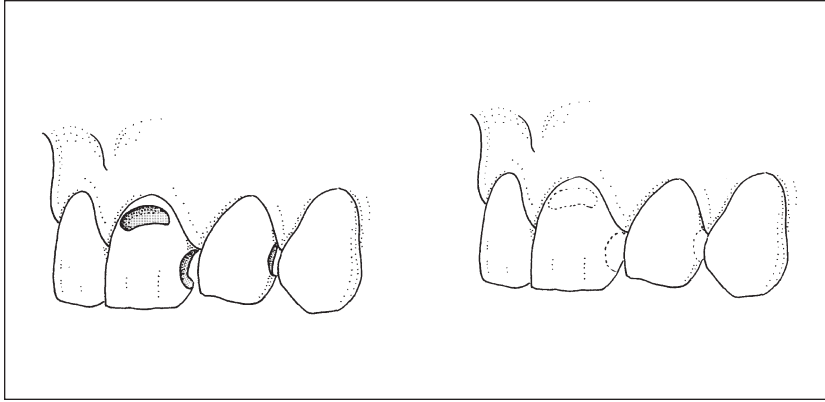


Fig 6-6 Composite resin is commonly used to restore Class III and Class V lesions on anterior teeth.

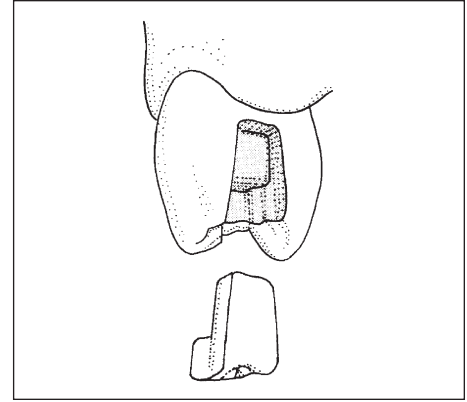


Fig 6-7 Indirect inlays of composite resin can be used for proximo-occlusal restorations on posterior teeth.

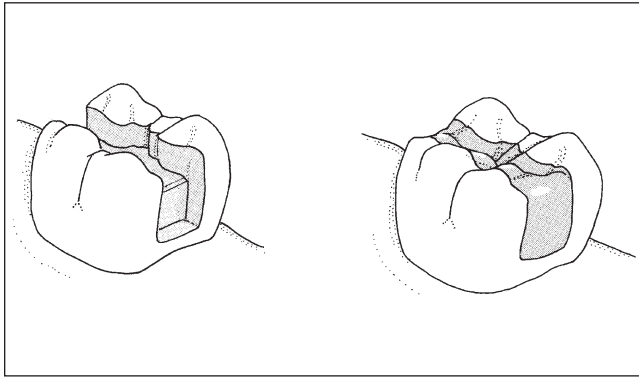


Fig 6-8 A simple amalgam restoration placed in an MOD preparation on a molar.

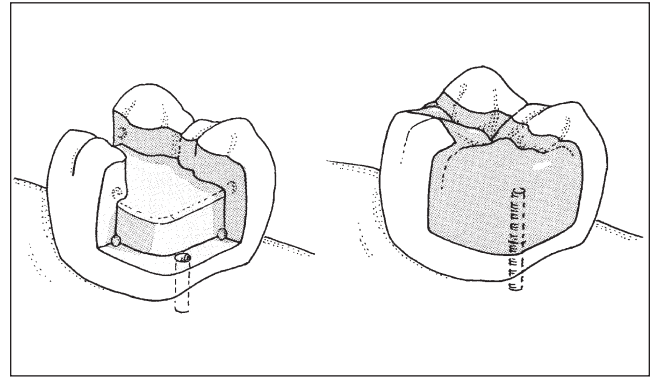


Fig 6-9 A complex amalgam restoration replaces a missing cusp on a molar.

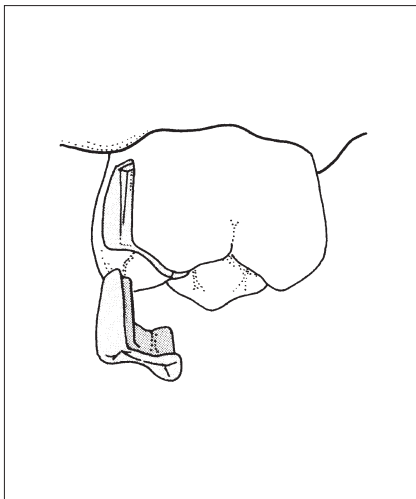


Fig 6-10 A metal inlay is used to restore a molar.

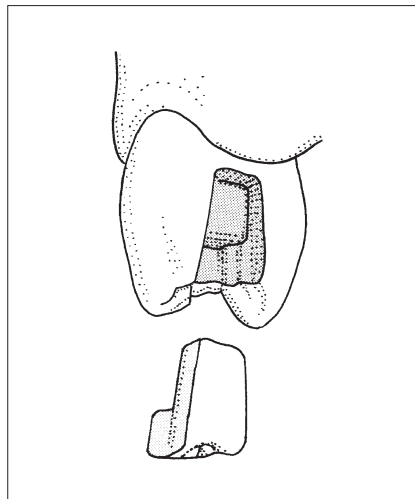


Fig 6-11 Ceramic inlays can be used to restore posterior teeth.

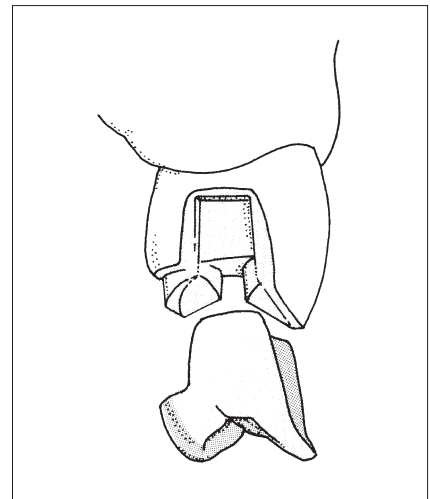


Fig 6-12 An MOD onlay for a maxillary premolar.

tically treated premolars and molars—teeth that ordinarily would be restored with mesio-occlusodistal (MOD) onlays or other extracoronary restorations. In such situations, amalgam is used to replace or overlay the cusp to provide the protection of occlusal coverage. Although amalgam produces good strength in the restored tooth,¹⁰ ideally a crown should be constructed over the pin-retained amalgam, using it as a core, or foundation restoration.

Metal inlay

Teeth with low esthetic requirements and small- to moderate-sized lesions can be restored with metal inlay restorations (Fig 6-10). Although usually made of softer gold alloys, metal inlays also can be fabricated of etchable base metal alloys if a bonding effect is desired.^{11,12} The preparation isthmus should be narrow to minimize stress in the surrounding tooth structure. Premolars should have one intact marginal ridge to preserve structural integrity and minimize the possibility of coronal fracture.

The additional bulk of tooth structure found in a molar permits the use of this restoration type in an MOD configuration. The indications for this type of restoration are much the same as those for an amalgam because this restoration only replaces lost tooth structure and will not protect remaining tooth structure. Because of the amount of destruction of tooth structure required by this restoration, it is not recommended for incipient lesions.

Ceramic inlay

Ceramic inlay restorations are used to restore teeth with small- to moderate-sized lesions that permit a narrow preparation isthmus in an area of the mouth where the esthetic demand is high. Premolars should have one intact marginal ridge, but MOD ceramic inlays can be used in molars (Fig 6-11). This type of restoration can also be etched to enhance bonding, and there is some evidence that the structural integrity of the tooth cusps may be stabilized by bonding.¹³ The relatively large size of the cavity preparation required for this restoration precludes its use in the treatment of incipient lesions.

Mesio-occlusodistal onlay

This design can be used for restoring moderately large lesions on premolars and molars with intact facial and lingual surfaces (Fig 6-12). It will accommodate a wide isthmus and up to one missing cusp on a molar. If a cast metal restoration is needed on a premolar with both marginal ridges compromised, it should include occlusal coverage to protect the remaining tooth structure. This restoration also can be considered an extracoronary restoration because of the occlusal coverage that overlays and protects the tooth cusps.

The MOD onlay does not have the necessary resistance to be used as a fixed partial denture retainer. Although ordinarily fabricated of a gold alloy, this restoration design has been used with cast glass and other types of ceramics. Ceramic MOD onlays should be used very cautiously. Without generous occlusal thickness, these restorations are susceptible to fracture.

Extracoronary Restorations

If insufficient coronal tooth structure exists to retain the restoration within the crown of the tooth, an extracoronary restoration, or *crown*, is needed. It may also be used where there are extensive areas of defective axial tooth structure or if there is a need to modify contours to refine occlusion or improve esthetics.

Partial coverage crown

This is a crown that leaves one or more axial surfaces uncovered (Fig 6-13). Therefore, it can be used to restore a tooth with one or more intact axial surfaces with half or more of the coronal tooth structure remaining. It will provide moderate retention and can be used as a retainer for short-span fixed partial dentures. If tooth destruction is not excessive, a partial coverage crown with a minimally extended preparation and carefully finished margins can satisfy moderate esthetic demands in the maxillary arch.

All-metal crown

The all-metal conventional crown can be used to restore teeth with multiple defective axial surfaces (Fig 6-14). It will provide the maximum retention possible in any given situation, but its use must be restricted to situations where there are no esthetic expectations. This will usually limit it to second molars, some mandibular first molars, and occasionally mandibular second premolars. Because less tooth structure must be removed for its preparation than for crowns with a ceramic component, and because its fabrication is the simplest of any crown, this restoration should remain among those designs considered in planning single-tooth restorations on molars as well as posterior fixed partial dentures.

Metal-ceramic crown

A metal-ceramic crown also can be used to restore teeth with multiple defective axial surfaces (Fig 6-15). It, too, is capable of providing maximum retention, but it also will meet high esthetic requirements. It can be used as a fixed partial denture retainer where full coverage and a good cosmetic result must be combined.

6 Treatment Planning for Single-Tooth Restorations

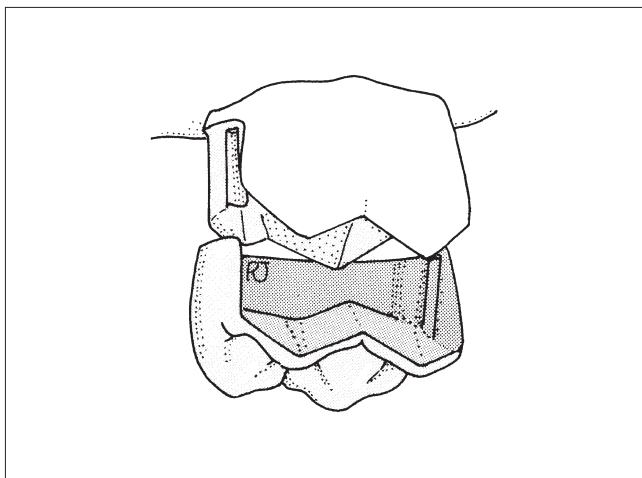


Fig 6-13 A three-quarter crown being seated on a molar.

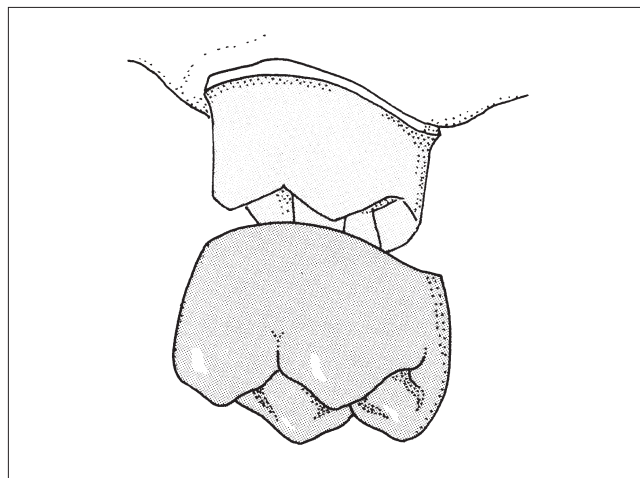


Fig 6-14 An all-metal full crown on a maxillary second molar.

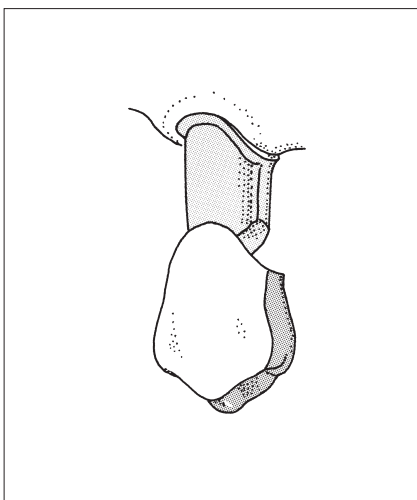


Fig 6-15 A metal-ceramic crown on a maxillary premolar.

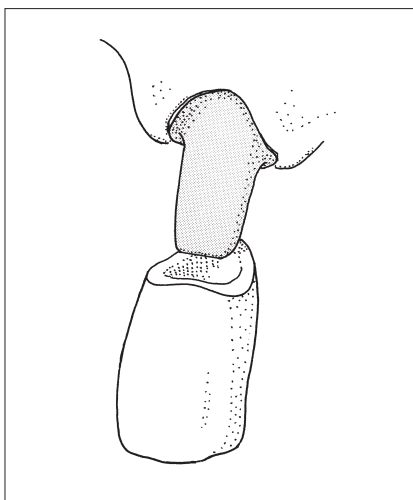


Fig 6-16 An all-ceramic crown on an incisor.

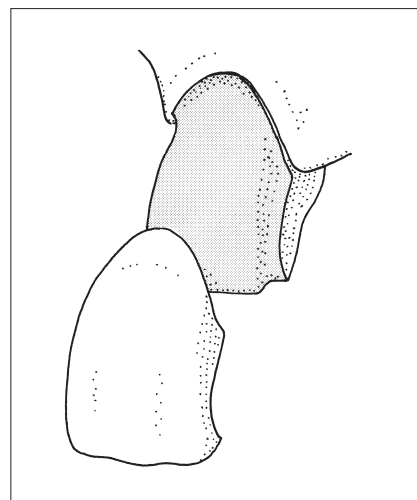


Fig 6-17 A ceramic veneer on a maxillary incisor.

All-ceramic crown

When full coverage and maximum esthetics must be combined, an all-ceramic crown is the treatment of choice (Fig 6-16). All-ceramic crowns are not as resistant to fracture as metal-ceramic crowns, so their use must be restricted to situations likely to produce low to moderate stress. They are usually used for incisors, although cast glass ceramics are also employed in the restoration of posterior teeth. Preparations for this type of restoration on premolars and molars require the removal of large quantities of tooth structure.

Ceramic veneer

Because all-ceramic and metal-ceramic crowns require the removal of such large quantities of tooth structure, there has been considerable interest in less destructive alternatives. The ceramic veneer has emerged as a means of producing an esthetic result on otherwise intact anterior teeth that are marred by severe staining or developmental defects restricted to the facial surface of the tooth (Fig 6-17). This restoration also can be used to restore moderate incisal chipping and small proximal lesions. The use of a veneer requires only minimal tooth preparation and therefore offers an alternative to crowns that is attractive to the patient and dentist alike.

The features and capabilities of the 12 types of single-tooth restorations described in this chapter are shown in Table 6-1.

Table 6-1 Features and applications of single-tooth restorations

Restoration	Size of lesion	Longevity rating	FPD abutment	RPD abutment	Esthetics	Retention	Protects tooth	Replaces cusp	Occlusal restoration	Incisal restoration	Facial restoration	Endodontic restoration
Intracoronar												
Glass ionomer	Incipient	5	No	No	Adequate	NA	No	No	Poor	Poor	Class V	No
Composite resin	Incipient to moderate	4	No	No	Good	NA	No	No	Poor	Adequate	Class V	No
Simple amalgam	Incipient to moderate	1	No	Yes	Poor to adequate*	NA	No	No	Class II	No	Class V	No
Complex amalgam	Large	3	No	Yes	Poor to adequate*	NA	Some	Yes	Adequate	No	All†	Yes‡
Metal inlay	Moderate	2	No	Yes	Poor to adequate*	Minimal	No§	No	Class II	Poor	Class V	No
Ceramic inlay	Moderate	3	No	No	Good	Minimal	No§	No	Class II	Adequate	Class V	No
MOD onlay	Moderate to large	1	No	Yes	Poor to adequate*	Moderate	Yes	Yes	Good	No	No	Yes
Extracoronar												
Partial coverage crown	Large	1	Yes	Yes	Poor to adequate	Moderate	Yes	Yes	Good	Poor	Rev ¾; Prox ½†	Yes
All-metal crown	Large	1	Yes	Yes	Poor	Good	Yes	Yes	Good	Poor	All†	Yes
Metal-ceramic crown	Large	2	Yes	Yes	Good	Good	Yes	Yes	Good	Good	All	Yes
All-ceramic crown	Large	3	No	No	Good	Good	Yes	Yes¶	Adequate	Good	All	Yes
Ceramic veneer	Incipient	3	No	No	Good	Adequate	No	No¶	Poor	Good	All	No

FPD, fixed partial denture; RPD, removable partial denture; NA, not applicable; rev, reverse; prox, proximal.

*Dependent on tooth position, location of restoration (mesial or distal), and patient expectation.

†Structurally sound, but not esthetic.

‡An acceptable compromise treatment if cusps are capped with amalgam.

§May offer some protection in conjunction with etching and bonding.

¶When used with a core or foundation restoration.

*Can be used to replace an incisal corner.

6 Treatment Planning for Single-Tooth Restorations

Restoration Longevity

Every dentist would like to be able to answer the patient's question, "How long will my restoration last?" Logical though this question may be, unfortunately it is impossible to answer directly. We cannot predict the life span of a pair of shoes or a television set, and these everyday items are not custom made, nor do they perform their service in a hostile biologic environment, submerged in water.

Clinical studies of restoration longevity have produced widely disparate figures. As a general rule, cast restorations will survive in the mouth longer than amalgam restorations, which in turn will last longer than composite resin restorations.¹⁴ A compilation of five studies of 676 patients concluded that amalgam restorations exhibit a 50% failure rate between 5.5 and 11.5 years, with an extrapolated life expectancy of 10 to 14 years.¹⁵

Meeuwissen et al¹⁶ reported a 10-year survival rate of 58% for amalgam restorations in Dutch military patients; Arthur et al¹⁷ reported an 83% survival rate for the same time span in a US military population. Qvist et al¹⁸ found that 50% of the amalgam restorations in a group of Danish patients had failed at 7 years. Christensen¹⁹ estimated a 14-year longevity for amalgam restorations. In selected populations, amalgam restorations of unspecified types or sizes in one study¹⁴ have shown 10-year survival rates as high as 72%. A 15-year survival rate of 72.8% was reported for simple amalgams in another study.²⁰

A survey of 571 fixed prosthodontists, nonspecialist restorative dentists, and dental school faculty projected an average life span of 11.2 years for simple amalgams and 6.1 years for complex amalgams.²¹ One group of 125 complex amalgams was reported to have a 76% survival rate at 15 years,²⁰ whereas another group of 171 complex amalgam restorations exhibited a 50% survival rate at 11.5 years.²²

Composite resin restorations have not been included in many longevity studies. A study of dental school patients that did incorporate them reported a 10-year survival rate of 55.9%.¹⁴ Another report, based on a general patient population, described a shorter life span for composite resin restorations, with 50% of them having failed in 6.1 years.²³

Mount²⁴ disclosed an overall success rate of 93% for 1,283 glass-ionomer restorations for up to 7 years, with the rate varying from 2% to 36% depending on the class of cavity and the brand of cement. In that study, the patients evaluated had been treated by only two dentists, and not all of the restorations had been in place for the full 7-year span of the study. While promising, these figures must be assessed cautiously until longer studies of a broader population have been completed.

Schwartz et al,²⁵ after studying a group of 791 failed restorations, reported mean life spans, at failure, of 10.3 years for full crowns, 11.4 years for three-quarter crowns, and 8.5 years for porcelain jacket crowns (anterior all-ceramic crowns). The mean life span for all fixed prosthodontic restorations was 10.3 years. Walton and associates,²⁶ evaluating a group of 424 restorations, found full crowns lasting 7.1 years, partial veneer crowns 14.3 years, metal-ceramic crowns 6.3 years, inlays and onlays 11.2 years, and porcelain jacket crowns 8.2 years.

The dentists responding to Christensen's survey estimated the longevity of crowns to be from 21 to 22 years.¹⁹ The estimates supplied by the respondents to a survey by Maryniuk and Kaplan²¹ were 12.7 years for metal-ceramic crowns and 14.7 years for all-gold restorations. Kerschbaum,²⁷ examining German insurance records, found 91.5% of gold crowns still in the mouth after 8 years. In a review of records in 40 Dutch dental offices, Leempoel et al²⁸ told of 10-year survival rates of 98% and 95.3% for full crowns and metal-ceramic crowns, respectively.

A compilation of longevity studies from several studies is presented in Table 6-2.

The question of longevity is an important one to consider when choosing treatment for a patient. The more destructive the preparation required for the restoration, the greater the potential risk for the tooth and ultimately the greater expense. In 1989, it was estimated that if a crown were placed in a patient's mouth at age 22, at a fee of \$425, attendant services and replacements of that crown would cost the patient nearly \$12,000 considering an average life expectancy of 75 years.³² Today, the original fee may be double, or \$850, with a corresponding doubling of the subsequent effect, resulting in a cost to the patient of nearly \$24,000.

Table 6-2 Longevity of single-tooth restorations

Investigator(s)	Type of study	No. of restorations	Restoration type										
			Glass ionomer	Composite resin	Simple amalgam	Complex amalgam	Metal inlay	Ceramic inlay	MOD onlay	Partial coverage crown	All-metal crown	Metal-ceramic crown	All-ceramic crown
Bentley and Drake ¹⁴	Clinical	1,207	—	55.9% at 10 y	72.0% at 10 y	—	87.3% at 10 y	—	87.3% at 10 y	—	86.3% at 10 y	—	—
Maryniuk ¹⁵	Clinical*	1,940	—	—	10 to 14 y	—	—	—	—	—	—	—	—
Meeuwissen et al ¹⁶	Clinical	8,492	—	—	58.0% at 10 y	—	—	—	—	—	—	—	—
Arthur et al ¹⁷	Clinical	2,200	—	—	83% at 10 y	—	—	—	—	—	—	—	—
Qvist et al ^{18,23}	Clinical	442	—	50% at 6.1 y	50% at 7.0 y	—	—	—	—	—	—	—	—
Christensen ¹⁹	Survey	731	—	7.3 y	13.8 y	—	20.6 y	12.7 y	20.6 y	20.6 y	22.2 y	—	—
Smales ²⁰	Clinical	768	—	—	72.8% at 15 y	72.6% at 15 y	—	—	—	—	—	—	—
Maryniuk and Kaplan ²¹	Survey	571	—	—	11.2 y	6.1 y	12.7 y	—	—	14.7 y	12.7 y	—	—
Robbins and Summitt ²²	Clinical	128	—	—	—	50% at 11.5 y	—	—	—	—	—	—	—
Mount ²⁴	Clinical	1,283	93% at 7 y	—	—	—	—	—	—	—	—	—	—
Schwartz et al ²⁵	Clinical	791	—	—	—	—	11 y	—	—	10.3 y	—	8.5 y	—
Walton et al ²⁶	Clinical	451	—	—	—	—	11.2 y	—	—	7.1 y	6.3 y	8.2 y	—
Kerschbaum ²⁷	Clinical	9,737	—	—	—	—	—	—	—	91.5% at 8 y	—	—	—
Leempoel et al ²⁸	Clinical	10,000	—	—	—	—	—	—	—	98% at 10 y	95.3% at 10 y [†]	82% at 10 y	—
Swift and Friedman ²⁹	Clinical	372	—	—	—	—	—	—	—	—	—	—	50% at 6.5 y
Burke and Lucarotti ³⁰	Clinical	2,562	—	—	—	—	—	—	—	—	—	—	53% at 11 y
Bernardo et al ³¹	Clinical	1,748	—	50.0%–93.6% at 7 y [‡]	90.5% at 7 y	81.8% at 7 y	—	—	—	—	—	—	—

—, not included in study. *A compilation and interpretation of five clinical studies. †Average of survival rates for anterior, premolar, and molar crowns. ‡Inversely varied with no. of surfaces restored.

6 Treatment Planning for Single-Tooth Restorations

References

- Potts RG, Shillingburg HT Jr, Duncanson MG Jr. Retention and resistance of preparations for cast restorations. *J Prosthet Dent* 1980;43:303–308.
- Kishimoto M, Shillingburg HT Jr, Duncanson MG Jr. Influence of preparation features on retention and resistance. Part I: MOD onlays. *J Prosthet Dent* 1983;49:35–39.
- Holt RA, Nordquist RE. Effect of resin/fluoride and holmium:YAG laser irradiation on the resistance to the formation of caries-like lesions. *J Prosthodont* 1997;6:11–19.
- Hicks J, Winn D 2nd, Flaitz C, Powell L. In vivo caries formation in enamel following argon laser irradiation and combined fluoride and argon laser treatment: A clinical pilot study. *Quintessence Int* 2004;35:15–20.
- American Dental Association Council on Scientific Affairs. Statement on Dental Amalgam. Revised August 2009. <http://www.ada.org/1741.aspx>. Accessed 29 May 2011.
- European Commission, Scientific Committee on Emerging and Newly Identified Health Risks. The Safety of Dental Amalgam and Alternative Dental Restoration Materials for Patients and Users, 6 May 2008. http://ec.europa.eu/health/ph_risk/committees/04_scenihp/docs/scenihp_o_016.pdf. Accessed 29 May 2011.
- Kidd EA, O'Hara JW. The caries status of occlusal amalgam restorations with marginal defects. *J Dent Res* 1990;69:1275–1277.
- Krupa D. Press Release: Review and Analysis of the Literature on the Potential Health Effects of Dental Amalgams. 9 December 2004. http://www.lsr.org/amalgam/frames_amalgam_home.html.
- Mondelli J, Steagall I, Ishikiriama A, de Lima Navarro MF, Soares FB. Fracture strength of human teeth with cavity preparations. *J Prosthet Dent* 1980;43:419–422.
- Reagan SE, Schwandt NW, Duncanson MG Jr. Fracture resistance of wide-isthmus mesio-occlusodistal preparations with and without amalgam cuspal coverage. *Quintessence Int* 1989;20:469–472.
- Kent WA, Shillingburg HT, Duncanson MG, Nelson EL. Fracture resistance of ceramic inlays with three luting materials. *J Dent Res* 1991;70(1 suppl):561.
- Livaditis GJ. Etched-metal resin-bonded intracoronal cast restorations. Part II: Design criteria for cavity preparation. *J Prosthet Dent* 1986;56:389–395.
- Bodell RW, Kent WA, Shillingburg HT, Duncanson MG. Fracture resistance of intracoronal metallic restorations and three luting materials. *J Dent Res* 1991;70(1 suppl):562.
- Bentley C, Drake CW. Longevity of restorations in a dental school clinic. *J Dent Educ* 1986;50:594–600.
- Maryniuk GA. In search of treatment longevity—A 30-year perspective. *J Am Dent Assoc* 1984;109:739–744.
- Meeuwissen R, van Elteren P, Eschen S, Mulder J. Durability of amalgam restorations in premolars and molars in Dutch servicemen. *Community Dent Health* 1985;2:293–302.
- Arthur JS, Cohen ME, Diehl MC. Longevity of restorations in a U.S. military population. *J Dent Res* 1988;67(1 suppl):388.
- Qvist V, Thylstrup A, Mjör IA. Restorative treatment pattern and longevity of amalgam restorations in Denmark. *Acta Odontol Scand* 1986;44:343–349.
- Christensen GJ. The practicability of compacted golds in general practice—A survey. *J Colo Dent Assoc* 1971;49:18–22.
- Smales RJ. Longevity of cusp-covered amalgams: Survivals after 15 years. *Oper Dent* 1991;16:17–20.
- Maryniuk GA, Kaplan SH. Longevity of restorations: Survey results of dentists' estimates and attitudes. *J Am Dent Assoc* 1986;112:39–45.
- Robbins JW, Summitt JB. Longevity of complex amalgam restorations. *Oper Dent* 1988;13:54–57.
- Qvist V, Thylstrup A, Mjör IA. Restorative treatment pattern and longevity of resin restorations in Denmark. *Acta Odontol Scand* 1986;44:351–356.
- Mount GJ. Longevity of glass ionomer cements. *J Prosthet Dent* 1986;55:682–685.
- Schwartz NL, Whitsett LD, Berry TG, Stewart JL. Unserviceable crowns and fixed partial dentures: Life-span and causes for loss of serviceability. *J Am Dent Assoc* 1970;81:1395–1401.
- Walton JN, Gardner FM, Agar JR. A survey of crown and fixed partial denture failures: Length of service and reasons for replacement. *J Prosthet Dent* 1986;56:416–421.
- Kerschbaum T. Long-term prognosis of crowns and bridges today [in German]. *Zahnärztl Mitt* 1986;76:2315–2320.
- Leempoel P, de Haan A, Reintjes A. The survival rate of crowns in 40 Dutch practices. *J Dent Res* 1986;65:565.
- Swift EJ, Friedman MJ. Critical appraisal. Porcelain veneer outcomes. Part I. *J Esthet Restor Dent* 2006;18:54–57.
- Burke FJ, Lucarotti PS. Ten-year outcome of porcelain veneers placed within the general dental services in England and Wales. *J Dent* 2009;37:31–38.
- Bernardo M, Luis H, Martin MD, et al. Survival and reasons for failure of amalgam versus composite posterior restorations placed in a randomized clinical trial. *J Am Dent Assoc* 2007;138:775–783.
- Cohen BD, Milobsky SA. Monetary damages in dental-injury cases. *Trial Lawyers Quarterly* 1989;20:80–81.

Treatment Planning for the Replacement of Missing Teeth

7

The need to replace missing teeth is obvious to the patient when the edentulous space is in the anterior segment of the mouth, but it is equally important in the posterior region. It is tempting to think of the dental arch as a static entity, but that is certainly not the case. It is in a state of dynamic equilibrium, with the teeth supporting each other (Fig 7-1). When a tooth is lost, the structural integrity of the dental arch is disrupted, and there is a subsequent realignment of teeth as a new state of equilibrium is achieved. Teeth adjacent to or opposing the edentulous space frequently move into it (Fig 7-2). Adjacent teeth, especially those distal to the space, may drift bodily, although a tilting movement is a far more common occurrence.

If an opposing tooth intrudes severely into the edentulous space, it is not enough just to replace the missing tooth (Fig 7-3). To restore the mouth to complete function, free of interferences, it is often necessary to restore the tooth opposing the edentulous space (Fig 7-4). In severe cases, this may necessitate the devitalization of the supererupted opposing tooth to permit enough shortening to correct the plane of occlusion; in extreme cases, extraction of the opposing tooth may be required.

Selection of the Type of Prosthesis

Missing teeth may be replaced by one of three prosthesis types: a removable partial denture, a tooth-supported fixed partial denture, or an implant-supported fixed partial denture (Table 7-1). Several factors must be weighed when choosing the type of prosthesis to be used in any given situation. Biomechanical, periodontal, esthetic, and financial factors, as well as the patient's wishes, are some of the more important ones. It is not uncommon to combine two types in the same arch, such as a removable partial denture and a tooth-supported fixed partial denture. Combining teeth and implants in the support of the same fixed partial denture, however, is not recommended.

In treatment planning, there is one principle that should be kept in mind: treatment simplification. There are many times when certain treatments are technically possible but too complex. It is important to narrow the possibilities and present a recommendation that will serve the patient's needs and still be reasonable to accomplish. At such times, the restorative dentist, or prosthodontist, is the one who should manage the sequencing and referral to other specialists. He or she will be finishing the treatment and should act as the quarterback. The restorative dentist must communicate and be open to suggestions but should not allow someone else to dictate the restorative phase of the treatment, which may result in carrying out a treatment plan that seems unfeasible. As the clinician who is providing the restoration, the restorative dentist is the one the patient will return to if it fails; therefore, he or she must be comfortable with the planned treatment.

The following are guidelines, not laws, and they are not absolute. However, when a preponderance of these items is used in the consideration of the planning for one arch or one mouth, a compelling reason exists for the selection of the type of prosthesis described.

Removable partial denture

A removable partial denture is generally indicated for edentulous spaces greater than two posterior teeth, anterior spaces greater than four incisors, or spaces that include a canine and two other contiguous teeth (ie, central incisor, lateral incisor, and canine; lateral incisor, canine, and first premolar; or the canine and both premolars).

An edentulous space with no distal abutment will usually require a removable partial denture. There are exceptions in which a cantilever fixed partial denture can be used, but this solution should be approached cautiously. See the section on cantilevers later in the chapter for a more detailed description of this type of restoration. Multiple edentulous spaces, each of which may be restorable with a fixed partial denture, nonetheless may call for the use of a removable partial denture because of the expense and technical complexity. Bilateral

7 Treatment Planning for the Replacement of Missing Teeth

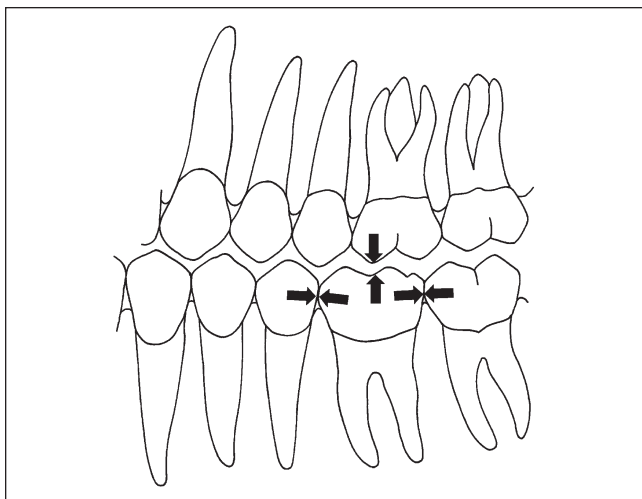


Fig 7-1 Tooth position and alignment are maintained in part by the interaction between teeth (arrows).

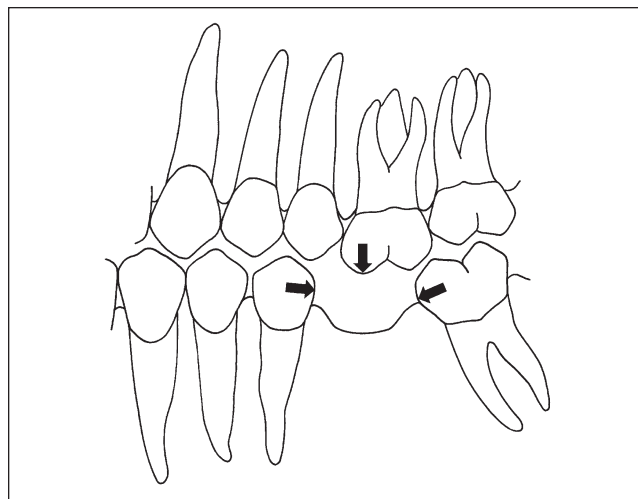


Fig 7-2 When a tooth is removed or lost, adjacent teeth often migrate into the vacated space.

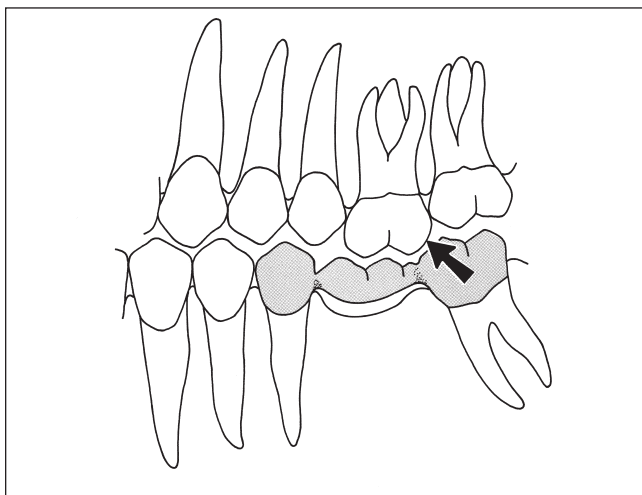


Fig 7-3 If a fixed partial denture is fabricated without first re-establishing the occlusal plane, an occlusal interference may be created (arrow).

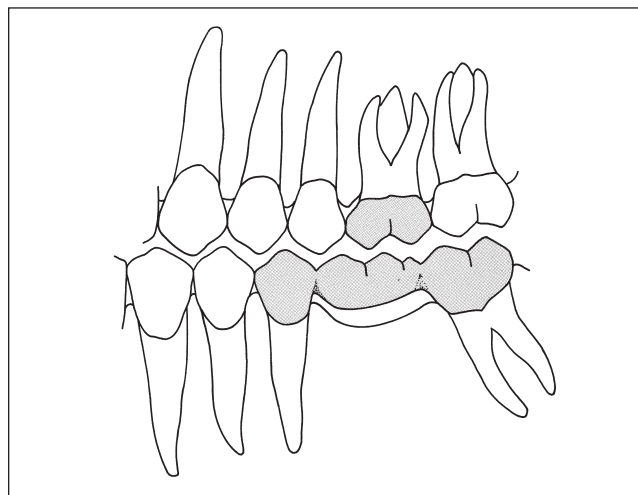


Fig 7-4 Occlusion is properly restored by correction of the occlusal plane in conjunction with placement of a fixed partial denture.

edentulous spaces with more than two teeth missing on one side also may call for the use of a removable prosthesis instead of two fixed prostheses.

The requirements of an abutment for a removable partial denture are not as stringent as those for a fixed partial denture abutment. Tipped teeth adjoining edentulous spaces and prospective abutments with divergent alignments may lend themselves more readily to use as removable rather than fixed partial denture abutments. Periodontally weakened primary abutments may serve better in retaining a well-designed removable partial denture than in bearing the load of a fixed partial denture. It is also possible to de-

sign the partial denture framework so that retentive clasps will be placed on teeth other than those adjacent to the edentulous space.

Short teeth or those with short clinical crowns usually are not good fixed partial denture abutments for anything other than a single pontic prosthesis. An insufficient number of abutments may also be a reason for selecting a removable rather than a fixed partial denture.

If there has been a severe loss of tissue in the edentulous ridge, a removable partial denture can more easily be used to restore the space both functionally and esthetically. For successful removable partial denture treatment, the patient

Table 7-1 Types of prostheses used for the replacement of missing teeth

	Removable partial denture	Conventional tooth-supported fixed partial denture	Resin-bonded tooth-supported fixed partial denture	Implant-supported fixed partial denture
Span length	Posterior spans longer than 2 teeth Anterior spans longer than 4 incisors Canine + 2 or more contiguous teeth	Posterior span: 2 or fewer Incisors: 4 or fewer	Single tooth Possible for 2 incisors	Single tooth 2- to 6-unit span
Span configuration	No distal abutment Multiple or bilateral edentulous spaces	Usually has distal abutment but can be used with short cantilever pontic	Abutments mesial and distal to pontic	No distal abutment Pier in 3+ pontic span All abutments at ends and as pier(s) of long span
Abutment alignment	Tipped abutments can be tolerated Widely divergent abutment alignment	Less than 25-degree inclination can be accommodated by preparation modification	Less than 15-degree inclination mesiodistally Should be in same faciolingual plane Preparations are not easily modified because of minimal reduction	Need for implant/abutment alignment requires close coordination between surgeon and restorative dentist
Abutment condition	Short clinical crowns Insufficient abutments	Good if abutments need crowns Nonvital teeth can be used if there is sufficient coronal tooth structure	Defect-free abutments Incisor, premolar replacements	Defect-free abutments requiring no restoration
Occlusion	More adaptable to irregularities in a healthy opposing natural dentition	Favorable loading (magnitude, direction, frequency, duration)	Cannot be used for incisor replacement in presence of deep vertical overlap	Occlusal forces must be as nearly vertical as possible to prevent unfavorable lateral loading of implants
Periodontal condition	Can use alternate (secondary) abutments when primary abutments are weakened	Good alveolar bone support Crown-root ratio 1:1 or better No mobility Favorable root morphology Provides rigid stabilization	No mobility Periodontal splints (with auxiliary resistance in tooth preparation)	Dense bone
Ridge form	Gross tissue loss in residual ridge	Moderate resorption No gross soft tissue defects	Moderate resorption No gross soft tissue defects	Broad, flat ridge
General features	Dry mouth: poor prognosis Limited patient finances Acceptable oral hygiene Reliable recall candidate Treatment simplification Advanced age Systemic health problems More adaptable to dentition in transition to edentulous state	Dry mouth: high caries risk Muscular discoordination Mandibular tori Palatal soft tissue lesions Large tongue Exaggerated gag reflex Unfavorable attitude toward RPD Patient can't cope with aging, tooth loss Favorable opposing occlusion: removable prosthesis or periodontally weakened natural dentition may permit FPD in less than optimal situations Must be within dentist's skills	Well suited for young patients Can be used for replacing molars if masticatory muscles are not too well developed	Able to survive in dry mouth May be better choice if teeth will require extensive treatment and will still be weak, questionable abutments Unfavorable attitude toward RPD Must be within dentist's skills

RPD, removable partial denture; FPD, fixed partial denture.

7 Treatment Planning for the Replacement of Missing Teeth

should demonstrate acceptable oral hygiene and show signs of being a reliable recall candidate.

Patients of advanced age who are on fixed incomes or have systemic health problems may require special treatment simplification efforts, either to cut down on the amount of appointment time required to restore the mouth or to make the treatment affordable. Cajoling patients of limited means into overinvesting their resources is not in their best interest.

A large tongue is a good reason to avoid a removable prosthesis if at all possible, as is a lack of muscular coordination. An unfavorable attitude toward a removable partial denture also makes it a poor choice.

Conventional tooth-supported fixed partial denture

When a missing tooth is to be replaced, a fixed partial denture is preferred by the majority of patients. The usual configuration for a fixed partial denture uses an abutment tooth on each end of the edentulous space to support the prosthesis. If the abutment teeth are periodontally sound, the edentulous span is short and straight, and the retainers are well designed and executed, the fixed partial denture can be expected to provide a long life of function for the patient. Several factors influence the decisions of whether to fabricate a fixed partial denture, what teeth to use as abutments, and what retainer designs to use (see Table 7-1).

There should be no gross soft tissue defect in the edentulous ridge. If there is, it may be possible to augment the ridge with grafts to enable the construction of a fixed prosthesis. This treatment is reserved for patients who are both highly motivated and able to afford this special procedure. If the patient does not meet these criteria, a removable partial denture should be considered.

A dry mouth creates a poor environment for any crown. The margins of the retainers will be at great risk from recurrent caries, limiting the life span of the prosthesis. However, an absence of moisture in the mouth also will hinder the success of a removable partial denture. In either case, the patient must be made aware of the high risk involved. The risk may be minimized through home fluoride application and frequent recall, but it cannot be eliminated.

Resin-bonded tooth-supported fixed partial denture

The resin-bonded fixed partial denture is a conservative restoration that is reserved for use on defect-free abutments in situations where there is a single missing tooth, usually an incisor or premolar. A single molar can be replaced by this type of prosthesis if the patient's muscles of mastication are not too well developed, thus assuring that a minimum load will be placed on the retainers. The resin-bonded fixed partial denture requires an abutment both mesial and distal to the edentulous space.

This prosthesis utilizes a standard pontic form, accommodating an edentulous ridge with moderate resorption and no gross soft tissue defects. Because it requires a shallow preparation that is restricted to enamel, the resin-bonded fixed partial denture is especially useful in younger patients whose immature teeth with large pulps are poor candidates for endodontic-free abutment preparations.

Tilted abutments can be accommodated only if there is enough tooth structure to allow a change in the normal alignment of axial reduction. This is limited by the need to restrict most of the reduction to enamel. Rarely can a mesio-distal difference in abutment inclination greater than 15 degrees be accommodated. There can be little or no difference in the inclination of the abutments faciolingually.

The resin-bonded prosthesis cannot be used for replacing missing anterior teeth where there is a deep vertical overlap. Reduction deep into the underlying dentin of the abutment teeth will be required in this situation, so a conventional fixed partial denture should be employed.

Although this type of prosthesis has been described for periodontal splints, it should be used with extreme care in those situations. Preparations will demand additional resistance features, such as long, well-defined grooves. Abutment mobility has been shown to be a serious hazard in the successful use of this type of restoration.

Implant-supported fixed partial denture

Fixed partial dentures supported by implants are ideally suited for use where there are insufficient numbers of abutment teeth or inadequate strength in the abutments to support a conventional fixed partial denture and when patient attitude and/or a combination of intraoral factors make a removable partial denture a poor choice. Implant-supported fixed partial dentures can be employed in the replacement of teeth when there is no distal abutment. Span length is limited only by the availability of alveolar bone with satisfactory density and thickness in a broad, flat ridge configuration that will permit implant placement.

A single tooth can be replaced by a single implant, saving defect-free adjacent teeth from the destructive effects of retainer crown preparations. A span length of two to six teeth can be replaced by multiple implants, either as single-unit restorations or as implant-supported fixed partial dentures. In fact, an entire arch can be replaced by an implant-supported complete prosthesis, but that type of restoration lies outside the realm of this discussion.

The retainers used for most implant systems require a great degree of abutment alignment precision, as do the retainers for a tooth-supported fixed partial denture. If implants are placed by someone other than the restorative dentist, implant/abutment alignment demands close coordination between surgeon and restorative dentist. The abutments should be positioned so that the occlusal forces will be as nearly vertical to the implants as possible to prevent destructive lateral forces.

Implants should be better able than natural teeth to survive in a dry mouth. Implants may be a better choice for fixed partial denture abutments if prospective tooth abutments would require endodontic therapy with or without dowel cores, periodontal surgery, and possibly root resections to support a long-span, complex, and expensive prosthesis.

No prosthetic treatment

If a patient presents with a long-standing edentulous space into which there has been little or no drifting or elongation of the adjacent or opposing teeth, the question of replacement should be left to the patient's wishes. If the patient perceives no functional, occlusal, or esthetic impairment, it would be a dubious service to place a prosthesis. This in no way contradicts the recommendation that a missing tooth routinely should be replaced. The teeth adjoining an edentulous space *usually* move, but they do not *always* move. When meeting the occasional patient who has beaten the odds, the dentist should recognize it for what it is, congratulate the patient for being fortunate, and tend to his or her other needs.

Case presentation

In cases in which the choice between a fixed partial denture and a removable partial denture is not clear cut, two or more treatment options should be presented to the patient along with their advantages and disadvantages. The dentist is in the best position to evaluate the physical and biologic factors present, while the patient's feelings should carry considerable weight on matters of esthetics and finances.

Both dentist and patient must agree on the definitive treatment plan. If the patient understands and is willing to accept the risks associated with the dentist's second-choice treatment, it is prudent to make a notation to that effect and have it signed by the patient. If the restorative dentist is convinced that a particular type of treatment desired by the patient is absolutely wrong for a given situation, an attempt should be made to educate the patient by explaining the reasons behind this opinion. If the patient remains unconvinced, the patient should be referred to someone else. Life is too short for the aggravation that may otherwise follow.

Abutment Evaluation

Every restoration must be able to withstand the constant occlusal forces to which it is subjected. This is of particular significance when designing and fabricating a fixed partial denture because the forces that would normally be absorbed by the missing tooth are transmitted, through the pontic, connectors, and retainers, to the abutment teeth. Abutment teeth are therefore called upon to withstand the forces nor-

mally directed to the missing teeth in addition to those usually applied to the abutments.

If a tooth adjacent to an edentulous space needs a crown because of damage to the tooth, the restoration usually can double as a fixed partial denture retainer. If several abutments in one arch require crowns, there is a strong argument for the selection of a fixed partial denture rather than a removable partial denture.

Whenever possible, an abutment should be a vital tooth. However, a tooth that has been endodontically treated and is asymptomatic, with radiographic evidence of a good seal and complete obturation of the canal, can be used as an abutment. However, the tooth must have some sound, surviving coronal tooth structure to ensure longevity. Even then, some compensation must be made for the coronal tooth structure that has been lost. This can be accomplished through the use of a dowel core or a pin-retained amalgam or composite resin core.

Teeth that have been pulp capped in the process of preparation should not be used as fixed partial denture abutments unless they are endodontically treated. There is too great a risk that they will require endodontic treatment later, with the resultant destruction of retentive tooth structure and of the retainer itself. This is a situation that is better handled before the fixed partial denture is made.

The supporting tissues surrounding the abutment teeth must be healthy and free from inflammation before any prosthesis can be contemplated. Normally, abutment teeth should not exhibit mobility because they will be carrying an extra load. The roots and their supporting tissues should be evaluated for three factors:

1. Crown-root ratio
2. Root configuration
3. Periodontal ligament area

Crown-root ratio

The *crown-root ratio* is a measure of the length of tooth occlusal to the alveolar crest of bone compared with the length of root embedded in the bone. As the level of the alveolar bone moves apically, the lever arm of the portion out of bone increases, and the chance for harmful lateral forces increases. The optimum crown-root ratio for a tooth to be used as a fixed partial denture abutment is 2:3; a ratio of 1:1 is the maximum ratio that is acceptable for a prospective abutment under normal circumstances (Fig 7-5).

However, there are situations in which a crown-root ratio greater than 1:1 might be considered adequate. If the occlusion opposing a proposed fixed partial denture is composed of artificial teeth, occlusal force will be diminished, with less stress on the abutment teeth. The occlusal force exerted against prosthetic appliances has been shown to be considerably less than that against natural teeth: 26.0 lbs for removable partial dentures and 54.5 lbs for fixed partial dentures versus 150.0 lbs for natural teeth.¹

7 Treatment Planning for the Replacement of Missing Teeth

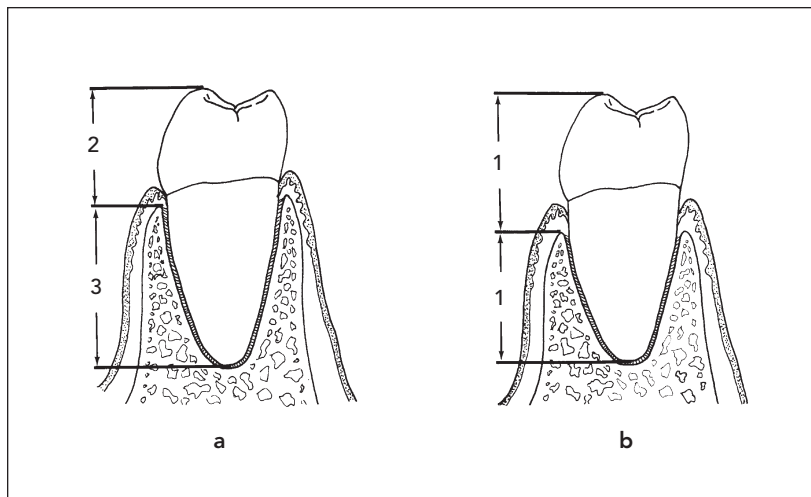


Fig 7-5 (a) The optimum crown-root ratio for a fixed partial denture abutment is 2:3. (b) A ratio of 1:1 is the maximum that is acceptable.

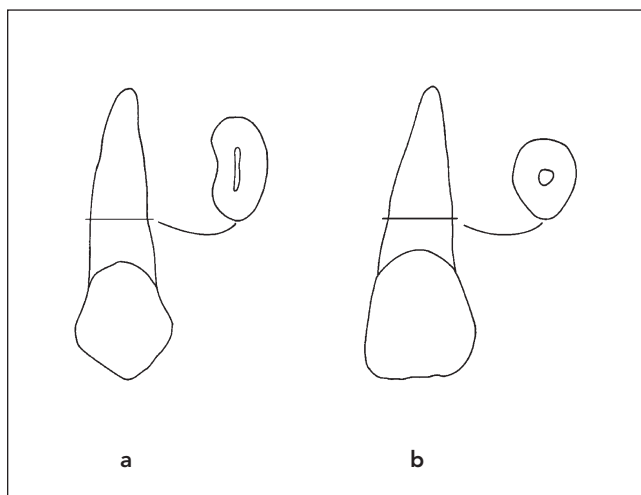


Fig 7-6 Although the root surface area of these teeth is similar, the root configuration of the maxillary premolar (a), with its greater faciolingual dimension, makes it a superior abutment to the maxillary central incisor (b), whose root is essentially circular in cross section.

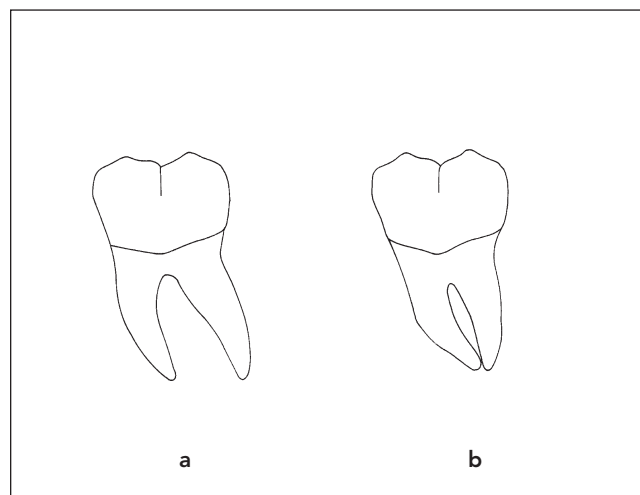


Fig 7-7 The molar with divergent roots (a) will be a better abutment tooth than one whose roots are fused (b).

For the same reasons, an abutment tooth with a less-than-desirable crown-root ratio is more likely to successfully support a fixed partial denture if the opposing occlusion is composed of mobile, periodontally involved teeth than if the opposing teeth are periodontally sound. The crown-root ratio alone is not an adequate criterion for evaluating a prospective abutment tooth.²

Root configuration

Root configuration is an important part of the assessment of an abutment's suitability from a periodontal standpoint. Roots that are broader labiolingually than they are mesiodistally are preferable to roots that are round in cross section

(Fig 7-6). Multirooted posterior teeth with widely separated roots will offer better periodontal support than roots that converge, fuse, or generally present a conical configuration (Fig 7-7). The tooth with conical roots can be used as an abutment for a short-span fixed partial denture if all other factors are optimal. A single-rooted tooth with evidence of irregular configuration or with some curvature in the apical third of the root is preferable to the tooth that has a nearly perfect taper.

Periodontal ligament area

Another consideration in the evaluation of prospective abutment teeth is the root surface area, or the area of periodon-

Fig 7-8 Comparative root surface areas of maxillary teeth. The number in parentheses above each tooth is the ratio between the root surface area of the respective tooth and the root surface area of the smallest tooth in the arch, the lateral incisor (based on data by Jepsen³).

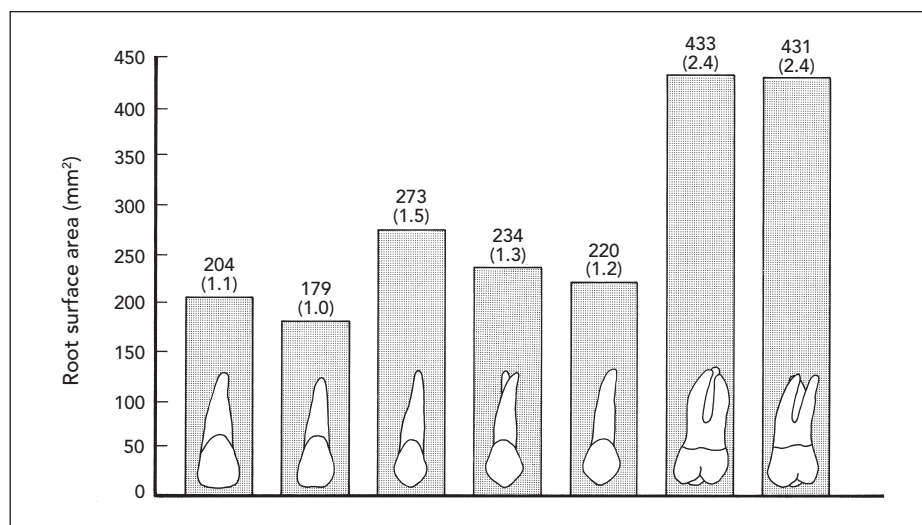
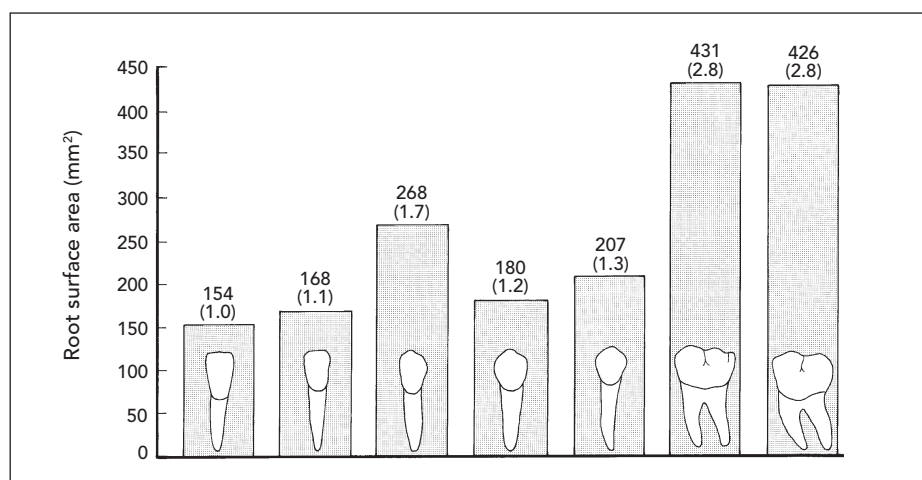


Fig 7-9 Comparative root surface areas of mandibular teeth. The number in parentheses above each tooth is the ratio between the root surface area of the respective tooth and the root surface area of the smallest tooth in the arch, the central incisor (based on data by Jepsen³).



tal ligament attachment of the root to the bone. Larger teeth have a greater surface area and are better able to bear added stress. The areas of the root surfaces of the various teeth have been reported by Jepsen³ and are shown in Figs 7-8 and 7-9. The actual values are not as significant as the relative values within a given mouth and the ratios between the various teeth in one arch. When supporting bone has been lost because of periodontal disease, the involved teeth have a lessened capacity to serve as abutments. Millimeter per millimeter, the loss of periodontal support from root resorption is only one-third to one-half as critical as the loss of alveolar crestal bone.⁴ The planned treatment should take this into account.

The length of the pontic span that can be successfully restored is limited in part by the abutment teeth and their

ability to accept the additional load. Traditionally, there has been general agreement on the number of missing teeth that can be restored successfully. Tylman stated that two abutment teeth could support two pontics.⁵ In a statement designated as *Ante's Law* by Johnston et al,⁶ the root surface area of the abutment teeth had to equal or surpass that of the teeth being replaced with pontics.⁷

According to this premise, one missing tooth can be successfully replaced if the abutment teeth are healthy (Fig 7-10). If two teeth are missing, a fixed partial denture probably can replace the missing teeth, but the limit is being approached (Fig 7-11). When the root surface area of the teeth to be replaced by pontics surpasses that of the abutment teeth, a generally unacceptable situation exists (Fig 7-12).

7 Treatment Planning for the Replacement of Missing Teeth

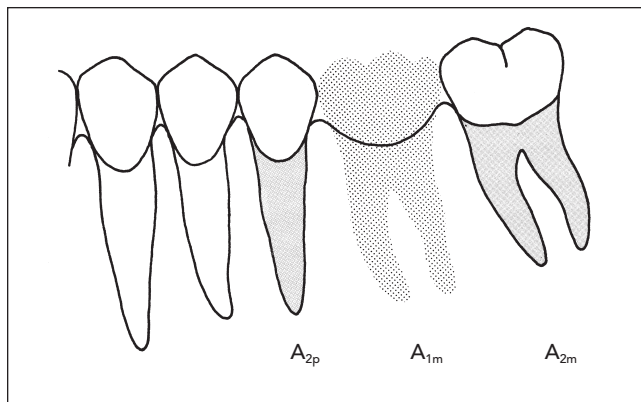


Fig 7-10 The combined root surface area of the second premolar and the second molar ($A_{2p} + A_{2m}$) is greater than that of the first molar being replaced (A_{1m}).

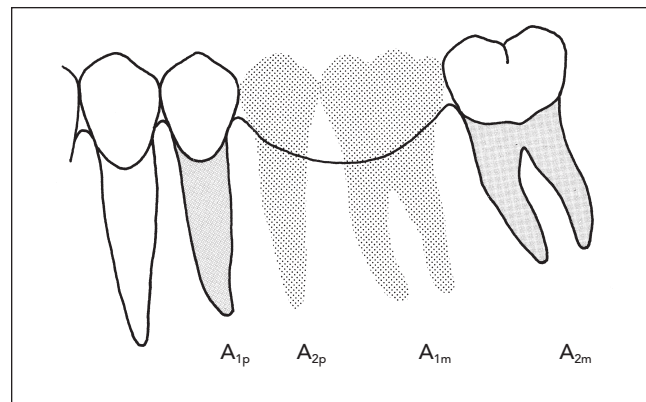


Fig 7-11 The combined root surface area of the first premolar and the second molar abutments ($A_{1p} + A_{2m}$) is approximately equal to that of the teeth being replaced ($A_{2p} + A_{1m}$).

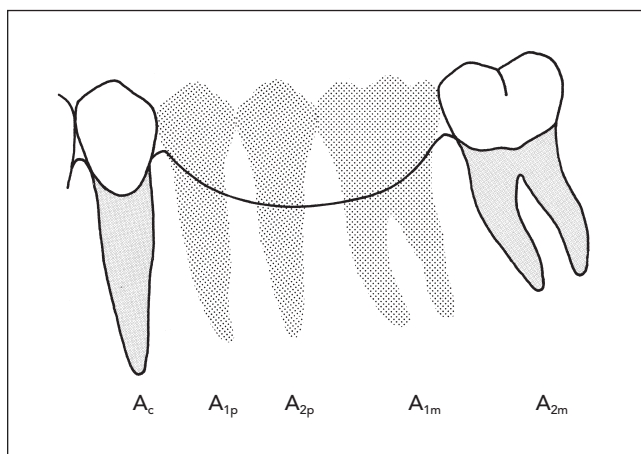


Fig 7-12 The combined root surface area of the canine and second molar ($A_c + A_{2m}$) is exceeded by that of the teeth being replaced ($A_{1p} + A_{2p} + A_{1m}$). A fixed partial denture would be a poor choice in this situation.

It is possible for fixed partial dentures to replace more than two teeth, the most common examples being anterior fixed partial dentures replacing the four incisors. Canine to second molar fixed partial dentures also are possible (if all other conditions are ideal) in the maxillary arch, but not as often in the mandibular arch. However, any fixed prosthesis replacing more than two teeth should be considered a high risk.

As a clinical guideline, there is some validity in the Ante's Law concept. Fixed partial dentures with short pontic spans have a better prognosis than do those with excessively long spans. It would be an oversimplification to attribute this merely to overstressing of the periodontal ligament, however. Failures from abnormal stress have been attributed to leverage and torque rather than overload.¹ Biomechanical factors and material failure play an important role in the potential for failure of long-span restorations.

There is evidence that teeth with very poor periodontal support can serve successfully as fixed partial denture abutments in carefully selected cases. Teeth with severe bone loss and marked mobility have been used as fixed partial denture and splint abutments.⁸ Elimination of mobility is not the goal in such cases but rather the stabilization of the teeth in a status quo to prevent an increase of mobility.⁹

Abutment teeth in these situations can be maintained free of inflammation in the face of mobility if the patients are well motivated and highly proficient in plaque removal.¹⁰ Crowns that anchor rigid prostheses to mobile teeth do require greater retention than do crowns attached to relatively immobile abutments, however.¹¹ Follow-up studies of these patients with so-called terminal dentitions indicate a surprisingly low failure rate—less than 8% of 332 fixed partial dentures exhibited technical failure in a time span that averaged slightly more than 6 years.¹²

What is the impact of the success of this type of treatment on fixed partial dentures for the average patient? The successful restoration of mouths with severe periodontal disease does have significance in everyday practice. It emphasizes the extreme importance of carefully evaluating the strengths and weaknesses of the remaining dentition on an individual basis.

This should not be a signal for every dentist with a hand-piece to start using severely periodontally involved teeth as abutments. One should bear in mind that the successful treatments that have been cited are the work of well-trained and highly skilled clinicians on selected, highly motivated patients.

This type of heroic treatment (*herodontics*, if you will) is very demanding technically and expensive as well. Performed by a well-trained, skilled clinician on an informed, motivated patient who dreads tooth loss, understands the patient's role in the success of the treatment, and accepts the risk (and expense) of failure, it can be a good service. "Sold" by a practitioner without special qualifications to an unmotivated and ill-informed patient, this type of treatment easily could result in a lawsuit.

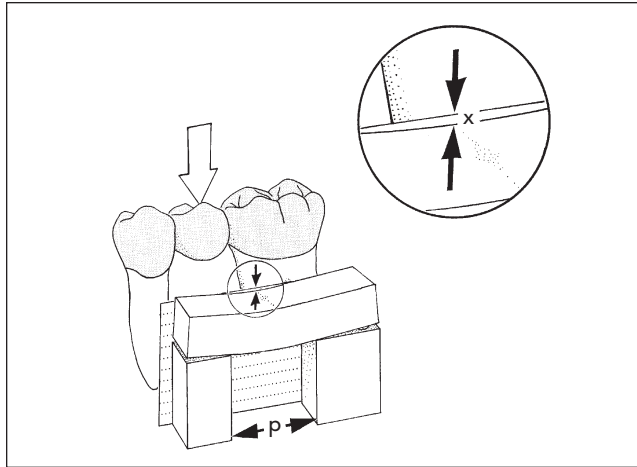


Fig 7-13 There is one unit of deflection (x) for a given span length (p).

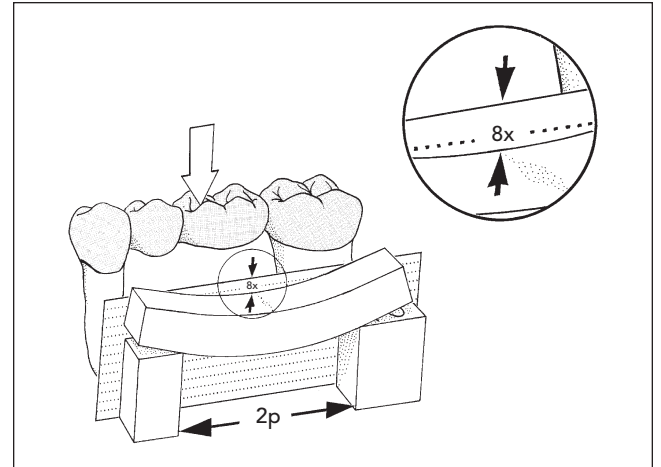


Fig 7-14 The deflection will be eight times as great ($8x$) if the span length is doubled ($2p$).

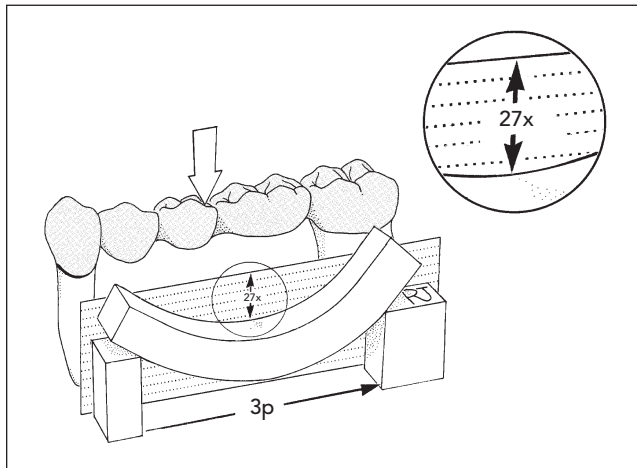


Fig 7-15 The deflection will be 27 times as great ($27x$) if the span length is tripled ($3p$).

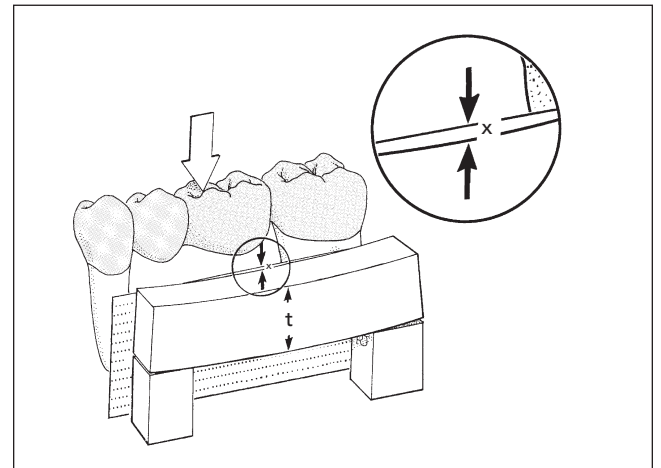


Fig 7-16 There is one unit of deflection (x) for a pontic with a given thickness (t).

Biomechanical Considerations

In addition to the increased load placed on the periodontal ligament by a long-span fixed partial denture, longer spans are less rigid. Bending or deflection varies directly with the cube of the length and inversely with the cube of the occlusolingival thickness of the pontic. Compared with a fixed partial denture having a single-tooth pontic span (Fig 7-13), a two-tooth pontic span will bend 8 times as much (Fig 7-14). A three-tooth pontic will bend 27 times as much as a single pontic¹³ (Fig 7-15).

A pontic with a given occlusolingival dimension (Fig 7-16) will bend eight times as much if the pontic thickness is halved (Fig 7-17). Therefore, a long-span fixed partial denture on short mandibular teeth could have disappointing results. Longer pontic spans also have the potential for producing more torquing forces on the fixed partial denture, especially

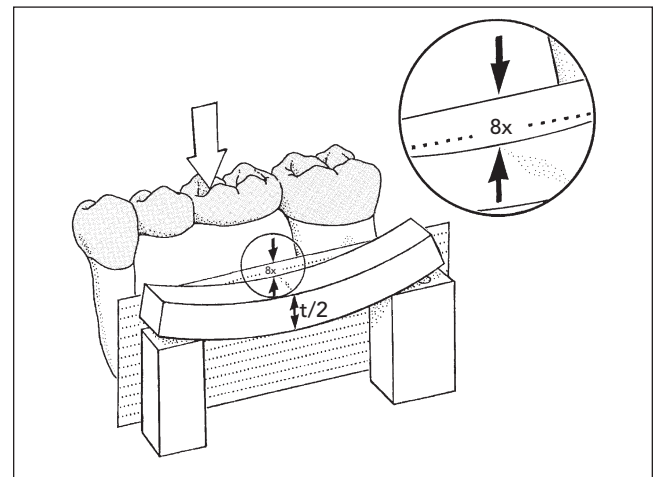


Fig 7-17 There will be eight times as much deflection ($8x$) if the thickness is decreased by one-half ($t/2$).

7 Treatment Planning for the Replacement of Missing Teeth

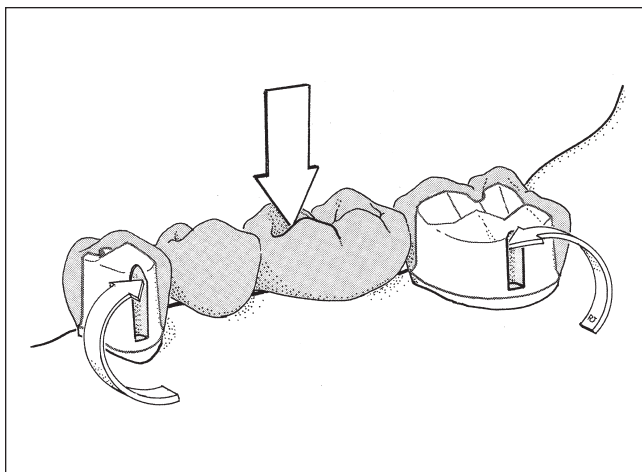


Fig 7-18 The walls of facial and lingual grooves counteract mesio-distal torque resulting from force applied to the pontic.

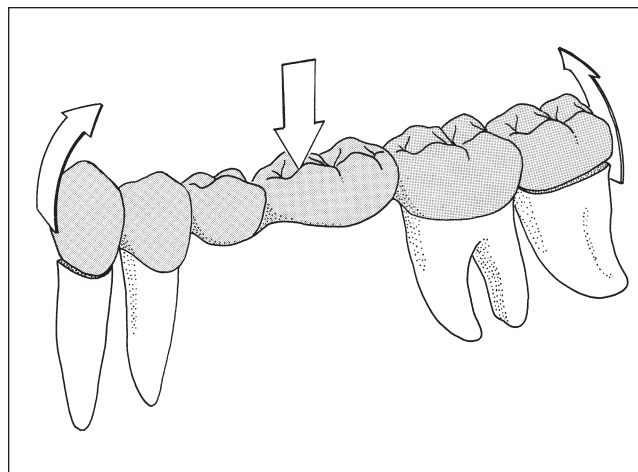


Fig 7-19 The retainers on secondary abutments will be placed in tension when the pontics flex, with the primary abutments acting as fulcrums.

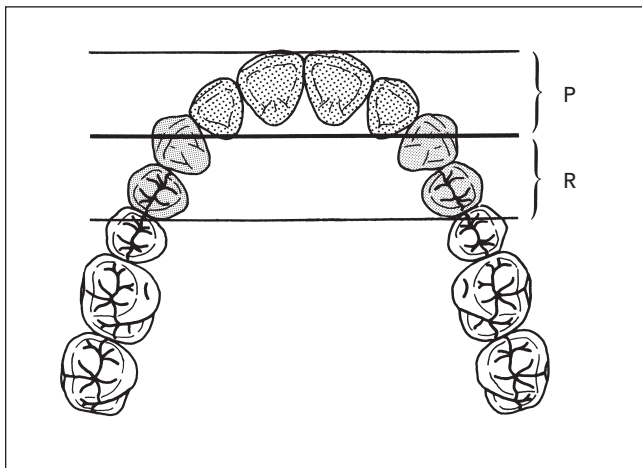


Fig 7-20 Secondary retention (R) must extend a distance from the primary interabutment axis equal to the distance that the pontic lever arm (P) extends in the opposite direction.

on the weaker abutment. To minimize flexing caused by long and/or thin spans, pontic designs with a greater occlusogingival dimension should be selected. The prosthesis may also be fabricated of an alloy with a higher yield strength, such as nickel-chromium.

All fixed partial dentures, long or short, flex to some extent. Because of the forces being applied through the pontics to the abutment teeth, the forces on castings serving as retainers for fixed partial dentures are different in magnitude and direction from those applied to single restorations.¹⁴ The dislodging forces on a fixed partial denture retainer tend to act in a mesiodistal direction, as opposed to the more common faciolingual direction of forces on a single restoration. Preparations should be modified accordingly to

produce greater resistance and structural durability. Multiple grooves, including some on the facial and lingual surfaces, are commonly employed for this purpose (Fig 7-18).

Double abutments are sometimes used as a means of overcoming problems created by unfavorable crown-root ratios and long spans. There are several criteria that must be met if a secondary (remote from the edentulous space) abutment is to strengthen the fixed partial denture and not become a problem itself. A secondary abutment must have at least as much root surface area and as favorable a crown-root ratio as the primary (adjacent to the edentulous space) abutment it is intended to bolster. As an example, a canine can be used as a secondary abutment to a first premolar primary abutment, but it would be unwise to use a lateral incisor as a secondary abutment to a canine primary abutment. The retainers on secondary abutments must be at least as retentive as the retainers on the primary abutments. When the pontic flexes, tensile forces will be applied to the retainers on the secondary abutments (Fig 7-19). There also must be sufficient crown length and space between adjacent abutments to prevent impingement on the gingiva under the connector.

Arch curvature has its effect on the stresses occurring in a fixed partial denture. When pontics lie outside the interabutment axis line, the pontics act as a lever arm, which can produce a torquing movement. This is a common problem in replacing all four maxillary incisors with a fixed partial denture, and it is most pronounced in the arch that is pointed in the anterior. Some measure must be taken to offset the torque. This can best be accomplished by gaining additional retention in the opposite direction from the lever arm and at a distance from the interabutment axis equal to the length of the lever arm¹⁵ (Fig 7-20). The first premolars sometimes are used as secondary abutments for a maxillary four-pontic canine-to-canine fixed partial denture. Because of the tensile forces that will be applied to the premolar retainers, they must have excellent retention.

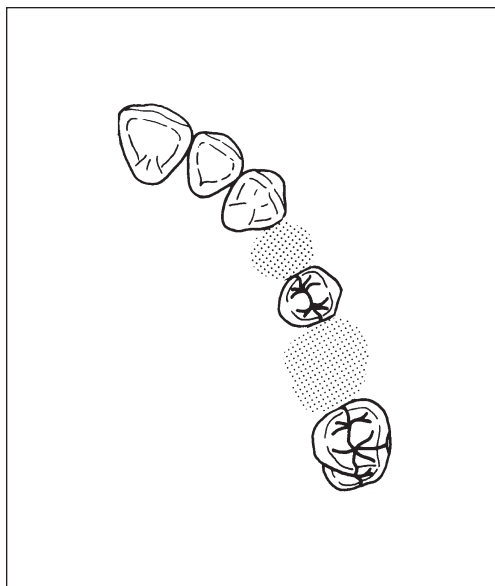


Fig 7-21 In this frequently occurring situation, the maxillary first premolar and molar are missing, leaving the second premolar as a pier abutment.

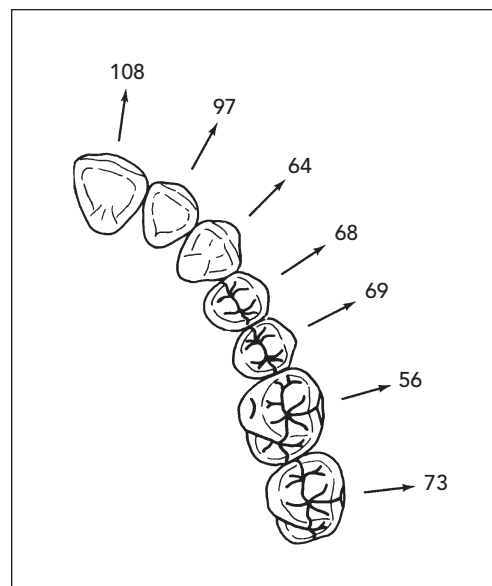


Fig 7-22 The amount of faciolingual movement (in μm) for each tooth in the maxillary arch (based on data by Rudd et al¹⁶). The direction of movement, indicated by arrows, varies considerably from the anterior to the posterior segment of the arch.

Special Problems

Some problem situations occur often enough to deserve mention. Some of the commonly used solutions to the problems are also presented.

Pier abutments

Rigid connectors (eg, solder joints) between pontics and retainers are the preferred way of fabricating most fixed partial dentures. A fixed partial denture with the pontic rigidly fixed to the retainers provides desirable strength and stability to the prosthesis while minimizing the stresses associated with the restoration.

However, a completely rigid restoration is not indicated for all situations requiring a fixed prosthesis. An edentulous space can occur on both sides of a tooth, creating a lone, freestanding pier abutment (Fig 7-21). Physiologic tooth movement, arch position of the abutments, and a disparity in the retentive capacity of the retainers can make a rigid five-unit fixed partial denture a less-than-ideal treatment plan.

Studies in periodontometry have shown that the faciolingual movement ranges from 56 to 108 μm ,¹⁶ and intrusion is 28 μm .¹⁷ Teeth in different segments of the arch move in different directions.¹⁸ Because of the curvature of the arch, the faciolingual movement of an anterior tooth occurs at a considerable angle to the faciolingual movement of a molar (Fig 7-22).

These movements of measurable magnitude and in divergent directions can create stresses in a long-span prosthesis that will be transferred to the abutments. Because of the distance through which movement occurs, the independent direction and magnitude of movements of the abutment teeth, and the tendency of the prosthesis to flex, stress can be concentrated around the abutment teeth as well as between retainers and abutment preparations.

It has been theorized that forces are transmitted to the terminal retainers as a result of the middle abutment acting as a fulcrum, causing failure of the weaker retainer.¹⁹ However, photoelastic stress analysis and displacement measurement indicate that the prosthesis bends rather than rocks. Standlee and Caputo²⁰ suggest that tension between the terminal retainers and their respective abutments, rather than a pier fulcrum, is the mechanism of failure. Intrusion of the abutments under the loading could lead to failure between any retainer and its respective abutment.

The loosened casting will leak around the margin, and caries is likely to become extensive before discovery. The retention on an anterior tooth is usually less than that of a posterior tooth because of its generally smaller dimensions. Because there are limits to increasing a retainer's capacity to withstand displacing forces, some means must be used to neutralize the effects of those forces. The use of a nonrigid connector has been recommended to reduce this hazard.¹⁹

In spite of an apparently close fit, the movement in a nonrigid connector is enough to prevent the transfer of stress from the segment being loaded to the rest of the fixed partial denture (Fig 7-23). The nonrigid connector is a broken-stress

7 Treatment Planning for the Replacement of Missing Teeth

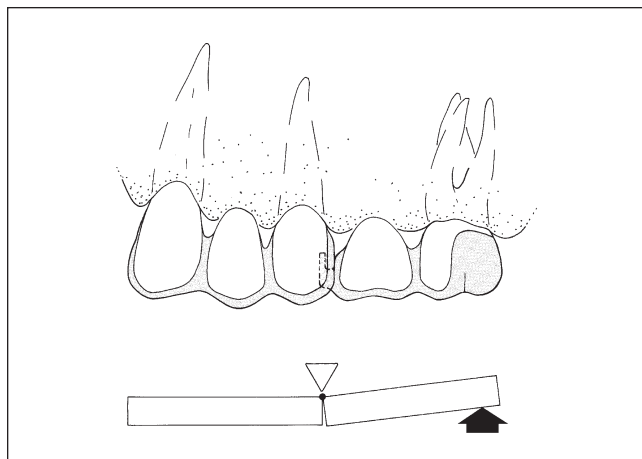


Fig 7-23 A nonrigid connector on the middle abutment isolates force to the segment of the fixed partial denture to which it is applied. (Reprinted from Shillingburg and Fisher¹⁹ with permission.)

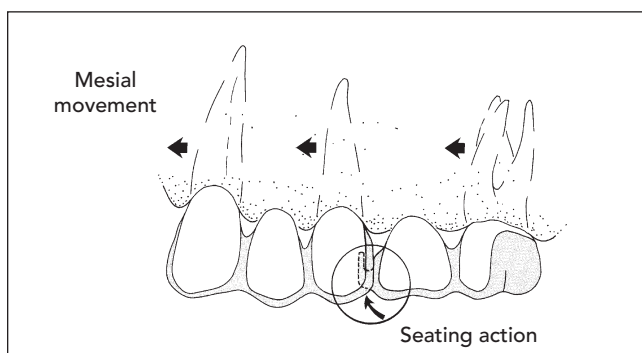


Fig 7-24 If a nonrigid connector is placed on the distal side of the retainer on a middle abutment, movement in a mesial direction will seat the key into the keyway. (Reprinted from Shillingburg and Fisher¹⁹ with permission.)

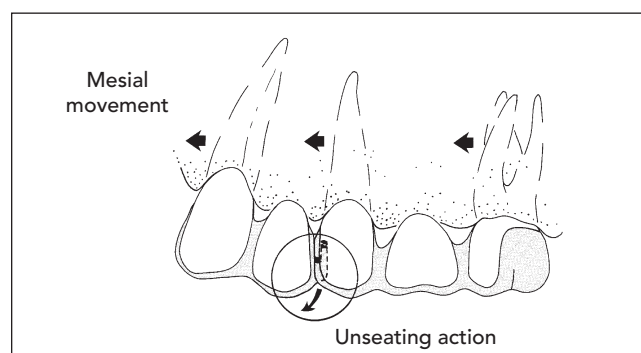


Fig 7-25 If a nonrigid connector is placed on the mesial side of the middle abutment, mesially directed movement will unseat the key. (Reprinted from Shillingburg and Fisher¹⁹ with permission.)

mechanical union of retainer and pontic instead of the usual rigid connector. The most commonly used nonrigid design consists of a T-shaped key that is attached to the pontic and a dovetail keyway placed within a retainer.

Use of the nonrigid connector is restricted to a short-span fixed partial denture replacing one tooth.²¹ The magnification of force created by a long span is too destructive to the abutment tooth under the soldered retainer. Prostheses with nonrigid connectors should not be used if prospective abutment teeth exhibit significant mobility. There must be equal distribution of occlusal forces on all parts of the fixed partial denture.

A nonrigid fixed partial denture transfers shear stress to supporting bone rather than concentrating it in the connectors. It appears to minimize mesiodistal torquing of the abutments while permitting them to move independently.²² A rigid fixed partial denture distributes the load more evenly than a nonrigid design, making it preferable for teeth with decreased periodontal attachment.²³ If the posterior abutment and pontic are either opposed by a removable partial denture or unopposed, and if the three anterior units are op-

posed by natural teeth, the key and the posterior units that are subjected to little or no occlusal forces may supererupt.

The location of the stress-breaking device in the five-unit pier-abutment restoration is important. It is usually placed on the middle abutment because placement on either of the terminal abutments could result in the pontic acting as a lever arm.

The keyway of the connector should be placed within the normal distal contours of the pier abutment, and the key should be placed on the mesial side of the distal pontic. The long axes of the posterior teeth usually lean slightly in a mesial direction, and vertically applied occlusal forces produce further movement in this direction. Nearly 98% of posterior teeth tilt mesially when subjected to occlusal forces.²⁴ If the keyway of the connector is placed on the distal side of the pier abutment, mesial movement seats the key into the keyway more solidly¹⁹ (Fig 7-24). Placement of the keyway on the mesial side, however, causes the key to be unseated during mesial movements²⁰ (Fig 7-25). In time, this could produce a pathologic mobility in the canine or failure of the canine retainer.

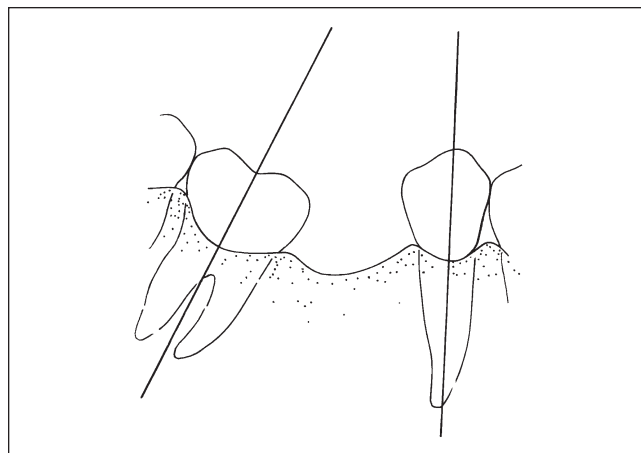


Fig 7-26 When a mandibular molar tilts mesially, there is a discrepancy between its long axis and that of the premolar.

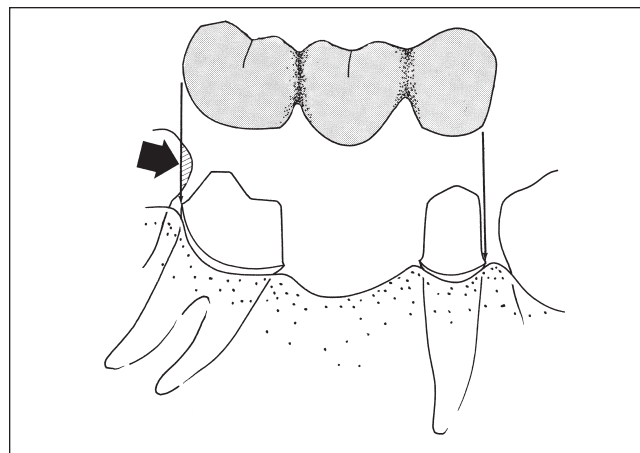


Fig 7-27 This fixed partial denture will not seat because the tooth distal to the fixed partial denture intrudes on the path of insertion (arrow).

Tilted molar abutments

A problem that occurs with some frequency is a mandibular second molar abutment that has tilted mesially into the space formerly occupied by the first molar. It is impossible to prepare the abutment teeth for a fixed partial denture along the long axes of the respective teeth and achieve a common path of insertion (Fig 7-26).

There is further complication if the third molar is present. It usually will have drifted and tilted with the second molar. Because the path of insertion for the fixed partial denture will be dictated by the smaller premolar abutment, it is probable that the path of insertion will be nearly parallel to the former long axis of the molar abutment before it tilted mesially. As a result, the mesial surface of the tipped third molar will encroach upon the path of insertion of the fixed partial denture, thereby preventing it from seating completely (Fig 7-27).

If the encroachment is slight, the problem can be remedied by restoring or recontouring the mesial surface of the third molar. However, the overtapered second molar preparation must have its retention bolstered by the addition of facial and lingual grooves. If the tilting is severe, more extensive corrective measures are called for. The treatment of choice is the uprighting of the molar by orthodontic treatment. In addition to placing the abutment tooth in a better position for preparation and for distribution of forces under occlusal loading, uprighting the molar also helps to eliminate bony defects along the mesial surface of the root.

Uprighting is best accomplished through the use of a fixed appliance.²⁵ Both premolars and the canine are banded and tied to a passive stabilizing wire (Fig 7-28). A helical uprighting spring is inserted into a tube on the banded molar and activated by hooking it over the wire on the anterior segment.^{25,26} This is frequently followed by the use of an open coil spring to complete the uprighting and bring the tooth into the best possible alignment for fabrication of

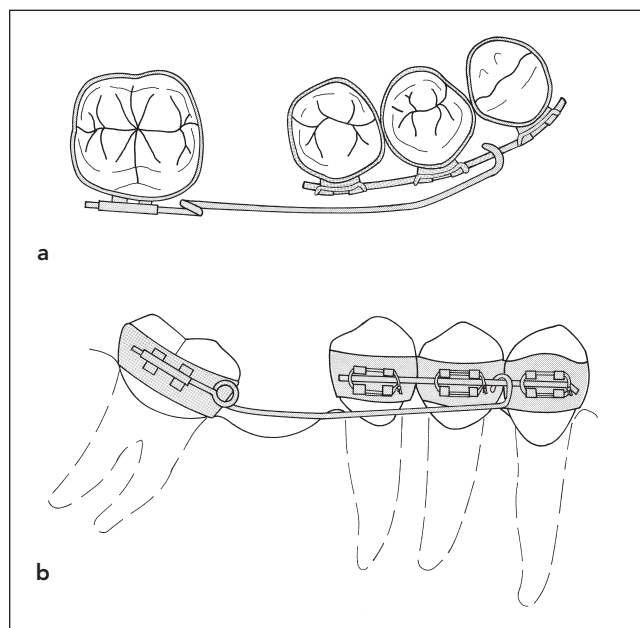


Fig 7-28 Orthodontic appliance for uprighting a tilted molar: (a) occlusal view; (b) facial view.

the fixed restoration. The average treatment time required is 3 months.²⁷

The third molar, if present, is often removed to facilitate the distal movement of the second molar. The second molar will arc occlusally as it moves distally; therefore, it must be watched closely and ground out of occlusion to allow it to continue moving. Immediately upon removal of the appliance, the teeth are prepared, and a provisional fixed partial denture is fabricated to prevent posttreatment relapse.²⁸

7 Treatment Planning for the Replacement of Missing Teeth

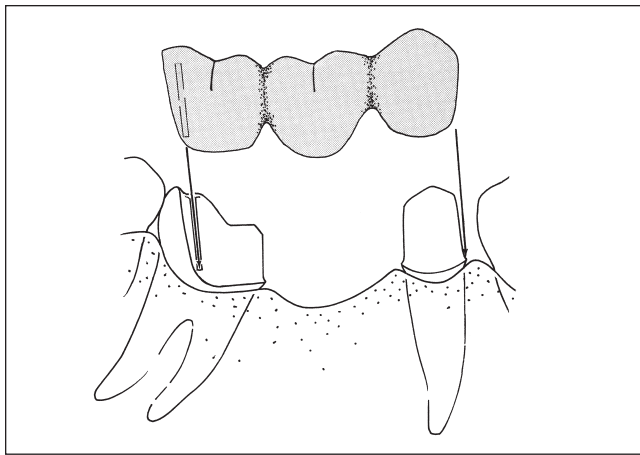


Fig 7-29 Fixed partial denture using a proximal half crown as a retainer on a tilted molar abutment.

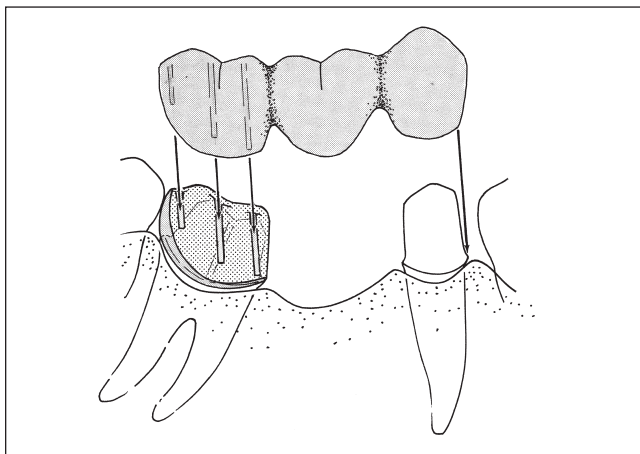


Fig 7-30 Fixed partial denture using a telescope crown and coping as a retainer on a tilted molar abutment.

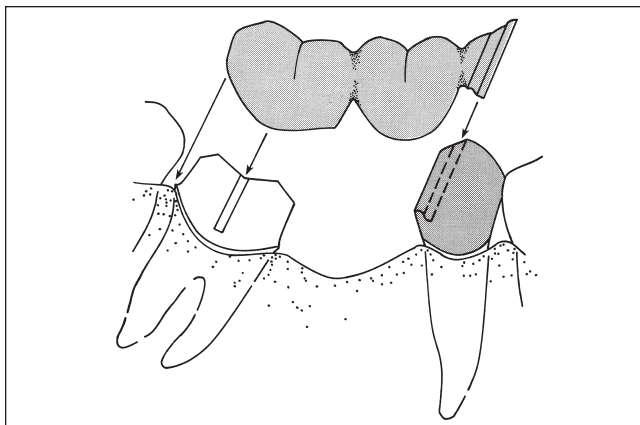


Fig 7-31 A nonrigid connector on the distal aspect of the premolar retainer compensates for the inclination of the tilted molar.

If orthodontic correction is not possible, or if it is possible to achieve only a partial correction, a fixed partial denture can still be made. It has been suggested that the long axis of the prospective abutments should converge by no more than 25 to 30 degrees.²⁹ Photoelastic³⁰ and finite element³¹ stress analyses have shown that a molar that has tipped mesially will actually exhibit less stress in the alveolar bone, along the mesial surface of its mesial root, with a fixed partial denture than without it. There will be an increase in stress along the premolar, however.

A proximal half crown sometimes can be used as a retainer on the distal abutment³² (Fig 7-29). This preparation design is simply a three-quarter crown that has been rotated 90 degrees so that the distal surface is uncovered. This retainer can be used only if the distal surface itself is untouched by caries or decalcification and if there is a very low incidence of proximal caries throughout the mouth. The patient must also demonstrate an ability to keep the area exceptionally clean. If there is a severe marginal ridge height discrepancy between the distal of the second molar and the mesial of the third molar as a result of tipping, the proximal half crown is contraindicated.

A telescope crown and coping can also be used as a retainer on the distal abutment.³³ A full crown preparation with heavy reduction is made to follow the long axis of the tilted molar. An inner coping is made to fit the tooth preparation, and the proximal half crown that will serve as the retainer for the fixed partial denture is fitted over the coping (Fig 7-30). This restoration allows for total coverage of the clinical crown while compensating for the discrepancy between the paths of insertion of the abutments. The marginal adaptation for this restoration is provided by the coping.

The nonrigid connector is another solution to the problem of the tilted fixed partial denture abutment (Fig 7-31). A full crown preparation is done on the molar, with its path of insertion parallel with the long axis of that tilted tooth. A box form is placed in the distal surface of the premolar to accommodate a keyway in the distal of the premolar crown. It is tempting to place the connector on the mesial aspect of the tipped molar, but this could lead to even greater tipping of the tooth. A nonrigid connector for the tipped molar abutment is most useful when the molar exhibits a marked lingual as well as mesial inclination. Preparing a tooth with a combined mesial and lingual inclination as an abutment for a routine fixed partial denture can lead to a drastically over-tapered preparation with no retention.

Because telescope crowns and nonrigid connectors both require tooth preparations that are more destructive than normal, the selection of one of these would be influenced by the nature of previous destruction of the prospective abutment teeth. The presence of a dowel core or a disto-occlusal amalgam on the premolar, for example, would favor placement of a nonrigid connector on that tooth, while extensive facial and/or lingual restorations on the tilted molar would call for the use of a telescope crown.

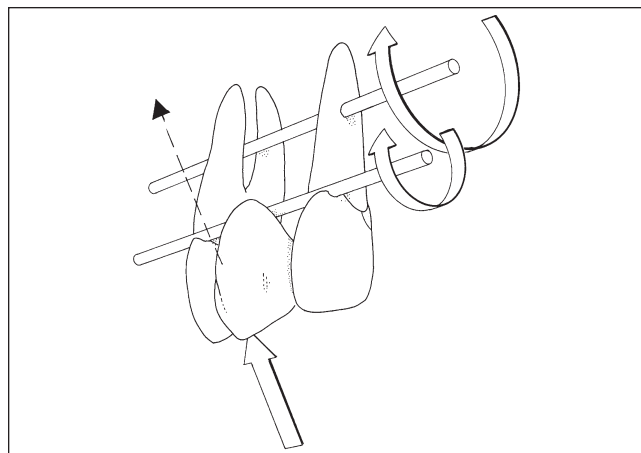


Fig 7-32 A fixed partial denture replacing a maxillary canine is subjected to more damaging stresses than that replacing a mandibular canine because the forces are directed outward and the pontic lies farther outside the interabutment axis.

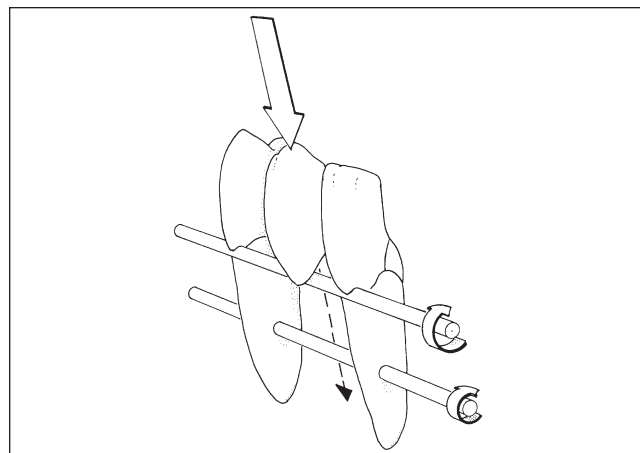


Fig 7-33 A fixed partial denture replacing a mandibular canine has a more favorable prognosis than that replacing a maxillary canine because the forces are directed inward and the pontic will be closer to the interabutment axis.

Canine-replacement fixed partial dentures

Fixed partial dentures replacing canines can be difficult because the canine often lies outside the interabutment axis. The prospective abutments are the lateral incisor, usually the weakest tooth in the entire arch, and the first premolar, the weakest posterior tooth. A fixed partial denture replacing a maxillary canine is subjected to more stresses than that replacing a mandibular canine because forces are transmitted outward (labially) on the maxillary arch, against the inside of the curve (its weakest point) (Fig 7-32). On the mandibular canine, the forces are directed inward (lingually), against the outside of the curve (its strongest point) (Fig 7-33). Any fixed partial denture replacing a canine should be considered a complex fixed partial denture. No fixed partial denture replacing a canine should replace more than one additional tooth. An edentulous space created by the loss of a canine and any two contiguous teeth is best restored with a removable partial denture.

Cantilever fixed partial dentures

A cantilever fixed partial denture is one that has an abutment or abutments at one end only, with the other end of the pontic remaining unattached. This is a potentially destructive design with the lever arm created by the pontic, and it is frequently misused.

In the routine three-unit fixed partial denture, force that is applied to the pontic is distributed equally to the abutment teeth (Fig 7-34). If there is only one pontic and it is near the interabutment axis line, less leverage is applied to the abutment teeth and to the retainers than with a cantilever. When a cantilever pontic is employed to replace a missing tooth, forces applied to the pontic have an entirely different effect on the abutment tooth. The pontic acts as a lever that tends to be depressed under forces with a strong occlusal vector (Fig 7-35).

Prospective abutment teeth for cantilever fixed partial dentures should be evaluated with an eye toward lengthy roots with a favorable configuration, long clinical crowns, good crown-root ratios, and healthy periodontium.³⁴ Generally, cantilever fixed partial dentures should replace only one tooth and have at least two abutments.^{35,36}

A cantilever can be used for replacing a maxillary lateral incisor (Fig 7-36). There should be no occlusal contact on the pontic in either centric or lateral excursions.³⁷ The canine must be used as an abutment, and it can serve in the role of solo abutment only if it has a long root and good bone support. There should be a rest on the mesial of the pontic against a rest preparation in an inlay or other metallic restoration on the distal of the central incisor to prevent rotation of the pontic and abutment. The mesial aspect of the pontic can be slightly wrapped around the distal portion of the uninvolved central incisor to stabilize the pontic faciolingually.³⁷ The root configuration of a central incisor makes it an undesirable cantilever abutment.

7 Treatment Planning for the Replacement of Missing Teeth

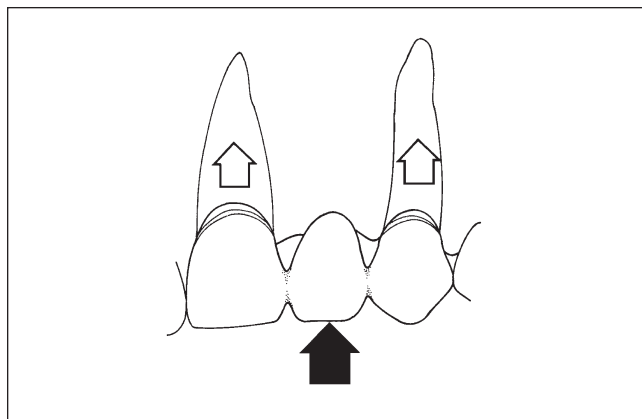


Fig 7-34 Forces applied to the pontic of a routine fixed partial denture are transmitted to both abutment teeth.

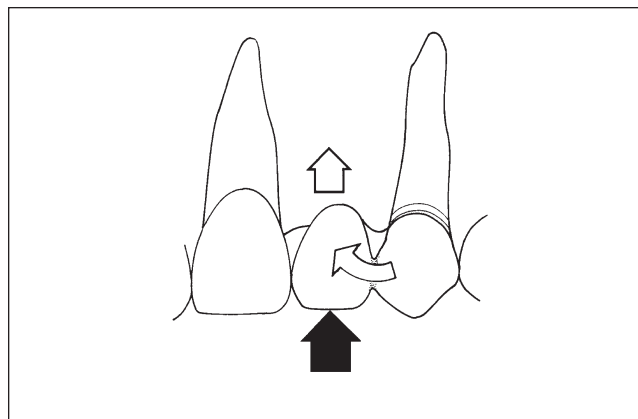


Fig 7-35 Forces on the pontic of a cantilever fixed partial denture tend to tip the fixed partial denture or the abutment tooth.

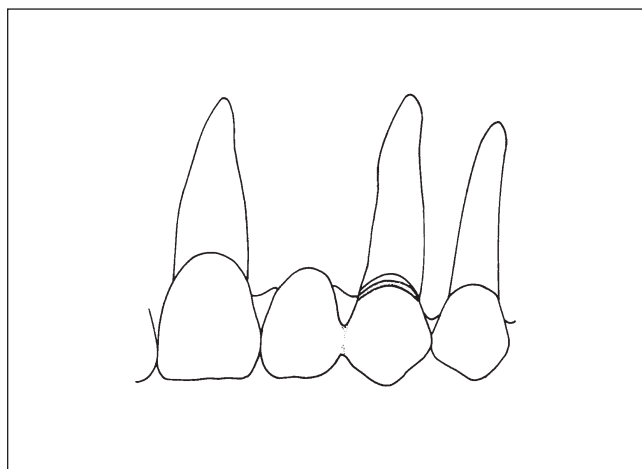


Fig 7-36 Cantilever fixed partial denture replacing a maxillary lateral incisor, using the canine as the abutment.

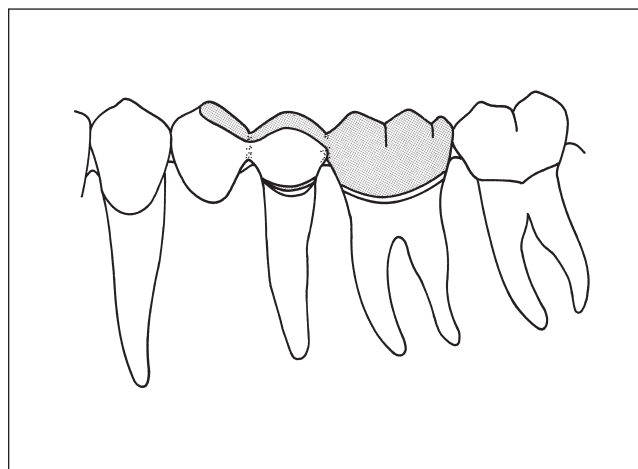


Fig 7-37 A cantilever pontic can be used to replace a first premolar if full veneer retainers are used on the second premolar and first molar abutments.

A cantilever pontic can also be used to replace a missing first premolar (Fig 7-37). This scheme will work best if occlusal contact is limited to the distal fossa. Full veneer retainers are required on both the second premolar and first molar. These teeth must exhibit excellent bone support. This design is attractive if the canine is unmarred and if a full veneer restoration is required for the first molar under any circumstances.

Cantilever fixed partial dentures can also be used to replace molars when there is no distal abutment present. When used judiciously, it is possible to avoid the insertion of a unilateral removable partial denture.³⁴ Most commonly, this type of fixed partial denture is used to replace a first molar, although occasionally it is used to replace a second molar to prevent supereruption of opposing teeth.

When the pontic is loaded occlusally, the adjacent abutment tends to act as a fulcrum, with a lifting tendency on the farthest retainer³⁸ (Fig 7-38). To minimize the leverage

effect, the pontic should be kept as small as possible, more nearly representing a premolar than a molar (Fig 7-39). There should be light occlusal contact with absolutely no contact in any excursion. The pontic should possess maximum occluso-gingival height to ensure a rigid prosthesis.

A posterior cantilever pontic places maximum demands on the retentive capacity of the retainer.³⁹ Its use, therefore, should be reserved for those situations in which there is adequate clinical crown length on the abutment teeth to permit preparations of maximum length and retention. The success of cantilevers in the restoration of the periodontally compromised dentition is probably due at least in part to the fact that periodontally involved abutments do have extremely long clinical crowns. While cantilever fixed partial dentures appear to be a conservative restoration, the potential for damage to the abutment teeth requires that they be used sparingly.

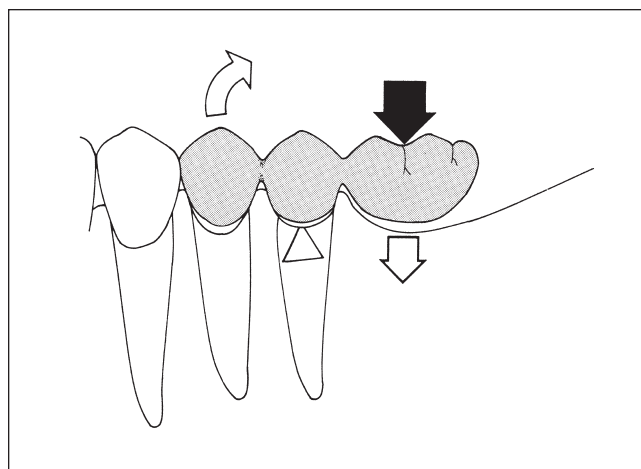


Fig 7-38 Forces on a full-size molar cantilever pontic place great stress on the mesial abutment.

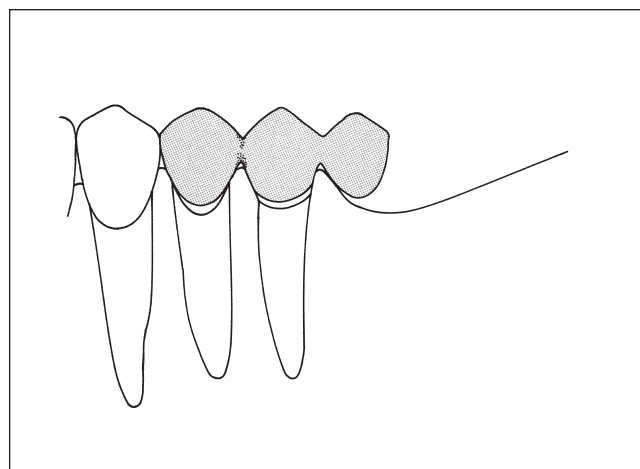



Fig 7-39 Cantilever fixed partial denture replacing a mandibular first molar, using both premolars as abutment teeth. To minimize stress on the abutments, the pontic is the size of a premolar rather than a molar.

References

- Klaffenbach AO. Gnathodynamics. *J Am Dent Assoc* 1936;23:371–382.
- Penny RE, Kraal JH. Crown-to-root ratio: Its significance in restorative dentistry. *J Prosthet Dent* 1979;42:34–38.
- Jepsen A. Root surface measurement and a method for x-ray determination of root surface area. *Acta Odontol Scand* 1963;21:35–46.
- Kalkwarf KL, Krejci RF, Pao YC. Effect of apical root resorption on periodontal support. *J Prosthet Dent* 1986;56:317–319.
- Tylman SD. *Theory and Practice of Crown and Fixed Partial Prosthodontics (Bridge)*, ed 6. St Louis: Mosby, 1970:17.
- Johnston JF, Phillips RW, Dykema RW. *Modern Practice in Crown and Bridge Prosthodontics*, ed 3. Philadelphia: Saunders, 1971:11.
- Ante IH. The fundamental principles of abutments. *Mich State Dent Soc Bull* 1926;8:14–23.
- Nyman S, Lindhe J. Prosthetic rehabilitation of patients with advanced periodontal disease. *J Clin Periodontol* 1976;3:135–147.
- Nyman S, Lindhe J, Lundgren D. The role of occlusion for the stability of fixed bridges in patients with reduced periodontal tissue support. *J Clin Periodontol* 1975;2:53–66.
- Lindhe J, Nyman S. The role of occlusion in periodontal disease and the biologic rationale for splinting in treatment of periodontitis. *Oral Sci Rev* 1977;10:11–43.
- Jacobi R, Shillingburg HT Jr, Duncanson MG Jr. Effect of abutment mobility, site, and angle of impact on retention of fixed partial dentures. *J Prosthet Dent* 1985;54:178–183.
- Nyman S, Lindhe J. A longitudinal study of combined periodontal and prosthetic treatment of patients with advanced periodontal disease. *J Periodontol* 1979;50:163–169.
- Smyd ES. Mechanics of dental structures: Guide to teaching dental engineering at undergraduate level. *J Prosthet Dent* 1952;2:668–692.
- Smyd ES. Advanced thought in indirect inlay and fixed bridge fabrication. *J Am Dent Assoc* 1944;31:759–768.
- Dykema RW. Fixed partial prosthodontics. *J Tenn Dent Assoc* 1962;42:309–321.
- Rudd KD, O'Leary TJ, Stumpf AJ. Horizontal tooth mobility in carefully screened subjects. *Periodontics* 1964;2:65–68.
- Parfitt GJ. Measurement of the physiological mobility of individual teeth in an axial direction. *J Dent Res* 1960;39:608–618.
- McCall JO, Hugel IM. Movable-removable bridgework: Principles and practice as developed by Herman ES Chayes, DDS. *Dent Items Interest* 1949;71:512–525.
- Shillingburg HT Jr, Fisher DW. Nonrigid connectors for fixed partial dentures. *J Am Dent Assoc* 1973;87:1195–1199.
- Standlee JP, Caputo AA. Load transfer by fixed partial dentures with three abutments. *Quintessence Int* 1988;19:403–410.
- Markley MR. Broken-stress principle and design in fixed bridge prosthesis. *J Prosthet Dent* 1951;1:416–423.
- Sutherland JK, Holland GA, Sluder TB, White JT. A photoelastic analysis of the stress distribution in bone supporting fixed partial dentures of rigid and nonrigid design. *J Prosthet Dent* 1980;44:616–623.
- Landry KE, Johnson PF, Parks VJ, Pelleu GB Jr. A photoelastic study to determine the location of the nonrigid connector in a five-unit intermediate abutment prosthesis. *J Prosthet Dent* 1987;57:454–457.
- Picton DC. Tilting movements of teeth during biting. *Arch Oral Biol* 1962;7:151–159.
- Khouw FE, Norton LA. The mechanism of fixed molar uprighting appliances. *J Prosthet Dent* 1972;27:381–389.
- Norton LA, Profitt WR. Molar uprighting as an adjunct to fixed prostheses. *J Am Dent Assoc* 1968;76:312–315.
- Simon RL. Rationale and practical technique for uprighting mesially inclined molars. *J Prosthet Dent* 1984;52:256–259.
- Norton LA, Parker WT. Management of repositioned teeth in preparation for fixed partial dentures. *J Am Dent Assoc* 1970;81:916–922.
- Reynolds JM. Abutment selection for fixed prosthodontics. *J Prosthet Dent* 1968;19:483–488.
- Hood JA, Farah JW, Craig RG. Modification of stresses in alveolar bone induced by a tilted molar. *J Prosthet Dent* 1975;34:415–421.
- Yang HS, Thompson VP. A two-dimensional stress analysis comparing fixed prosthodontic approaches to the tilted molar abutment. *Int J Prosthodont* 1991;4:416–424.
- Smith DE. Fixed bridge restorations with the tilted mandibular second or third molar as an abutment. *J South Calif Dent Assoc* 1939;6:131–138.
- Shillingburg HT Jr. Bridge retainers for tilted abutments. *N M Dent J* 1972;22:16–19.

7 Treatment Planning for the Replacement of Missing Teeth

- 
34. Ewing JE. Re-evaluation of the cantilever principle. *J Prosthet Dent* 1957;7:78–92.
 35. Wright KW, Yettram AL. Reactive force distributions for teeth when loaded singly and when used as fixed partial denture abutments. *J Prosthet Dent* 1979;42:411–416.
 36. Wright WE. Success with the cantilever fixed partial denture. *J Prosthet Dent* 1986;55:537–539.
 37. Goldfogel MH, Lambert RL. Cantilever fixed prosthesis replacing the maxillary lateral incisor: Design consideration. *J Prosthet Dent* 1985;54:477–478.
 38. Schweitzer JM, Schweitzer RD, Schweitzer J. Free-end pontics used on fixed partial dentures. *J Prosthet Dent* 1968;20:120–138.
 39. Nyman S, Lindhe J. Considerations on the design of occlusion in prosthetic rehabilitation of patients with advanced periodontal disease. *J Clin Periodontol* 1977;4:1–15.

Fixed Partial Denture and Implant Configurations

8

The replacement of missing teeth with fixed restorations has changed considerably in the last 20 years. No longer is it simply a choice between a fixed partial denture and a removable partial denture. Osseointegrated dental implants have developed into a reliable treatment modality that can be depended upon to provide long-term replacement of a single missing tooth as well as multiple missing teeth. By no means, though, should the fixed partial denture be regarded as a thing of the past. Not all patients or situations are suitable for implants, just as not all patients or situations are suitable for fixed partial dentures. Judicious treatment planning is still of critical importance.

The implant is ideally suited for the replacement of a single tooth if the teeth that would have served as abutments are untouched by caries or previous restorations. On the other hand, if those teeth need extensive restorations, the patient can be saved expense and additional treatment if the restorations also serve as retainers for a fixed partial denture. Long-span prostheses that will place greater demands on the skills of the dentist, on the resistance of the retainers, and on the abutments and their periodontal support can be avoided by using implant-supported fixed partial dentures instead of tooth-supported fixed partial dentures.

The maximum number of posterior teeth that can be safely replaced with a fixed partial denture is usually two. In rare circumstances, three can be replaced, but that should be attempted only under ideal conditions. An edentulous space created by the loss of four adjacent teeth, other than four incisors, is best restored with implant-supported crowns or a removable partial denture. If more than one edentulous space exists in the same arch, even though each could be individually restored with a fixed partial denture or implants, finances may dictate the use of a removable partial denture. This is especially true when the spaces are bilateral and each involves two or more teeth.

Third molars are not shown in any of the examples in this chapter, and no situation is shown in which a third molar would be a prospective abutment. Rarely can third molars be used as abutments because they have been removed

from the mouths of so many patients. Even when they are present, they frequently display incomplete eruption; short, fused roots; and/or a marked mesial inclination in the absence of a second molar.

A third molar should be considered as a potential abutment only if it is upright and completely erupted, with little or no mesial inclination and with long, distinctly separate roots. It also must have a healthy cuff of attached, keratinized gingiva that completely surrounds the tooth. The unattached mucosal tissue that frequently surrounds the distal 30% to 60% of third molars will become inflamed adjacent to even a well-fitting crown margin, and the abutment is likely to fail periodontally.

The following examples are given as a reference that applies under ideal conditions, listing the abutment teeth that normally would be used. Retainer designs should be based on adequate retention, esthetics, and conservation of tooth structure. Clinical situations vary widely, and less conservative designs are required when caries, decalcification, or morphologic traits (such as short clinical crowns) dictate. The configurations in the following scenarios assume that the prospective abutments are still in their original positions. If the abutments have drifted, the situation could become less, and on occasion more, demanding, depending on the current position of the tooth. Fewer or additional abutments may become necessary if there has been drifting or bone loss. The ratios shown for root surface areas are intended as a general guideline, based on average tooth dimensions^{1,2} and root surface areas.³ An abutment-pontic root ratio of 1.0 or greater is considered to be favorable.⁴

Conventional partial coverage retainers could be used for many of the prostheses described. However, the reluctance of many patients to accept any display of metal and the lack of dentist familiarity with these preparations require that this design be used only on selected posterior abutments. Likewise, while resin-bonded fixed partial dentures (ie, Maryland bridges) can provide a suitable replacement for single missing teeth, experience with this type of retainer has shown that it demands a well-defined, albeit a very conservative prepa-

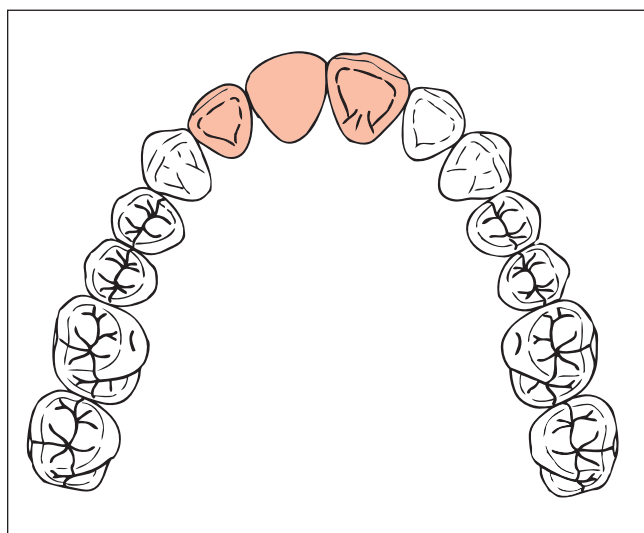
8 Fixed Partial Denture and Implant Configurations

ration. They are not the “quick and dirty” restorations that some people thought when they first appeared on the scene in the 1980s. They may be used as an intermediate retainer on young patients with teeth that are not fully formed or fully erupted or whose bone is not developmentally stable.

A fixed partial denture can be classified as either simple or complex, depending on the number of teeth to be replaced and the position of the edentulous space in the arch. The classic simple fixed partial denture is one that replaces a single tooth. Dental implants have expanded the treatment possibilities for the replacement of missing teeth markedly. Two scenarios are presented for each missing tooth, describ-

ing the use of a conventional tooth-borne fixed partial denture and an implant-supported crown. There are some situations in which a fixed partial denture cannot be placed with a reasonable expectation of success.

In the scenarios that appear on the following pages, the fixed partial denture solution is followed by the implant solution. In the illustrations, implant restorations are indicated by a shaded tooth with a circle in the center; tooth-borne fixed partial denture retainers are represented by a shaded tooth with contours; and fixed partial denture pontics are shown as a shaded outline of the tooth with no morphology.



Simple Fixed Partial Dentures (One Tooth)

Missing: Maxillary central incisor

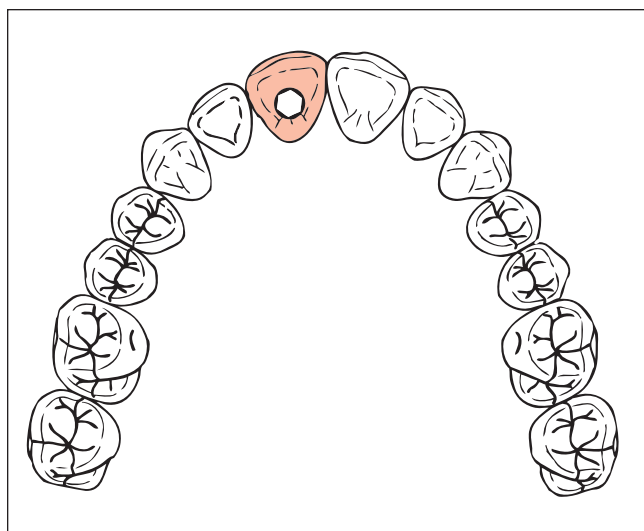
Abutments: Central incisor and lateral incisor

Considerations: Abutment discoloration or rotation, improper width of edentulous space, or proximal caries will require metal-ceramic restorations (MCRs). In that eventuality, the crowns can double as retainers, and the space can be restored with a fixed partial denture.

Retainers: MCR crowns. Resin-bonded retainers might be used if the patient is very young and if the abutments are healthy teeth that have never been restored.

Pontic: Modified ridge lap MCR

Abutment-pontic root ratio: 1.9



Missing: Maxillary central incisor

Implant: 4.0 × 12 mm

Considerations: A large nasopalatine foramen (incisive canal) may interfere with implant placement. Loss of the facial bone plate may necessitate bone grafting.

Restoration: MCR over a custom abutment (UCLA, Atlantis [Astra Tech], or preparable abutment)

Missing: Mandibular central incisor

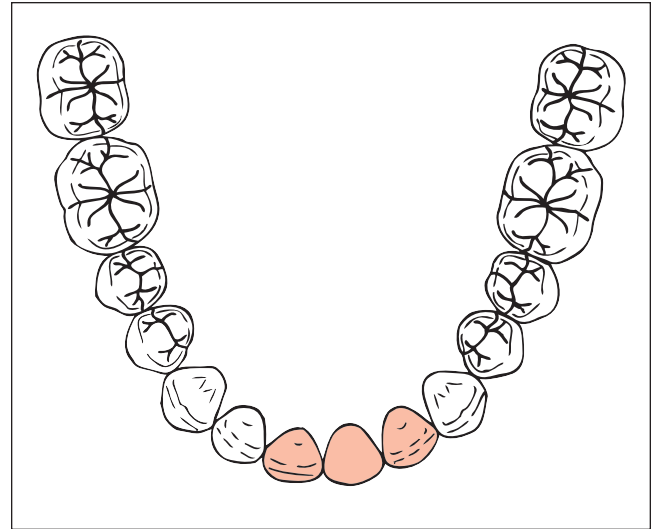
Abutments: Central incisor and lateral incisor

Considerations: If at all possible, an implant should be used to support this restoration if there is 7.3 mm between the prospective abutments. If there is not, a fixed partial denture will be required. Severely rotated, malposed, or mobile abutments will contraindicate the use of resin-bonded retainers and might dictate the removal of all of the mandibular incisors. In that instance, implants would be placed in the positions of the lateral incisors. If MCR retainers are required for a tooth-borne fixed partial denture, the preparations very easily could encroach on the pulp, and the patient should be so advised. Endodontic treatment and a dowel core would then be necessary.

Retainers: Resin-bonded retainers

Pontic: Ovate or modified ridge lap MCR (depending on ridge configuration)

Abutment-pontic root ratio: 2.1

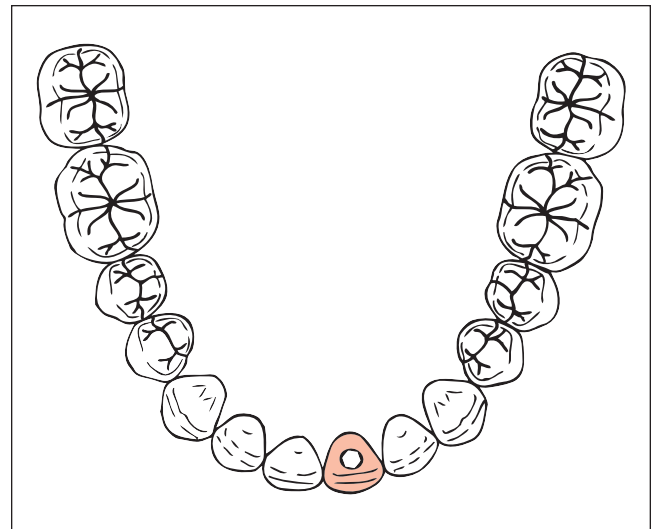


Missing: Mandibular central incisor

Implant: 3.3 × 12 mm

Considerations: A dental implant is the restoration of choice. The factor limiting replacement of a mandibular central incisor with a dental implant is the mesiodistal space available. Ideally there should be 7.3 mm of interproximal space. If inadequate space is available, consider extraction of all mandibular incisors. Place two 4.0 × 12-mm dental implants in the lateral incisor positions and fabricate a four-unit restoration.

Restoration: MCR crown over a one-piece implant



Missing: Maxillary lateral incisor

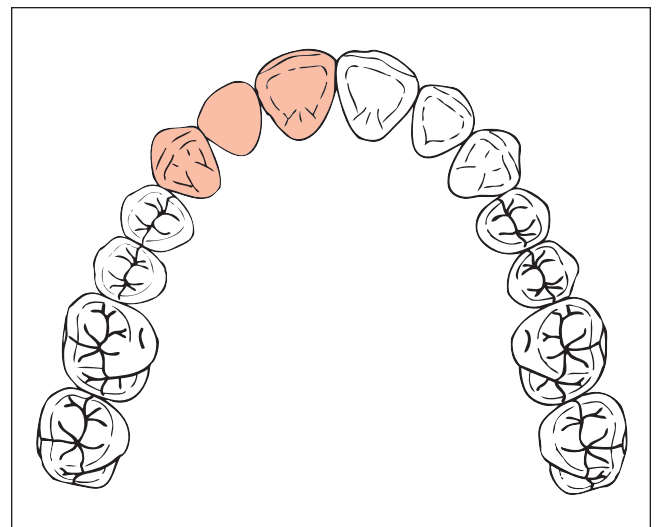
Abutments: Central incisor and canine

Considerations: Caries and/or restorations on the abutments would require MCR retainers. If the canine is long, well-supported periodontally, and in need of restoration, and if the pontic will not contact in centric relation or excursions, a single-abutment cantilever fixed partial denture could be used. An untouched central incisor and a first premolar in need of restoration would allow a pontic cantilevered from MCRs on the canine and first premolar.

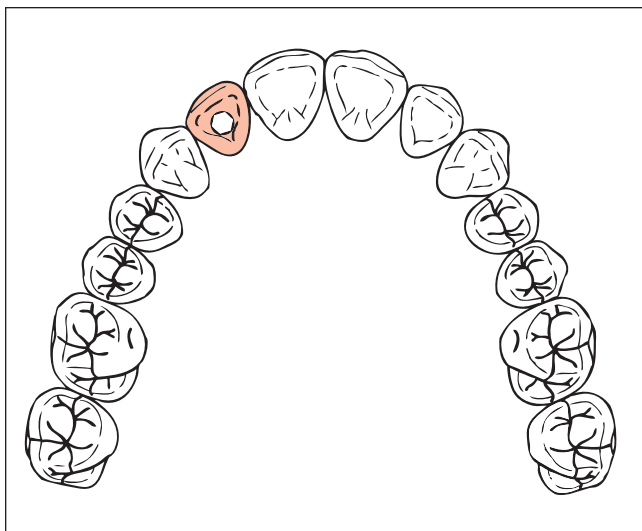
Retainers: Resin-bonded retainers

Pontic: Modified ridge lap MCR

Abutment-pontic root ratio: 2.6



8 Fixed Partial Denture and Implant Configurations

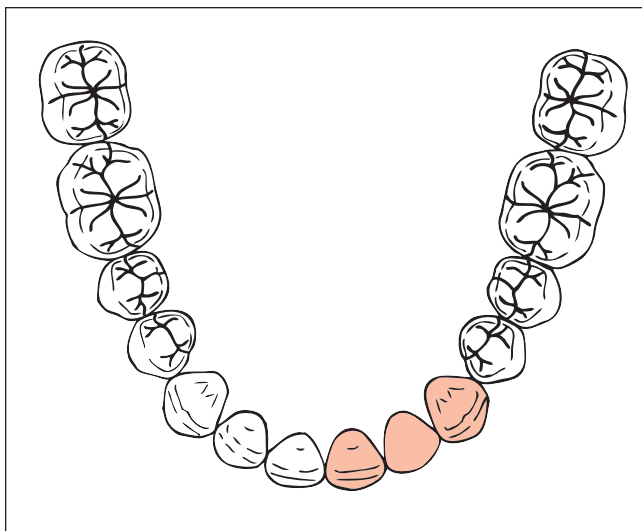


Missing: Maxillary lateral incisor

Implant: 3.5 × 12 mm

Considerations: The loss of a maxillary lateral incisor frequently results in the collapse of the facial plate of bone. The loss of the facial plate of bone often leads to a facial concavity requiring implant placement too far to the lingual. This will result in an unnatural lingual contour of the crown and a poor implant emergence profile. To correct this problem, bone grafting is required to eliminate the facial concavity.

Restoration: MCR over a custom abutment (UCLA, Atlantis, or preparable abutment)



Missing: Mandibular lateral incisor

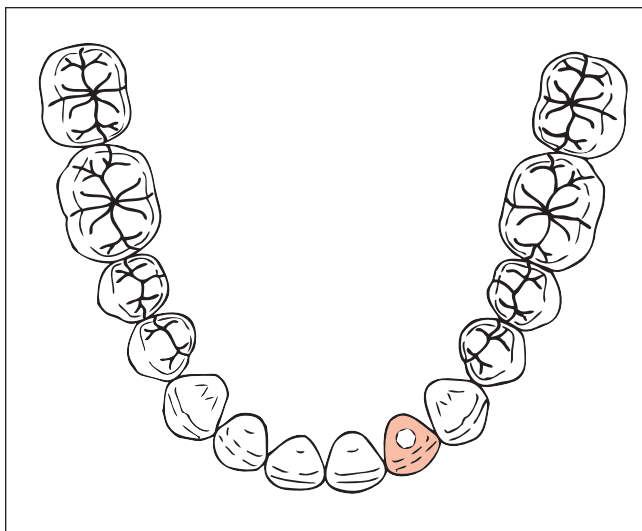
Abutments: Central incisor and canine

Considerations: An implant-supported MCR is the overriding choice for restoring this space. Caries and/or restorations on the abutments would require MCR crowns and a fixed partial denture. The patient should be warned of the potential for pulpal involvement with resultant endodontic treatment and a dowel core. Double abutting the central incisors for a fixed partial denture would complicate this case immensely. Cantilever fixed partial dentures are not an option for the replacement of mandibular lateral incisors. Severely rotated, malposed, or mobile abutments may contraindicate the use of a fixed partial denture using adjacent teeth as abutments. In such cases, the removal of all of the mandibular incisors would be necessary. The treatment then would be a canine-to-canine fixed partial denture.

Retainers: Resin-bonded retainers

Pontic: Modified ridge lap MCR

Abutment-pontic root ratio: 2.5



Missing: Mandibular lateral incisor

Implant: 3.3 × 12 mm

Considerations: A dental implant is the restoration of choice. The factor limiting replacement of a mandibular lateral incisor with a dental implant is the mesiodistal space available. Ideally there should be 7.3 mm of interproximal space. If inadequate space is available, consider extraction of all mandibular incisors. Place two 4.0 × 12-mm dental implants in the lateral incisor positions and fabricate a four-unit restoration.

Restoration: MCR over a one-piece implant

Missing: Maxillary first premolar

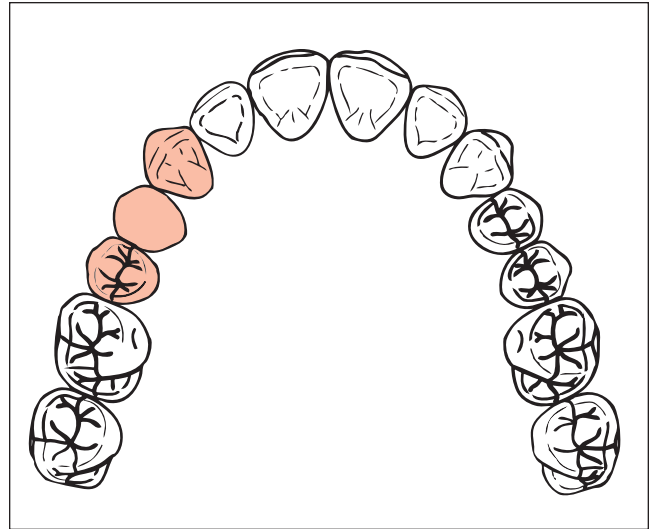
Abutments: Canine and second premolar

Considerations: An implant-supported MCR crown would be the restoration of choice. If the canine is unblemished and the second premolar and first molar are restored or will need restoration, a cantilever prosthesis using MCR retainers on the second premolar and first molar is worthy of consideration. A canine-guided occlusal scheme would be necessary to prevent excessive forces on the cantilever pontic.

Retainers: MCRs

Pontic: Modified ridge lap MCR

Abutment-pontic root ratio: 2.1

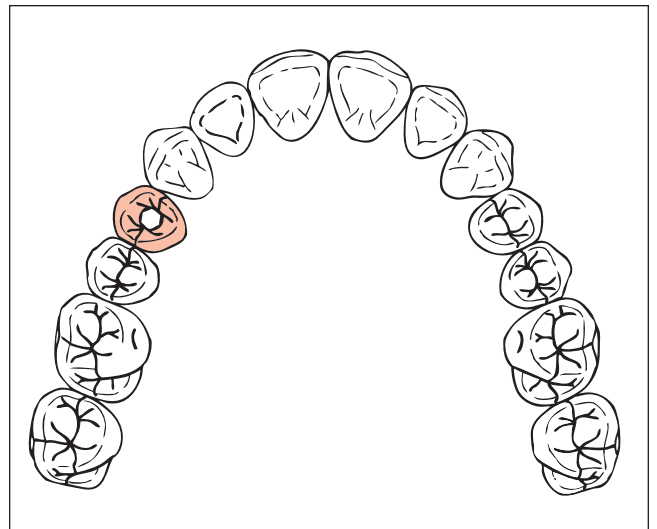


Missing: Maxillary first premolar

Implant: 4.0 × 13 mm

Considerations: Inadequate facial bone will require bone grafting for dental implant placement. Implant placement may impinge upon the anterior wall of the maxillary sinus. In this event, sinus modification surgery such as sinus grafting or vertical upfracture may be indicated.

Restoration: MCR over a custom abutment (UCLA, Atlantis, or preparable abutment)



Missing: Mandibular first premolar

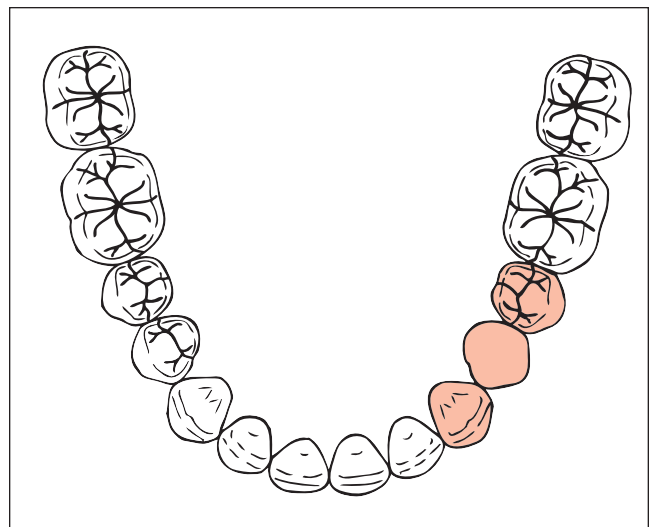
Abutments: Canine and second premolar

Considerations: Facial caries or any proximal caries other than incipient will necessitate MCR retainers. If the canine is intact and the second premolar and first molar are restored or will need restoration, a cantilever fixed partial denture can be used, with MCR retainers on the second premolar and first molar abutments. If the patient does not object, an all-metal crown can be substituted on the molar.

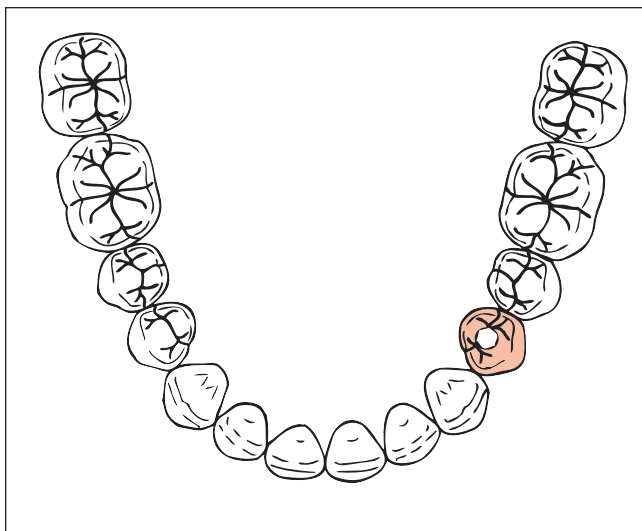
Retainers: MCRs

Pontic: Modified ridge lap or ovate MCR

Abutment-pontic root ratio: 2.5



8 Fixed Partial Denture and Implant Configurations

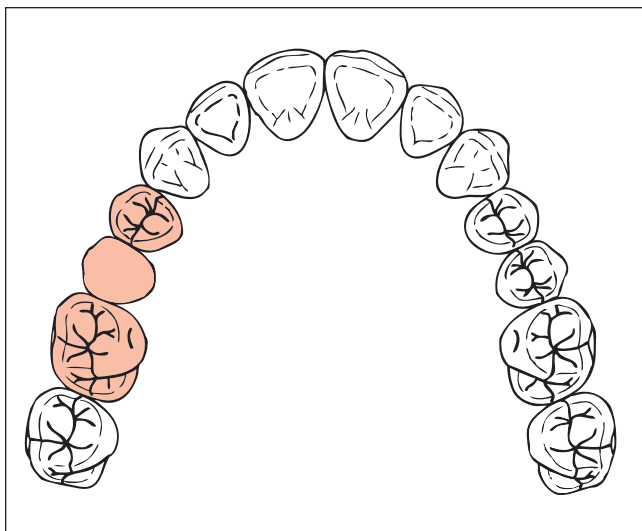


Missing: Mandibular first premolar

Implant: 4.3×11.5 mm

Considerations: The position of the anterior loop of the mandibular canal may interfere with implant placement.

Restoration: MCR over a custom abutment (UCLA, Atlantis, or preparable abutment)



Missing: Maxillary second premolar

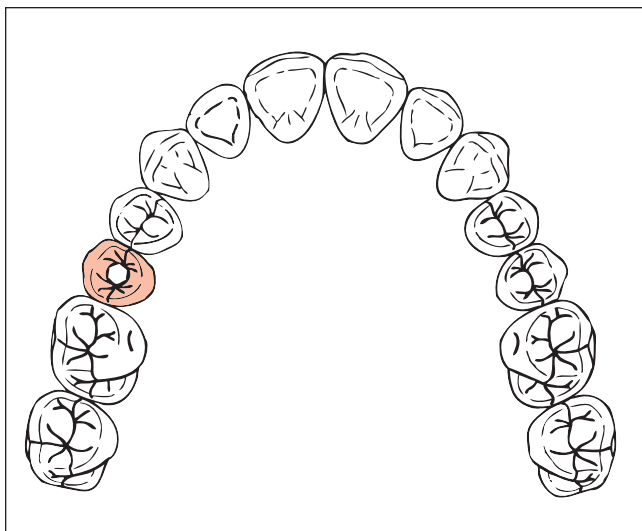
Abutments: First premolar and first molar

Considerations: MCR retainers will be required in cases with facial defects such as abfraction or decalcification or when they are requested by the patient.

Retainers: MCR on the first premolar and MCR or full coverage gold crown (FGC) on the first molar

Pontic: Modified ridge lap MCR

Abutment-pontic root ratio: 3:1



Missing: Maxillary second premolar

Implant: 4.3×11.5 mm

Considerations: The maxillary sinus will likely interfere with the placement of an implant of desirable length, necessitating sinus modification surgery such as a sinus graft or a vertical upfracture.

Restoration: MCR over a custom abutment (UCLA, Atlantis, or preparable abutment)

Missing: Mandibular second premolar

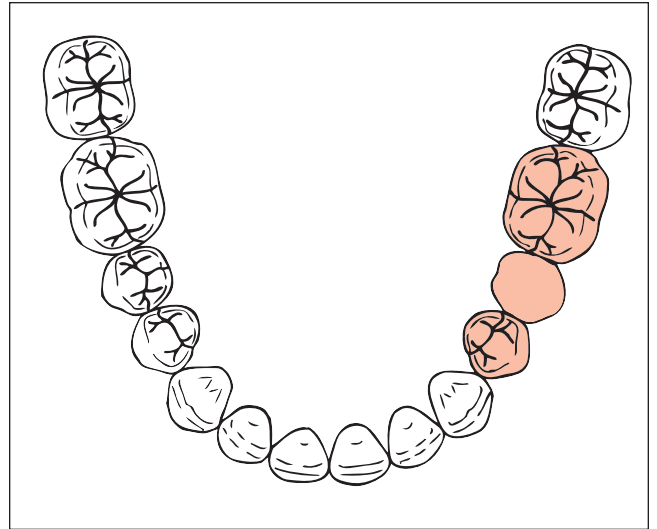
Abutments: First premolar and first molar

Considerations: Esthetic requirements of the patient may necessitate an MCR retainer on the molar. Resin-bonded retainers can be used if the first premolar is large and if the abutments are caries-free or only minimally affected by caries.

Retainers: MCR crown on the premolar and FGC on the molar

Pontic: Modified ridge lap or ovate MCR

Abutment-pontic root ratio: 3:1

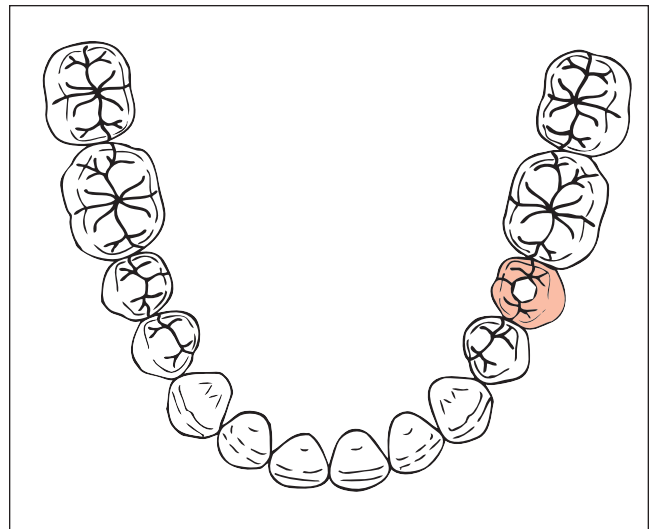


Missing: Mandibular second premolar

Implant: 4.3 × 10 mm

Considerations: Loss of the facial plate of bone may result in inadequate alveolar width. Alveolar resorption may result in insufficient height of bone above the mental foramen and mandibular canal. The correction of this anatomical difficulty requires the placement of an onlay bone graft to allow the placement of an implant of sufficient width and length.

Restoration: MCR over a custom abutment (UCLA, Atlantis, or preparable abutment)



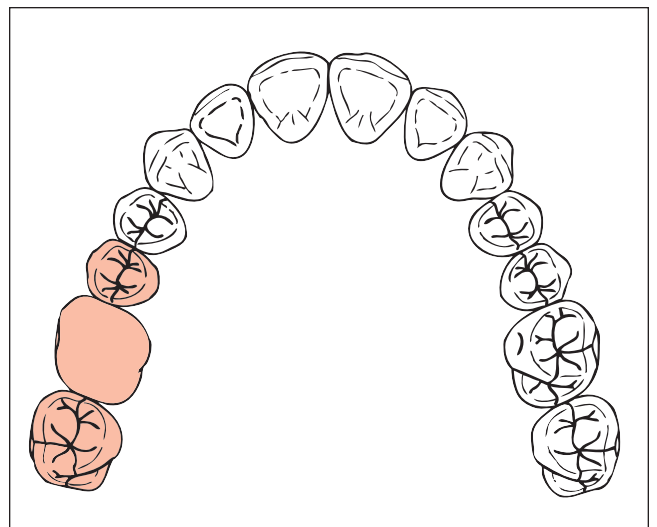
Missing: Maxillary first molar

Abutments: Second premolar and second molar

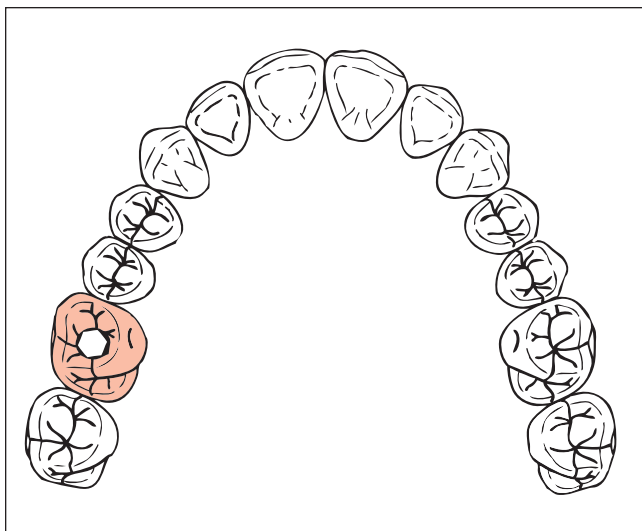
Retainers: MCR or $\frac{3}{4}$ crown on the premolar and $\frac{7}{8}$ crown on the molar

Pontic: Modified ridge lap MCR

Abutment-pontic root ratio: 1.5



8 Fixed Partial Denture and Implant Configurations

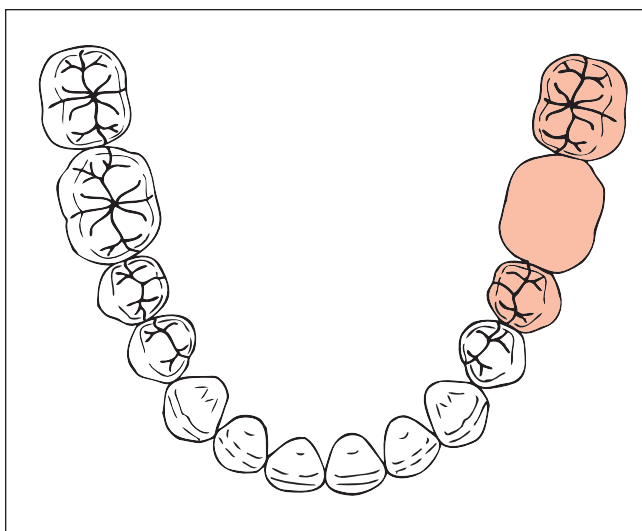


Missing: Maxillary first molar

Implant: 5.0 × 11.5 mm

Considerations: The maxillary sinus will likely interfere with the placement of an implant of desirable length, necessitating sinus modification surgery such as a sinus graft or a vertical upfracture.

Restoration: MCR over a custom abutment (UCLA, Atlantis, or preparable abutment)



Missing: Mandibular first molar

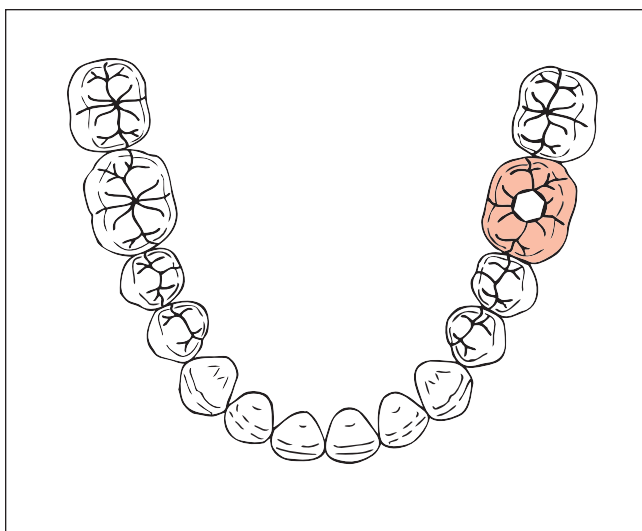
Abutments: Second premolar and second molar

Considerations: A tilted molar may require orthodontic up-righting, a proximal half crown, or a telescope crown (see chapter 7).

Retainers: MCR crown on the premolar and FGC on the molar

Pontic: All-metal hygienic, if patient is agreeable. If the patient demands a ceramic occlusal portion, a pontic design that touches the ridge is needed, and metal should extend fully to the ridge to provide rigidity.

Abutment-pontic root ratio: 1.5



Missing: Mandibular first molar

Implant: 5.0 × 10 mm

Considerations: Loss of the facial plate of bone may result in inadequate alveolar width. Alveolar resorption may result in insufficient height of bone above the mandibular canal. The correction of this anatomical difficulty requires the placement of an onlay bone graft to allow the placement of an implant of sufficient width and length.

Restoration: MCR over a custom abutment (UCLA, Atlantis, or preparable abutment)

Missing: Maxillary second molar

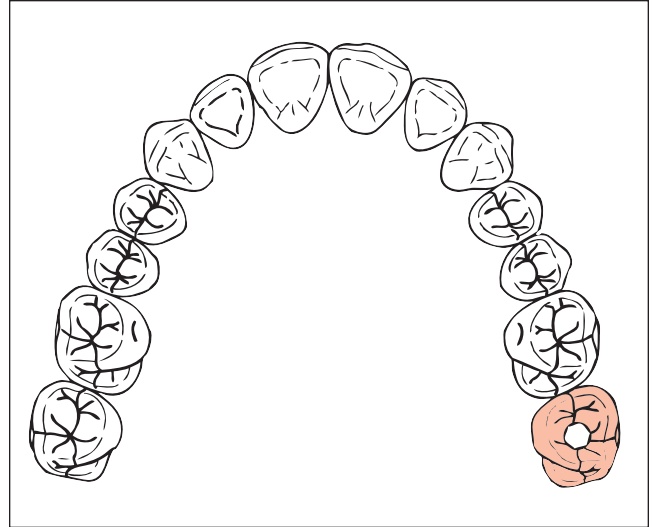
Considerations: Restoration with a cantilevered fixed partial denture is not recommended due to the excessive tensile stresses placed on the premolar abutment and the retainer.

Missing: Maxillary second molar

Implant: 5.0 × 11.5 mm

Considerations: The maxillary sinus will likely interfere with the placement of an implant of desirable length, necessitating sinus modification surgery such as a sinus graft or a vertical upfracture.

Restoration: MCR over a custom abutment (UCLA, Atlantis, or preparable abutment)



Missing: Mandibular second molar

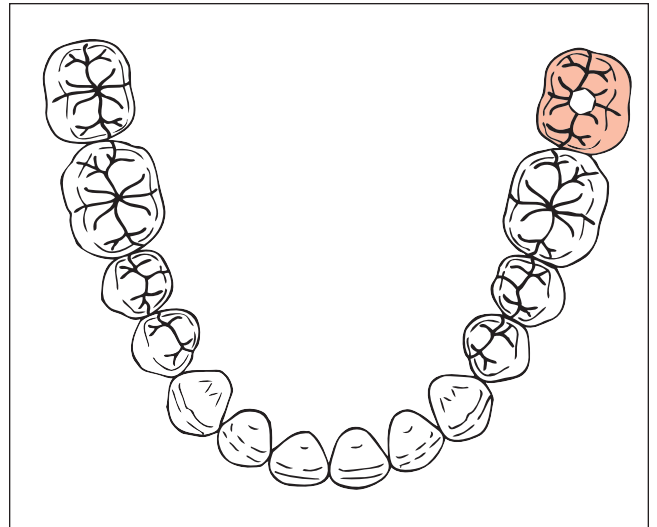
Considerations: Restoration with a cantilevered fixed partial denture is not recommended due to the excessive tensile stresses placed on the premolar abutment and the retainer.

Missing: Mandibular second molar

Implant: 5.0 × 10 mm

Considerations: Loss of the facial plate of bone may result in inadequate alveolar width. Alveolar resorption may lead to insufficient height of bone above the mental foramen and mandibular canal. The correction of this anatomical difficulty requires the placement of an onlay bone graft to allow the placement of an implant of sufficient width and length.

Restoration: MCR over a custom abutment (UCLA, Atlantis, or preparable abutment)



Complex Fixed Partial Dentures (One Tooth)

Missing: Maxillary canine

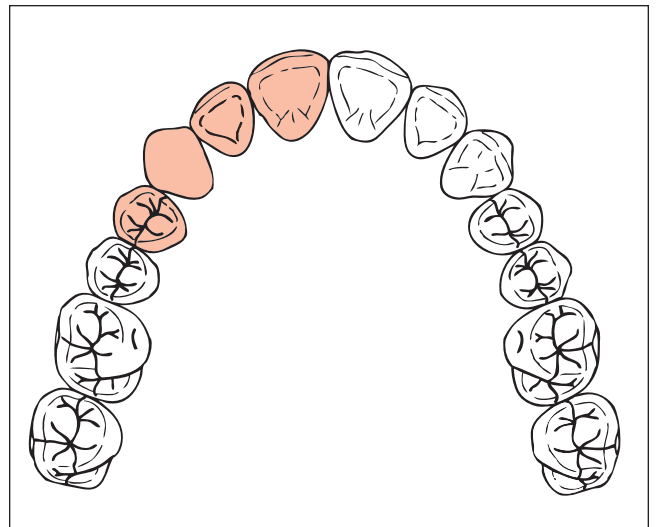
Abutments: Central incisor, lateral incisor, and first premolar

Considerations: A single implant-supported MCR crown would be the restoration of choice here. Restore the occlusion to group function. Using the two premolars and the lateral incisor as abutments is not desirable because it places too heavy a burden on the smaller single abutment, the lateral incisor.

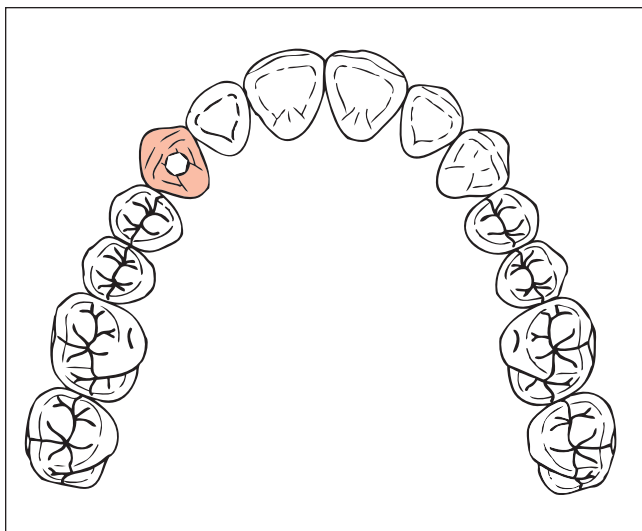
Retainers: MCR crowns

Pontic: Modified ridge lap or ovate MCR, depending on the faciolingual dimension of the ridge

Abutment-pontic root ratio: 2.3



8 Fixed Partial Denture and Implant Configurations

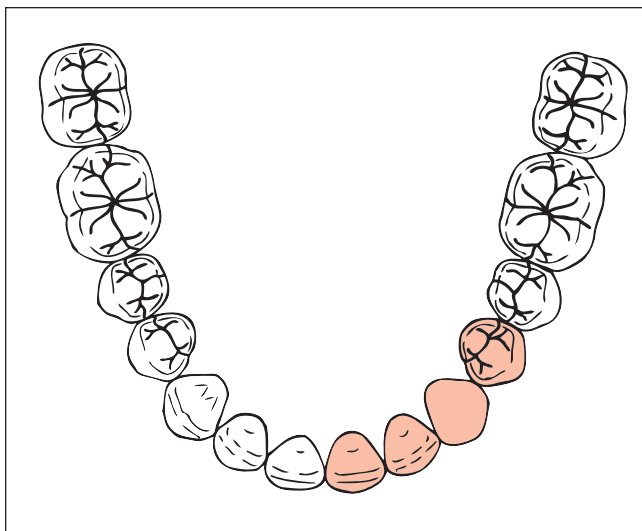


Missing: Maxillary canine

Implant: 4.5 × 15 mm

Considerations: A dental implant is the restoration of choice.

Restoration: MCR over a custom abutment (UCLA, Atlantis, or preparable abutment)



Missing: Mandibular canine

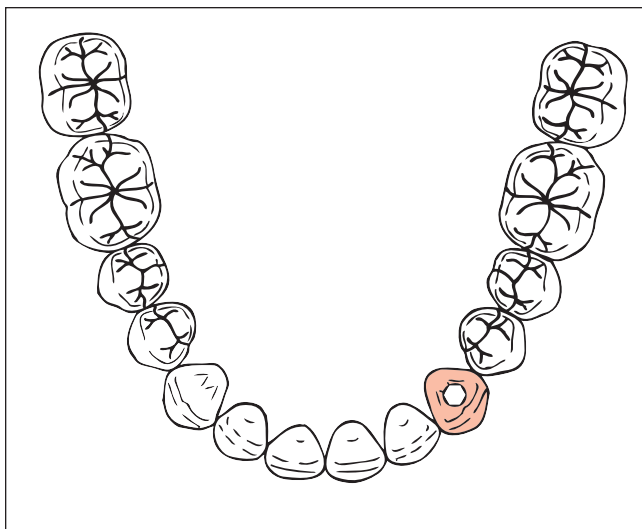
Abutments: Central incisor, lateral incisor, and first premolar

Considerations: An implant-supported MCR is the restoration of choice in the mandible as well. Use group function to restore the occlusion. If there has been extensive bone loss around the lateral incisor, or if it is tilted to produce a line of draw discrepancy, remove the lateral incisor and use both central incisors as abutments if a fixed partial denture is used. Fortunately, the need to replace this tooth is not common.

Retainers: MCRs

Pontic: Ovate MCR

Abutment-pontic root ratio: 1.9



Missing: Mandibular canine

Implant: 4.5 × 15 mm

Considerations: A dental implant is the restoration of choice.

Restoration: MCR over a custom abutment (UCLA, Atlantis, or preparable abutment)

Simple Fixed Partial Dentures (Two Teeth)

Missing: Maxillary central incisor and lateral incisor

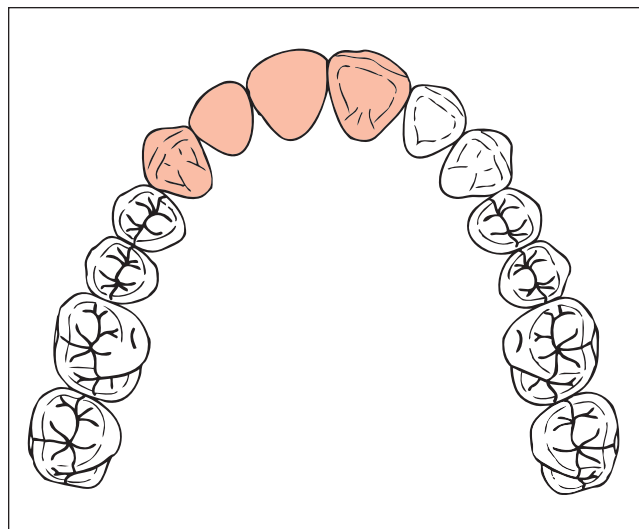
Abutments: Central incisor and canine

Considerations: If the central incisor and canine are unblemished and unusually large, pin-modified partial coverage crowns could be used. Patient acceptance and dentist skill are strong considerations.

Retainers: MCRs

Pontics: Modified ridge lap MCR

Abutment-pontic root ratio: 1.2

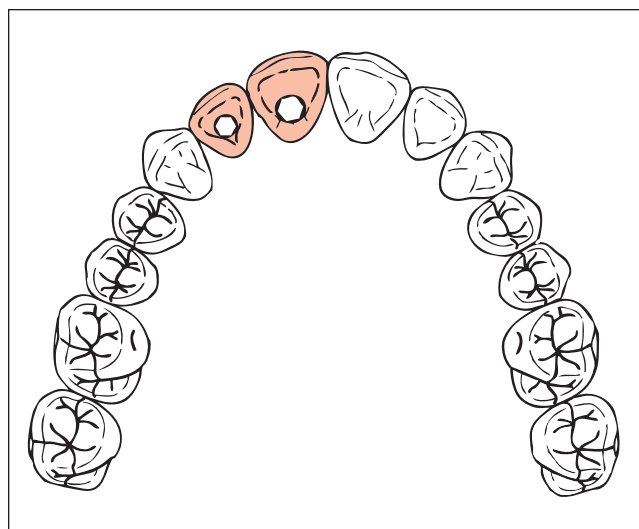


Missing: Maxillary central incisor and lateral incisor

Implants: 4.0 × 12 mm (central incisor), 3.5 × 12 mm (lateral incisor)

Considerations: A large nasopalatine foramen (incisive canal) may interfere with implant placement. If loss of the lateral incisor has caused loss of the facial plate of bone, the resulting facial concavity will place the implant too far to the lingual. This may necessitate bone grafting to eliminate the facial concavity. Splinting the dental implant restoration will reduce rotational forces on the abutment screws, lessening the possibility of screw loosening. Splinting the dental implants will increase restoration strength and stress distribution.

Restorations: MCRs over custom abutments (UCLA, Atlantis, or preparable abutments)



Missing: Mandibular central incisors

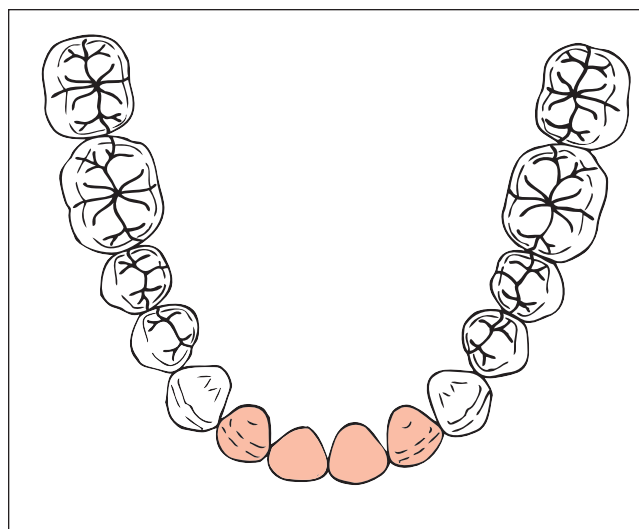
Abutments: Lateral incisors

Considerations: If there has been any bone loss around the lateral incisors, or if they are malpositioned, remove them. Use MCR retainers on the canines for a tooth-borne fixed partial denture.

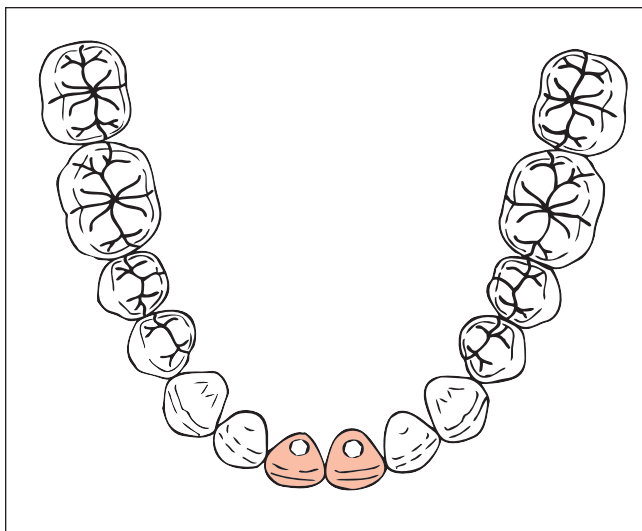
Retainers: Resin-bonded retainers if the abutments are unblemished

Pontics: Ovate MCRs or one-piece pontics with a modified ridge lap of pink porcelain

Abutment-pontic root ratio: 1.1



8 Fixed Partial Denture and Implant Configurations

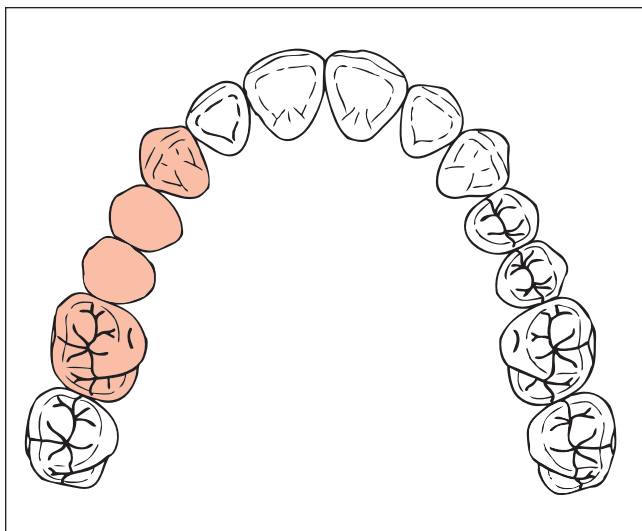


Missing: Mandibular central incisors

Implants: 3.3×12 mm

Considerations: The factor limiting replacement of mandibular central incisors with dental implants is the mesiodistal space available. Ideally there should be 12.6 mm of interproximal space. If inadequate space is available, consider extraction of the lateral incisors. Place two 4.0×12 -mm dental implants in the lateral incisor positions and fabricate a four-unit fixed partial denture. Splinting the dental implant restoration will reduce rotational forces on the abutment screws, lessening the possibility of screw loosening. Splinting the dental implants will increase restoration strength and stress distribution.

Restorations: MCRs over one-piece implants



Missing: Maxillary first and second premolars

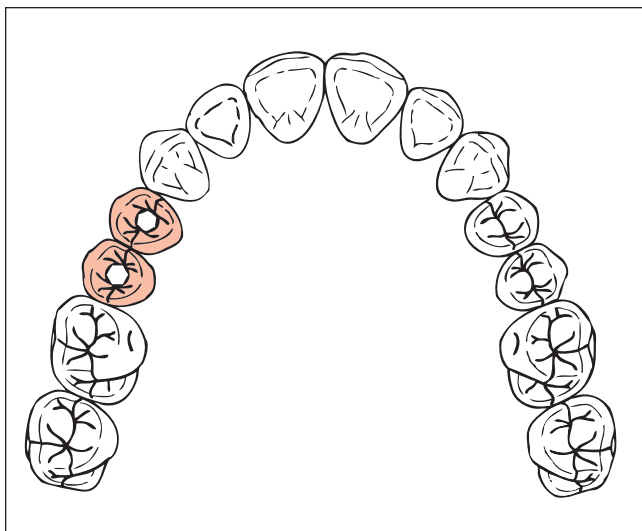
Abutments: Canine and first molar

Considerations: An MCR crown may be used on the molar if the mesiofacial cusp is damaged or undermined or if the patient requests it. An MCR will be required on the canine.

Retainers: MCR on the canine and $\frac{7}{8}$ crown or MCR on the molar

Pontics: Modified ridge lap MCRs

Abutment-pontic root ratio: 1.6



Missing: Maxillary first and second premolars

Implants: 4.0×13 mm (first premolar), 4.3×11.5 mm (second premolar)

Considerations: The loss of the facial plate of bone will frequently result in a facial concavity, requiring implant placement too far to the lingual. This will result in an unnatural lingual contour of the crown and a poor implant emergence profile. To correct this problem, bone grafting is required to eliminate the facial concavity. The maxillary sinus will likely interfere with the placement of an implant of desirable length, necessitating sinus modification surgery such as a sinus graft or a vertical upfracture. Splinting the dental implant restoration will reduce rotational forces on the abutment screws, lessening the possibility of screw loosening. Splinting the dental implants will increase restoration strength and stress distribution.

Restorations: MCRs over custom abutments (UCLA, Atlantis, or preparable abutments)

Missing: Mandibular first and second premolars

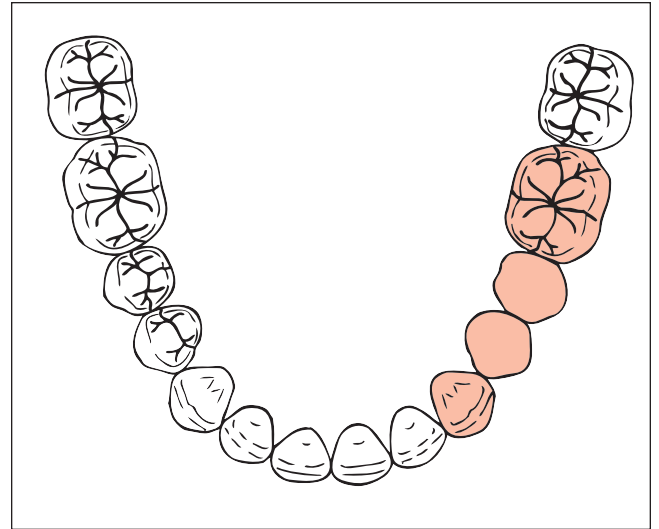
Abutments: Canine and first molar

Considerations: If the molar has tilted mesially, orthodontic uprighting or preparation modification will be required. The patient's esthetic expectations may require an MCR crown on the molar.

Retainers: MCR crown on the canine and FGC on the molar

Pontics: Ovate MCRs

Abutment-pontic root ratio: 1.8

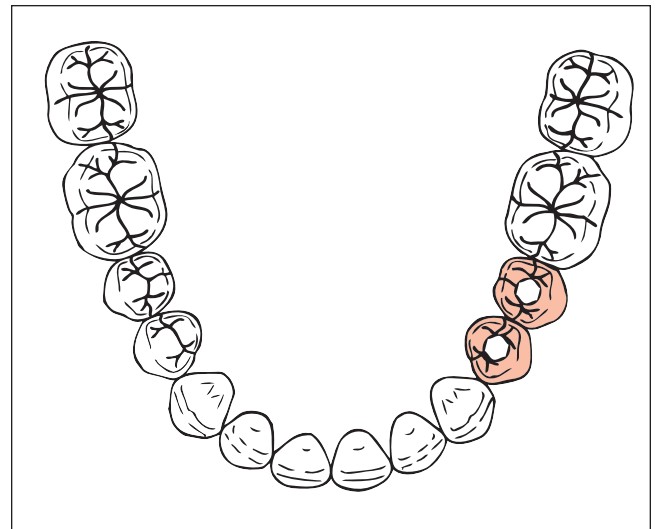


Missing: Mandibular first and second premolars

Implants: 4.3 × 11.5 mm (first premolar), 4.3 × 10 mm (second premolar)

Considerations: The position of the anterior loop of the mandibular canal may interfere with implant placement. Loss of the facial plate of bone may result in inadequate alveolar width. Alveolar resorption may result in insufficient height of bone above the mandibular canal. The correction of this anatomical difficulty requires the placement of an onlay bone graft to allow the placement of an implant of sufficient width and length. Splinting the dental implant restoration will reduce rotational forces on the abutment screws, lessening the possibility of screw loosening. Splinting the dental implants will increase restoration strength and stress distribution.

Restorations: MCRs over custom abutments (UCLA, Atlantis, or preparable abutments)



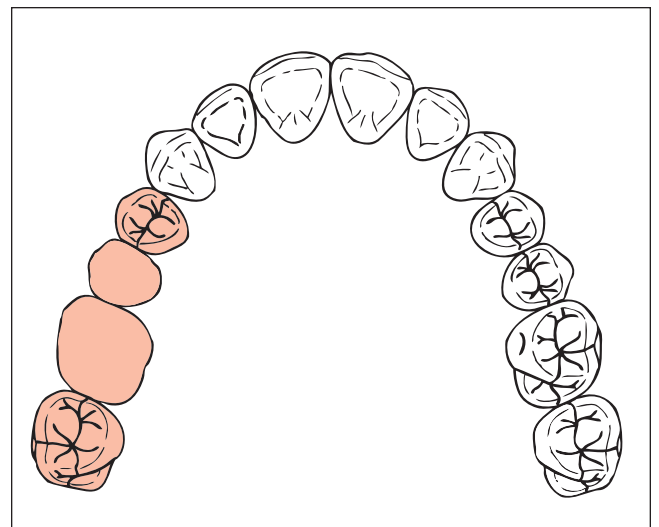
Missing: Maxillary second premolar and first molar

Abutments: First premolar and second molar

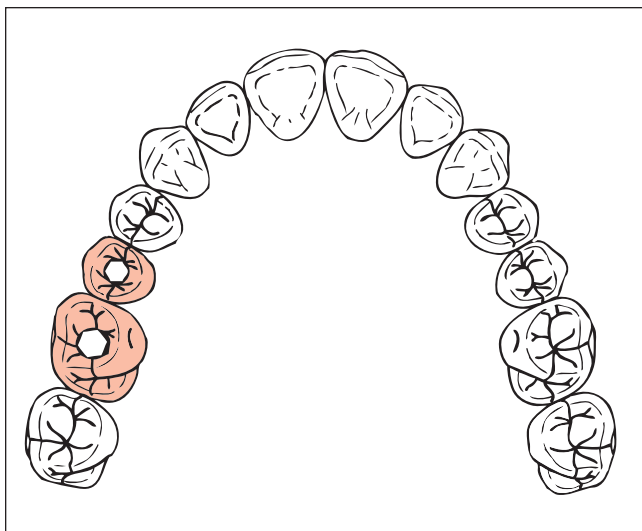
Retainers: MCR crown on the premolar and FGC on the molar. Discourage the patient from choosing an MCR for the molar. An FGC probably will not be visible, and its preparation does not require the destruction of nearly as much tooth length or bulk.

Pontics: Modified ridge lap MCRs

Abutment-pontic root ratio: 1.0



8 Fixed Partial Denture and Implant Configurations

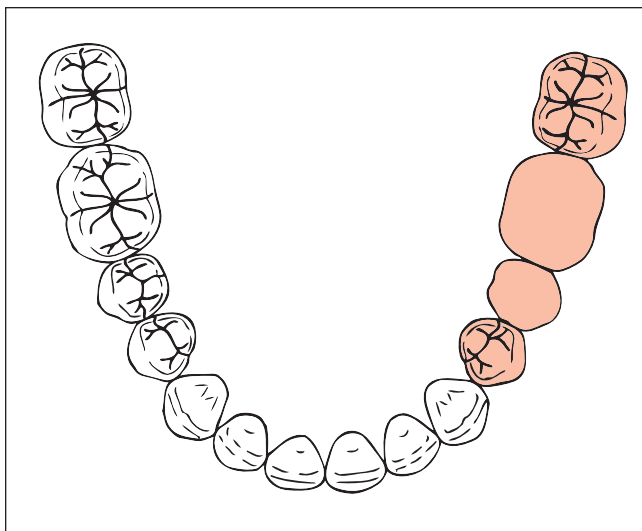


Missing: Maxillary second premolar and first molar

Implants: 4.3×11.5 mm (second premolar), 5.0×11.5 mm (first molar)

Considerations: The loss of the facial plate of bone will frequently result in a facial concavity requiring implant placement too far to the lingual. This will result in an unnatural lingual contour of the crown and a poor implant emergence profile. To correct this problem, bone grafting is required to eliminate the facial concavity. The maxillary sinus will likely interfere with the placement of an implant of desirable length, necessitating sinus modification surgery such as a sinus graft or a vertical upfracture. Splinting the dental implant restoration will reduce rotational forces on the abutment screws, lessening the possibility of screw loosening. Splinting the dental implants will increase restoration strength and stress distribution.

Restorations: MCRs over custom abutments (UCLA, Atlantis, or preparable abutments)



Missing: Mandibular second premolar and first molar

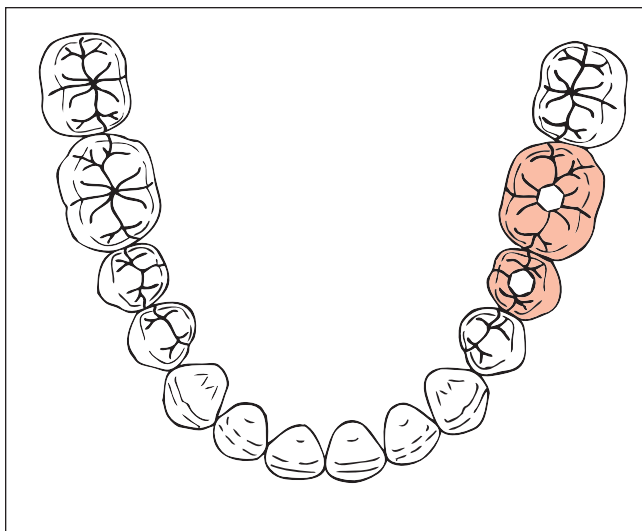
Abutments: First premolar and second molar

Considerations: If the premolar root is short or thin, or if the clinical crown is very small, the canine should be included as a secondary abutment.

Retainers: MCR crown on the premolar and FGC on the molar

Pontics: Modified ridge lap or ovate MCRs

Abutment-pontic root ratio: 1.0



Missing: Mandibular second premolar and first molar

Implants: 4.3×10 mm (second premolar), 5.0×10 mm (first molar)

Considerations: Loss of the facial plate of bone may result in inadequate alveolar width. Alveolar resorption may result in insufficient height of bone above the mandibular canal. The correction of this anatomical difficulty requires the placement of an onlay bone graft to allow the placement of an implant of sufficient width and length. Splinting the dental implant restoration will reduce rotational forces on the abutment screws, lessening the possibility of screw loosening. Splinting the dental implants will increase restoration strength and stress distribution.

Restorations: MCRs over custom abutments (UCLA, Atlantis, or preparable abutments)

Missing: Maxillary first and second molars

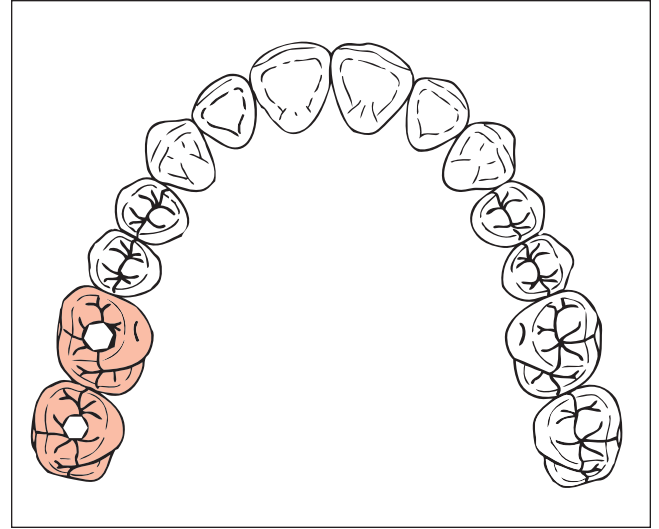
Considerations: A fixed partial denture cannot be used in this situation because there is no distal abutment.

Missing: Maxillary first and second molars

Implants: 5.0×11.5 mm

Considerations: The placement of a dental implant in the second molar position provides increased strength and stress distribution of occlusal and antirotational forces. The maxillary sinus will likely interfere with the placement of an implant of desirable length, necessitating sinus modification surgery such as a sinus graft or a vertical upfracture. Splinting the dental implant restoration will reduce rotational forces on the abutment screws, lessening the possibility of screw loosening. Splinting the dental implants will increase restoration strength and stress distribution.

Restorations: MCR over a custom abutment (UCLA, Atlantis, or preparable abutment) for the first molar and FGC or MCR over a custom abutment for the second molar



Missing: Mandibular first and second molars

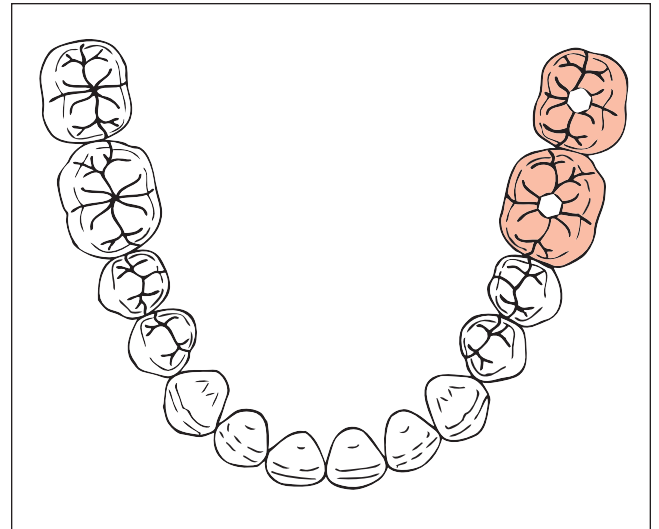
Considerations: A fixed partial denture cannot be used in this situation because there is no distal abutment and a cantilever would place excessive force on the premolars.

Missing: Mandibular first and second molars

Implants: 5.0×10 mm

Considerations: The placement of a dental implant in the second molar position provides increased strength and stress distribution of occlusal and antirotational forces. Loss of the facial plate of bone may result in inadequate alveolar width. Alveolar resorption may lead to insufficient height of bone above the mandibular canal. The correction of this anatomical difficulty requires the placement of an onlay bone graft to allow the placement of an implant of sufficient width and length. Splinting the dental implant restoration will reduce rotational forces on the abutment screws, lessening the possibility of screw loosening. Splinting the dental implants will increase restoration strength and stress distribution.

Restorations: MCRs or FGCs over custom abutments (UCLA, Atlantis, or preparable abutments)



Complex Fixed Partial Dentures (Two Teeth)

Missing: Mandibular central incisor and lateral incisor

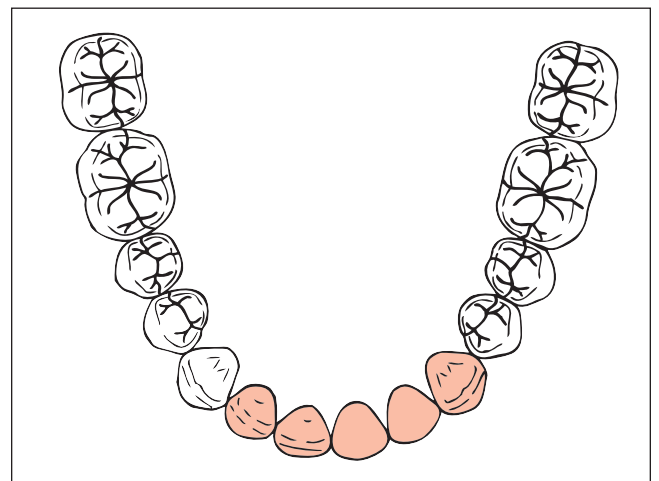
Abutments: Central incisor, lateral incisor, and canine

Considerations: Inadequate bone support around central and lateral incisors often necessitates their removal. This would require a six-unit fixed partial denture with MCR retainers on the canines. The patient should be warned of the potential for pulpal involvement with resultant endodontic treatment and dowel cores. Anterior guidance should not be excessive to avoid undue lingually directed forces.

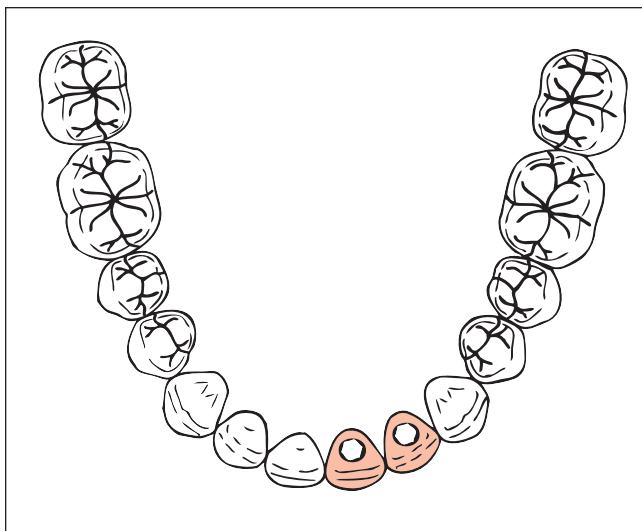
Retainers: Resin-bonded retainers (only if prospective abutments are large and ideally located)

Pontics: Ovate MCRs

Abutment-pontic root ratio: 1.8



8 Fixed Partial Denture and Implant Configurations

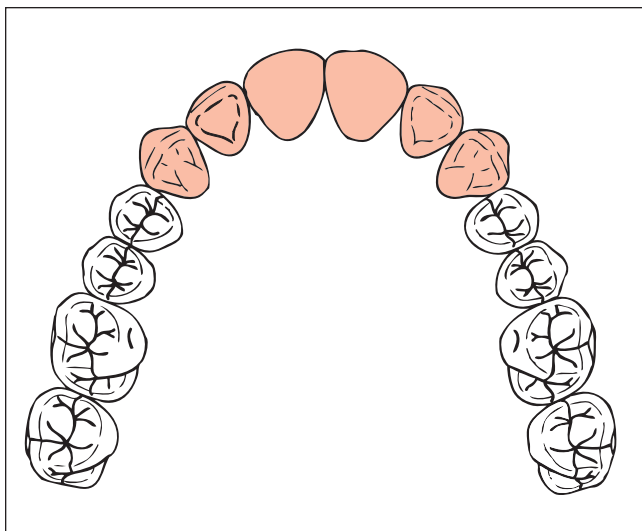


Missing: Mandibular central incisor and lateral incisor

Implants: 3.3×12 mm

Considerations: The factor limiting replacement of mandibular incisors with dental implants is the mesiodistal space available. Ideally there should be 12.6 mm of interproximal space. If inadequate space is available, consider extraction of all mandibular incisors. Place two 4.0×12 -mm dental implants in the lateral incisor positions and fabricate a four-unit fixed partial denture. Splinting the dental implant restoration will reduce rotational forces on the abutment screws, lessening the possibility of screw loosening. Splinting the dental implants will increase restoration strength and stress distribution.

Restorations: MCRs over one-piece implants



Missing: Maxillary central incisors

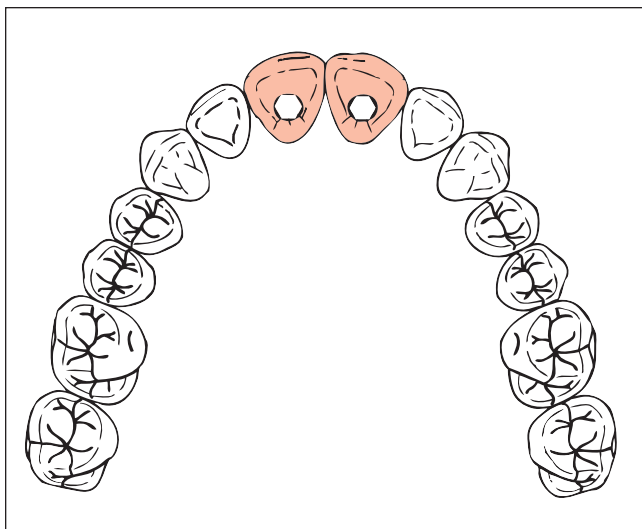
Abutments: Both canines and lateral incisors

Considerations: When the bony support for the lateral incisors is poor, it is often best to extract them and lengthen the fixed partial denture span. If the lateral incisors have long roots and crowns, they alone can be used as abutments.

Retainers: MCRs

Pontics: Modified ridge lap MCRs

Abutment-pontic root ratio: 2.3



Missing: Maxillary central incisors

Implants: 4.0×12 mm

Considerations: A large nasopalatine foramen (incisive canal) may interfere with implant placement. Loss of the facial bone plate may necessitate bone grafting. Splinting the dental implant restoration will reduce rotational forces on the abutment screws, lessening the possibility of screw loosening. Splinting the dental implants will increase restoration strength and stress distribution.

Restorations: MCRs over custom abutments (UCLA, Atlantis, or preparable abutments)

Missing: Maxillary lateral incisor and canine

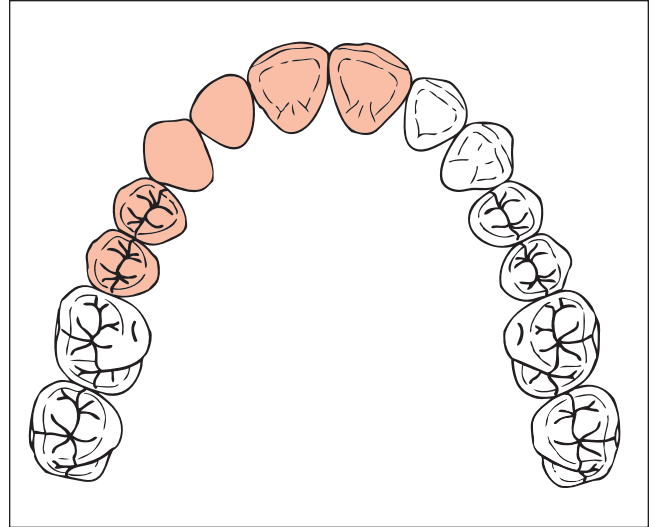
Abutments: Both central incisors and premolars

Considerations: Span length, abutment position, and root configuration can make the use of four abutments desirable. All retainers must have good retention. If the premolars have drifted mesially, it may not be necessary to include the second premolar. Use group function to restore the occlusion.

Retainers: MCRs

Pontics: Modified ridge lap MCRs

Abutment-pontic root ratio: 1.9

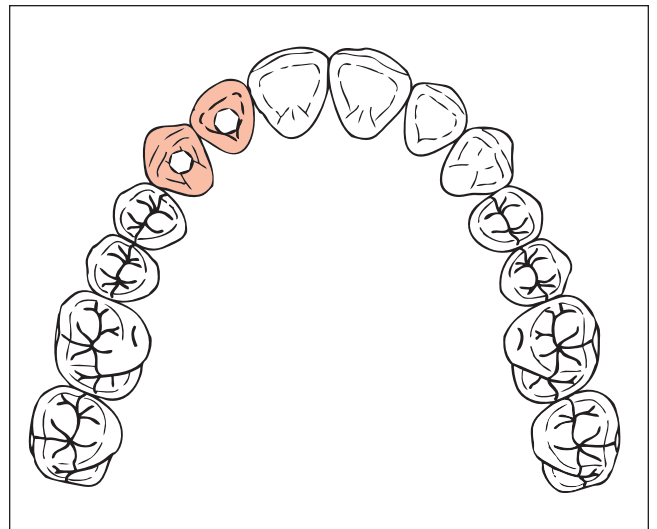


Missing: Maxillary lateral incisor and canine

Implants: 3.5 × 12 mm (lateral incisor), 4.5 × 15 mm (canine)

Considerations: The loss of a maxillary lateral incisor may result in the collapse of the facial plate of bone, producing a facial concavity, which will require bone grafting. Splinting the dental implant restoration will reduce rotational forces on the abutment screws, lessening the possibility of screw loosening. Splinting the dental implants will increase restoration strength and stress distribution.

Restorations: MCRs over custom abutments (UCLA, Atlantis, or preparable abutments)



Missing: Mandibular lateral incisor and canine

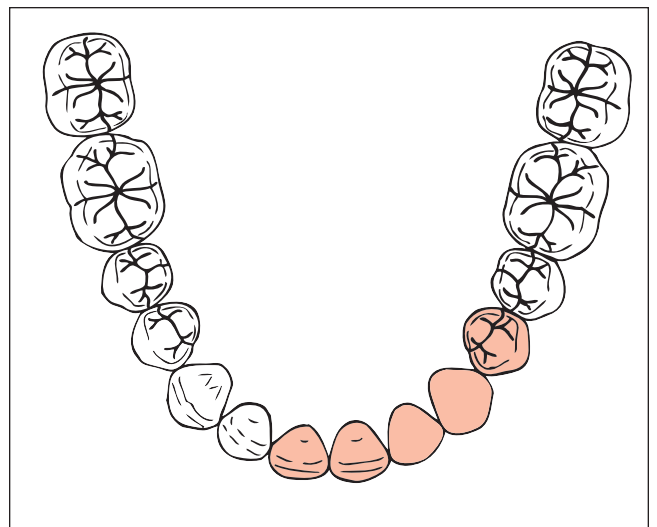
Abutments: Both central incisors and first premolar

Considerations: The short edentulous span and the direction of forces on the mandibular canine do not require the use of the second premolar as an abutment.

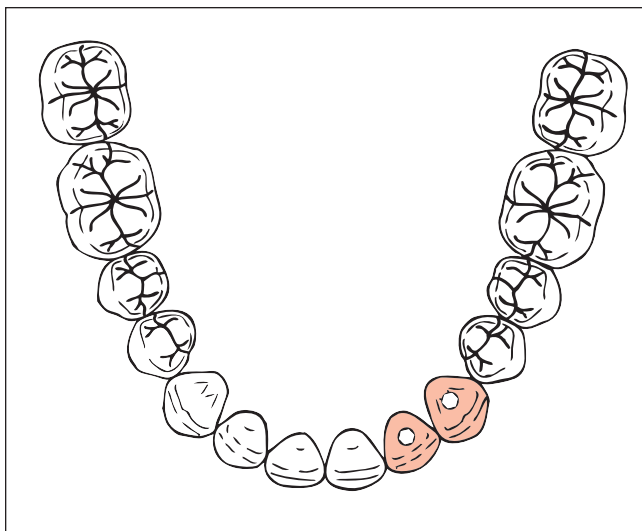
Retainers: MCRs

Pontics: Modified ridge lap MCRs

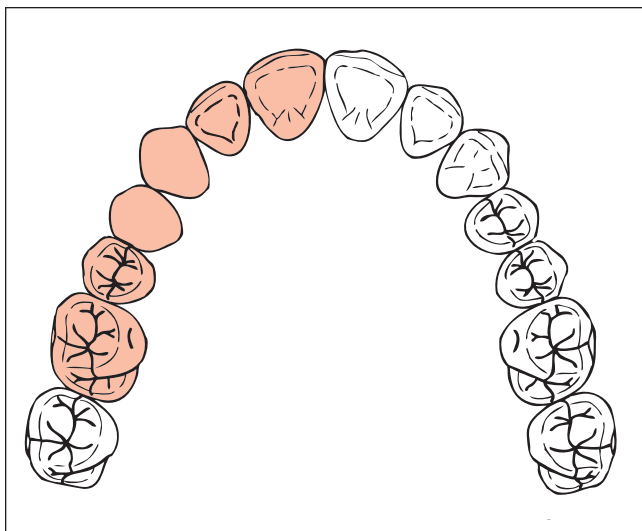
Abutment-pontic root ratio: 1.1



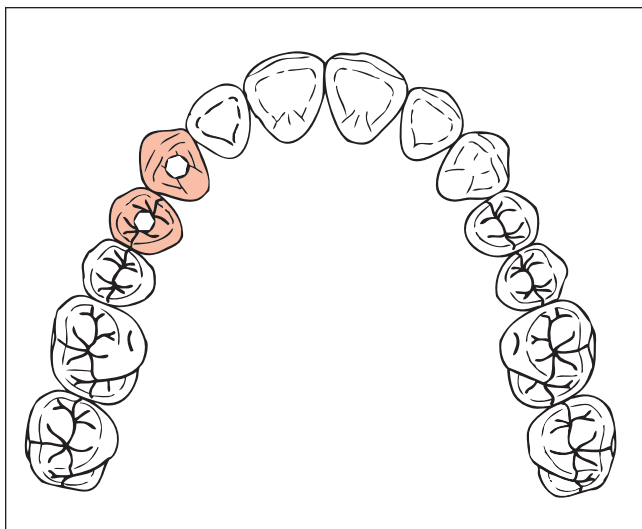
8 Fixed Partial Denture and Implant Configurations



Missing: Mandibular lateral incisor and canine
Implants: 3.3×12 mm (lateral incisor), 4.5×15 mm (canine)
Considerations: A dental implant is the restoration of choice. Splinting the dental implant restoration will reduce rotational forces on the abutment screws, lessening the possibility of screw loosening. Splinting the dental implants will increase restoration strength and stress distribution.
Restorations: MCRs over custom abutments (UCLA, Atlantis, or preparable abutments)



Missing: Maxillary canine and first premolar
Abutments: Central incisor, lateral incisor, second premolar, and first molar
Considerations: Group function should be used. This can be a difficult restoration.
Retainers: MCRs on the incisors and second premolar and $\frac{7}{8}$ crown on the molar
Pontics: Modified ridge lap MCRs
Abutment-pontic root ratio: 2.0



Missing: Maxillary canine and first premolar
Implants: 4.5×15 mm (canine), 4.0×13 mm (first premolar)
Considerations: The loss of the facial plate of bone will frequently result in a facial concavity requiring implant placement too far to the lingual. This will result in an unnatural lingual contour of the crown and a poor implant emergence profile. To correct this problem, bone grafting is required to eliminate the facial concavity. First premolar implant placement may impinge on the anterior wall of the maxillary sinus. In this event, sinus modification surgery such as sinus grafting or vertical upfracture may be indicated. Splinting the dental implant restoration will reduce rotational forces on the abutment screws, lessening the possibility of screw loosening. Splinting the dental implants will increase restoration strength and stress distribution.
Restorations: MCRs over custom abutments (UCLA, Atlantis, or preparable abutments)

Missing: Mandibular canine and first premolar

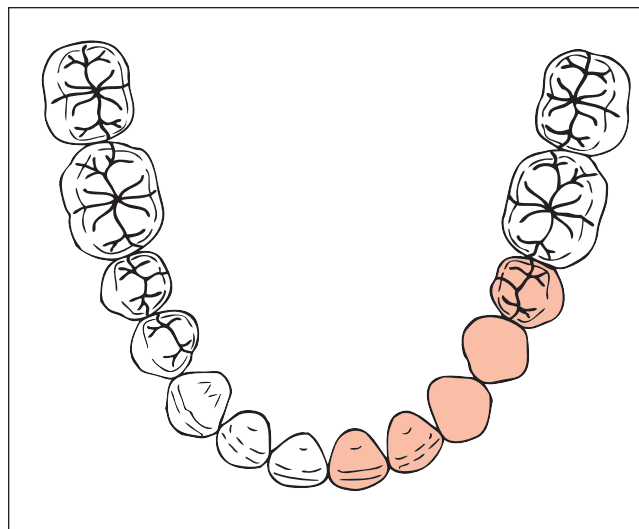
Abutments: Central incisor, lateral incisor, and second premolar

Considerations: Use group function in restoring the occlusion. This can be a difficult fixed partial denture, but fortunately it is rarely encountered.

Retainers: MCRs

Pontics: Modified ridge lap MCRs

Abutment-pontic root ratio: 1.5

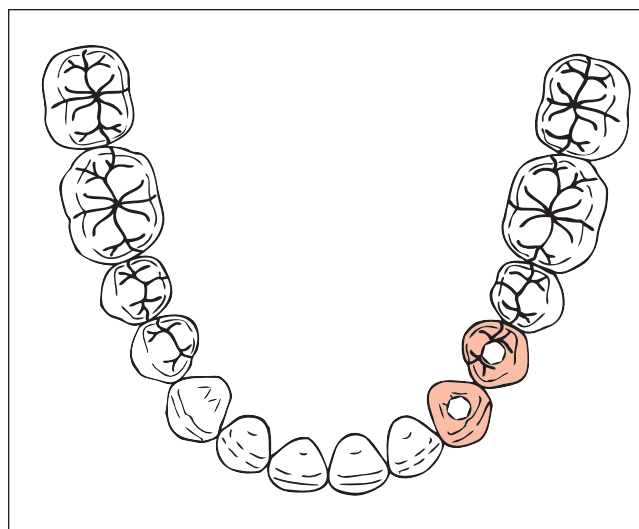


Missing: Mandibular canine and first premolar

Implants: 4.5 × 15 mm (canine), 4.3 × 11.5 mm (first premolar)

Considerations: The position of the anterior loop of the mandibular canal may interfere with implant placement. Loss of the facial plate of bone may result in inadequate alveolar width. Alveolar resorption may result in insufficient height of bone above the mental foramen. The correction of this anatomical difficulty requires the placement of an onlay bone graft to allow the placement of an implant of sufficient width and length. Splinting the dental implant restoration will reduce rotational forces on the abutment screws, lessening the possibility of screw loosening. Splinting the dental implants will increase restoration strength and stress distribution.

Restorations: MCRs over custom abutments (UCLA, Atlantis, or preparable abutments)



Complex Fixed Partial Dentures (More Than Two Teeth)

Missing: Both maxillary central incisors and one lateral incisor

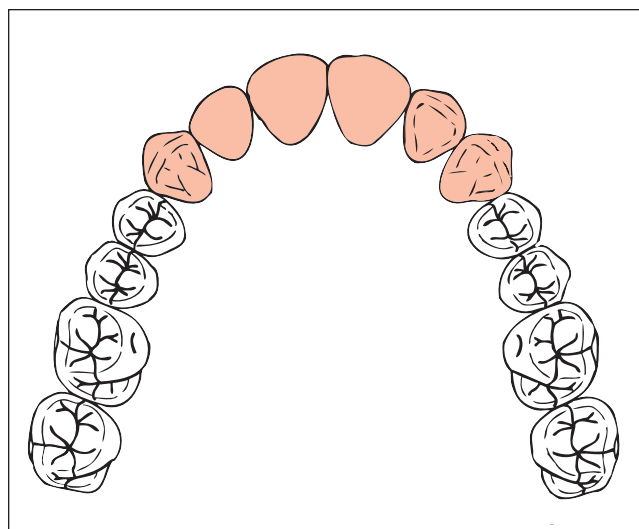
Abutments: Both canines and the remaining lateral incisor

Considerations: If the remaining lateral incisor is questionable, it should be extracted and the fixed partial denture lengthened to include the first premolars. Inclusion of first premolars as abutments will depend on span length and curvature.

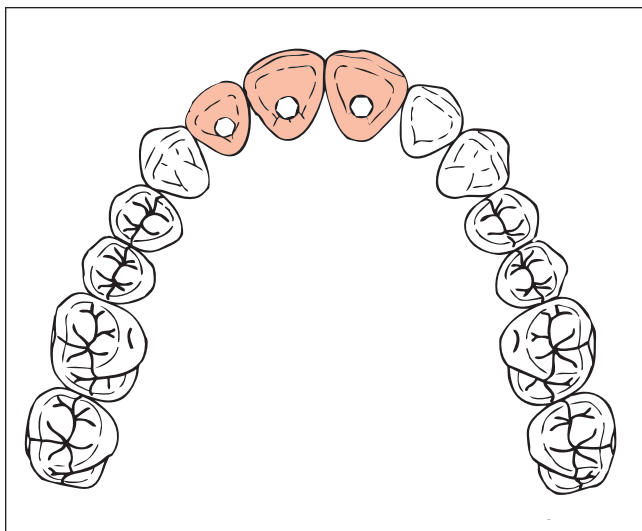
Retainers: MCRs

Pontics: Modified ridge lap MCRs

Abutment-pontic root ratio: 1.3



8 Fixed Partial Denture and Implant Configurations

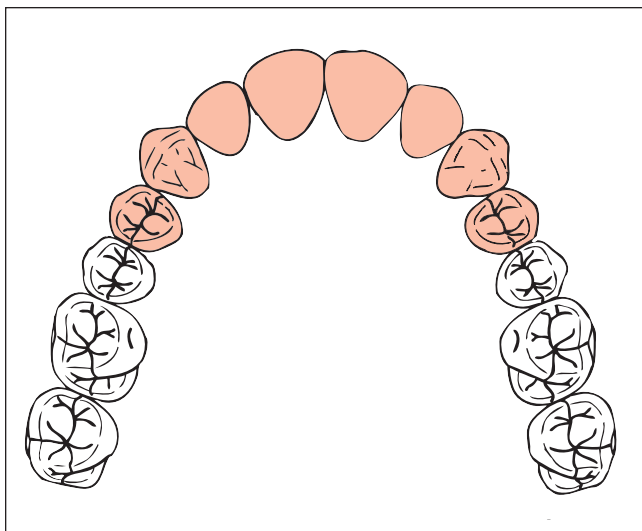


Missing: Both maxillary central incisors and one lateral incisor

Implants: 4.0×12 mm (central incisors), 3.5×12 mm (lateral incisor)

Considerations: A large nasopalatine foramen (incisive canal) may interfere with implant placement. The loss of a maxillary lateral incisor frequently results in the collapse of the facial plate of bone, which can cause a facial concavity that will require implant placement too far to the lingual. This will result in an unnatural lingual contour of the crown and a poor implant emergence profile. To correct this problem, bone grafting is required to eliminate the facial concavity. Splinting the dental implant restoration will reduce rotational forces on the abutment screws, lessening the possibility of screw loosening. Splinting the dental implants will increase restoration strength and stress distribution.

Restorations: MCRs over custom abutments (UCLA, Atlantis, or preparable abutments)



Missing: All maxillary incisors

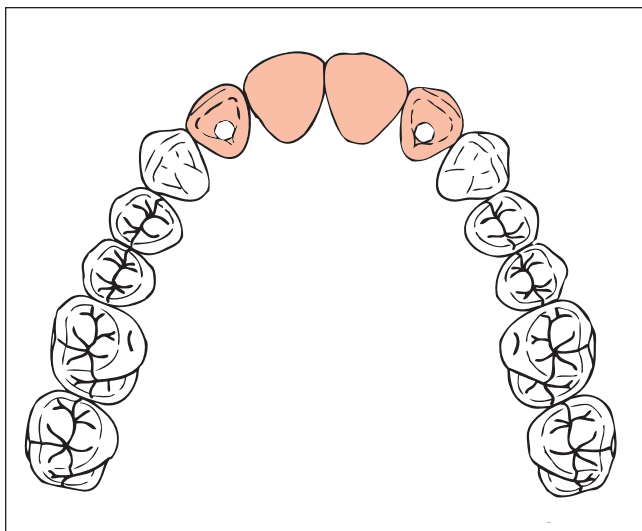
Abutments: Both canines and first premolars

Considerations: To counteract the lever arm created by the curve of the anterior segment of the arch, double abutments are often used with full coverage retainers to assure maximum retention. If the anterior curvature is slight and/or the canines are exceptionally large, the premolars may be omitted as abutments.

Retainers: MCRs

Pontics: Modified ridge lap MCRs

Abutment-pontic root ratio: 1.3



Missing: All maxillary incisors

Implants: 4.0×12 mm (lateral incisors)

Considerations: The loss of maxillary incisors frequently results in the collapse of the facial plate of bone, producing a facial concavity, which requires implant placement too far to the lingual. This will result in an unnatural lingual contour of the crown and a poor emergence profile. Bone grafting will be required to eliminate the facial concavity.

Restorations: MCRs over custom abutments (UCLA, Atlantis, or preparable abutments)

Missing: All mandibular incisors

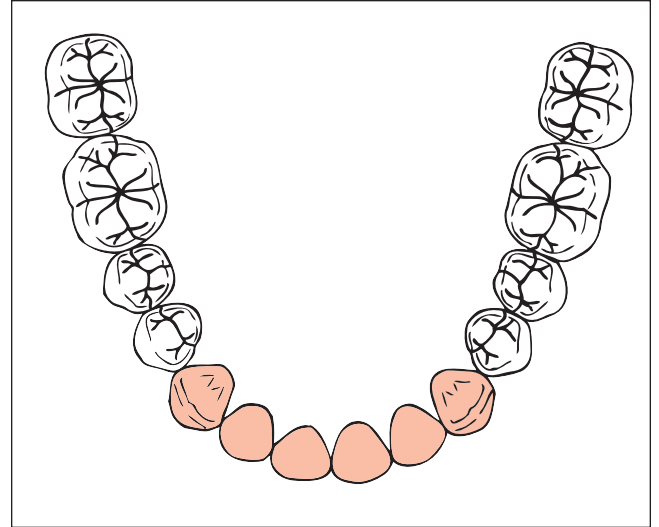
Abutments: Both canines

Considerations: There is no need to use double abutments on the mandibular canine-to-canine fixed partial denture because the forces are less destructive. If a patient has a lone lateral or central incisor remaining, it is usually extracted. It would complicate the fixed partial denture without adding any appreciable support.

Retainers: MCRs

Pontics: Modified ridge lap MCRs

Abutment-pontic root ratio: 0.8

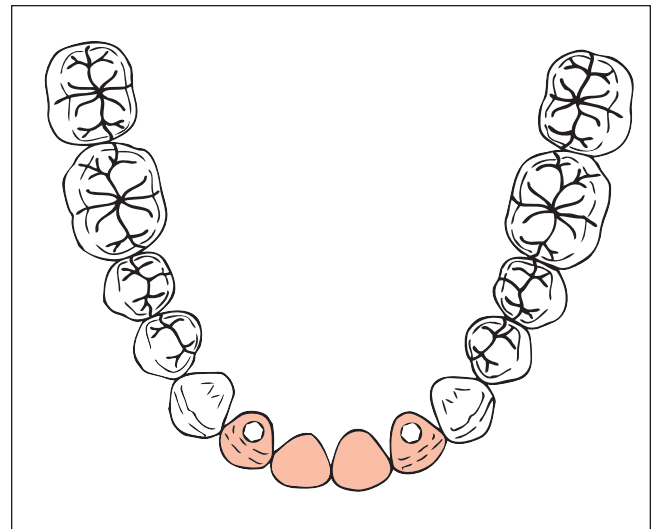


Missing: All mandibular incisors

Implants: 4.0 × 12 mm (lateral incisors)

Considerations: Increased available space allows for the use of the larger 4.0-mm-diameter implants when replacing all four mandibular incisors.

Restorations: MCRs over custom abutments (UCLA, Atlantis, or preparable abutments)



Missing: Maxillary first and second premolars and first molar

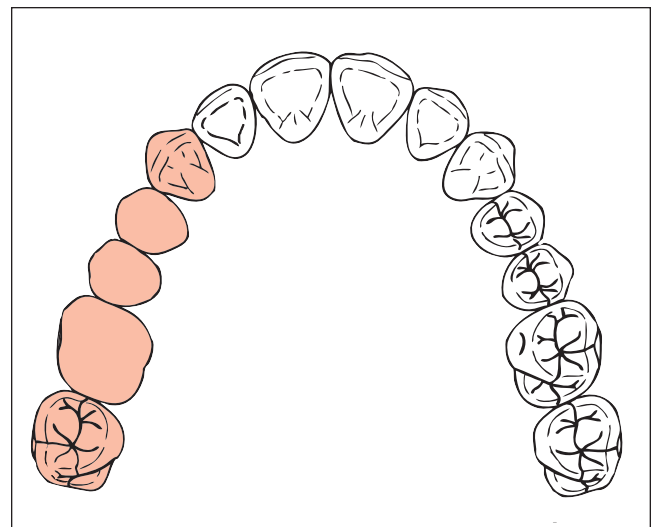
Abutments: Canine and second molar

Considerations: This fixed partial denture can be made only if the clinical crowns of the abutments are long and perfectly aligned. The occlusogingival dimension of the edentulous space must be ample to provide adequate rigidity. This fixed partial denture is possible only if the opposing occlusion is a removable partial denture. Canine guidance is important in this situation.

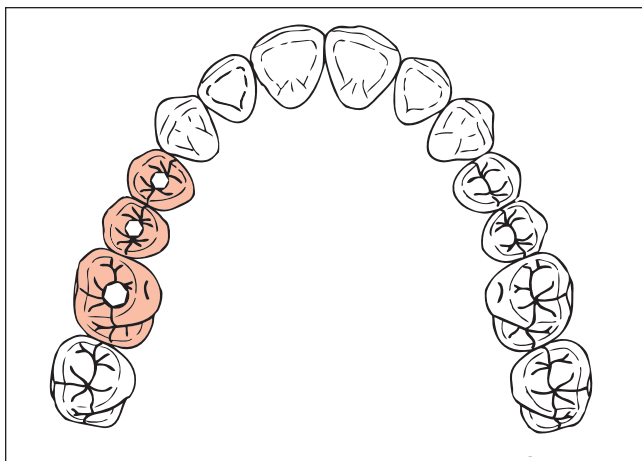
Retainers: MCR on the canine and FGC on the molar

Pontics: MCRs

Abutment-pontic root ratio: 0.8



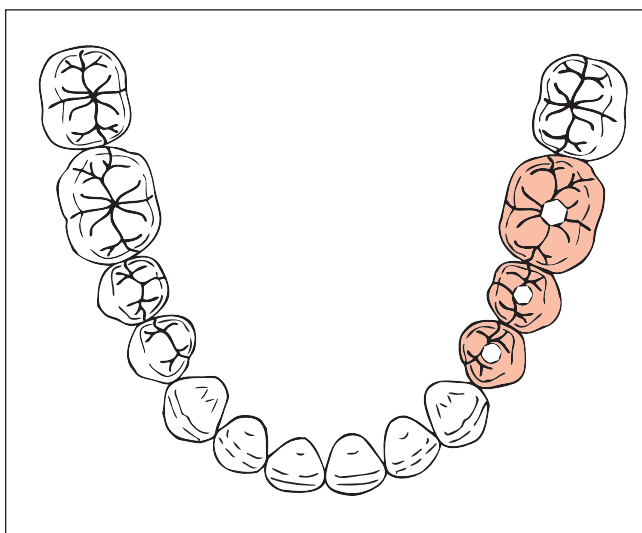
8 Fixed Partial Denture and Implant Configurations



Missing: Maxillary first and second premolars and first molar
Implants: 4.0 × 13 mm (first premolar), 4.3 × 11.5 mm (second premolar), 5.0 × 11.5 mm (first molar)

Considerations: Three implants are preferable, but not if it requires placing them too close together. The maxillary sinus will likely interfere with the placement of an implant of desirable length, necessitating sinus modification surgery such as a sinus graft or a vertical upfracture. Splinting the dental implant restoration will reduce rotational forces on the abutment screws, lessening the possibility of screw loosening. Splinting the dental implants will increase restoration strength and stress distribution.

Restorations: MCRs over custom abutments (UCLA, Atlantis, or preparable abutments)



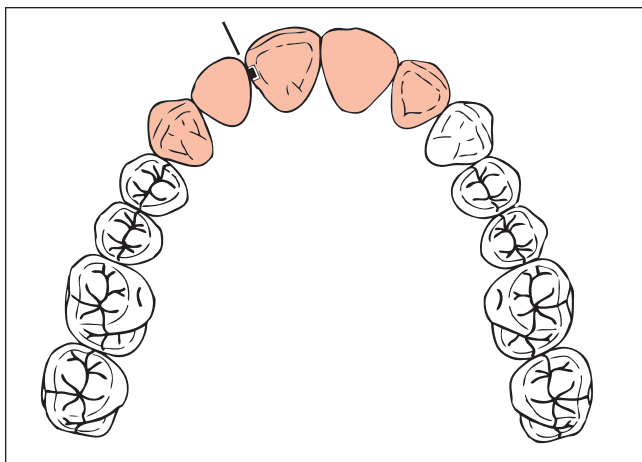
Missing: Mandibular first and second premolars and first molar

Considerations: A fixed partial denture should not be used in this situation because the interarch space is usually insufficient and occlusal force will be directed against the inner curvature of the occlusal plane, with resultant lifting forces on the retainers.

Missing: Mandibular first and second premolars and first molar
Implants: 4.3 × 11.5 mm (first premolar), 4.3 × 10 mm (second premolar), 5.0 × 10 mm (first molar)

Considerations: Three implants are preferable, but not if it requires placing them too close together. The position of the anterior loop of the mandibular canal may interfere with implant placement. Loss of the facial plate of bone may result in inadequate alveolar width. Alveolar resorption may lead to insufficient height of bone above the mental foramen and mandibular canal. The correction of this anatomical difficulty requires the placement of an onlay bone graft to allow the placement of an implant of sufficient width and length. Splinting the dental implant restoration will reduce rotational forces on the abutment screws, lessening the possibility of screw loosening. Splinting the dental implants will increase restoration strength and stress distribution.

Restorations: MCRs over custom abutments (UCLA, Atlantis, or preparable abutments)



Complex Fixed Partial Dentures (Pier Abutment)

Missing: Maxillary central incisor and opposite-side lateral incisor

Abutments: Lateral incisor, central incisor, and canine

Considerations: A keyway is placed at the distal aspect of the central incisor retainer to accommodate a key on the mesial aspect of the lateral incisor pontic. If the central incisor is malpositioned or rotated, its extraction will simplify the restoration and improve its prognosis.

Retainers: MCRs

Pontics: Modified ridge lap MCRs

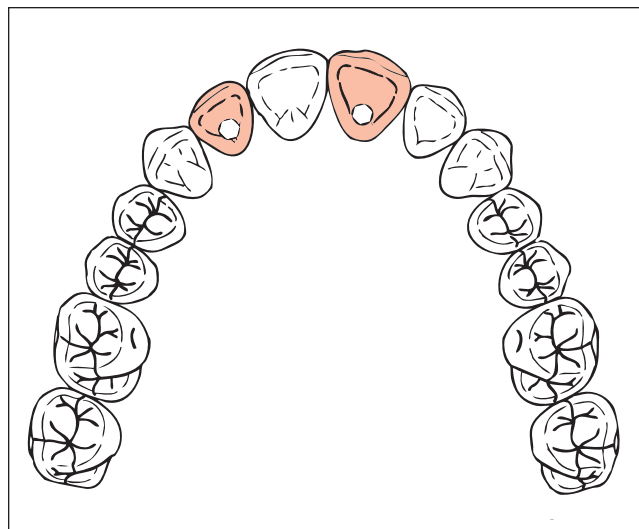
Abutment-pontic root ratio: 1.7

Missing: Maxillary central incisor and opposite-side lateral incisor

Implants: 4.0 × 12 mm (central incisor), 3.5 × 12 mm (lateral incisor)

Considerations: The loss of the facial plate of bone will frequently result in a facial concavity requiring implant placement too far to the lingual. This will result in an unnatural lingual contour of the crown and a poor implant emergence profile. To correct this problem, bone grafting is required to eliminate the facial concavity.

Restorations: MCRs over custom abutments (UCLA, Atlantis, or preparable abutments)



Missing: Mandibular central incisor and opposite-side lateral incisor

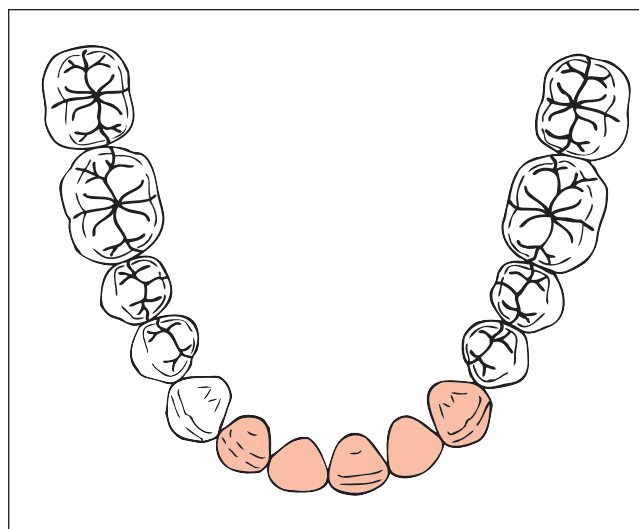
Abutments: Lateral incisor, central incisor, and canine

Considerations: A completely rigid fixed partial denture is used in this situation because of short span length and small teeth. Extracting the central incisor would simplify and improve the prognosis of a fixed partial denture. MCR crowns on incisors may necessitate endodontic treatment and dowel cores.

Retainers: MCRs will usually be used, but resin-bonded retainers are a possibility.

Pontics: Modified ridge lap or ovate MCRs

Abutment-pontic root ratio: 1.8

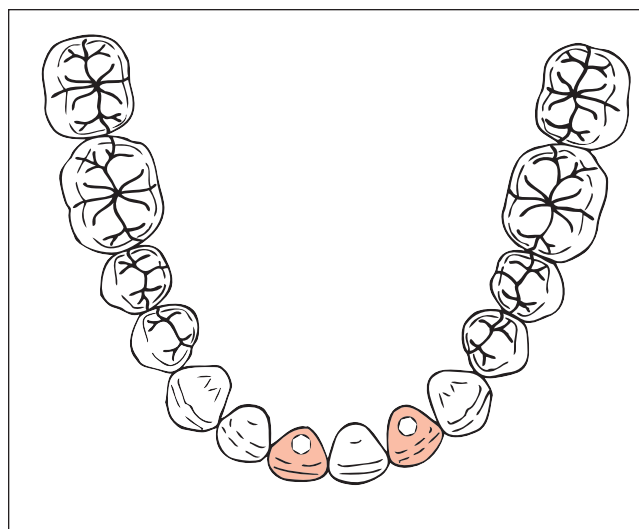


Missing: Mandibular central incisor and opposite-side lateral incisor

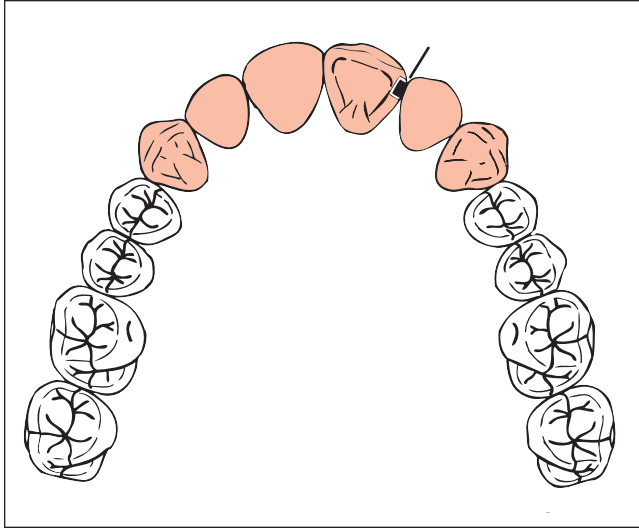
Implants: 3.3 × 12 mm

Considerations: The factor limiting replacement of mandibular incisors with dental implants is the mesiodistal space available. Ideally there should be 7.3 mm of interproximal space. If inadequate space is available, consider extraction of all mandibular incisors. Place two 4.0 × 12-mm dental implants in the lateral incisor positions and fabricate a four-unit prosthesis.

Restorations: MCRs over one-piece implants



8 Fixed Partial Denture and Implant Configurations



Missing: Both maxillary lateral incisors and one central incisor

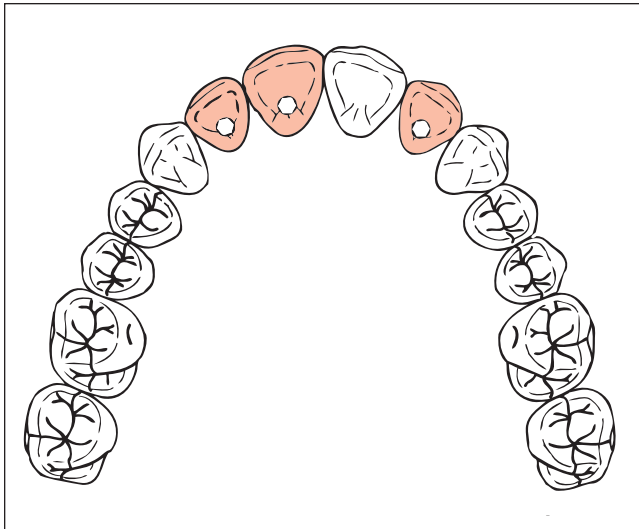
Abutments: Central incisor and both canines

Considerations: There should be a nonrigid connector between the distal aspect of the central incisor retainer and the mesial aspect of the adjacent lateral incisor pontic. If the central incisor is malposed or periodontally compromised, it should be extracted.

Retainers: MCRs

Pontics: Modified ridge lap MCRs

Abutment-pontic root ratio: 1.3

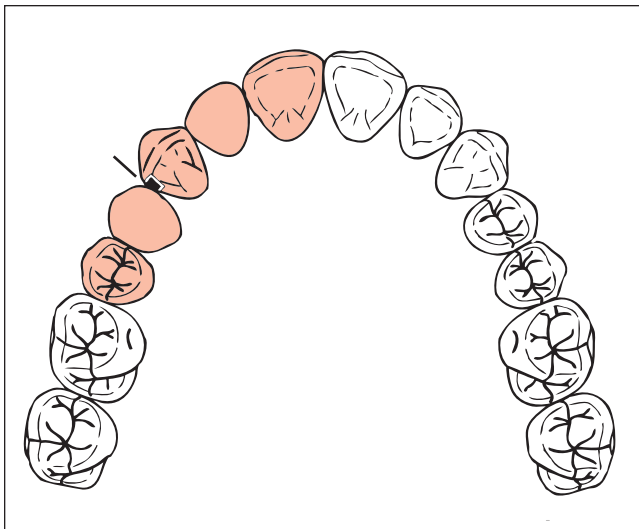


Missing: Both maxillary lateral incisors and one central incisor

Implants: 4.0 × 12 mm (central incisor), 3.5 × 12 mm (lateral incisor)

Considerations: A large nasopalatine foramen (incisive canal) may interfere with implant placement. The loss of the facial plate of bone will frequently result in a facial concavity requiring implant placement too far to the lingual. This will result in an unnatural lingual contour of the crown and a poor implant emergence profile. To correct this problem, bone grafting is required to eliminate the facial concavity. Splinting the dental implant restoration will reduce rotational forces on the abutment screws, lessening the possibility of screw loosening. Splinting the dental implants will increase restoration strength and stress distribution.

Restorations: MCRs over custom abutments (UCLA, Atlantis, or preparable abutments)



Missing: Maxillary lateral incisor and first premolar

Abutments: Central incisor, canine, and second premolar

Considerations: A nonrigid connector should be placed between the canine and first premolar.

Retainers: MCR crowns

Pontics: Modified ridge lap MCRs

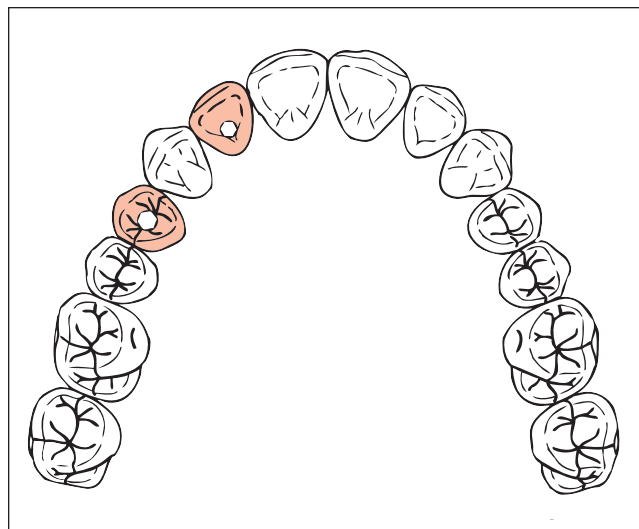
Abutment-pontic root ratio: 1.7

Missing: Maxillary lateral incisor and first premolar

Implants: 3.5 × 12 mm (lateral incisor), 4.0 × 13 mm (first premolar)

Considerations: A dental implant is the restoration of choice. The loss of the facial plate of bone will frequently result in a facial concavity requiring implant placement too far to the lingual. This will result in an unnatural lingual contour of the crown and a poor implant emergence profile. To correct this problem, bone grafting is required to eliminate the facial concavity. Implant placement may impinge on the anterior wall of the maxillary sinus. In this event, sinus modification surgery such as sinus grafting or vertical upfracture may be indicated.

Restorations: MCRs over custom abutments (UCLA, Atlantis, or preparable abutments)



Missing: Mandibular lateral incisor and first premolar

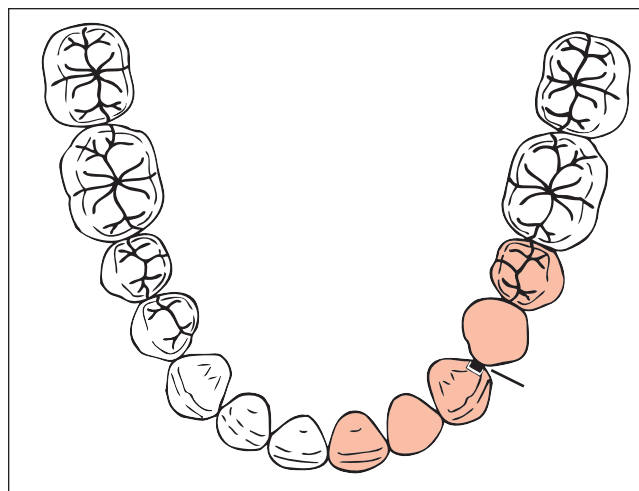Abutments: Central incisor, canine, and second premolar

Considerations: A nonrigid connector should be placed between the canine and first premolar.

Retainers: MCR crowns

Pontics: Modified ridge lap MCRs

Abutment-pontic root ratio: 1.7

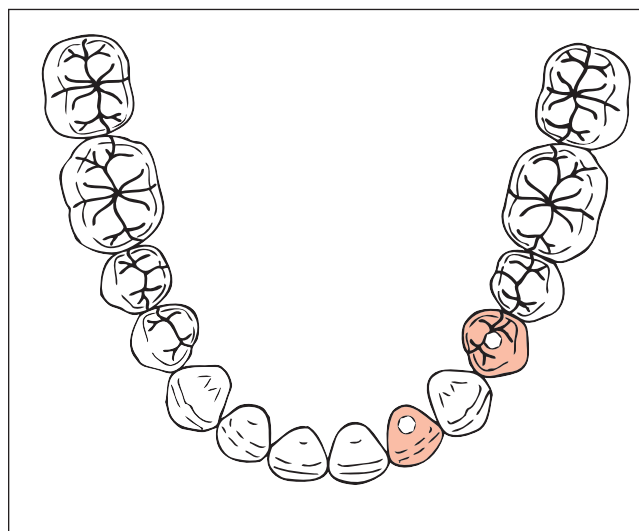


Missing: Mandibular lateral incisor and first premolar

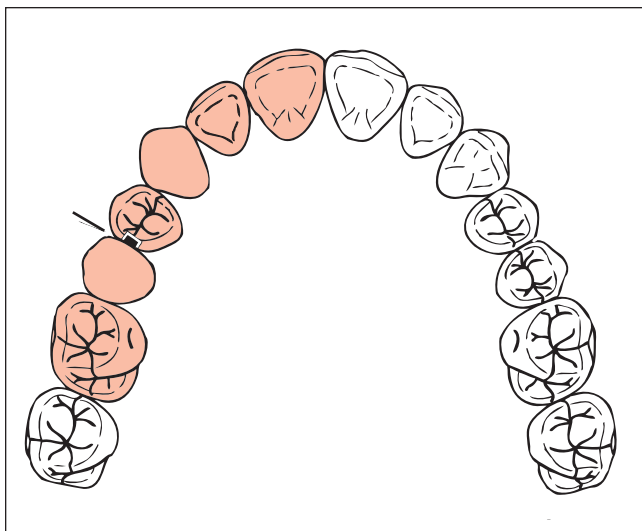
Implants: 3.3 × 12 mm (lateral incisor), 4.3 × 11.5 mm (first premolar)

Considerations: A dental implant is the restoration of choice. The factor limiting replacement of a mandibular lateral incisor with a dental implant is the mesiodistal space available. Ideally there should be 7.3 mm of interproximal space. If there is inadequate space, consider extraction of all mandibular incisors. Place two 4.0 × 12-mm dental implants in the lateral incisor positions and fabricate a four-unit fixed partial denture. The position of the anterior loop of the mandibular canal may interfere with first premolar implant placement. Loss of the facial plate of bone may result in inadequate alveolar width. Alveolar resorption may lead to insufficient height of bone above the mental foramen and mandibular canal. The correction of this anatomical difficulty requires the placement of an onlay bone graft to allow the placement of an implant of sufficient width and length.

Restorations: MCR over a one-piece implant on the lateral incisor and MCR over a custom abutment (UCLA, Atlantis, or preparable abutments) on the first premolar



8 Fixed Partial Denture and Implant Configurations



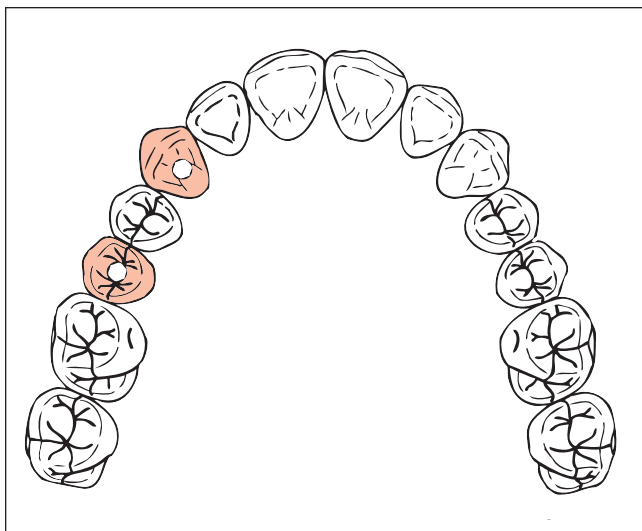
Missing: Maxillary canine and second premolar
Abutments: Central incisor, lateral incisor, first premolar, and first molar

Considerations: A nonrigid connector should be placed between the first premolar retainer and second premolar pontic.

Retainers: MCRs on the incisors and premolar and $\frac{7}{8}$ crown or MCR on the molar

Pontics: Modified ridge lap MCRs

Abutment-pontic root ratio: 2.1

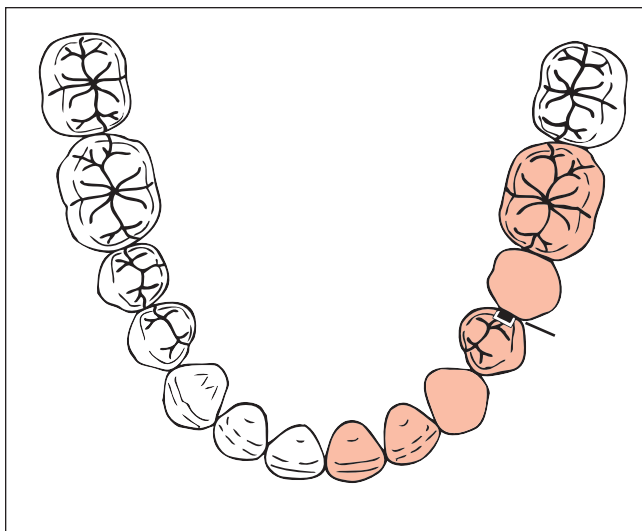


Missing: Maxillary canine and second premolar

Implants: 4.5 × 15 mm (canine), 4.3 × 11.5 mm (second premolar)

Considerations: A dental implant is the restoration of choice. The loss of the facial plate of bone will frequently result in a facial concavity requiring implant placement too far to the lingual. This will result in an unnatural lingual contour of the crown and a poor implant emergence profile. To correct this problem, bone grafting is required to eliminate the facial concavity. The maxillary sinus will likely interfere with the placement of an implant of desirable length, necessitating sinus modification surgery such as a sinus graft or a vertical upfracture.

Restorations: MCRs over custom abutments (UCLA, Atlantis, or preparable abutments)



Missing: Mandibular canine and second premolar

Abutments: Central incisor, lateral incisor, first premolar, and first molar

Considerations: A nonrigid connector should be placed between the first premolar retainer and second premolar pontic.

Retainers: MCRs on the incisors and premolar and FGC or MCR on the molar

Pontics: Modified ridge lap MCR

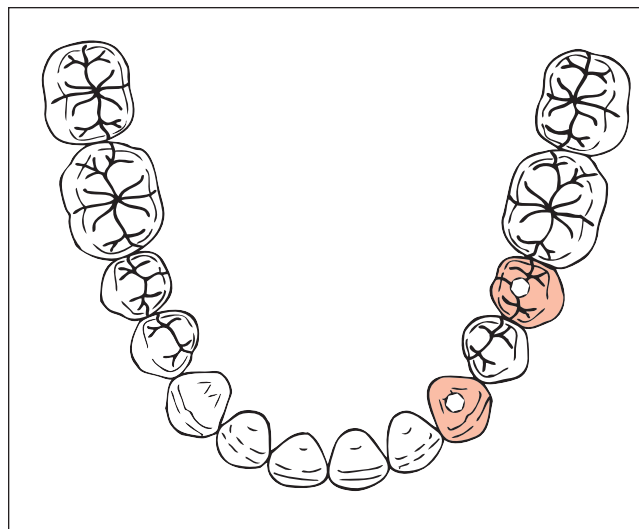
Abutment-pontic root ratio: 2.1

Missing: Mandibular canine and second premolar

Implants: 4.5 × 15 mm (canine), 4.3 × 10 mm (second premolar)

Considerations: A dental implant is the restoration of choice. Loss of the facial plate of bone may result in inadequate alveolar width, and alveolar resorption may lead to insufficient height of bone above the mental foramen and mandibular canal. The correction of this anatomical difficulty requires the placement of an onlay bone graft to allow the placement of an implant of sufficient width and length.

Restorations: MCRs over custom abutments (UCLA, Atlantis, or preparable abutments)



Missing: All maxillary incisors and one first premolar

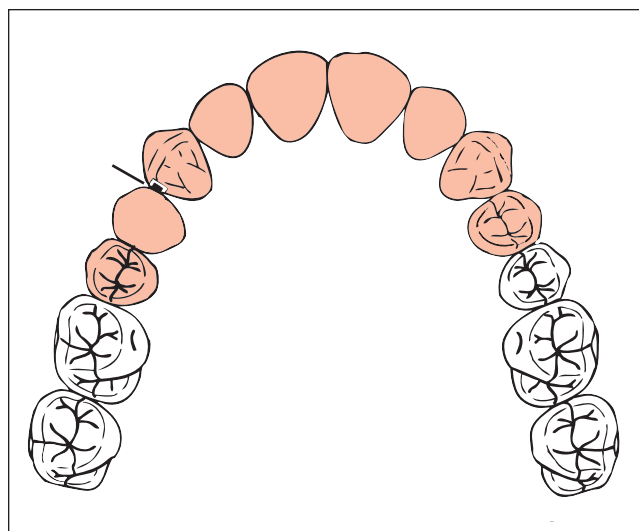
Abutments: Both canines, the opposite-side first premolar, and the second premolar

Considerations: A nonrigid connector should be placed at the distal aspect of the retainer on the canine pier abutment.

Retainers: MCRs

Pontics: Modified ridge lap MCRs

Abutment-pontic root ratio: 1.0

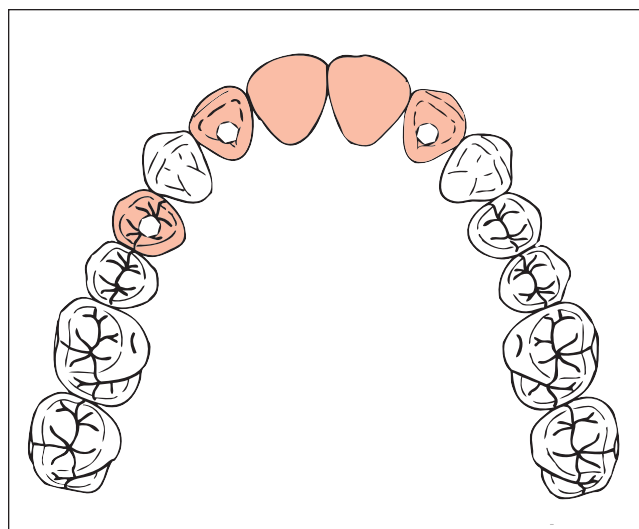


Missing: All maxillary incisors and one first premolar

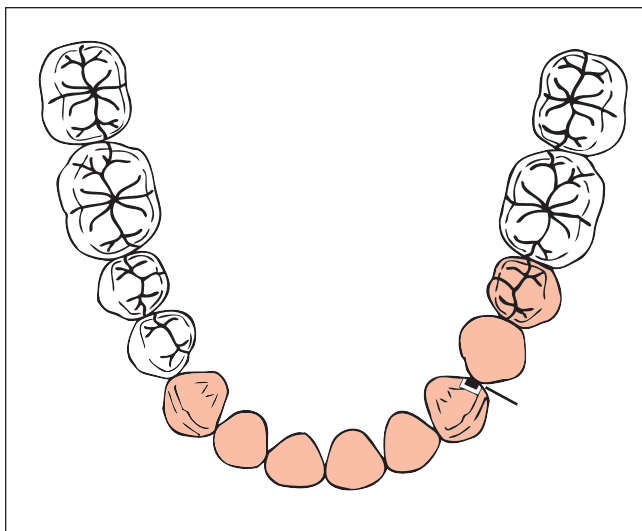
Implants: 4.0 × 12 mm (lateral incisors), 4.0 × 13 mm (first premolar)

Considerations: A dental implant is the restoration of choice. The loss of maxillary incisors frequently results in the collapse of the facial plate of bone, which produces a facial concavity requiring implant placement too far to the lingual. This will result in an unnatural lingual contour of the crown and a poor emergence profile. This will require bone grafting to eliminate the facial concavity. Implant placement at the first premolar may impinge on the anterior wall of the maxillary sinus, in which case sinus modification surgery such as sinus grafting or vertical upfracture may be indicated.

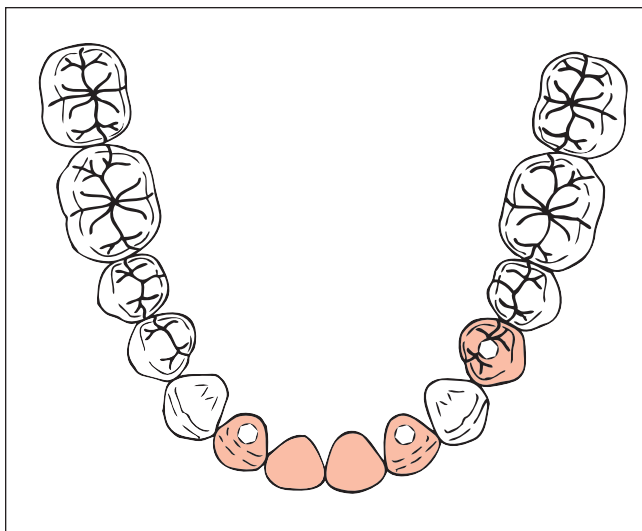
Restorations: MCRs over custom abutments (UCLA, Atlantis, or preparable abutments)



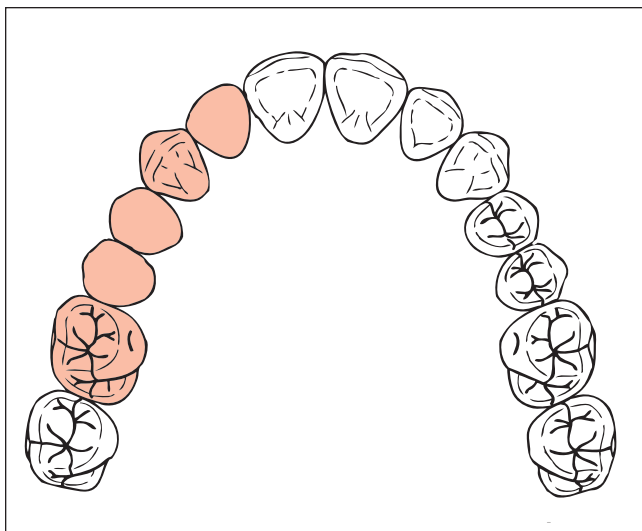
8 Fixed Partial Denture and Implant Configurations



Missing: All mandibular incisors and one first premolar
Abutments: Both canines and the second premolar
Considerations: A nonrigid connector should be placed at the distal aspect of the retainer on the canine pier abutment.
Retainers: MCRs
Pontics: Modified ridge lap MCRs
Abutment-pontic root ratio: 1.0



Missing: All mandibular incisors and one first premolar
Implants: 4.0 × 12 mm (lateral incisors), 4.3 × 11.5 mm (first premolar)
Considerations: A dental implant is the restoration of choice. Increased available space allows for the use of the larger 4.0-mm-diameter implants when replacing all four mandibular incisors. The position of the anterior loop of the mandibular canal may interfere with implant placement.
Restorations: MCRs over custom abutments (UCLA, Atlantis, or preparable abutments)



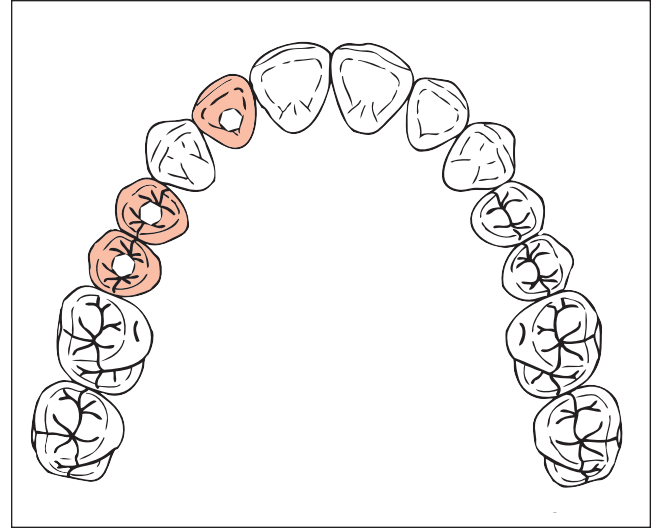
Missing: Maxillary lateral incisor and first and second premolars
Abutments: Canine and first molar
Considerations: Canine-guided posterior disocclusion. The short lever arm created by the lateral incisor cantilever should be adequately offset by the long span from first molar to canine.
Retainers: MCRs
Pontics: Modified ridge lap MCRs
Abutment-pontic root ratio: 1.1

Missing: Maxillary lateral incisor and first and second premolars

Implants: 3.5 × 12 mm (lateral incisor), 4.0 × 13 mm (first premolar), 4.3 × 11.5 mm (second premolar)

Considerations: A dental implant is the restoration of choice. The loss of the facial plate of bone will frequently result in a facial concavity requiring implant placement too far to the lingual. This will result in an unnatural lingual contour of the crown and a poor implant emergence profile. To correct this problem, bone grafting to eliminate the facial concavity is required. The maxillary sinus will likely interfere with the placement of an implant of desirable length, necessitating sinus modification surgery such as a sinus graft or a vertical upfracture. Splinting the dental implant restoration will reduce rotational forces on the abutment screws, lessening the possibility of screw loosening. Splinting the dental implants will increase restoration strength and stress distribution.

Restorations: MCRs over custom abutments (UCLA, Atlantis, or preparable abutments)



Missing: Mandibular lateral incisor and first and second premolars

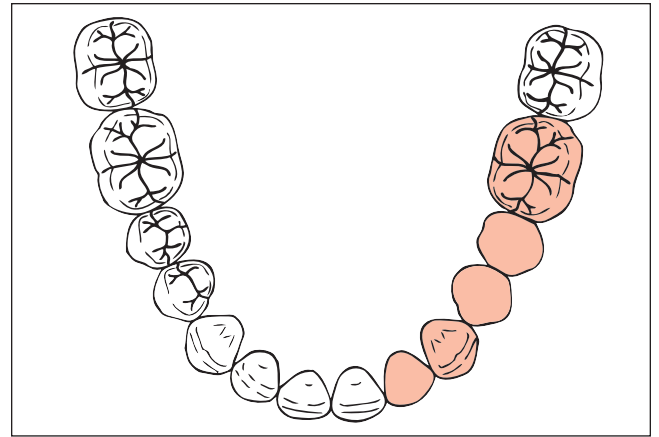
Abutments: Canine and first molar

Considerations: Canine-guided posterior disocclusion. The short lever arm created by the lateral incisor cantilever should be adequately offset by the long span from first molar to canine.

Retainers: MCRs

Pontics: Modified ridge lap MCRs

Abutment-pontic root ratio: 1.1

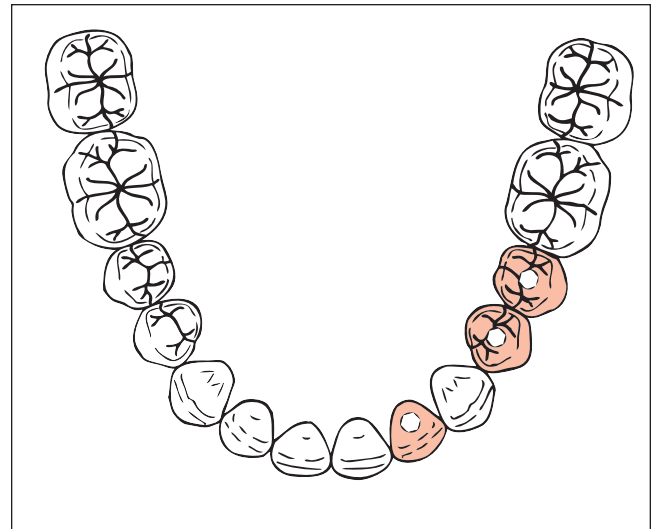


Missing: Mandibular lateral incisor and first and second premolars

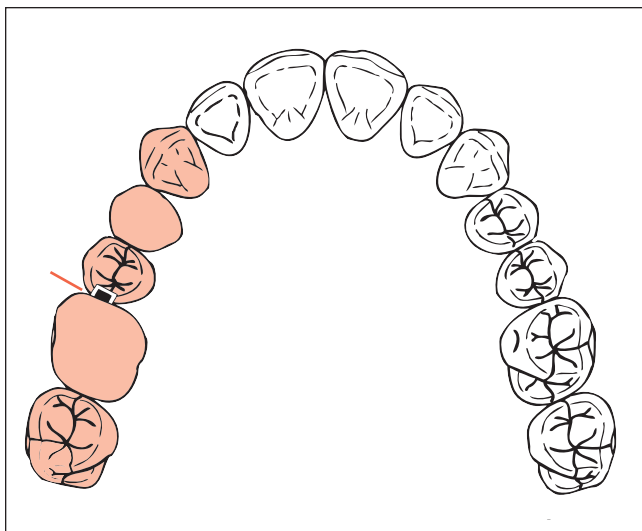
Implants: 3.3 × 12 mm (lateral incisor), 4.3 × 11.5 mm (first premolar), 4.3 × 10 mm (second premolar)

Considerations: A dental implant is the restoration of choice. The factor limiting replacement of a mandibular lateral incisor with a dental implant is the available mesiodistal space. Ideally there should be 7.3 mm of interproximal space. If inadequate space is available, consider extraction of all mandibular incisors. Place two 4.0 × 12-mm dental implants in the lateral incisor positions and fabricate a four-unit restoration. The position of the anterior loop of the mandibular canal may interfere with implant placement. Loss of the facial plate of bone may result in inadequate alveolar width. Alveolar resorption may lead to insufficient height of bone above the mental foramen and mandibular canal. The correction of this anatomical difficulty requires the placement of an onlay bone graft to allow the placement of an implant of sufficient width and length. Splinting the dental implant restoration will reduce rotational forces on the abutment screws, lessening the possibility of screw loosening. Splinting the dental implants will increase restoration strength and stress distribution.

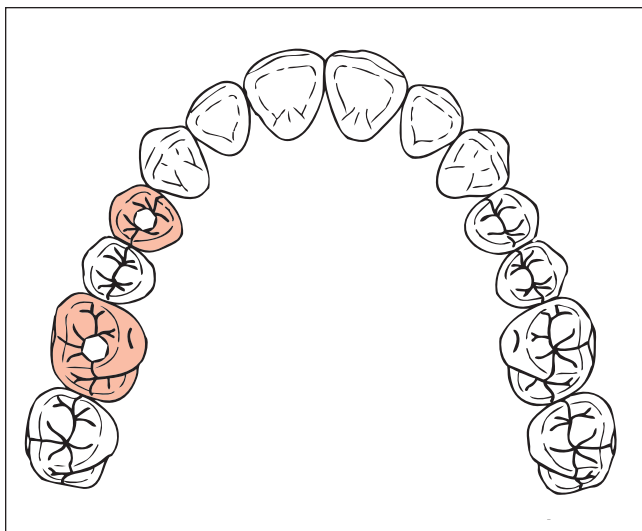
Restorations: MCRs over custom abutments (UCLA, Atlantis, or preparable abutments)



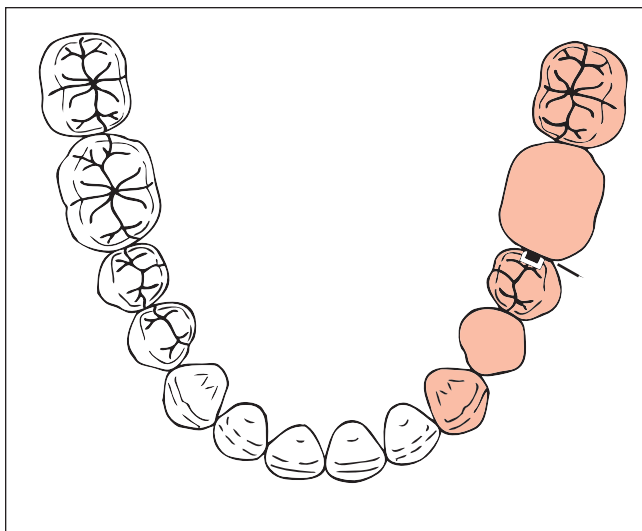
8 Fixed Partial Denture and Implant Configurations



Missing: Maxillary first premolar and first molar
Abutments: Canine, second premolar, and second molar
Considerations: A nonrigid connector should be placed on the distal aspect of the second premolar retainer.
Retainers: MCRs on the canine and second premolar and FGC on the second molar
Pontics: Modified ridge lap MCRs
Abutment-pontic root ratio: 1.4



Missing: Maxillary first premolar and first molar
Implants: 4.0 × 13 mm (first premolar), 5.0 × 13 mm (first molar)
Considerations: The loss of the facial plate of bone will frequently result in a facial concavity requiring implant placement too far to the lingual. This will result in an unnatural lingual contour of the crown and a poor implant emergence profile. To correct this problem, bone grafting to eliminate the facial concavity is required. The maxillary sinus will likely interfere with the placement of an implant of desirable length, necessitating sinus modification surgery such as a sinus graft or a vertical upfracture.
Restorations: MCRs over custom abutments (UCLA, Atlantis, or preparable abutments)

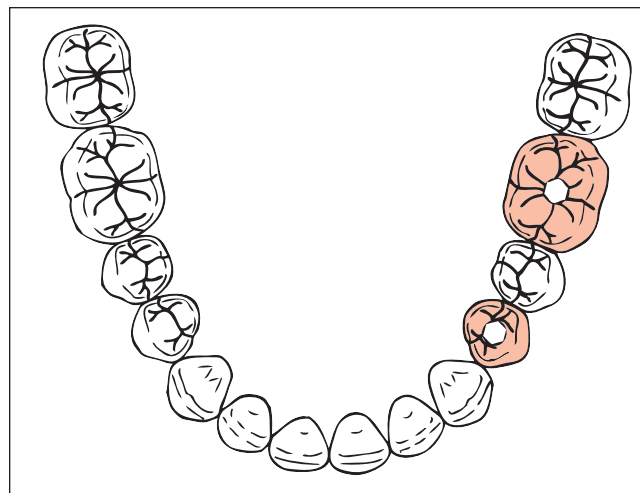


Missing: Mandibular first premolar and first molar
Abutments: Canine, second premolar, and second molar
Considerations: A nonrigid connector should be placed on the distal aspect of the second premolar retainer.
Retainers: MCRs on the canine and second premolar and FGC on the second molar
Pontics: Modified ridge lap MCR on the first premolar and all-metal hygienic pontic on the first molar
Abutment-pontic root ratio: 1.4

Missing: Mandibular first premolar and first molar
Implants: 4.3 × 11 mm (first premolar), 5.0 × 10 mm (first molar)

Considerations: A dental implant is the restoration of choice. Loss of the facial plate of bone may result in inadequate alveolar width. Alveolar resorption may lead to insufficient height of bone above the mental foramen and mandibular canal. The correction of this anatomical difficulty requires the placement of an onlay bone graft to allow the placement of an implant of sufficient width and length.

Restorations: MCRs over custom abutments (UCLA, Atlantis, or preparable abutments)



Missing: Maxillary central incisor, lateral incisor, and first and second premolars on one side

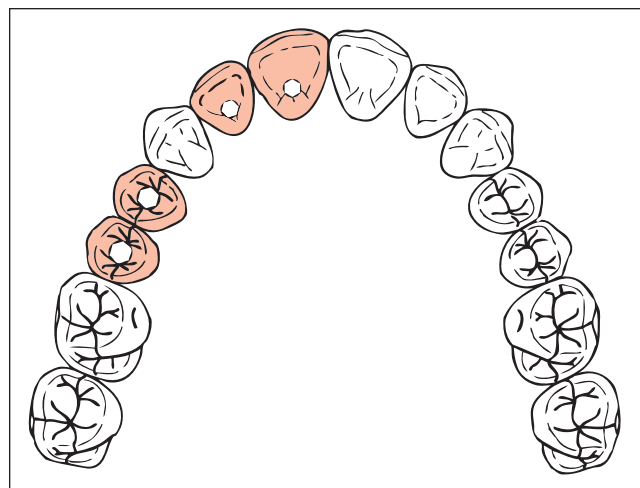
Considerations: This would be an extremely difficult fixed partial denture in either the maxillary or mandibular arch. The span lengths of both edentulous spaces are too great for nonrigid connectors with either pontic. Implant-supported MCRs or a removable partial denture are preferable.

Missing: Maxillary central incisor, lateral incisor, and first and second premolars on one side

Implants: 4.0 × 12 mm (central incisor), 3.5 × 12 mm (lateral incisor), 4.0 × 13 mm (first premolar), 4.3 × 11.5 mm (second premolar)

Considerations: A dental implant is the restoration of choice. A large nasopalatine foramen (incisive canal) may interfere with implant placement. The loss of the facial plate of bone will frequently result in a facial concavity requiring implant placement too far to the lingual. This will result in an unnatural lingual contour of the crown and a poor implant emergence profile. To correct this problem, bone grafting to eliminate the facial concavity is required. The maxillary sinus will likely interfere with the placement of an implant of desirable length, necessitating sinus modification surgery such as a sinus graft or a vertical upfracture. Splinting the dental implant restoration will reduce rotational forces on the abutment screws, lessening the possibility of screw loosening. Splinting the dental implants will increase restoration strength and stress distribution.

Restorations: MCRs over custom abutments (UCLA, Atlantis, or preparable abutments)



References

1. Shillingburg HT Jr, Kaplan MJ, Grace CS. Tooth dimensions—A comparative study. J South Calif Dent Assoc 1972;40:830–839.
2. Shillingburg HT, Kessler JC, Wilson EL. Root dimensions and dowel size. CDA J 1982;10:43–49.
3. Jepsen A. Root surface measurement and a method for x-ray determination of root surface area. Acta Odontol Scand 1963;21:35–46.
4. Ante IH. The fundamental principles of abutments. Mich State Dent Soc Bull 1926;8:14–23.

Principles of Tooth Preparations

9

The design of a preparation for a cast restoration and the execution of that design are governed by five principles:

1. Preservation of tooth structure
2. Retention and resistance
3. Structural durability
4. Marginal integrity
5. Preservation of the periodontium

Preservation of Tooth Structure

In addition to replacing lost tooth structure, a restoration must preserve remaining tooth structure. Intact surfaces of tooth structure that can be maintained while producing a strong, retentive restoration should be saved if patient acceptance and retention requirements will permit it. Whole surfaces of tooth structure should not be needlessly sacrificed to the bur in the name of convenience or speed.

Preservation of tooth structure in some cases may require that limited amounts of sound tooth structure be removed to prevent subsequent uncontrolled loss of larger quantities of tooth structure. This is the rationale for the removal of 1.5 mm of occlusal tooth structure when preparing a tooth for a mesio-occlusodistal (MOD) onlay. The metal on the occlusal surface can protect against dramatic failures, such as fracture of tooth structure, as well as the less obvious failures that may be caused by the flexure of tooth structure.

Retention and Resistance

For a restoration to accomplish its purpose, it must stay in place on the tooth. No cements that are compatible with living tooth structure and the biologic environment of the oral cavity possess adequate adhesive properties to hold a restoration in place solely through adhesion. The geometric configuration of the tooth preparation must place the cement in compression to provide the necessary retention and resistance.

Retention prevents removal of the restoration along the path of insertion or long axis of the tooth preparation. *Resistance* prevents dislodgment of the restoration by forces

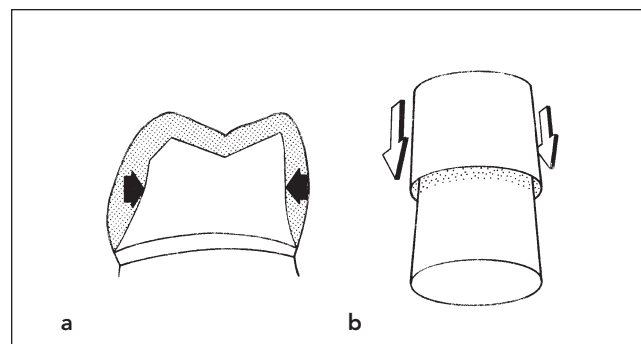


Fig 9-1 An extracoronary restoration (a) uses opposing external surfaces for retention (b).

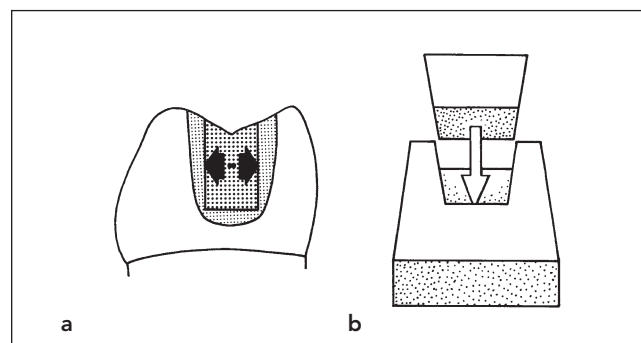


Fig 9-2 An intracoronary restoration (a) uses opposing internal surfaces for retention (b).

directed in an apical or oblique direction and prevents any movement of the restoration under occlusal forces. Retention and resistance are interrelated and often inseparable qualities.

The essential element of retention is two opposing vertical surfaces in the same preparation. These may be external surfaces, such as the facial and lingual walls of a full coverage crown (Fig 9-1a). An extracoronary restoration is an example of veneer, or sleeve, retention (Fig 9-1b). The opposing surfaces can also be internal, such as the facial and lingual walls of the proximal box of a proximo-occlusal inlay (Fig 9-2a). An intracoronary restoration resists displacement by wedge retention (Fig 9-2b). Many restorations are a combination of the two types.

9 Principles of Tooth Preparations

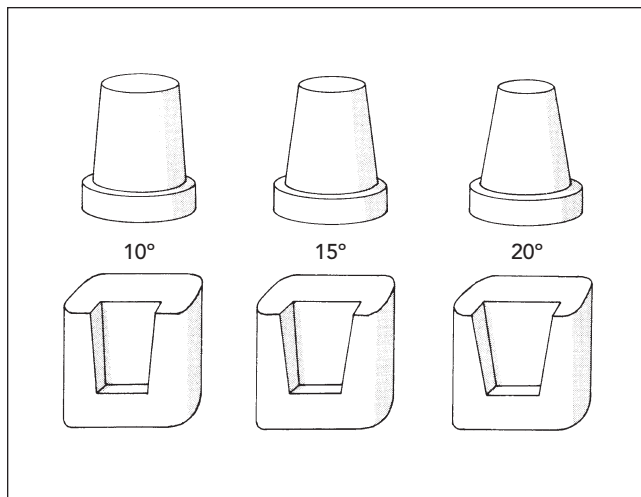


Fig 9-3 External (top row) and internal (bottom row) opposing surfaces demonstrate tapers of 10, 15, and 20 degrees.

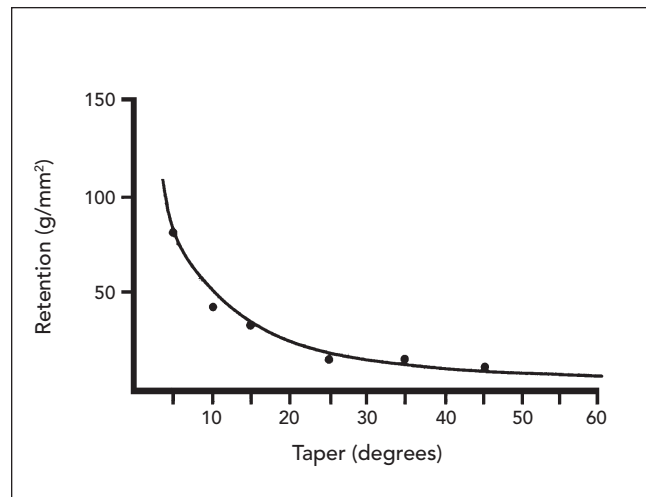


Fig 9-4 As taper increases, retention decreases. (Modified from Jorgensen⁴ with permission.)

Taper

Because a cast metal or ceramic restoration is placed on or in the preparation after the restoration has been fabricated in its final form, the axial walls of the preparation must taper slightly to permit the restoration to seat; ie, in the occlusal direction, two opposing external walls must gradually converge or two opposing internal surfaces of tooth structure must diverge (Fig 9-3). The terms *angle of convergence* and *angle of divergence* can be used to describe the respective relationships between the two opposing walls of a preparation.

The relationship of one wall of a preparation to the long axis of that preparation is the *inclination* of that wall. A tapered diamond or bur will impart an inclination of 2 to 3 degrees to any surface it cuts if the shank of the instrument is held parallel to the intended path of insertion of the preparation. Two opposing surfaces, each with a 3-degree inclination, would give the preparation a 6-degree taper.

Theoretically, the more nearly parallel the opposing walls of a preparation, the greater should be the retention. The most retentive preparation should be one with parallel walls. Indeed, parallel walls were advocated by some early authors.^{1,2} However, parallel walls are impossible to create in the mouth without producing preparation undercuts. Preparation walls are tapered to allow their visualization, prevent undercuts, compensate for inaccuracies in the fabrication process, and permit more nearly complete seating of restorations during cementation.

Ward³ was one of the first to recommend tapering as such, prescribing 5% to 20% per inch (3 to 12 degrees, respectively). Jorgensen⁴ and Kaufman et al⁵ have demonstrated experimentally that retention decreases as taper is increased (Fig 9-4). Recommendations for optimum axial wall taper of tooth preparations for cast restorations have ranged from 3 to 5 degrees⁶ to 6 degrees⁷ to 10 to 14 degrees.⁸ To minimize stress in the cement interface between the preparation and restoration, a taper of 2.5 to 6.5 degrees has been suggested as optimum. There is only a slight increase in stress as taper is increased from 0 to 15 degrees⁹; however, at 20 degrees, stress concentration was found to increase sharply.

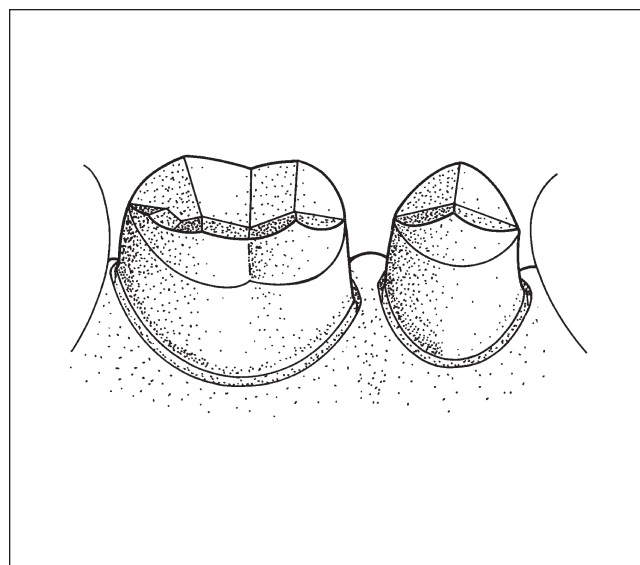
Studies of actual crown preparations have shown average tapers that have been much greater than the values recommended. Ohm and Silness¹⁰ reported mean tapers of 19.2 degrees mesiodistally and 23.0 degrees faciolingually on vital teeth and 12.8 degrees mesiodistally and 22.5 degrees faciolingually on nonvital teeth. Mack¹¹ found an average clinical taper of 16.5 degrees. Weed et al¹² found that dental students could produce full veneer crown preparations with a taper of 12.7 degrees on typodonts, but their clinical preparations had a mean taper of 22.8 degrees. Noonan and Goldfogel,¹³ surveying 909 student-prepared full gold crown preparations, reported an overall mean taper of 19.2 degrees. On proficiency examinations, preparation tapers were decreased by 20%. Dies taken at random from commercial laboratories by Eames et al¹⁴ were found to have an average overall taper of 20 degrees.

Table 9-1 Optimum degree of tooth preparation taper

Tooth	M/D	F/L	Overall
Maxillary			
Anterior tooth*	10	10	10
Premolar*	14	14	14
Molar*	17	21	19
Isthmus [†]	NA	NA	7
Box [†]	NA	NA	7
Mandibular			
Anterior tooth*	10	10	10
Premolar*	16	12	14
Molar*	24	20	22
Isthmus [†]	NA	NA	12
Box [†]	NA	NA	12

M/D, mesiodistal; F/L, faciolingual; NA, not applicable.

*Convergence angle.

[†]Divergence angle.**Fig 9-5** A full crown preparation is more retentive on a molar than on a premolar because the molar preparation has greater surface area.

Kent and associates¹⁵ evaluated the degree of taper of 418 preparations, cut over 12 years by one operator. They found a mean of 15.8 degrees between mesial and distal walls and 13.4 degrees between facial and lingual walls for preparations in all areas of the mouth, with an overall mean of 14.3 degrees. The lowest combined taper (9.2 degrees) was seen on 145 anterior metal-ceramic crown preparations, while the greatest (22.2 degrees) was measured on 88 mandibular full crowns. Nordlander et al,¹⁶ analyzing 208 preparations done by 10 dentists, reported a low of 17.3 degrees for premolars and a high of 27.3 degrees for molars, with an overall mean of 19.9 degrees.

Tooth preparation taper should be kept minimal because of its adverse effect on retention, but Mack¹¹ estimates that a minimum taper of 12 degrees is necessary just to ensure the absence of undercuts. The tendency to overtaper preparations is one that must be vigilantly guarded against in order to produce preparations with the least possible taper and the greatest possible retention. Consciously attempting to create a taper can easily result in an overtapered and non-retentive preparation. A taper or total convergence of 16 degrees has been proposed as being achievable clinically while still affording adequate retention.^{17,18} This is probably an acceptable overall target. It can be as low as 10 degrees on preparations on anterior teeth and as high as 22 degrees on molars. Recommendations for degree of taper for specific teeth are given in Table 9-1.

Cement creates a weak bond, largely by mechanical interlocks, between the inner surface of the restoration and the axial wall of the preparation. Therefore, the greater the surface area of a preparation, the greater its retention.^{5,19} Simply stated, preparations on large teeth are more retentive than preparations on small teeth (Fig 9-5). This is a factor that must be considered when a preparation is done on a small tooth, especially when it is an abutment for a fixed partial denture or a splint. Surface area can be increased somewhat by adding boxes and grooves. However, the benefits derived from such features may relate more to their limiting the freedom of movement than to the increase in surface area.

Freedom of displacement

Retention is improved by geometrically limiting the numbers of paths along which a restoration can be removed from the tooth preparation.²⁰ Maximum retention is achieved when there is only one path. A full veneer preparation with long, parallel axial walls and grooves would produce such retention (Fig 9-6a). On the opposite extreme, a short, overtapered preparation would be without retention because the restoration could be removed along an infinite number of paths (Fig 9-6b). The best preparation, then, is one that approaches the ideal and can be achieved within the limits of operator skill, accessibility, and laboratory technology.

9 Principles of Tooth Preparations

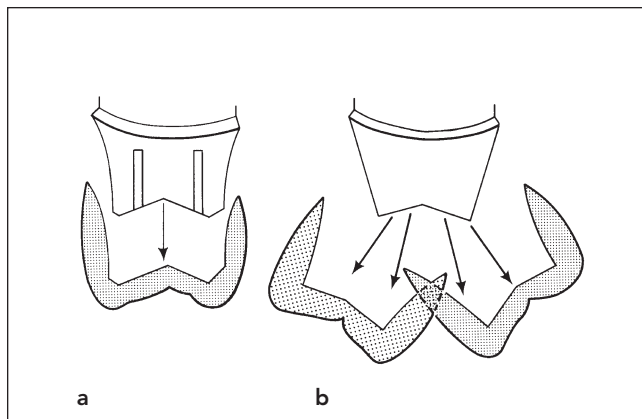


Fig 9-6 (a) By limiting the paths of withdrawal, retention is improved. (b) A preparation with unlimited freedom of displacement is much less retentive.

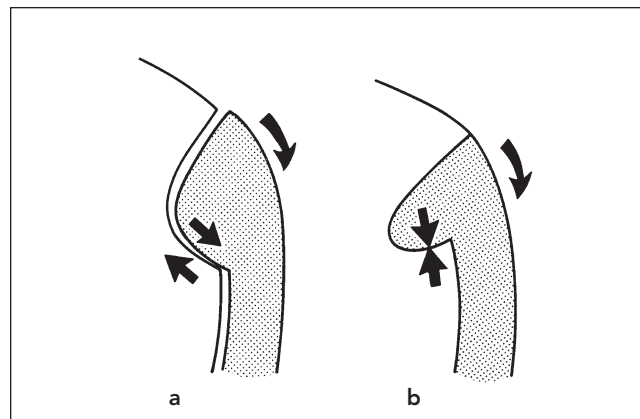


Fig 9-7 (a) The walls of a groove that meet the axial wall at an oblique angle do not provide the necessary resistance. (b) The walls of a groove must be perpendicular to rotating forces to resist displacement.

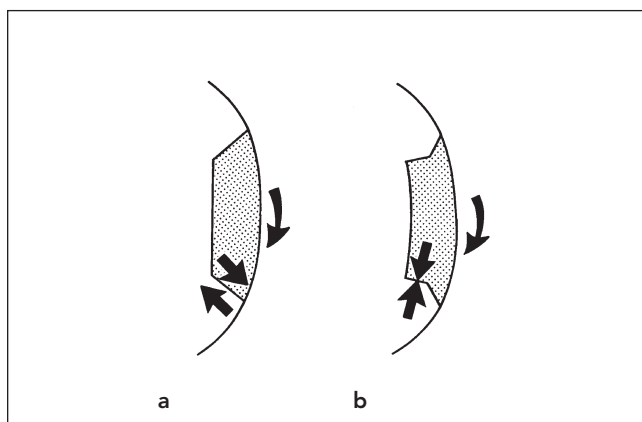


Fig 9-8 (a) The facial and lingual walls of a box will not resist rotational displacement if they form oblique angles with the pulpal wall. (b) They must meet the pulpal wall at angles near 90 degrees.

Limiting the freedom of displacement from torquing or twisting forces in a horizontal plane increases the resistance of a restoration. A groove whose walls meet the axial wall at an oblique angle does not provide the necessary resistance (Fig 9-7a). V-shaped grooves produce roughly one-half as much resistance to lingual displacement as do grooves with a definite lingual wall.²¹ Forces that produce rotating movement in the restoration can produce shear and eventual slippage along the surfaces oblique to the direction of the force. There must be a definite wall perpendicular to the direction of the force to sufficiently limit the freedom of displacement and provide adequate resistance (Fig 9-7b).

A proximal box must be treated in a similar manner. If its facial and lingual walls form oblique angles with its pulpal wall, there will not be adequate resistance to rotating forces (Fig 9-8a). The facial and lingual walls must meet the pulpal wall at angles near 90 degrees so that these walls will be perpendicular to any forces that would tend to rotate the restoration (Fig 9-8b). A flare is then added to the box so that there can be an acute edge of gold at the cavosurface margin of the restoration.

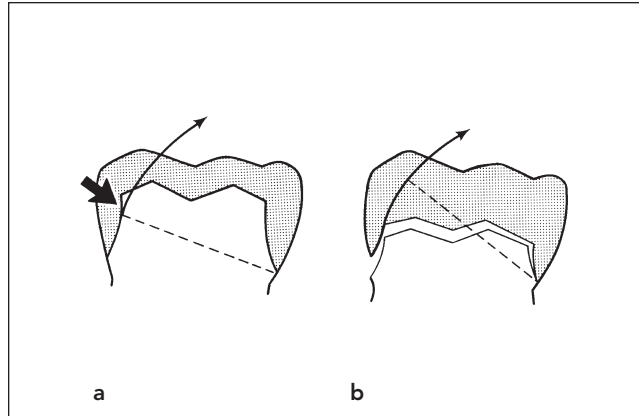


Fig 9-9 The preparation with longer walls (a) interferes with the tipping displacement of the restoration better than the short preparation (b).

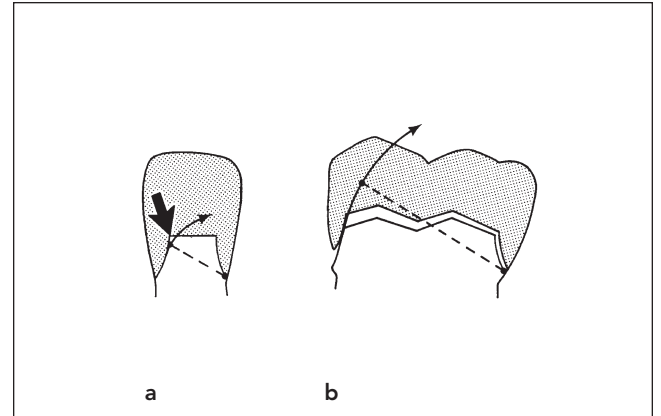


Fig 9-10 A preparation on a tooth with a smaller diameter (a) resists pivoting movements better than a preparation of equal length on a tooth of larger diameter (b).

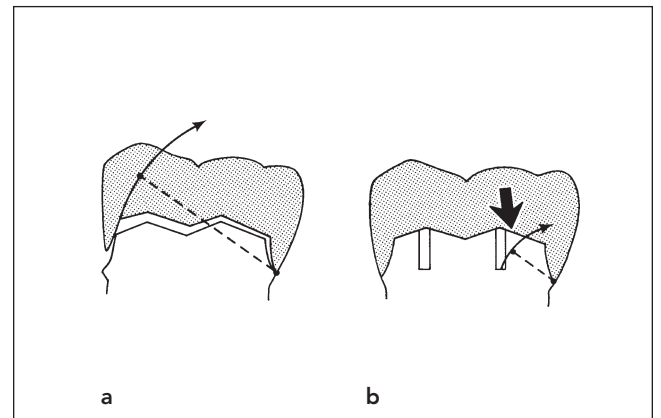


Fig 9-11 The resistance of a short preparation (a) can be improved by adding grooves (b).

Length

Occlusogingival length is an important factor in both retention and resistance. Longer preparations will have more surface area and therefore will be more retentive. Because the axial wall occlusal to the finish line interferes with displacement, the length and inclination of that wall become factors in resistance to tipping forces.

For the restoration to succeed, the length must be great enough to interfere with the arc of the casting pivoting about a point on the margin on the opposite side of the restoration²² (Fig 9-9a). The shorter wall does not afford this resistance (Fig 9-9b). The shorter the wall, the more important its inclination. The walls of shorter preparations should have as little taper as possible to increase the resistance. However, even this will not help if the walls are too short.

It may be possible to successfully restore a tooth with short walls if the tooth has a small diameter. The preparation on the smaller tooth will have a short rotational radius for the arc of displacement, and the incisal portion of the axial wall will resist displacement (Fig 9-10a). The longer rotational radius on the larger preparation allows for a more gradual arc of displacement, and the axial wall does not resist removal (Fig 9-10b). Parker et al²³ found that approximately 95% of anterior preparations analyzed had resistance form, while only 46% of those on molars did.

Resistance to displacement for a short-walled preparation on a large tooth can be improved by placing grooves in the axial walls. In effect, this reduces the rotational radius, and the portion of the walls of the grooves near the occlusal surface of the preparation will interfere with displacement (Fig 9-11).

9 Principles of Tooth Preparations

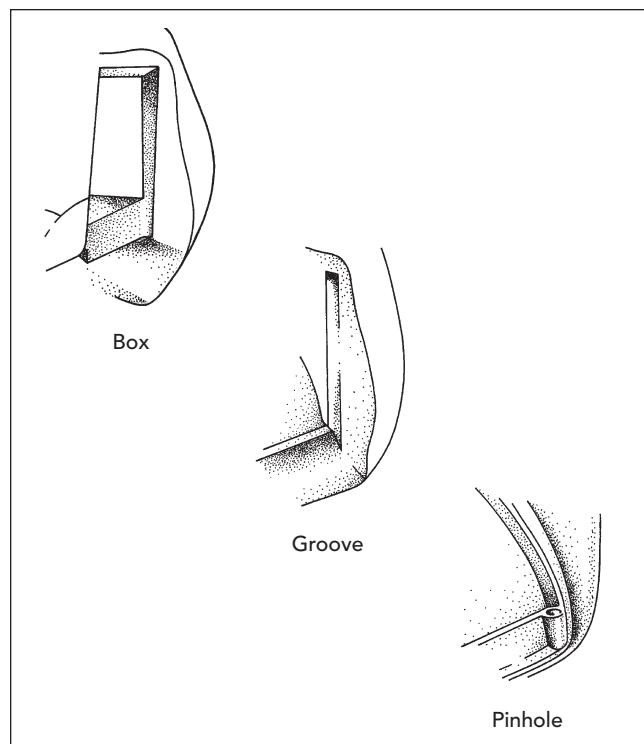


Fig 9-12 Internal preparation features such as the box, groove, and pinhole are frequently substituted for each other.

Substitution of internal features

The basic unit of retention for a cemented restoration is two opposing axial walls with a minimal taper. It may not always be possible to use opposing walls for retention: One may have been destroyed previously, or it may be desirable to leave a surface uncovered for a partial coverage restoration. It may also be that the walls are present but have a greater-than-desirable inclination. Generally, internal features such as the groove, the box form, and the pinhole are interchangeable and can be substituted for an axial wall or for each other (Fig 9-12). Substitution is important because conditions often preclude making an ideal preparation.

Kent et al¹⁵ reported a marked difference between the degree of taper of full crown preparations (18.4 to 22.2 degrees) and that of boxes and grooves in the axial surfaces of those preparations (7.3 degrees). The taper of these internal features is nearly the same as the taper of the instruments used to cut them (4 to 6 degrees). Apparently the widely separated axial walls of the preparations are overinclined because of access, visibility, or both. In preparing an internal feature such as a groove or a box, however, the much shorter distance between the walls allows the dentist to prepare them more precisely. These features offer an excellent means of enhancing the overall retention and resistance of an otherwise overinclined axial wall. Woolsey and Matich²⁴ found that proximal grooves on short 15-degree dies provide complete resistance to faciolingual horizontal displacement.

Path of insertion

The *path of insertion* is an imaginary line along which the restoration will be placed onto or removed from the preparation. It is determined mentally by the dentist before the preparation is begun, and all features of the preparation are cut to coincide with that line. The path of insertion is not arbitrarily set at the completion of the preparation by adding a feature, such as grooves. It is of special importance when preparing teeth to be fixed partial denture abutments because the paths of all the abutment preparations must parallel each other.

The correct technique must be used to survey a preparation visually because this is the primary means of ensuring that the preparation is neither undercut nor overtapered. If the center of the occlusal surface of a preparation is viewed with one eye from a distance of approximately 30 cm (12 inches), it is possible to sight down the axial walls of a preparation with a minimum taper (Fig 9-13). However, it is also possible to sight down the axial walls of a preparation with a reverse (ie, undercut) taper of 8 degrees when both eyes are open (Fig 9-14). This occurs because of the distance between the eyes, which is responsible for binocular vision. Therefore, it is important that preparations be viewed with one eye closed.

For a preparation to be surveyed in the mouth, where direct vision is rarely possible, a mouth mirror is used (Fig 9-15). It is held at an angle approximately ½ inch above the preparation, and the image is viewed with one eye. If fixed partial denture abutment preparations are being evaluated for a common path of insertion, a firm finger rest is established, and the mirror is maneuvered until one preparation is centered. Then, pivoting on the finger rest, the mirror is moved, without changing its angulation, until it is centered over the second preparation.

The path of insertion must be considered in two dimensions: faciolingually and mesiodistally. The faciolingual orientation of the path can affect the esthetics of metal-ceramic or partial veneer crowns. For metal-ceramic crowns, the path is roughly parallel with the long axis of the teeth (Fig 9-16). A facially inclined path of insertion on a preparation for a metal-ceramic crown will leave the facio-occlusal angle too prominent, resulting in overcontouring of the restoration, opaque show-through, or both.

Leaning the path to the facial will force the overcutting of the mesiofacio-occlusal corner of a three-quarter crown preparation, leading to an unnecessary display of gold. For three-quarter crowns on anterior teeth, the path of insertion should parallel the incisal one-half to two-thirds of the labial surface (Fig 9-17). If it is inclined more facially, short grooves and an unnecessary display of gold will result.

The mesiodistal inclination of the path must parallel the contact areas of adjacent teeth. If the path is inclined mesially or distally, the restoration will be held up at the proximal contact areas (ie, locked out) (Fig 9-18). This is a particular problem when restoring a tilted tooth. In this situation, making the path of insertion parallel with the long axis of the tooth will cause the contacts of the adjacent teeth to encroach on the path of insertion.

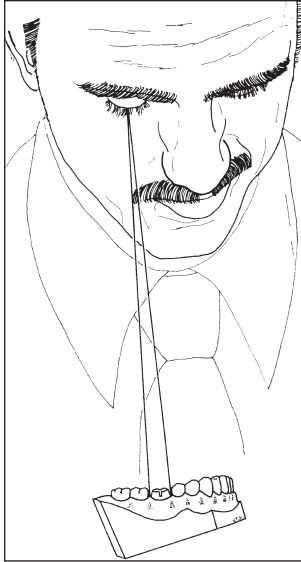


Fig 9-13 To examine a preparation for undercuts, one eye should be closed.

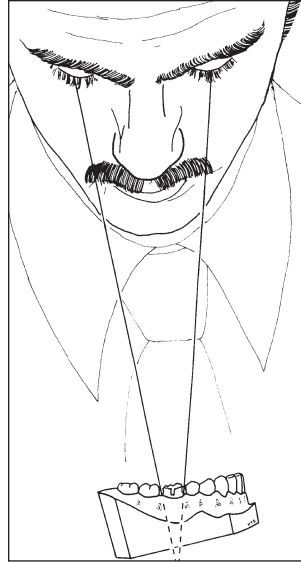


Fig 9-14 If both eyes are open when the preparation is viewed, undercuts may remain undetected.

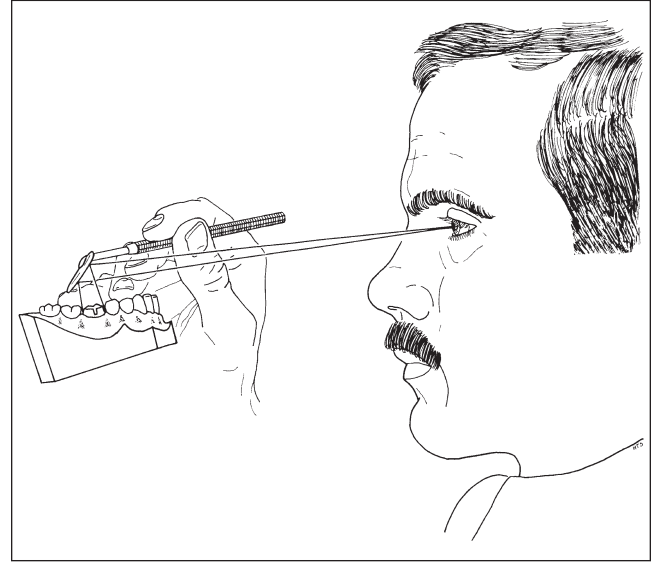


Fig 9-15 Preparations in the mouth are viewed through a mouth mirror using one eye.

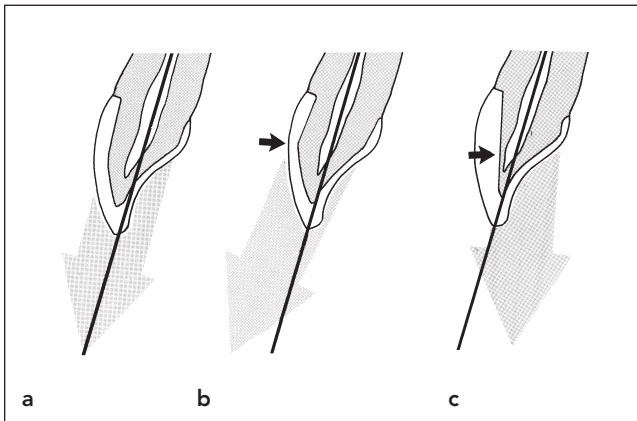


Fig 9-16 (a) The path of insertion of a preparation for a metal-ceramic crown should parallel the long axis of the tooth. (b) If the path is directed facially, the prominent facioincisal angle may create esthetic problems of overcontouring or opaque show-through. (c) However, if the path is directed lingually, the facial surface will intersect the lingual surface, creating a shorter preparation. It also may encroach on the pulp.

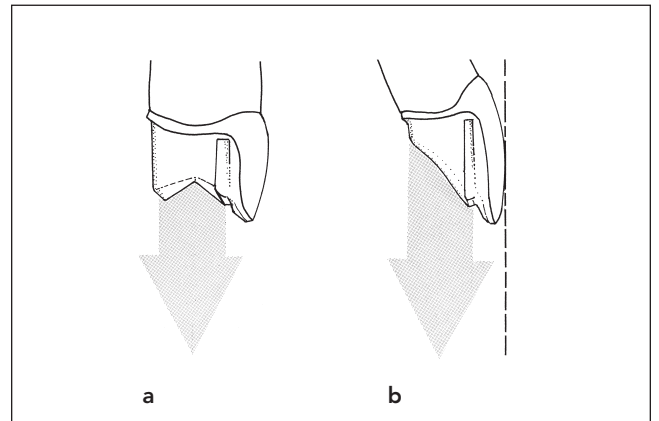


Fig 9-17 The path of insertion of a three-quarter crown on a posterior tooth parallels the long axis of the tooth (a), whereas on an anterior tooth it parallels the incisal one-half to two-thirds of the labial surface (b).

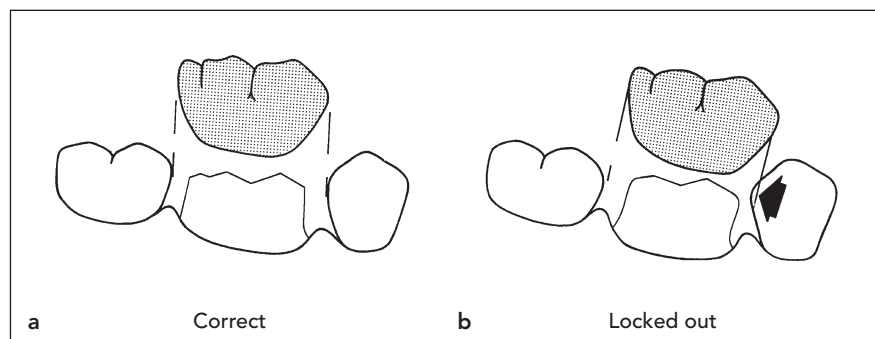


Fig 9-18 The path of insertion of a preparation must parallel the adjacent proximal contacts (a) or it will be prevented from seating (b).

9 Principles of Tooth Preparations

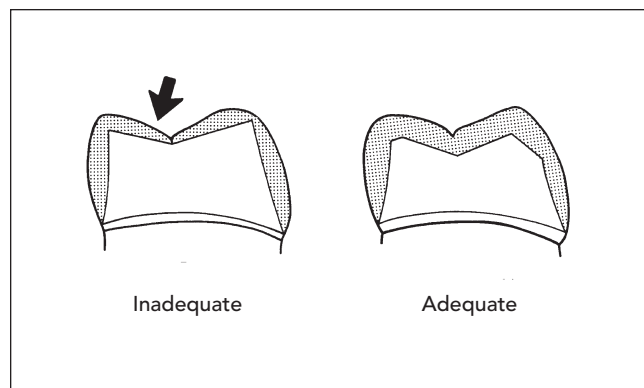


Fig 9-19 Inadequate occlusal reduction does not provide the needed space for a cast restoration of adequate thickness.

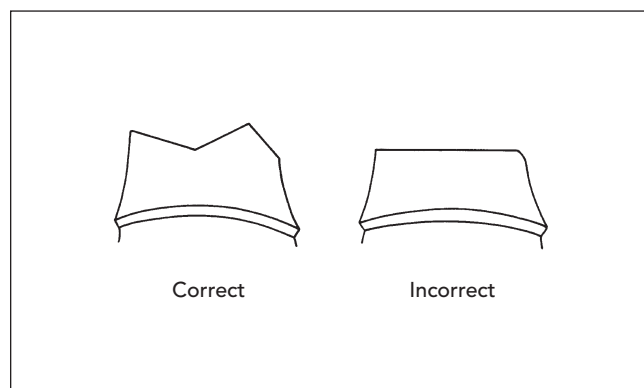


Fig 9-20 Occlusal reduction should reproduce basic inclined planes rather than being cut as one flat plane.

Structural Durability

A restoration must contain a bulk of material that is adequate to withstand the forces of occlusion. This bulk must be confined to the space created by the tooth preparation. Only in this way can the occlusion on the restoration be harmonious and the axial contours normal, preventing periodontal problems around the restoration.

Occlusal reduction

One of the most important features for providing adequate bulk of metal and strength to the restoration is occlusal clearance (Fig 9-19). For gold alloys, there should be 1.5 mm of clearance.

Metal-ceramic crowns will require 2.0 mm of clearance to receive ceramic coverage. There should be 2.0 mm of clearance on preparations for all-ceramic crowns. Malposed teeth

may have occlusal surfaces that are not parallel with the occlusal table. Therefore, it may not be necessary to reduce the occlusal surface by 1.0 mm to achieve 1.0 mm of clearance.

The basic inclined plane pattern of the occlusal surface should be duplicated to produce adequate clearance without overshortening the preparation (Fig 9-20). A flat occlusal surface may overshorten a preparation that is already of minimal length to provide adequate retention. Inadequate clearance makes a restoration weaker. In addition, inadequate reduction under the anatomical grooves of the occlusal surface will not provide adequate space to allow good functional morphology. The restoration also will be much more easily perforated by finishing procedures or by wear in the mouth.

Functional cusp bevel

An integral part of the occlusal reduction is the functional cusp bevel (Fig 9-21). A wide bevel on the palatal inclines of the maxillary palatal cusps and the facial inclines of mandibular facial cusps provides space for an adequate bulk of metal in an area of heavy occlusal contact.

If a wide bevel is not placed on the functional cusp, several problems may occur. If the crown is waxed and cast to normal contour, the casting will be extremely thin in the area overlying the junction between the occlusal and axial reduction (Fig 9-22). To prevent a thin casting when there is no functional cusp bevel, an attempt may be made to wax the crown to optimal thickness in this area. An overcontoured restoration will result, and a defective occlusal contact is likely to occur unless the opposing tooth is reduced (Fig 9-23).

If an attempt is made to obtain space for adequate bulk in a normally contoured casting without a bevel, the result will be an overcut axial surface (Fig 9-24). In addition to the unnecessary destruction of tooth structure, the severe inclination of the surface renders it useless for retention.

Axial reduction

Axial reduction also plays an important role in securing space for an adequate thickness of restorative material (Fig 9-25). If restorations are made with normal contours over preparations with inadequate axial reduction, they will have thin walls that will be subject to distortion. Laboratory technicians often attempt to compensate for this by overcontouring the axial surfaces. While this intended solution to the problem strengthens the restoration, it can have a disastrous effect on the periodontium.

There are other features that serve to provide space for metal that will improve the rigidity and durability of the restoration: the offset, the occlusal shoulder, the isthmus, the proximal groove, and the box (Fig 9-26). The isthmus connects the boxes, and the offset ties the grooves together to enhance the reinforcing "truss effect."²⁵

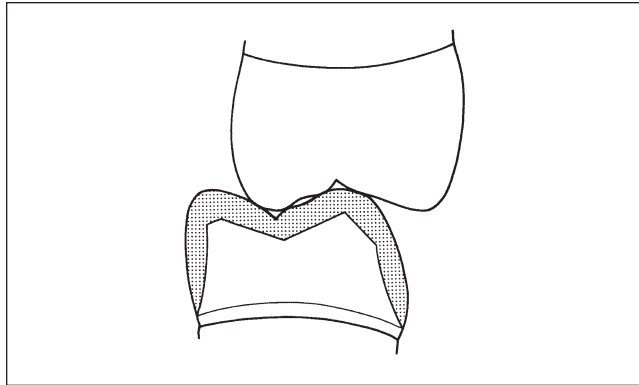


Fig 9-21 The functional cusp bevel is an integral part of occlusal reduction.

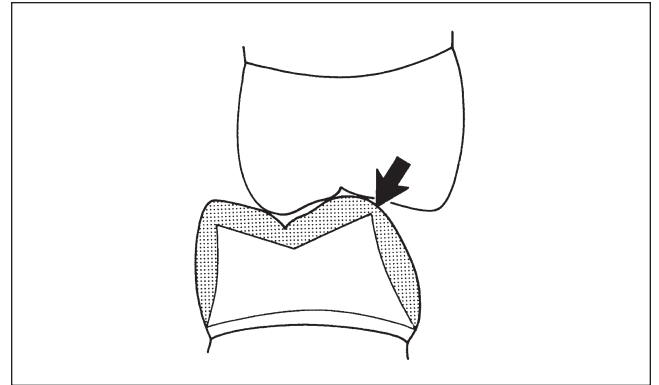


Fig 9-22 Lack of a functional cusp bevel can cause a thin area or perforation in the casting.

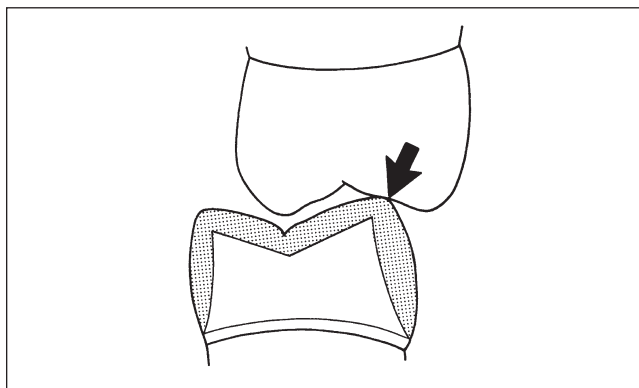


Fig 9-23 Lack of a functional cusp bevel may result in overcontouring and poor occlusion.

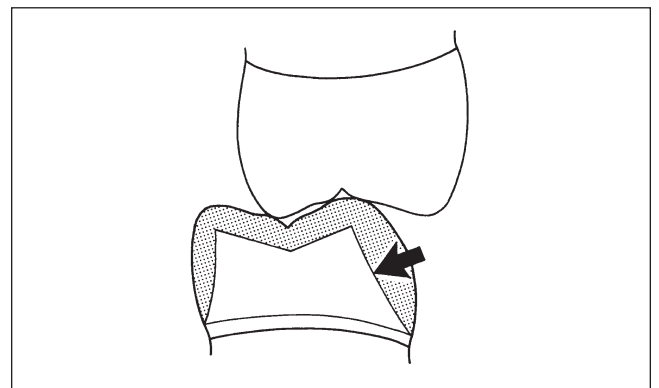


Fig 9-24 Overinclination of the facial surface will destroy excessive tooth structure and lessen retention.

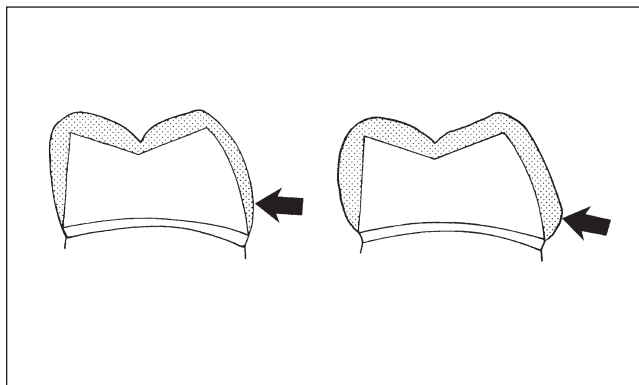


Fig 9-25 Inadequate axial reduction can cause thin walls and a weak restoration (a) or a bulbous, overcontoured restoration (b).

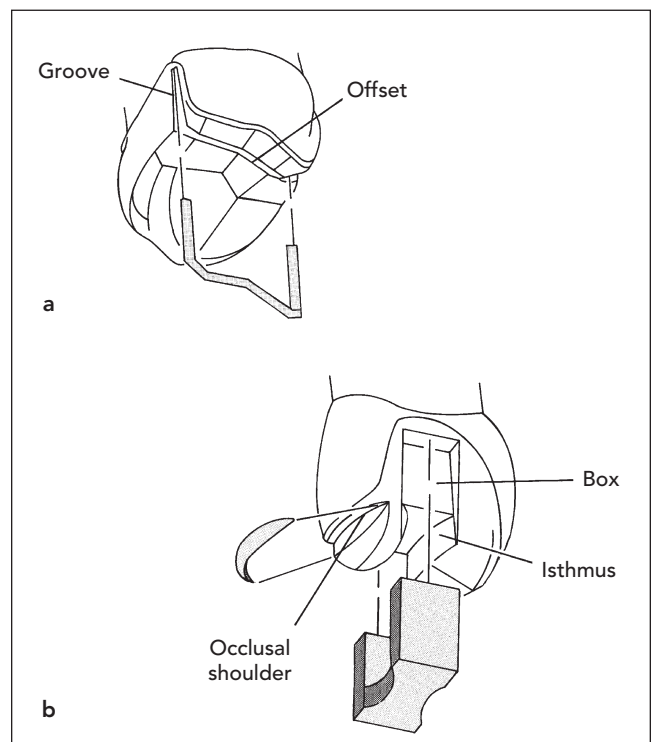


Fig 9-26 (a) The three-quarter crown is reinforced by the bulk of gold that fills the offset and grooves. (b) The occlusal shoulder strengthens the lingual margin, and the isthmus and boxes reinforce the main body of an MOD onlay.

9 Principles of Tooth Preparations

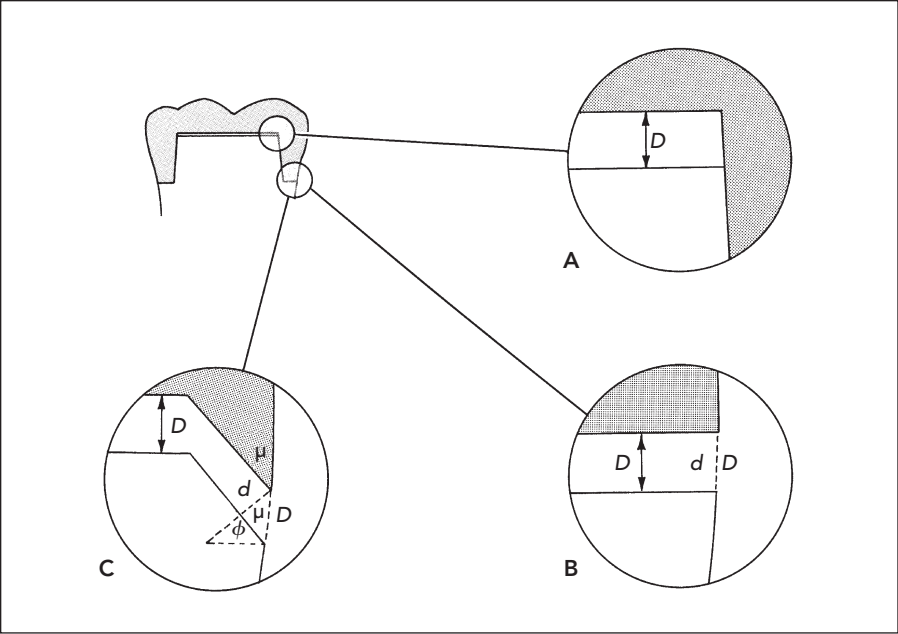


Fig 9-27 Any failure of the restoration to seat (D in inset A) is reflected as a marginal opening of the same dimension on a shoulder perpendicular to the path of insertion (inset B). As the angle of the margin (μ) approximates 0 degrees (inset C), the distance between the margin and the tooth (d) approaches 0, based on the assumption that the gap can be closed completely. (Modified from Rosner²⁶ with permission.)

Marginal Integrity

The restoration can survive in the biologic environment of the oral cavity only if the margins are closely adapted to the cavosurface finish line of the preparation. The configuration of the preparation finish line dictates the shape and bulk of restorative material in the margin of the restoration. It also can affect both marginal adaptation and the degree of seating of the restoration.

To bevel . . .

Cast metal restorations can be made to fit preparations with a high degree of precision, but even in well-fitting castings there is some discrepancy between the margin of the restoration and the preparation. Bevels have been advocated as a means of diminishing marginal discrepancy.²⁶ If the vertical discrepancy in fit is designated as D , the distance between the restoration and preparation (A in Fig 9-27) occurs unchanged between the margin and the finish line (B in Fig 9-27). However, the closest distance between the margin and the surface of the preparation is a line, d , that is perpendicular to the surface of the tooth (C in Fig 9-27). It can be stated as a function of D and the sine of angle μ or the cosine of angle ϕ :

$$\begin{aligned} d &= D \sin \mu \\ \text{or} \\ d &= D \cos \phi \end{aligned}$$

Table 9-2 Trigonometric functions of angles 0 to 90 degrees

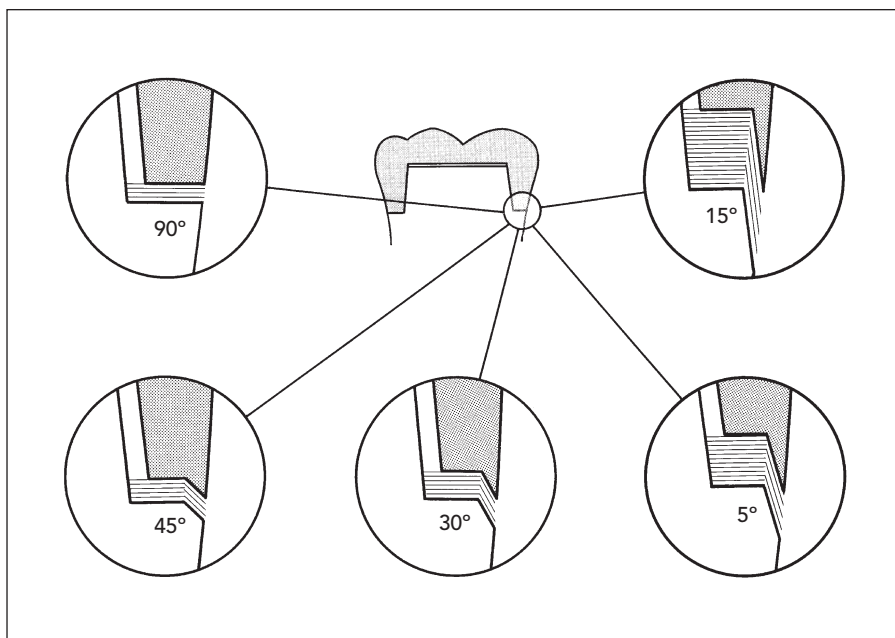
Angle (degrees)	Sine	Cosine
0	0	1.000
15	0.259	0.966
30	0.500	0.866
45	0.707	0.707
60	0.866	0.500
75	0.966	0.259
90	1.000	0

As angle μ becomes smaller (more acute), the sine of μ becomes smaller (Table 9-2); as angle ϕ becomes larger (more obtuse), the cosine of ϕ becomes smaller. By either computation, d diminishes by the same amount. The more acute the angle of the margin (μ) or the more obtuse the angle of the finish line (ϕ), the shorter the distance between the restoration margin and the tooth. This argument is based on the premise that the distance between the margin and tooth structure is infinitely closeable, and as long as there is no cement between the restoration and the preparation, that is true.

. . . Or not to bevel

However, as shown so convincingly by Ostlund,²⁷ the presence of cement changes the scenario completely. The film thickness of the cement will prevent the complete seating

Fig 9-28 The cement film thickness prevents complete closure of the marginal gap. If a bevel of 45 degrees is added to a shoulder, the crown will be prevented from seating by a factor of 1.4. However, as the margin is decreased to an angle of 30 degrees, the crown is displaced twice as much as it would be with a shoulder. Margins of 15 and 5 degrees would prevent seating by factors of 3.9 and 11.5, respectively. If the marginal gap for the shoulder were 25 μm , the American Dental Association specification for cement film thickness, the addition of a 5-degree bevel could keep the casting from seating by nearly 0.3 mm. All spaces in the insets are drawn to scale.



of a casting with bevels that are nearly parallel with the path of insertion of the restoration, just as Jorgensen,⁴ Kaufman et al,⁵ and Eames and associates¹⁴ found that crowns did not seat completely on dies with minimal taper.

The film thickness of the cement imposes a limit on the reduction of the perpendicular distance from the margin to the tooth, d . This distance therefore becomes a constant, and the previous equation is solved for D instead of d :

$$D = d/\sin \mu$$

or

$$D = d/\cos \phi$$

As the angle of the margin bevel becomes more acute, its sine becomes smaller, and as the angle of the finish line becomes more obtuse, its cosine becomes smaller, and D becomes larger. The more nearly the bevel parallels the path of insertion, the greater the distance by which the restoration fails to seat (Fig 9-28).

McLean and Wilson²⁸ have disputed the use of bevels for metal-ceramic crowns because the bevel margin must be 10 to 20 degrees to noticeably improve adaptation. The finish line must also be placed too far subgingivally to hide the resultant metal collar. Pascoe²⁹ demonstrated that slightly oversized castings with shoulders exhibit the least marginal discrepancy. Gavelis et al³⁰ found a better marginal seal with acute-edged margins, but they found that shoulders permitted the most complete seating of a crown. Panno and associates³¹ reported no better adaptability of crowns with highly acute 80-degree bevels than those with less acute 45-degree bevels.

Empirical clinical results dictate that the acute angle margin should continue to be used on metal restorations but that the angle should be in the 30- to 45-degree range. The tapered edge in a wax pattern margin produced by a bevel is more readily adapted to a die than is a butt joint, and a gold margin can be burnished to slightly improve its adaptation after casting.

Finish line configurations

Wide, shallow bevels that are nearly parallel with the outer surface of the tooth should be avoided. They are likely to lead to overcontouring. Even if the axial surfaces of the overlying crown are not overcontoured, the resultant thin, unsupported wax at the margin potentially will break or distort when the wax pattern is withdrawn from the die and invested. The optimum margin for a gold alloy casting is an acute edge with a nearby bulk of metal.

The preferred gingival finish line for veneer metal restorations is the chamfer (Fig 9-29). This finish line has been shown experimentally to exhibit the least stress, so the cement underlying it will have less likelihood of failure.^{32,33} It can be cut with the tip of a round-end diamond while the axial reduction is being done with the side of that instrument. However, a torpedo diamond is less likely to produce a butt joint. The margin of the cast restoration that fits against it combines an acute edge with a nearby bulk of metal.

A deep chamfer (also known as a *heavy chamfer*) is used to provide a 90-degree cavosurface angle with a large-radius rounded internal angle (Fig 9-30). The radius of curvature

9 Principles of Tooth Preparations

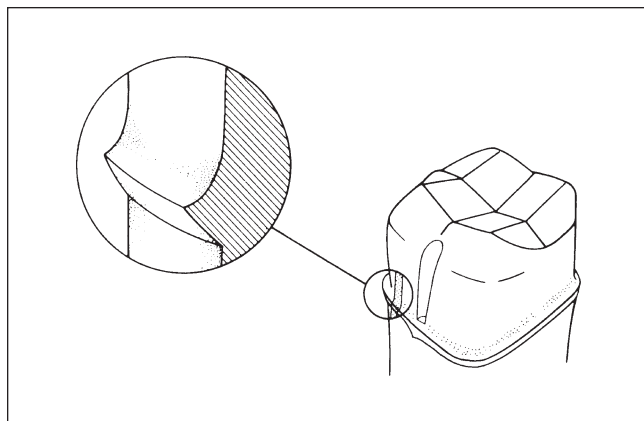


Fig 9-29 Chamfer finish line demonstrated on a full veneer crown preparation.

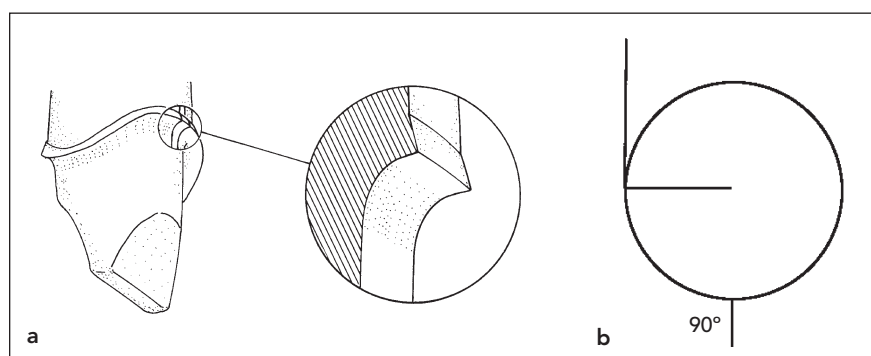


Fig 9-30 (a) Deep chamfer on a preparation for an all-ceramic crown. (b) Ninety-degree finish line formation.

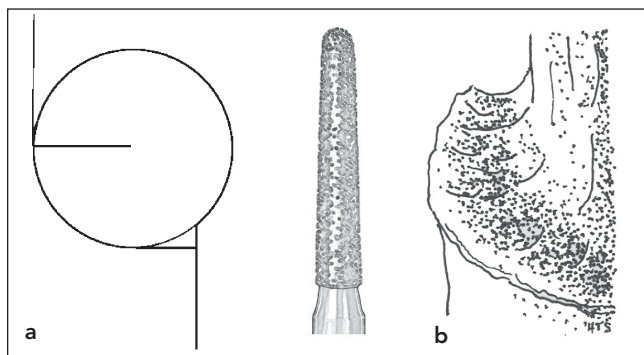


Fig 9-31 (a and b) Lip formation.

equals the depth of axial reduction. It is created with a round-end tapered diamond, which, in the hands of an unskilled operator, can create an undesirable fragile lip of enamel at the cavosurface (Fig 9-31). This friable, unsupported enamel is very easily fractured during or after cementation of the restoration. The deep chamfer provides better support for a ceramic crown than does a conventional chamfer, but it is not as good as a shoulder. A bevel can be added to the deep chamfer for use with a metal restoration.

The classic shoulder was long the finish line of choice for the all-ceramic crown (Fig 9-32). The wide ledge provides resistance to occlusal forces and minimizes stresses that might

lead to fracture of the porcelain. It produces the space for healthy restoration contours and maximum esthetics. However, it does require the destruction of more tooth structure than any other finish line. The sharp, 90-degree internal angle associated with the classic variety of this finish line concentrates stress in the tooth and is conducive to coronal fracture. The shoulder generally is not used as a finish line for cast metal restorations.

The radial shoulder is a modified form of shoulder finish line (Fig 9-33a). The initial instrumentation of the ledge is accomplished with the coarse, flat-end tapered diamond. A small-radius rounded internal angle is instrumented with the

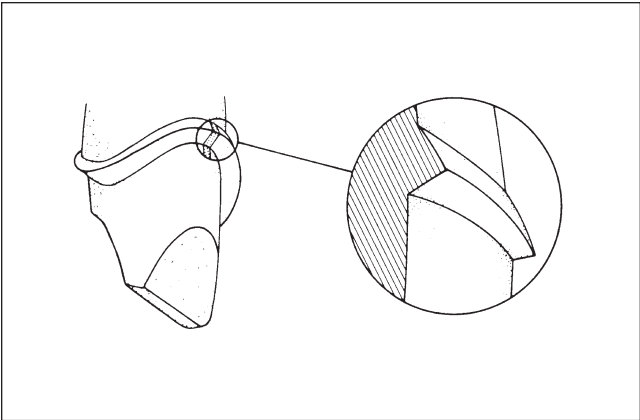


Fig 9-32 Classic shoulder on a preparation for an all-ceramic crown (a traditional porcelain jacket crown).

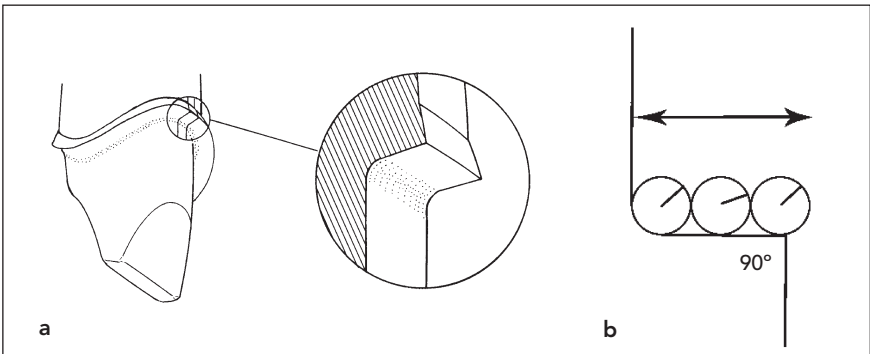


Fig 9-33 (a) A radial shoulder on an all-ceramic crown preparation combines maximum support of the ceramic with a stress-reducing, rounded gingivoaxial angle. (b) Minimal radius of curvature reduces stress.

Table 9-3 Finite element analysis of preparation finish lines*

Finish line	Stress (psi)	Reduction (%)	Change (%)
Classic shoulder	2,885	NA	NA
Radial shoulder	2,101	27	27
Deep chamfer	1,897	34	7

NA, not applicable.
*Based on data from Mullasseril.³⁴

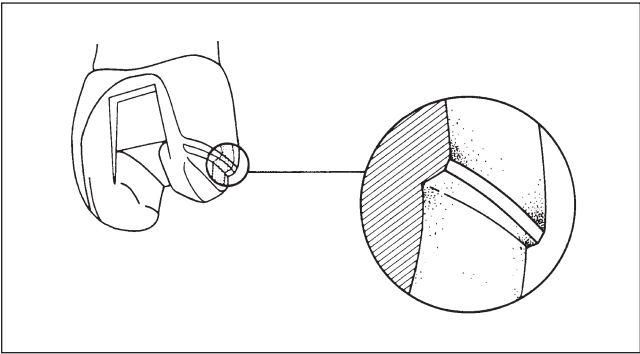


Fig 9-34 Shoulder with a bevel on the occlusal shoulder of an MOD onlay.

fine, flat-end tapered diamond, and finishing is completed with a specially modified binangle chisel. The cavosurface angle is 90 degrees, and shoulder width is only slightly lessened by the rounded internal angle. The radius of curvature equals one-fourth to one-fifth the depth of the axial reduction (Fig 9-33b). Stress concentration is less in the tooth structure than with a classic shoulder, and support for ceramic restoration walls is good. The destruction of tooth structure required for this configuration is not significantly less than that required for a classic shoulder, however. While a deep chamfer will produce slightly less stress than a radial shoulder, it only amounts to a 7% decrease³⁴ (Table 9-3).

The shoulder with a bevel is used as a finish line in a variety of situations (Fig 9-34). It is utilized as the gingival finish line on the proximal box of inlays and onlays and for the occlusal shoulder of onlays and mandibular three-quarter crowns. This design can also be used for the facial finish line of metal-ceramic restorations where gingival esthetics is not critical. It can be used in those situations where a shoulder is already present either because of destruction by caries or the presence of previous restorations. It is also a good finish line for preparations with extremely short walls because it facilitates axial walls that are nearly parallel.³⁵

9 Principles of Tooth Preparations

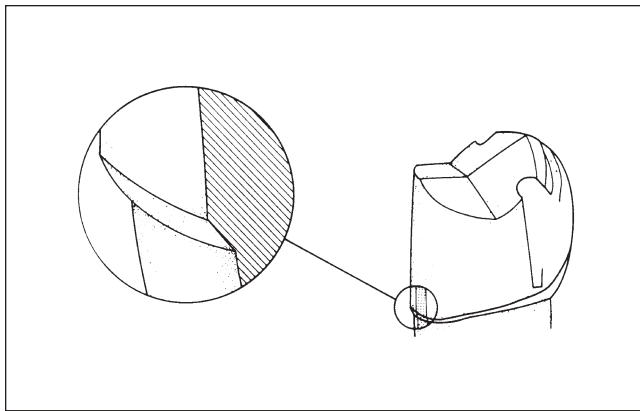


Fig 9-35 Knife edge on the lingual of a mandibular three-quarter crown.

Table 9-4 Advantages and disadvantages of finish lines

Finish line	Advantages	Disadvantages
Chamfer	Minimal tooth destruction Minimal stress	Reduces crown strength (ceramic) Poor esthetics (ceramic)
Deep chamfer	Moderate tooth destruction Minimal stress in tooth	Reduces crown strength Potential lip formation
Classic shoulder	Maximal esthetics Maximal crown strength Prevents overcontouring	Maximal destruction Maximal tooth stress
Radial shoulder	Maximal esthetics Excellent crown strength Less stress than classic shoulder	Destructive of tooth More stress than chamfer
Radial shoulder with a bevel	Excellent crown strength Less stress than classic shoulder	Destructive of tooth More stress than chamfer Poor esthetics (necessitates metal collar)
Knife edge	Minimal destruction	Overcontouring (ceramic) Poor esthetics Weaker crown margin

By adding a bevel to an existing shoulder, it is possible to create an acute edge of metal at the margin. The shoulder with a bevel should not be used routinely for full veneer restorations because the axial reduction required to obtain it is unnecessarily destructive of tooth structure. Some variation of a shoulder, with or without a bevel, may afford some resistance against distortion during porcelain firing.³⁶

The ultimate in finish lines that permit an acute margin of metal is the *knife edge* (Fig 9-35). Unfortunately, its use can create problems. Unless it is carefully cut, the axial reduction may fade out instead of terminating in a definite finish line. The thin margin of the restoration that fits this finish line may be difficult to accurately wax and cast. It is also more susceptible to distortion in the mouth when the casting is subjected to occlusal forces.

The use of the knife edge can result in overcontoured restorations when an attempt is made to obtain adequate bulk by adding to the external axial contours of the restoration. In spite of its drawbacks, it is sometimes necessary to use the knife edge. It may have to be used on the lingual surface of mandibular posterior teeth, on teeth with very convex axial surfaces, and on the surface toward which a tooth may have tilted. The advantages and disadvantages of these finish line choices are summarized in Table 9-4.

The finish line used for the facio-occlusal margin of maxillary partial coverage and MOD onlay restorations is worthy of attention. It, too, must meet the requirement of providing an acute edge with a nearby bulk of metal. The enamel must also be protected by a finishing bevel that will leave the tooth structure at the cavosurface angle with sufficient

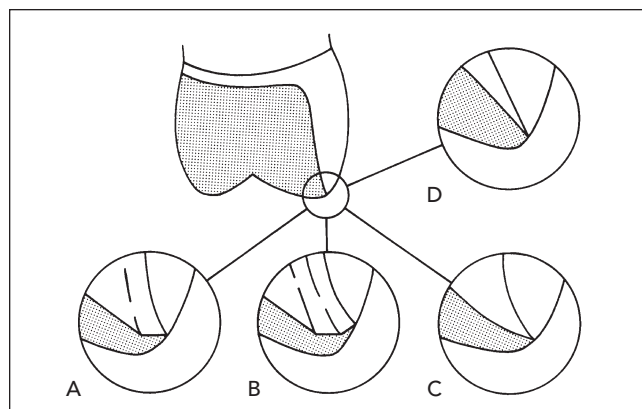


Fig 9-36 Facio-occlusal finish lines on a maxillary three-quarter crown. A flat bevel (A), a contra-bevel (B), and, when the cusp is bulky, a knife edge (C), are acceptable finish lines. The knife edge is not an acceptable finish line on small, sharp cusps (D). (Adapted from Ingham et al³⁷ and Richter and Ueno.³⁸)

bulk to resist fracture and chipping.³⁷ The most commonly used form is a narrow (0.3- to 0.5-mm) finishing bevel perpendicular to the path of insertion of the restoration (A in Fig 9-36). A contra-bevel may also be used where function is heavy and esthetic requirements are minimal (B in Fig 9-36). There are a few situations in which no bevel is required (C in Fig 9-36), but this can only be accomplished on a cusp that is bulky enough to allow the acute edge of metal and still finish the enamel at the cavosurface angle. A bevel is mandatory if its elimination will create an unsupported edge of enamel (D in Fig 9-36).

Preservation of the Periodontium

The placement of finish lines has a direct bearing on the ease of fabricating a restoration and on the ultimate success of the restoration. The best results can be expected from margins that are as smooth as possible and are fully exposed to cleansing.³⁹ Whenever possible, the finish line should be placed in an area where the margins of the restoration can be finished by the dentist and kept clean by the patient. In addition, finish lines must be placed so that they can be duplicated by the impression, without tearing or deforming the impression when it is removed past them.

Finish lines should be placed in enamel when it is possible to do so. In the past, the traditional concept was to place margins as far subgingivally as possible, based on the mistaken concept that the subgingival sulcus is caries free.⁴⁰ The practice of routinely placing margins subgingivally is no longer acceptable. Subgingival restorations have been de-

scribed as a major etiologic factor in periodontitis.⁴¹⁻⁴⁸ The deeper the restoration margin resides in the gingival sulcus, the greater the inflammatory response.⁴⁹⁻⁵²

Although Richter and Ueno³⁸ reported no difference between subgingival and supragingival margins in a 3-year clinical study, they recommended that placement be supragingival whenever possible. Eissmann et al³⁹ made a similar recommendation. Koth⁵³ also failed to find a link between margin location and gingival health in a selected patient population on a strict hygiene regimen.

These studies do not refute the evidence that subgingival margins are likely to cause gingival inflammation. They merely demonstrate that margin location is not as crucial when placed by a highly skilled dentist in the mouth of a motivated, cooperative patient. Ego may tempt a dentist to believe that he or she has the skills to achieve well-fitting subgingival margins on a crown. However, subgingival margins can be very difficult to evaluate.

Christensen⁵⁴ demonstrated that experienced restorative dentists can miss marginal defects as great as 120 μ m when the margins are subgingival. In a radiographic study, Bjorn et al⁵⁵ found that more than half of the proximal margins of gold crowns had defects greater than 0.2 mm and more than 40% of the proximal margins of ceramic crowns had defects that exceeded 0.3 mm.

Nonetheless, there will be many situations in which subgingival margins are unavoidable. Because preparation length is such an important factor in resistance and retention, preparations are frequently extended subgingivally to increase retention.^{47,56-59} The placement of finish lines can also be altered from ideal locations by caries,^{47,56-59} the extensions of previous restorations,^{47,56-58} trauma,^{47,58} or esthetics.^{47,56-59}
















Caution should be exercised if conditions require that the finish line be placed any closer to the alveolar crest than 2.0 mm, which is the combined dimension of the epithelial and connective tissue attachments.⁶⁰ Placement of a restoration margin in this area probably will result in gingival inflammation, loss of alveolar crest height, and formation of a periodontal pocket.⁶¹ Crown lengthening may be performed to surgically move the alveolar crest 3.0 mm apical to the location of the proposed finish line to guarantee the biologic width and prevent periodontal pathology. This will allow space for the connective and epithelial attachments and a healthy gingival sulcus. If the deep finish line is located interproximally and will require extensive removal of bone between the tooth being restored and the adjacent tooth, it may be better to extract the tooth in question rather than periodontally compromise its healthy neighbor.

Instrumentation

The preparation of teeth to receive cast metal or ceramic restorations does not require an extensive armamentarium (Table 9-5).

9 Principles of Tooth Preparations

Table 9-5 Rotary instruments for tooth preparations

Shape	ISO no.	Silhouette	Use
Round-end tapered diamond	6856-016		Depth-orientation grooves Occlusal reduction Functional cusp bevel
Round-end tapered finishing diamond	8856-016		Occlusal finishing Functional cusp bevel finishing
Flat-end tapered diamond	6847-016		Axial reduction (MCR, all-ceramic crown) Shoulder (MCR, all-ceramic crown)
Flat-end tapered finishing diamond	8847KR-016		Axial wall finishing (MCR, all-ceramic crown) Radial shoulder (MCR, all-ceramic crown)
Tapered torpedo diamond	6877K-014		Axial reduction Chamfer finish line
Tapered torpedo finishing diamond	8877K-014		Axial wall finishing Chamfer finishing
Short needle diamond	852-012		Initial proximal reduction (posterior teeth)
Long needle diamond	850-012		Initial proximal reduction (anterior teeth)
Small football-shaped diamond	6379-021		Lingual reduction (anterior teeth)
Small football-shaped finishing diamond	8379-021		Lingual reduction finishing (anterior teeth)
Flame diamond	862-010		Proximal flare Gingival bevel
Flame finishing diamond	8862-010		Flare and bevel finishing
Tapered fissure bur	171L-012		Seating groove Proximal groove (posterior teeth) Offset Occlusal shoulder Isthmus Proximal box Smoothing and finishing Occlusal and incisal bevels
Tapered groove alignment fissure burs	170L-010 169L-009	 	Initial groove alignment Angles of proximal boxes Smoothing and finishing Occlusal and incisal bevels

MCR, metal-ceramic restoration.

The excavation of caries should be accomplished with sharp spoon excavators and round burs (no. 4 or no. 6) mounted in a contra-angle handpiece. Hand chisels may be used to accentuate the facial and lingual walls of proximal boxes. All other procedures usually are accomplished with a high-speed air turbine handpiece.

Small diamond points, used with an air-water spray in a high-speed handpiece, will remove precisely controlled amounts of tooth structure. The surface that remains can be easily smoothed. There is no indication for the use of large diamond cutting disks in low-speed contra-angle or straight handpieces. They frequently overextend preparations, and their potential for injury to the patient is great.

It is important that the cavosurface finish line be smooth and continuous to facilitate the fabrication of restorations with well-adapted margins. Gross reduction is most efficiently accomplished with coarse diamonds. However, they leave irregular cavosurface finish lines^{62,63} and should not be used to obtain a smooth finish line. Using fine diamonds of the same size and shape, it is possible to maintain the finish line configuration developed by the coarse diamond instrument. Acceptable finish lines on vertical flares can be obtained through the use of abrasive paper disks,⁶⁴ but they should be used with a rubber dam to protect soft tissue.

Nondentate tapered burs (169L, 170L, and 171L) are used for grooves, boxes, isthmuses, and offsets where they are needed. They are also used for smoothing any surface that will not terminate in a curved finish line, which they would nick, and for creating occlusal and incisal bevels. Cross-cut or dentate burs are employed for removal of old restorations, but the horizontal ridges they leave on tooth structure make them unacceptable for planing tooth surfaces.

References

- Conzett JV. The gold inlay. *Dent Cosmos* 1910;52:1339–1346.
- Ferrier WI. Cavity preparation for gold foil, gold inlay, and amalgam operations. *J Natl Dent Assoc* 1917;4:441–447.
- Ward ML. *The American Textbook of Operative Dentistry*, ed 6. Philadelphia: Lea & Febiger, 1926:381–395.
- Jorgensen KD. The relationship between retention and convergence angle in cemented veneer crowns. *Acta Odontol Scand* 1955;13:35–40.
- Kaufman EG, Coelho DH, Colin L. Factors influencing the retention of cemented gold castings. *J Prosthet Dent* 1961;11:487–502.
- Dykema RW, Goodacre CJ, Phillips RW. *Johnston's Modern Practice in Crown and Bridge Prosthodontics*, ed 4. Philadelphia: Saunders, 1986:24.
- Shillingburg HT, Hobo S, Fisher DW. *Preparations for Cast Gold Restorations*. Chicago: Quintessence, 1974:16.
- Tylman SD, Malone WFP. *Tylman's Theory and Practice of Fixed Prosthodontics*, ed 7. St Louis: Mosby, 1978:103.
- El-Ebrashi MK, Craig RG, Peyton FA. Experimental stress analysis of dental restorations. IV. The concept of parallelism of axial walls. *J Prosthet Dent* 1969;22:346–353.
- Ohm E, Silness J. The convergence angle in teeth prepared for artificial crowns. *J Oral Rehabil* 1978;5:371–375.
- Mack PJ. A theoretical and clinical investigation into the taper achieved on crown and inlay preparations. *J Oral Rehabil* 1980;7:255–265.
- Weed RM, Suddick RP, Kleffner JH. Taper of clinical and ty-podont crowns prepared by dental students. *J Dent Res* 1984;63:286.
- Noonan JE Jr, Goldfogel MH. Convergence of the axial walls of full veneer crown preparations in a dental school environment. *J Prosthet Dent* 1991;66:706–708.
- Eames WB, O'Neal SJ, Monteiro J, Miller C, Roan JD Jr, Cohen KS. Techniques to improve the seating of castings. *J Am Dent Assoc* 1978;96:432–437.
- Kent WA, Shillingburg HT Jr, Duncanson MG Jr. Taper of clinical preparations for cast restorations. *Quintessence Int* 1988;19:339–345.
- Nordlander J, Weir D, Stoffer W, Ochi S. The taper of clinical preparations for fixed prosthodontics. *J Prosthet Dent* 1988;60:148–151.
- Weed RM. Determining adequate crown convergence. *Tex Dent J* 1980;98(5):14–16.
- Dodge WW, Weed RM, Baez RJ, Buchanan RN. The effect of convergence angle on retention and resistance form. *Quintessence Int* 1985;16:191–194.
- Lorey RE, Myers GE. The retentive qualities of bridge retainers. *J Am Dent Assoc* 1968;76:568–572.
- Rosenstiel E. The retention of inlays and crowns as a function of geometrical form. *Br Dent J* 1957;103:388–394.
- Kishimoto M, Shillingburg HT Jr, Duncanson MG Jr. Influence of preparation features on retention and resistance. Part II: Three-quarter crowns. *J Prosthet Dent* 1983;49:188–192.
- Smyd ES. Advanced thought in indirect inlay and fixed bridge fabrication. *J Am Dent Assoc* 1944;31:759–768.
- Parker MH, Malone KH 3rd, Trier AC, Striano TS. Evaluation of resistance form for prepared teeth. *J Prosthet Dent* 1991;66:730–733.
- Woolsey GD, Matich JA. The effect of axial grooves on the resistance form of cast restorations. *J Am Dent Assoc* 1978;97:978–980.
- Willey RE. The preparation of abutments for veneer retainers. *J Am Dent Assoc* 1956;53:141–154.
- Rosner D. Function, placement and reproduction of bevels for gold castings. *J Prosthet Dent* 1963;13:1160–1166.
- Ostlund LE. Cavity design and mathematics: Their effect on gaps at the margins of cast restorations. *Oper Dent* 1985;10:122–137.
- McLean JW, Wilson AD. Butt joint versus bevelled gold margin in metal ceramic crowns. *J Biomed Mater Res* 1980;14:239–250.
- Pascoe DF. Analysis of the geometry of finishing lines for full crown restorations. *J Prosthet Dent* 1978;40:157–162.
- Gavelis JR, Morency JD, Riley ED, Sozio RB. The effect of various finish line preparations on the marginal seal and occlusal seat of full crown preparations. *J Prosthet Dent* 1981;45:138–145.
- Panno FV, Vahidi F, Gulker I, Ghalili KM. Evaluation of the 45-degree labial bevel with a shoulder preparation. *J Prosthet Dent* 1986;56:655–661.
- El-Ebrashi MK, Craig RG, Peyton FA. Experimental stress analysis of dental restorations. III. The concept of the geometry of proximal margins. *J Prosthet Dent* 1969;22:333–345.
- Farah JW, Craig RG. Finite element stress analysis of a restored axisymmetric first molar. *J Dent Res* 1974;53:859–866.
- Mullasseril PM. *Finite Element Analysis of Preparation Finish Lines* [thesis]. Norman, OK: University of Oklahoma College of Dentistry, 1994.
- Gage JP. Rationale for bevelled shoulder veneer crown preparations. *Aust Dent J* 1977;22:432–435.
- Shillingburg HT Jr, Hobo S, Fisher DW. Preparation design and margin distortion in porcelain-fused-to-metal restorations. *J Prosthet Dent* 1973;29:276–284.
- Ingraham R, Bassett RW, Koser JR. *An Atlas of Cast Gold Procedures*, ed 2. Los Angeles: University of Southern California School of Dentistry, 1969:34.
- Richter WA, Ueno H. Relationship of crown margin placement to gingival inflammation. *J Prosthet Dent* 1973;30:156–161.
- Eissmann HF, Radke RA, Noble WH. Physiologic design criteria for fixed dental restorations. *Dent Clin North Am* 1971;15:543–568.

9 Principles of Tooth Preparations

40. Black GV. The management of enamel margins. *Dent Cosmos* 1891;33:85–100.
41. Waerhaug J. Histologic considerations which govern where the margins of restorations should be located in relation to the gingiva. *Dent Clin North Am* 1960;4:161–176.
42. Mormann W, Regolati B, Renggli HH. Gingival reaction to well-fitted subgingival proximal gold inlays. *J Clin Periodontol* 1974;1:120–125.
43. Janenko C, Smales RJ. Anterior crowns and gingival health. *Aust Dent J* 1979;24:225–230.
44. Romanelli JH. Periodontal considerations in tooth preparation for crowns and bridges. *Dent Clin North Am* 1980;24:271–284.
45. Wilson RD, Maynard G. Intracrevicular restorative dentistry. *Int J Periodontics Restorative Dent* 1981;1(4):34–49.
46. Silness J. Periodontal conditions in patients treated with dental bridges. 3. The relationship between the location of the crown margin and the periodontal condition. *J Periodontol Res* 1970;5:225–229.
47. Larato DC. Effect of cervical margins on gingiva. *J Calif Dent Assoc* 1969;45:19–22.
48. Reeves WG. Restorative margin placement and periodontal health. *J Prosthet Dent* 1991;66:733–736.
49. Silness J. Fixed prosthodontics and periodontal health. *Dent Clin North Am* 1980;24:317–329.
50. Karlsen K. Gingival reactions to dental restorations. *Acta Odontol Scand* 1970;28:895–904.
51. Newcomb GM. The relationship between the location of subgingival crown margins and gingival inflammation. *J Periodontol* 1974;45:151–154.
52. Jameson LM, Malone WF. Crown contours and gingival response. *J Prosthet Dent* 1982;47:620–624.
53. Koth DL. Full crown restorations and gingival inflammation in a controlled population. *J Prosthet Dent* 1982;48:681–685.
54. Christensen GJ. Marginal fit of gold inlay castings. *J Prosthet Dent* 1966;16:297–305.
55. Björn AL, Björn H, Grkovic B. Marginal fit of restorations and its relation to periodontal bone level. II. Crowns. *Odontol Revy* 1970;21:337–346.
56. Berman MH. The complete coverage restoration and the gingival sulcus. *J Prosthet Dent* 1973;29:301–309.
57. Stein RS, Kuwata M. A dentist and a dental technologist analyze current ceramo-metal procedures. *Dent Clin North Am* 1977;21:729–749.
58. Behrend DA. Ceramometal restorations with supragingival margins. *J Prosthet Dent* 1982;47:625–632.
59. Gardner FM. Margins of complete crowns—Literature review. *J Prosthet Dent* 1982;48:396–400.
60. Garguilo AW, Wentz FM, Orban B. Dimensions of the dentogingival junction in humans. *J Periodontol* 1961;32:261–267.
61. Ingber JS, Rose LF, Coslet JG. The “biologic width”—A concept in periodontics and restorative dentistry. *Alpha Omegan* 1977;70(3):62–65.
62. Barnes JE. The production of inlay cavity bevels. *Br Dent J* 1974;137:379–390.
63. Kinzer RL, Morris C. Instruments and instrumentation to promote conservative operative dentistry. *Dent Clin North Am* 1976;20:241–258.
64. Tronstad L, Leidal TI. Scanning electron microscopy of cavity margins finished with chisels or rotating instruments at low speed. *J Dent Res* 1974;53:1167–1174.

Preparations for Full Coverage Crowns

10



There are numerous situations that call for the use of a full coverage restoration. Clinicians have long considered it to be the most retentive of crown preparations.¹ Controlled laboratory studies have shown that when compared with partial coverage designs, the full coverage crown exhibits superior retention^{2,3} and resistance.⁴ This does not mean that a full coverage design must be used on every tooth. Instead, it should be used on those teeth whose restoration demands maximum retention.

A requirement for maximum retention is not commonly seen in the placement of single restorations. This need is more likely to be manifested in the design of retainers for fixed partial dentures, where additional demands are placed on the preparation and restoration. The selection of a full coverage crown retainer becomes mandatory when the abutment tooth is small or when the edentulous span is long.

Variations of the full coverage crown, the metal-ceramic crown and the all-ceramic crown, are used in situations that require a good esthetic result. The full coverage crown should be used when less extensive and less destructive designs have been considered and found lacking in retention, resistance, coverage, or esthetics to properly restore the tooth.

Full coverage in the right circumstances can be excellent treatment, but it is overused. More conservative dentistry has become easier, and the preservation of tooth structure is important.⁵ A report of dental insurance data in 1979 indicated that nearly 93% of the cast restorations done by dentists submitting claims to that company were of a full-coverage design.⁶ Undoubtedly, the percentage would be greater today. The indications for full coverage have increased because of the preservation of teeth that may have been removed in the past. Further, as patients' life expectancies have increased, so has the cumulative damage to teeth. There is also a greater need for the protection afforded by encircling the vulnerable parts of the endodontically treated tooth with full coverage.⁷ However, the removal of all morphologic form of the tooth is radical treatment, and restoring it properly can be difficult.⁸ The dentist should be certain it is necessary before placing a full coverage restoration.

Full Metal Crown Preparation

When all of the axial surfaces of a posterior tooth have been attacked by decalcification or caries or have been previously

restored, the tooth is a candidate for a full metal crown. By tying together the remaining tooth structure, a full metal crown can strengthen and support the tooth.⁹ It should be used judiciously, however, because it does require a destructive preparation. It may weaken rather than strengthen the remaining tooth structure when there has been previous extensive destruction in the center of the tooth. However, the preparation for a full metal crown is less destructive than that required for either a metal-ceramic or an all-ceramic crown.

Full coverage should not be used in mouths with uncontrolled caries. A full coverage crown is a restoration that replaces lost tooth structure and imparts some measure of structural support to the tooth. However, it does not protect the tooth against the biologic causes of the caries. These processes must be controlled by other means before any restoration can be successful.

Armamentarium

- Handpiece
- No. 171L bur
- Coarse-grit round-end tapered diamond (6856-016)
- Fine-grit round-end tapered diamond (8856-016)
- Medium-grit short needle diamond (852-012)
- Coarse-grit tapered torpedo diamond (6877K-014)
- Fine-grit tapered torpedo diamond (8877K-014)
- Red utility wax

Technique

The preparation for a full coverage crown is begun with occlusal reduction, creating about 1.5 mm of clearance on the functional and nonfunctional cusps. By accomplishing this step first, the occlusogingival length of the preparation can be determined. The potential retention of the preparation can then be assessed, and auxiliary features can be added if necessary.

Depth-orientation grooves are placed on the occlusal surface of the tooth to provide an easy reference to determine when reduction is sufficient. If reduction is begun without orientation marks, time will be wasted in repeated checks for adequate clearance. A coarse-grit round-end tapered diamond is used to place the grooves on the ridges and the primary grooves of the occlusal surface. If there is al-

10 Preparations for Full Coverage Crowns

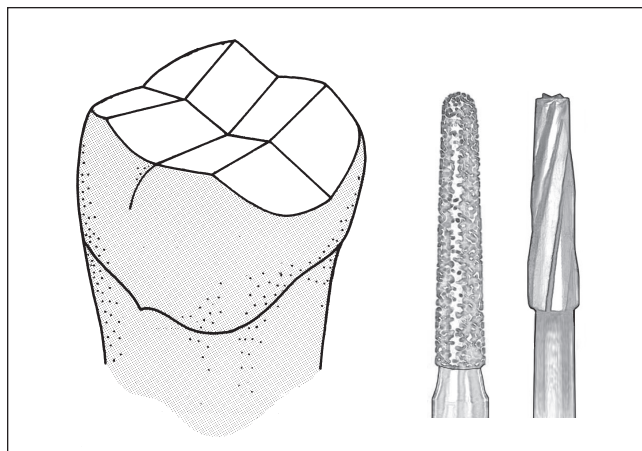


Fig 10-1 Occlusal reduction: coarse-grit round-end tapered diamond and no. 171L bur.

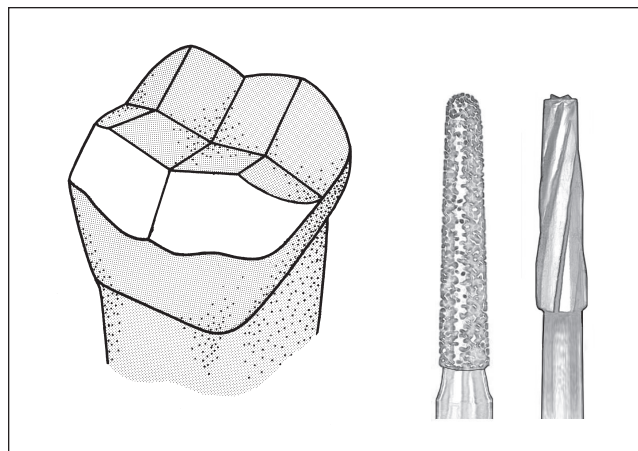


Fig 10-2 Functional cusp bevel: coarse-grit round-end tapered diamond and no. 171L bur.

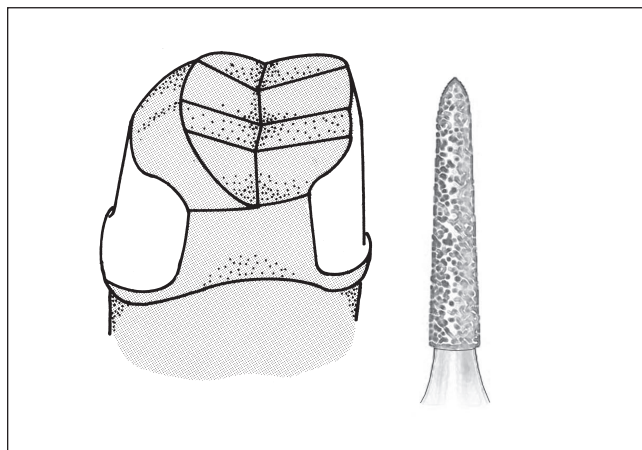


Fig 10-3 Facial and lingual axial reduction: coarse-grit tapered torpedo diamond.

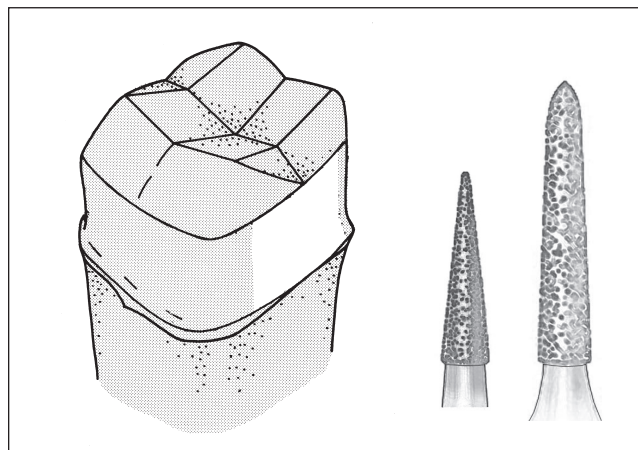


Fig 10-4 Proximal axial reduction: medium-grit short needle and coarse-grit tapered torpedo diamonds.

ready some clearance with the opposing tooth because of malpositioning or fracture of the tooth being prepared, the grooves need not be as deep.

The tooth structure remaining between the orientation grooves is removed to accomplish the occlusal reduction (Fig 10-1). Any roughness left by the grooves should be removed, keeping the occlusal surface in the configuration of the geometric inclines that make up the occlusal surface of any posterior tooth.

A wide bevel is placed on the functional cusp, again using the coarse-grit round-end tapered diamond (Fig 10-2). Depth-orientation grooves are also helpful in obtaining this reduction. The functional cusp bevel, placed on the facial inclines of mandibular facial cusps and the palatal inclines of maxillary palatal cusps, is an integral part of the occlusal reduction. Failure to place this bevel can produce a thin casting or poor morphology in the restoration.

Occlusal clearance is checked by having the patient close on a 2-mm-thick strip of red utility wax held over the preparation. The wax is then held up to a light to determine the

adequacy of the occlusal clearance. Any part of the preparation that has insufficient occlusal clearance will be readily detectable as a thin spot in the wax. Additional tooth structure should be removed from the indicated areas and rechecked.

The occlusal reduction and functional cusp bevel are planed smooth with a no. 171L bur now or when the bur is used to instrument the seating groove. This can also be done with a fine-grit round-end tapered diamond. There should not be sharp angles or ridges where the planes or bevel join. If there are, they should be removed.

The facial and lingual walls are reduced with a coarse-grit tapered torpedo diamond, whose sides produce the desired axial reduction, while its tapered tip forms a chamfer finish line (Fig 10-3). A definite, even finish line is necessary to enable the fabrication of a restoration with a good fit,¹⁰ and the chamfer is the best for providing the bulk needed for strength while still allowing good adaptation.¹

The initial proximal cuts are made with a short needle diamond (Fig 10-4). The thin diamond is worked through the proximal area in an occlusogingival or faciolingual sawing

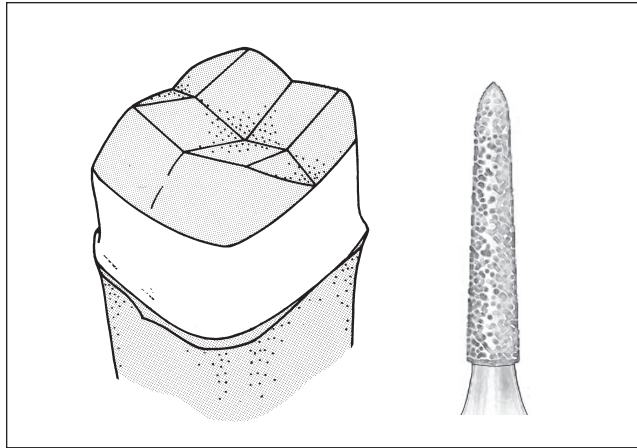


Fig 10-5 Chamfer and axial finishing: fine-grit tapered torpedo diamond.

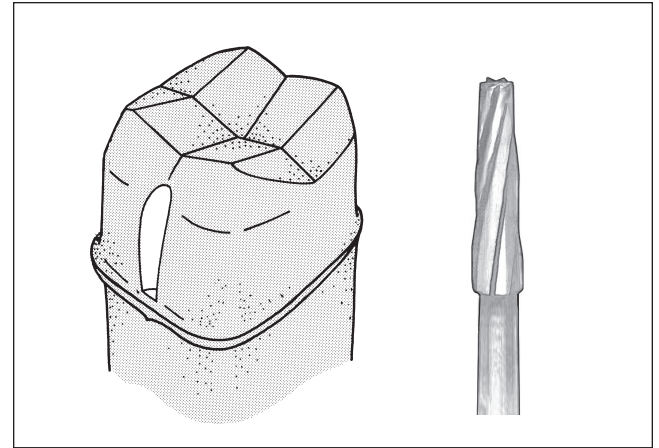


Fig 10-6 Seating groove: no. 171L bur.

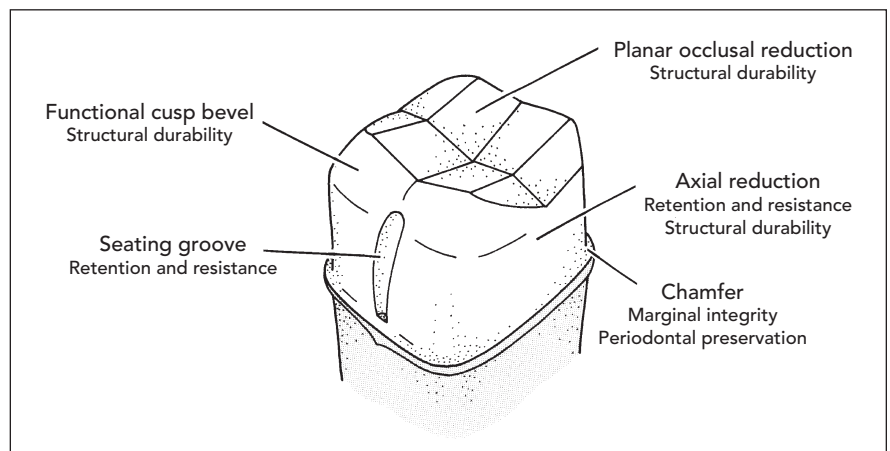


Fig 10-7 Features of a mandibular full metal crown preparation and the function(s) served by each.

motion, carefully avoiding the adjacent teeth. Once sufficient maneuvering room has been obtained, the coarse-grit tapered torpedo diamond is introduced to plane the walls while simultaneously forming a chamfer as the interproximal gingival finish line.

All of the axial surfaces are smoothed with a fine-grit tapered torpedo diamond, whose size and shape enable it to finish the chamfer finish line as well (Fig 10-5). Special care should be taken in rounding the corners from the facial or lingual surfaces to the proximal surfaces to ensure that the finish line will be smooth and continuous.

The final step in the full coverage crown preparation is the placement of a seating groove (Fig 10-6). It will prevent any rotational tendencies during cementation, and it will help guide the casting into place. The groove is formed with a no. 171L bur and is placed in the axial surface with the greatest bulk. This usually will be on the facial surface of mandibular preparations and on the palatal surface of maxil-

lary preparations. On preparations for long-span fixed partial dentures, there should be both a facial and a lingual groove to increase the resistance to mesiodistal movement. The features of a preparation for a full veneer metal crown and the function served by each are shown in Fig 10-7.

Metal-Ceramic Crowns

The metal-ceramic restoration, also called a *porcelain-fused-to-metal restoration*, consists of a ceramic layer bonded to a thin cast metal coping that fits over the tooth preparation. Such a restoration combines the strength and accurate fit of a cast metal crown with the cosmetic effect of a ceramic crown. With a metal understructure, metal-ceramic restorations have greater strength than restorations made of ceramic alone. Friedlander et al¹¹ found the metal-ceramic

10 Preparations for Full Coverage Crowns

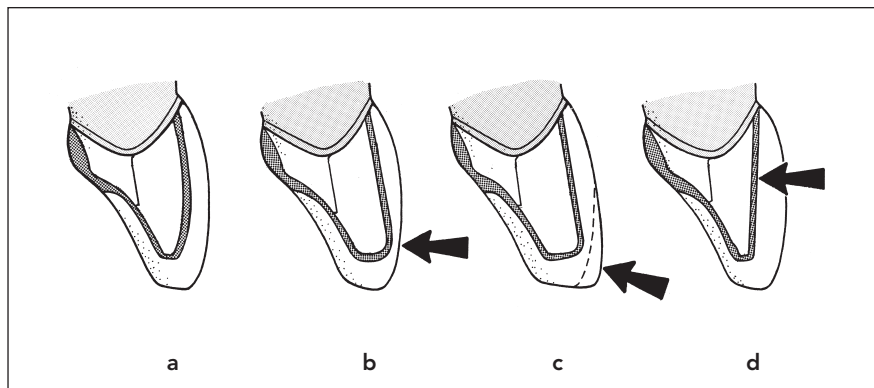


Fig 10-8 It is important to reduce the labial surface in two planes to receive a metal-ceramic restoration (a). If only one plane is reduced, opaque porcelain may show through (b), the labial surface may be overcontoured (c), or the pulp may be encroached upon (d).

restoration to be 2.8 times as strong as ceramic restorations. As a result, the longevity of metal-ceramic restorations is greater and it can be used in a wider variety of situations, including the replacement of missing teeth with fixed partial dentures.

Because the restoration is a combination of metal and ceramic, it is not surprising that the tooth preparation for it is likewise a combination. There is deep reduction on the facial surface to provide space for the coping and a ceramic layer thick enough to achieve the desired esthetic result. On the lingual surface, fading proximally, there is shallower reduction similar to that used for a full metal crown. There may be a wing on each proximal surface where the deep facial reduction ends and the shallower proximal reduction begins.¹² The transition between these reductions need not be dramatic, though, because extreme concentration on the necessity of a wing often results in inadequate axial reduction for metal or excessive axial reduction for ceramic. Rather than being sharply delineated, the transition is often gradual. This is especially true for anterior teeth because of their narrow interproximal contact areas and diminished faciolingual dimension.

Adequate reduction is essential to achieving a good esthetic result. Without the space for a sufficient thickness of ceramic material, two things can happen: (1) The restoration will be poorly contoured, adversely affecting both the esthetic effect of the crown and the health of the surrounding gingiva, and/or (2) the shade and translucency of the restoration will not match adjacent natural teeth.

Anterior metal-ceramic crowns

A uniform reduction of approximately 1.2 mm is needed over the entire facial surface. To achieve adequate reduction without encroaching on the pulp, the facial surface must be prepared in two planes that correspond roughly to the two geometric planes present on the facial surface of an uncut tooth (Fig 10-8). If the facial surface is reduced in one plane

that is an extension of the gingival plane, the incisal edge will protrude, resulting in a bad shade match or an overcontoured block. If the facial surface is prepared in one plane that has adequate facial reduction in the incisal aspect, the facial surface will be overtapered and too close to the pulp.

Armamentarium

- Laboratory knife with no. 25 blade
- Silicone putty and accelerator
- Handpiece
- Coarse-grit flat-end tapered diamond (6847-016)
- Coarse-grit football-shaped diamond (6379-023)
- Medium-grit long needle diamond (850-012)
- Coarse-grit tapered torpedo diamond (6877K-014)
- Fine-grit tapered torpedo diamond (8877K-014)
- Fine-grit flat-end tapered diamond (8847KR-016)
- CP-11/12 (Hu-Friedy)

Technique

An index made before the preparation is begun makes it possible to have a positive check on reduction produced by the preparation. If the contours of the existing tooth are correct, the index can be made intraorally while waiting for the anesthetic to take effect. However, if the tooth is badly broken down, or if contours are to be changed in the finished restoration, the index should be made from a preoperative wax-up on the diagnostic cast.

A half-scoop of putty is mixed with the appropriate amount of accelerator and kneaded in the palm of the hand until all streaks of the accelerator have disappeared. The putty is then adapted with a thumb and forefinger over the tooth to be prepared (Fig 10-9). It should be allowed to polymerize on the tooth, which should take about 2 minutes. The index should cover the entire labial and lingual surface of the tooth to be prepared, plus the corresponding surfaces of at least one adjacent tooth (Fig 10-10).

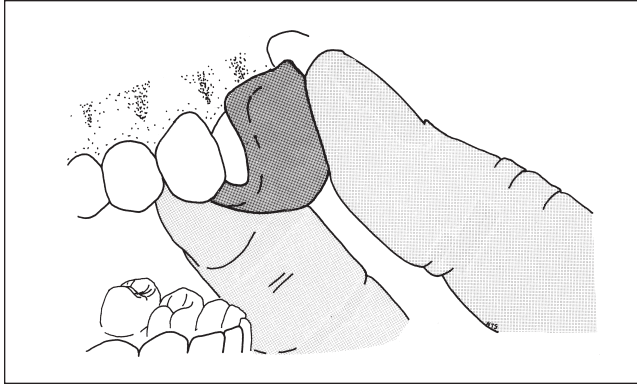


Fig 10-9 Silicone putty is molded on the labial and lingual surfaces of the tooth to be prepared and the teeth adjacent to it.

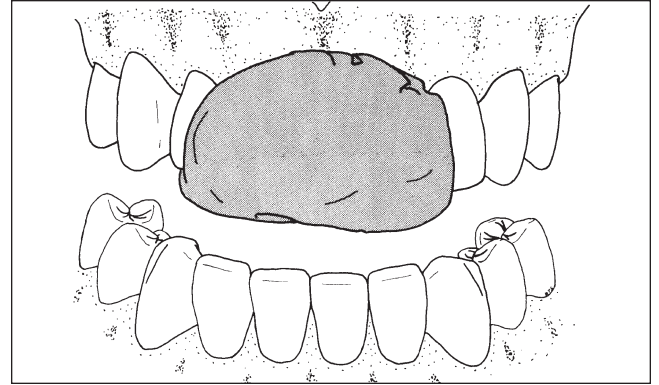


Fig 10-10 The index should contact the labial and lingual surfaces of the teeth on either side of the tooth to be prepared.

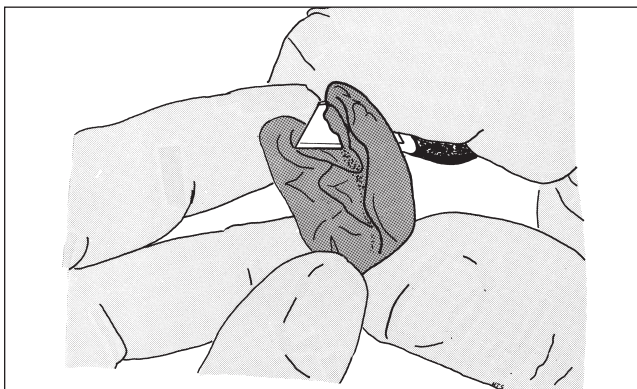


Fig 10-11 The index is cut into a labial and a lingual half.

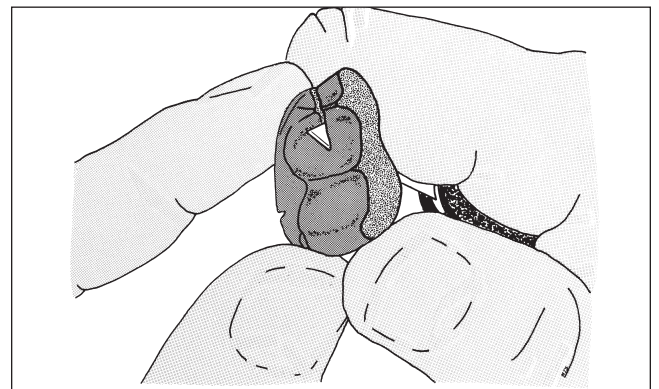


Fig 10-12 The labial half of the index is cut into a gingival and an incisal half.

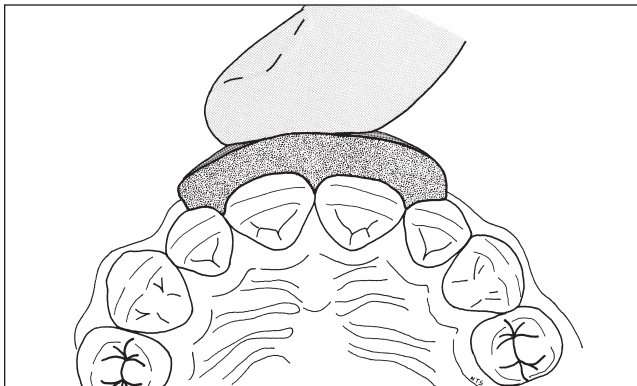


Fig 10-13 The gingival half of the index is placed on the teeth to see if it fits accurately.

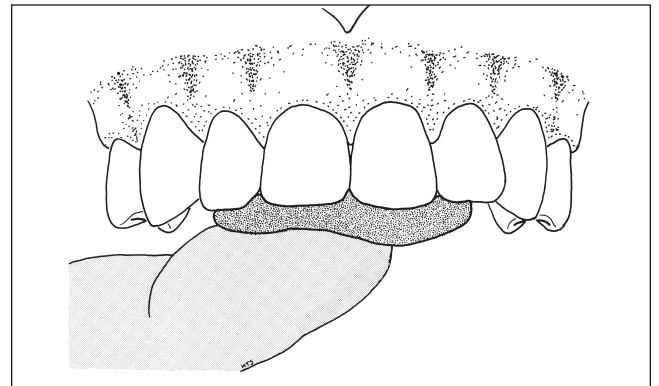


Fig 10-14 The lingual index is placed in position to check its accuracy.

The index is then removed from the teeth. A laboratory knife with a no. 25 blade is used to cut along the incisal edges of the tooth imprints to separate the index into a labial and a lingual half (Fig 10-11). The lingual half is set aside for the time being. The labial portion of the index is cut from mesial to distal across the imprints of the labial surfaces of the teeth to produce an incisal half and a gingival half (Fig 10-12).

The gingival half of the labial portion is positioned on the teeth to ensure that it is closely adapted to the labial surfaces (Fig 10-13). After removing the labial index, the lingual index is put in position, and its adaptation to the incisal edges of the teeth is checked (Fig 10-14).

The labial and lingual indices are set aside until the preparation is completed. Then the gingival half of the labial index

10 Preparations for Full Coverage Crowns

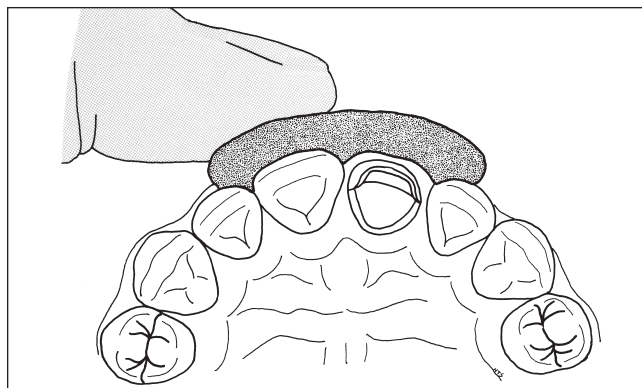


Fig 10-15 The gingival half of the index is positioned over the preparation to check the labial reduction.

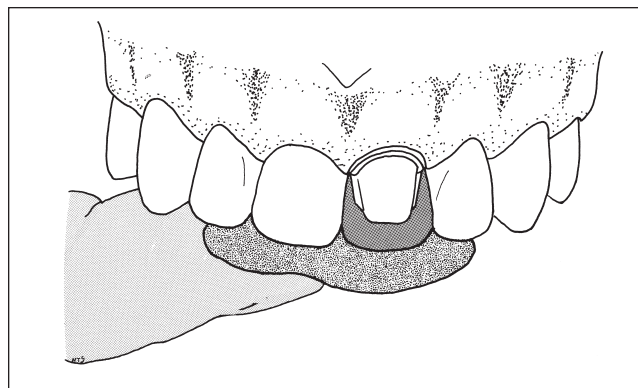


Fig 10-16 The lingual index is placed in position to evaluate the incisal reduction.

is positioned and checked for adequate labial clearance for a metal coping and porcelain (Fig 10-15). If the reduction is inadequate, the index is removed from the mouth and more tooth structure is removed. The incisal clearance is checked by putting the lingual index in place and evaluating the distance between the incisal edge of the prepared tooth and the incisal edge of the tooth imprint on the index (Fig 10-16).

The initial step in the preparation for a metal-ceramic crown is the placement of depth-orientation grooves on the labial and incisal surfaces with a coarse-grit flat-end tapered diamond. These orientation cuts, recommended by Preston¹² and Miller,¹³ are a means of judging the amount of tooth structure to be removed. The full diameter of an instrument of known dimension is sunk into the tooth with light pressure, keeping the diamond moving incisogingivally. Putting excessive pressure on the handpiece and burying the diamond in the facial surface causes excessive heat that will likely result in pulpal damage. Lockard¹⁴ attributes his lack of pulpal sequelae to using new diamonds with very light pressure and a constant sweeping motion.

The depth of reduction can be measured using the uncut outer surface of the remaining tooth structure as a reference point.¹³ If reduction is done without grooves, time will be wasted in repeatedly rechecking reduction with the index. The labial grooves should be cut in two sets: one set parallel with the gingival half of the labial surface and one set parallel with the incisal half of the labial surface (Fig 10-17). These grooves should be 1.2 mm deep. The incisal grooves should be cut all the way through the incisal edge and should extend 2.0 mm gingivally.

Incisal reduction is done with the coarse-grit flat-end tapered diamond so that it parallels the inclination of the unprepared incisal edge (Fig 10-18). This is done first to allow easy instrument access to the axial surfaces and the gingival finish line. Inadequate incisal reduction results in poor incisal translucency in the finished restoration.

Reduction of the incisal portion of the labial surface is done with the same flat-end tapered diamond. All tooth structure is planed off to the depth of the orientation grooves (Fig

10-19). The gingival portion of the labial surface is likewise reduced to the depth of the grooves with the flat-end tapered diamond. The reduction is carried around the labio-proximal line angles to a point 1.0 mm lingual to the proximal contacts (Fig 10-20). Although the resulting wings of tooth structure can provide some resistance to rotation, that is not the primary reason for their existence. They conserve tooth structure, if in fact there is still sound tooth structure left on the proximal surfaces. It is important that the portion of each wing that faces labially has the same inclination as the gingival portion of the labial surface; otherwise, an undercut will be created.

The lingual surface (incisal to the cingulum) is reduced with a coarse-grit football-shaped diamond to obtain a minimum of 0.7 mm of clearance with the opposing teeth (Fig 10-21). Those portions of the lingual surface that will have a ceramic veneer should have 1.0 mm of clearance. The junction between the cingulum and the lingual wall (apical to the cingulum) must not be overreduced. Overshortening the lingual wall will reduce retention.

A long needle diamond is used to complete access through the proximal areas to minimize the chances of nicking the adjacent teeth (Fig 10-22). Much of the axial reduction in the region of the proximal contact will have been accomplished already by the flat-end tapered diamond. The lingual aspect of the proximal axial walls, as well as the lingual surface, are reduced with the coarse-grit tapered torpedo diamond (Fig 10-23). The lingual and proximal axial surfaces are smoothed with the fine-grit tapered torpedo diamond, accentuating the chamfer on the lingual and proximal surfaces at the same time (Fig 10-24).

A fine-grit flat-end tapered diamond bur is used to smooth the labial surface (Fig 10-25). All angles and edges on the preparation are rounded with the sides of the diamond to facilitate seating of the restoration later. At the same time that the labial surface is being planed by the side of the diamond, the end is forming a radial shoulder finish line.

Shoulders have been advocated for gingivofacial finish lines of metal-ceramic preparations alone¹⁵⁻¹⁹ or with narrow




Fig 10-17 Depth-orientation grooves: coarse-grit flat-end tapered diamond.

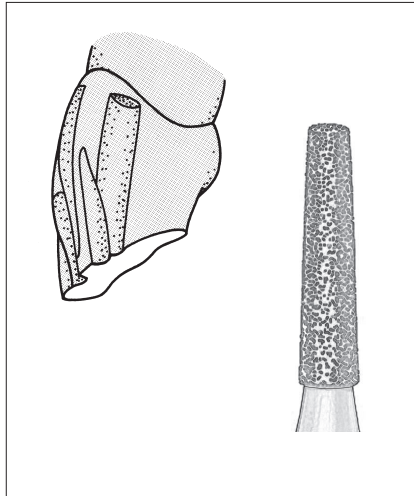


Fig 10-18 Incisal reduction: coarse-grit flat-end tapered diamond.




Fig 10-19 Labial reduction (incisal half): coarse-grit flat-end tapered diamond.

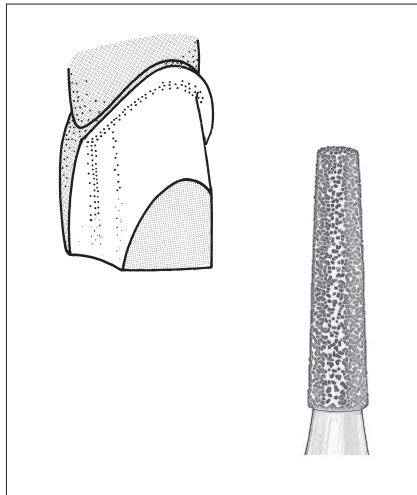


Fig 10-20 Labial reduction (gingival half): coarse-grit flat-end tapered diamond.

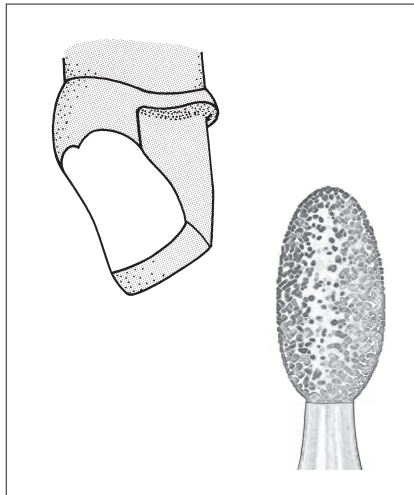


Fig 10-21 Lingual reduction: coarse-grit football-shaped diamond.




Fig 10-22 Initial proximal reduction: medium-grit long needle diamond.

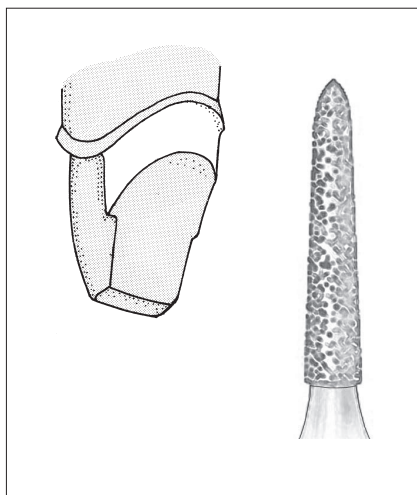


Fig 10-23 Lingual axial reduction: coarse-grit tapered torpedo diamond.

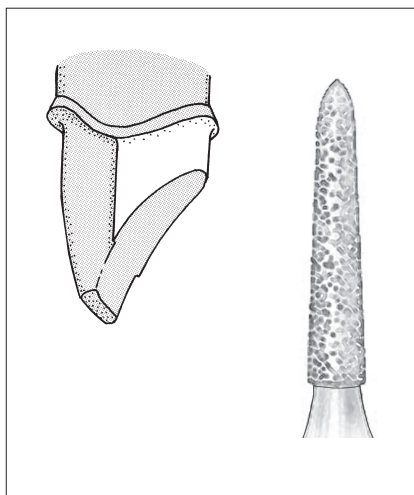


Fig 10-24 Axial finishing: fine-grit tapered torpedo diamond.




Fig 10-25 Axial and shoulder finishing: fine-grit flat-end tapered diamond.

10 Preparations for Full Coverage Crowns

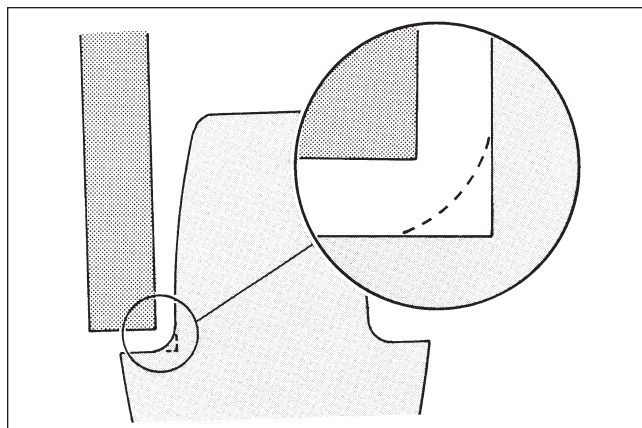


Fig 10-26 The sharp corners of a conventional chisel will gouge the gingivoaxial angle (inset) of a radial shoulder.

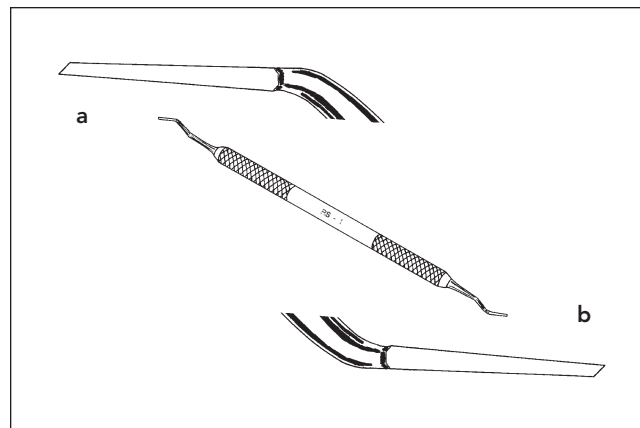


Fig 10-27 (a and b) The CP-11/12 is a modified 15-8-8 chisel with the same hoe (pull stroke) blade on both ends.

bevels.^{12,20-23} Some investigators have reported that metal-ceramic crowns with metal gingivofacial margins made over shoulder finish lines distort less during porcelain firing.^{24,25} A possible explanation is that the shoulder configuration provides space for an internal rib of metal to buttress the margin.^{12,26} Other investigators have reported not finding a difference in marginal fit. They hypothesize that marginal gaps following ceramic firing may be caused either by technical difficulties in forming a knife edge of metal and ceramic²⁷ or by differences in metal-ceramic combinations.²⁸

However, there is a compelling reason for not using a metal margin at all. The metal collar that accompanies a bevel on a shoulder²⁹ often requires the finish line to be placed deep in the gingival sulcus to hide the metal.³⁰ If some form of shoulder without a bevel is used, an all-ceramic margin can be fabricated. This eliminates a metal collar at the faciogingival margin of the finished metal-ceramic restoration, and there is no need to bury the margin beneath the gingiva. Quantitative evaluations of the marginal fit of all-ceramic shoulders on metal-ceramic crowns have found satisfactory adaptation of the ceramic to the preparation finish line. Belser et al³¹ reported in vivo marginal discrepancies of 46 μ m on cemented metal-ceramic crowns with all-ceramic facial margins. They found no significant differences among crowns with all-ceramic margins and those with metal collar margins over shoulder and beveled shoulder finish lines. In vitro studies by West and associates³² and Hunt et al³³ found minimal marginal discrepancies in all-ceramic shoulder margins on metal-ceramic crowns. Of course, a dentist can use all-ceramic margins on metal-ceramic crowns only if

the technician is capable of producing restorations with accurate ceramic margins.

Zena et al³⁴ demonstrated that all-ceramic margins made over hand-planed shoulders fit significantly better than margins made over finish lines cut solely with rotary instruments. However, if a conventional enamel chisel is used for planing a radial shoulder, the sharp angles at the ends of the cutting blade will destroy the rounded internal angle of the finish line (Fig 10-26).

A modified 15-8-8 binangle chisel, the CP-11/12, is recommended to avoid this problem (Fig 10-27). This instrument has a hoe (pull stroke) blade at both ends, unlike a conventional 15-8-8 binangle chisel, which has a hoe (pull stroke) blade at one end and a chisel (push stroke) blade at the other (Fig 10-28). One corner of a CP-11/12 blade is rounded with a mounted Arkansas stone (Fig 10-29a), and the opposite corner is rounded on the other end (Fig 10-29b).

One end, with the rounded corner against the gingivoaxial junction, is used to instrument the radial shoulder on half of the preparation (Fig 10-30). The other end, with its modified corner also against the rounded gingivoaxial junction, is used to smooth the finish line on the other half of the preparation. The 1.5-mm-wide blade will extend over the actual finish line, which is 1.2 to 1.5 mm wide. This will remove any lip of enamel that might extend incisally from the cavosurface angle.

The features of a preparation for an anterior metal-ceramic restoration and the function served by each are shown in Fig 10-31.

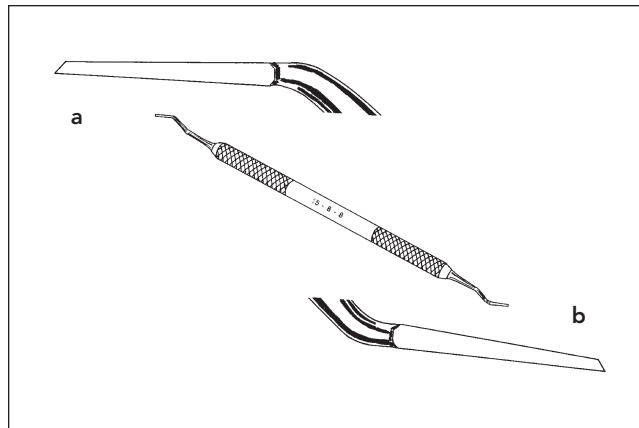


Fig 10-28 A conventional 15-8-8 binangle chisel has a hoe (pull stroke) blade on one end (a) and a chisel (push stroke) blade on the other (b).

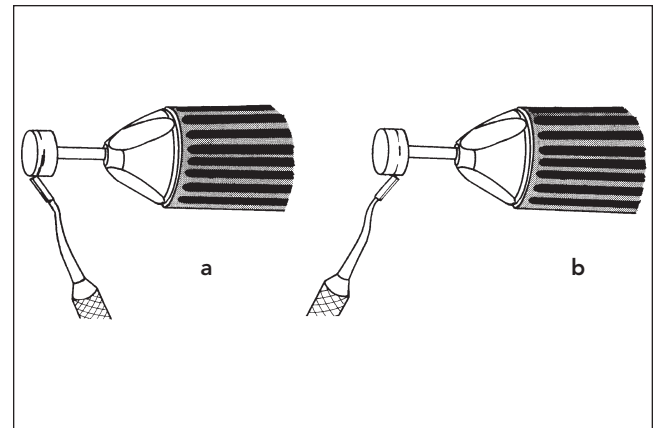


Fig 10-29 Round an angle at one end of the CP-11/12 (a) and the opposite angle on the other end (b).

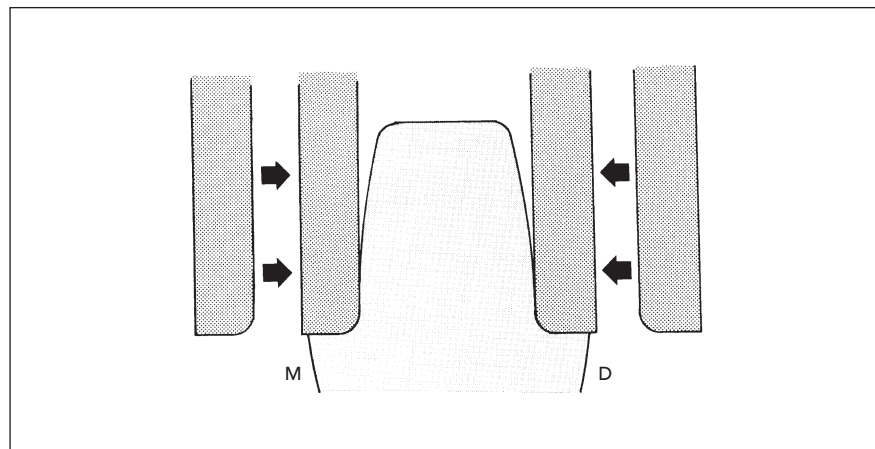


Fig 10-30 The rounded corner of one end of the CP-11/12 is placed against the gingivoaxial angle while planing the mesial half of the shoulder (M). The other end is used to instrument the distal half of the finish line (D).

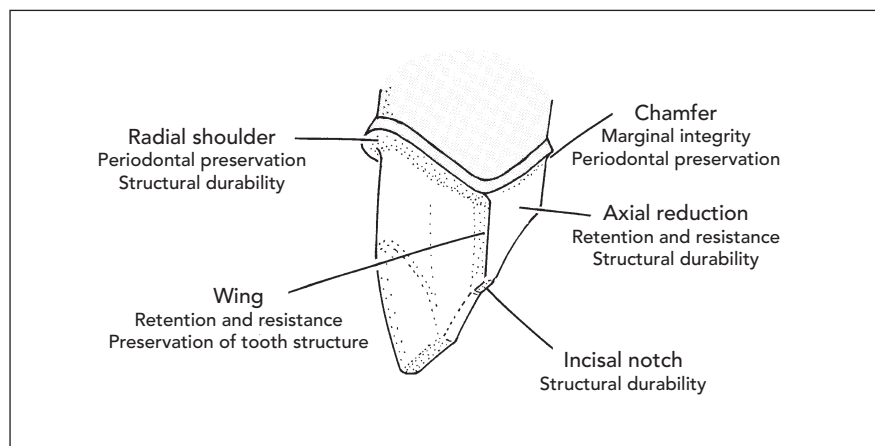


Fig 10-31 Features of an anterior metal-ceramic preparation and the function(s) served by each.

10 Preparations for Full Coverage Crowns

Posterior metal-ceramic crowns

The use of metal-ceramic crowns on posterior teeth allows the creation of an esthetic restoration on a posterior tooth needing a full crown. Maxillary premolars and first molars and mandibular first premolars are almost always visible in the full smile. Mandibular second premolars also can fall into this category. Maxillary second molars and mandibular molars may require metal-ceramic crowns if a patient will not accept all-metal crowns on those teeth, although they are rarely seen in most mouths.

Routinely placing metal-ceramic crowns on all premolars and molars is overtreatment because of the additional tooth structure that must be destroyed to accommodate the combined thickness of metal and ceramic. Often, there is added expense for the patient because of higher laboratory fees as well as an increased risk of failure from ceramic veneer fracture.

The routine use of all-ceramic occlusal surfaces has been criticized.³⁵ This restoration design offers maximum esthetic effect when required by location in a highly visible area or by patient preference. Patients who demand ceramic occlusal surfaces should know of the potential problems. The use of all-ceramic occlusal surfaces requires the removal of more tooth structure, and the completed restorations pose a threat to the structural integrity of opposing occlusal surfaces. Conventional glazed dental porcelain is approximately 40 times as abrasive as gold to tooth enamel.³⁶ Some newer, ultra-low-fusing ceramics have shown improved wear rates against enamel.³⁷ However, their abrasiveness is still significantly higher than that of polished metal.³⁷ Preparations for metal-ceramic crowns should be done with a plan for the extent of ceramic coverage in mind because the areas to be veneered with ceramic require deeper reduction than those portions of the tooth that will be overlaid with metal alone.

Armamentarium

- Laboratory knife with no. 25 blade
- Silicone putty and accelerator
- Handpiece
- Coarse-grit round-end tapered diamond (6856-016)
- Fine-grit round-end tapered diamond (8856-016)
- Coarse-grit flat-end tapered diamond (6847-016)
- Medium-grit short needle diamond (852-012)
- Coarse-grit tapered torpedo diamond (6877K-014)
- Fine-grit tapered torpedo diamond (8877K-014)
- Fine-grit flat-end tapered diamond (8847KR-016)
- Coarse-grit flame diamond (862-010)
- Fine-grit flame diamond (8862-010)
- CP-11/12 binangle chisel

Technique

Before the preparation is begun, silicone putty is adapted to the facial, lingual, and occlusal surfaces of the tooth to be prepared as well as to one tooth on each side. After polym-

erization, a midsagittal index can be formed by cutting the silicone in half along the faciolingual midline of the tooth to be prepared. The putty is placed back on the tooth to ensure good adaptation. If the clinical crown of the tooth being restored is severely damaged, the index should be made from a diagnostic wax-up.

A facial index is made by cutting through the silicone along the facial cusps of the teeth. The facial piece is divided along a line midway between the cervical lines of the teeth and the facial cusp tips. The occlusal portion is discarded, and the gingival portion is used as an index.

The occlusal reduction is begun by making depth-orientation grooves with a round-end tapered diamond. In the areas where there will be ceramic coverage, reduction should ultimately be 2.0 mm.^{12,20,38,39} The occlusal reduction is completed by removing the strips of intact enamel between the depth-orientation grooves with the same diamond. The reduction should take the form of definite planes reproducing the general occlusal morphology⁴⁰ or the basic geometric shape of the occlusal surface (Fig 10-32).

The functional cusp bevel, which allows a uniform bulk of restorative material on the palatal inclines of maxillary palatal cusps and the facial inclines of mandibular facial cusps, is also begun with depth-orientation grooves (Fig 10-33). The depth required is 1.5 mm if the coverage will be metal only and 2.0 mm if the metal will be veneered with ceramic. The functional cusp bevel is completed by removing the tooth structure between the depth-orientation grooves. The angulation of the bevel approximates the inclination of the opposing cusps.

A no. 171L bur or fine-grit round-end tapered diamond is used to smooth the planes of the occlusal reduction to remove any roughness or pits that might interfere with the complete seating of the finished restoration. Any sharp corners or edges on the preparation that might cause problems in impression pouring, investing, casting, and ultimately in the seating of the completed crown should be rounded over.

The coarse-grit flat-end tapered diamond is aligned with the occlusal segment of the facial surface, and three vertical grooves are cut in the occlusal portion of the facial surface. These are nearly the full diameter of the instrument, fading out gingivally (Fig 10-34). The same diamond is aligned with the gingival component of the facial surface, and the side of the instrument is used to cut into the tooth surface. The full diameter of the instrument must cut into the tooth. The instrument tip should be slightly supragingival at this point, even if the intended location of the finish line is flush with or slightly below the gingival crest. At least two more orientation grooves should be placed near the line angles of the tooth.

All tooth structure remaining between the depth-orientation grooves in the occlusal segment of the facial surface is removed with the flat-end tapered diamond (Fig 10-35). The gingival portion of the facial surface is then reduced, extending it well into the proximal surface (Fig 10-36). If facial reduction of less than 1.2 mm is done for a base metal-ceramic crown or 1.4 mm for a noble metal-ceramic crown, the restoration will be either opaque or overcontoured.

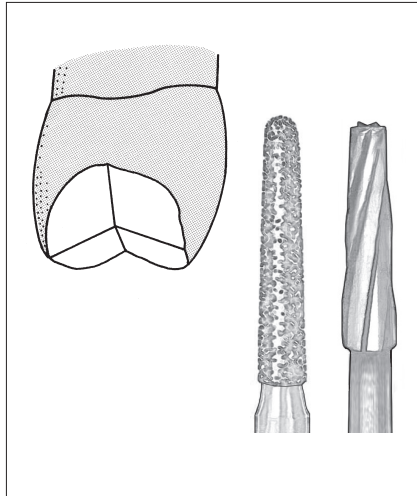


Fig 10-32 Planar occlusal reduction: coarse-grit round-end tapered diamond and no. 171L bur.

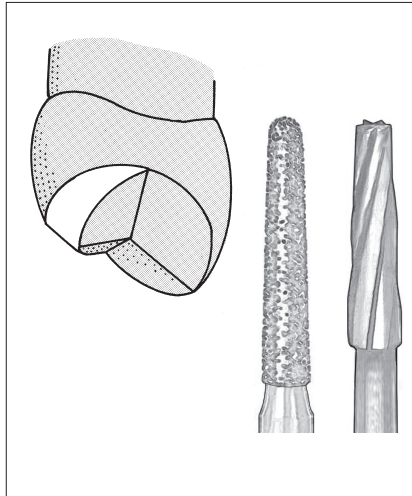


Fig 10-33 Functional cusp bevel: coarse-grit round-end tapered diamond and no. 171 bur.



Fig 10-34 Depth-orientation grooves: coarse-grit flat-end tapered diamond.

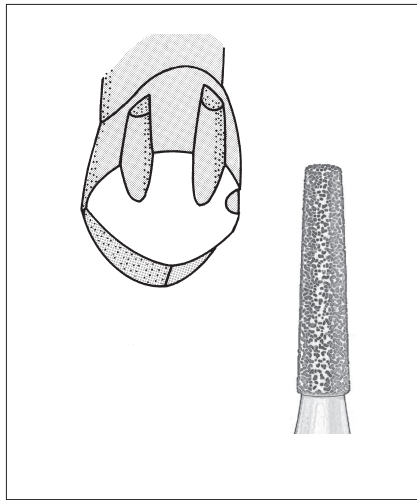


Fig 10-35 Facial reduction (occlusal half): coarse-grit flat-end tapered diamond.

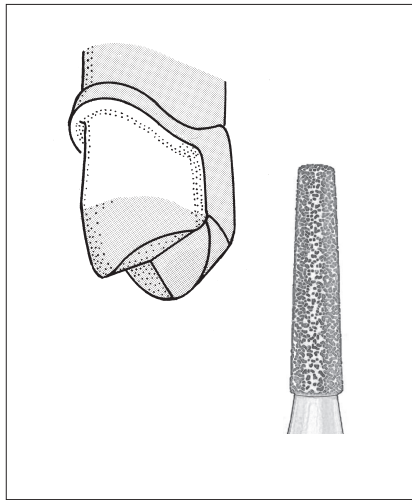


Fig 10-36 Facial reduction, (gingival half): coarse-grit flat-end tapered diamond.

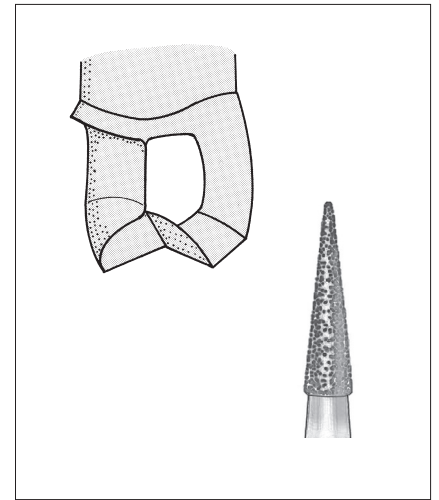


Fig 10-37 Proximal axial reduction: medium-grit short needle diamond.

The proximal axial reduction is begun with a short needle diamond (Fig 10-37). Its narrow diameter allows interproximal reduction without nicking adjacent teeth. The instrument can be used with an up-and-down motion on the facial aspect of the interproximal tooth structure, or it can be used on the occlusal portion with a faciolingual movement. Initially, the objective is to achieve separation between the teeth without overtapering the prepared walls or mutilating the adjacent tooth. The proximal axial surfaces are then planed with the needle diamond.

The lingual axial wall is reduced with a coarse-grit tapered torpedo diamond (Fig 10-38). Enough tooth structure is removed on both the lingual and proximal axial walls to create a distinct chamfer finish line wherever there will not be a ceramic veneer. The chamfer finish line and the axial surfaces adjacent to it are smoothed with a fine-grit tapered torpedo diamond. All axial surfaces that will be veneered only with metal are finished in this way.

The facial surface and those parts of the proximal surfaces to be veneered with ceramic are smoothed with a fine-grit

10 Preparations for Full Coverage Crowns

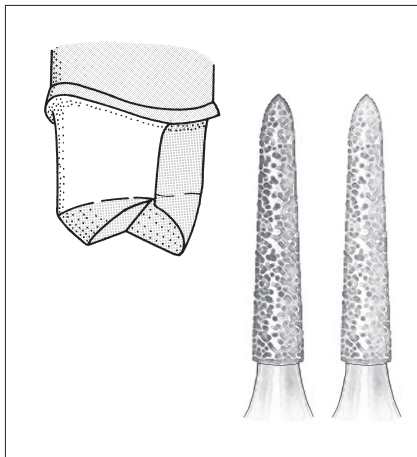


Fig 10-38 Lingual axial reduction and finishing: coarse- and fine-grit tapered torpedo diamonds.

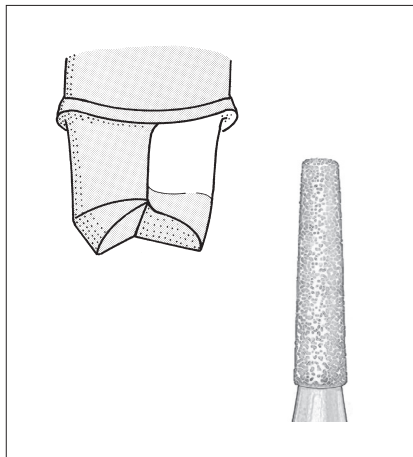


Fig 10-39 Facial axial and radial shoulder finishing: fine-grit flat-end tapered diamond.




Fig 10-40 Gingival bevel: medium- and fine-grit flame diamonds.

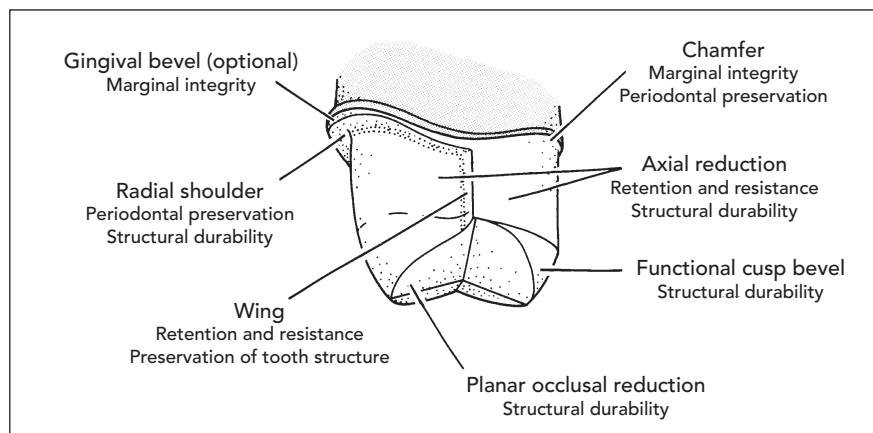


Fig 10-41 Features of a preparation for a metal-ceramic crown on a posterior tooth and the function(s) served by each.

flat-end tapered diamond (Fig 10-39). At the most lingual extension of the facial reduction, lingual to the proximal contact, the transition from the deeper facial reduction to the relatively shallower lingual axial reduction results in a vertical wall or “wing” of tooth structure. The wings must not be undercut with the facial or lingual axial walls of the preparation.

If the shoulder and wings are not lingual to the proximal contact, the proximal area of the ceramic veneer will lack translucence. If there was an amalgam restoration in the tooth prior to this preparation, the wing is made to coincide with the lingual wall of the amalgam’s proximal box. If the entire proximal surface is to be veneered with ceramic, the shoulder is extended across the proximal surface with no wing.

The radial shoulder, started with the flat-end tapered diamond at the time the facial reduction was accomplished, is finished now with the radial shoulder fine-grit flat-end tapered diamond. On highly visible posterior teeth, such as the maxillary premolars, an all-ceramic margin is frequently used to achieve a good esthetic result without intruding into the gingival sulcus. The 1.0-mm-wide shoulder is smoothed

by planing it with the CP-11/12 modified binangle chisel, which will preserve the rounded internal angle created by the radial shoulder diamond. Any “lip” or reverse bevel of enamel at the cavosurface angle should be removed. Small, sharp edges in this area may not be reproduced when the impression is poured, and they are susceptible to fracture on the cast or on the tooth in the mouth.

There are occasions when a shoulder with a bevel is the finish line of choice: when esthetic needs are not as critical or the dental technician is unable to consistently produce a precise all-ceramic margin. A narrow bevel, no wider than 0.3 mm, can be placed on the shoulder with the tip of a medium-grit flame diamond (Fig 10-40). The bevel should be kept narrow because the metal collar on the resulting crown must be as wide as the bevel. It is easier to wax and cast to the bevel if the diamond is leaned toward the center of the tooth as much as possible. The bevel is finished with a fine-grit flame diamond to create a finish line that is as clear as possible. The features of a preparation for a posterior metal-ceramic restoration and the function served by each are shown in Fig 10-41.

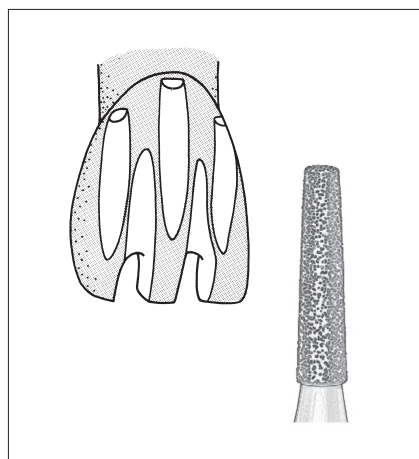


Fig 10-42 Depth-orientation grooves: coarse-grit flat-end tapered diamond.

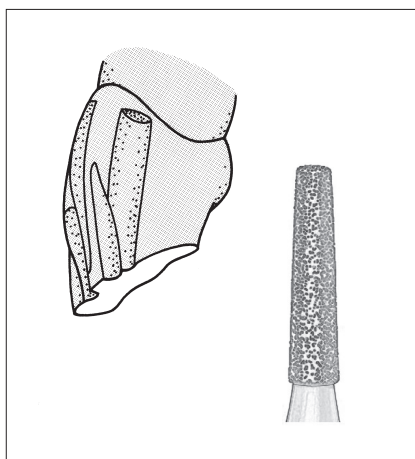


Fig 10-43 Incisal reduction: coarse-grit flat-end tapered diamond.

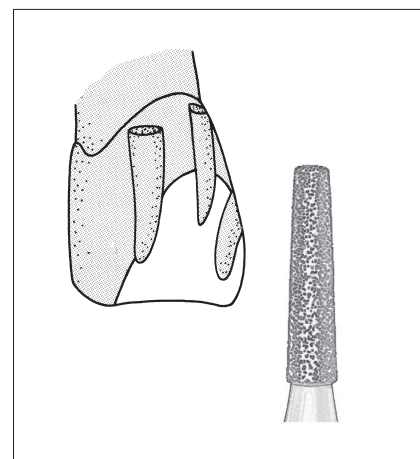

Fig 10-44 Labial reduction (incisal half): coarse-grit flat-end tapered diamond.

All-Ceramic Crowns

The all-ceramic crown differs from other cemented veneer restorations because it is not cast in gold or some other metal. It is capable of producing the best esthetic effect of all dental restorations. However, because it is made entirely of ceramic, a brittle substance, it is more susceptible to fracture. The development of dental porcelain reinforced with alumina in the 1960s created renewed interest in the restoration.⁴¹ In recent years, this interest has mushroomed with the use of new reinforcement materials such as lithium disilicate and zirconia.^{42,43}

Preparations for this type of crown should be left as long as possible to give maximum support to the porcelain. An overshortened preparation will create stress concentrations in the labiokingival area of the crown,³ which can produce a characteristic half-moon fracture in the labiokingival area of the restoration.⁴⁴⁻⁴⁶ A shoulder of uniform width (approximately 1 mm) is used as a gingival finish line to provide a flat seat to resist forces directed from the incisal.^{44,47} The incisal edge is flat and placed at a slight inclination toward the linguokingival to meet forces on the incisal edge and prevent shearing.^{48,49} Finally, all sharp angles of the preparation should be slightly rounded to reduce the danger of fracture caused by points of stress concentration.^{44,48,49}

The position of the tooth in the arch, factors relating to occlusion, and morphologic features of the tooth all should be weighed when an all-ceramic crown is considered for a restoration. All-ceramic crowns are best suited for use on incisors. If they are used on other teeth, patients should know that there is an increased risk of fracture.

Use of the all-ceramic crown should be avoided on teeth with an edge-to-edge occlusion that will produce stress in the incisal area of the restoration. It likewise should not be used when the opposing teeth occlude on the cervical fifth of the lingual surface. Tension will be produced, and a

half-moon fracture is likely to occur. Teeth with short cervical crowns also are high risks for all-ceramic crowns because they do not have enough preparation length to support the lingual and incisal surfaces of the restoration.

Armamentarium

- Handpiece
- Coarse-grit flat-end tapered diamond (6847-016)
- Coarse-grit football-shaped diamond (6379-023)
- Fine-grit flat-end tapered diamond (8847KR-016)
- CP-11/12 binangle chisel

Technique

Depth-orientation grooves are placed on the labial and incisal surfaces with the coarse-grit flat-end tapered diamond before any reduction is done (Fig 10-42). Without grooves it is impossible to accurately gauge the depth of reduction done on the labial surface. The grooves are 1.2 to 1.4 mm deep on the labial and 2.0 mm deep on the incisal. Three labial grooves are cut with the diamond held parallel to the gingival one-third of the labial surface. A second set of two grooves is made parallel to the incisal two-thirds of the uncut labial surface. The labial surface of an all-ceramic preparation is done in two planes to achieve adequate clearance for good esthetics without encroaching on the pulp.⁴⁸

Incisal reduction is done with the coarse-grit flat-end tapered diamond so that it will be possible for instruments to reach the finish line area of the preparation in subsequent steps. Approximately 1.5 to 2.0 mm of tooth structure is removed (Fig 10-43).

The tooth structure still remaining between the depth-orientation grooves on the incisal portion of the labial surface is planed away (Fig 10-44). The gingival portion of the

10 Preparations for Full Coverage Crowns



Fig 10-45 Labial reduction (gingival half): coarse-grit flat-end tapered diamond.

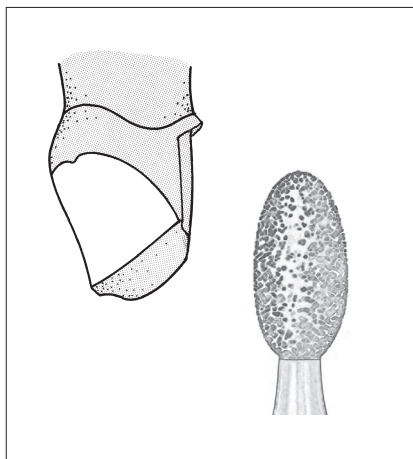


Fig 10-46 Lingual reduction: coarse-grit football-shaped diamond.

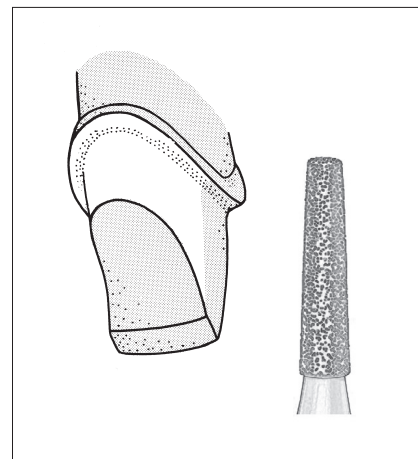


Fig 10-47 Lingual axial reduction: coarse-grit flat-end tapered diamond.

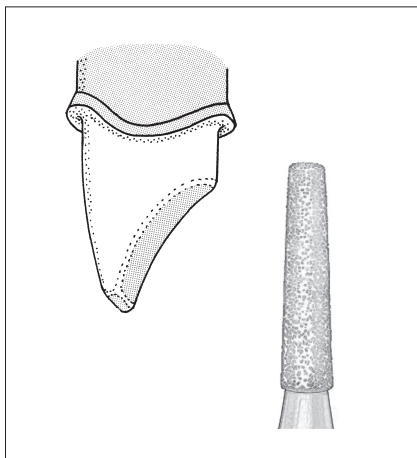

Fig 10-48 Axial wall and radial shoulder finishing: fine-grit flat-end tapered diamond.

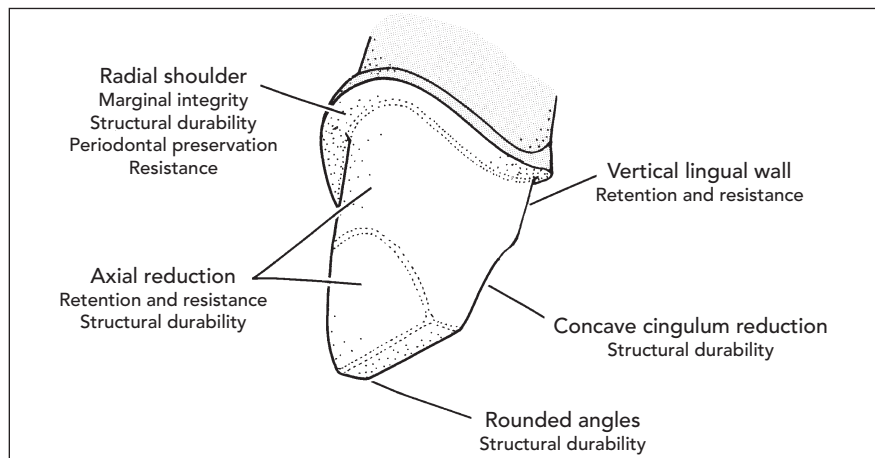


Fig 10-49 Features of an all-ceramic crown preparation and the function(s) served by each.

labial surface is reduced with the coarse-grit flat-end tapered diamond to a depth of 1.2 to 1.4 mm. This reduction extends around the labioproximal line angles and fades out on the lingual aspects of the proximal surfaces (Fig 10-45). The end of the coarse-grit flat-end tapered diamond bur will form the shoulder finish line, while the axial reduction is done with the sides of the diamond. The shoulder should be a minimum of 1.0 mm wide. Lingual reduction incisal to the cingulum is done with the coarse-grit football-shaped diamond, with care taken not to overreduce the junction between the cingulum and the lingual wall (apical to the cingulum) (Fig 10-46). Overshortening the lingual wall will reduce the retention of the preparation.

Reduction of the lingual axial surface is done with the coarse-grit flat-end tapered diamond (Fig 10-47). The wall

should form a minimum taper with the gingival portion of the labial wall. The radial shoulder is at least 1.0 mm wide and should be a smooth continuation of the labial and proximal radial shoulders. All-ceramic crowns made over shoulder finish lines exhibit greater strength than those made over chamfers.^{11,50} All of the axial walls should be smoothed with a fine-grit flat-end tapered diamond, accentuating the shoulder at the same time (Fig 10-48). All sharp angles should be rounded over at this time. The CP-11/12 modified binangle chisel is used to smooth the shoulder, removing any loose enamel rods at the cavosurface angle. Care must be taken not to create undercuts in the axial walls where they join the shoulder. The features of a preparation for an all-ceramic crown and the purpose served by each are shown in Fig 10-49.

References

- Thom LW. Principles of cavity preparation in crown and bridge prostheses: I. The full crown. *J Am Dent Assoc* 1950;41:284–289.
- Lorey RE, Myers GE. The retentive qualities of bridge retainers. *J Am Dent Assoc* 1968;76:568–572.
- Reisbick MH, Shillingburg HT Jr. Effect of preparation geometry on retention and resistance of cast gold restorations. *J Calif Dent Assoc* 1975;3:51–59.
- Potts RG, Shillingburg HT Jr, Duncanson MG Jr. Retention and resistance of preparations for cast restorations. *J Prosthet Dent* 1980;43:303–308.
- Christensen GJ. What has happened to conservative tooth restorations? *J Am Dent Assoc* 2005;136:1435–1437.
- Howard WW. Full coverage restorations: Panacea or epidemic? *Gen Dent* 1979;27:6–7.
- Tucker RV. The full gold crown: An overview. *Oper Dent* 2000;25:130–133.
- Wheeler RC. The implications of full coverage restorative procedures. *J Prosthet Dent* 1955;5:848–851.
- Smith GP. What is the place of the full crown in restorative dentistry? *Oral Surg Oral Med Oral Pathol* 1947;33:471–478.
- Smith GP. The marginal fit of the full cast shoulderless crown. *J Prosthet Dent* 1957;7:231–243.
- Friedlander LD, Munoz CA, Goodacre CJ, Doyle MG, Moore BK. The effect of tooth preparation design on the breaking strength of Dicor crowns: Part 1. *Int J Prosthodont* 1990;3:159–168.
- Preston JD. Rational approach to tooth preparation for ceramo-metal restorations. *Dent Clin North Am* 1977;21:683–698.
- Miller L. A clinician's interpretation of tooth preparation and design of metal substructures for metal-ceramic porcelain restorations. In: McLean JW (ed). *Dental Ceramics: Proceedings of the First International Symposium on Ceramics*. Chicago: Quintessence, 1983:173–206.
- Lockard MW. A retrospective study of pulpal responses in vital adult teeth prepared for complete coverage restorations at ultra high speed using only air coolant. *J Prosthet Dent* 2002;88:473–478.
- Johnston JF, Mumford G, Dykema RW. The porcelain veneered gold crown. *Dent Clin North Am* 1963;7:853–864.
- Shelby DS. Practical considerations and design of porcelain fused to metal. *J Prosthet Dent* 1962;12:542–548.
- Romanelli JH. Periodontal considerations in tooth preparation for crowns and bridges. *Dent Clin North Am* 1980;24:271–284.
- Grundy JR. *Color Atlas of Conservative Dentistry*. Chicago: Year Book Medical, 1980:68–75.
- Behrend DA. Ceramometal restorations with supragingival margins. *J Prosthet Dent* 1982;47:625–632.
- Brecker SC. Porcelain baked to gold—A new medium in prosthodontics. *J Prosthet Dent* 1956;6:801–810.
- Silver M, Howard MC, Klein G. Porcelain bonded to a cast metal understructure. *J Prosthet Dent* 1961;11:132–145.
- Hobo S, Shillingburg HT Jr. Porcelain fused to metal: Tooth preparation and coping design. *J Prosthet Dent* 1973;30:28–36.
- Goldstein RE. Esthetic principles for ceramo-metal restorations. *Dent Clin North Am* 1977;21:803–822.
- Shillingburg HT, Hobo S, Fisher DW. Preparation design and margin distortion in porcelain-fused-to-metal restorations. *J Prosthet Dent* 1973;29:276–284.
- Faucher RR, Nicholls JL. Distortion related to margin design in porcelain-fused-to-metal restorations. *J Prosthet Dent* 1980;43:149–155.
- Engelman MA. Simplified, esthetic ceramo-metal restorations. *N Y J Dent* 1979;49:252–261.
- Hamaguchi H, Cacciato A, Tueller VM. Marginal distortion of the porcelain-bonded-to-metal complete crown: An SEM study. *J Prosthet Dent* 1982;47:146–153.
- DeHoff PH, Anusavice KJ. Effect of metal design on marginal distortion of metal-ceramic crowns. *J Dent Res* 1984;63:1327–1331.
- Strating H, Pameijer CH, Gildenhuys RR. Evaluation of the marginal integrity of ceramo-metal restorations. Part I. *J Prosthet Dent* 1981;46:59–65.
- Wilson RD, Maynard G. Intracrevicular restorative dentistry. *Int J Periodontics Restorative Dent* 1981;1:34–49.
- Belser UC, MacEntee MI, Richter WA. Fit of three porcelain-fused-to-metal marginal designs in vivo: A scanning electron microscope study. *J Prosthet Dent* 1985;53:24–29.
- West AJ, Goodacre CJ, Moore BK, Dykema RW. A comparison of four techniques for fabricating collarless metal-ceramic crowns. *J Prosthet Dent* 1985;54:636–642.
- Hunt JL, Cruickshanks-Boyd DW, Davies EH. The marginal characteristics of collarless bonded porcelain crowns produced using a separating medium technique. *Quintessence Dent Technol* 1978;2(9):21–26.
- Zena RB, Khan Z, von Fraunhofer JA. Shoulder preparations for collarless metal ceramic crowns: Hand-planing as opposed to rotary instrumentation. *J Prosthet Dent* 1989;62:273–277.
- Nabers CL, Christensen GJ, Markley MR, et al. Porcelain occlusals—To cover or not to cover? *Tex Dent J* 1983;100:6–10.
- Jacobi R, Shillingburg HT Jr, Duncanson MG Jr. A comparison of the abrasiveness of six ceramic surfaces and gold. *J Prosthet Dent* 1991;66:303–309.
- Anusavice KJ, Phillips RW. *Phillips' Science of Dental Materials*, ed 11. St Louis: Saunders, 2003:707.
- Goldstein RE. *Esthetics in Dentistry*. Philadelphia: Lippincott, 1976:65–85,332–341.
- Anusavice KJ, Phillips RW. *Phillips' Science of Dental Materials*, ed 11. St Louis: Saunders, 2003:710.
- Tjan AH, Miller GD. Common errors in tooth preparation. *Gen Dent* 1980;28:20–25.
- McLean JW, Hughes TH. The reinforcement of dental porcelain with ceramic oxides. *Br Dent J* 1965;119:251–267.
- Anusavice KJ, Phillips RW. *Phillips' Science of Dental Materials*, ed 11. St Louis: Saunders, 2003:655–719.
- Christensen GJ. The all-ceramic restoration dilemma: Where are we? *J Am Dent Assoc* 2011;142:668–671.
- Pettrow JN. Practical factors in building and firming characteristics of dental porcelain. *J Prosthet Dent* 1961;11:334–344.
- Nuttal EB. Factors influencing success of porcelain jacket restorations. *J Prosthet Dent* 1961;11:743–748.
- Bartels JC. Preparation of the anterior teeth for porcelain jacket crowns. *J South Calif Dent Assoc* 1962;30:199–205.
- Bastian CC. The porcelain jacket crown. *Dent Clin North Am* 1959;3:133–146.
- Bartels JC. Full porcelain veneer crowns. *J Prosthet Dent* 1957;7:533–540.
- Fairley JM, Deubert LW. Preparation of a maxillary central incisor for a porcelain jacket restoration. *Br Dent J* 1958;104:208–212.
- Sjögren G, Bergman M. Relationship between compressive strength and cervical shaping of the all-ceramic Cerestore crown. *Swed Dent J* 1987;11:147–152.

Preparations for Partial Coverage Crowns

11

The partial coverage crown is a conservative restoration that requires less destruction of tooth structure than does a full coverage crown. Its use is based on the premise that an intact surface of tooth structure should not be covered by a crown if its inclusion is not essential to the retention, strength, or esthetic result of the definitive restoration. No technician can exactly duplicate the texture and appearance of untouched enamel. Gingival health near a partial coverage crown is protected by the supragingival margin,¹⁻⁴ and a tooth with a full coverage crown is about 2.5 times as likely to have a pulpal problem as one with a partial coverage crown.⁵

A partial coverage restoration should be considered first when a cast restoration is needed. A full coverage crown should be chosen only when the coverage or retention afforded by a partial coverage crown is found wanting. Reluctance to use a three-quarter crown because it has more margin than a full crown is unfounded; the additional margin is vertical, which fits better than a horizontal margin.⁶

There are many advantages to the use of partial coverage restorations:

- Tooth structure is spared.
- Much of the margin is accessible to the dentist for finishing and to the patient for cleaning.
- Less restoration margin is in proximity to the gingival crevice, reducing the possibility of periodontal irritation.
- An open-faced partial coverage crown is more easily seated completely during cementation, whereas a full coverage crown tends to act like a hydraulic cylinder containing a highly viscous fluid.⁷
- With some of the margin visible, complete seating of a partial coverage crown is more easily verified.
- If an electric pulp test ever needs to be conducted on the tooth, a portion of enamel is unveneered and accessible.⁸

A partial coverage crown is not as retentive as a full coverage crown,⁹⁻¹¹ but it has adequate retention for single restorations and retainers for short-span fixed partial dentures. A preparation feature must be substituted to compensate for the retention and resistance lost when an axial surface is not covered. The most commonly used feature is a groove.

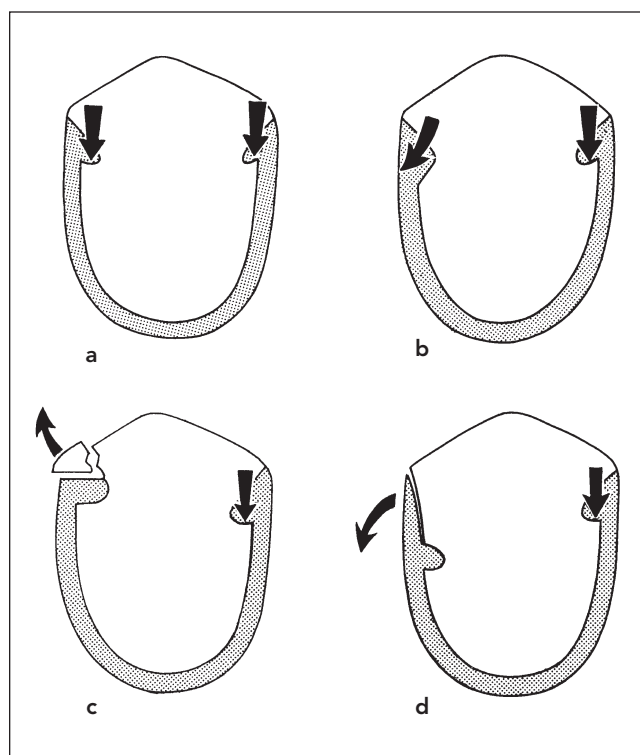


Fig 11-1 (a) Definite lingual walls resist displacement. (b) An oblique lingual wall offers poor resistance. (c) An undermined facial enamel plate may fracture. (d) A groove that is too far lingual does not provide bulk of metal to support the margin.

To achieve maximum effectiveness, grooves must have definite lingual walls¹² (Fig 11-1). Resistance to torquing is produced by achieving a lingual hook⁸ or a lock effect¹³ by directing the bur (and groove) slightly to the opposite corner of the tooth. A V-shaped groove, without a definite lingual wall, provides only 68% of the retention and 57% of the resistance of a concave groove with a lingual wall.¹⁴

11 Preparations for Partial Coverage Crowns

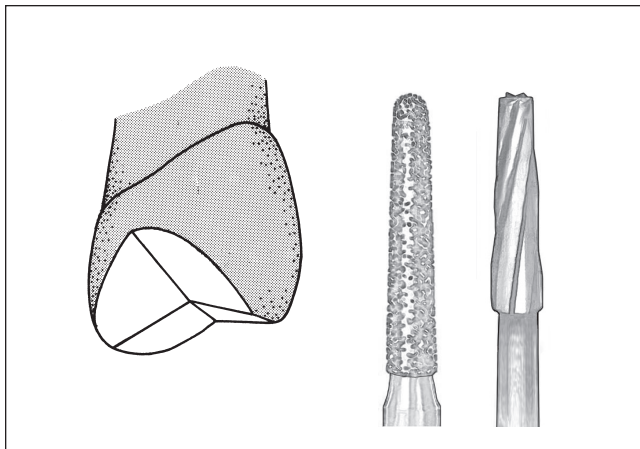


Fig 11-2 Occlusal reduction: coarse-grit round-end tapered diamond and no. 171L bur.

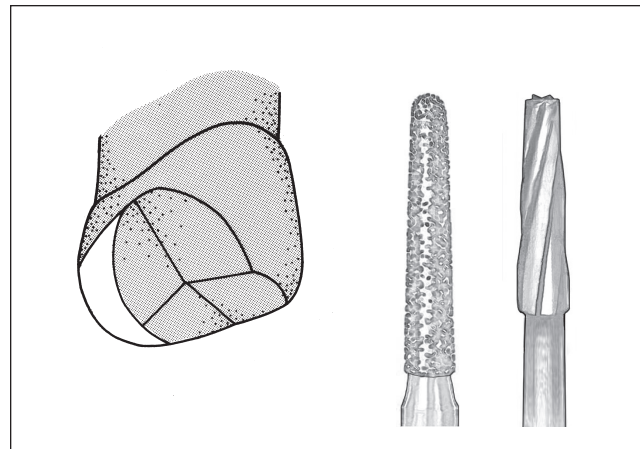


Fig 11-3 Functional cusp bevel: coarse-grit round-end tapered diamond and no. 171L bur.

Maxillary Posterior Three-Quarter Crowns

The standard three-quarter crown is a partial coverage crown in which the facial surface is left uncovered. It is the most commonly used partial coverage crown. The occlusal finish line on a maxillary tooth terminates near the facio-occlusal angle. If designed skillfully, the three-quarter crown can be very esthetic.¹⁵ It can be used successfully on maxillary posterior teeth. It satisfies the requirement of so-called conversational esthetics, in which esthetic demands are moderate and reasonable. However, it will not satisfy the patient who demands absolute esthetics because metal will not be invisible, even though it will not be seen in normal conversation.

Armamentarium

- Handpiece
- Coarse-grit round-end tapered diamond (6856-016)
- Medium-grit short needle diamond (852-012)
- Coarse-grit tapered torpedo diamond (6877K-014)
- Fine-grit tapered torpedo diamond (8877K-014)
- No. 169L bur
- No. 170L bur
- No. 171L bur
- Coarse-grit flame diamond (862-010)
- Fine-grit flame diamond (8862-010)
- Flame bur (H48L-010)
- 15-8-8 binangle chisel
- 15-8-14 enamel hatchet

Technique

Occlusal reduction is the first step in preparing a tooth for a three-quarter crown. Depth-orientation grooves are cut on the anatomical ridges and grooves of the occlusal surface with a round-end tapered diamond. Clearance should be 1.5 mm on the occlusal surface. The depth-orientation grooves should be made that deep on the respective cusps. The grooves extend through the occlusofacial line angle, but they will be only 0.5 mm deep there.

Occlusal reduction is completed by removing the tooth structure between the depth-orientation grooves (Fig 11-2), reproducing the geometric inclined-plane pattern of the cusps. The depth decreases at the occlusofacial line angle to minimize the display of metal.^{15,16}

Next, the functional cusp bevel is produced. Holding the round-end tapered diamond at a 45-degree angle to the long axis of the preparation, three to five depth-orientation grooves are placed on the lingual or outer incline of the lingual cusp. The grooves are 1.5 mm deep at the cusp tip and fade out at their apical end.

The functional cusp bevel is completed by removing the tooth structure between the grooves with the same diamond (Fig 11-3). The bevel extends from the central groove on the mesial to the central groove on the distal. It makes space for metal on the lingual-facing incline of the lingual cusp to match the space on the facial-facing incline created by the occlusal reduction. The occlusal reduction and functional cusp bevel are smoothed with a no. 171L bur or fine-grit round-end tapered diamond.

Axial reduction is begun by reducing the lingual surface with a coarse-grit tapered torpedo diamond, taking care not to overincline the lingual wall. The cut is extended in-

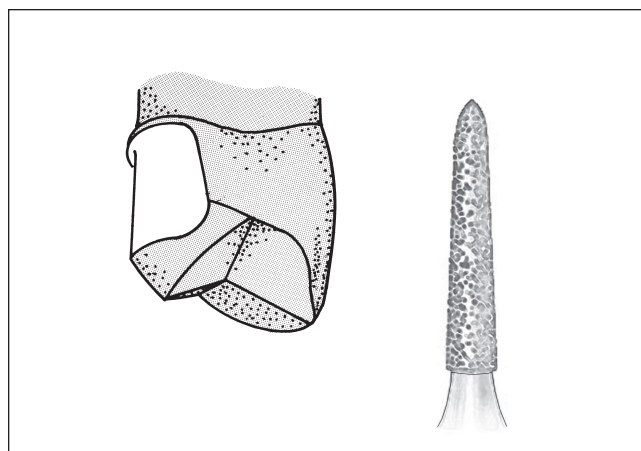


Fig 11-4 Lingual axial reduction: coarse-grit tapered torpedo diamond.

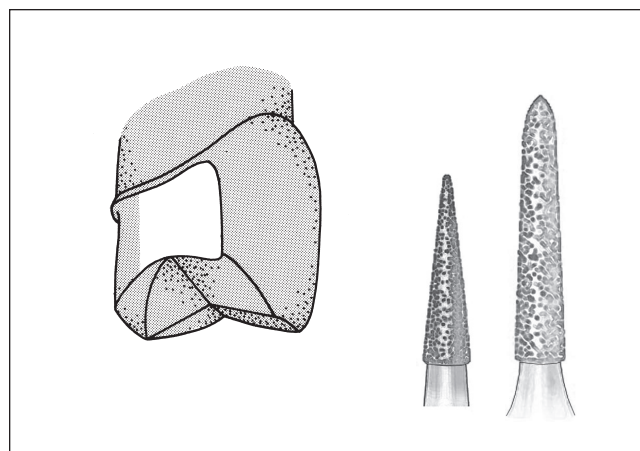


Fig 11-5 Proximal axial reduction: medium-grit short needle and coarse-grit tapered torpedo diamonds.

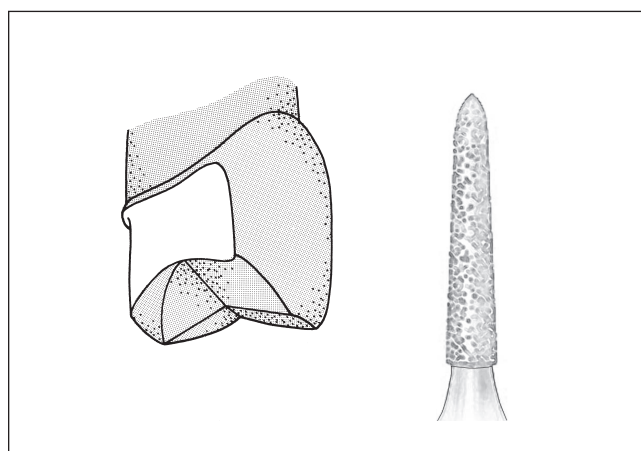


Fig 11-6 Axial finishing: fine-grit tapered torpedo diamond.

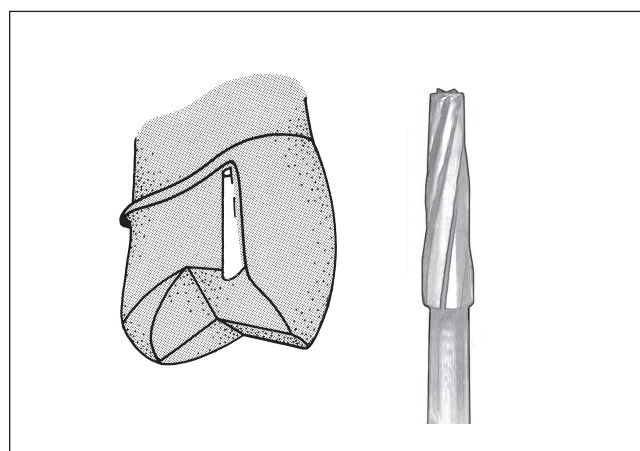


Fig 11-7 Proximal grooves: no. 171L bur.

terproximally on each side as far as possible without nicking the adjacent teeth (Fig 11-4). As the axial reduction is done, a chamfer finish line is formed. A smooth, continuous transition should be made from the lingual to the proximal surface with no sharp angles in the axial reduction or in the chamfer.

Proximal access is gained by using a short needle diamond in an up-and-down sawing motion, approaching from the lingual. This is continued facially until contact with the adjacent tooth is broken and maneuvering space is produced for larger instruments. Final extension to the facial is achieved with the short needle diamond or, in esthetically critical areas, with a 15-8-8 binangle chisel on a maxillary tooth or a 15-8-14 enamel hatchet on a mandibular tooth. The gingivofacial angle should not be underextended; it is the area where a three-quarter crown is most likely to fail.¹⁷

A coarse-grit flame diamond, with its long, thin tip, can be used as an intermediate instrument where there is minimal proximal clearance. It is followed by the coarse-grit tapered torpedo diamond to complete the axial reduction and form a chamfer (Fig 11-5). The axial wall and chamfer are finished with the fine-grit tapered torpedo diamond of the same size and configuration (Fig 11-6).

Proximal grooves are approximately the size of a no. 171L bur (Fig 11-7), but an inexperienced student may find it easier to begin the groove with a no. 169L bur, followed by a no. 170L bur, leaving room for minor adjustment. A groove must be cut into the tooth to the full diameter of the bur to create a definite lingual wall.

The outline form of the finished groove is drawn on the occlusal surface with a sharp pencil (Fig 11-8). The pencil

11 Preparations for Partial Coverage Crowns

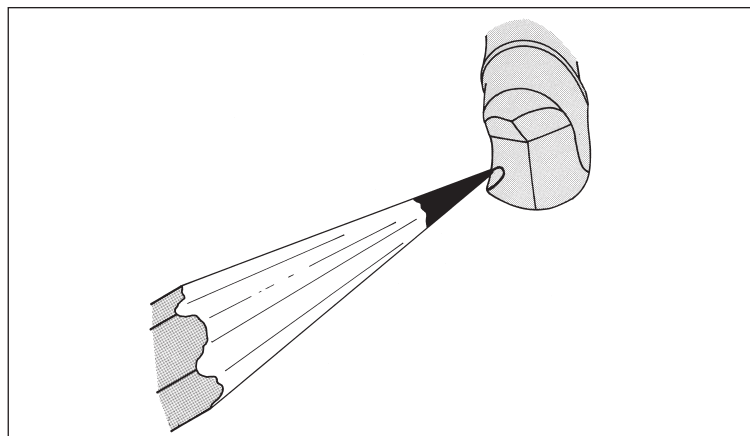


Fig 11-8 The outline of the groove is drawn on the occlusal surface of the tooth.

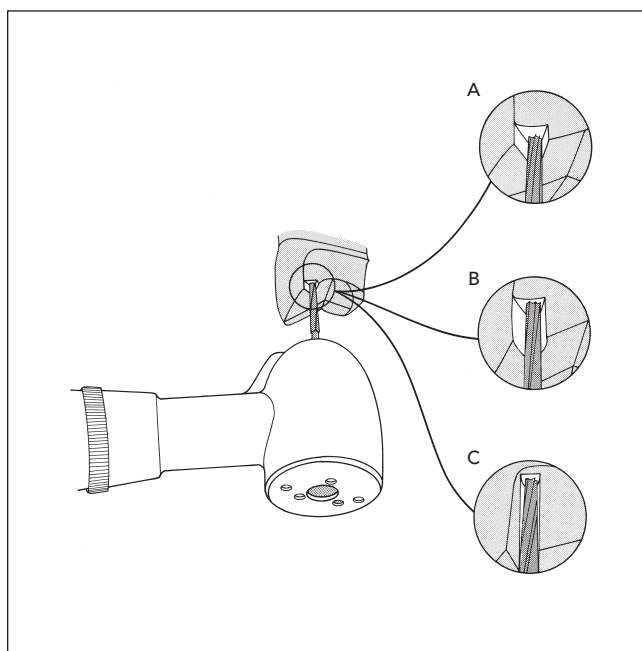


Fig 11-9 The groove is prepared in stages: shallow occlusal template (A), extension to half length (B), and completion to full length (C).

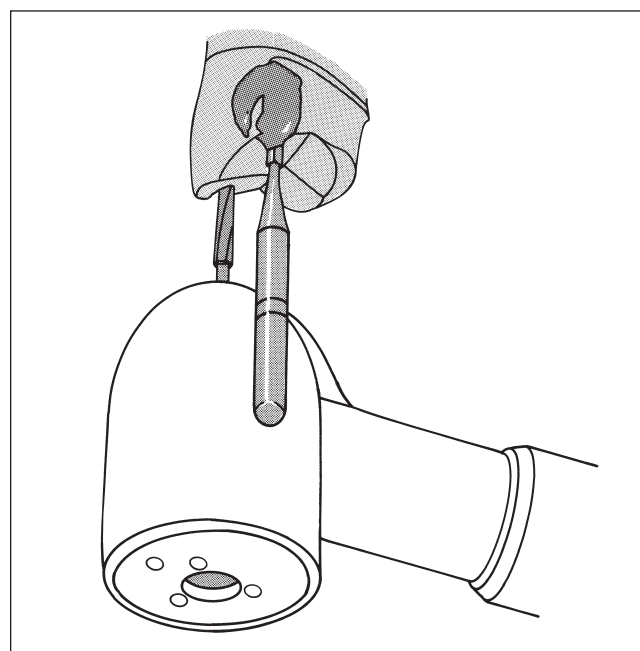


Fig 11-10 To help align the second groove, a bur may be held in the first groove with utility wax.

outline is followed to cut a template approximately 1.0 mm deep (A in Fig 11-9). This template is used as a guide to extend the groove to half its length, keeping the bur aligned with the path of insertion (B in Fig 11-9). If examination of the groove shows it to be properly aligned and directed, it should be extended to its full length, ending about 0.5 mm occlusal to the chamfer¹⁸ (C in Fig 11-9).

Grooves should be placed as facially as possible without undermining the facial surface, paralleling the long axis of a posterior tooth. Grooves are done first on the more inaccessible proximal (ie, distal) surface of molars and the more esthetically critical (ie, mesial) surface of premolars. If a prob-

lem is encountered in placing the first groove, alignment of the second can be altered in a more accessible area or without adversely affecting the esthetic result. The first few times that grooves are prepared, it may help to place a bur in the first groove as an alignment guide while the second groove is made (Fig 11-10).

A *flare* is a flat plane that removes equal amounts of the facial wall of the groove and the outer surface of the tooth. It is cut from the groove outward with the tip of a flame diamond to prevent overextension (Fig 11-11). The flare is reachable by explorer and toothbrush, but there should not be a noticeable display of metal. The flare should be smoothed with

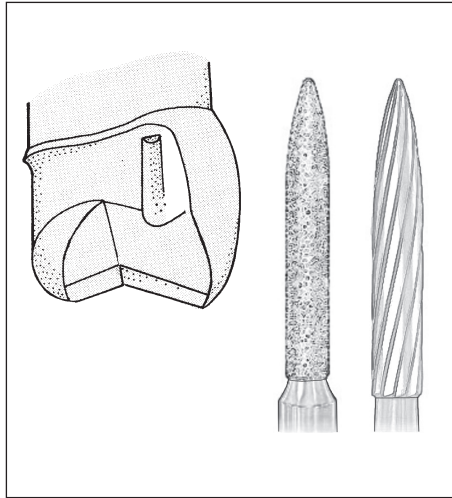


Fig 11-11 Proximal flares: flame diamond and bur.

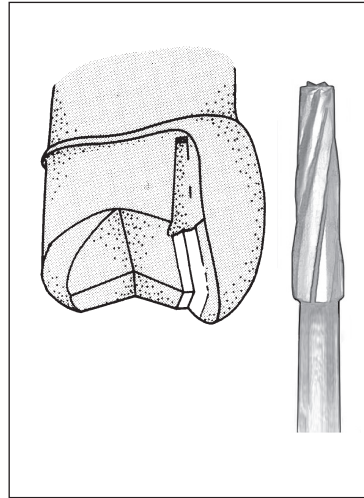


Fig 11-12 Occlusal offset: no. 171L bur.

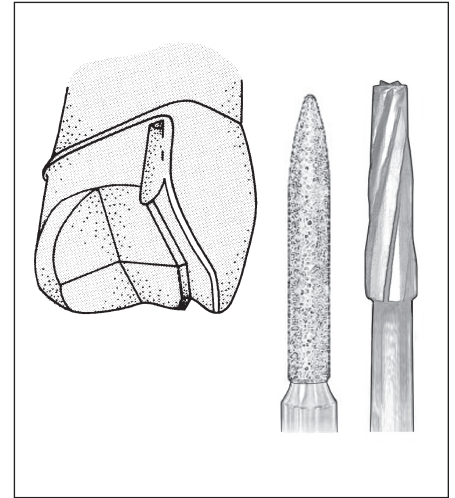


Fig 11-13 Facial bevel: flame diamond and no. 171L bur.

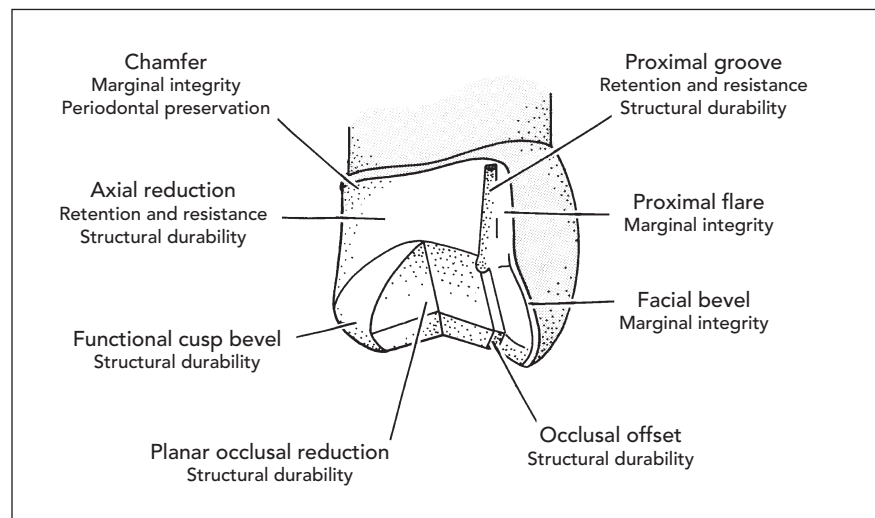


Fig 11-14 Features of a maxillary three-quarter crown preparation and the function(s) served by each.

a fine-grit flame diamond and then with a carbide bur matching the configuration of the flame diamond. Short, crisp strokes of the bur in one direction prevent rounding of the finish line. Where facial extension is critical, the flare can be formed with a wide enamel chisel.

The occlusal offset, a 1.0-mm-wide ledge on the lingual incline of the facial cusp, is made with a no. 171L bur (Fig 11-12). It forms an inverted V that lies a uniform distance from the finish line. It provides space for a truss of metal that ties the grooves together to form a reinforcing staple.¹⁵⁻²² The angle between the upright wall of the offset and the

lingual slope of the facial cusp is rounded. Any sharp corners between the lingual inclines of the facial cusp and the flares are removed.

A fine-grit flame diamond and a no. 171L bur are used to place a 0.5-mm bevel along the facio-occlusal finish line, perpendicular to the path of insertion (Fig 11-13). It rounds over the mesial and distal corners and blends into the proximal flares. The functions served by each of the features of the maxillary posterior three-quarter crown preparation are shown in Fig 11-14.

11 Preparations for Partial Coverage Crowns

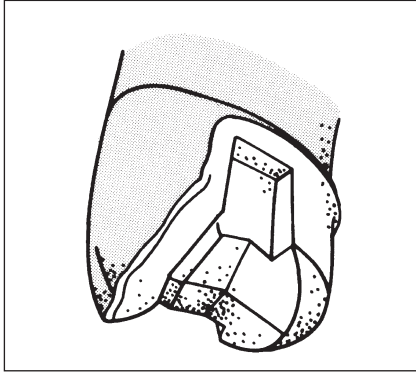


Fig 11-15 Maxillary three-quarter crown preparation with proximal boxes.

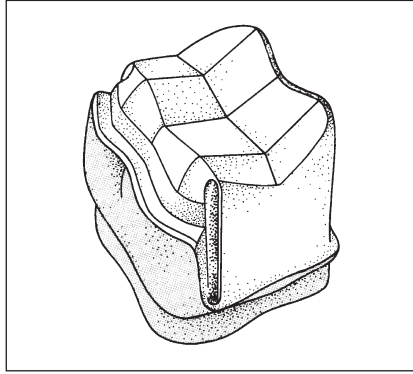


Fig 11-16 Three-quarter crown preparation on a mandibular molar.

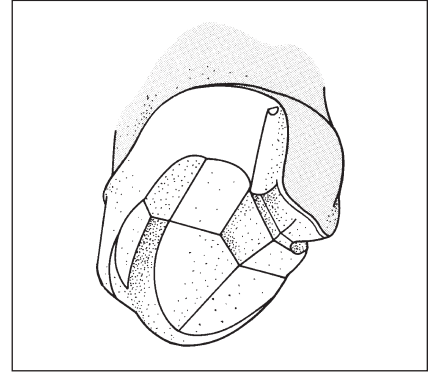


Fig 11-17 Seven-eighths crown preparation on a maxillary molar.

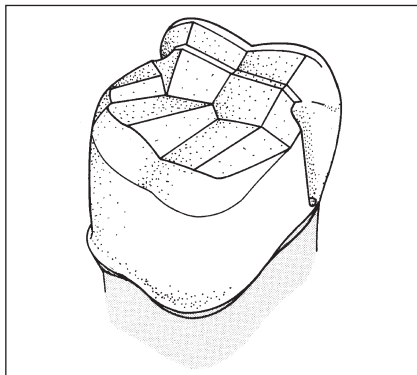


Fig 11-18 Reverse three-quarter crown preparation on a mandibular molar.

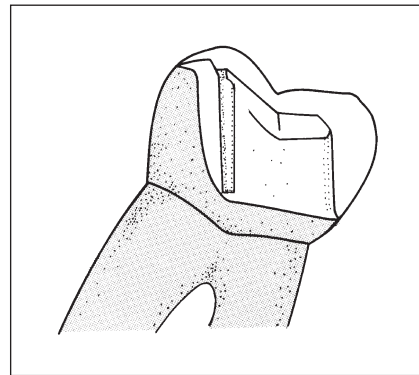


Fig 11-19 Proximal half crown preparation on a tilted mandibular molar.

Posterior Partial Coverage Variations

There are several modifications of posterior partial coverage crowns that can be used. A three-quarter crown preparation with proximal boxes (Fig 11-15) is more retentive than a standard preparation with grooves,^{10,23} but boxes are very destructive. They can be justified only if there has been proximal caries or previous restorations. A less destructive way to augment retention and resistance is to use four grooves,²⁴ which is not significantly less retentive than two boxes.²³

A three-quarter crown preparation on a mandibular molar or premolar has many features found in the preparation of a maxillary tooth (Fig 11-16). The biggest difference is the location of the occlusal finish line on the facial surface, which is gingival to occlusal contacts. The occlusal shoulder on the facial aspect of the facial cusp(s) serves the same purpose as the offset on the maxillary preparation, tying the grooves together and strengthening the nearby facio-occlusal margin. There is no need for an offset on the lingual inclines of the mandibular facial cusps.

The seven-eighths crown is a three-quarter crown whose vertical distofacial margin is positioned slightly mesial to the middle of the facial surface (Fig 11-17). Esthetics are good

because the veneered distofacial cusp is obscured by the mesiofacial cusp. With more of the tooth encompassed, resistance is better than that of the three-quarter crown.¹¹ The accessible location of the distofacial finish line makes the preparation easy to perform. Margin finishing by the dentist and cleaning by the patient are also facilitated.

The seven-eighths crown can be used on any posterior tooth needing a partial coverage restoration where the distal cusp must be covered.^{19,25} It is most commonly used on maxillary molars, but it also can be placed on mandibular premolars and molars.²⁶ It is good for restoring teeth with caries or decalcification on the distal aspect of the facial surface, and it is an excellent fixed partial denture retainer.

The reverse three-quarter crown is used on mandibular molars²² to preserve an intact lingual surface. It is useful on fixed partial denture abutments with severe lingual inclinations, preventing the destruction of large quantities of tooth structure that would occur if a full coverage crown were used. The grooves at the linguoproximal line angles are joined by an occlusal offset on the facial slope of the lingual cusps. This preparation closely resembles a maxillary three-quarter crown preparation because the axial surface of the nonfunctional cusp is uncovered (Fig 11-18).

The proximal half crown is a three-quarter crown that is rotated 90 degrees, with the distal rather than the facial surface left intact (Fig 11-19). It can be a retainer on a tilted

mandibular molar fixed partial denture abutment.^{27,28} This design can be used only in mouths with excellent hygiene and a low incidence of interproximal caries. It is contraindicated if there is a blemish on the distal surface.

The mesial surface parallels the path of insertion of the mesial abutment preparation. Clearance of 1.5 mm is obtained from occlusal reduction that terminates at the distal marginal ridge, with little or no reduction of the mesial cusps. Grooves paralleling the mesial surface are placed in the facial and lingual axial walls. A heavy channel or occlusal offset connects the grooves to strengthen the disto-occlusal margin. An occlusal isthmus augments retention and rigidity. A countersink in the distal channel helps resist mesial displacement.

Anterior Three-Quarter Crowns

Demands for the avoidance of any display of metal, coupled with the ease of preparing a tooth for a metal-ceramic crown, have led to the near-total demise of the anterior three-quarter crown. Unsightly, unnecessary displays of metal in poor examples of this restoration made it unpopular with both the public and the profession. When partial coverage is used, it is usually a pin-modified three-quarter crown in which metal coverage is minimized using pins.

However, a well-executed standard three-quarter crown on a maxillary incisor or canine need not show much metal. It can be used as a retainer for short-span fixed partial dentures on restoration- and caries-free abutments.^{29,30} Well-aligned, thick, square anterior teeth with a large faciolingual bulk of tooth structure are the best candidates for three-quarter crowns.¹³

Two factors must be controlled successfully to produce a restoration with a minimal display of metal: (1) path of insertion and groove placement and (2) placement and instrumentation of extensions. The path of insertion of an anterior three-quarter crown parallels the incisal one-half to two-thirds of the labial surface, not the long axis of the tooth.¹³ This gives the grooves a slight lingual inclination, placing their bases more apically and labially and making the grooves longer. If the grooves incline labially, the labio-incisal corners are overcut, displaying metal. The bases of the grooves then move lingually, becoming shorter and less retentive.³¹

Proximal extensions are done with thin diamonds or hand instruments with a lingual approach to minimize the display of metal. Use of a large instrument or a labial approach will result in overextension and an unsightly display of metal.

Armamentarium

- Handpiece
- Coarse-grit ball-shaped diamond (6801-023)
- Coarse-grit football-shaped diamond (6379-023)
- Medium-grit long needle diamond (850-012)
- Coarse-grit tapered torpedo diamond (8877K-014)

- Fine-grit tapered torpedo diamond (8877K-014)
- No. 169L bur
- No. 170L bur
- Coarse-grit flame diamond (862-010)
- Fine-grit flame diamond (8862-010)
- Flame bur (H48L-010)
- 15-8-8 binangle chisel
- 15-8-14 enamel hatchet

Technique

A coarse-grit football-shaped diamond is used to create a concave lingual reduction incisal to the cingulum (Fig 11-20). It is necessary to create 0.7 mm or more clearance with opposing teeth. To ensure adequate reduction, depth-orientation cuts are made on the lingual surface with a coarse-grit ball-shaped diamond whose head has a diameter 1.4 mm larger than its shaft. Buried in enamel to the shaft, the diamond penetrates 0.7 mm. Reduction is done to the depth of the orientation cuts. The lingual reduction of a canine is done in two planes, with a slight ridge extending incisogingivally down the middle of the lingual surface. On incisors, the entire surface is smoothly concave. The junction between the cingulum and the lingual wall must not be overly reduced. If excessive tooth structure is removed, the lingual wall will be too short to provide retention.

Incisal reduction is done with the flat side of the medium-grit long needle diamond (Fig 11-21). It generally parallels the inclination of the uncut incisal edge and barely breaks through the labioincisal line angle. Near the junction between the incisal edge and the lingual surface, it is about 0.7 mm deep. On a canine, the natural mesial and distal inclines of the incisal edge are followed. On an incisor, a flat plane is cut from mesial to distal.

The lingual axial wall is reduced with a coarse-grit tapered torpedo diamond, and a chamfer finish line is created at the same time (Fig 11-22). The diamond is kept parallel with the incisal two-thirds of the labial surface to initiate the path of insertion of the preparation.

The vertical lingual wall is essential to retention. If the cingulum is short, wall length can be increased with a lingual beveled shoulder that moves the wall farther into the tooth. A 3.0-mm-deep pinhole can be placed in the cingulum to compensate for a very short lingual wall. This common variation of the anterior three-quarter crown is frequently used on abutments for fixed partial dentures.

Proximal reduction is started with a medium-grit long needle diamond (Fig 11-23). The instrument comes from the lingual to minimize the display of metal later. An up-and-down motion is used, with care taken not to nick the adjacent tooth or lean the diamond too far into the center of the prepared tooth. The labial proximal extensions are completed, and contact with the adjacent tooth should be barely broken with an enamel hatchet or binangle chisel, not with the diamond.

The axial reduction is completed, and the finish line is accentuated with a coarse-grit tapered torpedo diamond. To

11 Preparations for Partial Coverage Crowns

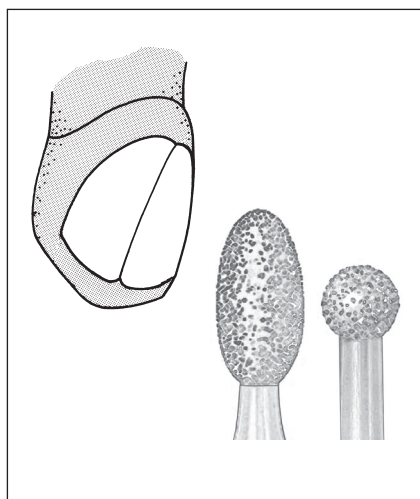


Fig 11-20 Lingual reduction: small football-shaped and coarse-grit ball-shaped diamonds.

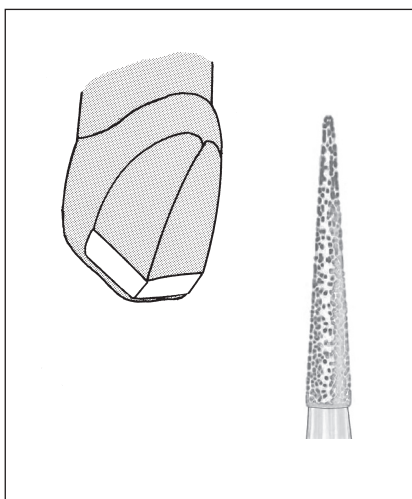


Fig 11-21 Incisal reduction: long needle diamond.

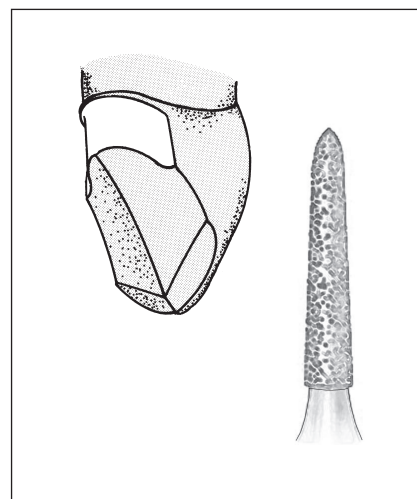


Fig 11-22 Lingual axial reduction: tapered torpedo diamond.



Fig 11-23 Proximal axial reduction: long needle and tapered torpedo diamonds.

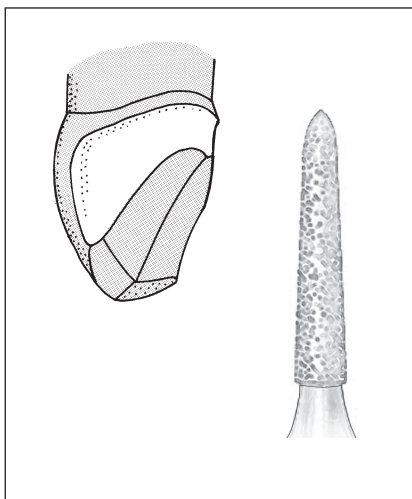


Fig 11-24 Axial finishing: fine-grit tapered torpedo diamond.

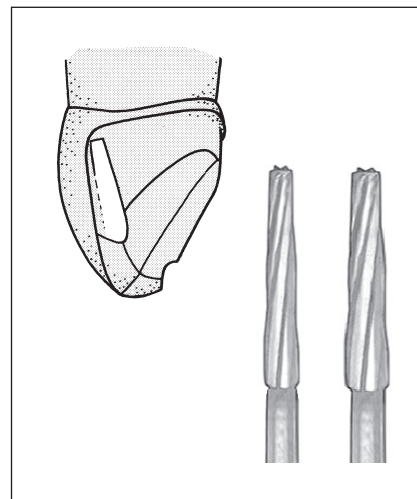


Fig 11-25 Proximal grooves: no. 169L and 170L burs.

prevent binding between the prepared proximal axial wall and the adjacent tooth, it may be necessary to use a flame diamond before the torpedo diamond. The axial surface and chamfer are then planed with the fine-grit tapered torpedo diamond (Fig 11-24).

The grooves are placed as far labially as possible without undermining the labial enamel plate. To implement groove placement, outlines of the grooves are drawn on the lingual incisal area of the preparation. The first groove is begun by cutting a 1.0-mm-deep template within the penciled outline using a no. 169L bur. The groove is extended gingivally in increments to its full length. This small diameter allows adjustment of the groove without overcutting it.

The second groove is cut parallel with the first, with both ending just short of the chamfer (Fig 11-25). Remember that grooves in an anterior three-quarter crown preparation parallel the incisal one-half to two-thirds of the facial surface, unlike those in a posterior tooth, which parallel the long axis of the tooth. Boxes may be substituted for grooves if there are existing proximal restorations or caries. Boxes must be narrow to be resistant because the lingual wall of a box shortens drastically as it is moved lingually.

On the facial aspect of each groove, a flare is started at the gingival end with the thin tip of a flame diamond (Fig 11-26). It is finished with the fine-grit flame diamond and flame bur to make a smooth flare and a sharp, definite finish




Fig 11-26 Proximal flares: flame diamond and bur.

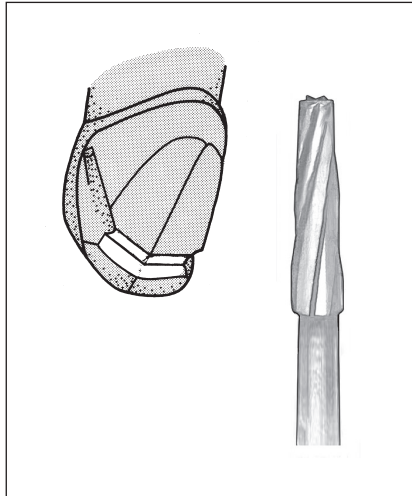


Fig 11-27 Incisal offset: no. 171L bur.

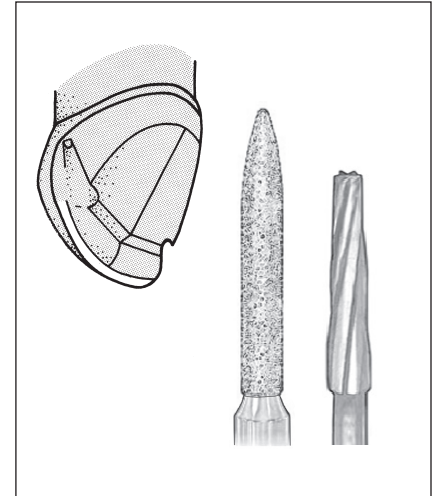


Fig 11-28 Incisal bevel: fine-grit flame diamond and no. 170L bur.

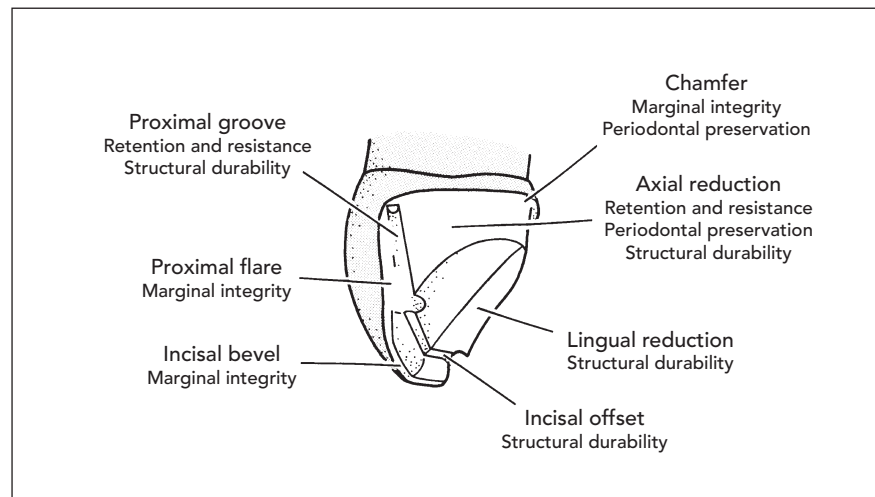


Fig 11-29 Features of an anterior three-quarter crown preparation and the function(s) served by each.

line. If a very minimal extension is desired, a wide enamel chisel or hatchet should be used instead.

Using a no. 171L bur, the grooves are connected with an incisal offset, with a uniform distance from the incisal edge maintained (Fig 11-27). The offset is a definite step on the sloping lingual surface, placed near the opposing occlusal contact. The metal that occupies the space reinforces the margin.^{15,18,21} On a canine it forms a V, but on an incisor it is a straight line.

The angles between the incisal edge and the upright wall of the offset and between the incisal reduction and each flare are rounded. A 0.5-mm-wide bevel is placed on the labioincisal finish line using a no. 170L bur (Fig 11-28). This

can also be done with a flame diamond and bur, but finishing is still done with a bur to create the sharpest finish line. The bevel is perpendicular to the path of insertion along the mesial incline. A contrabevel can be placed on the distal incline, where esthetic considerations are not as critical. However, a contrabevel should never be used on an incisor.

Conservative extension and careful finishing of the gold incisal margin will cause light to be reflected downward, making the incisal edges appear dark rather than metallic to the viewer.¹⁵ As a result, it will blend in with the dark background of the oral cavity. The functions served by each of the features of the anterior three-quarter crown preparation are shown in Fig 11-29.

11 Preparations for Partial Coverage Crowns

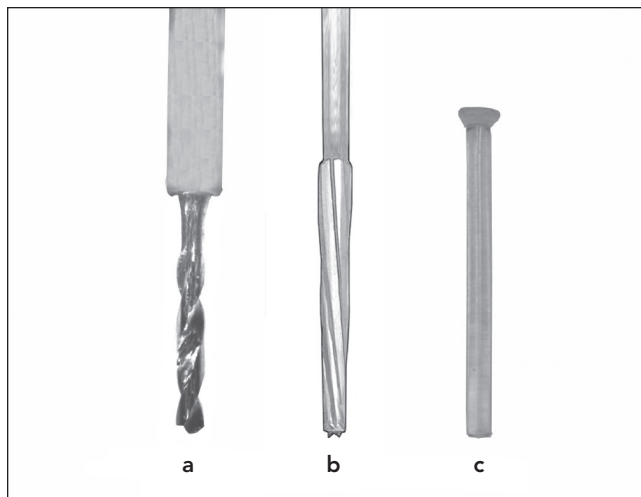


Fig 11-30 Retentive pins are made by using a 0.675-mm twist drill (a) for the pinhole, a no. 169L carbide bur (b) to carefully enlarge the pinhole, and a smaller-diameter nylon bristle (c) for the impression and as part of the restoration.




Fig 11-31 Finishing a pinhole with a no. 169L bur.

Pin-Modified Three-Quarter Crowns

There are situations calling for a partial coverage crown that will not permit the use of a classic preparation design. The pin-modified three-quarter crown is an esthetic modification that has long been considered the retainer of choice on unblemished teeth used as fixed partial denture abutments in esthetically critical areas.³² Although resin-bonded retainers gained popularity in such situations in the 1980s, the pin-modified three-quarter crown is still an excellent retainer for short-span fixed partial dentures. Over³³ describes their use for this purpose and their use as splint retainers.

The pin-modified three-quarter crown preserves the facial surface and one proximal surface. With minimal subgingival margins, it is periodontally preferable to a full crown. An unsightly display of metal is avoided without resorting to a destructive full veneer metal-ceramic restoration. The pin-modified three-quarter crown is good for repairing incisors and canines with severe lingual abrasion.^{32,34,35} It should not be used on teeth with caries or restorations, on surfaces that are not to be covered, or in mouths with extensive caries.

Although this restoration design is conservative in the amount of enamel that is untouched, a variety of factors could place the pinholes near or even in the pulp. Therefore, pin-modified three-quarter crowns should not be used on teeth that are small,³⁶ thin,^{29,37} malpositioned, or that have large pulps.³⁸ They also should not be placed by unskilled dentists.

Pins are likely to produce less retention, and pin-retained castings are less retentive than standard three-quarter crowns.⁹ However, the greater the number, depth, or diameter of pins, the greater the retention.³⁹ The pin-modified three-quarter crown is an old restoration that was revived in the 1960s by the development of small twist drills to make pinholes and nylon bristles to accurately reproduce them.

Pinholes are usually made with a 0.675-mm drill (Kodex K97 non-depth-limiting twist drills, Coltene/Whaledent)^{35,36,40–42} (Fig 11-30a). These pins should be 4 mm deep for optimum retention and resistance.⁴³ The operator must be cautious, however, when extending to the full depth in areas where limited tooth structure is available. The twist drill is followed with a no. 169L carbide bur, which is 0.6 mm in diameter at its tip and has a slight taper so that its diameter approaches 0.9 mm at its widest (Figs 11-30b and 11-31). Nylon bristles, which are ideally 25 to 50 μ m smaller in diameter than the drill, are placed in the pinholes^{40,41} because the pinholes are too small to be reproduced by impression material. The nylon bristles (Fig 11-30c), easily placed with a flame, should have a retentive feature on their protruding ends to allow them to be picked up during the impression (Fig 11-32). Impression material surrounds the pin and incorporates it into the impression. When the impression is poured, the nylon bristles protruding from it reproduce the pinholes. A monofilament nylon fishing line cut to an appropriate length and of the appropriate diameter is used. One manufacturer (Momi) sells a 30-lb test monofilament nylon line (Diamond Hi-Catch Leader Line) with a diameter of 0.59 mm, which is 85 μ m smaller in diameter than the 0.675-mm-diameter twist drill.

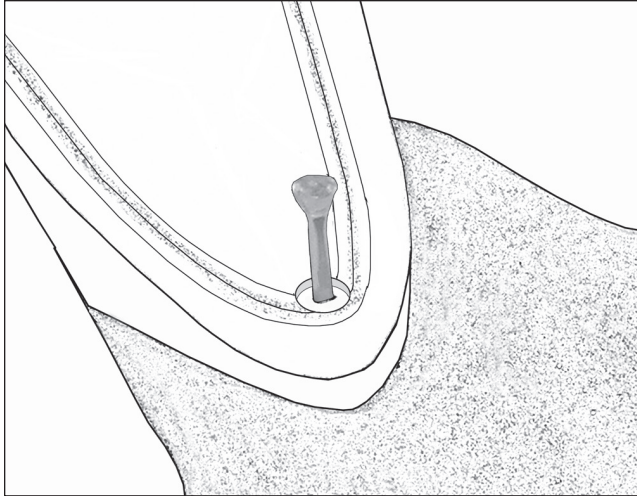


Fig 11-32 Nylon bristle in prepared pinhole to be picked up in the impression.

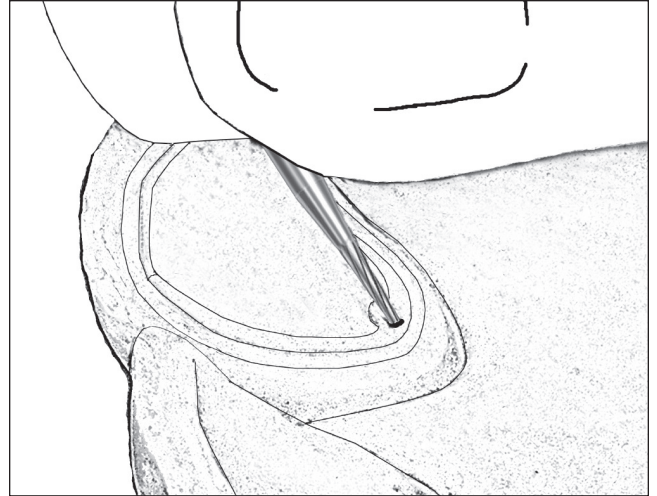


Fig 11-33 Hand-twisting the no. 169L bur in the pinhole of the working cast.




Fig 11-34 Nylon bristle in pinhole of working cast, ready for wax addition.

Serrated pins produce more retention than smooth pins.^{39,44,45} Lengths of the same size monofilament nylon line as used for the impression (ideally 25 to 50 μm smaller than the pinholes in the stone cast),⁴⁰ which have been very slightly serrated on the last 2 mm with a bur, are incorporated into the wax pattern. The bur should not be used around the base of the bristles to avoid weak areas there. The pinholes in the cast must first be carefully enlarged by hand-twisting the no. 169L bur (Fig 11-33) so that the bristles will slide into the pinhole and will be removable with the wax pattern. These bristles must also have a retentive feature on their protruding end, placed with a flame, to be incorporated into the wax pattern (Fig 11-34). The resulting pins in the casting

are ideally 50 to 100 μm smaller than the original pinholes in the preparation. In this example, they would be 85 μm smaller.

Pins should be at least 2.0 to 3.0 mm long.^{36,40,41,46} Adequate pin length is essential to retention, and short pins will cause the failure of a conservative fixed partial denture. These are very destructive failures because the pinholes become channels for oral fluids and microorganisms to penetrate deep into the tooth. Considerable damage may occur before a loose retainer is detected. If adequate pinhole depth is not possible, a different retainer design should be used.

11 Preparations for Partial Coverage Crowns

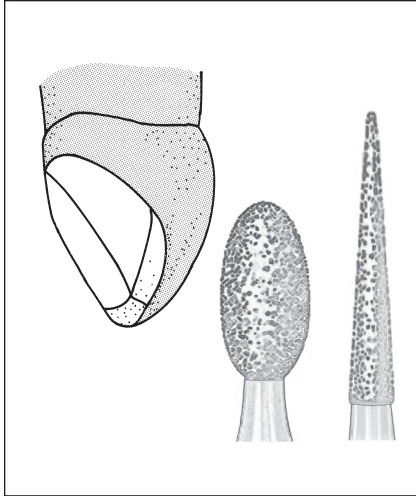


Fig 11-35 Lingual reduction: small coarse-grit football-shaped diamond. Incisal bevel: medium-grit long needle diamond.

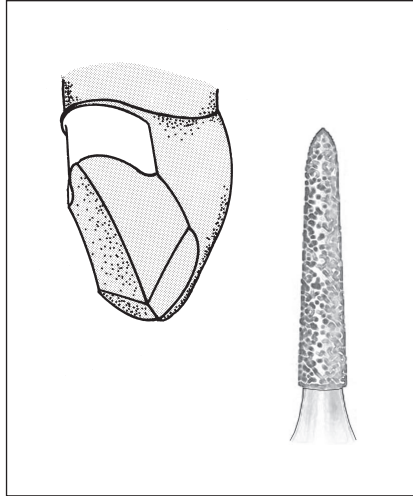


Fig 11-36 Lingual axial reduction: coarse-grit tapered torpedo diamond.

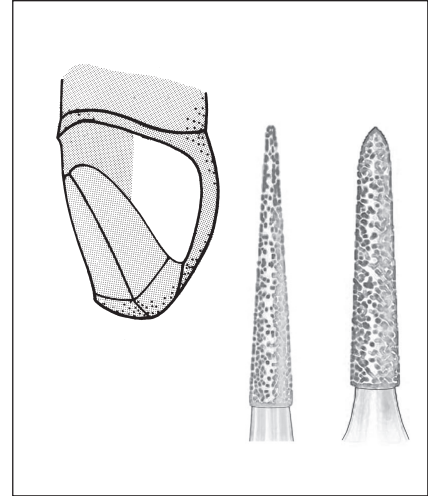


Fig 11-37 Proximal axial reduction: medium-grit long needle and coarse-grit tapered torpedo diamonds.

Armamentarium

- Handpieces
- Coarse-grit ball-shaped diamond (6801-023)
- Coarse-grit football-shaped diamond (6379-023)
- Medium-grit long needle diamond (850-012)
- Coarse-grit tapered torpedo diamond (6877K-014)
- Fine-grit tapered torpedo diamond (8877K-014)
- No. 169L bur
- No. 170L bur
- Medium-grit flame diamond (862-010)
- Fine-grit flame diamond (8862-010)
- Flame bur (H48L-010)
- 15-8-8 binangle chisel
- 15-8-14 enamel hatchet
- No. ½ round bur
- No. 4 round bur
- 0.027-inch twist drill
- Nylon bristle

Technique

Concave reduction of the lingual aspect of the tooth is done with a small coarse-grit football-shaped diamond to produce a minimum clearance of 0.7 mm with adjacent teeth (Fig 11-35). Depth-orientation cuts can be made using a coarse-grit ball-shaped diamond with a head diameter 1.4 mm greater than its shaft diameter. It is sunk into enamel down to the shaft to make a cut approximately 0.7 mm deep. Excessive shortening of the vertical wall of the cingulum should be avoided.

A lingual incisal bevel generally paralleling the uncut surface of the incisal edge is prepared with the flat edge of the medium-grit long needle diamond (see Fig 11-35). This bevel is approximately 1.5 mm wide, but it may vary on teeth with

unusually thick or thin incisal edges. It should stop lingual to the labioincisal line angle to prevent a display of metal.

Using a coarse-grit tapered torpedo diamond, the lingual axial wall is reduced to parallel the incisal two-thirds of the labial surface (Fig 11-36), simultaneously forming a chamfer finish line. Care should be taken not to extend too far labially into the lingual proximal embrasure on the proximal surface opposite the retentive feature. The finish line must be far enough lingual to the proximal contact so that the restoration margin can be finished by the dentist and cleaned by the patient. If the cingulum is short, a beveled shoulder should be used to move the lingual wall toward the center of the tooth, making it longer.

The medium-grit long needle diamond is used to begin axial reduction from the lingual facially almost through the contact area, and the coarse-grit tapered torpedo diamond is used to continue the axial reduction to its most facial extension near the labioproximal line angle (Fig 11-37). The contact area can be broken with the binangle chisel or enamel hatchet. The reduction is diminished at the finish line. The location of this finish line is critical. If it is not far enough facial, it can cause an undersized, weak connector³⁵ and a margin that would be impossible to finish properly. The axial reduction and the chamfer finish line should be smoothed with a fine-grit tapered torpedo diamond (Fig 11-38).

The primary axial retention/resistance features, two grooves, are placed next to the edentulous space (Fig 11-39). If the proximal surface is carious or has been restored previously, a box form is used. The box is too destructive to use routinely on unblemished proximal surfaces. Kishimoto et al¹⁴ demonstrated that two grooves are equal to a box on a premolar. On an anterior tooth, they are probably superior. Because the lingual surface slopes linguogingivally, moving the lingual wall a slight distance lingually shortens it and decreases resistance (Welk DA, 1982, personal communication). By using two grooves, there will be two lingual walls. The wall of the more

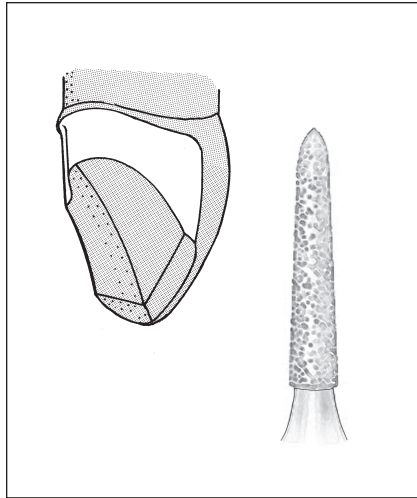


Fig 11-38 Axial finishing: fine-grit tapered torpedo diamond.

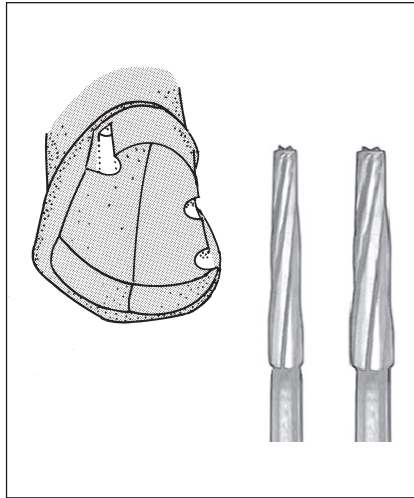


Fig 11-39 Proximal grooves: no. 169L and 170L burs.




Fig 11-40 Proximal flares: fine-grit flame diamond and bur.

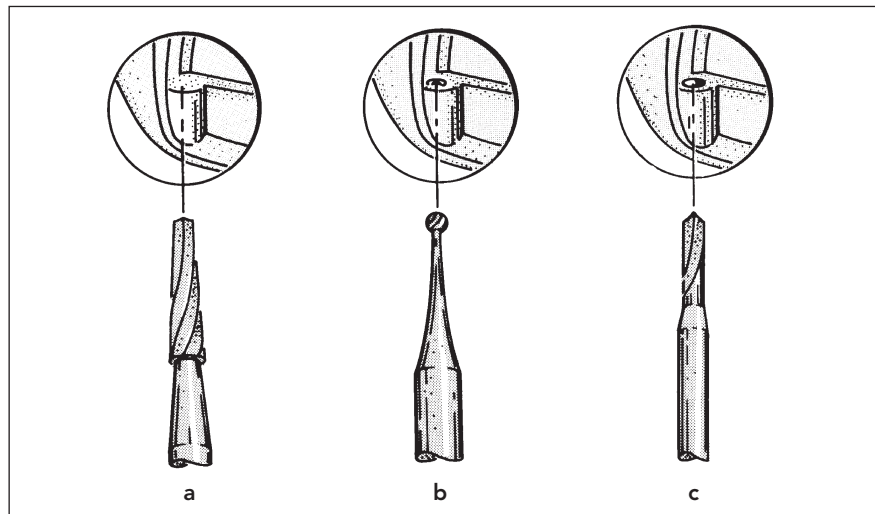


Fig 11-41 Instrument sequence for cutting pinholes: (a) Form the ledge with a tapered fissure bur. (b) Start the pinhole with a small round bur. (c) Finish the pinhole with a twist drill.

facially positioned groove will be longer and more resistant than the single shorter lingual wall of a box.

The facial groove is placed with a no. 170L bur. An inexperienced dentist may want to start the grooves with a no. 169L bur to avoid overcutting. Shallow pilot grooves are made and checked for location and direction. Then a no. 170L bur is sunk into the track of the trial groove to the full diameter of the bur.

The lingual groove is placed next, paralleling it with the first. A third, much shorter groove is placed on the opposite side of the cingulum near the vertical finish line on that surface. This groove enhances the restoration resistance slightly, and it accommodates a bulk of metal to reinforce the margin.

Proximal flares are formed with a medium-grit flame diamond (Fig 11-40). For the flare to draw, it must be wider incisally than it is gingivally. It nearly eliminates the facial wall

of the groove at its incisal end. A slight flare is placed on the mesial groove. The distal and mesial flares are reinstrumented with a matching fine-grit flame diamond and flame bur. Care should be taken not to round over the finish line.

A flat ledge or countersink is cut in the incisal corner opposite the site of the proximal grooves using a no. 170L bur. It must be gingival to the incisal edge, in dentin, and lingual to the finish line. A ledge is also placed in the middle of the cingulum. These flat areas on the sloping lingual surface provide easy starts for precise pinhole placement (Fig 11-41), and they create space for a reinforcing bulk of metal at the base of the pins.⁴⁷

The no. 170L bur is used to connect the incisal ledge and the facialmost proximal groove with an incisal offset. A V-shaped trough is cut along the side of the lingual surface from the incisal ledge to the short cingulum groove. The

11 Preparations for Partial Coverage Crowns

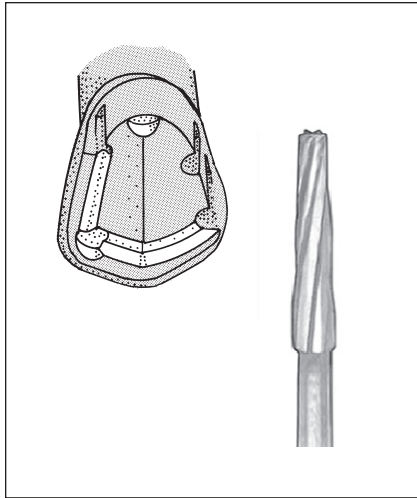


Fig 11-42 Ledge, offset, and trough: no. 170L bur.

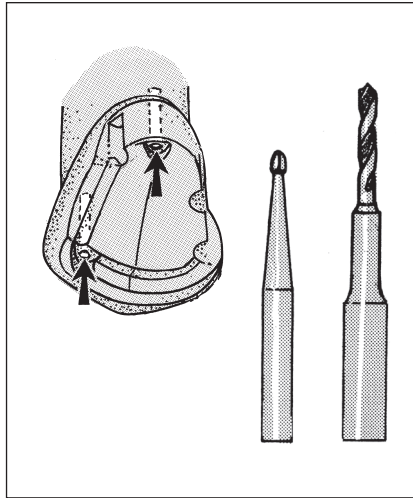


Fig 11-43 Pinholes: no. 1/2 round bur and 0.675-mm twist drill.




Fig 11-44 Incisal bevel: fine-grit flame diamond and bur.

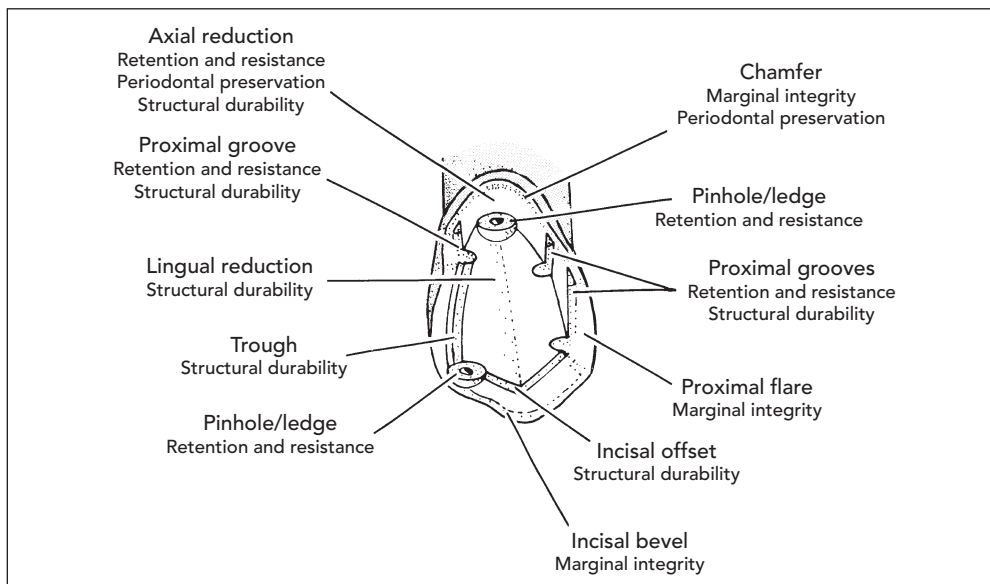


Fig 11-45 Features of a pin-modified three-quarter crown preparation and the function(s) served by each.

metal in the trough will reinforce the linguoproximal margin of the restoration (Fig 11-42).

A shallow depression to begin a pinhole in the center of each ledge is made using a no. 1/2 round bur. To initiate the first pinhole, a 0.675 × 5-mm non-depth-limiting twist drill (Kodex) in a low-speed contra-angle handpiece is carefully aligned with the grooves. The handpiece is started before touching the tooth and should not be stopped while the drill is in the pinhole because the drill will snap off. When the first pinhole is approximately 3 mm deep, the handpiece is withdrawn, and a nylon bristle is placed in the pinhole. Using the bristle and grooves as guides, a 3-mm-deep pinhole is made in the other ledge (Fig 11-43).

The angle between the facial wall of the offset and the incisal edge of uncut tooth structure is beveled. Care should be taken not to extend this bevel too far facially because

metal will show. A finishing bevel is placed on the functional area of the incisal edge using a fine-grit flame diamond (Fig 11-44). Care is taken to prevent an unnecessary display of metal, but it may be necessary to extend the bevel on the distal incline of the incisal edge of a canine onto the labial surface. This is not likely to be unacceptable esthetically because it is usually hidden from view. However, this should not be done on an incisor. The incisal bevel is blended into the flare, and the bevel is redefined on the marginal ridge next to the incisocingulum trough.

The areas just described are smoothed with a flame bur. Acute angles between the lingual and proximal surfaces are blunted, and any sharp corners at the incisal ends of the grooves are eliminated. The functions served by each of the features of a pin-modified three-quarter crown preparation on a maxillary canine are shown in Fig 11-45.

Resin-Bonded Fixed Partial Dentures

Unquestionably, one of the disadvantages of a conventional fixed partial denture with either full coverage or partial coverage crown retainers is the destruction of tooth structure required for the abutment preparations upon which the retainers are placed. The prospect of the destruction of sound tooth structure has troubled conscientious dentists when prescribing the replacement of a missing tooth.

Various solutions for this problem have been tried. Inlay retainers were used to save tooth structure and time before the advent of air-turbine handpieces. Some dentists have tried to minimize the problem by fabricating cantilever fixed partial dentures. However, this type of restoration can result in failures that are costly both in money spent for subsequent replacement and in loss of periodontal support around previously sound teeth. Unilateral removable partial dentures to avoid undesirable destruction of tooth structure are usually wanting in both retention and stability, and they present the risk of aspiration if they become dislodged.

The development of acid etching of enamel to improve the retention of resin, first described by Buonocore⁴⁸ in 1955, has proven to be a means of attaching fixed partial dentures to teeth by less destructive means. Ibsen⁴⁹ first described the attachment of an acrylic resin pontic to an unprepared tooth using a composite bonding resin.

Metal framework

The addition of a metal substructure and wings, or retainers, extending onto the abutment teeth was a logical progression. The classification of resin-bonded fixed partial dentures (ie, Rochette, Maryland, and Virginia bridges) is a reflection of the metal surface finishing technique.

Rochette bridge

The first use of wing-like retainers, with funnel-shaped perforations through them to enhance resin retention, is attributed to Rochette,⁵⁰ who in 1973 combined mechanical retention with a silane coupling agent to produce adhesion to the metal.⁵¹

Maryland bridge

Livaditis and Thompson adapted an electrochemical pit corroding technique that had been used by Dunn and Reisbick⁵² in a study of ceramic bonding to base metal alloys. This type of etched-metal prosthesis is frequently called the *Maryland bridge*. The acid solution and technique were specific to the nonberyllium nickel-chromium alloy that they tested.

Subsequently, Thompson et al⁵³ reported that 10% sulfuric acid at 300 mA/cm², followed by the same cleaning procedures, would produce similar results with a beryllium-

containing nickel-chromium alloy. Sloan et al⁵⁴ found tremendous variability from one laboratory to another and from one retainer to another.

McLaughlin⁵⁵ proposed a much faster technique for etching retainers by immersing them in a beaker of a combined solution of sulfuric and hydrochloric acids placed in an activated ultrasonic cleaner for 99 seconds while electrical current is passed through the fixed partial denture and solution. Subsequent in vitro testing of specimens treated by the one- and two-step techniques showed retainers treated by the one-step technique to be equally as retentive as those treated by the two-step method.⁵⁶

Electrochemical etching is technique sensitive. Overetching produces an electropolished surface, and contamination of the surface reduces bond strength.⁵⁷ There has been interest in alternative ways of creating metal surfaces capable of retaining resin-bonding materials.

Other surface treatment techniques have been developed. Livaditis⁵⁸ reported acceptable results with a nonelectrolytic technique that requires a nickel-chromium-beryllium alloy to be placed in an etching solution for 1 hour in a water bath at 70°C (158°F). A form of chemical etching with a stable aqua regia gel was substituted for electrochemical etching by Doukoudakis et al.⁵⁹

Air abrading metal with 250- μ m abrasive increases bonding strength remarkably when used in conjunction with silane.⁶⁰

Virginia bridge

Moon^{61,62} and Hudgins et al⁶³ produced particle-roughened retainers by incorporating salt crystals into the retainer patterns to produce roughness on the inner surfaces. This method is also known as the *lost salt technique* for producing Virginia bridges. Sieved cubic salt crystals (NaCl), ranging in size from 149 to 250 μ m, were sprinkled over the outlined area.⁶⁴ The retainer patterns were fabricated from resin, with a 0.5- to 1.0-mm-wide crystal-free margin around the outlined area.

After the resin was polymerized, the patterns were removed from the cast, cleaned with a solvent, and placed in water in an ultrasonic cleaner to dissolve the salt crystals. This left cubic voids in the surface that were reproduced in the cast retainers, producing retention for the fixed partial denture.

Air abrasion with aluminum oxide has been used as the sole means of surface treatment, as well as the precursor for other treatments. Tanaka et al⁶⁵ used 50- μ m aluminum oxide air abrasion to prepare cobalt-chromium castings for bonding with 4-methacryloxyethyl trimellitate anhydride (4-META) resin. The difference here was not in the treatment of the metal surface as much as it was in the adhesive properties of the cement. Nickel-chromium alloys required oxidation with a dilute solution of sulfuric acid and potassium manganate as well.

Tanaka et al⁶⁶ were also able to create a suitable surface for bonding with the same 4-META resin by inducing a heat-accumulated copper oxide deposit on noble-metal alloys

11 Preparations for Partial Coverage Crowns

in conjunction with 50- μ m aluminum oxide air abrasion. Wiltshire⁶⁷ used air abrasion with 250- μ m aluminum oxide and found that it was not significantly different from electrochemical etching in effectiveness, while other investigators obtained better retention by air abrading with 250- μ m aluminum oxide particles than they did with electrochemical etching.⁶⁸

Resin cements

The first resin-bonded restorations described by Rochette,⁵⁰ which were splints, were held in place by an unfilled resin, polymethyl methacrylate (Sevriton, Dentsply), attached to etched enamel, based on the work of Laswell et al.⁶⁹ While a whole generation of resin-bonded fixed partial dentures would bear the title of *Rochette bridges*, they made use only of the perforated retainers described by Rochette, ignoring the silane coupling with which he augmented resin attachment to the metal framework.⁵⁰

Unfilled/filled composite resins (Adaptic/Adaptic Bonding Agent, Johnson & Johnson Dental⁷⁰; Concise Composite and Enamel Bond system, 3M ESPE^{71,72}) were used with perforated retainers. Then a modified unfilled/filled composite resin with a thin film thickness specifically intended for luting resin-bonded fixed partial dentures was released, closely following the development of electrolytic etching.^{73,74}

The next development was chemically active⁵¹ (adhesive) resin cements: 4-META (C&B-Metabond, Parkell)⁶⁵ and 10-methacryloyloxydecyl dihydrogen phosphate (MDP)^{75,76} (Panavia 21 EX, Kuraray). These cements rely on adhesion to the metal and not on microretention in the surface of the metal for bond strength. Etching was no longer necessary.⁷⁷

Air abrasion with small-particle aluminum oxide (50 μ m or less) thus becomes part of the cleaning of the metal surface in preparation for chemical bonding and not a mechanism for roughening the surface to provide microscopic undercuts for the resin. Tin plating can make noble metals very good candidates for bonding.⁷⁸ Imbery et al⁷⁹ found the greatest bonding strength with a gold-palladium alloy (Olympia, Jelenko) that had been air abraded, tin plated, and bonded with a filled bisphenol glycidyl methacrylate (bis-GMA) resin and phosphate ester monomer (Panavia 21 EX) and a nickel-chromium-beryllium alloy (Rexillium III, Jeneric/Pentron) that had been air abraded, silicoated, and cemented with a 4-META resin (C&B-Metabond). Breeding and Dixon⁸⁰ reported similar results: High noble (Olympia) and noble (Jelstar, Jeneric/Pentron) metals displayed shear bond strengths similar to that of a base metal alloy (Rexillium III).

Treatment planning

There are situations in which resin-bonded fixed partial dentures should or should not be used, as well as features that should be considered in deciding that one is the treatment of choice for replacing a lost tooth.

Advantages

Reduced cost

The cost difference is not as significant as was first thought when little or no preparation was involved with the technique. However, with the increased use of preparation features, more of the dentist's time and skill are required, and the cost differential between a conventional prosthesis and a resin-bonded fixed partial denture has decreased.

No anesthetic needed

An anesthetic is often not required because most of the preparation will be done in enamel. However, there are some cases in which anesthetic is required.

Supragingival margins

Although supragingival margins can be used with conventional retainers, they are mandatory for the resin-bonded fixed partial denture.

Minimal tooth preparation

Less tooth structure has to be removed for this technique, making it more conservative and less likely to create problems in unblemished abutment teeth.

Disadvantages

Irreversible

The resin-bonded fixed partial denture requires the removal of enough tooth structure that it should be considered irreversible. Whether this is really a disadvantage is debatable, but the point is raised simply to remind the reader that it is necessary to do some preparation of the tooth.

Longevity

There is concern about the longevity of this type of prosthesis. The results of several studies on resin-bonded fixed partial denture longevity are shown in Table 11-1. In a study by Marinello et al,⁹⁴ the success rate dropped from 95% after 3 months to 91% at 6 months, 81.5% at 1 year, and 73% at 18 months.

A review of about 60 publications on the clinical survival of resin-bonded fixed partial dentures put the 4-year survival rate at 74%.¹⁰⁵ By contrast, a similar study done on 552 three-unit conventional fixed partial dentures by Kerschbaum and Gaa¹⁰⁶ showed that 96% of those prostheses were still in use after 4 years. Another study of 487 metal-ceramic fixed partial denture retainers 18 to 23 years after their placement revealed a success rate of 95%.¹⁰⁷ As an indication of what can be done with careful planning and attention to detail, Barrack and Bretz⁸¹ reported a success rate of nearly 93% on 127 resin-bonded restorations placed in the mouths of their private patients over a span of 11 years.

No alignment correction

It is impossible to correct alignment problems with this restoration because nothing is done to the facial, proximal, and incisal areas of the abutment teeth.

Table 11-1 Longevity of resin-bonded fixed partial dentures

Author(s)	Year	Type of retention	Months in mouth	Number placed	Number retained	Percent successful
Barrack/Bretz ⁸¹	1993	Etched	68	127	118	93
Bergendal et al ⁸²	1983	Perforated	33	100	71	71
Chang et al ⁸³	1991	Etched	47	43	28	53
Clyde/Boyd ⁸⁴	1988	Etched	60	122	109	89
Creugers et al ⁸⁵	1986	Perforated	18	32	24	75
		Perforated (prox ext)	18	29	23	79
		Etched metal	18	40	38	95
Creugers et al ⁸⁶	1990	Unspecified	60	203	126	62
Denehy/Howe ⁷¹	1979	Perforated	36	30	27	90
Ekstrand ⁸⁷	1984	Unspecified	36	120	98	82
Eshleman et al ⁸⁸	1979	Perforated	36	39	33	85
Ferrari et al ⁸⁹	1989	Etched	30	209	188	90
Hansson/Moberg ⁹⁰	1992	Etched	41	34	32	94
Hudgins et al ⁶³	1985	Particle roughened	18	27	26	96
Kuhlke/Drennon ⁹¹	1977	Perforated	48	23	20	87
LaBarre/Ward ⁹²	1984	Etched	12	45	41	91
Livaditis ⁹³	1981	Etched	12	66	64	96
Marinello et al ⁹⁴	1987	Etched-metal FPD	18	153	127	83
		Cast metal FPD	18	127	112	88
		Perforated FPD	18	44	25	57
		Air-abraded FPD	18	54	48	89
Marinello et al ⁹⁵	1988	Etched-metal splints	18	95	66	70
		Cast mesh splints	18	17	11	65
		Air-abraded splints	18	5	4	80
Olin et al ⁹⁶	1991	Etched	60	96	85	89
Priest/Donatelli ⁹⁷	1988	Perforated	51	3	1	33
		Cast mesh	42	2	2	100
		Electrochemical etch	26	38	30	79
		Chemical etch	7	15	15	100
Rammelsberg et al ⁹⁸	1993	Etched	84	141	117	83
Shaw/Tay ⁷²	1982	Perforated	44	46	37	80
Thayer et al ⁹⁹	1993	Perforated	87	44	27	61
		Etched metal	87	41	25	61
Thompson/Wood ¹⁰⁰	1986	Unspecified	41	180	140	78
van der Veen et al ¹⁰¹	1987	Perforated	72	64	54	84
Williams et al ¹⁰²	1984	Perforated	72	63	53	84
Williams et al ¹⁰³	1989	Perforated and etched	120	90	100	83
Yankelson/Myers ¹⁰⁴	1980	Perforated	24	97	75	77

prox ext, proximal extension; FPD, fixed partial denture.

11 Preparations for Partial Coverage Crowns

Table 11-2 Lingual enamel thickness of maxillary anterior teeth (in mm)

Tooth	Distance from cemento-enamel junction (mm)					
	1	2	3	4	5	6
Central incisor	0.3	0.5	0.6	0.7	0.7	0.7
Lateral incisor	0.4	0.5	0.5	0.6	0.7	0.7
Canine	0.2	0.4	0.6	0.7	0.9	0.9

*Data from Shillingburg and Grace.¹²¹

Indications

Caries-free abutment teeth

If the edentulous span is not too long, the resin-bonded fixed partial denture allows tooth replacement with minimal destruction of tooth structure on undamaged abutment teeth.

Mandibular incisor replacements

The acid-etched resin-bonded fixed partial denture can be used to replace one or two missing mandibular incisors when the abutment teeth are unblemished.

Maxillary incisor replacements

Maxillary incisors can be replaced if there is little or no vertical overlap.

Periodontal splints

The splinting of periodontally involved teeth comprised the first published report of the use of a resin-bonded prosthesis by Rochette,⁵⁰ and other authors described the use of resin-bonded, perforated,¹⁰⁸ and etched-metal¹⁰⁹ splints for long-term usage. However, abutment mobility has been cited as one of the causes of failure by Barrack,¹¹⁰ and the study by Marinello et al⁹⁵ indicated that the failure rate for splints was 13% greater than that for fixed partial dentures. If a resin-bonded prosthesis is to be used as a splint, careful attention must be paid to resistance features on the abutment preparations. In the previously cited study by Marinello et al,⁹⁵ the use of grooves on abutments for splints improved the chances for success by nearly 15%.

Single posterior tooth replacements

Resin-bonded fixed partial dentures of more than three units have a 10% higher failure rate than those that are only three units in length.⁹⁵ Resin-bonded fixed partial dentures consisting of greater than three units should be used only if there is some mitigating treatment-planning consideration, such as opposing a removable partial denture, which would result in less occlusal stress. Fixed partial dentures with more than two retainers have a failure rate 2.5 times that of resin-bonded fixed partial dentures with only two retainers.⁸³

Contraindications

Extensive caries

Because the resin-bonded fixed partial denture covers relatively little surface area and relies on bonding to enamel for its retention, the presence of caries lesions of any size will require the use of a more conventional prosthesis.

Nickel sensitivity

Tin-plated high noble alloys can be used to avoid this problem.

Deep vertical overbite

So much enamel must be removed from the lingual surface of a maxillary incisor in this occlusal relationship that retention would be drastically reduced because of the poor bonding strength afforded by the exposed dentin.

Tooth preparation

The early use of acid-etched resin-bonded fixed partial dentures was accomplished with no preparation of the abutment teeth.^{50,70} Although some authors advocate little or no tooth preparation for this type of prosthesis, emphasizing its reversibility,^{111,112} preparation features are used by many to enhance the resistance of resin-bonded fixed partial dentures.

The tooth preparation includes axial reduction and guide planes on the proximal surfaces with a slight extension onto the facial surface to achieve a faciolingual lock.¹¹³⁻¹¹⁵ The preparation should encompass at least 180 degrees of the tooth to enhance the resistance of the retainer.¹¹⁶ The preparation must be extended as far as possible to provide maximum bonding area. This has been a problem in the past. A number of the early restorations that failed covered too little surface area to give them adequate strength to resist displacement.¹¹⁷ There should be a finish line even though it will be nothing more than a very light chamfer, and it should be placed about 1.0 mm supragingivally.^{72,110,116,118}

Occlusal clearance is needed on very few teeth that are prepared as abutments for acid-etched resin-bonded fixed partial dentures. Specifically, 0.5 mm is needed on maxillary incisors, where preparation is done on the lingual surface of the teeth.^{102,119,120} The thicknesses of enamel on the lingual surfaces of maxillary anterior teeth are shown in Table 11-2.¹²¹ Because of the limited thickness of enamel near the cemento-enamel junction, this type of restoration cannot be used on patients with a severe Class II vertical overlap.¹²²

Vertical stops are placed on all the preparations. This will consist of two or three flat countersinks on the lingual surface of an incisor,^{110,117,123} a cingulum rest on a canine,¹¹³ or an occlusal rest seat on a premolar or molar.^{77,124} Wilkes¹²⁵ found rests to be the dominant feature in a preparation, contributing to both resistance and rigidity. The occlusal rest directs the applied force from the pontic to the abutments.¹²⁶ Pegoraro and Barrack strongly recommend the use of two rests.^{77,127}

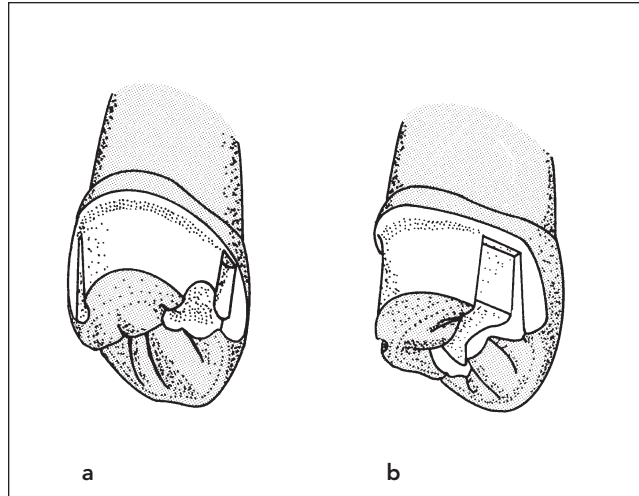


Fig 11-46 Grooves are most commonly employed as resistance features on resin-bonded fixed partial denture abutments (a), but the box form of an existing amalgam can also be converted for that purpose (b).

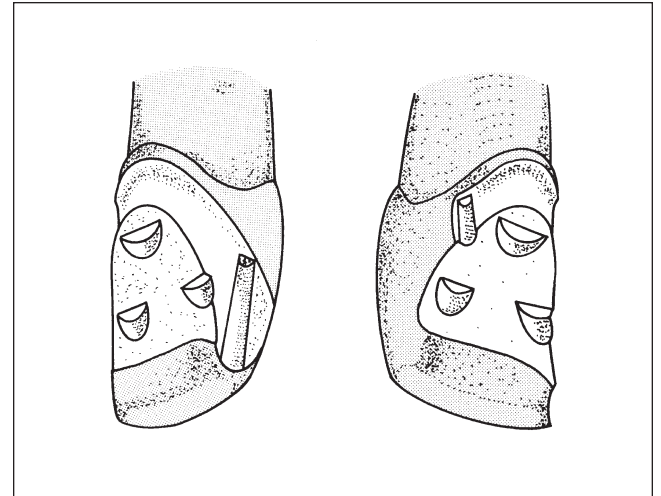


Fig 11-47 Resin-bonded abutment preparation for a maxillary incisor.

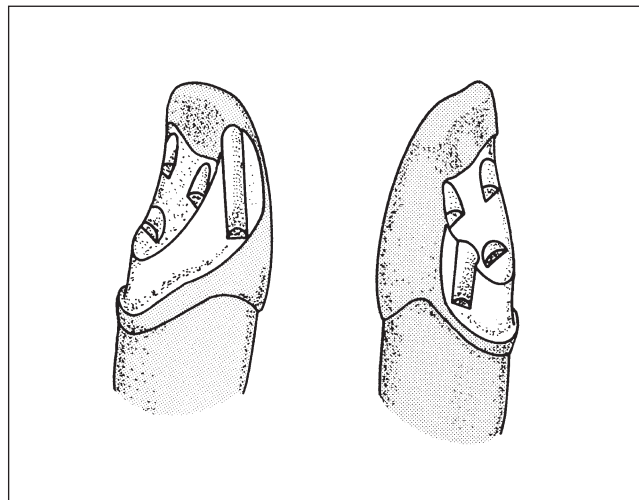


Fig 11-48 Resin-bonded abutment preparation for a mandibular incisor.

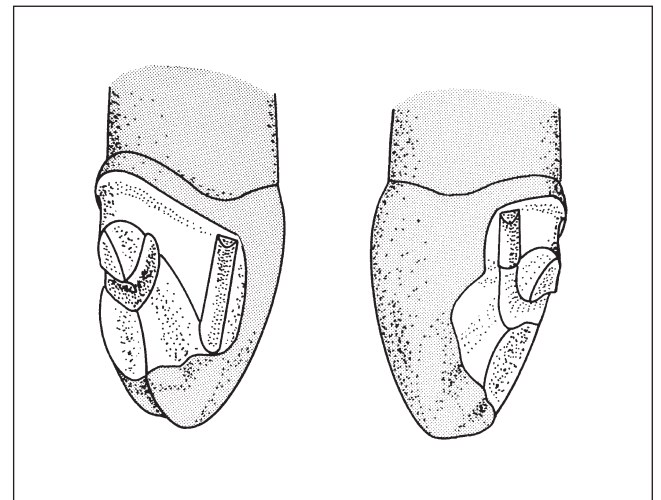


Fig 11-49 Resin-bonded abutment preparation for a maxillary canine.

The resistance features used in a tooth preparation for an acid-etched resin-bonded retainer will normally be grooves^{92,116,128,129} (Fig 11-46a). Grooves were found to increase resistance to displacement on anterior preparations 31% to 77% in one study¹³⁰ and 81% in another.¹¹³ However, if there is an existing amalgam, all of the amalgam, or at least all of its surface, is removed so that the box form can be utilized¹³¹ (Fig 11-46b). The entire occlusal outline of the existing amalgam restoration is included within the outline of the retainer's occlusal rest.⁸¹ If the retainer margins cross

over an amalgam-enamel margin, there is a high probability of leakage occurring around that margin.¹³¹

Examples of the preparations used on the different teeth include those made for a maxillary (Fig 11-47) or mandibular incisor (Fig 11-48) and maxillary canine (Fig 11-49), all of which have a proximal groove near the facioproximal line angle adjacent to the edentulous space. There is a second groove on the opposite side of the cingulum or lingual cusp of the tooth, which creates a wraparound effect in the retainer and produces resistance in the process. Both grooves should be placed in enamel.

11 Preparations for Partial Coverage Crowns

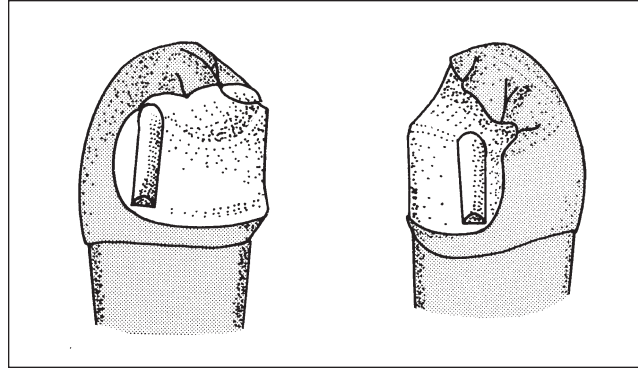


Fig 11-50 Resin-bonded abutment preparation for a mandibular first premolar.

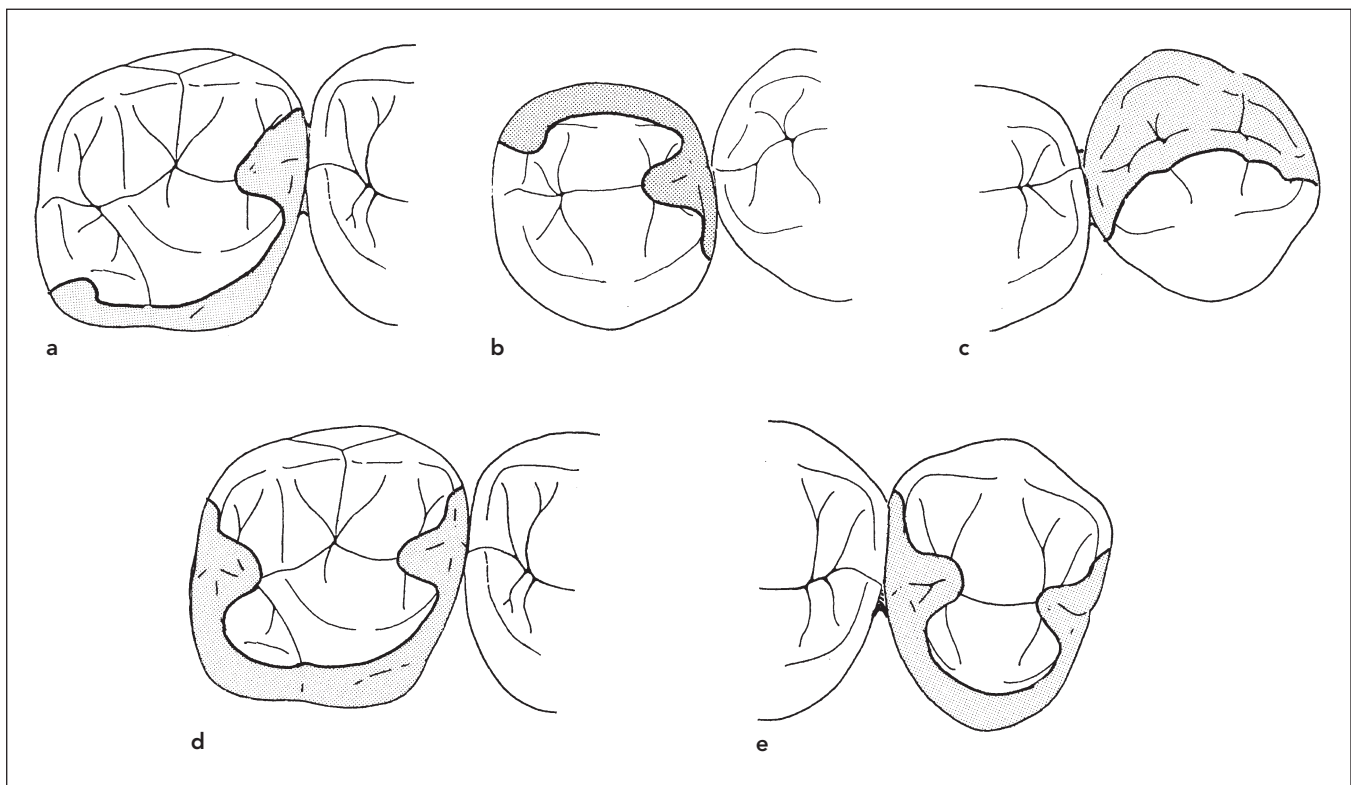


Fig 11-51 Posterior resin-bonded fixed partial denture framework configurations. (a to c) Standard. There are two grooves, one near the facio-proximal angle adjacent to the edentulous space and one at the opposite linguoproximal corner, with greater than 180 degrees of axial wall coverage. (d and e) Two rests. This variation, suggested by Barrack,¹¹⁰ has axial coverage on both proximal walls and two rest seats located near the central groove at the mesio-occlusal and disto-occlusal. They resist displacement by occlusal forces.

The preparation for a mandibular first premolar (Fig 11-50) is slightly different than that for other premolar preparations. Because the placement of a rest seat would leave very little solid tooth structure in the small lingual cusp of many first premolars, coverage of the entire small lingual cusp is substituted. Lingual cusp coverage, when it does not interfere with occlusion, is an excellent means of increasing surface area and reinforcing the retainer.¹³² The framework should be bolstered to produce rigidity (Fig 11-51).

Preparation armamentarium

- High-speed handpiece
- Articulating ribbon
- Football-shaped diamond
- Small wheel and short needle diamonds
- Flat-end and round-end tapered diamonds

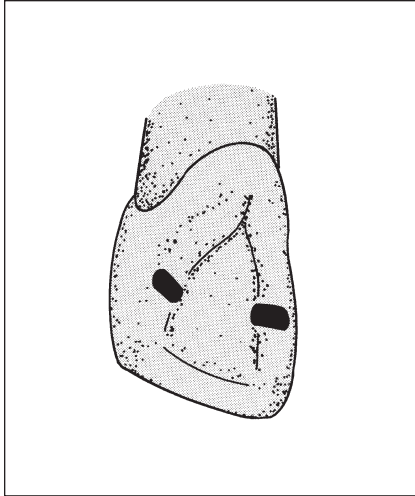


Fig 11-52 Occlusal marking: articulation paper.

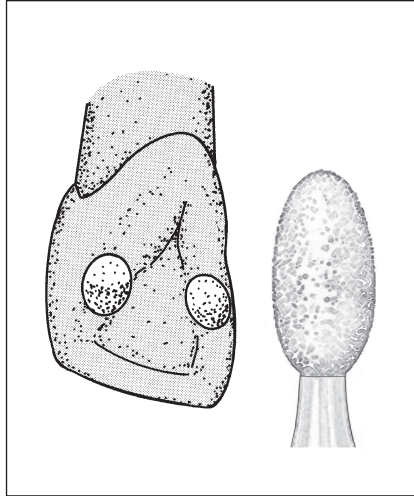


Fig 11-53 Occlusal clearance: football-shaped diamond.

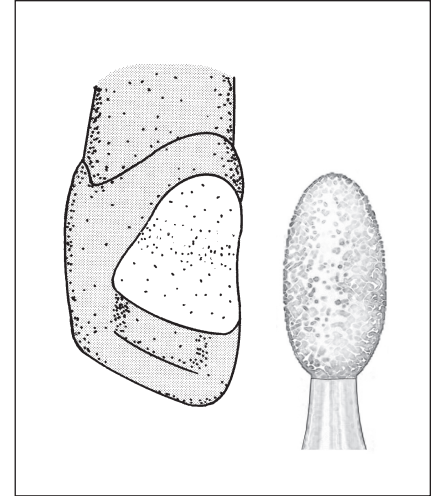


Fig 11-54 Lingual reduction: football-shaped diamond.

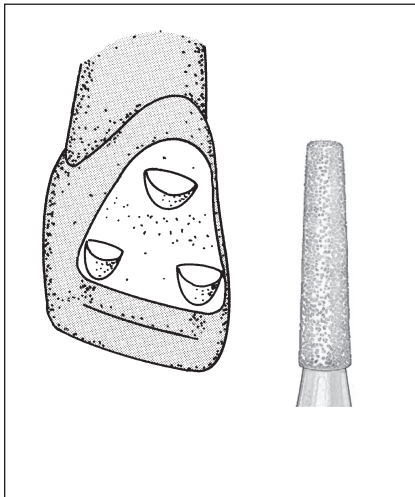


Fig 11-55 Countersinks: flat-end tapered diamond.

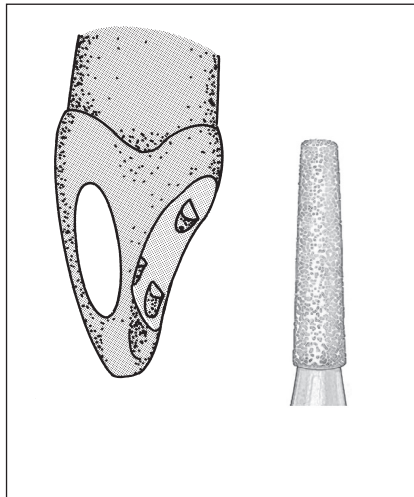


Fig 11-56 Proximal reduction (facial segment): flat-end tapered diamond.

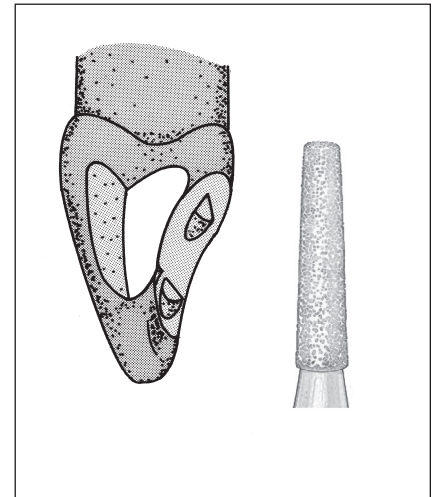


Fig 11-57 Proximal reduction (lingual segment): flat-end tapered diamond.

Preparation sequence

The preparation sequence shown is for a maxillary incisor. First, the centric occlusal contacts are marked with articulating ribbon¹²³ (Fig 11-52). To ensure adequate occlusal clearance in this area, a football-shaped diamond is used to remove 0.5 mm of tooth structure (Fig 11-53). This particular step is necessary only on maxillary anterior teeth.

The same football-shaped diamond is used to create a concave reduction on the entire cingulum surface of the incisor, producing 0.5 mm of lingual clearance (Fig 11-54). This reduction should end 1.5 to 2.0 mm from the incisal edge, or just incisal to the most incisal occlusal contact, whichever is closer to the incisal edge. A flat-end tapered diamond is

used to prepare flat notches or countersinks on the lingual surface of the tooth to provide resistance to gingival displacement (Fig 11-55).

Proximal reduction on the surface adjacent to the edentulous space is done with a flat-end tapered diamond, producing a small plane that extends slightly facial to the facioproximal line angle (Fig 11-56). This helps produce facial wraparound to enhance resistance, a feature that will be less prominent on maxillary anterior teeth than on mandibular teeth. A second plane is produced lingual to the first with the same diamond (Fig 11-57).

Light upright lingual axial reduction is done from the biplanar proximal axial reduction around the cingulum to a point just short of the proximal contact on the opposite

11 Preparations for Partial Coverage Crowns

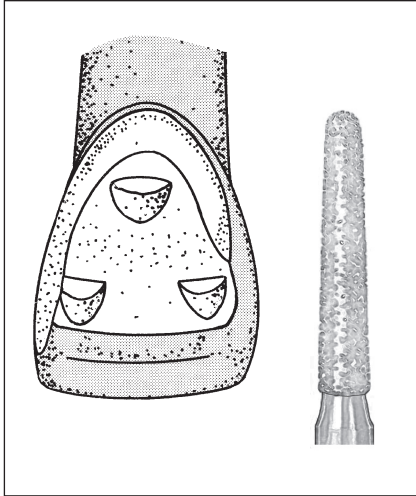


Fig 11-58 Lingual axial reduction: round-end tapered diamond.

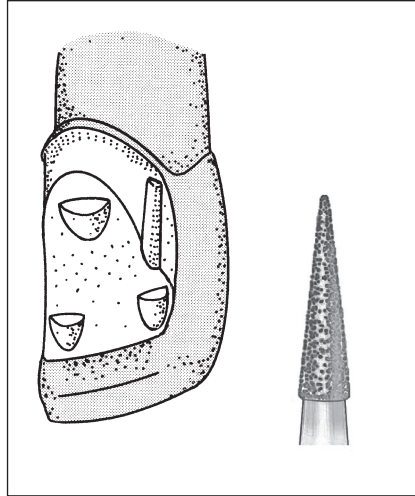


Fig 11-59 Cingulum groove: short needle diamond.

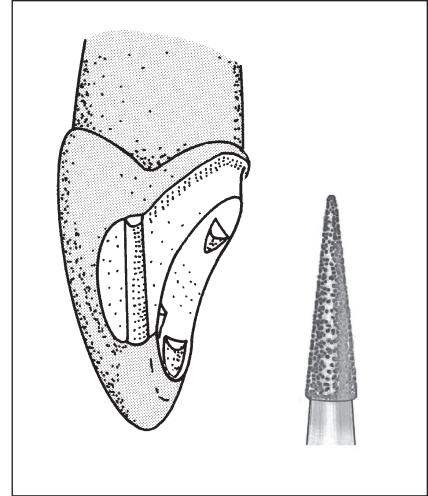


Fig 11-60 Proximal groove: short needle diamond.

side of the cingulum from the edentulous space (Fig 11-58). The thickness of the axial walls of the retainer will be greater than the amount of axial tooth structure removed, leading to overcontouring of the axial walls of the cast retainer. To minimize any deleterious effect on the periodontium, the very light chamfer finish line should remain approximately 1.0 mm supragingival throughout its length.

A short groove is placed at the facialmost extension of the reduction on the opposite side of the cingulum with a short needle diamond (Fig 11-59). In addition to bolstering the rigidity of the retainer, the groove will serve to enhance its resistance. The same thin diamond is used to place a groove in the vicinity of the wraparound or break between the facial and lingual planes of proximal axial reduction adjacent to the edentulous space (Fig 11-60).

Delivery

Delivery armamentarium

- Rubber dam, clamp, and frame
- Low-speed contra-angle handpiece, rubber prophyl cup, pumice
- Etchant, cotton pellets
- Small brush, mixing well
- Mixing pad, plastic spatula
- Mylar strip, dental floss
- Explorer, scaler
- Complete adhesive resin kit

Delivery sequence

The delivery sequence is an important procedure that must be accomplished efficiently because of the limited working time of bonding resins. It is also critically important to the

longevity of the prosthesis. Contamination or improper seating of the fixed partial denture at this time will adversely affect the success of the restoration. The technique described here is for Panavia 21.

The process begins with the isolation of the abutment teeth with rubber dam^{116,124,133} (Fig 11-61). The tooth-facing surfaces of the retainers are again air abraded just before insertion of the restoration using 30- to 50- μ m aluminum oxide with a handheld etcher (MicroEtcher, Danville). Two to three seconds per cm^2 at 4.2 to 7 kg/cm^2 (60 to 100 psi) pressure should be sufficient to restore the matte finish. The casting is washed in running water for 1 minute, placed in dishwashing liquid in an ultrasonic unit for 2 minutes, and then rinsed.

If the fixed partial denture is made of a high noble alloy, such as Olympia, the inner surfaces of the retainers should now be plated with a layer of tin approximately 0.5 μ m thick. Ground the tin plating instrument (MicroTin, Danville) to the pontic metal. Rub the active tip with a pellet soaked with plating solution over the inner surfaces of the retainers for 5 to 10 seconds each. The surface will become a slightly lighter shade of gray.¹²⁴ The restoration should be rinsed thoroughly in water and again for 2 minutes in detergent in an ultrasonic cleaner. The fixed partial denture should be rinsed, blown dry, and placed in an accessible but protected place.

The next step is to clean the tooth preparations with unflavored, nonfluoridated pumice and a rubber prophyl cup (Fig 11-62). The pumice is washed off, and a 40% to 50% phosphoric acid solution is applied to the abutment preparations with a cotton pellet¹³⁴ (Fig 11-63). The etchant is left on for 60 seconds and, after the preparations are rinsed and dried, reapplied for 15 seconds.¹²⁴ The abutment preparations are washed thoroughly with water for 20 seconds (Fig 11-64), then dried (Fig 11-65). A light stream of air is played over the preparation. A Mylar strip is placed between each abutment and its neighboring tooth.

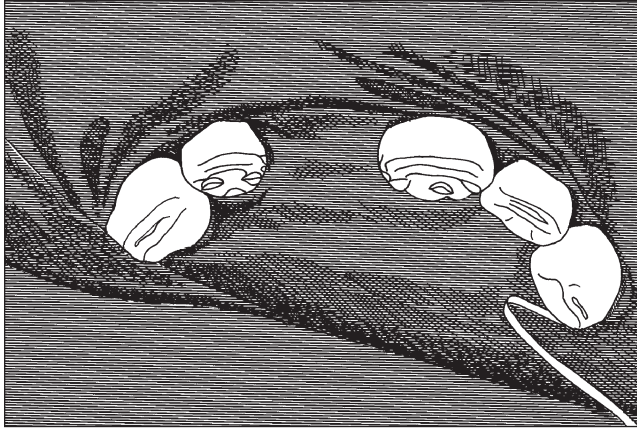


Fig 11-61 Abutment teeth are isolated with a well-inverted rubber dam.

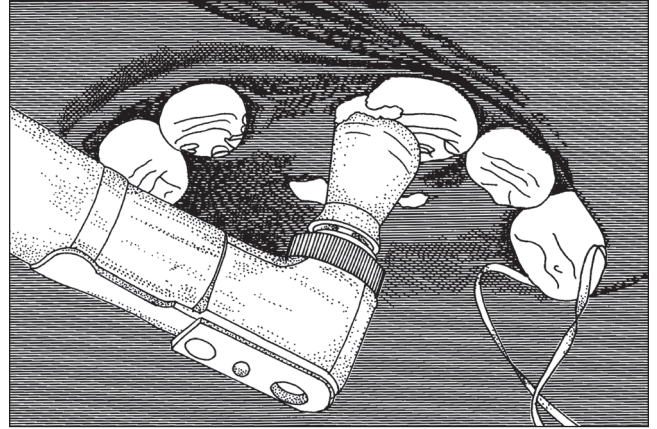


Fig 11-62 Abutments are cleaned with pumice and a rubber cup.

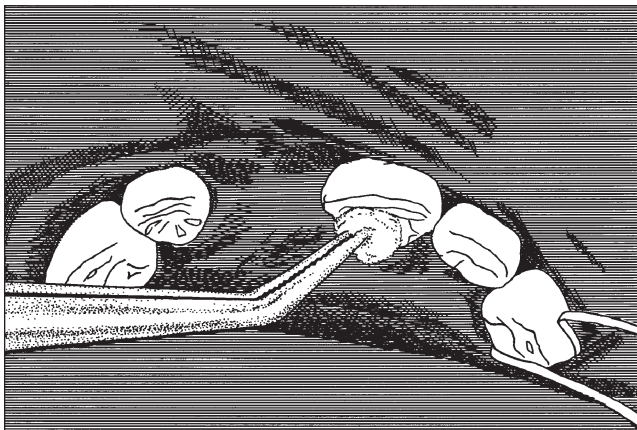


Fig 11-63 Etchant is applied to the teeth with a cotton pellet or small rubber sponge.

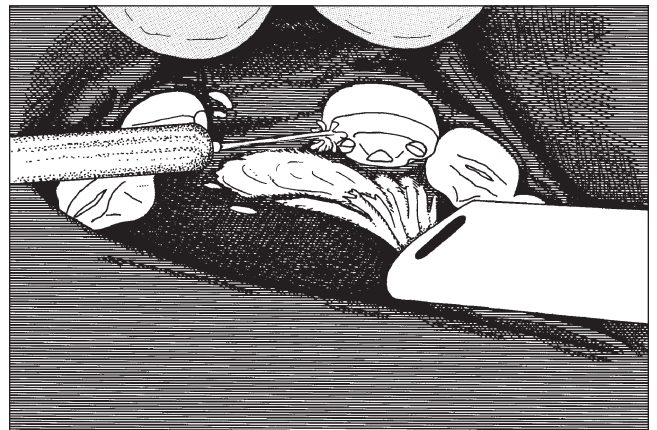


Fig 11-64 Etched surfaces of the abutments are washed with water.

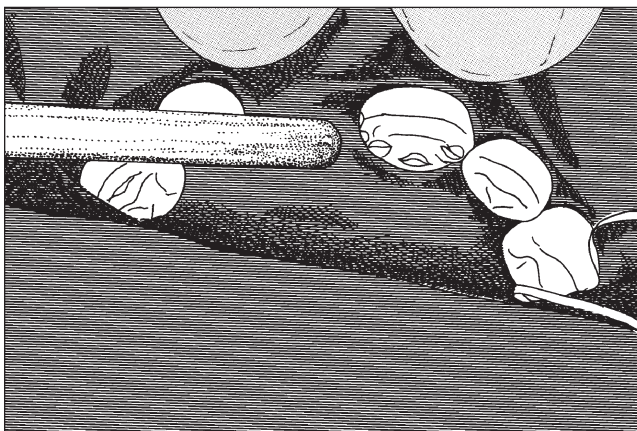


Fig 11-65 The preparations are dried with compressed air.

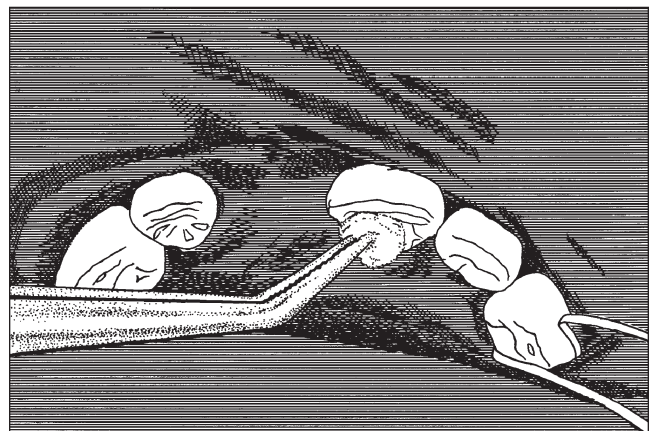


Fig 11-66 ED Primer is applied to the teeth with a cotton pellet or small pledget.

The next step is to mix the primer and the resin to bond the prosthesis in place. One drop each of ED Primer (Kuraray) liquids A and B is dispensed into a well in the mixing dish and mixed for 4 seconds. A sponge pledget is used to apply the mixture to the preparations (Fig 11-66). It is allowed to set for 60 seconds, and then a gentle stream of

air is applied to evaporate the volatile substances, leaving a glossy surface. Primer is not applied to the metal, and it should not be rinsed.

The cap is removed from the dispenser, and the rectangular knob is slowly rotated clockwise one full turn, dispensing the material onto the mixing pad. Stop when it clicks. If the

11 Preparations for Partial Coverage Crowns

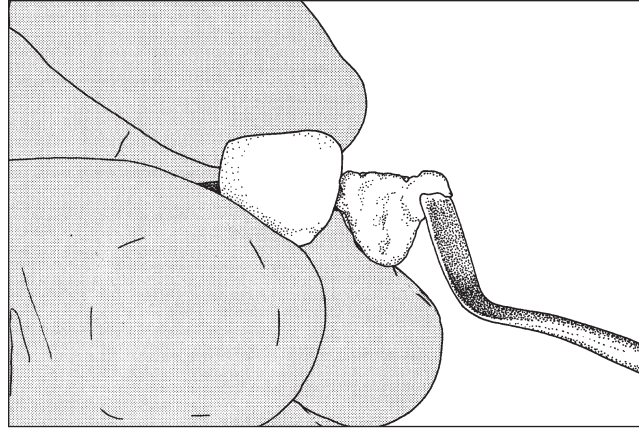


Fig 11-67 A thin layer of mixed resin is applied to the retainers.

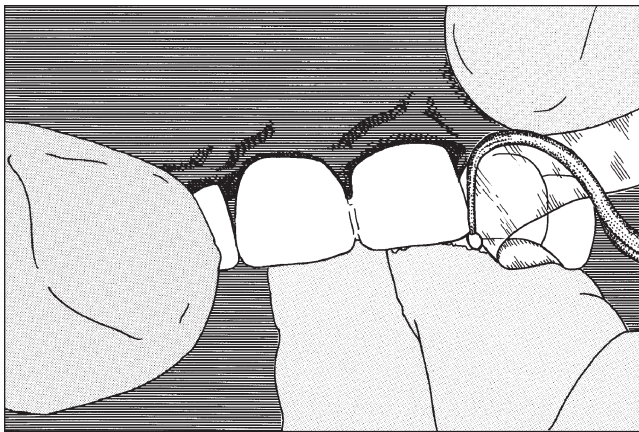


Fig 11-68 The fixed partial denture is held securely in place for 60 seconds.

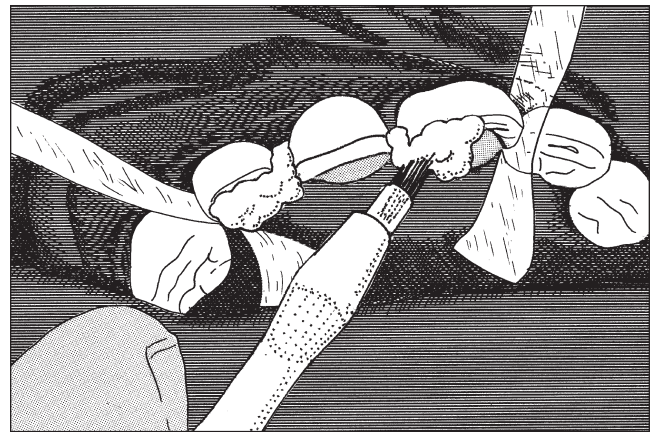


Fig 11-69 Oxyguard II is applied to protect the resin from exposure to oxygen.

quantity dispensed seems too small for the restoration being placed, the knob can be turned another full turn until it clicks again. The two stripes of paste should be mixed for 20 to 30 seconds over a wide area. The material is anaerobic, so it will set only if oxygen is kept from it. Therefore, spreading it out will keep it from setting prematurely.

A thin, bubble-free layer of paste is applied to the retainers (Fig 11-67). No paste should be placed on the tooth because the primer will accelerate it, and the restoration will not seat completely. The restoration is seated with firm finger pressure (Fig 11-68) and held for 60 seconds. A small brush (Proxabrush, John O. Butler) is used to clean away excess resin.

A disposable brush is used to apply Oxyguard II (Kuraray) to the margins of the retainers to keep oxygen away from the setting resin (Fig 11-69). The Mylar strips placed between

each abutment tooth and its adjacent tooth will ensure that they do not bond together. A piece of floss can also be positioned between the abutment tooth and its neighbor when the fixed partial denture is placed. It is pulled out through the contacts before the resin has set completely. After 3 minutes, the Oxyguard II is removed with cotton rolls and water spray.

Before the resin has become too hard, the excess must be removed because it will become irritating to the gingival tissue. An explorer or scaler can be used around the gingival margins and those exposed areas that can be reached. Floss should be run through the proximal contacts of the abutment teeth as well as the adjacent teeth. The interproximal area between each retainer and its adjacent neighbor should be very carefully cleaned and examined.

References

- Kahn AE. Partial versus full coverage. *J Prosthet Dent* 1960;10:167-178.
- Maxwell EL, Wasser VE. Debate: Full vs. partial coverage as the abutment of choice in fixed bridgework. *J Dist Columbia Dent Soc* 1961;36:9-11.
- Miller LL. Partial coverage in crown and bridge prosthesis with the use of elastic impression materials. *J Prosthet Dent* 1963;13:905-910.
- Silness J. Periodontal conditions in patients treated with dental bridges. 2. The influence of full and partial crowns on plaque accumulation, development of gingivitis and pocket formation. *J Periodontal Res* 1970;5:219-224.
- Felton D, Madison S, Kanoy E, Kantor M, Maryniuk G. Long-term effects of crown preparation on pulp vitality [abstract 1139]. *J Dent Res* 1989;68:1008.
- Kishimoto M, Hobo S, Duncanson MG Jr, Shillingburg HT Jr. Effectiveness of margin finishing techniques on cast gold restorations. *Int J Periodontics Restorative Dent* 1981;1(5):20-29.
- Jorgensen KD. Structure of the film of zinc phosphate cements crowns. *Acta Odontol Scand* 1960;18:491-501.
- Ho G. Lecture notes. Los Angeles: University of Southern California School of Dentistry, 1959.
- Lorey RE, Myers GE. The retentive qualities of bridge retainers. *J Am Dent Assoc* 1968;76:568-572.
- Reisbick MH, Shillingburg HT Jr. Effect of preparation geometry on retention and resistance of cast gold restorations. *J Calif Dent Assoc* 1975;3:51-59.
- Potts RG, Shillingburg HT Jr, Duncanson MG Jr. Retention and resistance of preparations for cast restorations. *J Prosthet Dent* 1980;43:303-308.
- Shillingburg HT Jr, Fisher DW. A partial veneer restoration. *Aust Dent J* 1972;17:411-417.
- Cowger GT. Retention, resistance and esthetics of the anterior three-quarter crown. *J Am Dent Assoc* 1961;62:167-171.
- Kishimoto M, Shillingburg HT Jr, Duncanson MG Jr. Influence of preparation features on retention and resistance. Part II: Three-quarter crowns. *J Prosthet Dent* 1983;49:188-192.
- Ingraham R, Bassett RW, Koser JR. *An Atlas of Cast Gold Procedures*, ed 2. Los Angeles: University of Southern California School of Dentistry, 1969:161-165.
- Racowsky LP, Wolinsky LE. Restoring the badly broken-down tooth with esthetic partial coverage restorations. *Compend Contin Educ Dent* 1981;2:322-335.
- Tinker HA. The three-quarter crown in fixed bridgework. *J Can Dent Assoc* 1950;16:125-129.
- Tjan AH, Miller GD. Biogeometric guide to groove placement on three-quarter crown preparations. *J Prosthet Dent* 1979;42:405-410.
- Wiley RE. The preparation of abutments for veneer retainers. *J Am Dent Assoc* 1956;53:141-154.
- Guyer SE. Multiple preparations for fixed prosthodontics. *J Prosthet Dent* 1970;23:529-553.
- Smith DE. Abutment preparations. *J Am Dent Assoc* 1931;18:2063-2075.
- Rhoads JE. Preparation of the teeth for cast restorations. In: Hollenback GM (ed). *Science and Technic of the Cast Restoration*. St Louis: Mosby, 1964:66.
- Kishimoto M, Shillingburg HT Jr, Duncanson MG Jr. Influence of preparation features on retention and resistance. Part I. MOD onlays. *J Prosthet Dent* 1983;49:35-39.
- Tanner H. Ideal and modified inlay and veneer crown preparations. *Ill Dent J* 1957;26:240-244.
- Ingraham R, Bassett RW, Koser JR. *An Atlas of Cast Gold Procedures*, ed 2. Los Angeles: University of Southern California School of Dentistry, 1969:34.
- Kessler JC, Shillingburg HT Jr. The seven-eighths crown. *Gen Dent* 1983;31:132-133.
- Smith DE. Fixed bridge restorations with the tilted mandibular second or third molar as an abutment. *J South Calif Dent Assoc* 1939;6:131-138.
- Shillingburg HT Jr. Bridge retainers for tilted abutments. *N M Dent J* 1972;22:16-19.
- Hughes HJ, Barrett PJ. Are there alternatives to the porcelain fused to gold bridge? *Aust Dent J* 1970;15:281-287.
- Leander CT. Preparation of abutments for fixed partial dentures. *Dent Clin North Am* 1959;3:59-72.
- Tinker ET. Fixed bridgework. *J Natl Dent Assoc* 1920;7:579-595.
- Baum L. New cast gold restorations for anterior teeth. *J Am Dent Assoc* 1960;61:1-8.
- Over LM. Using the pinledge as a conservative retainer: A clinical report. *J Prosthodont* 2008;17:490-494.
- Arbo MA. A simple technique for castings with pin retention. *Dent Clin North Am* 1970;14:19-29.
- Clyde JS, Sharkey SW. The pin ledge crown. A reappraisal. *Br Dent J* 1978;144:239-245.
- Baum L, Contino RM. Ten years of experience with cast pin restorations. *Dent Clin North Am* 1970;14:81-91.
- Crispin BJ. Conservative alternative to full esthetic crowns. *J Prosthet Dent* 1979;42:392-397.
- Bruce RW. Parallel-pin splints for periodontally involved teeth. *J Prosthet Dent* 1964;14:739-745.
- Moffa JP, Phillips RW. Retentive properties of parallel pin restorations. *J Prosthet Dent* 1967;17:387-400.
- Shooshan ED. A pin-ledge casting technique—Its application in periodontal splinting. *Dent Clin North Am* 1960;4:189-206.
- Mosteller JH. *Parallel Pin Gold Castings*, Practical Dental Monographs. Chicago: Year Book Medical, 1963:5-29.
- Burns BB. Pin retention of cast gold restorations. *J Prosthet Dent* 1965;15:1101-1108.
- Dilts WE, Welk DA, Stovall J. Retentive properties of pin materials in pin-retained silver amalgam restorations. *J Am Dent Assoc* 1968;77:1085-1089.
- Lorey RE, Embrell KA, Myers GE. Retentive factors in pin-retained castings. *J Prosthet Dent* 1967;17:271-275.
- Courtade GL, Timmermans JJ. *Pins in Restorative Dentistry*. St Louis: Mosby, 1971:6.
- Mann AW, Courtade GL, Sanell C. The use of pins in restorative dentistry. I. Parallel pin retention obtained without using paralleling devices. *J Prosthet Dent* 1965;15:502-516.
- Pruden WH II. Partial coverage retainers: A critical evaluation. *J Prosthet Dent* 1966;16:545-548.
- Buonocore MG. A simple method of increasing the adhesion of acrylic filling materials to enamel surfaces. *J Dent Res* 1955;34:849-853.
- Ibsen RL. One-appointment technic using an adhesive composite. *Dent Surv* 1973;49(2):30-32.
- Rochette AL. Attachment of a splint to enamel of lower anterior teeth. *J Prosthet Dent* 1973;30:418-423.
- Saunders WP. Resin bonded bridgework: A review. *J Dent* 1989;17:255-265.
- Dunn B, Reisbick MH. Adherence of ceramic coatings on chromium-cobalt structures. *J Dent Res* 1976;55:328-332.
- Thompson VP, Del Castillo E, Livaditis GJ. Resin-bonded retainers. Part I: Resin bond to electrolytically etched nonprecious alloys. *J Prosthet Dent* 1983;50:771-779.
- Sloan KM, Lorey RE, Myers GE. Evaluation of laboratory etching of cast metal resin-bonded retainers [abstract 1220]. *J Dent Res* 1983;62:305.
- McLaughlin G. One hundred second etch technique for etched-metal bridges. *J Mich Dent Assoc* 1982;64:347-349.
- McLaughlin G, Masek J. Comparison of bond strengths using one-step and two-step alloy etching techniques. *J Prosthet Dent* 1985;53:516-520.
- Wiltshire WA, Ferreira MR. A classification of resin-bonded bridges based on the evolutionary changes of the different technique types. *Quintessence Dent Technol* 1987;11:253-258.
- Livaditis GJ. A chemical etching system for creating micromechanical retention in resin-bonded retainers. *J Prosthet Dent* 1986;56:181-188.
- Doukoudakis S, Cohen B, Tsoutsos A. A new chemical method for etching metal frameworks of the acid-etched prosthesis. *J Prosthet Dent* 1987;58:421-423.

11 Preparations for Partial Coverage Crowns

60. Mukai M, Fukui H, Hasegawa J. Relationship between sand-blasting and composite resin-alloy bond strength by a silica coating. *J Prosthet Dent* 1995;74:151–155.
61. Moon PC. The Virginia resin bonded bridge: A restoration materials report. *Va Dent J* 1984;61(3):9–11.
62. Moon PC. Bond strengths of the lost salt procedure: A new retention method for resin-bonded fixed prostheses. *J Prosthet Dent* 1987;57:435–439.
63. Hudgins JL, Moon PC, Knap FJ. Particle-roughened resin-bonded retainers. *J Prosthet Dent* 1985;53:471–476.
64. Moon PC. The laboratory procedure for the Virginia resin bonded bridge. *Trends Tech Contemp Dent Lab* 1985;2(6):22–28.
65. Tanaka T, Fujiyama E, Shimizu H, Takaki A, Atsuta M. Surface treatment of nonprecious alloys for adhesion-fixed partial dentures. *J Prosthet Dent* 1986;55:456–462.
66. Tanaka T, Atsuta M, Nakabayashi N, Masuhara E. Surface treatment of gold alloys for adhesion. *J Prosthet Dent* 1988;60:271–279.
67. Wiltshire WA. Tensile bond strengths of various alloy surface treatments for resin bonded bridges. *Quintessence Dent Technol* 1986;10:227–232.
68. el-Sherif MH, el-Messery A, Halhoul MN. The effects of alloy surface treatments and resins on the retention of resin-bonded retainers. *J Prosthet Dent* 1991;65:782–786.
69. Laswell HR, Welk DA, Regenos JW. Attachment of resin restorations to acid pretreated enamel. *J Am Dent Assoc* 1971;82:558–563.
70. Howe DF, Denehy GE. Anterior fixed partial dentures utilizing the acid-etch technique and a cast metal framework. *J Prosthet Dent* 1977;37:28–31.
71. Denehy GE, Howe DF. A conservative approach to the missing anterior tooth. *Quintessence Int Dent Dig* 1979;10(7):23–29.
72. Shaw MJ, Tay WM. Clinical performance of resin-bonded cast metal bridges (Rochette bridges). A preliminary report. *Br Dent J* 1982;152:378–380.
73. Livaditis GJ. Cast metal resin-bonded retainers for posterior teeth. *J Am Dent Assoc* 1980;101:926–929.
74. Livaditis GJ, Thompson VP. Etched castings: An improved retentive mechanism for resin-bonded retainers. *J Prosthet Dent* 1982;47:52–58.
75. Thompson VP, Grolman KM, Liao R. Bonding of adhesive resins to various nonprecious alloys [abstract 1258]. *J Dent Res* 1985;64:314.
76. Jenkins CB, Aboush YE. The bond strength of a new adhesive recommended for resin bonded bridges [abstract 18]. *J Dent Res* 1985;64:664.
77. Barrack G. The etched cast restoration—Clinical techniques and long-term results. *Quintessence Int* 1993;24:701–713.
78. Eakle WS, Lacy AM. A clinical technique for bonding gold castings to teeth. *Quintessence Int* 1991;22:491–494.
79. Imbery TA, Burgess JO, Naylor WP. Tensile strength of three resin cements following two alloy surface treatments. *Int J Prosthodont* 1992;5:59–67.
80. Breeding LC, Dixon DL. The effect of metal surface treatment on the shear bond strengths of base and noble metals bonded to enamel. *J Prosthet Dent* 1996;76:390–393.
81. Barrack G, Bretz WA. A long-term prospective study of the etched-cast restoration. *Int J Prosthodont* 1993;6:428–434.
82. Bergendal B, Hallonsten AL, Koch G, Ludvigsson N, Olgart K. Composite retained onlay bridges. A follow-up study in adolescents. *Swed Dent J* 1983;7:217–225.
83. Chang HK, Zidan O, Lee IK, Gomez-Marín O. Resin-bonded fixed partial dentures: A recall study. *J Prosthet Dent* 1991;65:778–781.
84. Clyde JS, Boyd T. The etched cast metal resin-bonded (Maryland) bridge: A clinical review. *J Dent* 1988;16:22–26.
85. Creugers NH, Van't Hof MA, Vrijhoef MM. A clinical comparison of three types of resin-retained cast metal prostheses. *J Prosthet Dent* 1986;56:297–300.
86. Creugers NH, Snoek PA, Van't Hof MA, Käyser AF. Clinical performance of resin-bonded bridges: A 5-year prospective study. Part III: Failure characteristics and survival after rebonding. *J Oral Rehabil* 1990;17:179–186.
87. Ekstrand K. Experience with 120 composite-retained fixed bridges [in Swedish]. *Tandlakartidningen* 1984;76:987–993.
88. Eshleman JR, Douglas HB Jr, Barnes D. The acid etch bonded porcelain fused to metal bridge. *Va Dent J* 1979;56(5):16–19.
89. Ferrari M, Mason PN, Cagidiaco D, Cagidiaco MC. Clinical evaluation of resin bonded retainers. *Int J Periodontics Restorative Dent* 1989;9:207–219.
90. Hansson O, Moberg LA. Clinical evaluation of resin-bonded prostheses. *Int J Prosthodont* 1992;5:533–541.
91. Kuhlke KL, Drennon DC. An alternative to the anterior single-tooth removable partial denture. *J Int Assoc Dent Child* 1977;8:11–15.
92. LaBarre EE, Ward HE. An alternative resin-bonded restoration. *J Prosthet Dent* 1984;52:247–249.
93. Livaditis GJ. Resin-bonded cast restorations: Clinical study. *Int J Periodontics Restorative Dent* 1981;1(4):70–79.
94. Marinello CP, Kerschbaum T, Heinenberg B, et al. Experiences with resin-bonded bridges and splints—A retrospective study. *J Oral Rehabil* 1987;14:251–260.
95. Marinello CP, Kerschbaum T, Heinenberg B, et al. First experiences with resin-bonded bridges and splints—A cross-sectional retrospective study. Part II. *J Oral Rehabil* 1988;15:223–235.
96. Olin PS, Hill EM, Donahue JL. Clinical evaluation of resin-bonded bridges: A retrospective study. *Quintessence Int* 1991;22:873–877.
97. Priest GF, Donatelli HA. A four-year clinical evaluation of resin-bonded fixed partial dentures. *J Prosthet Dent* 1988;59:542–546.
98. Rammelsberg P, Pospiech P, Gernet W. Clinical factors affecting adhesive fixed partial dentures: A 6-year study. *J Prosthet Dent* 1993;70:300–307.
99. Thayer KE, Williams VD, Diaz-Arnold AM, Boyer DB. Acid-etched, resin-bonded cast metal prostheses: A retrospective study of 5- to 15-year-old restorations. *Int J Prosthodont* 1993;6:264–269.
100. Thompson VP, Wood M. Etched casting bonded retainer recalls: Results at 3–5 years [abstract 1282]. *J Dent Res* 1986;65:311.
101. van der Veen H, Bronsdijk B, van de Poel F. Clinical evaluation of resin-bonded fixed partial dentures with perforated retainers—Six-year results. *Quintessence Dent Technol* 1987;11:51–56.
102. Williams VD, Denehy GE, Thayer KE, Boyer DB. Acid-etch retained cast metal prostheses: A seven-year retrospective study. *J Am Dent Assoc* 1984;108:629–631.
103. Williams VD, Thayer KE, Denehy GE, Boyer DB. Cast metal, resin-bonded prostheses: A 10-year retrospective study. *J Prosthet Dent* 1989;61:436–441.
104. Yankelson M, Myers GE. Acid-etch bridges: Results of a 24 month clinical trial [abstract 917]. *J Dent Res* 1980;59:496.
105. Creugers NHJ, Van't Hof MA. An analysis of clinical studies on resin-bonded bridges. *J Dent Res* 1991;70:146–149.
106. Kerschbaum T, Gaa M. Longitudinal analysis of fixed dentures in private insurance patients [in German]. *Dtsch Zahnärztl Z* 1987;42:345–351.
107. Palmqvist S, Swartz B. Artificial crowns and fixed partial dentures 18 to 23 years after placement. *Int J Prosthodont* 1993;6:279–285.
108. Buchanan WT. Periodontal splinting: Two conservative procedures. *Gen Dent* 1984;32:486–488.
109. Lyon HE. Etched-metal splint: A conservative approach to long-term splinting. *Gen Dent* 1984;32:512–514.
110. Barrack G. Etched cast restorations. *Quintessence Int* 1985;16:27–34.
111. Denehy GE. Cast anterior bridges utilizing composite resin. *Pediatr Dent* 1982;4:44–47.
112. Yanover L, Croft W, Pulver F. The acid-etched fixed prosthesis. *J Am Dent Assoc* 1982;104:325–328.
113. Burgess JO, McCartney JG. Anterior retainer design for resin-bonded acid-etched fixed partial dentures. *J Prosthet Dent* 1989;61:433–436.
114. Livaditis GJ. Etched metal resin-bonded restorations: Principles in retainer design. *Int J Periodontics Restorative Dent* 1983;3(4):34–47.

115. Simon JF, Gartrell RG, Grogono A. Improved retention of acid-etched fixed partial dentures: A longitudinal study. *J Prosthet Dent* 1992;68:611–615.
116. Barrack G. Recent advances in etched cast restorations. *J Prosthet Dent* 1984;52:619–626.
117. Eshleman JR, Moon PC, Barnes RF. Clinical evaluation of cast metal resin-bonded anterior fixed partial dentures. *J Prosthet Dent* 1984;51:761–764.
118. Thompson VP, Livaditis GJ. Etched casting acid etch composite bonded posterior bridges. *Pediatr Dent* 1982;4:38–43.
119. Heymann HO. Resin-retained bridges: The porcelain-fused-to-metal “winged” pontic. *Gen Dent* 1984;32:203–208.
120. Wood M. Etched casting resin bonded retainers: An improved technique for periodontal splinting. *Int J Periodontics Restorative Dent* 1982;2(4):8–25.
121. Shillingburg HT Jr, Grace CS. Thickness of enamel and dentin. *J South Calif Dent Assoc* 1973;41:33–36.
122. Synnott SA. Resin-bonded bridges: An update. *Gen Dent* 1984;32:211–215.
123. Simonsen R, Thompson VP, Barrack G. General considerations in framework design and anterior tooth modification. *Quintessence Dent Technol* 1983;7:21–25.
124. Wood M, Thompson VP. Resin-bonded prosthodontics. An update. *Dent Clin North Am* 1993;37:445–455.
125. Wilkes PW. Effects of Resistance Form on Bonding Strength of Resin Retained Castings [thesis]. Oklahoma City: University of Oklahoma Health Sciences Center, 1992.
126. Caputo AA, Gonidis D, Matyas J. Analysis of stresses in resin bonded fixed partial dentures. *Quintessence Int* 1986;17:89–93.
127. Pegoraro LF, Barrack G. A comparison of bond strengths of adhesive cast restorations using different designs, bonding agents, and luting resins. *J Prosthet Dent* 1987;57:133–138.
128. Eshleman JR, Janus CE, Jones CR. Tooth preparation designs for resin-bonded fixed partial dentures related to enamel thickness. *J Prosthet Dent* 1988;60:18–22.
129. Rubinstein S, Jekkals V. Preparations for anterior resin-bonded retainers. *Compend Contin Educ Dent* 1986;7:631–634.
130. Saad AA, Claffey N, Byrne D, Hussey D. Effects of groove placement on retention/resistance of maxillary anterior resin-bonded retainers. *J Prosthet Dent* 1995;74:133–139.
131. Hembree JH Jr, Sneed WD, Looper S. In vitro marginal leakage of acid-etched composite resin bonded castings. *Quintessence Int* 1986;17:479–482.
132. Murakami I, Barrack GM. Relationship of surface area and design to the bond strength of etched cast restorations: An in vitro study. *J Prosthet Dent* 1986;56:539–545.
133. McLaughlin G. Composite bonding of etched metal anterior splints. *Compend Contin Educ Dent* 1981;2:279–283.
134. McLaughlin G. Composite bonding for the clinician. *N Y State Dent J* 1982;48:232–235.

Preparations for Intracoronal Restorations

12



The intracoronal inlay is the simplest of the cast restorations and has been used for the restoration of occlusal, gingival, and proximal lesions. Intracoronal restorations utilize wedge retention, which exerts some outward pressure on the tooth. This pressure is exerted first during try-in and cementation, but it occurs again when occlusal force is applied. For the restoration to be successful, there must be some form of counteraction. When an inlay is placed in a tooth with ample bulk of tooth structure, the tooth structure itself resists the force.

The use of cast metal inlays, at one time considered the mark of quality restorative care, has declined in recent years. A group of US dental educators concluded in 1979 that "Cast gold restorations should be limited to those teeth which need cusp coverage for protection and reinforcement of the tooth. The true cast gold inlay is no longer a reasonable consideration in the conservative treatment of unrestored teeth."¹ A survey of North American dental faculty in the early 1980s indicated that nearly one-third of their schools taught limited use of inlays or none at all.²

The indications for an inlay are virtually the same as for an amalgam restoration. The inlay simply replaces missing tooth structure without doing anything to reinforce that which remains.³ If the tooth requires protection from occlusal forces, the protection must be gained by the use of some other type of restoration that incorporates a veneer of casting alloy over the occlusal surface.⁴ Inlays tend to wedge cusps apart,⁵ and a lone-standing, unsupported cusp is at risk for fracture.⁶

Mechanical cusp height is normally equal to anatomical cusp height, measured from the cusp tip to the bottom of the central groove. An occlusal intracoronal preparation increases mechanical cusp height to a hazardous extent⁷; it becomes the distance from the cusp tip to the gingival extension of the preparation. In premolars, this elongation of the lever arm can increase stress.

Stress concentrations can manifest themselves in various forms of clinical failure. The most dramatic and the most evident is the loss of a whole cusp because of fracture. Failure also may occur in less obvious ways. The cement seal can rupture, with ensuing marginal leakage, when tooth structure flexes in weakened cusps and preparation walls bend without actually fracturing⁸ or spring away from the restoration.⁷ This may not become apparent for some period of time, but it would eventually surface as an open margin, possibly with recurrent caries. This type of failure

may escape being identified as an ill-designed restoration that did not protect the tooth from destructive, occlusally generated stresses.

Analysis has detected greater stress when intracoronal preparations are wide.^{9,10} Because a wider isthmus can lead to failure^{8,11,12} and an inlay that is one-third the faciolingual width of the occlusal surface can wedge the cusps apart,¹³ the recommended isthmus width has been reduced to one-fourth the intercuspal distance.¹⁴

Vale¹⁵ found a 35% decrease in the fracture resistance of a maxillary premolar when the isthmus of a proximo-occlusal preparation was widened from one-fourth to one-third the intercuspal distance. Mondelli et al¹⁶ reported decreases of 42%, 39%, and 29% with similar isthmus widening of proximo-occlusal, occlusal, and mesio-occlusodistal (MOD) preparations, respectively.

Depth, combined with width, decreased the fracture strength of teeth in studies by Blaser and associates¹¹ and Re et al.¹⁷ This corroborates clinical observations of inlays acting as wedges between the facial and lingual cusps of teeth.^{5,7} Deepening an isthmus to increase resistance or inlay strength is not a good practice.

Proximo-occlusal Inlays

A proximo-occlusal inlay is indicated for premolars or molars with minimal caries or previous restoration that need a mesio-occlusal or disto-occlusal restoration. It offers a superior material and margins that will not deteriorate with time. The restoration will be visible on premolars, although careful extensions on mesiofacial flares should keep the display minimal. MOD inlays that can be kept narrow are acceptable for molars. If a premolar is damaged badly enough to warrant even a conservative MOD cast restoration, that restoration should be an onlay.

Class II inlays should be used in mouths that have shown a low caries rate for some time preceding the placement of the restoration. It is a dubious service to place a two-surface restoration in a tooth that has a high likelihood of requiring that the third surface be restored in the not-too-distant future. Patients with accumulations of plaque or a recent history of caries, or those who are still in adolescence, are poor candidates for inlays.

12 Preparations for Intracoronal Restorations

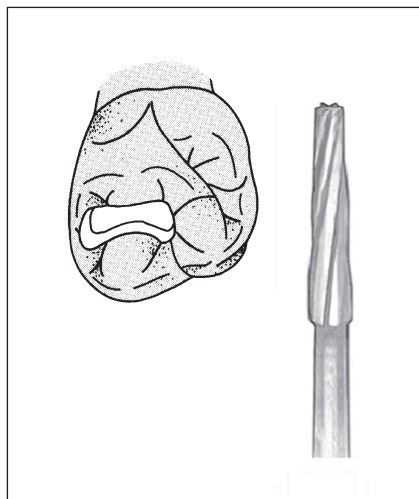


Fig 12-1 Occlusal outline: no. 170L bur.

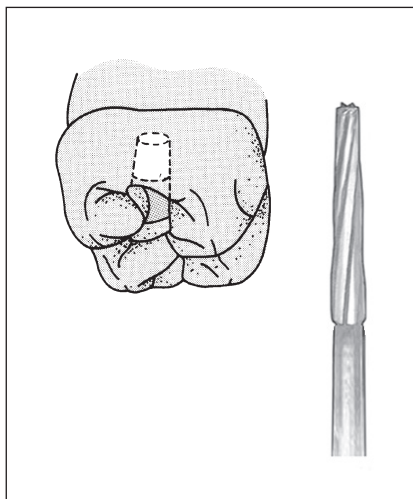


Fig 12-2 Undermining marginal ridge: no. 169L bur.

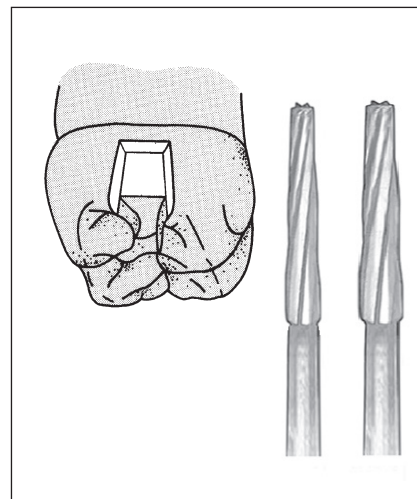


Fig 12-3 Proximal box: no. 169L and 170L burs.

Armamentarium

- Handpiece
- No. 170L bur
- No. 169L bur
- Coarse-grit flame diamond (862-010)
- Fine-grit flame diamond (8862-010)
- Flame bur (H4BL-010)
- Enamel hatchet (DE 15/16 or 15-8-14) (Hu-Friedy)
- Enamel hatchet (DE 17/18 or 10-6-14) (Hu-Friedy)
- Binangle chisel (DE 8/9 or 20-9-8) (Hu-Friedy)
- Gingival margin trimmer (10-95-7-14) (Hu-Friedy)
- Gingival margin trimmer (10-80-7-14) (Hu-Friedy)

Technique

A no. 170L bur is used to make the occlusal outline (Fig 12-1). Initial penetration is made in a fossa with the edge of the bur tip. The isthmus is then cut to its final extension by following the central groove and any deep or faulty grooves leading to it. The extension should be conservative because it will be widened later with an occlusal bevel.

A distinct dovetail extends facially, enhancing resistance and retention. The pulpal floor should be flat, at an even depth of approximately 1.5 mm, and perpendicular to the path of insertion for maximum resistance.⁷ The outline should avoid occlusal contacts marked with articulating paper. The initial cut extends far enough to undermine the marginal ridge, which will be removed shortly. The walls of the isthmus will be slightly inclined by the bur used to cut them. The walls should be checked to make sure there are no undercuts. Care should be taken not to err in the opposite direction by overtapering the walls.

If the tooth being prepared has not been previously restored, a no. 169L bur is used to complete the undermining of the marginal ridge. The cut should not extend all the way

through the enamel to the outer surface at this time. The bur should penetrate in an apical direction, with the tip apical to the contact (Fig 12-2). The gingival extension should not be too conservative because box length is an important factor in inlay retention.¹⁴ Cuts are made facially and lingually to the approximate width of the proposed box, just inside the cemento-enamel junction.

Either the no. 169L bur or an enamel chisel is used to break through the undermined enamel to rough out the proximal box. The no. 169L bur is used to finish smoothing the box. It is extended facially and lingually just far enough to barely break contact with the adjacent tooth (Fig 12-3). The final extension will be achieved when the facial and lingual flares are placed. The isthmus is widened where it joins the box, and any angle in the area where they meet is rounded.

The facioaxial and linguoaxial line angles of the box are accentuated with a no. 169L bur. The same bur is also used to form the facial and lingual walls of the box, and they are smoothed with an enamel chisel. The box walls, not the angles, resist displacement.¹⁴ Those walls should have a minimum degree of divergence of the facial and lingual walls to promote optimum retention and resistance. As taper increases, stress rises and retention decreases.

The pulpal floor of the isthmus and the gingival floor of the box should be flat. A gingival margin trimmer is used to form a V-shaped groove at the junction of the axial wall and the gingival floor of the box (Fig 12-4). This groove, sometimes referred to as the *Minnesota ditch*,¹⁸ is placed to enhance resistance to displacement by occlusal forces.¹⁹

Flares are flat planes added to the facial and lingual walls of the box using a flame diamond or an enamel hatchet (Fig 12-5). The hatchet is reserved for use in those areas where esthetics is an important consideration. The flares provide for the acute angle of gold to meet the finish line on the preparation. The flares should be checked to make sure that they "draw." The facial flare leans slightly to the facial, the lingual flare slightly to the lingual, and both flares slightly to

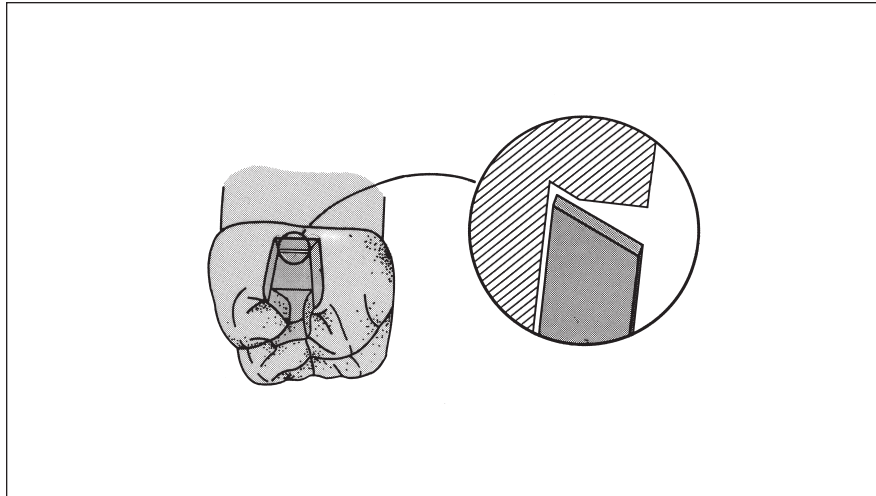


Fig 12-4 Gingivoaxial groove: gingival margin trimmer.

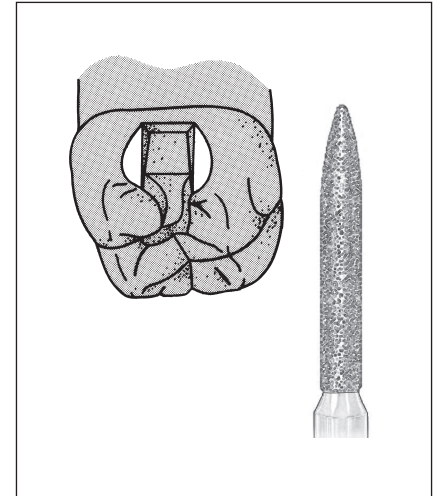


Fig 12-5 Proximal flares: coarse-grit flame diamond.

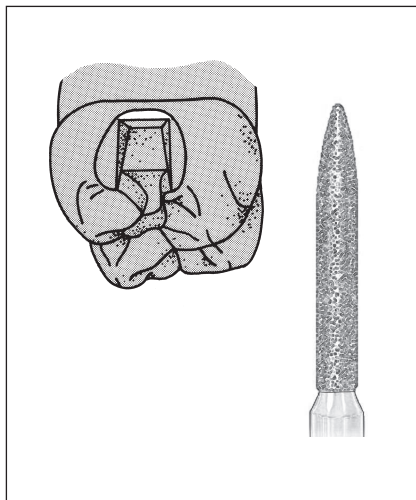


Fig 12-6 Gingival bevel: coarse-grit flame diamond.

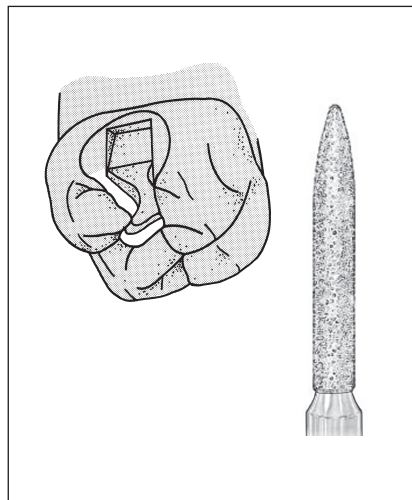


Fig 12-7 Isthmus bevel: fine-grit flame diamond.

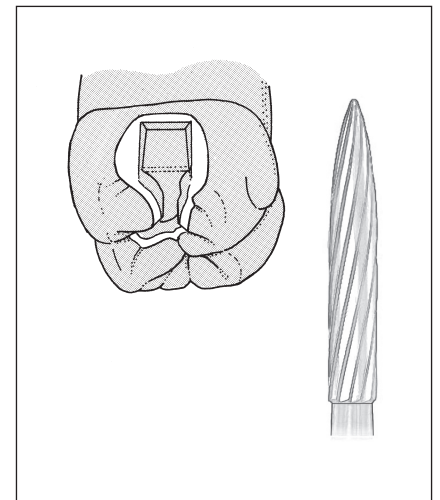


Fig 12-8 Bevel and flare finishing: flame bur.

the center of the tooth. A flare is cut equally at the expense of the wall of the box and of the outer enamel surface of the tooth. As a result, a flare is narrow at its gingival end and much wider at its occlusal end.

To start the flare, the flame diamond is placed in the proximal box, and the small-diameter tip is used to cut the cavosurface angle of the box from the gingival floor up. The occlusally directed sweep of the diamond tip is continued without changing the angle or direction of the instrument. The diamond should be cutting only when it is moving in the occlusal direction. If it is moved back and forth, the finish line may be rounded over.

The flame diamond is carried across the gingival cavosurface angle of the box, forming a gingival bevel on the box that is a smooth continuation of the facial and lingual flares (Fig 12-6). The creation of undercuts where the gingival bevel joins the flares should be avoided. Lean the flame diamond against the pulpal axial line angle. The bevel should lay between 30 and 45 degrees to provide an optimum blend of

strength and marginal fit.²⁰ A gingival margin trimmer is unacceptable because it will produce a ragged finish line.

The inlay preparation is finished by placing a bevel on the occlusal isthmus with a flame diamond (Fig 12-7). If a shallow bevel is used in this location, the result will be a thin flash of gold that will probably extend into areas of occlusal contact. The bevel on the isthmus begins at the junction of the occlusal one-third and the gingival two-thirds of the isthmus walls and should extend outward at an angle of 15 to 20 degrees.²¹

The bevel must be minimal because compressive stress increases as the inclination of the bevel increases.¹⁰ The bevel is likely to produce some stress, but it is a necessary risk to produce a finishable casting. The occlusal bevel is blended into the proximal flares to produce a smooth, continuous finish line. Use a flame carbide bur to go over the flares and the bevels (Fig 12-8). The flame bur produces the most consistent bevel,²² and carbide finishing burs produce the smoothest finish lines.²³

12 Preparations for Intracoronal Restorations

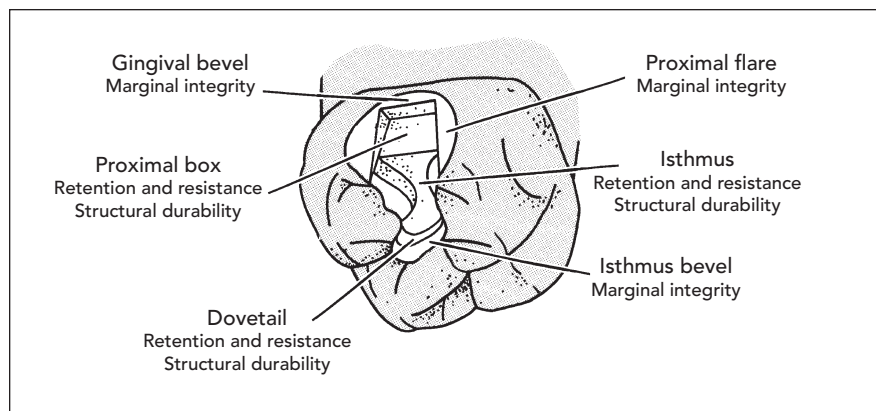


Fig 12-9 Features of a proximo-occlusal inlay preparation and the function(s) served by each.

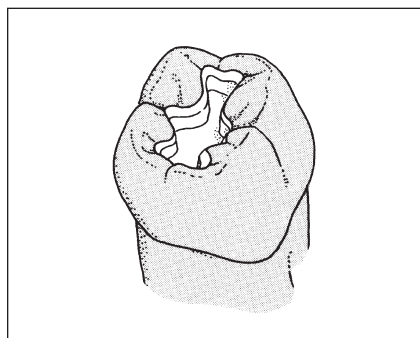


Fig 12-10 Class I inlay preparation on a mandibular molar.

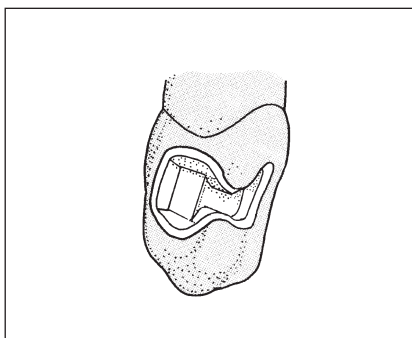


Fig 12-11 Class III inlay preparation on a maxillary canine.

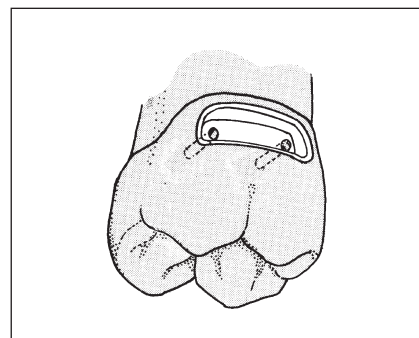


Fig 12-12 Class V inlay preparation on a maxillary molar.

A torpedo diamond can be used to create the bevel; it will produce one that is slightly concave, as suggested by Tucker.²⁴ The finish line is much more easily read. The features of the Class II inlay preparation and the functions served by each feature are shown in Fig 12-9.

Metal Inlay Variations

Other types of metal inlays are used even less frequently than the Class II restoration. A Class I inlay can be used to restore a moderately sized occlusal lesion in the mouth of a patient with predominantly gold restorations in other teeth. The 1.0-mm-wide isthmus follows the central groove, ending short of the marginal ridges or transverse ridge if there is one on the tooth.

The outline extends moderately into the facial and lingual grooves, with small "barbell" dovetails at each end (Fig 12-10). In addition to increasing retention and resistance, these extensions place the finish line on the slopes of the triangular and marginal ridges, where the inlay margins can be finished

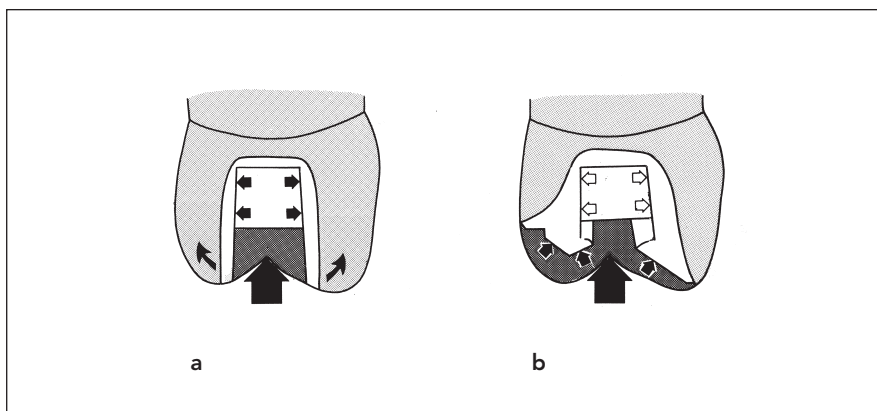
more easily. A 15- to 20-degree bevel extends one-third of the way down the sides of the isthmus wall. Overextending the bevel will make the restoration too wide, and the finish line will form such an obtuse angle with the enamel surface that it will be difficult to identify during margin finishing.

The Class III inlay shows metal, making it unacceptable for incisors. However, it is useful for restoring the distal surface of canines if a slight display of metal is acceptable to the patient.²⁵ A well-executed inlay in a canine will look better than an amalgam restoration, last longer than a composite resin restoration, and be much less destructive than a porcelain crown. It is not commonly used, but the restoration does have its applications.

The Class III inlay preparation has a 1.0-mm-deep lingual dovetail at the incisal end of the cingulum that resists displacement²⁶ (Fig 12-11). The proximal box is prepared with a lingual approach to minimize the display of metal.²⁷ An incisal approach will destroy excessive tooth structure and create an unesthetic restoration.

The Class V inlay is used to restore severe abrasion²⁸ or erosion as well as large caries on the gingivofacial aspect of molars (Fig 12-12). It cannot tie into other restorations with-

Fig 12-13 Occlusal forces applied to an MOD inlay produce stresses that tend to separate the cusps (a), whereas the same force applied to an MOD onlay is dissipated over a wide area in less destructive patterns (b).



out producing a poor marginal seal. The preparation should be 1.0 mm deep axially and extend to the line angles. The gingival finish line is supragingival, if damage permits, and approximately 0.5 mm above the jaw of the cervical rubber dam clamp placed for preparing the tooth.²⁹ The height of contour is the occlusal limit of the preparation.

To enhance retention and resistance,^{30,31} 0.675-mm-diameter pinholes are drilled to a depth of 3.0 mm at the proximal edges of the outline form. A 0.5-mm-wide, 45-degree bevel is placed around the periphery of the preparation. For the impression, a custom tray that draws facially is used.

Mesio-occlusodistal Onlays

The use of inlays to restore MOD lesions in premolars is questionable. Occlusal force on an inlay produces stress along the sides of the restoration and at its base as the inlay pushes against the tooth structure surrounding it. This could fracture the tooth,³² so the inlay must be modified to distribute the load evenly over a wide surface. Stress analysis has shown that covering the occlusal surface with metal will do much to minimize the potentially damaging effects of stress in an intracoronal restoration^{10,33} (Fig 12-13).

The MOD onlay is indicated for a variety of situations³:

- Deteriorating teeth with intact facial and lingual cusps
- MOD restorations with wide isthmuses
- Endodontically treated posterior teeth with sound facial and lingual tooth structure (access for root canal therapy weakens a tooth structurally, and the crown of the tooth must be protected after treatment is complete)

There has been a renewed interest in the MOD onlay based on an occlusion-centered approach to restorative dentistry rather than one that is solely tooth oriented. MOD onlays are significantly less retentive and resistant than three-quarter crowns³⁴ and should not be used as fixed par-

tial denture retainers. They lack sufficient retention to successfully resist the additional forces placed on an abutment tooth by a fixed partial denture.

Fisher et al³³ showed that onlays protect teeth from the high stress concentrations at the walls and line angles of the isthmus that are found under inlays. Studies by Craig et al³⁵ and Farah and associates¹⁰ also showed the superiority of MOD onlays in protecting teeth from stress.

Armamentarium

- Handpiece
- Round-end tapered diamond (6856-016)
- No. 171L bur
- No. 170L bur
- No. 169L bur
- Coarse-grit flame diamond (862-010)
- Fine-grit flame diamond (8862-010)
- Flame bur (H48L-010)
- Enamel hatchet (DE 15/16 or 15-8-14)
- Enamel hatchet (DE 17/18 or 10-6-14)
- Binangle chisel (DE 8/9 or 20-9-8)

Technique

The previous restoration should be removed at this point. The occlusal reduction is done with a round-end tapered diamond to establish preparation length. About 1.5 mm of clearance is gained on the occlusal surface (Fig 12-14). Orientation grooves are used to gauge the depth of reduction. There should be one on the crest of each triangular ridge and one in each major developmental groove.

On a maxillary tooth where the nonfunctional facial cusp will be highly visible, the facio-occlusal angle should not be overreduced or the restoration will show metal unnecessarily. The depth of the orientation grooves and the occlusal reduction should be about 0.5 mm at the line angle.

12 Preparations for Intracoronal Restorations

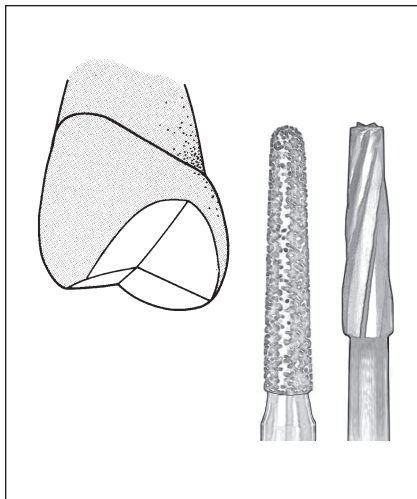


Fig 12-14 Planar occlusal reduction: round-end tapered diamond and no. 171L bur.

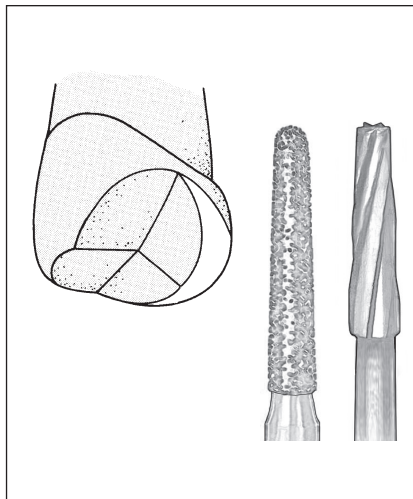


Fig 12-15 Functional cusp bevel: round-end tapered diamond and no. 171L bur.

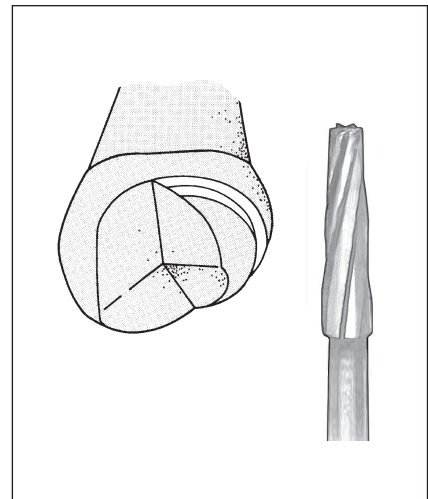


Fig 12-16 Occlusal shoulder: no. 171L bur.

Occlusal reduction is accomplished by removing the tooth structure left between the depth-orientation grooves with the round-end tapered diamond. The reduction follows the original contours of the cusp,³⁶ reproducing the geometric inclined planes of the occlusal surface.³⁷ It has been hypothesized that this corrugated multiplanar design enhances restoration strength.³⁸

A wide bevel is placed on the outer-facing inclines of the functional cusp with the round-end tapered diamond to ensure an adequate bulk of metal on the functional cusp (Fig 12-15). The functional cusp bevel approximates the inclination of the cusps in the opposing arch, extending from the central groove on the mesial surface to the central groove on the distal surface.

The depth-orientation cuts begin at a 1.5-mm depth at the cusp tip. They fade out along a line that will later be the occlusal shoulder, 1.0 mm apical to the lowest occlusal contact. The tooth structure left between the orientation grooves is removed. The occlusal reduction and functional cusp bevel are smoothed with the no. 171L bur. The inclined planes should be well defined, but there should be no sharp angles where they meet. The occlusal reduction should be checked visually in the facial half of the occlusal surface and with red utility wax on the lingual cusp.

An occlusal shoulder is cut on the functional cusp with a no. 171L bur at the level of the axial termination of the functional cusp bevel (Fig 12-16). The shoulder is 1.0 mm wide and extends from the central groove on the mesial surface to the central groove on the distal surface. It provides space for metal to reinforce the occlusal margin on the functional cusp.

There are two acceptable occlusal finish lines for the functional cusp of an MOD onlay: an occlusal shoulder and a heavy chamfer³⁹ (Fig 12-17). Both configurations provide an

acute edge of gold at the cavosurface angle with a nearby bulk of metal for strength. The shoulder with a bevel is easier to prepare properly and should be used by the novice.

The isthmus is made next with the no. 171L bur (Fig 12-18). If an old restoration was removed earlier, the isthmus is retouched to smooth the walls and impart a minimum taper. Besides removing caries and old restorations, the isthmus reinforces the restoration. It provides some retention and a great deal of resistance.⁴⁰ Because the occlusal surface already has been reduced, the isthmus of an onlay is shallower than that of an inlay.

The no. 170L bur is used to begin the proximal boxes (Fig 12-19). If the proximal surface is intact, it is easier to start with a no. 169L bur. The walls of the boxes are carried far enough facially and lingually to barely break contact with the adjacent teeth. The facial extension of the mesial box is usually more conservative than that of the distal box. Extensions will be finalized with a flame diamond on the flares later.

The facioaxial and linguoaxial line angles of each box are redefined with the no. 169L bur. Then an enamel chisel is used to plane the facial and lingual walls. Flat walls perpendicular to the direction of rotating forces, not box angles, give a restoration resistance. The boxes should have a common path of insertion. The pulpal floor of the isthmus, the 1.0-mm-wide occlusal shoulder on the functional cusp bevel, and the gingival floors of the proximal boxes, which are also 1.0 mm wide, should be smoothed.

Proximal flares are added after the boxes have been formed (Fig 12-20). If the flares were cut first, facial and lingual box walls will be poorly defined and retention will suffer. Flares are usually cut with the tip of the flame diamond, starting from within the box. A wide enamel hatchet can be used for mesiofacial flares in areas where the esthetic result is important.

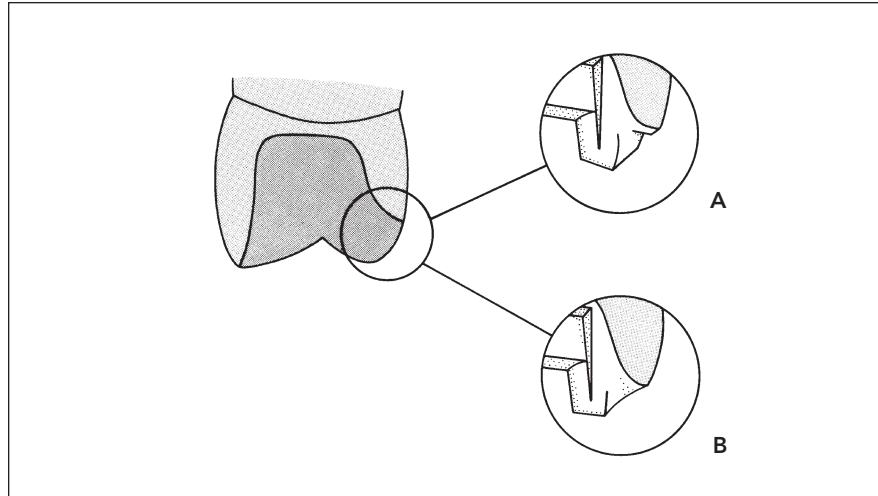


Fig 12-17 Functional cusp finish lines for an MOD onlay: occlusal shoulder (A) and chamfer (B). (Modified from Ingraham⁷ with permission.)

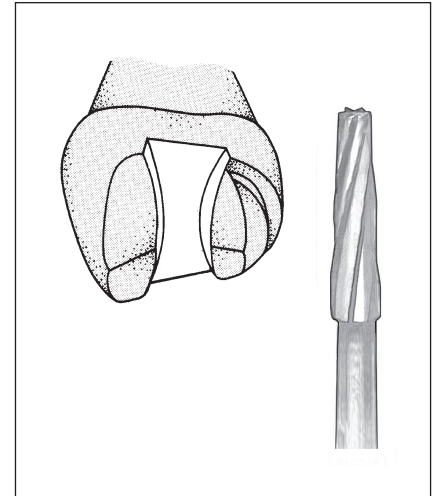


Fig 12-18 Isthmus: no. 171L bur.

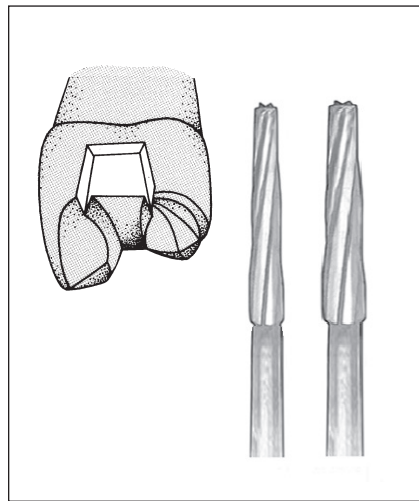


Fig 12-19 Proximal box: no. 169L and no. 170L burs.




Fig 12-20 Proximal flares: flame diamond and flame bur.

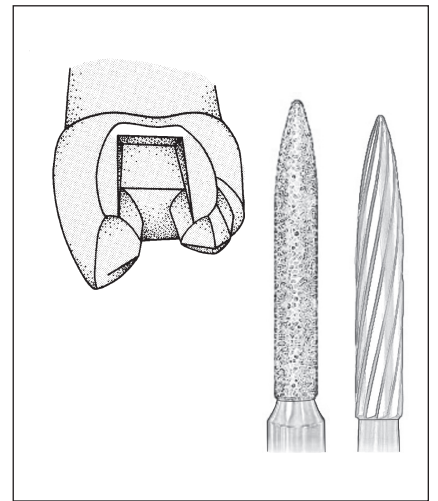


Fig 12-21 Gingival bevel: flame diamond and flame bur.

A flame diamond is used to add a bevel 0.5 to 0.7 mm wide to the gingival cavosurface angle of each box (Fig 12-21). It provides for an acute edge of metal in these areas. The instrument is leaned against the pulpal-axial line angle to prevent the bevel from being too long and having too sharp an angle. This may round the proximo-occlusal line angle, which is acceptable. The bevel is blended into the facial and lingual flares without creating an undercut. The flares and gingival bevel are smoothed with a flame carbide bur. This produces a sharp, distinct finish line that will facilitate marginal adaptation of the restoration.

Occlusal finishing bevels 0.5 to 0.7 mm wide are placed at the facial and lingual occlusal finish lines with a flame diamond followed by a no. 170L carbide bur (Fig 12-22). The facial bevel is perpendicular to the path of insertion where esthetics are important and forms a heavier contrabevel where they are not. The bevels are blended into the respective flares. If the bevel on the occlusal shoulder is too wide, a thin, unsupported margin will result in the wax pattern and the casting. Figure 12-23 identifies the features of an MOD onlay preparation on a maxillary premolar and the functions served by each feature.

12 Preparations for Intracoronal Restorations




Fig 12-22 Facial and lingual bevels: flame diamond and no. 170L bur.

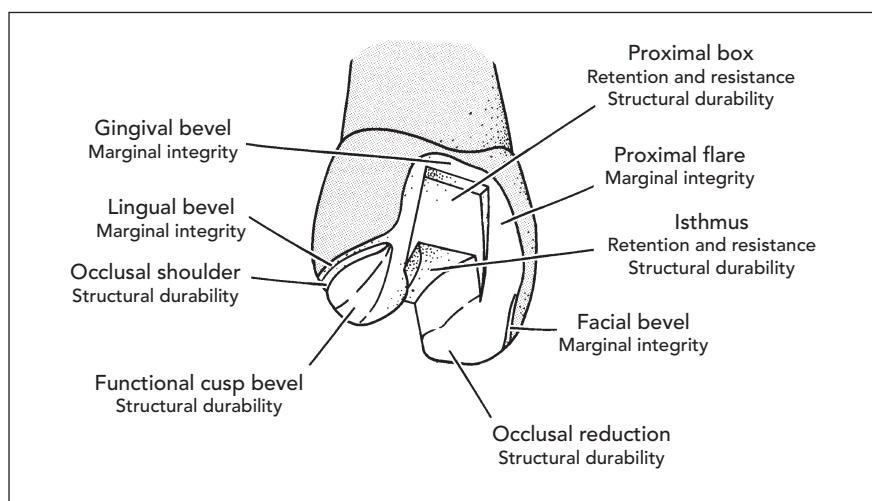


Fig 12-23 Features of a maxillary MOD onlay preparation and the function(s) served by each.

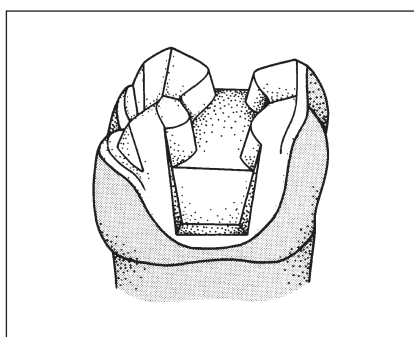


Fig 12-24 MOD onlay preparation on a mandibular molar.

The preparation on a mandibular molar differs from that on a maxillary tooth in that the functional cusp bevel and occlusal shoulder are located on the facial cusp (Fig 12-24). In addition, the lingual bevel is wider, and it can be a definite contrabevel because esthetics is not a consideration on the

lingual cusp of a mandibular tooth whereas structural durability is. These bevels should blend into the proximal flares, with the cavosurface line of the bevel continuous with the cavosurface line of the flare. There should not be a sharp occlusoproximal corner where the bevel and flare meet.

References

1. Nuckles DB. Inlay versus amalgam restorations. *S C Dent J* 1980; 38(4):23–25.
2. Clark NP, Smith GE. Teaching gold castings in North American dental schools. *Oper Dent* 1984;9:26–31.
3. Shillingburg HT, Fisher DW. The MOD onlay—A rational approach to a restorative problem. *N M Dent J* 1970;21:12–14.
4. Tanner H. Ideal and modified inlay and veneer crown preparations. *Ill Dent J* 1957;26:240–244.
5. Smith DE. Twenty-five years of fixed bridgework. *J South Calif State Dent Assoc* 1936;7:794–799.
6. McCollum BB. Tooth preparation and its relation to oral physiology. *J Am Dent Assoc* 1940;27:701–707.
7. Ingraham R. The application of sound biomechanical principles, in the design of inlay, amalgam, and gold foil restorations. *J Am Dent Assoc* 1950;40:402–413.
8. Mahler DB, Terkla LG. Relationship of cavity design to restorative materials. *Dent Clin North Am* 1965;23:149–157.
9. Granath LE. Photoelastic studies on certain factors influencing the relation between cavity and restoration. *Odontol Revy* 1963;14:278–293.
10. Farah JW, Dennison JB, Powers JM. Effects of design on stress distribution in intracoronal gold restorations. *J Am Dent Assoc* 1977;94:1151–1154.
11. Blaser PK, Lund MR, Cochran MA, Potter RH. Effects of designs of Class 2 preparations on resistance of teeth to fracture. *Oper Dent* 1983;8:6–10.
12. Larson TD, Douglas WH, Gustfeld RE. Effect of prepared cavities on the strength of teeth. *Oper Dent* 1981;6:2–5.
13. Werrin SR, Jubach TS, Johnson BW. Inlays and onlays: Making the right decision. *Quintessence Int Dent Dig* 1980;11:13–18.
14. Smith GE, Grainger DA. Biomechanical design of extensive cavity preparations for cast gold. *J Am Dent Assoc* 1974;89:1152–1157.
15. Vale WA. Cavity preparation. *Ir Dent Rev* 1956;2:33–41.
16. Mondelli J, Steagall L, Ishikiriama A, de Lima Navarro MF, Soares FB. Fracture strength of human teeth with cavity preparations. *J Prosthet Dent* 1980;43:419–422.
17. Re GJ, Norling BK, Draheim RN. Fracture resistance of lower molars with varying faciocclusolingual amalgam restorations. *J Prosthet Dent* 1982;47:518–521.
18. Frates FE Jr. Inlays. *Dent Clin North Am* 1967;11:163–173.
19. Gabel AB. Present-day concepts of cavity preparation. *Dent Clin North Am* 1957;1:3–17.
20. Rosenstiel E. To bevel or not to bevel? *Br Dent J* 1975;138:389–392.
21. Ingraham R, Bassett RW, Koser JR. *An Atlas of Cast Gold Procedures*, ed 2. Los Angeles: University of Southern California School of Dentistry, 1969:12.
22. Barnes JE. The production of inlay cavity bevels. *Br Dent J* 1974;137:379–390.
23. Christensen GJ. Clinical and research advancements in cast-gold restorations. *J Prosthet Dent* 1971;25:62–68.
24. Tucker RV. Variation of inlay cavity design. *J Am Dent Assoc* 1972;84:616–620.
25. Redfern ML. The dovetail class 3 inlay. *Oper Dent* 1983;8(2):67–72.
26. Thom LW. Principles of cavity preparation in crown and bridge prosthesis. III. The inlay abutment. *J Am Dent Assoc* 1950;41:541–544.
27. Gerson IV. Invisible gold restorations for anterior teeth. *J Prosthet Dent* 1961;11:749–764.
28. Mack AO, Allan DN. Reconstruction of a severe case of attrition and abrasion. *Br Dent J* 1974;137:379–390.
29. Ingraham R, Bassett RW, Koser JR. *An Atlas of Cast Gold Procedures*, ed 2. Los Angeles: University of Southern California School of Dentistry, 1969:209.
30. Finger EM. Restorations for class V cavities. *J Prosthet Dent* 1960; 10:775–778.
31. Howard WW. *Atlas of Operative Dentistry*, ed 2. St Louis: Mosby, 1973:73.
32. Maxwell EH, Braly BV. Incomplete tooth fracture: Prediction and prevention. *CDA J* 1977;5(6):51–55.
33. Fisher DW, Caputo M, Shillingburg HT, Duncanson MG. Photoelastic analysis of inlay and onlay preparations. *J Prosthet Dent* 1975;33:47–53.
34. Kishimoto M, Shillingburg HT Jr, Duncanson MG Jr. Influence of preparation features on retention and resistance. Part II: Three-quarter crowns. *J Prosthet Dent* 1983;49:188–192.
35. Craig RG, El-Ebrashi MK, LePeak PJ, Peyton FA. Experimental stress analysis of dental restorations. Part I. Two-dimensional photoelastic stress analysis of inlays. *J Prosthet Dent* 1967;17: 277–291.
36. Draheim RN. Current concepts in intracoronal casting preparations: A new look at the gold casting preparation. *Compend Contin Educ Dent* 1985;6:373–380.
37. Shillingburg HT Jr. Conservative preparations for cast restorations. *Dent Clin North Am* 1976;20:259–271.
38. Racowsky LP, Wolinsky LE. Restoring the badly broken-down tooth with esthetic partial coverage restorations. *Compend Contin Educ Dent* 1981;2:322–335.
39. Ingraham R, Bassett RW, Koser JR. *An Atlas of Cast Gold Procedures*, ed 2. Los Angeles: University of Southern California School of Dentistry, 1969:35.
40. Kishimoto M, Shillingburg HT Jr, Duncanson MG Jr. Influence of preparation features on retention and resistance. Part I: MOD onlays. *J Prosthet Dent* 1983;49:35–39.

Preparations for Severely Debilitated Teeth

13

One of the criteria for the use of a cast metal, metal-ceramic, or all-ceramic restoration is a tooth that has been damaged to the extent that it must be reinforced and protected. It should not be surprising that unmodified classic preparation designs are infrequently used for this purpose. They are applicable only on intact fixed partial denture abutments and on severely damaged teeth following the replacement of coronal bulk with an amalgam or resin core or with a dowel core.

The types of damage that may be encountered in debilitated teeth include loss of crown, pulpal involvement, loss of attachment, and loss of root(s). The loss of a clinical crown and/or pulpal involvement necessitates endodontic therapy and a subsequent dowel core and crown in a single-rooted tooth. The same damage in a multirrooted molar will require an amalgam or a composite resin buildup or core. The loss of periodontal attachment leads to gingival surgery and an altered finish line and crown. Nonrestorable roots require total endodontic therapy, resection (removal of the affected root), and an altered tooth preparation and crown.

Most individual teeth requiring cemented restorations, as well as many fixed partial denture abutments, have been damaged enough to require modification of a classic prepa-

ration design. The amount of tooth structure destroyed is only one factor to consider in selecting a restorative material and designing a preparation. Equally important is the location of the destruction and the amount of tooth surface involved. Various tooth conditions require different interventions (Table 13-1). Location can be classified as peripheral, occurring on the axial surfaces of the tooth; central, in the center of the tooth; or combined, with destruction in both sites.¹

Peripheral destruction, even when it does not threaten the pulp, may require an extensive restoration such as a full crown because of the wide expanses of enamel that have been affected (Fig 13-1). A large central lesion that has undermined much of the enamel may require the placement of an amalgam core followed by a crown (Fig 13-2). However, less extensive damage in the central region, with or without proximal involvement, may be better restored with a less destructive mesio-occlusodistal (MOD) onlay that gains retention from peripheral tooth structure rather than destroying it (Fig 13-3). Combined destruction of severe dimensions may also require the placement of a core or foundation restoration followed by a crown (Fig 13-4).

Table 13-1 Tooth conditions and interventions

Condition	Characteristics	Preparation features
Moderate loss	Sufficient length Wall thickness ≥ 1.0 mm All cusps present	Cement base block out of undercuts Classic preparation
Moderate/severe loss	Short preparation 50% of crown remaining Wall thickness = 1.0 mm Thickness/length ratio > 1.0 Excessive taper More serious if an abutment	Modified preparation Existing features retained New features added (boxes, grooves, pinholes, vertical walls)
Severe destruction	$< 50\%$ of crown remaining Short preparation-crown ratio Wall thickness < 1.0 mm Thickness-height ratio < 1.0	Possible elective devitalization and dowel core Walls with thickness-height ratio $< 1:2$ shortened or removed Walls with thickness-height ratio of 1:1 to 1:2 supported with core Ferrule effect in preparation Pin(s) integrated into casting
Total coronal loss	Central destruction Enamel (if any) is undermined	Dowel core + crown on single-rooted tooth Pin-retained core + crown on molar

13 Preparations for Severely Debilitated Teeth

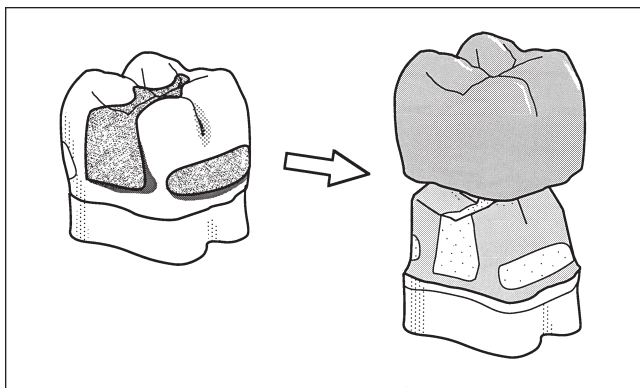


Fig 13-1 Teeth with large areas of enamel involvement may require full coverage restorations regardless of the amount of dentin that has been destroyed.

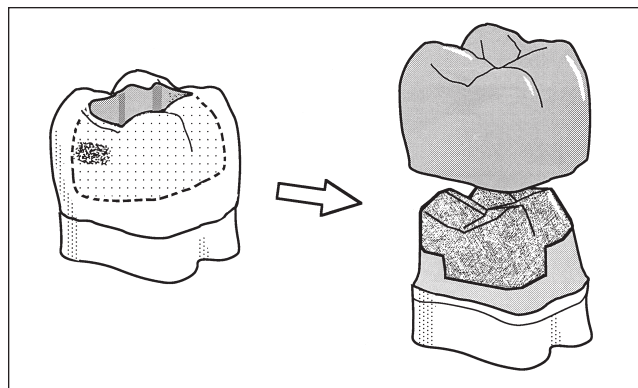


Fig 13-2 A large central lesion may require a full coverage restoration, but only after the tooth is built up with a core.

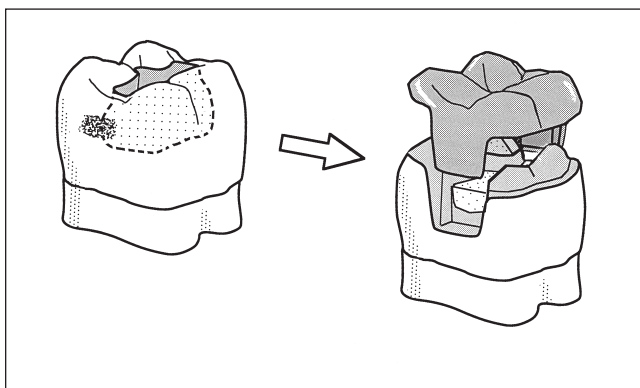


Fig 13-3 Moderate central damage can be restored with a restoration that preserves and uses sound peripheral tooth structure rather than destroying it.

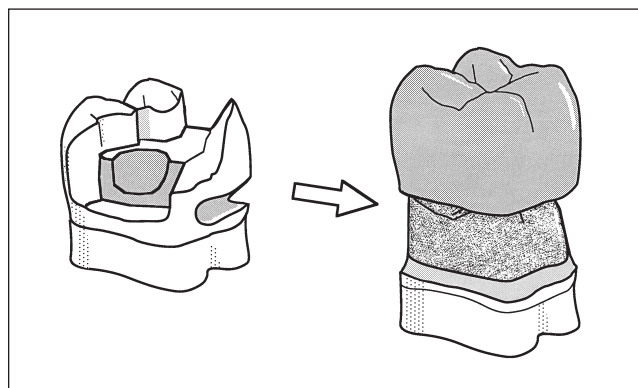


Fig 13-4 Severe combined destruction will require a core and a full coverage restoration.

Principle of Substitution

When it is necessary to compensate for mutilated or missing cusps, inadequate length, and in extreme cases even a missing clinical crown, the principle of substitution is employed. For those teeth with moderate to severe damage that test a dentist's ingenuity, a preparation may be modified by squaring the walls of defects left by caries and old restorations and by adding features to enhance retention and resistance. Boxes may be substituted where grooves might ordinarily be used. Grooves may be used to augment retention and resistance where axial walls have been shortened. Pins may be employed where much of the supragingival tooth structure has been destroyed. More than one of these auxiliary features may be employed where damage is severe.

Two rules should be observed to avoid excessive tooth destruction while creating retention in an already weakened tooth:

1. The central "core" (the pulp and the 1.0-mm-thick surrounding layer of dentin) must not be invaded in vital teeth.² No retentive features should extend farther into the tooth than 1.5 mm at the cervical line or from the central fossa (Fig 13-5). If caries removal results in a deeper cavity, any part lying within the vital core should be filled with glass-ionomer cement. Any preparation feature added for mechanical retention is kept peripheral to the vital core.
2. No wall of dentin should be reduced to a thickness less than its height for the sake of retention. This may preclude the use of a full veneer crown, or, if one must be used, it might first require the placement of a core or foundation restoration.

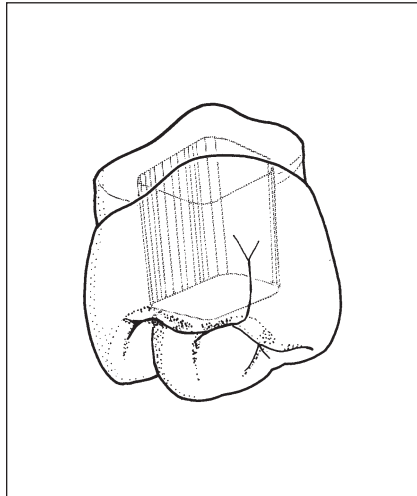


Fig 13-5 No retentive features may be cut into the vital core (center) of the tooth.

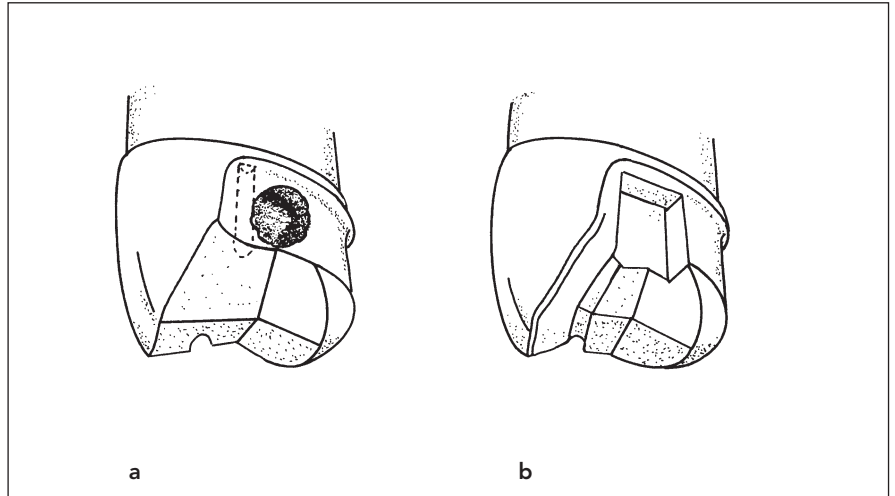
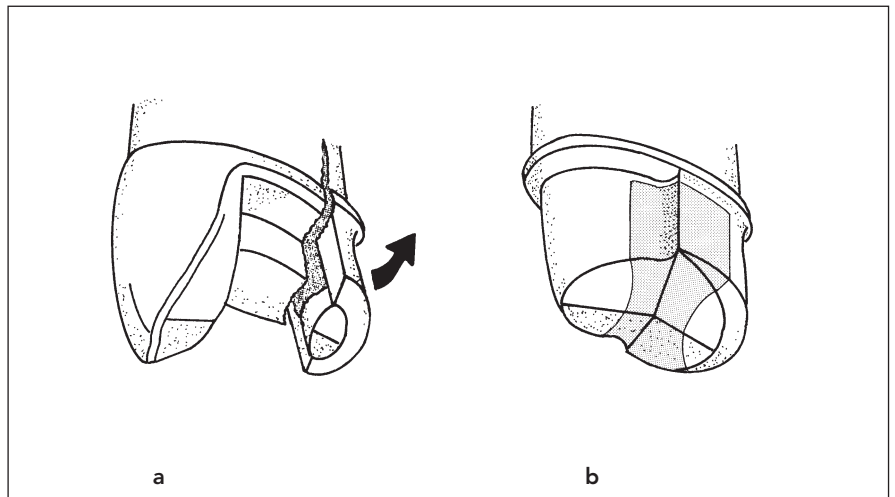


Fig 13-6 (a) Interproximal caries may preempt the use of a groove (dotted line). (b) Use of a box in this situation accommodates caries removal and provides retention.

Fig 13-7 (a) If significantly less than 180 degrees of the tooth's circumference remains between two boxes, the lingual cusp is susceptible to fracture during function, upon removal of the provisional restoration, or at try-in of the permanent restoration. (b) A core with a different preparation design will minimize the risk of fracture and provide better longevity for the crown.



Box forms

Small to moderate interproximal caries lesions or prior restorations can be incorporated into a preparation as a box form. This substitute for grooves serves the dual purpose of caries removal and retention form³⁻⁵ (Fig 13-6). Because large quantities of tooth structure must be removed for it, the box is not usually used on an intact surface.

Opposing upright surfaces of tooth structure adjacent to a damaged area can be used to create a box form if at least half the circumference (180 degrees) remains in the area outside the lingual walls of the boxes. The walls of the box, and not the line angles, will resist displacement.⁶ If the mesial and distal surfaces are extensively involved, another means must be used to compensate for the diminished lingual tooth structure (Fig 13-7). This situation may require a crown placed over a pin-retained amalgam core.

Grooves

Grooves placed in vertical walls of bulk tooth structure must be well formed, at least 1.0 mm wide and deep, and as long as possible to improve retention and resistance. Multiple grooves are as effective as box forms in providing resistance,⁷ and they can be placed in axial walls without excessive destruction of tooth structure. They may also be added to the angles of oversized box forms to augment the resistance provided by the box walls. This is particularly helpful when the facial and lingual walls of a box are a considerable distance apart. However, too many grooves in a crown preparation can adversely affect the seating of a full veneer crown.⁸

13 Preparations for Severely Debilitated Teeth

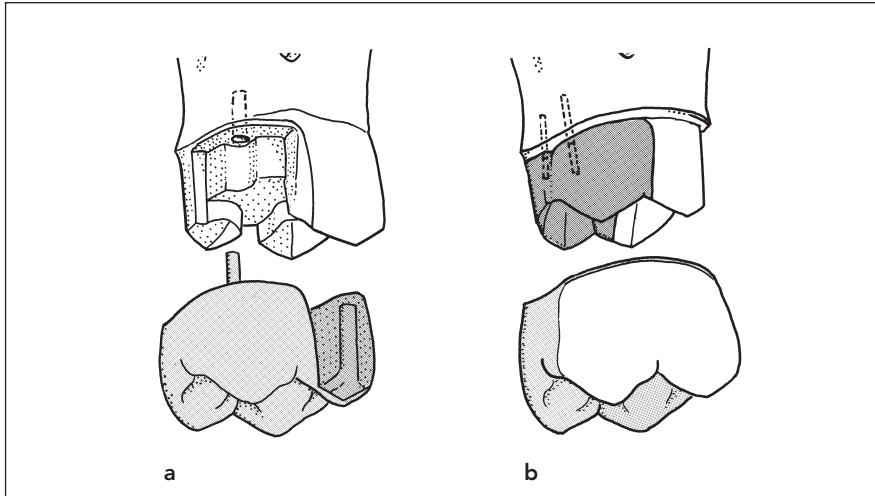


Fig 13-8 (a) A pin can be incorporated into a crown to augment retention and resistance. (b) Alternatively, pins can be used to retain a core, which in turn will help to retain a crown.

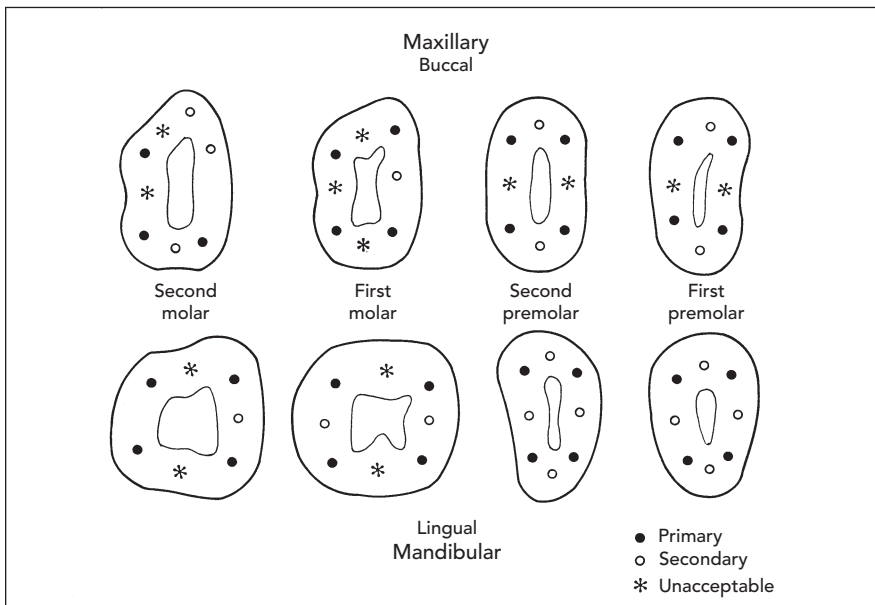


Fig 13-9 Areas for the placement of retentive pinholes in posterior teeth. (Modified from Fisher et al¹⁵ with permission).

Pins

Pins effectively increase retention^{9,10} by generating additional length internally and apically rather than externally.¹¹ They do not require vertical, supragingival tooth structure for their placement, and they can be used where there is insufficient axial wall length. They can extend apically beyond the gingival attachment without harming it.

Pins are commonly used in two ways: (1) Pinholes parallel the path of insertion of the preparation, receiving pins that are an integral part of the cast restoration (Fig 13-8a), or (2) nonparallel pins are placed in the tooth to retain an amalgam or composite resin core in which a classic preparation for a cast restoration can be formed (Fig 13-8b).

Careful pinhole placement is critical for restoration success. Four guidelines should be followed in drilling pinholes¹²:

1. They should be placed in sound dentin.
2. Enamel should not be undermined.
3. Perforation into the periodontal membrane should be avoided.
4. The pulp should not be encroached upon.

Pinholes should be placed vertically in shoulders or ledges halfway between the outer surface of the tooth and the pulp, surrounded by at least 0.5 mm of dentin.¹³ The safest locations for pinholes are the line angles or corners of the teeth¹⁴ (Fig 13-9). The least desirable area for placing pinholes is midway between the corners,¹⁴ especially in regions overlying the furcations.¹⁶

To avoid problems, the location and direction of the drill must be carefully controlled. After careful study of a radiograph, a probe¹⁴ or the drill itself¹⁷ is gently placed into the gingival sulcus, against the side of the tooth, to get a clear

picture of the direction of the outer tooth surface in the area of the pinhole. This limits the use of parallel pins that are part of the casting because the preparation path of insertion may dictate a pin direction that could cause pulpal or periodontal complications.

If bleeding occurs during drilling of a pinhole, it should be determined whether the misdirected drill has gone into the pulp or the periodontal membrane. If it is in the pulp, endodontic therapy is performed before the procedure continues. If the hole exits the root surface, the pin is measured before insertion so that it neither overfills nor underfills the hole. Healing is then possible, although not guaranteed. A pin that extends into the periodontium coronal to the alveolar crest should be exposed with a surgical flap and trimmed flush with the root surface.

The technique used for placing the pinholes and reproducing them in the impression is that described by Shooshan.¹⁸ It uses a 0.6-mm (0.024-inch) drill to cut the pinhole, a nylon bristle to reproduce the pinhole in the impression, and a nylon bristle or iridioplatinum pin to produce a pin in the restoration. The pinhole is countersunk slightly to form a funnel-shaped opening. This strengthens the pin where it joins the casting¹⁹ and guides the pin into the hole during seating.

Although retention increases as the number, depth, and diameter of pins increases,^{20,21} a point of diminishing returns occurs after four or five pins are placed.²² This experimental finding confirms the clinical recommendations that one pin should be used for each missing cusp,²³ line angle,²⁴ or axial wall²⁵ (a maximum total of four in any case). Self-threading pins are nearly five times more retentive than cemented pins and need to be placed to a depth of only 2.0 mm. However, cemented pins that are an integral part of the restoration need to extend 4.0 mm into the tooth.²⁶

Bases and Cores

When the destruction of tooth structure is more extensive, a decision must be made whether to augment the retention and resistance by adding auxiliary features or to build up the tooth preparation with a pin-retained core (Fig 13-10).

Bases

Cement bases are used only to protect the pulp and to eliminate undercuts in defects in tooth structure produced by the removal of caries or old restorations. They are used if there is adequate bulk of tooth structure to resist occlusal forces and enough axial wall surface to provide retention for the definitive restoration.

Glass-ionomer and polycarboxylate cements are excellent materials for this purpose. They are nonirritating to the pulp and have some adhesive properties that make them less likely to become dislodged during subsequent preparation of the tooth. Deep areas of the preparation near the pulp

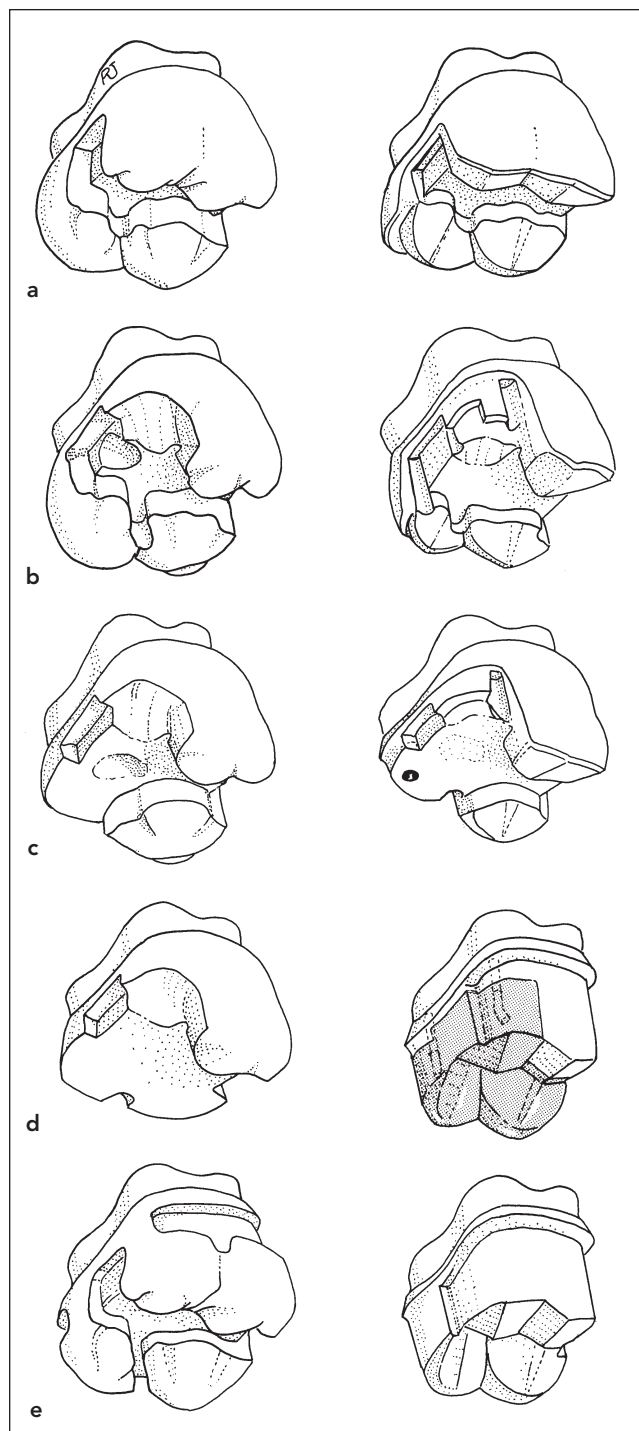


Fig 13-10 (a) If the tooth to be prepared for a cast restoration has been only moderately damaged (eg, by an old MOD amalgam), a standard MOD onlay preparation or a three-quarter crown preparation with boxes can be used. (b) If one cusp has been destroyed, a widened box with groove augmentation can be used. (c) When half of the crown has been destroyed, grooves may provide sufficient retention if the supragingival tooth structure in which they are placed has sufficient length. Pinholes may be added to the preparation. (d) If three or more cusps have been destroyed, a pin-retained core should be fabricated before proceeding to a full coverage cast restoration. (e) Extensive peripheral destruction often requires a full coverage cast restoration if caries has been controlled.

13 Preparations for Severely Debilitated Teeth

may be covered with calcium hydroxide. Cement bases do not have sufficient strength to effectively replace weakened dentinal walls, unless there are two walls of tooth structure remaining.²⁷ Amalgam or composite resin should be used for that purpose.

An undercut left by caries removal often can be eliminated by creating a box, if the additional retention is needed. However, if creation of a box will destroy excessive sound tooth structure, it is better to fill the defect with cement. If the defect is very close to a finish line, amalgam should be used because it is strong and insoluble.

Cores

If one-half or more of the clinical crown has been destroyed, an amalgam or composite resin core should be placed in the tooth. The core is then treated as though it were tooth structure, and a classic full coverage preparation is used. If less than half of a clinical crown has been destroyed, a preparation design that will employ auxiliary features for added retention in the area of missing cusps can be used.

All cusps thinner than one-half their height should be shortened or removed. Cavity floors and walls are flattened for increased resistance, with care taken not to traumatize the pulp or weaken the remaining walls. A core must be anchored firmly to the tooth and not just placed to fill the void. Otherwise, it offers no advantage over allowing the bulk of the casting to occupy the space.

Pin-retained cores have been used to retain cast restorations on severely damaged teeth for nearly 50 years.^{17,28,29} Both amalgam and composite resin have been used for this purpose. Composite resins are favored by some because they are easily molded into large cavities and they polymerize quickly, allowing the crown preparation to be done at the same appointment. However, composite resin cores exhibit greater microleakage than do amalgam cores,³⁰ and they are not as dimensionally stable as amalgam. In an *in vitro* study, crowns made for teeth with composite resin cores failed to seat by 226 μm more than crowns made for teeth with amalgam cores after immersion in body-temperature normal saline solution for 1 week.³¹ The surface of a composite resin core is affected adversely by exposure to zinc oxide–eugenol temporary cement,³² although that does not seem to have a negative effect on the tensile strength of the definitive crown.³³

Single-phase, copper-rich amalgams attain sufficient hardness to allow a crown preparation to be made after only 10 minutes.³⁴ Retention devices other than pins can be used for amalgam cores. Slots that are the width and depth of a no. 33½ bur can be placed around the periphery of the preparation.³⁵ Dentin chambers, or “pot holes,” 2 to 3 mm deep can be placed with a no. 1156, 1157, or 1158 bur. When amalgam is condensed into these holes, they become “amalgapins.”³⁶

Retentive features for the core must be deep enough to not be removed by the axial reduction done in the crown preparation. A properly contoured amalgam core can serve as a provisional restoration for several weeks, giving the tis-

sue an opportunity to recover while more urgent treatment is being performed.

The preparation finish line for the cast restoration should extend beyond the core into tooth structure.³⁷ The farther the core extends subgingivally, the more likely it is to have voids and overhangs that will make it unsuitable for exposure beyond the margin of the definitive restoration. If the core is amalgam, dissimilar metals in contact with it are more prone to corrosion when exposed to the oral environment. If the core is composite resin, it is susceptible to leakage.

Modifications for Damaged Vital Teeth

In the preparation of a damaged tooth (Fig 13-11a), an orderly sequence should be followed to take full advantage of the remaining tooth structure and attain the most retentive preparation possible.

The first step is to evaluate pulpal health. If it is questionable, or if there is an exposure, however small, endodontic therapy should be done before placing a cast restoration.³⁸ Otherwise, the restoration later may be compromised by the endodontic access. Nonetheless, every effort should be made to maintain the vitality of the pulp. Endodontic treatment is usually successful, but nothing is perfect. Even if it is successful, it weakens the tooth and increases the cost of restoring it.

The second step is to assess the periodontal condition. Periodontal tissues are examined for deep subgingival extensions of caries, fractures, or previous restorations. Finish line extensions that violate the biologic width of 2.0 mm of tissue attachment may require periodontal surgery before a restoration is made.^{39,40}

Next, a preliminary preparation design is made. A general concept can be formulated in advance, but the specific features to be used and their location cannot be ascertained until the initial phases of the preparation have been completed.

Previous restorations and bases, all caries, and any unsupported enamel are removed (Fig 13-11b). Even if an existing restoration appears sound, it may conceal caries or a pulp exposure and therefore is removed. Concave, roughened areas from which caries and previous restorations have been removed, or sloping surfaces remaining after cuspal fracture, must be oriented to enhance resistance and retention. They should be formed into vertical and horizontal components, or steps, with essentially vertical surfaces made parallel with the path of insertion (Fig 13-11c). They must be kept at the periphery of the preparation, with gingival shoulders and floors no wider than 1.5 mm. Horizontal surfaces are made perpendicular to the path of insertion to increase resistance to occlusal forces. No flat horizontal surface in the central portion of the tooth should be any deeper than the level of the pulpal floor of a classic isthmus.

Next, the strength of the remaining walls is evaluated. A decision is made whether to incorporate remaining defects

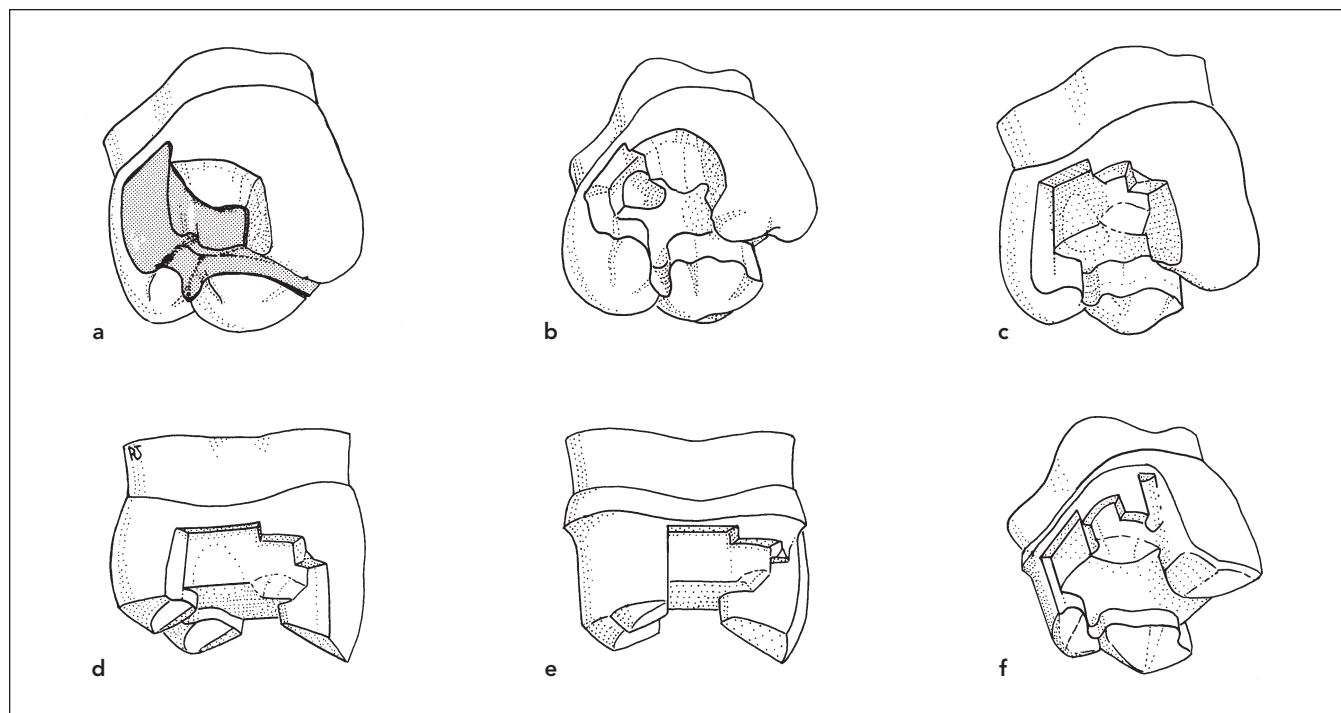


Fig 13-11 (a) Maxillary molar with a missing distofacial cusp and a defective MOD amalgam. (b) All caries, previous restorations, bases, and undermined enamel are removed. (c) Steps are formed in sloping areas with vertical surfaces made parallel with the path of insertion and horizontal surfaces perpendicular to it. Occlusal reduction (d) and axial reduction (e) are done on the remaining tooth structure. (f) Addition or refinement of auxiliary retention features completes the preparation.

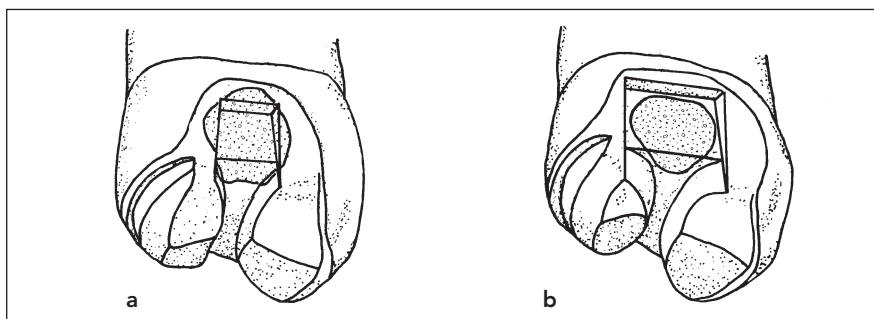


Fig 13-12 (a) A box placed in cement will not provide retention and resistance. (b) If the box is widened faciolingually and lengthened gingivally so that the facial and lingual walls are in solid tooth structure, retention will be improved.

into the preparation or to fill them in. If more than 50% of the coronal tooth structure of a posterior tooth is sound and the tooth will not be an abutment, sufficient retention can be achieved by adding supplemental features to the preparation. Internal features such as isthmuses or box forms must have surrounding walls of dentin that are at least as thick as they are high. If the thickness-height ratio of a wall lies between 1:1 and 1:2, it should be supported. Any wall with a thickness-height ratio of less than 1:2 is subject to fracture and should be shortened.

The last step is to finalize the preparation design, beginning with occlusal reduction (Fig 13-11d) and then axial reduction (Fig 13-11e). A base is used to fill in the central areas of the tooth that were too deep to be included in the orien-

tation of horizontal and vertical surfaces. It is not worthwhile to mold a large bulk of base to a classic preparation configuration because no retention is gained from a cement base.

The preparation is ready for the placement of its retention features. Only after all other portions of the preparation are complete can a decision be made about the type, number, and location of retentive features that will be used. Their addition completes the preparation (Fig 13-11f).

Placement of grooves, pinholes, and box walls in a base is the same as not using them at all (Fig 13-12a). Retention and resistance forms must be placed in solid tooth structure if they are to provide any resistance to dislodgment (Fig 13-12b). Because retentive features can be formed no more than 1.5 mm from the outer surface of the tooth, deep de-

13 Preparations for Severely Debilitated Teeth

struction of tooth structure requires that the axial wall of a box be placed in a nonretentive base rather than in dentin. If the facial and lingual walls are in dentin, the box will provide significant retention. The danger to the pulp from extending the box closer to the pulp would be an unacceptable risk for the little retention that might be added.

An important aspect of restoring damaged teeth is the protection of remaining tooth structure. Teeth already weakened by the loss of large amounts of tooth structure are ill-equipped to withstand occlusal forces unassisted. Protection can be provided by capping cusps with the cast restoration.^{41,42} The occlusal thickness in metal should be 1.0 mm over the nonfunctional cusps and 1.5 mm over the functional cusps.

The choices for anterior teeth are more limited because of esthetic requirements and the smaller bulk of dentin in which supplemental features can be placed. Modifications of classic anterior preparations are limited to substitution of a box for a groove to encompass a caries lesion or addition of extra grooves or pinholes. If more than one-third of the coronal structure is lost, placement of a pin-retained core followed by a metal-ceramic crown is usually indicated.

There will be times when it is necessary to devitalize a tooth to obtain retention. If a crown is to be placed on a narrow, single-rooted tooth with little or no coronal tooth structure, a core may not have sufficient resistance to dislodgment without a dowel that extends into the root.

Orthodontic Adjuncts to Restoring Damaged Teeth

Caries or trauma may produce tooth destruction of a magnitude or in a location that makes it difficult or impossible to restore the tooth without serious esthetic or periodontal compromise. Simple orthodontic procedures can be employed in some of these situations to make it possible to restore the teeth in a manner that will improve the prognosis for long-term success and provide a more pleasing esthetic result where required.

Regaining interproximal space

A long-standing caries lesion on the proximal surface of a molar often will result in migration of the adjacent molar into the void created by the caries (Fig 13-13). It is not enough just to excavate the caries and place a restoration in such a situation. The teeth frequently contact at, or apical to, the cemento-enamel junction. Simply placing a restoration in these circumstances would result in a concave proximal contour and a closed embrasure space that would wreak havoc on the periodontium. Instead, the space should be regained by separating the teeth with the brass wire technique described by Reagan.⁴³

A core or foundation restoration is placed in the tooth requiring restoration (Fig 13-14), which is then prepared for a full crown (Fig 13-15). An acrylic resin provisional crown is fabricated using the technique described in chapter 15. After adjusting and polishing the provisional crown, it is cemented. An elastic orthodontic separator is inserted into the proximal surface to initiate the movement of the adjacent tooth (Fig 13-16).

At a subsequent appointment, the elastic is removed, and a piece of 0.6-mm (0.025-inch) brass wire is threaded between the teeth from the facial side, apical to the contact. The wire is wrapped around the contact, bringing the two ends together on the facial side. There the wire is twisted together until the patient feels pressure. The twisted end of the wire is cut off, leaving a 5- to 6-mm tail. The cut end is bent over so that it will not pierce the patient's cheek (Fig 13-17).

At approximately 1-week intervals, the wire is tightened by twisting until the tooth shows no movement from the previous appointment. At this point the provisional restoration is removed, and the crown is built back into contact with the adjacent tooth by adding acrylic resin (Fig 13-18). The crown is repolished and recemented, and the brass wire is reapplied. As the adjacent tooth is tipped distally, it may move upward into the occlusal plane. If it does, it should be adjusted occlusally to permit it to continue to move distally (Fig 13-19).

Caries extensive enough to require orthodontic movement often extends far enough apically that some type of surgical crown-lengthening procedure will be required. This will not only facilitate successful completion of the crown, but it will also prevent subsequent periodontal inflammation around the crown margin. Then the full crown that will serve as the definitive restoration is fabricated and cemented (Fig 13-20).

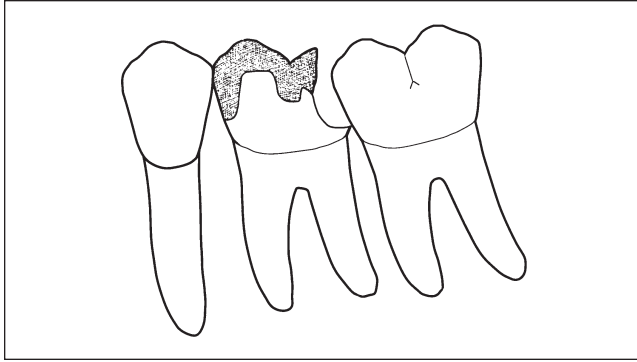


Fig 13-13 This second molar has migrated into the void produced by caries.

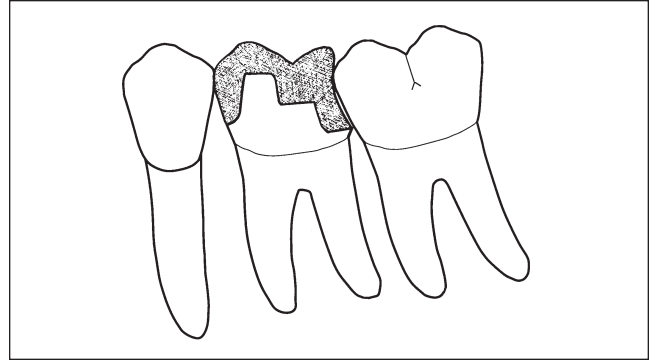


Fig 13-14 The tooth is first built up with a core.

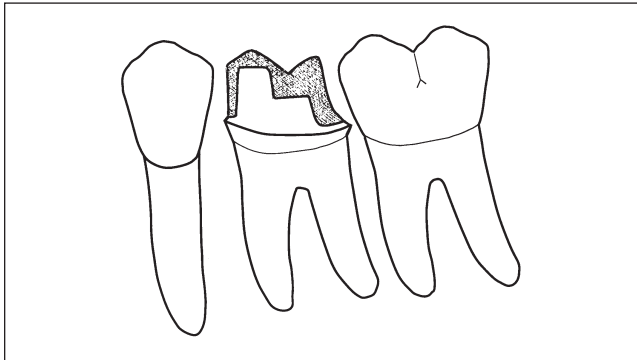


Fig 13-15 The tooth and core are prepared for a full veneer crown.

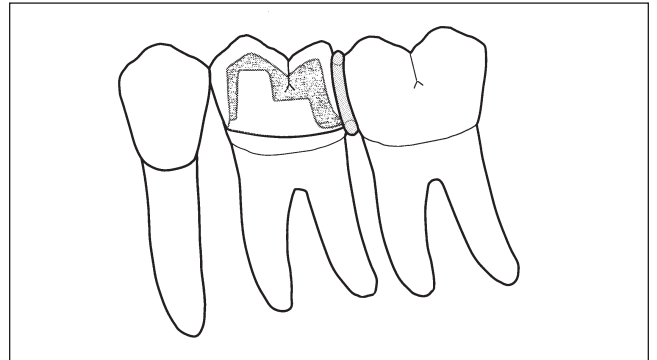


Fig 13-16 An elastic separator creates the initial space between the provisional crown and the adjacent tooth.

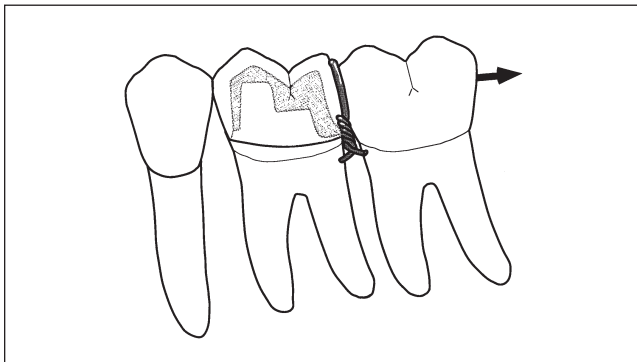


Fig 13-17 Brass wire is wrapped around the contact and twisted to further separate the teeth (arrow).

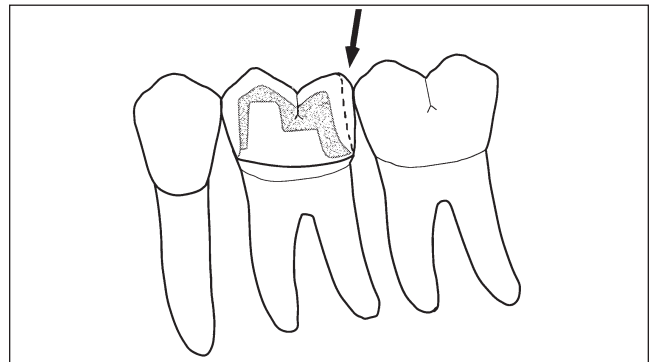


Fig 13-18 The contact is closed by adding resin to the distal aspect of the provisional restoration (arrow).

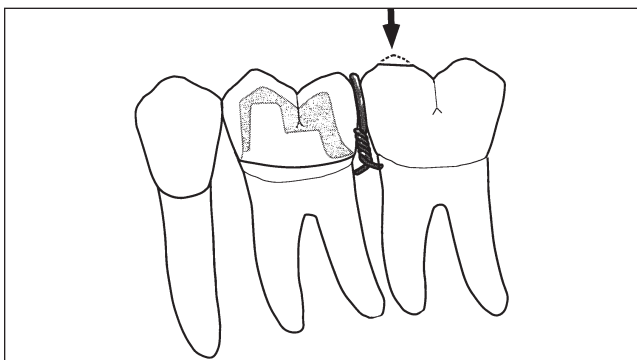


Fig 13-19 The occlusion is adjusted (arrow) to allow the tooth to continue moving distally.

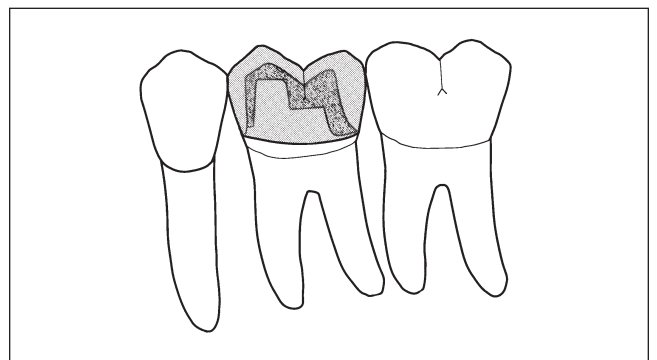


Fig 13-20 Treatment is completed by fabrication and cementation of the definitive crown.

13 Preparations for Severely Debilitated Teeth

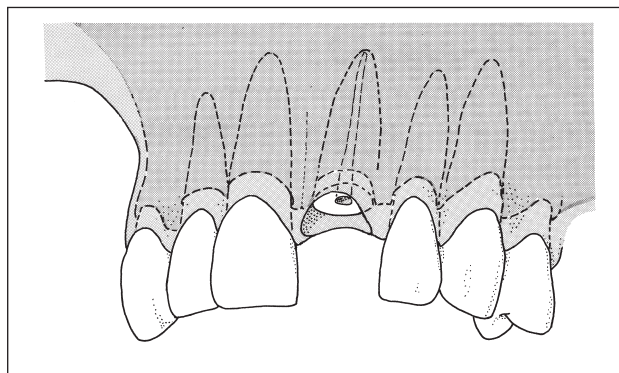


Fig 13-21 This central incisor is fractured to the level of the alveolar crest.

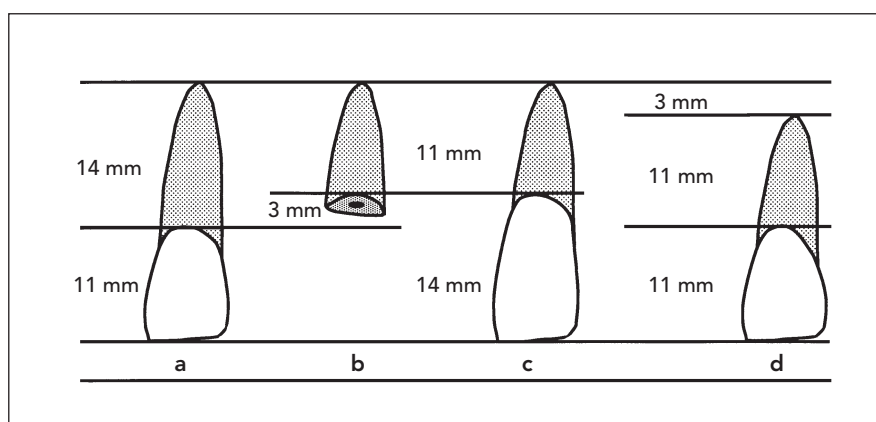


Fig 13-22 Extrusion versus surgical crown lengthening. (a) The normal anatomical crown-root ratio for an average central incisor is 11:14. (b) In this example, the tooth is fractured 3.0 mm beyond the cemento-enamel junction. (c) Surgical crown lengthening alone would produce an unstable and unesthetic crown-root ratio of 14:11. (d) Extrusion followed by crown lengthening produces a more stable crown-root ratio of 11:11 with a more esthetic, normal crown length.

Extrusion of teeth

When all tooth structure has been lost to the level of the alveolar crest or beyond because of either fracture or caries, the tooth cannot be satisfactorily restored without some extraordinary measure (Fig 13-21). Even if a dowel core is placed in the tooth, the root will remain susceptible to fracture without the crown encircling the tooth apical to the core. This ferrule effect around the tooth protects it from fracture by the dowel from within.³⁷ In fact, if tooth structure is lost to the level of the epithelial attachment, minor extrusion may be desirable to permit access to enough tooth structure apical to the finish line to produce a ferrule effect.

Burying the finish line subgingivally will not solve the problem. Rather, it will create new ones: the increased possibility of an ill-fitting crown and placement of the margin in an area that would violate the biologic width of soft tissue

attachment. This particular problem can be overcome by surgical crown lengthening alone, but the result will be most unesthetic. Surgery shortens the root and also increases the crown-root ratio (Fig 13-22).

Orthodontic extrusion has been used to move solid root structure into an accessible area.⁴⁴ The use of orthodontic brackets has been described for this purpose.⁴⁵⁻⁴⁸ However, they are bulky and unesthetic, and they may be difficult to place far enough apically to permit sufficient space for extrusion. Furthermore, their use may cause unwanted movement of the abutment teeth.⁴⁹ Removable appliances also can be used to extrude teeth,⁵⁰ but they require a high degree of patient compliance. The technique presented below utilizes an anchorage wire bonded to adjacent teeth as described by Oesterle and Wood.⁴⁹

The tooth first must be endodontically treated. The extrusion can be done with either a permanent or a temporary

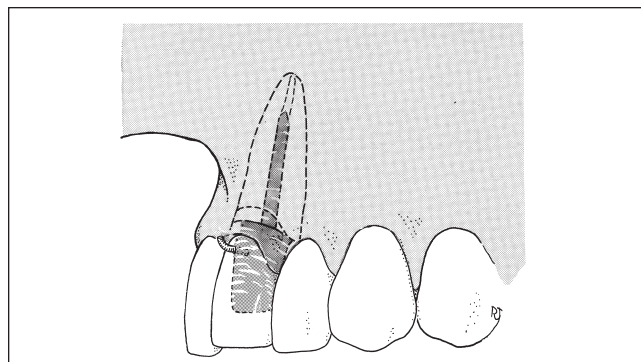


Fig 13-23 A bent pin is placed in the gingival area of the facial surface of the provisional crown.

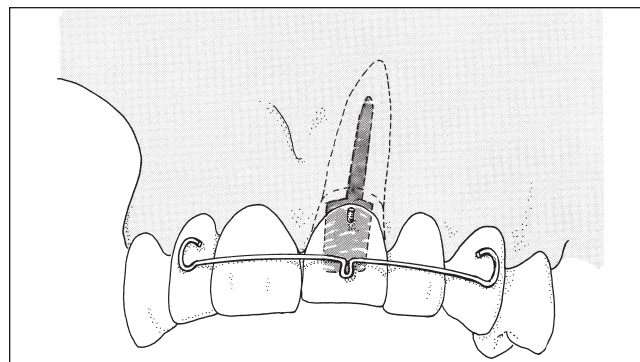


Fig 13-24 The archwire extends two teeth on either side of the tooth to be extruded. There is a loop in the wire over both terminal abutments to aid retention by resin and a loop in the middle over the tooth to be extruded.

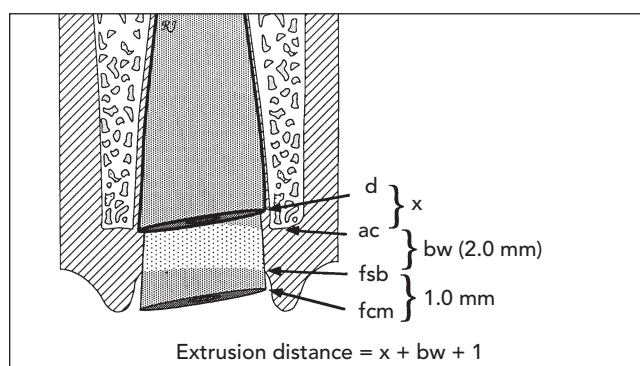


Fig 13-25 The amount of extrusion needed is determined by adding the distance (x) the destruction (d) extends beyond the alveolar crest (ac), the biologic width (bw) of 2.0 mm, and the 1.0 mm between the final sulcus bottom (fsb) and the final crown margin (fcm). If the destruction extends 1.0 mm beyond the alveolar crest, 4.0 mm of extrusion would be necessary.

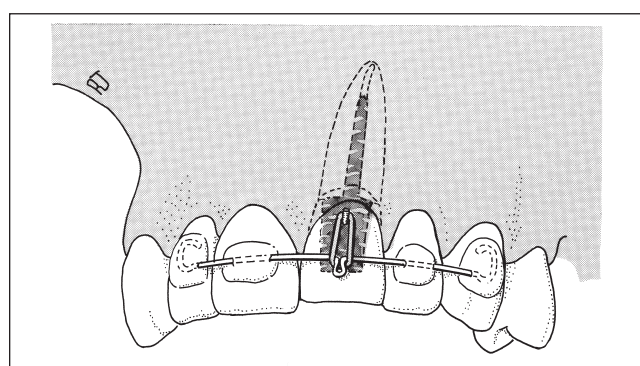


Fig 13-26 An elastic extends from the pin on the crown to the loop in the archwire.

dowel core in the tooth. In either case, a provisional crown is placed on the tooth to be extruded. This maintains space and provides an esthetic appearance during treatment. If the permanent dowel core is fabricated before extrusion, it should be made at least 3.0 mm short of its normal incisal length to allow space for extrusion.

A TMS LINK pin (Coltene/Whaledent) is embedded in the mesiodistal center of the facial surface of the provisional crown, as near the gingiva as possible. The pin is either directed slightly gingivally or bent to facilitate retention of the elastic that will be placed on it later (Fig 13-23).

A facial 0.018 × 0.025-inch stainless steel orthodontic archwire is bent with a small loop opposite the middle of the tooth to be extruded. The loop, an attachment for the elastic, is bent in an incisal direction to prevent the elastic from slipping off. The base of the loop should touch the facial surface of the tooth to prevent the tooth from moving lingually as it erupts. The archwire should extend the distance of two teeth on either side of the tooth to be extruded with a loop in each end of the wire for re-

tention (Fig 13-24). The use of this number of abutments minimizes the possibility of moving them rather than the intended tooth.

The archwire is placed at the incisogingival level to which the TMS LINK pin will be moved, equaling the amount of extrusion to be accomplished. The distance that the tooth is to be extruded is calculated by adding (1) the distance from the most apical point of fracture or caries to the alveolar crest (if the damage extends subcrestally), (2) 2.0 mm for the biologic width,³⁹ and (3) at least 1.0 mm to prevent placement of the crown margin too far subgingivally (Fig 13-25). If the damage is flush with the alveolar crest, a minimum of 3.0 mm of extrusion is required.⁴⁹

The archwire is affixed to each of the four abutment teeth using a light-activated resin. An occlusal clearance of 1.0 mm is created on the provisional crown, and an elastic is attached to the pin on the crown and the loop on the wire (Fig 13-26). The patient should be checked weekly.⁴⁶ The tooth will elongate at a rate of 1.0 to 1.5 mm per week.^{45,49,50} The occlusion is relieved again and the elastic replaced.

13 Preparations for Severely Debilitated Teeth

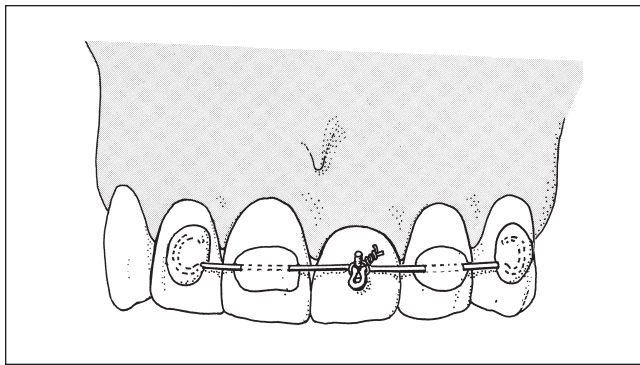


Fig 13-27 When the tooth has been extruded so that the pin on the crown contacts the loop in the archwire, it should be stabilized with ligature wire. The descended level of the gingiva makes the clinical crown shorter.

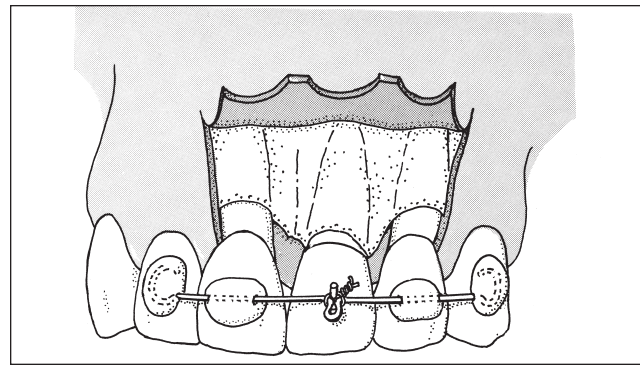


Fig 13-28 An elevated flap reveals that the alveolar level has descended with the tooth.

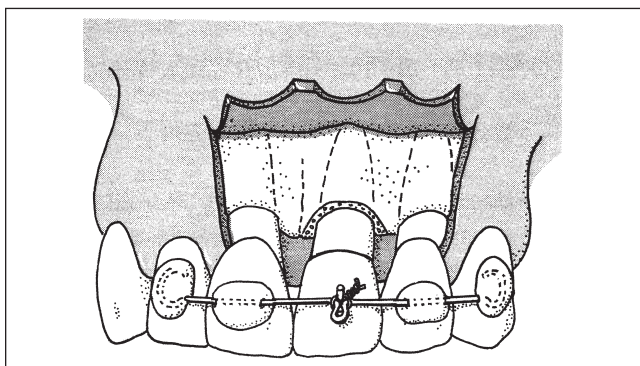


Fig 13-29 Bone is removed to the level of the adjacent teeth.

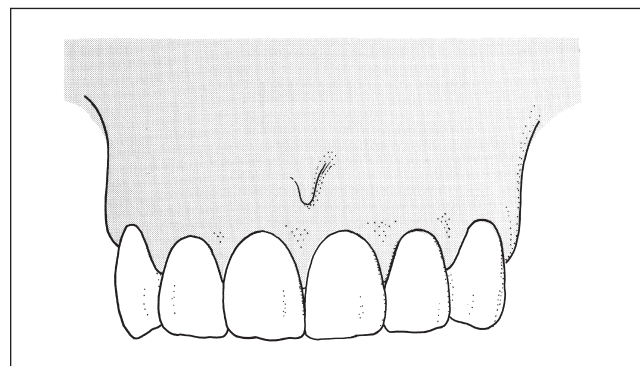


Fig 13-30 Definitive restoration on a tooth with a clinical crown whose length is similar to that of the adjacent teeth.

When the TMS LINK anchorage pin in the facial surface of the provisional crown is even with the archwire, the extrusion is completed. The elastic is removed and replaced with a ligature wire, and the pin on the crown is tied to the loop in the archwire (Fig 13-27). The occlusion is checked to ensure that there are no interferences. Traumatic occlusal contacts will interfere with healing and stabilization of the tooth. The teeth should remain ligated for at least 1 month before the next phase of the treatment is begun.⁴⁹

The alveolar bone and gingival attachment frequently will descend with the tooth (Fig 13-28). If there was a preexisting periodontal defect, it may be lessened or eliminated.^{48,51-53} However, if the periodontium was normal before the extrusion was undertaken, surgery may be necessary to bring the levels of the bone and the gingival crest into line with those of the adjacent teeth.^{49,53-55} A flap is reflected over the extruded tooth, and bone is removed to match the osseous level of the adjacent teeth (Fig 13-29). The definitive restoration can be started approximately 4 weeks after the surgery⁴⁹ (Fig 13-30).

Restoration of Endodontically Treated Teeth

The restoration to be used on an endodontically treated tooth is dictated by the extent of coronal destruction and by the type of tooth. Traditionally, a pulpless tooth received a dowel to reinforce it and a crown to protect it. Retrospective clinical surveys have led to a reappraisal of this thinking. In a study of 220 endodontically treated teeth, Ross⁵⁶ found that nearly 61% of the teeth that had been in service for 5 years or longer had not been restored with dowels. Sorensen and Martinoff⁵⁷ reported almost identical success rates for endodontically treated anterior teeth restored with and without dowels.

Rationale

In the same study by Sorensen and Martinoff,⁵⁷ there also was no significant difference between the success achieved with anterior pulpless teeth that had received crowns and

those that had not. This clearly demonstrates that endodontically treated anterior teeth do not automatically require crowns.⁵⁸⁻⁶⁰ If a moderate-sized anterior tooth is intact except for the endodontic access and one or two small proximal lesions, composite resin restorations will suffice. Placement of a dowel in such a tooth is more likely to weaken it than to strengthen it (Fig 13-31).

Lovdahl and Nicholls⁶¹ found that intact endodontically treated central incisors were three times as resistant to fracture as teeth that had been restored with dowel cores. For a tooth that has become discolored following devitalization, bleaching is preferable to crown placement if the tooth is relatively intact.⁵⁸ A laminate veneer offers a less destructive alternative if the facial surface of a reasonably intact tooth must be masked by a restoration.

However, the axial reduction for a crown preparation (peripheral destruction) combined with an endodontic access preparation (central destruction) frequently leaves insufficient sound dentin to support a crown unaided. If a metal-ceramic crown is required because of extensive coronal destruction, a dowel core probably is needed (Fig 13-32). A dowel is placed to provide the crown retention that ordinarily would have been gained from coronal tooth structure.^{62,63} Cementing the dowel with bonded resin cement strengthens the weakened coronal dentin around the dowel.⁶⁴ The use of a dowel requires that the canal be obturated with gutta-percha. It is difficult to ream out a canal filled with a silver point or other hard material. Lateral perforation of the root becomes highly likely. If a dowel is used, its extension into the root must at least equal the length of the crown for optimum stress distribution⁶⁵ and maximum retention, or the dowel should be two-thirds the length of the root, whichever is greater (Fig 13-33). A minimum length of 4.0 mm of gutta-percha, and more if possible, should remain at the apex to prevent dislodgment and subsequent leakage. If it is not possible to meet these criteria, the prognosis for the restoration will be compromised; therefore, an alternative plan should be explored.

The longer a dowel, the greater its retention.⁶⁶⁻⁶⁹ A tooth with a dowel that is three-quarters the length of the crown or shorter has less chance for success than a tooth that has no dowel at all.⁷⁰ However, the success rate of dowel-treated teeth can increase to more than 97.5% when dowel length equals or exceeds the length of the crown.⁷⁰

Posterior teeth must be treated differently. Because of their naturally divided occlusal surface, even caries-free teeth can fracture vertically under occlusal forces. The minimum treatment indicated for an endodontically treated molar or premolar is the placement of a cast restoration with occlusal coverage, such as an MOD onlay.⁷¹ Sorensen and Martinoff⁷⁰ found that 94% of endodontically treated molars and premolars that subsequently received coronal coverage were successful, while only 56% of occlusally unprotected endodontically treated posterior teeth survived.

Those endodontically treated posterior teeth with sufficient sound tooth structure to be restored with an MOD onlay are in a distinct minority. Many teeth that require endodontic

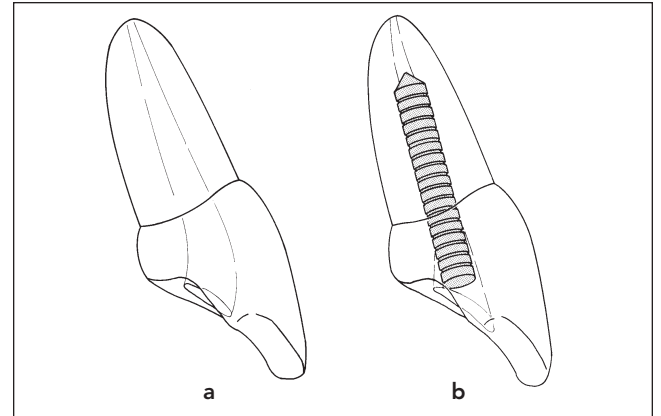


Fig 13-31 (a) A tooth with an intact clinical crown can be adequately restored with composite resin. (b) A dowel provides unnecessary "reinforcement" that may weaken the tooth instead. (Reprinted from Shillingburg and Kessler⁵⁹ with permission.)

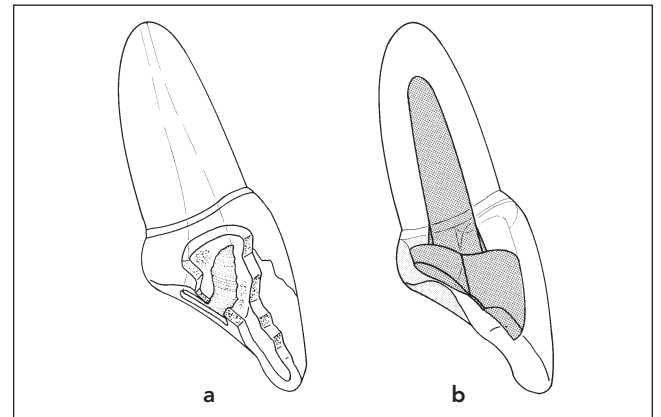


Fig 13-32 A single-rooted pulpless tooth with a severely damaged crown (a) usually will require a dowel core before placement of a crown (b). (Reprinted from Shillingburg and Kessler⁵⁹ with permission.)

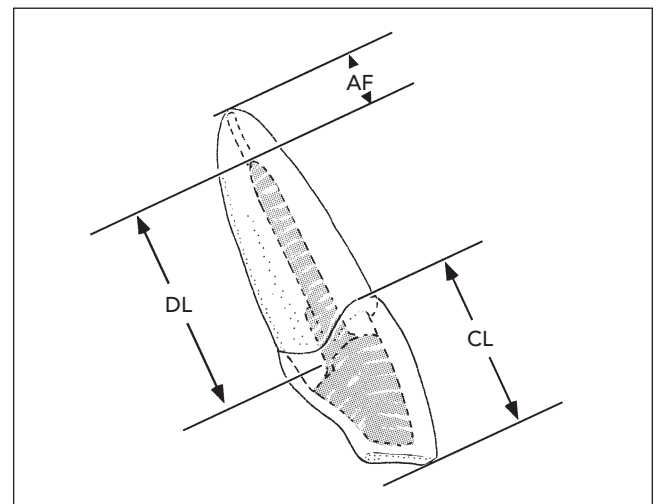


Fig 13-33 The length of the dowel (DL) should equal the crown length (CL) or two-thirds the length of the root, whichever is greater. The length of the remaining apical fill (AF) should be at least 4.0 mm.

13 Preparations for Severely Debilitated Teeth

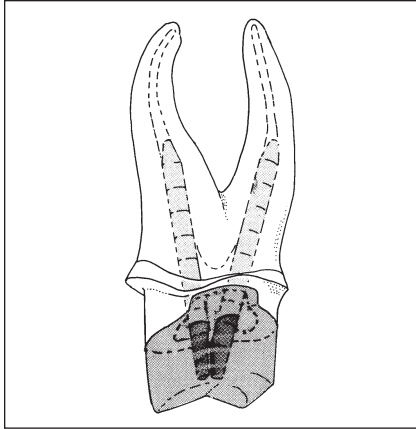


Fig 13-34 Roots of a premolar require bulk and length for the successful use of a dowel core. Both canals of a two-canal tooth are used if possible.

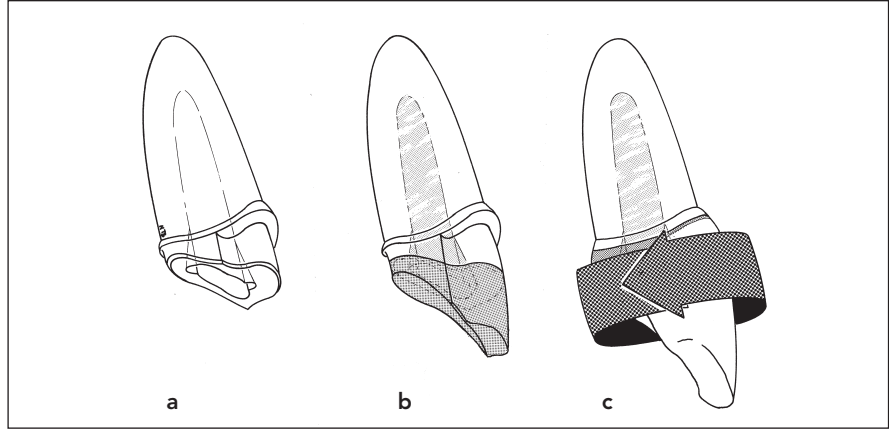


Fig 13-35 (a) The preparation for a dowel core should preserve solid tooth structure. (b) The crown preparation finish line should be apical to the dowel-core margin. (c) This enables the crown to girdle the tooth (arrow) and brace it externally. (Reprinted from Shillingburg and Kessler⁵⁹ with permission.)

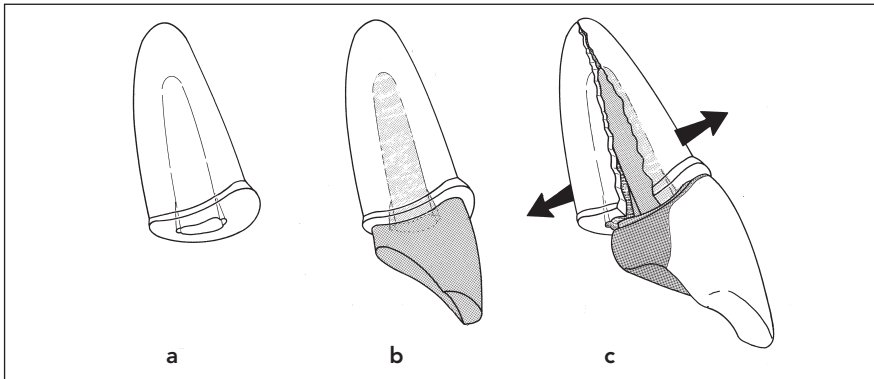


Fig 13-36 If a tooth is flush with the gingiva (a), fabrication of a dowel core and a crown without encirclement of tooth structure by the crown walls (b) could result in root fracture (c). (Reprinted from Shillingburg and Kessler⁵⁹ with permission.)

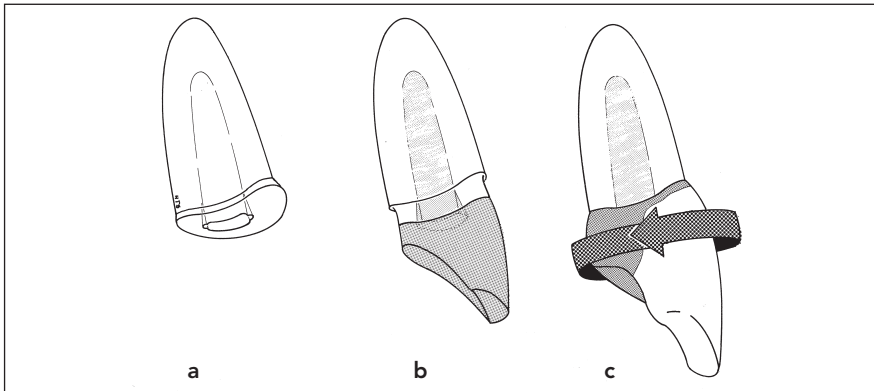


Fig 13-37 A tooth without coronal tooth structure (a) can be protected by moving the crown preparation finish line apically (b) to brace the tooth (arrow) against root fracture (c). (Reprinted from Shillingburg and Kessler⁵⁹ with permission.)

therapy have been so damaged by caries, previous restorations, and the endodontic access that limited coronal tooth structure remains to be used for retaining the definitive restoration.

Frequently a core must be substituted for the supragingival axial walls and auxiliary features that are customarily used. Maxillary premolars often have drastically tapering roots, thin root walls, and proximal root concavities or invaginations, all of which are predisposing factors to perforation or fracture.⁷² In a study of 468 teeth that had fractured *in vivo*, 78% were premolars, with 62% being maxillary premo-

lars.⁷³ A dowel core should be used on premolars only if the roots are adequately long, bulky, and straight (Fig 13-34).

Care must be exercised in the selection of restorations for teeth that have no remaining coronal tooth structure. The encirclement of 1.0 to 2.0 mm of vertical axial tooth structure within the walls of a crown creates a ferrule effect around the tooth to protect it from fracture³⁷ (Fig 13-35). If the crown margin is not placed onto solid tooth structure, the risk of root fracture is greatly increased (Fig 13-36). Orthodontic extrusion and crown-lengthening surgery may be needed to prevent encroachment on periodontal tissues (Fig 13-37).

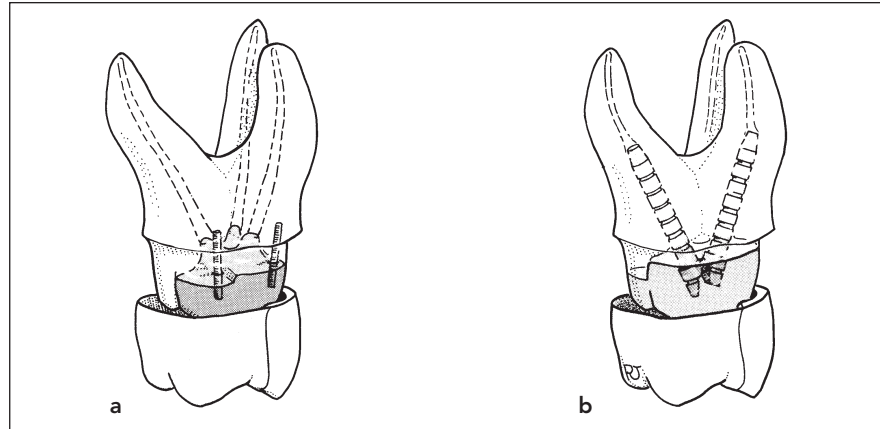


Fig 13-38 (a) A core retained by pins, slots, amalgapins, or extension into the pulp chamber is used to build up a molar with some coronal tooth structure. (b) However, if there is insufficient coronal tooth structure to support the core, two dowels are added for resistance.

Rosen⁷⁴ advocated a subgingival collar to act as an extra-coronal brace. Hoag and Dwyer⁷⁵ determined that the type of dowel core was not as important as the presence of a full crown with margins that extended beyond the core. Having 1.0 mm of vertical tooth wall between the margin of the core and the shoulder of the preparation was found by Sorensen and Engelman⁷⁶ to provide a ferrule effect, enhancing fracture resistance by 80% to 139%. Milot and Stein⁷⁷ demonstrated that a steep, 1.0-mm-wide bevel that is nearly parallel with the long axis of the preparation also strengthens the tooth against fracture.

If a minimum of 1.0 mm of vertical axial wall cannot be covered by a crown on a premolar that is to serve as an abutment, the tooth should be extracted. Endodontically treated teeth should not be used as abutments for distal extension removable partial dentures.⁷⁸ They are more than four times as likely to fail compared to pulpless teeth not serving as abutments.⁷⁹ Pulpless fixed partial denture abutment teeth fail nearly twice as often as single teeth.

Even with a ferrule effect, it is questionable whether a pulpless tooth should be used as an abutment for a fixed partial denture with a span longer than one pontic. The tooth is structurally compromised and susceptible to fracture if overloaded. The more extensive the restoration required for an endodontically treated tooth, the more time-consuming and technique-sensitive the restoration will be.⁸⁰ If a fixed partial denture must be used in such circumstances, strong consideration should be given to the use of an implant-supported prosthesis.

A pulpless molar with a moderately damaged clinical crown can be built up with an amalgam or composite resin core prior to placement of an artificial crown (Fig 13-38a). If there is one sound cusp, the core may be retained by gross extension of the amalgam into the pulpal chamber alone,⁸¹ or in conjunction with pins,⁸² peripheral slots,³⁵ or dentinal wells (ie, amalgapins).³⁶ A variation, usually employing two dowels, is used for molars that have little or no remaining coronal tooth structure (Fig 13-38b).

The core and its attachment(s) are made separately from the definitive restoration. The crown is then fabricated and cemented over the core just as a restoration would be placed over a preparation made in tooth structure. This two-unit system offers several advantages over a one-piece dowel crown. The marginal adaptation and fit of the restoration are independent of any dowel that must be used. The restoration can be replaced at some future time, if necessary, without disturbing the dowel core. If a dowel is necessary, the choice is not limited to a custom cast device. Prefabricated systems can be used if the dowel does not have to be incorporated into the crown. If the endodontically treated tooth must serve as a fixed partial denture abutment, it is not necessary to make the root canal preparation parallel with the path of insertion of other preparations.

Prefabricated dowel with amalgam or resin core

Numerous techniques have been described for the fabrication of dowel cores. Prefabricated dowels with amalgam or composite resin cores are the most commonly used dowel cores today, and there is a wide variety of dowel systems available. Kits for prefabricated dowels use special reamers or drills for canal preparations that are the same size and configuration as the dowels. Through the use of one of these systems, it is possible to complete the entire procedure in a single appointment.⁸³

Amalgam provides greater strength. Kovarik et al⁸⁴ found that 67% of the amalgam cores tested in an *in vitro* study survived 1,000,000 cycles of 75-lb loading, while only 17% of the composite resin cores survived. In that same study, all of the glass-ionomer cores had failed within the first 220,000 cycles. Composite resin remains popular because it is easily placed, polymerizing in minutes and allowing work on the core preparation to progress almost immediately. Resin requires less bulk of material than does amalgam, which makes it useful on small teeth.

13 Preparations for Severely Debilitated Teeth

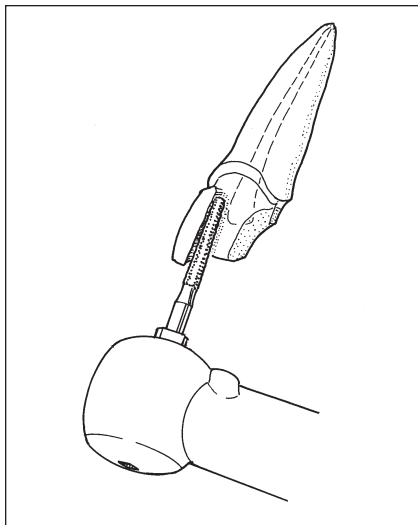


Fig 13-39 The initial step in a dowel core preparation is reduction for the crown preparation.

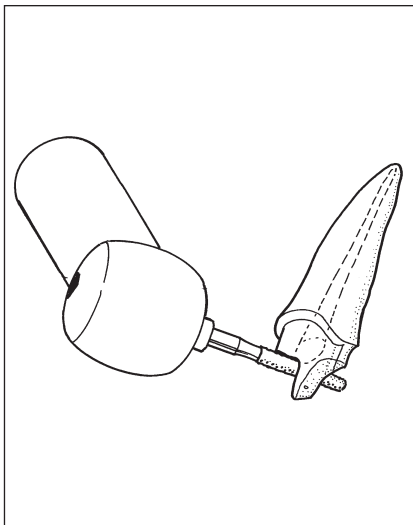


Fig 13-40 Unsupported tooth structure is removed next.

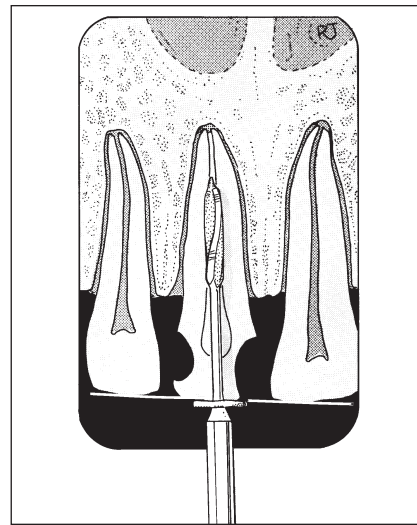


Fig 13-41 The depth of insertion of the Peeso reamer is determined by superimposing it over a radiograph of the tooth being restored.

A dowel increases resistance to lateral forces applied to the crown from 15%⁸⁵ to 48%.⁸⁶ Dowels can be made of stainless steel, titanium, brass, or a chromium-containing alloy. In recent years, carbon pyrolite fiber and fiberglass have been used in the manufacture of dowels.^{87,88} Ceramic dowels have also been advocated for use in anterior teeth where metal dowels could lead to darkening of the root and overlying gingiva. However, neither type of dowel is recommended for use with resin cements. Fiber dowels exhibited poor torsional resistance because of poor torsional stiffness of the dowel itself. Torsional resistance was poor with zirconia dowels because of a lack of bonding.⁸⁹ The preferred materials in light of current knowledge of galvanism and corrosion are titanium, high platinum, and cobalt-chromium-molybdenum alloys.⁹⁰ The least desirable are brass and chromium-nickel steel.⁹⁰ Prefabricated dowels are made in both parallel-sided and tapered configurations.

Dowel systems can be classified by their mechanism of retention: passive (cemented) or active (threaded). The threaded dowels are more retentive than the cemented, but they also produce more stress in the tooth.^{69,91,92} The techniques for all of these systems are similar, except for the final dowel space (canal) preparation instrumentation, which is usually specific for the particular dowel system being used.

Armamentarium

- Handpiece
- Coarse-grit flat-end diamond (6847-016)
- Fine-grit flat-end diamond (8847KR-016)
- Coarse-grit football-shaped diamond (6379-023)
- Fine-grit football-shaped diamond (8379-023)
- Coarse-grit flame diamond (862-010)
- Fine-grit flame diamond (8862-010)
- No. 171L bur

- No. 4 round bur
- Rubber dam
- Endodontic condenser
- Set of six Peeso reamers
- Dowel kit, including dowel, special reamer, pin(s), and drill
- Cement spatula and glass slab
- Amalgam
 - Copper band and wedges
 - Capsule(s) and amalgamator
 - Carrier
 - Condenser
 - Carver(s)
- Composite resin
 - Crown form (clear or polycarbonate)
 - Resin kit
 - Plastic filling instrument

Technique

The preparation for a dowel core is begun by preparing the coronal tooth structure for the crown that will be the definitive restoration for the tooth (Fig 13-39). Existing restorations, caries, bases, and thin or unsupported walls of tooth structure are removed (Fig 13-40). As much coronal tooth structure as possible should be preserved to enable the axial walls of the crown to externally brace the tooth.

A Peeso reamer is measured against a radiograph of the tooth being restored to determine the length to which the instrument (and later, the dowel) will be inserted into the canal (Fig 13-41). A silicone rubber endodontic stop is slid onto the shank of the reamer, aligning it with a landmark such as the incisal edge of the adjacent tooth to ensure insertion of the instrument to the proper depth in the tooth. Rubber dam is placed to prevent contamination of the canal and to protect nearby tissues. The dowel space preparation is

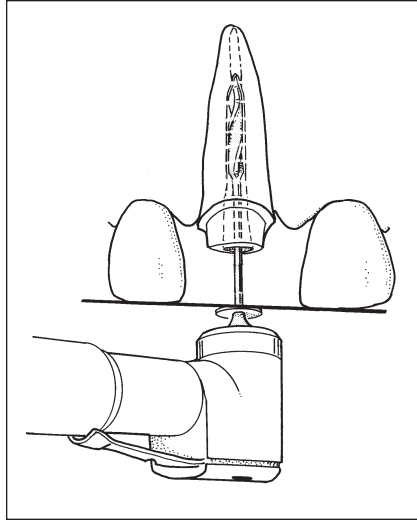


Fig 13-42 The canal is prepared with Peeso reamers.

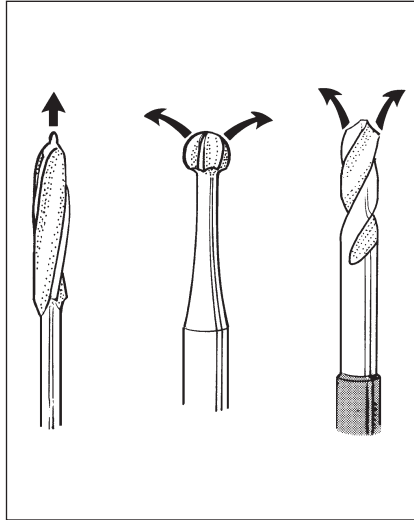


Fig 13-43 A Peeso reamer with a safety tip (a) will follow the path of least resistance, staying within the previously instrumented root canal. A bur (b) or a drill (c) can cut in any direction that it is pushed.

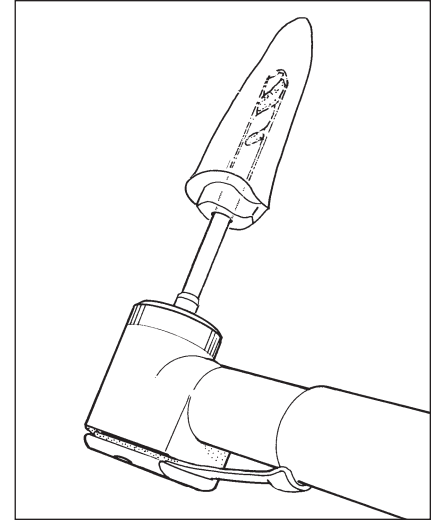



Fig 13-44 The dowel space preparation is finished with the specific drill or reamer for the dowel system being used.

Fig 13-45 The outlines of the roots (pictured at midroot) and the dowels are shown superimposed on the occlusal surfaces of the right teeth (left side of image). The recommended dowel diameters (in mm) are shown on the left teeth (right side of image).



begun by first removing gutta-percha in the canal with a hot endodontic condenser.⁸² Enlargement of the canal begins with the largest Peeso reamer or Gates Glidden drill that will fit into the canal (Fig 13-42).

Even if a specific reamer or drill is prescribed for a particular dowel system, safety-tipped instruments that will follow the path of least resistance (ie, where gutta-percha was previously placed in the canal) should be used in the beginning (Fig 13-43). With a series of successively larger reamers, the canal is enlarged to a diameter slightly smaller than that of the specific instrument required for the system being used.

Enlarging a previously instrumented canal in 0.2-mm increments diminishes the possibility of the instrument straying from the canal. Conventional drills used without any prior enlargement of the canal are more prone to stray from the original canal pathway than either Peeso reamers¹⁵ or Gates Glidden drills.⁹³ The preparation of the dowel space is completed with the prescribed drill or reamer for the system being used (Fig 13-44). General guidelines for the final dowel diameter are shown in Fig 13-45, but individual teeth may require smaller dowels.

13 Preparations for Severely Debilitated Teeth

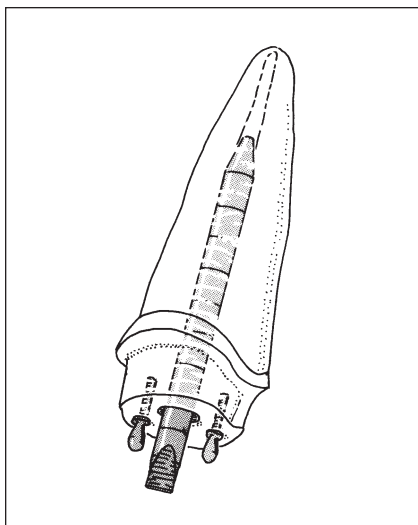


Fig 13-46 The prefabricated dowel will retain the core, and the pin(s) will give it resistance to rotation.

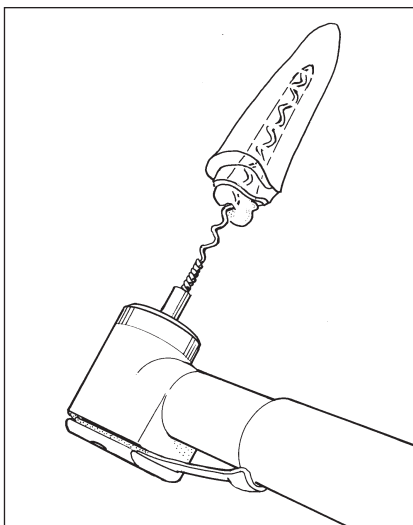


Fig 13-47 Cement is carried into the canal with a Lentulo spiral.

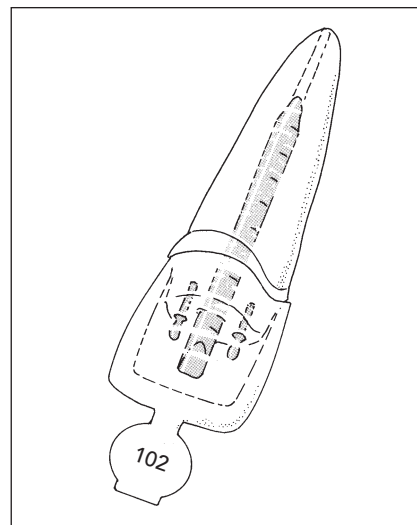


Fig 13-48 The gingival portion of a crown form is cut to follow the contours of the gingiva surrounding the tooth.

In the area of greatest bulk between the canal and the periphery of the tooth, one or two 0.6-mm pinholes are drilled to a depth of 2.0 mm. The pins are placed in these holes to provide antirotational resistance against forces transmitted from the incisal edge of the crown to the core under it. The dowel is tried in to confirm fit and length (Fig 13-46). When it is necessary to shorten the dowel, it should be done at the apical end if the dowel has a special shape to the head, such as the Parapost (Coltene/Whaledent). On the other hand, if the dowel has a specially shaped tip, such as the BCH (3M), any required shortening should be carried out at the coronal end.

A thin mix of cement is made, and the dowel is coated with it. Cement is introduced into the dowel space with a plastic instrument. A Lentulo spiral (Dentsply) is used to ensure that the walls of the canal are completely coated with cement (Fig 13-47). Retention can be increased by as much as 90% if a Lentulo spiral is used.⁹⁴ The dowel is pushed slowly into place, allowing the excess cement to escape. The dowel is held in place with finger pressure until initial set occurs. Then excess cement is removed from around the dowel head and pins.

If amalgam will be used for the core, a copper band of the correct diameter is selected to fit the tooth, and the gingival

end is festooned to follow the gingival contours. If the core is to be composite resin, a copper band can be used, but it is easier and faster to use a crown form. A clear crown form permits the use of a light-activated resin, while a polycarbonate form can be used with autopolymerizing resins (Fig 13-48).

If a polycarbonate crown form is used, a separating medium is placed in it. It is filled with light-bodied impression material, and the excess is blown out with an air syringe, leaving a thin film lining the walls of the crown (Fig 13-49). Then the crown form is filled with resin and held in position over the protruding dowel until the resin core material has polymerized (Fig 13-50). The matrix is removed, and the core is shaped with diamonds and burs to the form of a crown preparation (Fig 13-51). The gingival finish line must be on tooth structure.

A provisional restoration is fabricated, and the impression for the crown is made. If a polycarbonate crown was used as a matrix, it can be used as the provisional crown after the elastomeric material is peeled out and the margins are refined. The definitive restoration will be cemented at the return appointment (Fig 13-52).

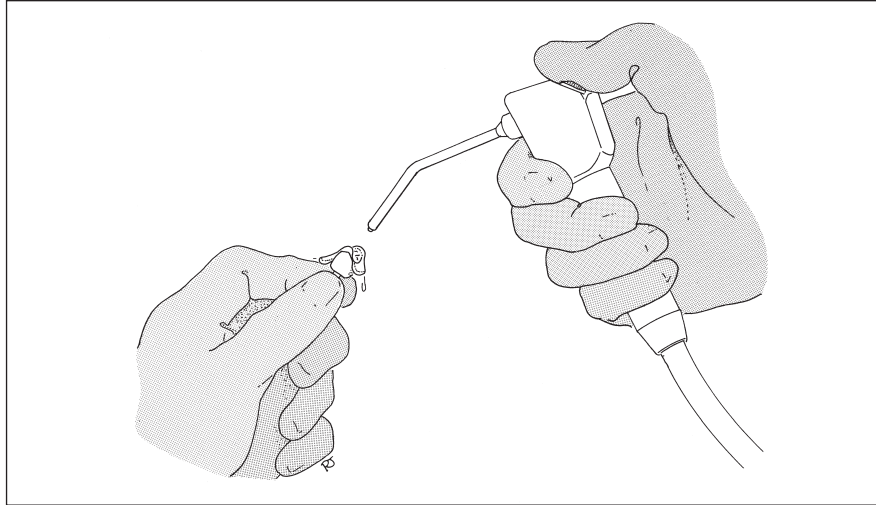


Fig 13-49 Excess separating material (impression material) is blown out of the crown form.

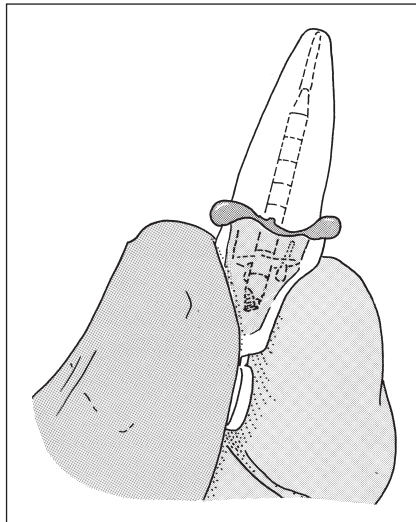


Fig 13-50 The crown form is held while the resin polymerizes.

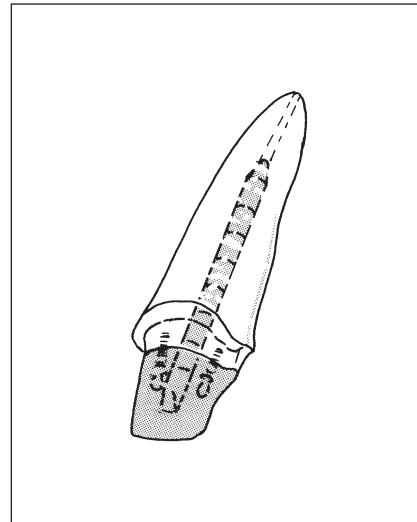


Fig 13-51 The tooth preparation for the definitive crown is completed.

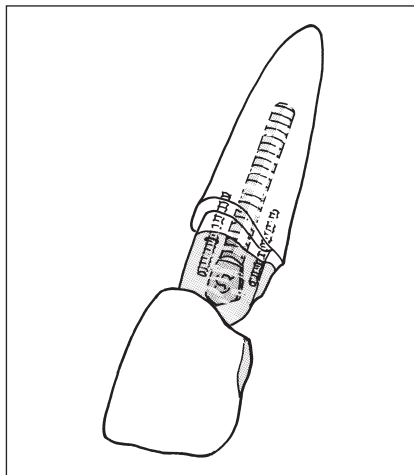


Fig 13-52 The crown is cemented over the prefabricated dowel and core.

13 Preparations for Severely Debilitated Teeth

Table 13-2 Instrument sizes

Instrument	Diameter (mm)						
	0.6	0.7	0.9	1.1	1.3	1.5	1.7
Peeso reamer	NA	1	2	3	4	5	6
Gates Glidden	1	2	3	4	5	6	NA

NA, not applicable.

Custom cast dowel cores

Prefabricated noble-metal dowels have been combined with wax cores.^{95,96} Direct wax patterns have been fabricated using either a fissure bur⁷⁴ or a paper clip⁹⁷ as reinforcement. A direct technique can be used to fabricate a dowel core pattern from acrylic resin.^{98–100}

The direct acrylic resin dowel core technique can be used for teeth with single or multiple roots. When a dowel core is made for a premolar with two canals, a dowel of optimal length is made for the most desirable canal, and the second canal accommodates a short key that serves as an antirotational device. It adds little or no retention.

The direct method for fabrication of a dowel core is accomplished in three steps:

1. Canal preparation
2. Resin pattern fabrication
3. Finishing and cementation of the dowel core

Armamentarium

- Handpiece
- Coarse-grit flat-end diamond (6847-016)
- Fine-grit flat-end diamond (8847KR-016)
- Coarse-grit football-shaped diamond (6379-023)
- Fine-grit football-shaped diamond (8379-023)
- Coarse-grit flame diamond (862-010)
- Fine-grit flame diamond (8862-010)
- No. 170L bur
- No. 4 round bur
- Endodontic condenser
- Set of six Peeso reamers
- Straight handpiece
- Coarse garnet disk on a Moore mandrel (E. C. Moore)
- Fine sandpaper disk on a Moore mandrel
- Large green stone
- Rubber abrasive wheel on mandrel
- 14-gauge solid plastic sprue
- Dappen dish
- Cement spatula
- Cotton pellets
- Petrolatum
- Resin monomer and polymer
- Medicine dropper
- IPPA plastic filling instrument

Canal preparation

The preparation for the definitive restoration is roughly approximated. For an anterior tooth, the definitive restoration will probably be a metal-ceramic crown. Axial reduction and incisal reduction of 2.0 mm are accomplished with a flat-end tapered diamond (see Fig 13-39). Facial reduction should be 1.0 to 1.2 mm deep axially. Lingual reduction is done with a small football-shaped diamond.

All caries, bases, and previous restorations are removed, and the remaining tooth structure is evaluated to determine which areas are sound enough to be incorporated into the definitive preparation. Thin walls of unsupported tooth structure should be removed at this time (see Fig 13-40). It is neither necessary nor desirable to remove all supragingival coronal tooth structure unless it is weak and undermined.

The tooth is now ready for preparation of the canal. The instruments of choice for removing the gutta-percha and enlarging the canal are Peeso reamers. They are available in sets of six graduated sizes ranging from 0.7 to 1.7 mm in diameter (Table 13-2), with noncutting tips that follow the path of least resistance (ie, where gutta-percha was placed in the canal).

The removal of gutta-percha in the canal is begun using a hot endodontic condenser. The largest Peeso reamer that will fit in the obturated canal is measured against a radiograph of the tooth being restored to determine the length to which the reamer will be inserted into the canal (see Fig 13-41). A landmark, such as the incisal edge of an adjacent tooth, is used to locate a stop on the shank of the reamer. A small square of rubber dam material is slid to the place on the reamer that will correspond with the landmark when the reamer is inserted to the proper depth in the canal.

The reamer is placed in the tooth to the predetermined depth, and a radiograph is exposed to check the accuracy of the length. This radiograph is used to establish the final length. Enlargement of the canal is continued with the graduated sizes of reamers until the size selected for that tooth is reached. The size of reamer used will depend on the diameter of the tooth. As a general rule, it will be no greater than one-third the diameter of the root at the cemento-enamel junction, and there should be a minimum thickness of 1.0 mm of tooth structure around the dowel at midroot and beyond (Fig 13-53).

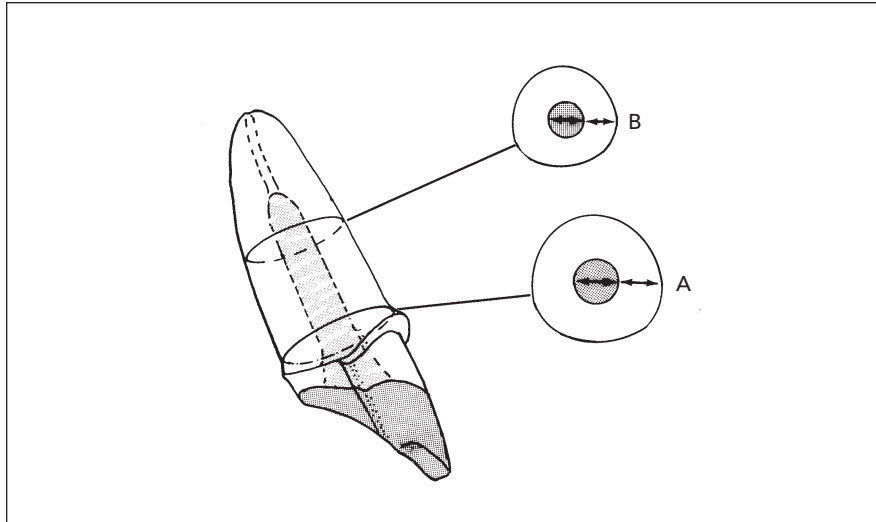


Fig 13-53 Dowel diameter should be no more than one-third the root diameter at the cemento-enamel junction (A). It should be at least 2.0 mm less than the crown diameter at midroot (B).

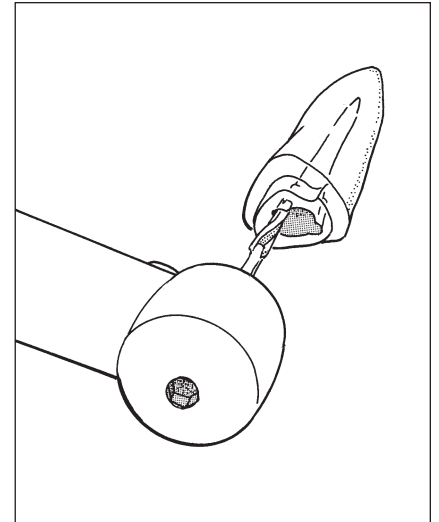


Fig 13-54 A keyway is prepared with a no. 170L bur.

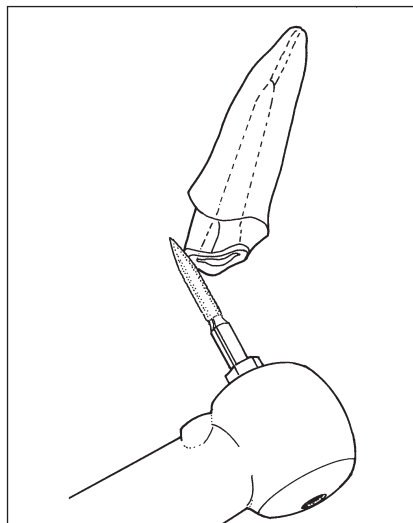


Fig 13-55 A flame diamond is used to place the contrabevel.

After the canal has been prepared for the dowel, a no. 170L bur is used to make a keyway, or groove, in the orifice of the canal. It is placed in the area of the tooth where there is the greatest bulk (Fig 13-54). The keyway should be cut to the depth of the diameter of the bur (approximately 0.6 mm) and up the canal to the length of the cutting blades of the bur (approximately 4 mm). On a premolar, the second canal serves the same antirotational function.

If there is supragingival tooth structure, a flame diamond is used to place a contrabevel around the external periphery of the preparation (Fig 13-55). This feature provides a metal collar around the occlusal circumference of the preparation

to aid in bracing the tooth against fracture of the remaining tooth structure.

Resin pattern fabrication

A Duralay plastic pin (Reliance) is trimmed so that it will slide easily into the canal to the apical end of the dowel preparation. It must not bind in the canal. A small notch is cut on the facial portion of the occlusal end of the plastic sprue to aid in orienting the dowel core pattern when it is resealed in subsequent steps (Fig 13-56).

13 Preparations for Severely Debilitated Teeth

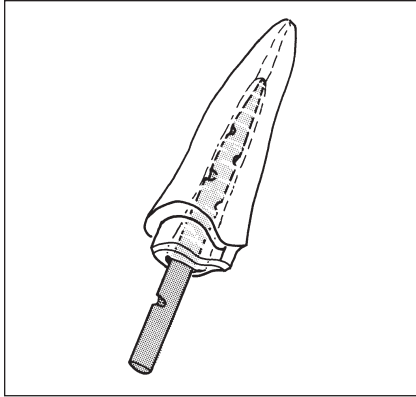


Fig 13-56 A resin sprue is trimmed to fit loosely in the canal.

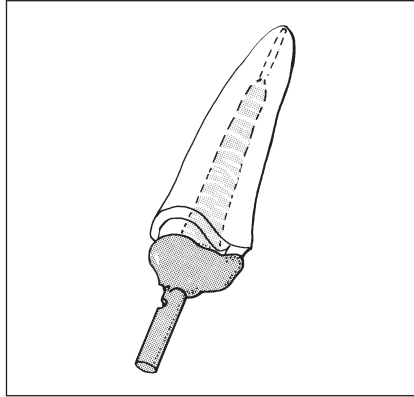


Fig 13-57 The first mix of resin in the canal should cover the contrabevel.

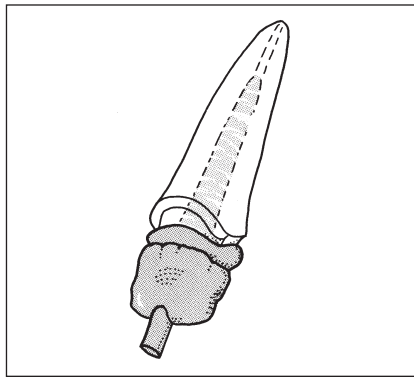


Fig 13-58 A second mix is added to build up the coronal portion of the dowel core.

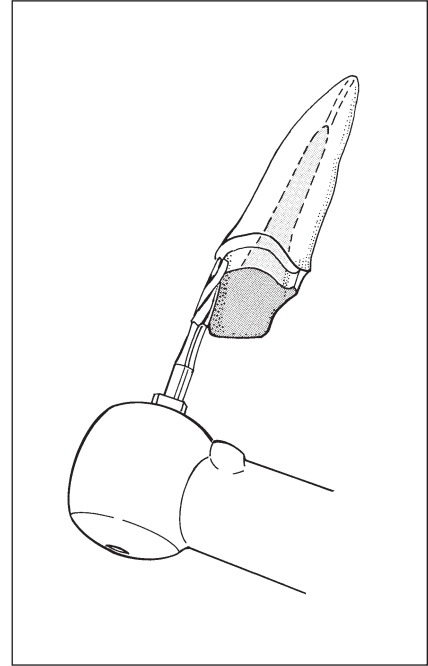


Fig 13-59 The coronal portion of the resin pattern is prepared to receive the definitive restoration.

In a dappen dish, acrylic resin monomer and polymer are mixed to a runny consistency. The canal is lubricated with petrolatum on a small piece of cotton on a Peeso reamer. The orifice of the canal is filled as full as possible with acrylic resin (Duralay) applied with an IPPA plastic filling instrument. The sprue is coated with monomer and seated completely in the canal. The external bevel must be covered at this time (Fig 13-57). Trying to cover the bevel later may disturb the fit of the dowel in the canal.

When the acrylic resin has become tough and doughy, the pattern is pumped in and out to ensure that it will not lock into any undercuts in the canal. As the resin polymerizes, the dowel is removed from the canal, with care taken to ensure that it extends to the apical end of the prepared canal. If there are any voids, they can be filled with a soft, dead wax, such as utility wax. The dowel is reinserted into the canal and moved up and down to ensure that it can be withdrawn easily at a later time.

After the resin in the dowel portion has polymerized, the canal is relubricated, and the dowel is resealed. A second mix of acrylic resin is made and placed around the exposed sprue to provide the bulk from which a preparation for the definitive restoration can be fashioned (Fig 13-58). While the resin is polymerizing, the coronal portion can be roughly

molded on the facial and lingual aspects by holding it between the thumb and forefinger.

The core can be roughly shaped in the hand with green stones and coarse garnet disks. The preparation for the definitive restoration is completed with the dowel core pattern in place (Fig 13-59). It is desirable to complete reduction and contouring in resin because it is both difficult and time-consuming to shape the metal after the dowel core has been cast. The finished pattern should be smoothed with fine sandpaper disks and a rubber abrasive wheel (classic blue, Dedeco). There should be no roughness or undercuts.

The dowel core pattern is wiped with an alcohol sponge to remove any residual lubricant that could displace investment or promote bubble formation. Either could result in metal projections that would interfere with complete seating of the cast metal dowel core.

Finishing and cementation of the dowel core

The dowel core pattern is sprued on the incisal or occlusal end (Fig 13-60). Extra water in the amount of 1.0 to 2.0 mL is added to 50 g of investment, and a liner is not used in the ring. These measures will result in a slightly smaller dowel core that should have less tendency to bind in the canal. The

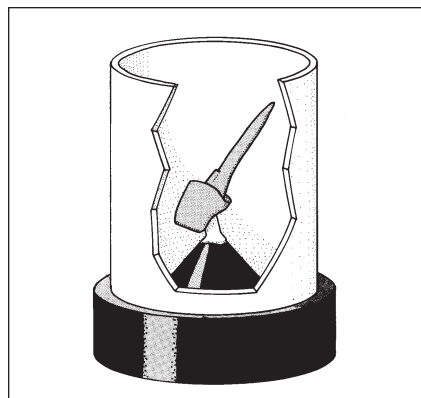


Fig 13-60 Sprued resin pattern in a ring ready for investing.

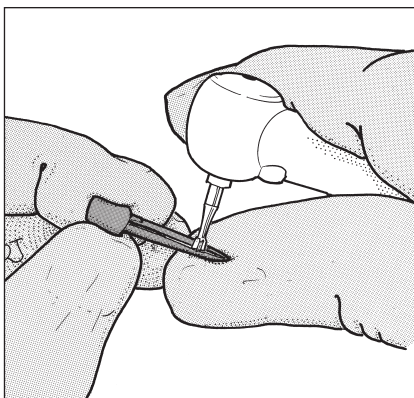


Fig 13-61 A groove is cut in the side of the dowel to allow cement to escape during cementation.

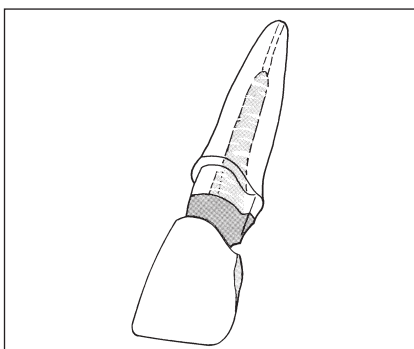


Fig 13-62 Cementation of the definitive restoration.

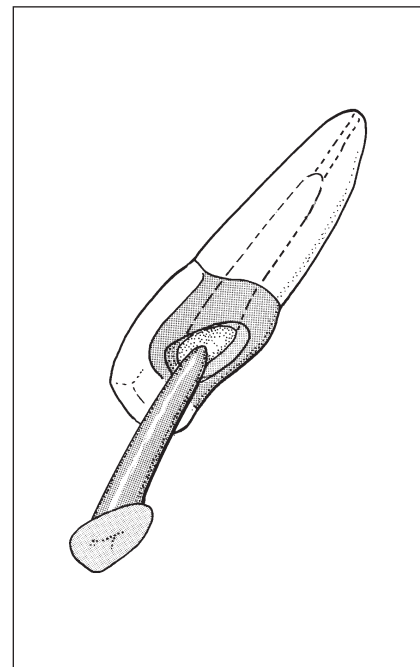


Fig 13-63 A dowel inlay is cemented through the access opening in the crown of an endodontically treated central incisor.

invested pattern should remain in the burnout oven for 30 minutes longer to ensure complete elimination of the resin. After the casting is removed from the investment, it is pickled, and the sprue is cut off.

The fit of the dowel core in the tooth is checked by seating it with light pressure. If it binds in the canal or will not seat completely, the dowel should be air abraded and reinserted in the canal. Any shiny spots are relieved. The core portion of the casting should be polished to a satin finish with a rubber abrasive wheel. A groove is cut on the side of the dowel from apical end to contrabevel to provide an escape vent for cement (Fig 13-61).

The cement is mixed, and some of it is inserted in the canal with a Lentulo spiral. The dowel core is slowly inserted into the canal so that the excess cement may escape, allowing the dowel core to seat completely. The preparation for the definitive restoration is touched up, if necessary, and the impression for it is made. The crown will be cemented at a subsequent appointment (Fig 13-62).

Cast dowel cores can be used on premolars. Mandibular premolars with a single root require no variations in procedure from dowel cores for anterior teeth. On maxillary premolars with two canals, one canal is employed for the dowel preparation, and a stabilizing keyway is placed in the other.

Cast dowel cores are very rarely done on molars because they have divergent canals that require elaborate, interlocking multipiece castings.

A parallel pin may be added to a prefabricated resin post (Parapost) for antirotational stabilization and some minimal additional retention. The canal is prepared with a special drill that is the same diameter as the dowel, and 0.6- or 0.7-mm pinholes are drilled parallel with the canal.¹⁰¹ A resin core is fabricated over the parallel-sided, serrated, preformed resin post in the canal, with nylon bristles in the pinholes. The pattern is invested, cast, and cemented in the same manner as a custom pattern.

If endodontic therapy must be done on a tooth after it has received a crown, the access opening will diminish crown retention by approximately 61%.¹⁰² Placement of a dowel inlay has been described for stabilizing the crown.¹⁰³ A cast dowel is fabricated on a cast of the prepared tooth, with a slightly flared segment at the coronal end seating into the beveled orifice of the canal (Fig 13-63). If a tooth preparation fractures under a crown, a retrofit dowel core can be fabricated under the dislodged crown. The crown is cleaned out, lubricated, and used as a matrix for forming the core portion after the dowel segment of the pattern has been completed in the usual manner.¹⁰⁴

13 Preparations for Severely Debilitated Teeth

References

- Shillingburg HT Jr, Jacobi R, Brackett SE. Preparation modifications for damaged vital posterior teeth. *Dent Clin North Am* 1985;29:305–326.
- Shillingburg HT, Jacobi R, Dilts WE. Preparing severely damaged teeth. *CDA J* 1983;11:85–91.
- Rhoads JE. Preparation of the teeth for cast restorations. In: Hollenback GM (ed). *Science and Technic of the Cast Restoration*. St Louis: Mosby, 1964:34–67.
- Ingraham R, Bassett RW, Koser JR. *An Atlas of Cast Gold Procedures*, ed 2. Los Angeles: University of Southern California School of Dentistry, 1969:161–165.
- Guyre SE. Multiple preparations for fixed prosthodontics. *J Prosthet Dent* 1970;23:529–553.
- Smith GE, Grainger DA. Biomechanical design of extensive cavity preparations for cast gold. *J Am Dent Assoc* 1974;89:1152–1157.
- Kishimoto M, Shillingburg HT Jr, Duncanson MG. Influence of preparation features on retention and resistance. Part II: Three-quarter crowns. *J Prosthet Dent* 1983;49:188–192.
- Tjan AH, Sarkissian R, Miller GD. Effect of multiple axial grooves on the marginal adaptation of full cast-gold crowns. *J Prosthet Dent* 1981;46:399–403.
- Lorey RE, Myers GE. The retentive qualities of bridge retainers. *J Am Dent Assoc* 1968;76:568–572.
- Pruden WH 2nd. Full coverage, partial coverage, and the role of pins. *J Prosthet Dent* 1971;26:302–306.
- Gilboe DB, Teteruck WR. Fundamentals of extracoronary tooth preparation. Part I. Retention and resistance form. *J Prosthet Dent* 1974;32:651–656.
- Ingraham R, Bassett RW, Koser JR. *An Atlas of Cast Gold Procedures*, ed 2. Los Angeles: University of Southern California School of Dentistry, 1969:176.
- Clyde JS, Sharkey SW. The pin ledge crown. A reappraisal. *Br Dent J* 1978;144:239–245.
- Gourley JV. Favorable locations for pins in molars. *Oper Dent* 1980;5:2–6.
- Fisher DW, Jeannet DJ, Kwan SK. An evaluation of methods for preparing teeth to receive retentive posts [abstract 532]. *J Dent Res* 1982;61:237.
- Dilts WE, Mullaney TP. Relationship of pinhole location and tooth morphology in pin-retained silver amalgam restorations. *J Am Dent Assoc* 1968;76:1011–1015.
- Markley MR. Pin retained and reinforced restorations and foundations. *Dent Clin North Am* 1967;11:229–244.
- Shooshan ED. A pin-ledge casting technique—Its application in periodontal splinting. *Dent Clin North Am* 1960;4:189–206.
- Racowsky LP, Wolinsky LE. Restoring the badly broken-down tooth with esthetic partial coverage restorations. *Compend Contin Educ Dent* 1981;2:322–335.
- Lorey RE, Embrell KA, Myers GE. Retentive factors in pin-retained castings. *J Prosthet Dent* 1967;17:271–275.
- Moffa JP, Phillips RW. Retentive properties of parallel pin restorations. *J Prosthet Dent* 1967;17:387–400.
- Fujimoto J, Norman RD, Dykema RW, Phillips RW. A comparison of pin-retained amalgam and composite resin cores. *J Prosthet Dent* 1978;39:512–519.
- Courtade GL. Pin pointers. 3. Self-threading pins. *J Prosthet Dent* 1968;20:335–338.
- Roberts EW. Crown construction with pin reinforced amalgam. *Tex Dent J* 1963;81:10–14.
- Caputo AA, Standlee JP. Pins and posts—Why, when and how. *Dent Clin North Am* 1976;20:299–311.
- Dilts WE, Welk DA, Stovall J. Retentive properties of pin materials in pin-retained silver amalgam restorations. *J Am Dent Assoc* 1968;77:1085–1089.
- DeWald JP, Arcoria CJ, Ferracane JL. Evaluation of glass-cermet cores under cast crowns. *Dent Mater* 1990;6:129–132.
- Shooshan ED. The full veneer cast crown. *J South Calif Dent Assoc* 1955;23:27–38.
- Markley MR. Pin reinforcement and retention of amalgam foundations and restorations. *J Am Dent Assoc* 1958;56:675–679.
- Hormati AA, Denehy GE. Microleakage of pin-retained amalgam and composite resin bases. *J Prosthet Dent* 1980;44:526–530.
- Oliva RA, Lowe JA. Dimensional stability of silver amalgam and composite used as core materials. *J Prosthet Dent* 1987;57:554–559.
- DeWald JP, Moody CR, Ferracane JL. Softening of composite resins by moisture and cements. *Quintessence Int* 1988;19:619–621.
- Gabryl RS, Mayhew RB, Haney SJ, Wilson AH. Effects of a temporary cementing agent on the retention of castings for composite resin cores. *J Prosthet Dent* 1985;54:183–187.
- Nitkin DA, Goldberg AJ. Another look at placing and polishing amalgam in one visit. *Quintessence Int Dent Dig* 1983;14:507–512.
- Outhwaite WC, Twiggs SW, Fairhurst CW, King GE. Slots vs pins: A comparison of retention under simulated chewing stresses. *J Dent Res* 1982;61:400–402.
- Shavell HM. The amalgapin technique for complex amalgam restorations. *J Calif Dent Assoc* 1980;8:48–55.
- Eissmann HF, Radke RA. Post-endodontic restoration. In: Cohen S, Burns RC (eds). *Pathways of the Pulp*. St Louis: Mosby, 1976:537–575.
- Dilts WE. Pulpal considerations with fixed prosthodontic procedures. *Quintessence Int Dent Dig* 1982;13:1287–1294.
- Ingber JS, Rose LF, Coslet JG. The “biologic width”—A concept in periodontics and restorative dentistry. *Alpha Omegan* 1977;70(3):62–65.
- Murrin JR, Barkmeier WW. Restoration of mutilated posterior teeth: Periodontal, restorative, and endodontic considerations. *Oper Dent* 1981;6(3):90–94.
- Ingraham R. The application of sound biomechanical principles in the design of inlay, amalgam, and gold foil restorations. *J Am Dent Assoc* 1950;40:402–413.
- Holland CS. Cast gold restorations for teeth with large carious lesions. *Br Dent J* 1971;131:16–21.
- Reagan SE. Correcting space loss caused by severe decay: Report of case. *J Am Dent Assoc* 1988;116:878–879.
- Heithersay GS. Combined endodontic-orthodontic treatment of transverse root fractures in the region of the alveolar crest. *Oral Surg Oral Med Oral Pathol* 1973;36:404–415.
- Ingber JS. Forced eruption: Part II. A method of treating non-restorable teeth—Periodontal and restorative considerations. *J Periodontol* 1976;47:203–216.
- Simon JH, Kelly WH, Gordon DG, Ericksen GW. Extrusion of endodontically treated teeth. *J Am Dent Assoc* 1978;97:17–23.
- Ivey DW, Calhoun RL, Kemp WB, Dorfman HS, Wheeler JE. Orthodontic extrusion: Its use in restorative dentistry. *J Prosthet Dent* 1980;43:401–407.
- Ross S, Dorfman HS, Palcanis KG. Orthodontic extrusion: A multidisciplinary treatment approach. *J Am Dent Assoc* 1981;102:189–191.
- Oesterle LJ, Wood LW. Raising the root. A look at orthodontic extrusion. *J Am Dent Assoc* 1991;122:193–198.
- Ries BJ, Johnson GK, Nieberg LG. Vertical extrusion using a removable orthodontic appliance. *J Am Dent Assoc* 1988;116:521–523.
- Ingber JS. Forced eruption. I. A method of treating isolated one and two wall infrabony osseous defects—Rationale and case report. *J Periodontol* 1974;45:199–206.
- Garrett GB. Forced eruption in the treatment of transverse root fractures. *J Am Dent Assoc* 1985;111:270–272.
- Biggerstaff RH, Sinks JH, Carazola JL. Orthodontic extrusion and biologic width realignment procedures: Methods for reclaiming nonrestorable teeth. *J Am Dent Assoc* 1986;112:345–348.
- Johnson GK, Sivers JE. Forced eruption in crown-lengthening procedures. *J Prosthet Dent* 1986;56:424–427.
- Molina DG, Miller CS. An esthetic extrusion device. *Gen Dent* 1987;35:43–45.
- Ross IF. Fracture susceptibility of endodontically treated teeth. *J Endod* 1980;6:560–565.

57. Sorensen JA, Martinoff JT. Clinically significant factors in dowel design. *J Prosthet Dent* 1984;52:28–35.
58. Goerig AC, Muenninghoff LA. Management of the endodontically treated tooth. Part I: Concept for restorative designs. *J Prosthet Dent* 1983;49:340–345.
59. Shillingburg HT, Kessler JC. After the root canal. Principles of restoring endodontically treated teeth. *J Okla Dent Assoc* 1984;74(3):19–24.
60. Halpern BG. Restoration of endodontically treated teeth. A conservative approach. *Dent Clin North Am* 1985;29:293–303.
61. Lovdahl PE, Nicholls JL. Pin-retained amalgam cores vs. cast-gold dowel-cores. *J Prosthet Dent* 1977;38:507–514.
62. Gelfand M, Goldman M, Sunderman EJ. Effect of complete veneer crowns on the compressive strength of endodontically treated posterior teeth. *J Prosthet Dent* 1984;52:635–638.
63. Nathanson D, Ashayeri N. New aspects of restoring the endodontically treated tooth. *Alpha Omegan* 1990;83(4):76–80.
64. Eakle WS. Increasing the resistance of teeth to fracture: Bonded composite resin versus glass ionomer cement. *Dent Mater* 1985;1:229–230.
65. Standlee JP, Caputo AA, Collard EW, Pollack MH. Analysis of stress distribution by endodontic posts. *Oral Surg Oral Med Oral Pathol* 1972;33:952–960.
66. Colley IT, Hampson EL, Lehman ML. Retention of post crowns: An assessment of the relative efficiency of posts in different shapes and sizes. *Br Dent J* 1968;124:63–69.
67. Krupp JD, Caputo AA, Trabert KC, Standlee JP. Dowel retention with glass-ionomer cement. *J Prosthet Dent* 1979;41:163–166.
68. Johnson JK, Sakumura JS. Dowel form and tensile force. *J Prosthet Dent* 1978;40:645–649.
69. Standlee JP, Caputo AA, Hanson EC. Retention of endodontic dowels: Effects of cement, dowel length, diameter, and design. *J Prosthet Dent* 1978;39:400–405.
70. Sorensen JA, Martinoff JT. Intracoronal reinforcement and coronal coverage: A study of endodontically treated teeth. *J Prosthet Dent* 1984;51:780–784.
71. Frank AL. Protective coronal coverage of the pulpless tooth. *J Am Dent Assoc* 1959;59:895–900.
72. Gutmann JL. The dentin-root complex: Anatomic and biologic considerations in restoring endodontically treated teeth. *J Prosthet Dent* 1992;67:458–467.
73. Rud J, Omnell KA. Root fractures due to corrosion. Diagnostic aspects. *Scand J Dent Res* 1970;78:397–403.
74. Rosen H. Operative procedures on mutilated endodontically treated teeth. *J Prosthet Dent* 1961;11:973–986.
75. Hoag EP, Dwyer TG. A comparative evaluation of three post and core techniques. *J Prosthet Dent* 1982;47:177–181.
76. Sorensen JA, Engelman MJ. Ferrule design and fracture resistance of endodontically treated teeth. *J Prosthet Dent* 1990;63:529–536.
77. Milot P, Stein RS. Root fracture in endodontically treated teeth related to post selection and crown design. *J Prosthet Dent* 1992;68:428–435.
78. Kratochvil FJ. *Partial Removable Prosthodontics*. Philadelphia: Saunders, 1988:101.
79. Sorensen JA, Martinoff JT. Endodontically treated teeth as abutments. *J Prosthet Dent* 1985;53:631–636.
80. Colman HL. Restoration of endodontically treated teeth. *Dent Clin North Am* 1979;23:647–662.
81. Nayyar A, Walton RE, Leonard LA. An amalgam coronal-radicular dowel and core technique for endodontically treated posterior teeth. *J Prosthet Dent* 1980;43:511–515.
82. Goerig AC, Muenninghoff LA. Management of the endodontically treated tooth. Part II: Technique. *J Prosthet Dent* 1983;49:491–497.
83. Baum L. Dowel placements in the endodontically treated tooth. *J Conn State Dent Assoc* 1979;53:116–117.
84. Kovarik RE, Breeding LC, Caughman WF. Fatigue life of three core materials under simulated chewing conditions. *J Prosthet Dent* 1992;68:584–590.
85. Christian GW, Button GL, Moon PC, England MC, Douglas HB. Post core restoration in endodontically treated posterior teeth. *J Endod* 1981;7:182–185.
86. Kern SB, von Fraunhofer JA, Muenninghoff LA. An in vitro comparison of two dowel and core techniques for endodontically treated molars. *J Prosthet Dent* 1984;51:509–514.
87. Duret PB, Reynaud M, Duret F. New concept of coronaradicular reconstruction: The Composipost (1) [in French]. *Chir Dent Fr* 1990;60:131–141.
88. Fredriksson M, Astbäck J, Pamenius M, Arvidson K. A retrospective study of 236 patients with teeth restored by carbon fiber-reinforced epoxy resin posts. *J Prosthet Dent* 1998;80:151–157.
89. Shah S. Torsional resistance of zirconia and fibre-reinforced posts [thesis]. Sheffield: University of Sheffield, 2001:46.
90. Wirz J, Graber G, Widmer W. *Metallische Verankerungselemente in der Restaurativen Zahnmedizin: Theorie und Klinik für Studium und Praxis*. Berlin: Quintessenz, 1987:41,51,66,105.
91. Standlee JP, Caputo AA, Holcomb J, Trabert KC. The retentive and stress-distributing properties of a threaded endodontic dowel. *J Prosthet Dent* 1980;44:398–404.
92. Standlee JP, Caputo AA. The retentive and stress distributing properties of split threaded endodontic dowels. *J Prosthet Dent* 1992;68:436–442.
93. Gegauff AG, Kerby RE, Rosenstiel SF. A comparative study of post preparation diameters and deviations using Para-Post and Gates Glidden drills. *J Endod* 1988;14:377–380.
94. Goldman M, DeVitre R, Tenca J. Cement distribution and bond strength in cemented posts. *J Dent Res* 1984;63:1392–1395.
95. Christy JM, Pipko DJ. Fabrication of dual-post veneer crown. *J Am Dent Assoc* 1967;75:1419–1425.
96. Gerstein H, Burnell SC. Prefabricated precision dowels. *J Am Dent Assoc* 1964;68:787–791.
97. Taylor AG. Dowel abutment crown. *R Can Dent Corps Q* 1963;4:1–4.
98. Bartlett SO. Construction of detached core crowns for pulpless teeth in only two sittings. *J Am Dent Assoc* 1968;77:843–845.
99. Dewhirst RB, Fisher DW, Shillingburg HT. Dowel-core fabrication. *J South Calif Dent Assoc* 1969;37:444–449.
100. Shillingburg HT, Fisher DW, Dewhirst RB. Restoration of endodontically treated posterior teeth. *J Prosthet Dent* 1970;24:401–409.
101. Baraban DJ. A simplified method for making posts and cores. *J Prosthet Dent* 1970;24:287–297.
102. McMullen AF 3rd, Himel VT, Sarkar NK. An in vitro study of the effect endodontic access preparation has upon the retention of porcelain fused to metal crowns of maxillary central incisors. *J Endod* 1989;15:154–156.
103. Shillingburg HT, Kessler JC. Restoration of crowned teeth after endodontic treatment. *Quintessence Int* 1982;13:635–641.
104. Shillingburg HT Jr, Jacobi R. Two-piece retrofit dowel-core: A case report. *Int J Periodontics Restorative Dent* 1987;7(4):31–41.

Preparations for Periodontally Weakened Teeth

14

Teeth that have been saved by periodontal therapy often need cast restorations. This may occur because of caries or previous damage, or the teeth may need to be splinted together to improve their stability. These teeth also may be needed as abutments for prostheses replacing missing teeth. If there have been numerous teeth lost to periodontal disease, or if the loss of bone height around one tooth has been severe, discretion may be the better part of valor, ie, the entire tooth may need to be extracted and replaced with an implant-supported restoration (see chapters 27 to 29).

Preparation Finish Line

Restoration of a tooth around which there has been a loss of gingival height or other change in gingival architecture frequently requires modification of the tooth preparation. The type and location of the finish line may have a significant impact on the success of the restoration. An improperly designed preparation can unnecessarily damage the tooth and potentially compromise the longevity of the restoration and of the tooth itself. The proximity of the preparation finish line

to the furcations can necessitate further modification of the tooth preparation.

Location

The optimum location for the gingival finish line of a crown preparation is on enamel, away from the gingival sulcus. However, it is frequently necessary for the restoration margin to extend apically to cover an expanse of root surface that may have been affected by caries or erosion.

If an all-ceramic shoulder is used as the gingivofacial margin for a metal-ceramic crown, a 1.0-mm-wide shoulder will be required as the gingival finish line. This configuration is destructive under the best of circumstances when it is placed in the enamel of the clinical crown (Fig 14-1). Nevertheless, it is generally well tolerated in mature teeth.

A shoulder is a poor choice when the margin must be placed on the root surface. The constricted, smaller diameter of the root will require that the axial reduction be extended into the tooth to a pulp-threatening depth to achieve the same 1.0-mm-wide shoulder (Fig 14-2). Aside from possible pulpal encroachment, this gross destruction of axial tooth

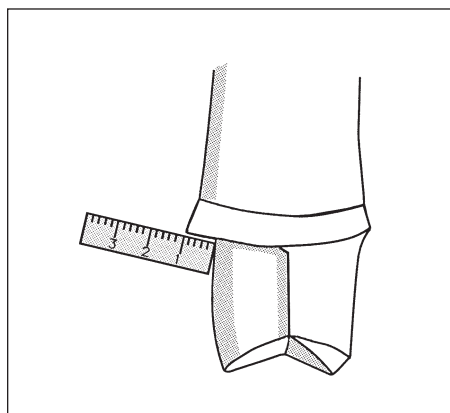


Fig 14-1 Preparation for a metal-ceramic crown on a maxillary premolar with a 1.0-mm shoulder in the usual position.

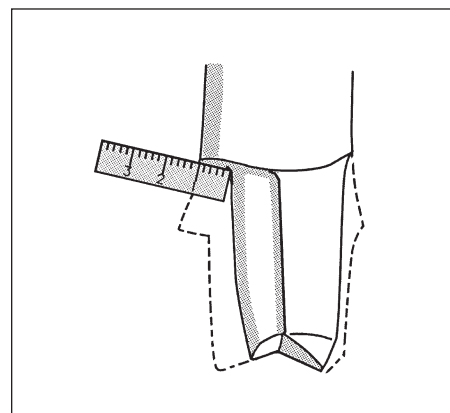


Fig 14-2 Preparation for a metal-ceramic crown on a maxillary premolar with a 1.0-mm shoulder apical to the cemento-enamel junction. Notice the additional destruction of axial tooth structure required to produce the shoulder at this level.

14 Preparations for Periodontally Weakened Teeth

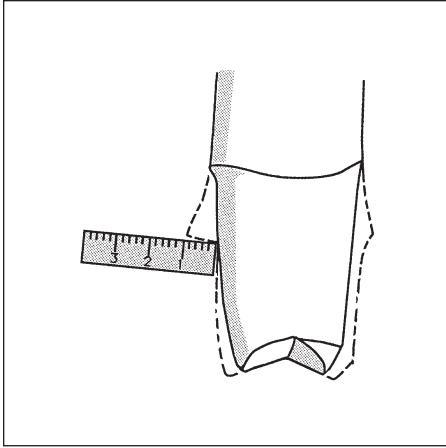


Fig 14-3 Preparation for a metal-ceramic crown on a maxillary premolar with a chamfer apical to the cemento-enamel junction. The amount of axial reduction is similar to that required for a shoulder at the usual position.

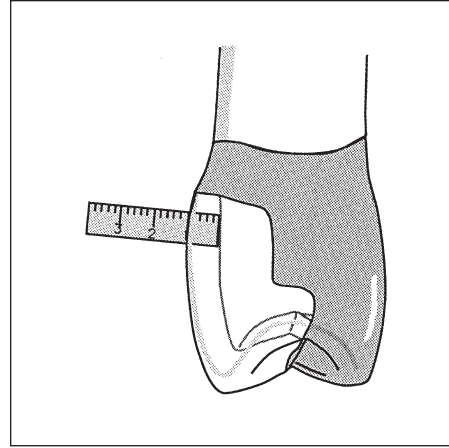


Fig 14-4 A wide gingival collar is used to blend the root contour with that required for a ceramic veneer of adequate thickness.

structure weakens the natural structural durability of the tooth. Additionally, the shoulder has a greater potential for concentrating stresses that could ultimately lead to fracture of the tooth.

A chamfer finish line on the facial surface in this apical position will result in approximately the same depth of axial reduction as would a shoulder at the usual level (Fig 14-3). A metal-ceramic crown fabricated in such circumstances should have a wide metal gingival collar (Fig 14-4). Extension of the ceramic veneer to the gingival margin will create overcontouring or will require use of the more destructive shoulder.

Furcation flutes

Sometimes the crown margins on a molar must extend far enough apically that the preparation finish line approaches the furcation, where the common root trunk divides into two or three roots (Fig 14-5). The designs of both the tooth preparations and the crowns for these teeth must be different from those customarily used. This is caused by the intersection of the preparation finish line with the vertical flutes or concavities in the common root trunk, extending from the actual furcation in the direction of the cemento-enamel junction. When that occurs, the axial surface(s) of the tooth preparation occlusal to the inversion of the gingival finish line must also have vertical concavities or flutes¹ (Fig 14-6).

Examples can be seen in the mandibular furcation, which is frequently encountered by crown preparations that do

not extend very far apically. The entrances to the facial and lingual furcations are, respectively, 3 and 4 mm apical to the cemento-enamel junction on mandibular first molars.² On the mesial, facial, and distal surfaces of maxillary first molars, the furcation entrances are 3.6, 4.2, and 4.8 mm from the cemento-enamel junction, respectively.³ The flutes on a maxillary molar are seen less frequently, and their presence often is an indication of greater gingival recession and vertical bone loss.

The axial contours of crowns placed on teeth whose furcation flutes are intercepted by preparation finish lines must likewise reflect the concavity rising from the furcation flute (Fig 14-7). The artificial crown should re-create the contours of the furcation flute and not follow the original crown contours.⁴ The facial surface should be invaginated into a concavity above the bifurcation that extends occlusally until it meets the facial groove in the occlusal one-third of the facial surface.⁵ The concavities usually merge with features originating on the occlusal surface. There must be no interruption in the vertical concavity rising at the margin of the restoration. Any horizontal ridge on the facial or lingual surface of the tooth that intersects with this concavity and blocks it will result in a plaque-retaining area (Fig 14-8).

There also will be concavities on the mesial and distal aspects of a maxillary molar arising from their respective furcations. They should be "softened" or blended into the surrounding axial surfaces of the crown. This will minimize the difficulty of cleaning those areas in the less accessible lingual embrasures of the posterior segments of the maxillary arch.

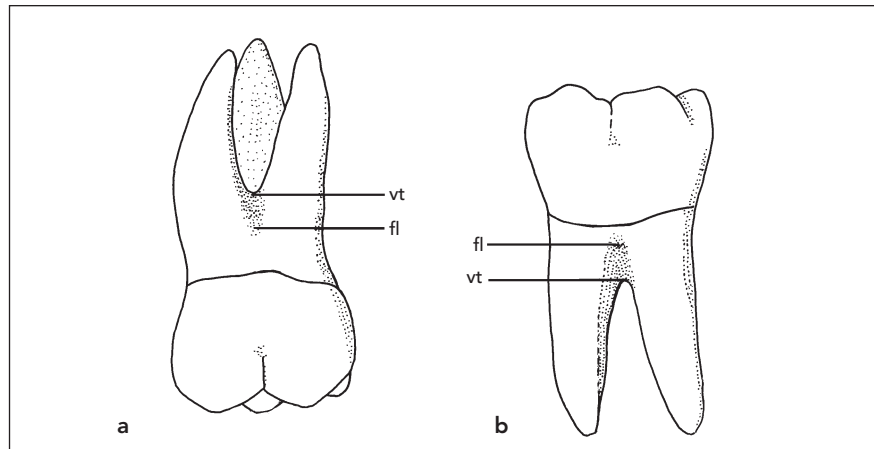


Fig 14-5 Facial furcations for a maxillary (a) and a mandibular (b) first molar. The portion of the furcation facing apically or toward the bone is the vault (vt), or roof. The vertical concavity on the common root trunk is the flute (fl).

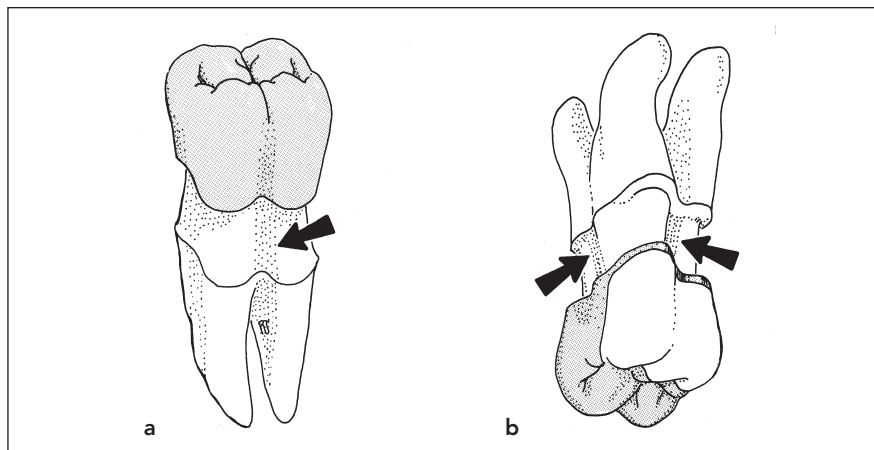


Fig 14-6 Vertical concavities in the axial walls of the tooth preparations (arrows) extend occlusally from the invaginations where the finish lines cross the furcation flutes on a mandibular (a) and a maxillary (b) molar.

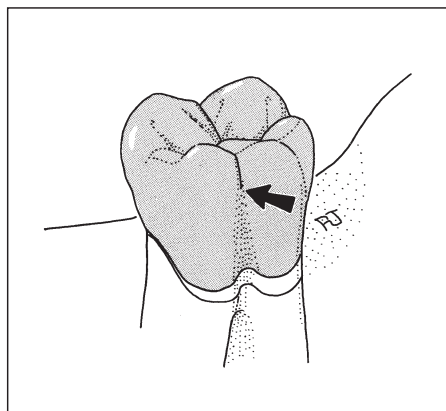


Fig 14-7 Anatomical facial groove of this mandibular first molar merges (arrow) with the vertical concavity extending from the furcation flute.

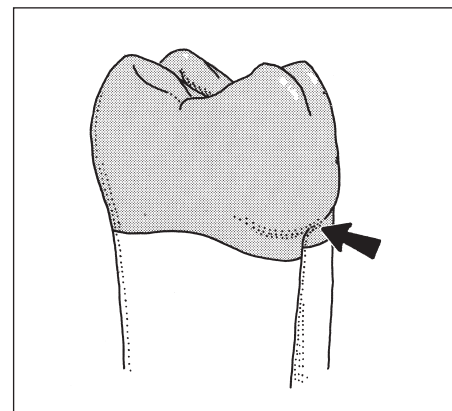


Fig 14-8 A horizontal ridge in the gingival third of the axial surface above the furcation flute will create a plaque-retaining area that is difficult to keep clean (arrow).

14 Preparations for Periodontally Weakened Teeth

Root Resection

Root resection is a procedure in which the root is removed, irrespective of what is done with the crown.¹ The resection of a root also may be called a *radectomy*.⁶ *Root amputation* is removal of a root without disturbing the crown.¹ A *hemisection* is a procedure in which the tooth is separated through the crown and the furcation,^{1,7} producing two essentially equal-sized teeth. Although the widespread use of these procedures is fairly recent, similar procedures were described in the literature more than 100 years ago by Farrar,⁸ Black,⁹ and Tomes and Tomes.¹⁰

Indications

One or more roots of a molar may be removed to eradicate areas of the tooth that create problems in the maintenance of good hygiene and plaque control. One or more roots can be eliminated because of an invasion or uncovering of the furcation by severe vertical bone loss.^{7,11–13} The severe loss of bone or attachment around one root may also necessitate the removal of a root.^{1,14–16} The concept of *periodontal strategic extraction* may simplify the periodontal treatment of an entire quadrant.¹⁷ It also reduces the risk of extension of the lesion to the surviving roots of that tooth or to neighboring teeth.

In 58% of the maxillary and mandibular first molars examined by Bower,¹⁸ furcation entrances were narrower than the width of the smallest curettes available. When the furcation entrance is that narrow, maintenance may be compromised by instrument inaccessibility, and resection may be the only way to create an area that can be adequately cleaned. Root removal can aid in reestablishing furcation control¹⁵ by changing furcation anatomy to facilitate cleaning.¹⁹

Nevertheless, involvement of a furcation does not automatically require resection of a root. Hamp et al²⁰ reported a clinical study of 100 patients with 175 multirooted teeth afflicted with varying degrees of salvageable furcation involvement. About half were treated with root resection, while the others received scaling and root planing, furcation operations, or other procedures. Both groups retained all of their teeth during the 5-year period of the study. The actual percentages will vary among practitioners based on individual philosophies, patient acceptance, and a number of other factors.

Resection may be performed to salvage teeth with endodontic problems.^{1,6,11–13,15,16} These encompass a wide variety of situations including perforations, irretrievable broken instruments, anatomical anomalies that would prevent successful instrumentation or obturation of a canal, and other nonspecific failures.

A tooth that has other sound roots can be saved by removing a root that has fractured^{11,13,16} or one afflicted with untreatable caries^{14–16} that extends into it. Root resection is also done where roots of two adjacent teeth are in such close proximity that embrasure space is obliterated.^{1,11,13,15}

Resection of a root on one tooth may facilitate retention of both teeth. Indeed, the removal of a particular root may be accomplished as much to improve the prognosis of an adjacent tooth as that of the tooth being sectioned.

Contraindications

Fused roots,¹¹ or those that approximate other roots of the same tooth,¹⁵ are contraindicated for resections. If the furcation is too far apical, roots cannot be resected because there will be too little bone left to support the remaining roots.¹¹ The furcation must be in the coronal one-third to perform a hemisection on a mandibular molar, and resections cannot be done on maxillary first premolars.¹⁹

If excessive alveolar support has been lost uniformly around all of the roots, nothing is gained by removing a root. The remaining roots will have no better support than the one removed. A root resection also may not be used if the root that is to be kept cannot be successfully treated endodontically.

Capacity of resected roots

Teeth that have been resected can be used as abutment teeth for fixed partial dentures, splints, or vertical stops for cantilever fixed partial dentures.²¹ The retention of a strategic tooth by root resection may preclude the need for a removable partial denture.²² Keep in mind, however, that their load-bearing ability has been lessened by their diminished attachment area. As the level of bone is lowered by periodontal disease, the surface area of periodontal attachment diminishes (Fig 14-9).

The mesial root of a mandibular first molar provides 37% of the attachment surface area, while the distal provides 32%.²³ If the furcation is uncovered, 31% of the attachment area, which is imparted by the root trunk, has been lost. The mesiofacial, distofacial, and palatal roots of a maxillary first molar furnish 25%, 19%, and 24% of the attachment area, respectively.²⁴ The root trunk supplies 32% of the attachment for the tooth.

Removal of a corresponding root on a second molar will probably result in a similar loss of support. However, the length of the root trunks of second molars tends to be both more variable and somewhat greater than that of first molars.² The total root surface areas of first and second molars differ by only 0.5% to 1.2%.²⁵

Resection technique

It is usually desirable to complete endodontic treatment before removing the root^{6,11,13–15,19} because a root canal will be transected during the surgery. However, often it is not possible to adequately evaluate the extent of furcation involvement until the flap has been reflected to permit a direct visual examination.²⁰ To avoid possible misunderstandings over

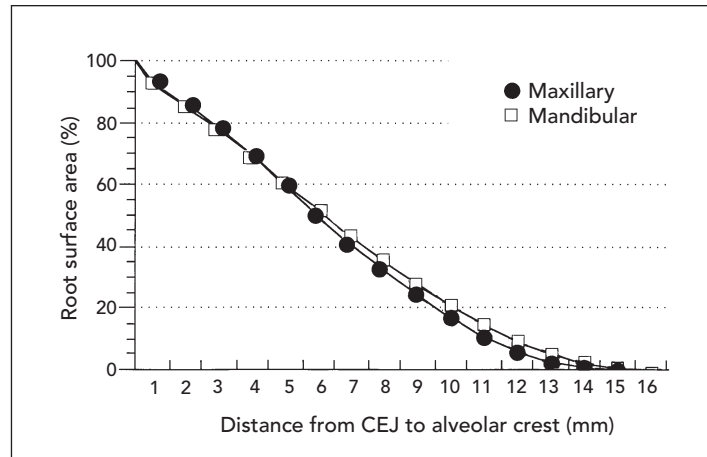


Fig 14-9 Relationship between vertical bone loss and the root surface area of maxillary³ and mandibular²³ first molars. CEJ, cemento-enamel junction.

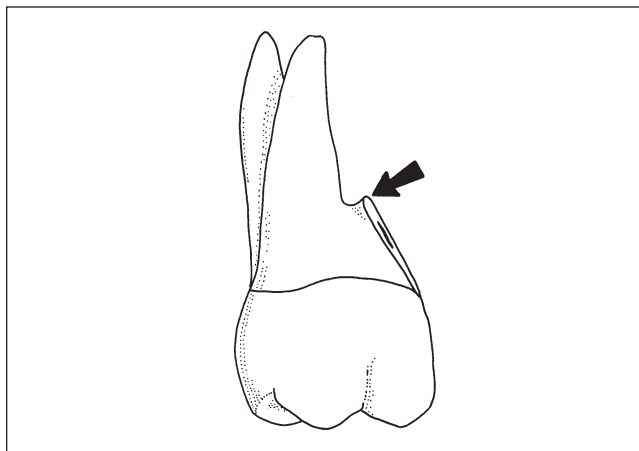


Fig 14-10 Any remnant of the resected root that is left (arrow) will impede plaque removal.

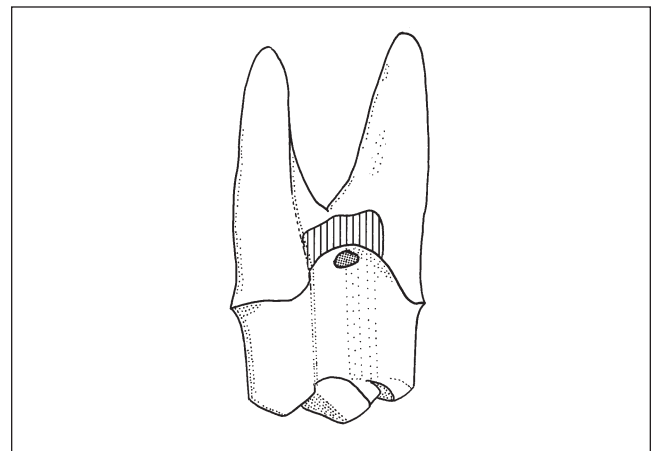


Fig 14-11 The crown preparation finish line extends beyond the pulp chamber (small shaded area), but it need not encompass the entire root removal site (cross-hatched area). Shown is a preparation on a maxillary molar with a resected distofacial root.

the time, discomfort, and expense of a “needless” endodontic procedure on a tooth that cannot be saved because of the inability to separate the targeted root from the others, it is often necessary to do the resection first. The pulp should be protected by a provisional restoration, and endodontic therapy should be scheduled as soon as possible.

The resection is begun with a long, thin diamond to cut through the vault of the furcation.¹⁵ All traces of the resected root are removed at the time of surgery. No vestigial remnants of the furcation vault should be left. They will act much as overhanging crown margins would, interfering with plaque removal and increasing tissue inflammation (Fig 14-10).

If any ridges are discovered at the time the tooth is prepared for a crown, they should be smoothed over. An intermediate bifurcational ridge is present in 73% of mandibular first molars,²⁶ and there is a “bridge” of tooth structure connecting the distofacial and palatal roots of maxillary molars.¹⁵

The finish line of the crown preparation should extend apically beyond the obturated pulp chamber (Fig 14-11). It is neither necessary nor desirable to extend the preparation finish line far enough apically to cover all areas of the root whose configuration has been altered by root removal.

If the root of a maxillary molar is being resected for periodontal reasons, there is usually enough coronal tooth structure so that the pulp chamber need only be filled with amalgam. A dowel is frequently not needed in this situation and might actually weaken a thin, isolated root rather than strengthen it.

If a dowel core is required because of coronal damage, a custom cast dowel core is preferable to a prefabricated dowel.²⁷ The minimal diameter of a periodontally weakened, root-resected segment does not permit a sufficient bulk of core material to remain around the dowel when the crown preparation is done.

14 Preparations for Periodontally Weakened Teeth

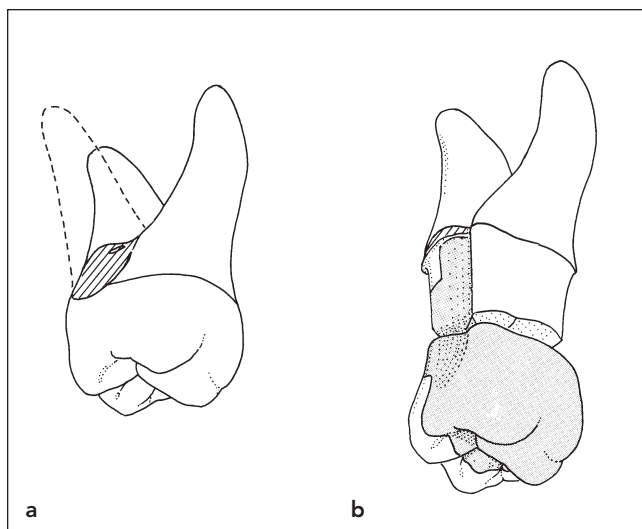


Fig 14-12 (a) Proper contours for a distofacial root resection on a maxillary molar after the surrounding area has been smoothed. (b) A metal-ceramic crown is fabricated for the preparation after a core is placed. The preparation does not cover all of the cut root surface.

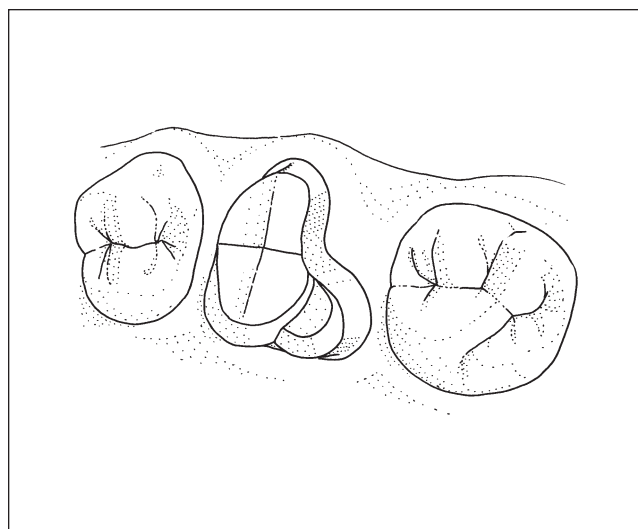


Fig 14-13 Occlusal view of a crown preparation on a maxillary first molar with no distofacial root.

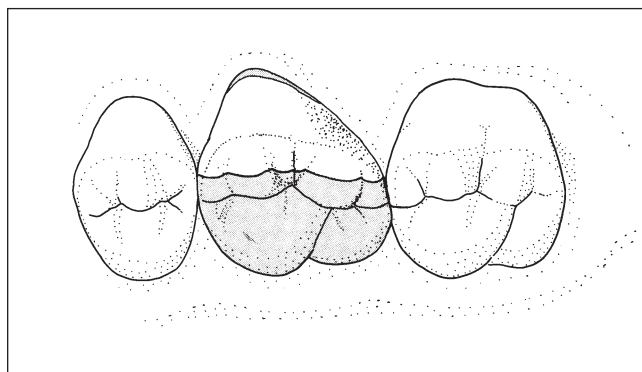


Fig 14-14 Occlusal view of a metal-ceramic crown on a maxillary molar with no distofacial root.

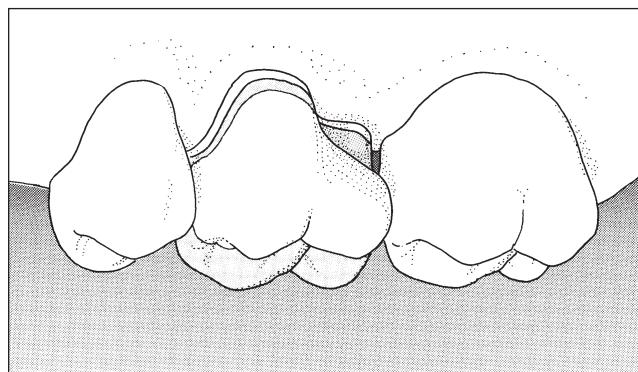


Fig 14-15 Facial view of a crown on a molar with a resected distofacial root. Note the pronounced concavity in the distogingival area.

Tooth preparation and crown configuration

When a root has been removed from a tooth, both the tooth preparation and the contours of the crown will be different because of the altered tooth shape.

Maxillary distofacial root

The distal furcation of the maxillary first molar is susceptible to frequent periodontal involvement because of the proximity of the divergent distofacial root to the nearby second molar² and its inaccessibility to the patient. The distofacial root of a maxillary molar is the one that is most frequently removed (Fig 14-12). Because the distofacial root is a relatively small one, the occlusal outline of the resulting preparation

commonly resembles a lamb chop when viewed from the occlusal direction (Fig 14-13).

The completed restoration placed in this situation usually will not restore the complete occlusal outline of the intact tooth. The distofacial embrasure is larger than usual, enabling the patient to keep the area clean (Fig 14-14). Making the distofacial cusp smaller generally does not create an esthetics problem because the distofacial cusp is hidden by the mesiofacial cusp in normal tooth alignment.

The proximal contact is restored to its normal faciolingual size. In the finished restoration, it is important that the contours of the distofacial cusp apical to the contact area have a definite concave shape¹⁵ (Fig 14-15). This ensures that crown contours will be aligned with the root configuration in that critical area, preventing impingement on the gingiva.

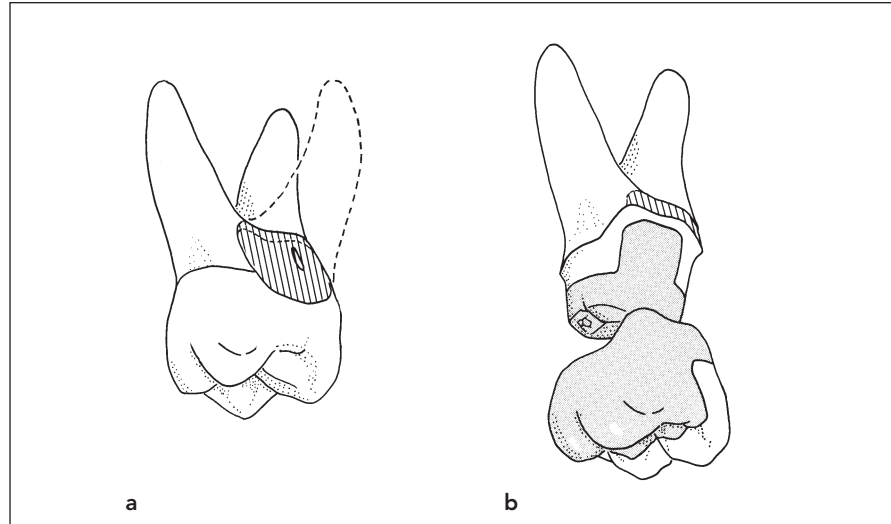


Fig 14-16 (a) Mesiofacial root resection on a maxillary molar after the area surrounding the root attachment has been contoured. (b) A metal-ceramic crown is used to restore the tooth after a core is placed.

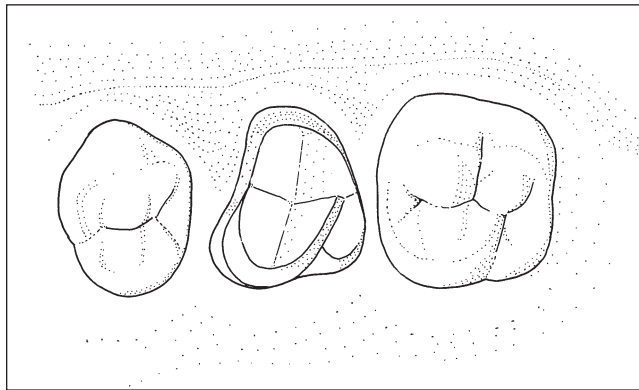


Fig 14-17 Occlusal view of the crown preparation on a maxillary molar with a resected mesiofacial root.

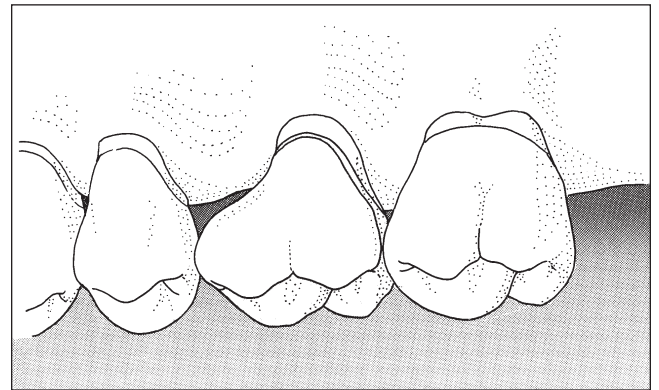


Fig 14-18 Facial view of a metal-ceramic crown on a maxillary molar whose mesiofacial root has been removed.

Maxillary mesiofacial root

Loss of the mesiofacial root (Fig 14-16) represents a greater loss of support for the remaining tooth than does the loss of the distofacial root. The mesiofacial root accounts for 25% to 36% of the first molar root area, depending on the amount of loss of bone around the root trunk.²³ If the mesiofacial root must be removed, the resulting occlusal out-

line tends to be more triangular in configuration because of the greater faciopalatal dimension of the root that has been removed (Fig 14-17). Again, the finish line will extend apically past the pulp chamber, but it will not include all of the area where the mesiofacial root was removed. There will be a concavity gingivofacial to the proximal contact on the mesial surface of the crown (Fig 14-18).

14 Preparations for Periodontally Weakened Teeth

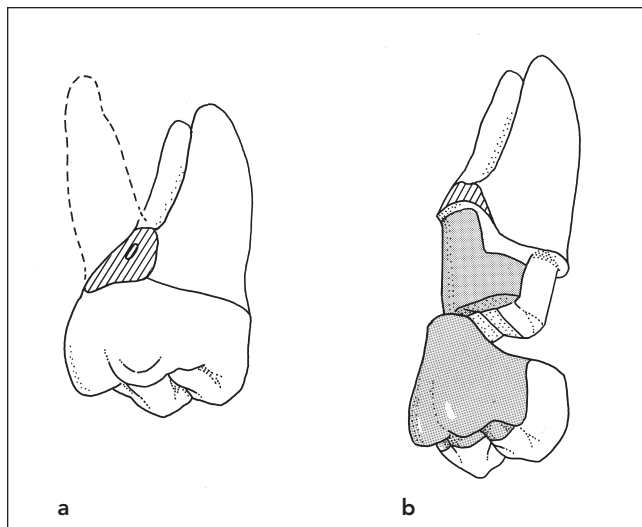


Fig 14-19 (a) Area surrounding the root attachment of the palatal root of a maxillary molar after removal and smoothing. (b) The tooth is restored with a metal-ceramic crown after it is built up with a core.

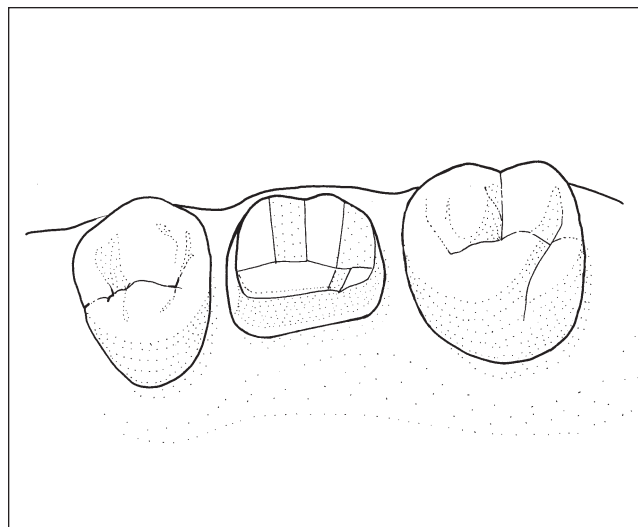


Fig 14-20 Occlusal view of a crown preparation on a maxillary molar with no palatal root.

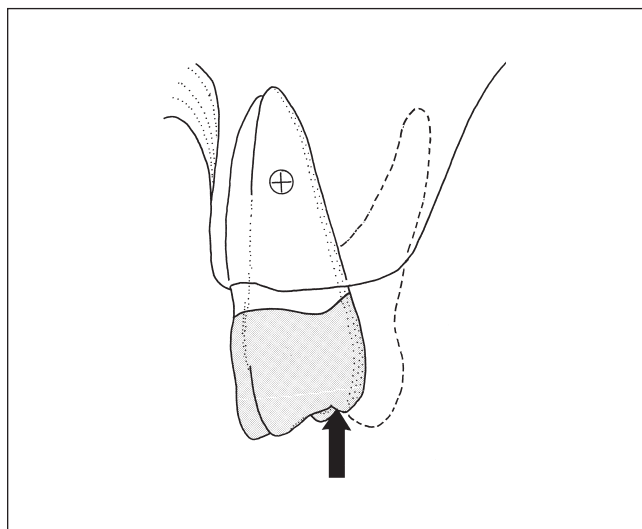


Fig 14-21 The palatal cusp on a crown made for a maxillary molar with no palatal root is very small.

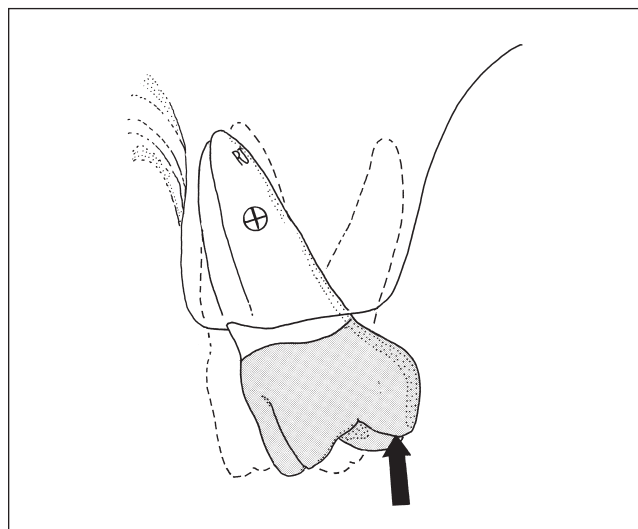


Fig 14-22 The presence of palatal cusps on a maxillary molar deprived of the support of its palatal root would subject the tooth to torquing forces (arrow) that could tip the tooth palatally.

Maxillary palatal root

In those situations where the palatal root has been removed from a maxillary molar, the palatal surface of the preparation will be flat, reflecting the general configuration of the remaining root stump (Fig 14-19). The tooth preparation will have an abbreviated faciopalatal dimension. The central groove of the preparation is aligned with those of the occlusal surfaces of adjacent teeth (Fig 14-20). The facial cusps of the preparation will be near normal faciopalatally. The palatal cusps will be quite small, possibly little more than a narrow ledge palatal to the central groove.

The preparation and resulting restoration usually will have a distinct concave flute on the facial surface arising from the facial bifurcation. Essentially there will be no palatal cusp¹⁵ (Fig 14-21). The presence of palatal cusps would produce an area inaccessible to hygiene maintenance in the palatogingival segment of the crown. It would also create a severe torquing moment on the tooth, which could either tip the tooth palatally or fracture the tooth preparation under the crown (Fig 14-22).

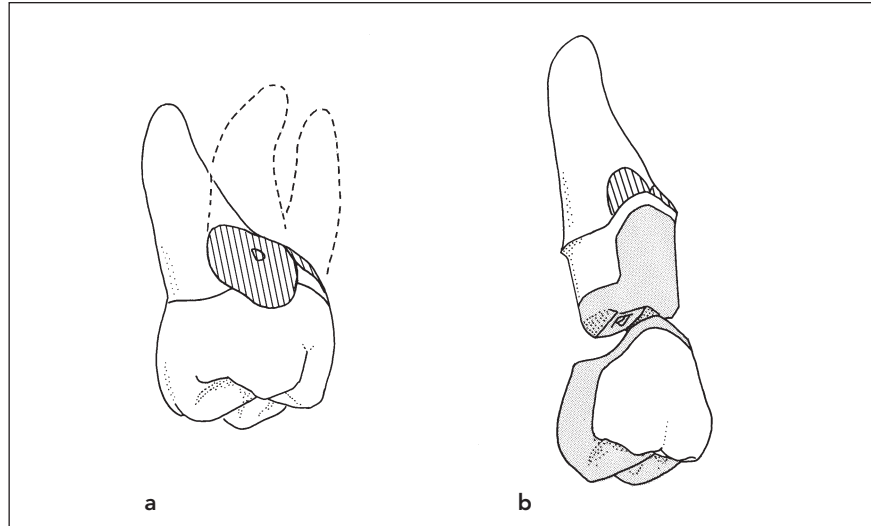


Fig 14-23 (a) Correct contours for the attachment sites of the facial roots of a maxillary molar after resection and smoothing. (b) A crown is placed over the preparation after core fabrication.

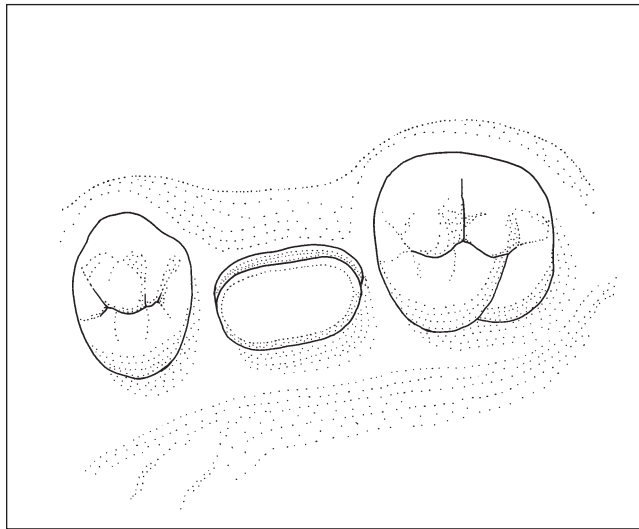


Fig 14-24 Occlusal view of a crown preparation on a palatal root reflects the cross-sectional shape of the root.

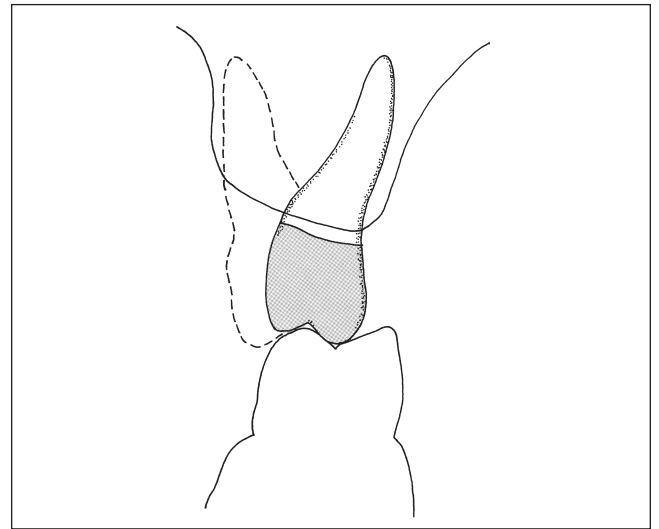


Fig 14-25 Occlusal contacts should occur on the palatal cusp tip. There should be minimal occlusion facial to the central groove of the crown.

Maxillary facial roots

When both of the maxillary facial roots are removed, only the palatal root remains (Fig 14-23). Preparation of the tooth overlying this root will result in either an oval or a circular configuration depending on the shape of the root itself (Fig 14-24). The resulting crown should occlude with its mandibular counterpart in such a way that occlusal forces cannot be directed facially. This will place it in a near reverse occlusal, or crossbite, relationship¹⁵ (Fig 14-25).

Mandibular hemisection

When separating the roots of mandibular molars, the possibilities are fewer because there are only two roots. Frequently one root is removed while the other remains. Saving the mesial segment would be desirable if the molar in question were the last tooth in the arch (Fig 14-26) and the opposing teeth did not extend very far distal to the mandibular first molar. The distal root could be used as an abutment for a short-span fixed partial denture replacing the mesial

14 Preparations for Periodontally Weakened Teeth

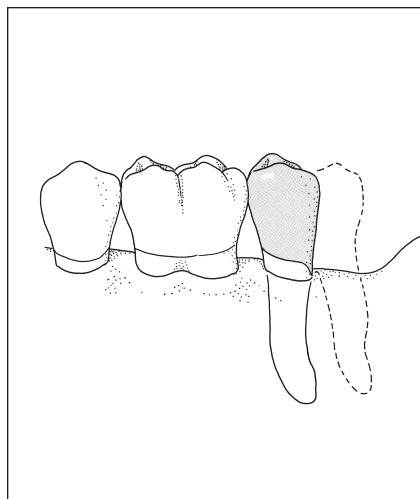


Fig 14-26 The mesial root of a mandibular second molar can effectively extend the occluding segment of the mandibular arch to serve as a stop for the opposing occlusion.

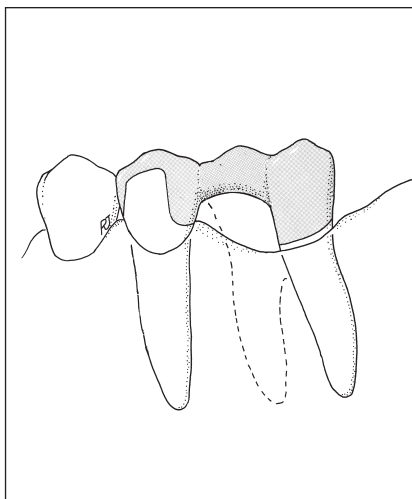


Fig 14-27 The distal root of a mandibular molar can serve as an abutment for a short-span prosthesis replacing the resected mesial root.

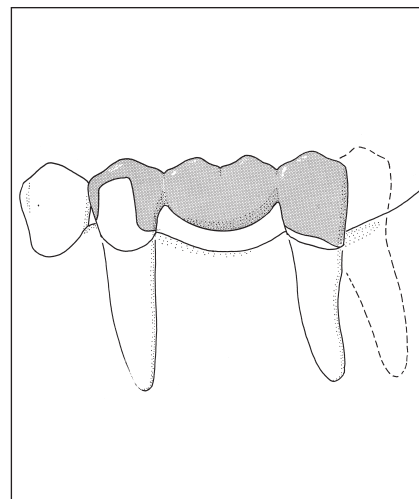


Fig 14-28 The mesial root of a mandibular second molar can be the abutment for a molar replacement fixed partial denture, but it offers less than one-third of the support of an unresected molar.

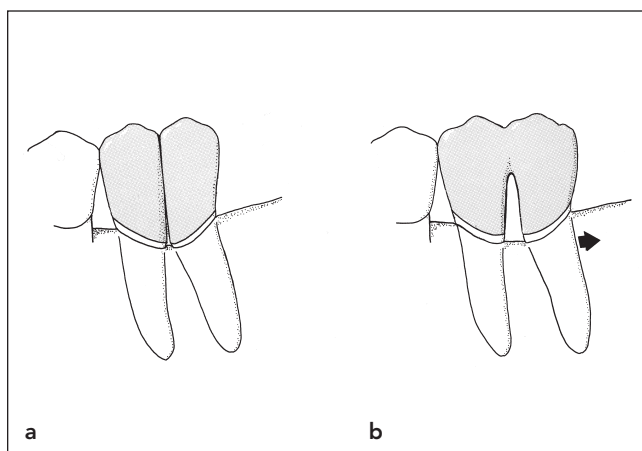


Fig 14-29 (a) If the roots are not separated after resection, there will be no gingival embrasure. (b) Orthodontic movement is one way of achieving separation.

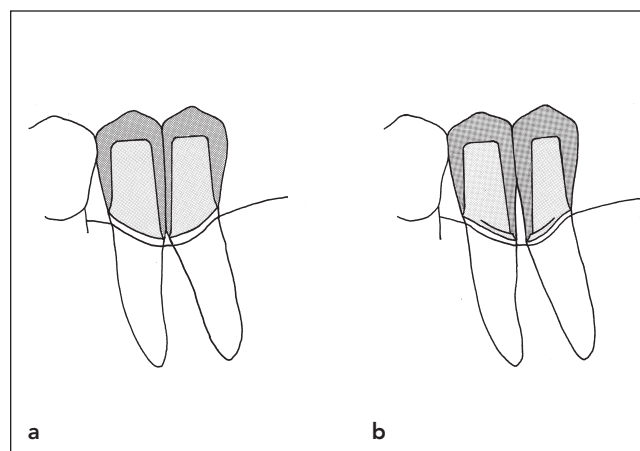


Fig 14-30 The contact that obliterates the gingival embrasures of restorations placed on a hemisected molar (a) can be alleviated in some cases by placing shoulders on the interradicular segments of the preparation that face each other across the former furcation (b).

root (Fig 14-27). Occasionally the one root may be used as the distal abutment for a longer-span fixed partial denture replacing an entire molar (Fig 14-28). However, this must be viewed as a high-risk prosthesis because the remaining distal root has slightly less than one-third of the alveolar support of the intact tooth with normal bone.²³

If an effort is made to save both roots of the molar following the resection, the process is described as *bicuspidization*.¹⁶ If both roots are maintained, it is important that they be separated from each other to allow normal gingival embrasure spaces. Sometimes the roots are distinctly separated,

angling out from the furcation and providing the separation naturally. However, if they are not naturally separated, some measure must be taken to accomplish it or the crowns placed over those roots will have no embrasure space. The result will be a proximal contact that extends subgingivally from the marginal ridge. The prognosis for teeth restored in such a manner is extremely poor. Separation may be accomplished by moving the roots apart orthodontically (Fig 14-29), or it may be accomplished with interradicular shoulders on the crown preparations on the separated roots¹⁵ (Fig 14-30).

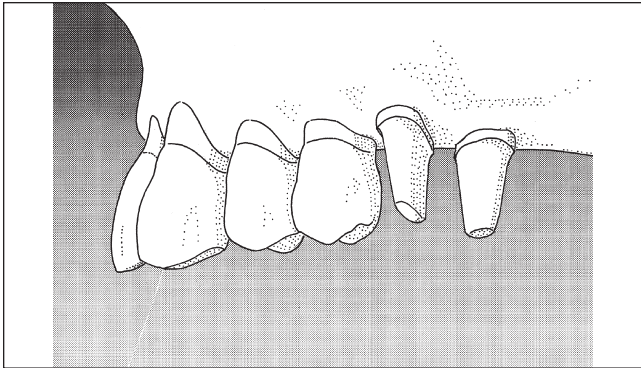


Fig 14-31 Roots of one tooth can be separated and prepared as individual teeth.

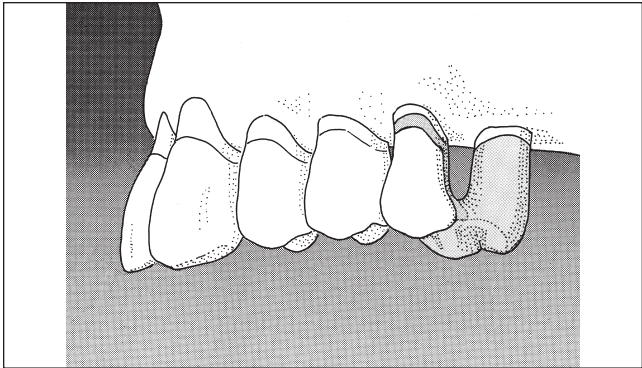


Fig 14-32 The crown placed over these resected roots reestablishes the furcation(s) in metal.

Table 14-1 Success rates of root resection

Investigator(s)	Years	Number of teeth	Percent success
Bergenholtz ⁶	1–10	45	93
Hamp et al ²⁰	5	87	100
Klavan ²⁷	1–7	34	97
Langer et al ²⁸	10	100	62
Erpenstein ¹²	1–7	34	79
Ehrlich et al ²⁹	10–18	75	87
Total	1–18	375	84

Table 14-2 Success rates of nonresection methods

Investigator(s)	Years	Number of teeth	Percent success
Ross and Thompson ³⁰	5–24	341	88
Hamp et al ²⁰	5	88	100
Total	5–24	429	90

“Skyfurcation”

Occasionally it may be desirable to separate the roots of a maxillary molar without removing a root. This is possible only if the roots are long, well supported by bone, and distinctly separate. The roots are cut apart (Fig 14-31) and then re-joined by a “crown” that in reality is a very short interradicular splint with concave connectors from one root to the other. The occlusal configuration of the splint is pretty much that of an ordinary molar. This procedure, in effect, makes the furcation metal and moves it occlusally while separating the roots (Fig 14-32). This improves access to the furcation and protects a caries-prone area.^{14,20}

Success and failure

Root resection does not guarantee success (Table 14-1). Ehrlich et al²⁹ reported an 87% success rate in furcation-involved teeth treated by root resection after 10 to 18 years. Ross and Thompson,³⁰ on the other hand, published a simi-

lar success rate (88%) for furcation-involved molars that were treated conservatively without root resection (Table 14-2). Hamp and associates²⁰ reported being able to maintain all 87 of the resected teeth in their study over a 5-year period, but they claimed equal success with 88 furcation-involved teeth that were kept intact over the same time period.

Langer et al²⁸ found that failures usually occurred 5 to 10 years after treatment, with 55% of the failures occurring in 5 to 7 years. The failure is more likely to be endodontic or restorative than periodontal in nature. This usually means that a root will fracture.

Mandibular roots are more likely to fail than maxillary roots. This probably is explained by the fact that resection of mandibular teeth always creates single-rooted segments. In the maxillary arch, a root resection will usually leave a tooth with two roots, providing it with additional support as well as stability.

Successful restoration of periodontally weakened teeth is aided by creating an occlusal scheme with canine-protected occlusion, decreased vertical overlap, and flattened posterior cusps.³¹

14 Preparations for Periodontally Weakened Teeth

References

1. Appleton IE. Restoration of root-resected teeth. *J Prosthet Dent* 1980;44:150–153.
2. Gher ME, Vernino AR. Root morphology—Clinical significance in pathogenesis and treatment of periodontal disease. *J Am Dent Assoc* 1980;101:627–633.
3. Gher MW Jr, Dunlap RW. Linear variation of the root surface area of the maxillary first molar. *J Periodontol* 1985;56:39–43.
4. Yuodelis RA, Weaver JD, Sapkos S. Facial and lingual contours of artificial complete crown restorations and their effects on the periodontium. *J Prosthet Dent* 1973;29:61–66.
5. Eissmann HF, Radke RA, Noble WH. Physiologic design criteria for fixed dental restorations. *Dent Clin North Am* 1971;15:543–568.
6. Bergenholtz A. Radectomy of multirooted teeth. *J Am Dent Assoc* 1972;85:870–875.
7. Amen CR. Hemisection and root amputation. *Periodontics* 1966;4:197–204.
8. Farrar JN. Radical and heroic treatment of alveolar abscess by amputation of roots of teeth. *Dent Cosmos* 1884;26:79–81.
9. Black GV. Abrasion of the teeth. In: Litch WF (ed). *American System of Dentistry*, vol 1. Philadelphia: Lea, 1886:997.
10. Tomes J, Tomes CS. *Dental Surgery*, ed 3. Philadelphia: P. Blakeston & Son, 1887:526.
11. Basaraba N. Root amputation and tooth hemisection. *Dent Clin North Am* 1969;13:121–132.
12. Erpenstein H. A 3-year study of hemisectioned molars. *J Clin Periodontol* 1983;10:1–10.
13. Marin C, Carnevale G, De Febo G, Fuzzi M. Restoration of endodontically treated teeth with interradicular lesions before root removal and/or root separation. *Int J Periodontics Restorative Dent* 1989;9:42–57.
14. Rosen H, Gitnick PJ. Separation and splinting of the roots of multirooted teeth. *J Prosthet Dent* 1969;21:34–38.
15. Abrams L, Trachtenberg DI. Hemisection—Technique and restoration. *Dent Clin North Am* 1974;18:415–444.
16. Grant DA, Stern IB, Listgarten MA. *Periodontics*, ed 6. St Louis: Mosby, 1988:921–949.
17. Amsterdam M, Rossman SR. Technique of hemisection of multirooted teeth. *Alpha Omegan* 1960;53:4–15.
18. Bower RC. Furcation morphology relative to periodontal treatment. Furcation entrance architecture. *J Periodontol* 1979;50:23–27.
19. Staffileno HJ. Surgical management of the furca invasion. *Dent Clin North Am* 1969;13:103–119.
20. Hamp SE, Nyman S, Lindhe J. Periodontal treatment of multirooted teeth. Results after 5 years. *J Clin Periodontol* 1975;2:126–135.
21. Reinhardt RA, Sivers JE. Management of Class III furcally involved abutments for fixed prosthodontic restorations. *J Prosthet Dent* 1988;60:23–28.
22. Lloyd RS, Baer PN. Periodontal therapy by root resection. *J Prosthet Dent* 1960;10:362–365.
23. Dunlap RM, Gher ME. Root surface measurements of the mandibular first molar. *J Periodontol* 1985;56:234–238.
24. Hermann DW, Gher ME Jr, Dunlap RM, Pelleu GB Jr. The potential attachment area of the maxillary first molar. *J Periodontol* 1983;54:431–434.
25. Jepsen A. Root surface measurement and a method for x-ray determination of root surface area. *Acta Odontol Scand* 1963;21:35–46.
26. Everett FG, Jump EB, Holder TD, Williams GC. The intermediate bifurcational ridge: A study of the morphology of the bifurcation of the lower first molar. *J Dent Res* 1958;37:162–169.
27. Klavan B. Clinical observations following root amputation in maxillary molar teeth. *J Periodontol* 1975;46:1–5.
28. Langer B, Stein SD, Wagenberg B. An evaluation of root resections. A ten-year study. *J Periodontol* 1981;52:719–722.
29. Ehrlich J, Hochman N, Yaffe A. Root resection and separation of multirooted teeth: A 10-year follow-up study. *Quintessence Int* 1989;20:561–564.
30. Ross IF, Thompson RH Jr. A long term study of root retention in the treatment of maxillary molars with furcation involvement. *J Periodontol* 1978;49:238–244.
31. Kois JC, Spear FM. Periodontal prosthesis: Creating successful restorations. *J Am Dent Assoc* 1992;123:108–115.

Provisional Restorations

It is important that the prepared tooth or teeth be protected and that the patient be kept comfortable while a cast restoration is being fabricated. Through successful management of this phase of the treatment, the dentist can gain the patient's confidence and favorably influence the ultimate success of the definitive restoration. During the time between the preparation of the tooth and the placement of the definitive restoration, the tooth is protected by a *provisional restoration*. This type of restoration has also been known for many years as a *temporary restoration*. A good provisional restoration should satisfy the following requirements:

- **Pulpal protection.** The restoration must be fabricated of a material that will prevent the conduction of temperature extremes. The margins should be adapted well enough to prevent leakage of saliva.
- **Positional stability.** The tooth should not be allowed to extrude or drift in any way. Any such movement will require adjustments or a remake of the definitive restoration at the time of cementation.
- **Occlusal function.** Being able to function occlusally with the provisional restoration will aid patient comfort, ward off tooth migration, and possibly prevent joint or neuromuscular imbalance.
- **Ease of cleaning.** The restoration must be made of a material and contour that will permit the patient to keep it clean during the time it is worn. If the gingival tissues remain healthy while the provisional crown is in place, there is less likelihood of a problem arising after cementation of the definitive restoration.
- **Nonimpinging margins.** It is of utmost importance that the margins of a provisional restoration not impinge upon the gingival tissue.¹⁻⁴ The resulting inflammation could cause gingival proliferation, recession, or at the very least hemorrhage during the impression or cementation. A damaging overhang can result from a preformed metal or resin provisional restoration that has not been contoured properly, while a custom resin provisional crown can produce a horizontal overhang if it is incorrectly trimmed. A restoration with drastically underextended margins also may result in a proliferation of gingival tissue.⁵
- **Strength and retention.** The restoration must stand up to the forces to which it is subjected without breaking or coming off the tooth. Replacement of a provisional restoration is time-consuming and detrimental to patient rap-

port. A broken provisional fixed partial denture can accelerate tooth movement. The restoration should also remain intact during removal so that it can be reused if necessary.

- **Esthetics.** In some cases, the restoration must provide a good esthetic effect, particularly on anterior teeth and premolars.

Types of Provisional Restorations

There are numerous ways of providing protective coverage for teeth while permanent restorations are being fabricated. These range from zinc oxide–eugenol cement for small intracoronal inlay preparations to provisional crowns and provisional fixed partial dentures.

Prefabricated versus custom restorations

Provisional restorations can be classified according to whether they are prefabricated or custom made. Prefabricated forms include stock aluminum cylinders ("tin cans"), anatomical metal crown forms, clear celluloid shells, and tooth-colored polycarbonate crown forms. They can be used only for single-tooth restorations. Custom crowns and fixed partial dentures can be fabricated of several different kinds of resins by a variety of methods, direct or indirect.

Direct versus indirect techniques

Provisional restorations also can be classified by the method used for adapting the restoration to the teeth: The direct technique is done on the actual prepared teeth in the mouth, and the indirect technique is accomplished outside of the mouth on a cast made of quick-set plaster.

The direct technique is inviting to novices because it eliminates the alginate impression and the plaster cast. However, the direct relined technique can be technique sensitive. If the direct technique has any place in restorative dentistry, it is using a resin other than polymethyl methacrylate.

The indirect technique is preferred over the direct technique for its accuracy.⁶ To avoid locking into undercuts, a directly fabricated resin provisional restoration must be re-

15 Provisional Restorations

Table 15-1 Characteristics of resins used for provisional restorations^{8,11,15–23}

Type	Advantages	Disadvantages
Polymethyl methacrylate	Good marginal fit ¹⁵ Good strength ¹⁵ Good polishability ¹⁵ Durability ¹⁶	High exothermic heat increase ^{17,18} Low abrasion resistance ¹⁵ Free monomer toxic to pulp ¹⁶ High volumetric shrinkage ¹⁶
Polyethyl methacrylate	Good polishability ¹⁵ Minimal exothermic heat increase ¹⁷ Good stain resistance ¹⁵ Low shrinkage ⁸	Surface hardness ¹⁵ Strength ¹⁵ Durability ¹⁶ Fracture toughness ¹⁹
Polyvinylethyl methacrylate	Good polishability ¹⁵ Low exothermic heat increase ¹⁷ Good abrasion resistance ¹⁵ Good stain resistance ¹⁵ Flexibility ⁸	Surface hardness ¹⁵ Strength ¹⁵ Esthetics ⁸ Fracture toughness ¹⁹
Bis-acryl composite	Good marginal fit ¹⁵ Low exothermic heat increase ¹⁸ Good strength ^{15,20} Low shrinkage ⁸	Surface hardness ¹⁵ Less stain resistance ¹⁵ Limited shade selection ⁸ Limited polishability ⁸ Brittle ^{16,21}
VLC urethane dimethacrylate	High surface hardness ¹⁵ Good strength ¹⁵ Good abrasion resistance ¹⁵ Controllable working time ²² Color stability ¹⁵	Marginal fit ¹⁵ Less stain resistance ¹⁵ Limited shade selection ²² Expensive ^{11,23} Brittle

moved from the tooth before it has completely polymerized. Because pure methyl methacrylate monomer has a 21% volumetric shrinkage when it polymerizes,⁷ polymerization outside the mouth without a supporting form results in distortion and a less-than-optimal fit.^{8,9} In a study of the marginal adaptation of provisional restorations, Crispin et al¹⁰ showed that the marginal fit of polymethyl methacrylate provisional restorations could be improved nearly 70% by fabricating them indirectly.

The fit of provisional restorations made from many resins can be improved by using the indirect technique. For some materials, the improvement in fit obtained by using the indirect technique is as much or more than the improvement seen with polymethyl methacrylate.¹⁰ Monday and Blais¹¹ found better margins on polyvinylethyl methacrylate crowns made indirectly than those made either directly or by relining.

The indirect technique also is preferred for the protection that it provides the pulp,⁶ particularly if polymethyl methacrylate is used. The placement of polymerizing polymethyl methacrylate on freshly cut dentin could lead to thermal irritation from the exothermic reaction or chemical irritation from the free monomer.^{12,13} It has been reported that this produces an acute pulpal inflammation, as evidenced by an accumulation of neutrophilic leukocytes in the pulp horns.¹⁴

This is another irritant added to a tooth that in most cases has already been subjected to caries, previous restorations, and high-speed cutting in the preparation of the tooth. It is an additional insult that should be avoided whenever possible. A further advantage of the indirect technique is that much of the work can be delegated to auxiliary personnel.

Resins for Provisional Restorations

There are several types of resins that can be used for making custom provisional restorations. Polymethyl methacrylate has been in use the longest. Polyethyl methacrylate, polyvinylethyl methacrylate, bis-acryl composite resin, and visible light-cured (VLC) urethane dimethacrylate have come into common usage in recent years. There are more than 50 provisional restorative materials currently available. No one resin is superior in all respects,¹⁵ and the restorative dentist must assess the advantages and disadvantages of each in selecting which to use (Table 15-1).

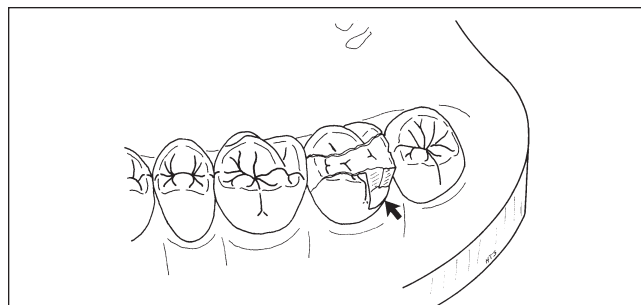

Fig 15-1 Defects, such as a missing cusp (arrow), should be filled in on the cast.

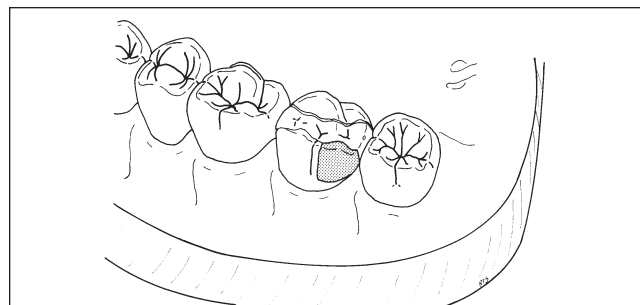


Fig 15-2 Utility wax is placed in the defect.

Techniques for Custom Provisional Restorations

The requirements for a good provisional restoration are most easily and completely met by a custom indirect restoration. There are a variety of techniques for making a mold to form the outer surface of a custom provisional restoration that provides the appearance of a tooth where needed, physiologic axial contours adjacent to the gingiva, occlusion with opposing teeth, proximal contact, and marginal fit. The inner surfaces will be shaped by a cast of the preparation(s).

Both elastomeric^{1,2,8,16,18,22,23} and alginate^{5,6,24} overimpressions have been used to shape the provisional restoration. An overimpression is made on the diagnostic cast or in the mouth before the tooth preparation is begun. An elastomeric impression provides excellent stability, although it is more expensive than alginate.

A template formed from clear thermoplastic resin also can be used for this purpose.^{3,25-27} It is shaped on a diagnostic cast using a vacuum forming machine or an impression tray filled with silicone putty. The template is filled with resin and applied to the prepared teeth or to a fast-setting plaster cast of the prepared teeth. Templates are very stable and can be adapted sufficiently to be used for checking preparation reduction or starting wax patterns.²⁷

A thin shell crown or fixed partial denture can be made of autopolymerizing resin in an impression prior to the preparation appointment by alternately dripping monomer and gently blowing polymer with an atomizer.²⁸⁻³⁰ The resulting form is relined after the tooth or teeth are prepared.^{16,28} A second shell can be made from the same impression as a spare.²⁸ The shell also can be heat processed in a laboratory.¹⁶

Selected techniques are discussed in detail in the following pages. Although an overimpression is shown for making a provisional crown and a clear resin template is shown for making a provisional fixed partial denture, they are interchangeable.

Overimpression-fabricated provisional crown

The use of an alginate overimpression remains a popular technique because it is always readily available in the dental operatory. In addition, it is easily adapted to intraoral use in the event that the plan for restoration of a tooth with amalgam is unexpectedly changed to a cast restoration.

Overimpression armamentarium

- Diagnostic cast
- Utility wax
- No. 7 wax spatula
- Quadrant impression trays (two, same side)
- Alginate
- Rubber bowl
- Spatula
- Quick-set plaster
- Laboratory knife with no. 25 blade
- Heavy-duty laboratory knife
- Large camel-hair brush
- Cement spatula
- Dappen dish
- Separating medium
- Monomer and polymer
- Medicine dropper
- Heavy rubber band
- Straight handpiece
- Acrylic burs
- Abrasive Moore disks and Moore mandrel (E. C. Moore)

Overimpression technique

The overimpression frequently is made in the patient's mouth while waiting for the anesthetic to take effect. However, if the tooth to be restored has any obvious defects, the overimpression should be made from the diagnostic cast (Fig 15-1). After any defects are filled and smoothed over with red utility wax (Fig 15-2), the diagnostic cast is immersed in a rubber bowl of water for 5 minutes. Wetting the cast in this manner will keep the alginate from adhering to it.

15 Provisional Restorations

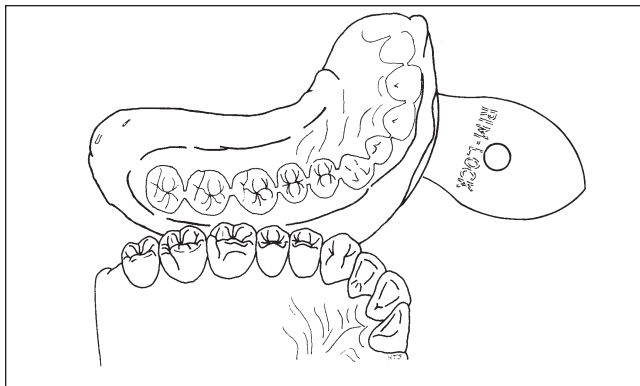


Fig 15-3 Overimpression is made from the diagnostic cast.

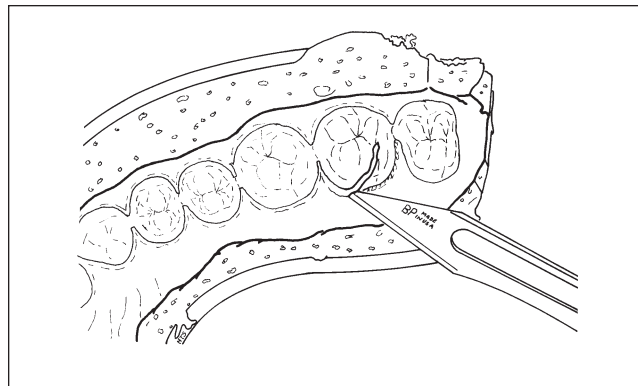


Fig 15-4 Thin edges in the gingival areas of the overimpression are cut away.

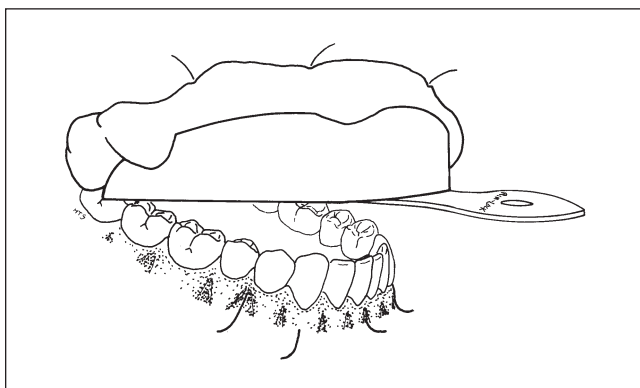


Fig 15-5 An alginate impression is made of the prepared tooth.

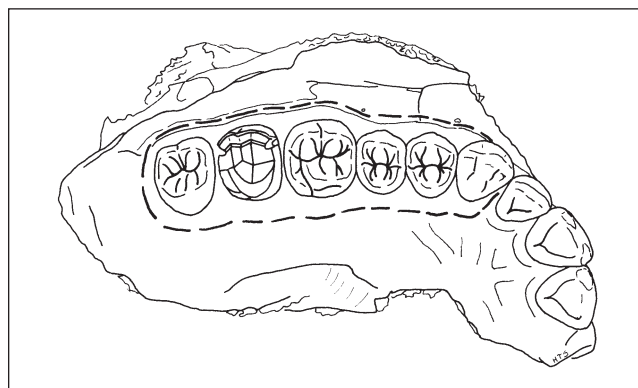


Fig 15-6 Untrimmed quick-set plaster cast.

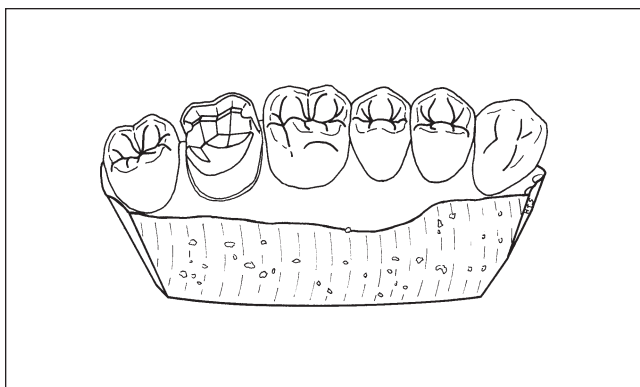


Fig 15-7 Properly trimmed plaster cast.

When the alginate has set, the overimpression is removed from the diagnostic cast and checked for completeness (Fig 15-3). A laboratory knife with a no. 25 blade is used to trim off all excess alginate. Thin flashes of impression material that replicate the gingival crevice are removed to ensure that there will be no impediments to the complete seating of the

cast into the overimpression later (Fig 15-4). The impression is wrapped in a wet paper towel and placed in a resealable zipper plastic bag for later use.

When the tooth preparation is completed, another quadrant impression is made in alginate (Fig 15-5). This impression is poured with a thin mix of quick-setting plaster (eg, Whip Mix mounting plaster) (Fig 15-6). Excess material should be trimmed off on a cast trimmer when the plaster has set. The trimmed cast should have at least one tooth on either side of the prepared tooth if possible. Areas of the cast that duplicate the soft tissues should be reduced as much as possible (Fig 15-7).

The occlusal surfaces and gingival crevices should be checked for any plaster nodules that will prevent complete seating. Then the trimmed quick-set plaster cast is tried in the overimpression to make sure that it will seat completely (Fig 15-8). The prepared tooth and adjacent areas of the cast are coated liberally with an algin-based "tin foil substitute" separating medium (Alcote, Dentsply) (Fig 15-9). The material should be allowed to dry before mixing the acrylic resin. Drying can be accelerated by the use of an air syringe.

Tooth-colored acrylic resin is mixed in a dappen dish with a cement spatula (Fig 15-10). Twelve drops of monomer are

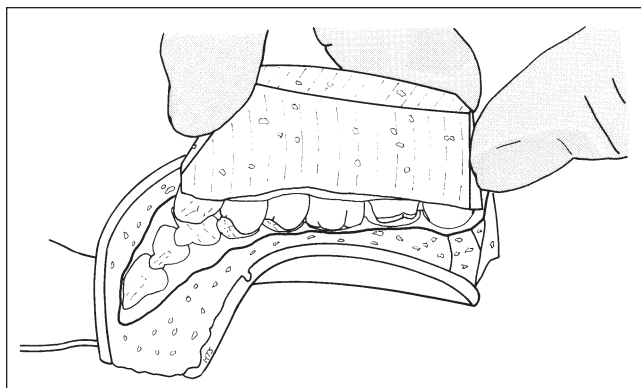


Fig 15-8 The cast is tried in the overimpression before proceeding.

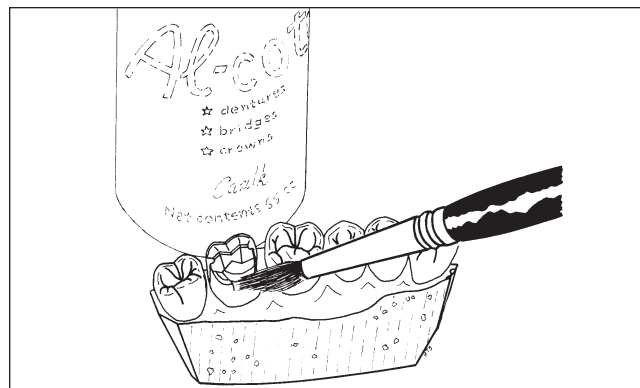


Fig 15-9 Separating medium is painted on the plaster cast.

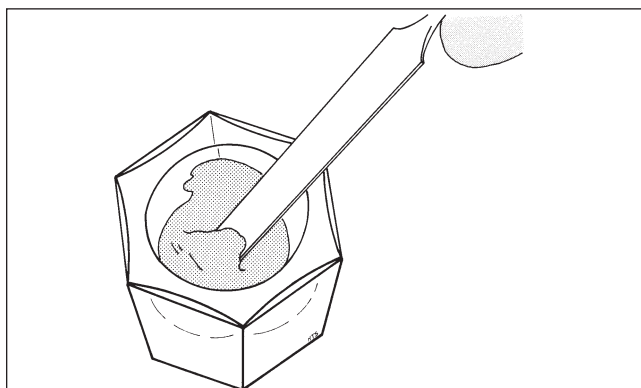


Fig 15-10 Acrylic resin is mixed in a dappen dish.

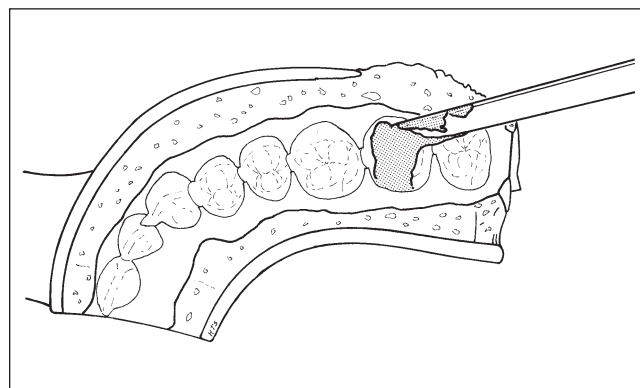


Fig 15-11 Resin is placed into the overimpression.

used for each tooth being restored. The resin is placed in the overimpression so that it completely fills the crown area of the tooth for which the provisional restoration is being made (Fig 15-11).

The cast is seated into the overimpression, making sure that the teeth on the cast are accurately aligned with the tooth impressions (Fig 15-12). The force used to seat the cast into the alginate impression is critical.³¹ Excessive force can overseat the cast, and uneven force can torque the cast, either of which will affect the restoration.

Once the cast has been firmly seated and the excess resin has been expressed, the cast should be held in place with a large rubber band (Fig 15-13). It is important that the cast be oriented securely in an upright position so that the space between the cast and the impression that is filled with the resin forming the provisional restoration will not be distorted (Fig 15-14a). If the cast is torqued to one side by the rubber band, the cast may be forced through the soft resin in some areas, resulting in a provisional restoration that may be thin in those areas and thicker than desirable in others (Fig 15-14b). If the cast is seated with too much force, or if the rubber band is wrapped around the assembly too many times, the cast may be forced through the resin occlusally, resulting in a pro-

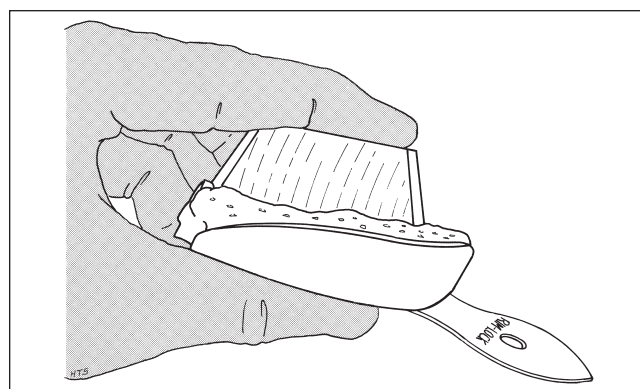


Fig 15-12 The cast is seated firmly in the overimpression.

visional restoration with an occlusal surface that is too thin (Fig 15-14c).

The overimpression–plaster cast assembly is placed in a rubber bowl full of warm tap water for approximately 5 minutes or into a pressure pot if one is available. Allowing a polymethyl methacrylate provisional restoration to polymer-

15 Provisional Restorations

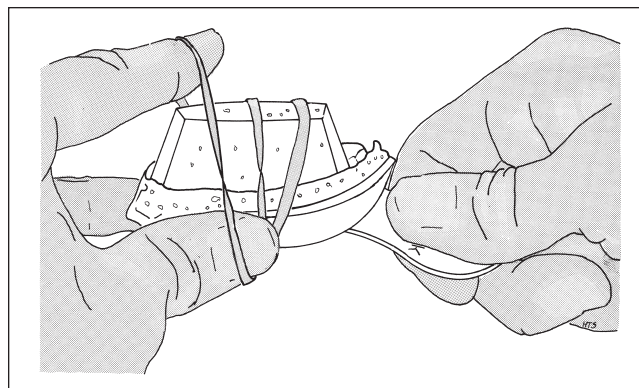


Fig 15-13 The cast is held in place with a rubber band.

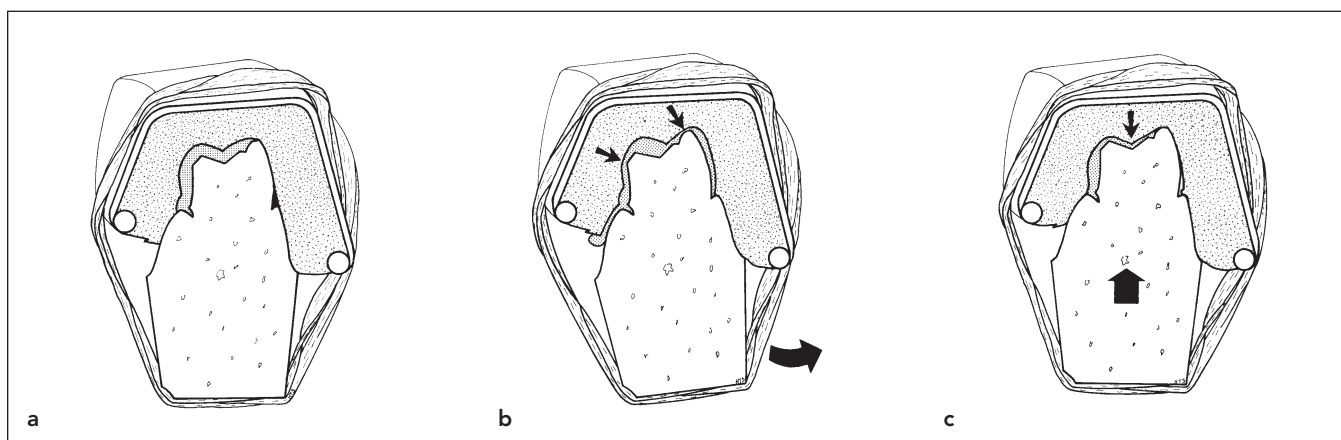


Fig 15-14 Cross sections of casts seated in overimpressions. (a) Correct seating. (b) If the cast is pushed to one side, the provisional restoration will be deficient. (c) Overseating of the cast will produce a provisional restoration with a thin occlusal surface.

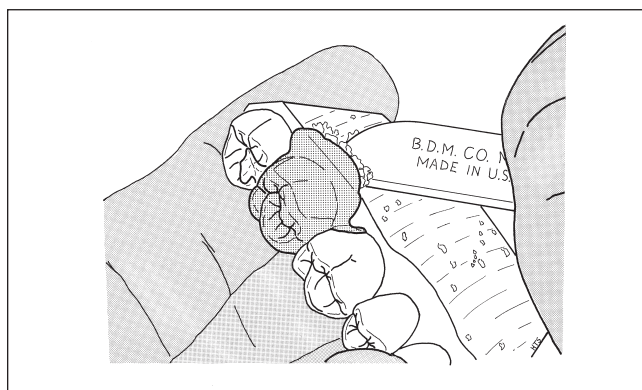


Fig 15-15 The cast can be broken to remove the provisional restoration.

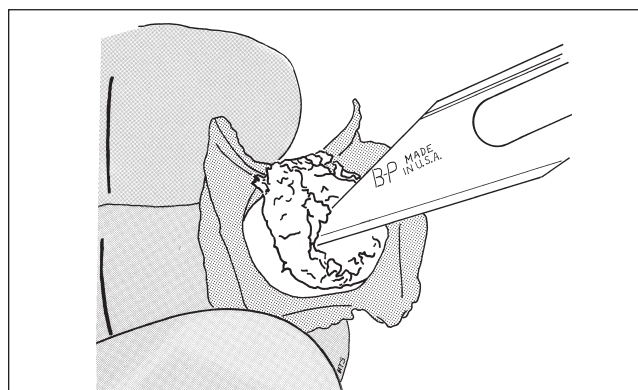


Fig 15-16 Any plaster remaining in the provisional restoration is removed.

ize in a pressure pot (Acridense VI Pneumatic Curing Unit, GC) under 20 psi will decrease porosity and increase the transverse strength of the restoration by 28%.³²

When the resin has polymerized, the rubber band is removed to disassemble the quick-set plaster cast from the overimpression. If the restoration is not easily removed from

the cast, the tooth can be broken off the plaster cast with a heavy-bladed laboratory knife (Fig 15-15). The sharp end of a thin-bladed knife or some other small, pointed instrument is used to remove any plaster that remains in the provisional restoration (Fig 15-16). Ease of removal is one of the advantages of using the weak, quick-set plaster.

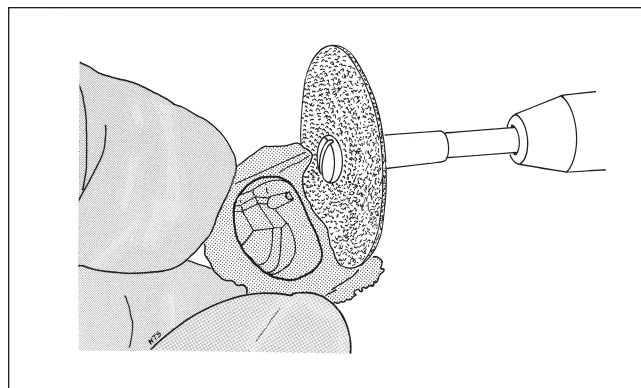


Fig 15-17 Resin flash is ground off with a carbundum disk.

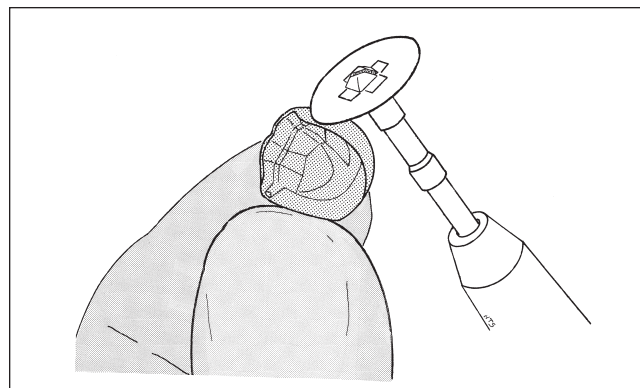


Fig 15-18 The margins are smoothed with a sandpaper disk.

Acrylic burs or coarse Moore disks are used to trim the excess resin from the provisional restoration (Fig 15-17). Before attempting to seat the restoration on the tooth, all resin extending beyond the preparation finish line into undercut areas must be removed. The axial surfaces near the margins of the restoration are smoothed with a fine sandpaper disk (Fig 15-18).

Cementation armamentarium

- Articulating paper
- Miller forceps
- Straight handpiece
- High-speed handpiece
- No. 171L FG bur
- Muslin rag wheel
- Pumice
- Cement spatula
- Paper pad
- Zinc oxide–eugenol cement
- Petrolatum
- Explorer
- Mouth mirror
- Dental floss

Cementation technique

The provisional restoration is seated on the tooth in the mouth. The occlusion is checked with thin articulating paper (Fig 15-19). The restoration is removed from the tooth, and a nondentate bur is used to adjust the occlusal prematurities (Fig 15-20). When the occlusion has been adjusted to make the patient comfortable, the restoration is polished first with damp pumice and then polishing compound (Acrilustre, Buffalo Dental) on a dry muslin rag wheel (Fig 15-21). Besides making the provisional restoration easier to clean and more comfortable for the patient, polished materials are much less likely to discolor.³³

To fit a provisional crown under an existing removable partial denture, the crown should be undercontoured so it does

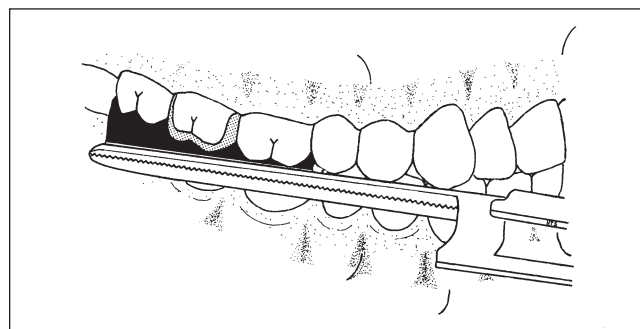


Fig 15-19 Occlusion on the restoration is checked in the mouth with thin articulating paper.

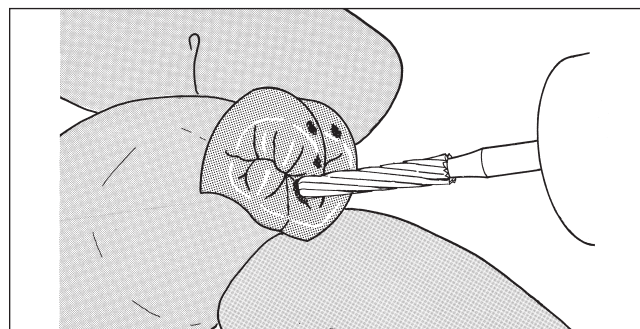


Fig 15-20 Occlusion is adjusted outside the mouth.

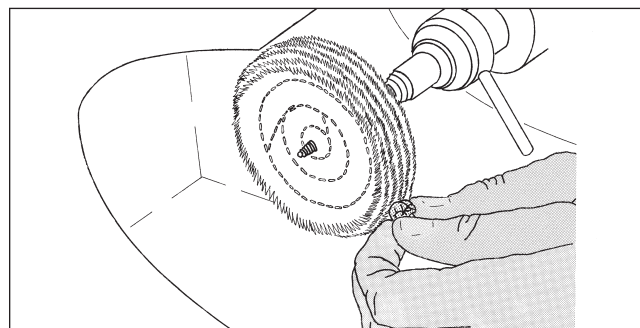


Fig 15-21 The restoration is polished with pumice.

15 Provisional Restorations

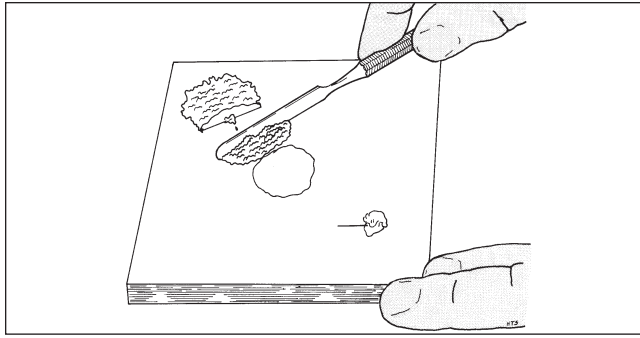


Fig 15-22 Zinc oxide–eugenol cement is often mixed with a small amount of petrolatum.

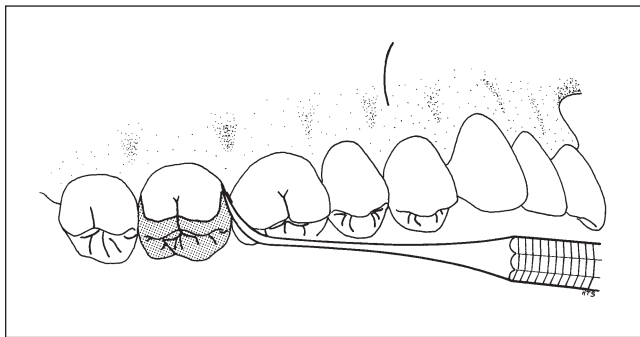


Fig 15-23 An explorer is used to remove cement from the gingival crevice.

not touch any rests or clasps on that tooth. Resin is added to the outside of the crown, and while the resin is still soft, the crown is seated on the tooth. To form the rest seat and guide planes on the crown, the partial denture is lubricated with petrolatum and seated over the provisional crown. The partial denture should be pumped up and down several times to ensure that it is not locked into any undercuts. The crown is removed from the tooth, any rough areas are smoothed, and the crown is polished.

The restoration should be cemented with a temporary cement of moderate strength. After the zinc oxide–eugenol cement has been mixed to a thick, creamy consistency, an amount of petrolatum equal to 5% to 10% of the cement volume is incorporated to slightly reduce the strength of the cement (Fig 15-22). This will facilitate removal of the provisional restoration at a subsequent appointment. If the preparation is short or otherwise lacking in retention, the petrolatum should not be added.

It is not necessary to keep zinc oxide–eugenol cement dry while it is setting. In fact, moisture will accelerate the hardening. Coating the outside of the restoration with a thin film of petrolatum prior to cementation will aid in the removal of excess cement. After the cement has hardened, all excess must be removed from the gingival crevice. Use an explorer in accessible areas and knotted dental floss interproximally (Fig 15-23).

Template-fabricated provisional fixed partial denture

When a fixed partial denture is to be made for a patient, the provisional restoration should also be in the form of a fixed partial denture rather than individual crowns. In the anterior region it will provide a better esthetic result, and in the posterior region a provisional fixed partial denture will better stabilize the teeth and will afford the patient the opportunity to become accustomed to having a tooth in the edentulous space again.

Template armamentarium

- Diagnostic cast
- Mor-Tight putty (TP Orthodontics)
- No. 7 wax spatula
- Denture tooth
- Crown form
- Vacuum forming machine
- Coping material or temporary splint material
- Quadrant impression trays
- Silly Putty (Crayola)
- Wire frame
- Bunsen burner
- Scissors
- Laboratory knife with no. 25 blade
- Heavy-duty laboratory knife
- Large camel-hair brush
- Cement spatula
- Dappen dish
- Separating medium
- Monomer and polymer
- Medicine dropper
- Heavy rubber band
- Straight handpiece
- Acrylic burs
- Abrasive disks and Moore mandrel

Template technique

To make a template, place a metal crown form or a denture tooth in the edentulous space on the diagnostic cast (Fig 15-24). All of the embrasures should be filled with putty (Mor-Tight) to eliminate undercuts during adaptation of the resin template.

To facilitate removal of the template, a thin strand of putty can be placed around the periphery of the cast and on the lingual surface of the cast, apical to the teeth (Fig 15-25). A large acrylic bur is used to cut a hole through the middle of the cast (midpalatal or midlingual). A 5 × 5-inch sheet of 0.020-inch-thick resin (clear temporary splint vacuum forming material, Buffalo Dental) is placed in the frame of the vacuum forming machine (Sta-Vac II, Buffalo Dental) (Fig 15-26). The heating element of the machine is turned on and swung into position over the plastic sheet.

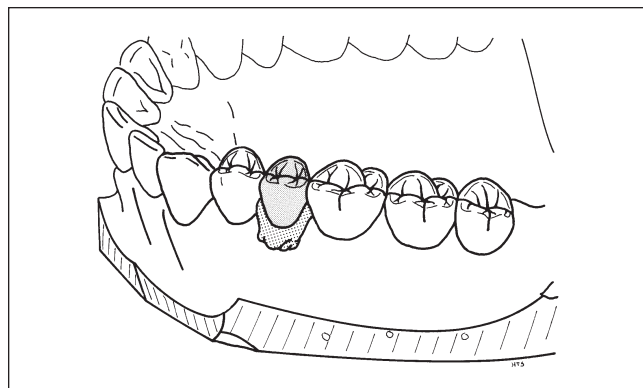


Fig 15-24 A crown form or a denture tooth is placed in the edentulous space on the diagnostic cast.

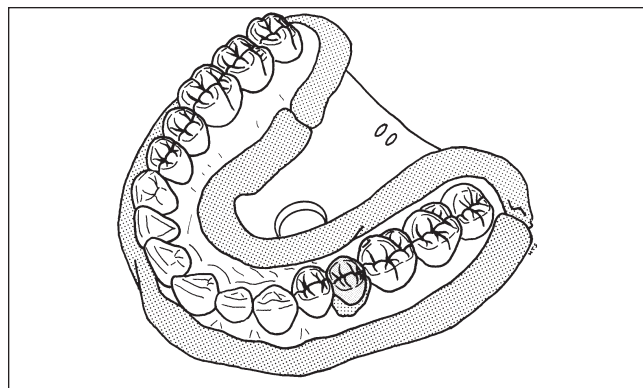


Fig 15-25 A rope of Mor-Tight is placed around the periphery of the cast.

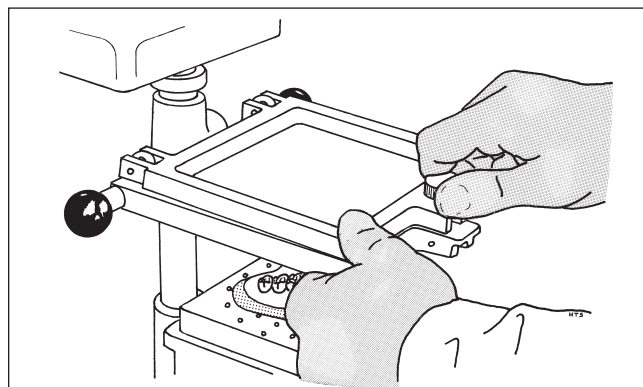


Fig 15-26 The plastic sheet is secured in the frame of the vacuum forming machine.

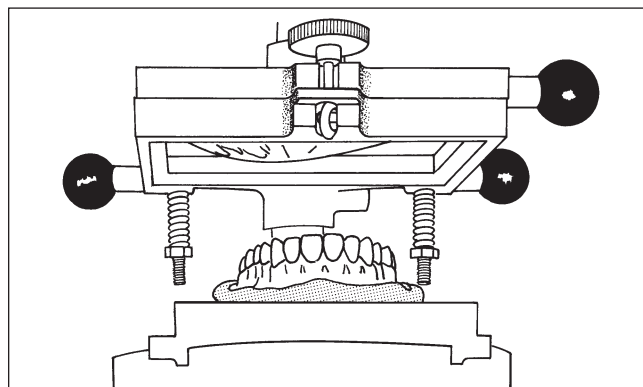


Fig 15-27 The plastic sags as it is heated to the proper temperature.

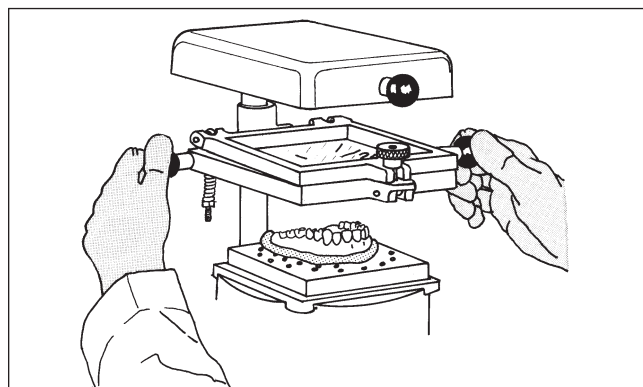


Fig 15-28 The frame is pulled down over the perforated stage of the vacuum forming machine.

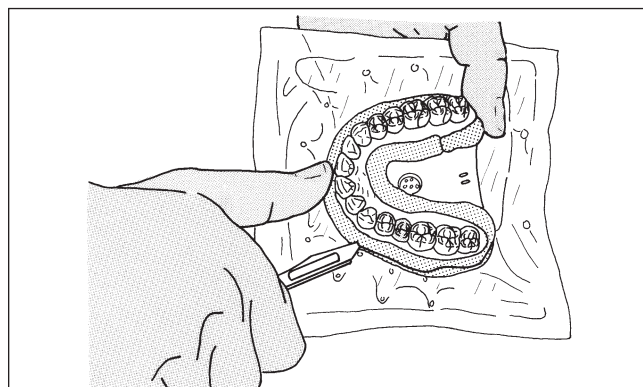


Fig 15-29 The plastic is cut to remove the template from the diagnostic cast.

As the resin sheet is heated to the proper temperature, it will droop or sag about 1.0 inch in the frame. If a coping material is used, it will lose its cloudy appearance and become completely clear (Fig 15-27). The cast should be in position in the center of the perforated stage of the vacuum forming machine. Then the vacuum is turned on.

The handles on the frame that holds the heated coping material are grasped while the frame is forcefully lowered over the perforated stage (Fig 15-28). The heating element

is turned off and swung to the side. After approximately 30 seconds, the vacuum is turned off, and the resin sheet is released from the holding frame. After the resin sheet is removed from the frame, a laboratory knife with a sharp no. 25 blade is used to cut through the resin over the Mor-Tight strand (Fig 15-29).

If a vacuum forming machine is not available, it is still possible to fabricate a template for a provisional restoration. A quadrant impression tray is filled with Silly Putty, a soft sili-

15 Provisional Restorations

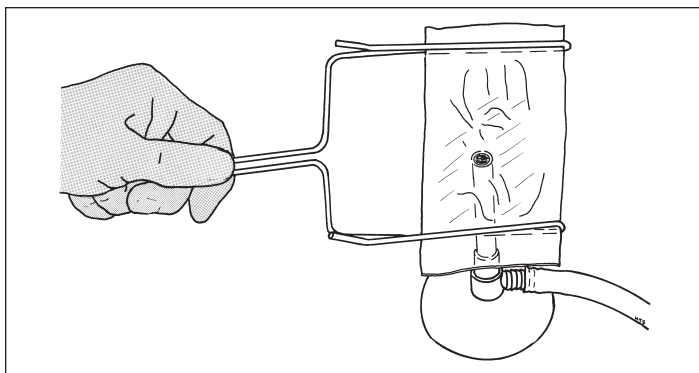


Fig 15-30 The plastic can be heated in a wire frame over a Bunsen burner.

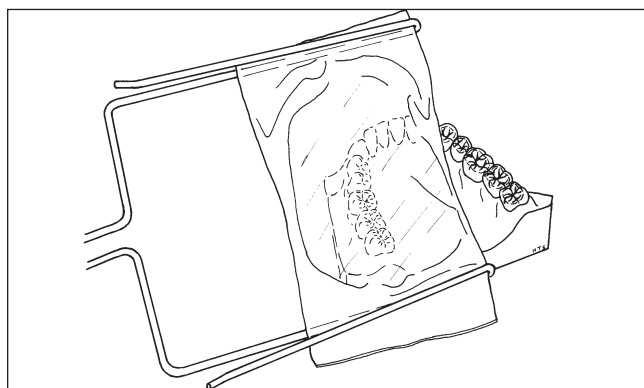


Fig 15-31 The plastic sheet is positioned over the diagnostic cast.

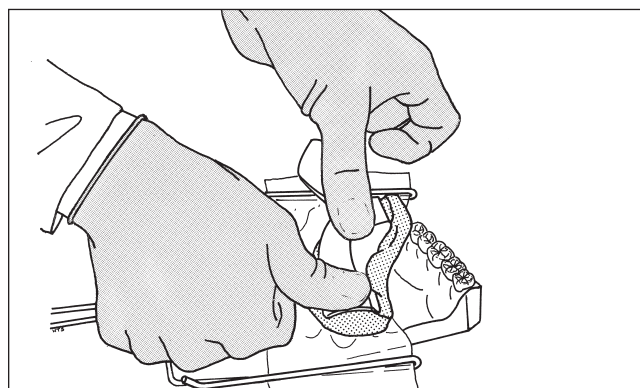


Fig 15-32 The plastic template is adapted by exerting heavy force on the impression tray of silicone putty.

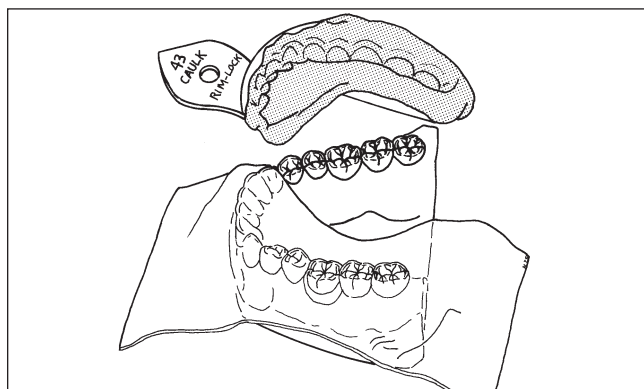


Fig 15-33 The tray full of putty is pulled off the adapted plastic template.

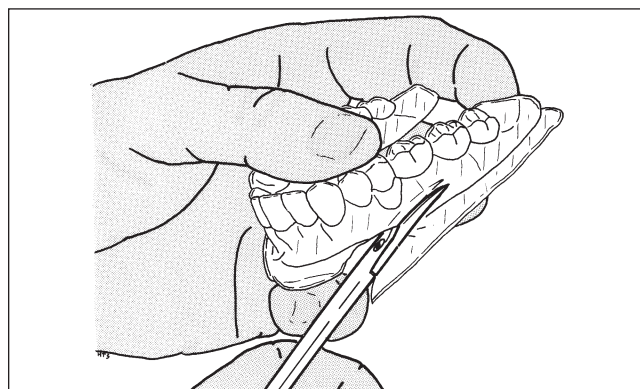


Fig 15-34 Excess is trimmed from the periphery of the template.

cone putty available in most variety or toy stores. A sheet of coping material is cut in half and inserted, shiny side down, into a wire frame bent from a coat hanger. The resin sheet is heated over a Bunsen burner flame until it sags and becomes clear, which usually occurs in about 10 seconds (Fig 15-30).

The softened sheet is placed over the cast (Fig 15-31). The tray of silicone putty is forcefully seated over the coping material (Fig 15-32). To accelerate cooling, compressed air can be blown on the plastic sheet and the impression tray. After about a minute, the tray is snapped off the cast (Fig 15-33).

If the silicone putty sticks to the resin sheet, the putty can be easily removed by pulling it off in quick jerks. Rapid separation causes the silicone putty to exhibit brittleness that will result in easy removal. The putty is replaced in its original container for later reuse. The template is separated from the diagnostic cast.

The template is trimmed, regardless of how it was fabricated, with a pair of scissors (Fig 15-34). It should extend to at least one tooth on either side of the prepared teeth. Those portions not needed can be saved for possible later use.

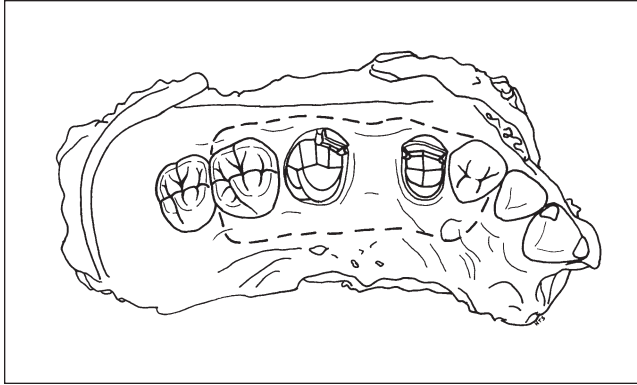


Fig 15-35 The quick-set plaster cast should be trimmed back to the dotted line.

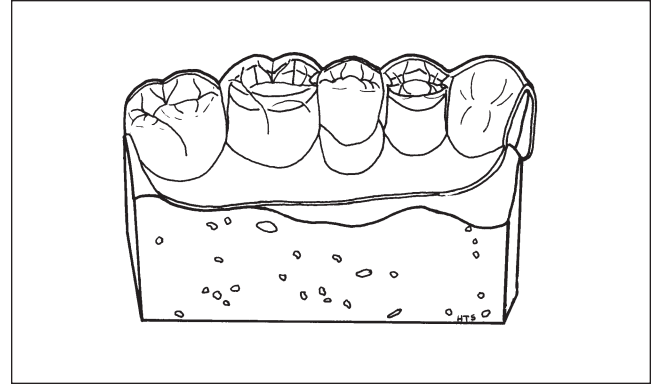


Fig 15-36 The template is tried on the cast to verify the fit.

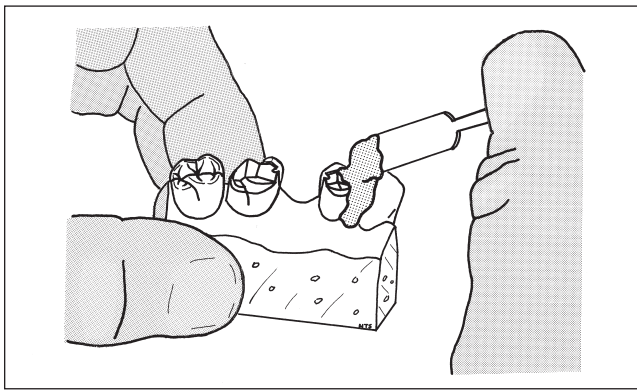


Fig 15-37 Some acrylic resin is placed in the interproximal areas of the cast.

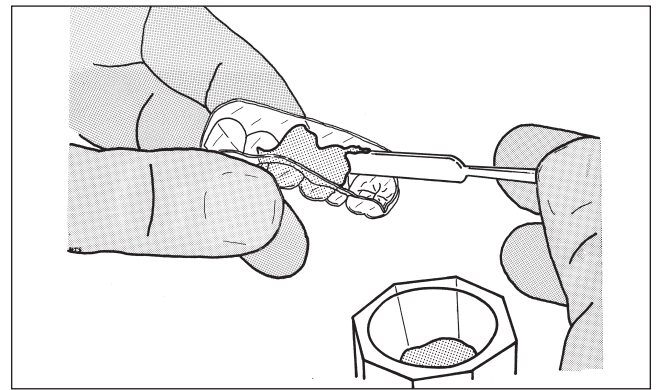


Fig 15-38 Resin is placed in the template.

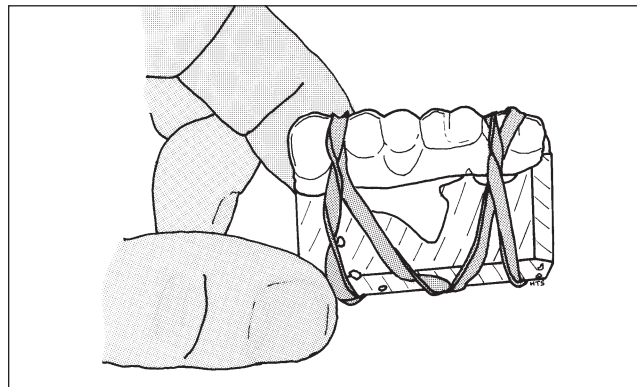


Fig 15-39 The template is held in position with rubber bands.

Template-fabricated provisional fixed partial denture technique

Upon completion of the preparations, an alginate impression is taken of them and poured in fast-setting plaster. The plaster cast will include replicas of soft tissue and teeth that are not needed (Fig 15-35). The cast is trimmed so that it includes only one tooth on either side of the prepared teeth. The template is tried on to verify its fit (Fig 15-36).

The cast is coated with Alcolac separating medium and allowed to dry. The acrylic resin is mixed in a dappen dish,

and some is placed on protected areas of the cast such as interproximal spaces and in grooves and boxes (Fig 15-37). As the resin begins to lose its surface gloss and becomes slightly dull, the area for which the provisional fixed partial denture is being made is filled (Fig 15-38). Some extra bulk is placed in the portion that will serve as the pontic.

Rubber bands are wrapped around the template and cast (Fig 15-39), with care taken not to place them over the abutment preparations, lest they cause the template to collapse in that area. The cast is placed in a pressure pot if one is available. Otherwise, it is placed in warm (not hot) tap water

15 Provisional Restorations

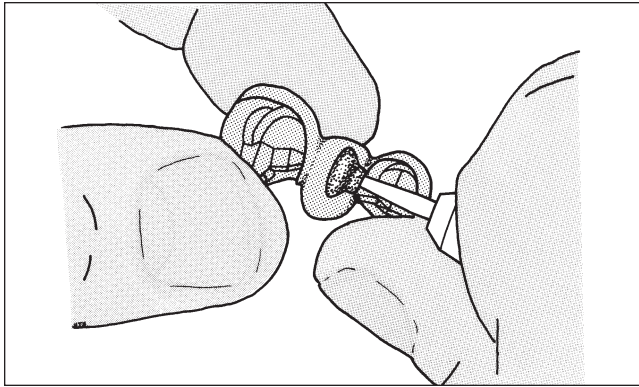


Fig 15-40 The pontic is trimmed to widen the embrasures and create cleanable contours.

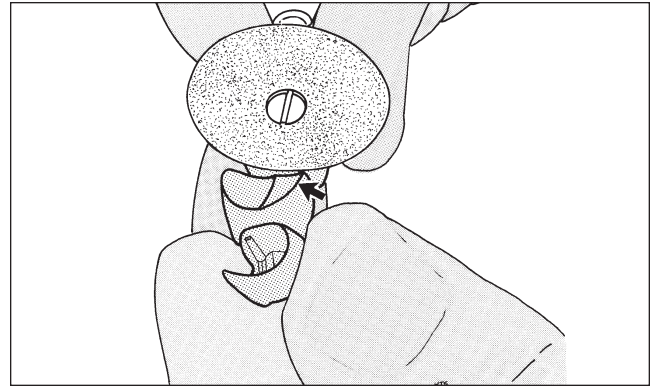


Fig 15-41 The lingual ridge of the saddle (arrow) is removed to open the lingual embrasure of the pontic.

to hasten polymerization. Hot water will cause the monomer to boil, increasing porosity. After 5 minutes, the template is pried off and saved in case it is needed again. Before the provisional restoration is removed from the cast, resin is added to any voids or thin spots, and the cast is placed back in warm water. The template is not replaced for the correction. Placing the unpolymerized resin back into water will prevent evaporation of monomer and the formation of a granulated, "frosted" surface.

The fixed partial denture is removed from the cast. The cast should be broken if necessary. The excess acrylic resin is trimmed off. Disks are used to trim the axial surfaces down to the margins. The pontic should be trimmed with disks and burs to open the proximal embrasures (Fig 15-40). The saddle configuration that was created by the crown form in the edentulous space is removed (Fig 15-41). The pontic should have the same general shape that the pontic on the permanent prosthesis will have. This will ensure that the patient will be comfortable and satisfied with the pontic form before the completed fixed partial denture is inserted.

Template-fabricated VLC provisional restoration

A transparent template is essential to the use of a VLC resin (Triad, Dentsply) because the clear matrix allows the light access to the resin to initiate polymerization. Alternatively, a VLC urethane dimethacrylate putty stick resin (Revotek LC, GC) can be used without a clear matrix. The resin is hand-molded to the prepared teeth, and the occlusion is functionally generated by the patient's opposing dentition. Preliminary light curing is done before removal from the patient's mouth. After removal, final light curing, trimming, and polishing are accomplished. Similarly, a malleable composite-based material (Protemp Crown, 3M ESPE) is anatomically preformed, adapted to the prepared tooth, and light cured.

Bis-acryl composite provisional crown materials exhibit brittleness. A very short elastic stage makes it difficult to remove it from adjacent undercut areas without fracture. One dual-cure bis-acryl material (Luxatemp Solar Plus, DMG America) provides an extended elastic stage and delayed light curing. A VLC polymethyl methacrylate resin (Unifast LC, GC) allows user-controlled advancement from slurry through doughy and elastic stages to final cure.

Armamentarium

- Items in template armamentarium (see page 248)
- Silicone impression putty
- Triad resin
- Triad model release agent (MRA)
- Triad air barrier coating (ABC) material
- Triad curing unit
- Items in cementation armamentarium (see page 247)

Technique

A template is fabricated on the diagnostic cast. If the restoration is to be a fixed partial denture, a metal crown form or denture tooth is set in Mor-Tight putty in the edentulous space. If a diagnostic wax-up has been made, the cast is soaked for 5 minutes and duplicated with an alginate impression. The impression is poured in quick-set plaster.

A template is produced from a resin sheet on the vacuum forming machine. The template is trimmed and replaced on the cast. A scoop of silicone impression putty (Extrude XP putty, Kerr) is mixed with accelerator and molded around the template on the cast (Fig 15-42). This is needed to reinforce the unsupported template and prevent displacement by the highly viscous resin later.³⁴ Quick-set plaster also can be used to make this reinforcing index. The template and the index are set aside until the teeth have been prepared.

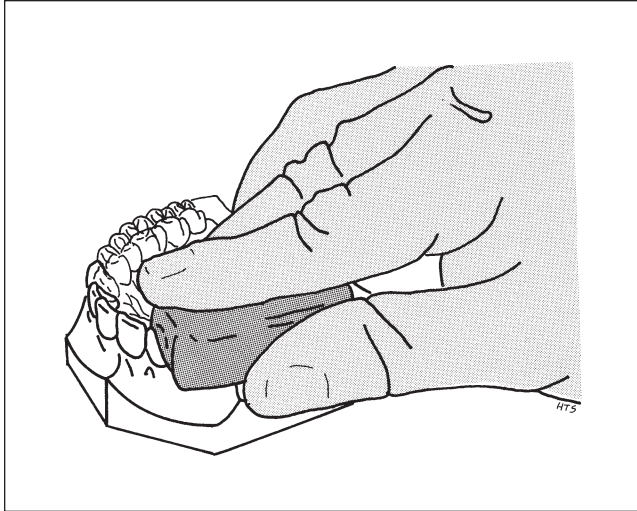


Fig 15-42 A silicone putty index is formed over the template on the diagnostic cast.

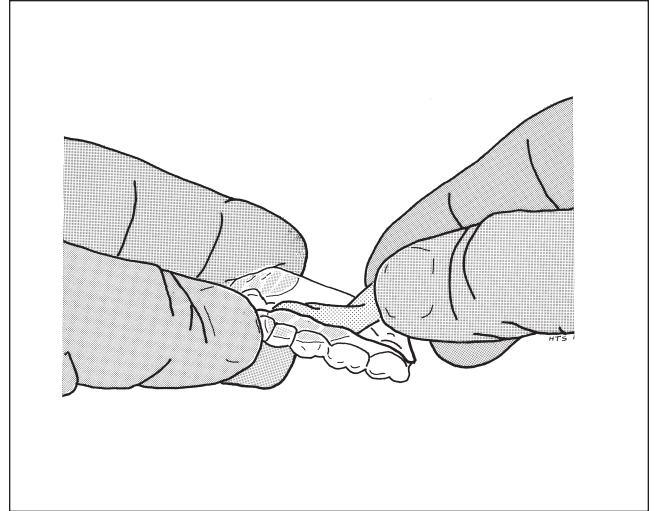


Fig 15-43 VLC resin is placed in the clear template.

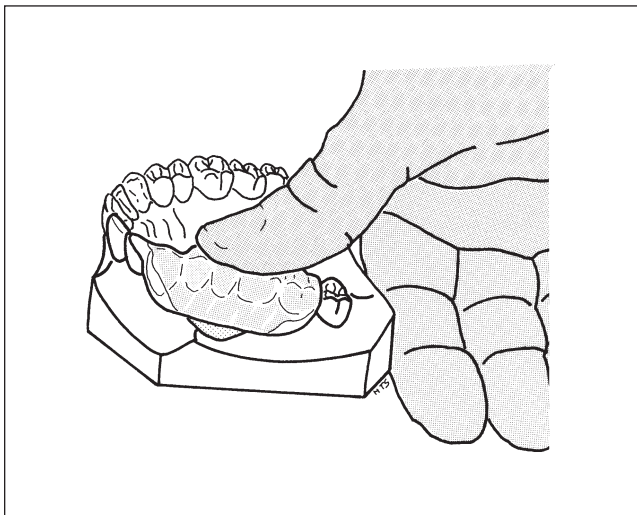


Fig 15-44 The resin-loaded template is forcefully seated on the quick-set plaster cast.

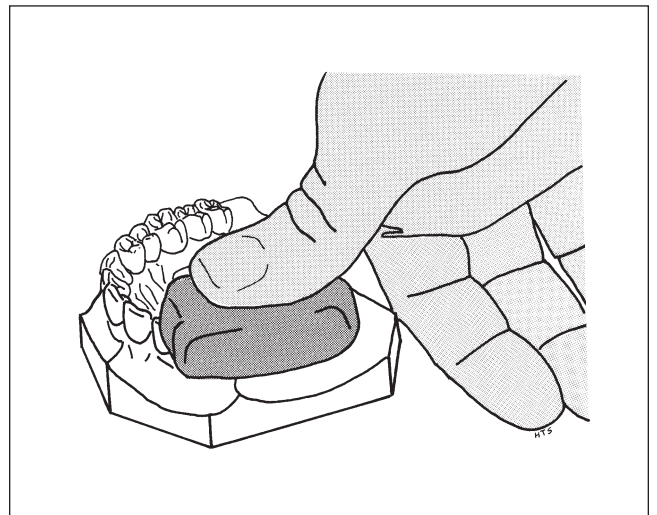


Fig 15-45 The silicone putty index is seated over the template.

An alginate impression of the prepared abutment teeth is made, and a cast of quick-set plaster is poured. The cast is coated with a layer of MRA, which is part of the resin system. Then some of the Triad resin is placed around the finish lines of the abutment preparations. A strand of resin is laid inside the clear template (Fig 15-43). Enamel resin can be placed in the incisal or occlusal portion of the template first to enhance esthetics.

Firm pressure is used to seat the loaded template on the quick-set plaster cast of the prepared abutments (Fig 15-44). The silicone putty index is compressed over the template to ensure complete seating of the template and an even thickness of resin in the provisional restoration (Fig 15-45). In an alternative technique, the template can be seated into the silicone putty index before the resin is loaded into the template.³⁴ The putty index is removed from the cast, leaving the resin and template in position on the cast.

15 Provisional Restorations

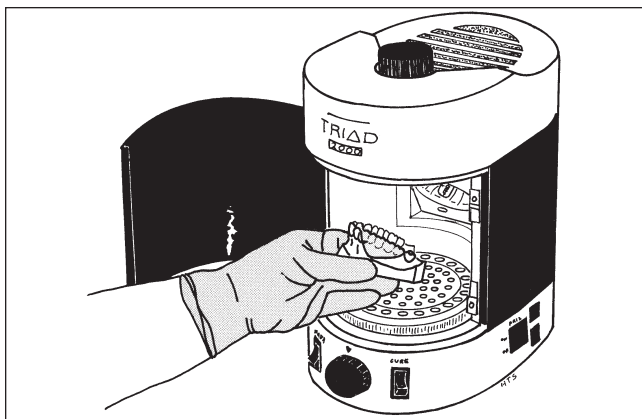


Fig 15-46 The cast with the resin-loaded template is placed in the light-polymerizing unit.

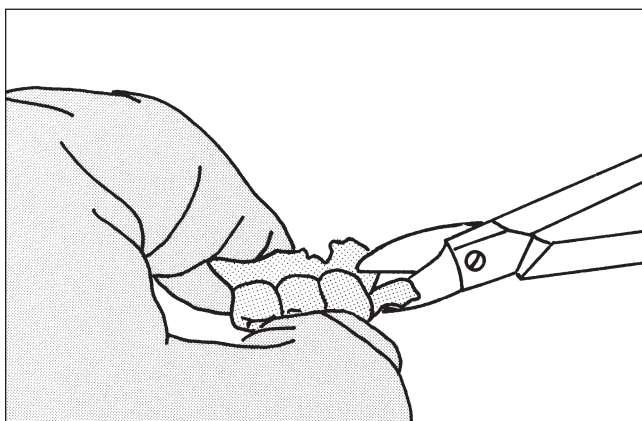


Fig 15-47 Excess resin is cut off with crown and bridge scissors.

The cast is placed in the Triad curing unit to polymerize the resin in the template for 4 minutes (Fig 15-46). The template and then the provisional restoration are carefully removed from the cast. All surfaces of the restoration are painted with ABC material. The provisional restoration is placed back in the curing unit, tissue side up, for an additional 6 minutes. The restoration is retrieved from the curing unit, and all of the ABC is removed with a brush and water.

As much excess material as possible is trimmed with a pair of curved scissors (Fig 15-47). Disks are used to finish trimming the axial surfaces to the margins. Disks and burs are used to open the embrasures around the pontic. The saddle form produced by the template must be removed. The restoration is polished with pumice and a high-shine polishing material (Acrilustre polishing compound).

Another technique has been described in which the restoration is started in a template on the prepared teeth in the mouth.³⁵ Polymerization of the restoration is initiated by a 10-second application of a handheld curing light. After the restoration is partially set in this manner, it is removed from the mouth and further exposed to the high-intensity curing light in the laboratory.

Shell-fabricated provisional restoration

A thin shell crown or fixed partial denture can be made from any of the acrylic resins, and then that shell can be relined indirectly on a quick-set plaster cast. It also can be relined directly in the mouth.^{16,28,36,37} If the reline is done directly, a methacrylate other than polymethyl should be used. This technique can save chair time because the restoration is partially fabricated prior to the preparation appointment.

Care must be taken not to make the shell too thick. If too thick, the shell will not seat completely over the prepared teeth and will need to be trimmed internally. This can be time-consuming and defeats any advantage gained by making it before the preparation appointment.

Armamentarium

- Items in overimpression armamentarium (see page 243)
- Items in cementation armamentarium (see page 247)
- Liquid applicator
- Powder blower

Technique

An overimpression is made from a diagnostic wax-up before the preparation appointment. It should be checked for completeness. Thin flashes of impression material created by the gingival crevice are trimmed off to produce an extra bulk of resin near the margins. A plastic squeeze bottle with a fine tip is used to deposit one drop of monomer on the facial and one drop on the lingual surface of the imprint of each tooth to be restored³⁰ (Fig 15-48). The monomer is kept near the gingival portion of the impression to prevent excess from accumulating in the incisal or occlusal area. The coverage by the resin is extended to one tooth imprint on either side of the teeth being restored.²⁸

An insufflator (DeVilbiss Plastic Powder Blower, DeVilbiss) is used to gently spray enough polymer onto the surface of the impression to absorb the monomer³⁰ (Fig 15-49). The process is repeated four times, with the impression inverted frequently to allow the material to run down to the margins rather than puddling in the incisal or occlusal areas of the impression. The shell is gently removed from the impression after 4 minutes. An abrasive disk is used to trim the flash from the gingival area and open the gingival embrasures (Fig 15-50).

When the teeth have been prepared, a quadrant alginate impression is taken and poured with a thin mix of quick-setting plaster. Excess plaster is trimmed off on a cast trimmer. One tooth on either side of the prepared tooth should be saved if possible. Areas of the cast that duplicate soft tissues should be removed. The cast is examined for nodules that would prevent complete seating.

The shell is tried gently on the cast to make sure it seats completely without binding. If it does bind, the inner surfaces of the shells should be relieved until the restoration seats completely and passively. The tooth preparations on the cast are liberally coated with separating medium, which must be dry before the acrylic resin is mixed.

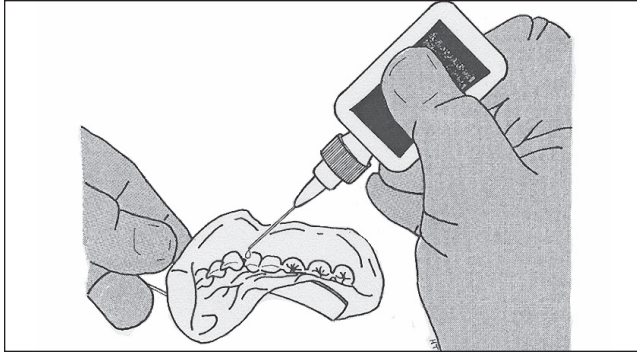


Fig 15-48 Monomer is applied to the overimpression with a needle-tipped liquid applicator.

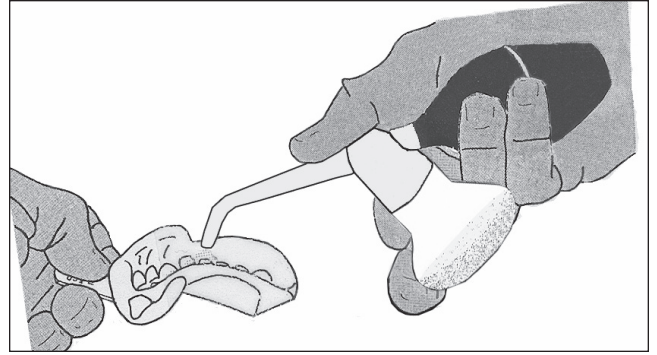


Fig 15-49 Enough polymer is applied to turn the surface of the impression dull.

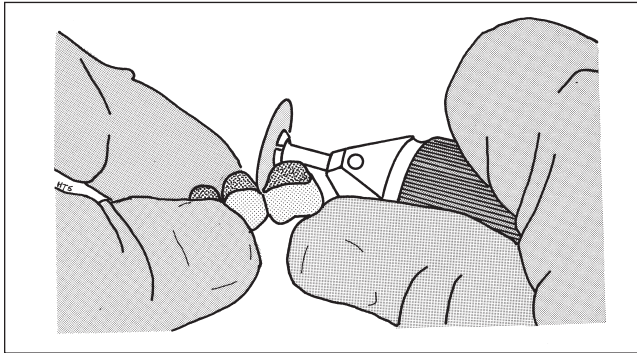


Fig 15-50 A fine sandpaper disk is used to remove gingival flash and open the gingival embrasures.

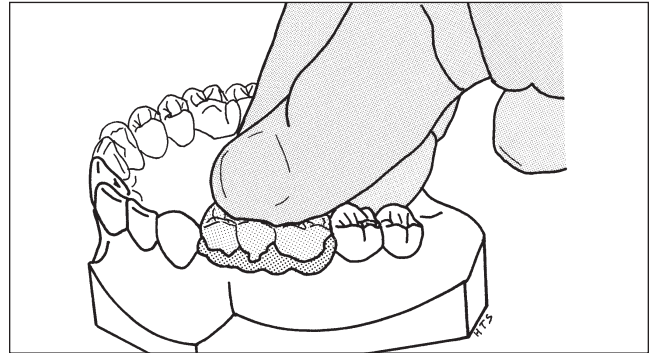


Fig 15-51 The resin-filled shell is seated on the prepared teeth on the cast.

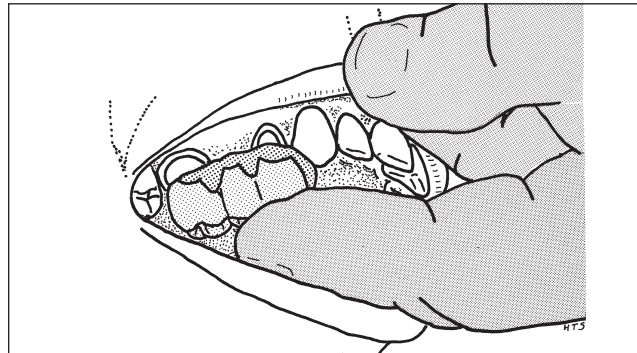


Fig 15-52 The resin-filled shell is seated on the prepared teeth in the mouth.

Monomer and polymer can be added directly to the shell and mixed there. The resin also can be mixed in a dappen dish and then transferred to the shell, completely filling each tooth. The shell is seated onto the prepared teeth on the cast (Fig 15-51). A rubber band is wrapped around the shell and cast, which are placed in a rubber bowl, or preferably in a pressure pot, full of warm tap water for approximately 5 minutes. The use of a pressure pot will significantly increase the strength of the restoration.³²

If the direct technique is employed, the shell is seated on the prepared teeth in the mouth (Fig 15-52). When the resin becomes rubbery, the restoration is elevated 2.0 mm, and the teeth under it are flushed with water.³⁶ The restoration is

pumped up and down several times to eliminate undercuts. The restoration is then removed from the mouth and placed in warm water.

When the resin has polymerized, the rubber band is removed, and the shell is disassembled from the plaster cast. If the restoration resists removal from the plaster cast, the teeth are broken off with a heavy-bladed laboratory knife. A small, pointed instrument is used to remove any plaster left in the provisional restoration. Excess resin is trimmed from the provisional restoration with acrylic burs or coarse Moore disks. The axial surfaces of the restoration are smoothed with a fine sandpaper disk, followed by pumice and polishing compound on a muslin rag wheel.

15 Provisional Restorations

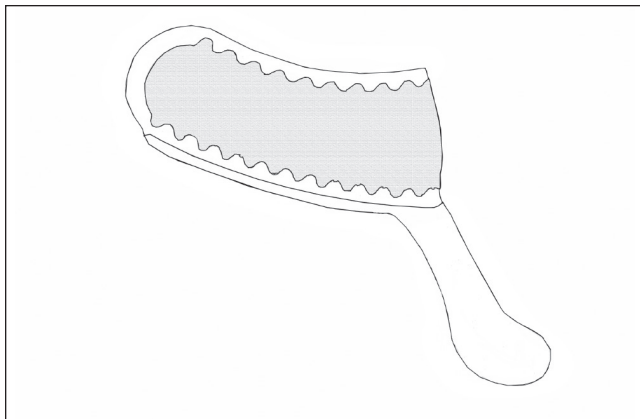


Fig 15-53 Plastic posterior dual-arch tray.

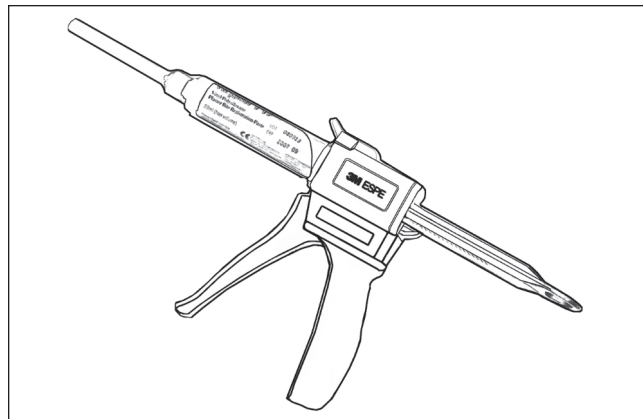


Fig 15-54 Polyvinyl siloxane impression material applicator.

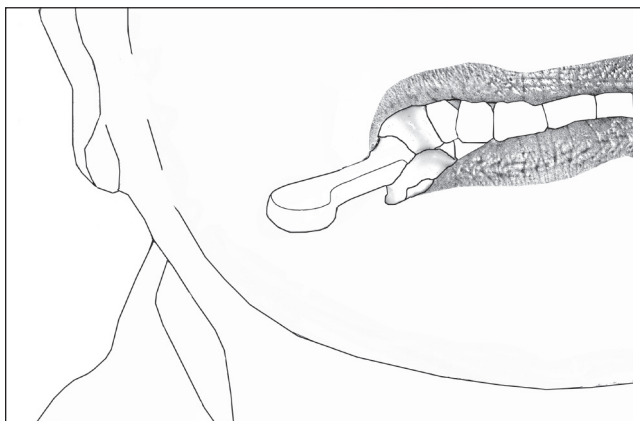


Fig 15-55 Dual-arch tray inserted over tooth to be prepared.

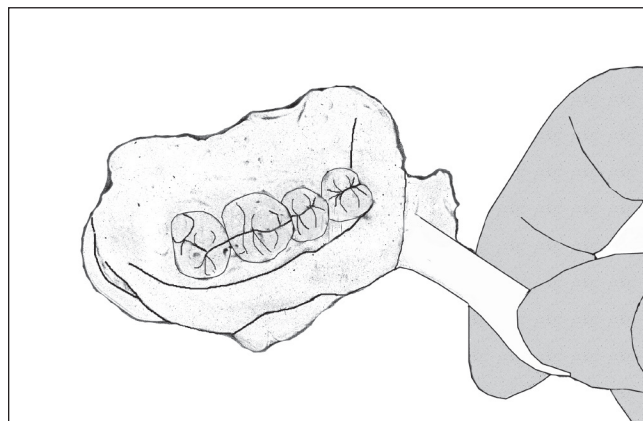


Fig 15-56 Dual-arch impression.

Overimpression-fabricated bis-acryl composite crown

Bis-acryl composite resin (Integrity, Dentsply) can be used to fabricate a provisional restoration on a quick-set plaster cast. Its polymerization produces very little heat, and it has minimal toxic effect on soft tissues and the pulp. It is well suited for use in a direct technique.^{15,38} Its use in making a direct provisional restoration is presented here.

An elastomeric impression material, polyvinyl siloxane (Extrude Extra, Kerr), is used. A heavy-bodied elastomeric material has the advantages of being very stable and difficult to distort. Its disadvantages include greater expense and extra time required for the impression material to polymerize.

A disposable plastic dual-arch impression tray (Fig 15-53) is loaded with impression material (Fig 15-54), and the overimpression is made while the anesthesia is allowed to take effect (Figs 15-55 and 15-56). The excess is trimmed from

the borders of the impression (Fig 15-57) and undercut areas gingival to heights of contour on adjacent teeth (Figs 15-58 and 15-59) to facilitate accurate placement back in the mouth. The webs of material between the imprints of individual teeth in the impression should be removed because these could interfere with complete reseating of the overimpression. The webs from the embrasures directly adjacent to the prepared teeth should be left intact. They help to form the proximal surfaces of the provisional restoration and should also help to avoid trapping the brittle bis-acryl resin in adjacent undercuts.

The margins of a provisional restoration may be thin or deficient because the overimpression was not seated straight or because the thickness required for a resin restoration is greater than that needed for a metal restoration. To avoid this problem, a no. 8 round bur or a no. H379-023 football-shaped carbide bur is used to cut a trough in the gingival area of the facial and lingual surfaces of the tooth imprint(s)

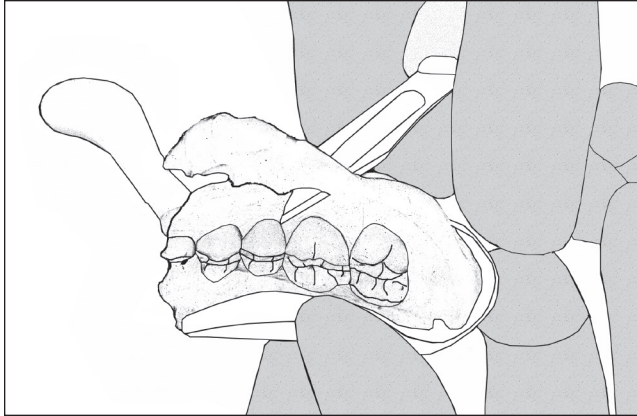


Fig 15-57 Border excess is trimmed with a laboratory knife with a no. 25 blade.




Fig 15-58 Straight- and curved- edge high-speed carbide burs.

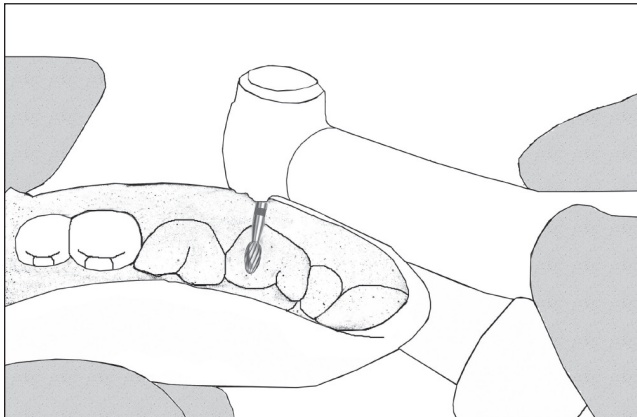


Fig 15-59 Embrasure and cervical material that would impede complete closure is removed.

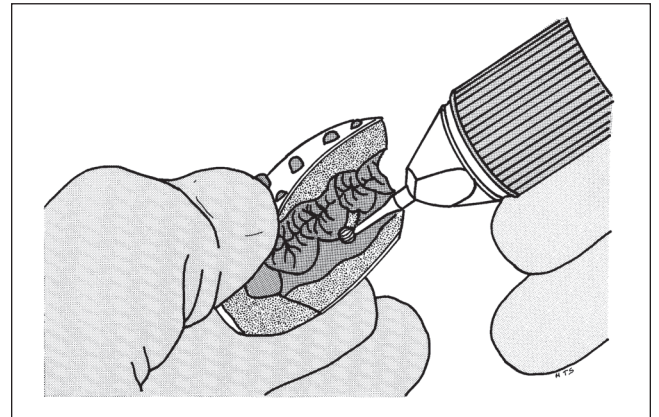


Fig 15-60 A gingival trough is cut with a no. 8 bur in the facial and lingual surfaces of the imprint of the tooth being restored.

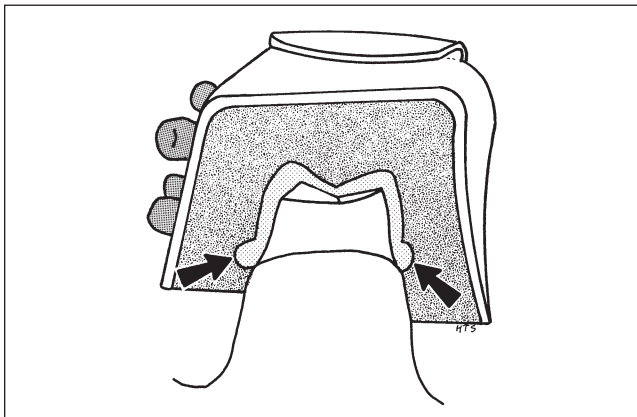


Fig 15-61 A midsagittal section of the overimpression and the provisional restoration shows a bulk of material (arrows) near the margins.

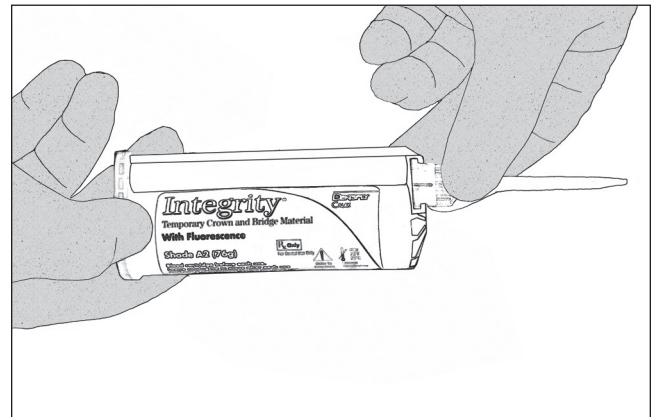

Fig 15-62 Previously used mixing tip with polymerized Integrity is removed.

in which the restoration will be fabricated (Fig 15-60). This will produce a bead of material parallel with the margin of the resulting restoration (Fig 15-61). This ensures adequate material in the margin. The excess can be trimmed off during finishing.

After the tooth preparation has been completed, the provisional restoration is begun by selecting the desired shade for the provisional restoration. There is enough material in each cartridge for multiple uses. The mixing tip that is left in place from a previous use is removed (Fig 15-62). There is a

15 Provisional Restorations

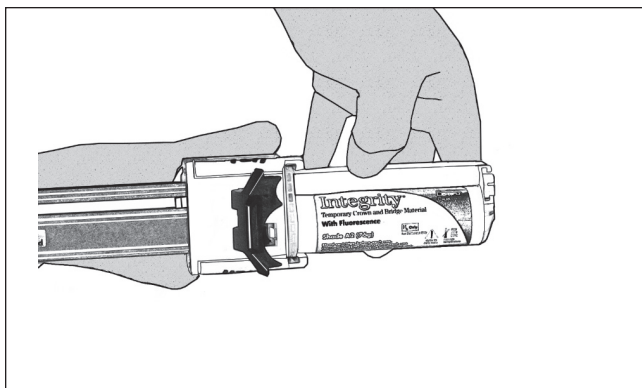


Fig 15-63 The Integrity cartridge is inserted into the dispenser.

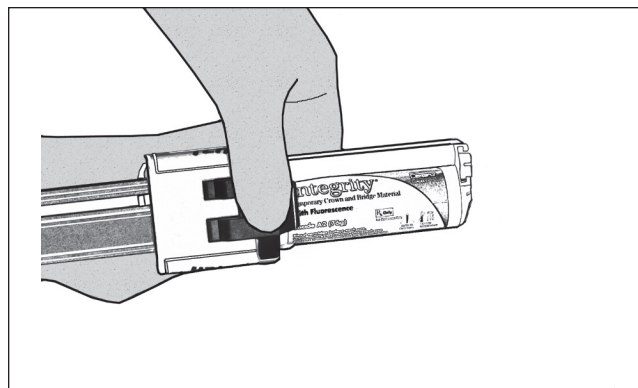


Fig 15-64 The stabilizing clasp is snapped closed.

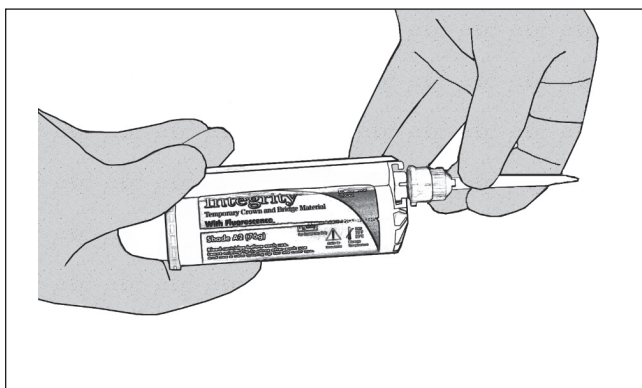


Fig 15-65 A new mixing tip is attached.

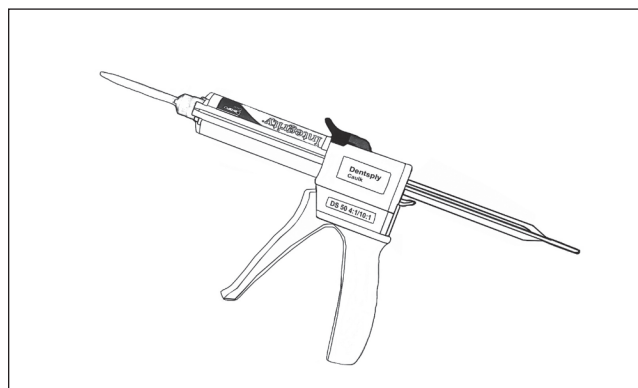


Fig 15-66 Integrity dispenser ready for use.

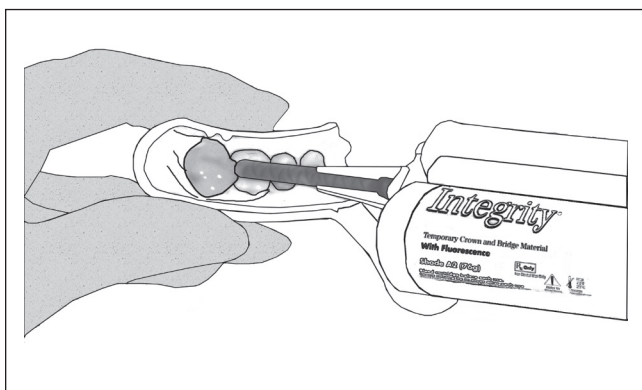


Fig 15-67 Mixed resin is expressed into the imprint of the tooth for which the provisional restoration is being fabricated.

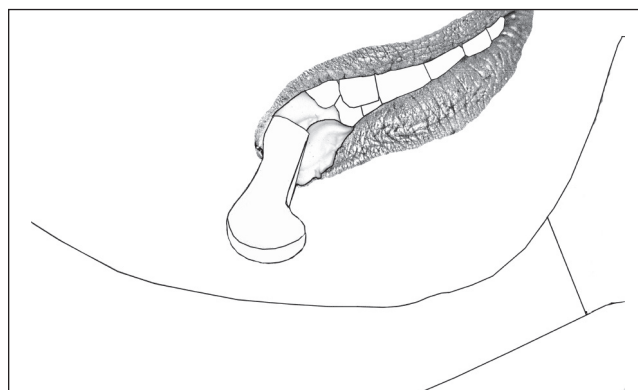


Fig 15-68 The resin-filled tray should be oriented correctly and completely seated.

specific dispenser for Integrity. The cartridge of the selected shade of Integrity should be loaded into the dispenser (Figs 15-63 and 15-64), and a small bead of material should be extruded and discarded to ensure even flow. Then the mixing tip is attached (Fig 15-65), and the dispenser is ready for use (Fig 15-66).

Petrolatum should be thinly applied to the prepared tooth and adjacent teeth before placing the resin if the core or adjacent restorations also consist of resin. Integrity is extruded directly into the overimpression of the prepared tooth

(Fig 15-67), keeping the tip of the mixing tube buried in the resin to fill the cusp tip or incisal edge areas from the bottom up to prevent voids in the completed provisional restoration. Within 45 seconds, the overimpression with the Integrity is inserted into the mouth until it is completely seated (Fig 15-68), and the patient is instructed to bite into the opposing side of the dual-arch tray.

The overimpression is removed from the mouth within 2 minutes from the start of the mix (Fig 15-69). The provisional restoration is removed directly from the tooth or from the

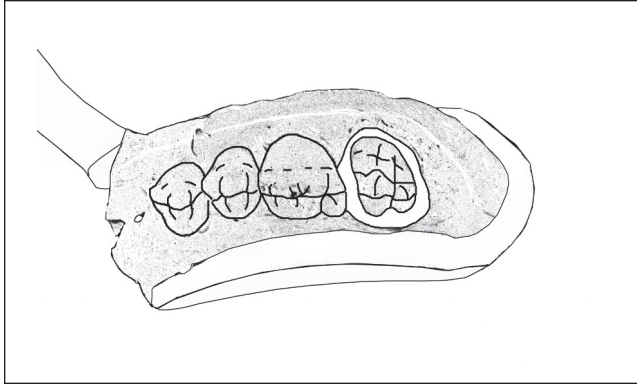


Fig 15-69 The tray is removed, and resin remains in the overimpression tray.

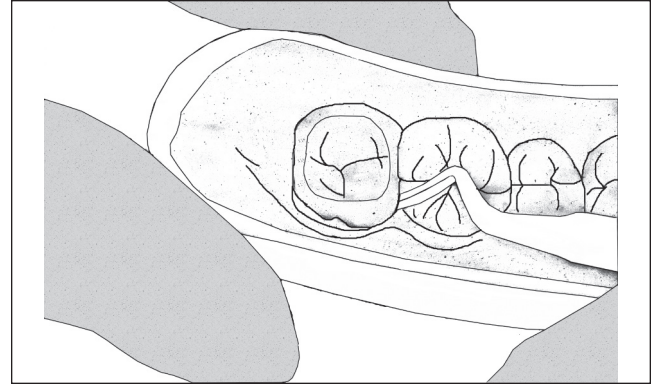


Fig 15-70 The resin provisional restoration is pried from the overimpression.

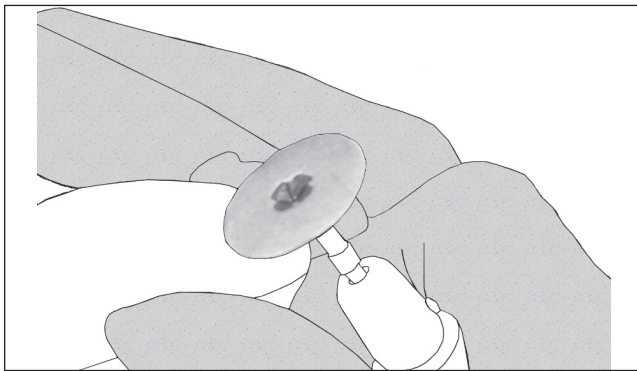


Fig 15-71 A sandpaper disk is used to refine the margins of the provisional restoration.

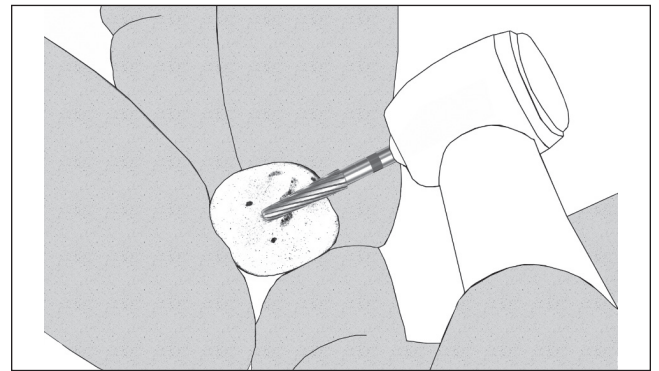


Fig 15-72 Occlusion is marked intraorally and trimmed extraorally with a high-speed carbide bur.

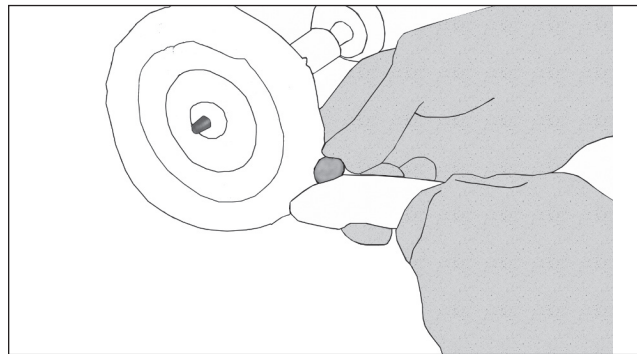


Fig 15-73 Rag wheel polishing.

overimpression (Fig 15-70). The provisional restoration should be allowed to self-cure for 7 minutes from the start of the mix.

A freshly made Integrity provisional restoration with evidence of an air-inhibited surface is amenable to addition of new Integrity to correct flaws. The additional Integrity will cohere. After the loss of that fresh surface, many light-cured flowable composite resins can be used to repair voids or deficient margins and to adjust contour or to customize esthetics. The excess near the margins (including the intentional

bead, if used) is removed, and the restoration is contoured, finished, and polished with disks (Fig 15-71), slow-speed acrylic burs, and/or high-speed finishing carbide burs. The restoration is placed back on the tooth in the mouth. The occlusion is tested and adjusted if necessary (Fig 15-72). By using a dual-arch tray, it is possible to produce a restoration that will require minimal or no adjustment. Pumice and polishing compound can be used (Fig 15-73). The restoration is seated with a temporary cement.

15 Provisional Restorations

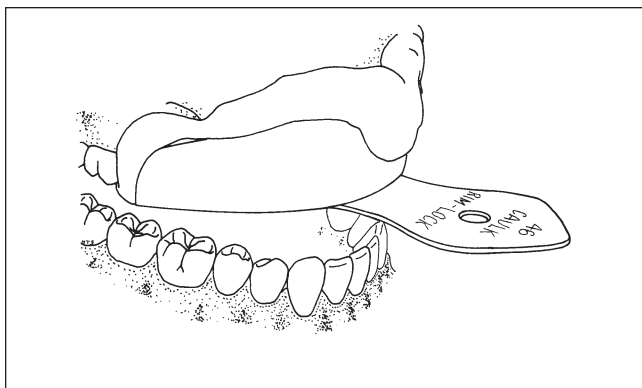


Fig 15-74 An anterior sectional tray is used to make an alginate impression of the prepared tooth.

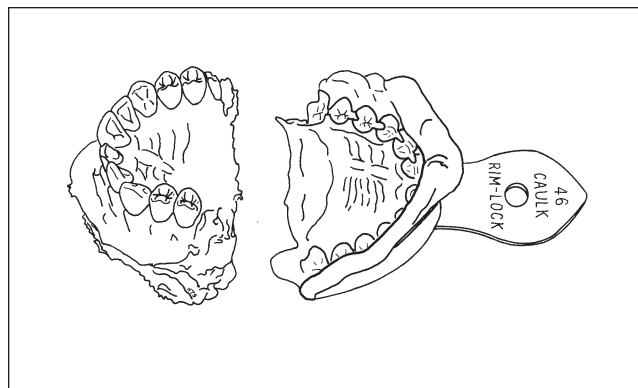


Fig 15-75 Quick-set plaster cast and the impression in which it was made.

Techniques for Prefabricated Provisional Restorations

There are clinical situations in which it may not be possible or desirable to make a custom resin provisional crown. Prefabricated polycarbonate or polymethyl methacrylate crowns are easily adapted to produce esthetic provisional crowns in an expeditious manner on prepared single anterior teeth in most patients.³⁹ A patient may present with an emergency situation in which a posterior tooth has fractured and there is not time available for a definitive tooth preparation and a custom provisional crown. In those cases, a preformed anatomical metal crown form can be employed to protect the tooth and make the patient comfortable until sufficient time can be arranged for completing the treatment.

Anterior polycarbonate crown

A suitable provisional restoration can be made for single anterior teeth through the use of polycarbonate crowns. However, they frequently will require extensive alteration to correct morphologic discrepancies and improper contours.³² If they are not carefully contoured, they will have horizontal overhangs that are damaging to the gingiva.⁵ To accomplish the recontouring that is required and to provide the necessary retention, the tooth-colored crown form must be relined with a resin. This can be accomplished with the greatest accuracy by doing the reline on a quick-set plaster cast of the prepared tooth.

Armamentarium

- Anterior sectional impression tray (one only)
- Alginate
- Rubber bowl
- Spatula

- Quick-set plaster
- Polycarbonate crown kit
- Pencil
- Straight handpiece
- Acrylic bur
- Coarse garnet disk on Moore mandrel
- Dedeco jeweler's wheel on mandrel
- Large camel-hair brush
- Cement spatula
- Dappen dish
- IPPA plastic instrument
- Separating medium
- Monomer and polymer
- Medicine dropper
- Muslin rag wheel
- White polishing compound
- Miller forceps
- Scissors
- Articulating paper
- Paper pad
- Zinc oxide–eugenol cement
- Petrolatum
- Explorer
- Mouth mirror
- Dental floss

Technique

When the tooth preparation has been completed, an alginate impression of the prepared tooth is made using an anterior sextant tray (Fig 15-74). Alginate is applied around the prepared tooth with the tip of the index finger. After the impression has been removed from the mouth, it is poured with a thin mix of fast-setting plaster (mounting plaster, Whip Mix). The cast is separated from the impression as soon as a fingernail cannot score the cast (Fig 15-75).

The mold guide provided with the kit to determine the proper mesiodistal size for the crown form is used (Fig 15-76). The corresponding size of crown is removed from its com-

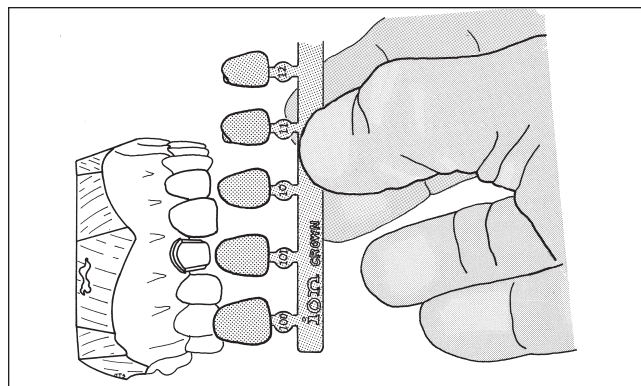


Fig 15-76 The mold guide is held adjacent to the cast to select the correct crown size.

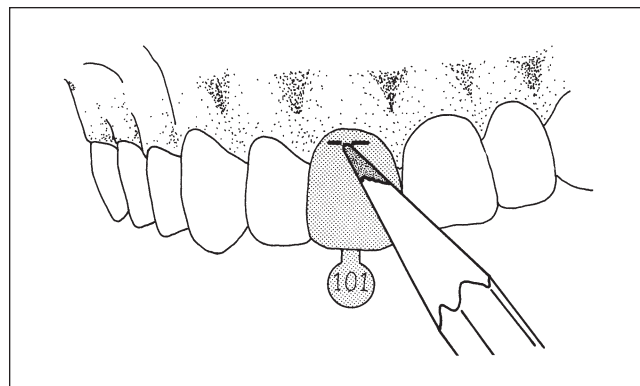


Fig 15-77 With the crown on the preparation, a mark is made at a distance from the gingival margin that is equal to the amount by which the crown exceeds the height of adjacent teeth.

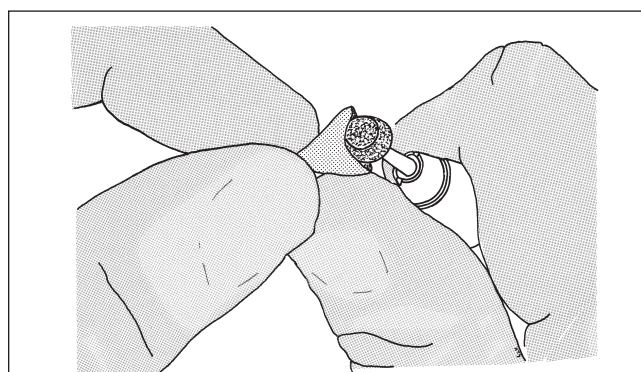


Fig 15-78 Excess gingival length that extends beyond the mark is trimmed.

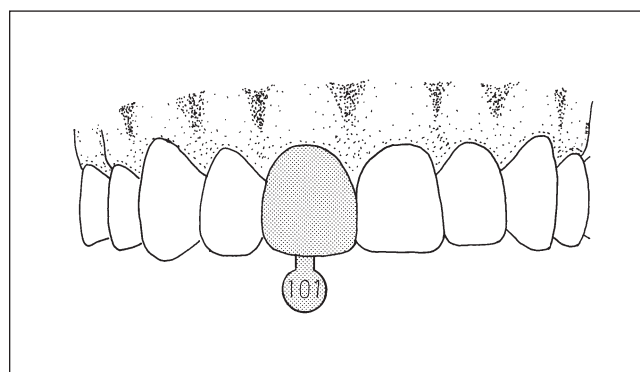


Fig 15-79 Polycarbonate crown after removal of the excess length. The tab is left on at this point to facilitate handling.

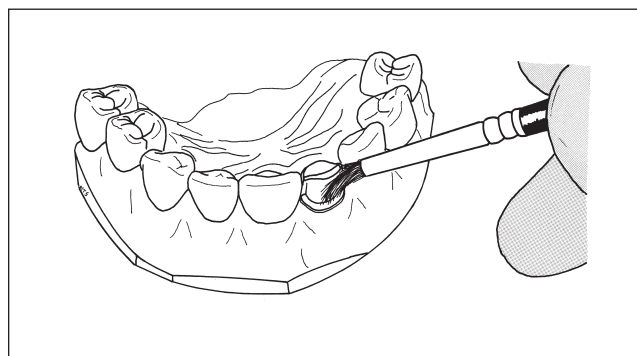


Fig 15-80 The preparation and adjacent portions of the plaster cast are painted with separating medium.

partment in the kit and placed on the prepared tooth on the cast or in the mouth. With a pencil, a mark is made on the gingival portion of the labial surface (Fig 15-77). The distance from the pencil mark to the gingival margin should equal the length discrepancy between the incisal edge of the crown form and the incisal edges of the adjacent teeth.

The excess gingival length is trimmed away with a large carborundum stone or an acrylic bur, using the pencil line as

a reference mark (Fig 15-78). The shortened crown is tried back onto the prepared tooth (Fig 15-79). If it is too tight interproximally, it is adjusted.

The cast of the prepared tooth and the surrounding area are painted with liberal amounts of a tin foil substitute separating medium (Alcote) (Fig 15-80). The drying is accelerated with an air syringe; the cast must be dry before mixing of the resin begins.

15 Provisional Restorations

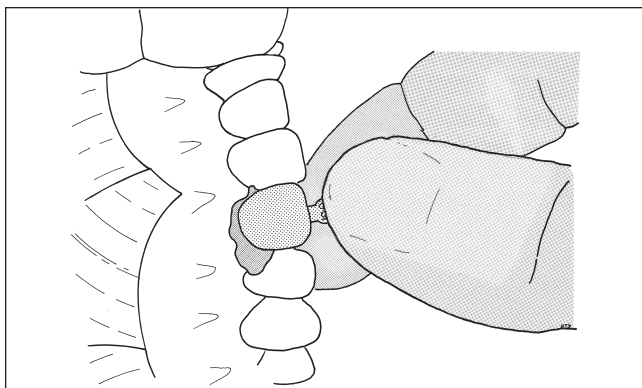


Fig 15-81 The crown filled with resin is placed onto the prepared tooth on the plaster cast.

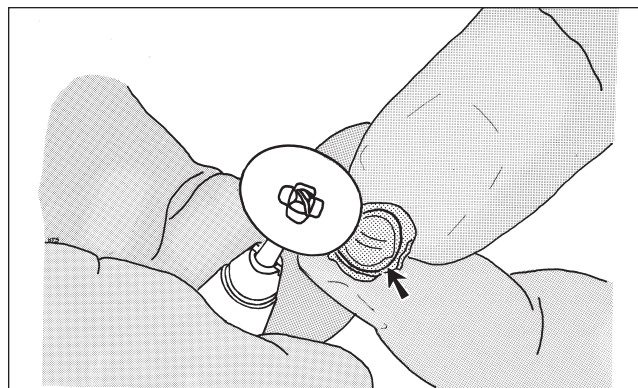


Fig 15-82 Gingival excess created by the expressed acrylic is trimmed back with a garnet disk until the margin coincides with the imprint of the finish line (arrow).

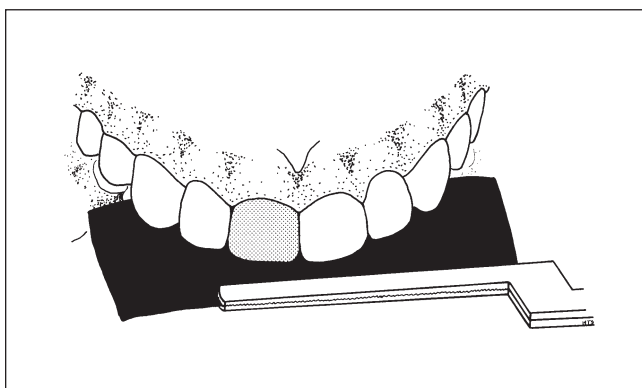


Fig 15-83 Occlusion is checked with articulating paper.

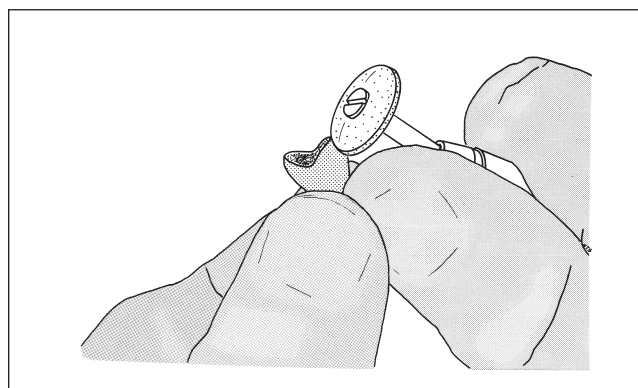


Fig 15-84 Axial surfaces near the margin are smoothed with a Dedeco jeweler's wheel.

Four drops of monomer are placed into a dappen dish, and tooth-colored polymer is added. While polycarbonate crowns are available in only one shade, it is possible to modify that shade somewhat by the shade of acrylic resin used to reline it. The crown form is filled with resin applied with an IPPA plastic instrument. When the acrylic resin just begins to lose its gloss, the crown form is seated on the plaster cast, and all the excess resin is slowly expressed around the margins (Fig 15-81). Once complete seating is confirmed, it is placed in a bowl of warm tap water to accelerate polymerization.

When the resin has polymerized completely, the provisional crown is removed from the cast, which should be broken if necessary. A coarse garnet disk on the straight handpiece is used to trim away the excess at the margins (Fig 15-82). In many cases, this will mean that part of the original polycarbonate crown will be cut into and recontoured. No sharp ledges or abrupt contour changes should be left near the margin. If necessary, the gingival half of the axial contours

should be recontoured. This is the only way to obtain a satisfactory provisional restoration using this technique.

If the tooth is nonvital, or if a resin other than polymethyl methacrylate is used, the crown can be relined on the prepared tooth in the mouth. The preparation is coated with petrolatum, and the crown must be removed before the resin has polymerized to a stiffness that locks it into interproximal undercuts. As much of the rubbery excess as possible is cut off with a pair of curved scissors. The crown is repeatedly resealed and removed until the relining resin has completely polymerized.

The crown is placed on the prepared tooth in the mouth, and the occlusion is checked with articulating paper (Fig 15-83). Any high spots are adjusted with a nondentate bur after the crown is removed from the tooth. The rough abraded areas in the lingual and incisal areas, as well as those surfaces recontoured near the margin, are smoothed out with a Dedeco jeweler's wheel in the straight handpiece (Fig 15-84).

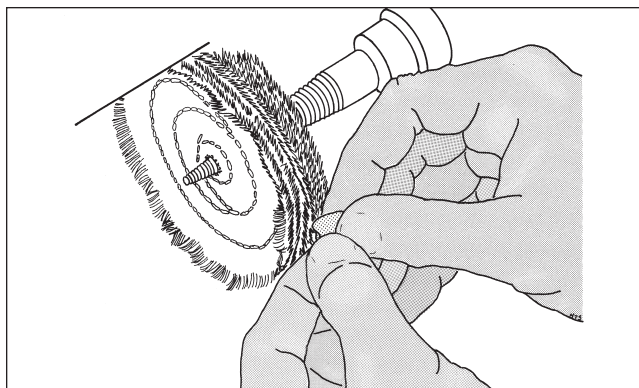


Fig 15-85 Axial surfaces are polished with white polishing compound on a muslin rag wheel.

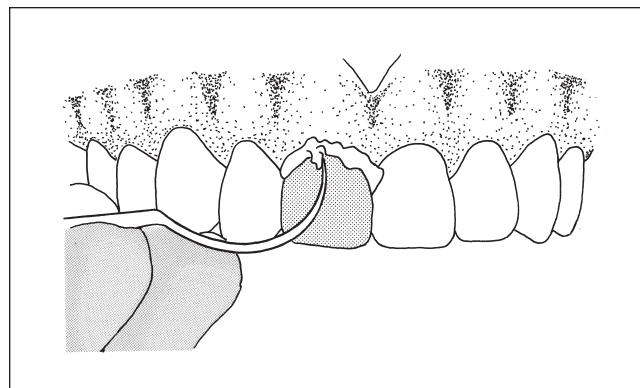


Fig 15-86 All cement is removed from the gingival crevice with an explorer.

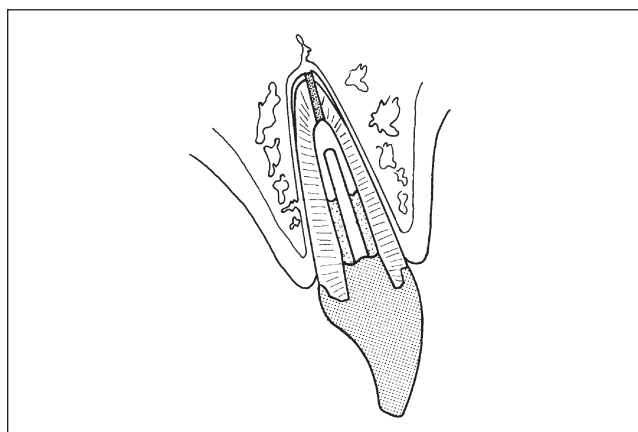


Fig 15-87 A pin is incorporated into a polycarbonate crown for use as a provisional restoration on a tooth prepared for a post and core.

All surfaces of the provisional restoration are polished with polishing compound (Acrilustre) on a muslin rag wheel (Fig 15-85). It is possible to return the crown to its original luster by this means. The outer surface of the crown is coated with petrolatum to prevent the cement from sticking to it. The restoration is cemented with zinc oxide–eugenol cement. An explorer is used to make certain that all cement has been removed from the gingival crevice (Fig 15-86). Knotted dental floss is used interproximally to remove any cement left there.

Provisional crown for an endodontically treated tooth

It is often difficult to fabricate a provisional restoration for a tooth that has been prepared for a post and core because there is so little intact supragingival tooth structure. This can be accommodated for in the use of a standard polycarbonate crown by placing a piece of paper clip or other stiff wire into the canal and placing the resin-filled crown over that^{1,2,5} (Fig 15-87).

Preformed anatomical metal crown

Emergency cases involving fractured molars are one of the best indications for the use of preformed metal crowns. Zinc oxide and eugenol alone will not adhere to the tooth, and there is rarely enough time at the emergency appointment to fabricate a custom acrylic resin provisional crown. By using the preformed anatomical metal crown, it is possible to provide the patient with temporary coverage to protect the fractured tooth and prevent irritation of the tongue and mucosa.

There are several systems available for this purpose, using the same general principles. The procedure consists of:

1. Minimal tooth preparation
2. Measurement and selection of crown
3. Trimming and adaptation of gingival margin
4. Occlusal adjustment
5. Cementation

15 Provisional Restorations

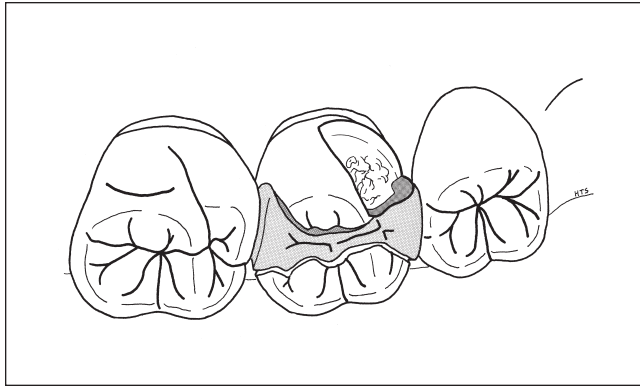


Fig 15-88 Maxillary second molar with a fractured distopalatal cusp.

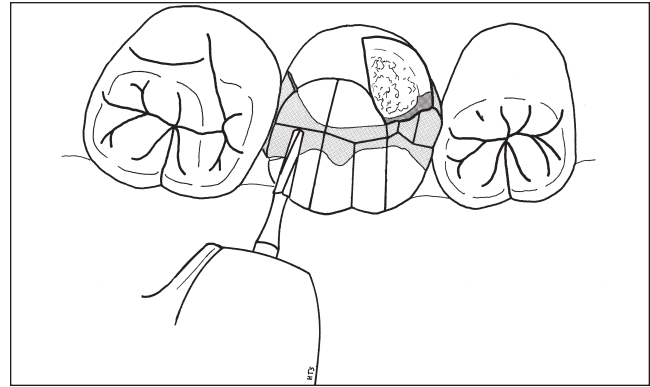


Fig 15-89 Occlusal clearance is obtained with a diamond or no. 170 bur.

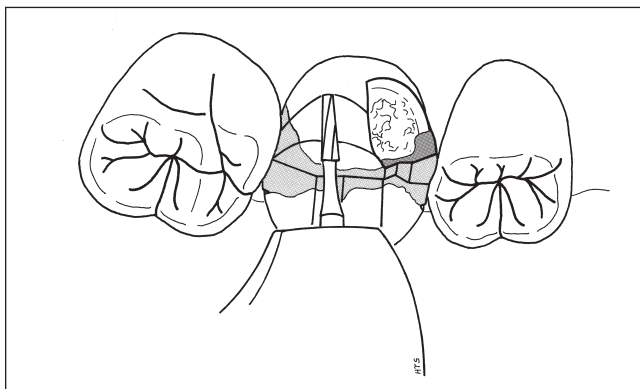


Fig 15-90 A functional cusp bevel is placed with the same instrument.

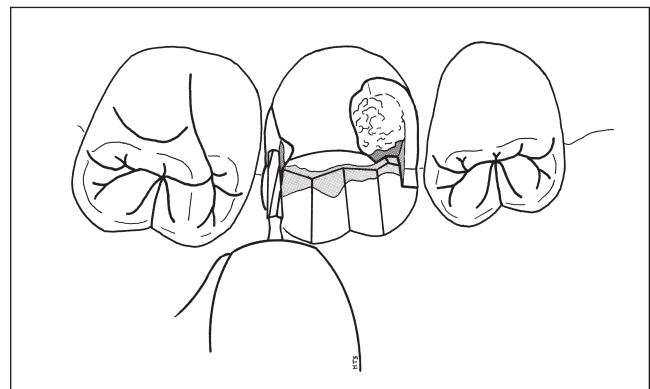


Fig 15-91 Proximal reduction usually consists of removing an existing amalgam restoration.

Armamentarium

- High-speed handpiece
- No. 170L bur
- No. 171L bur
- Measuring gauge
- Crown forms
- Stretching block
- Crown and bridge scissors
- Contouring pliers
- Straight handpiece
- Sandpaper disk on Moore mandrel
- Articulating paper
- Miller forceps
- Cement spatula
- Paper pad
- Zinc oxide–eugenol cement
- Petrolatum
- LL 6-7 curved explorer
- Mouth mirror
- Dental floss

Technique

The maxillary molar with a palatal cusp fractured off is not an uncommon dental emergency (Fig 15-88). It is most easily protected on a short-term basis with a preformed metal crown (Iso-Form temporary crown, 3M ESPE).

The tooth must be prepared minimally to create space for the restoration. The initial step is occlusal reduction, which follows the inclined planes of the occlusal surface (Fig 15-89). The depth will be 1.0 mm on the nonfunctional cusps and 1.5 mm on the functional cusps. A functional cusp bevel (on the palatal incline of the maxillary palatal cusp) is placed to a depth of 1.5 mm to complete the occlusal reduction (Fig 15-90).

Only enough proximal reduction to permit the seating of the crown is done. If a mesio-occlusodistal amalgam restoration is present in the tooth, the proximal reduction is most easily accomplished by removing the amalgam in the boxes (Fig 15-91). The boxes are cut with a no. 170L or 171L bur. All caries is removed at this time. No effort is made to remove all of the existing restoration or to provide permanent bases or a completed preparation.

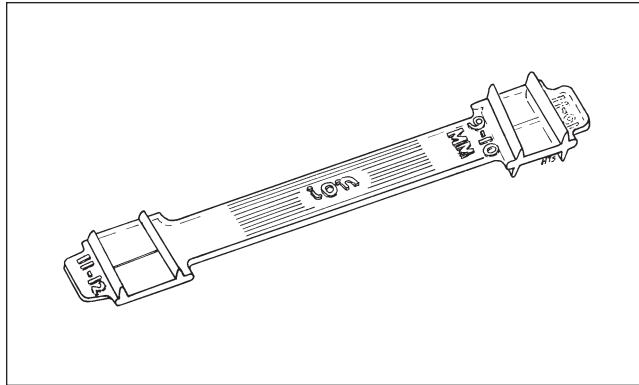


Fig 15-92 Measuring gauge for selecting a preformed metal crown.

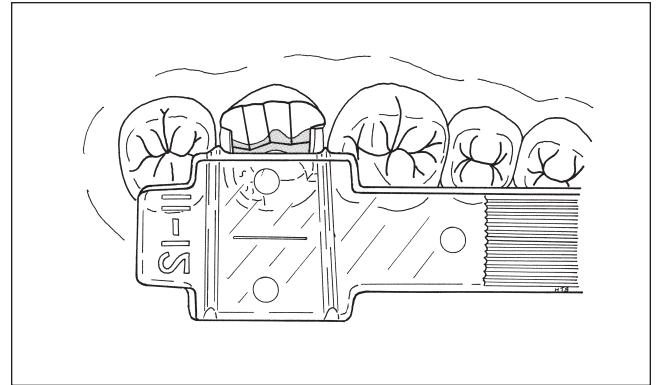


Fig 15-93 Mesiodistal measurement of the space is obtained.

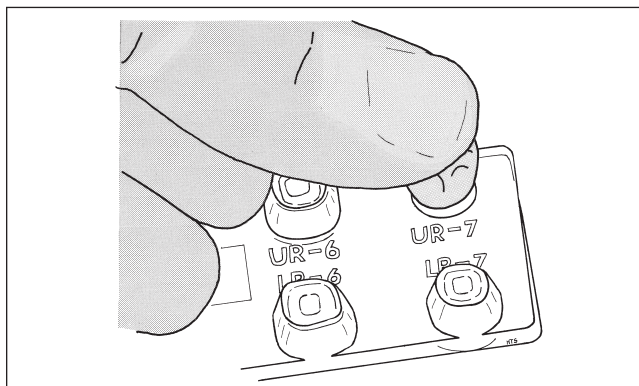


Fig 15-94 Gingival margins can be flared slightly on the stretching block.

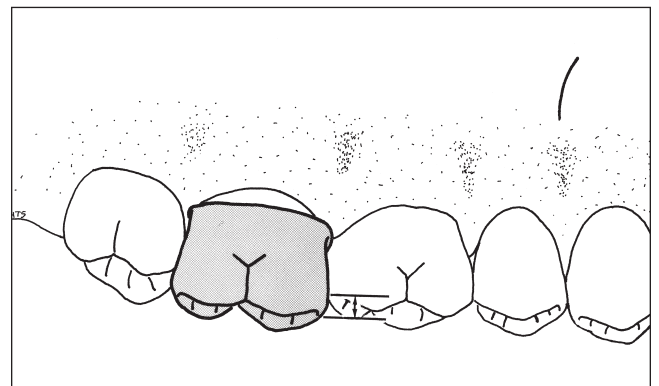


Fig 15-95 The marginal ridge height discrepancy between the restoration and the adjacent tooth is estimated.

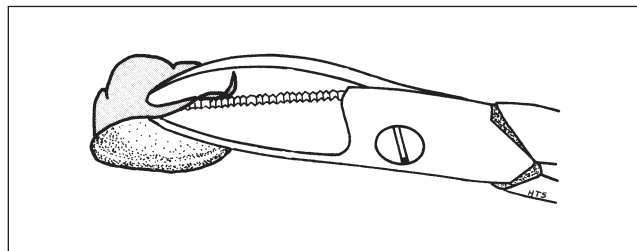


Fig 15-96 Estimated excess height is removed from the gingival margin.

Each of the three measuring heads in the metal crown form kit has converging blades that measure a 1.0-mm range: 9 to 10, 10 to 11, and 11 to 12 mm (Fig 15-92). The gauge is held in line with the contact points and rested on the occlusal surfaces of the other teeth in the arch. The blades are slid until they wedge between the contacts of the teeth on either side of the preparation (Fig 15-93). The point at which the blades wedge indicates the dimension to be used for selection of the proper crown form.

The crown is tried on the tooth. If the gingival collar is too tight, the crown is placed on the appropriate post of the stretching block (Fig 15-94). There is a tapered post cor-

responding to each of the maxillary and mandibular molars, left and right. Flaring the margins is also required when there is a shoulder finish line. The crown is pushed down on the post until an adequate amount of gingival flare is obtained.

The crown is placed on the tooth to evaluate its occluso-gingival length. The height of each marginal ridge of the crown is compared with that of the adjacent tooth (Fig 15-95). Crown and bridge scissors are used to remove an amount at the gingival margin equal to the marginal ridge height discrepancy (Fig 15-96). The margin is festooned to follow the contours of the gingival tissue.

15 Provisional Restorations

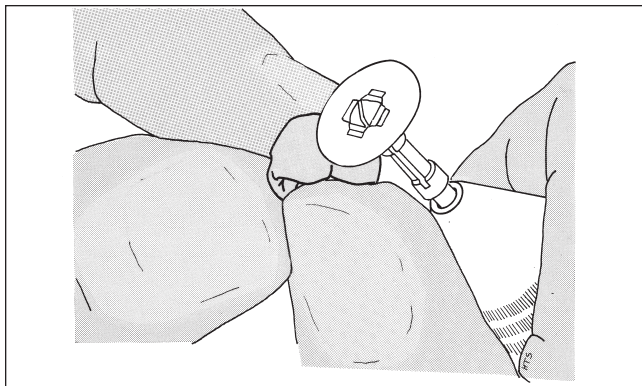


Fig 15-97 The gingival margin is smoothed.

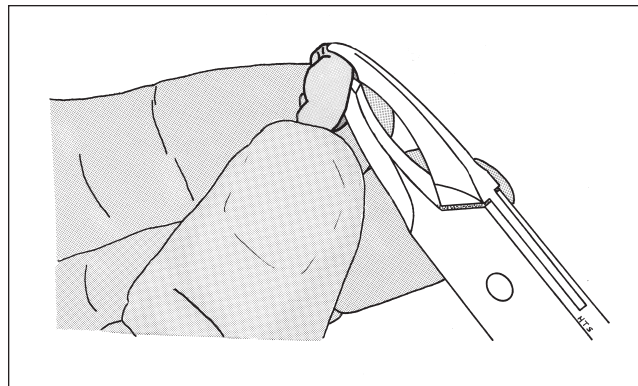


Fig 15-98 Axial surfaces are contoured with pliers.

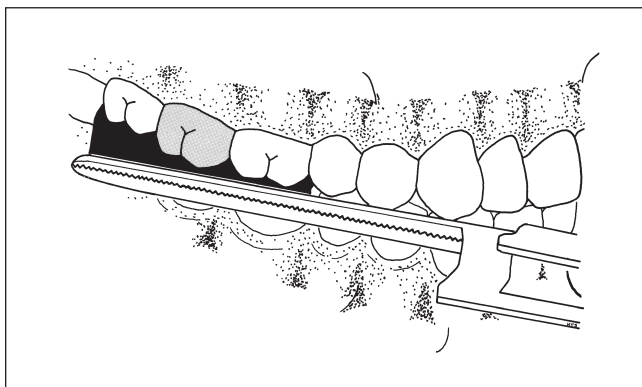


Fig 15-99 Occlusion is checked with articulating paper.

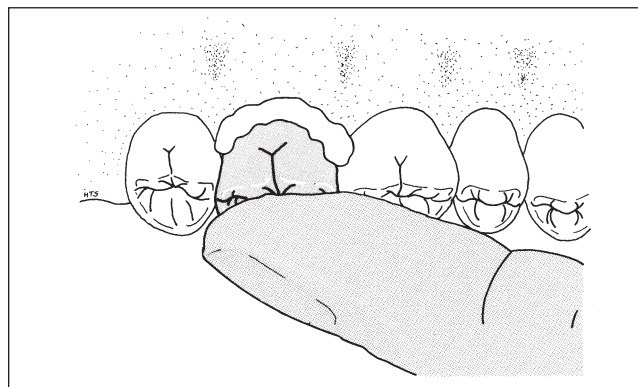


Fig 15-100 Crown filled with zinc oxide–eugenol cement is seated.

Rough spots and any irregularities in the gingival margin are smoothed with a sandpaper disk (Fig 15-97). A no. 114 contouring pliers is used to produce a slightly convex contour occlusal to the margins (Fig 15-98). The margin will be slightly constricted as a result.

The crown is placed on the tooth, and the occlusion is checked with articulating paper (Fig 15-99). The crown is removed, and areas on the occlusal surface that are in hy-

perocclusion are burnished. Open proximal contacts can be corrected by burnishing the proximal area from the inside of the crown.

The outside of the crown is coated with petrolatum to facilitate the removal of excess cement later. Zinc oxide and eugenol are mixed to a thick, creamy consistency on a paper pad. The crown is filled with the cement and seated on the prepared tooth with finger pressure (Fig 15-100).

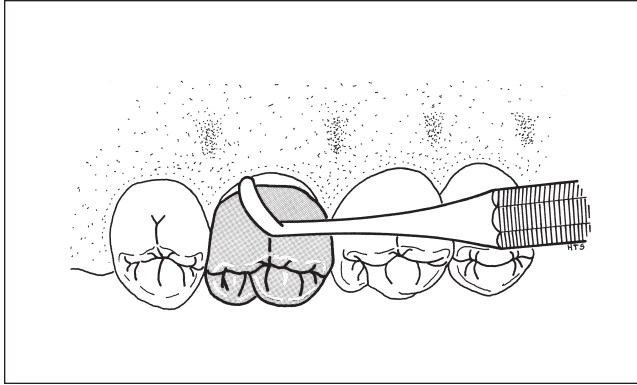


Fig 15-101 The margin is burnished.

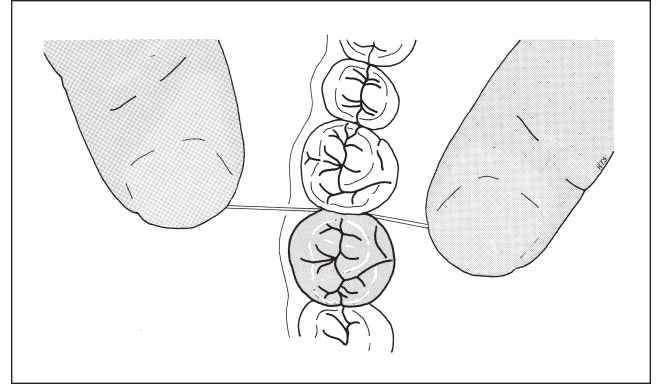


Fig 15-102 Excess cement is removed from the interproximal region with dental floss.

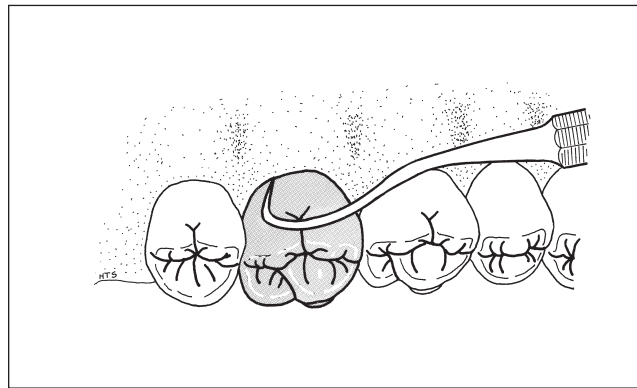


Fig 15-103 All cement remaining in the crevice must be removed with an explorer.

The margins of the crown are burnished with an LL 6-7 curved burnisher before the cement hardens (Fig 15-101). Dental floss is run through the proximal contacts to remove hardened cement from the interproximal areas (Fig 15-102).

An explorer is used to remove all remaining subgingival cement (Fig 15-103). A final check of the margins should be made to ensure that they are not impinging on the gingiva.

15 Provisional Restorations

References

- Mumford JM, Ferguson HW. Temporary restorations and dressings. *Dent Pract Dent Rec* 1959;9:121–124.
- Segat L. Protection of prepared abutments between appointments in crown and bridge prosthodontics. *J Mich Dent Assoc* 1962;44:32–35.
- Knight RM. Temporary restorations in restorative dentistry. *J Tenn State Dent Assoc* 1967;47:346–349.
- Rose HP. A simplified technique for temporary crowns. *Dent Dig* 1967;73:449–450.
- Behrend DA. Temporary protective restorations in crown and bridge work. *Aust Dent J* 1967;12:411–416.
- Fisher DW, Shillingburg HT Jr, Dewhirst RB. Indirect temporary restorations. *J Am Dent Assoc* 1971;82:160–163.
- Anusavice KJ, Phillips RW. *Phillips' Science of Dental Materials*, ed 11. St Louis: Saunders, 2003:166.
- Lui JL, Setcos JC, Phillips RW. Temporary restorations: A review. *Oper Dent* 1986;11:103–110.
- Lockard MW, Wackerly J. Excellence in dentistry: Acrylic provisional crowns. *Dent Manage* 1987;27(11):60–62.
- Crispin BJ, Watson JF, Caputo AA. The marginal accuracy of treatment restorations: A comparative analysis. *J Prosthet Dent* 1980;44:283–290.
- Monday JJ, Blais D. Marginal adaptation of provisional acrylic resin crowns. *J Prosthet Dent* 1985;54:194–197.
- Grossman LI. Pulp reaction to the insertion of self-curing acrylic resin filling materials. *J Am Dent Assoc* 1953;46:265–269.
- Kramer IRH, McLean JW. Response of the human pulp to self-polymerizing acrylic restorations. *Br Dent J* 1952;92:255–261,281–297,311–315.
- Langeland K, Langeland LK. Pulp reactions to crown preparation, impression, temporary crown fixation, and permanent cementation. *J Prosthet Dent* 1965;5:129–143.
- Young HM, Smith CT, Morton D. Comparative in vitro evaluation of two provisional restorative materials. *J Prosthet Dent* 2001;85:129–132.
- Vahidi F. The provisional restoration. *Dent Clin North Am* 1987;31:363–381.
- Driscoll CF, Woolsey G, Ferguson WM. Comparison of exothermic release during polymerization of four materials used to fabricate interim restorations. *J Prosthet Dent* 1991;65:504–506.
- Moulding MB, Teplitsky PE. Intrapulpal temperature during direct fabrication of provisional restorations. *Int J Prosthodont* 1990;3:299–304.
- Gegauff AG, Pryor HG. Fracture toughness of provisional resins for fixed prosthodontics. *J Prosthet Dent* 1987;58:23–29.
- Nejatidanesh F, Momeni G, Savabi O. Flexural strength of interim resin materials for fixed prosthodontics. *J Prosthodont* 2009;18:507–511.
- Balkenhol M, Köhler H, Orbach K, Wöstmann B. Fracture toughness of cross-linked and non-cross-linked temporary crown and fixed partial denture materials. *Dent Mater* 2009;25:917–928.
- Freese AS. Impressions for temporary acrylic resin jacket crowns. *J Prosthet Dent* 1957;7:99–101.
- Leary JM, Aquilino SA. A method to develop provisional restorations. *Quintessence Dent Technol* 1987;11:191–192.
- Leff A. An improved temporary acrylic fixed bridge. *J Prosthet Dent* 1953;3:245–249.
- Fiasconaro JE, Sherman H. Vacuum-formed prostheses. I. A temporary fixed bridge or splint. *J Am Dent Assoc* 1968;76:74–78.
- Sotera AJ. A direct technique for fabricating acrylic resin temporary crowns using the Omnivac. *J Prosthet Dent* 1973;29:577–580.
- Preston JD. Ceramometal restorations and fixed prosthodontic esthetics. Presented at the University of Oklahoma College of Dentistry, Oklahoma City, 12 Sept 1975.
- Ferencz JL. Fabrication of provisional crowns and fixed partial dentures utilizing a "shell" technique. *N Y J Dent* 1981;51:201–206.
- Elledge DA, Hart JK, Schorr BL. A provisional restoration technique for laminate veneer preparations. *J Prosthet Dent* 1989;62:139–142.
- Elledge DA, Schorr BL. A provisional and new crown to fit into a clasp of an existing removable partial denture. *J Prosthet Dent* 1990;63:541–544.
- Fritts KW, Thayer KE. Fabrication of temporary crowns and fixed partial dentures. *J Prosthet Dent* 1973;30:151–155.
- Donovan TE, Hurst RG, Campagni WV. Physical properties of acrylic resin polymerized by four different techniques. *J Prosthet Dent* 1985;54:522–524.
- Crispin BJ, Caputo AA. Color stability of temporary restorative materials. *J Prosthet Dent* 1979;42:27–33.
- Haddix JE. A technique for visible light-cured provisional restorations. *J Prosthet Dent* 1988;59:512–514.
- Goldfogel M. Direct technique for the fabrication of a visible light-curing resin provisional restoration. *Quintessence Int* 1990;21:699–703.
- Yuodelis RA, Faucher R. Provisional restorations: An integrated approach to periodontics and restorative dentistry. *Dent Clin North Am* 1980;24:285–303.
- Chiche GJ, Avila R. Fabrication of a preformed shell for a provisional fixed partial denture. *Quintessence Dent Technol* 1986;10:579–581.
- Givens EJ Jr, Neiva G, Yaman P, Dennison JB. Marginal adaptation and color stability of four provisional materials. *J Prosthodont* 2008;17:97–101.
- Nayyar A, Edwards WS. Fabrication of a single anterior intermediate restoration. *J Prosthet Dent* 1978;39:574–577.

Fluid Control and Soft Tissue Management

16

Complete control of the environment of the operative site is essential during restorative dental procedures. For the patient's comfort and safety and for the operator's access and clear visibility, saliva, as well as water introduced during instrumentation, must be removed from the mouth.

Control of the oral environment extends to the gingiva surrounding the teeth being restored. The gingiva must be displaced to make a complete impression and sometimes even to permit completion of the preparation and cementation of the restoration. Occasionally it is necessary to permanently alter the contours of the gingival tissues around the teeth or of the edentulous ridge to ensure a better, longer-lasting result for the fixed restoration.

Fluid Control

The need for removal of fluids varies depending on the task being performed. During the preparation of teeth, it is necessary to remove large volumes of water produced by handpiece spray and to control the tongue to prevent accidental injury. When an impression is made or a restoration is cemented, there is a much smaller volume of fluid to be removed, but a much greater degree of dryness is required. Several types of attachments can be used with low-volume (saliva ejector) or high-volume vacuum outlets to remove fluids (Fig 16-1). Some combine the functions of fluid removal with isolation.

Rubber dam

Rubber dam is the most effective of all isolation devices used in restorative dentistry. Its use is valuable in the removal of old restorations or excavation of caries when exposure of the pulp is a possibility. It also provides excellent isolation and access when a pin-retained amalgam or composite resin core is required before a cast restoration can be fabricated. Teeth with old or questionable endodontic treatments should be isolated in this manner for post and core preparation, pattern fabrication, and cementation.

If the premise is accepted that rubber dam is meant to be an instrument of convenience, it has only limited direct ap-

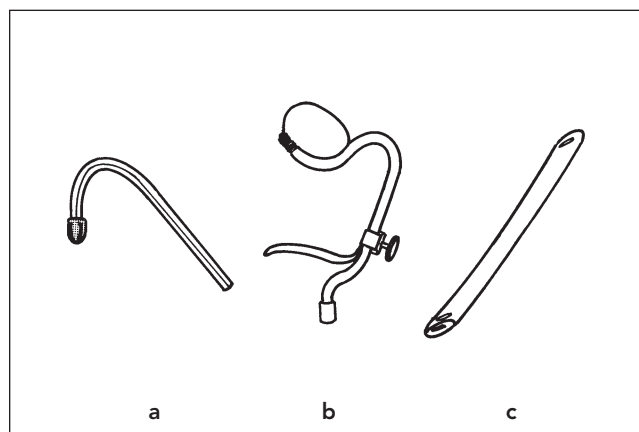


Fig 16-1 Three commonly used vacuum attachments: (a) saliva ejector; (b) Svedopter; and (c) vacuum tip.

plication in the area of cast restorations. It can be used during tooth preparation for inlays and onlays (if the occlusal reduction is done before dam is placed), and it can be readily used for making impressions and cementing the same types of restorations. When used with elastomeric impression materials, the dam must be lubricated, and the clamp must be removed or avoided. It should not be used with polyvinyl siloxane impression material because rubber dam will inhibit its polymerization.¹

The occlusion must be adjusted on onlays before the actual cementation. Some would argue that rubber dam can be used for preparation, impression, and cementation of all cast restorations. However, it is likely to produce more aggravation than assistance for the majority of dentists when its use is attempted with most full or partial coverage crowns.

High-volume vacuum

A high-volume suction tip is extremely useful during the preparation phase and is most effectively used with an assistant. When wielded by a knowledgeable assistant, it makes

16 Fluid Control and Soft Tissue Management

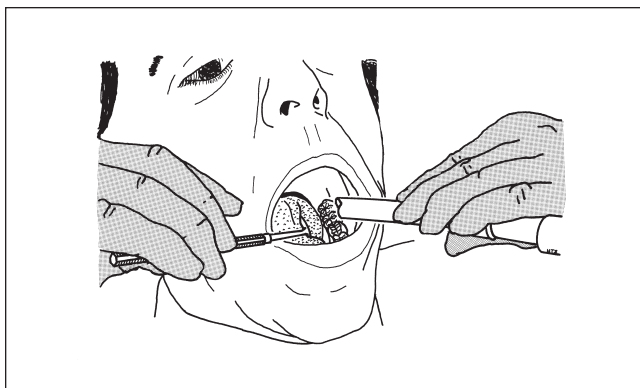


Fig 16-2 The vacuum tip can double as a cheek or tongue retractor.

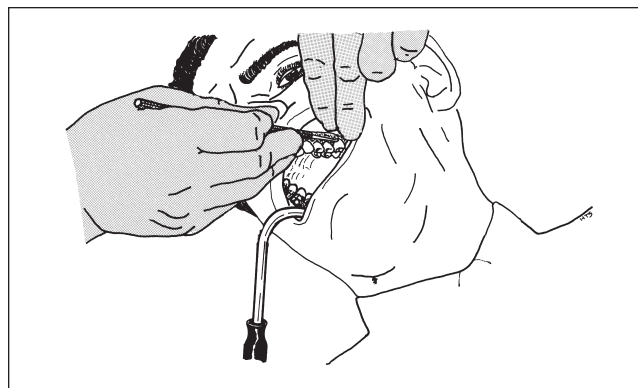


Fig 16-3 The saliva ejector can be used for evacuation when the maxillary arch is being treated.

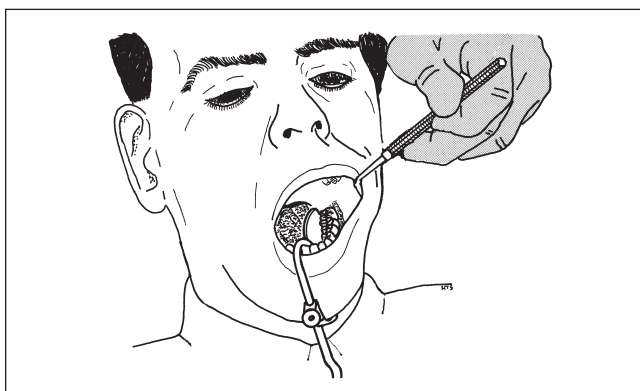


Fig 16-4 The Svedopter can be used on the mandibular arch during the preparation phase.

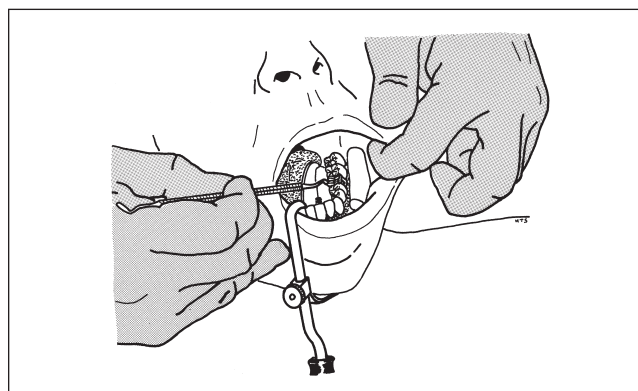


Fig 16-5 With cotton rolls, the Svedopter provides excellent isolation of a mandibular quadrant during the impression phase.

an excellent lip retractor while the operator uses a mirror to retract and protect the tongue (Fig 16-2). Its use is not practical during the impression or cementation phases.

Saliva ejector

The simple saliva ejector can be used effectively in some situations by the dentist working without an assistant. It is most useful as an adjunct to high-volume evacuation, but it can be used alone for the maxillary arch. The saliva ejector is placed in the corner of the mouth opposite the quadrant being treated, and the patient's head is turned toward it (Fig 16-3). It can also be used very effectively on the maxillary arch for impressions and cementation simply by adding cotton rolls in the vestibule facial to the teeth being isolated. It can be used on the mandibular arch while a cotton roll holder positions cotton rolls facial and lingual to the teeth. However, tongue control and fluid removal in this application may be less than ideal.

Svedopter

For isolation and evacuation of the mandibular teeth, the metal saliva ejector with attached tongue deflector is excellent. It can be used without cotton rolls during the preparation phase, with a mouth mirror as a lip retractor (Fig 16-4). By adding facial and lingual cotton rolls, excellent tongue control and isolation is provided for impression taking or cementation (Fig 16-5).

The Svedopter is most effective when it is used with the patient in a nearly upright position. In this position, water and other fluids collect on the floor of the mouth, where they are pulled off by the vacuum (Fig 16-6). If the patient is in a supine position, the throat and back of the mouth must fill with fluid before it reaches the level of the evacuation device.

Although this is an excellent device for the operator with no or only intermittent chairside assistance, it is not without its drawbacks. Access to the lingual surfaces of the mandibular teeth is limited. Because the device is made of metal,

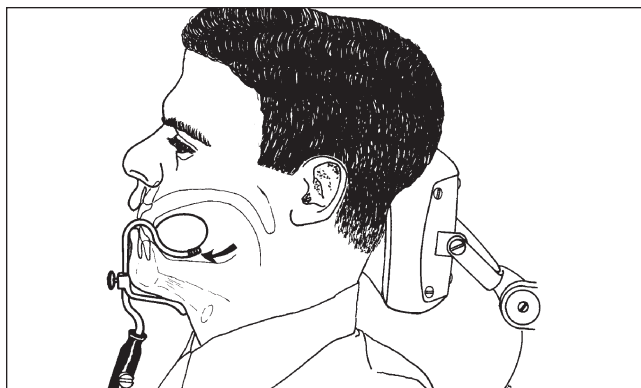


Fig 16-6 If the patient's head is upright, fluids collect on the floor of the mouth, where they are easily picked up by the Svedopter (arrow).

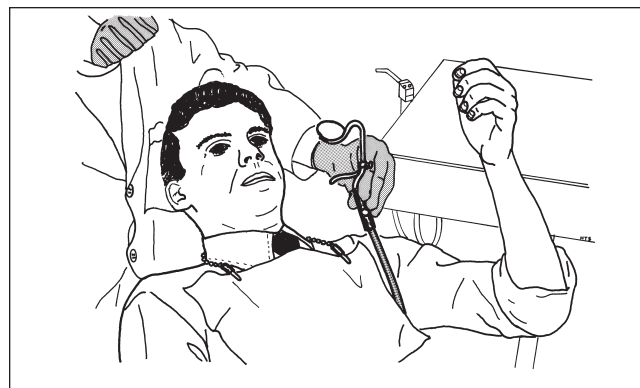


Fig 16-7 The tubing for the Svedopter is placed under the patient's arm to prevent any jerking on the attachment while it is in the mouth.

care must be exercised to avoid bruising the tender tissue in the floor of the mouth by overzealously cinching down the clamp that fits under the chin. The presence of mandibular tori usually precludes its use. Selection of an oversized reflector should be avoided because it could cut into the palate above or trigger the gag reflex. The medium size seems to work best in most mouths.

For better positioning, the anterior part of the Svedopter should be placed in the incisor region, with the tubing under the patient's arm (Fig 16-7). This provides the security of having the tubing firmly under the patient's control. This is especially important if the saliva ejector tubing originates from a movable assistant's cart, a common design feature of many dental units.

Antisialagogues

There are some patients for whom no mechanical device is effective in producing a sufficiently dry field for impression taking or cementation. For the patient who salivates excessively, some other measure may be necessary. There are no drugs that have the specific purpose of decreasing salivary flow to facilitate dental impressions (Britton ML, personal communication, 2009). However, glycopyrrolate, a synthetic anticholinergic medication, is used in its injectable form (Robinul, Baxter) to reduce salivary secretions before surgery.² Glycopyrrolate in its oral form (Robinul, Shionogi Pharma) is indicated for adjunctive treatment of peptic ulcers.³ However, dry mouth is a side effect,³ and this side effect may be utilized with care. As with any medication that is not routinely used in dentistry, it is prudent to consult your patient's physician before using the medication for an "off-label" purpose.

A 1-mg tablet of Robinul, taken 30 minutes before the impression (its half-life is reported to be 0.6 to 1.2 hours)^{4,5} may

be considered. If experience proves that this is inadequate, a 2-mg tablet (Robinul Forte, Shionogi Pharma) is available.

This medication may produce drowsiness and blurred vision, so a designated driver should accompany the patient (its duration of action is reported to be up to 7 hours).⁴ There is a risk of heat prostration if the patient is exposed to high ambient temperatures. Caution should be exercised in the elderly and in patients with autonomic neuropathy, hepatic/renal disease, ulcerative colitis, hyperthyroidism, coronary heart disease, congestive heart failure, tachyarrhythmias, tachycardia, hypertension, prostatic hypertrophy, and hiatal hernia associated with reflux esophagitis.³

Absolute contraindications include hypersensitivity or allergy to glycopyrrolate, glaucoma, obstructive uropathy, obstructive disease of the gastrointestinal tract, paralytic ileus, intestinal atony of the elderly or debilitated patient, unstable cardiovascular status in acute hemorrhage, severe ulcerative colitis, toxic megacolon complicating ulcerative colitis, and myasthenia gravis.³ According to the manufacturer, the safe use of glycopyrrolate for pregnant or lactating females has not been proven.⁶

Another drug that has been shown to be effective as an antisialagogue is clonidine hydrochloride (Catapres, Boehringer Ingelheim). Wilson et al⁷ demonstrated that a 0.2-mg dose of this drug is effective in diminishing salivary flow. Clonidine hydrochloride is an antihypertensive agent, and it should be used cautiously in patients who are receiving other antihypertensive medication. Its principal side effect, besides a dry mouth, is drowsiness, which is not altogether undesirable in a patient undergoing a lengthy restorative dental appointment. The dose of 0.2 mg should be administered an hour before the appointment, and a designated driver should accompany the patient because of the sedative effect of the drug.

16 Fluid Control and Soft Tissue Management

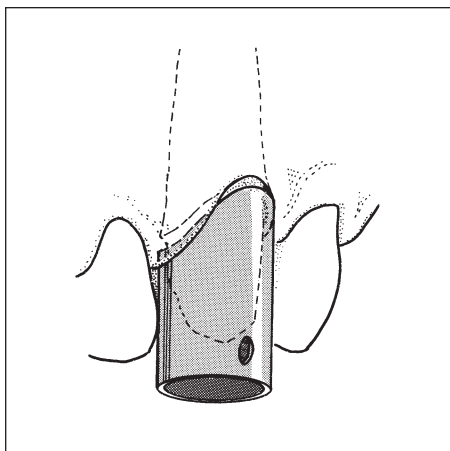


Fig 16-8 The end of a copper band is trimmed to follow the preparation finish line.

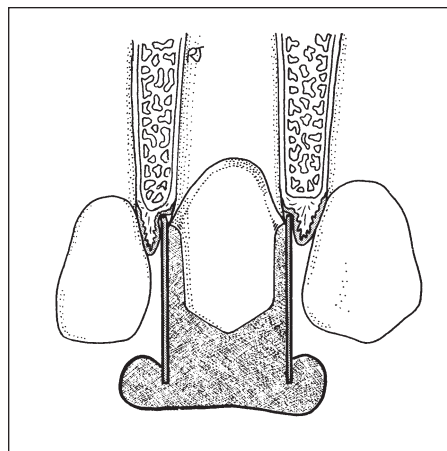


Fig 16-9 In a copper band impression, the band displaces the free gingiva.

Finish Line Exposure

It is essential that gingival tissue be healthy and free of inflammation before cast restorations are begun.^{8,9} Starting tooth preparations in the face of untreated gingivitis makes the task more difficult and seriously compromises the chances for success. Because the marginal fit of a restoration is essential in preventing recurrent caries and gingival irritation, the finish line of the tooth preparation must be reproduced in the impression.

Obtaining a complete impression is complicated when some or all of the preparation finish line lies at or apical to the crest of the free gingiva. In these situations, the preparation finish line must be temporarily exposed to ensure reproduction of the entire preparation. Control of fluids in the sulcus, particularly when a hydrophobic impression material is used, is also necessary because liquids can cause an incomplete impression of the critical finish line area. These measures are accomplished by one or more of three techniques: mechanical, chemicochemical, and surgical.¹⁰ The surgical techniques can be further broken down into rotary curettage and electrosurgery.¹¹

Mechanical

Physically displacing the gingiva was one of the first methods used for ensuring adequate reproduction of the preparation finish line. A copper band or tube can serve as a means of carrying the impression material as well as a mechanism for displacing the gingiva to ensure that the gingival finish line is captured in the impression.

One end of the tube is festooned, or trimmed, to follow the profile of the gingival finish line, which, in turn, often follows the contours of the free gingival margin (Fig 16-8). The tube is filled with modeling compound, then seated carefully

in place along the path of insertion of the tooth preparation (Fig 16-9). The technique has been used in restorative dentistry for many years.¹² It has been used with impression compound¹²⁻¹⁵ and elastomeric materials.¹⁶ Several types of die material can be used, depending on the material used for the impression. If the impression is made with an elastomeric material, the die can be formed of stone or electroplated metal¹⁶; if the impression is compound, the die can be made of amalgam^{12,16} or electroplated metal.^{13,14}

The use of copper bands can cause incisional injuries of gingival tissues,¹⁷ but recession following their use is minimal, ranging from 0.1 mm in healthy adolescents¹⁷ to 0.3 mm in a general clinic population.¹⁸ Copper bands are especially useful for situations in which several teeth have been prepared. The likelihood of capturing all of the finish lines in one impression decreases as the number of prepared teeth increases. The use of a copper band could negate the necessity of remaking an entire full-arch impression just to capture one or two preparations.

Rubber dam also can accomplish the exposure of the finish line.¹⁹ Generally it is used when a limited number of teeth in one quadrant are being restored and in situations in which preparations do not have to be extended very far subgingivally. It can be used with modified trays if the bow and wings of the clamp are blocked out. As mentioned previously, rubber dam should not be used with polyvinyl siloxane impression material because the rubber inhibits its polymerization.¹

With the introduction of elastic impression materials, new means had to be used for displacing the gingiva. Plain cotton cord was used for sulcus enlargement,²⁰ physically pushing away the gingiva from the finish line. Unfortunately, its effectiveness was limited because the use of pressure alone often will not control sulcular hemorrhage. One group of investigators found that over half of the impressions preceded by the use of plain cotton cord had to be remade²¹; however, this may have been exaggerated by the fact that the cord was used dry.

Table 16-1 Results of surveys of material preferences for gingival retraction

Investigators	Year published	Number of respondents	Epinephrine cord	Astringent cord	Electrosurgery	Miscellaneous or none
Shillingburg et al ²⁵	1980	3,737	73%	24%	11%	7%
Donovan et al ²⁶	1985	495	79%	19%	5%	18%
Shaw and Krejci ²⁷	1986	814	55%	33%	2%	10%

Chemicomechanical (retraction cord)

By combining chemical action with pressure packing, enlargement of the gingival sulcus as well as control of fluids seeping from the walls of the gingival sulcus is more readily accomplished. Laufer et al²² found a sulcular width of at least 0.2 mm was required to prevent distortion of the sulcular impression. Caustic chemicals such as sulfuric acid,¹⁰ trichloroacetic acid,^{10,23} negatol (a 45% condensation product of metacresol sulfonic acid and formaldehyde),¹¹ and zinc chloride²⁴ were tried in the search for an effective chemical for gingival retraction, but their undesirable effects on the gingiva led to their abandonment.

Over the years, racemic epinephrine emerged as the most popular chemical for gingival retraction. Surveys published in the 1980s document that cord impregnated with 8% racemic epinephrine was the most commonly used means of producing gingival retraction²⁵⁻²⁷ (Table 16-1).

The three criteria for a gingival retraction material are (1) effectiveness in gingival displacement and hemostasis, (2) absence of irreversible damage to the gingiva, and (3) minimal untoward systemic effects.^{26,28} Epinephrine produces hemostasis, and it causes local vasoconstriction, which in turn results in transitory gingival shrinkage. In research conducted on dogs, epinephrine produced slight tissue injury that healed in 6 days²⁹ to 10 days.²⁴ A study using human subjects showed that epinephrine cord did not produce significantly greater gingival inflammation than did potassium aluminum sulfate or aluminum chloride.³⁰

However, there is controversy surrounding the use of epinephrine for gingival retraction,³¹ and its use has declined, particularly among dentists who have graduated since 1980 and practicing prosthodontists.^{27,32} Epinephrine causes an elevation of blood pressure and increased heart rate. Some investigators have found that the physiologic changes that occur when epinephrine-impregnated cord is placed in an intact gingival sulcus are minimal.³³⁻³⁶ However, the heart rate increase and blood pressure elevation are more dramatic when the cord is applied to a severely lacerated gingival sulcus or when cotton pellets soaked in epinephrine are applied.³⁶ The use of liquid epinephrine-containing hemostatic agents is therefore not warranted in this situation; there are effective hemostatic agents without epinephrine available for such use.

For those patients with cardiovascular disease, hypertension, diabetes, hyperthyroidism, or a known hypersensitivity to epinephrine, a cord impregnated with some other agent

must be substituted. Epinephrine also should not be used on patients taking rauwolfia compounds, ganglionic blockers, or epinephrine-potentiating drugs³⁷ or on patients taking monoamine oxidase inhibitors for depression.²⁶

Patients without the aforementioned contraindications can also exhibit so-called epinephrine syndrome (tachycardia, rapid respiration, elevated blood pressure, anxiety, and postoperative depression).¹¹ The amount of epinephrine absorbed is highly variable, depending on the degree of exposure of the vascular bed³⁸ as well as the time of contact and the amount of medication in the cord.^{36,39} The amount of epinephrine lost (and presumed absorbed) from 2.5 cm of typical retraction cord during 5 to 15 minutes in the gingival sulcus is 71 µg.⁴⁰ This amount is slightly less than that obtained from receiving the injection of four carpules of local anesthetic containing a 1:100,000 concentration of epinephrine.⁴⁰ It also is approximately one-third the maximum dose of 0.2 mg (200 µg) for a healthy adult and nearly twice the recommended amount of 0.04 mg (40 µg) for a cardiac patient.⁴¹

Although the absorbed amounts reported by Kellam et al⁴⁰ are lower than estimates by some authors,²⁶ the patient nonetheless is receiving a large dose from the cord around one tooth. If cord is placed around more than one tooth, if more than one impression is made of a single tooth (not an uncommon occurrence in a teaching institution), and/or if an epinephrine-containing anesthetic is used, a patient could easily exceed the recommended maximum dosage of epinephrine.

Donovan and associates²⁶ report that only 3% of the dentists they surveyed recorded the patient's pulse, and fewer than 10% recorded blood pressures routinely. Given this, it is likely that few patients would receive even a rudimentary cardiovascular evaluation. Therefore, the routine use of epinephrine in dentistry, even on healthy patients, has been questioned.⁴¹

Because epinephrine has been used successfully for nearly half a century, there is reluctance to abandon its use. However, the fact that many dentists manage without it proves that it is not indispensable. Its proper niche probably lies in utilization as an adjunct method in difficult situations where other agents have been ineffective. Even then it must be used only on healthy patients with no history of cardiovascular problems.

Aluminum chloride [AlCl₃], alum (aluminum potassium sulfate) [AlK(SO₄)₂], aluminum sulfate [Al₂(SO₄)₃], and ferric sulfate [Fe₂(SO₄)₃] are also used for gingival retraction⁴² (Table 16-2). O'Mahony et al⁴³ report that these medicaments have

16 Fluid Control and Soft Tissue Management

Table 16-2 Principal chemical in brands of gingival retraction cord

Manufacturer	AlCl ₃	AlK(SO ₄) ₂	Al ₂ (SO ₄) ₃	Fe ₂ (SO ₄) ₃	Epinephrine	Combination	None
Aseptico	—	Sulpak K-Alum Astringent R-24, 25, 26 (T)	—	—	Sulpak Epinephrine Vasoconstrictor R-34, 35, 36, (T)	Astringent Plus Vasoconstrictor R-44, 45-46 (T) (epinephrine + alum)	Sulpak Plain R-14, 15, 16 (T)
Belpart	Gingi-Aid (T,W)	—	—	—	Gingi-Pak (T,W)	—	Gingi-Plain (T,W)
Miles Dental Prod	—	—	Cutter Cord Aluminum Sulfate (W)	—	Cutter Cord Epinephrine (W)	—	—
Pascal Dental	—	—	Pascord (T) Siltrax A.S. (W)	—	Racord (T) Siltrax Epi (W)	Racord II (T,W) (epinephrine + zinc phenolsulfonate)	Retrax (T) Siltrax (W)
Premier	Hemodent (T,W)	—	—	—	—	—	—
Sultan Dental Prod	—	Sulpak (T) Ultrapak (W)	—	—	Sulpak (T) Ultrapak (W) (4% epinephrine)	Sulpak (T) Ultrapak (W) (4% epinephrine + alum)	—
Ultradent	—	—	—	Ultrapak & Astringedent (W)	—	—	Ultrapak (W)
Van R	GingiGel (W)	FlexiBraid (W) GingiYarn (T) UniBraid (W)	—	—	GingiYarn (T) UniBraid (W)	GingiBraid (W) FlexiBraid (W) GingiCord (T) (epinephrine + alum)	GingiBraid (W) GingiYarn (T)

T, twisted; W, woven (braided or knitted).



Fig 16-10 Unit-dose retraction cord.

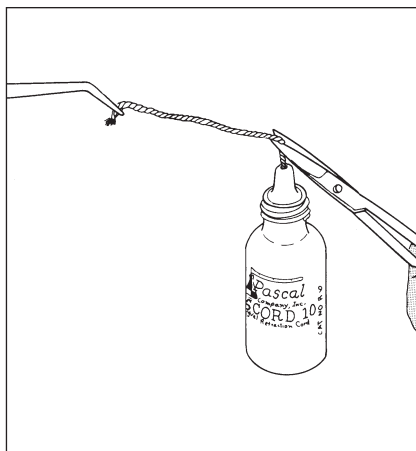


Fig 16-11 A 2-inch piece of retraction cord is cut off.

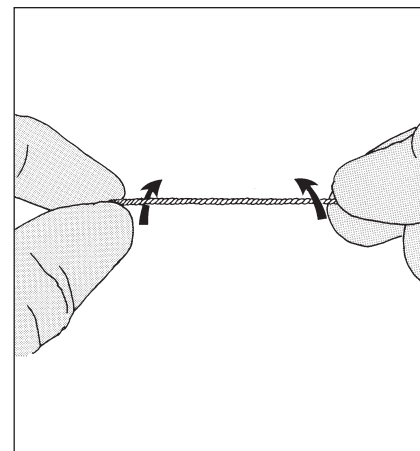


Fig 16-12 The cord is twisted to make it as tight and as small as possible.

an adverse effect on surface detail reproduction, and they recommend removing all traces of them prior to polyvinyl siloxane impressions. Investigators have compared several of these agents with epinephrine for displacement effectiveness, hemostasis, and tissue irritation.

No significant difference was found in sulcular width around teeth treated with alum- and epinephrine-impregnated cord before impressions (0.49 and 0.51 mm, respectively).⁴⁴ In an *in vivo* study of 120 human teeth, Weir and Williams⁴⁵ found no significant difference between the hemorrhage control offered by cords impregnated with aluminum sulfate and those impregnated with epinephrine.

In a study conducted on dogs, Shaw et al⁴⁶ found no additional inflammation in gingival crevices in which dilute aluminum chloride (0.033%) was placed, but those receiving concentrated solutions (60%) demonstrated severe inflammation and necrosis. Another study on human subjects found no significant difference in gingival inflammation produced by alum-, aluminum chloride-, or epinephrine-impregnated cords.³⁰

Over-the-counter drugs commonly used as nasal and ophthalmic decongestants show promise as gingival retraction agents.⁴⁴ Phenylephrine hydrochloride 0.25% (Neo-Syneprine, Bayer) was found to be as effective as epinephrine and alum in widening the gingival sulcus, while oxymetazoline hydrochloride 0.05% (Afrin, Schering-Plough) and tetrahydrozoline hydrochloride 0.05% (Visine, Johnson & Johnson) were 57% more effective.⁴⁴

There is evidence to suggest that tissue hemorrhage can also be controlled indirectly by the adjunctive use of antimicrobial rinses. Sorensen et al⁴⁷ reported lowered plaque, bleeding, and gingivitis indices with the administration of 0.12% chlorhexidine gluconate (Peridex, Procter & Gamble) 2 weeks before tooth preparation, 3 weeks during provisional restorations, and 2 weeks after definitive restoration cementation.

Armamentarium

- Evacuator (saliva ejector, Svedopter)
- Scissors
- Cotton pliers
- Mouth mirror
- Explorer
- Fischer Ultrapak Packer (small) (Ultradent)
- Double-ended (DE) plastic filling instrument IPPA
- Cotton rolls
- Retraction cord
- Hemodent liquid
- Dappen dish
- Cotton pellets
- 2 × 2-inch gauze sponges

Technique

In the interest of infection control, it is common practice to pre-position unit-dose consumable supplies for each patient encounter. The retraction cord pictured (Fig 16-10) is available impregnated with 8% racemic epinephrine and 7% aluminum potassium sulfate or with 10% aluminum potassium sulfate.

Bulk dispenser bottles are also available. The operating area must be dry. An evacuating device is placed in the mouth, and the quadrant containing the prepared tooth is isolated with cotton rolls. The retraction cord is drawn from the dispenser bottle with sterile cotton pliers, and a piece approximately 5 cm (2 inches) long is cut off (Fig 16-11). If a twisted or wound cord is used, the ends are grasped between the thumb and forefinger of each hand. The cord is held taut, and the ends are twisted to produce a tightly wound cord of small diameter (Fig 16-12). If a braided or woven cord is used, twisting is not necessary.

Care should be taken not to touch any part of the cord other than the ends, which will be cut off later, with your

16 Fluid Control and Soft Tissue Management

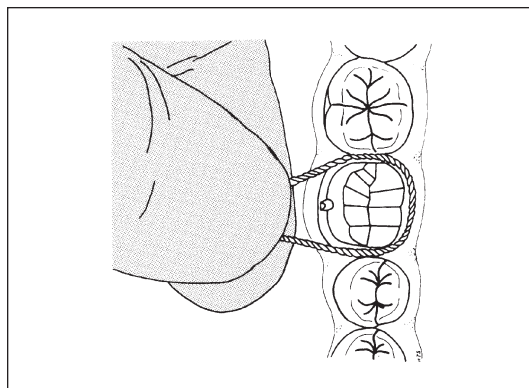


Fig 16-13 A loop of retraction cord is formed around the tooth and held tautly with the thumb and forefinger.

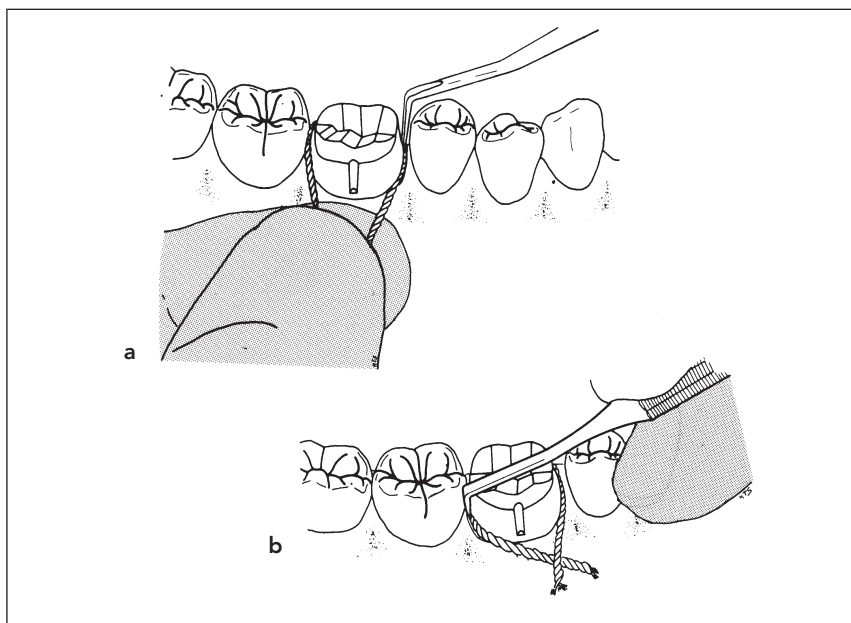


Fig 16-14 (a) Placement of the retraction cord is begun by pushing it into the sulcus on the mesial surface of the tooth. (b) It should also be tacked lightly into the distal crevice to hold the cord in position while it is being placed.

gloved fingers. It has been postulated that handling the cord with latex gloves may indirectly inhibit polymerization of a polyvinyl siloxane impression.⁴⁸ If that happens, it will occur in that segment of the impression replicating the gingival crevice and the gingival finish line of the preparation.

The retraction cord should be moistened by dipping it in buffered 25% aluminum chloride solution (Hemodent, Premier Dental) in a dampen dish. Cords impregnated with either epinephrine or aluminum sulfate are twice as effective when saturated with aluminum chloride solution prior to insertion into the gingival crevice.⁴⁵ If there is slight hemorrhage in the gingival crevice, it can be controlled by the use

of a hemostatic agent, such as Hemodent liquid (aluminum chloride). In any event, the cord must be slightly moist before it is removed from the sulcus.⁴⁹ Removing dry cord from the gingival crevice can cause injury to delicate epithelial lining that is not unlike the so-called cotton roll burn produced by prying an adhering cotton roll off the desiccated mucous membrane of the mouth.

The cord is formed into a U and looped around the prepared tooth (Fig 16-13). The cord is held between the thumb and forefinger, and slight tension is applied in an apical direction. The cord is gently slipped between the tooth and the gingiva in the mesial interproximal area with a Fischer pack-

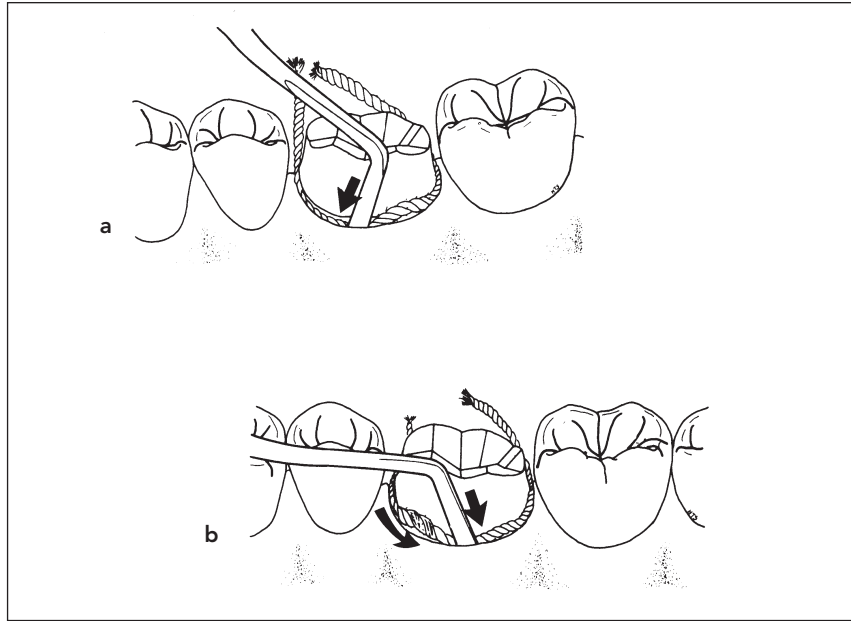


Fig 16-15 (a) As the cord is being placed subgingivally, the instrument must be pushed slightly toward the area already tucked into place. (b) If the force of the instrument is directed away from the area previously packed, the cord already packed will be pulled out.

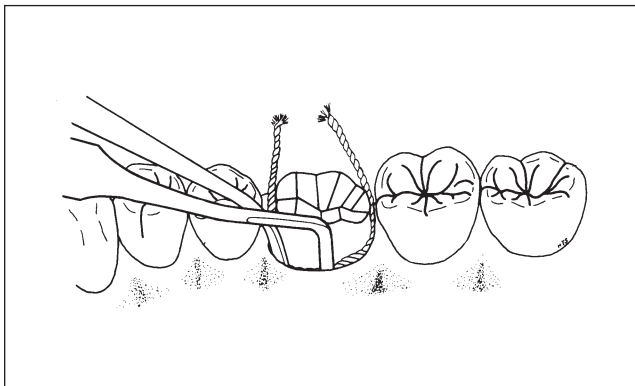


Fig 16-16 Occasionally it is necessary to hold the cord with one instrument while packing with the second.

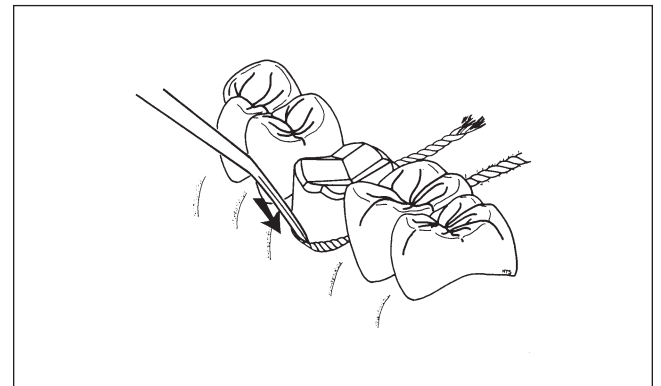


Fig 16-17 The instrument must be angled slightly toward the root to facilitate the subgingival placement of the cord.

ing instrument or a DE plastic instrument IPPA (Fig 16-14a). Cord placement should be performed with finesse, not force. Once the cord has been tucked in on the mesial, the instrument is used to lightly secure it in the distal interproximal area (Fig 16-14b).

Work then proceeds to the lingual surface, beginning from the mesiolingual corner around to the distolingual corner. The tip of the instrument should be inclined slightly toward the area where the cord has already been placed (ie, the mesial) (Fig 16-15a). If the tip of the instrument is inclined away from the area in which the cord has been placed, the cord may be displaced and pulled out (Fig 16-15b).

In some instances where there is a shallow sulcus or a finish line with drastically changing contours, it may be necessary to hold the cord already placed in position with a Gregg 4-5 instrument held in the left hand. Placement of the cord can then proceed with the packing instrument held in the right hand (Fig 16-16). The cord is gently pressed apically with the instrument, directing the tip slightly toward the root (Fig 16-17). The cord is slid gingivally along the preparation until the finish line is felt. Then the cord is pushed into the crevice.

If the instrument is directed totally in an apical direction, the cord will rebound off the gingiva and roll out of the sulcus (Fig 16-18). If cord persists in rebounding from a par-

16 Fluid Control and Soft Tissue Management

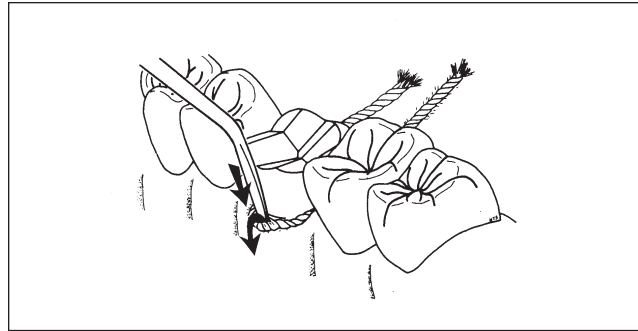


Fig 16-18 If the instrument is held parallel to the long axis of the tooth, the retraction cord will be pushed against the wall of the gingival crevice, and it will rebound.




Fig 16-19 Excess cord is cut off in the mesial interproximal area.

ticularly tight area of the sulcus, greater force should not be applied. Instead, gentle force should be maintained for a longer time. If it still rebounds, a smaller or more pliable (ie, twisted rather than braided) cord should be used.

Work continues around to the mesial, firmly securing the cord where it was lightly tacked before. The length of cord protruding from the mesial sulcus is cut off as closely as possible to the interdental papilla (Fig 16-19). Packing of the cord continues around the facial surface, overlapping the cord in the mesial interproximal area. The overlap must always occur in the proximal area, where the greater bulk of tissue will tolerate the extra bulk of cord. If the overlap occurs on the facial or lingual surface where the gingiva is tight, there will be a gap apical to the crossover, and the finish line in that area may not be replicated in the impression.

All but the last 2 or 3 mm of cord is packed (Fig 16-20). This tag is left protruding so that it can be grasped for easy removal. Tissue retraction should be done firmly but gently so that the cord will rest at the finish line (Fig 16-21a). Heavy-handed operators can traumatize the tissue, create gingival problems, and jeopardize the longevity of the restorations that they place. It is essential to avoid overpacking (Fig 16-21b).

A large bulk of gauze is placed in the patient's mouth. This makes the patient more comfortable by providing some-

thing to close on, and at the same time, it will keep the area dry (Fig 16-22). After 10 minutes, the cord is removed slowly to avoid bleeding. Impression material is injected only if the sulcus remains clean and dry. It may be necessary to gently rinse away any coagulum and then lightly blow air on it. If active bleeding persists, the impression attempt should be aborted. Electrocoagulation and ferric sulfate are sometimes effective in stopping persistent bleeding.

If ferric sulfate (Astringent, Ultradent) is used as the chemical, a plain knitted cord is soaked in it and placed in the gingival sulcus as just described. After 3 minutes, the cord is removed. The 1.0-mL special syringe (ViscoStat Dento-Infusor, Ultradent) is loaded with the astringent chemical, and a tip is placed on the syringe. The fibrous syringe tip is used to rub or burnish cut sulcular tissue until all bleeding stops (Fig 16-23). Using the tip in this manner will wipe off excess coagulum.

The sulcus should be kept moist so that the coagulum will be easy to remove. Circling of the preparation continues until bleeding has stopped completely. The solution usually will puddle in the sulcus when hemostasis is complete. This should be verified by thorough rinsing of the preparation with air-water spray. The coagulum is black, and traces may linger in the sulcus for a few days.

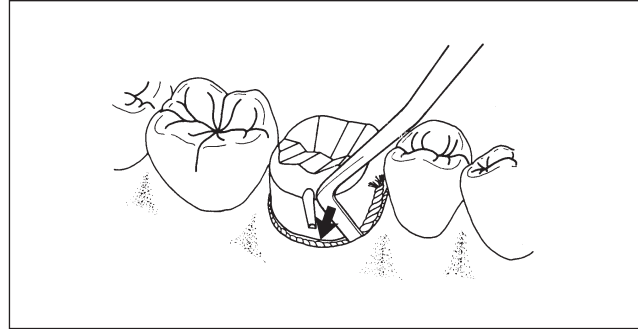


Fig 16-20 Placement of the distal end of the cord is continued until it overlaps the mesial end. The force of the instrument must be directed toward the cord previously packed (to the distal in this case).

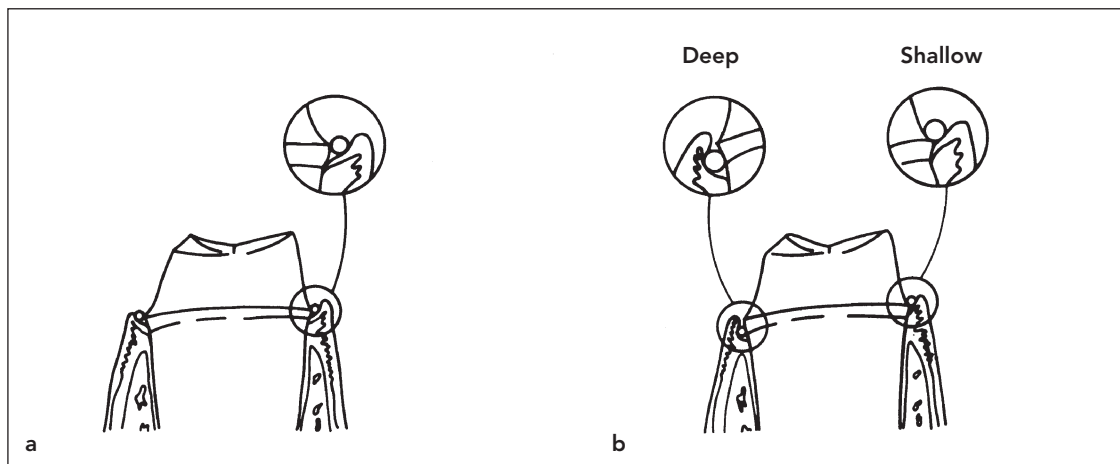


Fig 16-21 Placement of the retraction cord in the sulcus: (a) correct; (b) incorrect.

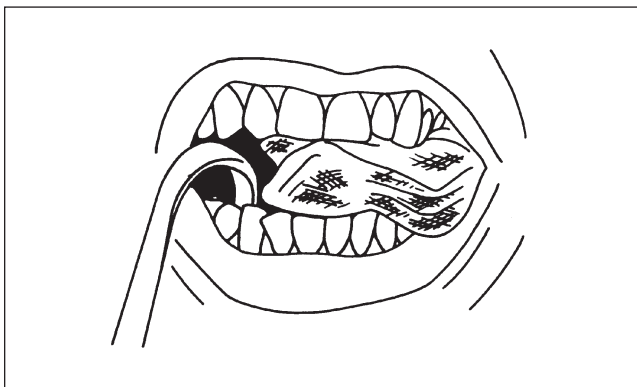


Fig 16-22 Gauze pack in place.

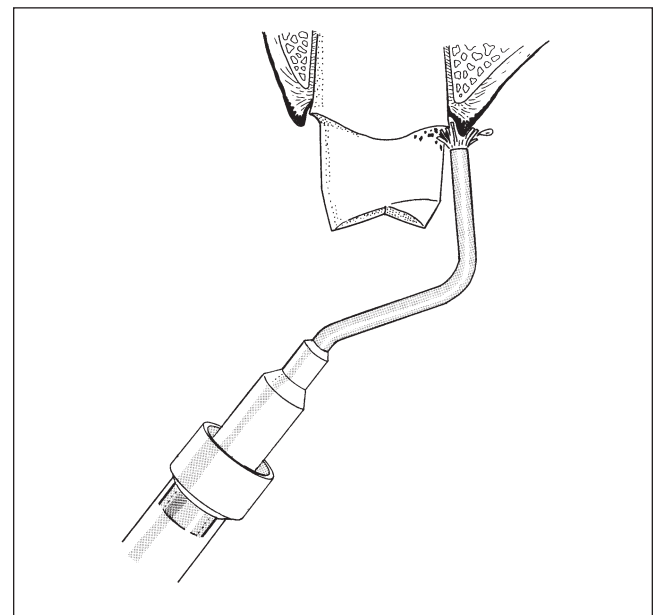


Fig 16-23 Ferric sulfate solution is applied to the gingiva with the tip of the special syringe.

16 Fluid Control and Soft Tissue Management

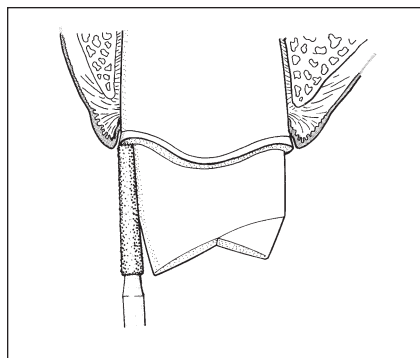


Fig 16-24 Prior to rotary curettage, a shoulder is formed at the level of the gingival crest.

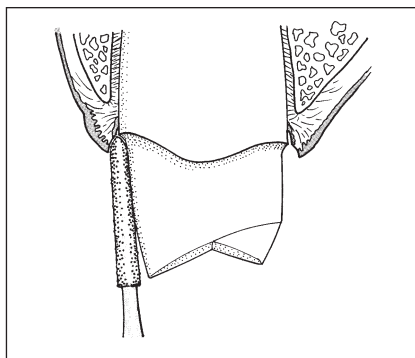


Fig 16-25 A torpedo-shaped diamond simultaneously forms a chamfer finish line and removes the epithelial lining of the sulcus.

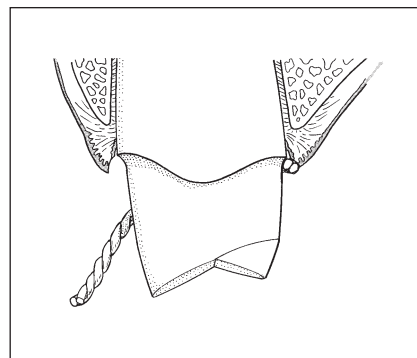


Fig 16-26 A cord is placed in the "troughed" sulcus for hemostasis.

Surgical

Rotary curettage

Rotary curettage is a "troughing" technique, the purpose of which is to produce limited removal of epithelial tissue in the sulcus while a chamfer finish line is being created in tooth structure.⁵⁰ The technique, which also has been called "gingetage,"^{51,52} is used with the subgingival placement of restoration margins. It has been compared with periodontal curettage, but the rationale for its use is decidedly different.⁵⁰ Periodontal curettage is used to debride diseased tissue from the sulcus to allow re-epithelialization and healing.

The removal of epithelium from the sulcus by rotary curettage is accomplished with little detectable trauma to soft tissue, although there is a lessened tactile sense for the dentist.⁵³ Rotary curettage, however, must be done only on healthy, inflammation-free tissue^{50,52} to avoid the tissue shrinkage that occurs when diseased tissue heals.⁵⁰

The concept of using rotary curettage was described by Amsterdam in 1954.⁵³ The technique described here was developed by Hansing and subsequently expanded upon by Ingraham.^{52,54} Suitability of gingiva for the use of this method is determined by three factors: (1) absence of bleeding upon probing, (2) sulcus depth less than 3.0 mm, and (3) presence of adequate keratinized gingiva.⁵² The latter is determined by inserting a periodontal probe into the sulcus. If the segment of the probe in the sulcus cannot be seen, there is sufficient keratinized tissue to employ rotary curettage. Kamansky et al⁵⁵ found that thick palatal tissues responded better to the technique than did the thinner tissues on the facial aspect of maxillary anterior teeth.

In conjunction with axial reduction, a shoulder finish line is prepared at the level of the gingival crest with a flat-end tapered diamond (Fig 16-24). Then a torpedo-nosed diamond of 150 to 180 grit is used to extend the finish line apically, one-half to two-thirds the depth of the sulcus, converting the finish line into a chamfer⁵⁰ (Fig 16-25). A generous water spray is used while preparing the finish line and curetting the adjacent gingiva. Cord impregnated with aluminum chloride^{50,55} or alum^{51,52} is gently placed to control hemorrhage

(Fig 16-26). The cord is removed after 4 to 8 minutes, and the sulcus is thoroughly irrigated with water. This technique is well suited for use with reversible hydrocolloid.⁵²

Several studies have been done to compare both the efficacy and the wound healing of rotary curettage with those of conventional techniques. Kamansky and associates⁵⁵ reported less change in gingival height with rotary curettage than with lateral gingival displacement using retraction cord. With curettage there was an apparent disruption of the apical sulcular and attachment epithelium, resulting in apical repositioning and an increase in sulcus depth. The changes were quite small, however, and they were not regarded as clinically significant.

Tupac and Neacy⁵¹ found no significant histologic differences between retraction cord and rotary curettage. Ingraham et al⁵⁰ reported slight differences in healing among rotary curettage, pressure packing, and electrosurgery at different time intervals after the tooth preparation and impression. However, complete healing had occurred by 3 weeks with all techniques.

There is poor tactile sensation when using diamonds on sulcular walls, which can produce deepening of the sulcus.⁵⁵ The technique also has the potential for destruction of periodontium if used incorrectly,⁵² making this a method that is probably best used only by experienced dentists.

Electrosurgery

There are situations in which it may not be feasible or desirable to manage the gingiva with retraction cord alone. Even if the general condition of the gingiva in a mouth is healthy, areas of inflammation and granulation tissue may be encountered around a given tooth. This can be caused by overhangs on previous restorations or by the caries itself. It may have been necessary to place the finish line of the preparation so near the epithelial attachment that it is impossible to retract the gingiva sufficiently to get an adequate impression. In these cases, it may be necessary to use some means other than cord impregnated with chemicals to gain access and stop minor bleeding.

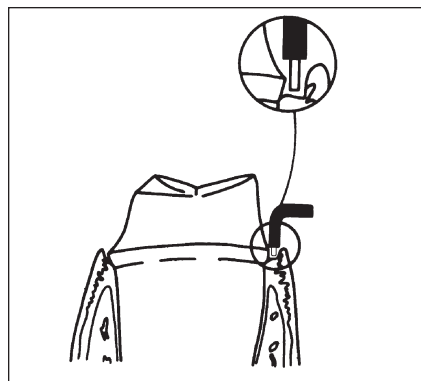


Fig 16-27 Electrosurgical electrode enlarges the gingival sulcus.


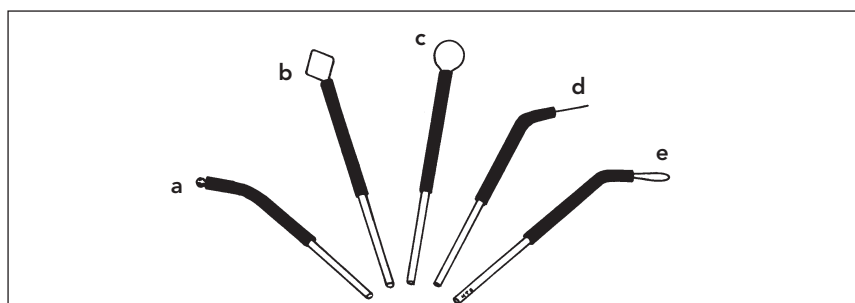


Fig 16-28 Typical electrocautery unit with ground electrode (a) and active electrode (b).

Fig 16-29 Five commonly used electrocautery electrodes: coagulating (a), diamond loop (b), round loop (c), small straight (d), and small loop (e).



The use of electrocautery has been recommended for enlargement of the gingival sulcus and control of hemorrhage to facilitate impression making⁵⁶⁻⁵⁸ (Fig 16-27). Strictly speaking, electrocautery cannot stop bleeding once it starts. If hemorrhage occurs, it first must be controlled with pressure and/or chemicals, and then the vessels can be sealed with a coagulating ball electrode.⁵⁹

Electrocautery has been described for the removal of irritated tissue that has proliferated over preparation finish lines,⁶⁰ and it is commonly used for that purpose. There has been concern expressed about the use of electrocautery on inflamed tissue based on an exaggerated response to an electrocautery procedure.⁶¹ Proximity to bone and lateral heat production may have been responsible for the response because bone is very sensitive to heat.⁶²

Electrocautery is unquestionably capable of tissue damage. Most surgical instruments are dangerous if used improperly. Tremendous iatrogenic damage has been done over the years by the rotary handpiece, but no one has suggested that it not be used. Kalkwarf et al⁶³ reported that wounds created by a fully rectified, filtered current in the healthy gingiva of adult males demonstrated epithelial bridging at 48 hours and complete clinical healing at 72 hours. In a double-blind study on 27 patients, Aremband and Wade⁶⁴ detected no difference in healing in gingivectomies done by scalpel or electrocautery. When variables are properly controlled in electrocautery, untoward events in wound healing are rare.⁶⁵

An electrocautery unit is a high-frequency oscillator or radio transmitter that uses either a vacuum tube or a transistor

to deliver a high-frequency electrical current of at least 1.0 MHz (one million cycles per second) (Fig 16-28). It generates heat in a way that is similar to a microwave oven heating food or a diathermy machine producing heat in muscle tissue for physical therapy. Electrocautery has been called *surgical diathermy*.⁵⁹

Credit for being the direct progenitor of electrocautery is generally given to d'Arsonval.^{66,67} His experiments in 1891 demonstrated that electricity at high frequency will pass through a body without producing a shock (pain or muscle spasm), producing instead an increase in the internal temperature of the tissue. This discovery was used as the basis for the eventual development of electrocautery.

Electrocautery produces controlled tissue destruction to achieve a surgical result. Current flows from a small cutting electrode that produces a high current density and a rapid temperature rise at its point of contact with the tissue. The cells directly adjacent to the electrode are destroyed by this temperature increase. The current concentrates at points and sharp bends. Cutting electrodes are designed to take advantage of this property so they will have maximum effectiveness (Fig 16-29). The circuit is completed by contact between the patient and a ground electrode that will not generate heat in the tissue because its large surface area produces a low current density, even though the same amount of current passes through it.⁶⁸ The cutting electrode remains cold; this differs from electrocautery, in which a hot electrode is applied to the tissue.

16 Fluid Control and Soft Tissue Management

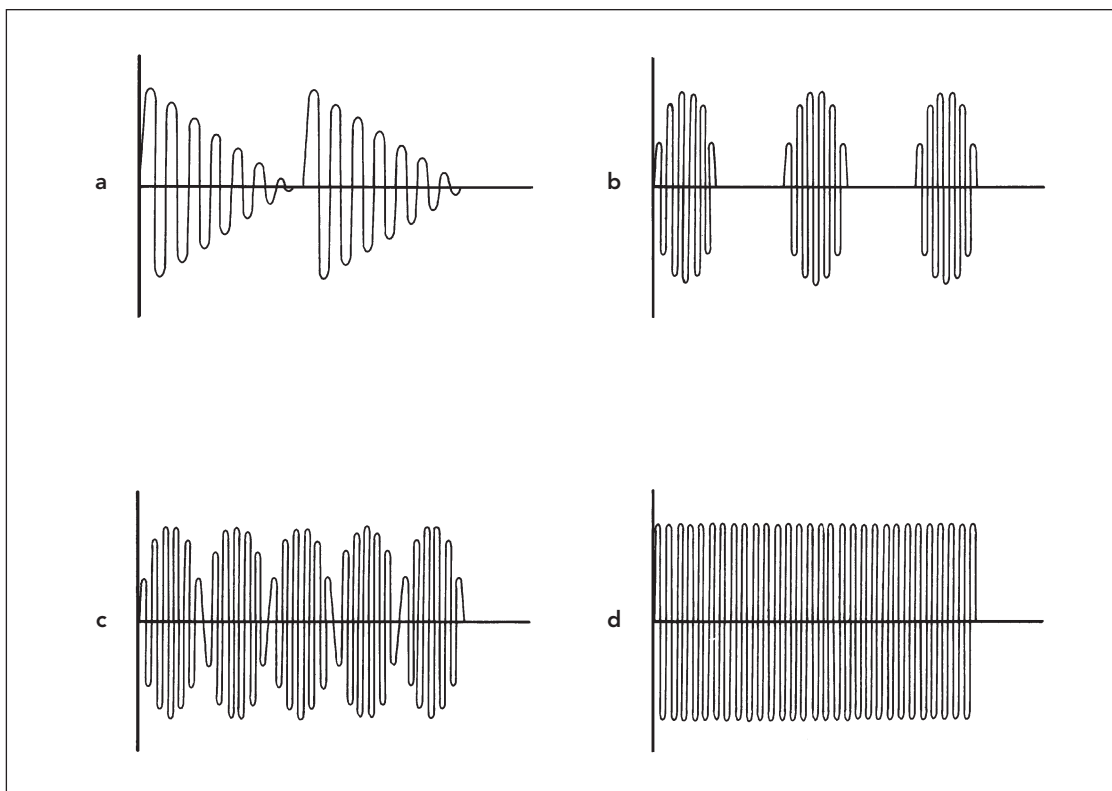


Fig 16-30 Four forms of electrosurgery current: (a) unrectified, damped; (b) partially rectified, damped (half-wave modulated); (c) fully rectified (full-wave modulated); and (d) fully rectified, filtered (filtered).

Types of current

There are different forms of current that can be generated for electrosurgical use, depending on the type of machine (and circuitry) used or the setting on any given machine. These currents exhibit different wave forms when viewed on an oscilloscope. They are significant because each produces a different tissue response.

The unrectified, damped current is characterized by recurring peaks of power that rapidly diminish (Fig 16-30a). It is the current produced by the old hyfrecator or spark gap generator, and it gives rise to intense dehydration and necrosis. It causes considerable coagulation, and healing is slow and painful. Sometimes referred to as the *Oudin* or *Tesla current*, it is not used routinely in dental electrosurgery today.

A partially rectified, damped (half-wave modulated) current produces a wave form with a damping in the second half of each cycle (Fig 16-30b). There is lateral penetration of heat, with slow healing occurring in deep tissues. The damping effect produces good coagulation and hemostasis, but tissue destruction is considerable, and healing is slow.

A better current for enlargement of the gingival sulcus is found in the fully rectified (full-wave modulated) current that produces a continuous flow of energy (Fig 16-30c). Cutting characteristics are good, and there is some hemostasis.

The fully rectified, filtered (filtered) current is a continuous wave that produces excellent cutting (Fig 16-30d). Healing of tissues cut by a continuous wave current will be better initially than tissues cut by a modulated wave. The continuous wave produces less injury to the tissue than does a modulated wave.⁶⁹ However, a controlled histologic study⁷⁰ found that after 2 weeks, healing of wounds produced by filtered current was not remarkably better than healing of wounds produced by nonfiltered full-wave modulated current.

Filtered current probably produces better healing in situations requiring an incision and healing by primary intention because there is less coagulation of the tissues in the walls of the wound. This is not critical in those procedures done in conjunction with restorative dentistry, when either the inner wall of the gingival sulcus is removed or modified gingivoplasty is accomplished by planing the surface of the tissue. In these cases, hemostasis is required and moderate tissue coagulation is not only tolerated but desired.

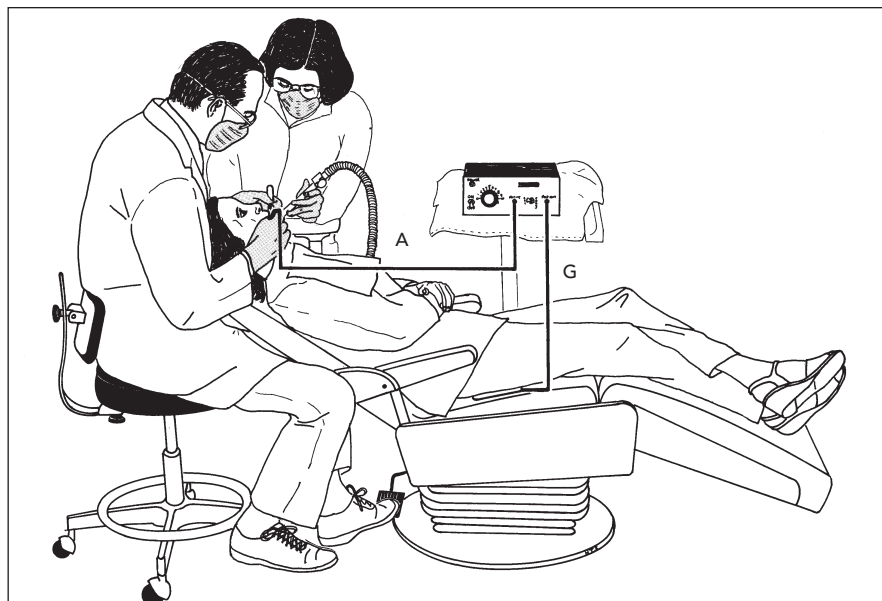


Fig 16-31 Electrosurgical current flows from the unit to the active (cutting) electrode (A) to the ground (G) and back to the unit.

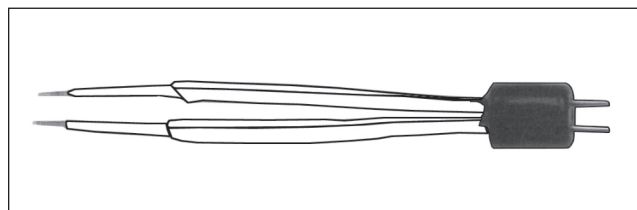


Fig 16-32 A bipolar tip converts a monopolar unit and eliminates need for the grounding plate.

Grounding

For the patient's safety, it is important that the circuit be completed by the use of the ground electrode,⁷¹ which is also known as a *ground plate*, *indifferent plate*, *indifferent electrode*, *neutral electrode*, *dispersive electrode*, *passive electrode*, or *patient return* (Fig 16-31). Some dentists, prompted by the unfortunate advertising of a few electrosurgical manufacturers, have chosen to dispense with the use of this vital piece of equipment. An electrosurgery unit will work without one, but it is neither as efficient nor as safe.

Grounding the chair is not an acceptable alternative. Current will be dissipated through the path of least resistance, and patient contact with a piece of equipment, including metal parts of the chair, could cause a burn.⁷² It is acceptable, however, to permanently attach a metallic mesh grounding antenna to the chair under the upholstery and insulated from all metal chair parts. This can do much to reduce patient anxiety.

The safe use of electrosurgery dictates that current flow be facilitated along the proper circuit from the generator to

the active electrode, the patient, and back to the generator.⁷³ Because patient burns have been attributed to faulty grounding in many cases,^{72,74,75} the proper grounding of a patient is considered to be the single most important safety factor when electrosurgery is used.⁷⁶

Oringer⁷⁷ recommended that the ground be placed under the thigh rather than behind the back, as is often done. Contact with a small, bony protuberance, such as a vertebra or shoulder blade, could produce a sufficiently high current density to cause a burn. The only precaution to be observed in placing the ground under the legs is that the patient does not have keys in a pants pocket or is not wearing metal garters (although the latter is unlikely).

There are "bipolar" units that eliminate the need for a grounding plate. These units have dual tips, one of which serves as the active electrode and the other as the passive electrode. This may be an advantage as it helps to avoid current passing through adjacent bone, implants, or restorations.⁷⁸ The unit shown in Fig 16-28, although a "monopolar" unit, has bipolar forceps (Fig 16-32), which the manufacturer claims converts this unit into a bipolar coagulator.

16 Fluid Control and Soft Tissue Management

Contraindications

For reasons of safety, electrosurgery should not be used in some circumstances. It should not be employed on patients with cardiac pacemakers. The demand (synchronous) type of pacemaker, which is the most common, is designed to sense cardiac impulses (the R wave).⁷⁹ When bradycardia occurs because the heart does not emit an impulse, the pacemaker fires at an appropriate rate to keep the heart beating. External electromagnetic interference hinders the pacemaker's sensing function.⁸⁰ Incorrectly sensing the interference as an intrinsic myocardial impulse, the generator shuts down until the interference ceases, with consequences that could be quite serious for the patient. Electrosurgery will alter the normal function of a pacemaker,⁸¹ and it presents a hazard to the patient who wears one.⁸² Shielding in recent pacemaker models diminishes the risks from extraneous electromagnetic interferences, but the use of electrosurgery is still contraindicated for those patients who wear pacemakers.⁸³

Because it can produce sparks in use, electrosurgery should not be used in the presence of flammable agents. This does not present the risk in dentistry that it does in medicine because flammable gases are not routinely employed as dental anesthetic agents. However, the use of topical anesthetics such as ethylchloride and other flammable aerosols should be avoided when electrosurgery is to be used.

Many fires in hospital operating rooms do not involve flammable anesthetics. Instead they occur when ordinary combustible materials are ignited in an oxygenated atmosphere that will support a fire.^{71,73} There is a slight danger attached to the use of nitrous oxide with electrosurgery because of the enriched oxygen atmosphere that will be present in the oral cavity and nasopharynx. The number of reported cases involving flash fires caused by dental electrosurgery in the presence of nitrous oxide–oxygen analgesia is minimal. Oringer⁸⁴ describes two such occurrences. Given the right circumstances with an extremely dry mouth and an accumulation of oxygen, a small spark caused by the electrode touching a metallic restoration could conceivably set off a dry cotton packing. Therefore, whenever electrosurgery is used in the presence of nitrous oxide–oxygen analgesia, any cotton packing in the mouth should be kept slightly moist⁷¹ if it is not already that way from absorption of oral fluids.

Armamentarium

- Electrosurgery unit
- Set of cutting electrodes
- Cotton pliers
- Mouth mirror
- Fischer Ultrapak Packer
- DE plastic filling instrument
- High-volume vacuum with plastic tip

- Wooden tongue depressor
- Cotton rolls
- Cotton-tipped applicator
- Aromatic oil
- Hydrogen peroxide
- Dappen dish
- Alcohol sponges (gauze, 4 × 4-inch)
- Retraction cord

Technique

Before an electrosurgical procedure is done, verify that anesthesia is profound and reinforce it if necessary. With a cotton-tipped applicator, place a drop of a pleasant-smelling aromatic oil, such as peppermint, at the vermilion border of the upper lip (Fig 16-33). The odor from it will help to mask some of the unpleasant odor emanating from the mouth during electrosurgery. Smelling their own flesh burning is not reassuring to patients.

Check the equipment to make sure all the connections are solid. Be especially certain that the cutting electrode is seated completely in the handpiece (Fig 16-34). If any un-insulated portion of it other than the cutting tip is exposed outside the handpiece chuck, it could produce an accidental burn on the patient's lip.

Proper use of electrosurgery requires that the cutting electrode be applied with very light pressure and quick, deft strokes. The pressure required has been described as the same needed to draw a line with an ink-dipped brush without bending the bristles (Fig 16-35). It is obvious that the electrode is being guided, not pushed, through the tissue.

To prevent lateral penetration of heat into the tissues with subsequent injury, the electrode should move at a speed of no less than 7 mm per second.⁶² If it is necessary to retrace the path of a previous cut, 8 to 10 seconds should be allowed to elapse before repeating the stroke.⁶² This will minimize the buildup of lateral heat that could disrupt normal healing.

The power selector dial is initially set at the level recommended by the manufacturer, and adjustments are made as necessary. As the electrode passes through the tissue, it should do so smoothly without dragging or charring the tissue. If the tip drags and collects shreds of clinging tissue, the unit has been placed on a setting that is too low. On the other hand, if the tissue chars or discolors, or if there is sparking, the setting is too high. If an error must be made initially, it is better to have a setting that is slightly too high. Moist tissue will cut best. If it dries out, it should be sprayed lightly. Collection of water should be avoided, however, because it will increase resistance and decrease efficiency.

A high-volume vacuum tip should be kept immediately adjacent to the cutting electrode at all times to draw off the unpleasant odors that are generated (Fig 16-36). The tip

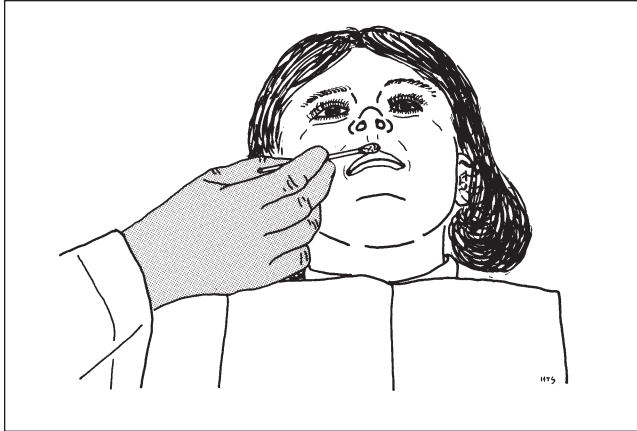


Fig 16-33 A small drop of a strongly scented oil is placed on the upper lip to help mask the unpleasant odor associated with electrosurgery.

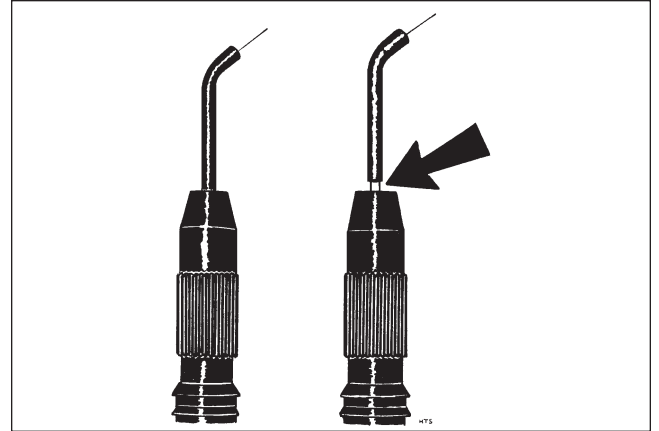


Fig 16-34 Electrodes must be completely seated in the handpiece (*left*). If bare metal is left exposed (*arrow*) anywhere but at the tip, the patient or the operator could be burned.

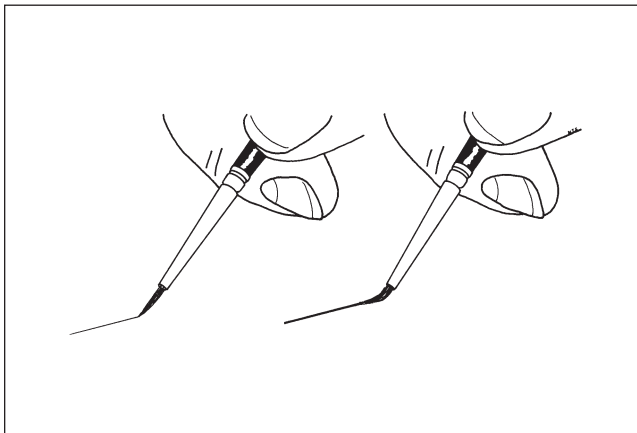


Fig 16-35 The cutting electrode should be used with the same light pressure used to draw a straight line with a brush without bending it (*left*). The pressure exerted on the brush on the right would be excessive.

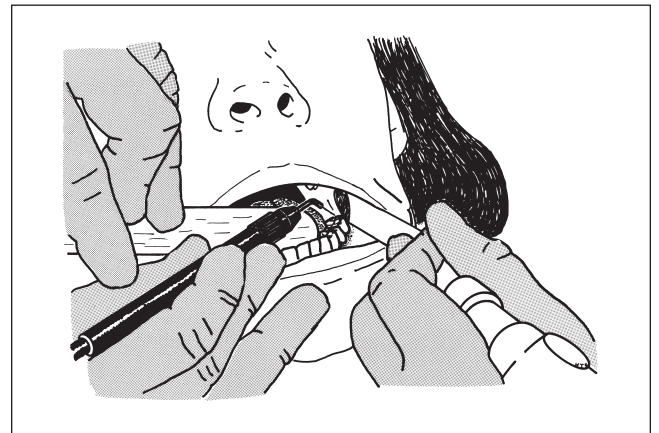


Fig 16-36 A plastic vacuum tip should be kept close to the surgical site, and a wooden tongue blade should be used as a tongue retractor.

must be plastic to prevent any burns that might be caused by accidental contact with the electrode. For the same reason, a wooden tongue depressor or plastic-handled mirror should be used rather than the metal-backed mouth mirror that would customarily be employed.

Cutting should be stopped frequently to clean any fragments of tissue from the electrode by wiping it with an alcohol-soaked 4 × 4-inch sponge (Fig 16-37). The electrode is completely safe as soon as the foot switch has been released. Proper technique with the cutting electrode can be summed up in three points:

1. Proper power setting
2. Quick passes with the electrode
3. Adequate time intervals between strokes




Fig 16-37 An alcohol sponge is used to wipe tissue debris from the cutting electrode.

16 Fluid Control and Soft Tissue Management

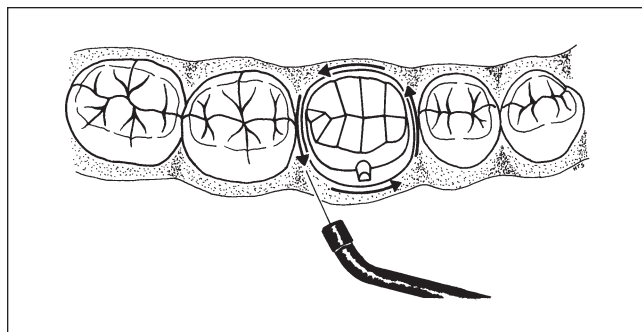


Fig 16-38 Passes to be made with the electrode can be practiced before turning on the power.

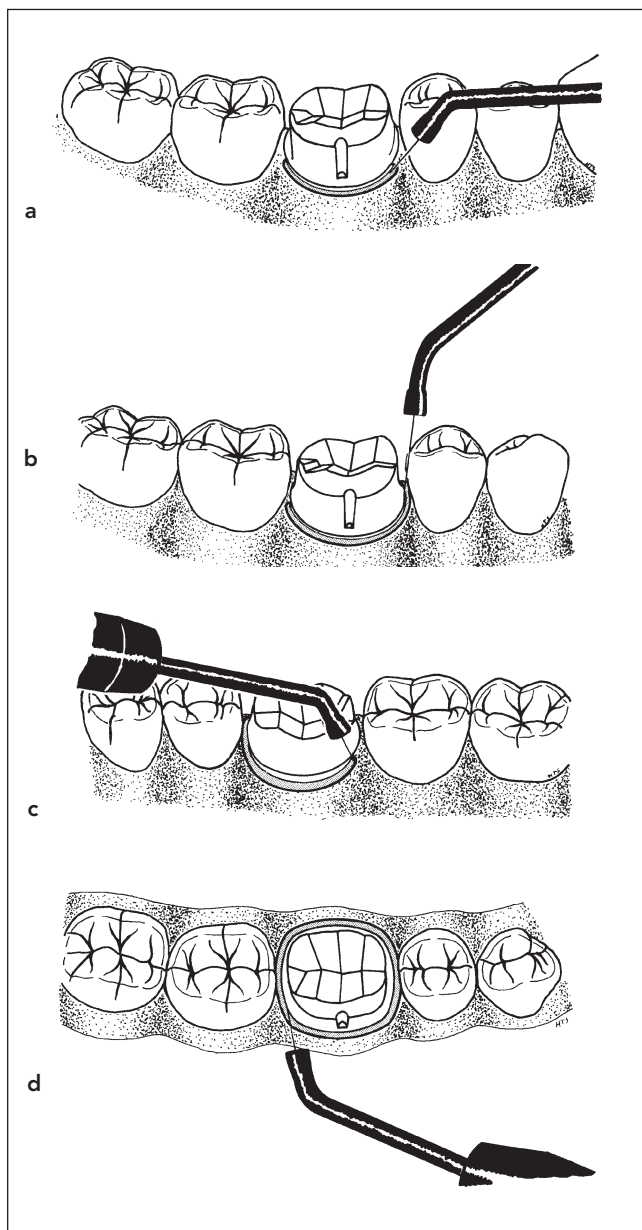


Fig 16-39 Cuts for gingival crevice enlargement are made with a small, straight electrode, without repeating any strokes until all others in the series have been made: (a) facial; (b) mesial; (c) lingual; (d) distal.

Gingival sulcus enlargement

Before any tissue is removed, it is important to assess the width of the band of attached gingiva. The electrosurgery tip is a surgical instrument; it cannot restore lost gingiva. If there is unattached alveolar mucosa too near the gingival crest, periodontal surgery, probably in the form of a gingival graft, must be employed to reinstate an adequate band of healthy, attached tissue.

To enlarge the gingival sulcus for impression making, a small, straight or J-shaped electrode is selected. It is used with the wire parallel to the long axis of the tooth so that tissue is removed from the inner wall of the sulcus.⁵⁸ If the electrode is maintained in this direction, the loss of gingival height will be about 0.1 mm.⁵⁶ Holding the electrode at an angle to the tooth, however, is likely to result in a loss of gingival height.

Around those teeth where the attached gingival tissue is thin and stretched tightly over the bone on the labial surface, there is a greater chance for a loss of gingival height. This is frequently true of maxillary anterior teeth, particularly the canines, and is worth bearing in mind if the esthetic requirements are great and any gingival recession will be unacceptable.

With the electrosurgery unit off, the electrode is held over the tooth to be treated, and the cutting strokes are traced over the tissue (Fig 16-38). The foot switch is depressed before contact is made with the tissue, and then the electrode is moved through the first pass. A whole tooth should be encompassed in four separate motions—facial, mesial, lingual, and distal—at a speed of no less than 7 mm per second⁶² (Fig 16-39). If a second pass is necessary in any one area, 8 to 10 seconds should be allowed before that stroke is repeated.⁶² This will minimize the production of lateral heat. Tissue debris should be cleaned off the electrode tip after each stroke. A cotton pellet dipped in hydrogen peroxide is used to clean debris from the sulcus (Fig 16-40). Better results are usually obtained if retraction cord is loosely packed in the enlarged sulcus before the impression is made.

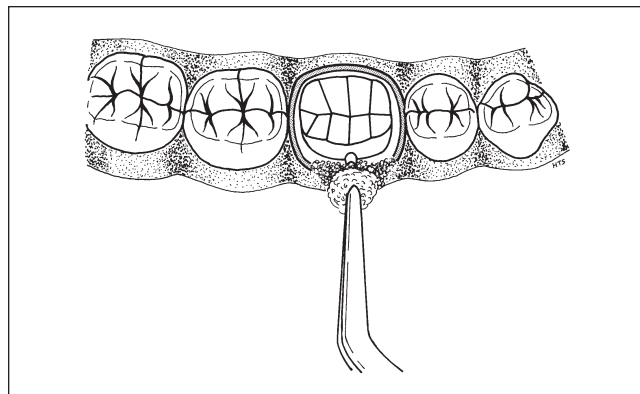


Fig 16-40 Debris from the enlarged sulcus is cleaned with hydrogen peroxide on a cotton pellet.

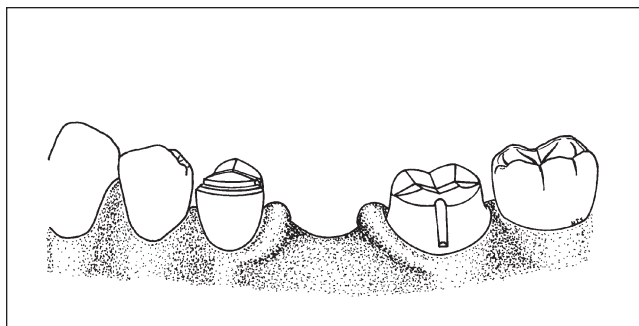


Fig 16-41 The cuff of tissue adjacent to the edentulous space interferes with a cleanable pontic and strong connectors.

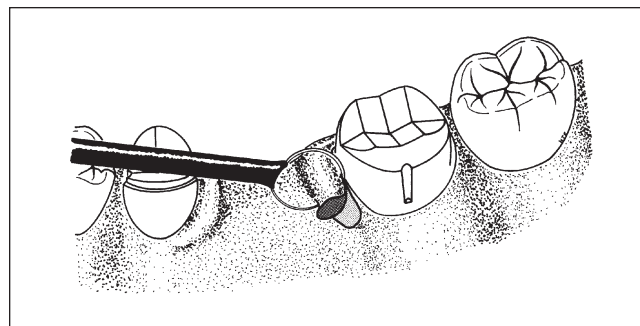


Fig 16-42 A large loop is used to remove the cuff.

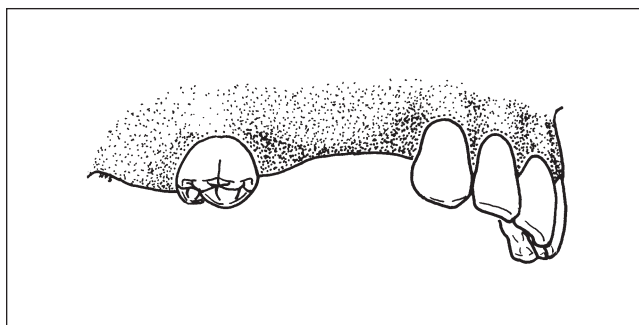


Fig 16-43 It is possible to lengthen the crown of a tooth if there is a wide band of attached gingiva.

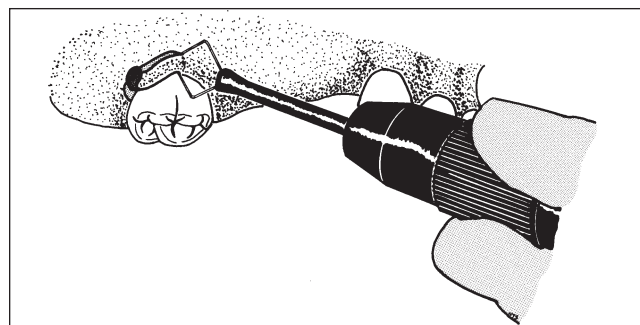


Fig 16-44 Gingivectomy is done with a loop electrode.

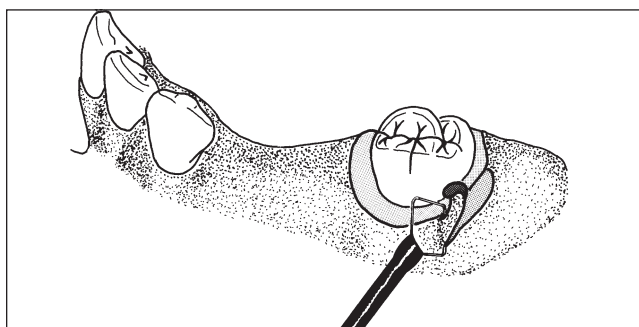


Fig 16-45 The same instrument is used to shape the edges of the previous cut to prevent a ledge of gingival tissue adjacent to the tooth.

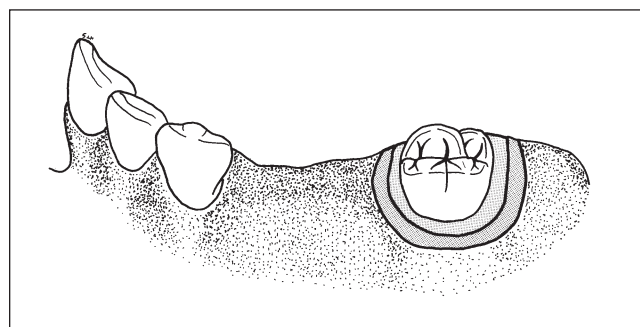


Fig 16-46 Lengthened tooth after completion of minor gingivectomy.

Removal of an edentulous cuff

Frequently, the remnants of the interdental papilla adjacent to an edentulous space will form a roll or cuff that will make it difficult to fabricate a pontic with cleanable embrasures and strong connectors. Before a pontic is fabricated, an edentulous ridge should be examined carefully. If there are cuffs, they should be removed (Fig 16-41). Malone and Manning⁵⁷ found in a bilateral comparative study of gingivoplasties on 10 patients that there was no difference in healing between conventional surgery and electrosurgery. A large loop electrode is used for planing away the large roll of tissue (Fig 16-42). When this larger electrode is used, it requires a higher power setting of the unit.

Crown lengthening

There are circumstances in which it may be desirable to have a longer clinical crown on a tooth than is present (Fig 16-43). If there is a sufficiently wide band of attached gingiva surrounding the tooth, this can be accomplished with a gingivectomy using a diamond electrode (Fig 16-44). It is frequently necessary to do a second series of cuts to produce a bevel around the first (Fig 16-45). This will produce a better tissue contour without hard-to-clean edges near the tooth (Fig 16-46). This bevel also must be done only on attached gingiva. When surgery leaves an extensive postoperative wound, as in this case, it is necessary to place a periodontal dressing, which should be changed in about 7 days.

16 Fluid Control and Soft Tissue Management

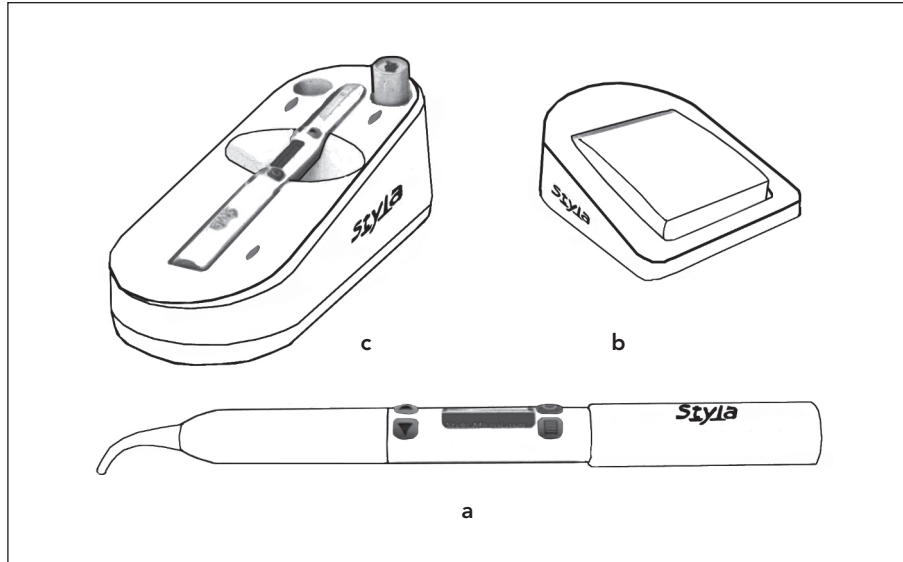


Fig 16-47 Cordless laser with stylus (a), foot control (b), and charger (c).

The lengthened tooth that results from this surgery should afford better retention for any crown placed on it, with margin placement in an area of the tooth more accessible for cleaning. If the band of attached gingiva is too narrow, it must be made wider with a graft or an alternative restoration must be made for the tooth.

Lasers

As with electrosurgery devices, the practicality of lasers for dental treatment increases as time passes and the devices, which were once bulky and expensive, become smaller and less expensive. At the time of this writing, there is a cordless and space-friendly dental laser (Fig 16-47) costing \$12,400; the cost of dental lasers ranges from \$8,000 to \$15,000.⁸⁵ The current cost of electrosurgery units ranges from \$500 to \$10,000⁷⁸; it is evident that the cost difference is narrowing. In a survey by the American Dental Association, 88% of the 700 respondents used electrosurgical devices, but of those who did not use them, 30% had switched to lasers from electrosurgical devices.⁷⁸

Regarding lasers, three areas may guide the dentist's choice. They are wavelength, pulse characteristics, and maximum wattage.⁸⁵ Generally, the shorter the wavelength, the better the hemostasis, and the longer the wavelength, the cleaner the incision.⁸⁵ Lasers provide both continuous wave and pulse modes, and some have variable pulse modes.⁸⁵ Pulse modes allow for tissue cooling and less thermal damage.⁸⁵ Tough, fibrous connective tissue such as a frenum requires more wattage for incision than does alveolar gingival

tissue.⁸⁵ Most soft tissue procedures done with dental diode lasers require 1 to 2 watts of power.⁸⁵

The term laser stands for *light amplification by stimulated emission of radiation*. This is nonionizing radiation, so it does not have the same long-term risks as x-radiation, but education, planning, and training are still extremely important.⁸⁶ Lasers for professional use could cause serious damage if used improperly.⁸⁶ The hazards include eye damage, skin damage, and fire hazard.⁸⁶

Several manufacturers have received clearance from the Food and Drug Administration (FDA) for lasers for tooth whitening and periodontal treatment.⁸⁷ Since 1997, lasers have been cleared by the FDA for the treatment of caries but not for the removal of tooth enamel.⁸⁷

The dental literature has numerous articles concerning the use of lasers in dentistry. These devices have been used for incision, excision, vaporization, ablation, and coagulation.⁸⁵ Among the uses are gingival troughing for crown impressions, gingivectomy, gingivoplasty, hemostasis, papillectomies, reduction of gingival hypertrophy, and soft tissue crown lengthening.⁸⁵

The use of these devices for chronic periodontitis is still being evaluated and is controversial.⁸⁸⁻⁹³ However, their utility in orthodontic and esthetic restorative dentistry practices is evident.⁹⁴⁻⁹⁷ Their use in fixed prosthodontics is also being developed.^{98,99} For example, Holt and Nordquist¹⁰⁰ used a holmium-doped yttrium aluminum garnet (Ho:YAG) laser at the margins of restorations to increase their resistance to acid/mechanical destruction (caries) on cementum/dentin root surfaces. Any of the procedures described in the previous section on electrosurgery also can be accomplished with lasers.

References

- Noonan JE, Goldfogel MH, Lambert RL. Inhibited set of the surface of addition silicones in contact with rubber dam. *Oper Dent* 1985;10(2):46–48.
- Accepted Dental Therapeutics, ed 40. Chicago: American Dental Association, 1984:344–345.
- PDR website. <http://www.pdr.net>. Accessed 2 December 2011.
- Robinul monograph. <http://www.drugs.com/monograph/robinul/html>. Accessed 28 November 2011.
- Glycopyrrolate. <http://www.answers.com/topic/glycopyrrolate>. Accessed 28 November 2011.
- Daily Med website. <http://www.dailymed.nlm.nih.gov>. Accessed 2 December 2011.
- Wilson EL, Whitsett LD, Whitsett TL. Effects of methantheline bromide and clonidine hydrochloride on salivary secretion. *J Prosthet Dent* 1984;52:663–665.
- Perakis N, Belser UC, Magne P. Final impressions: A review of material properties and description of a current technique. *Int J Periodontics Restorative Dent* 2004;24:109–117.
- Sadan A. Selection of hemostatic agents for tissue displacement. *Pract Proced Aesthet Dent* 2001;13:512.
- Thompson MJ. Hydrocolloid—Its treatment and application in securing consistent accurate models for indirect inlays and fixed bridges. *Bull Okla State Dent Assoc* 1949;38:7–24.
- Benson BW, Bomberg TJ, Hatch RA, Hoffman W Jr. Tissue displacement methods in fixed prosthodontics. *J Prosthet Dent* 1986;55:175–181.
- Hovestad JF. *Practical Dental Porcelains*. St Louis: Mosby, 1924:34–36.
- Miller IF. Fixed dental prosthesis. *J Prosthet Dent* 1958;8:483–495.
- Lucca JJ. The tube impression technique. *Dent Clin North Am* 1959;3:113–123.
- Ewing JE. Beautiful but glum—Porcelain jacket crowns. *J Prosthet Dent* 1954;4:94–103.
- Johnston JF, Mumford G, Dykema RW. *Modern Practice in Dental Ceramics*. Philadelphia: Saunders, 1967:84–94.
- Ruel J, Schuessler PJ, Malament K, Mori D. Effect of retraction procedures on the periodontium in humans. *J Prosthet Dent* 1980;44:508–515.
- Coelho DH, Brisman AS. Gingival recession with modeling-plastic copper-band impressions. *J Prosthet Dent* 1974;31:647–650.
- Ingraham R, Bassett RW, Koser JR. *An Atlas of Cast Gold Procedures*, ed 2. Los Angeles: University of Southern California School of Dentistry, 1969:47–48.
- Thompson MJ. Exposing the cavity margin for hydrocolloid impressions. *J South Calif Dent Assoc* 1951;19:17–24.
- Pelzner RB, Kempler D, Stark MM, Lum LB, Nicholson RJ, Soelberg KB. Human blood pressure and pulse rate response to racemic epinephrine retraction cord. *J Prosthet Dent* 1978;39:287–292.
- Laufer BZ, Baharav H, Ganor Y, Cardash HS. The effect of marginal thickness on the distortion of different impression materials. *J Prosthet Dent* 1996;76:466–471.
- Sears AW. Hydrocolloid impression technique for inlays and fixed bridges. *Dent Dig* 1937;43:230–234.
- Harrison JD. Effect of retraction materials on the gingival sulcus epithelium. *J Prosthet Dent* 1961;11:514–521.
- Shillingburg HT Jr, Hatch RA, Keenan MP, Hemphill MW. Impression materials and techniques used for cast restorations in eight states. *J Am Dent Assoc* 1980;100:696–699.
- Donovan TE, Gandara BK, Nemetz H. Review and survey of medicaments used with gingival retraction cords. *J Prosthet Dent* 1985;53:525–531.
- Shaw DH, Krejci RF. Gingival retraction preference of dentists in general practice. *Quintessence Int* 1986;17:277–280.
- Nemetz H, Donovan T, Landesman H. Exposing the gingival margin: A systematic approach for the control of hemorrhage. *J Prosthet Dent* 1984;51:647–651.
- Loe H, Silness J. Tissue reactions to string packs used in fixed restorations. *J Prosthet Dent* 1963;13:318.
- de Gennaro GG, Landesman HM, Calhoun JE, Martinoff JT. A comparison of gingival inflammation related to retraction cords. *J Prosthet Dent* 1982;47:384–386.
- Buchanan WT, Thayer KE. Systemic effects of epinephrine-impregnated retraction cord in fixed partial denture prosthodontics. *J Am Dent Assoc* 1982;104:482–484.
- Hansen PA, Tira DE, Barlow J. Current methods of finish-line exposure by practicing prosthodontists. *J Prosthodont* 1999;8:163–170.
- Pogue WL, Harrison JD. Absorption of epinephrine during tissue retraction. *J Prosthet Dent* 1967;18:242–247.
- Houston JB, Appleby RC, DeCounter L, Callaghan N, Funk DC. Effect of r-epinephrine-impregnated retraction cord on the cardiovascular system. *J Prosthet Dent* 1970;24:373–376.
- Goldberg AT, Yoder JL, Thayer KE. Analysis of heart rate in dogs during retraction and impression procedures. *J Dent Res* 1971;50:645–648.
- Woychesin FF. An evaluation of the drugs used for gingival retraction. *J Prosthet Dent* 1964;14:769–776.
- Fisher DW. Conservative management of the gingival tissue for crowns. *Dent Clin North Am* 1976;20:273–283.
- Gogerty JH, Strand HA, Ogilvie AL, Dillie JM. Vasopressor effects of topical epinephrine in certain dental procedures. *Oral Surg Oral Med Oral Pathol* 1957;10:614–622.
- Forsyth RP, Stark MM, Nicholson RJ, Peng CT. Blood pressure responses to epinephrine-treated gingival retraction strings in the rhesus monkey. *J Am Dent Assoc* 1969;78:1315–1319.
- Kellam SA, Smith JR, Scheffel SJ. Epinephrine absorption from commercial gingival retraction cords in clinical patients. *J Prosthet Dent* 1992;68:761–765.
- Malamed SF. *Medical Emergencies in the Dental Office*, ed 6. St Louis: Mosby, 2007:31,381–384.
- Nemetz EH, Seibly W. The use of chemical agents in gingival retraction. *Gen Dent* 1990;38:104–108.
- O'Mahony A, Spencer P, Williams K, Corcoran J. Effect of 3 medicaments on the dimensional accuracy and surface detail reproduction of polyvinyl siloxane impressions. *Quintessence Int* 2000;31:201–206.
- Bowles WH, Tardy SJ, Vahadi A. Evaluation of new gingival retraction agents. *J Dent Res* 1991;70:1447–1449.
- Weir DJ, Williams BH. Clinical effectiveness of mechanical-chemical tissue displacement methods. *J Prosthet Dent* 1984;51:326–329.
- Shaw DH, Krejci RF, Cohen DM. Retraction cords with aluminum chloride: Effect on the gingiva. *Oper Dent* 1980;5:138–141.
- Sorensen JA, Doherty F, Flemmig T, Newman MG. Gingival enhancement in fixed prosthodontics: I. Clinical findings [abstract 2091]. *J Dent Res* 1988;67:374.
- de Camargo LM, Chee WW, Donovan TE. Inhibition of polymerization of polyvinyl siloxanes by medicaments used on gingival retraction cords. *J Prosthet Dent* 1993;70:114–117.
- Anneroth G, Nordenram A. Reaction of the gingiva to the application of threads in the gingival pocket for taking impressions with elastic material. An experimental histological study. *Odontol Revy* 1969;20:301–310.
- Ingraham R, Sochat R, Hansing FJ. Rotary gingival curettage—A technique for tooth preparation and management of the gingival sulcus for impression taking. *Int J Periodontics Restorative Dent* 1981;1(4):8–33.
- Tupac RG, Neacy K. A comparison of cord gingival displacement with the gingitage technique. *J Prosthet Dent* 1981;46:509–515.
- Brady WF. Periodontal and restorative considerations in rotary curettage. *J Am Dent Assoc* 1982;105:231–236.
- Moskowitz BS. The response of the gingival sulcus to instrumentation. *J Periodontol* 1964;35:112–126.
- Ingraham R, Evens JK. I. Tissue management in cavity preparation. *Dent Dimens* 1975;9:9–11,32.
- Kamansky FW, Tempel TR, Post AC. Gingival tissue response to rotary curettage. *J Prosthet Dent* 1984;52:380–383.
- Klug RG. Gingival tissue regeneration following electrical retraction. *J Prosthet Dent* 1966;16:955–962.

16 Fluid Control and Soft Tissue Management

57. Malone WF, Manning JL. Electrosurgery in restorative dentistry. *J Prosthet Dent* 1968;20:417–425.
58. Podshadley AG, Lundeen HC. Electrosurgical procedures in crown and bridge restorations. *J Am Dent Assoc* 1968;77:1321–1326.
59. Flocken JE. Electrosurgical management of soft tissues and restorative dentistry. *Dent Clin North Am* 1980;24:247–269.
60. Patel MG. Electrosurgical management of hyperplastic tissue. *J Prosthet Dent* 1986;56:145–147.
61. Ferreira PM, Fugazzotto PA, Parma-Benfenati S. Implications of the use of electrosurgical techniques in the presence of gingival inflammation. *Gen Dent* 1987;35:17–21.
62. Kalkwarf KL, Krejci RF, Edison AR, Reinhardt RA. Lateral heat production secondary to electrosurgical incisions. *Oral Surg Oral Med Oral Pathol* 1983;55:344–348.
63. Kalkwarf KL, Krejci RF, Wentz FM. Healing of electrosurgical incisions in gingiva: Early histologic observations in adult men. *J Prosthet Dent* 1981;46:662–672.
64. Aremband D, Wade AB. A comparative wound healing study following gingivectomy by electrosurgery and knives. *J Periodont Res* 1973;8:42–50.
65. Williams VD. Electrosurgery and wound healing: A review of the literature. *J Am Dent Assoc* 1984;108:220–222.
66. Gonser DI. Theory of electrosurgical instrumentation. In: Malone WF (ed): *Electrosurgery in Dentistry—Theory and Application in Clinical Practice*. Springfield, IL: Thomas, 1974:3.
67. Oringer MJ. *Electrosurgery in Dentistry*, ed 2. Philadelphia: Saunders, 1975:4.
68. Friedman J. The technical aspects of electrosurgery. *Oral Surg Oral Med Oral Pathol* 1973;36:177–187.
69. Maness WL, Roeber FW, Clark RE, Cataldo E, Riis D, Haddad AW. Histologic evaluation of electrosurgery with varying frequency and waveform. *J Prosthet Dent* 1978;40:304–308.
70. Sozio RB, Riley EJ, Shklar G. A histologic and electronic evaluation of electrosurgical currents: Nonfiltered full-wave modulated vs. filtered current. *J Prosthet Dent* 1975;33:300–312.
71. Annex 2—The safe use of high frequency electricity in health care facilities. In: NFPA 99, *Standard for Health Care Facilities*. Quincy, MA: National Fire Protection Association, 1993:201–215.
72. Adams I. Potential hazards of an electro-surgical unit. *Hosp Admin Can* 1971;13:37–38.
73. Neufeld GR. Principles and hazards of electrosurgery including laparoscopy. *Surg Gynecol Obstet* 1978;147:705–710.
74. Battig GG. Electrosurgical burns and their prevention. *AORN J* 1968;8:48–54.
75. Becker CM, Malhotra IV, Hedley-Whyte J. The distribution of radiofrequency current and burns. *Anesthesiology* 1973;38:106–122.
76. Billin AG. Patient safety and electrosurgery. *AORN J* 1971;14:62–68.
77. Oringer M. *Electrosurgery in Dentistry*, ed 2. Philadelphia: Saunders, 1975:26.
78. ADA Professional Product Review. 2009;4(3):3–9.
79. Smyth NP, Parsonnet V, Escher DJ, Furman S. The pacemaker patient and the electromagnetic environment. *JAMA* 1974;227:1412.
80. Simon AB, Linde B, Bonnette GH, Schlentz RJ. The individual with a pacemaker in the dental environment. *J Am Dent Assoc* 1975;91:1224–1229.
81. Walter C. Dental treatment of patients with cardiac pacemaker implants. *Quintessence Int* 1975;8:57–58.
82. Rezai FR. Dental treatment of patient with a cardiac pacemaker. Review of the literature. *Oral Surg Oral Med Oral Pathol* 1977;44:662–665.
83. Stamps JT, Muth ER. Reducing accidents and injuries in the dental environment. *Dent Clin North Am* 1978;22:389–402.
84. Oringer M. *Electrosurgery in Dentistry*, ed 2. Philadelphia: Saunders, 1975:89.
85. Waugh RL. Learn to laser: Ground rules for implementing a diode laser in your practice. http://www.orthodonticproducts.com/issues/articles/2007-09_05.asp. Accessed 16 June 2011.
86. Guidelines for Laser Safety and Hazard Assessment. http://www.osha.gov/pls/oshaweb/owadisp.show_document?p_table=DirectIVES&p_id=1705. Accessed 28 November 2011.
87. Radiation-Emitting Products. <http://www.fda.gov/Radiation-EmittingProducts/ResourcesforYouRadiationEmittingProducts/ucm252761.htm>. Accessed 28 November 2011.
88. Cobb CM. Lasers in periodontics: A review of the literature. *J Periodontol* 2006;77:545–564.
89. Ziada H, Irwin C, Mullally B, Byrne PJ, Allen E. Periodontics: 5. Surgical crown lengthening. *Dent Update* 2007;34(8):462–464, 467–468.
90. Moritz A, Gutknecht N, Doertbudak O, et al. Bacterial reduction in periodontal pockets through irradiation with a diode laser: A pilot study. *J Clin Laser Med Surg* 1997;15:33–37.
91. Neill ME, Mellonig JT. Clinical efficacy of the Nd:YAG laser for combination periodontitis therapy. *Pract Periodontics Aesthet Dent* 1997;9(6 suppl):1–5.
92. Ozelik O, Cenk Haytac M, Kunin A, Seydaoglu G. Improved wound healing by low-level laser irradiation after gingivectomy operations: A controlled clinical pilot study. *J Clin Periodontol* 2008;35:250–254.
93. Harris DM. Dosimetry for laser sulcular debridement. *Lasers Surg Med* 2003;33:217–218.
94. Lee EA. Aesthetic crown lengthening: Classification, biologic rationale, and treatment planning considerations. *Pract Proced Aesthet Dent* 2004;16(10):769–778.
95. Lee EA. Laser-assisted gingival tissue procedures in esthetic dentistry. *Pract Proced Aesthet Dent* 2006;18(9 suppl):S2–S6.
96. Sarver DM, Yanosky M. Principles of cosmetic dentistry in orthodontics: Part 2. Soft tissue laser technology and cosmetic gingival contouring. *Am J Orthod Dentofacial Orthop* 2005;127:85–90.
97. Adams TC, Pang PK. Lasers in aesthetic dentistry. *Dent Clin North Am* 2004;48:833–860.
98. Jetter C. Soft-tissue management using an ER,Cr:YSGG laser during restorative procedures. *Compend Contin Educ Dent* 2008;29:46–49.
99. Abdel Gabbar F, Aboulazm SF. Comparative study on gingival retraction using mechanochemical procedure and pulsed Nd = YAG laser irradiation. *Egypt Dent J* 1995;41:1001–1006.
100. Holt RA, Nordquist RE. Effect of resin/fluoride and holmium:YAG laser irradiation on the resistance to the formation of caries-like lesions. *J Prosthodont* 1997;6:11–19.

Impressions

17



An *impression* is an imprint or negative likeness. It is made by placing some soft, semi-fluid material in the mouth and allowing the material to set. Depending on the material used, the set impression will be either hard or elastic. The impression materials most frequently used for cast restorations are elastic when removed from the mouth. From this negative form of the teeth and surrounding structures, a positive reproduction, or cast, is made.

The indirect technique for fabricating inlays, crowns, and fixed partial denture retainers has been a boon to the practice of dentistry. It allows most of the laboratory procedures involved in the fabrication of a restoration to be done away from the chair, substituting a gypsum cast for the actual tooth. If the restoration is to fit precisely, the cast on which it is made must be as nearly an exact duplicate of the prepared tooth in the mouth as possible. This means an accurate, undistorted impression of the prepared tooth must be made.

Therefore, the impression must be handled properly until it is poured in a gypsum product. Impression making is an area of restorative dentistry where much abuse of materials occurs; many an accurate impression has been distorted by improper handling or untoward delays between removal from the mouth and pouring.

An impression for a cast restoration should meet the following requirements:

- It should be an exact duplication of the prepared tooth, including all of the preparation and enough uncut tooth surface beyond the preparation to allow the dentist and technician to be certain of the location and configuration of the finish line.
- Other teeth and tissue adjacent to the prepared tooth must be accurately reproduced to permit proper articulation of the cast and contouring of the restoration.
- It must be free of bubbles, especially in the area of the finish line and occlusal surfaces of the other teeth in the arch.

It has been reported that impressions sent to laboratories sometimes have more than 50% of the preparation finish line not discernible. Voids and bubbles, impression material separated from trays, embedded retraction cords, and preparation debris make usable, accurate casts questionable.¹ Of course, it is critical to have accurate casts because it is critical to have well-fitting restorations. The second cannot exist without the first.

Comparison of Impression Materials

There are several types of impression materials that are accurate enough to be considered for cast restorations. The choice is based on personal preference, ease of manipulation, and, to some extent, economics. Accuracy is not a consideration in the choice among these materials because there are no clinically significant differences. The materials described here are reversible hydrocolloid, polysulfide, condensation silicone, polyvinyl siloxane (PVS), and polyether. The attributes of each² are listed in Table 17-1.

Wettability

Each impression material has different handling characteristics. Finding the characteristics with which the dentist and auxiliaries can best work is an important consideration in choosing an impression material. Ease of pouring with gypsum products varies among the different impression materials.³ Impression materials can be classified as readily wettable by gypsum (*hydrophilic*) or resistant to wetting (*hydrophobic*).

Irreversible hydrocolloid (alginate), reversible hydrocolloid, and polyether are hydrophilic and the easiest to pour. Polysulfide, PVS materials, and condensation-reaction silicones are the most hydrophobic, in ascending order, as indicated by their high contact angles⁴ (Fig 17-1). The greater the contact angle, the greater the probability of air entrapment during pouring. Not only is the incidence of voids in the stone cast greater,^{5,6} but the voids are larger in size.⁶ Of at least equal clinical significance is the fact that materials exhibiting large contact angles are also more readily repelled by hemorrhage or other moisture in the gingival sulcus.

These findings certainly do not contraindicate the use of PVS materials, nor do they guarantee a good cast every time hydrocolloid is used. They require that caution be exercised in pouring an impression made of one of the materials whose surface is more difficult to wet. The use of a surfactant is also effective in reducing both the contact angle⁴ and the number of voids trapped in the resulting cast.⁶⁻⁸

Table 17-1 Comparative properties of impression materials*

Type	Type of tray	Setting time	Ease of removal	Finish line readability	Moisture tolerance	Pouring time	Tear strength	Pouring ease	Mixing ease	Odor/taste	Radio-paque	Shelf life
Reversible hydrocolloid	Water-cooled stock metal	5 min	Very easy to easy	Poor	Excellent	15 min	Weak	Good to excellent	None is needed, but conditioning is complicated	Good	No	24–48 months
Polysulfide rubber base	Custom	8–14 min	Easy to moderate	Good	Acceptable	60 min	Good	Adequate to excellent	Moderate to difficult	Poor	Yes	18 months
Condensation silicone	Custom: two paste systems Stock: putty/reline	6–10 min	Easy to moderate	Good	Poor	60 min	Adequate	Poor to fair	Easy	Good	No	12 months
Polyether rubber base	Custom: 4.0-mm spacer Stock	4.5–6 min	Moderate to difficult	Good	Good	7 days	Adequate	Good	Moderate for hand-mixed; very easy for mechanically mixed	Poor	No	24 months
Polyvinyl siloxane	Stock: single units Custom: fixed partial denture Stock: putty/reline	3–8 min	Moderate to difficult	Good	Poor for standard hydrophobic brands; adequate for hydrophilic brands	7 days	Adequate	Poor for standard hydrophobic brands; adequate for hydrophilic brands	Easy for hand-mixed; very easy for cartridge systems	Good	No	24 months

*Based on data from O'Brien.²

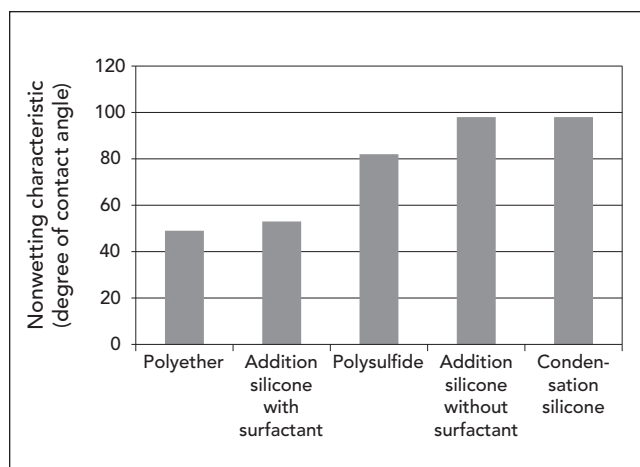


Fig 17-1 Likelihood of trapping bubbles while pouring an impression as measured by the contact angle of gypsum on their surfaces. (Based on data from McCormick et al⁴ and Powers and Sakaguchi.⁷)

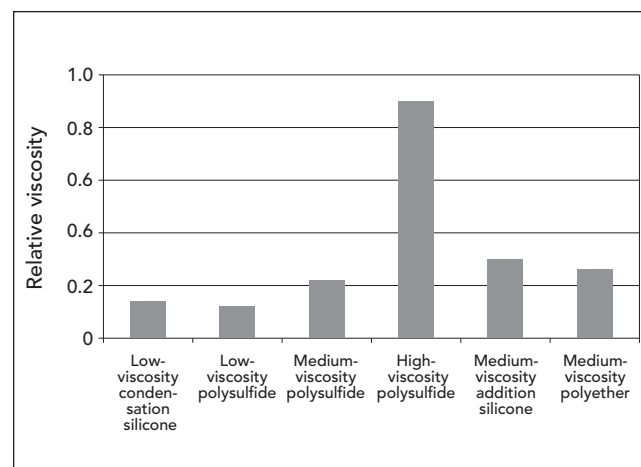


Fig 17-2 Comparison of the relative viscosity of six impression materials 45 seconds after mixing. (Based on data from Powers and Sakaguchi.⁹)

Viscosity

Viscosities for impression materials vary with the type of material. Light-body polysulfide and condensation silicone are the least viscous, and heavy-body polysulfide is the most viscous⁹ (Fig 17-2). Viscosity will increase as time elapses after the start of mixing.^{10,11}

These materials exhibit lower viscosity when the *shear rate* (the speed at which a liquid flows under external forces) increases, which occurs when a material is expressed through a syringe. This effect, called *shear thinning*, explains why a single-viscosity monophasic material can be placed in a tray, where false body (a higher apparent standing consistency) permits the material to stay in the tray without sagging or dripping, and yet the same material still can have sufficiently high fluidity (low viscosity) to be used in a syringe. A material that exhibits this property of becoming more fluid when the shear rate is increased by deforming or disturbing it (eg, shaking, spatulating, or injecting through a syringe) is described as *thixotropic*.

Depending on the impression material, its viscosity could decrease when syringing by eight to eleven times compared with its viscosity when only spatulating.⁹ The force required of the dentist is dependent on both the material and the syringe used. Forces as low as 2.6 lbs for a condensation silicone/metal reusable syringe combination and as high as 112 lbs for a polysulfide/large-diameter plastic disposable syringe combination have been reported.¹²

Cost

While cost is not the primary factor in the selection of an impression material, it is one to be considered. At the time of this writing, a US discount mail order dental supplier lists

over 45 PVS impression material brands. It lists only slightly more than five brands of each of the other impression materials. It is clear that PVS is currently the most popular impression material. Accordingly, cartridge-dispensed PVS is used here to analyze the cost for dental impressions.

Although uniformly thin elastomeric impressions are more accurate,¹³⁻¹⁵ only about one-third of surveyed dentists routinely employ custom trays.¹⁶ Therefore, for this comparison, calculations were made for disposable stock plastic trays, stock metal trays, and custom resin trays. A volume of 33.3 mL was used for disposable trays, based on the mean volume of six sizes of spacer trays¹⁷ (GC). A volume of 38.4 mL was the mean for the 10 sizes of full-arch trays in the rim-lock set¹⁷ (Dentsply).

The total volumes used for each type of impression are as follows: disposable stock plastic tray, 33.3 mL + 3.3 mL waste of heavy body + 4.0 mL of light body for the syringe; stock metal tray, 38.4 mL + 3.8 mL waste of heavy body + 4.0 mL of light body for the syringe; custom resin tray, 16.5 mL + 2.0 mL waste of heavy body + 4.0 mL of light body for the syringe. Additional expenses include \$0.54 (range, \$0.54 to \$3.25) for a disposable tray, \$0.20 (range, \$0.20 to \$1.30) for a mixing tip, and \$2.27 (range, \$2.27 to \$2.92) for a visible light-cured (VLC) custom tray. The cost of a custom tray used here is that of a sheet of the VLC material only, assuming that office personnel make it. If a custom tray were to be fabricated by a commercial laboratory, the expense would be prohibitive.

The range of cost for light-body PVS is from \$0.12 to \$0.77 per mL.¹⁸ The range of cost for heavy-body PVS is from \$0.12 to \$0.51 per mL.¹⁸ So, for a PVS impression using the least expensive combination of expendable supplies and a disposable stock plastic tray, the cost would be \$5.61; for a stock metal tray the cost would be \$5.74, and for a custom resin tray the cost would be \$5.17.

17 Impressions

Reversible Hydrocolloid

Reversible hydrocolloid (agar) has seen extensive use as an impression material in the fabrication of cast gold restorations for more than 70 years.¹⁹ Hydrocolloid was patented in 1925,²⁰ and it was introduced to the United States in the late 1920s.²¹ Credit for its first use in the United States for fabricating cast restorations is given to J. D. Hart of Wewoka, Oklahoma, who began using it for that purpose in 1930.²¹

Reversible hydrocolloid is packaged as a semi-solid gel in polyethylene tubes. It is liquefied in a hydrocolloid conditioner by placing it in boiling water. As a liquid sol at this temperature, it is obviously too hot for intraoral use, so it is cooled in two stages: storage and tempering. In addition to lowering the temperature of the sol, tempering helps to increase the viscosity of the material in the tray so that it is more easily managed.

After the tray filled with tempered sol is placed in the mouth, cool tap water is circulated through the double-walled jacket of the tray to complete the gelation process. The material begins to gel near the cool tray first, spreading to the material adjacent to the oral tissues. Rapid cooling by excessively cold water can result in stress concentrations near the tray with possible distortion of the impression. The temperature should be 64°F to 70°F.²² When the material is completely gelled, the impression is removed from the mouth and is ready to be poured. The cycle is thereby completed:

gel tube → sol container → gel impression tray

Hydrocolloid is approximately 85% water, and the balance of this constituent is critical to the impression's accuracy. It can lose water by syneresis (water seeping from the surface) or by evaporation. It can also absorb water (if placed in contact with it) by imbibition. Numerous ways of storing impressions following removal from the mouth have been advocated: wet towels, humidors, water baths, and 2% potassium sulfate solution baths. The fact is that none is totally effective in preventing distortion; the impression begins distorting when it is removed from the mouth. The sooner it is poured, the less distortion there will be in the resulting cast.

The agar in hydrocolloid is a polysaccharide (a sulfuric ester of a linear polymer of galactose), which is obtained from seaweed.²² Certain modifiers are added to improve the properties of the material. Sodium tetraborate increases the strength of the gel and the viscosity of the sol. The set of gypsum is retarded by contact with any gel, and the presence of borax tends to enhance this undesirable feature. The result could be a soft surface on the cast poured in the impression. Therefore, potassium sulfate is added to the hydrocolloid by the manufacturer to accelerate and harden the stone when it is poured into the impression. It also increases rupture strength and improves plastic deformation properties of the hydrocolloid.²³

Reversible hydrocolloid impression materials have been strengthened considerably since their introduction,²⁴ and the process is ongoing. Some stones are more compatible with hydrocolloid impression material than others, reproducing surface detail more completely.²⁵ It is wise to check this feature before using a particular brand of stone with hydrocolloid. A bactericide such as thymol may be added to reduce bacterial growth. Plasticizers, fillers, flavoring agents, and pigments are added to the formula to constitute the final commercial product.

The ideal conditioner for preparing hydrocolloid for use has three baths (Fig 17-3):

1. *Liquefying bath.* Tubes of impression material and loaded syringes are boiled for 10 minutes in this bath (Fig 17-4). If the material is being reliquefied, it should be boiled for 12 minutes. To reach a boiling temperature of 212°F at higher altitudes, it is necessary to substitute propylene glycol for water in the boiling bath.
2. *Storage bath.* The tubes filled with liquefied material are moved to this bath, where they are stored at 150°F for a minimum of 10 minutes (Fig 17-5). Heavier-body materials may require storage at 152°F to 155°F.²⁴ Storage at higher altitudes also may require a higher storage temperature. The material can be stored for 5 days. If it has not been used by that time, it should be reliquefied by boiling it for 12 minutes.
3. *Tempering bath.* Loaded impression trays are tempered in this bath at 110°F to 115°F for 5 to 10 minutes immediately before placing them in the mouth. Heavier-body materials require less time, and a lower temperature requires less time. The tray should remain in the tempering bath for no less than 3 minutes.

The temperature in these three baths should be checked with a thermometer at regular intervals because temperature variations can affect the viscosity and handling characteristics of the material. Water in the baths should be changed daily to minimize bacterial growth that occurs in many conditioners.²⁶ Iodophor disinfectant can be added to the water to further reduce the risk of cross-contamination.²⁶

A technique combining reversible and irreversible hydrocolloid was described in 1951,²⁷ and a modified reversible hydrocolloid that could bond to alginate (irreversible hydrocolloid) was introduced in the late 1970s.²⁸ This system, also known as the *lamine technique*,²⁹ has the advantage of requiring less complicated (and less expensive) equipment for liquefaction and storage. The alginate in the tray, mixed with water at 70°F, cools the reversible hydrocolloid that has been injected around the prepared tooth, causing it to solidify. This eliminates the need for water-jacketed trays and tubing. The impression should be ready to remove from the mouth in 3 minutes, which is faster than other elastic materials. It is also less expensive.³⁰

The principal disadvantage of combining reversible and irreversible hydrocolloids is the fast gelation time of the syringe material, which requires the impression to be handled

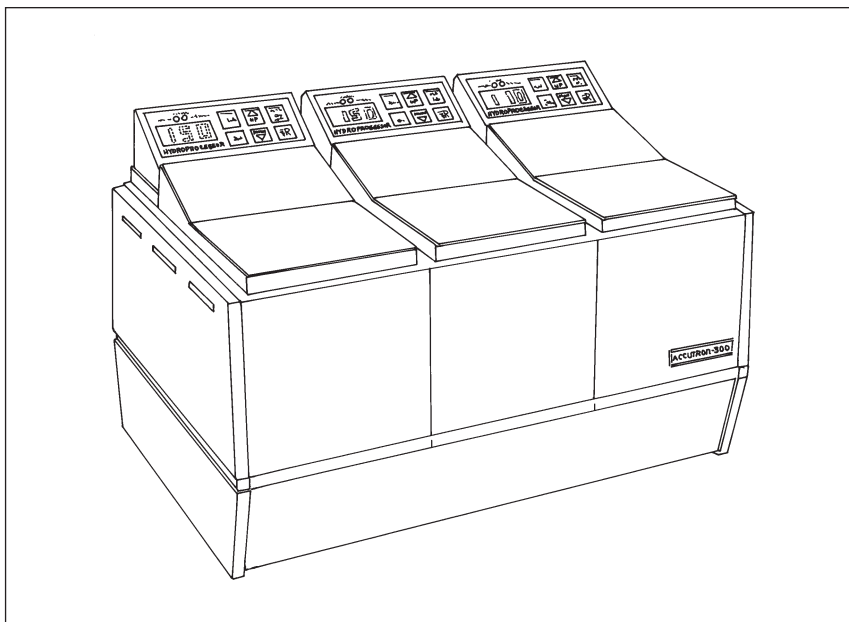


Fig 17-3 Hydrocolloid conditioner with three baths: liquefying (left), storage (center), and tempering (right).

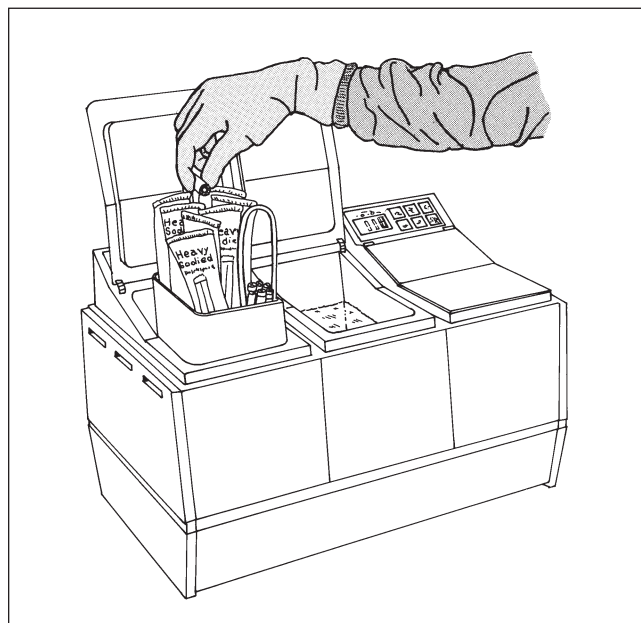


Fig 17-4 Tubes and cartridges of hydrocolloid are placed into the liquefying bath.

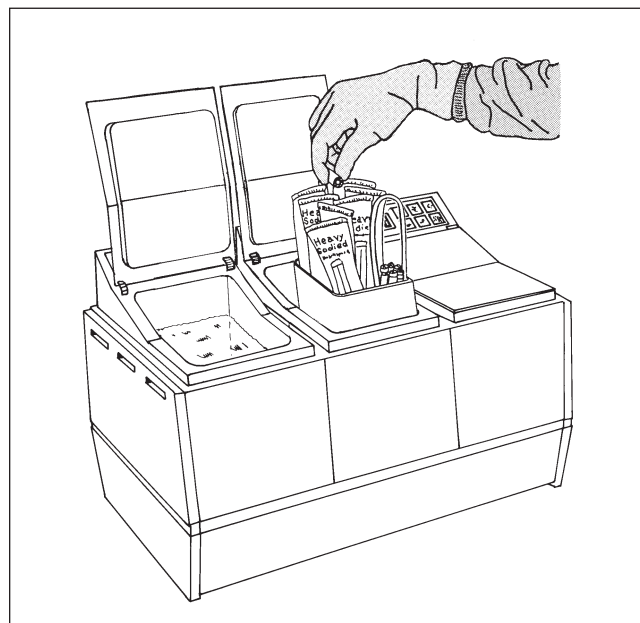


Fig 17-5 Tubes and cartridges are transferred from the liquefying bath to the storage bath.

very quickly.³¹ There also have been problems with the syringe material separating from the alginate in the tray. Testing of the materials used has shown that some combinations of reversible hydrocolloid and alginate bond together better than others³² and that reversible-irreversible combination impressions have sufficient accuracy for clinical use.^{28,31-33} Not

surprisingly, bond strengths are greater between reversible and irreversible components made by the same manufacturer.³⁴ These combination systems are used by many dentists, but they have not supplanted the conventional reversible hydrocolloid impression materials.

17 Impressions

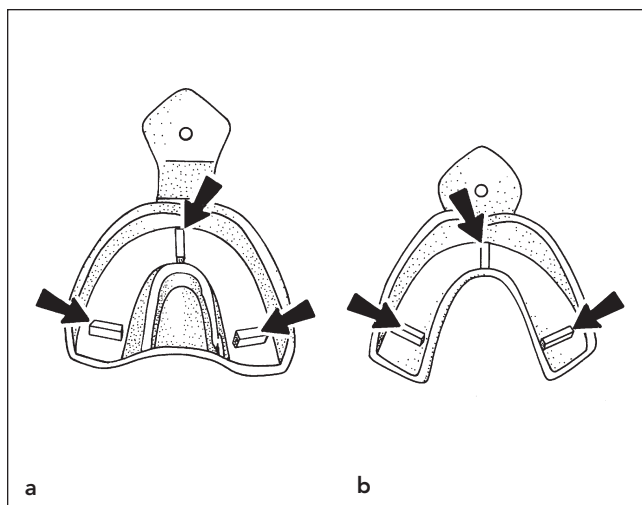


Fig 17-6 Rim-lock full-arch hydrocolloid impression trays, showing the optimal location of stops (arrows). (a) Maxillary; (b) mandibular.

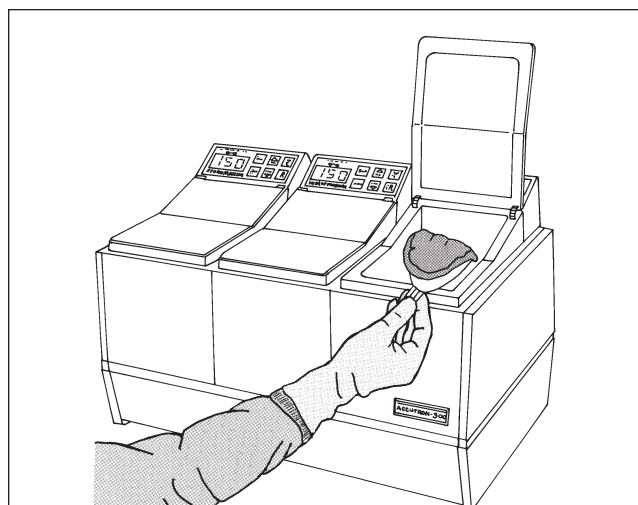


Fig 17-7 A tray filled with impression material is placed in the tempering bath.

Armamentarium

- Hydrocolloid conditioning unit
- Hydrocolloid in polyethylene tubes
- Hydrocolloid in plastic cartridge
- Nonaspirating anesthetic syringe
- Water-cooled rim-lock sectional impression tray
- Water-cooled rim-lock full-arch impression tray
- Tacky Stops (DUX Dental)
- Tubing for trays

Impression making with reversible hydrocolloid

Because only one accurate cast can be made from a hydrocolloid impression, two impressions are made: a sectional (quadrant) impression for making a die and a full-arch impression for the working cast. It should be confirmed that the patient has adequate anesthesia. If the impression is being made at a separate appointment subsequent to the preparation of the tooth, it is necessary to anesthetize the area again. The tray to be used is selected and tried in the mouth to make certain that it fits.

Adhesive plastic strips (Tacky Stops) are placed into the tray to keep the teeth from pushing all the way through to the tray when it is seated in the mouth. Two of the stops, one on top of the other, are positioned at the rear of each side and in the front of the tray on full-arch trays (Fig 17-6). On quadrant trays, stops are placed at the front and rear. It is confirmed that the stops will contact unprepared teeth.

The quadrant containing the prepared tooth is isolated, the retraction cord is inserted, and a large gauze pack is placed in the mouth. The impression tray is filled with a tube taken from the storage bath, and the filled tray is placed

in the tempering bath (Fig 17-7). It should be allowed to temper for 10 minutes. Because tempering is a function of time as well as temperature, leaving the hydrocolloid in the tempering bath too long may bring it too near gelation and make it too stiff for making an impression. It is unacceptable to cool the material on the countertop at room temperature, as this is likely to cool only the surface layer.²⁰

A short, blunt 19-gauge needle is screwed onto the end of an anesthetic-type syringe that does not have a barb on the end of the plunger (Fig 17-8). A plastic, anesthetic-type cartridge containing hydrocolloid is removed from the storage bath (Fig 17-9). It is inserted into the syringe (Fig 17-10), and a small amount of material is expressed to make sure it is flowing freely.

The 2 × 2-inch gauze squares are removed from the patient's mouth. A very light air-water mist is blown on the prepared tooth before the retraction cord is removed. The cord should be slightly moist, but not wet. Compressed air should not be blown on the tooth after the retraction cord has been removed because this may induce hemorrhage in the sulcus.

The cord is carefully removed from the sulcus by grasping the free end in the mesial interproximal area with a pair of cotton pliers. The cord is teased out gently to avoid inducing hemorrhage (Fig 17-11). If an impression is being made of multiple preparations, the cord is removed from the sulcus around each tooth, one at a time, immediately before the material is injected. Hydrocolloid is injected from the syringe into the sulcus, starting in an interproximal area first (Fig 17-12). The tip is held above the mouth of the crevice, with care taken not to drag the tip along the gingiva. Injection proceeds smoothly around the entire circumference of the preparation, pushing impression material before the tip.

An alternative way of applying the syringe material is called the *wet field technique*.²² The prepared teeth are

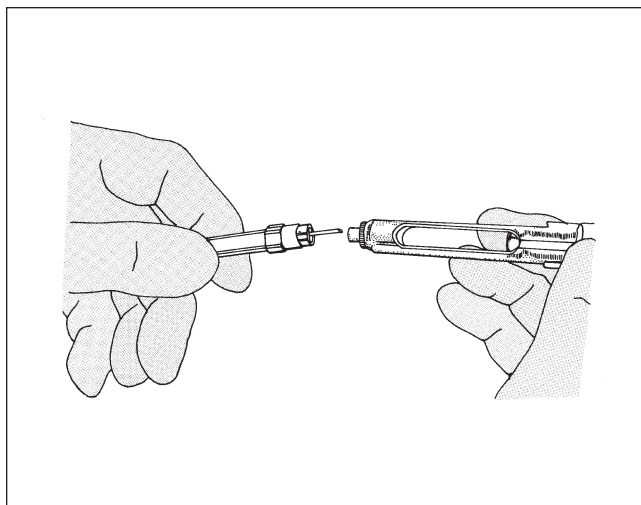


Fig 17-8 A blunt needle is attached to the impression syringe.

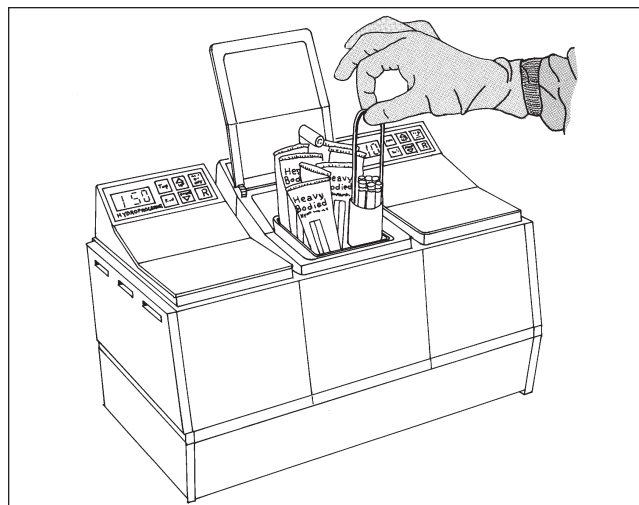


Fig 17-9 A cartridge of liquefied hydrocolloid is removed from the storage bath.

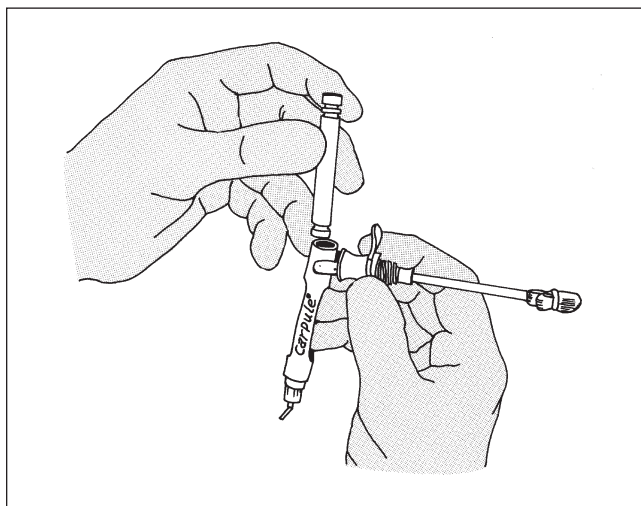


Fig 17-10 A cartridge of impression material is loaded into the syringe.

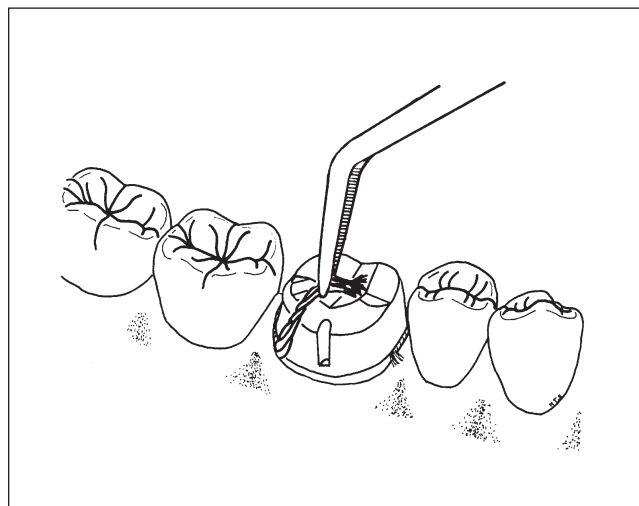


Fig 17-11 Cord is removed from the sulcus with cotton pliers.

bathed in warm water, and syringe material is deposited in generous quantities only on the occlusal surfaces of the teeth. The relatively viscous tray material is counted on to force the lighter-body syringe material into the sulcus as the tray is seated. This technique should be used only on preparations that do not contain internal features, such as grooves, boxes, or isthmuses.

The assistant should remove the sectional tray from the tempering bath, wipe the surfaces of the hydrocolloid free of water, and connect the tray to the hoses. The dentist gives the syringe to the assistant in exchange for the tray. The dentist seats the tray while the assistant connects the hoses to the unit. The tray is held in place for 6 minutes while cool water flows through its tubes. The patient should not hold the hydrocolloid tray. It is too unstable, and a distorted impression could result.

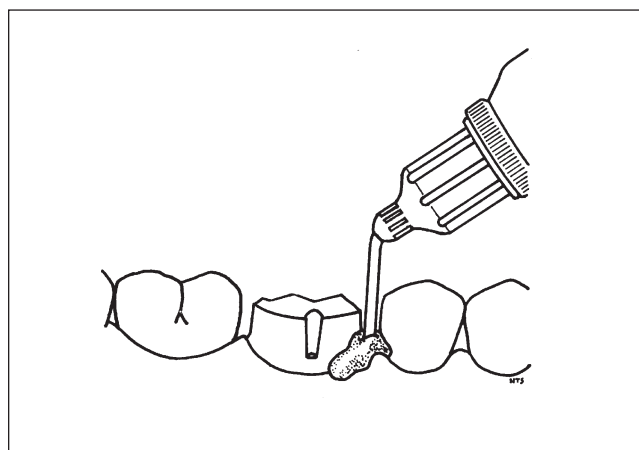


Fig 17-12 Hydrocolloid is injected into the sulcus.

17 Impressions

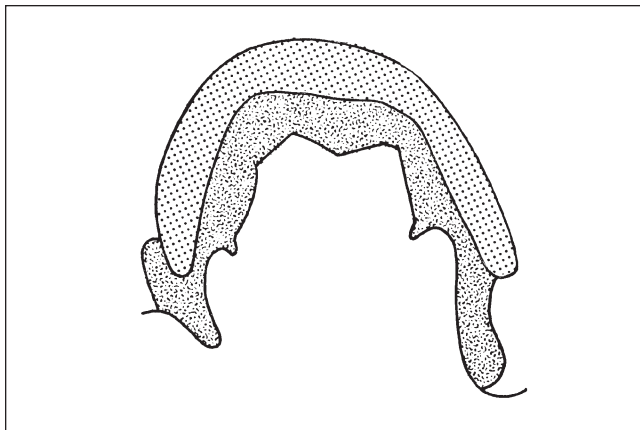


Fig 17-13 Faciolingual section of a custom impression tray, impression, and tooth preparation.

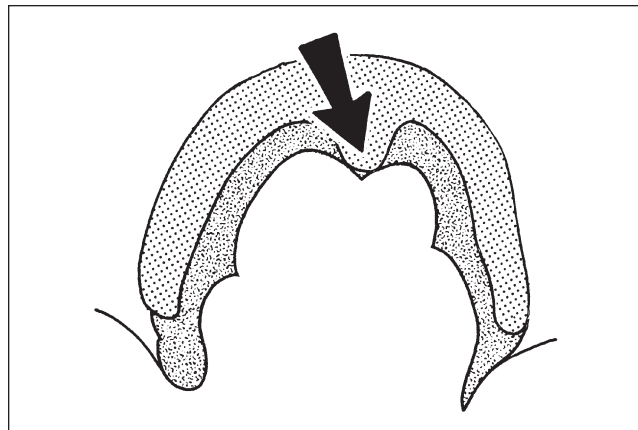


Fig 17-14 Faciolingual section of the stop (arrow) on a custom impression tray and impression.

While the sectional tray is setting in the patient's mouth, the assistant can fill the full-arch tray and place it in the tempering bath. The sectional impression is removed with a quick motion along the long axes of the teeth.²⁰ It is checked for completeness and washed in cold tap water. The excess moisture is removed from the surface of the impression with air, but the material should not be desiccated. The impression is sprayed or placed in an appropriate solution to disinfect it before pouring it.

A very light air-water mist is blown on the preparation, and hydrocolloid is injected around it again. It is usually not necessary to repack the sulcus with cord for the working cast impression. The full-arch tray is placed, and the tubes are connected to the unit. It is held in place for 6 minutes. It is removed with a snap. The impression of the opposing arch can be made with alginate (irreversible hydrocolloid).

Custom Resin Trays

Custom resin trays have been used in elastomeric impression techniques because these materials are more accurate in uniform, thin layers of 2 to 3 mm (Fig 17-13). Some authors have advised against the use of stock trays because the uneven bulk of impression material is conducive to distortion.¹³⁻¹⁵ However, it has been reported that the mean difference in material thickness between custom and stock trays is less than 1.0 mm and that variations from uniform thickness exist in both custom and stock trays.³⁵

Tray space seems to have no effect on the dimensional accuracy of monophasic PVS impressions, except for the distance between fixed partial denture abutment preparations.³⁶ This distortion of interpreparation distance was first described by Gordon et al,³⁷ who reported that the inter-

preparation distance in casts made from polysulfide, PVS, and polyether impressions was 45 to 100 μ m greater when stock trays were used instead of custom acrylic resin or thermoplastic trays. They also reported 260- μ m cross-arch discrepancies, which they attributed to stock tray flexibility.³⁷

Smaller discrepancies have been reported for the length of dies poured in PVS impressions in custom trays than those made from impressions in stock trays.³⁸ However, Bomberg et al³⁹ found no significant difference in the marginal fit of single-tooth restorations on casts made from PVS impressions in stock and custom trays. Carrotte et al,⁴⁰ on the other hand, report that even with a semi-rigid plastic stock tray, using a soft putty and wash technique, there is significantly more distortion than with a stock metal tray. Stock trays probably provide sufficient accuracy for single-tooth restorations, particularly if PVS or polyether is used. However, if one-piece fixed partial dentures of three or more units are to be fabricated on the cast, the interpreparation and cross-arch discrepancies could have a significant impact on the fit of the restoration.

The custom tray must be rigid, and it should have stops on the occlusal surfaces of the teeth to orient the tray properly when it is seated in the mouth (Fig 17-14). The impression material must adhere firmly to the tray. This is achieved with a rubber adhesive packaged with the impression material. These adhesives are not interchangeable, so only the type packaged with the brand of material being used should be employed. The adhesives used for polyether have the best tensile strength.^{41,42} Condensation silicone adhesives exhibit the weakest tensile and peel bond strengths.⁴³ The strengths of some adhesives for PVS materials equal,^{42,43} and others surpass, the strength of those used with polysulfide.^{41,43,44}

The bonding strength of adhesives used with PVS materials can be improved by nearly 50% by adding perforations to the tray and by approximately 140% by roughening the inner

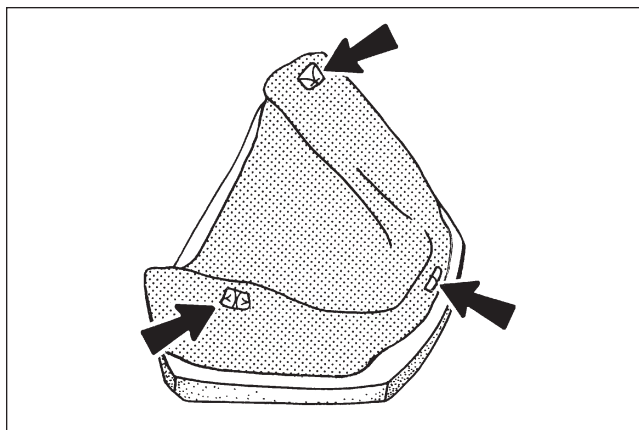


Fig 17-15 Cutouts for stops (arrows) in the spacer for fabrication of a custom impression tray.

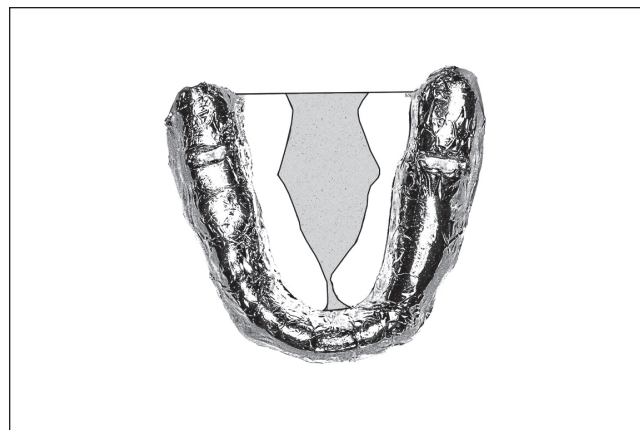


Fig 17-16 Foil penetrated over stop cutouts.

surface of an acrylic resin tray with 80-grit silicon carbide paper before adding the adhesive.⁴⁵ PVS putty does not adhere to its adhesive,^{42,46} making good mechanical retention in the tray, such as perforations, mandatory when putty is used.

The composition of the tray also may have an effect on retention of the impression within the tray. The bonding of PVS to trays made of a VLC urethane dimethacrylate resin (Triad custom tray material, Dentsply) seems to vary with the brand of impression material.^{47,48} Dixon et al⁴⁸ reported the adhesion of Reprosil (Dentsply) to VLC tray material to be about twice its retention to acrylic resin. However, Payne and Pereira⁴⁷ found the bonding of Hydrosil (Dentsply) to the same urethane dimethacrylate resin to be weak. The bond strength was nearly tripled by roughening the tray surface with a carbide bur.⁴⁷

Polysulfide adhesive adheres at least as well to trays made of thermoplastic material as it does to acrylic resin if the tray is formed over a foil-covered wax spacer.⁴⁴ Polysulfide and condensation silicones do not adhere as well to stock polystyrene trays as they do to custom acrylic resin trays, but polyether and PVS adhere better to the former than to the latter.⁴² Tjan and Whang⁴⁹ found no clinically significant differences in the accuracy of dies poured in PVS impressions made in custom trays with adhesive only, perforations only, or both, on first pours. However, on second pours, impressions made in adhesive-coated trays were more accurate.

Tray armamentarium

- Diagnostic casts
- Autopolymerizing acrylic resin (monomer and polymer)
- Measuring vial for monomer
- Measuring scoop for polymer
- Waxed paper cup
- Spatula
- Baseplate wax
- Aluminum foil

- Laboratory knife with no. 25 blade
- Bunsen burner
- Matches
- Arbor bands
- Adhesive for impression material used
- Triad model release agent (MRA)
- Triad TruTray custom tray material
- Triad light-curing unit
- Triad air barrier coating (ABC)

Tray preparation for VLC

A sheet of baseplate wax is heated in a flame until it is softened. It is then folded in half and placed on the diagnostic cast of the arch to be restored. It is adapted to the cast, and any excess that extends more than 2 to 3 mm beyond the necks of the teeth is neatly trimmed. The wax will form a spacer for the impression material. A horseshoe-shaped form is used for both arches, with no palatal coverage on the maxillary arch.

A 3 × 3-mm hole is cut through the wax over the posterior teeth on both sides of the arch and in the incisor area. The tray resin will touch the teeth in these areas, forming solid stops for the tray (Fig 17-15). On the side where the prepared tooth is situated, the stop should be distal to the preparation. There should be a protective layer between the wax and the tray resin to prevent the wax from impregnating the surface of the tray during the exothermic polymerization of the resin. Petrolatum should not be used. A waxy layer (or a petrolatum/waxy layer) on the inner surface of the tray will diminish bonding by the tray adhesive applied before placement of the impression material, resulting in distortion of the impression. A piece of aluminum foil is adapted over the wax and stone cast to provide separation.⁵⁰ The foil is removed over the 3 × 3-mm holes (Fig 17-16).

Triad MRA is applied to any part of the cast that the tray will touch, including in the holes, but not to the foil. A sheet of

17 Impressions

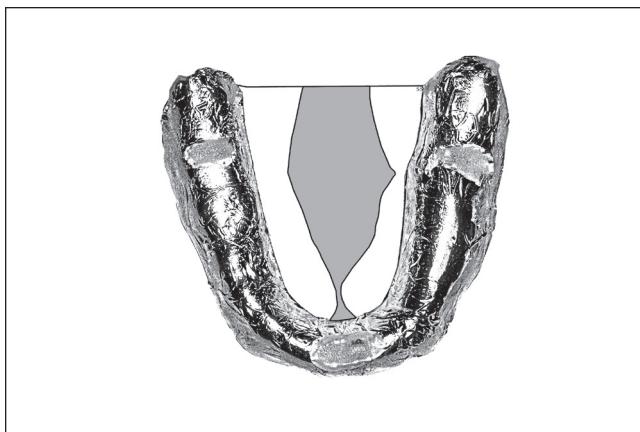


Fig 17-17 Triad pieces in stop cutouts.

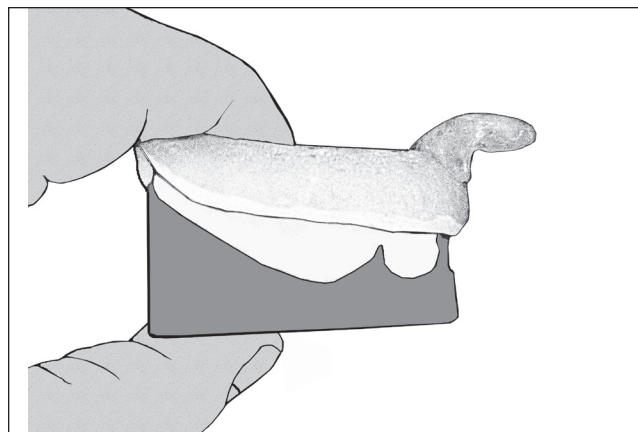


Fig 17-18 Tray on cast with correctly placed handle.



Fig 17-19 Light-curing unit.

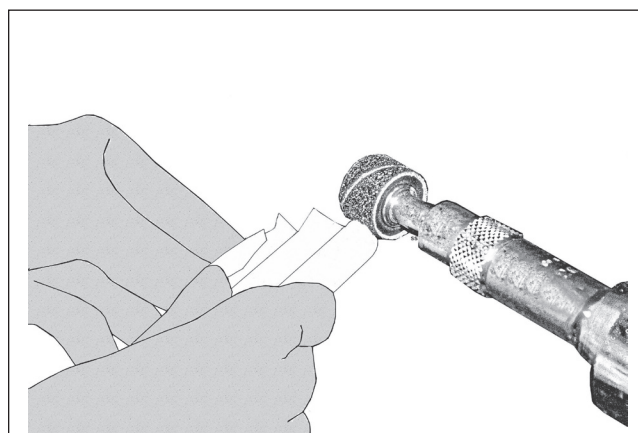


Fig 17-20 Arbor band on lathe.

Triad TruTray custom tray material is removed from its light-protected pouch. A wax spatula or laboratory knife is used to trim small pieces of tray material from the large piece. These small pieces are packed into the holes for the stops (Fig 17-17). The sheet of tray material is adapted over the stops and horseshoe-shaped foil-covered arch. Excess is removed from the palate or tongue space and used to form the handle (Fig 17-18). The edge of the tray should lightly touch the cast all around its periphery, including the retromolar areas, when the stops are fully seated. This encirclement limits the free flow of impression material out of the tray, which then forces the material toward the teeth as the tray is seated.

The cast is placed with the tray material and foil into the light-curing unit (Fig 17-19) for an initial 1-minute curing time. Because the handle will tend to slump, about 30 seconds into the initial 1-minute curing time, the door should be opened, the handle lifted, and the cast replaced back into the light-curing unit for the remaining 30 seconds. The cast is removed, and smoothing and forming of the tray material is finished. The cast is placed back into the curing unit for another 1-minute curing time. When the cast is removed this time, the tray material will be tacky. The wax liner and foil

are removed from the tray at this time. An arbor band on a lathe or acrylic bur on a laboratory handpiece is used to trim and smooth the tray (Fig 17-20). Triad ABC is applied to the tray, which is placed in the curing unit for its final 2-minute curing time. The tray is removed and cleaned with soapy water to remove the ABC. Final smoothing of edges/surfaces that may contact the patient should be accomplished (Fig 17-21). The tray, ready to be disinfected and used, is viewed on the cast (Fig 17-22). The intaglio (inner) surface view with stops and the occlusal view of the tray are shown in Figs 17-23 and 17-24.

Tray preparation for autopolymerizing acrylic resin

The diagnostic cast is prepared with the wax spacer and foil in the same manner as described for the VLC tray. The resin is mixed in the waxed paper cup, using one measure of powder and one vial of liquid. As soon as it is pliable and does not stick to the fingers, it is formed into a rod that is approximately the length of the dental arch (molar to molar, around

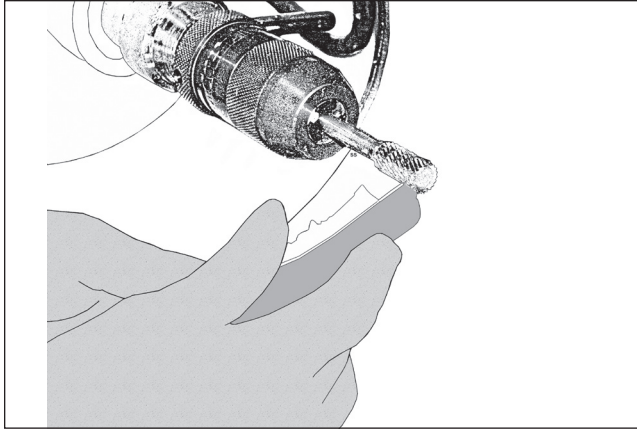


Fig 17-21 Acrylic bur on lathe.

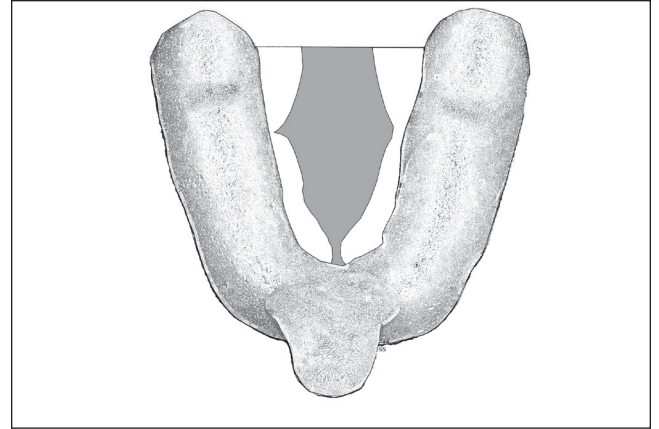


Fig 17-22 Tray on cast.

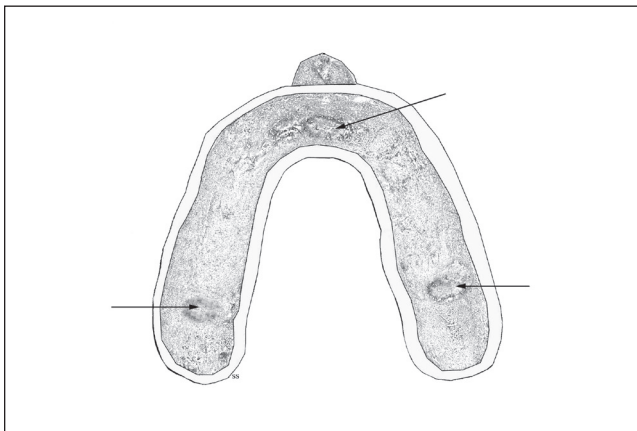


Fig 17-23 Intaglio (inner) view of tray with stops (arrows).

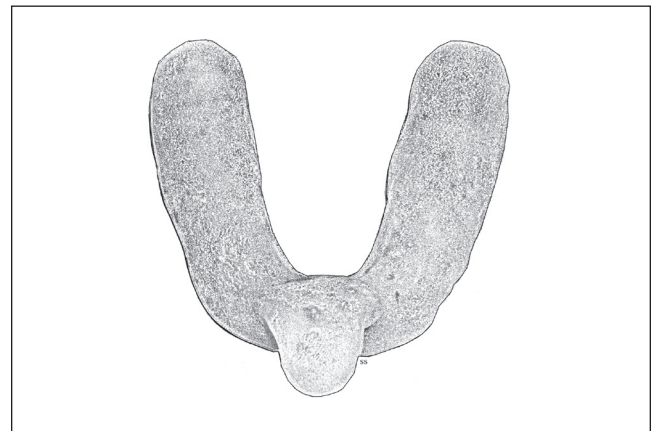


Fig 17-24 Occlusal view of tray.

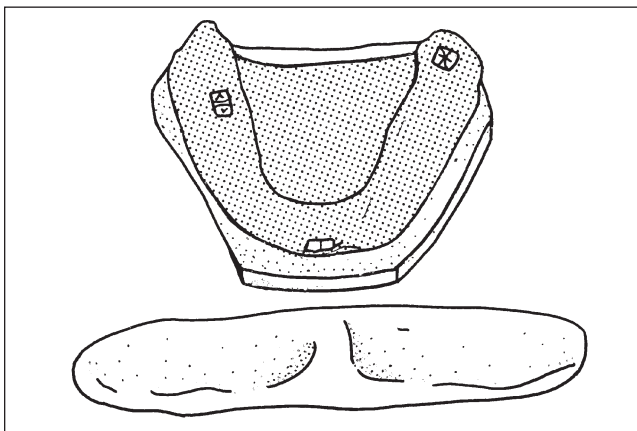


Fig 17-25 Tray resin ready for adaptation to the cast.

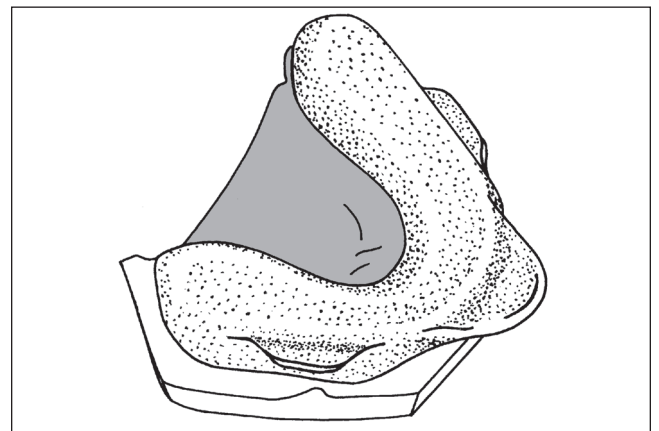


Fig 17-26 Finished custom impression tray with a handle in front and wings on the side to facilitate removal.

the incisors). It is flattened out to form an oblong shape about 1 inch (2.5 cm) wide and $\frac{3}{16}$ inches (5.0 mm) thick. Some extra bulk should be left in the middle (Fig 17-25).

The acrylic resin is placed on the arch and adapted over the foil-covered wax. It should be molded so that it extends just to the edge of the wax spacer under the foil. It should

end at the distal surface of the last tooth on each side of the arch. The tray should not extend beyond the trimmed distal border of the cast in the retromolar area. The bulk left in the middle of the tray should be used to shape a horizontal handle in the middle and a narrow ledge or "wing" on either side of it (Fig 17-26). The wings can be used for better lever-

17 Impressions

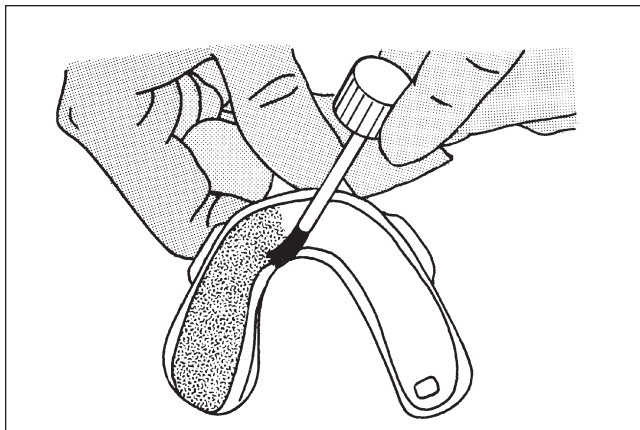


Fig 17-27 The inside of the tray is painted with adhesive.

age on the tray during removal from the mouth. The resin is allowed to polymerize.

When the tray is hard but still warm to the touch, it is removed from the cast and the aluminum foil, and any wax adhering to it is peeled out. The tray is tried back on the cast to check for uniform clearance. An arbor band is used to cut back any areas that come too close to the cast, especially in the area of the prepared teeth. If any grinding must be done on the tray, those areas that will contact soft tissue are smoothed and polished before the tray is taken to the mouth. A rough, sharp border on the tray can lacerate the angles of the mouth when the tray is inserted.

The tray should be prepared at least 6 hours in advance of making the impression. As the monomer undergoes polymerization, it shrinks. The dough could shrink as much as 8% before curing is completed.⁵¹ Significant linear changes occur during the first 40 minutes of the fabrication of a tray, with some changes continuing to occur for up to 6 hours.⁵² An acceptable result can be obtained with a tray that is at least 40 minutes old if the impression is poured quickly.⁵² An acrylic resin tray can be stabilized against further shrinkage and distortion by boiling it before placing impression material in it.⁵³

If the tray is made immediately before the impression is made, however, polymerization shrinkage and stress relaxation will be occurring while the impression is in the tray, resulting in distortion of that impression. Elastomeric impressions should not be stored in a moist environment because an acrylic resin tray may imbibe water and distort.

The inside of the tray is painted with a thin, uniform coat of the adhesive specified for the impression material being used (Fig 17-27). To achieve maximum adhesion of the impression material to the tray, allow it to dry for a minimum of 15 minutes.⁵⁰ If the adhesive has not been allowed to dry, the impression material may separate from the tray when it is removed from the mouth.

Dual-Arch Impressions

Dual-arch impressions have some significant advantages over conventional full-arch impression techniques. These include the use of only one tray, which captures an impression of the prepared tooth, the adjacent and opposing teeth, and the relationship between them in maximal intercuspation without the need for an interocclusal record. This type of impression tray produces extremely accurate occlusion in the resultant mounted casts. The average occlusal error for articulated casts made from this type of impression is 5 μm , opposed to an average error of 72 μm for mounted casts made from full-arch impressions.⁵⁴ In addition, less impression material is needed.⁵⁵

This technique is best used for a patient with an intact, mutually protected Angle Class I occlusion. The restoration should be for a single tooth with intact adjacent and opposing teeth. There should be no arc-of-closure interference in closure to maximal intercuspation.⁵⁵

There are many variations of dual-arch impression trays. Some have short sidewalls; others have taller sidewalls; and they capture various segments of a dental arch. All but the anterior segment tray have a distal bar connecting the lingual to the facial side. This bar must not interfere with closure to maximal intercuspation. The trays are available in reusable metal or disposable plastic.

Kaplowitz⁵⁶ states that the use of a flexible tray and a flexible impression material has the lowest chance of success. Barzilay and Myers⁵⁷ report a clinical example in which the alveolar structure displaced the side of a plastic tray, and, when the side rebounded after removal from the patient's mouth, the resulting die was undersized in the faciolingual dimension. Cox et al⁵⁸ report that the use of plastic trays with heavy-body material may not be clinically reliable for indirect restorations. Breeding and Dixon⁵⁹ report larger discrepancies in dies produced from impressions in plastic dual-arch trays than in those from impressions with metal dual-arch trays. However, Wöstmann et al⁶⁰ report that less rigid dual-arch trays performed better than rigid ones for inlays and partial veneer cast restorations.

Armamentarium

- Elastomeric impression material (high viscosity for tray)
- Elastomeric impression material (low viscosity for syringe)
- Coe #72 bite registration tray and insert (GC)
- Appropriate adhesive
- Impression syringe with disposable tip
- Rubber abrasive wheel
- Foster spring chrome articulator (Keystone)
- Die stone
- Mounting stone or plaster

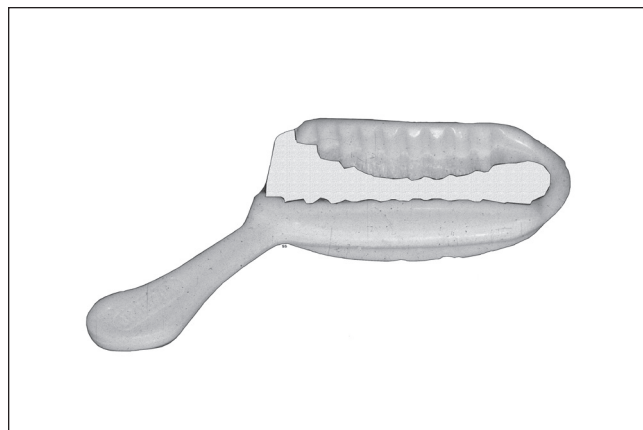


Fig 17-28 Typical plastic posterior quadrant tray.

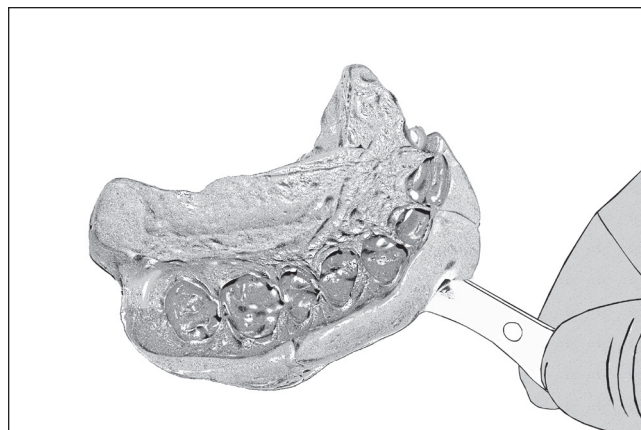


Fig 17-29 Quadrant overimpression.

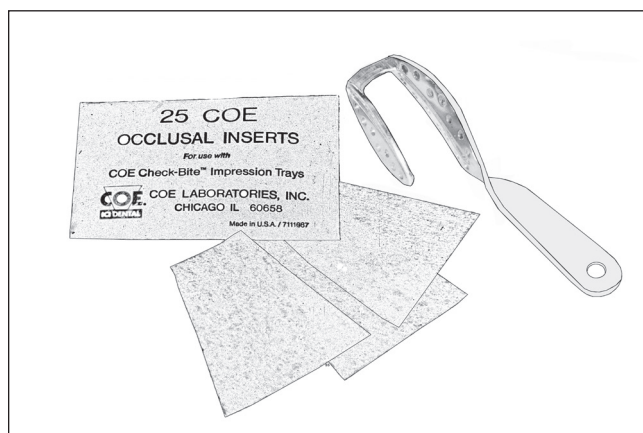


Fig 17-30 Metal posterior segment tray with inserts.

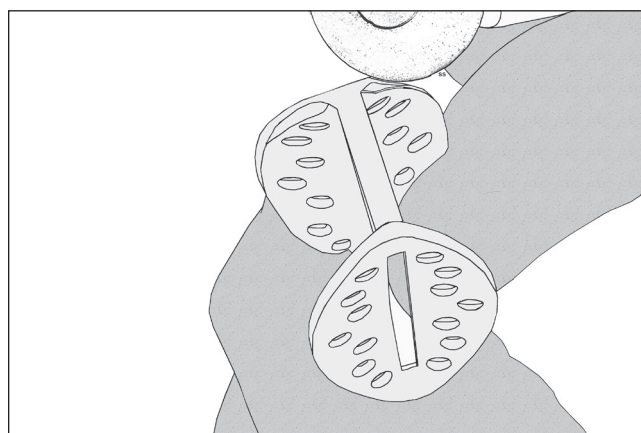


Fig 17-31 Use of abrasive wheel to soften sharp edges.

Technique

This technique is used when uncomplicated circumstances require a single cast restoration to be made. In such a circumstance, the tooth to be prepared has an adequate core with adequate contours and occlusion. A plastic quadrant tray (Fig 17-28) may be used for an initial overimpression (Fig 17-29). This will facilitate a subsequent provisional restoration.

A Coe #72 bite registration tray is used for posterior single units (Fig 17-30). As with any tray used for dental impressions, attention to patient comfort is important. Figure 17-31 shows a sharp edge of the tray being rounded off with an abrasive wheel before the tray is sterilized for patient use.

Before the tray is tested for fit, an easily seen interocclusal relationship in maximal intercuspation is found. The tray is then tried in, and that same relationship must be seen (ie, no part of the tray should interfere with complete closure to maximal intercuspation). It should be noted that the distal connecting bar (Fig 17-32) can potentially interfere with complete closure.

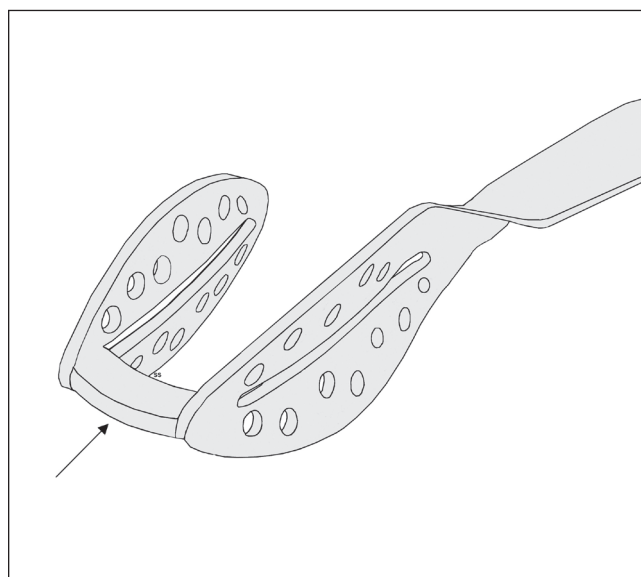


Fig 17-32 The connecting bar (arrow) is a potential interference to complete closure.

17 Impressions

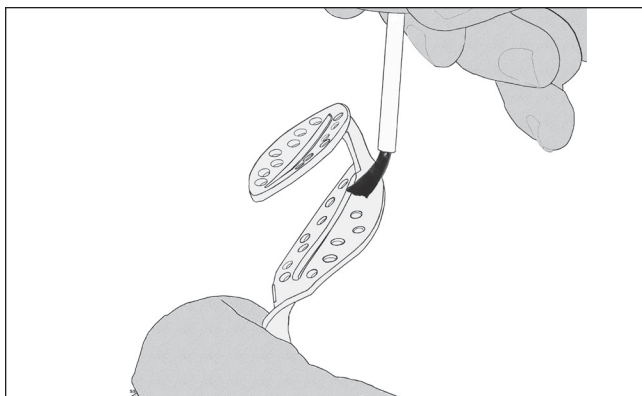


Fig 17-33 Application of adhesive.

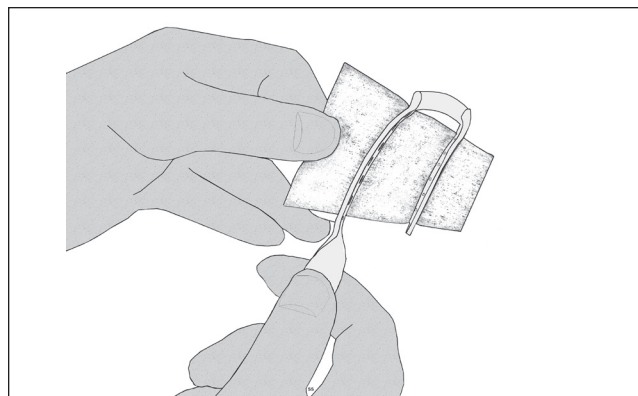


Fig 17-34 Placement of insert.

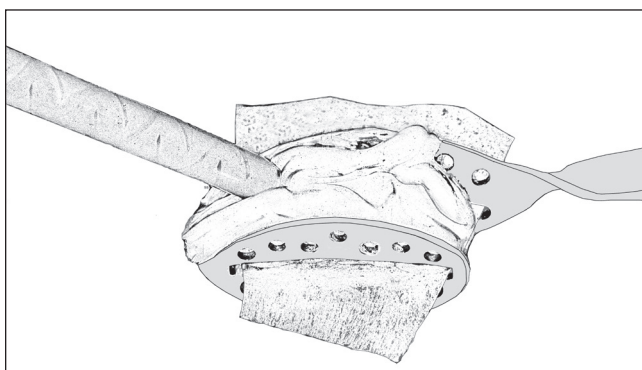


Fig 17-35 Placement of high-viscosity impression material.

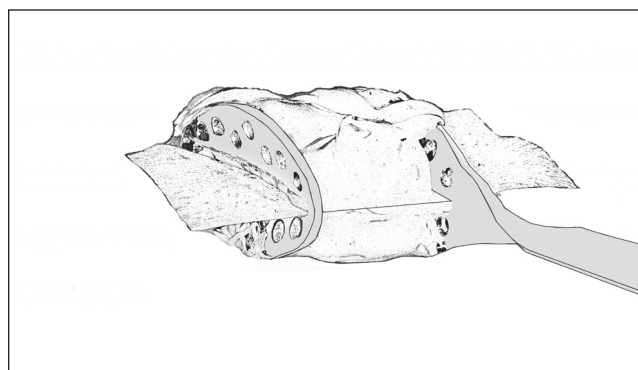


Fig 17-36 Both sides of the tray filled.

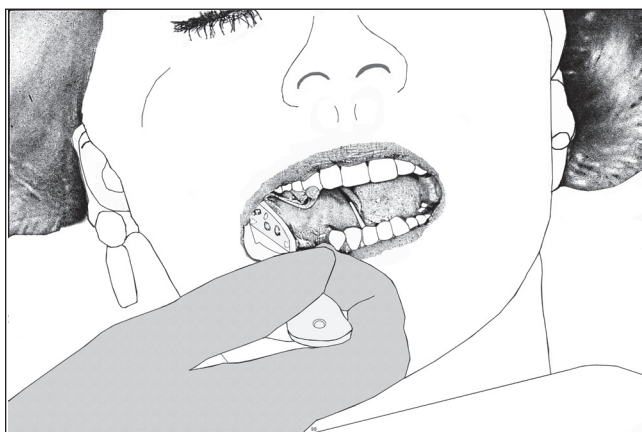


Fig 17-37 Insertion of tray for impression.

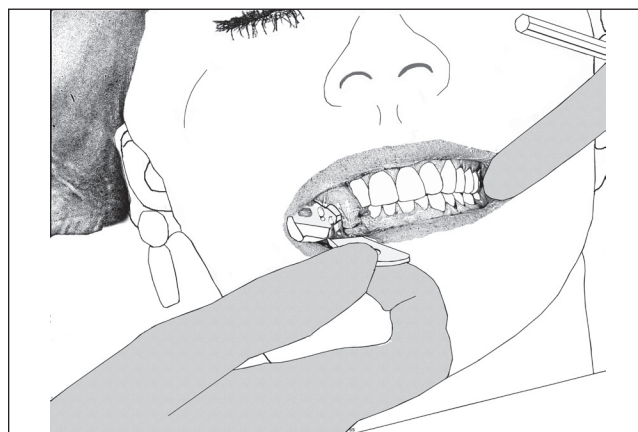


Fig 17-38 Complete closure verified.

Necessary isolation and gingival retraction is accomplished. Appropriate adhesive is applied to the internal vertical walls of the tray, but not to the insert (Fig 17-33). The insert is placed into the tray (Fig 17-34). Low-viscosity impression material is loaded into an impression syringe. The low-viscosity impression material is injected around the prepared tooth. While this is occurring, the dental assistant loads the high-viscosity material into the tray (Fig 17-35). When both sides have been filled with the high-viscosity im-

pression material (Fig 17-36), the tray is inserted immediately (Fig 17-37). Minimal time must elapse between the completion of the syringing of the low-viscosity material around the prepared tooth and the introduction of the loaded tray. The same interocclusal relationship noted previously must be observed (ie, the patient should close into the acquired maximal intercuspation) (Fig 17-38). A shim stock strip can be placed on the contralateral teeth to ensure complete closure.

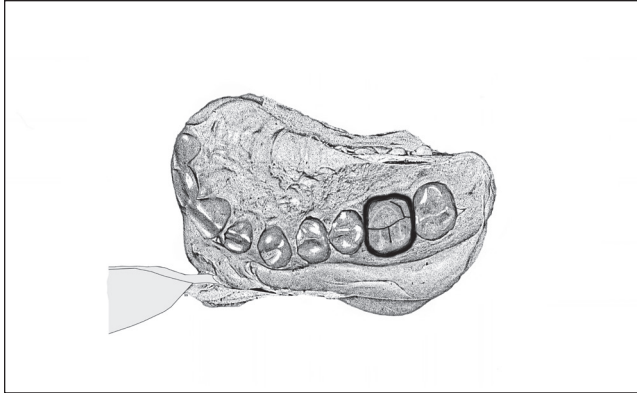


Fig 17-39 Impression held up to light to check for occlusal contacts.

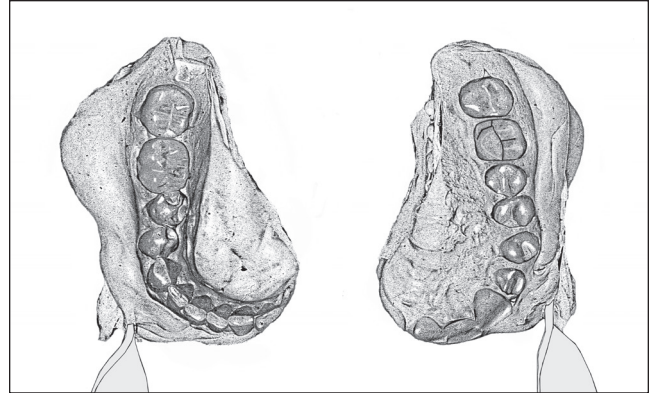


Fig 17-40 Adequacy of impression is evaluated.

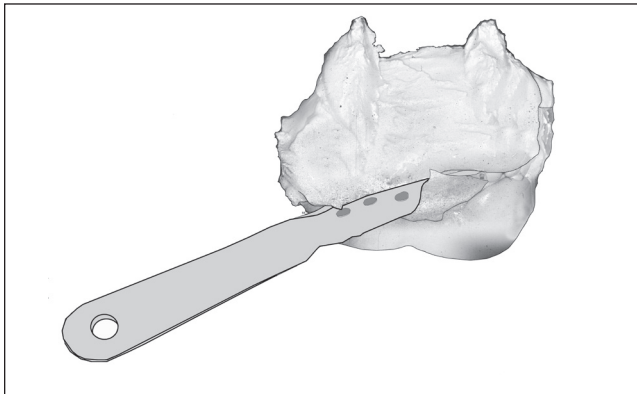


Fig 17-41 Die stone in one side of the impression.

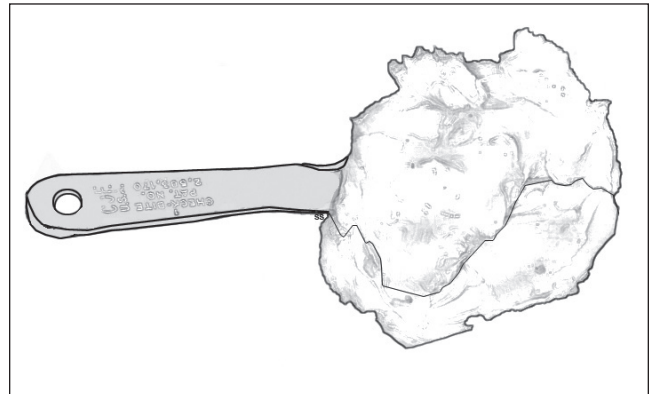


Fig 17-42 Both sides with completely set die stone.

When removed, the impression is evaluated for adequacy as usual (eg, checking for the absence of voids and complete capture of the finish line). The impression will have translucent areas where the adjacent occluding teeth are closed into maximal intercuspation (Fig 17-39).

This type of impression is also sometimes known as a *double-bite impression*. Figure 17-40 shows both sides of the impression; one side will be the opposing cast segment, and the other side will be the working cast with the prepared tooth segment. The impression also captures the relationship between the two opposing casts.

First, the side of the impression containing the prepared tooth is poured in vacuum-mixed die stone (Fig 17-41). After at least the initial set of this die stone, the second side is also poured in vacuum-mixed die stone (Fig 17-42). A removable die and cast or solid casts can be made (see chapter 18).

The casts are mounted in a Foster spring chrome articulator (Fig 17-43). The upper and lower members of this articulator are attached to the casts with mounting plaster or mounting stone (Fig 17-44) before separating the impression tray from the casts (Fig 17-45).

Great care must be taken to ensure that maximal intercuspation was accomplished during the impression and to produce complete closure of the casts (Fig 17-46). Because the distance from the hinge axis to the prepared tooth is much shorter on this articulator than actually exists in the patient, it is critical that there is no change required in the vertical dimension of occlusion. Changing this would result in occlusal errors in the fabricated restoration.

When these casts are mounted (Fig 17-47), the springs need to be in a neutral, unstressed position so that the casts will return to their maximal intercuspusal position at the desired vertical dimension of occlusion. Figure 17-48 shows the action of the vertical springs as the casts are moved away from the neutral position. This flexibility allows evaluation of the occlusion (particularly wear facets) and their potential effect on the restoration during its fabrication. This figure also illustrates one of the limitations of this system in that the contralateral guidance is absent in this mediotrusive movement.

17 Impressions

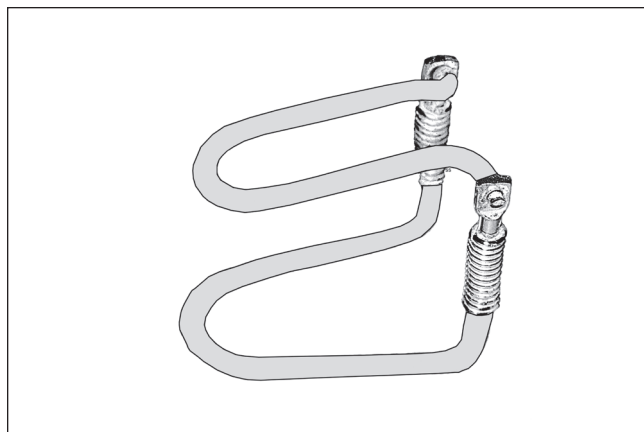


Fig 17-43 Simple metal articulating device with springs.

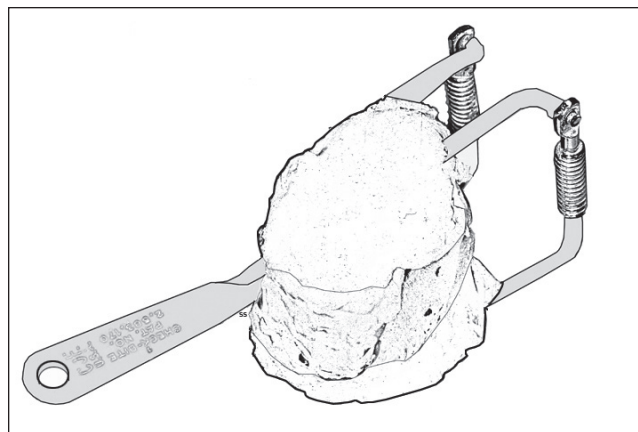


Fig 17-44 Mounted casts before separation from impression tray.

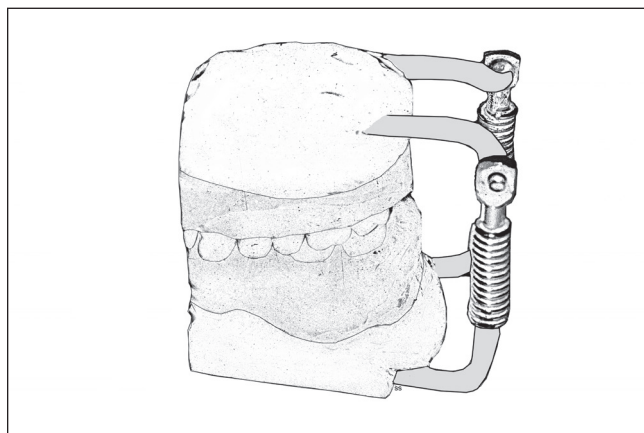


Fig 17-45 Mounted casts after separation from impression tray.

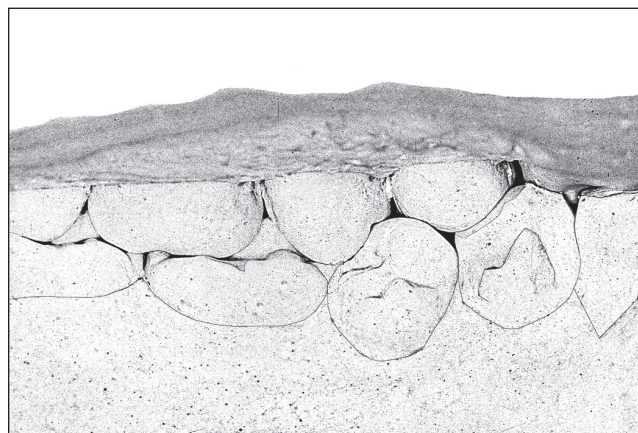

Fig 17-46 Close approximation of occluding surfaces checked on the articulating device.

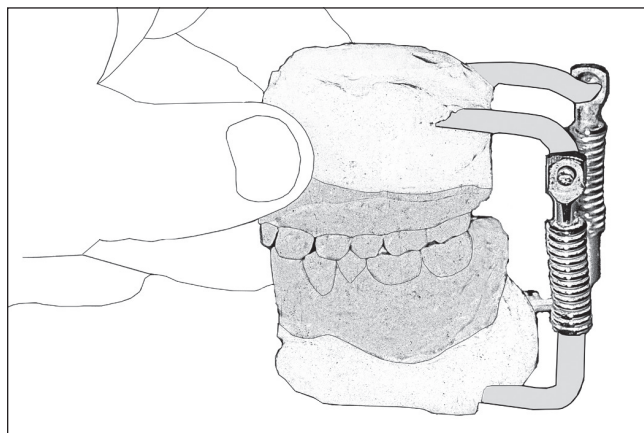


Fig 17-47 Articulated casts in neutral position.

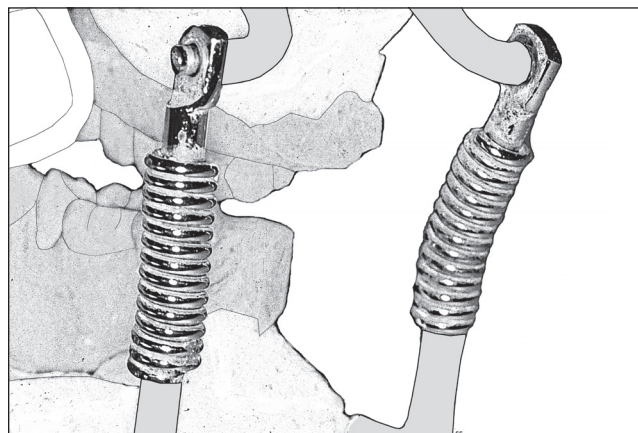


Fig 17-48 Springs allow good lateral movement.

Polysulfide

Polysulfide is an elastomer that is also known as *mercaptan*, *Thiokol*, or simply as *rubber base*. The latter term alone is incomplete and should be avoided. The material was developed as the matrix for solid-state fuels and oxidizers used in many space vehicles, including the boosters for the space shuttle program. The impression material is packaged in two tubes: a base and an accelerator. The base contains a liquid polysulfide polymer mixed with an inert filler. The accelerator, which is usually lead dioxide mixed with small amounts of sulfur and oil, acts as an oxidation initiator on terminal thiol groups on the polymer.

When these two pastes are mixed, the polymer chains are lengthened and cross-linked through the oxidized thiol groups. In clinical terms, this results first in an increased viscosity and finally in an elastic material. This polymerization is affected significantly by moisture and temperature.⁶¹

Polysulfide rubber base possesses much greater dimensional stability than does hydrocolloid. However, the polysulfide polymer does contract as curing occurs. Therefore, if maximum accuracy is to be obtained, a polysulfide impression should be poured within approximately 1 hour of removal from the mouth⁶² or less.^{63,64} Unpoured polysulfide impressions should not be sent to a laboratory.

Large undercut areas in the interproximal region should be blocked out in the mouth with soft wax. Otherwise, the impression may get locked in the mouth and distorted by the excessive force that must be used to remove the tray.

Because of the hydrophobic nature of this material, special care must be taken to ensure that there is no moisture on the preparation when the impression is made. Thin layers of moisture on the surface can make the cast slightly larger, and moisture that becomes incorporated during the injecting process can cause folds, creases, and voids in the impression. This, in turn, will result in fins and assorted projections on the cast, rendering it useless. Any hemorrhage or fluid seepage in the sulcus will result in voids and bubbles that will obscure the finish line.

Polysulfide is unique among impression materials because it is radiopaque.⁶⁵ If a fragment becomes entrapped in the gingival sulcus or in a tissue space beyond a ruptured epithelial attachment, its exact location can be easily determined radiographically.⁶⁶ This property is the result of the presence of lead dioxide in the formula, which unfortunately contributes to its toxicity and tendency to irritate soft tissues when it does become trapped.

Other impression materials can be made radiopaque by substituting the normal fillers used in making the impression material with radiopaque substances.⁶⁷ However, if the filler is not selected carefully, the altered composition may affect other properties of the impression material, such as setting or shelf life.

Armamentarium

- Polysulfide impression kit (regular base and accelerator)
- Polysulfide impression kit (light base and accelerator)
- Adhesive (butyl rubber cement)
- Two disposable mixing pads
- Two stiff spatulas
- Syringe with disposable tip
- Two 2 × 2-inch gauze sponges
- Alcohol
- Custom resin tray

Impression making with polysulfide

It should be confirmed that the patient has adequate anesthesia. If the impression is being made at a separate appointment subsequent to the preparation of the tooth, it is necessary to anesthetize the area. The custom tray is tried in the mouth to make sure it fits without impinging on the prepared tooth. The retraction cord is inserted, and a large gauze pack is placed in the mouth.

The following steps require an assistant. On one disposable mixing pad, 1.5 inches (4.0 cm) each of light (syringe) base and accelerator are squeezed out. On a second pad, 5.0-inch (12.5-cm) strips of regular (tray) base and accelerator are placed. The plunger is pulled from the injection syringe and set aside. The tip and cap (if removable) should be on the barrel of the syringe.

The assistant should start mixing the tray material on one pad 30 seconds before the operator begins mixing the syringe material on the other. The dark accelerator is picked up on the spatula and incorporated into the white base (Fig 17-49). With the spatula held flat against the pad, the material is mixed with a back-and-forth motion, pressing hard against the pad. Changing directions often produces a smooth, homogenous mixture (Fig 17-50). Care should be taken not to incorporate bubbles, and mixing should not take more than 1 minute.

A sheet previously removed from the mixing pad is folded in half (Figs 17-51 and 17-52) and then folded to make a cone (Fig 17-53). It is opened up, and the syringe material is wiped from the spatula onto the crease (Fig 17-54). The cone is folded over (Fig 17-55). The syringe material is squeezed from the cone into the back end of the syringe (Fig 17-56). The plunger is inserted, and all the air is expressed from the syringe (Fig 17-57).

In a second method of loading the syringe, the back end of the syringe is brought in contact with the pad, and quick, closely spaced sweeps of the syringe will fill it with a minimum of material spilled (Fig 17-58). In a third method, the syringe tip is removed and the front end of the syringe is buried in a collected mass of material on the pad (Fig 17-59) or in a dappen dish. This technique unquestionably works, but the novice in a hurry can suck a lot of air into the syringe and make a mess in the process.

17 Impressions

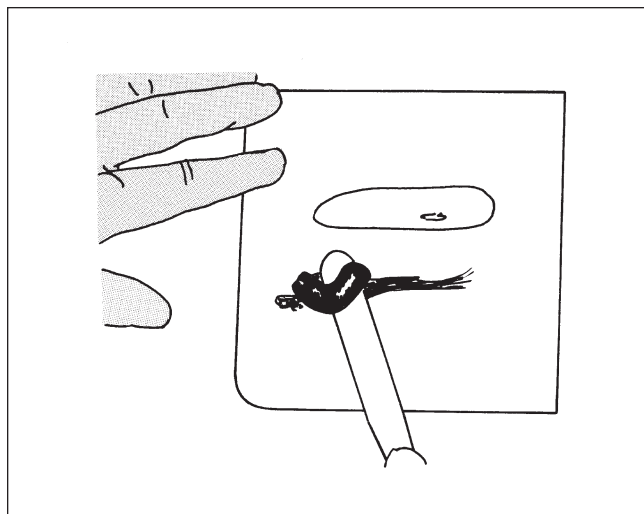


Fig 17-49 Mixing is started with the dark accelerator.




Fig 17-50 The mixture should be free of streaks and bubbles.

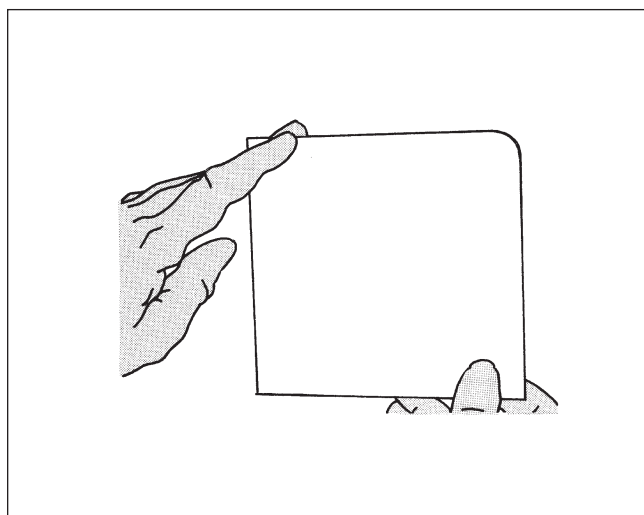


Fig 17-51 Fully extended mixing pad sheet.

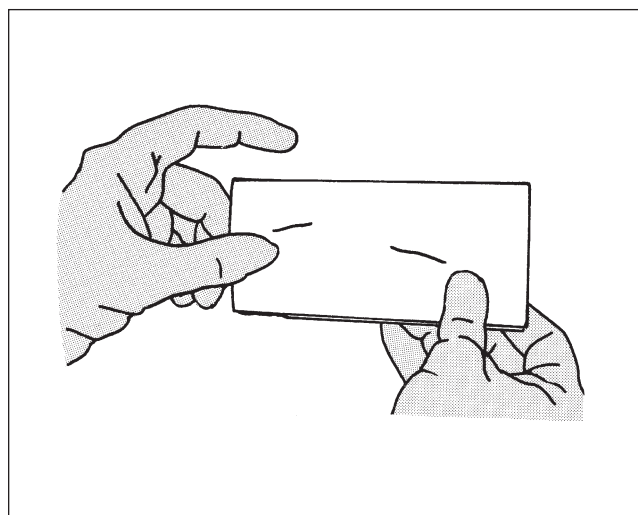


Fig 17-52 The sheet is folded in half.

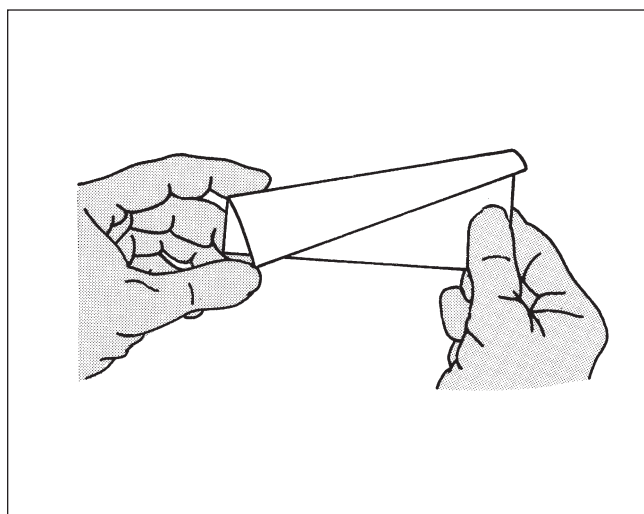


Fig 17-53 The sheet is folded once more to form a cone.

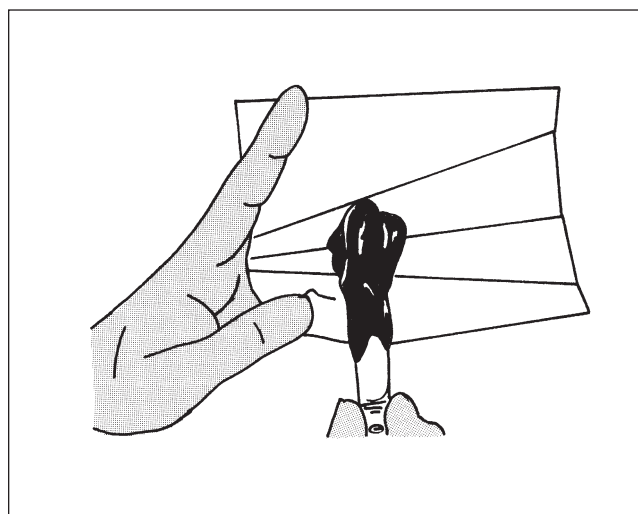


Fig 17-54 Impression material is wiped on the crease.

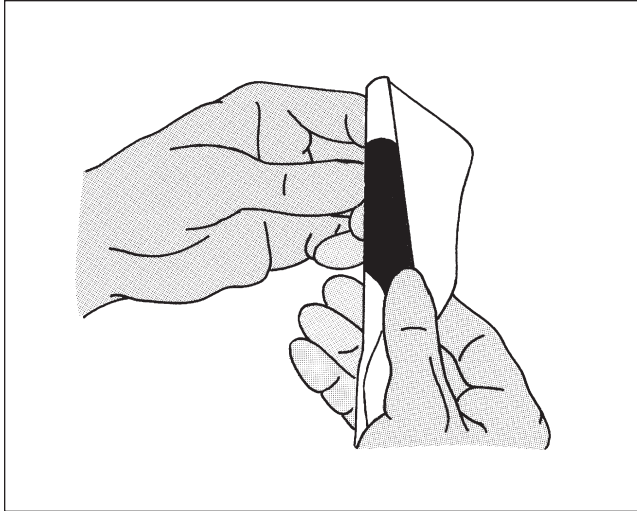


Fig 17-55 The paper is refolded to form the cone again.

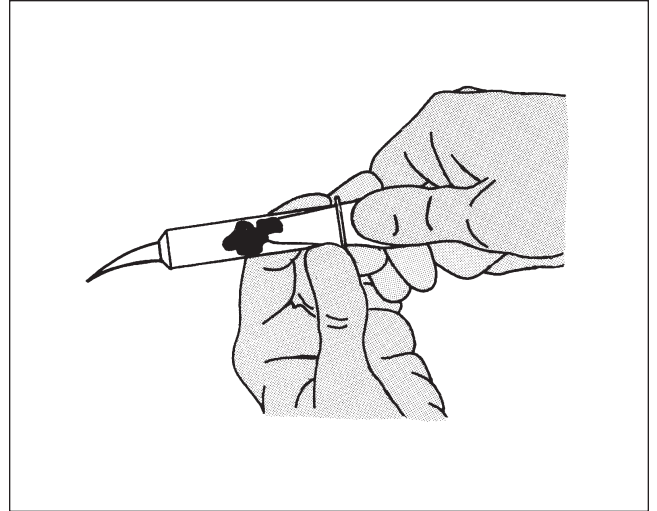


Fig 17-56 The cone is inserted into the syringe, and the material is squeezed from the cone into the syringe.

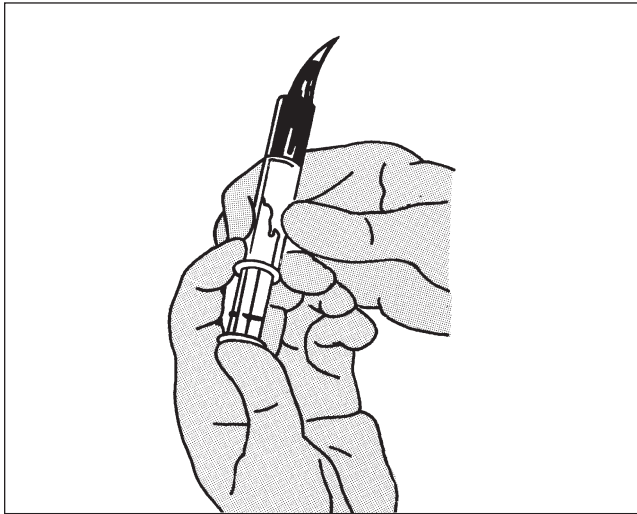


Fig 17-57 The plunger is placed into the syringe.

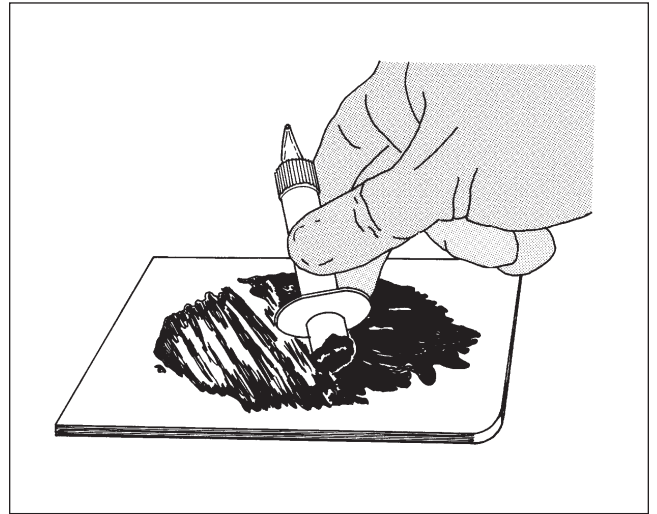


Fig 17-58 A syringe also can be loaded by scraping the back end across the mixing pad to scoop up material.

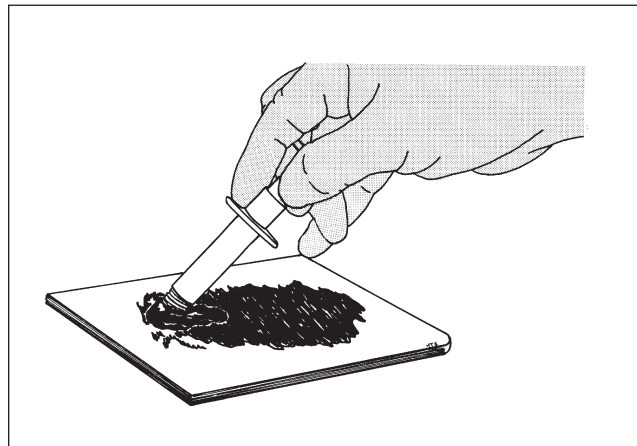


Fig 17-59 The syringe is loaded through the front end by aspirating the material.

17 Impressions

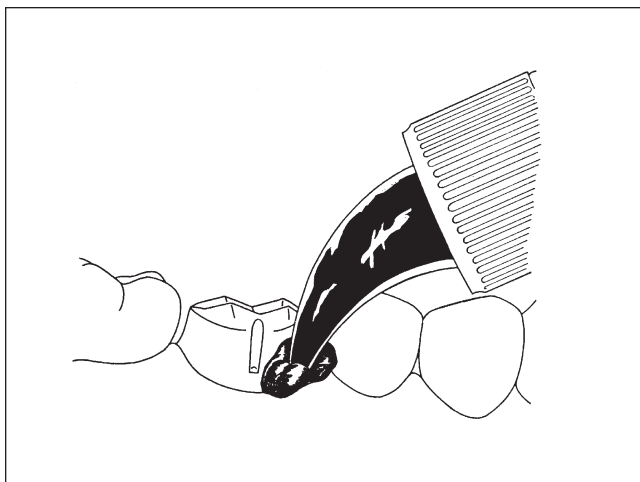


Fig 17-60 Impression material is injected into the sulcus.

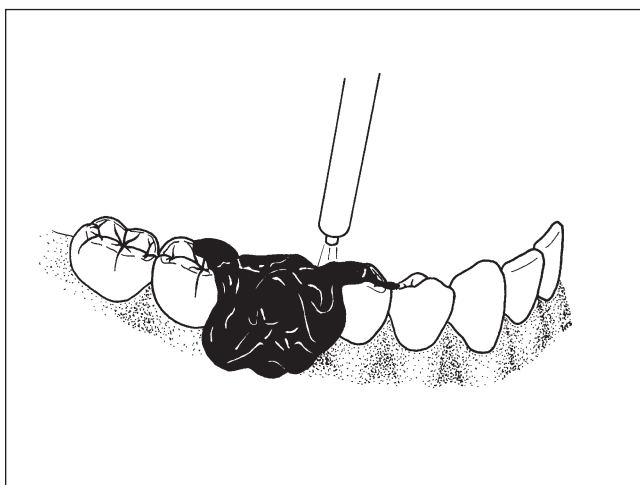


Fig 17-61 An air syringe is used to drive the impression material into the sulcus and preparation detail.

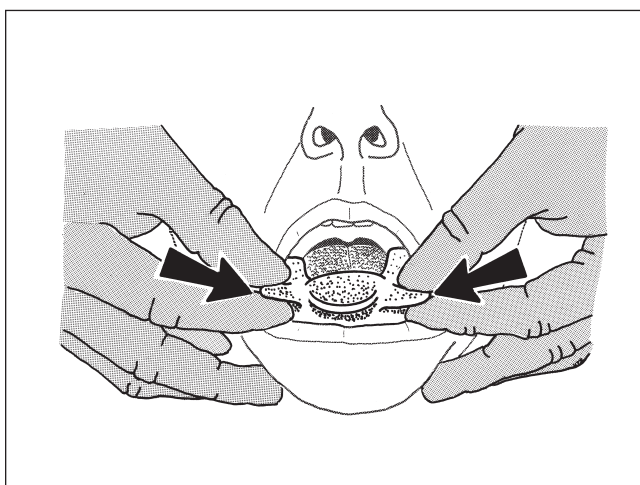


Fig 17-62 Wings on either side of the tray (arrows) are grasped to remove the impression from the mouth.

The 2 × 2-inch gauze squares are removed from the patient's mouth. The retraction cord should be checked to make sure it is slightly damp, but not wet, before it is removed from the sulcus. Polysulfide syringe material is immediately injected into the sulcus (Fig 17-60). The tip is held just above the mouth of the crevice. The tip should not be dragged along the gingiva. Injection of material should proceed smoothly around the entire circumference of the preparation, with impression material pushed ahead of the tip, and continue around the preparation until the entire tooth is covered.

An air syringe is used to direct a stream of air against the material (Fig 17-61) to spread it evenly over the surface of the preparation and drive it into small details such as grooves and boxes.^{68,69} Impression material is also forced more completely into the gingival crevice. Excessive pressure, prolonged air application, and use on patients with a thin band of attached gingiva should be avoided because of the possibility of producing interstitial emphysema. The tray is seated slowly until the stops hold the tray solidly in one position. The tray should be held with light pressure for 8 to 10 minutes without movement. The set of the material can be tested with a blunt instrument. When the material rebounds completely without leaving any trace, polymerization is complete.

After the material has polymerized, the impression is removed. The wings on the sides of the tray can be used for added leverage in this task (Fig 17-62). While it is customary to call for removing the tray suddenly or with a snap, it is more realistic to ask that the removal be as fast and in as straight a direction as possible. Only a silverback highland gorilla could remove a full-arch polysulfide impression with a snap. The impression is rinsed to remove blood and saliva then blown dry and inspected. An impression of the opposing arch can be made with alginate. The impression is soaked in an appropriate disinfectant solution before pouring it.

Condensation Silicone

Condensation-reaction silicones are so named because of the nature of their polymerization reaction. They also could be called *organo-tin silicones*, which is a reference to their catalyst. The base paste is a liquid silicone polymer with terminal hydroxyl groups, mixed with inert fillers. The reactor, a viscous liquid, consists of a cross-linking agent, ethyl silicate, with an organo-tin activator, tin octoate. When the two are mixed, the materials are cross-linked by a reaction between terminal hydroxyl groups on the polymer and ethyl orthosilicate.⁷⁰

The condensation reaction occurs by the elimination of ethyl or methyl alcohol. The evaporation of this alcohol is believed to be responsible for shrinkage of the material and resultant poor dimensional stability.⁷¹ Impressions made in silicone should be poured soon after removal from the mouth.^{62,64} One of the problems in using condensation sili-

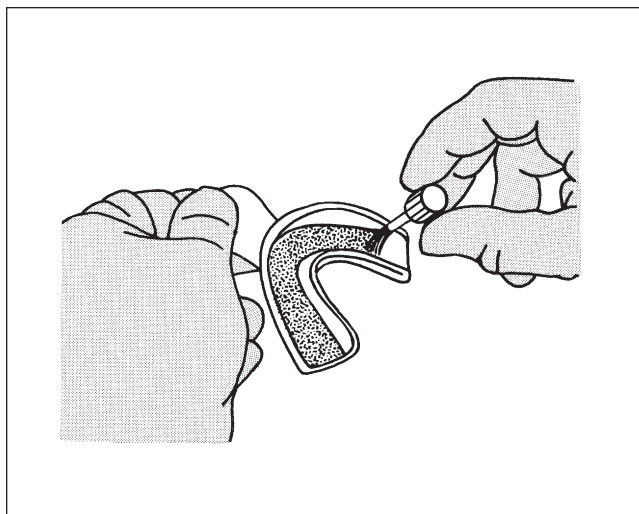


Fig 17-63 The intaglio (inside) of the stock impression tray is painted with adhesive.

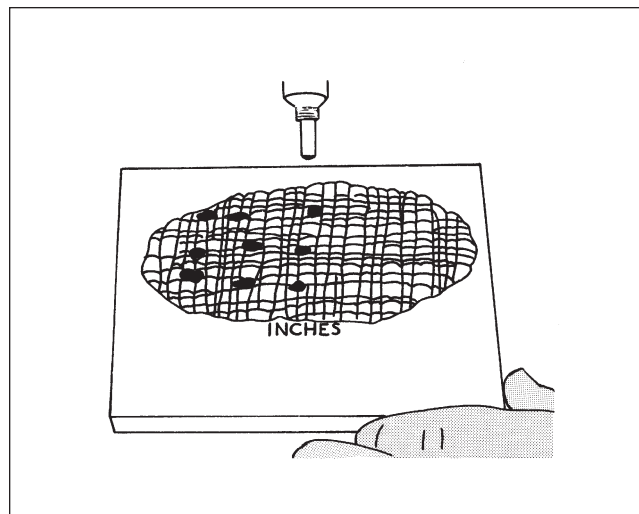


Fig 17-64 Accelerator is added to the putty.

cones has been its limited shelf life. This is caused by the instability of alkyl silicates in the presence of organo-tin compounds, which may result in oxidation of the tin.⁷²

The technique for condensation silicone rubber base materials is similar in many ways to that for polysulfide. Two inches (5.0 cm) of base are mixed with two drops of accelerator to provide the material used in the syringe. Eight inches (20 cm) of base and eight drops of accelerator are used to form the quantity required to fill the average full-arch impression tray. Other aspects of the technique for the use of condensation silicone rubber base impressions are the same as those used for polysulfide impressions.

There are some condensation silicone impression materials that utilize a heavy-body putty relined with a thin wash. These were developed to reduce the sizable dimensional change that begins to occur when a condensation silicone impression is not poured immediately. The putty has a silica filler content of 75%, which is more than double that in the wash.⁷³ As a result, there is a much lower dimensional change in the bulk of the impression. A preliminary impression is made with the highly filled, heavy-body putty in a stock tray with a thin plastic spacer. After removing the sheet of spacing material, this will serve as a custom tray for a thin wash of a less highly filled, low-viscosity silicone.

The accuracy of the putty/reline has been found to be quite satisfactory,⁷⁴ with minimal effect from a delayed pouring of up to 6 hours.⁷⁵ It does produce very slightly undersized dies.^{75,76} The putty/reline condensation silicones have become much more popular with dentists than double-mix condensation silicones because they provide reasonable accuracy with delayed pouring and do not require a custom tray.

Armamentarium

- Silicone impression kit (putty, base, and accelerator)
- Tray adhesive—polydimethylsiloxane and ethyl silicate
- Measuring scoop
- Disposable mixing pad
- Stiff spatula
- Syringe with disposable tip
- 2 × 2-inch gauze sponges
- Stock trays (rim-lock or perforated)
- Laboratory knife with no. 25 blade

Impression making with condensation silicone

Before the preparation is begun, a stock tray that fits the arch is selected. The inside of the tray is coated with a thin, even coat of adhesive and allowed to dry (Fig 17-63). For a full-arch impression tray, two scoops of putty (base) are placed on the pad. One scoop is used for a sectional tray. Six drops of accelerator are added for each scoop of base (Fig 17-64) and are incorporated on the pad with a spatula for a few seconds. The material is then transferred to the palm of the hand and kneaded for 30 seconds. The material should be free of streaks.

The base is rolled into a cigar shape and placed into a stock impression tray (Fig 17-65). The base is covered with a polyethylene spacer, and the tray is seated in the mouth (Fig 17-66). The tray is removed from the mouth after the initial set has occurred (about 2 minutes). The spacer is peeled off, and any excess on the periphery of the tray is removed with

17 Impressions

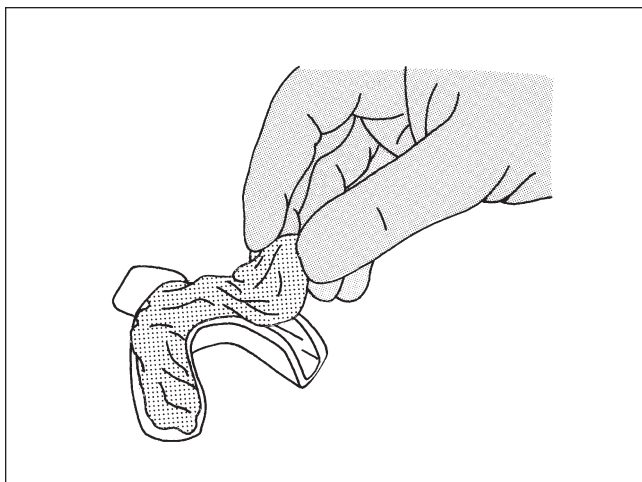


Fig 17-65 Putty is placed in the tray.

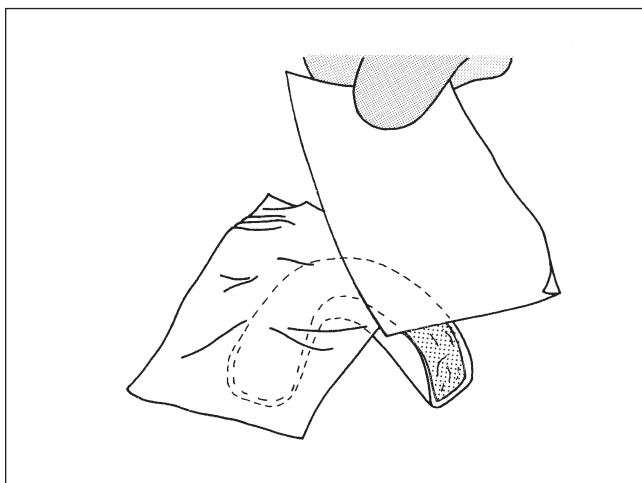


Fig 17-66 A spacer is placed over the tray.

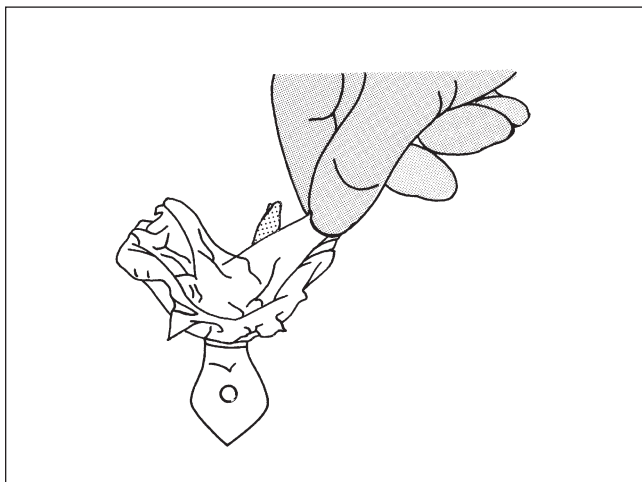


Fig 17-67 The spacer is removed from the tray.

a sharp knife (Fig 17-67). The tray is set aside for use after the tooth has been prepared.

Adequate anesthesia should be confirmed. The quadrant containing the prepared tooth is isolated, the retraction cord is placed, and a large gauze pad is inserted in the mouth. The following steps require an assistant. Eight inches (20 cm) of the thin-wash silicone base are squeezed out onto the disposable mixing pad. Four inches (10 cm) are used for a sectional tray. One drop of accelerator is added per inch of base. A spatula is used to mix the base and accelerator for 30 seconds; the mix should be free of streaks. About one-third of the wash material is placed into the back end of the syringe. While the dentist is inserting the plunger and expressing air, the assistant should place the rest of the material into the tray.

The 2 × 2-inch gauze squares are removed from the patient's mouth. It should be confirmed that the retraction cord is slightly damp (not wet) before it is removed from the sulcus. If necessary, air is blown gently on the prepared tooth to remove moisture from the tooth itself before the retraction cord is removed from the sulcus. If compressed air is blown on the tooth after the cord has been removed, hemorrhage may result.

The cord is carefully removed from the sulcus by grasping the free end in the interproximal region with cotton pliers. The cord is teased out gently to prevent hemorrhage. Syringe material is immediately injected into the sulcus. The tip is held just above the mouth of the crevice. The tip should not drag along the gingiva. Impression material is pushed ahead of the tip as progress continues smoothly around the entire circumference of the preparation. No areas should be skipped, and the entire tooth should be covered. The dentist then gives the syringe to the assistant in exchange for the loaded tray.

The tray is seated slowly until it is firmly in place. It should be held in place with no downward pressure for 6 minutes. Pressure exerted on the tray while the wash is polymerizing will produce stresses in the semi-rigid putty lining the impression tray. When the impression is removed from the mouth, the stresses will relax, resulting in deformation and distortion of the impression.

After the material has set, the impression is removed as quickly and in as straight a path as possible to prevent plastic deformation of the material. The impression is rinsed to remove blood and saliva, blown dry, and inspected. The impression is soaked in an appropriate disinfectant solution before it is poured. An impression of the opposing arch can be made with alginate.

Polyvinyl Siloxane

The dimensional stability of this group of impression materials is so much better than that of condensation silicone, and its reaction is so different, that it deserves treatment as a separate variety of material. PVS silicone also is commonly

called *addition silicone* because of its setting reaction and sometimes *vinyl polysiloxane* or even *vinyl silicone*.

The material usually is packaged as two pastes. One paste contains silicone with terminal silane hydrogen groups and an inert filler. The other paste is made up of a silicone with terminal vinyl groups, chloroplatinic acid catalyst, and a filler.⁷³ Upon mixing equal quantities of the two materials, there is an addition of silane hydrogen groups across vinyl double bonds with the formation of no by-products.⁷¹ The result is an exceptionally stable material.^{64,71,73}

PVS is the impression material least affected by pouring delays or by second pours,⁷⁶ and it is still accurate, even when poured 1 week after removal from the mouth.⁷⁷ Early formulations of this material released hydrogen gas from the impression surface, resulting in voids in the surface of the setting stone cast.⁷⁸ If the impression was not poured within 15 minutes, then the best results were obtained by waiting 24 hours before pouring.⁷⁸ Modification of the formula by the addition of palladium to absorb the hydrogen has minimized this problem. Pouring should now be delayed for a short time (ie, 15 to 30 minutes) rather than a day.

In its unaltered form, PVS is hydrophobic.⁴ Surfactants can be incorporated into the material to make it less hydrophobic and easier to pour. Casts poured in impressions made with altered hydrophilic PVS exhibit 26% to 55% fewer trapped voids than casts poured in unaltered or conventional PVS.⁷⁹ However, casts made in unaltered PVS impressions whose surfaces have been treated with a surfactant at the time of pouring show a reduction in voids of 86%.⁷⁹

Casts poured in hydrophilic PVS materials with intrinsic surfactants produce slightly less accurate casts with surfaces that are 14% to 33% softer than those poured in conventional PVS materials.⁷⁹ The incorporated surfactant also makes the impression material more sensitive to the retardant action of sulfur.⁸⁰ Nonetheless, hydrophilic PVS materials will continue to be used because they are more convenient.

The two pastes can be packaged in separate tubes, or more commonly, they are placed in a twin-barreled cartridge. The cartridge is placed in a dispenser, from which the contents of the two barrels are extruded through a mixing tip with multiple vanes or baffles that mix the two materials together. Mixing dispensers have become the most popular method of dispensing and mixing the material, eliminating the need for a spatula and mixing pad.

In addition to the standard 50-mL cartridge (Fig 17-68b), one manufacturer offers a 75-mL cartridge for heavy-body PVS for trays (Fig 17-68c). It requires a 75-mL dispenser. The same manufacturer offers a 25-mL cartridge of light-body PVS for the syringe (Fig 17-68a), requiring a 25-mL dispenser (Fig 17-69). The cartridge is loaded (Fig 17-70), and the cap is removed (Fig 17-71). As with any cartridge, it is important to express a small amount of impression material before attaching the mixing tip (Fig 17-72). Occasionally, the patency of the orifices is occluded by set material. The exacting process of fluid control, tissue retraction, and isolation is frustratingly negated if the impression material will not come out when desired. This relatively small unit (Fig 17-73) offers

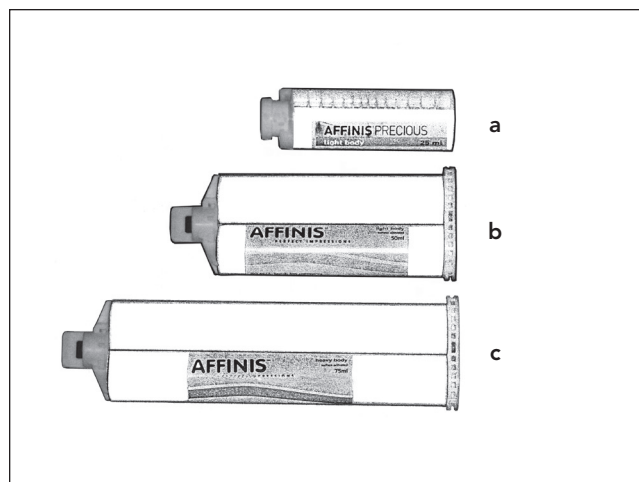


Fig 17-68 Polyvinyl siloxane cartridges: (a) 25 mL; (b) 50 mL; (c) 75 mL.

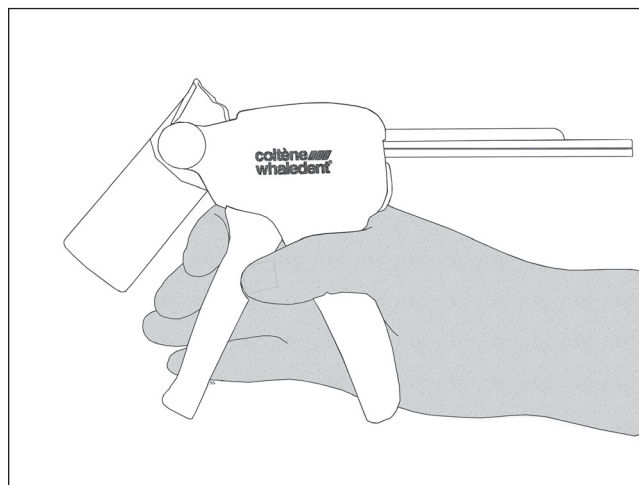


Fig 17-69 Small (25-mL) impression dispenser.

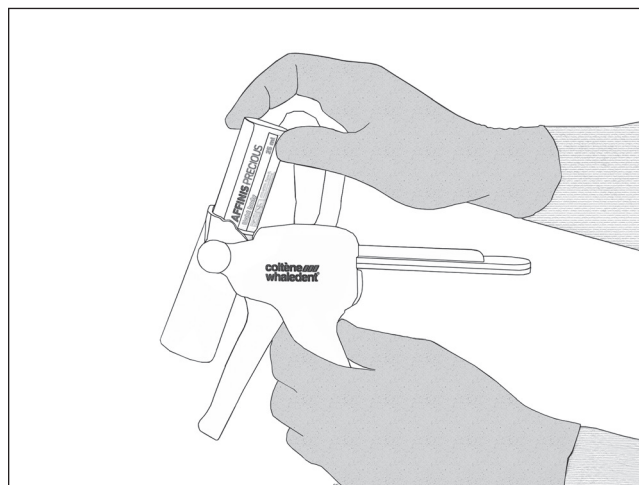


Fig 17-70 Loading the cartridge into the dispenser is similar to loading a shotgun.

17 Impressions

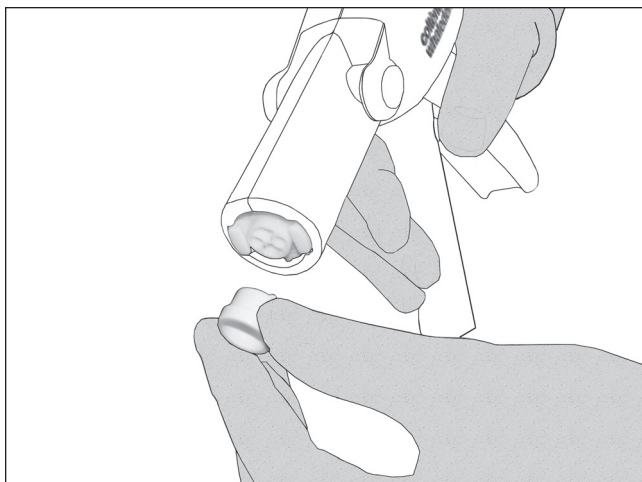


Fig 17-71 The cap is removed.

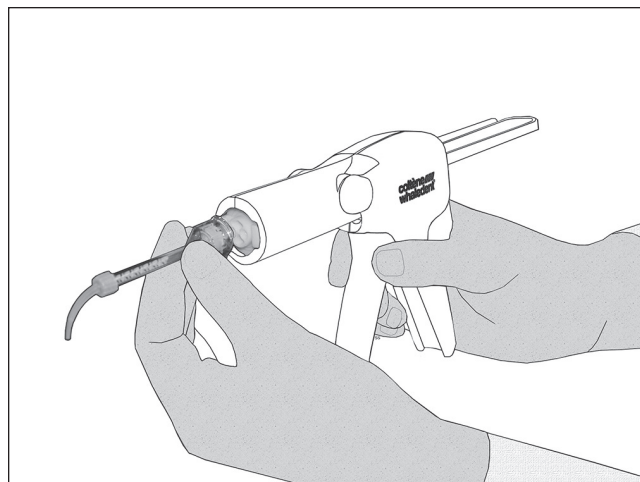


Fig 17-72 The mixing tip is attached.

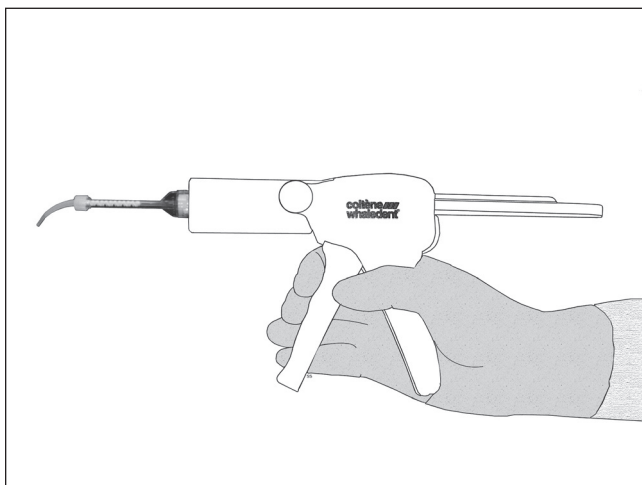


Fig 17-73 Small impression dispenser ready for use.

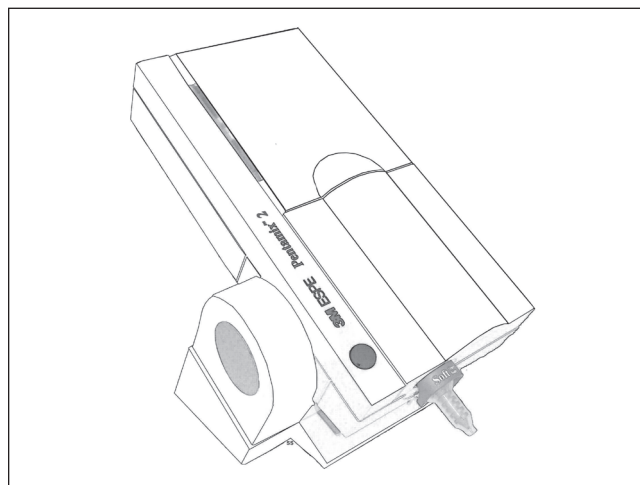


Fig 17-74 Automix machine.

good maneuverability for the initial application of the low-viscosity impression material.

Material dispensed and mixed in this manner costs more per milliliter, but reduced waste keeps the cost of the impression down.⁸¹ There is no need for the assistant to drag his or her knuckles through the mixed material, and there is nothing else to clean up. The system eliminates air entrapment, ensures consistently uniform ratios of catalyst and base, and prevents contamination.⁸² Generally, automixed addition silicones exhibit fewer voids in an impression than do hand-mixed elastomers of the same type, although hand-mixing with some brands may produce fewer voids than automixing will with some other brands.⁸³

Putty and light-body wash consistencies are also made for this type of silicone. The light-body syringe material is avail-

able in cartridges. If putty is used, it should not be dispensed or mixed while wearing latex gloves because setting of the material may be impeded. The polymerization retardation probably results from sulfur derivatives in the latex.^{18,80,84} The inhibition is not restricted to putty,⁸⁵ but the putty is more easily contaminated because it is hand mixed.

The difficulty is not universal; only some brands of impression material, in combination with some brands of gloves, cause retarded setting.⁸⁶ It also can result from contact with other latex items, such as rubber dam.⁸⁷ This can even occur indirectly, when the impression material comes in contact with an object, such as a tooth, that has been touched by a glove, and not with the glove itself. This problem can be avoided by using vinyl gloves or overgloves during the handling of the impression material.⁸⁸ But care must be taken

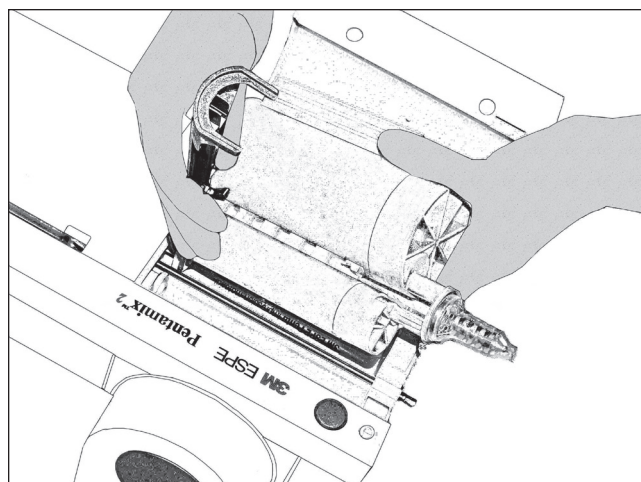


Fig 17-75 Impression material is loaded into the automix machine.

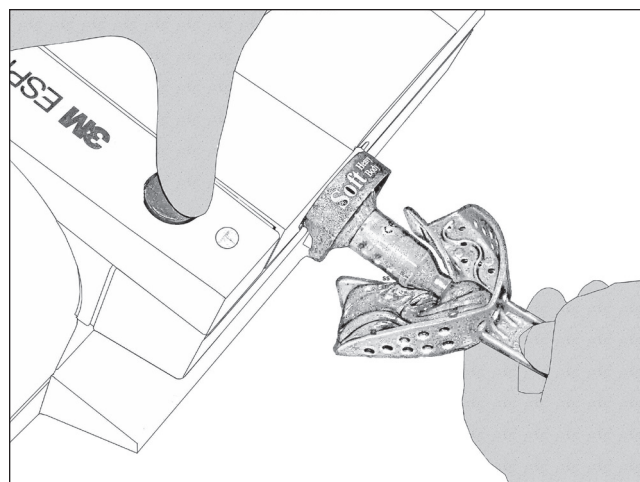


Fig 17-76 Delivery of automixed impression material into tray.

still to ensure that these gloves have never contacted latex because residual elemental sulfur has been shown to remain on them and is not removable.⁸⁹

Both PVS and polyether mechanical mixers are available for higher-volume use. A polyether impression material is offered in a 300-mL base foil bag, which combines with a 60-mL catalyst foil bag into a reusable plastic cartridge. This cartridge is then inserted into the automix machine (Figs 17-74 and 17-75) and delivered into trays and impression syringes mechanically (Fig 17-76). Another manufacturer offers a pouchless 380-mL plastic cartridge, which also mechanically delivers impression material.

Di Felice et al⁹⁰ report significantly fewer voids in impression material that is mechanically mixed than in that which is hand-mixed.

Armamentarium

- Dispenser
- Cartridge (base and accelerator)
- Mixing tip
- Disposable mixing pad
- Syringe with disposable tip
- 2 × 2-inch gauze sponges
- Custom impression tray
- Tray adhesive

Impression making with PVS

The custom tray is painted with adhesive at least 15 minutes before the impression is to be made. A cartridge of light-body material is loaded into one dispenser, and a cartridge

of medium- or heavy-body material is loaded into another. It is still possible to use two cartridges even if only one dispenser is available. The dispenser is prepared by pulling the ratcheted double plunger all the way back while pushing on the plunger release lever at the rear of the dispenser body (Fig 17-77). The retainer cap (a hinged locking device or removable locking plate) on the top of the dispenser—if there is one on the particular model in use—is lifted up (Fig 17-78). The rear flange of the cartridge is slid down into the slots on either side of the front of the dispenser until the cartridge is completely seated (Fig 17-79). The retainer cap is closed (or replaced if it is removable) on the top of the dispenser, securing the cartridge flange to the dispenser (Fig 17-80).

The cap is removed from the front of the cartridge (Fig 17-81) and placed in a safe location where it will not be thrown out in the cleanup following the impression. A small quantity of impression material is expressed from the end of the cartridge before the mixing tip is attached (Fig 17-82). This will ensure that both barrels of the cartridge are clear and ready for use. Sometimes the ends of the barrels become cross-contaminated, causing the formation of polymerized plugs in one or both sides of the nozzle. If this is not eliminated before adding the mixing tip and mixing the material, the dispenser will jam, and the impression attempt will have to be aborted. Attempts should not be made to overpower a jammed dispenser by using more force on the trigger or handle. The end result could be a ruptured cartridge and a multicolored eruption of sticky impression material. The 48-mL cartridge, though still available, has been replaced with a 50-mL cartridge, which has its orifices more widely separated and a notch to control the placement of the mixing tip to avoid contamination of the base and accelerator pastes. This cartridge is also stronger to guard against rupture.

17 Impressions

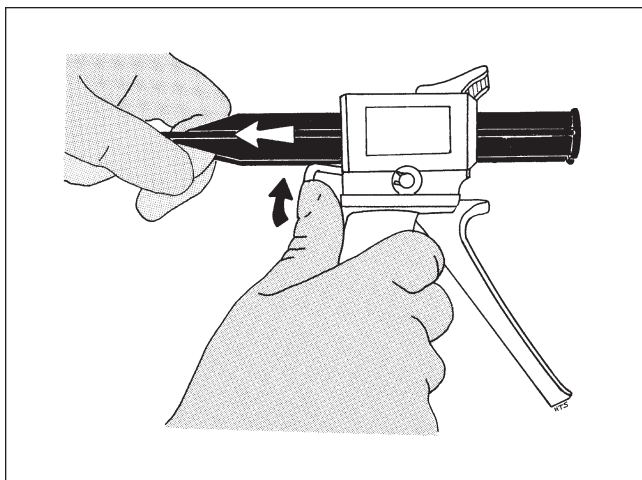


Fig 17-77 The release lever is pushed up with a thumb while the plunger is pulled back.

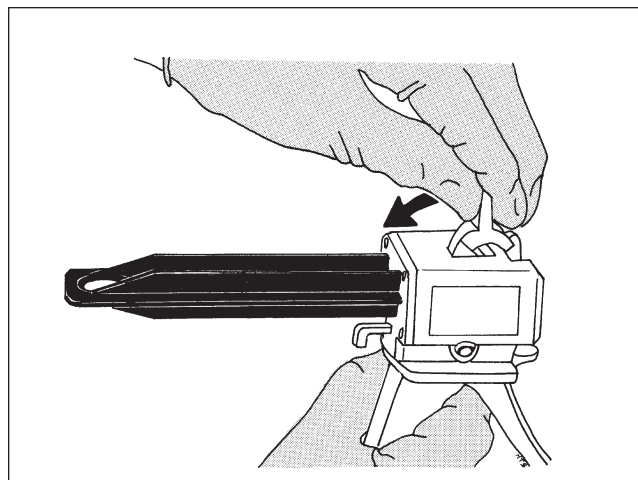


Fig 17-78 The retainer cap on top of the dispenser block is released.

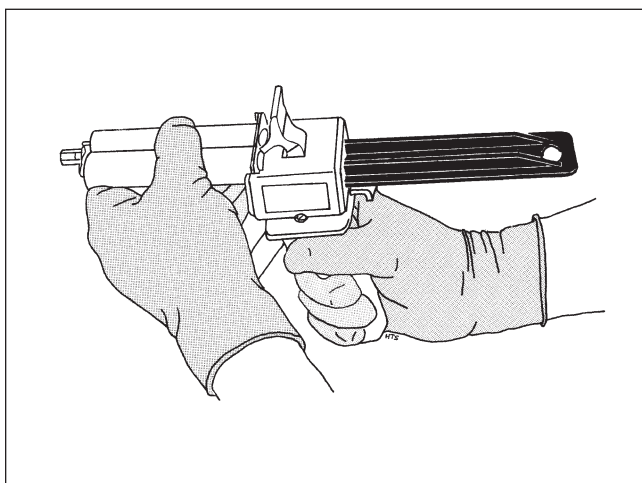


Fig 17-79 The cartridge flange is slid into the slots on the front of the dispenser.

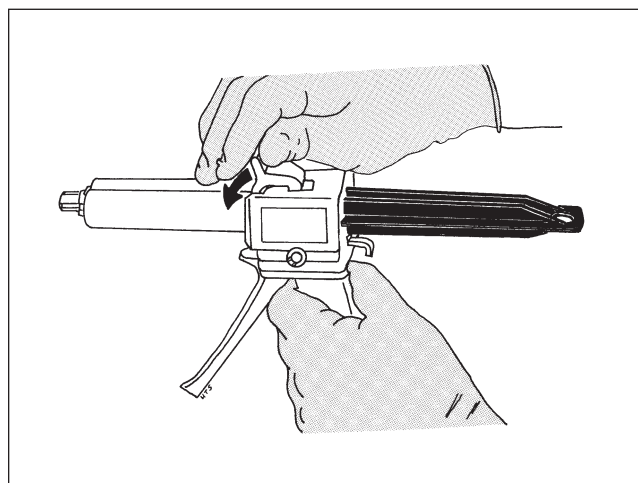


Fig 17-80 The cartridge is secured by closing the retainer cap.

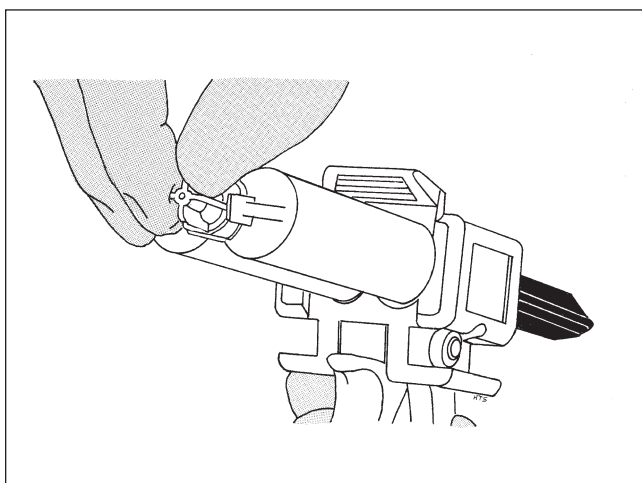


Fig 17-81 The cap is removed from the front of the cartridge.

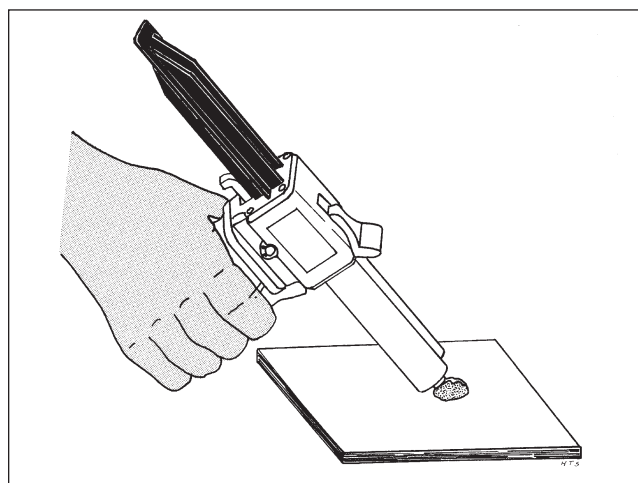


Fig 17-82 A small quantity of material is expressed to ensure that the outlets are clear.

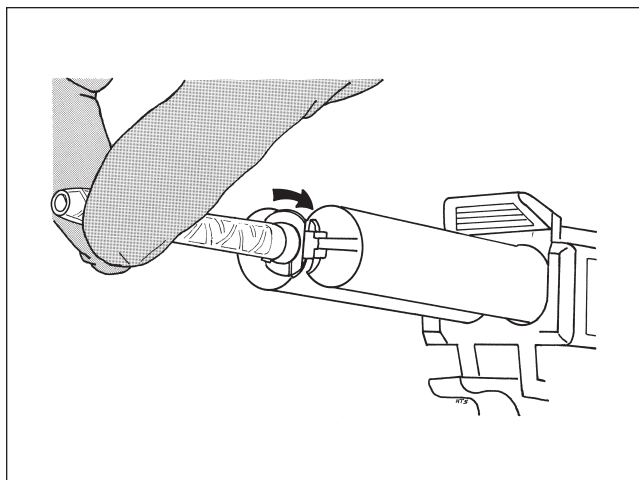


Fig 17-83 The mixing tip is attached to the end of the cartridge.

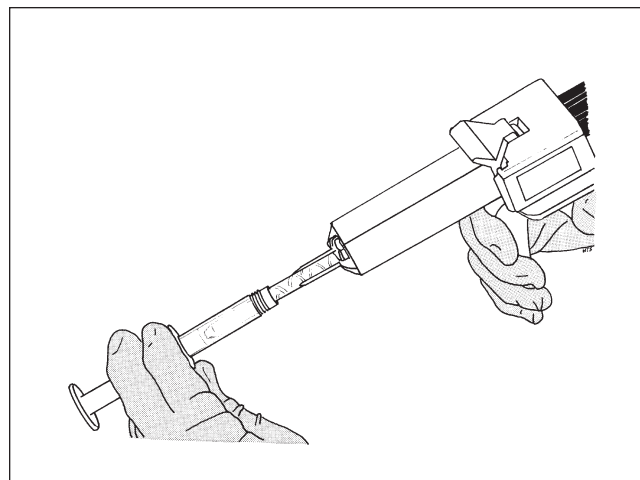


Fig 17-84 Material from the mixing tip is expressed into the syringe.

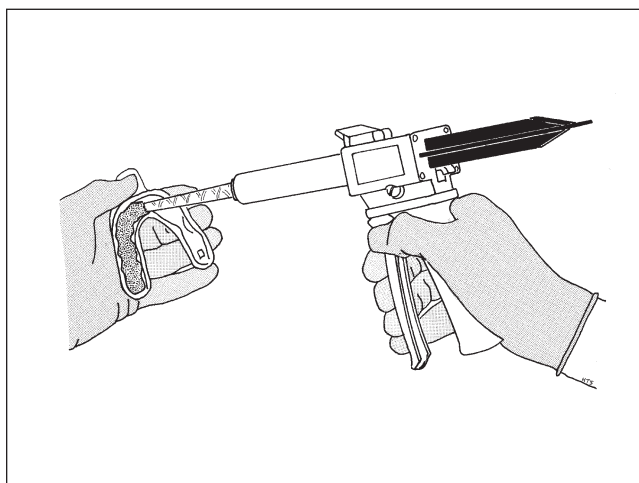


Fig 17-85 The tray is loaded from the dispenser mixing tip.

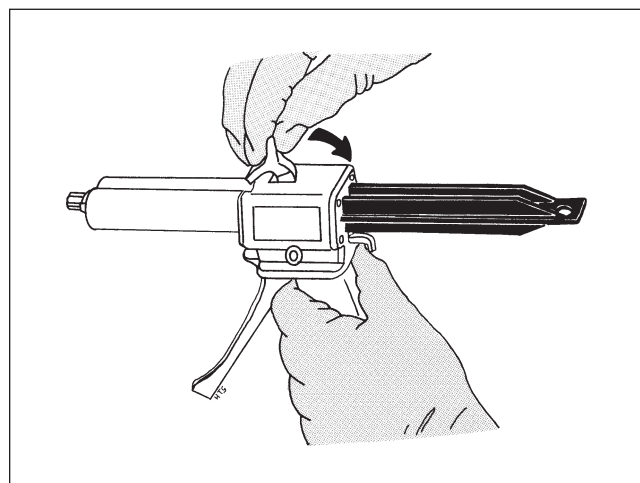


Fig 17-86 To remove the cartridge, the plunger is pulled back and the retainer cap or locking plate is opened.

The mixing tip is placed on the nozzle at the end of the cartridge of light-body material and rotated 90 degrees to lock it in place (Fig 17-83). Force is applied to the handle of the dispenser until the mixing tip is filled with impression material. The mixing tip is inserted into the front end of an impression syringe until it touches the face of the drawn-back plunger of the syringe (Fig 17-84). Material is expressed into the syringe, with the mixing tip of the dispenser slowly withdrawn as the syringe is filled. The clear tip is secured on the syringe with the locking ring. The gauze pack is removed. It is confirmed that the retraction cord is slightly damp before it is removed from the sulcus. The cord is carefully removed, and the impression material is injected, starting in one interproximal area and pushing the material ahead of the tip.

While the dentist applies the light-body material with a syringe, the assistant loads the tray with the medium- or heavy-body material (Fig 17-85). The syringe is exchanged for the loaded tray, which is seated firmly in the mouth. It is held in place for 7 minutes from the start of mixing.

The impression is removed as quickly and in as straight a path as possible to prevent distortion. It is then rinsed, blown dry, inspected, and placed in a disinfectant solution before it is poured. The impression of the opposing arch can be made with alginate. The mixing tip can be left on the cartridge as a cap. If it was contaminated, or if its bulk creates a storage problem, it should be removed from the cartridge and discarded. The cap is replaced on the nozzle of the cartridge. The locking plate is removed from the top of the dispenser body (Fig 17-86). The cartridge is removed from the dispenser.

17 Impressions

Polyether

Polyether is another type of elastomeric impression material that has become popular in the last 25 years. It is a copolymer of 1,2-epoxyethane and tetrahydrofuran that is reacted with an α,β -unsaturated acid, such as crotonic acid, to produce esterification of the terminal hydroxyl groups.⁹¹ The double bonds are reacted with ethylene amine to produce the final polymer. An aromatic sulfonate produces cross-linking by cationic polymerization. Polyether is packaged in two tubes using a much larger volume of base than accelerator (slightly less than 8:1).

The impression material exhibits accuracy on par with, or somewhat superior to, that of other elastomers. It has excellent dimensional stability even when pouring is delayed for prolonged periods of time.^{62,64,92} It is accurate when poured 1 week after removal from the mouth.⁷⁷ Polyether has an affinity for water, making it hydrophilic. Impressions should not be stored in a humid or moist environment. The material is stiff, and undercuts must be blocked out. Its resistance to tearing upon removal is roughly equal to that of silicone and less than that of polysulfide.⁹¹ It is somewhat brittle.

Users of this impression material have experienced some problems with allergic reactions.^{93,94} It was estimated that approximately 0.5% of those exposed to it exhibited a reaction to the aromatic sulfonate catalyst.⁹⁵ A material for provisional restorations that was capable of cross-sensitization has since been removed from the market, reducing potential sensitizing exposure to the allergen. When a patient experiences an allergic response to this material, however minor, polyether should not be used on that patient again.⁹⁶ This would be true with any material.

Armamentarium

- Impression kit
- Tray adhesive
- Dispenser with mixing tip
- Mechanical automix dispenser
- Syringe with disposable tip
- 2 × 2-inch gauze sponges
- Custom resin tray

Impression making with polyether

Because of the accelerated setting time of this material, it is imperative that the operator be well organized and execute swiftly. The custom tray is coated with the adhesive supplied with the polyether. The dispenser is used to mix the light-body polyether. The gun is inserted with its attached mixing tip into the front end of an impression syringe until it touches the face of the drawn-back plunger of the syringe. Material is expressed into the syringe as the tip is slowly removed. The clear tip is inserted into the locking ring, and the locking ring is attached to the syringe. The assistant should load the tray

while the operator proceeds. The medium- or heavy-body polyether is expressed from the mechanical mixer into the tray. The gauze pack is removed.

It should be confirmed that the retraction cord is slightly damp before it is removed from the sulcus. The cord is carefully removed from the sulcus, and the impression material is injected, quickly but carefully, starting in one interproximal area. The syringe is exchanged for the loaded tray, which is seated firmly in place in the mouth. The tray is held in place for 4 minutes. The impression is removed, rinsed, and blown dry. It is then inspected and treated with disinfectant. Because of polyether's tendency to absorb moisture, it is probably better to spray it than to soak it. The impression of the opposing arch can be made with alginate.

Impressions for Pin-Retained Restorations

To make an impression of a preparation for a pin-retained restoration, nylon bristles must be used to duplicate the pinholes. Impression materials will not fill the small-diameter holes being used. A monofilament nylon fishing line cut to an appropriate length and of the appropriate diameter can be used. It should be approximately 0.002 inches smaller in diameter than the pinhole (see "Pin-Modified Three-Quarter Crowns" in chapter 11.) To prevent distortion, the bristle should not touch the impression tray. If necessary, a sharp scalpel blade can be used to cut the end that enters the pinhole (Fig 17-87). Scissors should not be used because they will bur the end of the bristle, making it difficult to remove from the pinhole. The protruding end, however, should have a retentive feature so that the impression material will pick up the bristles. This feature can be accomplished by crimping or by flattening it with a hot no. 7 wax spatula.

A bristle is placed in each of the pinholes (Fig 17-88). The impression procedures should be followed in the usual manner, with care taken to inject all the way around the head of the bristle. The impression is withdrawn in the line of draw of the preparation and pins. Pulling the impression off in another line may tear the bristle out.

The impression is poured in the usual way. When the stone has set, the impression and cast are separated. The nylon bristle used to duplicate the pinhole will remain in the cast. It is removed by pulling it out with office pliers. If a second cast for a working cast is made, the pinhole will not be accurately reproduced. In this case, a bur is used to create an oversized pinhole in the second cast so that the pin in the wax pattern will not touch stone when the pattern is transferred from the die to the working cast. Use of a working cast with a removable die eliminates the need for a second pour.

A piece of the same size monofilament nylon line used for the impression is incorporated into the wax pattern and will burn out with the wax. The pinhole in the master cast will need to be very slightly enlarged by hand-turning the same-sized twist drill so the nylon line will completely enter

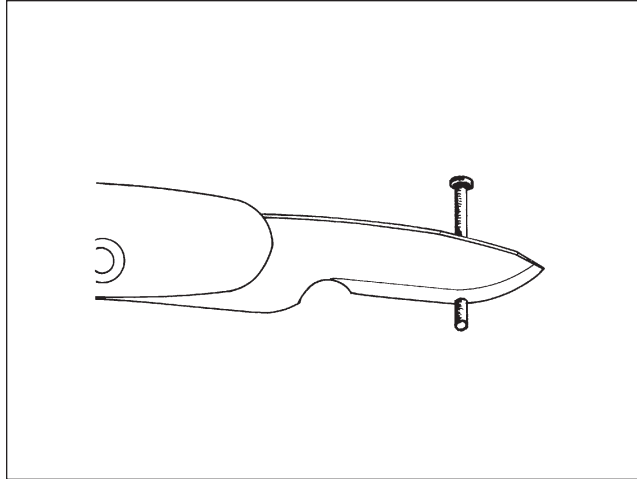


Fig 17-87 The bristle is cut with a sharp scalpel.

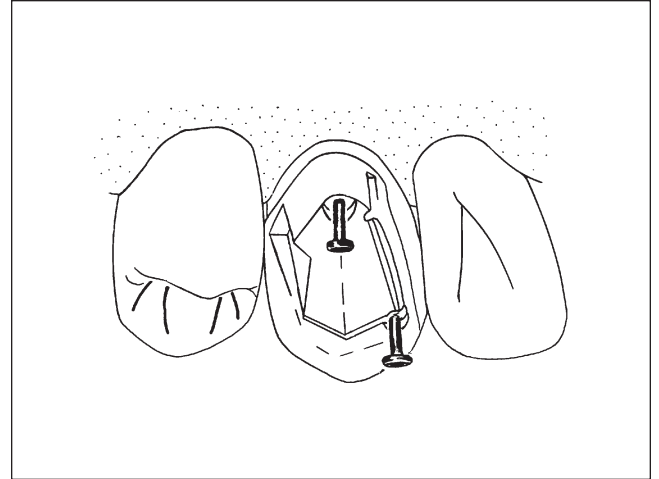


Fig 17-88 Bristles are used to duplicate the pinholes in the impression.

the pinhole without binding. The base of the pin must not be nicked because this will produce a weak area in the pin. The protruding end must also have a retentive feature to hold the wax. The die is lubricated with die lubricant, and the wax pattern is fabricated around the monofilament nylon pin. The pattern is withdrawn and invested in the usual way. The bristle is incorporated in the wax pattern and burns out in the oven.

There are often discrepancies at the bases of pins caused by breakdown of investment in that area.⁹⁷ If this prevents seating of the casting in the mouth, the orifice of the pinhole should be countersunk using a no. 2 or no. 4 round bur. Burring around the base of the pins in the casting may weaken them and therefore should be avoided. A small reamer (reserved for this purpose) is used to apply cement to the pinhole. The reamer is rotated in a counterclockwise manner to carry the cement to the full depth of the pinhole. Cement is applied to the pins themselves to ensure they will be covered.

Disinfection of Impressions

Public as well as professional concern regarding AIDS has forced a reevaluation of how the profession deals with blood-borne pathogens. These measures probably are as important, if not more so, for the prevention of the more prevalent hepatitis B virus (HBV) and the resurgent, drug-resistant strain of tuberculosis (multidrug-resistant tuberculosis [MDR-TB]). The dental impression certainly is one of the ways by which pathogens can leave the operatory and spread their risk broadly.

A detailed protocol is now required to ensure that the previously overlooked impression is handled properly. The

impression must be rendered harmless before being passed on to other people who will work with it, or with the gypsum cast made from it, outside the dental operatory. There are five types of chemical disinfectants that can be used for this purpose: (1) chlorine compounds, (2) combination synthetic phenolic compounds, (3) glutaraldehydes, (4) iodophors, and (5) phenol-alcohol combinations.⁹⁸

A prolonged immersion in 2% glutaraldehyde or hypochlorite solution with 10,000 ppm available chlorine for 1 hour was recommended for disinfecting impressions in a 1973 World Health Organization report.⁹⁹ The recommendation of a 1-hour treatment has been reiterated on the rationale that all impressions are as potentially infectious as those coming from high-risk patients and should be treated accordingly.¹⁰⁰

The most recent recommendations for the disinfection of impressions and casts published by the American Dental Association (ADA) Council on Dental Materials, Instruments, and Equipment; Council on Dental Practice; Council on Dental Therapeutics in 1988¹⁰¹ and amended in August 1991¹⁰² call for the immersion of polysulfide, condensation-reaction silicone, PVS, polyether, and agar hydrocolloid in ADA-accepted disinfecting solutions that require immersion for no longer than 30 minutes.

An alternative technique, spraying, can be used on those materials most vulnerable to distortion.¹⁰² This is done by rinsing the impression under running water; trimming excess impression material; spraying the entire impression, top and bottom (including the tray); and then sealing the impression tray in the bag for the time recommended for the disinfectant used.⁹⁸ One disinfectant spray, Dispatch Hospital Cleaner Disinfectant with Bleach (Caltech), claims 1-minute efficacy on bacteria, viruses, and fungi. If an impression material is susceptible to fluid imbibition, then minimizing exposure time to fluids may minimize distortion. Diluted bleach solu-

17 Impressions

tions (1:10) must be prepared daily, but this product is stable as supplied for its 2-year shelf life. The surface quality and dimensional stability of disinfected impressions have been the focus of numerous published reports.¹⁰³ Solutions requiring shorter immersion times should be selected for materials that are prone to distortion when immersed in water. Several investigators have found the surface detail and dimensional stability of alginate (irreversible) hydrocolloid impressions to be acceptable if immersed in sodium hypochlorite for 10 minutes.^{104–106} Westerholm et al¹⁰⁷ found full-strength (5.25%) sodium hypochlorite to be the most effective disinfectant when sprayed on alginate. Similar treatment with some types of glutaraldehydes also produced acceptable results,^{105,106,108} while others did not.^{109,110} One manufacturer incorporates a quaternary ammonium compound into its irreversible hydrocolloid and claims an antimicrobial effect.

There have been far fewer published studies of the effects of disinfectant solutions on agar (reversible) hydrocolloid. Those that have been done show that it is unaffected by a 10-minute immersion in 2% alkaline glutaraldehyde,¹¹¹ but immersion for 20 minutes or longer in the same solution will adversely affect dimensional stability^{111–113} and surface detail.¹¹² Polyether, because of its hydrophilic properties, could present problems when immersed. However, it has been demonstrated to be dimensionally stable when immersed from 10 to 30 minutes in sodium hypochlorite,^{109,110,114} glutaraldehyde,^{108–110,114,115} iodophor,^{108,110,114} and phenol solutions.^{115,116} However, on a newly formulated polyether, surface quality was severely affected by exposure to 0.5% sodium hypochlorite for 10 minutes.¹¹⁷

Polysulfide has been demonstrated to have sufficient dimensional stability when immersed in sodium hypochlorite,^{109,110,114,118,119} glutaraldehyde,^{109,110,114,118,119} iodophor,^{110,114,119} and phenol.^{109,116,118,120} Sodium hypochlorite,^{104,105} glutaraldehyde,^{105,121} and phenol¹⁰⁵ can be used with conventional (condensation) silicones as long as immersion times do not exceed the recommended pouring times for the material.

Prior to disinfection, significantly fewer microorganisms are retained on the surface of PVS impressions than on other materials.¹²² PVS materials generally display excellent tolerance to immersion in sodium hypochlorite,^{104,105,109,114,115,118,119} glutaraldehyde,^{109,114,115,118,119,121} iodophor,^{110,114,119,121} and phenols.^{105,109,116,118,120,121}

Disinfection of casts also has been attempted. Gypsum casts that were irradiated with microwave energy showed better disinfection than casts from chemically disinfected impressions.¹²³ Multiple casts can be effectively disinfected simultaneously.¹²⁴ The effect of the microwave energy on surface quality or dimensional stability has not been reported.

Incorporation of 1% or 2% chlorhexidine or 1% or 2% glutaraldehyde aqueous solutions instead of 100% water did not harm detail reproduction or setting expansion of gypsum.¹²⁵ However, setting time was increased, but within ISO standards.¹²⁵ The use of 0.5% or 1.0% dilution of sodium hypochlorite caused unacceptable changes in dimensional stability, setting time, and detail reproduction.¹²⁵

The Environmental Protection Agency (EPA) registers disinfectants for use in dentistry. Their guidelines published with the disinfectants should be followed.¹²⁶

Digital Impressions

The great success of the indirect fabrication of intracoronal or extracoronal restorations such as inlays and onlays, advancing to full coverage gold, metal-ceramic, or all-ceramic crowns, has been facilitated by the development of accurate elastomeric impression materials and die stones.

Duret and Termoz¹²⁷ were granted the first US patent for a computer-aided design/computer-assisted manufacture (CAD/CAM) device for making a dental prosthesis in 1987. The first commercially available CAD/CAM system for fabricating dental restorations was also introduced in 1987 (CEREC [chairside economical restoration of esthetic ceramics], Sirona). This technology uses optical scanning and requires the entire area to be captured in the impression to be coated with a reflective powder. The E4D Dentist system (D4D Technologies) was introduced in 2008. This system uses laser scanning and requires no reflective powder. Like the CEREC system, the E4D system can be connected directly to a milling machine to create the restoration.

There are two digital impression systems introduced in 2008 that are not connected directly to a milling machine. The iTero system (Cadent) (Fig 17-89) uses a laser scanner (Fig 17-90) that does not require reflective powder to facilitate the impression. The Lava Chairside Oral Scanner (COS) (3M ESPE) uses light powder to facilitate scanning by an optical video system. The scanning data from these two systems is used to create articulated casts and dies. The desired type of restoration is then completed by a dental laboratory. It is important to remember that all of these systems still require adequate tissue retraction and fluid control.

On its website, Cadent states that the iTero system is indicated for crowns, fixed partial dentures, inlays/onlays, veneers, and abutment-level implant impressions. The scan always begins with a clean sleeve on the scanner for infection control. A dual-cord retraction technique is recommended. After the preparation, a thin cord is placed and an initial scan is made (Figs 17-91 and 17-92). The areas on the preparation that need modification are identified (Fig 17-93), and the preparation is refined. A hemostatic agent is used, as required, and a thicker cord is placed for 5 minutes. The final scan is then accomplished.

Audible prompts guide the scanning of required fields. Inadequate scans can be deleted and rescanned. These scans are all digitally merged. The system selects full-arch or quadrant scanning according to the teeth that were selected for restorations. The opposing teeth, the prepared teeth, and the relationship between them are scanned. With the patient present, the scan is reviewed, and its accuracy is confirmed. A provisional restoration is required with this technique, just as it would be if a conventional impression were used.

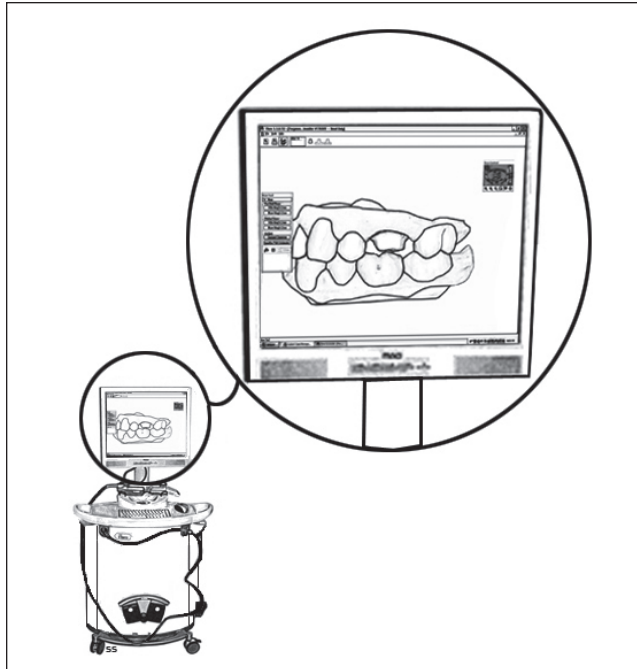


Fig 17-89 iTero scanning unit.

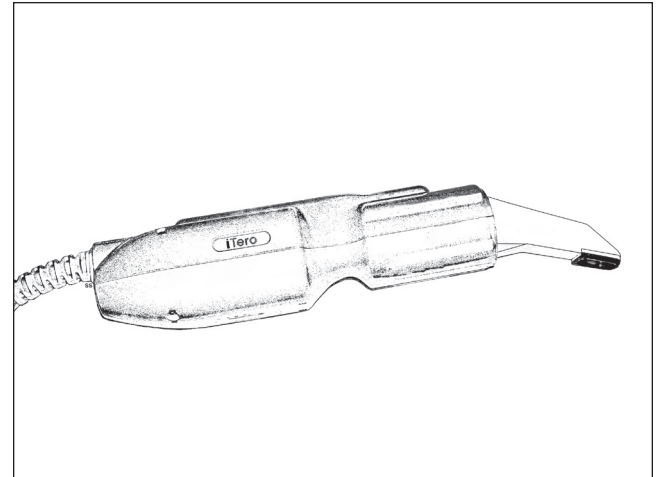


Fig 17-90 iTero scanning head.

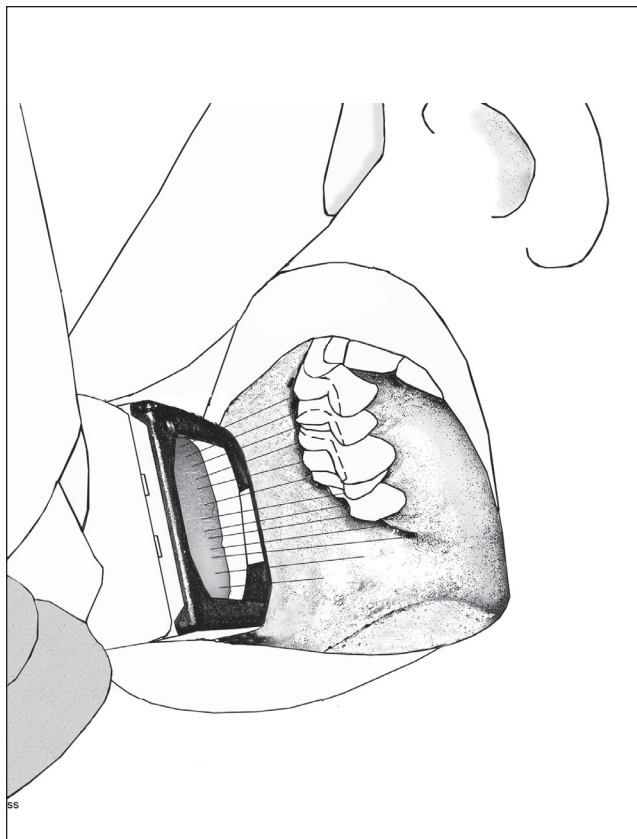


Fig 17-91 iTero scanning head in position.

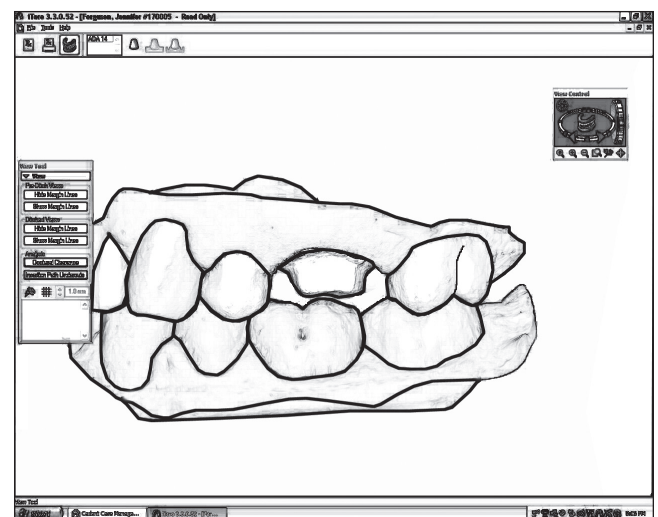


Fig 17-92 Facial view of prepared maxillary molar on a monitor.

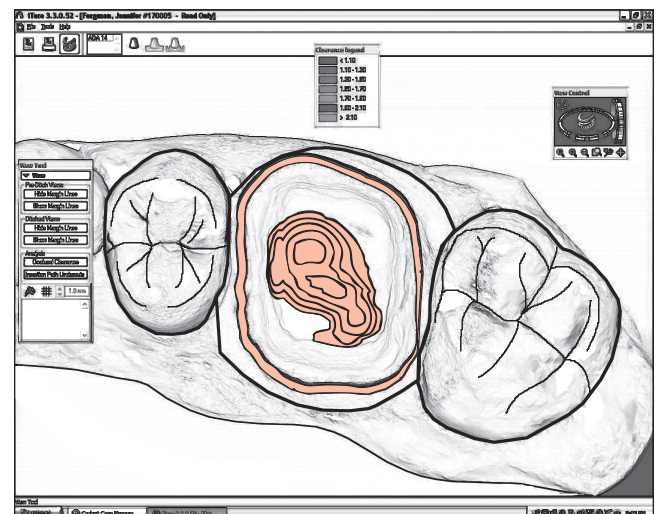


Fig 17-93 Occlusal view of prepared maxillary molar on a monitor with highlighted area of inadequate occlusal reduction.

17 Impressions

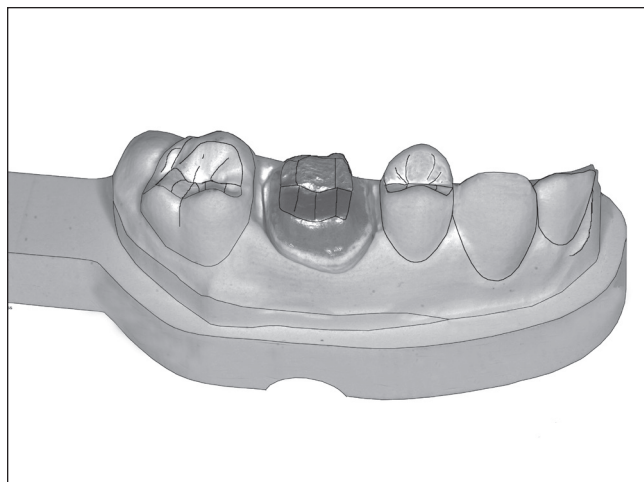


Fig 17-94 Mounted polyurethane cast and die of prepared maxillary molar.

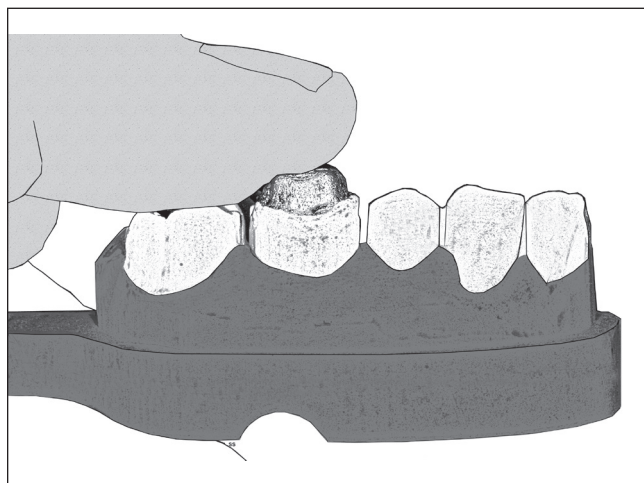


Fig 17-95 Lateral view of partially removed die.

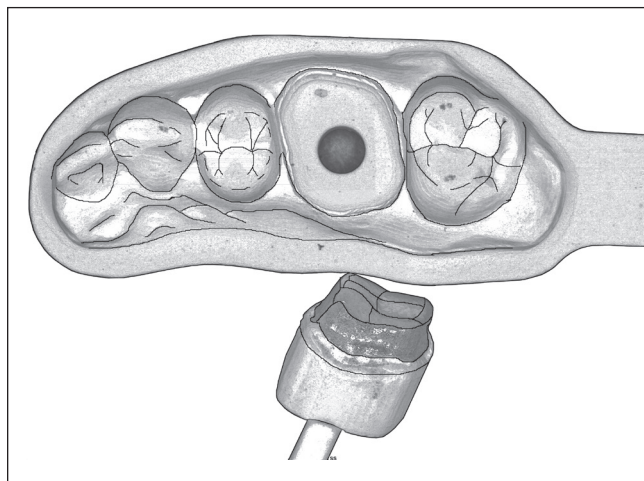


Fig 17-96 Occlusal view of removed die and its socket in the cast.

The scan is sent via the Internet to Cadent, where the finish line is identified. The dentist has an opportunity to review that identified finish line before the polyurethane articulated casts with removable dies are made (Figs 17-94 to 17-96). The scan is then sent to the dentist's commercial dental laboratory, where the restoration is fabricated on the articulated casts according to the dentist's work authorization.

The casts are mounted on a nonadjustable articulator, which does not facilitate analysis of excursive mastication. Whip Mix makes adapters to transfer these casts to a semi-adjustable articulator. This allows inspection of excursive guidance before the delivery appointment.

References

1. Christensen GJ. The state of fixed prosthodontic impressions: Room for improvement. *J Am Dent Assoc* 2005;136:343–346.
2. O'Brien WJ. Impression materials. In: O'Brien WJ (ed). *Dental Materials and Their Selection*, ed 4. Chicago: Quintessence, 2008:96.
3. Schelb E, Jones JD, Prihoda TJ. Compatability of type IV dental stone with polysulfide impression materials. *J Prosthodont* 1992;1:32–36.
4. McCormick JT, Antony SJ, Dial ML, Duncanson MG Jr, Shillingburg HT Jr. Wettability of elastomeric impression materials: Effect of selected surfactants. *Int J Prosthodont* 1989;2:413–420.
5. Lorren RA, Salter DJ, Fairhurst CW. The contact angles of die stone on impression materials. *J Prosthet Dent* 1976;36:176–180.
6. Cullen DR, Mikesell JW, Sandrik JL. Wettability of elastomeric impression materials and voids in gypsum casts. *J Prosthet Dent* 1991;66:261–265.
7. Powers JM, Sakaguchi RL. *Craig's Restorative Dental Materials*, ed 12. St Louis: Mosby, 2006:299.
8. Hosseinpour D, Berg JC. The dynamic interaction of water with four dental impression materials during cure. *J Prosthodont* 2009;18:292–300.
9. Powers JM, Sakaguchi RL. *Craig's Restorative Dental Materials*, ed 12. St Louis: Mosby, 2006:293.
10. Herfort TW, Gerberich WW, Macosko CW, Goodkind RJ. Viscosity of elastomeric impression materials. *J Prosthet Dent* 1977;38:396–404.
11. Powers JM, Sakaguchi RL. *Craig's Restorative Dental Materials*, ed 12. St Louis: Mosby, 2006:72.
12. Kishimoto M, Shillingburg HT Jr, Duncanson MG Jr. A comparison of six impression syringes. *J Prosthet Dent* 1980;43:546–551.
13. Schnell RJ, Phillips RW. Dimensional stability of rubber base impressions and certain other factors affecting accuracy. *J Am Dent Assoc* 1958;57:39–48.
14. Gilmore WH, Schnell RJ, Phillips RW. Factors influencing the accuracy of silicone impression material. *J Prosthet Dent* 1954;4:94–103.
15. Eames WB, Sieweke JC, Wallace SW, Rogers LB. Elastomeric impression materials: Effect of bulk on accuracy. *J Prosthet Dent* 1979;41:304–307.
16. Shillingburg HT Jr, Hatch RA, Keenan MP, Hemphill MW. Impression materials and techniques used for cast restorations in eight states. *J Am Dent Assoc* 1980;100:696–699.
17. Shillingburg HT Jr, Brackett SE. Impression materials—A cost comparison. *J Okla Dent Assoc* 1984;75:21–24.
18. Farah JW, Powers JM. Elastomeric impression materials. *Dental Advisor* 2008;25:1–9.
19. Hart JD, Howard B. Hydrocolloids started here. *J Okla Dent Assoc* 1956;45:10–12.
20. Engelman MA. Hydrocolloid: A reassessment for better dentistry. *N Y State Dent J* 1979;45:383–388.

21. Hollenback GM. Science and Technic of the Cast Restoration. St Louis: Mosby, 1964:86–87.
22. Anusavice KJ, Phillips RW. Phillips' Science of Dental Materials, ed 11. St Louis: Saunders, 2003:235–237.
23. Asgar K. Elastic impression materials. Dent Clin North Am 1971; 15:81–98.
24. Engelman MA, Kessler H, McEvoy R. New reversible hydrocolloid for recording the retracted gingival sulcus in fixed prosthodontics: Laboratory and clinical evaluation. N Y J Dent 1980;50:151–162.
25. Eames WB, Rogers LB, Wallace SW, Suway NB. Compatibility of gypsum products with hydrocolloid impression materials. Oper Dent 1978;3:108–112.
26. Powell GL, Fenn JP, Runnells R. Hydrocolloid conditioning units: A potential source of bacterial cross contamination. J Prosthet Dent 1987;58:280–283.
27. Schwartz JR. The use of the hydrocolloids or alginates as impression materials for indirect or indirect-direct inlay construction procedure. Dent Items Interest 1951;73:269–278.
28. Appleby DC, Pameijer CH, Boffa J. The combined reversible hydrocolloid/irreversible hydrocolloid impression system. J Prosthet Dent 1980;44:27–35.
29. Fusayama T, Kurosaki N, Node H, Nakamura M. A laminated hydrocolloid impression for indirect inlays. J Prosthet Dent 1982;47:171–176.
30. Appleby DC, Cohen SR, Racowsky LP, Mingledorff EB. The combined reversible hydrocolloid/ irreversible hydrocolloid impression system: Clinical application. J Prosthet Dent 1981;46:48–58.
31. Herring HW, Tames MA, Zardiackas LD. Comparison of the dimensional accuracy of a combined reversible/irreversible hydrocolloid impression system with other commonly used impression materials. J Prosthet Dent 1984;52:795–799.
32. Johnson GH, Craig RG. Accuracy and bond strength of combination agar/alginates hydrocolloid impression materials. J Prosthet Dent 1986;55:1–6.
33. Linke BA, Nicholls JI, Faucher RR. Distortion analysis of stone casts made from impression materials. J Prosthet Dent 1985; 54:794–802.
34. Heisler WH, Tjan AH. Accuracy and bond strength of reversible with irreversible hydrocolloid impression systems: A comparative study. J Prosthet Dent 1992;68:578–584.
35. Bomberg TJ, Hatch RA, Hoffman W Jr. Impression material thickness in stock and custom trays. J Prosthet Dent 1985;54:170–172.
36. Tjan AH, Nemetz H, Nguyen LT, Contino R. Effect of tray space on the accuracy of monophasic polyvinylsiloxane impressions. J Prosthet Dent 1992;68:19–28.
37. Gordon GE, Johnson GH, Drennon DG. The effect of tray selection on the accuracy of elastomeric impression materials. J Prosthet Dent 1990;63:12–15.
38. Johnson GH, Craig RG. Accuracy of addition silicones as a function of technique. J Prosthet Dent 1986;55:197–203.
39. Bomberg TJ, Goldfogel MH, Hoffman W Jr, Bomberg SE. Considerations for adhesion of impression materials to impression trays. J Prosthet Dent 1988;60:681–684.
40. Carrotte PV, Johnson A, Winstanley RB. The influence of the impression tray on the accuracy of impressions for crown and bridge work—An investigation and review. Br Dent J 1998;185: 580–585.
41. Nicholson JW, Porter KH, Dolan T. Strength of tray adhesives for elastomeric impression materials. Oper Dent 1985;10:12–16.
42. Chai JY, Jameson LM, Moser JB, Hesby RA. Adhesive properties of several impression material systems: Part I. J Prosthet Dent 1991;66:201–209.
43. Grant BE, Tjan AHL. Tensile and peel bond strengths of tray adhesives. J Prosthet Dent 1988;59:165–168.
44. Hogans WR 3rd, Agar JR. The bond strength of elastomer tray adhesives to thermoplastic and acrylic resin tray materials. J Prosthet Dent 1992;67:541–543.
45. Sulong MZ, Setchell DJ. Properties of the tray adhesive of an addition polymerizing silicone to impression tray materials. J Prosthet Dent 1991;66:743–747.
46. On making good impressions. Dental Advisor 1984;1(1):1–8.
47. Payne JA, Pereira BP. Bond strength of three nonaqueous elastomeric impression materials to a light-activated tray. Int J Prosthodont 1992;5:55–58.
48. Dixon DL, Breeding LC, Bosser MJ, Nafso AJ. The effect of custom tray material type and surface treatment on the tensile bond strength of an impression material/adhesive system. Int J Prosthodont 1993;6:303–306.
49. Tjan AH, Whang SB. Comparing effects of tray treatment on the accuracy of dies. J Prosthet Dent 1987;58:175–178.
50. Davis GB, Moser JB, Brinsden GI. The bonding properties of elastomer tray adhesives. J Prosthet Dent 1976;36:278–285.
51. Phillips RW, Skinner EW. Skinner's Science of Dental Materials, ed 9. Philadelphia: Saunders, 1991:193.
52. Fehling AW, Hesby RA, Pelleu GB Jr. Dimensional stability of autopolymerizing acrylic resin impression trays. J Prosthet Dent 1986;55:592–597.
53. Pagniano RP, Scheid RC, Clowson RL, Dagefoerde RO, Zardiackas LD. Linear dimensional change of acrylic resins used in the fabrication of custom trays. J Prosthet Dent 1982;47:279–283.
54. Parker MH, Cameron SM, Hughbanks JC, Reid DE. Comparison of occlusal contacts in maximum intercuspation for two impression techniques. J Prosthet Dent 1997;78:255–259.
55. Kaplowitz GJ. Trouble-shooting dual arch impressions. J Am Dent Assoc 1996;127:234–240.
56. Kaplowitz GJ. Trouble-shooting dual arch impressions II. J Am Dent Assoc 1997;128:1277–1281.
57. Barzilay I, Myers ML. The dual-arch impression. Quintessence Int 1987;18:293–295.
58. Cox JR, Brandt RL, Hughes HJ. A clinical pilot study of the dimensional accuracy of double-arch and complete-arch impressions. J Prosthet Dent 2002;87:510–515.
59. Breeding LC, Dixon DL. Accuracy of casts generated from dual-arch impressions. J Prosthet Dent 2000;84:403–407.
60. Wöstmann B, Rehmann P, Balkenhol M. Accuracy of impressions obtained with dual-arch trays. Int J Prosthodont 2009;22:158–160.
61. Anusavice KJ, Phillips RW. Phillips' Science of Dental Materials, ed 11. St Louis: Saunders, 2003:212.
62. Luebke RJ, Scandrett FR, Kerber PE. The effect of delayed and second pours on elastomeric impression material accuracy. J Prosthet Dent 1979;41:517–521.
63. Hembree JH Jr. Comparative accuracy of elastomer impression materials. J Tenn Dent Assoc 1974;54:164–167.
64. Eames WB, Wallace SW, Suway NB, Rogers LB. Accuracy and dimensional stability of elastomeric impression materials. J Prosthet Dent 1979;42:159–162.
65. Shillingburg HT Jr, Case JC, Duncanson MG Jr, Kent WA. Radiopacity and color of elastomeric impression materials. Quintessence Int 1988;19:541–548.
66. Kent WA, Shillingburg HT Jr, Tow HD. Impression material foreign body: Report of a case. Quintessence Int 1988;19:9–11.
67. Shillingburg HT Jr, Wilkerson-Lyman SL, Duncanson MG Jr. Radiopacity enhancement of an experimental vinyl polysiloxane impression material. Quintessence Int 1989;20:657–663.
68. Harrop TJ, Middaugh DG. Forced air impression technique. J Can Dent Assoc (Tor) 1967;33:673–675.
69. Going RE. Accurate rubber-base impressions. J Prosthet Dent 1968;20:339–344.
70. Braden M, Elliott JC. Characterization of the setting process of silicone dental rubbers. J Dent Res 1966;45:1016–1023.
71. McCabe JF, Wilson HJ. Addition curing silicone rubber impression materials. Br Dent J 1978;145:17–20.
72. Anusavice KJ, Phillips RW. Phillips' Science of Dental Materials, ed 10. Philadelphia: Saunders, 1996:155.
73. Craig RG. A review of properties of rubber impression materials. J Mich Dent Assoc 1977;59:254–261.
74. Reisbick MH, Matyas J. The accuracy of highly filled elastomeric impression materials. J Prosthet Dent 1975;33:67–72.
75. Tjan AHL, Whang SB, Tjan AH. Clinically oriented assessment of the accuracy of three putty-wash silicone impression techniques. J Am Dent Assoc 1984;108:973–975.
76. Johnson GH, Craig RG. Accuracy of four types of rubber impression materials compared with time of pour and a repeat pour of models. J Prosthet Dent 1985;53:484–490.

17 Impressions

77. Tjan AH, Whang SB, Sarkissian R. Clinically oriented evaluation of the accuracy of commonly used impression materials. *J Prosthet Dent* 1986;56:4-8.
78. Dhuru VB, Asgharnia MK, Mayer JC, Hassan K. Surface porosity of stone casts made from vinyl polysiloxane impression materials. *Oper Dent* 1986;11:3-7.
79. Panichuttra R, Jones RM, Goodacre C, Munoz CA, Moore BK. Hydrophilic poly(vinyl siloxane) impression materials: Dimensional accuracy, wettability, and effect on gypsum hardness. *Int J Prosthodont* 1991;4:240-248.
80. Anusavice KJ, Phillips RW. *Phillips' Science of Dental Materials*, ed 11. St Louis: Saunders, 2003:216.
81. Crown and bridge impression materials. *Dental Advisor* 1989;6(2):1-8.
82. Keck SC. Automixing: A new concept in elastomeric impression material delivery systems. *J Prosthet Dent* 1985;54:479-483.
83. Chong YH, Soh G, Lim KC, Teo CS. Porosities in five automixed addition silicone elastomers. *Oper Dent* 1991;16:96-100.
84. Cook WD, Thomasz F. Rubber gloves and addition silicone materials. Current note no. 64. *Aust Dent J* 1986;31:140.
85. Kahn RL, Donovan TE, Chee WW. Interaction of gloves and rubber dam with a poly(vinyl siloxane) impression material: A screening test. *Int J Prosthodont* 1989;2:342-346.
86. Reitz CD, Clark NP. The setting of vinyl polysiloxane and condensation silicone putties when mixed with gloved hands. *J Am Dent Assoc* 1988;116:371-375.
87. Noonan JE, Goldfogel MH, Lambert RL. Inhibited set of the surface of addition silicones in contact with rubber dam. *Oper Dent* 1985;10:46-48.
88. Council on Dental Materials, Instruments, and Equipment. Retarding the setting of vinyl polysiloxane impressions. *J Am Dent Assoc* 1991;122(8):114.
89. Kimoto K, Tanaka K, Toyoda M, Ochiai KT. Indirect latex glove contamination and its inhibitory effect on vinyl polysiloxane polymerization. *J Prosthet Dent* 2005;93:433-438.
90. Di Felice R, Scotti R, Belser UC. The influence of the mixing technique on the content of voids in two polyether impression materials. *Schweiz Monatsschr Zahnmed* 2002;112:12-16.
91. Braden M, Causton B, Clarke RL. A polyether impression rubber. *J Dent Res* 1972;51:889-896.
92. Sawyer HF, Dilts WE, Aubrey ME, Neiman R. Accuracy of casts produced from three classes of elastomer impression materials. *J Am Dent Assoc* 1974;89:644-648.
93. Nally FF, Storrs J. Hypersensitivity to a dental impression material: A case report. *Br Dent J* 1973;134:244-246.
94. Duxbury AJ, Turner EP, Watts DC. Hypersensitivity to epimine containing dental materials. *Br Dent J* 1979;147:331-333.
95. van Groeningen G, Nater JP. Reactions to dental impression materials. *Contact Dermatitis* 1975;1:373-376.
96. Blankenau RJ, Kelsey WP, Cavel WT. A possible allergic response to polyether impression material: A case report. *J Am Dent Assoc* 1984;108:609-610.
97. Schnepfer HE, Baum L. Miniature parallel pins for retention of cast restorations. *J Prosthet Dent* 1961;11:772-780.
98. Naylor WP. Infection control in fixed prosthodontics. *Dent Clin North Am* 1992;36:809-831.
99. World Health Organization. *Viral Hepatitis [Technical Report Series 512]*. Geneva: World Health Organization, 1973.
100. Bergman B. Disinfection of prosthodontic impression materials: A literature review. *Int J Prosthodont* 1989;2:537-542.
101. Council on Dental Materials, Instruments, and Equipment; Council on Dental Practice; Council on Dental Therapeutics. Infection control recommendations for the dental office and the dental laboratory. *J Am Dent Assoc* 1988;116:241-248 [erratum 1988;116:614].
102. Council on Dental Materials, Instruments, and Equipment. Disinfection of impressions. *J Am Dent Assoc* 1991;122(9):110.
103. Owen CP, Goolam R. Disinfection of impression materials to prevent viral cross contamination: A review and a protocol. *Int J Prosthodont* 1993;6:480-494.
104. Minagi A, Fukushima K, Maeda N, et al. Disinfection method for impression materials: Freedom from fear of hepatitis B and acquired immunodeficiency syndrome. *J Prosthet Dent* 1986;56:451-454.
105. Matyas J, Dao N, Caputo AA, Lucatorto FM. Effects of disinfectants on dimensional accuracy of impression materials. *J Prosthet Dent* 1990;64:25-31.
106. Dellinger EL, Williams KJ, Setcos JC. Influence of immersion and spray disinfectants on alginate impressions [abstract 2045]. *J Dent Res* 1990;69:364.
107. Westerholm HS 2nd, Bradley DV Jr, Schwartz RS. Efficacy of various spray disinfectants on irreversible hydrocolloid impressions. *Int J Prosthodont* 1992;5:47-54.
108. Johnson GH, Chellis KD, Gordon GE. Dimensional stability and detail reproduction of disinfected alginate and elastomeric impressions [abstract 2078]. *J Dent Res* 1990;69:368.
109. Herrera SP, Merchant VA. Dimensional stability of dental impressions after immersion disinfection. *J Am Dent Assoc* 1986;113:419-422.
110. Tullner JB, Commette JA, Moon PC. Linear dimensional changes in dental impressions after immersion in disinfectant solutions. *J Prosthet Dent* 1988;60:725-728.
111. Minagi S, Yano N, Yoshida K, Tsuru H. Prevention of acquired immunodeficiency syndrome and hepatitis B. II: Disinfection method for hydrophilic impression materials. *J Prosthet Dent* 1987;58:462-465.
112. Olsson S, Bergman B, Bergman M. Agar impression materials, dimensional stability and surface detail sharpness following treatment with disinfectant solutions. *Swed Dent J* 1987;11:169-177.
113. Merchant VA, Radcliffe RM, Herrera SP, Stroster TG. Dimensional stability of reversible hydrocolloid impressions immersed in selected disinfection solutions. *J Am Dent Assoc* 1989;119:533-535.
114. Langenwalter EM, Aquilino SA, Turner KA. The dimensional stability of elastomeric impression materials following disinfection. *J Prosthet Dent* 1990;63:270-276.
115. Drennon DG, Johnson GH. The effect of immersion disinfection of elastomeric impressions on the surface detail reproduction of improved gypsum casts. *J Prosthet Dent* 1990;63:233-241.
116. Drennon DG, Johnson GH, Powell GL. The accuracy and efficacy of disinfection by spray atomization on elastomeric impressions. *J Prosthet Dent* 1989;62:468-475.
117. Walker MP, Rondeau M, Petrie C, Tasca A, Williams K. Surface quality and long-term dimensional stability of current elastomeric impression materials after disinfection. *J Prosthodont* 2007;16:343-351.
118. Merchant VA, McNeight MK, Ciborowski CJ, Molinari JA. Preliminary investigation of a method for disinfection of dental impressions. *J Prosthet Dent* 1984;52:877-879.
119. Merchant VA, Herrera SP, Dwan JJ. Marginal fit of cast gold MO inlays from disinfected elastomeric impressions. *J Prosthet Dent* 1987;58:276-280.
120. Bergman M, Olsson S, Bergman B. Elastomeric impression materials. Dimensional stability and surface detail sharpness following treatment with disinfectant solutions. *Swed Dent J* 1980;4:161-167.
121. Johnson GH, Drennon DG, Powell GL. Accuracy of elastomeric impressions disinfected by immersion. *J Am Dent Assoc* 1988;116:525-530.
122. Jennings KJ, Samaranayake LP. The persistence of microorganisms on impression materials following disinfection. *Int J Prosthodont* 1991;4:382-387.
123. Berg E, Nielsen O, Skaug N. High-level microwave disinfection of dental gypsum casts. *Int J Prosthodont* 2005;18:520-525.
124. Berg E, Nielsen O, Skaug N. Efficacy of high-level microwave disinfection of dental gypsum casts: The effects of number and weight of casts. *Int J Prosthodont* 2007;20:463-464.
125. Lucas MG, Arioli-Filho JN, Nogueira SS, Batista AUD, Pereira RDP. Effect of incorporation of disinfectant solutions on setting time, linear dimensional stability, and detail reproduction in dental stone casts. *J Prosthodont* 2009;18:521-526.
126. Anusavice KJ, Phillips RW. *Phillips' Science of Dental Materials*, ed 11. St Louis: Saunders, 2003:225-226.
127. Duret F, Termoz C. Method of and apparatus for making a prosthesis, especially a dental prosthesis. US patent 4,663,720. 5 May 1987.

Working Casts and Dies

When good impressions have been made of the teeth prepared in the mouth, it is important that they be handled properly to ensure that accurate and detailed casts will result. Obtaining good impressions requires the expenditure of time and effort by the operator, and it is a tedious procedure for the patient. A few simple steps should be followed in handling the casts to ensure that costly and time-consuming remakes will not be required. The ease with which a restoration is fabricated and the accuracy with which it will fit the mouth are materially affected by the cast.

There are three requirements for good casts:

1. They must be free of bubbles, especially along the finish lines of the prepared teeth.
2. All portions of the cast must be free of distortion.
3. The casts must be trimmed to ensure access for carving wax pattern margins.

The working cast is the cast that is mounted on an articulator. To provide the most accurate articulation, it normally should represent the entire arch.¹ In the fabrication of the wax pattern, it is used to establish interproximal contacts, facial and lingual contours, and occlusion with the opposing teeth. The die is a model of the individual prepared tooth on which the margins of the wax pattern are finished. There are two basic working cast and die systems: a working cast with a separate die and a working cast with a removable die.

Working Cast with a Separate Die

The working cast with a separate die is the simplest means of fabricating a working cast and die because no procedures are required to create a die other than making a sectional cast and a full-arch cast. In addition to ease of fabrication, an advantage is that it keeps the relationship between abutments fixed and immovable. This is a sure method of accurately orienting the preparation casts to each other, which is considered an important step in minimizing casting adjustments.² Because the gingival tissue and other landmarks are intact, it is easier to obtain physiologically harmonious restoration contours when fabricating the wax pattern (Yamada

HN, personal communication, 1972). One of the disadvantages encountered in the use of a working cast with a separate die is that the wax pattern must be transferred from one to the other. Inexperienced technicians are prone to do this more often than necessary, and in the process they destroy some of the internal adaptation of the wax pattern.

The working cast and the sectional cast for the die can be obtained from separate impressions or by pouring an elastomeric full-arch impression twice. If a double pour is utilized, the first cast is used for fabrication of the die.³ This technique, unfortunately, can be used only with elastomeric impressions because hydrocolloid is torn and distorted too much to be used for an accurate second pour.

Armamentarium

- 500-mL Vac-U-Mixer (Whip Mix) and vacuum tubing
- Vibrator
- Water measure
- Large and small spatulas
- Die stone (Silky-Rock [Whip Mix], Vel-Mix [Kerr])
- Humidor
- Cast trimmer
- Straight handpiece and pear-shaped acrylic bur
- Laboratory knife with no. 25 blade
- Tanner carver
- Prismacolor red pencil

Impression pouring

The die and cast should have a hard enough surface to prevent surface abrasion when the wax pattern is fabricated. Therefore, one of the high-strength type IV (class II, Densite) or high-strength, high-expansion type V stones should be used for fabricating the die.⁴ An impression should be washed under cold running tap water to remove mucus and saliva that may cover it before disinfecting it in an appropriate solution.

A measured amount of water is placed in a plastic mixing bowl (Vac-U-Mixer), and a measured amount of die stone is added to the water. Die impressions can be poured with 50 to 70 g of stone. It takes about 200 g for a full-arch impression. The manufacturer's instructions should be followed for

18 Working Casts and Dies

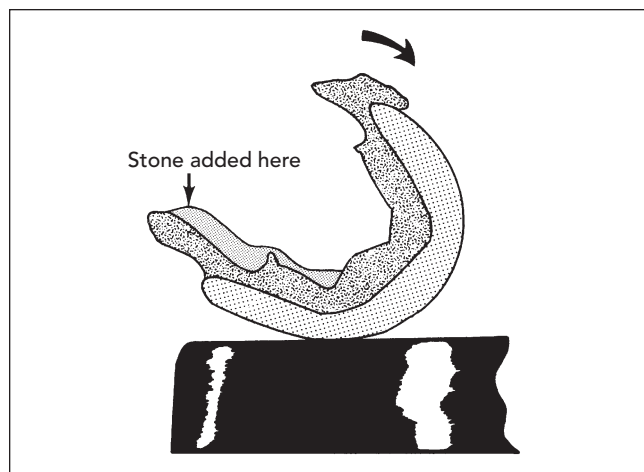


Fig 18-1 Stone is added to the impression in small increments above the preparation.

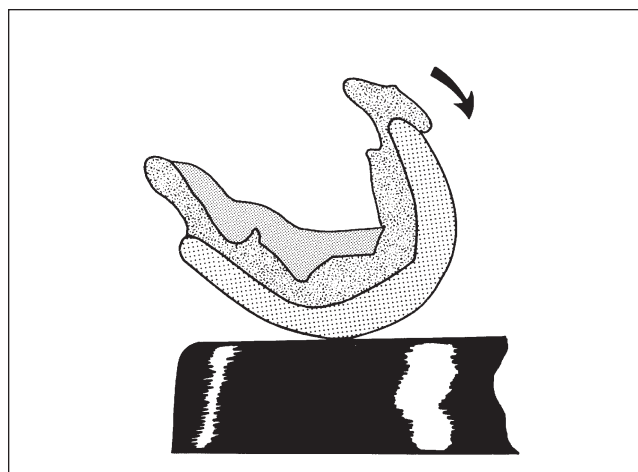


Fig 18-2 The tray is tilted to fill the preparation.

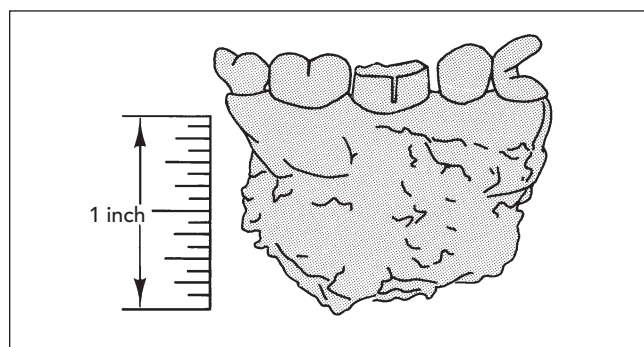


Fig 18-3 Stone is added to the impression so that the base of set stone will be 1 inch thick.

the correct water-powder ratio. This ratio can affect many of the properties of the set stone, including setting time, porosity, setting expansion, and the ultimate strength. It is important that the technique be standardized.

Water and stone are mixed by hand with the spatula until the powder is completely wet. The lid is placed on the bowl, the vacuum tube is attached to the plastic lid, and the drive nut on the top of the bowl is engaged in the larger drive chuck of the power unit. Vacuum mixing is performed for a minimum of 20 seconds. The drive nut is disengaged from the drive chuck, and the stone is vibrated to the bottom of the bowl. The machine is turned off, the vacuum is allowed to drop to zero, and then the vacuum tubing is disconnected.

Excess moisture should be removed from elastomeric impressions. The wettability or pourability of an impression made of a hydrophobic impression material can be improved by using a surfactant on the impression.⁵ Surfactants, applied by spraying and allowed to dry, reduce the number of voids trapped in the cast and increase the probability of obtaining a void-free cast.⁶ Excess moisture also should be gently blown from the surface of a hydrocolloid impression without

actually desiccating it. The surface should be free of visible water, but it should still be shiny. If the surface of the hydrocolloid appears dull, it has been overdried, and some distortion may occur.

A small instrument is used to carry stone to the impression of the prepared tooth. A small amount of stone is placed on the side of the impression above the preparation, and the impression is vibrated until stone reaches the "bottom" (ie, incisal or occlusal surface) of the preparation (Fig 18-1).

The impression is tilted so that stone flows slowly across the "bottom" of the preparation, displacing air as it moves (Fig 18-2). Stone should be added in small increments. If a large amount of stone is dropped into the preparation area, air will be trapped, and a void in the cast will result. Addition of stone continues in small increments from the original point so that the preparation will fill from the bottom up. After the preparation has been filled, stone is poured into a tooth on either side of it in the impression. The stone is built up to a height of approximately 1 inch (2.5 cm) over the preparation to allow bulk for an adequate handle on the die (Fig 18-3).

To pour a full-arch impression, the tray is placed on the vibrator. It should not be rested on the impression material. Small increments of stone are added to the distalmost area of one side of the impression. The distal end of the impression is slowly raised so that stone will move mesially, flowing from tooth to tooth and filling each tooth imprint from the bottom. By tilting the impression tray in different directions, the flow of the stone can be controlled so that air will not be trapped. Stone is added and vibrated until all the teeth in the arch are filled. If the impression being poured is of the mandibular arch, the impression is set on the benchtop, and the open lingual space is filled in with a wet paper towel. This will enable a full base to be poured. The impression should not be inverted before the initial set has occurred.⁷ The poured impression is allowed to set for at least 1 hour.⁸ The cast should not be separated from the impression, and preparation of the dies should not begin until the hour has elapsed. If the impression is hydrocolloid, it should be placed in a humidifier during this time.

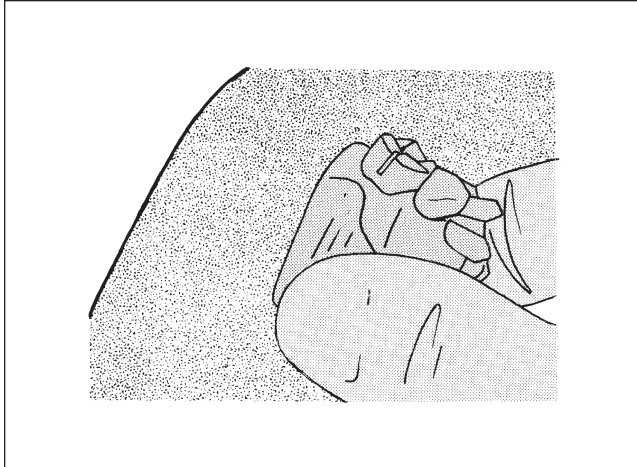


Fig 18-4 The die is first trimmed on a cast trimmer.

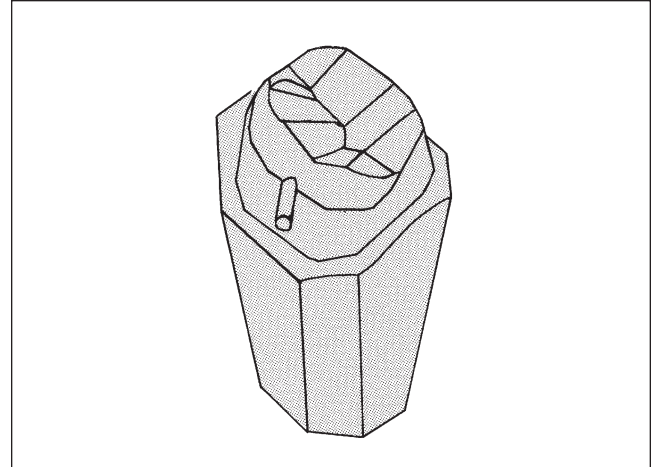


Fig 18-5 A properly trimmed die handle is slightly larger in diameter than the preparation.

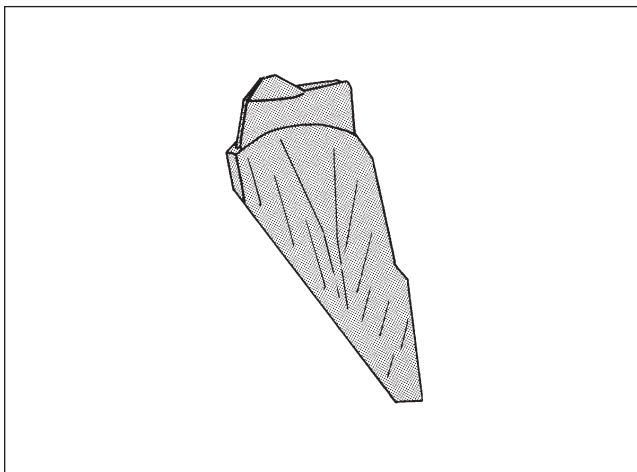


Fig 18-6 Improperly trimmed die with a handle that meets the preparation at an angle.

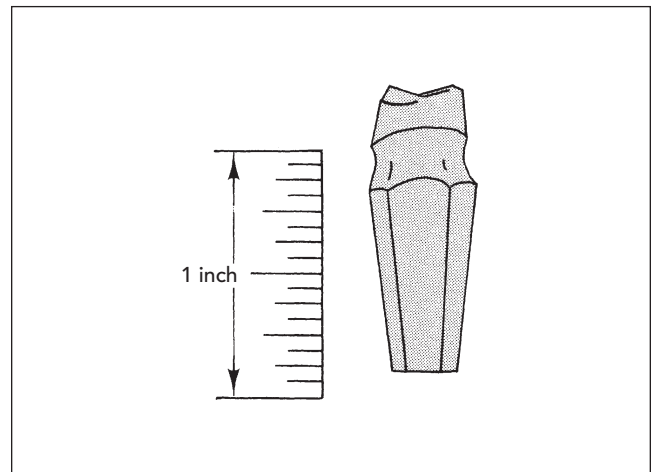


Fig 18-7 The handle should be 1 inch long.

Die preparation

The poured cast is carefully separated from the impression. A material such as Super-Sep (Kerr) may be painted on the surface of the prepared teeth on the cast to guard against surface erosion or etching when the casts are trimmed. Liquid, prevulcanized latex has also been suggested for this purpose.⁹ The cast is wet thoroughly before trimming excess stone from the working casts on the cast trimmer. There should be no stone duplicating soft tissue in the peripheral area beyond the gingiva left on the cast.

The cast from which the die is made should be trimmed on a cast trimmer to remove all excess stone around the prepared tooth (Fig 18-4). The cast is held by the base while it is cut down to form a handle on the die. If the die is held by the preparation portion while the handle is being trimmed, the die may be worn or chipped, resulting in an ill-fitting casting later.

The handle of the die should be slightly larger in diameter than the preparation and octagonal in cross section (Fig 18-5).

Its sides ought to be parallel or slightly tapered toward the base. The handle should parallel the long axis of the tooth. If the handle is made at an angle to the long axis of the tooth preparation, it will be more difficult to adapt the wax pattern margins (Fig 18-6). The handle should be approximately 1 inch (2.5 cm) long (Fig 18-7). If it is any shorter, it will be difficult to hold when the wax pattern is on it.

A pear-shaped acrylic bur is used to trim the die apical to the finish line of the preparation (Fig 18-8). Final trimming of the die is begun with a sharp no. 25 blade (Fig 18-9). The area apical to the finish line should be smoothed and made free of ridges with the discoid end of a no. 5 Tanner carver (Fig 18-10). Irregularities in the stone will produce ripples in the wax when the margin-finishing instrument rises and falls as it is guided over those rough spots in the stone. There also must be adequate access to rest a burnisher on this part of the stone die when the margins are finished (Fig 18-11).

The contour of the die apical to the finish line should approximate that of the root to facilitate good axial contours in the finished restoration (Fig 18-12). Sharply undercutting

18 Working Casts and Dies

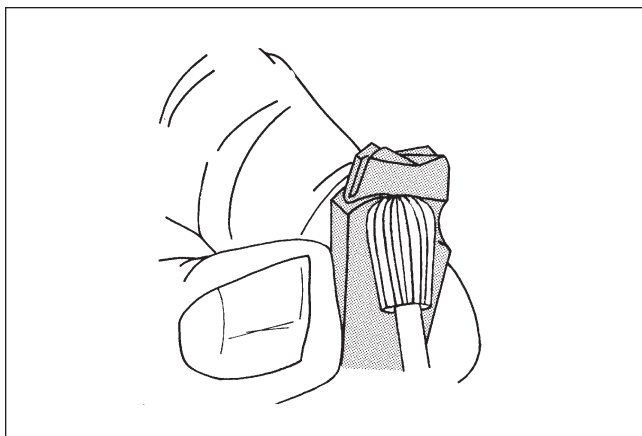


Fig 18-8 The die is trimmed with an acrylic bur.

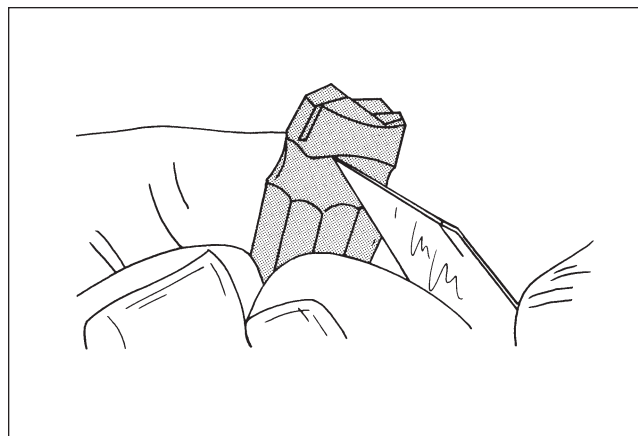


Fig 18-9 Shaping of the die handle near the finish line is completed with a scalpel.

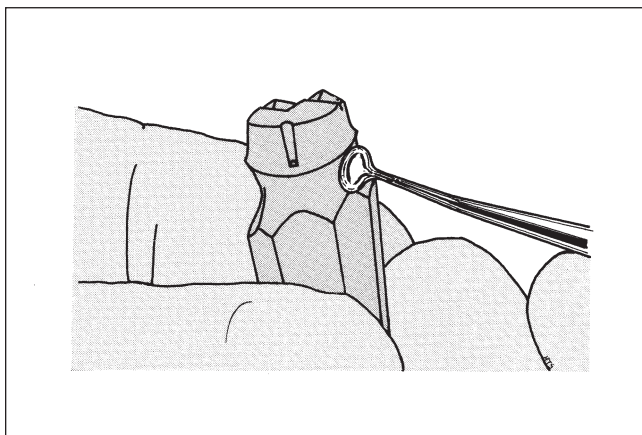


Fig 18-10 The die is smoothed below the finish line with the discoid end of a Tanner carver.

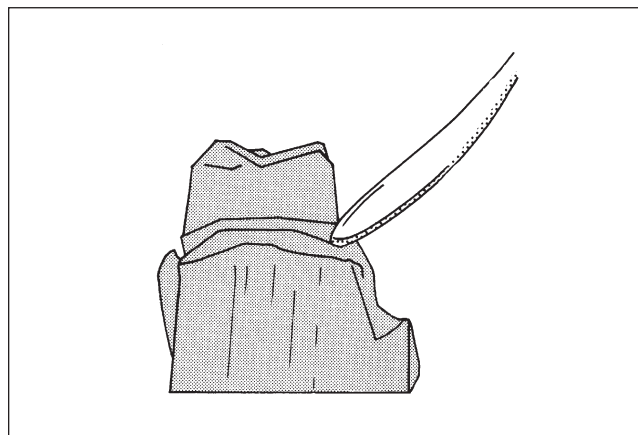


Fig 18-11 This die is too short, and it does not allow adequate access for margin finishing.

or "ditching" the die below the finish line is not advised and should not be required if there is an adequate finish line on the preparation. Because the instrument used for finishing the margins of the wax pattern will rest against this portion of the die, its angulation can be exaggerated by the undercut. This will result in a thick gingival area on the restoration and an axial contour that is not conducive to good gingival health (Fig 18-13).

After the die has been trimmed, the finish line should be highlighted with a sharp Prismacolor red pencil (Fig 18-14). This facilitates carving the margins of the wax pattern when wax obscures the preparation finish line. Excessive pressure should not be used when marking the finish line because this may cause it to be rounded over. A black, graphite pencil should not be used for this purpose. When used with the usual blue or green inlay waxes, a finish line outlined in black does not become more visible but instead makes every wax pattern margin appear unsealed, or "open." In addition, the graphite, with its clay binder, may be carried into the investment on the pattern. Remnants of the clay binder could contaminate the margin of the casting.

A die-hardening agent (cyanoacrylate or acrylic resin lacquer) can be applied to the die to prevent abrasion by waxing instruments during margining of the wax pattern. This also prevents the die spacer from seeping into the die, which would result in an indefinite thickness of die spacer. However, the coating material should be used with care. It must have a low viscosity, and it must be applied lightly. The thickness of cyanoacrylates at the finish line can range from 1.0 to 2.5 μm , while acrylic lacquers can add 4.0 to 10.0 μm of thickness.¹⁰ Unless the hardening agent is a thin one that is applied in a careful manner, it is possible to create an unacceptably thick relief over the finish line, which may produce an ill-fitting margin in the resultant casting.

Relief should be applied to the preparation area of the die to provide space for cement.¹¹ Enamels and lacquers have been used for this purpose.^{11,12} The thickness of the overall relief varies with the number of coats applied,¹³ the brand used, and the care with which it is applied.¹⁴ As a bottle of enamel or lacquer ages, the contents thicken due to evaporation.¹³ Thinner must be added periodically. The number of coats will depend on the material, but a relief of 20 to 40 μm

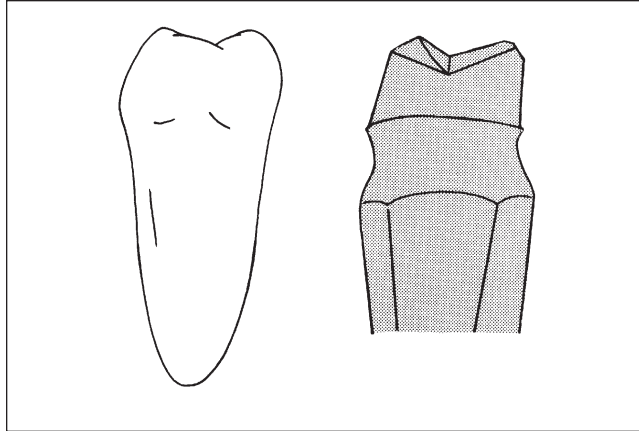


Fig 18-12 Die contours should be similar to those of a natural tooth.

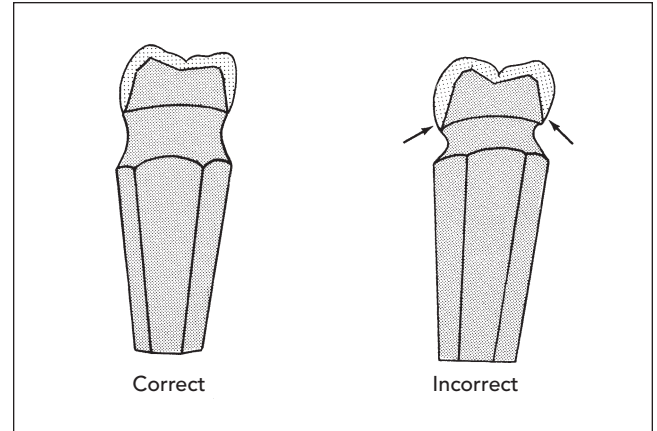


Fig 18-13 Axial contours of the wax pattern are influenced by die trimming.

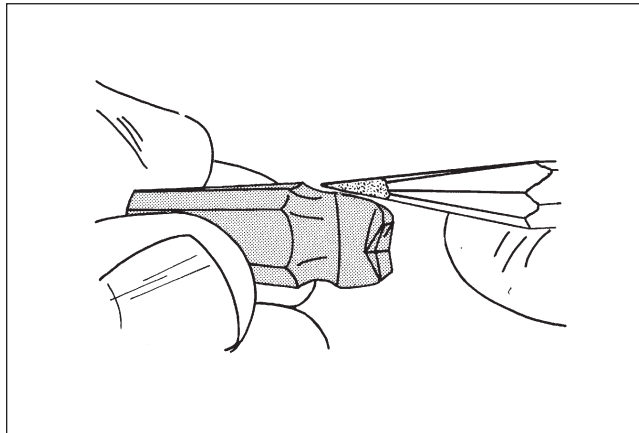


Fig 18-14 The preparation finish line on the die should be outlined with a red pencil.

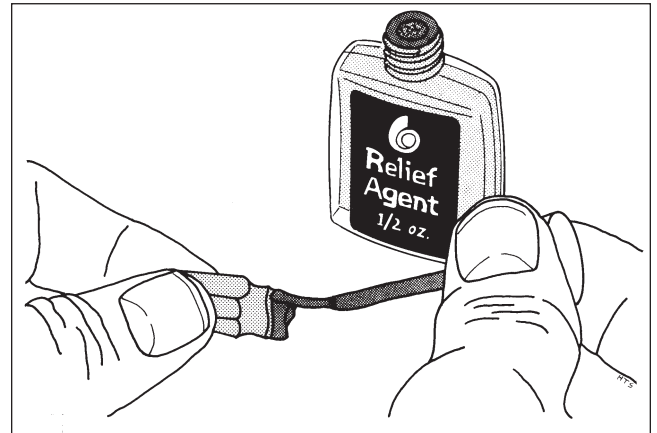

Fig 18-15 Die relief agent is painted on the preparation portion of the die.

is desired.^{12,15} The tooth preparation on the die is painted to within 0.5 mm of the finish line (Fig 18-15).

A casting made on a relieved die will have space between it and the preparation when it is placed on the tooth in the mouth. When it is applied carefully, die relief material can be used on preparations with grooves and other internal features, although thicker relief agents tend to pool in the ends and corners of grooves.¹⁴ Full veneer crowns with grooves will seat more completely if a spacer is used, whether or not it is actually placed in the grooves.¹⁶ A more detailed discussion can be found in chapter 21.

When a one-piece casting without a solder joint is attempted in the fabrication of a fixed partial denture, a one-piece die will produce the most predictable result. The die for each preparation is left joined to the other by means of a common base (Fig 18-16). The edentulous ridge area is cut back to provide good access for visual examination and finishing of the margin.

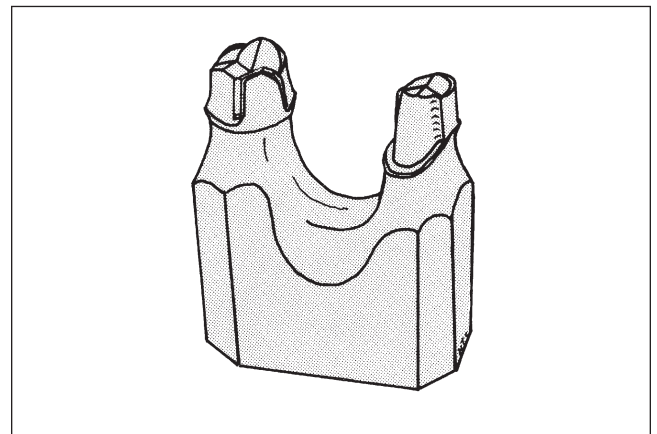


Fig 18-16 One-piece die for a fixed partial denture extending from second premolar to second molar.

18 Working Casts and Dies

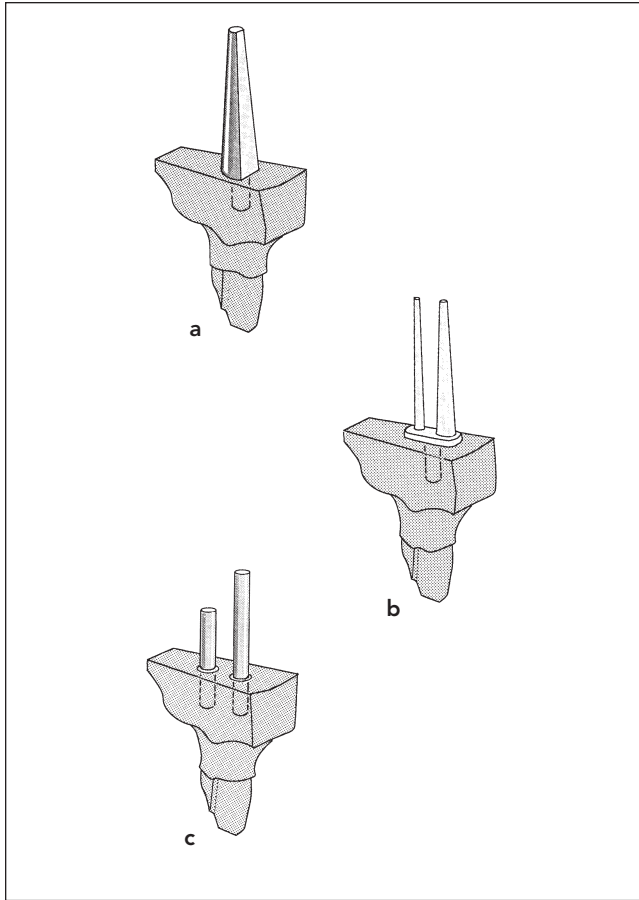


Fig 18-17 Types of antirotational devices used for removable dies: (a) flat-sided single dowel; (b) double straight dowels with a common head; (c) two separate parallel dowels.

Working Cast with a Removable Die

Dies that can be removed from the working cast have become very popular. They are convenient to use because wax patterns or copings need not be removed from their respective dies when they are transferred to the working cast. This is particularly important when making ceramic restorations because the unfired material is quite fragile. A removable die eliminates discrepancies between a separate die and working cast that may be caused by impression distortion or deterioration between pours or by a cast and die made from separate impressions that are not identical. A removable die also eliminates discrepancies that can occur when the die is coated with a relief agent and the working cast is not or when they are coated with different thicknesses. The principal disadvantage of a removable die system is the risk of introducing an error in the pattern if the die does not reseat accurately in the working cast.

If a removable die system is used, it should satisfy these three requirements¹⁷:

1. The dies must return to their exact original positions.
2. The dies must remain stable, even when inverted.
3. The cast containing the dies must be easy to mount on an articulator.

Several methods can be employed to allow the repositioning of a die in its working cast (Fig 18-17). Most of these devices can either be oriented in the impression before it is poured (prepour technique) or attached to the underside of a cast that has already been poured (postpour technique). A tapered, flat-sided brass dowel pin can be used to orient the die of the prepared tooth into the working cast before^{1,18-20} or after^{21,22} pouring. Flat-sided, stainless steel dowel pins with attached positioning wires also can be prepositioned.^{23,24} The dowel tip protrudes from the side rather than the bottom of the base of the cast.

Single dowels are simple to use, but they do not provide as much antirotational resistance as double dowels (Twin Pin, Denerica; J-Pin, Keystone). Two separate dowels also can be cemented into parallel pinholes drilled in the underside of a cast, using a special drill press (Pindex, Coltene/Whaledent).

Two systems are presented here:

1. Straight dowel pin
2. Pindex system

A third system, the Accu-Trac, is described in chapter 23 in connection with the fabrication of veneers.

Straight dowel pin

The straight dowel pin as a means of orienting dies has been in use for a number of years,²⁵ and most of the dowel systems are modifications of it. The brass dowel pin is one of the most accurate dowel types in terms of resisting horizontal displacement²⁶⁻²⁸ and the second lowest in vertical deviation of four types of removable dies.²⁷ A dowel pin is positioned over each prepared tooth in the impression. The accurate placement of the dowels can be a problem: If the dowel pins are positioned inaccurately, they may impinge on the margins, weaken the die, or prevent the die from being easily removed from the cast.

Marking the desired location of the dowel on the periphery of the impression and then placing the dowel freehand after the stone has been poured can result in the dowel settling into the stone.²¹ More consistently accurate placement can be achieved by prepositioning the dowel and stabilizing it in place before the stone is poured into the impression.²⁴

There are devices made specifically for precise positioning of dowels before the pouring of an impression. One such device utilizes putty on a movable table to hold an impression in an exact, repeatable position, while pins are suspended above the impression from magnets on a larger immovable table.²⁹ Wire clips that can be stuck into the periphery of the

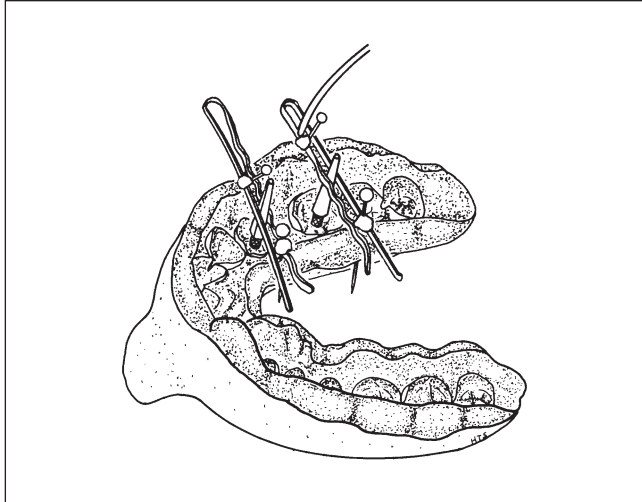


Fig 18-18 Dowel pins are positioned over the impression with bobby pins.

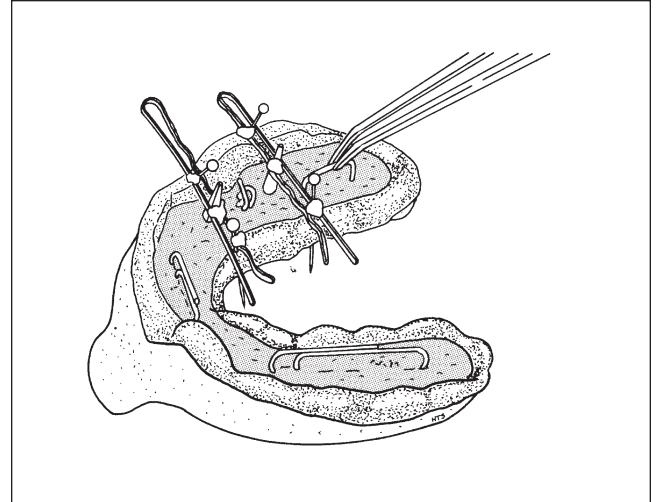


Fig 18-19 Paper clips are added to nonremovable parts of the unset first pour to provide retention for the second pour of stone.

impression can be purchased or fashioned from orthodontic wire.³⁰ The flat side of dowels also can be stabilized against the heads of horizontal straight pins protruding from putty along the periphery of the impression. A pin is positioned over the space above each tooth preparation.³¹ Unfortunately, the dowels are guided by, but not attached to, the pins in this technique. It could work in the hands of an experienced technician, but it is not recommended for the novice.

Armamentarium

- 500-mL Vac-U-Mixer and vacuum tubing
- Vibrator
- Water measure
- Large and small spatulas
- Die stone (Silky-Rock, Vel-Mix)
- Humidor
- Dowel pins
- Straight pins, bobby pins, and paper clips
- Sticky wax and utility wax
- Beavertail burnisher
- Bunsen burner
- Cotton pliers
- Sable brush
- Petrolatum
- Cast trimmer
- Saw frame with blade
- Laboratory knife with no. 25 blade
- Straight handpiece and pear-shaped acrylic bur
- Prismacolor red pencil

Technique

A number of items found in a dental laboratory are commonly used for orienting dowels: anesthetic needles, paper clips, bobby pins, and paper matches.³² A dowel is placed between the arms of a bobby pin, with the round side of the dowel in one of the corrugations and the flat side of the dowel against the flat arm of the bobby pin. The bobby pin is then positioned faciolingually across the impression so that the dowel pin will be centered directly over the preparation. A straight pin is pushed between the arms of the bobby pin and into the impression material on both the facial and the lingual surfaces of each tooth to have a dowel pin placed over it. The dowel is stabilized in the bobby pin, and the bobby pin itself is stabilized against the straight pins with sticky wax (Fig 18-18).

Die stone is poured into the impression, filling the impressions of the teeth and covering the knurled end of the dowel pin. The pin should parallel the long axis of the preparation and must not touch the impression. Paper clips or lock washers can be set into the stone before it sets to provide retention for the base that will be added later (Fig 18-19). These retentive devices should be placed in other parts of the cast that are not to be removed from the completed cast. It may facilitate removal of the die later if the teeth distal to the prepared tooth also are made removable by positioning a dowel pin over that segment of the cast.

When the stone has set, the straight pins and bobby pins are removed from the impression. A small ball of soft utility wax is placed on the tip of each dowel. A 1-inch (2.5-cm)

18 Working Casts and Dies

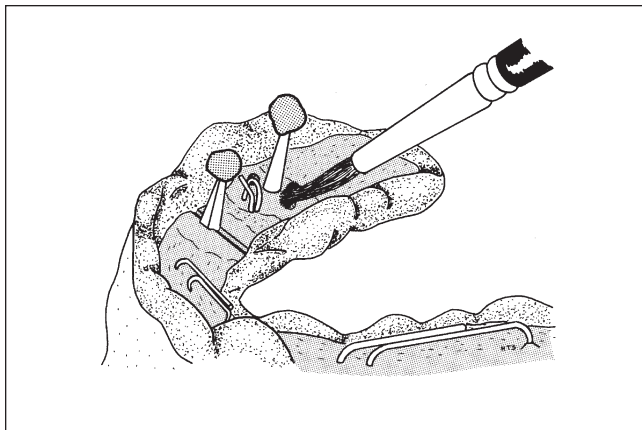


Fig 18-20 The stone around the dowel pins is lubricated.

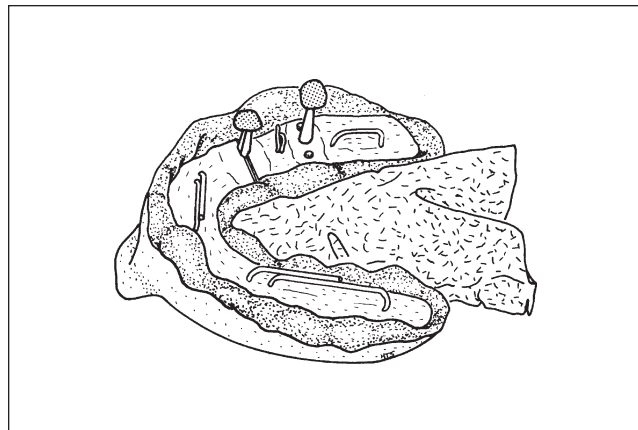


Fig 18-21 A wet paper towel can be used to fill in the open center portion of the impression.

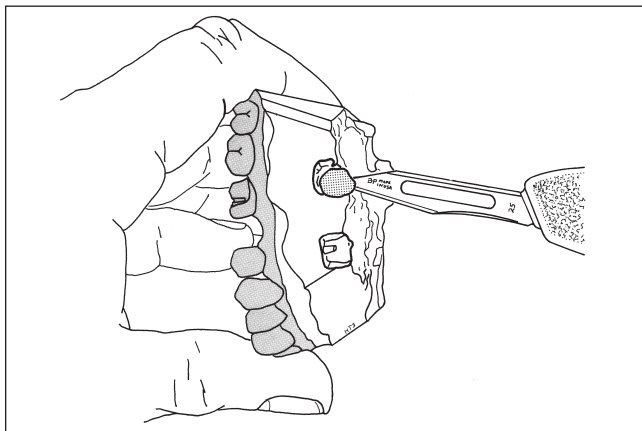


Fig 18-22 Wax at the ends of the dowel pins is located and removed.

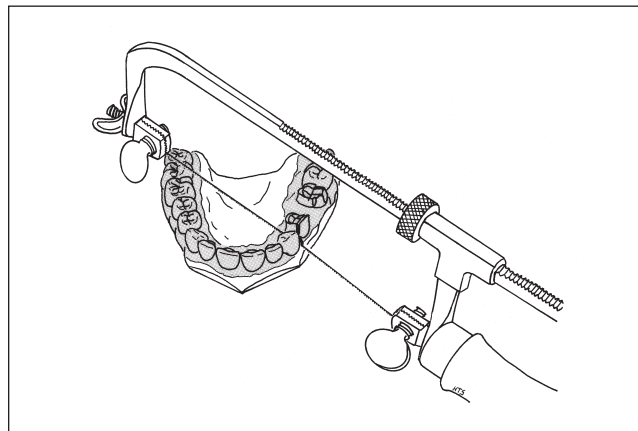


Fig 18-23 Dies are separated from the rest of the cast with a fine saw.

length of plastic tubing with an inner diameter of approximately 0.5 inch also can be placed on the end of the dowel as an aid in locating the dowels after the base has been poured.³³ A V-shaped faciolingual orientation groove or a round dimple is cut on each die to aid in reseating the die completely and accurately during use. The stone then is lubricated around each dowel with a thin coat of petrolatum or commercially available separating medium to permit easy separation of the dies from the working cast later (Fig 18-20). Any excess lubricant is removed.

A wet paper towel is placed into the open lingual space. This will create a complete base for the cast to be poured (Fig 18-21). When the base is poured, peaks and curls of stone are left projecting from the top of it to provide retention for the mounting plaster later. After the stone has set, the cast is removed from the impression, and the excess is trimmed on a cast trimmer. A sharp knife is used to uncover

the spheres of utility wax and remove them (Fig 18-22). It should be confirmed that all wax is removed and that no stone chips are left around the apex of the dowel pin. The stone is allowed to harden for 24 hours.

When the stone is hard and dry, a saw frame with a thin blade is used to cut through the layer of die stone (Fig 18-23). There should be a cut on the mesial and distal side of each die, and the cuts should taper toward each other slightly from occlusal to gingival. An instrument handle is used to gently tap on the end of the dowel to loosen the die (Fig 18-24). The die is taken from the cast, and excess stone gingival to the finish line is trimmed away (Fig 18-25). The trimming of the die is completed with a no. 25 blade in the laboratory knife, and then the finish line is marked with the red pencil.

The procedure is repeated for each die on the cast. The surfaces of the working cast and tapered dowel hole are checked to confirm that they are free of any particles or

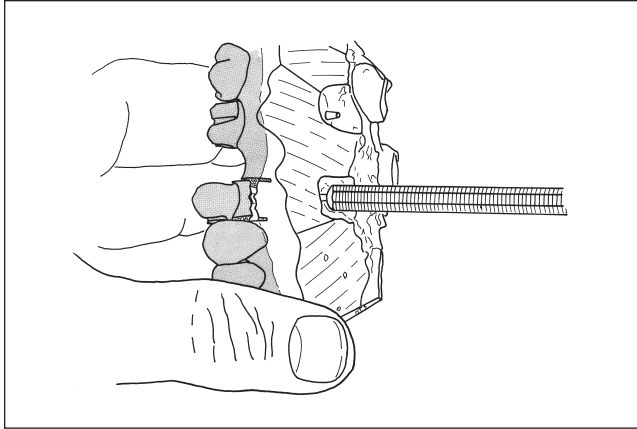


Fig 18-24 After the dies have been separated from the cast, the ends of the dowel pins are tapped to loosen the dies from the cast.

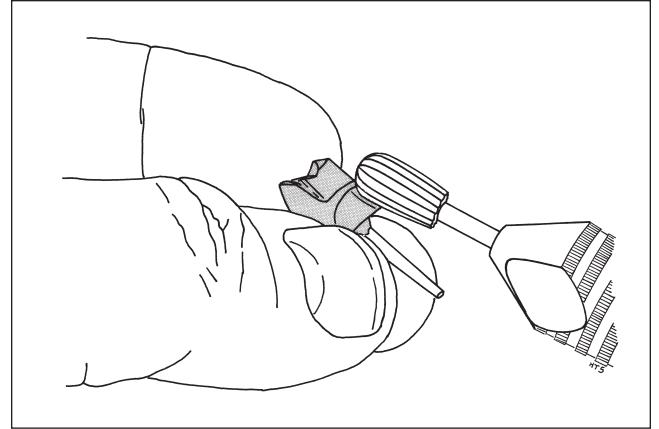


Fig 18-25 The base of the die is trimmed with an acrylic bur.

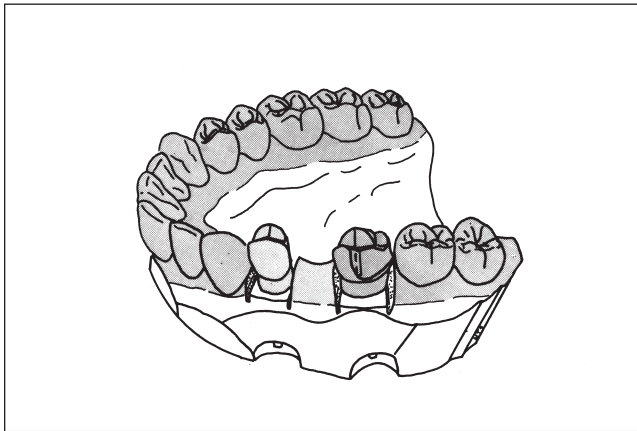


Fig 18-26 The dies are resealed into the cast.

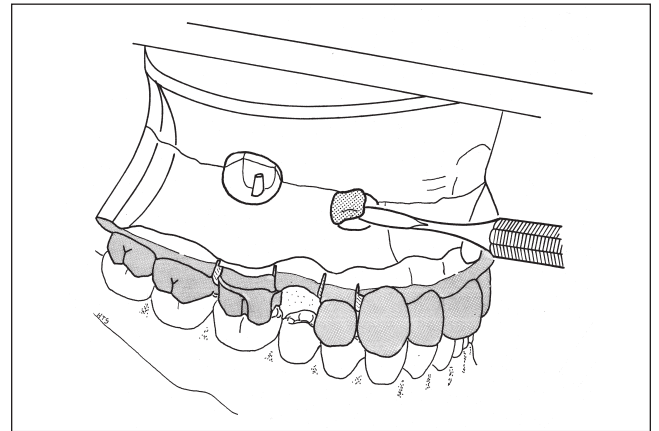


Fig 18-27 After the casts have been mounted, wax is removed from the ends of the dowel pins.

debris. The successful use of any removable die technique is contingent upon keeping the dies and cast free of stone chips, wax shavings, or any other debris. The failure of dies to reseat completely is probably caused by debris in the keyways,²⁷ and the resultant wax patterns will be inaccurate. The dies are resealed to make certain that they will seat completely and be stable (Fig 18-26).

Utility wax is placed back into the wells around the tips of the dowels to protect them from plaster contamination. The cast is soaked in water and mounted on the articulator using mounting stone. When the stone has set, the wax covering the tips of the dowels is removed (Fig 18-27). It should be confirmed again that no chips of stone or wax are left in the wells. This type of dowel also can be cemented into holes drilled into the flat underside of a cast that has already been poured.²²

Pindex system

In the Pindex system, a reverse drill press is used to create a master cast with dies that can be removed and replaced repeatedly with great precision (Fig 18-28). The impression is poured without positioning and attaching dowel pins beforehand. The machine accurately drills parallel holes from the underside of a trimmed cast.

The impression is poured in the usual manner, adding approximately 20 mm of stone beyond the edge of the tray (Fig 18-29). This should allow enough stone to trim the cast to a desired thickness later without having to add more die stone. If stone is added to the base, the additional stone may separate from the underside of the dies when the pins are placed or when the dies are removed for trimming.

18 Working Casts and Dies

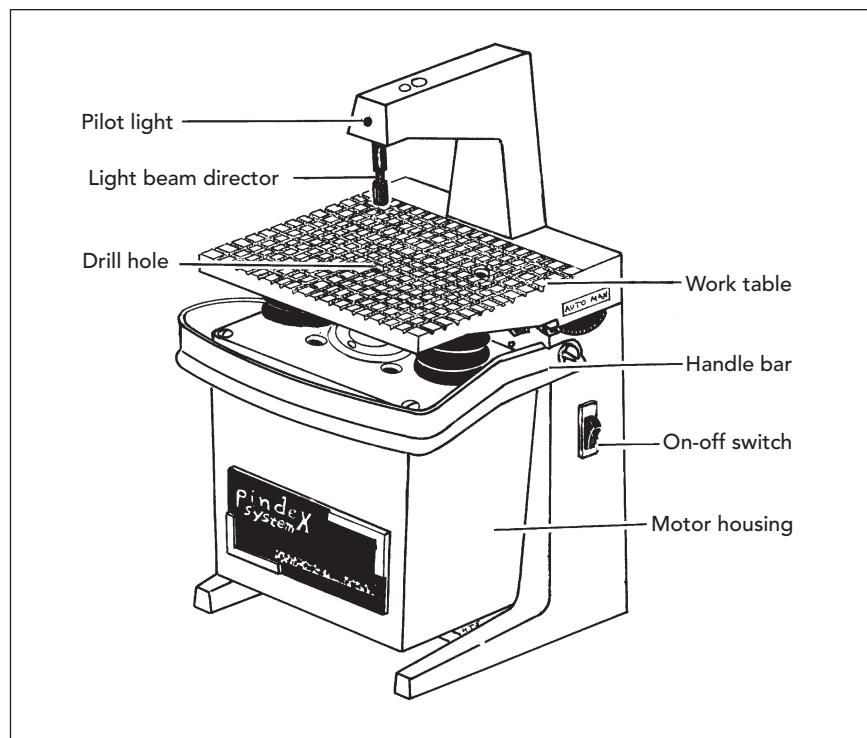


Fig 18-28 Parts of the Pindex machine.

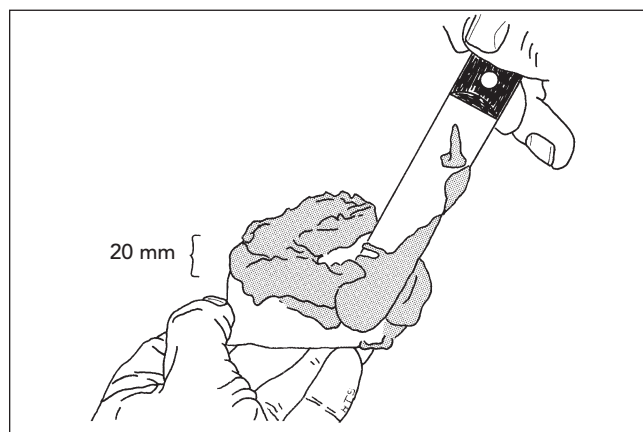


Fig 18-29 Sufficient stone to allow for trimming is added.




Fig 18-30 The bottom of the cast is trimmed on the cast trimmer.

The cast is allowed to set for 60 minutes and then removed from the impression, and the impression is repoured for a backup cast. The cast is thoroughly wet prior to trimming to prevent the accumulation of sludge on the prepared teeth. A cast trimmer is used to flatten the heels of the cast. The bottom of the cast is then trimmed, with the heels resting on the table of the trimmer (Fig 18-30). The cast should be trimmed until all rough, irregular, and undercut areas are

removed from its underside. It should sit perfectly flat on a tabletop, and its thickness from base to preparation finish line must be a minimum of 15 mm (Fig 18-31). If the bottom of the cast is flat, it ensures that the pinholes drilled into it will be parallel.³⁴

The cast trimmer is used to remove the excess stone on the periphery of the cast (Fig 18-32). The cast is washed to remove any debris that was deposited on it during grinding.

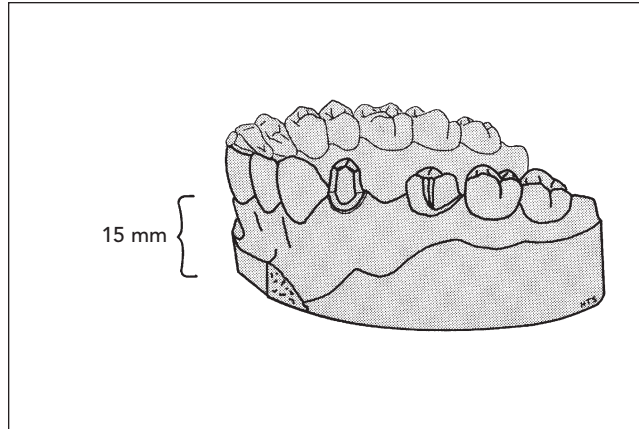


Fig 18-31 The cast should be 15 mm thick, exclusive of the teeth.

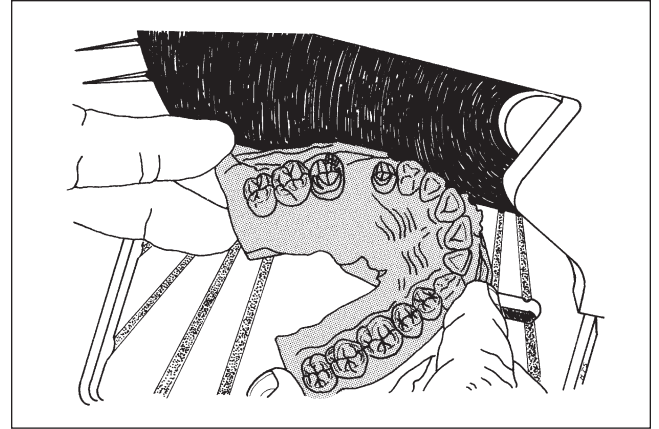


Fig 18-32 The periphery of the cast is trimmed on the cast trimmer.




Fig 18-33 The palate/tongue area is trimmed with an arbor band.

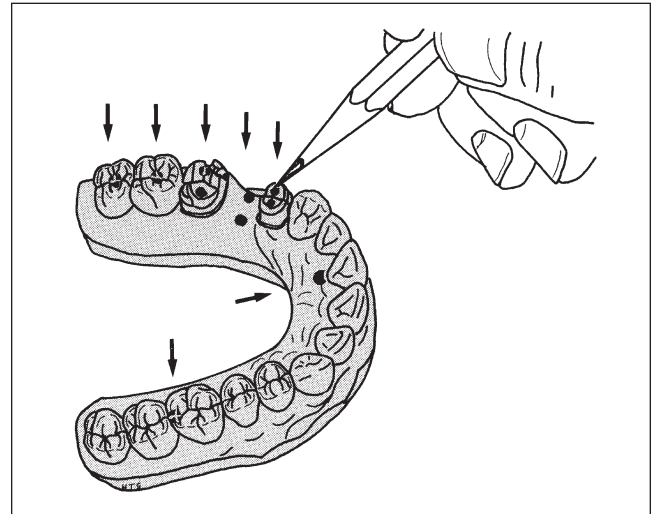


Fig 18-34 The location of the pinholes is marked with a pencil.

Any excess stone in the palate/tongue area is removed with an arbor band on a lathe (Fig 18-33). The lingual border of the cast should taper slightly toward the base to facilitate removal of the dies from the cast later. The faciolingual width of the cast should be approximately 20 mm. A pencil is used to mark the desired location of the pins on the occlusal surfaces of the teeth or preparations. There should be two pins for each die, two for each pontic (edentulous) area, and two pins in each terminal segment containing unprepared teeth (Fig 18-34).

The machine is turned on using the switch on the side. A red pilot light indicates that it is running. The prepared cast is placed on the worktable, and the first pencil mark is aligned with the illuminated dot from the light beam director (Fig 18-35). Both thumbs are used to exert firm downward pressure on the cast.

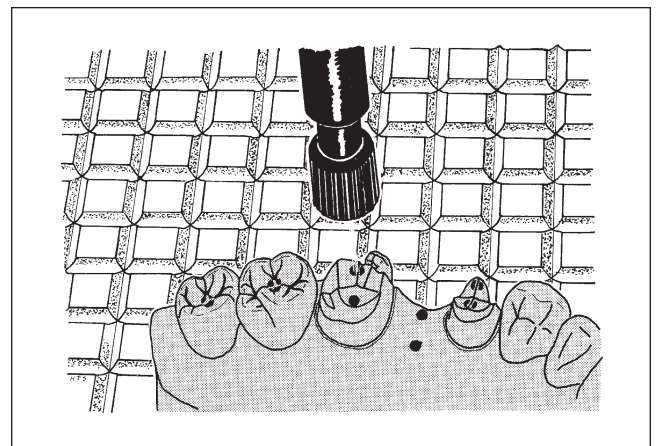


Fig 18-35 Pencil marks are placed under the illuminated dot.

18 Working Casts and Dies

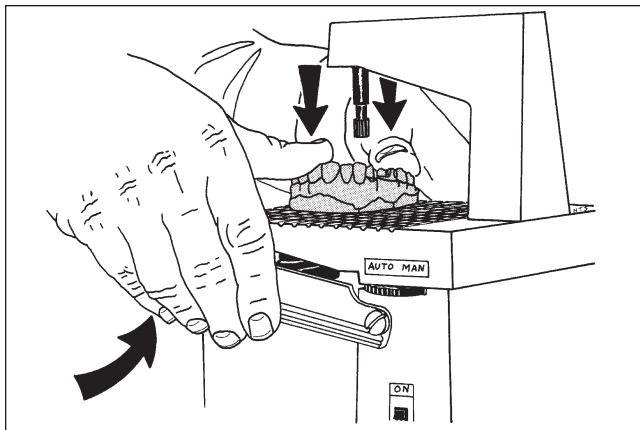


Fig 18-36 The thumbs are used to stabilize the cast while lifting the handle bar with the fingers.

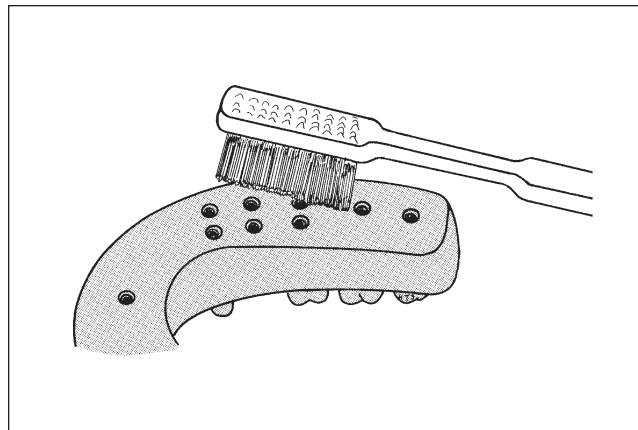


Fig 18-37 Debris is removed from the pinholes.

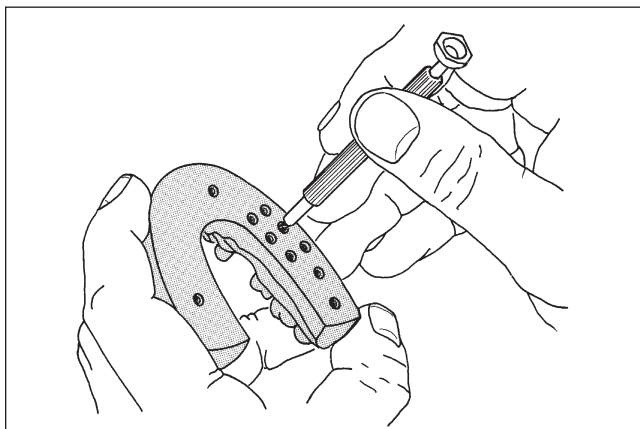


Fig 18-38 The pinholes are refined with a hand reamer.

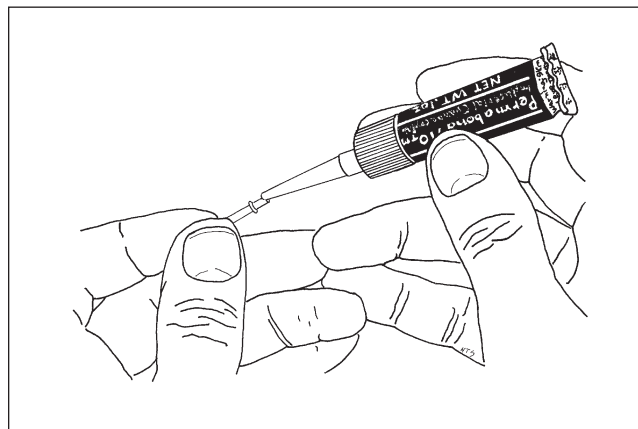


Fig 18-39 Cyanoacrylate cement is placed on the pins prior to cementing the pin tips.

The handle bar is grasped with the remaining fingers (Fig 18-36). This enables the operator to stabilize the cast as the drill assembly moves upward, cutting the pinholes. The handle bar is raised with slow, even pressure, timing the cycle to take 3 to 5 seconds. When the proper depth has been reached, the red pilot light will go off, indicating that the hole is finished. The bar should not be forced any farther. Using the above technique, the drilling of all the pinholes should be completed. For best results, the cast should be slightly damp (but not dripping wet) to prevent dust formation and excessive chipping around the pinholes.

Compressed air and a toothbrush are used to remove debris from the pinholes (Fig 18-37). A hand reamer is used to remove any residual debris from the pinholes (Fig 18-38). Prior to cementation, the pins are tried in to ensure complete seating. The collar of the pin should be flush with the

base of the cast to avoid creating an undercut. The few minutes required for a precementation try-in can prevent the cast from being ruined during cementation.

Any commercially available cyanoacrylate cement can be used to lute the pins in their holes. The cast must be thoroughly dry. A small amount of cement is applied to the end of each pin (Fig 18-39). Excess cement in a closely fitting pinhole may create enough hydraulic pressure to prevent complete seating. Pin placement is facilitated by placing the short pins in the lingual/palatal holes first (Fig 18-40). Placing the long pins in the facial holes makes the ends of the dowel pins more accessible for easy die removal after the casts are mounted.

When the cement has dried, the sleeves are placed over the pins with the flat sides of their bases facing each other. The white sleeves are placed on the long pins, and the gray

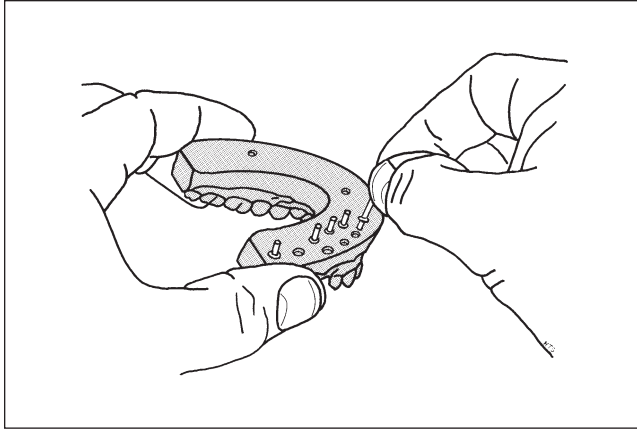


Fig 18-40 Shorter pins are placed before the long pins.

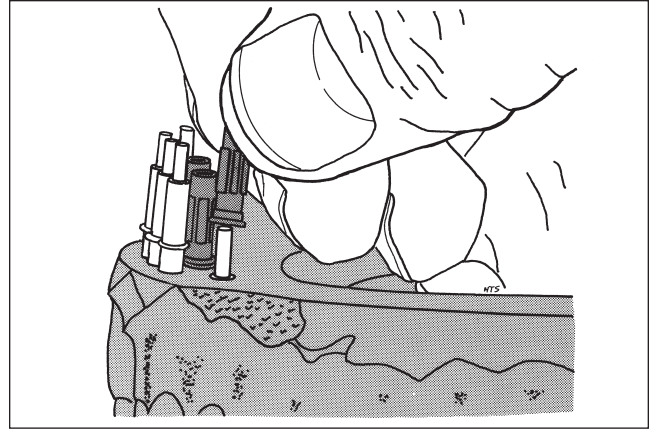


Fig 18-41 Placement of white sleeves on the long pins and gray sleeves on the short pins.

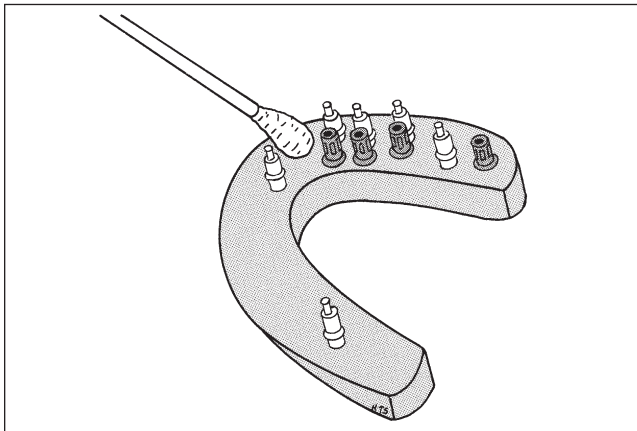


Fig 18-42 The bottom of the cast is lightly coated with petrolatum.

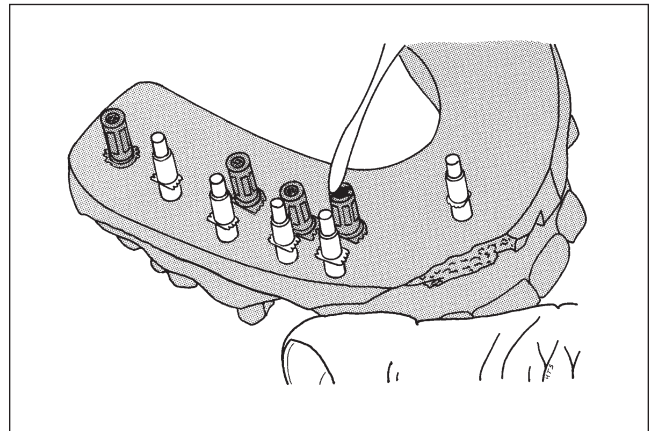


Fig 18-43 The ends of the gray sleeves are blocked with wax.

sleeves are placed on the short pins (Fig 18-41). A thin coat of petrolatum is applied to the bottom of the cast as a separating agent (Fig 18-42). All excess is wiped off with a cotton roll, a finger tip, or a dry cotton-tipped applicator. Visible excess lubricant left on the cast will create a space between the cast and its base, which could cause seating errors when the dies are repositioned after separation from the cast.

A small amount of molten wax is placed in the ends of the short sleeves to prevent the sleeve from filling with stone when the secondary base is added (Fig 18-43). A strip of utility wax is run along the ends of the long pins to facilitate removal of the dies later (Fig 18-44). A small ball of wax is placed on the ends of isolated pins on the contralateral side of the cast.

Two methods can be used to add the base to the cast. The first is the conventional method of boxing a cast. Using the cast as a template, a palate/tongue filler is cut from a strip of

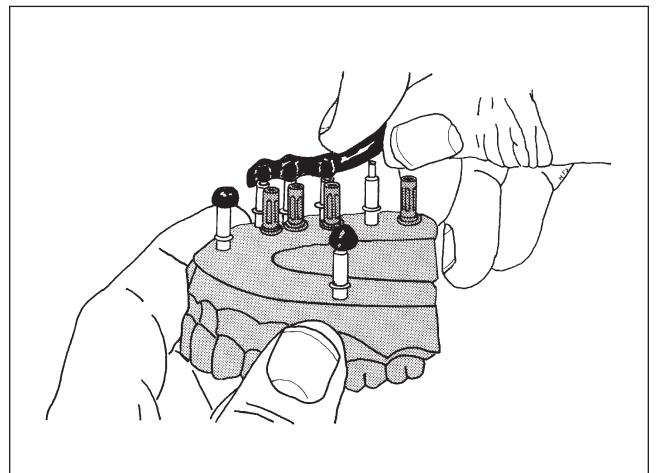


Fig 18-44 Utility wax is placed on the ends of the long pins.

18 Working Casts and Dies

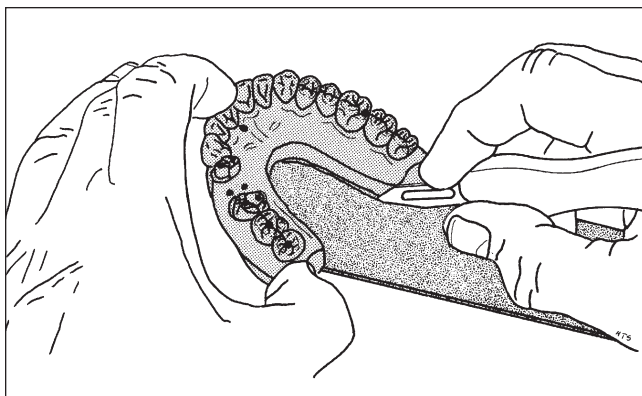


Fig 18-45 A palate/tongue filler is made of boxing wax.

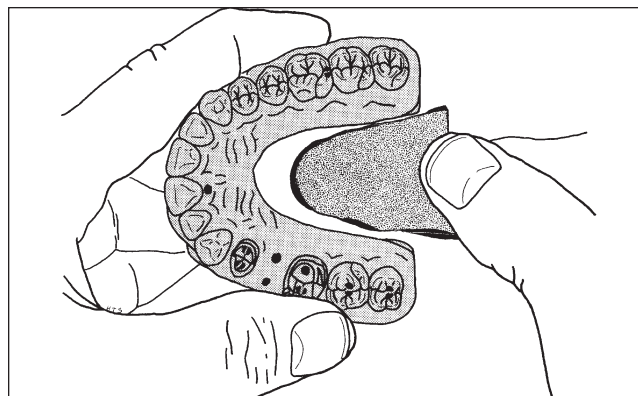


Fig 18-46 The filler is placed on the cast.

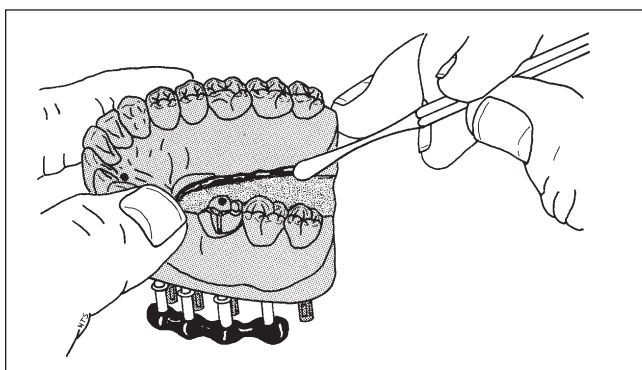


Fig 18-47 The filler is sealed to the cast.

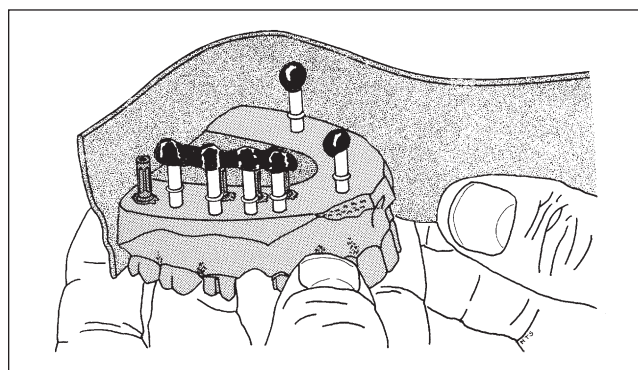


Fig 18-48 Boxing wax is applied around the cast.

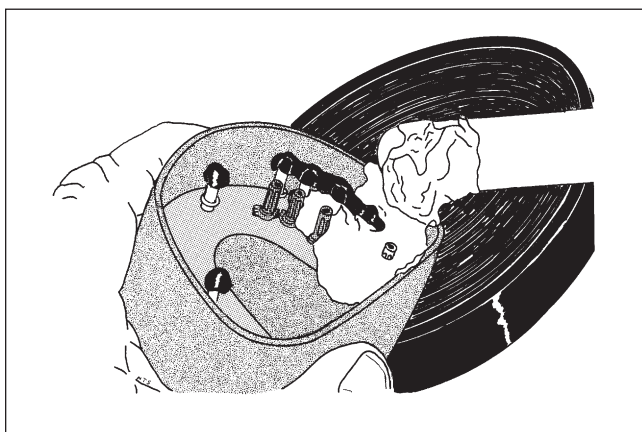


Fig 18-49 The base is poured in Microstone.

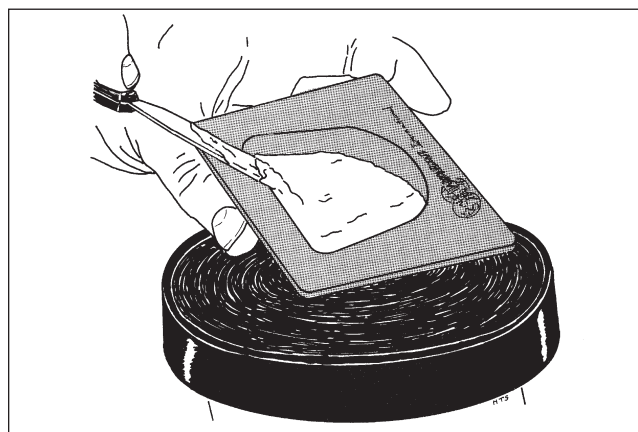

Fig 18-50 The base former is filled with Microstone.

boxing wax (Fig 18-45). The U-shaped piece of wax is placed in the appropriate area (Fig 18-46) and secured to the stone die cast with a hot no. 7 wax spatula (Fig 18-47).

A strip of boxing wax is adapted around the periphery of the cast and sealed with a hot instrument (Fig 18-48). The utility wax should be closely adapted to keep stone from leaking into the gingival crevices and axial surfaces of the teeth. The base is poured in type III stone (Microstone, Whip Mix). Beginning in the area of the pins, small increments of stone are added until it completely covers the pins (Fig 18-49).

The second technique utilizes specially designed base formers that are available in both full-arch and quadrant molds. The depth of the mold is identical to the length of the long pins. Once again, Microstone is used for the base. Using a vibrator, the base former is filled with stone (Fig 18-50). A small amount of stone is added to the bottom of the cast in the area of the pins, carefully vibrating it between the pins (Fig 18-51).

The cast is inverted and seated slowly in the base former until the wax on the ends of the pins contacts the bottom

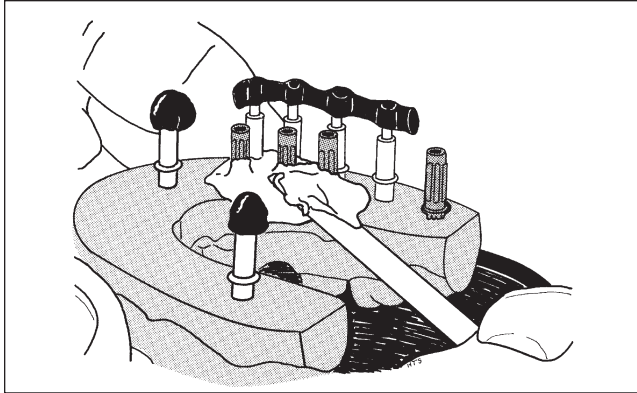


Fig 18-51 Stone is vibrated around the bases of the pins.

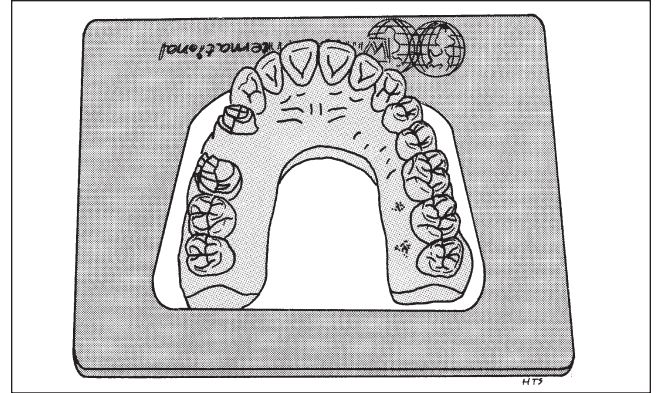


Fig 18-52 The cast is seated in the base former.

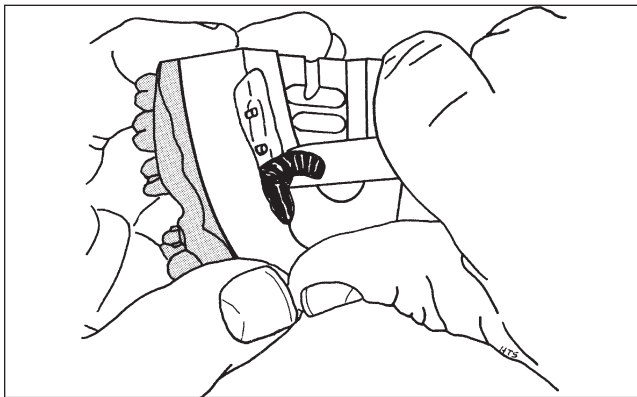


Fig 18-53 Wax over the long pins is removed.

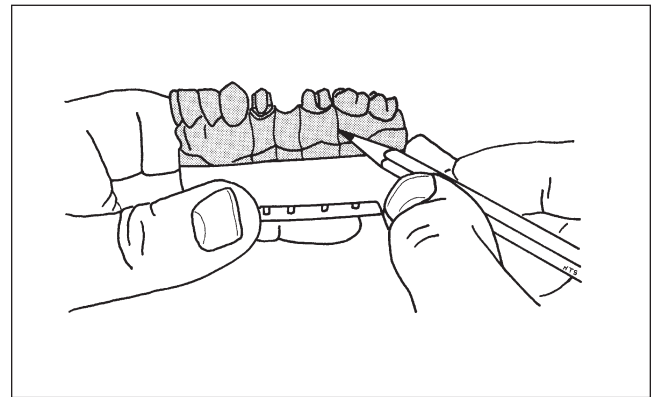
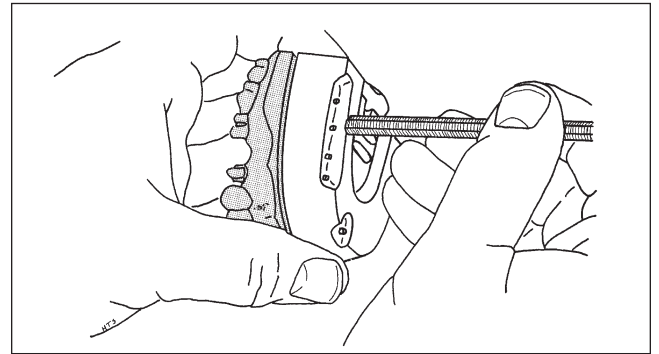


Fig 18-54 The saw cuts are premarked with a pencil.

Fig 18-55 The cast is removed by tapping the pins with an instrument handle.



of the mold (Fig 18-52). Care must be taken not to bury the cast in the stone. Excess is removed as it wells up around the periphery of the cast. The base should set for a minimum of 30 minutes. After removal of the wax or the base former, the cast is wetted and then trimmed on a cast trimmer. The periphery of the cast should be trimmed until the junction of the die stone and the base stone is smooth and distinct.

The cast is allowed to dry before sectioning and trimming of the dies are attempted. The pinned cast can be removed from the base in one piece, which permits sectioning of the cast into dies from the underside. This is particularly desirable in cases in which there is limited interdental space and

therefore the possibility of damage to the finish lines.³⁵ For a routine three-unit fixed partial denture, the dies usually can be sectioned from the occlusal aspect. Because the finish lines are visible in this approach, the novice usually finds it less intimidating.

With either method of sectioning the dies, the first step is to remove the utility wax placed on the ends of the long pins (Fig 18-53). Next, the desired locations of the saw cuts are marked on the facial and lingual aspects of the cast with pencil lines (Fig 18-54). To remove the cast in one piece, the handle of an instrument is used to lightly tap all of the exposed pins (Fig 18-55). The tapping is continued until the

18 Working Casts and Dies

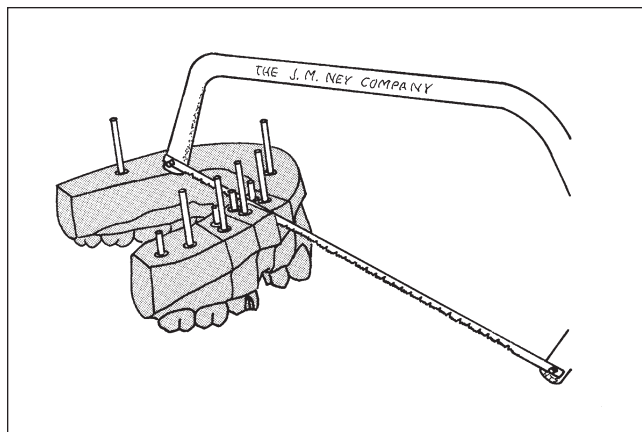


Fig 18-56 Dies are sectioned from the underside.

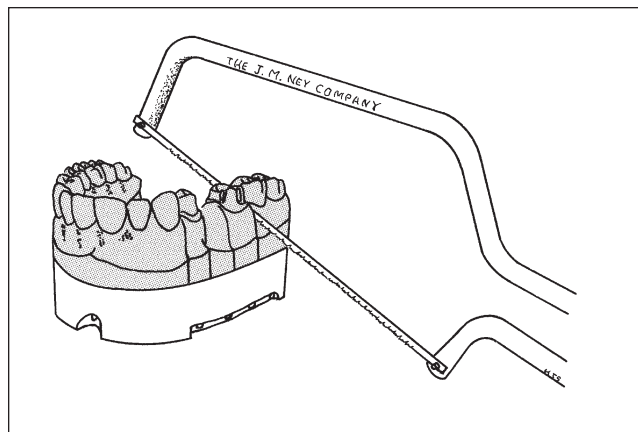


Fig 18-57 Dies may also be sectioned from the occlusal aspect of the cast.

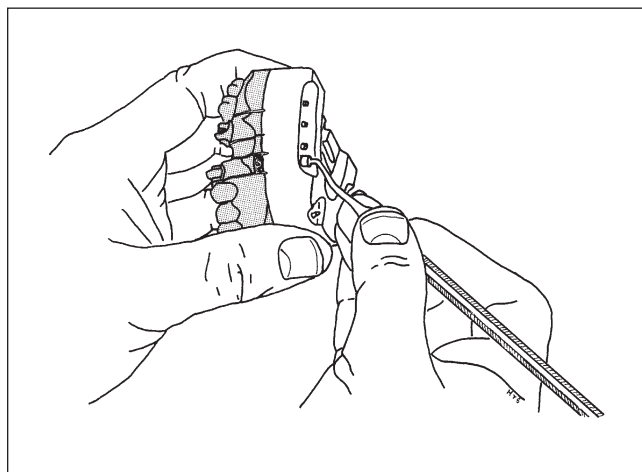


Fig 18-58 A large condenser can also be used to loosen the dies.

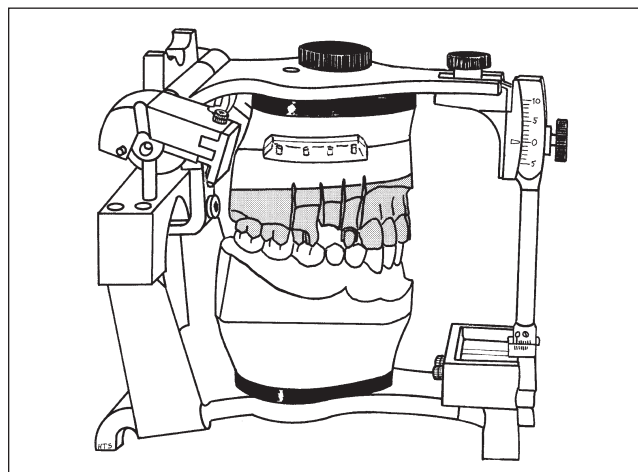


Fig 18-59 The completed cast on the articulator.

pinned cast is loosened from the base. The cast is removed, and the pencil lines are extended onto the underside of the cast to indicate the location of the desired saw cuts.

A saw is used to section the dies from the underside (Fig 18-56). The saw cut should end approximately 1 to 2 mm short of the finish line with the final separation accomplished by squeezing the two parts gently together. In this manner, the parts can be broken cleanly without damage to the finish lines.

To section the dies from the occlusal aspect, the operator must initiate the saw cut slowly, carefully avoiding the finish line of the preparation (Fig 18-57). To prevent scoring of the contralateral teeth, the first saw cut should be made mesial to the section containing the prepared teeth. The uninvolved section or quadrant is removed. This allows ready access and freedom of movement when the dies are sectioned. The saw cut must be carried all the way through the stone before attempting to remove the die.

To remove a single die, a large amalgam condenser or the handle of an instrument is used to push on the end of the exposed pin until the die is loosened from the base (Fig

18-58). To allow easy removal of the dies during the subsequent laboratory procedures, the saw cuts should be parallel or taper slightly in toward the pins. If the base of the die is wider than the preparation, the die will be locked in, and much of the efficiency of a removable die system will be lost.

After the dies are sectioned, they are trimmed in the conventional manner. The finish lines are marked with a red pencil. Die hardener and die spacer are applied according to the manufacturer's instructions. Before the cast is mounted on the articulator, the height of the base is evaluated. If the height of the base is too great, it will prevent closure of the articulator. This should be checked before the mounting stone is mixed. If the base needs to be reduced, the pinned sections of the cast are removed before grinding the base on a cast trimmer.

The two sections are reassembled, and a small amount of utility wax is placed on the ends of the die pins. This will prevent the mounting stone from blocking access to the pins. Once the mounting stone has set, the wax on the pins is removed. The cast is ready for fabrication of the wax pattern (Fig 18-59).

References

- Rudd KD, Strunk RR, Morrow RM. Removable dies for crowns, inlays, and fixed partial dentures. *J Prosthet Dent* 1970;23:337–345.
- Saunders M. The orientation of dies in restorative dentistry. *Br Dent J* 1964;117:133–138.
- Thompson MJ. A standardized indirect technic for reversible hydrocolloid. *J Am Dent Assoc* 1953;46:1–18.
- Phillips RW, Skinner EW. *Skinner's Science of Dental Materials*, ed 9. Philadelphia: Saunders, 1991:86.
- McCormick JT, Antony SJ, Dial ML, Duncanson MG Jr, Shillingburg HT Jr. Wettability of elastomeric impression materials: Effect of selected surfactants. *Int J Prosthodont* 1989;2:413–420.
- Cullen DR, Mikesell JW, Sandrik JL. Wettability of elastomeric impression materials and voids in gypsum casts. *J Prosthet Dent* 1991;66:261–265.
- Rudd KD, Morrow RM, Bange AA. Accurate casts. *J Prosthet Dent* 1969;21:545–554.
- Phillips RW, Ito BY. Factors affecting the surface of stone dies poured in hydrocolloid impressions. *J Prosthet Dent* 1952;2:390–400.
- Wiskott A. Laboratory procedures and clinical implications in the making of casts. *Quintessence Int* 1987;18:181–192.
- Campagni WV, Prince J, Defreese C. Measurement of coating agents used for surface protection of stone dies. *J Prosthet Dent* 1986;55:470–474.
- Fusayama T, Ide K, Hosada H. Relief of resistance of cement of full cast crowns. *J Prosthet Dent* 1964;14:95–106.
- Eames WB, O'Neal SJ, Monteiro J, Miller C, Roan JD Jr, Cohen KS. Techniques to improve the seating of castings. *J Am Dent Assoc* 1978;96:432–437.
- Gardner FM, Vermilyea SG. The variability of die-spacer film thickness. *Gen Dent* 1985;33:502–503.
- Donovan T, Wright W, Campagni WV. Use of paint-on die spacers in preparations with grooves. *J Prosthet Dent* 1984;52:384–388.
- Campagni WV, Preston JD, Reisbick MH. Measurement of paint-on die spacers used for casting relief. *J Prosthet Dent* 1982;47:606–611.
- Campagni WV, Wright W, Martinoff JT. Effect of die spacer on the seating of complete cast gold crowns with grooves. *J Prosthet Dent* 1986;55:324–328.
- Cowell TA, Moore J. New technic for sectional model production for inlay and bridgework. *J Am Dent Assoc* 1965;71:1387–1390.
- Kimball HD. Hydrocolloid in restorative operative dentistry; Technique and principles. *Dent Dig* 1949;55(2):64–71.
- Mann AW. A critical appraisal of the hydrocolloid technique: Its advantages and disadvantages. *J Prosthet Dent* 1951;1:733–749.
- Dilts WE, Podshadley AG, Ellison E, Neiman R. Accuracy of a removable die-dowel pin technique. *J Dent Res* 1971;50:1249–1252.
- Carl W, Garlapo DA, Brown MH. Modified impression procedure and removable die preparation. *Quintessence Int Dent Dig* 1974;5(3):39–44.
- Smith CD, Nayyar A, Koth DL. Fabrication of removable stone dies using cemented dowel pins. *J Prosthet Dent* 1979;41:579–581.
- Reed GM. New concept in precision dowels. *J Am Dent Assoc* 1968;76:321–324.
- Stern AJ, Vernon HM. Development of a new tool in restorative dentistry. *J Prosthet Dent* 1969;21:536–544.
- Hohlt FA, Phillips RW. Evaluation of various methods employed for constructing working dies from hydrocolloid impressions. *J Prosthet Dent* 1956;6:87–93.
- Covo LM, Ziebert GJ, Balthazar Y, Christensen LV. Accuracy and comparative stability of three removable die systems. *J Prosthet Dent* 1988;59:314–318.
- Dilts WE, Podshadley AG, Sawyer HF, Neiman R. Accuracy of four removable die techniques. *J Am Dent Assoc* 1971;83:1081–1085.
- Myers M, Hembree JH Jr. Relative accuracy of four removable die systems. *J Prosthet Dent* 1982;48:163–165.
- Troendle KB, Troendle GR Jr, Cavoza E Jr. Positioning dowel pins for removable dies. *J Prosthet Dent* 1981;46:575–578.
- George TA, Holmes JR. The dowelclip. A device for dowel pin placement. *J Prosthet Dent* 1985;53:276–278.
- Robinson FB, Block B. Dowel pin positioning technique for fixed partial denture working casts. *J Prosthet Dent* 1981;46:215–216.
- Balshi TJ, Minglehoff EB. Matches, clips, needles, or pins. *J Prosthet Dent* 1975;34:467–472.
- Stone TE, Welker WA. A method for locating dowel pins in artificial stone casts. *J Prosthet Dent* 1980;44:345–346.
- Miranda FJ, Dilts WE, Duncanson MG Jr, Collard EW. Comparative stability of two removable die systems. *J Prosthet Dent* 1976;36:326–333.
- Netti CA, Yard RA, Withrow G, Nagy WW. Saw modification for underside die cutting. *J Prosthet Dent* 1990;64:621–624.

Wax Patterns

19



The wax pattern is the precursor of the finished cast restoration that will be placed on the prepared tooth. Inasmuch as the wax pattern will be duplicated exactly through the investing and casting technique, the definitive restoration can be no better than its wax pattern (ie, errors and oversights in the wax pattern will be perpetuated in the casting). A few extra minutes spent on the wax pattern can often save hours that might be spent correcting the casting.

There are two accepted ways of fabricating a wax pattern:

1. The direct technique, in which the pattern is waxed on the prepared tooth in the mouth
2. The indirect technique, in which the pattern is waxed on a stone cast made from an accurate impression of the prepared tooth

The indirect technique offers the advantage of allowing most of the procedure to be done away from the chair. It affords an opportunity for visualization of the restoration and ready access to waxing the margins. Because it allows a technician to fabricate the pattern, the indirect technique has become the most popular means of fabricating cast restorations.

The selection of the wax used in fabricating a wax pattern is important. Type I waxes are formulated for making intraoral wax patterns. Type II waxes, made for the fabrication of wax patterns extraorally, have a slightly lower melting point. Therefore, when an indirect wax pattern is made, the wax used should meet American Dental Association (ADA) specification no. 4, type II. The wax should have a color such as blue, green, or red that will contrast with and be easily distinguishable from the stone die and indicated margin. There are several requirements of a good inlay wax¹:

- It must flow readily when heated, without chipping, flaking, or losing its smoothness.
- When cooled, it must be rigid.
- It must be capable of being carved precisely, without chipping, distorting, or smearing.

Stresses occur in the inlay wax as a result of the heating and manipulation of the wax during fabrication of the pattern. Wax, a thermoplastic material, relaxes as these stresses are released. The result is distortion, which is exhibited as a

poor fit. To minimize this distortion, patterns should never be left off the die, and they should be invested as soon as possible after fabrication.

Wax Pattern Fabrication

Armamentarium

- P. K. Thomas (PKT) waxing instruments (nos. 1 to 5) (Osung)
- Beavertail burnisher
- No. 7 wax spatula
- Sable brush
- Colored pencil
- Laboratory knife with no. 25 blade
- Cotton pliers
- Bunsen burner
- Inlay casting wax
- Zinc stearate powder
- Die lubricant

Coping fabrication technique

The first step in making a wax pattern is the fabrication of a thin coping, or thimble, on the die. The coping is usually made of wax, but heated resin sheets also can be used for this purpose. Vacuum-adapted polystyrene² and pressure-formed polypropylene³ have been used to make metal-ceramic crown patterns. This type of coping also can be used with partial veneer crowns⁴ and even pin-retained castings.⁵ If the coping is made on a separate die, it then will be transferred to the articulated working cast, where it will serve as the foundation for the axial contours and occlusal morphology to be added there. If it is formed on a removable die, the die is replaced in the master cast.

To prevent the wax from sticking to the die stone, the die is thoroughly coated with die lubricant, which is allowed to soak in for several minutes (Fig 19-1). If the surface of the die appears dry after this period of time, application is repeated. Any excess lubricant is removed with a gentle stream of compressed air.

19 Wax Patterns

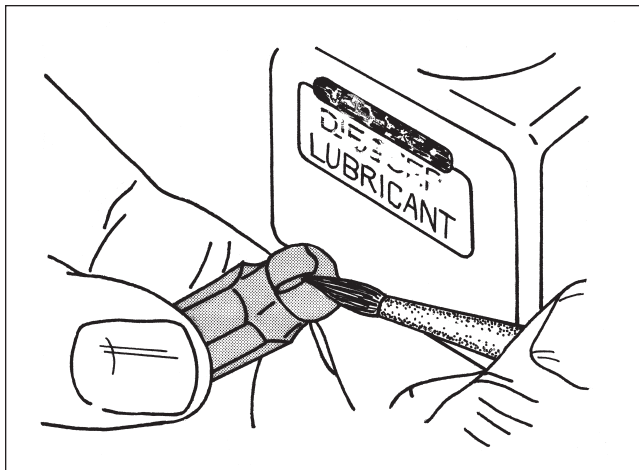


Fig 19-1 The die is lubricated before waxing.

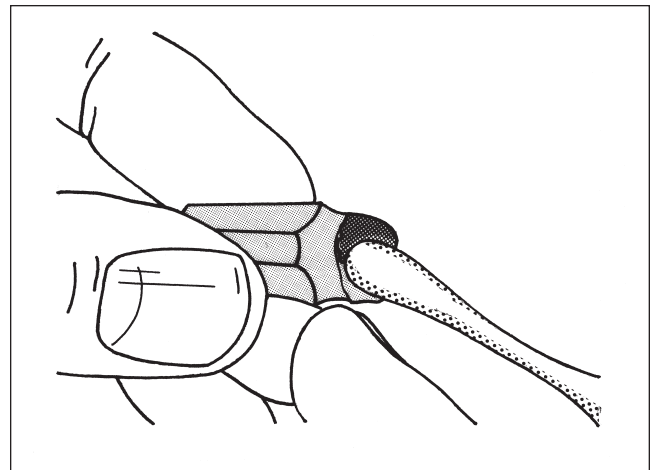


Fig 19-2 Wax coping is formed with a no. 7 wax spatula.

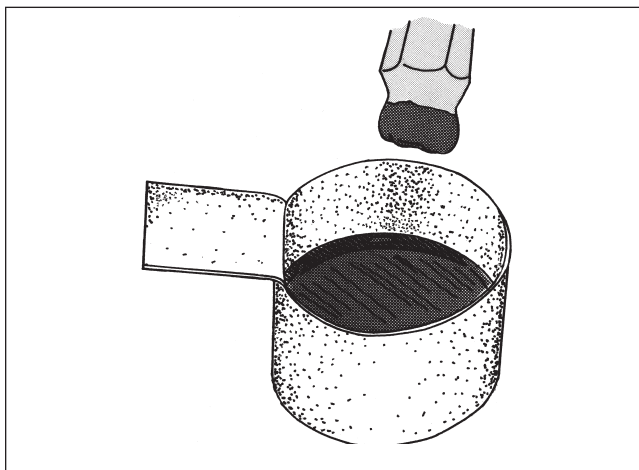


Fig 19-3 The coping can also be formed by dipping the die in molten wax.

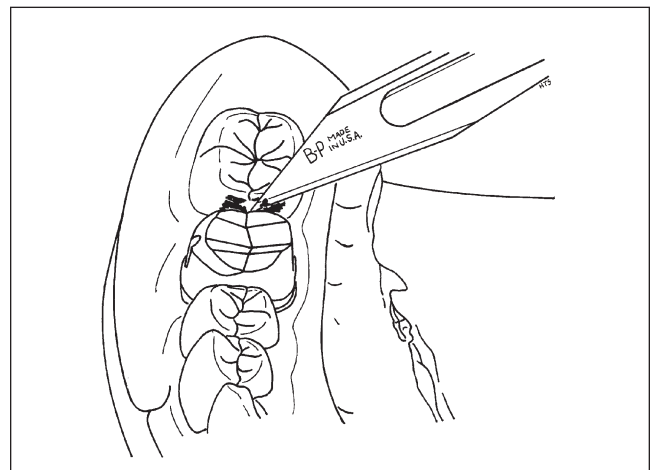


Fig 19-4 Proximal contacts on adjacent teeth are lightly scraped.

Wax is flowed over the surface of the preparation on the die using quick strokes of a hot no. 7 wax spatula (Fig 19-2). The margins of wax already placed on the die are overlapped and remelted. If small amounts of wax are placed on the die without remelting the edges of the previously applied wax, or if wax is applied with an instrument that is not hot enough, flow lines, or voids, will be produced on the internal surface of the wax pattern. Dipping the die into a small metal container filled with molten wax is yet another method that can be used for developing a uniform, thin initial coping of wax on the die (Fig 19-3).

To ensure that the finished restoration will have adequate proximal contact with the teeth adjacent to it, the wax pattern should be slightly oversized mesiodistally. This will provide enough bulk in the contact areas to allow casting,

finishing, and polishing without creating an open contact in the finished restoration. The best way of achieving this is to remove a small amount of stone from the proximal surfaces of the teeth on the cast on either side of the prepared tooth. To control the amount of stone removed from the proximal surfaces of the cast, they are blackened with a colored pencil. Then a laboratory knife with a sharp no. 25 blade is used to lightly scrape off the colored marking (Fig 19-4).

If a separate die is used, the working cast is lubricated, and the wax coping is placed on it. It may be necessary to remove the wax 1.0 mm from the marginal periphery of the pattern to ensure that it will seat all the way on the working cast. Stone also may be removed from the area of the cast that reproduces gingiva adjacent to the finish line of the prepared tooth.

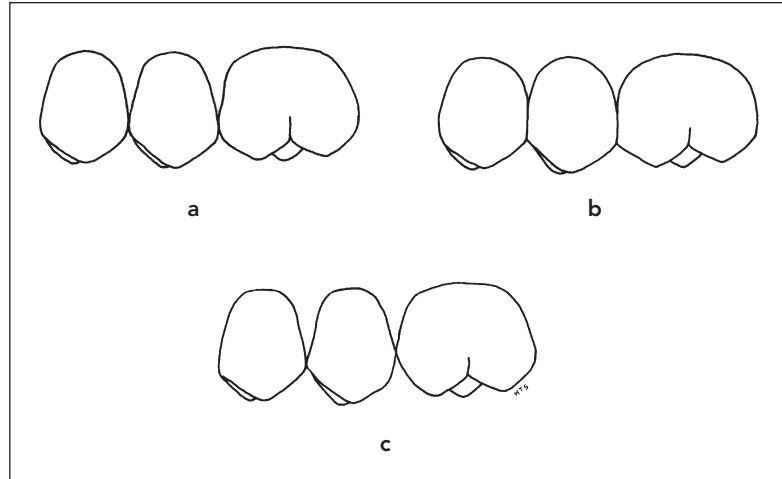


Fig 19-5 Occlusogingival dimension of proximal contacts: (a) correct; (b) too broad; (c) too narrow.

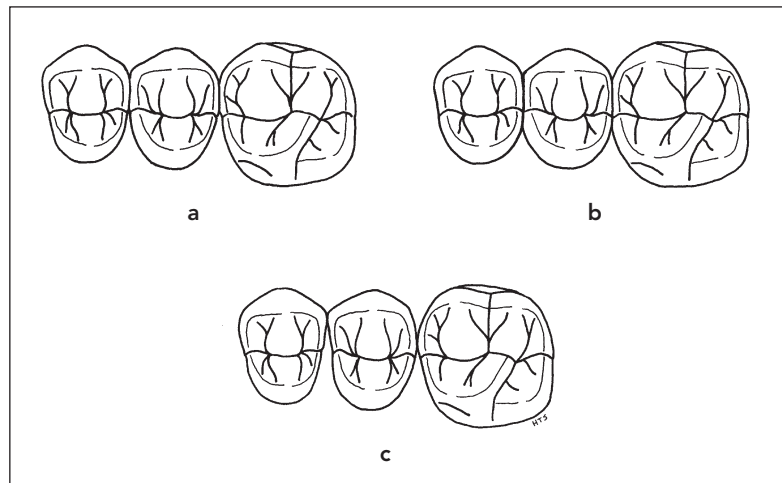


Fig 19-6 Faciolingual dimension of proximal contacts: (a) correct; (b) too broad; (c) too narrow.

Axial Contours

The proximal contacts and the facial and lingual axial contours of the wax pattern should be established at this time. The proximal contacts of posterior teeth are located in the occlusal third of the crowns, except for the contacts between the maxillary first and second molars, which are located in the middle third.⁶ It should be noted that the occlusal and middle thirds are not those of the proximal surface but those of the anatomical crown. The contact must be more than just a point occlusogingivally, but it must not extend far enough cervically to encroach on the gingival embrasure (Fig 19-5). The axial surface of the crown cervical to the proximal contact should be flat or slightly concave. There can be no encroachment upon the interdental papilla.^{7,8} A flat contour may be the optimum shape because it is easiest to floss.⁹ Overcontouring the proximal surfaces apical to the contacts

by making these areas convex will produce severe inflammation of the gingiva.¹⁰ When complete, the proximal surface of the wax pattern should be a mirror image of the proximal surface of the adjacent tooth.

The proximal contacts are located slightly to the facial aspect of the middle of the posterior teeth, except for the contacts between maxillary first and second molars, which are generally centered faciolingually.⁶ As a result, the lingual embrasures are slightly larger than the facial embrasures. Contacts that are too narrow allow fibrous foods to wedge between the teeth, and contacts that are excessively wide faciolingually do not adequately deflect food from the gingival tissue (Fig 19-6).

The corresponding surfaces of the adjacent teeth make an excellent guide for judging the contours of the facial and lingual surfaces of the wax pattern. If these teeth are in a position that is nearly normal, and if they have not been subjected to poorly contoured axial restorations, the facial and

19 Wax Patterns

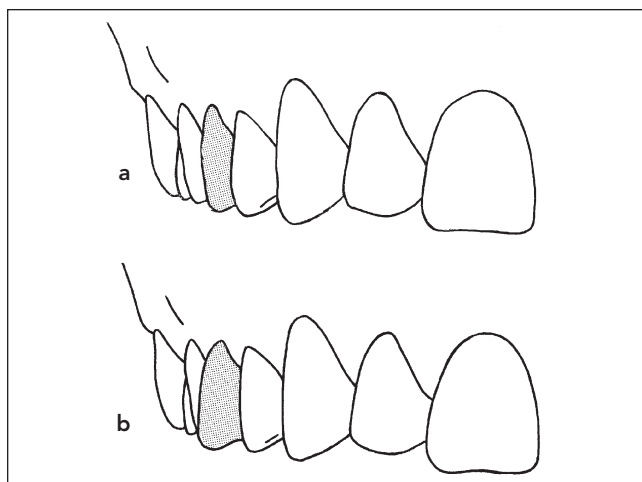


Fig 19-7 Facial contours of a restoration should be in harmony with those of adjacent teeth: (a) correct; (b) incorrect.

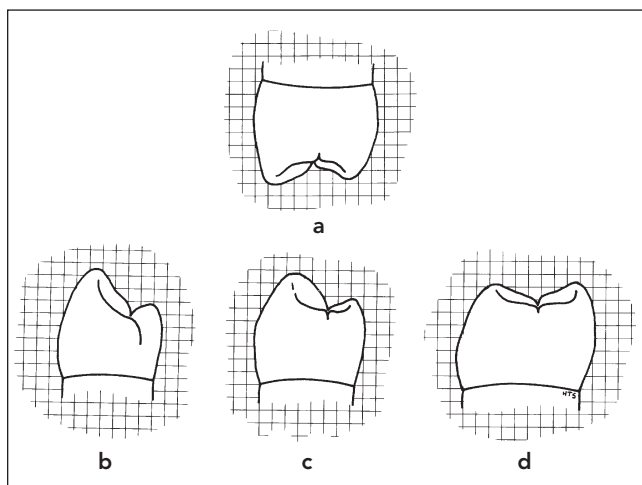


Fig 19-8 Height of contour on the facial surface of all posterior teeth extends horizontally 0.5 mm beyond the plane of the root. On the lingual surface of maxillary teeth (a) and mandibular first premolars (b), the height of contour also extends 0.5 mm, but it increases to 0.75 mm on mandibular second premolars (c) and 1.0 mm on mandibular molars (d).

lingual contours of the wax pattern should be harmonious with them (Fig 19-7).

The height of contour on the facial surface of posterior teeth usually occurs in the cervical third. It occurs in the middle third on the lingual surface of premolars and molars. The facial contours of both maxillary and mandibular posterior teeth extend approximately 0.5 mm beyond the outline of the root at the cemento-enamel junction (Fig 19-8). The amount of lingual prominence differs between maxillary and mandibular teeth. It is 0.5 mm on maxillary teeth and mandibular first premolars, about 0.75 mm on mandibular second premolars, and nearly 1.0 mm on mandibular molars.¹¹

Emergence profile

The part of the axial contour that extends from the base of the gingival sulcus past the free margin of the gingiva has been described as the *emergence profile* by Stein and Kuwata¹² (Fig 19-9). The emergence profile extends to the height of contour, producing a straight profile in the gingival third of the axial surface. The apparent curvature of an axial surface usually breaks down into a series of intersecting straight lines when it is examined closely. This has been confirmed by photographic analysis of several hundred natural teeth.¹³ Production of a straight profile should be a treatment objective in restoring a tooth^{14,15} because it facilitates access for oral hygiene measures (Fig 19-10). In addition, the straight profile is easily evaluated with a periodontal probe.

The most common error relating to axial contour is the creation of a bulge or excessive convexity (Fig 19-11). Parkinson¹⁶ reported that metal-ceramic crowns had a mean faciolingual width 0.71 mm greater than that of unrestored contralateral teeth serving as controls. Full gold crowns were 0.36 mm wider. Facial and lingual contours of teeth have been described in some detail.^{11,17} Through the years, undue importance probably has been attributed to the protective role of the axial contour in the cervical region. As a result, both dentists and dental technicians frequently create a bulge where there should be none and place it apically in the cervical region. Overcontoured restorations with large convexities promote the accumulation of food debris and encourage rather than prevent plaque and gingival inflammation.^{10,18-25}

There does not seem to be any justification for a protective bulge. The small amount of facial bulge that exists in primary human teeth and the dentitions of other species lies subgingivally without any apparent trauma to the gingiva from lack of protection. Peg lateral incisors also lack cervical bulges, but they exhibit no deleterious gingival effects.²¹ In addition, many clinicians have observed the phenomenon of prepared teeth that have gone without provisional restorations for a considerable amount of time with no gingival overgrowth or inflammation.

Experimental data indicate that while overcontouring produces gingival inflammation, undercontouring does not. In a study on dogs, Perel²⁶ found that overcontouring produced inflammatory and hyperplastic changes in 4 weeks, while undercontouring produced no significant changes. This was subsequently verified in human subjects by Sackett and Gildenhuys,²³ who found that the gingiva around nearly two-thirds of overcontoured restorations showed degradation, inflammation, and alteration of morphology 6 to 7 weeks after restoration placement. Because of its destructive potential, overcontouring should be avoided. It is better to undercontour than to overcontour.^{24,26,27}

If the restoration is an onlay or a partial veneer crown, the areas in which it meets the axial surface of the tooth should be blended into smooth, continuous contours (Fig 19-12). Bulges, depressions, and other discrepancies should be eliminated in the wax pattern before proceeding to investing and casting.

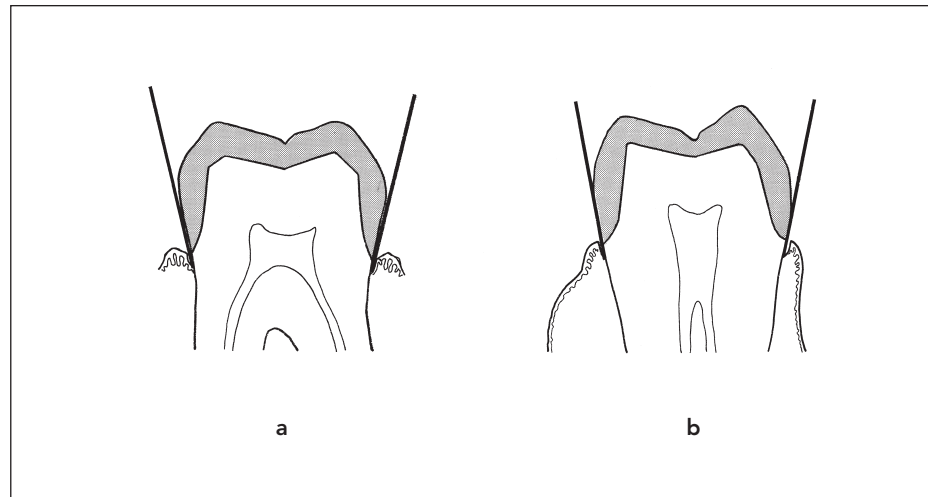


Fig 19-9 Emergence profile of the proximal surfaces (a) and of the facial and lingual contours (b).

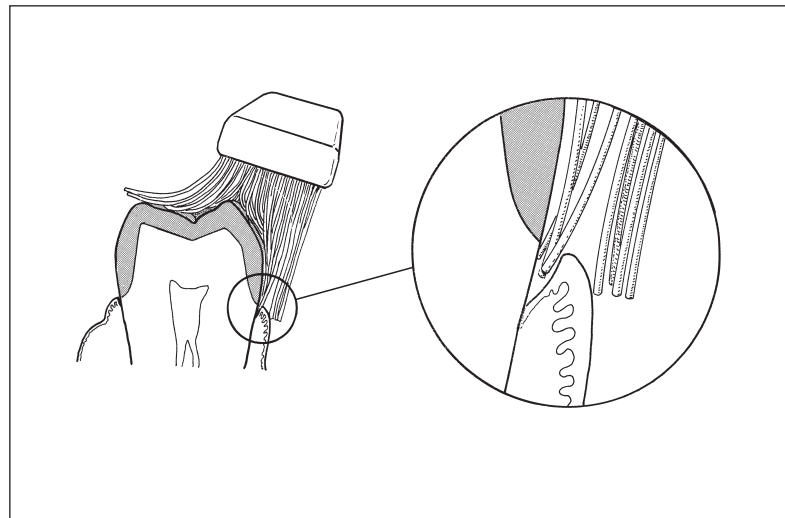


Fig 19-10 A straight emergence profile allows toothbrush bristles to reach into the gingival sulcus.

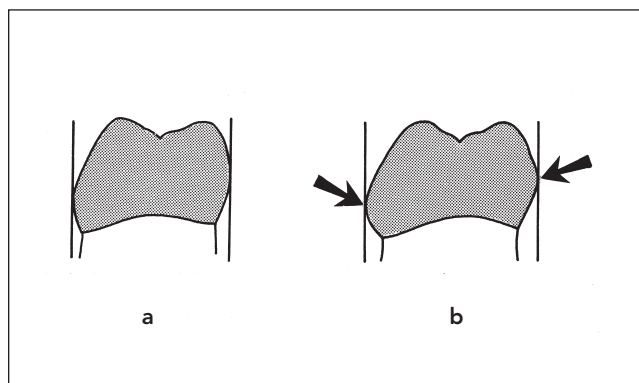


Fig 19-11 Axial contours of a full veneer crown on a mandibular molar: (a) correct; (b) overcontoured.

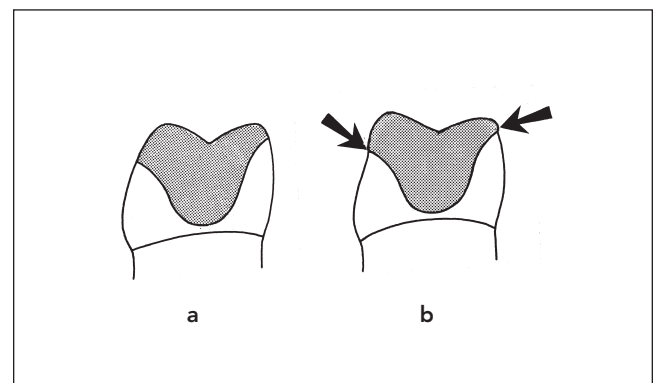


Fig 19-12 Restoration contours should blend smoothly with the contours of surrounding tooth structure: (a) correct; (b) incorrect.

19 Wax Patterns

Table 19-1 Classification of occlusal arrangements

	Cusp-fossa	Cusp–marginal ridge
Location of occlusal contact on opposing teeth	Occlusal fossae only	Marginal ridges and occlusal fossae
Relation with opposing tooth (teeth)	Tooth-to-tooth	Tooth-to-two teeth
Advantages	Occlusal forces are directed parallel with the long axis of the tooth; these forces are near the center of the tooth, placing very little lateral stress on the tooth.	This is the most natural type of occlusion and is found in 95% of all adults; it can be used for single restorations.
Disadvantages	Because this type of occlusion is rarely found in natural teeth, it usually can be used only when restoring several contacting teeth and the teeth opposing them.	Food impaction and the displacement of teeth may arise if the functional cusps wedge into a lingual embrasure.
Application	Full-mouth reconstruction	Most cast restorations done in daily practice

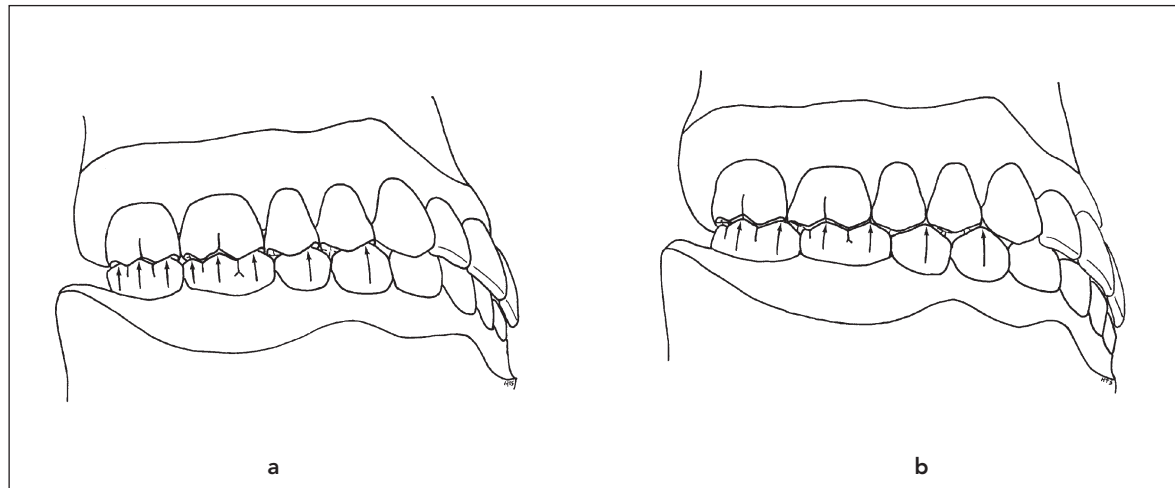


Fig 19-13 Cusp alignment for a cusp-fossa occlusion (a) and a cusp–marginal ridge occlusion (b).

Occlusal Morphology

Waxing of the occlusal surface is deferred until the axial surfaces are essentially complete. Because the occlusal scheme for the restoration is established in the wax pattern, no discussion of wax patterns would be complete without mention

of occlusal theory and the effects of articulation on the occlusal surface of the wax pattern.

During centric closure in the normal dentition, the palatal cusps of the maxillary posterior teeth and the facial cusps of the mandibular posterior teeth make contact with the occlusal fossae or the marginal ridges of the opposing teeth. They grind food like a mortar during mastication and are called

Table 19-2 Mandibular cusp placement

Mandibular buccal cusps	Maxillary occlusal surfaces	
	Cusp-fossa	Cusp–marginal ridge
First premolar	Mesial fossa of the first premolar	Mesial marginal ridge of the first premolar
Second premolar	Mesial fossa of the second premolar	Distal marginal ridge of the first premolar and mesial marginal ridge of the second premolar
Mesiofacial cusp of the first molar	Mesial fossa of the first molar	Distal marginal ridge of the second premolar and mesial marginal ridge of the first molar
Distofacial cusp of the first molar	Central fossa of the first molar	Central fossa of the first molar
Distal cusp of the first molar	Distal fossa of the first molar	Usually nonfunctional
Mesiofacial cusp of the second molar	Mesial fossa of the second molar	Distal marginal ridge of the first molar and mesial marginal ridge of the second molar
Distofacial cusp of the second molar	Central fossa of the second molar	Central fossa of the second molar
Distal cusp of the second molar	Usually nonfunctional	Usually not present

Table 19-3 Maxillary cusp placement

Maxillary palatal cusps	Mandibular occlusal surfaces	
	Cusp-fossa	Cusp–marginal ridge
First premolar	Distal fossa of the first premolar	Distal fossa of the first premolar
Second premolar	Distal fossa of the second premolar	Distal fossa of the second premolar
Mesiopalatal cusp of the first molar	Central fossa of the first molar	Central fossa of the first molar
Distopalatal cusp of the first molar	Distal fossa of the first molar	Distal marginal ridge of the first molar and mesial marginal ridge of the second molar
Mesiopalatal cusp of the second molar	Central fossa of the second molar	Central fossa of the second molar
Distopalatal cusp of the second molar	Distal fossa of the second molar	Distal marginal ridge of the second molar

functional cusps. On the other hand, the facial cusps of the maxillary molars and the lingual cusps of the mandibular molars do not contact the opposing teeth. These cusps act like the rim of a pestle to prevent food from overflowing, and they protect the buccal mucosa and the tongue by keeping them away from the functional cusps. Because these cusps do not make direct contact with opposing teeth, they are called *nonfunctional cusps*.

The occlusal scheme can be classified by the location of the occlusal contact made by the functional cusp on the opposing tooth in intercuspal position (Table 19-1). There are two types: cusp-fossa (Fig 19-13a) and cusp–marginal ridge (Fig 19-13b). The locations of the occlusal contacts in each type are listed in Tables 19-2 and 19-3.

19 Wax Patterns

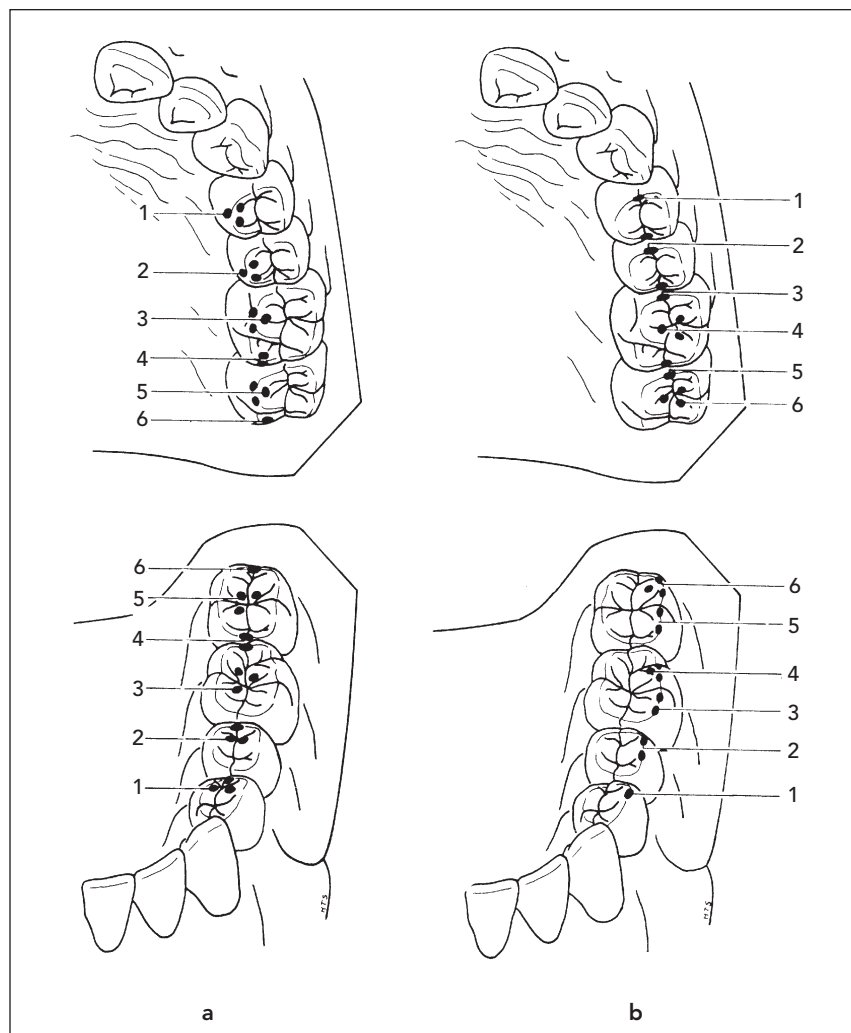


Fig 19-14 Cusp placement and occlusal contacts for a cusp-marginal ridge occlusion: (a) contacts of maxillary palatal cusps on mandibular teeth; (b) contacts of mandibular facial cusps on maxillary teeth. The cusps and the matching areas of contact on the opposing teeth are numbered sequentially from anterior (1) to posterior (6).

Cusp-marginal ridge arrangement

The cusp-marginal ridge relation is the type of occlusal scheme in which the functional cusp contacts the opposing occlusal surfaces on the marginal ridges of the opposing pair of teeth or in a fossa (Fig 19-14). Therefore, a cusp-marginal ridge occlusion is basically a one tooth-to-two teeth arrangement. Because the majority of adults exhibit the cusp-marginal ridge type of occlusion, it is an occlusal pattern widely utilized in daily practice.

The waxing technique used for cusp-marginal ridge occlusion was originally devised by E. V. Payne and was the first wax-added technique for functional waxing.²⁸ The

same technique, modified by the use of color-coded waxes, has become a widely used method for teaching functional waxing.²⁹

Maxillary teeth

When making a maxillary wax pattern, cones for the facial cusps are placed with a PKT no. 1 instrument. They should be placed as far facially as possible (Fig 19-15). The length of a maxillary facial cusp is determined by moving the articulator into a protrusive and a working lateral excursion. The tip should be shortened so that it barely misses the opposing mandibular cusp tip if a canine-protected occlusion is being

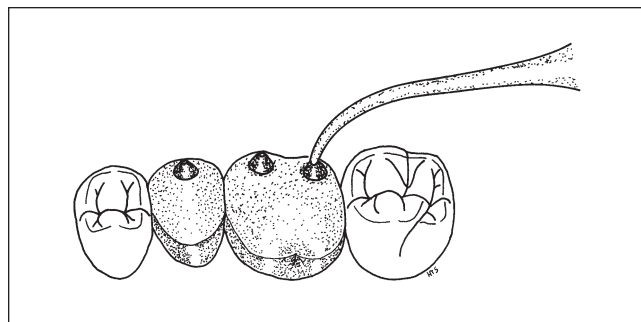


Fig 19-15 Cones for facial cusps: PKT no. 1.

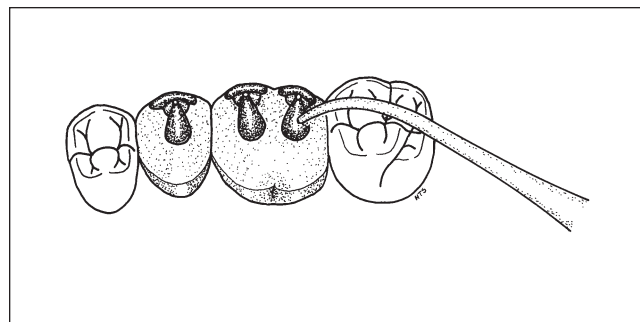


Fig 19-16 Facial ridges and triangular ridges: PKT no. 1.

developed. If the cusp tips of the wax pattern are longer than the cusps of adjacent natural teeth, the cones should be shortened on the pattern.

The facial ridges of the facial cusps are formed by adding wax to the facial aspect of the facial cones (Fig 19-16). These ridges, when viewed in profile from the mesial, give the facial surface its proper overall contour. The triangular ridges are added with a PKT no. 1 instrument. Each triangular ridge extends from the central groove of the tooth to the cusp tip. These ridges are called *triangular* because they are much wider at their base than at the cusp tip. They should be convex to allow for occlusal contact points. Occlusal contacts on the triangular ridges should be evaluated. The occlusal surface is dusted with zinc stearate, and then the articulator is closed and moved through excursions. Unwanted contacts are removed, and those that are too large are trimmed.

Mesial and distal cusp ridges are formed on each cone with the PKT no. 1. These ridges should form inclines away from the cusp tip (Fig 19-17). The articulator is placed into lateral and protrusive excursions to check the mesial and distal ridges. The inclines of these ridges should mirror the inclines of the mesial and distal cusp ridges of the opposing teeth. The inclines of the cusp ridges on the maxillary wax pattern should not touch the opposing teeth.

The cones for the palatal (functional) cusps are positioned (Fig 19-18). Each cone should be located mesiodistally so that it will be in line with the opposing fossa or marginal ridge with which it should occlude. The cones for a maxillary premolar are usually located slightly mesial to the mesiodistal center of the tooth. The mesiopalatal cones for molars are centered between the two facial cusps. Each mesiopalatal cusp should be located so that it will fall opposite the faciopalatal center of the opposing tooth. The cone is dusted with zinc stearate, and the articulator is closed to check its height. Contacts should occur on the sides of the cone near the tip, but not actually on the tip itself.

The mesial and distal ridges are added to the palatal cusps with the PKT no. 1 (Fig 19-19). The addition of these ridges completes the palatal perimeters of the occlusal table. The cusp ridges diminish in height from the cusp tip to the marginal ridges. The pattern is dusted with zinc stearate, and the occlusal contacts are checked.

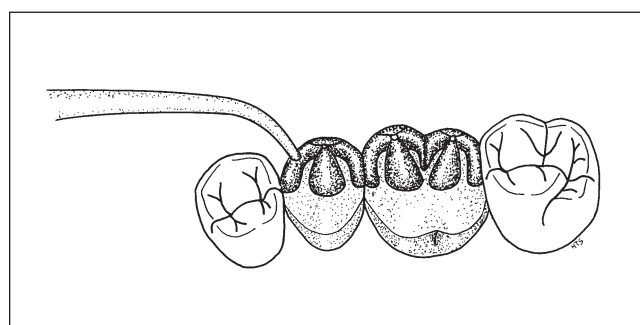


Fig 19-17 Mesial and distal cusp ridges for facial cusps: PKT no. 1.

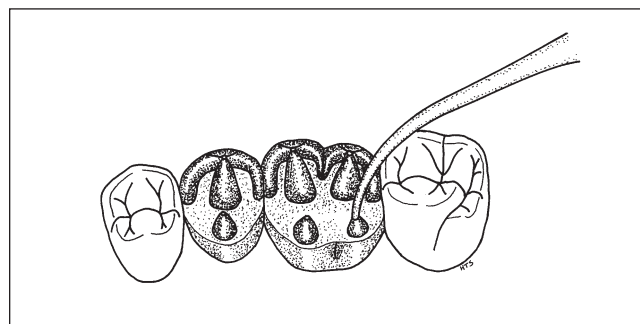


Fig 19-18 Cones for palatal cusps: PKT no. 1.

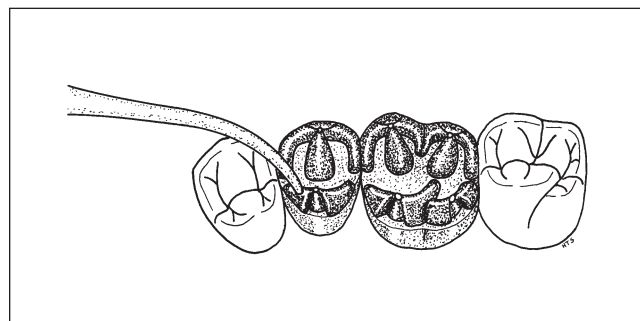


Fig 19-19 Mesial and distal cusp ridges for palatal cusps: PKT no. 1.

19 Wax Patterns

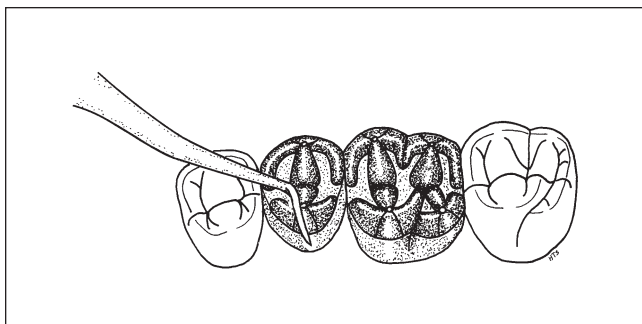


Fig 19-20 Palatal ridges and triangular ridges: PKT nos. 1 and 4.

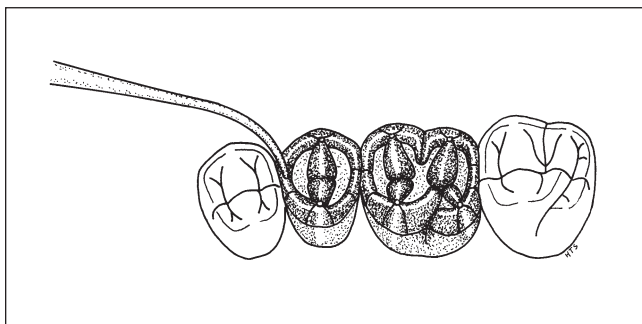


Fig 19-21 Marginal ridges: PKT no. 1.

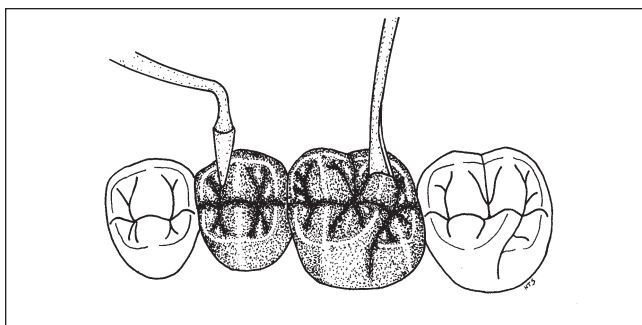


Fig 19-22 Supplemental anatomy: PKT nos. 3 and 5.

Palatal ridges are added to the cusps to complete the palatal axial contour (Fig 19-20). They are smoothed with a PKT no. 4. Triangular ridges also are added to the cusps at this time. The triangular ridges should be convex to form contact points with opposing cusps.

Marginal ridges are formed by uniting the mesial and distal ridges of the facial cusps with the mesial and distal ridges of the palatal cusps (Fig 19-21). The height is determined by the height of the cusp tips of the opposing teeth.

Supplemental anatomy is formed by the junction between triangular ridges and the adjacent cusp or marginal ridges (Fig 19-22). A PKT no. 5 is used to refine the ridges, and a PKT no. 3 is used to smooth the grooves. The grooves should not be carved with these instruments.

Mandibular teeth

The facial cusps of mandibular premolars are approximately one-third the mesiodistal width of the teeth. They are placed at the junction of the facial one-third and the lingual two-thirds of the mandibular tooth (Fig 19-23). This positioning will place them near the faciolingual center of the opposing teeth. They are placed mesiodistally so that they will be in line with the opposing fossae or marginal ridges with which they should occlude. The length of the mandibular facial cusp is determined by contact in the fossa or on the marginal ridges of the maxillary teeth. The cone is dusted with zinc stearate, and the articulator is closed to adjust its height.

Facial ridges are placed on the facial cusps by applying wax from the tip of the cone to its base with a PKT no. 1 (Fig 19-24). This will produce the outline of the final contour of the facial surface. The pattern is dusted and checked in centric and lateral excursions to make sure that it is not over-contoured. Care must be taken not to melt the tips of the cones at this time.

Mesial and distal ridges are added to the facial cusps, and the facial contour is completed by blending these ridges into the facial surface (Fig 19-25). The inclines of these new ridges are checked for compatibility by moving the articulator through excursions.

Triangular ridges are added to the facial cusps with a PKT no. 1 (Fig 19-26). The base of these ridges should form the central groove of the occlusal surface. The ridges are convex to ensure contact points with opposing teeth.

Next, the cones are positioned for the lingual (nonfunctional) cusps. They should be placed as far lingually as possible (Fig 19-27). To prevent working-side interferences on molars, the cones should be placed as far apart mesiodistally as possible. On premolars, they should be positioned mesially or distally to avoid any working-side interference. The lingual cusps should be shorter than the facial cusps. In natural teeth, the lingual cusp is 3.3 mm shorter than the facial cusp on the mandibular first premolar and 2.0 mm shorter than the facial cusp on the mandibular second premolar.³⁰

After all the mandibular lingual cusps have been placed, they are viewed from the lingual as the articulator is moved through a working-side excursion. This ensures that the lingual cusps will function opposite a maxillary embrasure or groove without interference.

Lingual ridges are added to the lingual cusps to form the outline of the lingual contour. Broad-based, convex triangular ridges are then added with a PKT no. 1 (Fig 19-28). They will converge slightly toward the central fossa. The contacts formed by each opposing cusp should form a tripod configuration.

Marginal ridges are formed by joining the facial and lingual cusp ridges (Fig 19-29). The form of the mesial marginal ridges on mandibular premolars and first molars is determined arbitrarily because they are not ordinarily in occlusion.²⁹ All grooves and fossae are smoothed with a PKT no. 3 (Fig 19-30). The ridges are rounded and finished with the PKT no. 5.

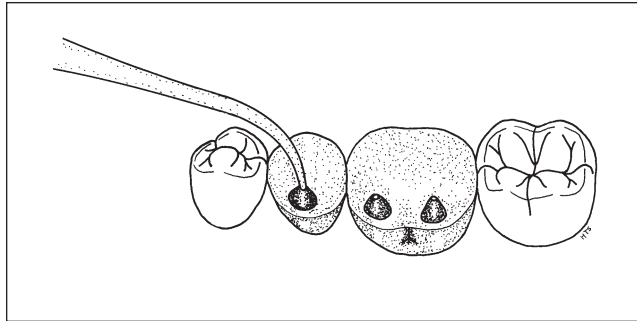


Fig 19-23 Cones for facial cusps: PKT no. 1.

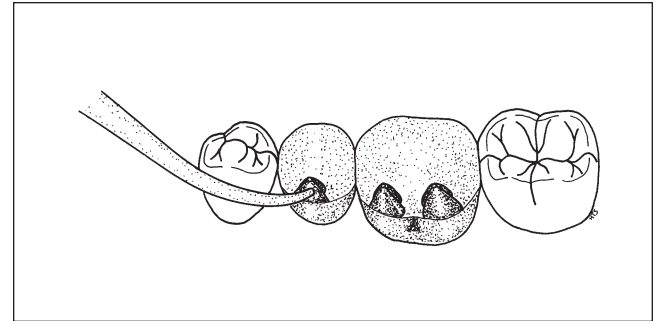


Fig 19-24 Facial ridges: PKT no. 1.

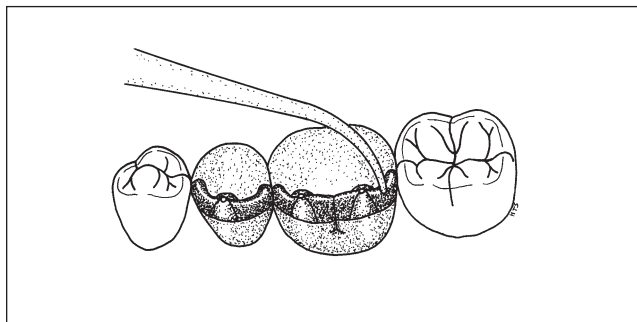


Fig 19-25 Mesial and distal cusp ridges for facial cusps: PKT no. 1.

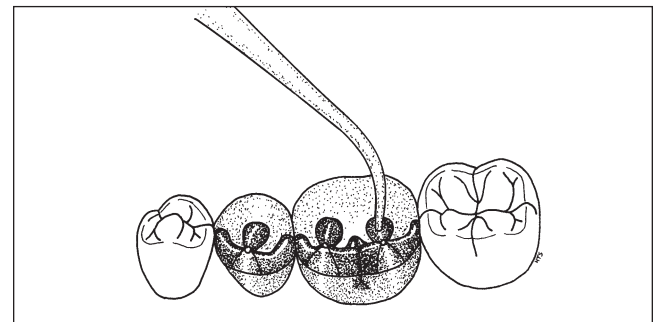


Fig 19-26 Triangular ridges: PKT no. 1.

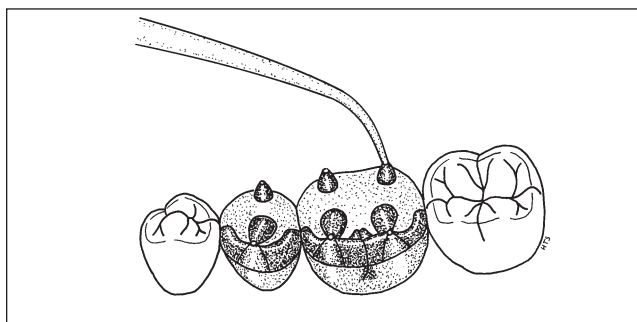


Fig 19-27 Cones for lingual cusps: PKT no. 1.

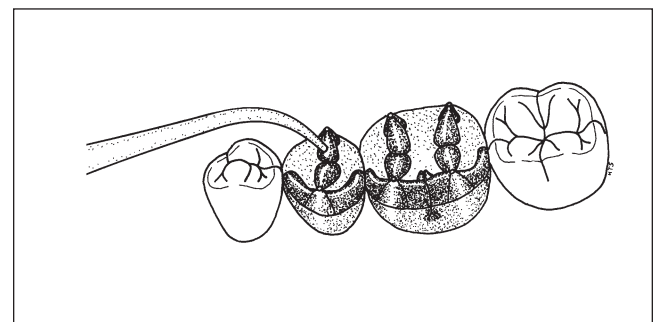


Fig 19-28 Triangular ridges: PKT no. 1.

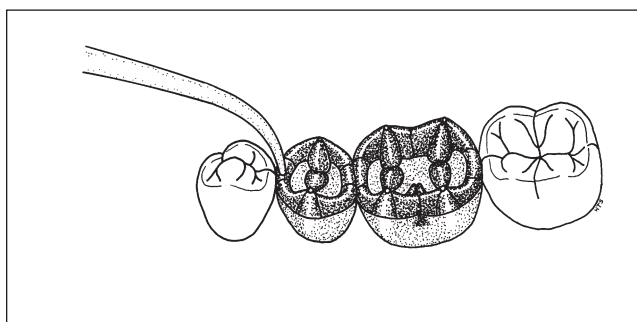


Fig 19-29 Marginal ridges: PKT no. 1.

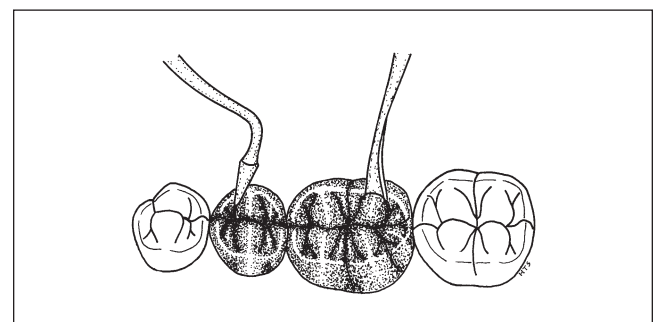


Fig 19-30 Supplemental anatomy: PKT nos. 3 and 5.

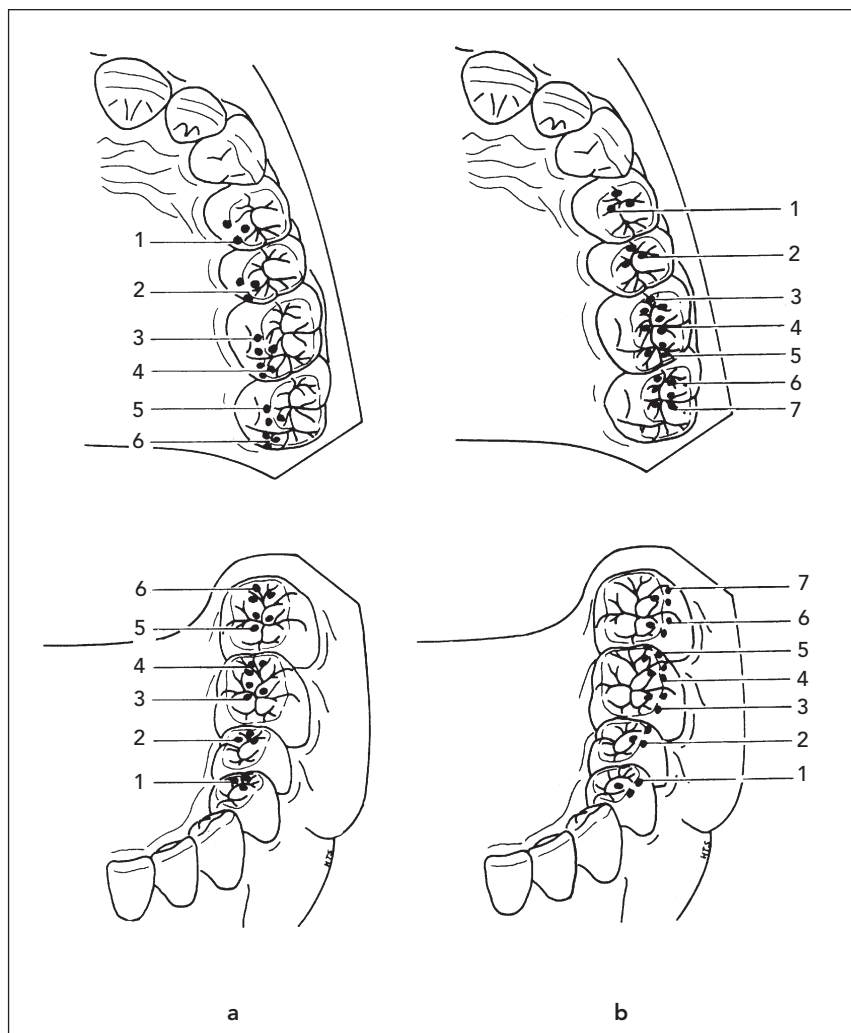


Fig 19-31 Cusp placement and occlusal contacts for a cusp-fossa occlusion: (a) contacts of maxillary lingual cusps on mandibular teeth; (b) contacts of mandibular cusps on maxillary teeth. The cusps and the matching areas of contact on the opposing teeth are numbered sequentially from anterior (1) to posterior (6 or 7).

Cusp-fossa arrangement

The cusp-fossa relation is an occlusal pattern in which each functional cusp is nestled into the occlusal fossa of the opposing tooth (Fig 19-31). It is a tooth-to-tooth arrangement. Although considered to be an ideal occlusal pattern, it is rarely found in its pure form in natural teeth.

Each centric cusp should make contact with the occlusal fossa of the opposing tooth at three points. The contact points are on the mesial and distal incline and the inner-facing incline of the cusp, producing a tripod contact. Because the cusp tip itself never comes in contact with the opposing tooth, the cusp tip can be maintained for a long time with a minimum of wear.

The mandibular functional cusps arise opposite the center (faciolingually) of the maxillary tooth. Similarly, the maxillary functional cusps are positioned halfway between the mandibular facial and lingual cusp tips. Therefore, occlusal forces are transmitted along the long axes of the teeth.

The functional cusps of the maxillary posterior teeth become slightly shorter as they progress distally. Nonfunctional cusps are made slightly shorter than functional cusps to ensure clearance in excursive movements. The nonfunctional cusps also become slightly shorter from anterior to posterior. The resulting anteroposterior curvature of the occlusal plane is called the *curve of Spee*. Presence of this feature in a reconstructed mouth helps to prevent protrusive interferences. The left-right curvature resulting from the nonfunc-

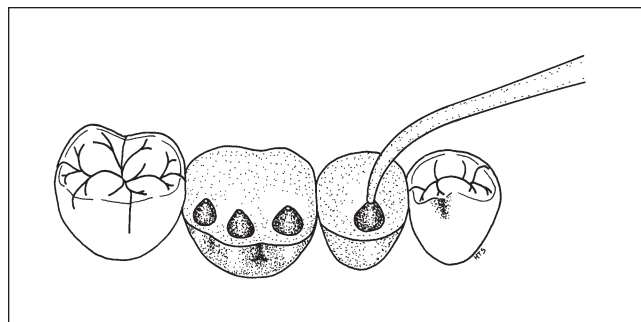


Fig 19-32 Cones for mandibular facial cusps: PKT no. 1.

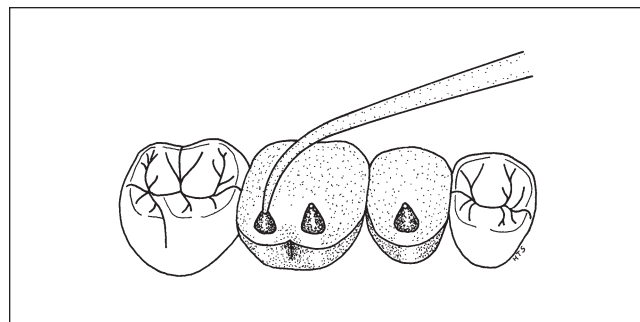


Fig 19-33 Cones for maxillary palatal cusps: PKT no. 1.

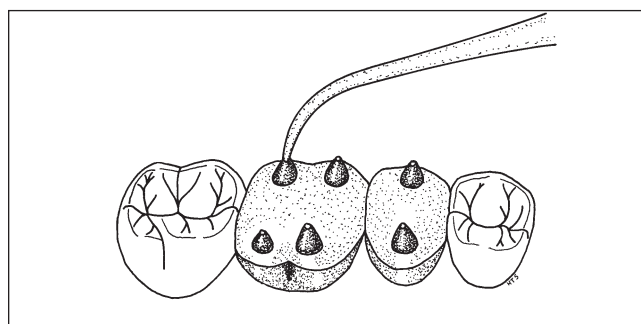


Fig 19-34 Cones for maxillary facial cusps: PKT no. 1.

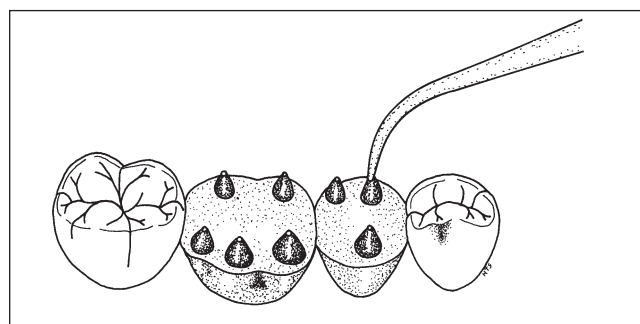


Fig 19-35 Cones for mandibular lingual cusps: PKT no. 1.

tional cusps being shorter than the functional cusps is the *curve of Wilson*. Its presence prevents interferences in lateral excursions.

The technique used for producing wax patterns with an exclusively cusp-fossa occlusion was developed by P. K. Thomas.³¹ The method, as described in the following pages, will develop a cusp-fossa relationship. It is important to keep in mind, however, that the same technique, using the same sequence of morphologic development, can be used with excellent results for developing a cusp-marginal ridge occlusal relationship. When the cusp-marginal ridge arrangement is the desired end result, cusp placement is altered slightly.

The development of a cusp-fossa occlusion is best accomplished by waxing two opposing quadrants simultaneously. Therefore, this description will present the waxing of maxillary and mandibular occlusal surfaces in a concurrent stepwise progression.

First, the functional cusps are located. The mandibular facial cusps will nestle in the fossae of the opposing maxillary teeth. To accomplish this, the cones for the mandibular facial cusps are placed with a PKT no. 1 instrument (Fig 19-32). They should be located at approximately one-third the distance from the facial to the lingual surface. They are posi-

tioned mesiodistally to fall into the appropriate fossae (see Table 19-2).

Then the cones for the maxillary palatal cusps are placed (Fig 19-33). They are positioned faciopalatally over the center of the opposing mandibular tooth. The mesiopalatal cusp cones on the maxillary molars should be located as far distally as possible. The distopalatal cones should have no contacts with opposing teeth.

Next, the nonfunctional cusps are placed. The maxillary facial cusp cones and the mandibular lingual cusp cones should be formed slightly shorter than the functional cusp cones (Fig 19-34). However, esthetic considerations should be given to the lengths of the facial cusp cones of the maxillary premolars. The mandibular lingual cusps are placed as far lingually and, on molars, as far from each other as possible (Fig 19-35). They are also shorter than the facial cusps.

When nonworking movements are induced, the mesio-palatal cusp cone of the maxillary molars should pass between the distal and the distofacial cones of the mandibular teeth. During lateral excursions to the working side, the facial cones of the maxillary premolars will pass distal to the facial cones of the mandibular premolars.

19 Wax Patterns

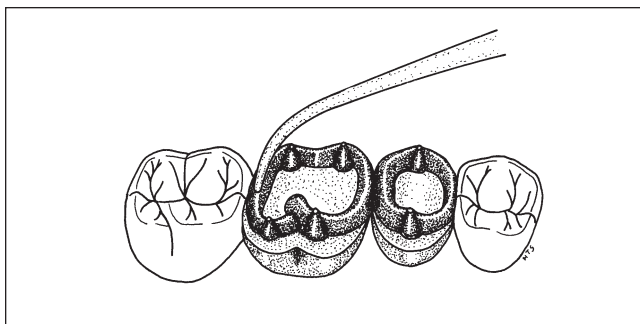


Fig 19-36 Maxillary marginal ridges and cusp ridges: PKT no. 1.

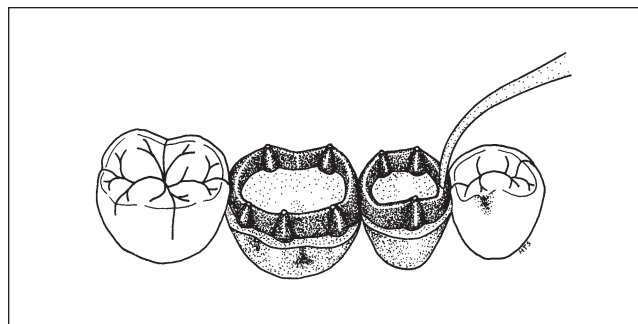


Fig 19-37 Mandibular marginal ridges and cusp ridges: PKT no. 1.

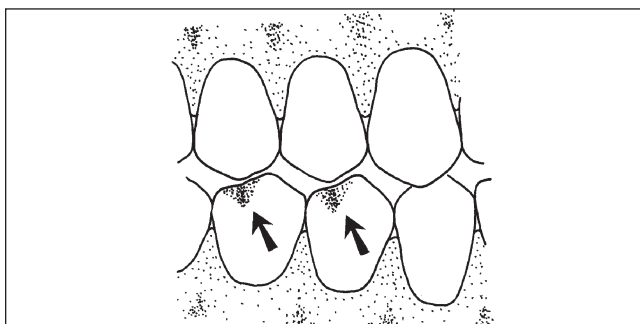


Fig 19-38 Concavities may have to be placed on the distal inclines of the facial cusps of mandibular premolars (arrows) to accommodate the free passage of the facial cusps of the maxillary premolars in a working-side excursion.

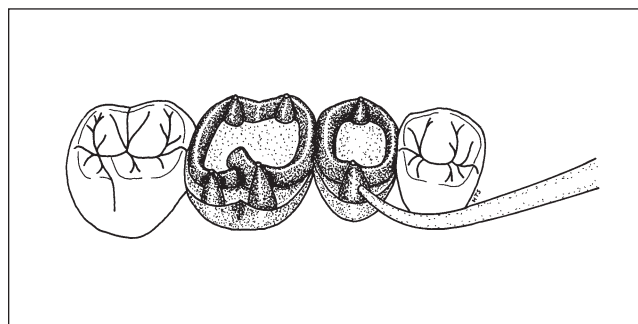


Fig 19-39 Maxillary palatal ridges: PKT no. 1.

The marginal ridges and cusp ridges (both mesial and distal) are added next, starting on the mesial of the maxillary teeth, with a PKT no. 1 (Fig 19-36). The highest points on the occlusal surfaces are the tips of the cusp cones. The marginal ridges should never be higher than the cusps. The mandibular cusp and marginal ridges are formed in a like manner, starting from the distal aspect (Fig 19-37). The cusp tips and the edges of the marginal ridges should be as sharp as possible. The faciolingual dimension of each occlusal table formed by the ridges should be approximately 55% of the overall faciolingual dimension of the respective tooth.

The occlusal surfaces are dusted with zinc stearate, and the casts are closed together on the articulator. The marginal ridges of opposing arches should be in close contact in the intercusp position. Care must be taken to avoid leaving spaces between the maxillary and mandibular teeth. The side being waxed is placed into both working and nonworking lateral excursions to remove any interferences.

During the working movement, the facial cusp of each maxillary premolar passes distal to the facial cusp of its counterpart in the mandibular arch. Therefore, it may be necessary to place a small depression in the distal incline of the facial cusp of the mandibular premolar to allow the facial cusp of the maxillary tooth to pass through easily without interference (Fig 19-38). This depression has been referred to as the *Thomas notch*.

In a working excursion, the mesiofacial cusp of a maxillary molar will pass through the facial groove, distal to the mesiofacial cusp of the mandibular molar. At the same time, the distofacial cusp of the maxillary molar will pass through the distofacial groove distal to the distofacial cusp of the mandibular molar. The lingual cusps of the mandibular molars must be short enough so that they will not collide with the cusps of the maxillary molars during the working movement.

The maxillary palatal ridges are waxed in to provide the silhouette of the final contour of the palatal surface (Fig 19-39). The facial cusp ridges are formed on the mandibular facial cusps in a similar manner (Fig 19-40). The PKT no. 1 is used to fill in any voids or discrepancies between the crest of the cusp ridges and the facial and palatal axial contours of the maxillary teeth. The contours are smoothed with a PKT no. 4 (Fig 19-41). The process is repeated on the mandibular teeth (Fig 19-42). This completes the "fish's mouth," so named because of the appearance of the cusp and marginal ridges at this point.

The triangular ridges for each of the cusps of the maxillary teeth are built up with the PKT no. 1 (Fig 19-43). The bases of these ridges will form the central groove of the occlusal surface. The bases should be broader than the apex (at the cusp tip), and the ridges should be convex to provide contact points with the opposing cusps. The process is repeated for the mandibular cusps (Fig 19-44). The occlusion is checked in the intercusp position and the excursions as well.

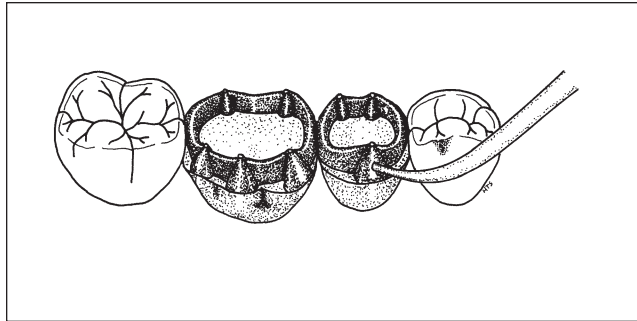


Fig 19-40 Mandibular facial ridges: PKT no. 1.

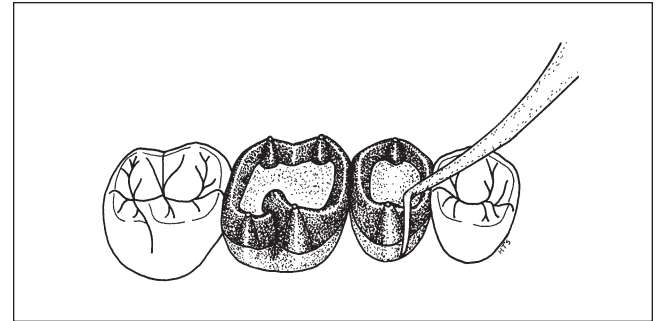


Fig 19-41 Smoothing maxillary axial contours: PKT no. 4.

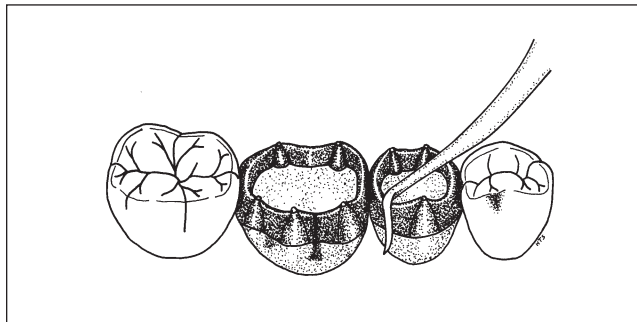


Fig 19-42 Smoothing mandibular axial contours: PKT no. 4.

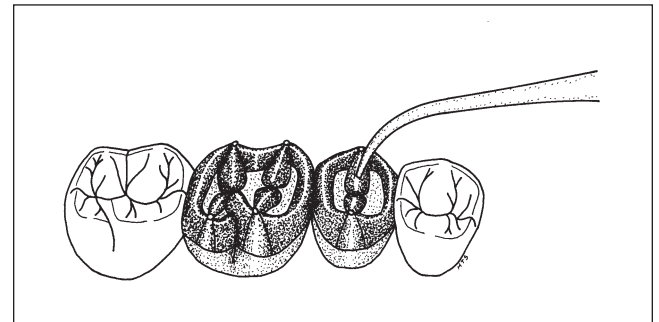


Fig 19-43 Maxillary triangular ridges: PKT no. 1.

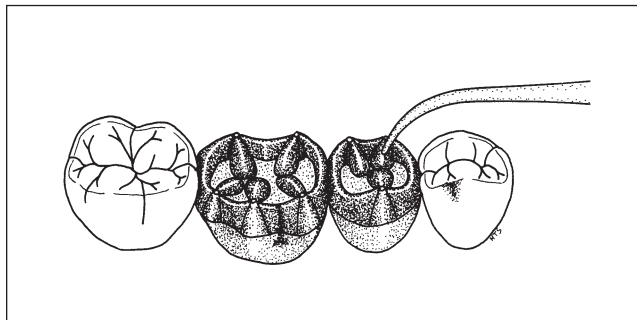


Fig 19-44 Mandibular triangular ridges: PKT no. 1.

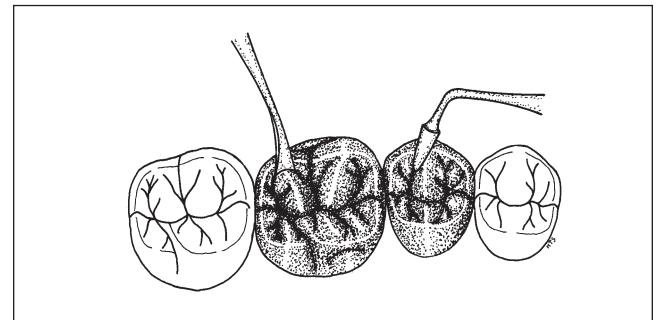


Fig 19-45 Maxillary supplemental anatomy: PKT nos. 3 and 5.

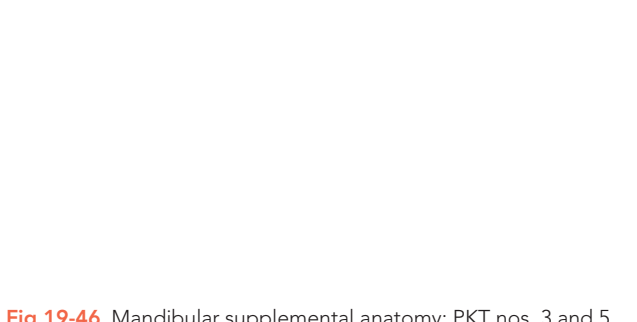


Fig 19-46 Mandibular supplemental anatomy: PKT nos. 3 and 5.

All voids remaining on the occlusal surface of the maxillary teeth are eliminated (Fig 19-45). Wax is placed with a PKT no. 2. Supplemental anatomy is formed by the junction between the triangular ridge and the adjacent cusp or marginal ridges. A PKT no. 5 is used to refine the ridges. The same

procedure is followed on the mandibular teeth (Fig 19-46). Developmental and supplemental grooves are formed in a combination of U and V shapes in cross section. The grooves are smoothed with a PKT no. 3. However, they should not be carved with this instrument.

19 Wax Patterns

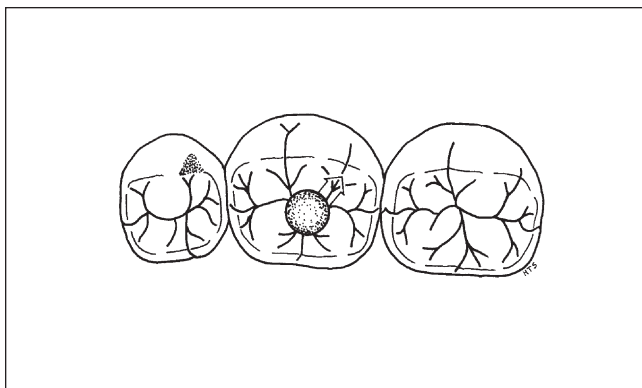


Fig 19-47 Path followed by the mesiopalatal cusp of a maxillary molar on the occlusal surface of a mandibular molar during a nonworking excursion.

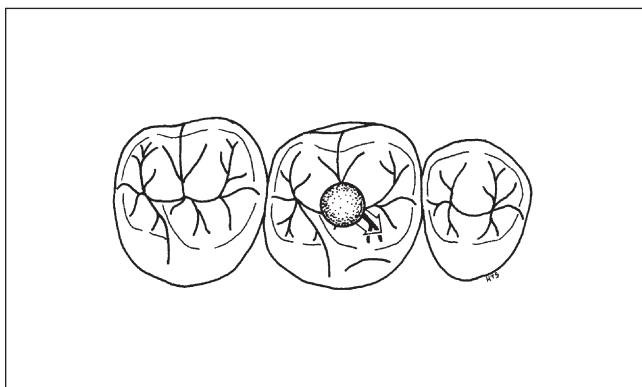


Fig 19-48 Path followed by the distofacial cusp of a mandibular molar on the occlusal surface of a maxillary molar during a nonworking excursion.

The wax patterns are dusted with zinc stearate, and the occlusal contacts are checked in the intercusp and excursive positions. Tripod contacts should be formed around the cusp tips and in the fossae.

In nonworking movement, the mesiopalatal cusp of a maxillary molar passes through the area distal to the distofacial cusp of the mandibular molar (Fig 19-47). Therefore, a notch or groove should be formed on the distal incline of the distofacial cusp. As a result, in a cusp-fossa occlusion, all mandibular molars are formed with three facial cusps.

At the same time, the distofacial cusp of the mandibular molar moves in a mesiolingual direction across the facial incline of the mesiopalatal cusp of the maxillary molar (Fig 19-48). This may produce a nonworking interference. To prevent such an interference, it is often necessary to place a groove on the mesiopalatal cusp of the maxillary molar. This groove, often referred to as *Stuart's groove*, begins in the central fossa and is directed mesiopalatally. It provides an escape path for the mandibular distofacial cusp in a nonworking movement.

Margin Finishing

The pattern is removed from the working cast and placed back on the freshly lubricated die, making certain that the red line on the die finish line is still distinct. Any roughness on the axial surfaces is smoothed with a slightly warm beavertail burnisher. The entire marginal periphery is remelted with a hot PKT no. 1, making sure that the wax is melted through to the die (Fig 19-49).

This will result in a depression or trough 1 to 2 mm wide and extending along the entire length of the marginal periphery of the wax pattern (Fig 19-50). The depression is eliminated by adding wax with a hot beavertail burnisher (Fig 19-51).

The excess wax is carved almost to the margin with a PKT no. 4 (Fig 19-52). Carving of the margin is finished with a warm beavertail burnisher (Fig 19-53). The instrument and the way in which it is used results in a combination of melting, burnishing, and carving of the margins.

The reader may, in time, develop a technique with specific instruments that differs from those above. One principle is of paramount importance: Do not approach the finish line on the die with a sharp instrument. Any sharp instrument that can remove die material as the wax margins are carved will produce a casting that will not fit the prepared tooth.

The margin is a critically important area of any wax pattern. While a good margin may not ensure the success of a casting, a poor one can almost guarantee its failure.

The margin should be checked carefully for the following discrepancies:

1. *Overwaxed margins.* Areas in which wax has been carried past the finish line may break off when a pattern is withdrawn from the die, resulting in a short, or "shy," margin. If the overwaxed area does not break during withdrawal of the pattern, it may spring back. When cast in metal, this area will no longer bend as it once did in wax, and the casting may be prevented from seating all the way on the tooth.
2. *Short margins.* A margin that is not waxed all the way to the red finish line will not provide an adequate seal for the finished restoration.
3. *Ripples.* Any roughness in the wax near the margin will be duplicated in the casting. If allowed to remain on the finished, cemented restoration, these rough areas will serve as a collecting point for plaque and may lead to irritation and inflammation of the adjacent gingival tissues. Removal of these irregularities should not be delayed until after the casting has been made because their elimination at that time frequently entails an undesirable change in contour.
4. *Thick margins.* A thick, rounded margin will result in poor sealing of the restoration and poor axial contours that will ultimately cause periodontal problems. The margin of a wax pattern must come to a fine edge.
5. *Open margins.* The open margin is a gremlin that haunts the wax pattern. It can be the result of any of the previ-

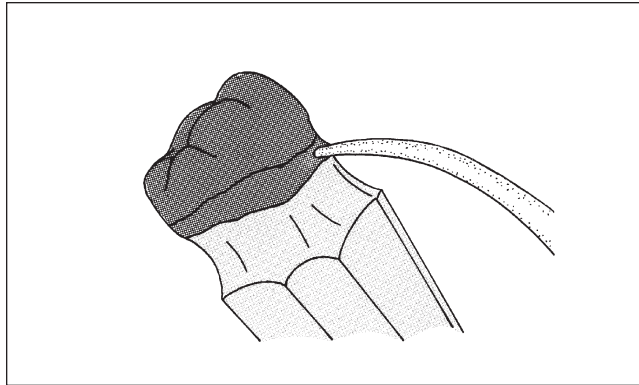


Fig 19-49 Margin is remelted with a PKT no. 1.

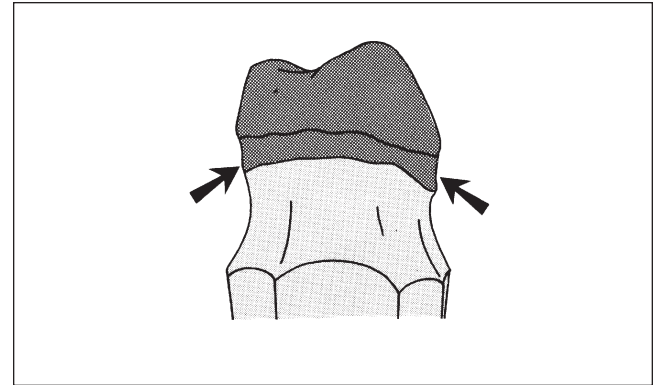


Fig 19-50 A depression (arrows) remains near the margin.

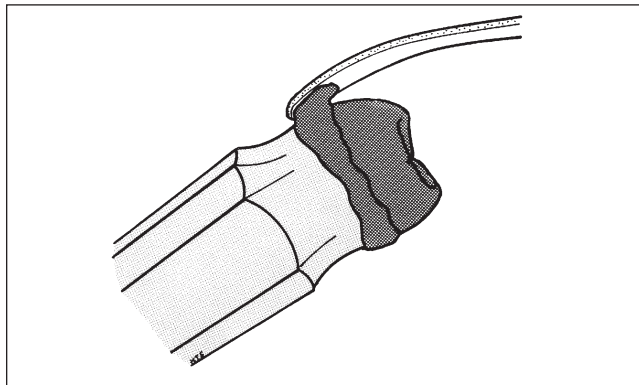


Fig 19-51 Wax is added to the margin with a beavertail burnisher.

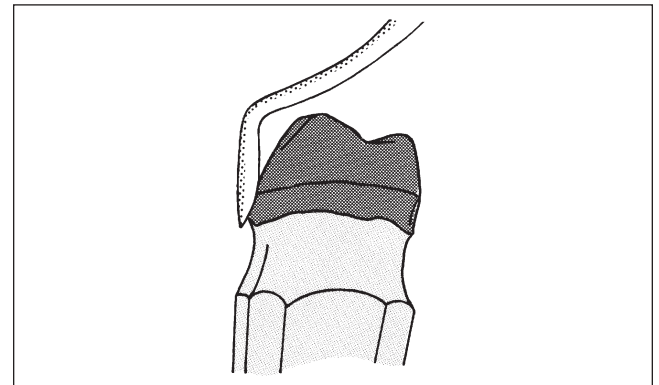


Fig 19-52 Excess wax is removed with a PKT no. 4.

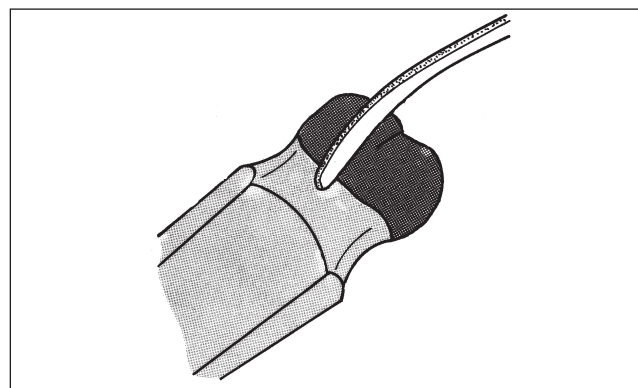


Fig 19-53 Margins are finished with a beavertail burnisher.

19 Wax Patterns



Fig 19-54 Finished margin is viewed from an "apical" direction.

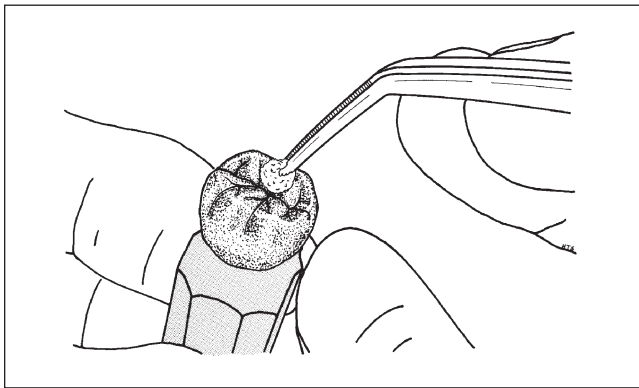


Fig 19-55 Grooves are finished with a cotton pellet.

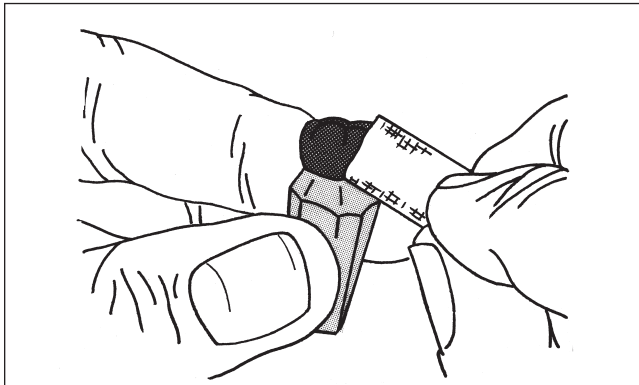


Fig 19-56 Axial surfaces are smoothed with a cotton roll dipped in die lubricant.

ously mentioned problems. Attention to detail is essential to produce closed margins. The wax pattern margins must be burnished and melted, as well as cut, to ensure close adaptation of the wax to the die in the marginal area.

For careful inspection of the margin, the die is turned so that the margin can be viewed from an "apical" direction (Fig 19-54). This is one of the great advantages of the in-

direct technique. A properly trimmed die will aid in this inspection, just as it facilitated access to the margin during the marginal adaptation phase.

To finish the occlusal grooves, a very small cotton pellet is held in cotton pliers and dipped in the die lubricant. The pellet is run carefully through the grooves with the cotton pliers (Fig 19-55). Caution must be exercised to avoid destroying the occlusal contacts so painstakingly developed in the waxing phase.

To finish the axial surface, a cotton roll, one end of which has been dipped in die lubricant, is used (Fig 19-56). This end is rubbed across the surfaces to be smoothed. The dry end of the roll is buffed across the wet wax until a smooth surface is obtained. Excessive or prolonged buffing action should not be employed near the margins because they would be destroyed in the process. All lubricant should be removed from the pattern when polishing is completed. Any lubricant left on the pattern when it is invested can cause surface roughness in the casting.

Depressions cannot be polished away. They can be removed only by eliminating the material around the depression, resulting in a change in contour. However, depressions are better removed by filling them with wax and then smoothing them.

The purpose of finishing is to provide a smooth surface for casting. Tricks employed to polish the surface only serve to highlight the irregularities they seek to cover. The ultimate goal is a truly smooth surface—not a highly polished, irregular one. With a good investing and casting technique, the casting should be quite smooth and will require a minimum of finishing. Wax is softer than metal. Anything that can be done in wax, as opposed to creating it later in metal, should be done. In wax, anything can be done in a fraction of the time, with less effort, and with better results.

Functionally Generated Path Technique

The functionally generated path technique is an alternative way of forming the occlusal surface of a wax pattern or porcelain restoration. Rather than employing an articulator to simulate the movement of the mandible, this technique uses a tracing made in the mouth to capture the pathways traveled by the opposing cusps in mandibular function. In this situation, the articulator is reduced to the role of a simple hinge.

The functionally generated path technique relies on recording in a simple yet precise manner the pathways traveled by the cusps in the border movements of the mandible. Wax is adapted over the occlusal surface of the prepared tooth. The patient closes into an intercuspal position and moves the mandible through all excursions. By this process, the tips of the opposing cusps act as recording styli that carve, in three dimensions in wax, a record of the border movements in all mandibular positions.³² Stone is brushed

and poured onto the wax record in the mouth to produce a functional core. The stone core is then utilized in the fabrication of posterior tooth restorations.

This method was first described by Meyer as a means of obtaining the "functional occlusal path" for partial dentures fabricated by a direct/indirect technique³³ and for complete dentures.³⁴ At one time it was identified quite strongly with bilateral balanced occlusion, but it is also possible to use the technique to obtain a unilateral balanced occlusion or a mutually protected occlusion.

The technique does have the advantage of permitting simple, inexpensive instrumentation for single-tooth restorations. This constitutes an appropriate use for the straight line articulator.^{35,36} It demands a minimum of chair time, especially during the try-in and cementation phase.³⁷

The technique perpetuates existing occlusion, good or bad. Therefore, a prerequisite for the use of this technique for the restoration of a single tooth is the presence of an optimal occlusion. Correct anterior guidance must be present, and there must be an absence of posterior interferences when the restoration is made. If there are any interferences, they will guide the mandible and help perpetuate the occlusal discrepancy. There can be no missing or deteriorated opposing teeth. Badly rotated, carious, or poorly restored teeth will not provide the occlusal pathways needed for shaping the occlusal surface.

References

1. Phillips RW, Skinner EW. *Skinner's Science of Dental Materials*, ed 9. Philadelphia: Saunders, 1991:387.
2. Weiss PA. New design parameters: Utilizing the properties of nickel-chromium superalloys. *Dent Clin North Am* 1977;21:769-785.
3. el-Sherif MH, Shillingburg HT Jr, Smith KS. A plastic shell technique for fabricating porcelain-fused-to-metal coping patterns. *Quintessence Dent Technol* 1987;11:383-388.
4. Dumais MH. Use of polypropylene copings to simplify the waxing procedure for mesio-occlusodistal and partial veneer crowns. *Quintessence Int* 1990;21:897-902.
5. Dumais MH. Using polypropylene copings to simplify the laboratory phase of making pin-retained castings. *QDT Yearbook* 1988;12:135-139.
6. Burch JG, Miller JB. Evaluating crown contours of a wax pattern. *J Prosthet Dent* 1973;30:454-458.
7. Skurow HM, Lytle JD. The interproximal embrasure. *Dent Clin North Am* 1971;15:641-647.
8. Tjan AHL, Freed H, Miller GD. Current controversies in axial contour design. *J Prosthet Dent* 1980;44:536-540.
9. Burch JG. Ten rules for developing crown contours in restorations. *Dent Clin North Am* 1971;15:611-618.
10. Morris ML. Artificial crown contours and gingival health. *J Prosthet Dent* 1962;12:1146-1156.
11. Jordan RE, Abrams L, Kraus BS. *Kraus' Dental Anatomy and Occlusion*, ed 2. St Louis: Mosby, 1992:265.
12. Stein RS, Kuwata M. A dentist and a dental technologist analyze current ceramo-metal procedures. *Dent Clin North Am* 1977;21:729-749.
13. Croll BM. Emergence profiles in natural tooth contour. Part I: Photographic observations. *J Prosthet Dent* 1989;62:4-10.
14. Koidis PT, Burch JG, Melfi RC. Clinical crown contours: Contemporary view. *J Am Dent Assoc* 1987;114:792-795.
15. Croll BM. Emergence profiles in natural tooth contour. Part II: Clinical considerations. *J Prosthet Dent* 1990;63:374-379.
16. Parkinson CF. Excessive crown contours facilitate endemic plaque niches. *J Prosthet Dent* 1976;35:424-429.
17. Ash MM, Wheeler RC. *Wheeler's Dental Anatomy, Physiology, and Occlusion*, ed 7. Philadelphia: Saunders, 1993:119.
18. Herlands RE, Lucca JJ, Morris ML. Forms, contours, and extensions of full coverage restorations in occlusal reconstruction. *Dent Clin North Am* 1962;6:147-162.
19. Hazen SP, Osborne JW. Relationship of operative dentistry to periodontal health. *Dent Clin North Am* 1967;11:245-254.
20. Perel ML. Periodontal considerations of crown contours. *J Prosthet Dent* 1971;26:627-630.
21. Yuodelis RA, Weaver JD, Sapkos S. Facial and lingual contours of artificial complete crown restorations and their effects on the periodontium. *J Prosthet Dent* 1973;29:61-66.
22. Ehrlich J, Hochman N. Alterations on crown contour—Effect on gingival health in man. *J Prosthet Dent* 1980;44:523-525.
23. Sackett BP, Gildenhuys RR. The effect of axial crown overcontour on adolescents. *J Periodontol* 1976;47:320-323.
24. Jameson LM, Malone FP. Crown contours and gingival response. *J Prosthet Dent* 1982;47:620-624.
25. Sorensen JA. A rationale for comparison of plaque-retaining properties of crown systems. *J Prosthet Dent* 1989;62:264-269.
26. Perel ML. Axial crown contours. *J Prosthet Dent* 1971;25:642-649.
27. Wagman SS. The role of coronal contour in gingival health. *J Prosthet Dent* 1977;37:280-287.
28. Huffman RW. Occlusal morphology. In: Guichet NF. *Procedures for Occlusal Treatment—A Teaching Atlas*. Anaheim, CA: Denar, 1969:98.
29. Lundeen HC. *Introduction to Occlusal Anatomy*. Lexington, MA: Lexington Books, 1969.
30. Shillingburg HT Jr, Kaplan MJ, Grace CS. Tooth dimensions—A comparative study. *J South Calif Dent Assoc* 1972;40:830-839.
31. Thomas PK. *Syllabus on Full Mouth Waxing Technique for Rehabilitation*. San Diego: Instant Printing Services, 1967.
32. Zimmerman EM. Modifications of functionally generated path procedures. *J Prosthet Dent* 1966;16:1119-1126.
33. Meyer FS. Cast bridgework in functional occlusion. *J Am Dent Assoc* 1933;20:1015-1030.
34. Meyer FS. A new simple and accurate technique for obtaining balanced and functional occlusion. *J Am Dent Assoc* 1934;21:195-203.
35. Meyer FS. Can the plane line articulator meet all the demands of balanced and functional occlusion in all restorative work? *J Colo Dent Assoc* 1938;17:6-16.
36. Meyer FS. The generated path technique in reconstruction dentistry. Part II. Fixed partial dentures. *J Prosthet Dent* 1959;9:432-440.
37. Benfield JW. Advantages of functional bite technic in reducing chair time. *N Y J Dent* 1962;32:296-297.

Investing and Casting

Arriving at a completed casting after fabrication of a wax pattern involves three steps: (1) investing—surrounding the wax pattern with a material that can accurately duplicate its shape and anatomical features, (2) burnout—removal of the wax pattern so that a mold is created into which the molten alloy can be placed, and (3) casting—introducing the molten alloy into the previously prepared mold. The apparent simplicity of the above steps may belie their importance in obtaining accurately fitting castings. Few experiences in dentistry are more frustrating than having finished a casting that will not fit and therefore cannot be used in the patient's mouth.

Dental Casting Alloys

A brief review of the alloys used for casting restorations should aid in an understanding of the laboratory procedures employed to obtain well-fitting castings. Many different classification systems have been devised for the alloys used in dentistry, based on either noble metal content (noble, semi-noble, base), cost (precious, semiprecious, nonprecious), or physical properties (types I to IV).

Alloys of the noble metals (gold, platinum, and palladium) with additional silver, copper, and zinc have been used for cast restorations since the introduction of the lost wax technique to dentistry around the turn of the 20th century. There is evidence that Philbrook first described the lost wax method in 1897.¹ However, Taggart is generally credited with introducing the technique to the profession in 1906¹⁻³ because he seemed to appreciate the significance of the idea and expended considerable time and effort in developing it.¹

The most widely used alloy for cast all-metal restorations contains approximately 75% gold and is therefore designated as 18-karat gold, which means that it is $\frac{18}{24}$ pure. The noble metals impart tarnish resistance and ductility to dental alloys, silver lightens the color and adds ductility, copper increases the hardness and strength, and zinc reduces oxidation.⁴

Noble alloys are gold and members of the platinum group, which include platinum, palladium, rhodium, iridium, osmium, and ruthenium. The noble alloys are sometimes referred to as *precious metals*, but the terms are not synonymous.

The term *precious* alludes to the cost of the metal, while *noble* refers to its chemical behavior.⁵ The elements gold and platinum happen to be both noble and precious. Palladium is noble but is much less expensive. At times, silver has gained enough in value to approach the classification of precious, but it tarnishes and is not a noble metal.

The American Dental Association (ADA) and Identallloy Classification System for Noble Dental Alloy^{6,7} has been adopted for the purpose of filing claims with third-party payers. This classification is as follows:

- *High-noble alloys* have a noble metal content of 60% or greater. At least 40% of the alloy must be gold.
- *Titanium and titanium alloys* must be at least 85% titanium.
- *Noble alloys* must be at least 25% noble metal.
- *Predominantly base alloys* have a noble metal content of less than 25%.

Often the major constituents of an alloy will be used to describe it (eg, gold-palladium, silver-palladium, nickel-chromium).

From 1934 to 1968, the US government maintained the price of gold at \$35 an ounce. Since this price control has ended, the price of gold has risen greatly on the world market, creating increasing pressure to use alloys that cost less. Semiprecious (seminoble, economy) alloys meet this requirement. They include the silver-palladium alloys and all alloys that contain more than 10% and less than 75% gold.⁸

The mechanical properties and handling characteristics of semiprecious alloys are much like those of standard gold alloys. However, lower noble metal content is associated with greater corrosion. Many of the alloys with lower gold content can be used with the same investments and with similar casting techniques as alloys with higher gold content. Silver-palladium alloys melt at slightly above 2,000°F (1,090°C) and therefore can only be melted with gas-oxygen torches or electric induction casting machines. The higher silver content of these alloys precludes their use for metal-ceramic restorations.⁹

Palladium-silver alloys require electric induction casting.⁹ They are more commonly used in dentistry because they are superior to silver-palladium alloys in yield strength, corrosion resistance, elastic modulus, and hardness. The higher elastic modulus of palladium-silver alloys makes these noble alloys useful for longer-span metal-ceramic fixed partial dentures.⁹

20 Investing and Casting

A steep rise in the cost of the noble metals and silver in 1973–1974 led to a widespread interest in base metal alloys, which are also referred to as *nonprecious* or *non-noble*. A logical transition was the adaptation of materials similar to those already in common usage for the fabrication of removable partial denture frameworks. These alloys possess desirable properties such as low cost, increased strength and hardness, higher fusion temperature, and less distortion during porcelain firing. They have been promoted for use in all-metal crowns, metal-ceramic crowns, long-span fixed partial dentures, and resin-bonded fixed partial dentures. There are several formulas utilizing nickel, chromium, and cobalt, with nickel-chromium alloys being the most popular. In the absence of noble metals, these alloys achieve their tarnish resistance in the mouth by formation of a surface monolayer of chromium oxide.¹⁰

Disadvantages of nickel-chromium alloys include possible excessive oxide formation, difficulty in finishing and polishing, and questionable biocompatibility. Beryllium is a common component of some alloys, added to limit oxide formation and improve castability. It has been identified as a potential carcinogen¹¹ and poses a potential hazard to laboratory personnel who might inhale beryllium or beryllium compounds as dust if appropriate precautions are not observed.¹² Beryllium concentration at the surface of the casting is far out of proportion to the percentage of beryllium in the rest of the casting, and the beryllium and nickel each potentiate the dissolution of the other in an acidic solution.¹³ Occlusal wear as well as dissolution can be a factor in the release of nickel and beryllium in an artificial oral environment.¹⁴ The extent of ingestion of the dissolved beryllium is unknown, but it is thought to be cumulative.¹³ Its long-term effects, if any, are not known.

Nickel is capable of eliciting an allergic response from sensitive individuals. It produces more cases of allergic dermatitis than do all other metals combined.¹⁵ Approximately 4.5% of the general population demonstrate a sensitivity to nickel, with a reaction being 10 times more likely to occur in women than in men.¹⁶ Therefore, the use of nickel-chromium restorations is definitely contraindicated for patients with a known sensitivity to nickel. However, a retrospective study of 915 cast restorations in 335 patients found no higher rate of adverse responses of the mucosa around cemented base-metal restorations than around restorations made of gold alloys.¹⁷

An argument can be made for caution in adopting newer low-cost alloys. Even if no actual harm comes to the patients, there is always the danger that the news media will seize upon isolated reports of health hazards as they have with amalgam in the US and palladium-copper alloys in Europe.¹⁸ The prospect of frightened patients demanding removal of previously placed restorations should make dentists think long and hard about utilizing untried alloys. At today's prices, the cost of the alloy in a crown, even if it has a high noble metal content, constitutes a relatively minor part of the fee to the patient.

Base metal alloys also present a challenge to both dentists and dental technicians because of the many ways in which

they differ from gold alloys in physical properties, handling characteristics, and fabrication techniques. Because of the presence of high-fusing elements, these alloys have a much higher melting temperature (2,300°F to 2,600°F, or 1,260°C to 1,430°C).¹⁹ This necessitates the use of a multiorifice gas-oxygen torch and phosphate-bonded investment with a high-heat burnout (1,500°F to 1,700°F, or 815°C to 930°C).²⁰ It has been reported that more consistent castings can be obtained through the use of induction casting, which requires the use of expensive equipment.²¹ The yield strength for nickel-chromium alloys can be as low as 260 MPa (37,700 psi), but the majority of them are above 517 MPa (75,000 psi), and many exceed 690 MPa (100,000 psi). This is much higher than the 207- to 275-MPa (30,000- to 40,000-psi) yield strength of Firmilay (Jelenko), a type III gold. The percent elongation is also high, with many alloys exceeding 25%.¹⁹ However, the ability to manipulate the alloy is limited by the great force required to effect deformation (as evidenced by the high yield strength).

Titanium and its alloys have attracted great interest in recent years as alternatives to gold. Titanium's great biocompatibility has been proven through its widespread use as an implant material. Although chemically active and therefore non-noble, it rapidly forms a thin, inert oxide layer when exposed to air. Among its other advantages are low cost, low thermal conductivity, and capability of bonding to resin cements²² and to porcelain.²³ Its principal drawback is the difficulty in making castings. Pure titanium melts at 3,035°F (1,668°C) and reacts readily with conventional investments and oxygen. Therefore, it must be cast and soldered with special equipment in an oxygen-free environment. New alloys of titanium with nickel that can be cast by more conventional methods are being developed. These are reported to release very little ionic nickel and bond well to porcelain.²³ New methods of forming titanium crowns and copings by computer-aided design/computer-assisted manufacture (CAD/CAM) technology avoid the problems of casting altogether.^{7,24}

For many years, dental alloys were classified by the ADA according to physical properties and noble metal content as either type I, II, III, or IV. The American National Standards Institute (ANSI)/ADA specification no. 5 for dental casting alloys was revised in 1988, dropping reference to composition because of the successful use of a great number of new alloys with little or no noble metal content.²⁵ Yield strength and elongation are still specified for the four types, but now an alloy's composition, hardness, and melting range are only required to be within a certain percentage of that stated by the manufacturer.

The specification calls for type III alloys to have a yield strength between 200 and 340 MPa and an elongation of at least 12% in the annealed state. The percent of elongation is a measurement of ductility and determines how well margins can be closed by burnishing. An alloy of a lower type (eg, type I) will be softer, more burnishable (higher percent elongation), and weaker (lower yield strength) than an alloy of a higher type (eg, type IV). Type I alloys are recommended for small inlays; type II for larger inlays and onlays; type III for

onlays, crowns, and short-span fixed partial dentures; and type IV for thin veneer crowns, long-span fixed partial dentures, and removable partial dentures.

Independent of these classifications, special alloys are required for veneering with porcelain. They vary widely in their composition, and they also may be classified as either high-noble, seminoble, or base metal alloys. They share the unique requirements of having a fusion temperature 300°F to 500°F (165°C to 280°C) higher than that of porcelain, a coefficient of thermal expansion near that of porcelain, and the ability to form an oxide layer that will provide a strong bond to porcelain. They all tend to have a higher yield strength and lower percent elongation than type III gold.¹⁹

The ultimate choice of an alloy will depend on a variety of factors, including cost, rigidity, castability, ease of finishing and polishing, corrosion resistance, compatibility with specific brands of porcelain, and the personal preferences of both the dentist and the technician fabricating the restoration.

Investment Materials

An investment must fulfill three important requirements:

1. It must precisely reproduce the detailed form of the wax pattern.
2. It must provide sufficient strength to withstand the heat of burnout and the actual casting of the molten metal.
3. It must expand sufficiently to compensate for the solidification shrinkage of the alloy.

Shrinkage compensation

Of great importance in the investing of wax patterns is the fact that the molten alloys used for dental restorations shrink upon solidification: gold alloys by approximately 1.5%²⁶ and nickel-chromium alloys by as much as 2.4%.¹⁰ If the mold is not made correspondingly larger than the original wax pattern, the resultant casting will be that much smaller. For inlays and cast dowel cores, which are intracoronal and intraradicular, respectively, a slight net shrinkage is acceptable. However, if the restoration is a crown, which is extracoronal, net shrinkage may prevent it from seating completely on the tooth preparation. For crowns, therefore, it is necessary to compensate for the solidification shrinkage of the specific alloy used by expanding the mold enough to at least equal the shrinkage.

There are four mechanisms that can play a role in producing an expanded mold: (1) setting expansion of the investment, (2) hygroscopic expansion, (3) wax pattern expansion, and (4) thermal expansion. Regardless of which technique is employed, a precise routine for investing, burning out, and casting must be adhered to in order to achieve consistent results.

Setting expansion

Setting expansion of the investment occurs as a result of normal crystal growth. The expansion probably is enhanced by silica particles in the investment interfering with the forming crystalline structure of the gypsum, causing it to expand outward.²⁷ This type of expansion in air is normally about 0.4%, but expansion is partially restricted by the metal investment ring.

Hygroscopic expansion

Hygroscopic expansion may be employed to augment normal expansion. The investment is allowed to set in the presence of water, producing additional expansion.^{28,29} Hollenback³⁰ reported that maximum expansion could be achieved by immersing an investment-filled ring in a 100°F (38°C) water bath. This often has been interpreted as being due to hygroscopic expansion of the investment. It has been theorized that the water in which the investment is immersed replaces the water used by the hydration process. This maintains the space between the growing crystals, allowing them to continue expanding outward rather than restricting them.²⁹

Hygroscopic expansion ranges from 1.2% to 2.2%.²⁷ More controlled amounts of hygroscopic expansion may be achieved by adding a measured amount of water to the setting investment.³¹ Hygroscopic expansion does occur in an unrestricted trough or an expandable investment ring.^{28,29} However, in a lined, rigid, metal ring, the expansion attributed to hygroscopic expansion is more likely due to expansion of the wax pattern caused by the elevated temperature of the water in which the pattern has been immersed.³²

Wax pattern expansion

Expansion of the wax pattern while the investment is still fluid occurs when the wax is warmed above the temperature at which it was formed. The heat may come from the chemical reaction of the investment or from a warm water bath in which the ring is immersed. Invested wax patterns allowed to set under water at room temperature actually exhibit slightly less expansion than do those that set in air at the same temperature, whereas invested patterns that set at 100°F without immersion in water expand just as much as those that set under water at the same temperature.³²

The low-temperature burnout technique employs a combination of wax pattern expansion and thermal expansion of the mold. After the investment-filled ring is removed from a 100°F (38°C) water bath, the ring is heated to only 900°F (482°C) before casting to produce the additional expansion needed.

Thermal expansion

Thermal expansion of the investment occurs when the investment is heated in the burnout oven. Heating of the mold also serves to eliminate the wax pattern and to prevent the

20 Investing and Casting

alloy from solidifying before it completely fills the mold. The high-temperature burnout technique relies primarily on thermal expansion of the mold. The investment around the wax pattern is allowed to harden in air at room temperature, and then it is heated to approximately 1,200° F (650°C). At this temperature, the investment and metal ring expand enough to compensate for the shrinkage of the gold alloy.

Types of Investments

Two kinds of investments are in common usage for the fabrication of cast restorations: Those bonded with gypsum are used for alloys that fuse below 1,975°F (1,080°C), and those bonded with phosphate are used for higher-fusing alloys. The two types of investment are incompatible with each other, so mixing bowls used for one should not be used for the other. The manufacturer's instructions for a particular brand should be followed.

Gypsum-bonded investments

The gypsum-bonded investments are used with types I, II, and III gold alloys. These investments are themselves classified as type I for use with the high-temperature technique or type II for the low-temperature technique. After setting, both types of investment are composites containing a matrix of gypsum with silica as a refractory filler and certain chemical modifiers. The gypsum matrix, a calcium sulfate hemihydrate, comprises 30% to 35% of the investment and acts as a binder. The refractory material, either quartz or cristobalite, makes up 60% to 65% of the investment and provides the thermal expansion for the investment.³³

The rigid metal ring in which setting takes place must be lined with a compressible material to allow setting expansion to occur in a radial direction. Expansion can be controlled to some extent by varying the thickness of the liner.³⁴ Thermal expansion is achieved in the burnout oven through the normal expansion that occurs upon heating the silica (quartz and cristobalite), as well as through phase changes that occur in the material.

Investing armamentarium

- 200-mL Vac-U-Spat (Whip Mix) bowl and lid
- Vacuum tubing
- Vac-U-Vestor (Whip Mix)
- Rubber crucible former
- Casting ring (32-mm diameter)
- Plastic water measure
- Spatula
- P. K. Thomas (PKT) waxing instruments (nos. 1 and 4) (Osung)
- Cotton pliers
- Bunsen burner
- Matches

- Sticky wax
- Sprue formers (hollow plastic)
- One package (50 g) of investment
- 4-inch (10-cm) strip of cellulose ring liner

Sprue former attachment

The sprue former is a small-diameter pin or tube made of wax, plastic, or metal. A 10-gauge (2.6-mm-diameter) sprue former can be used on most patterns, while the 12-gauge (2.0-mm-diameter) sprue former is used on small premolar patterns. One end of the sprue former is attached to the wax pattern and the other end to the crucible former (a conical rubber base). After the investment has hardened, the crucible former is removed from the ring, leaving a funnel-shaped entrance to the mold. The channel left by the sprue former following burnout is the sprue, an inlet for the gold that will be forced into the mold. A sprue former as large as possible should be used on each pattern.³⁰ If the sprue is too thin or too long, the gold may solidify in the sprue before it does in the larger cavity formed by the wax pattern. If this happens, molten gold cannot be drawn from the reservoir ("button") as the casting solidifies, and shrink-spot porosity will occur in the bulkiest part of the casting.

The sprue former should be attached to the wax pattern at its point of greatest bulk, avoiding centric occlusal contacts if possible. It is attached at an angle to allow the incoming gold to flow freely to all portions of the mold (Fig 20-1). If the sprue is directed at a right angle to a flat wall of the mold, a "hot spot" may be created at that point, or mold erosion may occur. This will keep the alloy adjacent to it molten after the rest of the casting has solidified, causing suck-back porosity.²⁷ Uneven expansion of the mold and entrapment of air bubbles in the occlusal fossae may also result from this position of the sprue.

A hollow plastic sprue former is selected and placed inside the crucible former and casting ring for measurement. The sprue former should be just long enough so that the highest point on the wax pattern will be 6.0 mm from the end of the ring. If the pattern is too close to the end of the ring, the molten alloy may blast through the investment during casting; if it is too far, gases may not escape rapidly enough to permit complete filling of the mold with alloy. The sprue former is removed from the crucible former and shortened with a sharp knife if necessary.

If the hole in the crucible former is too large to firmly grasp the sprue former, the hole should be filled with soft wax. With a PKT no. 1 instrument, a small bead of pliable sticky wax is dropped onto the proposed site of attachment on the pattern. The sprue former is placed into the molten bead of sticky wax. If the wax is hot enough, a small amount will be drawn into the lumen of the sprue by capillary action. This creates a strong union between sprue former and pattern, provided there is no movement as the wax hardens.

The sticky wax is melted around the sprue former-wax pattern junction with the PKT no. 1 instrument to provide a smooth conduit for the molten alloy (Fig 20-2). The wax pattern should not be exposed to prolonged heat during this

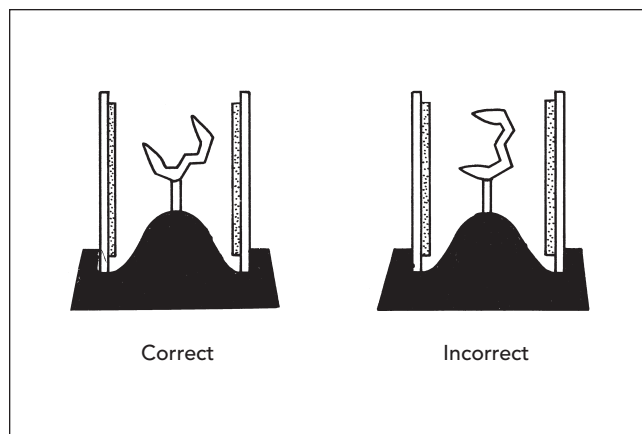


Fig 20-1 Sprue placement on the wax pattern and orientation of the pattern in the ring.

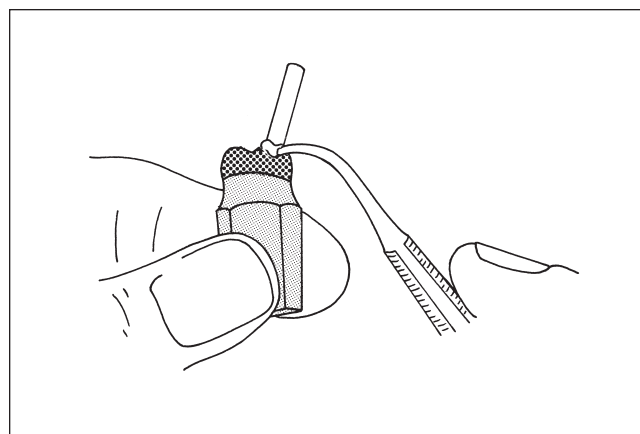


Fig 20-2 Attachment of the sprue to the wax pattern.

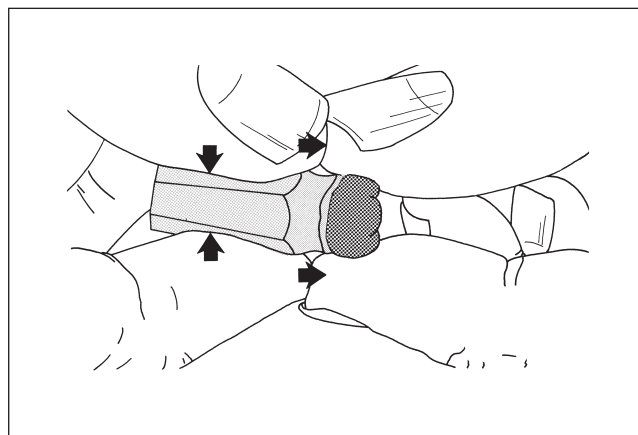


Fig 20-3 The wax pattern is removed from the die by indirect finger pressure.

procedure. Overbulking the sprue former attachment should be avoided because this will increase the risk of shrink-spot porosity and also make removal of the sprue from the casting more difficult. The sprue former also should not be constricted at its attachment to the wax pattern. The best castability and least porosity is produced by a sprue former–wax pattern junction that is either straight or slightly flared.³⁵

During the time period between removal of the wax pattern from the die and hardening of the investment, deformation will occur as stresses in the wax are released. To minimize this time, the entire armamentarium must be at hand, the ring liner should be in place, and the water should be measured out before the pattern is removed. For removal of the wax pattern from the die, it is lightly grasped on the proximal surfaces with the thumb and forefinger of the left hand, with care taken not to exert any pressure on the sprue former. The die is held between the thumb and forefinger of the right hand, which are gently squeezed together. This

squeezing action by the right hand will exert gentle pressure against the tips of the fingers of the left hand and will usually lift the pattern from the die (Fig 20-3). If gentle pressure will not lift the pattern, a small piece of rubber dam is placed over the pattern to prevent slippage by the fingers. The left hand should not exert a direct pulling action. Except in the situation described below, a pattern should not be removed by the sprue former.

Difficulty can be encountered in removing an inlay pattern from the die because there is usually insufficient bulk to draw the pattern without exerting distorting force on the sprue former. In this situation, the sprue should parallel the path of insertion of the restoration to prevent torquing of the pattern with attendant distortion of its margins. A small loop of gold zephyr wire with turned-up ends can be heated and embedded into the occlusal surface of the wax pattern and used as a handle for removal with cotton pliers.

20 Investing and Casting

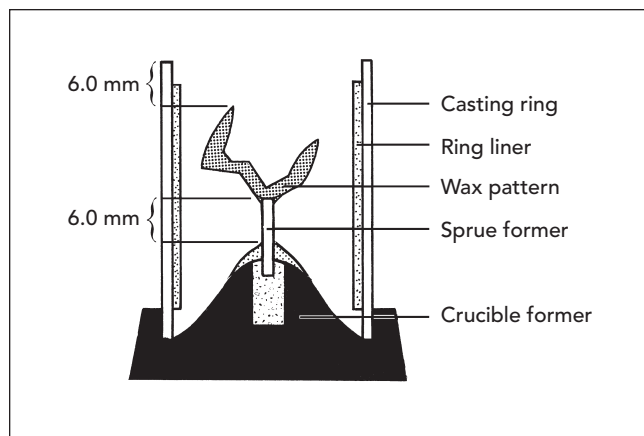


Fig 20-4 Wax pattern ready for investing.

To produce uniform expansion, the pattern is surrounded on all sides with investment that is as uniform in thickness as possible. The closer the pattern is placed to the center of the ring, the greater the expansion will be.^{36,37} With pliers, the sprue former is pushed down into the soft wax in the top of the crucible former until the top of the pattern is 6.0 mm below the end of the ring (Fig 20-4). To provide adequate bulk of gold during solidification, the sprue itself should be no longer than 6.0 mm (it can be shorter). To correct any discrepancy in length, soft wax is added onto the sprue former, thus lengthening the crucible former and shortening the exposed sprue former. The wax is smoothed around the base of the sprue former.

Investing procedure

For a single crown or onlay, a metal casting ring with an outside diameter of 32 mm is used. A resilient liner is placed on the inside of the ring to provide a buffer of pliable material against which the investment can expand to enlarge the mold. If there is no room for expansion outward, the expansion forces will be exerted inward toward the mold, resulting in distortion of the casting. The layer of soft material between the investment and the wall of the ring also permits easier removal of the investment and casting from the ring later.

An alternative method that is gaining in popularity uses a split plastic casting ring that offers no resistance to the setting expansion. The plastic ring is removed before the invested pattern is placed into the oven. This technique allows easier escape of gases from the mold during casting, but the mold is more vulnerable to cracking.

For many years, asbestos was used to line casting rings, but it has been removed from the market because of concern over its carcinogenic properties.³⁸ Ceramic paper (Kaoliner, Dentsply) and cellulose paper (Ring Liner [Non-Asbestos, Cellulose], Whip Mix) are now used as substitutes for asbestos. It has been pointed out, however, that the ceramic ma-

terial contains fibers in the size range likely to produce lung tumors in rats and therefore may be no less hazardous than asbestos.^{39,40}

The ceramic material does not readily absorb water except under vacuum.⁴¹ The cellulose material, on the other hand, does absorb water and in doing so becomes thicker and more compressible.⁴² Cellulose liners burn out before the casting is made, allowing unrestricted thermal expansion and easy escape of gases from the mold during casting. However, this deprives the investment of support by the ring and may result in cracking of the investment and fins on the casting. The manufacturers recommend that approximately 3.0 mm of ring at each end be left unlined so that the investment will be partially supported by direct contact with the ring after the liner has burned out.

A dry strip of cellulose liner approximately 9.5 cm long is placed into a 32-mm-diameter casting ring, carefully adapting the strip to the walls of the ring with no overlap. The liner should be 3.0 mm short of both ends of the ring. This will allow supporting contact of the investment with the ring after the cellulose liner has burned out. It is also theorized that this restriction near the open end will provide for more uniform expansion.⁴³ The ring is dipped into water to wet the liner, and then the excess is gently shaken off. Theoretically, the water in the liner adds a degree of hygroscopic expansion to the setting expansion, but it also reduces the powder-water ratio, which in turn will reduce the thermal expansion of the investment.

As a result, the net expansion with a dry liner will be slightly greater than that with a wet liner.⁴⁴ However, because the effect of a dry liner depends on its volume relative to that of the investment, which varies with the diameter of the ring, a damp liner is preferred for the sake of consistency. The wet liner should not be compressed against the ring because its cushioning effect will be reduced. The ring is rotated firmly onto the crucible former, with care taken to avoid snapping movements or contact of the wax pattern with the ring.

Air bubbles in the investing material adjacent to the wax pattern will result in nodules on the casting. The incidence of visible nodules on the internal surface of full gold crowns with five commonly employed methods of investing was reported by Johnson.⁴⁵ Vacuum mixing produced the best results with open or vacuum pouring, allowing the investment to set under pressure or in open atmosphere. Hand-mixing with an open pour produced nearly 3 times as many nodules, while open pouring and allowing the invested pattern to set under vacuum produced 10 times as many nodules. The same study reported that painting the wax pattern with a surface tension-reducing agent produced mixed results. This agent produced castings with 12% fewer nodules with the open pour technique and 22% more nodules with the vacuum pour technique.

In another study, only 17% of the castings produced by open investing were bubble free, while 95% of those done in molds made by vacuum investing were free of bubbles.⁴⁶ Experienced technicians probably can obtain smooth castings with either vacuum pouring or open pouring.⁴⁷ Although the open pour technique is more popular with experienced

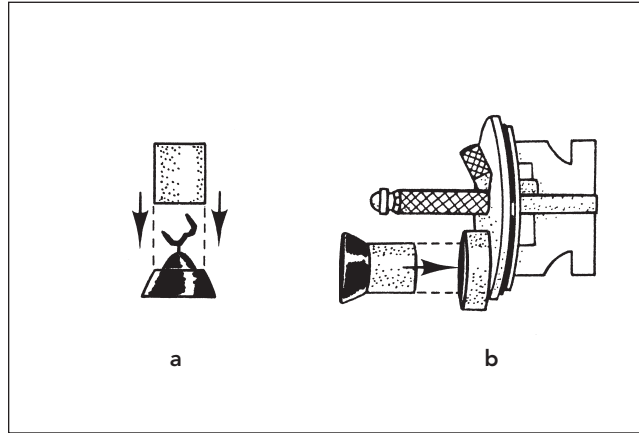


Fig 20-5 The ring is seated on the crucible former (a) and then is placed in the Vac-U-Spat lid (b).

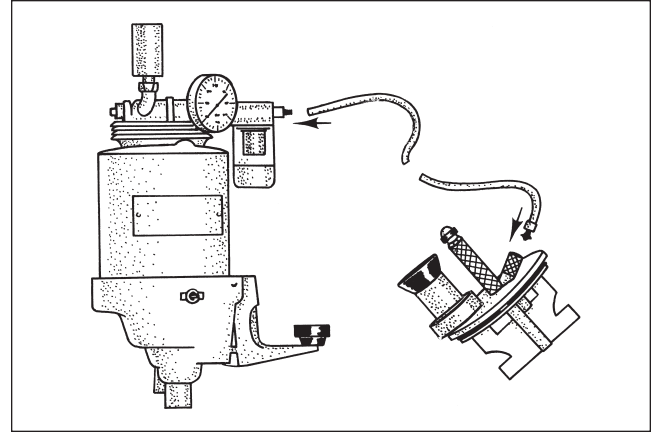


Fig 20-6 Tubing is connected for investing.

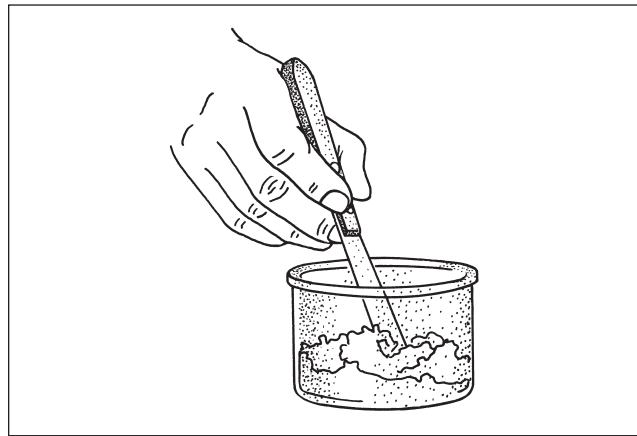


Fig 20-7 Investment is wetted completely by hand spatulation.

technicians because of the unimpeded view of the pattern as it is covered with investment, it is easier for the novice to obtain good results with vacuum pouring.

The procedure for investing a pattern for a single-tooth restoration to be cast in type II or III gold with the open pour technique is similar to that described in the section on phosphate-bonded investments. The procedure for investing with the vacuum mix, vacuum pour technique follows.

The assembled ring and crucible former are placed into the hole at the top of the Vac-U-Spat investor (Fig 20-5). The lid is held by the spindle with the paddle toward the operator and the inlay ring toward the bottom. The operator should then look into the aperture through which the investment will flow into the ring and make sure that the internal portion of the wax pattern is visible.

One end of the clear plastic vacuum tubing is connected to the vacuum outlet on the Vac-U-Vestor. The metal connector is inserted on the other end of the tubing into the hole in the lid of the Vac-U-Spat (Fig 20-6). The Vac-U-Vestor is turned on briefly. The gauge should read approximately 5 to 10 inches

of mercury. If the gauge shows a vacuum of 20 inches of mercury or more when the lid has not been set on the bowl, the tube is blocked. The machine should be turned off and the tubing cleared before proceeding. The lumen in the metal nozzle at the end of the tubing and the gauze filter just beyond the nozzle are the most common sites of blockage.

The recommended amount of room temperature water is poured into the bowl. This must be carefully measured because the water-powder ratio has a critical effect on expansion (ie, more water results in less expansion). A package of investment is added to the water, which is mixed with a handheld spatula until all of the investment has become wet (Fig 20-7). The lid is placed on the bowl and checked to make sure it is firmly sealed.

The Vac-U-Vestor is turned on, and the spindle of the lid of the Vac-U-Spat is inserted into the smaller of the two drive chucks on the bottom of the unit (Fig 20-8a). The gauge should register a vacuum. If it does not, there is probably leakage between the bowl and lid or between the lid and hose. The manufacturer's instructions should be followed for

20 Investing and Casting

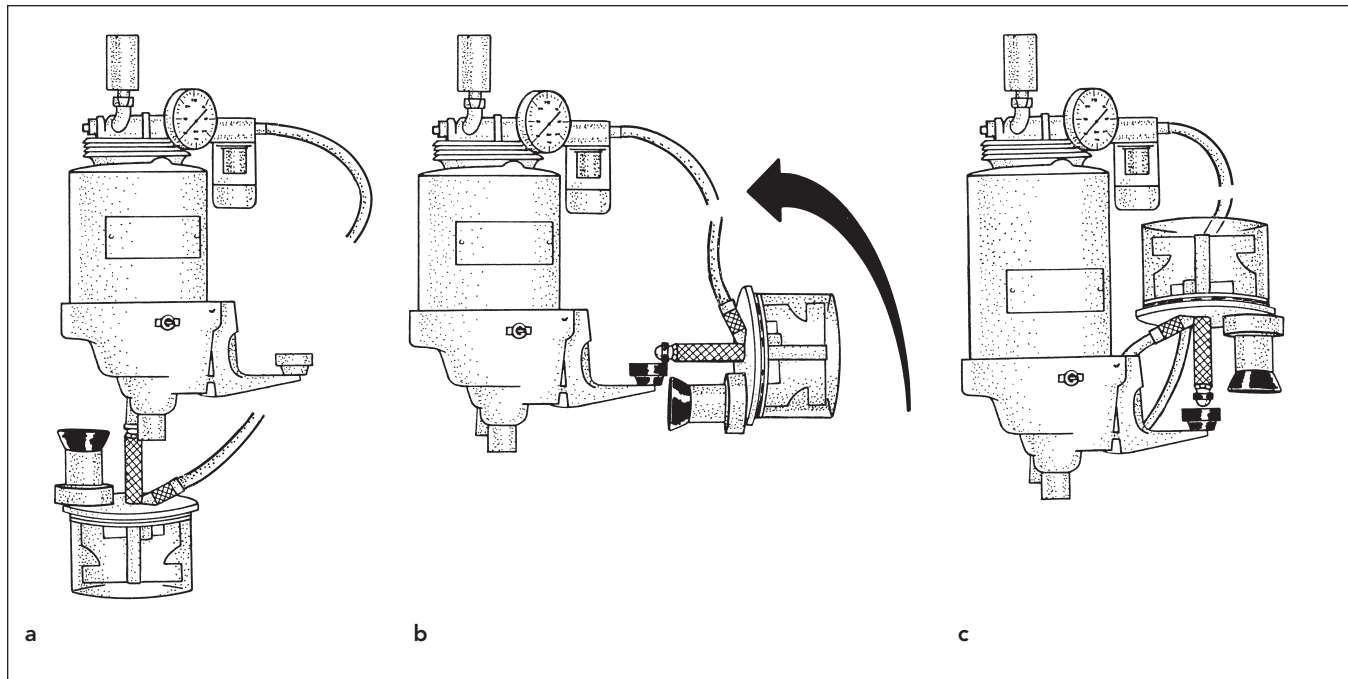


Fig 20-8 (a) Vac-U-Spat in position for power spatulation. (b) Starting position for pouring investment into the ring. (c) Vac-U-Spat inverted after filling the ring.

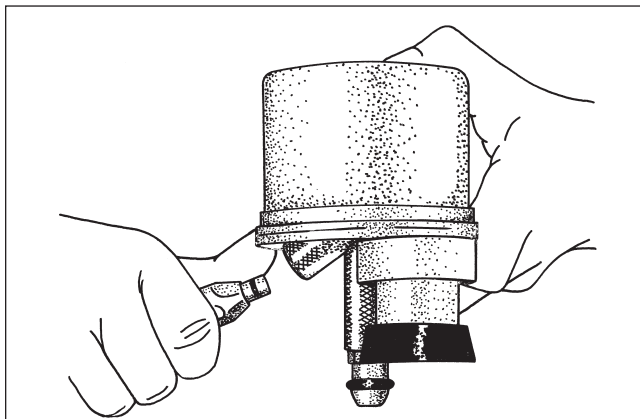


Fig 20-9 Tubing is disconnected while the Vac-U-Spat is still inverted.

mixing the investment. Because the length of spatulation can affect expansion of the investment, the time of spatulation should be measured precisely. Overspatulation will increase thermal expansion.³⁷ It is important to avoid introducing another variable into the technique.

The drive chuck is removed from the spindle. The Vac-U-Vestor should not be turned off, and the vacuum should not be disconnected at this point. The drive nut of the Vac-U-Spat spindle is placed on the vibrator knob. It is ensured that the shaft is horizontal and the casting ring is in the lowest

position on the circumference of the lid. The Vac-U-Spat is held in this position for a few seconds until the investment has run to the lower side of the bowl (Fig 20-8b).

The Vac-U-Spat is slowly inverted until the shaft points straight down, with the drive nut kept in contact with the vibrator (Fig 20-8c). It should take slightly less than 30 seconds to traverse the 90-degree arc from the horizontal to the vertical position.

The drive nut is removed from the vibrator knob, with the Vac-U-Spat kept inverted. While it is still in this position, the vacuum pump is turned off, and the vacuum hose is disconnected (Fig 20-9). The casting ring and crucible former are then removed from the Vac-U-Spat lid. The crucible former is placed on the vibrator knob for a few seconds to settle any investment that might have spilled during separation of the ring from the lid. Overvibration should be avoided because it may cause air to slip around the seal between the ring and the crucible former, rise up, and lodge on the underside of the pattern.

If a high-temperature (1,200°F, 650°C) burnout technique will be used, the casting ring and crucible former are placed into a humidor (a covered plastic container or sealed plastic bag with wet paper towels in the bottom) and allowed to set at room temperature. If a low-temperature (900°F, 480°C) burnout technique is to be used, the ring is immediately immersed in a 100°F (38°C) water bath to produce expansion of the wax pattern. The investment is allowed to set for a minimum of 30 minutes. The ring is left in the humidor until it is time for burnout and casting.

To prevent clogging the drains with accumulated investment, the unused portion of investment remaining in the Vac-U-Spat bowl is emptied into the investment envelope (Fig 20-10). The top of the package is folded over so that the waste can be disposed of neatly. A brush and running water are used to clean the bowl, lid, and paddle before the investment hardens on them.

Casting armamentarium for types II and III gold alloys

- Casting ring with invested pattern
- Furnace
- Centrifugal casting machine with crucible
- Gas-air blowpipe
- Matches
- Casting alloy
- Casting flux
- Casting tongs
- Toothbrush
- Explorer
- Pro-Craft Pickling Compound (Grobet USA)
- Porcelain casserole dish
- Plastic-coated forceps
- Bunsen burner

Burnout

Burnout prepares the mold for the molten alloy and allows thermal expansion to occur. If thermal expansion alone will provide the compensation expansion, a high-temperature technique (1,200°F, 650°C) is employed. If a 100°F water bath (hygroscopic technique) was used to expand the wax pattern, a lower temperature (900°F, 480°C) can be utilized. Heating must be gradual to allow steam to escape without cracking the mold. The crucible former is carefully separated from the ring. The crater and bottom of the ring are checked for any small chips of investment, and any that are found are removed because they could contaminate the casting later. The casting ring, with the crater down, is placed into a 600°F (315°C) oven and left for 30 minutes. By burning out in an inverted position, much of the wax will run out of the mold as it is melted, carrying any loose chips of investment with it. Casting tongs are used to transfer the ring to a hotter furnace (either 900°F [482°C] or 1,200°F [650°C], depending on the technique used) for 1 hour.

As an alternative, the ring can be placed in a cold oven and heated slowly to the casting temperature. The ring should be set crater up about 10 minutes before the casting is made. This allows oxygen to contact the internal area of the mold to ensure complete wax residue elimination. A black appearance of the investment surrounding the sprue hole is an indication that there are still carbon particles from the wax permeating the investment. These can impede the escape of gases through the investment as the casting alloy enters the mold and prevent the margins from being completely cast. A bright, clean appearance of the casting is the result of the reducing action of residual carbon and may indicate that it was cast too soon.

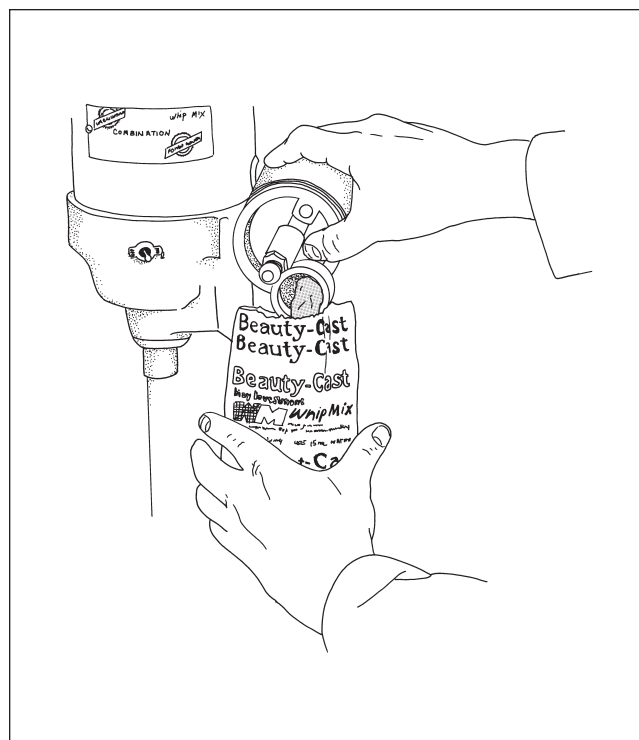


Fig 20-10 Unused investment is vibrated into the original envelope and disposed of in a trash receptacle.

Casting technique for types II and III gold alloys

No more than 30 seconds should be allowed to elapse between the time the ring is removed from the oven and the molten alloy is centrifuged into the mold. Any undue delay will cause heat loss and resultant mold contraction. Therefore, it is imperative that all materials and equipment used in casting be ready ahead of time. It is also helpful to enlist an assistant to transfer the hot ring from oven to cradle until more experience is gained.

The crucible is placed in its bracket on the arm of the casting machine (Fig 20-11). Gold should not be melted in a crucible that has been used with a base metal alloy. The counterweight of the casting machine is wound clockwise three times with the right hand. The pin is raised from the base of the machine in front of the crucible assembly. The right hand slowly releases the counterweight until the pin rests against the arm, preventing it from unwinding.

The casting alloy is placed in the crucible. Enough bulk of metal must be used in casting to fill the mold, the sprue, and part of the crucible former to ensure sharp, complete detail in the casting. Four pennyweights (dwt) of gold will usually suffice for most premolar restorations, while six are needed for molar castings. Buttons from previous castings can be reused provided they are well cleaned. Traces of sulfur from investment materials left on used buttons will reduce the alloy's ductility and increase pitting.⁴

20 Investing and Casting

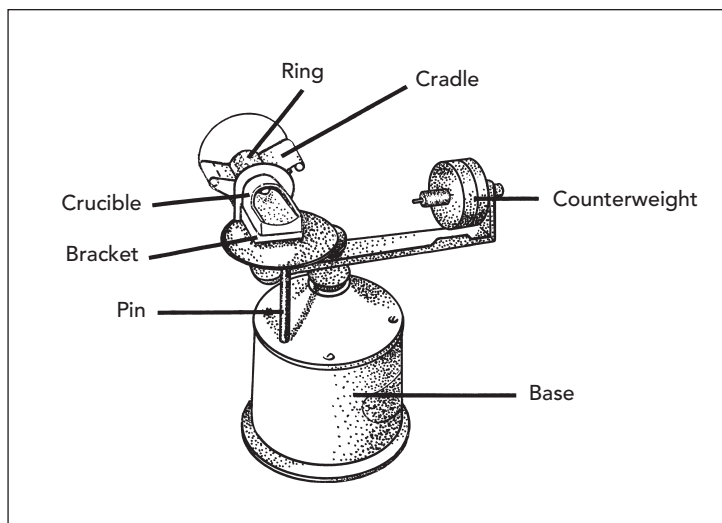


Fig 20-11 Centrifugal casting machine.

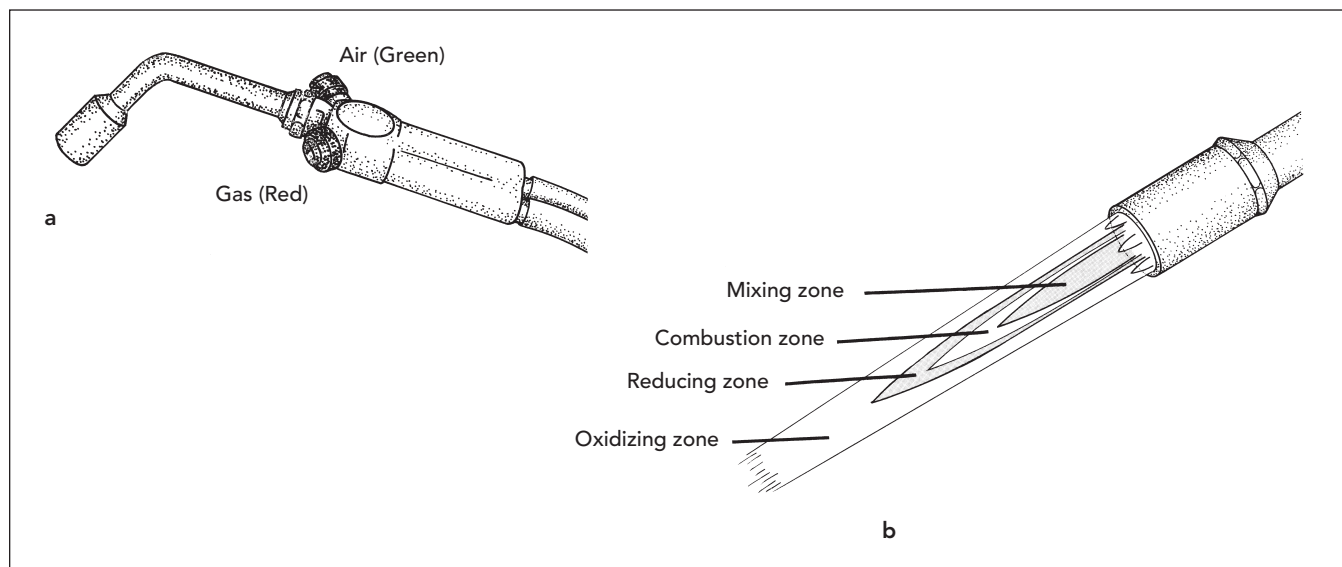


Fig 20-12 The gas-air blowpipe (a) and the zones of the flame used for melting gold (b).

The gas-air blowpipe is lit, and the red gas and green air knobs are adjusted to produce a conical flame (Fig 20-12a). The first cone, the mixing zone, is a cool, colorless one. Around this area is a greenish-blue combustion zone in which partial combustion takes place; this is an oxidizing zone (Fig 20-12b). Next is a dim blue tip, the reducing zone. This is the hottest area in the flame and the only part of the flame used to heat the casting alloy. Beyond this is another oxidizing zone in which final combustion between the gas and surrounding air occurs.

Neither of the oxidizing zones should be used for heating. They are not as hot as the reducing zone, and if the alloy comes in contact with them, copper and other non-noble

metals will be oxidized, changing the properties of the alloy. This can result in reduced strength and altered solidification shrinkage. The oxides also may become incorporated in the casting as impurities. Location of the reducing zone should be practiced by directing the flame against the crucible to form a glowing hot area. The flame is slowly moved closer. When it is too close, a central dark spot will be formed by the cooler combustion zone. The torch is withdrawn until the dark spot just disappears. This is the ideal distance of the torch from the gold.

A small amount of flux should be sprinkled onto the warmed metal (Fig 20-13). Borax, used by itself as a flux, will help to exclude oxygen from the surface of the alloy and




Fig 20-13 Application of casting flux before the ring is placed in the machine.

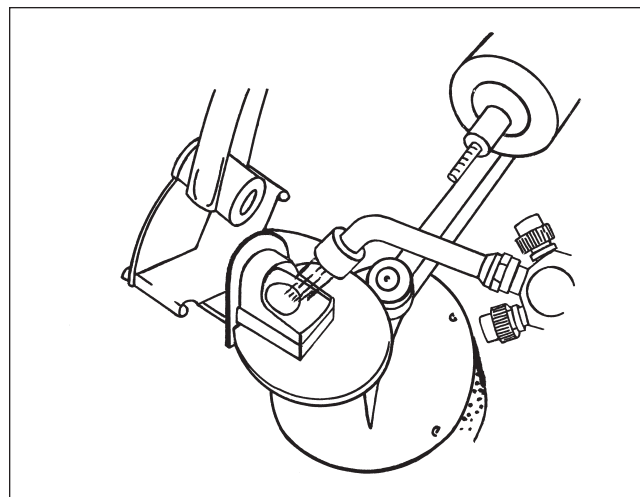


Fig 20-14 The casting ring is set in the cradle with casting tongs.

dissolve any oxides that are formed. Reducing flux, which contains carbon in addition to borax, will also reduce back to clean metal any oxides that happen to form. This helps to maintain the original composition of the alloy.⁴⁸ Heating of the gold continues until it balls up. As it approaches the casting temperature, the gold will become straw yellow in color. It will wiggle easily in the crucible when it is tapped and will follow the flame if it is moved slightly. If the reducing zone has been used properly, the molten gold will appear mirror-like and shiny.

With the flame maintained on the gold, the casting ring is removed from the oven with casting tongs and carefully placed in the cradle (Fig 20-14). The platform on which the crucible rests is slid gently against the ring and cradle. It should be checked for a snug fit, which will prevent the ring from rolling when the arm is released.

The blowpipe is held in one hand while gentle clockwise pressure is applied on the counterweight with the other hand until the pin drops (Fig 20-15). The weight is jiggled slightly to see that the gold moves freely. The weight is released, allowing the machine to spin. To ensure maximum fluidity of the gold, the torch should not be lifted out of position until the arm of the casting machine has been released. The centrifuge is allowed to slow to a stop by itself.

Cleaning the casting

After the gold button has lost its glow, the casting ring is removed with the tongs and thrust into a pan of cold water. For a casting of Firmilay in a small ring, this quenching should occur about 5 minutes after casting to achieve the best grain structure. If it is quenched while it is too hot, the gold will be softer and weaker. If it is allowed to bench cool completely, the grain structure will be too large.⁴⁹ An ad-

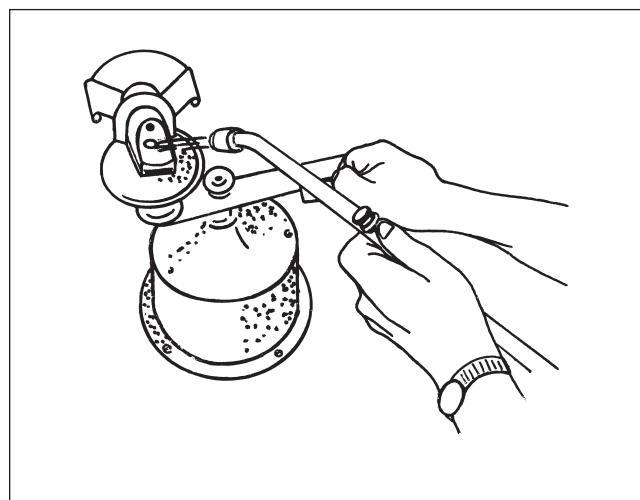


Fig 20-15 The arm of the casting machine is prepared for release.

ditional benefit of quenching is the disintegration of the hot investment when it contacts the cold water.

The ring is removed from the water, and the investment and casting are pushed out of the ring, if they have not already fallen out. As much of the investment as possible is broken off by hand or with an old instrument, and then the casting and button are scrubbed with a stiff brush. The casting should appear smooth, with a dull, dark oxide layer. The oxide layer and any remaining particles of investment are

20 Investing and Casting

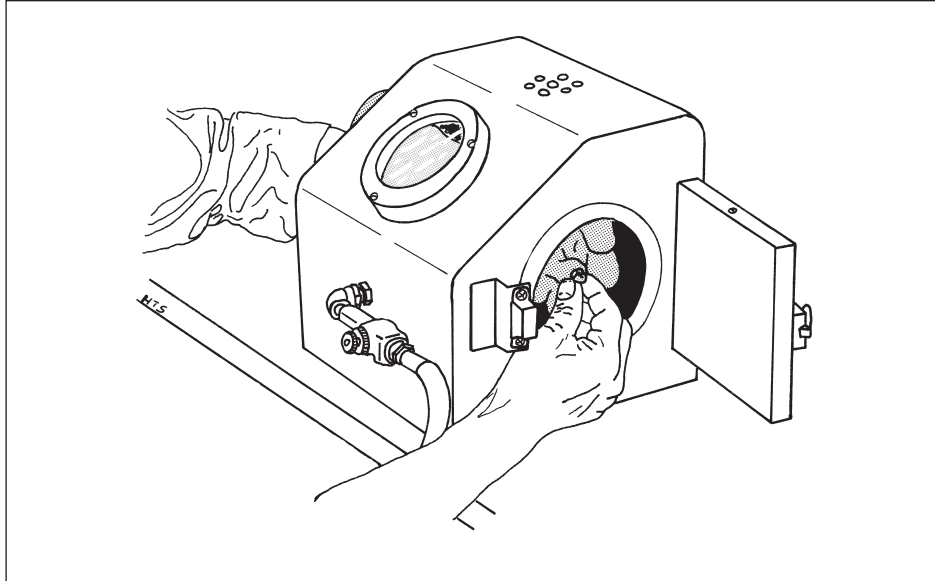


Fig 20-16 The casting is cleaned with a fine, air-propelled abrasive.

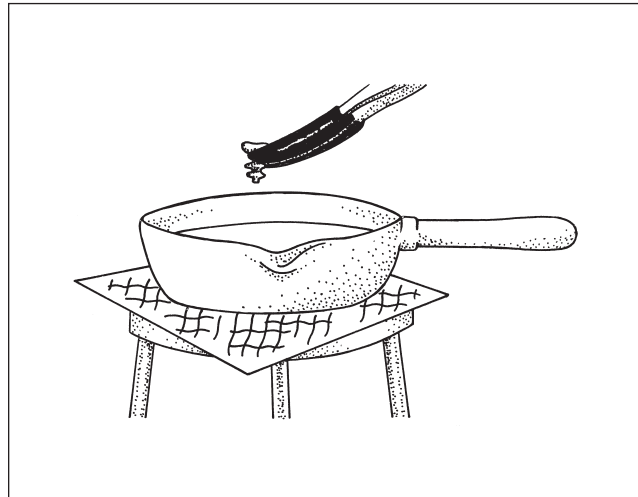


Fig 20-17 The casting is placed in a porcelain casserole dish for pickling.

removed by lightly air abrading all surfaces with a 50- μ m abrasive, taking care not to abrade thin margins (Fig 20-16).

A process called *pickling* also has been widely used for cleaning gold castings. This involves soaking the casting in a hot acid solution for several minutes. Pro-Craft Pickling Compound is a much safer and less corrosive pickling agent than the formerly used sulfuric or hydrochloric acid. Still, contact with the skin and inhalation of vapors must be avoided. A porcelain casserole dish is used to contain the pickling solution, and plastic-covered pliers are used to introduce and remove the casting from the solution (Fig 20-17). Metal in-

struments must not come into contact with gold in strong solution because electrodeposition may occur on the surface of the casting. Only gold castings may be cleaned by pickling. Because of the health and environmental hazards associated with pickling solutions, air abrasion with small-particle-size abrasives is the preferable means of cleaning castings.

The casting should be examined closely for casting defects. Figure 20-18 shows some common problems and their causes. It is important to remember that a mistake is a failure only if we fail to learn from it.

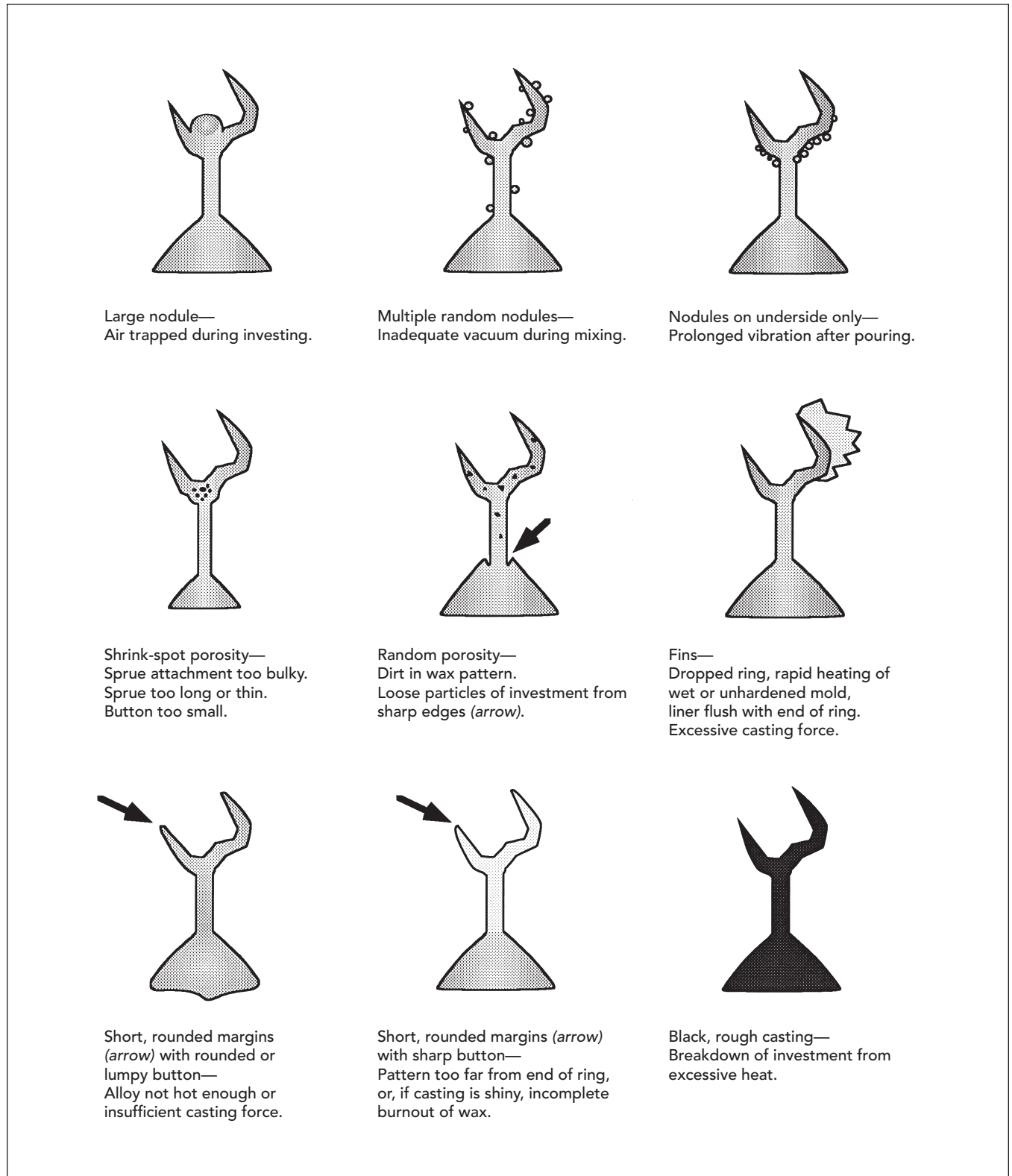


Fig 20-18 Some common casting defects and their causes.

20 Investing and Casting

Investment of inlay and dowel-core patterns

Less mold expansion is required for dowel cores and inlays than for crowns. If the casting is the least bit larger than the pattern, it will not fit into the tooth. Omitting the ring liner or increasing the investment water-powder ratio by 1.0 mL will result in a slightly undersized casting that will fit more easily into the cavity prepared in the tooth.

The following technique is recommended for investing and casting a dowel-core pattern in a silver-palladium alloy (Albacast, Jelenko). The pattern is invested in Beauty-Cast (Whip Mix) using the standard water-powder ratio, without a ring liner, and with burnout at 1,200°F (650°C). Because the casting temperature of Albacast is 2,150°F (1,177°C), a gas-oxygen torch or electric induction casting machine must be used to melt the alloy.

It is possible for an experienced operator to cast and cement gold inlays and dowel cores on the same day that the teeth are prepared by using the following accelerated technique for investment and burnout:

1. The pattern is invested in a phosphate-bonded investment (Ceramigold, Whip Mix) using a ring liner and standard special liquid dilution of 50/50.
2. The investment is allowed to harden for 12 to 15 minutes. It should feel firm and warm.
3. The invested pattern is placed directly into a 1,300°F (705°C) oven; 12 to 15 minutes are allowed for burnout.
4. The investment is cast in gold alloy (type II or III for inlays, type III or IV for dowel cores).
5. In this way, investment, burnout, and casting can be completed in 1 hour, saving the patient an additional appointment.⁵⁰

Phosphate-bonded investments

Phosphate-bonded investments are much stronger and withstand much higher temperatures than do gypsum-bonded investments. They are used for investing and casting alloys with higher melting temperatures (eg, silver-palladium, gold-platinum, and nickel-chromium). To obtain sufficient expansion for crowns of these alloys, the mold must be heated to 1,400°F (760°C) or higher, temperatures that would cause decomposition of the calcium sulfate in a gypsum binder with the resultant release of contaminating sulfur into the mold.⁵¹ In general, any alloy with a casting temperature in excess of 2,100°F (1,150°C), as differentiated from the fusion temperature, which is 100°F to 150°F lower, should be cast into an investment with a binder other than gypsum. (Because dowel cores do not require as much expansion of the mold as do crowns, they can be cast with a silver-palladium alloy into a gypsum-bonded mold heated to only 1,200°F [650°C], as described earlier.)

The powder contains phosphates of magnesium and ammonium, graphite (carbon), and large silica particles, while the special liquid provided with these investments contains an aqueous suspension of colloidal silica. Carbon-free phos-

phate investments (Hi-Temp, Whip Mix) are available for use with base alloys that are made brittle in the presence of carbon.

Magnesium phosphate reacts with primary ammonium phosphate to produce magnesium ammonium phosphate, which gives the investment its strength at room temperature.⁵² At higher temperatures, silicophosphates are formed; they give the investment its great strength.

Expansion can be varied by the proportions of silica sol and water:

- More silica sol and less water = more expansion
- Less silica sol and more water = less expansion

The usual proportion is three parts silica sol liquid to one part distilled water. The overall liquid-powder ratio for Ceramigold investment should remain constant: 9.5 mL liquid to 60 g of powder.

Investing armamentarium

- 200-mL Vac-U-Spat bowl and lid
- Vacuum tubing
- Vac-U-Vestor
- Rubber crucible former
- Casting ring
- Plastic water measure
- Spatula
- PKT waxing instruments (nos. 1 and 4)
- Cotton pliers
- Bunsen burner and matches
- Sticky wax
- Sprue formers (hollow plastic or wax)
- One package (60 g) of Ceramigold investment
- Special liquid
- Strip of liner 9.5 cm long
- Small camel-hair brush

Investing procedure

A 10-gauge (2.6-mm) plastic sprue former is attached to the tip of the incisal portion of a single crown wax pattern with sticky wax using a PKT no. 1 instrument to melt and blend the junction. If there is a broad expanse of paper-thin wax between the sprue and the margin, it is bridged with a narrow (0.5-mm-thick) strip of wax (Fig 20-19) that will serve as an internal sprue. This will provide a channel through which the molten alloy can flow more readily to reproduce the margin. The resulting ridge can be easily trimmed back to the desired thickness after the casting is made.

The pattern is carefully removed from the die and the sprue former grasped with cotton pliers. The sprue former is seated into the soft wax in the center of the crucible former (Fig 20-20). The sprue former's length should be adjusted so that the pattern will be 6.0 mm from the end of the ring when it is in place. The crucible former is built up with wax, if necessary, so that no more than 6.0 mm of the sprue former is exposed.

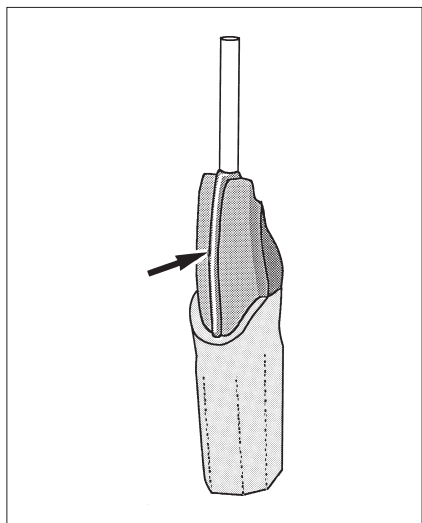


Fig 20-19 Castability of a thin cutback area is improved by the addition of an internal sprue (arrow).

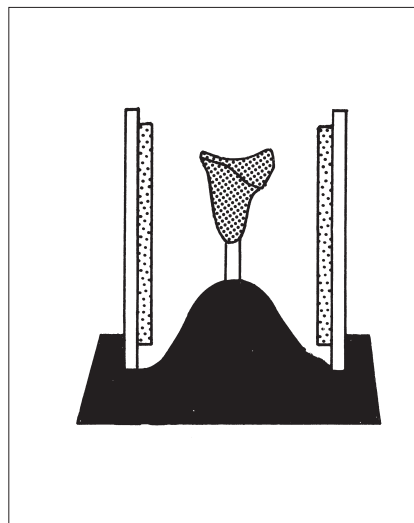


Fig 20-20 Anterior metal-ceramic coping wax pattern ready for investing.

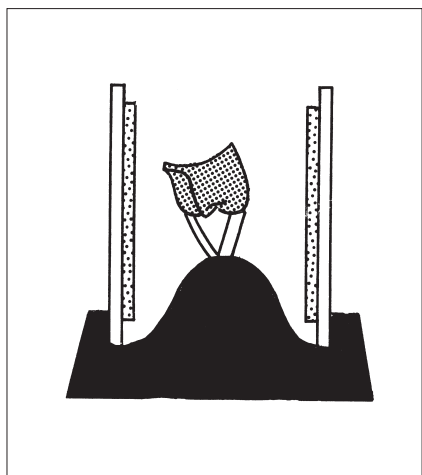


Fig 20-21 Premolar metal-ceramic coping wax pattern ready for investing.

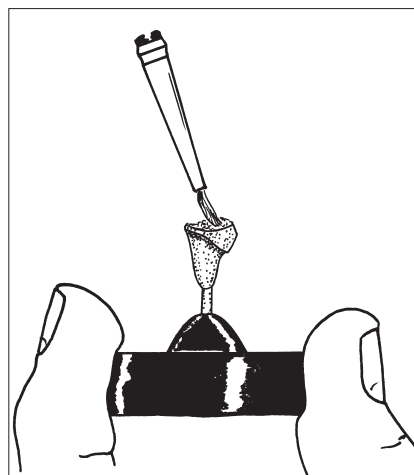


Fig 20-22 It may be necessary to paint phosphate-bonded investment into the wax pattern with a small brush.

Posterior patterns are sprued on the tip of the cusp with the greatest bulk. An 18-gauge wax sprue former (0.8-mm-diameter) should connect the other cusp tip (in the veneering area) with the base of the crucible former (attached to the pattern while it is still on the die). The tip of this cusp should be lower than the point of entry of the main sprue (Fig 20-21).

A layer of dry cellulose liner is adapted to the inside of the ring. The ring is immersed briefly in a bowl of water to moisten the liner. The ring, crucible former, and Vac-U-Spat lid are assembled. Then 9.5 mL of the liquid is placed in the Vac-U-Spat bowl, and the contents of a 60-g package of Ceramigold investment are added. The vacuum tubing is connected, and the mixture is mechanically spatulated un-

der a vacuum for approximately 15 seconds. The vacuum is disconnected, and the ring is removed from the lid.

This type of investment possesses poor surface-wetting characteristics. Because of this, the problem of trapping air bubbles during investing is even greater than with gypsum investments. Either vacuum or open investing can be used. Allowing the investment to set in a pressure pot will further reduce the size and number of bubbles.⁴⁵ If there are small, restricted areas in the interior of a wax pattern (eg, long, thin crowns on incisors), the investment is gently brushed into the pattern with a small brush (Fig 20-22). The ring is then placed over the crucible former, and the investment is slowly poured down one side of the ring with vibration. A small stream of investment should be seen flowing over the

20 Investing and Casting

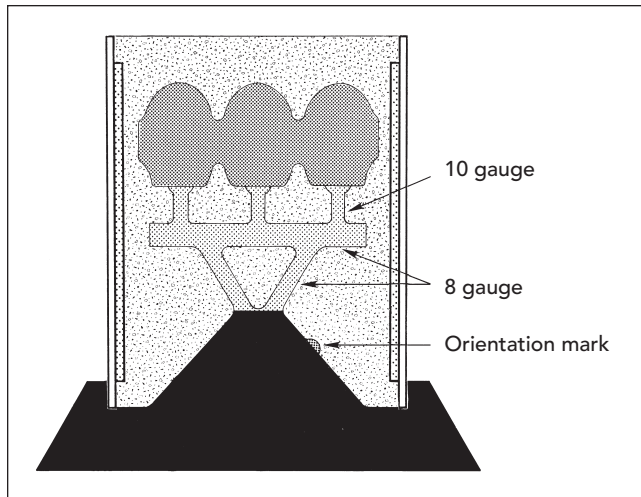


Fig 20-23 Pattern for a metal-ceramic fixed partial denture is sprued indirectly. The feeder sprues and the horizontal runner are 8 gauge, and the manifold sprues are 10 gauge. The inscribed line is opposite the wax dot.

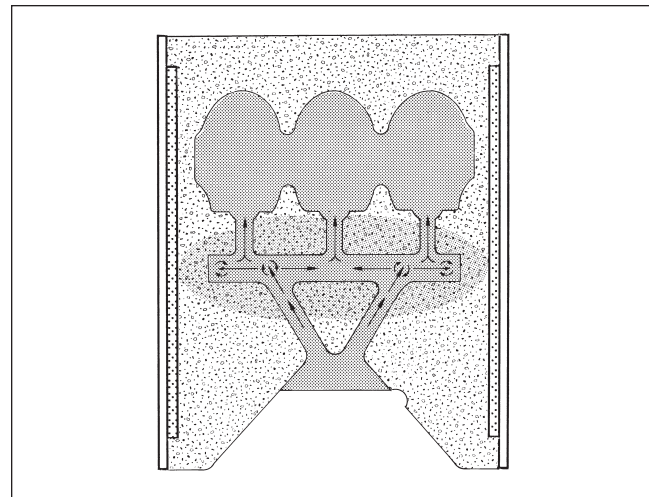


Fig 20-24 Molten alloy swirls through the manifold system, raising the temperature of the surrounding investment (shaded area).

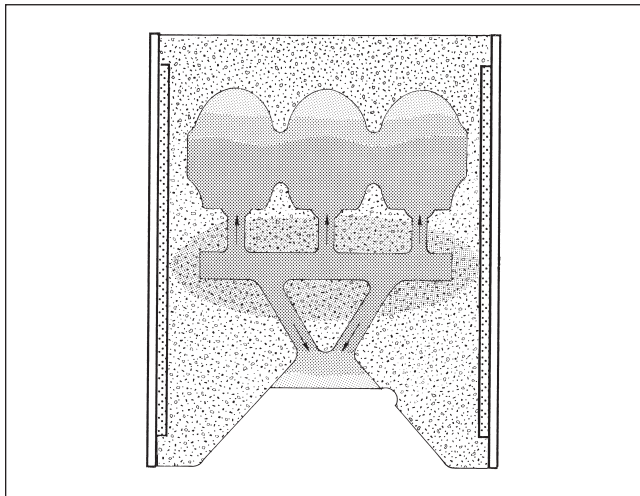


Fig 20-25 As the alloy begins to solidify, the heat around the manifold (dark shading) keeps it molten longer, preventing porosity in the partial denture.

margin on one side of the pattern, down into the deepest recess, and gradually filling the pattern from the bottom up.

Once the pattern is covered, the ring can be filled the rest of the way with a minimum of vibration. There should be an excess of investment above the end of the ring so that the hardened glaze can be easily ground away on a cast trimmer. If it is needed, an additional 0.7% of expansion can be obtained by placing the investment-filled ring into a 100°F (38°C) water bath before it has hardened.⁵² If this is done, the surface of the investment should be protected from the softening effect of water by a thin sheet of rubber or plastic wrap held in place by a rubber band.

Wax patterns for metal-ceramic fixed partial dentures are invested and cast as one unit whenever possible because

of the difficulty encountered in soldering the alloys used for this type of restoration. In these situations, the wax pattern should be fabricated on a one-piece die on which the dies of the individual abutment preparations have not been separated. The wax pattern for a fixed partial denture should be invested in a large ring (round or oval, with a diameter of approximately 6.3 cm) to produce the most accurate casting.⁵³

For lower-fusing gold alloy castings, sprue formers run directly from crucible former to wax pattern to provide rapid, turbulence-free access of the metal to the mold during casting. Patterns for metal-ceramic fixed partial dentures, however, must be sprued by an indirect method because the alloys used fuse and solidify at much higher temperatures.⁴ Because the ambient air is much colder than the molten metal, the exposed button is likely to solidify while the metal at the center of the ring is still liquid. This means that the button cannot serve as a reservoir to prevent shrink-spot porosity. Instead, a bulky horizontal runner bar is placed between crucible former and pattern. The runner bar should be as thick as the thickest part of the pattern.

A piece of 8-gauge (3.4-mm-diameter) hollow plastic sprue former material is placed horizontally into the sprue former network to form a manifold between the crucible former and the wax pattern (Fig 20-23). Both ends of the hollow sprue former should be plugged with wax to avoid the formation of thin projections of investment that might break off in the mold. As the alloy makes its way through the feeder sprues, runner, and manifold sprues, the temperature of the surrounding investment is elevated (Fig 20-24). The metal farthest from the manifold—the margins and the surface of the button exposed to ambient room temperature—will cool first while the feeder bar is still fluid and can serve as a reservoir for solidification contraction in the fixed partial denture (Fig 20-25). The runner bar also helps to stabilize the pattern

against distortion during investing, and it equalizes the flow of metal so that all parts of the mold will be filled evenly and simultaneously during casting.⁵⁴

Orientation of invested fixed partial dentures in the casting machine can affect the flow of metal into the mold. The pattern is placed in a vertical position on the horizontal centrifugal casting machine to ensure that all parts of the mold will fill simultaneously. To facilitate proper orientation, a substantial line can be carved into the exterior of the casting ring with the edge of a carborundum disk (often called a Joe Dandy disk), and a wax dot can be placed on the crucible former, which will leave an imprint on the surface of the investment. The casting ring is rotated so that the inscribed line is opposite the wax dot. When the ring is placed in the casting machine, the inscribed line will be up and the imprint of the wax dot will be down (see Fig 20-23).

Casting armamentarium for gold-palladium alloys

- Casting ring with invested wax pattern
- Furnace
- Centrifugal casting machine with quartz crucible
- Colored safety glasses
- Gas-oxygen torch
- Matches
- Metal-ceramic alloy
- Casting tongs
- Laboratory knife
- Toothbrush
- Explorer

Casting technique for gold-palladium alloys

Special gold-palladium alloys are used for metal-ceramic restorations and where greater strength than that provided by type III gold is required. After the investment has set for 1 hour on the benchtop, some of the excess investment beyond the end of the ring should be ground or scraped away. This will remove the smooth, dense surface layer and allow gases to escape more readily from the mold during casting. The crucible former is removed, and the ring is placed in a 600°F (315°C) oven. After 30 minutes in the low-heat oven, the ring is placed in a 1,300°F (704°C) oven for 1 hour. If the ring is left at this temperature any longer, the investment will start to break down.

Because of the higher melting temperature of the metal-ceramic alloy, the gas-air blowpipe is inadequate. A multi-orifice, gas-oxygen torch should be used. To prevent accidents, caution should be exercised in the use of this torch. Oxygen always should be added to a gas flame, and the gas flame always should remain on until the oxygen has been turned off. If the gas is turned off first, there will be a small explosion inside the torch when the gas-oxygen ratio reaches a critical level. To start the torch:

1. Gas is turned on and ignited.
2. Oxygen is slowly added.

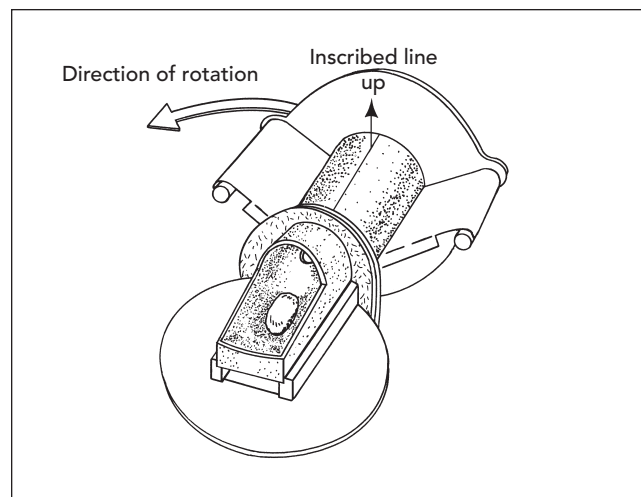


Fig 20-26 Correct positioning of the ring in the casting machine, with the inscribed line facing upward.

To turn off the torch:

1. The oxygen is turned off.
2. The gas is turned off.

A quartz crucible is preferred to a clay crucible. No flux should be used with metal-ceramic alloys; it may upset the balance of the alloy and interfere with bonding later. The torch is turned on, and the flame is adjusted to make the inner cone 0.25 to 0.5 inch (6 to 12 mm) long. Light blue or other colored protective goggles are worn to protect the eyes from the intense light. The crucible is preheated with the torch, and then the alloy is placed in the crucible.

The alloy is heated until it liquefies. It will go through four stages:

1. Red
2. Orange
3. Dull white
4. Mirror-like white

When the gold is orange, the ring is transferred from the furnace to the cradle of the casting machine. In casting a fixed partial denture, it should be ensured that the inscribed line on the ring is in the up position and the imprint of the wax dot is in the down position, indicating that the mold of the framework is vertical (Fig 20-26).

Heating of the gold continues. As it becomes white, a light fog or scum forms on the surface. As soon as that scum disappears and the metal is shiny, the machine and cast are released. The ring is cooled to room temperature on the bench. Metal-ceramic alloys should not be quenched. When it has cooled, the casting is removed, and the remnants of the investment are picked off. The casting is then washed in water and lightly air abraded. Metal-ceramic alloys should not be pickled.

20 Investing and Casting

Casting technique for base metal alloys

These high-fusing alloys experience a high degree of shrinkage on cooling. To achieve the necessary mold expansion, the invested pattern should be placed in a water bath at 100°F (38°C) for 1 hour. Best results are obtained if the investment is allowed to cure overnight before proceeding with burnout. The ring is placed in a cold oven that is brought up to 1,500°F (815°C) in approximately 1 hour. It is allowed to heat soak at this temperature for approximately 2 hours to eliminate all traces of carbon. The recommended temperature may vary slightly for different alloys. The quartz crucible is preheated in the oven.

The casting machine is wound and given one or two extra winds to compensate for the much lighter density of the base metal alloy. The quartz crucible is removed from the oven with casting tongs and placed in the bracket on the casting machine. The metal ingots are placed in the crucible.

Dark protective goggles should be worn for casting. As with gold-palladium alloys, a gas-oxygen torch must be used, but the higher casting temperatures of the base metal alloys require the use of a multiorifice tip. The gas is turned on first, adding oxygen to the gas flame. The flame is adjusted to make the inner cones approximately 0.5 inch (12 mm) long. The alloy is heated evenly by moving the torch around to cover all ingots. They will not liquefy. The ingots, glowing a uniform color, will slump, and their edges will round over, but tough oxide skins will prevent them from coalescing. Technicians who are used to melting alloys that form into a shiny pool may overheat the base metal alloys. This common error can burn off lower-melting constituents and create bonding problems when the porcelain is later applied.⁵⁵ If the alloy is overheated or burned, it should be thrown out.

Casting is performed immediately to avoid overheating. The ring is bench cooled to room temperature. The casting is removed, and the remnants of investment are picked off. The metal is cleaned with an air abrasion unit using 50- μ m alumina. Base metal castings should not be pickled.

References

- Hollenback GM. Science and Technic of the Cast Restoration. St Louis: Mosby, 1964:21.
- Taggart WH. A new and accurate method of making gold inlays. Dent Cosmos 1907;49:1117–1121.
- O'Brien WJ. Evolution of dental casting. In: Valega TM (ed). Alternatives to Gold Alloys in Dentistry [proceedings of a conference held at the National Institutes of Health, 24–26 Jan 1977, Bethesda, MD]. DHEW publication no. (NIH) 77-1227. Bethesda, MD: US Department of Health, Education, and Welfare, 1977:2–9.
- Peebles J (ed). Dental Technology Reference for Fixed Restorations, ed 7. Armonk, NY: Jelenko, 1983:IV–4.
- Duncanson MG Jr. Nonprecious metal alloys for fixed restorative dentistry. Dent Clin North Am 1976;20:423–433.
- American Dental Association. Current Dental Terminology (CDT 2009–2010). Chicago: American Dental Association, 2008.
- ADA Council on Scientific Affairs. Titanium applications in dentistry. J Am Dent Assoc 2003;134:347–349.
- Gettleman L. Status report on low-gold-content alloys for fixed prostheses. Council on Dental Materials, Instruments, and Equipment. J Am Dent Assoc 1980;100:237–240.
- Wataha JC, Messer RL. Casting alloys. Dent Clin North Am 2004;48:499–512.
- Gourley JM. Current status of semi-precious and conventional gold alloys in restorative dentistry. Dent J 1975;41:453–455.
- Kuschner ML. The carcinogenicity of beryllium. Environ Health Perspect 1981;40:101–105.
- Moffa JP, Guckes AD, Okawa MT, Lilly GT. An evaluation of non-precious alloys for use with porcelain veneers. Part II. Industrial safety and biocompatibility. J Prosthet Dent 1973;30:432–441.
- Covington JS, McBride MA, Slagle WF, Disney AL. Quantization of nickel and beryllium leakage from base metal casting alloys. J Prosthet Dent 1985;54:127–136.
- Tai Y, De Long R, Goodkind RJ, Douglas WH. Leaching of nickel, chromium, and beryllium ions from base metal alloy in an artificial oral environment. J Prosthet Dent 1992;68:692–697.
- Fisher AA. Contact Dermatitis, ed 3. Philadelphia: Lea and Febiger, 1986:745.
- Peltonen L. Nickel sensitivity in the general population. Contact Dermatitis 1979;5:27–32.
- Mjör IA, Christensen GJ. Assessment of local side effects of casting alloys. Quintessence Int 1993;24:343–351.
- Wirz J. What is the controversy about palladium—Is it better than its reputation? [in German]. Phillip J 1993;9:407–408.
- Moffa JP. Physical and mechanical properties of gold and base metal alloys. In: Valega TM (ed). Alternatives to Gold Alloys in Dentistry [proceedings of a conference held at the National Institutes of Health, 24–26 Jan 1977, Bethesda, MD]. DHEW publication no. (NIH) 77-1227. Bethesda, MD: US Department of Health, Education, and Welfare, 1977:81–93.
- Jendresen MD. Non-precious metals and the ceramo-metal restoration. J Indiana Dent Assoc 1975;54:6–10.
- Preston JD, Berger R. Some laboratory variables affecting ceramo-metal alloys. Dent Clin North Am 1977;21:717–728.
- Lorey RE, Edge MJ, Lang BR, Lorey HS. The potential for bonding titanium restorations. J Prosthodont 1993;2:151–155.
- Akagi K, Okamoto Y, Matsuura T, Horibe T. Properties of test metal ceramic titanium alloys. J Prosthet Dent 1992;68:462–467.
- Rekow ED. Dental CAD-CAM systems. What is the state of the art? J Am Dent Assoc 1991;122(12):42–48.
- Revised ANSI/ADA specification no. 5 for dental casting alloys. Council on Dental Materials, Instruments, and Equipment. J Am Dent Assoc 1989;118:379.
- Hollenback GM, Skinner EW. Shrinkage during casting of gold and gold alloys. J Am Dent Assoc 1946;33:1391–1399.
- Phillips RW, Skinner EW. Skinner's Science of Dental Materials, ed 9. Philadelphia: Saunders, 1991:393–412.
- Scheu CH. A new precision casting technic. J Am Dent Assoc 1932;19:630–633.
- Mahler DB, Ady AB. An explanation for the hygroscopic setting expansion of dental gypsum products. J Dent Res 1960;39:578–589.
- Hollenback GM. Simple technic for accurate castings: New and original method of vacuum investing. J Am Dent Assoc 1948;36:391–397.
- Asgar K, Mahler DB, Peyton FA. Hygroscopic technic for inlay casting using controlled water additions. J Prosthet Dent 1955;5:711–724.
- Mahler DB, Ady AB. The effect of the water bath in hygroscopic casting techniques. J Prosthet Dent 1965;15:1115–1121.
- Craig RG. Restorative Dental Materials, ed 8. St Louis: Mosby, 1989:360.
- Davis DR, Nguyen JH, Grey BL. Ring volume/ring liner ratio and effective setting expansion. Int J Prosthodont 1992;5:403–408.
- Verrett RG, Duke ES. The effect of sprue attachment design on castability and porosity. J Prosthet Dent 1989;61:418–424.
- Mumford GM, Phillips RW. Measurement of thermal expansion of cristobalite type investments in the inlay ring—Preliminary report. J Prosthet Dent 1958;8:860–864.

37. Mahler DB, Ady AB. The influence of various factors on the effective setting expansion of casting investments. *J Prosthet Dent* 1963;13:365–373.
38. Priest G, Horner JA. Fibrous ceramic aluminum silicate as an alternative to asbestos liners. *J Prosthet Dent* 1980;44:51–56.
39. Davis DR. Potential health hazards of ceramic ring lining material. *J Prosthet Dent* 1987;57:362–369.
40. Naylor WP, Moore BK, Phillips RW. A topographical assessment of casting ring liners using scanning electron microscopy (SEM). *Quintessence Dent Technol* 1987;11:413–420.
41. Earnshaw R, Morey EF. The fit of gold-alloy full-crown castings made with ceramic casting ring liners. *J Dent Res* 1992;71:1865–1870.
42. Morey EF, Earnshaw R. The fit of gold-alloy full-crown castings made with pre-wetted casting ring liners. *J Dent Res* 1992;71:1858–1864.
43. Craig RG. *Restorative Dental Materials*, ed 8. St Louis: Mosby, 1989:465.
44. Earnshaw R. The effect of casting ring liners on the potential expansion of a gypsum-bonded investment. *J Dent Res* 1988;67:1366–1370.
45. Johnson A. The effect of five investing techniques on air bubble entrapment and casting nodules. *Int J Prosthodont* 1992;5:424–433.
46. Lyon HW, Dickson G, Schoonover IC. Effectiveness of vacuum investing in the elimination of surface defects in gold castings. *J Am Dent Assoc* 1953;46:197–198.
47. Phillips RW. Relative merits of vacuum investing of small castings as compared to conventional methods. *J Dent Res* 1947;26:343–352.
48. J.M. Ney Company. *Ney Bridge and Inlay Book*. Hartford, CT: J.M. Ney, 1955:67.
49. Du Bois LM, Ritnour KL, Weins WN, Rinne VW. The effect of the temperature at quenching on the mechanical properties of casting alloys. *J Prosthet Dent* 1987;57:566–571.
50. Campagni WV, Majchrowicz M. An accelerated technique for casting post and core restorations. *J Prosthet Dent* 1991;66:155–156.
51. O'Brien WJ, Nielson JP. Decomposition of gypsum investments in the presence of carbon. *J Dent Res* 1959;38:541–547.
52. Schnell RJ, Mumford GM, Phillips RW. An evaluation of phosphate bonded investments used with a high fusing alloy. *J Prosthet Dent* 1963;13:324–336.
53. Saas FA, Eames WB. Fit of unit-cast fixed partial dentures relating to casting ring size and shape. *J Prosthet Dent* 1980;43:163–167.
54. Wetterstrom ET. An innovation in sprue design for Ceramico castings. *Thermotrol Technician* 1966;20:3–4.
55. Weiss PA. New design parameters: Utilizing the properties of nickel-chromium superalloys. *Dent Clin North Am* 1977;21:769–785.

Cementation and Bonding

The surface of the casting that is retrieved from investment is too rough for use in the mouth. Five preparatory procedures need to be performed on any type of cemented restoration after it has been fabricated in the laboratory: (1) preliminary finishing, (2) try-in and adjustment, (3) precementation polishing, (4) cementation, and (5) postcementation finishing. With skilled laboratory support, adjustments should be minimal, and the polishing may be done before try-in.

The intaglio and external aspects of a restoration are handled differently. The correct internal configuration allows a restoration to seat completely without binding, provides space for a film of cement, allows the margins to lie in intimate contact with the finish line of the tooth preparation, and provides an internal surface that is conducive to a strong cement bond. Airborne-particle abrasion on metals leaves a clean, textured surface that is ideal for conventional non-adhesive luting. Special surface treatments are indicated for bonding with resin cements and are discussed later.

The external surface of a cemented restoration must be smooth, and it should create a transition from restorative material to tooth that is as perfectly uninterrupted as possible. A rough surface accumulates plaque that is injurious

to the health of the periodontal tissues,¹ and the amount of plaque is directly related to the roughness of the surface² (Fig 21-1). Metallic surfaces may be brought to only a satin finish before try-in, but they must be given a high luster following chairside adjustments. Porcelain that has been roughened by grinding must be polished and also may be reglazed after it is polished, although polishing alone can produce a surface that is as smooth as glazed porcelain^{3,4} and slightly less abrasive on opposing enamel.⁵

Finishing and polishing should be accomplished by following a fixed routine, starting with an abrasive that is coarse enough to remove gross irregularities. The particles in any abrasive leave scratches on the surface. The surface is smoothed with abrasives of progressively smaller particle size, thereby substituting increasingly smaller scratches until the scratches are eliminated or reduced to microscopic size. It has been theorized that as a gold surface is polished, minute amounts (possibly even of molecular size) of the abraded surface material are filled into surface irregularities. This results in a microcrystalline surface layer that is known as the *Beilby layer*.⁶

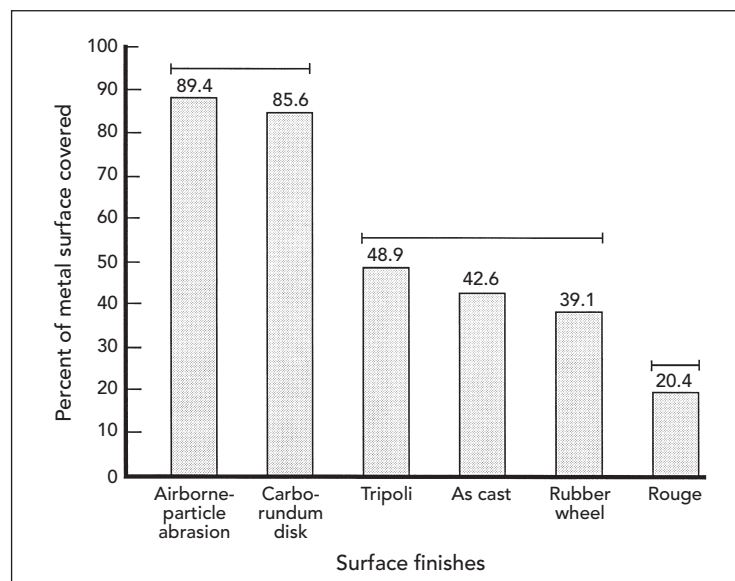


Fig 21-1 Plaque accumulation on six gold surface finishes at 72 hours ($P < .05$). (Reprinted from Keenan et al² with permission.)

21 Cementation and Bonding

Table 21-1 Knoop hardness number (KHN) of dental substances and materials

Substance (material)	KHN
Cementum	40 ⁷
Dentin	68 ⁷
Gold alloy (type III)	145 ^{7*}
Amalgam	155 ⁸
Gold-platinum MCR alloy	192 ^{8*}
Gold-palladium MCR alloy	230 ^{8*}
Nickel-chromium MCR alloy	267 ^{8*}
Enamel	343 ⁷
Nickel-chromium-beryllium MCR alloys	367 ^{8*}
Porcelain	460 ⁷
Pumice	560 ⁸
Sand (flint)	800 ⁹
Aluminum oxide	1,900 ⁸
Emery	2,000 ⁹
Silicon carbide	2,500 ⁹
Diamond	8,000+ ¹⁰

MCR, metal-ceramic restoration.

*Calculated from Vickers hardness number.

Abrasives and Polishing Materials

Abrasives are exceptionally hard materials that develop sharp cutting edges when they are chipped. Polishing materials consist of abrasives and softer materials that are reduced to extremely fine particle size. For maximum cutting efficiency, the abrasive must be appreciably harder than the material on which it is used. The Knoop hardness numbers of commonly used abrasives, dental materials, and tooth structure are listed for comparison in Table 21-1.⁷⁻¹⁰ In determining the effectiveness of an abrasive, factors other than hardness alone can be significant. The toughness of the binder and the ability of abrasive chips to break sharply, rather than rounding, can alter the effectiveness of an abrasive. Some commonly used abrasives and polishing materials are described briefly below.

- **Diamond.** Chips are bound to a metal shape by a ceramic bond or by metal electroplating. The hardest of all abrasives, diamond should be reserved for use on hard, brittle substances such as enamel or porcelain. When used on ductile substances, such as gold, the abrasive particles become clogged with the material being abraded, and the diamond wheel or point becomes inefficient.

- **Silicon carbide.** This commonly used laboratory abrasive is the basic material of carborundum. It is pressed into many shapes to form separating disks and the many points and wheels known as *green stones*.
- **Emery.** This hard, black natural mineral is a mixture of aluminum oxide and iron oxide. Bound to paper disks with glue or resins, emery can be used on gold or porcelain.
- **Aluminum oxide.** This material is a synthetic abrasive produced by purifying bauxite to crystalline form in ovens. Coarse-grit aluminum oxide is the abrasive in the brown, pink, or coral stones used for finishing metal-ceramic copings. A very fine *grit* (400), or particle size, is used to manufacture white polishing stones, which are sometimes called *poly stones*.
- **Garnet.** Available in many grits, this red abrasive is composed primarily of the silicates of aluminum and iron, with some silicates of magnesium, cobalt, and manganese as well. It will cut both metal and porcelain. Garnet is bound to paper disks with glue.
- **Sand.** Sandpaper disks are coated with a dense crystalline form of quartz, called *flint*. Flint is a naturally occurring mineral that chips to form sharp cutting edges. It is not as durable or as strong as some other abrasives, but it is a useful abrasive in finishing cast gold. It is available in various grits.
- **Cuttle.** A fine, relatively soft polishing agent made from the calcified internal shell of the cuttlefish, cuttle is used on paper disks.
- **Tripoli.** A fine siliceous polishing powder that is combined with a wax binder to form light brown cakes, tripoli is used in the initial polishing step of gold on either a cloth buff wheel or a soft bristle brush.
- **Rouge.** Composed of iron oxide (Fe_2O_3), rouge is supplied in cake form. It is the finest of the polishing agents used extraorally on gold castings. It is applied with a soft bristle brush or a small muslin buff wheel. Rouge is also used to fabricate crocus disks.
- **Tin oxide.** This is used as a fine powder on a brush or rubber cup for final intraoral polishing of metal restorations.

These materials are bonded to a paper backing or mixed with a binder and pressed into various shapes to form stone or rubber wheels, disks, and points for specific processes. They are also incorporated into pastes for use on brushes, cloth wheels, or rubber cups. Some commonly used forms are as follows:

- **Separating disks** (also called *Joe Dandy disks*) are stiff and will cut on the edges as well as on the sides. They are useful for removing sprues from castings, for sectioning fixed partial dentures, and for contouring embrasures around pontics.
- **Moore disks** (E. C. Moore) are flexible paper disks coated on one side with various grits of garnet, sand, emery, and cuttle and are used for contouring and smoothing large convex areas on gold and resins. Each disk has a square hole for mounting on a special mandrel, which allows it to be rotated in reverse.

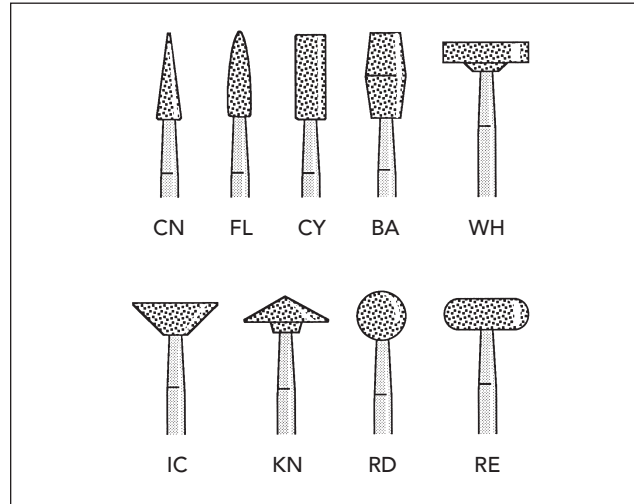


Fig 21-2 Common shapes of abrasive stones are: cone (CN), flame (FL), cylinder (CY), barrel (BA), wheel (WH), inverted cone (IC), knife edge (KN), round (RD), and round edge (RE).

- *Heatless stones* are extremely coarse stones for bulk removal of metal.
- *Busch Silent Stones* (Pfingst) are large, fine-grained stones for reducing broad areas of porcelain.
- *Green stones* contain silicon carbide and are manufactured in many different shapes (Fig 21-2). They are permanently mounted to their mandrels and can be rotated in reverse as well as forward. They are of medium grit and are used for shaping metal and porcelain.
- *Pink stones* are made of porcelain-bonded aluminum oxide and are used only for finishing the areas of metal copings to which porcelain is to be fired.
- *White stones* contain fine-grained aluminum oxide. They are useful for smoothing the rough surfaces left by green stones and for adapting gold margins to enamel intra-orally.
- *Rubber wheels and points* are used for polishing metals and ceramics. Examples of coarser disks are Cratex (Cratex), White Flexies (Dedeco), and brown disks (Dedeco). Finer disks that will produce a satin finish include blue disks, points, and wheels (Dedeco). Brownies and Greenies (Shofu) are fine-grit disks that are capable of producing a fairly high polish.

Preliminary Finishing of Gold Restorations

To minimize the expenditure of valuable chair time, preliminary adjustments using the die and master cast should be completed on the internal and external surfaces of the

restoration prior to the cementation appointment. A dentist who can seat a crown that is comfortable with a minimum amount of chairside adjustments will win the confidence of the patient.

Armamentarium

- High-speed handpiece
- Straight handpiece
- Separating disk on mandrel
- Cratex disk on mandrel
- 5/8-inch blue wheel on mandrel
- Blue mounted knife-edge disk
- No. 0 bud finishing bur (Pfingst)
- No. 330 friction-grip bur
- Articulating paper
- Green stone (Dura-Green, Shofu)

Technique

The internal portions of the casting are inspected under magnification for small nodules or bubbles of gold. Any that are found are removed with a no. 330 bur in a high-speed handpiece (Fig 21-3). All of the negative angles are traced on the inside of the occlusal surface with the tip of the bur. When there are no obvious artifacts in the casting, it is seated gently on the die. Then the casting is removed, and the preparation portion of the die is inspected. If there are any small scratches on the surface, the corresponding areas of the internal portion of the casting are examined, and the side of the no. 330 bur is used to relieve any areas of

21 Cementation and Bonding

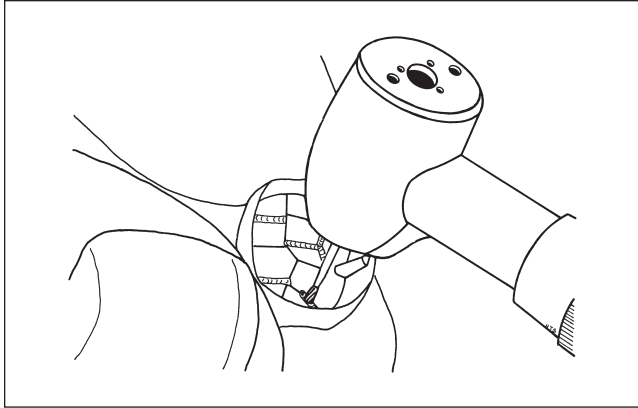


Fig 21-3 A no. 330 bur is used to remove nodules from the inside of a casting.

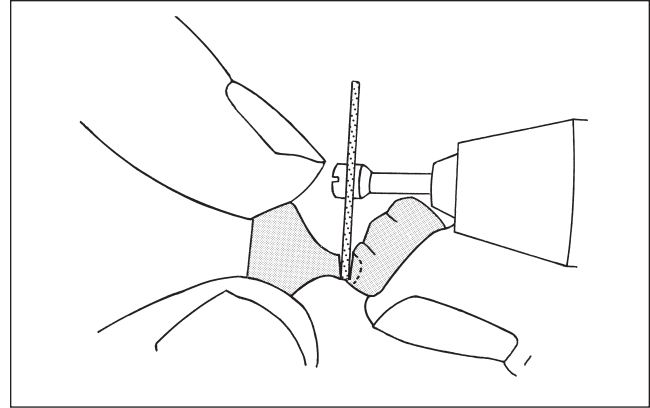


Fig 21-4 The sprue immediately adjacent to the casting is removed with a separating disk.

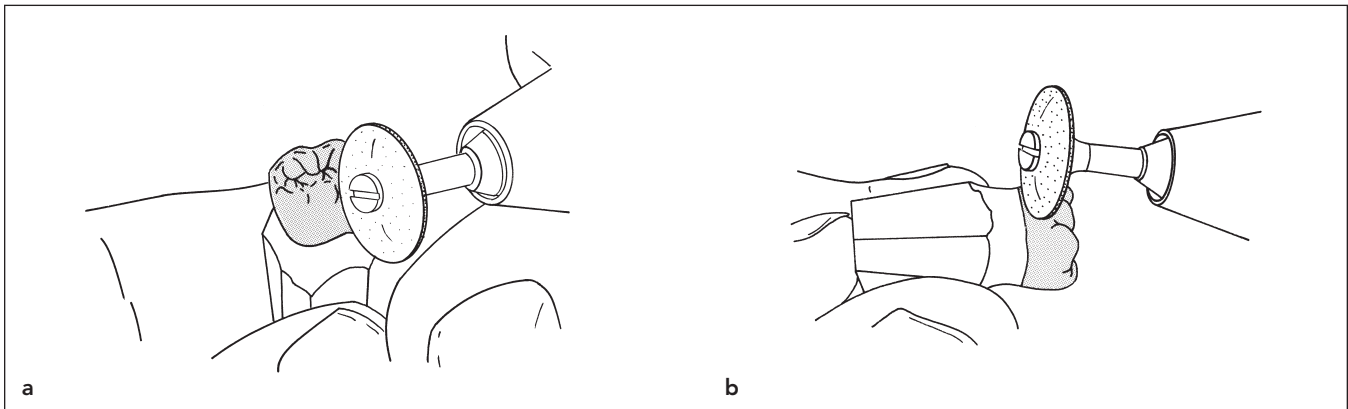


Fig 21-5 (a) Axial surfaces are smoothed with a blue disk. (b) While the area very near the margins is being smoothed, the disk should be turned parallel with the margin.

the casting where small particles of stone or smudges of die spacer are found clinging.

Ideally, the casting should touch the die only in the marginal region. There should be a slight gap everywhere else for the future cement film. The optimum film thickness of zinc phosphate cement is approximately 30 to 40 μm .^{11,12} The space allows cement to escape as the crown is seated and provides some thermal insulation under metal crowns. If adequate relief has not been created in the laboratory, it can be added by chemical or electrolytic etching until the restoration can be seated and removed from the die with gentle finger pressure. Mechanical grinding for this purpose must be done judiciously because it can easily destroy retentive features or create marginal defects.

When the fit on the die is satisfactory, the restoration is ready for finishing of the external surface. The procedure described here for finishing the external surface of a gold alloy is essentially the same as that developed by Tanner and described in detail by Troxell.¹³

A separating disk is used to cut the sprues from the casting (Fig 21-4). Diagonal cutting pliers may be used, but the stress generated by them could distort a thin casting.

The handpiece is held with a firm palm grasp while cutting the sprue next to the casting. Tipping the disks must be avoided—if a disk binds in the cut groove, it may flip the casting out of the hand. After the sprue is removed, the separating disk is used to trim the remaining portions of the sprue attachment on the casting until the contour in that area is continuous with the contour of the restoration surrounding the sprue.

A coarse rubber disk (eg, Cratex or White Flexie) is used to smooth away the roughness left by the separating disk. Light pressure is applied, and the disk is moved around quickly to avoid the formation of facets or flat spots. A finer blue disk is used in a similar manner after the coarse disk (Fig 21-5a). The entire external surface of the casting should now be smooth, with a satin finish. The axial surface should be finished to the margin, but finishing should not extend over the margin. To accomplish this, the disk should be rotated parallel with the margin rather than perpendicular to it (Fig 21-5b).

The restoration is seated on the mounted working cast. If a separate die and working cast have been used, some of the stone replicating the gingiva may need to be removed to seat the restoration completely. The gold in the interproximal

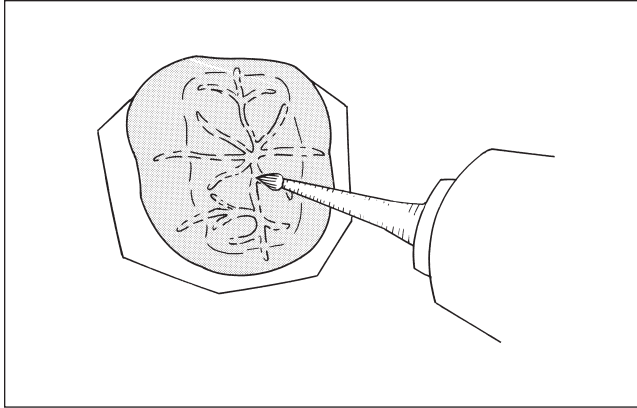


Fig 21-6 Grooves are finished with a small bud finishing bur.

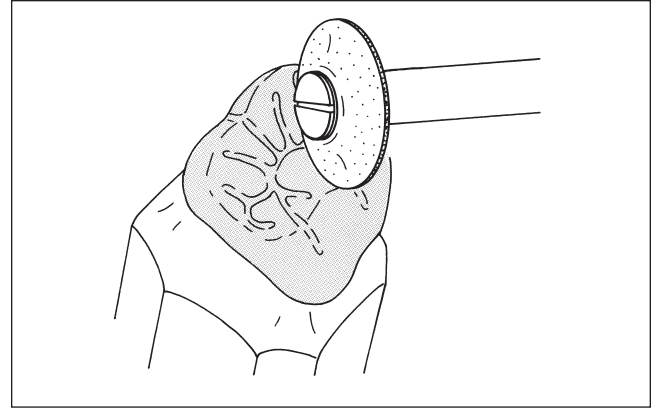


Fig 21-7 Cusp ridges are finished with a small, rubber knife-edge disk.

areas is slowly adjusted until the restoration seats completely but still contacts the adjacent teeth. Coarse disks or stones should not be used for this purpose because an open contact will result when the restoration is given its final polish.

The casting must be completely seated before the occlusion is checked on the articulator. Otherwise, it may be ground out of occlusion before it is even tried in the mouth. Any excessive centric and eccentric contacts are adjusted using marking ribbon and green stones.

The restoration is removed from the working cast and placed back on the die. A no. 0 bud finishing bur is used to smooth out the grooves on the occlusal surface (Fig 21-6). The cusp ridges are smoothed and blended into the grooves on the occlusal surface with a small, rubber knife-edge disk (Fig 21-7). External gold surfaces should have a satin-like finish produced by a blue rubber polishing wheel at try-in. For a novice, a highly polished surface is not desired at this time because it will make detection of excessive occlusal and proximal contacts more difficult. The inner (tooth-facing) surface should be air abraded in preparation for try-in.

Try-in and Adjustment of Gold Restorations

If performed carefully and gently, the try-in procedure can be accomplished on many patients without administering an anesthetic. The patient's unimpaired tactile sense can be valuable during the adjustment of the occlusion, and the annoyance of lingering anesthesia is avoided. If the patient is made uncomfortable by the procedure, however, an anesthetic most certainly should be given.

Cementation should be postponed if the patient reports that the tooth has been hypersensitive under the provisional crown. The tooth would be subjected to even greater chemical and thermal trauma by placement of a metal crown. In these cases, it should be verified that the provisional restoration is not in hyperocclusion and that it covers all prepared tooth surfaces. It should be recemented for several days. If pulpitis persists, endodontic therapy will be necessary before the permanent restoration can be cemented. A crown should never be permanently cemented over a symptomatic tooth.

Armamentarium

- 2 × 2-inch gauze squares
- Mallet
- No. 15 straight chisel
- Backhaus towel forceps
- Miller forceps
- Cotton pliers
- Cotton pellets
- Dental floss
- Plastic bite wafer
- Articulating paper
- Silver plastic shim stock (13-μm thick) (Artus)
- Straight handpiece
- 5/8-inch blue wheel on mandrel
- Green stones
- No. 2 round bur
- Spratley knife
- Contra-angle handpiece
- Tapered white polishing stone
- Petrolatum
- 3/8-inch cuttle disk on mandrel

21 Cementation and Bonding

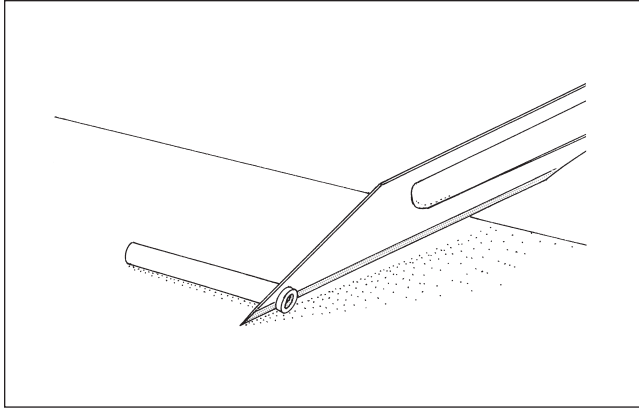


Fig 21-8 A safety ring may be fashioned by cutting a thin slice from a hollow sprue.

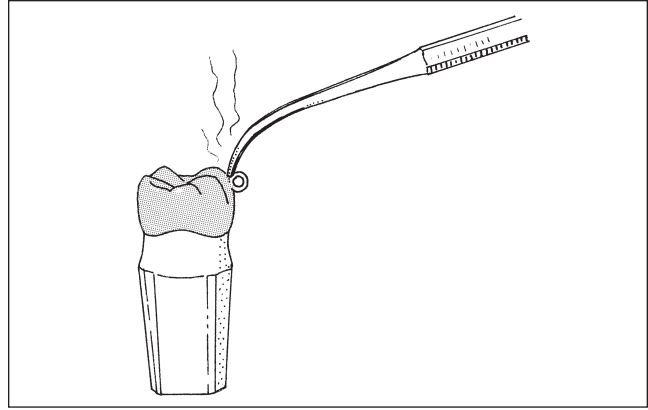


Fig 21-9 The ring is luted to the wax pattern.

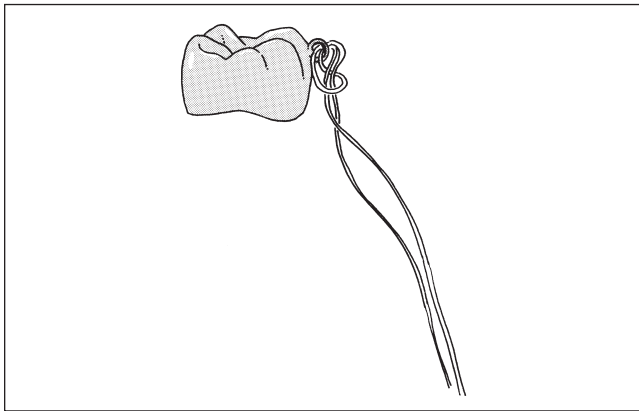


Fig 21-10 A length of dental floss is looped through the ring on the casting.

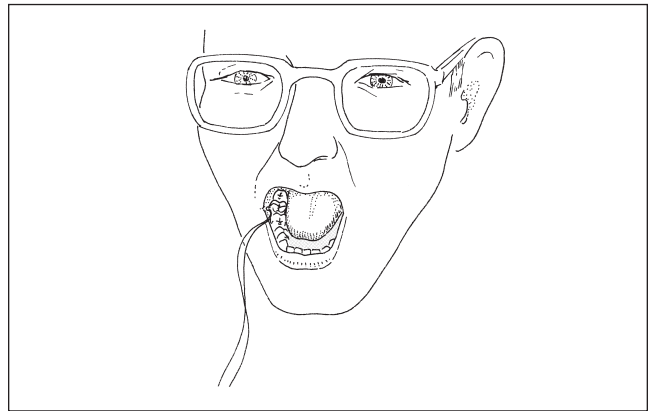


Fig 21-11 The floss is allowed to hang out of the corner of the mouth.

Technique

Precautions must be taken during try-in to minimize the risk of the restoration being swallowed or aspirated. This is especially important with patients whose reflexes are diminished, such as those who are elderly or sedated. A small safety ring can be provided on metal crowns by cutting a thin slice from a hollow sprue (Fig 21-8). It is attached to the wax pattern where it will not interfere with the occlusion¹⁴ (Fig 21-9). Floss is threaded through the ring before the casting is tried in the mouth (Fig 21-10). The floss is left hanging out of the mouth during try-in and adjustments (Fig 21-11). This also makes removal of tightly fitting castings easier. If a safety line is not used, a gauze square should be placed on the floor of the mouth.

The provisional restoration is removed by grasping the facial and lingual surfaces with the tips of a Backhaus towel forceps and rocking it to the facial and lingual (Fig 21-12). An alternative technique uses a small mallet and a straight enamel chisel with a 1.5-mm-wide blade. The tip of the chisel

is pointed in an occlusal direction and engaged under a bulge on the buccal surface of the restoration near one of the proximal embrasures (Fig 21-13). The chisel is tapped lightly to loosen the restoration.

Most of the temporary cement will adhere to the inside of the provisional restoration. Any cement left on the surface of the preparation is carefully picked off. A dry cotton pellet held in cotton pliers is run over the preparation surface to wipe off small clinging particles, and then the preparation is washed with lukewarm water. Cold water will make the unanesthetized patient uncomfortable.

Evaluation of a restoration should be carried out in the following sequence:

1. Proximal contacts
2. Margins (completeness of seating)
3. Occlusion
4. Contours
5. Esthetics

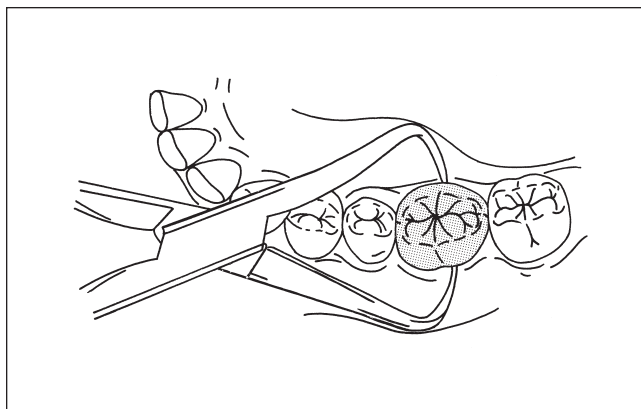


Fig 21-12 The provisional restoration can be removed with a Backhaus forceps.

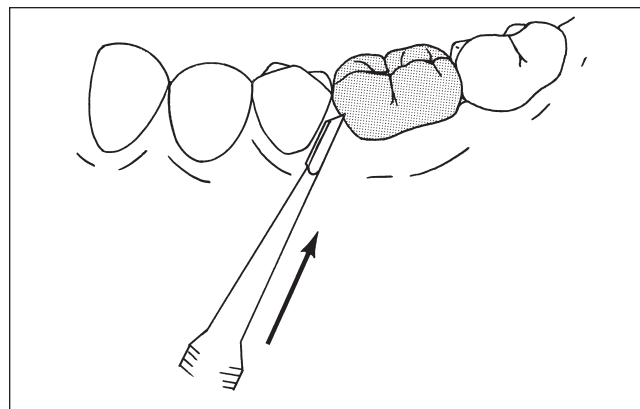


Fig 21-13 A straight chisel can also be used to remove the provisional restoration.

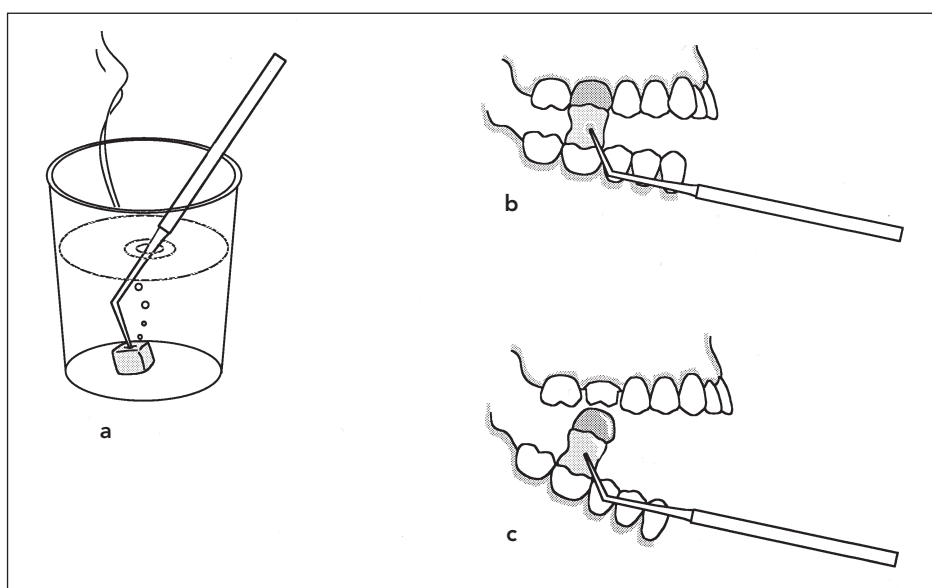


Fig 21-14 (a) A Richwil crown remover is soaked in hot tap water for 1 minute. (b) The patient closes on the softened cube. (c) The patient opens quickly and forcefully to remove the crown.

Adjustment of proximal contacts

The proximal contacts of a restoration must be neither too tight nor too light. If they are too tight, they will interfere with correct seating of the restoration, produce discomfort, and make it difficult for the patient to floss. A proximal contact that is too light will allow impaction of strands of food, which is deleterious to the gingiva and annoying to the patient.

The restoration is placed on the tooth and seated with firm finger pressure. Neither a mallet nor occlusal pressure by the patient should be used. Forcing the restoration onto

the tooth at this time may make it extremely difficult to remove. A crown should be able to be removed if it is grasped with a dry gauze sponge and rocked slightly. A crown that cannot be removed with the fingers may be removed using a Richwil crown remover (Almore), which is a green, sticky cube. The cube is softened in hot water and placed over the crown (Fig 21-14a). The patient is instructed to bite into the cube and hold for a few seconds (Fig 21-14b). Then a quick opening movement should remove the crown from the tooth preparation (Fig 21-14c). Obviously, this requires the presence of firm, natural opposing teeth with no cemented restorations on them.

21 Cementation and Bonding

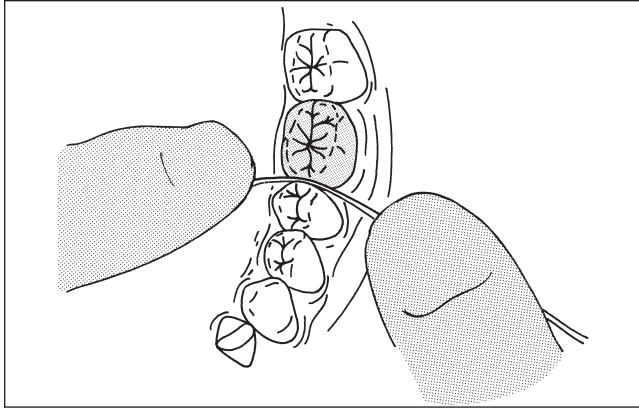


Fig 21-15 Proximal contacts are tested with dental floss.

Using the straight chisel and mallet as described for provisional crown removal may be necessary. Often a crown will be easier to remove after being worn for 24 hours without cement. If all else fails, the restoration must be cut off.

A frequent cause for failure of a restoration to seat completely is an overcontoured proximal surface. The restoration is held firmly in place, and both proximal contacts are tested with waxed floss (Fig 21-15). If the crown is not held firmly enough, it may become slightly elevated or tipped, allowing the floss to pass through even though the contact is actually too tight. Each contact should be as tight as the others in the mouth. If floss will not pass through the contact, the restoration should be removed and the proximal surfaces examined.

At this point, the desirability of leaving a satin finish on a gold restoration becomes apparent because there will be a shiny burnished area where the tight contact occurred. A blue or Cratex wheel is used to remove the shiny mark, and then the casting is tried back on the tooth. This is repeated until floss can pass through with the same amount of resistance offered by the other contacts. If both proximal contacts feel too tight, the tighter contact should be adjusted first. Sometimes this will relieve the pressure on the second contact, precluding the need for its adjustment.

Care must be taken not to remove too much material from the contact area. If the proximal contact is open or too light, this must be corrected by adding solder before cementation.

Marginal adaptation (completeness of seating)

After the proximal contacts have been corrected, the restoration is seated, and the margins are examined closely. An acceptable margin is not overextended, underextended, too thick, or open (Fig 21-16). A margin is generally considered

to be open if the gap is greater than 50 μm , which means the tip of a sharp explorer can be inserted between the restoration and tooth. A restoration that rocks perceptibly on the tooth cannot have closed margins on both sides at once. Subgingival marginal discrepancies are the most difficult to detect and the most detrimental to gingival health.

The most common cause of poorly adapted margins is failure of the restoration to seat completely. If the proximal contacts are not too tight and the margins are still short or open, there may be some minute undercut, unseen defect, or distortion preventing seating. A convenient technique for improving the seating of castings of softer gold alloys is to produce a matte surface on the inner surface with an airborne particle-abrasion instrument or airbrush, seat the restoration firmly on the tooth, remove it, and relieve any shiny areas with a no. 330 bur. Care must be taken not to destroy the metal projections that fit into grooves or boxes.

There are a number of materials that can be used for locating internal discrepancies. The inside of the crown may be painted with chloroform and rouge or thinned correction fluid or sprayed with a thin layer of a dry aerosol indicator (Occlude, Pascal) (Fig 21-17). Disclosing wax (Kerr) indicates not only points of interference but also the thickness and configuration of the future cement film, which in turn reveals the completeness of seating and the closeness of adaptation of subgingival margins.¹⁵ The restoration is filled half full of disclosing wax and heated in a flame just enough to make the wax flow and adhere to the inner surface. The tooth must be wet with saliva to keep the wax from sticking to it. When the wax has resolidified, the restoration is seated, held in place for approximately 10 seconds, and removed. Areas of metal-tooth contact will appear inside a crown as shiny spots devoid of wax. Ideally, the margins (where no cement spacer was used on the die) should show intimate contact, and the remainder of the restoration should have a thin coating of wax representing the cement space.

Relief of impinging areas with a no. 330 bur will usually allow the restoration to seat further. Impression-type materials, such as Fit Checker (GC) or alginate, can also be used, but they are more time-consuming. All disclosing materials must be completely removed from inside the restoration by swabbing with chloroform and air abrading prior to cementation so that retention will not be diminished. The tooth may be cleaned with Cavidry (Parkell).

Gold margin finishing

Type III and softer golds differ from other materials in that they can be burnished against the tooth to some extent. This must not be attempted until it is certain that the casting is seated as far as it will go.

Two types of margins need to be considered: subgingival and supragingival. Those margins that will be subgingival can be burnished on the die with a beavertail burnisher or fine stone. No intraoral finishing procedure is indicated for subgingival margins because of the risk of damage to the tooth and periodontal structures. Supragingival margins of inlays, onlays, and partial veneer crowns can be finished on

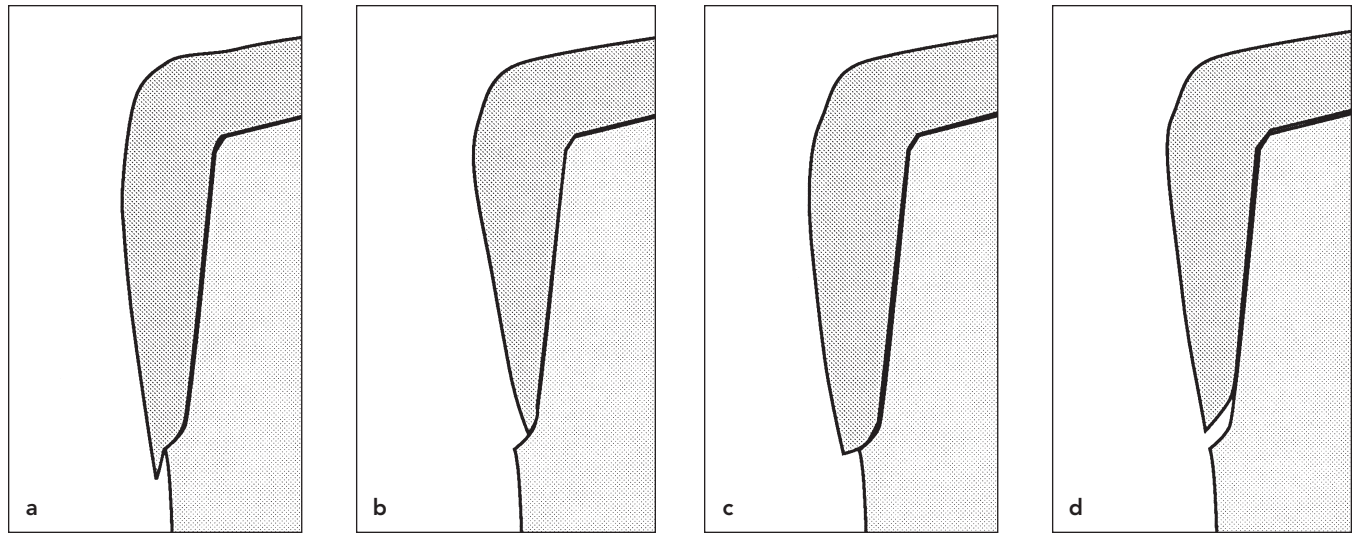


Fig 21-16 Types of defective margins: (a) overextended; (b) underextended; (c) thick; and (d) open.

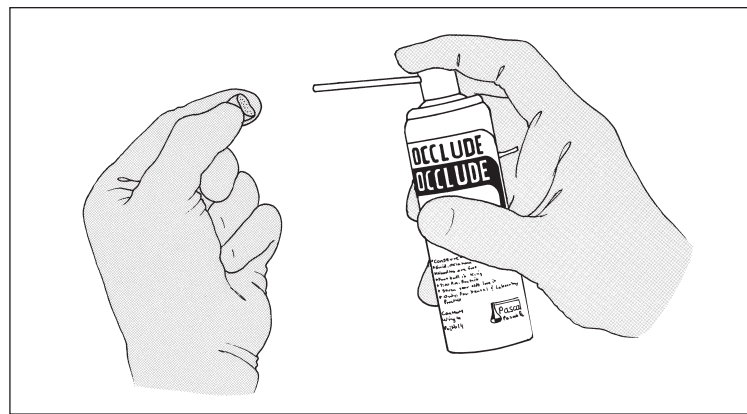


Fig 21-17 The inside of the casting is coated with an indicator that will show the location of areas that prevent complete seating.

the tooth. With proper finishing procedures, margins can be adapted to reduce the opening between the margin and tooth to less than the film thickness of the cement.¹⁶

The casting is placed on the prepared tooth and seated firmly by the patient closing on a plastic bite wafer or a wooden stick. Complete seating of the restoration and adequate fit of the margins are verified. No attempt should be made to close gross marginal openings because gold that has been moved or dragged by a coarse abrasive forms a soft, granular lip that can be easily broken or deformed during subsequent manipulation.¹⁷

A burnisher, such as a dull Spratley knife, can be used to press the margins against the tooth surface (Fig 21-18). The restoration must be held in place with another instrument or by having the patient close on a bite wafer during burnishing.

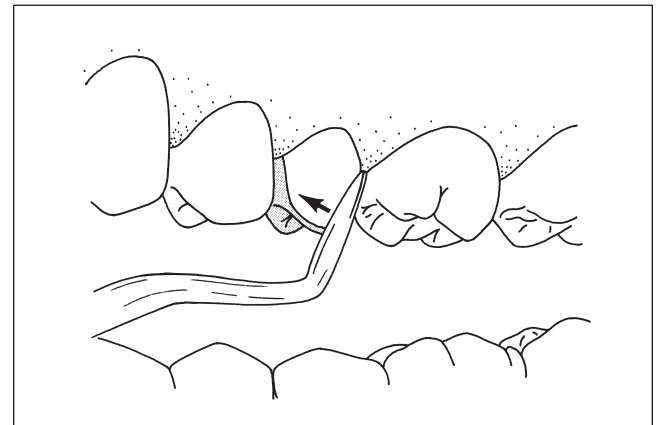


Fig 21-18 All accessible margins are burnished intraorally with a smooth, dull instrument.

21 Cementation and Bonding

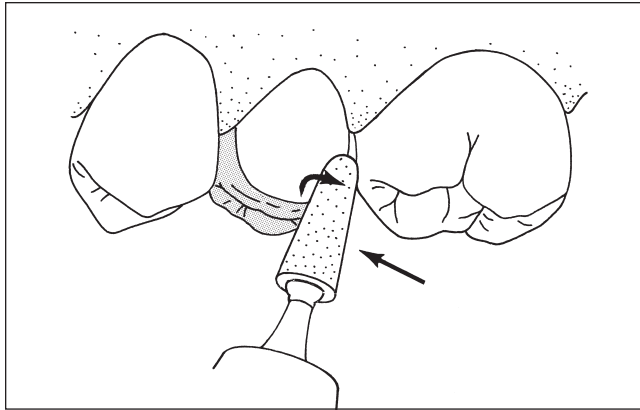


Fig 21-19 Margins are finished with a white stone rotating from gold to tooth.

The use of a Spratley knife has been shown to improve marginal adaptation by as much as 30 μm .¹⁸ If a white polishing stone lubricated with petrolatum is also used and followed by a cuttle disk, the adaptation of the margin can be improved by nearly 60 μm . Therefore, a white polishing stone and petrolatum are used for finishing after the burnishing. The white stone should always rotate from casting to tooth surface, under heavy pressure and at low speed (Fig 21-19). Slight amounts of gold and tooth structure are cut. An explorer is used to check for open margins. If slight defects exist, the procedure should be continued until the margin is smooth. Green stones are not recommended because they may abrade too much tooth structure and gold. A final precementation smoothing can be achieved with a $\frac{3}{8}$ -inch cuttle disk.

Care should be exercised in removing the casting to prevent damage to the margins. A dull chisel can be placed under a proximal area, and several light taps with a mallet will remove the casting. The Backhaus towel forceps can also be used, with care taken not to damage the margins. If there are sound opposing teeth, the Richwil crown remover can be used as described previously. A safety ring made as an integral part of the restoration to prevent aspiration (see Fig 21-8) can also be used as an aid in removing a crown following try-in. When the casting has been removed for the last time, the ring is removed and the area polished.

If a restoration persists in not seating completely, it is important to recognize that inordinate amounts of time can be spent in attempting to make a poor restoration fit, and yet the end result of this expenditure of time will be a mediocre restoration at best. If a restoration will not fit and the cause cannot be quickly determined and corrected, the restoration should be remade. If the discrepancy in fit appears to be similar on the die and on the tooth, a new restoration can be fabricated on the same die, provided the die has not been damaged.

Occlusal adjustment

Only after complete seating of the restoration has been assured should any occlusal adjustments be performed. To provide a basis for comparison, the patient is instructed to close into the customary position of maximal intercuspation with the restoration removed. The position of the teeth and the completeness of closure and contact are noted. A pair of teeth near the prepared tooth where the patient can hold a strip of 13- μm (0.0005-inch) shim stock is located. The restoration is inserted, and it is determined whether the patient can still hold the shim between the same pair of nearby teeth. If not, the crown is high in the intercuspital position (Fig 21-20). A thumb is placed on the patient's chin, and the mandible is arced open and closed until it is slowly guided into its most retruded position; the patient is instructed to close until the first tooth contact occurs. The patient is asked to point to the tooth that is touching. If the restoration is indicated, it is high and needs occlusal adjustment.

The patient is asked to close together forcefully and try to make all teeth touch. If the mandible shifts to the side where the restoration is located, the buccal incline of the maxillary palatal cusp or the lingual incline of the mandibular buccal cusp needs adjustment (Fig 21-21). If the mandible shifts to the side away from the restoration, one of two deflective contacts requires correction. There is a possibility of a heavy contact between the palatal incline of the maxillary buccal cusp and the buccal incline of the mandibular buccal cusp (Fig 21-22). There also may be excessive contact between the palatal incline of the maxillary palatal cusp and the buccal incline of the mandibular lingual cusp that needs correction (Fig 21-23).

A piece of thin articulating paper the width of the restoration is cut and placed in a Miller forceps. It is held between the restoration and the opposing tooth, and the patient is asked to close. The restoration is removed from the mouth, and only the carbon marks on the appropriate surfaces are removed. Other markings on the restoration are ignored at this time. This procedure should be continued until no mandibular shift is evident and shim stock can be held between adjacent pairs of teeth. Due to the resiliency of the bones and joints, the patient's ability to hold shim stock on the opposite side of the arch is not a sure indication that the restoration is adequately adjusted.

Care must be taken not to overcorrect the occlusion. The amount of correction can be monitored by placing a narrow strip of plastic shim stock over the restoration and having the patient close on it. The shim stock should offer the same amount of resistance when tugged from the side as it does between the adjacent teeth (Fig 21-24). If the shim stock holds on the adjacent teeth and not on the restoration, the restoration has been overadjusted and must be either added to or remade. Ideally, the anterior teeth should not touch in the centric position; they should miss by the thickness of the 13- μm (0.0005-inch) shim stock.

Adjustment of the restoration in excursive movements is essential. This can be tested by again using the narrow strip of plastic shim stock. It is placed between the restoration and

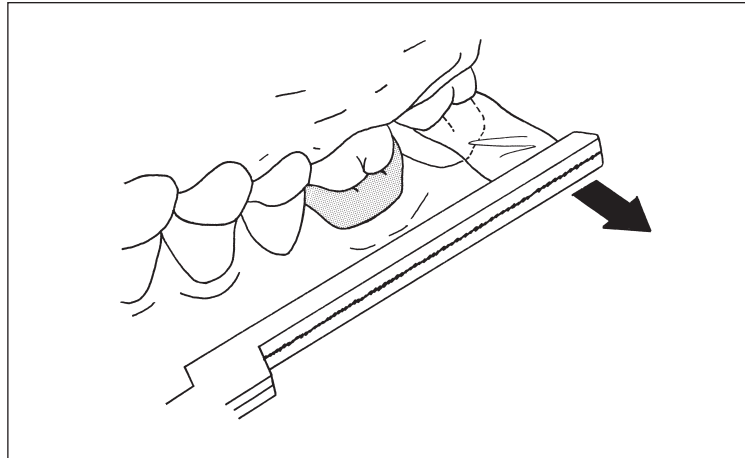


Fig 21-20 If the patient can hold shim stock on adjacent teeth without but not with the crown, the crown is too high.

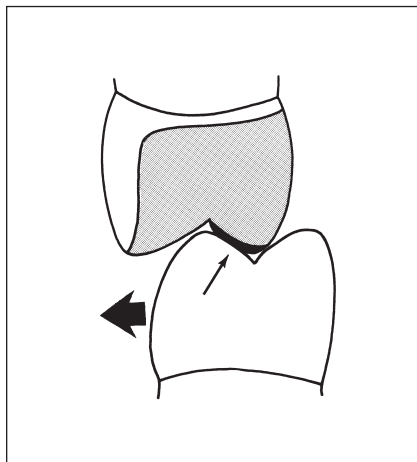


Fig 21-21 A premature contact (*small arrow*) on the buccal incline of the maxillary palatal cusp produces a buccal shift (*large arrow*) of the mandible.

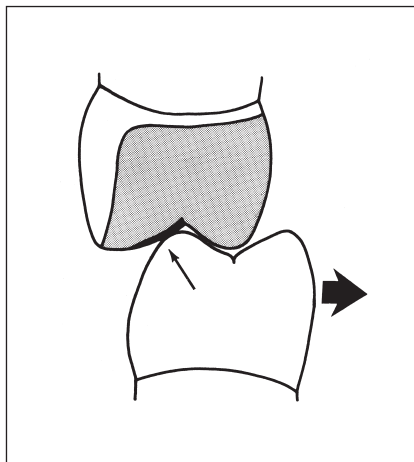


Fig 21-22 A premature contact (*small arrow*) on the palatal slope of the maxillary buccal cusp produces a lingual shift (*large arrow*) of the mandible.

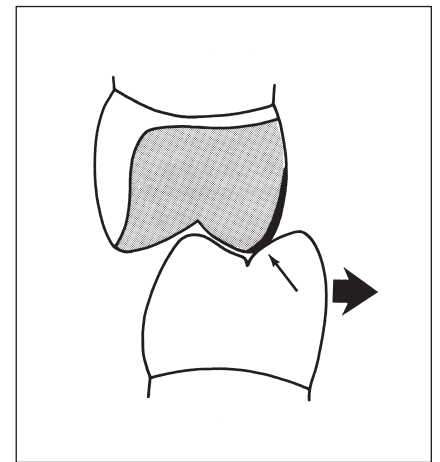


Fig 21-23 A premature contact (*small arrow*) on the palatal incline of the maxillary palatal cusp produces a lingual shift (*large arrow*) of the mandible.

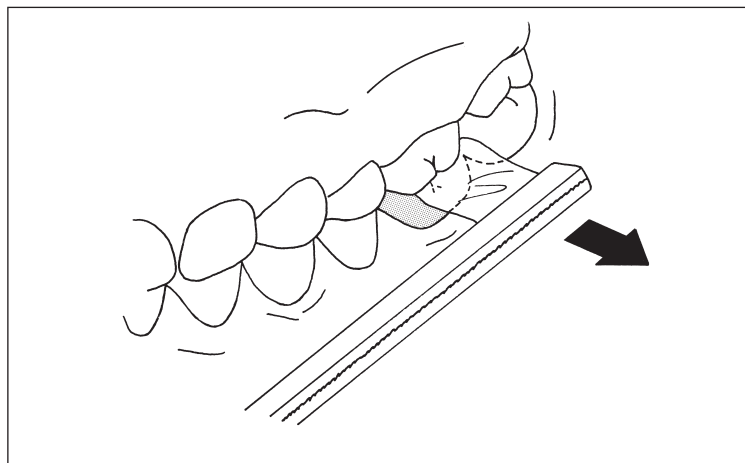


Fig 21-24 If the patient can hold shim stock over the crown, the crown has been correctly adjusted. If not, it has been overadjusted.

21 Cementation and Bonding

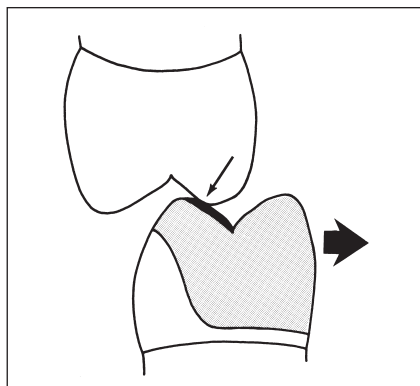


Fig 21-25 Nonworking interference.

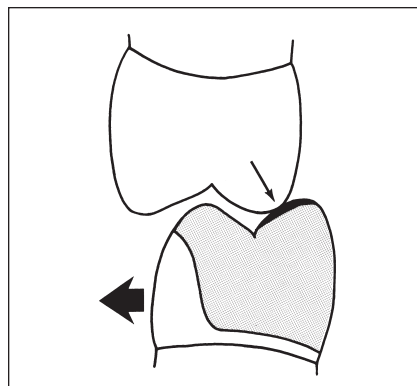


Fig 21-26 Working interference.

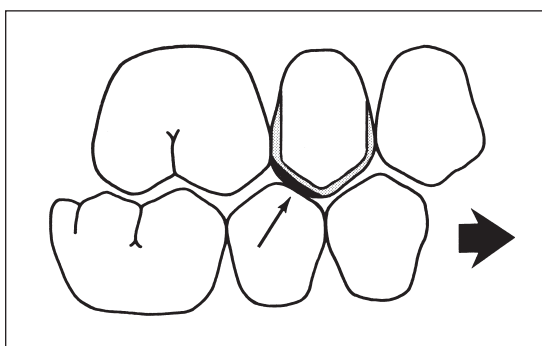


Fig 21-27 Protrusive interference.

the opposing tooth, and the patient is asked to close firmly; then the patient is instructed to move into a working relationship on the side of the mouth opposite the restoration. The shim stock should be held tightly in the intercuspal position, but as soon as the nonworking movement starts, it should be able to be removed easily from between the restoration and opposing teeth. If not, the shim stock should be replaced with articulating paper and the area of contact located.

For adjustment of the nonworking movement, the marks that are found on the buccal inclines of the maxillary palatal cusps and the lingual inclines of the mandibular buccal cusps must be eliminated (Fig 21-25). Working-side interferences on the restoration may be adjusted by having the patient move into a working relationship on the side of the mouth where the restoration is located. For the adjustment of working-side interferences, contacts on palatal inclines of maxillary palatal cusps and buccal inclines of mandibular lingual cusps are removed (Fig 21-26).

Contacts between the palatal inclines of the maxillary buccal cusps and buccal inclines of mandibular buccal cusps may or may not be removed depending on the occlusal scheme that is being established. If the goal is a canine-guided or mutually protected occlusion, these contacts should be removed. However, if group function is desired, these contacts are desirable and should be reduced only to the level at which they no longer cause disocclusion of the canine teeth. Teeth that are mobile may move during excursions, giving a false indication on the articulating ribbon. To detect move-

ment, a fingernail is held against the facial surface of the restored tooth and its neighbor during excursions.

Finally, protrusive interferences are identified and removed. Again the patient closes on plastic shim stock in a retruded position and then moves the mandible forward. The distal inclines of the maxillary teeth and the mesial inclines of the mandibular teeth should be adjusted to relieve protrusive interferences (Fig 21-27). Contacts should appear on anterior teeth during excursive movements. Because anterior teeth help to disengage posterior teeth during excursive movements, these are considered desirable contacts. Whenever possible, anterior guidance should be shared by two or more pairs of occluding teeth.

Premature contacts on smooth surfaces can be located with great accuracy by adapting a strip of occlusal indicator wax (Kerr) to the teeth of the restored quadrant with the shiny, adhesive side toward the restoration. The patient is instructed to moisten the wax with saliva to prevent it from sticking to the opposing teeth and then tap the jaws in the maximal intercuspal position several times. The wax over the restoration should appear perforated to the same degree as the wax on the neighboring teeth. Excessive contacts will appear as bright spots uncovered by wax. These are relieved directly through the wax using a large high-speed round bur on metals and a diamond stone on ceramics. After these contacts have been equilibrated, more wax is applied, and the patient executes several chewing strokes. Interferences will appear as wax-free areas not present in maximal intercuspation.

Contours

Improper contours may impair gingival health and detract from a natural appearance, as described in chapter 19. They must be corrected before cementation. Excessive convexity near the gingival margin promotes accumulation of plaque. Surfaces directly occlusal to furcations are usually concave, and the concavity should extend occlusally on the axial surface of the restoration to improve access for a toothbrush.

Esthetics

The restoration should be viewed from a conversational distance to determine if its contours harmonize with the rest of the patient's dentition. The patient should be allowed to look in a mirror so that any objections to the appearance can be dealt with before the restoration is cemented.

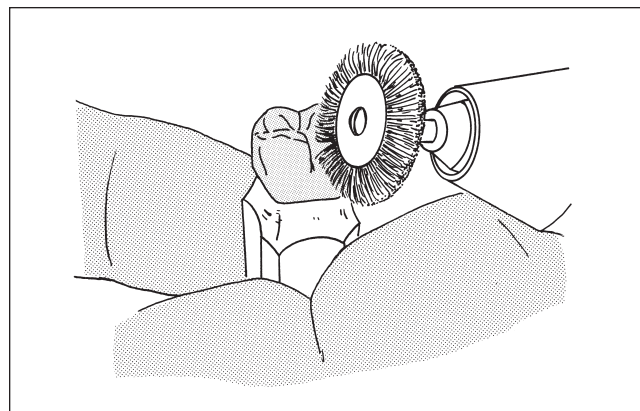


Fig 21-28 Casting is polished with soft Robinson brushes using first tripoli and then gold rouge.

Precementation Polishing of Gold Restorations

After the occlusion has been adjusted and accessible margins have been finished in the mouth, the restoration is polished to a high shine.

Armamentarium

- Straight handpiece
- $\frac{5}{8}$ -inch blue wheel on mandrel
- Mounted knife-edge blue disk
- No. 0 bud finishing bur
- Mounted Robinson brushes (soft)
- Tripoli
- Gold rouge
- 1-inch masking tape
- Airborne particle-abrasion instrument

Technique

Any rough spots on the axial surfaces are removed with a $\frac{5}{8}$ -inch blue wheel. A distance of 1.0 mm should be maintained from any margins that have already been finished in the mouth because they are fragile and may be bent or polished away with this abrasive wheel. Then all the axial surfaces are polished with tripoli on a soft-bristle brush (Fig 21-28). The handpiece should be run in reverse to minimize the amount of material thrown back in the operator's face. The axial surface is polished with rouge on a second soft-bristle brush reserved only for this purpose. This should be done with the restoration on a die to avoid rounding over the thin margins. Until this time, manipulation of the gingival margins has been avoided, but now they must be polished to a high shine, especially where they will lie subgingivally. Polishing of

supragingival margins that were finished in the mouth may be postponed until after the restoration is cemented.

Occlusal anatomy that has been lost through adjustments is restored with a no. 171L carbide bur. Then the re-created occlusal grooves are refined with a no. 0 bud finishing bur. Cusp ridges may be smoothed with a knife-edge blue disk, with care taken not to destroy the occlusal contacts so carefully developed earlier. From this point, the occlusal surface can be treated in one of two ways: It can be carefully polished to a high shine, or it can be air abraded to provide a matte finish. The dull matte surface will enable observation of facets or burnishing produced by occlusal contacts after the casting has been in the mouth for a short time. The use of a matte finish in no way implies that the occlusal surface is unfinished or left in a roughly ground condition.

When an airborne particle-abrasion instrument is used to produce the matte finish on the occlusal surface, the polished axial surfaces and margins should be protected by wrapping the casting in 1-inch-wide masking tape (Fig 21-29a). The edge of the tape should be tightly adapted around the marginal ridges and cusp ridges because any area not covered by the tape will be air abraded. The excess width of tape left projecting beyond the margin forms a handle by which the casting can be held in the unit (Fig 21-29b). The casting is placed in the unit (Fig 21-30), and the occlusal surface is given a uniformly dull surface by a stream from the nozzle from a distance of about 3 inches.

A less coarse matte finish can be produced by a handheld air abrasion unit with fine aluminum oxide abrasive (Micro-etcher II, Danville; Airbrush, Paasche Airbrush) (Fig 21-31). The nozzle is moved around until all exposed areas of the crown have been dulled to a uniform matte finish. The restoration is rinsed in water and dried with air. A final check is made to be sure that there are no remnants of polishing agent or abrasive inside the restoration.

21 Cementation and Bonding

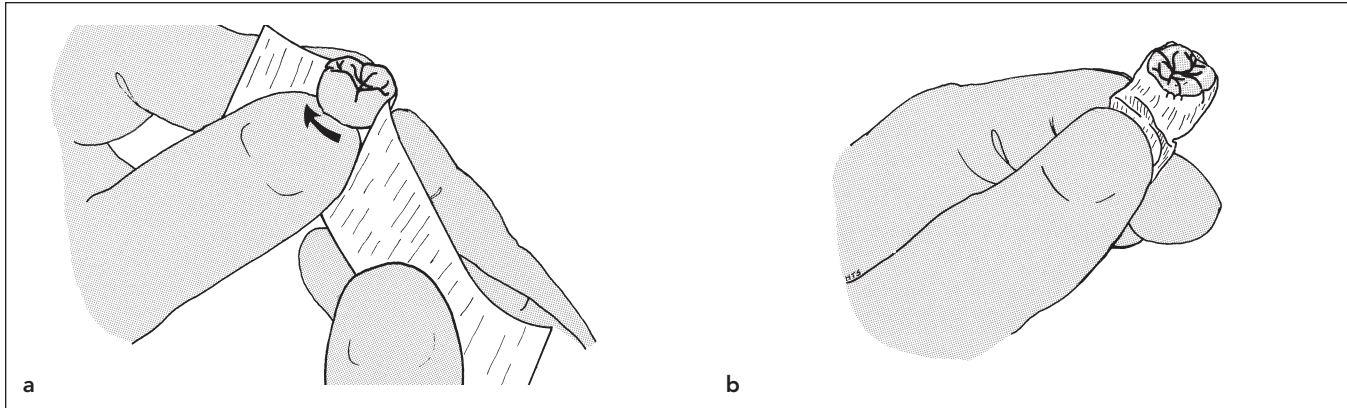


Fig 21-29 Masking tape is wrapped around the casting (a) so that only the occlusal surface is left uncovered (b).

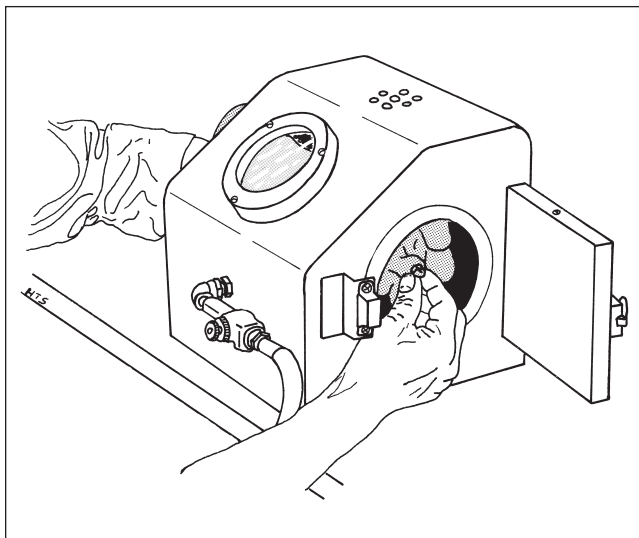


Fig 21-30 Casting is placed in the airborne particle-abrasion unit.

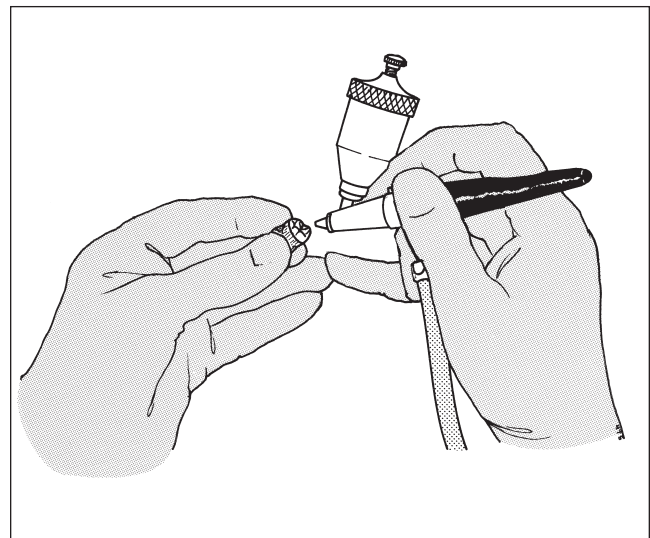


Fig 21-31 An airbrush also can be used to apply a matte finish to the occlusal surface of the casting.

Postcementation Finishing of Gold Restorations

After cementation, the occlusion should be tested again to make sure that there has been no increase in vertical dimension. There also may be excursive prematurities that escaped detection at try-in because of movement of the uncemented restoration. The patient should be asked how the restoration feels. Any report of a strange feeling in centric occlusion or a statement that the restoration “bumps” or “catches” during excursions means that there is a premature contact or an excursive interference. If not corrected, these can cause tooth hypersensitivity, tenderness, and even myofascial disturbances.

As a final check of the occlusion on a polished restoration, occlusal indicator wax is used as previously described.

Then the wax is removed, the anatomy refined with pointed stones, and all ground surfaces repolished using fine-grit rubber points.

The white polishing stone lubricated with petrolatum may again be used on the accessible margins of gold castings to reduce any minute projections of gold or enamel. However, after the cement has hardened, no further closing of the margins can be accomplished, and the result of attempts to do so is likely to be excessive removal of gold and exposure of even more underlying cement. The white stone may be followed by a fine cuttle disk, which has been lubricated to make it flexible, and several grits of wet pumice on a rubber cup.

Final polishing of the gold restoration can be accomplished intraorally with tin oxide on a rubber cup or brush. An anesthetized tooth can be easily overheated during polishing. To avoid this, only light intermittent contact is used, and one finger is kept on the restoration to monitor its temperature.

Preliminary Finishing of Base Metal Restorations

Base metals have grown in popularity in the last couple of decades because they are significantly less expensive than gold alloys. They also provide greater strength than do gold alloys, making them desirable for long-span prostheses. They are commonly used for resin-bonded fixed partial dentures because they provide a strong bond to resin cements when properly etched.

Armamentarium

- High-speed handpiece
- Straight handpiece
- 1.5-inch cutoff disk on mandrel
- No. 8 coral stone on mandrel
- No. 330 bur
- No. 1 round bur
- Aluminum oxide tapered stone
- Aluminum oxide inverted cone
- Blue rubber wheels and mounted points

Technique

The technique for finishing castings made of a base metal alloy is similar to that employed for gold alloys. The major difference lies in the use of coarser and harder abrasives on base metals. If the alloy being finished contains beryllium, standards of the Occupational Safety and Health Administration (OSHA) of the US Department of Labor require that it be ground only where there is adequate exhaust ventilation or if the technician is wearing an approved respirator.¹⁹

A 1.5-inch-diameter cutoff disk is used to remove the sprues. The contouring of the surfaces where the sprues were attached is completed with a no. 8 aluminum oxide coral wheel on a mandrel. The internal aspect of the casting is examined for small nodules of metal. They are removed with a no. 330 bur in a high-speed handpiece. When all such defects, as well as all investment, have been removed, the casting is tried on the working cast. If it binds, the casting is removed. The inside of the restoration is examined for particles of stone or smudges of die relief agent; any that are found are removed with the no. 330 bur. The casting is re-seated for finishing.

The occlusal grooves are smoothed with a no. 1 carbide bur. The rough finishing on all accessible areas is then performed with the no. 8 aluminum oxide coral wheel. Occlusal morphologic features (triangular ridges, cusp ridges, and cusp inclines) are finished with a mounted coral aluminum oxide tapered stone and inverted cone. The casting is smoothed with blue rubber wheels and mounted points.

Try-in, Adjustment, and Polishing of Base Metal Restorations

The fit of a base metal restoration is adjusted in much the same way as for a gold restoration. Because of the greater hardness of base metals, air abrasion will not disclose binding areas; therefore, disclosing paints or sprays must be depended upon. Smooth, highly polished axial surfaces are of equal importance in castings made of base metals. Because of the hardness of these alloys, some adjustments in technique and materials are required.

Armamentarium

- Straight handpiece
- Blue disk on mandrel
- White disk on mandrel
- No. 1 round bur
- Felt wheels
- Felt cones
- Polishing compound (Nobilium)
- Fine-grit polishing compound
- Mounted Robinson brushes (soft)
- Tripoli
- Palladius polishing paste (Vident)
- 1-inch masking tape
- Air abrader

Technique

Blue wheels and tips are used to smooth areas that were roughened during chairside adjustments. All of the accessible areas are then smoothed over with a white rubber wheel. The casting should be held so that the wheel is running parallel with the margin, which will allow finishing to the margins. The bottom of each groove can be finished with a no. 1 carbide bur. Steel burs are not very effective on base metal alloys, so bud finishing burs cannot be used for finishing grooves on base metal castings.

The next step will vary depending on the hardness of the metal used. If it is an extremely hard metal, polishing compound is used on a felt disk for axial surfaces and on felt cones for occlusal anatomy. The casting is thoroughly cleaned, and the high shine is applied with a finer-grit polishing compound on felt disks and cones. If a somewhat softer base metal alloy such as Rexillum III (Jeneric/Pentron) is used, the final polish can be achieved through the use of tripoli on a bristle brush, followed by Palladius on another bristle brush. Rouge can also be used for the final step, although it is not quite as effective. A matte finish on metal occlusal surfaces can be provided with an air abrasion unit if desired; however, the polished axial surfaces should be protected with masking tape.

21 Cementation and Bonding

Because the long-term success of any restoration is strongly influenced by the quality of the patient's oral hygiene, home care instructions and dispensing of appropriate cleaning aids (eg, floss threaders, interproximal brushes) must be considered an essential part of the cementation appointment.

Cements

The gap between an indirect fixed restoration and the tooth is filled with a cement or luting agent. The mechanisms that hold a restoration on a prepared tooth can be divided into nonadhesive (mechanical) luting, micromechanical bonding, and molecular adhesion. In many cases, combinations of these mechanisms are at work.

Bonding mechanisms

Nonadhesive luting

Originally, as the name implies (Latin *lutum* = mud), the luting agent served primarily to fill the gap and prevent entrance of fluids. Zinc phosphate cement, for example, exhibits no adhesion on the molecular level. It holds the restoration in place by engaging small irregularities on the surfaces of both tooth and restoration. The nearly parallel opposing walls of a correctly prepared tooth make it impossible to remove the restoration without shearing or crushing the minute projections of cement extending into recesses in the surfaces (Fig 21-32).

Micromechanical bonding

Resin cements have tensile strengths in the range of 30 to 40 MPa,²⁰ which is approximately five times that of zinc phosphate cement. When used on pitted surfaces, they can provide effective micromechanical bonding (Fig 21-33). The tensile strength of such bonds can sometimes exceed the cohesive strength of enamel. This allows the use of less extensive tooth preparation for restorations such as ceramic veneers and resin-bonded fixed partial dentures.

The deep irregularities necessary for micromechanical bonding can be produced on enamel surfaces by etching with a phosphoric acid solution or gel²¹; on ceramics by etching with hydrofluoric acid²²; and on metals by electrolytic etching, chemical etching, air abrading, or by incorporating salt crystals into the preliminary resin pattern.²³

Molecular adhesion

Molecular adhesion involves physical forces (bipolar, Van der Waals) and chemical bonds (ionic, covalent) between the molecules of two different substances (Fig 21-34). Newer cements, such as polycarboxylates and glass ionomers, possess some adhesive capabilities, although this is limited by

their relatively low cohesive strength. They still depend primarily on nearly parallel walls in the preparation to retain restorations.

Limited success has been achieved in attempts to develop resin cements and coupling agents that will exhibit strong, durable molecular adhesion to tooth structure, base metals, and ceramics. Noble metal alloys are not well suited for direct molecular bonding. However, a thin layer of silane can be bonded to a gold alloy with special equipment (Silicoater, Kulzer; Rocatec, 3M ESPE) to serve as a coupling agent by bonding chemically to resin cements. Equally effective is a layer of tin electroplated onto the gold alloy.²⁴

By applying a silane coupler to roughened porcelain, shear bond strengths in excess of the cohesive strength of the porcelain (approximately 30 MPa) have been achieved in the laboratory. However, such bonds tend to become weaker after thermocycling in water.²⁵ At this time, molecular adhesion should be looked upon only as a way to enhance mechanical and micromechanical retention and reduce microleakage, not as an independent bonding mechanism.

Cement selection

There are several types of cement available for the permanent retention of indirect restorations. These include zinc phosphate, zinc silicophosphate, polycarboxylate (zinc polyacrylate), glass-ionomer, resin-modified glass-ionomer, and composite resin cements. Cements based on zinc oxide and eugenol are not indicated for permanent cementation. Resin cements have the greatest compressive strength and the lowest solubility,²⁶ but, unfortunately, there is no cement that offers superior properties in all areas of concern.

Resin luting cements

Resin cements are composites made of a resin matrix (eg, bisphenol glycidyl methacrylate [bis-GMA] or diurethane methacrylate) and a filler of fine inorganic particles. They differ from restorative composites primarily in their lower filler content and lower viscosity. Resin cements are virtually insoluble and are much stronger than conventional cements. It is their high tensile strength that makes them useful for micromechanically bonding etched ceramic veneers and pitted fixed partial denture retainers to etched enamel on tooth preparations that would not be retentive enough to succeed with conventional cements.

Some of these cements are autopolymerizing for use under light-blocking metallic restorations, while others are either entirely photocured or dual-cured (light-activated) for use under translucent ceramic veneers and inlays. In dual-cured cements, a catalyst is mixed into the cement so that it will eventually harden within shadowed recesses after a rapid initial hardening is achieved with a curing light.

Problems that have been reported with the use of resin cements for luting full crowns include excessive cement film thickness,^{27,28} marginal leakage because of setting shrinkage, and severe pulpal reactions when applied to cut vital dentin.

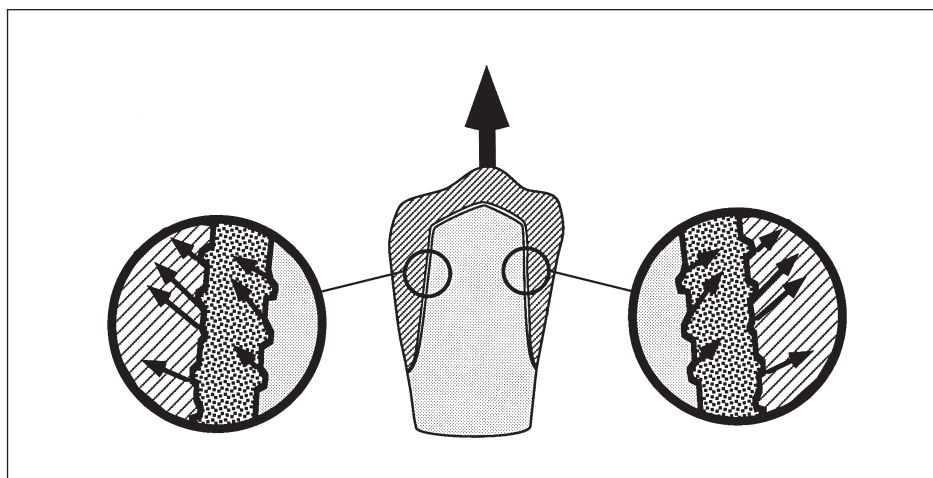


Fig 21-32 Nonadhesive luting. The crown can be removed only along the path (large arrow) determined by the axial walls of the preparation. Cement extending into small irregularities of the adjoining surfaces (insets) prevents removal along any path more vertical than the sides of the irregularities (small arrows).

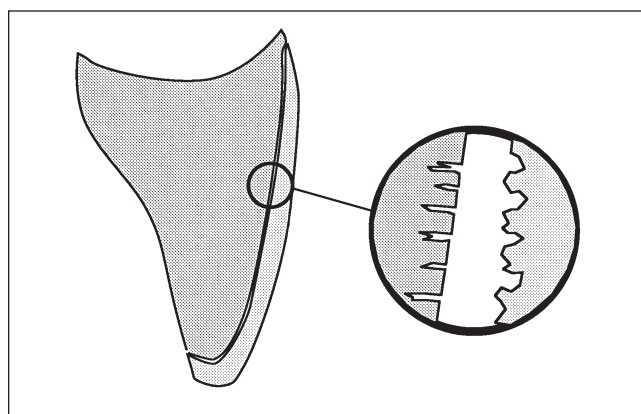


Fig 21-33 Micromechanical bonding. Composite resin cement holds the restoration to the tooth by penetrating into small, deep surface pits.

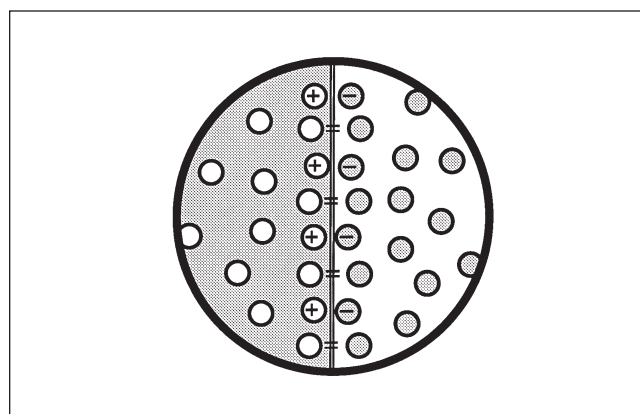


Fig 21-34 Molecular adhesion. True adhesion is the molecular attraction exerted between the surfaces of bodies in contact.

However, the latter may be related more to bacterial infiltration than to chemical toxicity. Use of a dentin bonding agent under a resin cement is critical to its success, unless the preparation has been cut in enamel.

Dentin bonding agents have been reported to reduce pulpal response, presumably by sealing the dentinal tubules and reducing microleakage.²⁹ Adhesive resin cement was found to produce a better marginal seal than zinc phosphate cement.³⁰ Even if the problems of film thickness and microleakage were solved, the problem of adequately removing hardened excess resin from inaccessible margins may preclude the use of resin cement for full crowns with subgingival margins.

A number of systems utilizing different mechanisms for bonding to the dentinal surface³¹ have been developed:

- Tags in dentinal tubules
- Bonding to precipitates on pretreated dentin

- Chemical union with inorganic components
- Chemical union with organic components
- Production of a resin-impregnated layer of dentin

In researching the mechanism of attachment to tooth structure, it was found that resin tags in excess of 200 μm were reported when resin was applied to the dentin surface of extracted teeth. However, the resin penetrated only 10 μm into the dentinal tubules of vital teeth, forming a resin-reinforced layer of tooth structure, the *hybrid layer*.³²

Chemical bonds are subject to degradation when they are exposed to the oral environment.³³ Microleakage may occur as a result of bond disruption, causing recurrent caries, sensitivity, and pulpal necrosis after restoration placement.³⁴ The *smear layer*, a 1- to 5- μm -thick³⁵ grinding debris-laden layer of dentin produced during tooth preparation, is a critical barrier that protects the tooth from the oral environment.

21 Cementation and Bonding

If bonding directly to the smear layer is attempted, however, tensile failure can occur between it and the cement or within the layer itself. Therefore, to enhance bonding to tooth structure, the tooth preparation is usually etched. This step alters the dentin surface by removing the smear layer, opening the tubules, and increasing the permeability of the dentin.³⁶ If the smear layer is to be removed, an effective dentin bonding agent must be employed, with true adhesion between the restorative material and the tooth.³¹

The practice of total etching (etching dentin as well as enamel) was described by Fusayama et al in 1979.³⁷ Caution has been urged in approaching the pulp with acids, with the use of passive (soaking) rather than active (scrubbing) methods of application and careful timing.³⁸ Weaker concentrations of acid not only pose less risk to the pulp but also may produce greater bond strengths.³⁵ Solutions of 10% phosphoric acid are preferable to those containing nearly 40%.³⁹ Other etchants effectively used include a 2.5% solution of nitric acid⁴⁰; a 10% citric acid, 20% calcium chloride solution⁴¹; and a 10% citric acid, 3% ferric chloride solution called simply 10-3, which dissolves a thin layer of calcium on the surface of the dentin without affecting the collagen.⁴² Each system requires a particular acid, so the one specified for the dentin bonding agent in use should always be employed. Many current resin cements are self-etching and require no specific pretreatment of dentin other than cleaning contaminants from the dentin.

There is controversy about the use of acids because pulpal damage has been attributed to their application near the pulp.^{43,44} Kanca⁴⁵ interprets the pulpal irritation as being caused by the eugenol used as a cavity sealer in earlier studies rather than by the phosphoric acid itself. Brännström^{46,47} and Cox et al⁴⁸ also have questioned a link between sensitivity and toxicity. Instead they conclude that it is the result of bacterial infection.

Zinc phosphate cement

First introduced in 1878,⁴⁹ zinc phosphate cement possesses high compressive strength (96 to 110 MPa).⁵⁰ It exhibits a pH of 3.5 at the time of cementation,⁵¹ and it has been widely blamed for contributing to pulpal irritation.⁵²⁻⁵⁵ Brännström and Nyborg,^{56,57} however, found no irritating effect on the pulp from zinc phosphate per se. Cavity varnishes partially reduce the exposure of the pulp to the cement,^{58,59} but, unfortunately, they also reduce retention.⁶⁰ Zinc silicophosphate cement, which also has been in use since 1878,⁶¹ exhibits a high compressive strength (152 MPa) and a moderate tensile strength (9.3 MPa).⁶² However, its film thickness can be excessive (88 μm at the occlusal surface under an actual casting),⁶³ and it also has an acidic pH⁵¹ that may be harmful to the pulp.

Polycarboxylate cement

While polycarboxylate cement has a higher tensile strength than zinc phosphate,^{64,65} its compressive strength at 24 hours is significantly lower.⁶⁶ Its pH is also low (4.8), but, because

of the large size of the polyacrylic acid molecule, there is apparently little penetration into the dentinal tubules.⁶⁴ As a result, it seems to cause little pulpal irritation.^{58,67} This cement has shown a moderately high bond strength to enamel (9 MPa) and to dentin (3.3 MPa).⁶⁷ Polycarboxylate will also bond to stainless steel, but not to gold.⁵⁴

Zinc oxide–eugenol cement

Cements based on zinc oxide and eugenol cause virtually no pulpal inflammation as long as they make no direct contact with the pulp. They have long been used as temporary cements. Attempts have been made to create more biocompatible permanent cements by adding o-ethoxybenzoic acid (EBA) to zinc oxide and eugenol and by reinforcing it with aluminum oxide and polymethyl methacrylate. Based on in vitro tests, this type of cement was reported to have good strength and be less soluble than zinc phosphate cement.^{68,69} Unfortunately, its clinical performance was much poorer than its laboratory performance, and in vivo studies have shown that it deteriorates much more rapidly in the mouth compared to other cements.^{70,71} Zinc oxide–eugenol cements are still used largely for temporary cementation.

Glass-ionomer cement

Glass ionomer has many properties of an ideal cement. The powder is mainly composed of a calcium fluoroaluminosilicate glass, with fluoride content ranging from 10% to 16% by weight.⁷² In some brands, the liquid is an aqueous solution of copolymers of polyacrylic acid with itaconic or maleic acid and tartaric acid. In others, the polyacrylic acid or copolymer is dried and incorporated into the powder, with the liquid consisting of only water or a tartaric acid solution.

Glass ionomer has been in general use as a restorative material in Europe since 1975 and in the United States since 1977 and has gradually gained in popularity as a luting agent. Both its compressive strength (127 MPa) and its tensile strength (8 MPa) are quite good.⁶² Its bond to tooth structure is comparable to that of polycarboxylate.⁷³ Bonding of both glass-ionomer and polycarboxylate cements to the restoration can be produced by tin-plating the inner surfaces of the restoration. A tin–polyacrylic acid product overlying the tin layer on the restoration establishes the bond.⁷⁴

Glass-ionomer cement is bacteriostatic during its setting phase,⁷⁵ is less soluble than zinc phosphate cement,⁷¹ and releases fluoride at a greater rate than does silicate cement. This has been shown to reduce the solubility of adjacent enamel and therefore should inhibit secondary caries.⁷⁶ In one study,⁷⁷ glass-ionomer cement was found to be 65% more retentive than zinc phosphate cement. In another,⁷⁸ premolars with inlays cemented with glass ionomer were slightly more resistant to fracture than were premolars with inlays cemented with zinc phosphate.

Glass-ionomer cement is not without its disadvantages. Its pH is even lower than that of zinc phosphate cement during setting, and some concern has been expressed regarding postcementation hypersensitivity.^{79,80} Because the molecules

of polyacrylic or polymaleic acid used in glass ionomers are large, it is assumed that they are less likely than phosphoric acid to penetrate the dentinal tubules, and varnish is not generally recommended. However, a calcium hydroxide coating should be applied to areas close to the pulp.⁸¹ Its solubility in water is much higher than that of other dental cements.²⁶ Its use has diminished, and the use of resin-modified glass-ionomer cements has increased.

Clinical success with glass-ionomer cement depends on early protection from both hydration and dehydration.⁸² It is weakened by early exposure to moisture, while desiccation, on the other hand, produces shrinkage cracks in the recently set cement.⁸³ Therefore, the cement at the crown margins must be protected by a coating of petrolatum or varnish.⁸² Glass ionomer is more translucent than zinc phosphate, and this property often makes the enamel adjacent to metal castings appear slightly gray, particularly on partial veneer crowns.

This material continues to be improved, but its efficacy is difficult to assess accurately. Tyas⁸⁴ sums it up: "Because of constant improvements in glass ionomers, there have been too few studies on any one material, and comparisons between studies are further complicated by differences in evaluation criteria."

Hybrid ionomer cements

The hybrid cements, or resin-modified polyalkenoate cements, are purported to combine the strength and insolubility of resin with the fluoride release of glass ionomer. They differ from other composite resin cements in that the glass filler particles react with the liquid during the hardening process.

Summary

The selection of a cement for the placement of a cast restoration is not a clear-cut decision. Zinc phosphate is a strong cement that has proven itself over many years of use, outliving numerous would-be replacements. When depth of the preparation or history of hypersensitivity raises some concern for the vitality of the pulp, a more biologically compatible cement (eg, polycarboxylate) should be used. Cement deteriorates much more rapidly in some patients than in others.⁷⁰ If a particular patient has a history of rapid failure of previous crowns due to washout of zinc phosphate cement and marginal caries, use of a glass-ionomer cement might help to prevent recurrence. Resin cements are indicated where micromechanical bonding is desired. They are especially useful when the tooth preparation is largely in enamel and all finish lines are accessible.

Cementation

Regardless of the material used, cementation involves a number of steps, which, if not carried out meticulously, can result in early failure of an otherwise technically excellent

restoration. Some of the problems that can be caused by improper cementation technique are premature occlusion, pulpitis, loosening of the restoration, and recurrent caries.

Many problems are the result of incomplete seating of the restoration. Factors that can influence the completeness of seating are the viscosity of the cement, the morphology of the restoration, vibration,⁸⁵ venting, and seating force.²⁷ Mesio-occlusodistal onlays seated an average of 34 μm farther than did full crowns in a study by de Freitas Oliveira et al.⁸⁶ In the same study, vibration produced an improvement of 27 μm in the seating of full crowns.

Seating force must be adequate to ensure complete seating, but excessive force of brief duration may produce elastic strains in the dentin, creating a rebound that dislodges the restoration when the force is relaxed.⁸⁷ A study by Karipidis and Pearson⁸⁸ found that crowns seated on preparations in bovine dentin with a force of 300 N/cm² could be removed more easily than those cemented with half the force; the reverse was true when crowns were cemented on more rigid metal dies.

Venting full crowns will facilitate the escape of cement from crowns and allow more complete seating.^{63,89-91} Normally, adequate seating can be achieved without venting. Problems can be encountered, however, over preparations with unusually long, nearly parallel axial walls or multiple fixed partial denture abutments with greater-than-normal mobility. The most effective venting is provided by drilling a hole in or near the occlusal surface (Fig 21-35), but that leaves a defect in the crown after cementation.

Various methods have been proposed for sealing the vent hole, including placement of direct filling materials, metal screws, and cemented plugs. Venting can be achieved without perforating the crown by creating an internal escape channel in the form of an unoccupied vertical groove in the axial wall of the preparation (Fig 21-36) or in the internal surface of the crown. The groove should begin at the occlusal surface and end short of the finish line.⁹²⁻⁹⁴

Techniques for using resin-modified glass-ionomer, resin, zinc phosphate, and polycarboxylate cements follow.

Cementation with resin-modified glass-ionomer cement

The RelyX Luting Plus cement (3M ESPE) is indicated for the permanent cementation of all-metal, metal-ceramic, and all-ceramic (with zirconia or alumina cores) restorations.

Complete isolation and protection from moisture is essential with this type of cement. The quadrant is well isolated with cotton rolls and a saliva ejector or with a tongue guard (Svedopter, Pfingst). If a dry field cannot be adequately maintained in this way, a rubber dam is placed. The outside of the crown may be coated with petrolatum to make the hardened cement easier to remove, but care must be taken not to allow any lubricant to contaminate the internal surface.

The tooth is cleaned and lightly dried. The tooth preparation is cleaned with wet (oil-free) flour of pumice on a rubber cup (Fig 21-37). It will improve the retention some-

21 Cementation and Bonding

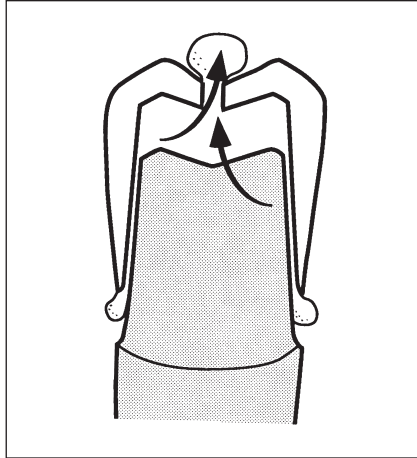


Fig 21-35 A vent hole in the occlusal surface allows cement to escape readily from under crowns. The hole must then be sealed.

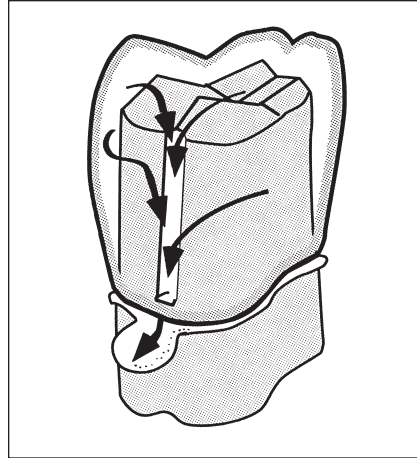


Fig 21-36 A vertical groove in the tooth preparation provides an internal escape channel for cement without perforating the crown.

what.⁹⁵ The pumice is rinsed away (Fig 21-38), and the tooth preparation is then lightly dried (Fig 21-39). The smear layer should not be removed with acids as is sometimes done prior to application of the more viscous glass-ionomer filling materials.⁹⁶ This might have an untoward effect on the pulp, and it has been shown to produce little or no improvement in retention.^{95,97,98} Varnish should not be applied to the tooth because that would negate the benefit of the cement's adhesiveness, and the tooth should not be overdried.

The desired amount of cement is dispensed onto a mixing pad (one or two "clicks" is usually a sufficient amount) and mixed with a cement spatula for 20 seconds. A thin layer is applied to the inside of the restoration. There are 2.5 minutes of working time. The restoration is seated with light finger pressure and held for 2 minutes, at which time the excess cement can be removed with a scaler or explorer. However, because there is an "air-inhibited layer" with this cement, the cement should be left for the full setting time before the excess is removed. This allows the cement at the marginal gap to completely set. The set time is 5 minutes after placement. Removal of excess cement at the margin is easier than it was with pure glass-ionomer cement.

Cementation with resin cement

There are many types of resin cement, and each has specific mixing instructions that should be reviewed before use. If resin cement hardens under a restoration that is improperly seated, it is almost always necessary to destroy the restoration in order to remove it. Furthermore, the tooth surface will usually have to be re-prepared to remove resin tags projecting into the etched enamel and dentinal tubules. Therefore, it is imperative that the dentist has a clear understanding of the necessary steps and carries them out in an efficient,

deliberate manner. Use of a chairside assistant is highly recommended.

The techniques for cementing metal restorations with two autopolymerizing resin cements are described here. Use of a dual-curing cement under translucent ceramic restorations is discussed in chapter 23.

Although bonding can be accomplished while using cotton roll isolation,⁷³ it requires immediate placement of the bonding agent. A delay of as little as 1 minute can reduce the bonding strength by 50%.⁹⁹ Barghi et al¹⁰⁰ demonstrated superior results using rubber dam. Even if the system used will tolerate moisture, better control is maintained through the use of rubber dam.

The first technique is for C&B-Metabond (Parkell), a popular material among practicing dentists. The material and the mixing dish should be kept in the refrigerator until it is time to use them. The inside of the crown is air abraded with 50- μ m aluminum oxide at 80 psi or more. Then it is rinsed and dried with compressed, oil-free air. The tooth preparation is cleaned with pumice, washed, and dried. Any enamel in the preparation is etched for 30 seconds with a foam plastic pellet saturated with enamel etchant. A dabbing, not a rubbing, motion should be used. The tooth is rinsed and dried. Dentin activator is applied to the dentin for 10 seconds, and then it is rinsed and dried lightly. The dentin should not be desiccated.

Four drops of base are placed into one of the three wells in the chilled (16°C to 22°C or 61°F to 72°F) ceramic mixing dish. One drop of catalyst is added from the syringe. Each container should be recapped immediately after its use to prevent evaporation. The two liquids are mixed for no more than 5 seconds. Both the tooth preparation and the inside of the restoration are painted with the mixture.

The mixing of four drops of base to one drop of catalyst is repeated in a second well of the mixing dish. More is used

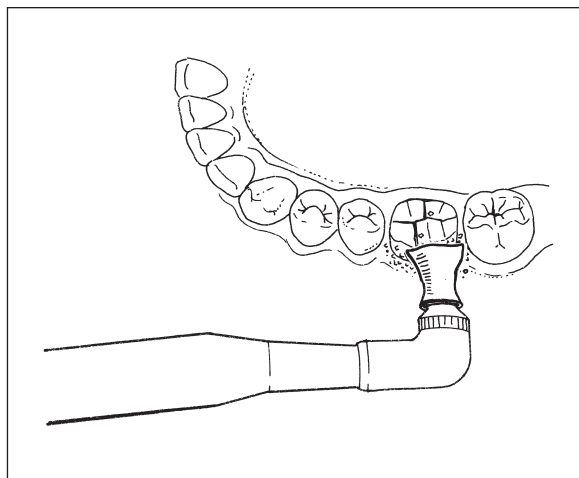


Fig 21-37 The tooth preparation is cleaned with a rubber cup and pumice.

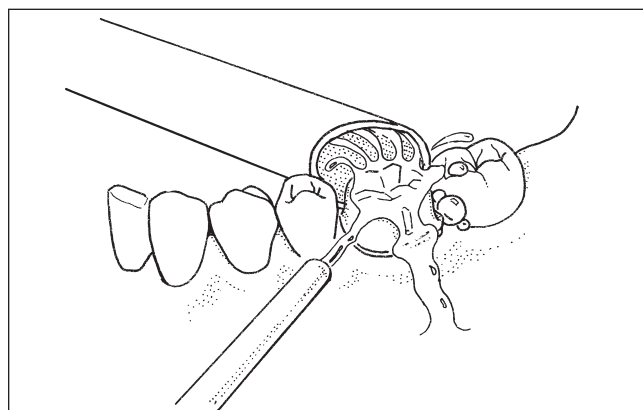


Fig 21-38 The tooth preparation should be rinsed thoroughly with a water syringe.

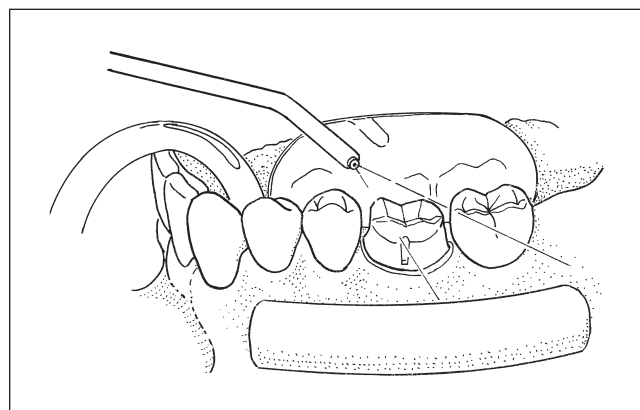


Fig 21-39 The preparation is dried with an air syringe.

for a larger casting or for multiple retainers on a fixed partial denture, always maintaining the 4:1 base-catalyst ratio. Again, the solution is stirred gently for no more than 5 seconds. Two level scoops of powder are added for every unit of liquid (four drops of base + one drop of catalyst). The solution is stirred gently for 5 to 10 seconds to produce a creamy mixture. The cement is applied to the restoration. If the restoration or the tooth is no longer wet, more liquid is applied to them from the first well *before* the mixed cement is placed into the restoration. The restoration is seated quickly because the normal working time is slightly less than 1 minute. To increase the working time to more than 2 minutes, the base and the mixing dish, but not the etchants, can be chilled further in the freezer for 15 minutes.

Although the material has a very short working time, it takes at least 10 minutes to set and should be held during that time. Excess is wiped off while it is soft with a cotton pellet wetted with a drop of base liquid. Cement should not be removed from the casting once it becomes rubbery because

it will be torn out from under the margin of the restoration, creating voids under the margin. Cement remaining after setting must be removed with a scaler.

The second technique utilizes a bonding agent, All-Bond 2 (Bisco), that works well with most resin luting materials¹⁰¹ and a resin cement, C&B Cement (Bisco). The inside of the crown is air abraded, rinsed, and dried with compressed, oil-free air. Superficial dentin is treated with a dentin bonding agent, while deeper dentin may be protected with a glass-ionomer base. A 10% phosphoric acid gel (All-Etch, Bisco) is applied to dentin and enamel for 15 seconds, using a brush to agitate the etchant over the enamel. The acid is thoroughly rinsed off with a water spray. Then the tooth is air dried very briefly to remove excess moisture without desiccating the dentin. This particular bonding agent tolerates the presence of some moisture; however, this does not mean that contamination by saliva is acceptable.

Primer A and B are mixed, and five coats are brushed onto enamel and dentin with a disposable brush. Drying should

21 Cementation and Bonding

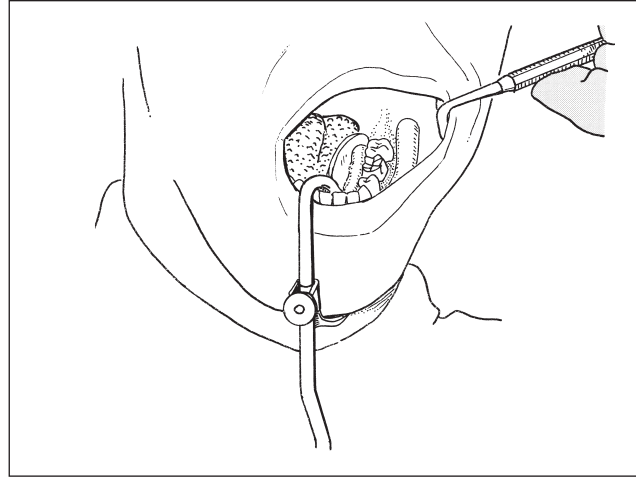


Fig 21-40 Mandibular isolation with a Svedopter and cotton rolls.

not occur between any of the five coats. After all coats are applied, all surfaces are dried with an air syringe for 5 seconds to remove any remaining solvent or water. The tooth surface, which should have a glossy appearance, is light cured for 20 seconds.

If the dentin bonding agent has been used as a cavity sealer for a nonresin cement, the following step is eliminated. If the bonding agent is being used as part of an all-resin luting, a thin layer of Pre-Bond resin (Bisco) is brushed on immediately before cementation. Excess resin is blown off, but light curing should not be performed. Two coats of primer B are brushed on the inside of the crown and dried with an air syringe.

The base and catalyst of an autopolymerizing resin cement (C&B Cement) are mixed and quickly spread in a thin layer on the inside of the crown. The restorations are seated with gentle pressure, and then excess resin is wiped from the margin with a cotton roll or cotton pellets. It should be obvious from these two descriptions that the techniques vary widely from one brand to another. In the interest of obtaining the best possible result, it is essential to precisely follow the instructions for the material being used.

Cementation with zinc phosphate cement

The field must be kept dry during definitive placement of the restoration and hardening of the cement. The quadrant containing the tooth being restored is isolated with cotton rolls and a suction device such as a saliva ejector for the maxillary arch or a Svedopter for the mandibular arch (Fig 21-40). Inlays should be cemented with rubber dam in place. If petrolatum was used during finishing of margins, the tooth must be carefully cleaned with Cavidry on cotton pellets.

If the tooth is vital, it is customarily protected from the acidity of the cement. It has been reported that nearly 18% of teeth restored with cores and full crowns later experienced pulpal necrosis.¹⁰² More often than not, a tooth

receiving a crown has already been subjected to multiple insults from caries and previous restorations in addition to the crown preparation and impression procedures. Possible trauma from zinc phosphate cement should be minimized.

Partial protection of the pulp can be provided by the application of two thin layers of copal cavity varnish (Copalite, Cooley & Cooley). It is applied to the dry tooth with cotton pellets and lightly blown dry after each application. This partially seals the dentinal tubules and protects the pulp from the phosphoric acid. The fact that the cement is irritating to the pulp is evidenced by the pain an unanesthetized patient sometimes experiences when a crown is cemented over a vital, unvarnished tooth. Because varnish reduces the retention of a crown,⁶⁰ it should not be used on nonvital teeth or with other types of cement. A dentin bonding agent can also be used for this purpose.

Powder is placed on one end of a glass slab that has been cooled in tap water and wiped dry. At the center of the slab, approximately six drops of liquid are measured out for each unit to be cemented. The composition of the liquid may be altered by prolonged exposure to air. Both the loss and gain of water adversely affect the properties of zinc phosphate cement.¹⁰³ Therefore, the bottle should be kept capped, and the liquid should not be dispensed until just before it is mixed. Bottles that are less than one-quarter full of liquid should be discarded, as should bottles in which the color of the liquid has changed. It is not "good to the last drop."

The spatula is used to divide the powder into small increments, approximately 3 mm on a side. One increment is moved across the slab and mixed into the liquid for 20 seconds across a wide area (Fig 21-41). This will aid in neutralizing the acid and retarding the setting time. The addition of small increments of powder continues, with each mixed for 10 to 20 seconds using a circular motion and covering a wide area of the slab (Fig 21-42).

During mixing, zinc phosphate cement liberates heat that can unduly accelerate its setting. Therefore, it must be mixed slowly over a wide area on a cool glass slab to ensure that a

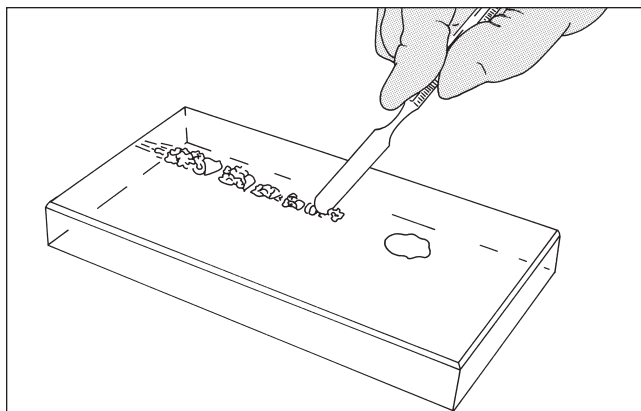


Fig 21-41 Small increments of powder are introduced into the liquid.

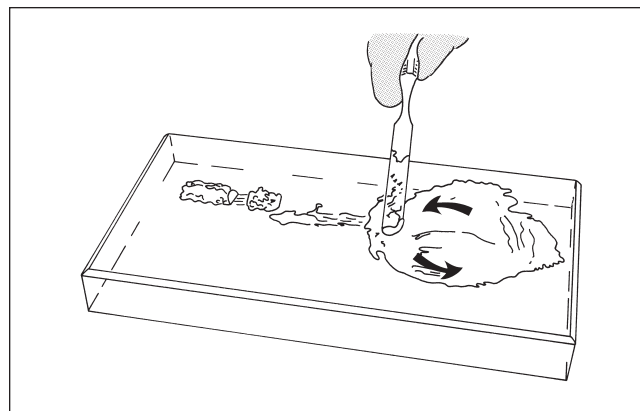


Fig 21-42 Cement is mixed with a circular motion over a wide area.

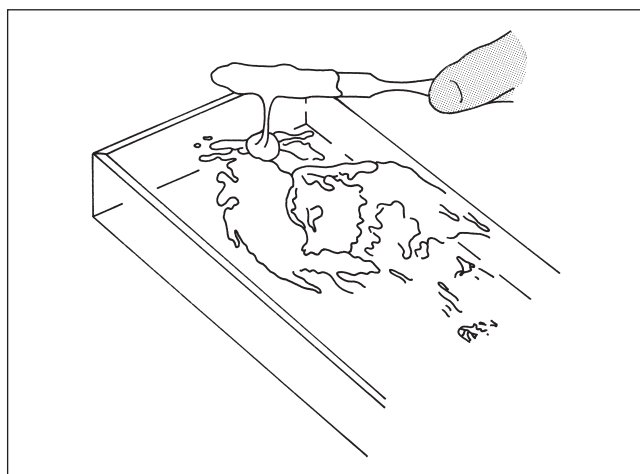


Fig 21-43 Cement that is ready to use will string out from a lifted spatula.

maximum amount of powder can be incorporated into a mix that is still workable. The more powder incorporated into a given amount of liquid, the stronger and less acidic the resulting cement will be.⁸⁷ On the other hand, if the mixture becomes too thick, the restoration may be prevented from seating completely.

The setting time can be controlled by the rate at which powder is incorporated into the mix. If powder is added slowly, the setting time will be prolonged. If powder is added more rapidly, the setting time will be shortened, less powder will be incorporated, and the resultant cement will be weaker and more acidic.

The consistency is checked by slowly lifting the spatula (Fig 21-43). When the consistency is right, it will string out about 10 mm between the spatula and slab before it runs back onto the slab. If it runs quickly off the spatula, it is too thin, and if it must be nudged off the spatula, it is too thick. A mixture that is too thick cannot be salvaged by adding more liquid. Clean the slab and start over.

The clean, dry restoration is quickly loaded with cement by brushing or wiping it on the inner surfaces of the restoration (Fig 21-44). Brushed-on cement produces a seating

discrepancy one-third less than that resulting from filling the crown half full and more than two-thirds less than that resulting from filling the crown completely full.¹⁰⁴ If there are recessed features on the preparation, such as box forms or grooves, some cement is applied directly to the preparation with a plastic applicator (IPPA). Cement is inserted into pinholes with a small Lentulo spiral (Dentsply) or the tip of a periodontal probe. Cement is placed directly into inlay cavity preparations. At this time, the tooth should still be dry. If there is persistent contamination from gingival fluids, it may be necessary to place retraction cord in the sulcus for a few minutes and make a fresh mix of cement.

The restoration is seated on the tooth, and if it is a posterior tooth with uniform occlusion, the patient is instructed to apply force to the occlusal surface of the restoration by closing on a plastic wafer (E-Z Bite Cementation Wafers, HAL Products) (Fig 21-45a). An orangewood stick also can be used for this purpose (Fig 21-45b). However, the stick may apply force to only one cusp, causing the crown to be crooked. It also requires the patient to open wider to apply seating force, which could cause discomfort in the temporomandibular joint.

21 Cementation and Bonding

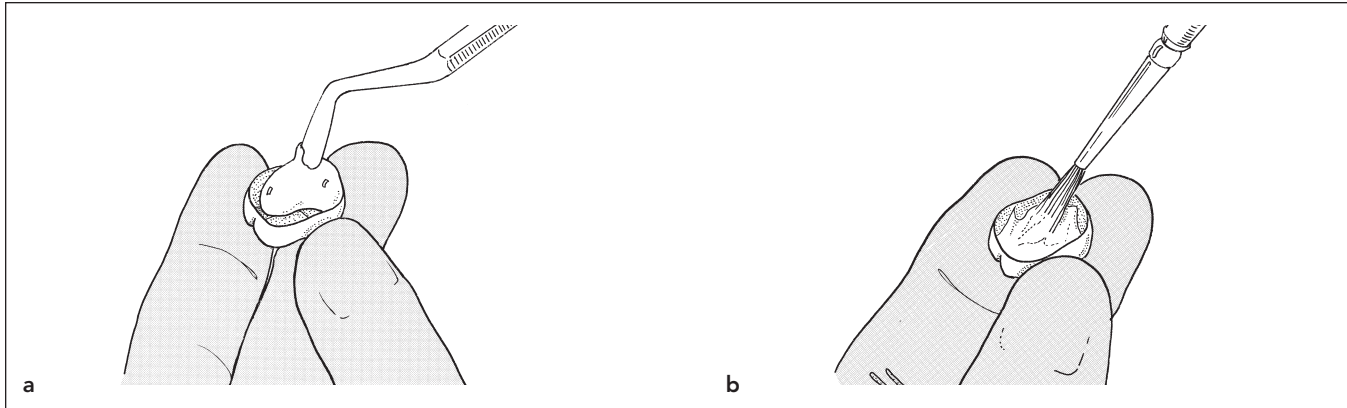


Fig 21-44 The inner walls of the crown are coated with a thin layer of cement using the small end of an instrument (a) or a brush (b).

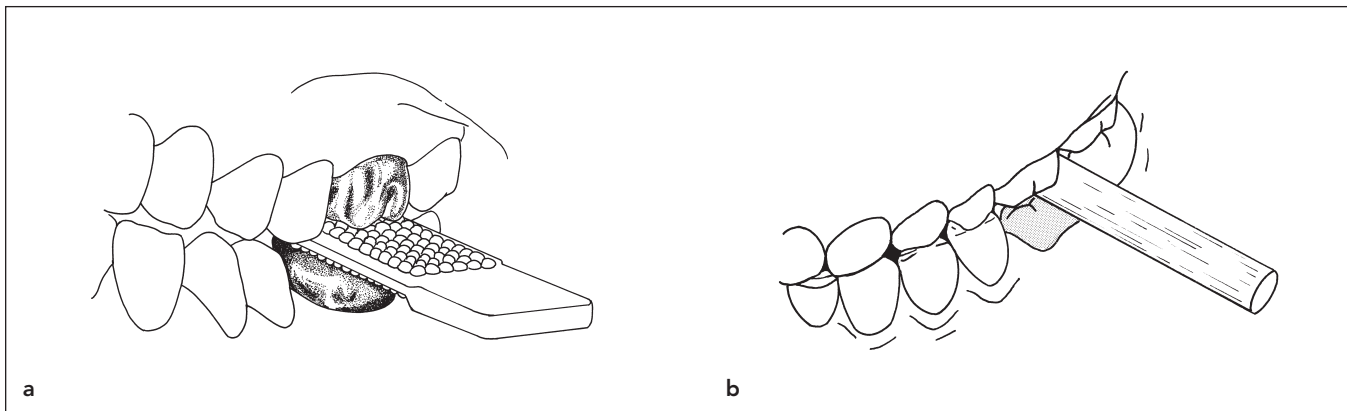


Fig 21-45 While the cement hardens, the patient maintains pressure by biting on a resilient plastic wafer (a) or a wooden stick (b).

Anterior crowns and crowns that occlude on only one corner might become tipped by pressure from the opposing teeth even on a cementation wafer. In these cases, it is better to apply force with a finger padded by a cotton roll. The force must be sufficient to seat the crown completely. Vibration can be applied by gently tapping the side of a crown or the wafer with a mirror handle. Vibration will produce more complete seating than static force alone.⁸⁶

Complete seating of the restoration is checked by palpating a supragingival margin with an explorer through the soft extruded cement or by removing the bite stick and having the patient close with shim stock between nearby teeth. This must be done quickly and with cotton rolls in place to avoid contamination of the cement by saliva. If the restoration is not completely seated, it should be removed before the cement hardens, the restoration and tooth should be thoroughly cleaned, and another attempt to seat it should be made. If the restoration cannot be removed intact, it may be ground into occlusion to serve temporarily while a new restoration is fabricated. At the following appointment, the unintentional provisional restoration will have to be sectioned and removed.

After the restoration is completely seated, the field must be kept dry until the cement has hardened. The solubility of zinc phosphate is greatly increased by premature contact with moisture.¹⁰⁵ If the patient salivates heavily, the suction device must be left in place during seating of the restoration and hardening of the cement. This makes it necessary to place a thicker object, such as a wooden stick on top of a bite wafer, to maintain pressure on the restoration without allowing the anterior teeth to strike the suction device.

No attempt should be made to remove excess cement while it is still soft. The excess helps protect the margins during setting. Furthermore, large masses of hardened cement will break away more easily and cleanly than will thin, smeared films. Once the cement has completely set, all excess is removed with a scaler, explorer, and knotted dental floss. Cement left in the gingival crevice can be very irritating to the tissue. The entire crevice should be checked with an explorer several times to ensure that all of the cement has been removed.

Cementation with polycarboxylate cement

Cotton rolls are used to isolate the quadrant containing the tooth being restored. The tooth should be thoroughly clean. Drying can be accomplished by blotting because absolute dryness is not required. Following try-in, the restoration is washed in water and dipped in alcohol to remove all contaminants. The inside of the casting is air abraded to ensure maximum retention. The outside of the casting to be cemented is coated with petrolatum to prevent the cement from sticking where it is not needed.

The powder-liquid ratio for this type of cement is 1.5 parts powder to 1.0 part liquid, which can be dispensed with some degree of accuracy. One measure of powder is dispensed for each restoration to be cemented. The powder is picked up by pressing the measuring stick, scoop down, into the bottle of powder. The excess is scraped off, and the powder is placed on a glass slab or a special impermeable mixing pad provided with the cement. A standard, porous parchment pad should not be used.

Liquid is expressed from the graduated syringe in 1.0-mL amounts for each measure of powder, and mixing begins immediately. The powder should be incorporated quickly (Fig 21-46), and the spatulation should be completed within 30 seconds. Because the liquid has a honey-like consistency, the cement may seem too viscous. This is normal and is not a matter of concern.

The inside of the casting is coated with cement, and some is placed on the tooth while the cement is still glossy. The casting is placed on the tooth with firm finger pressure, and then the patient is instructed to bite on a plastic wafer or a wooden stick. If the cement becomes dull in appearance before the casting is cemented, the cement is removed from the casting and the procedure is repeated. There is approximately 3 minutes of working time after the 30-second spatulation is completed.

The instruments and the slab are cleaned with water before the cement has set. Cement is removed from the casting in the mouth before it becomes rubbery or after it has set. Removing the cement while it is in its elastic, semi-set stage may pull some out from under the margin of the restoration, leaving a void in the cement near the margin. The restored tooth should be kept isolated and dry until the cement has set completely.

Special Considerations

Following is a discussion of the special requirements for inserting gold inlays, custom cast dowel cores, all-ceramic restorations, metal-ceramic crowns, and fixed partial dentures.

Gold inlays

Because of their smaller size, inlays are more difficult to handle and more readily aspirated by the patient than are

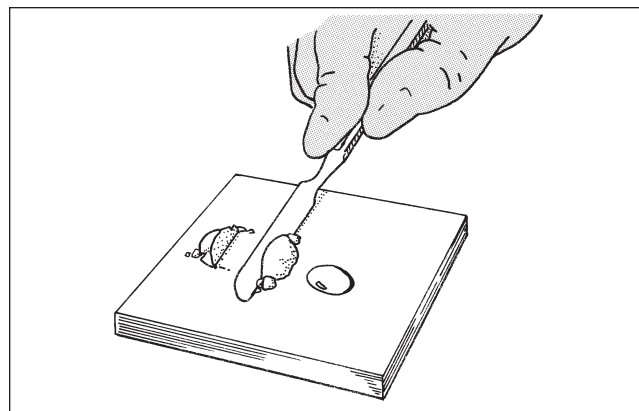


Fig 21-46 Powder is added quickly, in large quantities.

crowns. Therefore, trial insertion and cementation should be carried out with rubber dam in place. Intraoral refinement of occlusal anatomy and margins can be accomplished simultaneously by extending the natural grooves onto the metal with a cone-shaped white stone under heavy pressure. Where space permits, the inlay is held firmly in place with a small blunt instrument. The tip of the stone must be kept sharp by frequently spinning it against a truing stone.

The inlay is removed from its preparation by teasing it loose with an explorer. If difficulty is encountered, a blast of compressed air can be used. If this fails, a corner of a Richwil crown remover can be softened in hot water, pressed against the inlay for several seconds, and then removed with the inlay.

The inlay is placed back on the die for polishing. The white stone is followed with sharp-tipped brown and green rubber points. The final polish is applied with tripoli on a rotary brush, followed by gold rouge on a separate brush.

Before cementation, the tooth preparation is coated with varnish or a dentin bonding agent. Then the cavity preparation is filled with cement before the inlay is inserted. The inlay can be safely carried to the mouth by sticking it to a gloved fingertip in the correct orientation with a small piece of double-sided carpet tape or a spot of tray adhesive.¹⁰⁶

After the cement has thoroughly hardened, the rubber dam is removed and the occlusion is checked. If adjustments must be made, the occlusal surface is repolished with several grades of progressively finer pumice, followed by tin oxide on a rubber cup or small brush. Again, care must be taken to avoid overheating the tooth.

Custom cast dowel cores

The casting is cleaned by air abrasion, and any visible casting nodules are removed with a bur. A longitudinal groove should be cut in the side of the dowel to create a cement escape channel.

If a dowel core is swallowed during try-in, the risk of intestinal obstruction or perforation is even greater than that

21 Cementation and Bonding

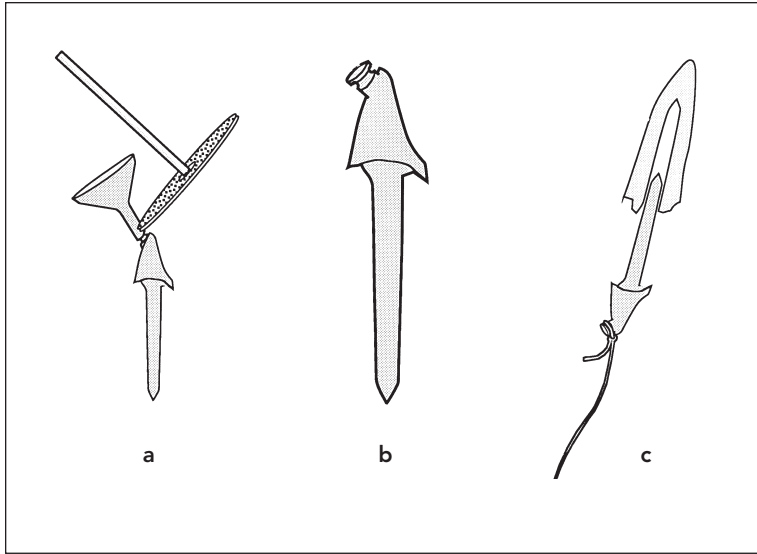


Fig 21-47 A safety knob is formed on a dowel core by leaving a 2-mm stub of sprue (a) and notching the stub (b). (c) A floss safety line is then tied to the knob.

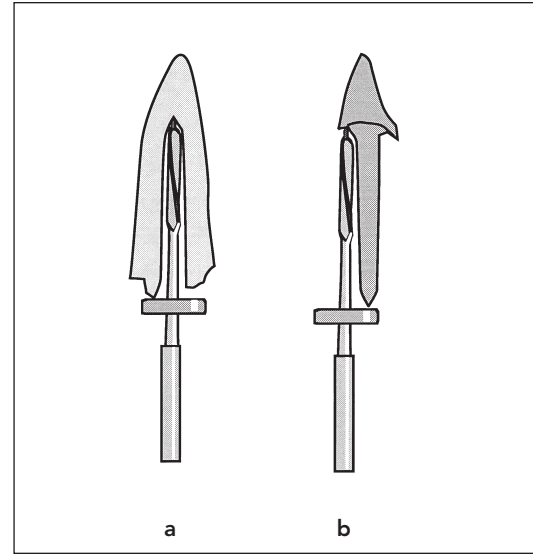


Fig 21-48 To verify that the dowel is as long as the dowel space, the preparation depth is marked on a reamer (a), and this length is compared with that of the dowel (b).

associated with a full crown. To reduce the risk, rubber dam can be used. As an alternative, about 2 mm of the sprue can be left attached to the casting. This stub is notched with a separating disk, and dental floss is tied to it to act as a safety line (Fig 21-47).

Rubber dam or a gauze throat pack is inserted. The provisional restoration is removed. A Peeso reamer is gently rotated in the canal with the fingertips to ensure that no cement remains in the dowel space and to measure its length (Fig 21-48a). The depth of the dowel space is compared with the length of the dowel to be certain that the casting is complete (Fig 21-48b). The restoration is seated with light force. Heavy force should never be used because the root may be split by the wedging action of the dowel. Any areas that prevent complete seating are removed.

If the dowel core becomes progressively tighter as it is inserted and resists removal, the interfering area is on the side of the dowel. If it abruptly stops short of seating and offers no resistance to removal, the obstruction is either on the underside of the core or at the tip of the dowel. Once the casting seats completely without binding, the safety knob is removed and the axial and occlusal surfaces are evaluated. The contours should be those of an ideal crown preparation with adequate occlusal clearance and no undercuts. Adjustments are made if necessary, and then all surfaces are cleaned by air abrasion. Polishing should not be performed.

Armamentarium

- High-speed handpiece
- Straight handpiece
- Separating disk
- Cavidry
- Lentulo spiral

- Zinc phosphate cement
- Mixing slab and spatula

Technique

The dowel space is cleaned with paper points or a wisp of cotton wrapped around a reamer and moistened with Cavidry. A slightly thin mix of zinc phosphate cement is made. If the mix is too thick, or if it sets too rapidly, the dowel may not seat completely. Cement is spun into the dowel space using a Lentulo spiral. This has been shown to provide twice as much retention as merely coating the dowel with cement.¹⁰⁷ The dowel core is seated slowly to allow excess cement to escape without building up hydraulic pressure that might “blow out” the apical seal or crack the root. When the cement is hard, the excess is removed and a provisional crown is placed.

All-ceramic restorations

Full crowns, labial veneers, and inlays are sometimes made entirely of ceramic materials. The techniques for adjusting, cementing, and finishing these vary significantly from those used for metal restorations and are described in detail in chapter 23.

Armamentarium

- Busch Silent Stone on straight handpiece mandrel
- Fine diamond stones
- Carborundum stones
- Porcelain finishing kit

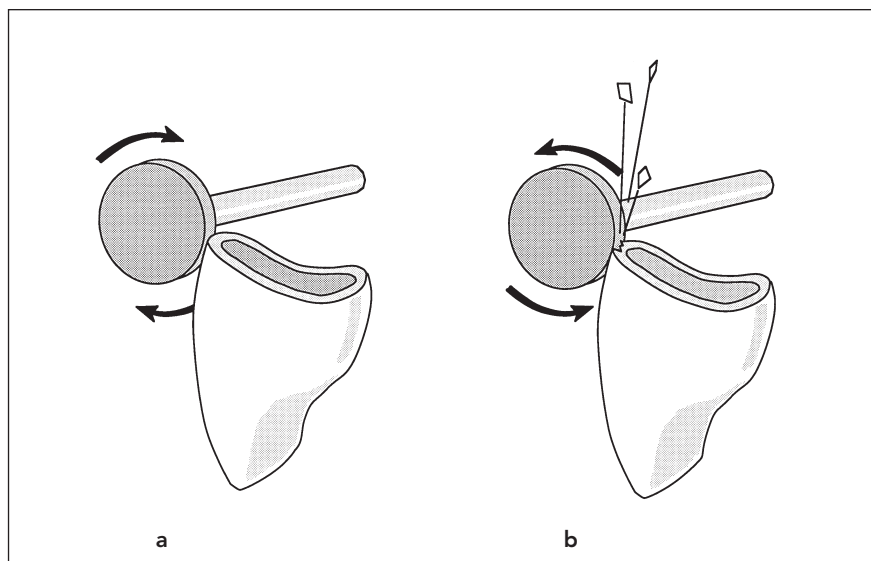


Fig 21-49 (a) Rotation of a stone toward the greatest bulk of porcelain prevents chipping. (b) Rotating away from the bulk can lead to fracture.

Technique

A tight proximal contact will not produce a visible burnished area on porcelain. A thin coating of a pressure indicator such as Occlude can be applied to these materials before seating to reveal the exact location of the contact. Only gentle forces should be used when inserting and testing ceramic restorations because fracture may result if forces are too heavy. Internal support for a ceramic crown or onlay can be provided during occlusal adjustment by temporarily “cementing” the restoration to the tooth with a low-viscosity elastomeric impression material.

Broad, relatively flat surfaces are best reduced extraorally with the large, smooth-cutting Busch Silent Stone, while grooves and ridges are reshaped with smaller pointed diamond stones and green stones. Instruments that have been used on metals should not be used on porcelain, lest particles of metal become imbedded in pores within the porcelain and cause discoloration. When working near an acute edge of porcelain, the stone is held so that it is always moving from the edge toward the greater bulk to reduce the danger of chipping the fragile edge (Fig 21-49). This is the opposite of the technique used in finishing metal margins. It is best to postpone minor grinding adjustments on thin veneers and inlays until after they are permanently bonded to the tooth.

Any roughened ceramic surfaces are smoothed with clean white stones and polished with rubber wheels of progressively finer grit such as those found in the Ceramisté Porcelain Adjustment Kit (Shofu). These grits are indicated by stripes around the shank of the instrument: no stripe (coarsest), one yellow stripe (medium), and either two yellow stripes or one white stripe (finest). Diamond-impregnated Dialite wheels

and points (Brasseler) may also be used for this purpose. Pastes containing diamond dust are also available for use on cups and brushes. Porcelain may also be reglazed after it is polished. It is often desirable to leave grooves and ridges on labial surfaces to simulate the texture of young enamel, but surfaces touching the gingiva and opposing teeth should be made as smooth as possible.

The patient is asked to moisten the ceramic and adjacent teeth with saliva, and the shade is reevaluated. The patient must always be allowed to see the completed restoration in a mirror and express approval before it is cemented.

Ceramic crowns may be cemented with zinc phosphate, glass-ionomer, or composite resin cements. Ceramic crowns that are etched internally and bonded with a composite resin cement have been shown to be 50% stronger than similar crowns cemented with a conventional zinc phosphate cement.¹⁰⁸ Ceramic veneers and inlays should be etched, silanated, and bonded to the underlying enamel with resin cements. This not only provides better retention and color control but also makes the ceramic material less susceptible to fracture than if it were cemented with nonresin cement.¹⁰⁹

Ceramic veneers and inlays are cemented with a selected shade of a dual-cure composite resin cement such as Calibra esthetic resin cement (Dentsply). This cement can be used for inlays in its dual-cure modality. Veneers that are relatively thin and transparent can be cemented by using the base paste only and light curing the cement. Resin cements should be stored in a refrigerator to prolong shelf life. The cementation kit is removed from the refrigerator before the appointment to allow it to approach room temperature.

The final appearance of an all-ceramic restoration is affected by the shade of cement used. The correct shade or blend of shades is determined by seating the veneer or inlay

21 Cementation and Bonding

on the unetched tooth with a choice of five water-soluble try-in pastes. This cement has five available shades ranging from transparent to opaque. Opacity can be controlled by varying the proportions of opaque and translucent catalyst. The shade or blend of try-in paste selected is recorded, and the veneer is cleaned thoroughly with a stream of water.

The tooth is isolated and cleaned with a mixture of pumice and water and then rinsed and dried with oil-free air. Thin plastic strips are placed interproximally. Transparent wedges are used. A piece of heavy black silk suture placed into the sulcus will help prevent contamination by sulcular fluid and will limit the entrance of cement into the sulcus. A self-priming, light-cured bonding agent (Prime & Bond NT, Dentsply) is applied with a disposable brush. The adhesive should not be allowed to pool. Direct intensive light should be avoided.

Immediately, equal amounts of base and catalyst resin are mixed. The mixed resin is applied directly onto the veneer. Direct intensive light should be avoided while seating the restoration. If the veneer is sufficiently thin to allow good light penetration, the base paste can be used alone. The plastic interproximal strips may be left in place if they will not interfere with seating of the restoration. Excessive pressure at this time could fracture the veneer. In the case of an inlay, the cement is placed into the cavity.

The excess cement is removed with a suitable instrument. For the dual-cure modality, working time is approximately 2.5 minutes. After excess cement is removed, a gentle, extra pressure will extrude another small amount of cement. A small central area of the veneer is "tack-welded" with a very short curing light application. Direct curing light on a margin should be avoided. Any remaining excess resin should be removed.

The polymerizing cement at the margin can be covered with a glycerine gel, which allows the marginal cement to completely polymerize. Final polymerization begins at the margins with a curing light of correct wavelength and output strength. The light can be transmitted through the transparent wedges. Step-by-step curing is continued for 20 seconds per segment. Complete polymerization in "self-cure" mode occurs 6 minutes from the beginning of mixing.

Any overbulk margins or premature occlusal contacts are adjusted with a fine diamond stone. If suture material was placed in the sulcus, it is removed. Proximal margins of veneers can be polished with fine finishing strips. Occlusal surfaces are polished with the rubber wheels and points of a porcelain adjustment kit. The cement margins are finished with carbide finishing burs, fine paper disks, and porcelain polishing paste on a rubber cup.

Metal-ceramic crowns

The metal portion is adjusted and finished in the same manner as a full gold crown, except that it is somewhat harder than type III gold. The porcelain portions are handled much the same as all-ceramic restorations, except that there is less risk of breakage, and the shade is unaffected by the cement. Normally, ceramic restorations will be received from the laboratory with a glazed surface. If it is anticipated that the contours and color will be modified substantially during try-in, they can be left unglazed until after these adjustments are made.

The internal fit is checked in the mouth to be sure there are no heavy contacts on axial walls near porcelain cervical margins. Undue pressure here can cause flaking of the porcelain, either during cementation or later during function. Insufficient contact areas and marginal gaps may be corrected chairside by adding the appropriate shade of porcelain and firing it in a glazing oven. As an alternative, the restoration can be returned to the laboratory. If the defects are not apparent on the cast, or if the cast has been altered or damaged, new impressions may be necessary.

Each porcelain manufacturer provides a shade modification kit for its porcelain, permitting the alteration of shades chairside if there is a staining furnace nearby. If any shade modification or glazing is required, the exposed metal is re-polished with rubber wheels, beginning with a coarse one, such as Cratex, to remove the black oxide layer. If a film of shading porcelain or glaze extends over the metal surface, it must be removed with a stone before the metal can be polished. Metal-ceramic crowns are cemented in the same manner as gold crowns. The patient should not be asked to bite on a hard object to seat the crown because the porcelain may fracture.

Fixed partial dentures

Procedures for adjusting, polishing, and cementing a fixed partial denture are the same as for a single crown, except for a few special considerations. A piece of dental floss should be tied around one of the connectors to act as a safety line during try-in and cementation. If the restoration fails to seat properly after removal of internal nodules and adjustment of the proximal contacts, it should be sectioned with a thin separating disk through the connector of the larger retainer, and the two halves should be tried in separately. If both retainers fit well after sectioning, the fixed partial denture can be reassembled and soldered using a soldering index (see chapter 26).

References

- Gildenhuys RR, Stallard RE. Comparison of plaque accumulation on metal restorative surfaces. *Dent Surv* 1975;51:56-59.
- Keenan MP, Shillingburg HT, Duncanson MG, Wade CK. Effects of cast gold surface finishing on plaque retention. *J Prosthet Dent* 1980;43:168-173.
- Klausner LH, Cartwright CB, Charbeneau GT. Polished versus autoglaized porcelain surfaces. *J Prosthet Dent* 1982;47:157-162.
- Raimondo RL, Richardson JT, Wiedner B. Polished versus autoglaized dental porcelain. *J Prosthet Dent* 1990;64:553-557.
- Jacobi R, Shillingburg HT, Duncanson MG. Comparison of the abrasiveness of six ceramic surfaces and gold. *J Prosthet Dent* 1991;66:303-309.
- Skinner EW, Phillips RW. *Science of Dental Materials*, ed 7. Philadelphia: Saunders, 1973:631.
- Craig RG. *Restorative Dental Materials*, ed 8. St Louis: Mosby, 1989:100.
- O'Brien WJ. *Dental Materials: Properties and Selection*. Chicago: Quintessence, 1989:271,322,438.
- Phillips RW, Skinner EW. *Skinner's Science of Dental Materials*, ed 9. Philadelphia: Saunders, 1991:563.
- Lee PW. *Ceramics*. New York: Reinhold, 1961:143.
- Cherberg JW, Nicholls JL. Analysis of gold removal by acid etching and electrochemical stripping. *J Prosthet Dent* 1979;42:638-644.
- Campagni WV, Preston JD, Reisbick MH. Measurement of paint-on die spacers used for casting relief. *J Prosthet Dent* 1982;47:606-611.
- Troxell RR. The polishing of gold castings. *J Prosthet Dent* 1959;9:668-675.
- Jacobi R, Shillingburg HT Jr. A method to prevent swallowing or aspiration of cast restorations. *J Prosthet Dent* 1981;46:642-645.
- Kaiser DA, Wise HB. Fitting cast gold restorations with the aid of disclosing wax. *J Prosthet Dent* 1980;43:227-228.
- Christensen GJ. Marginal fit of gold inlay. *J Prosthet Dent* 1966;16:297-305.
- Eames WB, Little RM. Movement of gold at cavosurface margins with finishing instruments. *J Am Dent Assoc* 1967;75:147-152.
- Kishimoto M, Hobo S, Duncanson MG Jr, Shillingburg HT Jr. Effectiveness of margin finishing techniques on cast gold restorations. *Int J Periodontics Restorative Dent* 1981;1(5):20-29.
- Moffa JP, Guckes AD, Okawa MT, Lilly GE. An evaluation of non-precious alloys for use with porcelain veneers. Part II. Industrial safety and biocompatibility. *J Prosthet Dent* 1973;30:432-441.
- Kohli S, Levine WA, Grisius UF, Fenster RK. The effect of three different surface treatments on the tensile strength of the resin bond to nickel-chromium-beryllium alloy. *J Prosthet Dent* 1990;63:4-6.
- Buonocore MG. A simple method of increasing the adhesion of acrylic filling materials to enamel surface. *J Dent Res* 1955;34:849-853.
- Simonsen RJ, Calamia JR. Tensile bond strength of etched porcelain [abstract 1154]. *J Dent Res* 1983;62:297.
- Moon PC. Bond strengths of the lost salt procedure: A new retention method for resin-bonded fixed prostheses. *J Prosthet Dent* 1987;57:435-439.
- LaBarre E, Belser U, Meyer JM. Shear strength of resins bonded to a precious alloy [abstract 2003]. *J Dent Res* 1990;69:359.
- Matsumura H, Kawahara M, Tanaka T, Atsuta M. A new porcelain repair system with a silane coupler, ferric chloride, and adhesive opaque resin. *J Dent Res* 1989;68:813-818.
- Anusavice KJ, Phillips RW. *Phillips' Science of Dental Materials*, ed 11. St Louis: Saunders, 2003:451.
- White SN, Yu Z, Kipnis V. Effect of seating force on film thickness of new adhesive luting agents. *J Prosthet Dent* 1992;68:476-481.
- White SN, Kipnis V. Effect of adhesive luting agents on the marginal seating of cast restorations. *J Prosthet Dent* 1993;69:28-31.
- Qvist V, Stoltze K, Qvist J. Human pulp reactions to resin restorations performed with different acid-etch restorative procedures. *Acta Odontol Scand* 1989;47:253-263.
- Tjan AHL, Dunn JR, Grant BE. Marginal leakage of cast gold crowns luted with an adhesive resin cement. *J Prosthet Dent* 1992;67:11-15.
- Nakabayashi N. Adhesive bonding with 4-META. *Oper Dent* 1992;17:125-130.
- Fusayama T. Total etch technique and cavity isolation. *J Esthet Dent* 1992;4:105-109.
- Nakabayashi N, Nakamura M, Yasuda N. Hybrid layer as a dentin-bonding mechanism. *J Esthet Dent* 1991;3:133-138.
- Cox CF. Effects of adhesive resins and various dental cements on the pulp. *Oper Dent* 1992;17(suppl 5):165-176.
- Bertolotti RL. Conditioning of the dentin substrate. *Oper Dent* 1992;17:131-136.
- Pashley DH, Michelich V, Kehl T. Dentin permeability: Effects of smear layer removal. *J Esthet Dent* 1981;46:531-537.
- Fusayama T, Nakamura M, Kurosaki N, Iwaku M. Non-pressure adhesion of a new adhesive restorative resin. *J Dent Res* 1979;58:1364-1370.
- Stanley HR. Pulpal consideration of adhesive material. *Oper Dent* 1992;17(suppl 5):151-164.
- Kanca J 3rd. Dental adhesion and the All-Bond system. *J Esthet Dent* 1991;3:129-132.
- Blosser RL, Bowen RL. Effects of purified ferric oxalate/nitric acid solutions as a pretreatment for the NTG-GMA and PMDM bonding system. *Dent Mater* 1988;4:225-231.
- Hosoda H, Fujitani T, Negishi T, Hirasawa K. Effect of a series of new cavity treatments on bond strength and wall adaptation of adhesive composite resins. *Jpn J Conserv Dent* 1989;32:656-665.
- Nakabayashi N, Kojima K, Masuhara E. The promotion of adhesion by the infiltration of monomers into tooth substrates. *J Biomed Mater Res* 1982;16:265-273.
- Retief DH, Austin JC, Fatti LP. Pulpal response to phosphoric acid. *J Oral Pathol* 1974;3:114-122.
- Macko DJ, Rutberg M, Langeland K. Pulpal response to the application of phosphoric acid to dentin. *Oral Surg Oral Med Oral Pathol* 1978;45:930-946.
- Kanca J 3rd. An alternative hypothesis to the cause of pulpal inflammation in teeth treated with phosphoric acid on the dentin. *Quintessence Int* 1990;21:83-86.
- Brännström M. The cause of postrestorative sensitivity and its prevention. *J Endod* 1986;12:475-481.
- Brännström M. Infection beneath composite resin restorations: Can it be avoided? *Oper Dent* 1987;12:158-163.
- Cox CF, Keall CL, Keall HJ, Ostro E, Bergenholtz G. Biocompatibility of surface-sealed dental materials against exposed pulps. *J Prosthet Dent* 1987;57:1-8.
- Dennison JD, Powers JM. A review of dental cements used for permanent retention of restorations. Part I: Composition and manipulation. *J Mich State Dent Assoc* 1974;56:116-121.
- Swartz ML, Phillips RW, Norman RD, Oldham DF. Strength, hardness, and abrasion characteristics of dental cements. *J Am Dent Assoc* 1963;67:367-374.
- Norman RD, Swartz ML, Phillips RW, Raibley JW. Direct pH determination of setting cements. 2. The effects of prolonged storage time, powder/liquid ratio, temperature, and dentin. *J Dent Res* 1966;45:1214-1219.
- Powers JM, Dennison JD. A review of dental cements used for permanent retention of restorations. Part II: Properties and criteria for selection. *J Mich State Dent Assoc* 1974;56:218-225.
- Smith DC. Dental cements. *Dent Clin North Am* 1971;15:3-31.
- Grieve AR. A study of dental cements. *Br Dent J* 1969;127:405-410.
- Langeland K, Langeland LK. Pulp reactions to crown preparation, impression, temporary crown fixation, and permanent cementation. *J Prosthet Dent* 1965;15:129-143.
- Brännström M, Nyborg H. Bacterial growth and pulpal changes under inlays cemented with zinc phosphate cement and Epoxy-lite CBA 9080. *J Prosthet Dent* 1974;31:556-565.
- Brännström M, Nyborg H. Pulpal reaction to polycarboxylate and zinc phosphate cement used with inlays in deep cavity preparations. *J Am Dent Assoc* 1977;94:308-310.
- Going RE, Mitchem JC. Cements for permanent luting: A summarizing review. *J Am Dent Assoc* 1975;91:107-117.

21 Cementation and Bonding

59. Swartz ML, Phillips RW, Norman RD, Niblack BF. Role of cavity varnishes and bases in the penetration of cement constituents through tooth structure. *J Prosthet Dent* 1966;16:963–972.
60. Chan KC, Svare CW, Horton DJ. The effect of varnish on dental bonding strength of five dental cements. *J Prosthet Dent* 1976;35:403–406.
61. Anderson JN, Paffenbarger GC. Properties of silicophosphate cements. *Dent Progress* 1962;2:72–75.
62. Wilson AD, Crisp S, Lewis BG, McLean JW. Experimental luting agents based on the glass-ionomer cements. *Br Dent J* 1977;142:117–122.
63. Hembree JH Jr, George TA, Hembree ME. Film thickness of cements beneath complete crowns. *J Prosthet Dent* 1978;39:533–535.
64. Craig RG, Farah JW, Powers JM. Modulus of elasticity and strength properties of dental cements. *J Am Dent Assoc* 1976;92:588–591.
65. Richter WA, Mitchem JC, Brown JD. Predictability of retentive values of dental cements. *J Prosthet Dent* 1970;24:298–303.
66. Branco R, Hegdahl T. Physical properties of some zinc phosphate and polycarboxylate cements. *Acta Odontol Scand* 1983;41:349–353.
67. Smith DC. A new dental cement. *Br Dent J* 1968;125:381–384.
68. Brauer GM, McLaughlin R, Huget EF. Aluminum oxide as a reinforcing agent for zinc oxide-eugenol-o-ethoxy-benzoic acid cements. *J Dent Res* 1968;47:622–628.
69. Phillips RW, Swartz ML, Norman RD, Schnell RJ, Niblack BF. Zinc oxide and eugenol cements for permanent cementation. *J Prosthet Dent* 1968;19:144–150.
70. Osborne JW, Swartz ML, Goodacre CJ, Phillips RW, Gale EN. A method for assessing the clinical solubility and disintegration of luting cements. *J Prosthet Dent* 1978;40:413–417.
71. Mesu FP, Reedijk T. Degradation of luting cements measured in vitro and in vivo. *J Dent Res* 1983;62:1236–1240.
72. Wilson AD, McLean JW. *Glass-Ionomer Cement*. Chicago: Quintessence, 1988.
73. Jemt T, Ståhlblad PA, Øilo G. Adhesion of polycarboxylate-based dental cements to enamel: An in vivo study. *J Dent Res* 1986;65:885–887.
74. Smith DC. Polyacrylic acid-based cements: Adhesion to enamel and dentin. *Oper Dent* 1992;17(suppl 5):177–183.
75. Behen MJ, Setcos JC, Paleik CJ, Miller CH. Antibacterial abilities of various glass ionomers [abstract 626]. *J Dent Res* 1990;68:312.
76. Maldonado A, Swartz ML, Phillips RW. An in vitro study of certain properties of glass ionomer cement. *J Am Dent Assoc* 1978;96:785–791.
77. McComb D. Retention of casting with glass ionomer cement. *J Prosthet Dent* 1982;48:285–288.
78. Kent WA, Shillingburg HT, Duncanson MG, Nelson EL. Fracture resistance of ceramic inlays with three luting materials [abstract 2364]. *J Dent Res* 1991;70:561.
79. Smith DC, Ruse ND. Acidity of glass ionomer cements during setting and its relation to pulp sensitivity. *J Am Dent Assoc* 1986;112:654–657.
80. Simmons JJ. Post-cementation sensitivity commonly associated with the “anhydrous” forms of glass ionomer luting cements: A theory. *Tex Dent J* 1988;103(10):7–8.
81. Pameijer CH, Stanley HR. Primate response to anhydrous Chem-bond [abstract 1]. *J Dent Res* 1984;63:171.
82. McLean JW. Clinical applications of glass-ionomer cements. *Oper Dent* 1992;17(suppl 5):184–190.
83. Mount GJ, Makinson OF. Clinical characteristics of a glass-ionomer cement. *Br Dent J* 1978;14:67–71.
84. Tyas MJ. Clinical studies related to glass ionomers. *Oper Dent* 1992;17(suppl 5):191–198.
85. Koyano E, Iwaku M, Fusayama T. Pressuring techniques and cement thickness for cast restorations. *J Prosthet Dent* 1978;40:544–548.
86. de Freitas Oliveira J, Ishikiriyama A, Vieira DF, Mondelli J. Influence of pressure and vibration during cementation. *J Prosthet Dent* 1979;41:173–177.
87. Smith DC. Dental cements. Current status and future prospects. *Dent Clin North Am* 1983;27:763–792.
88. Karipidis A, Pearson GJ. The effect of seating pressure and powder/liquid ratio of zinc phosphate cement on the retention of crowns. *J Oral Rehabil* 1988;15:333–337.
89. Jørgensen KD. Factors affecting the film thickness of zinc phosphate cements. *Acta Odontol Scand* 1960;18:479–490.
90. Van Nortwick WT, Gittleman L. Effect of internal relief, vibration, and venting on the vertical seating of cemented crowns. *J Prosthet Dent* 1981;45:395–399.
91. Ishikiriyama A, Oliveira JF, Vieira DF, Mondelli J. Influence of some factors on the fit of cemented crowns. *J Prosthet Dent* 1981;45:400–404.
92. Webb EL, Murray HV, Holland GA, Taylor DF. Effects of preparation relief and flow channels on seating full coverage castings during cementation. *J Prosthet Dent* 1983;49:777–780.
93. Miller GD, Tjan AHL. An internal escape channel. A solution to incomplete seating of full cast crowns. *J Am Dent Assoc* 1982;104:322–324.
94. Brose MO, Woelfel JB, Rieger MR, Tanquist RA. Internal channel vents for posterior complete crowns. *J Prosthet Dent* 1984;51:755–760.
95. Button GL, Moon PC, Barnes RF, Gunsolley JC. Effect of preparation cleaning procedures on crown retention. *J Prosthet Dent* 1988;59:145–148.
96. Council on Dental Materials, Instruments, and Equipment. Using glass ionomers. *J Am Dent Assoc* 1990;121:181–186.
97. Tamura N, Lim HD, Carroll TD, Woody RD, Nakajima H, Okabe T. Retentive strength of crown by different cleaning procedures [abstract 537]. *J Dent Res* 1990;69:176.
98. Hewlett ER, Caputo AA, Wrobel DC. Concentration of smear removal agents vs. glass ionomer bond strength [abstract 558]. *J Dent Res* 1989;68:251.
99. Nikaido T, Inai N, Satoh M, et al. Effect of an artificial oral environment on bonding of 4-META/MMA-TBB resin to dentin. *Jpn J Conserv Dent* 1991;34:1430–1434.
100. Barghi N, Knight GT, Berry TG. Comparing two methods of moisture control in bonding to enamel: A clinical study. *Oper Dent* 1991;16:130–135.
101. Suh BI. All-Bond—Fourth generation dentin bonding system. *J Esthet Dent* 1991;3:139–147.
102. Felton D, Madison S, Kanoy E, Kantor M, Maryniuk G. Long term effects of crown preparation on pulp vitality [abstract 1139]. *J Dent Res* 1989;68:1009.
103. Norman RD, Swartz ML, Phillips RW, Sears CR. Properties of cements mixed from liquids with altered water content. *J Prosthet Dent* 1970;24:410–418.
104. Tan K, Ibbetson RJ. The effect of cement volume on crown seating [abstract 169]. *J Dent Res* 1995;74:422.
105. Swartz ML, Sears C, Phillips RW. Solubility of cement as related to time of exposure in water. *J Prosthet Dent* 1971;26:501–505.
106. Jacobi R, Shillingburg HT Jr. A method to prevent swallowing or aspiration of cast restorations. *J Prosthet Dent* 1981;46:642–645.
107. Goldman M, DeVitre R, Tenca J. Cement distribution and bond strength in cemented posts. *J Dent Res* 1984;63:1392–1395.
108. Ludwig K, Joseph K. Untersuchungen zur Bruchfestigkeit von IPS-Empress-Kronen in Abhängigkeit von den Zementiermodalitäten. *Quintessenz Zahntech* 1994;20:247–256.
109. Dérand T. Stress analysis of cemented or resin-bonded loaded porcelain inlays. *Dent Mater* 1991;7:21–24.

Esthetic Considerations

22

The analysis of natural dentitions and the development of the concept of dental esthetics have been used in the arrangement of denture teeth. To contribute to a pleasing facial appearance, particularly when the patient smiles, contours, size, incisal edges, occlusal plane, and midline must be in harmony. Many of these principles can be applied to fixed restorations in the *esthetic zone*, also called the *appearance zone* (Richter WA, personal communication, 1973), which is the part of the mouth where high visibility requires a restoration or tooth replacement to simulate the appearance of a tooth.

Esthetic Zone

A 1984 study of 454 smiles,¹ using both men and women aged 20 to 30 years, noted that when a person smiles, the individual typically displays the maxillary anterior and premolar teeth. The esthetic zone frequently also includes maxillary first molars. It varies from person to person, depending on mouth size, smile width, tooth length, lip size and tightness, and perhaps most importantly, the patient's self-image.

The *smile line* or *incisal curve* is composed of the incisal edges of the maxillary anterior teeth and parallels the inner curvature of the lower lip.¹⁻³ It is parallel with the interpupillary axis,² and it is perpendicular to the midline (Fig 22-1). Nearly 80% of the young subjects in the study by Tjan et al¹ displayed the entire length of the maxillary anterior teeth. With the upper lip at rest, women show nearly twice as much of their maxillary central incisors as men do (3.4 and 1.9 mm, respectively),⁴ and men are 2.4 times more likely to have a low smile line than women.¹

The length of maxillary incisors cannot be established by esthetics alone because they play an important role in both anterior guidance and phonetics. If the length is correct, the maxillary incisal edges should be placed against the inner edge of the vermillion border (the "wet-dry line") of the lower lip when the patient sounds the letter *f* (Fig 22-2).³ The incisal edges of mandibular incisors are established both by occlusal contact with the maxillary incisors and by their position 1.0 mm behind and 1.0 mm below the edges of the maxillary teeth when the patient pronounces an *s* (Fig 22-3).³

Relatively little is seen of mandibular central incisors in people younger than 30 years, and the relationship between men and women is the opposite of that seen in the maxillary incisors (1.2 mm and 0.5 mm, respectively). As time

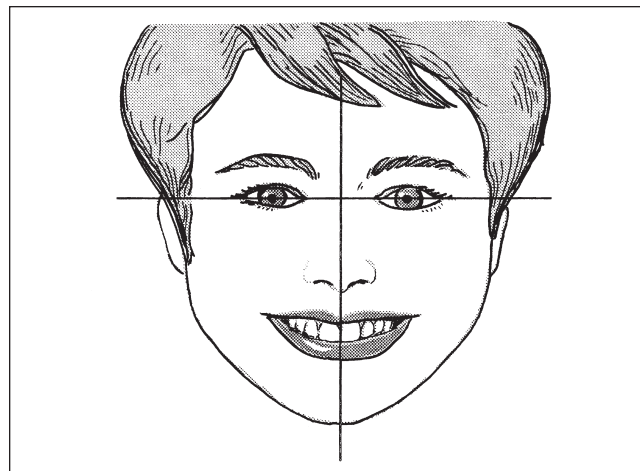


Fig 22-1 The incisal curve should be perpendicular to the midline, which is in the middle of the face, and parallel with the interpupillary line.

and gravity win out, the tissues surrounding the mouth sag. The length of maxillary incisors exposed diminishes, and the amount of mandibular incisor that is seen increases (Fig 22-4). At the age of 60 years, the length of maxillary central incisor showing below the upper lip is 0.0 mm, while nearly 3.0 mm of the mandibular incisors is exposed.⁴

In a study of 120 casts of teeth in nonorthodontic normal occlusion (ie, in subjects who had not received orthodontic treatment and did not need it), the crowns were angled so that the incisal portions of the long axes of the crowns were more mesial than the gingival segments⁵ (Fig 22-5). There is likewise a lingual inclination of the incisal or occlusal segment of the facial surfaces of canines, premolars, and especially molars⁵ (Fig 22-6). This esthetic requirement necessitates biplanar facial reduction in tooth preparations for all-ceramic or metal-ceramic crowns on anterior or posterior teeth (described in chapter 10).

The midline, which is centered on the face,⁶ is perpendicular to the interpupillary line.^{7,8} It is the focal point of the smile. Total symmetry is rare, and if compromises must be made, the midline of the smile should correspond to the features nearest it, such as the column of the nose or the philtrum² (Fig 22-7). The teeth on either side of the midline should be balanced. Perfect *horizontal symmetry* occurs when all anterior teeth have the same shape, looking more or less like central incisors.⁹ It is monotonous, and it appears artificial.

22 Esthetic Considerations

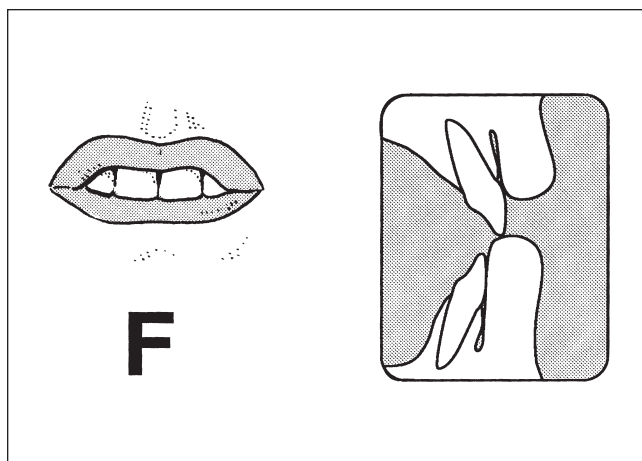


Fig 22-2 The incisal edges of the maxillary incisors touch the inner edge of the vermillion border of the lower lip when making the *f* sound: frontal view (*left*) and midsagittal view (*right*).

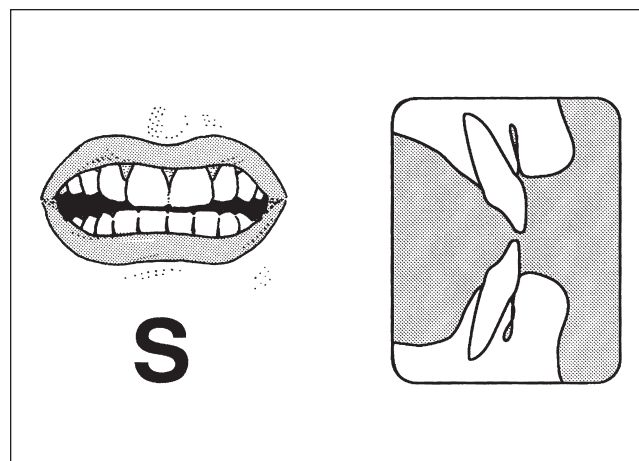


Fig 22-3 The incisal edges of the mandibular incisors are 1.0 mm inferior and 1.0 mm lingual to the incisal edges of the maxillary incisors when making the *s* sound: frontal view (*left*) and midsagittal view (*right*).

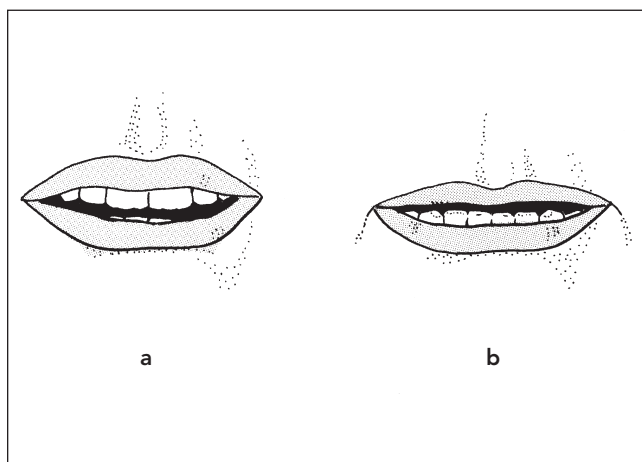


Fig 22-4 In the younger smile, the maxillary incisors are more prominent (*a*), while the mandibular incisors become more visible as the individual ages (*b*).

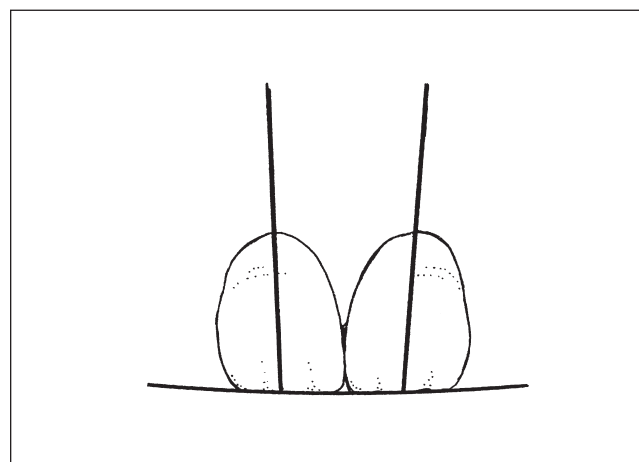


Fig 22-5 The long axes of the maxillary incisor crowns converge slightly toward the midline.

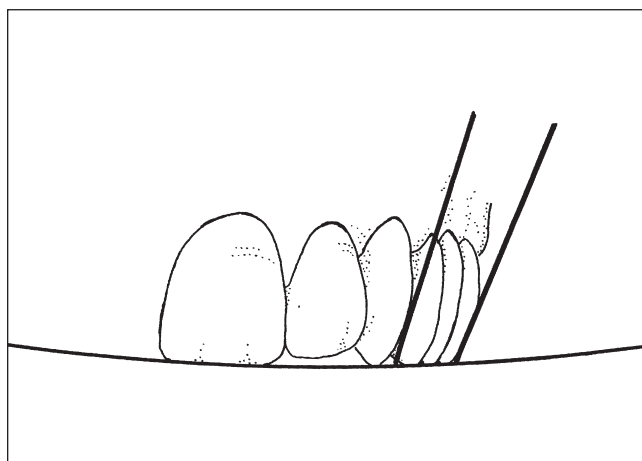


Fig 22-6 The long axes of the crowns of posterior teeth are inclined toward the lingual.

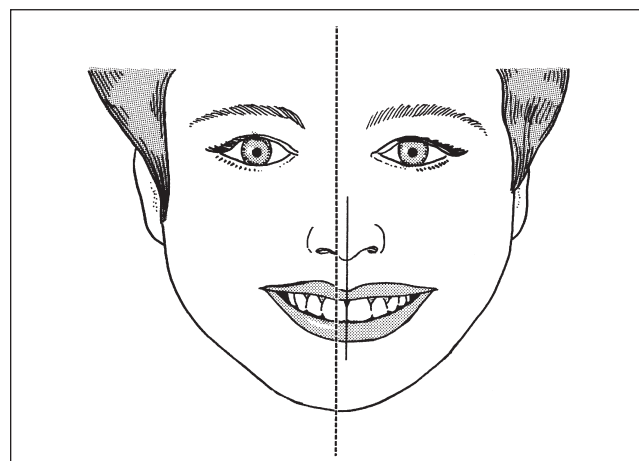


Fig 22-7 If the mouth is not centered in the face, the midline of the smile should be in harmony with facial features nearest the mouth, such as the nose and philtrum.




Fig 22-8 There should be slight irregularities on either side of the midline, even though the teeth are similar in size, shape, and alignment.

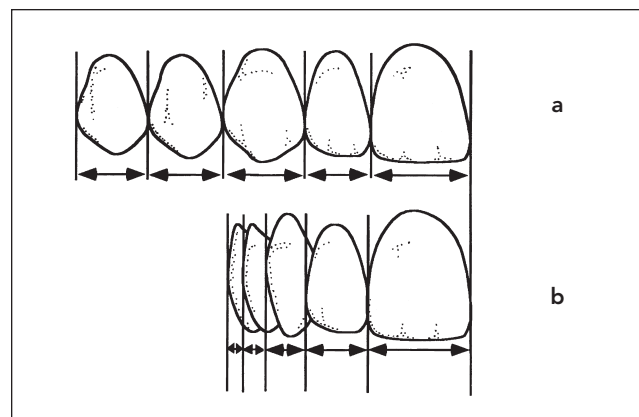


Fig 22-9 (a) When each tooth is viewed from the facial aspect, the canines are second in width to the central incisors. (b) However, when viewed from the midline, each tooth appears narrower than the tooth mesial to it. It is suggested that the apparent width be 60% of the apparent width of the adjacent mesial tooth.

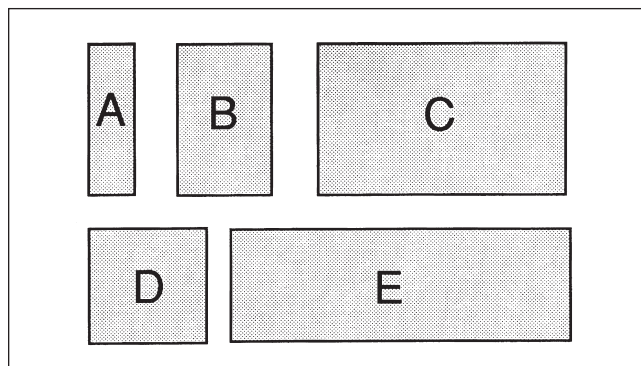


Fig 22-10 Which of these five rectangles is most pleasing to the eye? Both B and C are golden rectangles.

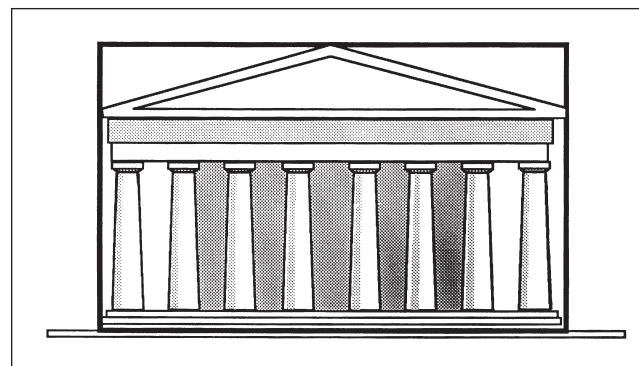


Fig 22-11 The front of the Parthenon fits within a golden rectangle.

If the teeth have different shapes but the left side is a mirror image of the right, *radiating symmetry* results. A more natural appearance can be produced by introducing slight variations to each side⁹ (Fig 22-8). Dentists prefer more irregularities than patients do, and dentists tend to prefer more elongated incisors. Variety in arrangement and shape unquestionably produces a more natural appearance. However, the dentist must discuss the concept beforehand to develop in the patient an appreciation for the role played by subtle irregularities in the creation of a more natural appearance. The patient may have desired "straight, white teeth" for a lifetime. Teeth that do not meet this long-held vision of dental perfection could be rejected by the patient if they suddenly appear in the mouth without warning. It is also quite possible that they may be rejected even after attempting to prepare the patient.

Maxillary central incisors are positioned in the middle of the smile, making them the most prominent teeth. Their crowns are the widest of the anterior teeth.^{10,11} Canines are the next widest, and lateral incisors are the narrowest^{10,11} (Fig 22-9a). However, from a frontal view, the apparent sizes of

teeth should become progressively smaller from the midline distally (Fig 22-9b). It has been suggested that this apparent reduction in size should approximate the proportion of the golden ratio (0.618) as a guide for dental compositions.^{7,12,13} Starting at the midline, this geometric formula of proportionality would require that each of the anterior teeth should be slightly less than 40% narrower than the tooth immediately mesial to it.¹⁴

The ratio of 1.618 to 1.0 is a constant that is designated as ϕ (phi). *Golden mean*,¹⁵ *golden section*,¹⁶ *golden rectangle*,¹⁷ *golden proportion*,² and *divine proportion*¹⁸ are all terms that have been used to describe various aspects of this proportion. The ratio has been celebrated as the standard of visual esthetics since ancient times. In 1876, Fechner found that 75.6% of the subjects that he tested expressed a preference for rectangles with ratios ranging from 0.57 to 0.67, with 35% selecting the golden rectangle (with a ratio of 0.62) as the most visually pleasing^{15,18} (Fig 22-10). The dimensions of the Parthenon, built in Athens in the fifth century BC, fit within the golden rectangle^{13,18} (Fig 22-11).

22 Esthetic Considerations

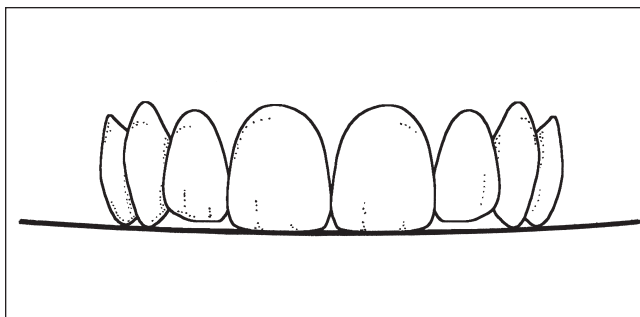


Fig 22-12 Incisal edges of central incisors and cusp tips of canines lie on the same curved line, with the incisal edges of lateral incisors being about 1.0 mm above that same line.

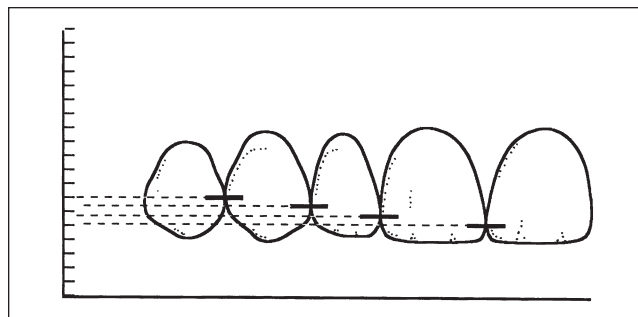


Fig 22-13 Interproximal contacts of the maxillary anterior teeth are situated progressively closer to the gingiva the more distal they are located from the midline.

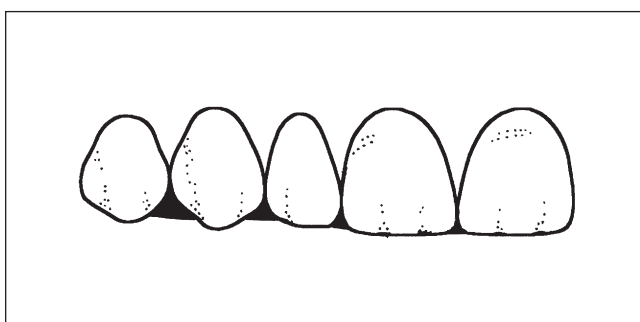


Fig 22-14 Incisal embrasures become progressively larger from central incisor to lateral incisor to canine.

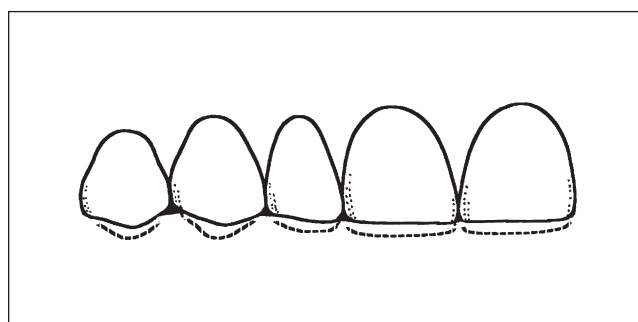


Fig 22-15 Incisal embrasures found in the younger person become smaller, sometimes to the point of disappearing, as the teeth wear.

Phi is related to a sequence of numbers that are called the *Fibonacci series*, in which each number is the sum of the two numbers preceding it: 0, 1, 1, 2, 3, 5, 8, 13, 21, 34, 55, 89 . . . ($n_1 + n_2 = n_3$). The ratio between any number and the number preceding it approximates 1.618 or ϕ , (eg, $34/21 = 1.6190$). Conversely, the ratio of any number and the number following it approximates the reciprocal of 1.618, which is 0.618 (eg, $21/34 = 0.6176$). As the numbers in a series become larger, their ratios more closely approximate 1.618 or 0.618. The series appeared as a “brain teaser” in a book, *Liber abaci*, published in 1202 by the mathematician Leonardo of Pisa, also known as Fibonacci.¹⁹ The book eventually came to be regarded as the most influential work on the introduction of the Hindu-Arabic decimal number system to Christian Europe.¹⁹

This series is one that is seen in nature, occurring in the intertwining equiangular left- and right-handed spirals of a sunflower, in which the number of clockwise and counter-clockwise spirals are most commonly the adjacent Fibonacci numbers, 21 and 34. Similar opposing spirals that are also Fibonacci numbers are found in pine cones (5, 8) and pineapples (8, 13).¹⁸ The series is seen again in phyllotaxis, or the arrangement of leaves on the stems of plants, and in the number of petals of common flowers.^{15,18} It would appear that the series is connected to patterns of growth, making it an underlying factor in morphology.²⁰

The incisal edges of the maxillary central incisors and the cusp tips of the canines should be on the same gently curved horizontal line, with the lateral incisors approximately 1.0 mm above the line (Fig 22-12). Beginning with the mesial of the central incisors, the interproximal contacts of the maxillary anterior teeth are situated successively more gingivally, all the way to the distal of the canines (Fig 22-13). As the contacts become located farther gingivally, the incisal embrasures become larger, creating a more dynamic and youthful smile (Fig 22-14). With age and increased wear, the incisal embrasures become minimal (Fig 22-15). The patient’s input should be solicited when deciding which “look” to try to achieve.

In the majority of anterior restorative situations, fewer problems will be encountered if the patient’s original tooth position is approximated. However, when the original positions of anterior teeth have been lost through disease or trauma, or if significant changes are to be made for the sake of esthetics, the new tooth position should first be tried in the provisional restoration. Patient satisfaction can be strongly influenced by comments made away from the office by friends or family members. Only after the provisional restoration has passed this “trial by fire” should the changes be incorporated into a definitive restoration.

Ideal esthetics vary between cultures, generations, and gender, and the dentist’s view of esthetics must not be the

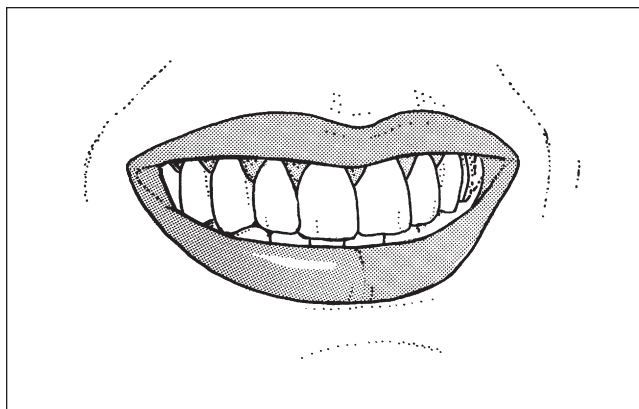


Fig 22-16 If a patient accepts "conversational esthetics," there may be moderate amounts of metal visible when the teeth are viewed critically that will not be seen in normal conversation.

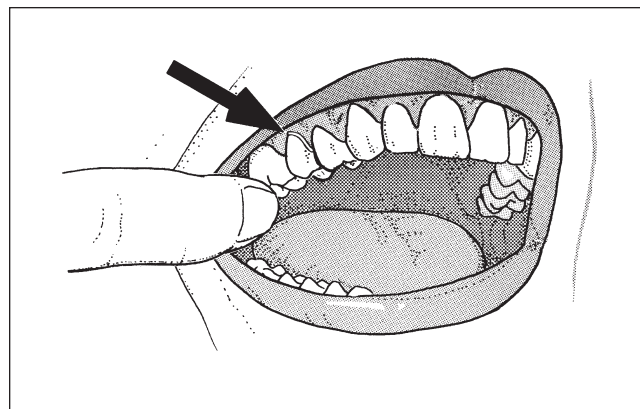


Fig 22-17 Metal collars (arrow) and occlusal surfaces will be unacceptable if a patient insists on "absolute esthetics."

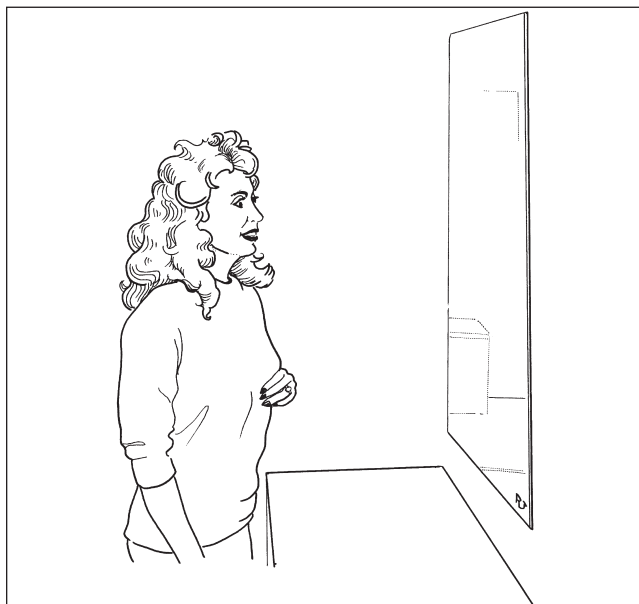

Fig 22-18 Looking at the teeth in a wall mirror shows a patient how the restored tooth will look to others at a normal conversational distance.



Fig 22-19 Using a hand mirror held only inches from the mouth results in the patient seeing the teeth as no one else will.

only determinant of the final result.¹⁴ It is important that the patient's esthetic expectations be discussed and understood before a restoration is fabricated. "Absolute esthetics" require that there be no metal visible, even if one were to look carefully. A restoration containing surface metal that is not visible in normal conversation will satisfy "conversational esthetics" (Fig 22-16). On the other hand, if there is metal that can be seen when the lip is retracted and a strong light shone in the mouth, the restoration or replacement does not meet the requirements of "absolute esthetics" (Fig 22-17).

It may be maddening for the dentist if a patient objects to metal being present even if it is normally not visible. A den-

tist will do well to remember that the patient is the ultimate judge of an "esthetic" crown or fixed partial denture.¹² It is the patient's mouth, and it is the patient's definition of the appearance zone that must be used. It is far better to learn the patient's boundaries before the restoration is made.

If at all possible, the esthetic requirements of the patient should be discussed in front of a wall mirror (Fig 22-18) and not at chairside with the patient wielding a hand mirror under a dental unit light (Fig 22-19). Second molars, maxillary or mandibular, are rarely in the appearance zone, and the dentist should be as persuasive as possible to get the patient to permit full metal crowns on these teeth. They are

22 Esthetic Considerations

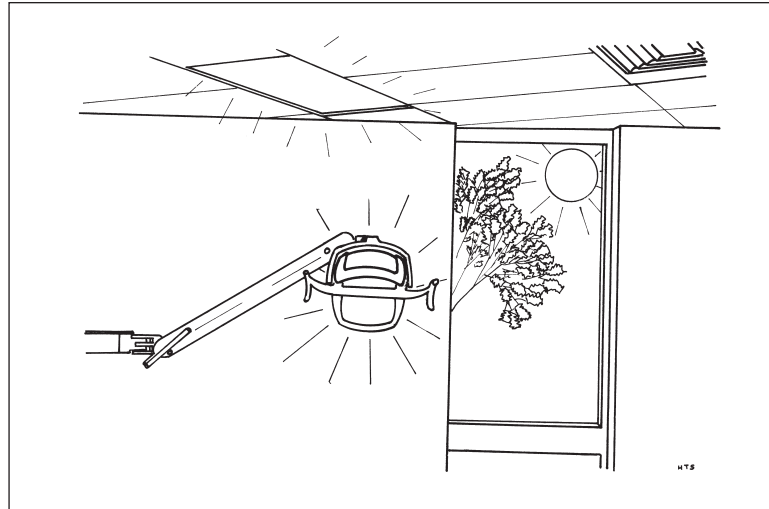


Fig 22-20 The three light sources common to the dental operator are (clockwise from top) fluorescent, natural, and incandescent.

usually short, and reducing them enough to permit a metal-ceramic crown may leave very little tooth structure, with an attendant loss of retention. This could be especially critical if the molar is to serve as a fixed partial denture abutment. The dentist has a responsibility to inform the patient of the disadvantages associated with the use of ceramic materials (greater tooth reduction, increased risk of fracture, and increased abrasion of opposing teeth) to secure a truly informed consent.

Shade Selection

To provide the patient with an esthetic restoration, the dentist must consider the scientific basis of color as well as the artistic aspects of shade selection. Color is a phenomenon of light (red, green, brown, yellow) or visual perception that permits the differentiation of otherwise identical objects. There are three factors upon which color is dependent: (1) the observer, (2) the object, and (3) the light source.²¹ Each of these three factors is a variable, and when any one is altered, the perception of color changes.

Many individuals have some form of color blindness and are incapable of seeing certain colors. It is well documented that color vision deficiency is more common in men than in women, with a study finding 9.3% of the men and 0% of the women deficient.²² At the 1981 American Dental Association convention, color vision testing of 670 dentists (635 men, 35 women) was included in the Health Assessment Program. Sixty-five (9.8%) men and one (0.1%) woman demonstrated color vision deficiency, and individuals with a red-green deficiency showed lower color vision scores in the yellow region

of the visible light spectrum.²³ The majority of the dentists in the United States are men, so it is important to be aware of this condition. If the condition is severe, the dentist can have a laboratory technician or a well-trained assistant match shades.

The object being viewed modifies the light that falls on it by absorbing, reflecting, transmitting, or refracting part or all of the light energy, thereby producing the quality of color. Furthermore, different parts of the same object can exhibit varying amounts of these phenomena. Perception of the object can be influenced by scattered or reflected light from operatory walls, cabinets, and furniture. The walls in a room used for shade selection should be a neutral color, and intense colors should be avoided when selecting cabinets and furniture for this room.

The light source utilized can have a definite effect on the perception of color. There are three light sources commonly found in the dental office: natural, incandescent, and fluorescent (Fig 22-20). The visible portion of the electromagnetic spectrum lies between 380 and 750 nm. Each light source will produce a distinctive distribution of color in the light that it emits.

Natural sunlight itself is extremely variable. The sky appears blue at noon when the sun has less atmosphere to penetrate. There is an uneven distribution of colors in the morning or evening, when the shorter blue and green rays are scattered by the atmosphere surrounding the earth and the longer red and orange rays of the spectrum are able to penetrate the atmosphere without being scattered. The sky appears red or orange as a result.

Artificial light sources are also lacking in an equal distribution of color. Incandescent light is predominantly red-yellow and lacking in blue. This type of light tends to make reds

and yellows stronger and blues weaker. Conversely, under a cool-white fluorescent light source that is high in blue-green energy and low in red, blues are strong and reds are weak.

There are special lights that are “color corrected” to emit light with a more uniform distribution of color. Initial shade selection should be made using color-corrected lights, but any shade should be matched under more than one type of light to overcome the problem of metamerism.²¹ *Metamerism* is the phenomenon of an object appearing to be different colors when viewed under different light sources. The different spectrophotometric curves in the light from the surface of a porcelain restoration and from the enamel of an intact tooth may give the appearance of similar colors when viewed under a light source with a particular color distribution. However, they may appear to be different colors when viewed under a light source with a different color distribution. It is better to select a compromise shade that looks reasonably good under all three types of light than to choose one that may look nearly perfect in sunlight, for example, but appear to be badly mismatched in the patient's home or office.

The three characteristics of color are (1) hue, (2) chroma, and (3) value.²⁴ To facilitate communication with ceramists, the dentist should be thoroughly familiar with these terms and their definitions. *Hue* is that quality that distinguishes one color from another. It is the name of a color, such as red, blue, or yellow. Hue may be a primary color or a combination of colors. *Chroma* is the saturation, intensity, or strength of a hue. For example, a red and a pink may be of the same hue. The red has a high chroma, while the pink, which is actually a weak red, has a low chroma.

Value, or brightness, is the relative amount of lightness or darkness in a hue. Value is the most important color characteristic in shade matching. If it is not possible to achieve a close match with a shade guide, a lighter shade should be selected because it can be stained more easily to a lower value. It is impossible to stain a tooth to obtain a lighter shade (higher value) without producing opacity. If major changes are attempted in the hue or chroma, there will be an accompanying decrease in value.

A number of related factors must be incorporated in ceramic restorations to achieve natural-appearing results. These factors include color, translucency, contour, surface texture, and luster.²⁵ Selecting the basic shade or color of the restoration is merely the first step. Commercially available shade guides do not adequately cover the entire range of tooth color as seen in nature.^{26–29} These guides are made of porcelain without a metal backing, and the thickness of the porcelain is much greater than the veneer on a metal-ceramic restoration. The porcelain used for the shade tab is different from that used for fabricating restorations.³⁰ It is often a higher-fusing porcelain used for denture teeth with extrinsic colorants to develop the desired shade.^{31,32} It is easy to see why the color is simply a starting point; natural teeth are much more complicated than shade tabs, and all the individual variations cannot be completely covered by a commercial guide with 16 selections (eg, Vita Classical shade guide, Vident). The Vita 3D-Master shade system (Vident)

has 29 selections. This guide's shades and their corresponding porcelains are purported to be evenly spread throughout the spectrum of naturally occurring tooth shades.

With the modern prevalence of bleached teeth, Vident also offers a Vita Bleachedguide 3D-Master shade system with 15 selections, which include 7 intermediate shades. This guide is used to keep track of vital bleaching treatment.

Handheld shade-selecting spectrophotometers are also available. Their sensor data can be linked to computer software, which maps the shades on digitized tooth forms. Computer-aided design/computer-assisted manufacture (CAD/CAM) blocks can also be chosen with this data. Customized “staining” can be prescribed and communicated to dental laboratories.

To successfully reproduce natural teeth in ceramic restorations, the various patterns of translucency must be recognized.³³ The translucency pattern contributes to the shade by affecting value: As the translucency increases, the value decreases. The amount, location, and quality of translucency varies with individuals and with age. Young teeth often exhibit a great deal of incisal translucency, with the enamel appearing almost transparent at times. Over years of function, the incisal edges wear, and this highly translucent enamel is lost.

From daily functions such as eating and toothbrushing, the facial enamel layer becomes thinner, allowing the dentin to dominate the shade. In general, older individuals exhibit teeth that are lower in value and higher in chroma compared with what is commonly seen in young adults.^{12,14,25} The pattern of translucency will dictate the depth and extent of the enamel and translucent porcelains built into the restoration.³⁴

Because tooth color occurs in a very narrow range of the visible light spectrum, the form and contours of the restoration play a major role in esthetics. Matching the outline form is just as important as matching the shade correctly.³⁵ There can be a slight mismatch in color, but, with proper contours, the crown will blend in.²⁵ The contralateral tooth can provide valuable information regarding the proper contours, embrasure form, and subtle characterizations of the facial surface.

The surface texture of a tooth or a ceramic restoration influences esthetics by determining the amount and direction of light reflected off the facial surface. To harmonize with the natural dentition, the surface texture of a crown must be designed to simulate the reflectance pattern of the adjacent natural teeth.^{34,35} Typically, young teeth exhibit a great deal of surface characterization, including stippling, ridges, striations, and evidence of developmental lobes. These surface features are gradually worn away with daily function, leaving older teeth with a much smoother, highly polished surface.³⁶ Communicating the amount and quality of surface texture is very difficult. Some authors suggest the use of sterilized extracted teeth or custom shade tabs as a guide.³⁵

The key to the success of natural-appearing restorations is a team approach by the dentist and the technician. Often the ceramist does not participate in the shade selection, making it imperative that the dentist communicate detailed information to the technician. The methods used to relay the

22 Esthetic Considerations

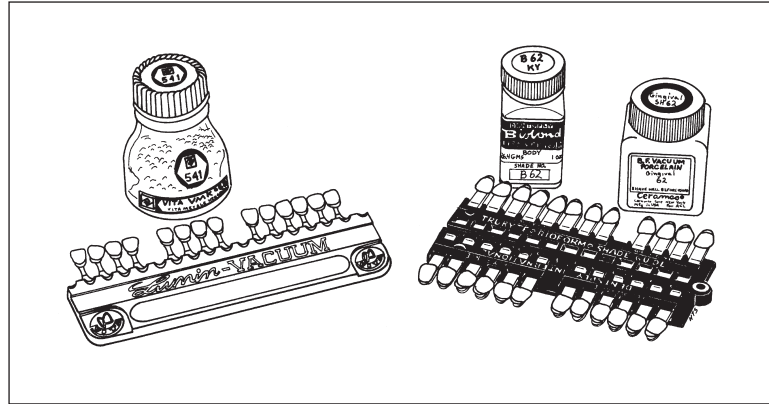


Fig 22-21 The shade guide should match the porcelain: Vita Lumin for Vita porcelain and Bioform for Biobond and Ceramco porcelain.

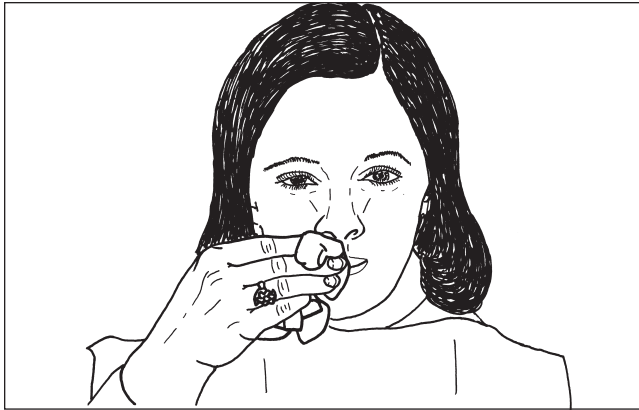

Fig 22-22 The patient should remove cosmetics and other distractions before a shade match is performed.

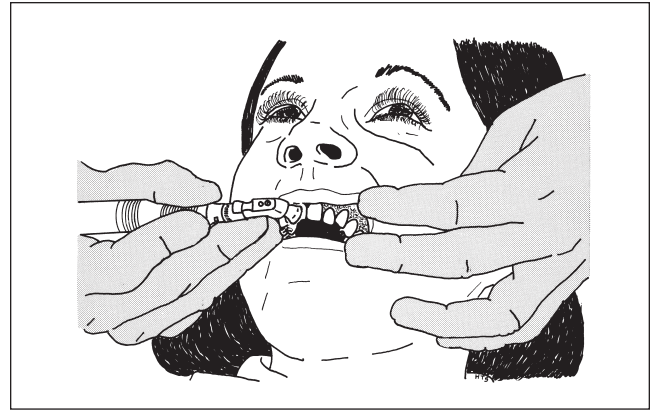

Fig 22-23 Teeth should be cleaned before an attempt is made to match shades.

different factors include a written work authorization with the patient's age and gender, a detailed shade diagram, diagnostic and working casts, and photographs.³⁴ Custom shade tabs can also aid in the determination of the shade, internal characterization, and surface texture.^{35,37} Because ceramists rarely get to see the final result, it is extremely important for the dentist to provide feedback, both positive and negative.

Shade selection sequence

There are a few simple guidelines that should be followed by novice and experienced practitioners alike. While following them will not guarantee a perfect match every time, it will eliminate many sources of error and help to standardize the process.

The shade guide used should match the porcelain the technician is using (Fig 22-21). Every porcelain is different, and best results are obtained when the clinician uses the same guide the manufacturer used in designating the colors

of the product. This is preferred to making the technician resort to conversion charts.

The shade should always be matched prior to preparation of the tooth to be restored. Not only can teeth become dehydrated and change color during preparation, but the debris generated in the form of enamel, metal, and cement grindings can coat everything in the mouth.

The patient should be asked to remove all distractions before a shade match is attempted. Lipstick in particular should be removed (Fig 22-22). Large, bright items, such as earrings or glasses, can also distract the eye from the intended focus of attention on the teeth. Heavy facial makeup, such as rouge, could also interfere with an accurate match and would need to be removed or masked. The teeth need to be clean and unstained before an attempt is made to match a shade. A quick rubber cup and paste prophylaxis is performed in the area of the mouth where the shade is to be matched (Fig 22-23). The area is rinsed thoroughly to remove any traces of the prophylaxis paste; otherwise, the prophylaxis will do more harm than good.

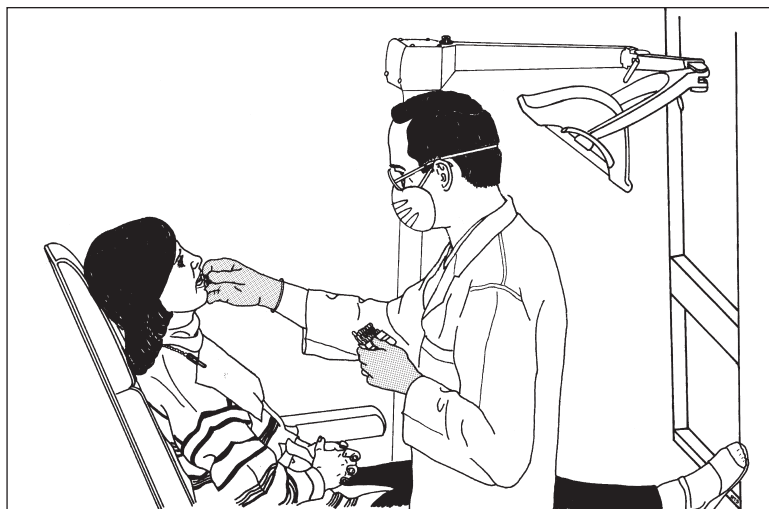

Fig 22-24 When matching a shade, the operator should stand between the patient and the light source.




Fig 22-25 The matching process is begun by quickly scanning the guide

The classical shade guide is used in the following sequence. The patient is seated in an upright position with the mouth at the operator's eye level. The operator should be positioned between the patient and the light source (Fig 22-24). Observations should be made quickly (5 seconds or less) to avoid fatiguing the cones in the retina.^{38,39} The longer the observer's gaze is held, the less ability there is to discriminate, and the cones will become sensitized to the complement of the observed color. Because blue fatigue accentuates yellow sensitivity, the dentist should glance at a blue object (wall, drape, card, etc) while resting the eyes. The shade should be matched by value, chroma, and hue, in that order.

Alternatively, some practitioners choose the hue first (group A, B, C, or D in the classical shade guide). The canine is often used to choose the hue group because it is often unrestored and has significant chroma. Chroma and value are closely tied; therefore, after the hue group is chosen, the final shade tab (eg, A2) is chosen while both properties are concurrently considered.

Following the sequence of considering value first, the entire shade guide is scanned quickly (Fig 22-25), with the tabs that are the worst match selected first and eliminated. By process of elimination, this will leave the few tabs that are the closest matches. They should be moistened as they are used.

22 Esthetic Considerations

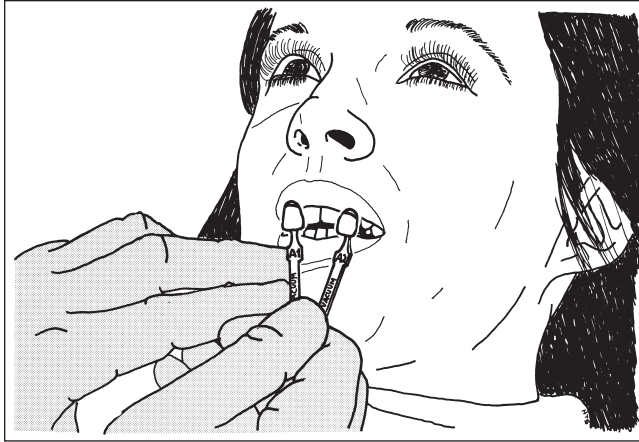


Fig 22-26 The tabs are held on either side of the tooth when making a choice between two closely matching shade tabs.

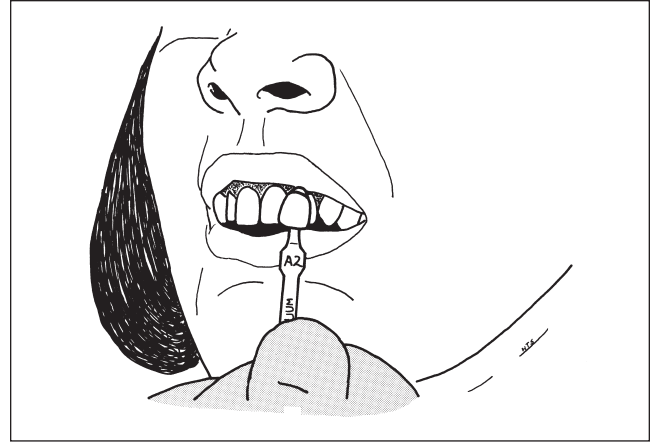


Fig 22-27 The gingival portion of the shade tab is matched with the gingival segment of the tooth.

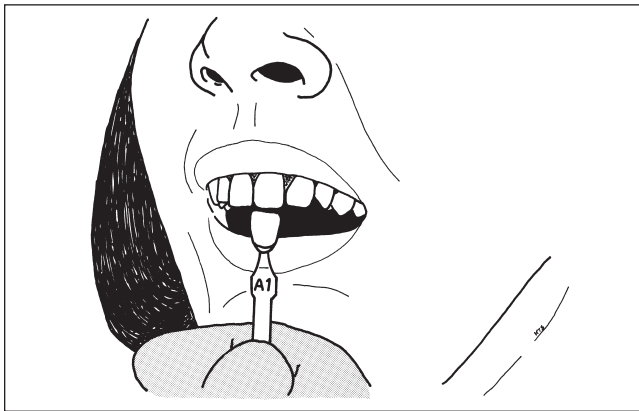


Fig 22-28 The incisal end of the tab is compared with the incisal area of the tooth.

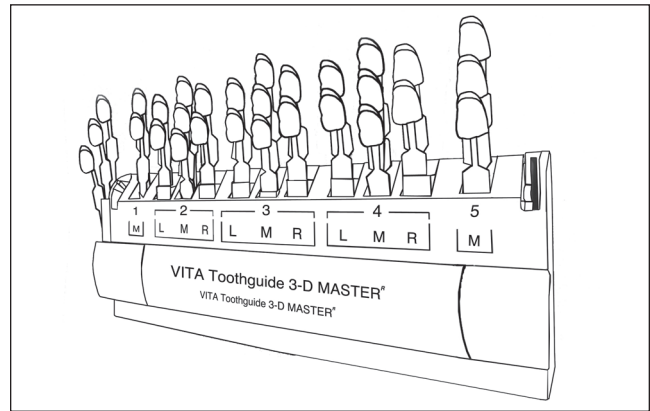


Fig 22-29 Vita 3D-Master shade guide.

If a decision cannot be made between two tabs, they should be held on either side of the tooth being matched (Fig 22-26). If no tab will permit a good match, then the gingival portion of the shade tabs should be matched with the gingival area of the tooth (Fig 22-27).

The necks of the shade tabs often exhibit a great deal of extrinsic colorants. The necks of the tabs should be removed to eliminate this very artistic but distracting aspect prior to matching the gingival one-third to one-half of the tooth.^{39,40} The matching process is completed by comparing the incisal segments of those tabs that most nearly match with the incisal portion of the tooth (Fig 22-28). Initially, the shade is selected using a color-corrected light (color rendering index of 90 or greater), and then the process is repeated under at least one other light source to minimize metamerism.

Because value is the most important dimension of color when selecting porcelain shades, the tabs should be viewed

through half-closed eyes. Although this decreases the ability to discriminate color, it increases the ability to match value. Arranging the shade guide according to value may also facilitate the correct selection of the tooth's relative lightness or darkness.

The sequence of value, chroma, and hue is also followed with the Vita 3D-Master shade guide (Fig 22-29). Including the "bleached" group, there are six groups of shades arranged in decreasing value. Each group has the same value but contains two to seven tabs that vary in chroma and hue. The chroma level is chosen next using the middle (M) group tabs. Then the final choice of hue is made. The tab of the chosen chroma level and its adjacent tabs in the same value group are compared to determine if the tooth exhibits more red (R) or more yellow (L) than the middle (M) tab. For many practitioners accustomed to choosing the hue first, this technique may seem counterintuitive.

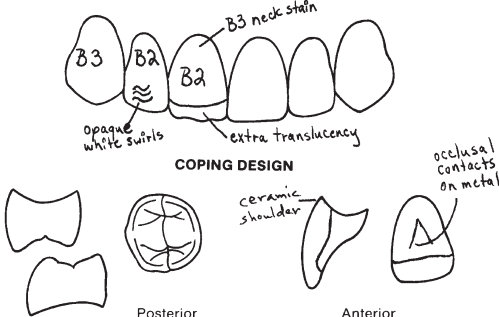
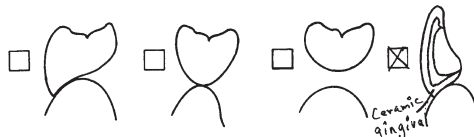
DENTAL LABORATORY WORK AUTHORIZATION			
PATIENT <u>Thomas Edwards</u> LABORATORY <u>Tri-State Crown & Bridge Lab</u> ADDRESS <u>1801 Central Avenue</u> DATE SUBMITTED <u>Nov 1, 1996</u> IMPRESSION / CAST DISINFECTED YES <input checked="" type="checkbox"/> NO <input type="checkbox"/> TRY-IN YES <input checked="" type="checkbox"/> NO <input type="checkbox"/> DATE <u>Nov 15, 1996</u>	TYPE RESTORATION <u>Metal Ceramic Fixed Partial Denture</u> TEETH <u>Maxillary right central, lateral, & canine</u> ALLOY (MCR) <u>Olympia</u> PORCELAIN <u>Vita VMK-68</u> SHADE <u>B2, B3 See below</u> FINISH DATE <u>Dec 6, 1996</u>		
CHARACTERIZATION AND SHADE VARIATIONS  <p style="text-align: center;">COPING DESIGN</p> <p style="text-align: center;">Posterior Anterior</p> <p style="text-align: center;">PONTIC DESIGN</p> 	SPECIAL INSTRUCTIONS <p>Please fabricate max anterior MCR FPD Return framework for try-in 1) occlusion in metal 2) all ceramic facial shoulder Please add porcelain, glaze and finish Note characterization at left</p> <p style="text-align: center;">Thanks</p> <p>DENTIST <u>Larry Chisholm, DDS</u> ADDRESS <u>1001 North 10th St, Midwest City</u> DENTAL LICENSE NO. <u>61580</u></p>		

Fig 22-30 The prescription should be precise and detailed in its description of the restoration to be fabricated.

The tooth is carefully examined to determine the pattern of translucency and any unique characterizing features such as craze lines, areas of hypocalcification, etc. A periodontal probe or other millimeter-measuring device is used to establish the location and extent of these distinguishing features. Developing color, translucency, and characterizations within the porcelain will create a more lifelike restoration than simply applying extrinsic colorants after the porcelain is fired.

A drawing of the facial surface of the tooth is made in the patient's chart, and all pertinent information is recorded graphically. Different shades are indicated if more than one is selected for different parts of the tooth. This information is transferred to the laboratory work authorization, making it as complete as possible (Fig 22-30). It is a good idea, whenever possible, to send the shade tab, a cast including the contralateral tooth, and a photograph to the dental laboratory.

Before putting the shade guide away, it must be disinfected (Fig 22-31). Because parts of most shade guides are made of plastic, the autoclave or other processes involving heat should be avoided.

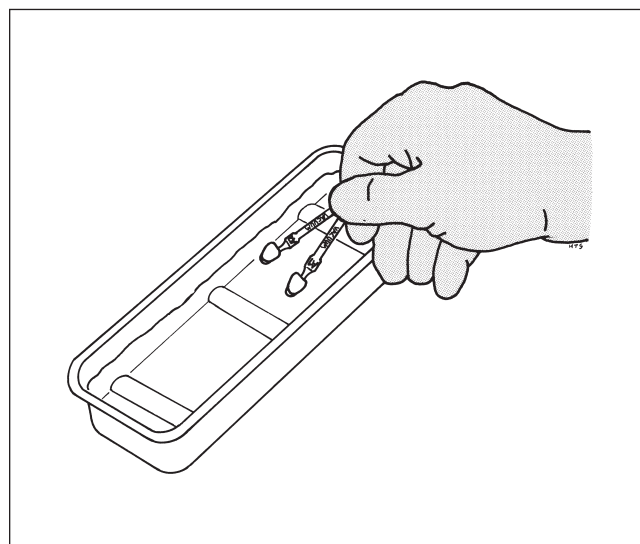


Fig 22-31 Shade tabs should be placed in a disinfecting solution when the shade matching has been completed.

22 Esthetic Considerations

References

1. Tjan AH, Miller GD, The JG. Some esthetic factors in a smile. *J Prosthet Dent* 1984;51:24–28.
2. Moskowitz ME, Nayyar A. Determinants of dental esthetics: A rationale for smile analysis and treatment. *Compend Contin Educ Dent* 1995;16:1164–1186.
3. Heinlein WD. Anterior teeth: Esthetics and function. *J Prosthet Dent* 1980;44:389–393.
4. Vig RG, Brundo GC. The kinetics of anterior tooth display. *J Prosthet Dent* 1978;39:502–503.
5. Andrews LF. The six keys to normal occlusion. *Am J Orthod* 1972;62:296–309.
6. Powell N, Humphreys B. Proportions of the Aesthetic Face. New York: Thieme-Stratton, 1984;2,4–9,50.
7. Lombardi RE. The principles of visual perception and their clinical application to denture esthetics. *J Prosthet Dent* 1973;29:358–382.
8. Cipra DL, Wall JG. Esthetics in fixed and removable prosthodontics: The composition of a smile. *J Tenn Dent Assoc* 1991;71(4):24–29.
9. Brisman AS. Esthetics: A comparison of dentists' and patients' concepts. *J Am Dent Assoc* 1980;100:345–352.
10. Black GV. Descriptive Anatomy of the Human Teeth. Philadelphia: Wilmington Dental, 1890:14–15.
11. Shillingburg HT Jr, Kaplan MJ, Grace SC. Tooth dimensions—A comparative study. *J South Calif Dent Assoc* 1972;40:830–839.
12. Brisman A, Hirsch SM, Paige H, Hamburg M, Gelb M. Tooth shade preferences in older patients. *Gerodontology* 1985;1:130–133.
13. Levin EI. Dental esthetics and the golden proportion. *J Prosthet Dent* 1978;40:244–252.
14. Heymann HO. The artistry of conservative esthetic dentistry. *J Am Dent Assoc* 1987;115(special issue):14E–23E.
15. Barratt K. Logic and Design in Art, Science and Mathematics. New York: Design Books, 1980:108–111.
16. Ricketts RM. The golden divider. *J Clin Orthod* 1981;15:752–759.
17. Pedoe D. Geometry and the Visual Arts. New York: Dover, 1983:69,70.
18. Huntley HE. The Divine Proportion—A Study in Mathematical Beauty. New York: Dover, 1970:23,62,64,161.
19. Gardner M. The multiple fascinations of the Fibonacci sequence. *Sci Am* 1969;220:116–120.
20. Ricketts RM. Divine proportion in facial esthetics. *Clin Plast Surg* 1982;9:401–422.
21. Sproull RC. Color matching in dentistry. Part III. Color control. *J Prosthet Dent* 1974;31:146–154.
22. Wasson W, Schuman N. Color vision and dentistry. *Quintessence Int* 1992;23:349–353.
23. Moser JB, Wozniak WT, Naleway CA, Ayer WA. Color vision in dentistry: A survey. *J Am Dent Assoc* 1985;110:509–510.
24. Sproull RC. Color matching in dentistry. Part I. The three-dimensional nature of color. *J Prosthet Dent* 1973;29:416–424.
25. Winter RR. Achieving esthetic ceramic restorations. *J Calif Dent Assoc* 1990;18(9):21–24.
26. Clark EB. Tooth color selection. *J Am Dent Assoc* 1933;20:1065–1073.
27. Sproull RC. Color matching in dentistry. Part II. Practical applications of the organization of color. *J Prosthet Dent* 1973;29:556–566.
28. Preston JD. The metal-ceramic restoration: The problems remain. *Int J Periodontics Restorative Dent* 1984;4(5):9–23.
29. Miller LL. Organizing color in dentistry. *J Am Dent Assoc* 1987;115(special issue):26E–40E.
30. Preston JD. Current status of shade selection and color matching. *Quintessence Int* 1985;16:47–58.
31. Bergen SF. Color in esthetics. *N Y State Dent J* 1985;51:470–471.
32. Wall JG, Cipra DL. Esthetics in fixed and removable prosthodontics: Shade selection in metal-ceramics. *J Tenn Dent Assoc* 1992;72(3):10–12.
33. Yamamoto M. Metal-Ceramics: Principles and Methods of Makato Yamamoto. Chicago: Quintessence, 1985:350.
34. Kessler JC. Dentist and laboratory: Communication for success. *J Am Dent Assoc* 1987;115(special issue):97E–102E.
35. Sorensen JA, Torres TJ. Improved color matching of metal ceramic restorations. Part II: Procedures for visual communication. *J Prosthet Dent* 1987;58:669–677.
36. Pilkington EL. Esthetics and optical illusions in dentistry. *J Am Dent Assoc* 1936;23:641–651.
37. Seluk LW, LaLonde TD. Esthetics and communication with a custom shade guide. *Dent Clin North Am* 1985;29:741–751.
38. Yamamoto M. Metal-Ceramics: Principles and Methods of Makato Yamamoto. Chicago: Quintessence, 1985:240.
39. Sorensen JA, Torres TJ. Improved color matching of metal-ceramic restorations. Part I: A systematic method for shade determination. *J Prosthet Dent* 1987;58:133–139.
40. O'Keefe KL, Strickler ER, Kerrin HK. Color and shade matching: The weak link in esthetic dentistry. *Compendium* 1990;11:116–120.

All-Ceramic Restorations

Evolution of All-Ceramic Crowns

The first all-ceramic crown was developed by Land¹ in 1886 and was known as the *porcelain jacket crown* (PJC). For many decades, it was the most esthetic full-veneer restoration dentistry had to offer. The PJC was once made from high-fusing porcelains, using platinum foil for support during firing. It relied on the support of the underlying tooth preparation during function. Because of the tendency of this type of restoration to fracture, its use usually was limited to single anterior teeth, primarily incisors.

As the demand for more natural-looking crowns increased, dentists, laboratory technicians, and porcelain manufacturers investigated a variety of methods to reinforce ceramics with the ultimate goal of a ceramic material that possesses not only a high level of esthetics and soft tissue acceptance but also sufficient strength to allow the fabrication of fixed partial dentures.

In 1965, McLean and Hughes² developed a PJC with an inner core of aluminous porcelain containing 40% to 50% alumina crystals to block the propagation of cracks (Fig 23-1). The reinforcing inner core of the restoration surrounding the preparation was layered with conventional porcelain, resulting in a restoration approximately twice as strong as the traditional PJC. The use of this type of reinforcement revived the use of PJCs. Unfortunately, the strength was still insufficient for anything but single anterior crowns.

Fracture resistance in the aluminous PJC was improved by a technique in which the platinum matrix was left in the completed restoration.^{3,4} The strength of the crown was augmented even more by this so-called twin foil technique.⁵ The platinum foil matrix not only provided additional support to the porcelain, but it also allowed a chemical bond between the tin-plated foil and oxides in the porcelain. Glass-ceramics do not fail because they are weak; they fail as a result of propagation of defects or flaws. It seems that the bond formed with foil helped to minimize crack proliferation that often led to failure. However, the residual platinum foil did decrease the amount of light transmitted, which diminished the esthetic advantage of an all-ceramic restoration.

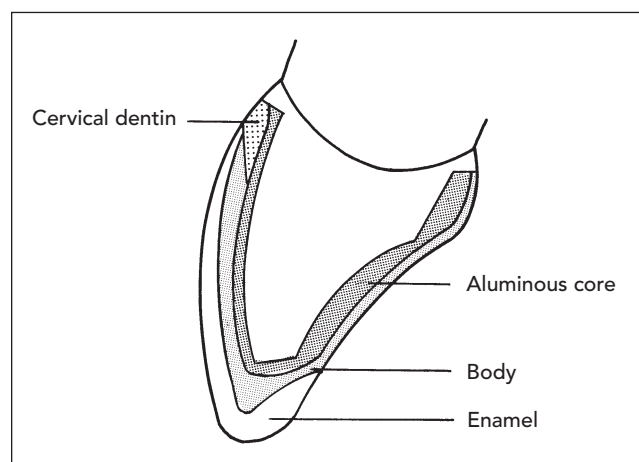


Fig 23-1 The layers of an aluminous PJC (after McLean and Hughes²).

Overview of Available All-Ceramic Systems

In the last three decades, research has focused on strengthening dental ceramics by modification of the porcelain's microstructure and by developing high-strength core materials. The driving force behind the research and development of all-ceramic restorative materials is the demand for a more esthetic option than metal-ceramic restorations (MCRs). Another major reason for the interest in high-strength substructure materials has been to develop nonmetallic systems that can be predictably used for fixed partial dentures and other high-stress situations. An added incentive is the ever-increasing cost of gold and other metals traditionally used in dental alloys. To date, none of the all-ceramic systems have proven to be as predictable as MCRs, and neither all-ceramics nor MCRs even begin to approach the track record of gold restorations.

The various all-ceramic systems have been described based on several criteria: microstructural classification,⁶ fabrication

23 All-Ceramic Restorations

methods, and strength. However, the variation that seems to be most significant clinically is whether the all-ceramic restoration from a given system can be etched and bonded or is primarily a cemented restoration. Bonded all-ceramic restorations have completely different indications, preparation demands, and cementation protocols than do cemented all-ceramic restorations.

In the early 1980s, the concept of etching ceramic with hydrofluoric acid and subsequently bonding the etched ceramic to enamel with a resin luting medium was introduced. The ceramic materials that are susceptible to hydrofluoric acid etching are glass-based systems, composed of a glass matrix with filler particles. Exposure of such materials to hydrofluoric acid allows for the filler particles to be selectively removed, leaving a micromechanical network ideal for bonding to resin cements. The three ceramic materials that can be etched and bonded are the traditional hand-stacked feldspathic porcelains, the leucite-reinforced glass-ceramics, and the lithium disilicate-reinforced glass-ceramics. The glass-ceramic restorations can be designed and fabricated as one-piece (monolithic) restorations, or they can act as core materials with more translucent porcelains layered for esthetic enhancement.

The nonetchable all-ceramic restorations are fabricated with high-strength core materials and veneered with weaker but more translucent porcelains to establish the desired contours and esthetic result. The high-strength core materials are composed of alumina-reinforced ceramic, zirconia-reinforced ceramic, or some combination or modification of the two.

Bonded ceramic restorations

Bonded ceramic restorations provide several advantages to the restorative dentist and the esthetically driven patient. Arguably, the most significant advantage is that these are the most conservative of the tooth-colored indirect restorative options, requiring the least amount of tooth reduction while at the same time offering the most esthetic potential. Another advantage of indirect bonded restorations is that there are minimal demands for retention and resistance form in the tooth preparation. They do not require features such as increased axial wall length, grooves, or boxes solely for the purpose of retaining the restoration. Retention and resistance are accomplished through the bonding process and rely much less on mechanical retention.

The materials that can be etched with hydrofluoric acid and bonded with resin cements are the conventional hand-stacked feldspathic porcelains, highly filled glass-ceramics, and lithium disilicate glass-ceramics. While there are similarities among these materials in tooth preparation designs as well as etching and bonding procedures, there are also significant differences as far as inherent material strength and clinical indications. Each of the individual classes of bonded ceramic materials offers its own unique advantages and disadvantages that will be discussed, along with the indications and preparation designs for each.

Feldspathic porcelain restorations

These conventional porcelains, with minor modifications, are the same materials that are veneered on metal substructures to produce MCRs as well as on high-strength ceramic core restorations. These materials have also been used over the years to produce PJC's, porcelain inlays and onlays, and porcelain veneers. With the advent of the other two classes of bonded glass-ceramic restorative materials (leucite- and lithium disilicate-reinforced), which have superior strength and more efficient production techniques, the use of the hand-stacked feldspathic materials for construction of all-ceramic restorations has diminished and is now primarily limited to anterior veneer restorations. However, in the hands of an accomplished ceramist, the hand-stacked feldspathic porcelain veneer is the most esthetic and requires the least amount of tooth reduction of any available restoration. These veneers can be fabricated to a minimum thickness of 0.5 mm.

Because these restorations are hand-stacked with fragile porcelain powders, they must be built on a foundation material on which they can be carried to the porcelain furnace and fired. This requires that the foundation is able to withstand the high firing temperatures of the porcelain. The two common foundations used in building these restorations are a refractory die and a platinum foil matrix. With the refractory cast, the porcelain is built up, fired, and finished directly on the refractory die. The platinum foil matrix technique involves first adapting the foil to the die and then layering, lifting, and firing the porcelain while on the foil support. After completion of the restoration, the foil is stripped away, and the veneer is fit to the master die. Both of these methods of fabrication are technique sensitive and require strict attention to detail during every step of the fabrication process. With both techniques, the substrate on which the porcelain is built and finished must be destroyed in order to retrieve the restoration prior to fitting on the master die. Therefore, they require a ceramist dedicated to perfection; if the finished restoration is found to be unacceptable, it usually means that the entire process will have to be redone.

Conventional feldspathic porcelain veneers are indicated when the patient presents with high esthetic expectations, and anterior partial veneer restorations are an appropriate choice. Because these restorations are hand-stacked, the translucency or opacity as well as color modifications can be built internally. In experienced and talented hands, this can produce the most lifelike restorations available.

However, these restorations present with significant disadvantages as well. The first and most obvious is finding a ceramist that offers this restoration and is willing and capable of consistently producing these demanding works of art and science. As was mentioned previously, with the increasing availability of other glass-ceramic materials that can be produced either with a familiar lost-wax pressed technique or through computer-aided design/computer-assisted manufacture (CAD/CAM) technology, the number of ceramists that still produce hand-stacked veneers is diminishing. Another significant consideration is that these fragile restorations require a very technique-sensitive delivery protocol.

Highly filled glass-ceramic restorations

The highly filled glass-ceramic restorative materials were introduced in 1990 as IPS Empress, now known as IPS Empress Esthetic (Ivoclar Vivadent). This original pressed ceramic is fabricated with a familiar wax-up, investment, and burnout technique similar to that used for decades in the dental laboratory. The leucite-reinforced glass-ceramic is heat-pressed into a phosphate-bonded investment, forming either a core or a completed monolithic restoration.

The IPS Empress system does not require a second heating cycle to initiate the crystalline phase of leucite crystals. Instead, they are formed within the glass matrix of feldspathic porcelain throughout various temperature cycles.⁷

With the increasing popularity of CAD/CAM technology, ceramic blocks are available for the production of milled restorations in both feldspathic ceramic (Vitablocs Mark II, Vident) and highly filled leucite-reinforced ceramic (IPS Empress CAD, Ivoclar Vivadent). The two systems that dominate the CAD/CAM market today are CEREC (Sirona) and E4D (D4D Technologies). For the purposes of this discussion, the CAD/CAM-produced and pressed versions of these restorations share the same indications, limitations, and delivery techniques.

These materials are recommended for anterior full coverage and veneer applications, as well as inlay, onlay, and full coverage restorations for premolars. Leucite-reinforced glass-ceramic materials have enjoyed some success with molar inlays and onlays. However, as with any all-ceramic restoration, the failure rate is higher in molars.⁸

The second restorative option in the highly filled glass-ceramic family is the lithium disilicate-reinforced material, e.max (Ivoclar Vivadent). As with the leucite-reinforced material, e.max is available in both pressed ceramic (e.max Press) and CAD/CAM (e.max CAD) versions. The reported fracture strength for lithium disilicate-reinforced ceramic is 350 MPa⁹ as compared to 120 MPa¹⁰ for the leucite-reinforced material. Esquivel-Upshaw et al¹¹ report the flexural strength of leucite-reinforced material to be 164 to 180 MPa. Initial studies of the durability of lithium disilicate glass-ceramics have been promising. The manufacturer currently recommends these for all single-unit applications and certain three-unit anterior fixed partial dentures where there is adequate bulk in the connector area.

As previously mentioned, the leucite- and lithium disilicate-reinforced materials share several commonalities. The first is that they can be fabricated as either monolithic or layered restorations. As one would expect, the monolithic or nonlayered restorations have proven to be immune to the common fracture of the weaker veneer porcelains used in layered application. Because the solid restorations are either pressed or milled, they are also not subject to the fabrication imperfections that can plague any hand-layered restoration. The esthetic demands for most posterior and even certain anterior applications can be satisfied by monolithic restorations. With the variety of available material translucencies and the ability to characterize the restorations with surface stains, these can be esthetically satisfactory restorations in many situations.

A unique opportunity offered by milled feldspathic and leucite-reinforced materials is that, in addition to the standard monochromatic blocks, they are available in blocks with varying translucency (eg, IPS Empress CAD Multi [Ivoclar Vivadent] and Vitablocs TriLux [Vident]). The translucency of these ceramic blocks varies from a high chroma gingival neck shade on one side of the block to a dentin shade in the center of the block to an enamel translucency on the opposite side of the block. During the digital design phase of the CAD/CAM process, the restoration can be digitally positioned in the block to either increase or decrease the translucency in the finished, milled crown. This allows for the fabrication of a monolithic restoration with variations of shading within the finished product, thus allowing for the best of both worlds: no hand-layering and variable translucency. At the time of this writing, these multilayered blocks are available in feldspathic and highly filled leucite-reinforced versions but not in lithium disilicate-reinforced materials.

An important consideration when planning glass-ceramic restorations is the color or discoloration of the prepared tooth. Because these materials are available in a variety of opacities and translucencies, it is of paramount importance that the presence or absence of discoloration of the underlying tooth is communicated to the dental laboratory along with the standard shade selection. In situations where the prepared tooth is of a uniform and desirable shade, the best esthetics is obtained with a more translucent ceramic. When a translucent ceramic restoration is bonded with a translucent resin, allowing subtle show-through of the natural tooth shade, it usually results in the most life-like result possible.

However, when a prepared tooth presents with an undesirable tooth shade, discoloration, or metallic buildup and the plan is to restore that tooth with an all-ceramic restoration, the situation is complicated. The so-called preparation shade or stump shade can be conveyed by written communication, by selection of a stump shade from a special shade guide provided by the manufacturer, by selection and communication of a standard shade for the prepared tooth, or by digital photographs of the preparations. Even with the high-opacity versions of glass-ceramics, it is difficult or impossible to block out some discolorations. How effective a given restoration is at blocking out the underlying discoloration is dependent on several factors in addition to the opacity of the ceramic from which the restoration is fabricated. The thickness of the completed restoration plays a significant role in how effectively it blocks out discolored preparations. Another factor, often overlooked, is the actual hue and intensity of the discoloration. Evaluation of the ability of various ceramic restorations to block out different discolorations has shown that those discolorations in the silver to dark gray range are the most difficult to block, while the yellow to gold hues can be effectively masked more predictably. The shade of the resin cement used to bond the restoration can also impact the final shade. Many manufacturers of resin cements supply try-in pastes. These are materials that can be used during the try-in of translucent restorations to simulate the shades of the various cements available in a given system. After the best cement shade is determined, the try-in paste

23 All-Ceramic Restorations

can simply be rinsed from the inside of the restoration and from the tooth surface. However, because of minor differences between the shades and opacities of try-in pastes and those of the actual resin, one cannot observe the final result until the restoration is bonded. The ability of shaded cements to alter shades and block out discolorations is often overemphasized, and the actual effect of the cement is usually negligible. Therefore, when faced with the challenge of a discolored preparation, it is more predictable to plan based on the opacity of the restoration than it is to rely on the shaded cement to significantly alter the final appearance of the restoration. The high-strength core restorations can be more effective at blocking out underlying discolorations than the more translucent glass-ceramic materials. In general, glass-ceramic restorations should be avoided when the underlying preparation presents significant discolorations.

High-strength core restorations

The high-strength core restorations are composed of a substructure of ceramic veneered with feldspathic porcelain for esthetics. These cores are made of alumina, zirconia, or a combination of the two. These high-strength core materials are not amenable to standard ceramic etching techniques using hydrofluoric acid. Therefore, while these can be cemented with resin cement, the bond between the resin and the core material is minimal.

Alumina-reinforced substructures

The first high-strength core ceramic was a glass-infiltrated alumina, In-Ceram (Vident). This system evolved from research by Sadoun in 1985, in which alumina was used as the core material.¹² A suspension of finely ground material (slip) mixed to a thin, creamy consistency is brushed onto the die in a method called *slip casting*. The alumina is fired, or *sintered*, in a furnace, which fuses particles together without completely melting them.¹³ In a second firing process, glass is applied to the surface of the porous core and *infused*, or absorbed, into the porous core material by capillary action. The densely packed alumina crystals limit crack propagation, and glass infiltration eliminates residual porosity.¹⁴

Although the sintered alumina core is relatively weak, there is a marked elevation of strength following glass infusion.¹⁵ The flexural strength of the finished substructure material is reported to be 256 to 500 MPa.¹⁶ Wagner and Chu¹⁷ report the biaxial flexural strength to be 352 MPa. The design of the core resembles the coping of an MCR. It provides a strong substructure that resists flexure and supports the veneer. Conventional porcelain (eg, Vitadur-N or Vitadur Alpha, Vident) is applied to the core to develop the final contours and color.

Another system that takes advantage of the high-strength alumina core is the Procera AllCeram system (Nobel Biocare). The Procera material is a densely sintered alumina, and the reported flexural strength is 420 to 770 MPa.¹⁸ Wagner and Chu¹⁷ measured the biaxial flexural strength to be

687 MPa. The manufacturer recommends these restorations for both anterior and posterior single-unit restorations and selected three-unit anterior fixed partial dentures. However, with the advent of zirconia substructures, the indications for alumina-reinforced fixed partial denture frameworks are questionable.

This core is fabricated with a completely different set of technologies. First, the die is scanned in the dental laboratory with a touch scanner (NobelProcera Forte scanner, Nobel Biocare) or with the recently introduced NobelProcera optical scanner. Either the master die or the impression can be scanned. The information gathered by the scanner is then opened as a three-dimensional image in the NobelProcera CAD program, allowing for the coping to be digitally designed. The design information is then sent electronically via the Internet to a milling center, where the core is fabricated.

The first step in the core fabrication is the die milling. This die or press tool is designed using the information from the scan of the original master die and is milled from a precast gypsum block to produce the internal shape and detail of the final coping. This die is precisely milled to an oversized dimension in anticipation of the shrinkage that the core will undergo when fired.

This oversized gypsum die is first coated with a special ceramic material that will eventually become the intaglio surface of the coping. The coated die is then transferred to an isostatic press, where the core material is compacted at high pressure onto the die. This oversized, unfired core is now transferred to a milling machine, where the CAD outer contour is milled. At this point in the process, the coping has the internal detail obtained from the milled gypsum die and the original CAD outer contour, but dimensionally it is still oversized.

The coping is now transferred from the gypsum die to a refractory tray, where it goes through two heat cycles. The first is a presintering oven where the binder is burned off, and the second is the high-heat sintering furnace.

While the milling, pressing, and firing processes are taking place, a separate, second die is milled from polyvinyl chloride (PVC) material. This is an exact duplicate of the master die that was originally scanned back in the dental laboratory. This PVC die is used as a check die to confirm proper fit of the completed coping. Prior to shipping, the coping is checked under magnification for fit, cracks, color, and thickness and to confirm a smooth margin. The coping is then sent back to the laboratory of origin for the application and firing of the veneering porcelain.

Both In-Ceram and Procera are available in a variety of translucencies, varying from the original In-Ceram alumina core, which is virtually opaque, to the In-Ceram Spinell (magnesium aluminum oxide), which is more translucent. Therefore, while communication of an exact stump shade is not as critical as it is with the highly translucent glass-ceramic restorations, it remains very important to report discolorations or metallic cores to the dental laboratory so they can make an educated decision regarding core opacity. The wide variety of core translucencies available is unique to these systems. One caveat is that strength inversely varies with translucency.

Therefore, the more translucent cores, while more esthetic, are also weaker.

Zirconia-reinforced substructures

Zirconia-reinforced materials are the strongest tooth-colored substructure materials available to date. In its natural state at room temperature, zirconia is in a relatively weak, monoclinic phase. At its melting point, 2,680°C, zirconia assumes a cubic structure; as it cools, the material undergoes a phase change to a tetragonal phase at 2,370°C and finally, at 1,170°C, to the original monoclinic phase. As the material undergoes this final phase change, it increases in volume 3% to 5%, which causes high internal stresses.¹⁹ The addition of yttrium oxide stabilizes zirconia in its tetragonal phase at room temperature. It is this partially stabilized zirconia that exhibits the high tensile strength and fracture toughness required for dental restorations.

The mechanism that results in the high strength of the yttria-stabilized zirconia is called *transformation toughening*. This phenomenon occurs when a crack is initiated and the tensile stresses at the crack tip cause the tetragonal phase to transform into the monoclinic phase. As mentioned earlier, there is an accompanying increase in volume when the material makes this tetragonal to monoclinic phase change, and this volume increase is thought to create compressive forces at the crack tip and retard its propagation. The resultant material has extremely high flexural strength and fracture toughness. A review of the currently available clinical studies reveals that there have been almost no reports of substructure failure with yttrium oxide-stabilized zirconia substructures. This predictability assumes that recommended parameters for coping thickness and connector dimensions are followed.

Zirconia-reinforced substructures are fabricated using CAD/CAM technology. The exact scanning and design process varies among the different systems; however, most frameworks are milled from presintered zirconia and subsequently fired. The fully sintered materials are simply too hard to mill without quickly destroying the milling instruments, and there is evidence that milling of a fully sintered blank may weaken the material.²⁰ The challenge with milling the presintered material is that there is 20% to 25% shrinkage during the final sintering, which must be accurately compensated for when the green-state material is milled. Therefore, the presintered coping is significantly oversized and cannot be tried on or seated on the die until the sintering is completed.

As with the alumina-reinforced materials, the final esthetic results with zirconia-reinforced restorations are achieved by the addition of a hand-stacked veneer of feldspathic porcelain or a veneer of pressed ceramic. Manufacturers recommend these restorations for any single-unit restorations and most posterior, as well as anterior, fixed partial dentures. Although the reported incidence of substructure failure has been extremely low, significant percentages of restorations exhibit fracture and chipping of veneering porcelains.²¹

Several factors have been identified as the possible reasons for the significant levels of veneer chipping with these

restorations. Early in the development of these technologies, the design software with several of the systems did not allow for a convenient way to evaluate for anatomical framework contours. In other words, the coping was often just a thimble of a uniform thickness of zirconia with no control of the veneer thickness. Porcelain veneers of more than 2 mm in thickness are susceptible to fracture, and the same has proven to be true with zirconia and alumina substructures. Anatomical framework design with a uniform thickness of veneering porcelain of 1 to 2 mm has proven to have fewer chips and fractures in the veneer. The chipping that does occur is smaller in size.

A second possible cause for the fractures has been the brittle properties of the early veneering materials themselves. Because the traditional metal-ceramic veneering porcelains did not have coefficients of thermal expansion that were compatible with zirconia, they required modification, and some of these modified materials seemed to be more brittle, and their initial strength degraded more rapidly. Veneering porcelains have evolved as the interest in and use of zirconia frameworks have increased, and the inherent brittleness of veneering materials may no longer be the issue that it once was.

Another possible reason given for these fractures is that zirconia is a good insulator or, conversely, a poor conductor. In fact, zirconia has a thermal conductivity about 12 times less than that of alumina ceramic. The result is thought to be that there is insufficient heat distribution during firing of the porcelain veneer, which results in underfired, brittle porcelain.²² In an attempt to overcome this concern, most manufacturers now recommend an initial application of a "liner" porcelain with the goal of increased bonding to and wetting of the zirconia substructure.²³ This layer, as well as subsequent porcelain additions, is fired with a slow rate of temperature increase and a prolonged cooling time. The result seems to be more complete temperature distribution and more uniform porcelain firing.

All-ceramic crown fabrication

All-ceramic crowns demand a significant amount of tooth reduction to allow for a minimum thickness of core material, development of internal shade characterization, and the maintenance of biologically acceptable contours. Tooth preparation for all-ceramic restorations should provide a minimum overall reduction of 1.0 mm.¹⁴ However, 1.5 mm on the facial and 1.5 to 2.0 mm on the occlusal aspects are preferred. All line and point angles should be rounded.^{12,15} (See chapter 10 for a complete description of the tooth preparation for an all-ceramic crown.)

The finish line is a radial shoulder that is 1.0 mm wide on the facial and 0.5 to 0.7 mm wide in other areas¹² (Fig 23-2). A study comparing the marginal adaptation of In-Ceram crowns with varying finish lines found that all three of the configurations tested (chamfer, 50-degree shoulder, and 90-degree shoulder) yielded acceptable results.²⁴

23 All-Ceramic Restorations

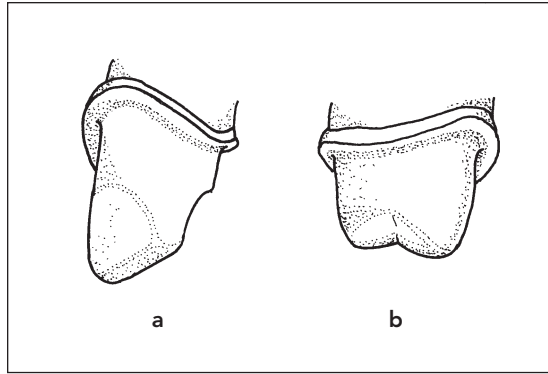


Fig 23-2 Tooth preparations for all-ceramic crowns: (a) anterior; (b) posterior.

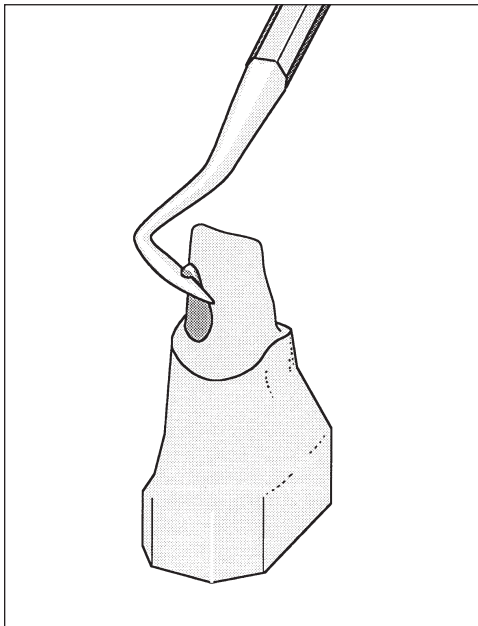


Fig 23-3 Undercuts are blocked out in axial walls.

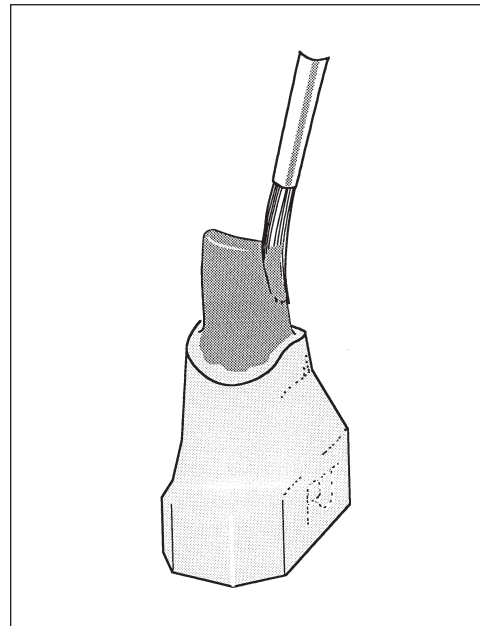


Fig 23-4 Die spacer is applied to the preparation away from the finish line.

Following the impression of the prepared tooth, a master cast with removable dies is constructed. The dies are trimmed, and any undercuts are blocked out (Fig 23-3). Cement spacer is applied to the dies, with a distance of 0.5 to 1.0 mm maintained from the finish line (Fig 23-4). An addition silicone impression material is used to duplicate the master cast (Fig 23-5), and the mold is poured in a specially formulated stone (Fig 23-6). The expansion of this stone corresponds to the contraction of the slip casting material during the initial sintering process. After the duplicate dies are trimmed, the finish line is marked (Fig 23-7). A sealant is ap-

plied to act as a surface wetting agent, decreasing absorption of liquid slip by the die (Fig 23-8).

An ultrasonic device (Vitasonic, Vident) is used for the preparation of the alumina slip material (Fig 23-9). Liquid, alumina powder, and an additive are combined and mixed on a vibrator (Fig 23-10) until they become a homogenous mass. The slip should exhibit rheopectic properties (ie, the liquid mass should stiffen under pressure). This property may cause the ceramist a few moments of frustration and require some additional practice.

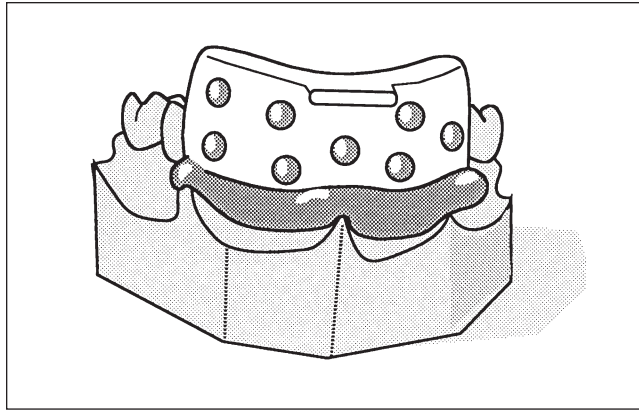


Fig 23-5 A sectional impression of the master cast is made with an addition silicone material.

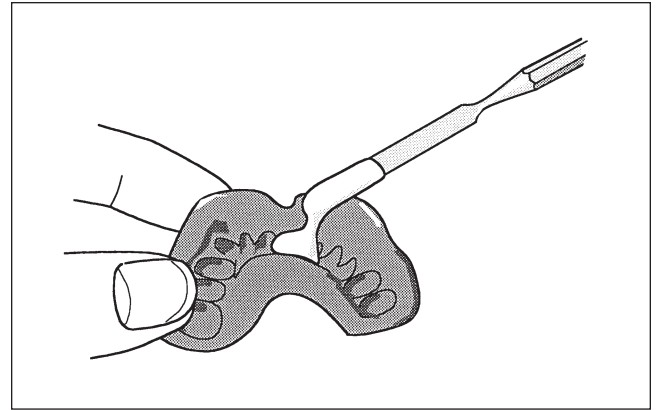


Fig 23-6 The mold is poured in a special refractory material.

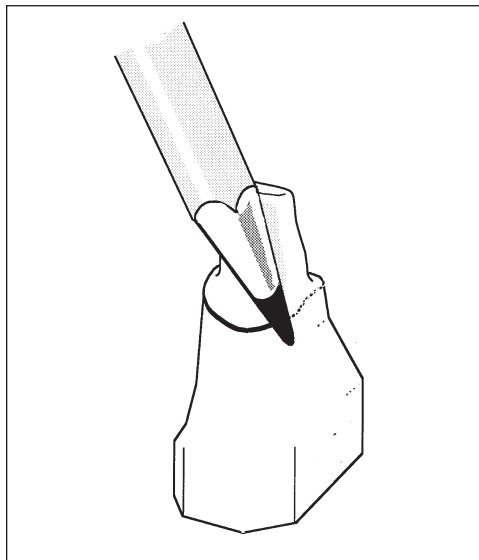


Fig 23-7 Finish line is marked.

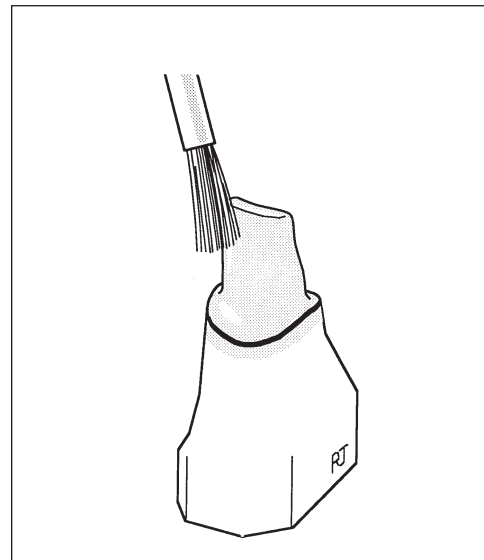


Fig 23-8 Sealant is applied.

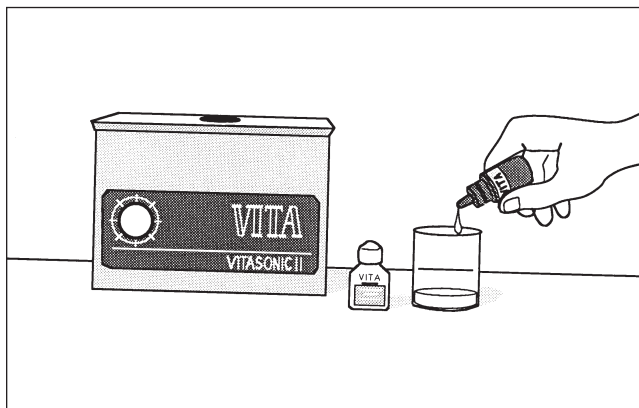


Fig 23-9 One drop of additive is introduced to one ampule of mixing fluid.

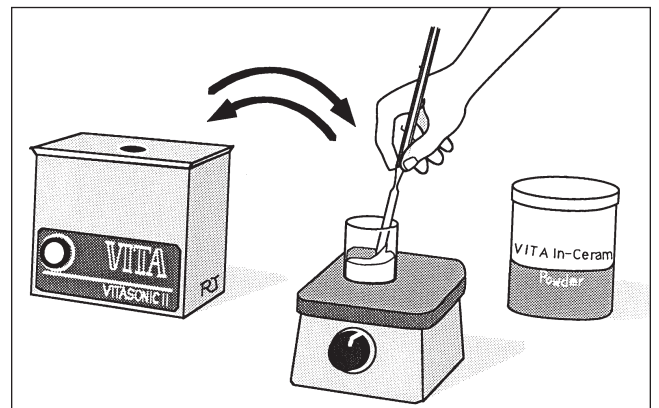


Fig 23-10 Alumina slip is mixed in an ultrasonic unit. As liquid is added to the container, the mixture is vibrated.

23 All-Ceramic Restorations

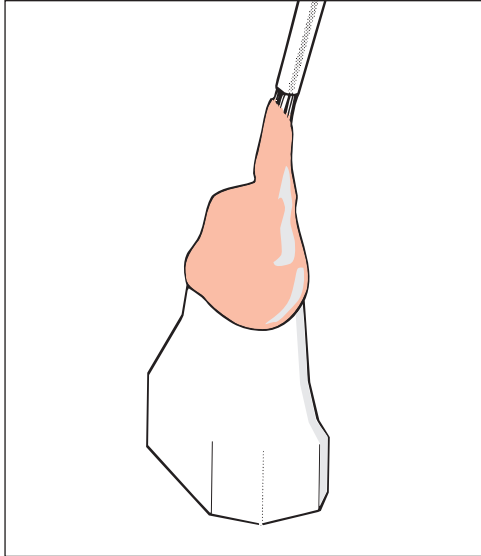


Fig 23-11 The slip is applied with a synthetic brush.

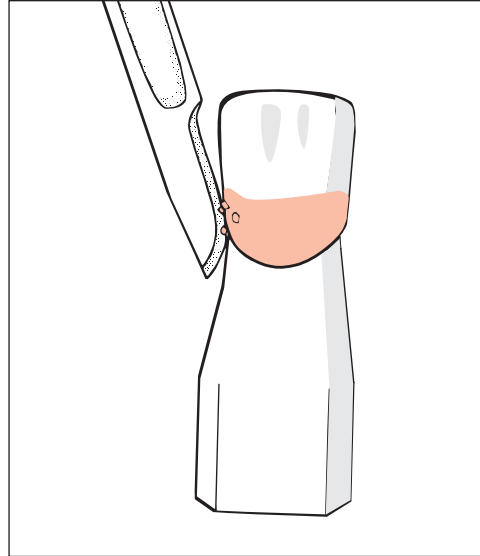


Fig 23-12 The coping is carved with a scalpel.

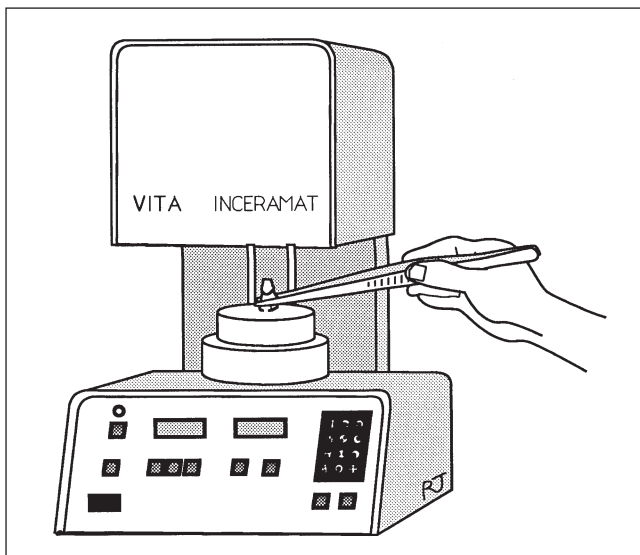


Fig 23-13 The coping is placed in the furnace and sintered for 10 hours.

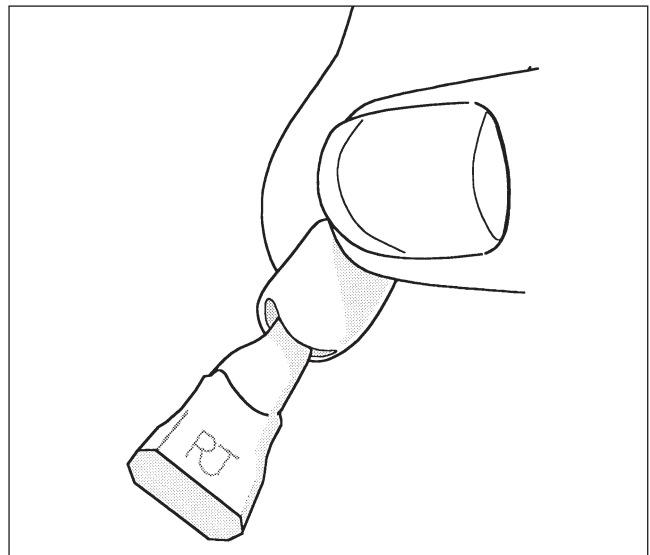


Fig 23-14 The coping is easily removed from the die, which shrinks during the heat treatment.

The slip is rapidly applied with a synthetic brush, building up the desired coping configuration (Fig 23-11). The die readily absorbs the fluid, aiding the condensation of alumina particles. The consistency of the applied slip materials resembles wax and carves easily. A scalpel and other carving instruments are used for initial shaping of the coping (Fig 23-12). The completed alumina coping is allowed to dry for 30 minutes. Then a liquid stabilizer is applied to the framework to facilitate correction after firing.

The framework is sintered in a furnace designed for long-duration firing (Fig 23-13). During the 10-hour firing cycle, temperatures reach 1,120°C. When the cycle reaches its maximum temperature, the copings are held at 1,120°C for 2 hours to allow the development of alumina crystals. During the sintering process, the duplicate dies shrink, making the removal of the copings extremely easy (Fig 23-14). Final shaping of the framework is accomplished with rotary stones and diamond burs.

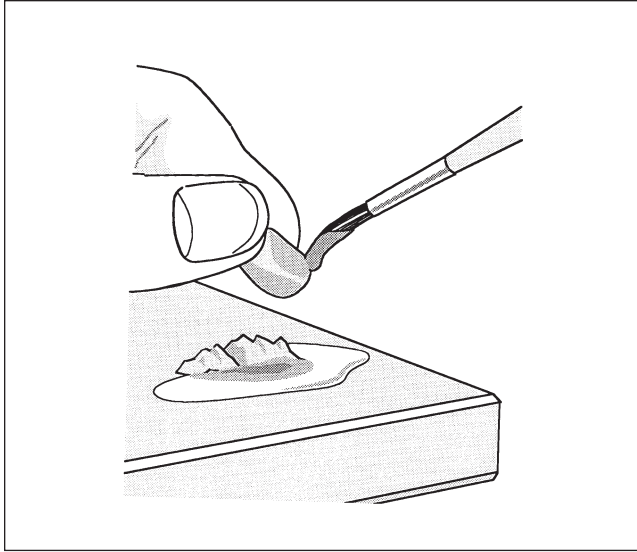


Fig 23-15 Glass infiltrate is applied to the coping.

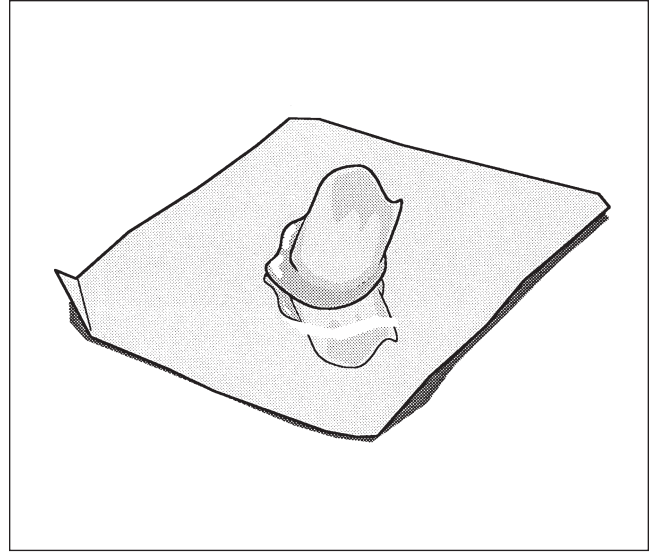


Fig 23-16 The coping is set on platinum foil to fire the glass infiltrate.

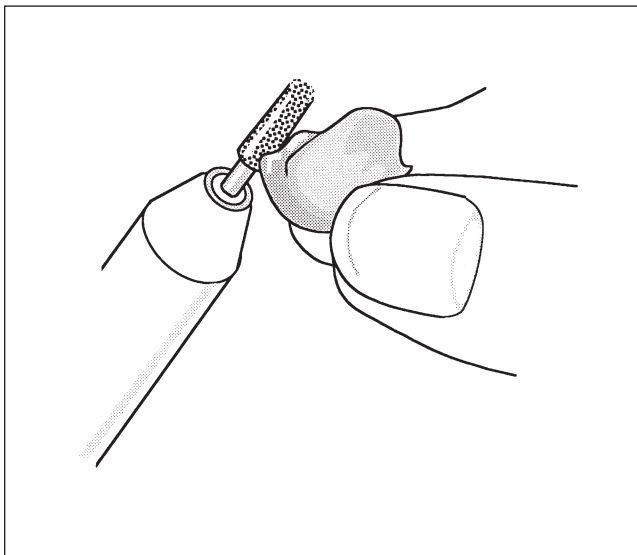


Fig 23-17 After firing the glass infiltrate, excess is removed with a diamond.

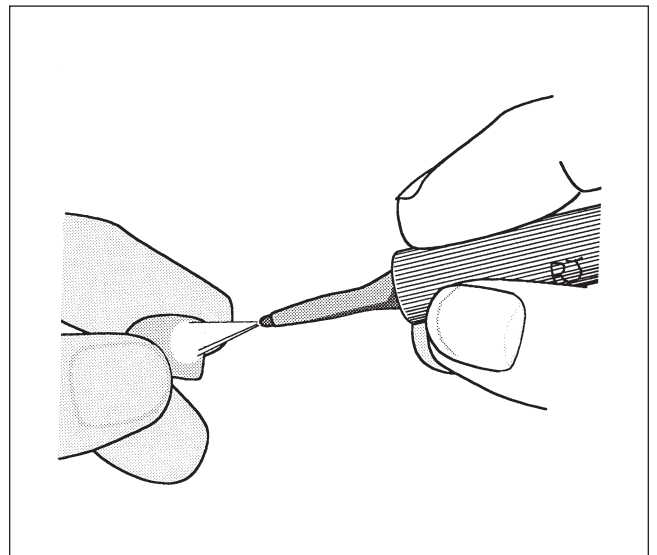


Fig 23-18 The coping is air abraded.

Glass infiltration provides the coping with its final shade, translucency, and strength. The glass powders are coordinated with the shades in the Vita Lumin shade guide (Vident). The desired shade of glass powder is mixed with distilled water. The mixture is generously applied to the coping (Fig 23-15), leaving a small area uncovered to facilitate an escape of air as the glass fills the porosities. The coping is placed on platinum foil in preparation for firing (Fig 23-16). The infiltration firing cycle at 1,100°C requires 4 hours for single crowns and 6 hours for fixed partial denture frameworks.

During this cycle, the glass infiltrates the alumina core materials via capillary action, very much like coffee soaks into a lump of sugar. When infiltration is complete, excess bulk of glass is removed with diamond burs (Fig 23-17). The coping is then air abraded (Fig 23-18). Excess infiltration glass (0.1 to 0.3 mm) on the surface of the core does not appear to adversely affect the compressive strength of In-Ceram crowns.²⁵ However, it could increase the chroma of the restoration and decrease light transmission.

23 All-Ceramic Restorations

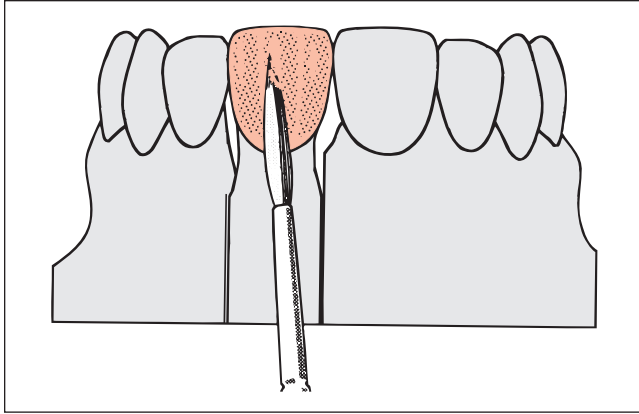


Fig 23-19 Crown form is built up with feldspathic porcelain.

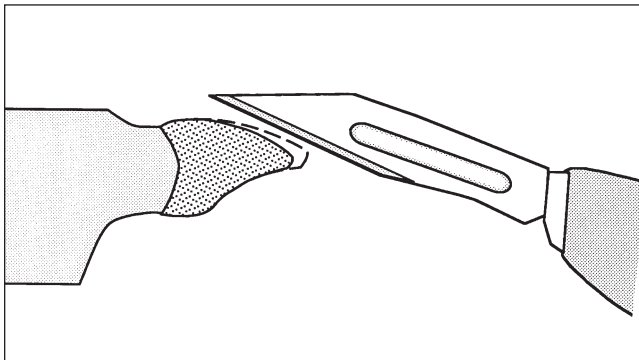


Fig 23-20 Incisal area is cut back.

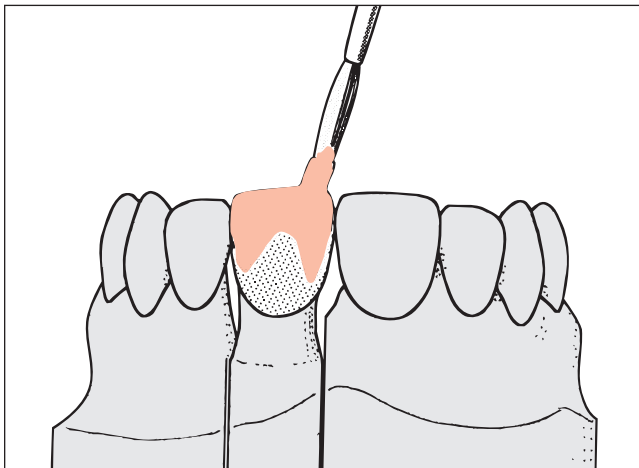


Fig 23-21 Incisal porcelain is added to the part of the buildup that has been cut back.

Following glass infiltration, conventional porcelain (Vitadur Alpha) is added to the coping, restoring the correct anatomical form and occlusal function (Fig 23-19). The incisal area is cut back in "green" porcelain (Fig 23-20). Incisal porcelain is added back to restore full contour (Fig 23-21). After the necessary correction bakes, the crown is glazed and ready for cementation.

Porcelain Laminate Veneers

The laminate veneer is a conservative alternative to full coverage for improving the appearance of an anterior tooth.²⁶ Laminate veneers have evolved over the last several decades to become one of esthetic dentistry's most popular restorations. A porcelain laminate veneer is an extremely thin shell of porcelain applied directly to tooth structure.²⁷ This restoration may be used to improve the color of stained teeth, alter contours of misshapen teeth, and close interproximal spaces. Tooth preparation is minimal, remaining within enamel. The restoration derives its strength from the ability of a composite resin luting agent, with a silane coupling agent, to bond with etched porcelain and etched enamel.

The idea of porcelain veneers is not new. In the 1930s and 1940s, Dr Charles Pincus used thin porcelain veneers to improve the esthetics of movie stars' teeth.²⁸ Unfortunately, he had to use denture adhesive to hold the veneers in place. The development of bisphenol glycidyl methacrylate (bis-GMA) and composite resin restorative materials provided innovative opportunities to restore discolored or malposed teeth.

In the mid-1970s and early 1980s, the composite resin laminate veneer, with or without a facing, evolved. At first composite resin was added directly to the facial surface of a tooth to restore fractured, discolored, and malformed permanent incisors in a procedure commonly known as *bonding*.²⁹ The early composite resin bonding presented several problems, including a monochromatic appearance, with staining and a loss of luster occurring over time. Early composite resin veneers typically did not employ any tooth preparation, and a bulk of material was necessary to obtain a pleasing appearance.³⁰ Unfortunately, the overcontoured restorations contributed to gingival inflammation.

The second evolution of veneers involved the development of preformed veneers or crown forms that were joined to the etched tooth structure. Constructing a veneer (without regard to the material) and bonding it to etched tooth structure is referred to as *laminating*.³⁰ Indications for these laminate veneers included use as an interim restoration for esthetic improvement of badly discolored anterior teeth, especially in young patients.³¹ The application of preexisting facings became a popular practice. The three types of facings commonly used were hollow-ground denture teeth, preformed stock laminates, and custom-fabricated laminates of processed acrylic resin.^{26,32}

The preformed veneers were a definite improvement over bonding. However, color instability, surface staining, loss of surface luster, low abrasion resistance, biologic incompatibility, and a poor bond between the veneer and the tooth still persisted.^{33,34} The bond between the acrylic resin laminate and the composite resin was weak, allowing the veneer to be removed easily or simply to fall off. Surface pretreatments helped, but the effectiveness was technique sensitive.³² These problems eventually led to the diminished use of acrylic resin and/or composite resin veneers.

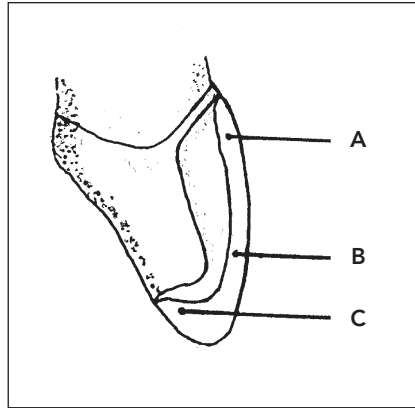


Fig 23-22 Cervical reduction, 0.5 mm (A); midfacial reduction, 0.7 mm (B); incisal reduction, 1.5 mm (C).

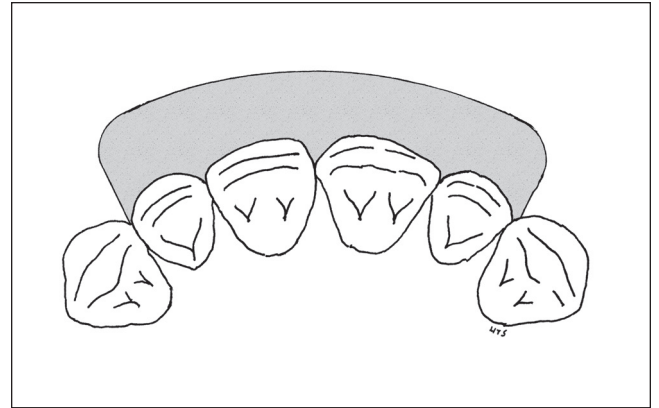


Fig 23-23 Incisal view of a silicone putty reduction guide.

Glazed porcelain is nonporous, resists abrasion, possesses esthetic stability, and is well tolerated by gingiva.^{33,34} In the early 1980s, a method of bonding porcelain to acid-etched enamel was developed. Etching the porcelain, usually with hydrofluoric acid or a derivative, is the most important factor in determining bond strength between the composite resin luting agent and the porcelain veneer.^{35,36} The mechanical retention obtained by etching the porcelain increases the shear bond strength by a factor of four when compared with unetched porcelain.³⁷

The application of a silane coupling agent also improves the bond strength.³⁸ The silane coupling agent initiates a weak chemical bond³⁹ between the SiO_2 of the porcelain and the bis-GMA polymer of the composite resin.²⁶ Scanning electron microscope examination of the porcelain-resin interface exhibits a smaller gap when the etched porcelain is treated with a silane coupling agent.³⁷ Thermocycling does not significantly reduce the strength of etched enamel-composite-etched porcelain bonding when a silane coupling agent is first applied to the porcelain.⁴⁰

The improved shear bond strength of etched porcelain-silane-resin-etched enamel permits an expanded use of veneers, but sufficient enamel must remain to achieve an adequate bond. Indications for porcelain laminate veneers include enamel hypoplasia, tooth discoloration, intrinsic staining (such as tetracycline staining), fractured teeth, closure of diastemas, and correction of anatomically malformed anterior teeth.²⁹ Porcelain laminate veneers can be considered a conservative approach to restoring anterior guidance, especially on worn mandibular incisors. An increase in incisal length up to 2.0 mm does not significantly change the fracture resistance of either the restoration or the tooth.⁴¹ The popularity of this restoration has increased significantly over the last several years.

Tooth preparation

Porcelain laminate veneers require preparation of the tooth. Although this preparation is minimal and limited to the enamel of the tooth, sufficient enamel thickness must be removed to provide adequate space for a correctly contoured restoration.⁴² The preparation should provide a reduction of approximately 0.5 mm.^{39,42,43} Ideally, the finish line should be a slight chamfer placed within enamel at the level of the gingival crest or slightly subgingival.

Enamel provides a better seal and more effectively diminishes marginal leakage than a finish line in either cementum or glass ionomer.⁴⁴ Due to the relatively thin enamel in the gingival half of the labial surface of most anterior teeth,⁴⁵ the desired reduction for feldspathic porcelain in that area is 0.3 mm. The minimal thickness for a porcelain laminate veneer is 0.3 to 0.5 mm. Because of the use of materials other than hand-stacked feldspathic porcelain, like those used in the lost-wax pressed technique or in CAD/CAM technology, the desired thickness of a porcelain veneer ranges from 0.5 mm to 1.5 mm (Fig 23-22).

Prior to initiating a veneer preparation, the amount of tooth reduction required should be evaluated. The foundation for this is the diagnostic wax-up. A silicone putty reduction guide can be made from the diagnostic wax-up to visualize the desired final contour (Fig 23-23). When this reduction guide is placed on the diagnostic cast (before the diagnostic wax-up), the various areas of reduction to accomplish the necessary space can be evaluated.

When a veneer is done to make shade changes only (ie, there is no change in actual contour), depth orientation grooves may be the simplest method for guiding the reduction. When contour changes are desired, depth orientation and final tooth reduction are increased or decreased accordingly so that the definitive restoration has a consistent thickness.

23 All-Ceramic Restorations

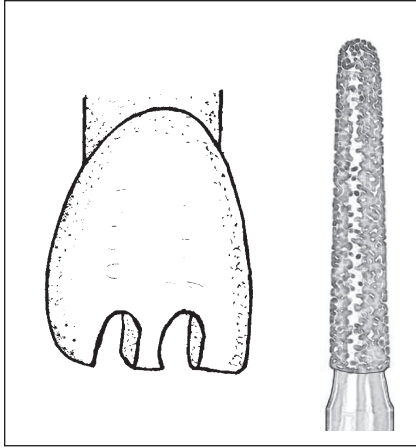


Fig 23-24 Incisal depth reduction grooves.

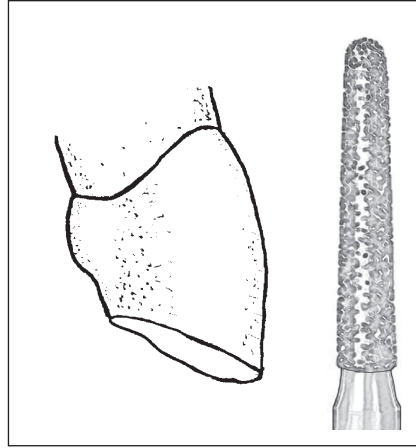


Fig 23-25 Finished incisal reduction.

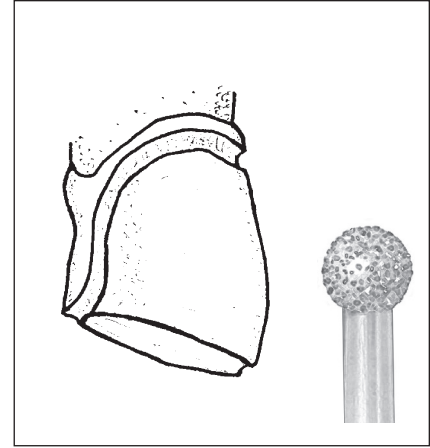


Fig 23-26 Axial outline with ball diamond.

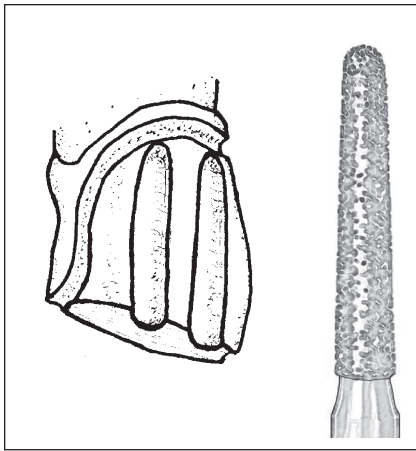


Fig 23-27 Facial depth reduction grooves.

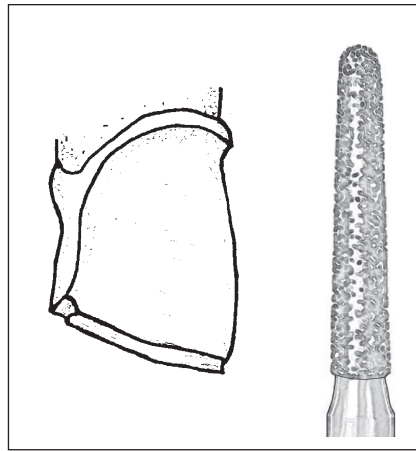


Fig 23-28 Facial reduction completed.

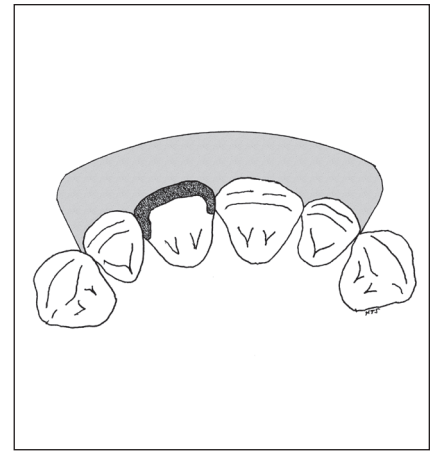


Fig 23-29 Evaluating reduction incisally using the silicone putty reduction guide.

Incisal reduction

A 6856-016 round-end tapered diamond is used to place two depth-orientation grooves so that the incisal thickness of the restoration will be 1.5 mm (Fig 23-24). The incisal reduction is finished by connecting these grooves with the same diamond (Fig 23-25).

Axial outline

Appropriate reduction is indicated at the gingival and interproximal marginal extent of the restoration. Inadequate reduction in these areas may result in either an overcontoured restoration or a thin, fragile margin. Inadequate interproximal reduction does not provide the ceramist adequate space for a sufficient thickness of material, resulting in unnatural contours and poor translucency.

An axial outline of the desired perimeter of the restoration is placed with an 801-012 ball diamond. Sinking the ball diamond to half its depth results in 0.6 mm of reduction

interproximally without damage to the adjacent tooth (Fig 23-26). The putty reduction guide is placed to verify appropriate reduction. There is a wing of tooth structure interproximally that will be eliminated later.

Axial reduction

Depth-orientation grooves are placed between the outline grooves with the 6856-016 round-end tapered diamond (Fig 23-27). More reduction is indicated for a pressed leucite-reinforced veneer than for a pressed lithium-disilicate veneer. The same round-end tapered diamond is used to remove tooth structure between the grooves to complete the facial reduction (Fig 23-28). The reduction guide is used to evaluate the reduction (Fig 23-29). The overall facial reduction is compared in silhouette with the adjacent teeth. When viewed like this, the reduction should appear to be uniform. It provides the ceramist a better opportunity to optimize the emergence profile and produce more interproximal translucency.

Tissue management

A cord is placed into the gingival sulcus to slightly displace the tissue. A cord that creates only minor apical displacement of soft tissue should be chosen. The gingival finish line is extended to the free gingival margin. The cord can remain in place during scanning or impressions. The tissue rebounds so that the finish line will be subgingival.

Proximal refinement

A chisel is used to remove the wings resulting from the outline reduction. This will move the finish line lingually. A diamond strip is used to further open the interproximal space, making the space wide enough for a saw blade to pass through. This is important for sectioning dies, reproducing the finish line in scanning, and taking an impression. The desired shape of the interproximal finish line may be reestablished with the ball diamond, if needed, to prevent the margin of the veneer from being thin and friable.

Incisal finish line

A shoulder is preferred as an incisal finish line. Magne and Douglas⁴⁶ demonstrated that marginal stress occurs when the finish line is wrapped onto the lingual surface. It is not unusual, however, for the incisal finish line to deviate from this to accommodate existing restorations or defects.

The junction of the interproximal and incisal line angle is often sharp or underreduced; therefore, the ball diamond is used to continue the interproximal reduction onto the incisal corners. Also, the incisal corners often require significant translucency and are subject to a heavier load, requiring slightly more reduction.

Final finishing

The 8856-016 fine-grit round-end tapered diamond is used for refinement of the preparation. It softens any sharp internal line or point angles (Fig 23-30). The final preparation is evaluated with the putty reduction guide.

Impression

Gingival retraction is usually necessary for making an impression of laminate veneer preparations because the cervical finish line is terminated at or slightly below the gingival margin. Some patients may require anesthesia for cord placement, while others will tolerate the procedure without it. This is an individual judgment. Small-diameter retraction cord will reduce or eliminate discomfort.

Any impression material suitable for fixed prosthodontics can be employed. If the impression will be sent to the laboratory for pouring, a stable material such as polyvinyl siloxane or polyether should be used. In most cases, porcelain laminate veneers will play a role in some aspect of the patient's occlusal scheme by providing protrusive or lateral

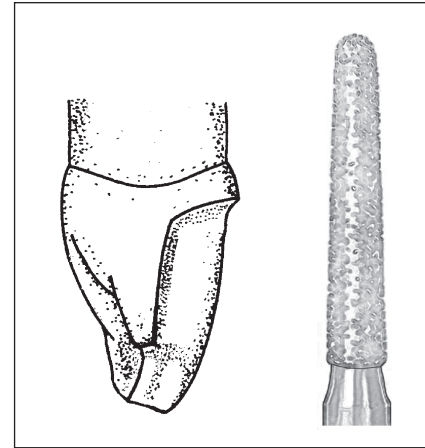


Fig 23-30 Proximal view of final preparation after rounding sharp internal angles.

guidance. For this reason, the casts should be made from full-arch impressions and must be articulated.

Provisional restorations

Because the preparation remains in enamel, most patients will not require a provisional restoration.²⁸ For patients who insist on a provisional veneer, light-activated microfilled composite resins may be used. One or two dots of etchant are placed on the facial surface, and then the lost tooth structure is built up with composite resin with or without the use of a clear stint. Great care must be taken to avoid the finish line when removing excess composite resin. Provisional restorations for veneer preparations are time-consuming, and the results can be disappointing. Avoiding provisional restorations in this situation will decrease frustration.

Fabrication of working casts and dies

Many laboratories use a removable die system that is a modification of a plastic tray with internal orientation grooves and notches (eg, Accu-Trac, Coltene/Whaledent). The impression is poured in die stone with a minimum base of 20 mm. After the stone has set, the cast is removed from the impression and trimmed to a height of 15 mm and a faciolingual width of 10 mm on a cast trimmer and arbor band. The trimmed cast should fit loosely in the tray. The base of the die stone is scored. The stone is mixed and vibrated into the assembled tray. The trimmed cast is seated with a jiggling motion until the cervical areas of the teeth are approximately 5.0 mm above the edge of the tray. Excess stone is removed, and the stone is allowed to set until it is hard and dry.

23 All-Ceramic Restorations

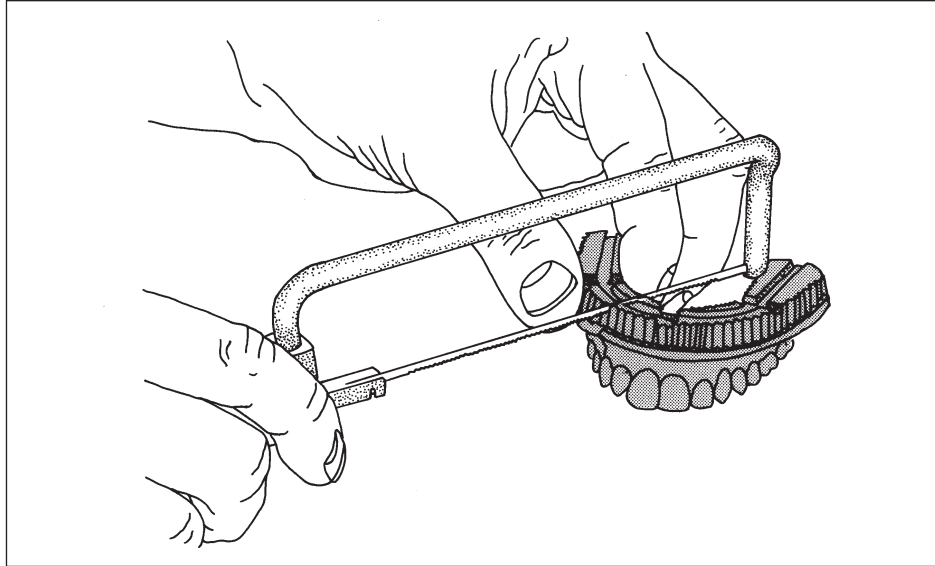


Fig 23-31 The base of the cast is sawed through on both sides of the prepared tooth.

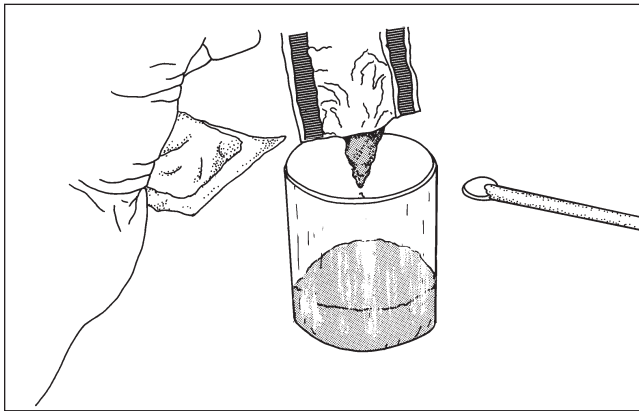


Fig 23-32 Packets of duplicating paste, liquid, and catalyst are emptied into the plastic cup.




Fig 23-33 Duplicating paste is mixed in the cup.

Next, the tray is disassembled to allow separation of the die. A saw is used to separate the die from the base of the cast to avoid damage to the interproximal finish lines (Fig 23-31). The saw cut should extend through the interdental papillae and stop 1.0 mm short of the interproximal finish line. Finger pressure is used to break the die and attached teeth from the cast by squeezing the two pieces together. The process is repeated to separate the die from the teeth attached to it. The die is trimmed, and the finish line is marked with a red pencil. A minimum of two coats of cement spacer is applied to the die, with a 1.0-mm distance from the finish line maintained. The die and working cast are then reassembled in the tray.

Fabrication of the refractory die

Low-viscosity polyvinyl siloxane duplicating material is used to reproduce the die; the low viscosity allows registration of minute details. It is supplied in packets of paste, liquid, and catalyst (Fig 23-32) that are mixed in a clear plastic cup (Fig 23-33). Putty is adapted to the working cast and die to limit the flow of the mold material. It should extend several teeth beyond the die and beyond the edge of the tray on both the facial and lingual sides (Fig 23-34). To avoid air entrapment, the putty reservoir is filled with the mixture (Fig 23-35). The duplicating material should be at least 3.0 mm thick, and it should extend 3.0 mm beyond the incisal edges of the teeth to provide adequate support for the refractory material.

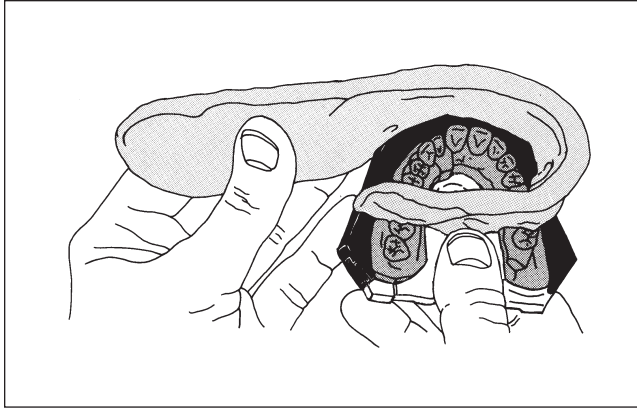


Fig 23-34 A strip of putty is wrapped around the part of the cast that contains the die of the prepared tooth.

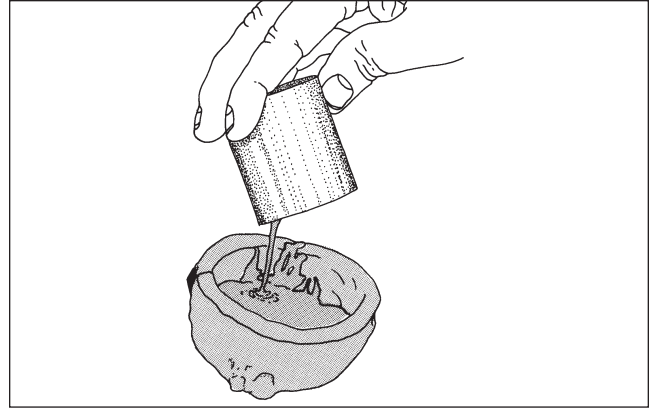


Fig 23-35 Duplicating paste is carefully poured into the area encircled by the strip of putty.

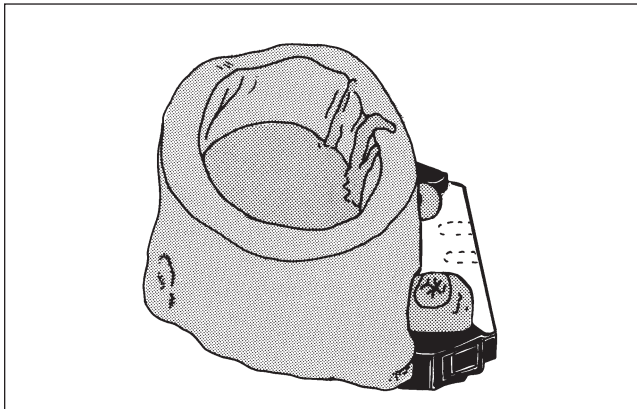


Fig 23-36 The mold is allowed to set for at least 30 minutes.

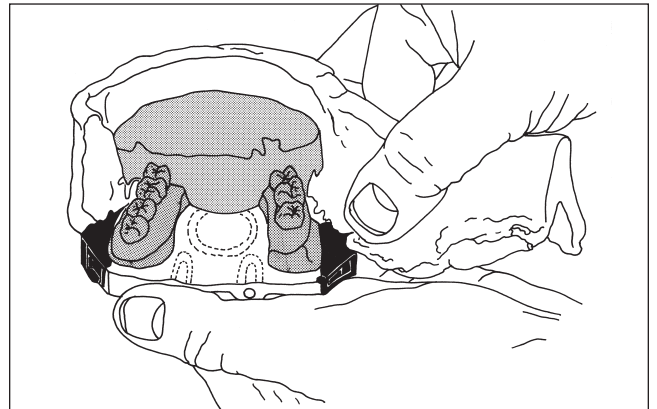


Fig 23-37 The strip of putty is removed from the mold.

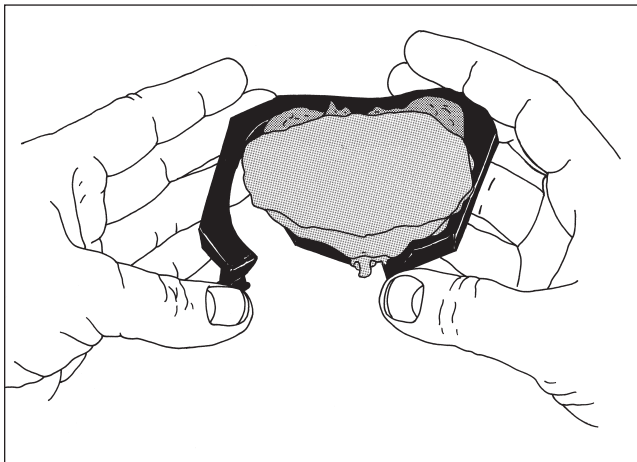


Fig 23-38 The tray is carefully disassembled.

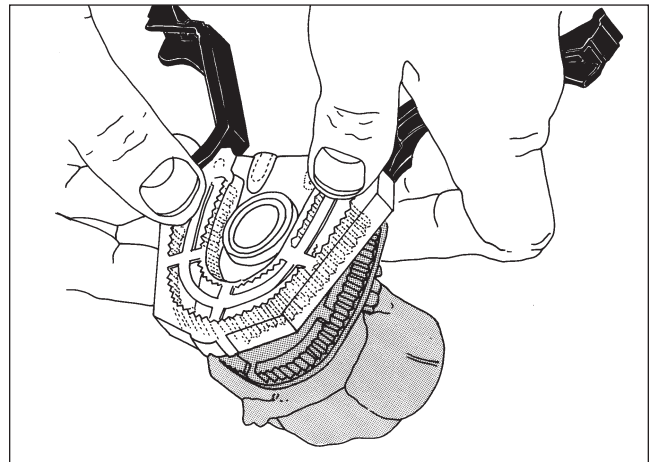


Fig 23-39 The tray is removed from the cast without disturbing the mold.

The setting time may vary due to room temperature and humidity, but the minimum time before separation is 30 minutes (Fig 23-36). When the duplicating medium has set, the silicone putty reservoir is removed (Fig 23-37) and the plastic tray disassembled (Fig 23-38). Pressure is applied to the base of the tray to loosen the master cast with the du-

plicating material intact (Fig 23-39). The master die of the prepared tooth can be removed from the cast (Fig 23-40) and then from the duplicating material.

At this point, it is easy to see that the larger the area duplicated, the greater the stability of the cast in the duplicating material. The plastic tray is reassembled without the bottom

23 All-Ceramic Restorations

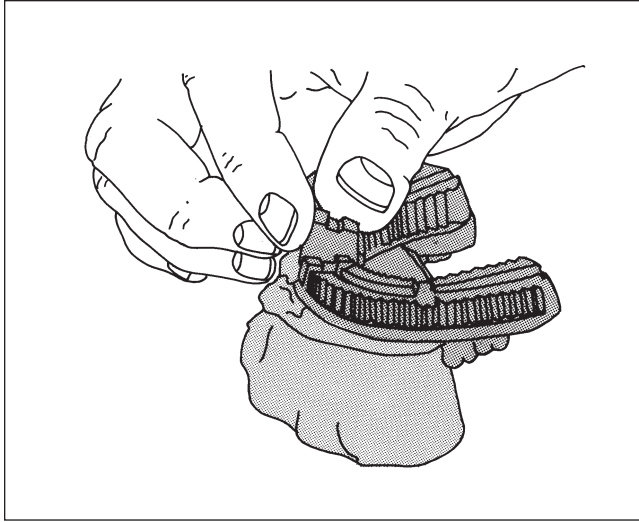


Fig 23-40 The master die is removed from the mold.

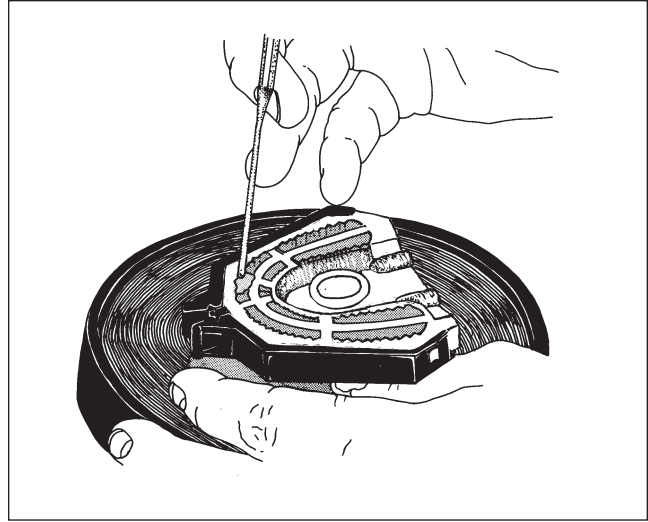


Fig 23-41 Refractory material is poured through openings in the underside of the die tray.

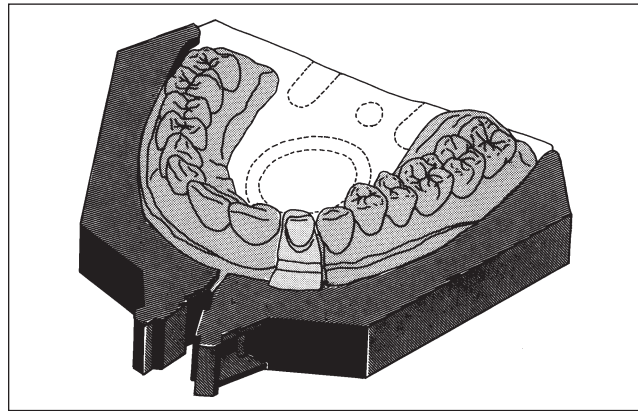


Fig 23-42 The refractory die duplicates the master die in relation to other teeth as well as in configuration.

articulating plate. The absence of this plate allows access for pouring the refractory material in the area of the missing die while maintaining the stability and orientation of the cast in the duplicating material.

A number of refractory investments suitable for porcelain laminate veneer fabrication are commercially available. Selection will depend on porcelain compatibility and personal preference. The refractory material should be mixed according to the manufacturer's directions, and the recommended liquid-powder ratio must be followed. Deviation from this precise ratio may cause uncontrolled expansion or shrinkage during setting and possibly a weakened die.

The refractory die material is mixed and carefully vibrated through the opening in the base of the tray to fill the space vacated by the die (Fig 23-41). Because the orientation and

stability of the die depend on the grooves and notches of the tray, the entire opening must be filled with refractory material. The refractory die is allowed to set for the manufacturer's recommended time, which is usually 1 to 2 hours. When the duplicating mold is removed, the refractory die should occupy the exact location and orientation of the master die (Fig 23-42).

Preparation of the refractory die

Prior to feldspathic porcelain application, the refractory die is degassed to eliminate ammonia and sulfur gases that would contaminate the porcelain. These noxious gases also can contaminate the muffle of a porcelain furnace. Therefore, the

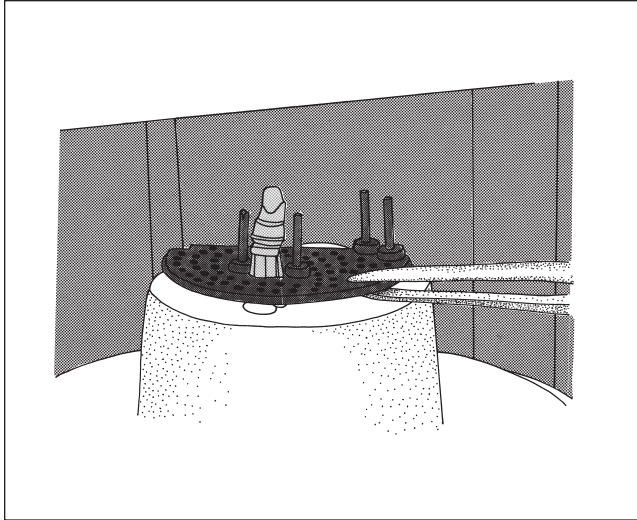


Fig 23-43 After preheating in a burnout furnace, the die is transferred to a porcelain furnace.

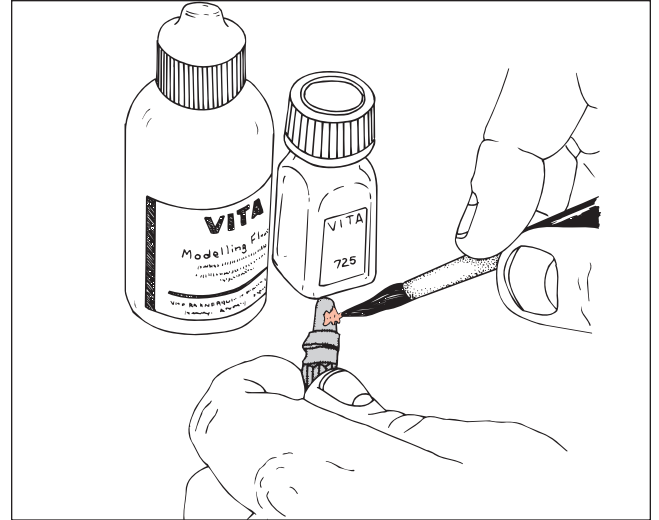


Fig 23-44 The die is sealed by applying dentin porcelain and glaze to it.

initial stage of the degassing process is completed in a casting burnout oven. The die is placed in a room-temperature oven, heated, and held to a specified temperature. Then the die is transferred to a preheated porcelain furnace, and the heating cycle is continued without vacuum (Fig 23-43). The refractory die is allowed to cool to room temperature.

Following burnout, the refractory die should appear uniform in color with no dark gray streaks. The finish line is marked with an underglaze clay pencil. The die is soaked in water until no more bubbles are emitted. To seal the die, a thin wash of half glaze, half dentin porcelain is applied to it and fired (Fig 23-44). Two applications of this mixture may be necessary to completely seal the die. Without a sealant, the porous refractory material will absorb water from the porcelain, making it difficult to apply and shape the porcelain.

Porcelain application

To produce a natural-looking porcelain laminate veneer, the technician must have information regarding the shade of the unprepared tooth, the desired shade, and the location of discolored areas. Discoloration associated with intrinsic staining often appears more intense following tooth preparation. The technician should receive diagrams and photographs of the teeth pre- and postpreparation to facilitate the fabrication of customized porcelain veneers.⁴⁷

Perhaps one of the greatest challenges of porcelain veneers is maintaining a natural appearance while masking dis-

colorations. Opaque porcelains or luting agents can be used to mask the colors but produce a dull, whitish result. There are two methods of adding color to porcelain veneers: (1) adding color and characterization to the porcelain itself and (2) adding tints to the luting agent.⁴⁷

The addition of tints to the luting agents requires knowledge of the subtractive color system and the use of complements to neutralize the discolored areas.^{47,48} The tinted resin is applied directly to the tooth in thin layers, followed by enhancers to raise the value. A cement spacer must be applied to the master die to allow for this additional luting agent.

The use of complementary colors to mask discolorations also has been applied to porcelain addition. Special complementary-color porcelain (a mixture of dentin and modifier porcelain) neutralizes the existing prepared tooth color. This produces a grayish tone that requires a white modifier to increase the value.⁴⁹

Another technique uses a masking dentin porcelain to block the color of the underlying tooth structure before dentin, enamel, and translucent porcelains are added. The masking dentin is effective in a very thin layer (0.1 mm) and acts as internal shading and as a light diffuser.⁵⁰ The other porcelains continue to develop the color and translucency of the restoration. The dentist and technician must communicate to select the technique of color modification. With a cooperative effort, the desired esthetic result can be achieved.

The application of the porcelain is similar to a layered buildup of a conventional ceramic restoration. First, the

23 All-Ceramic Restorations

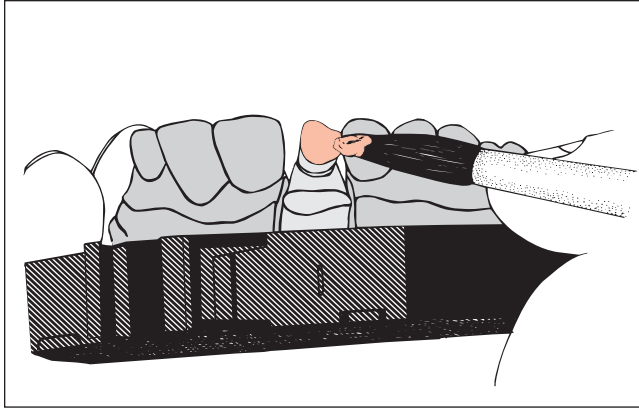


Fig 23-45 Dentin porcelain is applied first.

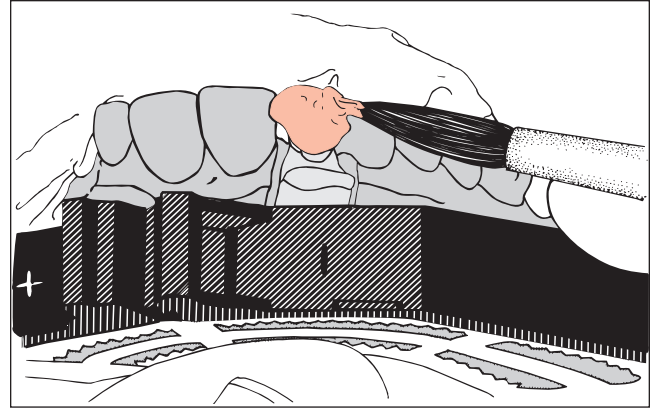


Fig 23-46 Dentin porcelain is built up to full contour with a brush.

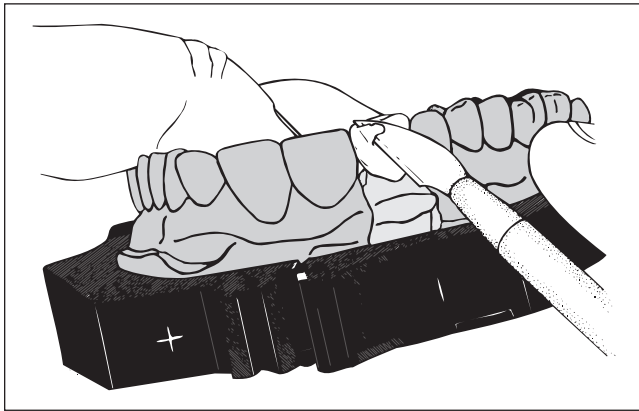


Fig 23-47 Mesioincisal area is cut back with a sharp knife.

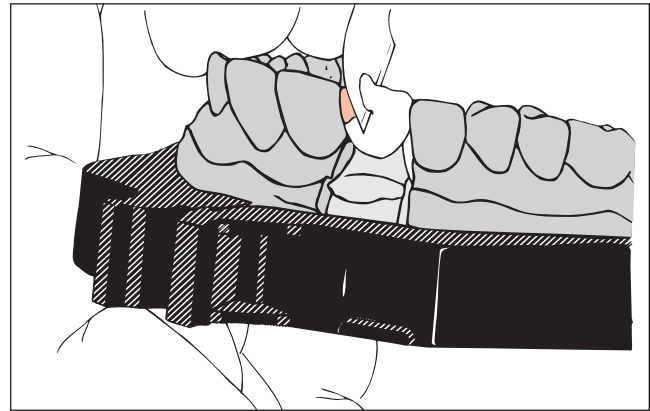


Fig 23-48 Distoincisal area is cut back with a sharp knife.

dentin porcelain is applied (Fig 23-45), and then it is built up to the full contour. A sable brush or spatula is used to apply and shape the porcelain to the desired contour (Fig 23-46). The excess moisture is removed using a tissue and a slight amount of condensation. The porcelain should remain slightly damp but carve easily.

Gingival contours are finalized, and a sharp blade is used to cut back the incisal one-third to one-half to allow for the enamel porcelain (Figs 23-47 and 23-48). The desired amount of translucency determines the depth and extent of the cutback. The enamel porcelain should be supported by the dentin porcelain. If the cutback is straight across the incisal edge without any supporting dentin, the fired porcelain will be too translucent and will lack color and vitality as well.

Like dentin porcelain, enamel porcelain is applied with either a damp sable brush or a spatula (Fig 23-49). It should be blended with the dentin porcelain on the facial, and the

incisal edge should be slightly overbuilt to compensate for shrinkage. A tissue and a small amount of condensation are used to remove any excess moisture. The axial contours of the porcelain are finalized and smoothed (Fig 23-50). The die is removed from the working cast, and porcelain is added to the proximal contours. The margins are carefully examined, and even the slightest amount of excess porcelain is removed.

The refractory die with the porcelain buildup is placed on a sagger tray in front of the muffle to dry. The porcelain is then fired according to the manufacturer's recommendations. The die is allowed to cool completely to room temperature and then is resealed on the working cast. After the contours and occlusion of the fired porcelain are evaluated, corrections may be made by grinding with a fine-grit diamond or green stone or by adding an appropriate porcelain and refiring at a slightly lower temperature.

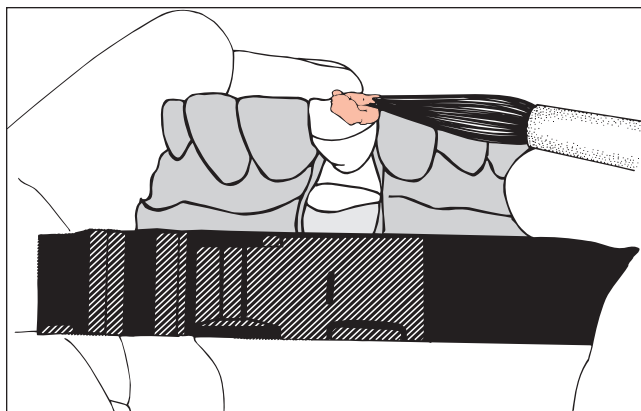


Fig 23-49 Enamel is applied to the cutback areas with a damp sable brush.

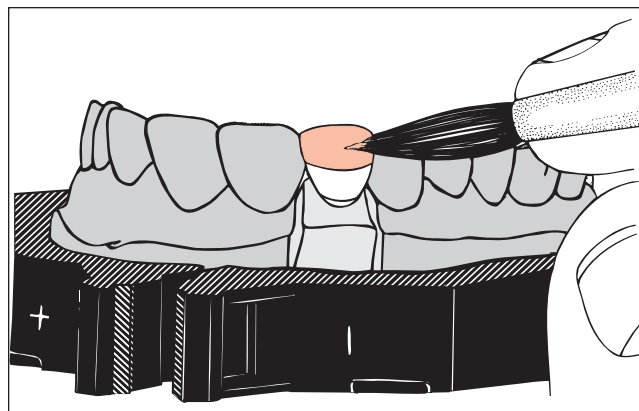


Fig 23-50 Contours of the porcelain are smoothed with a brush.

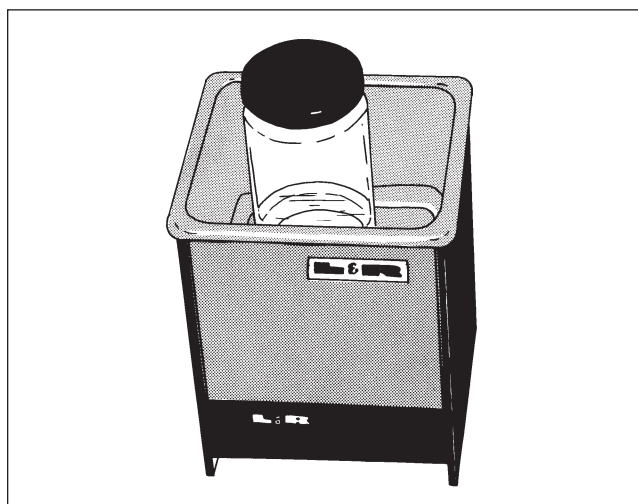

Fig 23-51 The veneer is placed on a piece of gauze in a jar, and the jar is placed into an ultrasonic cleaner.

When the desired contours, margins, and occlusion have been produced, the porcelain veneer is glazed on the refractory die. After cooling, the die is carefully removed from the veneer by glass-bead air abrasion on the die. Marginal integrity of the veneer is confirmed on the original stone die. The veneer is placed in a jar in the ultrasonic cleaner (Fig 23-51). The veneer should rest on a piece of gauze to prevent its fracture against the hard glass bottom of the jar.

To bond the porcelain laminate veneer to the composite resin luting agent, it is necessary to acid-etch the internal aspect of the glazed veneer. A 5% hydrofluoric acid solution is applied and allowed to remain in contact with the porcelain for 30 seconds. A gel etchant is easily confined to the internal aspect of the veneer. If a liquid etchant is used, the glazed porcelain should be protected. When applied to porcelain, the acid produces microstructural pits that enhance the mechanical interlocking with the composite resin.

Cementation and Finishing of All-Ceramic Restorations

The techniques for adjusting, cementing, and finishing all-ceramic crowns, labial veneers, and inlays vary significantly from those used for metal restorations.

A tight proximal contact will not produce a visible burished area on porcelain. A thin coating of a pressure indicator such as Occlude (Pascal) can be applied to these materials before seating to reveal the exact location of the contact. To avoid fracture, only gentle forces should be used for inserting and testing ceramic restorations. Internal support for a ceramic crown or onlay can be provided during occlusal adjustment by temporarily attaching the restoration to the tooth with a low-viscosity elastomeric impression material.

23 All-Ceramic Restorations

Broad, relatively flat surfaces are best reduced extraorally with a large, smooth-cutting Busch Silent Stone (Pfingst), while grooves and ridges are reshaped with smaller pointed diamond stones and green stones. Instruments that have been used on metals should not be used on porcelain. Metal particles become embedded in pores in the porcelain and cause discoloration. When working near an acute edge of porcelain, the stone should be applied so that it is moving from the edge toward the greater bulk to prevent chipping the fragile edge. This is opposite of the technique used in finishing metal margins. It is best to postpone minor grinding adjustments on thin veneers and inlays until after they are permanently bonded to the tooth.

Roughened ceramic surfaces are smoothed with clean white stones and polished with rubber wheels of progressively finer grit such as those found in the Ceramisté porcelain adjustment kit (Shofu) or diamond-impregnated wheels and points (Dialite, Brasseler). Grit in the Ceramisté kit is indicated by stripes around the shank of the instrument: No stripe is coarse, one yellow stripe is medium, and either two yellow stripes or one white stripe is fine. Pastes containing diamond dust are available for use on cups and brushes. Porcelain also may be reglazed after it is polished.

At try-in, the patient is asked to moisten the ceramic and adjacent teeth with saliva. The shade is evaluated under incandescent, fluorescent, and natural light. To minimize the effects of metamerism, it is better to accept a shade that matches reasonably well under all lighting conditions than one that matches perfectly under natural light but appears discolored under artificial light. The patient should be allowed to look at the completed restoration in a wall mirror and approve it before cementation.

Crown cementation

Ceramic crowns may be cemented with zinc phosphate, glass ionomer, or a dual-polymerizing resin cement such as RelyX Unicem (3M ESPE). Ceramic crowns that have been etched internally and bonded with a composite resin cement are 50% stronger than similar crowns cemented with zinc phosphate cement.⁵¹

The crown should be clean, etched, and silanated. Any organic debris is removed with ethanol or acetone, and then the restoration is placed in an ultrasonic cleaner. Further cleaning can be accomplished by applying liquid phosphoric acid etchant. If the crown was not silanated at the laboratory, it can be done at this time with a silane coupling agent. One drop of silane primer and one drop of silane activator are dispensed into a dappen dish. The liquid is stirred in the dish for 10 to 15 seconds with a brush. The mixture is set aside for no less than 5 minutes but no more than 10 minutes before application. It is applied to the internal surface of the crown and gently air dried. These steps are repeated once. Application of the activated silane to the external surface of the crown is avoided by covering the outside of the crown with wax. The cement and mixing dish are removed from the refrigerator and allowed to warm to room temperature.

The crown is rinsed and then dried with compressed air. The tooth preparation is cleaned with a rubber cup and flour of pumice, washed, and dried.

A thin layer of cement is applied to the internal surfaces of the crown. The crown is seated, and excess cement is removed from the marginal areas with an explorer and a clean brush. A slight excess is left to avoid ditching the cement at the margin. The curing light is aimed at marginal areas from facial, lingual, and occlusal directions for 40 seconds. When light activation is not used, 6 minutes should be allowed for autopolymerization. Bulky margins or premature occlusal contacts are adjusted with a fine diamond stone. Occlusal surfaces are polished with wheels from a porcelain adjustment kit.

Veneer cementation

Ceramic veneers and inlays should be etched, silanated, and bonded to the underlying enamel with a selected shade of dual-polymerizing hybrid composite resin cement such as Calibra esthetic resin cement (Dentsply). This type of composite resin has a superior coefficient of thermal expansion, low water absorption, and a surface smoothness similar to microfilled composite resins. The luting agent comes in several shades coordinated with the shade of porcelain selected. Other kits that include colored modifiers and opaque modifiers may be used for special needs. This not only provides better retention and color control, but it also makes the ceramic material less fragile than if it were cemented with nonresin cement.⁵²

The prepared tooth is cleaned with nonfluoride pumice, and the porcelain veneers are tried in. The marginal fit is verified. A drop of water or glycerine will help the veneer stay in place on the tooth during the try-in. If there is an overhang, it is trimmed with a fine-grit diamond. After the marginal fit is verified, the proximal contacts are evaluated.

The final appearance of a veneer is affected by the shade of cement used. The teeth are isolated with Mylar strips. The correct shade or blend of shades is determined by seating the veneer or inlay on the unetched tooth with resin cement. Exposure to high-intensity light is avoided to prevent bonding at this time. This resin cement has specific try-in pastes to aid in the choice of cement shade.

After try-in and shade determination, the veneer is cleaned with a solvent such as acetone. The teeth are pumiced to remove any traces of polymerized composite resin. A 30% phosphoric acid etchant gel is applied to the prepared tooth and allowed to remain 1 minute. The tooth is thoroughly rinsed with a steady stream of water for 30 seconds and dried with air. The tooth surface should have the dull, frosted white appearance of properly etched enamel.

The silane coupling agent or primer is applied to the internal surface of the veneer and allowed to remain in contact with the etched porcelain for 1 minute. At the end of that time, the veneer is dried with an air syringe, with the air blown parallel to and slightly above the veneer.

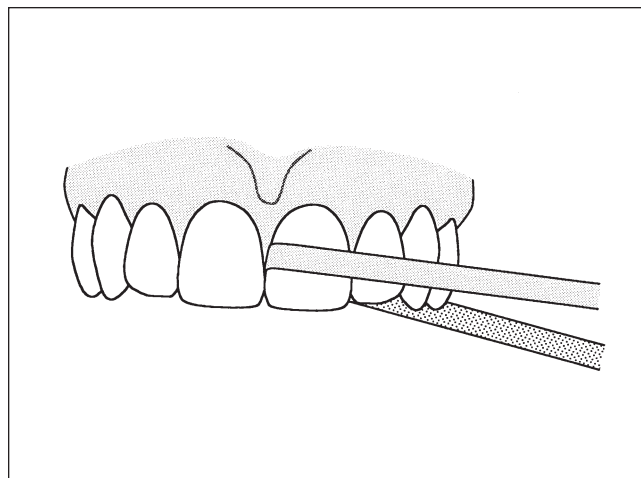


Fig 23-52 Proximal margins are polished with a finishing strip.

A small amount of the previously selected composite resin luting agent is applied to the internal surface of the veneer, and a brush is used to evenly distribute it over the surface. It is carefully seated on the dry, etched tooth. In the case of an inlay, the cement is placed into the cavity. The plastic interproximal strips may be left in place if they do not interfere with seating of the restoration. Using finger pressure, the veneer is gently seated from the labial surface. Excessive pressure at this time could fracture the veneer.

When the veneer is positioned correctly, it is held gently against the tooth with a finger, and a visible light-curing unit is applied for 10 seconds. Correct placement of the veneer on the tooth is verified. After the initial set, the flash may be carefully removed before the resin is completely polymerized. Polymerization continues for an additional 45 to 60 seconds, with the light directed from the lingual (through the tooth) so that shrinkage will occur toward the tooth. Then the light is directed from the labial (through the veneer) for an additional 60 seconds.

Once the luting agent is polymerized, fine-grit flame diamonds may be used to trim excess composite resin. The occlusion should be checked and adjusted only after the veneer is bonded to the tooth. Final finishing procedures can be accomplished with porcelain polishing agents, including rubberized abrasives and diamond polishing paste. The proximal areas can be finished with finishing strips (Fig 23-52).

References

1. Land CH. A new system of restoring badly decayed teeth by means of an enamelled coating. *Indep Pract* 1886;7:407–409.
2. McLean JW, Hughes TH. The reinforcement of dental porcelain with ceramic oxides. *Br Dent J* 1965;119:251–267.
3. McLean JW, Sced IR. The bonded alumina crown. 1. The bonding of platinum to aluminous dental porcelain using tin oxide coatings. *Aust Dent J* 1976;21:119–127.
4. Sced IR, McLean JW, Hotz P. The strengthening of aluminous porcelain with bonded platinum foils. *J Dent Res* 1977;56:1067–1069.
5. Munoz CA, Goodacre CJ, Moore BK, Dykema RW. A comparative study of the strength of aluminous porcelain jacket crowns constructed with the conventional and twin foil techniques. *J Prosthet Dent* 1982;48:271–281.
6. McLaren EA, Cao PT. Ceramics in dentistry—Part I: Classes of materials. *Inside Dent* 2009;5:93–104.
7. Seghi RR, Denry IL, Rosenstiel SF. Relative fracture toughness and hardness of new dental ceramics. *J Prosthet Dent* 1995;74:145–150.
8. Otto T, Schneider D. Long-term clinical results of chairside Cerec CAD/CAM inlays and onlays: A case series. *Int J Prosthodont* 2008;21:53–59.
9. Powers JM, Sakaguchi RL. *Craig's Restorative Dental Materials*, ed 12. St Louis: Mosby, 2006:452.
10. Powers JM, Sakaguchi RL. *Craig's Restorative Dental Materials*, ed 12. St Louis: Mosby, 2006:454.
11. Esquivel-Upshaw JF, Chai J, Sansano S, Shonberg D. Resistance to staining, flexural strength, and chemical solubility of core porcelains for all-ceramic crowns. *Int J Prosthodont* 2001;14:284–288.
12. Levy H, Daniel X. Working with the In-Ceram porcelain system. *Prothese Dent* 1990;44–45:1–11.
13. Phillips RW, Skinner EW. *Skinner's Science of Dental Materials*, ed 9. Philadelphia: Saunders, 1991:505–527.
14. Pröbster L, Diehl J. Slip-casting alumina ceramics for crown and bridge restorations. *Quintessence Int* 1992;23:25–31.
15. Giordano RA 2nd, Pelletier L, Campbell S, Pober R. Flexural strength of an infused ceramic, glass ceramic, and feldspathic porcelain. *J Prosthet Dent* 1995;73:411–418.
16. Anusavice KJ, Phillips RW. *Phillips' Science of Dental Materials*, ed 11. St Louis: Saunders, 2003:715.
17. Wagner WC, Chu TM. Biaxial flexural strength and indentation fracture toughness of three new dental core ceramics. *J Prosthet Dent* 1996;76:140–144.
18. Zeng K, Odén A, Rowcliffe D. Flexure tests on dental ceramics. *Int J Prosthodont* 1996;9:434–439.
19. Conrad HJ, Seong WJ, Pesun IJ. Current ceramic materials and systems with clinical recommendations: A systematic review. *J Prosthet Dent* 2007;98:389–404.
20. Luthardt RG, Holzhüter MS, Rudolph H, Herold B, Walter MH. CAD/CAM-machining effects of Y-TZP zirconia. *Dent Mater* 2004;20:655–662.
21. Guess PC, Zavanelli RA, Silva NR, Bonfante EA, Coelho PG, Thompson VP. Monolithic CAD/CAM lithium disilicate versus veneered Y-TZP crowns: Comparison of failure modes and reliability after fatigue. *Int J Prosthodont* 2010;23:434–442.
22. Edelhoff D, Beuer F, Weber V, Johnen C. HIP zirconia fixed partial dentures—Clinical results after 3 years of clinical service. *Quintessence Int* 2008;39:459–471.
23. Denry I, Kelly JR. State of the art of zirconia for dental applications. *Dent Mater* 2008;24:299–307.
24. Pera P, Gilodi S, Bassi F, Carossa S. In vitro marginal adaptation of alumina porcelain ceramic crowns. *J Prosthet Dent* 1994;72:585–590.
25. Carrier DD, Kelly JR. In-Ceram failure behavior and core-veneer interface quality as influenced by residual infiltration glass. *J Prosthodont* 1995;4:237–242.
26. Horn HR. Porcelain laminate veneers bonded to etched enamel. *Dent Clin North Am* 1983;27:671–684.

23 All-Ceramic Restorations

27. McLaughlin G. Porcelain fused to tooth—A new esthetic and reconstructive modality. *Compend Contin Educ Dent* 1984;5: 430–435.
28. Ibsen RL, Strassler HE. An innovative method for fixed anterior tooth replacement utilizing porcelain veneers. *Quintessence Int* 1986;17:455–459.
29. Goldstein RE. Diagnostic dilemma: To bond, laminate, or crown? *Int J Periodontics Restorative Dent* 1987;7(5):8–29.
30. Faunce FR, Myers DR. Laminate veneer restoration of permanent incisors. *J Am Dent Assoc* 1976;93:790–792.
31. Faunce FR. Tooth restoration with preformed laminate veneers. *Dent Surv* 1977;53(1):30–32.
32. Boyer DB, Chalkley Y. Bonding between acrylic laminates and composite resin. *J Dent Res* 1982;61:489–492.
33. Horn HR. A new lamination: Porcelain bonded to enamel. *N Y State Dent J* 1983;49:401–403.
34. Calamia JR. Etched porcelain facial veneers: A new treatment modality based on scientific and clinical evidence. *N Y J Dent* 1983;53:255–259.
35. Simonsen RJ, Calamia JR. Tensile bond strength of etched porcelain [abstract 1154]. *J Dent Res* 1983;62:297.
36. Stangel I, Nathanson D, Hsu CS. Shear strength of the composite bond to etched porcelain. *J Dent Res* 1987;66:1460–1465.
37. Hsu CS, Stangel I, Nathanson D. Shear bond strength of resin to etched porcelain [abstract 1095]. *J Dent Res* 1985;64:296.
38. Calamia JR, Simonsen RJ. Effect of coupling agents on bond strength of etched porcelain [abstract 79]. *J Dent Res* 1984; 63:179.
39. Calamia JR. Etched porcelain veneers: The current state of the art. *Quintessence Int* 1985;16:5–12.
40. Stacey GD. A shear stress analysis of the bonding of porcelain veneers to enamel. *J Prosthet Dent* 1993;70:395–402.
41. Wall JG, Reisbick MH, Johnston WM. Incisal-edge strength of porcelain laminate veneers restoring mandibular incisors. *Int J Prosthodont* 1992;5:441–446.
42. Cho GC, Donovan TE, Chee WW. Clinical experiences with bonded porcelain laminate veneers. *J Calif Dent Assoc* 1998;26: 121–127.
43. Quinn F, McConnell RJ, Byrne D. Porcelain laminates: A review. *Br Dent J* 1986;161:61–65.
44. Lacy AM, Wada C, Du W, Watanabe LP. In vitro microleakage at the gingival margin of porcelain and resin veneers. *J Prosthet Dent* 1992;67:7–10.
45. Shillingburg HT Jr, Grace CS. Thickness of enamel and dentin. *J South Calif Dent Assoc* 1973;41:33–36.
46. Magne P, Douglas WH. Design optimization and evolution of bonded ceramics for the anterior dentition: A finite-element analysis. *Quintessence Int* 1999;30:661–672.
47. Robbins JW. Color characterization of porcelain veneers. *Quintessence Int* 1991;22:853–856.
48. Reid JS. Tooth color modification and porcelain veneers. *Quintessence Int* 1988;19:477–481.
49. Yamada K. Porcelain laminate veneers for discolored teeth using complementary colors. *Int J Prosthodont* 1993;6:242–247.
50. Hobo S. Porcelain laminate veneers with three-dimensional shade reproduction. *Int Dent J* 1992;42:189–198.
51. Ludwig K, Joseph K. Untersuchungen zur Bruchfestigkeit von IPS-Empress-Kronen in Abhängigkeit von den Zementiermodalitäten. *Quintessenz Zahntech* 1994;20:247–256.
52. Dérand T. Stress analysis of cemented or resin-bonded loaded porcelain inlays. *Dent Mater* 1991;7:21–24.

Metal-Ceramic Restorations

24

Metal-ceramic restorations combine the strength and accuracy of cast metal with the esthetics of porcelain. Their use has grown markedly in the last 40 years as a result of technical improvements. However, restraint should be exercised in the selection of this type of restoration, particularly when restoring molars. Metal-ceramic restorations should not be substituted for less destructive types of restorations when the latter will serve as well. A 1986 survey of 80 dentists revealed that 70% of them placed metal-ceramic crowns on their patients' posterior teeth 70% to 100% of the time, but the same dentists indicated a preference for partial veneer gold crowns in their own mouths.¹ A more recent web-based survey arrived at similar conclusions, with the consensus being that the majority of dentists recognize cast gold and amalgam restorations as more predictable options for molars than more esthetic alternatives.²

The metal-ceramic crown has gone by a variety of names since its introduction to dentistry nearly five decades ago. It was called, at different times and in different parts of the United States, a *Ceramco crown* (for one of the first brands of porcelain used for fabricating this type of restoration), a *porcelain veneer crown (PVC)*, a *porcelain-fused-to-gold (PFG) crown*, and a *porcelain-fused-to-metal (PFM) crown*, a term commonly used in the dental literature during the 1970s and 1980s.

Metal-ceramic is a more precise term scientifically, and it is compatible with the term *all-ceramic*, used to describe restorations such as crowns, inlays, and veneers. Because there seems to be a proclivity in the English language for three-letter abbreviations, *MCR* is a reasonable abbreviation for *metal-ceramic restoration*.

The MCR is composed of a metal casting, or coping, that fits over the tooth preparation and ceramic that is fused to the coping. The coping may be little more than a thin thimble, or it may be clearly recognizable as a cast crown with some portion cut away. The contours in the area that has been cut away will be replaced with porcelain that will mask or hide the metal coping, produce the desired contours, and make the restoration esthetically pleasing.

The metal coping in an MCR is covered with three layers of porcelain (Fig 24-1):

1. *Opaque porcelain* conceals the metal underneath, initiates the development of the shade, and plays an impor-

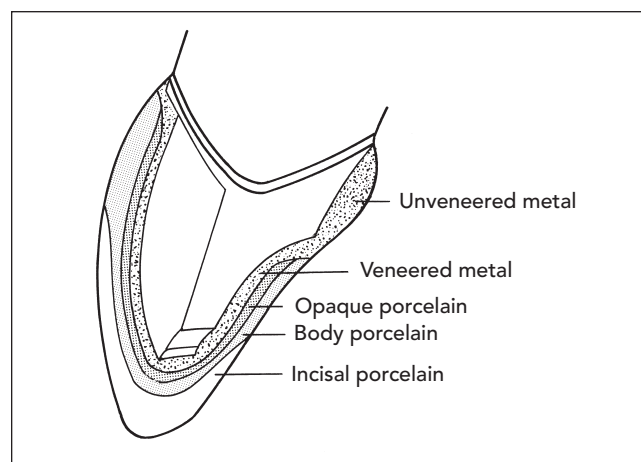


Fig 24-1 Layers of an MCR.

tant role in the development of the bond between the ceramic and the metal.

2. *Dentin*, or *body*, *porcelain* makes up the bulk of the restoration, providing most of the color, or shade.
3. *Enamel*, or *incisal*, *porcelain* imparts translucency to the restoration.

Other porcelains, such as opaque or dentin modifiers, porcelain stains, or porcelains of varying translucencies, are used within the three basic layers for special effects and characterization.

While current trends in research and development show a preference for all-ceramic restorations because of their inherent esthetic advantages, the MCR remains the "gold standard" of predictability with indirect tooth-colored systems. It is generally accepted that, in spite of development of high-strength ceramic materials, MCRs are more resistant to fracture.³ While ceramic technologies are rapidly evolving, the failure rates of various available systems are still higher than with metal-based restorations, particularly in high-stress clinical situations.

An indication for MCRs has been the fabrication of fixed partial dentures in the esthetic zone. With the development of predictable techniques for the fabrication of high-strength

24 Metal-Ceramic Restorations

zirconia frameworks, there is increased evidence that all-ceramic restorations can be predictably used in certain fixed partial denture applications. While ongoing clinical research indicates an extremely low rate of failure with zirconia frameworks, there remains evidence of a higher rate of failure with the veneering porcelains, particularly in molar restorations.^{4,5} Therefore, in situations where a full coverage restoration or fixed partial denture is indicated, esthetics remains the only reason for deserting cast gold or MCRs in favor of all-ceramic alternatives. Näpänkangas and Raustia⁶ report a success rate of 71% for metal-ceramic fixed partial dentures after 18 years of use. Just as there are advantages to using gold over MCRs, there remain many clinical situations where MCRs prove superior to all-ceramic options.

Bonding Mechanisms

Four mechanisms have been described to explain the bond between the ceramic veneer and the metal substructure:

1. Mechanical entrapment
2. Compressive forces
3. Van der Waals forces
4. Chemical bonding

Mechanical entrapment creates attachment by interlocking the ceramic with microabrasions in the surface of the metal coping, which are produced by finishing the metal with noncontaminating stones or disks and air abrasion. When compared with unprepared metal, surface finishing enhances the metal-ceramic bond.⁷ Air abrasion appears to enhance wettability, provide mechanical interlocking, and increase the surface area for chemical bonding.⁸ The use of a bonding agent, such as platinum spheres, 3 to 6 μm in diameter, also can increase bond strength significantly.⁹

When the coefficient of thermal expansion of a properly designed metal coping is slightly higher than that of the porcelain veneered over it, *compressive forces* develop. The slight difference in coefficients of thermal expansion, or thermal contraction as is the case during cooling, will cause the porcelain to draw toward the metal coping when the restoration cools after firing.

Van der Waals forces comprise an affinity based on a mutual attraction of charged molecules. They contribute to bonding, but they are a minor force that is not as significant as was once thought.¹⁰ Although the molecular attraction makes only a minor contribution to overall bond strength, it is significant in the initiation of the most important mechanism, the chemical bond.

Chemical bonding is indicated by the formation of an oxide layer on the metal^{11,12} and by bond strength that is increased by firing in an oxidizing atmosphere.^{13,14} When fired in air, trace elements in the gold alloy, such as tin, indium, gallium, or iron, migrate to the surface, form oxides, and subsequently bond to similar oxides in the opaque layer of the porcelain. A gold alloy containing minute amounts of tin

and iron creates a significantly stronger bond with porcelain than a pure gold alloy does.¹⁵ The bond strength of true adhesion is such that failure or fracture will occur in the porcelain rather than at the porcelain-metal interface.¹⁶ The clean separation of porcelain from the metal coping is evidence of either bond failure from contamination of the coping surface or an excessive oxide layer. Base metal alloys readily form chromium oxides that bond to the porcelain without the addition of any trace elements.

Alloys Used

The properties of the porcelain cannot be considered alone. The porcelain and metal used for a restoration must have compatible melting temperatures and coefficients of thermal expansion. Conventional gold alloys have a high coefficient of thermal expansion ($14 \times 10^{-6}/^{\circ}\text{C}$), while conventional porcelain possesses a much lower value (2 to $4 \times 10^{-6}/^{\circ}\text{C}$). A difference of only $1.7 \times 10^{-6}/^{\circ}\text{C}$ can produce sufficient shear stress to produce failure of the bond.¹⁶ The optimum difference between the two would be no greater than $1 \times 10^{-6}/^{\circ}\text{C}$. The coefficient of thermal expansion of porcelain can be increased to as much as 7 to $8 \times 10^{-6}/^{\circ}\text{C}$ by the addition of an alkali such as lithium carbonate. At the same time, the coefficient of the metal can be lowered to 7 to $8 \times 10^{-6}/^{\circ}\text{C}$ by adding palladium or platinum.

The melting range of the alloy used in the coping must be 170°C to 280°C (300°F to 500°F) higher than the fusing temperature of the porcelain applied to it. A similar melting range of the two materials would result in the distortion or melting of the coping during the firing and glazing of the porcelain. The greater the difference in melting ranges of the two materials, the fewer the problems that are encountered during firing. A noble metal coping is subject to flow, or creep, when it is heated to 980°C ($1,800^{\circ}\text{F}$).¹⁷ The porcelain used must not require that the metal be heated much beyond this point. Porcelains most commonly used for this purpose have a fusing temperature of approximately 870°C to 930°C ($1,600^{\circ}\text{F}$ to $1,710^{\circ}\text{F}$), and noble alloys melt at near $1,260^{\circ}\text{C}$ ($2,300^{\circ}\text{F}$).

Many alloys have been used for MCRs. A classification system proposed by the American Dental Association is based on noble metal content¹⁸ (Box 24-1). *High noble alloys* have a noble metal (gold, platinum, palladium) content greater than 60%, with at least 40% gold. *Noble alloys* have a noble metal content of at least 25%, and *predominantly base alloys* have less than 25% noble metal content.

Major constituents also are used to further describe an alloy and are generally listed in decreasing order of their concentration (eg, a gold-palladium alloy). The choice of an alloy will depend on a variety of factors, including cost, rigidity, castability, ease of finishing and polishing, corrosion resistance, compatibility with specific porcelains, and personal preference. No alloy system is superior in all aspects.

Gold-palladium alloys have proven most satisfactory for metal-ceramic crowns and fixed partial dentures. These al-

Box 24-1 Alloys used for fabricating MCRs

High noble
 Gold-platinum-palladium
 Gold-palladium-silver
 Gold-palladium

Noble
 Palladium-silver
 High palladium

Predominately base
 Nickel-chromium
 Nickel-chromium-beryllium
 Cobalt-chromium

loys are composed of gold (44% to 55%) and palladium (35% to 45%), with small amounts of gallium, indium, and/or tin. Gold-palladium alloys have excellent handling characteristics, sag resistance, esthetic potential, porcelain adherence, and biocompatibility. However, with rising metal prices, the cost of these alloys is making their use prohibitive.

The skyrocketing cost of gold in the late 1970s stimulated the development of alloys containing little or no gold. A logical transition was the application of materials commonly used in the fabrication of removable partial denture frameworks to fixed prosthodontics. These alloys possess desirable properties such as low cost, increased strength and hardness, high fusion temperatures, and greater resistance to distortion during porcelain firing. However, there are inherent problems with these alloys when used as an integral part of a metal-ceramic system. The disadvantages include excessive oxide formation, difficulty in finishing and polishing, and questionable biocompatibility.

Beryllium, which is added to alloys to control oxide formation, is a carcinogen. It can pose a hazard to laboratory personnel who may inhale it as dust in improperly ventilated work areas.¹⁹ Approximately 5% of the general population is sensitive to nickel, and that sensitivity has traditionally been estimated to be 10 times as prevalent in women as in men.²⁰ Contact dermatitis from nickel-containing prostheses appears to be a risk to some patients.²¹ Dissolution and occlusal wear affect the amount of nickel and beryllium released in an artificial oral environment, and there is evidence that nickel-chromium-beryllium alloys are significantly more susceptible to toothbrush abrasion than other casting alloys commonly used in dentistry.^{22,23} Nickel sensitivity should be considered in the diagnosis of any soft tissue changes that occur after crown placement.²¹

Another cost-cutting alternative to traditional alloys is the modification of existing noble metal alloys using less-

expensive metals, such as copper or cobalt, in the alloy. Unfortunately, the addition of these elements caused dark oxide formation and poor high-temperature strength.²⁴ Subsequent formulations replaced the copper or cobalt with a small amount of gold and silver. Originally, one of the most common disadvantages of the silver-containing alloys was the potential of porcelain discoloration, most commonly described as *greening*. With the increased popularity of silver-containing alloys, porcelain manufacturers have developed silver-compatible porcelains with which discoloration is minimized or no longer an issue. No system is without disadvantages, whether they be financial or technical. Therefore, the decision of which alloy to use must be made after weighing all factors.

Coping Design

The metal coping is an important part of the MCR and one that unfortunately is often overlooked. Its design can have an important effect on the success or failure of the restoration. To provide structural integrity in function, the coping must reflect the unique relationship of the two dissimilar materials used to fabricate MCRs. Because the kaolin content must be reduced to allow translucency, dental porcelains may behave more like glass than a true ceramic. Like glass, dental porcelains are significantly stronger in compression than in tension.

The coping must allow the porcelain to remain in compression by supporting the incisal region, the occlusal table, and the marginal ridges. Otherwise, occlusal forces will create a situation similar to applying a load to a pane of glass suspended between two sawhorses. Without any underlying support, the glass would break—and so will unsupported porcelain on a restoration.

There are six features of importance to be considered when designing the metal coping for an MCR:

1. Thickness of the porcelain veneer
2. Support of the porcelain veneer
3. Thickness of metal underlying and adjoining the porcelain
4. Placement of occlusal and proximal contacts
5. Extent of the area to be veneered for porcelain
6. Design of the facial margin

Thickness of the porcelain veneer

Porcelain should be kept at a minimum thickness that is still compatible with good esthetics. Relatively thin porcelain, of uniform thickness and supported by rigid metal, is strongest. The absolute minimum thickness of porcelain is 0.7 mm, and the desirable thickness is 1.0 to 1.5 mm. Extensions of porcelain beyond 2.0 mm are prone to fracture even if these thick areas of porcelain are not in areas of force concentration. An example is the improperly designed pontic

24 Metal-Ceramic Restorations

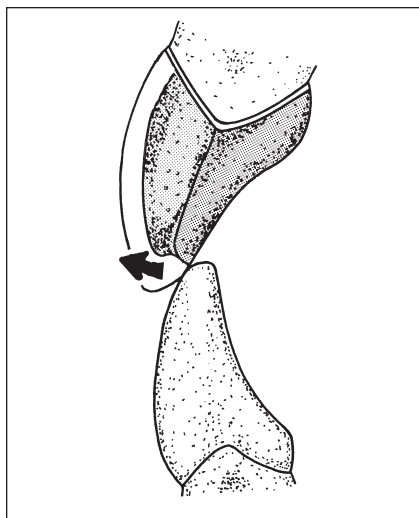


Fig 24-2 Porcelain may fracture if the metal extends too far incisally.

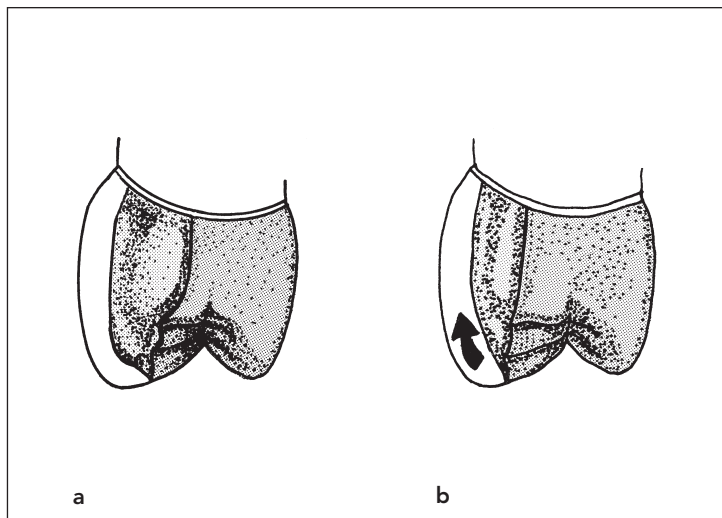


Fig 24-3 Proximal views of a maxillary posterior metal-ceramic coping with (a) and without (b) proper metal support under the facial cusp.

framework with a thick gingival extension of porcelain. Even though this extension is not exposed to any occlusal forces, it will be prone to premature failure because of stresses occurring in this thick bulk of porcelain during the initial firing and cooling. Deficiencies in the incisal edge, interproximal areas, or occlusal surface of the tooth preparation that have been caused by caries, tooth fracture, or previous restorations should be blocked out in the preparation or compensated for with extra thickness of the coping in those areas.

Porcelain support

An evenly flowing convex contour of the veneering area distributes stress best. Sharp angles and undercuts should be avoided. The outer junction of porcelain to metal should be at a right angle to avoid burnishing of the metal and subsequent fracture of the porcelain. An acute angle of metal at the metal-porcelain interface is more likely to produce porcelain crazing than an angle of 90 or 135 degrees.^{25,26} On the other hand, if the edge of metal at the porcelain-metal junction line is beveled or rounded, the porcelain will end in a feathered edge, through which the oxidized metal or opaque porcelain will show.

In addition to establishing uniform thickness of porcelain, the metal should be contoured so that the overlying veneer will be subject to compressive rather than shearing forces when a load is applied. Examples of this consideration include avoiding the extension of lingual metal to the incisal edge of a maxillary anterior restoration (Fig 24-2) and establishing a supporting ledge under the facial cusp of a maxil-

lary premolar or molar MCR (Fig 24-3). While failing to meet these criteria may not result in an excessive thickness of porcelain, it certainly can lead to premature porcelain fracture because the brittle porcelain veneer is exposed to shearing forces.

Thickness of metal

Maximum restoration strength and longevity is achieved by coping rigidity. The metal must not flex during seating or under occlusal forces because flexure places the porcelain in tension and leads to its shearing. The metal must be as hard as practical, and the coping design must ensure an optimum bulk for rigidity.

For adequate strength and rigidity, a noble metal coping should be at least 0.3 to 0.5 mm thick.²⁷ A base metal alloy with a higher yield strength and elevated melting temperature may be as thin as 0.2 mm.²⁸ The thickness of the coping may vary, depending on the configuration of the preparation. These values are only minimum thicknesses for different alloy systems. The ultimate goal of achieving a uniform thickness of approximately 1.0 mm of porcelain will dictate the thickness of the metal coping.

Occlusal and proximal contacts

If the coping is designed to place occlusal contacts on unveneered metal surfaces, their location and the area covered by ceramic can be more precisely controlled, with less re-

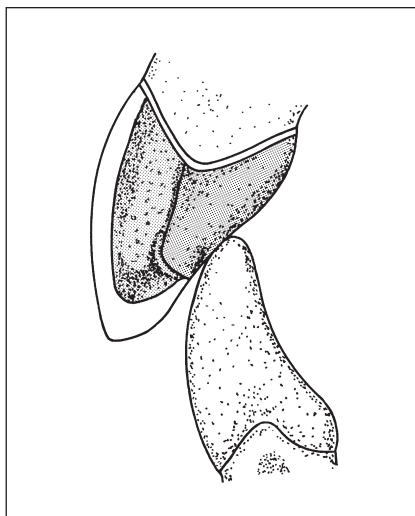


Fig 24-4 Metal occlusal contact on the palatal surface of a maxillary incisor.

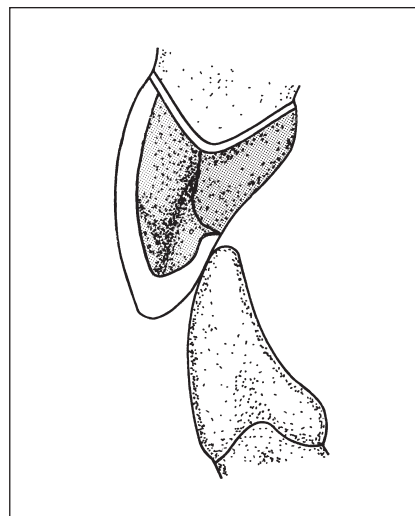


Fig 24-5 Porcelain occlusal contact on the palatal surface of a maxillary incisor.

sultant wear on opposing teeth. Studies and clinical experience have documented the highly abrasive nature of dental porcelain and its deleterious effects on enamel or gold.²⁹⁻³² Jacobi et al³¹ found that glazed porcelain removes 40 times as much opposing tooth structure as gold. Therefore, occlusal contacts should occur on metal whenever possible, well away from the porcelain-metal junction line. Contact near the junction can lead to metal flow and subsequent porcelain fracture. The porcelain-metal junction should be placed 1.0 mm from occlusal contacts at the position of maximal intercuspation (Fig 24-4).

To minimize stress resulting from occlusal contacts on the palatal surface of maxillary anterior restorations, the porcelain-metal junction should not be placed in the vicinity of those contacts with the mandibular teeth.³³ The porcelain-metal junction must not be placed too close to the incisal edge. Incisal translucency will be destroyed, and the chances of porcelain fracture will be increased greatly because the porcelain is no longer supported by metal. When occlusal forces are exerted, the porcelain will be placed in tension, a condition that it does not resist well (see Fig 24-2).

When there is inadequate vertical overlap to place the contact on metal, the porcelain-metal junction is placed far enough gingivally for the contact to occur on porcelain (Fig 24-5). When lingual contacts on maxillary restorations must be placed on porcelain, it should be recognized that there is a high potential for abrasion of the opposing natural teeth.

The patient should be cautioned that the opposing teeth eventually may require restorations.

Ideally, the collar of exposed metal on the lingual should be at least 3.0 mm wide incisogingivally. This small metal collar should not compromise esthetics. However, complete lingual porcelain coverage is becoming increasingly popular. The dentist must recognize that wherever there will be porcelain on the lingual surface, there must be greater tooth reduction. If the decision is made to place complete lingual coverage in porcelain, the lingual reduction necessary is 1.3 to 1.5 mm with a beveled shoulder finish line. Proximal contacts for anterior teeth should be on porcelain, which the dentist must facilitate during the tooth preparation by adequate reduction of the interproximal areas. The cosmetic effect is improved by placing the metal lingually so that proximal porcelain has greater depth and translucency. Interproximal metal tends to darken the unrestored proximal surfaces of adjacent teeth. An optimum stress distribution also occurs when the porcelain-metal junction is lingual to the proximal contact areas.³⁴

Extent of veneered area

A logical but underutilized framework design for maxillary posterior teeth is to veneer the esthetically critical facial surfaces with porcelain while maintaining the occlusal contacts

24 Metal-Ceramic Restorations

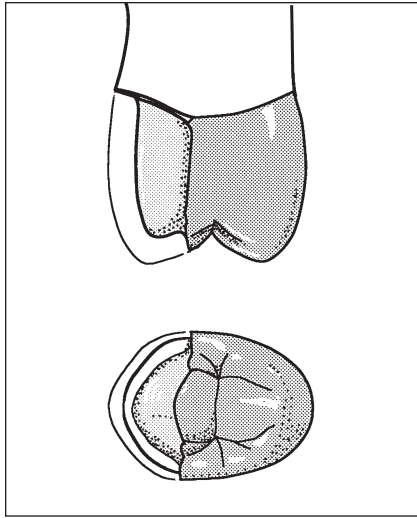


Fig 24-6 Mesial (top) and occlusal (bottom) views of a standard metal-ceramic coping design for a maxillary premolar.

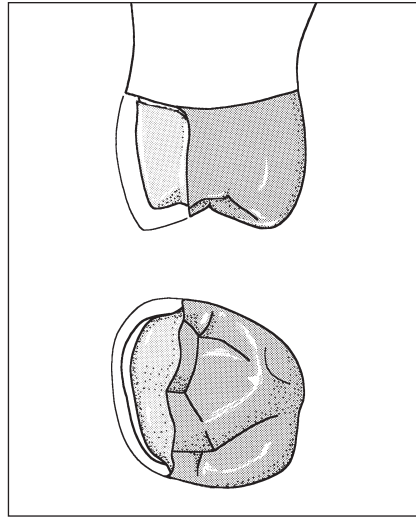


Fig 24-7 Mesial (top) and occlusal (bottom) views of a standard metal-ceramic coping design for a maxillary first molar.

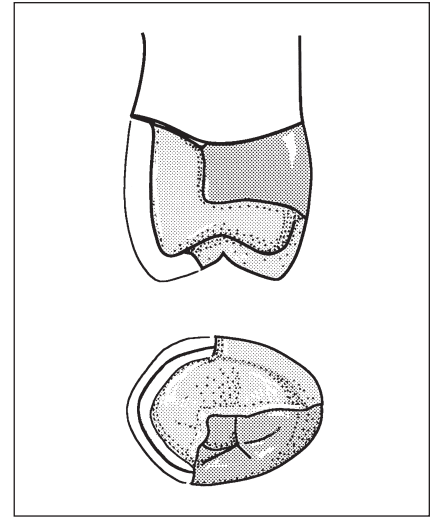


Fig 24-8 Mesial (top) and occlusal (bottom) views of a modified metal-ceramic coping design for a maxillary premolar.

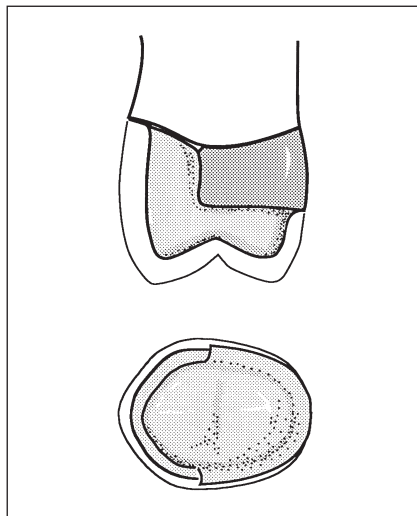


Fig 24-9 Mesial (top) and occlusal (bottom) views of a maxillary premolar metal-ceramic coping design with full porcelain occlusal coverage.

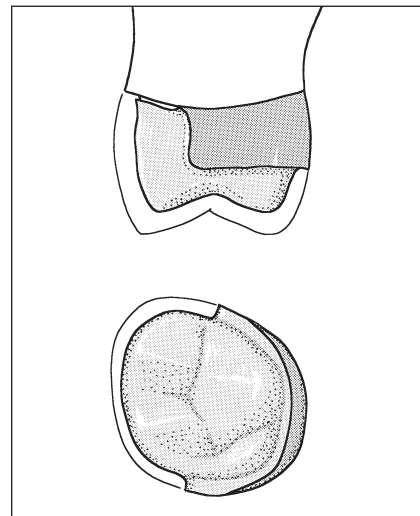


Fig 24-10 Mesial (top) and occlusal (bottom) views of a maxillary first molar metal-ceramic coping design with full porcelain occlusal coverage.

in metal. To place occlusal contacts in metal, the porcelain on the facial surface extends over the cusp tip and about halfway down the palatal incline of the facial cusp on maxillary premolars (Fig 24-6) and molars³⁵ (Fig 24-7). There must be a rounded ledge of metal under the facial cusp to support the porcelain (see Fig 24-3a). Without a supporting ledge, the ceramic will fracture (see Fig 24-3b). This configuration will satisfy the cosmetic requirements of most patients and provide longevity if the porcelain-metal junction is kept away from the occlusal contacts. This design is more resistant to fracture than those in which the porcelain extends to the central groove or covers the entire occlusal surface.³⁶

Variants for maxillary teeth include porcelain coverage of the mesial marginal ridge up to the middle of the triangular ridge (Fig 24-8) or, for those patients who demand absolute esthetics, complete coverage with porcelain of the occlusal surface of premolars (Fig 24-9) and molars (Fig 24-10).

Mandibular first premolars will often require complete porcelain coverage of the occlusal surfaces of metal-ceramic crowns placed on them (Fig 24-11). The degree of porcelain occlusal coverage on metal-ceramic crowns for mandibular molars and second premolars will be dictated by patient wishes, occlusal restoration of the opposing arch, and the presence or absence of wear associated with parafunction.

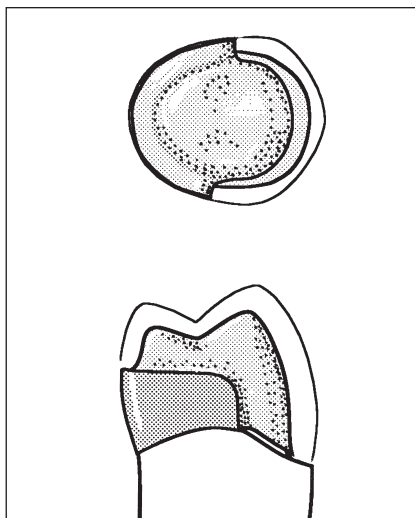


Fig 24-11 Occlusal (top) and mesial (bottom) views of a mandibular premolar metal-ceramic coping design (standard for first premolar, optional for second premolar).

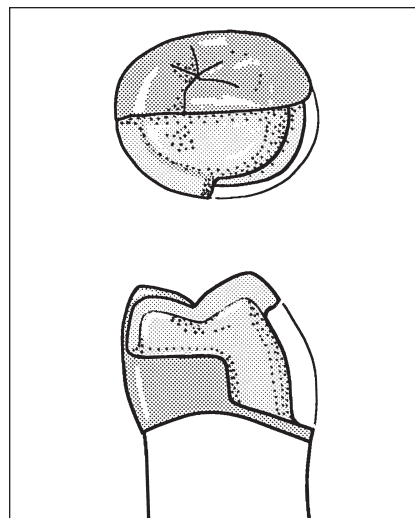


Fig 24-12 Occlusal (top) and mesial (bottom) views of a standard mandibular second premolar metal-ceramic coping design.

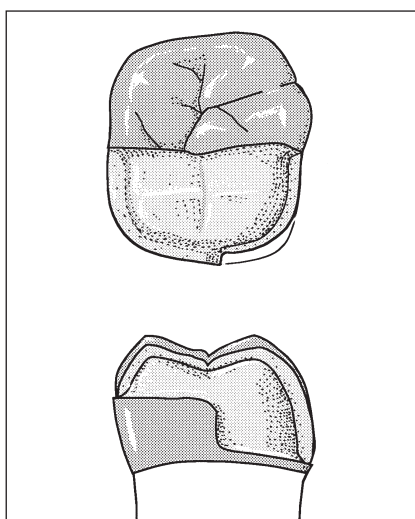


Fig 24-13 Occlusal (top) and mesial (bottom) views of a standard mandibular first molar metal-ceramic coping design.

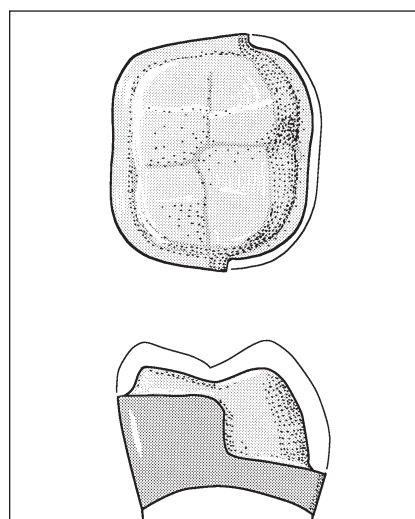


Fig 24-14 Occlusal (top) and mesial (bottom) views of an optional mandibular first molar metal-ceramic coping design.

The distal half of second premolars (Fig 24-12) and molars (Fig 24-13) can be unveneered to allow more occlusal contacts to be on metal if the patient can be satisfied with a tooth-colored veneer on the mesial marginal ridge, proximal contact, fossa, and cusp incline.

If the patient is extremely concerned about esthetics, the occlusal surfaces of mandibular molars can be covered with porcelain (Fig 24-14). A 1.0- to 2.0-mm-wide metal collar can be used on the facial surface to minimize the destruction of tooth structure for a facial shoulder. The patient should be informed of the potential damage to opposing teeth, the necessity for a more destructive crown preparation to provide

adequate space for the porcelain, and the propensity for porcelain fracture in high-stress areas such as molar occlusal surfaces. However, it is the patient's mouth, and the final decision is the patient's; be sure that it is an informed one.

A posterior crown with porcelain occlusal coverage should have a 3.0-mm metal collar on the lingual, with metal support under the marginal ridges. Although the greater portion of the crown will be veneered with porcelain, it should still be waxed to a full contour and then cut back to ensure a uniform thickness of porcelain and correct contours. A "thimble" coping may result in unsupported, fracture-prone porcelain.

24 Metal-Ceramic Restorations

Facial margins

For many years, the conventional facial margin for a metal-ceramic crown was a narrow metal collar. To avoid metal display on highly visible teeth, the facial finish line was often placed subgingivally, which contributed to chronic gingival inflammation or more serious periodontal problems. Gingival recession may occur from the trauma of tooth preparation, impression taking, or an improperly contoured provisional restoration. Following cementation, 60% of subgingival margins become visible within a 2-year period.³⁷ The association of subgingival crown margins and detrimental effects on the periodontium is well documented.^{38–41}

To avoid showing an unsightly band of metal, ceramists began to extend porcelain to cover the collar. This design met with problems when attempted on the same beveled finish line previously used for a metal collar. However, this porcelain-covered metal margin design has become increasingly popular. The finish line required to facilitate the design is either a heavy chamfer or an angled shoulder (bevel) with the metal coping extending to the cavosurface margin and thinned to the minimum thickness possible with the selected metal. The porcelain is extended to cover this metal. With low-fusing porcelains to avoid metal distortion and modern opaque-dentin porcelain combinations to avoid opaque show-through, in the hands of an accomplished ceramist this design can be produced with acceptable contours, marginal adaptation, and esthetic results.⁴²

The material and technical demands are high with this margin design. The likely problems are metal distortion during firing, metal flexure with resulting porcelain fracture as a result of excessive thinning of the coping, roughness at the margin because of exposed opaque porcelain, and inability to polish the thin metal. In addition, there remains a tendency for either show-through of opaque porcelain or overcontouring in an effort to overcome this display. The decision to use porcelain-covered metal margins is dependent on the availability of a laboratory technician capable of predictably fabricating this demanding restoration design.

Frustration with the esthetics of the conventional metal collar led to the use of the all-porcelain facial margin, which can be even with the gingiva or even slightly supragingival. An improvement in periodontal health was an unexpected bonus. Improved esthetics and periodontal health made the all-porcelain margin popular, and the demand spawned many ways of fabricating one. The first was a transition from a technique used for porcelain jacket crowns in which a platinum foil matrix supports the porcelain margin during firing.⁴³ Another technique employs a refractory die to support the porcelain margin during firing.^{44,45}

In an effort to simplify the fabrication of all-porcelain shoulders even more, direct-lift techniques were tried. Correction porcelain was added to the margin after a full-contour buildup of the crown. The porcelain was condensed by compression and fired to produce the final margin.⁴⁶ In 1979, Vryonis⁴⁷ described a method that required a tooth preparation with a 90-degree shoulder finish line and a metal coping that terminated at the gingivoaxial line angle.

Opaque porcelain was applied to the metal coping and the shoulder on a sealed stone die, forming the margin. After obtaining a satisfactory margin, dentin and enamel porcelains were added to complete the crown.

A blend of dentin and enamel porcelains was substituted to form the margin.⁴⁸ However, margins of conventional porcelain tend to round or slump during subsequent firings because the fusion temperatures are identical. To correct this problem, manufacturers created special shoulder porcelains containing aluminous porcelain that fuse at temperatures 30°C to 80°C higher than the dentin or enamel porcelains. The higher-fusing porcelain allows repeated firings of the crown buildup with no effect on the completed margin.⁴⁹ In addition to being stable during the firing cycle, shoulder porcelains are stronger in flexure than conventional porcelains, making the margin more resistant to fracture.⁵⁰

A number of studies have shown the accuracy of all-porcelain margins to be quite acceptable.^{51–55} Early studies used conventional porcelains for the margins. Studies using shoulder porcelains and the direct-lift technique have produced a consistent level of marginal adaptation with mean marginal openings of 15 to 23 μm ⁵⁶ and 8 to 11 μm ,⁵⁷ respectively.

A modification to the porcelain margin framework design is to stop the metal extension short of the junction of the axial wall and the shoulder preparation.⁵⁸ With this design, a portion of the axial wall, as well as the margin, must be constructed with porcelain. The purpose of this modification is to allow light transmission into the tooth root adjacent to the margin in an attempt to avoid the gray shadow in the soft tissue often observed even with standard porcelain margins. This increases the difficulty of an already demanding procedure, a fact that must be considered when choosing to request this margin design from even the most talented ceramist.

The demonstration of acceptable porcelain margins with a wide assortment of techniques, porcelains, and binders indicates that the quality of the margins is directly related to the skill of the ceramist. If a talented and conscientious ceramist is not available, all-porcelain facial margins are definitely contraindicated.

Single Coping Wax Pattern

Before a coping can be fabricated for a metal-ceramic crown, the wax pattern should be made to the complete contour of the finished restoration (Fig 24-15). Then the areas to be veneered with porcelain are cut back. Only by following this procedure can there be a smooth continuation of the lingual and proximal contours between the unveneered metal and the porcelain. If only the portion of the wax pattern that later will be unveneered metal is made, it is difficult to be sure that the contours of the unveneered portion of the coping will match the contours of the porcelain (Fig 24-16).

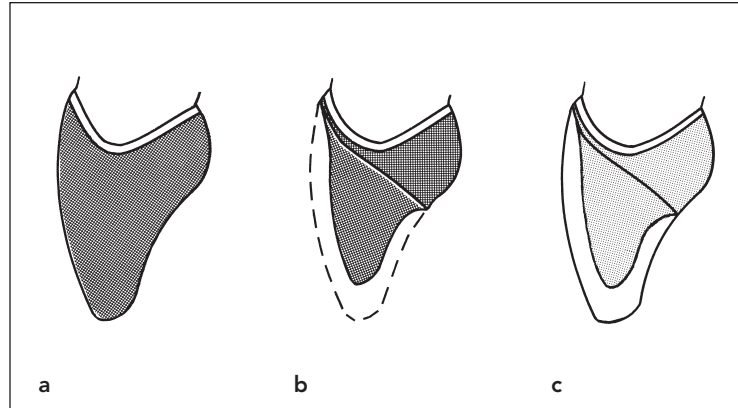


Fig 24-15 The correct steps in the fabrication of a metal-ceramic restoration: (a) full-contour wax pattern; (b) coping wax pattern cut back; (c) porcelain addition to metal coping.

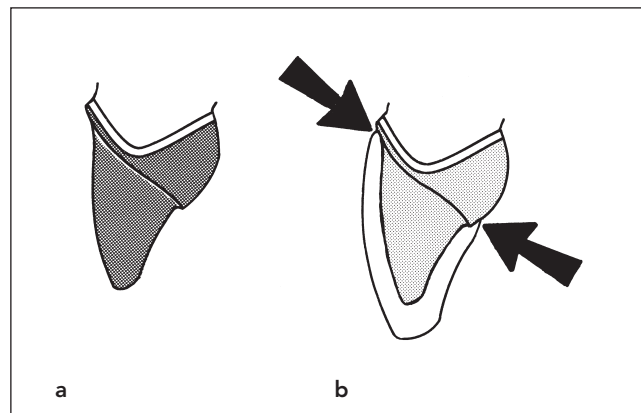


Fig 24-16 If the coping pattern (a) is the first step in fabrication, the porcelain veneer on the definitive restoration may have contours that are not continuous with those of the unveneered coping (b).

Waxing armamentarium

- P. K. Thomas (PKT) waxing instruments (nos. 1 to 5) (Osung)
- Beavertail burnisher
- No. 7 wax spatula
- Discoid carver
- Large spoon excavator
- Sable brush
- No. 2 pencil
- Laboratory knife with no. 25 blade
- Iwanson thickness gauge
- Cotton pliers
- Bunsen burner and matches
- Inlay casting wax
- Zinc stearate
- Die lubricant

All-wax technique

Wax is first applied to the lubricated die with a hot no. 7 wax spatula. The wax is trimmed back from the margins, and the wax thimble is transferred to the articulated working cast. The axial contours, including the proximal contacts, are built up in harmony with the adjacent teeth. The proper occlusal relationships are established with the opposing teeth. If the wax pattern is for a posterior tooth, the PKT instruments are used to build up the occlusal surface with cones and ridges to obtain good occlusion (see chapter 19).

When the full-contour wax pattern is completed, an impression of it is taken with a resilient condensation silicone putty impression material. This impression can be poured to produce a stone cast, providing a visual guide to the desired contours, or it can be sectioned horizontally to allow assessment of the amount and contours of the cutback.

24 Metal-Ceramic Restorations

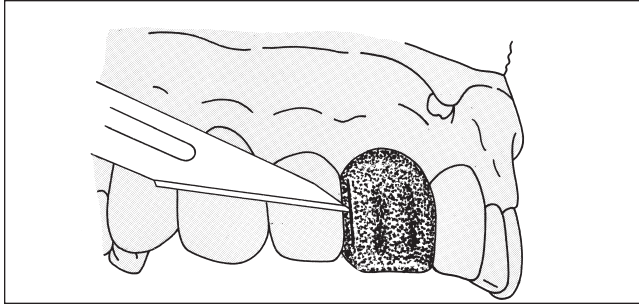


Fig 24-17 The proximal outline is traced with a sharp knife tip.

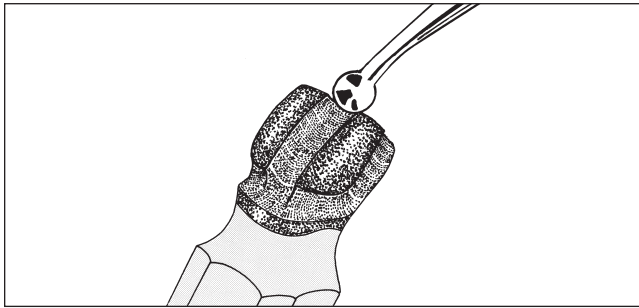


Fig 24-19 Orientation grooves are carved in the wax pattern with a discoid carver.

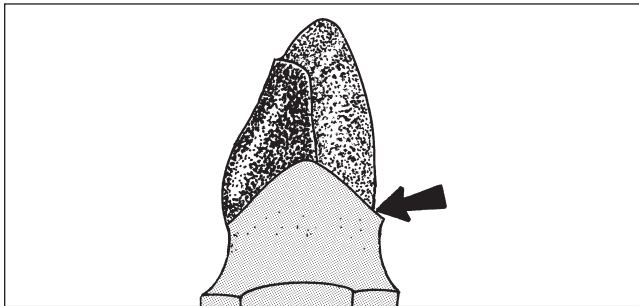


Fig 24-21 The facial axial wall of a wax pattern for a crown with an all-porcelain shoulder ends at the gingivofacial angle (arrow).

The first step in forming the veneering area is sketching the outline of that area on the wax pattern. The no. 25 blade is placed on the proximal surface of the adjacent tooth. Using this guide, a line is etched on the proximal surface of the pattern, placing it as far lingual as possible (Fig 24-17). With the same blade, a horizontal line is marked on both the facial and lingual surfaces, 1.5 mm from the incisal edge. Next, the position of the previously established occlusal contacts is observed. For a maxillary anterior tooth, now is the time to establish the position of the lingual porcelain-metal junction. The decision as to whether the lingual contact on a maxillary anterior MCR will be placed in metal or porcelain should be determined at the time of tooth preparation. As previously discussed, this should be based on the amount of vertical overlap and position of lingual contacts and will dictate the reduction necessary. It is determined whether the contacts

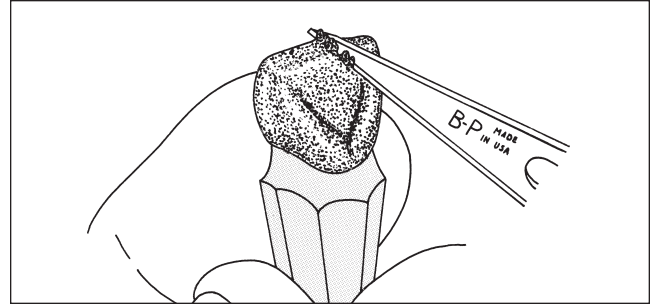


Fig 24-18 The knife is used to cut 1.5 mm from the incisal portion of the pattern.

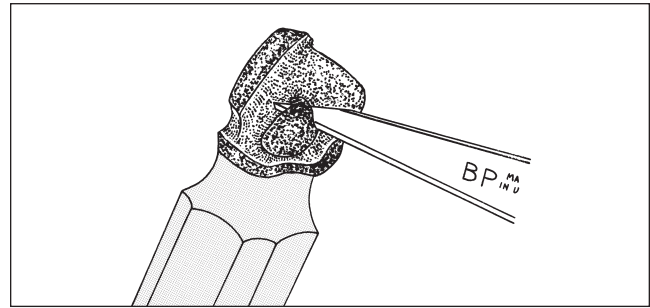


Fig 24-20 Wax is removed with a sharp knife to the desired depth.

will be established in metal or porcelain or a combination of the two. Then, following the guidelines previously discussed (see Figs 24-2, 24-4, and 24-5), a line is scribed with the no. 25 blade, marking the position of the lingual porcelain-metal junction. This line is connected with the previously marked proximal line.

After the outline is drawn on the pattern, it is placed on the die. With the knife, 1.5 mm is removed from the incisal portion of an anterior pattern (Fig 24-18). The proximal porcelain-metal junction is placed 0.5 mm to the lingual of the proximal contacts (which will be nearly 1.0 mm lingual to the proximal line drawn earlier). A discoid carver is used to finish the wax that will form the porcelain-metal junction on the proximal surface. A vertical groove is carved in the center of the labial surface with the discoid carver (Fig 24-19). Similar grooves are cut on the mesial and distal. From an incisal view, these grooves should be about 1.0 mm deep. They are used to gauge the depth of wax to be removed from the veneering area.

The design of the facial margin must be decided before preparing the tooth because it will be dictated by the facial finish line. For a metal collar, the bulk of the wax is removed with the knife, leaving a collar of wax 1.0 mm wide at the facial margin to reinforce it during investing and to ensure an adequate bulk to cast the margin (Fig 24-20). The collar will be narrowed to approximately 0.3 mm in metal. For an all-porcelain facial margin, the wax pattern terminates at the junction of the facial axial wall and the facial shoulder (Fig 24-21), or, if the shoulder preparation is wider than ideal, the wax is carried onto the shoulder to establish a uniform width of margin porcelain of 0.7 to 1.0 mm. The margins are adapted with a warm beavertail burnisher.

The thickness of the wax pattern is checked with a thickness gauge. It should be 0.4 to 0.5 mm thick in the veneering area. It will be thinned to about 0.3 mm after it has been cast. If it is made too thin at this point, it may not cast completely.

CAD/CAM pattern fabrication

Recent advances in computer-aided design/computer-assisted manufacture (CAD/CAM) technologies have allowed for the fabrication of milled patterns for MCR frameworks. These patterns are sprued, invested, and cast using conventional methods. A significant advantage with these technologies is that they are very efficient, they use materials more rigid than wax, and they involve a full-contour digital wax-up prior to the digital cutback.

Alloy surface treatment

The surfaces of a coping that are to receive porcelain must be properly finished to assure a strong bond and an esthetic restoration. Surface irregularities and small particles of investment may be embedded in the surface of the casting. Finishing can remove much of this residue while producing uniform striations in one direction to decrease the possibility of gas entrapment during the initial firing cycles.

Surface treatment armamentarium

- Straight handpiece
- Carborundum separating disk on mandrel
- Aluminum oxide separating disk on mandrel
- Aluminum oxide stones
- Carbide finishing burs (high-speed or low-speed)
- Cratex disk (Cratex) on mandrel
- Jeweler's blue disk (Dedeco) on mandrel
- Fine cuttle disk on mandrel

The intaglio surface of the casting is examined for bubbles, imperfections such as fins, or any residual investment, and these obvious impediments to seating are removed. The casting is carefully placed on the die and seated without force. Areas that bind or prevent seating should be identified and carefully removed with a small high-speed bur. Forcing a casting into place results in a casting that fits the die but not the prepared tooth. Identifying binding areas intraorally is more difficult and far more frustrating and time-consuming than meticulously fitting the casting to the die in the first place.

The sprue is removed with a carborundum separating disk. Only new, clean burs and noncontaminating stones and disks should be used to finish the veneering area. Instruments that have been previously used on other types of metal will contaminate the veneering area.

Aluminum oxide stones (Lab Series Pink Stones, Shofu) are used for rough finishing of the veneering area (Fig 24-22).

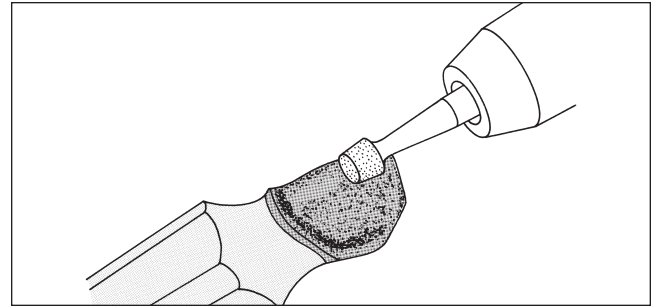


Fig 24-22 The veneering area is prepared with aluminum oxide stones.

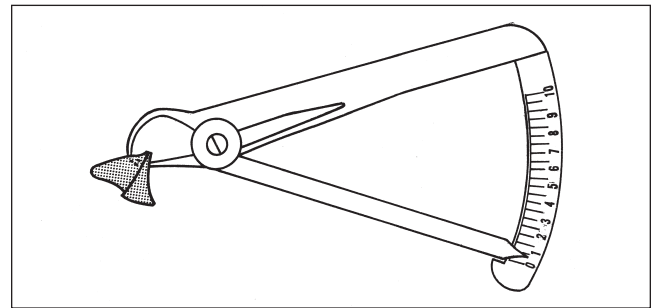


Fig 24-23 The coping thickness is checked with an Iwanson thickness gauge.

If a disk must be used, it also must be aluminum oxide because it will not contaminate the veneering area (Dura-Thin, Keystone). The demarcation line between the veneered and unveneered areas of the coping should be distinct, with an external angle of 90 degrees and a rounded internal angle. Clean carbide burs can be used when their size and shape simplify accessing difficult areas, and they are particularly useful in finishing a well-defined external angle.

The thickness of the metal to be veneered is checked with a thickness gauge (Fig 24-23). On noble metal castings, it should measure at least 0.3 mm, while on base metal copings it can be 0.2 mm. The cervical collar, if there is one, should be narrowed from 1.0 mm to about 0.3 mm. Care must be taken not to run over the margin. Cratex and jeweler's blue disks are used on the unveneered area, and the face of the collar is finished with a fine cuttle disk. Polishing compounds should not be used because they may contaminate the surface of the metal to be veneered later.

Novices would be wise to try the casting in the patient's mouth. Experienced operators will usually bypass this step unless there are a large number of single castings being done at one time or a long-span fixed partial denture is being made. The marginal adaptation of the casting is checked, and any occlusal or contour adjustments that are necessary are made.

24 Metal-Ceramic Restorations

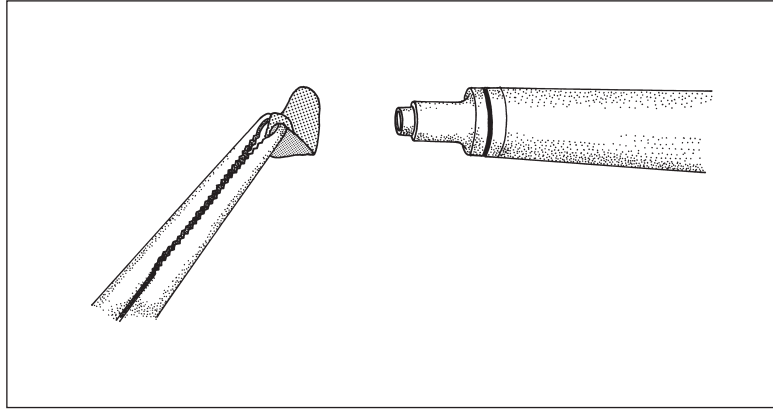


Fig 24-24 The final step in metal preparation is reduction of the oxide layer on the part of the coping to be veneered with porcelain by air abrading with 50- μ m aluminum oxide.

Oxidation

Any remaining investment or abrasive particles embedded in the surface of the casting could oxidize and release gases during firing. Oils from the skin left during handling of the casting are another significant form of contamination. "Live steam" is effective in removing residual contamination caused by surface deposits of abrasive particles.⁵⁹

The coping is ready for the oxidation cycle. Metal surface treatments are unique for each porcelain-alloy combination, and manufacturer's recommendations should be followed. Bond strength varies with the surface treatment. Unaltered, as-cast, gold-palladium and silver-palladium specimens produce low bond values.⁷ Typically, a coping is placed in a furnace at a relatively low temperature, and the temperature is raised 300°C to 400°C at a designated rate of climb. The atmosphere (air or vacuum) during this heating process, as well as the length of time at temperature, is dictated by the alloy.

Heat treatment of noble metal alloys causes the trace quantities of tin, gallium, indium, and zinc in the alloy to form oxides that enhance bonding with the porcelain.⁶⁰ Base metal alloys, on the other hand, readily oxidize, so oxide formation must be carefully controlled. Following oxidation, most alloys require air abrasion with 50- μ m aluminum oxide to reduce the layer of oxide (Fig 24-24) because excess oxide weakens the porcelain-to-metal bond.

Oxidation is only one of the functions of the initial firing. During casting, hydrogen gas is incorporated into the molten alloy. This gas, if left in the coping, can weaken the bond between porcelain and metal,¹⁰ causing the formation of bubbles in the porcelain.⁶¹ The hydrogen is released during the oxidation cycle, degassing the alloy as well as forming the important oxide layer.

Porcelain Addition

The buildup of porcelain is a skill that requires a great deal of practice to develop. Therefore, only a brief description for the sake of familiarization is given here.

Opaque porcelain application

The casting is now ready for the actual placement of porcelain. Opaque porcelain is applied first to mask the metal, to give the restoration its basic shade, and to initiate the porcelain-metal bond. The prepared coping is painted with a thin coating of distilled water or special liquid (Fig 24-25). A small amount of the appropriate opaque powder is mixed with distilled water or the specially formulated liquid, forming a thin wash, which is applied with a glass rod or brush (Fig 24-26).

No attempt should be made to thoroughly mask the metal with this initial application. It is intended to completely wet the metal and penetrate the striations created by finishing. The coping is dried and fired under vacuum to the specifications of the manufacturer.

The second application of opaque porcelain should mask the metal (Fig 24-27). The powder and liquid are mixed to a creamy consistency and applied to the coping with a brush in a vibrating motion. The opaque layer should be applied as thinly as possible to still mask the metal. The coping is gently vibrated to condense the porcelain, and excess water is removed with a dry tissue. The second layer of opaque porcelain is fired using the same firing cycle. The opaque layer of porcelain should be approximately 0.3 mm thick.

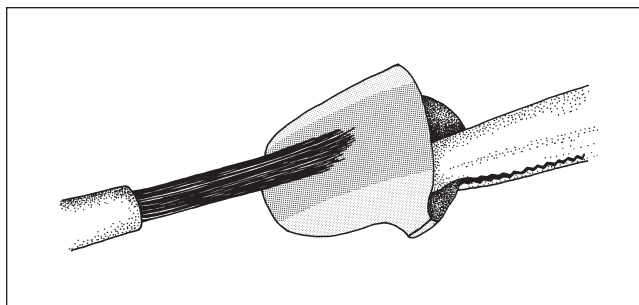


Fig 24-25 The veneering surface of the coping is wetted with distilled water or special liquid recommended by the manufacturer.

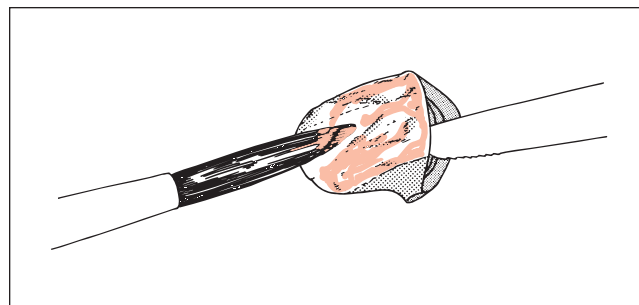


Fig 24-26 A thin "wash layer" of opaque porcelain is applied with a brush.

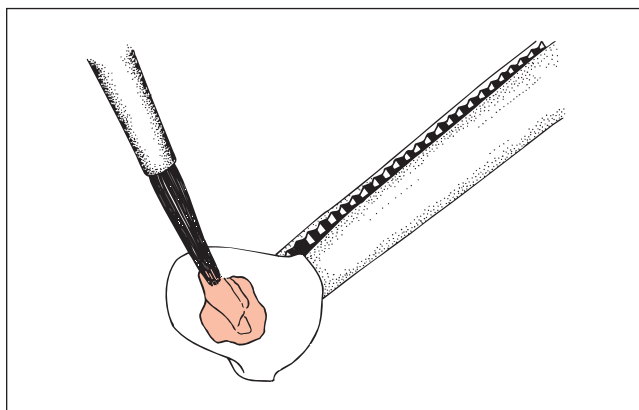


Fig 24-27 After the first layer of opaque porcelain is fired, a second coat is applied to completely cover the metal.

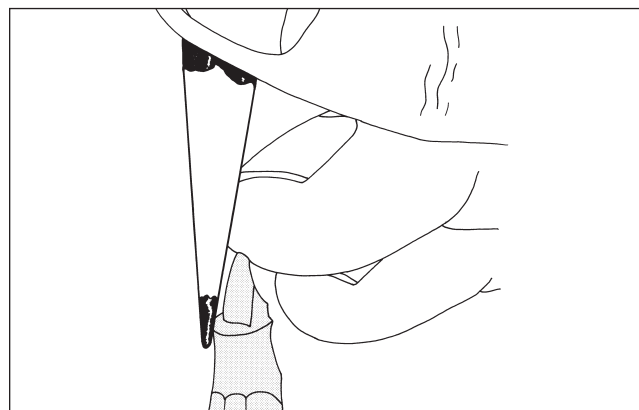


Fig 24-28 The facial shoulder finish line is marked with the side of a red pencil.

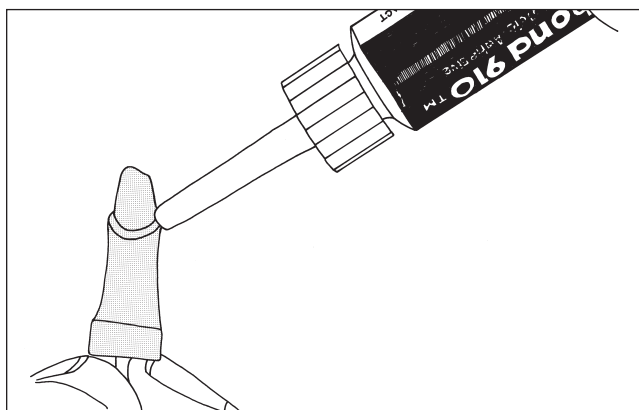


Fig 24-29 Cyanoacrylate cement is applied to seal the die in the area of the facial shoulder.

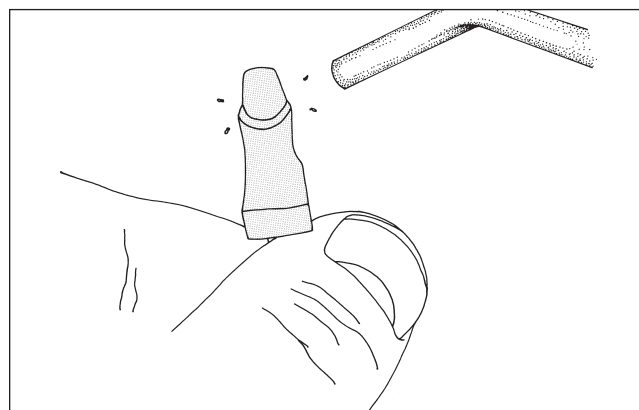


Fig 24-30 Excess liquid is blown off to ensure a thin, uniform coat.

All-porcelain margin fabrication

Restorations with a metal collar facial margin are now ready for the application of dentin and enamel porcelains following opaque porcelain application. For restorations with an all-porcelain facial margin, a few extra steps are necessary at this point. The additional time and skill required to fabricate a direct-lift porcelain margin will often translate into a higher laboratory fee for the restoration.

To fabricate an all-porcelain margin using the direct-lift technique, the shoulder finish line is marked on the die using the side of a red pencil (Fig 24-28). The porous surface of the gypsum die is then sealed by brushing on a special sealing material (Cerama Seal, Kerr) or by squeezing a thin layer of cyanoacrylate cement (Permabond 910, Permabond) onto the finish line area of the die (Fig 24-29). The excess liquid should be removed with compressed air to ensure a uniformly thin layer of sealant (Fig 24-30).

24 Metal-Ceramic Restorations

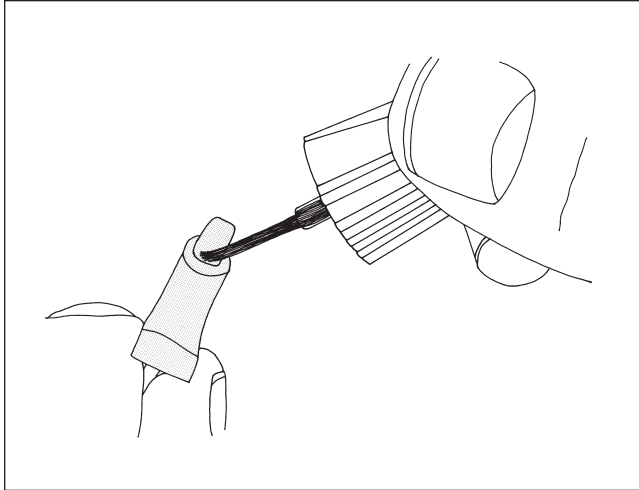


Fig 24-31 Porcelain release agent is applied to the die around the facial shoulder to prevent porcelain from sticking to the die.

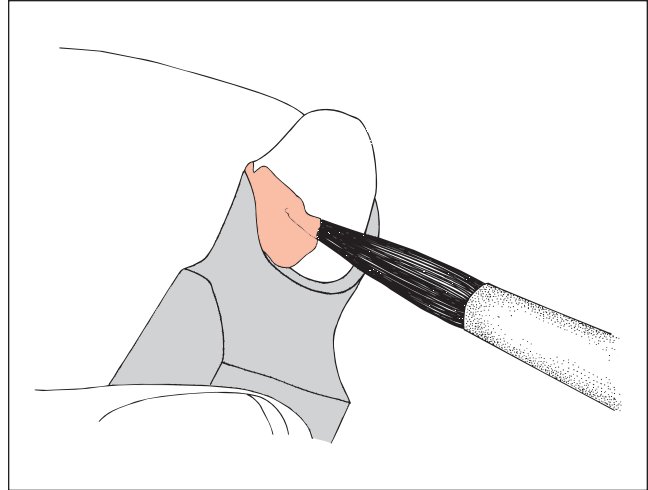


Fig 24-32 The first shoulder porcelain is applied to the facial shoulder of the die with a brush. It should extend 2 to 3 mm onto the metal coping.

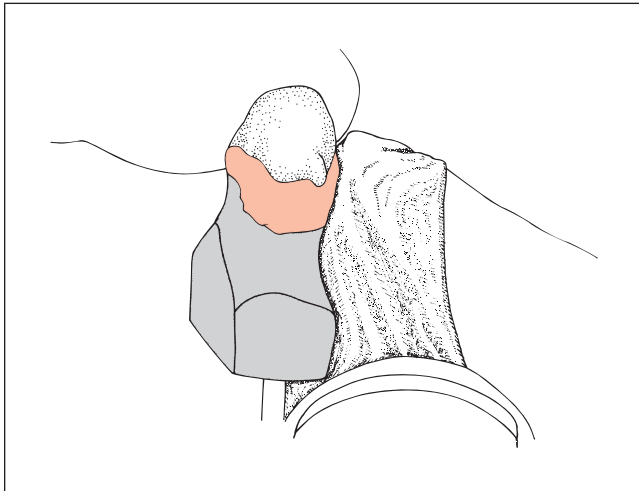


Fig 24-33 The porcelain is condensed by blotting it dry with tissue until no more liquid comes to the surface.

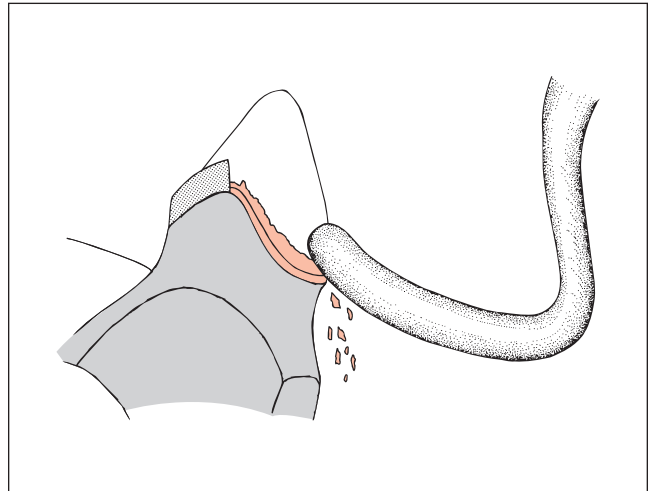


Fig 24-34 A large spoon excavator or a discoid carver is used to remove the excess "green" shoulder porcelain. Only the material directly over the shoulder and a slight extension (1.0 mm or less) onto the coping is left in place.

A special lubricant, or porcelain release agent (Ceramasep, Kerr), is applied to the facial shoulder of the sealed die with a brush (Fig 24-31). Then the opaqued coping is seated on the die. Shoulder porcelain powder should be mixed with distilled water or the manufacturer's recommended liquid. There are techniques using high-temperature investment liquid as the binder for direct-lift porcelain margins. The investment liquid hardens as the wet porcelain mixture dries on the die, making it easier to remove the coping from the die without fracturing the margin. However, after firing, residual silica particles act as inclusions in the porcelain, weakening it and making it more prone to fracture.⁵⁷

The initial increment of shoulder porcelain is added to the facial shoulder; it should extend approximately 2 to 3 mm

onto the coping (Fig 24-32). The porcelain is condensed by blotting it dry with tissue (Fig 24-33). The porcelain is carved with a large spoon excavator or a small cleoid (Fig 24-34) to produce a slight bevel or undercontour. This produces space for a narrow layer of dentin porcelain over the shoulder porcelain.

The shoulder porcelain is lightly smoothed at the margin with a no. 10 sable condensing brush (Fig 24-35). The coping is carefully teased from the die (Fig 24-36). The inside of the casting is inspected for any specks of porcelain, and any found are removed (Fig 24-37). Although they can be ground out after firing, they are more easily seen and removed in the prefired state. The coping is gently placed on a sagger tray (Fig 24-38).

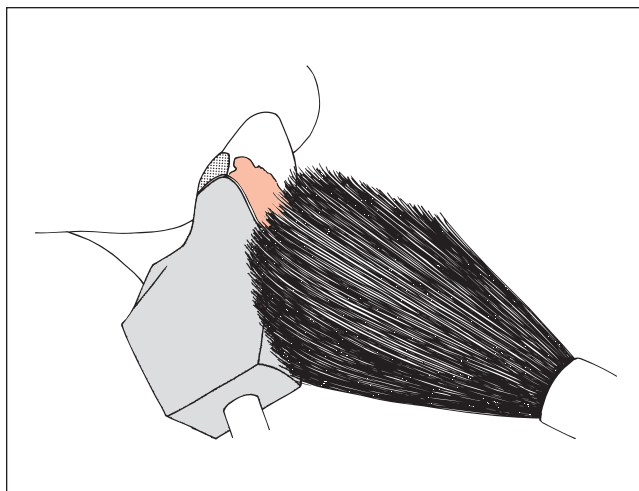


Fig 24-35 A large no. 10 sable brush is used to smooth the margin and remove excess bulk.

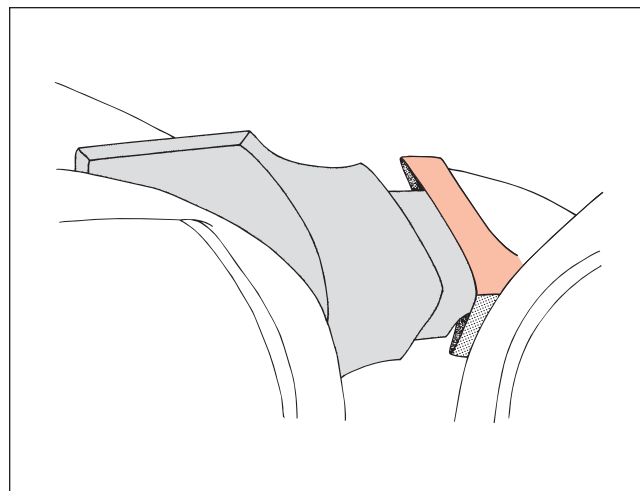


Fig 24-36 The coping is gently teased off the die, and the shoulder porcelain is inspected for defects.

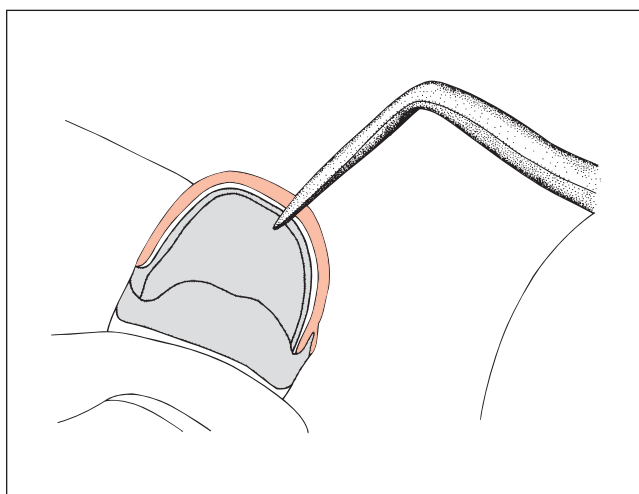


Fig 24-37 Any porcelain visible on the internal aspect of the coping is removed.

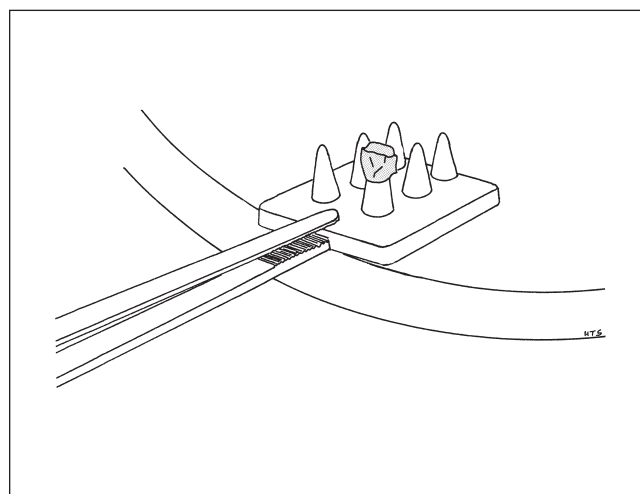


Fig 24-38 The coping is placed on a sagger tray and dried in front of the oven door.

The porcelain is thoroughly dried in front of the furnace. It is then fired under vacuum at a temperature approximately 30°C higher than the corresponding dentin and enamel porcelains. When the initial increment of shoulder porcelain is inspected on the die after firing, a small opening may be apparent at the facial margin (Fig 24-39). More shoulder porcelain can be added to the discrepancy with the crown seated on the die. It is vibrated into the opening with a small vibrating sable brush.

Some ceramists prefer to add a very small amount of shoulder porcelain of a runny consistency to the gingival aspect of the fired margin to correct the discrepancy (Fig 24-40). The coping is placed back onto the die, and application of firm seating pressure (Fig 24-41) is alternated with vibration of the die. The metal margin on the lingual of the casting should seat completely. If it does not seat, the coping should be removed from the die, and some of the newly

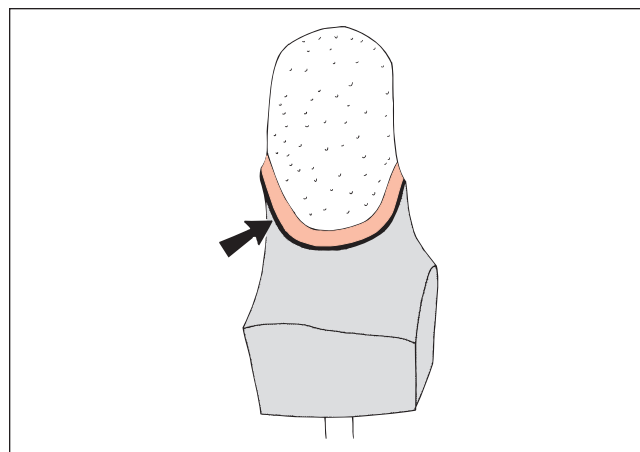


Fig 24-39 Following the first firing of the shoulder porcelain, porcelain shrinkage will cause a slight marginal gap (arrow).

24 Metal-Ceramic Restorations

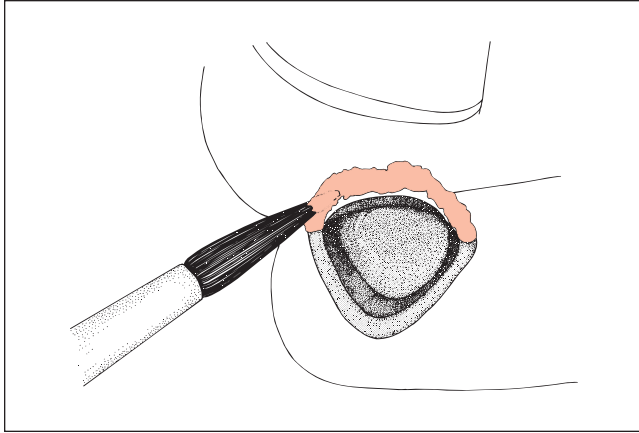


Fig 24-40 A uniform layer of shoulder porcelain is applied with a brush to the underside of the already fired porcelain.

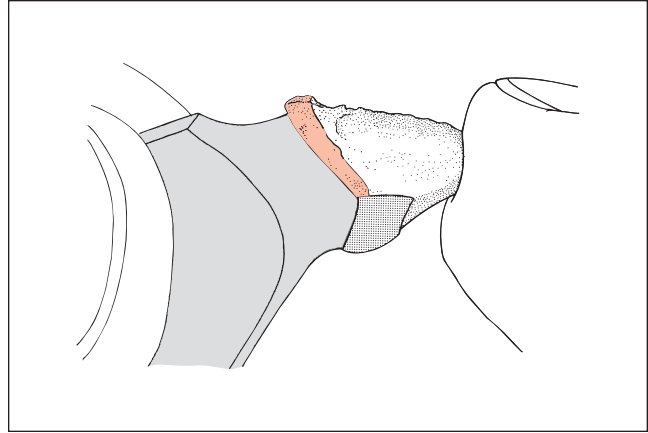


Fig 24-41 The coping is placed back on the die, maneuvering it to completely seat it.

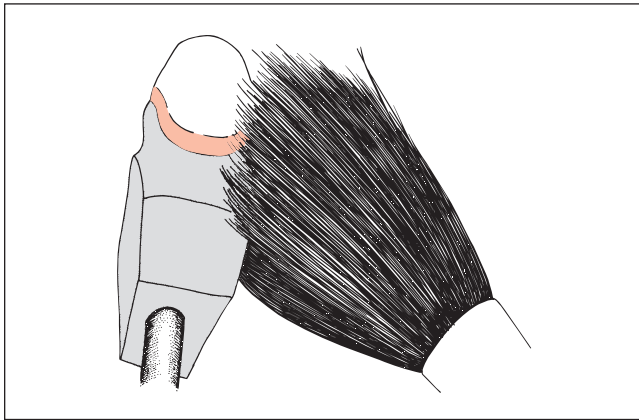


Fig 24-42 The corrected porcelain application is condensed and smoothed with a large condensing brush.

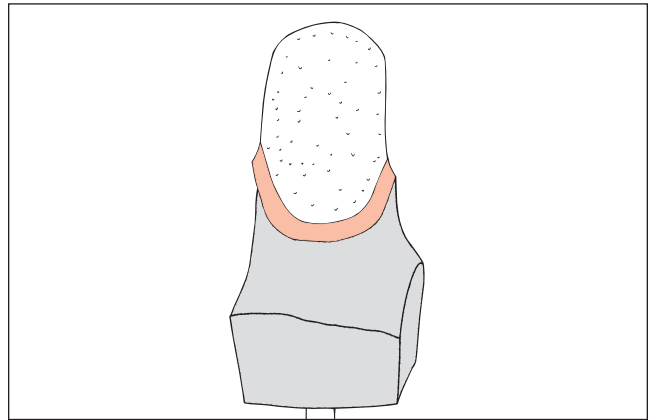


Fig 24-43 The marginal gap between the shoulder porcelain and the finish line must be closed before proceeding.

added "correction porcelain" should be scraped away. The porcelain is condensed and smoothed (Fig 24-42). The same firing cycle as used in the initial application is used for the correction bake. When the margin is satisfactory (Fig 24-43), the dentin and enamel buildup should proceed.

Problems that can be encountered during try-in and delivery of restorations with porcelain margins are incomplete seating of the restoration due to overextension of the porcelain margin material or binding caused by residual porcelain left inside the casting. These problems can be minimized by meticulous attention to detail on the part of the ceramist. It is valuable to maintain an unused die for final seating and margin verification prior to patient try-in.

Dentin and enamel porcelain application

Dentin porcelain is mixed to a creamy consistency with distilled water or the manufacturer's recommended liquid. It is then applied over the opaque porcelain with a sable brush

or small spatula, starting at the gingivofacial aspect of the coping, which is seated on the working cast (Fig 24-44). First the full contour of the crown is developed in dentin porcelain with a brush. The porcelain is vibrated to condense it, and the liquid is absorbed with tissue (Fig 24-45). It is then brushed with a no. 10 sable condensation brush (Fig 24-46). The completed buildup should be overcontoured (Fig 24-47). When the porcelain is condensed and dried to a consistency of wet sand, the dentin is carved back to allow the placement of the enamel porcelain.

The desired translucency pattern dictates the amount and design of the cutback. It will commonly produce some form of bevel on the incisofacial segment of the buildup in dentin porcelain (Fig 24-48). Frequently the cuts at the incisoproximal corners overlap in the center (Fig 24-49). The enamel porcelain is applied to restore the full contour of the restoration (Fig 24-50). Carving instruments or brushes are used to shape the porcelain to its final contours (Fig 24-51). The porcelain is condensed by blotting from the lingual (Fig 24-52a) and the facial (Fig 24-52b).

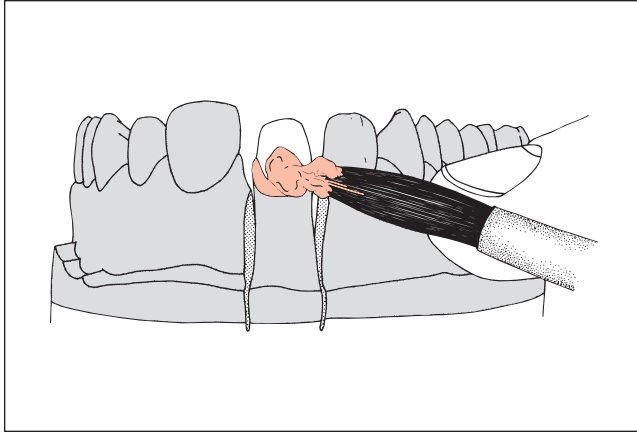


Fig 24-44 The initial application of the dentin porcelain is made with a brush.

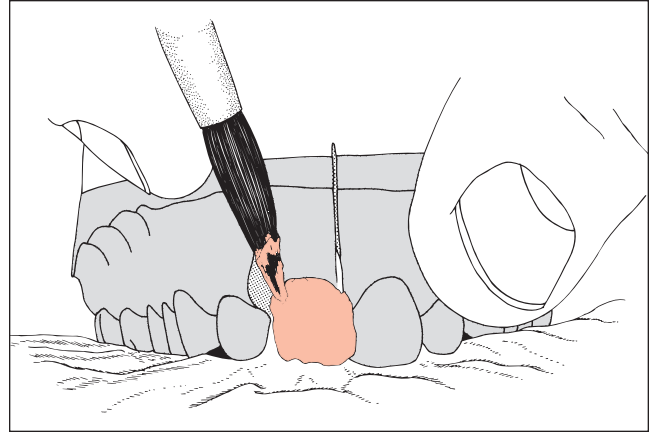


Fig 24-45 Buildup of the dentin porcelain is continued with the brush while holding a piece of tissue behind the incisal edge to absorb water.

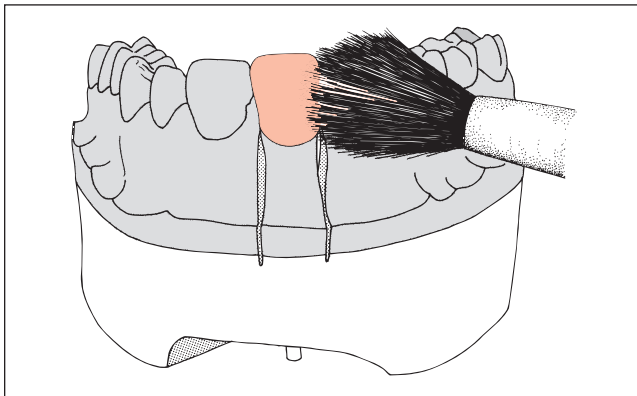


Fig 24-46 Final condensation is done with a no. 10 sable brush.

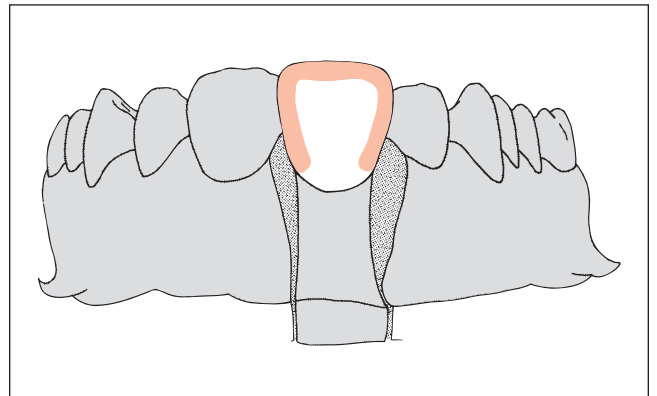


Fig 24-47 Dentin porcelain is overbuilt slightly beyond the intended final contour of the crown.

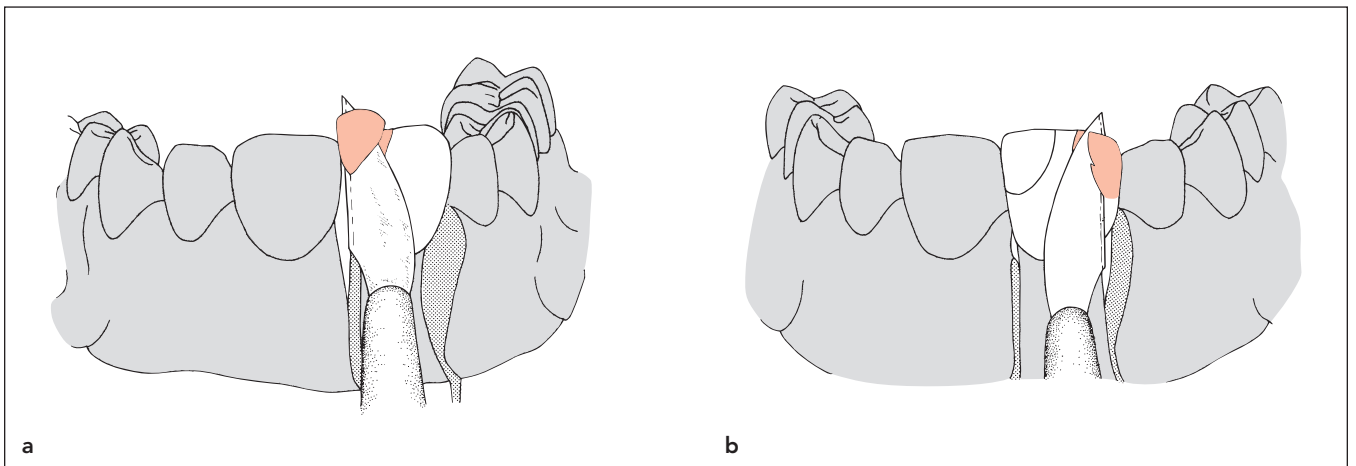


Fig 24-48 (a) The dentin porcelain is cut back to allow placement of the incisal porcelain. (b) The amount and extent are dictated by the translucency pattern desired for the restoration. It could require the removal of nothing more than the corners.

24 Metal-Ceramic Restorations

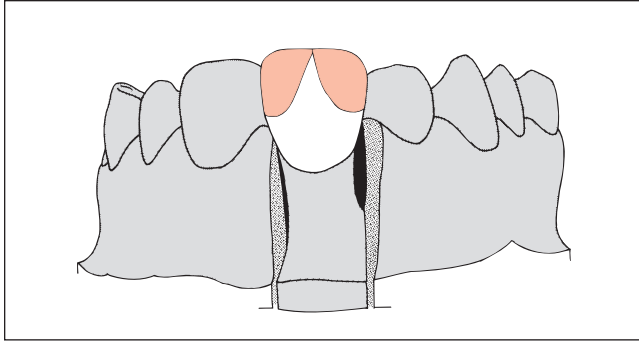


Fig 24-49 Completion of cutback for the incisal porcelain.

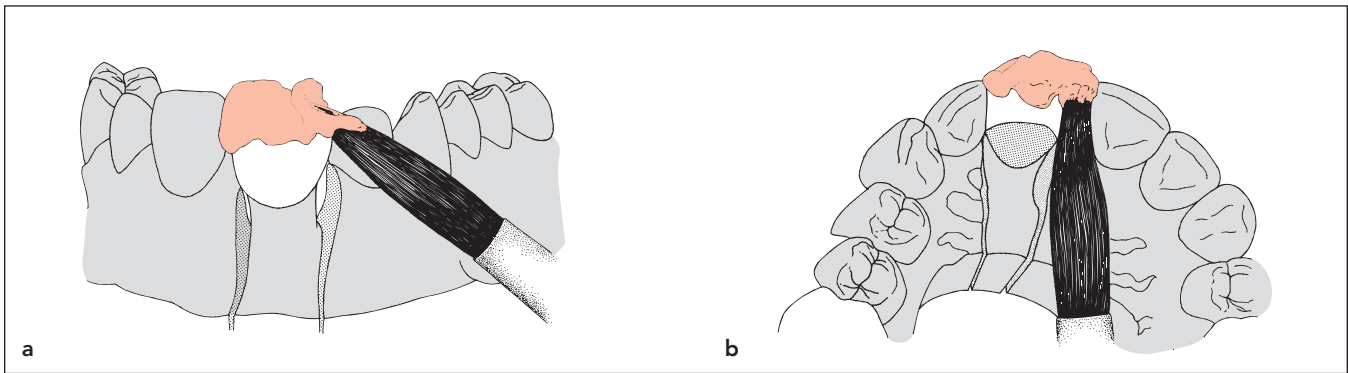


Fig 24-50 Enamel porcelain is added with a brush to the cutback areas: frontal view (a) and incisal view (b).

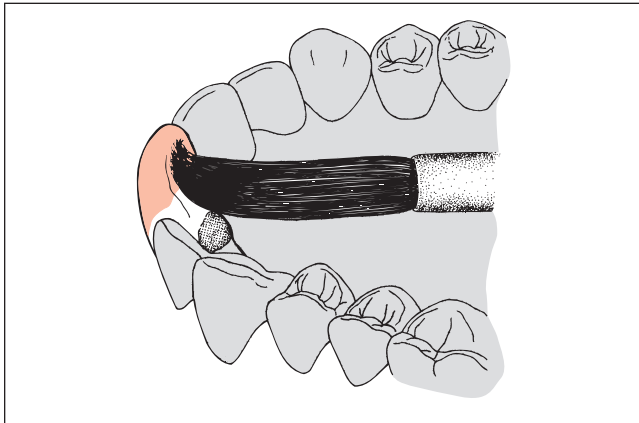


Fig 24-51 The enamel porcelain is carried onto the lingual surface. The lingual fossa is shaped with a brush.

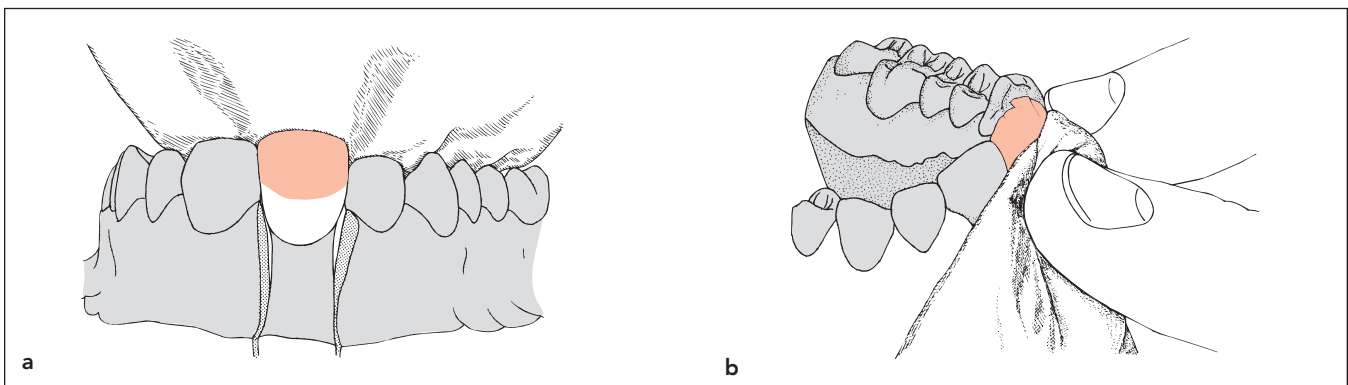


Fig 24-52 The newly added porcelain is shaped by blotting it from the lingual (a) and from the facial (b).

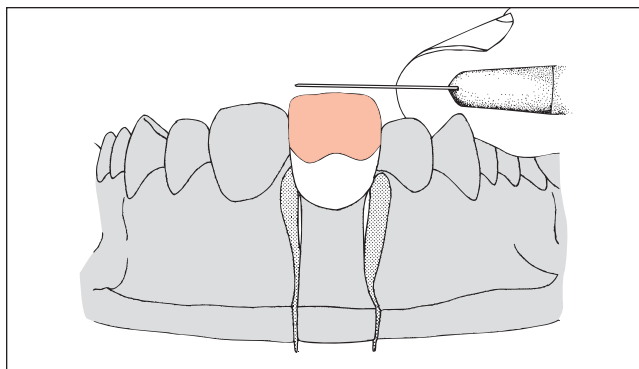


Fig 24-53 The enamel porcelain is slightly overbuilt to compensate for shrinkage during firing.

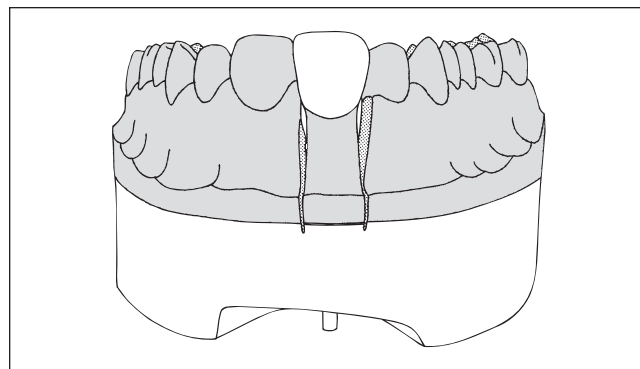


Fig 24-54 Facial view of completed porcelain buildup on the working cast.

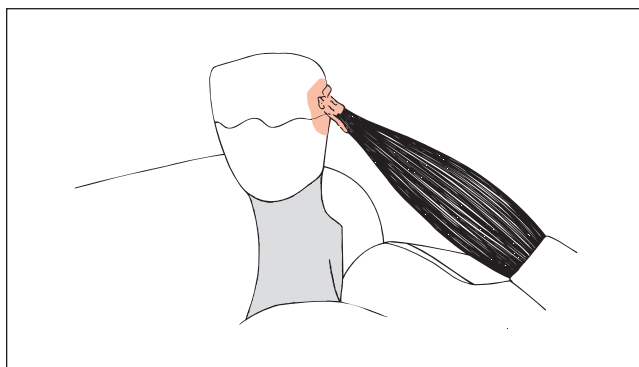


Fig 24-55 The die is removed from the cast, and a small amount of porcelain is added to the two interproximal surfaces.

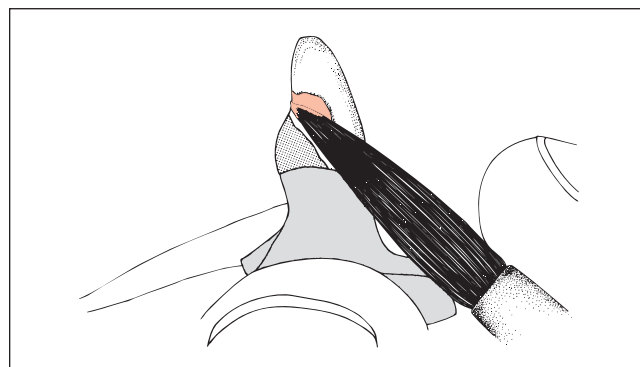


Fig 24-56 The proximal addition is blended into the facial and lingual contours.

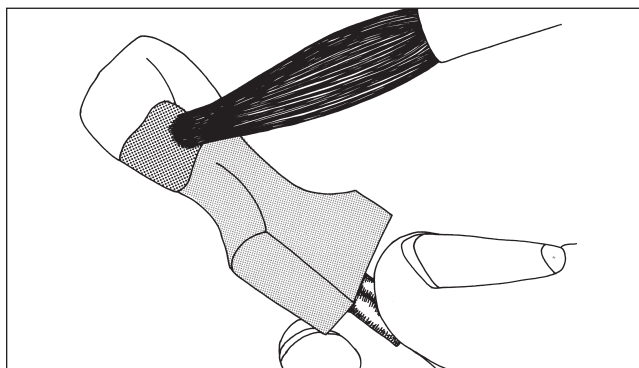


Fig 24-57 Any porcelain that extends onto the metal is removed prior to firing.

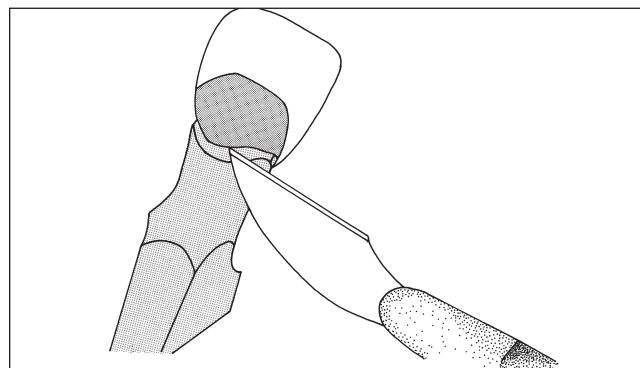


Fig 24-58 The completed crown is carefully removed from the die.

Commercially available porcelains exhibit significant linear firing shrinkage, with a typical central incisor metal-ceramic crown shrinking 0.9 mm at the incisal edge.⁶² When completed, the restoration should be slightly larger incisally to compensate for this shrinkage (Fig 24-53). Overall, the crown should be made about one-fifth larger than the desired size to compensate for the 20% shrinkage that will occur during firing (Fig 24-54).

The restoration is cautiously removed from the working cast, and porcelain is added to the interproximal areas (Fig

24-55). The proximal addition is blended into the surrounding contours of the crown (Fig 24-56). Excess porcelain is removed from the unveneered metal at the porcelain-metal junction (Fig 24-57). The crown is teased off the die by placing the tip of a sharp instrument under the lingual metal margin (Fig 24-58). Any ceramic margin should be avoided while removing the crown.

The condensation is completed by vibrating the forceps while holding the crown with the serrations on a Roach carver (Fig 24-59). Any moisture brought to the surface by this

24 Metal-Ceramic Restorations

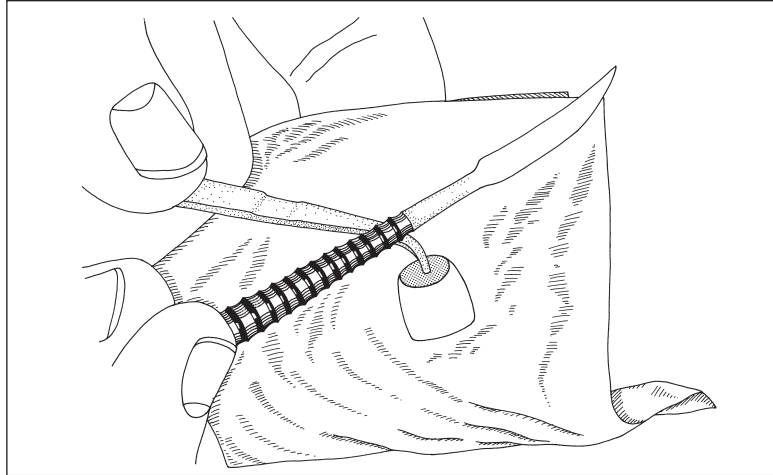


Fig 24-59 The condensation of the porcelain is completed, using a tissue to absorb the excess moisture.

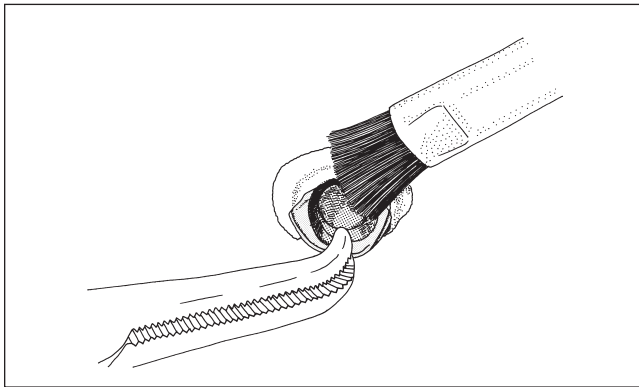


Fig 24-60 Any porcelain that extends inside the crown is removed with a dry brush.

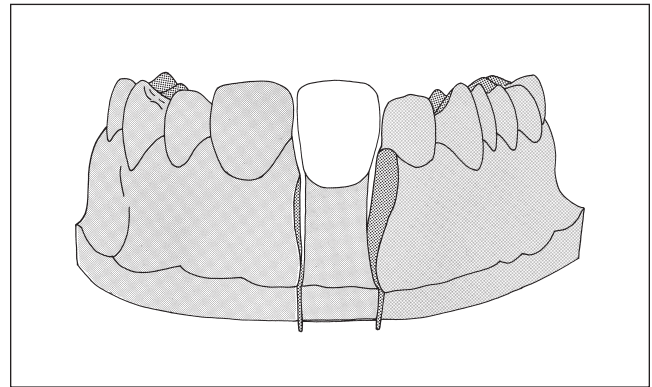


Fig 24-61 After the initial firing, the crown is tried back on the cast, and the contours are evaluated.

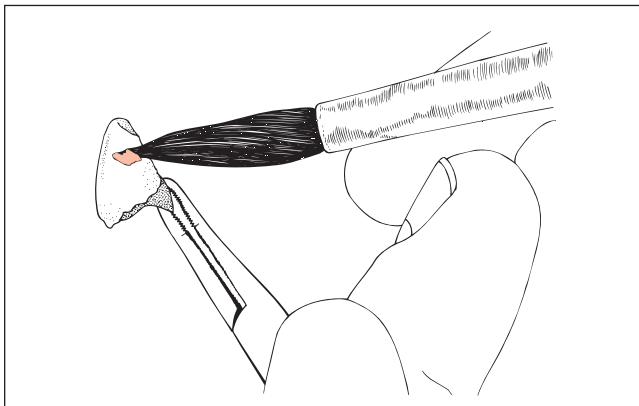


Fig 24-62 A small amount of porcelain is added to the proximal surfaces to restore contact.

process is blotted up. A brush is used to remove any bits of porcelain that may have strayed into the crown (Fig 24-60). The initial buildup is dried in front of the furnace for several minutes, and then it is fired under vacuum and carried to the temperature specified by the manufacturer of that porcelain.

The restoration is tried back on the working cast, and the contours as well as occlusal and proximal contacts are evalu-

ated because these will often require adjustment or additions (Fig 24-61). Insufficient contours can be corrected by adding the appropriate porcelain. The crown is removed from the die and grasped on the unveneered metal in the beaks of a modified mosquito hemostat, which prevents damage to the margin.⁶³ Porcelain is added to the proximal contacts and blended in the contours (Fig 24-62). The restoration is fired

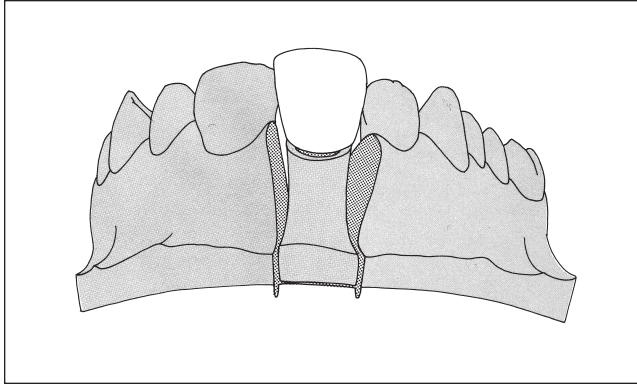


Fig 24-63 Following the correction bake, minor adjustments may be necessary, such as reducing the heavy proximal contact demonstrated here.

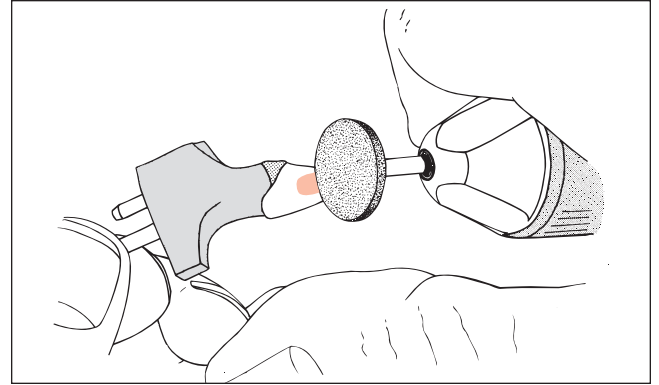


Fig 24-64 A clean green stone or diamond is used to recontour the porcelain.

at a temperature about 10°C to 20°C lower than the initial bake. The higher-fusing porcelain forming the facial margin should not be affected by these subsequent firings.

Following the correction bake, the crown may not seat completely or may have other minor deficiencies (Fig 24-63). Adjustments are made on the porcelain with diamond disks, aluminum oxide stones, or carborundum stones (Fig 24-64).

Porcelain surface treatment

Once the desired contours and occlusion have been achieved, the restoration must receive a surface treatment. Three commonly used treatments include: (1) natural or autoglaze, (2) applied overglaze, and (3) polishing. Commercially available kits of rubberized abrasives and polishing compounds are available to polish porcelain.

Porcelain has the ability to glaze itself when held at its fusing temperature under air for 1 to 4 minutes. Many ceramists prefer this treatment, feeling that it preserves the surface character and texture of the porcelain. Applied overglaze is a low-fusing clear porcelain that is painted on the surface of the restoration and fired at a fusing temperature much lower than the fusing temperature of the dentin and enamel porcelains.

Because porcelain loses its ability to form a natural glaze after multiple firings, an applied overglaze may be indicated on large restorations that have required numerous corrections. However, caution must be exercised not to overfire the porcelain. It may return to a more crystalline state and become milky or cloudy in appearance, a condition known as *devitrification*. Devitrification causes a loss of natural appearance, and no surface treatment can revive the porcelain.

Polishing lends itself to use on relatively small areas of adjustment such as proximal contacts and limited areas of occlusal contact. Traditionally, polished porcelain has been regarded as a rougher surface than glazed porcelain.⁶⁴ However, qualitative and quantitative evaluations of polished

porcelain surfaces indicate that an acceptable surface may be obtained by using a commercially available system (DirectDia paste, Shofu).⁶⁵ Jacobi et al³¹ showed polished porcelain to be less destructive of tooth structure in the opposing arch than glazed porcelain.

Finishing and Cementation

The metal portion is adjusted and finished as described in chapter 21. Ceramic portions are handled much the same as all-ceramic restorations. If the contours or shade will be modified substantially during try-in, the restoration can be left unglazed until after the adjustments are made. If the dental office is equipped with a porcelain furnace, insufficient proximal contacts and marginal gaps or minor shade modifications can be accomplished as an in-office procedure. This is a valuable skill set for the dentist to have because otherwise the restoration must be returned to the laboratory for such corrections.

Shade modification

If the shade of a metal-ceramic crown is too dark (its value too low or chroma too high), it is almost impossible to lighten it by custom staining without making the tooth appear too opaque. However, if it is too light (its value too high or chroma too low), it can be modified. Fracture lines and areas of discoloration also can be simulated to give a more natural appearance.

Porcelain stains used for shade modification and characterizations consist of metal oxide pigments in low-fusing porcelain. These stains are applied to an unglazed surface and fired, either at the same time that an autoglaze or applied glaze is accomplished or as a separate firing to be followed by an applied glaze.

24 Metal-Ceramic Restorations

Chairside correction

With MCRs there are several procedures that can be safely and predictably carried out to either enhance the restoration quality or correct minor imperfections. The simplest procedure is recontouring and subsequently polishing modified areas. Porcelain contouring can be accomplished with clean contouring stones in a high-speed handpiece. It is important that the instrument chosen for porcelain contouring has not been contaminated by use on other materials such as acrylic or metal. Equally critical is that the clinician use a light touch, especially with high-speed instruments. Two enemies of ceramic materials are the heat and vibration that can be generated with heavy-handed adjustment techniques. Excessive heat and vibration can initiate microfractures that may lead to premature failure of the porcelain. Following contouring, the surface can be effectively polished, leaving a smooth surface with a luster rivaling that of a glazed surface.

Another procedure that can be available in-office is the ability to add and fire small increments of porcelain such as for perfecting proximal contacts, occlusal contacts, pontic tissue contact areas, or other minor contour additions. The significant piece of equipment necessary for these procedures is a stain and glaze furnace or porcelain furnace. The ability to fire porcelain opens the door for the dentist to accomplish shade modification and characterization with surface stains as a chairside procedure. While a detailed description of these procedures is outside the scope of this text, these are skills that can be easily learned and incorporated into practice.

References

- Christensen GJ. The use of porcelain-fused-to-metal restorations in current dental practice: A survey. *J Prosthet Dent* 1986;56:1–3.
- Rosenstiel SF, Land MF, Rashid RG. Dentists' molar restoration choices and longevity: A web-based survey. *J Prosthet Dent* 2004;91:363–367.
- Rekow D, Zhang Y, Thompson V. Can material properties predict survival of all-ceramic posterior crowns? *Compend Contin Educ Dent* 2007;28:362–368.
- Sailer I, Pjetursson BE, Zwahlen M, Hämmerle CH. A systematic review of the survival and complication rates of all-ceramic and metal-ceramic reconstructions after an observation period of at least 3 years. Part II: Fixed dental prostheses. *Clin Oral Implants Res* 2007;18(suppl 3):86–96.
- Raigrodski AJ, Chiche GJ, Potiket N, et al. The efficacy of posterior three-unit zirconium-oxide-based ceramic fixed partial dental prostheses: A prospective clinical pilot study. *J Prosthet Dent* 2006;96:237–244.
- Näpänkangas R, Raustia A. An 18-year retrospective analysis of treatment outcomes with metal-ceramic fixed partial dentures. *Int J Prosthodont* 2011;24:314–319.
- Jochen DG, Caputo AA, Matyas J. Effect of metal surface treatment on ceramic bond strength. *J Prosthet Dent* 1986;55:186–188.
- Carpenter MA, Goodkind RJ. Effect of varying surface texture on bond strength of one semiprecious and one nonprecious ceramo-alloy. *J Prosthet Dent* 1979;42:86–95.
- Gavelis JR, Lim SB, Guckes AD, Morency JD, Sozio RB. A comparison of the bond strength of two ceramometal systems. *J Prosthet Dent* 1982;48:424–428.
- McLean JW, Sced IR. Bonding of dental porcelain to metal. I. The gold alloy/porcelain bond. *Trans J Br Ceram Soc* 1973;72:229–233.
- Knap FJ, Ryge G. Study of bond strength of dental porcelain fused to metal. *J Dent Res* 1966;45:1047–1051.
- Anusavice KJ, Horner JA, Fairhurst CW. Adherence controlling elements in ceramic-metal systems. I. Precious alloys. *J Dent Res* 1977;56:1045–1052.
- Von Radnoth MS, Lautenschlager EP. Metal surface changes during porcelain firing. *J Dent Res* 1969;48:321–324.
- Dent RJ, Preston JD, Moffa JP, Caputo A. Effect of oxidation on ceramometal bond strength. *J Prosthet Dent* 1982;47:59–62.
- Vickery RC, Badinelli LA. Nature of attachment forces in porcelain-gold systems. *J Dent Res* 1968;47:683–689.
- Shell JS, Nielson JP. Study of the bond between gold alloys and porcelain. *J Dent Res* 1962;41:1424–1437.
- Phillips RW, Skinner EW. *Skinner's Science of Dental Materials*, ed 9. Philadelphia: Saunders, 1991:505–527.
- Classification system for cast alloys. Council on Dental Materials, Instruments, and Equipment. *J Am Dent Assoc* 1984;109:766.
- Moffa JP, Guckes AD, Okawa MT, Lilly GE. An evaluation of non-precious alloys for use with porcelain veneers. Part II. Industrial safety and biocompatibility. *J Prosthet Dent* 1973;30:432–441.
- Peltonen L. Nickel sensitivity in the general population. *Contact Dermatitis* 1979;5:27–32.
- Kelly JR, Rose TC. Nonprecious alloys for use in fixed prosthodontics: A literature review. *J Prosthet Dent* 1983;49:363–370.
- Tai Y, De Long R, Goodkind RJ, Douglas WH. Leaching of nickel, chromium, and beryllium ions from base metal alloy in an artificial oral environment. *J Prosthet Dent* 1992;68:692–697.
- Wataha JC, Lockwood PE, Messer RL, Lewis JB, Mettenberg DJ. Brushing-induced surface roughness of nickel-, palladium-, and gold-based dental casting alloys. *J Prosthet Dent* 2008;99:455–460.
- Naylor WP. *Introduction to Metal Ceramic Technology*, ed 2. Chicago: Quintessence, 2009:44–49.
- Fisher RM, Moore BK, Swartz ML, Dykema RW. The effects of enamel wear on the metal-porcelain interface. *J Prosthet Dent* 1983;50:627–631.
- Woods JA, Cavazos E Jr. Effects of porcelain-metal junction angulation on porcelain fracture. *J Prosthet Dent* 1985;54:501–503.
- Mumford G. The porcelain fused to metal restoration. *Dent Clin North Am* 1965;23:241–249.
- Weiss PA. New design parameters: Utilizing the properties of nickel-chromium superalloys. *Dent Clin North Am* 1977;21:769–785.
- Monasky GE, Taylor DF. Studies on the wear of porcelain, enamel, and gold. *J Prosthet Dent* 1971;25:299–306.
- Mahalik JA, Knap FJ, Weiter EJ. Occlusal wear in prosthodontics. *J Am Dent Assoc* 1971;82:154–159.
- Jacobi R, Shillingburg HT Jr, Duncanson MG Jr. A comparison of the abrasiveness of six ceramic surfaces and gold. *J Prosthet Dent* 1991;66:303–309.
- Wiley MG. Effects of porcelain on occluding surfaces of restored teeth. *J Prosthet Dent* 1989;61:133–137.
- Craig RG, el-Ebrashi MK, Peyton FA. Stress distribution in porcelain-fused-to-gold crowns and preparations constructed with photoelastic plastics. *J Dent Res* 1971;50:1278–1283.
- Craig RG, el-Ebrashi MK, Farah JW. Stress distribution in photoelastic models of transverse sections of porcelain-fused-to-gold crowns and preparations. *J Dent Res* 1973;52:1060–1064.
- Hobo S, Shillingburg HT Jr. Porcelain fused to metal: Tooth preparation and coping design. *J Prosthet Dent* 1973;30:28–36.
- Marker JC, Goodkind RJ, Gerberich WW. The compressive strength of nonprecious versus precious ceramometal restorations with various frame designs. *J Prosthet Dent* 1986;55:560–567.

37. Weir D, Stoffer W, Irvin D, et al. The stability of crown margin placement vs. time [abstract 1154]. *J Dent Res* 1986;65:297.
38. Waerhaug J. Histologic considerations which govern where the margins of restorations should be located in relation to the gingiva. *Dent Clin North Am* 1960;4:161–176.
39. Silness J. Periodontal conditions in patients treated with dental bridges. III. The relationship between the location of the crown margin and the periodontal condition. *J Periodontal Res* 1970;5:225–229.
40. Silness J. Fixed prosthodontics and periodontal health. *Dent Clin North Am* 1980;24:317–329.
41. Loe H. Reactions of marginal periodontal tissues to restorative procedures. *Int Dent J* 1968;18:759–778.
42. Jalalian E, Jannati H, Mirzaei M. Evaluating the effect of a sloping shoulder and a shoulder bevel on the marginal integrity of porcelain-fused-to-metal (PFM) veneer crowns. *J Contemp Dent Pract* 2008;9(2):17–24.
43. Goodacre CJ, Van Roekel NB, Dykema RW, Ullmann RB. The collarless metal-ceramic crown. *J Prosthet Dent* 1977;38:615–622.
44. Schneider DM, Levi MS, Mori DF. Porcelain shoulder adaptation using direct refractory dies. *J Prosthet Dent* 1976;36:583–587.
45. Sozio RB, Riley EJ. A precision ceramic-metal restoration with a facial butted margin. *J Prosthet Dent* 1977;37:517–521.
46. Toogood GD, Archibald JF. Technique for establishing porcelain margins. *J Prosthet Dent* 1978;40:464–466.
47. Vryonis P. A simplified approach to the complete porcelain margin. *J Prosthet Dent* 1979;42:592–593.
48. Vryonis P. A Manual for the Fabrication of the Complete Porcelain Margin. Adelaide, South Australia: Stock Journal, 1982:27.
49. Kessler JC, Brooks TD, Keenan MP. The direct lift-off technique for constructing porcelain margins. *Quintessence Dent Technol* 1986;10:145–150.
50. Prince J, Donovan T. The esthetic metal-ceramic margin: A comparison of techniques. *J Prosthet Dent* 1983;50:185–192.
51. Belser UC, MacEntee MI, Richter WA. Fit of three porcelain-fused-to-metal marginal designs in vivo: A scanning electron microscope study. *J Prosthet Dent* 1985;53:24–29.
52. Hunt JL, Cruickshanks-Boyd DW, Davies EH. The marginal characteristics of collarless bonded porcelain crowns produced using a separating medium technique. *Quintessence Dent Technol* 1978;2(9):21–26.
53. West AJ, Goodacre CJ, Moore BK, Dykema RW. A comparison of four techniques for fabricating collarless metal-ceramic crowns. *J Prosthet Dent* 1985;54:636–642.
54. Arnold HN, Aquilino SA. Marginal adaptation of porcelain margins in ceramometal restorations. *J Prosthet Dent* 1988;59:409–417.
55. Wanserski DJ, Sobczak KP, Monaco JG, McGivney GP. An analysis of margin adaptation of all-porcelain facial margin ceramometal crowns. *J Prosthet Dent* 1986;56:289–292.
56. Boyle JJ Jr, Naylor WP, Blackman RB. Marginal accuracy of metal ceramic restorations with porcelain facial margins. *J Prosthet Dent* 1993;69:19–27.
57. Brackett SE, Leary JM, Turner KA, Jordan RD. An evaluation of porcelain strength and the effect of surface treatment. *J Prosthet Dent* 1989;61:446–451.
58. Swain VL, Pesun IJ, Hodges JS. The effect of metal ceramic restoration framework design on tooth color. *J Prosthet Dent* 2008;99:468–476.
59. Stein RS, Kuwata M. A dentist and a dental technologist analyze current ceramo-metal procedures. *Dent Clin North Am* 1977;21:729–749.
60. McLean JW. The Science and Art of Dental Ceramics, Vol I. The Nature of Dental Ceramics and Their Clinical Use. Chicago: Quintessence, 1979:71.
61. McLean JW, Hubbard JR, Kedge MI. The Science and Art of Dental Ceramics, Vol II. Bridge Design and Laboratory Procedures in Dental Ceramics. Chicago: Quintessence, 1980:242.
62. Rosenstiel SF. Linear firing shrinkage of metal-ceramic restorations. *Br Dent J* 1987;162:390–392.
63. Brooks TD. Instrumentation that facilitates porcelain restoration construction. *J Prosthet Dent* 1983;49:446.
64. Klausner LH, Cartwright CB, Charbeneau GT. Polished versus autoglaized porcelain surfaces. *J Prosthet Dent* 1982;47:157–162.
65. Goldstein GR, Barnhard BR, Penugonda B. Profilometer, SEM, and visual assessment of porcelain polishing methods. *J Prosthet Dent* 1991;65:627–634.

Pontics and Edentulous Ridges

25

The pontic, or artificial tooth, is the *raison d'être* of a fixed partial denture. Its name is derived from the Latin *pons*, meaning bridge. It is not a simple replacement because placing an exact anatomical replica of the tooth in the space would be hygienically unmanageable. The design of the prosthetic tooth will be dictated by esthetics, function, ease of cleaning, maintenance of healthy tissue on the edentulous ridge, and patient comfort.¹

Pontics may be metal-ceramic, cast metal, or, less commonly today, resin processed to metal (Fig 25-1). Several clinical studies have indicated that all materials used for pontics are tolerated equally, although some inflammation can occur in the gingival tissue in response to any of them.²⁻⁴ Porcelain has been observed to be easily cleanable and hygienic,^{3,4} and many clinicians have advocated glazed porcelain as the preferred, or only, material that should touch the edentulous ridge.⁵⁻¹⁰ Because of the porous nature of resin and the difficulty in maintaining a highly polished surface on it, resins should not be used on pontics near the tissue.¹¹ Glazed or highly polished porcelain and gold with a mirror-like finish are preferred for tissue contact.

Proper design is more important to cleanability and good tissue health than is the choice of materials.¹² The surround-

ing tissues change with the loss of a tooth; therefore, a pontic cannot exactly duplicate the lost tooth. Alveolar resorption and remodeling reshape the edentulous area, rounding over sharp edges and filling the socket itself. If there is trauma or periodontal disease associated with the loss of the tooth, the final healed ridge shape may be an even greater departure from the original configuration. Because some of the supporting tissues are lost when the tooth is removed, and because the pontic lies over the tissue instead of growing from it, modifications must be made in basic tooth morphology to ensure that the pontic will be cleanable and noninjurious to soft tissues.

The contours in the apical half of the facial surface cannot match those of the tooth that originally occupied the space or those of the remaining natural teeth (Fig 25-2). If they do, the facial surface will be too long and will look artificial (Fig 25-3). The pontic must be shortened apically, but it cannot simply be clipped off because the result would be an uncleanable gingivofacial ledge (Fig 25-4). The facial surface must be altered to curve gently from the gingivofacial angle to the middle of the facial surface (Fig 25-5).

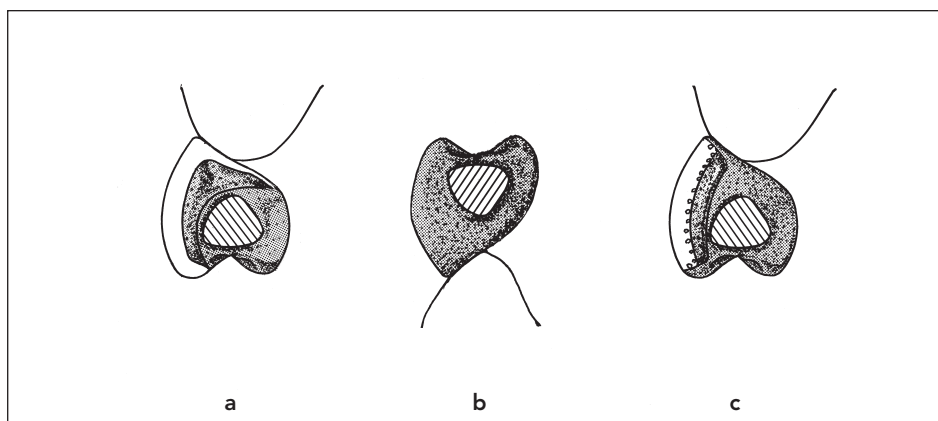


Fig 25-1 Proximal views of metal-ceramic (a), all-metal (b), and resin-processed-to-metal (c) pontics.

25 Pontics and Edentulous Ridges

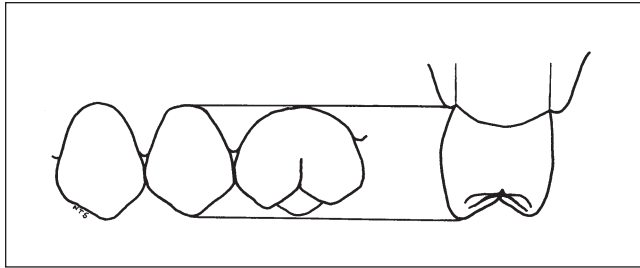


Fig 25-2 Facial (left) and proximal (right) views of the contours of a maxillary second premolar.

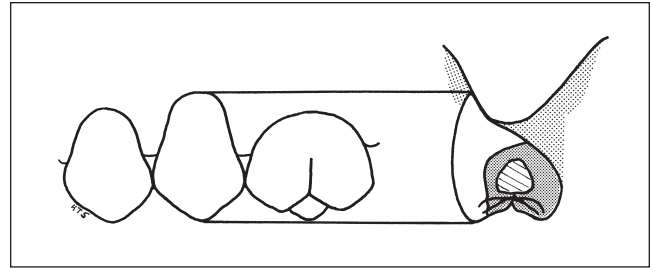


Fig 25-3 Because a ridge resorbs after extraction of a tooth, an attempt to follow the exact contours of the original tooth will result in an elongated pontic. The dotted area shows contours of the tooth and soft tissue before extraction.

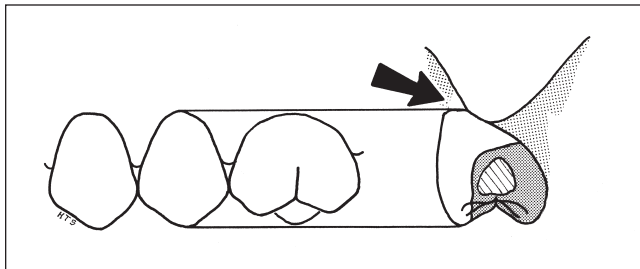


Fig 25-4 Cutting off the apical end of the pontic would solve the length problem, but an unacceptable debris-trapping shelf would result.

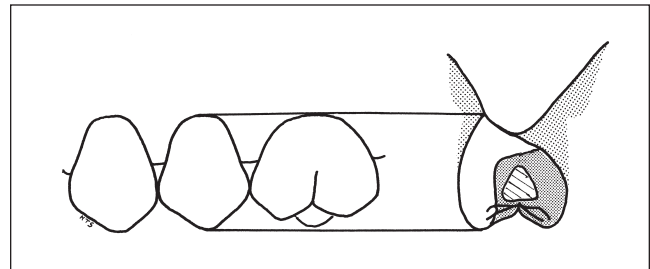


Fig 25-5 Modifying the apical segment of the facial surface will help the pontic blend in without compromising hygiene or esthetics.

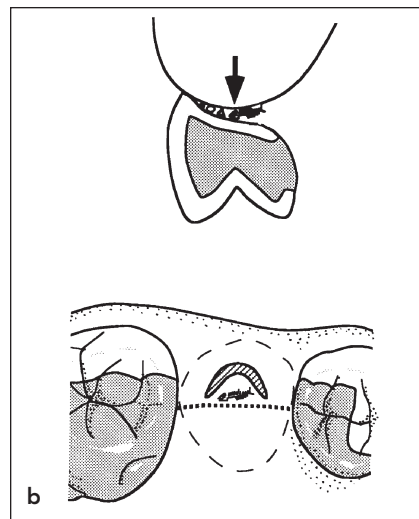
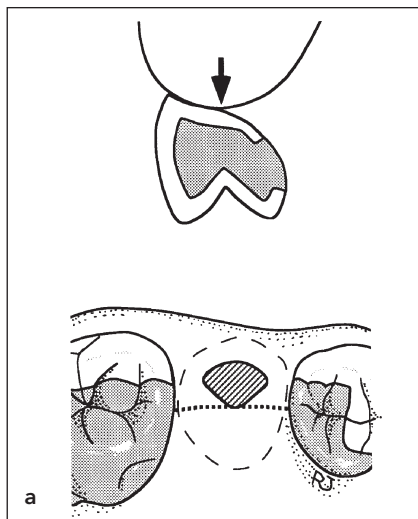


Fig 25-6 (a) Pontic contact with the ridge should be compact, facial to the crest of the ridge, slightly wider mesiodistally at the facial, and narrower at the lingual aspect. (b) Contact with the tissue should not fall just along the gingivofacial line angle; if there is a space between it and the crest, a debris trap will result.

Tissue Contact

The extent and shape of the pontic contact with the ridge is very important. Excessive tissue contact has been cited as a major factor in the failure of fixed partial dentures.⁵ There is widespread agreement that the area of contact between the pontic and the ridge should be small^{2,9,11,13} (Fig 25-6a), and

the portion of the pontic touching the ridge should be as convex as possible.^{2,6,9,14} However, if there is contact along the gingivofacial angle of the pontic, there must be no space between pontic and soft tissue on the facial side of the ridge (Fig 25-6b). If the tip of the pontic extends past the mucogingival junction,¹⁵ an ulcer will form there (Fig 25-7a). The pontic should contact only attached keratinized gingiva^{5,15} (Fig 25-7b).

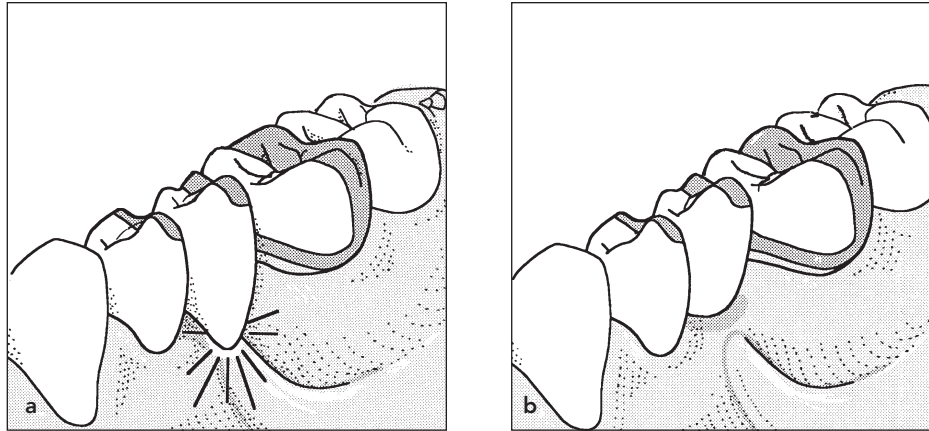


Fig 25-7 (a) If the pontic encroaches on unattached mucosa, an ulcer will form. (b) The tip must be restricted to keratinized gingiva.

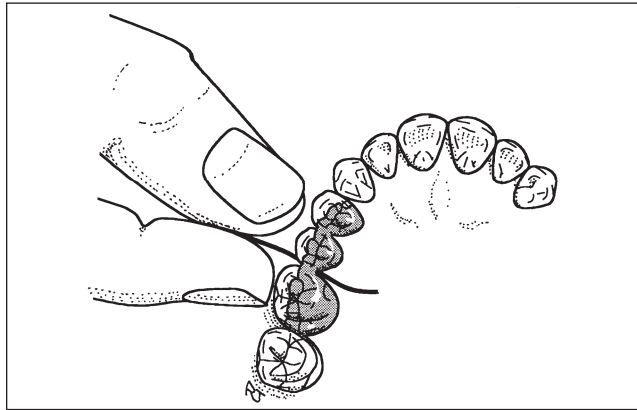


Fig 25-8 Floss is fed through the gingival embrasure and run under the pontics and connectors by the patient. If the space is tight, a monofilament floss threader can be used.

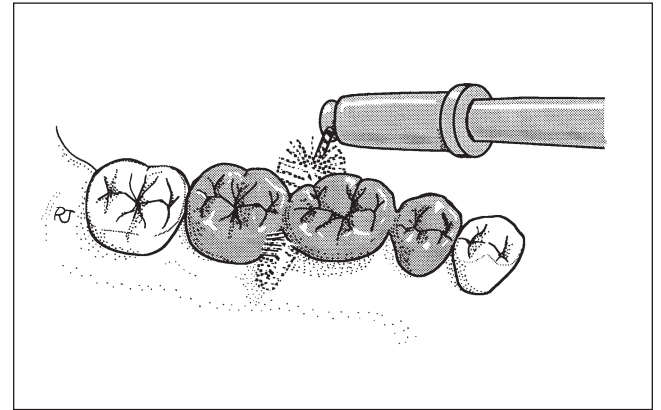


Fig 25-9 Interproximal brushes are excellent for cleaning the gingival embrasures around pontics.

The once-popular practice of scraping the ridge on the cast to obtain close adaptation of the pontic with tissue compression is not indicated because the resultant pressure on the ridge is likely to cause inflammation.⁹ It is generally accepted that the pontic should exert no pressure on the ridge.^{2,3,16} One author has gone so far as to suggest that the contact be with the film of saliva on the ridge.¹³ Others flatly state that the pontic should not contact the tissue at all.^{12,17} However, pontics not contacting the ridge at the time of insertion of a prosthesis may become surrounded by hypertrophied tissue over time in the mouth.¹⁸

Although one study has shown that the tissues under a pontic can be maintained in an inflammation-free state if the patient flosses vigorously at least once a day,¹⁹ there will be an imprint, or "footprint," of the pontic on the ridge even without inflammation. There is an increased risk of clinical failure if success depends too much on a patient's cooperation.

Postinsertion Hygiene

The mesial, distal, and lingual gingival embrasures of the pontic should be wide open to allow the patient easy access for cleaning,^{3,5,12,16,20} and the contact between pontic and tissue must allow the passage of floss from one retainer to the other. After the fixed partial denture is cemented, the patient should be taught appropriate technique(s) that can be mastered. The individual should be motivated to practice good hygiene around and under the pontic with dental floss (Fig 25-8), interproximal brushes (Fig 25-9), or pipe cleaners. The method used will depend on embrasure size, accessibility, and patient skill.

The patient should be given time to learn the techniques and demonstrate the ability to clean the underside of the pontic and the adjacent areas of the abutment teeth. Home care is evaluated at each appointment, and the necessity for

25 Pontics and Edentulous Ridges

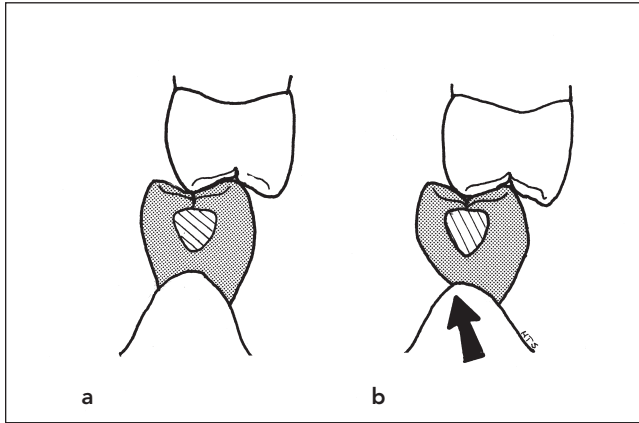


Fig 25-10 (a) A classic saddle or ridge lap pontic. (b) A linguogingival ridge (arrow) or extension past the crest of the ridge, although less severe, still constitutes a saddle.

good hygiene and the skills to accomplish it are reinforced. Even the smoothest pontic surface must be cleaned well and often to prevent the accumulation of plaque.²¹ If cleaning is not done at frequent, regular intervals, the tissue around the pontic will become inflamed.¹⁸

Pontics designed for placement in highly visible areas (called the *esthetic zone* or the *appearance zone* [Richter WA, personal communication, 1973]) must produce the illusion of being teeth, esthetically, without compromising cleanability. Those pontics placed in less visible areas (usually mandibular posterior replacements) are there to restore function and prevent the drifting of teeth. Because esthetics is usually a minor consideration in this area of the mouth, it may not be necessary to utilize materials or contours that suggest the presence of a tooth.

The pontic should be on as straight a line as possible between the retainers to prevent any torquing of the retainers and/or abutments. The pontic will be slightly narrower than the natural tooth, partly because of the effort to place it on the interabutment axis. The pontic may also be somewhat narrower at the expense of the lingual surface in an effort to avoid the formation of an uncleanable, overhanging shelf in the pontic overlying the lingual aspect of the ridge. However, no attempt is made to make the pontic narrower by a set percentage (eg, 10% per pontic). Doing so does not alter the plaque index.¹ Narrowing the pontic is not practical if an effort is being made to maintain occlusal contacts on cusps or in fossae.

Pontic Designs

There are several designs available for use in situations requiring pontics in the fabrication of fixed partial dentures. These include: saddle (ridge lap), modified ridge lap, hygienic, conical, ovate, prefabricated pontic facings, and metal-ceramic pontics.

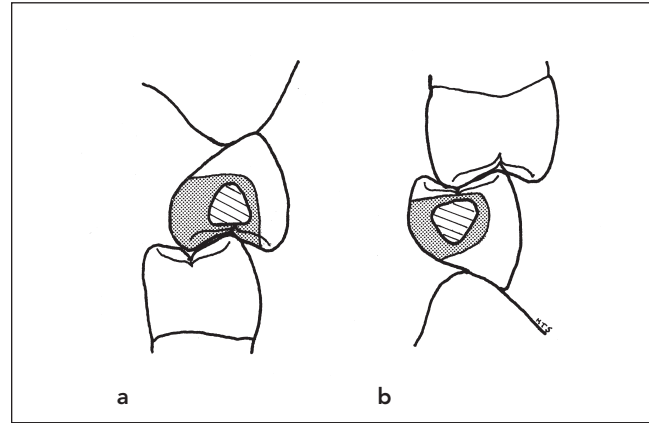


Fig 25-11 Modified ridge lap pontics: (a) maxillary; (b) mandibular.

Saddle

The saddle pontic looks most like a tooth, replacing all the contours of the missing tooth. It forms a large concave contact with the ridge (Fig 25-10a), obliterating the facial, lingual, and proximal embrasures. It is also called a *ridge lap* because it overlaps the facial and lingual aspects of the ridge. A contact with the ridge that extends beyond the midline of the edentulous ridge, or a sharp angle at the linguogingival aspect of the tissue contact, constitutes a ridge lap (Fig 25-10b). This design has long been recognized as being unclean and uncleanable,²² and it still is.^{23,24} The saddle is impossible to clean because floss cannot traverse the tissue-facing area of the pontic, which bridges the linguogingival and faciogingival angles of the pontic. The saddle causes tissue inflammation, and it should not be used.²⁵

Modified ridge lap

The modified ridge lap design gives the illusion of a tooth, but it possesses all or nearly all convex surfaces for ease of cleaning. The lingual surface should have a slight deflective contour to prevent food impaction and minimize plaque accumulation.¹⁴ There may be a slight faciolingual concavity on the facial side of the ridge, which can be cleaned and tolerated by the tissue as long as the tissue contact is narrow mesiodistally and faciolingually.

Ridge contact must extend no farther lingually than the midline of the edentulous ridge, even on posterior teeth. Whenever possible, the contour of the tissue-contacting area of the pontic should be convex, even if a small amount of soft tissue on the ridge must be surgically removed to facilitate it. This design, with a porcelain veneer, is the most commonly used pontic design in the esthetic zone for both maxillary and mandibular fixed partial dentures (Fig 25-11).

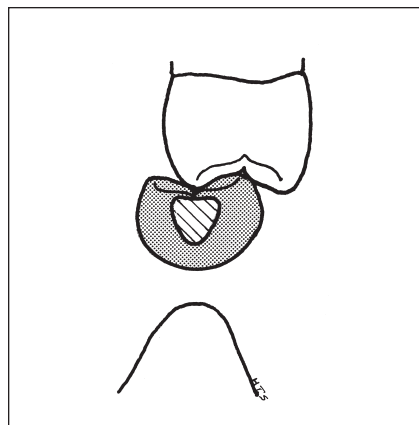


Fig 25-12 Hygienic or sanitary pontic.

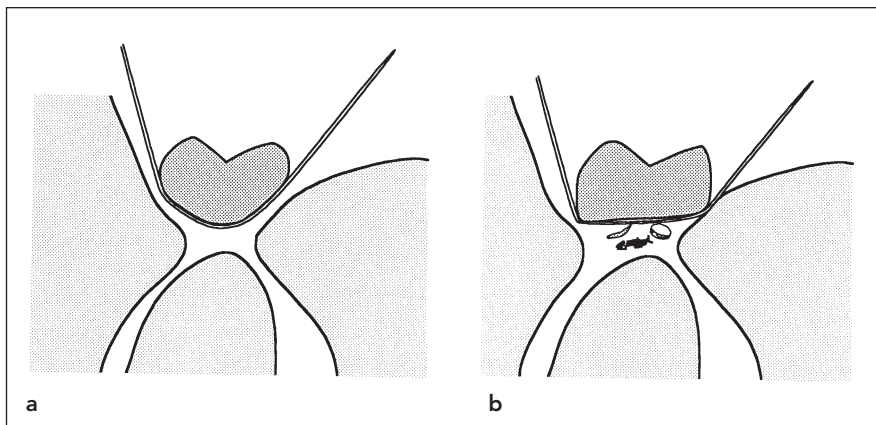


Fig 25-13 Floss passes over a smooth, round surface (a) more easily than over a flat surface and sharp angles (b).

Hygienic

The term *hygienic* is used to describe pontics that have no contact with the edentulous ridge (Fig 25-12). This pontic design is frequently called a “sanitary pontic,” which in years past was the trade name for a prefabricated, convex facing with a slot back, used for mandibular molar pontics.

The hygienic pontic is used in areas that are not easily visible, particularly for replacing mandibular first molars. It restores occlusal function and stabilizes adjacent and opposing teeth. If there is no requirement for esthetics, it can be made entirely of metal. The occlusogingival thickness of the pontic should be no less than 3.0 mm, and there should be adequate space under it to facilitate cleaning. The hygienic pontic is frequently made in an all-convex configuration, faciolingually and mesiodistally.

Making the undersurface of the pontic round without angles allows for easier flossing (Fig 25-13a). It is more difficult to get floss to pass over a flat undersurface evenly or to get over sharp faciogingival and linguogingival line angles (Fig 25-13b). The round design has been described as a “fish belly” (Fig 25-14a).

An alternative design, in which the pontic is made in the form of a concave archway mesiodistally (Fig 25-14b), has been suggested. The undersurface of the pontic is convex faciolingually, giving the tissue-facing surface of the pontic the configuration of a hyperbolic paraboloid. There is added bulk for strength in the connectors, and access for cleaning is good.²⁶ Stress is reduced significantly in the connectors, and deflection is diminished in the center of the pontic, with less gold used.²⁷ An esthetic version of this pontic can be created by veneering with porcelain those parts of the pontic that are likely to be visible: the occlusal surface and the occlusal half of the facial surface, which happens to be all of the facial surface on this pontic. This design has been called an *arc-fixed partial denture*,²³ a *modified sanitary pontic*,²⁷ or simply a *Perel pontic*.

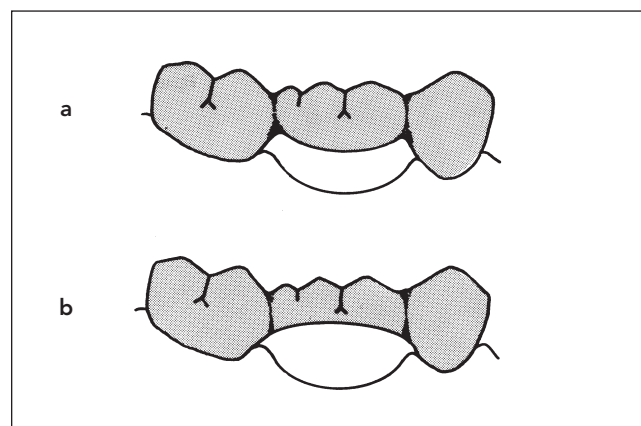


Fig 25-14 Facial view of hygienic, or sanitary, pontics: (a) conventional (“fish belly”); (b) modified (Perel).

Conical

The conical pontic is rounded and cleanable, but the tip is small in relation to the overall size of the pontic. It is well suited for use on a thin mandibular ridge (Fig 25-15a). However, when used with a broad, flat ridge, the resulting large triangular embrasure spaces around the tissue contact have a tendency to collect debris¹⁰ (Fig 25-15b). This pontic is related to the “sanitary dummy” described by Tinker in 1918.²⁸ Its use is limited to replacement of teeth over thin ridges in areas that are not highly visible.

Ovate

The ovate pontic is a round-end design currently in use where esthetics is a primary concern.²⁵ Its antecedent was the porcelain root-tipped pontic,^{22,28–32} which was used con-

25 Pontics and Edentulous Ridges

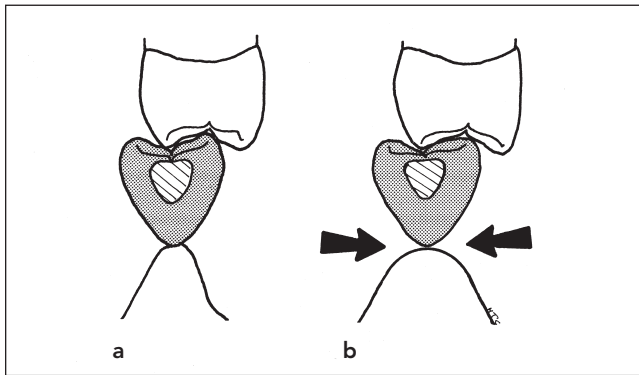


Fig 25-15 Conical pontic used correctly with a thin ridge (a) and incorrectly with a broad, flat ridge (b). The arrows indicate debris-trapping embrasure spaces.

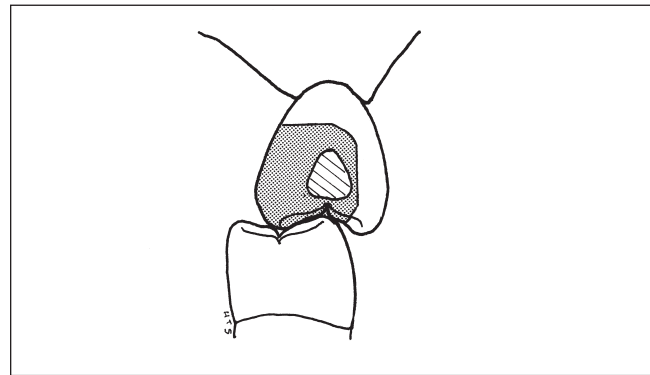


Fig 25-16 The round-end ovate pontic fits into a depression in the ridge.

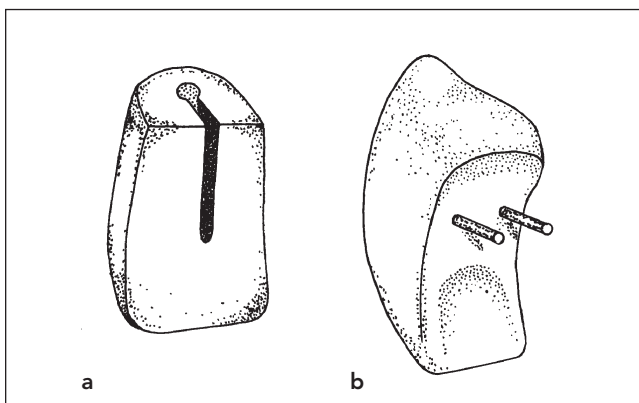


Fig 25-17 Prefabricated facings: (a) slot-back; (b) Harmony pin facing.

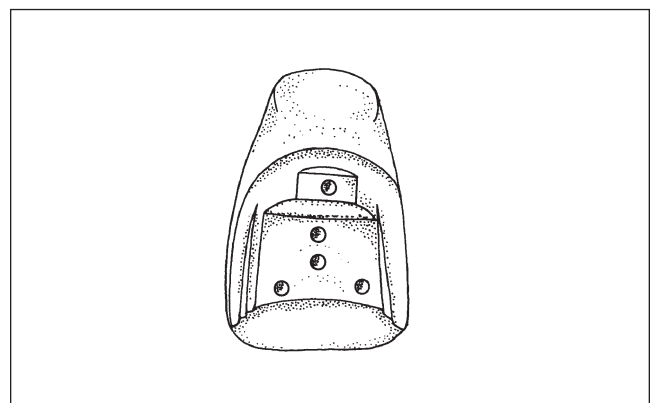


Fig 25-18 Reverse pin facing made from a denture tooth.

siderably before 1930 as an esthetic and sanitary substitute for the saddle pontic. The tissue-contacting segment of the ovate pontic is bluntly rounded, and it is set into a concavity in the ridge (Fig 25-16). It is easily flossed. The concavity can be created by placement of a provisional fixed partial denture with the pontic extending one-quarter of the way into the socket immediately after extraction of the tooth. It also can be created surgically at some later time.²⁵ This pontic works well with a broad, flat ridge, giving the appearance that it is growing from the ridge.

Prefabricated pontic facings

Historically, preformed porcelain facings were popular for fabricating pontics.⁷ They required adaptation to a specific edentulous space,^{16,33} after which they were reglazed. Some, such as Trupontics, Sanitary Pontics, and Steele's Facings (Franklin Dental), relied on a lug in a custom cast metal backing to engage a slot in the occlusal or lingual surface of the facing (Fig 25-17a). The large bulk of porcelain could result in a thin gold backing susceptible to flexing. Harmony (Harmony Dental) and Trubyte (Dentsply) facings used horizontal pins that fit into the gold backing (Fig 25-17b). They were

difficult to use in patients with limited occlusogingival space, and refitting the pins into a backing after casting was demanding.

Porcelain denture teeth also were modified to use as pontic facings. Multiple pinholes 2.0 mm deep were made with a drill press in the lingual surface of the reverse pin facing³³ (Fig 25-18). The pins protruded from the backing, providing retention where a deep overbite would have overshortened conventional pins. Unfortunately, the pinholes in the facing were stress points that led to fracture.

Metal-ceramic pontics

With the widespread use of metal-ceramic restorations, metal-ceramic pontics have replaced other types of pontics employing porcelain. Metal-ceramic pontics have the greatest esthetic potential as prosthetic replacements for missing teeth.³⁴ Additionally, metal-ceramic pontics are stronger because the porcelain is bonded to the metal substrate rather than cemented to it. They are easier to use because the backing is custom made for a space (no need to adapt a premade porcelain facing to the space).

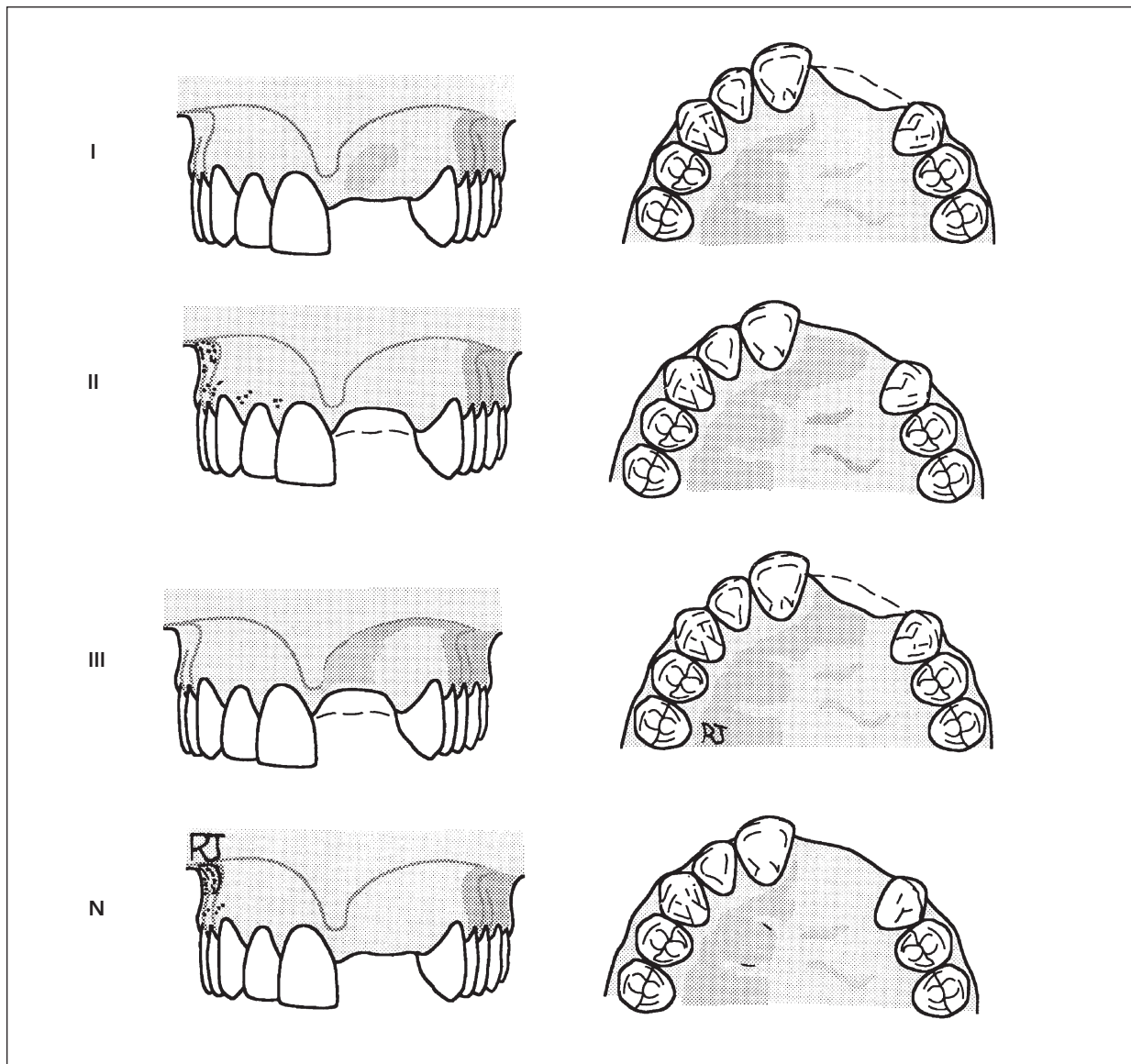


Fig 25-19 The three types of ridge deformities described by Seibert³⁵ (I to III) plus the normal category (N).

The Edentulous Ridge

Before a fixed partial denture is undertaken, the edentulous ridge should be examined carefully. The type and amount of destruction that has occurred will play a role in selecting the pontic to be used and also may indicate the necessity for reshaping the ridge surgically.

Classification

Ridge deformities have been grouped into three categories by Seibert³⁵ (Fig 25-19), and this classification has been widely accepted^{11,36}:

- Class I: Loss of faciolingual ridge width with normal apico-coronal height
- Class II: Loss of ridge height with normal width
- Class III: Loss of both ridge width and height

If a "normal" classification (Class N) with minimal deformity is added, there are four classes of ridge contours. In a study of 416 diagnostic casts, Abrams et al³⁷ showed Class I defects to constitute 32.4% of the edentulous ridges, with 2.9% being Class II, 55.9% being Class III, and only 8.8% having no defects.

25 Pontics and Edentulous Ridges

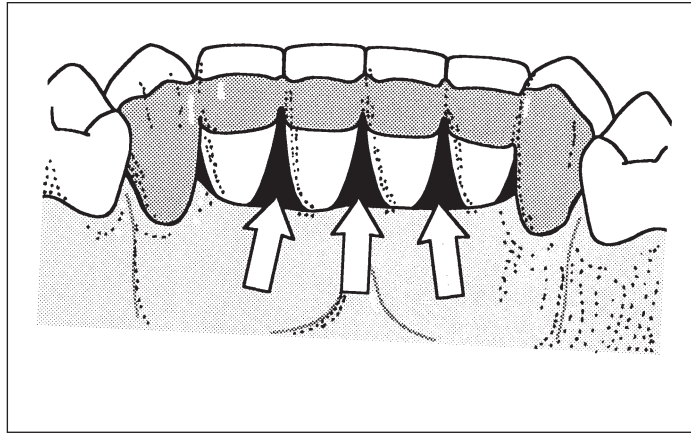


Fig 25-20 Lingual view of open gingival embrasures (ie, black triangles, arrows) on a fixed partial denture replacing mandibular incisors.

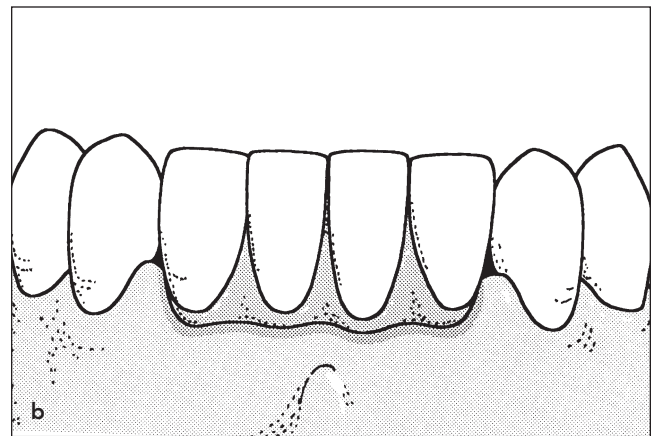
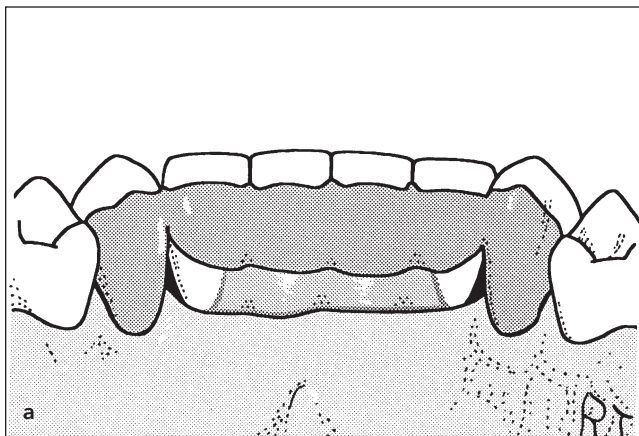


Fig 25-21 Lingual (a) and facial (b) views of a fixed partial denture with embrasures filled with pink porcelain. This is esthetic as long as the patient does not show the porcelain-gingiva junction.

Pontic modification

At one time, it was common to modify a pontic to fit an edentulous space, no matter what the esthetic consequences were. Developments in surgical techniques have made it simpler to change the configuration of a ridge to create a more esthetic and easily cleanable shape. It has become more common to modify the ridge than to suffer the rigors of "making do" with a deficient ridge.

There are nonetheless situations in which a more conservative approach may be desired. The patient's inability to undergo surgery, or an unwillingness to consider it, will force the consideration of an alternative form of pontic. In ridges with severe defects, where two or more pontics must be used to fill the space, it is not uncommon to eliminate gingival embrasure spaces between the pontics.

So-called black triangles can be very unesthetic (Fig 25-20), and they serve no useful purpose. They collect plaque, interfere with the passage of floss, and may reduce the rigidity of the pontic span.^{38,39} Pink porcelain can be added to the gingival embrasure area of the pontic to simulate interdental papilla^{40,41} (Fig 25-21), although the shade rarely matches the particular hue of the patient's gingiva. The gingival extension of porcelain must be supported by the metal framework. If not, all of the gingival porcelain, as well as much of the facial porcelain, is at risk of fracturing.⁴² Elimination of interpontic gingival embrasures in a multitooth pontic may limit or eliminate soft tissue proliferation.⁴³

Embrasure spaces filled with porcelain can be satisfactory when replacing mandibular molars³⁸ and mandibular incisors,^{39,42} where the gingival area is not subject to close scrutiny. However, it is more difficult to achieve an esthetic result

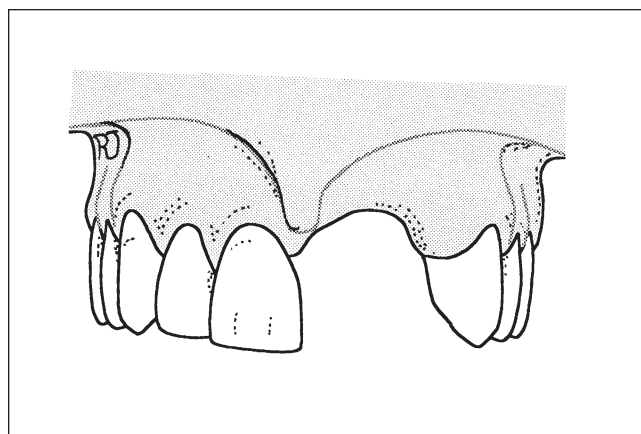


Fig 25-22 This large ridge defect in the maxillary anterior region is not a good candidate for pontic modification.

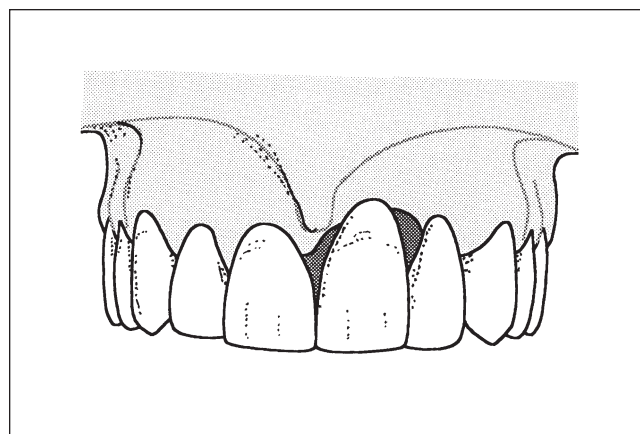


Fig 25-23 An ordinary pontic in this defect space will result in an elongated pontic with large, highly visible embrasures.

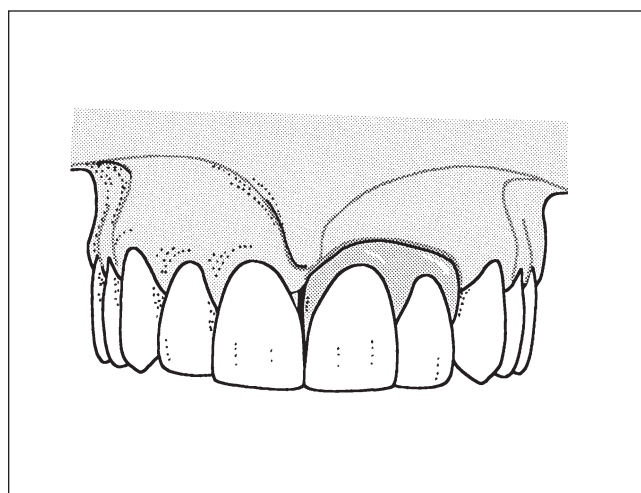


Fig 25-24 Modification of the pontic with pink porcelain in this situation would be conspicuous.

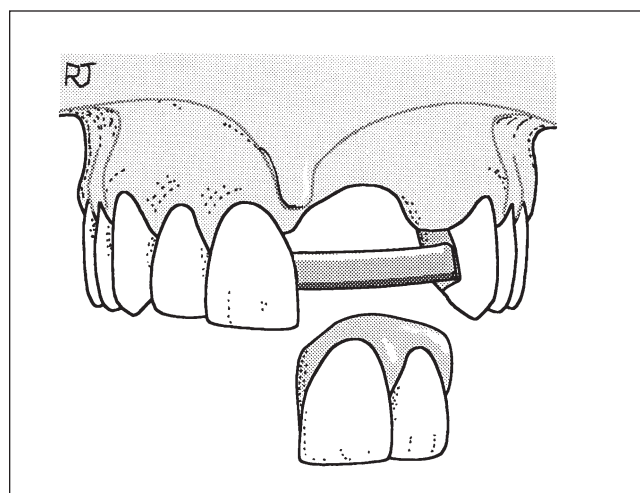


Fig 25-25 In some cases, larger anterior defects may be better managed by an Andrews bridge system with a removable acrylic insert that clamps down over a bar linking the abutments.

simply by modification of the embrasure spaces in a high-profile area such as the maxillary incisor region (Fig 25-22). In the presence of a large deformity, an unmodified pontic would leave large, unsightly gingival embrasures (Fig 25-23), and the addition of a gingival flange may be too conspicuous (Fig 25-24).

One solution used in the restoration of large ridge defects, particularly in the anterior segment, is the Andrews bridge system.⁴⁴ It uses fixed retainers that are connected by a rectangular bar that follows the curve of the ridge under it (Fig 25-25). The prosthesis consists of teeth set in a patient-removable flange of gingiva-colored acrylic resin that clips over and is stabilized by the rectangular bar. Unfortunately, the flange is a food and plaque trap that is difficult to keep clean. In spite of its drawbacks, it still may be the best way of handling some large ridge defects.⁴⁴

Surgical correction

Ridge augmentation can be accomplished by the addition of soft or hard tissue, although filling a ridge defect with bone is not essential unless the ridge is to be used for implants.⁴⁵ Excellent esthetic results in Class I defects can be obtained by connective tissue plastic surgery⁴⁶ in the form of a subepithelial or submucosal connective tissue graft.^{46,47}

The technique for a connective tissue graft is based on procedures described by Langer and Calagna⁴⁷ and Kaldahl et al.⁴⁶ A horizontal incision is made on the palate 1.0 mm apical to the free gingival margin of the molars. The length of the incision is dependent on the size of the defect being repaired. Vertical releasing incisions are made at both ends of the incision to allow the reflection of a split-thickness flap from the underlying connective tissue. The connective tissue

25 Pontics and Edentulous Ridges

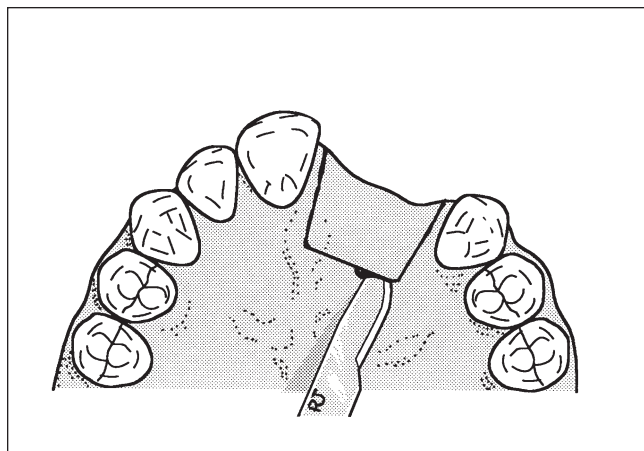


Fig 25-26 Incisions for flap to allow ridge augmentation.

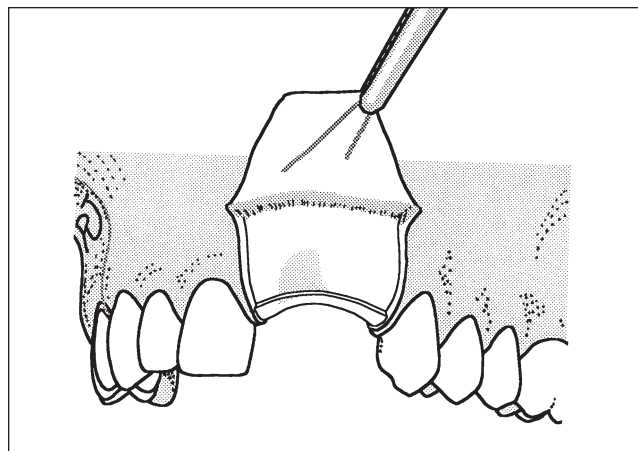


Fig 25-27 Reflection of flap.

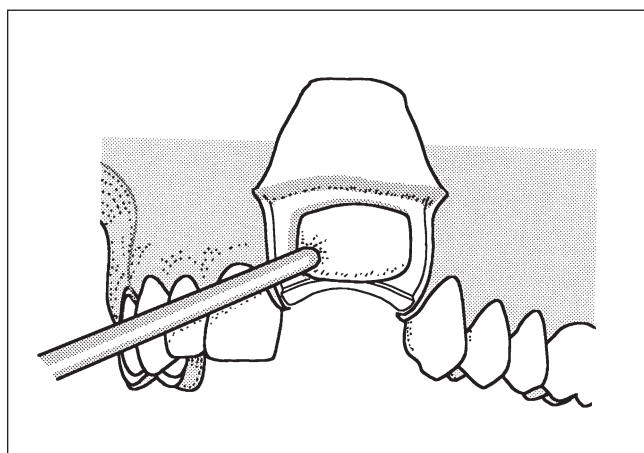


Fig 25-28 Donor tissue is placed at the base of the flap.

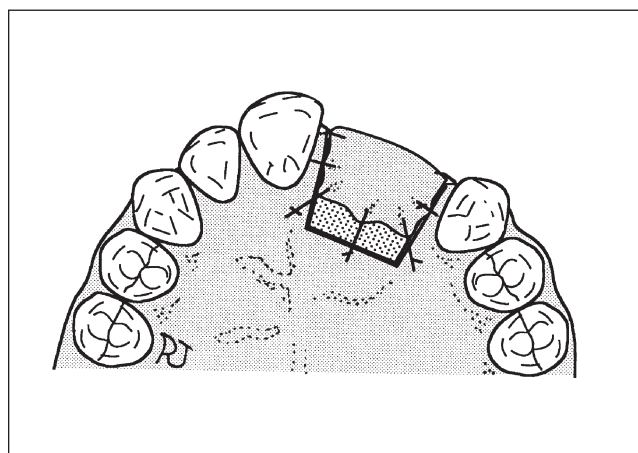


Fig 25-29 The flap is sutured, stabilizing the material in place.

base is dissected from the flap and removed for later use as the donor material. The incision is then sutured.

Incisions are made 1.0 mm on either side of the defect in the edentulous ridge. An incision paralleling the crest of the ridge joins them (Fig 25-26). A partial-thickness pedicle flap is dissected to a depth of 1.5 to 2.0 mm in the palatal area. On the facial it can remain a partial-thickness flap,⁴⁶ or it can become a full-thickness flap⁴⁷ (Fig 25-27). The donor tissue is placed into the defect under the base of the flap on the facial side of the ridge (Fig 25-28) until the defect is filled. The flap is sutured, stabilizing the donor material in position (Fig 25-29).

Unfortunately, apicocoronal Class II and Class III defects cannot be adequately treated by a pouch type of ridge augmentation. These types of defects are better treated using an onlay graft, which Seibert describes as a *thick free gingival graft*.^{44,48} The surface of the edentulous ridge is planed with a no. 15 scalpel blade to remove as much epithelium as possible (Fig 25-30), followed by parallel striations cut into the exposed lamina propria 1.0 mm apart and perpendicular to the curvature of the alveolar ridge³⁵ (Fig 25-31).

These cuts create bleeding, which greatly improves the adaptation of the graft to the ridge. The anesthetic used for the procedure should provide minimal vasoconstriction and be delivered as far from the surgical site as possible so as not to interfere with bleeding. The full-thickness donor tissue is harvested from the gingival zone or the palatal area of the tuberosity. The more fatty tissue that is included, the more the graft will shrink over time as the tissue is resorbed.

The premolar/first molar vault area is an excellent donor source. It provides the greatest volume, and the gingiva there is pliable and easily adapted.⁴⁹ The graft is placed over the prepared area and sutured in place (Fig 25-32). The procedure is limited by donor site availability. Ridges with severe defects may require more than one surgery, with 8 weeks allowed between the procedures.^{11,48} The patient should be forewarned of this possibility before the first surgery. After the graft has healed (Fig 25-33), the definitive fixed partial denture can be fabricated with a natural-looking pontic (Fig 25-34).

If the facial contour of a ridge has a convex shape or irregularities that will prevent the use of a convex pontic,

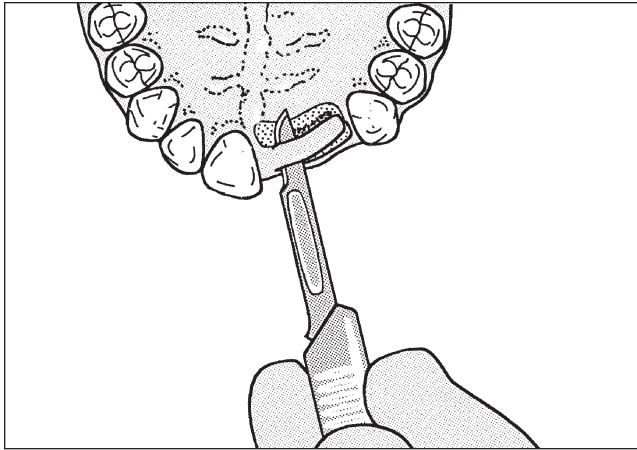


Fig 25-30 As much epithelium as possible is planed off from the crest of the ridge.

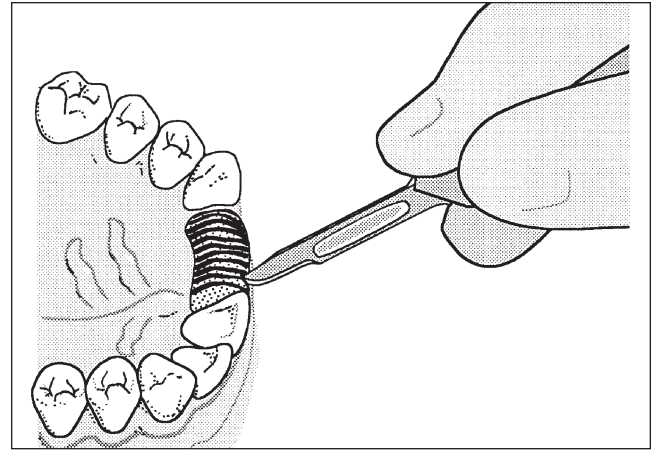


Fig 25-31 Striations are cut in the ridge to encourage bleeding.

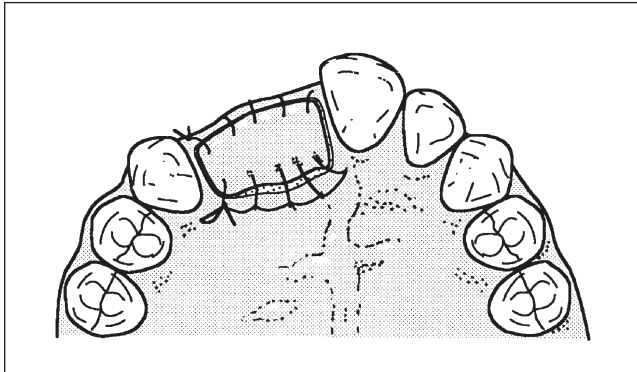


Fig 25-32 The onlay graft is sutured over the prepared area on the ridge.

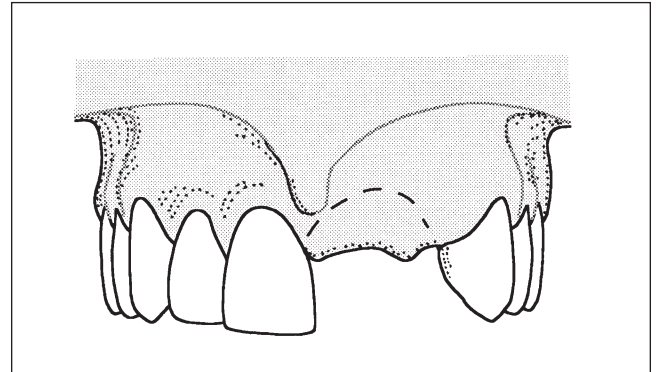


Fig 25-33 The healed, augmented ridge. It may be necessary to do more than one surgical procedure to achieve the desired contour in the ridge.

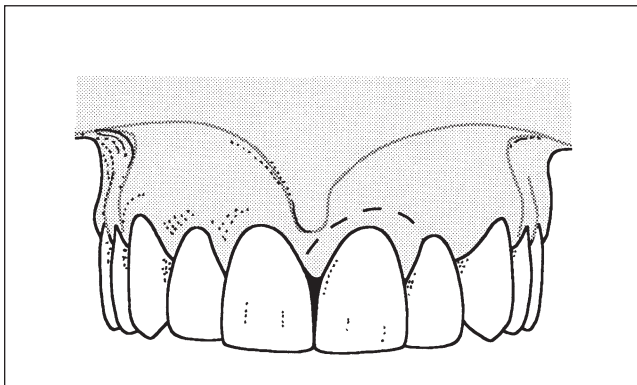


Fig 25-34 Pontics over the surgically enhanced ridge should have a natural appearance.

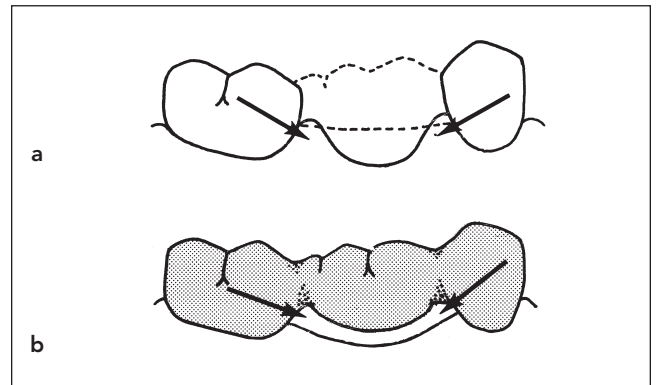


Fig 25-35 Excessive gingival tissue (arrows) adjacent to the edentulous space (a) is removed by electrosurgery before the fixed partial denture is made (b).

the soft tissue may be recontoured surgically to provide an easily cleanable and esthetic pontic. Another problem frequently encountered is a large "cuff" of tissue adjacent to the edentulous space. If left there, this tissue will force the connectors to be made too small occlusogingivally and will

probably result in uncleanable embrasures under the solder joints after the fixed partial denture is seated (Fig 25-35a). This roll of gingival tissue should be removed before the impressions are made for fabrication of the fixed partial denture (Fig 25-35b).

25 Pontics and Edentulous Ridges

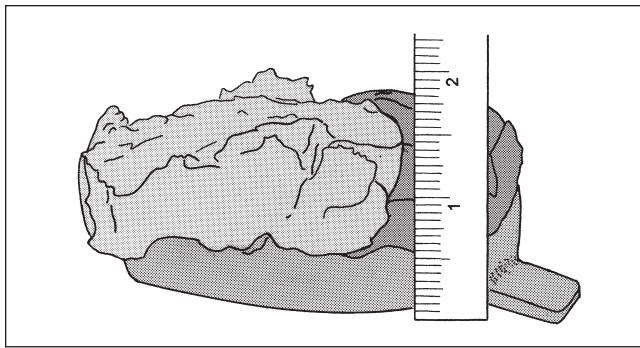


Fig 25-36 Full-arch impression poured to a thickness of approximately 1.5 inches.

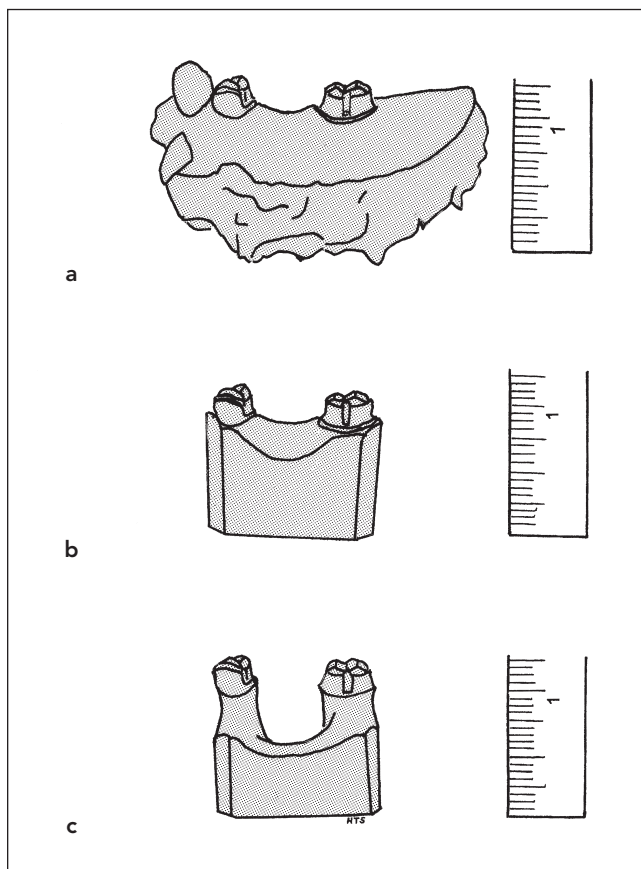


Fig 25-37 (a) An untrimmed die should measure approximately 1.25 inches from preparation to base. (b) Everything but the prepared teeth is trimmed from the poured cast. (c) The edentulous segment between preparations is reduced to allow access to finish lines from an apical direction.

Pontic Fabrication

Following are the techniques for waxing (1) an all-metal mandibular posterior fixed partial denture with a hygienic pontic and (2) a metal-ceramic maxillary posterior fixed partial denture³³ with a modified ridge lap pontic.

Armamentarium

- Sable brush
- Plaster bowl
- Spatula
- Quick-setting plaster
- Bunsen burner and matches
- P. K. Thomas (PKT) waxing instruments (nos. 1 to 5) (Osung)
- Beavertail burnisher
- No. 7 wax spatula
- Inlay casting wax
- Die lubricant
- Zinc stearate
- Cotton pliers
- Hollow plastic sprue

All-metal hygienic pontic fabrication

The full-arch impression is poured, filling the prepared teeth and one tooth on either side of them to a height of 3.8 cm (1.5 inches) off the tabletop (Fig 25-36). The die is trimmed to an overall height of about 3.2 cm (1.25 inches). The dies are left attached with a common base, which will retain the exact relationship of the two preparations. The stone is trimmed away 1.2 cm (0.5 inch) apical to the finish line (Fig 25-37) to produce a U-shaped die. The dies are coated with cement spacer and lubricant.

Wax is placed on the lubricated dies; to accomplish this, the dies can be dipped in a small container of molten wax (Fig 25-38), or dollops of wax can be added with the large end of a no. 7 wax spatula (Fig 25-39). A warm beavertail burnisher is used to trim off excess wax beyond the retainer margins on the die (Fig 25-40). The wax patterns are placed on the working cast, and axial contours are corrected as needed (Fig 25-41). The retainer patterns are replaced onto the die and connected with a short stick of inlay wax (Fig 25-42).

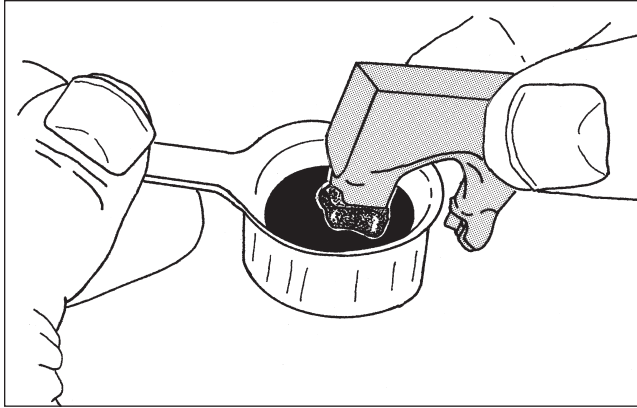


Fig 25-38 The wax coping can be started by dipping the die into molten wax.

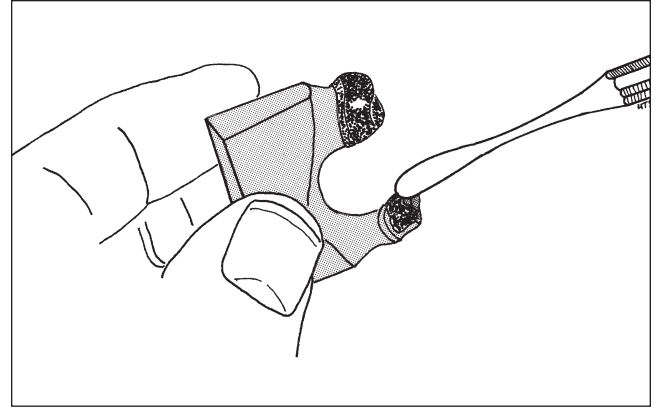


Fig 25-39 The coping can also be started by adding wax with the wide end of a no. 7 wax spatula.

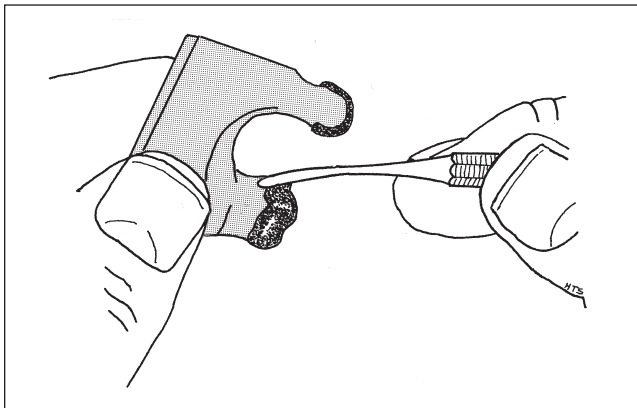


Fig 25-40 Excess wax beyond the finish lines is removed with a warm beavertail burnisher.

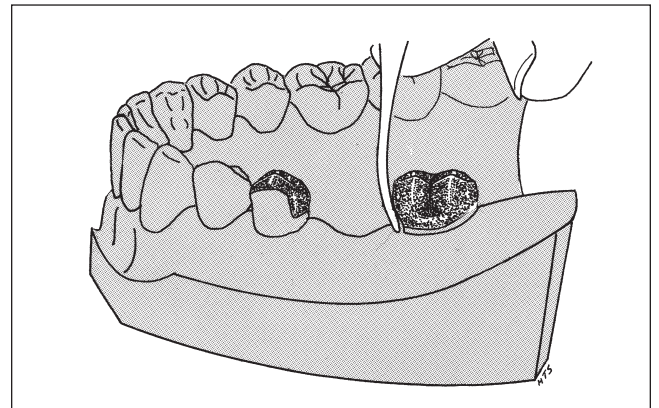


Fig 25-41 Axial contours are adjusted on the working cast.

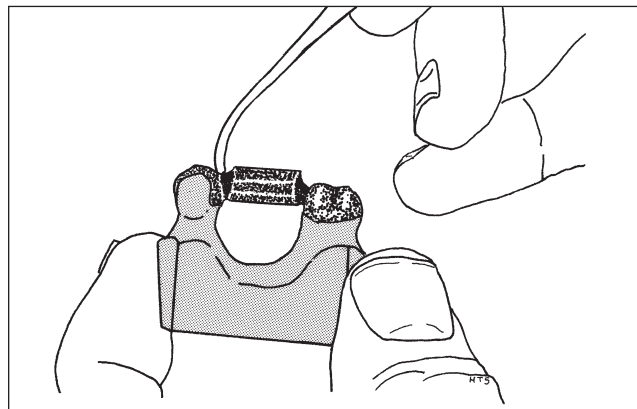


Fig 25-42 A stick of inlay wax is attached to the retainer wax patterns.

25 Pontics and Edentulous Ridges

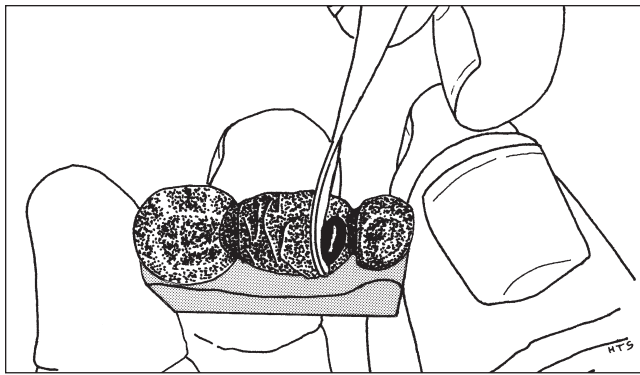


Fig 25-43 Excess wax is removed from the occlusal aspect of the stick of wax with a hot beavertail burnisher.

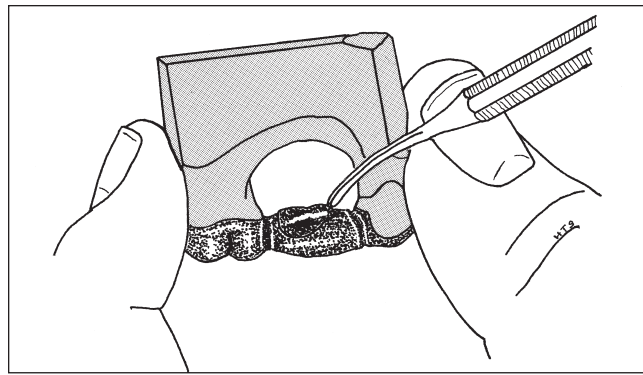


Fig 25-44 Wax removed in the previous step is added to the underside of the pontic.

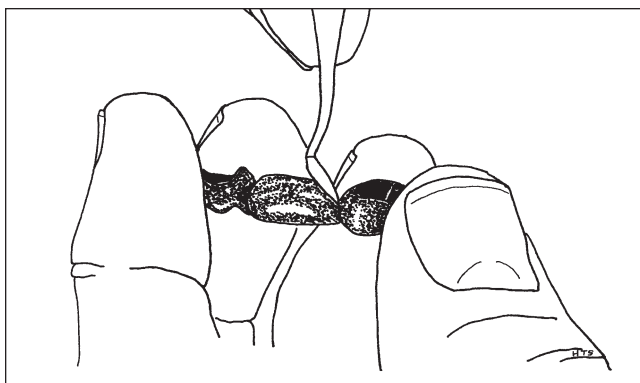


Fig 25-45 A PKT no. 4 is used to define the gingival embrasure and smooth the undersurface of the pontic.

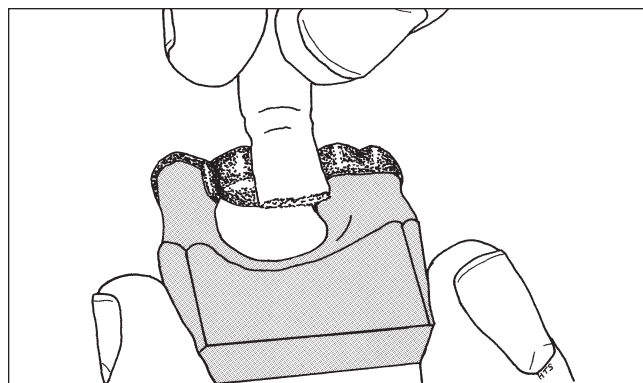


Fig 25-46 Die lubricant on a cotton roll is used to finish smoothing the underside of the pontic.

With a hot beavertail burnisher, wax is carved off the occlusal aspect of the stick of wax connecting the two retainers (Fig 25-43). The die is turned over, and the molten wax is deposited on the underside of the pontic (Fig 25-44). The undersurface of the pontic is carved to produce the totally convex "fish belly" (Fig 25-45). The undersurface of the pontic is smoothed and rounded with instruments and a clean cotton roll dipped in die lubricant (Gator die lube, Whip Mix) (Fig 25-46).

Plaster matrix

The fixed partial denture wax pattern is placed on the working cast, and the configuration of the underside of the pontic is evaluated in relation to the edentulous ridge (Fig 25-47). The following parameters should be checked: clearance with the ridge, impingement on the interdental papilla adjacent to the edentulous space, smoothness, and degree of curvature on the undersurface of the pontic. If any aspect requires adjustment, the wax pattern is removed from the working cast and the necessary changes made. Then the pattern is replaced on the cast.

The area of the cast adjacent to the edentulous ridge is lubricated with a light coating of petrolatum. A matrix is con-

structed on the facial and lingual surfaces of the cast with quick-setting plaster. A sable brush or instrument is used to place the plaster in the embrasure spaces around the lingual (Fig 25-48) and facial aspects of the wax pattern to ensure complete support of the pontic and connectors later. A thin mixture of plaster is applied over the facial surface of the cast and the pontic (Fig 25-49).

The brush must be washed before the plaster sets on it. When the plaster has set on the cast, the wax pattern is removed, and the matrix is trimmed so that none of it overlaps the prepared teeth (Fig 25-50). The edge of the matrix should be about 1.0 mm below the occlusal edge of the pontic.

With the wax pattern on the cast, the articulator is closed, and all functional mandibular movements are reproduced to test opposing cusp relationships. The occlusal surface is developed by the placement of cones and ridges that are utilized for the waxing of any occlusal surface (Fig 25-51). If the fixed partial denture is to be cast as two pieces with assembly following try-in, the larger connector is sawed through with a piece of 3-0 suture silk (Fig 25-52). The margins are finished on the U-shaped die (Fig 25-53).

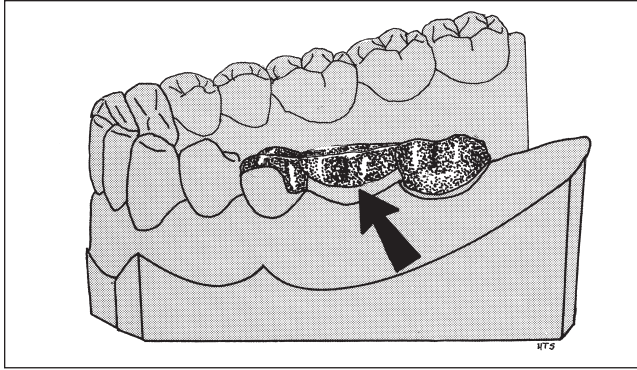


Fig 25-47 The pattern is placed on the working cast, and the contours of the pontic are checked one last time.

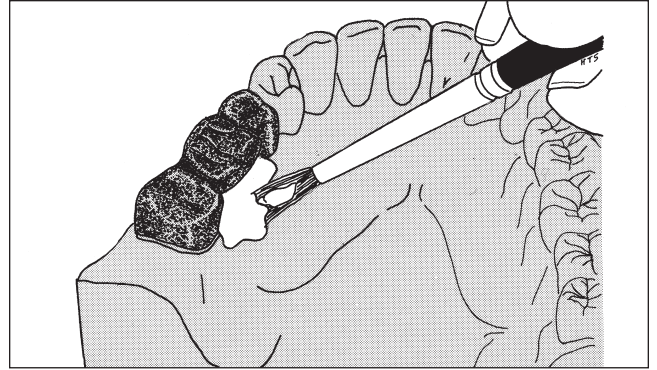


Fig 25-48 A runny mix of quick-set plaster is painted around the undersurface of the pontic.

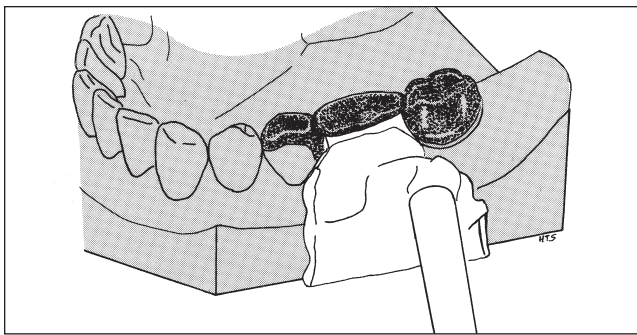


Fig 25-49 More plaster is added to the facial surface of the pontic.

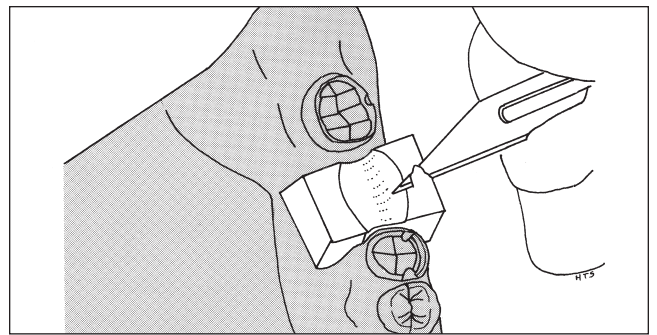


Fig 25-50 When the plaster has set, the wax pattern is removed and the plaster matrix is trimmed so that the occlusal surface is free of plaster.

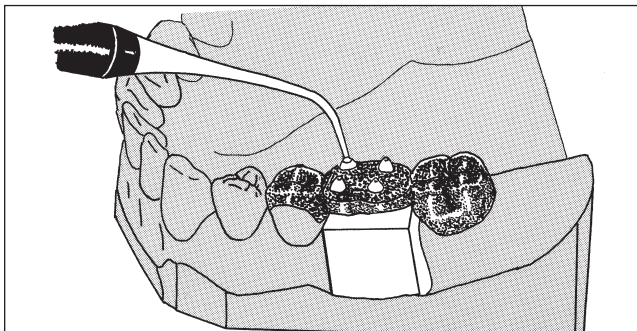


Fig 25-51 The occlusal surface is built up with a wax-added technique.

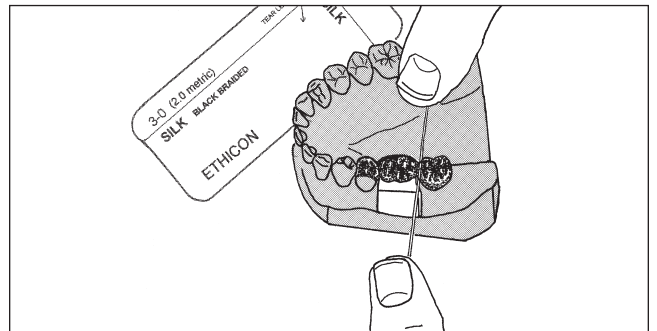
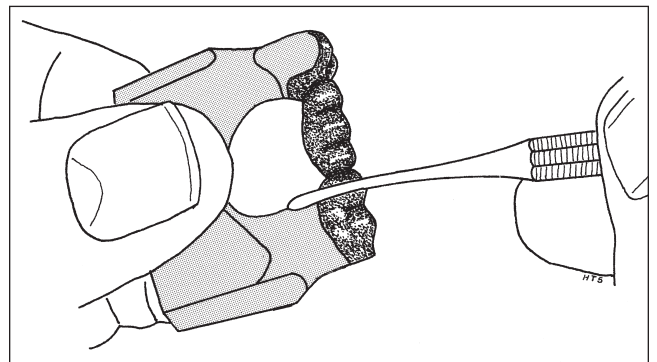


Fig 25-52 If the fixed partial denture is to be cast in two pieces, 3-0 suture silk can be used to saw through the connector.

Fig 25-53 The margins are finished on the U-shaped die with a beavertail burnisher.



25 Pontics and Edentulous Ridges

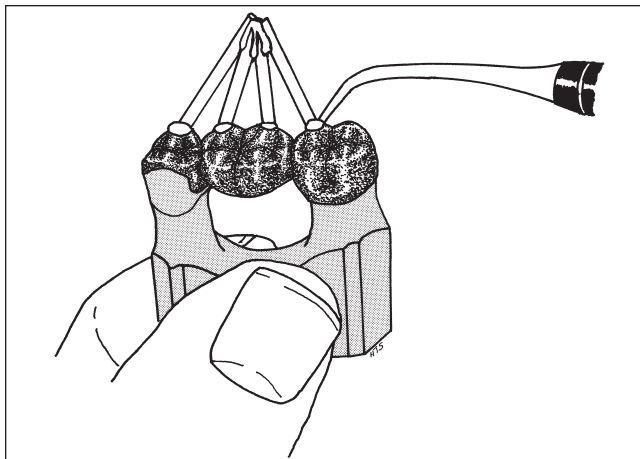


Fig 25-54 One sprue is attached to each retainer and to each cusp of the pontic.

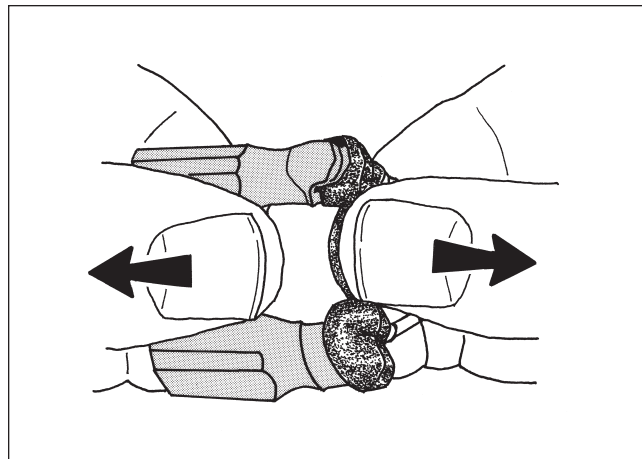


Fig 25-55 The pattern is removed by grasping the facial and lingual surfaces of the pontic.

Investing and casting

A 10-gauge hollow plastic sprue is attached to a nonfunctional cusp of each of the fixed partial denture retainer wax patterns. One sprue is placed on each of the nonfunctional pontic cusps (Fig 25-54). The free ends of the multiple sprues are connected with sticky wax. The wax pattern is removed from the die by grasping the facial and lingual surfaces of the pontic wax pattern between the thumb and forefinger (Fig 25-55). The sprue should not be used as a handle to loosen the pattern from the die. The wax pattern is carefully taken by the sprue between the thumb and forefinger of the left hand. The tips of the fingers should support the pattern without distorting it. The sprues are attached to the crucible former. The pattern should not be held by the proximal surfaces.

The fixed partial denture wax pattern is invested and cast in the usual manner. Note that more casting alloy is used than would be used for crowns because the pontic is solid. After the casting is retrieved from the investment, it is scrubbed clean. The sprues are cut off, and the casting is finished. The plaster matrix is removed from the working cast, and the casting is placed on the working cast. It is now ready for try-in.

Metal-ceramic fixed partial denture fabrication

Metal frameworks or copings for metal-ceramic fixed partial dentures should be constructed with these requirements in mind: (1) There must be an adequate bulk of metal to ensure rigidity for strength, and (2) porcelain should be of nearly equal thickness throughout to avoid the possibility of weakening the porcelain through uneven stress concentrations. To meet these requirements, there should be a continuous strip of exposed metal on the lingual surface, extending

from the metal portion of one retainer, across the lingual of the pontic, to the metal portion of the other retainer.

The incisal configuration of the lingual aspect of the coping may be straight, if occlusion permits (Fig 25-56a), or scalloped⁵⁰ (Fig 25-56b). The scalloped or "trestle" design is indicated when the connector is diminished in its faciolingual dimension to allow for the porcelain in the embrasures. By increasing the height of the strut incisogingivally, the strength of the connector will increase.⁵¹ This provides a bulk of metal for rigidity in the connector areas between the pontic and the respective retainers; if soldering should be necessary, it provides adequate metal for a strong solder joint.

Porcelain coverage of the retainers is the same as that for single units, except in the area adjacent to the pontic. The porcelain veneer on the pontic is continuous with the porcelain veneering of the retainers. It covers the incisal portion of the lingual surface, the labial surface, and the entire area adjacent to or contacting the ridge. Porcelain terminates against the metal on the lingual surface, about 1.0 mm incisal to the ridge (Fig 25-57). Porcelain tissue contact allows for better esthetics and removes the potentially rough porcelain-metal junction from contact with the tissue, where it could cause irritation.⁵²

The metal coping on the underside or gingival aspect of the pontic follows the same contours that the porcelain will; it is not just a straight bar of metal between the retainer copings. This makes the pontic esthetically similar to the retainers in the gingival area and provides support for the porcelain. The tissue contact of the porcelain should be a modified ridge lap on the facial aspect of the ridge. There must be no saddle contact.

An exception to the recommended porcelain coverage on the gingival aspect of a pontic occurs in those situations where an all-porcelain occlusal surface is used and the occlusogingival space is limited. To ensure rigid support for the porcelain, the gingival aspect of the pontic should remain

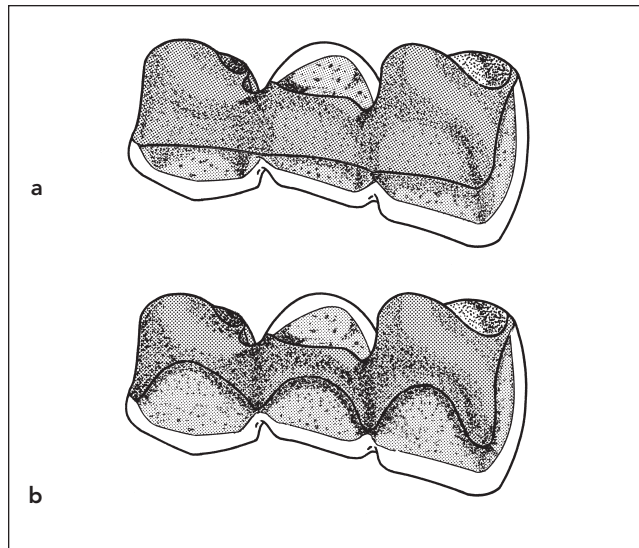


Fig 25-56 (a) The unveneered metal strip extending from retainer to retainer on the lingual surface of a metal-ceramic fixed partial denture is straight across at the incisal aspect. (b) If occlusion requires the metal strip to be narrower, the connectors can be bolstered by increasing the length of the struts incisally.

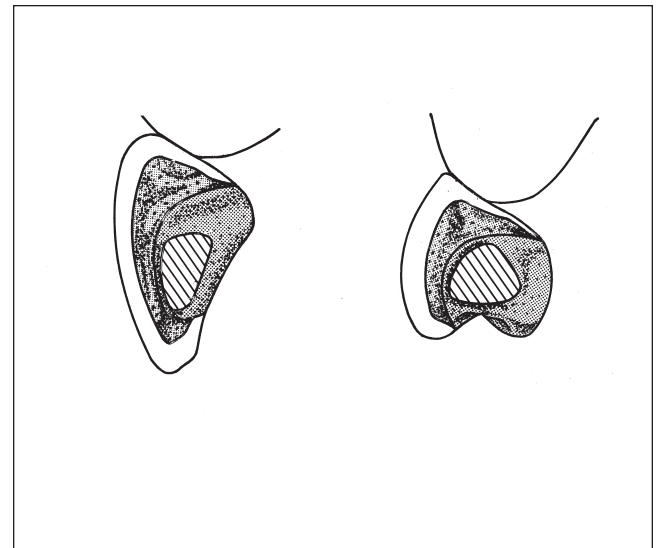


Fig 25-57 Metal-ceramic pontics: (a) anterior; (b) posterior.

in metal, with the porcelain-metal junction located on the gingivofacial aspect of the pontic.

An attempt at producing an esthetic posterior fixed partial denture will require the use of all-porcelain occlusal surfaces, especially in the mandibular arch, because only the occlusal aspect of premolars and molars is seen, if any part is seen at all. Any time that an all-porcelain occlusal surface is used on a pontic, a judgment must be made regarding the occlusogingival thickness of the metal in the pontic. To ensure adequate rigidity, the undersurface of the pontic may have to be metal to compensate for the metal removed from the occlusal aspect (Fig 25-58).

Fixed partial denture coping wax pattern

Portions of any metal-ceramic fixed partial denture will remain unveneered, and, in the posterior region, unveneered metal may constitute the majority of the surface area of the fixed partial denture. To produce a continuous contour between metal and porcelain and to provide a uniform thickness of porcelain, it is important to fabricate the wax pattern to full contour and then cut it back.

Copings are fabricated on the lubricated die of the abutment preparations with a no. 7 wax spatula. The excess is trimmed from the margins, and the copings are transferred to the working cast. The axial contours are formed facially, lingually, and interproximally. On posterior teeth, the occlusion is developed in the usual manner (see chapter 19).

A short section of a stick of blue inlay wax is cut off, and one end of it is heated in a Bunsen burner flame until the wax has been softened. The piece of wax is placed into the

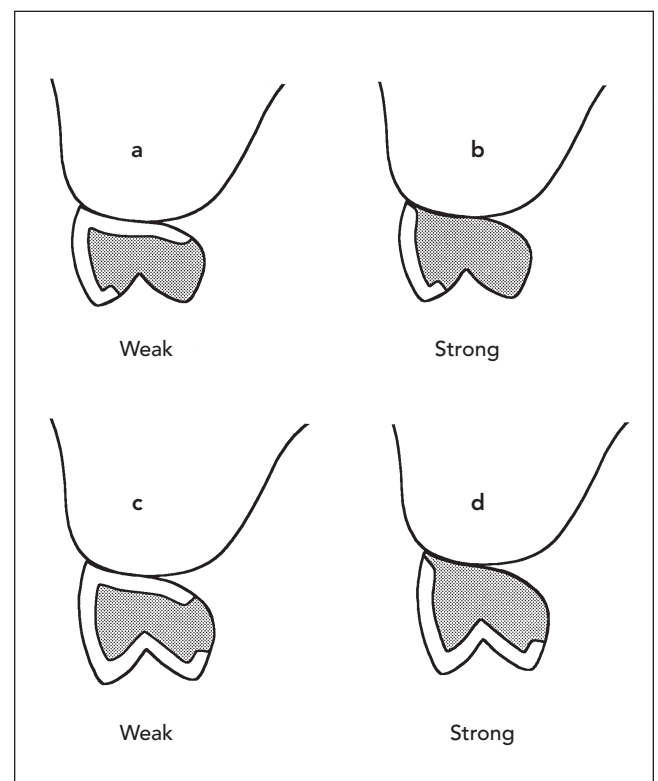


Fig 25-58 (a) A pontic with a short occlusogingival dimension may be too weak with a ceramic ridge contact. (b) It could be strengthened by changing the ridge contact to metal. (c) A pontic may be weakened by covering the occlusal surface with porcelain. (d) The loss of metal bulk can be compensated by using a metal ridge contact.

25 Pontics and Edentulous Ridges

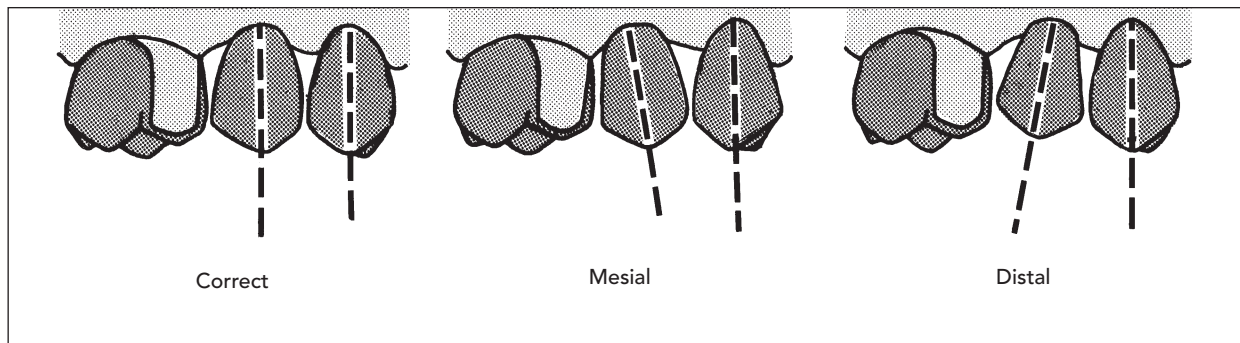


Fig 25-59 The mesiodistal inclination of the facing must be in harmony with that of the adjacent teeth.

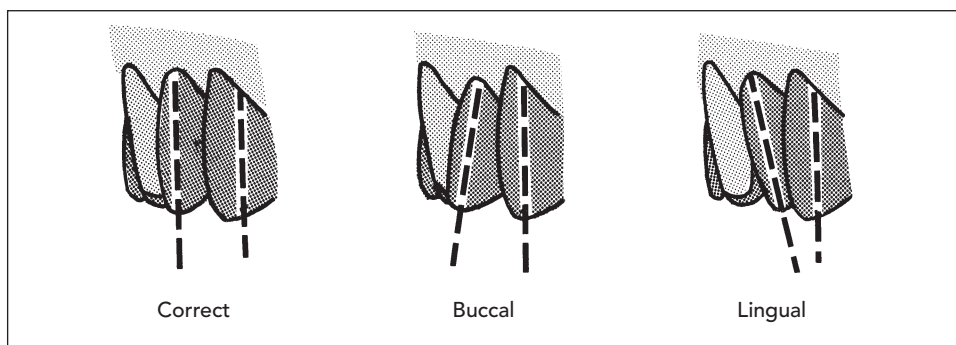


Fig 25-60 The facial profile should be consistent with that of the other teeth in the quadrant.

edentulous space on the cast, with the softened end pressing against the lubricated edentulous ridge. When the wax has hardened, wax is flowed into the interproximal areas to attach it to the retainer wax pattern on either side of it. Using wax addition and carving, the desired axial contours are produced in the pontic.

The mesiodistal alignment of the pontic is checked to prevent any “leaning” (Fig 25-59). The alignment of the occlusal two-thirds of the facial surface must also be checked to make sure that it is in harmony with the facial surfaces of the other teeth in the arch (Fig 25-60).

The assembled wax pattern is removed to carve the tissue side of the pontic to produce the desired open embrasures in the mesiogingival, distogingival, and linguogingival aspects. In the esthetic zone, the pontic should be a modified ridge lap design. When completed, the full-contour wax pattern is duplicated with a resilient impression putty material, such as condensation silicone. This impression can be poured to produce a stone cast, providing a visual guide to the desired contours, or it can be sectioned horizontally to allow assessment of the amount and contours of the cutback.

The pattern is replaced on the working cast, and the outline of the area to be veneered is sketched with a no. 25 blade in a laboratory knife (Fig 25-61). The mark is placed as far to the lingual as possible in the interproximal areas. The fixed partial denture wax pattern is removed from the

working cast and placed on the single-piece die of the abutment preparation. A discoid carver is used to place a groove adjacent to the outline of the boundaries of the veneering area. The groove is placed just facial to the proximal contact on a pattern for a posterior tooth so that the contact will be on metal. On a pattern for an anterior tooth, the groove is placed lingual to the contact so that the contact will be on porcelain.

A discoid carver is used to place grooves on the facial surface of the pontic and on any retainers that are to be veneered (Fig 25-62). These grooves should be 0.7 to 1.0 mm deep. With grooves it is possible to gauge the depth of the wax that will be removed from the veneering area to make room for porcelain. A similar groove is placed on the lingual surface of the pontic to mark the linguogingival porcelain-metal junction line (Fig 25-63).

A sharp no. 25 blade is used to remove the bulk of wax left between the grooves (Fig 25-64). A 1-mm-wide collar of wax is left at the gingival margin to ensure an adequate bulk to be invested and cast accurately. The collar will be thinned markedly after casting. The discoid carver is used to blend in all cuts made near the porcelain-metal junction line (Fig 25-65).

The cutback of the pontic should follow the general contours of the original full-contour wax-up, with a bulk of wax underlying the cusp tip and gingival tip of the pontic so that

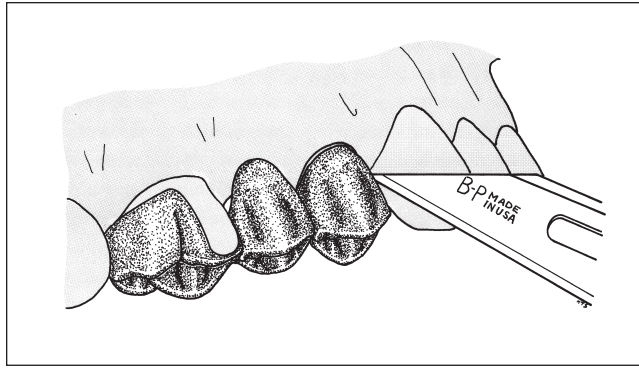


Fig 25-61 Proximal extensions of the porcelain-metal junction line are marked on the wax pattern with a knife tip.

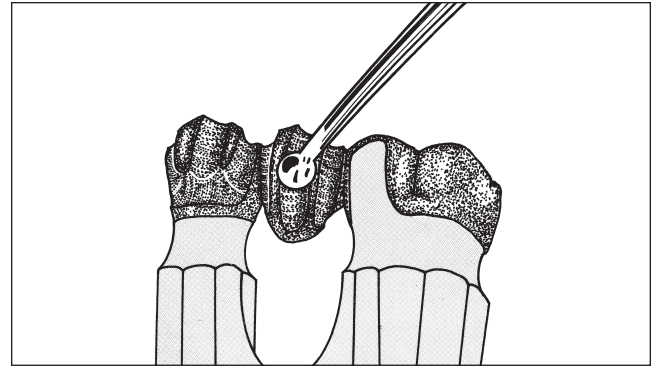


Fig 25-62 Orientation grooves are cut with a disoid carver on all surfaces of the retainer and pontic that are to be veneered.

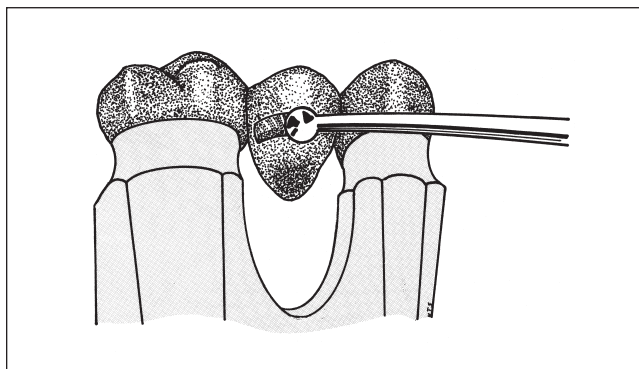


Fig 25-63 An orientation groove is carved along the location of the linguogingival porcelain-metal junction line on the pontic.

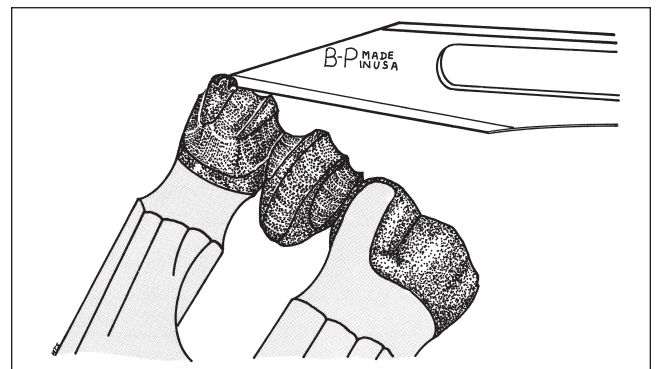


Fig 25-64 Wax remaining between the orientation grooves is removed with a sharp knife.

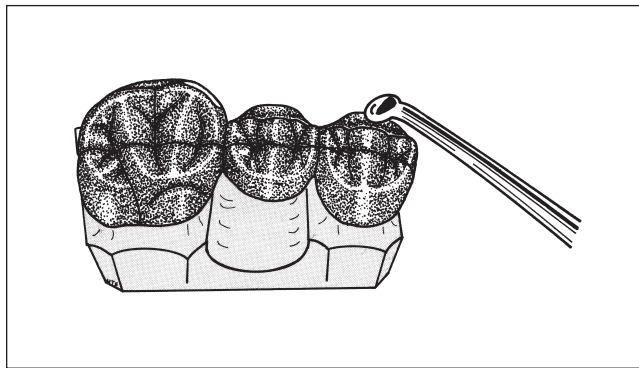


Fig 25-65 The porcelain-metal junction line is accentuated with a disoid carver.

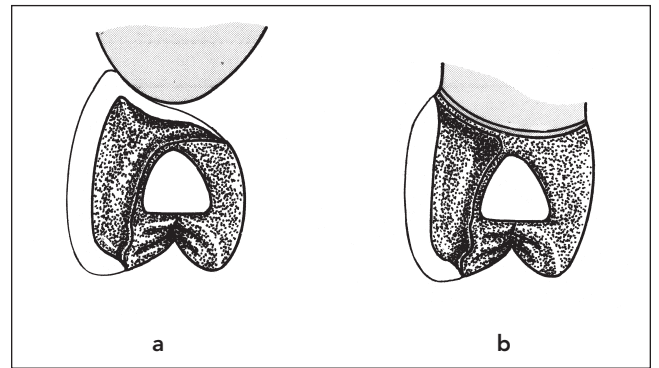


Fig 25-66 Proximal views of the components of a wax pattern for a maxillary posterior metal-ceramic fixed partial denture: (a) pontic; (b) retainer.

the porcelain that will ultimately be placed over those contours will be supported by metal (Fig 25-66a). On maxillary posterior teeth, it should be confirmed that there is a ledge of smoothly contoured wax underlying the eventual location of the facial cusp tips on both the pontic and retainers (Fig 25-66b).

There should not be any sharp angles in the area to be veneered. The porcelain-metal junction line should have the configuration of a deep chamfer with a crisp 90-degree angle in the wax pattern at the porcelain-metal junction. The veneering area is smoothed with a cotton pellet dipped in die lubricant. The excess is washed off, and the pattern is

25 Pontics and Edentulous Ridges

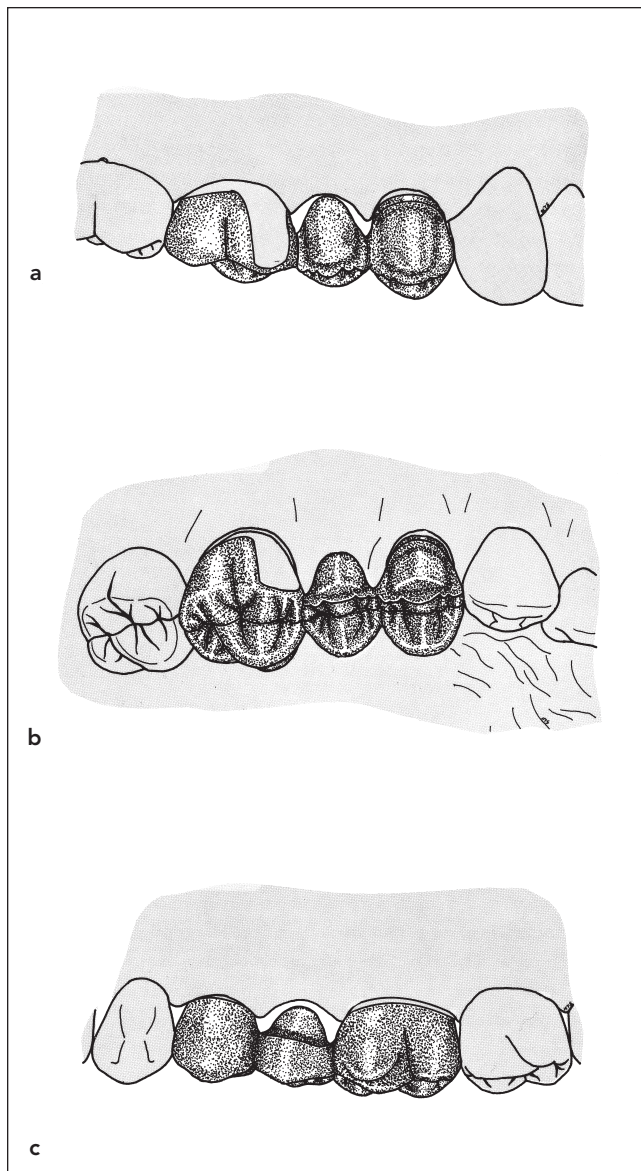


Fig 25-67 Wax pattern for a maxillary posterior metal-ceramic fixed partial denture from the facial (a), occlusal (b), and lingual (c) aspects.

blown dry. The pattern of the fixed partial denture is placed on the working cast, and the area to be veneered is carefully inspected from the facial (Fig 25-67a), occlusal (Fig 25-67b), and lingual (Fig 25-67c) aspects. It should be confirmed that all angles that will be covered with porcelain are rounded, all contours are smoothed, and all aspects of the porcelain-metal junction line are sharply defined. The pattern is returned to the freshly lubricated die, and the margins are re-adapted. The pattern is prepared for investing by attaching the sprues (see chapter 20).

References

1. Parkinson CF, Schaberg TV. Pontic design of posterior fixed partial prostheses: Is it a microbial misadventure? *J Prosthet Dent* 1984;51:51–54.
2. Stein RS. Pontic-residual ridge relationship: A research report. *J Prosthet Dent* 1966;16:251–285.
3. Henry PJ, Johnston JF, Mitchell DF. Tissue changes beneath fixed partial dentures. *J Prosthet Dent* 1966;16:937–947.
4. Podshadley AG. Gingival response to pontics. *J Prosthet Dent* 1968;19:51–57.
5. Smith DE, Potter HR. The pontic in fixed bridgework. *Dent Dig* 1937;43:16–20.
6. Klaffenbach AO. Biomechanical restoration and maintenance of the permanent first molar space. *J Am Dent Assoc* 1952;45:633–644.
7. Boyd HR. Pontics in fixed partial dentures. *J Prosthet Dent* 1955;5:55–64.
8. Harmon CB. Pontic design. *J Prosthet Dent* 1958;8:496–503.
9. Cavazos E Jr. Tissue response to fixed partial denture pontics. *J Prosthet Dent* 1968;20:143–153.
10. Eissmann HF, Radke RA, Noble WH. Physiologic design criteria for fixed dental restorations. *Dent Clin North Am* 1971;15:543–568.
11. Johnson GK, Leary JM. Pontic design and localized ridge augmentation in fixed partial denture design. *Dent Clin North Am* 1992;36:591–605 [erratum 1993;37:vii].
12. Schield HW. The influence of bridge pontics on oral health. *J Mich State Dent Assoc* 1968;50:143–147.
13. Reynolds JM. Abutment selection for fixed prosthodontics. *J Prosthet Dent* 1968;19:483–488.
14. Hirshberg SM. The relationship of oral hygiene to embrasure and pontic design—A preliminary study. *J Prosthet Dent* 1972;27:26–38.
15. Tjan AH. Biologic pontic designs. *Gen Dent* 1983;31:40–44.
16. Johnston JF. Pontic form and bridge design: A new survey (Part I). *Ill Dent J* 1956;25:272–279.
17. Roid GH, Grenfell J, Ueno H, Wilson LG. *Bridging the Gap: Principles of Pontic Design*. Eugene, OR: Oregon State System of Higher Education, 1973:16.
18. Silness J, Gustavsen F, Mangersnes K. The relationship between pontic hygiene and mucosal inflammation in fixed bridge recipients. *J Periodontol Res* 1982;17:434–439.
19. Tripodakis AP, Constantinides A. Tissue response under hyper-pressure from convex pontics. *Int J Periodontics Restorative Dent* 1990;10:408–414.
20. Becker CM, Kaldahl WB. Current theories of crown contour, margin placement, and pontic design. *J Prosthet Dent* 1981;45:268–277.
21. Clayton JA, Green E. Roughness of pontic materials and dental plaque. *J Prosthet Dent* 1970;23:407–411.
22. Ante JH. Construction of pontics. *J Can Dent Assoc* 1936;2:482–486.
23. Tjan AHL. A sanitary “arc-fixed partial denture”: Concept and technique of pontic design. *J Prosthet Dent* 1983;50:338–341.
24. Yamashita A. Practical construction procedure for a new type of bridge pontic. *Quintessence Int* 1985;16:743–753.
25. Garber DA, Rosenberg ES. The edentulous ridge in fixed prosthodontics. *Compend Contin Educ Dent* 1981;2:212–223.
26. Perel ML. A modified sanitary pontic. *J Prosthet Dent* 1972;28:589–592.
27. Hood JA. Stress and deflection of three different pontic designs. *J Prosthet Dent* 1975;33:54–59.
28. Tinker ET. Sanitary dummies. *Dent Rev* 1918;32:401–408.
29. Dobson NJ. The value of porcelain in artificial root insertion. *Dent Cosmos* 1921;63:247–248.
30. Budde CC. Porcelain baked roots in fixed bridgework. *J Am Dent Assoc* 1928;15:1914–1916.
31. Bowles RO. Fixed bridges with special reference to tissue contact pontics and inlay abutments. *J Am Dent Assoc* 1931;18:1521–1537.

32. Dewey KW, Zugsmith R. An experimental study of tissue reactions about porcelain roots. *J Dent Res* 1931;13:459–472.
33. Shooshan ED. The reverse pin-porcelain facing. *J Prosthet Dent* 1959;9:284–301.
34. Faucher RR. A system for localizing pontics. *J Prosthet Dent* 1984;52:643–647.
35. Seibert JS. Reconstruction of deformed, partially edentulous ridges, using full thickness onlay grafts. Part I. Technique and wound healing. *Compend Contin Educ Dent* 1983;4:437–453.
36. Hawkins CH, Sterrett JD, Murphy HJ, Thomas JC. Ridge contour related to esthetics and function. *J Prosthet Dent* 1991;66:165–168.
37. Abrams H, Kopczyk RA, Kaplan AL. Incidence of anterior ridge deformities in partially edentulous patients. *J Prosthet Dent* 1987;57:191–194.
38. Behrend DA. The mandibular posterior fixed partial denture. *J Prosthet Dent* 1977;37:622–638.
39. Behrend DA. The design of multiple pontics. *J Prosthet Dent* 1981;46:634–638.
40. Schregle M. Firing of gingiva-colored ceramic powders. *Quintessence Dent Technol* 1981;5:245–252.
41. Vryonis P. Esthetics and function in multiple unit bridges. *Quintessence Dent Technol* 1981;5:237–241.
42. Porter CB Jr. Anterior pontic design: A logical progression. *J Prosthet Dent* 1984;51:774–776.
43. Crispin BJ. Tissue response to posterior denture base-type pontics. *J Prosthet Dent* 1979;42:257–261.
44. Seibert JS, Cohen DW. Periodontal considerations in preparation for fixed and removable prosthodontics. *Dent Clin North Am* 1987;31:529–555.
45. Seibert JS, Nyman S. Localized ridge augmentation in dogs: A pilot study using membranes and hydroxyapatite. *J Periodontol* 1990;61:157–165.
46. Kaldahl WB, Tussing GJ, Wentz FM, Walker JA. Achieving an esthetic appearance with a fixed prosthesis by submucosal grafts. *J Am Dent Assoc* 1982;104:449–452.
47. Langer B, Calagna L. The subepithelial connective tissue graft. *J Prosthet Dent* 1980;44:363–367.
48. Seibert JS. Ridge augmentation to enhance esthetics in fixed prosthetic treatment. *Compend Contin Educ Dent* 1991;12:548–560.
49. Orth CF. A modification of the connective tissue graft procedure for the treatment of type II and type III ridge deformities. *Int J Periodontics Restorative Dent* 1996;16:266–277.
50. Stein RS, Kuwata M. A dentist and a dental technologist analyze current ceramo-metal procedures. *Dent Clin North Am* 1977;21:729–749.
51. Miller LL. Framework design in ceramo-metal restorations. *Dent Clin North Am* 1977;21:699–716.
52. Hobo S, Shillingburg HT Jr. Porcelain fused to metal: Tooth preparations and coping design. *J Prosthet Dent* 1973;30:28–36.

Solder Joints and Other Connectors

26



Soldering is the joining of metal components by a filler metal, or solder, which is fused to each of the parts being joined. Strictly speaking, if the filler metal has a melting temperature greater than 450°C (840°F), the process is called *brazing*.¹ The term *soldering*, as commonly used in dentistry, will be used in this chapter. Bonding is contingent on wetting of the joined surfaces by the solder and not on melting of the metal components. When a solder joint is done properly, there should be no fusion or alteration of the two components joined.² Soldering differs in that respect from welding, another means of joining metals. In fusion welding, the pieces that are joined are melted or fused together, without solder.

Solder can be used for joining, as in the fabrication of a fixed partial denture, or it can be used for building, as when an addition is made to the proximal surface of a crown. Cleanliness is the prime prerequisite of soldering,³ inasmuch as the soldering process depends on wetting of the surface to achieve bonding. Corrosion products, such as oxides and sulfides, that are present as a result of the casting process or that occur on the surface of metals when they are heated interfere with bonding.

Flux is placed on the surfaces to be soldered before they are heated. Fluxes may provide surface protection, reduce oxides, or dissolve oxides.¹ Flux is displaced by solder, which then can form an interface with and bond to the surface being soldered. Soldering fluxes for noble metals are based on borate compounds. They form low-fusing glasses that protect the metal surface, and they also reduce oxides such as copper oxide. They often are too fluid for preceramic soldering.¹ Fluorides are used on base metal alloys to dissolve the stable oxides of chromium, cobalt, and nickel. In addition to acting as solvents, these fluxes also serve a protective role.¹

Flux is more easily applied if it is in paste form. While a flux paste can be made with alcohol, the most popular form for use with noble metal alloys employs petrolatum as a vehicle because it is more easily handled. It keeps air from the flux, and, when heated, the petrolatum burns off without leaving any residue. Fluxes made from common borax, or pastes made with water, tend to effloresce when they are heated, producing pits in the solder joint.

Antiflux is a material used to outline the area to be soldered in order to restrict the flow of solder. The most common antiflux is the mark of a soft graphite pencil, which works best on surfaces that do not have a high polish. Polishing rouge (iron oxide) suspended in chloroform can also

be painted around the area of the solder joint to prevent undesired spread of the solder.

Gold solders are classified by fineness and by carat. *Fineness* refers to parts per thousand of the solder that is gold. For example, a 600 fine solder would be 600 parts gold per 1,000, or 60% gold. When used to designate a casting alloy, *carat* refers to parts per 24 of a metal that are gold. As an example, an alloy that is 18 K is 18 parts gold per 24, or 75% gold. When used with solder, however, *carat* has a different meaning. A solder that is designated as 18 K does not have a 75% content of gold. Instead, the 18 K designation means that it was formulated to be used with 18 K casting alloys. The actual noble metal content of the solder would be given by its fineness rather than by its carat. The higher the fineness of a solder, the higher will be its melting range and the greater its corrosion resistance. While a solder with a lower fineness has a lower melting range, it also has poorer flow characteristics.³

Dental solder should be⁴:

- *Corrosion resistant.* Restorations, such as fixed partial dentures, which are permanently placed in the mouth, require the use of a solder of high fineness to resist corrosion. The minimum fineness that should be used is 580 fine, and a higher number would be better for preventing tarnish and discoloration.
- *Lower fusing than alloy.* The solder should possess a fusion temperature that is about 60°C (100 to 150°F) below that of the metal being soldered.³
- *Nonpitting.* Pitting in solder is not desirable. More pitting occurs when there is an increased amount of base metal in the solder, which may vaporize when the gap between the components is too narrow or when the solder is overheated.
- *Strong.* Solder should be as strong as the alloy with which it is used. The hardness of the solder decreases as the fineness (gold content) increases.
- *Free-flowing.* The solder should flow freely. Silver in the solder tends to make it adhere to metal and to flow more freely. Copper, on the other hand, makes it more sluggish. Solders that melt at higher temperatures have a lower surface tension and flow easily through narrow gaps. Low-fusing solders flow poorly through narrow gaps.⁵
- *Same color.* The color of the solder should match that of the alloy being soldered.

26 Solder Joints and Other Connectors

As is the case with many aspects of dentistry and life in general, soldering is much more complicated today than it used to be. Crowns and fixed partial dentures were made of a gold alloy, solders were gold, fluxes were borates, and, at least from a dental perspective, it was a fairly simple process. With the nearly 1,500 alloys available for use in dentistry today, a dentist cannot be proficient in every aspect of soldering.

However, soldering is still not in the exclusive domain of the dental laboratory. There are occasions when being able to solder in the office can be a great convenience for dentist and patient alike. An otherwise acceptable gold restoration may not have an adequate proximal contact. Adding that proximal contact is a simple procedure that can and should be done in the office. It usually does not require investing.

If a fixed partial denture must be sectioned because it does not seat completely, or if it was constructed in segments for intraoral try-in, the dentist must at least be able to index the components to ensure that the technician who does the actual soldering will have an accurate starting point. The components that are to be joined with solder must be stabilized in soldering investment to maintain the exact relationship throughout the soldering process.

The soldering procedures to be considered are:

- Gold alloy fixed partial denture soldering
- Adding proximal contact
- Repairing casting voids
- Breaking solder joints
- Preveneer metal-ceramic alloy soldering (presolder)
- Postveneer metal-ceramic alloy soldering (postsolder)

Gold Alloy Fixed Partial Denture Soldering

There are two ways in which a three-unit fixed partial denture can be fabricated. It can be made as a single casting, with the pontic wax pattern attached to that of each of the retainers. The fixed partial denture also may be cast as two units, with the pontic wax pattern attached to that of one of the retainers and cast with it, and the two units are then assembled by soldering.

Single-piece casting

Certainly it is possible to achieve an accurately fitting fixed partial denture by use of a single-piece casting.⁶ If this is to be attempted, a one-piece die in which the abutment preparations have not been separated from each other offers the greatest accuracy. (Refer to chapter 25 for a discussion of this type of die.) To achieve maximum accuracy, the wax pattern should be invested in a large-diameter casting ring (60 mm or larger) to assure uniform expansion.⁷ Either a round or an

oval casting ring can be used. Both investment expansion and pattern distortion can affect the accuracy of multiunit castings.⁸ There is less pattern distortion when investment is allowed to bench set compared to the hygroscopic technique.⁸

As the length of a single-piece fixed partial denture casting increases, so does its inaccuracy.⁹⁻¹¹ Distortion is three-dimensional, as though the pattern has elongated and twisted. Schiffleger et al¹¹ found the discrepancies greatest at the mesioingival aspect of the anterior retainer and the distolingual aspect of the posterior retainer. Four- and five-unit fixed partial dentures joined by soldering have better-fitting margins than do one-piece castings of the same length.¹² Any fixed partial denture larger than three units should still be cast in two pieces and soldered.¹³

A single-piece casting must be tried in the mouth with an awareness of some of the problems inherent in the technique. The single-piece casting offers no opportunity to verify the fit of the individual retainers. In an effort to make a nonfitting casting seat, there is a tendency to relieve the internal surfaces of the retainers so drastically that all retention is lost. In that event, the fixed partial denture cannot be saved even if it is later separated, indexed, and soldered. If the fixed partial denture will not completely seat after routine adjustments have been made, a thin (0.009-inch or 0.23-mm) separating disk (Ultra disks, Dedeco) is used to cut through one connector, and then the separate pieces of the fixed partial denture are tried back in the mouth.

Indexing

A two-piece casting can be used to fabricate a fixed partial denture with a solid pontic, such as a hygienic pontic. The technique described is used for soldering three-unit posterior fixed partial dentures. The pontic is cast with the smaller retainer. Then the retainer-pontic unit is soldered to the larger retainer, utilizing an index of the relationship of the fixed partial denture components in the patient's mouth. This provides for the most accurate relationship between the retainers and between each retainer and its abutment tooth.

The index must accurately maintain that relationship until the parts of the fixed partial denture have been embedded in soldering investment. Numerous materials have been described for transferring the relationship of the fixed partial denture components from mouth to laboratory bench: plaster,¹⁴⁻¹⁶ sticky wax,^{3,17} autopolymerizing acrylic resin (Duralay, Reliance),¹⁸ 4-methacryloxyethyl trimellitate anhydride (4-META) adhesive resin,¹⁹ and zinc oxide eugenol,²⁰ which has been shown to be a highly accurate material for indexing.²⁰

If plaster is used, the most accurate and consistent results will be obtained if the castings are not removed from the index prior to investing.²¹ Resin indices (Duralay) are as accurate as those made of plaster if the components are separated from and resealed in the plaster. However, excess bulk of a resin index will diminish accuracy because of additional polymerization shrinkage.²²

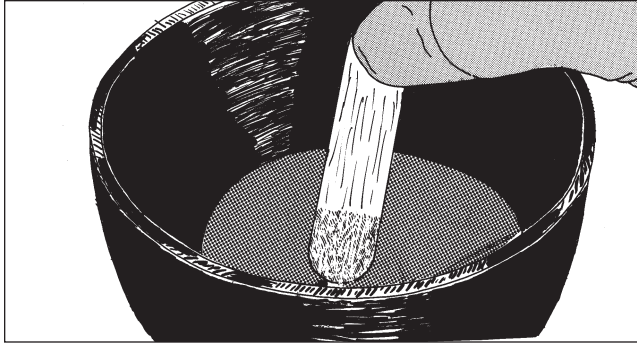


Fig 26-1 The tongue depressor is soaked in water before it is used to hold the plaster index.

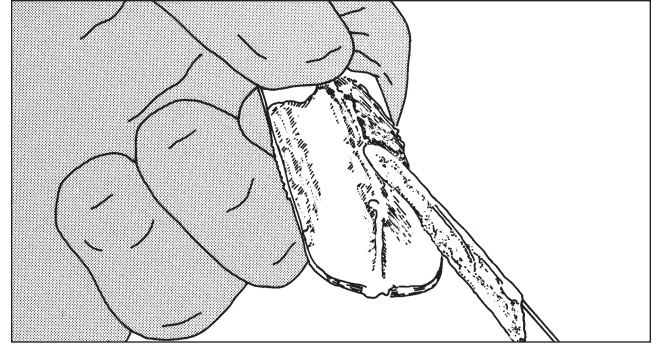


Fig 26-2 Plaster is troweled onto the tongue depressor to create a ridge that extends from one end of the index to the other.

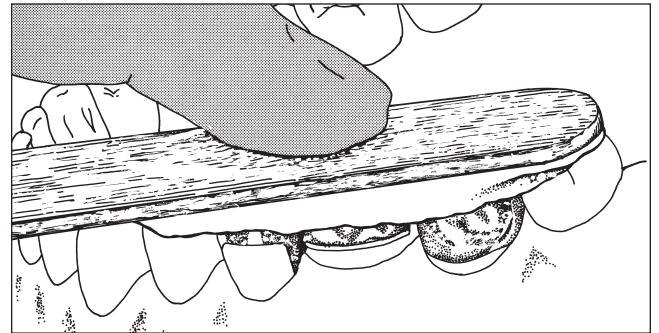


Fig 26-3 The seated index is stabilized over the fixed partial denture until the plaster sets.

Armamentarium

- Plaster bowl, spatula
- Impression plaster
- Bite registration paste, mixing pad
- Index tray or tongue blade
- Petrolatum
- Laboratory knife with no. 25 blade
- P. K. Thomas (PKT) waxing instruments (nos. 1 and 2) (Osung)
- Straight handpiece, no. 8 round bur
- Explorer
- Sticky wax, utility wax, boxing wax
- Soldering investment
- Vibrator
- No. 2 pencil
- Fisher burner, matches
- Tripod, screen
- Solder (650 fine), soldering flux
- Blowpipe, casting tongs
- Toothbrush

The provisional restoration is removed from the patient's mouth, and it is confirmed that there are no traces of temporary cement left on the tooth preparations. The single retainer is tried in first, then the retainer-pontic combination. On the first try-in for each, the other unit should not be left in place. The marginal fit of each retainer should be verified first. There should be a small gap between the pontic and the retainer to which it has not yet been soldered.

The occlusion is adjusted with green stones or other appropriate abrasives. Preliminary finishing procedures are performed on the retainer margins, if they are accessible. The occlusal surface is smoothed with a rubber sulci disk. The rough surface left on the casting by a green stone could create problems in seating the castings into the index. The castings should not be polished at this point because polishing rouge is iron oxide, a specific antilux for soldering.

A small amount of fast-setting impression plaster is mixed and placed on a plastic index tray or a thoroughly wet tongue depressor (Fig 26-1). The index material is arranged on the carrier so that a sharp ridge of material runs the length of the depressor (Fig 26-2) or tray. This ridge facilitates placement of index material into the central grooves of the casting. The index is carefully positioned on the occlusal surface of the castings and gently vibrated as it is seated (Fig 26-3).

When the material has set, the index is removed. Ideally, the castings will come out with it (Fig 26-4). A plaster index is most accurate when the crowns stay in it.²¹ It is carefully trimmed with a laboratory knife with a no. 25 blade so that all margins are exposed by at least 1.0 mm (Fig 26-5). The index should extend at least 3.0 mm mesially and distally past the crowns being soldered. This guarantees a symmetric, uniform bulk of investment surrounding the units to be soldered and should minimize distortion.¹⁵ The plaster index should be approximately 6 mm (0.25 inch) thick.

If the crowns separate from the index when it is removed from the cast, excess that might prevent the castings from seating completely back into the imprints is trimmed off. The area around the imprints is trimmed enough so that a sub-

26 Solder Joints and Other Connectors

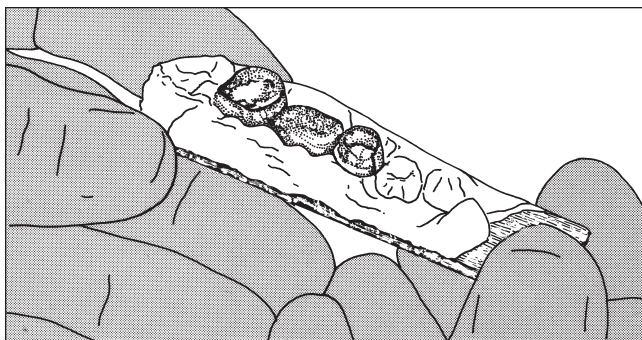


Fig 26-4 Plaster index with components trapped in it.

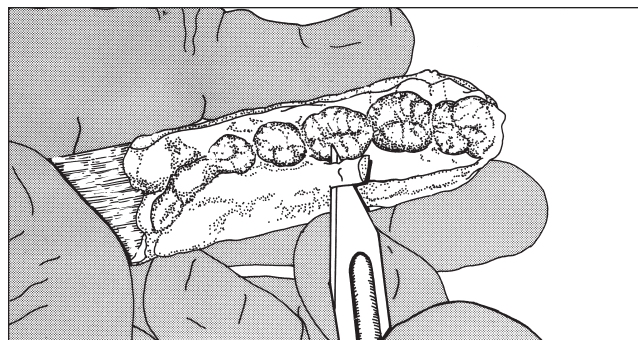


Fig 26-5 Excess plaster around the fixed partial denture imprint is trimmed off with a sharp knife.

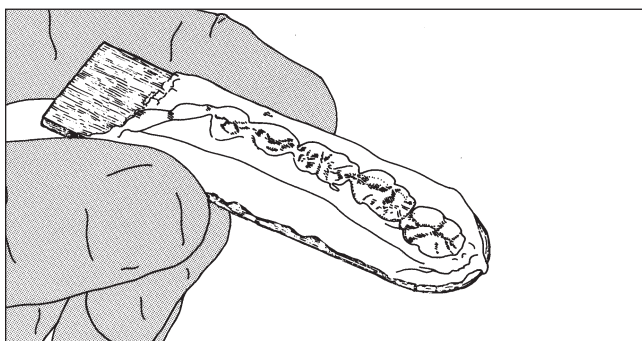


Fig 26-6 The trimmed index exhibits shallow imprints of the fixed partial denture components.

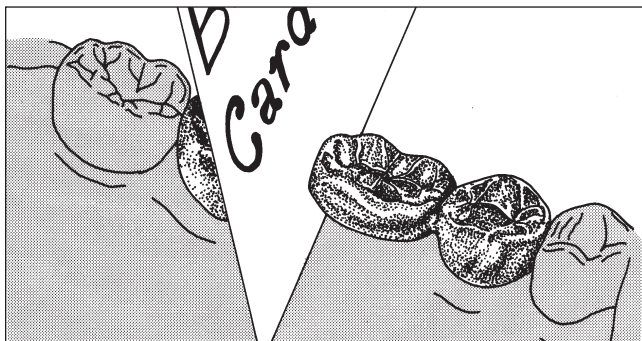


Fig 26-7 The gap width is measured by passing a business card through it.

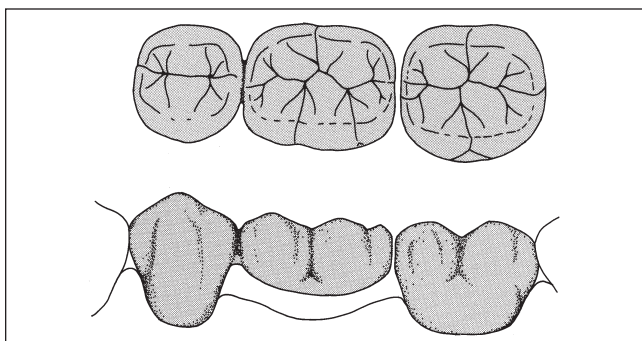


Fig 26-8 When the two surfaces to be soldered are parallel, there is less likelihood of distortion: occlusal view (top) and facial view (bottom).

stantial part of the axial walls will be covered by investment (Fig 26-6). The index is then thoroughly cleaned with compressed air. The slightest bit of debris between the index and crown will keep the crown from seating in the index and will make the relationship inaccurate. The occlusal surfaces of the crowns are scrubbed and cleaned in the ultrasonic cleaner before they are repositioned in the index. The index is placed on the bench, and the castings are carefully tried in their respective imprints.

If the castings touch, there is a likelihood of increased distortion.^{3,14,23} For this reason, it has been suggested that there be a gap of at least 0.005 inch (0.13 mm) between the pontic and the retainer.^{3,14} A conflict arises in determining the proper gap dimension for a solder joint. The wider the solder joint gap, the stronger the joint, apparently because there is less porosity in the joint.¹³ Therefore, a gap width of 0.012 inch (0.30 mm) is recommended for strength.

In another study, however, it was determined that increased gap width produces an increase in distortion. A gap width of 0.006 inch (0.15 mm) is recommended for greatest accuracy.²⁴ Obviously there is a need for some compromise. A gap width of 0.008 inch (0.20 mm) would appear to be optimum because it is intermediate between the narrow, undistorted joint and the wide, strong joint. Indeed, some investigators have used this distance as a standard.²⁵ Furthermore, it can be determined easily by inserting a business card into the gap (Fig 26-7) because the average card is 0.008 inch thick.

The opposing surfaces of the retainer and pontic on either side of the solder joint should parallel each other (Fig 26-8). If these surfaces diverge, the resulting wedge shape of the solder joint may produce distortion.²⁶ In addition, wherever there is contact, there will not be space for the solder and there will be no bonding. On the other hand, if the gap is too wide, it will be harder to solder because capillary action is more difficult to achieve. As a result, solder will be more likely to stick to one surface or the other instead of filling the gap and adhering to both surfaces.

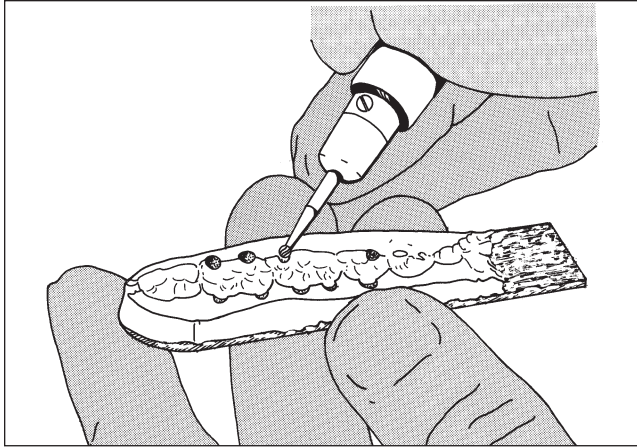


Fig 26-9 Wells are cut along the edges of the crown and pontic imprints to provide space for sticky wax.

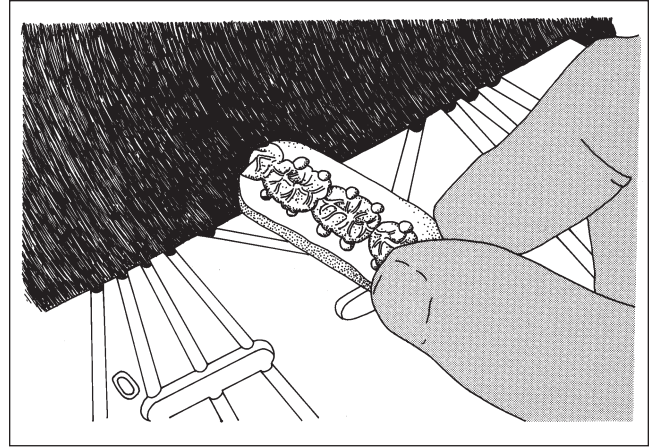


Fig 26-10 The periphery of the plaster index is trimmed on the cast trimmer so that there will be a 3.0-mm apron around the imprint of the fixed partial denture.

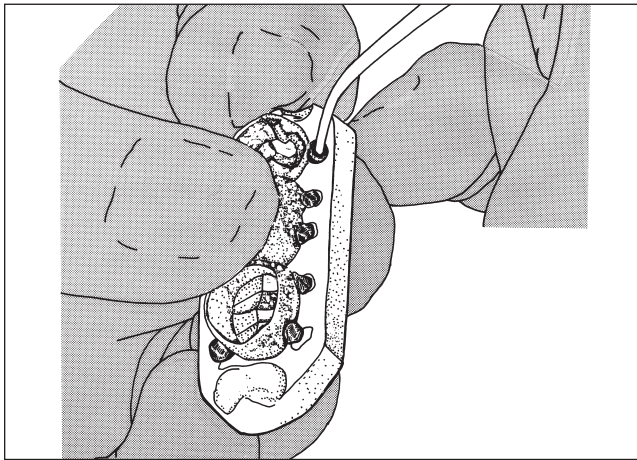


Fig 26-11 Sticky wax is used in the wells to attach the fixed partial denture to the index.

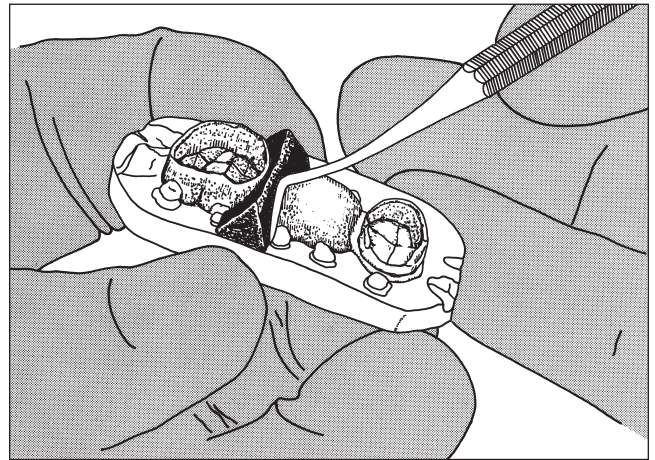


Fig 26-12 A triangular-shaped piece of utility wax is extended facially and lingually from the solder joint area. There must be no gaps.

Investing

Pontics and retainers that have come off the index should be luted back onto the index with sticky wax. It is often necessary to use a no. 8 round bur to cut a small "well" on the facial and lingual edges of each imprint in the index (Fig 26-9). This permits space for a bulk of sticky wax without forcing it over the margins. The tongue depressor is separated from the index if they have not already come apart. A cast trimmer is used to remove excess from the edge of the index, leaving approximately 3.0 mm all around the perimeter (Fig 26-10). The index is allowed to dry, and sticky wax is applied to each casting using a PKT no. 1 instrument (Fig 26-11). The sticky wax should not be allowed to cover occlusal margins (if any) on the facial surfaces.

Utility wax is flowed into the joint with a PKT no. 2 instrument to prevent the joint area from being filled with investment. The waxed area should be slightly larger than the solder joint will be. Any margin covered by wax at this point will not be covered by soldering investment. This could cause the margin to melt when heated by the blowpipe during soldering. A triangular-shaped extension of utility wax is run from the lingual side of the solder joint area of the index (Fig 26-12). There should be a slightly smaller one on the facial. These wax wedges will be narrower in the solder joint area than at the edge of the index. Complete seating of the castings should be double-checked.

A separating medium (Super-Sep, Kerr) may be painted over the index outside the castings to ensure easy separation later. Boxing wax is placed around the index (Fig 26-13).

26 Solder Joints and Other Connectors




Fig 26-13 A strip of boxing wax 2.5 cm (1.0 inch) wide is wrapped around the index.

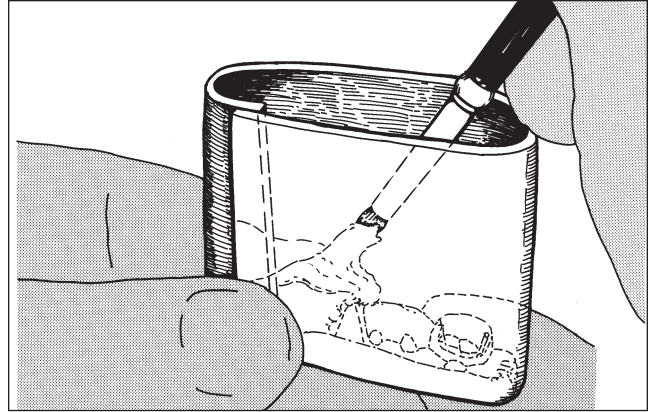


Fig 26-14 Investment is brushed into the retainers.

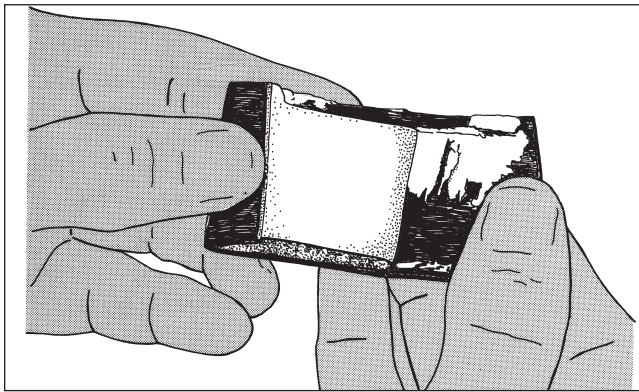


Fig 26-15 After the investment has set, the strip of boxing wax is removed from the index.

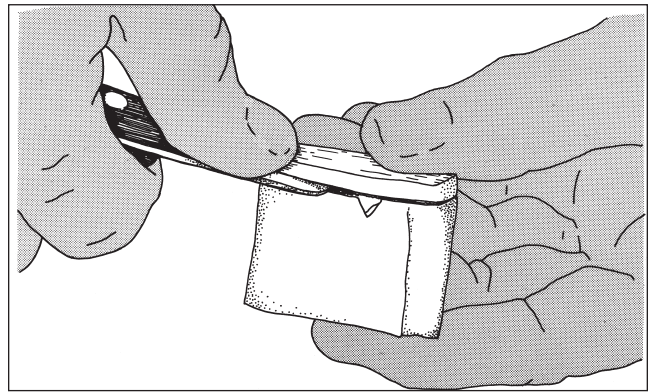


Fig 26-16 The index is pried loose from the block of investment.

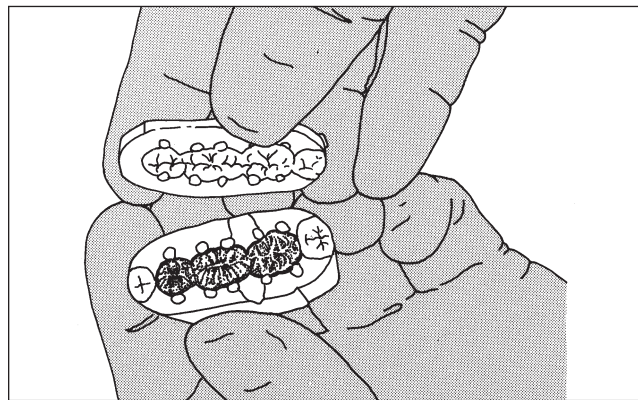


Fig 26-17 The index is separated from the block of investment and inspected.

There should be 3.0 mm of space between the castings and the boxing wax. A small amount of soldering investment (Whip Mix) is mixed. It is painted into the castings and carefully vibrated into the boxed area (Fig 26-14). The index is held so that there is a finger between it and the vibrator. Overzealous vibrating could jar one of the castings loose.

The investment is allowed to set for 1 hour, and then the boxing wax is removed (Fig 26-15). Hot water is run over the investment and index to soften the sticky wax. The index and the investment are separated with a heavy laboratory knife (Fig 26-16). The block of investment containing the fixed partial denture castings is inspected (Fig 26-17). The

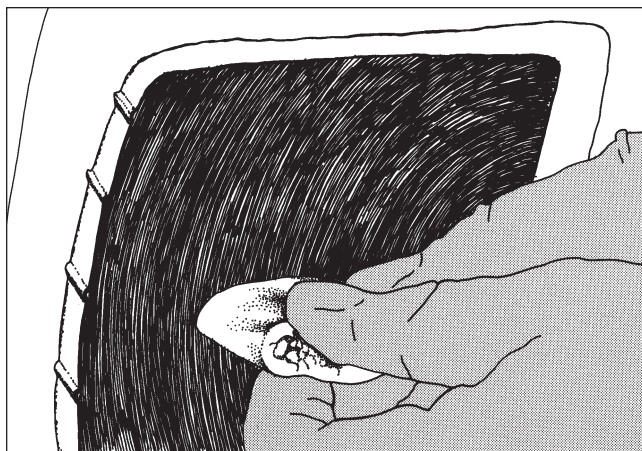

Fig 26-18 The cast trimmer is used to remove excess height from the block of investment.

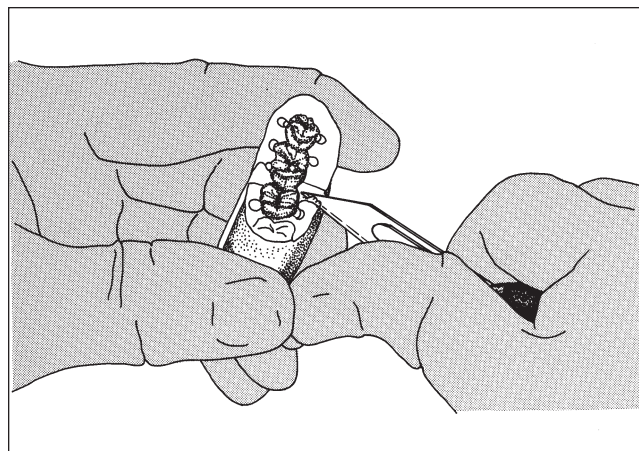


Fig 26-19 Facial and lingual notches are carved in the investment.

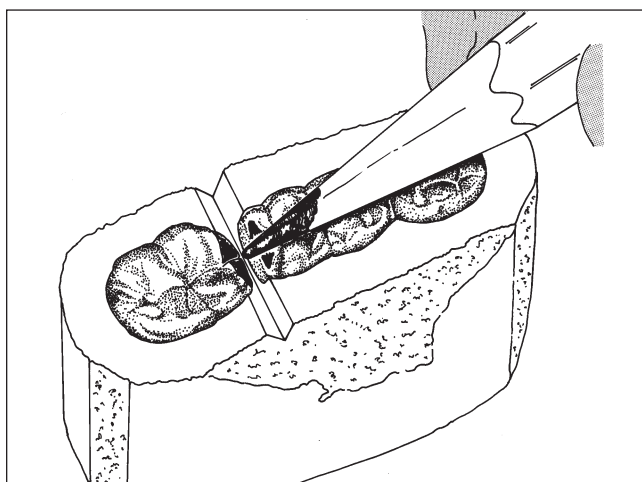


Fig 26-20 Pencil marks are used as an antflux on the occlusal surface of the castings.

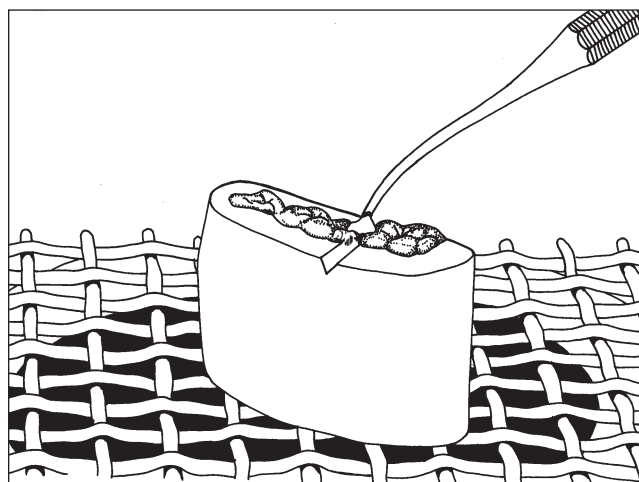


Fig 26-21 Flux is placed in the solder joint area.

investment should measure 2.5 cm (1.0 inch thick) top to bottom. If it is larger, the excess should be trimmed off from the bottom on a cast trimmer (Fig 26-18). A laboratory knife with a no. 25 blade is used to cut a V-shaped notch facial and lingual to the solder joint (Fig 26-19).

The wax extension placed earlier on the lingual will facilitate this step. The lingual notch is larger than the facial notch because the solder will be fed into the joint area from the lingual. The facial notch is necessary to gain access for heating the castings during soldering. If either of these notches is not placed, an incomplete solder joint is likely to result. The remaining wax is flushed out with boiling water from

a boil-out tank. A no. 2 pencil is used to draw a heavy line across the marginal ridges adjacent to the solder joint area (Fig 26-20). This will act as an antflux and will prevent solder from flowing onto the occlusal surfaces.

While the castings are still warm, flux paste is added with an explorer (Fig 26-21). It will melt, and capillary action will draw it through the entire solder joint. If flux is applied later when the castings are hot, it will bubble up and stick where it is applied rather than flowing into the joint where it is needed. Also, surface oxidation may occur before the protective flux is applied.

26 Solder Joints and Other Connectors

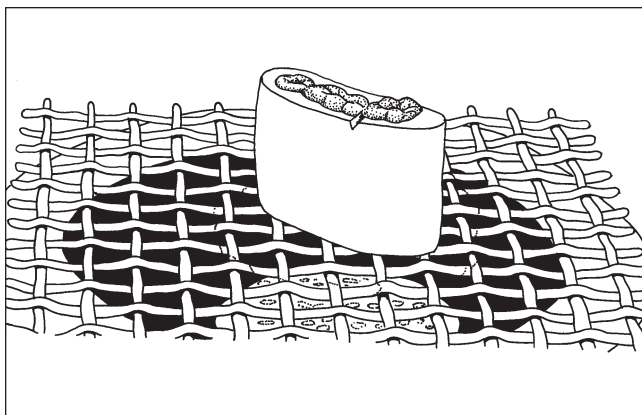


Fig 26-22 The invested casting is preheated over a Fisher burner for 10 to 15 minutes.

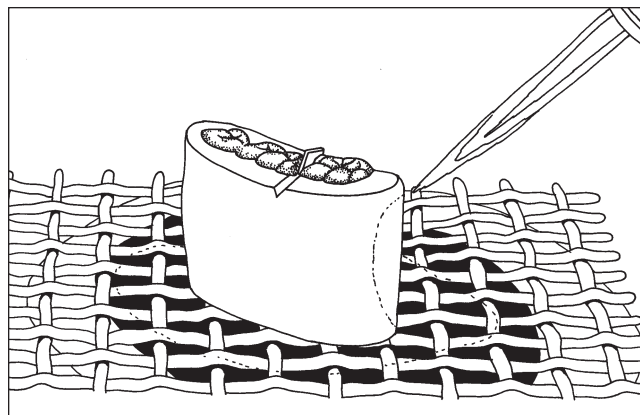


Fig 26-23 The flame is directed against the investment from all sides until it glows if the flame is left in one place for a few seconds.

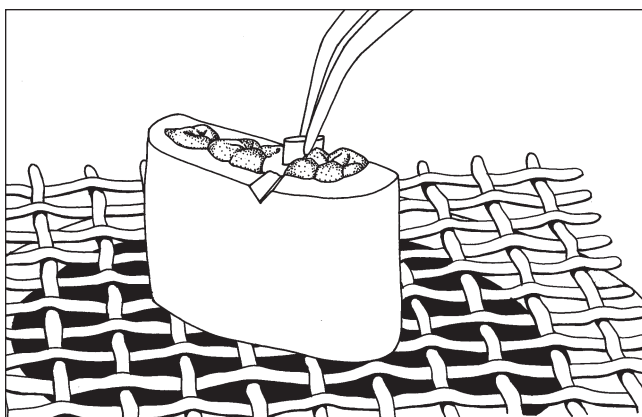


Fig 26-24 Solder is placed into the lingual notch.

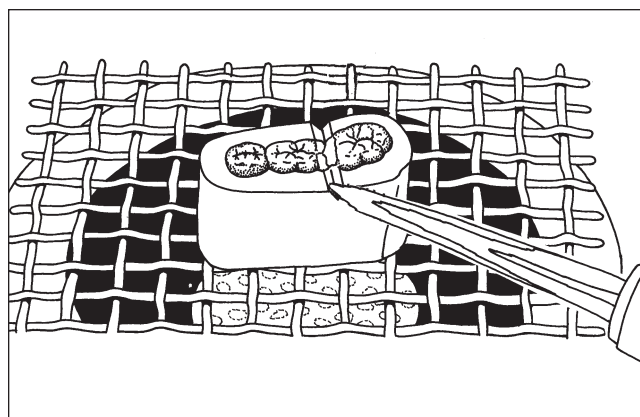


Fig 26-25 The flame is directed against the facial side of the investment and into the facial notch when the block is hot enough for soldering.

Soldering

The invested castings should be preheated to ensure even heating. If the castings are not preheated, the uneven heat distribution that will occur when the blowpipe is applied to a cold block may produce distortion of the finished joint.^{14,23} The investment block can be placed in an oven and brought from room temperature to 815°C (1,500°F).¹⁷ In an alternative method of preheating the invested castings, they are set on a tripod and screen over a Fisher burner. The castings are preheated for 10 to 15 minutes (Fig 26-22).

Heating begins with the blowpipe. The flame is brushed over the entire investment block repeatedly until it is so hot that the castings glow red when the flame is held on them for 2 or 3 seconds (Fig 26-23). The burner is left on throughout this process. Two or three 2 × 3-mm pieces of solder, covered with flux, are wedged into the lingual embrasure of the joint area (Fig 26-24). They will be melted by the heat of the castings, not by the blowpipe. If the blowpipe is used to melt the solder directly, the solder will “ball up” and not flow at all, or it will not flow through the entire joint. If too much sol-

der is used, it may run onto the occlusal surface; moreover, a larger bulk of solder is more likely to produce distortion.

The blowpipe is aimed obliquely at the investment because an obliquely directed flame results in more even heating and less distortion.¹⁴ The tip of the blue cone is concentrated on the facial side of the block near the open space between retainer and pontic (Fig 26-25). The solder on the lingual side of the castings will flow toward the source of heat on the facial. When the solder starts to flow, the torch is directed into the facial notch and kept there while the solder flows through the joint. The flame is held there a few seconds longer while the solder shimmers and appears to “roll” in the joint. Then the flame is turned off (Fig 26-26).

The investment block is removed from the tripod with casting tongs and placed somewhere where there is no chance of someone picking it up and getting burned. The bottom of a casting well is good for this purpose (Fig 26-27). If it must be placed on a benchtop, an area should be selected where there is little traffic, and it should be confirmed that the surface is heat resistant. A conspicuous sign should warn others not to touch the investment block. It should not be

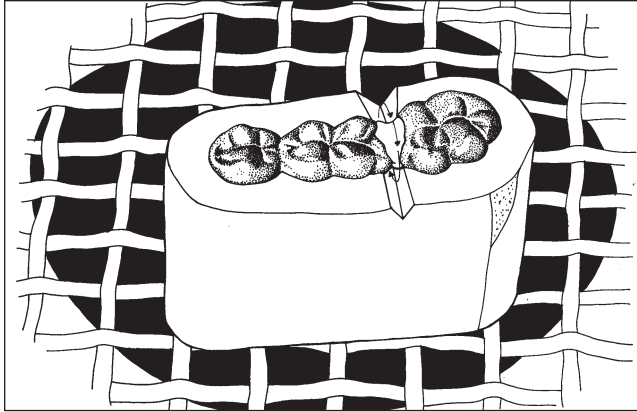


Fig 26-26 When the solder in the joint appears to “roll,” the flame is taken away.

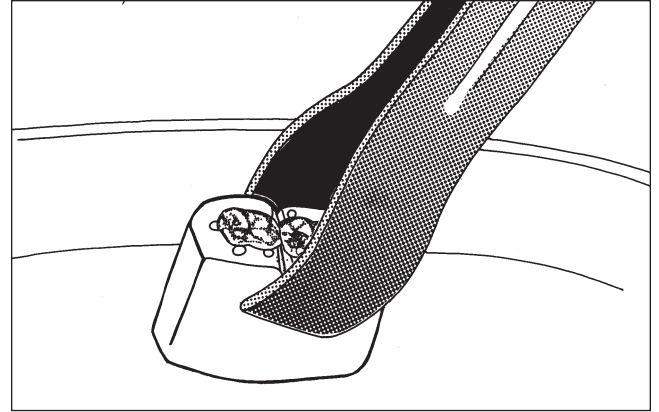


Fig 26-27 The investment block is removed from the tripod and put in a casting well.

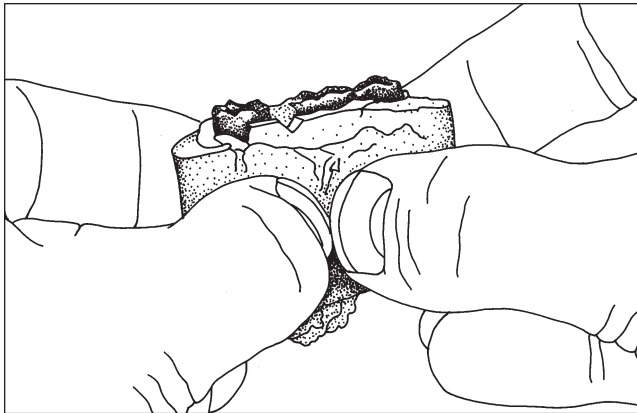


Fig 26-28 The investment is removed after placing it in water.

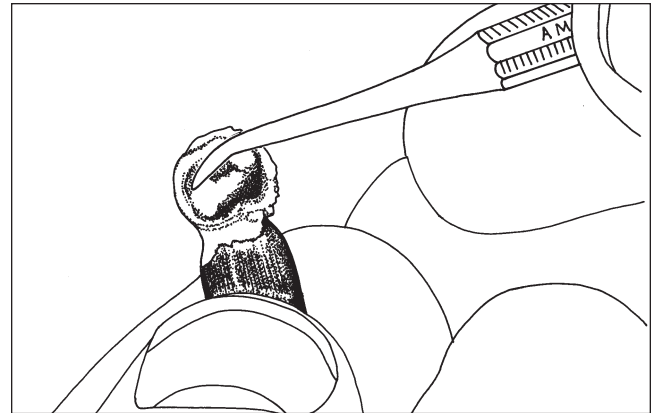


Fig 26-29 Any remaining investment is picked out with a sharp instrument.

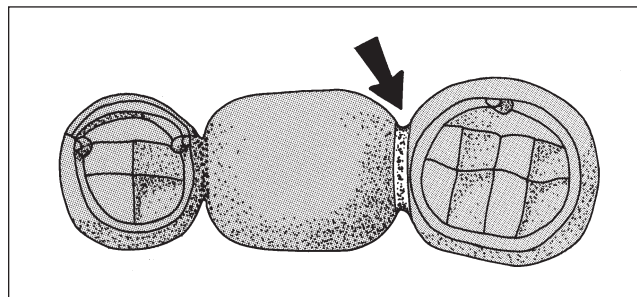


Fig 26-30 The solder joint (arrow) is inspected for size and completeness.

immediately quenched. Quenching shortly after soldering will produce thermal stresses that will result in distortion.²⁶

On the other hand, allowing the investment block to cool slowly to room temperature may produce excessive recrystallization and grain growth.³ The resulting solder joint will be weaker. If the invested fixed partial denture is allowed to bench cool for 5 minutes and is then quenched, distortion should be minimized. This allows time for the gold and solder to respond to an ordering heat treatment, which will increase hardness and strength while reducing elongation.

The invested block is placed in water and the investment removed (Fig 26-28). Portions that do not flake off should be picked off with a sharp instrument and an old toothbrush (Fig 26-29). The solder joint is examined to make sure that it is pit free. Its size is evaluated (Fig 26-30). If it is too bulky, it can be trimmed down with a carborundum disk. Inadequate bulk or the presence of pits requires reinvestment and resoldering. The castings are air abraded with 50- μ m aluminum oxide. The fixed partial denture is ready to be finished and tried in the patient's mouth.

26 Solder Joints and Other Connectors

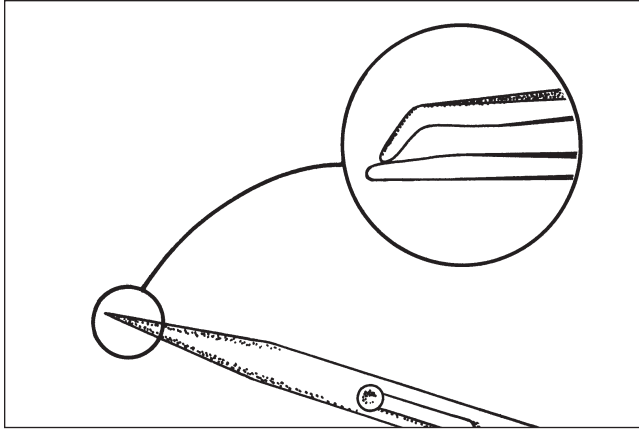


Fig 26-31 Soldering pliers with modified tip (*inset*).

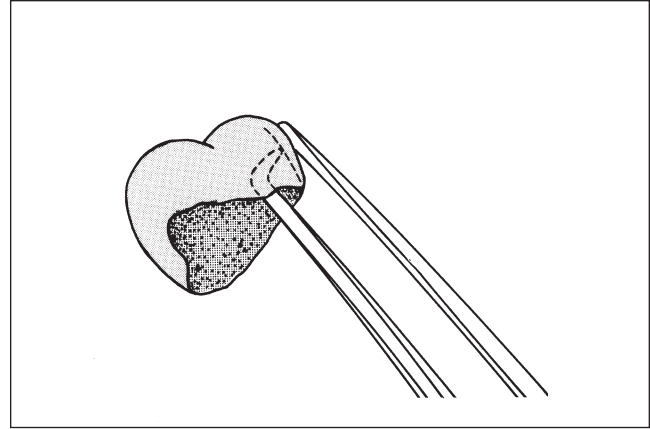


Fig 26-32 Holding the crown with soldering pliers.

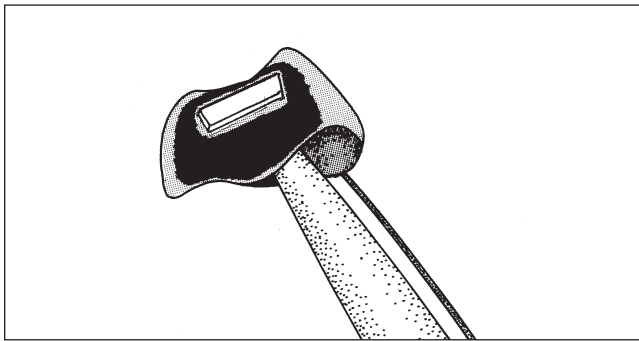


Fig 26-33 Solder on the proximal surface surrounded by an antflux (pencil mark).

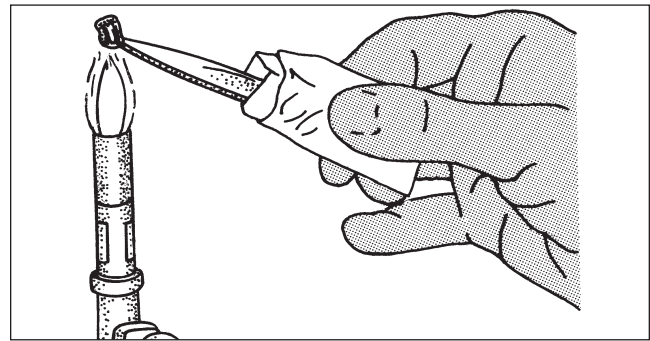


Fig 26-34 The crown is held over a burner flame until the solder melts.

Adding Proximal Contacts

The addition of solder to a proximal contact area is done to build up a contour that may be deficient for any number of reasons. It can easily be done freehand on a single restoration. A fixed partial denture must be invested before the addition.

Armamentarium

- Straight handpiece
- 5/8-inch Burlew disk
- Bunsen burner, matches
- No. 2 pencil
- Locking soldering pliers
- Solder (650 fine), soldering flux

The proximal area to be soldered is finished with a Burlew disk. The interproximal surface to be soldered is outlined with a no. 2 pencil. The area to be soldered must be wider than the contact. It should extend across the entire proximal surface, just apical to the marginal ridge. The periphery of this new bulk will be blended into the contours of the

crown, rather than being a bump on the side of the crown. A 1.5-cm-long piece of ceramic ring lining material can be rolled and packed into the restoration, leaving some to overlap the crown margins.²⁷ This step will be of greater benefit for smaller crowns.

One tip of a pair of locking soldering pliers is bent so that a crown can be held by its axial wall without the pliers touching the margin (Fig 26-31). The crown is grasped with the locking soldering pliers. The bent beak should be inside the casting, and there should be no contact at any other point (Fig 26-32). A wet paper towel is wrapped around the handle of the soldering pliers.

The casting is warmed slightly, and a small drop of soldering flux is placed on the contact to be soldered, staying within the pencil outline. A 2- to 4-mm piece of solder (more or less, depending on the size of the casting) is dipped into the flux. The solder is placed on the proximal surface (Fig 26-33). While the soldering pliers are held with the wet towel, the casting is placed over the burner, with the casting kept in the blue reducing tip of the flame (Fig 26-34). It is held there until the casting glows a bright red, allowing the solder to melt and adapt itself to the casting.

The casting is removed from the flame. A gold alloy casting is allowed to cool until the metal loses its glow and then is quenched in water. It is air abraded with 50- μ m aluminum

oxide. If the casting is made of a base metal alloy, it is allowed to cool for at least 5 minutes before it is quenched and then cleaned with aluminum oxide abrasive. The casting is then finished to the proper contour and returned to the mouth for final adjustment of the contact area.

Repairing Casting Voids

There are some deficiencies in casting that can be repaired by soldering. Blowholes (ie, voids extending all the way through a casting on an axial surface) and pits that do not extend all the way through are candidates for solder repairs. Solder should not be used to repair:

- *Deficient margins.* It is impossible to get an acceptably adapted margin by adding solder.
- *Occlusal holes.* Holes in the occlusal surface cannot be successfully soldered because of the risk of solder running over the entire surface. Aside from the technique difficulties, the presence of a hole on the occlusal surface of a crown is usually symptomatic of inadequate occlusal reduction in the preparation.

Efforts to “patch” poor castings of this variety result in a compromise at best (and more often in a casting that is still poor). Inordinate amounts of time can be expended to salvage a restoration of questionable value when that same time could have been spent in remaking it properly. A remake is never a satisfying effort, but as Forrest Gump said, “It happens.”

Armamentarium

- Straight handpiece, no. 2 round bur
- Bunsen burner, tripod, and screen
- Matches
- No. 2 pencil
- Locking soldering pliers
- Solder (650 fine), soldering flux
- Platinum foil
- PKT instrument (no. 1)
- Sticky wax
- Blowpipe, casting tongs

To repair a pit, the area around it is outlined with a no. 2 pencil. The crown is grasped with the modified locking soldering pliers, the handle of which is wrapped in a wet paper towel. The casting is warmed slightly, and a dab of flux is placed into the pit. A corner of a triangular-shaped, 1- to 2-mm piece of solder is inserted into the pit. The casting is held over the Bunsen burner until the solder flows, removed from the flame, allowed to cool, and then quenched. It is air abraded with 50- μ m aluminum oxide and washed, and the newly soldered area is finished down.

To repair a hole that extends all the way through a crown, the die is marked through the hole with a very fine graphite pencil. The casting is removed, and a small piece of platinum foil is placed over the mark on the die. The crown is reseated over the foil, and a bead of sticky wax is applied to the hole with a PKT no. 1. When it has cooled, the casting is removed from the die. The small piece of foil should be stuck to the inside of the casting. It will serve as a matrix over which the solder can flow. The casting is filled with investment and set down in a small patty of investment.

When the investment has set, the bead of sticky wax over the hole to be repaired is picked off. The area around the hole is antiluxed with a no. 2 pencil. The casting is placed on a tripod and warmed slightly. A small amount of flux is applied to the hole and the foil that is visible through the hole. Heating of the casting is continued, and a square of solder slightly larger than the hole is added. The casting, not the solder, is heated. When the solder flows, the flame is removed. The invested casting is placed in a casting well or on a heat-safe benchtop. If it is a gold casting, 2 or 3 minutes should be allowed before quenching. Then it is air abraded with 50- μ m aluminum oxide. The casting is washed, and the outward-facing surface of the axial wall is finished. The platinum foil will be stuck to the inside of the casting. If it is left there, it will prevent the casting from seating completely. A no. 2 round bur is used to remove it.

Breaking Solder Joints

It is sometimes necessary to break a previously soldered fixed partial denture. The most common reason for this is the failure of the soldered fixed partial denture to fit the abutment teeth. The following technique will work on a soldered type III gold fixed partial denture. It cannot be used on prostheses with ceramic or resin veneers.

Armamentarium

- Bunsen burner, matches
- Locking soldering pliers
- Paper towel
- No. 7 wax spatula
- Straight handpiece, carborundum disk on mandrel

A wadded-up wet paper towel is placed on the bench next to the Bunsen burner. The fixed partial denture is grasped by the pontic with locking soldering pliers whose handle has been wrapped with a wet paper towel. Care must be taken not to contact the margins with the pliers. Contrary to the principles of soldering, in this situation the joint is heated directly. The solder joint to be unsoldered is held directly at the tip of the blue cone of the Bunsen burner. When the solder starts to get glossy, the fixed partial denture is quickly moved over the wet paper towel. While the fixed partial

26 Solder Joints and Other Connectors

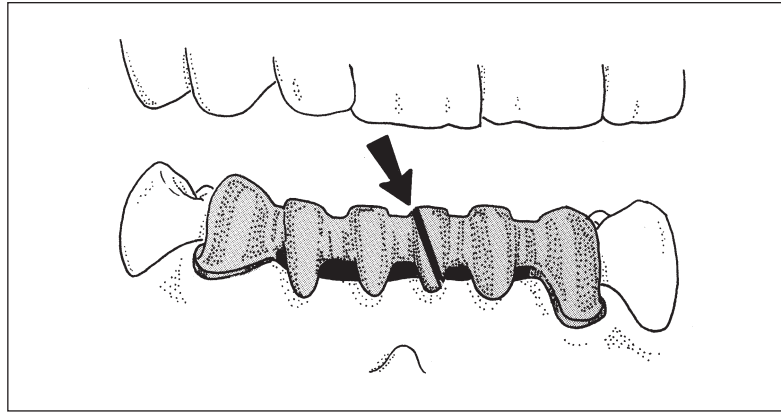


Fig 26-35 The diagonal cut across the left central incisor (arrow) provides more surface area for greater strength of the solder joint than would an interproximal joint.

denture is held about 0.5 inch above the table, the crown is tapped next to the melted joint. If the joint was heated sufficiently, the crown will fall off.

The parts of a gold fixed partial denture are cleaned by aluminum oxide air abrasion. Normally, some solder will remain on each of the parts. All of this solder is ground off with a carborundum disk, and the surfaces are finished with a Burlew disk before resoldering.

Soldering Metal-Ceramic Alloys

Although an effort is made to fabricate metal-ceramic fixed partial dentures as a single unit, it is sometimes necessary to solder the units together. This may occur if: (1) there is distortion in a single-piece fixed partial denture casting, (2) one retainer has inadequate margins and must be redone, (3) the fixed partial denture length is too great for an accurate single-piece casting, or (4) type III partial veneer retainers are used in an otherwise metal-ceramic fixed partial denture.

If all units of the fixed partial denture requiring soldering are of a metal-ceramic alloy, the fixed partial denture may be assembled in one of two ways. Preventer soldering uses a high-fusing solder that is melted by torch before porcelain is added. Preceramic pontic soldering allows a diagonal joint through the middle of a pontic²⁵ (Fig 26-35), which produces stronger joints than soldering in the interproximal connector area,²⁸ and it is technically easier.²⁹ In postveneer soldering, a low-fusing solder is melted in the oven after porcelain has been baked on the fixed partial denture. Postceramic soldering compensates for any tooth movement in the mouth between final impression and restoration, and it eliminates the significance of any distortion that might occur during porcelain firing.

If the fixed partial denture includes a type III gold alloy retainer, it can be assembled only by postveneer soldering.

The high temperatures reached during the porcelain firing cycle would melt the type III gold alloy if it were soldered to the fixed partial denture before the porcelain had been added.

For many years, soldering was done with a gas-air blowpipe. With the development of metal-ceramic restorations, a need for oven soldering developed. Oven-soldered postveneer solder joints are at least as strong as torch-soldered preventer solder joints,³⁰ and several investigators found the postveneer joints to be stronger.^{13,31-33} Certainly, postveneer soldering does present special problems. Soldering investment, flux, and solder must be kept from contacting the porcelain to prevent discoloration or fracture of the porcelain.

A third method of soldering utilizes an infrared soldering machine (J. M. Ney). The device focuses a concentrated beam of infrared energy from a tungsten iodine lamp that operates at 3,400°C in a closed chamber under a controlled atmosphere. No apparent differences in porosity and strength have been found between torch-soldered and infrared-soldered joints,^{34,35} although infrared soldering has been found to require more time than torch soldering.³⁴

In recent years, a fourth method has been developed that uses laser welding. Laser welding in an argon-rich environment is the preferred method of effectively joining titanium components. The advantage of this technique is that it preserves titanium as the sole substrate component, maintaining its biocompatibility and preventing unnecessary oxidation, which could lead to spontaneous debonding.³⁶

Soldering is very technique sensitive, and the combination of alloys and joining methods are very specific to each other. What works very well with one combination does not necessarily work well with another. For example, there is evidence that in preventer joining of gold-palladium alloys by torch or furnace methods, fatigue resistance is greater than with infrared or laser welding.³⁷ Likewise, the use of argon shielding during laser welding is necessary for titanium and titanium alloys but not for gold or cobalt-chromium alloys.³⁸

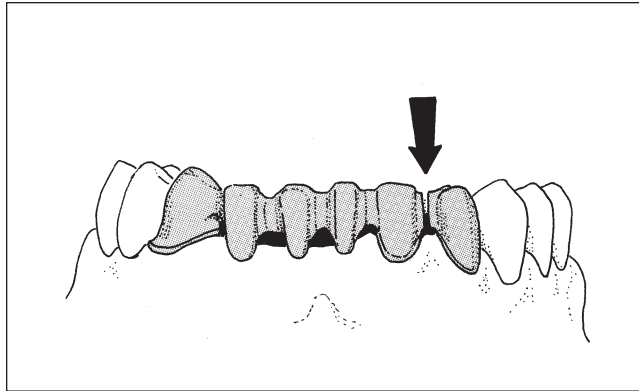


Fig 26-36 Facial view of a single-piece fixed partial denture casting with right canine and left lateral incisor retainers and an as-yet-unattached left canine retainer. The arrow marks the area to be soldered.

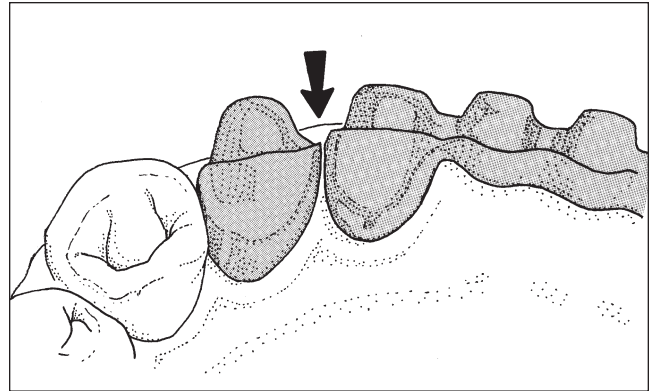


Fig 26-37 Lingual view of proposed solder joint (arrow) showing separation and alignment of surfaces to be joined.

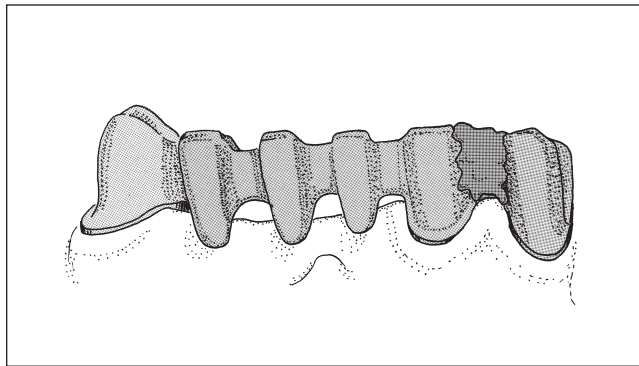


Fig 26-38 Facial view of crowns to be joined by soldering attached with autopolymerizing acrylic resin (Duralay).

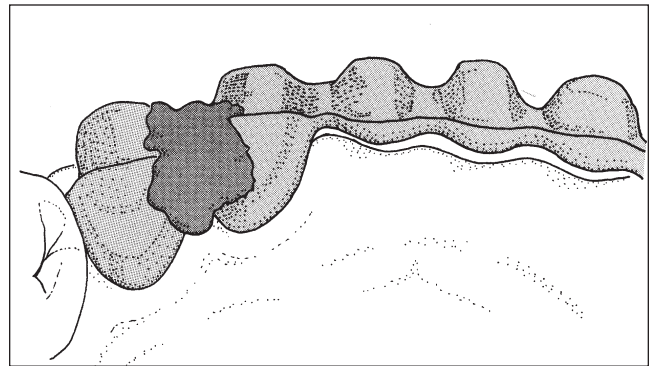


Fig 26-39 Lingual view of resin index between the canine and lateral incisor retainers.

Preveneer Metal-Ceramic Alloy Soldering

Although some investigators have found postveneer to be stronger than preveneer solder joints,^{13,31-33} preveneer soldering remains more popular with ceramists. This is because postveneer soldering takes more time, skill, and attention to detail to keep the investment, flux, and solder from touching porcelain. When it does, there may be "greening" or crazing of the porcelain, which in turn can require the reapplication of porcelain and resoldering.

The apparent superiority of the postveneer solder joints also may be offset by the fact that unlike the standardized joint size in the laboratory studies, clinical postveneer joints frequently are smaller because of the ceramist's fear of causing damage to the ceramic by contacting it with solder.

The example demonstrated here is of a six-unit metal-ceramic fixed partial denture with two retainers at one end, fabricated as a five-unit fixed partial denture (canine to lateral incisor) with the second retainer, a canine, made separately to facilitate margination of the proximal surfaces of the contiguous retainers (Fig 26-36). These restorations should

be fabricated so that there will be parallel surfaces in the solder joint area, with adequate separation for a solder joint with optimum strength and minimum distortion (Fig 26-37).

To accurately transfer the segments to be joined to the laboratory bench, they are tacked together with an autopolymerizing acrylic resin (Duralay) index (Fig 26-38). Monomer and polymer are placed in separate dappen dishes or medicine cups. It should be confirmed that the segments of the fixed partial denture are completely seated and stable in the mouth. If one is not stable, it should be held down with a finger. The area is dried with compressed air and isolated with cotton rolls. A disposable brush is used to apply a few drops of monomer between the two retainers. Then the brush is dipped in polymer, and a small amount of powder is applied to the joint. Alternation of small quantities of liquid and powder continues, with care taken to ensure that the material between the retainers is always wet. The index is built so that it extends onto adjacent surfaces of the two retainers (Fig 26-39).

A backup plaster index is made on a tongue depressor. Quick-setting plaster is mixed and placed on a wet depressor, creating a ridge of plaster that extends the length of the tongue depressor. It is applied to the teeth while the plaster is still fluid. If any cracks appear in the plaster, the material

26 Solder Joints and Other Connectors

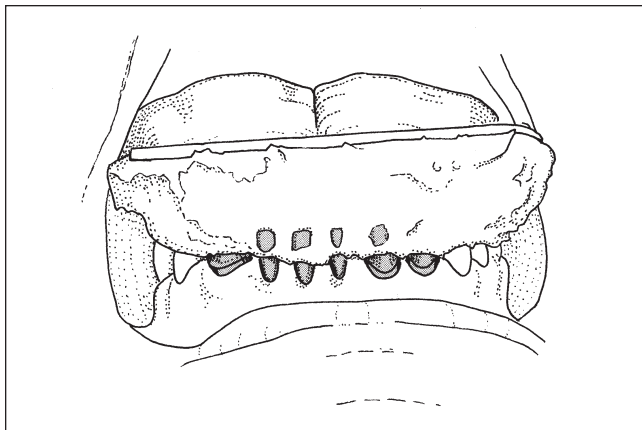


Fig 26-40 Quick-setting plaster index on a tongue depressor is shown in place in the mouth.

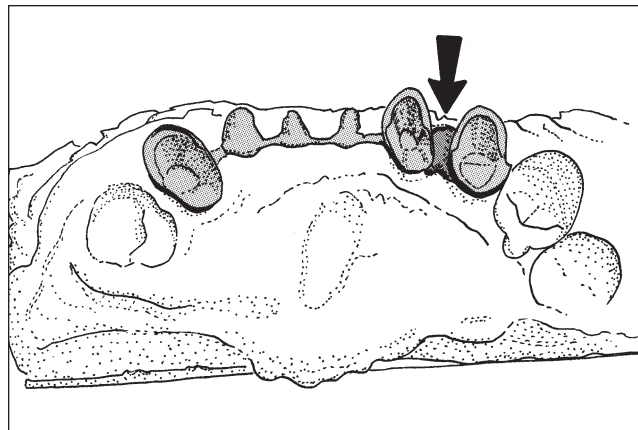


Fig 26-41 Inverted view of the fixed partial denture embedded in the plaster index after removal from the mouth. The arrow indicates the resin index.

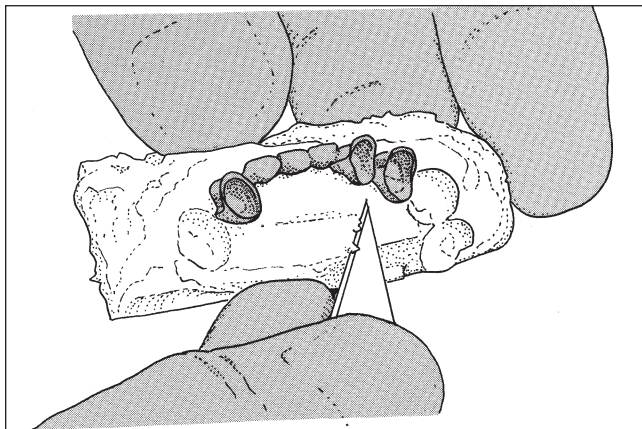


Fig 26-42 The level of plaster is carved down from the fixed partial denture.

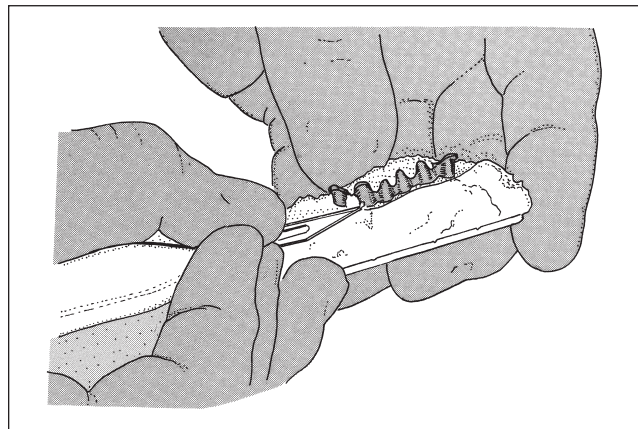


Fig 26-43 Each pontic and retainer is carefully cut around.

is removed, the fixed partial denture is washed thoroughly, and the index is remade. The index is held until the plaster is completely set (Fig 26-40). If left untended, it could shift or slip, necessitating a remake. The index is removed along the path of insertion of the abutment preparations. It is examined thoroughly to see if the components are securely embedded (Fig 26-41).

The surface of the index surrounding the fixed partial denture is carved, exposing the pontics and retainers (Fig 26-42). Each pontic and retainer is very carefully exposed (Fig 26-43). The resin is cut around, but not disturbed. If the components are still firmly embedded in the plaster, they can be left there and invested from the plaster index using the technique previously described. The resin will serve as a filler in the solder joint.

Those who are more experienced at soldering may prefer to lift the components from the plaster. If the resin remains intact, some investment (Hi-Heat soldering investment, Whip Mix) is mixed and gently vibrated into the retainers (Fig 26-44). The fingers are used as a cushion between the vibrator and the fixed partial denture components. A quantity of

investment large enough to contain the fixed partial denture is placed on a ceramic or hard resin tile (Fig 26-45).

The framework, whose retainers are filled with investment, is inverted and placed into the top of the soft mound of investment (Fig 26-46). With light finger pressure, the luted-together castings are partially submerged into the investment. The incisal half (approximately) of the castings should protrude from the investment. A little investment is added over the units that will not be directly involved in soldering (Fig 26-47). The investment is allowed to set hard. When it does, the periphery is trimmed to produce a near-even bulk of investment around the castings (Fig 26-48).

The invested castings are preheated in a burnout furnace at 650°C to 815°C (1,200°F to 1,500°F, depending on availability of furnaces). When the invested block has reached the desired temperature, casting tongs are used to transfer it to the wire mesh or some other area that will not be damaged by flame. Several 2- to 3-mm pieces of solder can be laid in the lingual notch, or a strip of solder in a hemostat can be fed into the embrasure after it gets hot. The solder used is Olympia presolder (Jelenko), whose melting range is

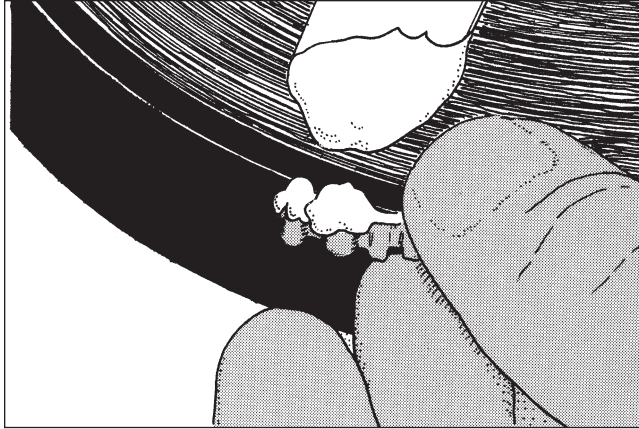


Fig 26-44 Investment is gently vibrated into the retainers.

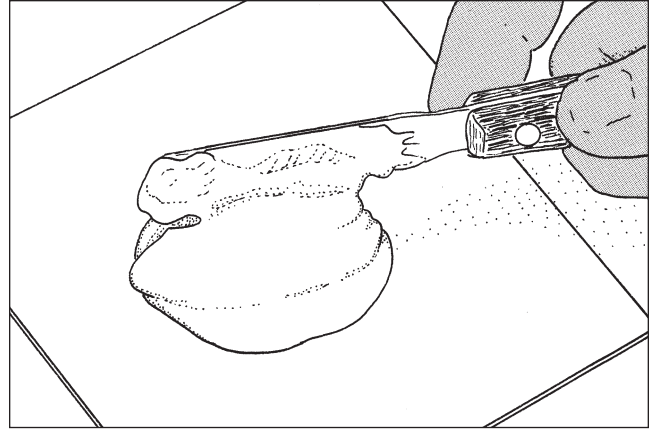


Fig 26-45 A mound of investment is placed on a tile.

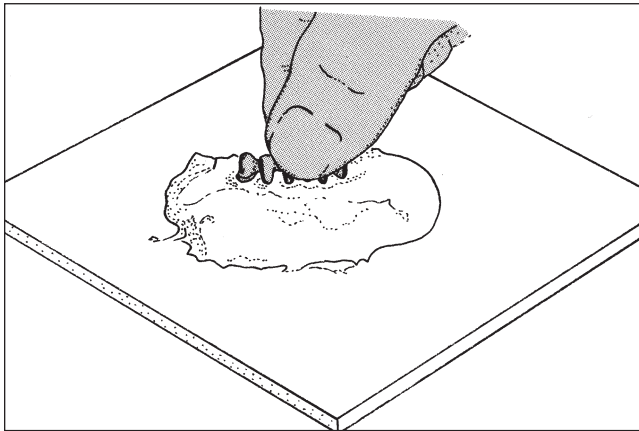


Fig 26-46 The fixed partial denture is set into the investment, margins down.

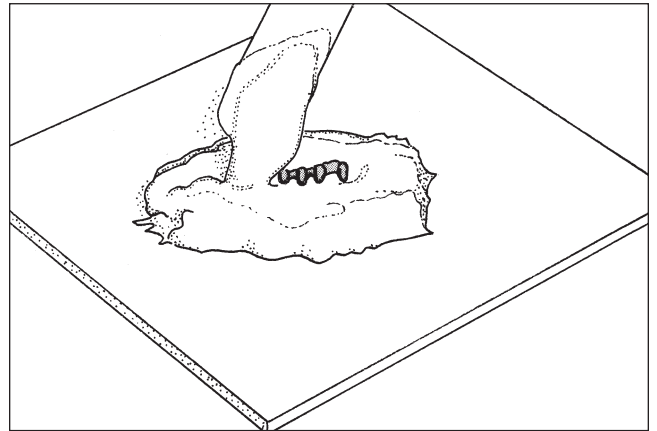


Fig 26-47 The retainer and pontics that will not be soldered with investment are covered.

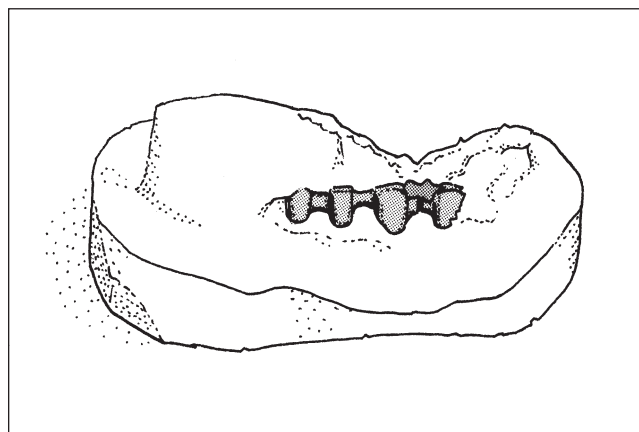


Fig 26-48 The edge of the block is trimmed to produce an even bulk of investment.

26 Solder Joints and Other Connectors

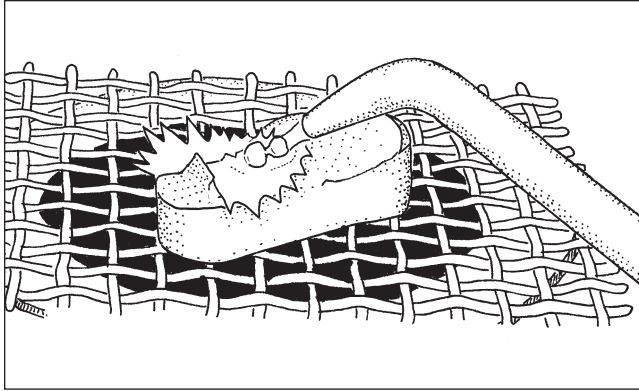


Fig 26-49 The flame is directed against the lingual surface of the block of investment.

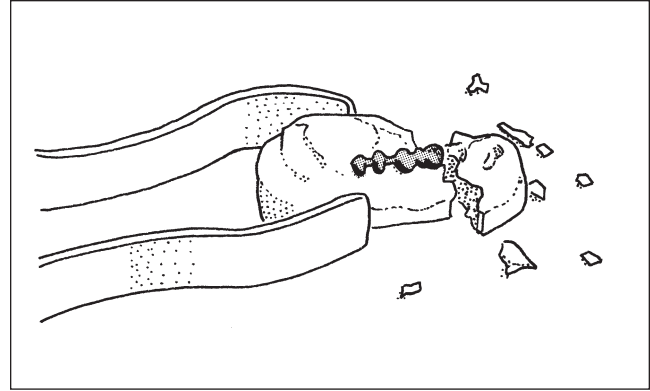


Fig 26-50 Casting tongs are used to break up the investment by tapping it on a benchtop.

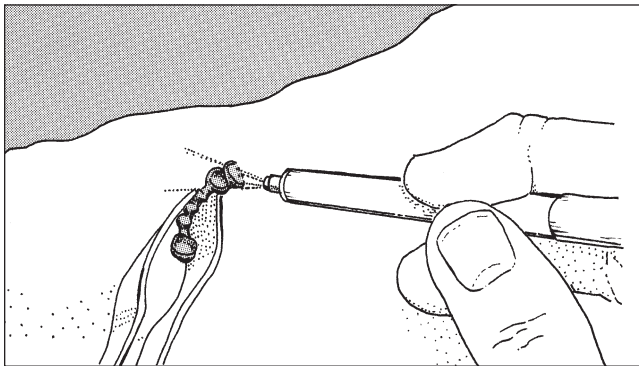


Fig 26-51 The casting is air abraded with aluminum oxide to clean the casting surface.

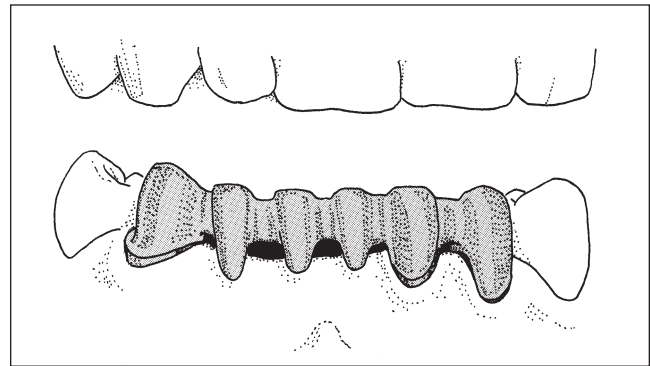


Fig 26-52 Facial view of the soldered framework at try-in.

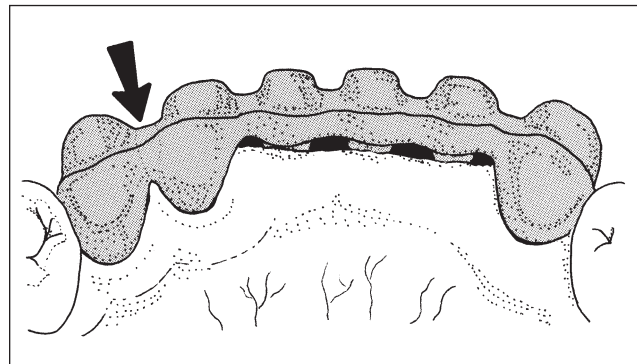


Fig 26-53 Lingual view of soldered area (arrow).

1,110°C to 1,127°C (2,030°F to 2,060°F). The investment is brushed with a gas-oxygen flame until the block glows if the flame is held in one spot for a few seconds. The flame is held on the lingual surface of the block of investment (Fig 26-49). The torch is then directed into the lingual notch as solder is fed into the facial notch. Heat will draw the solder through the joint area.

The soldered fixed partial denture is removed from the tripod and placed in a casting well or some other safe place where someone will not be able to touch it and be burned. When it has cooled to room temperature, the investment is

broken by picking it up with casting tongs and tapping it on the bottom of a casting well or a heat-resistant benchtop (Fig 26-50). The fixed partial denture is retrieved from among the bits of soldering investment and cleaned up. The surface is air abraded with 50- μ m aluminum oxide (Fig 26-51).

When the restoration is tried in (Fig 26-52), all margins should be closed without any special force needing to be applied anywhere. It should be checked for any encroachment on the interdental papilla on the facial or especially on the lingual aspect (Fig 26-53). If any is found, the restoration is removed from the mouth, and the affected area is relieved.

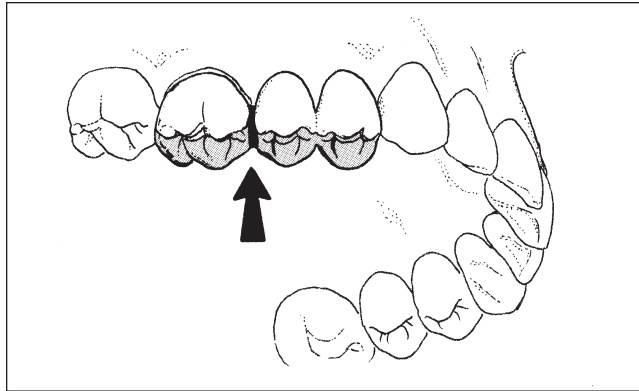


Fig 26-54 Three-unit maxillary metal-ceramic fixed partial denture. The arrow marks the area to be soldered between the premolar pontic and the molar retainer.

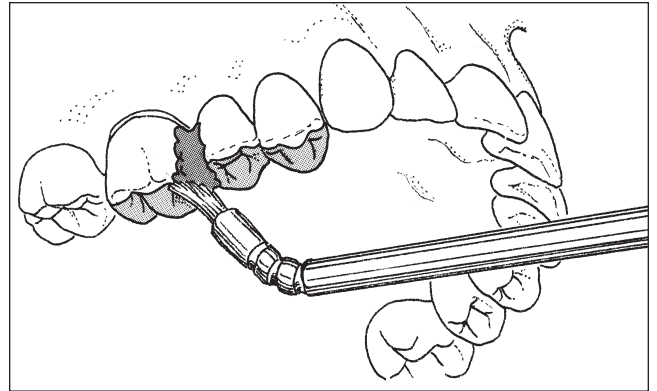


Fig 26-55 A disposable brush is used to apply monomer and polymer between the retainer and the pontic.

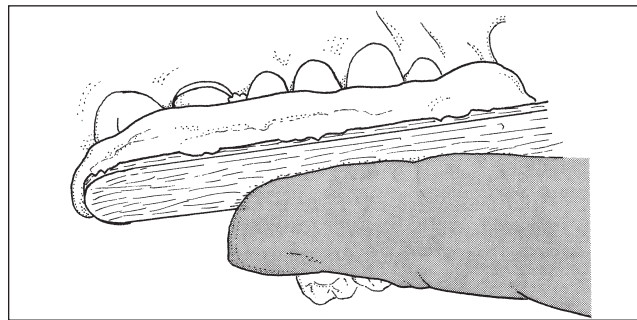


Fig 26-56 A tongue depressor is used to support a plaster index.

Postveneer Metal-Ceramic Alloy Soldering

The technique that follows is for the soldering of a gold-palladium alloy (Olympia). Both preveneer and postveneer soldering produce a stronger joint in Olympia than was possible previously with Jelenko O.³⁹ All phases of the porcelain addition, including glazing, must be completed before the soldering process. The solder (Alboro LF [low fusing], Jelenko) has a melting range of 700°C to 760°C (1,292°F to 1,400°F), and it is used with M20-129 flux paste (Vident).

The units are tried in the mouth, and any necessary adjustments are made. This technique is often employed without prior intent (ie, a fixed partial denture is carried to completion in expectation of cementing it without any type of try-in), only to find that it does not seat. The best joint in terms of esthetics, strength, or both, is selected for separation, using a very thin (0.009-inch or 0.23-mm) disk (Ultra disks).

The fixed partial denture is removed from the mouth. The joint is cut using the disk on a lathe. This allows the use of both hands to hold the fixed partial denture, and the disk remains steady, which definitely would not be the case if it were in a handpiece. These disks are very easily broken. After separation of the two parts of the prosthesis, the retainers are tried in the mouth to see if they fit individually. If

they do, the soldering procedure is continued. A soldering index can be made of quick-setting impression plaster, resin, or zinc oxide-eugenol bite registration paste as previously described.

The areas of the crown that are to be soldered are finished with extra-fine sandpaper disks. Neither rouge nor polishing compounds should be used. The area to be soldered is outlined with a no. 2 pencil, which will serve as an antirflux. The components of the fixed partial denture are resealed in the mouth (Fig 26-54). With the two parts of the fixed partial denture firmly seated, monomer and polymer are poured into separate containers. The area is dried with compressed air and isolated with cotton rolls. A disposable brush is used to apply monomer between the retainer and the pontic.

Next, the brush is dipped in polymer, and a small amount is applied to the joint. Alternation of small quantities of liquid and powder continues, with care taken to ensure that the material between the retainer and the pontic is always wet. The index is built so that it extends onto adjacent surfaces of the two castings (Fig 26-55).

A secondary plaster index is fabricated on a tongue depressor. A quick-setting plaster is arranged on a wet depressor, making a ridge of plaster that extends the length of the tongue depressor. It is applied to the teeth while the plaster is fluid. The index is stabilized until the plaster is completely set (Fig 26-56). The index is removed along the path of insertion of the abutment preparations.

26 Solder Joints and Other Connectors

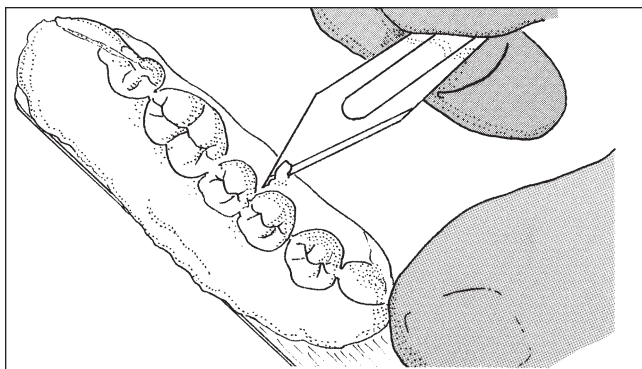


Fig 26-57 A flat surface with shallow imprints is carved on the index.

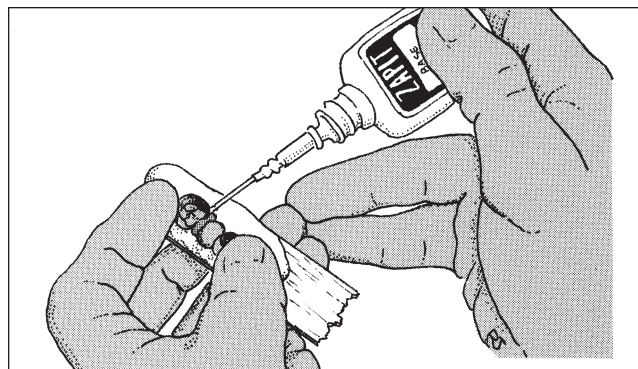


Fig 26-58 Zapit cyanoacrylate liquid resin is squeezed into the joint.

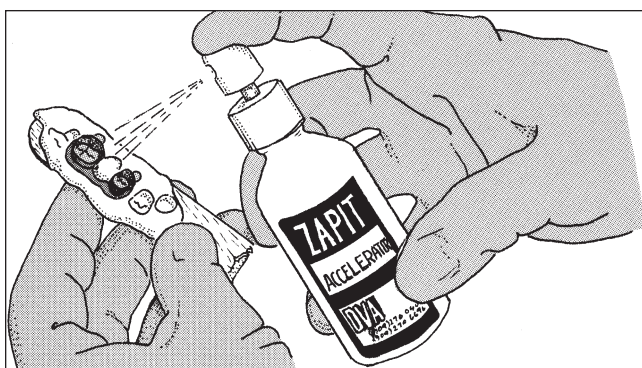

Fig 26-59 Zapit accelerator is sprayed into the joint.

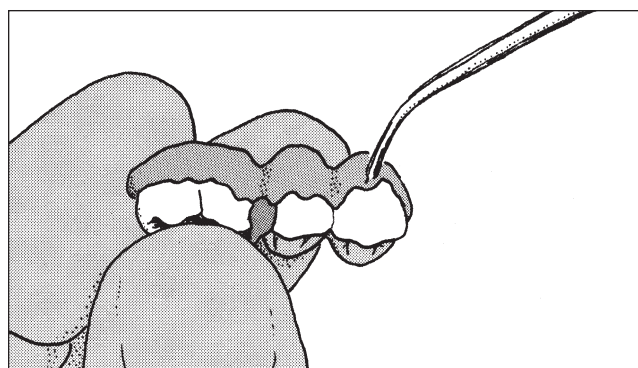


Fig 26-60 The gingival segment of the facial surfaces of the fixed partial denture is covered with 1.0-mm-thick wax.

The surface of the index is carved around the fixed partial denture components, creating a flat surface with shallow imprints (Fig 26-57). The parts of the fixed partial denture are rearranged on the plaster index. If the resin index has come loose, it should be put back in place between the segments of the fixed partial denture without any spaces. A cyanoacrylate liquid resin (Zapit, Dental Ventures) is squeezed in and around the joint while the parts are held securely (Fig 26-58). The Zapit accelerator is then sprayed over the joint (Fig 26-59). Zapit is the material of choice when indexing on a cast in the laboratory, but it should not be used in the oral cavity because its safety has not been proven.²² Duralay is the material of choice for use in the mouth.²²

To prevent investment from contaminating the ceramic veneer covering much of the fixed partial denture, a 1.0-mm-thick layer of ivory wax is placed over the gingival one-half to two-thirds of the facial surfaces of the retainers and pontic (Fig 26-60). The wax for this step and those following should overlap the metal by 1.0 mm. The restoration

is turned over, and a coat of wax is applied to the gingival and lingual aspects of the pontic (Fig 26-61). Wax must be applied to any exposed ceramic that is part of a porcelain shoulder (Fig 26-62). Wax is added to the joint area to ensure access for the solder after the restoration has been invested (Fig 26-63).

A small amount of soldering investment is mixed and carefully vibrated into the crowns (Fig 26-64). It should be ensured that the metal-ceramic crowns are filled completely with investment because this is the major support for the crowns in the block. Direct vibration of the castings should be avoided to prevent loosening of the crowns. A mound of investment is built on a flat surface (Fig 26-65), and the inverted fixed partial denture is set, margins first, into the investment (Fig 26-66). A ridge of investment is pushed up with a spatula to cover most of the lingual surfaces of the retainers and pontic (Fig 26-67).

When the investment has set, it is trimmed to within 3.0 mm of the castings. A wide bevel is created around the en-

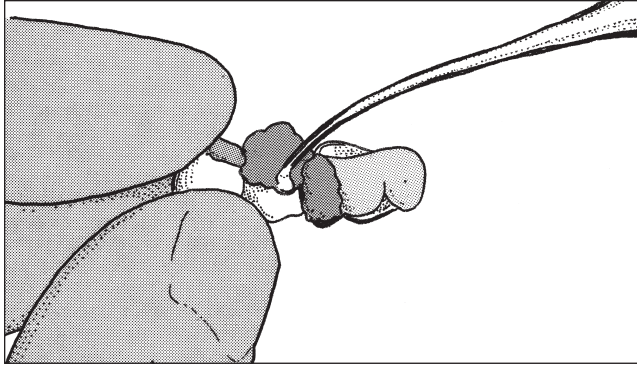


Fig 26-61 The gingival aspect of the pontic is covered with wax.

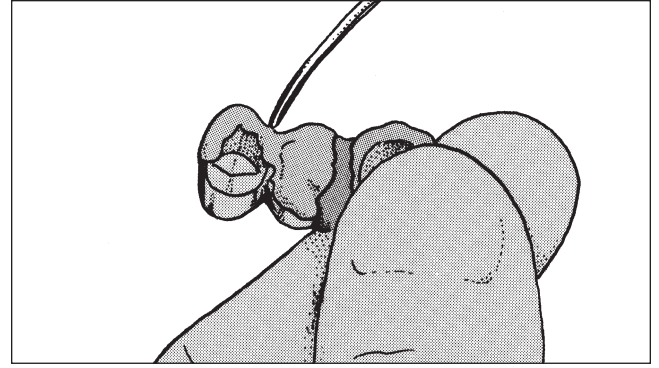


Fig 26-62 Wax is applied to the exposed porcelain shoulder.

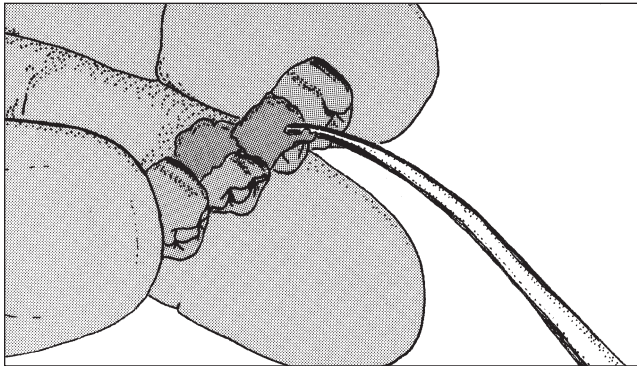


Fig 26-63 Wax is added to the joint area to increase access for solder.

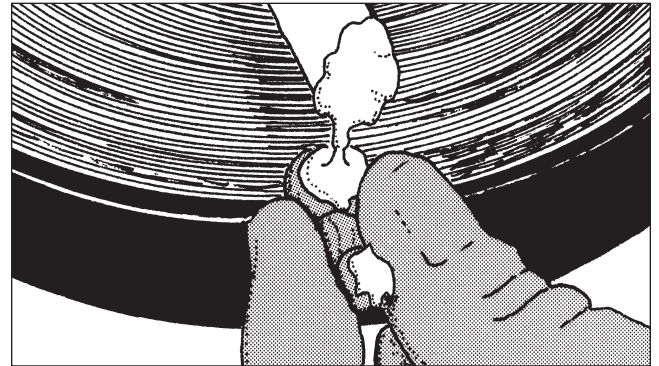


Fig 26-64 Crowns are filled with soldering investment.




Fig 26-65 Soldering investment is placed on a flat surface.

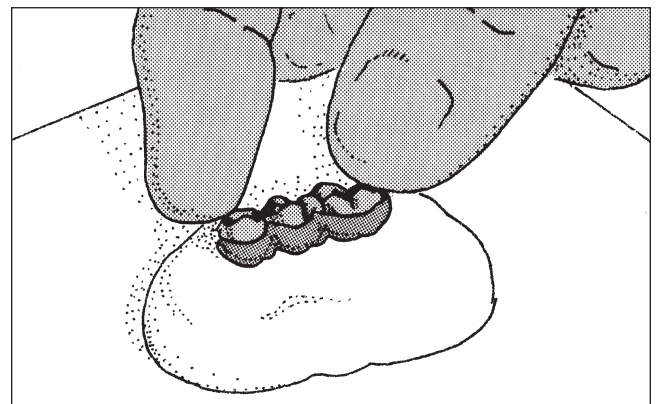
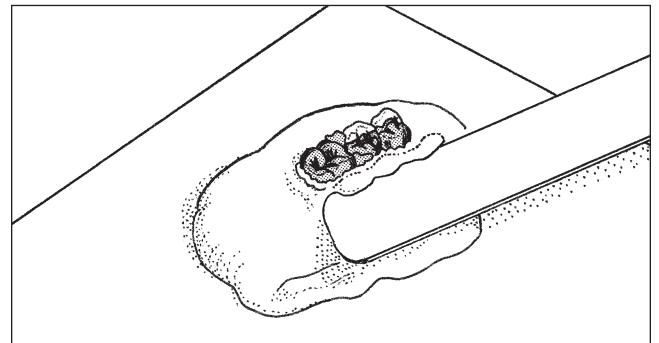


Fig 26-66 The fixed partial denture is put into the investment.

Fig 26-67 Investment is pushed up over the lingual surfaces of the fixed partial denture.



26 Solder Joints and Other Connectors

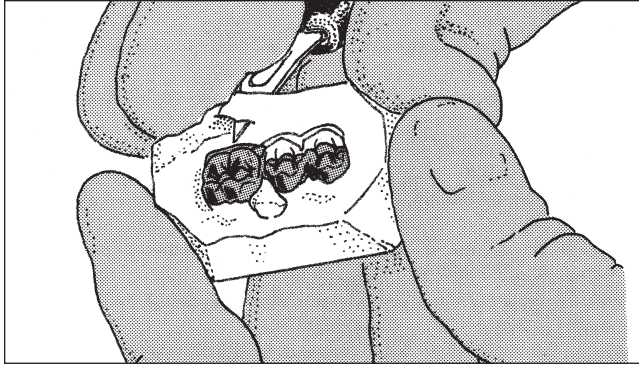


Fig 26-68 The investment is trimmed, leaving 3.0 mm around the castings. The entire block is beveled.

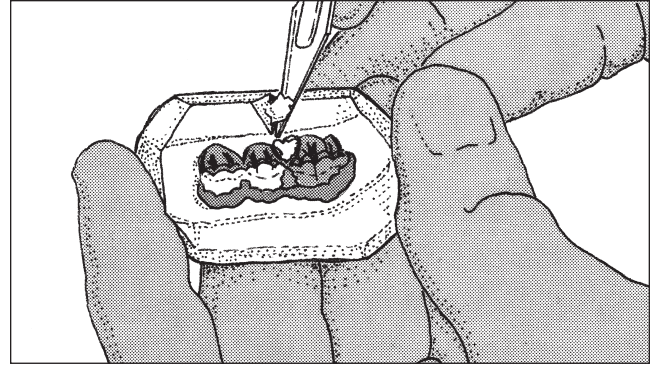


Fig 26-69 A V-shaped notch is carved on the lingual.

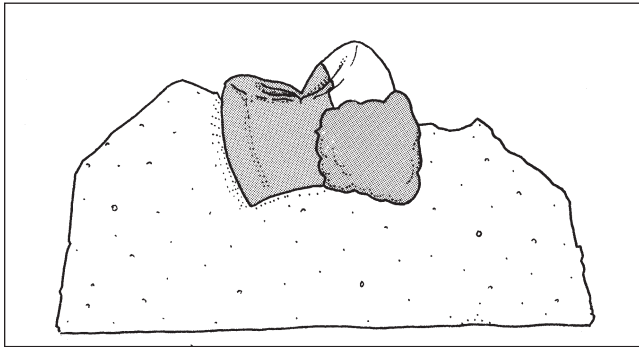


Fig 26-70 The wax layer separates the investment and porcelain.

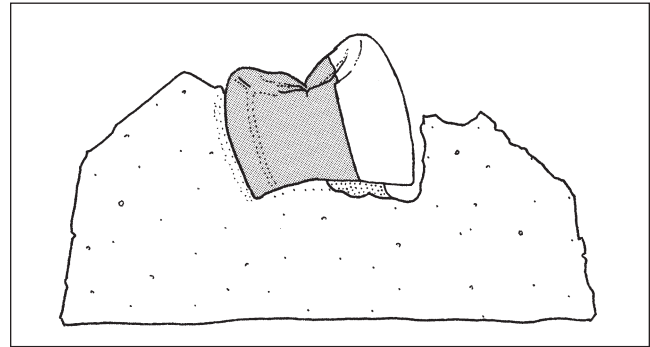


Fig 26-71 After wax removal, a space between the porcelain and investment material protects the porcelain.

tire periphery of the invested block with a laboratory knife equipped with a no. 25 blade (Fig 26-68). Then a V-shaped notch is carved on the lingual aspect to ensure adequate access to the solder joint (Fig 26-69). The wax is flushed out with boiling water. When the fixed partial denture was embedded in investment, the wax prevented contact between investment and porcelain (Fig 26-70). After the wax has been removed, there is a space surrounding the porcelain, including any all-porcelain shoulders (Fig 26-71).

The invested castings are placed in front of a porcelain oven to warm slowly for 10 minutes. The muffle of the oven (set at approximately 540°C or 1,000°F) is then opened, and the castings are warmed for 5 more minutes.

A couple of 2- to 3-mm pieces of fluxed solder are added to the solder joint; they should contact only the metal framework of the fixed partial denture. The castings are placed in the oven, the vacuum is turned on, and the temperature is raised to 815°C (1,500°F) at the rate of 42°C (75°F) per minute. The castings are checked for completion of soldering. If the solder has not yet fused, the temperature in the oven should continue to be raised until it reaches 870°C (1,600°F). The final temperature used will vary with different solders. It is important to use the solder recommended by the manufacturer for the specific alloy being used.

The vacuum is broken, and the invested fixed partial denture is removed from the oven. The casting is allowed to cool

to room temperature. The castings cannot be quenched because the porcelain may fracture. When the fixed partial denture has cooled, the investment is removed. The porcelain is covered with masking tape, and the fixed partial denture is air abraded.

Soldering can be done on base metal fixed partial dentures with gold solder in a manner similar to that used for gold-palladium metal-ceramic alloys.⁴⁰⁻⁴² While restorations of base metal alloys can be soldered, they tend to be quite technique sensitive⁴²⁻⁴⁵ and have variable results.⁴⁶ Overheating of the metal substrate and excessive flux have been faulted by some,⁴³ while surface oxides have been blamed by others.⁴⁴ Closed vacuum furnaces were suggested as a solution for this problem,⁴⁴ and testing by Lima Verde and Stein⁴⁵ confirmed that soldering under vacuum resulted in mean tensile strengths that were as much as 40% greater than those soldered in air. High- and low-temperature solders are capable of producing joints with adequate tensile strength that will not be lost in a corrosive environment.⁴⁷ Gold solder used with high-resistance nickel-chromium alloy prevents corrosion, while silver solder used on the same alloy permits corrosion.⁴⁸ Silver solder joints become porous from corrosion along the interface between the solder and the nickel-chromium substrate. This does not occur with gold solder.⁴⁹

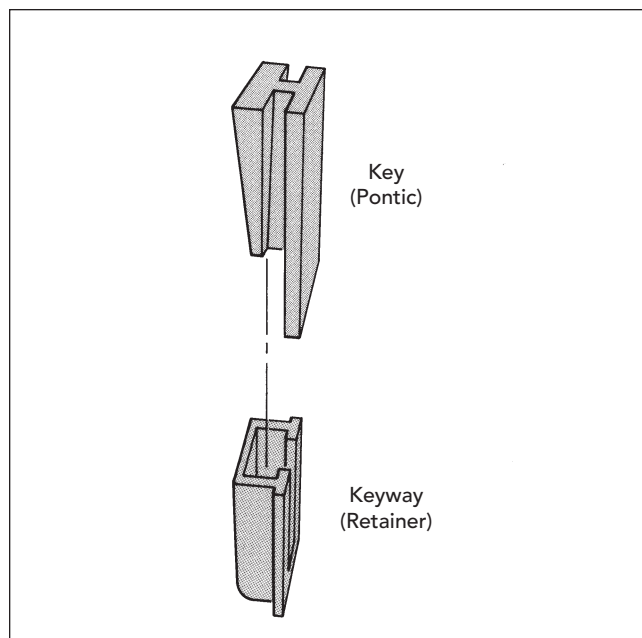


Fig 26-72 The nonrigid connector is composed of a key and keyway. The keyway is recessed into the proximal contour of the retainer, and the key extends from the pontic. (Reprinted from Shillingburg and Fisher⁵⁰ with permission.)

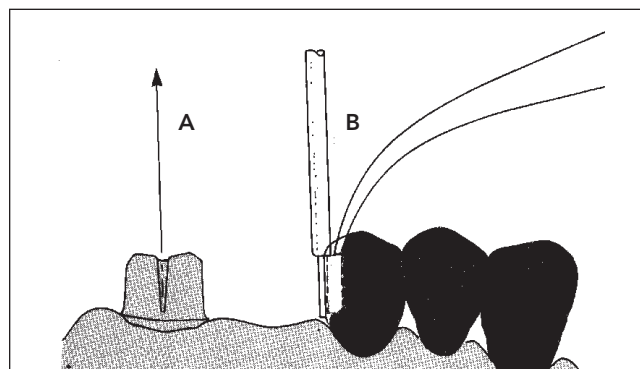


Fig 26-73 The cast is manipulated until the insertion path (A) of the distal abutment preparation parallels the mandrel (B) projecting from the key-keyway assembly. The keyway pattern is luted to the retainer wax pattern on the surveyor to maintain this relationship. (Reprinted from Shillingburg and Fisher⁵⁰ with permission.)

Nonrigid Connectors

There are several situations in which the use of nonrigid connectors is indicated, either to relieve stress or to accommodate poorly aligned fixed partial denture abutments. Among those used are dovetails (key-keyways),⁵⁰ split pontics (connector inside the pontic),⁵¹ and tapered pins.⁵²

Dovetail

When a fixed partial denture is fabricated with a nonrigid connector, it is necessary to align the path of insertion of the keyway with that of the distal abutment. This technique is best suited for relieving stress at midspan on long pontics.

The wax pattern for the retainer on the pier abutment is fabricated on the working cast. When a plastic pattern is used for the key and keyway (Plastic Dovetail [PD], Stern-gold) (Fig 26-72), a deep box form is carved into the distal surface of the wax pattern to create space for the placement of the plastic keyway pattern. Adequate depth and a parallel path of insertion are essential when preparing the box form in the distal aspect of this abutment. The working cast, with the wax pattern seated, is placed on the table of a surveyor. The key and keyway portions of the connector are as-

sembled, and the mandrel that extends from the top of the key portion of the pattern is locked into the vertical spindle of the surveying instrument. The surveyor table is manipulated until the mandrel and attachments are parallel with the path of insertion of the distal preparation. Then the plastic pattern is lowered to the middle retainer wax pattern and luted in place with sticky wax (Fig 26-73). The key portion is removed, and the middle retainer wax pattern is completed by blending the distal surface with the keyway.

The pattern is then invested, burned out, and cast. After the casting has been cleaned and air abraded, any part of the keyway portion of the attachment that protrudes above the occlusal surface is carefully cut off. The casting is placed on the working cast, and the prefabricated plastic pattern for the key is placed into the keyway. At this point, the pontic wax pattern is attached to the plastic key. The pontic pattern is completed, removed from the working cast, invested, burned out, and cast. After the casting is recovered from the investment, the mandrel and any excess on the top portion of the key are carefully reduced so that the key and keyway are flush.

For a semiprecision attachment, the wax pattern for the middle retainer is first completed. A keyway or T-shaped preparation is cut in the distal surface of the wax pattern with a no. 170L bur. The path of insertion of the keyway can be checked against the path of insertion of the tooth prepa-

26 Solder Joints and Other Connectors

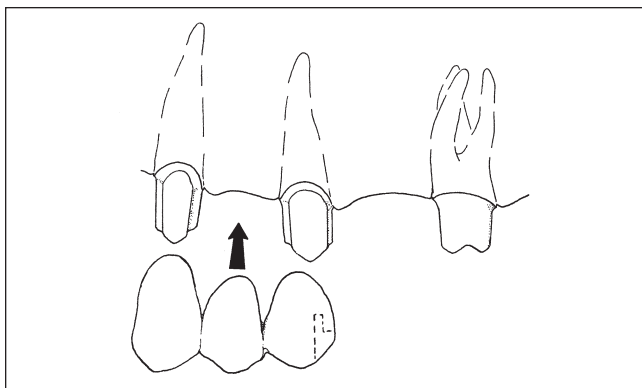


Fig 26-74 The mesial segment, with the keyway, is cemented first.

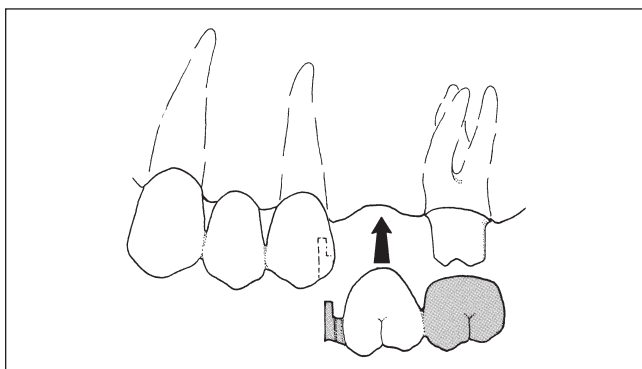


Fig 26-75 The distal segment, with the key, is cemented immediately after the mesial segment.

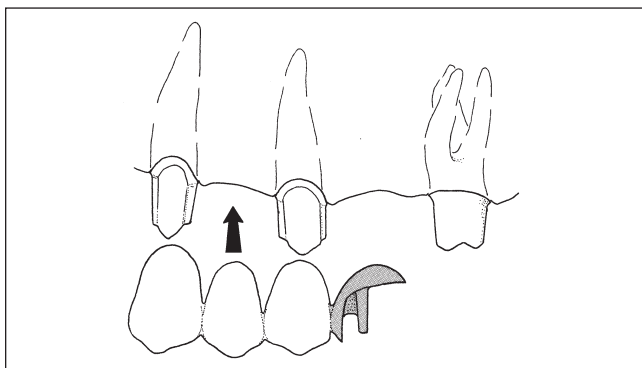


Fig 26-76 The mesial segment, which is cemented first, has a distal shoe that is the gingival portion of the pontic.

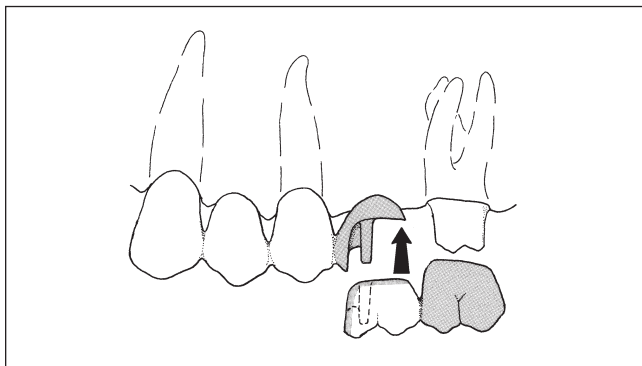


Fig 26-77 The distal segment of the pontic covers the mesiogingival part of the pontic when the distal retainer is cemented.

ration for the distal retainer by use of a surveyor or by visual examination. After the prepared wax pattern has been cast in gold, it is returned to the working cast. The tapered keyway preparation in the casting is refined and finished with a no. 169L or no. 170L bur. The casting is lubricated, and the key is formed by placing acrylic resin in the keyway. After the acrylic key has polymerized, it is attached to the wax pontic. The pontic wax pattern, incorporating the resin key, is then removed, invested, burned out, and cast. Because a precise fit is essential to prevent undue movement and stress in this long-span fixed partial denture, the rigid three-unit anterior segment is joined before try-in.

At the time of try-in, the fit of each individual unit is verified. Then a trial seating is performed with all of the units: the three-unit anterior combination with the distal pontic keyed into it, the pier abutment retainer, and the distal retainer. A soldering index of all the units is made with zinc oxide–eugenol bite registration paste or fast-setting impression plaster. The distal two units are placed in their respective imprints and invested for soldering.

The finished soldered components are tried in the mouth again at a subsequent appointment, and occlusal adjustments are made if necessary. When the restoration is cemented, the mesial three-unit segment is placed first (Fig 26-74), and the distal two-unit portion is seated immediately afterward. No cement should be placed in the keyway (Fig 26-75).

Split pontic

A *split pontic* is an attachment that is placed entirely within the pontic. It is particularly useful in tilted abutment cases, where the use of a conventional dovetail would necessitate the preparation of a very drastic box in the distal aspect of the pier abutment.⁴⁸ The wax pattern for the anterior three-unit segment (mesial retainer–pontic–pier retainer) is fabricated first, with a distal arm attached to the pier retainer. The underside of the arm is shaped like the tissue-contacting area of a pontic (which, in fact, it is). A surveyor is used to position either the key or the keyway segment of a PD pattern (see Fig 26-72), pointing occlusally. This segment must align (draw) with the distal abutment preparation.

The mesial three-and-a-half-unit segment is invested, burned out, and cast. After preliminary finishing, the cast segment is seated on the working cast. The plastic pattern is placed down into it (if the keyway is in the casting) or down onto it (if the key was left facing upward on the pontic base). The distal retainer and the disto-occlusal two-thirds of the pontic pattern are waxed. The pontic can be metal-ceramic, but there should be a thin collar of metal around the periphery of the ceramic section. It is tried on the prepared teeth in the mouth, making adjustments as necessary. The mesial segment is cemented first (Fig 26-76), followed immediately by the distal segment (Fig 26-77). No cement should be placed between the two segments of the pontic.

Cross-pin and wing

The cross-pin and wing are the working elements of a two-piece pontic system that allows the two segments to be rigidly fixed after the retainers have been cemented on their respective abutment preparations.⁴⁹ The design is used primarily to accommodate abutment teeth with disparate long axes. The path of insertion of each tooth preparation is made to parallel the long axis of that tooth.

A vertical wing, cut out of a piece of baseplate wax, is attached to the mesial surface of the distal retainer wax pattern. The wing should parallel the path of insertion of the mesial abutment preparation, extend out 3.0 mm mesially from the distal retainer, have a 1.0-mm thickness faciolingually, be 1.0 mm short of the occlusal surface, and have an undersurface that follows the intended contour of the underside of the pontic.⁴⁹

The distal retainer, with the wing, is invested, burned out, and cast. The retainer is seated on the cast, and a 0.7-mm hole is drilled through the wing with a twist drill in a hand-piece. A 0.7-mm-diameter pencil lead is placed through the hole, and the wax pattern is built around the lead and the wing. The lead is removed, the retainer-pontic wax pattern is withdrawn, and the 0.7-mm lead is replaced in the hole in the pontic pattern to maintain the patency of the hole during investing and casting.

The two parts of the fixed partial denture are assembled on the working cast. A tapered 8/0 machinist reamer is used to ream a smooth, tapered hole through the pontic and wing, following the pilot hole produced by the 0.7-mm pencil lead.

A pin of the same alloy used for the fixed partial denture casting is fabricated. A mold can be made by drilling a hole in a piece of aluminum with the machinist reamer and filling the hole with autopolymerizing resin (Duralay). An impression of the reamer can be made with polyvinyl siloxane impression material and filled with resin or molten wax. It is invested, burned out, and cast. It must be long enough to extend all the way through the pontic-wing assembly. The pin is tried for fit in the components on the cast.

The retainer with the wing is cemented first (Fig 26-78), followed by the retainer-pontic segment (Fig 26-79). The pin is seated in the hole with a punch and mallet (Fig 26-80). Excess length is removed from the pin both facially and lingually. If it is ever necessary to remove part of the fixed partial denture, the pin can be tapped out and the parts dealt with separately. This technique requires no special patterns and allows for a completely rigid prosthesis when completed (Fig 26-81).

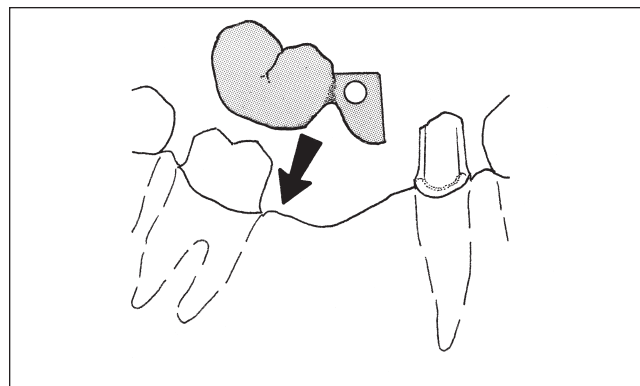


Fig 26-78 The distal retainer and wing are cemented first.

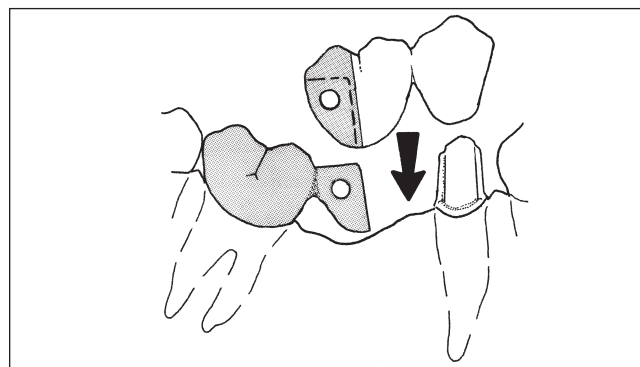


Fig 26-79 The retainer-pontic segment is seated last.

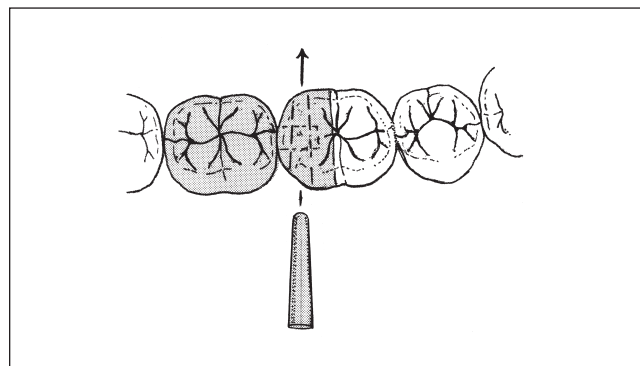


Fig 26-80 A tapered pin is driven through the pontic, the wing, and back out through the pontic.

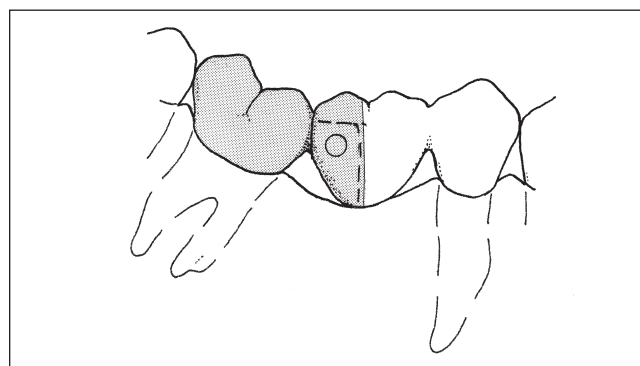


Fig 26-81 Completed cross-pin and wing fixed partial denture.

References

- Anusavice KJ, Phillips RW. Phillips' Science of Dental Materials, ed 11. St Louis: Saunders, 2003:608–620.
- el-Ebrashi MK, Asgar K, Bigelow WC. Electron microscopy of gold soldered joints. *J Dent Res* 1968;47:5–11.
- Ryge G. Dental soldering procedures. *Dent Clin North Am* 1958;2:747–757.
- Skinner EW, Phillips RW. Skinner's Science of Dental Materials, ed 8. Philadelphia: Saunders, 1982:534–546.
- Rasmussen EJ, Goodkind RJ, Gerberich WW. An investigation of tensile strength of dental solder joints. *J Prosthet Dent* 1979;41:418–423.
- Fusayama T, Wakumoto S, Hosoda H. Accuracy of fixed partial dentures made by various soldering techniques and one-piece casting. *J Prosthet Dent* 1964;14:334–342.
- Saas FA, Eames WB. Fit of unit-cast fixed partial dentures related to casting ring size and shape. *J Prosthet Dent* 1980;43:163–167.
- Hinman RW, Tesk JA, Parry EE, Eden GT. Improving the casting accuracy of fixed partial dentures. *J Prosthet Dent* 1985;53:466–471.
- Bruce RW. Evaluation of multiple unit castings for fixed partial dentures. *J Prosthet Dent* 1964;14:939–943.
- Bruce RW. Clinical applications of multiple unit castings for fixed prostheses. *J Prosthet Dent* 1967;18:359–364.
- Schiffleger BE, Ziebert GJ, Dhuru VB, Brantley WA, Sigaroudi K. Comparison of accuracy of multiunit one-piece castings. *J Prosthet Dent* 1985;54:770–776.
- Ziebert GJ, Hurtado A, Glapa C, Schiffleger BE. Accuracy of one-piece castings, preceramic and postceramic soldering. *J Prosthet Dent* 1986;55:312–317.
- Stade EH, Reisbick MH, Preston JD. Preceramic and postceramic solder joints. *J Prosthet Dent* 1975;34:527–532.
- Stackhouse JA Jr. Assembly of dental units by soldering. *J Prosthet Dent* 1967;18:131–139.
- Johnston JF, Dykema RW, Mumford G, Phillips RW. Construction and assembly of porcelain veneer gold crowns and pontics. *J Prosthet Dent* 1962;12:1125–1137.
- Pruden WH 2nd. Solder connections with porcelain fused to gold. *J Prosthet Dent* 1969;22:679–681.
- Meyer FS. The elimination of distortion during soldering. *J Prosthet Dent* 1959;9:441–447.
- Patterson JC Jr. A technique for accurate soldering. *J Prosthet Dent* 1972;28:552–556.
- Chang JC, Hurst TL, Johnson CD, Duong J. A soldering index made with 4-META adhesive resin. *J Prosthet Dent* 1994;72:430–432.
- Harper RJ, Nicholls JL. Distortion in indexing methods and investing media for soldering and remounting procedures. *J Prosthet Dent* 1979;42:172–179.
- Moon PC, Eshleman JR, Douglas HB, Garrett SG. Comparison of accuracy of soldering indices for fixed prostheses. *J Prosthet Dent* 1978;40:35–38.
- Dixon DL, Breeding LC, Lindquist TJ. Linear dimensional variability and tensile strengths of three solder index materials. *J Prosthet Dent* 1992;67:726–729.
- Smyd ES. Wax, refractory investments and related subjects in dental technology. *J Prosthet Dent* 1955;5:514–526.
- Willis LM, Nicholls JL. Distortion in dental soldering as affected by gap distance. *J Prosthet Dent* 1980;43:272–278.
- Butson TJ, Nicholls JL, Ma T, Harper RJ. Fatigue life of preceramic soldered and postsoldered joints. *Int J Prosthodont* 1993;6:468–474.
- Steinman RR. Warpage produced by soldering with dental solders and gold alloys. *J Prosthet Dent* 1954;4:384–395.
- Kimondollo PM. A procedure for restoring proximal contact surfaces of cast gold restorations with solder. *J Prosthet Dent* 1991;66:408–409.
- Ferencz JL. Tensile strength analysis of midpontic soldering. *J Prosthet Dent* 1987;57:696–703.
- Foerster JG, Meyers RD, Butler GV, Brousseau JS. Midpontic soldering of the modified sanitary pontic. *J Prosthet Dent* 1994;71:541.
- Monday JJ, Asgar K. Tensile strength comparison of presoldered and postsoldered joints. *J Prosthet Dent* 1986;55:23–27.
- Staffanou RS, Radke RA, Jendresen MD. Strength properties of soldered joints from various ceramic-metal combinations. *J Prosthet Dent* 1980;43:31–39.
- Lorenzana RE, Staffanou RS, Marker VA, Okabe T. Strength properties of soldered joints for a gold-palladium alloy and a palladium alloy. *J Prosthet Dent* 1987;57:450–454.
- Rosen H. Ceramic/metal solder connectors. *J Prosthet Dent* 1986;56:671–677.
- Cattaneo G, Wagnild G, Marshall G, Watanabe L. Comparison of tensile strength of solder joints by infrared and conventional torch technique. *J Prosthet Dent* 1992;68:33–37.
- Tehini GE, Stein RS. Comparative analysis of two techniques for soldered connectors. *J Prosthet Dent* 1993;69:16–19.
- Anusavice KJ, Phillips RW. Phillips' Science of Dental Materials, ed 11. St Louis: Saunders, 2003:616–617.
- Wiskott HW, Macheret F, Bussy F, Belser UC. Mechanical and elemental characterization of solder joints and welds using gold-palladium alloy. *J Prosthet Dent* 1997;77:607–616.
- Watanabe I, Topham DS. Laser welding of cast titanium and dental alloys using argon shielding. *J Prosthodont* 2006;15:102–107.
- Nicholls JL, Lemm RW. Tensile strength of presoldered and postsoldered joints. *J Prosthet Dent* 1985;53:476–482.
- Blustein R, DePaul BM, Barnhart RC Jr, Green KA. A reliable technique of post soldering of nonprecious ceramic units. *J Prosthet Dent* 1976;36:112–114.
- Saxton PL. Post-soldering of nonprecious alloys. *J Prosthet Dent* 1980;43:592–595.
- Sloan RM, Reisbick MH, Preston JD. Post-ceramic soldering of various alloys. *J Prosthet Dent* 1982;48:686–689.
- Anusavice KJ, Okabe T, Galloway SE, Hoyt DJ, Morse PK. Flexure test evaluation of presoldered base metal alloys. *J Prosthet Dent* 1985;54:507–517.
- Kaylakie WG, Brukl CE. Comparative tensile strengths of non-noble dental alloy solders. *J Prosthet Dent* 1985;53:455–462.
- Lima Verde MA, Stein RS. Evaluation of soldered connectors of two base metal ceramic alloys. *J Prosthet Dent* 1994;71:339–344.
- Townsend LW, Vermilyea SG, Griswold WH. Soldering nonnoble alloys. *J Prosthet Dent* 1983;50:51–53.
- Hawbolt EB, MacEntee MI, Zahel JL. The tensile strength and appearance of solder joints in three base metal alloys made with high- and low-temperature solders. *J Prosthet Dent* 1983;50:362–367.
- Shigeto N, Yanagihara T, Hamada T, Budtz-Jørgensen E. Corrosion properties of soldered joints. Part I: Electrochemical action of dental solder and dental nickel-chromium alloy. *J Prosthet Dent* 1989;62:512–515.
- Shigeto N, Yanagihara T, Murakami S, Hamada T. Corrosion properties of soldered joints. Part II: Corrosion pattern of dental solder and dental nickel-chromium alloy. *J Prosthet Dent* 1991;66:607–610.
- Shillingburg HT Jr, Fisher DW. Nonrigid connectors for fixed partial dentures. *J Am Dent Assoc* 1973;87:1195–1199.
- O'Connor RP, Caughman WF, Bemis C. Use of the split pontic connector with the tilted molar abutment. *J Prosthet Dent* 1986;56:249–251.
- Eichmiller FC, Parry EE. Tapered cross-pin attachments for fixed bridges. *Oper Dent* 1994;19:7–10.

Restoration of Osseointegrated Dental Implants

27

The clinical success of dental implants is well documented. This success, which began with totally edentulous patients, is possible with partially edentulous patients as well.¹⁻⁴ Dental implants allow a greater variety of options when treating some of the complex restorative situations encountered in partially edentulous patients.

Dental implants can be used in partially edentulous patients to:

- Replace one or more teeth when restoration of the adjacent teeth is not required (Fig 27-1).
- Replace posterior teeth when there is no distal abutment and the edentulous space is too long for a cantilever (Fig 27-2).
- Avoid using teeth that have been weakened by previous dental restorations as fixed partial denture abutments.
- Assist in restoring teeth that are unevenly spaced.

History of Dental Implants

There are three main types of dental implants.⁵ A *subperiosteal implant* rests on the surface of the bone beneath the periosteum, with posts protruding through the mucosal tissue to support a removable prosthesis (Fig 27-3). A *transosseous mandibular bone plate* (Fig 27-4) penetrates the inferior border of the mandible, projecting through the alveolar ridge and oral mucosa to support a removable prosthesis. An *endosseous implant* is embedded in the maxilla or mandible and projects through the mucosa covering the edentulous ridge. There are two types of endosseous implants, the plate form (blade vent) and root form (Fig 27-5). The root-form dental implant can be either a threaded cylinder or a nonthreaded cylinder with a press-fit design. The endosseous implant can support a fixed partial denture as a single-

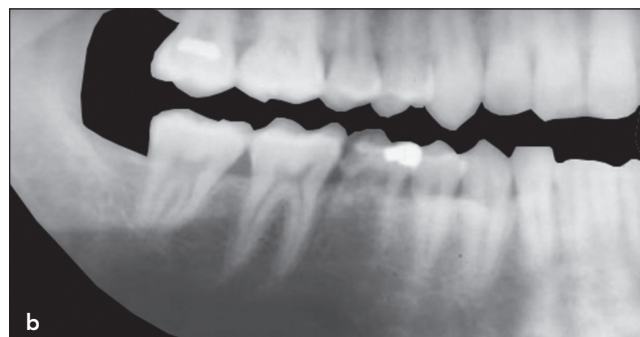
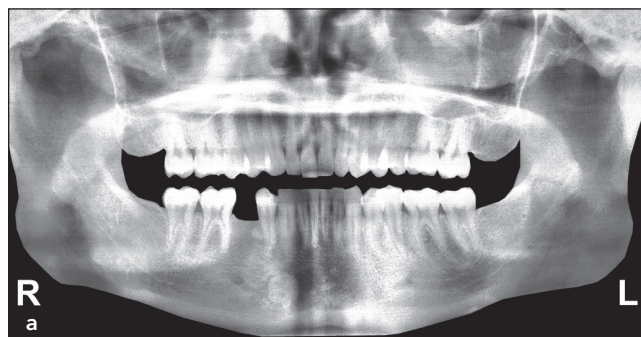

Fig 27-1 Panoramic view (a) and quadrant view (b) of potential implant sites.

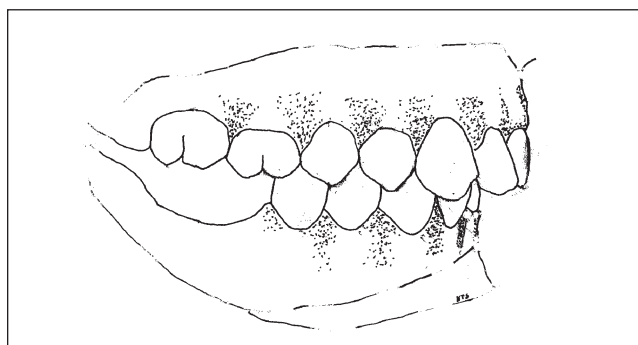


Fig 27-2 Posterior edentulous space with no distal abutment.

27 Restoration of Osseointegrated Dental Implants

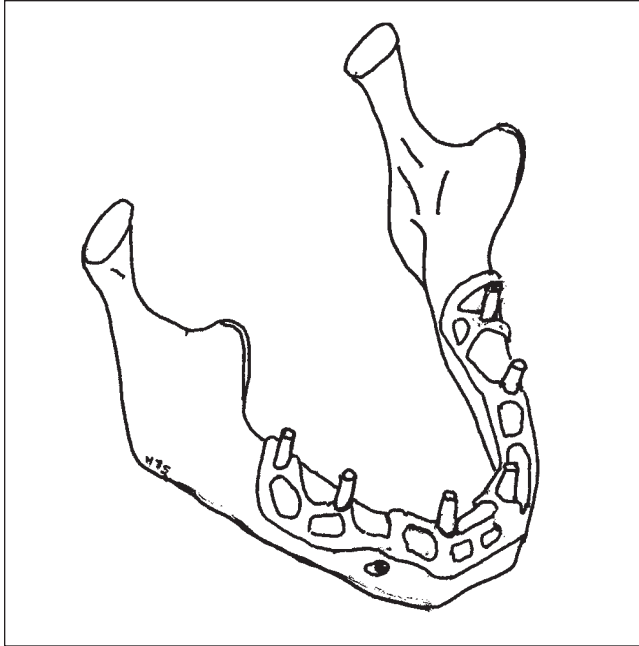


Fig 27-3 A subperiosteal implant sits on the bone beneath the periosteum with posts protruding through the mucosal tissue to support a removable prosthesis.

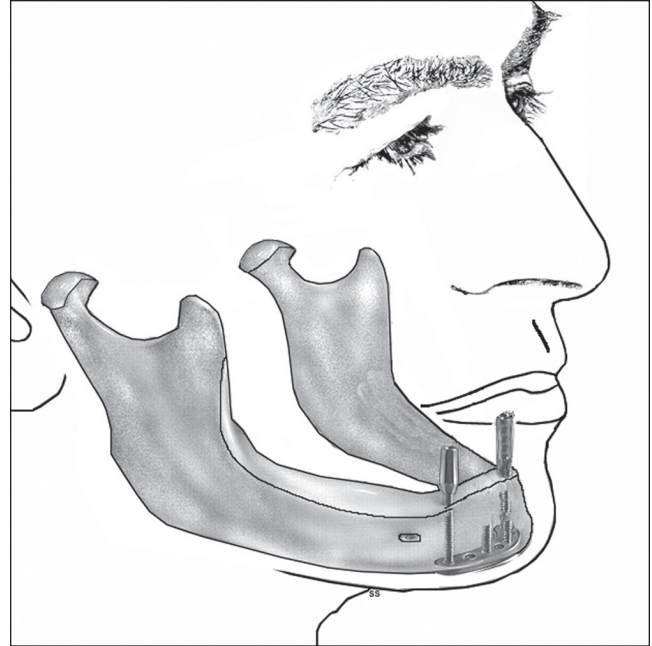


Fig 27-4 A transosseous mandible bone plate penetrates the inferior border of the mandible, projecting through the alveolar ridge and oral mucosa to support a removable prosthesis.

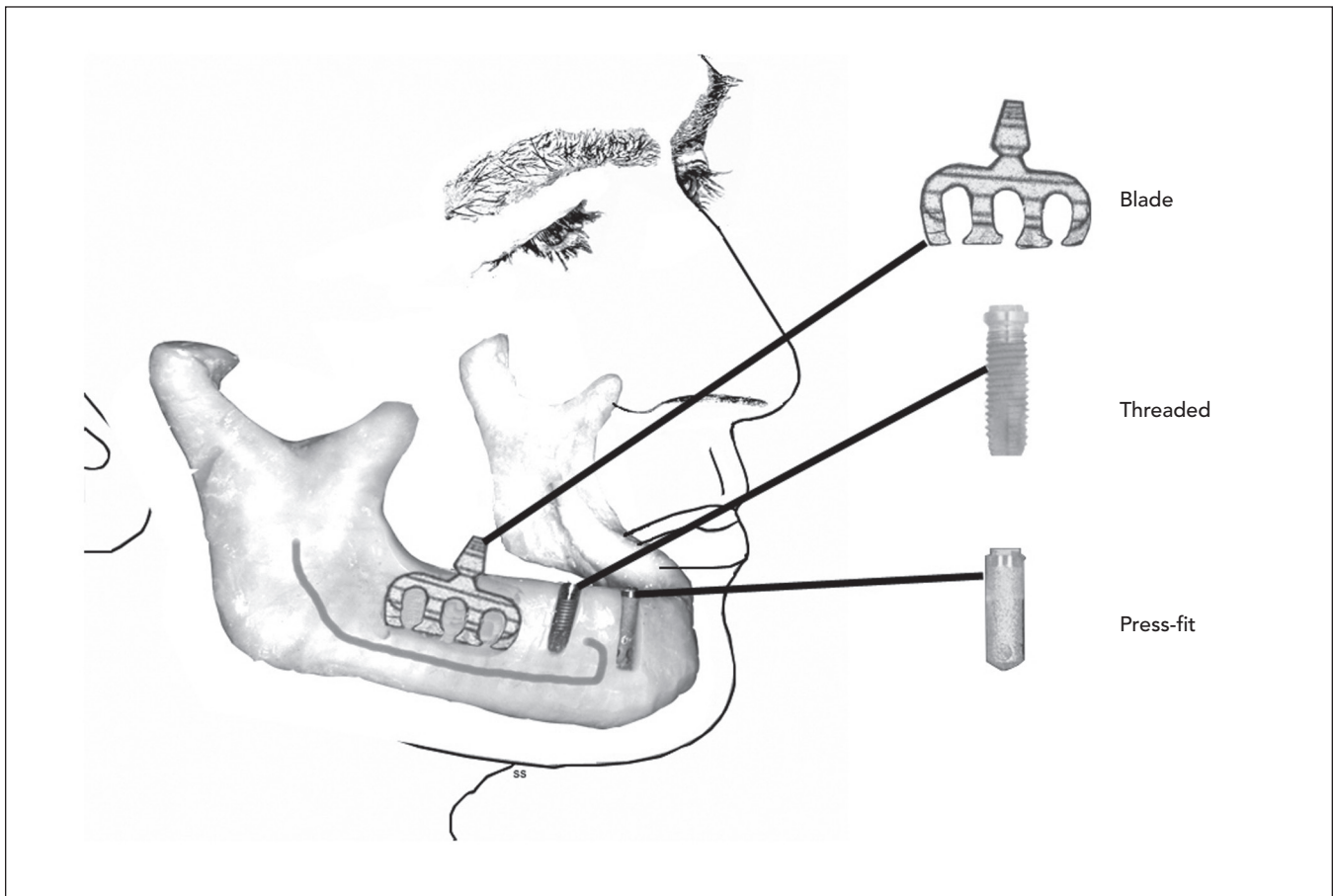


Fig 27-5 Endosseous implants may be either plate or root form.



Fig 27-6 Endosseous implants were first introduced as a threaded root form with an external hex.

or multiple-unit prosthesis. The endosseous implant is the most suitable implant for a partially edentulous patient.

The root-form endosseous dental implant, with its great variety of clinical applications, has proven to be the most useful. Its lengthy history dates back to both Egyptian and ancient South American Indian cultures.⁶ A gold root-form endosteal implant was placed in a fresh extraction socket by Maggiola in 1809.^{7,8} It was allowed to heal passively, and a crown was added later.

Modern implant dentistry began in the 1930s with the development of the surgical-quality chrome-cobalt-molybdenum alloy Vitallium (Dentsply) by Venable.⁹ The first dental implant made of this alloy was placed by Strock in 1938.¹⁰ Formiggini, Chercheve, and Linkow worked with endosseous implants of different designs, trying to develop one that was both useful and reliable.¹¹⁻¹³ Clinical success, however, proved to be highly variable. A perplexing problem with early implants was the production of a fibrous encapsulation around the device, resulting in mobility and eventual failure.

It was not until Brånemark's work that intimate contact between bone and metal was demonstrated microscopically, in a process he called *osseointegration*. He showed that a pure titanium dental implant placed with an atraumatic surgical technique could be consistently reliable.¹⁴ His work began with a serendipitous discovery while recovering titanium optical chambers used in a hematologic study with rabbits in 1952.¹⁴ It was noted that there was an intimate attachment of the bone to the titanium optical chamber. The optical chambers were developed into a clinical dental implant in 1965, which was introduced to the profession in North America as the Brånemark Implant in 1982¹⁵ (Fig 27-6). The development of a reliable, stable dental implant attracted much interest.¹⁶

When the Brånemark dental implant was developed, its original clinical application was for the edentulous mandible. Five implants were placed and connected with a rigid bar. The external hex was present to aid in the surgical placement of the dental implant. This was adequate until

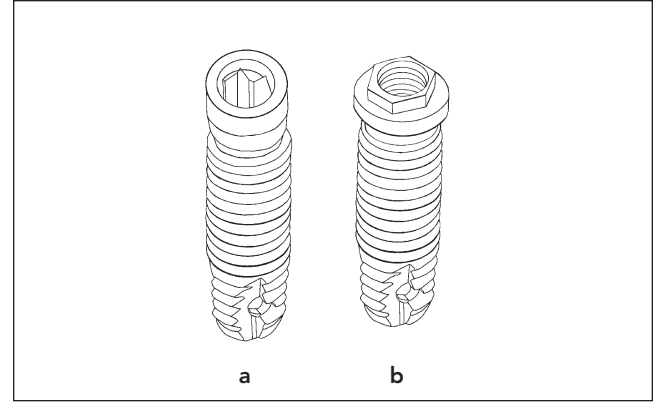


Fig 27-7 Endosseous implants with an internal hex (a) and external hex (b).

dental implants were used in partially edentulous patients. The initial result with the external hex dental implant used to replace a single tooth was screw loosening of the clinical crown in some patients. This necessitated the development of the internal hex as a mechanism for attachment (Fig 27-7). There was a meteoric rise in companies offering the internal hex dental implant. Recent studies have now shown that the external hex can be used for partially edentulous patients when multiple implants are splinted, the cast parts fit accurately, and the retention screw is tightened to the correct torque.^{17,18} The internal hex is the superior attachment mechanism for the single dental implant restoration because it offers superior antirotational characteristics. The internal hex also offers an easier "feel" for fitting the impression copings and parts together during the restoration fabrication process.

There has been concern about connecting an immobile osseointegrated implant to a natural tooth with a periodontal ligament. It is not recommended to attach a dental implant to a natural tooth due to the different anchorage mechanisms within the bone. The dental implant has no mobility because it is ankylosed, while the natural tooth has microscopic mobility due to the periodontal ligament. The rigid attachment of a dental implant to a natural tooth presented clinical problems such as natural tooth intrusion and failure of the cement layer. Resolution of these potential problems was attempted with the use of a key and keyway to splint the natural tooth to the dental implant.¹⁹ However, the problems persisted. Another approach to the problem was proposed by Kirsch, who used a polyoxymethylene resin element in the implant to allow normal micromovement of a natural tooth attached to an unmoving, osseointegrated dental implant fixture. This device was marketed as the Intra-Mobile Zylinder (IMZ) implant (Interpore International).²⁰ It was clinically successful but is no longer manufactured because the cost and time factors were not well received by the public and patients could not be relied upon to return for replacement of the polyoxymethylene resin element.

27 Restoration of Osseointegrated Dental Implants

Treatment Planning

The patient evaluation begins with a consultation,²¹ which should provide insight into the patient's motivation for seeking implants. Prospective patients should be evaluated to identify conditions that might jeopardize the success of a dental implant. This consultation is an opportunity to explain the advantages, disadvantages, and limitations of dental implants as well as the need for routine maintenance to the patient. A candid discussion is vitally important during this appointment because the mention of any limiting or negative factors at a later time will be seen by the patient as an excuse.

Oral examination and health history

A thorough oral examination should be performed. An important esthetic consideration for dental implants in the anterior maxillary region is the smile line or the position of the upper lip. If the patient displays gingival tissue during upper lip movement, the esthetic restoration of a dental implant will be more complex. The remaining dentition should be examined for caries, hygiene, and mobility. The health of the soft tissues, including the facial mucosa and attached gingiva surrounding the remaining teeth, is also assessed. Pocket depths are probed and charted. The edentulous spaces are evaluated in terms of ridge size and shape, and the interarch relationship is checked for interocclusal space. The loss of a tooth or teeth to periodontitis is not a contraindication for dental implant placement.²² The health history is important in determining the general medical condition of the patient for an elective surgical procedure such as dental implant placement.²³ Any conditions that would hinder the patient's ability to heal must be identified because these would contraindicate the use of dental implants. Included are hematologic disorders such as leukemia, therapeutic doses of irradiation, autoimmune diseases,²⁴ bisphosphonate therapy, or poorly controlled diabetes, which may compromise repair. Patients with diseases of unknown etiology, such as autoimmune diseases, should be considered only after extensive medical consultation because these patients are often prescribed regular doses of steroids as anti-inflammatory agents and these can inhibit the healing process. A serum C-terminal cross-linking telopeptide of type I collagen (CTX) test²⁵ is indicated for patients who have had exposure to long-term use (3 years or more) of oral bisphosphonates or high-dose use of intravenous bisphosphonates.²⁶ A patient's diabetes control can be evaluated with an HbA_{1c} blood test, which measures a patient's glucose control over the past few months. This test can determine if a patient is successfully controlling his or her diabetes and is a suitable candidate for a dental implant. Patients should be physically able to tolerate the surgical and restorative procedures proposed. For example, a patient with muscular dystrophy might not be a good dental implant candidate.

Patients with psychologic problems such as schizophrenia, paranoia, presenile dementia, dysmorphobia (an unreasonable fear of disfigurement),²⁷ and extreme or unrealistic expectations regarding the esthetic results are not candidates for implants. Chronic drug abusers and alcoholics are likewise not suitable candidates. Tobacco use has been shown to impair healing.²⁸ While tobacco use is not a contraindication to dental implant placement, patients who use tobacco should be advised of an associated increased failure rate.

The presence of controlled diseases or conditions that do not impede postoperative healing, while requiring precautions to prevent possible postoperative problems, do not necessarily contraindicate the use of implants. For example, a history of cardiac valve replacement or rheumatic or congenital heart disease may require premedication before surgical placement but does not preclude the use of an implant.²⁴

Medications such as anticoagulants, used in the treatment of arrhythmias and other cardiovascular problems, should be monitored prior to any surgical procedures to minimize postoperative bleeding (see chapter 1). The dental history should include past experience with removable and fixed prostheses. Previous oral surgical procedures with postoperative complications or undesirable consequences should be investigated in detail.

Imaging

A radiographic examination is performed to identify the quantity and quality of bone and the location of anatomical structures. The occlusal view should show mandibular facial and lingual cortical thickness as well as tori or exostoses. Periapical radiographs provide the greatest detail for evaluating remaining teeth, including bone height and trabeculation. The panoramic radiograph provides a single view of both the maxilla and mandible, showing ridge height, location of the mandibular canal and mental foramen, trabecular bone pattern, and cortical bone thickness (Fig 27-8). This radiograph is usually used only as a general survey because of its non-uniform magnification, distortion, and overlapping images. Magnification can be from 13% to 24% in the horizontal axis and from 15% to 36% in the vertical axis.^{23,29,30}

Cone beam computed tomography (CBCT), a form of computerized axial tomography (CAT), is particularly valuable in preoperative surgical planning for the placement of dental implants.^{31–34} The CBCT scans are noninvasive and can provide the surgeon with vital information about the quantity, quality, and shape of the bone as well as the location of nerves, sinuses, and adjacent teeth (Fig 27-9). It consists of a series of radiographic images that are sagittal, coronal, or axial with the dental arch. These cross-sectional cuts are usually taken from 1 to 2 mm apart for dental treatment planning. It is analogous to lifting a slice of bread from a loaf for examination. This provides an accurate three-dimensional preoperative evaluation of the maxilla and mandible that helps to prevent undesirable implant placement into anatomical structures such as the mandibular canal or the maxil-

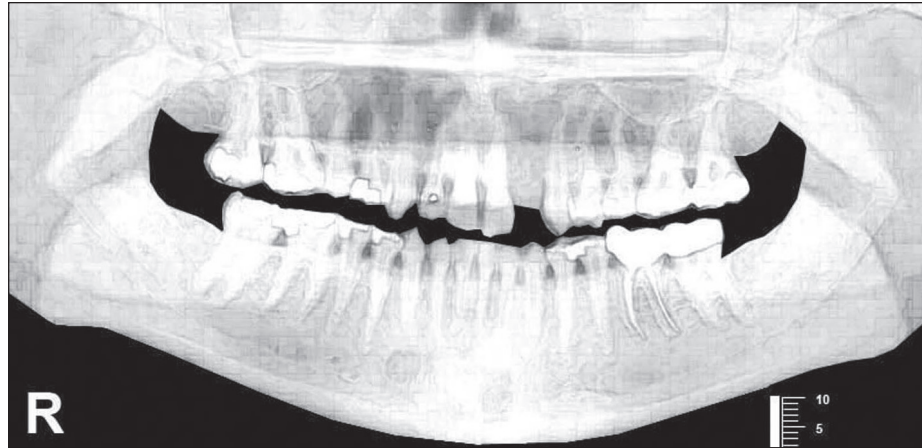


Fig 27-8 A panoramic radiograph provides basic dental implant treatment-planning information.

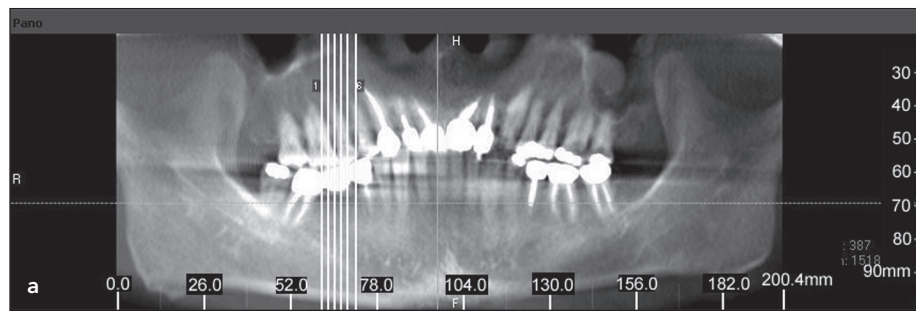


Fig 27-9 (a) A CBCT scan with white lines showing the cross-sectional radiographic views (called cuts) to be evaluated for dental implant placement. (b) A CBCT scan showing width and height of bone above the mandibular canal.

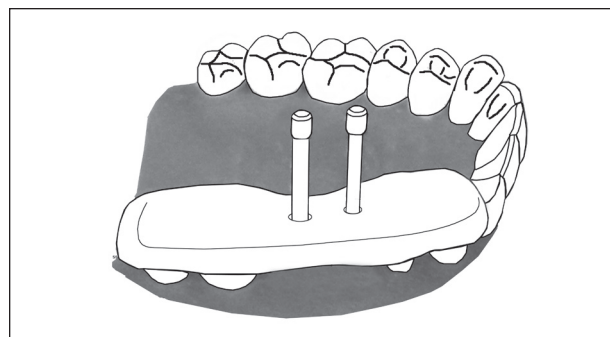
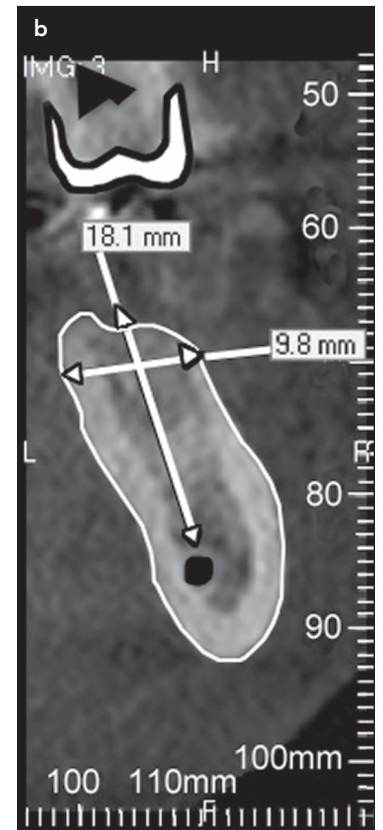


Fig 27-10 A custom surgical guide with guide pins representing desired implant placement.

lary sinus.^{35–37} The CBCT scan uses a lower radiation dose than conventional CAT scans^{38–40} and produces a three-dimensional, minimally distorted image of the planned dental implant site.

Analysis of the CBCT scan aids in the development of the treatment plan, including number, length, width, and location of dental implants to be placed. There are computer

programs and companies that can use the CBCT scan information to fabricate a custom surgical guide (Fig 27-10). A custom surgical guide results in a safer and more predictable surgical outcome that should subsequently allow an optimal restorative result. The greatest aid to achieving an esthetic dental implant restoration is a well-placed dental implant.

27 Restoration of Osseointegrated Dental Implants

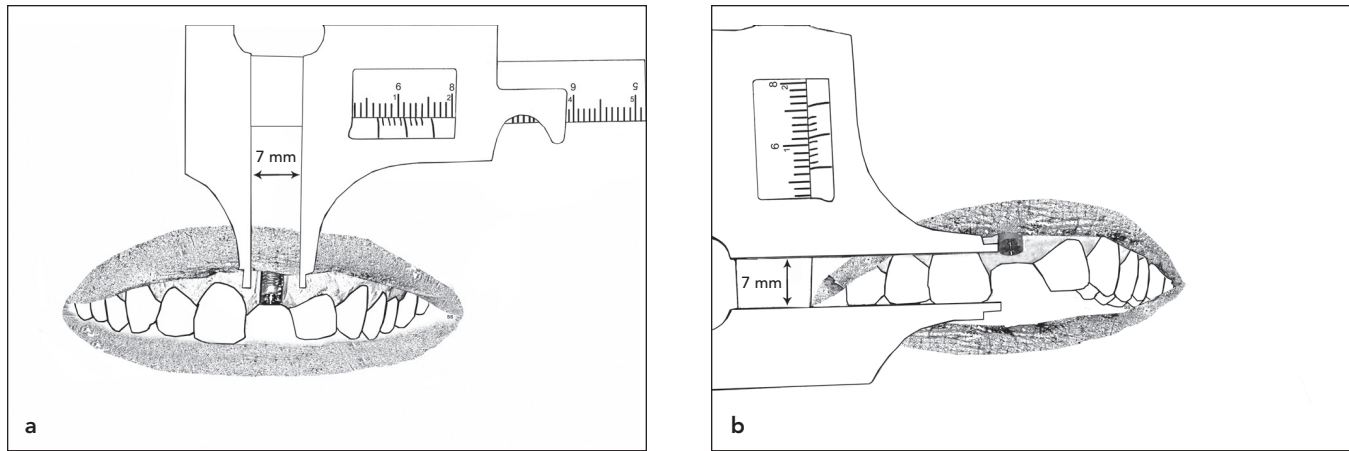


Fig 27-11 (a and b) As a general rule, 7 mm of horizontal and vertical space is necessary for a dental implant restoration.

Diagnostic casts

Diagnostic casts on a semi-adjustable articulator, necessary for any fixed prosthodontic treatment planning, are important for treatment planning of implants as well. They allow a three-dimensional evaluation of the vertical space between the crest of the residual ridge and the occlusal surface of the opposing dentition, as well as the faciolingual position of the dental implant. As a general rule, 7 mm is both the minimum mesiodistal (horizontal) space and the minimum vertical space for the implant and crown⁴¹ (Fig 27-11). The casts can also be used for occlusal analysis with a diagnostic wax-up and for surgical splint fabrication.

Evaluation of bone at the prospective implant site

The decision to place a dental implant ultimately depends on the quantity and quality of the receptor site bone. The general rule for the quantity of bone is a width of 6 mm. This allows for the placement of a 4-mm-diameter dental implant with 1 mm of bone on the facial and lingual surfaces.⁴¹ The vertical height of bone is ideally not less than 10 mm. This allows the placement of a 10-mm-long dental implant, which has been shown to be more successful than implants shorter than 10 mm.^{42,43}

The quantity of bone available is determined by the rate of alveolar resorption after tooth loss and is quite variable. According to Atwood,⁴⁴ the rate of resorption is related to anatomical, metabolic, functional, and prosthetic factors. Anatomical factors include the size, shape, and density of the alveolar ridges, the quality of the mucosal covering, and the state of periodontal health at the time of tooth loss. Metabolic factors are nutritional and hormonal, which influence the activity of the osteoblasts and osteoclasts. Functional factors include the frequency, intensity, duration, and direction of forces applied to the bone. Presumably these forces translate into osteoblastic or osteoclastic cellular ac-

tivity. Prosthetic factors are those that relate to the use of a prosthesis and are dependent on the techniques, materials, and concepts incorporated in its fabrication.

The quality of the receptor site bone is dependent on the ratio of the dense outer cortical layer to the softer inner cancellous layer, whose quality depends on the degree of trabeculation. The greater the number of supporting fibers traversing the cancellous bone, the stronger it is. Although we often think of bone solely in terms of quantity, internal quality is also very important. Lekholm and Zarb⁴⁵ have described a classification of jaw morphology and differing rates of resorption following tooth loss. They are the following:

- A. Most of the alveolar ridge is present (may be too much bone)
- B. Moderate residual ridge resorption (best)
- C. Advanced residual ridge resorption; only basal bone remains (may present inadequate bone volume)
- D. Some resorption of basal bone (inadequate bone volume)
- E. Extreme resorption of basal bone (inadequate bone volume)

The same authors have also proposed a classification of bone quality⁴⁵:

1. Almost the entire jaw is homogenous cortical bone (this dense bone has reduced vascularity and recovers more slowly postoperatively)
2. A thick layer of cortical bone surrounding a core of cancellous bone with a dense trabecular pattern (provides good dental implant anchorage)
3. A thin layer of cortical bone surrounding a core of cancellous bone with a dense trabecular pattern (provides good dental implant anchorage)
4. A thin layer of cortical bone surrounding a core of cancellous bone with a low-density trabecular pattern (provides poor implant anchorage unless the opposite cortical plate is also engaged by the dental implant)

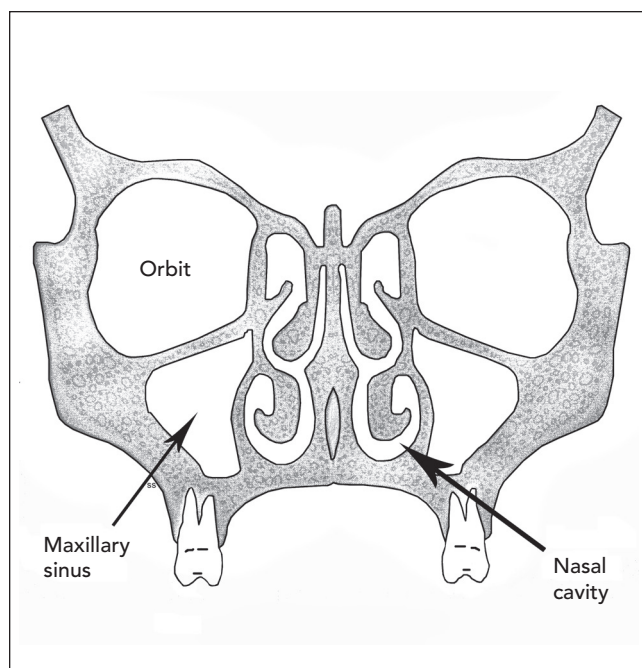


Fig 27-12 Anteroposterior view of the maxilla showing the location of the maxillary sinus and nasal cavity.

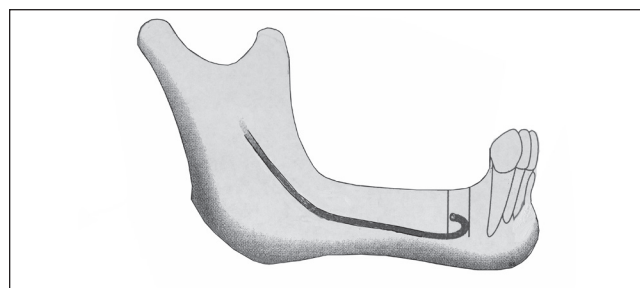


Fig 27-13 Mandibular canal loops anteriorly before forming the mental foramen.

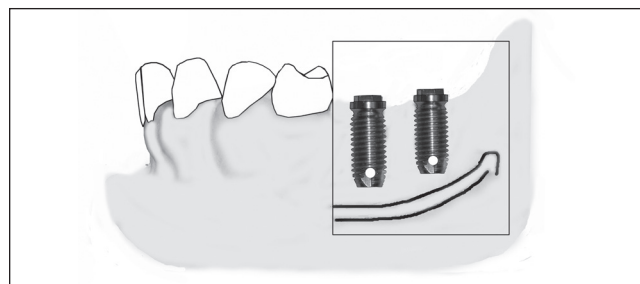


Fig 27-14 Vertical space of 2 mm is desirable between the dental implant and the mandibular canal.

Location of important anatomical structures

The maxillary anatomical structures of importance to dental implant placement are the following (Fig 27-12):

- The *incisive canal*, which extends from the floor of the nasal cavity to the incisive fossa on the palatal surface of the maxilla.
- The *nasal cavity*, which extends from the nares anteriorly to the nasopharynx posteriorly. It communicates with the paranasal sinuses through their orifices and is divided medially by the nasal septum. The floor is formed by the palatine bone, and the lateral wall is formed by the maxilla.
- The *maxillary sinuses*, which are paranasal sinuses in the posterior body of the maxilla that communicate with the middle meatus of the nasal cavity. Because both quantity and quality of bone in the maxilla are usually less than that in the anterior mandible, dental implant success rates are usually lower in the maxilla.¹⁶

The usual bone resorption pattern of the maxilla makes the identification of the anatomical structures critical. The nasal cavity and maxillary sinuses usually interfere with fixture site selection in patients with severe bone resorption. Should an implant inadvertently penetrate the nasal cavity or the maxillary sinus, it will probably heal uneventfully,⁴⁶ but the thin bone provides a poor site for implant anchorage. Therefore, the presence of the maxillary sinus usually precludes the placement of an implant fixture posterior to the premolars without sinus elevation and/or onlay bone grafting.⁴⁷ The canine eminence is the best site and will usually accept a long fixture.

The primary anatomical structure of importance in the mandible is the 2-mm-diameter *mandibular canal*, which carries the inferior alveolar vessels and nerve diagonally from the mandibular foramen in the posterolingual aspect to the mental foramen in the anterolabial area of the mandible.³⁵ The mandibular canal usually extends anterior and medial to the mental foramen before looping posteriorly and facially to form the mental foramen below the apex of the second premolar (Fig 27-13). This anterior loop ranges from 0 to 4 mm 90% of the time but may extend to 9 mm.⁴⁸

The quantity and quality of mandibular bone is usually very good between the mental foramina; therefore, this area contains the most desirable implant sites. The mandibular posterior region presents greater difficulty in terms of implant placement because of the inferior alveolar nerve in the mandibular canal. Careful radiographic evaluation is essential to avoid damaging the nerve. Damage to the mandibular nerve can result in paresthesia of the chin and lower lip; therefore, care is required not to impinge upon it before it exits the mental foramen. The placement of an implant in close proximity to the nerve can also produce discomfort when the implant fixture is loaded, which may stimulate the mandibular nerve fibers.

In the event that implant placement is attempted superior to the mandibular canal, a margin of safety of 2 mm vertical clearance should be provided between the dental implant and the mandibular canal (Fig 27-14). Therefore, a greater number of implants may be required in the posterior mandible to achieve a desirable crown-root ratio for the prosthesis. It is possible, through the use of CBCT scans, to place an implant facial to the mandibular canal in the posterior aspect of the mandible, although this is a risky procedure.

27 Restoration of Osseointegrated Dental Implants

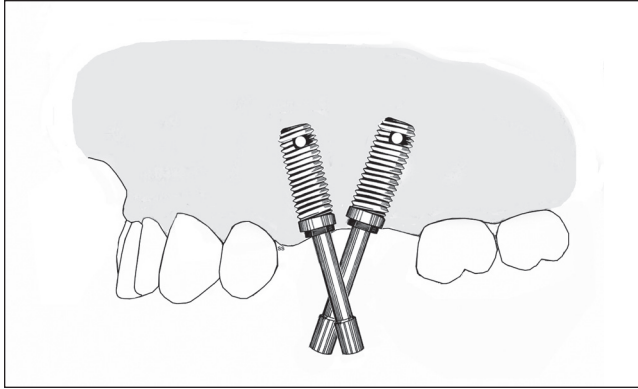


Fig 27-15 Poorly aligned dental implants complicate restoration.

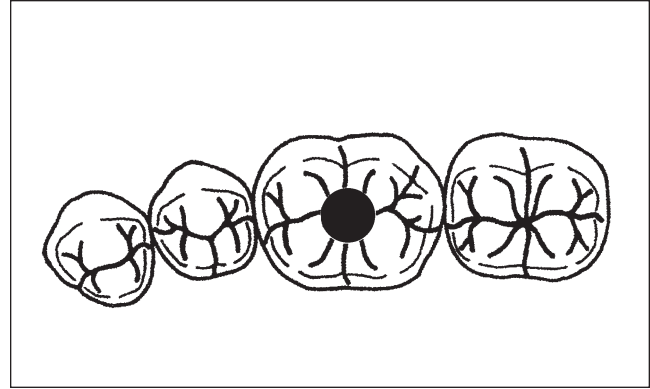


Fig 27-16 The access hole for posterior teeth should be in the central fossa.

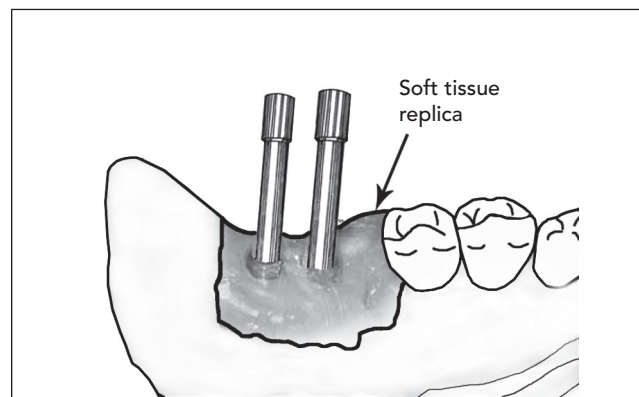


Fig 27-17 A dental cast of posterior dental implants demonstrating guide pins with a slight mesial inclination.

Determination of ideal implant positioning

Dental implants should not be placed less than 2 mm, although 3 mm is preferred, from a natural tooth or another implant to avoid impinging upon the apex of that tooth and to permit adequate oral hygiene. The vitality of the interim-plant bone and soft tissue is also negatively affected when dental implants are placed too close together.⁴⁹⁻⁵¹ Implants that converge coronally or are too close together may also create difficulties in placing or removing prosthesis attachment screws (Fig 27-15). Implants replacing posterior teeth should be positioned so that the access holes for prosthesis attachment screws will be in the central fossa of the teeth (Fig 27-16). The implants should be vertical or inclined slightly to the mesial (Fig 27-17). Access to an implant with a distal inclination can be very difficult.

Implant Restoration Retention

Retention of a crown over a dental implant may be accomplished by two different methods. The first is screw retention.

A screw enters through the occlusal aspect or cingulum and is used to attach the crown to the dental implant (see Fig 27-16). This method of attachment has the advantage of retrievability to allow for hygiene, repair, and/or future modification. It does require a precision fit of the crown to the implant because it is metal to metal. It is also a useful technique with reduced interarch space, allowing a shorter restoration without compromising retention.⁵² An additional advantage of not using dental cement is the absence of cement to remove. When dental cement is used, postcementation clean-up is critical because any remaining dental cement will irritate the gingival tissue.

The second method of retaining an implant crown is with dental cement. A cemented restoration has the possible advantage of improved esthetics because there is no screw access hole (Fig 27-18). The fabrication technique for a cemented dental implant crown is the same as for a crown on a natural tooth from the perspective of the dentist and the laboratory technician. An abutment is screwed to the dental implant, and the cast restoration is fabricated to fit the abutment. It is not necessary that the cast restoration fit with the same degree of precision as a screw-retained restoration because there is a cement layer between the cast crown and

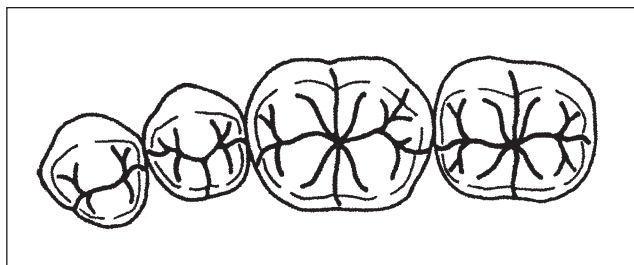


Fig 27-18 A cemented implant restoration with normal occlusal anatomy.

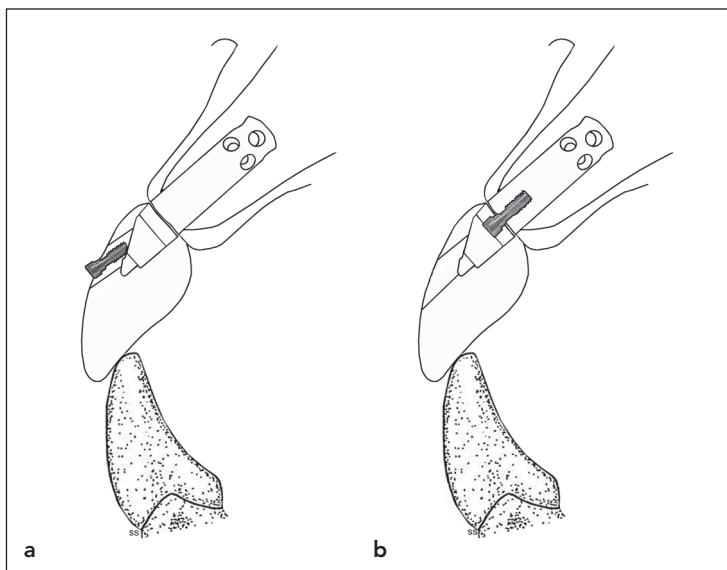


Fig 27-19 (a and b) Labial inclination of an anterior implant will result in an unesthetic screw access hole.

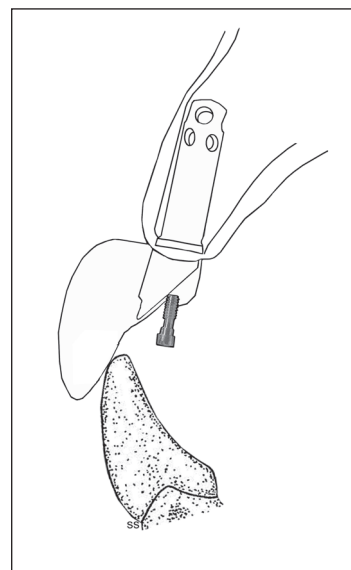


Fig 27-20 Upright inclination of an anterior implant will result in distorted palatal contours of the restoration.

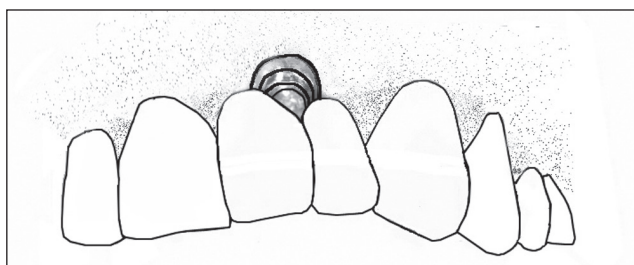


Fig 27-21 Placement of a dental implant in an interproximal space creates an unesthetic result.

the abutment, resulting in a passive fit. A cemented restoration is not as easily retrieved to correct hygiene problems, to repair, or to modify. A cemented restoration may have to be sacrificed to be removed. Caries is not an issue because all parts are metal or porcelain.

Implant Placement

Inclination

Implants replacing maxillary anterior teeth require special care in planning and placement because of esthetic de-

mands. The natural resorption of the maxilla (superiorly and posteriorly) tends to dictate the placement of an implant with too great a labial inclination. If this occurs, the access hole for the prosthesis fixation screw will be through the labial surface of the prosthesis (Fig 27-19). On the other hand, placement of an implant in too upright a position will produce a distorted palatal contour on the prosthesis, which can alter speech patterns and be annoying to the patient (Fig 27-20).

The replacement of two maxillary anterior teeth should not be attempted with one implant in the interproximal space between the two teeth to be replaced. Such a placement makes it impossible to create an esthetic interproximal space (Fig 27-21).

27 Restoration of Osseointegrated Dental Implants

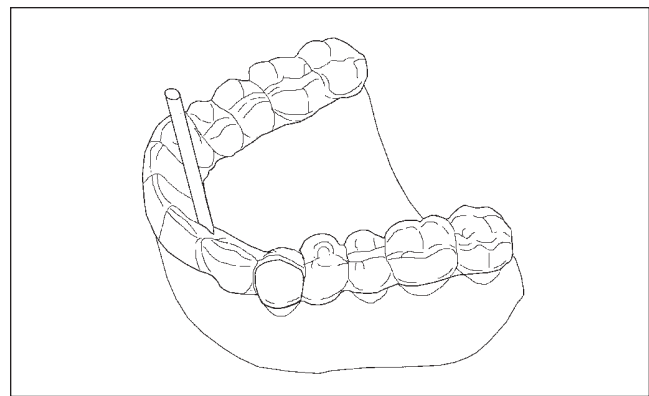


Fig 27-22 A surgical splint with an anterior lingual access hole for the surgical pilot drill.

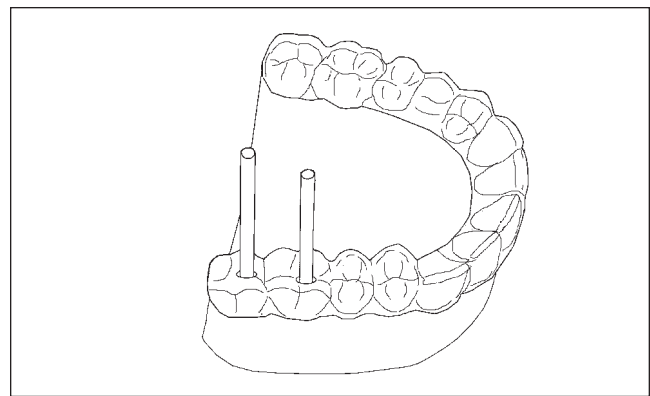


Fig 27-23 A surgical splint with posterior occlusal access holes for the surgical pilot drill.

Table 27-1 Mean root surface areas of permanent teeth*

Tooth	Maxilla		Mandible	
	Surface area (mm ²)	Relative surface area [†]	Surface area (mm ²)	Relative surface area [†]
Central incisor	204	1.1	154	1.0
Lateral incisor	179	1.0	168	1.1
Canine	273	1.5	268	1.7
First premolar	234	1.3	180	1.2
Second premolar	220	1.2	207	1.3
First molar	433	2.4	431	2.8
Second molar	431	2.4	426	2.8

*Data from Jepsen.⁵⁸
†Compared with the smallest tooth in the arch.

Use of a surgical splint

The importance of a diagnostic wax-up on articulated diagnostic casts in treatment planning cannot be overemphasized. Together with radiographs, it enables the optimum placement of an implant. The wax-up can be used for the freehand construction of a surgical splint that will facilitate the desired placement of the implant. In the event that anatomical features seen at the time of surgery will not allow implant placement in the desired location, the freehand surgical splint will aid in determining a suitable alternative.

The freehand surgical splint is fabricated by making an alginate impression of the diagnostic wax-up. On the resultant cast, a 0.020-inch-thick vacuum-formed splint is shaped. After removing the splint from the diagnostic cast, the tooth to be replaced by the implant is filled with autopolymerizing acrylic resin. This is to provide a channel for the surgical guide drill. The desired access holes are drilled in the splint material on the lingual of an anterior tooth (Fig 27-22) and the occlusal of a posterior tooth (Fig 27-23). The wax is removed from the original diagnostic cast, and the coping material matrix is positioned on it. Considering the known radio-

graphic and morphologic qualities of the partially edentulous space, a bur is inserted through the access holes to score the cast. The scored cast will identify the ideal point of surgical entry for the implant. At the time of surgery, the splint will be used to guide a surgical drill in achieving the desired implant placement and inclination.⁵³⁻⁵⁵ The use of a CBCT scan in the fabrication of a surgical splint, as mentioned earlier in this chapter, results in improved precision of surgical implant placement compared with the use of a surgical splint made freehand on a diagnostic cast.

Number, length, and diameter of implants

The number, length, and diameter of dental implants to be used when replacing a missing natural tooth or teeth is an important restorative issue. The replacement of natural teeth should be in accordance with Ante’s Law^{56,57} (ie, the root surface area of the abutment teeth should be equal to or greater than that of the teeth being replaced [Table 27-1]). The surface area of dental implants is dependent on diameter, length, and surface coating. Using this concept, the great-

Table 27-2 Commonly used dental implant sizes

Implant length (mm)	Implant diameter (mm)					
	3.0–3.3	3.5–3.7	4.0–4.3	4.5–4.8	5.0	6.0
5–7			X	X		
8–9	X	X	X		X	X
10	X	X	X	X	X	X
11–12	X	X	X	X	X	X
13	X	X	X	X	X	X
14–16	X	X	X	X	X	X
17–20		X	X	X	X	

Table 27-3 Suggested implant sizes

Tooth	Implant size (mm)	
	Maxilla	Mandible
Central incisor	4.0 × 12.0	3.3 × 12.0
Lateral incisor	3.5 × 12.0	3.3 × 12.0
Canine	4.5 × 15.0	4.5 × 15.0
First premolar	4.0 × 13.0	4.3 × 11.5
Second premolar	4.3 × 11.5	4.3 × 10.0
First molar	5.0 × 11.5	5.0 × 10.0
Second molar	5.0 × 11.5	5.0 × 10.0

est number, largest diameter, and greatest length of implant that the anatomical site will allow should be used (Tables 27-2 and 27-3). As a general rule, the concept of *bank vault construction* generally serves the restorative dentist well.

Occlusal Considerations


The occlusion of partially edentulous patients is dependent on various factors, such as number of missing teeth, their position in the arch, existing occlusal scheme (canine guidance or group function), and opposing dentition (natural or artificial). A dental implant lacks a periodontal membrane; therefore, a single-tooth implant restoration should have only light occlusal contact in maximal intercuspation. The implant crown should have no contacts in excursive movements if possible. Dental implant contacts in excursive movements, if present, should be protected by group function.⁴¹

The occlusion of a single posterior dental implant tooth ideally should be centered over the implant. A centric occlusal contact too far facial, lingual, mesial, or distal from the center of the implant will impart a bending force that may result in screw loosening or breakage. The reduction of the faciolingual width of posterior dental implant crowns may decrease the possibility of interferences in lateral excursive movements and/or excessive bending forces.⁵⁹

The occlusion of multiple units of dental implants in a partially edentulous patient should have light occlusal contact in maximal intercuspation. Ideally there should be no lateral or protrusive contacts on the implant-borne fixed partial denture. In the event that this is not possible, a mutually protected group function occlusion that distributes the lateral and/or protrusive contacts over as many dental implants and natural dentition as possible is used.

References

- Albrektsson T, Brånemark PI, Hansson HA, Lindström J. Osseointegrated titanium implants. Requirements for ensuring a long-lasting, direct bone-to-implant anchorage in man. *Acta Orthop Scand* 1981;52:155–170.
- Ericsson I, Lekholm U, Brånemark PI, Lindhe J, Glantz PO, Nyman S. A clinical evaluation of fixed-bridge restorations supported by the combination of teeth and osseointegrated titanium implants. *J Clin Periodontol* 1986;13:307–312.
- van Steenberghe D, Lekholm U, Bolender C, et al. Applicability of osseointegrated oral implants in the rehabilitation of partial edentulism: A prospective multicenter study on 558 fixtures. *Int J Oral Maxillofac Implants* 1990;5:272–281.
- Jemt T. Single implants in the anterior maxilla after 15 years of follow-up: Comparison with central implants in the edentulous maxilla. *Int J Prosthodont* 2008;21:400–408.
- Bolender CL. Indications and contraindications for different types of implant therapy. *J Dent Educ* 1988;52:757–759.
- Anjard R. Mayan dental wonders. *J Oral Implantol* 1981;9:423–426.
- Kirk EC. Academy of Stomatology of Philadelphia regular monthly meeting, Jan 28, 1913. *Dent Cosmos* 1913;55:429–441.
- Driskell TD. History of dental implants. *CDA J* 1987;15(10):16–25.
- Venable CS, Stuck WG, Beach A. The effects on bone of the presence of metals: Based upon electrolysis. *Ann Surg* 1937;105:917–938.
- Strock EA. Experimental work on a method of the replacement of missing teeth by direct implantation of a metal support into the alveolus: Preliminary report. *Am J Orthod Oral Surg* 1939;25:467–472.
- Linkow LI. Clinical evaluation of the various designed endosseous implants. *J Oral Implant Transplant Surg* 1966;12:35–46.
- Kibrick M, Munir ZA, Lash H, Fox SS. The development of a materials system for an endosteal tooth implant: I. Critical assessment of previous designs. *Oral Implantol* 1975;6:172–192.
- Chercheve R. The philosophies which governed the origin, development and present-day use of endosseous dental implants. *J Oral Implant Transplant Surg* 1966;12:28–34.
- Brånemark PI. Introduction to osseointegration. In: Brånemark PI, Zarb G, Albrektsson T (eds). *Tissue-Integrated Prostheses: Osseointegration in Clinical Dentistry*. Chicago: Quintessence, 1985:26–31.
- Brånemark PI. Osseointegration and its experimental background. *J Prosthet Dent* 1983;50:399–410.
- Adell R, Lekholm U, Rockler B, Brånemark PI. A 15-year study of osseointegrated implants in the treatment of the edentulous jaw. *Int J Oral Surg* 1981;10:387–416.
- Theoharidou A, Petridis HP, Tzannas K, Garefis P. Abutment screw loosening in single-implant restorations: A systematic review. *Int J Oral Maxillofac Implants* 2008;23:681–690.
- Piermatti J, Yousef H, Luke A, Mahevich R, Weiner S. An in vitro analysis of implant screw torque loss with external hex and internal connection implant systems. *Implant Dent* 2006;15:427–435.
- Sullivan DY. Prosthetic considerations for the utilization of osseointegrated fixtures in the partially edentulous arch. *Int J Oral Maxillofac Implants* 1986;1:39–45.
- Babbush CA, Kirsch A, Mentag PJ, Hill B. Intramobile cylinder (IMZ) two-stage osteointegrated implant system with the intramobile element (IME): Part I. Its rationale and procedure for use. *Int J Oral Maxillofac Implants* 1987;2:203–216.
- Laney WR. Selecting edentulous patients for tissue-integrated prostheses. *Int J Oral Maxillofac Implants* 1986;1:129–138.
- Schou S, Holmstrup P, Worthington HV, Esposito M. Outcome of implant therapy in patients with previous tooth loss due to periodontitis. *Clin Oral Implants Res* 2006;17(suppl 2):104–123.
- Engelman MJ, Sorensen JA, Moy P. Optimum placement of osseointegrated implants. *J Prosthet Dent* 1988;59:467–473.
- Hwang D, Wang HL. Medical contraindications to implant therapy: Part 1: Absolute contraindications. *Implant Dent* 2006;15:353–360.
- Marx RE, Cillo JE Jr, Ulloa JJ. Oral bisphosphonate-induced osteonecrosis: Risk factors, prediction of risk using serum CTX testing, prevention, and treatment. *J Oral Maxillofac Surg* 2007;65:2397–2410.
- Grant BT, Amenedo C, Freeman K, Kraut RA. Outcomes of placing dental implants in patients taking oral bisphosphonates: A review of 115 cases. *J Oral Maxillofac Surg* 2008;66:223–230.
- Blomberg S. Psychological responses. In: Brånemark PI, Zarb G, Albrektsson T (eds). *Tissue-Integrated Prostheses: Osseointegration in Clinical Dentistry*. Chicago: Quintessence, 1985:165–174.
- Bain CA, Moy PK. The association between the failure of dental implants and cigarette smoking. *Int J Oral Maxillofac Implants* 1993;8:609–615.
- Rowse CW. Notes on interpretation of the orthopantomogram. *Br Dent J* 1971;130:425–434.
- Christen AG, Segreto VA. Distortion and artifacts encountered in Panorex radiography. *J Am Dent Assoc* 1968;77:1096–1101.
- Spector L. Computer-aided dental implant planning. *Dent Clin North Am* 2008;52:761–775.
- Ganz S. Computer-aided design/computer-aided manufacturing applications using CT and cone beam CT scanning technology. *Dent Clin North Am* 2008;52:777–808.
- Angelopoulos C, Thomas SL, Hechler S, Parisis N, Hlavacek M. Comparison between digital panoramic radiography and cone-beam computed tomography for the identification of the mandibular canal as part of presurgical dental implant assessment. *J Oral Maxillofac Surg* 2008;66:2130–2135 [erratum 2008;66:2657].
- Almog DM, LaMar J, LaMar FR, LaMar F. Cone beam computerized tomography-based dental imaging for implant planning and surgical guidance. Part 1: Single implant in the mandibular molar region. *J Oral Implantol* 2006;32:77–81.
- Schwarz MS, Rothman SL, Rhodes ML, Chafetz N. Computed tomography: Part I. Preoperative assessment of the mandible for endosseous implant surgery. *Int J Oral Maxillofac Implants* 1987;2:137–141.
- Schwarz MS, Rothman SL, Rhodes ML, Chafetz N. Computed tomography: Part II. Preoperative assessment of the maxilla for endosseous implant surgery. *Int J Oral Maxillofac Implants* 1987;2:143–148.
- McGivney GP, Haughton V, Strandt JA, Eichholz JA, Lubar DM. A comparison of computer-assisted tomography and data-gathering modalities in prosthodontics. *Int J Oral Maxillofac Implants* 1986;1:55–68.
- Bamgbose BO, Adeyemo WL, Ladeinde AL, Ogunlewe MO. Conebeam computed tomography (CBCT): The new vista in oral and maxillofacial imaging. *Nig Q J Hosp Med* 2008;18:32–35.
- White SC. Cone-beam imaging in dentistry. *Health Phys* 2008;95:628–637.
- Chau AC, Fung K. Comparison of radiation dose for implant imaging using conventional spiral tomography, computed tomography, and cone-beam computed tomography. *Oral Surg Oral Med Oral Pathol Oral Radiol Endod* 2009;107:559–565.
- Engelman MJ. *Clinical Decision Making and Treatment Planning in Osseointegration*. Chicago: Quintessence, 1996:81–94.
- Olate S, Lyrio MC, de Moraes M, Mazzonetto R, Moreira RW. Influence of diameter and length of implant on early dental implant failure. *J Oral Maxillofac Surg* 2010;68:414–419.
- Renouard F, Nisand D. Impact of implant length and diameter on survival rates. *Clin Oral Implants Res* 2006;17(suppl 2):35–51.
- Atwood DA. Some clinical factors related to rate of resorption of residual ridges. *J Prosthet Dent* 1962;12:441–450.
- Lekholm V, Zarb GA. Patient selection and preparation. In: Brånemark PI, Zarb G, Albrektsson T (eds). *Tissue-Integrated Prostheses: Osseointegration in Clinical Dentistry*. Chicago: Quintessence, 1985:199–209.
- Brånemark PI, Adell R, Albrektsson T, Lekholm U, Lindström J, Rockler B. An experimental and clinical study of osseointegrated implants penetrating the nasal cavity and maxillary sinus. *J Oral Maxillofac Surg* 1984;42:497–505.

- 
47. Wallace SS, Froum SJ. Effect of maxillary sinus augmentation on the survival of endosseous dental implants. A systematic review. *Ann Periodontol* 2003;8:328–343.
 48. Uchida Y, Noguchi N, Goto M, et al. Measurement of anterior loop length for the mandibular canal and diameter of the mandibular incisive canal to avoid nerve damage when installing endosseous implants in the interforaminal region: A second attempt introducing cone beam computed tomography. *J Oral Maxillofac Surg* 2009;67:744–750.
 49. Engelman MJ. *Clinical Decision Making and Treatment Planning in Osseointegration*. Chicago: Quintessence, 1996:105.
 50. Gastaldo JF, Cury PR, Sendyk WR. Effect of the vertical and horizontal distances between adjacent implants and between a tooth and an implant on the incidence of interproximal papilla. *J Periodontol* 2004;75:1242–1246.
 51. Martin W, Lewis E, Nicol A. Local risk factors for implant therapy. *Int J Oral Maxillofac Implants* 2009;24(suppl):28–38.
 52. Misch C. *Contemporary Implant Dentistry*, ed 2. St Louis: Mosby, 1999:549–556.
 53. Preston JD. A systematic approach to the control of esthetic form. *J Prosthet Dent* 1976;35:393–402.
 54. Blustein R, Jackson R, Rotskoff K, Coy RE, Godar D. Use of splint material in the placement of implants. *Int J Oral Maxillofac Implants* 1986;1:47–49.
 55. Edge MJ. Surgical placement guide for use with osseointegrated implants. *J Prosthet Dent* 1987;57:719–722.
 56. Johnston JF, Phillips RW, Dykema RW. *Modern Practice in Crown and Bridge Prosthodontics*, ed 3. Philadelphia: Saunders, 1971:11.
 57. Ante IH. The fundamental principles of abutments. *Mich State Dent Soc Bull* 1926;8:14–23.
 58. Jepsen A. Root surface measurement and a method for x-ray determination of root surface area. *Acta Odontol Scand* 1963; 21:35–46.
 59. Rangert B, Jemt T, Jörneus L. Forces and moments on Bråne-mark implants. *Int J Oral Maxillofac Implants* 1989;4:241–247.

Single-Tooth Implant Restoration

28

The use of dental implants has become a popular way to replace missing dentition. This is especially true when the teeth adjacent to the edentulous space are unrestored or unsuitable as fixed prosthodontic abutments. The replacement of a maxillary anterior tooth seems simple because of accessibility, but it can be one of the most challenging applications for the use of a single dental implant because of the esthetic demands.¹⁻⁵ There are numerous dental implant systems currently available in the marketplace, and each system has its own specific components and instruments. While these parts and instruments may be interchangeable between systems, it is best to use the restorative components of the manufacturer of the dental implant to be restored. The primary reason for this is compatibility (fit) of the various restorative components. Although different dental implant manufacturers may use different names, often trademarked, for similar components, a common terminology has evolved for dental implant components and instruments, and this terminology is used throughout this chapter.⁶

Implant Placement and Healing

A patient presenting with a missing central incisor is not an uncommon occurrence. After a dental implant has been placed, it is allowed to heal for the prescribed time,⁷ which is usually 3 months in the mandible and 4 to 6 months in the maxilla, before the dental implant is uncovered and a healing abutment is placed (Figs 28-1a and 28-1b). The dental implant is then ready for restoration.

The desired emergence of the dental implant is shown by the position of the healing abutment (Fig 28-1c). The antero-posterior position of the dental implant is important for a suitable esthetic result in the definitive restoration. A dental implant that is placed too far to the facial will create an unnatural soft tissue emergence profile,^{3,4} and a dental implant placed too far to the lingual will create an unnatural lingual contour of the definitive restoration.

The process of fabricating a dental implant-supported restoration requires a series of individual steps, beginning with the removal of the healing abutment with a hex driver (Fig 28-2), which exposes the top of the dental implant (Fig 28-3).

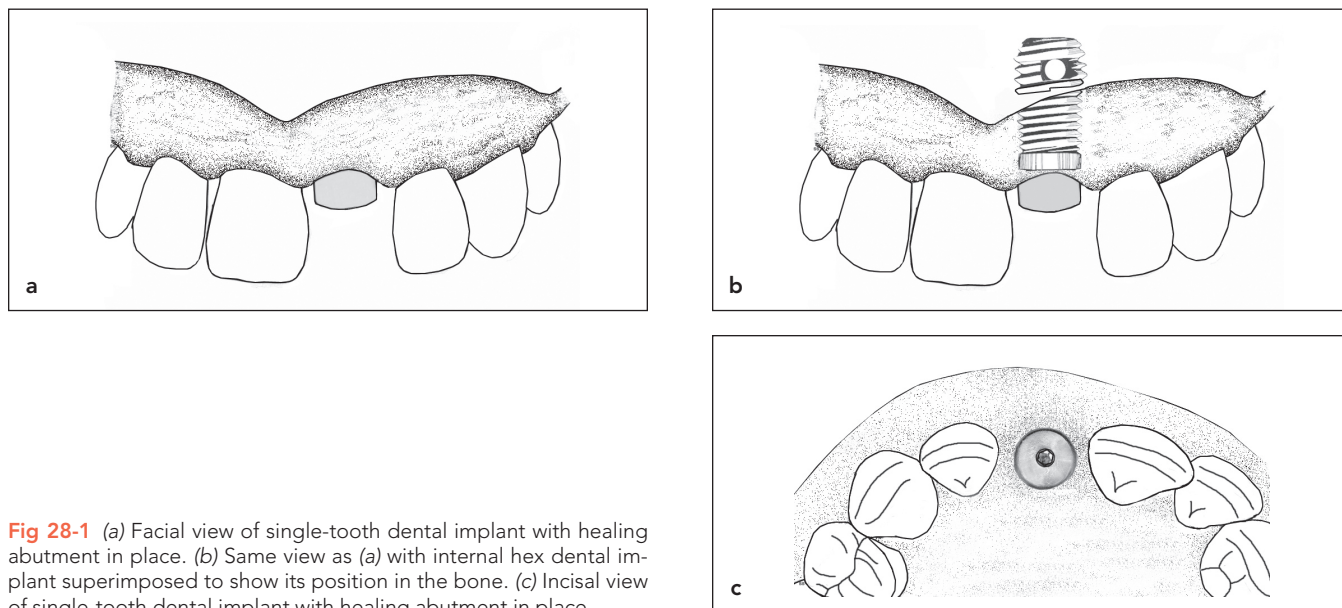


Fig 28-1 (a) Facial view of single-tooth dental implant with healing abutment in place. (b) Same view as (a) with internal hex dental implant superimposed to show its position in the bone. (c) Incisal view of single-tooth dental implant with healing abutment in place.

28 Single-Tooth Implant Restoration

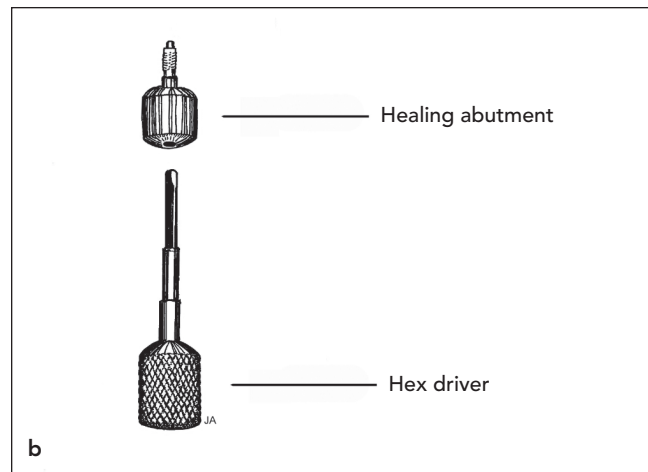
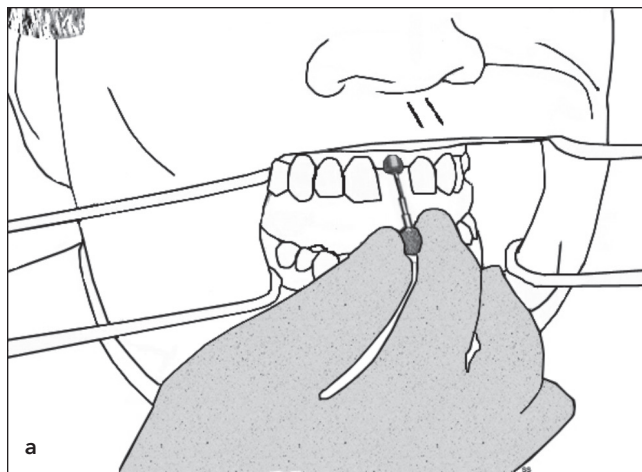


Fig 28-2 (a) Hex driver removing healing abutment from patient. (b) Hex driver for insertion and removal of healing abutment.

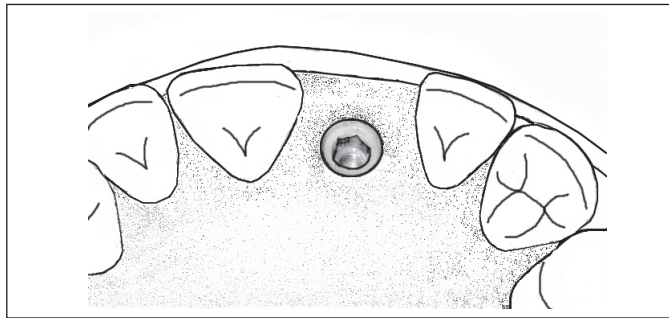


Fig 28-3 Incisal view of top of implant with healing abutment removed.

Evaluation of Gingival Tissue

The gingival tissue surrounding the dental implant should be evaluated for health and thickness. The gingival tissue should be the same color as the healthy tissue surrounding the natural dentition. The depth of the gingival cuff (thickness) surrounding the dental implant is important; this depth preferably should be 2 to 3 mm. A gingival cuff deeper than 3 mm is prone to suffer from chronic irritation due to difficulty with hygiene procedures.^{3,8} A depth less than 1 mm may present an esthetic problem by displaying metal at the gingival margin of the restoration. A gingival cuff that is too deep or too shallow may require periodontal therapy to provide the optimum environment for restoration fabrication.

Impression Taking and Cast Fabrication

The general process of fabricating a dental cast upon which a dental restoration can be fabricated begins with taking an impression. Dental implant impressions are taken after re-

moving the healing abutment and attaching an impression coping to the dental implant. The shape of the impression coping is captured in the impression.

Closed and open tray impression techniques

Impression copings are fabricated for both a closed tray and an open tray impression technique. In the closed tray impression technique, the impression coping remains attached to the dental implant when the impression is removed from the mouth. In an open tray impression technique, the impression coping remains in the impression when the impression is removed from the mouth.⁹

To accomplish the removal of the implant impression coping with the impression, the impression coping is attached to the dental implant with a separate long attachment screw. This attachment screw must be removed prior to the impression tray removal from the mouth. This requires an opening in the impression tray that allows access to the attachment screw. This opening is the reason it is referred to as an *open tray impression technique*.

Upon removal of the closed tray impression from the patient's mouth, the impression coping is removed from the

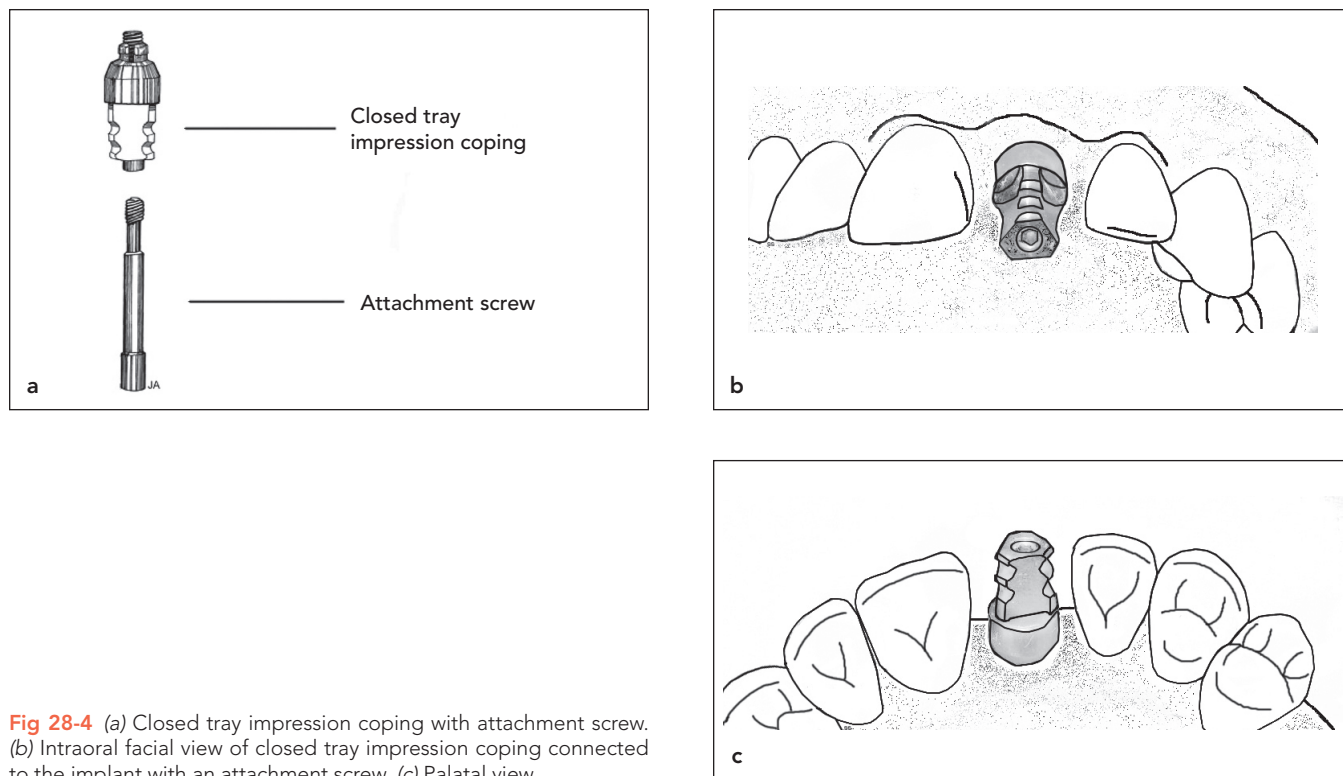


Fig 28-4 (a) Closed tray impression coping with attachment screw. (b) Intraoral facial view of closed tray impression coping connected to the implant with an attachment screw. (c) Palatal view.

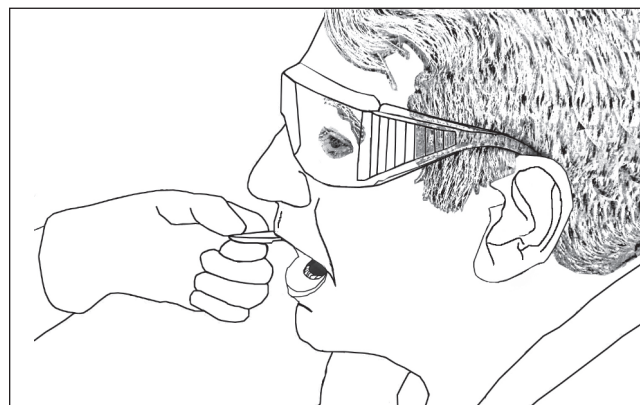

Fig 28-5 Taking the preliminary closed tray alginate impression.

dental implant, attached to a laboratory implant analog, and reinserted into the impression. The open tray impression technique only requires the attachment of the laboratory implant analog to the impression coping, which remains within the impression. The impression can then be poured in dental stone, recording the location of the dental implant in the dental arch.

Preliminary alginate impression and study cast fabrication

A closed tray impression technique is routinely used for a preliminary alginate impression. The open tray impression

technique, which will produce a more accurate cast¹⁰ because the impression coping remains undisturbed in the impression material, is employed for the final impression.

An internal hex dental implant is generally used with an impression coping that is retained with an attachment screw for both the closed tray and the open tray impression techniques. The primary difference between the two impression copings is that the open tray impression coping is more irregular in shape and has a longer attachment screw to protrude through the impression tray than the closed tray impression coping (Fig 28-4a). Intraoral facial (Fig 28-4b) and palatal (Fig 28-4c) views show a closed tray impression coping attached to a dental implant, so the preliminary alginate impression can be taken (Fig 28-5).

28 Single-Tooth Implant Restoration

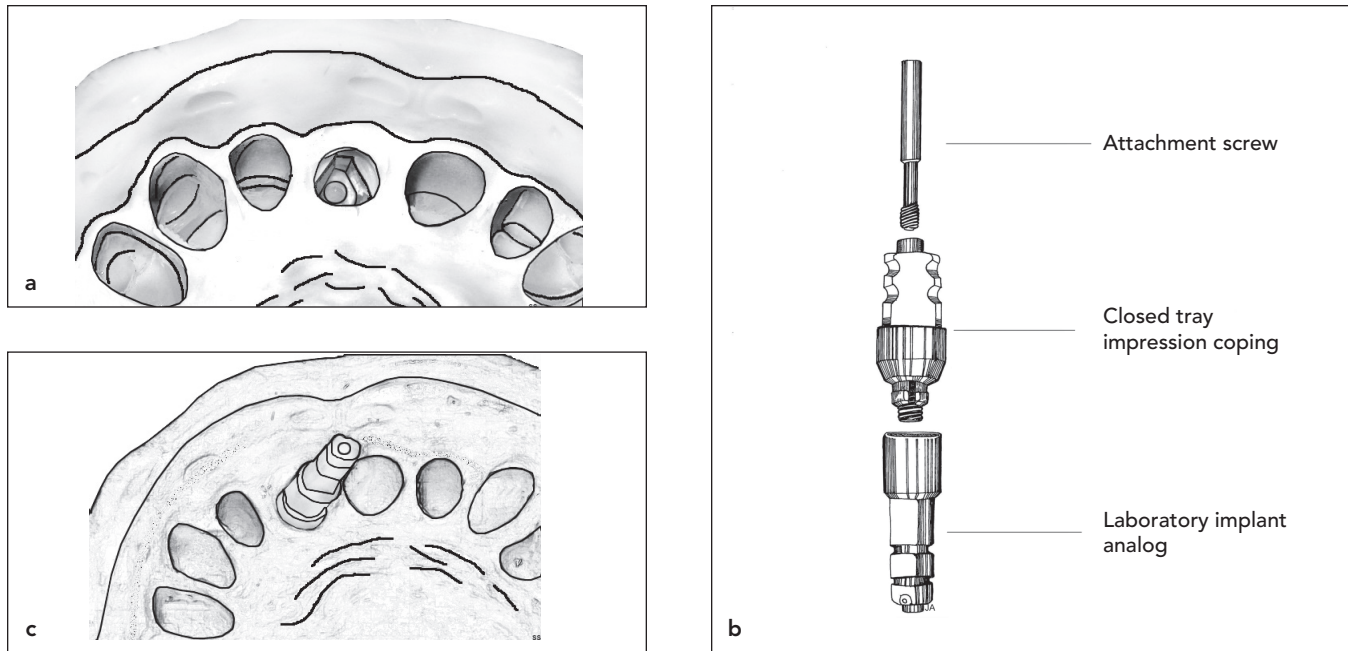


Fig 28-6 (a) Intaglio view of preliminary closed tray alginate impression. Note the detail of the impression coping in the impression material. (b) Closed tray impression coping with attachment screw and laboratory implant analog. (c) Closed tray impression coping with attached laboratory implant analog inserted into the preliminary alginate impression.

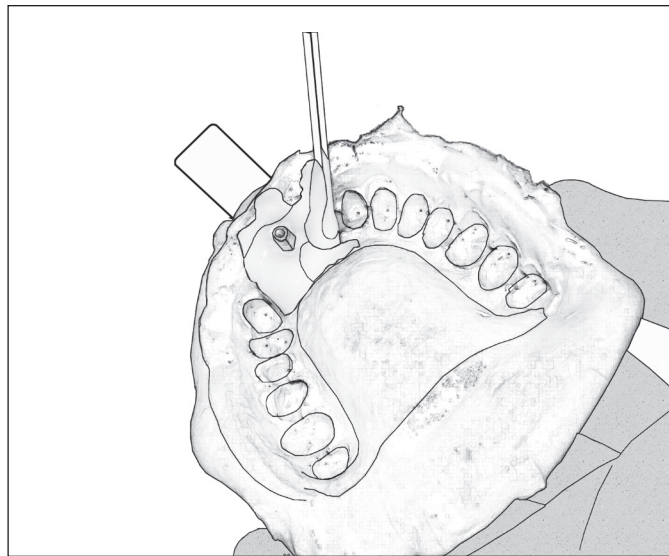


Fig 28-7 Dental stone is poured around the laboratory implant analog.

The preliminary alginate impression (Fig 28-6a) is removed from the patient's mouth, revealing the negative of the closed tray impression coping and the natural dentition. The closed tray impression coping of each manufacturer has a unique shape that allows it to be accurately reinserted into the preliminary alginate impression. A laboratory implant analog is a replica of the top of the dental implant.

After the preliminary alginate impression is made, the closed tray impression coping is removed from the dental implant, and the healing abutment is replaced. The closed

tray impression coping is then secured to the laboratory implant analog with the attachment screw (Fig 28-6b). The combined impression coping, attachment screw, and laboratory implant analog are reinserted into the preliminary alginate impression in preparation for diagnostic cast fabrication (Fig 28-6c). The cast is poured by initially placing dental stone around the exposed laboratory implant analog (Fig 28-7) and then filling the remaining impression with dental stone.

The closed tray impression coping will remain attached to the laboratory implant analog when the preliminary alginate

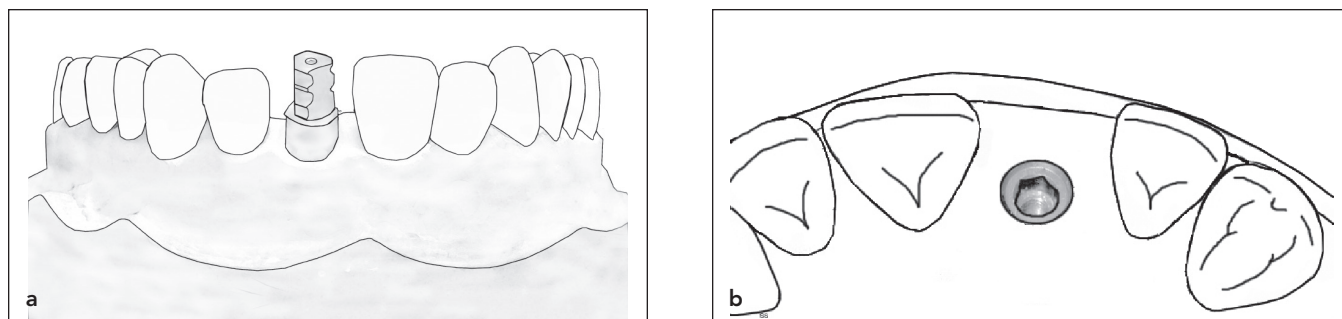


Fig 28-8 (a) Diagnostic cast following impression separation with closed tray impression coping in place. (b) Diagnostic cast with preliminary impression coping removed, showing the top of the implant analog.

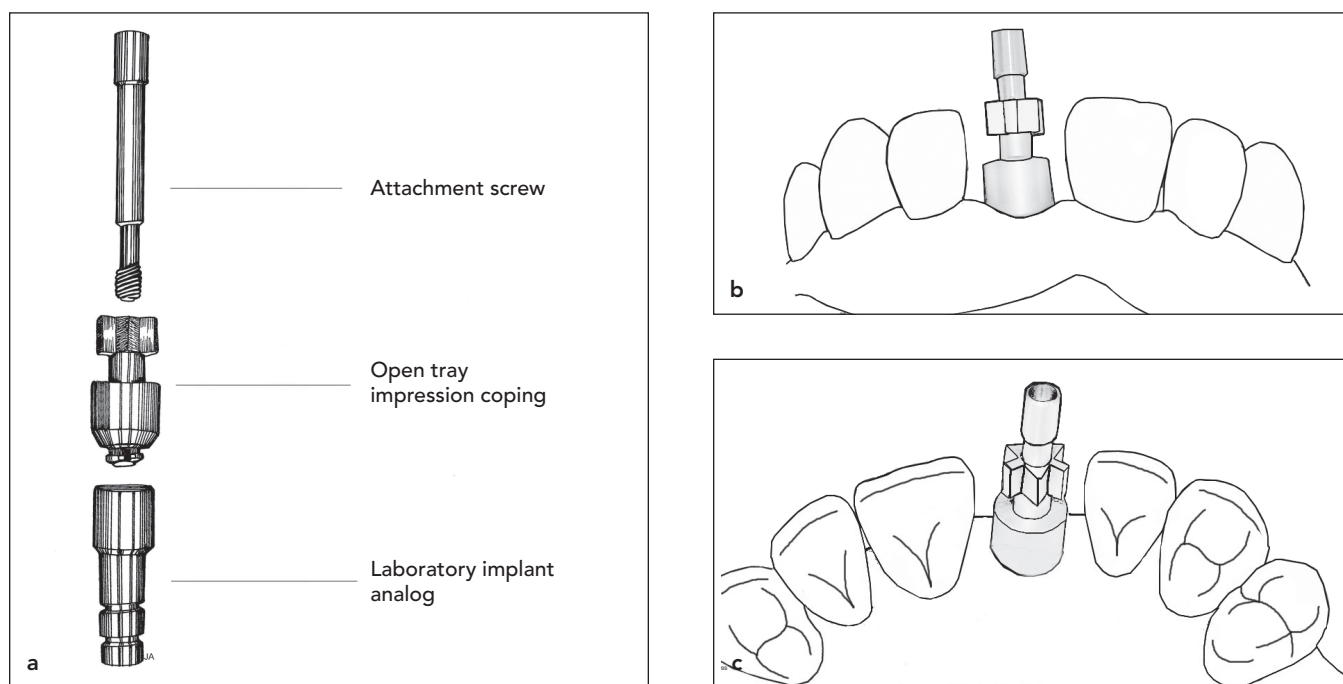


Fig 28-9 (a) Open tray impression coping with attachment screw and laboratory implant analog. (b) Facial view of open tray impression coping seated on diagnostic cast with attachment screw. (c) Palatal view.

impression tray is separated from the cast (Fig 28-8a). The closed tray impression coping is removed from the cast by unscrewing the attachment screw. This will reveal the top of the laboratory implant analog, which is a replica of the patient's dental implant with the internal hex (Fig 28-8b). The detailed shape of a closed tray impression coping, while well recorded within impression material, can present a challenge when reseating the impression coping in the impression for cast fabrication.

Final impression and master cast fabrication

The open tray impression coping (Fig 28-9a) has an even more detailed shape and a longer attachment screw than

the closed tray impression coping. As stated earlier, an open tray impression technique will produce a more accurate cast than a closed tray impression technique because the impression coping remains within the impression material when the impression tray is removed from the mouth. Therefore, the open tray impression technique is recommended for taking a final impression and fabricating a master cast.

The open tray is fabricated on the diagnostic cast with the open tray impression coping attached to the laboratory implant analog with the attachment screw (Figs 28-9b and 28-9c). The diagnostic cast is blocked out around the dentition with two sheets of pink baseplate wax (approximately 2 mm thick), leaving the top two-thirds of the attachment screw exposed. Four vertical stops are cut through the occlusal surface of the block-out wax. The stops should be well spaced to provide impression tray stability during the

28 Single-Tooth Implant Restoration

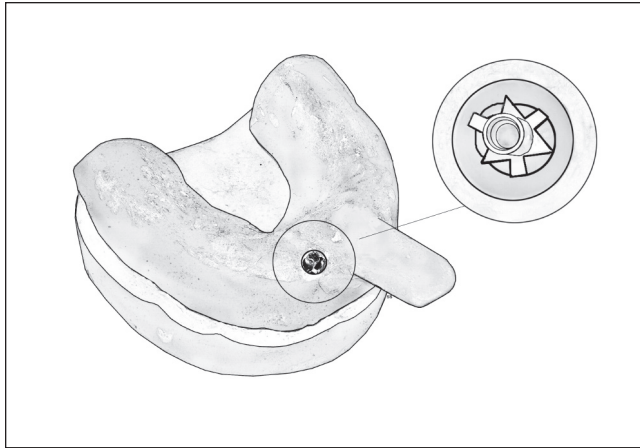


Fig 28-10 Custom open tray impression. Note opening in impression tray for access to attachment screw. (inset) Close-up of opening to gain access to the impression coping attachment screw when the impression is made.

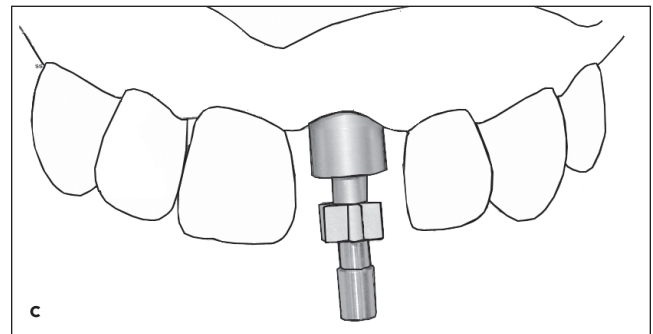
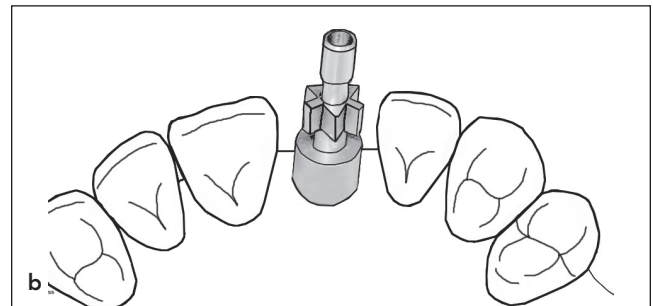
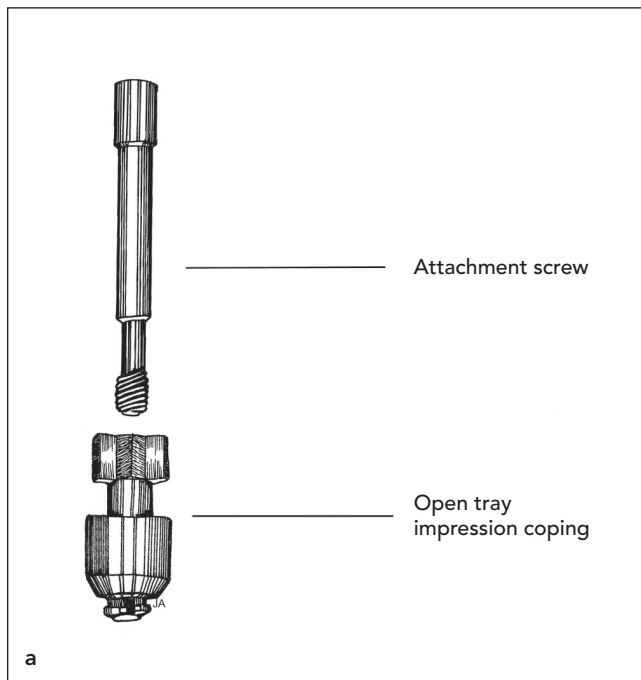


Fig 28-11 (a) Open tray impression coping with attachment screw. (b) Palatal view of open tray impression coping seated with attachment screw. (c) Facial view of open tray impression coping seated in the patient's mouth with attachment screw.

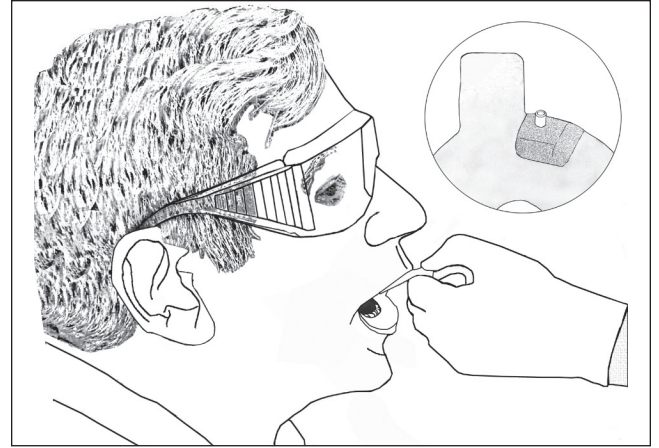
impression-taking process. They should not be placed immediately adjacent to the implant site because the impression tray may need adjustment in this area, and the vertical stops could be destroyed if they are too close. The custom impression tray may be fabricated from the tray material of choice. The tray material should be pressed firmly to record the vertical wax cutouts and the location of the impression coping attachment screw.

After the impression tray material has polymerized, the impression tray is removed from the diagnostic cast. Any block-out wax remaining in the custom impression tray is removed. A hole is created in the custom impression tray to provide

access to the impression coping attachment screw (Fig 28-10). The access hole in the top of the open tray should provide at least 2 mm of space around the impression coping attachment screw. A piece of boxing wax is placed over the access hole to contain the impression material within the impression tray while it is being carried and seated in the patient's mouth.

To begin the final impression process, the implant healing abutment is removed, and the open tray impression coping with the attachment screw (Fig 28-11a) is transferred from the diagnostic cast to the patient (Figs 28-11b and 28-11c). A radiograph should be taken at this time to ensure that the

Fig 28-12 Taking the final impression with a custom open tray impression. (*inset*) Custom open tray impression with attachment screw protruding through boxing wax to contain impression material while seating the tray.



impression coping is fully seated onto the dental implant.¹¹ This radiograph will also provide information regarding the amount and quality of the bone surrounding the dental implant at the time of implant restoration. This is the first time during patient restorative treatment that a radiograph needs to be taken. This radiograph will serve as a baseline radiograph to monitor long-term implant health.

A piece of boxing wax is placed over the opening for the abutment screw on the open impression tray to contain the impression material in the custom impression tray. The use of the final impression material is opposite that of the standard impression technique in that the heavy-body impression material is injected around the open tray impression coping and the impression tray is filled with medium-body impression material. The heavy-body impression material is placed around the open tray impression coping to minimize any movement that may occur during the removal of the impression tray and pouring of the master dental cast.

During the impression-taking process, the custom impression tray must be oriented to allow the impression coping abutment screw to penetrate the boxing wax placed over the abutment screw hole (Fig 28-12) before the impression material sets. Upon polymerization of the impression material, any wax around the implant abutment screw is removed to provide access to the implant abutment screw. The implant abutment screw is unscrewed and removed from the top of the open impression tray. The final impression is removed from the patient's mouth, and the healing abutment is replaced on the dental implant. The heavy-body impression material stabilizes the open tray impression coping, which remains undisturbed within the impression material until the master cast is poured in dental stone.

The final impression is inspected for completeness. The surface of the open tray impression coping that was in contact with the dental implant should be free of impression material¹¹ (Fig 28-13a). The open tray impression coping at-

tachment screw that had been removed from the impression tray in order to remove the impression tray from the patient's mouth is reinserted into the open tray impression coping (Fig 28-13b).

The laboratory implant analog is secured to the open tray impression coping with the attachment screw^{9,11} (Fig 28-13c). The laboratory implant analog hex must be correctly aligned with the open tray impression coping hex to be seated fully (Fig 28-13d). When the attachment screw is secured with the hex driver, care must be taken to not overtighten the attachment screw because there is a risk of the open tray impression coping moving, which will render the master cast inaccurate.

Improved restorative esthetics can be achieved when the top of the dental implant is approximately 2 to 3 mm below the surrounding gingival tissue. An impression of a dental implant that is lower than the surrounding gingival tissue will yield a stone cast with a dental implant analog that is below the level of the surrounding dental stone. This dental stone will restrict access to the top of the laboratory implant analog during restoration fabrication. To facilitate restoration fabrication, a soft tissue replica material (Gingitech, Ivoclar Vivadent) is placed around the portion of the open tray impression coping that was below the level of the gingival tissue intraorally but is now exposed because the impression is a negative representation of the patient's intraoral situation. The presence of the soft tissue replica material on the master cast is helpful because it is removable, allowing access to the top of the laboratory implant analog during restoration fabrication.⁹

Soft tissue replica material will adhere to many impression materials. Therefore, the separating medium provided by the manufacturer of the soft tissue replica material should be applied to the intaglio surface of the final impression surrounding the exposed portion of the open tray impression coping and approximately 1 mm onto the laboratory implant

28 Single-Tooth Implant Restoration

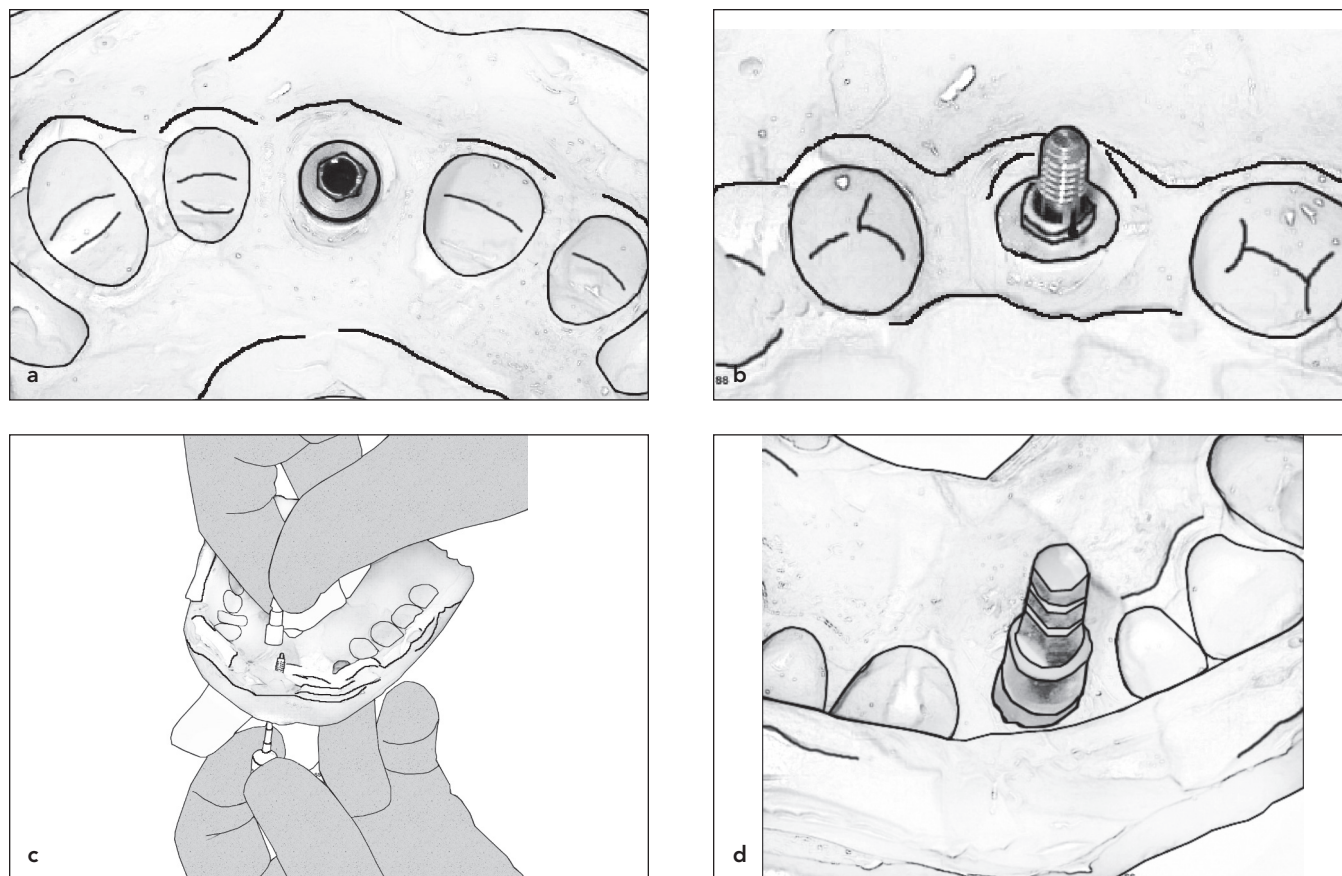


Fig 28-13 (a) Intaglio surface of final impression. Note the impression coping surface that was in contact with the dental implant. (b) Intaglio surface of final impression with the attachment screw ready for the laboratory implant analog. (c) Hex driver is stabilizing the attachment screw during connection of the laboratory implant analog to the impression coping. (d) Final impression with laboratory implant analog secured to the impression coping with an attachment screw.

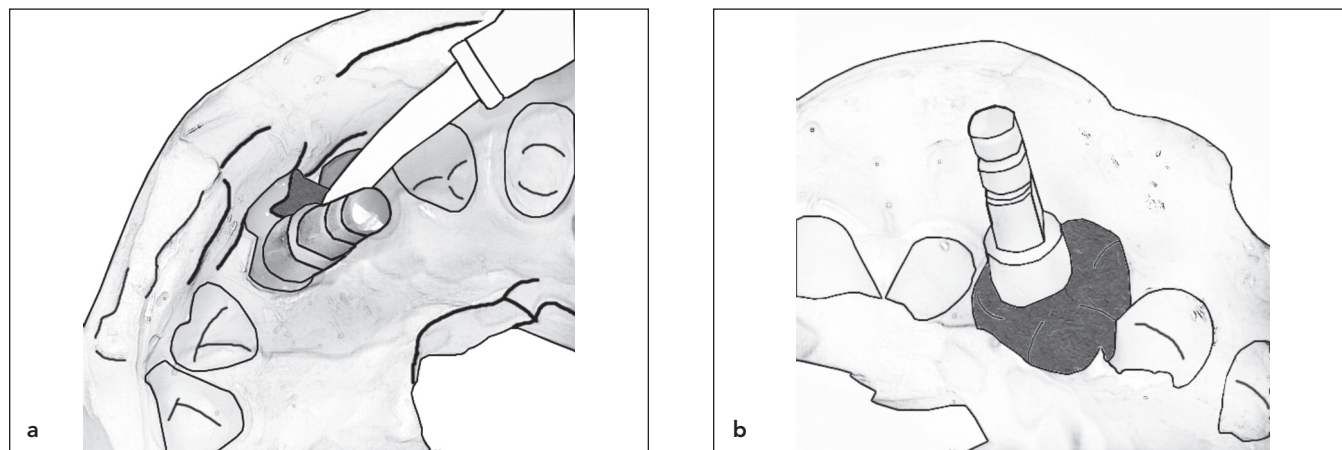


Fig 28-14 (a) Placing gingival tissue material in the final impression to simulate patient soft tissue. (b) Gingival tissue material is only placed around the portion of the impression coping that was subgingival in the patient's mouth.

analog. The soft tissue replica material is applied around the exposed open tray impression coping and approximately 1 mm onto the laboratory implant analog (Fig 28-14a). The soft tissue replica material should not extend into the impression of the teeth proximal to the dental implant (Fig

28-14b). Pouring of the final impression is begun by placing dental stone around the laboratory implant analog (Fig 28-15a). The remainder of the impression is then poured in dental stone to fabricate the master cast. Separation of the master cast from the final impression requires removal of the

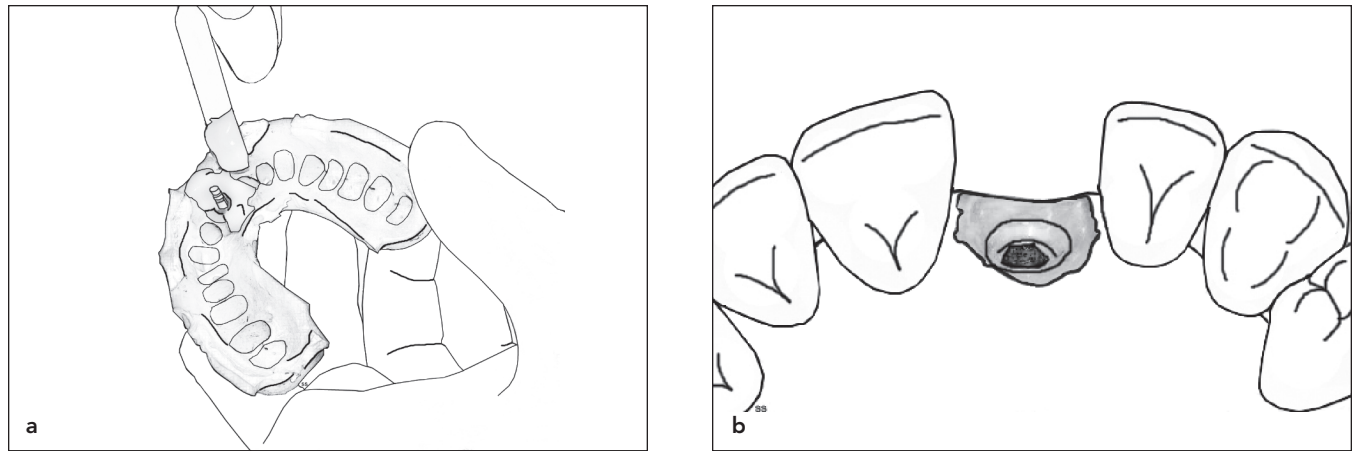


Fig 28-15 (a) Pouring dental stone around the laboratory implant analog. (b) Master cast with laboratory implant analog surrounded by gingival soft tissue replica material.

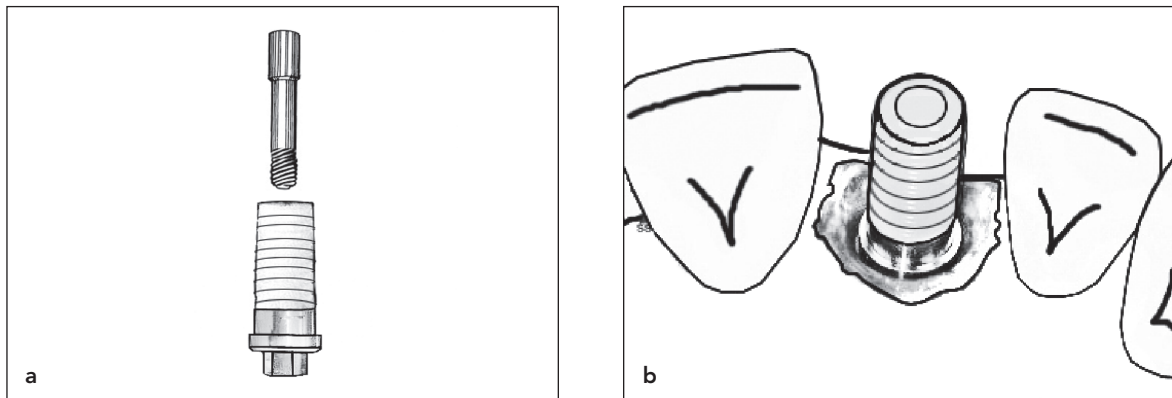


Fig 28-16 (a) Internal hex machined metal cylinder with waxing sleeve and abutment screw. (b) Palatal view of internal hex machined metal cylinder with waxing sleeve and abutment screw on master cast.

attachment screw. The master cast will have the soft tissue replica material surrounding the top of the laboratory implant analog (Fig 28-15b).

Definitive Implant Restoration

Articulation of the master cast

The maxillary master cast and opposing mandibular cast are articulated. A prefabricated, machined hex metal cylinder with attached plastic waxing sleeve (waxing abutment) (Fig 28-16a) is secured to the laboratory implant analog on the master cast with an abutment screw (Fig 28-16b). When the

waxing abutment is in place on the articulated master cast, it will create a premature incisal contact (Fig 28-17a) requiring equilibration¹² (Fig 28-17b). Completion of the waxing abutment equilibration will reestablish normal occlusion (Figs 28-17c and 28-17d). The plastic sleeve of the waxing abutment has horizontal ridges placed by the manufacturer to aid in wax retention. However, it is often necessary to place additional retention to prevent wax rotation around the waxing abutment. Roughening and/or placing vertical grooves on the plastic sleeve of the waxing abutment for additional wax retention is strongly recommended. The abutment screw access hole in the plastic sleeve of the waxing abutment should be obturated with a cotton pellet prior to initiating restoration waxing to prevent wax from obstructing the hex of the abutment screw.

28 Single-Tooth Implant Restoration

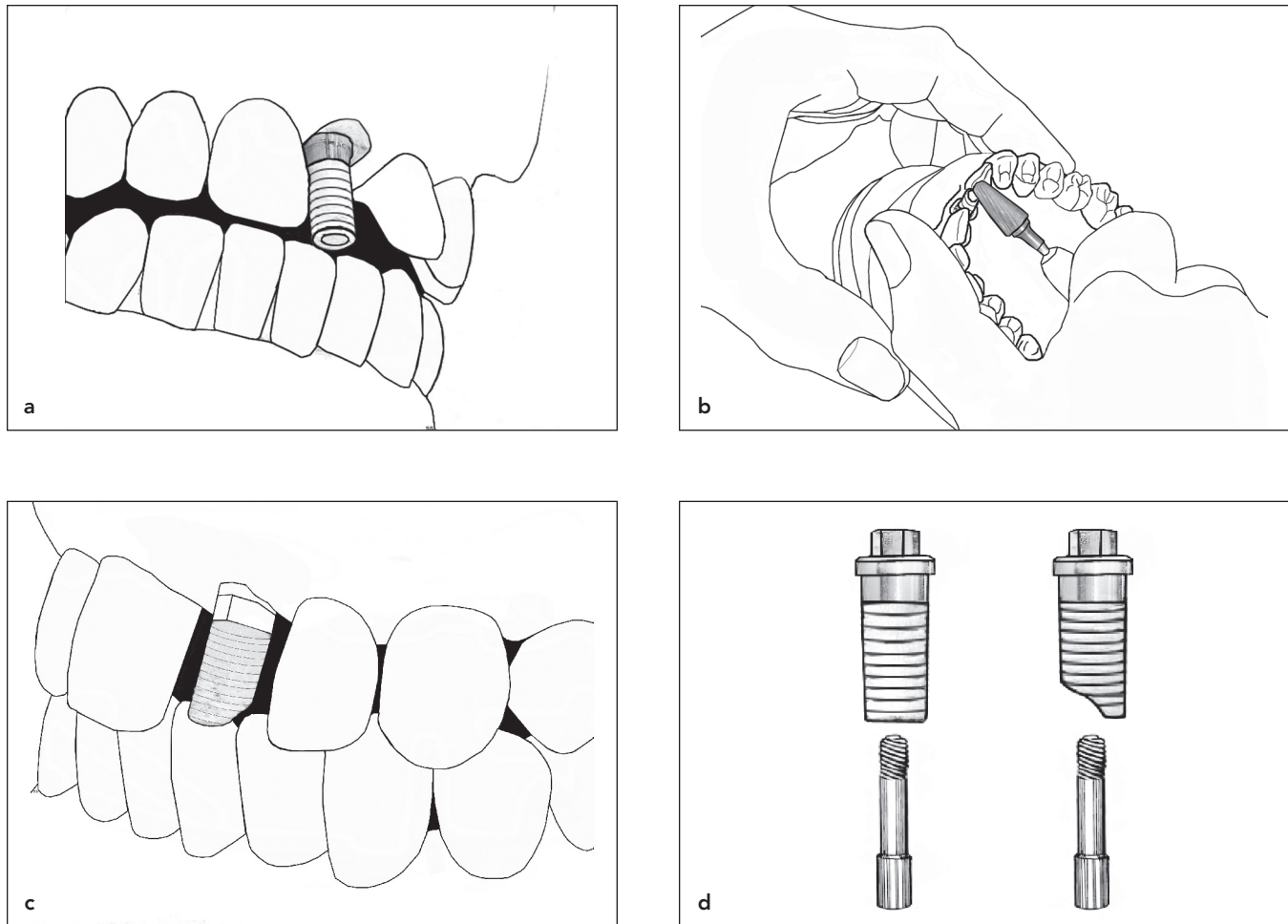


Fig 28-17 (a) Premature incisal contact of waxing cylinder on articulated casts. (b) Equilibration of waxing cylinder to eliminate premature incisal contact. (c) Waxing cylinder equilibrated into occlusion. (d) Note the amount of equilibration of waxing cylinder required to achieve centric occlusion.

Restoration wax-up

Waxing of the restoration begins with the addition of wax to the waxing abutment with a no. 7 wax spatula (Fig 28-18a). Additional wax may be added with the aid of a beavertail burnisher (Fig 28-18b). The restoration is waxed to full contour (Fig 28-18c). The palatal view of the contour wax-up reveals the access hole for the abutment screw (Fig 28-18d). The full-contour wax-up is then cut back to allow room for the addition of porcelain. The palatal (or lingual) cutback should allow for the abutment screw access hole to be surrounded by metal (Fig 28-19). The incisal cutback should be marked at 3 mm to allow for translucency of the incisal porcelain (Fig 28-20). A facial groove depth of 1 mm will assist

in achieving adequate, uniform facial reduction (Fig 28-21). The incisal aspect may now be reduced to the desired level (Fig 28-22). The next step is proximal reduction (Fig 28-23). The completed wax pattern reduction is shown in Figs 28-24 and 28-25.

Restoration placement

The completed dental implant restoration can provide a natural appearance (Fig 28-26a). The abutment screw access hole is encircled with metal to prevent the fracture of unsupported porcelain (Fig 28-26b). The abutment screw access hole is closed by first placing cotton pellets over the top

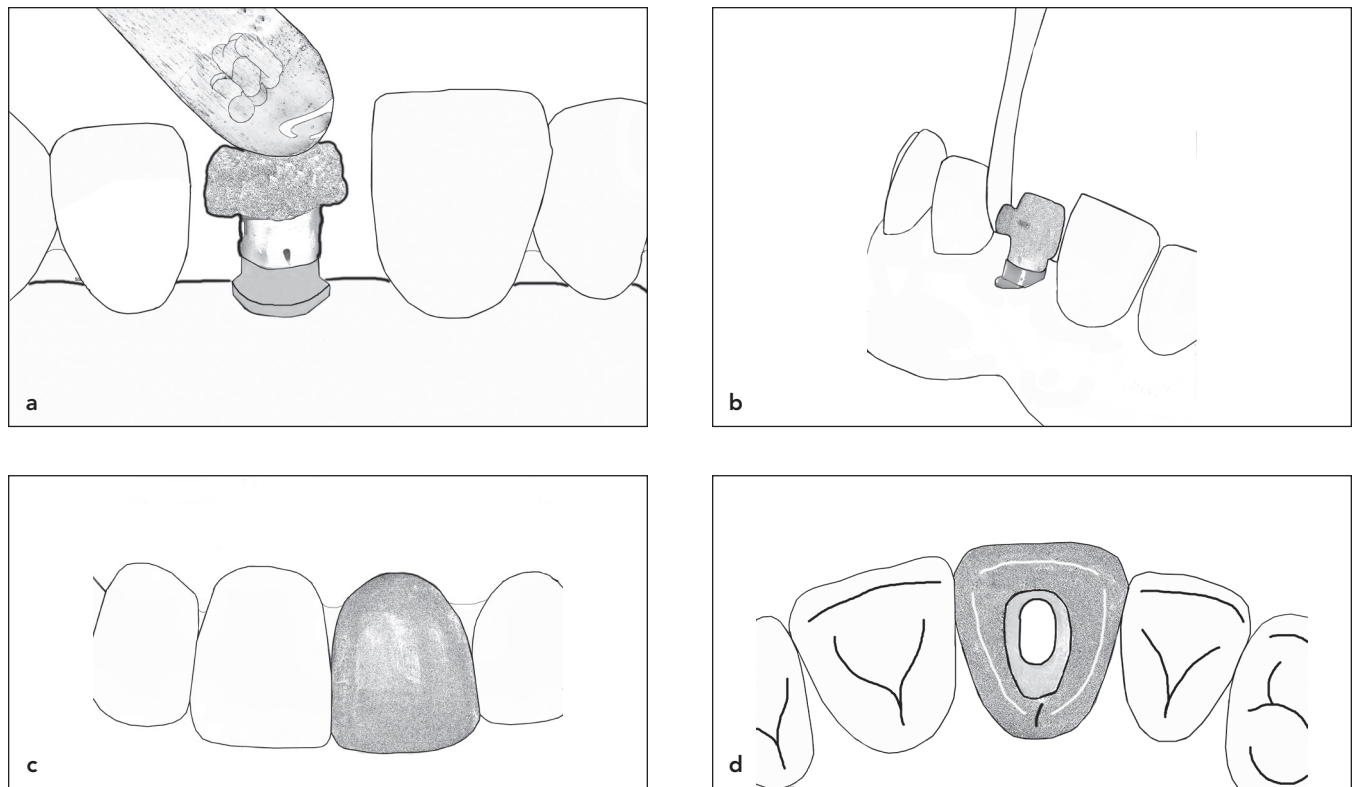


Fig 28-18 (a) Adding wax to implant waxing cylinder with a no. 7 wax spatula. (b) Adding more wax to implant waxing cylinder with a beavertail burnisher. (c) Labial view of full-contour wax-up of the implant-retained restoration. (d) Palatal view of full-contour wax-up showing screw access hole.

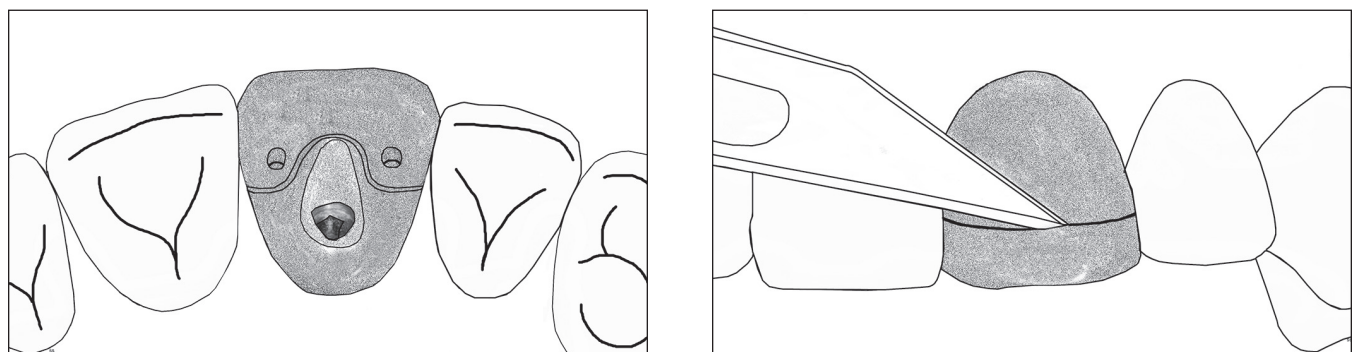


Fig 28-19 Outline of the palatal wax pattern cutback around the waxing cylinder.

Fig 28-20 Facial view of wax pattern incisal reduction.

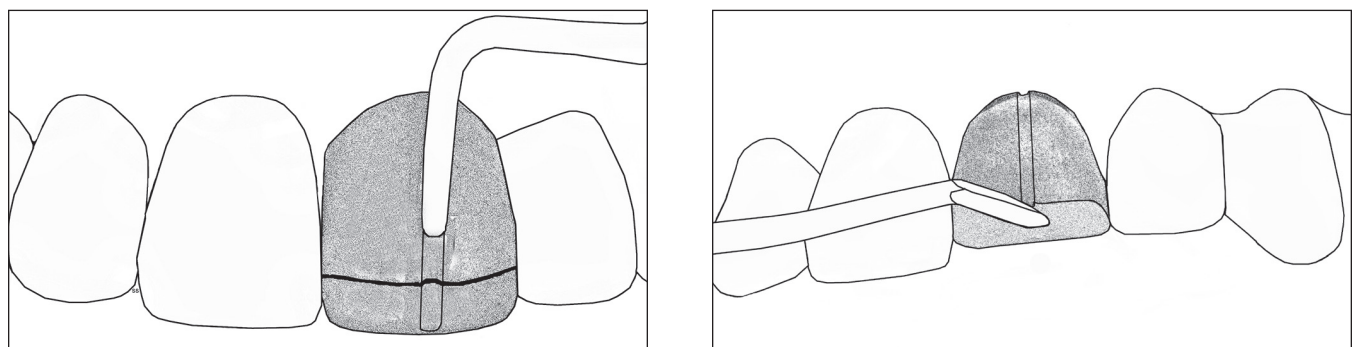


Fig 28-21 Facial reduction groove on wax pattern.

Fig 28-22 Incisal reduction of wax pattern.

28 Single-Tooth Implant Restoration

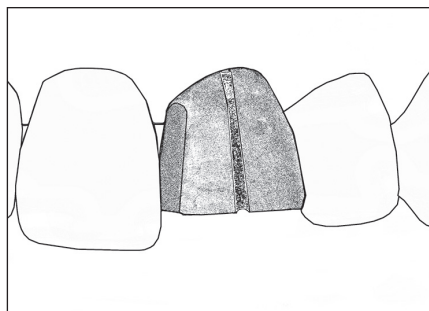


Fig 28-23 Proximal reduction of wax pattern.

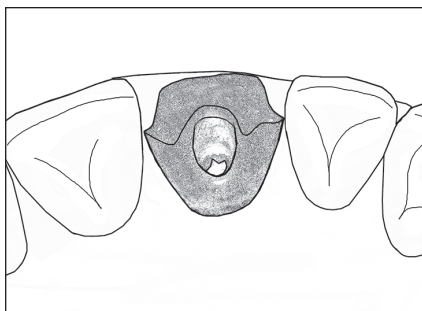


Fig 28-24 Palatal view of completed wax pattern cutback.

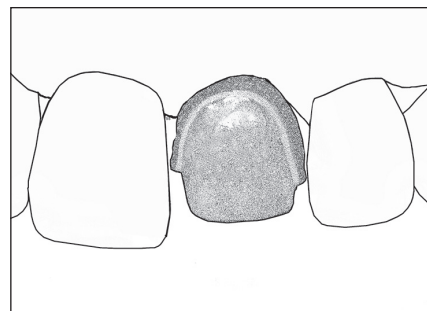


Fig 28-25 Facial view of completed wax pattern cutback.

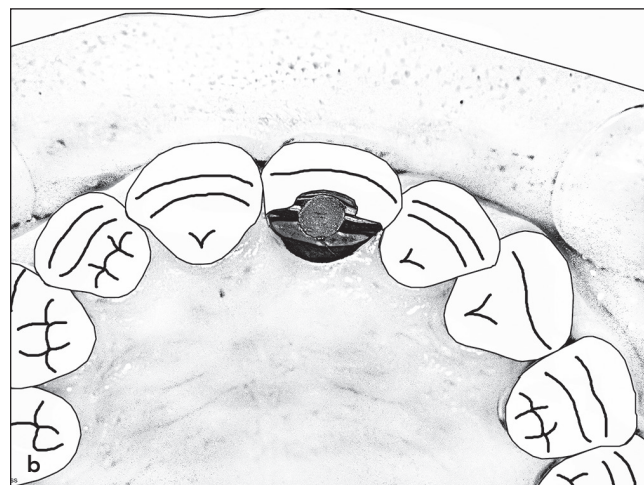
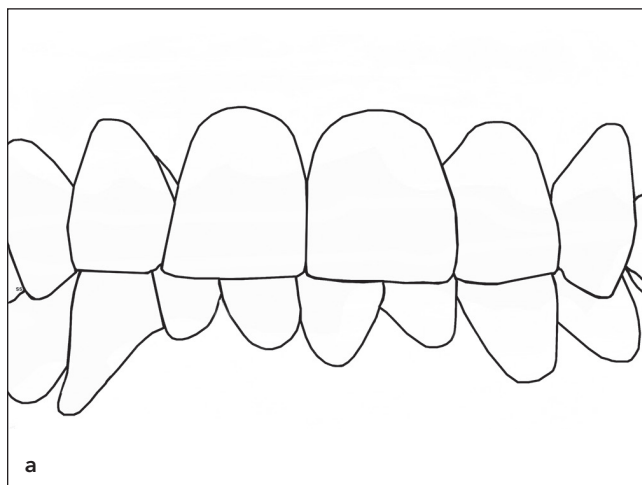


Fig 28-26 (a) Facial view of definitive restoration. (b) Palatal view of definitive restoration. Note that the palatal screw access hole is surrounded by metal.

of the abutment screw to within 2 mm of the access hole opening to protect the hex of the abutment screw. The cotton pellets are then covered with a 2-mm layer of light-polymerizing resin.¹² The use of a wet cotton-tipped applicator to smooth and remove excess light-polymerizing resin prior to polymerization will produce a surface that will require no further finishing.

References

1. Lewis SG, Beumer J, Perri GR, Hornburg WP. Single tooth implant supported restorations. *Int J Oral Maxillofac Implants* 1988; 3:25–30.
2. Laney WR, Jemt T, Harris D, et al. Osseointegrated implants for single-tooth replacement: Progress report from a multicenter prospective study after 3 years. *Int J Oral Maxillofac Implants* 1994;9:49–54.
3. Rungcharassaeng K, Kan JY. Management of unfavorable implant placement: A clinical report. *J Prosthet Dent* 2000;84:264–268.
4. Tarlow JL. Procedure for obtaining proper contour of an implant-supported crown: A clinical report. *J Prosthet Dent* 2002;87:416–418.
5. Jemt T. Single implants in the anterior maxilla after 15 years of follow-up: Comparison with central implants in the edentulous maxilla. *Int J Prosthodont* 2008;21:400–408.
6. Misch CE, Misch CM. Generic terminology for endosseous implant prosthodontics. *J Prosthet Dent* 1992;68:809–812.
7. Zarb GA, Schmitt A. The longitudinal clinical effectiveness of osseointegrated dental implants: The Toronto study. Part I: Surgical results. *J Prosthet Dent* 1990;63:451–457.
8. Weber HP, Cochran DL. The soft tissue response to osseointegrated dental implants. *J Prosthet Dent* 1998;79:79–89.
9. Centerpulse Dental Inc. Tapered Screw-Vent and AdVent Restorative Manual, 2002: 12–14, 15–17.
10. Vigolo P, Majzoub Z, Cordioli G. Evaluation of the accuracy of three techniques used for multiple implant abutment impressions. *J Prosthet Dent* 2003;89:186–192.
11. BIOMET 3i Inc. Restorative Manual for Osseotite Certain and Osseotite External Hex Implant System, 2003:11–13.
12. Zimmer Dental Inc. Dental Tapered Screw-Vent and AdVent Restorative Manual, 2006:52–58.

Multiple-Tooth Implant Restoration

29

The use of dental implants to replace multiple missing teeth is one way to avoid the use of a long-span fixed partial denture or a removable partial denture. Traditionally, a very long-span or distal extension edentulous area was restored with a removable partial denture or was not restored at all. The use of dental implants now provides options for these more challenging restorations.¹⁻³

Implant Placement and Healing

In the example illustrated throughout this chapter, the patient has lost the maxillary left second premolar and first molar. The missing teeth have been replaced with dental implants, which have been allowed to heal for the prescribed time after placement. The dental implants have been uncovered, and healing abutments have been placed (Fig 29-1a). The dental implants are now ready for restoration.

The process of fabricating a dental implant-supported restoration requires a series of individual steps. The removal of the healing abutment with a hex driver (Figs 29-1b and 29-1c) exposes the top of the dental implants (Fig 29-2). The gingival tissue surrounding the dental implant should be evaluated for health and thickness. The gingival tissue should be the same color as the healthy tissue surrounding the natural dentition. The depth of the gingival cuff (thickness) surrounding the dental implant is important; this preferably should be 2 to 3 mm. A gingival cuff deeper than 3 mm is prone to suffer from chronic irritation due to hygiene difficulty,⁴ and a gingival cuff depth less than 1 mm may present an esthetic problem such as metal display at the gingival margin of the restoration. A gingival cuff that is too deep or too shallow may require periodontal therapy to provide the optimum environment for restoration fabrication.

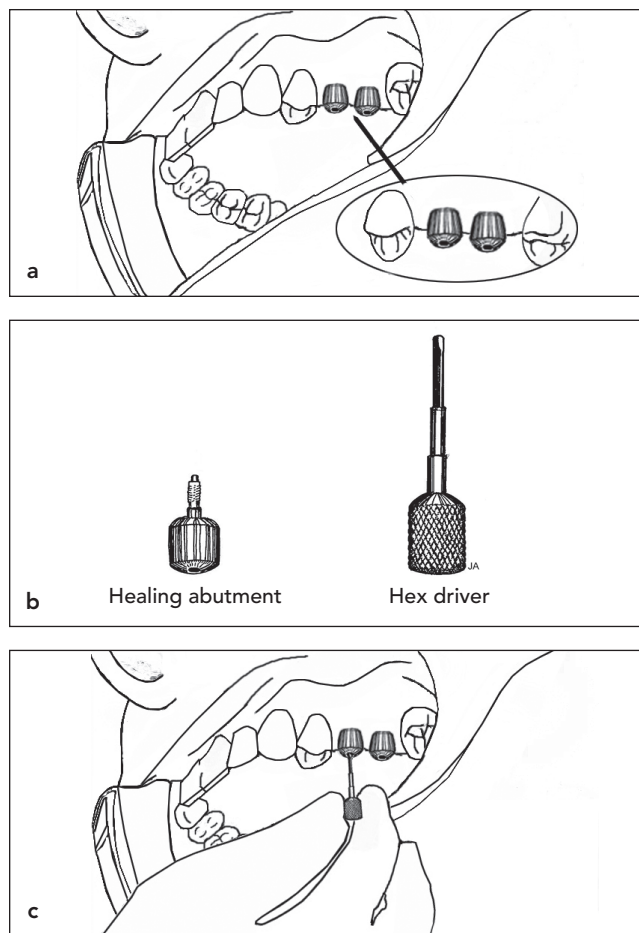


Fig 29-1 (a) Intraoral view of two dental implants with healing abutments in place. (b) Hex driver for insertion and removal of healing abutments from the patient's mouth. (c) Intraoral view of the hex driver engaging the healing abutment.

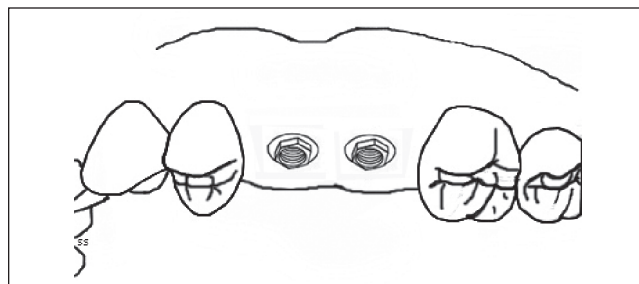


Fig 29-2 Intraoral view of the top of the external hex implants with healing abutments removed.

29 Multiple-Tooth Implant Restoration

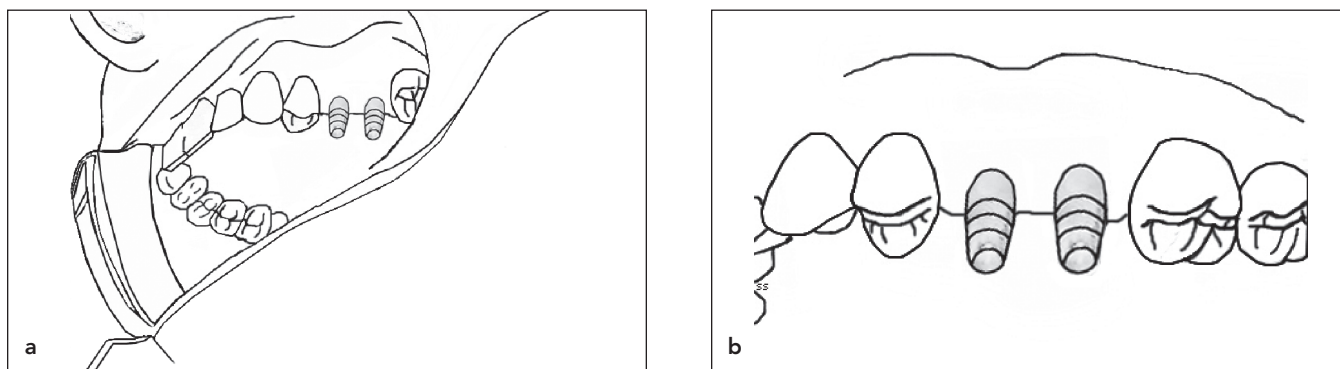


Fig 29-3 (a and b) Views of closed tray impression copings connected to implants in the patient's mouth.

Impression Taking and Cast Fabrication

The general process of fabricating a dental cast upon which dental restorations can be fabricated begins with taking an impression. Dental implant impressions are taken after removing the healing abutments and attaching impression copings to the dental implants. The shapes of the impression copings are captured in the impression.

Closed and open tray impression techniques

Impression copings are fabricated for both a closed tray and an open tray impression technique. In a closed tray impression technique, the impression copings remain attached to the dental implants when the impression is removed from the mouth. In an open tray impression technique, the impression copings remain in the impression when the impression is removed from the mouth.⁵

To accomplish the removal of the implant impression coping with the impression, the impression coping is attached to the dental implant with a separate long attachment screw. This attachment screw must be removed prior to removal of the impression tray from the mouth. This requires an opening in the impression tray that allows access to the attachment screw. This opening is the reason it is referred to as an *open tray impression technique*.

Upon removal of a closed tray impression from the patient's mouth, the impression copings are removed from the dental implants, attached to laboratory implant analogs, and reinserted into the impression. The open tray impression technique only requires the attachment of the laboratory implant analogs to the impression copings, which remain

within the impression. The impression can then be poured in dental stone, recording the location of the dental implant in the dental arch.

Preliminary alginate impression and study cast fabrication

The authors routinely use a closed tray impression technique for a preliminary alginate impression but prefer to use an open tray impression technique for the final impression. This is based on the belief that the open tray impression technique will produce a more accurate cast because the impression coping remains undisturbed in the impression material.

An external hex dental implant generally uses a thread start impression coping with the closed tray impression technique. A thread start impression coping does not record the implant hex; it only records the flat top of a dental implant, which is sufficient for a study cast. The open tray impression technique uses an impression coping secured with a long attachment screw. The primary difference between the two impression copings is that the open tray impression coping is more irregular in shape and has a long attachment screw that protrudes through the impression tray, while the closed tray impression coping does not have an attachment screw and instead has a thread start. Figure 29-3 shows closed tray impression copings attached to dental implants in the patient's mouth, so the preliminary alginate impression can be taken (Fig 29-4a).

The preliminary alginate impression is removed from the patient's mouth, revealing the negative of the closed tray impression copings and the natural dentition (Fig 29-4b). The closed tray impression coping of each manufacturer has a unique shape that allows it to be accurately reinserted into the preliminary alginate impression. A laboratory implant analog is a replica of the top of the dental implant.

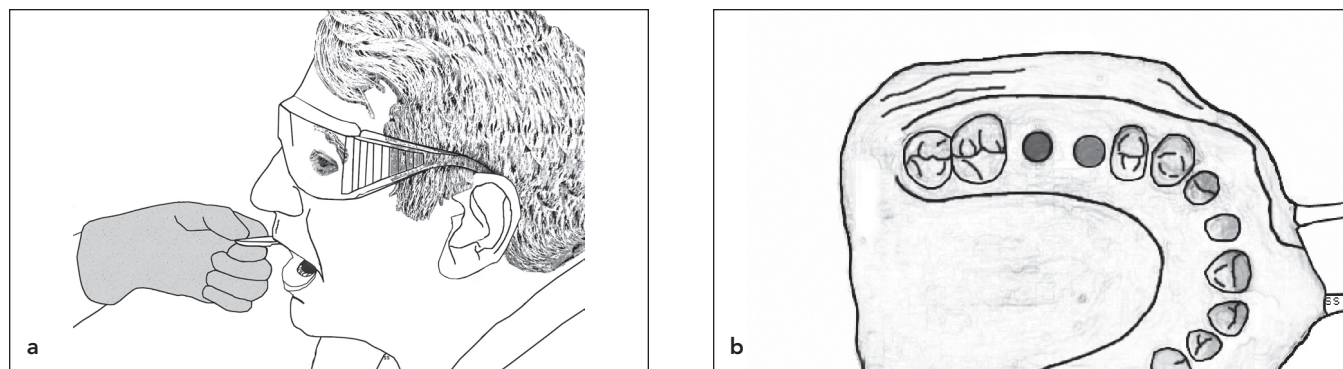


Fig 29-4 (a) Taking the preliminary closed tray alginate impression. (b) Intaglio view of the preliminary closed tray alginate impression. Note the detail of the impression copings in the impression material.

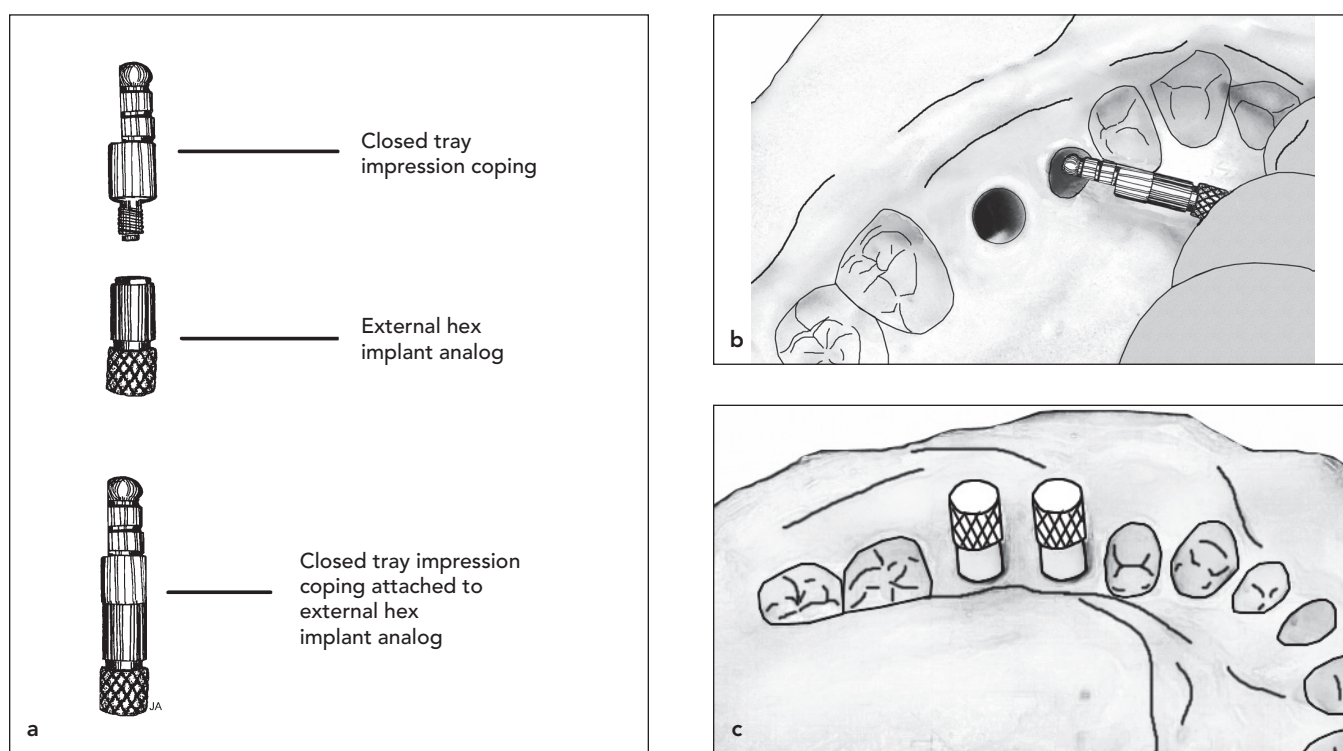


Fig 29-5 (a) Attaching the closed tray impression coping to the laboratory implant analog. (b) Impression coping with laboratory implant analog being inserted into the preliminary alginate impression. Note that the flat surface of the impression coping is aligned with the flat surface in the impression. (c) Closed impression tray with attached laboratory implant analogs inserted into the preliminary alginate impression.

After the preliminary alginate impression is made, the closed tray impression copings are removed from the dental implants, and the healing abutments are replaced. The closed tray impression copings are then secured to the laboratory implant analogs (Fig 29-5a). The combined impression coping and laboratory implant analogs are reinserted into the preliminary alginate impression in preparation for study cast fabrication (Figs 29-5b and 29-5c). The study cast is poured by initially placing dental stone around the ex-

posed laboratory implant analogs (Fig 29-6a) and then filling the remaining impression with dental stone.

The closed tray impression copings will remain attached to the laboratory implant analogs when the preliminary alginate impression tray is separated from the study cast. Removal of the closed tray impression copings from the study cast by unscrewing will reveal the top of the laboratory implant analogs, which are replicas of the patient's external hex dental implants (Fig 29-6b). The shape of a closed tray

29 Multiple-Tooth Implant Restoration

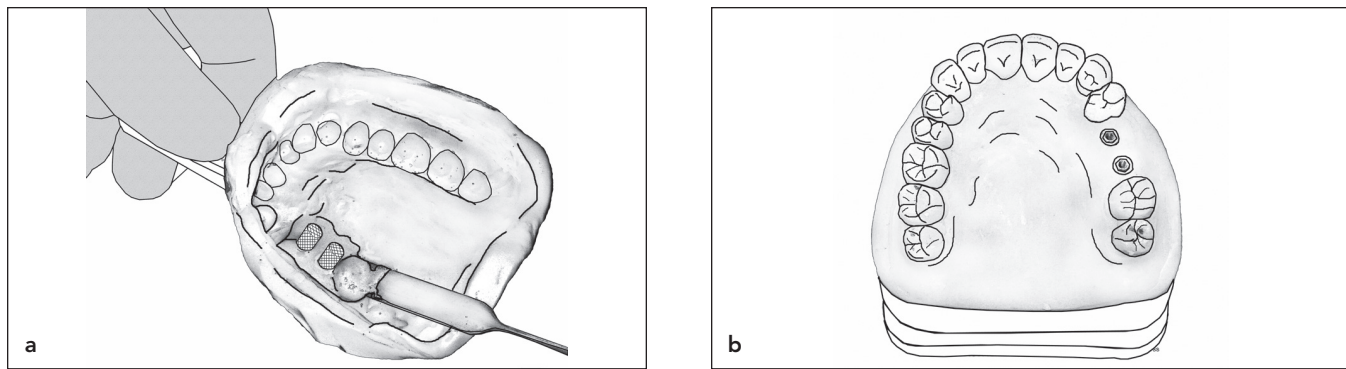


Fig 29-6 (a) When the study cast is poured, dental stone is first poured around the laboratory implant analogs. (b) Study cast with preliminary impression copings removed, showing the top of the external hex laboratory implant analogs.

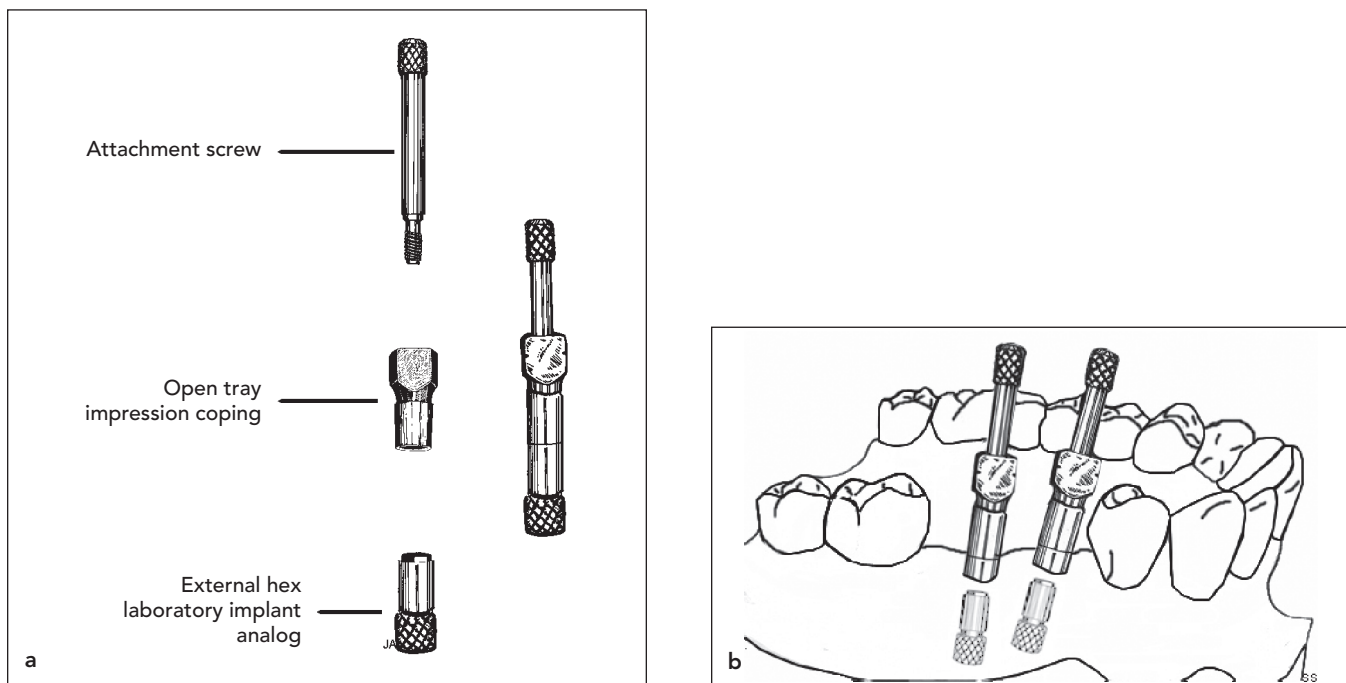


Fig 29-7 (a) Open tray hex impression coping with attachment screw and laboratory implant analog, shown separately and combined. (b) Buccal view of open tray impression copings seated on study cast with attachment screws.

impression coping, while well recorded within impression material, can present a challenge when reseating the impression coping in the impression for cast fabrication. However, as previously mentioned, open tray impression copings (Fig 29-7a) have long attachment screws that preclude their use with the closed tray impression technique.

Final impression and master cast fabrication

As explained earlier, the authors believe the open tray impression technique will produce a more accurate cast than a closed tray impression technique because the impression

coping remains within the impression material when the impression tray is removed from the mouth.⁶⁻⁹ The authors recommend the use of the open tray impression technique for taking a final impression and fabricating a master cast. The open tray is fabricated on the study cast with the open tray impression coping attached to the laboratory implant analog with the attachment screw (Fig 29-7b).

The fabrication of a multiple-tooth dental implant restoration requires a very accurate cast in order to avoid the need for cutting and soldering the definitive restoration. The reason the master cast must have a high degree of accuracy is because the definitive restoration contains machined components that must have a passive fit. To achieve a master cast of the desired quality, the open tray impression copings

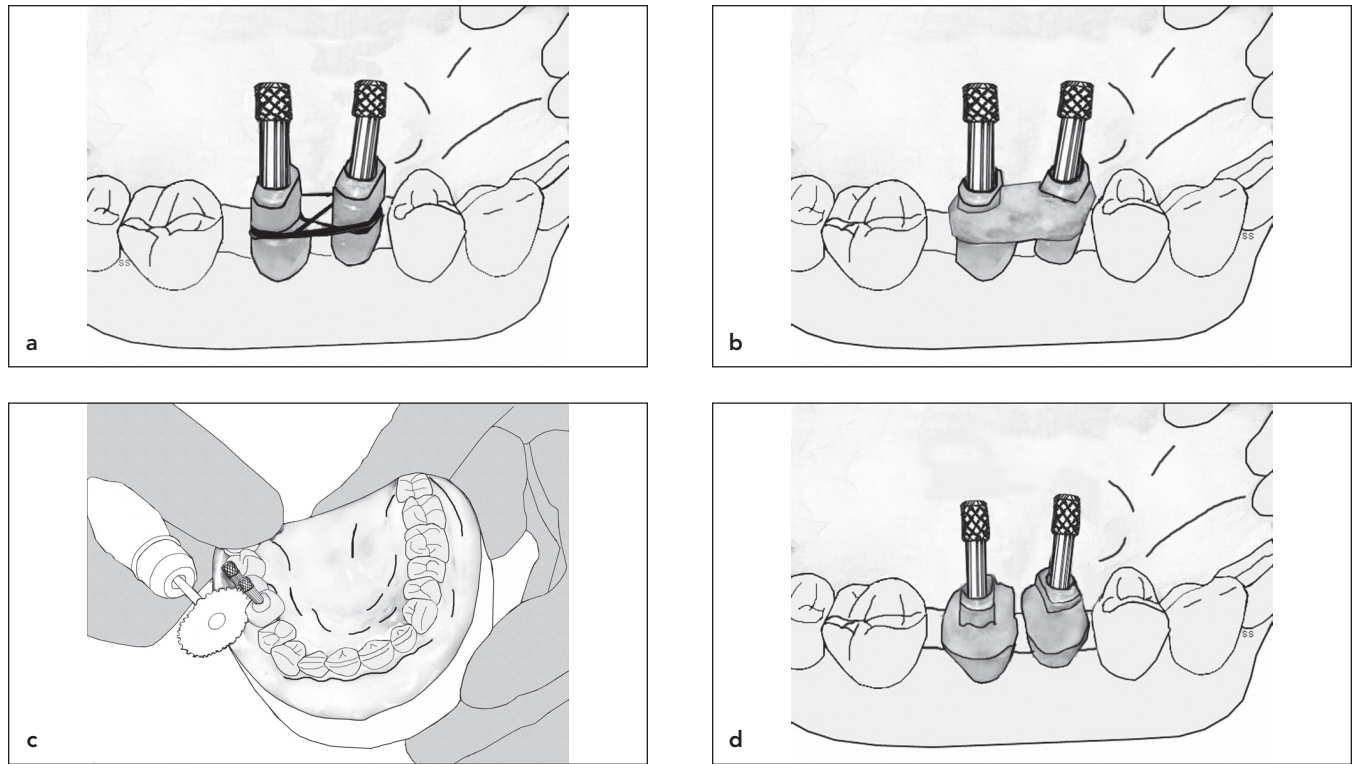


Fig 29-8 (a) Buccal view of open tray impression copings seated on study cast with attachment screws. Note the use of dental floss as a scaffold for the autopolymerizing acrylic resin. (b) Buccal view of open tray impression copings seated on study cast with attachment screws. Note the addition of autopolymerizing acrylic resin. (c) A separating disk is used to section the acrylic resin between the open tray impression copings. (d) Note the separation between open tray impression copings.

should be luted together in the mouth prior to taking the final impression. An initial laboratory procedure will facilitate this clinical step of luting the open tray impression copings together intraorally. This initial laboratory procedure consists of placing the open tray impression copings on the study cast with attachment screws. The open tray impression copings are to be enclosed in autopolymerizing acrylic resin to accurately record their relationship to each other. To facilitate the addition of the acrylic resin around the top of the open tray impression copings, a scaffold is formed with dental floss to support the autopolymerizing acrylic resin (Fig 29-8a). The dental floss scaffold should be in the middle third of the open tray impression coping. One end of the dental floss is secured around one of the open tray impression copings with an overhand knot. Next, a figure eight is formed around the open tray impression copings, and the scaffold is finished with a circumferential wrap. The ending portion of the dental floss is tied off with the loose end of the starting piece of floss. Autopolymerizing acrylic resin is then placed around the open tray impression copings with a paintbrush. The dental floss scaffold supports the autopolymerizing acrylic resin, which should not be in contact with the study cast (Fig 29-8b), so that it will be surrounded by impression material when the final impression is made. After polymerization of the autopolymerizing acrylic resin, a separating disk (Fig 29-8c) is used to separate the open

tray impression copings (Fig 29-8d). The addition of all of the autopolymerizing acrylic resin can be done intraorally. However, the authors prefer to perform this initial procedure in the laboratory because it reduces chair time and a smaller volume of autopolymerizing acrylic resin, with its inherent shrinkage, is used intraorally.

The study cast is blocked out around the dentition with two sheets of pink baseplate wax (approximately 2 mm thick), leaving the top two-thirds of the attachment screws exposed. Four vertical stops for the impression tray during the impression-taking process are cut through the occlusal surface of the block-out wax. The vertical stops should be well spaced to provide impression tray stability. They should not be placed immediately adjacent to the implant site because the impression tray may need adjustment in this area, which may eliminate the vertical stops. The custom impression tray may be fabricated from the tray material of choice. The tray material should be pressed firmly to record the vertical wax cutouts and over the impression coping attachment screws to record their location. After the impression tray material has polymerized, the impression tray is removed from the study cast. Any block-out wax remaining in the custom impression tray is removed. A hole is created in the custom impression tray to provide access to the impression coping attachment screws (Fig 29-9). The access hole in the top of the open tray should allow at least 2 mm of space around the

29 Multiple-Tooth Implant Restoration

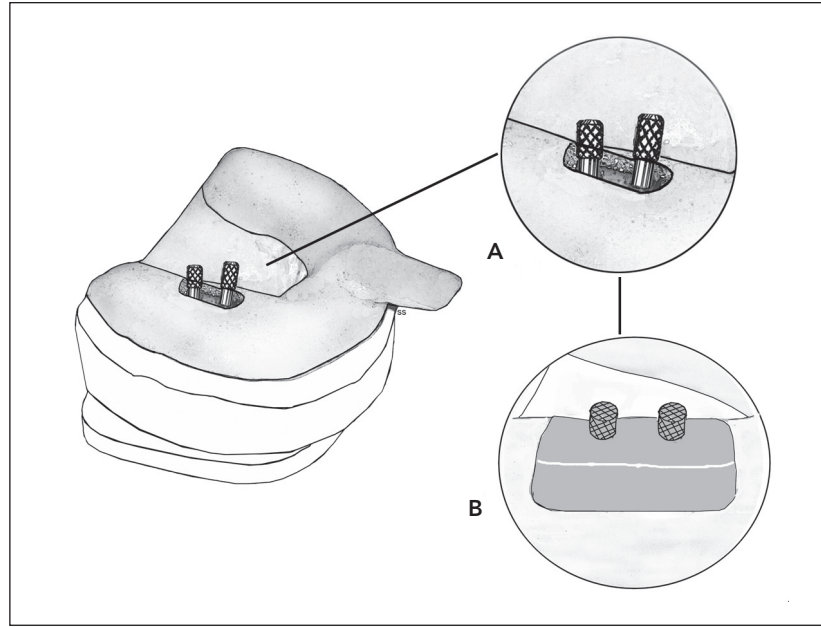


Fig 29-9 Custom open impression tray. Note the opening in the impression tray (A) to gain access to the impression coping attachment screws when the impression is taken. Note that boxing wax is placed (B) prior to impression taking to contain impression material while seating the impression tray.

impression coping attachment screws. A multiple-implant open tray impression will likely have the impression coping attachment screw holes joined, forming one large opening (Fig 29-9, inset A). A piece of boxing wax will be placed over the access hole to contain the impression material within the impression tray while it is being carried and seated in the patient's mouth (Fig 29-9, inset B).

To take the final impression, the implant healing abutments are removed from the patient's mouth, and the open tray impression copings with their attachment screws are transferred from the study cast to the patient (Fig 29-10a). The authors strongly recommend that a radiograph be taken at this time to ensure that the impression copings are fully seated onto the dental implants before luting them together.¹⁰ This radiograph will also provide information regarding the amount and quality of the bone surrounding the dental implant at the time of implant restoration. This is the first time during patient restorative treatment that a radiograph needs to be taken. This radiograph will serve as a baseline to monitor long-term implant health. After radiographic verification that the open tray impression copings are fully seated on the dental implants, autopolymerizing acrylic resin is used to reconnect the previously sectioned open tray impression copings intraorally (Fig 29-10b). The luted open tray impression copings are examined to make sure that the autopolymerizing acrylic resin does not contact the proximal teeth or the gingival tissue (Fig 29-10c).

A piece of boxing wax is placed over the opening for the abutment screws on the open tray impression to contain the

impression material in the custom impression tray. The use of the final impression material is opposite that of the standard fixed prosthodontic technique in that the heavy-body impression material is injected around the open tray impression copings, and the impression tray is filled with medium-body impression material. The heavy-body impression material is placed around the open tray impression copings to minimize any movement that may occur during the removal of the impression tray and pouring of the master dental cast.

During the impression-taking process, the custom impression tray must be oriented to allow the impression coping abutment screws to penetrate the boxing wax placed on the custom impression tray (Fig 29-11) before the impression material sets. Upon polymerization of the impression material, any wax around the implant abutment screws is removed to provide access to them. The implant abutment screws are unscrewed and removed through the top of the open impression tray. The final impression is removed from the patient's mouth, and the healing abutments are replaced on the dental implants. The authors believe the open tray impression is the most accurate technique because the heavy-body impression material stabilizes the open tray impression copings, which remain undisturbed within the impression material before the master cast is poured in dental stone.

The final impression is evaluated for completeness, and it is confirmed that the surface of the open tray impression copings that were in contact with the dental implants is free of impression material¹⁰ (Fig 29-12). The open tray impression coping attachment screws, which had been removed

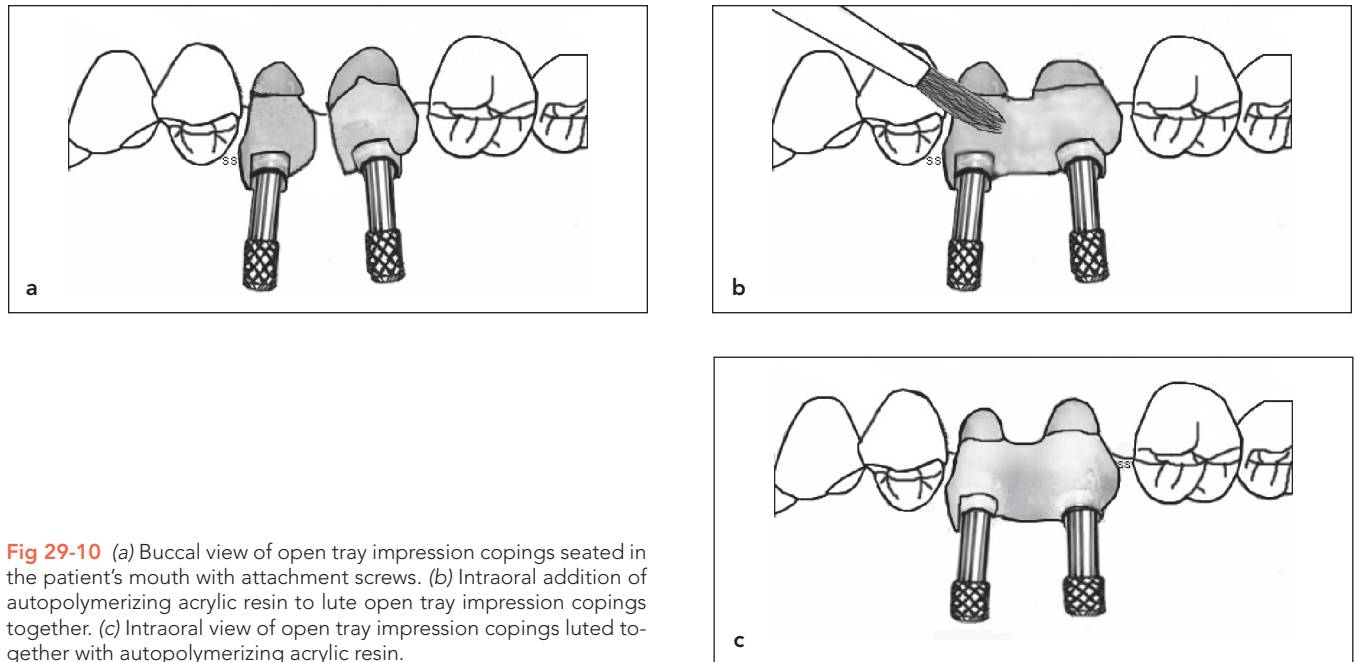


Fig 29-10 (a) Buccal view of open tray impression copings seated in the patient's mouth with attachment screws. (b) Intraoral addition of autopolymerizing acrylic resin to lute open tray impression copings together. (c) Intraoral view of open tray impression copings luted together with autopolymerizing acrylic resin.

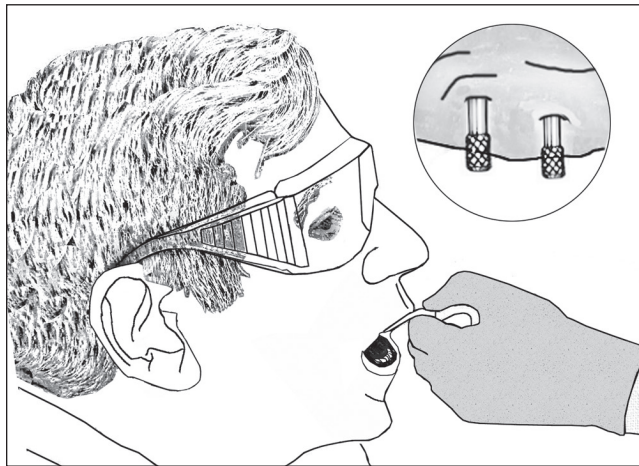


Fig 29-11 Taking the final impression with a custom open tray technique. (inset) Custom open tray impression with attachment screws protruding through boxing wax placed to contain the impression material while seating the tray.

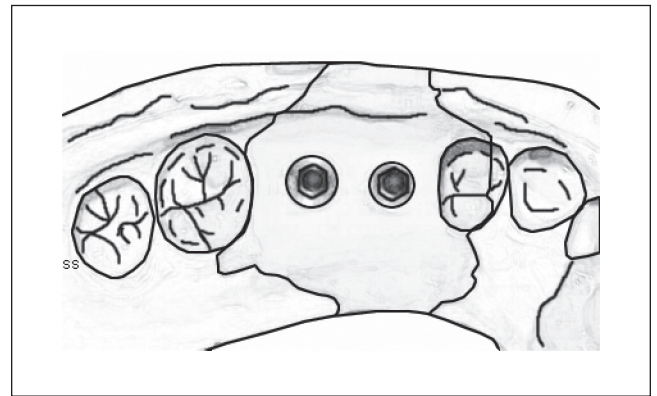


Fig 29-12 Intaglio surface of the final impression. Note the impression coping surface that was in contact with the dental implant is impression material free. The two different impression materials used can also be seen.

29 Multiple-Tooth Implant Restoration

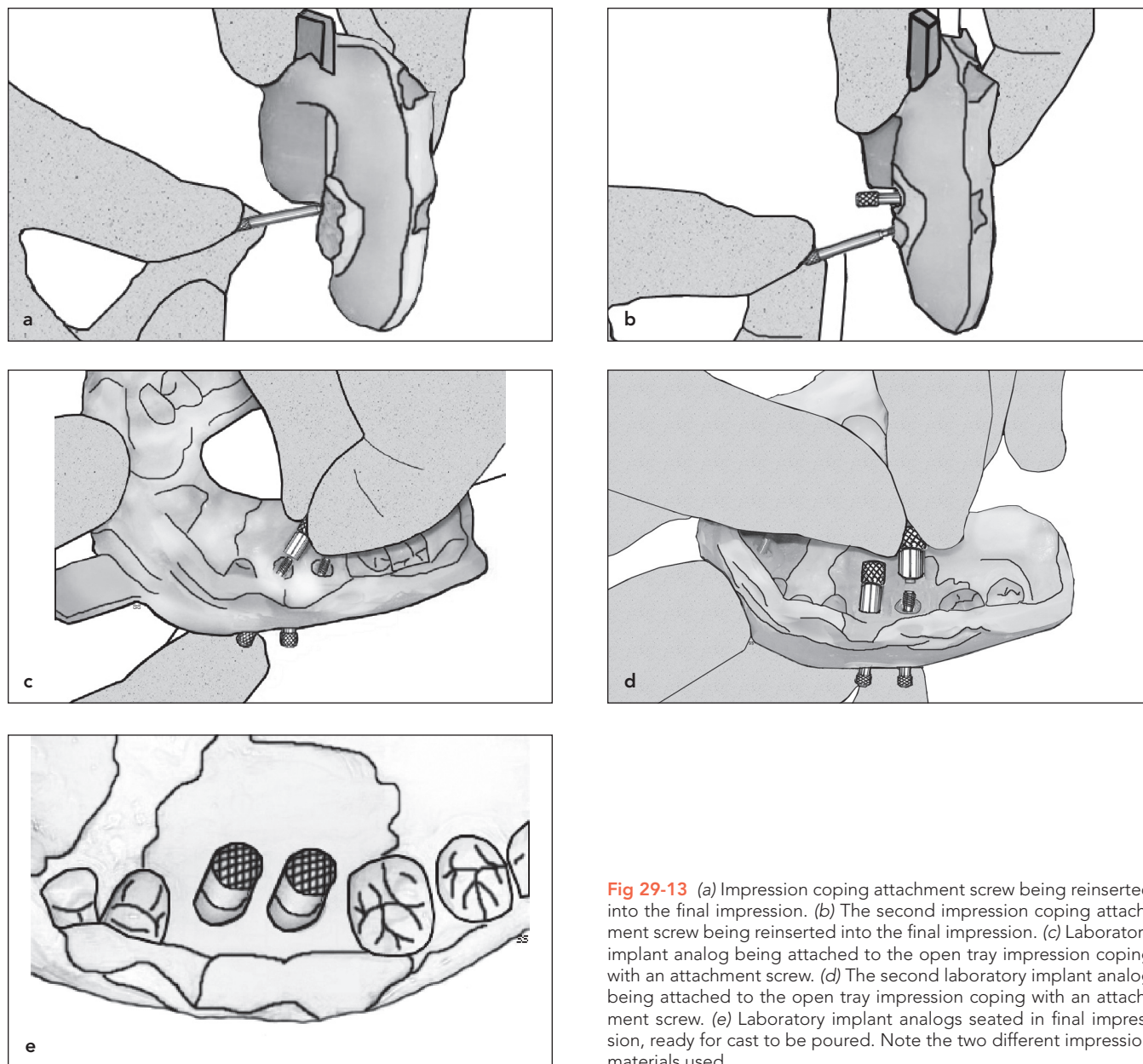


Fig 29-13 (a) Impression coping attachment screw being reinserted into the final impression. (b) The second impression coping attachment screw being reinserted into the final impression. (c) Laboratory implant analog being attached to the open tray impression coping with an attachment screw. (d) The second laboratory implant analog being attached to the open tray impression coping with an attachment screw. (e) Laboratory implant analogs seated in final impression, ready for cast to be poured. Note the two different impression materials used.

from the impression tray in order to remove the impression tray from the patient's mouth, are reinserted into the open tray impression copings (Figs 29-13a and 29-13b). The laboratory implant analogs are secured to the open tray impression copings with the attachment screws (Figs 29-13c and 29-13d). The laboratory implant analog hex must be correctly aligned with the open tray impression coping hex to be seated fully (Fig 29-13e). Care must be taken when securing the attachment screws with the hex driver not to overtighten the attachment screws. There is a risk of dislodging the open tray impression copings from the autopolymerizing acrylic resin that is luting them together if too much torque is ap-

plied to the attachment screw with the hex driver. This would render the master cast inaccurate.

Improved restorative esthetics can be achieved when the top of the dental implant is approximately 2 to 3 mm below the surrounding gingival tissue. However, an impression of a dental implant that is lower than the surrounding gingival tissue will yield a stone cast with a laboratory implant analog that is below the level of the surrounding dental stone. The surrounding dental stone will restrict access to the top of the laboratory implant analog during restoration fabrication. To facilitate restoration fabrication, a soft tissue replica material is placed around the portion of the open tray impression coping that was below the level of the gingival tissue intra-

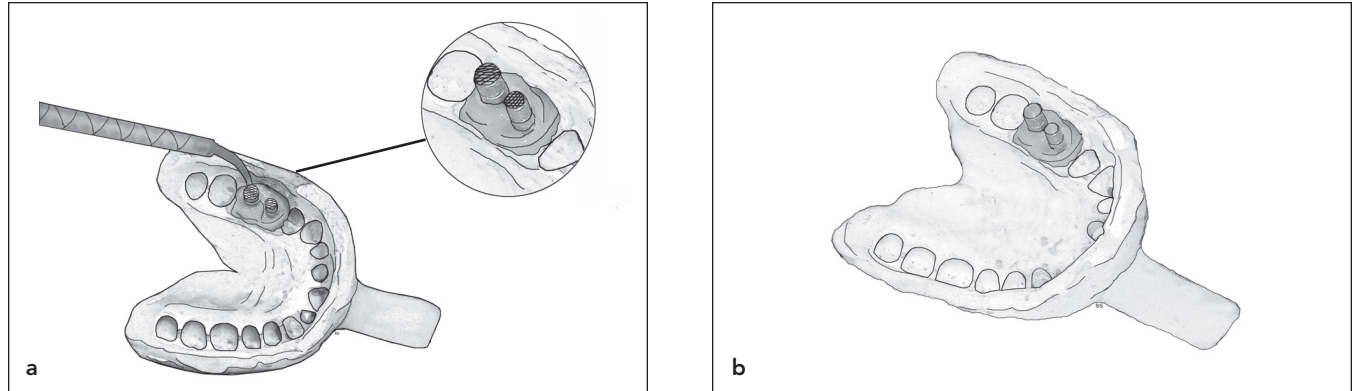


Fig 29-14 (a) Placing soft tissue replica material in the final impression to simulate gingival tissue. (b) Soft tissue replica material is only placed around the impression copings that were subgingival in the patient's mouth.

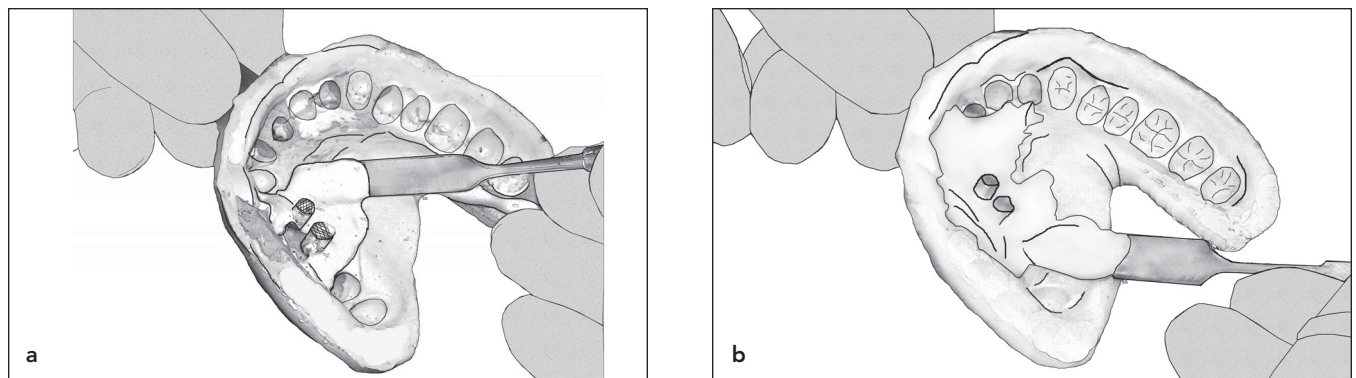


Fig 29-15 (a) Pouring dental stone around the laboratory implant analogs. (b) Pouring the remainder of the impression.

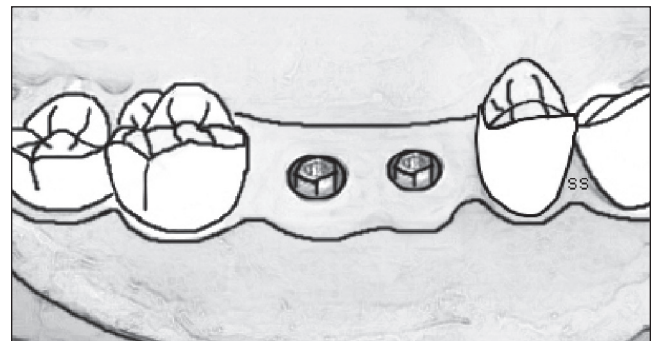


Fig 29-16 Master cast with external hex laboratory implant analogs surrounded by soft tissue replica material.

orally but is now exposed because the impression is a negative representation of the intraoral morphology. The presence of the soft tissue replica material on the master cast is helpful because it is removable, allowing access to the top of the implant laboratory analog during restoration fabrication.

Soft tissue replica material will adhere to many impression materials. A separating medium provided by the soft tissue replica manufacturer should be applied to the area of the intaglio surface of the final impression that surrounds the exposed portion of the open tray impression copings and approximately 1 mm onto the laboratory implant analogs. The soft tissue replica material is applied around the exposed

open tray impression coping and up approximately 1 mm onto the laboratory implant analogs (Fig 29-14a). The soft tissue replica material should not extend into the impression of the teeth proximal to the dental implants (Fig 29-14b). Pouring of the final impression is begun by placing dental stone around the laboratory implant analogs (Fig 29-15a). The remainder of the impression is then poured in dental stone to fabricate the master cast (Fig 29-15b). Separation of the master cast from the final impression requires removal of the attachment screws. In the master cast, the soft tissue replica material surrounds the top of the laboratory implant analogs (Fig 29-16).

29 Multiple-Tooth Implant Restoration

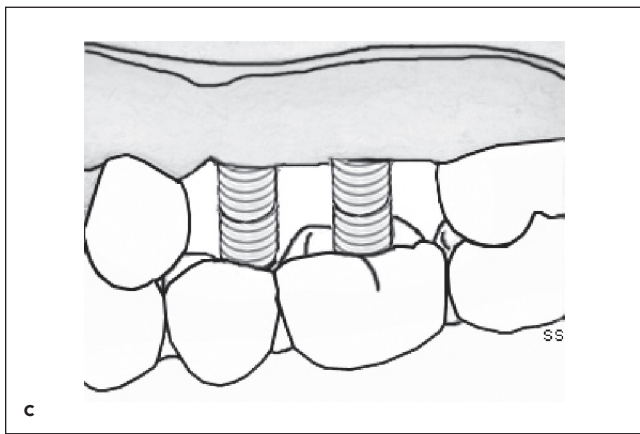
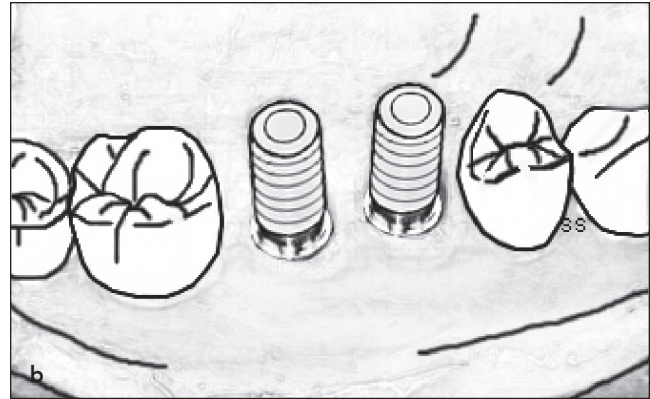
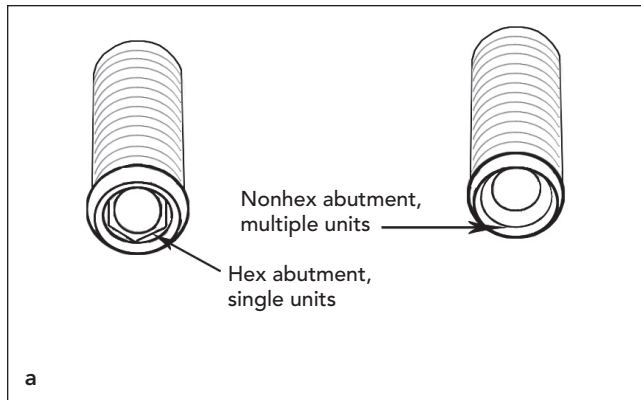


Fig 29-17 (a) Internal hex and nonhex machined metal cylinders with waxing sleeves. Note internal differences. (b) Occlusal view of nonhex machined metal cylinders with waxing sleeve secured with abutment screws on master cast. (c) Waxing cylinders equilibrated into occlusion.

Definitive Implant Restoration

Prefabricated cast machined metal cylinder abutments with plastic waxing sleeves are used as the foundation upon which the definitive restoration is built. The prefabricated cast machined metal cylinder abutment with plastic waxing sleeve comes in two styles, hex and nonhex (Fig 29-17a). An internal or external hex machined metal cylinder abutment is needed for a single dental implant restoration to prevent restoration rotation. The hex surfaces of the prefabricated machined metal cylinders fit precisely with the vertical machined surfaces of the internal or external hex dental implant. However, it is almost impossible to surgically place two or more dental implants perfectly parallel to each other. Attempting to use two or more hex machined metal cylinders that are luted together may cause difficulty in seating the definitive restoration on the dental implants. This is due to the interference of the machined metal surfaces with the path of insertion. The use of a nonhex machined metal abutment reduces the possibility of this problem.¹¹

Articulation of the master cast

The maxillary master cast and opposing mandibular cast are articulated. Prefabricated machined metal nonhex cylinders with attached plastic waxing sleeves (waxing abutments) are secured to the laboratory implant analogs in the master cast with abutment screws (Fig 29-17b). The waxing abutments, when in place on the articulated master cast, will create a premature occlusal contact requiring equilibration.¹¹ Completion of the waxing abutment equilibration will reestablish normal occlusion (Fig 29-17c). The plastic sleeve of the waxing abutment has horizontal ridges placed by the manufacturer to aid in wax retention. However, there is often a need for the placement of additional retention to prevent wax rotation around the waxing abutment. It is strongly recommended to roughen the plastic sleeve of the waxing abutments and/or place vertical grooves for additional wax retention. The abutment screw access hole in the plastic sleeve of the waxing abutment should be obturated with a cotton pellet prior to initiating restoration waxing to prevent wax from obstructing the hex of the abutment screw.

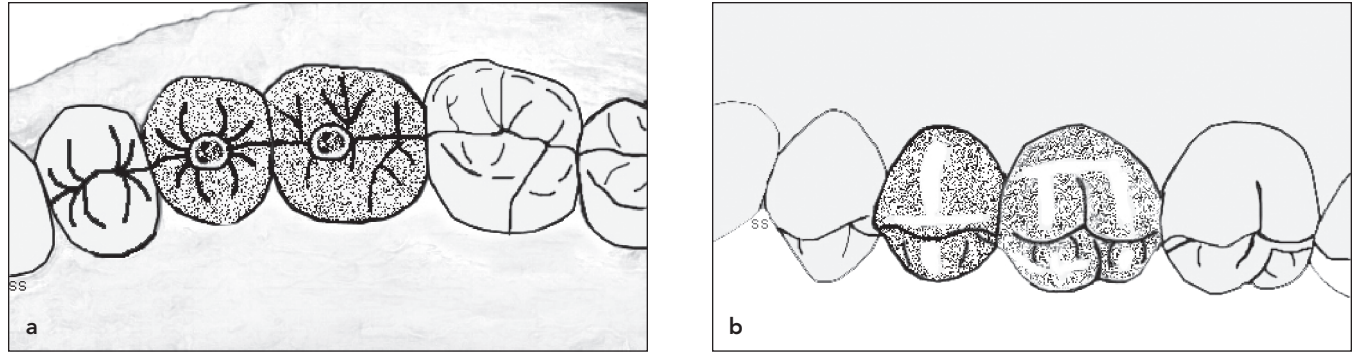


Fig 29-18 (a) Occlusal view of full-contour wax-up showing lingual screw access hole. (b) Buccal view of full-contour wax-up of the implant-retained restoration. (c) Occlusal view of wax pattern with buccal and occlusal buccal cusp reduction. Note that there is no occlusal wax reduction around the abutment screw access holes.

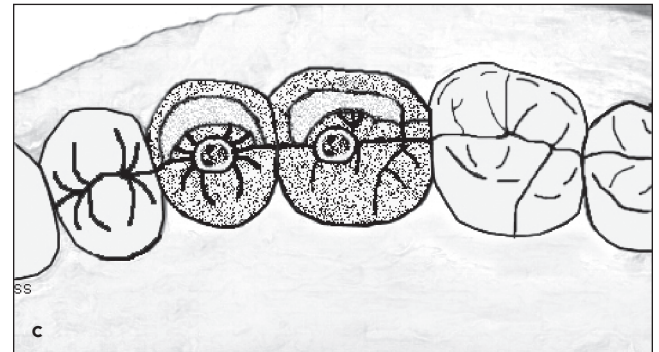


Fig 29-19 Definitive restoration. Note the porcelain-metal junction. Retention screw access holes should be in metal.

Restoration wax-up

The restoration is waxed to full contour (Figs 29-18a and 29-18b). The full-contour wax-up is then cut back to allow for the addition of porcelain. The preferred cutback retains a metal occlusal surface with the abutment screw access holes in metal to avoid fracture of unsupported porcelain. Metal occlusal surfaces are preferred because they are easier to equilibrate and repolish and are less damaging to the opposing dentition than porcelain. The desired wax cutback includes the buccal surface, extending to one-third of the lingual surface of the buccal cusps (Fig 29-18c).

Restoration placement

The completed dental implant restoration can provide a natural-looking restoration (Fig 29-19). The abutment screw access holes are encircled with metal to prevent the fracture of unsupported porcelain. The abutment screw access holes are closed by first placing cotton pellets over the top of the abutment screws to within 2 mm of the access hole openings to protect the hex of the abutment screws. The cotton pellets are then covered with a 2-mm layer of light-polymerizing resin.¹¹ The use of a wet cotton-tipped applicator to remove excess and smooth the light-polymerizing resin prior to polymerization should produce a surface that will require no further finishing.

29 Multiple-Tooth Implant Restoration

References

1. van Steenberghe D. The application of osseointegrated oral implants in the rehabilitation of partial edentulism: A prospective multi-center study on 558 fixtures. *Int J Oral Maxillofac Implants* 1990;5:272–281.
2. Jemt T, Lekholm U. Oral implant treatment in posterior partially edentulous jaws: A 5-year follow-up report. *Int J Oral Maxillofac Implants* 1993;8:635–640.
3. Chiche GJ, Pinault A. Considerations for fabrication of implant-supported posterior restorations. *Int J Prosthodont* 1991;4:37–44.
4. Weber HP, Cochran DL. The soft tissue response to osseointegrated dental implants. *J Prosthet Dent* 1998;79:79–89.
5. Centerpulse Dental Inc. Tapered Screw-Vent and AdVent Restorative Manual, 2002:12–14,15–17.
6. Naconecy MM, Teixeira ER, Shinkai RS, Frasca LC, Cervieri A. Evaluation of the accuracy of 3 transfer techniques for implant-supported prostheses with multiple abutments. *Int J Oral Maxillofac Implants* 2004;19:192–198.
7. Filho HG, Mazaro JV, Vedovatto E, Assunção WG, dos Santos PH. Accuracy of impression techniques for implants. Part 2—Comparison of splinting techniques. *J Prosthodont* 2009;18:172–176.
8. Dumbrigue HB, Gurun DC, Javid NS. Prefabricated acrylic resin bars for splinting implant transfer copings. *J Prosthet Dent* 2000;84:108–110.
9. Hariharan R, Shankar C, Rajan M, Baig MR, Azhagarasan NS. Evaluation of accuracy of multiple dental implant impressions using various splinting materials. *Int J Oral Maxillofac Implants* 2010;25:38–44.
10. BIOMET 3i Inc. Restorative Manual for Osseotite Certain and Osseotite External Hex Implant System, 2003:11–13.
11. Zimmer Dental Inc. Dental Tapered Screw-Vent and AdVent Restorative Manual, 2006:104–108.

Index

Page numbers followed by “f” indicate figures;
those followed by “t” indicate tables

A

Abrasives

- definition of, 384
- forms of, 384–385
- Knoop hardness numbers, 384t

Abutments

- contraindications, 85
- criteria for
 - crown-root ratio, 85–86
 - overview, 85
 - periodontal ligament area, 86–88, 88f
 - root configuration, 86
 - root surface areas, 86f, 86–88
- definition of, 1
- diagnostic casts of, 9
- endodontically treated teeth, 217
- pier, 91f, 91–92
- secondary, criteria for selecting, 90
- tilted molar, 94–95
- tooth-supported fixed partial dentures
 - conventional, 84
 - resin-bonded, 84

Acid etching, 179, 426

Addition silicone. See Polyvinyl siloxane.

Adjustments, for gold restorations

- contours, 395
- esthetics, 395
- margin finishing, 390–392
- marginal adaptation, 390, 391f
- occlusal
 - nonworking movement, 394, 394f
 - overcorrection, 392, 393f
 - protrusive interferences, 394, 394f
 - working movement, 394, 394f
- proximal contacts, 389f, 389–390
- seating completeness, 390

Agar. See Reversible hydrocolloid.

Air brush, 396f

Alginate impressions

- multiple-tooth implant, 544–546, 545f–546f
- overimpression-fabricated custom provisional restorations
 - armamentarium, 243
 - cementation process
 - armamentarium, 247

- procedure, 247–248, 247f–248f
- technique, 243–247, 243f–247f
- tooth preparation, 243–247
- single-tooth implant, 533–535, 533f–535f

All-ceramic crowns

- attributes, 77t
- cementation
 - armamentarium, 408
 - cements
 - removal of excess, 410
 - selection of, 409
 - shade, 409–410
 - finishing of rough surfaces, 409, 444
 - proximal contacts, 409, 443
 - stone smoothing, 444
 - technique, 409f, 409–410
- contraindications for, 161
- description of, 76
- evolution of, 425
- fabrication of, 429–434, 430f–434f
- fracture susceptibility of, 161
- illustration of, 76f
- indications, 149
- longevity of, 78, 79t
- occlusal reduction, 138, 138f
- tooth preparations
 - armamentarium, 161
 - depth-orientation grooves, 161, 161f
 - incisal reduction, 161, 161f
 - labial reduction, 161–162, 161f–162f
 - lingual reduction, 162, 162f
 - overview, 162f
 - radial shoulder, 162, 162f, 429
 - shoulders, 161

All-ceramic restorations

- bonded
 - advantages of, 426
 - feldspathic porcelain restorations, 426
 - highly filled glass-ceramic restorations, 427–428
 - cementation of, 443–444
 - crowns. See All-ceramic crowns.
 - finishing of, 443–444
 - high-strength core restorations
 - alumina-reinforced substructures, 428–429
 - zirconia-reinforced substructures, 429
 - overview of, 425–426
- Allergies, 3–4

Index

- All-metal crown
 - characteristics of, 77t
 - longevity of, 79t
- All-metal hygienic pontic, fabrication
 - casting, 486, 486f
 - die trimming, 482, 482f–483f
 - excess wax removal, 482, 484f
 - investing, 486, 486f
 - plaster matrix, 484, 485f
 - wax coping, 482–483
- Alloys
 - ADA classification, 364
 - base metal. *See* Base metal alloys.
 - casting of. *See* Casting.
 - factors that affect choice of, 364–365
 - gold
 - base metal alloys and, differences, 363
 - investing of, 365
 - types II and III, casting of
 - armamentarium, 371
 - burnout, 371
 - cleaning the cast, 373–374, 374f
 - common defects, 375f
 - pickling, 374, 374f
 - procedure, 371–373, 372f–373f
 - gold-palladium
 - casting
 - armamentarium, 379
 - procedure, 379, 379f
 - for metal-ceramic restorations, 448–449
 - soldering
 - burnout, 512
 - casting, 512
 - indexing, 509–510
 - investing, 510–511
 - preparatory procedures, 509
 - noble. *See* Noble alloys.
 - recommended uses, 364–365
- Alumina-reinforced materials, 428–429
- Alveolar bone loss, 232
- Amalgam
 - cores for, 208
 - indications for, 71–72, 193
 - longevity of, 78, 79t
 - plaque control, 71
 - for prefabricated dowels, 217
 - restorations
 - complex
 - attributes, 77t
 - description of, 73, 75
 - illustration of, 74f
 - longevity of, 78, 79t
 - simple
 - attributes, 77t
 - description of, 72–73
 - illustration of, 74f
 - longevity of, 78, 79t
 - strength of, 217
- Angle of convergence, 132
- Angle of divergence, 132
- Anterior guidance, 17f
 - Denar facebow and articulator, 61–62, 62f
 - Hanau facebow and articulator
 - custom settings, 68, 68f
 - mechanical, 69, 69f
 - Whip Mix facebow and articulator, 55–56, 55f–56f
- Anterior teeth
 - dowel cores, for endodontically treated teeth
 - illustration of, 215f–216f
 - length determinations, 215f
 - rationale for, 214–217
 - retentive properties, 215
 - guidance of mandible, 55–56, 61–62, 68, 69
 - metal-ceramic crowns. *See* Metal-ceramic crowns, anterior teeth.
 - three-quarter crown, tooth preparations for. *See* Three-quarter crowns, anterior teeth.
 - vertical overlap of, 23f
- Ante's Law, 87, 526
- Anticoagulants, 520
- Anticoagulation, 4
- Antirrotational devices, for die in working casts
 - Pindex system, 333–340
 - straight dowel pin, 330–333, 331f–333f
- Antisialogogues, 271
- Appearance zone
 - definition of, 413, 474
 - incisors
 - incisal lines, 416
 - interproximal contacts, 416
 - midline, 413
 - pontics, 474
 - smile line, 413
- Arcon articulators
 - advantages of, 30–31
 - description of, 30
- Articular disc, 13
- Articulators
 - arcon, 30–31
 - border movements duplicated by, 27
 - condylar movements, 33f, 33–34
 - definition of, 27
 - Denar, 57
 - fully adjustable, 28–29
 - Hanau, 63–69
 - nonadjustable, 27, 28f
 - nonarcon, 30–31
 - principles of, 27, 28f
 - semiadjustable, 27
 - tooth–transverse horizontal axis relationship, 31f, 31–32
 - Whip Mix, 45
- Aspiration of restorations, 407
- Autopolymerizing acrylic resin, 300–302, 301f–302f
- Axial contours
 - full veneer crown, 347f
 - wax patterns
 - bulges, 346, 347f
 - emergence profile, 346, 347f
 - faciolingual, 345–346, 345f–346f
 - proximal, 345

Axis, hinge
 arbitrary location of, 32
 articulator hinge axis and, effect of dissimilarities, 27, 28f–29f
 trial and error method to determine, 31

B

Base, 207–208, 209f
 Base metal alloys
 advantages, 364
 beryllium content, 364
 fluoride use, 493
 gold alloys and, differences, 363
 melting temperatures, 364
 for metal-ceramic restorations, 448–449
 nickel-chromium, 364
 soldering, 512
 Base metal restorations
 adjustments, 397
 finishing, preliminary
 armamentarium, 397
 procedure, 397
 polishing, 397
 try-in, 397
 Bennett angle, 16, 16f
 Beryllium
 carcinogenic properties of, 364, 449
 description of, 364
 Bevels
 contraindications for, 140–141, 140f–141f
 facial, 169f
 functional cusp
 description of, 138, 139f
 for full veneer crown, 150
 metal-ceramic crown, 158, 159f
 three-quarter partial coverage crowns, 166, 166f
 indications for, 140
 mesio-occlusodistal onlays, 197–200, 198f–200f
 proximo-occlusal inlays, 195f, 195–196
 three-quarter crown, 171, 173f
 Bilateral balanced occlusion, 20, 361
 Binangle chisel, 156, 156f–157f
 Biologic width, 212
 Bis-acryl composite
 characteristics of, 242t
 overimpression-fabricated crowns
 description of, 256
 procedure for creating, 256–259, 256f–259f
 Bisphosphonate-related osteonecrosis of the jaws, 6
 Bite fork, 46f, 49f, 58
 Black triangles, 478
 Blow holes, soldering repair of, 503
 Bonded ceramic restorations
 advantages of, 426
 feldspathic porcelain restorations, 426
 highly filled glass-ceramic restorations, 427–428
 Bonding, 434
 Border movements, 27
 Box form
 for damaged teeth, 205, 205f
 substitution of, 136

Bridge. See Fixed partial denture.
 Brightness. See Value.
 Bruxism, occlusion and, 19
 Bur(s), 146t, 174f–175f, 194f. See also *specific procedure, armamentarium*.

Burnout
 definition of, 363
 gold alloys, types II and III, 371
 high-temperature, 366
 low-temperature, 365

C

CAD/CAM system, 320, 427, 457
 Canines
 in appearance zone, 415
 fixed partial dentures for
 configurations, one tooth, 107–108
 description of, 95, 95f
 resin-bonded, 183f
 incisal lines, 416f
 mandible, 117, 124–125
 maxillary, 115f, 124
 root surface area of, 526t
 Cantilever fixed partial dentures, 95–96, 96f–97f
 Caries
 resin-bonded fixed partial denture and, 182
 restoration of, glass ionomer use, 72, 73f
 Casting
 alloys, 363–365
 definition of, 363
 dowel-core patterns, 376
 gold alloys, types II and III
 armamentarium, 371
 burnout, 371
 procedure, 371–373, 372f–373f
 gold-palladium alloys
 armamentarium, 379
 procedure, 379, 379f
 inlay patterns, 376
 investing for, 368–371, 369f–371f
 voids, soldering repair of
 armamentarium, 503
 contraindications, 503
 indications for, 503
 Casting rings, for gypsum-bonded investments, 368
 Casting temperature, 376
 Casts, working
 mounting of
 Denar facebow and articulator
 mandibular, 59–60
 maxillary, 59, 59f
 Hanau facebow and articulator
 mandibular, 65–66, 66f
 maxillary, 65, 65f
 Whip Mix facebow and articulator
 mandibular, 52–53
 maxillary, 50–52
 with removable die
 advantages over separate die, 330
 antirotational devices, 330, 330f
 methods of orienting die in cast

Index

- Pindex system, 333–340, 334f–340f
 - requirements, 330
 - straight dowel pin, 330–333, 331f–333f
 - requirements for, 325
 - with separate die
 - armamentarium, 325
 - description of, 325
 - die preparation, 327–329, 327f–329f
 - difficulties associated with, 325
 - finish lines, 327–328, 329f
 - hardening agents, 328
 - impression pouring, 325–326, 326f
 - Cellulose liners, for casting rings, 368
 - Cement(s)
 - bonding mechanisms
 - micromechanical bonding, 398, 399f
 - molecular adhesion, 398
 - nonadhesive luting, 398, 399f
 - glass ionomer. *See* Glass-ionomer cement.
 - polycarboxylate. *See* Polycarboxylate cement.
 - resin. *See* Resin cements.
 - selection of, 398–401
 - zinc oxide–eugenol. *See* Zinc oxide–eugenol cement.
 - zinc phosphate. *See* Zinc phosphate.
 - Cement film, 141f
 - Cementation
 - all-ceramic restorations
 - armamentarium, 408
 - cements
 - removal of excess, 410
 - selection of, 409
 - shade, 409–410
 - finishing of rough surfaces, 409
 - proximal contacts, 409
 - technique, 409f, 409–410
 - ceramic crowns, 444–445
 - description of, 401
 - dowel cores, 407–408, 408f
 - fixed partial dentures, 410
 - gold inlays, 407
 - metal-ceramic crowns, 410
 - with polycarboxylate cement, 407
 - with resin cements, 402–404, 403f
 - with resin-modified glass-ionomer cement, 401–402
 - vent holes for cement escape, 402f
 - with zinc phosphate cement
 - cement preparation, 404–405, 405f
 - mandibular isolation, 404, 404f
 - pulp protection, 404
 - removal of excess cement, 406
 - restoration seating, 405–406, 406f
 - vital tooth considerations, 404
- Cemented restorations
 - external surface
 - finishing of, 383
 - plaque accumulation on, 383, 383f
 - indications for, 71–72
 - internal surface, 383
 - plaque control, 71
- provisional
 - armamentarium, 247
 - procedure, 247–248
- Central incisors
 - fixed partial dentures for
 - complex
 - more than two teeth, 117–118
 - two teeth, 113–114
 - pier abutments, 120–122, 129
 - simple
 - one tooth, 100–101
 - two teeth, 109–110
 - root surface area of, 526t
- Centric occlusal interference, 17, 18f
- Centric relation, 13
- Centric relation record
 - armamentarium, 35
 - description of, 35
 - technique
 - anterior programming device, 37, 37f
 - baseplate wax adaptation to maxillary teeth, 37–38
 - bimanual manipulation, 35–36, 36f
 - manipulation of mandible, 36f, 36–37
 - patient positioning, 36–37
 - registration base use, 37–38, 38f–39f
- Ceramic liners, for casting rings, 368
- Ceramic restorations. *See also* All-ceramic restorations.
 - etching of, 426
 - inlays
 - attributes, 77t
 - description of, 75
 - illustration of, 74f
 - longevity of, 78, 79t
 - veneer crowns
 - all. *See* All-ceramic crowns.
 - attributes, 77t
 - cementation, 444–445
 - description of, 76
 - illustration of, 76f
 - longevity of, 78, 79t
- Chamfers. *See also* Finish line(s).
 - advantages of, 144t
 - description of, 141
 - disadvantages of, 144t
 - full veneer crown, 150
 - heavy, 141
 - illustration of, 142f
 - resin-bonded fixed partial denture, 182
- Chemical bonding, 448
- Chroma, 419
- Classic shoulder finish line, 142, 143f, 144t
- Clenching, occlusion and, 19
- Colloid solutions. *See* Hydrocolloid.
- Color, for shade selection of ceramic restorations
 - characteristics of, 419
 - daily functions' effect on, 419
 - factors that affect, 418
 - light sources' effect on
 - artificial, 418f, 418–419
 - natural, 418, 418f

- Color blindness, 418
- Composite resin restorations
 - attributes, 77t
 - criteria for, 71–72
 - inlays, 72, 74f
 - longevity of, 78, 79t
- Condensation silicones
 - armamentarium, 311
 - characteristics of, 292t
 - disadvantages, 310–311
 - impression making, 311–312, 311f–312f
 - putty/reline, 311
 - reaction of, 310
 - viscosity, 293, 293f
 - wettability, 291
- Condyles
 - guidance
 - on Denar facebow, 60–61, 61f
 - effect on posterior teeth, 21–22, 21f–22f
 - on Hanau facebow, 66–67, 67f–68f
 - on Whip Mix facebow, 50f, 53f–54f, 53–55
 - inclination of, on arcon and nonarcon articulators, 30, 30f
 - movements of
 - articulator reproduction of, 27, 33f, 33–34
 - pantographic recordings, 33f, 33–34
 - positioning of, 13
- Cone beam computed tomography, 520–521, 521f
- Connectors
 - definition of, 1
 - nonrigid
 - cross-pin and wing, 515, 515f
 - dovetail, 513–514, 513f–514f
 - for pier abutments, 91–92, 92f, 513–514
 - split pontic, 514
 - for tilted molar abutments, 94, 94f
 - rigid, contraindications for, 91–92
 - soldering. *See* Soldering.
- Contacts, proximal
 - adjustments for, 389f, 389–390
 - all-ceramic restorations, 409, 443
 - metal-ceramic restorations, 450–451
 - soldering
 - armamentarium, 502, 502f
 - indications for, 502
- Coping
 - for fabrication of wax patterns, 343–344, 344f
 - metal-ceramic restorations
 - alloy used, melting range of, 448
 - description of, 447
 - extent of veneered area, 451–453, 452f–453f
 - facial margins, 454
 - metal collar, 454
 - occlusal contacts, 450–451, 451f
 - overview, 449
 - porcelain support, 450, 450f
 - porcelain veneer, 449–450
 - proximal contacts, 450–451
 - thickness of metal, 450
 - pin-retained, 207f, 208
- Core
 - composite resin, 208
- Cross-pin and wing, 515, 515f
- Crown-root ratio, for abutment teeth, 85–86
- Crowns
 - all-ceramic. *See* All-ceramic crowns.
 - cement retention of, 524, 525f
 - definition of, 1
 - endodontic access preparation, 215
 - full coverage. *See* Full coverage crown.
 - lengthening of, for gingival exposure, 287–288
 - longevity of, 78, 79t
 - metal-ceramic, 75, 151–152, 158–160
 - partial coverage. *See* Partial coverage crowns.
 - pin placement, 206f, 206–207
 - preformed anatomical metal
 - armamentarium, 264
 - procedure, 263–267, 264f–267f
 - provisional, for endodontically treated tooth, 263, 263f
 - removal force resistance by, 72f
 - retention and resistance, 131, 131f
 - tapering of, 132–133
 - three-quarter, 171–178
- Crucible, 371
- C-terminal cross-linking telopeptide, 520
- Curve of Spee, 354
- Curve of Wilson, 355
- Cusp(s)
 - mandibular teeth, 349t
 - maxillary teeth, 349t
- Cusp-fossa
 - curve of Spee, 354
 - curve of Wilson, 355
 - cusp placement and occlusal contacts, 354f
 - definition of, 354
 - description of, 348t
 - illustration of, 348f
 - wax patterns of, 355–358, 355f–358f
- Cusp-marginal ridge
 - cusp placement and occlusal contacts, 350f
 - description of, 348–349
 - wax patterns of
 - mandibular teeth, 352, 353f
 - maxillary teeth, 350–352, 351f–352f
- Custom provisional restorations
 - overimpression-fabricated. *See* Overimpression-fabricated custom provisional restorations.
 - shell-fabricated
 - armamentarium, 254
 - description of, 254
 - procedure, 254–255, 255f
 - template-fabricated
 - armamentarium, 248
 - fabrication process, 248–252, 248f–252f
 - visible light-cured
 - armamentarium, 252
 - fabrication process, 252–254
- Custom resin trays
 - adhesives, 298–299
 - armamentarium, 299
 - autopolymerizing acrylic resin, 300–302, 301f–302f

Index

composition of, 299
 faciolingual section of, 298f
 preparation, 299–302
 stock trays and, comparison, 298
 uses of, 298
 for VLC, 299f–300f, 299–300
 Cutback areas, 462, 463f–464f
 Cuttle, 384

D

Dam, rubber, 269, 272
 Damaged teeth
 destruction areas, 203, 204f
 orthodontic adjuncts
 extrusion, 212f, 212–214, 214f
 regaining interproximal space, 210
 preparations for
 bases, 207–208
 cores, 208
 retention and space
 methods to avoid excessive destruction, 203–204
 substitutive methods for creating
 box forms, 205, 205f
 overview, 204
 pins, 206–207
 vital teeth, modifications for, 208–210, 209f
 Deep chamfer finish line, 141–142, 143f, 144t
 Dental implants. *See* Implants.
 Depth-orientation grooves
 all-ceramic crowns, 161, 161f
 full veneer crown, 149–150
 metal-ceramic crowns, 154, 155f
 Devitrification, 467
 Diagnostic casts, 9, 522, 522f
 Diagnostic work-up
 casts, 9
 elements of, 1–2
 full-mouth radiographs, 9
 history taking, 2–6
 intraoral examination, 8f, 8–9
 Die, for working casts
 removable
 advantages over separate die, 330
 antirotational devices, 330, 330f
 methods of orienting die in cast
 Pindex system, 333–340, 334f–340f
 straight dowel pin, 330–333, 331f–333f
 requirements, 330
 separate
 armamentarium, 325
 description of, 325
 die preparation, 327–329, 327f–329f
 difficulties associated with, 325
 finish lines, 327–328, 329f
 hardening agents, 328
 impression pouring, 325–326, 326f
 Die milling, 428
 Digital impressions, 320–322, 321f
 Disinfection, of impressions, 319–320
 Disocclusion, 21
 Distofacial root, of maxillary molar, 234, 234f

Double-bite impression, 305
 Dovetail connector, 513–514, 513f–514f
 Dowel cores
 aspiration during try-in, 407–408
 cemented vs threaded, 218
 classification of, 218
 for damaged teeth, 215f–217f
 diameter of, 223f
 endodontically treated teeth
 for anterior teeth
 illustration of, 215f–216f
 length determinations, 215f
 rationale for, 214–217
 retentive properties, 215
 illustration of, 215f–217f
 insertion procedure, 220, 220f–221f
 length determinations, 215f
 for posterior teeth, 215–216
 prefabricated, with amalgam or resin core, 217–218
 rationale for, 214–217
 retentive properties, 215
 tooth preparation for
 armamentarium, 218
 custom cast
 armamentarium, 222
 canal preparation, 222–223
 finishing and cementation, 224–225, 225f
 instrumentation, 222t
 resin pattern fabrication, 223–224, 224f
 Peeso reamer use, 218–219, 218f–219f
 pin placement, 220, 220f
 prefabricated with amalgam or composite resin core
 armamentarium, 218
 diameter recommendations, 219, 219f
 Peeso reamer use, 218–219, 218f–219f
 pin placement, 220, 220f
 technique, 218–220
 for pulpless teeth, 215f
 wax patterns, 376

Dowel inlays, 222

Dowel pins
 armamentarium, 331
 location, 330
 procedure, 331–333

Dry mouth, 5–6

Dual-arch impressions
 advantages of, 302
 armamentarium for, 302
 technique for, 303–306, 303f–306f
 variations of, 302

E

Edentulous ridge
 classification of, 477, 477f
 deformities, 477, 477f
 pontic modification, 478–479, 478f–479f
 surgical correction
 Class II and III defects, 480, 481f
 donor tissue, 480
 incisions, 479–480, 480f

- Edentulous spaces
 fixed partial denture, 84–85, 99–100
 removable partial denture, 81–82, 84
- Electrochemical etching, 179
- Electrosurgery
 armamentarium, 284
 contraindications, 284
 crown lengthening, 287–288
 current types, 282, 282f
 edentulous cuff removal, 287, 287f
 gingival sulcus enlargement, 286
 grounding, 283, 283f
 recommended uses, 281, 281f
 technique, 284–285, 285f–286f
 tissue damage from, 281
- Emergence profile, 346, 347f
- Endodontically treated teeth
 abutment use, 217
 anterior teeth, 215
 dowel cores. *See* Dowel cores, endodontically treated teeth.
 technique, 218–220
- Endosseous implants, 517, 518f–519f, 519
- Epinephrine
 cardiovascular disease contraindications, 4
 in gingival retraction cord, 273, 273t
- Esthetic zone, 474
- Esthetics
 absolute, 417
 appearance zone
 definition of, 413
 incisors
 incisal lines, 416
 interproximal contacts, 416
 midline, 413
 smile line, 413
 conversational, 417
 ideal, 416–417, 417f
- Etching
 acid, 179, 426
 electrochemical, 179
- Examination, intraoral, 8f, 8–9
- Expansion methods, for shrinkage during investing
 hygroscopic, 365
 setting, 365
 thermal, 365–366
 wax pattern, 365
- Extracoronary restorations, 75–76
- Extrusion, for damaged teeth, 212f, 214f
 arch wire, 213, 213f
 biologic width, 212
 determination of amount needed, 213f
 endodontic treatment, 212–214
 ferrule effect, 212
 pin placement, 213, 213f
 surgical crown lengthening vs, 212f
- F**
- Facebows
 articulator use, 31–32
 caliper-style, 32, 32f
- Denar
 anterior guidance settings, 61–62, 62f
 armamentarium, 57
 cast mountings, 59–60
 components of, 57f
 condylar guidance settings, 60–61, 61f
 description of, 57
 facebow records, 57–58, 60f–61f
 description of, 31
- Hanau
 anterior guidance
 custom settings, 68, 68f
 mechanical, 69, 69f
 armamentarium, 63
 cast mountings, 65–66
 components of, 63f
 condylar guidance, 66–67, 67f
 facebow record, 63–65, 64f
 hinge axis points, arbitrary, 32
 transverse horizontal axis recordings, 31
- Whip Mix
 anterior guidance, 55–56, 55f–56f
 armamentarium, 45
 cast mountings, 50–53
 components of, 45f
 condylar guidance, 50f, 53f–54f, 53–55
 facebow records, 45–46, 45–48, 46f
- Facial bevel, 169f
- Facial roots, of maxillary molar, 237
- Faciolinguaxial contours, 345–346, 345f–346f
- Facio-occlusal finish line, 144, 145f
- Feldspathic porcelain restorations, 426
- Ferrule effect, 212
- Fineness, 493
- Finish line(s)
 advantages of, 144t
 bevels, 141
 chamfer, 141, 142f, 144t
 classic shoulder, 142, 143f, 144t
 configurations for marginal integrity, 141–145
 deep chamfer, 141–142, 143f, 144t
 disadvantages of, 144t
 facio-occlusal, 144, 145f
 knife edge, 144, 144f, 144t
 placement of
 near alveolar crest, 145
 subgingival, 145
 supragingival, 145
 radial shoulder, 142–143, 143f, 144t
 shoulder with a bevel, 143f, 143–144
- Finish line exposure
 chemomechanical, 273–278
 criteria for, 273
 decongestants, 275
 electrosurgery. *See* Electrosurgery.
 lasers for, 288f, 288–289
 mechanical, 272, 272f
 retraction cord
 armamentarium, 275
 chemical types, 274t
 epinephrine, 273

Index

- placement of, 275–278, 275f–279f
- rotary curettage, 280, 280f
- rubber dam, 272
- Finishing
 - base metal restorations, preliminary, 397
 - gold restorations
 - postcementation, 396
 - preliminary
 - armamentarium, 385
 - procedure, 385–387, 386f–387f
 - margins, for wax patterns, 358–360, 359f–360f
- Fixed partial dentures
 - abutment teeth
 - crown-root ratio, 85–86
 - ideal types, 84
 - arch curvature, 90, 90f
 - biomechanical considerations, 89–90, 89f–90f
 - canine-replacement, 95, 95f
 - cantilever, 95–96, 96f
 - casting of, single-piece, 494
 - cementation, 410
 - configurations
 - complex
 - more than two teeth, 117–120
 - one tooth, 107–108
 - two teeth, 113–117
 - simple
 - one tooth, 100–107
 - two teeth, 109–113
 - connectors, 91–94, 94, 513–515
 - definition of, 1
 - deflection of, 89f, 89–90
 - faciolingual movement, 91, 91f
 - illustration of, 3f
 - implant-supported, 84–85
 - metal-ceramic
 - coping wax pattern, 487–490, 488f–490f
 - incisal configuration, 486
 - metal coping, 486
 - rigidity, 486–487
 - soldering
 - indications for, 504
 - methods, 504, 504f
 - postveneer, 509–512, 509f–512f
 - preveneer, 505–508, 505f–508f
 - occlusal interferences, 82f
 - pontics, 477
 - for posterior teeth
 - description of, 99
 - template-fabricated provisional restorations, 248–252, 248f–252f
 - resin-bonded. *See* Resin-bonded fixed partial dentures.
 - soldering
 - breaking of joint, 503–504
 - distortions, 496
 - gold alloy
 - distortions, 496
 - indexing, 494
 - investing, 497–499, 497f–499f
 - procedure, 500–501, 500f–501f
 - single-piece casting, 494
 - metal-ceramic alloys
 - indications for, 504
 - methods, 504, 504f
 - postveneer, 509–512, 509f–512f
 - preveneer, 505–508, 505f–508f
 - methods of, 504, 504f
 - preveneer, 504
 - proximal contacts, 502–503
 - repair of casting voids, 503
 - requisites for, 493
 - single-piece casting, 494
 - tooth-supported
 - conventional, 84
 - resin-bonded, 84
 - wax patterns, 378
- Fluid control methods
 - antisialagogues, 271
 - high-volume vacuum, 269–270, 270f
 - rubber dam, 269
 - saliva ejector, 270
 - Svedopter, 270–271, 270f–271f
 - vacuum attachments, 269f
- Freedom of displacement, 133–134, 134f
- Full coverage crown
 - axial contours, 347f
 - definition of, 1
 - esthetics, 71
 - illustration of, 2f
 - indications for, 149
 - partial coverage crown and, comparison, 149, 165
 - prevalence of, 149
 - retention of, 71–72
 - tooth preparation for
 - armamentarium, 149
 - axial reduction, 150, 150f
 - chamfer, 150
 - depth-orientation grooves, 149–150
 - finishing lines, 150
 - functional cusp bevel, 150
 - occlusal reduction, 149, 150f
 - overview, 149, 151f
 - seating groove, 151
 - venting of, 401
- Functional cusp bevel
 - description of, 138, 139f
 - for full coverage crown, 150
 - for metal-ceramic crown, 158
 - for MOD onlay, 198
 - for partial coverage crown, 166
- Functionally generated path technique
 - advantages, 361
 - definition of, 360
 - functional core, 360
- Furcation
 - definition of, 230
 - flutes, 230
 - preparation finish lines, 229f, 229–230, 231f
 - root resections affected by, 232
- Fusion temperature, 376

G

Gingiva, finish line exposure of. *See* Finish line exposure.

Gingival collar, 230f

Gingival sulcus, 281, 286

Glass-ionomer cement

attributes of, 77t

bacteriostatic properties, 400

composition of, 400

disadvantages, 400–401

factors that affect, 401

hybrid, 401

indications for, 72, 73f

longevity of, 78, 79t

properties, 400–401

pulp protection for damaged teeth, 207

resin-modified, 401–402

Glass-ceramic restorations, highly filled, 427–428

Glenoid fossae, 13

Glycosylated hemoglobin, 5, 5t

Gold alloys

casting of, 371–373

casting defects, 375f

cleaning the castings, 373–374, 374f

pickling the castings, 374, 374f

investing of, 365

properties of, 363

Gold restorations

adjustments

contours, 395

esthetics, 395

margin finishing, 390–392

marginal adaptation, 390, 391f

occlusal, 392–394

proximal contacts, 389f, 389–390

seating completeness, 390

cementation, 401–407

finishing

postcementation, 396

precementation polishing, 395, 395f–396f

preliminary, 385–387, 386f–387f

try-in

anesthesia use, 387

armamentarium, 387

precautionary procedures, 388, 388f

provisional crown

patient hypersensitivity, 387

removal, 388

Golden rectangle, 415, 415f

Gold-palladium alloys

casting, 379, 379f

for metal-ceramic restorations, 448–449

soldering

burnout, 512

indexing, 509–510

investing, 510–511

preparatory procedures, 509

Grooves

depth-orientation

all-ceramic crowns, 161, 161f

full coverage crown, 149–150

metal-ceramic crowns, 154, 155f

retentive, 136

Group function, 20

H

Hemisection, 232, 237–238, 238f

Hepatitis B, 9–10

Highly filled glass-ceramic restorations, 427–428

Hinge axis

accuracy of, 32t

arbitrary location of, 32

and articulator hinge axis, effect of dissimilarities, 27, 28f–29f

trial and error method to determine, 31

History, patient, 3–6

Horizontal symmetry, 413

Hue, 419

Hybrid ionomer cements, 401

Hydrocolloids, reversible, 294–298

irreversible hydrocolloids and

concomitant use, 294

disadvantages of, 294–295

origins of, 294

storage of impressions, 294

wettability, 291

Hygienic pontic, all-metal

casting, 486, 486f

die trimming, 482, 482f–483f

excess wax removal, 482, 484f

investing, 486, 486f

plaster matrix, 484, 485f

wax coping, 482–483

Hygroscopic expansion, 365

I

Implants

Brånemark, 519

crown retention, 524

diameter of, 526–527

endosseous, 517, 518f–519f, 519

history of, 517–519

ideal positioning of, 524, 524f

inclination of, 525, 525f

length of, 526–527

number of, 526–527

occlusal considerations, 527

in partially edentulous patients, 517, 517f

placement of, 525f–526f, 525–527

restoration retention over, 524–525

single-tooth. *See* Single-tooth implant.

size of, 527t

subperiosteal, 517, 518f

surgical splint for, 526, 526f

treatment planning of

anatomical structures, 523, 523f

cone beam computed tomography, 520, 521f

diagnostic casts, 522, 522f

health history, 520

imaging, 520–521

oral examination, 520

Index

- Implant-supported fixed partial denture
 - characteristics of, 83t
 - description of, 84
 - retainers, 84
 - span length, 83t, 84
- Impressions
 - alginate. *See* Alginate impressions.
 - condensation silicones. *See* Condensation silicones.
 - criteria, 291
 - definition of, 291
 - digital, 320–322, 321f
 - disinfection of, 319–320
 - dual-arch. *See* Dual-arch impressions.
 - factors in selecting
 - cost, 293
 - viscosity, 293, 293f
 - wettability, 291
 - hydrophilic vs hydrophobic, 291
 - pin-retained restorations, 318–319, 319f
 - polyether. *See* Polyether.
 - polysulfide. *See* Polysulfide.
 - polyvinyl siloxane. *See* Polyvinyl siloxane.
 - shear rate, 293
 - single-tooth implant
 - alginate, 533–535, 533f–535f
 - closed tray, 532–533, 533f
 - final, 535–539, 535f–539f
 - open tray, 532–533, 533f
- Incisal curve, 413
- Incisal reduction
 - all-ceramic crowns, 161, 161f
 - lamine veneer, 436, 436f
 - metal-ceramic crowns, 154, 155f
 - three-quarter crown, 171, 172f
- Incisive canal, 523
- Incisors
 - central, fixed partial dentures for
 - complex
 - more than two teeth, 117–118
 - two teeth, 113–114
 - pier abutments, 120–122, 129
 - simple
 - one tooth, 100–101
 - two teeth, 109–110
 - esthetic length of, 413, 414f
 - incisal edges, 416
 - mandibular, 126
 - maxillary, 115f, 125
 - preparation of, for resin-bonded fixed partial denture, 183f
 - root surface area of, 526t
- Index, soldering
 - armamentarium, 495, 495f–496f
 - function of, 494
 - gap width, 496
 - procedure, 495–496
- Infectious disease
 - patient history taking for, 3
 - protective measures, 9–10, 10f
- Inlays
 - cementation, 407
 - ceramic
 - cementation, 444–445
 - description of, 75
 - definition of, 1
 - dowel-inlay, 222
 - illustration of, 2f
 - indications, 193
 - metal. *See* Metal inlays.
 - proximo-occlusal
 - armamentarium, 194
 - bevel, 195f, 195–196
 - flares, 194–195, 195f
 - gingivoaxial groove, 194, 195f
 - marginal ridge, 194
 - occlusal outline, 194
 - overview, 196f
 - proximal box, 194
 - wax patterns, 343
- Interferences, occlusal, 17–18, 18f
- Interocclusal records, 42f
 - articulator use of, 30
 - centric relation. *See* Centric relation record.
 - definition of, 30
 - maximal intercuspation, 40–41
- Interproximal space
 - loss from tooth migration, 211f
 - methods to regain, 210
- Intracoronar restorations
 - amalgam, 71–79, 208, 217
 - composite resin
 - attributes, 77t
 - criteria for, 71–72
 - inlays, 72, 74f
 - glass ionomer, 72, 207, 400–401
 - inlays. *See* Inlays.
 - retention and resistance, 131, 131f
 - stress concentrations, 193
- Investing
 - for casting
 - base metal alloys, 380
 - crowns, gold alloy, 371–373, 372f–373f
 - dowel-cores, 376
 - expansion methods, 365–366, 376
 - fixed partial denture, gold alloy, 497–499, 497f–499f
 - general procedure, 368–371, 369f–371f
 - gold-palladium alloys, 379, 379f
 - inlays, gold, 376
 - definition of, 363
 - for soldering
 - metal-ceramic alloys, 506–508, 510–511
 - type III gold, 497–499, 497f–499f
- Investments, casting
 - gypsum-bonded, 366–376
 - phosphate-bonded, 377f
 - requirements of, 365
- Irreversible hydrocolloid, 291, 294

J

Joining, 493
Joints, solder. *See* Soldering.

K

Keyway, 223, 223f, 513
Knife edge finish line, 144, 144f, 144t
Knoop hardness numbers, 384t

L

Laminate veneer
 composite resin, 434
 definition of, 1
 porcelain. *See* Porcelain laminate veneer.
 working casts, 437–438
Laminating, 435
Lasers, for finish line exposure, 288f, 288–289
Lateral incisors
 fixed partial dentures for
 complex, 113–116
 pier abutments, 120–123, 126–127, 129
 simple
 one tooth, 101–102
 two teeth, 109
 root surface area of, 526t
Lateral interocclusal record, 42–43
Lateral translation, 24f
Leucite-reinforced material, 427
Light
 artificial, 418f, 418–419
 natural, 418, 418f
Lingual index, 154f
Lingual reduction
 all-ceramic crowns, 162, 162f
 metal-ceramic crowns, 154
 resin-bonded fixed partial dentures, 185f
 three-quarter crown, 171, 172f
Lithium disilicate-reinforced material, 427
Lost salt technique, 179

M

Mandible
 movement
 Bennett angle, 16, 16f
 determinants
 anterior guidance, 22–24
 condylar guidance, 21–22, 21f–22f
 description of, 17
 molar disocclusion, 21
 posterior. *See* Temporomandibular joint.
 effect of anterior teeth, 17
 excursion, 15–16, 16f
 protrusive, 15, 16f
 types of, 15, 15f
 positioning of
 dysfunctional, 14f
 healthy, 14f
 methods to guide, 13
 terminal hinge axis theory, 15
Mandibular canal, 523, 523f

Mandibular teeth
 cusp placement, 349t
 cusp–marginal ridge, 352, 353f
 hemisection, 237–238, 238f
 incisors
 esthetic length of, 413, 414f
 preparation for resin-bonded fixed partial denture, 183f
 root surface areas, 87f
Margins
 beveling vs not beveling, 140–141, 140f–141f
 finishing
 for gold restorations, 390–392
 for wax patterns, 358–360, 359f–360f
Maryland bridge, 179
Master cast
 multiple-tooth implant, 552, 552f
 single-tooth implant, 539, 539f–540f
Maxillary sinuses, 523
Maxillary teeth
 cusp placement, 349t
 incisors
 esthetic length of, 413, 414f
 incisal edges, 416
 preparation for resin-bonded fixed partial denture, 183f
 root resections of
 distofacial root, 234
 mesiofacial root, 235, 235f
 root surface areas, 87f
 wax patterns of cusp–marginal ridge, 350–352, 351f–352f
Maximal intercuspation record, 40–41, 41f
MCR. *See* Metal-ceramic restorations.
Mesiofacial root, of maxillary molar, 235, 235f
Mesio-occlusodistal onlays
 attributes, 77t
 description of, 75
 illustration of, 74f
 indications for, 197
 longevity of, 78, 79t
 mandibular molar preparations for, 200f
 maxillary teeth preparations for, 197–200
 stress concentrations, 197, 197f
Metal inlays
 attributes of, 77t
 Class 1, 196, 196f
 Class 3, 196, 196f
 Class 5, 196f, 196–197
 description of, 75
 illustration of, 74f
 longevity of, 79t
 tooth preparations for, 196–197
Metal-ceramic crowns
 anterior teeth
 armamentarium, 152
 axial reduction, 154, 155f
 depth-orientation grooves, 154, 155f
 finish lines, 154, 156
 incisal reduction, 154, 155f
 labial reduction, 154, 155f
 lingual reduction, 154

Index

- occlusal reduction, 152, 152f
 - overview, 157f
 - proximal reduction, 154
 - putty molds, 152, 153f
 - radial shoulder, 154, 156, 156f
 - shoulders, 154, 156
 - technique, 152–157, 153f–157f
 - attributes, 77t
 - cementation, 410
 - description of, 75, 151–152
 - illustration of, 76f
 - indications, 149
 - longevity of, 78, 79t
 - path of insertion, 137f
 - on periodontally weakened teeth, 229
 - plaque accumulation, 383, 383f
 - posterior teeth
 - axial reduction, 159f–160f
 - depth-orientation grooves, 159f
 - facial reduction, 159f
 - functional cusp bevel, 159f
 - gingival bevel, 160
 - indications, 158
 - occlusal reduction, 158, 159f
 - preparation for
 - armamentarium, 158
 - axial reduction, 159
 - depth-orientation grooves, 158
 - facial reduction, 158
 - functional cusp bevel, 158
 - gingival bevel, 160f
 - occlusal reduction, 138, 138f
 - overview, 160f
 - radial shoulder, 160
 - selective use of, 158
 - thickness requirements, 152
 - Metal-ceramic restorations
 - all-ceramic restorations and, comparison, 447
 - alloy types, 448–449, 449t
 - bonding mechanisms, 448
 - CAD/CAM application to, 457
 - cementation, 467–468
 - chairside correction of, 468
 - composition of, 447
 - coping design
 - extent of veneered area, 451–453, 452f–453f
 - facial margins, 454
 - metal collar, 454
 - occlusal contacts, 450–451, 451f
 - overview, 449
 - porcelain support, 450, 450f
 - porcelain veneer, 449–450
 - proximal contacts, 450–451
 - thickness of metal, 450
 - crowns. *See* Metal-ceramic crowns.
 - finishing, 467–468
 - fixed partial dentures
 - coping wax pattern, 487–490, 488f–490f
 - incisal configuration, 486
 - metal coping, 486
 - requirements, 486
 - rigidity, 486–487
 - soldering, 504, 504f
 - layers of, 447f
 - maxillary molar, 234f
 - metal coping, 447
 - pontics, 471, 471f, 476
 - porcelain addition
 - all-porcelain margin fabrication, 459–462, 459f–462f
 - dentin and enamel porcelain, 462–467, 463f–467f
 - opaque application, 458, 459f
 - soldering of, 504, 504f
 - surface treatment, 467
 - wax pattern
 - alloy surface treatment, 457, 457f
 - all-wax technique, 455–457
 - heat treatment, 458
 - single coping, 454–458, 455f–458f
 - Metamerism, 419
 - Micromechanical bonding, of cements
 - description of, 398
 - illustration of, 399f
 - Missing teeth, treatment options for
 - case presentation, 85
 - considerations, 81, 85
 - removable partial denture, 81–82, 83t, 85
 - MOD onlay, 75, 197–200
 - Molars
 - first, 119
 - fixed partial dentures
 - cantilever, 96
 - configurations for
 - one tooth, 105–107
 - pier abutments, 128–129
 - two teeth, 111–113
 - resin-bonded, preparations for, 184f
 - reverse three-quarter crown, 170, 170f
 - root surface area of, 526t
 - Molecular adhesion, of cements, 398
 - Multiple-tooth implant
 - healing of, 543
 - impressions
 - alginate, 544–546, 545f–546f
 - closed tray, 544
 - final, 546–551, 546f–551f
 - open tray, 544
 - master cast articulation, 552, 552f
 - placement of, 543, 543f, 553, 553f
 - study cast for, 544–545, 545f–546f
 - wax-up, 553, 553f
 - Mutually protected occlusion, 20, 361
- N**
- Nasal cavity, 523
 - Nickel-chromium alloys, 364
 - Noble alloys
 - ADA classification system, 363
 - gold content, 363
 - heat treatment, 458
 - melting temperature, 448
 - types of, 363
 - Nonadhesive luting, 398

Nonarcon articulators, 30
 Nonrigid connectors. *See* Connectors, nonrigid.
 Nonworking interference, 18f, 394

O

Occlusion
 bilateral balanced, 20
 diagnostic casts, 9
 disharmony of, 19f
 evaluation of, 6–8
 implant considerations, 527
 interferences, 17–18
 mandibular movement. *See* Mandible, movement.
 mutually protected, 20
 normal vs pathologic, 19
 unilateral balanced, 20
 wax patterns
 cusp-fossa
 cusp placement and occlusal contacts, 354f
 definition of, 354
 description of, 349t
 illustration of, 348f
 origins, 355
 procedure, 355–358, 355f–358f
 cusp-marginal ridge
 cusp placement and occlusal contacts, 350f
 description of, 348–349
 for mandibular teeth, 352, 353f
 for maxillary teeth, 350–352, 351f–352f
 Onlay
 definition of, 1
 illustration of, 3f
 mesio-occlusodistal. *See* Mesio-occlusodistal onlays.
 Organo-tin silicones, 310–312
 Osseointegration, 519
 Osteonecrosis, 6
 Overimpression-fabricated custom provisional restorations
 alginate
 armamentarium, 243
 cementation process
 armamentarium, 247
 procedure, 247–248, 247f–248f
 technique, 243–247, 243f–247f
 tooth preparation, 243–247
 bis-acryl composite crown, 256–259, 256f–259f
 Oxidation cycle, 458, 458f

P

Palatal root, of maxillary molar, 236–237, 236f–237f
 Palladium alloys
 gold
 casting, 379, 379f
 for metal-ceramic restorations, 448–449
 soldering, 509–512, 509f–512f
 silver, 363
 Pantograph
 air-activated, 33f
 condylar movement recordings, 33f, 33–34
 description of, 33
 fully adjustable articulator use with, 34

Partial coverage crowns
 advantages of, 165
 characteristics of, 77t
 definition of, 1
 full coverage crown and, comparison, 149, 165
 illustration of, 2f
 indications, 165
 lingual grooves, 165, 165f
 longevity of, 79t
 retention of, 165
 seven-eighths crown, 170, 170f
 three-quarter, tooth preparations for
 anterior teeth
 overview, 173f
 path of insertion, 171
 tooth preparation, 171–173
 pin-modified, 174–178
 posterior teeth, 166–170
 Partial dentures
 fixed. *See* Fixed partial dentures.
 removable, 81–82, 84, 247–248
 Path of insertion, 136, 137f
 Periodontal ligament area, 86–88, 88f
 Periodontically weakened teeth
 finish line modifications
 furcation flutes, 230, 231f
 location, 229f, 229–230
 nonresection methods, 239t
 root resection. *See* Root resection.
 Periodontium, finishing line effects on, 145
 Phosphate-bonded investments
 alloy types, 376
 armamentarium, 376
 casting
 base metal alloys, 380
 gold-palladium alloys, 379, 379f
 expansion methods, 376
 indications for, 376
 investing procedure, 376–379, 378f
 sprue former, 376–377
 Pickling, 374, 374f
 Pier abutments
 description of, 91–92
 fixed partial denture configurations, 120–129
 illustration of, 91f
 nonrigid connectors, 91–92, 92f
 Pin(s)
 for damaged teeth, 206–207
 dowel
 armamentarium, 331
 location, 330
 procedure, 331–333
 in restorations, impressions for, 318–319, 319f
 retentive, 174f
 uses of, 206
 Pinhole
 drilling of, 206–207
 placement areas, 206f
 substitution of, 136

Index

- Pindex system
 base to cast, process for adding, 337–339
 components, 334f
 description of, 333
 pinholes, 335–336
 pouring of impression, 333
 technique, 334f–340f
- Pin-modified three-quarter crown
 indications for, 174
 retention, 174
 tooth preparation for
 armamentarium, 176
 axial reduction, 176, 176f
 bevel, 178
 cutting holes, 174–175
 flares, 177
 grooves, 176–177, 177f
 offset, 177, 178f
 overview, 178f
- Pitting, 493
- Plasma glucose, 5, 5t
- Polishing materials
 abrasives, 384–385
 description of, 384
- Polycarbonate crown, anterior, 260–263
- Polycarboxylate cements
 cementation, 407, 407f
 compressive strength, 400
 indications, 400
 pulp protection for damaged teeth, 207
- Polyether
 armamentarium, 318
 characteristics of, 292t
 description of, 318
 effect of disinfectant solutions, 319–320
 impression making, 318
 wettability, 291
- Polyethyl methacrylate, 242t
- Polymerization, 242
- Polymerization shrinkage, 72
- Polymethyl methacrylate, 241–242, 242t
- Polysulfide
 armamentarium, 307
 characteristics of, 292t
 in custom resin trays, 299
 effect of disinfectant solutions, 319–320
 hydrophobic nature, 307
 impression making, 307–310, 308f–310f
 packaging of, 307
 viscosity, 293f
- Polyvinyl siloxane
 armamentarium, 315
 bonding strength of, 298–299
 characteristics of, 292t
 description of, 312–313
 effect of disinfectant solutions, 319–320
 formulations, 313–315
 hydrophobic nature, 313
 impression making, 315–317, 316f–317f
 overimpression-fabricated crowns, 256–259, 256f–259f
 packaging of, 313
 technique for, 313f–315f
 viscosity, 293f
- Polyvinylethyl methacrylate, 242t
- Pontic
 all-metal hygienic
 armamentarium, 482
 casting, 486, 486f
 die trimming, 482, 482f–483f
 excess wax removal, 482, 484f
 investing, 486, 486f
 plaster matrix, 484, 485f
 wax coping, 482–483
 in appearance zone, 474
 cantilever, 96
 definition of, 1, 471
 designs
 conical, 475, 476f
 considerations for, 471
 hygienic, 475, 475f
 ovate, 475–476, 476f
 ridge lap, modified, 474
 saddle, 474
 metal-ceramic, 476
 modifications
 for edentulous ridge, 478–479, 478f–479f
 of surfaces, 471, 472f
 postinsertion hygiene, 473–474, 473f–474f
 prefabricated facings, 476
 span length, deflection created by, 89, 89f
 split, 514
 tissue contact with ridge, 472f, 472–473
 types of, 471, 471f
 use of, 9
- Porcelain
 addition of, to metal-ceramic restorations
 all-porcelain margin fabrication, 459–462, 459f–462f
 dentin and enamel porcelain, 462–467, 463f–467f
 opaque application, 458, 459f
 contouring of, 468
 glazed, 435
 Porcelain jacket crown, 425, 425f. *See also* All-ceramic crowns.
- Porcelain laminate veneer
 description of, 434
 developmental stages of, 434–435
 dies
 fabrication of, 437–438, 438f
 gingival retraction, 437
 illustration of, 3f
 impression, 437
 refractory, 438f–441f, 438–441
 removable, 437–438
 indications, 435
 porcelain application
 color, 441
 procedure for, 441–443, 442f–443f
 shade selection, 441
 preformed, 434
 provisional restorations, 445

- removable, 437–438
 - silane coupling agent, 435
 - tooth preparation
 - axial outline, 436, 436f
 - axial reduction, 436, 436f
 - depth-reduction grooves, 436f
 - facial reduction, 435, 435f–436f
 - finish line, 435, 437
 - finishing, 437, 437f
 - incisal finish line, 437
 - incisal reduction, 436, 436f
 - proximal refinement, 437
 - tissue management, 437
 - tooth reduction, 435
 - working casts, 437–438
 - Porcelain release agent, 460
 - Porcelain-fused-to-metal restoration. *See* Metal-ceramic crowns.
 - Posterior teeth
 - contact with mandible, 20
 - fixed partial dentures for, 99
 - metal-ceramic crowns. *See* Metal-ceramic crowns, posterior teeth.
 - three-quarter crowns. *See* Three-quarter crowns, posterior teeth.
 - Precious metals. *See* Noble alloys.
 - Prefabricated provisional restorations
 - anterior polycarbonate crown
 - armamentarium, 260
 - overview of, 260
 - procedure, 260–263, 260f–263f
 - preformed anatomical metal crown
 - armamentarium, 264
 - procedure, 263–267, 264f–267f
 - Premolars
 - dowel cores, 222
 - fixed partial dentures
 - configurations for
 - one tooth, 103–105
 - pier abutments, 122–129
 - two teeth, 110–112
 - resin-bonded, preparations for, 184f
 - mandibular first, 120
 - maxillary first, 119–120
 - maxillary second, 119
 - root surface area of, 526t
 - Preparations, tooth. *See* Tooth preparations.
 - Protrusive incisal path, 22
 - Protrusive incisal path inclination, 22
 - Protrusive occlusal interference
 - adjustments, for gold restorations, 394, 394f
 - definition of, 18
 - illustration of, 18f
 - Provisional restorations
 - classifications
 - direct vs indirect, 241–242
 - prefabricated vs custom, 241
 - criteria for, 241
 - custom. *See* Custom provisional restorations.
 - definition of, 241
 - endodontically treated teeth, 263, 263f
 - prefabricated, techniques for
 - anterior polycarbonate crown, 260–263, 260f–263f
 - preformed anatomical metal crown, 263–267, 264f–267f
 - removal of, 388
 - resins, 242, 242t. *See also* specific resin.
 - Proximal contacts
 - adjustments for, 389f, 389–390
 - all-ceramic restorations, 409
 - metal-ceramic restorations, 450–451
 - soldering, 502–503
 - Proximo-occlusal inlays
 - armamentarium, 194
 - bevel, 195f, 195–196
 - flares, 194–195, 195f
 - gingivoaxial groove, 194, 195f
 - marginal ridge, 194
 - occlusal outline, 194
 - overview, 196f
 - proximal box, 194
 - Pulpless tooth. *See* Endodontically treated teeth.
- Q**
- Quick Mount facebow, 45–48
- R**
- Radial shoulder, 142–143, 143f, 154, 156, 160, 429
 - Radiating symmetry, 415
 - Radiographs, full-mouth, 9
 - Reduction. *See* specific reduction.
 - Removable die, for working casts
 - antirotational devices, 330, 330f
 - orientation methods for
 - Pindex system, 333–340, 334f–340f
 - straight dowel pin, 330–333, 331f–333f
 - requirements, 330
 - separate die vs, 330
 - Removable partial dentures
 - abutment teeth requirements, 81–82
 - characteristics of, 83t
 - indications for, 81
 - provisional crown placement under, 247–248
 - Resin cements
 - autopolymerizing, 398
 - cementation, 402–404, 403f
 - composite
 - dentinal bonding agent use with, 402–404
 - description of, 398
 - problems associated with, 402
 - restorations
 - criteria for, 71–72
 - inlays, 72
 - longevity of, 79t
 - problems associated with, 398–400
 - restorations
 - inlays, 74f
 - longevity of, 78
 - Resin-bonded fixed partial dentures
 - advantages, 180

Index

- cements, 180
- contraindications, 182
- delivery
 - armamentarium, 186
 - sequence
 - abutment teeth, 186, 187f
 - air abrading, 186, 187f
 - bonding, 187–188
 - excess removal, 188
 - Oxyguard II, 188, 188f
 - primer, 187
 - pumice cleaning, 186
- disadvantages, 180
- framework configurations, 184f
- longevity uncertainties, 180, 181t
- Maryland bridge, 179
- Rochette bridge, 179
- tooth preparation
 - armamentarium, 184
 - axial reduction, 182, 186f
 - countersinks, 185f
 - examples of, 183f–184f
 - finish lines, 182
 - grooves, 183, 183f–184f, 186f
 - lingual reduction, 185f
 - occlusal reduction, 182, 185f
 - proximal reduction, 185f
 - rests, 184f
 - sequence, 185–186
 - vertical stops, 182
 - Virginia bridge, 179–180
- Resin-modified glass-ionomer cement, 401–402
- Resistance, 131–137
- Restorations
 - all-ceramic. *See* All-ceramic restorations.
 - base metal
 - adjustments, 397
 - finishing, preliminary, 397
 - polishing, 397
 - try-in, 397
 - ceramic. *See* Ceramic restorations.
 - considerations for, 71–72
 - gold
 - adjustments
 - contours, 395
 - esthetics, 395
 - margin finishing, 390–392
 - marginal adaptation, 390, 391f
 - occlusal
 - nonworking movement, 394, 394f
 - overcorrection, 392, 393f
 - protrusive interferences, 394, 394f
 - working movement, 394, 394f
 - proximal contacts, 389f, 389–390
 - seating completeness, 390
 - finishing
 - postcementation, 396
 - preliminary, 385–387
 - precementation polishing, 395, 395f–396f
 - try-in
 - anesthesia use, 387
 - armamentarium, 387
 - precautionary procedures, 388, 388f–389f
 - provisional crown
 - patient hypersensitivity, 387
 - removal, 388
 - marginal integrity
 - beveling vs not beveling, 140f–141f, 140–141
 - finish line configurations, 141–145
 - metal-ceramic. *See* Metal-ceramic restorations.
 - provisional. *See* Provisional restorations.
 - retention and resistance of
 - extracoronaral, 131, 131f
 - factors that affect
 - freedom of displacement, 133–134, 134f
 - internal feature substitution, 136, 136f
 - occlusogingival length, 135, 135f
 - path of insertion, 136, 137f
 - intracoronaral, 131, 131f
 - overview, 131
 - small teeth vs large teeth, 133, 133f
 - shade selection. *See* Shade selection.
 - structural durability, factors that affect
 - axial reduction, 138, 139f
 - functional cusp bevel, 138, 139f
 - occlusal reduction, 138
 - tooth preparation for. *See* Tooth preparation.
 - tooth structure preservation, 131
- Retainers
 - definition of, 1
 - implant-supported fixed partial denture, 84
- Retentive pins, 174f
- Retraction cord
 - armamentarium, 275
 - chemical types, 274t
 - epinephrine, 273, 275–278
 - placement of, 275–278, 275f–279f
- Reverse occlusion, 20
- Reversible hydrocolloid
 - agar content, 294
 - armamentarium, 296
 - characteristics of, 292t
 - conditioner for, 294, 295f
 - cooling of, 294
 - impression making, 294, 296f–297f, 296–298
 - irreversible, 294
 - origins of, 294
 - storage of impressions, 294
 - wettability, 291
- Ridges
 - cusp–marginal
 - cusp placement and occlusal contacts, 350f
 - description of, 348–349
 - wax patterns of
 - mandibular teeth, 352, 353f
 - maxillary teeth, 350–352, 351f–352f
 - edentulous
 - classification of, 477, 477f
 - deformities, 477, 477f
 - pontic modification, 478–479, 478f–479f
 - surgical correction
 - Class II and III defects, 480, 481f

donor tissue, 480
 incisions, 479–480, 480f
 Rochette bridge, 179
 Root
 configuration of, 86
 crown-root ratio, 85–86
 Root amputation, 232
 Root canal. *See* Endodontically treated teeth.
 Root caries. *See* Caries.
 Root resection
 capacity of resected roots, 232
 contraindications, 232
 description of, 232
 effect of narrow furcations, 232
 failure rates, 239
 indications, 232
 success rates, 239, 239t
 technique, 232–233, 233f
 tooth preparation and crown configurations
 mandibular hemisection, 237–238, 238f
 maxillary distofacial root, 234
 maxillary facial roots, 237
 maxillary mesiofacial root, 235, 235f
 maxillary palatal root, 236, 236f, 237, 237f
 skyfucation, 239, 239f
 Rotary curettage, 280, 280f
 Rouge, 384
 Rubber base. *See* Polyether; Polysulfide.
 Rubber dam, 269, 272
 Rubber points, 385
 Rubber wheels, 385
S
 Saliva ejector, 270
 Separating disks, 384
 Seven-eighths crown, 170, 170f
 Shade selection
 color
 characteristics of, 419
 daily functions' effect on, 419
 light sources' effect on
 artificial, 418f, 418–419
 factors that affect, 418
 natural, 418, 418f
 glass-ceramic restorations, 427
 metal-ceramic restorations, 467
 sequence for
 illustration of, 420f–423f
 patient positioning, 421
 recording of findings, 423
 removal of distractions, 420
 shade guide, 420
 shade tabs, 421–423
 translucency, 419
 Shade tabs, 421–423
 Shear thinning, 293
 Shell-fabricated provisional restorations, 254–255, 255f
 Shoulder
 all-ceramic crowns, 161–162, 162f
 mesio-occlusodistal onlays, 198f
 metal-ceramic crowns, 154, 156, 156f

Shrinkage, during investing
 description of, 365
 expansion methods
 hygroscopic, 365
 setting, 365
 thermal, 365–366
 wax pattern, 365
 Shrink-spot porosity, 367, 375f
 Silane coupling agent, 435
 Silicon carbide, 384
 Silicone
 Condensation. *See* Condensation silicones.
 polyvinyl siloxane. *See* Polyvinyl siloxane.
 Silicone putty index, 253f
 Silver-palladium alloys, 363
 Single-tooth implant
 cast fabrication, 532, 535–539
 description of, 531
 facial view of, 531f
 gingival tissue evaluation, 532
 healing of, 531, 532f
 impression techniques
 alginate, 533–535, 533f–535f
 closed tray, 532–533, 533f
 final, 535–539, 535f–539f
 open tray, 532–533, 533f
 master cast articulation, 539, 539f–540f
 placement of, 531, 542, 542f
 wax-up for, 540, 541f–542f
 Single-tooth restorations
 attributes of, 77t
 extracoronaral. *See* Crowns.
 intracoronaral
 amalgam
 complex, 73, 75
 simple, 72–73
 composite resin. *See* Composite resin restorations.
 glass ionomer, 72, 207, 400–401
 inlays. *See* Inlays.
 mesio-occlusodistal onlays. *See* Mesio-occlusodistal.
 longevity of, 78
 treatment planning, considerations for, 71–72
 Skyfucation, 239, 239f
 Smile line
 effect of mouth on, 414f
 illustration of, 413f
 Solder
 breaking of, 503–504
 characteristics of, 493
 gold, 493
 noble metal content, 493
 Soldering
 definition of, 493
 difficulty associated with, 494
 fixed partial denture
 gold alloy
 distortions, 496
 indexing, 494
 investing, 497–499, 497f–499f
 single-piece casting, 494
 soldering, 500–501, 500f–501f

Index

- metal-ceramic alloys
 - indications for, 504
 - methods, 504, 504f
 - postveneer
 - burnout, 512
 - casting, 512
 - indexing, 509–510
 - investing, 510–511
 - preparatory procedures, 509
 - preveneer
 - burnout, 506–508
 - indexing, 506
 - investing, 506–508
 - margin finishing, 508
 - postveneer and, comparison, 505
 - procedure, 505–508, 505f–508f
 - methods of, 504, 504f
 - preveneer, 504
 - proximal contacts, 502–503
 - repair of casting voids, 503
 - requisites for, 493
 - Sprue former
 - for all-metal hygienic pontics, 486
 - description of, 366
 - in gypsum-bonded investments, 366–368, 368f
 - illustration of, 367f
 - in phosphate-bonded investments, 376–377
 - Stones, abrasive
 - green, 385
 - pink, 385
 - shapes of, 385f
 - white, 385
 - Stress concentrations, in intracoronal restorations, 197
 - Structural durability, of restorations
 - axial reduction, 138, 139f
 - functional cusp bevel, 138, 139f
 - occlusal reduction, 138
 - Subgingival margins, 145
 - Subperiosteal implants, 517, 518f
 - Supragingival margins, 145
 - Surgical crown lengthening, 212f
 - Svedopter, 270–271, 270f–271f
 - Symmetry, of face, 413
- T**
- Taper
 - definition of, 132
 - optimum degree of, 132, 133t
 - retention and, relationship between, 132f
 - Teeth. *See also* Mandibular teeth; Maxillary teeth; *specific teeth*.
 - abutment use. *See* Abutments.
 - alignment of, 82f
 - damaged. *See* Damaged teeth.
 - endodontically treated. *See* Endodontically treated teeth.
 - mandibular movement affected by, 17
 - missing. *See* Missing teeth.
 - Telescope crown, 94, 94f
 - Templates, for provisional restorations
 - fixed partial denture, 248–252, 248f–252f
 - visible light-cured, 252–254
 - Temporomandibular joint
 - anatomy of, 13, 14f
 - evaluation of, 6–8
 - mandibular movement and, 27
 - Terminal hinge axis theory, 15
 - Three-quarter crowns
 - anterior teeth
 - armamentarium, 171
 - axial reduction, 171–172, 172f
 - bevels, 171, 173f
 - flares, 172–173, 173f
 - grooves, 172f, 172–173
 - incisal reduction, 171, 172f
 - lingual reduction, 171, 172f
 - offset, 173, 173f
 - overview, 173f
 - path of insertion, 171
 - for mandibular molar, 170, 170f
 - pin-modified
 - indications for, 174
 - retention, 174
 - tooth preparation for
 - armamentarium, 176
 - axial reduction, 176, 176f
 - bevel, 178
 - cutting holes, 174–175, 177f–178f
 - flares, 177
 - grooves, 176–177, 177f
 - offset, 177, 178f
 - overview, 178f
 - posterior teeth
 - armamentarium, 166
 - axial reduction, 166–167, 167f
 - finishing lines, 167, 167f
 - flares, 168–169, 169f
 - functional cusp bevel, 166, 166f
 - grooves, 167–168, 167f–168f
 - occlusal reduction, 166, 166f
 - offsets, 169
 - overview, 169f
 - reverse, 170, 170f
 - Tilted molar
 - abutments
 - corrective methods, 93–94
 - description of, 93–94
 - fixed partial dentures, 93–94
 - split pontics, 514
 - proximal half crown, 170f, 170–171
 - uprighting of, 93, 93f
 - Titanium alloy, 364
 - TMJ. *See* Temporomandibular joint.
 - Tooth conditions, 203t
 - Tooth preparations
 - all-ceramic crowns. *See* All-ceramic crowns, tooth preparations.
 - damaged teeth. *See* Damaged teeth, preparations for.
 - full coverage crown. *See* Full coverage crown, tooth preparation for.

instrumentation, 145–147, 146t
 laminate veneers, porcelain
 depth-reduction grooves, 436f
 facial reduction, 435, 435f–436f
 finish line, 435
 finishing, 437
 incisal reduction, 436, 436f
 marginal integrity
 beveling vs not beveling, 140–141, 140f–141f
 finish line configurations, 141–145
 mesio-occlusodistal onlays
 for mandibular molars, 200f
 for maxillary teeth
 armamentarium, 197
 bevel, 198–199, 198f–200f
 finish lines, 198, 199f
 flares, 198, 199f
 isthmus, 198
 occlusal reduction, 197–198, 198f
 overview, 200f
 proximal box, 198
 shoulder, 198f
 metal-ceramic crowns. *See* Metal-ceramic crowns.
 periodontium preservation, 145
 retention and resistance
 extracoronaral, 131, 131f
 factors that affect
 freedom of displacement, 133–134, 134f
 internal feature substitution, 136, 136f
 occlusogingival length, 135, 135f
 path of insertion, 136, 137f
 intracoronaral, 131, 131f
 overview, 131
 taper, 132–133
 small teeth vs large teeth, 135f
 structural durability, factors that affect
 axial reduction, 138, 139f
 functional cusp bevel, 138, 139f
 occlusal reduction, 138
 tooth structure preservation, 131, 208–210
 Tooth structure preservation, 131, 208–210
 Transformation toughening, 429
 Transosseous mandibular bone plate, 517, 518f
 Tripoli, 384
 Try-in
 base metal restorations, 397
 gold alloy restorations
 anesthesia use, 387
 armamentarium, 387
 precautionary procedures, 388, 388f–389f
 provisional crown
 patient hypersensitivity, 387
 removal, 388

U
 Undercuts
 box form to eliminate, 208
 visual examination for, 136, 137f
 Unilateral balanced occlusion, 20, 361

V

Vac-U-Spat investor, 369–371
 Value, 419
 Van der Waals forces, 448
 Veneer crowns. *See* Full coverage crown; Partial coverage crowns.
 Veneer restorations. *See* Laminate veneer.
 Vent holes, 401
 Virginia bridge, 179–180
 Visible light-cured provisional restorations, template-fabricated, 252–254
 Visible light-cured urethane dimethacrylate, 242t
 Vital teeth
 abutment use of, 85
 damaged, modifications for restorative procedures, 208–210, 209f
 Voids, casting
 armamentarium, 503
 contraindications, 503
 indications for, 503

W

Wax interocclusal records. *See* Interocclusal records.
 Wax patterns
 axial contours
 bulges, 346, 347f
 emergence profile, 346, 347f
 faciolingual, 345–346, 345f–346f
 proximal, 345
 fabrication
 armamentarium, 343
 coping, 343–344, 344f
 methods of, 343
 margin finishing
 common problems, 358
 occlusal grooves, 360
 occlusal scheme
 classification of, 349t
 cusp-fossa
 curve of Spee, 354
 curve of Wilson, 355
 cusp placement and occlusal contacts, 354f
 definition of, 354
 description of, 349t
 illustration of, 348f
 origins, 355
 procedure, 355f–358f, 355–358
 cusp-marginal ridge
 cusp placement and occlusal contacts, 350f
 description of, 348–349
 for mandibular teeth, 352, 353f
 for maxillary teeth, 350–352, 351f–352f
 single coping, 454–458, 455f–458f
 wax types, 343
 Wax wafers, 45, 46f
 Wet field technique, 296–297
 Working casts
 mounting of
 Denar facebow and articulator, 59–60

Index

Hanau facebow and articulator, 65–66
 Whip Mix facebow and articulator, 50–53
 with removable die
 advantages over separate die, 330
 antirotational devices, 330, 330f
 methods of orienting die in cast
 Pindex system. *See* Pindex system.
 straight dowel pin, 330–333, 331f–333f
 requirements, 330
 requirements for, 325
 with separate die
 armamentarium, 325
 description of, 325
 die preparation, 327–329, 327f–329f
 difficulties associated with, 325
 finish lines, 327–328, 329f
 hardening agents, 328
 impression pouring, 325–326, 326f
 Working occlusal interference
 adjustments, for gold restorations, 394, 394f
 description of, 17, 18f

X

Xerostomia, 5–6

Z

Zinc oxide–eugenol cement
 indications, 400
 performance of, 400
 provisional crowns, 248, 248f
 Zinc phosphate
 cementation
 cement preparation, 404–405, 405f
 mandibular isolation, 404, 404f
 pulp protection, 404
 removal of excess cement, 406
 restoration seating, 405–406, 406f
 vital tooth considerations, 404
 compressive strength, 400
 indications, 400
 Zirconia-reinforced materials, 429